

**A text-book of histology : arranged upon an embryological basis / by
Frederic T. Lewis and Philipp Stöhr.**

Contributors

Lewis, Frederic T. 1875-1951
Stöhr, Philipp, 1849-1911.

Publication/Creation

Philadelphia : P. Blakiston, [1913]

Persistent URL


<https://wellcomecollection.org/works/axfwzp8k>


License and attribution

Conditions of use: it is possible this item is protected by copyright and/or related rights. You are free to use this item in any way that is permitted by the copyright and related rights legislation that applies to your use. For other uses you need to obtain permission from the rights-holder(s).



Wellcome Collection
183 Euston Road
London NW1 2BE UK
T +44 (0)20 7611 8722
E library@wellcomecollection.org
<https://wellcomecollection.org>






22500461032

Med
K7886



A TEXT-BOOK OF HISTOLOGY

LEWIS AND STÖHR



A
TEXT-BOOK
OF
HISTOLOGY

ARRANGED UPON AN EMBRYOLOGICAL BASIS

BY

DR. FREDERIC T. LEWIS

ASSISTANT PROFESSOR OF EMBRYOLOGY AT THE HARVARD MEDICAL SCHOOL

AND

DR. PHILIPP STÖHR

FORMERLY PROFESSOR OF ANATOMY AT THE UNIVERSITY OF WÜRZBURG

UNIVERSITY
COLLEGE
LONDON

SECOND EDITION, WITH 495 ILLUSTRATIONS

Being the Seventh American Edition of Stöhr's Histology
From the Fifteenth German Edition, edited by Dr. O. Schultze

PHILADELPHIA
P. BLAKISTON'S SON & CO.
1012 WALNUT STREET

COPYRIGHT, 1913, BY P. BLAKISTON'S SON & CO.

14796934

WELLCOME INSTITUTE LIBRARY	
Coll.	WelMOMec
Coll.	
No.	QS

PREFACE

PHILIPP STÖHR, whose *Lehrbuch der Histologie* is here presented with many additions and changes, was born at Würzburg, June 13, 1849, and died in his native city, November 4, 1911. It was his good fortune to study under the most eminent of all histologists, Albert von Kölliker, whose assistant he became in 1877, and whom he succeeded as Professor of Histology and Embryology at Würzburg in 1902. During these years he enriched anatomy with a whole series of important contributions, and he continued his researches until the time of his death, dealing with the relation of lymphocytes to epithelium, the degeneration of glands in the vermiform process, the development of hairs, the nature of the cells of the thymus, and many other subjects. But as stated by Professor Schultze in a memorial address (Verh. phys.-med. Ges., Würzburg, 1912, vol. 42), "Stöhr's position as an anatomist doubtless depends upon his surpassing gifts as a teacher." He considered that the instruction of young men in an intricate science was worthy of his best efforts, and his time was freely given to preparing demonstrations, and to writing and revising his *Lehrbuch der Histologie und der mikroskopischen Anatomie des Menschen*.

The first edition of the *Lehrbuch* appeared in 1887, and the fifteenth, edited by Schultze on the basis of memoranda which Stöhr had prepared, was published in 1912. Meanwhile the volume nearly doubled in size. It has been translated into many languages, including the Japanese, and the late editions have been issued in very large numbers. As principal characteristics of the book, there may be mentioned, first, its clear and concise style, somewhat dogmatic because of the omission of essentially all references to authorities. Since Stöhr considered that adequate references would be impossible in a book of small size, he omitted them altogether. Second, the almost entire absence of borrowed illustrations. As Schultze remarks, Stöhr possessed unusual artistic talent, and many of the excellent figures were drawn by Stöhr himself. Third, the full directions for the preparation of every specimen illustrated. In addition to these special characteristics, the book has the advantages of being essentially a résumé of Kölliker's exhaustive *Gewebelehre*, adapted to the use of students.

The first American edition of *Stöhr's Histology* was edited by Dr. Alfred Schaper, at that time Demonstrator of Histology and Embryology

at the Harvard Medical School, and was published by Messrs. P. Blakiston, Son & Co. in 1896. This edition was essentially a literal translation, to which Dr. Schaper added a chapter on the placenta and membranes; a corresponding chapter was later incorporated in the German *Lehrbuch*. In the four American editions which followed, Dr. Schaper made a limited number of further additions, and supplied some excellent drawings of his own.

After the death of Dr. Schaper, Professor Stöhr generously consented to allow more extensive modifications, provided that he should not be held responsible for them, as stated in the following note:

In the new edition of the American translation of my handbook a number of additions and changes have been made by the translator with my permission. It is therefore reasonable that I should not take the same responsibility for the translation as for the text of the German original, and I would ask those of my colleagues who wish to question the correctness of my assertions in their papers, to convince themselves, by making comparisons with my last German edition, that the paragraphs in question were written by me.

(Signed) PHILIPP STÖHR.

At the suggestion of Professor Minot, the writer undertook to prepare the sixth American edition. Because of the great importance of embryological interpretations in understanding adult tissues, it was decided to arrange the text-book on an embryological basis, but this necessitated more radical changes than were originally contemplated. In describing the result, Professor Stöhr wrote that the character of his book had been completely changed. "With all that has been left out of some parts and added to other parts, it may without exaggeration be said that with the appearance of this sixth American edition my book has ceased to exist in America."

The writer, therefore, must assume the principal responsibility for the book in its present form. There are certain sections, as those on hair, the eye, and the ear, which are largely literal translations, but elsewhere Stöhr's text has been freely paraphrased. Of the 376 figures which illustrate the 15th German edition, 275 will be found in the following pages; 220 additional figures have been supplied from other sources, and of these 95 are original. Although the changes in the text are relatively greater than in the figures, much of the work is clearly Professor Stöhr's, and in order to give full credit for the part which has been retained, this edition is published as of joint authorship. The changes which have been introduced are designed to make the text-book more useful in certain American schools where it has been adopted, and the nature of these changes may be explained as follows.

First, the book has been arranged on an embryological basis and has

become the only available text-book—in so far as the writer is aware—in which the development of each organ is described as an introduction to the study of its microscopic structure in the adult. This method of presentation is believed to be interesting, logical, and pedagogically practicable. It proceeds from simple arrangements to those which are complex, and it emphasizes fundamental features in distinction from those which are secondary.

Secondly, a large number of citations and references to original papers, both ancient and modern, have been inserted. Since the most obvious facts of anatomy were observed first and details were learned subsequently, an historical presentation serves to differentiate between the important and the trivial, being comparable in this respect with an embryological presentation. At the same time it is shown that anatomy has been a subject of absorbing interest, and its possibilities are by no means exhausted, contrary to an opinion often expressed. Thus in 1821, when Charles Bell made his great discoveries concerning nerves, he stated that scientists had often remarked to him—"In your department we can hope for nothing new. After so many eminent men in a succession of ages have laboured on your subject, no further discovery can be expected." Similarly, forty years later, an American professor of anatomy described his science as "a well reaped field"; shortly after this, the discovery of the islands in the pancreas was announced, and they constituted an essentially new and important organ. Thus while morphology continues to be discredited as an effete and superficial science, dealing merely with shapes and relations, it still reveals new structures in the human body, some of which are of obvious significance, whereas others await explanations by the physiologists and chemists. In order that students may have an idea of the important work now being done by anatomists, references to a selection of recent papers have been introduced in this edition. American publications have perhaps been given particular prominence, but this is because they are more accessible to the students for whom this book is written.

As a third modification, microscopic technique is described in a single chapter, revised by Mr. L. G. Lowrey, now in charge of the instruction in this subject at the Harvard Medical School. It furnishes directions for a brief but practical course in microscopic technique, especially adapted to the needs of medical students.

In preparing this edition, the writer has received valuable assistance from many sources. The account of the rectum was written by Dr. F. P. Johnson, and Professor Huber has assisted in revising the description of the kidney. The account of spermatogenesis is based on specimens made by Dr. Scammon, and important illustrations have been supplied by Professors Mark, Mallory, Minot, and Mall. Numerous crude figures in the earlier edition have been replaced by excellent drawings made by Miss

Mabel Herford. To these and to many others who have offered suggestions, the author makes grateful acknowledgment. Messrs. P. Blakiston's Son & Co. have supplied several figures from their anatomical publications, and have endeavored to maintain the high standard of press work which has characterized previous editions.

FREDERIC T. LEWIS.

CAMBRIDGE, MASSACHUSETTS,
September, 1913.

CONTENTS

PART I.

MICROSCOPIC ANATOMY.

I. CYTOLOGY.

	PAGE		PAGE
THE CELL,	I	VITAL PHENOMENA,	11
Protoplasm.		Amœboid Motion.	
Nucleus.		FORMATION AND REPRODUCTION OF	
Centrosome.		CELLS,	12
Cell Wall.		Amitosis.	
Form and Size of Cells.		Mitosis.	
CYTOMORPHOSIS,	9	Spermatogenesis.	
		Oögenesis.	
		Fertilization.	

II. GENERAL HISTOLOGY.

HISTOGENESIS,	35	NERVOUS TISSUE,	130
Segmentation and the Formation		General Features.	
of the Germ Layers.		Development of—	
The Fundamental Tissues.		The spinal nerves	
EPITHELIUM,	46	The sympathetic system	
Shapes of Epithelial Cells and the		The cerebral nerves.	
Number of Layers.		Structure of—	
Peripheral Differentiation.		Nervous tissue	
Processes of Secretion.		Ganglia	
The Nature and Classification of		Nerves.	
Glands.		Nerve Endings.	
MESENCHYMAL TISSUES,	59	VASCULAR TISSUE,	163
Reticular Tissue.		Blood Vessels.	
Mucous Tissue.		General features.	
Connective Tissue.		Development.	
Adipose Tissue.		Capillaries.	
Tendon.		Arteries.	
Cartilage.		Veins.	
Bone.		The Heart.	
Joints.		Lymphatic Vessels.	
Teeth (including the Ectodermal		Blood.	
Enamel Organs).		Red corpuscles.	
MUSCULAR TISSUE,	113	White corpuscles.	
Smooth Muscle.		Blood plates.	
Skeletal Muscle.		Plasma.	
Cardiac Muscle.		Lymph.	

III. SPECIAL HISTOLOGY.

	PAGE		PAGE
BLOOD FORMING AND BLOOD DESTROY- ING ORGANS,.....	202	MALE GENITAL ORGANS.—(<i>Continued.</i>)	
Bone Marrow.		Urethra and Penis.	
Lymph Nodules and Lymph Glands.		FEMALE GENITAL ORGANS,.....	349
Hæmolymp Glands.		Development and General Features.	
Spleen.		Ovary.	
THE ENTODERMAL TRACT,.....	215	Uterine Tubes.	
Mouth and Pharynx,.....	215	Uterus.	
Development.		Menstruation.	
Tonsils.		Decidual Membranes of the Uterus and Embryo.	
Thymus.		Development and General Fea- tures.	
Thyroid Gland.		Decidua vera, Amnion and Chorion læve.	
Parathyroid Glands.		Placenta.	
Glomus Caroticum.		Umbilical Cord.	
Tongue.		Vagina and External Genital Or- gans.	
Oral and Pharyngeal Cavities.		SKIN,.....	384
Glands of the Oral Cavity.		Nails.	
Digestive Tube,.....	245	Hair.	
Development.		Sebaceous Glands.	
Œsophagus.		Sweat Glands.	
Stomach.		Mammary Glands.	
Duodenum.		SUPRARENAL GLANDS,.....	404
Jejunum and Ileum.		CENTRAL NERVOUS SYSTEM,.....	409
Mesentery and Peritoneum.		Spinal Cord,.....	409
Vermiform Process.		Development and General Fea- tures.	
Cæcum and Colon.		Adult Structure.	
Rectum.		Brain,.....	418
Liver,.....	276	Development and General Fea- tures.	
Pancreas,.....	289	Medulla Oblongata.	
Respiratory Apparatus,.....	295	Cerebellum.	
Development.		Hemispheres.	
Larynx.		Hypophysis.	
Trachea and Bronchi.		Pineal Body.	
Lungs.		Meninges.	
Pleura.		EYE,.....	439
URINARY ORGANS,.....	306	Development and General Anatomy.	
Wolffian Bodies and Wolffian Ducts.		Retina.	
Kidney.		Optic Nerve.	
Renal Pelvis and Ureter.		Lens.	
Bladder.		Vitreous Body.	
Urethra (in the female).		Tunica Vasculosa.	
MALE GENITAL ORGANS,.....	326	Tunica Fibrosa.	
Development and General Features.		Vessels, Chambers, and Nerves.	
Testis.		Eyelids.	
Epididymis.		Lachrymal Glands.	
Ductus deferens.			
Seminal Vesicles and Ejaculatory Ducts.			
Appendices and Paradidymis.			
Prostate.			

	PAGE		PAGE
EAR,.....	465	EAR.—(<i>Continued.</i>)	
Development and General Anatomy.		Vessels of the Labyrinth.	
Sacculus, Utriculus, and Semi-		Middle Ear.	
circular Ducts.		External Ear.	
Cochlea.		NOSE,.....	481
Nerves of the Labyrinth.			

PART II.


MICROSCOPICAL TECHNIQUE.

I. THE PREPARATION OF MICROSCOPICAL SPECIMENS.

	PAGE		PAGE
FRESH TISSUES,.....	487	PERMANENT PREPARATIONS.—(<i>Continued.</i>)	
ISOLATION,.....	488	General Stains.	
PERMANENT PREPARATIONS,.....	489	Selective Stains.	
Fixation.		Clearing and Mounting.	
Decalcification.		SLIDES AND COVER GLASSES,.....	508
Imbedding.		INJECTIONS,.....	509
Cutting and Handling Sections.		SPECIAL METHODS,.....	510
Staining.			

II. THE EXAMINATION OF MICROSCOPICAL SPECIMENS.

	PAGE
THE MICROSCOPE,.....	514
RECONSTRUCTIONS,.....	516
DRAWINGS,.....	518



PART I.

MICROSCOPIC ANATOMY.

I. CYTOLOGY.

THE CELL.

Since 1838 it has been known that all plants and animals are composed of small structural elements called cells (Latin, *cellula*; Greek, κύτος). The lowest forms of animals and of plants are alike in being single cells throughout life. The more complex organisms are groups of cells, which have been derived by process of repeated division from a single cell, the fertilized ovum. Thus the human body, which begins as one cell, becomes in the adult an aggregation of cells variously modified and adapted to perform special functions. Since the liver is a mass of essentially similar cells, the problems of its functional activity are the problems of the functions of a single one of its cells. The diseases of the liver are the result of changes occurring in these cells, which must be restored to a normal condition to effect a cure. As this is equally true of other organs, it is evident that cytology, the science of cells, is a basis for both physiology and pathology.

A cell may be defined as a structural element of limited dimensions, which under certain conditions can react to external stimuli and perform the functions of assimilation, growth, and reproduction. Because of these possibilities a cell may be considered an elementary organism. It is described as a mass of protoplasm containing a nucleus. A third element, the centrosome, is found in the cells of animals, but it is doubtful whether it exists in the cells of the higher plants. It becomes prominent when a cell is about to divide. Some authorities regard the centrosome as a temporary structure, which forms shortly before division begins and disappears after it is completed. Others consider it as a permanent and essential part of a cell, which accordingly consists of protoplasm, nucleus, and centrosome.

PROTOPLASM.

Protoplasm is the living substance of which cells are composed. More specifically the term is applied to this living substance exclusive of the nucleus, or to the corresponding dead material, provided that death has not changed its physical properties. It has been proposed to substitute the name *cytoplasm* for protoplasm in the restricted and earlier sense of the term, to call the nuclear substance *karyoplasm*, and to consider both cytoplasm and karyoplasm as varieties of protoplasm. Although these names are often employed, the cell substance apart from the nucleus is ordinarily called protoplasm.

Protoplasm is a heterogeneous mixture of substances forming a soft viscid mass of slightly alkaline or neutral reaction. ("The terms may

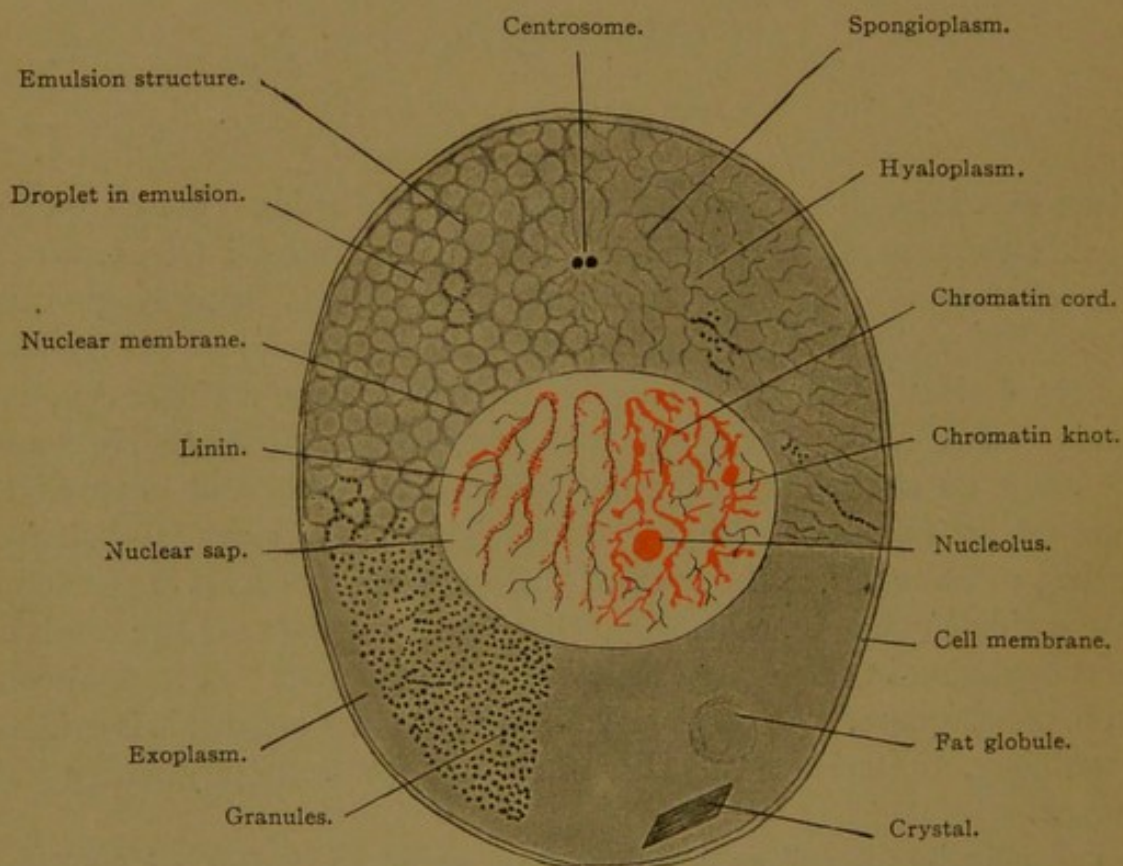


FIG. 1.—DIAGRAM OF A CELL.

In the four quadrants different types of protoplasmic structure are represented—namely, homogeneous, granular, foam-like, and fibrillar.

be used interchangeably for an alkalinity which is so slight"—Henderson.) It is ordinarily more than three-fourths water, and the remainder consists of salts and organic substances, some in solution and some in a colloidal state. The organic bodies are classed as proteins, glycogen or some allied carbohydrates, and lipid (fat-like) bodies. Protoplasm may exist in a numberless variety of forms.

On microscopic examination, even with lenses of the highest power, the protoplasm of certain living cells appears homogeneous and structureless. But most of the cells which the histologist examines are not living.

They have been killed by various reagents, selected as causing the most rapid fixation possible. The protoplasm of such cells usually exhibits granules, fibrils, or networks with closed or open meshes. Whether these structures are wholly due to precipitation and coagulation is difficult to determine, but indications that they preexist have been observed in certain living cells. In any case, the various forms of coagulation occur with such constancy that their study is of the utmost importance to the histologist.

Even the ground substance of protoplasm, in which the fibrils or granules are imbedded, is not necessarily homogeneous. According to Bütschli's interpretation it has the structure of foam or of an emulsion—that is, it consists of minute droplets of one substance completely surrounded by walls of another substance. In these walls, granules and filaments may be lodged, as seen at the margins of the upper right quadrant of Fig. 1. The complex chemical activities of a cell are said to be manifestly impossible in any homogeneous mass; but in such a heterogeneous medium as an emulsion, they are conceivable (Alsberg). In other words, the vital qualities of protoplasm may not depend so much on hypothetical complex and unstable living molecules, as upon the interaction of various substances, made possible by their arrangement in droplets and investing films.

The various structures commonly observed in protoplasm may be grouped as follows:

1. *Granules.* Ultra-microscopic granules doubtless exist in protoplasm, since the smallest of those observed approach the limit of visibility. The minute granules, if abundant, give the protoplasm a dark color. Often they are absent from the peripheral layer of protoplasm, or *exoplasm*, which is then clear, somewhat firmer, and chemically different from the inner *endoplasm* (Fig. 1). In addition to minute granules such as may be found in most preserved protoplasm, certain cells contain larger granules, which are important secretory products elaborated by the cell. In active gland cells these granules are well defined and abundant, and they diminish as the cell becomes exhausted. Various forms of white blood corpuscles may be distinguished by the size and staining reaction of the granules imbedded in their protoplasm. In certain nerve cells (Fig. 2) granules occur in large groups, known as Nissl's bodies. As Crile has shown, these become disorganized as a result of surgical shock or muscular

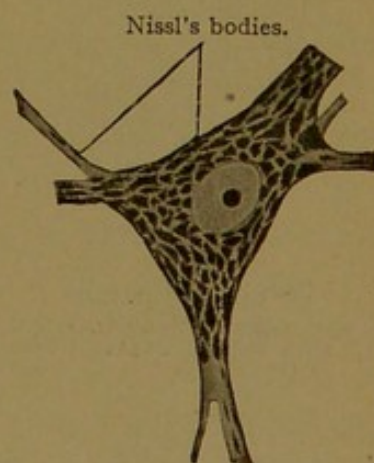


FIG. 2.—CLUMPS OF GRANULES (NISSL'S BODIES) IN A NERVE CELL.

fatigue. It is evident, therefore, that the careful observation of protoplasmic granules is of very great importance.

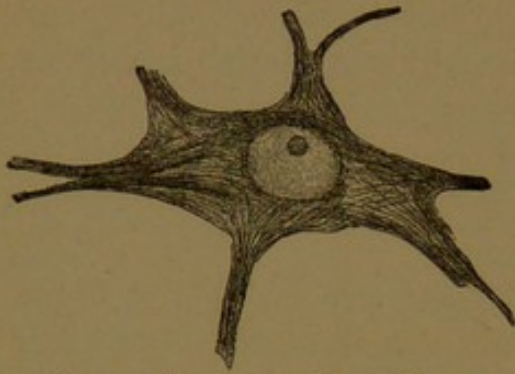


FIG. 3.—FIBRILS IN A NERVE CELL.

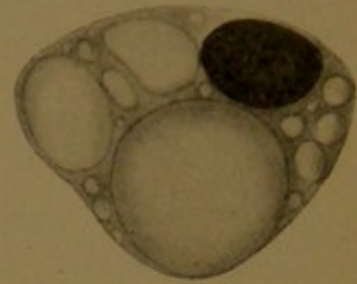


FIG. 4.—VACUOLES IN A YOUNG FAT CELL.

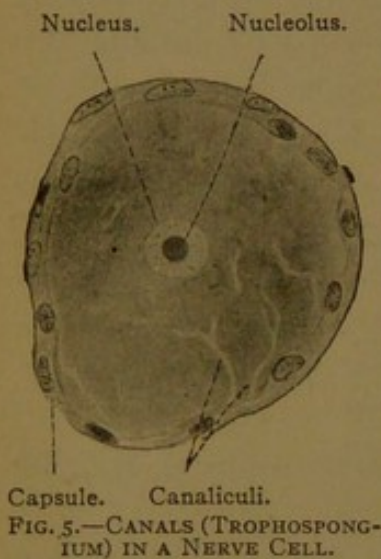


FIG. 5.—CANALS (TROPHOSPONGIUM) IN A NERVE CELL.

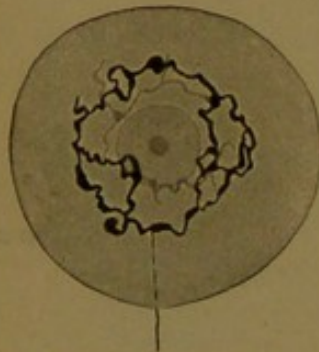


FIG. 6.—RETICULAR NETWORK IN A NERVE CELL. (After Golgi.)

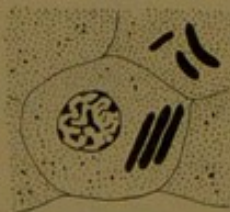

FIG. 7.—CRYSTALLOID INCLUSIONS. INTERSTITIAL CELLS OF THE TESTIS.

2. *Fibrils*. Protoplasm may be permeated with a delicate meshwork of fibrils, which collectively constitute the *spongioplasm*, or filar mass. This is imbedded in the clear *hyaloplasm*, or interfilar mass (Fig. 1). In certain cells there are filaments, known as *mitochondria*, which are formed by the coalescence of rows of granules. The relation between these structures and the reagents used is discussed by Kingsbury (Anat. Rec., 1912, vol. 6, pp. 39-52). The spongioplasm may form an irregular network, or its constituent fibrils may be parallel, passing from one end of the cell to the other. In oblique and transverse sections of such cells, the filaments are cut across, so that they appear as short rods, or even as granules. Fibrils may be extremely slender, as in the case of those which radiate through the protoplasm at the time when the cell divides; or they may be quite coarse, like the permanent fibrils characteristic of certain muscle and nerve cells (Fig. 3).

3. *Vacuoles*. Protoplasm often contains large or small drops of clear fluid, fat, or some other substance less highly organized than the surrounding material (Fig. 4). In preserved cells the spaces which were occupied by these droplets appear clear and empty, and are known as vacuoles. They vary greatly in size, and one or several of them may be found in a single cell.

4. *Canals*. The protoplasm of certain cells is said to contain fine tubes or clefts which communicate with lymphatic spaces outside of the cell

(Fig. 5). Prolongations from the surrounding capsule-cells have been described as entering these canals and as performing, together with the lymph, a nutritive function. Hence the network of canals has been called *trophospongium*. But it has not been shown conclusively that these canals open to the exterior of the cell. They may be similar to the closed networks or "reticular apparatus" lying wholly within the protoplasm, shown in Fig. 6. Such networks have been described in nerve cells, cartilage cells and gland cells. The network is said to be of a thick fluid consistency. In certain gland cells there are canals within the protoplasm, which convey the secretion to the free surface of the cell. These may be simple, branched, or arranged in a network. Like the other forms of intracellular canals, they can be studied only in special preparations.

5. *Inclusions*. Various foreign bodies, such as other cells or bacteria, which may have been ingested by the protoplasm, are grouped as inclusions. This term is applied also to crystalloid substances formed within the protoplasm (Fig. 7), and to coarse masses of pigment granules which appear extraneous.

NUCLEUS.

The nucleus (Latin, *nucleus*, "the kernel of a nut"; Greek, *κάρυον*, "a nut") is typically a well-defined round body, situated near the center of the cell, appearing denser or more coarsely granular than the surrounding protoplasm (Fig. 1). There are characteristic variations in the shapes of nuclei, in their position within the cells and in their structure.

Ordinarily the karyoplasm, or nuclear substance, is sharply marked off from the cytoplasm by the *nuclear membrane*. Sometimes, in preserved tissues, the cytoplasm has shrunk away from the nuclear membrane, so as to leave a narrow space partially encircling it; and in certain living cells, the nucleus migrates through cytoplasm, as if it were an independent body. But there are phases of cell-development in which the nuclear membrane disappears and no line can be drawn between karyoplasm and cytoplasm. At all times they have a common structural basis. The ground substance of the nucleus, corresponding with the hyaloplasm, is the *nuclear sap*; and it contains, for spongioplasm, a meshwork of delicate *linin* fibrils. These help to form the nuclear membrane, in which they terminate. The nuclear membrane, nuclear sap, and linin reticulum do not stain deeply, and are therefore grouped together as the achromatic constituents of the nucleus.

The principal chromatic constituent of the nucleus is known as *chromatin*. It stains deeply, since it contains a large amount of nucleic acid, which has a marked affinity for basic stains. Chromatin occurs in the form of granules, which are bound together in strands or masses by the

linin fibers (Fig. 1). The masses, known as chromatin knots, occur especially at the points of intersection in the linin meshwork. Sometimes they are attached to the nuclear membrane, or so distributed over its surface that it appears to consist of chromatin. It forms morphologically the most important part of the nucleus.

Certain nuclei contain one or more round bodies, which belong with the chromatic elements because of their deep staining, but which are chemically different from chromatin. These bodies, known as *nucleoli*, are stained with acid or neutral dyes. They are said to be composed of paranuclein, whereas chromatin is composed of nuclein. In distilled water the structures formed of nuclein disappear, but those consisting of paranuclein remain. The nuclei of nerve cells contain typical nucleoli (Figs. 3 and 5). Sometimes a nucleolus, lodged in the nuclear reticulum, is more or less covered with chromatin (Fig. 9, A), but the term should not be applied to irregular knots of chromatin, even when most of the chromatic material within a nucleus is gathered into one or two such bodies. These are the so-called false nucleoli (pseudonucleoli).

Every nucleus, therefore, consists of ground substance or nuclear sap, a network of linin, and granules and masses of chromatin. Usually it is surrounded by a membrane, and sometimes it contains a nucleolus. Most cells contain a single nucleus; but occasionally a single cell contains two nuclei, as is frequent in the liver, or even several nuclei, as in certain cells associated with bone. Non-nucleated bodies, like the mammalian red blood corpuscles, and the dead outer cells of the skin, have lost their nuclei in the course of development.

Functionally the nucleus is regarded as a center for chemical activities necessary for the life of the cell. It is believed to produce substances which pass out into the cytoplasm, where they may be further elaborated. Evidences of nuclear extrusions into the cytoplasm have been frequently recorded. But the interactions between nucleus and cytoplasm, of such nature that they cannot be observed under the microscope, are presumably of far greater biological importance.

CENTROSOME.

The centrosome is typically a minute granule in the center of a small sphere of differentiated protoplasm. Often the term is applied to this entire structure, but it refers particularly to the central granule; the enveloping sphere is known as the *attraction sphere*, and it is composed of *archoplasm*. When a cell is about to divide, delicate fibrils, either rearranged from the protoplasmic reticulum or formed anew, radiate from the archoplasm toward the periphery of the cell. The central granule becomes subdivided into two, which then move apart. In *resting cells*,

or those which are not undergoing division, the centrosome may already have divided into a double body or *diplosome* preparatory to the next division of the cell (Fig. 1).

Centrosomes have been detected in many forms of resting cells, and it is assumed by some authorities that the centrosome is an invariable constituent of the cells of the higher vertebrates. According to this opinion the centrosome may become inconspicuous but it never loses its identity. Often they are found very close to the nuclear membrane, which may be indented to accommodate them; and rarely, as in certain cancer cells and in one form of the worm *Ascaris*, they have been reported as within the nucleus. They may occur near the free surface of certain cells, usually in the form of diplosomes, as shown in cell *a*, Fig. 8. Just above the diplosome, such cells may send out contractile projections of protoplasm (pseudopodia), with the activity of which the diplosome may be in some way associated. Pseudopodia, with an underlying diplosome, have been observed in the columnar cells of the human large intestine. In cell *b* of Fig. 8 there are four diplosomes, one of which lies beneath the protoplasmic projections. It is believed that the diplosomes may multiply by fission, and that thus they may give rise to the numerous motile hairs, or *cilia*, which project from certain cells. Of these they form the *basal bodies* (Fig. 8, *c*). In many gland cells the centrosome lies in the midst of the protoplasm where the secretion accumulates. The discharge of the secretion is accomplished by the contraction of the protoplasmic strands in which the centrosome is lodged. In all these relations the centrosome appears to be a center for motor activities, and it is described as the kinetic or dynamic center of the cell.

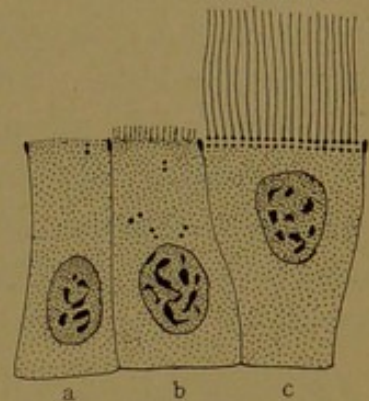


FIG. 8.—CELLS OF THE EFFERENT DUCTS OF THE TESTIS OF A MOUSE. (After Fuchs.) To show diplosomes, and (in *c*) cilia with basal bodies.

CELL WALL.

The protoplasm at the surface of certain cells floating in the blood or lymph forms a thin pellicle, apparently as a result of protoplasmic concentration, or other reaction to the surrounding medium. Cells which line the greater part of the digestive tube, and have only one surface directed toward the intestinal contents, are provided with a thick wall on the exposed surface. Such a wall is called a cuticular border, or *cuticula*. On the other sides of these cells, the membrane is much thinner, and on the basal surface it is sometimes lacking. In such cases the protoplasm appears to be continuous with that of the underlying cells. In other cases

the entire cell is devoid of any membrane. The cell membrane, therefore, is not an essential part of a cell; if present it ranges from a thin pellicle, on the border line of visibility, to a well-defined wall, which may be formed as a secretion of the underlying protoplasm. If the several surfaces of the cell are in relation to different environments, there is often a corresponding difference in the structure of their walls.

In examining a group of cells, it will be important to determine whether they are merely in contact, or actually continuous. Sometimes cells are so completely fused that their nuclei are irregularly distributed through a single mass of protoplasm. Such a formation is a *syncytium* in which the position of the nuclei is the only means of estimating the territory of a single cell. A syncytium may arise from the fusion of cells, or, as in striated muscle fibers, it may be due to the multiplication of nuclei in an undivided mass of protoplasm. Instead of being completely fused, cells are often joined to one another by protoplasmic processes of varying length and width, thus forming cellular networks. Fibrils within such a syncytium may pass continuously from the protoplasm of one cell into that of another.

Although cell membranes are often inconspicuous in animal cells, they cannot be overlooked in plants. Thus cork is a mass of dead cells from which nuclei and protoplasm have disappeared, leaving only the cell walls. In describing cork, Robert Hooke introduced the name "cell," in 1664. He wrote: "I took a good clear piece of Cork and with a Pen-knife sharpen'd as keen as a Razor, I cut a piece of it off, and thereby left the surface of it exceeding smooth, then examining it very diligently with a Microscope, me thought I could perceive it to appear a little porous. . . . These pores, or cells, were not very deep, but consisted of a great many little Boxes——." In this way one of the briefest and most important of scientific terms was introduced.

FORM AND SIZE OF CELLS.

Cells are regarded as primarily spherical in form. Spherical cells are comparatively numerous in the embryo, and in the adult the resting white blood corpuscles, which float freely in the body fluids, assume this shape. Such cells are circular in cross section. When spherical cells are subjected to the pressure of similar neighboring cells, they become polyhedral and usually appear six-sided in cross section. Such cells, as a whole, may be cuboidal, columnar, or flat. Certain cells become fusiform (spindle-shaped) or are further elongated so as to form fibers; others send out radiating processes and are called stellate. Thus the form of cells is extremely varied. The shape of the nucleus tends to correspond with that of its cell. It is usually an elliptical body in elongated cells, and spherical in round or cuboidal cells. In stellate cells it is either spherical or somewhat elongated. Crescentic nuclei, and others more

deeply and irregularly lobed, are found in some of the white blood corpuscles and in giant cells.

The size of cells ranges from that of the yolks of birds' eggs—which are single cells, at least shortly before being laid—down to microscopic structures four thousandths of a millimeter in diameter. The thousandth of a millimeter is the unit employed in microscopic measurements. It is called a *micron*, and its symbol is the Greek letter μ . The small cells referred to are therefore four microns (4μ) in diameter. The size of any structure in a section of human tissue may be roughly estimated by comparing its dimensions with the diameter of a red blood corpuscle found in the same section. These red corpuscles are quite uniformly 7.5μ in diameter.

CYTOMORPHOSIS.

Cytomorphosis is a comprehensive term for the structural modifications which cells, or successive generations of cells, undergo from their origin to their final dissolution.¹ In the course of their transformation, cells divide repeatedly, but the new cells begin development where the parent cells left off. Cell division, therefore, is an unimportant incident in cytomorphosis.

Cytomorphosis is a continuous advance in which four successive stages are recognized—first, the stage in which the cells are undifferentiated; second, the stage of specialization or differentiation; third, the stage of degeneration; and fourth, the stage in which the cells die and are removed. These may be considered in turn.

Undifferentiated cells, as can be seen in sections of young embryos, are characterized by large nuclei and little protoplasm. They multiply rapidly, but the rate of division declines with the gradual increase of the protoplasm and the consequent functional differentiation of the cell. In the adult, relatively undifferentiated cells are found in many situations, as, for example, in the deepest layer of the epidermis. As the cells at the surface die and are cast off, new ones come up from below to take their places. But since the basal cells can produce only epidermal cells, they are themselves partly differentiated. From this point of view the fertilized ovum, which can produce all kinds of cells, must be regarded, in spite of its size and great mass of yolk-laden protoplasm, as the least differentiated cell.

Differentiated cells may preserve a round or cuboidal form, but usually they are elongated, flattened, or stellate. The cytoplasm usually contains coarse granules, fibrils, masses of secretion or other special forma-

¹ The term *cytomorphosis* was introduced by C. S. Minot in 1901 in a lecture entitled "The Embryological Basis of Pathology" (Science, 1901, vol. 13, p. 494). Cytomorphosis is further discussed by Professor Minot in "The Problem of Age, Growth, and Death," published by G. P. Putnam's Sons, 1908.

tions. As a result of their own protoplasmic activity, the cells of many tissues become surrounded by *intercellular substances*, which may far exceed in bulk the cells which produced them. Intercellular substances may be solid or fluid. When present in small amount they form thin layers of *cement substance* between closely adjacent cells; in large amount these substances constitute a ground work in which the cells are imbedded, as, for example, in cartilage and bone.

Although the differentiation of cells is chiefly cytoplasmic, there is some evidence of corresponding nuclear changes. Thus while the muscle

cells of the salamander are elaborating complex fibrils, the nuclei become modified as shown in Fig. 9. The significance of the nuclear changes is unknown.

Degeneration is the manifestation of the approaching death of the cell. In nerve cells this process normally takes place very slowly. These cells remain active throughout life, and if destroyed, they can never be replaced. In many glands, in the blood and in the skin, however, the cells are constantly dying and new ones are being differentiated. In a few organs the cells perish, but no new ones form, so that the organ to which they belong atrophies. Thus a large part of the mesonephros (Wolffian body) disappears during embryonic life; the thymus becomes vestigial in the

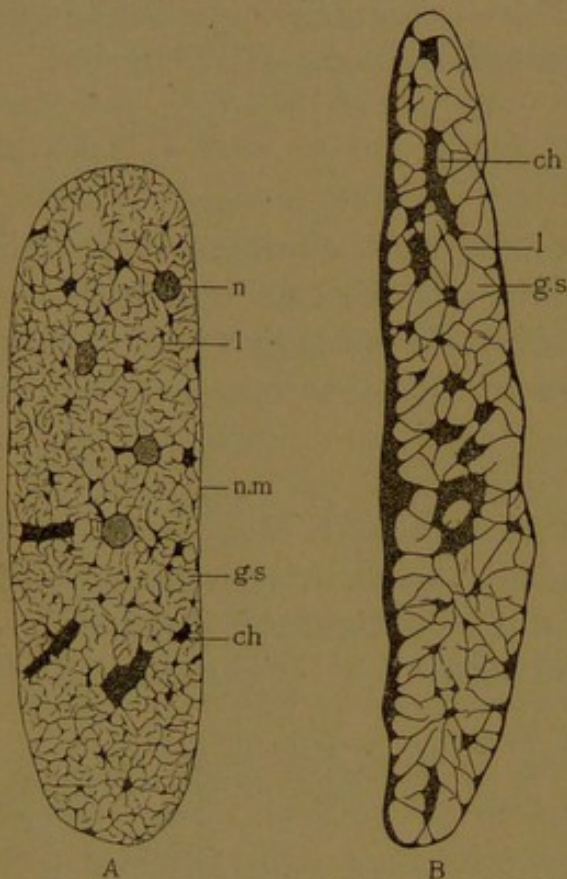


FIG. 9.—NUCLEI OF STRIATED MUSCLE FIBERS FROM YOUNG SALAMANDERS (NECTURUS). (Eycleshymer.)

A, From a 7 mm. embryo; B, from one of 26 mm.; ch, chromatin knot; g. s, ground substance; l, laminar fibril; n, nucleolus; n.m, nuclear membrane.

adult; and the ovary in later years loses its chief function through the degeneration of its cells.

The optical effects of degeneration cannot at present be properly classified. In a characteristic form, known as "cloudy swelling," the cell enlarges, becoming pale and opaque. In another form the cell shrinks and stains deeply, becoming either irregularly granular or homogeneous and hyaline. The nucleus may disappear as if in solution (karyolysis, chromatolysis); or it may become densely shrunken or *pycnotic*, and finally break into fragments and be scattered through the protoplasm (karyorhexis). If the process of degeneration is slow, the cell may divide by amitosis. It may be able to receive nutriment which it cannot assimilate, and thus

its protoplasm may be infiltrated with fat and appear vacuolated. It may form abnormal intercellular substances, for example, amyloid; or the existing intercellular substances may become changed to mucoid masses, or have lime salts deposited in them. Thus an impairment or perversion of function is often associated with optical changes in the cell substance.

The removal of dead cells is accomplished in several ways. Those near the external or internal surfaces of the body are usually shed or desquamated, and such cells may be found in the saliva and urine. Those which are within the body may be dissolved by chemical action or devoured by phagocytes.

Every specimen of human tissue exhibits some phase of cytomorphosis. In some sections a series of cells may be observed from those but slightly differentiated, to those which are dead and in process of removal. Because of the similarity and possible identity of this normal "physiological" regression, with that found in diseased tissues, such specimens should be studied with particular care.

VITAL PHENOMENA.

The vital properties of cells are fully treated in text-books of physiology. They include the phenomena of irritability, metabolism, contractility, conductivity, and reproduction. Under irritability may be grouped the response of cells to stimuli of various sorts, such as heat, light, electricity, chemical reagents, the nervous impulse, or mechanical interference. Metabolism, in a wide sense, includes the ingestion and assimilation of food, the elaboration and secretion of desirable products, together with the elimination of waste products. Contractility may be manifest in the locomotion of the entire cell, in the vibratile action of slender hair-like processes, the *cilia*, or in contraction of the cell body. Conductivity is the power of conveying impulses from one part of the cell to another. Reproduction is seen in the process of cell division. Many phases of these activities are observed in microscopic sections and as such they will be referred to in later chapters. A few which are of general occurrence will be described presently.

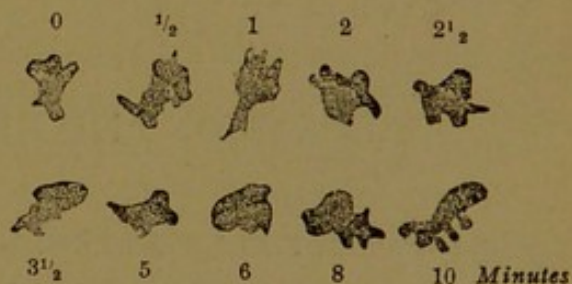


FIG. 10.—LEUCOCYTES OF A FROG. $\times 560$.
Changes in form observed during ten minutes;
0, at the beginning of the observation;
 $\frac{1}{2}$, a half minute later, etc.

AMÆBOID MOTION.

The unicellular animal, *Amœba*, exhibits a type of motility known as *amœboid*, which has been observed in many sorts of cells in the verte-

brate body. In marked cases, as in certain white blood corpuscles (the leucocytes), the cell protoplasm sends out fine or coarse processes which divide or fuse with one another, causing the cell to assume a great variety of forms. The processes may be retracted, or they may become attached somewhere and draw the remainder of the cell body after them, the result of which is locomotion or the so-called *wandering* of the cell. Such wandering cells play an important part in the economy of the animal body. Their processes can flow around granules or cells and thus enclose them in protoplasm. Some of these ingested bodies may be assimilated by the cell as a result of complex chemical and osmotic reactions. Cells which feed on foreign particles and can alter or digest them are known as *phagocytes*. Amoeboid movements take place very slowly. In preparations from warm-blooded animals they may be accelerated by gently heating the object.

Another form of motion is that which occurs within the protoplasm of fresh cells, whether living or dead, and consists in a rapid oscillation of minute granules, due to diffusion currents. Although these movements were first observed within protoplasm, it was soon shown that they occurred when various inert particles were suspended in a liquid. Robert Brown described the motion in 1828, in an essay entitled "On the General Existence of Active Molecules in Organic and Inorganic Bodies," and the phenomenon is called the molecular or Brownian movement. It may often be seen in salivary corpuscles.

FORMATION AND REPRODUCTION OF CELLS.

In the past, two sorts of cell formation have been recognized, namely the spontaneous generation of cells, and the origin of cells through the division of pre-existing cells. According to the theory of spontaneous generation it was once thought that animals as highly organized as intestinal worms came into existence from the fermentation of the intestinal contents. After this had been disproved, it was still thought that unicellular animals arose spontaneously and that cells might be formed directly from a suitable fluid, the cytoblastema. Something of the sort may have occurred when life began, and it is the expectation of certain investigators that conditions may yet be produced which shall lead to the formation of organic bodies capable of growth and reproduction. At present, however, only one source of cells is recognized—the division of existing cells. "Omnis cellula e cellula." A nucleus likewise can arise only by the division of an existing nucleus; it cannot be formed from non-nucleated protoplasm.

AMITOSIS.

The simplest form of cell division is one which rarely occurs. Ordinarily the division of the cell is accompanied with the production of protoplasmic filaments, and the process is therefore called *mitosis* (Greek, *μίτος*, a thread). But in *direct division* or *amitosis* these filaments are not developed. The nucleus merely becomes increasingly constricted at the middle until divided in two; or it may be bisected by a deep cleft or fissure. Preceding the division of the nucleus, the nucleolus, if present, may subdivide and supply each half of the nucleus with a nucleolus (Fig. 11). Cells which divide by this method are usually degenerating, and

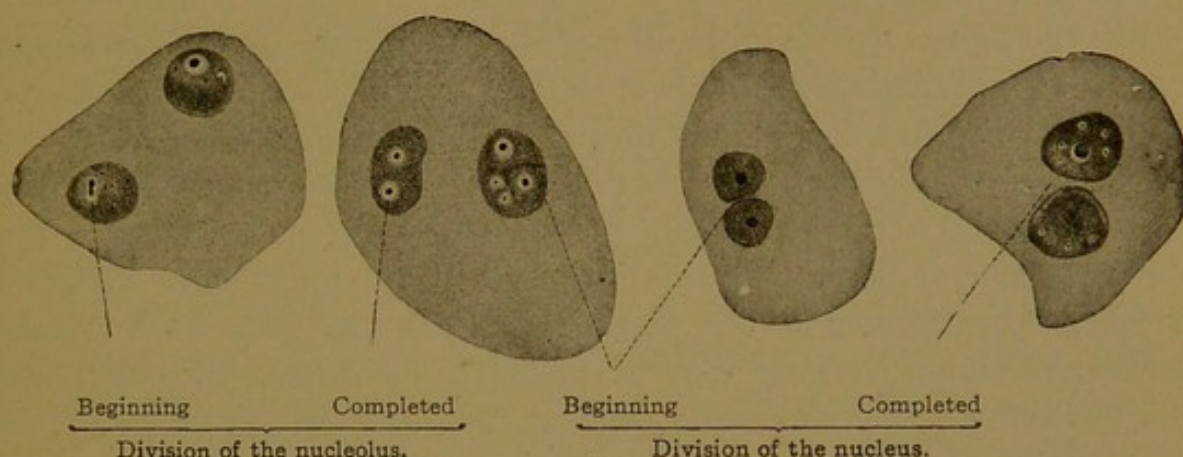


FIG. 11.—AMITOSIS IN EPITHELIAL CELLS FROM THE BLADDER OF A MOUSE. $\times 560$.

Such preparations as that shown in the figure are made by pressing the lining of a freshly obtained piece of the bladder against a clean cover-glass. Certain of the superficial cells adhere to it, and they are then fixed and stained.

the process may terminate with the multiplication of nuclei. If carried to completion, the protoplasm also divides, and a cell membrane develops between the daughter nuclei. The rôle of the centrosome in amitosis has not been determined. Maximow finds it in a passive condition between the two halves of the nucleus, or beside the stalk connecting these halves if the division is not complete (Anat. Anz., 1908, vol. 33, p. 89). He states that certain mesenchymal cells which divide by amitosis in the rabbit embryo are not degenerating, but may later divide by mitosis, and thus he confirms Patterson's similar conclusion in regard to certain cells in the pigeon's egg. These instances are regarded as exceptional.

In the human body the detachment of a portion of the lobate nucleus of certain leucocytes has been described as amitotic division, but the superficial cells of the bladder furnish more typical examples. E. F. Clark has found many cells dividing by amitosis in the degenerating parts of a human cancer. The occurrence of two nuclei within one cell by no means indicates this form of division. Associated with such cells, others containing nuclei of the dumb-bell shape, or those partially bisected by clefts must be found, in order to prove that amitotic division is taking place.

MITOSIS.

Mitosis, also called indirect division and karyokinesis, is the ordinary mode of cell division. Although it is a continuous process, it has been conveniently divided into four successive phases—the *prophase*, *metaphase*, *anaphase*, and *telophase*. During the prophase the chromatic material of the nucleus prepares for division and collects in the center of the cell. It is divided in halves in the metaphase, and the two halves move apart during the anaphase. The chromatic material becomes reconstructed into resting nuclei during the telophase. The various patterns which the chromatic material and protoplasmic fibrils present during these phases are known as *mitotic figures*.

Mitotic figures are found in all rapidly growing tissues, but especially favorable for preliminary study are the large cells in the root tips of plants. In longitudinal sections of root tips, the cells are cut at right angles to the plane of cell division, which is desirable; and often in a single section 5 mm. long, all the fundamental stages may be quickly located. The following general description of mitosis is based upon such easily obtained preparations, and the plant selected is the spiderwort (*Tradescantia virginiana*).¹ They may be satisfactorily stained with saffranin, or with iron hæmatoxylin and a counter stain such as orange G. There are many descriptions of mitosis in root tips, among them the following:

Rosen, (*Hyacinthus orientalis*) Beitr. zur Biol. der Pflanzen, 1895, vol. 7, pp. 225-312; Němec, (*Allium cepa*) Sitz.-ber. kön. Ges. der Wiss. Prag, 1897, No. 33, pp. 25-26, and Jahrb. für wiss. Bot., 1899, vol. 33, pp. 313-336; Schaffner, (*Allium cepa*) Bot. Gaz., 1898, vol. 26, pp. 225-238; Hof, (*Ephedra major*) Bot. Centralbl., 1898, vol. 76, pp. 63-69, 113-118, 166-171, 221-226; Grégoire and Wygaerts, (*Trillium grandiflorum*) La Cellule, 1904, vol. 21, pp. 1-76; Farmer and Shove, (*Tradescantia virginiana*) Quart. Journ. Micr. Sci., 1905, vol. 48, pp. 559-569; Richards, (*Podophyllum peltatum*) Kansas Univ. Sci. Bull., 1909, vol. 5, p. 87-93.

The cells to be described are found in the interior of the root tip, just back of the protecting cap of cells which covers its extremity. They are oblong in shape and their long axis corresponds with that of the root. The walls are very distinct, and the cells consist of granular vacuolated protoplasm, which in preserved specimens is generally irregularly shrunken.

The resting cells (Fig. 12, A) contain large round nuclei in which the chromatin is in the form of fine granules evenly distributed throughout the nucleus. A nucleus usually contains from two to five round nucleoli, each of which, when in focus, is seen to be surrounded by a clear zone. The nuclear membrane is distinct.

¹ Good specimens may be obtained from any rapidly growing root tip. Those starting from hyacinth bulbs placed in water are very favorable. Onion root tips have been extensively used, and also those of bean and corn seedlings. The pointed ends are snipped off and dropped into Flemming's stronger solution.

Prophase. The first indication of approaching division is a change in the chromatin, which becomes gathered into fewer and coarser granules and takes a deeper stain. Portions of the linin network break down, so that the chromatin granules come to be arranged in long convoluted threads. Such threads are developing in the cell, Fig. 12, B, but are more perfectly formed in C. It is possible that at a certain stage the nucleus contains only a single continuous thread, but this condition cannot be demonstrated in *Tradescantia*. The stage of nuclear division in which the chromatic material appears to be arranged in a coiled thread or skein is called a *spireme*. The "close spireme" (B) is succeeded by the "loose spireme" (C). Successive stages in the development of the spireme in animal cells are seen in Fig. 20, D, E, and F.

As the spireme develops, the nuclear membrane becomes less distinct, and the clear zones disappear from around the nucleoli. The nucleoli become apparently less regular in outline, and forms which suggest that two of them have fused (Fig. 12, B) are perhaps more frequently seen than in resting cells. Usually it is stated that the nucleoli break up into smaller bodies toward the time of their dissolution, and that some of these escape into the cytoplasm after the disappearance of the nuclear membrane. Farmer and Shove believe that the nucleoli contribute to the chromatin; Richards regards them as a store of food material for the rest of the cell; and others believe that they form the achromatic "spindle" which will be described presently. Their function in animal cells is equally uncertain.

In the stage shown in Fig. 12, D, which may be regarded as the end of the prophase, the nuclear membrane and the nucleoli have disappeared, and the spireme thread has become divided into a number of segments or *chromosomes*. These are straight or curved rods of different lengths. Sometimes they appear as bent V-shaped bodies, but these often represent two chromosomes with their ends together. J-shaped forms, with one long and one short arm, have been described in various plants. The chromosomes become so arranged that one end of the rods, or the apices of the V's, are situated in the equatorial plane, which extends transversely across the middle of the cell. Often it is temporarily tilted (as in D and E) as if the mitotic apparatus had shifted to a position in which it obtained more space. It may do this mechanically if the contents of the cell are under pressure. When the chromosomes are gathered at or in the equatorial plane, they constitute collectively the *equatorial plate*. Because of their stellate arrangement at this stage, which is best seen in transverse sections of the cell, this mitotic figure is known as the *aster*.

The manner in which the chromosomes are formed from the spireme thread is difficult to determine. According to Grégoire and Wygaerts, the linin and chromatin, which have often been regarded as closely related

substances, are identical, and linin is merely a name for slender filaments of chromatin. Accordingly the chromatin simply draws together to




FIG. 12.—MITOTIC CELL DIVISION IN THE ROOT TIP OF *Tradescantia virginiana*. $\times 125$ diam.
A, resting cell; B, C, D, prophase; E, metaphase; F, anaphase; G, H, I, telophase.

form chromosomes, and the beaded appearance of the spireme thread is due to alternate enlargements and constrictions of one substance. Others consider that a different substance connects the granules of chromatin

with one another; and Rosen states that each chromatin granule is completely imbedded in a broad strand of linin. Davis similarly interprets the spireme shown in Fig. 20, F. Whatever the actual structure may be, the chromatin granules in the spireme thread early divide in two, so that the thread appears double. When the thread shortens and condenses to form the chromosomes, the rows of granules may coalesce so as to produce a rod already divided lengthwise, although its halves are in close apposition. Occasionally the ends of the chromosomes are seen to be slightly separated.

Metaphase. In the metaphase (Fig. 12, E), the two longitudinal halves of each chromosome are being drawn apart toward the opposite poles of the cell. If the chromosome is V-shaped, the separation of the two halves begins at the apex of the V.

At this stage an achromatic figure, known as the *spindle*, is evident in plant cells, but it is more sharply defined in those of animals. As seen in the diagram (Fig. 13), it consists of fibrils which pass from the equatoria

Polar radiation. Nuclear spindle.

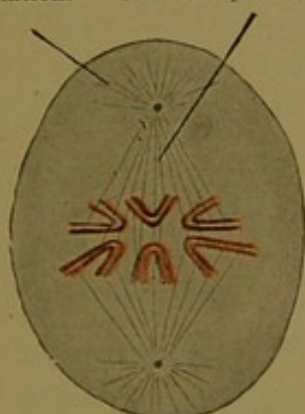


FIG. 13.—EARLY METAPHASE.

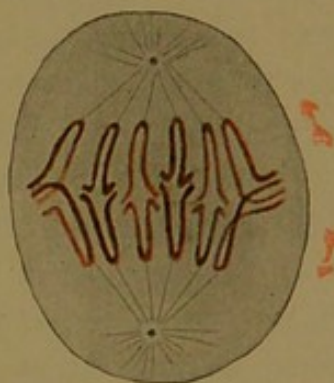


FIG. 14.—LATE METAPHASE.

plate toward either pole, where, in animal cells, there is a well-defined granule, the centrosome. Around each centrosome there are radiating protoplasmic fibrils, forming the *polar radiation* (Figs. 13 and 14). The polar radiation is also called an aster, and the two asters connected by the spindle are known as the *amphiaster*. Some of the spindle fibers are attached to the chromosomes and appear to pull their halves apart; others pass from pole to pole without connecting with the chromosomes. In animal cells the spindle arises as the two centrosomes, lying beside the nucleus, move apart (Fig. 20, A). As they pass to the opposite poles of the nucleus, the spindle forms between them, either from the nuclear reticulum, or the cytoplasmic reticulum, or in part from both. These conditions appear to vary in different animals.

In the cells of root tips, a condensation of protoplasm forms a cap at the poles of the nucleus at the time when the nuclear membrane and nucleoli are disappearing. From the "polar cap," spindle fibers develop

which invade the nucleus, and also radiations which have been traced even to the cell walls. But as Rosen states, sun-like figures, such as certain botanists have pictured, do not occur. Schaffner has described a distinct centrosome or central granule in the root tip of the onion, but Richards finds that in *Podophyllum* there is no such structure, and the weight of evidence appears to be against the existence of a definite centrosome in the higher plants.

Anaphase. In the anaphase the halves of each chromosome move to the opposite poles (Fig. 12, F). The figure thus produced is known as a double star or *diaster*. Since each chromosome has divided into two, the original number of chromosomes is preserved, and an equal number of rods will be found in either star. They cannot all be brought into focus together, and because of overlapping, they are hard to count. Sometimes one chromosome, longer than the others, remains for a time as a continuous bar from one aster to the other. Between the asters there are always straight spindle fibers, but they vary in distinctness. (The anaphase in an animal cell is well shown in Fig. 21, D.)

Telophase. After the chromosomes have reached the opposite poles, they form two dense masses. They are generally said to unite end to end, thus forming a spireme thread. But in the root tips of *Trillium*, Grégoire and Wygaerts state that they come into contact with one another laterally; and as they separate, transverse connections are retained, which, with the vacuolization of the chromosomes, restore the nuclear reticulum. This may not be the correct interpretation, but immediately after the anaphase the chromosomes form a very compact mass, easily overstained so that it appears solid. Subsequently the mass enlarges (Fig. 12, H), and the chromosomes become coarsely granular, taking the form of wide bands. Nucleoli reappear, and according to Richards, "it is a general rule that they arise on the side of the nucleus nearest the new cell wall." This accords with Němec's statement that they form from the outer fibers of the spindle. Němec and Rosen agree that they first appear outside of the nucleus, which they enter before the nuclear membrane develops. These are details which require confirmation.

The new cell wall arises in plants as a series of thickenings of the interzonal spindle fibers, which at this stage form a barrel-shaped bundle (Fig. 12, G). The thickenings coalesce to form a membrane which does not at first reach the sides of the cell. While this wall is developing the nuclei are in a condition resembling the spireme stage of the prophase. The entire mitotic figure is therefore called the double spireme or *dispireme*. The cell wall is soon completed and the nuclei return to the resting condition (Fig. 12, I).

The time required for mitotic cell division varies from half an hour (in man) to five hours (in amphibia). After death, if the tissues are not

hardened by cold or reagents, it is thought that mitoses go on to completion. Forty-eight hours may elapse before they entirely disappear from the human body.

Pluri-polar mitosis. Under abnormal conditions, as in the cancer cells shown in Fig. 15, spindles may develop simultaneously in connection with three or four centrosomes. Similar pluri-polar spindles have been produced experimentally, by treating cells with various poisonous solutions. An unequal distribution of chromatin may occur under such conditions, and this may happen also with bipolar spindles, as shown in Fig. 15, a.

Number and individuality of the chromosomes. It is now generally believed that every species of plant or animal has a fixed and characteristic number of chromosomes, which regularly recurs in the division of all

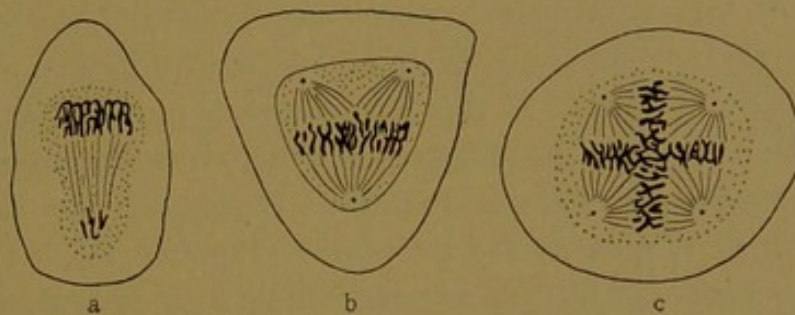


FIG. 15.—MITOSES IN HUMAN CANCER CELLS. (From Wilson, after Galeotti.)

a, Asymmetrical mitosis with unequal distribution of chromatin; b, tripolar mitosis; c, quadripolar mitosis.

its cells, with the exception of the germ cells, in which the number is reduced. In certain species, however, the two sexes regularly differ from one another in the number of their chromosomes, and one sex may contain an odd number. Usually the number of chromosomes is believed to be even.

There is considerable difficulty in counting the chromosomes. Generally it is possible that some have been cut away in the process of sectioning, so that, if the number is believed to be invariable, the highest number found in any cell is assumed to occur regularly. Another source of error lies in the fact that a bent chromosome may be counted as two, or rods with their ends overlapping may appear as one. Farmer and Shove have ventured to state that the number in *Tradescantia* "varies from about twenty-six to thirty-three." Němec found that twelve chromosomes occur regularly in young tissues of the onion, but that in older tissues the number diminishes even to four. Sixteen have been recorded in the onion by other botanists. *Podophyllum* is said to have sixteen (Mottier), but Richards records counts of fourteen. In man the number has been placed at 16 and 32, but it is now believed to be 24. Guthertz, with particularly favorable material, emphasizes the difficulty of counting

the chromosomes in man. He found only two cells in which a count could be made, in neither case with absolute certainty. But he agrees with Duesberg that the reduced number is twelve, according to which the whole number should be twenty-four. Recently, however, Wieman has found cells in the brain of a 9-mm. human embryo which contained 33 chromosomes. Some cells in the nasal epithelium and mesenchyma of this specimen contained 34, and others 38. Thus Wieman concludes that the number in man is certainly greater than 24 and is perhaps variable (Amer. Journ. Anat., 1913, vol. 14, pp. 416-471).

In the grasshoppers, which are among the most favorable objects for the study of mitosis, not only is the number of chromosomes for a given species believed to be constant, but each cell appears to contain a definite series of chromosomes, the members of which vary somewhat in shape and size. Recent studies of such cells favor Rabl's hypothesis of the *individuality of the chromosomes*, according to which the chromosomes persist in the resting nucleus, although disguised by their lateral branches and diffuse granular form. If this hypothesis is correct, when a nucleus prepares for division the same chromosomes which entered it will reappear. Sometimes in the prophase the bands of chromatin are arranged in a *polar field* such as is seen in the telophase (Fig. 12, H). This arrangement has been observed by Farmer and Shove in the prophase of *Tradescantia*, and by others in various plants and animals. It is regarded as evidence that the chromosomes are "independent and continuously perpetuated organs of the cell." Nevertheless it is generally true that in resting nuclei no trace of individual chromosomes can be made out. The great importance of accurate knowledge of the chromosomes is shown by the following considerations.

As a result of mitotic cell division, it is evident that every new cell regularly receives one-half of each chromosome found in the parent cell, and thus the number of chromosomes remains constant. But in the germ cells the number is invariably reduced, and in some animals it becomes exactly one-half of the number found elsewhere in the body. In such a case, when the male sexual cell, or *spermatozoon*, unites with the female sexual cell, or *mature ovum*, in the process of fertilization, the original number is restored. Each parent thus contributes one-half of the chromosomes found in the cell which gives rise to a new individual; and since each of these divides with every subsequent cell division, it is evident that one-half of the chromatin in every cell of the adult body is of maternal origin and one-half of paternal origin. The process by which the sexual cells acquire the reduced number of chromosomes and become ready for fertilization is known as *maturation*. The production of the sexual cells in the male is called *spermatogenesis* and in the female *oögenesis*.

SPERMATOGENESIS.

In its essential features, the process of spermatogenesis in insects corresponds with that in mammals, and very favorable material can be obtained in abundance from grasshoppers of various genera.

The males may be distinguished from the females by the shape of the abdomen. In males it is more rounded (Fig. 16) with various appendages directed dorsally. The abdomen of the female is pointed, terminating in the ovipositor, the parts of which as seen from the side may be together, or widely separated dorso-ventrally. The genital glands can be readily removed by dissecting as follows: Male grasshoppers, which have been chloroformed, are opened by a mid-ventral incision. The abdominal walls are pinned out on a wax plate under normal salt solution (0.6 per cent.). The intestinal tube, which is usually black or green, is taken out with forceps, and the yellow or orange testes are seen close together at the upper end of the abdomen, attached to the back. Each testis consists of a number of separate cylindrical lobes, and it should

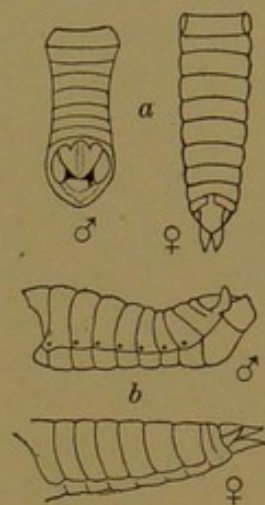


FIG. 16.—DORSAL (a) AND LATERAL (b) VIEWS OF THE ABDOMEN OF GRASSHOPPERS. (After Hyatt and Scudder.)

be worked loose from the surrounding tissue with forceps in such a way that these lobes remain together. The tissue may be preserved in Flemming's strong solution or in Hermann's fluid, and stained with iron hæmatoxylin.

Among the many publications upon spermatogenesis in the grasshoppers, the following may be cited: McClung, C. E., The accessory chromosome—sex determinant? Biol. Bull., 1902, vol. 3, pp. 43-84; Sutton, W. S., On the morphology of the chromosome group in *Brachystola magna*, Biol. Bull., 1902, vol. 4, pp. 24-39; McClung, C. E., The chromosome complex of orthopteran spermatocytes, Biol. Bull., 1905, vol. 9, pp. 304-340; Robertson, W. R. B., The chromosome complex of *Syrbula admirabilis*, Kansas Univ. Sci. Bull., 1908, vol. 4, pp. 273-305; Davis, H. S., Spermatogenesis in Acrididæ and Locustidæ, Bull. Mus. Comp. Zool., 1908, vol. 53, pp. 57-157; Wilson, E. B., The sex chromosomes, Arch. für mikr. Anat., 1911, vol. 77, pp. 249-371.

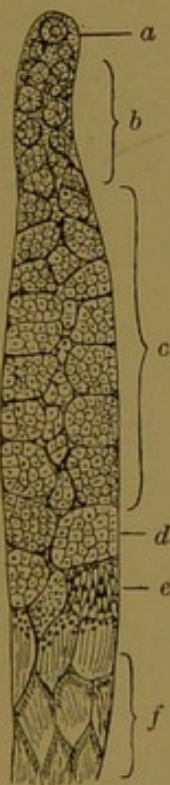


FIG. 17.—LOBE OF THE TESTIS OF A GRASSHOPPER. X 50. (After Davis.)

- a, apical cell.
- b, spermatogonia.
- c, spermatocytes.
- d, spermatocytes dividing.
- e, spermatids.
- f, spermatozoa.

As seen in sections, each lobe of the testis of the grasshopper contains a considerable number of closed sacs or cysts, which are filled with sexual cells; and all the cells within a cyst are in approximately the same stage of development. The cysts are shown in Fig. 17, which represents a longitudinal section of a single lobe. Usually the testis is sectioned as a whole, and the specimen consists of a group of lobes cut transversely or obliquely. Cross sections from the apical portion, furthest from the outlet, will contain younger stages than the sections

lower down in the lobe, since the cysts form at the apex and gradually move downward. At the apex, according to Davis, there is an *apical cell* which is surrounded by young sexual cells known as *spermatogonia* (Fig. 17, a). The spermatogonia move away from the apical cell, and each becomes enclosed in a cyst-wall derived from the surrounding tissue. Within the cysts thus formed, the spermatogonia multiply, and the cysts in the upper part of the lobe are filled with spermatogonia (Fig. 17, b). After repeated divisions the spermatogonia pass through a period of growth, accompanied by a rearrangement of their nuclear contents. The large cells with characteristic nuclei which are thus produced, are known as *primary spermatocytes*. They fill the cysts further down in the lobe (Fig. 17, c). Each primary spermatocyte divides into two

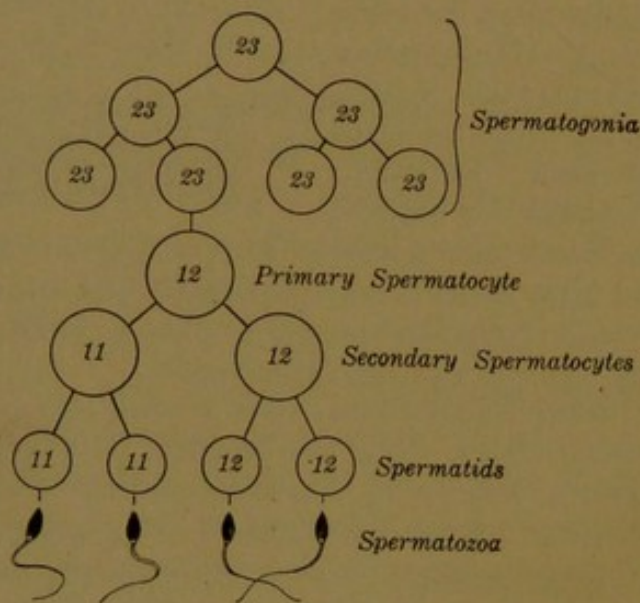


FIG. 18.—DIAGRAM OF THE CELL DIVISIONS IN SPERMATOGENESIS. The figures indicate the number of chromosomes found in the cells of certain grasshoppers.

secondary spermatocytes, and each of these divides into two *spermatids*, after which no further cell division is possible until fertilization takes place. But each spermatid becomes transformed from a round cell into a linear body with a whip-like tail, and is then capable of independent motion. Since in this form these cells were once thought to be parasitic animals living in the spermatogenic fluid, they received the name *spermatozoa*, which they still retain.¹ Cysts contain-

ing spermatozoa occur near the outlet of the lobe, or if the grasshoppers are collected late in the season, they may be found throughout most of the testis. Specimens from young grasshoppers, in which the spermatocyte divisions are abundant, are more desirable, even though no spermatozoa have become fully developed.

The succession of cell divisions described in the preceding paragraph is shown in tabular form in Fig. 18. Except for the number of chromosomes within the various cells, this diagram is quite as applicable to man as to the grasshopper. In this figure, however, only two spermatogonial divisions have been included. The number of times which the spermatogonia may divide before becoming spermatocytes is considerable and

¹ It has been proposed to substitute the term *spermium* for *spermatozoon*; and consequently *spermiocyte*, *spermid*, etc., for spermatocyte and spermatid. The secondary spermatocytes are sometimes called *præ-spermatids* or *præ-spermids*; but these changes in names are of questionable value.

presumably indefinite. As seen in sections, the spermatogonia, spermatocytes, and spermatids may be described as follows, using for illustrations Davis's figures of a common grasshopper—*Dissosteira carolina*.

Spermatogonia. The nucleus of each spermatogonium contains the full number of chromosomes, which in most of the grasshoppers (Acrididæ) is 23. With every spermatogonial division, each chromosome is split lengthwise. In this and other respects the mitotic figures are quite like those occurring elsewhere in the body. They are shown in Fig. 20, A, B, and C. When the twenty-three chromosomes have formed the equatorial plate, it is sometimes possible to see all of them in a single transverse section of the cell (Fig. 19, A). It then appears, as found by Montgomery (1901) in certain Hemiptera, and a year later by Sutton in grasshoppers, that the chromosomes vary in size, but the "gradations in volume are not between individual chromosomes but between pairs, the two members of which are of approximately equal size." In Fig. 19, A, twelve forms of chromosomes have been identified by Davis; and all of these are paired except the one numbered 4. The members of a pair are often, but by no means invariably, side by side. In some cases, owing to foreshortening, their resemblance in size is not apparent in the drawing. The behavior of the odd or *accessory chromosome* is of special interest, since according to McClung's hypothesis, now well established, this accessory chromosome is the bearer of those qualities which determine sex.

Primary spermatocytes. After the last spermatogonial division, the cells begin their "growth period." At this time the chromatin tends to collect on one side of the nucleus, in a condition known as *synapsis* (or more recently as *synizesis*). This distribution of the chromatin has been frequently observed, but it has not been shown to be of special significance. In the primary spermatocytes drawn in Fig. 20, D, E, and F, the chromatin is evenly distributed. All of the chromosomes, except the accessory chromosome, have become filamentous, but the accessory chromosome remains as a compact, darkly staining body close to the nuclear membrane. It resembles a nucleolus, for which in fact it has been mistaken. True nucleoli may occur in these cells, together with the accessory chromosome, but they stain differently.

As the primary spermatocytes prepare for the next division, the spireme becomes resolved into *eleven* loops, each of which represents the two members of a pair of chromosomes joined end to end. The granules imbedded in the linin thread divide as usual, so that each loop contains a double row of granules (Fig. 20, F). These loops contract to form eleven chromosomes, which, because of their four parts, are known as *tetrads*. The structure of the tetrads is shown in Fig. 19, B-G. The filaments seen in the upper row of drawings contract into corresponding solid forms of

chromosomes seen in the lower row, in which the place of attachment to the spindle fibers has been indicated.

Each tetrad represents two chromosomes joined end to end and split lengthwise. The simplest forms are shown in Fig. 19, B and C, which illustrate respectively two ways in which the tetrad may later divide. The two component chromosomes may simply be pulled apart, as indicated in Fig. 19, B, in which the spindle fibers are attached to the ends of the rod. If this takes place, each secondary spermatocyte will receive one member of every pair of chromosomes which occurred in the spermatogonium, but no part of the other member. Such a division, which eliminates one-half of the chromosomes from the daughter cell, is known as a *reductional division*. The other form of chromosome division is known as *equational*. When it takes place, every chromosome divides lengthwise, and the daughter cells receive one-half of every chromosome in the parent cell. This occurs in ordinary cell division, and also in the division of the tetrads provided that the spindle fibers are attached to the place where the two component chromosomes come together (Fig. 19, C).

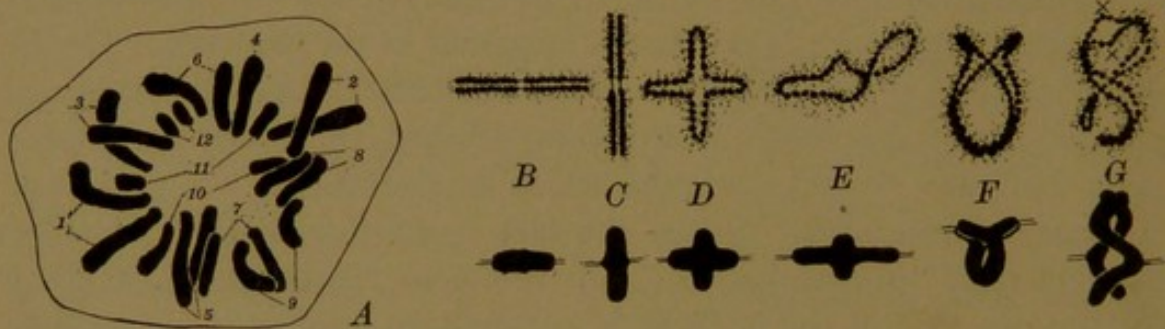


FIG. 19.—A, POLAR VIEW OF THE METAPHASE OF A SPERMATOGENIC DIVISION IN *Dissosteira carolina*. $\times 1450$ (After Davis.) The pairs of chromosomes have been numbered. B-G, various forms of tetrads, from primary spermatocytes. (After Davis and Robertson.)

As a stage in the separation of the two halves of a rod-shaped tetrad, cross-shaped forms are produced (Fig. 19, D). If the separation is almost complete, such shapes are seen as in Fig. 19, E. The arms of the tetrad which are not attached to the spindle fibers may bend toward one another and unite, so as to form rings (F), or they may twist about like a figure 8, as shown in G. If the spindle fibers are attached to the points xx in the upper figure in G, the division will be equational; if as shown in the lower figure it will be reductional.

Usually it is considered that the division of the tetrads into double bodies or *dyads*, is equational, and that the division of the dyads, which takes place when the secondary spermatocytes divide, is reductional. According to Davis, however, the first division of the tetrads is reductional and the second division is equational. In either case the end-result is the same. Each spermatid will contain one of the four parts of each tetrad, and thus one member of every pair of chromosomes will be eliminated from any given spermatid.

Since in the testis tetrads occur only in the primary spermatocytes, the cells shown in Fig. 20, G-J, are easily identified. These are success-

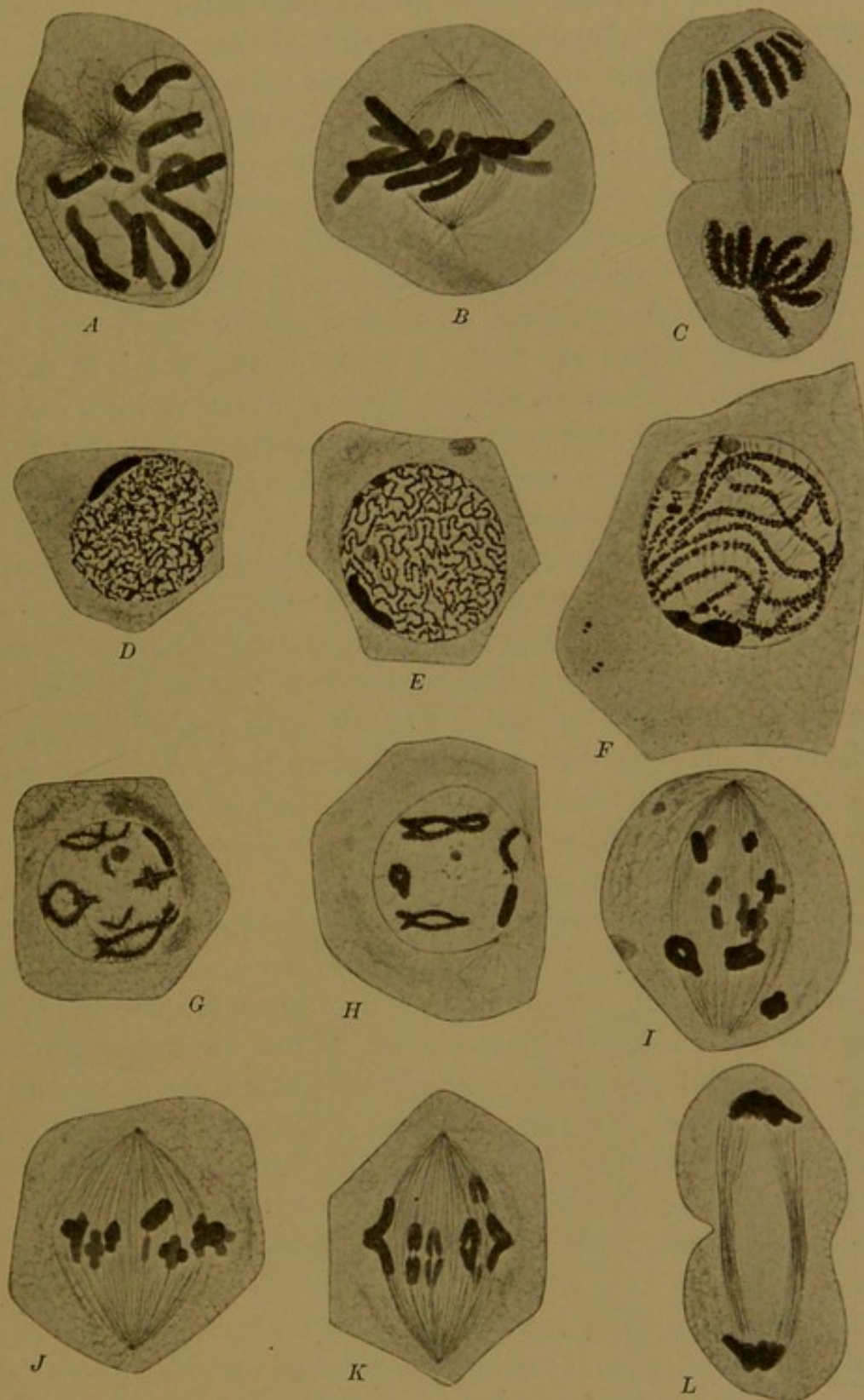


FIG. 20.—SPERMATOGENESIS IN *Dissosteira carolina* A-F $\times 1450$; G-L $\times 966$. (Davis.)
A, B, C, prophase, metaphase, and telophase of a spermatogonial division. D-L, successive stages in the division of a primary spermatocyte into secondary spermatocytes.

ive stages in the division of the primary spermatocyte. In G the accessory chromosome is seen as a rod-shaped body above and to the right; in H it is below and to the right. In J it is obliquely placed just above the equatorial

plate and in K it is passing to the upper pole of the spindle. In the spermatogonial divisions the accessory chromosome always divides with the others; but in the division of the primary spermatocyte it passes undivided into one of the daughter cells. Thus one secondary spermatocyte will receive eleven chromosomes (dyads) and the other will receive twelve (eleven dyads and the accessory chromosome). In the late anaphase shown in Fig. 20, L, the accessory chromosome cannot be recognized.

Secondary spermatocytes. The secondary spermatocytes pass rapidly from the condition shown in Fig. 20, L, to that of Fig. 21, A. A nuclear membrane has developed, and the dyads have become somewhat filamentous. Without passing through a complete resting stage they proceed to divide as shown in Fig. 21, B-F. The dyads separate into their component halves. In those secondary spermatocytes which received the accessory chromosome, that body will be seen dividing with the dyads, and each spermatid will receive one-half of it. It has been questioned whether the division of the accessory chromosome is longitudinal and therefore equational, or transverse and reductional. Many cytologists consider that if a chromosome splits lengthwise, all of its parts will be represented in the resulting halves, but if it divides transversely, essential elements will be lost. This conception lends importance to the question of transverse or longitudinal division of the accessory chromosome. By the division of this chromosome it comes about that one-half of the spermatids contain twelve chromosomes, and one-half contain eleven, as indicated in the diagram, Fig. 18. The spermatids shown in Fig. 21, F, contain the accessory chromosome.

Spermatids and Spermatozoa. In forming spermatozoa, the spermatids become elongated, passing from the condition shown in Fig. 21, F, to that of Fig. 21, G. The chromatin within the nucleus is distributed in fine granules throughout the linin reticulum. Close to the nuclear membrane a small dark body has appeared, from which a slender filament has grown out. This body is usually described as the centrosome. A condensation within the cytoplasm, seen also in F, is known as the *paranucleus*. It is of uncertain origin, but may proceed from the cytoplasmic structure called mitochondrion. The paranucleus forms a sheath about the axial filament.

Successively later stages are shown in Fig. 21, H, I, and J. The chromatin within the nucleus becomes homogeneous and very dense; at the same time the nucleus elongates and forms the *head* of the spermatozoon. This is enveloped by the cell membrane, but there is no appreciable layer of protoplasm around it. The centrosome elongates and forms the *middle piece* of the spermatozoon; and the axial filament, with a covering derived from the paranucleus and cytoplasm, constitutes the *tail*. Only a portion of the tail is included in the figure. The human spermatozoon likewise

consists of a head, which is essentially the nucleus, a middle piece containing the centrosome, and a tail; but the form of the head is very different from

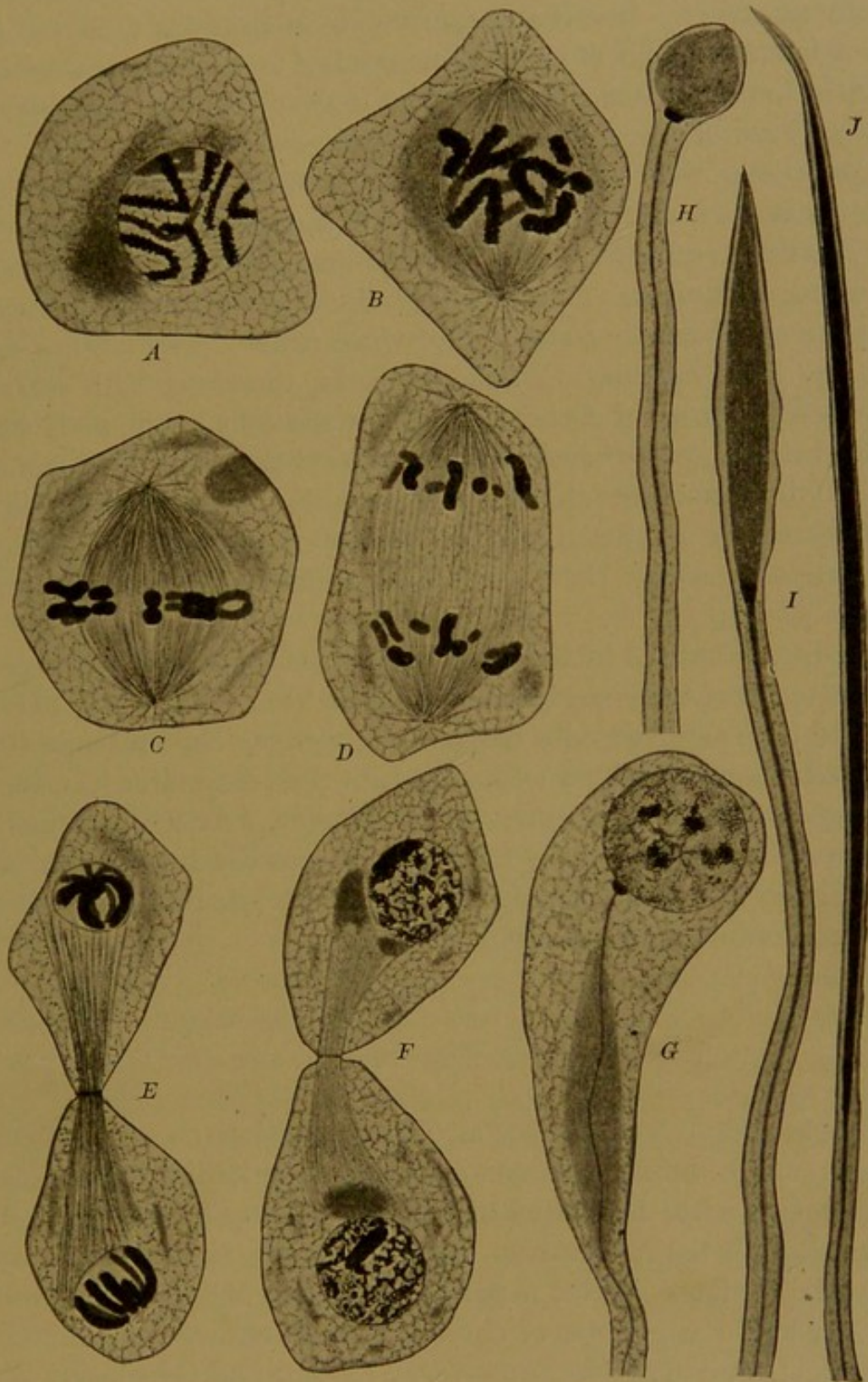


FIG. 21.—SPERMATOGENESIS IN *Dissosteira carolina*. $\times 1450$. (Davis.)
A-F, successive stages in the division of a secondary spermatocyte into spermatids. G-J, successive stages in the transformation of spermatids into spermatozoa.

that in the grasshopper. It will be described in a later chapter.

Although the spermatozoa of the grasshopper appear alike, it has been shown that one-half of them contain eleven chromosomes, and one-half

contain twelve. The mature ova all contain twelve chromosomes. If a spermatozoon with eleven chromosomes unites with an ovum with twelve, a male animal will be produced, in every cell of which there will be twenty-three chromosomes. But if the spermatozoon contains twelve chromosomes, a female animal is formed, containing twenty-four chromosomes in every cell. Thus sex appears to be determined by the presence or absence of a chromosome within the spermatozoon.

In some cases, as in several Hemiptera described by Wilson, the accessory chromosome is paired, but its mate is of small size. Thus the spermatozoa all have the same number of chromosomes; but half of them contain the large member of the pair and will produce females, and the other half contain the small member and will produce males. The mature ova all contain the large member. In these insects, therefore, both sexes contain the same *number* of chromosomes, but the cells of the male contain a small chromosome, whereas the corresponding one in the female is large. From these observations it is reasonable to conclude that sex may be determined by a difference in the *nature* of certain chromosomes in those animals in which there are no appreciable differences in size or number.

In man, a difference in the number of chromosomes in the sexes has been reported, but the observations have not been confirmed. It is supposed that the spermatogonia contain twenty-four chromosomes, but it has not been shown that they exist as pairs. The spermatocytes, spermatids and spermatozoa apparently contain twelve. As the principal constituents of the spermatozoon, the chromosomes are believed to be the essential agents in the transmission of all qualities inherited from the male parent, and certain of them may determine sex.

OÖGENESIS.

Mature ova result from a succession of cell divisions closely comparable with those which produce spermatozoa. The primitive female sexual cells correspond with the spermatogonia, and are called *oögonia*. They are provided with the full number of chromosomes, and divide an indefinite number of times. After a period of growth they become *primary oöcytes*, in which the number of chromosomes is reduced one-half. The primary oöcytes divide to form *secondary oöcytes*; and these again divide to produce the *mature ova*, which are incapable of further division unless fertilization takes place. (The term *ovum* is ordinarily loosely applied, so that it includes not only the mature cells, but also oöcytes, and the clusters of cells resulting from the division of the fertilized ovum.)

Although the mature ovum and the spermatozoon are closely similar

in their nuclear constitution, they differ radically as to form, size, and cytoplasmic structure. The ova are very large cells, stored with nutriment for the embryo which each one may later produce. In the higher vertebrates they are formed in relatively small numbers. According to Hensen's estimate, about two hundred, ready for fertilization, are produced by the human female in a life-time. But the male, according to Lode, produces 340 billion spermatozoa, or, as stated by Waldeyer, nearly 850 million per ovum. A large number must be produced, since many will fail to traverse the uterus and tube so as to find the ovum at the time of its discharge from the ovary. The ova of lower vertebrates, which are fertilized and develop outside of the body, are discharged in great numbers; in certain fishes from three to four million are produced annually.

The multiplication of oögonia in the human ovary takes place before birth, and about fifty thousand are produced. At birth, or shortly thereafter, all the oögonia have become primary oöcytes (Keibel). At first the oöcytes are small, but they enlarge at varying rates, and the largest are indistinguishable from mature ova except by their nuclear contents. Since some grow more rapidly than others, the ovary in childhood contains primary oöcytes of many sizes. Each oöcyte becomes enclosed in a cyst or follicle. The way in which these follicles develop, and the manner in which the oöcyte escapes into the uterine tube by the rupture of these follicles, will be described in connection with the ovary. Between the cells of the follicle and the oöcyte, there is a broad, radially striated membrane, known as the *zona pellucida* or *zona radiata* (Fig. 22). This zona has sometimes been regarded as a cell membrane, but the oöcyte divides within it as if enclosed in a capsule. It does not invest the daughter cells like a membrane. The radial striations have been interpreted as slender canals containing processes of the follicular cells, and the zona has been considered as a product of these cells. In certain cases a perivitelline space has been described as encircling the oöcyte and thus separating it from the zona, but this space has been considered as artificial, or as a refractive line wrongly interpreted as a space.

The cytoplasm of the oöcyte becomes charged with yolk granules or spherules. They constitute the *deuterooplasm* (or deutoplasm), but this term is equally applicable to fat droplets and other secondary products of the protoplasm. In the human oöcyte the granules are centrally placed (Fig. 22), and they are so transparent, when fresh, as to cause only a slight opacity. In the eggs of many animals the yolk is more highly developed, and it may be evenly distributed or gathered at one pole. Within the cytoplasm of the developing oöcyte, a large dark body of radiate structure is sometimes conspicuous. It is inappropriately known as the *yolk nucleus*, and is probably a derivative of the centrosome and surrounding archo-

plasm. Other "vitelline bodies," of uncertain origin and significance, have been described. Some have been considered as nuclear extrusions.

The nucleus of the oöcyte is very large and vesicular. The chromatin occurs chiefly along the nuclear membrane and about the nucleolus. The nucleolus is also very large, and Nagel stated that in the fresh condition it exhibits amoeboid movements, but this observation has not been verified. The nuclei of the oöcytes ordinarily show no signs of mitosis, and they may remain in the resting condition for thirty years or more and then divide. Many of them, however, will degenerate without division.

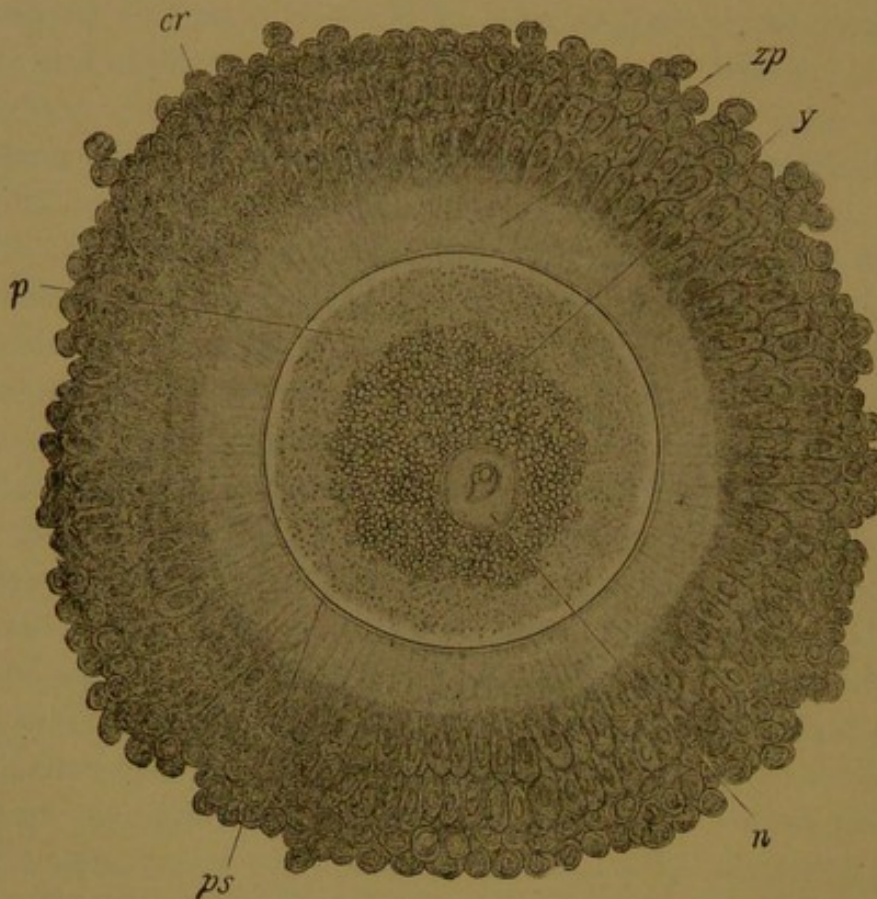


FIG. 22.—THE OVUM AS DISCHARGED FROM A VESICULAR FOLLICLE OF AN EXCISED OVARY OF A WOMAN THIRTY YEARS OF AGE. Examined fresh in the liquor folliculi. (Nagel.)
c. r., Corona radiata composed of cells of the follicle; n., nucleus; p., granular protoplasm; p. s., perivitelline space; y., yolk; z. p., zona pellucida. (From McMurrich's "Embryology.")

The cell divisions which give rise to the secondary oöcyte and the mature ovum respectively, have never been observed in man. Some of the cells within the ovary may be secondary oöcytes and the cell shown in Fig. 22 may be of this sort, or possibly a mature ovum, but this cannot be determined. From what is known of other mammals, however, it may confidently be assumed that the cell divisions take place as shown in the diagram, Fig. 23.

When the primary oöcyte divides, the chromosomes, reduced in number, also divide and are equally distributed to the daughter cells; but the great mass of cytoplasm remains with one of these cells, namely, the secondary

oöcyte. The other cell, which is relatively very small, is known as the *first polar body*, or polar cell. It has the same nuclear contents as the secondary oöcyte, and may divide into two other polar bodies, equivalent to mature ova. More often it degenerates without division. When the secondary oöcyte divides, it likewise produces one large cell, the *mature ovum*, and one small cell, the *second polar body*. The latter is said to be capable of fertilization, but to what extent it may develop is unknown. Functionally the production of polar bodies serves to prevent the subdivision and distribution of the nutritive material elaborated within the primary oöcyte. One mature ovum with abundant yolk is provided at the expense of three ova (polar bodies) which degenerate.

Although the maturation of the ovum has not been observed in man, nor even the presence of definite polar bodies, the entire process has been

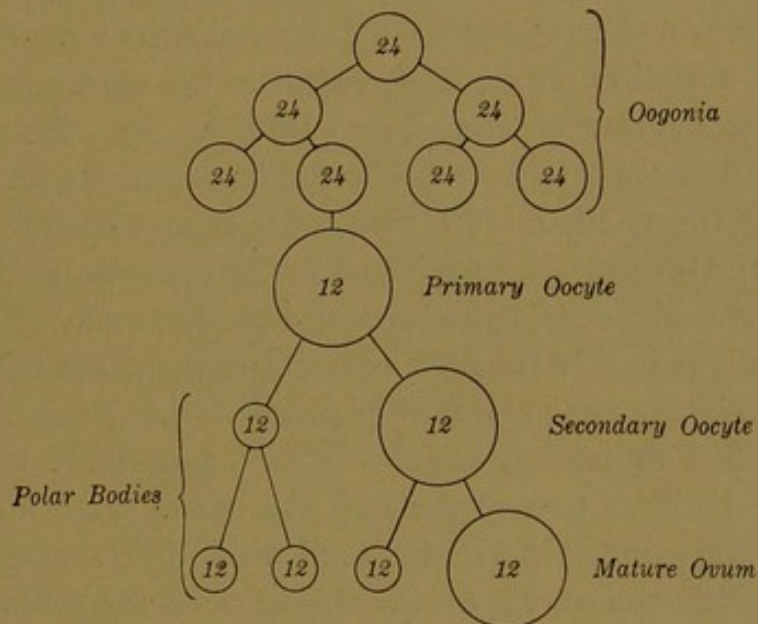


FIG. 23.—DIAGRAM OF THE CELL DIVISIONS IN OÖGENESIS. (Compare with Fig. 18.)

carefully studied in other mammals, notably in the mouse.¹ It has been shown that the maturation of the ovum of the mouse takes place rapidly, both of the oöcyte divisions being accomplished within from four to fifteen hours. The first polar body usually forms before the oöcyte is discharged from the ovarian follicle—in other words, before *ovulation* takes place. The second polar body is usually formed in the uterine tube, after the spermatozoon has entered the oöcyte. Long and Mark have found that the chromosomes of the primary oocyte are tetrads, or bodies showing transverse and longitudinal divisions; and that those of the secondary oöcyte are dyads. They believe that the first division is transverse or reductional, and that the second is equational.

¹ Among the most important papers are: Sobotta, J., *Die Befruchtung und Furchung des Eies der Maus*. Arch. mikr. Anat., 1895, vol. 45, pp. 15-91.

Long, J. A., and Mark, E. L. The maturation of the egg of the mouse. Carnegie Inst. Publ. No. 142, 1911, pp. 1-72.

The difficulty of counting chromosomes is apparent from the varying numbers which have been reported in the mouse. After reduction the number has been placed at 8, 12, 16, 18 and 20 by different observers.

The polar bodies in the mouse are relatively large. In the upper part of Fig. 24, A, a polar body is about to be formed, and it is completely cut off from the oöcyte in Fig. 24, C. In D and G, two polar bodies are shown.

FERTILIZATION.

In the mouse, from six to ten hours after coitus, spermatozoa have made their way to the distal end of the uterine tube, where fertilization takes place. According to Long and Mark, the maturation of ova usually occurs at some time during the period from " $13\frac{3}{4}$ to $28\frac{1}{2}$ hours" after the mouse has given birth to a litter; and during the process of their maturation, the oöcytes are discharged from the ovary and enter the distal end of the tube. Here, if fertilization takes place, a single spermatozoon penetrates the zona pellucida. In a section obtained by Sobotta, the entrance of the spermatozoon has been partially accomplished (Fig. 24, B). Its tail lies outside of the zona, and appears to have become thickened. In another specimen Sobotta found the head, middle piece and a part of the tail within the cytoplasm of the oöcyte. The tail had broken as it crossed the zona, and the portion remaining outside had drawn together and was disintegrating. In some animals it is said that the entire spermatozoon enters the ovum, but in others only the head and middle piece. In any case the tail appears to be a propelling apparatus which becomes functionless after the head and middle piece have passed through the zona. It has entirely disappeared in the stage shown in Fig. 24, A, in which the head of the spermatozoon is seen within the oöcyte on the right side of the figure. Meanwhile the oöcyte is becoming a mature ovum by undergoing divisions and producing the second polar body; and the anaphase of this division is shown in Fig. 24, A. Sobotta stated that no centrosomes occur in connection with the spindles of the maturation divisions, and Long and Mark have likewise failed to find any "typical centrosomes."

In Fig. 24, C, the second polar body has become a separate cell. The chromosomes of the ovum, which is now mature, have formed a compact mass. They next become resolved into a chromatic reticulum, and a resting nucleus is produced, provided with a nuclear wall and distinct nucleoli (Fig. 24, D and E). This nucleus, which becomes large and moves toward the center of the cell, is known as the *female pronucleus*. Meanwhile the head of the spermatozoon has enlarged and formed the *male pronucleus*, as shown in Fig. 24, C, D and E.

The two pronuclei, which are very similar, develop rapidly, "probably within a few minutes after the entrance of the spermatozoon." Simultaneously they prepare for division, and the chromatic reticulum of each

becomes resolved into the reduced number of chromosomes which it received during maturation (Fig. 24, F). A centrosome with astral radiations is now seen between the two groups. In Fig. 24, G, it has divided in two, and the spindle has developed. There has been much discussion as to the origin of these centrosomes. Since in this case they arise by the division of a single body, the possibility that one comes from the sper-

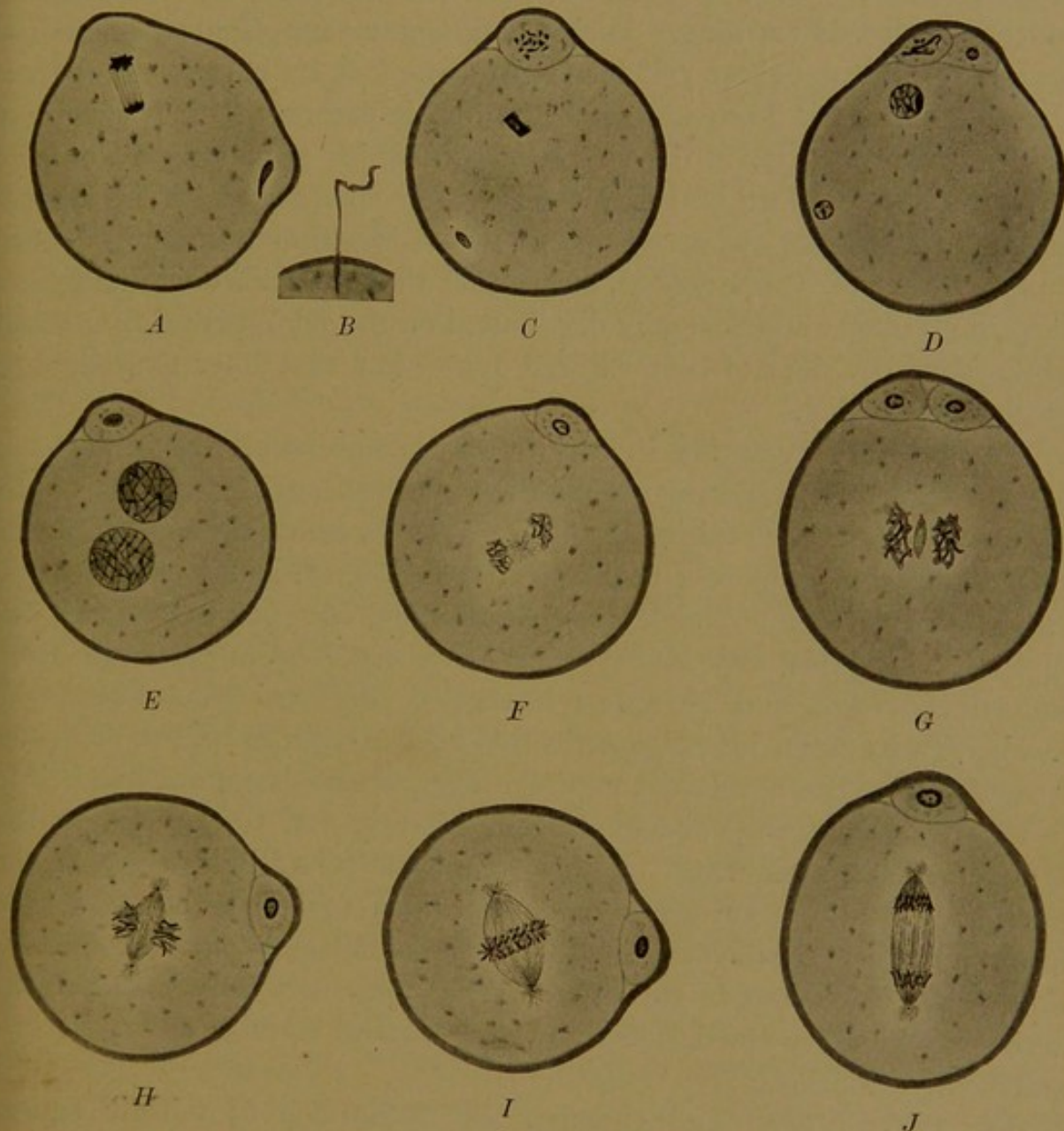


FIG. 24.—MATURATION AND FERTILIZATION OF THE OVUM OF THE MOUSE .A,C-J, $\times 500$; B $\times 750$.
(After Sobotta.)
A-C, entrance of the spermatozoon and formation of the second polar body. D-E, development of the pronuclei. F-J, successive stages in the first division of the fertilized ovum.

matozoon and one from the ovum has been eliminated. Moreover in the mouse they cannot be derived from the surviving centrosome of the last maturation division of the ovum, for that division takes place without centrosomes. Therefore the centrosome must either be brought in by the spermatozoon as a constituent of its middle piece, or it must be a new formation. Sobotta accepted the former alternative, and he observed a centro-

some in connection with the head of the spermatozoon in certain stages (Fig. 24, C) but not in all. It is probable, according to Conklin, that "the source of the cleavage centrosomes may differ in different animals, or even in the same animal under different conditions."

Later stages in the division or "cleavage" of the fertilized ovum into two cells are shown in Fig. 24, H-J. The two groups of chromosomes come together upon the spindle so that the full number, characteristic of the species, is restored. Each chromosome then divides lengthwise, and thus each daughter cell receives one-half of its chromosomes from the male parent and one-half from the female parent. This is strikingly evident when the eggs of the fish *Fundulus*, which have long rod-shaped chromosomes, are fertilized with the sperm of *Menidia*, which has shorter rods. Moenkhaus, who performed this experiment (Amer. Journ Anat., 1904, vol. 3, pp. 29-64), states that the two kinds of chromosomes remain grouped and bilaterally distributed on the spindles during the first and second divisions of the fertilized ovum, but that later they become gradually mingled.

Important information in regard to the nature of fertilization has been obtained by experiments upon unfertilized eggs. Changes in the concentration or composition of the sea water in which the eggs of marine animals have been placed, mechanical agitation, or, in the case of frogs' eggs, puncturing the outer layer with a needle, have led to repeated cell divisions. In this way embryos or larvæ have been produced from unfertilized eggs, and, in a few instances, adult animals. Loeb, who has been a foremost investigator in this field, concludes that the spermatozoon causes the development of the egg by carrying a substance into it which liquefies the cortical layer of the egg, and thereby causes the formation of a membrane. "This membrane formation, or rather the modification of the surface of the egg which underlies the membrane formation, starts the development." At the same time there is an acceleration of the oxidations in the egg. "What remains unknown at present is the way in which the destruction of the cortical layer of the egg accelerates the oxidations."

For the physicist and chemist, the production of mitotic figures and the process of fertilization, have been subjects of great interest, and discussions of their significance will be found in various text-books of physiology and biological chemistry. For further morphological details the student is referred to "The Cell in Development and Inheritance," by E. B. Wilson (2nd ed., New York, 1900) and to the chapters on "Die Geschlechtszellen" and "Eireife, Befruchtung und Furchungsprozess," by W. Waldeyer and R. Hertwig respectively, in vol. 1 of Hertwig's "Handbuch der vergl. u. exp. Entwicklungslehre der Wirbeltiere," (Jena, 1906).

II. GENERAL HISTOLOGY.

HISTOGENESIS.

SEGMENTATION AND THE FORMATION OF THE GERM LAYERS.

The body is composed of groups of similarly differentiated cells, similar therefore in form and function. Such groups are known as *tissues*. Histology (Greek, *ιστός*, "a textile fabric") is the science of tissues, and histogenesis deals with their origin. There are as many tissues in the body as there are "sorts of substance;" thus the liver consists essentially of hepatic tissue, and the bones of osseous tissue. All of these, however, are modifications of a small number of fundamental tissues, the development of which may now be considered.

It has already been stated that a new individual begins existence as a single cell, the fertilized ovum. This cell then divides by mitosis into a pair of cells, Fig. 25, A; and these again divide, making a group of four, Fig. 25, B. By repeated mitosis a mass of cells is produced, which because of its resemblance to a mulberry, is called a *morula* (Fig. 25, C). Development to this point is known as the *segmentation* of the ovum.

A section through the morula of the rabbit is shown in Fig. 25, D. An outer layer of cells surrounds the *inner cell mass*. Soon a cup-shaped cleft, crescentic in vertical section, forms between the outer and inner cells as shown in E, and this cleft enlarges until the entire structure becomes a thin-walled vesicle, within and attached to one pole of which is the inner cell mass (Fig. 25, F). Cells from this mass gradually spread beneath the outer layer until they form a complete lining for the vesicle. The inner layer is called *entoderm*, and the outer layer *ectoderm*.

Before the entoderm has encircled the vesicle, a third layer has appeared between the other two. This middle layer is the *mesoderm* (Fig. 25, G). It arises from the place where the ectoderm and entoderm blend with one another. The layers may be separated and floated apart except at this spot where they are "tied together." This place is therefore called the *primitive knot*. The mesoderm also spreads laterally from a longitudinal thickening of the ectoderm, which extends backward from the primitive knot and marks out the future longitudinal axis of the embryo. This thickening is the *primitive streak*. Arising from the primitive knot and primitive streak, the mesoderm spreads out rapidly between the ectoderm and entoderm, and very soon it splits into two layers (Fig. 25, H). One of them (the *somatic layer*) is closely applied to the ecto-

derm, and the other (the *splanchnic* layer) to the entoderm. Between them is a cavity, known as the *body cavity* or *cælom*, which in the adult becomes subdivided into the peritoneal, pleural, and pericardial cavities. The ectoderm and the somatic mesoderm together form the body wall or *somatopleure*; the entoderm and the splanchnic mesoderm together form the intestinal wall or *splanchnopleure*.

Reviewing the preceding paragraphs it is seen that the fertilized ovum, through segmentation, forms a morula, which later becomes a vesicle composed of three *germ layers*, the outer or ectoderm, inner or entoderm, and middle or mesoderm. By the folding of these layers the body as a whole acquires its form; and by their growth and differentiation all the organs and tissues are produced, together with the *fetal membranes* which surround the embryo. Omitting for the present all reference to the membranes, the fundamental changes which the germ layers undergo may be briefly considered, as follows:

Ectoderm. A portion of the ectoderm forms a layer of cells covering the body of the embryo. In the adult this becomes the outer layer of the skin, or the *epidermis*, and from it, hairs, nails and the mammary, sebaceous and sweat glands develop. It is reflected under the eyelids and over the front of the eye, and forms the lachrymal glands. It extends into the external auditory opening and there forms the ceruminous glands; and into the nasal, oral, anal and urogenital apertures. Within the mouth it forms the salivary glands, the enamel of the teeth, and the cells associated with the sense of taste. Thus it extends far back toward the pharynx, and dorsally, in its deepest part, it produces the anterior lobe of the hypophysis, which will be described in a later chapter. In the nose it also extends far inward, so that it lines the accessory cavities which push out from the nasal cavity into certain bones of the head, and it forms the olfactory cells. An inpocketing of the ectoderm produces the lining of the deep portion of the ear, including the auditory cells, and, as will be seen, the ectoderm gives rise to the lens and retina of the eye. Thus the ectoderm not only forms the outer covering of the body, with extensions into the several apertures, but it produces various sensory cells which are stimulated from external sources.

The second great derivative of the ectoderm is the nervous system. It arises in young embryos as the *medullary groove*. This is a longitudinal groove or furrow, situated in front of the primitive knot and appearing in cross section as a median dorsal depression (Fig. 25, G and H). Later the groove becomes a tube by the coalescence of its dorsal edges, which are about to unite in Fig. 25, H. The tube then becomes completely separated from the epidermal layer of ectoderm, as in Fig. 29.

The closure of the medullary groove to form a tube begins near the anterior end of the embryo and proceeds backward. Thus for a time the

tube opens to the exterior both anteriorly, at the *anterior neuropore*, and posteriorly, at the *posterior neuropore*. Eventually the neuropores become closed over, and the tube is then wholly detached from the epidermal layer. The form of the tube is shown in Fig. 27, which represents a dissected reconstruction of a chick embryo. In this dissection the epidermal layer, which covers the upper or dorsal surface of the embryo, has been almost all removed. A portion of it which forms a fold under the head and around the anterior neuropore has been left in place, and also a portion around the *rhomboidal sinus*, which may be regarded as an expanded posterior neuropore. By removing the epidermal layer, the medullary tube has been exposed. Anteriorly it shows a succession of expansions

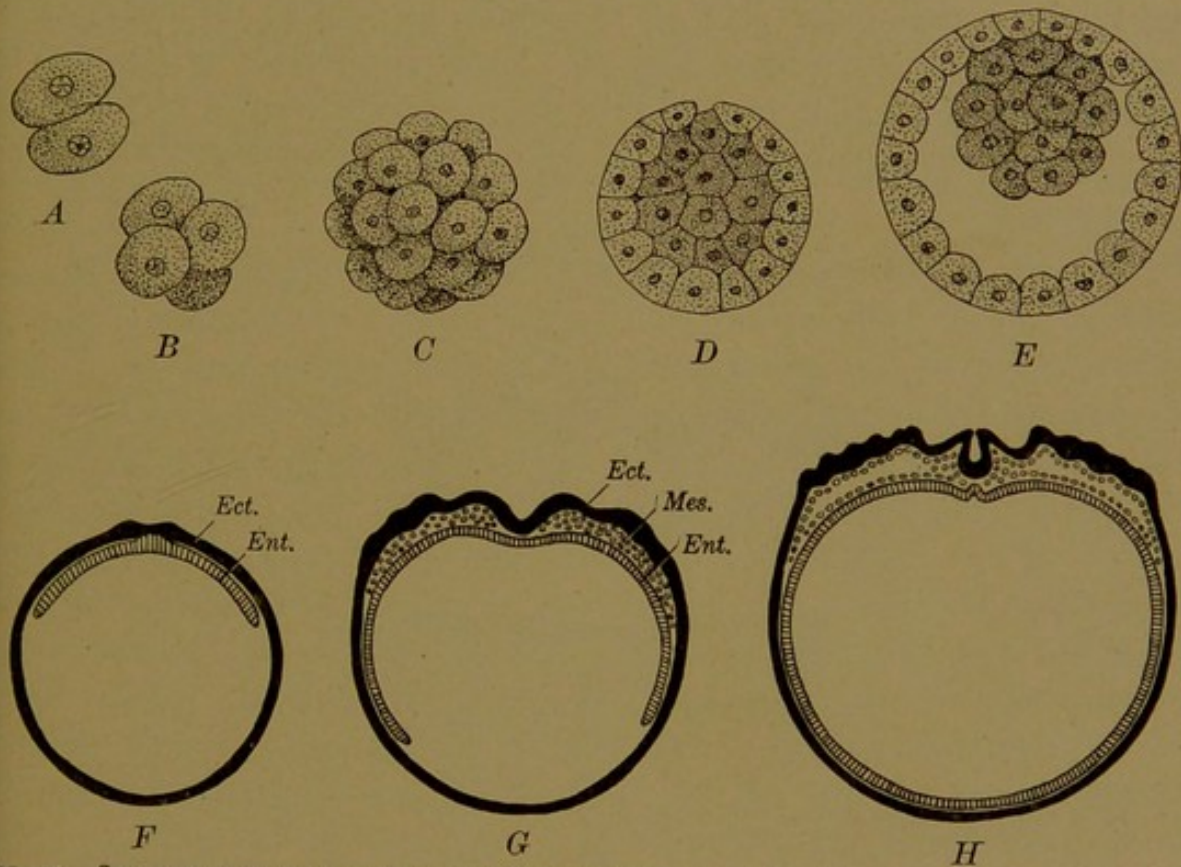


FIG. 25.—SEGMENTATION OF THE OVUM AND FORMATION OF THE GERM LAYERS IN THE RABBIT. (A-E after van Beneden; F-H, after Duval.)

A-C represent surface views of the two-cell stage, four-cell stage and morula respectively. D-H are vertical sections. In D and E the inner cell mass is heavily shaded. Ect., ectoderm. Ent., entoderm. Mes., mesoderm.

which are to form the brain, and also a pair of lateral outpocketings, or *optic vesicles*, each of which will become the retina of an eye. Posteriorly the tube is slender, and this part becomes the spinal cord. The brain and spinal cord, which are derived directly from the medullary tube, constitute the *central* nervous system. The *peripheral* nervous system consists of bundles of nerve fibers which ramify throughout the body, together with masses of nerve cells associated with these fibers. The nerve cells are detached ectodermal cells, arising chiefly from the dorsal part of the medullary groove, and the fibers are protoplasmic outgrowths of these detached cells and of others which remain in the wall of the medul-

lary tube. Thus the entire nervous system, central and peripheral, is ectodermal in origin.

Entoderm. Before considering the chief derivatives of the entoderm, the *notochord* (or *chorda dorsalis*) may be briefly described. In the lowest vertebrates it is an important supporting structure, and is regarded as "the primitive forerunner of the vertebral column." It arises in young mammalian embryos as a median longitudinal band of cells in the entodermal layer, immediately below the floor of the medullary groove. In the diagram, Fig. 25, H, it is shown as an elevation; in Fig. 29, it appears as a group of cells completely detached from the underlying entoderm. It then forms a longitudinal rod extending forward from the primitive knot to the under side of the brain, as seen in the longitudinal section of the chick embryo, Fig. 28. Later it becomes surrounded by mesodermal cells, which develop into the bodies (or centra) of the vertebræ together with the intervertebral ligaments between them. These are

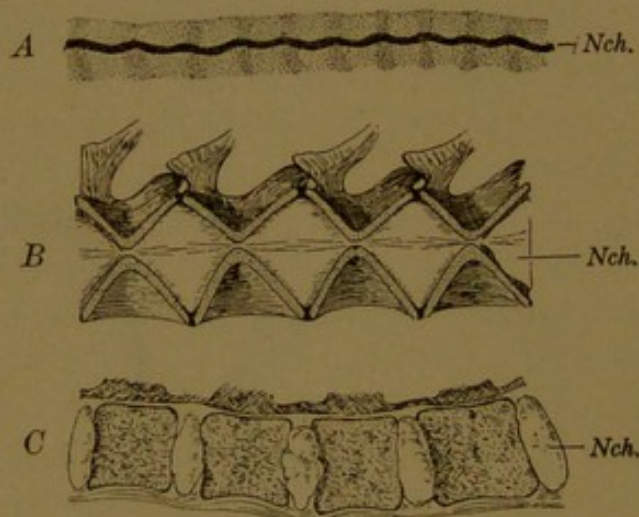


FIG. 26.—THE NOTOCHORD.

A, in a sheep embryo of 14.6 mm. (after Minot); B, in a cod fish; C, in man (after Dwight).

shown in Fig. 26, A, as alternating light and dark areas respectively. The notochord in passing through them shows "segmental flexures" (Minot). In the vertebral column of a fish (Fig. 26, B) the central notochordal rod has expanded between the bodies of the vertebræ so as to form large lenticular masses of gelatinous pulp. These retain a very slender connection with one another. In the human adult, the notochord is represented by the series of detached expansions, or *nuclei pulposi*, one of which occurs in each intervertebral ligament (Fig. 26, C). These nuclei are composed of a peculiar tissue, the development of which has been described by L. W. Williams (Amer. Journ. Anat., 1908, vol. 8, pp. 251-284). The notochord is very rarely the source of tumors. Occasionally, owing to its connection with the entoderm, which is retained longest anteriorly, it gives rise to a pharyngeal recess (Huber, Anat. Record, 1912, vol. 6, pp. 373-404).

In young mammalian embryos the entire entoderm, with the notochordal cells included in its dorsal part, forms the lining of a spherical sac, known as the *yolk-sac* (Fig. 25, H). In birds the mass of yolk, which may be regarded as lodged in the thickened ventral wall of the yolk-sac, is so extensive that the cavity of the sac is merely a flattened dorsal cleft. The yolk-sac gives rise to the entire intestinal tube, together with all its outgrowths. They are therefore lined with entoderm, and they develop as follows.

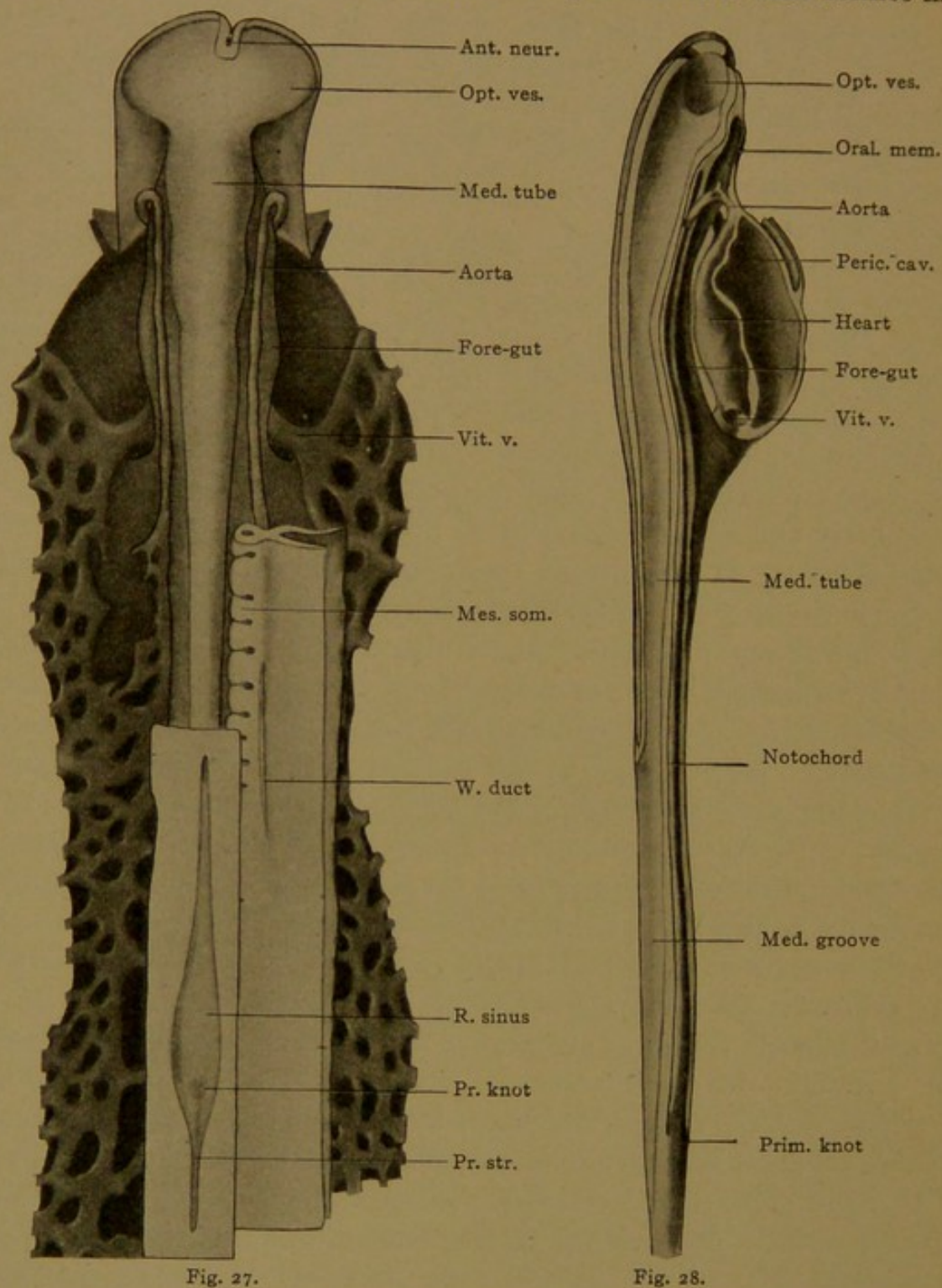
At first, in the chick embryo (Figs. 27 and 28) a flattened finger-like extension of the yolk-sac projects forward into the head, under the notochord. This outpocketing is the *fore-gut*, which gives rise to the pharynx, œsophagus, stomach, and anterior part of the small intestine. Near its anterior extremity it comes in contact with the entoderm and fuses with it, thus forming the oral membrane. By the rupture of this membrane, an opening from the exterior into the pharynx is produced.

Similarly the *hind-gut* develops as a pocket from the posterior part of the yolk-sac. It gives rise to the lower portion of the small intestine and the entire large intestine, and fuses with the ectoderm, forming the cloacal membrane. In later stages the ventral part of the posterior end of the hind-gut becomes cut off from the dorsal part; the ventral subdivision forms the bladder, and the dorsal subdivision becomes the lowest part of the rectum. At the same time the cloacal membrane is correspondingly subdivided into the urogenital membrane which closes the outlet of the bladder, and the anal membrane which closes the rectum. Later these membranes rupture, and the line of separation between ectoderm and entoderm is then difficult to determine. The entoderm apparently lines the entire urethra in the female, but only the upper or prostatic portion in the male; the remainder is lined with ectoderm.

In addition to forming the lining of the pharynx and entire digestive tube, together with the bladder and its outlet, the entoderm lines the following important organs, which arise as outgrowths of the pharynx and digestive tube: the auditory tube, extending from the pharynx to the ear; the thyreoid gland and certain constituents of the thymus; the entire respiratory tract, including the larynx, trachea and lungs; the liver; and the pancreas.

Mesoderm. The mesoderm has already been described as forming splanchnic and somatic layers. These are indicated in the diagram Fig. 25, H, but are more accurately shown in Fig. 29, which corresponds to the upper part of Fig. 25, H, under higher magnification. Where the somatic and splanchnic layers come together they are greatly thickened, and the thickened part becomes cut into block-like masses by a series of transverse clefts. The masses are called *mesodermic somites*, and a pair of them occurs in each transverse segment of the body. They in-

crease in number as new ones become cut off from the unsegmented mesoderm in the posterior part of the embryo. At first each somite may



FIGS. 27 AND 28.—RECONSTRUCTIONS OF A CHICK EMBRYO, INCUBATED APPROXIMATELY 30 HOURS. $\times 30$. FIG. 27 represents a dorsal view. The ectoderm has been removed except around the rhomboidal sinus and under the head. On the left side, all the mesoderm except the blood vessels has also been removed; a portion including nine somites remains on the right side. The lowest layer beneath the vessels, is the entoderm. FIG. 28 is a median sagittal section, except that the entire heart has been included. Ant. neur., anterior neuropore; Med. groove, medullary groove; Med. tube, medullary tube; Mes. som., mesodermic somite; Opt. ves., optic vesicle; Oral mem., oral membrane; Peric. cav., pericardial cavity; Pr. knot, primitive knot; Pr. str., primitive streak; R. sinus, rhomboidal sinus; Vit. v., vitelline vein; W. duct, Wolffian duct.

contain a cavity, which is an extension of the coelom, but the cavity is soon obliterated by a plug of cells. In dorsal view some of the somites are shown on the right side of Fig. 27; the rest have been cut away.

In later stages each somite gives rise to a stream of cells which spread around the medullary tube, notochord and aorta. After these cells have been given off, the somite appears as a plate-like structure (Fig. 30), known as the *dermo-myotome*. The principal derivative of the dermo-myotome is the voluntary musculature of the body. In producing the various voluntary or skeletal muscles, certain cells of the dermo-myotome become transformed into muscle fibers. These are at first arranged in segmental masses, but the masses become subdivided into groups representing the individual muscles. The groups become separated from one another and shift to their final positions. Subsequently they

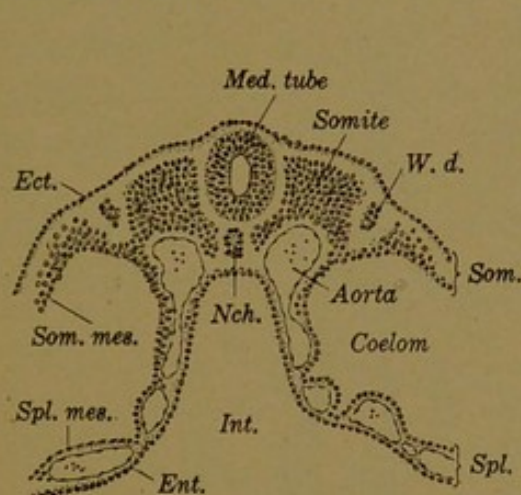


FIG. 29.

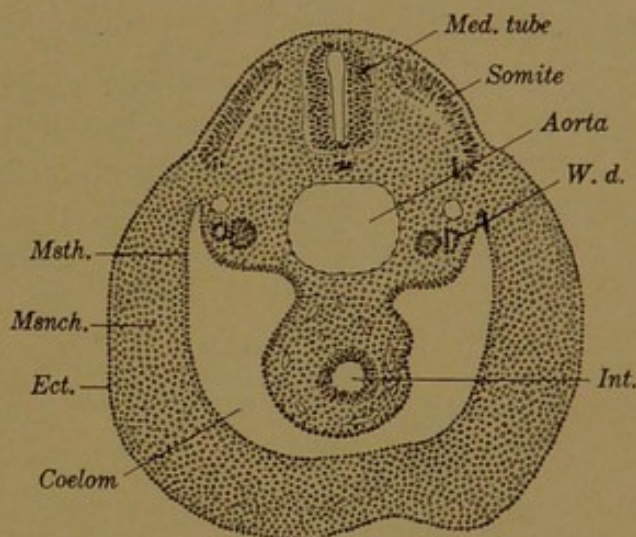


FIG. 30.

FIG. 29.—TRANSVERSE SECTION OF A RABBIT EMBRYO MEASURING 4.4 MM. (9½ DAYS). ×60.

FIG. 30.—TRANSVERSE SECTION OF A RABBIT EMBRYO MEASURING 5 MM. (11 DAYS). ×40.

Ect., ectoderm; Ent., entoderm; Int., intestine; Med. tube, medullary tube; Msnch., mesenchyma; Msth., mesodermal epithelium; Nch., notochord; Som., somatopleure; Som. mes., somatic mesoderm; Spl., splanchnopleure; Spl. mes., splanchnic mesoderm; W. d., Wolffian duct.

acquire their connections with the bones, which develop later than the muscles. The remainder of the dermo-myotome breaks up into cells which are contributed to the deep portion of the skin.

Connecting the somites with the lateral somatic and splanchnic layers of the mesoderm, there is a narrow neck of cells (as seen in cross section, Fig. 29) which is known as the intermediate cell mass, or *nephrotome*. The nephrotomes at first are not segmentally divided, but form the floor of a longitudinal groove in the mesoderm, lateral to the somites (Fig. 27). The nephrotomes give rise dorsally to a longitudinal cord of cells, which later becomes a tube, and is known as the *Wolffian duct* (Figs. 27, 29, and 30). It lies in the groove above the nephrotomes. This duct grows posteriorly and acquires an opening into the entodermal bladder. The nephrotomes then become separated from the somites and from the lateral layers of the mesoderm, and their cells become arranged so as to form coiled tubes, which empty into the Wolffian duct. In this way the mesoderm gives rise to the renal system, which consists essentially of coiled mesodermal tubes, receiving urinary products from

the blood and conveying them through the Wolffian duct to the bladder. Later, parts of the urinary system lose their primary function and become the ducts of the genital system.

The lateral somatic and splanchnic layers of the mesoderm produce the lining of the pleural, pericardial, and peritoneal subdivisions of the coelom, as already stated. They give rise also to an important tissue known as *mesenchyma*. With the production of mesenchyma the tissues

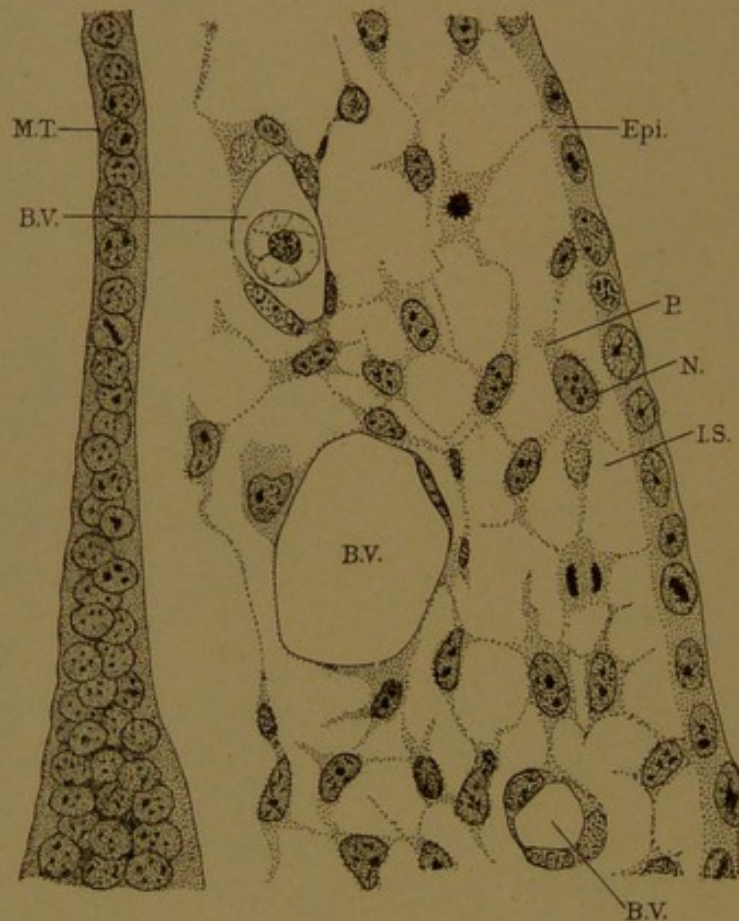


FIG. 31.—SECTION FROM THE HEAD OF A RABBIT EMBRYO OF 10½ DAYS, 4.4 MM., TO SHOW MESENCHYMA. Epi. and M. T., Ectodermal epithelium of the epidermis and medullary tube, respectively. N., nucleus, P., protoplasm, and I. S., intercellular substance of a mesenchymal cell. Two of these cells show mitotic figures. B. V., Blood vessel, lined with endothelium. One of the blood vessels contains an embryonic red blood corpuscle.

of the embryo may be divided into two sorts, namely, *epithelium* which covers an external or an internal surface of the body, and *mesenchyma* which fills the space between two layers of epithelium. These relations are clearly shown in the cross section of the abdomen (Fig. 30). The body wall consists of a layer of ectodermal epithelium externally, and of mesodermal epithelium internally, with a thick layer of mesenchyma between the two. Similarly the intestinal wall consists of mesodermal epithelium toward the coelom, and entodermal epithelium toward the intestine, with mesenchyma between them. Epithelium is thus produced by all the germ layers, but mesenchyma is almost exclusively the product of the mesoderm. It is formed not only from the lateral splanchnic

and somatic layers of the mesoderm, but also from the somites. The tissue which has been described as spreading from the somites around the medullary tube, notochord and blood vessels, and into the deep portion of the skin, is mesenchyma. It also surrounds the tubules derived from the nephrotome.

Under higher magnification, as in Fig. 31, it is seen that epithelium is a layer of closely compacted cells, but that mesenchyma is a protoplasmic network, the meshes of which are filled with a fluid intercellular substance. If this substance is abundant, the nuclei of the mesenchyma are widely separated, as in the figure; but if it is scanty they are quite close together. Mesenchyma gives rise to a great variety of tissues, including involuntary muscle, adipose tissue, cartilage, and bone. Both the cells and the intercellular substance may become variously modified. The most widespread derivative of mesenchyma is *connective tissue*, which invests the nerves, vessels, muscles and epithelial structures, binding them together in organs, and filling the interstices of the body.

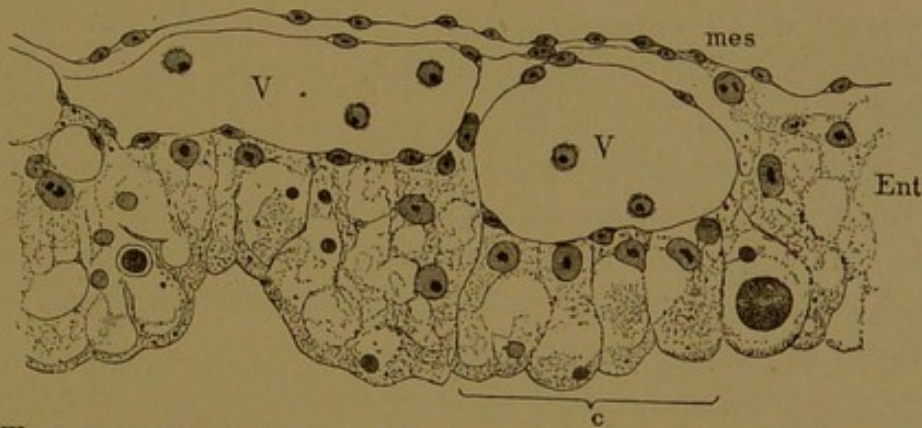


FIG. 32.—WALL OF THE YOLK-SAC FROM A CHICK OF THE SECOND DAY OF INCUBATION. (Minot.) Mes., Splanchnic mesoderm; Ent., entoderm., four distinct cells of which are shown at c; V, V, blood vessels containing a few young blood cells.

The origin of the blood and blood vessels remains to be considered. In very early stages the vessels appear as cellular strands, some of which contain a lumen, situated between the mesoderm and entoderm. Associated with these strands, but further out on the yolk-sac, there are clusters or "islands" of blood cells, surrounded by a thin layer of flattened cells known as *endothelium*. The entire system soon forms a network of distinct vessels situated in the splanchnopleure (Figs. 29 and 32). The formation of this primary vascular network in rabbit embryos has been described by Bremer (*Amer. Journ. of Anat.*, 1912, vol. 13, pp. 111-128). Generally the vessels and the corpuscles within them are considered to be mesodermal, but some authorities have regarded them as entodermal, and others have proposed to describe them as forming a separate germ layer or "angioblast" (more appropriately *angioderm*).

In the chick embryo shown in Figs. 27 and 28, the network of vessels

in the splanchnopleure has formed a complete circulatory system. By a process of folding, portions of the net have been brought together under the fore-gut, where the vessels from the two sides have fused and formed a single median tube, the heart. The two large trunks, derived from the network, which convey the blood from the yolk-sac to the heart are known as *vitelline veins*. The heart divides anteriorly into two vessels (the *aortæ*) which pass from the under side of the fore-gut to the upper side, and then extend posteriorly. They finally connect by branches with the network over the yolk, from which they have been derived. Through this system, nutriment taken from the yolk is brought to the heart by the vitelline veins, and distributed throughout the body by the *aortæ*.

In mammals also, a complete system of vessels is established early in development, and it is believed that all later vessels arise as branches of this primary endothelial network. If this opinion is correct, none of the later vessels are formed by the coalescence of mesenchymal spaces, or by transformation of mesenchymal cells into endothelial cells, but only as outgrowths of pre-existing endothelium. There is, however, a very close connection between the endothelium and the surrounding mesenchyma, as shown in Fig. 31.

The histogenesis of the blood is likewise very difficult to follow. The simplest interpretation is one which has not been disproven, namely, that all forms of blood corpuscles are descendants of the cells found in the blood islands of the yolk-sac. According to this hypothesis these cells multiply in certain places to which they have been carried by the circulating blood, for example in the liver in later embryonic life and in the bone marrow of the adult; and they differentiate into the red and white corpuscles of various kinds. The difficulties which this hypothesis encounters will be discussed in later chapters.

THE FUNDAMENTAL TISSUES.

From the foregoing outline of embryological development, it is clear that all the organs of the body are derived from a relatively small number of fundamental tissues. After the fertilized egg has segmented, it gives rise to layers of cells, of which the ectoderm and entoderm are epithelial from the beginning. The mesoderm very early divides into two tissues—epithelium, which lines the body cavity, and mesenchyma, which forms the internal substance of the body wall and intestinal wall. Thus *epithelium* and *mesenchyma* may be regarded as the primary tissues of the body. The groups of blood corpuscles, which are probably derived from the mesenchyma, and the endothelium which surrounds them, also arise very early, and these may be set apart as *vascular tissue*.

The nervous system develops from epithelium, but its cells, singly or in groups, become imbedded in strands and masses of nerve fibers which these same cells send out as processes. Thus little remains in the adult to suggest that the brain or peripheral nerves come from a layer of cells covering a surface, and the nervous system is therefore described as consisting of *nervous tissue*.

The voluntary muscles are formed from cells derived from the epithelium of the mesodermic somites, but they develop as the somite breaks up and its epithelial character is lost. The involuntary muscles are produced by a transformation of mesenchymal cells into elongated muscle cells. For physiological reasons these two kinds of muscle, which are of diverse origin and structure, are classed together as *muscular tissue*.

The relation of the germ layers to the five fundamental tissues which have now been recognized, is shown in the following summary.

ORIGIN OF THE TISSUES FROM THE GERM LAYERS.

The **ectoderm** produces:

1. EPITHELIUM of the following organs:—the skin (epidermis) including the cutaneous glands, hair and nails; the cornea and the lens; the external and internal ear; the nasal and oral cavities, including the salivary glands, the enamel of the teeth and anterior lobe of the hypophysis; the anus; the cavernous and membranous parts of the male urethra; together with that epithelium of the chorion which is toward the uterus and of the amnion which is toward the embryo.
2. NERVOUS TISSUE forming the entire nervous system, central, peripheral and sympathetic.
3. MUSCULAR TISSUE, rarely, as of the sweat glands, and iris.

The **mesoderm** produces:

1. EPITHELIUM of the following four sorts: (1) epithelium of the urogenital organs (except most of the bladder and the urethra) and the epithelioid cords of cells in the suprarenal gland; (2) epithelium of the pericardium, pleuræ, and peritoneum and the continuation of this layer over the contiguous surfaces of amnion and chorion; (3) epithelium lining the blood vessels and lymphatic vessels; and (4) epithelium lining the joint cavities and bursæ.
2. MUSCULAR TISSUE, striated (voluntary), cardiac, and smooth (involuntary).
3. MESENCHYMA, an embryonic tissue, which forms in the adult, connective and adipose tissue, bone (including the teeth except their enamel), cartilage, tendon, and various special cells.
4. VASCULAR TISSUE, the cells of the blood and lymph, consequently the essential elements of the lymph glands, red bone marrow and spleen.

The **entoderm** produces:

1. EPITHELIUM of the following organs:—the pharynx, including the auditory tube and middle ear, thyreoid and thymus glands; the respiratory tract, including larynx, trachea, and lungs; the digestive tract, including the œsophagus, stomach, small and large intestine, rectum, liver, pancreas, and the yolk-sac; and part of the urinary organs, namely most of the bladder, the female urethra, and prostatic part of the male urethra (including the prostate).
2. NOTOCHORDAL TISSUE, which occurs in the nuclei pulposi.

In the following pages the fundamental tissues will be considered in turn. In connection with them, certain *organs* will be examined. An organ is a more or less independent portion of the body, having a connective tissue framework, and a special blood, lymph, and nerve supply, in addition to its characteristic essential cells. The essential cellular substance of an organ, in distinction from the accessory tissues, is often called its *parenchyma*; the accessory supporting tissues constitute the *stroma* (Gr. στρώμα, bed), in which the parenchyma is imbedded.

Such structures as the pancreas and liver are obviously organs. An individual muscle or a particular bone, which has a connective tissue covering or framework, and a supply of vessels and nerves, besides its essential substance, may also be regarded as an organ. The organs which are of widespread occurrence, such as the bones, muscles, tendons and large vessels, will be described with the tissues. The more complex organs are reserved for a later section, entitled "Special Histology."

EPITHELIUM.

The Dutch anatomist, Frederik Ruysch, recognized that the covering of the margin of the lips is not identical with the epidermis. "Therefore," he wrote, "I shall call that covering the *epithelis*, or papillary integument of the lips" (Thesaurus anat. III, 1703, No. 23, p. 26). It is an unfortunate name (ἐπὶ, upon θηλή, Latin *papilla*, the nipple) since it does not refer to the layer upon the nipple, but to that which covers a great number of nipple-like elevations of the underlying tissue. Such elevations or *papillæ* are indeed abundant in the lips, but they occur also under the epidermis. Ruysch substituted *epithelia* for *epithelis* in other sections of his work, and Haller, writing some years later, used the neuter *epithelium*, so that epithelia thus became a plural.

As the term epithelium is now used, it includes the epidermis, and the lining of the various internal tubes and cavities. It has been defined as a layer of closely compacted cells, covering an external or internal surface of the body, having one of its surfaces therefore free, and the other resting on underlying tissue. But the term is also correctly applied to solid outgrowths from such layers, either in the form of cords or masses of cells. Usually these outgrowths subsequently acquire a cavity, or lumen, around which the cells become arranged in a layer.

The epithelia which cover the skin and line the digestive tube and urogenital organs are thick, as compared with those which line the body-cavity, the vessels, and the synovial cavities. For these thin layers His (1865) introduced the term *endothelium*. He wrote as follows:

We are accustomed to designate the layers of cells which cover the serous and vascular cavities as epithelia. Put all the layers of cells which line the cavities within

the middle germ layer have so much in common, and from the time of their first appearance differ so materially from those derived from the two peripheral germ layers, that it would be well to distinguish them by a special term—either to contrast them, as false epithelia, with the true, or to name them *endothelia*, thus expressing their relation to the inner surfaces of the body.

The name endothelium, etymologically absurd, has become generally accepted for the lining of the blood vessels and lymphatic vessels. For the other forms of epithelium which it was intended to include, special names have been proposed.

Minot (1890) introduced *mesothelium* to designate the layer of mesodermal cells which bounds the body cavity. Thus mesothelium does not include the endothelium of the vessels, or the lining of the synovial cavities; but it does include the cells of the nephrotome, through which the body cavity may extend, and also the epithelium which bounds the somites in early stages. Professor Minot applies the term also to the thick epithelium of the renal organs, which is derived from the cells of the nephrotome.

As seen in Fig. 33, the epithelium lining the vessels closely resembles that which lines the body cavities, and to a certain extent this justifies the use of the term endothelium for both layers as proposed by His. But it has been shown embryologically that the vessels and body cavity are of different origin, and are distinct even in the earliest stages. Moreover the linings of the synovial cavities, tendon sheaths, and the chambers of the eye form a third separate group. They arise relatively late in development by the confluence of intercellular spaces in the mesenchyma, and they are therefore bounded by flattened mesenchymal cells.

In accordance with these embryological facts, the following use of terms is here proposed:

Endothelium should be restricted to the lining of the blood vessels and lymphatic vessels.

Mesothelium, except in young embryos, should be restricted to the lining of the body cavity and its subdivisions.

Mesenchymal epithelium (or false epithelium) should be applied to the lining of joint cavities and bursæ.

All of these forms of epithelium are primarily thin and are derived from the mesoderm. The lining of the body cavity is, however, thickened in places. Thick epithelium may be ectodermal, entodermal or mesodermal in origin.

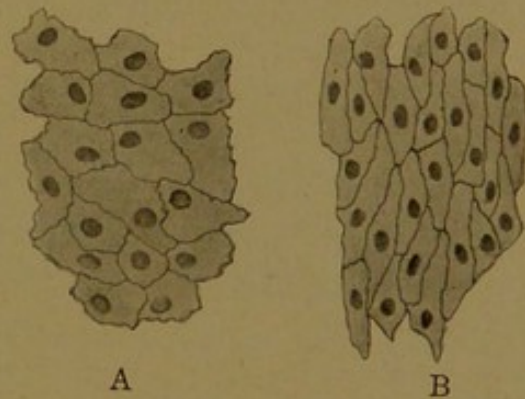


FIG. 33.
A, Surface view of mesothelium from the mesentery; B, surface view of endothelium from an artery.

Epithelia differ from one another, not only in origin, but also in the shape of their cells, the number of layers of which they are composed, and the differentiation of their cells. These features should be examined in every specimen studied, and something under each heading should be recorded in any complete description of an epithelium.

SHAPES OF EPITHELIAL CELLS AND THE NUMBER OF LAYERS.

An epithelium which consists of but one layer of cells is called a *simple epithelium*, and its cells may be *flat*, *cuboidal* or *columnar*. These terms refer to the appearance of the cells when cut in a plane perpendicular to the free surface. If in such a section the outlines of the cells are approximately square, as along the upper surface in Fig. 34, the epithelium is cuboidal; if they are stretched out in a thin layer so that they appear linear, as along the lower surface in Fig. 34, the epithelium is flat. Endothelium is an extremely flat epithelium, in which the cells are so thin that the nuclei cause local bulgings of the cell membrane. If the epithelial cells are laterally compressed, so that tall forms result as in Fig. 35, B, the epithelium is columnar. Such epithelium is less accurately called

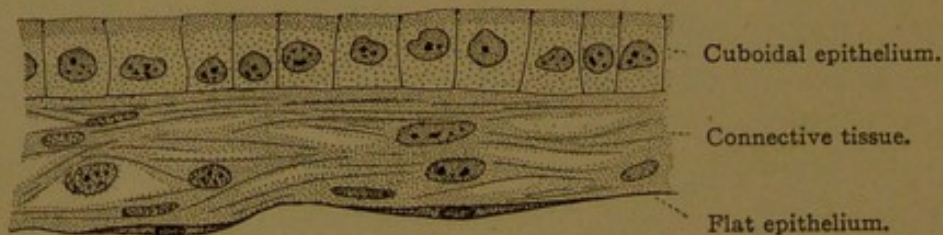


FIG. 34.—PORTION OF THE MEMBRANES SURROUNDING A PIG EMBRYO MEASURING 60 MM. (Allantioes above, and amnion below.)

cylindrical, and both cuboidal and flat epithelia are sometimes referred to as pavement epithelium. Intermediate forms, which are described as low columnar or low cuboidal, frequently occur. The cells of certain epithelia change their shape temporarily, as in the bladder during distention, in the œsophagus during deglutition, and, to some extent, in the arteries with every pulsation. During post-mortem contraction the arterial endothelium is considerably thickened. Moreover during embryonic development, epithelial cells may change from one form to another.

On surface view the epithelial cells of all types are polygonal and usually six-sided (Figs. 33 and 35, A). Geometrically a circle would come in contact with six surrounding circles of equal diameter, and a cell is usually in contact with six surrounding cells. The cells, however, vary in diameter, and are often surrounded by five or seven cells and occasionally by four or eight.

An epithelium which consists of several superimposed layers is known as *stratified epithelium* (Fig. 37). In such cases the basal cells are usually

columnar and closely crowded. They multiply by mitosis and give rise to cells which are pushed toward the free surface. After leaving the basal layer they enlarge and become polygonal in outline. Toward the free surface they become gradually flattened, and may be more or less cornified or transformed into horny material. These scale-like cells are called

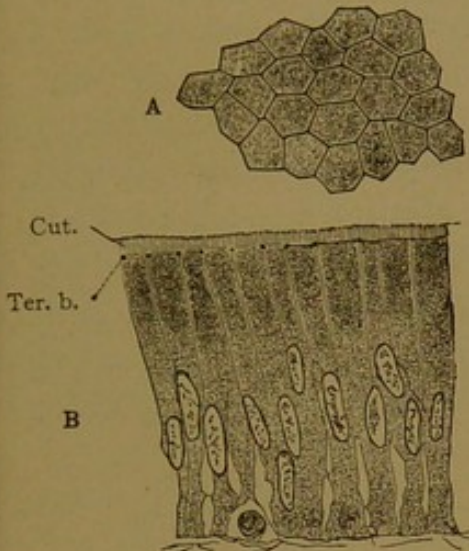


FIG. 35.—SIMPLE COLUMNAR EPITHELIUM FROM A HUMAN INTESTINAL VILLUS. A, Surface view; B, vertical section. The prominent cell outlines in A are due to terminal bars, shown in section in B. Cut., cuticular border.

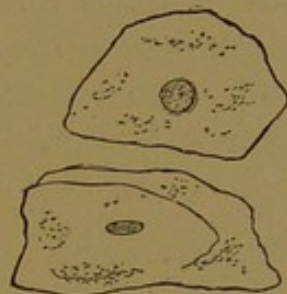

FIG. 36.—DETACHED SQUAMOUS CELLS FROM THE MOUTH.

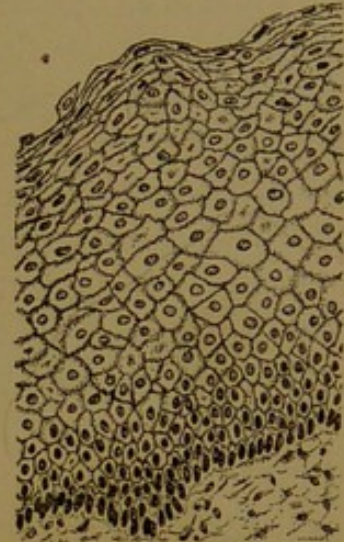


FIG. 37.—STRATIFIED EPITHELIUM FROM THE OESOPHAGUS OF A CHILD.

squamous cells and they readily become detached (Fig. 36). Stratified epithelium is found in the vagina, oesophagus, pharynx and oral cavity; and in its most complex form, with many layers, some of which are peculiarly modified, it constitutes the epidermis.

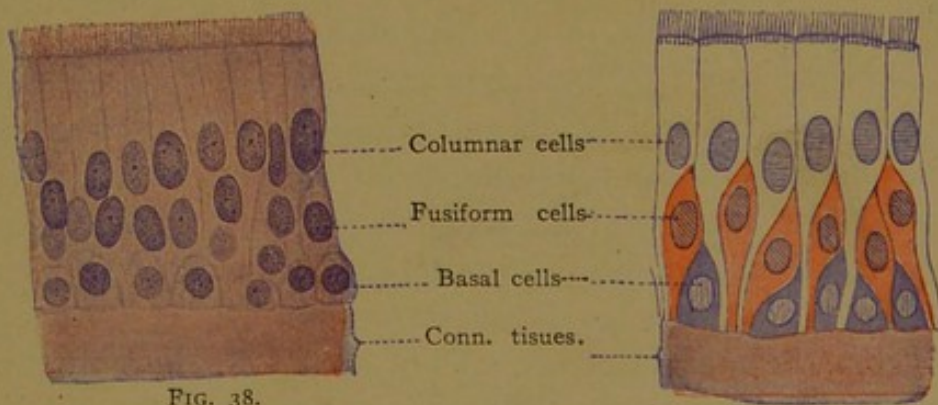


FIG. 38.

FIG. 39.

FIGS. 38 AND 39.—PSEUDO-STRATIFIED CILIATED EPITHELIUM FROM THE HUMAN RESPIRATORY TRACT. Fig. 39 is a diagram of the condition shown in Fig. 38. $\times 720$.

In certain organs and especially in embryos, simpler forms of stratified epithelium occur, which are described as four-layered, or two-layered as the case may be. The superficial cells may be flat, cuboidal, or columnar. A characteristic epithelium with dome-shaped outer cells and tall basal cells, found in the bladder and ureter, is known as "transitional epithe-

lium," as if it were intermediate between the simple and stratified forms. When the bladder contracts the cells are heaped up in several layers, but when distended the number may be reduced even to two.

If the cell walls are indistinct and the sections are thick or oblique, the number of layers in an epithelium may be very difficult to determine. Thus in a simple epithelium the nuclei may be at different levels (Fig. 35, B), and if the section is not vertical it will show several layers, approaching the condition of the tangential section, Fig. 35, A. Fig. 38 represents a vertical section of an epithelium with nuclei at three levels, and in two forms (the basal nuclei being round and the others elongated); but yet, as interpreted in Fig. 39, it is not stratified. It is of the form known as *pseudo-stratified*, in which all the cells reach the underlying connective tissue, but only a limited number extend to the free surface. Pseudo-stratified epithelium occurs in the upper part of the respiratory tract, including the trachea and larger bronchi, and in the epididymis.

PERIPHERAL DIFFERENTIATION OF EPITHELIAL CELLS.

Free surface. The free surface of epithelial cells is often provided with a thickened top-plate or *cuticula*. Under high magnification the cuticular border of the columnar cells in the intestine is seen to be vertically striated (Fig. 35, B), and these striations have been interpreted as minute canals through which protoplasmic processes may be sent out beyond the free surface. In some cases, however, the striated cuticula appears to consist merely of short, parallel protoplasmic rods. In certain cells of the kidney, the rods may become somewhat divergent, giving rise to what is known as the "brush border." Longer processes, which are vibratile but not retractile, are called *cilia* (the Latin term for eyelashes). They project from the free surface of certain epithelial cells in the trachea and bronchi (Figs. 38 and 39), in the uterus and uterine tube, in the efferent ducts of the testis, and in the nasal part of the pharynx together with the auditory tube and naso-lachrymal duct which open into it. In the living condition the motion of cilia may be observed in various unicellular animals. It may be studied advantageously in fragments from the margin of the gills of a clam, or in epithelium from the roof of the mouth of a frog. The cilia are numerous, and in the snail Heidenhain counted 110 arising from a single cell. They do not act together, but rapidly succeeding waves, due to the bending of the cilia, pass over the entire surface. By bending sharply downward, each cilium creates a forward current in the overlying fluid, and passes the particles above it to the cilium in front. No sooner does a cilium begin to bend than the next in front takes up the movement and thus the ciliary waves are propagated. In some animals, however, the wave proceeds

in a direction opposite to that of the effective stroke. The cilia in man produce currents toward the outlets of the body. In the uterine tube the stroke is toward the uterus, presumably favoring the passage of the ova, but the spermatozoa ascend this tube against the current.

The structure of cilia, because of their small size, is difficult to determine, but in many cases a differentiation between the exoplasm and endoplasm has been observed. The simplest cilia, as shown in the diagram (Fig. 40, a), are essentially permanent pseudopodia, with contractile sheaths and fluid contents. They may develop very rapidly in the protozoa. Thus Prowazek has seen processes grow out in eight minutes, which were then vibrating 19 times in 20 seconds. Schäfer

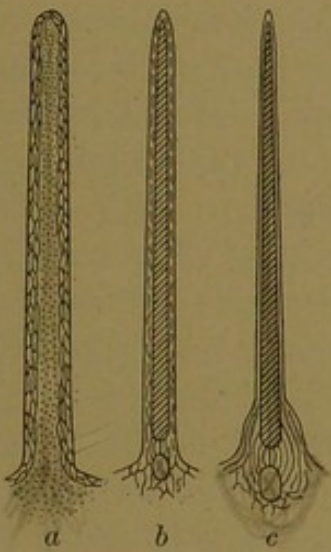


FIG. 40.

a, b, c, Diagrams to illustrate the structure of cilia. (After Williams.)

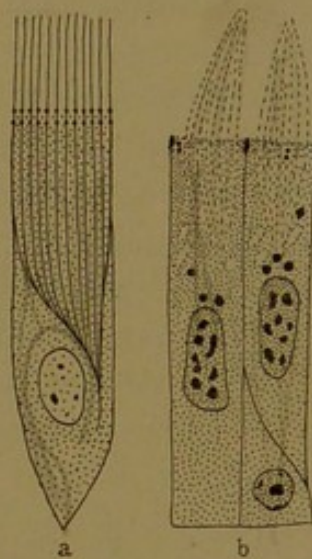


FIG. 41.

a, Diagram of a ciliated cell (after Prenant), showing vibratile cilia; b, cells of the human epididymis (after Fuchs), showing non-motile cilia.

considers that cilia are primarily pseudopodia, and that their motion is caused by the alternating ingress and egress of fluid to and from the central part, due to variations in the surface tension.

Many cilia, however, appear to contain more or less solid axial rods, which generally proceed from round basal bodies resembling centrosomes. That these bodies arise from the centrosome has recently been denied. Sometimes the bodies are double, and extensions from them downward into the cytoplasm may occasionally be observed (Fig. 41, a). These roots approach one another beside the nucleus, and it has been discussed whether or not they unite. The roots, and portions of the cytoplasmic reticulum at right angles to the shafts of the cilia, have been thought to act as levers. Others conjecture that the central shaft is a supporting structure, perhaps elastic, which is surrounded by a contractile sheath. The contractile elements may extend the whole length of the cilium or be confined to its base, as indicated in the diagram (Fig. 40, b and c). If

the sheath were equally developed about the entire circumference of the axis, the cilia should be able to strike in any direction. Usually the effective stroke is in one direction only, but in some cases it may be reversed. In reversible cilia, such as occur on the labia of the sea anemone, the effective stroke is either toward the mouth or away from it, according to the chemical composition of the substances in contact with the cilia (Parker, Amer. Journ. of Physiol., 1905, vol. 3, pp. 1-16). In such a case the contractile material is supposed to be gathered in two bands, on opposite sides of each cilium. In the irreversible cilia, such as are found elsewhere in the sea anemone and in man, the contractile material, according to Parker, must be gathered especially on one side of the supporting axis.

The whip-like processes, or *flagella*, which form the tails of spermatozoa, may be compared with single cilia. Each springs from a body resembling a centrosome, and consists of an axial filament with a surrounding sheath, but whether the filament or the sheath contains the contractile substance is still uncertain.

Non-motile projections, somewhat resembling cilia, are found in the cells of the epididymis (Fig. 41, b). They have no basal bodies, and lack the distinctness of true cilia. Generally they appear in conical clumps, which have been compared to the hairs of a wet paint brush. They may be concerned with the discharge of secretion. Other non-

motile processes of epithelial cells are the tapering projections of the sensory cells, apparently designed to receive stimuli. The lining of the central cavity of the spinal cord and ventricles of the brain is also provided with short projections, which may be degenerating cilia. It is questionable whether these are motile.

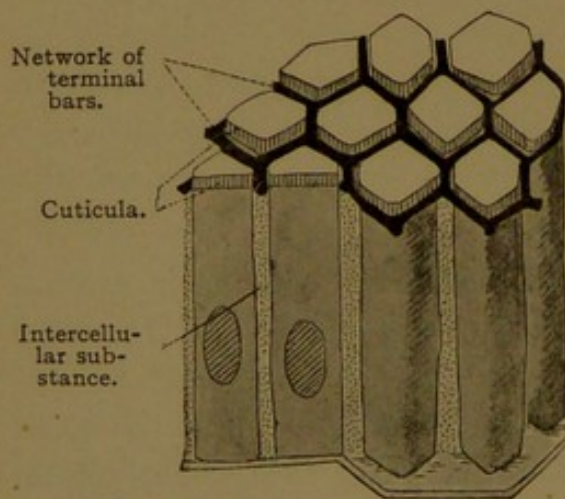


FIG. 42.—DIAGRAM OF THE NETWORK OF TERMINAL BARS.

The two cells on the left are divided lengthwise into halves; the two on the right are drawn as complete cylinders or prisms.

Lateral surface. The lateral surfaces of epithelial cells may be in close contact with one another, sometimes without intervening cell walls; or they may be separated by

a thin layer of intercellular substance, which is generally fluid. Immediately beneath the cuticular border of the cells lining the intestine, the intercellular substance takes the form of a more solid bar encircling each cell and binding it to those which surround it. The arrangement of these *terminal bars* is shown in the diagram, Fig. 42, and in the section Fig. 35, b. If the section passes down through the

middle of the cell, as on the left of Fig. 35, b, the bars are cut across and appear as points; but if either the proximal or distal side of the cell is included in the section, they appear as lines, as on the right of the figure. Terminal bars have been found in many epithelia, especially in mucous membranes and glands. They occur in the epididymis (Fig. 41, b) where they appear as thickenings of the cell wall. According to Stöhr they are found in the stratified epithelium of the tongue and bladder.

The intercellular substance in endothelium and mesothelium is ordinarily inconspicuous, but it may be demonstrated by treating the tissue with a solution of silver nitrate. The resulting precipitate occurs chiefly in the intercellular "cement substance," which then appears as a wavy black line bounding each cell (Fig. 33). It is of importance since various forms of blood corpuscles make their way through it from the vessels into the surrounding tissue.

In the lower layers of the epidermis and the thick oral epithelium, the intercellular substance is clearly seen, and here it is bridged by spiny processes from the adjacent cells. These *intercellular bridges* occur in endothelium and many forms of epithelium, but they are most readily observed in the deep layers of the thick stratified epithelia (Fig. 43). Within the bridges, fibrils pass from cell to cell. In the intercellular spaces between the spiny processes, nutrient fluid makes its way to the outer layers. Whatever nutriment they receive must be derived from the intercellular fluid or through the bodies of the underlying cells, since neither blood vessels nor lymphatic vessels penetrate the epithelium. This is probably true of all epithelia in man, but in the bladder and renal pelvis the blood vessels approach very close and may appear to enter, and in the amphibia, according to Maurer, capillaries may be observed well within the oral epithelium. Nerve fibers extend among the basal cells of the epidermis and other epithelia, and ramify in contact with these cells, but special methods are required to demonstrate them.

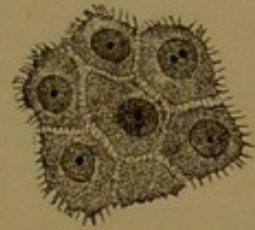

FIG. 43.—INTERCELLULAR BRIDGES, AS SEEN IN VERTICAL SECTIONS OF THE GERMINATIVE LAYER OF THE EPI- DERMIS.

Basal surface. The basal cells of an epithelium sometimes seem to send out processes which blend with the underlying connective tissue. Usually, however, the lower surface is well defined, and the epithelium is bound down by intercellular cement substance. Often, especially in glands, the epithelium rests upon a thin, well-defined *basement membrane* or *membrana propria*. This membrane is usually homogeneous and contains very few nuclei. Sometimes it is composed of elastic tissue. Certain basement membranes have been considered as derivatives of the epithelium, but generally they are clearly of mesenchymal origin.

PROCESSES OF SECRETION IN EPITHELIAL CELLS.

Many epithelial cells elaborate and discharge substances which do not become parts of the tissue. Such cells are called *gland cells*, and their products are either utilized by the body (secretions) or eliminated as waste products (excretions). The process of elaboration and discharge of the secretion or excretion may often be recognized by changes in the form and contents of the cell. A gland cell which is full of secretion, or discharging it, is called "active," and one in which the secretion is not apparent, though it may be in process of formation, is called "resting." The appearances during secretion differ in two types of gland cells—the *serous*, which produce watery secretions, like saliva; and the *mucous*, which form thick secretions, like those of the nose and throat. These will be considered in turn.

Serous gland cells, when empty, are small and darkly staining. As

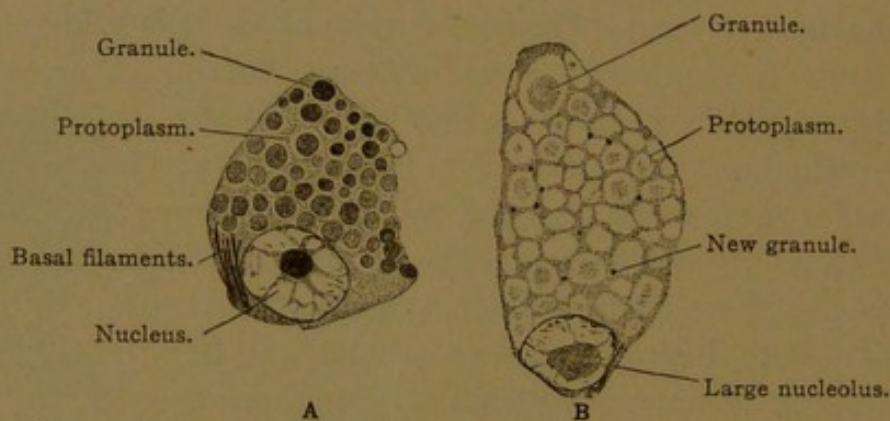


FIG. 44.—TWO SEROUS GLAND-CELLS FROM THE SUBMAXILLARY GLAND OF A GUINEA-PIG. $\times 1260$. In cell B the granules have passed into the unstainable state; new stainable granules are beginning to develop in the protoplasm.

the formation of secretion begins, the cells, if prepared with special methods, exhibit granules which stain intensely. These granules have become cut off from the basal filaments or *mitochondria* (Fig. 44, A). They enlarge, lose their staining capacity, and are transformed into drops of secretion. The entire cell becomes larger and clearer than before, and the alveolar structure of its protoplasm is well marked (Fig. 44, B). Finally the droplets become confluent and are discharged from the free surface of the cell. A portion of the mitochondria remains behind as the source of further secretion. In many gland cells the cytoplasmic differentiation is accompanied by changes in the nucleus. In the empty cell the nucleus has distinct nucleoli and a fine chromatic reticulum, but in cells full of secretion the nucleoli have enlarged or disappeared and the chromatin is in the form of coarse masses. Particles pass from the nucleus into the cytoplasm, and these have been said to give rise to secretory granules.

In mucous cells the process of secretion also begins with granule formation, but the mucigen granules gather near the free surface of the cell

where they become changed into clear droplets of mucus. A discoid mass of secretion is thus produced which is quite sharply marked off from the underlying cytoplasm (Fig. 45, a and b). As the cytoplasm becomes increasingly transformed into secretion, the elongated nucleus becomes at first round, and then flattened. It is forced to the base of the cell where it is lodged in a small amount of unchanged cytoplasm (Fig. 45, b-d). The secretion is then gradually discharged through the distended top-plate, which is often ruptured in sections, and the nucleus again becomes

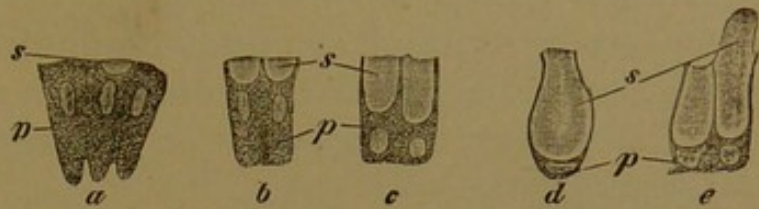


FIG. 45.—EPITHELIAL CELLS SECRETING MUCUS.

From a section of the mucous membrane of the human stomach $\times 560$. p, Protoplasm; s, secretion; a, three cells, two empty, the third showing the beginning of mucoid metamorphosis; e, the cell on the right is discharging its contents; the granular protoplasm has increased and the nucleus has become round again.

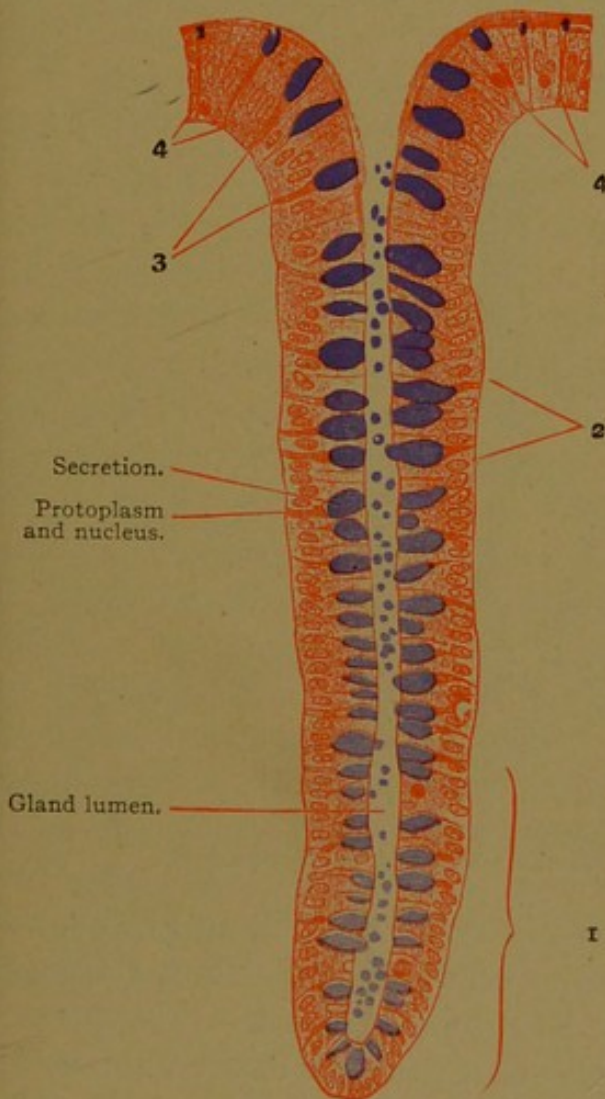


FIG. 46.—INTESTINAL GLAND FROM A SECTION OF THE HUMAN LARGE INTESTINE. $\times 165$.

The secretion formed in the goblet-cells is here colored blue; usually it is pale as in Fig. 45. In zone 1 the goblet-cells show the beginning of secretion; that expulsion has begun is evident from the presence of drops of secretion in the lumen of the gland. 2, Goblet-cells with much secretion. 3, Goblet-cells containing less secretion. 4, Dying goblet-cells, some of which still contain remnants of secretion.

round and moves toward the center of the cell. Most gland cells are not destroyed by the act of secretion, but may repeat the process several times. An exception occurs in the case of the sebaceous glands, in which the cells disintegrate and are cast off with their products. In the mucous cells of the intestine, secretion is formed below and discharged from the free surface at the same time. The cells, as seen in Fig. 46, arise near the bottom of tubular depressions lined with simple columnar epithelium. By the formation of new cells below them they are pushed toward the outlet of the tube. Thus the youngest cells are at the bottom of the pit and the oldest are at the top. For a time the secretion develops faster than it is discharged, and the cells enlarge as seen in the middle part of the gland; later, as elimination exceeds production, they become narrow, and their final stages, as compressed cells with

a remnant of secretion, are found near the orifice of the gland. Cells such as have been described, which appear like cups filled with mucus, are known as *goblet cells*.

In certain stratified or pseudo-stratified epithelia, the formation of mucus has been seen to take place in some of the deeper cells, but the discharge of the secretion can occur only when these cells have reached the free surface.

THE NATURE AND CLASSIFICATION OF GLANDS.

The simplest form of gland is merely a single secreting cell situated apart by itself in an epithelium. Such *unicellular glands* are abundant in invertebrates and are represented in man by scattered goblet cells. In the higher animals the secreting cells usually occur in groups, and they are generally found in tubular or saccular outpocketings of the epithelium.

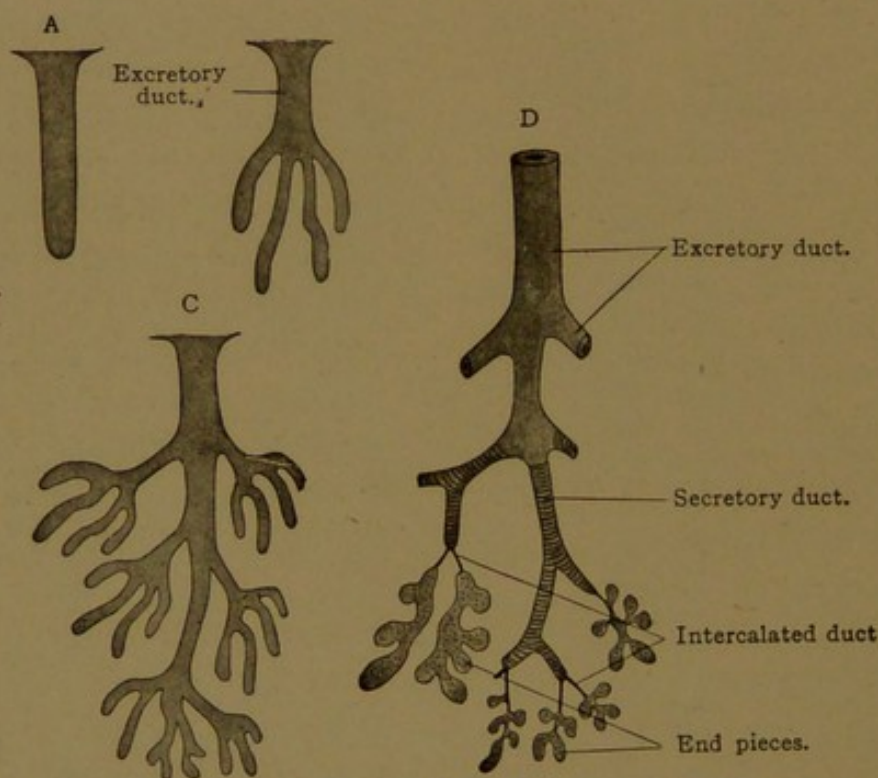


FIG. 47.—DIAGRAM OF VARIOUS FORMS OF GLANDS.
The arrangement of ducts in D is that of the human submaxillary gland.

An unbranched tubular gland is shown in vertical section in Fig. 46, and in the diagram, Fig. 47, A. The secreting cells may be distributed throughout the tube, or they may be limited to the lower part. In such cases the upper part forms the *duct* of the gland. Sweat glands are unbranched tubes, with a coiled secreting portion in the deeper part of the skin, and a relatively long duct which conveys the secretion to the surface. Many glands are branched, as in Fig. 47, B. The main stem becomes the duct, and the characteristic secretion is formed in saccular or tubular "end pieces."

Such glands as have been described, either branched or unbranched, occur in great numbers as constituent parts of some organ, and they are classed as *simple glands*. The sebaceous and sweat glands of the skin, intestinal glands, and uterine glands are examples of this class. Many glands are much larger than these, owing to the fact that the epithelial outgrowth has branched repeatedly. It becomes invested with a connective tissue capsule, which sends partitions, or *septa*, among the ramifications of the epithelial tube, thus dividing the gland into lobes and lobules. A lobule usually contains a terminal branch of the duct together with the cluster of end pieces which empty into it. The large glands not only have a connective tissue framework, but also a special supply of nerves, blood vessels and lymphatic vessels. Thus they form independent organs, and they are classed as *compound glands*. They include the liver, which discharges its secretion through a single duct; the pancreas, which is formed by the fusion of two glands and therefore has primarily two ducts; and many smaller organs, like the prostate, which is a compact group of glands each of which has a separate duct.

All the glands thus far considered are alike in being outpocketings of epithelium. Most of them develop as masses or cords of epithelial cells which later acquire a central cavity or *lumen*. The secreting cells may discharge their products from their free surfaces directly into the lumen; or the secretion may enter minute canals, either within the cells (*intracellular*), or between the cells (*intercellular*). *Intercellular* secretory canals (also called capillaries) are found in the serous glands of the tongue and in the serous portions of the salivary glands; they occur also in the liver, the gastric and pyloric glands, sweat glands, lachrymal gland and bulbo-urethral gland. Various forms are shown in the right half of the diagram Fig. 48. They occur where two or more cells come together and consequently they are in relation with two or more terminal bars. In longitudinal sections the bars may be seen to extend downward along the canals. Through such intercellular canals the basal cells in a glandular epithelium may discharge their secretion into the central cavity, as shown in Fig. 48. *Intracellular* secretory canals, shown in the left half of Fig. 48, are less definite in outline, and are never in relation with terminal bars. They may be transient vacuoles opening at the surface. Sometimes they anastomose and form a network of canals within the cell. They have been observed, together with intercellular canals, in the sweat

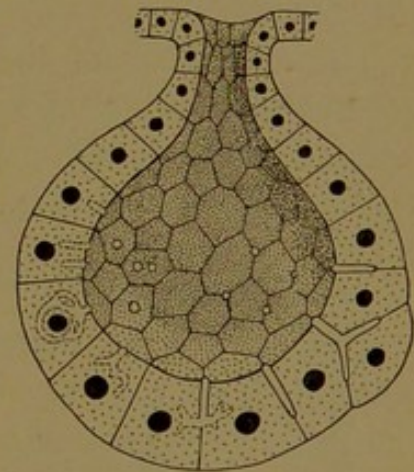


FIG. 48.—DIAGRAM OF A SIMPLE ALVEOLAR GLAND, SHOWING INTERCELLULAR SECRETORY CAPILLARIES OR CANALS ON THE RIGHT, AND INTRACELLULAR CANALS ON THE LEFT.

glands, the liver, and the gastric glands. There are apparently no secretory canals in any mucous gland, and they have not been found in the duodenal, intestinal, uterine and thyreoid glands, the kidney or the hypophysis.

The ducts have a clear-cut lumen and are typically lined with a very regular epithelium, showing distinct cell boundaries. The cells usually do not contain the rods, granules or vacuoles characteristic of secreting protoplasm, and the nuclei are not crowded to the base of the cells. In some cases, however, the ducts contain mucous cells, and in the salivary glands a specialized portion of the ducts is believed to discharge salts into the secretion as it passes through them. In such a gland (Fig. 47, D) the duct, as it leaves the end pieces, consists of simple flat epithelium. This *intercalated duct* gives place to the *secretory duct* which is lined with columnar epithelium, having basal rows of granules. The outer excretory portion consists of simple or stratified non-glandular epithelium.

The end pieces of the glands, as already noted, vary in shape from saccular to tubular. Usually a minute dissection or a reconstruction is necessary to determine what the shape may be. A round termination is called an *acinus* (Latin, a grape or berry) or an *alveolus* (Latin, a trough or tray). These terms are often used interchangeably. The elongated forms are called tubules.

During the development of the thyreoid gland the duct becomes obliterated, so that the secretion within the end pieces cannot escape. The end pieces become closed epithelial sacs, known as *follicles* (Latin, *folliculus*, a leather bag, shell, or husk). In addition to the material enclosed within the follicles, the thyreoid gland secretes substances which are taken up by the surrounding blood vessels and lymphatic vessels. Secretions of this sort are called *internal secretions*.

The *epithelioid glands* are masses or cords of cells which produce internal secretions only. They are never provided with a duct or lumen, although in some cases their cells arise from the wall of an epithelial tube. They are closely related to the glands with obliterated ducts.

Finally there are glands which produce cells and are therefore called *cytogenic glands*. These include the ovary and testis, which are epithelial structures consisting of follicles and tubules respectively. They produce the ova and spermatozoa. The other cytogenic glands are non-epithelial bodies which produce various forms of blood corpuscles. They will be considered in a later chapter.

The classification of glands, as presented in the preceding paragraphs, is summarized in the following table:

- I. *Epithelial glands, with persistent ducts, producing external secretions.*
 1. Unicellular glands.
 2. Simple glands.
 - a. Ectodermal, e.g., sweat and sebaceous glands.
 - b. Mesodermal, e.g., uterine glands.
 - c. Entodermal, e.g., gastric and intestinal glands.
 3. Compound glands.
 - a. Ectodermal, e.g., mammary and lachrymal glands.
 - b. Mesodermal, e.g., epididymis and kidney.
 - c. Entodermal, e.g., pancreas and liver.
- II. *Epithelial glands, with obliterated ducts, producing internal secretions.*
 - a. Ectodermal, anterior lobe of the hypophysis (the duct of the posterior lobe is partially obliterated).
 - b. Entodermal, thyroid gland.
- III. *Epithelioid glands, never having duct or lumen, producing internal secretions.*
 - a. Ectodermal (through their relation to the sympathetic nerves), chromaffin bodies; and medulla of the suprarenal gland.
 - b. Mesodermal, cortex of suprarenal gland; interstitial cells of the testis; corpus luteum.
 - c. Entodermal, islands of the pancreas; epithelioid bodies in relation with the thyroid gland; thymus (?)
- IV. *Cytogenic glands, producing cells.*
 - a. Mesodermal, *epithelial*—the ovary and testis.
 - b. Mesodermal, *mesenchymal*—the lymph glands, hæmolymph glands, spleen, red bone marrow, and many smaller lymphoid structures.

THE MESENCHYMAL TISSUES.

Mesenchyma (*mésos* middle, *ἐγχύμα*, an infusion) is a term introduced by O. Hertwig, in 1883, for the tissue produced by cells which have wandered out from the epithelial germ layers into the spaces between them. It is found only in young embryos. In the adult it is represented by a large group of derivatives, including connective tissue, adipose tissue, cartilage, bone, smooth muscle fibers, tendons, fasciæ, and various special forms of cells. Mesenchyma arises chiefly from different parts of the mesoderm, as already described (p. 42), but in the head of the chick embryo a portion of it comes from the ectoderm, and in the wall of the intestinal tube, according to Hertwig, the entoderm contributes to its formation. Together with the blood islands it constitutes the entire non-epithelial tissue of the embryo in early stages. It consists of a net-

work of branching cells, in the meshes of which there is a homogeneous, fluid, intercellular substance. The intercellular portion of the tissue becomes highly developed and variously modified.

Although typical epithelium and mesenchyma are radically different, as shown in Fig. 31, p. 42, there are conditions in which they are comparable. Thus dense mesenchyma, in which the cells are closely packed and have very little intercellular substance, resembles epithelium, and it may give rise to groups or cords of epithelioid cells. Moreover epithelium may resemble mesenchyma by forming a vacuolated syncytium, or as seen in Fig. 49, a branching protoplasmic network. In epithelium the intercellular spaces arise as vacuoles in the exoplasm, and the intercellular substance of mesenchyma may also be considered as occupying coalescent vacuoles.

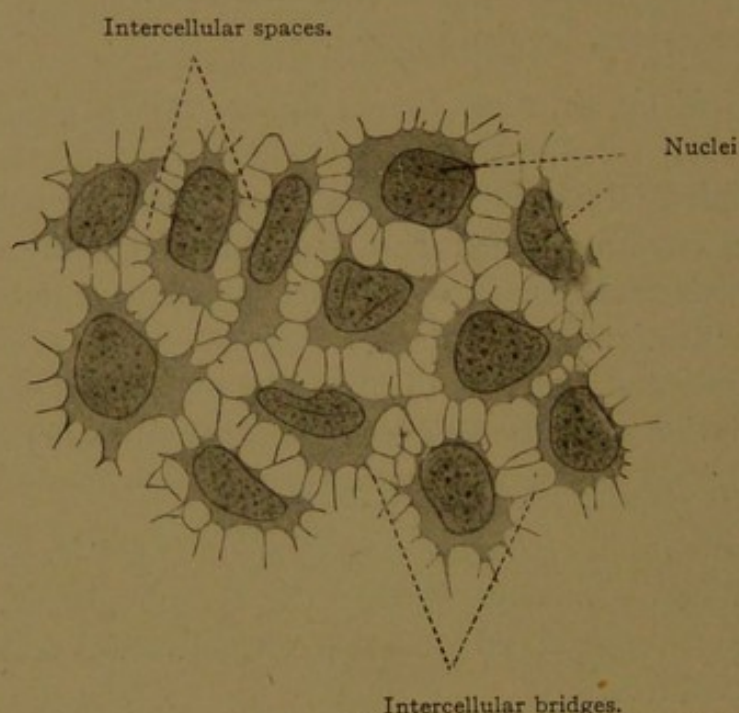


FIG. 49.—FLAT EPITHELIAL CELLS FROM THE BRANCHIAL PLATE OF A LARVAL SALAMANDER. $\times 300$

The tissue of the adult which most closely resembles mesenchyma is known as *reticular tissue*. It cannot, however, be regarded as an immature connective tissue, or a persistence of the primitive mesenchyma, since it arises rather late in embryonic development (*e.g.*, in the lymph glands which first appear in human embryos measuring about 45 mm., and in the œsophagus of embryos of 30 mm.). It is therefore considered to be a special form of connective tissue.

RETICULAR TISSUE.

Reticular tissue forms the framework of lymph glands, red bone marrow and the spleen; it occurs as a layer immediately beneath the epithelium of the digestive tract, and has been reported in many other organs. It consists of a network of cells in relation with an abundant

fluid intercellular substance (Fig. 50). The protoplasmic processes of the primitive mesenchyma have become transformed into flattened strands or slender fibers, which are clear and homogeneous, and anastomose freely. The cells associated with these fibers contain pale, flattened, oval nuclei, with few chromatin granules. In ordinary sections reticular tissue will be most readily recognized by the cells lodged in the fluid intercellular substance. These cells, which are chiefly lymphocytes, having round nuclei and a narrow rim of protoplasm, are often so abundant that the tissue appears as a dense cellular mass in which the framework of reticular tissue is almost completely hidden. Upon careful examination, however, some of its nuclei and fibers can always be detected.

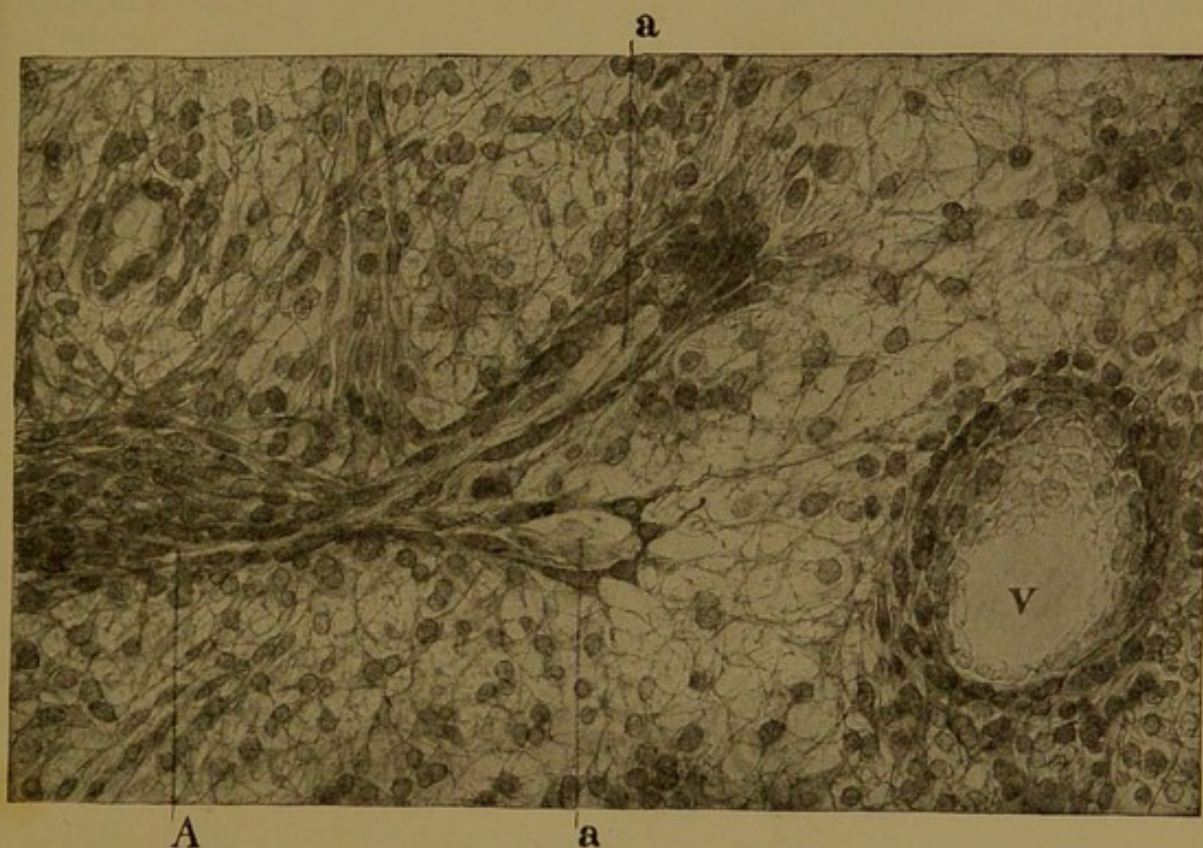

FIG. 50.—RETICULAR TISSUE SEEN IN A FROZEN SECTION OF A DOG'S SPLEEN WHICH HAD BEEN INJECTED WITH SILVER NITRATE. $\times 250$. (Mall.)
A, artery with its ampullae (a); V, vein.

In order to study reticular tissue advantageously, the lymphocytes and other forms of free cells should be disengaged from its meshes. This may be accomplished by shaking or brushing the sections; or by artificially digesting the specimen (which if properly done will destroy the cells, including those of the reticular tissue, but will leave the network of fibers); or by the following ingenious method devised by Mall. A piece of fresh spleen is distended by injecting gelatin into its substance; it is then frozen and sectioned. The sections are put in warm water, which dissolves out the gelatin, carrying the loose cells with it, and leaves areas of clear reticular tissue. Professor Mall has also shown how to wash out the

pulpy contents of the entire spleen, so as to leave the framework of connective and reticular tissue, which may be inflated and dried (Zeitschr. f. Morph., 1900, vol. 2, pp. 1-42). Such preparations give an idea of the intricacy of the reticular meshwork that can be obtained in no other way, and yet the finer ramifications have been destroyed by this process.

There has been considerable discussion as to whether the fibers of reticular tissue are chemically different from those of ordinary connective tissue. They differ from the elastic elements of connective tissue, since reticular fibers are dissolved by both acids and alkalis which leave the elastic fibers intact; and they are not destroyed by pancreatic digestion which causes the elastic fibers to disintegrate. But the differentiation of the reticular fibers from the "white fibers" of connective tissue has not been successfully accomplished. Mall has shown, however, that tendon, consisting largely of white fibers, is dissolved more readily by boiling in $\frac{1}{2}$ p.c. solutions of potassium hydrate or hydrochloric acid, respectively, than sections of lymph glands; and the name *reticulin* has been introduced for a constituent of the reticular fibers which does not yield gelatin on boiling. Reticulin is not generally recognized as an independent substance, and reticular tissue often appears to blend with white fibrous connective tissue.

The recognition of reticular tissue depends, therefore, on its form rather than on its chemical constitution.

MUCOUS TISSUE.

The substance of the umbilical cord is composed of *mucous tissue*. At birth it is a peculiar gelatinous mass of pearly luster, which has long been known anatomically as Wharton's jelly. During its development from mesenchyma, a large amount of mucus becomes deposited in its intercellular spaces. This mucus, like that produced in the goblet cells and that found in the cornea and vitreous body of the eye, is a translucent substance which contains *mucin*. Chemically there are many varieties of mucins. They are compound protein bodies containing a carbohydrate complex in their molecules, and are therefore known as glycoproteins. True mucins are formed in abundance in goblet cells and in mucous tissue; to a less extent they occur in all embryonic connective tissue. Related substances, called mucoids, have been obtained from tendon, cartilage and bone.

In the umbilical cord the mucus may be regarded as a secretion which is produced without the formation of special granules or vacuoles, and is discharged equally from all surfaces of the cells. It is a homogeneous ground-substance, in which extremely delicate fibrils are imbedded. These are gathered in wavy bundles (Fig. 51, a). Fibrils of the same sort, generally arranged in denser bundles, are found in ordinary connective tissue, and constitute the *white fibers*. Chemically they are said to consist of *collagen*, an albuminoid body which on boiling yields *gelatin*, the source of glue. The origin of the collagenous fibers has been the subject of repeated investigation. Henle (1841) considered that they arose in

the intercellular substance, apart from the cells, and Merkel defends this idea in the following passage, here somewhat abbreviated (Anat. Hefte, Abt. 1, 1909, vol. 38, pp. 323-392):

The mesenchymal syncytium secretes an amorphous gelatinous substance, which may be scanty (as in reticular tissue) or abundant (as in the umbilical cord). The fibers arise exclusively in this gelatinous substance; the cells take no direct part in the formation of the fibers but serve only for the production of the jelly. At their first appearance the fibers are not collagen, and generally they are not yet smooth and glistening like true connective tissue fibers. Instead they are granular, and not infrequently varicose. Later, though often very soon, they acquire the characteristic appearance of fully

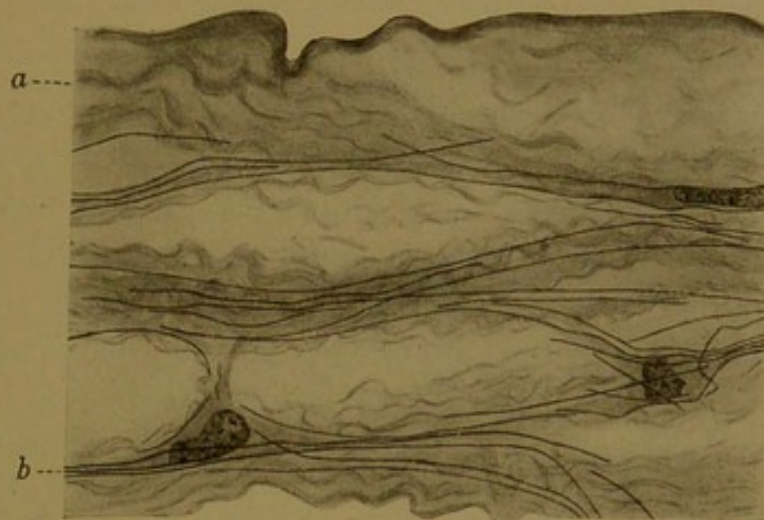


FIG. 51.—MUCOUS TISSUE OF THE HUMAN UMBILICAL CORD, STAINED WITH PHOSPHO-TUNGSTIC ACID HÆMATOXYLIN. (Mallory.)
a, White fiber. b, fibroglia.

formed connective tissue fibers. They may arise as a very delicate network, which, through the breaking down of the least utilized threads, becomes transformed into smooth and unbranched fibers. But in places where from the first there is a decided stretching, as in tendon, parallel unbranched fibers are formed directly. Professor Heiderich has shown me preparations of a mucin, in which, by the addition of acid, structures were formed which were strikingly similar to developing connective tissue—without any stretching, nets with round meshes; but with the slightest traction, long fibers isolated from one another. Thus connective tissue fibers are merely the effects of mechanical conditions upon the gelatinous intercellular substance.

A very different idea of the origin of the white fibers is that of Flemming, recently further elaborated by Meves (Arch. f. mikr. Anat., 1910, vol. 75, pp. 149-208), according to whom the fibers arise within the cytoplasm. By special methods Meves has demonstrated coarse filaments, which he names *chondrioconta*, within the protoplasm of both epithelium and mesenchyma. These granule-rods or *chondrioconta* (probably comparable with the mitochondria of gland cells) are regarded as a part of the fundamental protoplasmic network or spongioplasm. If they are short they are called *chondriosomes*. Meves describes the development of white fibers as follows:

Connective tissue fibrils are produced from the chondrioconta which come to lie at the surface of the cell. They then change their chemical constitution and are no longer stained by iron hæmatoxylin or fuchsin. At this stage those which are in a row unite end to end. Thus in the formation of a fibril numerous cells take part, each producing a section. The fibrils again change their chemical constitution and become intensely stained by the collagen stains. Finally they become free from the cells and lie in the intercellular spaces. From the time of their first formation they have a wavy course, which may become more marked later. This clearly means that the connective tissue fibers have grown in length more than the surrounding elements. They increase also in diameter through independent growth, and for a time new fibers are produced by the cells. . . . I differ with Flemming since I consider that connective tissue fibers are not formed within the cell body but are produced at the cell surface (by transformation of the chondrioconta); I agree with him in deriving them from the cytoplasmic-filaments.

The umbilical cord has long been regarded as a particularly favorable object for the study of white fibers, but the way in which they arise remains undetermined. In addition to these white fibers, the umbilical cord contains stiff fibers of a different nature, found at the periphery of the cells. They are similar to the fibers of a tissue which forms the framework for the branching nerve cells, thus binding them together, and accordingly named *neuroglia* (νεῦρον, nerve, γλία, glue). Fibers similar to those of the neuroglia, found at the periphery of muscle cells, are called *border fibrils* or *myoglia*. In 1903 Mallory described similar border fibrils in connective tissue and named them *fibroglia*. They are seen at the periphery of the cells in the umbilical cord (Fig. 51, b). Mallory describes them as follows (Journ. Med. Res., 1905, vol. 13, pp. 113-136):

Neuroglia, myoglia and fibroglia fibrils morphologically and in certain staining reactions more or less closely resemble one another. They touch or form part of the periphery of the cell protoplasm, but continue away from the cell in two directions, *i.e.*, they do not begin or end in the cell which produces them. How far the fibroglia are accompanied by protoplasmic processes cannot be determined. The number of these fibrils to a cell is not constant, but it is usually in the neighborhood of a dozen.

Professor Mallory has found no transitions between the fibroglia and the white fibers. Meves likewise considers them as entirely distinct, and states that the production of white fibers by the cells of the umbilical cord terminates by the fifth month. The fibroglia are present at birth, and probably no tissue is more favorable for their study than the umbilical cord at term.

In addition to the mucous matrix, the white fibers, and the fibroglia, mucous tissue contains cells and intercellular spaces. The cells, at first stellate with many anastomoses, become elongated and more or less disconnected from one another. Three of their nuclei are shown in Fig. 51, but their cytoplasm forms a thin layer, the limits of which can scarcely be determined. The intercellular spaces contain a fluid through which

cells may migrate. There are no capillaries, lymphatic vessels, or nerves within the mucous tissue of the umbilical cord, and no elastic fibers. The three large blood vessels which pass through the cord, and the tissue in their walls, will be considered later.

CONNECTIVE TISSUE.

Connective tissue occurs in various forms. Dense connective tissue is a tough fibrous substance, such as that part of the skin from which leather is made; and loose connective tissue, or *areolar tissue*, is a spongy cobweb of delicate filaments, such as occurs between the muscles. Both forms when fresh are very white, and they are composed of similar fibers. A small mass of fresh connective tissue, subcutaneous or inter-muscular, may be spread out with needles upon a slide, thus forming a thin film. After adding a drop of water and applying a cover glass, it will present



FIG. 52.—SUBCUTANEOUS TISSUE FROM A CAT.

The fiber *a* has been treated with dilute acetic acid; the other fibers have been teased apart and examined, unstained, in water. *a*, *c*, White fibers; *b*, fat cell; *d*, connective tissue cell; *e*, elastic fibers.

such an appearance as shown in Fig. 52. The bulk of the tissue is seen to consist of white or collagenous fibers felted together (Fig. 52, *c*). They are the same in origin and structure as those already described in the mucous tissue of the umbilical cord, but in ordinary connective tissue their fibrils are gathered into denser bundles. Each bundle or *fiber* is composed of exceedingly minute *fibrils*, bound together by a small amount of cement substance. The addition of picric acid causes the fibers to separate into their constituent elements. Often a bundle of fibrils turns aside from the main trunk, so that the fiber branches, but the fibrils themselves are unbranched.

Upon the addition of dilute acetic acid the white fibers swell and disintegrate, some of them passing through the condition shown in Fig. 52, *a*. Such fibers show a succession of constrictions at places where they are encircled by rings or spiral bands of a refractive substance not affected

by the acid. These rings have been observed by Ranvier in living connective tissue fibers, and it is therefore improbable that they are remnants of a sheath which surrounded the entire fiber, as some have thought. They are probably formed of elastic substance.

In addition to the white or collagenous fibers, connective tissue contains fibers of a second sort, known as *elastic fibers*. They are absent from corneal tissue, the mucous tissue of the umbilical cord and generally, though not always, from reticular tissue. Since they develop later than the white fibers, they are not found in young connective tissue; but other-

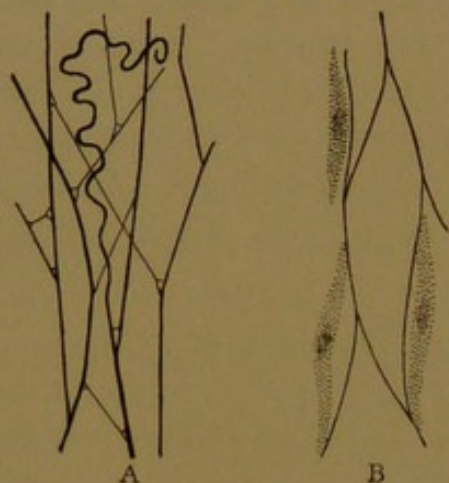


FIG. 53.

A, Elastic fibers of the subcutaneous areolar tissue of a rabbit. (After Schäfer.)
B, Cells in relation with elastic fibers, after treatment with acetic acid. Subcutaneous tissue of a pig embryo. (After Mall.)

wise they are present, though varying greatly in abundance, in all forms of connective tissue. They are not destroyed by dilute acids or alkalies, and are described as composed of *elastin*, an albuminoid body which does not yield gelatin on boiling. Unlike the white fibers they are not composed of smaller elements or fibrils, but each fiber is a structureless homogeneous thread. In favorable cases, however, an enveloping sheath may be seen. In tissue which has not been torn apart the elastic fibers form a net (Fig. 53, A). The fibers meet and fuse with one another; and across the angles thus formed, one or two

delicate strands are commonly to be found. When the tissue is pulled apart so that the net is broken, the fibers kink and recoil like tense wires (Fig. 52, e).

The origin of the elastic fibers has not been determined. They have been said to arise within the cells by the fusion of granules of elastin. Mall's idea of their exoplasmic origin is illustrated by their relation to the cells in Fig. 53, B. Others consider that they are formed from the intercellular substance.

Although elastic fibers are clearly seen in fresh connective tissue, they are often invisible in specimens stained with hæmatoxylin and eosin. In order to determine their presence, sections may be stained with resorcin-fuchsin, which leaves the white fibers nearly colorless, but makes the elastic fibers dark purple; or other special stains may be used. In some situations, however, the elastic tissue is highly developed and may be seen with any stain. This is true of the fenestrated membranes found in many blood vessels. A fenestrated membrane is a network of elastic fibers in which the fibers are so broad that they appear to form a perforated plate (Fig. 54, A). The greatest development of elastic tissue probably occurs in the ligament of the neck in grazing animals, which consists

of very coarse elastic fibers with very little white fiber. It is therefore commonly used for the histological and chemical study of elastic tissue (Fig. 54, B and C). In man the stylohyoid ligament and the *ligamenta flava* are of this class, and they exhibit the yellowish color which is characteristic of elastic tissue. Elastic fibers are found also in the ground substance of certain cartilages, which will be described later.

Connective Tissue Cells. In addition to white collagenous fibers and yellow elastic fibers, connective tissue contains cells and intercellular spaces. The cells which produce fibers are known as *fibroblasts* ($\beta\lambda\alpha\sigma\tau\acute{o}\varsigma$, a bud, is used in many terms to indicate a formative cell, with a prefix which usually designates the structure which it produces). Actively

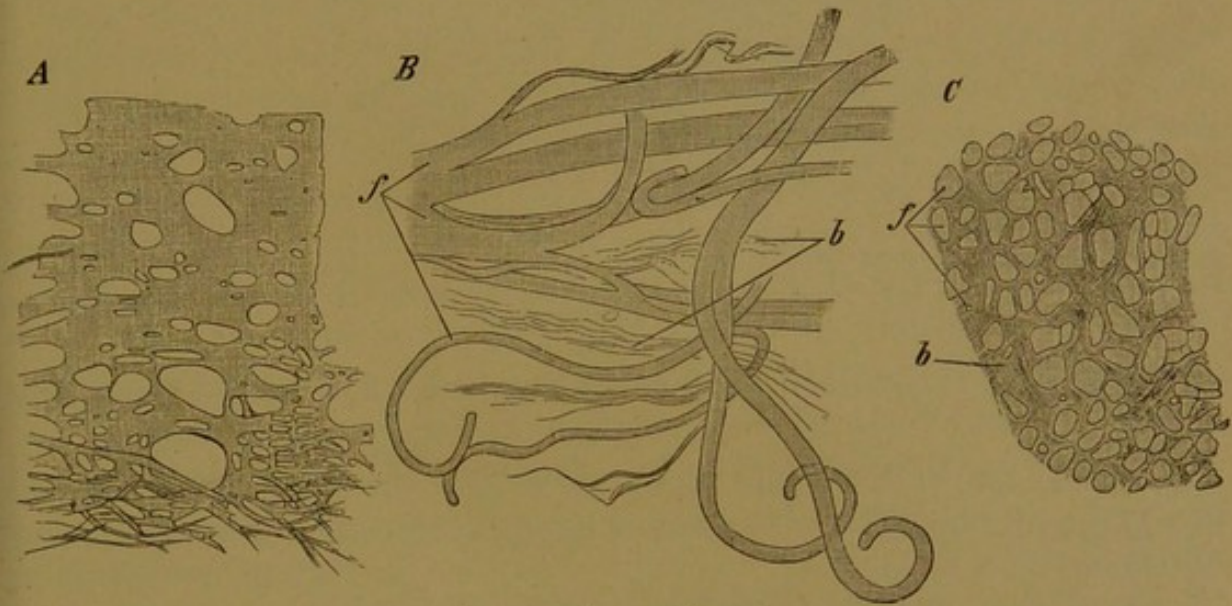


FIG. 54.—ELASTIC FIBERS.

A, Network of thick elastic fibers below, passing into a fenestrated membrane above. From the human endocardium. B, Thick elastic fibers (f) from the ligamentum nuchae of the ox; b, white fibers. C, Cross section of the ligamentum nuchae, lettered as in B.

growing fibroblasts, both in the embryo and in the adult, exhibit fibroglia fibrils at their borders, but in mature connective tissue these fibrils are seldom found. The cells of fully formed connective tissue are generally flattened or lamellar, consisting of a thin pale layer of almost homogeneous protoplasm, which is sometimes vacuolated. Such cells when seen on edge are spindle-shaped. They may be spread out in flat layers, retaining the protoplasmic connections characteristic of mesenchyma, as seen in the mesentery (Fig. 55, c). In dense connective tissue the cells also exhibit broad thin protoplasmic processes (Fig. 56, c), but they have become more or less detached from one another. The cells are bent to conform with the adjacent fibers, to which they are closely applied, and along which, in living tissue, they have been observed to migrate. The nuclei of these cells are elliptical on surface view, and rod-shaped when seen on edge. They contain fine chromatin granules, and sometimes a small but distinct nucleolus. Occasionally the nuclei are indented on one side. The centro-

some, in a clear area of protoplasm, has been found close beside the nucleus. In ordinary specimens, stained with hæmatoxylin and eosin, the centrosome is not seen, and the entire cytoplasm is quite inconspicuous;

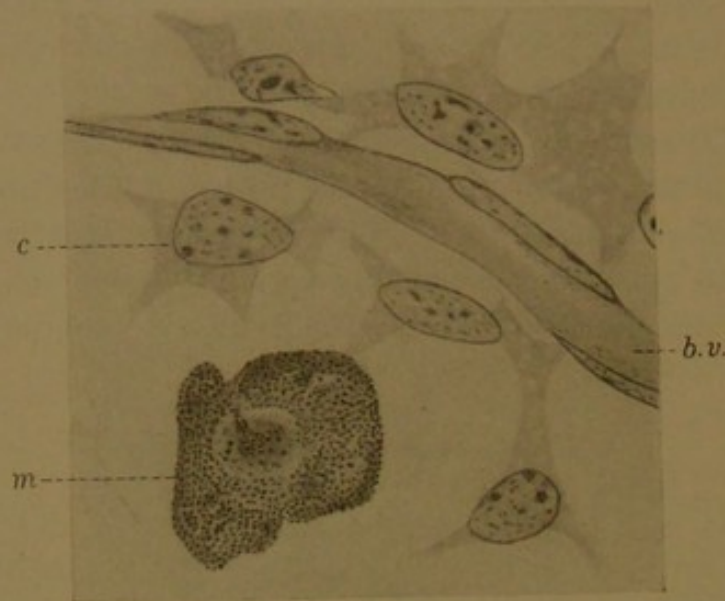


FIG. 55.—CONNECTIVE TISSUE CELLS (c) AND A MAST CELL (m) FROM THE MESENTERY OF A RAT. $\times 1000$; b.v. a small blood vessel lined with endothelial cells. The specimen was fixed in alcohol and stained with Unna's methylene blue.

but the nuclei stand out prominently along the edges of the fibers (Fig. 56, x).

Cells in connective tissue which differ from the fibroblasts by having abundant protoplasm in the form of large round cell bodies, were named

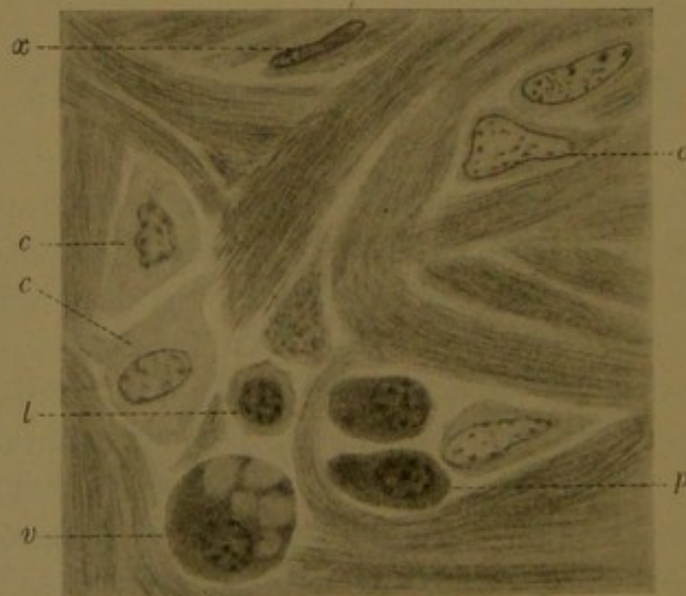


FIG. 56.—CONNECTIVE TISSUE CELLS (c) A LYMPHOCYTE (l) AND PLASMA CELLS (p) FROM A LACTATING HUMAN BREAST. $\times 1000$.

A vacuolated plasma cell is shown at v, and a connective tissue cell on edge is seen at x.

plasma cells by Waldeyer (Arch. f. mikr. Anat., 1875, vol. 11, pp. 176-194). He stated that they develop from connective tissue cells, and are always arranged about the blood vessels. Two years later, in the same

journal, Ehrlich published the first of his far-reaching investigations on the effects of various anilin dyes upon protoplasm. He showed that the plasma cells found near the vessels in the mesentery of the rat, when stained with basic dyes, exhibit very coarsely granular protoplasm (Fig. 55, m). Further studies led him to separate these *granular* cells from the other forms of plasma cells. He was inclined to believe that they arose from over-nourished connective tissue cells, and accordingly named them *mast cells* (Mastzellen), referring to the mast or acorns on which animals are fattened (Arch. f. Physiol., 1879, pp. 166-171). In another communication in the same volume (pp. 571-579), he introduced a further subdivision of cells which may be alike in form but which react differently to the anilin dyes. In contrast with the basic granules of the mast cells, which are not stained with the acid dye *eosin*, he found other granules which stain deeply with eosin but do not respond to the basic dyes. These granules are now generally known as eosinophilic, and the cells which contain them are called *eosinophiles*. Mast cell granules are often referred to as basophilic, but since some confusion results from calling the entire cells basophiles, they are still known as mast cells. Cells of both classes are found in the circulating blood, and will be described with the blood corpuscles; both kinds are found also in the intercellular spaces of connective tissue. It is known that various forms of blood corpuscles develop in the reticular tissue of lymph glands and bone marrow, from which they enter the blood vessels; and it is also very evident that cells leave the vessels and enter the intercellular spaces of connective tissue. There has been endless discussion as to whether the eosinophiles of connective tissue and blood are the same sort of cell; and also whether the "mast leucocytes" in the vessels and the mast cells in the surrounding tissue are identical. Maximow states that there is no genetic relation between mast cells and mast leucocytes in the adult, but "whether in embryonic life they are likewise independent is still undecided." As to the eosinophiles, he says: Those found in the connective tissue are generally eosinophilic corpuscles which have emigrated from the vessels. "Any proof of a local origin in connective tissue is lacking." But Weidenreich considers that eosinophilic granules are derived from broken-down red corpuscles, which are taken up by white blood corpuscles and by connective tissue cells, both of which become thereby eosinophilic.

In ordinary sections of connective tissue, stained with hæmatoxylin and eosin, eosinophiles are seldom overlooked, because of the brilliant color of their granules. Mast cells, however, should be sought for in tissue preserved either in formalin or alcohol, and stained with Unna's polychrome methylene blue or some other basic dye. The preparation shown in Fig. 55 is a portion of the mesentery preserved by being tied across the end of a short glass tube and immersed in alcohol. The tissue

was then stained with methylene blue, and mounted without being sectioned. Most of it is colored pale blue, but the granules of the mast cells are deep purple. Such granules, which assume a color different from that of the stain employed, are called by Ehrlich *metachromatic*. The granules of mast cells are so coarse that in favorable places, when examined with an immersion lens, they can readily be counted. They spread over and obscure the nucleus, which appears as a pale central area.

Mast cells and eosinophiles were removed by Ehrlich from the miscellaneous group of plasma cells described by Waldeyer. Another type of cell was discovered in syphilitic connective tissue by Cajal, and independently described in tuberculous tissue by Unna (*Monatsch. f. prakt. Dermatol.*, 1891, vol. 12, pp. 296-317). He states that these cells (to which the name *plasma cells* has come to be restricted) arise from normal connective tissue cells by the increase and rounding off of the cell body. As described by Unna, the granulation of the protoplasm is so fine that even with the highest magnification the individual granules cannot be distinctly recognized as such.

Typical plasma cells are shown in Fig. 56, p. They usually have very round nuclei with characteristic coarse masses of deeply staining chromatin. These masses may appear as wedge-shaped bodies with their broad ends against the nuclear membrane so that they resemble the spokes of a wheel ("Radkern"); or the chromatin blocks may suggest the squares of a checker-board. The nucleus occupies an eccentric position in the mass of dense and deeply staining protoplasm. Specific granulation, such as occurs in mast cells and eosinophiles, is absent. In certain plasma cells, vacuoles are seen (Fig. 56, v) which contain a "homogeneous, semifluid, colloid-like substance which has a strong affinity for acid dyes." If the affinity for such dyes has become well marked, these vacuoles form conspicuous structures, known as Russel's bodies. Usually they are regarded as degenerative products, but some investigators consider them as secretions.

Associated with plasma cells, *lymphocytes* are often found (Fig. 56, l). These cells constitute an important class of white blood corpuscles or leucocytes. They differ from plasma cells in having only a small rim of pale protoplasm about the nucleus, but the nuclei of these two sorts of cells are very similar. Although Ehrlich (1904) agreed with Unna that only one source for the plasma cells had been established, "namely, an origin from hypertrophied connective tissue cells," many authorities now believe that they develop from lymphoid cells or lymphocytes. Councilman expresses this opinion as follows (*Journ. Exp. Med.*, 1898, vol. 3, pp. 393-420):

As to their origin I hold the same opinion as Marschalkó, that they are derived from lymphocytes. In the kidney they enter into the interstitial tissue by emigration from

the blood vessels. They may emigrate from the vessels as plasma cells, or they may be formed from emigrated lymphoid cells. They have been seen in the act of emigration and the shapes of many of the cells in the interstitial tissue can leave no doubt as to their amœboid character. We are led to the belief that the plasma cells have their origin in the lymphoid cells from the similarity of their nuclei to those of lymphoid cells and from the presence of transitional forms.

Downey (*Folia hæmat.*, 1911, vol. 11, pp. 275-314) supplies a useful review of the literature of plasma cells, and expresses his opinion that they arise from several sources.

Plasma cells are found in connection with chronic inflammation of many sorts. They occur normally in abundance in the mucous membrane of the digestive tube from the stomach to the rectum, and they may be seen in bone marrow and in the lymphoid organs. Occasional plasma cells may be expected in subcutaneous tissue and in the breast.

Reviewing the preceding paragraphs it is seen that connective tissue contains fibroblasts or connective tissue cells, and that mast cells, eosinophilic cells, plasma cells and lymphocytes may be lodged in the intercellular spaces. Except the plasma cells, which probably develop from lymphocytes, these are all comparable with forms of blood corpuscles normally found within the vessels. The source of these corpuscles will be further considered with the blood, together with other forms which sometimes leave the vessels but which are never regarded as constituents of connective tissue.

In the connective tissue of amphibia and mammals, Ranvier described certain slender branched cells which he named *clasmatocytes* (*Arch. d'Anat. micr.*, 1900, vol. 3, pp. 122-139). This term refers to the detachment of portions of their processes, which Ranvier believed took place normally as a method of discharging a secretion. The breaking down was observed chiefly in amphibian cells which are now considered to be mast cells. Like other mast cells they are prone to distintegrate. The cells in mammals, to which Ranvier referred, are regarded by Maximow as derived from wandering lymphocytes. He believes that these may send out several processes, or become spindle-shaped, thus producing "clasmatocytes," but since this name is inappropriate he calls them resting wandering-cells. He finds that they contain a limited number of vacuoles and coarse granules, but the granules are said to differ from those of mast cells (*Arch. f. mikr. Anat.*, 1906, vol. 67, pp. 680-757). The significance of these cells is uncertain.

Connective tissue contains two additional types of cells, which are so distinct that they may be regarded as separate tissues. These are the pigment cells and the fat cells; the latter will be described as adipose tissue.

Pigment cells. The color of the various tissues is due to pigments, which may be in solution, like the hæmoglobin in red blood corpuscles and the lipochromes in fat; or they may occur as granules imbedded in the protoplasm. The granules, which are yellow, brown, or black, often

retain their natural color in stained specimens. They are said to consist of "melanin," which represents an ill-defined group of substances, some of which are hæmoglobin derivatives. In the lung, inhaled soot is taken into the protoplasm of certain cells which thus become pigmented with extraneous material. Pigment granules are widely distributed, and may be found in the liver, spleen, heart, brain, and other organs.

In certain situations, pigment is extensively developed in branched connective tissue cells such as are shown in Fig. 57, A. In man these are of limited occurrence, being found near the eye, and in the pia mater, especially under the medulla oblongata and upper portion of the spinal cord. Weidenreich con-

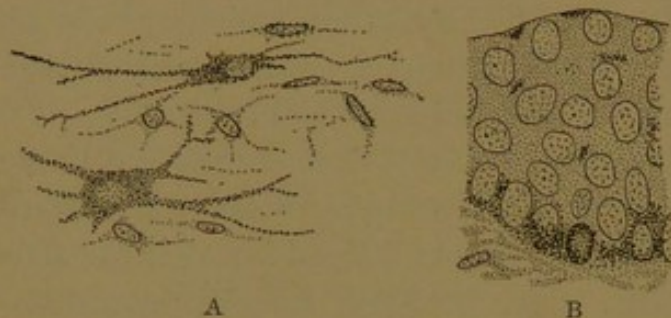


FIG. 57.—A, Two pigment cells from the deep, peripheral part of the cornea of the rabbit. B, Pigmented epithelium from the conjunctiva of the guinea-pig. The pigment is chiefly in the basal layer.

siders that this represents the remains of a general pigmented sheath for the entire nervous system. In lower vertebrates branching pigment cells are often abundant in the subcutaneous tissue, and changes in color, such as occur in frogs, are due to the extension or retraction of these processes.

Such pigmented connective tissue cells are called chromatophores or *chromatocytes*. But in the human skin the pigment granules are in the epidermis, chiefly in the basal layers. In the stratified epithelium of the conjunctiva of the eye, toward the cornea, numerous pigment granules are found in the basal layers, and scattered groups occur also in the outer layers, as shown in Fig. 57, B. Pigment in this situation occurs frequently in the Caucasian race, and regularly in the other human races. Simple epithelium may be densely pigmented, as in the external epithelium of the retina. Thus it is seen that pigment cells are by no means limited to connective tissue.

ADIPOSE TISSUE.

If in a freshly killed animal a loop of intestine is drawn out of the abdominal cavity, the blood vessels ramifying in its mesentery will be seen to be imbedded in a band of fat, which branches when the vessels branch, and diminishes in width toward the intestine as the vessels become small. The close relation between the distribution of fat and the course of the vessels is notable also in sections. Fat cells occur in groups or lobules around the vessels, and are found, with few exceptions, wherever there is loose connective tissue. They may also occur singly, as in some parts of the denser connective tissue of the breast.

When examined fresh, each fat cell appears as a large round oil-drop, which is more or less compressed into a polyhedral shape by the surrounding cells. It is highly refractive, having a border which becomes alternately bright and dark on changing the focus. The liquid fat or oil which fills the cell, leaving only an imperceptible film of protoplasm around it, may escape by the rupture of the membrane, thus forming smaller drops. In the specimen shown in Fig. 52 the fat was seen coming out from the upper surface of one of the cells, and the droplets thus emerging ran together forming larger ones. As fat cells develop, a coalescence of small drops occurs in the protoplasm.

The earliest formation of adipose tissue is said to occur in human embryos of the fourth month. It may be studied advantageously in the subcutaneous tissue of embryos of the fifth month (Fig. 58). In such specimens there are areas of loose and very vascular mesenchyma, found at the level of the roots of the hairs, in which certain cells exhibit vacuoles. These cells are at first quite like the surrounding fibroblasts,

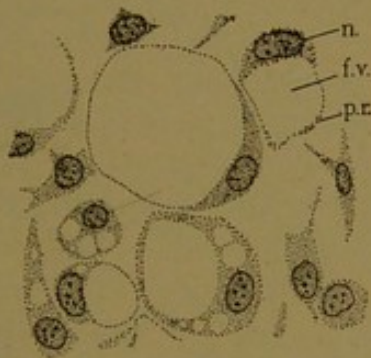


FIG. 58.—SUBCUTANEOUS FAT CELLS FROM A HUMAN EMBRYO OF THE FIFTH MONTH. $\times 520$.
n Nucleus; f.v., fat vacuole; p. r., protoplasmic rim.

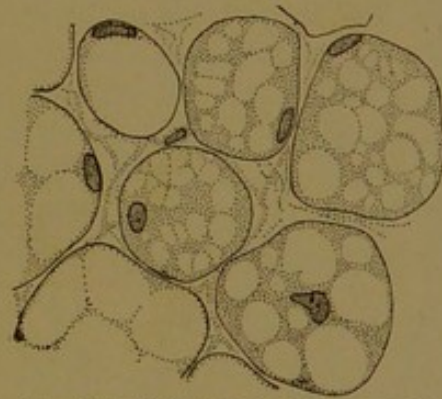


FIG. 59.—FAT CELLS FROM NEAR THE KIDNEY OF A NEW-BORN CHILD. $\times 520$.

being fusiform or stellate. Their protoplasm contains several small vacuoles, some of which unite to form one large drop, and the nucleus together with the greater part of the protoplasm, is pushed to one side (Fig. 58, n). Sections of such cells have the form of "signet rings." Frequently small vacuoles are seen in the accumulation of protoplasm beside the nucleus. With further development the fat droplet becomes so large that the protoplasmic rim appears as a mere line or membrane, just within which is the greatly flattened nucleus. During the formation of the fat cells, the branching processes become very short, but it is doubtful whether they are altogether lost.

For some years after birth fat cells containing several vacuoles are found in certain situations, as around the kidney (Fig. 59) and in the outer layer of the œsophagus. Usually these are regarded as immature forms.

Adipose tissue of the adult, when well preserved, presents cells of

rounded form as shown in Fig. 60; often, however, their thin walls are bent or collapsed. If the sections are thick, a network of a different pattern, representing another layer of cells, will come into view on changing the focus. The nuclei of the fat cells are pale oval bodies, with finely granular chromatin (Fig. 60, *n*), often containing one or two small vacuoles. The protoplasm around the nucleus forms such a thin layer that it is scarcely appreciable on surface view. Both nucleus and protoplasm are much darker when seen on edge, since a thicker layer of substance is thus presented. When sectioned in this position the nuclei within the cells must be carefully distinguished from those of the connective tissue just outside. Many of the fat cells will show no nuclei, since the entire cell is usually not included within the limits of one section.

In extreme emaciation, the fat cells become small and the protoplasmic rim thickens, so that the cells again assume the signet-ring form. A

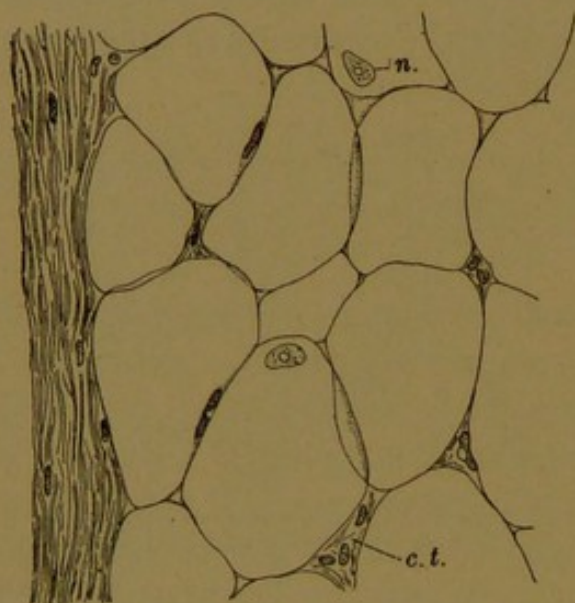


FIG. 60.—NORMAL ADIPOSE TISSUE FROM AN ADULT. $\times 400$.

Connective tissue is seen at the left of the figure and (as at *c. t.*) between the fat cells; *n*, nucleus of a fat cell.

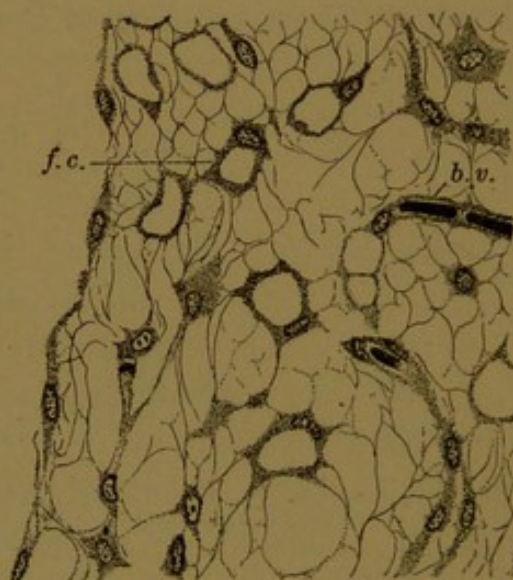


FIG. 61.—FAT CELLS FROM THE OMENTUM IN A CASE OF EXTREME EMACIATION. $\times 520$.

b. v., blood vessel; *f. c.*, fat cell.

delicate reticulum appears between the shrunken cells as shown in Fig. 61. Some of the fibers proceed directly from the fat cells, indicating that the processes have never wholly disappeared. Others come from the fibroblasts which from the first are scattered among the fat cells.

The great difference between the appearance of fresh fat cells and those seen in sections is due to the fact that fat is dissolved by the reagents ordinarily used in preserving the tissue. Thus the sections usually show empty vacuoles and no fat whatever. Occasionally, as a result of cooling, the fat has formed insoluble crystals in the shape of radiating needles, and these, or an amorphous precipitate which takes a bluish stain with hæmatoxylin, may be seen within the cells. Although fat is the commonest substance to be found within the vacuoles in human

tissues, it is not the only material which may have filled them, and therefore to demonstrate the presence of fat, special methods must be employed. Fresh tissue may be preserved in osmic acid, which blackens not only fat but some related substances; or frozen sections of tissue may be stained with Sudan III or Scharlach R, which color fat droplets red and demonstrate them even when minute. These stains may also be used after preservation of the tissue in formalin. It may be noted that Sudan III has been fed to animals, thus imparting a pink color to the living adipose tissue. If the animal is lactating, the fat globules in the milk also become pink.

Fat vacuoles occur in many sorts of cells which do not belong to adipose tissue, such as the cells of the liver, cartilage, and striated muscle. These cells are not called fat cells, even if their protoplasm contains many vacuoles, and they do not resemble the cells of adipose tissue.

Since fat cells occur in lobular masses in definite places, as under the skin, around the kidney, in the bone marrow, etc., and since they supply the body with nutriment, it has been proposed to regard them as constituting glandular organs. They receive fat from the adjacent vessels and store it, or quite possibly they absorb carbohydrates and convert them into fats. The formation of fat has been said to begin in or near the nucleus with the production of granules, but the part which the nucleus plays is uncertain. The small vacuoles often seen within it apparently arise after the cell is full of fat. Mast cells have often been found associated with fat cells and it has been supposed that they contained secretory granules which were concerned with fat production. Like an internal secretion, fat is taken from the cells into the vessels and distributed over the body.

TENDON.

Tendons consist essentially of very dense connective tissue. They are composed almost wholly of parallel white or collagenous fibrils, com-

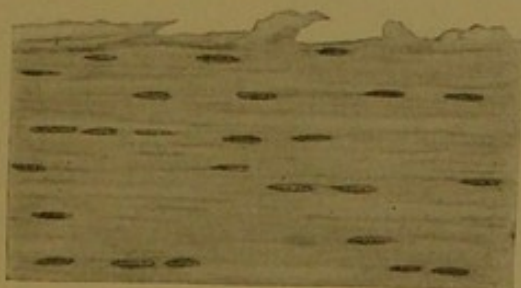


FIG. 62.—LONGITUDINAL SECTION OF THE TENDON OF THE FLEXOR LONGUS DIGITORUM. X 160.

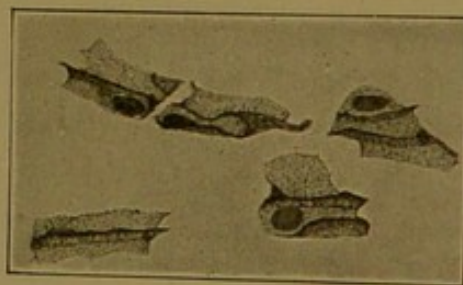


FIG. 63.—TENDON CELLS FROM THE TAIL OF A RAT. STAINED WITH METHYLENE BLUE, INTRA VITAM. (Huber.)

pactly bound together in bundles. The cementing matrix contains *tendomucoid*. Closely applied to the bundles are the tendon cells which produced them. In ordinary longitudinal sections of tendon, the protoplasm of the cells is indistinct or imperceptible, but the nuclei appear in rows as seen in Fig. 62. In special preparations, particularly in those of the

delicate tendons found in the tail of a rat or mouse (Fig. 63), it is seen that the cytoplasm of tendon cells forms a plate-like layer which is folded about the fiber bundles, tending to encircle them. Moreover the cells

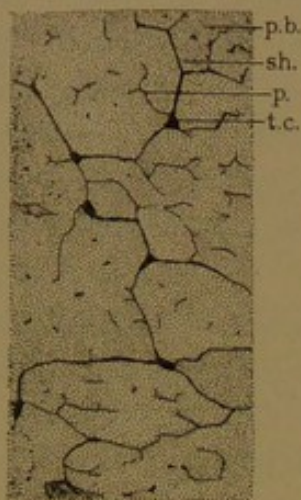


FIG. 64.—FROM THE CALCANEAN TENDON (TENDO ACHILLIS) OF A RABBIT. (After Prenant.)

p. b., Primary bundle bounded by a cytoplasmic sheath, sh., which extends from a tendon cell, t.c. p., process extending into a primary bundle. The entire figure is a portion of a secondary bundle.

are provided with lamellar or wing-like projections, which extend out between adjacent fiber bundles. Apparently there are protoplasmic connections, end to end, between the cells, which thus form longitudinal rows or chains; and in cross sections of the tendon some of the wing-like projections anastomose as seen in Fig. 64. Thus, as in connective tissue, the original syncytial arrangement of the mesenchyma is partially preserved.

The primary tendon bundles, which consist chiefly of white fibers and tendon cells, contain also a small amount of elastic tissue in the form of fine, wide-meshed networks. The elastic fibers are said to occur especially near the cells and their processes. The primary bundles are generally grouped in secondary bundles or fasciculi, which are bounded by partitions or septa of looser connective tissue (Fig. 65). Within the septa there are nerves and blood vessels, in relatively small number. Lymphatic vessels are said to be

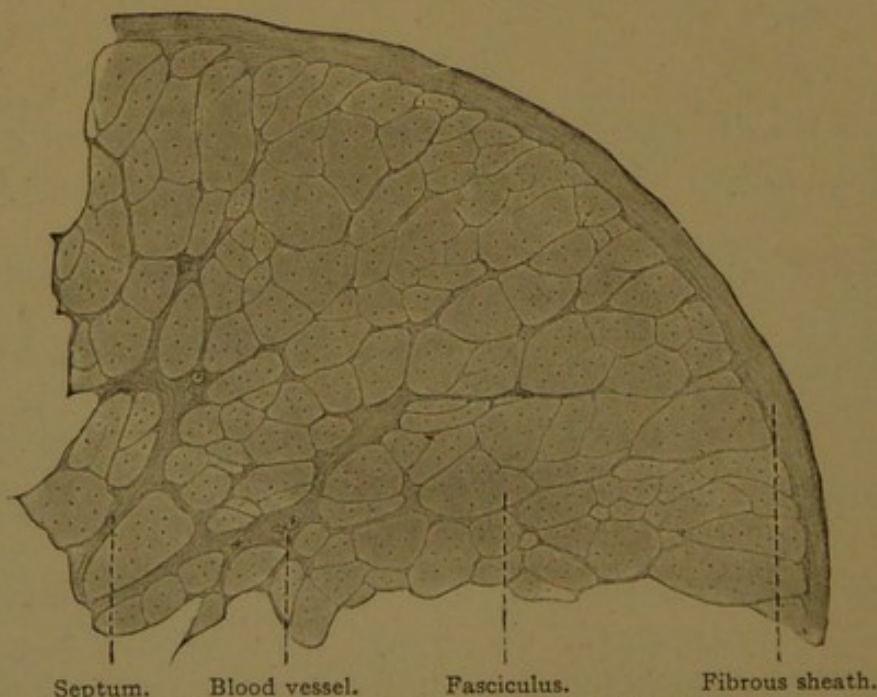


FIG. 65.—FROM A CROSS SECTION OF A TENDON FROM AN ADULT MAN. $\times 40$.

confined to the sheath of connective tissue which surrounds the entire tendon, with which the septa are continuous (Fig. 65).

The fibrous sheath or *vagina fibrosa*, which surrounds the tendon,

may contain a cavity filled with fluid. It is then called a mucous sheath or *vagina mucosa*. The cavity arises as a cleft in the embryonic connective tissue and its walls are formed of mesenchymal epithelium. The cells have become flattened and the fibers felted together to bound the space. It contains a fluid like that of the joint cavities, being chiefly water and a mucoid substance which renders it viscid, together with protein material and salts. The function of the mucous sheath is to facilitate the movements of the tendon. By its formation the tendon is freed from the local connection with surrounding tissue, and the sheath generally occurs where such connection would especially interfere with motion. The *mucous bursæ* are similar structures in relation with muscles or bones. The joint cavities, to be described later, belong in the same class, having a similar origin and function.

Aponeuroses, fasciæ and ligaments are connective tissue formations, resembling tendon in possessing a more or less regular arrangement of cells and fibers. Elastic elements may be abundant.

CARTILAGE.

Cartilage is a mesenchymal derivative, the development of which it is difficult to follow, since at certain stages its nuclei are so crowded that they obscure the transformation of the intercellular substance. Two

interpretations of its development are illustrated in Fig. 66, A and B. As represented in A, the mesenchymal cells multiply and come together so that the intercellular spaces are obliterated. Thus *pre-cartilage* is formed, consisting of large closely adjacent cells, separated from one another by thin walls which stain red with eosin. This type of pre-cartilage has been frequently described in the lower verte-

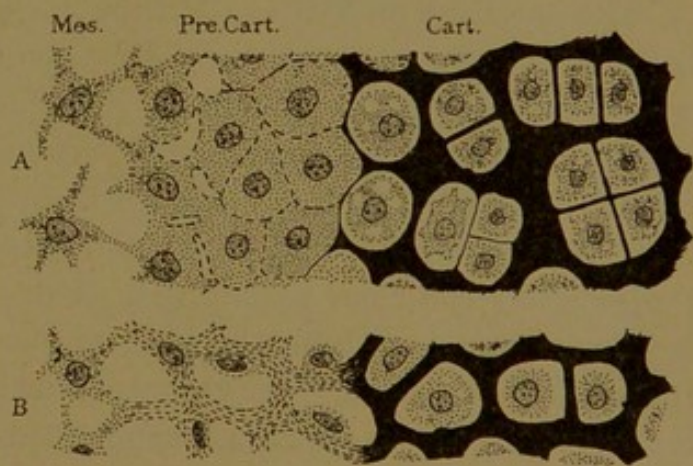


FIG. 66.—DIAGRAMS OF THE DEVELOPMENT OF CARTILAGE FROM MESENCHYMA.

A, Based upon Studnička's studies of fish; B, upon Mall's study of mammals. Mes., Mesenchyma; Pre. Cart., precartilage; Cart., cartilage.

brates. It becomes cartilage by the thickening and chemical transformation of its exoplasmic walls. They form an intercellular ground substance or matrix, which stains blue with hæmatoxylin. According to Professor Mall the same result is produced in another way, as shown in Fig. 66, B. The mesenchymal cells in becoming precartilage produce a fibrillated exoplasm. The nuclei with the surrounding endoplasm then become "extruded from the syncytium" and lie in the intercellular spaces.

At the same time the fibrillated exoplasm becomes transformed into the homogeneous matrix of the cartilage, which stains blue with hæmatoxylin. Whether or not the cells are extruded may be questioned, but the relation of the fibrous to the homogeneous matrix, which is shown in the figure, may readily be observed around the vertebræ in pig embryos.

After the cartilage has formed, the cells occupy cavities, or *lacunæ*, in the matrix. It is probable that in the living condition the cartilage cells completely fill their lacunæ, but in preserved specimens they are often irregularly shrunken. Usually the protoplasm of each cell is of a spongy vacuolated texture, which is in part due to fat droplets and in part to glycogen; in ordinary sections, both of these substances have disappeared, leaving empty spaces.

Glycogen is a carbohydrate which resembles starch and is therefore sometimes called "animal starch." It is soluble in water, and soon after death it becomes converted into glucose. For both of these reasons it disappears from ordinary sections. Fresh tissues, preserved in strong alcohol and stained with tincture of iodine, exhibit glycogen as brownish-red granules which may be aggregated in masses of considerable size. Glycogen is found not only in cartilage cells but also in striated muscle and in the cells of the liver. In the embryo it has a wider distribution. At certain stages of development, according to Gage, it occurs in the cells of the nervous system and is abundant in the epidermis, the digestive tube, and the cœlomic epithelium. Its production, like that of fat, varies with nutritive conditions, and it accumulates in well-nourished individuals.

The cartilage cells are said to be enclosed in *capsules*, which are often transparent and inconspicuous linings of the lacunæ. Sometimes they appear as rather broad bands which are concentrically striated, indicating that they were deposited in successive layers. The layers of newly formed matrix, which bound the lacunæ, usually stain very dark blue with hæmatoxylin. The deep color is probably due to *chondromucoid*. Peripherally the color blends with that of the older matrix, which takes a pale blue stain. Like the intercellular substance of connective tissue the matrix of cartilage may contain white and elastic fibers, but in its commonest form it appears homogeneous and hyaline. Chemically it is a mixture of *collagen*, *chondromucoid*, *chondroitin sulphuric acid* in combination, and *albuminoid substances* (albumoid). The old term "chondrin" really means little else than the matrix of cartilage, which on superficial examination is found to be a dense body. Within it, however, the cells produce new ground substance and push themselves apart from one another by *interstitial growth*. The cells in the interior of the cartilage are often much larger than those at the periphery, and the increase in the size of their lacunæ is probably accomplished by the resorption of the adjacent matrix. The cells divide by mitosis, and after division two of them are found in a single capsule. They then move apart, and a partition, at first very slender, is formed between them. They may remain

grouped as a pair, forming a bisected elliptical figure, or they may divide again, producing either a row of cells or a cluster of three or four (Fig. 66). Since the cells change their positions with difficulty in the dense matrix, they are regularly found in very characteristic groups. It has been asserted that certain cartilage cells undergo mucoid degeneration and become lost in the matrix. In old cartilage dark spots, staining intensely with hæmatoxylin, are suggestive of such a process. Such cells must be carefully distinguished from tangential sections of the deeply staining pericapsular matrix.

Cartilage grows not only by the interstitial increase of the cells and matrix in its interior, but more especially by *appositional growth*, through

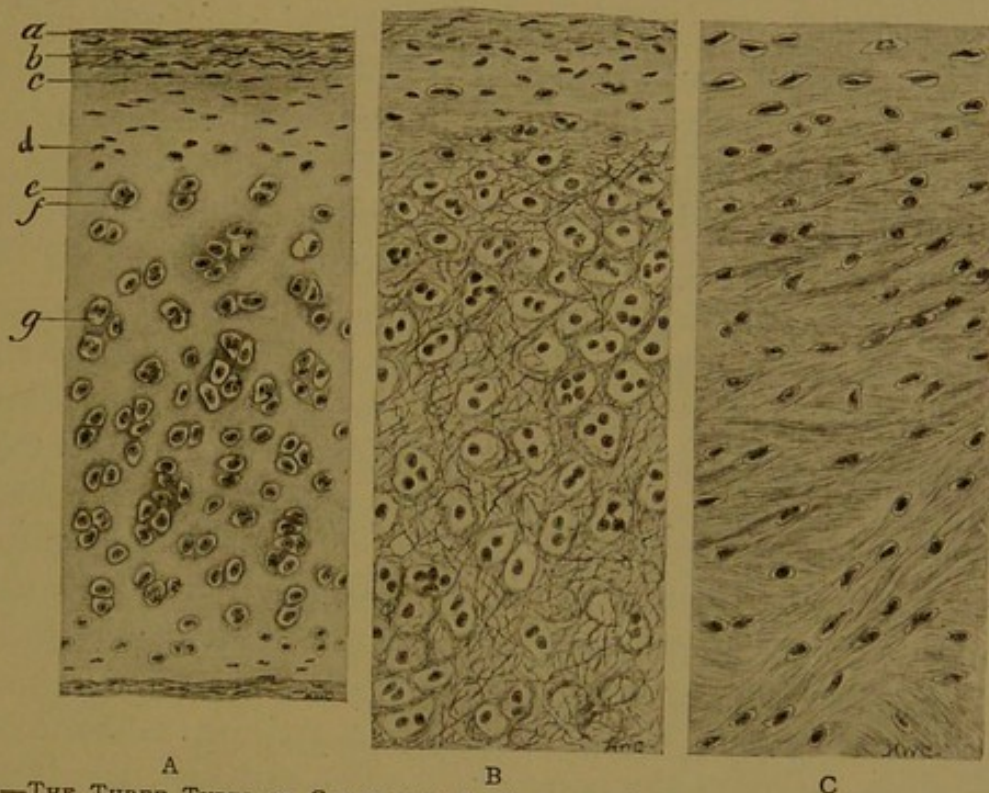


FIG. 67.—THE THREE TYPES OF CARTILAGE: A, HYALINE; B, ELASTIC; C, FIBROUS. (Radasch).
a, b, Outer and inner layers of perichondrium; c, young cartilage cells; d, older cartilage cells; e, f, capsule surrounded by deeply staining matrix; g, lacuna.

the formation of new cartilage over its external surface. Around every cartilage in the adult, there is a connective tissue envelope, the *perichondrium*, containing undifferentiated cells which multiply and become transformed into cartilage cells (Fig. 67, A). These are added at the surface, undergoing in a thin layer such changes as are shown in Fig. 66. The young generations of cells are therefore at the periphery of the cartilage, and the oldest cells, or the groups which they have produced, are in the center. Between them an interesting series of cytomorphic changes may be observed. Since the perichondrium is the formative layer, a more or less perfect regeneration of cartilage may occur after surgical operations if the perichondrium is left in place, but not otherwise. The perichondrium contains vessels and nerves, none of which pene-

trate the matrix of the cartilage. In some cases, however, vascular connective tissue occupies an excavation in its peripheral portion. Whatever nutriment the cells in the interior of the cartilage receive is obtained by diffusion through the matrix. It has been asserted that this diffusion takes place through a system of canals penetrating the matrix, and passing from one lacuna to another as in bone. But in mammalian cartilage the only canals which have been recorded are presumably the result of shrinkage, such as may be produced by treating the specimen with absolute alcohol or ether.

The three principal forms of cartilage—hyaline, elastic, and fibrocartilage—and the exceptional “vesicular supporting tissue” may be further described as follows:

Hyaline cartilage, the commonest type, is characterized by its clear, pale bluish or pearly translucent matrix, which is ordinarily free from fibrils. The nasal cartilages, most of the laryngeal cartilages, and the tracheal and bronchial rings are of this variety, together with the xiphoid and costal cartilages, and the articular cartilages which cover the joint surfaces of the bones. In embryos the greater portion of the skeleton is at first formed of hyaline cartilage. Although the matrix usually appears homogeneous, it may be resolved into bundles of parallel fibers by artificial digestion, and its behavior toward polarized light indicates an underlying fibrillar structure. Sometimes, as a degenerative process, a network of fibers may appear in the matrix, staining red with eosin, and resembling the elastic fibers shown in Fig. 68, 3. Such a condition has been observed in the trachea. In degenerating portions of the laryngeal and costal cartilages, fibers having a luster like asbestos (or the mineral *amianthus*) are sometimes seen; according to Prenant these “amianthoid fibers” are neither white nor elastic. In old age a deposit of calcareous granules often occurs in the matrix of hyaline cartilage, and in some of the laryngeal cartilages this change may begin by the twentieth year. With the increase and coalescence of the granules, the cartilage becomes calcified, and blood vessels may enter it; but it does not form true bone. As with other calcified structures, such as tendon, treatment with acids shows that the underlying tissue has retained its characteristic features, and remains quite different from bone.

Elastic cartilage contains, in its matrix, granules, fibers or networks of elastic substance (Figs. 67, B, and 68); consequently its color is yellowish. It is found in the external ear, the auditory (Eustachian) tube, the epiglottis, and in certain small cartilages of the larynx, namely the corniculate and cuneiform cartilages and the vocal processes of the arytaenoid cartilages. It develops from hyaline cartilage, which it closely resembles. Within its matrix, granules of elastic material are deposited, which later coalesce to form fibers. Some authorities have stated that they

arise from the cells, but according to Schäfer "their formation apart from the cells can be easily verified in the arytaenoid cartilage of the calf."

The elastic nature of fibers within the cartilage matrix can be demonstrated by special stains, such as resorcin-fuchsin; they stain like the elastic fibers of connective tissue.

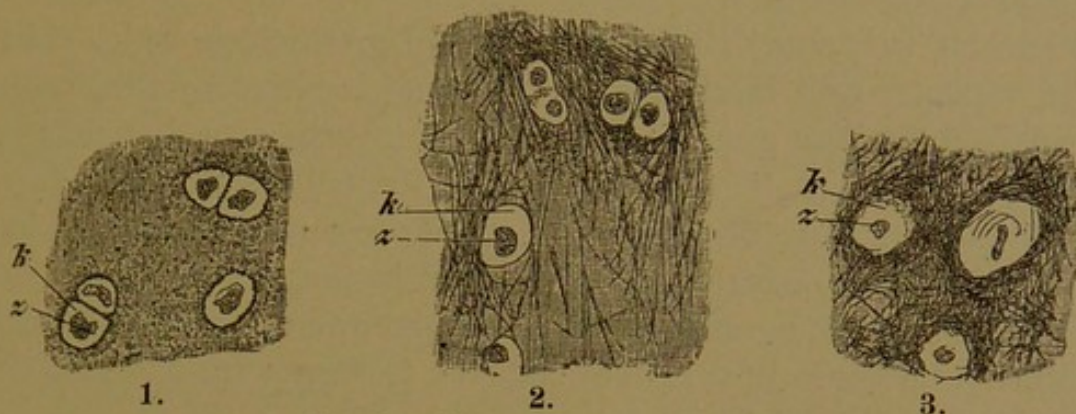


FIG. 68.—ELASTIC CARTILAGE. $\times 240$.

1, Portion of a section of the vocal process of an arytaenoid cartilage of a woman thirty years old; the elastic substance is in the form of granules. 2 and 3, Portions of sections of the epiglottis of a woman sixty years old; a fine network of elastic fibers in 2, a denser network in 3. z, Cartilage-cell, nucleus invisible; k, transparent capsule.

Fibro-cartilage cannot be regarded, like elastic cartilage, as a late modification of hyaline cartilage. In its early development, as seen in the intervertebral disc of an embryo, its matrix is primarily fibrous. It is composed of anastomosing bundles of fibers which blend with the hyaline matrix of the adjacent vertebral cartilage as shown in Fig. 66, B. Instead of becoming transformed into hyaline cartilage, however, it develops into a cartilaginous modification of dense connective tissue. It is found typically developed in the intervertebral and interpubic fibro-cartilages. According to Stöhr it forms the articular cartilage lining the sterno-clavicular, acromio-clavicular, and mandibular joints, together with the joints of the costal cartilages, and it covers the head of the ulna. Usually it is said to form the rims deepening the sockets of the shoulder and hip joints, together with the interarticular discs of the mandibular, sterno-clavicular and knee joints but these, according to Stöhr, consist of dense connective tissue without the characteristic cartilaginous matrix. A portion of their cells are round, however. Even when typically developed, fibro-cartilage consists chiefly of interwoven bundles of white fibers. With hæmatoxylin and eosin this ground substance is diffusely stained, since the fibers, colored by the eosin, are imbedded in a chondro-mucoid

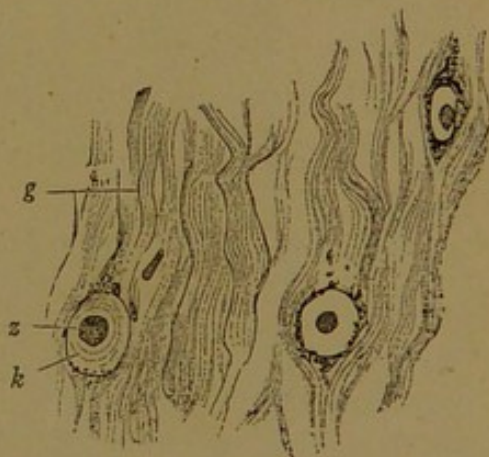


FIG. 69.—FROM A HORIZONTAL SECTION OF THE INTERVERTEBRAL DISC OF MAN. g, Fibrillar connective tissue; z, cartilage-cell (nucleus invisible); k, capsule surrounded by calcareous granules. $\times 240$.

matrix which stains with hæmatoxylin. The cells are not flattened as in connective tissue. They are lodged in well-rounded lacunæ (Fig. 69), bounded by capsules and zones of blue-staining matrix; and they are frequently arranged in pairs or small groups such as occur in other forms of cartilage. Their protoplasm is extensively vacuolated and is sometimes shrunken.

"*Vesicular supporting tissue*" is a form of precartilage which consists of large vesicular cells in close contact, bound together by firm walls; it is a "cartilage without a matrix." In many invertebrates it is an important tissue, but in adult mammals it is of limited occurrence. In man such a tissue is said to be present on the inner surface of the tendon of insertion of the *M. quadriceps femoris*, and in the sesamoid cartilage in the tendon of the *M. peronæus longus*. This form of cartilage resembles the notochordal tissue at a certain stage of development, and it is called "chordoid tissue" by Schaffer.

NOTOCHORDAL TISSUE.

Although the notochord is of entodermal origin (cf. p. 38), it gives rise to a tissue which has often been called cartilage. Notochordal tissue

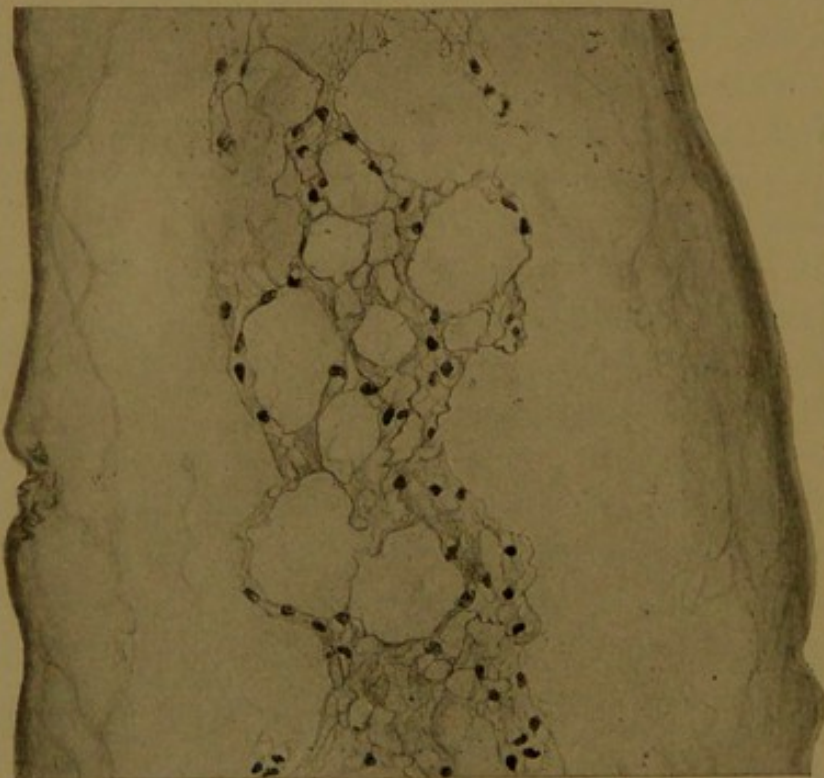


FIG. 70.—A PORTION OF A NUCLEUS PULPOSUS FROM A HUMAN EMBRYO OF THE SIXTH MONTH. $\times 225$. The notochordal syncytium is seen in the center of a mucoid matrix. The vertebræ are toward the right and left, beyond the limits of the figure.

differs, however, from any of the types thus far considered. The principal stages in its development in the pig have been described by Williams (*Amer. Journ. Anat.*, 1908, vol. 8, pp. 251-284), whose account may be summarized as follows:

In an embryo measuring 5.5 mm. the notochord is a rod of cells surrounded by a thin notochordal sheath. A cross section contains about eight wedge-shaped cells. In an embryo measuring 9 mm. it is larger, and a cross section shows about fifteen cells at the periphery, and three or four at the center. In an embryo of 11 mm. the cells have lost all definite arrangement and are more or less vacuolated. The vacuoles increase in size and number, and are found to contain mucin or a gelatinous mucin-like substance. In an embryo measuring 17 mm. the cell walls, which up to this time have remained intact, are breaking down (or being absorbed) and the mucin escapes from the vacuoles. The cells are united by strands of cytoplasm and the notochordal tissue now resembles mesenchyma. The syncytial network continues to enlarge, both by growth, and by the formation of a greater number of vacuoles. In a much older embryo (250 mm.) the formerly continuous peripheral sheet of syncytial tissue is broken in many places by large masses of mucin. In the center of this accumulation, the slender syncytial network seems suspended (cf. Fig. 70). In the adult the syncytium has become divided into groups of vacuolated cells imbedded in a gelatinous matrix. Thus it acquires a resemblance to cartilage in several particulars, but it should be regarded as a distinct tissue.

The human notochord undergoes a development similar to that of the pig. After it has ceased to be an epithelioid rod of cells, its most characteristic condition is that shown in Fig. 70, which includes a portion of the nucleus pulposus from an embryo of the fifth month. The notochordal tissue forms a vacuolated syncytium suspended in the gelatinous matrix, which, at the periphery of the nucleus pulposus, is bounded by a structureless membrane. Very rarely the notochord is the source of tumors which are composed of tissue similar to that normally found within the nucleus pulposus.

BONE.

Bone develops relatively late in embryonic life, after the muscles, nerves, vessels, and many of the organs have been formed. The skeleton at that time consists of hyaline cartilages, which are later replaced by the corresponding bones of the adult. According to Kölliker, Robert Nesbitt was the first to point out that the bones are not indurated or transmuted cartilages, but are new formations, produced around the cartilages which are later destroyed. Moreover, in his "Human Osteogeny Explained in Two Lectures" (London, 1736), Nesbitt showed that certain bones develop directly from connective tissue without having been preformed in cartilage. These are now called *membrane bones* in distinction from *cartilage bones*. The membrane bones are the bones of the face and the flat bones of the skull. They include the interparietal or upper part of the occipital, the squamous and tympanic parts of the temporal, the medial pterygoid plate of the sphenoid, the parietal, frontal, nasal, lachrymal, zygomatic (malar) and palate bones, together with the vomer, maxilla and almost the entire mandible. Nesbitt correctly

concluded that there is but one method of bone formation, whether or not it takes place in relation with cartilage, but he was unaware of the existence of cells, and believed that bones were produced from an ossifying juice derived from the blood.

Development of bone. Bone formation begins with the production of a layer or spicule of matrix which stains red with eosin. As to the origin of this matrix there is the same difference of opinion which obtains in regard to other intercellular products. It has been asserted that it proceeds from *osteogenic fibers*, which are modified white fibers of the connective tissue. Frequently a spicule of matrix is seen to fray out into the connective tissue, as shown in the lower part of Fig. 71. Between the osteogenic fibers, calcareous granules may then be deposited until

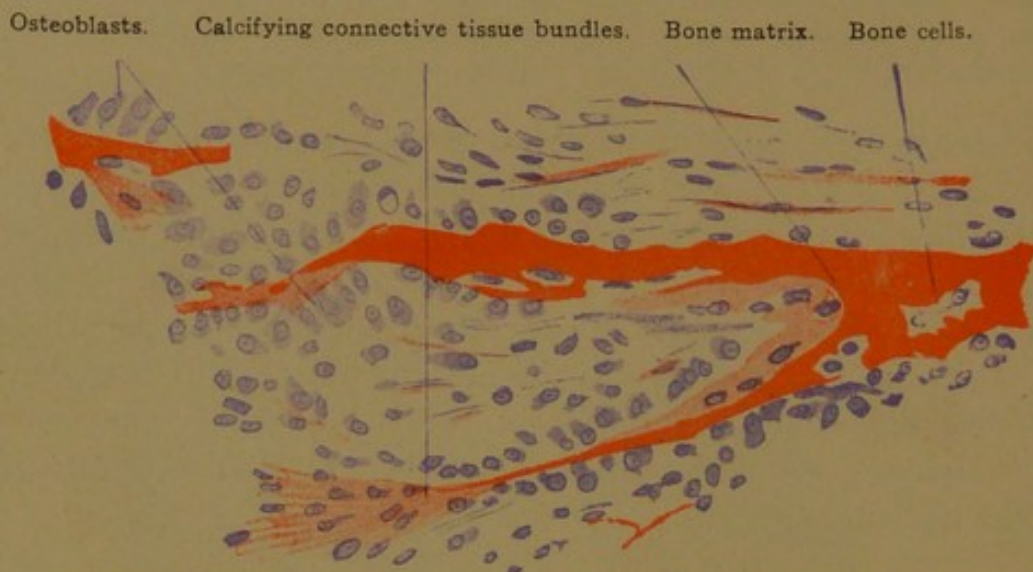


FIG. 71.—FROM A SECTION OF THE MANDIBLE OF A HUMAN EMBRYO OF FOUR MONTHS. $\times 240$.

the fibers are lost in a homogeneous calcified matrix. According to this opinion the matrix is essentially an intercellular formation. Others consider that the matrix is produced by a transformation of the exoplasm of bone-forming cells, or *osteoblasts*.

Osteoblasts are derived from mesenchymal or young connective tissue cells through an increase in their protoplasm and a shortening of their processes. They are found in contact with the surface of spicules of bone, arranged in an epithelioid layer (Fig. 72). There is great variation in their shape. Often they are pyramidal, but they may rest upon the bone either by a broad base or a pointed extremity. Their round nuclei may be in the part of the protoplasm next to the bone, or away from it as far as possible. Active osteoblasts tend to be cuboidal or columnar, but as bone production ceases they may become quite flat. They form bone only along that surface which is applied to the matrix. As the strand of bone grows broader through their activity, it encloses here and there an osteoblast, which thus becomes a *bone cell* (Fig. 72). Apparently bone cells do not divide, and if they produce matrix, thus

becoming more widely separated from each other, it is only to a slight extent and in young bones; they are therefore quite inactive. Each bone cell occupies a space in the matrix, called as in cartilage, a *lacuna*, but unlike the lacunæ of cartilage those in bone are connected by numerous delicate canals, the *canaliculi*. In ordinary specimens the canaliculi are visible only as they enter the lacunæ, which are thus made to appear stellate. The matrix around the lacunæ resists strong hydrochloric acid which destroys the ordinary matrix, and so may be isolated in the form of "bone corpuscles." The "corpuscles" correspond with the capsules of cartilage, which may be isolated in the same way. The bone cells nearly fill the lacunæ and send out very slender processes into the canaliculi. These may anastomose with the processes of neighboring cells, as

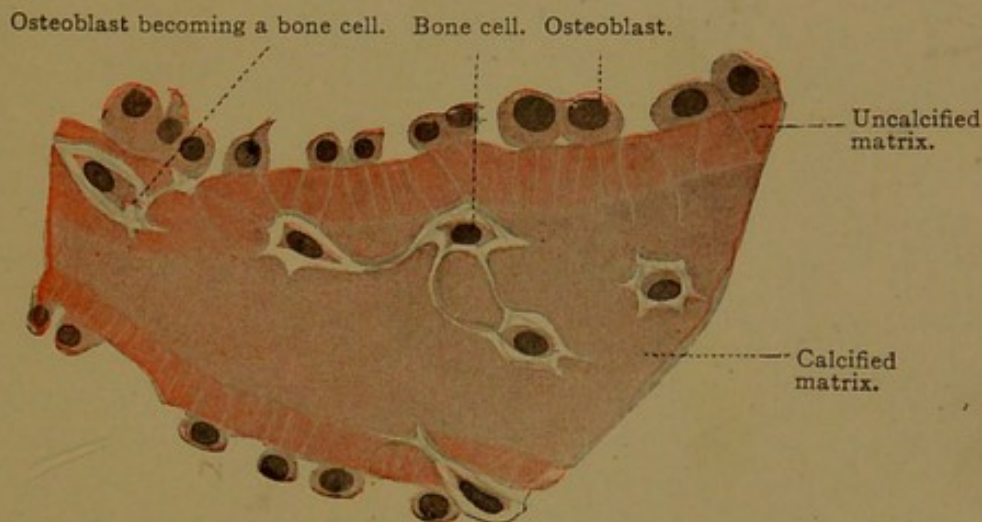


FIG. 72.—PART OF A CROSS SECTION OF THE SHAFT OF THE HUMERUS, FROM A HUMAN EMBRYO OF THE FOURTH MONTH. $\times 675$.

can be seen in the embryo, but it is doubtful if this condition is retained in the adult. The processes, moreover, are so fine that ordinarily they are invisible.

The spicules of bone, containing bone cells and beset with osteoblasts, increase in size and unite with one another, so as to form a spongy network enclosing areas of vascular connective tissue. These areas are not entirely surrounded by bone, but retain connections with the exterior, through which the vessels may enter and leave. It is evident that if the spicules continued to thicken, while new ones were added at the periphery, the bone would soon become quite solid and heavy. This is prevented by the destruction or resorption of certain spicules, which begins at a very early stage. It may be studied advantageously in the developing mandible of a pig embryo, 10 cm. in length. At this stage the teeth are growing rapidly, and around each tooth the spicules of bone are being destroyed so as to produce a larger socket; at the same time the jaw is increasing in thickness by the formation of new bone over its outer

surface. Toward the area of resorption the osteoblasts become flatter and less numerous, finally disappearing.

In sections of bone, the places where resorption is going on may be recognized by the presence of large multinucleate cells, which Kölliker in 1873 named "bone destroyers" or *osteoclasts* (preferably spelled *osteoclasts*). They are shapeless masses of protoplasm without any limiting membrane, containing usually from one to twenty nuclei (Fig. 73).— In the largest of them, Kölliker counted from fifty to sixty nuclei. He

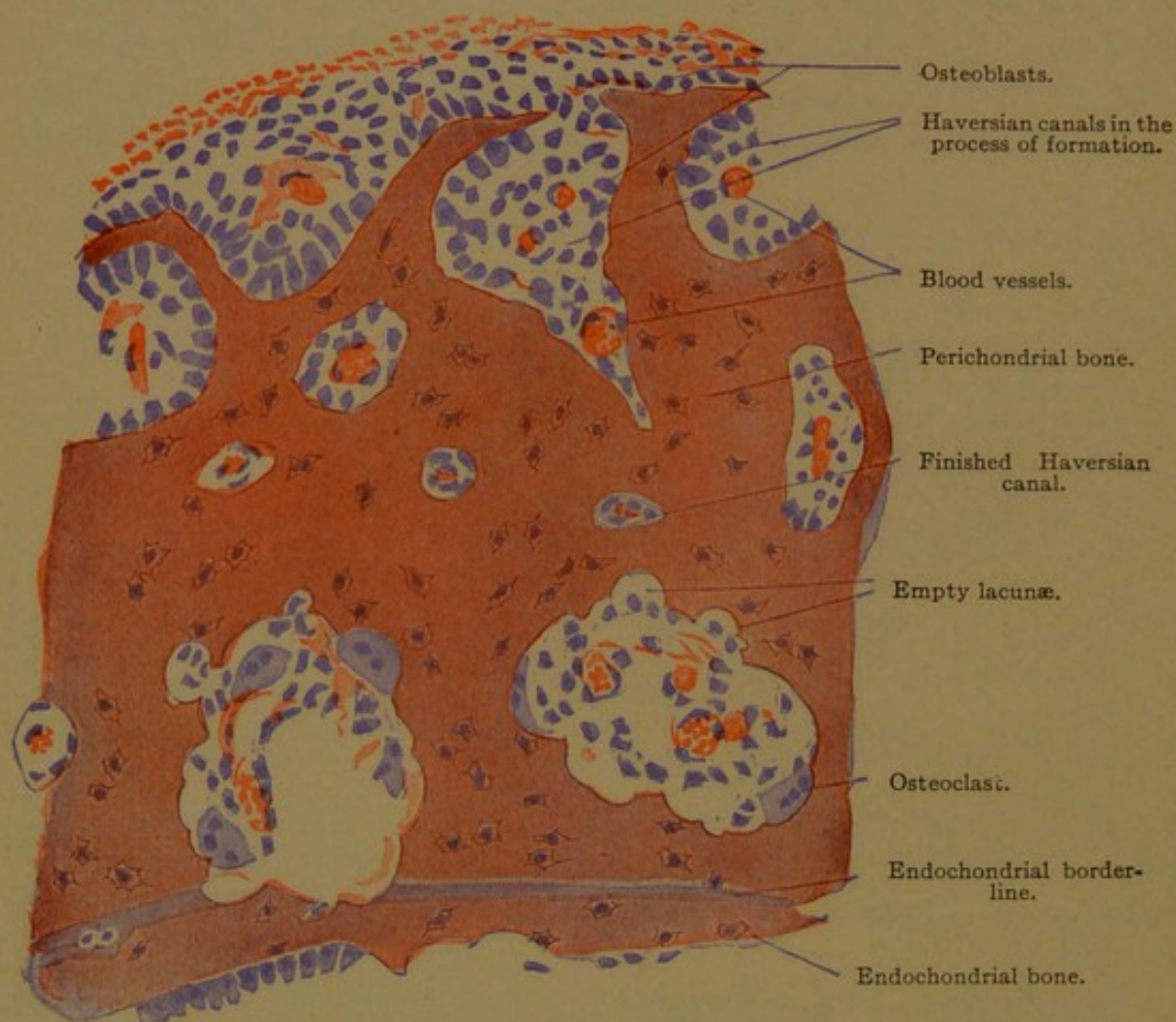


FIG. 73.—PORTION OF A CROSS SECTION OF A TUBULAR BONE OF A NEWBORN KITTEN.

believed that they arose from osteoblasts through repeated nuclear division. Apparently they are not due to a fusion of cells; and they have nothing in common, except their large size, with the giant cells of the bone marrow, which will be described in connection with the blood. Osteoclasts are found along the surface of the bone, sometimes forming rounded elevations or caps at the extremities of spicules, and sometimes imbedded in shallow excavations known as *Howship's lacunæ*. There seems to be no satisfactory evidence that the osteoclasts are the active cause of bone destruction. On the contrary they appear to be degenerating cells, produced by those conditions which lead to the dissolution of bone.

The processes of bone formation and resorption just described take place both in membrane and in cartilage bones. As the membrane bones enlarge, the central portion, through resorption, becomes loose spongy bone (*substantia spongiosa*), which is enclosed on all sides by an outer layer of compact bone (*substantia compacta*). In the flat bones of the skull the compact substance forms the outer and inner "tables," which have the spongy "diploë" between them. The cartilage bones likewise consist of spongy and compact portions.

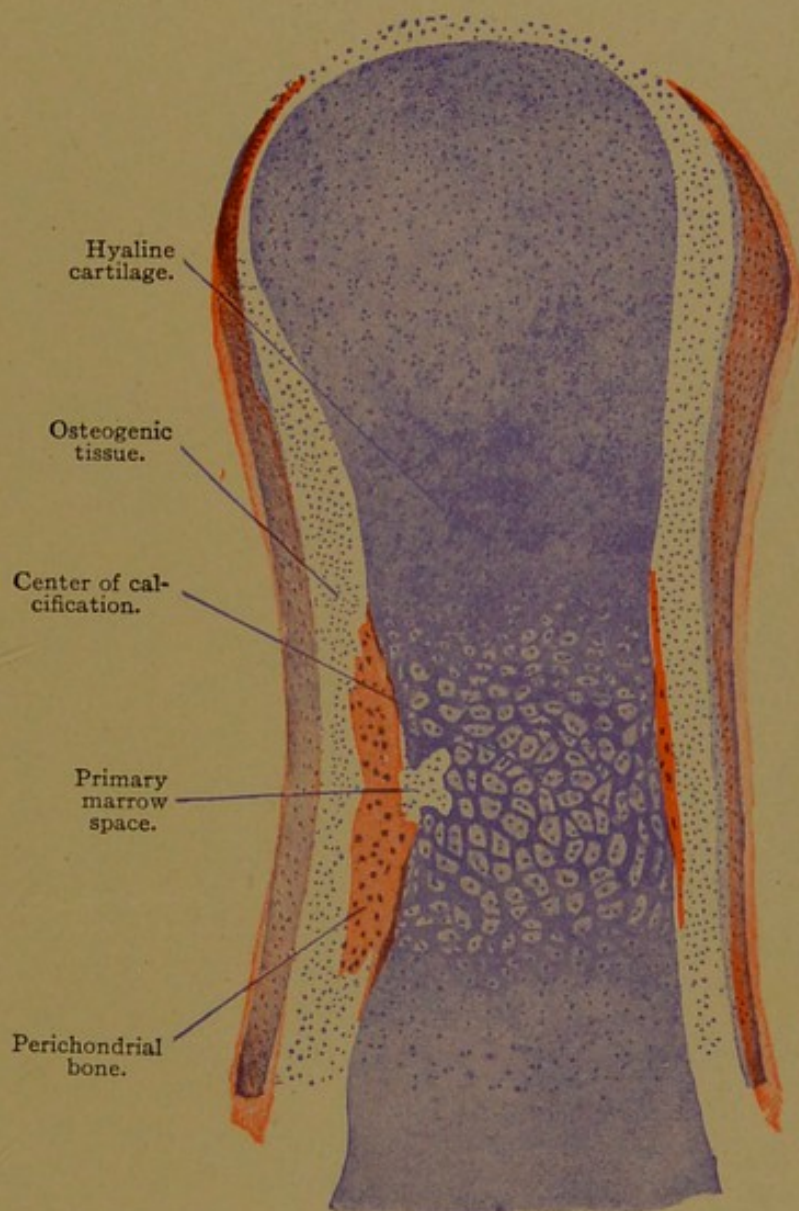


FIG. 74.—A DORSO-PALMAR LONGITUDINAL SECTION OF A PHALANX OF THE LITTLE FINGER, FROM A HUMAN EMBRYO OF THE SIXTH MONTH. $\times 60$.

Replacement of the skeletal cartilages. The changes within the skeletal cartilages during the formation of bone may be studied advantageously in longitudinal sections of any developing "long bone," or in transverse sections of the vertebræ from pig embryos measuring about 10 cm. The vertebræ exhibit several processes which will be cut lengthwise in transverse sections. Fig. 74 represents a longitudinal section of a phalanx

around which ossification has begun. On either side of the shaft of hyaline cartilage, the matrix of which stains blue with hæmatoxylin, there is a strip of bone, the matrix of which is stained red with eosin. These strips are sections of a band of bone which completely encircles the middle part of the cartilage. It has been formed by osteoblasts which developed in the perichondrium. The portion of the cartilage which is surrounded by bone has begun to degenerate. Its capsules have been

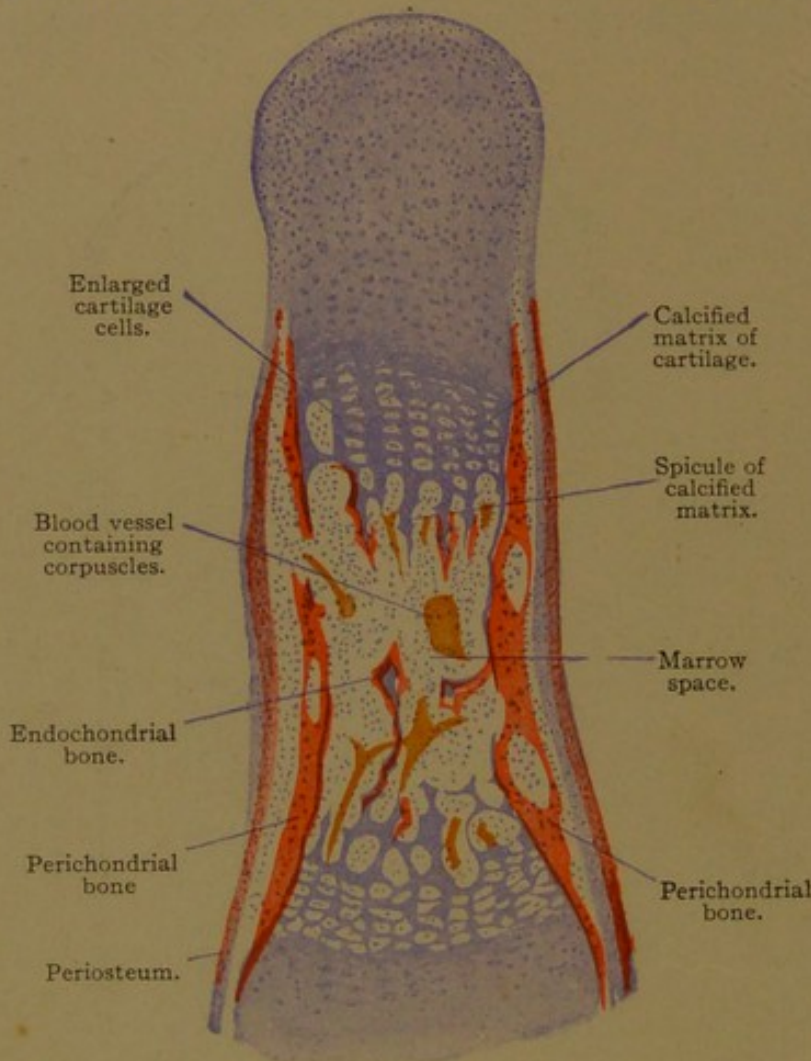


FIG. 75.—A DORSO-PALMAR LONGITUDINAL SECTION OF A MIDDLE-FINGER PHALANX, FROM A HUMAN EMBRYO OF THE FOURTH MONTH. $\times 60$.

resorbed, and the enlarged lacunæ are beginning to coalesce. The matrix of the cartilage in this region takes a deeper stain, and calcareous granules are being deposited within it.

On the left of Fig. 74, a bud of perichondrial tissue is seen entering the shaft of the cartilage, and similar buds may invade it from other sides. Within the cartilage the ingrowing perichondrial tissue forms the *primary marrow*, which is a very vascular connective tissue. As it advances, the walls of the lacunæ are resorbed, setting free the cartilage cells. Formerly it was thought that these cartilages cells became osteoblasts, but they are now considered to be dying cells, without further function.

Meanwhile the cartilage continues to grow, especially in length. This is brought about by successive transverse divisions of the cells of the shaft, so that they become arranged in more or less definite longitudinal rows (Fig. 75). The thin transverse walls of the lacunæ in these rows are

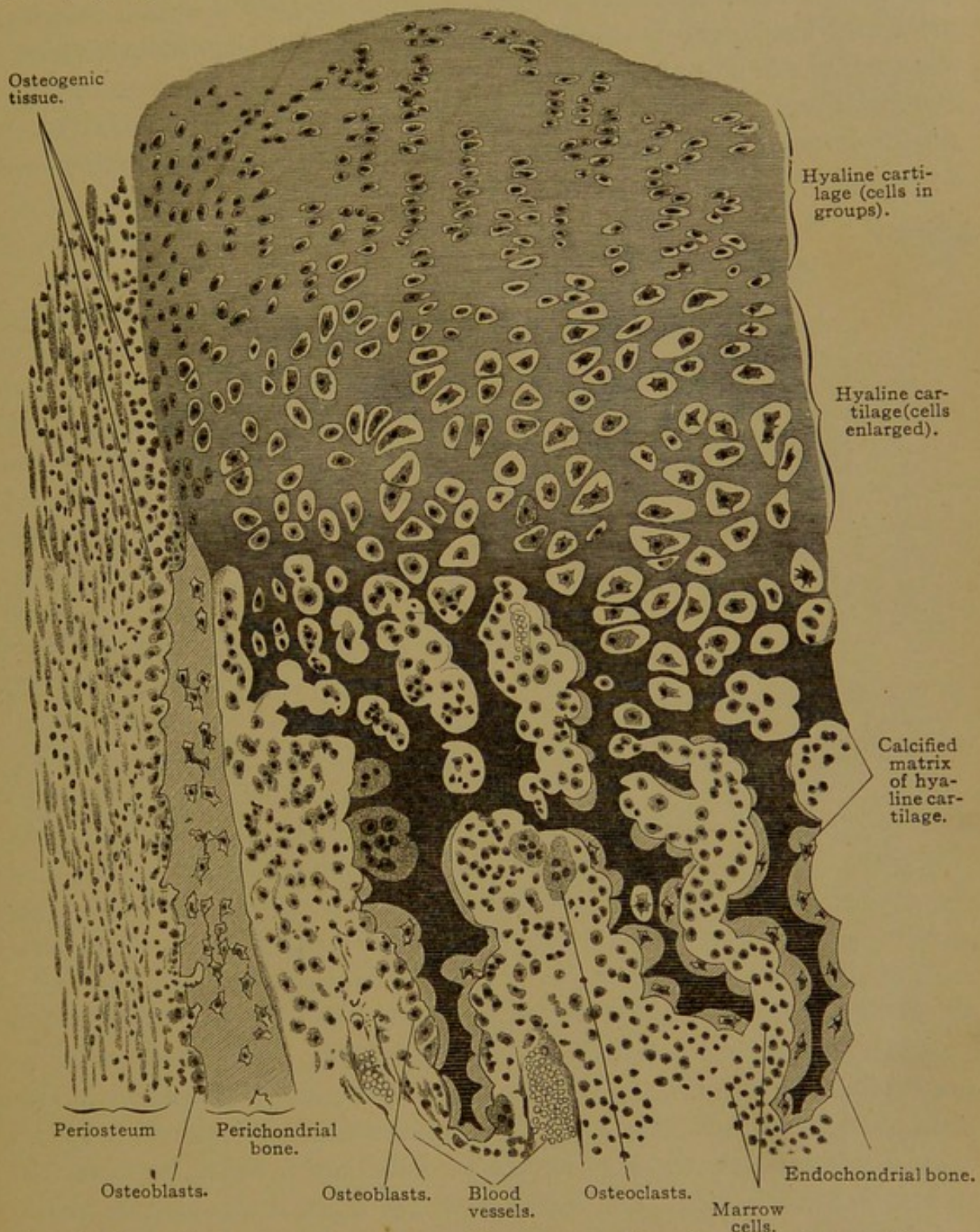


FIG. 76.—FROM A LONGITUDINAL SECTION OF THE PHALANX OF THE FIRST FINGER OF A HUMAN EMBRYO OF THE FOURTH MONTH. $\times 220$.

dissolved more readily than the thicker longitudinal walls, and the deep-blue ragged spicules of calcified matrix which are thus produced, are therefore generally elongated. Osteoblasts, derived from the primary marrow, arrange themselves on these spicules, and form bone in the same manner

as elsewhere. Thus the spicules of calcified matrix, staining blue, become encased in the matrix of bone which stains red (Figs. 75 and 76).

From what has been said, it is clear that bone is formed both around the cartilage (perichondrial bone) and within the cartilage (enchondrial bone). In long bones and flat bones, ossification is at first perichondrial and later enchondrial; in short bones it is enchondrial until the cartilage has been entirely replaced. Thus the part taken by enchondrial and perichondrial ossification varies greatly in different bones. As the bone grows, the older parts which have formed in relation with

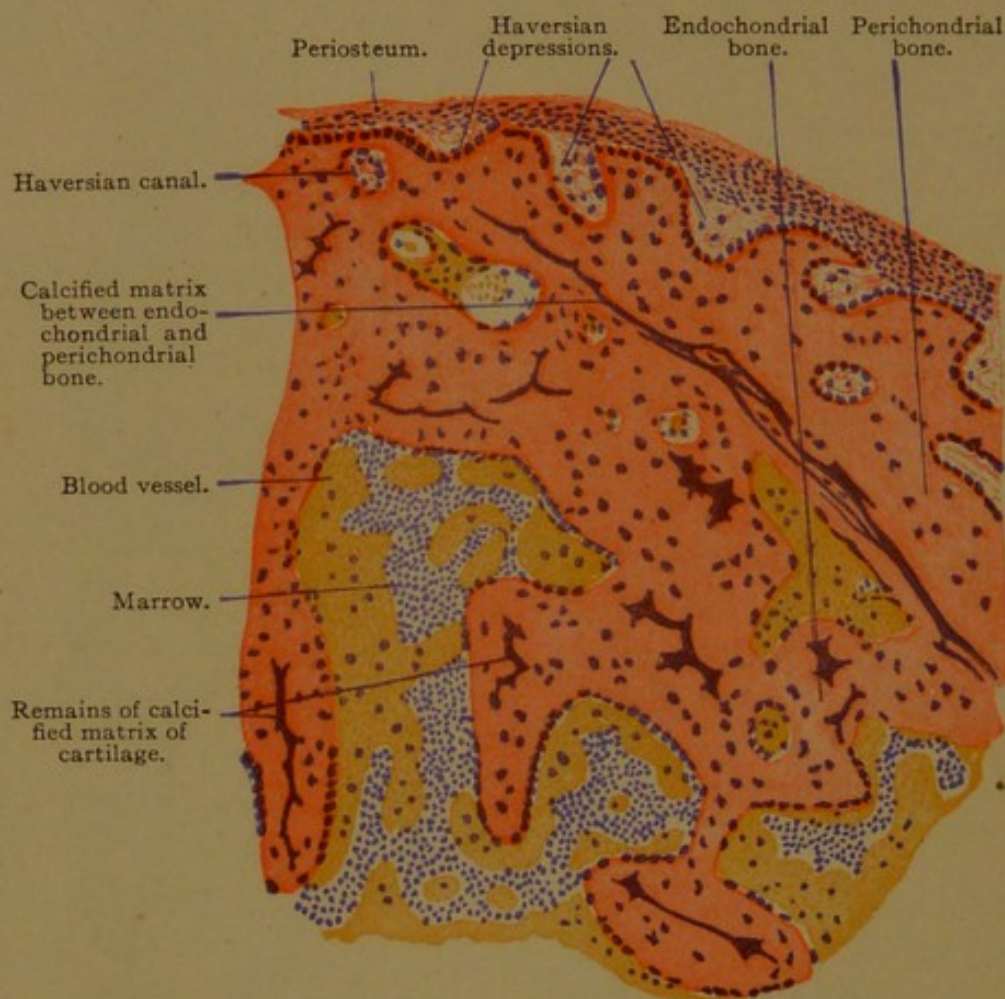


FIG. 77.—FROM A CROSS SECTION OF THE SHAFT OF THE HUMERUS, FROM A HUMAN EMBRYO OF THE FOURTH MONTH. $\times 80$.

the cartilage are resorbed. In the shaft of the humerus from a human embryo of the fourth month (Fig. 77), only a thin and interrupted layer of calcified cartilage remains to mark the boundary between perichondrial and enchondrial bone, and in the adult all traces of this layer have disappeared. This is true of most bones, but in the auditory ossicles calcified cartilage is found throughout life.

The final stages in the replacement of the cartilages by bone take place long after birth, when the bones have increased greatly in diameter and length. The growth in diameter is accomplished by the deposition of new layers externally, and the enlargement of the marrow cavity,

through resorption, internally. This explains why a band of metal placed around the bone of a young animal is later found within the marrow. The internal resorption takes place in such a way that a meshwork of spicules and plates, denser toward the periphery, remains within the shaft, and the marrow occupies its interstices. To a limited extent new bone is formed in the interior of the shaft by osteoblasts in its lining membrane, called the *endosteum*. The deposition of new layers externally is produced by osteoblasts in the *periosteum*, which is a specialized connective tissue layer surrounding the bone. It replaces, and apparently is derived from, the perichondrium of the original cartilage. The extent to which new bone is formed, and its distribution, may be determined by feeding madder to growing animals. This dye, as has long been known, imparts a red color to the matrix of bone deposited while it forms a part of the diet. By this means Kölliker determined that the deposition of periosteal bone is not uniform. In a given bone, there will be unstained areas, where no new bone is being formed, or where an external resorption is taking place. In this way the bones acquire their characteristic modelling.

Growth in length occurs chiefly through the activity of the uncalcified cartilage. In a long bone, ossification first produces a band of bone encircling the cartilage, and then a hollow shaft of bone with a rounded mass of cartilage at either end (Fig. 78, A, B). The cells in these masses continue to divide, prolonging the longitudinal rows of cells such as are seen in Fig. 75. As ossification takes place at one end of these rows, new cells are formed at the other, and thus the length of the shaft or *diaphysis* increases. Certain bones have been found to grow more at one end than at the other. After a time osteogenic tissue invades the cartilages at the extremities of the bone, extending into them from the marrow cavity of the shaft. It forms a small bone within each, and these are known as *epiphyses* (Fig. 78, D). Between the epiphysis and the diaphysis there remains a layer of cartilage, called the *epiphyseal synchondrosis*, which allows further growth in length. The cells which it produces are added chiefly to the shaft. The relation of the epiphyses to the growth of bone was demonstrated by early experiments, in which metal pegs were placed in the bones of young animals. Pegs in the shaft scarcely separate from one another during growth, but a peg in the epiphysis moves away from one in the diaphysis. The epiphyses are formed at

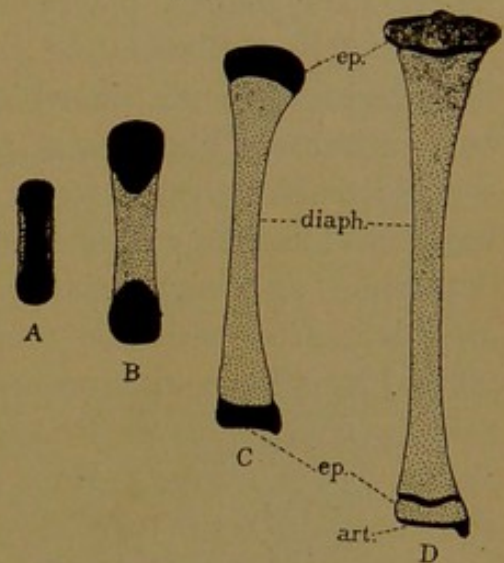


FIG. 78.—PLAN OF OSSIFICATION IN A LONG BONE, BASED UPON THE TIBIA. Cartilage is drawn in black, and bone is stippled. art., Articular cartilage; ep., epiphysis; diaph., diaphysis.

various times after birth, or, in the tibia, shortly before birth; they unite with the diaphyses usually between the eighteenth and twenty-second years, when the bones have acquired their full length. At that time nothing is left of the original cartilage except the layer of *articular cartilage* which covers the joint surfaces. Details in regard to the time when ossification begins in the various bones, the number of centers involved (for many bones have more than the three which have here been described), and the time when these join the main bone, will be found in textbooks of anatomy, and, together with many references to important studies of bone development, in Bidder's "Osteobiologie" (Arch. f. mikr. Anat., 1906, vol. 68, pp. 137-213).

Structure of Bone in the Adult. The properties of adult bone are essentially those of its matrix, which consists of organic and inorganic constituents intimately blended, and perhaps chemically combined. Of the inorganic matter, over 80% is calcium phosphate, $\text{Ca}_3(\text{PO}_4)_2$; the remainder includes chlorides, carbonates, fluorides and sulphates of calcium, sodium, potassium and magnesium. In order to cut sections of bone, this inorganic matter must be removed, and decalcification is usually accomplished by placing the specimen, after it has been preserved, in dilute nitric acid (3-5%) for several days or weeks. The matrix then has the consistency of cartilage. Its organic portion, which remains, is composed chiefly of collagen, together with osseo-mucoid. The collagen occurs in very fine white fibrils which are gathered in bundles, arranged in thin layers or *lamellæ*. Within these layers the fibers occur in parallel sets which tend to cross one another at right angles, thus producing a lattice work. These "decussating fibers" are seen only in special preparations in which a lamella has been peeled off, so that it can be examined in surface view. The calcareous matter is said to be deposited in the cement substance between the fibers, and not within them. Coarser uncalcified fibers are found in embryonic bone and in certain situations in adult bone—for example, at the sutures and the places where tendons are inserted. They also extend into the bone from the periosteum (Fig. 79), constituting the "perforating fibers" (Sharpey's fibers). The perforating fibers of the bones of the skull are entirely collagenous. These bones in the adult, together with the entire skeleton at birth, contain no elastic fibers; but in other bones of the adult elastic fibers accompany the perforating fibers (Schulz, Anat. Hefte, Abt. 1, 1896, vol. 6, pp. 117-153).

The *periosteum* consists of two layers. It has an outer layer of dense connective tissue, rich in blood vessels and containing also lymphatic vessels and nerves. It blends with the surrounding looser connective tissue and in places with fasciæ and tendons. The inner layer has few vessels but contains an abundance of elastic fibers. They are chiefly parallel with the long axis of the bone, but in the periosteum of the bones

of the roof of the skull they form an interlacing network (Schulz). Perforating fibers, such as were described in the preceding paragraph, may arise from this layer; and others, both white and elastic, derived from tendons, may pass through it into the bone. In this way the tendons acquire a very firm insertion. The cells of the inner layer of the periosteum are spindle-shaped or flattened connective tissue cells, together with the more cuboidal osteoblasts which rest against the bone. In young bones these are so numerous as to form a third layer of the periosteum. In the adult they are few in number, but are capable of proliferation, and together with those in the endosteum, they are the source of new bone after injury. The periosteum, in bodies which have been kept a week at 15° C., is said to be capable of producing bone when transplanted to another body; and after operations in which a shaft of bone has been shelled out from its periosteum, a new shaft may be formed.

Beneath the periosteum, as seen in the cross section of the shaft of a long bone (Fig. 80), there are layers or lamellæ of bone which are parallel

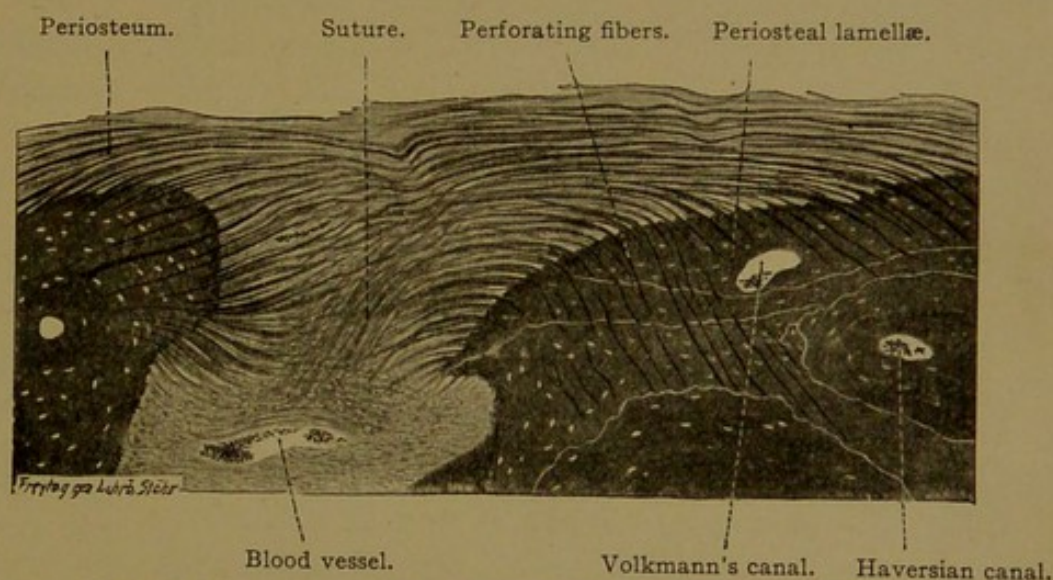


FIG. 79.—SECTION ACROSS A SUTURE IN THE SKULL OF AN ADULT.
Prepared by Bielschowsky's method. $\times 80$.

with the surface. These are the "outer ground lamellæ" or *periosteal lamellæ*. They are traversed by Sharpey's perforating fibers and by small blood vessels lodged in the so-called Volkmann's canals. The bone cells occupy lacunæ, situated between the lamellæ, and in Fig. 80 they are seen as small spots. In the lowest part of the figure, a portion of the marrow has been included. The marrow is surrounded by the endosteum, external to which are the "inner ground lamellæ" or *endosteal lamellæ*. These are parallel with the inner surface of the bone.

Between the periosteal and the endosteal lamellæ there is a dense mass of matrix unlike anything found in embryonic bone. Scattered through it, numerous blood vessels are seen in cross section. Each vessel is surrounded by *concentric lamellæ* which present a very charac-

teristic figure. Such vessels are said to occupy *Haversian canals* (named for the English anatomist, Clopton Havers). Volkmann's canals contain vessels, but they are not surrounded by concentric lamellæ. An Haversian canal often contains two vessels, an artery and a vein, together with a small amount of connective tissue and occasional fat cells; flattened osteoblasts may rest against the surrounding bone, and send processes into it. The concentric lamellæ enclosing an Haversian canal constitute

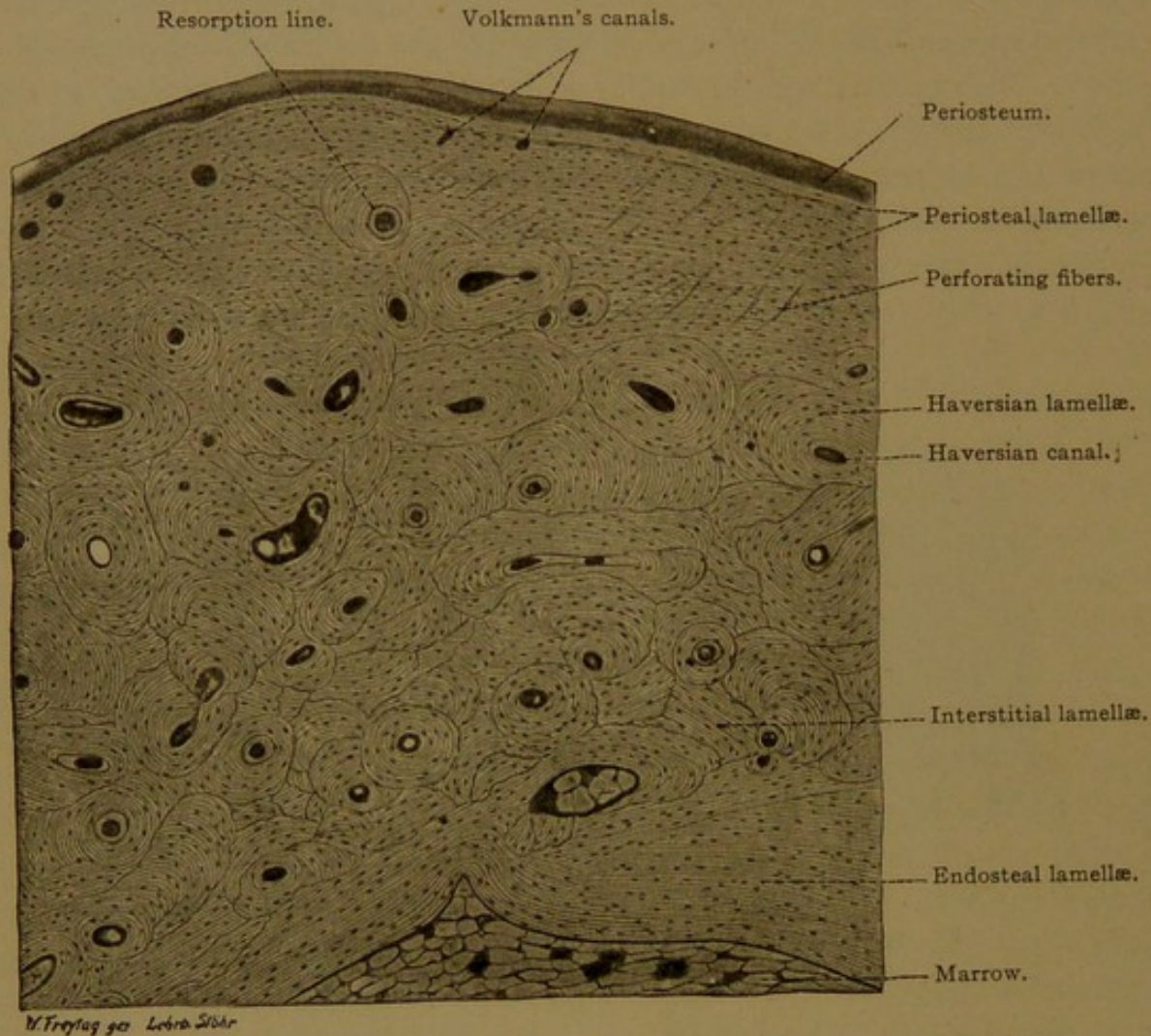


FIG. 80.—PART OF A CROSS SECTION OF A DECALCIFIED PHALANX FROM AN ADULT.

an Haversian system. *Interstitial lamellæ*, irregularly arranged, fill the intervals between the Haversian systems.

The way in which the compact bone of the adult is formed from the trabecular network of the embryo is indicated in the diagram, Fig. 81 (cf. also Fig. 73). After an area of vascular tissue has been surrounded by bone, the osteoblasts form lamellæ, gradually closing in from all sides until only a slender canal remains. Successive stages are shown in Fig. 81, B. V., H. C¹, and H. C², respectively. The deposition of the concentric lamellæ is not continuous. It is interrupted by periods of

resorption, after which the deposition of bone is resumed. *Resorption lines* are frequently seen in the Haversian systems (Fig. 80).

Longitudinal sections of decalcified bone show the way in which the Haversian canals connect with one another (Fig. 82). The lamellæ are not so strikingly subdivided into the groups seen in cross sections, since both the concentric lamellæ and the ground lamellæ are longitudinal layers. The lacunæ of the Haversian systems, however, are flattened, parallel with the course of the Haversian canals, whereas those of the interstitial lamellæ are more rounded or stellate.

The Haversian lacunæ have been described as shaped like melon seeds.

Certain features of bone which can scarcely be seen in decalcified

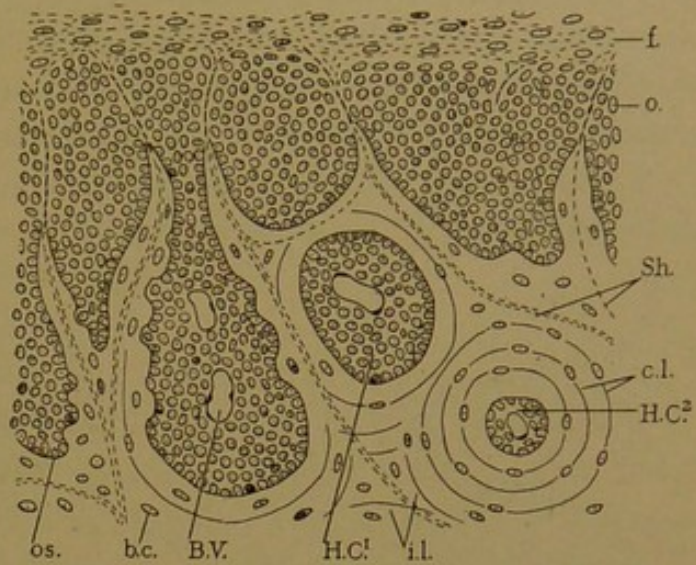


FIG. 81.—DIAGRAM OF THE DEVELOPMENT OF BONE.
(In part, after Duval.)

f., Fibrous layer of periosteum; o., osteogenic layer of periosteum; os., osteoblast; b.c., bone cell; B.V., blood vessel; H.C.¹, beginning Haversian canal; H.C.², complete Haversian canal; i.l., interstitial lamellæ; c.l., concentric lamellæ; Sh., Sharpey's perforating fibers.

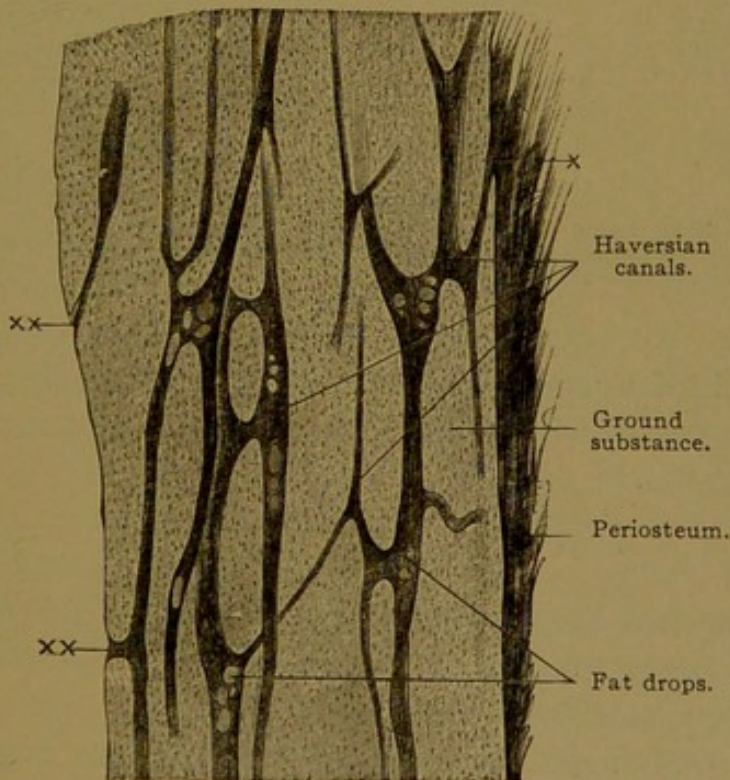


FIG. 82.—FROM A LONGITUDINAL SECTION OF A HUMAN METACARPAL. $\times 30$.
Fat drops are seen in the Haversian canals. At x Haversian canals open on the outer, and at xx on the inner surface of the bone.

specimens are rendered conspicuous in layers of dried bone, ground upon an emery wheel until thin enough to be translucent. The Haversian canals and lacunæ with the canaliculi projecting from them, are then empty, except for air and particles of bone dust. The specimens are mounted in thick balsam, which spreads over the bone without filling the lacunæ and canaliculi. When seen under the microscope these structures appear black (Fig. 83), the air

within them being highly refractive. In such preparations the way in which the canaliculi pass from one lacuna to another, their connections

with the Haversian canal, and their manner of branching may be readily observed. Although these canals are all present in the decalcified bone, they are usually inconspicuous and often invisible. It has been impossible to determine absolutely whether the bone-cells anastomose with one another through these canals, but it is considered probable that their processes do not extend very far into them.

Vessels and Nerves in Bone. The blood vessels of the marrow, bone and periosteum freely connect with one another. Small branches from

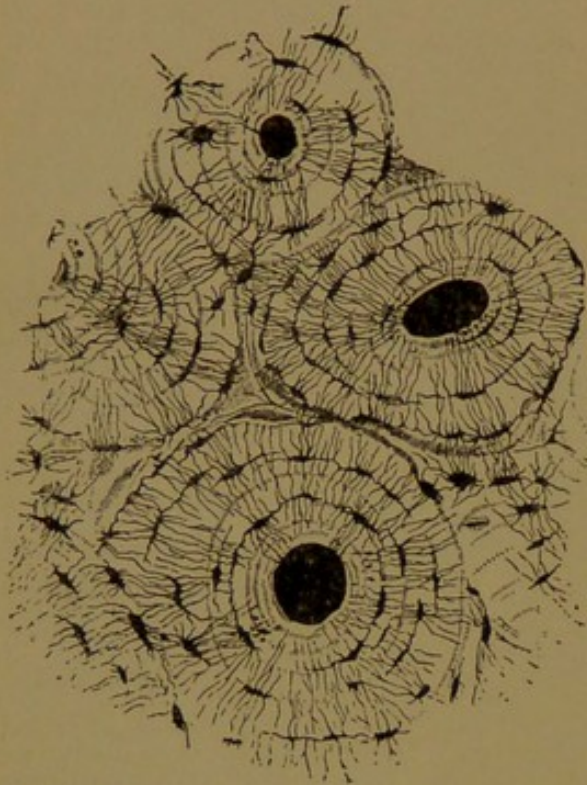


FIG. 83.—CROSS SECTION OF COMPACT BONE, FROM THE SHAFT OF THE HUMERUS, SHOWING THREE HAVERSIAN SYSTEMS AND PART OF A FOURTH. (Sharpey.)

the arteries and veins of the periosteum enter the bone everywhere, through the Volkmann's and Haversian canals, and anastomose with the vessels in the marrow. The marrow receives its blood from the *nutrient artery*, which gives off branches on its way through the compact bone and forms a rich vascular network in the marrow. Of the larger veins which drain this network, one passes out beside the nutrient artery and others connect freely with the vessels in the compact bone. Lymphatic vessels are found only in the outer layer of the periosteum. Numerous medullated and non-medullated nerves are present in the periosteum, where some of them end in lamellar

corpuscles. Others enter the Haversian canals and marrow, chiefly to innervate the vessels. The nerves will be described in a later chapter.

THE JOINTS.

Bones may be joined in two ways, either by a *synarthrosis* which allows little or no motion between them, or by a *diarthrosis* which permits them to move freely upon one another.

In a *synarthrosis* the mesenchymal tissue between the adjacent bones may form dense connective tissue, such as passes from one bone to another across the sutures of the skull (Fig. 79); or it may form cartilage, in which case the joint is known as a *synchondrosis*. The cartilage may be hyaline, as in the epiphyseal synchondroses, but often it is fibrous, as in the intervertebral synchondroses.

In a diarthrosis the connective tissue between the bones remains comparatively loose in texture, and a cleft forms within it, containing tissue fluid. This is the *joint cavity* (Fig. 84). It is bounded in part by flattened connective tissue cells, which spread out and form an imperfect epithelium (Fig. 85). This is not a continuous layer of cells, since in many places the fibrous tissue comes to the surface. The connective tissue layer blends with the perichondrium, which in turn passes into cartilage, and a portion of the cartilage, uncovered by perichondrium, helps to bound the joint cavity.

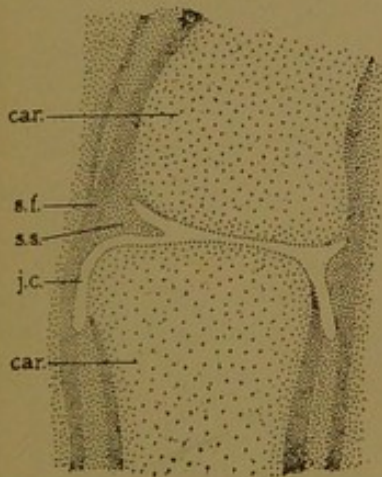


FIG. 84.—PHALANGEAL JOINT FROM A HUMAN EMBRYO OF THE FOURTH MONTH.

car., Cartilage; j. c., joint cavity; s. f., stratum fibrosum; s. s., stratum synoviale.

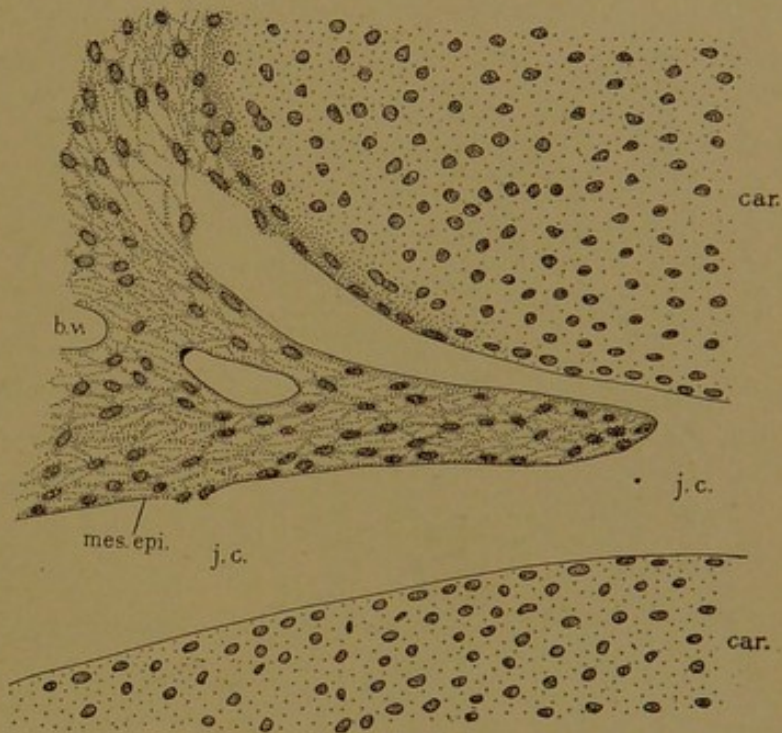


FIG. 85.—AN ENLARGED DRAWING OF THE LEFT PART OF THE JOINT SHOWN IN FIG. 84.

b. v., Blood vessel; car., cartilage; j. c., joint cavity; mes. epi. mesenchymal epithelium.

The articular cartilages are sometimes fibrous (as noted on p. 81) but usually they are hyaline. They vary in thickness from 0.2 mm. to 5 mm., being thinner at the periphery. The cells near the free surface are flattened. In the middle strata they are rounded and are often arranged in groups; in the deepest layers they tend to be in rows perpendicular to the surface. The matrix becomes calcified as the cartilage connects with the bone, and a line of demarcation separates the calcified from the uncalcified portion (Fig. 86). In the uncalcified cartilage, cells with processes extending into the adjacent matrix have been described, and the deeper layers of flattened cells may exhibit lobed nuclei.

The *joint capsule* consists of an outer layer of dense connective tissue, the *stratum fibrosum*; and an inner loose layer of which the mesenchymal epithelium is a part, the *stratum synoviale* (Fig. 84). The fibrous layer is specially thickened in various places to form the *ligaments* of the joint.

It may cover the end of the bone, coming between it and the joint cavity; thus the distal articular surface of the radius is covered with dense fibrous tissue. In other joints, as in the shoulder and hip, such tissue forms a rim, deepening the socket of the joint. These rims are called *labra glenoidalia*. Large folds or plates of dense fibrous tissue may project into the joint, covered by the synovial layer, thus forming the *menisci* of the knee joint, and the *articular discs* such as are interposed in the sternoclavicular and mandibular joints. Nerves and vessels are absent from the articular cartilages of the adult, and also from the labra and articular discs.

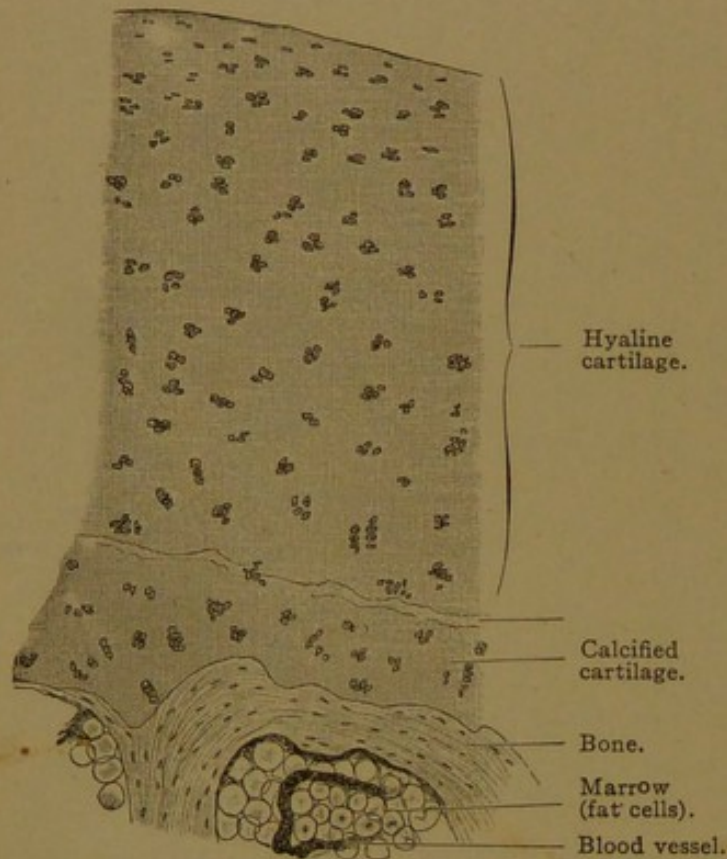


FIG. 86.—VERTICAL SECTION THROUGH THE HEAD OF A METACARPAL OF AN ADULT MAN. $\times 50$.

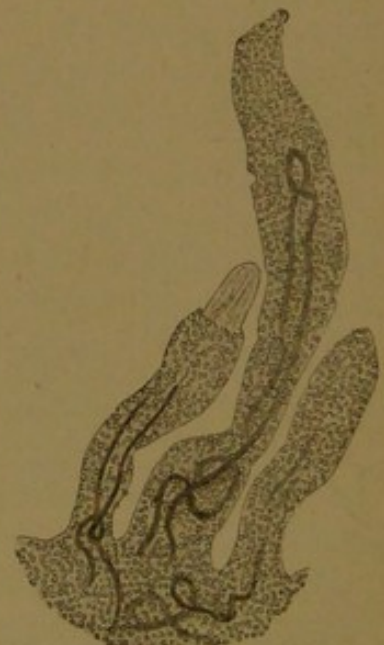

FIG. 87.—SYNOVIAL VILLI WITH BLOOD VESSELS FROM A HUMAN KNEE JOINT. $\times 50$.

The epithelium has fallen from the apex of the left villus, exposing the connective tissue.

The synovial layer consists of loose connective tissue, generally with abundant elastic elements. In many places it contains considerable quantities of fat. It has nerves which may terminate in lamellar corpuscles, numerous blood vessels, and lymphatic vessels which may extend close to the epithelium. The "epithelium" is a smooth glossy layer of connective tissue with parallel fibers and small round or stellate cells containing large nuclei. The cells are sometimes infrequent, as in places where there is unusual pressure. Elsewhere they may be spread in a single thin layer, or heaped together, making an epithelium of three or four strata. The synovial membrane may be thrown into coarse folds (*plicæ*) or into slender almost microscopic projections (*villi*). The latter impart a velvety appearance to the membrane on which they occur.

On microscopic examination the synovial villi are seen to vary greatly in shape. They are covered by a simple or double layer of synovial epithelium, and usually, but not invariably, they contain vessels. The *synovia* (synovial fluid) consists chiefly of water (94%), the remainder including salts, albumin, mucoid substances, fat droplets and fragments of cells shed from the membrane.

TEETH.

A tooth consists of three parts, *crown*, *neck*, and *root* or *roots*. The crown is that portion which projects above the gums; the root is the part inserted into the *alveolus* or socket in the bone of the jaw; and the neck, which is covered by the gums, is the connecting portion between the root and crown. A tooth contains a *dental cavity* filled with *pulp*. The cavity is prolonged through the *canal of the root* to the *apex of the root*, where it opens to the exterior of the tooth at the *foramen apicis dentis*. The foramen is shown, but is not labelled; in Fig. 88. The solid portion of the tooth consists of three calcified substances, the *dentine* or ivory (*substantia eburnea*), the *enamel* (*substantia adamantina*), and the *cement* (*substantia ossea*). Of these the dentine is the most abundant. It forms a broad layer around the dental cavity and root canal, and is interrupted only at the foramen. Nowhere does the dentine reach the outer surface of the tooth. In the root it is covered by the cement layer, which increases in thickness from the neck toward the apex; and in the crown it is enclosed by the broad layer of enamel. The enamel, however, becomes thin toward the neck, where it meets and is sometimes overlapped by the cement. The pulp, dentine, and cement are of mesenchymal origin, the dentine and cement being varieties of bone. The enamel is an ectodermal formation, but so intimately associated with the others that it may be described with them.

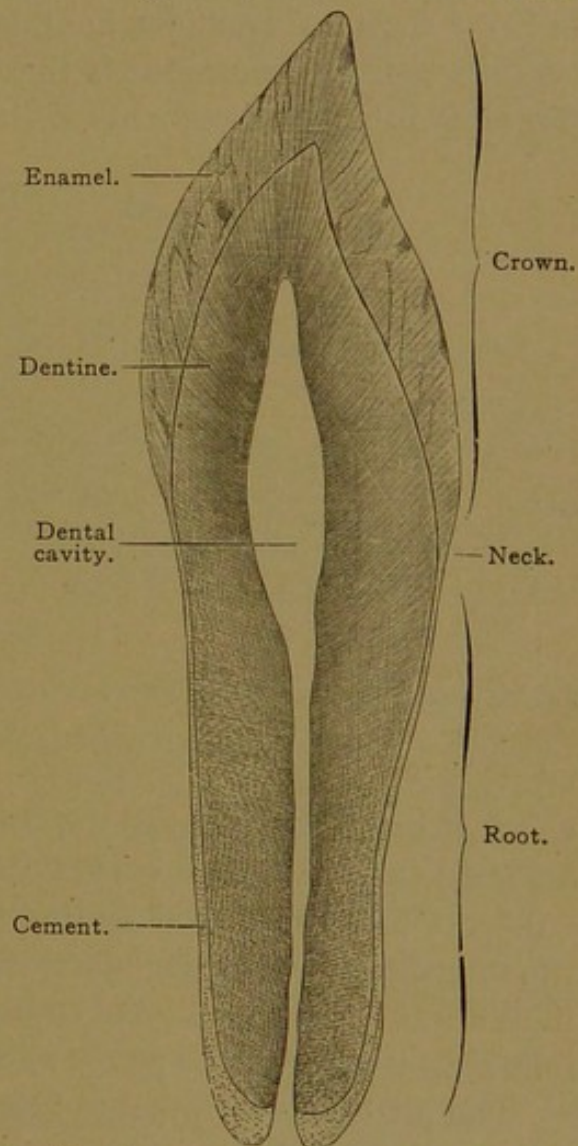


FIG. 88.—LONGITUDINAL GROUND SECTION OF A HUMAN INCISOR TOOTH. $\times 4$.

The Development of the Teeth. The first indication of tooth development in human embryos is a thickening of the oral epithelium, which has been observed in specimens measuring 11-12 mm. At this stage the oral plate, which marks the boundary between ectoderm and entoderm, has wholly disappeared, but it is evident that the thickening takes place in ectodermal territory. The tongue is well developed, but the upper and lower lips are not as yet separated by depressions from the structures within the mouth. Soon after the thickening has appeared, it grows upward in the upper jaw, and downward in the lower jaw, into the adjacent mesenchyma, thus forming an epithelial plate which follows the circumference of either jaw. It undergoes the same sort of transformation in both the maxilla and mandible, and the following description of the conditions in the mandible is therefore applicable to both. As the plate descends into the mesenchyma, it divides into a *labial lamina* in front,

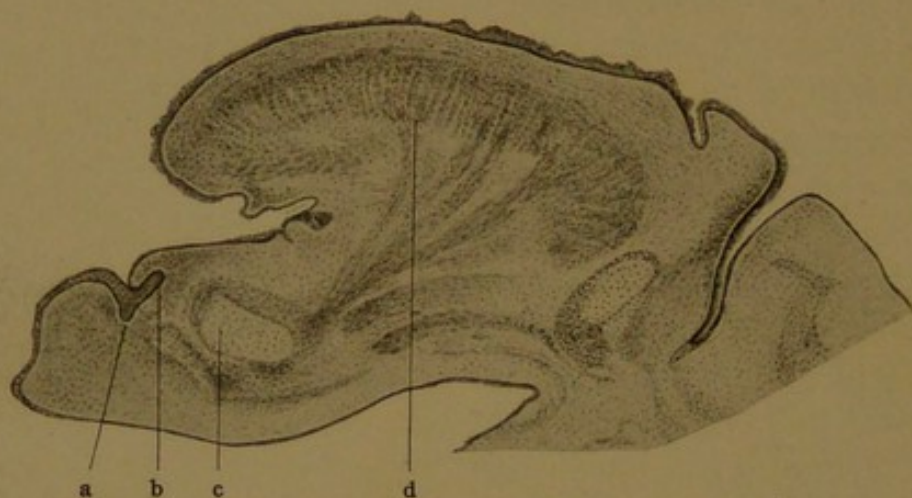


FIG. 89.—SAGITTAL SECTION THROUGH THE TONGUE AND LOWER JAW OF A HUMAN EMBRYO OF 22 MM.
X 20.
a, Labial lamina; b, dental lamina; c, Meckel's cartilage; d, tongue.

which brings about the separation of the lip from the gum, and a *dental lamina* behind, which is concerned with the production of the teeth (Fig. 89). At first the dental lamina is inclined decidedly inward or toward the tongue, as seen in the figure, but later it descends from the oral epithelium almost vertically. Taken as a whole it is a crescentic plate of cells following the line of the gums, along which the teeth will later appear.

The further development of the dental lamina is shown diagrammatically in Fig. 90, A-D, each drawing representing a part of the oral epithelium above and dental lamina below, freed from the surrounding mesenchyma. The labial side is toward the left and the lingual side toward the right. Almost as soon as the dental lamina has formed, it produces a series of inverted cup-shaped enlargements along its labial surface (Fig. 90, B), and these become the *enamel organs*. There is a separate enamel organ for each of the ten deciduous teeth in either jaw, and they are all present in embryos of two and one-half months (40 mm.). They not

only produce the enamel but extend over the roots, so that they are described as forming moulds for the teeth which develop within their cavities. The tissue enclosed by the enamel organ is a dense mesenchyma, constituting the *dental papilla*. It becomes the pulp of the tooth, and produces, at its periphery, the layer of dentine. As the tooth develops, the connection between its enamel organ and the dental lamina

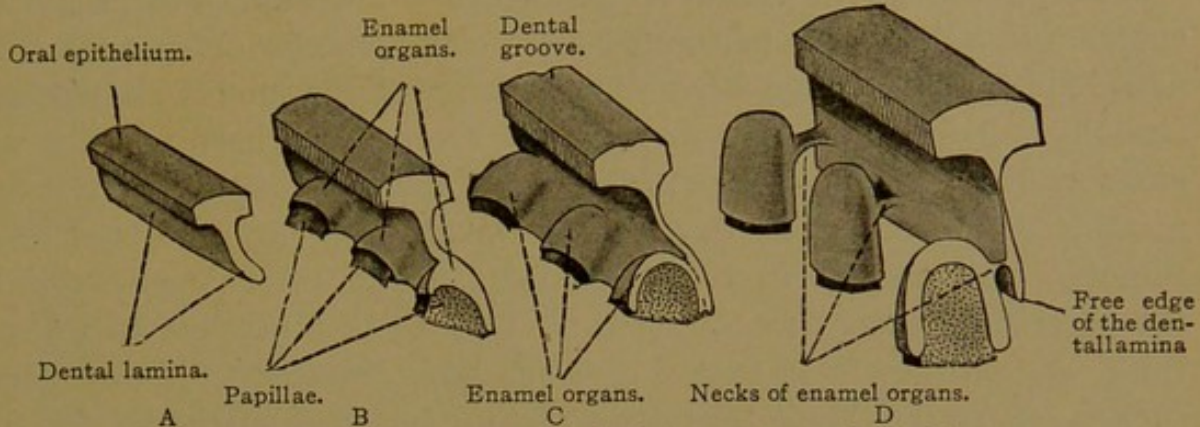


FIG. 90.—DIAGRAMS SHOWING THE EARLY DEVELOPMENT OF THREE TEETH.
(One of the teeth is shown in verticle section.)

becomes reduced to a flattened strand or neck of epithelial tissue, which subsequently disintegrates.

In order to produce enamel organs for the three permanent molars, which develop behind the temporary teeth on either side of the jaws, the dental lamina grows backward, free from the oral epithelium. This backward extension becomes thickened and then inpocketed by a papilla, thus forming the enamel organ for the first permanent molar in embryos of 17 weeks (180 mm.). It grows further back, and gives rise to the enamel organ for the second molar at about six months after birth, and for the third or *late molar* (wisdom tooth) at five years. In rare cases, several of which have been reported, there is a fourth molar behind the wisdom tooth, and it is assumed that in these cases the dental lamina continued its backward growth beyond the normal limits (Wilson, *Journ. Anat. and Physiol.*, 1905, vol. 39, pp. 119-134).

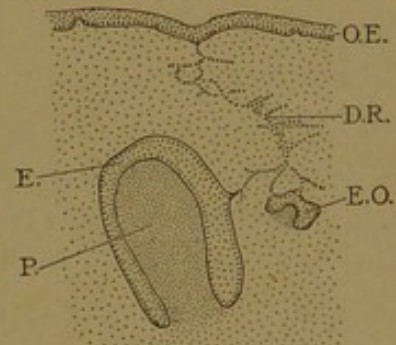


FIG. 91.—TEETH FROM A HUMAN EMBRYO OF 30 CM. (Modified from Röse.)

E. and E. O., Enamel organs of a deciduous and of a permanent tooth respectively; D. R., dental lamina; O. E., oral epithelium; P., papilla.

The permanent front teeth develop from enamel organs on the labial side of the deep portion of the dental lamina (Fig. 91). Owing to the obliquity of the lamina the permanent teeth are on the lingual side of the deciduous teeth. The enamel organs for the incisors develop slightly in advance of those for the canines, but all of these are indicated in an embryo of 24 weeks (30 cm.) described by Röse. He found the enamel organs for the first premolars in an embryo of 29 weeks (36 cm.) and for the second

premolars at 33 weeks (40 cm.). Each front tooth develops in the alveolus occupied by the corresponding deciduous tooth, but later a bony septum forms between the two teeth and subdivides the alveolus. When the deciduous teeth are shed, the partitions are resorbed, together with the dentine and cement of the roots of the deciduous teeth. This resorption is accompanied, as in bone, with the production of osteoclasts.

The portion of the dental lamina which is not utilized in producing enamel organs becomes perforated and forms irregular outgrowths (Fig. 91). This disintegration begins in the front of the mouth and spreads laterally. Epithelial remnants from the lamina have been found in the gums at birth and have been mistaken for glands. Like other epithelial remains they occasionally develop abnormally, forming cysts and other tumors. The deepest part of the lamina, below the enamel organs of the permanent teeth, is considered by Röse to be a possible source of a third set, and he states that a case has been reported to him in which such a set, consisting of thirty-two teeth, developed on the lingual side of the permanent teeth. The models which Röse prepared, showing the enamel organs in various stages of development, form the basis of present accounts of tooth development. They are described and well illustrated in the Arch. f. mikr. Anat., 1891, vol. 38, pp. 447-491.

ENAMEL ORGAN AND ENAMEL.

The basal cells of the oral epithelium may be followed as a distinct layer over the dental lamina and enamel organ, as shown in Fig. 92. This suggests that the enamel organ should be regarded as an infolding of the oral epithelium, and the occurrence of a transient *dental groove* immediately above the lamina (Fig. 90, C) favors this interpretation. The basal surface of the epithelium of the enamel organ is therefore directed toward the surrounding mesenchyma, and the superficial cells are found in the interior of the organ. At first these internal cells are in close contact, like those of ordinary epithelium, but later, through an accumulation of gelatinous intercellular substance, they constitute a protoplasmic reticulum which resembles mesenchyma, and is known as the *enamel pulp* (Fig. 93). No vessels or nerves penetrate this pulp. On the side away from the dental papilla the enamel pulp is bounded by the *outer enamel cells*. At first these are typical cuboidal epithelial cells, but later they become flattened and transformed into a feltwork of pulp fibers. Toward the dental papilla the enamel pulp is bounded by *inner enamel cells*, which develop differently over the upper and lower parts of the tooth respectively. Over the lower portion of the dental papilla they remain as cuboidal or low columnar cells. Here, through a thinning of the pulp, they are brought into contact with the outer enamel cells, and

the two layers together form the *epithelial sheath* of the root (Fig. 102). Over the upper part of the dental papilla, the inner enamel cells elongate and become enamel-producing cells or *ameloblasts* (Fig. 93).

The ameloblasts produce enamel along their basal surfaces, which are toward the dental papilla, but they become so transformed that their basal surfaces appear like free surfaces, and the entire cells seem inverted. In columnar epithelial cells the nuclei are generally basal, and the secretion gathers near the free surface, but in the ameloblasts these conditions are reversed. The nuclei are toward the enamel pulp,

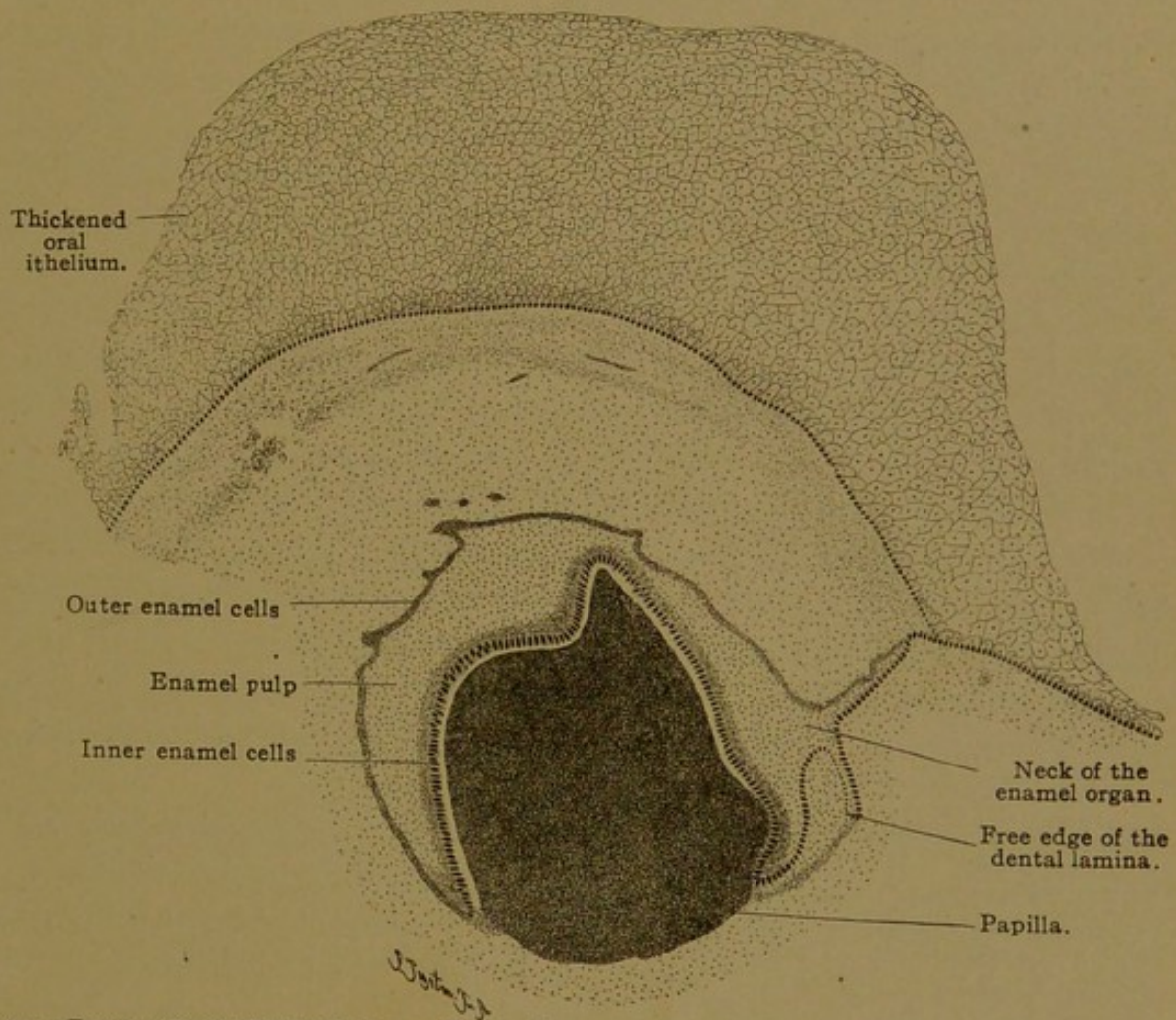


FIG. 92.—FROM A CROSS SECTION OF THE UPPER JAW OF A HUMAN EMBRYO OF FIVE MONTHS. $\times 42$.

and the latter forms a dense layer over the ameloblasts, suggesting a basement membrane (Fig. 93). According to Cohn (Verh. phys.-med. Ges. Würzburg, 1897, vol. 31, No. 4) both ends of the ameloblasts are encircled by terminal bars. These bars may be regarded as modifications of the thin film of cement substance found between the ameloblasts. Near the center of each cell, and therefore on the basal side of the nucleus, Cohn has described typical centrosomes or diplosomes.

Toward the dental papilla the protoplasm of the ameloblasts contains granules or droplets which blacken with osmic acid and presumably indicate secretory activity. The basal surface of each ameloblast presents

a cuticular border and gives rise to a tapering projection known as *Tomes's process*. Tomes's processes extend into the developing enamel, but they may readily be seen in specimens in which the layer of ameloblasts has shrunk away from the enamel, as in Fig. 93. Around these processes minute globules are deposited, which resemble the granules within the cells, since they blacken with osmic acid. They are described as composed of a horny substance similar to that found in the epidermis. This material may become fibrillar, and Tomes's processes also readily break up into fibrils. There is therefore an uncalcified fibrillar layer of

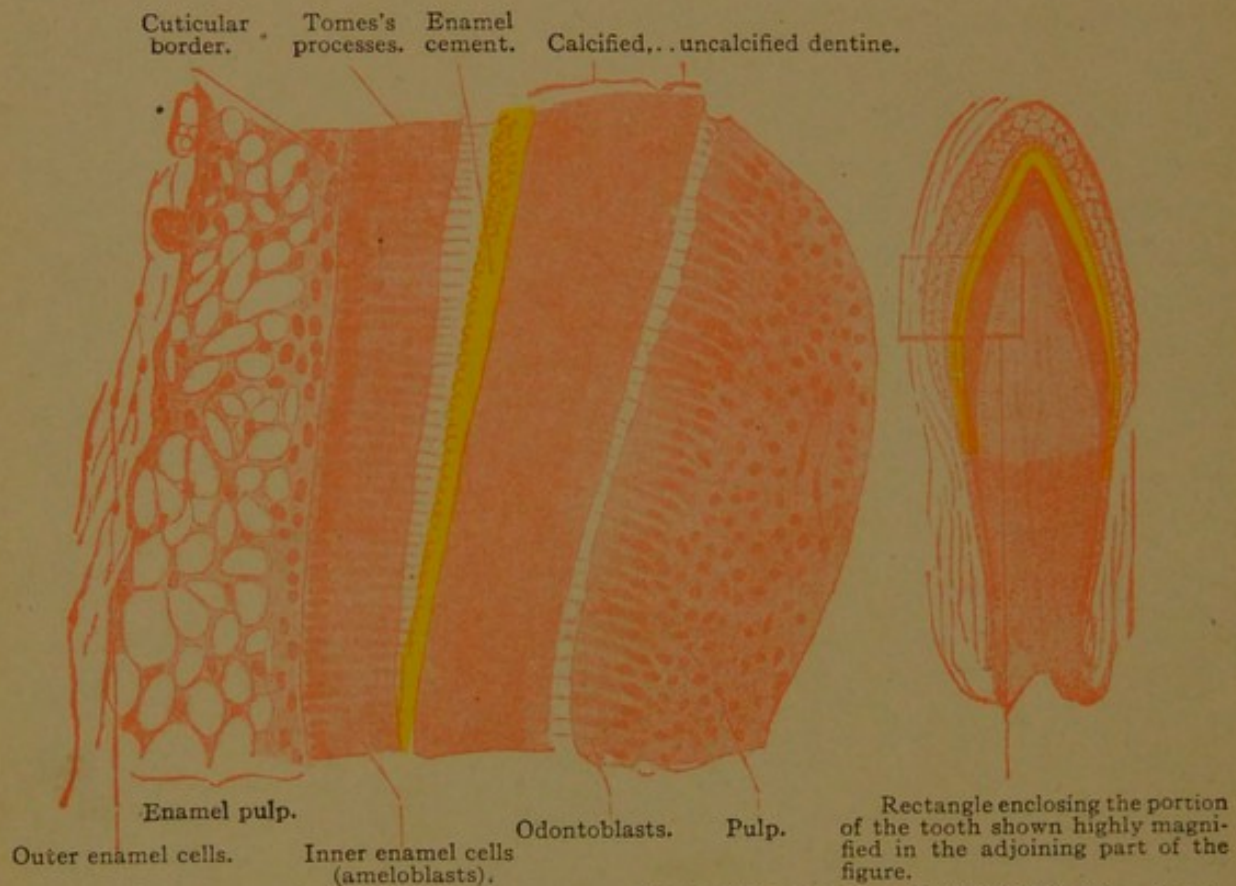


FIG. 93.—PORTION OF A LONGITUDINAL SECTION OF AN INCISOR TOOTH FROM A NEWBORN KITTEN. $\times 300$.
In this section the Tomes's processes have shrunk away from the enamel cement.

enamel next to the ameloblasts. Further from the ameloblasts the enamel is calcified and consists of rods known as *enamel prisms* (sometimes called enamel fibers) which are bound together by calcified matrix or *enamel cement*. The way in which the prisms develop has not been fully determined. They have been regarded as the calcified ends of the ameloblasts and also as intercellular deposits.

The formation of enamel begins at the top of the crown of each tooth and spreads downward over its sides. If the tooth has several cusps, a cap of enamel forms over each, and these caps later coalesce. The enamel increases in thickness by the elongation of the prisms, which extend across it from the inner to the outer surface.

When the tooth comes out through the gum, or *erupts*, the enamel is covered with a "persistent capsular investment" described by Nasmyth (1849) and called "Nasmyth's membrane" (*cuticula dentis*). Huxley studied this structure as it covers the teeth in an embryo of the seventh month (Trans. Micr. Soc. London, 1853, vol. 1, pp. 149-164). He found that the inner enamel cells could be easily removed, leaving the surface of the enamel covered with a finely wrinkled or reticulated structureless membrane. Upon adding strong acetic acid the membrane became voluminous and transparent, and was thrown into coarse folds. The ends of the enamel prisms could be seen through it. This dental cuticula is now generally considered to be composed of the last-formed uncalcified ends of the enamel prisms, which are composed of horny material. After the eruption of the tooth it is gradually worn away, remaining longest in the depressions of the enamel.

The fully developed enamel is the hardest substance in the body. Several analyses have shown that it contains less than 5% of organic matter. No cells or protoplasmic structures are found within it, but it exhibits various markings, shown in Fig. 94. The outer surface of the enamel of the permanent teeth, especially on the sides of the crown and on young teeth, presents a succession of circular ridges and depressions, which may be seen with a hand lens. These were discovered by Leeuwenhoek (1687), whose figure of them is reproduced in Fig. 94, A. He considered that they marked the intervals during the eruption of the tooth, and wrote, "For example, let us assume that the tooth has fifty circles or ridges; if this is so, the tooth has been pushed through the gum during fifty successive days or months." This explanation is not supported by any evidence.

The enamel, as seen in ground sections passing lengthwise through the tooth, shows numerous brownish bands which are broadest and most distinct toward the free surface (Fig. 94, B). These are the *contour lines* or *lines of Retzius*, first described in Müller's Archiv, 1837 (pp. 486-566). The coarsest of them may be seen with the naked eye, but upon magnification these are resolved into a number of finer lines, and many new lines appear. Their direction is shown in the figure; they arch over the apex of the crown, and on its sides tend to be parallel with the long axis of the tooth. Thus they cross the enamel prisms, and are not the lines along which the enamel most readily fractures. Apparently they indicate the shape of the entire enamel at successive stages in its development, and for this reason they are called contour lines. When Leeuwenhoek's ridges are present, the lines of Retzius end in the furrows between them. It was once supposed that their brown color was due to pigment, and it is well known that the enamel of certain teeth in rodents is deeply pigmented and brown. But when the lines are highly magnified, no pigment granules

are found. It then appears that the lines are due to imperfect calcification of the enamel cement, which is often vacuolated where a line crosses it.

Another set of lines crosses the enamel radially, taking the shortest course from the dentine to the free surface. These *radial lines* are due to the arrangement of the enamel prisms, and fractures of the enamel tend to follow them. As seen in reflected light, under low magnification, they appear as alternating light and dark bands, often called Schreger's lines. The prisms in crossing the enamel are bent in such a way that they are cut in alternating zones of cross and longitudinal sections, respectively (Fig. 94, C). These zones vary in shape and sometimes the prisms in cross section form an island surrounded by longitudinal sections. Since an entire prism cannot be isolated or included within the limits of a single section, the course which they take is difficult to determine. There is no

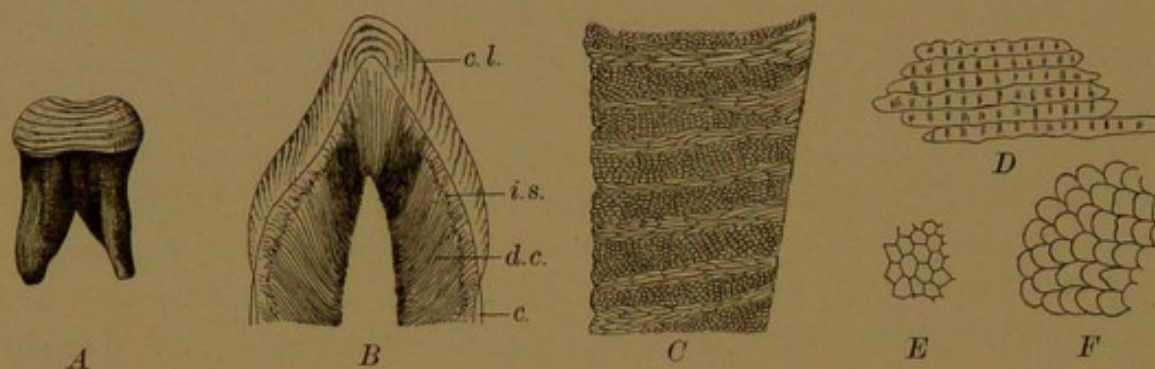


FIG. 94.—THE MARKINGS OF THE ENAMEL IN ADULT TEETH.

A, Leeuwenhoek's figure showing ridges encircling the enamel. B, Longitudinal ground section of a canine tooth; c, cement; c. l., contour lines (lines of Retzius); d. c., dentinal canals; i. s., interglobular spaces. C, Longitudinal section of the enamel of an incisor tooth, the dentinal surface being toward the left. The enamel shows zones of transverse and longitudinal sections of enamel prisms. D, Fragment of enamel showing prisms in longitudinal view, slightly affected by hydrochloric acid. $\times 350$ (Koelliker). E, Cross section of the decalcified enamel of a canine tooth from a child of three years. $\times 350$ (Koelliker). F, Cross section of enamel prisms of a permanent molar from a child of about eight years. (Smreker.)

evidence that they branch, and the greater surface which they cover at the periphery of the enamel, as compared with the dentinal surface, has been explained by an increase in the diameter of the prisms as they pass outward. Such an enlargement is not well marked, however, and is partly offset by an outward thinning of the interprismatic cement. Apparently there is an increase in the number of ameloblasts as the tooth becomes larger, and there may be some late-formed enamel prisms which do not reach the dentinal surface. The plan according to which the prisms bend is discussed in Koelliker's *Gewebelehre* (6th ed.) but it has never been fully explained.

The individual enamel prisms, when seen lengthwise, exhibit transverse markings. These may be made out in ground sections, but they become more evident after the prisms have been treated with acid (Figs. 94, D and 99). They have been regarded as artificial products, but probably they indicate successive stages in the elongation of the prism. Fre-

quently the prisms, when isolated, appear beaded, with transverse bands at the places of constriction.

When seen in cross section the prisms have highly refractive outlines, from $3-6\ \mu$ in diameter. They were formerly described as polygonal and primarily hexagonal (Fig. 94, E) but Smreker finds that they are crescentic, as shown in Fig. 94, F (Arch. f. mikr. Anat., 1905, vol. 66, pp. 312-331). The convex side of the crescent, along which the interprismatic cement is most abundant, is always toward the dentine. The hollow of the crescent receives an adjacent prism which appears to have been pressed into it. Isolated prisms of this sort are therefore hollowed out on one side, and it is possible that they connect with one another by flanges or bridges (von Ebner, Arch. f. mikr. Anat., 1905, vol. 67, pp. 18-81).

DENTAL PAPILLA, DENTINE, AND PULP.

The dental papilla has already been described as a mass of dense mesenchyma, enclosed and probably moulded by the enamel organ. At the end of the fourth month, shortly before the formation of enamel has begun, the outermost cells of the papilla become elongated and arranged in an epithelioid layer. Since they produce the dentine, which is the principal part of the tooth, these cells are known as *odontoblasts*. At first they rest against the inner enamel cells. Later a thin layer of *predentine* extends like a membrane between the ameloblasts and odontoblasts; it is seen as a white line in Fig. 92. As the layer of predentine widens and becomes calcified, the odontoblasts remain on its inner surface, which is toward the pulp. Five of them are shown in Fig. 95, together with their branching processes, one of which proceeds from the cuticular border of each cell and occupies a canal in the dentine. These dental or dentinal canals (*canaliculi dentales*) are readily observed in adult teeth. Their existence, and the fact that they open into the pulp cavity, were recorded by Leeuwenhoek in 1687. "The presence of fibrils of soft tissue within the dentinal tubes" was established by Tomes in 1856 (Phil. Trans., pp. 515-522). He found that if a section of a fresh tooth is placed in dilute hydrochloric acid and then torn across the tubes, fibrils will be seen projecting from the broken edges; and that if the pulp is pulled away from the dentine, fibrils can be drawn out from the tubes. By the latter method the cells shown in Fig. 96 were obtained. The fibers within the dentinal canaliculi are called *dentinal*, *dental* or *Tomes's fibers*.

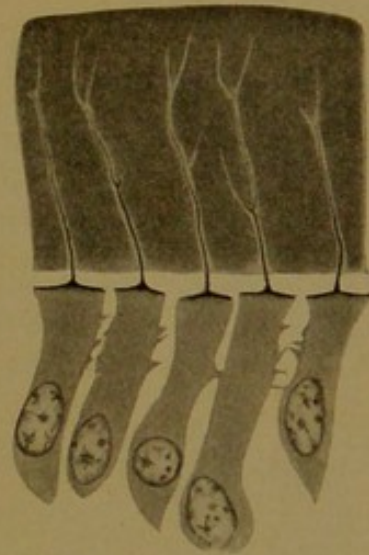

FIG. 95.—FIVE ODONTOBLASTS, FROM WHICH TOMES'S FIBERS EXTEND UPWARD INTO THE DENTINE, FROM A TOOTH OF A NEWBORN CAT. (Prenant.)

Recently von Korff, with special methods, has demonstrated another sort of fibers which lie between the odontoblasts and pass from the pulp into the predentine (Fig. 97, A). The fibers are apparently collagenous

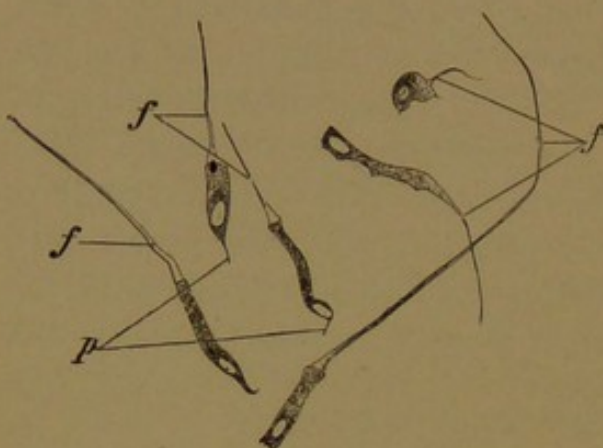

FIG. 96.
Six odontoblasts with dentinal (or Tomes's) fibers, f. p., pulp processes. From the pulp at birth. $\times 240$.

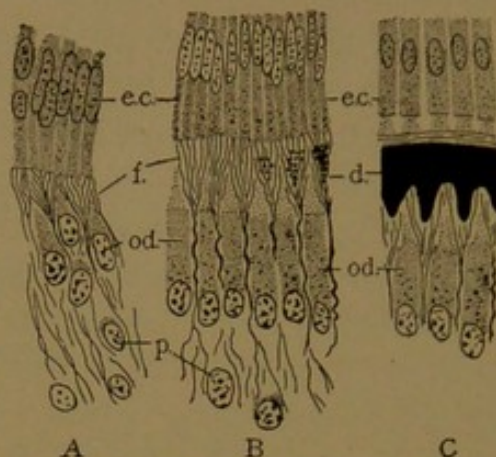


FIG. 97.—THE DEVELOPMENT OF DENTINE IN PIG EMBRYOS. (After v. Korff.)

d., Calcified dentine; e. c., inner enamel cells; f., fibrous ground substance of dentine; od., odontoblasts; p., mesenchymal cells.

and among them, immediately beneath the layer of enamel cells, calcareous granules begin to be deposited (Fig. 97, B). These granules become abundant, and fill the ground substance of the dentine. Von Korff

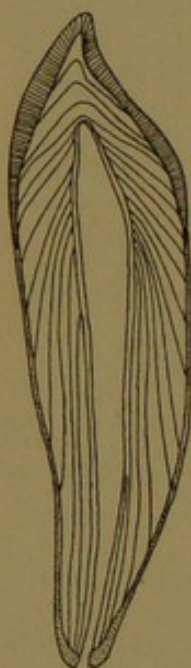

FIG. 98.—DIAGRAM OF THE ARRANGEMENT OF THE DENTINAL LAMELLÆ AND CONTOUR LINES IN AN INCISOR. (Koeliker.)

concludes that it is not the odontoblasts but the fibrils of the pulp which give rise to the dentine, and similarly he finds that in bone the osteogenic fibers develop from the surrounding mesenchyma rather than from osteoblasts (Arch. f. mikr. Anat., 1907, vol. 69, pp. 515-543). Studnička agrees with von Korff that "the odontoblasts are really gland cells, which are only secondarily concerned in the formation of dentine and do not produce ground substance; their processes (the Tomes's fibers) serve to convey certain nutrient material to the parts far removed from the inner surface, and thus nourish the dentine." (Anat. Anz., 1909, vol. 34, pp. 481-502.) Von Ebner, however, maintains that von Korff's fibers are produced by the odontoblasts as part of the process of dentine formation.

Other very fine collagenous fibrils in the dentinal matrix are arranged like the decussating fibers in the lamellæ of bone. They cross one another as they run longitudinally in the successively deposited layers of dentine. These layers are sometimes marked out by distinct *contour lines*, the direction of which is shown in Fig. 98. They indicate the shape of the entire dentine at various stages in its development, and show that

the root of the tooth forms after the crown is essentially complete. The innermost layers are formed last. In addition to the contour lines, dentine seen in reflected light shows the radial Schreger's lines, which follow the course of the dentinal canals but are said to be due to the fibrillar structure of the matrix between them.

Dentine when fully developed is not so hard as enamel and contains a much larger amount of organic matter (approximately 25%). When the inorganic substances are removed from enamel, the remaining tissue scarcely holds together, but dentine and bone, when so treated, leave a gelatinous matrix which preserves the form of the original object. The dentinal canaliculi pass radially through the dentine, often following a somewhat S-shaped course as shown in Fig. 94, B. In addition to these primary curves, they may show spiral twists and secondary curves. As they cross the dentine, they divide dichotomously a few times and give off many slender lateral branches, some of which anastomose with those from adjacent canaliculi (Fig. 99). They finally become very slender

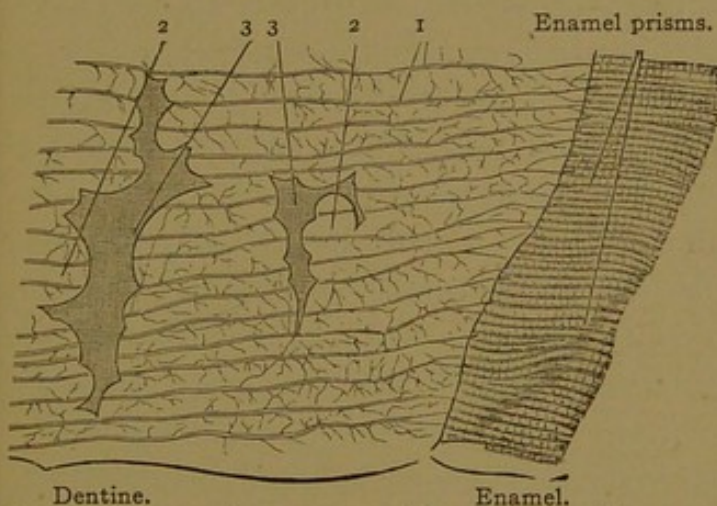


FIG. 99.—FROM A LONGITUDINAL SECTION OF THE LATERAL PART OF THE CROWN OF A HUMAN MOLAR TOOTH. $\times 240$.

1, Dentinal canaliculi, some extending into the enamel; 2, globules of calcified dentine projecting into the interglobular spaces, 3.

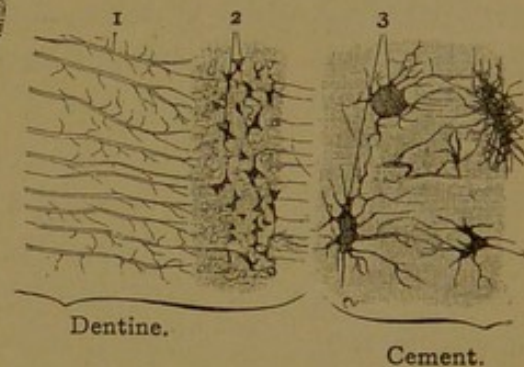


FIG. 100.—FROM A LONGITUDINAL SECTION OF THE ROOT OF A HUMAN MOLAR TOOTH. $\times 240$.

1, Dentinal canaliculi interrupted by a stratum with many small interglobular spaces, 2. 3, bone lacunae and canaliculi.

and generally end blindly, but some terminal loops have been described. Each canal is surrounded by a resistant uncalcified layer known as *Newmann's sheath*. This sheath may be isolated with acids, and thus it is comparable with the "corpuscles" of bone and the capsules of cartilage. It is difficult to determine whether the processes from the odontoblasts extend the whole length of the canaliculi, but they are believed to do so. Tomes observed that the peripheral portion of the dentine is more sensitive than the deeper part, and considered that the fine ramifications of the odontoblasts respond like nerve fibers to stimulation. Nerves have been traced to the odontoblast layer at the base of the dentine, but it is doubtful whether they extend into the dentinal canals as some have reported.

The contact between the dentine and enamel is usually quite smooth. Each enamel prism rests in a shallow socket on the dentinal surface, and in places the dentinal canals extend into basal clefts in the enamel cement. A short distance beneath the enamel the dentine exhibits a layer of spaces, which in ground sections are filled with air and appear black (Fig. 94, B, i.s.). They occur along the contour lines, and are due to imperfect calcification of the cement in that region of the matrix which was the first to form. Each space is bounded by spherules of calcified matrix which project into it from all sides, and the cavities are therefore known as *interglobular spaces* (Fig. 99). Toward the root of the tooth they are smaller and more numerous than in the crown. They are said to be particularly abundant in poorly developed teeth.

The *pulp* consists of a fine network of reticular tissue together with the peripheral layer of odontoblasts already described. The odontoblasts persist throughout life, and may continue to produce dentine so that the root canals may become nearly or quite obliterated. They are also active in repairing injuries. Some of the late-formed dentine contains blood vessels and resembles bone, so that it has been called osteo-dentine. The odontoblasts connect with one another and with the rest of the pulp by protoplasmic processes. The pulp tissue is free from elastic fibers and from bundles of white fibers. It is very vascular. The small arteries entering the apical foramina send capillaries close to the odontoblasts, but normally they do not enter the dentine. Lymphatic vessels, according to Schweitzer, are found by injection to begin as a tuft of branches in the pulp of the crown; they empty into one or a few very wide vessels passing through the root (Arch. f. mikr. Anat., 1907, vol. 69, pp. 807-908). The nerves of the pulp are the medullated dental branches of the alveolar nerves, which enter through the apical foramina, lose their sheaths and form a loose plexus beneath the odontoblasts, between which they terminate in free endings.

DENTAL SAC, CEMENT, AND PERIODONTAL TISSUE.

Each embryonic tooth, consisting of its enamel organ and papilla, is completely surrounded by mesenchyma, which extends from the oral epithelium to the bony trabeculæ of the developing jaw (Fig. 101). This mesenchyma gives rise to the *dental sacs* enclosing the teeth; each sac consists of a dense outer layer and a loose inner layer of young connective tissue (Fig. 102). Toward the base of the dental papilla the tissue of the sac is separated from the dentine by the epithelial sheath, which is a part of the enamel organ. After the crown of the tooth is well developed, the epithelial sheath disintegrates or becomes penetrated by cells of the dental sac, which are then transformed into osteoblasts and deposit bone directly

upon the outer surface of the dentine. This bone is a part of the tooth and is known as the *substantia ossea* or *cement*. It is thinnest at the neck of the tooth, and increases in thickness downward toward the apex of the root, over which it forms a considerable cap (Fig. 88). The deeper part of the root develops after the eruption of the crown.

The cement contains typical bone cells, enclosed in large lacunæ which connect with one another through canaliculi (Fig. 100). The dentinal surface sometimes appears resorbed and the dental canaliculi then end abruptly; occasionally they appear to anastomose with those of the cement.

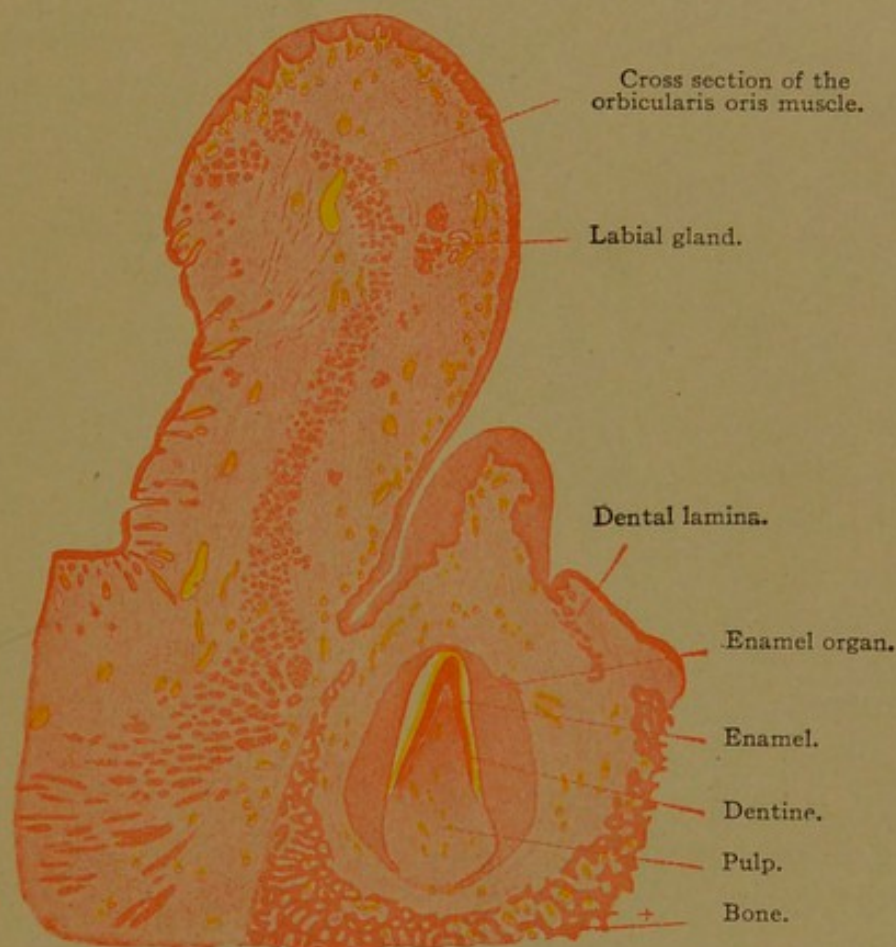


FIG. 101.—VERTICAL SECTION THROUGH THE LIP AND JAW OF A HUMAN EMBRYO OF SIX AND A HALF MONTHS. $\times 9$.

The lamellæ of the cement, which are seldom well marked, are concentrically placed around the root. In young teeth Haversian canals are absent, but in old teeth they occur in the outer layers near the apex of the root. Connective tissue fibers, comparable with Sharpey's fibers in bone, pass radially through the cement. They cross the dental sac and enter the bone of the alveolus, thus binding the tooth to its socket.

As the tooth enlarges and fills the socket, the dental sac becomes reduced to a thin layer consisting of the alveolar periosteum externally and the dental periosteum internally, with vascular connective tissue between. Frequently these are described as a single layer. It may contain fragments of the epithelial sheath. It has few elastic fibers, but is well supplied with

vessels and nerves which are branches of those about to enter the apical foramen. Around the neck of the tooth, dense connective tissue forms the circular ligament (*Lig. circulare dentis*).

The gum (*gingiva*) is the part of the lining of the mouth which surrounds the tooth. It is covered by the stratified oral epithelium, in which

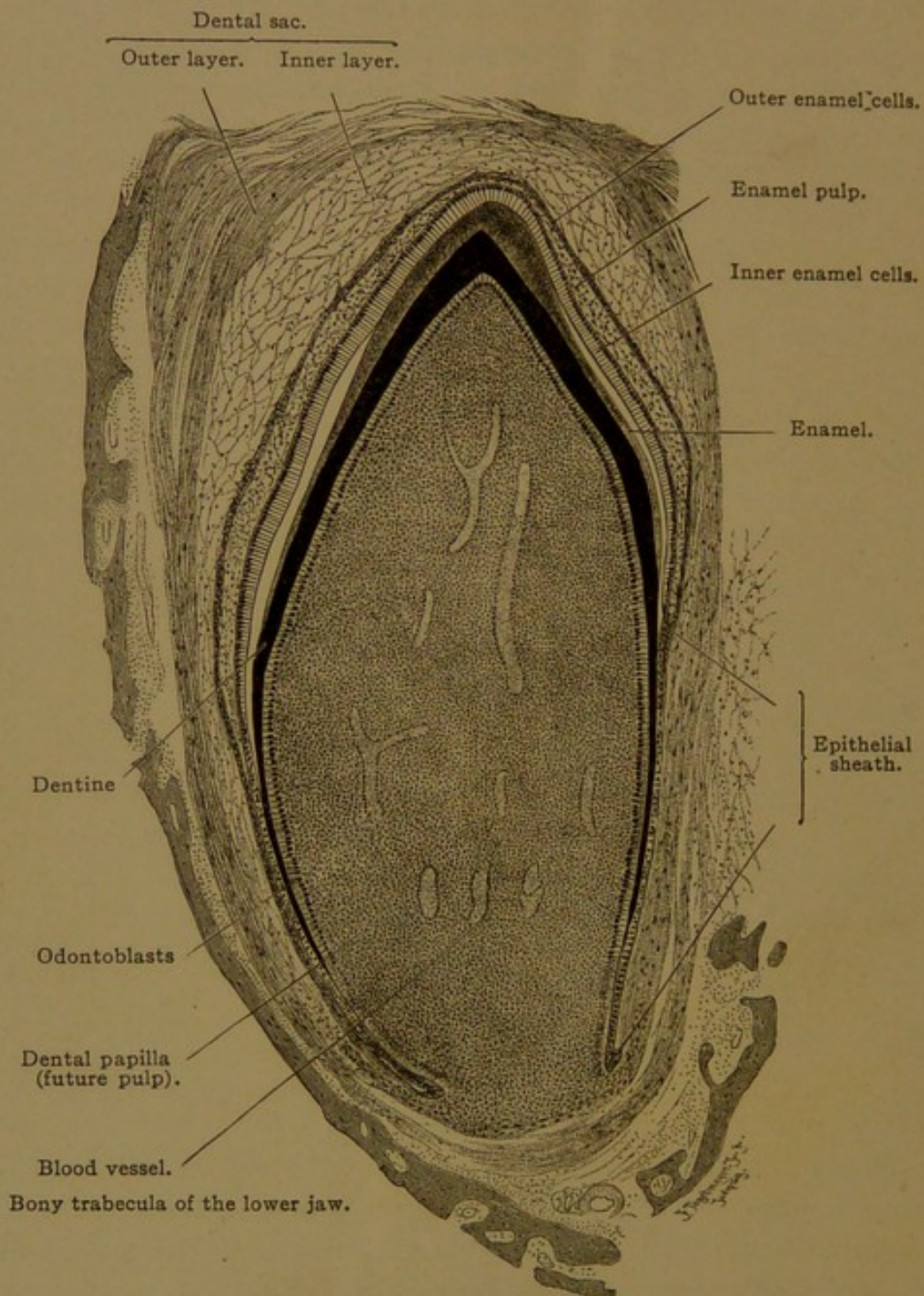


FIG. 102.—LONGITUDINAL SECTION OF A DECIDUOUS TOOTH OF A NEWBORN DOG. $\times 42$.
The white spaces between the inner enamel cells and the enamel are artificial, and due to shrinkage.

intercellular bridges are well developed, and this epithelium rests on tall connective tissue elevations or papillæ. There are no glands in the gums. When the tooth erupts it makes a hole through the epithelium, but the margins of the aperture become inverted. Thus the epithelium extends

close to the tooth and turns down as a sheath surrounding the neck. At the level of the upper part of the cement it ends abruptly. The connective tissue of the gums blends below with the circular ligaments. It contains few elastic fibers, but is very vascular and is often infiltrated with lymphocytes. Its lymphatic vessels drain outward, along the margin of the cheek and gums, and inward, over the floor or roof of the mouth, as shown by Schweitzer.

MUSCULAR TISSUE.

Contractility is a fundamental property of protoplasm. In muscle cells it attains its highest development. Muscle cells are elongated structures, known as *muscle fibers*, which contain numerous longitudinal fibrils within their protoplasm. By the shortening of these fibrillated cells, muscular action results. The muscle fibrils, or *myofibrils*, may be free from transverse markings, as in *smooth muscle*; or they may exhibit a succession of dark and light transverse bands, as in *striated muscle*. Smooth muscle fibers enter into the formation of the viscera, and their action, almost without exception, is *involuntary*. Striated muscle, in so far as it constitutes the entire system of skeletal muscles, is *voluntary*, or under the control of the will, but the striated fibers of the diaphragm and upper part of the œsophagus are apparently involuntary. The special form of striated muscle, known as *cardiac muscle*, which makes the bulk of the heart and extends some distance in the wall of the pulmonary veins, is involuntary. The three principal forms of muscle, smooth, skeletal, and cardiac, are mesodermal in origin. Within the basement membrane of the sweat glands there are elongated ectodermal cells which have been described as smooth muscle fibers, but their contractile nature is still questioned. It is well established, however, that the muscles of the iris, which control the size of the pupil, are derived from ectodermal cells which bud off from those forming the optic cup. Ectodermal muscles in man are limited to these examples.

SMOOTH MUSCLE.

Smooth muscle fibers are derived from mesenchymal or young connective tissue cells. Usually they are produced in layers which surround some tubular organ, such as a blood vessel, duct, or a part of the digestive tube. The fibers in these layers are generally parallel, and are usually either circular or longitudinal in relation to the organ which they envelop. Occasionally they are oblique, or irregularly interwoven. Fibers which encircle an organ are called *circular* or *transverse fibers*; they may be cut across or split lengthwise according to the plane in which the organ is sectioned. The same is true of the *longitudinal fibers*, which run lengthwise of the organ.

The formation of smooth muscle may be studied advantageously in the œsophagus of pig embryos, and its development in this position has been carefully described by Miss McGill (Internat. Monatschr. f. Anat. u. Physiol., 1907, vol. 24, pp. 209-245). A part of a longitudinal section of the œsophagus of a 27-mm. pig is shown in Fig. 103. In such a section the developing longitudinal smooth muscle fibers or *myoblasts* are cut lengthwise (*s.l.*); and the circular fibers, which form a layer internal to the longitudinal fibers, are cut across (*s.c.*). The loose mesenchymal network, from which these fibers arise, is continuous with them above and below. A third thin layer of muscle fibers is forming at *m.m.*, and at the top of the figure, the entodermal epithelium which lines the œsophagus has been included, together with the basement membrane beneath it.

In becoming smooth muscle cells, the mesenchymal cells change from a stellate to a spindle-shaped form and come closer together, but they do not lose their protoplasmic connections with one another. In the outer part of their protoplasm coarse *border fibrils* or *myoglia fibrils* are produced, which are similar to the fibroglia fibrils of connective tissue (p. 64). According to Meves, the fibroglia and myoglia are identical. The latter are at the periphery of the muscle cells and pass from one cell to another for long distances. These fibrils may be strikingly demonstrated in the œsophagus of a 24-mm. pig, stained with phospho-tungstic acid hæmatoxylin.

The coarse fibers shown by Miss McGill in both the circular and longitudinal muscle layers in Fig. 103 are "often found lying in part near the surface of the cell, resembling the border-fibrils of Heidenhain." She states that they are produced by a coalescence of granules within the protoplasm, forming at first spindle-shaped bodies which later join end to end, making varicose fibers. Subsequently they become smooth. They may split into fine fibrils, and usually they decrease in number as the embryo grows older. "In places they may be entirely absent in the adult tissue; rarely they are abundant."

In addition to the peripheral myoglia fibrils, the protoplasm of smooth muscle cells contains fine longitudinal fibrils, which have been described as the active agents in muscular contraction. Thus Miss McGill finds that in the contracted portions of the muscle fibers the myofibrillæ show "a distinct increase in caliber." She states that the fine myofibrils do not arise until the pig embryo reaches a length of about 30 mm. They are apparently homogeneous from the beginning, and are distributed uniformly throughout the protoplasm. Some of them are shown in the muscle layer *m.m.* in Fig. 103. Ordinarily these fibrils are indistinguishable in the close-grained, deeply staining protoplasm which characterizes the muscle cells.

Along the sides of the muscle fibers there are at first protoplasmic processes which bind them together. Later these seem to be replaced by white fibers, like those of ordinary connective tissue. They form a network investing the muscle cells, as shown in Fig. 104. This inter-muscular reticulum, produced directly from the muscle fibers, is unusually well shown in the walls of the blood vessels in the umbilical cord. To some extent, according to Miss McGill, it is produced from special mesen-

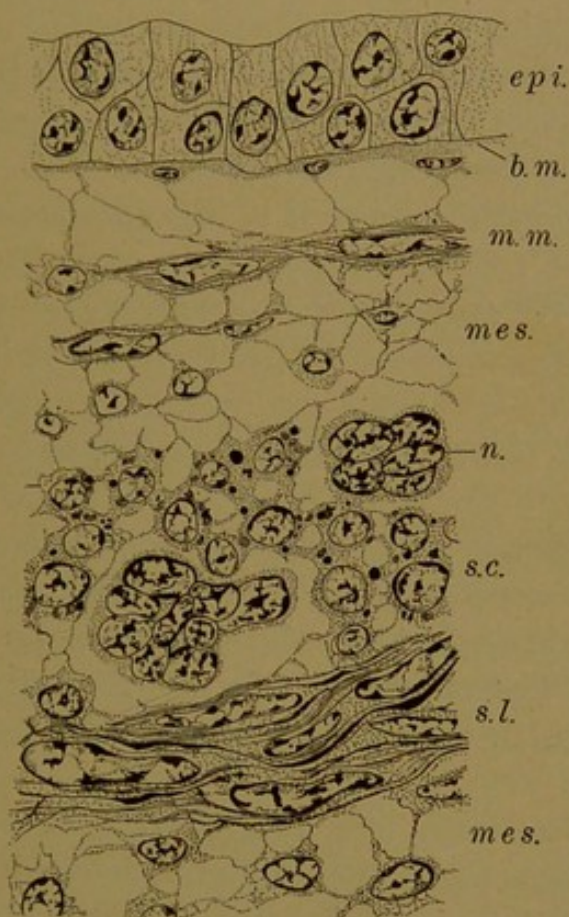


FIG. 103.—FROM A LONGITUDINAL SECTION OF THE OESOPHAGUS OF A 27-MM. PIG EMBRYO. X 700. (After McGill.)

b. m., Basement membrane; epi., epithelium; mes., mesenchyma; m. m., muscularis mucosae; n., nerve cells; s. c., circular smooth muscle cut across; s. l., longitudinal smooth muscle cut lengthwise.

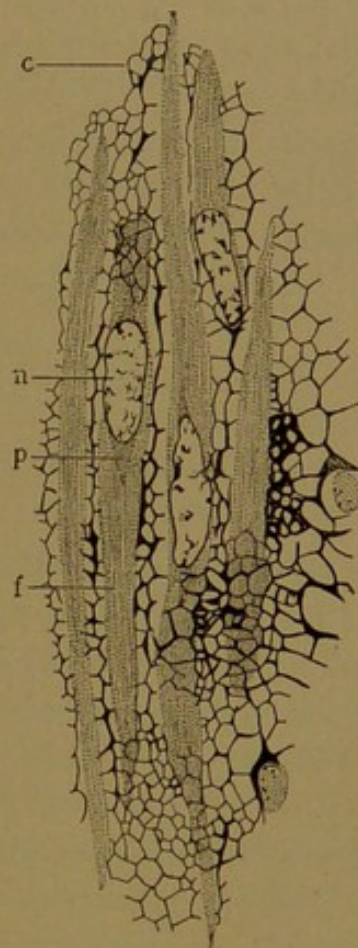


FIG. 104.—FIBROUS TISSUE IN RELATION WITH SMOOTH MUSCLE FIBERS, FROM THE BLADDER OF A PIKE. (After Prenant.)

c., Connective tissue network; n., p., f., nucleus, granular protoplasm, and fibrillar protoplasm of a muscle cell.

chymal cells within the muscle layer, which develop into connective tissue cells. In many layers of smooth muscle, however, connective tissue cells are difficult to demonstrate. Finally it should be noted that elastic fibers are found between the muscle cells. They vary greatly in number, being especially abundant in the walls of arteries.

From what has been said, it is evident that smooth muscle retains its original syncytial nature, and that to some extent it resembles connective tissue. It consists of elongated contractile cells which are joined together, especially toward their extremities, by myoglia fibrils, and which are bound together laterally by a white fibrous network containing inter-

spersed elastic fibers. These features, which are essential for understanding the action of smooth muscle, are usually difficult to observe in the compact tissue of the adult.

Smooth muscle fibers in the adult are fusiform, cylindrical or slightly flattened cells, varying in length from about 0.02 mm. in some blood vessels to approximately 0.5 mm. in the pregnant uterus. In the intestine they are said to measure about 0.2 mm. Their diameter, through the widest part, is from 4–7 μ . Owing to the length of these fibers and the fact that they are not perfectly straight, they are seldom wholly included in a single section. Moreover they are usually so closely packed that their outlines are hard to follow. They may be isolated, however, by treating fresh tissue with a 35% aqueous solution of potassium hydrate, or 20% nitric acid. The fibers when shaken apart appear as in Fig. 105. Owing

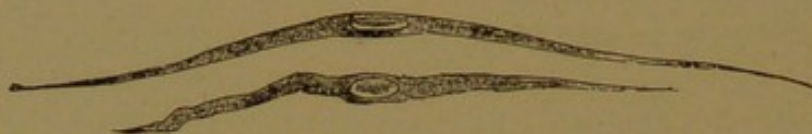

FIG. 105.—SMOOTH MUSCLE FIBERS FROM THE SMALL INTESTINE OF A FROG. $\times 240$.

to the readiness with which they may be disassociated, the existence of connections between them has sometimes been overlooked or underestimated; but it is evident that independent cells, by shortening cannot cause the contraction of a tube. Branching fibers have been isolated from the aorta, and are said to occur also in the ductus deferens and bladder.

The fibers when sectioned longitudinally (see Fig. 177, p. 186) somewhat resemble connective tissue, from which they may be distinguished by the staining and texture of their protoplasm and the position of their nuclei, which are within the fibers. With hæmatoxylin and eosin the muscle substance takes a deeper and more purple stain than the connective tissue fibers, and it is not so refractive. In doubtful cases Mallory's connective tissue stain may be used, which colors the muscle substance red and the white fibrous tissue blue.

The nuclei of smooth muscle fibers are elliptical or rod-like bodies, containing a characteristic chromatic reticulum and sometimes several nucleoli (Fig. 9, A, p. 10). When the muscle fiber contracts, the nucleus shortens and broadens, but according to measurements made by Miss McGill (*Anat. Rec.*, 1909, vol. 3, pp. 633–635) there is no change in its volume. She finds, however, that the chromatin tends to collect at the poles of the contracted nucleus, and states that "the nucleus appears to take an active part in the process of contraction." Frequently spirally twisted or bent nuclei are found in layers of contracted muscle (Fig. 106) and they have been regarded as occupying contracted fibers. It is

probable, however, that the spiral nuclei occur in relaxed fibers, which have been crumpled together by the contraction of adjacent fibers. Along one side of the nucleus the centrosome may be found, occupying a shallow indentation of the nuclear membrane.

At the poles of the nuclei there is often an accumulation of granular protoplasm (Fig. 104, p. 115) which is sometimes pigmented. The fibrils diverge to pass by the nucleus, and the granular protoplasm occupies the conical non-fibrillated space which is thus produced.

The surface of the smooth muscle fibers is covered by a delicate membrane, which is sometimes thrown into transverse wrinkles by the contraction of the fiber. Possibly the fibrils terminate in it. They do not appear to become more compact as they extend into the tapering ends of the fibers and presumably they do not all extend the whole length of the cell.

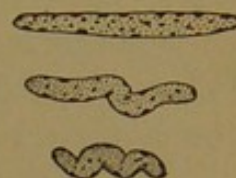


FIG. 106.—NUCLEI OF SMOOTH MUSCLE FIBERS FROM THE ARTERY OF A DOG.

In transverse sections the fibers present rounded or polygonal outlines (Fig. 107). They vary in size, since some are sectioned through the tapering extremity and others through the thick central part which contains the nucleus. In the figure the substance between the fibers appears solid, and it has sometimes been described as cement, or as a membrane rather than as a reticulum.

The relation of the myoglia, reticulum and muscle fibers to the process of contraction has never been adequately explained. In the intestine, with the normal accumulation of food, the diameter of the tube becomes four times as great as in the contracted state, and the muscle layer becomes reduced to somewhat less than one-fourth of its original thickness. The muscle cells appear to slip by one another and to form a layer only a few fibers thick. After a certain amount of distention the tube will expand no further, and added pressure causes it to rupture. Presumably the elastic and white fibers aid in restoring the normal caliber.

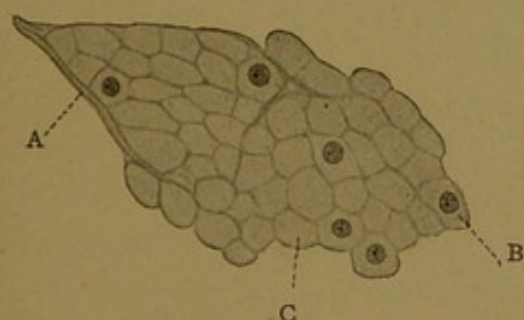


FIG. 107.—CROSS SECTION OF SMOOTH MUSCLE FIBERS FROM THE STOMACH. $\times 560$.

a, Connective tissue septum; b, section of a fiber distal to the nucleus; c, section of a fiber through the nucleus.

With extreme contraction, however, the white and elastic fibers no longer aid the muscles, but become crumpled into coarse folds, as seen frequently in contracted arteries. As to the muscle fibers themselves, Meigs concludes that during contraction fluid passes from them into the intercellular spaces, so that the fibers shrink in size and become darker; he states that they decrease greatly in length but remain of about the same diameter, while the spaces between the fibers become larger (Amer. Journ. Physiol., 1908, vol. 22, pp. 477-499). According to Miss

McGill, the deeply staining nodular thickenings of muscle fibers indicate a normal form of contraction in which the fiber does not contract as a whole, but a wave of contraction passes over it. In these contraction nodes the diameter of the fiber becomes increased (Amer. Journ. Anat., 1909, vol. 9, pp. 493-545). The enlargement of such muscular tubes as the vessels and intestine appears to be passive and due respectively to the pressure of the blood or food within. After extreme contraction the elastic tissue probably serves to dilate the tube to a certain size.

Smooth muscle is nourished by capillary blood vessels which tend to follow the course of the fibers, and it is innervated by slender branches of the sympathetic nervous system.

SKELETAL MUSCLE.

The skeletal muscles develop primarily from the mesodermic somites, which have been briefly described in a previous section (p. 39). The transformation of a portion of each of these blocks of tissue into layers and masses of skeletal muscle fibers has recently been reviewed by Williams, from whose work Fig. 108 has been taken (Amer. Journ. Anat., 1910, vol. 11, pp. 55-100). In Fig. 108, A, the core of the somite has fused with the ventral and medial walls of the mass, and the tissue thus formed is streaming over the aorta and toward the notochord. This tissue, the *sclerotome*, becomes mesenchyma and gives rise to smooth muscle and various other mesenchymal derivatives. In the part of the somite left in place, near the groove x, the striated muscle fibers begin to develop. The cells here elongate at right angles with the plane of the figure, and thus lengthwise of the embryo. In an older stage (Fig. 108, B) these myoblasts have multiplied and have begun to form a plate of muscle tissue, the *myotome*, which extends ventrally as shown in C and D. The dorso-lateral wall of the somite has meanwhile become a plate of tissue, the *dermatome*, which with the myotome associated with it, is often called the *dermo-myotome*. The dermatome according to Bardeen produces only striated muscle fibers; Williams finds that it forms only dermal connective tissue, and others consider that it gives rise both to muscle and connective tissue. The myotome is "entirely transformed into muscle fibers." The way in which the myotomes extend ventrally and break up into the ventro-lateral trunk and neck musculature, and the longitudinal fusion and splitting of the dorsal part of the myotomes to produce the deep back muscles of the trunk and neck, have been described by Warren Lewis (Keibel and Mall, Human Embryology, 1910). The skeletal muscles of the limbs have usually been described as arising from cells which have migrated into the limbs from the ventral part of the myotomes. If this takes place the cells which migrate become indistinguishable from mesen-

chymal cells, but Bardeen and Warren Lewis consider that "the myotomes play no part whatever in the origin of the musculature of the limbs." Moreover, Lewis states that "the idea that myotomes play a rôle in the origin of the muscles of the head must be abandoned." A radical differ-

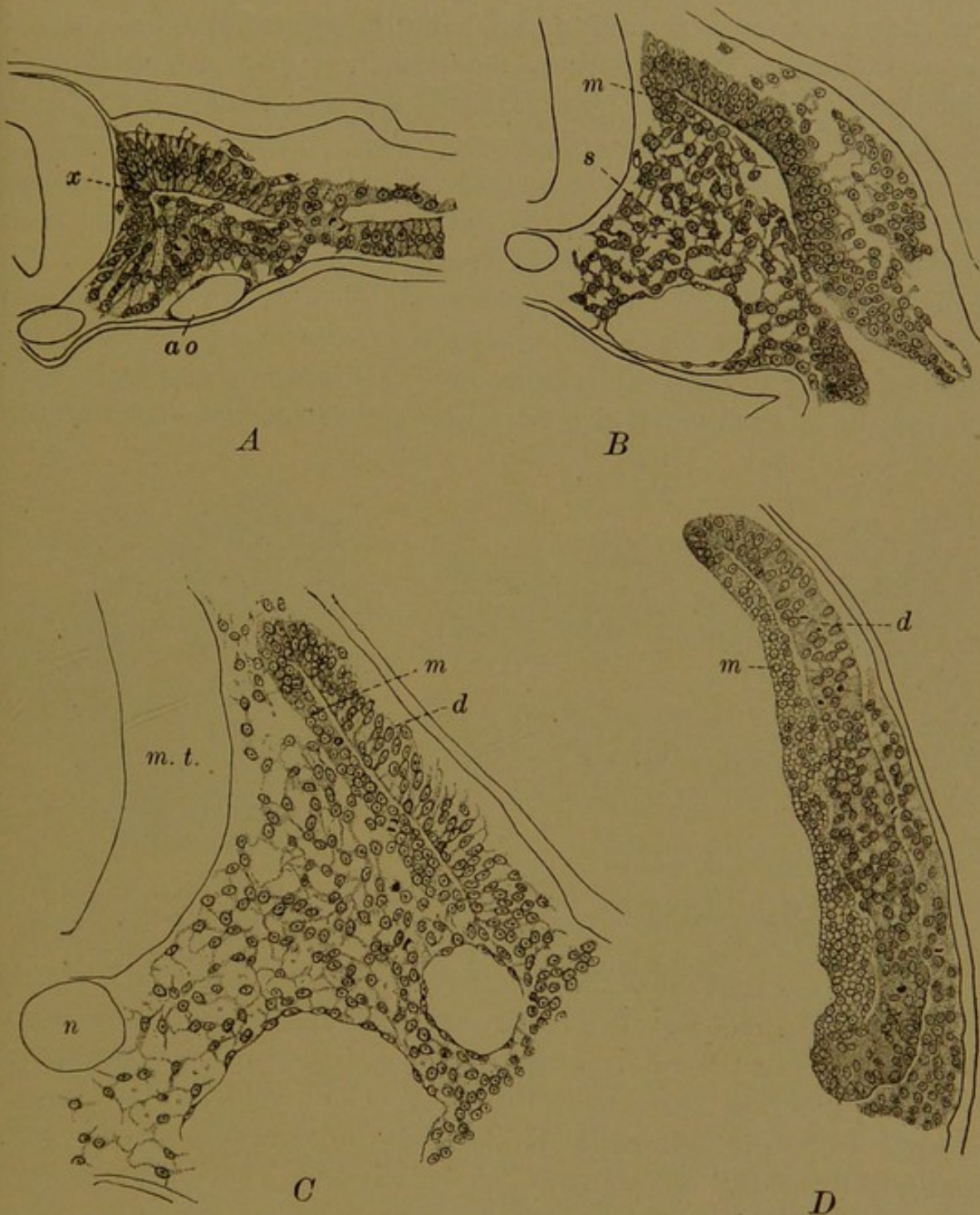


FIG. 108.—TRANSVERSE SECTIONS THROUGH THE MIDDLE OF CERTAIN SOMITES IN SUCCESSIVELY OLDER CHICK EMBRYOS. A, B, AND C., THROUGH ONE OF THE SECOND PAIR OF SOMITES IN EMBRYOS OF NINE, FIFTEEN, AND TWENTY-FIVE SEGMENTS RESPECTIVELY; D, THROUGH ONE OF THE FORTY-FOURTH PAIR IN AN EMBRYO OF FIFTY-TWO SEGMENTS. $\times 230$. (Williams.)
ao., Aorta; d, dermatome; m, myotome; m. t., medullary tube; n, notochord; s, sclerotome; x, angle at which the myotome develops.

ence in the source of smooth and striated fibers has therefore not been demonstrated, but the two forms of muscle develop very differently.

The myoblasts which produce striated muscle are found in the midst

of a mesenchymal or connective tissue network, thus differing from the myoblasts of smooth muscle. The latter unite with one another through protoplasmic or fibrous processes; the striated fibers are bound together by connective tissue sheaths. In producing striated fibers, the myoblasts become greatly elongated cylindrical structures, with rounded or blunt ends. Although according to Schäfer they generally do not exceed 36 mm. in length, they sometimes measure from 53–123 mm. (Stöhr); their diameter is 0.01–0.1 mm. During the growth of the myoblast, mitotic nuclear division takes place repeatedly, producing multi-nucleate cells; and in the adult fibers, a further multiplication of nuclei through amitosis has been reported. Each developing myoblast thus acquires a row of centrally placed nuclei, imbedded in granular protoplasm. In the outer part of the myoblasts coarse myofibrils develop, which, as seen in cross section, form an encircling ring about the nuclei and axial core of protoplasm (Fig. 109). The entire myoblast is surrounded by a membrane, to the formation of which the adjacent mesenchyma contributes.

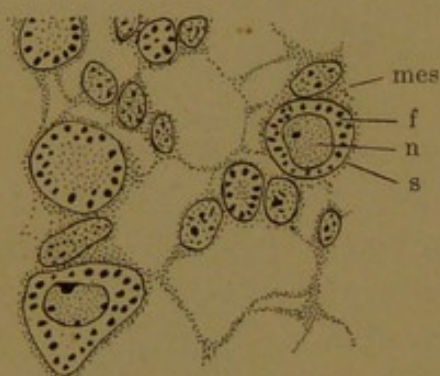


FIG. 109.—CROSS SECTION OF MYOBLASTS AND MESENCHYMAL CELLS FROM AN 18-MM. PIG.
mes., Mesenchymal cell; f., myofibril; n. nucleus of a myoblast; s., sarcolemma.

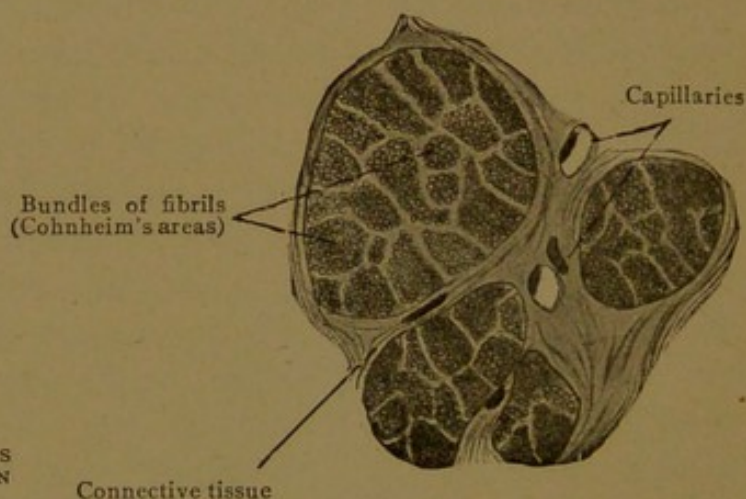


FIG. 110.—CROSS SECTION OF FOUR MUSCLE FIBERS OF THE HUMAN VOCAL MUSCLE. $\times 590$.

The group of cells shown in Fig. 109 corresponds with a portion of the myotome in Fig. 108, D. It is sectioned in the same plane, but represents a later stage. In the adult, such an area of tissue as shown in Fig. 109 becomes a group of fibers as in Fig. 110. The myoblasts have greatly enlarged, and their protoplasm is filled with myofibrils which are often arranged in "fields," known as Cohnheim's areas. These fields are cross sections of longitudinal bundles of fibrils known as *muscle columns*, which Schäfer later named *sarcostyles* (i.e., muscle columns). The term *sarcostyle* is, however, often loosely applied to the separate myofibrils. It has been supposed that the fibrils in a column arise by the longitudinal splitting of a primitive myofibril, but in sections it often appears that the areas or columns are due to shrinkage. As the fibrils multiply, the nuclei, each

surrounded by a small amount of granular protoplasm, migrate to the periphery of the fiber and rest just beneath the connective tissue investment. Occasionally a nucleus is found which has not reached the surface. Toward the end of the muscle fiber, the nuclei are numerous, and may retain their central position. The growth of the fiber in length is supposed to occur at the extremities.

The central position of the nuclei in myoblasts in pig embryos was clearly described by Schwann, in the second part of his treatise which established the cellular structure of animals (1839). He believed, however, that the myoblasts were formed by the coalescence of primary round cells arranged in a row. The gradual and nearly complete transformation of the protoplasm into longitudinal fibrils was correctly observed. Schwann found that the secondary cells, or mature fibers, were completely enclosed in structureless membranes, which were clearly seen in shrunken fibers (Cf. Fig. 111).

Every striated muscle fiber is completely invested by a membrane named the *sarcolemma* (σὰρξ, flesh; λέμμα, husk or shell). This term

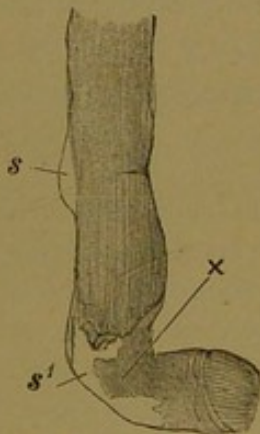


FIG. 111.—STRIATED MUSCLE FIBER OF FROG, TEASED APART IN WATER, BEING TORN AT X, AND SHOWING THE SARCOLEMMAS AT S AND S'.

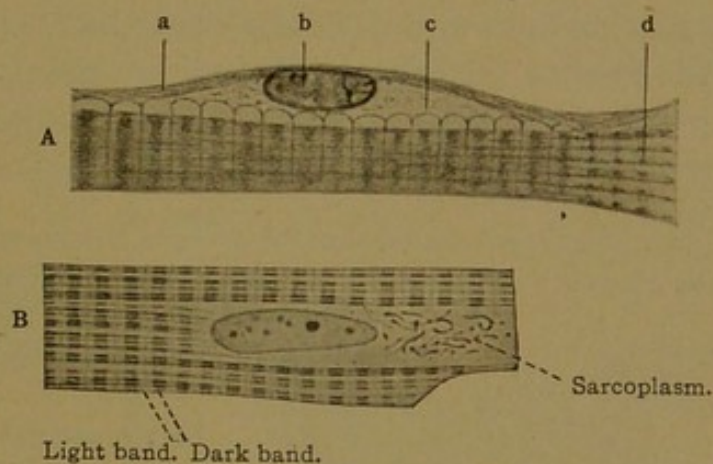


FIG. 112.—LONGITUDINAL SECTIONS OF STRIATED MUSCLE. A., Sketch to show the relation between the cells and fibers according to Baldwin. a., Fibrous membrane; b., nucleus of a muscle cell in vertical section; c., sarcolemma; d., myofibrils artificially separated. B., Part of a fiber from a straight muscle of the eye of a calf. $\times 1000$. The nucleus is seen in surface view; the sarcoplasm contains chondriocenta.

was introduced by Bowman (Phil. Trans., 1840) who described the membrane as "a tubular sheath of the most exquisite delicacy, investing every fasciculus (or fiber) from end to end, and isolating its fibrillæ from all the surrounding structures." He confirms Schwann's statement that it is not a fibrous structure derived from the surrounding connective tissue, and he states that the nuclei of the muscle come to lie "at or near the surface but within the sarcolemma." He adds, however, that he has seen similar cells in the sarcolemma itself. Since Bowman's time there has been prolonged discussion as to the nature of this membrane. The outer portion, which may occasionally contain nuclei, appears to be of connective tissue origin, and is comparable with a basement membrane. The inner

part, or true sarcolemma, is a structureless membrane closely applied to the surrounding connective tissue. It appears to be much more definite than any membrane which invests smooth muscle fibers, to which the term sarcolemma has been extended by Heidenhain and others. The sarcolemma of striated muscle, however, is not yet thoroughly understood. Although the muscle cells are generally said to be within it, Baldwin finds that they are outside of the sarcolemma, between it and the fibrous basement membrane (Fig. 112, A). Accordingly he agrees with Apáthy in regarding the myofibrils as comparable with connective tissue fibers. The possibility that the myofibrils are intercellular will be discussed under cardiac muscle.

The appearances of skeletal muscle which have caused it to be called *striated* are found only in longitudinal sections, including those which are obliquely longitudinal. It is then seen that the myofibrils, which run lengthwise, are composed of alternating light and dark portions, and that they are so arranged that the dark parts of one fibril are beside the dark parts of the adjacent fibrils. As a result of the close crowding of the fibrils, alternating light and dark transverse bands appear to pass from one side of the fiber to the other, and these are the striations. They are shown in Fig. 112, A and B (at the right of A, the fibrils are represented as artificially frayed apart).

Bowman (1840) stated that "a decisive characteristic of voluntary muscle consists in the existence of alternate light and dark lines, taking a direction across the fasciculi."

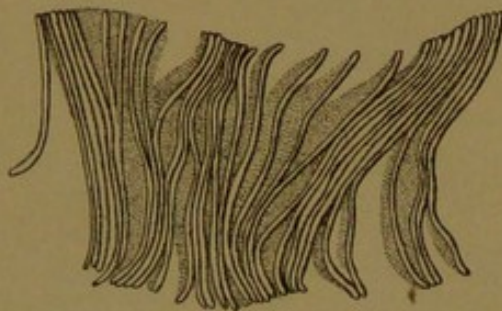


FIG. 113.—A HUMAN STRIATED MUSCLE FIBER SEPARATING INTO DISCS. (After Bowman.)

He added that Leeuwenhoek had described the striæ repeatedly, believing in the earlier years of his inquiry that they were circular bands around the fibrils, but later regarding them as of spiral arrangement, comparable with an elastic coil of wire, and in some way capable of retraction. Bowman recognized that they were caused by the "coaptation of the markings of neighboring fibrillæ." He found that the muscle fibers can readily be split into longitudinal fibrillæ with transverse markings, but that "in other cases their natural

cleavage is into discs, and in all instances these discs exist quite as unequivocally as the fibrillæ themselves." The discs are produced when the ends of a muscle fiber are pulled apart (Fig. 113). Bowman regarded each disc as a plate of agglutinated segments, receiving a single segment from every fibrilla which crossed it. These segments he named *sarcous elements*; they are united endwise to form the myofibrils and crosswise to form the discs. Usually the longitudinal cohesion is much greater than the lateral, and in the wing muscles of insects, according to Schäfer, the fiber "never, under any circumstances, cleaves across into discs."

The finer structure of the fibrils is illustrated in the diagram, Fig. 114, which represents a part of seven myofibrils, including three dark bands

and portions of four light bands. Under polarized light the dark bands are doubly refractive or *anisotropic*, and the light ones are singly refractive or *isotropic*. Following Rollett's suggestion, the striations are often designated by letters. The dark band is called *Q* (an abbreviation for *Querscheibe*, or transverse band) and the light band is called *J* (applied by Rollett to a subdivision of the isotropic layer). The light band is bisected by the ground membrane, or *Krause's membrane*, which appears as a very




FIG. 114. — DIAGRAM OF MUSCLE STRIATIONS. (After Heidenhain.)

The fibrils consist of alternating dark bands, *Q*, and light bands, *J*. *J* is traversed by the ground membrane *Z*, and *Q* by the median membrane *M*. In the right of the three muscle segments shown in the figure, the bands, *N*, have been drawn.

slender dark line, *Z* (*Zwischenscheibe*, or intermediate disc). The lines *Z* are believed to represent continuous membranes which divide the muscle fiber into compartments called muscle segments, or *sarcomeres*. At the sides of the fiber, Krause's membranes join the sarcolemma, which bulges between them when the fibers are contracted (Fig. 112, A). Between *Z* and *Q*, in the highly developed striated muscles of insects, a band *N* has been described (*Nebenscheibe*, or accessory band). The dark band

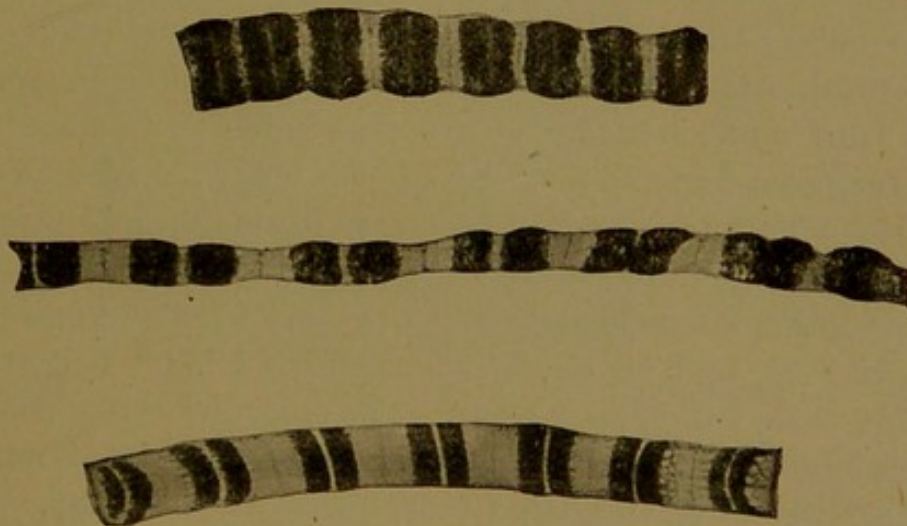

FIG. 115.—FIBRILS OF THE WING-MUSCLES OF A WASP; THE UPPER ONE CONTRACTED; THE MIDDLE ONE STRETCHED; AND THE LOWEST ONE UNCONTRACTED. $\times 2000$. (Schäfer.)

Q becomes gradually lighter toward its central part (thus forming *h* or *Qh*), and in its central part it is sometimes seen to be crossed by Hensen's median membrane, *M* (*Mittelscheibe*). The latter is believed to be similar to Krause's membrane, but more delicate. Like the other bands it may appear dark or light according to the focus. In the muscle fibrils shown in Fig. 115, the bands *Q*, *J*, and *Z* may be readily identified; *M* appears as a rather broad white line which may include *Qh*.

Between the myofibrils and completely surrounding them is the *sarcoplasm*, which is a fluid substance containing *interstitial granules*, fat droplets, and glycogen. It differs from the protoplasm of the muscle cells which is found about the nuclei, and which is cut off from the sarcoplasm, according to Baldwin, by the sarcolemma. The granules have been carefully studied by Bullard (Amer. Journ. Anat., 1912, vol. 14, pp. 1-46) who discusses their staining reactions and probable composition. The significance of the interstitial granules could not be determined. The fat droplets are regarded as reserved food material, and they vary in abundance according to the quantity of fat in the food. Schäfer has found no evidence that the isolated sarcoplasm of insect muscles is contractile, but he readily observed the contractility of isolated myofibrils. Moreover the activity of certain muscles in living embryos begins soon after the fibrils are differentiated.

In the process of contraction, according to Schäfer, the hyaline substance of the myofibril passes from the light segment *J* into the dark segment *Q*, so that each sarcomere becomes short and broad. He refers to the photograph of the lowest fibril in Fig. 115 as showing that the dark substance is porous (note the end of the fiber toward the right). The sarcolemma bulges between the successive Krause's membranes, which are brought closer together (Fig. 112, A), and the length of each sarcomere is greatly reduced. The dark band *Q* may become light through the accumulation of hyaline substance within it, and the shortened and condensed *J* may become quite dark, causing a reversal of the original color relations. The sarcoplasm is said to be forced from between the dilated myofibrils in *Q*, into *J*. Others consider that contraction is due to a passage of fluid from the sarcoplasm into the myofibrils, and that the beaded form which the myofibrils often present, results from an intake of fluid through the ultra-microscopic membranes which are supposed to surround them. The latter interpretation is defended by Meigs (Zeitschr. f. allg. Physiol., 1908, vol. 8, pp. 81-120), and vigorously attacked by Schäfer (Quart. Journ. Exp. Physiol., 1910, vol. 3, pp. 63-74). The older theories of contraction and the numerous papers on the finer structure of striated muscle are admirably reviewed by Heidenhain (Anat. Hefte, Abth. 2, 1899, vol. 8, pp. 1-111).

Adult muscle is composed of such fibers as have been described in the preceding paragraphs. They are arranged in compact bundles, shown in cross section in Fig. 116. Around all the larger muscles there is a connective tissue sheath, or *external perimysium*, which extends into the muscle in the form of septa, thus subdividing it into bundles or *fasciculi*. These septa constitute the *internal perimysium*, and the connective tissue extends from them around the individual muscle fibers, blending with the sarcolemma. In the connective tissue of the diaphragm, elastic fibers are

abundant; but the muscles of the extremities are poor in elastic tissue, containing only fine, chiefly longitudinal fibers, found especially in the perimysium externum.

Cross sections of striated muscle fibers are readily recognized. They have rounded-polygonal outlines formed by the sarcolemma and fibrous membrane, within which are the myofibrils, often shrunk from the membrane. The fibrils stain intensely with eosin. They appear as coarse granules, but their rod-like form becomes evident as they are followed up and down by changing the focus. The shifting picture thus presented is quite characteristic. Some fibers stain more darkly than others, owing to the varying abundance of sarcoplasmic granules.

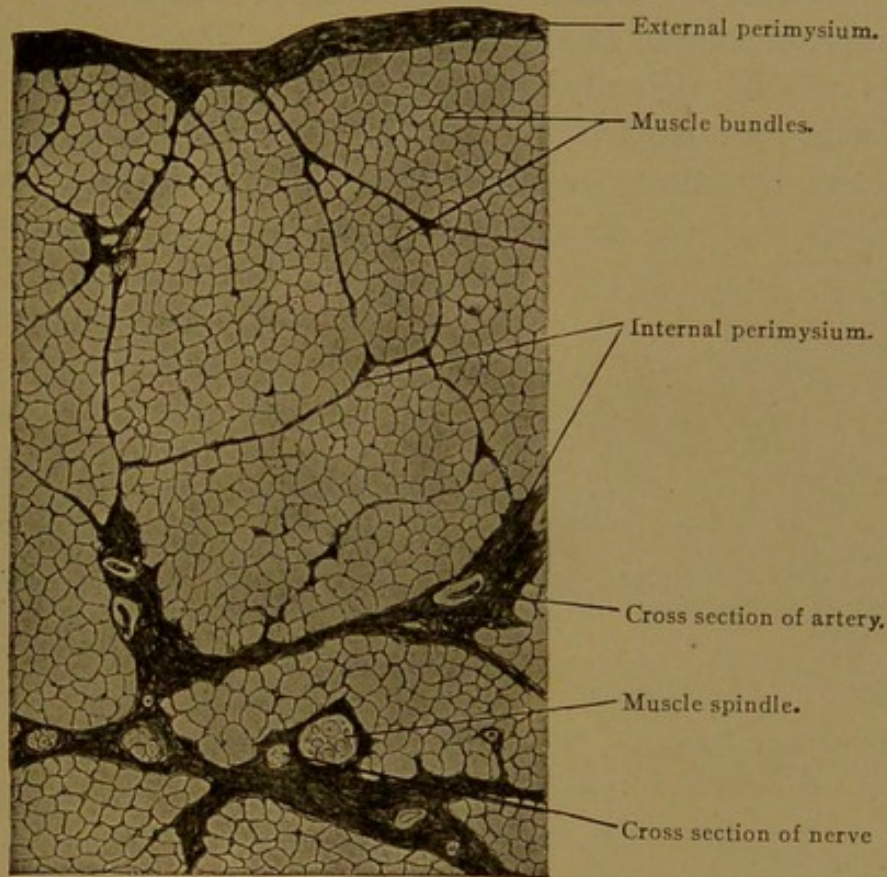


FIG. 116.—FROM A CROSS SECTION OF THE OMOHYOID MUSCLE OF MAN. $\times 60$.

In many animals, as in the rabbit, two sorts of striated muscles may be recognized—red muscle (*e.g.*, the *M. semitendinosus* and *M. soleus*); and pale or white muscle (*e.g.*, the *M. adductor magnus*). Correspondingly there are two sorts of fibers. First, there are dark fibers with abundant sarcoplasm, well defined longitudinal striation, and poorly developed transverse markings, having in general a small diameter; these occur in red muscles. Secondly, there are pale fibers, with less sarcoplasm and better defined transverse striations, having a greater diameter. These are the more highly differentiated fibers. Although in some animals these two sorts of fibers are found in separate muscles, in others, as in man, they are mingled in single muscles. In general the most constantly active muscles (cardiac, ocular, masticatory and respiratory) contain the most fibers with abundant sarcoplasm. The muscles having many fibers with scanty sarcoplasm contract more quickly but are exhausted sooner.

The size of the muscle fibers is subject to considerable variation. They are said to enlarge at a uniform rate throughout the body until birth, when their diameter is about twice as great as in embryos of four months. After birth the fibers of certain muscles become much coarser than those in others. Thus the gluteal muscles have large fibers (av. diam. 87.5μ) and the ocular muscles have small ones (av. diam. 17.5μ), as determined by Halban (*Anat. Hefte, Abth. 1, 1894, vol. 3, pp. 267-308*). He finds that the diameter of the adult fibers in general is about five times greater than at birth. As a result of exercise the diameter of muscle fibers in rats may show an average increase of 25% according to Morpurgo (*Arch. f. path. Anat., 1897, vol. 150, pp. 522-554*). He states that the enlargement of the muscle takes place without an increase in the number of its fibers, but merely through the thickening of existing elements. The fibers which grow most are those which originally were thinnest, and which act as a reserve material with great capacity for growth. The enlargement of fully formed fibers apparently takes place through an increase in the sarcoplasm, with-

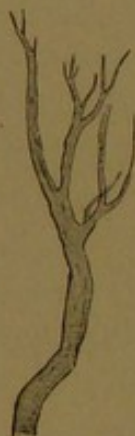

FIG. 117.—BRANCHED STRIATED MUSCLE FIBER FROM THE TONGUE OF A FROG.

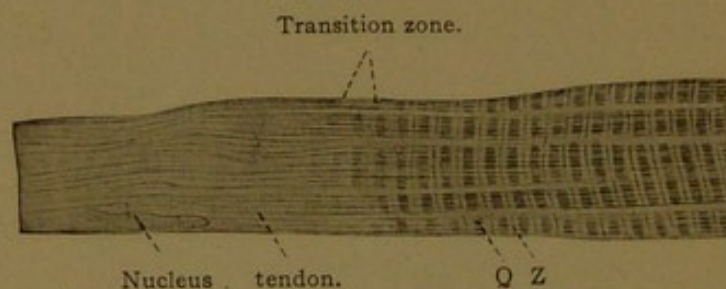


FIG. 118.—LONGITUDINAL SECTION OF A PART OF A MUSCLE FIBER FROM A HUMAN INTERNAL INTERCOSTAL MUSCLE, SHOWING ITS TRANSITION TO TENDON. $\times 750$.

out multiplication or thickening of the fibrils. After injury striated muscle gives slight evidence of regeneration, but it has been thought that latent myoblasts may become active. A proliferation of nuclei toward the injured ends of the muscle fibers has been recorded, but repair is chiefly through the production of connective tissue.

Longitudinal sections of skeletal muscles may be easily recognized by the presence of unbranched striated fibers, bounded by well-defined membranes, associated with which are the flattened peripheral nuclei. The striations *Q* and *J* are visible under low magnification. In a few situations, striated muscle fibers branch (Fig. 117). Branching has been reported toward the place where the muscle fibers of the tongue are inserted into the mucous membrane, and where the facial muscles end in the subcutaneous tissue. The way in which the fibers connect with tendon has

been studied with conflicting results. Schultze finds that at the end of the muscle fiber the myofibrils are no longer differentiated into light and dark bands, but pass directly into the tendon fibrils, with which they are continuous (Fig. 118). "Muscle fibrils and tendon fibrils are parts of a single structure." (Arch. f. mikr. Anat., 1912, vol. 79, pp. 307-331). But Baldwin finds that the ends of the muscle fibers are primarily conical and are covered with sarcolemma; and the tendon fibrils connect with the sarcolemma at the apices of the cones. The processes of sarcolemma are thus primarily "dovetailed" into the tendon. Secondarily the cones may blend to form a thickened flat layer to which perichondrial or periosteal fibers are attached. In no case is the sarcolemma penetrated by muscle fibrils or tendon fibrils, and therefore there is no continuity between them (Morph. Jahr., 1912, vol. 45, pp. 249-266). Thus Baldwin defends the generally accepted opinion.

Muscles are abundantly supplied with vessels and nerves, which are imbedded in the perimysium. The lymphatic vessels end in the septa without extending among the individual muscle fibers; but the blood vessels, through capillary branches, continue further and run between adjacent fibers, thus forming a plexus with elongated rectangular meshes. The nerves are chiefly motor, and a branch ends in contact with every muscle fiber, to which it transmits the impulse for contraction. Muscles also contain *sensory* nerves, having "free endings" and probably

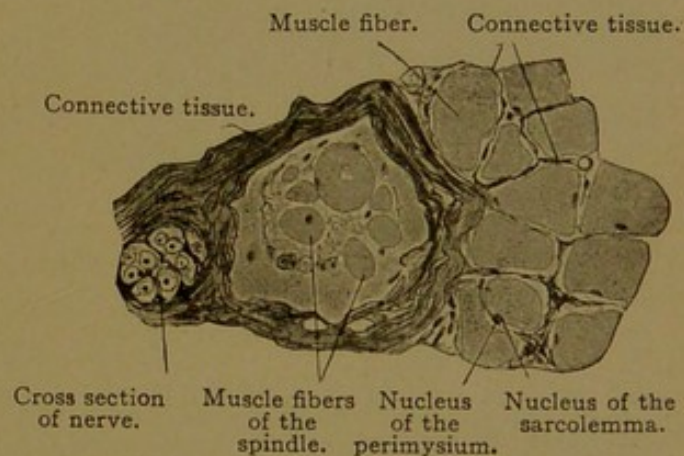


FIG. 119.—THE MUSCLE SPINDLE SHOWN IN FIG. 116.
X 240.

terminating also around the *muscle spindles*. The spindles are slender bundles of poorly developed fibers, generally situated near the septa formed by the internal perimysium, as seen in Figs. 116 and 119. All the muscle spindles are formed during embryonic life, and their abundance and distribution in the various muscles in embryos have been studied by Gregor (Arch. f. Anat. u. Entw., 1904, pp. 112-194). They have not been found in all muscles, and in certain muscles they are regularly more numerous than in others. Thus they have been reported as absent from the muscles of the eye, face, pharynx, small muscles of the larynx, the *Mm. ischiocavernosus* and *bulbocavernosus*, and certain others, including a large part of the diaphragm. They are numerous in the distal muscles of the limbs, and in certain muscles of the neck. The finer structure of the nerve terminations, both motor and sensory, will be considered with the nervous system.

CARDIAC MUSCLE.

A portion of the mesenchymal syncytium from which cardiac muscle develops is shown in Fig. 120. Its nuclei are found in the axial part of the protoplasmic strands, at varying intervals from one another. Peripherally a few myofibrils have developed from the chondrioconta, or protoplasmic granules, and these fibrils extend for considerable distances through the syncytium regardless of cell areas. They multiply rapidly, and form a peripheral layer of fibrils surrounding the central nuclei and axial protoplasm. Thus as seen in cross section, the strands of cardiac syncytium

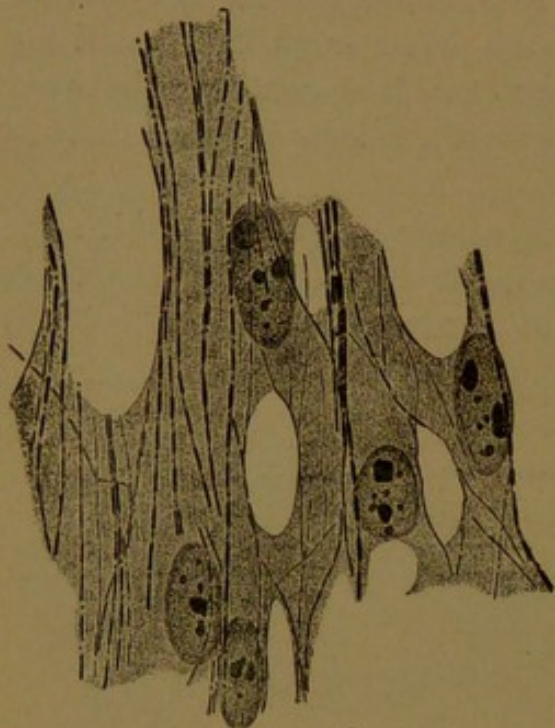


FIG. 120.—CARDIAC MUSCLE FROM A DUCK EMBRYO OF THREE DAYS. (M. Heidenhain, from McMurrich's "Embryology.")

and the myoblasts of skeletal muscle resemble one another. The fibrils exhibit alternating dark and light bands which are arranged as in skeletal muscle, and ground membranes (*Z*) develop across the fibers, bisecting the light bands (*J*). The striations, however, are not as regular and as highly developed as in skeletal muscle. At the periphery of the fibers there is a sarcolemma, which is thinner than that of skeletal muscle, and was formerly overlooked. In early stages the muscle fibers in many places rest close against the endothelium of blood vessels; later they are surrounded by more or less connective tissue.

In the adult the cardiac muscle fibers anastomose freely, thus retaining their original syncytial arrangement (Fig. 121). They do not, however, form an irregular network, but are arranged in layers, in which the fibers tend to be parallel. Thus they are cut longitudinally in Fig. 121 and transversely in Fig. 172 (p. 179). The nuclei retain their central position. They are elliptical bodies with a conical mass of protoplasm at either pole. This protoplasm, as in smooth muscle, occupies the interval left between the fibrils as they diverge to pass by the nucleus. It is granular, and frequently contains brown pigment.

According to Apáthy (Biol. Centralbl., 1888, vol. 7) "the contractile substance is a product of the muscle cell and the muscle cell is represented by the nucleus and surrounding area of protoplasm." "The myofibrils of the contractile substance are the histogenetic homologues of connective tissue fibrils, however much they may differ from them chemically or functionally." Baldwin has recently advanced a similar interpretation. He finds that the sarcoplasm between the fibrils differs from the protoplasm around the nucleus. Moreover he states that the perinuclear proto-

plasm, in both skeletal and cardiac muscle, is separated by the sarcolemma from the myofibrils and sarcoplasm (Fig. 112, A). In regard to smooth muscle, however, Baldwin merely notes that it should be reviewed in the light of these facts. The existence of a membrane around the nucleus and granular protoplasm at its poles would place smooth muscle in the same category, and make the fibrils extracellular. With muscle, therefore, as with connective tissue, the distinction between intracellular and extracellular appears to be arbitrary and conventional. It is interesting to note that the extrusion of the nuclei from the precartilaginous matrix to its surface, as described by Mall, may be comparable with the passage of the nuclei from the center to the surface of skeletal muscle fibers. Baldwin's papers are found in the *Zeitschr. f. allg. Physiol.*, 1912, vol. 14, pp. 130-160, and, as regards cardiac muscle, in the *Anat. Anz.*, 1912, vol. 42, pp. 177-181.

A feature of cardiac muscle which is unlike anything observed in smooth or skeletal fibers is the presence of *intercalated discs*. These are transverse lines across the fibers, which were formerly interpreted as cell boundaries, and some authorities still regard them as such. In the guinea-pig Jordan and Steele find that they first appear during the week before birth. Thus they are late in development, and they are relatively less abundant

Nucleus. Sarcoplasm. Fibrils. Lateral branch.

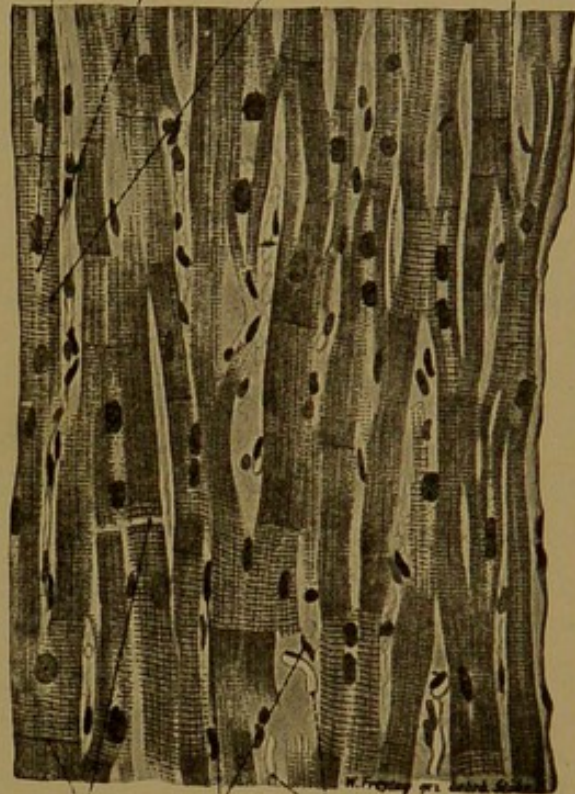

FIG. 121.—LONGITUDINAL SECTION OF A PAPILLARY MUSCLE FROM THE HUMAN HEART. $\times 240$ The transverse lines (x) are partly light (where the fiber has broken) and partly dark (intercalated discs.)

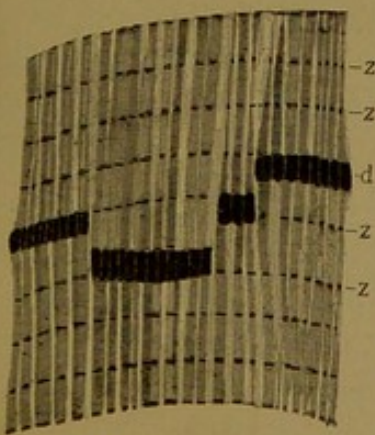


FIG. 122.—INTERCALATED DISC (d) FROM HUMAN CARDIAC MUSCLE, STAINED WITH THIAZIN RED AND TOLUIDIN BLUE. Z, Krause's membrane. (Heidenhain.)

and simpler in the young than in adults (*Amer. Journ. Anat.*, 1912, vol. 13, pp. 151-173). If the cardiac syncytium ultimately became resolved into cells, it would resemble certain other syncytia in this respect; and cardiac muscle can be broken up into cell-like blocks, apparently along these discs. However, the discs occur at variable distances from one another, and very frequently they mark off non-nucleated portions of the syncytium. As many as four of them may extend partly across a single nucleus, as shown by Jordan and Steele, indicating that they are peripheral modifications of the myofibrils, and cannot be regarded as cell walls. Heidenhain (*Anat. Anz.*, 1901, vol. 20, pp. 33-78) pictures them as always connected on one

side with a ground membrane Z (Fig. 122), and states that they are somewhat narrower than a sarcomere (*i.e.*, the distance between two successive ground membranes). He regards them as the places where new sarcomeres form, thus providing for the growth of the heart. Jordan and Steele, among others, consider that they are places where individual fibrils are contracted, and the fact that they are shorter than adjacent sarcomeres favors this interpretation. The discs may extend straight across the fiber, but frequently they are broken into "steps" as shown in the figure.

There are, therefore, three peculiarities of cardiac muscle through which it differs conspicuously from skeletal muscle, namely, its anastomosing fibers, central nuclei, and intercalated discs.

NERVOUS TISSUE.

General features. In nervous tissue the protoplasmic functions of irritability and conductivity attain their highest development. Irritability is that property which enables the cell to react to various stimuli, such as pressure or light; and through conductivity the effects of stimulation are transmitted to distant parts of the cell, or to adjacent cells. In all animals the cells of the outer or ectodermal layer are those most exposed to stimulation, and the ectoderm accordingly gives rise to the entire nervous system. In some animals all the ectodermal cells have been described as equally responsive to stimulation, and the name "sensory layer" has been applied to the ectoderm as a whole. Usually, however, the sensory cells become specialized in definite and limited areas of the ectoderm. M. Schultze (1862) showed that the sensory cells of the nose and eye are epithelial elements, the bases of which are prolonged into filaments which serve as nerves to convey sensation. He taught that the specific functions of the sense organs depend on their respective epithelial cells, which accordingly may be designated as olfactory, gustatory, auditory or visual cells.

Not only does the ectoderm produce sensory *neuro-epithelial cells*, the nucleated bodies of which remain in the epithelium, but it gives rise to more deeply placed *nerve cells*, which connect with the epithelial cells and place them in communication with the muscles. In simple forms of animals this connection is very direct, and the response of the muscle to epithelial stimulation is quite automatic. In the higher animals there are both direct and indirect paths from the sensory endings to the muscles, and muscular action may be inhibited or initiated by certain of the centrally placed nerve cells.

The centrally placed cells in vertebrates constitute the spinal cord and brain, which together form the *central nervous system*. The bundles of fibers which convey impulses to and from the central nervous system, together with the cells associated with them, constitute the *peripheral nervous system*.

In the olfactory epithelium of vertebrates there are neuro-epithelial cells which send fibers directly into the central nervous system, but in other cases the nucleated bodies of the sensory cells are not found in the epithelium. They occur in circumscribed masses or *ganglia*, from which fibers extend both into the central nervous system, and outward to various sensory structures, where they terminate in contact with cells which stimulate them. Thus the stimulus which gives rise to a tactile sensation is received by the terminal ramifications of a nerve fiber in the skin. The stimulus is conveyed along this fiber (Fig. 123, *a*), through the spinal ganglion (*b*), into the spinal cord, where it produces several branches (at *c*). One of these branches passes to a motor cell, *d*, to which, through contact, it

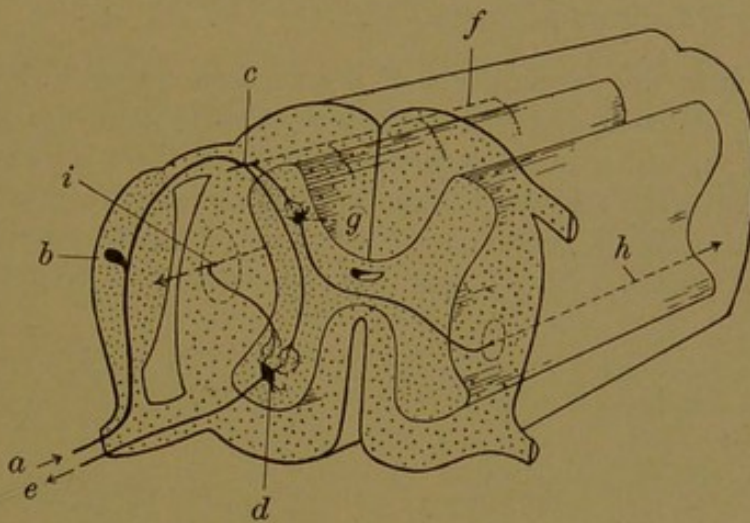


FIG. 123.—DIAGRAM OF THE SPINAL CORD SHOWING A SENSORY FIBER, *a*; A MOTOR FIBER, *e*; AND THE FIBERS WHICH CONNECT THEM WITH EACH OTHER AND WITH THE BRAIN.

transmits its stimulus. The motor cell sends a fiber outward (*e*) to terminate in contact with a striated muscle, which is thereby stimulated so that it contracts. This direct path from the sensory ending to the muscle, provides for reflex or unconscious action, such as is taken when the hand is suddenly withdrawn from a painful contact. In such a case a considerable group of muscles may contract together, since the sensory fiber sends branches up and down the cord (*f*), and these in turn give off *collateral branches* which pass to motor cells at different levels.

The cell which conveys the tactile sensation from the skin to the spinal cord gives rise to branches which terminate in contact with other cells in the spinal cord, as shown in Fig. 123, *g*. From these cells processes cross to the opposite side of the cord and pass up to the brain (*h*), where they connect with nerve cells through which the sensations become conscious. These brain cells presumably become permanently modified by the sensations which they receive, so that they store experiences. As a result of the sensation transmitted from the skin, certain cells in the brain may send stimuli downward to the motor cells of the cord, which then cause the

muscles to act voluntarily. The descending fiber crosses to the opposite side during its descent, and occupies the position in the cord shown in Fig. 123, *i*. A branch is shown passing to the motor cell, *d*.

From this sketch of the constitution of the nervous system, it is seen that it consists essentially of cells, made up of *cell bodies* and of *fibers*; the fibers are prolongations of the cell bodies. The cells are *sensory*, or *afferent*, conveying impulses toward the central nervous system; and *motor*, or *efferent*, conveying impulses away from the central system. Within the cord these cells connect with others, forming *ascending* and *descending tracts*, or bundles of fibers passing toward the brain and away from it, respectively. Fibers which serve to connect different levels of the cord with one another are known as *association fibers*; those which connect the opposite sides are *commissural fibers*.

Certain features in the development of the nervous system in lower animals, of interest in connection with the mammalian nervous system, are shown diagrammatically in Fig. 124. In sponges, according to Parker, there is no nervous tissue of any sort, but beneath the thin epithelium he finds elongated contractile cells which "resemble primitive smooth muscle fibers" (Fig. 124, A). They have been regarded as modified epithelial cells. Parker finds that they are stimulated directly, as a result

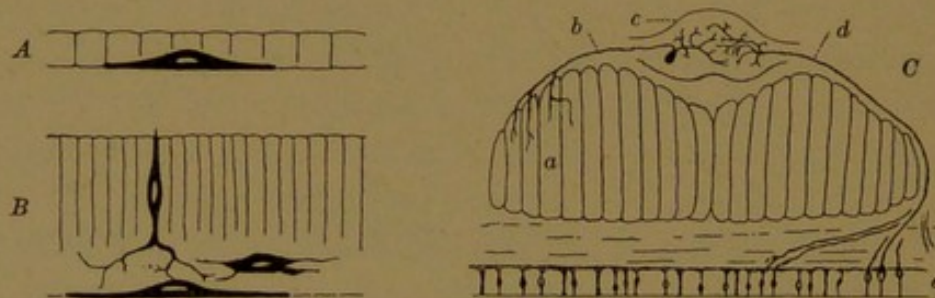


FIG. 124.—A, DIAGRAM OF THE MUSCULAR MECHANISM IN A SPONGE. (Parker.) B, DIAGRAM OF THE NEURO-MUSCULAR MECHANISM IN A MEDUSA. (Parker, after Hertwig.) C, DIAGRAM OF THE VENTRAL NERVOUS CHAIN (c) AND ADJACENT STRUCTURES IN AN EARTHWORM. (Parker, after Retzius.)

Longitudinal muscle; b, motor fiber; d, sensory fiber; e, epithelium on the under surface of the body, containing neuro-epithelial cells.

of changes in the sea-water, so that they slowly contract and close the orifices around which they are situated. Since the sponges are lower than any animals which are known to have nerve cells, Parker concludes that muscular tissue arose independently of nervous tissue, and is the more primitive (Journ. Exp. Zool., 1910, vol. 8, pp. 1-41).

In the medusæ, neuro-epithelial cells, nerve cells, and both smooth and striated muscle fibers are present. According to Oskar and Richard Hertwig, the muscle cells are derived from the deep part of the ectodermal epithelium, and from the first they are connected with nerve cells or neuro-epithelial cells (Fig. 124, B). In other words, in the medusæ muscle and nerve develop in primary communication with one another (Das Nervensystem der Medusen, Leipzig, 1878).

In the earthworm (Fig. 124, C) neuro-epithelial cells in the ventral body wall send fibers to a cord of nervous tissue which constitutes a central nervous system. From cells in this cord, processes extend to the muscles, as shown in the diagram. Thus the neuro-epithelial cell does not stimulate the muscle directly; it conveys an impulse to the motor cell which in turn acts upon the muscle. In addition to the

cells shown in the diagram the cord contains ramifying association and commissural cells. Thus stimulation at one point on the surface of the animal may cause coordinated muscular contractions in different parts of the body. As Retzius has pointed out, if the neuro-epithelial cells should withdraw into the interior of the animal, leaving their branching process in the epidermis, the conditions in vertebrates would be closely paralleled.

The development and structure of the central nervous system and the sense organs will be considered in a later chapter. The following account deals first with the development of the spinal nerves, the spinal sympathetic system, and the cerebral nerves; and secondly, with the adult structure of these parts, including the ganglia, nerve trunks, and nerve endings.

DEVELOPMENT OF THE SPINAL NERVES.

The formation of the medullary groove (or neural groove) as a longitudinal trough in the ectoderm, and its conversion into the medullary tube

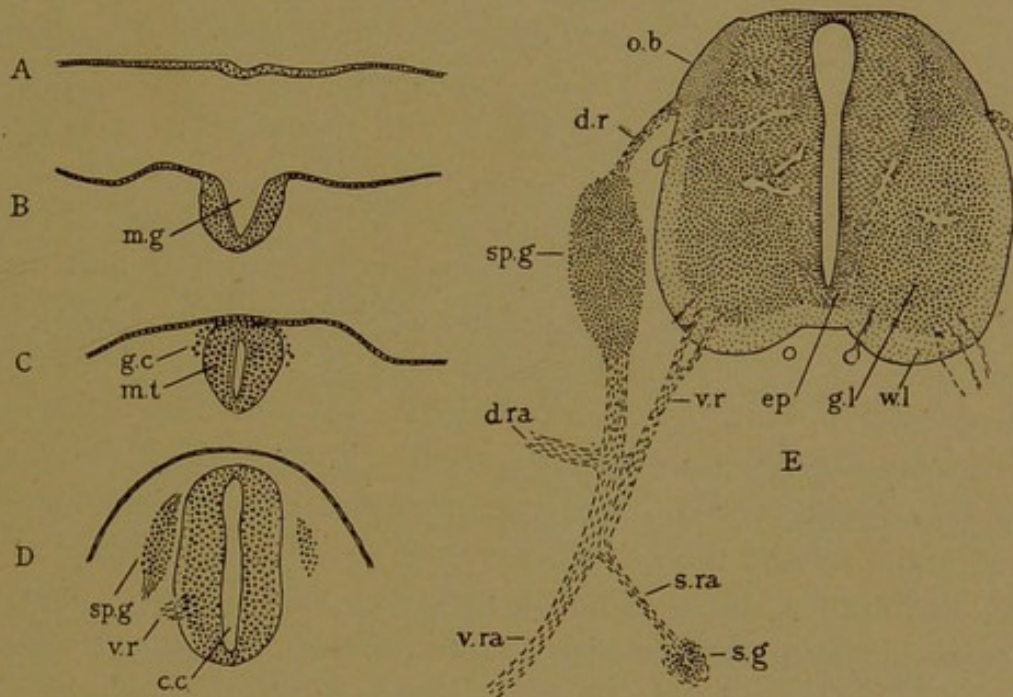


FIG. 125.—THE DEVELOPMENT OF THE NERVOUS SYSTEM AS SEEN IN CROSS SECTIONS OF RABBIT EMBRYOS: A, 7½ DAYS; B, 8½ DAYS; C, 9 DAYS; D, 10½ DAYS; E, 14 DAYS.
c. c., Central cavity; d. r., dorsal root; d. ra., dorsal ramus; ep., ependymal layer; g. c., ganglion cells; g. l., gray layer; m. g., medullary groove; m. t., medullary tube; o. b., oval bundle; s. g., sympathetic ganglion; sp. g., spinal ganglion; s. ra., sympathetic ramus; v. r., ventral root; v. ra., ventral ramus; w. l., white layer.

by the coalescence of its dorsal edges, have been described in a previous section (p. 37). The anterior part of the tube expands to form the brain; the posterior part becomes the relatively slender spinal cord.

At about the time when the medullary tube separates from the epidermal ectoderm, some cells become detached from the medial dorsal portion of the tube and pass down on either side of it, as shown in Fig. 125, C and D. These cells constitute the *neural crest*. They multiply by mitosis and accumulate in paired masses, corresponding in number with

the segments of the body. Thus they form the *spinal ganglia*. A typical cell of a spinal ganglion is at first round, but later becomes bipolar by sending out two processes, one toward the periphery and the other toward the medullary tube. These processes grow out from opposite ends of the cell (Fig. 126). With further growth the nucleated cell body passes to one side of the prolongations, with which it remains connected by a slender stalk. Such T-shaped cells are characteristic of the spinal ganglia. The fibers which grow toward the medullary tube enter its outer part and then bifurcate, sending one branch toward the brain and the other down the cord. These longitudinal fibers form distinct *oval bundles* just within

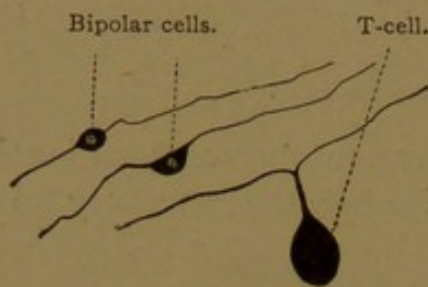


FIG. 126.—SPINAL GANGLION CELLS.
The bipolar forms are from a chick embryo incubated six days.

the cord, one on either side (Fig. 125, E). Since these bundles receive accessions of fibers from every spinal ganglion, they enlarge as they approach the brain. The fibers of the oval bundle branch freely at their terminations, and along their course they give off *collateral branches*, which enter the deep substance of the cord. The peripheral fibers from the spinal ganglia grow outward through the mesenchyma, and terminate in sense organs or sensory endings, which will be described presently. The fibers of the spinal ganglia are essentially sensory or *afferent*, conveying impulses from the periphery toward the cord, and up the cord toward the higher nervous centers.

The *efferent* or motor fibers arise chiefly from cells, the bodies of which remain within the central nervous system. Each of these nerve-forming cells, or *neuroblasts*, sends out one long process called a *neuraxon* (or axone). The neuraxons of the motor cells leave the spinal cord, near its ventral surface, in bundles which unite to form the *ventral roots*. The ventral roots correspond in number with the *dorsal roots*, which are the bundles of sensory fibers passing into the cord from each spinal ganglion. Peripherally the ventral root joins the bundle of fibers growing outward from the spinal ganglion, and the two together form a spinal nerve. Every spinal nerve consequently has a dorsal (sensory) root, and a ventral (motor) root. The fibers from the two roots travel in the same connective tissue sheath, but otherwise they remain entirely distinct.

The fundamental facts which have just been reviewed eluded anatomists for centuries. The nerves, extending from the brain and cord to all the important organs, were regarded as tubes, conveying a vital fluid necessary for organic activity; when this supply was cut off, the organs ceased to perform their functions. Thus if nerves to the skin were destroyed, the skin became insensible; or if those to muscles were cut, the muscles could not contract. The possible existence of sensory and motor nerves with different functions was debated and generally rejected, until Charles Bell proved conclusively that "nerves entirely different in function extend through the

frame; those of sensation; those of voluntary motion; . . . these nerves are sometimes separate, sometimes bound together; but they do not, in any case, interfere with or partake of each other's influence." This brilliant discovery was verified by physiological experiments to determine "whether the phenomena exhibited on injuring the separate roots of the spinal nerves corresponded with what was suggested by their anatomy." Bell found that such was the fact. (*An Exposition of the Natural System of the Nerves of the Human Body*, with a republication of papers delivered to the Royal Society, London, 1824.)

It was at first supposed that the nerves grew out from the cord and brain and acquired connections with their end-organs; but the apparent difficulty which the fibers would have in reaching them, and the fact that the connections must be established before the nervous system can be functional, have led to the idea that the nervous and muscular systems are connected at all stages of their development. In tadpoles, however, Harrison has shown that such connection is not an indispensable requisite for the normal development of the muscles, since they are formed in a normal manner after the medullary tube and neural crest have been removed from the entire posterior portion of the body. He finds further that nerves grow out into the adjacent

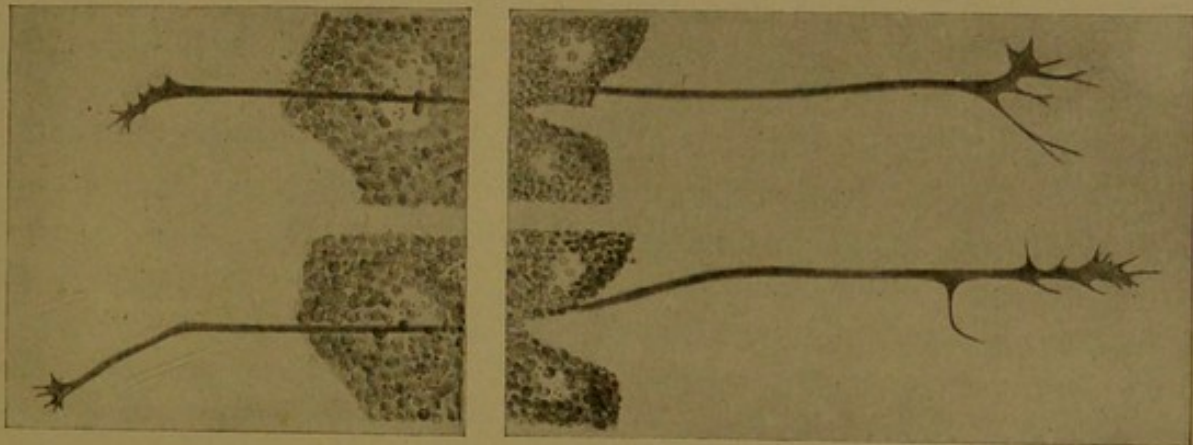


FIG. 127.—THE GROWTH OF NERVES IN TISSUE CULTURES. (Harrison.)

A, Two views of the same nerve fiber taken twenty-five minutes apart, during which time the fiber has grown 20 μ ; B, Two views of another fiber, at lower magnification, taken fifty minutes apart.

tissues from transplanted portions of the medullary tube. Therefore he concludes that the nerves normally grow out to their end-organs and unite with them, but that this takes place very early in development, when the paths are quite direct. Subsequent growth of the body causes the muscles to shift about and become widely separated from the central nervous system, so that the nerves become greatly elongated and follow irregular courses (*Amer. Journ. Anat.*, 1904, vol. 3, pp. 197-220; 1906, vol. 5, pp. 121-131).

The participation of the mesoderm in the formation of nerve fibers has repeatedly been asserted, and some authorities now consider that the long fibers passing from the spinal cord to distant muscles are formed from chains of cells, either mesodermal or ectodermal. Certain of Harrison's experiments were designed to show whether the nerve fibers are formed by peripheral cells or grow out from the central nervous system. In tissue cultures, made by placing fragments of the medullary tube of tadpoles in lymph, at a stage when the tube consists entirely of round cells, he observed the actual growth of the fibers. Examined after a day or two of cultivation, in a considerable number of cases, they were seen extending out into the lymph clot (Fig. 127). Harrison concludes that the nerve fibers begin as an outflow of hyaline proto-

plasm from the nerve cells. The protoplasm is actively amœboid, and, as a result of this activity, it extends farther and farther from its cells of origin, retaining its pseudopodia at its distal end. Similarly enlarged "cones of growth," provided with spiny processes, have been observed in preserved tissue by Cajal; and His, from embryological studies, had long maintained that the nerve fibers grow out from neuroblasts in the central nervous system and spinal ganglia. Harrison concludes that his experiments "place the outgrowth theory of His upon the firmest possible basis" (*Anat. Rec.*, 1908, vol. 2, pp. 385-410).

Dorsal and Ventral Rami. Every spinal nerve, near the junction of its ganglionic and motor roots, divides into a dorsal and a ventral branch

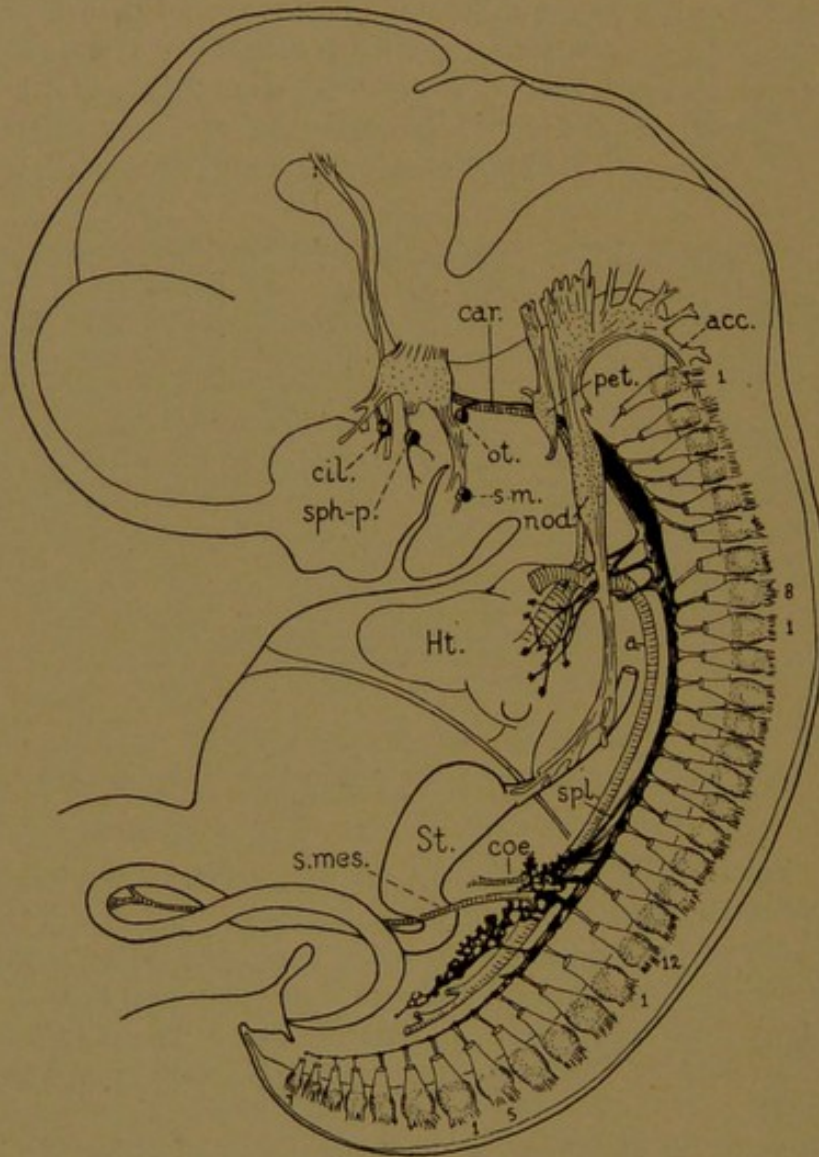


FIG. 128.—THE SYMPATHETIC SYSTEM IN A 16-MM. HUMAN EMBRYO. (After Streeter.) The ganglionated trunk is heavily shaded. The first and last cervical, thoracic, lumbar, sacral and coccygeal spinal ganglia are numbered. a, Aorta; acc, accessory nerve; car, carotid artery; cil, ciliary ganglion; coe, coeliac artery; Ht, heart; nod, nodose ganglion; ot, otic ganglion; pet, petrosal ganglion; s-m, submaxillary ganglion; s. mes., superior mesenteric artery; sph-p., sphenopalatine ganglion; spl, splanchnic nerve; st., stomach.

or *ramus* (Fig. 125, E). Each ramus receives both sensory and motor fibers, and is therefore a mixed nerve. The dorsal rami are distributed to the muscles and skin of the back; their terminal cutaneous branches enter the skin along a line extending from the neck down the trunk of the body,

as may readily be shown in dissections of the adult. In embryos of 10-12 mm. these rami are present as short branches, which can be followed to the muscular condensations derived from the myotomes, but apparently at that stage they do not enter the skin. The ventral rami are longer. Most of them anastomose with the ventral rami of adjacent nerves, thus giving rise to the cervical, brachial and lumbo-sacral plexuses. They are distributed to the muscles and skin of the ventral body wall.

DEVELOPMENT OF THE SPINAL SYMPATHETIC SYSTEM.

In mammalian embryos measuring 10-12 mm., each of the thoracic spinal nerves exhibits a branch directed toward the aorta, and ending in a rounded mass of ganglion cells. This is the *sympathetic* or *visceral ramus*, terminating in a sympathetic ganglion (Fig. 125, E). It is generally believed that the cells in the sympathetic ganglia migrate outward from those in the spinal ganglia, but an origin from cells of the medullary tube which wander out along the ventral roots has also been asserted. Although the cells of the sympathetic ganglia were formerly considered to be mesodermal (even after it had been shown that those of the spinal ganglia were ectodermal), it is now generally admitted that the entire sympathetic system is ectodermal. However, in the cervical region the spinal nerves at first do not have sympathetic rami, and the sympathetic ganglia consequently appear isolated in the mesenchyma. Their cells may have migrated in detached groups. Instead of eight ganglia on either side of the neck, corresponding in number with the spinal nerves, there are but three, known as the superior, middle and inferior cervical ganglia, respectively, and of these the middle ganglion may be merged with the superior. They are elongated structures, especially the superior ganglion, and presumably represent a fusion of segmental ganglia.

Each sympathetic ganglion in the thorax of the adult is connected with its spinal nerve by two *rami communicantes*, known as the white and gray rami, respectively. The white rami consist chiefly of fibers passing outward from the spinal nerve, and they are probably a persistence of the sympathetic rami of the embryo. The gray rami contain fibers passing from the sympathetic ganglia back to the spinal nerves, and apparently arise later. They are found not only in the thorax and abdomen, but also in the neck where, as usually described, they place the superior cervical ganglion in connection with the first four cervical nerves, the middle cervical ganglion in connection with the fifth and sixth, and the inferior in connection with the sixth, seventh and eighth. The succession of sympathetic ganglia on either side of the body, extending from the neck to the pelvis, become connected with one another through bundles of

longitudinal nerve fibers, and thus they form the ganglionated *trunk of the sympathetic nerve* (Fig. 128).

From the ganglia of the trunk, bundles of nerve fibers grow out ventrally to supply the blood vessels and viscera. It is characteristic of these branches that they unite with one another freely, forming net-like sympathetic plexuses, within which there are many scattered nerve cells. When the nerve cells in these ganglionated plexuses are particularly abundant, the structure is called a ganglion, though generally retaining a plexiform character.

The principal branches of the cervical sympathetic trunk are the superior, middle, and inferior cardiac nerves, which grow out from the corresponding cervical ganglia. They extend to the heart (Fig. 128) and form the cardiac plexus, associated with which is the cardiac ganglion, situated under the arch of the aorta. These nerves, which are joined by branches from the vagus, innervate the heart. The cervical sympathetic trunks also send out nerves which form plexuses around the aorta and the pul-

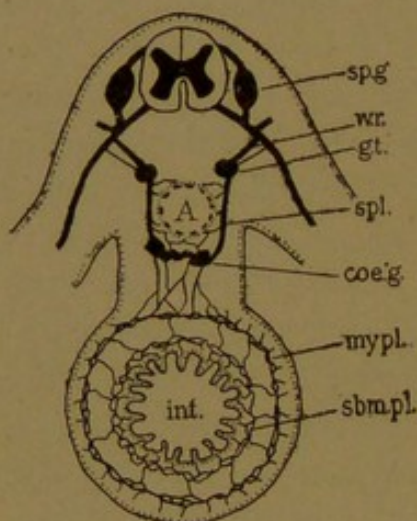


FIG. 129.

Diagram of the sympathetic system in its relation to the intestine. int.; A., aorta; sp. g., spinal ganglion; w. r., white ramus; g. t., ganglion of the sympathetic trunk; spl., splanchnic nerve; coe. g., coeliac ganglion; my. pl., myenteric plexus; sbm. pl., submucous plexus.

monary, subclavian and carotid arteries together with their branches. These innervate the smooth muscles in the walls of the vessels. Some of the fibers accompany the thyroid arteries into the thyroid gland and others are distributed to the pharynx and larynx.

The upper thoracic ganglia supply nerves to the aortic plexus and pulmonary plexus, and the latter enters the lungs. Large bundles of fibers proceeding from the "fifth or sixth to the ninth or tenth" thoracic ganglia of the sympathetic trunk, unite to form the *greater splanchnic nerves*, one on either side of the body, and branches from the remaining thoracic ganglia form the *lesser splanchnic nerves*. These splanchnic nerves pass into the abdominal cavity and join one another, forming a large ganglion-

ated plexus on the sides and front of the aorta (Fig. 128). The sympathetic trunks in the abdomen also send branches to join this plexus. The great plexiform ganglion found around the coeliac artery, as it leaves the aorta, is called the coeliac ganglion (or plexus). A similar plexus surrounds the superior mesenteric artery. From these plexuses, as shown in the diagram (Fig. 129), sympathetic nerves extend through the mesentery, and they form a microscopic ganglionated plexus surrounding the intestinal tube, lodged between the longitudinal and circular layers of smooth muscle. This is the myenteric plexus (*plexus myentericus*). It innervates the muscle and sends branches into the tissue beneath the mu-

cous membrane, where they form another plexus (the *plexus submucosus*). In this way the sympathetic system supplies the intestine. It sends its fibers into other organs, following the arteries, thus forming the hepatic, splenic, suprarenal and renal plexuses. In the pelvis the sympathetic rami form the hypogastric plexus, with branches distributed to the rectum, bladder and urogenital organs, and finally it accompanies the arteries down the legs, innervating the muscles in the walls of the vessels.

In 1664, Willis published a remarkably clear account of the nerve "commonly called intercostal because it rests against the roots of the ribs." This nerve, which is the ganglionated trunk of the sympathetic system, had generally been supposed to descend from the cerebral nerves. Willis described its connections with these nerves and, through each intercostal space, with the spinal cord. He noted the cardiac branches, and stated that the great mesenteric plexus, placed in the midst of the others, like a sun, sent its nerve fibers like rays in all directions (hence it came to be called the "solar plexus"). Willis found that this nerve sent branches to all the abdominal organs below the stomach. He considered that its function was to place the heart and viscera in connection with the brain so that they should act in harmony (*Anatome cerebri, Amstelodami, 1664*). Because of their frequent communications with other nerves, Winslow (1732) called the ganglionated trunks the *Nervi sympathetici maximi*.

Bichat (*Anatomie Générale, 1802*, translated by Hayward 1822) subdivided the nervous system into two parts "essentially distinct from each other, the one having the brain and its dependencies for its principal center, and the other having the ganglions." The latter is "almost everywhere distributed to the organs of digestion, circulation, respiration, and secretion." "Each ganglion is a distinct center, independent of the others in its action, furnishing or receiving particular nerves as the brain furnishes or receives its own. . . . The continuous thread that is observed from the neck to the pelvis is nothing but a series of communications. . . . These communications are often interrupted, without any inconvenience in the organs to which the great sympathetic goes." That the sympathetic system acts independently of the central nervous system, at least to a great extent, is its most prominent physiological characteristic.

Thus the sympathetic system merits to some extent the terms organic, visceral, or vegetative system, which have been applied to it. Burdach (1819) stated that it might be called the "automatic system," and the term "autonomic system" has more recently been used, but Burdach preferred *sympathetic system*, which has been internationally adopted by anatomists.

DEVELOPMENT OF THE CEREBRAL NERVES.

The nerves which are connected with the brain, supplying the skin and muscles of the head together with certain viscera, are built upon the same plan as the spinal nerves, of which they may be regarded as a continuation. They consist of dorsal sensory roots, and ventral motor roots which, however, do not unite to form single nerves. Certain cerebral nerves are wholly sensory and others consist merely of a ventral root, and

are therefore entirely motor. Still others have no ventral roots, but receive motor fibers through *lateral roots*. The fibers in the lateral roots are like motor fibers of the ventral roots in that they arise from cells within the central nervous system, but their processes emerge from the lateral wall of the brain instead of the ventral wall. They come out immediately below the entering sensory fibers of the dorsal roots.

Beginning at the anterior end of the brain and proceeding toward the spinal cord, the cerebral nerves occur in the following order: *olfactory*, *optic*, *oculomotor*, *trochlear*, *trigeminal*, *abducent*, *facial*, *acoustic*, *glossopharyngeal*, *vagus*, *accessory* and *hypoglossal*.

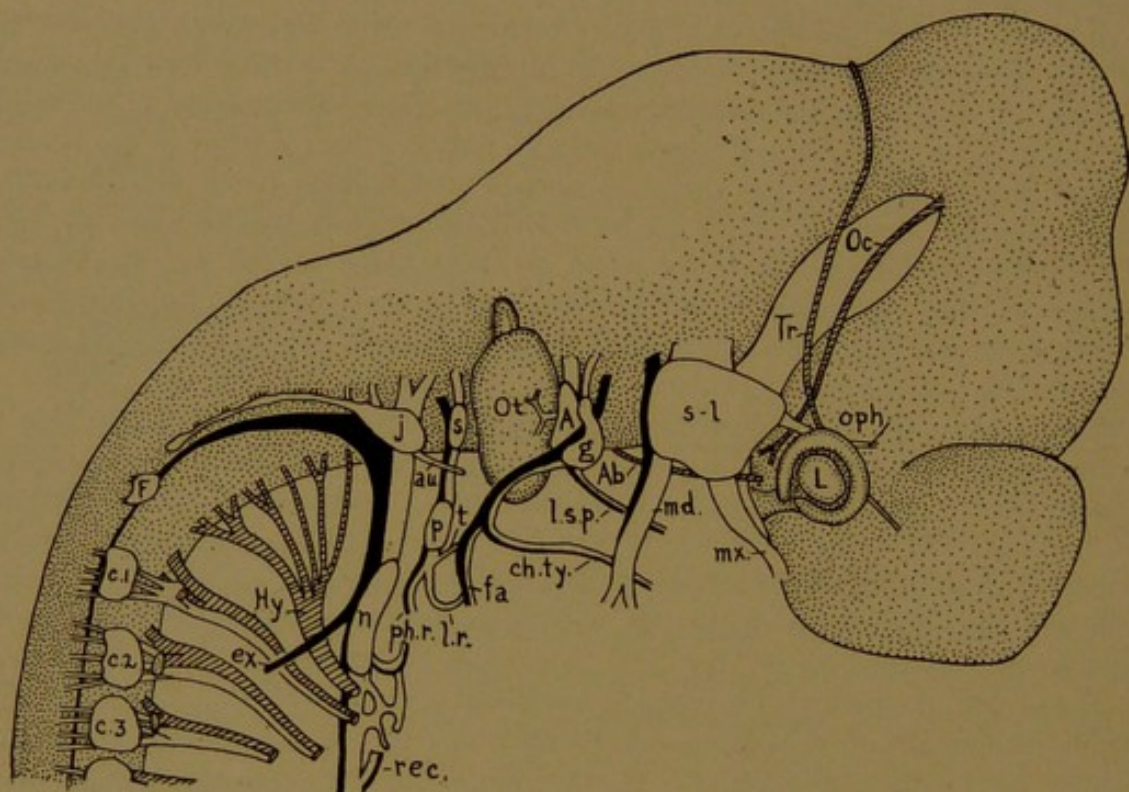


FIG. 130.—THE CEREBRAL NERVES OF A 12-MM. FIG.

Olfactory (not shown). *Optic* (fibers in the stalk of the eye, the lens of which is marked L). *Oculomotor* (Oc.). *Trochlear* (Tr.). *Trigeminal*,—semilunar ganglion (s.-l.); ophthalmic (oph.), maxillary (mx.) and mandibular (md.) branches. *Abducent* (Ab.). *Facial*,—geniculate ganglion (g.); large superficial petrosal (l. s. p.), chorda tympani (ch. ty.), and facial (fa.) branches. *Acoustic* (A.), supplying the otocyst (Ot.). *Glossopharyngeal*,—superior (s.) and petrosal (p.) ganglia; tympanic (t.), lingual (l. r.) and pharyngeal (ph. r.) branches. *Vagus*,—jugular (j.) and nodose (n.) ganglia; auricular (au.) and laryngeal branches, rec. being the recurrent nerve; the main stem proceeds to the abdomen. *Accessory*,—internal ramus joining the vagus, and external ramus (ex.). *Hypoglossal* (Hy.). Froriep's rudimentary hypoglossal ganglion (F.) sometimes sends fibers to the hypoglossal nerve. c.1, c.2, c.3, cervical nerves.

It is desirable to use the names of these nerves rather than the numbers often applied to them. The names are descriptive, but the numbers are arbitrary and were very variously employed in the older anatomical works. Unlike the spinal nerves, the cerebral nerves are not a series of similar structures. Moreover the recent demonstration of the *Nervus terminalis* in mammals indicates that the numbering may need further revision.

In embryos measuring about 10 mm., the cerebral nerves are all present and show their primary branches. Except the olfactory nerve, they are

included in Fig. 130, in which parts derived from dorsal roots are unshaded; those from lateral roots are black; and those from ventral roots are cross-hatched. They may be briefly described as follows.

The *olfactory nerve*, on either side of the head, consists of about twenty separate bundles of processes from the neuro-epithelial cells in the nasal mucous membrane. These bundles of neuro-epithelial fibers pass directly into the olfactory bulbs, which are portions of the brain. The *vomero-nasal nerve* is a bundle much longer than the others, which arises from a tubular epithelial pocket in the mucous membrane of the nasal septum. This pocket is a rudimentary organ of considerable interest, known as the vomero-nasal (or Jacobson's) organ. Associated with the vomero-nasal nerve, but said to be distinct from it, there is a small *ganglionated* nerve which sends its fibers into the brain caudal to the olfactory lobe. Distally it is "distributed chiefly to the vomero-nasal organ." This is the *Nervus terminalis*, discovered in fishes by Pinkus in 1894, and recently found in human and pig embryos and in adult dogs and cats (Johnston, Journ. Comp. Neur., 1913, vol. 23, pp. 97-120; and McCotter, *ibid.*, pp. 145-152).

The *optic nerve* is a round cord of fibers extending from ganglion cells in the retina to the brain. It is quite unlike any portion of a spinal nerve, and will be described in connection with the eye.

The *oculomotor nerve* has only a ventral root, and consequently it is entirely motor. It is distributed to four of the six muscles which move the eye-ball (namely, the inferior oblique and the superior, medial and inferior rectus muscles) and to the muscle which raises the upper eye-lid (*M. levator palpebræ superioris*).

The *trochlear nerve* arises from cells in the ventral part of the medullary tube, but its fibers, instead of passing directly outward, grow to the dorsal surface of the tube and cross to the opposite side before they emerge. Although the trochlear nerve must be regarded as a ventral root, its fibers leave the brain more dorsally than those of any other nerve. They come out at the notch or *isthmus* between the mid-brain and the hind-brain, and all of them pass to the superior oblique muscle of the eye-ball. This muscle, which runs through a fibrous ring or pulley (*trochlea*) attached to the frontal bone, turns the eye outward and downward.

The *trigeminal nerve* consists of dorsal and lateral roots. Its sensory cells form the *semilunar ganglion*, which gives rise to three large nerves, the ophthalmic, maxillary and mandibular (hence the name *trigeminal*). In general terms, the ophthalmic is the sensory nerve of the forehead and largely of the scalp; the maxillary is the sensory nerve of the front of the face and the upper teeth; and the mandibular distributes sensory fibers to the front of the tongue, the lower teeth, and the skin over the lower jaw. Unlike the ophthalmic and maxillary nerves, the mandibular is a mixed nerve, receiving all the motor fibers of the trigeminal. These motor fibers are distributed chiefly to the muscles of mastication, through the masticator nerve.

The *abducent nerve* is wholly a ventral root, and its fibers all pass to the lateral rectus muscle, which abducts the eye-ball (*i.e.*, turns it outward).

The *facial nerve* is largely a lateral root, and is the motor nerve of the facial muscles. It has, however, a dorsal root (the so-called *Nervus intermedius*) and a ganglion known as the *ganglion geniculi*, or geniculate ganglion, since it occurs at a bend in the nerve. The facial nerve has three fundamental branches, all of which contain both sensory and motor fibers; these are the large superficial petrosal nerve, the chorda tympani, and the facial nerve (the name of the entire nerve being applied to one of its parts).

The *acoustic nerve*, which is wholly associated with the internal ear, is entirely sen-

sory. Its large ganglion becomes subdivided into the *vestibular ganglion*, with fibers to the semicircular ducts or "organ of equilibration," and the *spiral ganglion*, which sends fibers to the auditory cells of the cochlea.

The *glosso-pharyngeal nerve* is chiefly sensory, but it has a small lateral motor root. It has two ganglia, one above the other, the superior ganglion (*ganglion superius*) and the petrosal ganglion (*ganglion petrosum*), respectively. The principal branches are the sensory tympanic nerve, which supplies the mucous membrane of the middle ear; the sensory lingual branch, which passes to the back of the tongue and ends in contact with cells of the taste buds, being the nerve of taste; and the mixed pharyngeal branch which is distributed to the pharynx. It supplies the stylo-pharyngeal muscle.

The *vagus nerve*, which is sensory, is joined by the accessory nerve, which is motor, so that the vagus is regarded as a mixed nerve. It has two ganglia, the jugular ganglion (*ganglion jugulare*) above, and the nodose ganglion (*ganglion nodosum*) below. Its principal branches are the sensory auricular branch, which is distributed to the skin of the external ear; the mixed superior laryngeal nerve, distributed to certain laryngeal muscles and to the mucous membrane of the larynx down to the vocal folds; the recurrent nerve, which terminates as the superior laryngeal in the vocal muscles and mucous membrane of the lower part of the larynx; cardiac branches, which anastomose with the cardiac sympathetic plexus; and finally, from the main trunk of the nerve as it passes through the thorax into the abdomen, branches to the œsophagus, trachea, lungs, stomach, small intestine, liver, spleen and kidneys. Many of these branches anastomose with the sympathetic system. The wide range of this nerve is indicated by the term *vagus*.

The *accessory nerve* is wholly motor, and consists of lateral roots which arise from the hind-brain, and also from the spinal cord as far down as the sixth cervical ganglion. Beginning as a small bundle of fibers underneath the dorsal roots on the side of the spinal cord, it increases in size as it passes upward toward the brain, receiving accessions of fibers in its course. It arches toward the vagus and descends in contact with it, finally dividing into external and internal branches. The external ramus supplies the sterno-mastoid muscle and a part of the trapezius; the internal ramus joins the vagus.

The *hypoglossal nerve* is made up entirely of ventral roots, and is the motor nerve for the lingual muscles.

In the head the sympathetic system is intimately associated with the cerebral nerves, along the main branches of which the ganglion cells migrate. They accumulate in four ganglia, all of which are associated with the trigeminal nerve. These are the ciliary, sphenopalatine, otic and submaxillary ganglia (Fig. 128).

The *ciliary ganglion* receives its cells from the ophthalmic nerve and in part from the oculomotor nerve, with both of which it remains permanently connected. The sympathetic plexus which ascends around the internal carotid artery also sends fibers to it. Branches from the ciliary ganglion are distributed to the front of the eye, especially to the ciliary muscles and the dilator of the iris.

The *sphenopalatine ganglion* derives most of its cells from the maxillary nerve, but it is in communication also with the large superficial petrosal nerve and the sympathetic plexus around the internal carotid artery. Some of its fibers reach the orbit, but most of them are distributed to the mucous membrane of the nose and palate.

The *otic and submaxillary ganglia* both receive cells from the mandibular nerve,

and both are in connection with the sympathetic plexus around neighboring arteries. The otic ganglion receives fibers from a prolongation of the tympanic nerve, and it sends branches to the parotid gland. The submaxillary ganglion is joined by the chorda tympani and sends branches to the submaxillary and sublingual glands.

The lower ganglia of the glossopharyngeal and vagus nerves—the petrosal and nodose ganglia—differ from the other ganglia in the head by being temporarily connected with rudimentary ectodermal sense organs. Their contact with the ectoderm is transient, however, and their cells are considered to have come down from the superior and jugular ganglia, respectively. They are thus strikingly analogous to the ganglia of the sympathetic trunk, and it may be considered that instead of being connected with their nerves by rami, they have remained in the main stems. Moreover the vagus nerves produce myenteric and submucous plexuses in the œsophagus and stomach, which are quite like those of the sympathetic system in the intestine, but the fibers pass from the nodose ganglion to these plexuses without the interposition of a ganglion comparable with the celiac ganglion. In addition to sympathetic fibers, the vagus contains many direct fibers, which probably come especially from the jugular ganglion. At present, however, both the upper and lower ganglia are described as similar in structure and as resembling the spinal ganglia. The opinion here advanced, that the nodose and petrosal ganglia are sympathetic, must therefore be regarded as tentative.

STRUCTURE OF NERVOUS TISSUE.

Owing to the extent of the ramifying processes characteristic of nerve cells, it is rare that an entire cell, even a small one, is included within a single section. A motor cell, such as sends its fibers from the cord to distant muscles, has never been seen as a complete, isolated structure. From what is known of its several parts, however, a diagram of such a cell may be put together, as shown in Fig. 131. At the top of the figure is the nucleated cell body, which in different nerve cells varies in diameter from 4–150 μ . Frequently this nucleated portion is referred to as the nerve cell in distinction from the processes which grow out from it. The processes include the relatively short and irregularly ramifying *dendrites*, which convey impulses toward the cell body, and a single fiber, the *neuraxon*, chemically and physically different from the others, which conveys impulses away from the cell body. If the various processes radiate from the cell body in several directions, as in Fig. 131, the cell is described as *multipolar*; if the neuraxon is at one end of the cell and a single dendrite at the other, the cell is *bipolar* (Fig. 126); sometimes the nerve cell has only one process and is *unipolar*, as in the mature cells of the spinal ganglion which have a T-shaped process, and in other cells in which dendrites

have not developed. The dendrites have the granular structure of the protoplasm from which they grow out, and were therefore originally named "protoplasmic processes." The neuraxon, although receiving delicate fibrils from the protoplasm, as shown by special methods, seems quite distinct from the cell body. At its origin it often appears as a clear slender cone, free from granules, implanted directly upon the cell body, or upon the root of one of the larger dendrites. It tapers as it passes outward, and its fibrils come close together so that they appear to unite. Beyond the apex of the cone, which is a place where the neuraxon is easily broken, the fiber enlarges and its constituent neurofibrils spread apart so that they are more readily distinguishable. They are imbedded in a fluid interfibrillar substance. The neuraxon may send out *collateral branches*, which are usually at right angles with the main fiber.

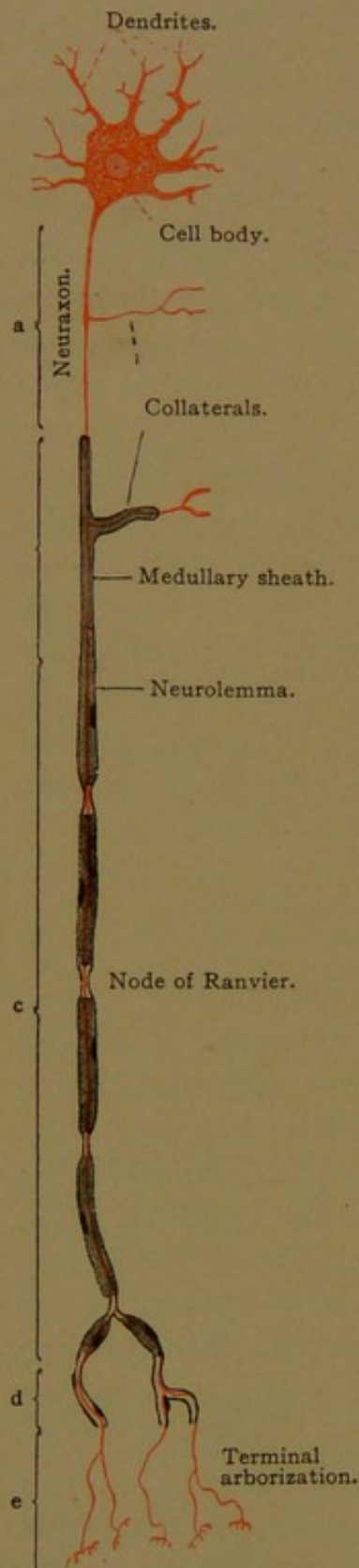


FIG. 131.—DIAGRAM OF A NERVE CELL.

As the neuraxon passes out from a motor cell it is at first free from any surrounding sheath (Fig. 131, a). In the outer layer of the spinal cord it becomes coated with a layer of the refractive fatty substance known as *myelin*. This is formed in the cord or *medulla spinalis*, and fibers which have this sheath are said to be *medullated fibers* (Fig. 131, b). The cells of the neuroglia network, through which the nerve passes while within the cord, may take part in forming the myelin, but they do not produce a membrane around each nerve, and they are not shown in the diagram. On leaving the cord, the neuraxon is still surrounded by the myelin sheath, but the latter is invested by a membrane called the *neurolemma* or sheath of Schwann (Fig. 131, c). At quite regular intervals along the course of the fiber, the myelin sheath is constricted or interrupted, forming the *nodes of Ranvier*. These are 0.08–1.00 mm. apart, being closer together in growing fibers, and in the distal part of adult fibers. Midway between two nodes

there is a nucleus, which may be found at any point in the circumference of the fiber, just within the neurolemma; it occupies a depres-

sion in the myelin. Toward its distal end the fiber usually branches, and the branches are given off at the nodes. The myelin then becomes thin, so that the fiber is surrounded merely by neurolemma (Fig. 131, d), and finally this ends. The naked axis cylinder then breaks up in its terminal arborization, forming the motor organs attached to striated muscle fibers. In comparison with the size of its cell body, the neuraxon shown in the diagram is too short; in extreme cases, as in the neuraxons extending from the spinal cord to muscles in the foot, it may be actually more than a meter long, or several thousand times the diameter of the cell body from which it comes.

The medullated nerve fibers were the first parts of the nerve to be studied microscopically, and were referred to as "cylinders;" the central fiber was called the *axis cylinder*. Remak (Obs. anat. et micr. de syst. nerv. structura, Berlin, 1838) was the first to describe non-medullated nerves, which are still known as "Remak's fibers," but their nervous nature was not readily admitted. Moreover, Remak recognized that nerve fibers proceed from cells. Deiters (Untersuchungen über Gehirn und Rückenmark, Braunschweig, 1865) supplemented these observations by showing that all "ganglion cells" (referring to nerve cells within the spinal cord and brain) are centers for *two systems of true nerve fibers*, (1) the generally broader and always single and undivided *axis cylinder process*; and (2) the *protoplasmic processes* with their extensive system of minute branches. He discussed whether the nerve cells anastomose with one another, and concluded that all such anastomoses which had been reported were due to deceptive appearances. Thus the nerve cells were believed to communicate by contact and not by continuity.

The confused mass of interwoven fibers which sections of nervous tissue ordinarily present, is, therefore, not a general syncytium from which sensory and motor fibers run out, but an orderly arrangement of branching cells. Striking proof of this was afforded in Golgi's description of the olfactory bulb (1875). In the plate which accompanied his publication, the cells in the different layers, and their various processes, were drawn in black with absolute assurance; similar figures of "Golgi preparations" are now seen in all treatises on the anatomy of the nervous system (Fig. 132). Golgi found that if fresh tissue is placed in a solution of potassium bichromate and osmic acid, and is later transferred to a solution of silver nitrate, a heavy black deposit occurs in certain nerve cells, extending throughout their minutest ramifications, whereas adjacent cells are wholly unaffected. The process must be carried out with great care, and even then it is capricious; but this method has afforded fundamental information in regard to the forms of individual nerve cells.

In order to emphasize that the nervous system is built up of separate cells, the term *neurone* has been widely used to designate a complete nerve cell, with all its branches. Fig. 131, therefore, represents a neurone, together with certain sheath cells.

Recently, however, there has been a tendency to regard such a neurone as a syncytium, and in the latest editions of his "Lehrbuch," Stöhr adopts this interpretation. He states that in so far as the neurone includes peripheral nerve fibers, it is a biological or syncytial unit, but not a single cell. It is considered to be a "biological unit" since it is well known that the cell body of the nerve cell is the nutritive or

controlling center for the entire fiber; and any part of the fiber which is cut off from the cell body undergoes degeneration. Stöhr considers that Schwann (1839) had the correct conception when he regarded the nerve fiber as "a secondary cell, developed by the coalescence of primary cells."

Opposed to the syncytial interpretation of a peripheral fiber are the experiments of Harrison, some of which have already been cited. He has shown that in the tadpole the sheath cells, or neurolemma cells, which are believed by some to produce the segments of the fiber which they surround, all migrate from the brain along the dorsal root. If the dorsal part of the cord is removed from tadpoles, the ventral roots are deprived of their sheath cells, but the fibers of the ventral roots grow out to their terminations nevertheless. If the ventral part of the cord is cut from beneath the dorsal part, the dorsal roots develop and have with them the sheath cells which

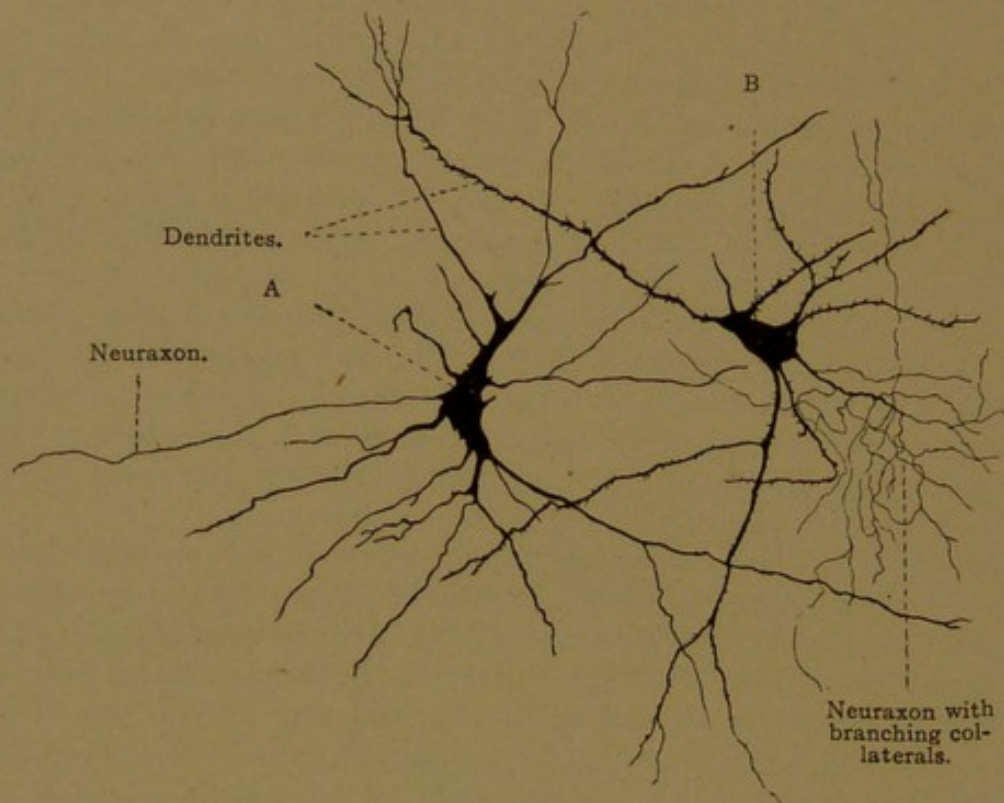


FIG. 132.—TWO NERVE CELLS FROM THE CENTRAL NERVOUS SYSTEM. GOLGI PREPARATIONS. $\times 200$. A, Cell of Deiter's type, having a neuraxon ending at a considerable distance from the cell body; B, cell of Golgi's type having a neuraxon with many branches ending near the cell body.

normally would enclose the fibers of the ventral root. These sheath cells do not produce nerve fibers. Therefore Harrison concludes that the peripheral fibers are not syncytial.

Recently W. H. and M. R. Lewis have caused sympathetic fibers to grow from pieces of the intestine of chick embryos placed in various saline solutions. These fibers show amoeboid endings. They branch freely and anastomose, but like the nerve fibers from the central nervous system "they are outgrowths from nerve cells and are not formed from pre-existing protoplasmic networks" (*Anat. Rec.*, 1912, vol. 6, pp. 7-31).

Another form of syncytium would result if neurofibrils passed across the places of contact between the neurones. According to Apáthy, who has studied the neurofibrils of invertebrates with special methods and faultless technique, the neurofibrils pass freely from cell to cell (*Mitth. Zool. Station, Naples*, 1897, vol. 12, pp. 495-748). It is possible that this takes place in the vertebrate nervous system also. Anastomoses

have been found between ganglion cells in the retina by Dogiel, and slender nerve fibers appear to anastomose in tissue cultures; but the staining of individual cells by the Golgi method, and the way in which degeneration may be limited to cell territories, are regarded as strong evidence against the existence of a general syncytium.

STRUCTURE OF GANGLIA.

Although a ganglion is characterized by the accumulation of the bodies of nerve cells, it is traversed by many fibers, as seen in the section of a spinal ganglion (Fig. 133). Under higher magnification the cell bodies appear as in Fig. 134. The nuclei are large vesicular structures, round or oval in outline, containing a characteristic prominent nucleolus. They are surrounded by abundant, darkly staining, finely granular proto-

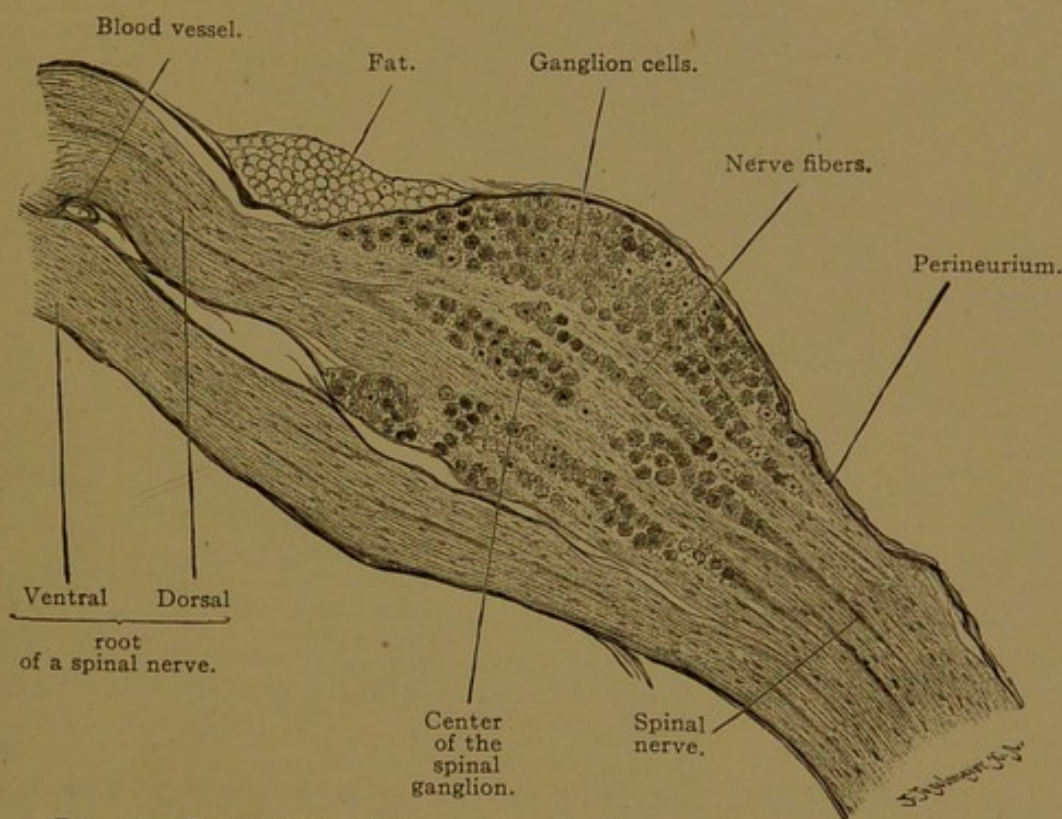


FIG. 133.—LONGITUDINAL SECTION THROUGH A SPINAL GANGLION OF A CAT. $\times 18$.

plasm, which exhibits its fibrillar structure only with special methods. Frequently the protoplasm contains pigment granules. The "reticular apparatus" is said to be present always, and slender intracellular canals (trophospongium) have been described (Figs. 5 and 6, p. 4). Fine-meshed reticular networks have been found covering the exterior of the nerve cells, and they have been ascribed both to the terminal ramification of nerve fibers and to branches of the supporting tissue. A ganglion cell is often surrounded by flat or stellate cells arranged in concentric layers so as to form a sheath. Within the sheath there is a homogeneous membrane or *capsule*, on the inner side of which are cells arranged in a single layer, corresponding to the cells within the neurolemma of peripheral

nerves. Connective tissue, containing small blood vessels, passes between the ensheathed cells of the ganglion.

In the embryo the cells of the spinal ganglia are bipolar, but generally they become unipolar, with T-shaped processes, as already described. In the ganglia of the acoustic nerve, however, the bipolar form is said to be retained, and these cells are not surrounded by capsule or "mantle" cells. In other ganglia of the cerebral nerves, and in spinal ganglia, the cells are arranged as shown in the diagram, Fig. 135. Their branches can be studied only in special preparations, made usually by Ehrlich's methylene blue method, or Cajal's silver nitrate method.

Cross section of a medullated nerve fiber.

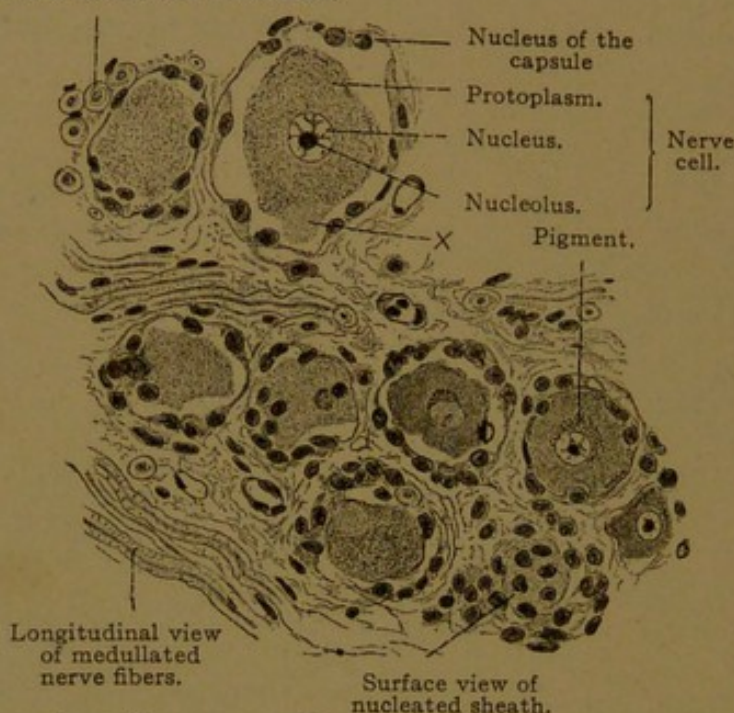


FIG. 134.—FROM A CROSS SECTION OF A HUMAN SEMILUNAR GANGLION. $\times 240$.

At x the beginning of a protoplasmic process has been included in the section; elsewhere the processes cannot be seen.

The most characteristic cells (Fig. 135, 3) have large round bodies and a single spirally coiled process, which arises from a conical projection of the protoplasm. The process often winds about the cell body. Soon after passing through the capsule it acquires a sheath of myelin, and is covered with neurolemma. It may give off collaterals before it divides into its two main branches, which correspond with dendrite and neuraxon respectively. Sometimes the process divides into three branches (Fig. 135, 2); the branching takes place at a node of Ranvier. Certain of the large cells, as found constantly in the human jugular ganglion, lack the coiled windings, so that the process passes directly through the capsule and divides at once into its two branches.

Frequently the ganglion cells are provided with short processes which end in rounded enlargements, either within the capsule (Fig. 135, 5) or outside of it (Fig. 135, 6). Collateral branches may end in this way.

These "end discs" were first observed by Huber in frogs (*Anat. Anz.* 1896, vol. 12, pp. 417-425). They are found not only in spinal ganglia but also in the central nervous system and in sympathetic ganglia; and

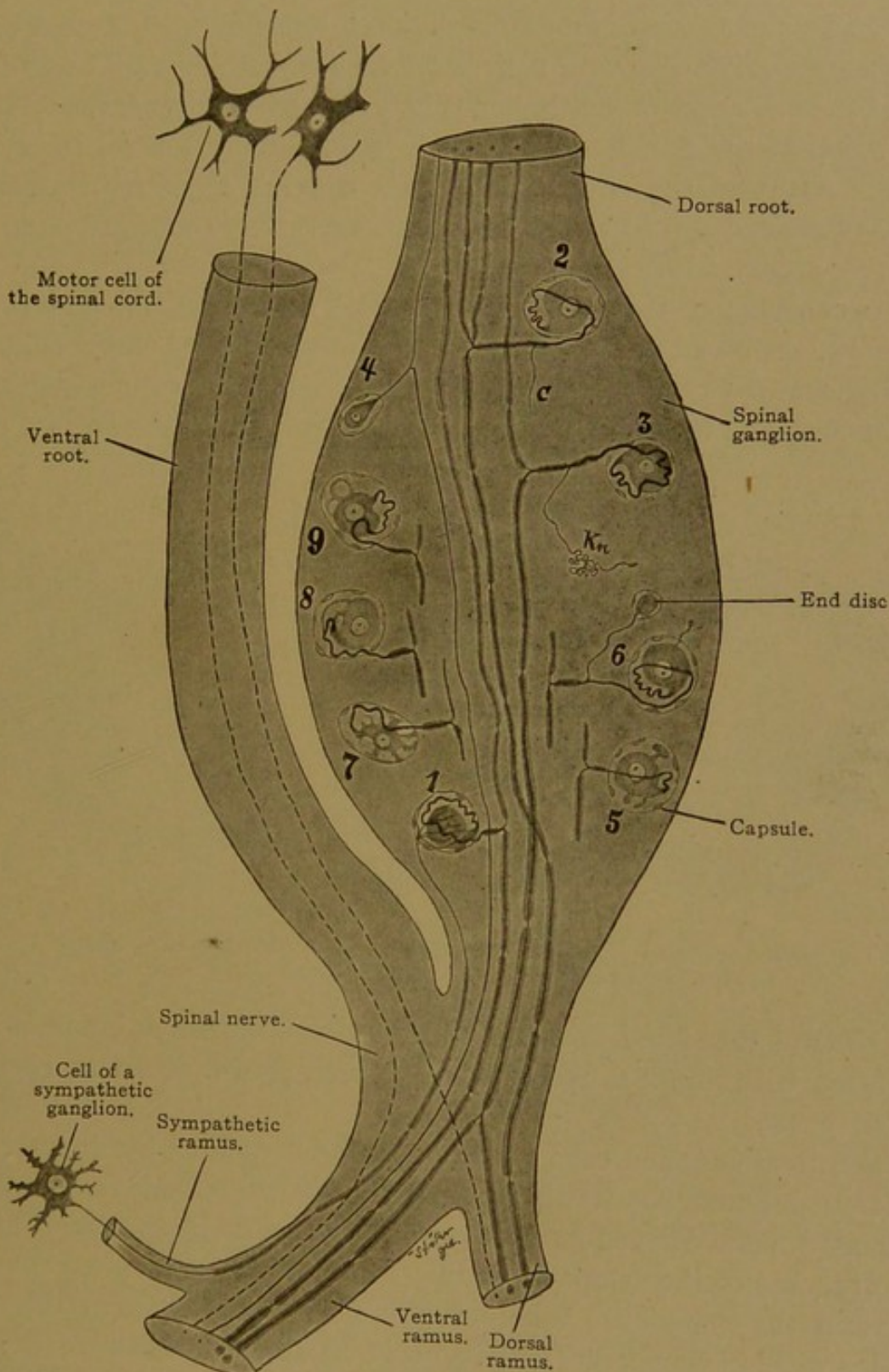


FIG. 135.—DIAGRAM OF THE NERVOUS ELEMENTS IN A HUMAN SPINAL GANGLION.

after the distal part of a nerve has been cut away, the axis cylinders of the proximal part send out many such buds, which grow into the myelin toward the place of injury. In all cases they are regarded as abortive

branches. They are said to occur normally only in adults, and especially in old age, being very numerous in the nodose ganglion of the vagus nerve.

Another feature which, in man, has been found almost exclusively in the nodose ganglion of adults, is the occurrence of "fenestrated cells." These are ganglion cells with peripheral vacuoles, which may break down so that the cell appears multipolar (Fig. 135, 7). Sometimes they are so arranged that the cell process seems to grow out by several roots (Fig. 135, 8). Although the fenestrated cells increase in number with advancing age, they are not considered pathological, since they occur in young dogs and other animals.

Less conspicuous than the large cells with medullated fibers, but more numerous, are small pyriform cells with non-medullated fibers (Fig. 135, 4). Ranson, from his own and previous observations, concludes that in the cat and rat, in which the cells have been carefully counted, about

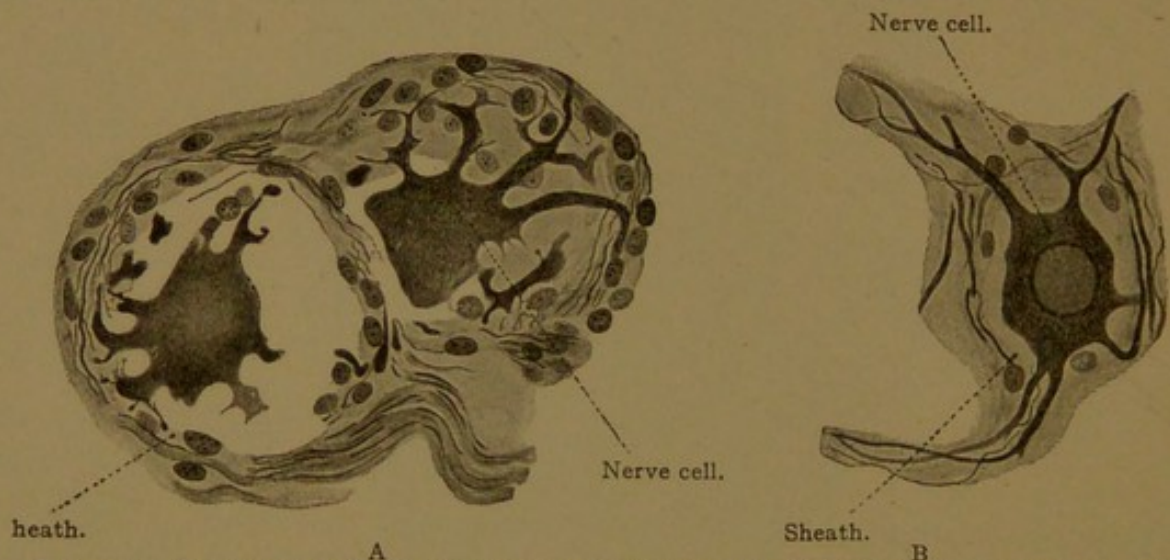


FIG. 136.—CELLS OF THE HUMAN SYMPATHETIC GANGLIA. (Prepared by L. R. Müller.) $\times 465$.
A, From the ciliary ganglion; B, from the superior cervical ganglion.

two-thirds of the spinal ganglion cells may be classified as small, and are associated with non-medullated fibers (Amer. Journ. of Anat., 1911, vol. 12, pp. 67-87).

The spinal ganglion cells are sometimes surrounded by fine networks of non-medullated fibers, which are probably the terminal branches of medullated fibers derived from cells in the sympathetic ganglia (Fig. 135, 1). Branches of the sympathetic fibers are also distributed to the blood vessels in the ganglion. Whether any fibers pass through the spinal ganglion without connecting with its nerve cells is still uncertain; they have not been demonstrated in mammals.

Sympathetic Ganglia. The sympathetic ganglia consist of multipolar cells which are smaller than those of spinal ganglia (Fig. 136). Their round or oval nuclei, often eccentric, have prominent nucleoli and a loose chromatin network, as in other nerve cells; some of them contain two

nuclei. The protoplasm is often pigmented. Around the cell bodies, nuclei of the sheath cells may be abundant. Three types of sympathetic ganglion cells are shown in Fig. 137. The motor cells, terminating in contact with smooth muscle fibers, are by far the most abundant (Fig. 137, 1). Their neuraxons are non-medullated fibers, which are provided with very slender collaterals. The cell body is stellate and its branching dendrites appear spiny. The second type (Fig. 137, 2) is possibly sensory,

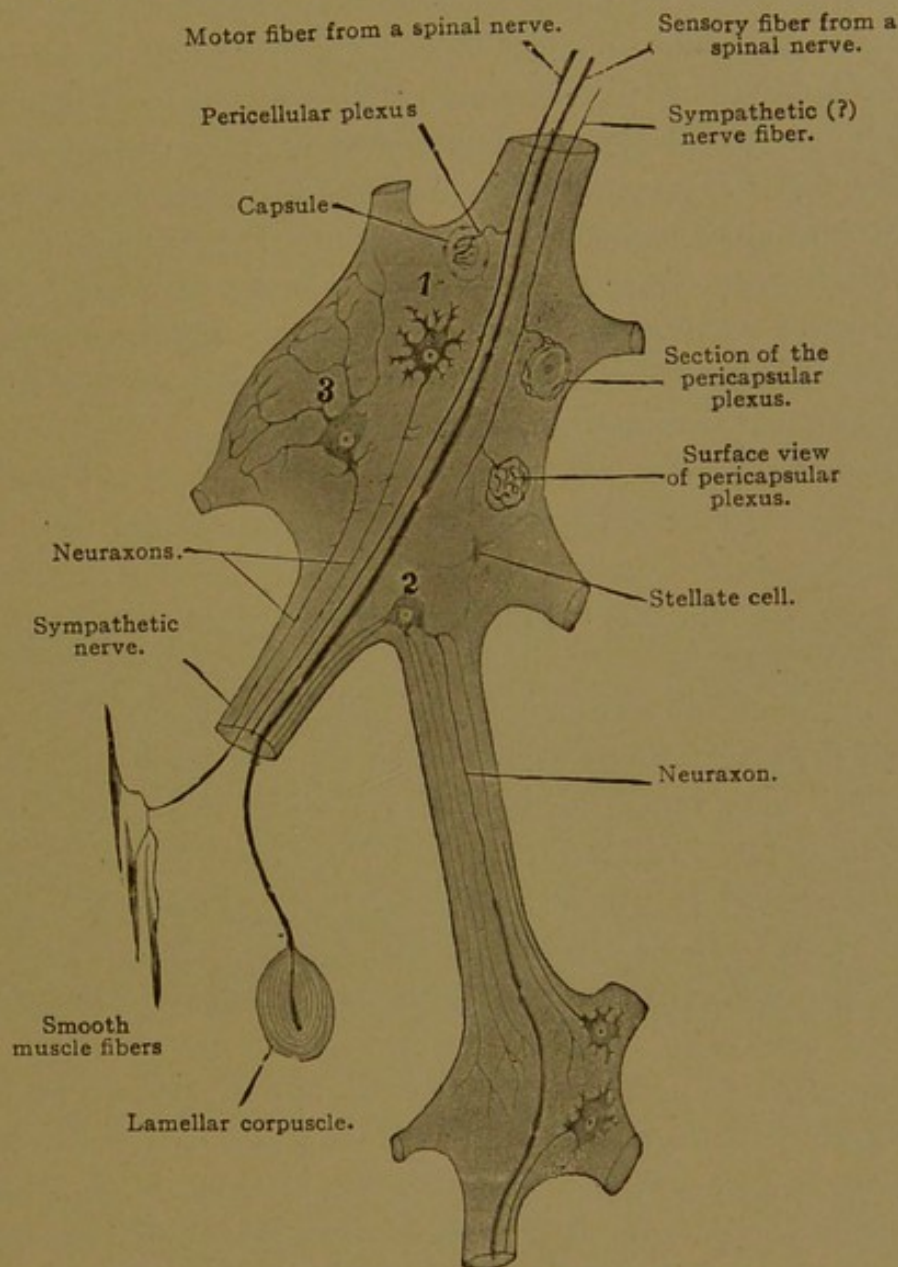


FIG. 137.—DIAGRAM OF THE ELEMENTS OF TWO SYMPATHETIC GANGLIA.

but the terminations of its fibers are not known. Its dendrites are long and slender and may extend from one ganglion to another. Some of them are accompanied by the neuraxon, which may acquire a medullary sheath, often at a considerable distance from the cell body. Cells of the third type (Fig. 137, 3) resemble those of the second type. They have long branching dendrites which pass between the adjacent cells to the periphery of the ganglion, where they form a plexus. Their non-medullated neurax-

ones pass out of the ganglion, but their terminations are unknown. Small stellate cells, one of which is shown in the figure, presumably belong with the supporting tissue.

Fibers from the spinal nerves may pass through the sympathetic ganglia, or terminate within them. Thus spinal motor fibers, after losing their myelin sheaths, form pericellular plexuses about the sympathetic motor cells, and their collaterals end in the same way. They are apparently indistinguishable from the sympathetic fibers which pass from one ganglion to another and terminate in pericellular networks. Medullated sensory fibers, some of which arise from lamellar corpuscles, extend through the sympathetic nerves to enter the spinal ganglia.

Chromaffin organs, or paraganglia, are masses or cords of cells which originate in close association with sympathetic ganglia. Although they have often been classed with nervous tissue, they are to be regarded as glands which produce an internal secretion. This secretion acts upon the smooth musculature in the walls of the blood vessels and causes it to maintain a proper state of contraction, or tonus.

When fresh, chromaffin tissue is darkly colored. If preserved in fluids containing chromic acid or salts of chromium, the cells which contain secretion acquire a yellowish-brown stain. The term *chromaffin* refers to this specific affinity for chromium, and does not mean that the cells stain deeply.

Groups of chromaffin cells are found in connection with the ganglionated trunk of the sympathetic system. In the new-born child these "chromaffin bodies" may reach a length of 1-1.5 mm. (Zuckerkindl) and several of them may be associated with a single ganglion. They are always found in the plexus at the bifurcation of the carotid artery, where they enter into the formation of the carotid gland (*glomus caroticum*). They occur in varying numbers in the coeliac, renal and hypogastric plexuses, and extend along the vessels so that chromaffin cells are found in relation with the kidneys, ureters, prostate, epididymis and ovary. The largest bodies (the *organs of Zuckerkindl*) are found on either side of the inferior mesenteric artery, and may connect with one another by a bridge across the front of the aorta. At birth "the average length of the right one is 11.6 mm., and of the left, 8.8 mm." Usually there are two chromaffin bodies on either side in the hypogastric plexus, but the total number of bodies connected with the abdominal plexuses varies greatly, "from 7 to 26, or even more; in one case nearly 70" (Zuckerkindl). Although they undergo regressive changes after birth, they do not disappear.

The medulla of the suprarenal glands consists of chromaffin tissue, which has very important functions throughout life; it will be described in connection with the suprarenal glands.

STRUCTURE OF NERVES.

Nerves are bundles of nerve fibers passing between the central nervous system and the various parts of the body; they are so widely distributed that they may be found in sections of most of the organs and tissues. When examined fresh, in reflected light, nerves are seen to be of two sorts, formerly known as white and gray nerves, respectively. Similarly, sections of the brain and spinal cord are formed of white substance and gray substance. The obvious distinction in color is due to the presence or absence of microscopic sheaths of myelin around the individual fibers. Nerves which contain a large proportion of myelinated or medullated fibers are white; and those which have few are gray. All nerve fibers when first formed are non-medullated, and most of the sympathetic nerves remain in this condition.

Non-medullated nerves can readily be found between the circular and longitudinal layers of smooth muscle in any part of the digestive tube. They are circumscribed bundles of fine fibers running through the coarser connective tissue (Fig. 138). Many of them contain nerve cells, unmis-

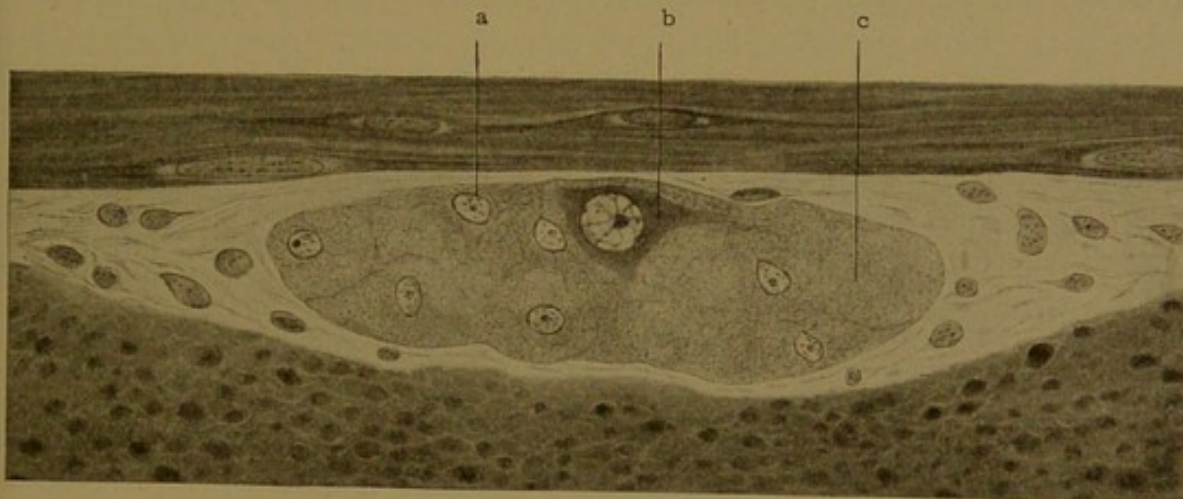


FIG. 138.—A SYMPATHETIC NERVE FROM THE MYENTERIC PLEXUS OF A CAT. $\times 775$.
a., Nucleus of a supporting cell; b., nerve cell; c., non-medullated nerve fibers. Above the nerve are circular smooth muscle fibers in longitudinal section; below it are longitudinal fibers in cross section.

takably characterized by large, round or oval, vesicular nuclei, having a prominent nucleolus. Around the nucleus is dense protoplasm, starting out in branching processes, all but the roots of which are cut away in sectioning. Other cells are found, having relatively small nuclei and very indefinite or wholly imperceptible protoplasmic bodies. These are supporting cells; they produce a syncytial framework in which the nerve cells and their very delicate ramifications are imbedded. The framework tends to form septa, subdividing the nerve into smaller bundles.

Some non-medullated fibers, but by no means all, are closely invested by sheath cells. According to Schäfer, the nuclei of these cells appear to be interpolated in the substance of the fiber, and it is impossible to demon-

strate a distinct sheath (Fig. 139). Similarly Bardeen has stated that it is "mainly a matter of judgment to decide whether the fibrils are surrounded by or imbedded within the sheath cells." They correspond with the neurolemma cells of medullated nerves.

Medullated Nerves. The larger sympathetic nerves contain a considerable number of medullated fibers, and the splanchnic nerves are described as white. In the trunks of the spinal nerves, however, the medullated fibers attain their maximum development. Examined with low magnifi-



FIG. 139.—NON-MEDULLATED NERVE FIBERS. $\times 400$. (After Schäfer.)

cation, such a nerve is seen to consist of round cords imbedded in loose connective tissue (Fig. 140). This loose tissue, which surrounds the entire nerve and its several cords, is the *epineurium*; its connective tissue bundles are chiefly longitudinal, and are associated with abundant elastic tissue and frequent fat cells; it contains the blood vessels which supply the nerve. Each cord is surrounded by a dense lamellar layer of connective tissue, which contains flattened cells in contact with one another so that they form more or less continuous membranes. This layer is the

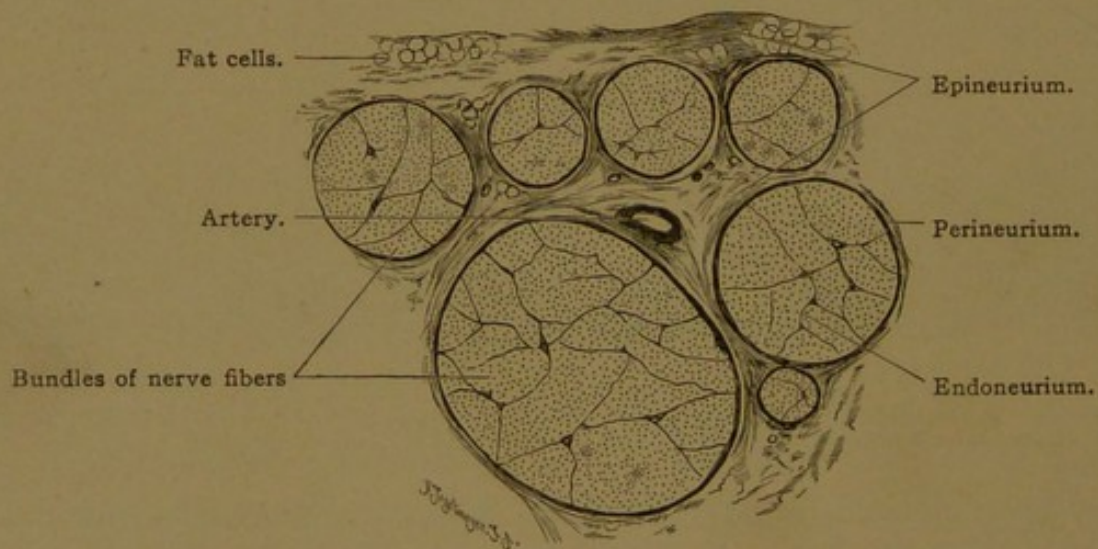


FIG. 140.—MEDULLATED NERVE. PART OF A CROSS SECTION OF THE HUMAN MEDIAN NERVE. $\times 20$.

perineurium. It is continuous with the outer membranes covering the cord, and contains cleft-like spaces which are said to communicate with the subdural and subarachnoid spaces, but which do not connect with lymphatic vessels in the epineurium. Prolongations of the perineurium extend as septa into the larger nerve bundles and constitute the *endoneurium*, which may penetrate between the individual nerve fibers, forming the so-called "sheaths of Henle." Their nuclei are always outside the neurolemma.

The individual nerve fibers vary in diameter, and the larger ones are probably those which have a longer course. It is impossible to distinguish histologically between sensory and motor fibers. The sheath of

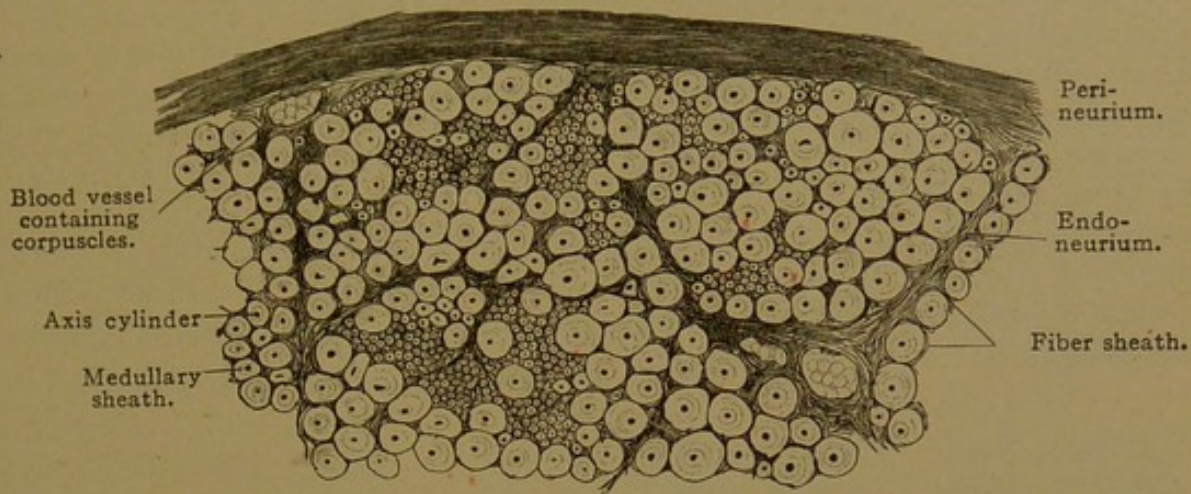


FIG. 141.—MEDULLATED NERVE. PART OF A CROSS SECTION OF THE HUMAN MEDIAN NERVE. $\times 220$.

myelin which surrounds the fiber varies greatly in thickness, as seen in the cross section, Fig. 141. In ordinary preparations it forms light zones around the dark fibers, suggesting the relation between protoplasm and nucleus; but the rod-like nature of the central fibers is evident on changing the focus. The myelin is surrounded by the membranous neurolemma, within which the single internodal nucleus is occasionally included in a given section. Portions of isolated fibers, viewed longitudinally, are shown in Fig. 142.

Myelin is a mixture of complex fats and lipid substances, some of which are combined with sugar. Like fat, it is dissolved by ether and blackens with osmic acid. In preserved specimens the emulsion breaks down, giving rise to various forms of shrinkage. A network which appears after fibers have been treated with alcohol and ether is said to be composed of *neurokeratin*, a substance insoluble in these reagents, which does not blacken with osmic acid. The size of the meshes varies (Fig. 143, A, B). In preparations blackened with osmic acid, the myelin is often traversed by oblique clefts, the *incisures* of Lantermann (Fig. 143, D). The arrangement of these characteristic clefts

may be pictured by imagining a succession of stemless funnels strung along the axis cylinder, not all of which are pointed the same way. The incisures are doubtless artificial, and their number is increased by pulling the nerve fibers apart; they appear to be empty or crossed by strands of myelin, but in the preparation shown in

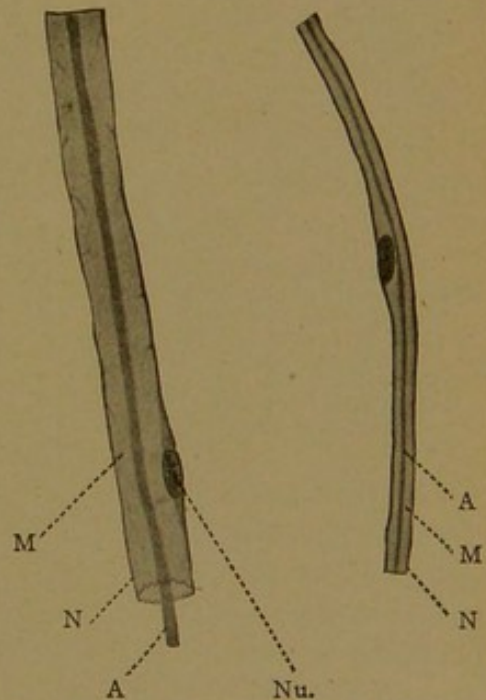


FIG. 142.—TWO NERVE FIBERS WITH SHRUNKEN AXIS CYLINDERS FROM THE SCIATIC NERVE OF A RABBIT. $\times 350$.

A, Axis cylinder; M, medullary sheath (myelin); N, neurolemma; Nu, nucleus of the neurolemma.

Fig. 143, C, the neurokeratin framework is so arranged as to correspond with these intervals. In transverse sections, incisures are included in Fig. 143, E and I; the concentric, vacuolated and radial appearances of the myelin are represented in F-H.

The nodes of Ranvier, shown in the diagram, Fig. 131, are conspicuous in isolated nerve fibers stained with osmic acid. Various interpretations of their structure are represented in Fig. 144. According to the first (Fig. 144, A) the myelin occurs like fat, within distinct cells wrapped around the nerve fibers; the node is the interval between successive cells. The nucleus, which is flattened by the myelin against the outer cell wall, mid-way between the nodes, is not shown. Corresponding with the neurolemma on the outside, there is an "axolemma" next the axis cylinder; neurolemma and axolemma come together at the node. If the nerve fibers are treated with silver nitrate, a black precipitate is produced at the nodes, as if an intercellular substance were present; the blackening may extend up the axis cylinder producing cross-shaped figures (Fig. 144, B).

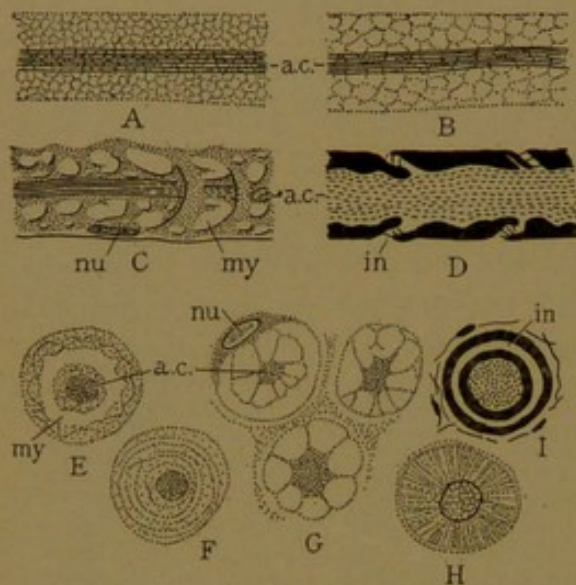


FIG. 143.—MEDULLATED NERVE FIBERS.

A-D, Longitudinal sections; E-I, cross sections. (A-B, after Gedoelst; C, E, F, after Hardesty; D and I, osmic acid preparations, after Prenant and Scymonowicz; G, alcoholic preservation, after Koelliker H, picric acid preservation, after Schäfer.) a. c., Axis cylinder; in., incisure; my., myelin; nu., nucleus of the neurolemma.

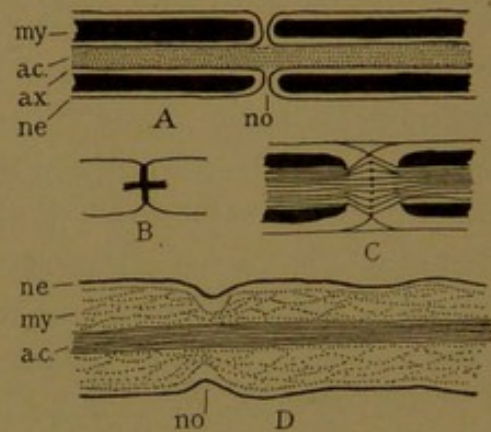


FIG. 144.—NODES.

A, Diagram of the intracellular explanation of myelin; B, the cross obtained with silver nitrate; C, the biconical enlargement (after Gedoelst); D, intercellular myelin (after Hardesty); a. c., axis cylinder; ax., axolemma; my., myelin; ne., neurolemma; no., node.

As the axis cylinder traverses the node, its fibrils may spread apart, forming a "biconical enlargement." The fibrils in the midst of the enlargement have been described as thickened (Fig. 144, C). The same figure shows no axolemma and suggests that the neurolemma passes across the node without interruption. This is clearly shown in D, where the myelin layer also, though constricted, is not completely divided. The myelin has accordingly been regarded as an exoplasmic part of the axis cylinder, and chemically it is said to be related to the interfibrillar substance or *neuroplasm*. Bardeen (Amer. Journ. Anat., 1903, vol. 2, pp. 231-257) considers that the myelin is derived from the intercellular substance between the fiber and the sheath, and is "due to influences exerted by the axis cylinder fibrils." That the axis cylinder plays the chief part in its production is indicated by the fact that the myelin breaks down when the fiber degenerates, and that it forms around fibers in the central nervous system where there are no continuous sheaths.

The production of myelin is said to begin at about the fourth month, at the central ends of the nerves. It begins at different times in different tracts and systems, and

the medullary sheaths of the spinal nerves are not all formed until two or three years after birth. They continue to increase in thickness into adult life.

NERVE ENDINGS.

SENSORY ENDINGS. The outward growth of nerve fibers from cells in the ganglia of the spinal and cerebral nerves has already been described. Near their terminations these fibers branch repeatedly at the nodes, lose their myelin sheaths, and form terminal arborizations in contact with epithelial, connective tissue, or muscle cells. These are the *sensory endings*, and apart from those connected with the eye, ear, and other organs of special sense, they may be described as follows.

Free Endings. Sensory fibers to the epidermis and to the corneal and oral epithelia penetrate the basal layer, passing between the cells as unsheathed fibers, and ramify among the cells in the outer layers (Fig. 145). The extremities of the fibers, which may be pointed or club-shaped, are in contact with the epithelial cells, but do not enter them. In the process of branching the neurofibrils become distributed



FIG. 145.—FREE NERVE ENDING, IN EPITHELIUM. GOLGI PREPARATION. (After Retzius.)

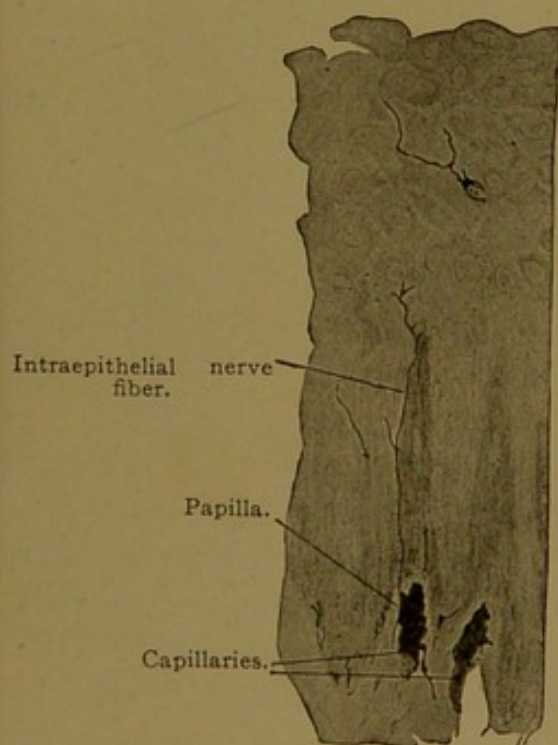


FIG. 146.

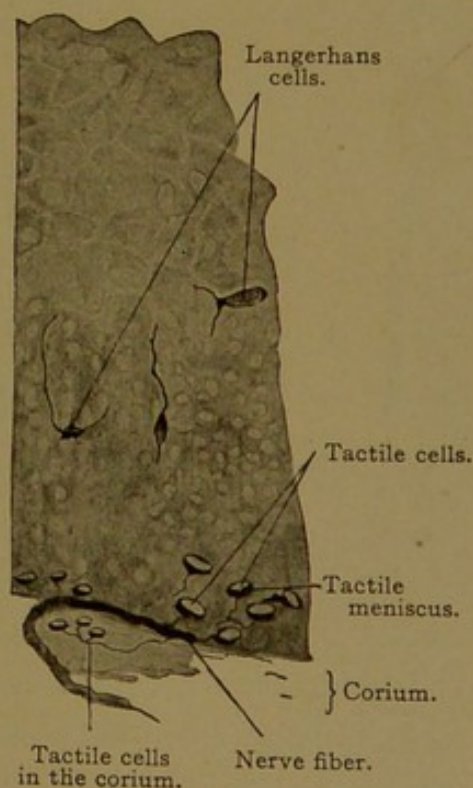


FIG. 147.

FIGS. 146 AND 147.—FROM VERTICAL SECTIONS THROUGH THE SKIN OF THE GREAT TOE FROM A MAN OF TWENTY-FIVE YEARS. $\times 360$.

in smaller and smaller bundles, which often anastomose, forming plexuses; but whether the interlacing constituent fibrils unite with one another so as to form a net has been questioned. At the ends of the branches, each

fibril has become separate from the others; frequently it shows varicose enlargements.

Free sensory endings occur not only in stratified epithelia, but also in

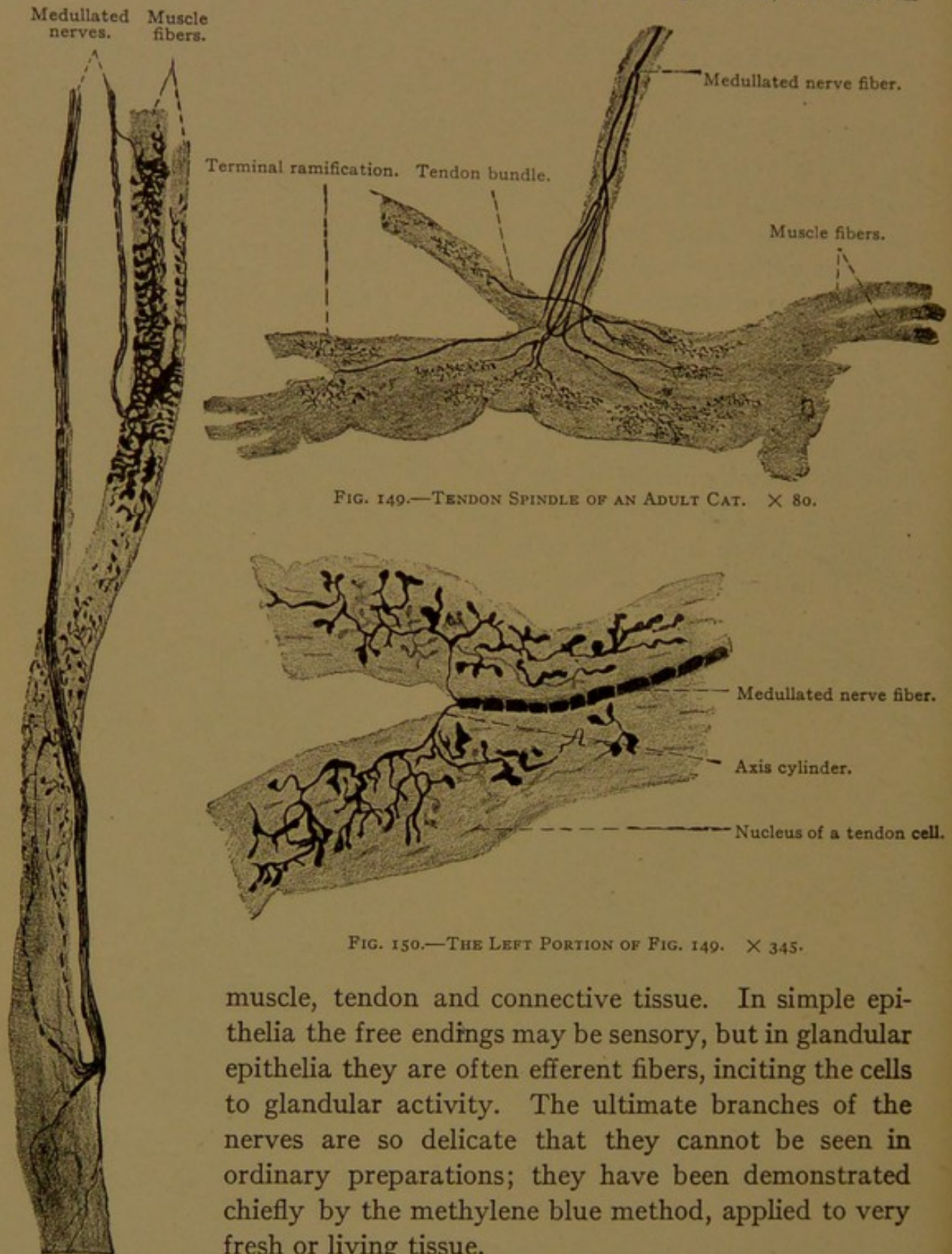


FIG. 148.—MUSCLE SPINDLE OF AN ADULT CAT. $\times 135$.

FIG. 149.—TENDON SPINDLE OF AN ADULT CAT. $\times 80$.

FIG. 150.—THE LEFT PORTION OF FIG. 149. $\times 345$.

muscle, tendon and connective tissue. In simple epithelia the free endings may be sensory, but in glandular epithelia they are often efferent fibers, inciting the cells to glandular activity. The ultimate branches of the nerves are so delicate that they cannot be seen in ordinary preparations; they have been demonstrated chiefly by the methylene blue method, applied to very fresh or living tissue.

In the epidermis, as a modification of the free endings, fibers are found terminating in disc-shaped networks (*tactile menisci*) at the base of modified cells (Fig. 147). These tactile cells may occasionally be seen in ordinary preparations.

The stellate "Langerhans cells" shown in Figs. 146 and 147 are usually regarded as wandering cells lodged in intercellular spaces, but Stöhr states that intergrading forms connect them with the epithelial cells; and they may act as sensory cells.

Muscle Spindles. As seen in ordinary preparations muscle spindles are shown in Fig. 119 (p. 127). They are slender groups of 3-20 muscle fibers, 1-4 mm. long and 0.08-0.2 mm. wide, around which nerve fibers terminate as shown in Fig. 148. The spindles are surrounded by a thick connective tissue sheath or capsule, continuous with the perimysium, and said to be divided into an inner and an outer layer by a space filled with fluid. The muscle fibers of the spindle are poorly developed. They are distinctly striated toward their tapering and very slender ends, but in their middle portions, sarcoplasm and nuclei are abundant and the striations ill defined. Three or four nerves terminate in each spindle. Their connective tissue sheaths blend with the perimysial capsule, and they branch

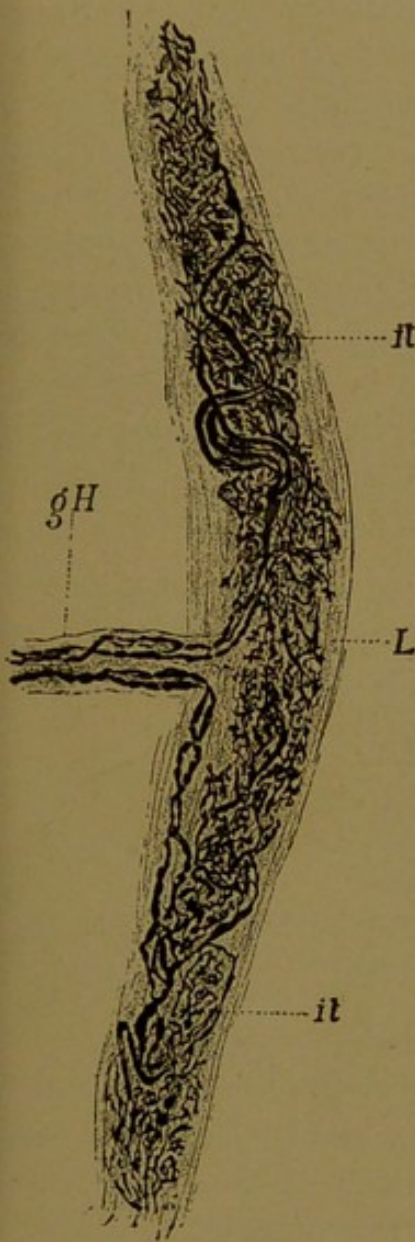


FIG. 151.—TERMINAL CYLINDER.
(After Ruffini, from Ferguson's Histology.)

gH, Medullary sheath; it, terminal ramifications of the axis cylinder; L, connective tissue.

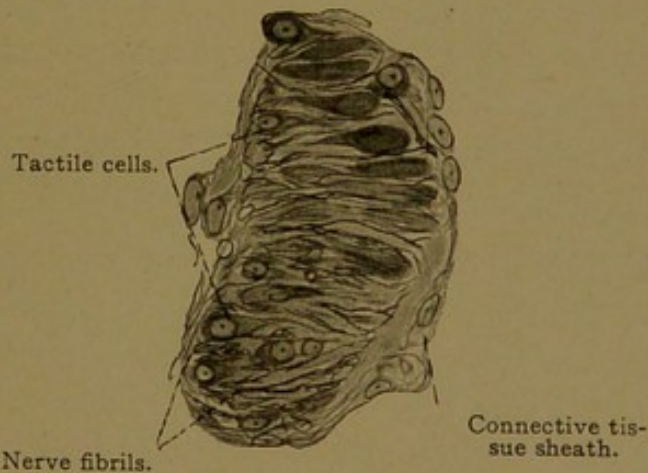


FIG. 152.—TACTILE CORPUSCLE FROM A SECTION OF THE SKIN OF A HUMAN FINGER. $\times 560$.

(Prepared by van der Velde, after the Bielschowsky method.)

and lose their myelin as they pass through it to the muscle cells. They may encircle the muscle fibers of the spindle, forming spirals or rings (as in the upper part of Fig. 148), or they may form a panicle of branches with enlarged club-shaped ends. Since they do not degenerate after the motor roots have been cut, they are supposed to be sensory fibers, but their function has not been established. Other sensory fibers to muscle have free endings, as shown in Fig. 157.

Tendon Spindles. Tendons possess free sensory endings, together with the tendon spindles. These are small portions of the tendon, 1-3 mm. long and 0.17-0.25 mm. wide, enclosed in sheaths of connective tissue. They stain more deeply than the surrounding tendon.

The few nerve fibers which terminate in a tendon spindle lose their sheaths and branch freely, ending in club-shaped enlargements (Figs. 149 and 150). They are found in all tendons and serve to transmit the sensation of tension, being active in connection with coördinated movements.

In connective tissue the sensory nerves may have free endings. In addition to these the subcutaneous tissue near the coils of the sweat glands, and in the corium of the fingers and toes, sometimes contains *terminal cylinders* (of Ruffini) which resemble tendon spindles in the way that their nerves ramify (Fig. 151). These cylinders lack the distinct capsules which characterize the nerve *corpuscles*.

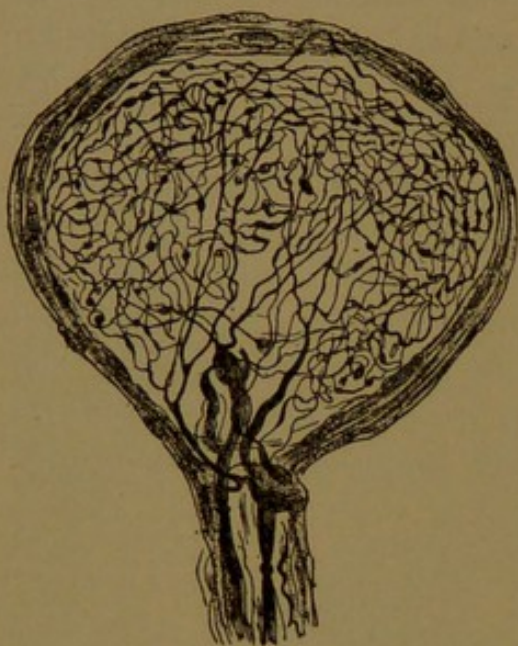


FIG. 153.—GENITAL CORPUSCLE FROM THE HUMAN GLANS PENIS. METHYLENE BLUE STAIN. (After Dogiel, from Böhm and von Davidoff.)

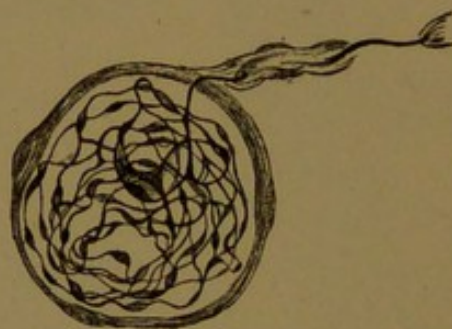

FIG. 154.—BULBOUS CORPUSCLE FROM THE HUMAN CONJUNCTIVA. METHYLENE BLUE STAIN. (After Dogiel, from Böhm and von Davidoff.)

Terminal corpuscles are nerve endings consisting of a coarse nerve fiber, or knot of small branches, surrounded by a semifluid intercellular substance (which is granular in preserved tissue), and enclosed in a connective tissue capsule. The terminal ramifications of the nerve show irregular swellings or *varicosities*, and apparently they unite so as to make a network. Often more than one fiber enters a corpuscle, and it has been suggested that they include afferent and efferent fibers. Generally the connective tissue sheaths of the entering fibers blend with the capsule, and the myelin sheaths are lost just within it. Terminal corpuscles have been grouped as *tactile*, *genital*, *bulbous*, *articular*, *cylindrical*, and *lamellar*.

Tactile corpuscles (or Meissner's corpuscles) are elliptical structures, 40-100 μ long and 30-60 μ broad (Fig. 152). They are characterized by transverse markings, due to the corresponding elongation of the capsule cells and the tactile cells within. From one to five medullated fibers enter the lower end of a tactile corpuscle, losing their sheaths soon after entering. They pursue a spiral course through the corpuscle, giving off

branches which end in enlarged terminal networks between and upon the tactile cells. These corpuscles are found in some of the papillæ, or connective tissue elevations just beneath the epidermis, being especially numerous in those of the soles and palms (23 in 1 sq. mm.) and in the finger tips; they occur also "in the nipple, border of the eyelids, lips, glans penis and clitoris."

Genital corpuscles are large, round or oval bodies 60-400 μ long (Fig. 153) which may receive as many as ten nerve fibers. These ramify and send branches to neighboring corpuscles, and also to the epidermis. The genital corpuscles are deeply placed beneath the epithelium of the glans penis, clitoris, and adjoining structures.

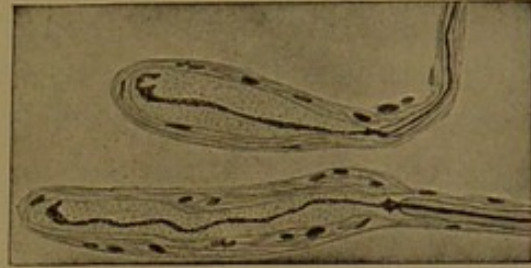


FIG. 155.—CYLINDRICAL CORPUSCLES, FROM INTER-MUSCULAR SEPTUM OF CAT. METHYLENE BLUE STAIN. (Huber.)

Bulbous corpuscles (of Krause) are smaller than the genital corpuscles, having a diameter of 20-100 μ (Fig. 154). They are most numerous (1-4 in a sq. mm.) in the superficial connective tissue of the glans penis and clitoris. Similar structures, either round or oval, are found in the conjunctiva and "edge of the cornea, in the lips and lining of the oral cavity, and probably in other parts of the corium." They have thinner

capsules and receive fewer nerves than the genital corpuscles, which they resemble. The articular corpuscles, found near the joints, belong in the same category.

Cylindrical corpuscles (cylindrical end bulbs of Krause) contain a single axial nerve fiber with few or no branches, terminating in a knob-like or rounded extremity (Fig. 155). The fiber is surrounded by a semi-fluid substance, sometimes described as an inner bulb, and this is enclosed in a few concentric layers of cells which are continuous with the sheath of the nerve. Cylindrical corpuscles are found in the mucous membrane of the mouth and in the connective tissue of muscles

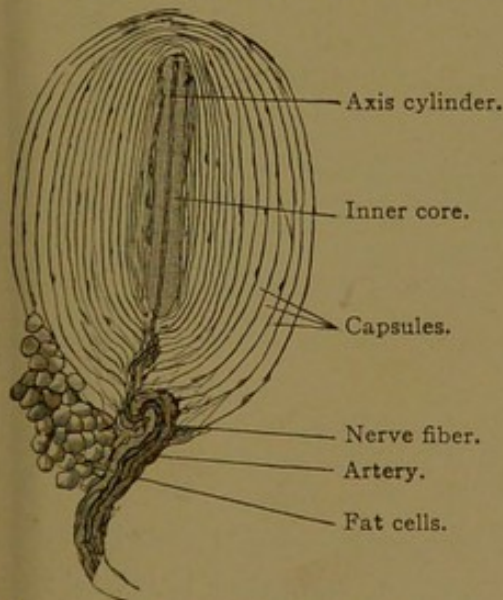


FIG. 156.—SMALL LAMELLAR CORPUSCLE FROM THE MESENTERY OF A CAT. $\times 50$. The nuclei of the capsule cells appear as thickenings. The myelin of the nerve fiber may be traced to the inner core.

and tendons.

Lamellar corpuscles (or Pacinian corpuscles) are macroscopic elliptical structures 0.5-4.5 mm. long and 1-2 mm. wide (Fig. 156). They were first observed in dissections, as minute vesicular bodies attached to the terminal branches of nerves. Microscopically they are striking objects,

suggesting an encysted foreign body. The axial core of the corpuscles is surrounded by concentric layers, sometimes as many as fifty, which represent a perineurium distended with fluid. A single large nerve fiber enters one end of the corpuscle and loses its myelin as it traverses the lamellæ. It extends through the semifluid core without obvious branches, sometimes being flattened and band-like; it may fork at its further end or form a coil of branches, and it has been observed to pass out and enter another such corpuscle. Usually the corpuscles are sectioned obliquely or transversely so that the concentric layers completely encircle the inner core.

Special methods have shown that the axial fiber may possess many short lateral branches ending in knobs, and that one or more delicate fibers may enter (or leave) the corpuscles in addition to the large one just

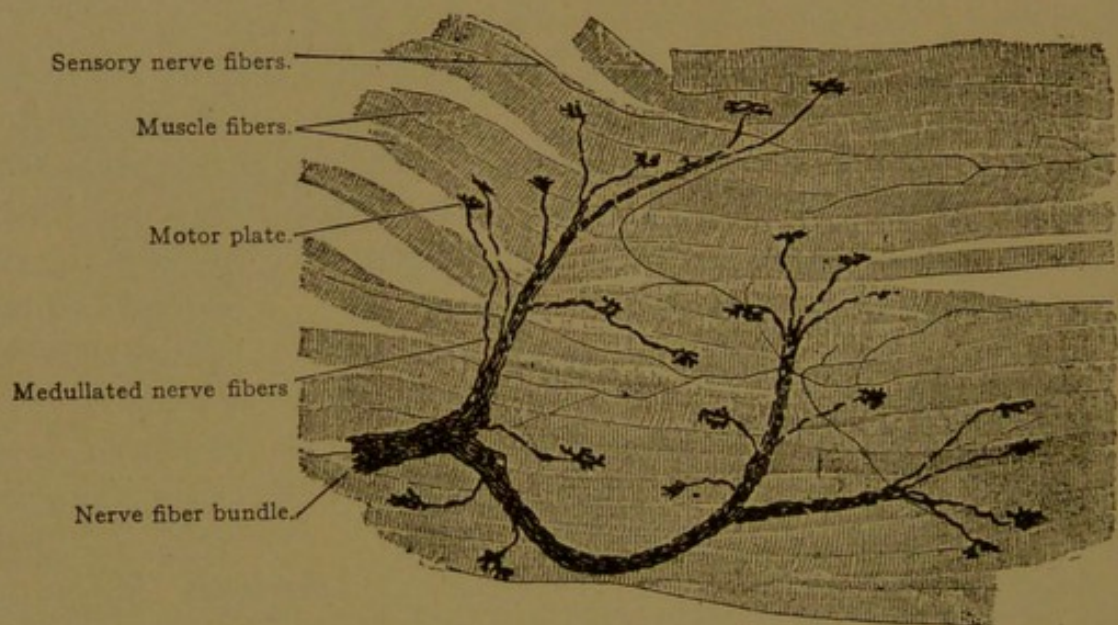


FIG. 157.—MOTOR NERVE ENDINGS OF INTERCOSTAL MUSCLE FIBERS OF A RABBIT $\times 150$.

described; they form a net surrounding the axial fiber. A small artery may pass into the corpuscle beside the nerve and supply the lamellæ with capillaries. Lamellar corpuscles are abundant in the subcutaneous tissue of the hand and foot and occur in other parts of the skin, in the nipple, and in the territory of the pudendal nerve; they are found near the joints (particularly on the flexor side) and in the periosteum and perimysium, in the connective tissue around large blood vessels and nerves, and in the tendon sheaths; also in the serous membranes, particularly in the mesenteries. According to Schumacher (*Arch. f. mikr. Anat.*, 1911, vol. 77, pp. 157-191) the lamellar corpuscles become inflated when the blood-pressure is increased, and "their structure and distribution, together with the results of experiments, indicate that they are regulators of the blood pressure."

MOTOR ENDINGS. The motor nerve endings are the terminations of efferent nerves, in contact with smooth, cardiac or striated muscle fibers. The nerves to the smooth muscles are a part of the sympathetic system. They are non-medullated fibers which branch repeatedly, forming plexuses. From the plexuses very slender varicose fibers proceed to the muscle cells, in contact with the surface of which they end in one or two terminal or lateral nodular thickenings. Probably each muscle cell receives a nerve termination. Except that the nerve endings in heart muscle are a little larger, often provided with a small cluster of terminal nodules, they are like those of smooth muscle.

Striated muscles are innervated by the neuraxons of the ventral roots, which grow out from cell bodies remaining within the central system. They form plexuses of medullated fibers in the perimysium, from which branching medullated fibers extend

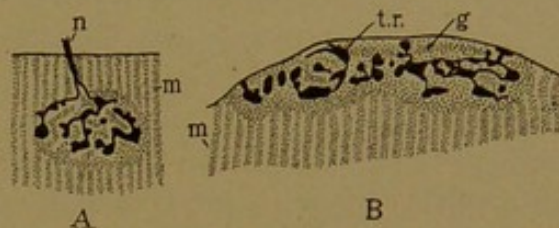


FIG. 158.—MOTOR PLATES.

A, Surface view, from a guinea-pig; B, vertical section, from a hedgehog. (After Böhm and von Davidoff.) g., Granular substance of the motor plate; m., striated muscle; n., nerve fiber; t. r., terminal ramifications of the nerve fiber.

into the fasciculi (Fig. 157). Each muscle fiber receives one of these branches, or sometimes two placed near together. They are usually implanted near the middle of the muscle fiber. The connective tissue sheath of the nerve blends with the perimysium, and the neurolemma is said to be continuous with the sarcolemma. On the inner side of the sarcolemma the myelin sheath ends abruptly, and the nerve fiber ramifies in a granular mass considered to be modified sarcoplasm, which may contain muscle nuclei. This entire structure appears as a distinct elevated area, estimated to average from 40 to 60 μ in diameter; it has been named the *motor plate*. A surface view and a section of a motor plate are shown in Fig. 158.

VASCULAR TISSUE.

Vascular tissue includes the blood vessels, the heart, and the lymphatic vessels, together with the blood and the lymph.

BLOOD VESSELS.

GENERAL FEATURES. The existence of blood vessels was well known to the ancient anatomists, and a distinction was sometimes made between pulsating and non-pulsating vessels. They were all included by Aristotle under the term *φλέψ* (vein). He described the two great vessels at the back of the thorax, one of which is the vena cava; the other, as he states, "by some is termed the *aorta*, from the fact that even in dead bodies

part of it is observed to be full of air." He added that "these blood vessels have their origins in the heart, for in whatever direction they happen to run, they traverse the other viscera without in any way losing their distinctive characteristics as blood vessels; whereas the heart is, as it were, a part of them" (*Historia Animalium*, Book 3, trans. by Thompson). Subsequently the term *artery* was applied to the aorta and its branches, which were found partly empty of blood after death, and were believed to convey air; the windpipe was called the *arteria aspera*.

Vesalius described an artery as "a vessel similar to a vein, membranous, round, and hollow like a pipe, by means of which vital spirit and warm blood, rushing impetuously, are distributed throughout the entire body; by the aid of these, and thus through the motion of the artery itself (which is by dilatation and contraction) the vital spirit and the natural warmth of the several parts are renewed" (*De corporis humani fabrica*, 1543, 4th ed., 1604). Vesalius described the arteries and veins as composed of coats (*tunicæ*) in which he found loose tissue and layers of fibers—circular, oblique, and longitudinal.

The valves of the veins, consisting of thin membranes projecting into their lumens, were first described and clearly figured by Fabricius, under whom Harvey studied at Padua (*De venarum ostiolis*, 1603). Fabricius observed that the ostiola are found chiefly in the veins of the limbs and are "open toward the roots of the veins but closed below." He considered that "to a certain extent they hold back the blood, lest, like a stream, it should all flow together either at the feet, or in the hands and fingers." He stated that the veins can be easily dilated and distended, since they are composed of a simple and thin membranous substance; and concluded that the veins have valves to prevent over-distention, but the arteries, because of the thickness and strength of their walls, do not require them.

In demonstrating the circulation of the blood (in 1628) Harvey contributed little to the knowledge of the structure of the vessels. He could not find the microscopic connections between the arteries and veins, but they were discovered not many years later by Malpighi (*De pulmonibus*, Ep. II, 1661). In the membranous lungs of frogs and turtles, Malpighi found a *rete* or network of vessels connecting the artery and vein, so that the blood was not poured out into spaces, but was driven through tubules. He concluded that if in one case the ends of the vessels are brought together in a rete, similar conditions exist elsewhere, and he observed the circulation taking place in the diaphanous anastomosing vessels of the distended bladder of frogs. Leeuwenhoek (1698) clearly figured the minute vessels which pass from the arteries to the veins in the caudal fin of eels, and noted that the line of separation between the artery and vein is arbitrary.

The vessels which connect the arteries with the veins, because of their hair-like minuteness, were later called *capillaries*. Physiologically they form the most important part of the vascular system, and anatomically they are the most fundamental. They consist merely of endothelial tubes. All larger vessels, not only the arteries and veins, but also the heart, are derived from endothelial tubes and retain their endothelial lining. The endothelium, however, becomes surrounded by layers of smooth muscle fibers and connective tissue, which form the substance of the

vessel walls. The arteries in general have thicker and more elastic walls than the veins, and tend to remain open after death; the thinner walls of the veins are prone to collapse.

DEVELOPMENT. In an early stage the blood vessels of the embryo form a network in the splanchnopleure. In mammals, as in the chick (Figs. 27 and 28, p. 40), the portion of the net nearest the median line forms, on either side of the body, a longitudinal vessel, the *dorsal aorta*. The part of the net folded under the pharynx constitutes successively (beginning posteriorly) the *vitelline veins*, the *heart*, and the *ventral aortæ*, and the latter are continuous in front of the pharynx with the dorsal aortæ. The heart first appears as two dilated vessels, one on either side, which are parts of the general network. They are brought together in the median line under the pharynx and fuse. At first the heart pulsates irregularly, but with the establishment of the circulation, its beats become rhythmical. The blood flows from the general network through the veins to the heart, and thence through the arteries back to the net. All the future vessels of the body are believed to be offshoots from the endothelial tubes just described. They grow out, as shown in Fig. 159, through the mesenchyma with which

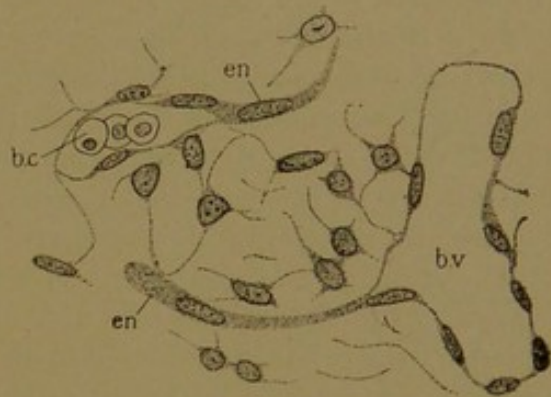


FIG. 159.

Blood vessels from a rabbit embryo of 13 days, developing as endothelial sprouts (en) from pre-existing vessels (b.v.); b.c., blood corpuscle within a vessel.

they often appear to be inseparably connected. The sprouts are at first solid, but soon become hollow except at the growing tips. They may encounter similar offshoots from the same or other vessels and fuse with them. Through the anastomosis of such sprouts new capillary nets are produced.

The formation of a definite system of arteries and veins out of a general network may be partly explained on mechanical principles. The vascular outgrowths must take certain courses marked out by the epithelial structures. Thus in early stages they may grow between the somites, but not into them, producing a series of segmental vessels; they pass around the front of the fore-gut and up and down between its lateral outpocketings, so that the regular system of aortic arches appears to depend upon these epithelial obstructions; and they are guided along the under surface of the developing brain in a very characteristic manner. Epithelial obstructions therefore determine the position of the capillary plexuses. In each plexus the favorable channels enlarge and become the main arteries and veins, sending forth new branches and acquiring thick walls; whereas the vessels in which the current is slow remain small or disappear.

These factors are further considered by Thoma (*Histomechanik des Gefäßsystems*, 1893).

The way in which main trunks develop from indifferent networks has been described by Evans on the basis of extraordinarily perfect injections; thin fluid introduced into the vessels of a living chick embryo is distributed throughout the vascular system by the action of the heart (*Anat. Rec.*, 1909, vol. 3, pp. 498-518). Obviously however if vessels are arising as mesenchymal spaces which subsequently become joined to the vascular system, they would not be revealed by this method. The existence of detached spaces in rabbit embryos has been denied by Bremer, after making very careful graphic reconstructions of all the vessels in the anterior end of the specimens studied. He finds that a network consisting largely of solid strands precedes the network of open tubes (*Amer. Journ. Anat.*, 1912, vol. 13, pp. 111-128). Schäfer, however, describes the formation of vessels by the vacuolization of connective tissue cells, which then become connected with processes from pre-existing capillaries, and so added to the endothelium. He states that "a more or less extensive capillary network is often formed long before the connection with the rest of the vascular system is established" (*Text-book of Micr. Anat.*, 1912). His observations were made upon subcutaneous tissue of the new-born rat. Similar appearances in the subcutaneous tissue of human embryos may be interpreted quite differently, and before it can be accepted that the cells containing red corpuscles are detached from the vascular system, careful reconstructions are required.

The formation of anomalous vessels readily takes place by the persistence and enlargement of channels usually unfavorable. This is discussed by S. R. Williams in explaining the condition observed in an adult salamander, in which one of the long and slender lungs received its artery at the anterior end and the other at the posterior end (*Anat. Rec.*, 1909, vol. 3, pp. 409-414). Innumerable forms of human vascular anomalies may thus be explained embryologically; some of them represent persistent vessels which are normally important at a certain stage of development, and others represent connections which are as abnormal in the embryo as in the adult (cf. Lewis, *Amer. Journ. Anat.*, 1909, vol. 9, pp. 33-42).

A very characteristic form of circulation occurs in certain organs, in which the endothelium of the vessel walls is closely applied to the epithelium of the secreting tubules, or other parenchymal structure (Fig. 160). The walls of the vessels are as thin as those of capillaries, but their diameter is much greater, so that they have been described as lacunar vessels or "*sinusoids*," the term *sinus* being generally applied to the large thin-walled veins in the dura mater about the brain (Minot, *Proc. Boston Soc. Nat. Hist.*, 1900, vol. 29, p. 185-215). Apparently the close apposition of the endothelium, on all sides, to the cells of the parenchyma is the most essential characteristic of these vessels and must be of considerable physiological significance. There are few or no connective tissue cells between the thin lining of the vessel and the epithelial tissue which it nourishes. Capillaries, on the contrary, are imbedded in connective tissue, even though occasionally they approach close to an epithelium, sometimes appearing to enter it. In the lungs the capillaries are compressed between epithelial plates, but they do not resemble the vessels shown in Fig. 160.

Where sinusoids are most highly developed, as in the liver and Wolffian body of embryos, they possess another very significant characteristic. They are not connections between an artery and a vein, like the capillaries, but are subdivisions of veins. Thus in the liver, as shown in the diagram, Fig. 161, the portal vein enters the organ and is subdivided by cords of hepatic cells into sinusoids, such as are shown in section in Fig. 160. These reunite to empty into the vena cava inferior. The sinusoids

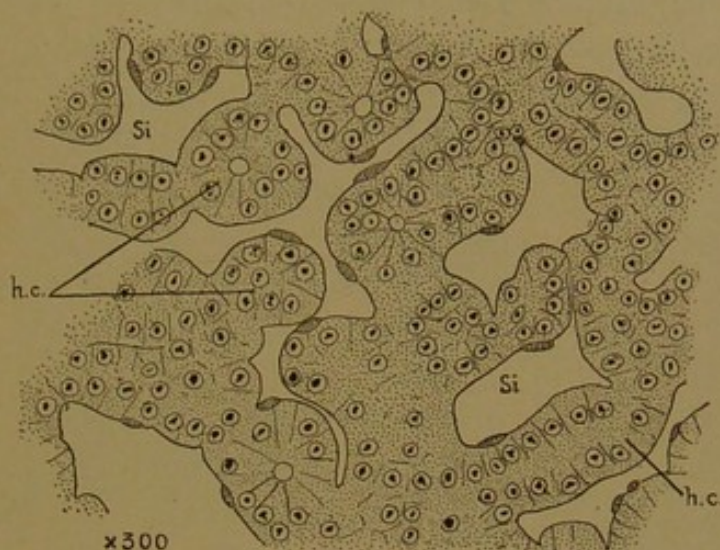


FIG. 160.—SINUSOIDS (Si) IN THE LIVER OF A CHICK EMBRYO OF ELEVEN DAYS. (Minot.)
h.c., Cords and tubules of hepatic cells.

of the liver have therefore been described as formed by the *intercrescence* of vascular endothelium and hepatic parenchyma. This arrangement of veins constitutes the hepatic portal circulation, taking its name from the entering vessel. The same type of venous circulation occurs in the Wolffian bodies, where it constitutes the "renal portal circulation," although it has no connection with the portal vein. It is probable that this form of circulation, which is generally lacunar or sinusoidal, represents a primitive

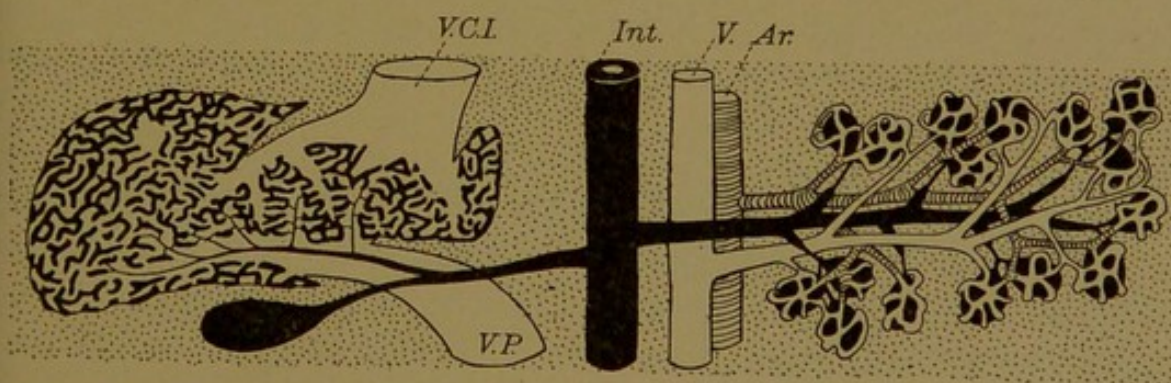


FIG. 161.—DIAGRAM SHOWING ON THE LEFT THE LIVER AND ITS SINUSOIDS; ON THE RIGHT THE PANCREAS AND ITS CAPILLARIES.
The connective tissue is represented by dots. Ar., Artery; Int., intestine; V., vein; V. C. I., vena cava inferior; V. P., portal vein.

type of vascularization, since a single vessel passing by or through an organ provides it with both afferent and efferent vessels. The arterio-venous circulation requires the presence of two vessels with currents flowing in opposite directions. There are indications that various organs in the human embryo have a transient "portal circulation" before the arteries connect with the network and become the main afferent channels.

CAPILLARIES. The capillaries are endothelial tubes of varying diameter, the smallest being so narrow that the blood corpuscles must pass

through them in single file. Their walls are composed of elongated, very flat cells, with irregularly wavy polygonal outlines which are clearly demonstrated in silver nitrate preparations (Fig. 162). Between the cells, the red and white corpuscles frequently make their way out of the vessel. There are no pre-formed openings for this purpose, and the endothelial cells come together after the corpuscles have passed out. Certain endothelial cells are phagocytic, devouring objects which float in the blood; some of them may become detached and enter the circulation. Moreover endothelial cells are contractile, and may be stimulated to activity

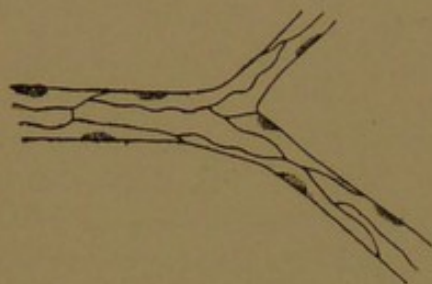


FIG. 162.—CAPILLARY FROM THE TAIL OF A TADPOLE. SILVER NITRATE PREPARATION. (After Koelliker.)

by the sympathetic fibers in the delicate perivascular plexus which is shown in methylene blue preparations. Some of the fibers end in contact with the cells and presumably control the caliber of the vessel; other fibers may be afferent and receive a stimulus when the vessel expands and stretches the plexus. The bulging of endothelial nuclei into the lumen of vessels, frequently seen in preserved specimens, is probably due to post-mortem contraction; in life the lining is presumably smooth.

Although capillaries vary in diameter ($4.5-12\ \mu$), those in a given territory are quite uniform, both as to caliber of individual vessels and the size and pattern of the meshes in the network. The closest meshes and largest capillaries occur in secretory organs and in the lungs, which are therefore abundantly supplied with blood. The muscles are well supplied by slender capillaries in a rectangular meshwork. Serous membranes and dense connective tissue have a scanty blood supply, from narrow capillaries in a coarse net.

Although capillaries vary in diameter ($4.5-12\ \mu$), those in a given territory are quite uniform, both as to caliber of individual vessels and the size and pattern of the meshes in the network. The closest meshes and largest capillaries occur in secretory organs and in the lungs, which are therefore abundantly supplied with blood. The muscles are well supplied by slender capillaries in a rectangular meshwork. Serous membranes and dense connective tissue have a scanty blood supply, from narrow capillaries in a coarse net.

ARTERIES. The walls of the arteries are composed of three layers—the *tunica intima*, *tunica media*, and *tunica externa*, respectively. The intima includes the endothelium and generally an underlying elastic membrane, separated from the endothelium by a small amount of fibrous tissue. The media is primarily a layer of circular smooth muscle fibers; and the externa (formerly called the tunica adventitia) consists chiefly of connective tissue. The thickness of all these layers is greatest toward the heart. They become thinner at the places where the arteries branch, and in the pre-capillary vessels nothing remains but the endothelium.

The small terminal arteries are called *arterioles*. They are endothelial tubes encircled by scattered smooth muscle fibers. In Fig. 163, C, the oval nuclei of the endothelium are seen to be elongated parallel with the course of the vessel. As is usually the case, the walls of the endothelial cells are not visible. The rod-shaped nuclei of the muscle fibers are at right angles with the axis of the vessel. In the somewhat larger artery,

B, the muscle fibers form a single but continuous layer, the media, outside of which the connective tissue is compressed to make the externa. Its fibers tend to be parallel with the vessel. The walls of such an artery are so thick that it is possible to focus on the layers separately; thus in A, the endothelium, which with a delicate elastic membrane beneath it constitutes the intima, is not seen, being out of focus. The nuclei of the

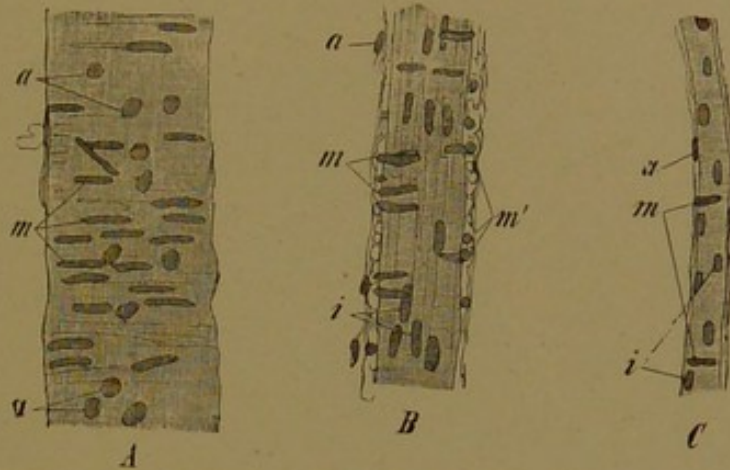


FIG. 163.—FRAGMENTS OF HUMAN ARTERIOLES. $\times 240$.

i, Nuclei of endothelial cells; m, nuclei of circular muscle fibers; a, nuclei of connective tissue. In A, since the endothelium is out of focus, its nuclei are not seen.

media and externa are evident. A cross section of such a vessel is seen in Fig. 177.

The larger arteries are lined with endothelium similar to that of the capillaries, as shown in silver nitrate preparations (Fig. 164). This endothelium rests on a layer of connective tissue containing flattened cells and a network of fine elastic fibers. The meshes of the fibrous and elastic

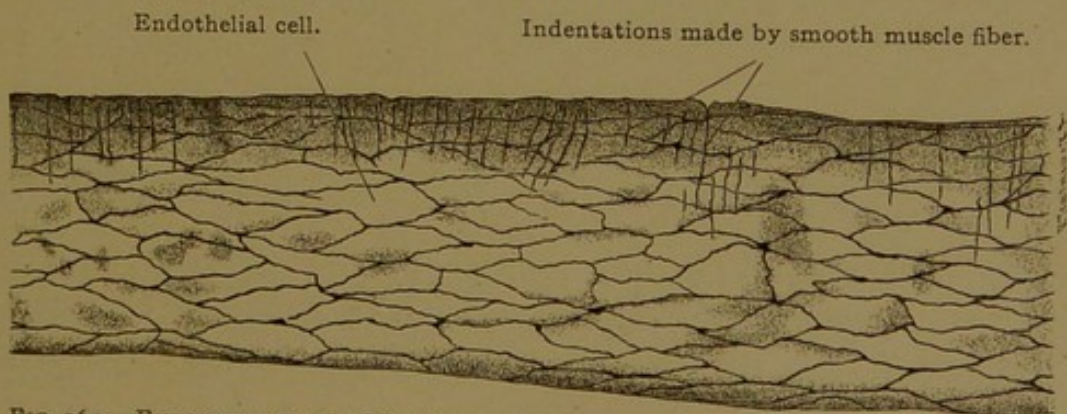


FIG. 164.—ENDOTHELIUM OF A MESENTERIC ARTERY OF A RABBIT. SURFACE VIEW. $\times 250$.

tissue are elongated lengthwise of the vessel, and on surface view they present a longitudinally striped appearance. In addition to this *subendothelial tissue* and the endothelium, the intima includes the *inner elastic membrane* (Fig. 165). This is usually a conspicuous layer thrown into wavy folds by the post-mortem contraction of the vessel. It is easily seen with ordinary stains, appearing as a refractive layer, and is deeply

colored by resorcin-fuchsin and other elastic tissue stains (upper segment in Fig. 165). In smaller arteries the endothelium appears to rest directly upon the elastic network which replaces this membrane; and in such large ones as the external iliacs, the principal branches of the abdominal aorta, and the uterine arteries in young persons, the subendothelial tissue is said to be lacking. The inner elastic membrane is not a continuous sheet of tissue, since it is perforated by elongated apertures; it forms a

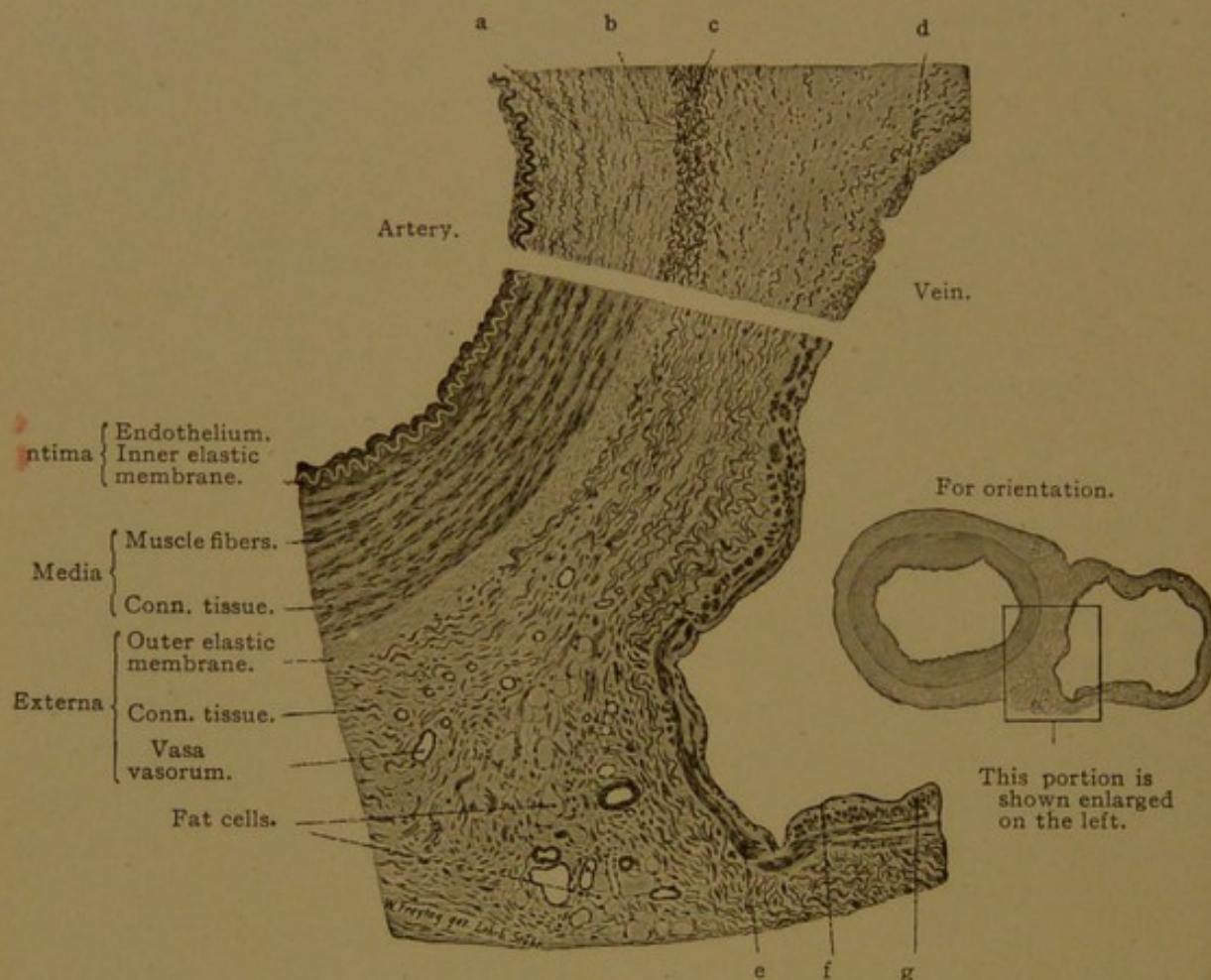


FIG. 165.—A SECTION THROUGH A HUMAN ULNAR ARTERY AND VEIN, SHOWING THE WALL OF THE ARTERY ON THE LEFT AND OF THE VEIN ON THE RIGHT. THE UPPER PART OF THE FIGURE (a-d) IS FROM A SECTION OF THE SAME VESSELS STAINED WITH RESORCIN-FUCHSIN, AN ELASTIC TISSUE STAIN. $\times 550$.

a, Circular, and b, radial elastic fibers of the media of the artery; c, external elastic membrane; d, elastic fibers in the media of the vein; e, circular, and g, longitudinal muscle fibers of the media; f, endothelium.

fenestrated membrane and the development of such membranes from elastic networks has already been described (cf. Fig. 54, p. 67). The membrane is particularly thick in the larger arteries of the brain, and it is sometimes double.

The media, which consists of but a single layer of circular muscle fibers in the pre-capillary vessels, becomes many-layered in larger arteries. Generally the fibers are all circular or perhaps oblique, but in the loose musculature of the umbilical arteries, longitudinal fibers are numerous. Longitudinal fibers are said to occur in certain other vessels near the intima, being especially well developed in the subclavian artery. The post-mortem contraction of the circular fibers, which throws the intima into folds,

causes a spiral crumpling of certain muscle nuclei, the significance of which has already been discussed (Fig. 106, p. 117). Between the muscle fibers there are circular elastic fibers, or plates in the larger vessels, which are thrown into wavy folds. Radial fibers, which connect these in a general network, are slender and require special staining. White fibers are present, apparently formed in considerable part by the muscle fibers which they bind together. The proportion between the muscular and elastic tissue in the media varies in different arteries. In the smaller vessels, the muscular tissue predominates, and this is true also of the celiac, femoral and radial arteries. But in the common iliac, axillary and carotid arteries the elastic tissue prevails, and in this respect they resemble the largest arteries—the aorta and pulmonary artery.

The externa is a connective tissue layer which sometimes contains scattered bundles of longitudinal muscle fibers. It has many longitudinal elastic fibers, which are particularly numerous toward the media, where they are often grouped as the *external elastic membrane* (Fig. 165). This is not a fenestrated membrane, but is merely a dense zone of longitudinal fibers. It is said to be well developed in the carotid, brachial, femoral, celiac and mesenteric arteries, and to be absent from the basilar and other cerebral arteries.

Nerves and vessels ramify in the externa. The walls of the larger arteries are supplied with small blood vessels, the *vasa vasorum*, derived from adjacent arteries. These are distributed chiefly to the externa; they may penetrate the outer part of the media but do not reach the intima. Lymphatic vessels form perivascular plexuses, and send branches into the externa. The nerves are medullated and non-medullated. They include vasomotor fibers which innervate the smooth muscle cells, and sensory or afferent nerves which have terminal arborizations in the intima and in the externa. Other nerve fibers end in lamellar corpuscles in the externa of the aorta and other large vessels.

Ganglia are not seen in the walls of the vessels, and the sympathetic fibers to the muscles therefore travel considerable distances to their terminations. In this respect the nerves to the smooth muscles of the vessels differ from those to the musculature of the digestive tube.

In the largest arteries (the aorta and pulmonary arteries) the intima is very broad (Fig. 166), and it increases in thickness with age. Its endothelial cells are less elongated than those of smaller arteries. They rest on a fibrous subendothelial tissue, containing flattened stellate or rounded cells, and networks of elastic tissue. The elastic fibers are thicker toward the media, finally producing a fenestrated membrane which corresponds with the inner elastic membrane of smaller vessels, but which is scarcely thicker than adjacent elastic lamellæ. The broad media consists of elastic membranes and muscle fibers, but the elastic tissue greatly

predominates. On section the wall of the fresh aorta consequently appears yellow, and not reddish like the more muscular walls of smaller arteries. The elastic tissue is arranged in a succession of circular fenestrated membranes connected with one another by oblique fibers. Between them are the muscle cells. According to Koelliker, in the inner layers of the media, the muscle cells form an anastomosing syncytium

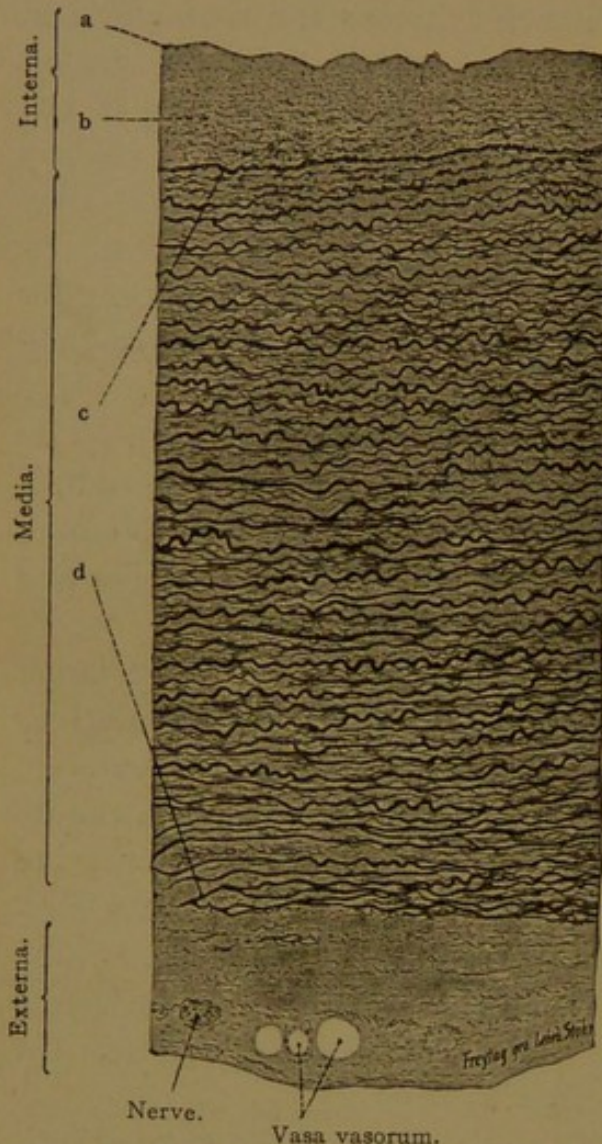


FIG. 166.—FROM A TRANSVERSE SECTION OF THE HUMAN THORACIC AORTA, STAINED WITH RESORCIN-FUCHSIN. $\times 80$.

a, Endothelium; b, subendothelial fibrous tissue; c, d, elastic membranes of the media.

of short, broad and flattened elements, somewhat resembling cardiac muscle (Fig. 167), but in the outer layers the fibers are of the ordinary type. The externa contains no outer elastic layer and is relatively thin; its inner elastic portion may have been taken over into the media.

VEINS. Since the artery to any structure and the returning vein are often side by side, they are frequently included in a single section and may readily be compared. In embryos the veins are of much larger diameter than the corresponding arteries, and they have thinner walls. Although

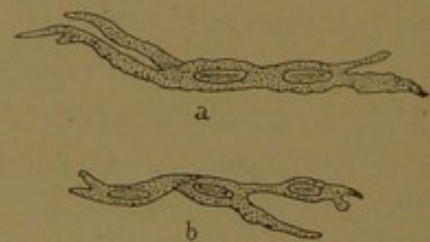


FIG. 167.—BRANCHED SMOOTH MUSCLE CELLS FROM THE THORACIC AORTA OF A CHILD AT BIRTH (a) AND AT FOUR YEARS (b). (After Koelliker.)

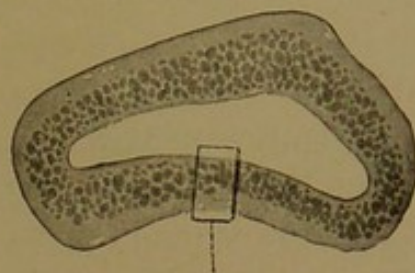
the difference in diameter is less marked in the adult, it generally remains a distinctive feature (Fig. 177, p. 186), and the difference in the thickness of the walls becomes accentuated (Fig. 165). In comparing the diameters of the ulnar vein and artery in Fig. 165, it should be remembered that the ulnar artery is usually accompanied by two returning veins, only one of which is shown in the figure. Because of their thinner walls, which contain relatively little elastic tissue, the veins are generally partly collapsed; the lumen is therefore irregular, whereas that of the arteries tends to be

round (Fig. 165). Small veins full of blood may be round, however, and the arteries are sometimes irregularly contracted.

The walls of the veins, like those of arteries, are composed of three layers, the intima, media, and externa. The intima includes the primary endothelium, which is composed of polygonal cells, generally shorter and broader than those of arteries. The endothelium rests on a thin layer of subendothelial fibrous tissue. The inner elastic membrane of arteries is represented in the smaller veins by a thin homogeneous membrane, but in larger veins it is replaced by a network of elastic fibers (Fig. 165). In addition to these structures the intima of certain veins contains scattered oblique and longitudinal muscle fibers; they are said to occur in the iliac, femoral, saphenous and intestinal veins, the intramuscular part of the uterine veins, and especially in the dorsal vein of the penis near the suspensory ligament.

The media shows great variations. It is generally a thin layer consisting of circular muscle fibers, elastic networks and relatively abundant connective tissue, and is best developed in the veins of the lower extremity (especially the popliteal). In those of the upper extremity it is not so well marked, and it is still thinner in the larger veins of the abdominal cavity; it is reduced to fibrous tissue and is essentially absent from the vena cava superior, the veins of the retina, of the pia and dura mater, and of the bones.

The externa is the most highly developed layer of the veins. It consists of interwoven bundles of connective tissue, elastic fibers, and longitudinal bundles of smooth muscles which are more abundant than in the



This portion is enlarged below
Endothelium.

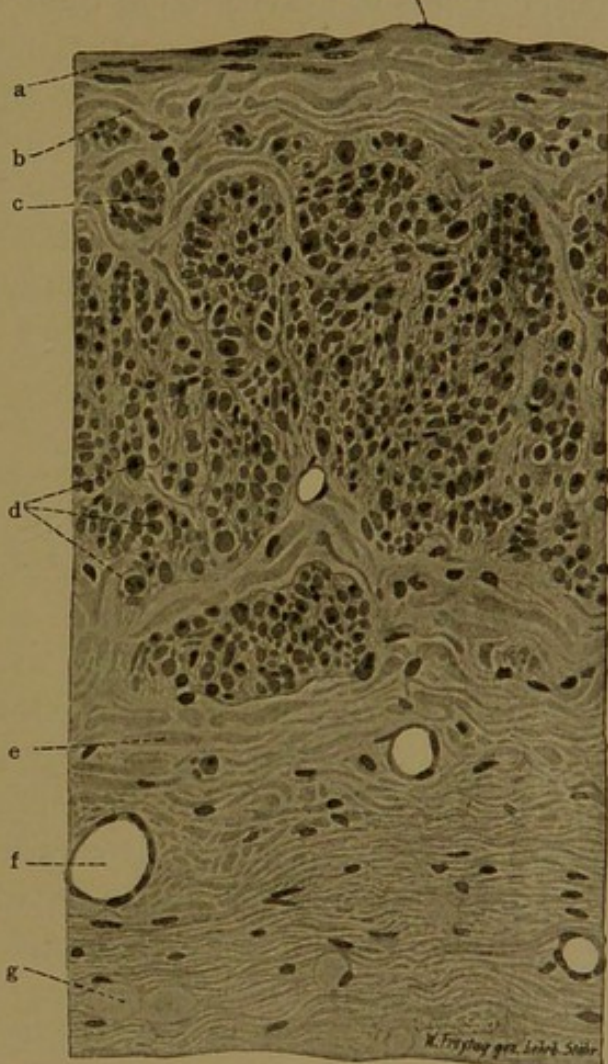


FIG. 168.—FROM A CROSS SECTION OF A HUMAN SUPRARENAL VEIN, STAINED WITH H&E. $\times 240$.
a, Circular muscle fibers of the media; b, connective tissue; c, d, longitudinal muscle fibers of the externa; e, connective tissue; f, small vein; g, fat cell.

arteries. In certain veins (*e.g.*, the main trunk of the portal, the renal and suprarenal veins) the longitudinal muscle forms an almost complete layer of considerable thickness (Fig. 168).

The valves of veins are paired folds of the intima, each shaped like half of a cup attached to the wall of the vein so that its convex surface is toward the lumen. In longitudinal section they appear like the valves of the lymphatic vessel shown in Fig. 179. The valves are generally found distal to the point where a branch empties into the vein, and they prevent its blood from flowing away from the heart. They are most numerous in the veins of the extremities, but appear also in the intercostal, azygos, spermatic, and certain other veins; none are found in the vertical trunks of the superior and inferior venæ cavæ. They counteract the effects of gravity upon the blood, and it has been suggested that their arrangement in man corresponds rather to a quadrupedal attitude than to an upright position. The endothelial cells on the surface of the valve toward the lumen of the vein are elongated parallel with the current, and beneath them there is a thick network of elastic tissue. On the side of the valve toward the wall of the vein, the long axis of the cells is transverse, and there the cells rest upon fibrous connective tissue.

THE HEART.

DEVELOPMENT. The heart has already been described as a median longitudinal vessel situated beneath the pharynx, formed posteriorly by the union of the vitelline veins, and terminating anteriorly in the two ventral aortæ (Figs. 27 and 28, p. 40). This endothelial tube is surrounded by the mesothelium of the body cavity, except along its dorsal border, where it is attached, as it were by a short mesentery, to the under side of the fore-gut. If the embryo is placed in an upright position, corresponding with that of the adult, the relations of the heart to the body cavity will be as shown in the diagram, Fig. 169, A. The posterior part of the body cavity, which becomes the peritoneal cavity, extends forward on either side and comes together across the median line beneath the heart, thus forming the *pericardial cavity*. As the heart develops it becomes bent upon itself as shown in Fig. 169, B; and below it, a shelf of tissue forms across the body, representing the future diaphragm. Dorsal to the diaphragm, the pericardial cavity still communicates with the peritoneal cavity, on either side of the body. In the region of this communication the lungs later develop, and partitions separate the part of the body cavity around them, namely the pleural cavity, from the pericardial and peritoneal cavities respectively. These partitions are the pleuro-pericardial membrane and the membranous part of the diaphragm (Fig. 169, C). Meanwhile the mesentery of

the heart has become thin and has ruptured in the hollow of the U-shaped bend, forming the *sinus transversus pericardii*, which persists throughout life as a small but very definite structure.

While the heart is still a simple tube consisting of endothelium internally and mesothelium externally, with a space between them bridged by protoplasmic strands, it beats regularly, although possessing neither nerves nor muscles. Without causing any interruption of the circulation the simple tube becomes divided into four chambers, namely the right and left *atria* (or auricles¹) and the right and left *ventricles*. The process of subdivision may be outlined as follows:

When the tube becomes bent into a U, the venous end of the heart is carried anteriorly, dorsal to the aortic end, as shown in Fig. 170, A-C.

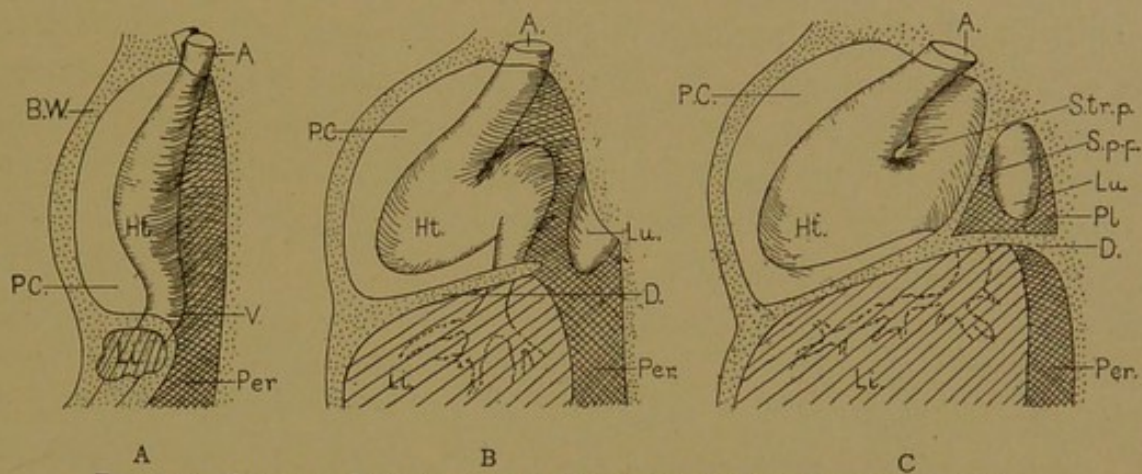


FIG. 169.—DIAGRAMS ILLUSTRATING THE FORMATION OF THE PERICARDIAL CAVITY.
A., Aortic end of heart; B. W., body wall; D., diaphragm; Ht., heart; Li., liver; Lu., lung; P. C., pericardial cavity; Per., peritoneal cavity; Pl., pleural cavity; S.p-p., pleuro-pericardial septum, S. tr. p., sinus transversus pericardii; V., venous end of the heart.

At the same time the ventral or aortic limb of the U is carried to the right of the median plane (C). The dorsal limb is divided into two parts by an encircling transverse constriction, the *coronary sulcus* (*s.c.*). Its thick-walled portion, ventral to the sulcus, forms the *ventricles*; the thin-walled dorsal portion becomes the *atria*. In the human embryo of three weeks (C) the atria are represented by a single cavity subdivided into right and left parts only by an external depression in the median plane. The right portion receives all the veins which enter the heart (the vitelline veins and their tributaries) and is much larger than the left portion. The cavities of the atria not only freely communicate with each other but they have a common outlet into the undivided ventricle. From the ventricle the blood flows out of the heart through the aortic limb. In a complex manner, described in text-books of embryology, a median septum develops, dividing the heart into right and left halves.

In the heart of a 12-mm. pig embryo this septum has already formed

¹ According to the anatomical nomenclature adopted at Basle, the term *auricle* (diminutive of *auris*, ear) is restricted to what was formerly called the *auricular appendix*, and the term *atrium* (chamber) is used for the cavity as a whole.

(Fig. 170, D) and has been exposed by cutting away most of the left atrium and left ventricle. The septum between the atria becomes perforated as it develops, so that in embryonic life the atria always communicate. The perforation in the septum is the *foramen ovale*.

Encircling the orifice which connects each atrium with the corresponding ventricle, there is a ring of mesenchyma which in the adult becomes dense fibrous tissue—the *annulus fibrosus*. Extending from this ring into the left ventricle there are two flaps of tissue partly detached from the ventricular walls. They constitute the *bicuspid valve* (or mitral valve). Toward the apex of the heart each flap passes into strands of tissue attached to the walls of the ventricle. These strands become the *chordæ ten-*

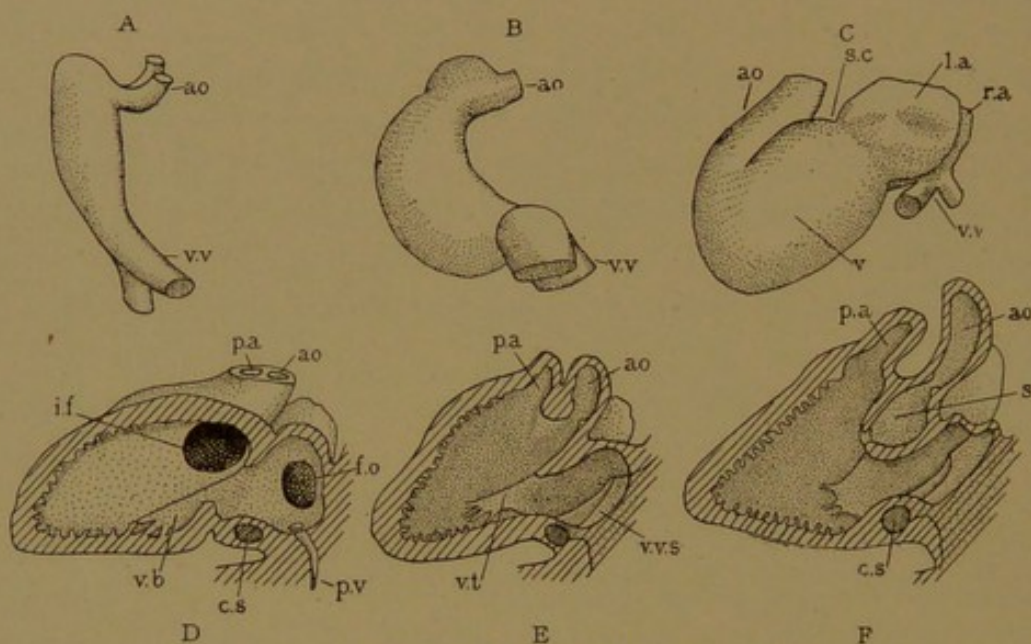


FIG. 170.—EMBRYONIC HEARTS.

A and B, From rabbits nine days after coitus; C, from a human embryo of three (?) weeks; D and E, from a 12-mm. pig (D sectioned on the left of the median septum, and E on the right of it); F, from a 13.6-mm. human embryo, sectioned like E. The hearts are all in corresponding positions with the left side toward the observer, the anterior end toward the top of the page, the dorsal side to the right. ao., Aorta; c. s., coronary sinus; f. o., foramen ovale; i. f., interventricular foramen; l. a., left atrium; p. a., pulmonary artery; p. v., pulmonary vein; r. a., right atrium; s., septum membranaceum separating the root of the aorta from the right ventricle; s. c., coronary sulcus; v., ventricle; v. b., bicuspid valve; v. t., tricuspid valve; v. v., vitelline vein; v. v. s., valves of the venous sinus.

dineæ of the adult, and the muscular elevations into which they are inserted are the papillary muscles (*musculi papillares*). The differentiation of these structures has not taken place in the stage shown in Fig. 170.

In the 12-mm. pig (Fig. 170, D) the median septum which has grown up from the apex of the heart, so as to separate the right and left ventricles from each other, is not complete. The ventricles still communicate through the *interventricular foramen*, and through this aperture the blood passes from the left side of the heart to enter the root of the aorta. The root of the aorta is shown in E, a section of the same heart made on the right of the median septum. The pulmonary artery and the part of the aorta near the heart develop first as a single vessel; they become separated from one another by the formation of a partition. As long as the dividing

wall is incomplete, the blood from either ventricle may pass out through either artery as shown in E. In the more advanced human embryo, F, the partition between the aorta and pulmonary artery has extended so that it joins the interventricular septum, and causes the interventricular foramen to open into the root of the aorta only (*s*). This portion of the interventricular wall which is the last to form, is translucent in the adult, and is known as the *septum membranaceum*.

As previously noted all the veins come together to enter the right atrium. The original vitelline veins are no longer directly connected with the heart, and their persistent cardiac outlet becomes the terminal part of several large branches. These are the *superior vena cava* from the head and arms, the *inferior vena cava* from the trunk and legs (receiving as branches the hepatic vein draining the portal system from the intestine, and the umbilical vein from the placenta); and the *coronary sinus* which, as it passes across the heart in the coronary sulcus, receives branches from the wall of the heart. All these veins come together in a cavity, ill defined in mammals, known as the *sinus venosus*, and this sinus empties into the right atrium through an orifice guarded by a valve with right and left flaps. With further growth the sinus venosus becomes a part of the atrium, and the superior and inferior venæ cavæ and coronary sinus open separately, guarded by imperfect valves derived from the valves of the sinus venosus. The left flap of this valve is said to assist in closing the foramen ovale; the right flap becomes subdivided into the rudimentary valve of the vena cava inferior (Eustachian valve) and the valve of the coronary sinus (Thebesian valve). The degeneration of the valve of the venous sinus seems to take place after the bicuspid and tricuspid valves have become well formed, and have rendered it superfluous. In early stages it must be regarded as the principal valve of the heart. The tricuspid valve, between the right atrium and right ventricle, develops from the cardiac walls in the same way as the bicuspid valve. Their formation is discussed by Mall (*Amer. Journ. Anat.*, 1912, vol. 13, pp. 249-298).

In the embryonic heart, the left atrium receives most of its blood through the foramen ovale, but the pulmonary veins early grow out from it as a small vessel (Fig. 170, D) which sends four branches to the lungs. These are given off near the heart, and with the enlargement of the atrium they come to open into it separately. After birth they are the only supply of the left atrium, and they convey the same quantity of blood as the veins which enter the right atrium.

LAYERS OF THE HEART. Early in the development of the heart a third layer, consisting of mesenchyma, forms between the endothelium and mesothelium. It gives rise to the cardiac musculature, and toward the primary layers it produces connective tissue. The wall of the heart

in the adult is divided into three layers, the *endocardium*, *myocardium* and *epicardium* respectively. The endocardium consists of the endothelium, which is continuous with that of the blood vessels, and of subendothelial fibrous tissue. According to Mall, this tissue is derived from the endothelium. The myocardium is the muscle layer, which is thin in the atria, but very thick in the ventricles; in the left ventricle it is much thicker than in the right. The epicardium consists of the pericardial epithelium together with underlying connective tissue. This layer is also called the *visceral pericardium*, and with the parietal pericardium it bounds the pericardial cavity, forming a closed sac containing the pericardial

fluid. The general relations of these layers in an embryonic heart are shown in Fig. 171. The epicardium is a smooth layer. The musculature of the ventricles is arranged in trabeculæ covered with endothelium, between which there are blood spaces classed as sinusoids. In the adult the musculature is more compact, but internally it is indented by many clefts and irregular spaces, extending among the *trabeculæ carneæ* and the conical papillary muscles.

Endocardium. The endocardium consists of endothelium which is a single layer of flat, irregularly polygonal cells, and of the underlying connective tissue which contains smooth muscle and many elastic fibers

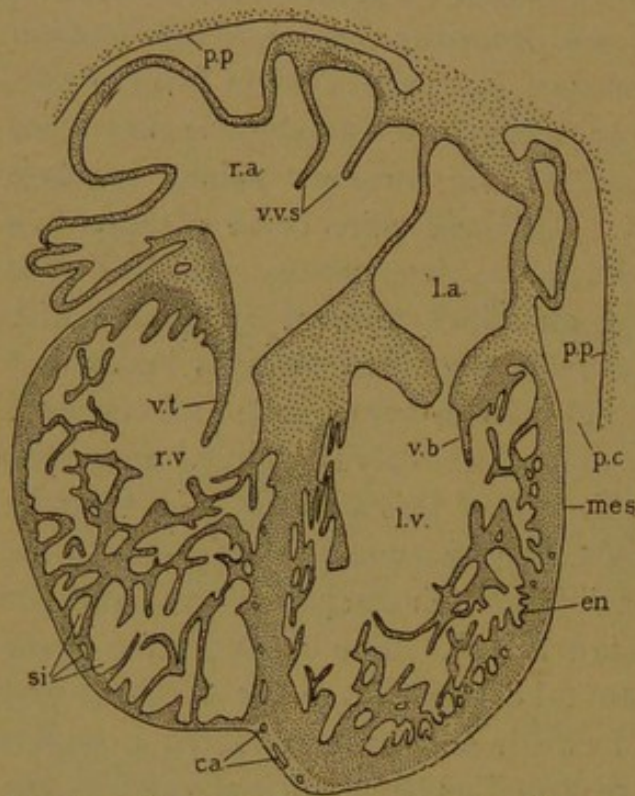


FIG. 171.—SECTION OF THE HEART SHOWN IN FIG. 170, F. ca., Capillaries; en., endothelium; l. a., left atrium; l. v., left ventricle; mes., mesothelium (of the epicardium or visceral pericardium); p. c., pericardial cavity; p. p., parietal pericardium; r. a., right atrium; r. v., right ventricle; si., sinusoids; v. b., bicuspid valve; v. t., tricuspid valve; v. v. s., valves of the venous sinus

(Fig. 172). Elastic fibers are more highly developed in the atria than in the ventricles; they occur either as networks of thick fibers or fuse to form fenestrated membranes. Smooth muscle fibers are more numerous where the wall of the heart is smooth; they are most abundant in front of the root of the aorta.

The atrio-ventricular valves are essentially folds of endocardium containing dense fibro-elastic tissue continuous with the similar tissue in the *annuli fibrosi*. The valves contain muscle fibers toward these rings, and elastic fibers which are prolonged into the *chordæ tendineæ*. Blood vessels are found only in the basal portion of the valves, where the muscle fibers occur. The semilunar valves of the pulmonary artery and

aorta contain neither muscle fibers nor vessels. Their elastic fibers are found chiefly on the ventricular sides of the valve, and in the *noduli* (which are thickenings in the middle of the circumference of each segment, to perfect their approximation when closed).

Myocardium. The myocardium consists of muscle fibers arranged in layers or sheets, which are wound about the ventricles in complex spirals, making a vortex at the apex of each ventricle. If the heart is boiled in dilute acid these layers may be unwound, and the heart has frequently been investigated in this way, most recently by Mall (Amer. Journ. Anat., 1911, vol. 11, pp. 211-266). The layers are composed of cardiac muscle, which is a syncytium of striated fibers with central nuclei and

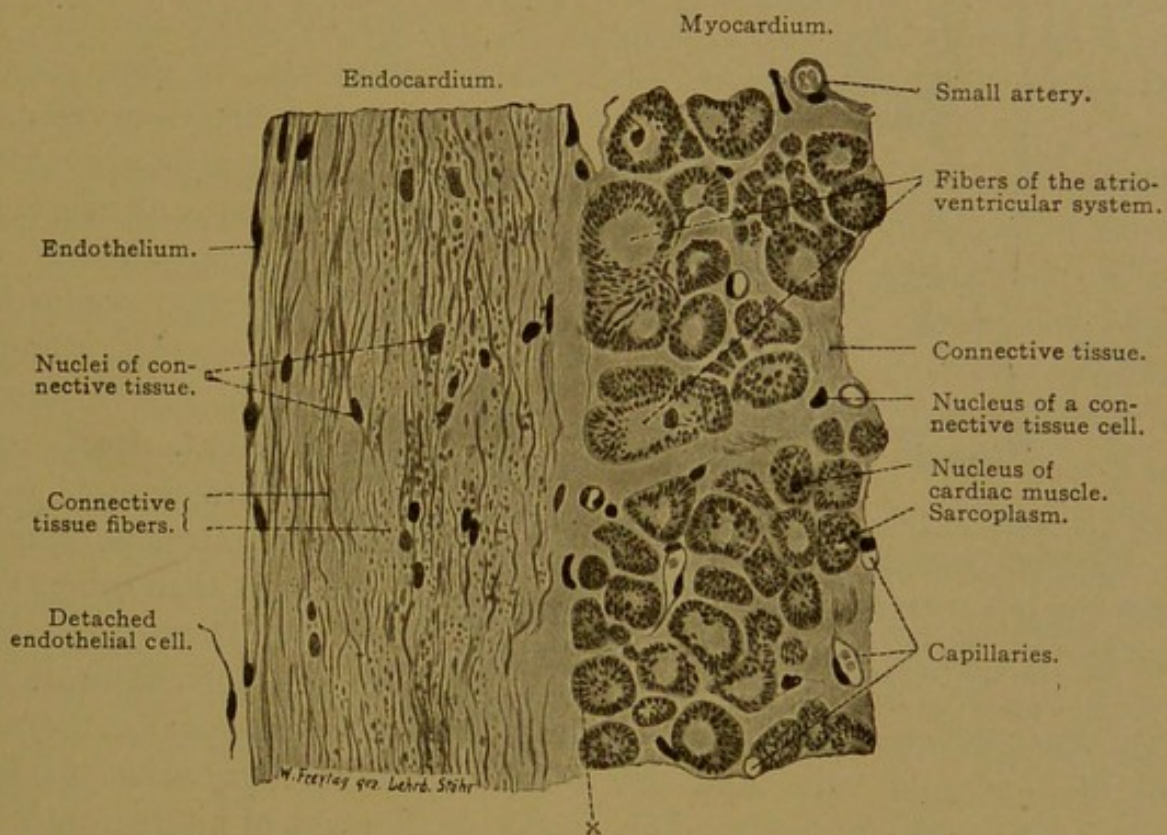


FIG. 172.—FROM A CROSS SECTION OF THE PECTINATE MUSCLES OF A HUMAN HEART (RIGHT ATRIUM).
X 240.

The muscle fibrils in transverse sections appear as points; at x they are radially arranged.

intercalated discs, as already described (p. 129). Cardiac muscle is shown in longitudinal section in Fig. 121 (p. 129), and in transverse section in Fig. 172. Between the muscle fibers there are capillary branches of the coronary vessels which ramify in the epicardium. The capillaries come into close relation with the muscle fibers and some of them extend into the endocardium. Certain vessels, especially in the right atrium, empty into the cavity of the heart as small veins known as the *venæ minimæ* (or veins of Thebesius). Minute veins in the papillary muscles have been described as opening into the ventricle at both ends.

In the heart of adult frogs, the system of intermuscular clefts or lacunar vessels is the only blood supply of the ventricular musculature; the coronary vessels are limited to the epicardium. In turtles the coronary vessels supply an outer layer of the ventricular muscles, but the greater part is still nourished by the central lacunæ or sinusoids. This sinusoidal circulation, which is characteristic of the adult heart in lower vertebrates, occurs also in mammalian embryos, but it becomes vestigial in adult mammals.

A structure which has recently received much attention because of its functional importance is a small band of muscle fibers, associated with nerves, which passes from the septum between the atria into the septum between the ventricles. This *atrio-ventricular bundle* or "bundle of His"

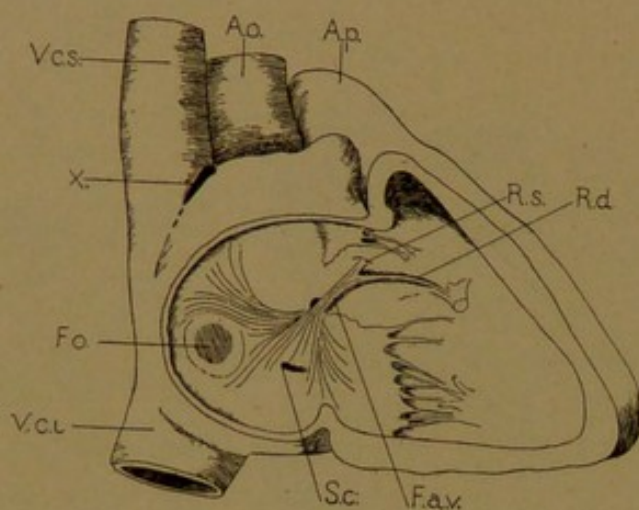


FIG. 173.—THE ATRIO-VENTRICULAR BUNDLE (F. a. v.), AND THE POSITION OF THE "SINO-ATRIAL NODE" (x) IN A HUMAN HEART. (After Curran and Aschoff.)

Ao., Aorta; A. p., pulmonary artery; F. o., fossa ovalis; S. c., coronary sinus; R. d., right branch of the atrio-ventricular bundle; and R. s., its left branch; V. c. i., vena cava inferior; V. c. s., vena cava superior.

(discovered independently in 1893 by Kent and His, Jr.) represents the only connection between the musculature of the atria and ventricles; it passes through the fibrous tissue where the *annuli fibrosi* come together. The position of the bundle is shown in Fig. 173, after Curran (*Anat. Rec.*, 1909, vol. 3, pp. 618-632). Curran finds more extensive branches in the atria than others have shown. They come from both sides of the heart into

the inter-atrial septum, and converge from the fossa ovalis, the roots of the tricuspid valve and the orifice of the coronary sinus to form the *atrio-ventricular node*. This is "a small mass of interwoven fibers in the central fibrous body of the heart," and the main bundle, 2-3 mm. wide, passes from it into the inter-ventricular septum. It passes under the *pars membranacea*, and divides into two branches which are distributed to the right and left ventricles, respectively. Their extensive ramifications have been modelled by Miss DeWitt. She describes the models, and briefly summarizes previous investigations of the bundle, in the *Anatomical Record* (1909, vol. 3, pp. 475-497); the subject is more fully considered by Aschoff (*Verh. d. deutsch. path. Gesellsch.*, 1910, pp. 3-35).

The atrio-ventricular bundle is composed of muscle fibers which are pale macroscopically. They are larger than those of ordinary cardiac muscle, but contain fewer fibrils, peripherally placed and surrounded by abundant sarcoplasm (Fig. 172). In the ventricle they are specially

rich in glycogen. In the node, however, according to Miss DeWitt, the fibers, though varying greatly in size, are much smaller than those found elsewhere in the heart. Several of them unite at a point, producing stellate groups, and the entire node is an intricate network.

The fibers of the atrio-ventricular bundle resemble those described by Purkinje in the sheep, horse, cow and pig, but which he could not find in the rabbit, dog and man (Arch. f. Anat., Physiol. u. wiss. Med., 1845, pp. 281-295). In the walls of the ventricle, immediately beneath the endocardium, he observed "first with the naked eye, a network of gray, flat gelatinous threads, which in part were prolonged into the papillary muscles, and in part passed like bridges across the separate folds and clefts." Under the microscope, they appeared very granular, but he decided that they were probably muscular. Purkinje's fibers are regarded as imperfectly developed muscle fibers. In the human heart they are not as distinct from the other cardiac muscle fibers as in the sheep. It is possible that they are directly continuous with the cardiac syncytium, although, as noted by Miss DeWitt, if the transition is gradual it will be very difficult to observe in sections.

At the junction of the superior vena cava and the atrium, Keith and Flack have described a peculiar musculature imbedded in densely packed connective tissue, composed of striated, fusiform fibers, plexiform in arrangement, with well-marked elongated nuclei, "in fact, of closely similar structure to the node" (Journ. Anat. and Physiol., 1907, vol. 41, pp. 172-189). These fibers are said to be in close relation with the vagus and sympathetic nerves; they have a special arterial supply. According to Keith and Flack they are situated at the junction of the sinus venosus and the atrium, and they form the *sino-atrial node* (sino-auricular node). The sino-atrial node is found immediately beneath the epicardium in the position shown in Fig. 173. In it the impulse for the heart beat is believed to originate, and to be transmitted to the atrio-ventricular node; the latter correlates the contraction of the atrium with that of the ventricle.

Epicardium. The epicardium is a connective tissue layer, covered with simple flat mesothelium and containing elastic fibers and many fat cells. The latter are distributed along the course of the blood vessels.

Vessels and Nerves. The branches of the coronary vessels pass from the epicardium into the myocardium, forming capillaries in intimate relation with the muscle fibers. The heart is thus supplied with aerated blood from the root of the aorta, as well as by the blood within its own cavities; on the left side this is aerated, but not on the right.

The lymphatic vessels, draining toward the base of the heart, are very abundant, and true lymphatic vessels are found in all layers of the heart. The tissue spaces in the myocardium are also extensive.

The nerves to the heart have already been described as forming the cardiac plexus. This plexus receives branches from the vagus, and from the sympathetic cardiac nerves proceeding from the cervical sympathetic

ganglia. It sends its fibers toward the heart, where they follow the coronary vessels in their ramifications. The *cardiac ganglion* is associated with the superficial part of the cardiac plexus, and is under the arch of the aorta. Other small ganglia occur on the posterior wall of the atria, and scattered ganglion cells are found along the atrio-ventricular bundle. They have been reported along the nerves elsewhere in the heart. The ganglion cells are probably in connection with efferent fibers from the central nervous system, which include two sorts—fibers from the ventral ramus of the accessory nerve, which pass out with the branches of the vagus and inhibit cardiac action; and fibers from the spinal nerves, by way of the inferior cervical ganglion, which accelerate it. Histologically nerve endings have been seen both within and around the capsules of cardiac ganglion cells. It is said that the medullated nerve fibers from the central system end within the capsules; and that non-medullated branches from adjacent sympathetic ganglia end outside of them. Motor endings in contact with cardiac muscle have also been found. Sensory endings have been described both in the epicardium and endocardium. They consist of terminal ramifications forming “end-plates.” Some of these fibers presumably connect with sympathetic cells near at hand; others are terminations of afferent medullated fibers which are said to pass to the medulla, along the vagus trunk, as the “depressor nerve.”

LYMPHATIC VESSELS.

GENERAL FEATURES. The lymphatic vessels are far less conspicuous than the blood vessels, but they are no less important and are widely distributed throughout the body. Those which occur in the mesentery and are filled with a milky fluid after intestinal digestion has been going on, are the most conspicuous. These “arteries containing milk” were observed by Erasistratus, an anatomist of Alexandria who died in 280 B. C., but the observation was discredited by Galen. When Aselli in 1622 found the white vessels in a living dog which he had opened, and had shown by cutting into them that they were not nerves, it was essentially a new and great discovery. Aselli observed that the vessels were filled only after digestion, at other times being scarcely visible. He traced them to a mass of lymph glands which he mistook for the pancreas, and believed that they passed on into the liver (*De lactibus sive lacteis venis*, 1627). Years before the physiological observations of Aselli, Eustachius (who died in 1574) had described the main trunk of the lymphatic system in his treatise on the azygos vein (*De vena sine pari*, *Syngramma XIII*, *Opusc. anat.*, 1707). He states that from the posterior side of the root of the left jugular vein (Fig. 174) “a certain

large branch is given off, which has a semicircular valve at its origin, and moreover is white and full of aqueous humor."

"Not far from its source, it splits into two parts which come together a little further on. Giving off no branches, and lying against the left side of the vertebræ, having penetrated the diaphragm, it is borne along to the middle of the loins. There, having become larger and folded around the great artery, it has an obscure ending, not clearly made out by me up to the present time."

The vessel so well described by Eustachius is now known as the *thoracic duct*. It has the structure of a vein, and empties its contents into the blood at the junction of the left internal jugular and left subclavian veins. It receives branches from the left side of the head and the left arm, as well as from the trunk of the body. There is a corresponding vessel on the right side, known as the *right lymphatic duct*. It drains the right side of the head, the right arm, and adjacent territory, emptying at the junction of the right internal jugular and subclavian veins. Having no connection with the abdominal lymphatic vessels, however, it is much smaller than the thoracic duct on the left.

The connection between the lacteal vessels in the mesentery, seen by Aselli, and the thoracic duct observed by Eustachius, was demonstrated physiologically by Pecquet (*Experimenta nova anatomica*, 1651). He found a whitish fluid coming from the vena cava superior of a dog from which the heart had been excised, and observed that its flow was increased by pressure on the mesenteries. Moreover he described the *receptaculum chyli*, or enlargement of the thoracic duct dorsal to the aorta, which receives the chylous fluid. This is now called the *cisterna chyli*. The distribution of the lymphatic vessels, which are ramifications of these main trunks, was followed out by skillful injections, and the results of such studies were presented in great folios by Mascagni (1787) and Sappey (1874). Considered as a whole the lymphatic system may be compared with a venous system which has no corresponding arteries; it is composed entirely of afferent vessels.

Recent anatomical studies of these vessels have been concerned with their origin, and their relation in the adult to the surrounding connective tissue. The vessels have long been known as *absorbents*, and it was thought that they opened freely at their distal ends into the connective tissue spaces; through these openings they were supposed to suck in the tissue fluid which had escaped from the vessels, and the chylous fluid,

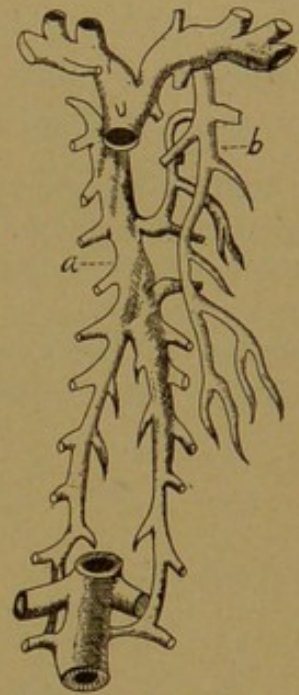

FIG. 174.—THE AZYGOS VEIN (a) AND THORACIC DUCT (b) AS FIGURED BY EUSTACHIUS.

charged with nutriment, which had entered the intestinal tissues, and to convey this material back to the blood vessels. Thus the lymphatic vessels were described as tissue spaces, which had elongated and coalesced so as to form tubes bounded by flattened connective tissue cells, and these vessels were thought subsequently to acquire openings into the veins. Opposed to this conception is the idea of Ranvier that the lymphatic vessels are primarily connected with the veins. They grow out from the veins as endothelial sprouts, which form a closed system of endothelial tubes, anastomosing freely with one another, but never with the blood vessels. Thus they are connected with the veins by main trunks comparable with the ducts of glands (Arch. d'Anat. micr., 1897, vol. 1, pp. 69-81). Fluids may pass through the thin endothelium almost as readily as through open orifices, so that functionally the distinction does not appear to be fundamental.

Ranvier's interpretation has been defended by MacCallum, on the basis of histological studies (Arch. f. Anat. u. Physiol., Anat. Abth., 1902, pp. 273-291), and by Miss Sabin, from the injection of the lymphatic vessels in embryos (Amer. Journ. Anat., 1902, vol. 1, pp. 367-389). The most convincing evidence in its favor has been supplied by Clark's observations on the growth of the lymphatic vessels in the tails of tadpoles. The tadpoles were anæsthetized with chloretone. The membranous part

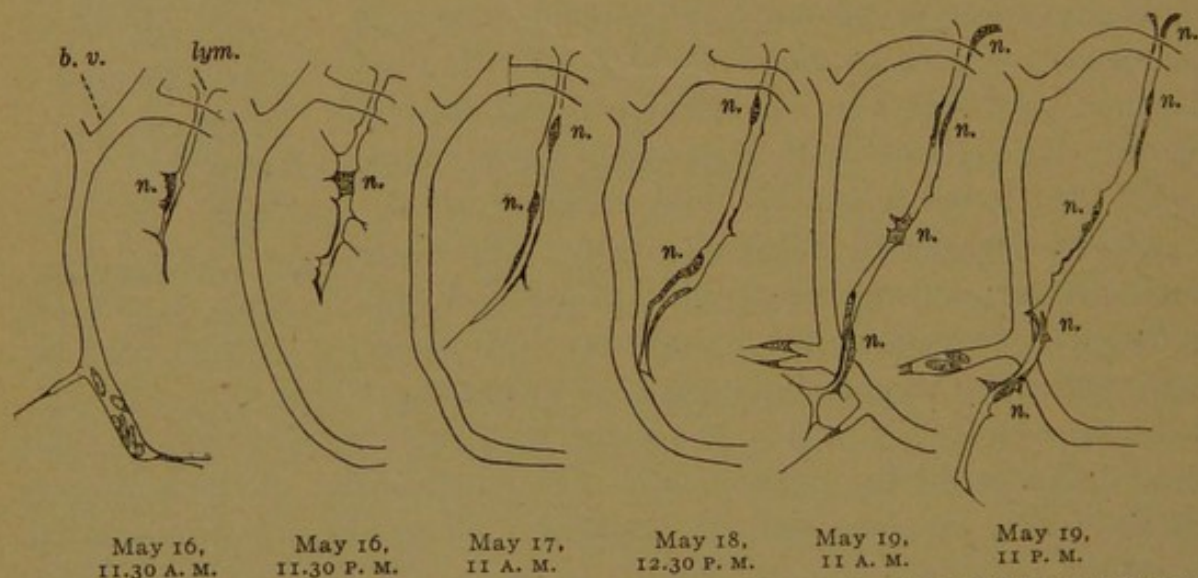


FIG. 175.—SUCCESSIVE STAGES IN THE GROWTH OF A LYMPHATIC VESSEL (lym.) IN THE TAIL OF A TADPOLE (*Rana palustris*). $\times 135$. (Clark.) b. v., Blood vessel; n., nucleus of the lymphatic vessel.

of the tail was then examined with immersion lenses, and certain of the lymphatic vessels were drawn. The animals were restored to normal condition and were re-examined at intervals of twelve hours. The growth of a given lymphatic vessel was thus demonstrated, as shown in Fig. 175. Its elongation and enlargement were seen to be independent of the surrounding connective tissue, through which it made its way.

In some cases a blood corpuscle had escaped into the intercellular spaces. Toward such a corpuscle the lymphatic vessel grew, and having reached it, the corpuscle was taken in by the endothelial cells and transferred to the lumen of the vessel, through which it was seen to travel toward the central vessels. As indicated in Fig. 175, the nuclei of the living endothelium could be observed, and the multiplication of the endo-

thelial cells during the growth of the lymphatic vessel was demonstrated (Anat. Rec., 1909, vol. 3, pp. 183-198).

DEVELOPMENT. The development of the mammalian lymphatic system begins with the formation of a pair of very large sacs lined with endothelium, situated at the junction of the jugular and subclavian veins (Fig. 176). These *jugular lymph sacs* were first described by Miss Sabin (*loc. cit.*); they appear in human embryos measuring about 10 mm. and are formed by the union of several outgrowths from the veins. In slightly older embryos, another lymph sac is produced at the root of the mesentery, below the place where the renal veins enter the vena cava inferior (Lewis, Amer. Journ. Anat., 1902, vol. 1, pp. 229-244). The opinion that this sac is a derivative of the adjacent veins has been confirmed by certain later embryological studies, and by finding permanent communications between the lymphatic and the venous system at the level of the renal veins in adult South American monkeys (Silvester, Amer. Journ. Anat., 1912, vol. 12, pp. 446-460). At other places,

which must be regarded as secondary centers, lymphatic vessels appear to be derived from the veins and to become detached from them. These vessels are seen in the mesenchyma as isolated spaces, usually along the course of the veins, at no great distance from the jugular and mesenteric lymphatics. Subsequently they become connected with one another 'by endothelial out-

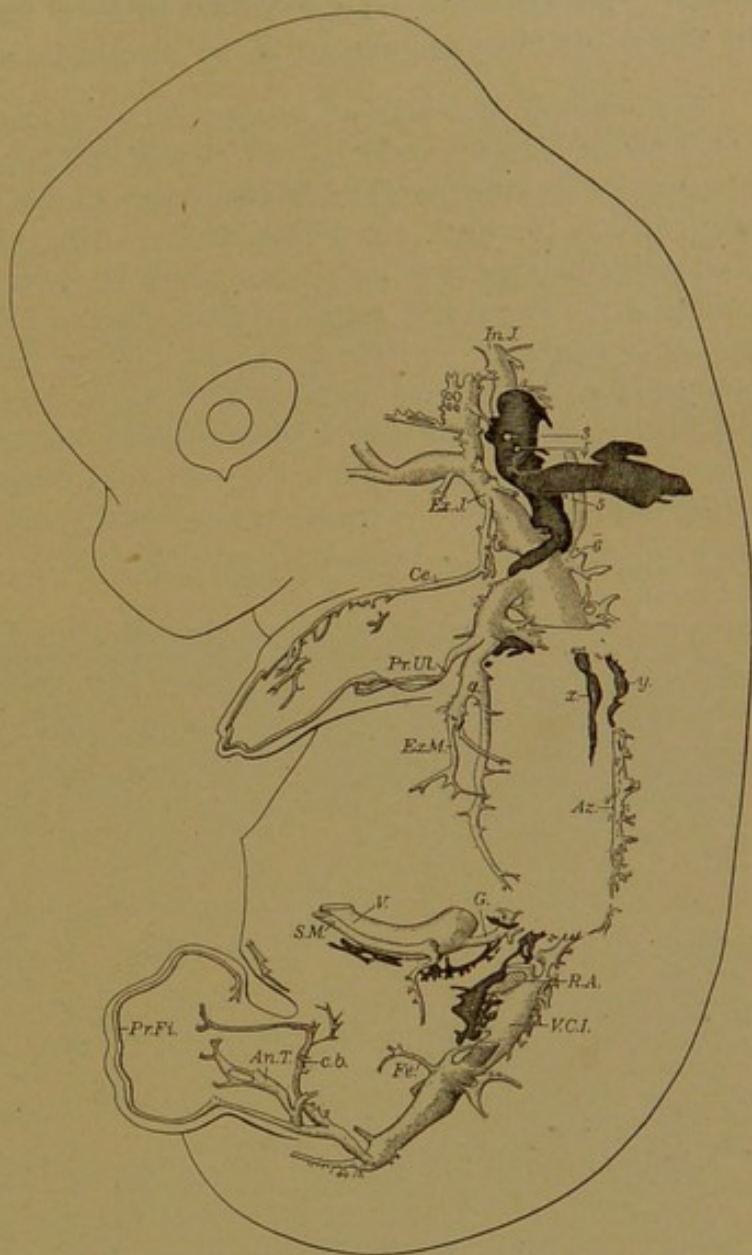


FIG. 176.—LYMPHATIC VESSELS AND VEINS IN A RABBIT OF FOURTEEN DAYS, EIGHTEEN HOURS; 14.5 MM. X 11.5.

The lymphatics are heavily shaded, x being a vessel along the left vagus nerve and y along the aorta. The large jugular lymph sac is in contact with the internal jugular vein, In. J.; it passes to the junction of the external jugular (Ex. J.) and subclavian veins, the latter being formed by the union of the primitive ulnar, Pr. UL., and external mammary veins, Ex. M. The mesenteric sac is in front of the vena cava inferior (V. C. I.) and below the renal anastomosis (R. A.). Other veins include Az., azygos; V., vitelline; G., gastric; S. M., superior mesenteric; etc. The figures indicate the position of the corresponding cervical nerves.

growths, such as extend from the lymphatic vessels into the peripheral tissues as described by Clark. The mesenteric sac thus becomes connected with the left jugular sac (symmetrical connections with both jugular sacs occur in some animals) and the connecting vessels constitute the thoracic duct. The cisterna chyli is a secondary enlargement dorsal to the aorta. In the adult the sacs are replaced by plexuses of smaller vessels.

The origin of the detached or apparently detached lymphatic spaces in embryos, which precede the formation of the well-defined vessels, has been studied with great diligence by Huntington (*The Anatomy and Development of the Lymphatic System*, Mem. Wistar Institute, 1911) and McClure (*Anat. Rec.*, 1912, vol. 6, pp. 233-248), to whose many contributions references will be found in the papers cited. They consider that the lymphatic spaces arise in large part as mesenchymal spaces, but the possibility suggested by Bremer's recent work on the blood vessels, that uninjectable endothelial strands of great delicacy may pass to these cavities, has not been set aside, and further work upon this subject is being conducted under Professor McClure's direction. The reasons which led the writer to consider the origin of the lymphatic vessels from mesenchymal spaces as improbable, were stated as follows (*Amer. Journ. Anat.*, 1905, vol. 5, pp. 95-120).

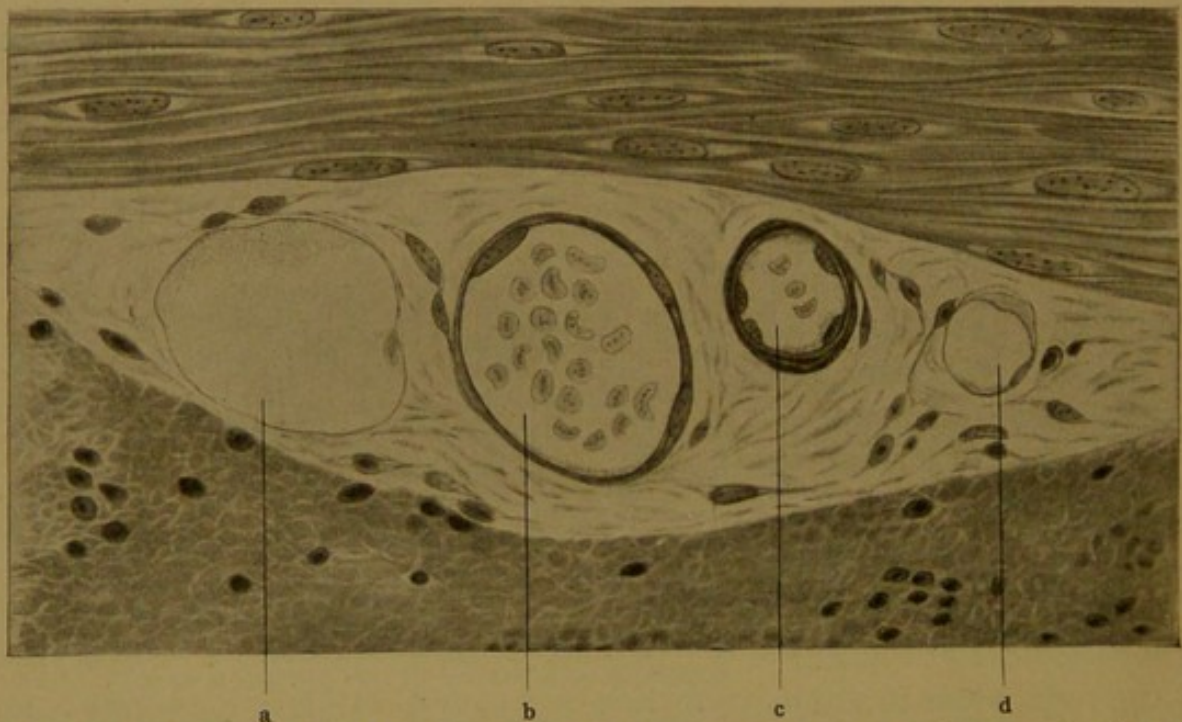


FIG. 177.—BLOOD VESSELS AND LYMPHATIC VESSELS BETWEEN THE CIRCULAR AND LONGITUDINAL LAYERS OF SMOOTH MUSCLE FIBERS IN THE SMALL INTESTINE OF A CAT. $\times 775$.
a, d., Lymphatic vessels; b, vein; c, artery.

"1. The lymphatic spaces do not resemble mesenchyma even when it is œdematous, but on the contrary, are scarcely distinguishable from blood vessels (Langer)."

"2. After being formed, the lymphatics increase like blood vessels, by means of blind endothelial sprouts, and not by connecting with intercellular spaces (Langer, Ranvier, MacCallum, Sabin)." The subsequent work of Clark is here conclusive.

"3. In early embryos detached blood vessels may be seen without proving that blood vessels are mesenchymal spaces. These detached vessels are not far from the main trunks, from which they may have arisen by slender endothelial strands, yet

often the connecting strands cannot be demonstrated." (Subsequently, Bremer demonstrated such strands in great abundance.)

"4. The endothelium of the embryonic lymphatics is sometimes seen to be continuous with that of the veins" *i.e.*, in certain places, as in connection with the jugular sac, the origin of the lymphatic vessels from the venous endothelium can be clearly seen; this fact is conclusively demonstrated by Huntington and McClure, who use the term "veno-lymphatic" for transitional vessels (Amer. Journ. Anat., 1910, vol. 10, pp. 177-311).

LYMPHATIC VESSELS IN THE ADULT. In sections of the intestine from an animal in which intestinal digestion was in progress, lymphatic vessels may readily be found between the muscle layers (Fig. 177). Their walls are decidedly thinner than those of blood vessels of the same caliber, and their contents are typically a granular or fibrinous coagulum free from red corpuscles, but containing an occasional lymphocyte. It

must be remembered, however, that blood vessels seen in sections are not infrequently empty, and that blood corpuscles may be taken into the lymphatic vessels. Having learned to recognize the lymphatics in such favorable situations as the intermuscular tissue, one may readily identify them in the connective tissue layer internal to the circular muscle of the intestine, and in the connective tissue around the bron-

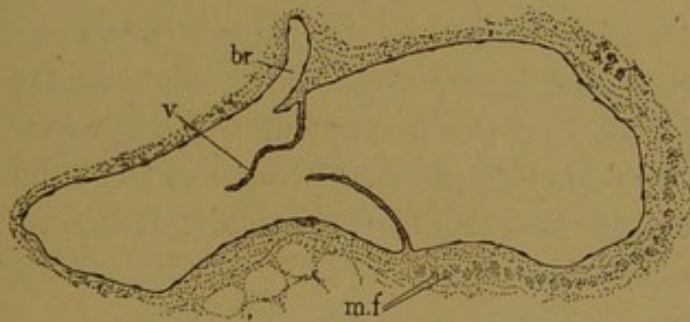


FIG. 179.

Lymphatic vessel from a section of a human bronchus, showing a valve, *v.*; distal to the branch, *br.* Bundles of smooth muscle fibers are seen at *m. f.*

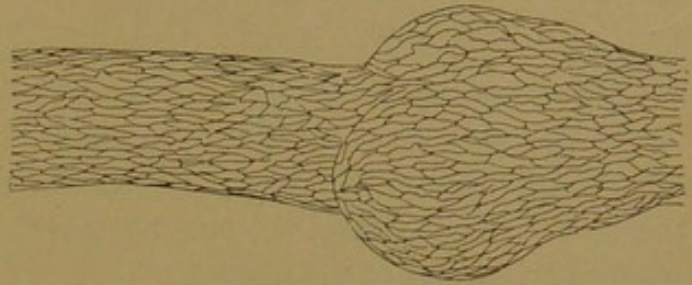


FIG. 178.—SILVER NITRATE PREPARATION OF A LYMPHATIC VESSEL FROM A RABBIT'S MESENTERY, SHOWING THE BOUNDARIES OF THE ENDOTHELIAL CELLS, AND A BULGING JUST BEYOND A VALVE.

chioles in the lung; in the embryonic lung they are very conspicuous. They may then be sought for in various organs, but a sharp distinction must be drawn between the endothelium-lined lymphatic vessels and the interfibrillar tissue spaces.

When prepared with silver nitrate, the outlines of the endothelial cells are seen to resemble those of blood vessels (Fig. 178), and in the larger lymphatic vessels the endothelium with the underlying connective tissue forms a *tunica intima*. These lymphatics (0.2-0.8 mm. in diameter), are often composed of three coats, though loose in texture. The media contains circular smooth muscle fibers and a small amount of elastic tissue; and the externa is composed of longitudinal connective tissue and scattered bundles of longitudinal muscle. Thus they resemble the veins

more closely than the arteries. Valves are very numerous in lymphatic vessels. They are shown in section in Fig. 179. In the small vessels the valves are described as folds of endothelium, such as would be produced if the distal part of the vessel were pushed forward into the proximal part. The vessels are often distended on the proximal side of the valve, producing bulbous enlargements, as shown in Fig. 178. Owing to the presence of these valves, compression of tissue containing lymphatic vessels, or the contraction of the muscles of the media, causes an onward flow of the lymph. The nerves to lymphatic vessels are like those of the blood vessels. Lymphatics are provided with vasa vasorum. As shown by Evans (Amer. Journ. Anat., 1907, vol. 7, pp. 195-208) very small lymphatic vessels are accompanied by blood capillaries, and the larger lymphatics are surrounded by a wide-meshed capillary network resting on the outer side of the lymphatic media. (In the same volume of the Journal, pp. 389-407, Miller describes the network of blood capillaries around the lymphatic vessels of the pleura.)

BLOOD.

Blood consists of round cells entirely separate from one another, floating in an intercellular fluid, the *plasma*. The plasma also contains as a regular and apparently important functional constituent, the *blood plates* (or platelets), together with smaller granular bodies. Blood cells or *corpuscles* are of two sorts, (1) *red corpuscles* or *erythrocytes*, which become charged with the chemical compound, *hæmoglobin*, and which lose their nuclei as they become mature; and (2) *white corpuscles* or *leucocytes*, which are of several kinds, all of them retaining their nuclei and containing no hæmoglobin. The redness of blood is not due to the plasma, but is an optical effect produced by superimposed layers of the hæmoglobin-filled red corpuscles. Thin films of blood, like the individual red corpuscles seen fresh under the microscope, are yellowish green. Blood has a characteristic odor which has been ascribed to volatile fatty acids; it has an oily feeling associated with its viscosity, an alkaline reaction, and a specific gravity said to average in the adult from 1.050 to 1.060.

RED CORPUSCLES. *Development.* The first cells in the embryonic blood are apparently all of one sort, derived from the blood islands. They are large, round cells with a delicate membrane and a pale granular protoplasmic reticulum; their relatively large nuclei contain a fine chromatin network with several coarse chromatin masses. Hæmoglobin later develops in their protoplasm, giving it a refractive homogeneous appearance. Stained with orange G or eosin it is clear and brightly colored, generally quite unlike any other portion of the specimen. Often the hæmoglobin has been more or less dissolved from the corpuscles, which then appear granular or reticular.

The developing red blood corpuscles are known as *erythroblasts*, especially in their younger stages when the nuclei are reticular. In later stages the nuclei become densely shrunken or pycnotic, and stain intensely with hæmatoxylin. The entire cells become smaller, and are then called *normoblasts*. The transition from an erythroblast to a normoblast is shown in Fig. 180, a; during this process the cells divide repeatedly by mitosis.

It will be noticed that the terms applied to developing corpuscles are compounded of words which describe the formative cells, instead of indicating what they produce. Thus *erythroblast* signifies a red formative cell. *Normoblast* (Lat. *norma*, model or type, and Gr. *βλαστός*) is an objectionable term to designate a nucleated red corpuscle of the usual size and form, in contrast with the large *megaloblasts* which occur in certain diseases of the blood. Megaloblasts have reticular nuclei and presumably represent a younger stage than the normoblasts. A reform in the nomenclature of blood cells based upon morphological principles, is advocated by Minot (Human Embryology, ed. by Keibel and Mall, 1912, vol. 2), and when agreement shall have been reached regarding the relationships of the cells, it will be possible to adopt a reasonable terminology.

In becoming mature red corpuscles the normoblasts lose their nuclei. Before they disappear, the pycnotic nuclei often assume mulberry, dumb-bell, trefoil or other irregular shapes. According to older observations they then fragment, and are dissolved within the normoblasts; but it is now generally believed that they are extruded from the cells, either in one mass (Fig. 180, b) or in detached portions, and that the extruded nuclei are devoured by phagocytes. The loss of the nuclei begins in human embryos of the second month. In embryos of the seventh month, nucleated corpuscles in the circulating blood have become infrequent, and after birth it is rare to find one, except under pathological conditions.

In withdrawing from the circulating blood the nucleated red corpuscles do not disappear from the body. Since 1868 it has been known that the red marrow, found within certain bones in the adult, contains an abundance of erythroblasts, which multiply by mitosis. They are the source of the new corpuscles constantly entering the circulation. In certain diseases of the blood, imperfectly developed normoblasts also leave the marrow, and circulate as in the embryo. Before the marrow assumes the blood-forming function, the liver is the chief hæmatopoietic organ. Beginning in embryos of about 7.5 mm., and continuing until birth, erythroblasts are found between the hepatic cells and the endothelial cells of the sinusoids, and in certain stages they occur in vast numbers. Toward birth,

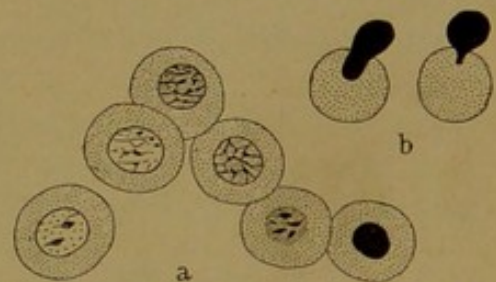
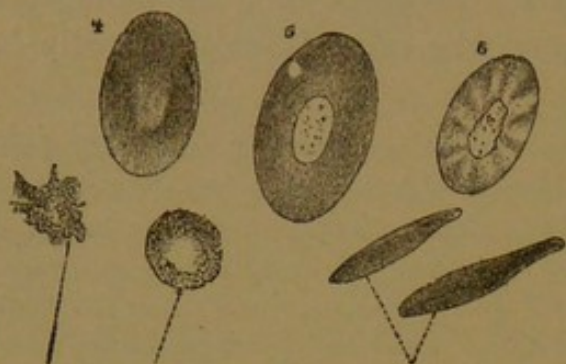


FIG. 180.—THE DEVELOPMENT OF RED CORPUSCLES IN CAT EMBRYOS. (Howell.)

a, Successive stages in the development of a normoblast; b, the extrusion of the nucleus.

however, the erythroblasts in the liver are no longer abundant, and in a few weeks after birth they are said to disappear entirely. Red blood corpuscles are formed also in the embryonic spleen, though to a less extent than in the liver, and in some mammals the spleen normally contains erythroblasts in the adult.



Leucocyte in motion; at rest.

Side view of red corpuscles.

FIG. 181.—BLOOD CORPUSCLES FROM A FROG. 4, 5, and 6, Surface views of red corpuscles; 6, after treatment with water. $\times 600$.

In regard to the source of the erythroblasts in the spleen, liver and red marrow, two opinions are held. It is well known that erythroblasts and fully-formed red corpuscles may wander out of the vessels into connective tissue. Accordingly it is often stated that the circulating erythroblasts, which at first multiply in the blood vessels, later withdraw to the reticular tissue of the liver, spleen, and

marrow and there proliferate. Others consider that the erythroblasts are formed *in situ* in these various places from the endothelial or reticular tissue cells.

Mature Red Corpuscles. In the lower vertebrates, the mature red

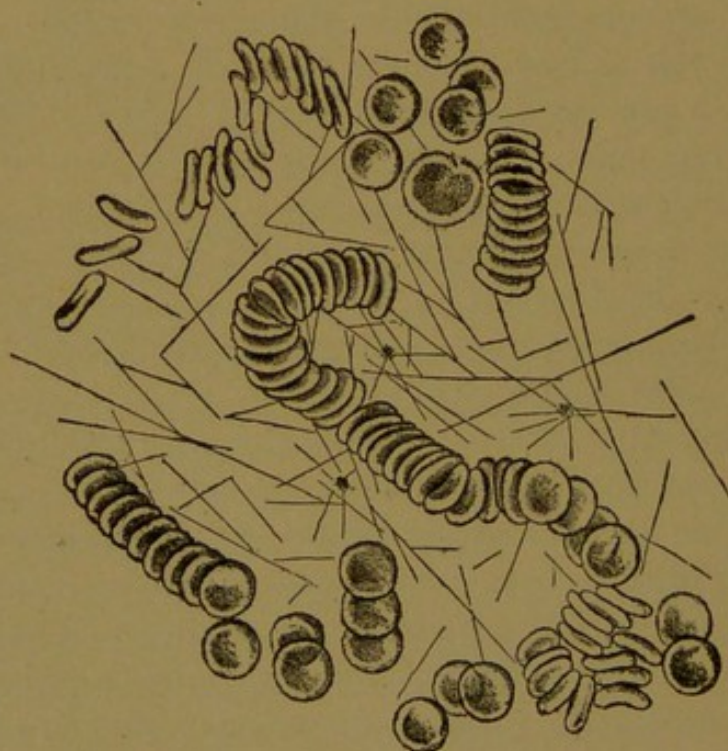


FIG. 182.—RED CORPUSCLES FORMING ROULEAUX. FIBRIN IN FILAMENTS RADIATES FROM THE BLOOD PLATES. (From Da Costa's Clinical Hæmatology.)

corpuscles or erythrocytes are oval nucleated bodies, more or less biconvex, thus differing radically from those of adult mammals. They are very large in the amphibia (Fig. 181). When a drop of freshly drawn mammalian blood is spread in a thin film on a glass slide, beneath a cover

glass, it is seen to consist chiefly of biconcave discs, and of those in the form of shallow saucers (Fig. 182). They have a remarkable tendency to pile up in *rouleaux*, like rolls of coins. It is said that discs of cork weighted so that they will float beneath the surface of water, will come together in a similar way if their surfaces have been coated with an oily substance. If the blood coagulates, filaments of fibrin will be seen in the plasma, as shown in the figure. In fresh specimens there is no fibrin, and within the blood vessels it does not form under normal conditions. Moreover when they are within the endothelial tubes, red corpuscles do not come together in *rouleaux*. It is evident that the thin film of blood, though very fresh, is examined under extremely artificial conditions; and from such preparations, conclusions as to the normal shape of the corpuscles should not be hastily drawn. Within the blood vessels the red corpuscles are typically cup-shaped.

Rindfleisch (Arch. f. mikr. Anat., 1880, vol. 17, pp. 21-42) found that the corpuscles in guinea-pig embryos, after losing their nuclei by extrusion, are at first bell-shaped; but he considered that afterward they become biconcave discs from impact with others in the circulating blood. Commenting upon this statement, Howell (Journ. of Morph., 1890, vol. 4, pp. 57-116) writes:

"I feel convinced that the bell shape which Rindfleisch ascribes to the corpuscles which have just lost their nuclei is a mistake. The red corpuscles even of the circulation, as is well known, frequently take this shape when treated with reagents of any kind, or even when examined without the addition of any liquid. It seems very natural to suppose that the biconcavity of the mammalian corpuscle is directly caused by the loss of the nucleus from its interior. Certainly as long as the corpuscles retain their nuclei, they are more or less spherical, and after they lose their nuclei they become biconcave."

In the year preceding Howell's publication, Dekhuyzen discussed *cup-shaped* corpuscles (Becherförmige rote Blutkörperchen, Anat. Anz., 1899, vol. 15, pp. 206-212) which he found as a transient stage in mammals, and which his assistant saw in blood drawn from his finger. Dujardin (Manuel de l'observateur au microscope, 1842) found many corpuscles shaped "like cups, or cupules (acorn cups) with thick borders" in blood altered by the action of phosphate of soda. The first reference to such forms is by Leeuwenhoek (1717) who put a drop of blood in a concoction of *pareira brava*, and found that most of the globules which make the blood red, have "a certain bend or sinus receding within, as if we had a vesicle full of water and by pressure of the finger should hollow out the middle of the vesicle as a pit or depression." Von Ebner, in Koelliker's Handbuch (1902), writes of bell or cap-shaped corpuscles produced in warmed blood by the thickening of the border on one surface of the disc. Weidenreich in 1902 (Arch. f. mikr. Anat., vol. 61, pp. 459-507) after thorough study of blood variously preserved, and also examined while circulating in the mesentery of a rabbit, concluded that "the red corpuscles of mammals have the form of bells (Glocken)." Weidenreich's conclusion has not been fully accepted by Jolly, David, Jordan, and Schäfer. Schäfer (in Quain's Anat., vol. 2, 1912) states that "this opinion, although shared by F. T. Lewis, Radasch and a few other histologists, cannot be accepted, for, of examining the circulating blood in the mesentery and other transparent parts in mammals, it is easy to observe that, with few exceptions, the erythrocytes are biconcave; this shape must therefore be regarded as the normal one."

That the shape of corpuscles in the circulating blood is not easy to observe, is shown by the fact that scientists have described it in very different ways. The circulating corpuscles may be seen by spreading the mesentery of an anæsthetized guinea-pig across the condenser of a microscope, having it preferably in a warm room, and then placing a cover glass directly over the vessels; they are examined with an immersion lens. Sketches made during such observations are reproduced in Fig. 183. The upper drawing shows a vessel stretched out abnormally, and the corpuscles are correspondingly elongated; the one at the left shows the hollow of the cup toward the ob-

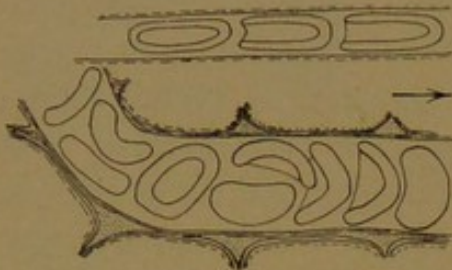

FIG. 183.—RED CORPUSCLES, SKETCHED WHILE CIRCULATING IN THE VESSELS OF THE OMENTUM OF A GUINEA-PIG.

server, the others are seen in lateral view. Presumably normal conditions are shown in the lower sketch, which includes two flat corpuscles, one of which is almost biconcave, but this form is exceptional. The corpuscles are very flexible, bending around any obstruction, and when free, again assuming their original form. They roll about as they flow through the vessels, and when, as the blood stagnates, the current in the vessels is sometimes reversed, their form does not change.

In 1903, following Weidenreich's publication, the writer demonstrated the circulating corpuscles to Professor Minot, who describes the cup-shape as the normal form in Keibel and Mall's "Embryology"; and in 1909 they were shown to Dr. Williams who was convinced that they are cup-shaped.

A very important result of recent studies (which Schäfer does not mention) is the recognition that in well preserved tissues of all sorts, and with all fixatives such as are relied upon to reveal the structure of other tissues, the mammalian erythrocytes are typically cup-shaped. Other forms are exceptional. In many specimens the corpuscles and other tissues are irregularly shrunken, but where the tissues in general are excellently preserved, the corpuscles appear as cups. The biconcave discs are flattened cups.

In examining films of fresh blood, the biconcave discs will be seen to change their appearance as the objective is lowered. When sharply in focus the thin central portion appears light (Fig. 184, A); but in high focus the center is dark, perhaps owing to the dispersal of light by the lenticular corpuscles. The biconcave shape is apparent when the corpuscle is seen on edge (Fig. 184, B). The cup-shaped forms are shown in Fig. 184, D; and E represents one of the innumerable shapes due to shrinkage. The cups may be irregularly infolded, presenting shapes which can be imitated by indenting a soft hat. If the corpuscles are placed in water or a dilute solution, their hæmoglobin passes out and water enters, so that they are reduced to transparent membranes or shadows (Fig. 184, F). Such forms are often seen in clinical examinations of urine. In dense solutions, and in fresh preparations as the plasma becomes thicker from evaporation, water leaves the corpuscles. They then shrink, producing spiny or nodular round masses of hæmoglobin, known as *crenated corpuscles* (Fig. 184, G). A 0.6 per cent. aqueous solution of common salt is said to cause the least distortion from swelling or shrinkage. In life the corpuscles doubtless change their shape, responding to the

variations in their hæmoglobin content and in the surrounding plasma. Occasionally they are spherical (according to Schultze, and others), and deviations from the primary cup-shaped form are to be expected. In these changes the corpuscles act like membranes filled with fluid. In the mature corpuscles, however, the outer layer is thick, blending with the contents within; and since no sharp bounding line can be seen histologically, the corpuscles have been described as lacking membranes. The plastic nature of the membrane is shown by heating the blood film. The corpuscles then become globular and send out slender varicose processes, or round knobs attached by pedicles (Fig. 184, H). These small spheres become detached in great numbers.

The dimensions of red corpuscles are quite constant. Those in human blood average $7.5\ \mu$ in diameter and ordinarily vary from 7.2 to $7.8\ \mu$. They sometimes surpass these limits. In biconcave form they are about $1.6\ \mu$ thick. The cups average $7\ \mu$ in diameter and are $4\ \mu$ in depth.

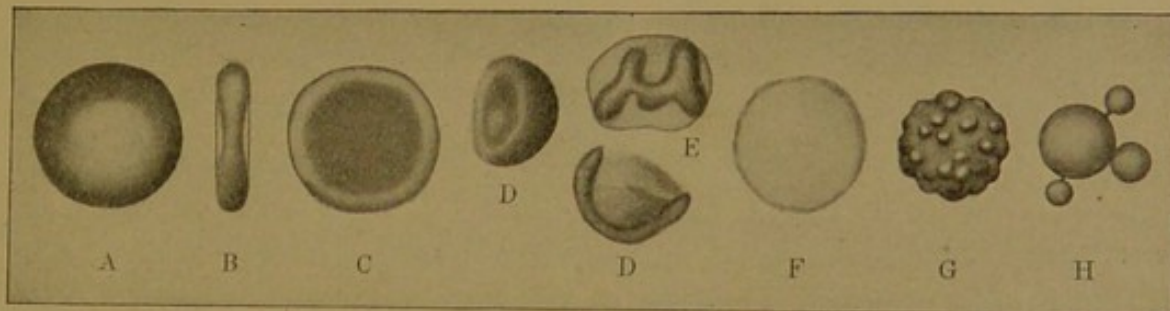


FIG. 184.—RED CORPUSCLES IN VARIOUS CONDITIONS.

Spherical corpuscles are said to be $5\ \mu$ in diameter. The blood of mammals other than man also contains cups which become discs. The latter are oval in the camel group but round in all others. Their average diameters are less than in man ($7.3\ \mu$ in the dog, $7.48\ \mu$ in the guinea-pig), but the species of animal cannot satisfactorily be determined from the diameter of the corpuscles. In a given section, as already noted, the red corpuscles furnish a useful gauge for estimating the size of other structures.

The number of red corpuscles in a cubic millimeter of human blood averages five million for men, and four million five hundred thousand for women. By diluting a small measured quantity of blood and spreading it over a specially ruled slide, the corpuscles may be counted, and the number per cubic millimeter calculated. A diminished number is of clinical importance.

Histologically the red corpuscles usually appear as homogeneous bodies, but with special methods a granular network has been found within them, which has been interpreted as a reaction of the hæmoglobin to reagents, and also as a persistence of the protoplasmic reticulum of the erythroblasts. It occurs especially in newly formed corpuscles (seen in cases of anæmia). Instead of a net, there may be rings or round

bodies, some of which have been considered to be nuclear remains. A few coarse granules of uncertain significance are sometimes conspicuous. The fatty exoplasmic layer which invests the corpuscle and serves as a membrane is not sharply marked out in stained specimens; it appears to blend with the contents of the corpuscle. Although the corpuscles may pass out of the vessels by "diapedesis," they are not actively motile, and their margins never present pseudopodia. The characteristics of hæmoglobin may be described as follows:

Hæmoglobin is an exceedingly complex chemical substance which combines readily with oxygen to form *oxyhæmoglobin*. To the latter the bright color of arterial blood is due. Venous blood becomes similarly red on exposure to air. Through the oxyhæmoglobin, oxygen is transferred from the lungs to the tissues. Hæmoglobin may be dissolved from the corpuscles by mixing blood with ether, and upon evaporation it crystallizes in rhombic shapes which vary with different animals. Those from the dog are shown in Fig. 185, 4; in man they are also chiefly prismatic. Hæmoglobin is readily

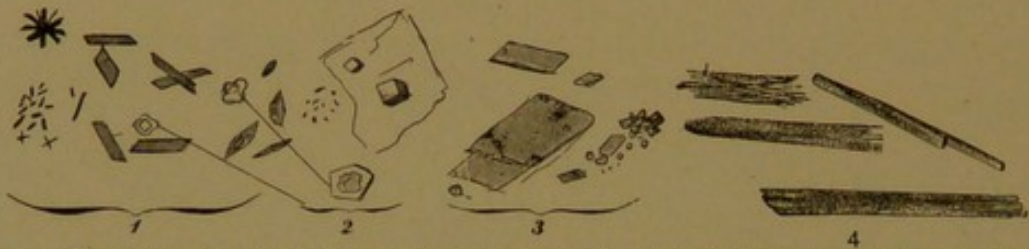


FIG. 185.—1, Hæmin crystals and 3, hæmatoidin crystals from human blood ($\times 560$); 2, crystals of common salt ($\times 560$); 4, hæmoglobin crystals from a dog ($\times 100$).

decomposed into a variety of substances, some of which retain the iron which is a part of the hæmoglobin molecule, others lose it. *Hæmatoidin*, considered identical with a pigment (bilirubin) of the bile, is an iron-free substance occurring either as yellow or brown granules, or as rhombic crystals. The crystals (Fig. 185, 3) may be found in old blood extravasations within the body, as in the corpus luteum of the ovary. *Hæmosiderin*, which contains iron, appears as yellowish or brown granules sometimes extremely fine, either within or between cells. The iron may be recognized by the ferrocyanide test which makes these minute granules bright blue. If dry blood from a stain is placed on a slide with a crystal of common salt the size of a pin-head, and both are dissolved in a large drop of glacial acetic acid which is then heated to the boiling point, a product of hæmoglobin is formed, called *hæmin*. It crystallizes in rhombic plates or prisms of mahogany brown color (Fig. 185, 1). Such crystals would show that a suspected stain was a blood stain, but they afford no indication of the species of animal from which it was derived.

The duration of the life of mature red corpuscles is unknown, but is supposed to be brief. They may be devoured intact by phagocytes, but generally they first break into numerous small granules. These may be ingested by certain leucocytes, or by the peculiar endothelial cells of the liver. Their products are thought to be eliminated in part as bile pigment. The destruction of red corpuscles occurs especially in the spleen and hæmolymp glands; to a less extent in the lymph glands and red bone marrow. Pigmented cells in some of these structures derive their pig-

ment from destroyed corpuscles. Sometimes a 'stippling' or granule formation occurs within the corpuscle, which has been ascribed to degeneration of the hæmoglobin. The dissolution of red corpuscles is known as *hæmolysis* and follows the injection of certain poisonous substances into the blood. It occurs in various diseases. The study of the effects of mixing the blood of one species of animal with that of another, has provided a very perfect means of distinguishing the species from which a blood stain of unknown origin may have been derived.

WHITE CORPUSCLES. The white corpuscles or leucocytes are those blood cells which retain their nuclei and do not contain hæmoglobin. The youngest stages of erythroblasts, according to this definition, are leucocytes, and like other leucocytes they are derived from the mesoderm. In 1890 Howell wrote, "Before 1869 it was quite generally believed that the red corpuscles are formed from the white corpuscles—in fact, some of the most recent investigations favor this view, although the evidence is so overwhelmingly against it." It is still advocated by foremost investigators of the blood, and is referred to as the "monophyletic theory." Those who believe in diverse origins of red and white corpuscles, and of the various forms of white corpuscles, support the "polyphyletic theory."

Maximow (Arch. f. mikr. Anat., 1909, vol. 73, pp. 444-561) states that "the first leucocytes, the lymphocytes, arise at the same time and from the same source as the primitive erythroblasts; the latter represent a specially differentiated form of cell, but the lymphocytes always remain undifferentiated. Therefore, like the primitive blood cells from which they directly proceed, they are undifferentiated rounded amœboid mesenchymal cells." Weidenreich (Anat. Rec., 1910, vol. 4, pp. 317-340) concludes that "the old, original view of the unified genetic character of all blood cells proves to be correct," and he regards the lymphocyte as the primitive or young form of white corpuscles. (For many other references, see Minot, in Keibel and Mall's Human Embryology, vol. 2.)

Against the monophyletic interpretation, it has been asserted that the lymphocytes of the adult are a different form of cell from the primitive blood cells, and that they are not found in embryos until the time when lymph glands develop. These arise rather late—in rabbits of 25 mm. and in human embryos of 40 mm. (Lewis, Anat. Rec., 1909, vol. 3, pp. 341-353). According to the polyphyletic view, the lymphocytes are first formed from the reticular tissue in these glands and from similar tissue elsewhere. If this is true, it becomes unnecessary to regard the lymph glands as organs for producing young cells, and the bone marrow as an organ for producing old cells. The relation of these organs to blood formation will be considered in a later chapter.

The number of white corpuscles in a cubic millimeter of human blood is about eight thousand. If it exceeds ten thousand the condition is called *leucocytosis* and becomes of clinical importance. There exists, therefore, normally but one leucocyte for five or six hundred red corpuscles. In the circulating blood the two sorts are said not to be evenly mixed; the leucocytes are more numerous in the slower peripheral part of the blood stream, near the endothelium. The leucocytes may be divided into three

classes according to their nuclear characteristics, namely, into *lymphocytes*, *large mononuclear leucocytes*, and *polymorphonuclear leucocytes*.

Lymphocytes have already been briefly described with the constituents of connective tissue (Fig. 56, p. 68). Ordinarily they are small cells, about the size of red corpuscles, 4–7.5 μ in diameter. Large ones may be double this diameter. Their protoplasm forms a narrow rim, sometimes almost imperceptible, about the dense round nucleus (Fig. 186, A). The chromatin is arranged in a network associated with coarse chromatic masses such as cause a characteristic checkered appearance. Some of the

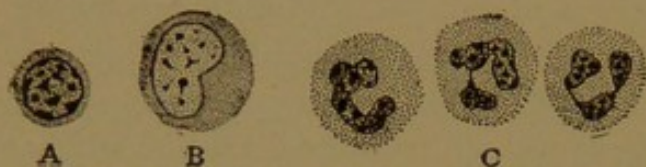

FIG. 186.—LEUCOCYTES AS SEEN IN A SECTION OF HUMAN TISSUE PRESERVED WITH ZENKER'S FLUID.

A, Lymphocyte; B, large mononuclear leucocyte; C, three polymorphonuclear neutrophils.

masses rest against the nuclear membrane. Lymphocytes are capable of amœboid motion but not to the extent of the polymorphonuclear type. They form from 22 to 25% of all leucocytes.

Large mononuclear leucocytes, sometimes 20 μ in diameter, form only from 1 to 3% of the leucocytes. They possess round, oval, slightly indented, or crescentic nuclei, which are vesicular and usually eccentric in position. Their chromatin occurs in a few large granules; as a whole the nucleus is clear and pale (Fig. 186, B). The protoplasm, which is abundant, usually lacks coarse granules or other distinctive features. Sometimes it contains a few deeply staining granules as shown in one of the cells in Fig. 187, II. The large mononuclear leucocytes are notably phagocytic. In certain respects they are intermediate between lymphocytes and polymorphonuclear cells, and they were formerly known as "transitional cells." Apparently, however, they are derived directly from the modified endothelial cells lining the sinuses of the lymph glands, and they have sometimes been regarded as the youngest of the forms of cells shown in Fig. 186.

Polymorphonuclear leucocytes are cells somewhat larger than red corpuscles, being from 7.5 to 10 μ in diameter. They are characterized by having nuclei with irregular constrictions leading to an endless variety of shapes (Fig. 186, C). The nodular subdivisions may be connected by broad bands or by slender filaments. It is said that in degenerating cells the nucleus becomes divided into several separate masses. Such forms can properly be called "polynuclear," an abbreviated term which is a misnomer as applied to the ordinary cells; "mononuclear" as designating the preceding types is also unfortunate since it implies that others have several nuclei. The irregular shape of the polymorphous nuclei has been ascribed to degenerative changes, comparable to those seen in the erythroblast nuclei. Within the concavity of the nucleus the centrosome may be found, surrounded by a light area; usually it occurs as a diplosome.

(In the forms of corpuscles with round nuclei eccentrically placed, the centrosome is on the side where the protoplasm is most abundant.) The polymorphonuclear leucocytes are actively amœboid, and particles readily pass through their superficial layer, but like other forms of leucocytes they are covered with a very delicate cell membrane.

Max Schultze in the first paper published in the *Archiv für mikroskopische Anatomie* (1865, vol. 1, pp. 1-42) described an apparatus for the examination of microscopic specimens at the body temperature, which he used in studying human blood. He observed the active creeping movements of the leucocytes, closely similar to those of the most delicate amœbæ, and watched them take up particles of carmine and other dyes placed in a drop of fresh blood. "The act of ingestion," as he describes it, "is accompanied by no striking maneuver." He adds that he has never seen special processes sent out to overcome foreign bodies, but that the creeping corpuscle, during its uniform advance, passes over them and presses them into its substance. He diluted the blood with two-thirds of its volume of fresh cow's milk, and observed that the leucocytes moved with the same rapidity as before, and ingested the oil globules which are much larger than the pulverized dye-stuff.

A fundamental characteristic of polymorphonuclear leucocytes is the development of distinct *granules* in their protoplasm. They can be seen in fresh unstained specimens, in which it is evident that some of the cells contain coarse granules, and others fine granules. The lymphocytes and the large mononuclear leucocytes contain neither sort, and are therefore described as *non-granular*. In order to study the granules a drop of blood is spread thinly over a cover glass and dried, afterward being stained with a "blood stain," which is a carefully prepared mixture of acid and basic dyes. The details of nuclear structure are not preserved by this method, but the granules are clearly differentiated (Fig. 187). With several of the blood stains the fine granules are colored purple or lilac; and the coarse granules are found to be of two sorts, one kind staining red with eosin, and the other blue with the basic dye. *Only one sort of granule occurs in a single cell.*

Leucocytes containing coarse blue granules, which often obscure the nucleus, are called *mast cells*. In order to distinguish between them and the mast cells of connective tissue, which contain similar granules (see Fig. 55, p. 68) those in the blood are often called *mast leucocytes*. They form only 0.5% of the leucocytes, and in sections special methods are required to demonstrate them. These cells have recently been interpreted as degenerating forms, but their significance has not been fully established.

Leucocytes with coarse granules which stain red with eosin, an acid stain, are called *eosinophiles* (sometimes oxyphiles, or acidophiles). They constitute from 2 to 4% of the leucocytes in the blood. Eosinophilic cells, apparently distinct from those of the blood, occur also in connective tissue, and since their granules are preserved by ordinary

methods, and eosin is a dye used in routine examinations, these cells are often seen. According to Weidenreich the eosinophilic granules are minute fragments of red corpuscles, or products of their degeneration, which have been ingested. Badertscher (*Amer. Journ. Anat.*, 1913, vol. 15, pp. 69-86) finds that eosinophiles are very numerous in the vicinity of the degenerating muscle fibers in salamanders, during the time when their gills atrophy. He agrees with Weidenreich that the eosinophilic granules are not products of protoplasmic activity but are derived from

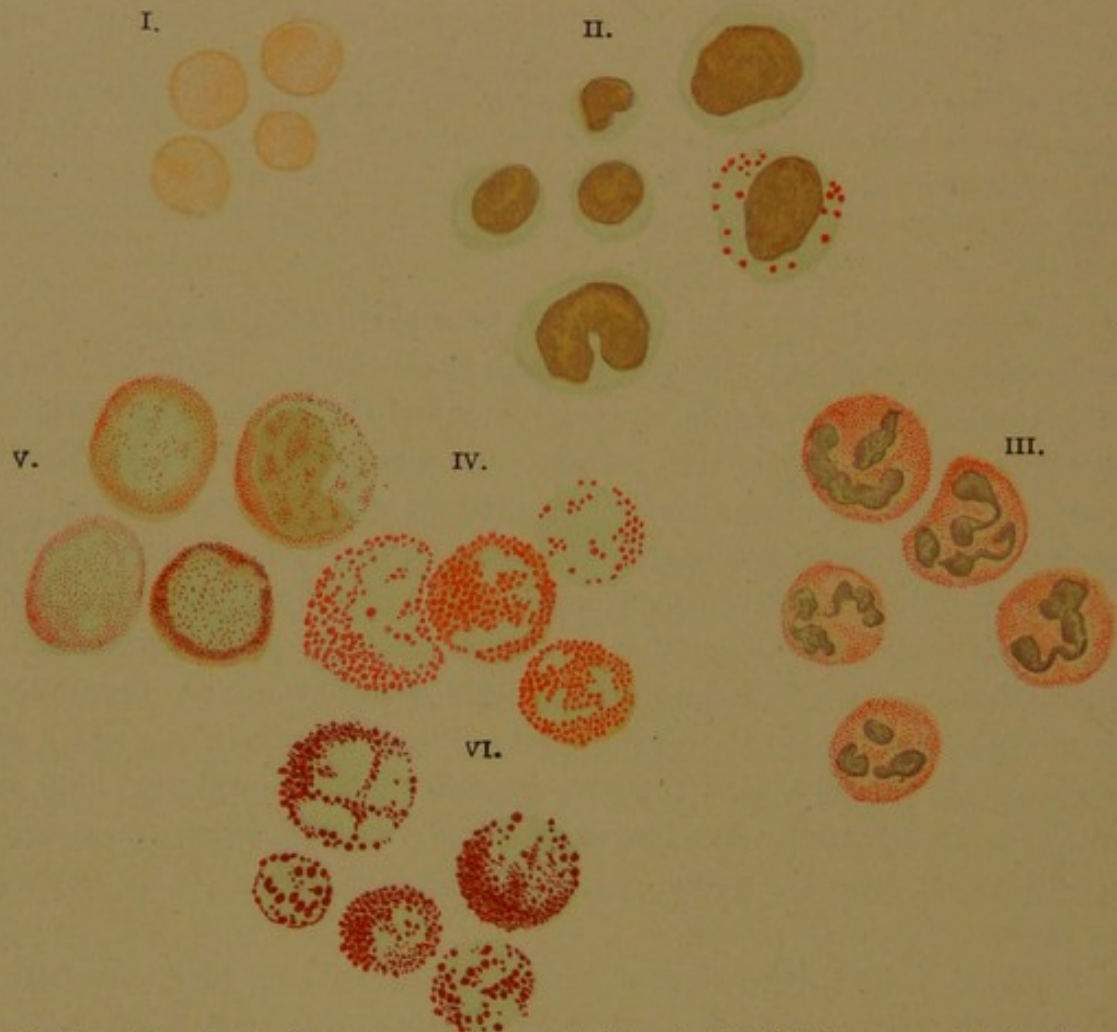

FIG. 187.—THE BLOOD CORPUSCLES. (WRIGHT'S STAIN.) (E. F. Faber, from Da Costa's *Clinical Hæmatology*.)

I, Red corpuscles: II, Lymphocytes and large mononuclear leucocytes. III, Neutrophils. IV, Eosinophiles. V, Myelocytes (not found in normal blood). VI, Mast cells.

material outside of the cells; and he likewise finds that they are taken up by lymphocytes which thus become eosinophiles. Badertscher's work is of interest in connection with cases of trichiniasis in man, in which the number of eosinophiles in the blood becomes greatly increased, and at the same time there is extensive degeneration of the muscles, caused by the parasites. There is, therefore, reason to believe that eosinophilic granules are hæmoglobin derivatives, but, as stated by Minot, "renewed investigation of the eosinophiles in man is very desirable."

The third type of granular cell, unlike the eosinophiles and mast cells, contains *fine* granules, and these stain purple or lilac by taking both acid and basic stains simultaneously. They are called *neutrophiles*, and form between 70 and 72% of the leucocytes in the blood. They are actively amœboid and are the principal wandering cells of the body, leaving the blood vessels more readily than other forms. In suppurative processes they accumulate around the centers of infection, and they are of very great clinical importance.

SUMMARY OF THE FORMS OF LEUCOCYTES.

Lymphocytes, 22 to 25% of the leucocytes, are small (about the size of a red corpuscle) or large (perhaps twice the diameter of a red corpuscle), non-granular, with round checkered nuclei.

Large mononuclear leucocytes, 1 to 3%, may be two or three times the diameter of red corpuscles. They are non-granular, or with few granules, and have pale vesicular nuclei, round or crescentic.

Polymorphonuclear leucocytes, larger than red corpuscles, are granular, with nuclei variously constricted or bent. They include—

Mast cells, 0.5%, with very coarse basophilic granules obscuring the nucleus.

Eosinophiles, 2 to 4%, with coarse eosinophilic granules.

Neutrophiles, 70 to 72%, with fine neutrophilic granules.

Blood plates (Fig. 188) are small granular bodies (*Körnchenplaques*) which were recognized as a normal constituent of the blood by Schultze in 1865. Previous references to them occur, and Zimmermann described them as "elementary corpuscles," believing that they gave rise to red corpuscles (Arch. f. path. Anat., 1860, vol. 18, pp. 221-242). They are 2-4 μ in diameter, and between 245,000 and 778,000 have been estimated to occur in a cubic millimeter of human blood. They are readily reduced to granular débris in ordinary sections, but when well preserved and properly stained,

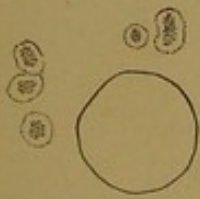

FIG. 188.—BLOOD PLATES BESIDE A RED CORPUSCLE.

they are found to consist of a central granular core and a hyaline outer layer. Often they appear stellate, and on a warm stage they exhibit amœboid movements. They are concerned in the clotting of the blood, or thrombus formation, and during coagulation threads of fibrin extend out from them as seen in Fig. 182. It is possible, however, that they are only passively involved in this process. In the amphibia certain small spindle-shaped cells appear to be similarly related to fibrin-formation, and they are called *thrombocytes*; the same term is sometimes applied to the blood plates. In blood clots several days old, blood plates are still found, indicating that they have more than a transient existence.

The source of the blood plates has been known to American histologists for several years, since they have had the opportunity of examining preparations made by J. H. Wright and described by him in 1906. The specimen shown in Fig. 189 is one of several which were entrusted to the writer for demonstration at the meeting of the American Association of Anatomists in 1906; figures of them are reproduced in color in the *Journal of Morphology* (1910, vol. 21, pp. 265-278). Fig. 189 represents a giant cell of the bone marrow, sending out two processes or pseudopodia into a blood vessel; the endothelium is interrupted at their place of entrance. By the special stain which Dr. Wright perfected, the central and large part of the cytoplasm of the giant cells is seen to consist of red or violet granules, identical in form and color with the granules in the center of the blood plates. Moreover the giant cells are shown to have a clear blue exoplasmic layer, which sends out slender processes, and this exoplasm also is identical in structure with that of the blood plates. Some of the blood plates are free in the vessels; others in rows or clumps are still connected with the giant cells. Fig. 189 shows a few detached

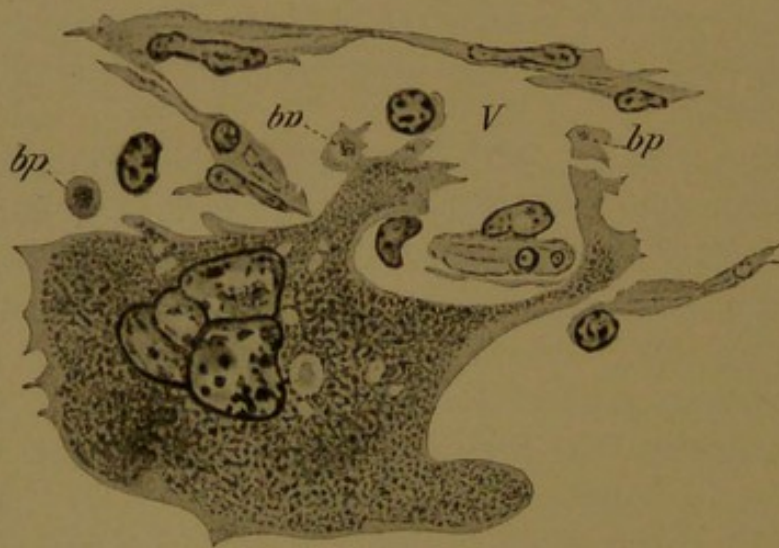


FIG. 189.—GIANT CELL FROM THE BONE MARROW OF A KITTEN, SHOWING PSEUDOPODIA EXTENDING INTO A BLOOD VESSEL (V), AND GIVING RISE TO BLOOD PLATES (bp). (J. H. Wright.)

plates, and one which is budding off from a pseudopodium, but the color-contrasts which make these preparations convincing are scarcely indicated. Through Wright's investigations it has been made clear that blood plates are detached portions of the cytoplasm of the giant cells in the bone marrow, and of similar giant cells in the spleen; their granular center is endoplasm, and their hyaline border is exoplasm.

According to Schäfer (1912) Wright's "suggestion" seems improbable; and the blood plates may be looked upon as minute cells. Others also have regarded the granular endoplasm as a nuclear structure. The blood plates are still described by many writers as fragments of disintegrating white corpuscles, or fragmenting nuclei of red corpuscles; and Stöhr records that their origin is obscure.

Plasma is the fluid intercellular substance of the blood. It contains various granules, some of which are small fat drops received from the thoracic duct. Others occurring in variable quantity are refractive particles, not fatty, either round or elongated; they are known as hæmatoconia (or hæmoconia). In ordinary sections the plasma appears as a granular coagulum. In the process of clotting, fibrin forms from the plasma, and with the entangled corpuscles, it constitutes the blood-clot; the fluid which remains is the serum. The process of fibrin formation is of considerable histological interest, owing to a possible analogy with fibril formation in connective tissue.

LYMPH.

The contents of the lymphatic vessels is called lymph. This fluid is not identical with plasma, or with tissue fluid, yet all three are similar. Nutrient material passes from the plasma into the tissue fluid and thence to epithelial cells; and in return the products of epithelial cells enter the tissue fluid from which they may be taken over either into the plasma or lymph, first passing through the endothelial walls of the vessels. Thus in the intestine much of the absorbed fat is transferred across the tissue spaces to the lymphatic vessels (lacteals) within which it forms a milky emulsion known as *chyle*. This form of lymph mingles with other varieties coming from the various parts of the body, and together they are poured into the plasma at the jugulo-subclavian junction. Histologically lymph appears as a fine coagulum, containing lymphocytes and large mononuclear phagocytic cells. The cells are not abundant. Occasionally other forms of blood corpuscles are found in lymphatic vessels, but the lymphocytes greatly predominate.

III. SPECIAL HISTOLOGY.

BLOOD FORMING AND BLOOD DESTROYING ORGANS.

BONE MARROW.

Bone marrow is the soft tissue found within the central cavities of bones. Its source in the embryo is the vascular mesenchyma invading a cartilage which is being replaced by bone. Early in its development it contains osteoblasts and osteoclasts, and these cells may be found in adult marrow, where it is in contact with the bone. The greater part of the mesenchyma becomes reticular tissue with fat cells intermingled. The meshes of the reticular tissue are occupied by an extraordinary variety of cells, most of which are called *myelocytes* (marrow cells). In ordinary

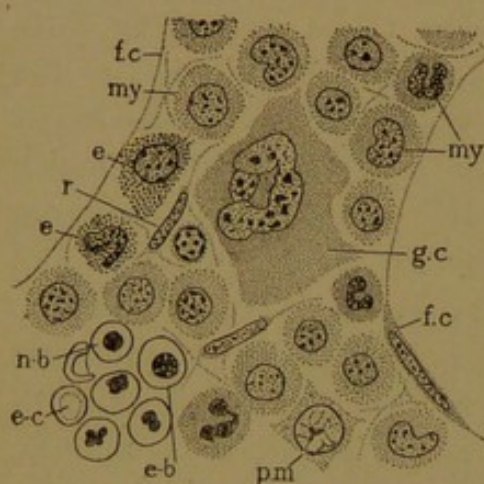


FIG. 190.—HUMAN BONE MARROW.
e., Eosinophilic myelocyte; e-b., erythroblast; e-c., erythrocyte; f. c., part of the protoplasmic rim of a fat cell; g. c., giant cell; my., neutrophilic myelocyte; n-b., normoblast; pm., premyelocyte; r., reticular tissue cell.

sections the tissue of the marrow appears to be riddled with large round holes. Under high magnification the holes are seen to be fat cells, the nuclei of which are here and there included in the section (Fig. 190.) The reticular tissue framework of the marrow consists of flattened cells, generally seen cut across; their nuclei then appear slender and elongated. The abundant meshwork of fibrils associated with these cells is not apparent in ordinary sections. In the meshes are found *giant cells*; *premyelocytes*; *myelocytes* which are *neutrophilic*, *basophilic* or *eosinophilic*; *erythrocytes*; *lymphocytes*; and mature corpuscles both red and white.

The giant cells of the marrow have a single polymorphous nucleus. They have therefore been named "megakaryocytes," in distinction from the multinucleate osteoclasts or "polykaryocytes." The nucleus is so large that it may be cut into several slices, and by combining these it has been found that the entire nucleus is a hollow sphere with perforated walls; the nuclei, however, are very irregular, and some may be of other forms. With Wright's stain the protoplasm clearly shows an outer hyaline exoplasm and an inner granular endoplasm. It has been said that the latter is divisible into two concentric zones, which differ from the protoplasm within the nuclear sphere. In ordinary preparations these details are

not evident (Fig. 191). A large number of centrosome granules (over one hundred) have been found, and pluripolar mitoses have been observed. A phagocytic function has been ascribed to these giant cells, but it has also been denied. Their origin is unknown, but is said to be from the leucocyte series of cells. Their important function of producing blood plates has already been described (p. 200).

Premyelocytes are cells with large round vesicular nuclei containing one or two coarse chromatin masses, and surrounded by basic protoplasm free from specific granules (Figs. 190 and 191). These cells are parents of

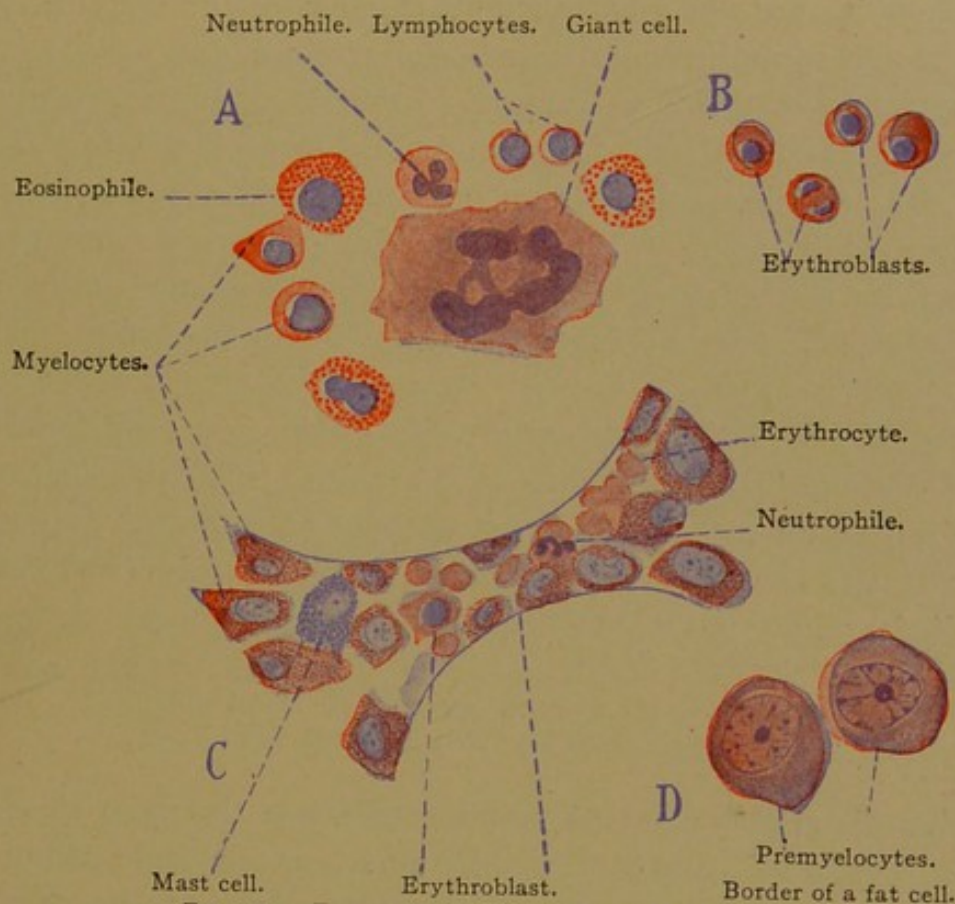


FIG. 191.—ELEMENTS OF HUMAN BONE MARROW.

A, From the femur at 10 years; B, from a cervical vertebra at 19 years; C, from the femur at 77 years; D, from a rib at 59 years.

myelocytes, and are sometimes called "myeloblasts"—a poor term, since they do not produce marrow. Stöhr refers to those in Fig. 191 as "plasma cells"; others describe them as primitive wandering cells. Apparently they are set free from the reticular tissue and they may produce not only myelocytes but also erythroblasts.

Myelocytes are cells larger than polymorphonuclear leucocytes, having round or crescentic nuclei and protoplasm containing a varying quantity of specific granules, either neutrophilic, basophilic, or eosinophilic. The young cells have round nuclei and few granules. The oldest become the granular leucocytes ready to enter the blood vessels. Several generations, derived by mitosis, intervene between the young myelocytes and the mature leucocytes. Most of the myelocytes are finely granular and neu-

trophilic. Some are coarsely granular and eosinophilic; others contain the basophilic mast cell granules, but these are not well preserved in ordinary specimens. In certain diseases myelocytes enter the circulating blood, and they appear in smears as shown in Fig. 187, p. 198.

Erythroblasts are generally found in clusters, some being young with vesicular nuclei, others being normoblasts with dense irregular nuclei, such as have already been described. Rarely a nucleus may be found which apparently is partly extruded. Cup-shaped corpuscles are seen in the tissue meshes.

Lymphocytes are not a conspicuous element of the marrow, yet they are present and sometimes in disease become abundant.

The relations of the blood vessels to the reticular tissue are of great interest. It has been thought that the endothelium blends with the reticulum so that no sharp distinction can be made between the two. It seems more probable that the endothelium is merely more permeable than usual, by a freer separation of its cells. The same problem is presented by the blood vessels and reticular tissue of the lymph glands and spleen.

The functions of the marrow are the production and dissolution of bone, the storing of fat, the formation of granular leucocytes (neutrophiles, eosinophiles, and mast cells), of red corpuscles, and to a less extent of lymphocytes; to these some would add the destruction of red corpuscles, as indicated by ingested fragments and intercellular granules.

LYMPH NODULES AND LYMPH GLANDS.

The lymph glands arise as nodules of dense tissue in close relation with an artery, a vein and a lymphatic vessel, as seen in the photographs, Figs. 192 and 193. The first distinct lymph glands in the body are a pair in the axillary region, a pair in the iliac region, and a pair or two in the maxillary region. They are found in rabbit embryos of about 30 mm., and in human embryos of about 40 mm. These first glands are soon followed by others in their vicinity, producing axillary, inguinal and cervical groups, respectively; and scattered glands more peripherally situated along the vessels develop later. At the same time, the tissue around the jugular and mesenteric lymph sacs becomes transformed into dense lymphoid tissue, which is resolved into the chains of deep lymphatic glands. These acquire a structure similar to that of the superficial glands. There is no satisfactory evidence that the dense lymphoid tissue of which the glands are composed is produced by the emigration of cells from either the arteries, veins or lymphatics associated with them.

In further development the lymph glands become organized as shown in the diagrams, Figs. 194 and 195. The left half of each diagram repre-

sents a younger stage than the right half. These instructive figures were prepared by Stöhr on the basis of Kling's studies (Arch. f. mikr. Anat., 1904, vol. 63, pp. 575-610). In the youngest stage (Fig. 194) it is seen that the blood vessels enter and leave the gland on one side, at a place called the *hilus* (Lat. *hilum*, a small thing, applied to the eye of a bean, and to similar hollows in bean-shaped organs). The lymphatic vessel, as a plexiform *peripheral sinus*, encircles the entire structure. After the gland has enlarged, lymphatic vessels extend into the mass of lymphoid tissue, as shown on the right of Fig. 194, and eventually they pass clear

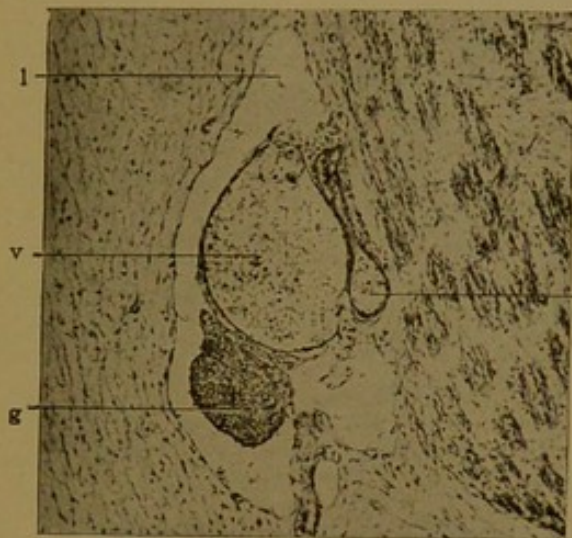


FIG. 192.—THE FIRST AXILLARY LYMPH GLAND OF THE RABBIT. FROM AN EMBRYO OF TWENTY DAYS, 29 MM. X 60.

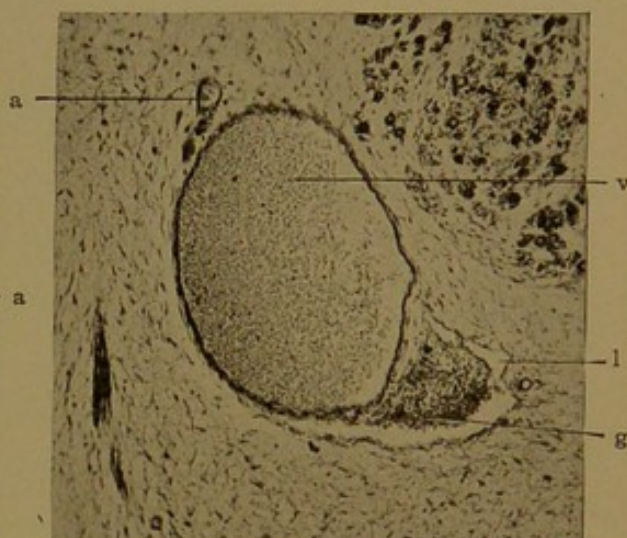


FIG. 193.—ONE OF THE EARLIEST CERVICAL LYMPH GLANDS. FROM A HUMAN EMBRYO OF 42 MM. X 60.

a, Artery; g, lymph gland; l, lymphatic vessel; v, vein.

through it in a system of anastomosing sinuses. The lymph then flows into the gland from the periphery, and out at the hilus; both the afferent and efferent vessels are shown in Fig. 195. Finally a connective tissue capsule develops around the larger glands, and in some of them it extends into the interior, producing a system of supporting *trabeculae*, either round or lamellar. These may unite with one another as shown on the right of Fig. 195. When present within the gland they are always found in the central axes of the lymph sinuses.

By the production of the internal lymph sinuses, the substance of the gland is subdivided into rounded *nodules* and elongated *cords* of lymphoid tissue. The nodules are found at the periphery of the gland and collectively they form its *cortex*; the cords constitute the *medulla*. Several other organs, *e.g.*, the kidney and suprarenal glands, are divided into an outer cortex (bark) and an inner medulla (pith). In the center of each cortical nodule there is often a light spot, seen with low power, which constitutes the *germinal center*. These general features of a lymph gland are shown in Fig. 196. It is evident that certain of the secondary

nodules in the cortex are imperfectly separated from one another, and that they are continuous below with the anastomosing medullary cords.

The lymph glands of the adult (*lymphoglandulæ*, also called lymph nodes) are round or reniform structures varying in length from a few millimeters

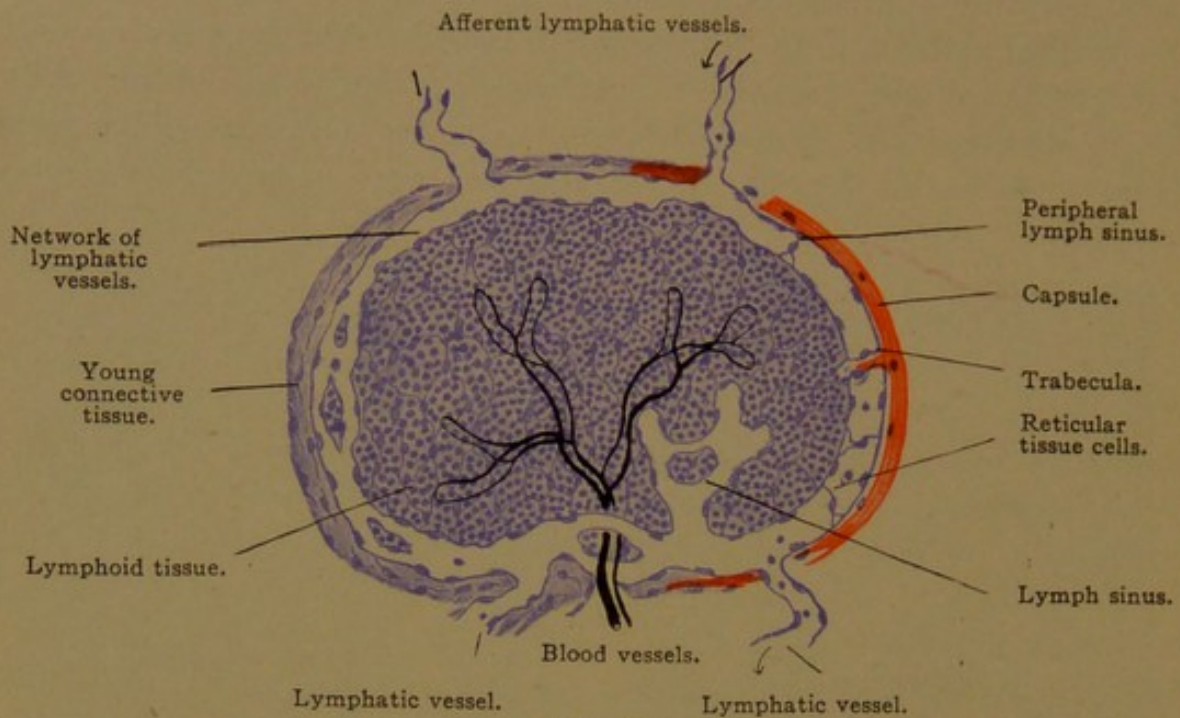


FIG. 194.

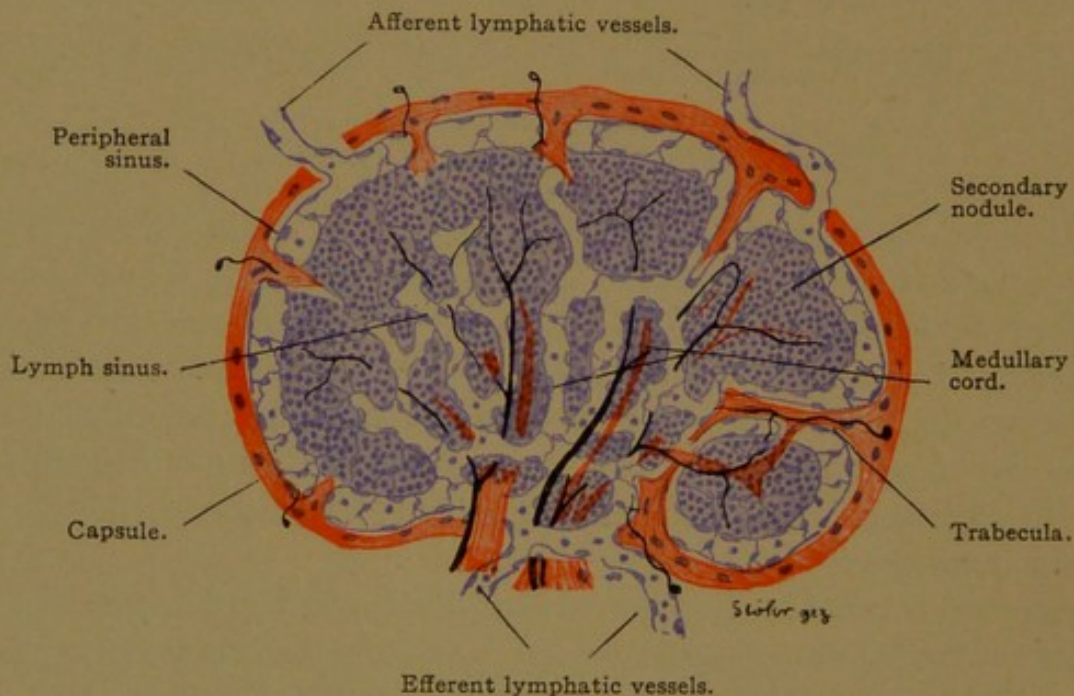


FIG. 195.—DIAGRAMS REPRESENTING FOUR STAGES IN THE DEVELOPMENT OF LYMPH GLANDS.

to a few centimeters. The largest of them show trabeculæ and are subdivided into cortex and medulla as above described; the small ones remain permanently in the various developmental stages shown in Figs. 194 and 195. The smallest structures consist of but a single nodule, with or without a germinal center; it contains a simple capillary network in its interior,

and a lymphatic plexus over its surface. Such *solitary nodules* occur in the mucous membranes of various organs. By contact with one another laterally they constitute the *noduli aggregati*, or "Peyer's patches" of the small intestine, which are macroscopic structures 1-5 cm. long. Lymphoid nodules irregularly massed about epithelial pits become the essential tissue of the tonsils. Wherever it occurs, lymphoid tissue has essentially the same structure as that observed in the lymph glands.

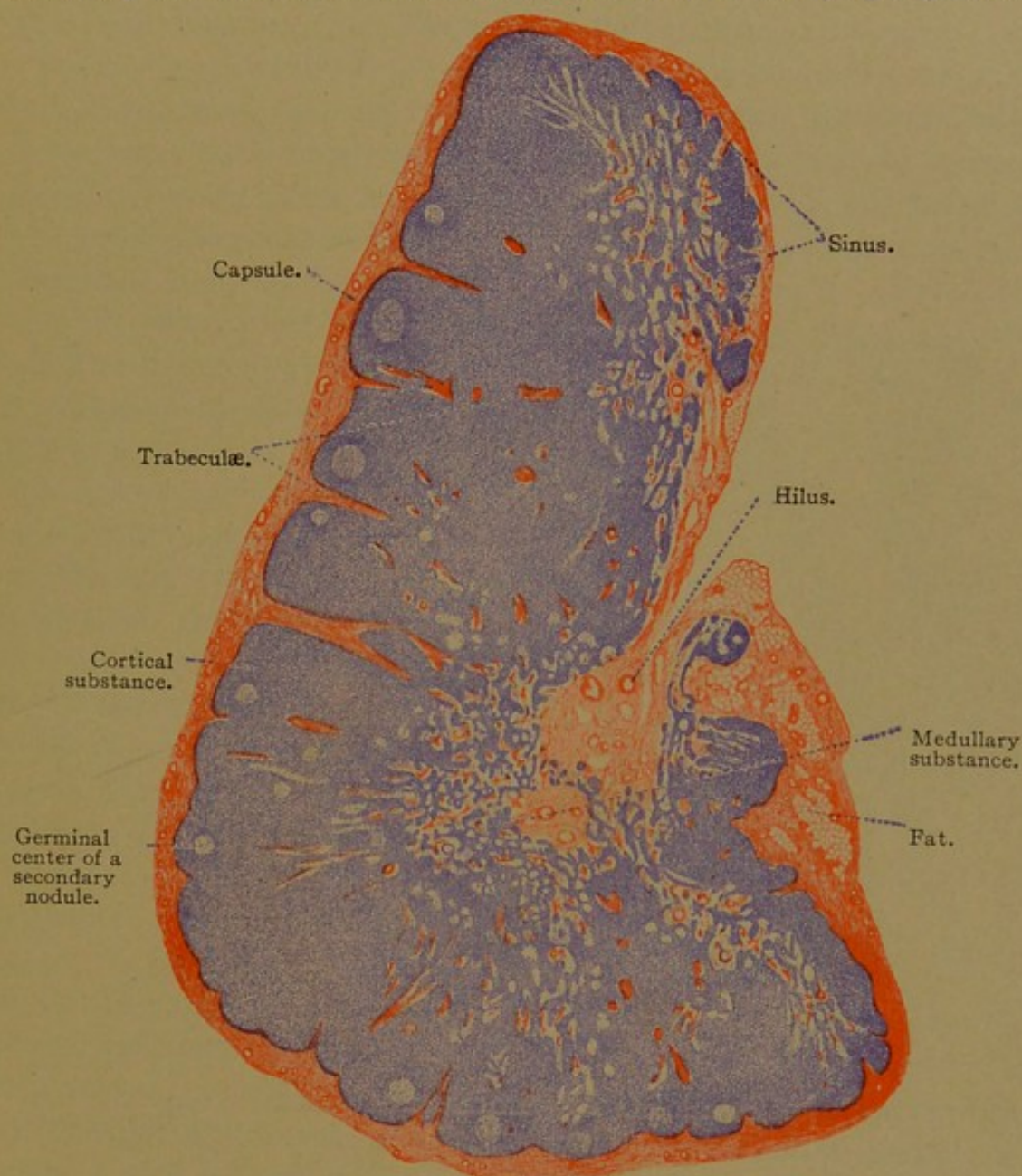


FIG. 196.—LONGITUDINAL SECTION OF A HUMAN CERVICAL LYMPH GLAND. $\times 12$.

Lymphoid tissue (formerly called adenoid tissue) consists of a framework of reticular tissue (see Fig. 50, p. 61, and the accompanying description), together with detached cells, chiefly lymphocytes, which fill its meshes. Eosinophiles and the various forms of blood corpuscles brought in by the blood vessels, are present in small numbers. The lymphocytes are like those of the blood, and the lymph glands are centers for their production. Stained with hæmatoxylin, lymphoid tissue, because

of the preponderance of nuclear material, is very dark, and its appearance even under low magnification is quite characteristic; it is shown in the medullary cords in Fig. 197, which illustrates also its relation to the lymph sinuses.

The lymph sinuses are not well-defined endothelial tubes, but appear rather as washed-out portions of the reticular tissue. If the endothelial tubes which line the lymphatic vessels enter the lymph gland to form the sinuses, it must be considered that their cells separate and that strands of reticular tissue pass across them. Some authorities consider that the endothelial tissue blends freely with the reticular tissue, so that any distinction is here arbitrary. The reticular tissue cells, or endothelial cells, lining the sinuses are highly phagocytic, and ingested fragments may be seen within them in sections. Certain of these cells become detached,

and there is reason to believe that they are the source of the large mononuclear leucocytes. Lymphocytes from the adjacent cords and nodules also enter the lymph as it passes through the sinuses, and thus they are added to the circulation. Within the cords and nodules they are enclosed in a closer meshed reticulum than that of the sinuses, which may prevent them from escaping too freely.

The germinal centers contain cells with larger and paler nuclei than those of lymphocytes. These central cells resemble premyelocytes, and

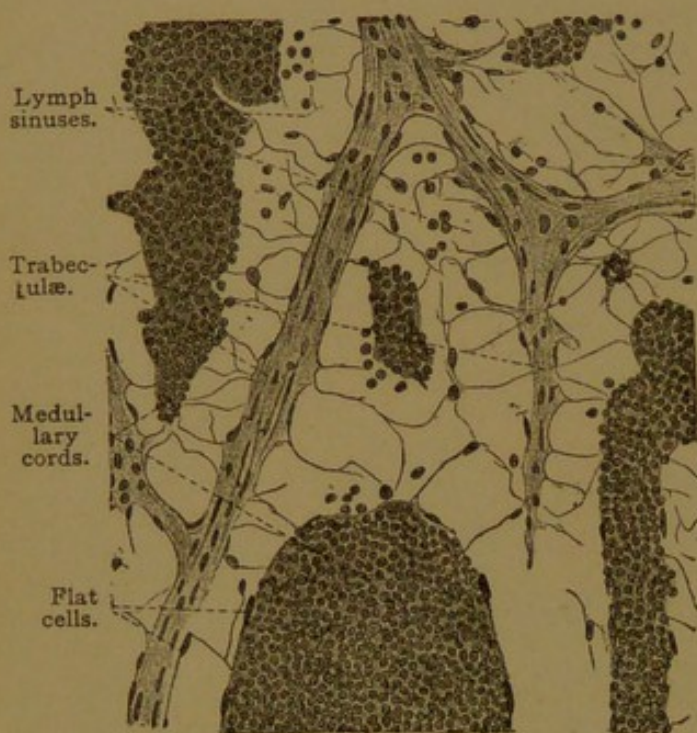


FIG. 197.—FROM THE MEDULLA OF A LYMPH GLAND OF AN OX. $\times 240$.

they are supposed to give rise to lymphocytes. Mitotic figures are abundant. The germinal centers, however, are not found in certain nodules, and they are absent from the medullary cords. This has been explained as due to the slower and more scattered multiplication of cells in those places, but the germinal centers are absent also from the early stages of embryonic glands. Presumably they are not adequately explained by stating that they are centers for lymphocyte production.

The capsules of the lymph glands consist of fibrous connective tissue, containing elastic elements which increase in abundance with age. Smooth muscle fibers are present as scattered cells or as slender bundles. The trabeculae, which are extensions of the capsule, are composed of the

same tissues. They are completely surrounded by the lymph sinuses as shown in Fig. 197. The flat cells over their surfaces may be regarded as endothelial cells.

The blood vessels of a lymph gland enter chiefly at the hilus, but in the larger glands some of them come in from the periphery and run in the trabeculæ; others however pass out through the trabeculæ into the capsule. The principal artery enters at the hilus and divides at once into several branches, which travel in the trabeculæ for a short distance, and then pass over into the medullary cords. They extend through the axes of the cords into the nodules, giving off small branches which form a venous network at the periphery of these structures. The veins which drain this network soon cross the sinuses and enter the trabeculæ, in which they travel toward the hilus alongside the arteries (Calvert, Anat. Anz., 1897, vol. 13, pp. 174-180). A central artery surrounded by lymphoid tissue and drained by peripheral veins is found not only in lymph glands, but also in the spleen.

Nerves to the lymph glands are not abundant. They consist of medullated and non-medullated fibers, which form plexuses about the blood vessels, and supply the muscle cells in the capsule and trabeculæ. They have not been found in the nodules and cords.

The function of the lymph glands is not only to produce lymphocytes which enter the lymphatic vessels and are conveyed through the thoracic duct into the blood, but also to "filter the lymph." If certain poisonous substances, inert particles, or bacteria are brought to the gland in the lymph, they may be removed by the phagocytic endothelial or reticular tissue cells. The gland at the same time may become enlarged by congestion, and by multiplication of its cells.

HÆMOLYMPH GLANDS.

Hæmolymp glands resemble small lymph glands, ranging in size from a "pin-head to an almond." They occur especially in the retroperitoneal tissue near the origin of the superior mesenteric and renal arteries, but are found elsewhere, and it has been said that their distribution coincides with that of ordinary lymph glands. They are darker than the lymph glands, and on section yield blood in place of lymph. No lymphatic vessels are associated with them, when typically developed, and instead of a lymph sinus they possess a similar structure filled with blood, the *blood sinus*. The lymphoid tissue with its blood supply, together with the capsule and trabeculæ, are like the corresponding structures in lymph glands. The capillary blood vessels, however, are readily permeable, so that their contents, both plasma and corpuscles, escape into the blood sinus. The hæmolymp gland is therefore a "blood filter." Many

blood corpuscles fragment in passing through it, and are removed from the circulation by phagocytic cells, which in consequence become pigmented. The eosinophilic cells which are found in hæmolymp glands have been explained as due to the ingestion of hæmogoblin products, but it has been questioned whether these cells are more abundant than in ordinary lymph glands. A second function of the hæmolymp glands, depending upon the lymphoid tissue around their arteries, is the production of lymphocytes which may enter the blood vessels directly.

According to von Schumacher (*Arch. f. mikr. Anat.*, 1912, vol. 81, pp. 92-150) the hæmolymp glands begin their development like ordinary lymph glands, but after the formation of the peripheral sinus, the connections with afferent and efferent lymphatic vessels are lost. He finds various intermediate forms between the lymph and hæmolymp glands, depending upon the extent of atrophy of the lymphatic connections, and the extent to which blood escapes from the intraglandular vessels. After accidents accompanied by extravasations of blood, the sinuses of ordinary lymph glands may become filled with red corpuscles, conveyed to them by the afferent lymphatic vessels. Such glands differ obviously from the true hæmolymp glands, which structurally and functionally are intermediate between lymph glands and the spleen.

SPLEEN.

The spleen, being five or six inches long and four inches wide, is much the largest organ of the lymph gland series. It is the first of them to develop, appearing in rabbits of 14 days (10 mm.) as a condensation of the mesenchyma in the dorsal mesentery of the stomach. At this stage the

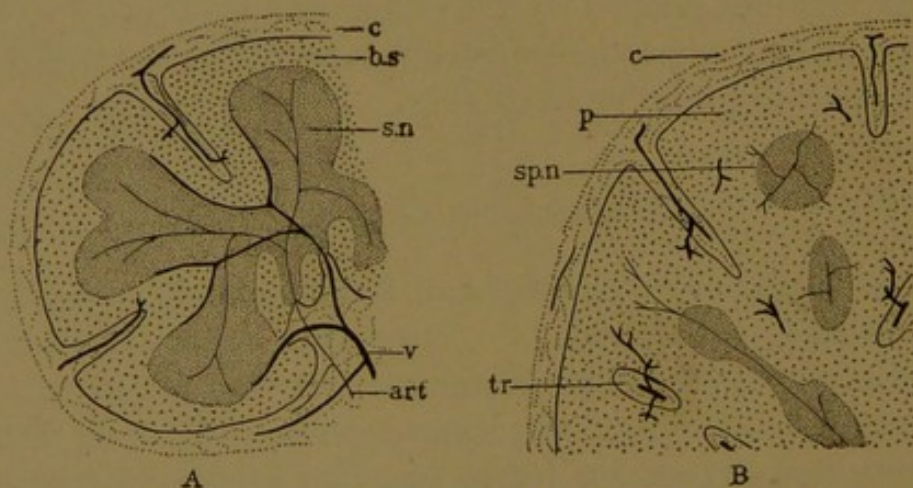


FIG. 198.—DIAGRAM OF A HÆMOLYMP GLAND, A, AND OF A PART OF THE SPLEEN, B. The arteries are shown as slender lines (art.) and the veins as heavy ones (v.); c., capsule; b. s., blood sinus, corresponding with the splenic pulp, p.; s. n., secondary nodule; sp. n., splenic nodule; tr., trabeculae.

only lymphatic vessels in the embryo are those near the jugular vein. Lymph glands are not indicated until six days later. The blood vessels enter the spleen at its hilus and branch freely. In early stages they form an ordinary capillary plexus, but subsequently their walls become so pervious that most of the blood escapes into the reticular tissue in passing

from the artery to the vein. Surrounding the arterial branches there is a zone of lymphoid tissue, which arises rather late in embryonic life. In reptilian spleens it is so abundantly developed that the organs resemble mammalian hæmolymp glands. In the guinea-pig the lymphoid sheath of the arteries is continuous, though narrow; in man it is so interrupted as to form a succession of spindle-shaped or spherical masses, called *splenic nodules* (Malpighian corpuscles). An arterial branch passes through each nodule. Thus, as compared with the hæmolymp

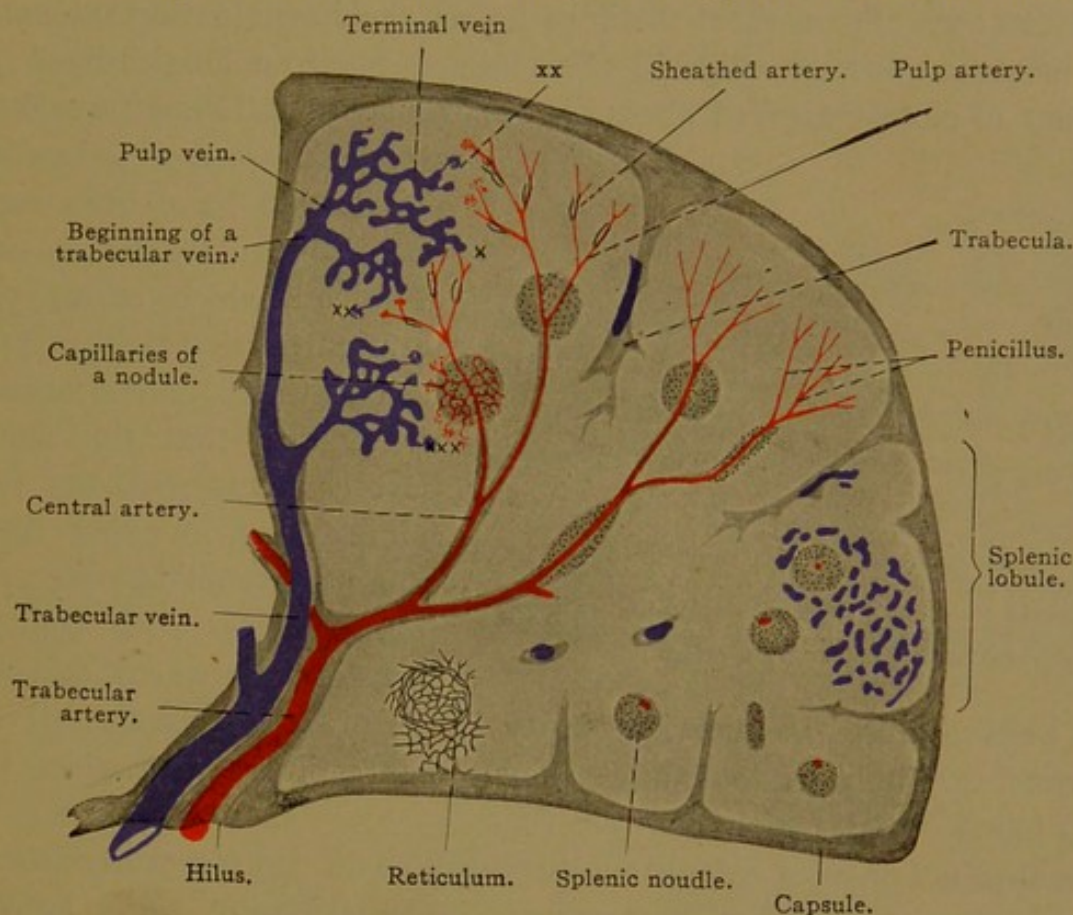


FIG. 199.—DIAGRAM OF THE BLOOD VESSELS OF THE HUMAN SPLEEN.

At **x** is shown the direct connection of terminal arteries with terminal veins (the existence of such a connection has been questioned). At **xx** and **xxx** are the free endings of the terminal veins in the pulp and near the nodules respectively.

gland, the spleen is deficient in lymphoid tissue (Fig. 198). The 'bulk' of the spleen is composed of *splenic pulp*, which corresponds with the blood sinus of the hæmolymp glands. Its framework of reticular tissue is continuous with that of the nodules, and it contains blood corpuscles of all sorts, special phagocytic cells known as *splenic cells*, and the terminal branches of both arteries and veins. There are no lymphatic vessels within the spleen. The capsule and trabecular framework are highly developed as in the largest lymph glands. The following features of the spleen may be described in turn—the blood vessels, the pulp, the nodules, the capsule and trabeculae, and finally the nerves.

As shown in the diagram, Fig. 199, the splenic artery enters at the hilus and, accompanied by veins, its branches are found in the largest trabeculae. When about 0.2 mm. in diameter the arteries leave the trabec-

ulæ, in which the veins continue further. The arteries, however, are still surrounded by a considerable connective tissue layer, the outer portion of which becomes reticular and is filled with the lymphocytes of the nodules. The nodules occur near where the artery branches. Small arterial twigs ramify in the nodules, in the periphery of which they anastomose before passing into the pulp. When the main stems are about $15\ \mu$ in diameter, they lose their surrounding lymphoid layer and pass into the pulp, where they form brush-like groups of branches (*penicilli*). These branches do not anastomose. For a short distance before their termination the walls of the branches possess ellipsoid thickenings, due to a longitudinal arrangement of closely applied fibers of reticular tissue. These "sheathed

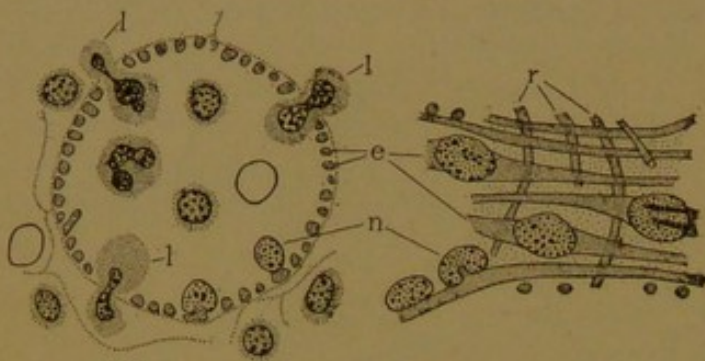


FIG. 200.—CROSS SECTION (A) AND SURFACE VIEW (B) OF TERMINAL VEINS FROM THE HUMAN SPLEEN
e., Rod shaped endothelial cells, with projecting nuclei, n; r., encircling reticular tissue; l, leucocytes passing between the endothelial cells. (After Weidenreich.)

others believe that the arteries empty only into the reticular tissue. Numerous careful injections have shown the readiness with which the arterial blood mingles with the pulp cells.

The *terminal veins* or splenic sinuses begin as dilated structures (sometimes unfortunately called "ampullæ," the latter term being applied also to the terminal arteries). Their endothelial cells are so long and slender as to suggest smooth muscle fibers, and like certain other endothelial cells they are contractile. Their edges are not closely approximated, so that corpuscles may pass between them freely (Fig. 200). Around them are encircling reticular tissue fibers, and a continuous basement membrane has been described as stretching across the intervals between the endothelial cells. The existence of such a membrane has recently been denied. The endothelial cells project into the lumen of the vessel, and their nuclei are at the summits of the elevations. Frequently the nuclei show one or two longitudinal rod-like markings, said to be due to folds in the nuclear membrane (Fig. 200, B). Several terminal veins unite to form a pulp vein, which enters a trabecula in which it passes toward the hilus. The trabecular veins join to form the splenic vein.

For further details regarding the circulation see Weidenreich (Arch. f. mikr. Anat., 1901, vol. 58, pp. 247-376) and Mall (Amer. Journ. Anat., 1903, vol. 2, pp. 315-332).

arteries" are $6-8\ \mu$ in diameter, and have been supposed to regulate the amount of blood which enters the terminal portion of the artery, beyond them. Some authorities state that this distal part connects with the terminal veins, meeting them at an acute angle. According to others such connections are infrequent, and still

The *splenic pulp* consists of a reticular tissue framework (Fig. 50, p. 61). It supports the terminal arteries and veins, and in its meshes are the white and red corpuscles passing between them.

The pulp appears as a diffuse mass of cells infiltrated with red corpuscles, and since the vessels within it are thin-walled and hard to follow, likewise containing corpuscles, it is often impossible in ordinary sections to determine which cells are inside and which are outside of the vessels (Fig. 201). The nodules are not sharply separated from the pulp, so that lymphocytes are abundant in their vicinity. These lymphocytes enter the terminal veins and thus are removed from the spleen. In the splenic vein the proportion of lymphocytes to red corpuscles is said to be seventy times as great as in the splenic artery. One for every four red

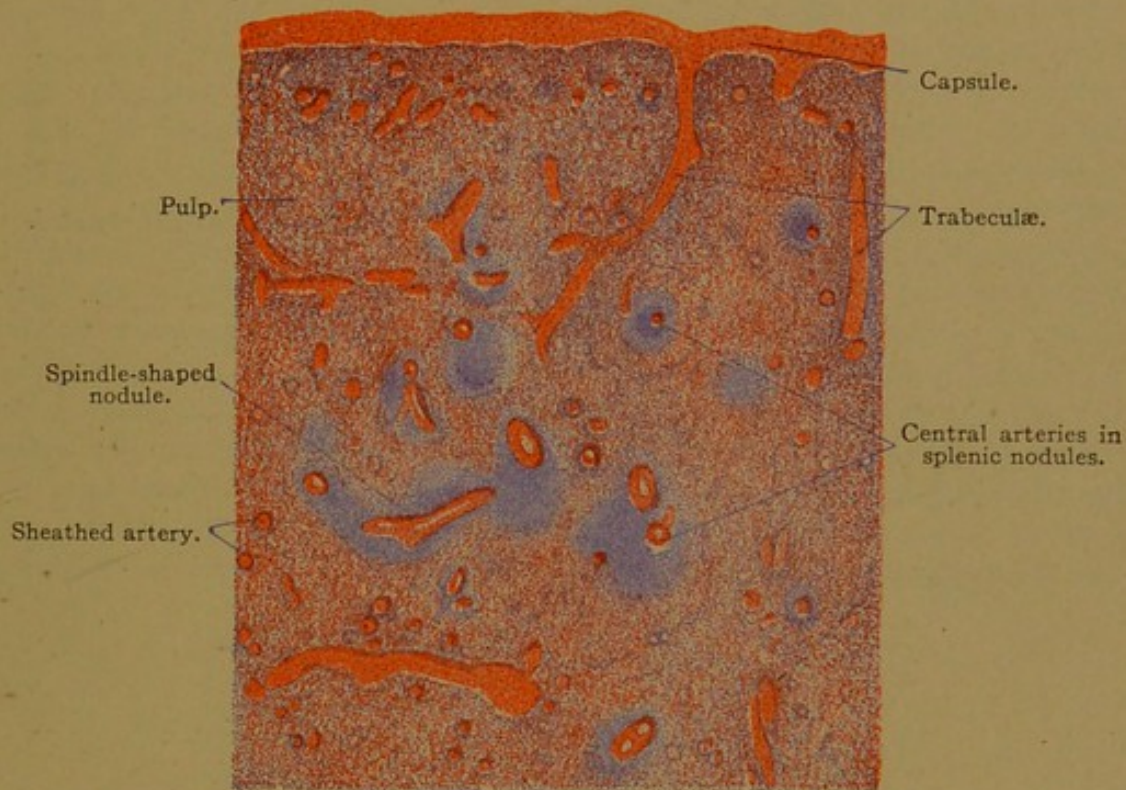


FIG. 201.—PART OF A SECTION OF THE SPLEEN FROM AN ADULT MAN. $\times 15$.

corpuscles has been reported by two investigators, but later estimates are lower. It seems evident that lymphocyte production is an important function of the spleen. Another is the filtration of the blood passing through the pulp. As in hæmolymph glands, granular debris is found, and there are phagocytic, pigmented, and eosinophilic cells. The phagocytes are cells with large round nuclei and considerable protoplasm. They vary in size, but the small forms are most numerous; these are called *splenic cells*. Some are described as multinucleate. Erythroblasts are not found in the normal adult human spleen; they occur, however, in certain blood diseases, and are normal in some adult mammals, as in the skunk. They are abundant in the spleens of human embryos. Giant cells are numerous in the spleens of young animals but are seldom found in the human adult.

They are described as megakaryocytes, and are like those in bone marrow. The formation of granular leucocytes, which has been asserted, presumably does not occur.

The *splenic nodules* are quite like the secondary nodules of lymph glands. They consist of a reticular tissue framework continuous with that of the pulp, but having coarser meshes. Fine elastic fibers are associated with it. It contains lymphocytes, and near the central arteries

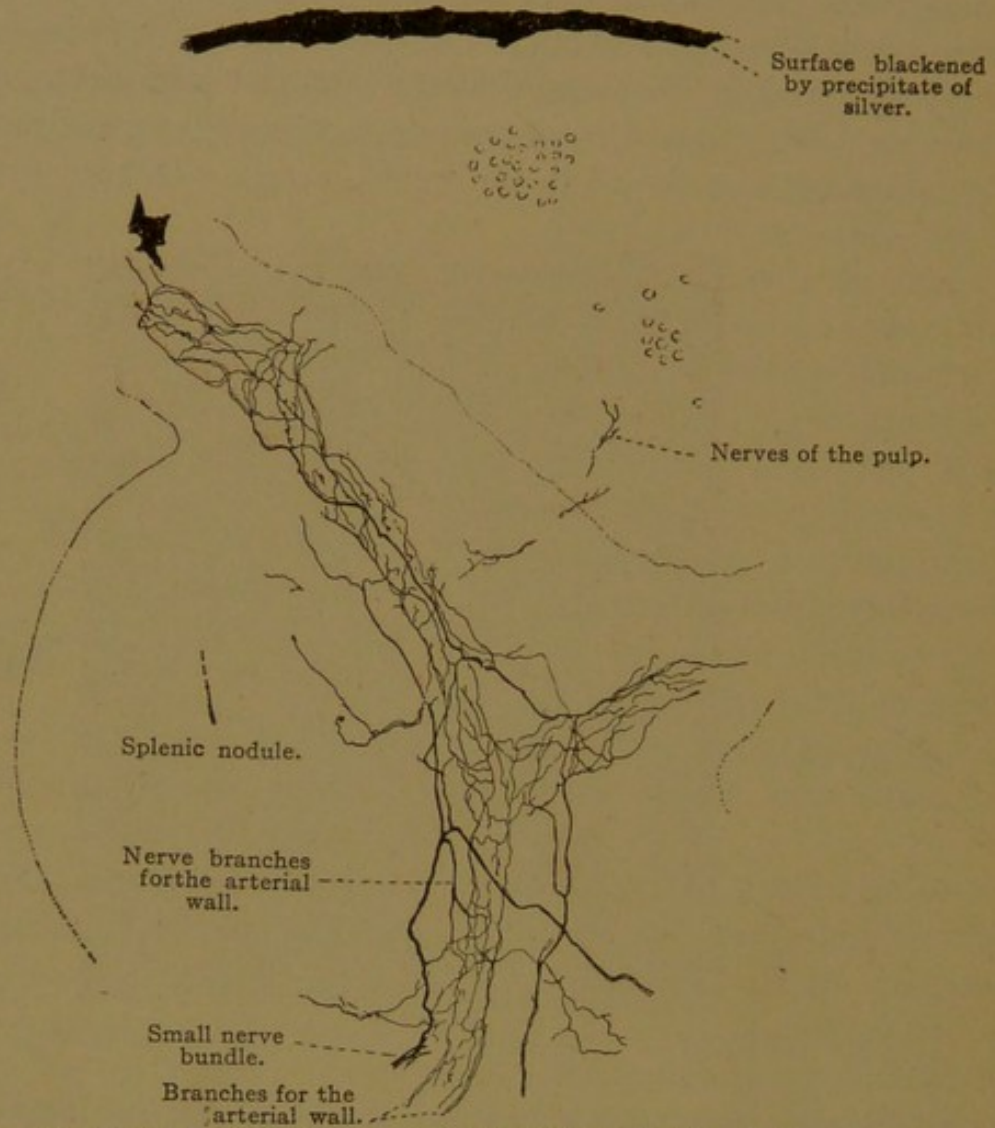


FIG. 202.—GOLGI PREPARATION OF THE SPLEEN OF A MOUSE. $\times 85$.
The boundary between the splenic pulp and the lymphoid tissue is indicated by a dotted line.
The nerves are chiefly in the wall of an artery.

germinal centers are sometimes distinct. The nodules have been regarded as varying in shape from time to time, being but transient accumulations of lymphocytes.

The *capsule* of the spleen is divided into two layers. The outer is the *tunica serosa* and the inner, the *tunica albuginea*. The serosa consists of the peritoneal mesothelium, which covers the spleen except at the hilus, and of the underlying connective tissue. The albuginea is a dense layer of connective tissue, containing elastic networks and smooth muscle fibers. Similar tissue is found in the trabeculae. The muscle

elements are less numerous in the human spleen than in those of many animals. By contraction they force blood from the pulp and cause the circulation to follow more definite channels. When they are paralyzed, the pulp becomes filled with the blood corpuscles.

The nerves of the spleen, from the right vagus and the celiac sympathetic plexus, are medullated and non-medullated fibers, chiefly the latter. They form plexuses around the blood vessels (Fig. 202) and send fibers into the pulp. Besides supplying the muscles of the vessels and trabeculæ, some of them are thought to have free sensory endings. Lymphatic vessels are said to occur in the capsule and trabeculæ, but not in the pulp or nodules of the spleen.

The spleen is a large organ, without obvious subdivisions. On its surface, when fresh, there is a mottled effect due to areas bounded more or less definitely by trabeculæ. Such areas, about 1 mm. in diameter, have been described by Mall as "lobules," and he states that they "can easily be seen on the surface of the organ or in sections." A lobule, as he describes it, has a central artery, and its base is where the lymphoid sheath of the artery terminates. It has peripheral veins, often three, enclosed in the trabeculæ. A lobule is composed of some ten structural (or histological) units, imperfectly separated from one another by branches of the trabeculæ. Each unit contains a central terminal artery (branches of the lobular artery) and has peripheral veins (branches of those about the lobule). Apparently, therefore, the lobules shown in the diagram, Fig. 199, except along its lower border, represent groups or pairs of Mall's lobules. Stöhr notes that "a division into lobules in the interior of the spleen is impossible." The arrangement of lobules at the periphery suggests an ill-defined cortex. Lobes have also been described, corresponding with the main branches of the splenic artery, but the lobes are not generally recognized. The spleen may present inconstant subdivisions, which sometimes produce detached portions called *accessory spleens*.

THE ENTODERMAL TRACT.

DEVELOPMENT OF THE MOUTH AND PHARYNX.

In a previous section the early development of the fore-gut or pharyngeal pocket of entoderm has been described and illustrated (Figs. 27 and 28). This fore-gut of the young embryo is to produce the pharynx, œsophagus, and stomach of the adult. Its anterior extremity encounters the ectoderm at the bottom of a depression. The ectoderm and entoderm there fuse to make the *oral plate* (Fig. 203), which becomes thin, ruptures, and disappears. Just anterior to the plate, in the median line, the ectoderm sends a gland-like projection toward the brain. It branches and becomes detached from the oral ectoderm, lying in the *sella turcica* of the adult. It is known as the *anterior lobe of the hypophysis*, and will be described with the brain, from which the posterior lobe develops. The ectoderm in front of the oral plate forms also the epithelium of the lips and of the peripheral part of the mouth, including the enamel organs, as has already been described. The salivary glands are also considered

ectodermal, but before they develop the oral plate has disappeared and the boundary between ectoderm and entoderm cannot be sharply drawn.

The entoderm of the mouth and pharynx is a layer of epithelium lining a broad, dorso-ventrally flattened cavity. From this cavity, a succession of paired outpocketings grow out laterally to meet the ectoderm on the side of the neck; these are the *pharyngeal pouches*. They reach the ectoderm at the bottom of furrows or clefts, corresponding in number with the pharyngeal pouches, and there the two germ layers fuse. The plates thus formed are comparable with the oral plate, and in fishes they rupture producing the *branchial clefts* (gill clefts).

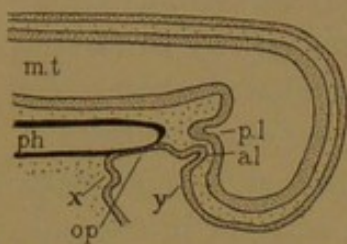


FIG. 203.—DIAGRAM SHOWING THE RELATIONS BETWEEN ECTODERM AND ENTODERM IN THE MOUTH OF A MAMMALIAN EMBRYO.

a. l., and p. l., Anterior and posterior lobes of the hypophysis; m. t., medullary tube; ph., pharynx; o. p., oral plate; x. and y., ectoderm which produces the lip and enamel of the teeth in the lower and upper jaws respectively.

Their arrangement in a young dog-fish is shown in Fig. 204. The mouth, *m*, leads into a cavity, the pharynx, which opens freely on the outer surface of the fish through five gill clefts, *g.c.* It also opens to the surface through the *spiracle*, *sp.*, a structure similar to the gill clefts, but anterior to them and having a more dorsal aperture. In respiration water is taken in through the mouth and spiracle, and passes out through the gill clefts; but sometimes water is ejected through the spiracle. In mammals the corresponding structure is counted as the first gill cleft.

In mammalian embryos there are four well-defined pharyngeal pouches on either side, which reach the ectoderm at the bottom of corresponding grooves; but if their closing plates ever rupture they are soon restored, and permanent openings from the pharynx on the side of the

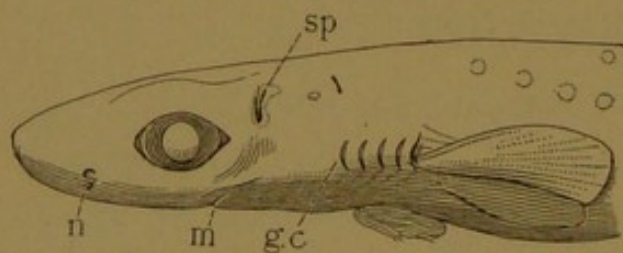


FIG. 204.—HEAD OF A YOUNG DOG-FISH.
g. c., Gill cleft; m., mouth; n., nasal pit; sp., spiracle.

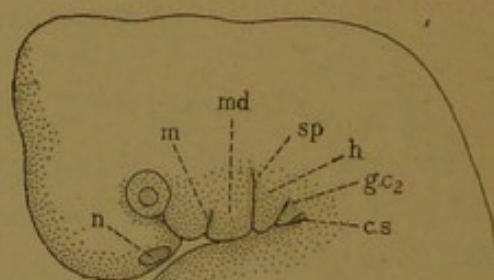


FIG. 205.—HEAD OF HUMAN EMBRYO OF 10 MM.
c. s., cervical sinus; g. c. 2., second branchial groove; h., hyoid arch; m., mouth; md., mandibular process; n., nasal pit; sp., auditory (spiracular) groove.

neck are not found. The first pouch, corresponding with the spiracle, connects with the auditory groove (Fig. 205, *sp.*). Around it the external ear develops, so that its position is always evident. The ectodermal depression which connects with the second pouch disappears, except in rare cases, where it forms a cervical fistula. This is a pit, or slender tube, in the skin of the neck, situated primarily between the hyoid bone and thyroid cartilage. The third and fourth pouches connect with the

ectoderm at the bottom of a single funnel-shaped depression known as the *cervical sinus* (Fig. 205, *c.s.*). This also wholly disappears normally, but it may remain as a cervical fistula low down on the neck, and its deeper parts may give rise to branchial cysts. Thus all the ectodermal branchial grooves except the first normally disappear before birth.

The pharyngeal pouches, or entodermal portions of the gill clefts, as they occur in a mammalian embryo are shown in Fig. 206. The pharynx opens to the exterior at the mouth, *m*, and divides posteriorly into the trachea, *tr*, and œsophagus, *oe*. In the median dorsal line it gives rise to the anterior lobe of the hypophysis, cut off at *a. l.*, and in the median ventral line to the *thyreoid gland*, *t*. This gland is a median structure, entirely separate from the pharyngeal pouches. It grows down through the hind part of the tongue, acquiring a position in front of the trachea. Its branching terminal part becomes separated from its outlet by the ob-

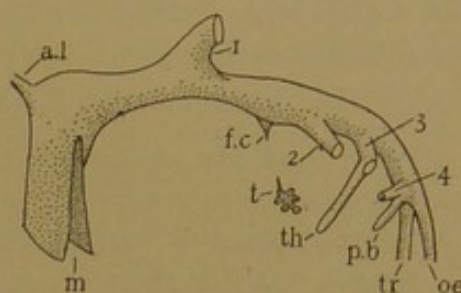


FIG. 206.—DIAGRAM OF THE PHARYNX OF A MAMMALIAN EMBRYO.

a. l., Anterior lobe of the hypophysis; *f. c.*, foramen cœcum; *m*, mouth; *oe*, œsophagus; *p. b.*, postbranchial body; *t*, thyreoid; *th*, thymus; *tr*, trachea; 1, 2, 3, 4, the pharyngeal pouches.

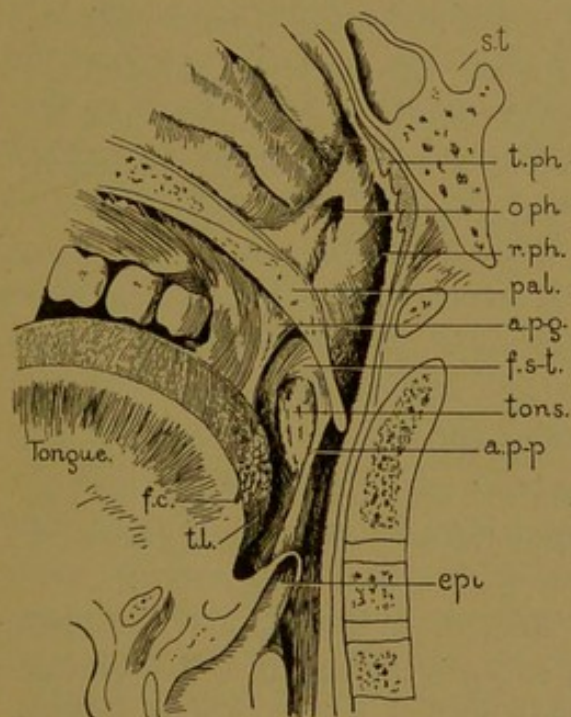


FIG. 207.—A MEDIAN SECTION THROUGH THE PHARYNX OF AN ADULT. (After Corning.)

a. p-g, Palato-glossal arch; *a. p-p*, palato-pharyngeal arch; *epi*, epiglottis; *f. c.*, foramen cœcum; *s-t*, supratonsillar fossa; *o. ph.*, pharyngeal orifice of the auditory tube; *pal.*, soft palate; *r. ph.*, pharyngeal recess; *s. t.*, sella turcica (which contains the hypophysis); *t. l.*, lingual tonsil; *tons.*, palatine tonsil; *t. ph.*, pharyngeal tonsil.

literation of its duct (called the *thyreoglossal duct*). A blind pit, the *foramen cœcum*, permanently retained at the back of the tongue, marks the former outlet of the duct (Fig. 207, *f. c.*). Thus the thyreoid gland is a detached clump of entodermal tubules in front of the trachea.

The entodermal portions of the gill clefts are four paired lateral outpocketings. The first (Fig. 206, 1) extends to the auditory groove in the ectoderm, and becomes the *auditory tube* (Eustachian tube). The pharyngeal orifice of this tube in the adult is shown in Fig. 207 (*o. ph.*); the outer end of the tube expands to form the tympanic cavity of the ear, and will be further considered with the sense organs.

The second pharyngeal pouch (Fig. 206, 2) loses its connection with the ectoderm and becomes a relatively shallow depression on the side of the pharynx. At a certain stage it is in close relation with the orifice of the

auditory tube, and it has been thought to give rise to the *pharyngeal recess* (fossa of Rosenmüller), but according to Hammar such is not the case. Instead, it produces only the *sinus tonsillaris*, into which a mound of lymphoid tissue, the *palatine tonsil*, later projects (Fig. 207, *tons.*). Above the tonsil the *supratonsillar fossa*, which may readily be seen on looking into the mouth, is to be regarded as a remnant of the original second pouch (Hammar, Arch. f. mikr. Anat., 1903, vol. 61, pp. 404-458).

The lingual and pharyngeal tonsils, which are similar in structure to the palatine tonsils, develop as median structures with no relation to the pharyngeal pouches. Therefore the second pouches are to be regarded as the site rather than the source of the palatine tonsils; there are no tonsils in the second pouches of the rat (Hammar).

The third pouch (Fig. 206, 3) near its junction with the ectoderm, sends a tubular diverticulum (*th*) down the neck behind the thyroid gland; it continues into the thorax, lying ventral to

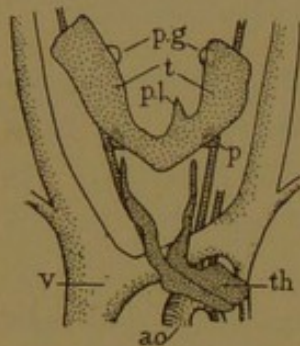


FIG. 208.

The thymus, *th.*, and thyroid, *t.*, of 29 mm. human embryo; *p.*, parathyroid gland (derived from the 3d pouch); *p. g.*, parathyroid gland (derived from the 4th pouch); *p. l.*, pyramidal lobe of the thyroid; *ao.* aorta; *v.*, vena cava superior. (After Verdun.)

the arch of the aorta (as seen in front view in Fig. 208). This diverticulum loses its lumen, becomes detached from the pharynx, and unites with its fellow on the opposite side to form the *thymus*. Besides this elongated structure, each third pouch produces an *epithelial body*, or *nodulus thymicus*, which is a round clump of cells detached from the pouch at the upper end of the thymic diverticulum. Each epithelial body becomes attached to the posterior surface of the thyroid gland, forming the inferior pair of *parathyroid glands* (Fig. 208, *p.*).

The fourth pouch on either side (Fig. 206, 4) gives rise to an epithelial body similar to the nodulus thymicus. These likewise become detached as *parathyroid glands*, and they constitute the superior pair (Fig. 208, *p. g.*). Sometimes a parathyroid gland degenerates and disappears, and in other cases one of them may become subdivided, but typically there are four in the adult.

Behind the fourth pouch, on either side, there is a tubular prolongation of the pharynx variously known as the postbranchial, ultimobranchial or telobranchial body. As the fourth pouch becomes well formed, the postbranchial body is so closely associated with it that together they form a Y-shaped structure, attached to the pharynx by a common stalk (Fig. 206). The postbranchial bodies then grow toward one another across the front of the neck, after the manner of the thymic diverticula. Their ventral ends become detached and imbedded in the thyroid gland, to the substance of which they were formerly believed to contribute. There is, however, no satisfactory evidence that they produce thyroid tissue, and they are generally supposed to disintegrate.

The first recognition of the significance of the mammalian gill clefts is credited to Rathke, in 1832, who published the following significant conclusions in his "Untersuchungen über den Kiemenapparat der Wirbelthiere."

"In all vertebrates without exception, in the earliest period of development, there are formed the beginnings of a branchial apparatus. Its elements vary in number in the different vertebrates, yet in tissue, form, position and connections they are very similar to one another, and are built upon the same plan. Their development, however, proceeds along different lines in the various animals. In some it is partly regressive, bringing about the most manifold and divergent modifications of these structures, not merely in form but also in tissue, type, and significance. Yet there always remains an analogy between them; and through easy transitions, the forms and types pass into one another from the bony fishes even to man. The branchial apparatus is most highly developed in fishes; in the other vertebrates its development is the less complete, the further, in general, these vertebrates are removed from the fishes."

The mammalian gill clefts, although rudimentary as branchial organs, are of the utmost anatomical importance. A single large artery passes from the ventral aorta to the dorsal aorta between the successive pouches, and also in front of the first and behind the last. These *aortic arches* therefore number one more than the series of pouches; from them, portions of the aorta, carotid and subclavian arteries are produced, as described in works on embryology. The nerves send trunks down between the pouches, the facial nerve being between the first and second, the glossopharyngeus between the second and third, and the superior laryngeal branch of the vagus between the third and fourth. Thus these structures determine the arrangement of the vessels and nerves.

On the basis of comparative studies the presence of a fifth pouch in mammals was predicted, and the posterior arm of the Y-shaped outgrowth, including the postbranchial body, is often described as such. A branch of the superior laryngeal nerve is said to pass between the arms of the Y, but a typical branchial relation between the nerves and the fifth pouch has not as yet been established. A "fifth aortic arch" is often represented as passing between the fourth pouch and the postbranchial body, but it has been shown that this arch differs from all the others in its order of development (forming only after the "sixth" is complete). Whereas the third, fourth, and last aortic arches all produce very important vessels, the questionable "fifth arch" is an insignificant plexiform anastomosis, which disappears rapidly. Small vessels, however, are always to be found near the postbranchial body in rabbit, pig and human embryos measuring 5-10 mm. The most convincing evidence of the presence of a fifth pouch is an actual contact with the ectoderm, posterior to the fourth pouch; this was recorded by Hammar in a 5-mm. embryo, but the contact on either side took place in only one 12 μ section. Grosser states that a closing membrane "is perhaps not always formed, and is at all events very transitory" (Human Embryology, ed. by Keibel and Mall, 1912, vol. 2). There are as yet very few observations to show that it ever occurs in mammalian embryos. The existence of a sixth pouch has been asserted on the basis of slight elevations which are perhaps inconstant.

TONSILS.

The *palatine tonsils* are two rounded masses of lymphoid tissue, one on either side of the throat, between the arches of the palate (Fig. 207.)

Frequently they have been called *amygdalæ* (almonds), but the older Latin term for them is *tonsilla* (a stake to which boats are tied). They are covered by the *mucous membrane* or *tunica mucosa*, which throughout the digestive tract consists of several layers. The soft moist entodermal *epithelium* rests on a connective or reticular tissue layer, the *tunica propria*. A structureless basement membrane, the *membrana propria*, is often present immediately beneath the epithelium. The epithelium, *membrana propria*, and *tunica propria* together form the mucous membrane, which in dissection would be stripped off as a single structure. Beneath it, and sometimes not clearly separable from the *tunica propria*, is the *submucous*

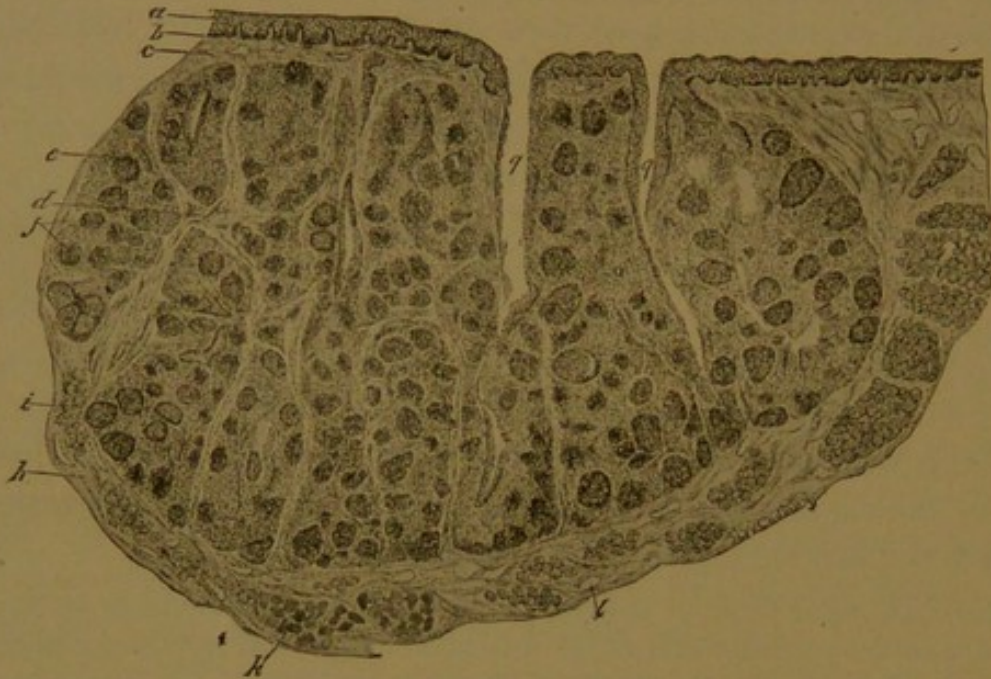


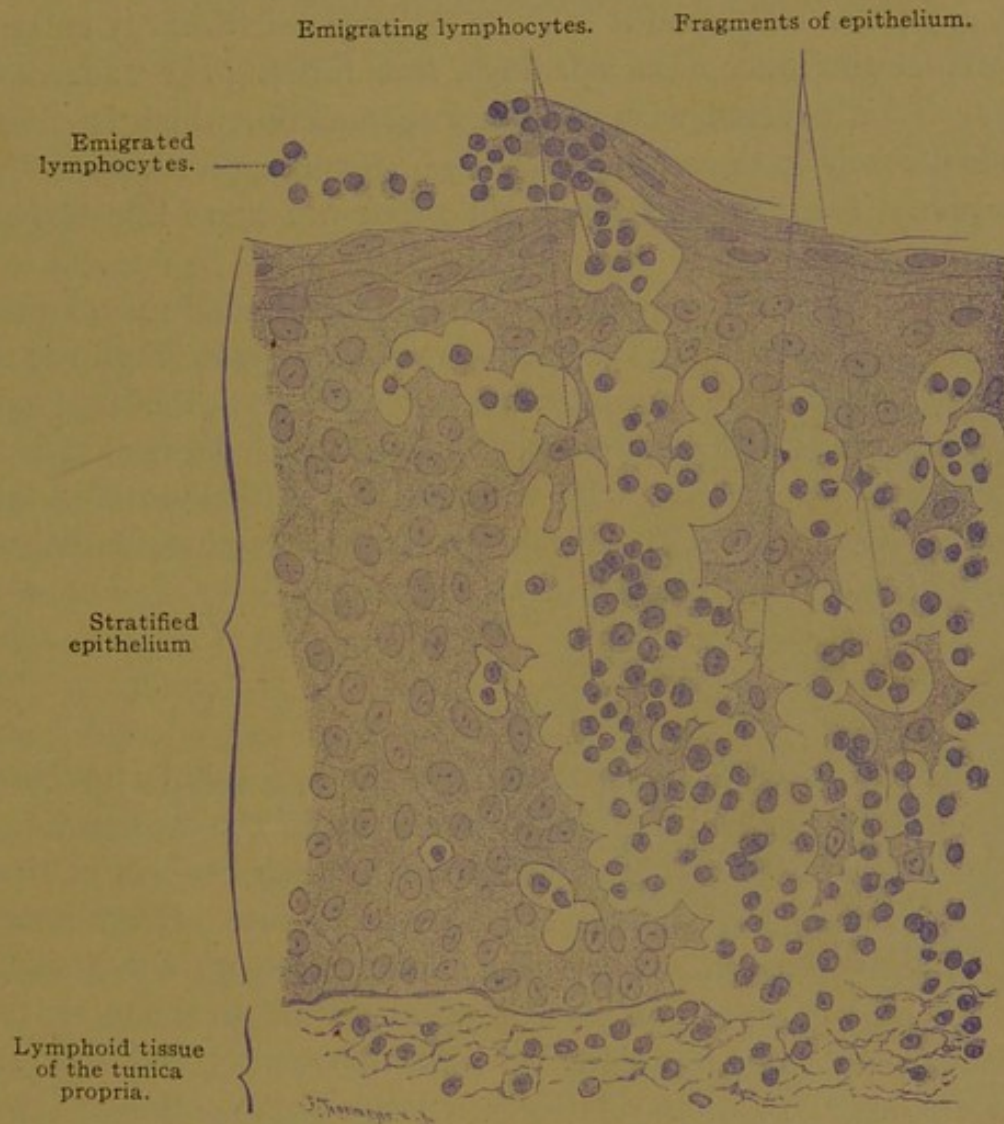
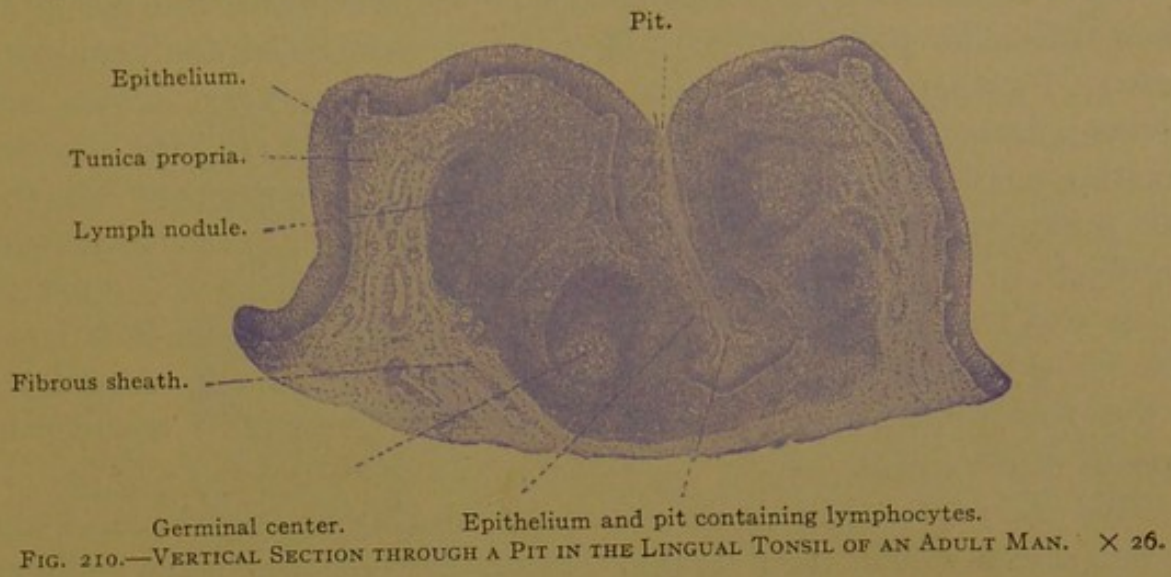
FIG. 209.—VERTICAL SECTION OF A HUMAN PALATINE TONSIL.

a, Stratified epithelium; b, basement membrane; c, tunica propria; d, trabeculae; e, diffuse lymphoid tissue; f, nodules; h, capsule; i, mucous glands; k, striated muscle; l, blood vessel; q, pits. (From Radasch.)

layer, or *tela submucosa*. It is a vascular connective tissue, by which the mucous membrane is attached to underlying muscles or bones. All the layers named are involved in the tonsils which, however, are essentially lymphoid accumulations in the tunica propria.

The epithelium of the palatine tonsils is a stratified epithelium of many layers, with flattened cells on its smooth free surface, and columnar cells beneath. Its attached surface is invaded by connective tissue elevations or papillæ, so that it appears wavy in sections (Fig. 209). The stratified epithelium lines from ten to twenty almost macroscopic depressions, called *tonsillar pits* or *fossulae* (crypts). These are irregularly tubular and sometimes branched. Many lymphocytes penetrate between the epithelial cells and escape from the free surface into the saliva, becoming "salivary corpuscles." In places the tonsillar epithelium is so full of lymphocytes as to appear disintegrated, a condition which was

first described by Stöhr (Biol. Centrabl., 1882, vol. 2). It occurs also in the epithelium of the lingual tonsil as seen in Fig. 211. In the reticular



On the left the epithelium is free from lymphocytes, on the right many lymphocytes are wandering through.

tissue of the tunica propria, especially around the pits, there are many lymph nodules, some of which are well defined, with germinative centers,

but many others are fused in indefinite masses. The lymphoid tissue constitutes the bulk of the tonsil.

The submucous layer forms a capsule for the organ, into which it sends trabecular prolongations. It contains many blood and lymphatic vessels, together with branches of the glossopharyngeal nerve and sphenopalatine ganglion which supply the tonsil. It contains also the secreting portions of small mucous glands, some of which empty into the pits, but most of their ducts terminate in the mucous membrane surrounding the tonsil. They resemble other mucous glands of the mouth which will be described presently. Beyond the submucosa is striated muscle, belonging to the arches of the palate and to the superior constrictor of the pharynx; striated muscle fibers are therefore readily included in sections of the tonsil.

The *pharyngeal tonsil* is an accumulation of lymphoid tissue on the median dorsal wall of the pharynx, between the openings of the auditory tubes (Fig. 207). In childhood it is liable to become irregularly enlarged so as to obstruct the inner nasal openings, thus forming the "adenoids" of clinicians. It is covered with stratified epithelium, which is ciliated in embryonic life; and in the adult, cilia may be found upon the epithelium within the pits. The pits and lymphoid tissue are quite like those of the palatine tonsils.

The *lingual tonsil* is an aggregation of pits surrounded by lymphoid tissue (Fig. 210). It is found in the back part of the tongue (Figs. 207 and 220), the surface of which is very different in texture from the front part, presenting low mounds with central depressions. Each depression is the outlet of a pit. Lymphocytes pass through the epithelium (Fig. 211) and become salivary corpuscles, which are said to produce substances protecting the tissue from bacterial invasion.

THYMUS.

The thymus (Gr. *θύμος*, thymus) arises from the two tubular prolongations of the third pharyngeal pouches, which meet in the median line as shown in Fig. 208, and become bound together by their connective tissue coverings. The lumen is lost, and the cells proliferate. They form a broad, flat, bilobed mass with a tapering prolongation up either side of the neck. The bulk of the organ is in the thorax, beneath the upper part of the sternum. At birth it weighs generally between 5 and 15 grams (about half an ounce), and is relatively a large organ. Haller (1761) described it in older embryos as "a huge gland, scarcely smaller than the kidney; but in the adult it is diminished, and having become constricted, dried up and much harder, it is almost buried in the surrounding fat." Meckel found ordinarily no trace of it at twelve years, and according to

Hewson it gradually wastes until the child has reached between its tenth and twelfth year, when ordinarily it is perfectly effaced, leaving only ligamentous remains. These older observations have been generally accepted, and the persistence of the thymus in the adult is regarded as of

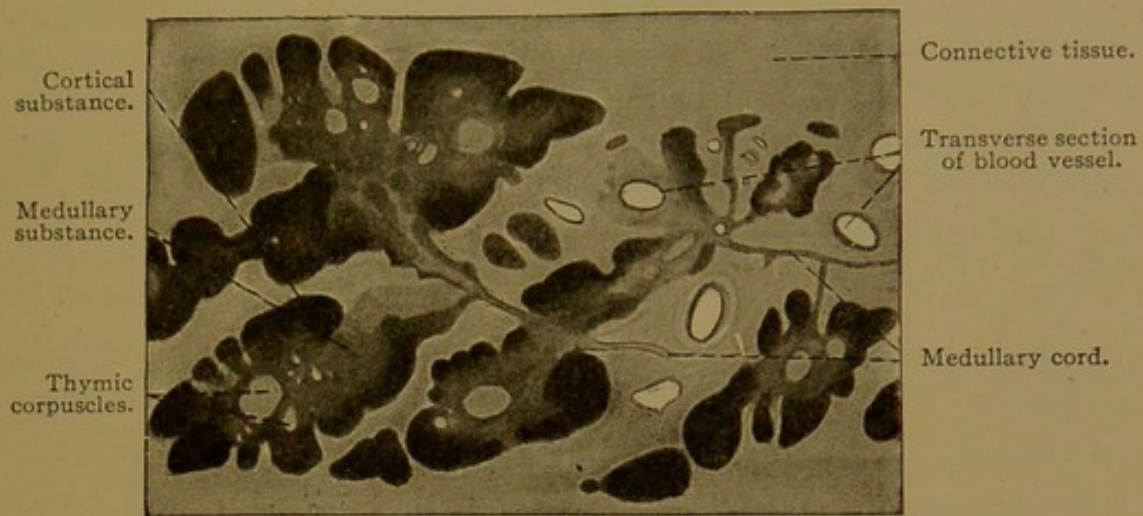


FIG. 212.—FROM A CROSS SECTION OF THE THYMUS OF A CHILD, ONE YEAR AND NINE MONTHS OLD. $\times 21$.

considerable pathological importance. According to Waldeyer and Hammar, however, it persists for a much longer time. It increases in size and weight for some years after birth, probably until puberty, and then slowly atrophies. At fifteen years it is said to weigh 40–50 grams. It is considered an active organ even to the fortieth year, losing its functions with beginning old age (50–60 years). The duration of the thymus has apparently been underestimated. (See Hammar, Arch. f. Anat. u. Entw., 1906, Suppl.-Bd. pp., 91–182; Anat. Anz., 1905, vol. 27, pp. 23–89; and for development, Anat. Hefte, Abth. I, 1911, vol. 43, pp. 203–242).

The thymus is subdivided by connective tissue layers into *lobes* from 4 to

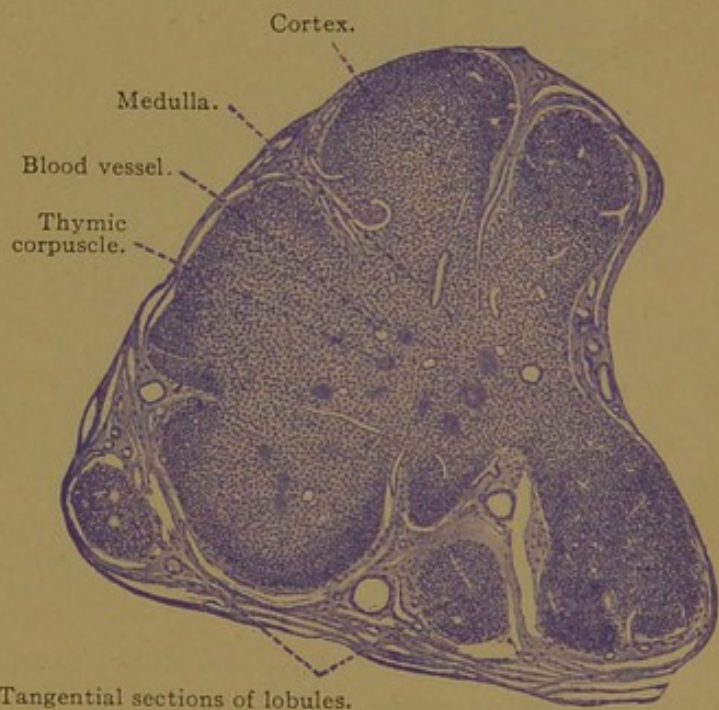


FIG. 213.—PART OF A SECTION OF THE THYMUS FROM A HUMAN EMBRYO OF FIVE MONTHS. $\times 50$.

11 mm. in diameter, and these are similarly subdivided into lobules of about 1 cu. mm. each. All the lobules in the right and left halves of the thymus, respectively, are attached to a cord of medullary substance, 1–3 mm. in diameter, as may be seen if the gland is pulled apart. This axial structure suggests the

original diverticulum. Each lobule consists of a pale *medulla*, extending from the cord, and a darker peripheral *cortex* (Figs. 212 and 213). The entire structure somewhat resembles a lymph gland, from which, however, germinal centers are absent. It might be inferred that lymphoid tissue had developed in the mesenchyma surrounding the diverticulum, in the same way that such tissue forms about the tonsillar pits, but careful study has shown that the thymus is largely of entodermal origin. Whether the cells of its cortex, which closely resemble lymphocytes, are true lymphocytes or "deceptively similar epithelial cells" has not been determined.

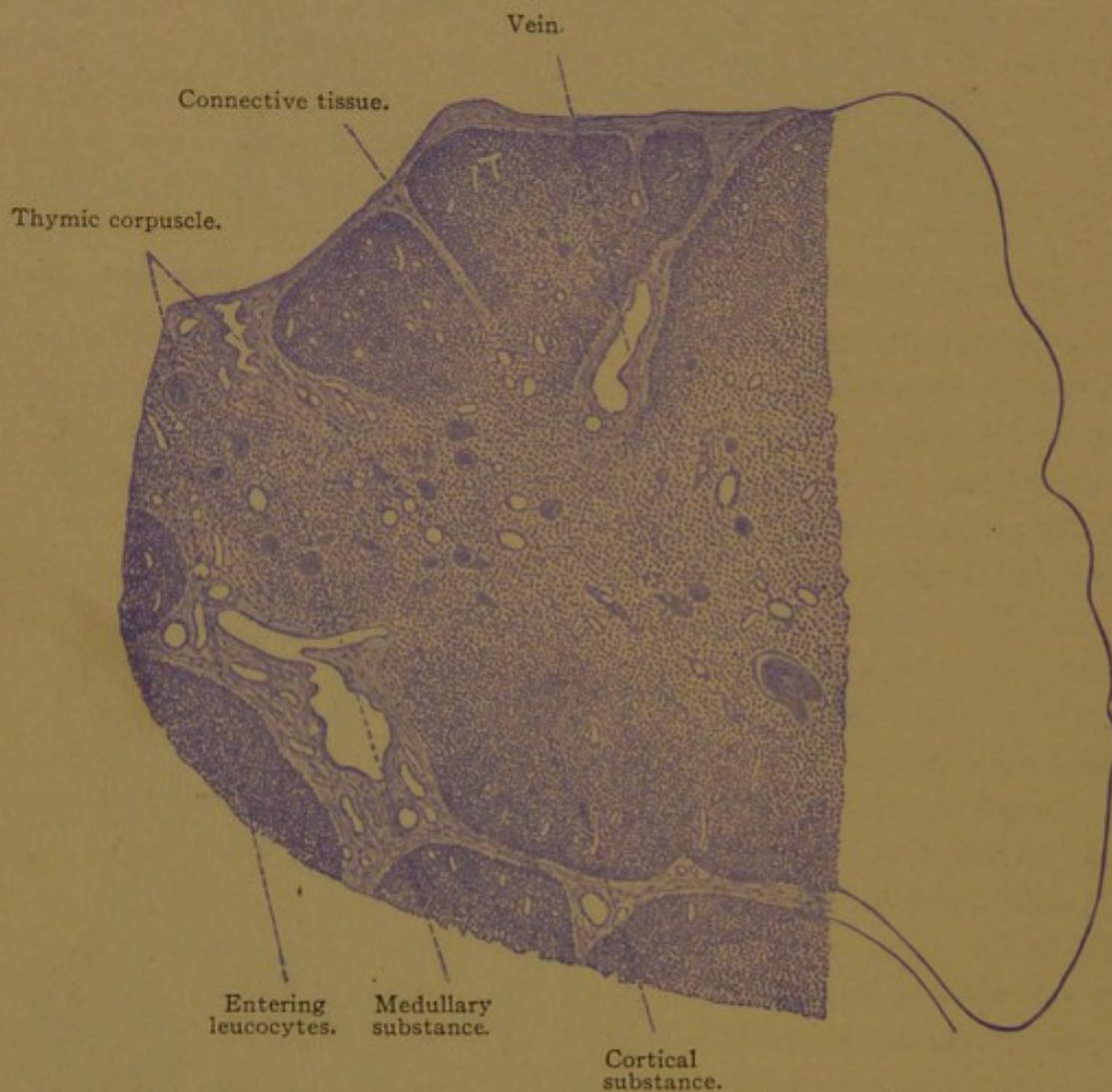


FIG. 214.—PART OF A SECTION OF THE THYMUS OF A CHILD AT BIRTH. $\times 50$.

According to Bell (*Amer. Journ. Anat.*, 1905, vol. 5, pp. 29-62) the thymus is at first a compact mass of entodermal cells. By vacuolization the cells form a reticulum, and certain of them become lymphocytes. The lymphocytes pass into the cortex where they are most abundant, and enter the vessels. The lymphoid transformation of the thymus "is noticeable in pigs of 3.5 cm. and is well advanced at 4.5 cm." Thus lymphocytes appear in the thymus at about the time that lymph glands develop. The first indication of lymph glands was found by Miss Sabin in pig embryos of 3 cm.

That the thymus cells are lymphocytes, however, is denied by Stöhr, who regards the cortex as composed of a network of stellate epithelial cells, containing in its meshes

small round epithelial cells deceptively similar to lymphocytes. Of true leucocytes in the thymus he says, "In the places where the medulla is directly in contact with the surrounding connective tissue—and such places become constantly larger and more numerous as the organ grows—many leucocytes wander into the medulla; they lie in the connective tissue surrounding the medulla but not in that around the cortex (Fig. 214)." He considers that the cortex with its many mitotic figures represents a zone of production, and the medulla, a zone of growth and degeneration (Anat. Hefte, Abth. 1, 1906, vol. 31, pp. 409-457). Hammar (1905, *loc. cit.*) is unable to determine the source of the "thymus lymphocytes," but is confident that the reticulum is of epithelial origin. He finds that in birds this reticulum produces cells resembling striated muscle fibers, and these "myoid cells" he considers to be entodermal. In his later work (1911, *loc. cit.*) he states that the lymphocytes enter the thymus chiefly from the thymic blood vessels.

Not only lymphocytes, but other leucocytes, eosinophilic cells, and multinuclear giant cells have been found in the medulla. Erythroblasts are said to occur in its outer portion and in the cortex. The thymus

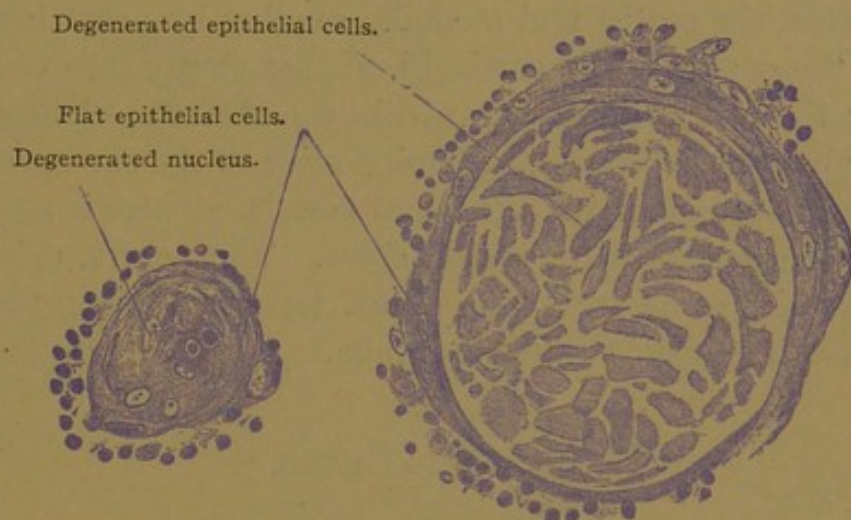


FIG. 215.—THYMIC CORPUSCLES, IN SECTION, FROM A MAN TWENTY-THREE YEARS OLD. $\times 360$.

therefore is sometimes considered a blood-forming organ. Sometimes the medulla contains cysts, which may be lined in part with typical ciliated cells. The most characteristic structures in the thymus are the *thymic corpuscles* (Hassall's corpuscles) which are found exclusively in the medulla. They are rounded bodies, at first few in number and small ($12-20\ \mu$ in diameter), but they increase rapidly in size (to a diameter of $180\ \mu$) and new ones are constantly forming. They are said to be present at about the fifth month, and at birth they are numerous, varying in size as shown in Fig. 215. To produce them, the nucleus and protoplasm of an entodermal reticular tissue cell enlarge, and the nucleus loses its staining capacity by changes in its chromatin. A layer of deeply staining hyaline substance develops in the protoplasm. This increases until it fills the entire cell, often being arranged in concentric layers, and the nucleus becomes obliterated. Neighboring cells are concentrically compressed by the enlargement of this structure, and by hyaline

transformation they may become a part of the corpuscle. The larger corpuscles are due to a fusion of smaller ones, or to hyaline changes occurring simultaneously in a group of cells. The central portion of a corpuscle may become calcified. Sometimes it is vacuolated, containing fat. The hyaline substance may respond to mucous stains, but generally it does not; it has been considered similar to the 'colloid' of the thyroid gland. Leucocytes are said to become imbedded in the corpuscles, or to enter them and assist in their disintegration. Thymic corpuscles have been regarded not only as degenerative products of the entodermal epithelium but also as concentric connective tissue masses, and as blood vessels with thickened walls and obliterated cavities. Injections show that they are not connected with the blood vessels. Although they have recently been described as active constituents of the thymus, they are generally regarded as degenerations.

The arteries of the thymus enter it along the medullary strand, and extend between the cortex and medulla, sending branches into both but chiefly into the cortex. The cortical branches empty into veins between the lobules; the others into veins within the medulla. There are many interlobular lymphatic vessels, beginning close to the surface of the gland substance, and accompanying the blood vessels. There is nothing in the thymus to correspond with a lymph sinus. The nerves, chiefly sympathetic fibers, with some from the vagus, terminate along the vessels; a very few have free endings in the medulla.

THYROID GLAND.

The thyroid (*i.e.*, shield-shaped) gland is a median, entodermal downgrowth from the tongue; its thyreoglossal duct becomes obliterated, leaving the foramen cæcum to mark its former outlet. The downgrowth is joined by cells from the postbranchial bodies, which fuse with it. This entire structure comes to lie beside and in front of the upper part of the trachea. It consists of two lateral lobes, each about two inches long and an inch wide, connected by an *isthmus*, about half an inch wide, which crosses the median line ventral to the second and third tracheal rings. An unpaired *pyramidal lobe* extends from the isthmus or adjacent part of the lateral lobe toward the tongue (Fig. 208). Irregular detached portions of the gland, such as occur especially along the course of the thyreoglossal duct, are called *accessory thyroid glands*.

The proliferating mass of entodermal cells forms at first a network of solid cords. This becomes separated into small masses, within each of which a lumen may appear. The lumen enlarges and becomes spheroidal; the entodermal cells which surround it form a simple epithelium, either coleumnar, cuboidal, or flat. Flat cells are said to occur especially in old

age; usually the cells are low columnar or cuboidal. The mature thyroid gland consists, therefore, of rounded, closed spaces, or *follicles*, bounded by a simple entodermal epithelium (Fig. 216). The follicles vary greatly in diameter. Generally they are rounded, but sometimes they are elongated, and occasionally they branch or communicate with one another. Among them are cords or clumps of cells which have not acquired a lumen.

Within the follicles, and forming the most conspicuous feature of the thyroid gland in ordinary sections, is a hyaline material which stains

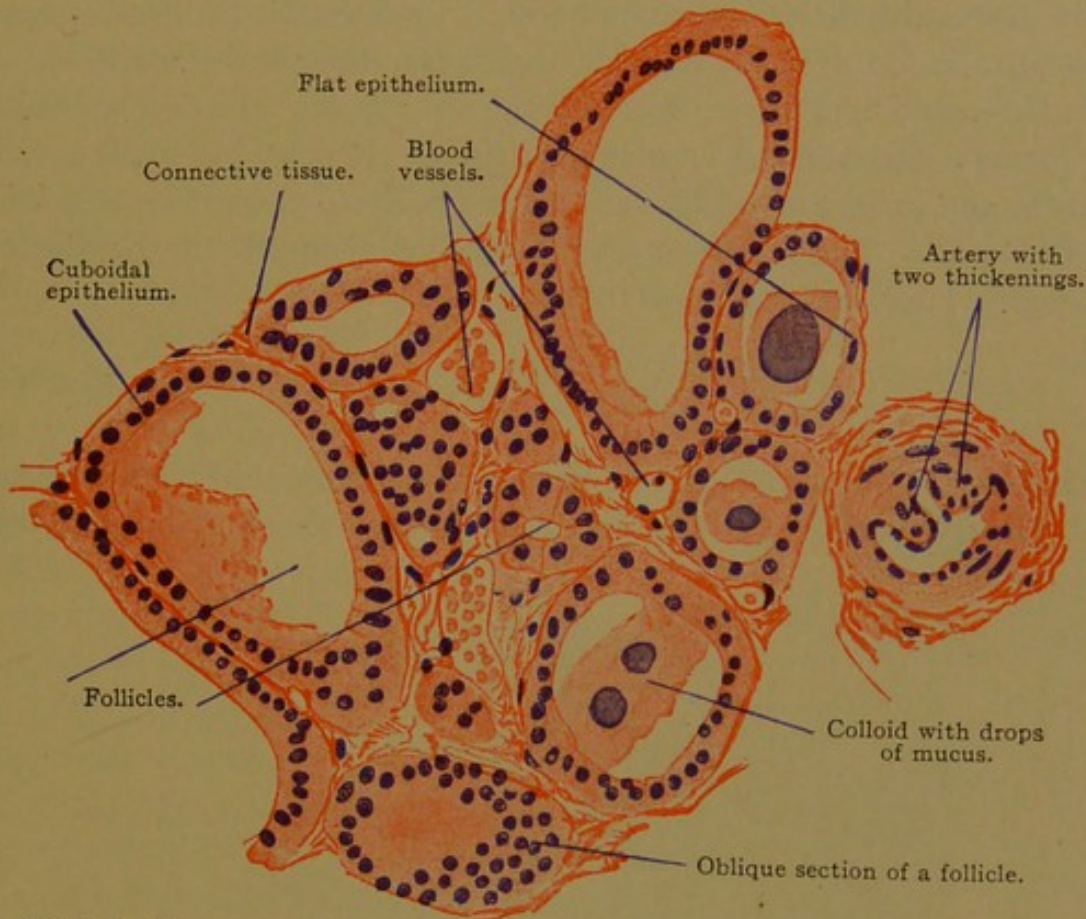


FIG. 216.—SECTION OF A LOBULE OF THE THYREOID GLAND FROM AN ADULT MAN. $\times 220$.

deeply with eosine and is named 'colloid.' The hyaline material in the thymic corpuscles, the hypophysis, and in the coagulum in the cervical blood and lymphatic vessels, has also been designated colloid. In sections of the thyroid gland it usually does not fill the follicle but has contracted, producing a spiny border. Granules, vacuoles and droplets of mucus, detached cells, leucocytes, and crystalloid bodies may be found in it. It is a product of the epithelial cells, in the protoplasm of which similar material has been detected. It has been said that it is transferred to the blood and lymphatic vessels, passing out between the epithelial cells.

As has been learned by experiment, the thyroid gland produces an internal secretion which is essential for the normal growth and development of the body. It is, however, not known whether this secretion leaves the basal or free surface of the thyroid epithelium, and its relation to the

colloid material is not clear. The finding of two sorts of thyreoid cells, one of which produces colloid, and the other does not, lacks confirmation. The cells may exhibit refractive, secretory granules, which are larger and coarser toward the free surface. Eosinophilic granules have been reported, and in certain animals other granules of fatty nature have been found, especially near the basal surface. Since the terminal bars are said to be deficient at the angles where the epithelial cells meet, an opportunity is afforded for the contents of the follicles to pass out between the epithelial cells to the vascular tunica propria.

The thyreoid follicles are surrounded by loose elastic connective tissue, said to be reticular near the follicles, which contains very many blood and lymphatic vessels in close relation with the epithelium. Denser connective tissue forms a capsule and lobular partitions. It contains small arteries, the media and intima of which are said normally to present local thickenings (Fig. 216). The nerves from the cervical sympathetic ganglia form perivascular plexuses, and pass to the follicles.

PARATHYREOID GLANDS.

It is generally stated that there are four parathyreoid glands in man, the anterior or upper pair being derived from the fourth pharyngeal

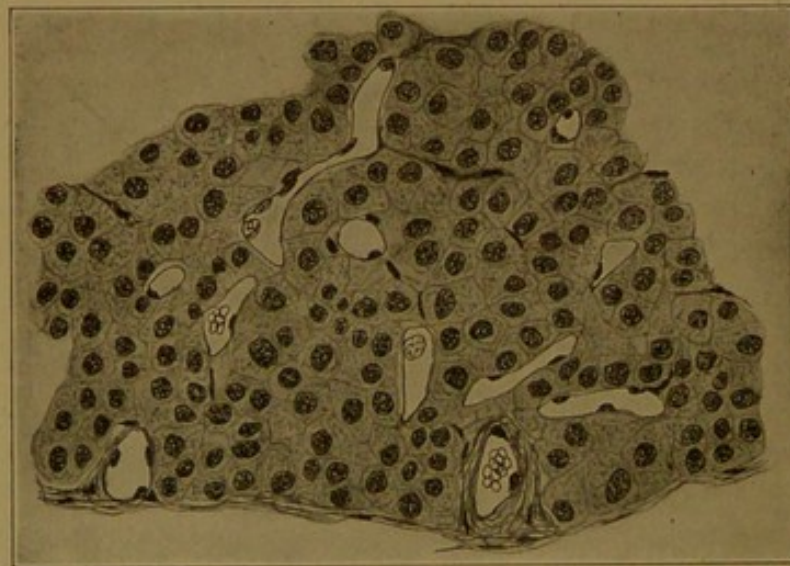

FIG. 217.—SECTION OF A HUMAN PARATHYREOID GLAND. (Huber.)

pouches, and the posterior or lower pair from the third (Fig. 208). They are therefore entodermal structures. In the adult they are round or oval bodies, said to measure from 3 to 13 mm., found on the dorsal or tracheal surface of the thyreoid gland. They may be imbedded in its capsule or attached to it by pedicles. Sometimes they (the lower pair?) are found in the thymus. The parathyreoid glands may be lacking on one side, where in other cases as many as four have been recorded; they may atrophy

and disappear, or increase in number by subdivision. Both pairs possess a similar structure unlike that of either the thyroid gland or the thymus, but resembling the corresponding *epithelial bodies* of the lower vertebrates. They consist of masses and cords of polygonal, entodermal cells containing round nuclei with networks of chromatin. The protoplasm is pale, "almost homogeneous" or "slightly granular," sometimes containing vacuoles. Cell membranes are not prominent. Between these cells and the large thin-walled blood vessels which pass among them (Fig. 217), there is only a very small amount of connective tissue. A capsule surrounds the entire structure. The blood vessels are branches of those which supply the thyroid gland. Little is known of the lymphatics or nerves.

GLOMUS CAROTICUM.

The glomus caroticum (carotid gland) is largely a knot of blood vessels at the bifurcation of the common carotid artery. It is a reddish body "5-7 mm. long, 2.5-4 mm. broad, and 1.5 mm. thick." Between its thin-walled, dilated capillaries there are strands of polygonal chromaffine cells, which are prone to disintegrate (Fig. 218). Many nerve fibers, both medullated and non-medullated, enter the glomus, and a few multipolar ganglion cells are associated with them. Since the nature of the glomus caroticum is undetermined, the three views regarding it may be mentioned. First, it has been consid-

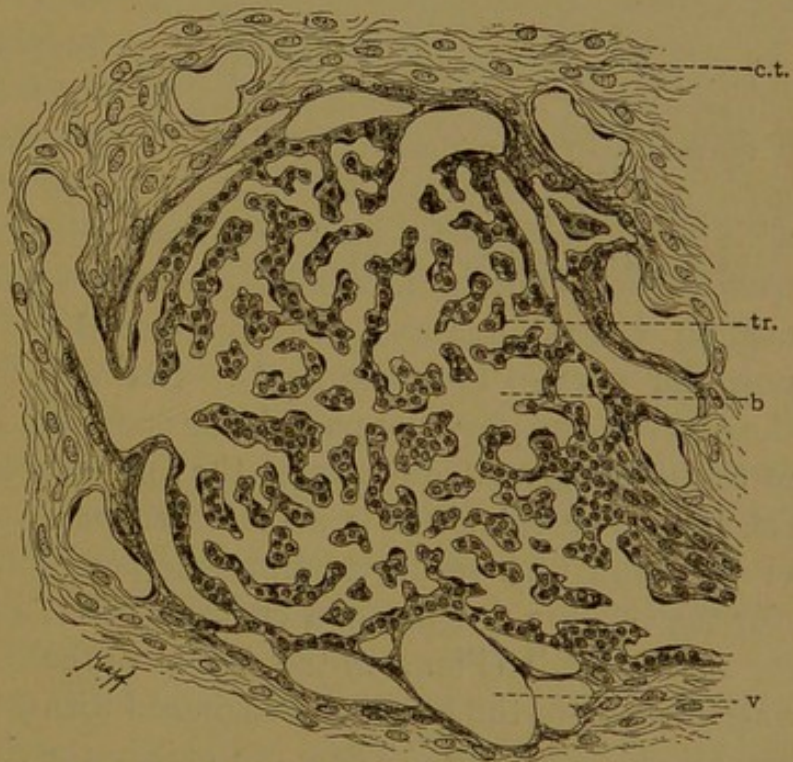


FIG. 218.—SECTION OF A PART OF THE GLOMUS CAROTICUM] OF MAN. (After Schaper.)

b.v., Blood vessels; e.v., efferent vein; tr., trabecula; c.t., connective tissue septum.

ered as derived from the third pharyngeal pouch. Since it has recently been asserted that the "carotid gland" of *Echidna* comes from the second pouch, the non-entodermal origin of the human glomus is perhaps not beyond question. Second, it has been considered ganglionic or paraganglionic in nature, so that it is classed with nervus structures, and this opinion is probably correct. Third, it is considered essentially a vascular formation, containing strands of modified mesenchymal cells.

DEVELOPMENT AND STRUCTURE OF THE TONGUE.

The tongue consists of two parts, an anterior and a posterior, which differ in origin and adult structure. Separating the branchial clefts from

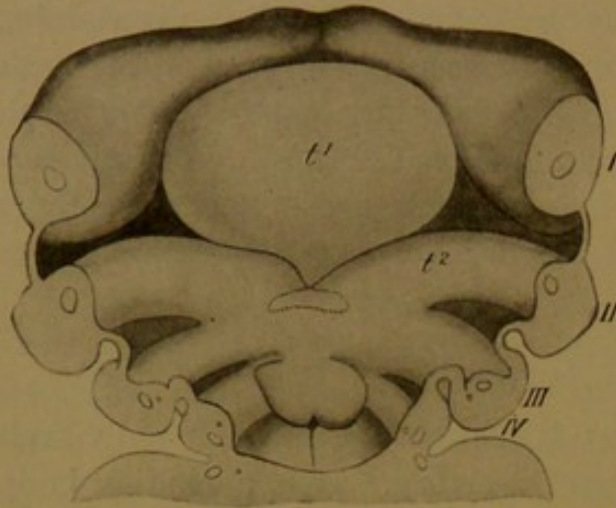


FIG. 219.—FLOOR OF THE PHARYNX OF A 10-MM. HUMAN EMBRYO.

I-IV. Branchial arches; t¹, anterior part of the tongue; t², second arch, joining the posterior part of the tongue toward the median line. The thyroid gland is dotted. The epiglottis extends over the fourth arch. (From McMurich, after His.)

one another there are columns of tissue known as *branchial arches*. They come together in the median ventral line to form the floor of the mouth (Fig. 219). In this figure the upper jaw and roof of the pharynx have been cut away; the branchial clefts are seen as dark depressions bounded laterally by thin plates. The first branchial arch (I) is between the oral and auditory clefts. In the median ventral line an elevation (*tuberculum impar*) arises between this arch and the second; it becomes continuous with a larger elevated portion of the mandibular arch to form the anterior part of the tongue (t¹). The second and third arches unite toward the median ventral line and there produce the posterior part of the tongue (t²). Between the anterior and posterior parts is the opening of the thyreoglossal duct, later the foramen cæcum. The epiglottis is an elevated part of the third arch separated from the posterior part of the tongue by a curved groove.

In the adult (Fig. 220) the *dorsum* of the anterior part of the tongue is roughened with elevations or *papillæ*. These are chiefly the slender *filiform papillæ* and *conical papillæ*; but knob-like forms, the *fungiform papillæ*, are scattered among them over the entire surface, and in life they can be easily distinguished owing to their red color. Near the junction of the anterior and posterior parts of the tongue there is a V-shaped row of larger papillæ, generally six to twelve in number, called *vallate papillæ*. Their name refers to the deep narrow depression which encircles them. Behind the apex of the V, which is directed

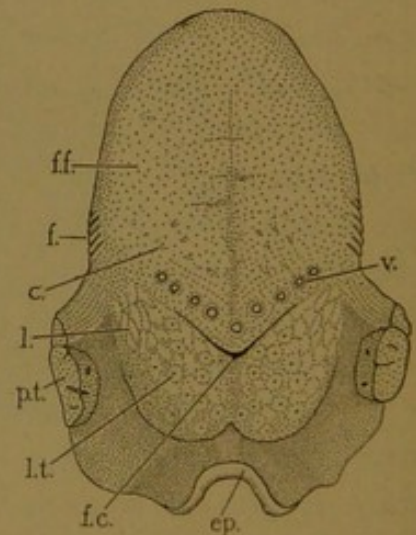


FIG. 220.—THE UPPER SURFACE OF THE ADULT TONGUE.

c., Conical papillæ; ep., epiglottis; f., filiform papillæ; f. c., foramen cæcum; f. f., position of the filiform and fungiform papillæ; l., lenticular papillæ; l. t., lingual tonsil; p. t., palatine tonsil; v., vallate papillæ.

toward the throat, is the foramen cæcum. On either side of the tongue, as indicated in the figure, there are from three to eight parallel vertical folds (2-5 mm. long) occurring close together; these are the *foliate papillæ*. In the foliate and vallate papillæ the organs of taste are most numerous. The under surface of the tongue is free from epithelial papillæ; its mucosa resembles that which lines the mouth. The posterior part of the tongue has a nodular surface covered with soft epithelium and contains the lingual tonsil, which has already been described. Laterally it presents fold-like elevations called *lenticular papillæ*.

Filiform papillæ (Fig. 221) are slender cornified epithelial projections, composed of pointed cells which are described as stacked like superimposed hollow cones. The cells have undergone a horny hyaline degeneration. These projections are arranged in clumps which rest upon a group of from five to twenty connective tissue elevations, or secondary papillæ; and these in turn are at the summit of a cylindrical or conical primary papilla, composed of vascular connective tissue with numerous elastic fibers. These primary papillæ form the basal portions of the filiform papillæ. They are well shown

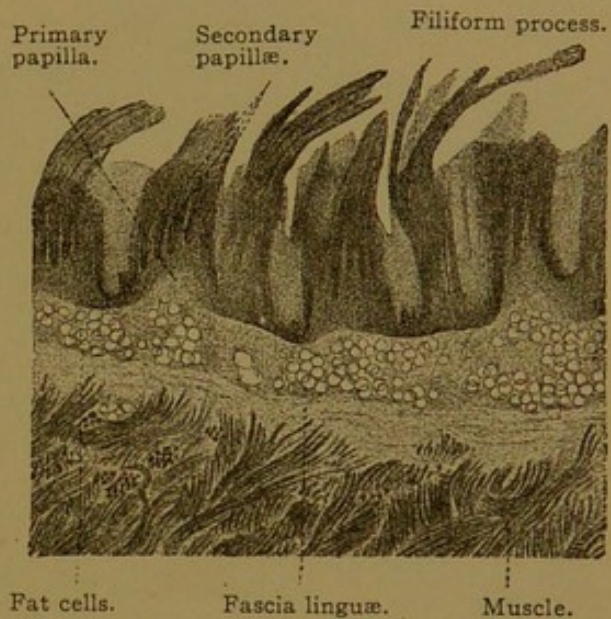


FIG. 221.—FROM A LONGITUDINAL SECTION OF THE DORSUM OF A HUMAN TONGUE. $\times 12$.

in Fig. 222, along with the secondary papillæ, but the cornified processes of the thick epithelium above them have undergone post-mortem disintegration. Most of the papillæ of the tongue are of the filiform type.

Fungiform papillæ (Fig. 222) are rounded elevations with a somewhat constricted base, varying in height from 0.5 to 1.5 mm. In life they are red, since their epithelium is not cornified and transmits the color of the blood beneath. They contain a primary connective tissue papilla, with but few elastic fibers, beset on all sides with secondary papillæ.

The vallate papillæ resemble broad fungiform papillæ. They are from 1 to 3 mm. broad and 1 to 1.5 mm. tall, each being surrounded by a deep groove (Fig. 223). Their connective tissue often contains longitudinal, oblique, or encircling smooth muscle fibers, the last named being found near the lateral walls. Secondary papillæ are confined to the upper wall. Occasionally the epithelium sends branched prolongations into the underlying tissue. These may become detached from the surface and appear as concentric bulb-like bodies such as are generally known as "epithelial pearls." There are also branched serous glands which grow

down from the epithelium, having ducts which open into the deep grooves (Fig. 223). The foliate papillæ are parallel folds of mucous membrane, in the epithelium of which there are many *taste buds*. These structures, which occur also in the lateral walls of the vallate papillæ (Fig. 223), will be described with the nerves of the tongue.

The tunica propria of the mucous membrane is a loose connective tissue layer containing fat. It is not sharply separated from the denser submucosa. At the tip of the tongue, or *apex linguæ*, and over the dorsum, the submucosa is particularly firm and thick, forming the *fascia linguæ*. Three sorts of glands branch in the submucosa and

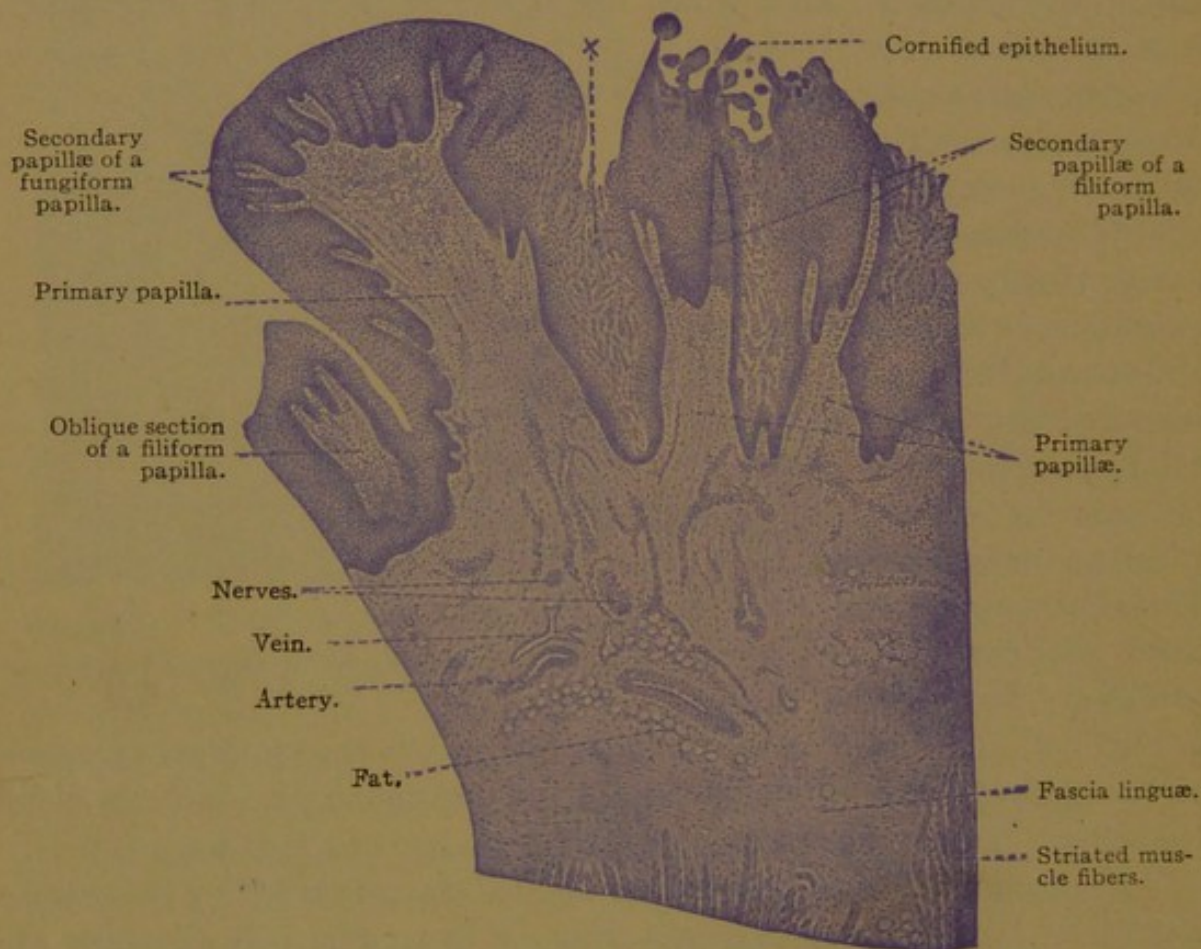


FIG. 222.—FROM A LONGITUDINAL SECTION OF THE HUMAN TONGUE. $\times 25$.
x, Epithelium showing post-mortem disintegration.

may extend into the superficial part of the muscle layer. These are the serous glands found near the vallate and foliate papillæ; mucous glands occurring at the root of the tongue, along its borders, and in an area in front of the median vallate papilla; and the two mixed *anterior lingual glands*, from half an inch to an inch long, each of which empties by five or six ducts on the under surface of the apex. The structure of these types of glands will be described in the section on oral glands.

The muscular layer consists of interwoven bundles of striated fibers which are inserted into the submucosa or into the intermuscular connect-

ive tissue. Some of these striated fibers are branched. The musculature of the tongue is partly divided into right and left halves by a dense median connective tissue partition, the *septum linguæ*, which begins low on the hyoid bone, attains its greatest height in the middle of the tongue, and becomes lower anteriorly until it disappears. It does not extend clear through the tongue since it ends 3 mm. beneath the dorsum. The muscles of the tongue are partly vertical (*Mm. genioglossus, hyoglossus, and verticalis linguæ*), partly longitudinal (*Mm. styloglossus, chondroglossus, superior and inferior longitudinalis linguæ*) and partly

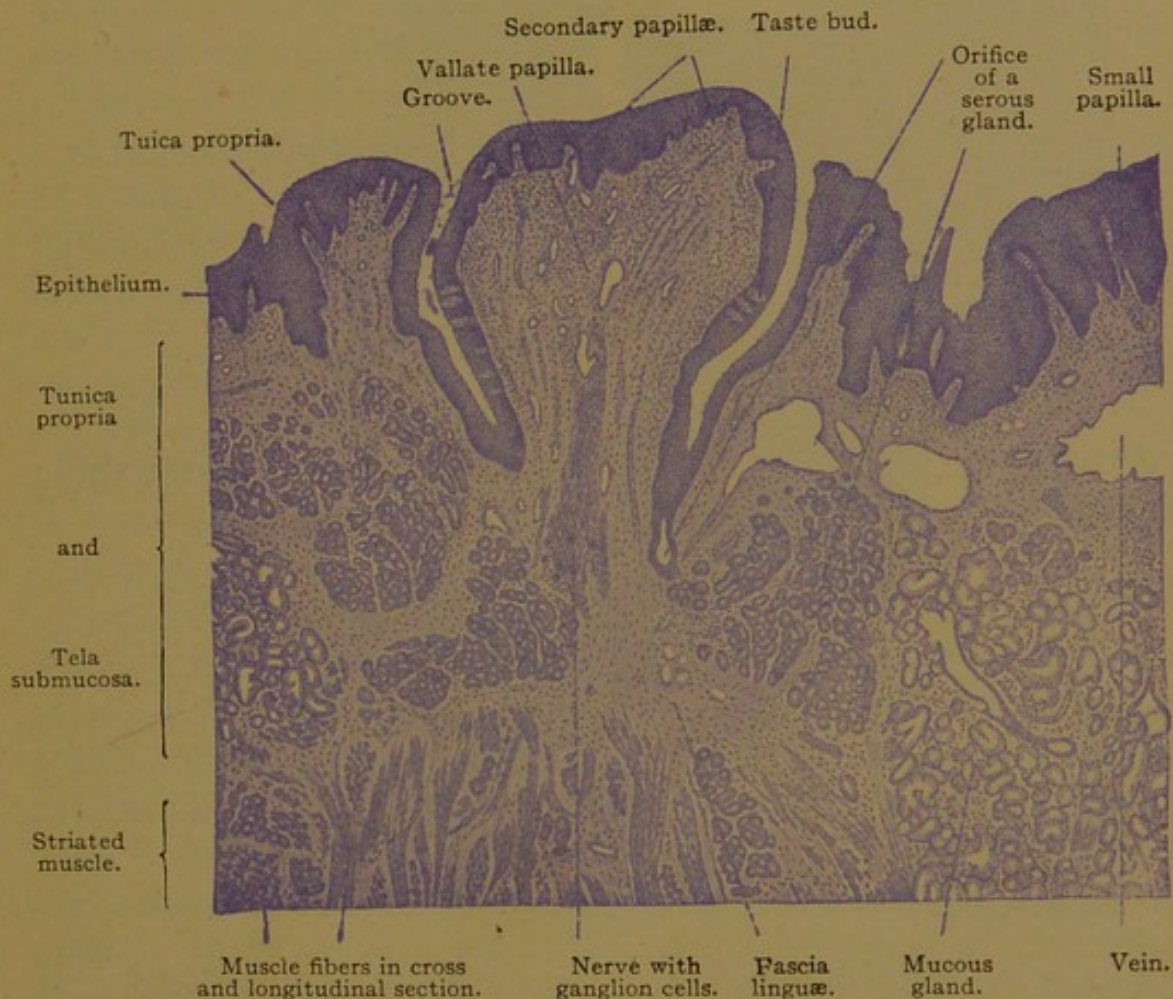


FIG. 223.—VERTICAL SECTION OF A HUMAN VALLATE PAPILLA. $\times 25$.

transverse (*M. transversus linguæ*). The *glossopalatine muscle* of the palatine group also enters the tongue. Some of the muscle fibers are oblique but many of the bundles cross at right angles. In the connective tissue between them, medullated nerves are abundant. Some are sensory nerves to the mucosa, but many of them are the lingual branches of the hypoglossal nerve which supply all the tongue muscles except the inferior longitudinal; the latter is supplied by fibers from the chorda tympani. Sensory spindles have been found in the lingual muscles.

Blood vessels are numerous in the submucosa and form extensive capillary networks in the tunica propria of both primary and secondary

papillæ. Small lymphatic vessels also form a network in the tunica propria, and this is continuous with a coarser net in the submucosa.

The sensory nerves are the terminations of the lingual branches of the mandibular nerve anteriorly, and of the lingual branches of the glossopharyngeus posteriorly. In the submucous connective tissue they form a plexus of medullated and non-medullated fibers, and in some places, notably beneath the vallate papillæ, nerve cells are found, grouped in small ganglia (Fig. 223). The terminal branches of these nerves probably end in part in bulbous corpuscles, but most of them, as non-medullated

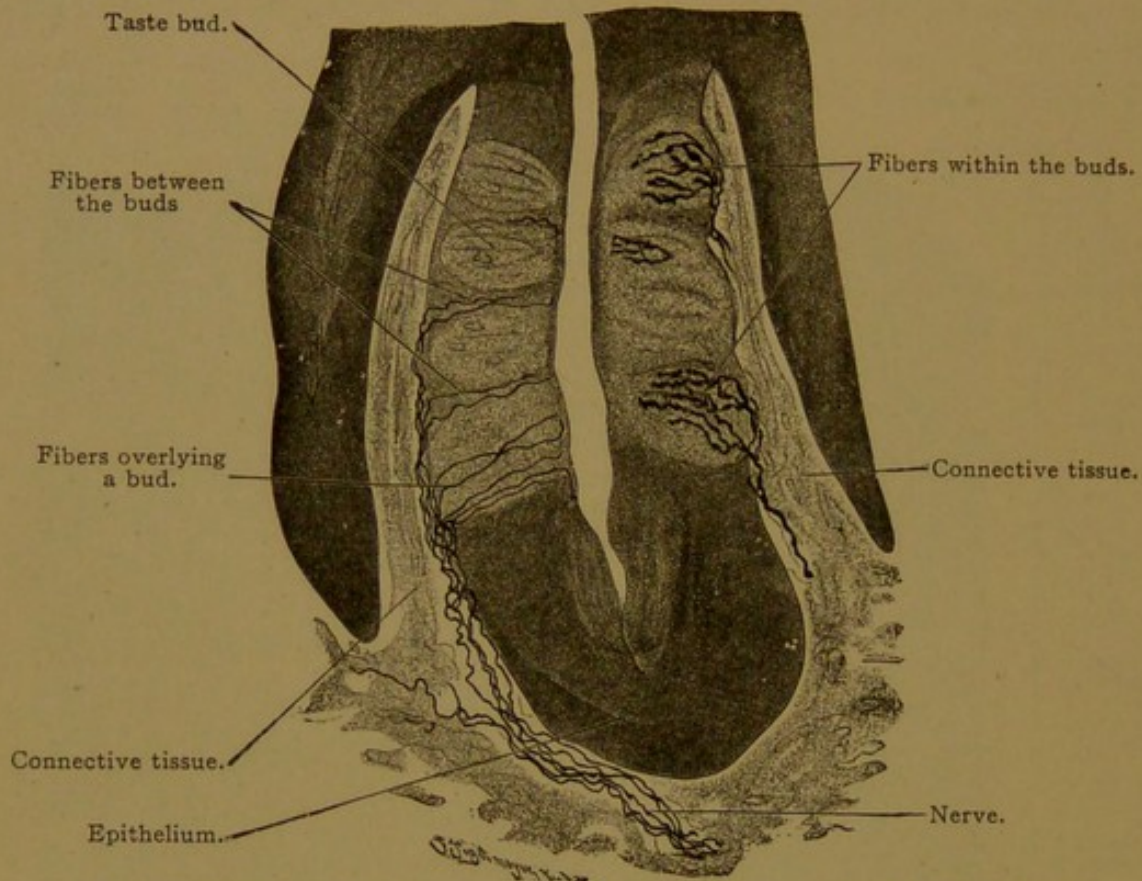


FIG. 224.—FROM A VERTICAL SECTION OF THE FOLIATE PAPILLA OF A RABBIT. $\times 220$.

fibers, enter the epithelium and extend to the outer epithelial cells, generally without branching (as on the left of Fig. 224). Others enter the groups of specialized epithelial cells, known as *taste buds*, which are believed to be the special organs of taste. Within the buds the nerves divide into coarse varicose branches which end freely, without uniting with the cells or anastomosing with one another (Fig. 224).

Taste buds are round or oval groups of elongated epithelial cells, most of which extend from the basal to the free surface of the epithelium. In embryos of from five to seven months they are more numerous than in the adult, occurring in many filiform papillæ, in all the fungiform, vallate and foliate papillæ, and also upon both sides of the epiglottis. Subsequently they are destroyed with an infiltration of leucocytes except on the lateral walls of the vallate and foliate papillæ, on the laryngeal surface of the

epiglottis, and a small portion of those on the anterior and lateral fungi-form papillæ. These remain in the adult. In the outer half of each bud the cells converge like the segments of a melon, so that their ends are brought together in a small area. This area is at the bottom of a little *pore* or short canal found among the outermost flat cells of the epithelium. The taste pore opens freely to the surface, but in oblique sections it may appear bridged as in Fig. 225.

Within the bud two sorts of elongated cells may be distinguished, namely, *supporting cells* which are chiefly peripheral, and *taste cells* which are central. There are also certain cells which lie wholly in the basal part of the bud, and lymphocytes which have entered the bud from below are frequently seen among the other cells. The supporting cells are paler than the gustatory cells, and may be uniform in diameter or tapering toward their ends; they are

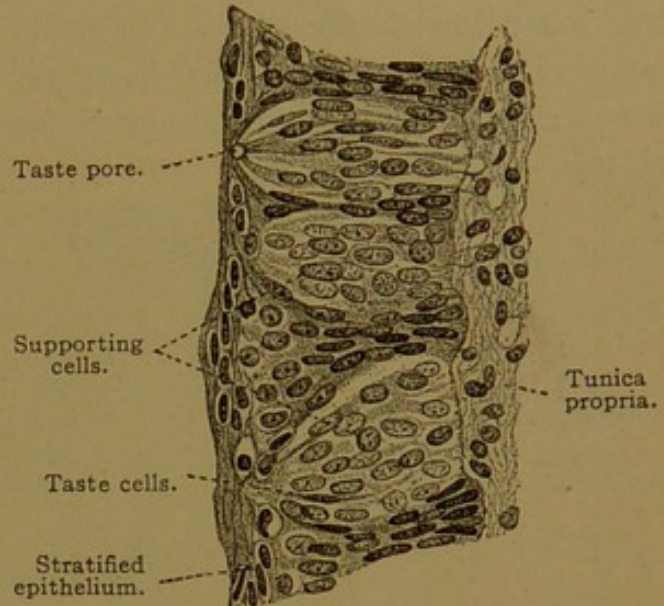


FIG. 225.—FROM A VERTICAL SECTION OF A HUMAN FOLIATE PAPILLA. $\times 330$.

sometimes forked or branched below. The taste cells are darker and more slender, being thickened to accommodate the narrow nucleus which is usually near the middle of the cell. At the taste pore these cells end in a stiff refractive process which is a cuticular formation. The processes extend into the deeper part of the pore but do not reach its outlet. These cells are believed to transmit the gustatory stimuli to the nerves which branch about them. To a less extent the nerves are said to ramify around the supporting cells, which perhaps have other functions than their name implies.

MOUTH AND PHARYNX.

The lining of the mouth, like the covering of the tongue, consists of epithelium, tunica propria, and submucosa. At the lips, toward the line of transition from skin to mucous membrane, hairs disappear from the skin. The epithelium becomes thicker but more transparent as it crosses the line (Fig. 226). Its outer cells are still cornified, but they are not so flat and compactly placed as in the skin. The deeper cells appear vesicular. Within the mouth, except on the tongue, cornified cells are absent, but granules of the refractive horny substance, *keratohyalin*, are said to occur in the outer cells, even in the œsophagus. The free surface of the epithelium

is generally smooth, but its under surface is indented by many connective tissue papillæ, which are particularly long and slender in the gums and lips (Fig. 226). At the inner border of the lips at birth, there are free papillary projections described as "true villi," but these later disappear. Cilia are found on the oral, pharyngeal and œsophageal epithelia in the embryo, but in the adult cilia persist only in certain parts of the pharynx.

The tunica propria in the mouth, as is generally the case in the digestive tract, has few elastic fibers. Some of its tissue is reticular, and in it, lymphoid accumulations are frequent; they may extend into the submucosa. On the oral surface of the soft palate there is a layer of elastic

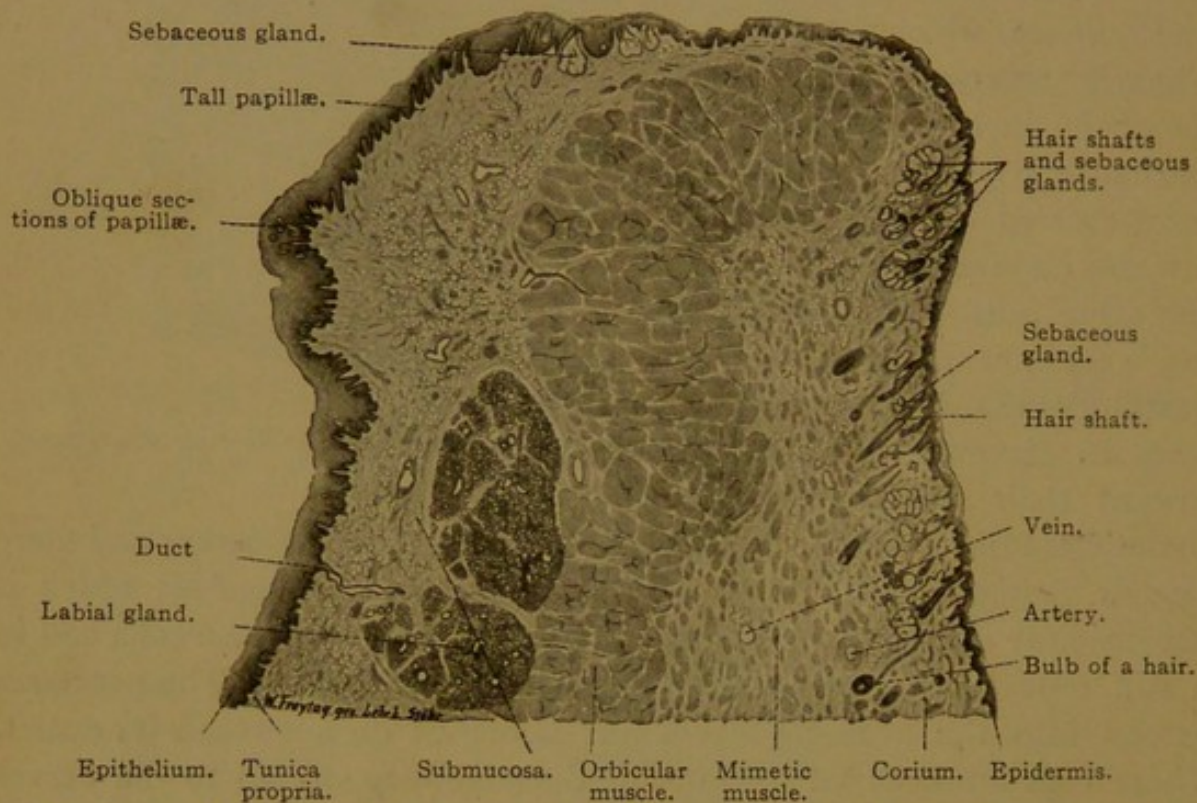


FIG. 226.—VERTICAL SECTION THROUGH THE LOWER LIP OF A MAN OF NINETEEN YEARS. $\times 10$. Epidermis and corium constitute the skin; epithelium, t. propria, and submucosa form the oral mucous membrane.

tissue between the propria and submucosa. A similar layer is found in the œsophageal end of the pharynx. It increases in thickness upward, at the expense of the submucosa, so that it forms a thick layer in the back of the pharynx in contact with the muscles, among the fibers of which it sends prolongations. This elastic layer, as the *fascia pharyngobasilaris*, is attached to the base of the skull.

In most of the oral region there is no sharp line of separation between the propria and the submucosa. The latter may be a loose layer containing fat, and allowing considerable movement of the mucosa, or, as in the gums and hard palate, it may be a dense layer binding the membrane closely to the periosteum. In the submucosa are the branches of various glands. On the inner border of the lips and the inner surface of the cheek,

there are *sebaceous glands* without hairs, which first develop during puberty. This type is described with the skin. The other oral glands are considered in the following section.

GLANDS OF THE ORAL CAVITY.

In the general account of glands (page 54) it has been stated that *serous gland cells* which produce a watery albuminoid secretion should be distinguished from the *mucous gland cells* which elaborate thick mucus. When examined fresh, serous cells are seen to contain many highly refractive granules. In fixed preparations they may appear dark and granular (empty of secretion) or enlarged and somewhat clearer (full of secretion), as shown in Fig. 44, p. 54. The round nucleus is generally in the basal half of the cell, not far from its center (Fig. 227). Mucous cells when

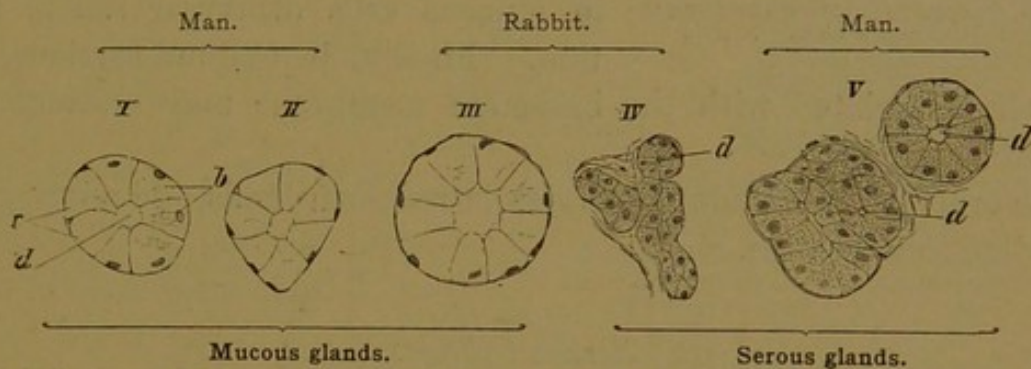


FIG. 227.—SECTIONS OF TUBULES, FROM LINGUAL GLANDS, ILLUSTRATING THE DIFFERENCES BETWEEN MUCOUS AND SEROUS GLAND CELLS.

b, Empty mucous cells; c, mucous cells full of secretion; d, lumen of the tubule. $\times 240$.

fresh are much less refractive than serous cells. In fixed preparations they are typically clear, since the large area occupied by mucous secretion stains faintly. Fully elaborated mucus, however, may be colored intensely with certain aniline dyes, such as mucicarmine and Delafield's hæmatoxylin. In certain types of mucous cells the pale secretion area is large in all stages of activity. When full of mucus, the nucleus is flattened against the base of the cell, and when empty, the nucleus becomes more oval without essentially changing its position (Fig. 227). This differs from the type of mucous cell found in the gastric epithelium, in which the secretion area varies considerably with the elaboration and discharge of secretion (Fig. 45, p. 55).

Glands may consist entirely of serous or of mucous cells, but frequently they include cells of both sorts and are called *mixed glands*. The mixed glands contain some purely serous tubules or alveoli; the rest consist of both mucous and serous cells, so arranged that the latter appear more or less crowded away from the lumen. Often they form a layer outside of the mucous cells, partly encircling the tubule or alveolus and constituting a *crescent* (demilune), as shown in Fig. 237. The serous cells of the cres-

cent are connected with the lumen by means of secretory capillaries (p. 57) which pass out to them between the mucous cells and branch around the serous cells, ending blindly (Fig. 228). Sometimes the cells of the crescent are directly in contact with the lumen. Since the serous crescents are always associated intimately and somewhat irregularly with mucous cells,

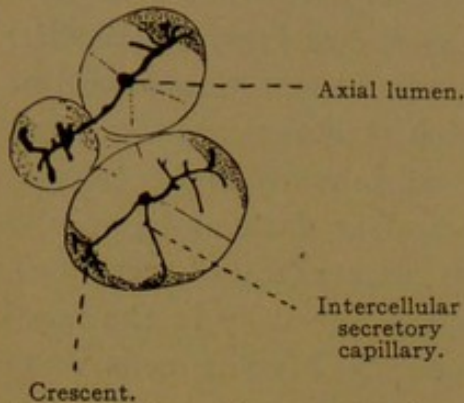


FIG. 228.—FROM A SECTION OF THE SUBMAXILLARY GLAND OF A DOG. $\times 320$.

they were naturally interpreted as a functional phase of the latter. It is probably true that some crescents represent empty mucous cells which have been crowded from the lumen by those full of secretion. No secretory capillaries lead to such mucous crescents, which moreover are not abundant. Another sort of crescentic figure is made by the basal protoplasm in mucous cells otherwise full of secretion. Finally, in oblique sections, stellate cells associated with the basement membrane may resemble true crescents.

The oral glands include serous glands, mucous glands, and mixed glands to be described in turn.

Serous Glands.

The serous oral glands are the parotid glands and the serous glands of the tongue (v. Ebner's glands). The latter are branched tubular glands limited to the vicinity of the vallate and foliate papillæ. Generally they open into the grooves which bound these papillæ. Their ducts are lined with simple or with stratified epithelium, which is occasionally ciliated. Their small tubules consist of a delicate *membrana propria* or basement membrane, which surrounds the low columnar or conical serous cells. In this simple epithelium, cell walls are lacking. With special stains and high magnification, a dark granular zone toward the lumen has been distinguished from the clear basal portion of the cell which contains the nucleus (Fig. 229). The lumen of the tubules is very narrow and receives the still narrower intercellular secretory capillaries (Fig. 230).

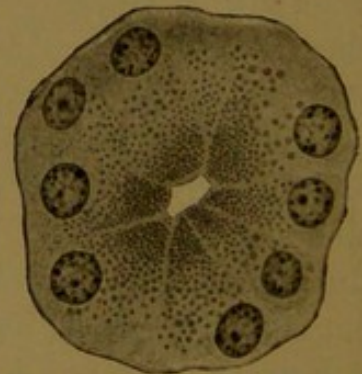


FIG. 229.—TUBULE OF A SEROUS GLAND FROM THE HUMAN TONGUE. $\times 750$.

Secretory granules toward the lumen are finer than those further out. The light intercellular lines represent the secretory capillaries.

The *parotid glands* are the largest oral glands. Each is situated in front of the ear and is folded around the ramus of the mandible; its duct, the *parotid duct* (Stenson's), empties into the mouth opposite the second

molar tooth of the upper jaw. The parotid gland is an organic, branched serous gland, subdivided into lobes and lobules. The *accessory parotid gland* appears as a lobe separated from the others. The parotid duct is

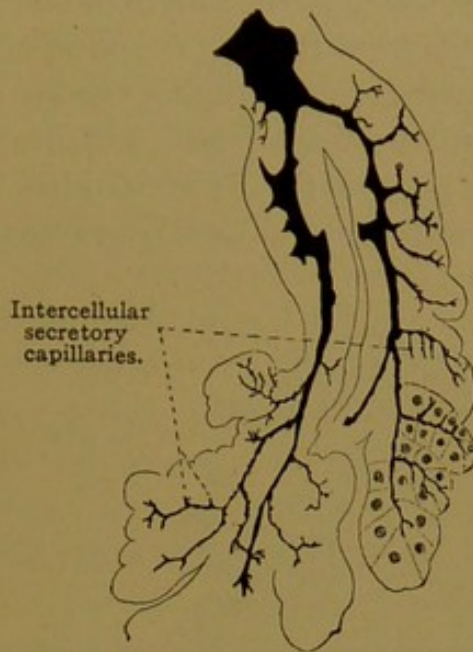


FIG. 230.—SECTION OF A SEROUS GLAND FROM THE TONGUE OF A MOUSE. $\times 240$. Prepared by Golgi's method, a precipitate has formed in the ducts. The right lower part of the figure has been completed by adding the cell outlines.

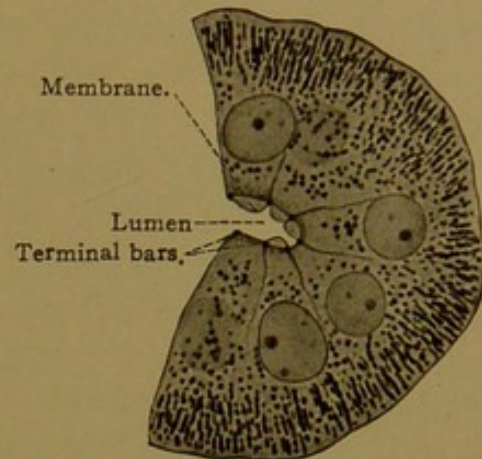


FIG. 231.—PART OF A CROSS SECTION OF THE SECRETORY DUCT FROM THE PAROTID GLAND OF A MOUSE.

The basal rods (mitochondria) toward the lumen break apart into secretory granules.

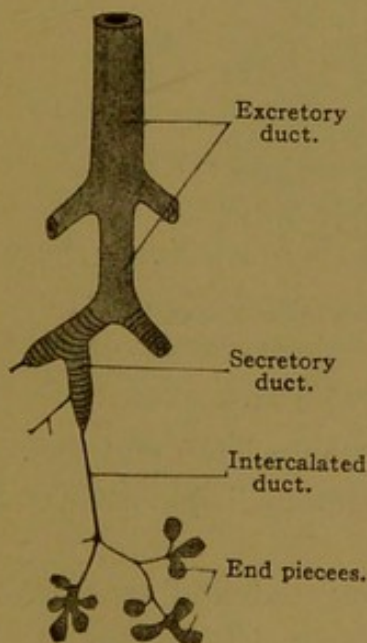


FIG. 232.—DIAGRAM OF THE HUMAN PAROTID GLAND.

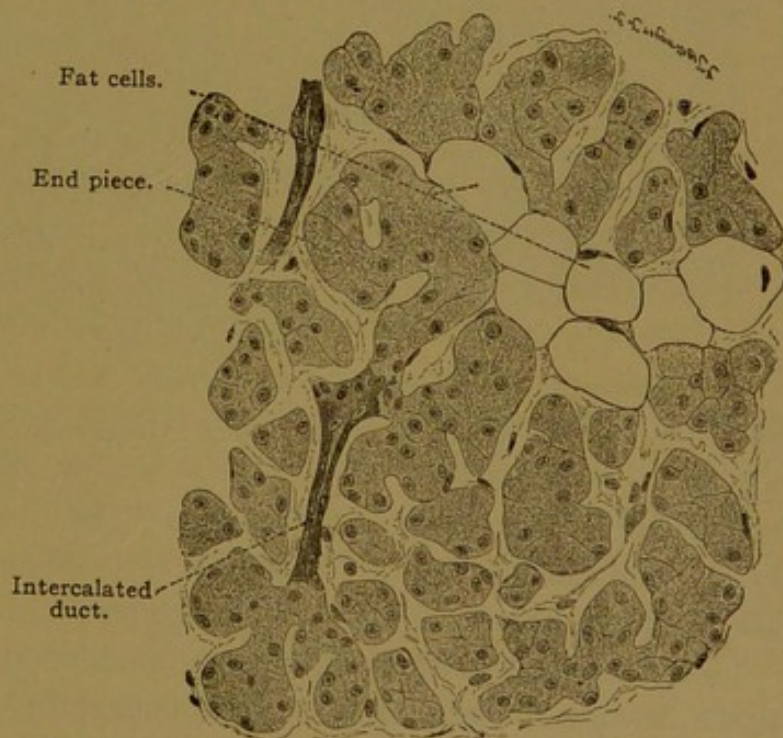


FIG. 233.—SECTION OF THE PAROTID GLAND OF AN ADULT MAN $\times 252$.

The very narrow lumen of the alveolo-tubular end pieces is not shown.

characterized by a thick membrana propria, and consists of a two-layered columnar epithelium with occasional goblet cells. As the duct branches repeatedly, the epithelium becomes a simple columnar epithelium, after

being pseudostratified, with two rows of nuclei (cf. Fig. 39, p. 49). Possibly the epithelium near the outlet of the duct is also pseudostratified. This *excretory* portion of the duct is followed by the *secretory* part, formed of simple columnar cells with basal striations, perhaps indicative of secretory activity (Fig. 231). As shown in the diagram (Fig. 232) and in the section (Fig. 233) the secretory ducts become slender, forming the *intercalated ducts*. These are lined with flat spindle-shaped cells which are continuous with the large cuboidal serous cells of the terminal alveoli. The gland cells when empty of secretion are small and darkly granular,

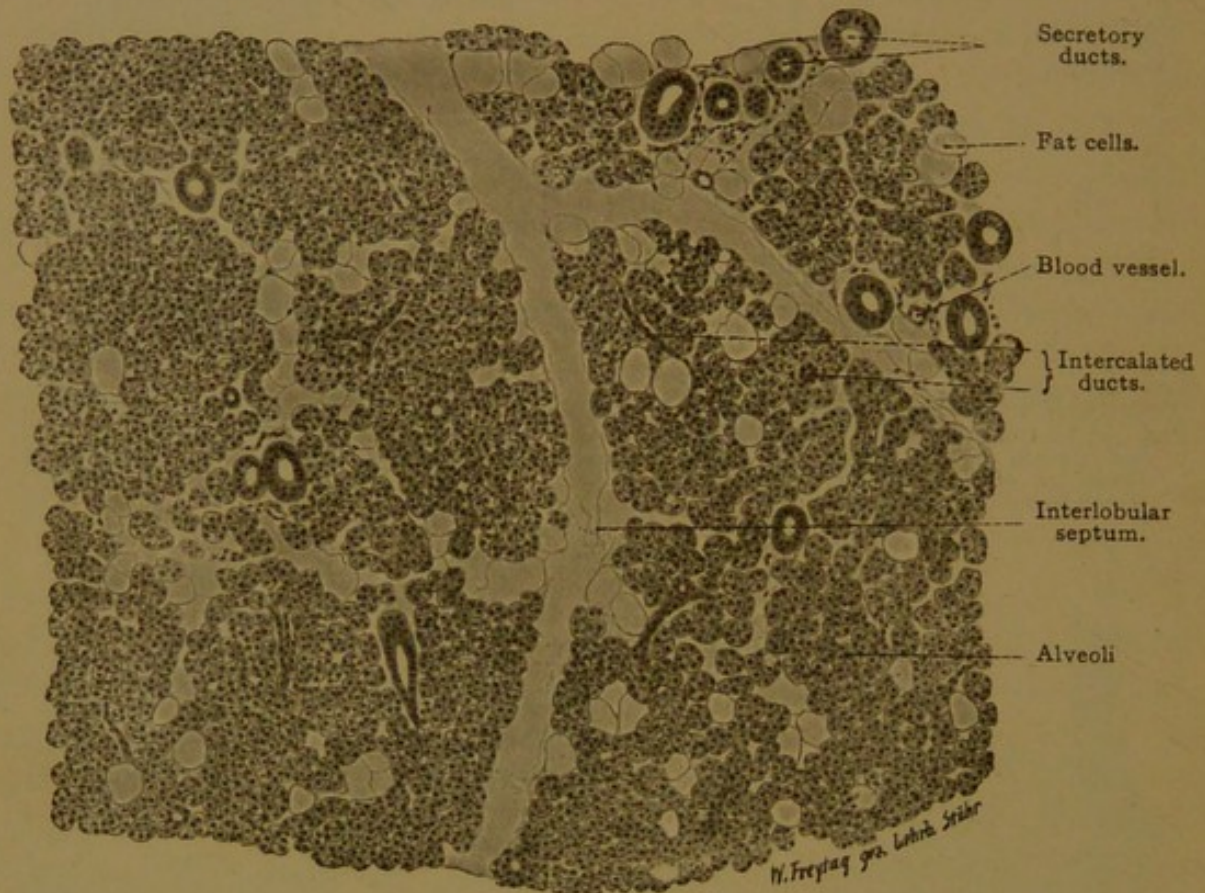

FIG. 234.—SECTION OF THE PAROTID GLAND FROM A MAN OF TWENTY-THREE YEARS. $\times 100$. Portions of three lobules are shown, which have drawn apart from one another in the process of preparation. Note the abundance of secretory ducts.

and when full are larger and clearer. They rest upon a basement membrane containing stellate cells. Intercellular secretory capillaries end blindly before reaching the basement membrane.

Between the alveoli, which are somewhat elongated and branched, there is vascular connective tissue containing fat cells. In denser form it surrounds the lobules and lobes of the gland, and the larger ducts. The ducts which are found in the connective tissue septa are called interlobular ducts, in distinction from those which are surrounded by the alveoli in which they and their branches terminate. The latter are intralobular ducts. They are smaller and have less connective tissue around them than the interlobular ducts, of which, however, they are continuations.

Vessels and Nerves. The arteries generally follow the ducts from the connective tissue septa into the lobules, where they produce abundant capillary networks close to the basement membranes. The veins derived from these soon enter the interlobular tissue, and may then accompany the arteries. The lymphatic vessels follow the ducts, and branch in the interlobular connective tissue, in which they terminate. Only tissue spaces have been found within the lobules. The nerve supply is from several sources. Sympathetic nerves from the plexus around the carotid artery accompany the blood vessels into the parotid gland, and by controlling the blood supply have an important bearing upon secretion. The nerves which reach the gland cells are in connection with the tympanic branch of the glossopharyngeal nerve. This branch extends to the otic ganglion, from which fibers pass to the parotid gland by way of an anastomosis with the auriculo-temporal branch of the mandibular nerve. Within the gland the nerves pass along the ducts, where they are associated with microscopic ganglia, and form plexuses beneath the basement membranes of the alveoli. From these plexuses, fibers penetrate the basement membranes and form simple or branched varicose endings in contact with the gland cells. Other nerves enter the substance of the gland, either to pass through it or to contribute to its nerve supply; these include branches of the trigeminal, facial and great auricular nerves, the last coming from the second and third cervical nerves. Free sensory endings of medullated fibers are said to occur in the epithelium of the ducts.

Mucous Glands.

The purely mucous glands of the mouth are simple branched alveolotubular glands found on the anterior surface of the soft palate and on the hard palate (*palatine glands*), along the borders of the tongue (*lingual glands*), and in greater numbers in the root of the tongue. There they may open into the tonsillar pits through ducts lined with columnar epithelium, sometimes ciliated. The wall of the tubules consists of a structureless basement membrane and of columnar mucous cells, varying according to their functional condition as shown in Fig. 227, I-II. The empty cells are narrower than the others, and the nuclei, though at the base of the cell and transversely oval, are not as flat as in cells full of secretion. Seldom can cells be found completely occupied by unaltered protoplasm. A single gland, or even a single alveolus, may contain cells in different phases of secretion, as is clearly seen when special mucin stains are used. Secretory capillaries are not found in the purely mucous glands.

Mixed Glands.

The mixed oral glands are the sublingual, submaxillary, anterior lingual, labial, buccal, and molar glands. They all possess crescents of

serous cells such as are to be described in the largest glands of this group—the sublingual and submaxillary.

The *sublingual glands* are two groups of glands, one on either side of the median line, under the mucous membrane in the front of the mouth. The largest component is an alveolo-tubular structure emptying by the

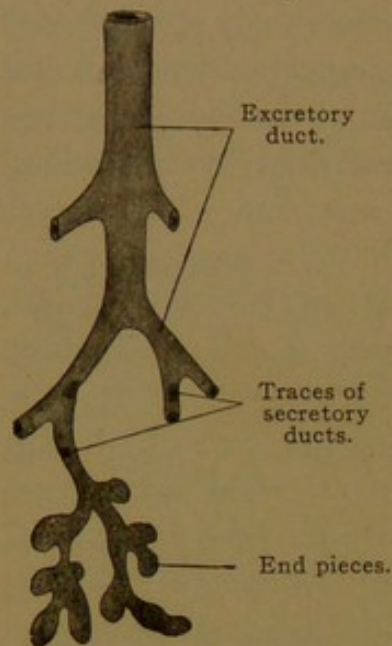


FIG. 235.—DIAGRAM OF THE HUMAN SUBLINGUAL GLAND.

ductus sublingualis major on the side of the *frenulum linguæ*. The main stem and the principal branches of the large sublingual duct are lined by a two-layered or pseudostratified columnar epithelium, as in the parotid duct. They are surrounded by connective tissue containing many elastic fibers. Ducts less than .05 mm. in diameter have a simple columnar epithelium, which in a few places becomes low and basally striated to form the secretory ducts. As shown in the diagram, Fig. 235, the secretory ducts are very short, and they are accordingly infrequent in sections; the slender intercalated ducts are absent. The terminal secreting portions of the gland are somewhat tortuous structures, often presenting outpock-

etings. They consist of mucous and serous cells quite evenly mixed, so that the gland has a characteristic appearance under low magnification (Fig. 236). The serous cells sometimes border upon the lumen, but often they are separated from it by the mucous cells so that they form crescents (Fig. 237). Only the serous cells are provided with the branched intercellular secretory capillaries. Around the tubules there is a basement membrane including certain stellate cells. The interlobular connective tissue contains many lymphocytes.

Near the gland just described, but apparently quite distinct from it, there is a group of 5 to 20 alveolo-tubular glands which open by separate ducts, the *ductus sublinguales minores*. These glands consist almost exclusively of mucous cells.

The sublingual gland as a whole receives fibers from the submaxillary ganglion, and so from the chorda tympani, which passes to this ganglion by way of an anastomosis with the lingual branch of the mandibular nerve. Its ducts are said to have sensory fibers, probably derived from the lingual nerve. Sympathetic fibers from the superior cervical ganglion, which have ascended the neck as perivascular plexuses, extend to the sublingual gland around its arteries.

The *submaxillary glands* are a pair of branched alveolar glands, in part tubulo-alveolar, found in the floor of the mouth, each being drained by a *submaxillary duct* (Wharton's) which opens on the sides of the frenulum

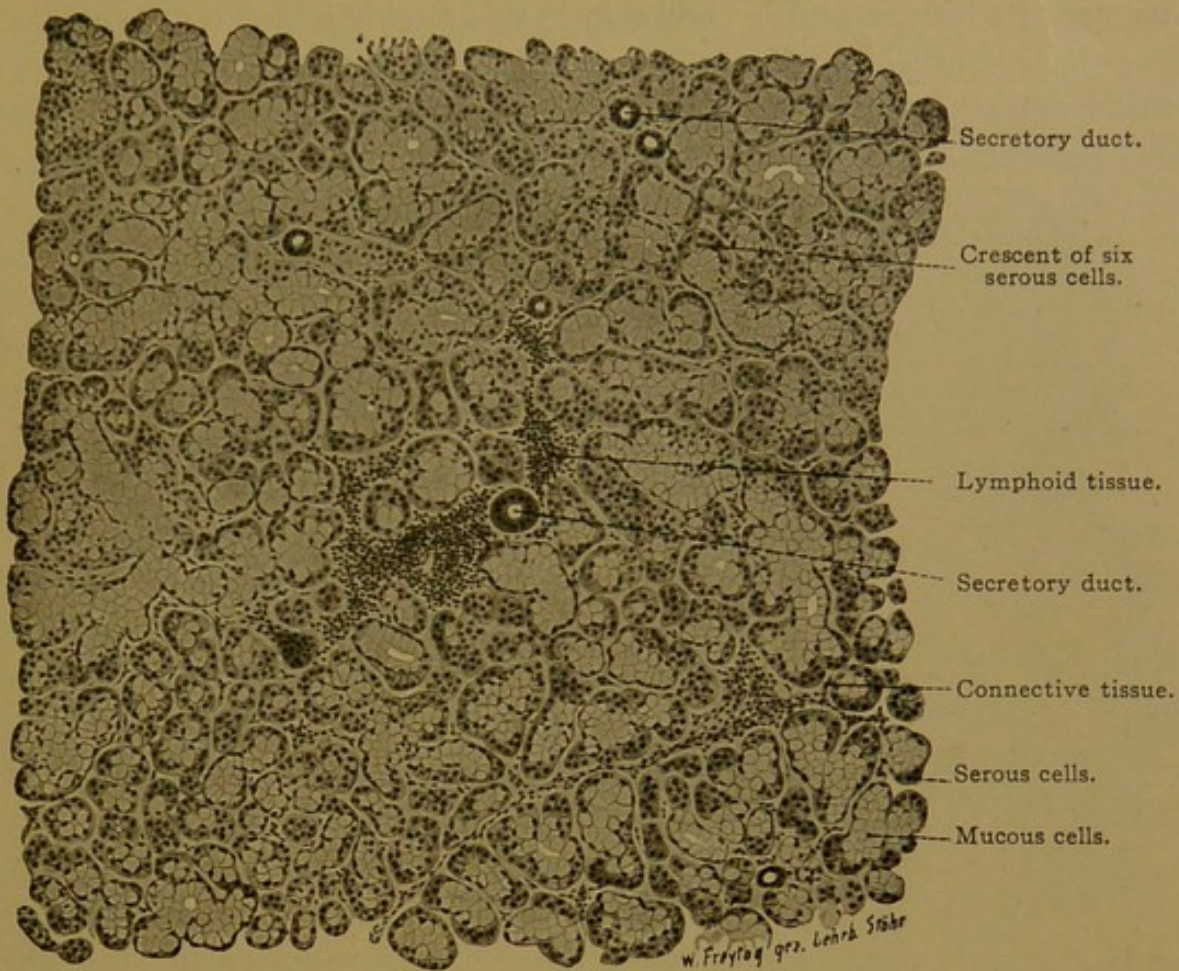


FIG. 236.—SECTION OF THE SUBLINGUAL GLAND (GL. SUBL. MAJOR) FROM A MAN OF TWENTY-THREE YEARS. $\times 100$.

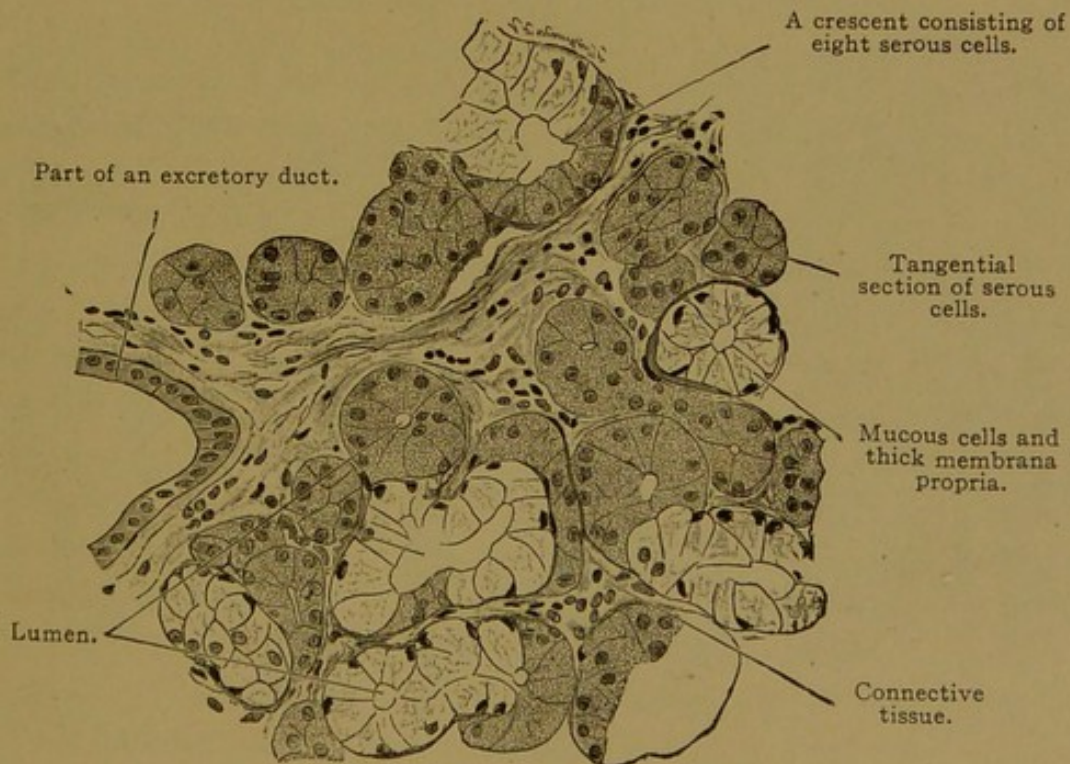


FIG. 237.—SECTION OF A HUMAN SUBLINGUAL GLAND. $\times 252$.

linguæ near its front margin. Sometimes this duct is joined by the *ductus sublingualis major* so that the two have a common outlet. Its orifice may be lined by stratified epithelium, but this soon gives place to the two layered form. Secretory ducts are well developed (Fig. 238) and their basally striated cells contain a yellow pigment. The intercalated ducts, which are lined with simple cuboidal epithelium, lead to terminations of two sorts. Most of these consist entirely of serous cells. The others are mixed, but the crescents are small, composed of only a few or even of single serous cells (Figs. 239 and 240). Secretory capillaries such as have already been described, are related only to the serous cells. Elastic tissue surrounding the alveoli has been thought to aid in expelling the secretion through the ducts. The nerves have the same origin as those of the sublingual gland.

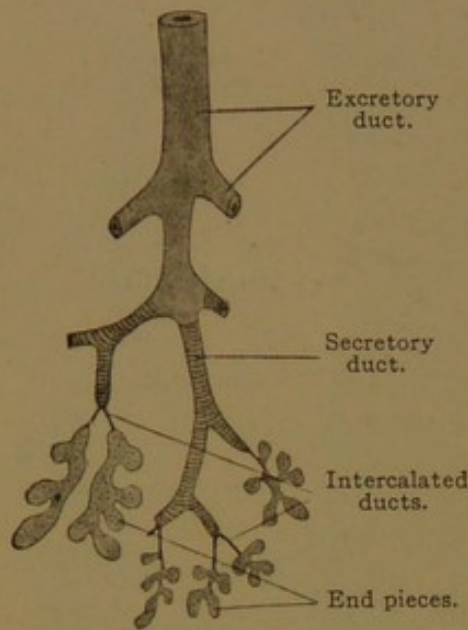


FIG. 238.—DIAGRAM OF THE HUMAN SUBMAXILLARY GLAND.

In the oral glands, not infrequently degenerating lobules occur, characterized by abundant connective tissue between tubules with wide lumens and low gland cells. Sometimes they are surrounded by leucocytes.

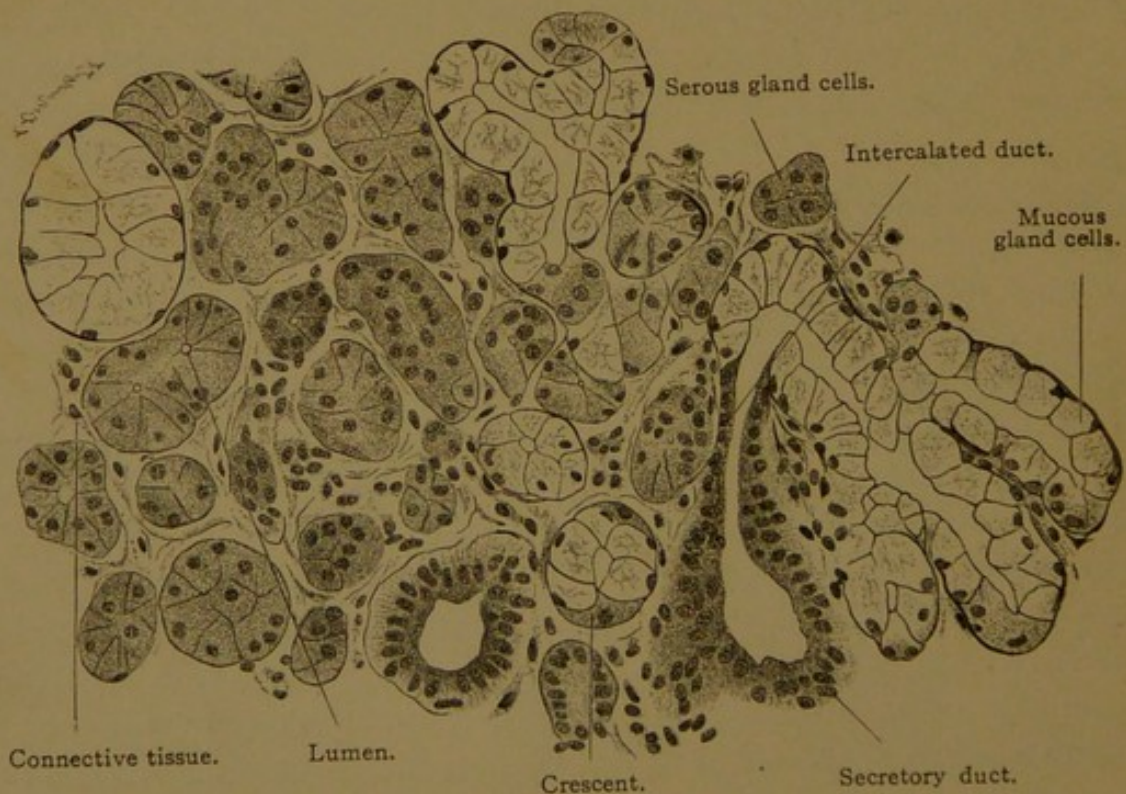


FIG. 239.—SECTION OF THE SUBMAXILLARY GLAND OF AN ADULT MAN. $\times 252$.

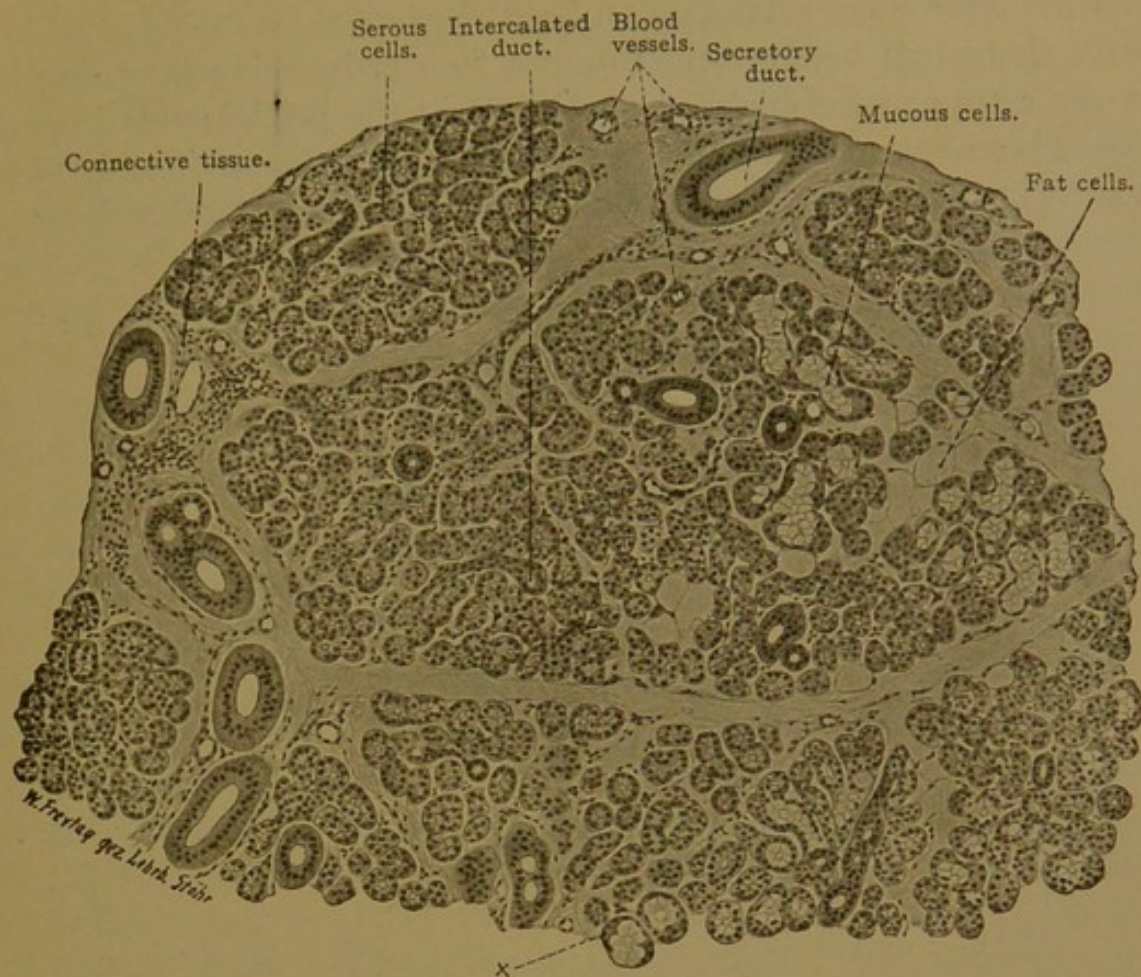


FIG. 240.—SECTION OF THE SUBMAXILLARY GLAND FROM A MAN OF TWENTY-THREE YEARS. $\times 100$. Note that the serous cells predominate, and that secretory ducts are abundant. (A characteristic crescent is shown at x.)

THE DEVELOPMENT OF THE DIGESTIVE TUBE.

The digestive tube of mammals arises as two outgrowths from the yolk-sac—the fore-gut and hind-gut respectively. They are shown in Fig. 241, A, which represents a young rabbit embryo placed in a vertical position. Most of the spherical yolk-sac has been cut away. Anteriorly the fore-gut (*ph*) is seen extending from the yolk-sac to the oral plate; posteriorly the sac has given rise to a short hind-gut from which a tubular ventral outgrowth, the *allantois*, has begun to develop. The allantois will be described with the membranes which surround the embryo. In an older stage (Fig. 241, B) the fore-gut and hind-gut have elongated, and the connection of the tube, which they form, with the yolk-sac is becoming reduced to a slender stalk. The entodermal tube within the stalk is called the *vitelline duct*. Posteriorly the intestine and allantois unite and form the *cloaca*, which is closed to the exterior by the *cloacal membrane*. (The marked bend in the intestinal tube shown in Fig. 241, B, which is often seen in human embryos, is exaggerated, if not produced altogether, by a post-mortem sagging of the yolk-sac.)

In the later stage (Fig. 24I, C) both the fore-gut and hind-gut have greatly elongated; together they form a loop of intestine extending out into the cavity of the umbilical cord. Near the bend in this loop the yolk-sac is still attached to the intestine by a stalk; the sac itself has been cut away in the figure. In addition to the pharynx already described, the

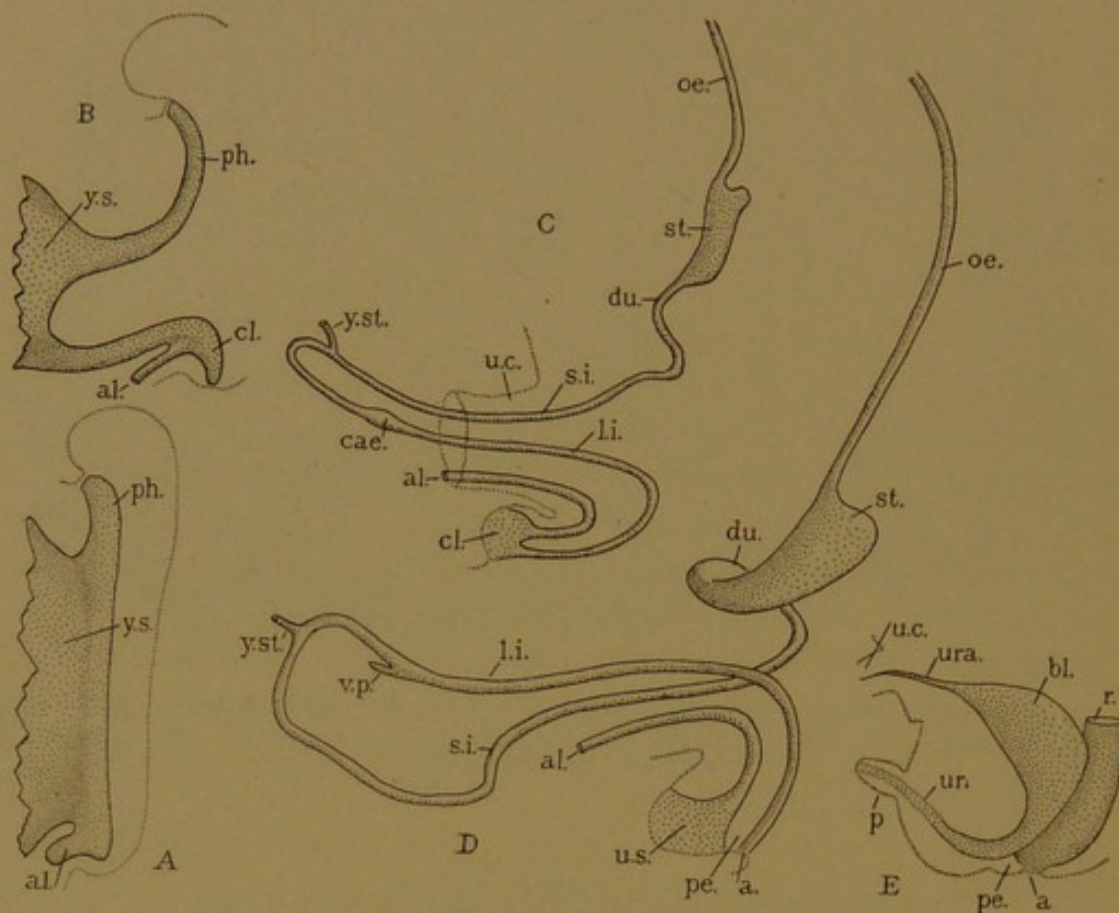


FIG. 24I.—STAGES IN THE DEVELOPMENT OF THE DIGESTIVE TUBE. A. Rabbit of nine days. B. Man 2.15 mm. (after His). C. Pig, 12 mm. D. Man, 17.8 mm. (after Thyng). E. Man, about five months. a., Anus; al., allantois; bl., bladder; cae., bulb of the colon; cl., cloaca; du., duodenum; l. i., large intestine; oe., oesophagus; p., penis; pe., perineum; ph., fore-gut; r., rectum; s. i., small intestine; st., stomach; u. c., umbilical cord; ur., urethra; ura., urachus; u. s., urogenital sinus; v. p., vermiform process; y. s., yolk-sac; y. st., vitelline duct within the yolk-stalk.

fore-gut has given rise to an expanded portion or *stomach*. Between the stomach and pharynx it remains tubular and becomes the *oesophagus*; posterior to the stomach it is likewise tubular and there it forms a part of the small intestine. The first portion of the small intestine is called the *duodenum*, and is followed by the *jejunum* which passes without demarcation into the *ileum*. The ileum includes the portion to which the yolk-stalk is attached, and terminates at a bulbous enlargement (Fig. 24I, C, *cae*) which gives rise to the *cæcum* and *vermiform process*. This *bulbus coli* (Johnson) marks the beginning of the large intestine or *colon*, and the *cæcum* and *vermiform process* are parts of the large intestine. Toward the cloaca the colon becomes the *rectum*, and near its termination it forms an elongated bulbous enlargement, the *bulbus analis*. As shown by F. P.

Johnson (in a paper about to be published) this bulb forms essentially the *zona columnaris* in the anal part of the rectum. The *anus* is produced after the cloaca has separated into dorsal and ventral portions. The ventral division, which carries with it the allantois, becomes expanded to form the bladder, but its outlet remains relatively narrow and becomes the urethra. The outlet of the rectum is the anus, which is at first closed by the *anal membrane*; this membrane ruptures in embryos measuring from 20 to 30 mm., except in the occasional cases of imperforate anus. The tissue which subdivides the cloaca reaches the surface and constitutes the perineum.

In human embryos of about 10 mm. the intestinal loop becomes twisted on itself (Fig. 241, D), and the large intestine is carried across the small intestine in the duodenal region. The vermiform process thus comes to lie on the right side of the body, and the colon, after it is withdrawn from the umbilical cord into the body, is so bent as to form *ascending*, *transverse*, and *descending* portions, below which, as the convoluted *sigmoid colon*, it connects with the rectum. The disposition of the adult intestines depends chiefly upon this primary torsion of the intestinal loop, and upon the subsequent elongation of the small intestine, which forms many loops and coils.

Meanwhile the yolk-sac has become detached, and its stalk has disappeared, usually leaving no indication of its former position. The stalk does not become the vermiform process, as was once supposed, but occasionally it produces a blind pouch of the ileum, 3-9 cm. long, situated about three feet above the beginning of the colon. This is the *diverticulum ilei*, described and correctly interpreted by Meckel in 1812.

The division of the intestine into six parts is a heritage from the Arabians. Duodenum, jejunum, ileum, cæcum, colon and rectum were well recognized in the fifteenth century, when, following Hippocrates, they were counted from below upward. The various names which have been applied to them are discussed by Hyrtl (*Das arabische und hebräische in der Anatomie*, Wien, 1879). Those which are now adopted have the following significance. The rectum is the *straight* terminal portion. "Colon is the κῶλον of Aristotle, which according to Pliny is a great source of pain (colic)." The cæcum, or blind intestine, was so named by Galen, who did not practice human dissection and so referred to the more elongated pouch in lower animals. The name has generally been considered inappropriate for the human cæcum. The Greek synonym τυφλόν (blind) is used in the medical term *typhlitis* (inflammation of the cæcum). The ileum (from εἰλέω) is the coiled portion, and is arbitrarily defined as the lower three-fifths of the small intestine. The jejunum (Lat., fasting) is the portion generally found void and empty (Avicenna), since food passes through it rapidly. The duodenum, which has no free mesentery, was originally considered a part of the stomach; its name indicates that its length is twelve finger-breadths. Hyrtl notes that the same term has sometimes been applied to the rectum.

Layers of the Digestive Tube. The wall of the digestive tube is com-

posed of four layers—(1) *tunica mucosa*, (2) *tela submucosa*, (3) *tunica muscularis*, and (4) *tunica adventitia* or *tunica serosa*. The parts which are covered with peritoneum have a serous coat for their outer layer; the parts imbedded in connective tissue have the adventitious coat instead.

The *tunica mucosa* consists of *epithelium*, *tunica propria*, and the *lamina muscularis mucosæ*. The epithelium is the entodermal lining of the tube, and is folded and inpocketed so as to form innumerable pits and glands, varying in their nature in different parts of the tube. The *tunica propria* consists of reticular tissue, which in places becomes characteristic lymphoid tissue. It is set apart early in development as a layer with abundant nuclei, thus differing from the underlying mesenchyma. At a later stage the *lamina muscularis mucosæ*, or muscle layer of the mucous membrane, develops beneath it, separating it from the submucosa. The *muscularis mucosæ* is a thin layer of smooth muscle fibers.

The *tela submucosa* (*tela*, tissue) is a connective tissue layer which contains many blood and lymphatic vessels, and the ganglionated *plexus submucosus*.

The *tunica muscularis* usually consists of an inner circular and an outer longitudinal layer of smooth muscle fibers, separated by a thin layer of connective tissue which contains the ganglionated *plexus myentericus*.

The *tunica serosa* is a connective tissue layer, covered by the peritoneal epithelium.

The layers enumerated are to be examined in the œsophagus, stomach and intestine, which differ from one another histologically, since these layers are variously modified.

ŒSOPHAGUS.

The œsophagus is a tube about nine inches long, the several layers of which are continuous anteriorly with those of the pharynx, and posteriorly with those of the stomach. The mucous membrane is thrown into folds, except when the tube is distended by the passage of food; but the *muscularis* merely thickens on contraction, so that it always forms a smooth round layer (Fig. 242).

The epithelium is thick and stratified like that of the pharynx. Its outer cells are flattened in the adult, but in the embryo they include numerous islands of tall ciliated cells, some of which are found at birth. The basal surface of the epithelium rests upon connective tissue papillæ or ridges.

The glands of the œsophagus are of two sorts, superficial and deep. The deep glands (*glandulæ œsophageæ profundæ*) develop as scattered tubular downgrowths which pass through the *tunica propria* and muscu-

laris mucosæ into the submucosa, where their blind ends expand and branch, producing a cluster of tubulo-alveolar end pieces. The terminal portions at birth are still poorly developed. The tubules are composed wholly of mucous cells, although the basal protoplasm sometimes simulates crescents. The ducts are slender tubes generally lined with simple epithelium. They tend to slant toward the stomach, and they enter the epithelium where it dips down between the connective tissue papillæ. The cells of the ducts become continuous with the basal layer of the epithelium. Large ducts are sometimes lined with stratified epithelium, often ciliated, and they may present cyst-like dilatations. Lymphocytes tend to accumu-

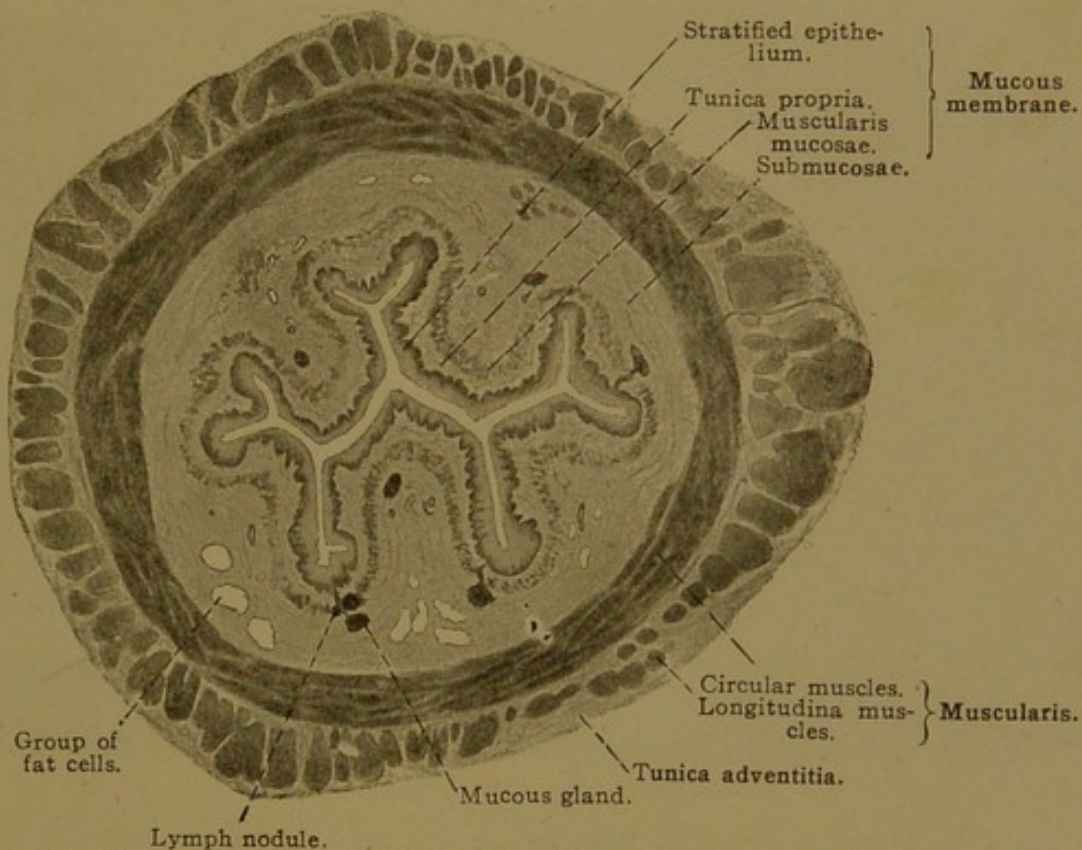


FIG. 242.—TRANSVERSE SECTION OF THE UPPER THIRD OF THE HUMAN ŒSOPHAGUS. X 5.

late around the ducts and occasionally they form nodules in the tunica propria. The glands may show signs of infiltration and degeneration. The number of deep glands varies greatly in different individuals. They are usually more numerous in the upper half of the œsophagus.

The superficial glands (*glandulæ œsophageæ superficiales*) are limited to two rather narrow zones near the ends of the œsophagus. They are always found at the entrance of the stomach, extending from 1 to 4 mm. up the œsophagus; and generally (in 70% of the cases examined by Schaffer) they occur between the level of the cricoid cartilage and fifth tracheal ring. They develop in the embryo much earlier than the deep glands, and appear as small areas of tall mucous cells which pass clear through the stratified epithelium. The islands of simple epithelium become depressed into shallow pockets from which a cluster of tubules grows

out, but they never pass through the muscularis mucosæ into the submucosa. In the adult the upper group may be seen with the naked eye as an "erosion" of the mucous membrane. The glands produce a form of mucus which stains less readily with the mucus-stains than that of the deep glands. No special function has been assigned to this secretion. Glands of the lower group are shown in Fig. 243. They are freely branching mucous glands, the ducts of which open at the tops of connective tissue papillæ. They very frequently show cystic enlargements.

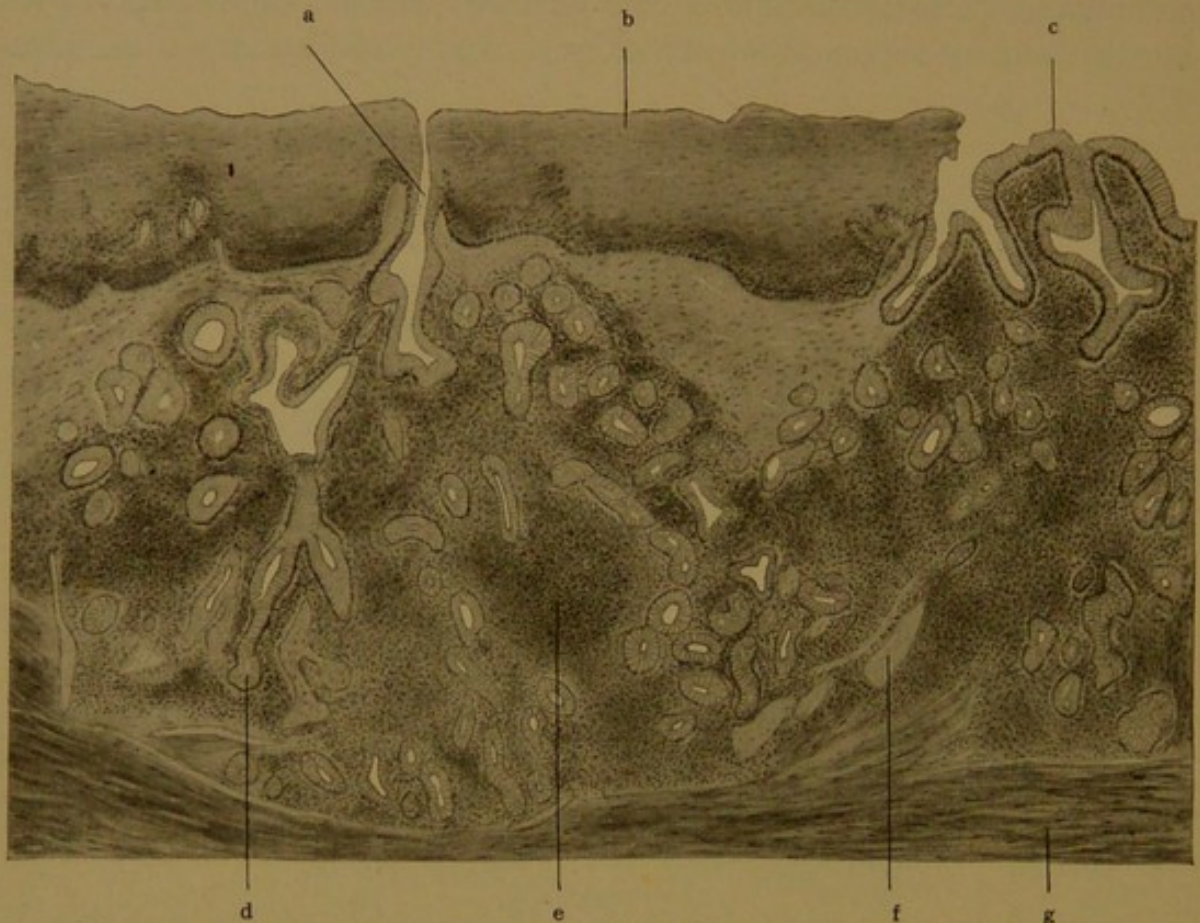


FIG. 243.—LONGITUDINAL SECTION THROUGH THE JUNCTION OF THE HUMAN ŒSOPHAGUS AND STOMACH. $\times 60$.

a, Duct of a superficial œsophageal gland; b, œsophageal epithelium; c, gastric epithelium; d, tubule of the gland a; e, lymphoid nodule; f, lymphatic vessel; g, lamina muscularis mucosæ.

The tunica propria in the œsophagus has fewer cells in its meshes than that of the lower parts of the digestive tube. In places it includes solitary lymph nodules. The muscularis mucosæ is very wide in the œsophagus. It is a layer of longitudinal smooth muscle fibers, which is thrown into longitudinal folds when the œsophagus is contracted. It begins anteriorly at the level of the cricoid cartilage, arising as scattered bundles inside the elastic layer of the pharynx. As the muscles increase to form a distinct layer, the elastic lamina terminates. The submucosa is a loose connective tissue layer, containing many vessels and nerves, groups of fat cells, and the bodies of the deep mucous glands. The muscularis consists of an inner circular and an outer longitudinal layer, as elsewhere in the digestive tube, but in the upper part of the œsophagus the layers are composed of striated

muscle fibers. These fibers are not a downward extension of the striated pharyngeal constrictors, but apparently develop from exactly such mesenchymal cells as produce smooth muscle further down. The striated muscles in man are limited to the upper half of the œsophagus; in the rabbit they extend its whole length.

The adventitia is loose connective tissue, containing many vessels and the plexiform branches of the vagus nerves. From these nerves, medullated and non-medullated fibers enter the œsophagus and form a ganglionated myenteric plexus between the muscle layers, and the plexus submucosus in the submucosa. Medullated fibers proceed from the vagus trunks to the motor end plates of the striated muscles, which are thus stimulated reflexly from the central nervous system. Other fibers pass from the myenteric plexus to the plexus submucosus and thence to the epithelium, in which free nerve endings have been found. Such fibers, together with those to the smooth muscles, provide for local reflex action, whereby the contents of the œsophagus causes contraction above, and relaxation below, the place of stimulation. This takes place independently of the central system, and is the form of innervation characteristic of the intestine.

STOMACH.

Form and Subdivisions. The opening through which the œsophagus connects with the stomach is the *cardia* (Gr. καρδία, heart), and the opening from the stomach to the intestine is the *pylorus* (Gr. πυλωρός, gate-keeper). The pylorus received its appropriate name from Galen (in the second century), who recognized that through its sphincter muscle it controlled the exit of food. The significance of cardia was discussed by Fabricius (1618) who cites Galen as stating that the upper orifice of the stomach is called the heart because the symptoms to which it gives rise are similar to those which sometimes affect the heart, sometimes even the brain; but for Fabricius, cardia, as applied to this orifice, merely indicates a chief part of the body. The stomach as a whole is termed *gaster*, from the Greek, but the Latin *ventriculus* was generally used by the early anatomists. Although flaccid and shapeless when seen in the dissecting room, the stomach has a very characteristic form. Its epithelium, from an embryo of 44.3 mm., is shown in Fig. 244, and an adult stomach is seen in Fig. 250. It is a tube which is greatly distended toward the left, where its border forms the greater curvature; its right border is the lesser curvature. As a whole the stomach is divided into two parts, the cardiac portion (*pars cardiaca*) and pyloric portion (*pars pylorica*). This fundamental subdivision occurs in many animals, as was recognized by Sir Everard Home in 1814. The pyloric part is relatively long in the embryo. It becomes subdivided into the *pyloric vestibule* and the *pyloric antrum*. The latter is its smaller part extending to the pylorus; between the two, on the greater curvature, is the *sulcus intermedius*, well shown in Fig. 250. (The term *pyloric antrum* has been variously employed, since in its original description by Willis (1674) the vestibule is not recognized; Cowper (1698) applies *antrum* to the terminal subdivision as above defined.) The cardiac part of the stomach is divided into a main portion, or body of the stomach (*corpus gastrici*), and a blind pouch, formerly called the *saccus cæcus*, but now less

appropriately known as the *fundus gastrici* (the bottom of the stomach). Recently the gastric canal (*canalis gastrici*) has been recognized along the lesser curvature of the human stomach. It is a channel, highly developed in ruminants, which conveys liquids from the cardia to the pars pylorica, when the stomach is filled with more solid contents. Ordinarily open toward the interior like a groove, it may become closed as a tube during its physiological activity. Beyond the cardia there is a conical expansion of the œsophagus, not always well defined, known as the *cardiac antrum*, and beyond the pylorus is the first part of the duodenum, or *duodenal antrum*. (A further account of the development of these subdivisions will be found in the Amer. Journ. Anat., 1912, vol. 13, pp. 477-503.)

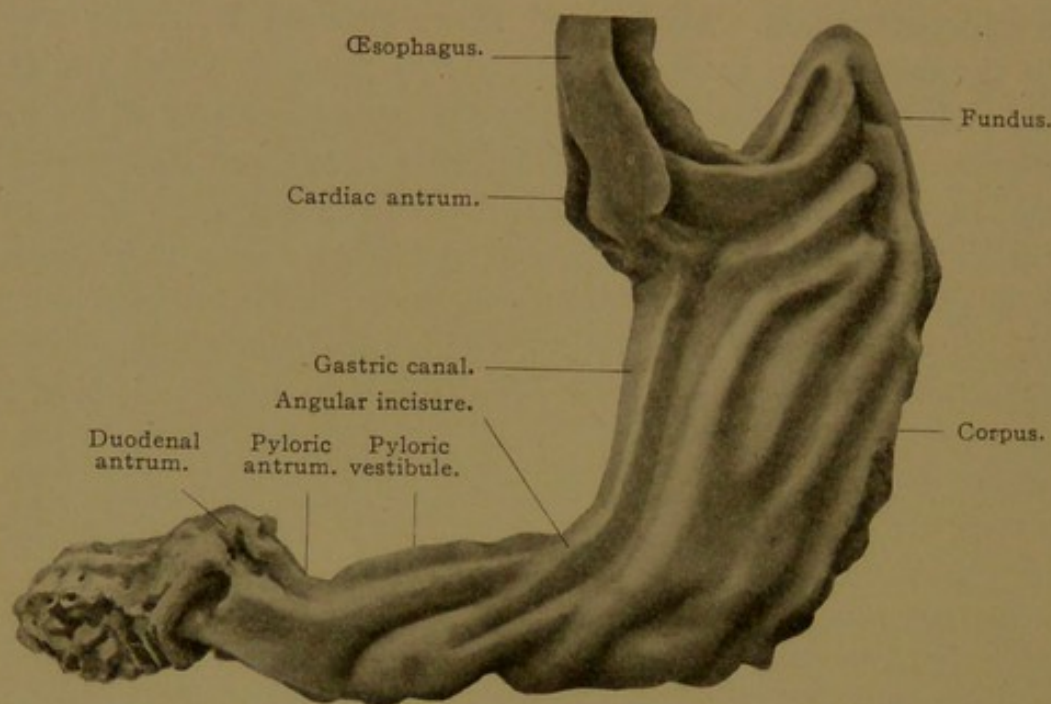


FIG. 244.—MODEL OF THE GASTRIC EPITHELIUM IN A HUMAN EMBRYO OF 44.3 MM. $\times 18$ diam.

The inner surface of the stomach presents macroscopic longitudinal folds, which become coarse and prominent as the organ contracts. They are sinuous, and anastomose in an irregular network. As finer markings, there are rounded or polygonal areas, 2-4 mm. in diameter, which may appear as elevations or depressions. They have been ascribed to the contraction of muscle fibers in the mucous membrane, to varying amounts of lymphoid tissue, and to the varying height of the glands. Toward the pylorus there are small leaf-like elevations, the *plicæ villosæ*, which may connect with one another in a network. The epithelium of the stomach is thin enough to transmit the color of the underlying tissue, and appears pinkish gray; whereas the color of the œsophagus, with a thicker epithelium, is white.

The gastric epithelium, like that of the entire intestine, is a single layer of columnar cells. In the stomach the cells are tall and contain mucus, but they do not ordinarily acquire the bulging goblet shape, since the adjacent cells likewise contain mucus. This simple layer of mucous cells is continuous at the cardia with the basal layer of the stratified epithelium of the

œsophagus, and the transition is abrupt. The outer strata of the œsophageal epithelium may form an overhanging wall (Fig. 243), or the number of layers may have become reduced so that such a wall is absent. Sometimes an island of stratified epithelium occurs just beyond the line of transition. The gastric epithelium forms three types of glands, known as cardiac, gastric, and pyloric glands respectively, none of which extend into the submucosa.

The *cardiac glands* are like the superficial glands at the lower end of the œsophagus, of which they may be regarded as a continuation. They extend only from 5 to 40 mm. into the stomach, and in the narrow zone which they occupy, they present a gradual transition to the gastric glands. Their branches, instead of continuing divergent, become groups of perpendicular tubes descending from epithelial pits; and deeply staining eosinophilic cells and the granular chief cells become included in their epithelium.

The cells characteristic of the cardiac glands contain a mucus which does not respond readily to mucin stains. Like the superficial glands of the œsophagus, the cardiac glands develop early, and they are found widely distributed among mammals.

The *gastric glands* (sometimes inappropriately called fundus glands) occur over the entire surface of the stomach, except near the cardia and pylorus. Each gastric gland is divided into an outer portion, or *gastric pit* (*foveola gastrica*), and a group of slender cylindrical tubules which empty into the bottom of the pit. During development, as the lining of the stomach expands greatly, the number of pits increases. Toldt estimated that there were 129,912 in the stomach at three months; 268,770 at birth and 2,828,560 at ten years. The increase is accomplished by division of the pits from below upward. In spite of the fact that many new branches develop, the average number of tubules emptying into each pit becomes reduced as the pits become subdivided; and the average of seven per pit observed at birth becomes three in the adult (Toldt, Sitz.-ber. Akad. d. Wiss. Wien, 1881, vol. 82, pp. 57-128).

The pits are often described as if they were epithelial depressions separate from the glands, since the same sort of epithelium which lines them is found on the free surface. Developmentally, however, they are to be regarded as parts of the glands, comparable with ducts. The epithelial cells of the pits (Fig. 245) consist of a basal protoplasmic portion containing elongated, round, or sometimes flattened nuclei, and an outer portion containing the centrosome and secretion. The mass of mucus may cause the thin top plate to bulge, and in preserved tissue to rupture, but this may be due to reagents. The mucus first appears in granular form.

The gastric tubules are straight or somewhat tortuous slender structures, with narrow lumens. The portion which joins the pit constitutes

the neck of the gland, and the slightly expanded basal end is the fundus. Apparently the neck is the zone of growth, since it is the place where

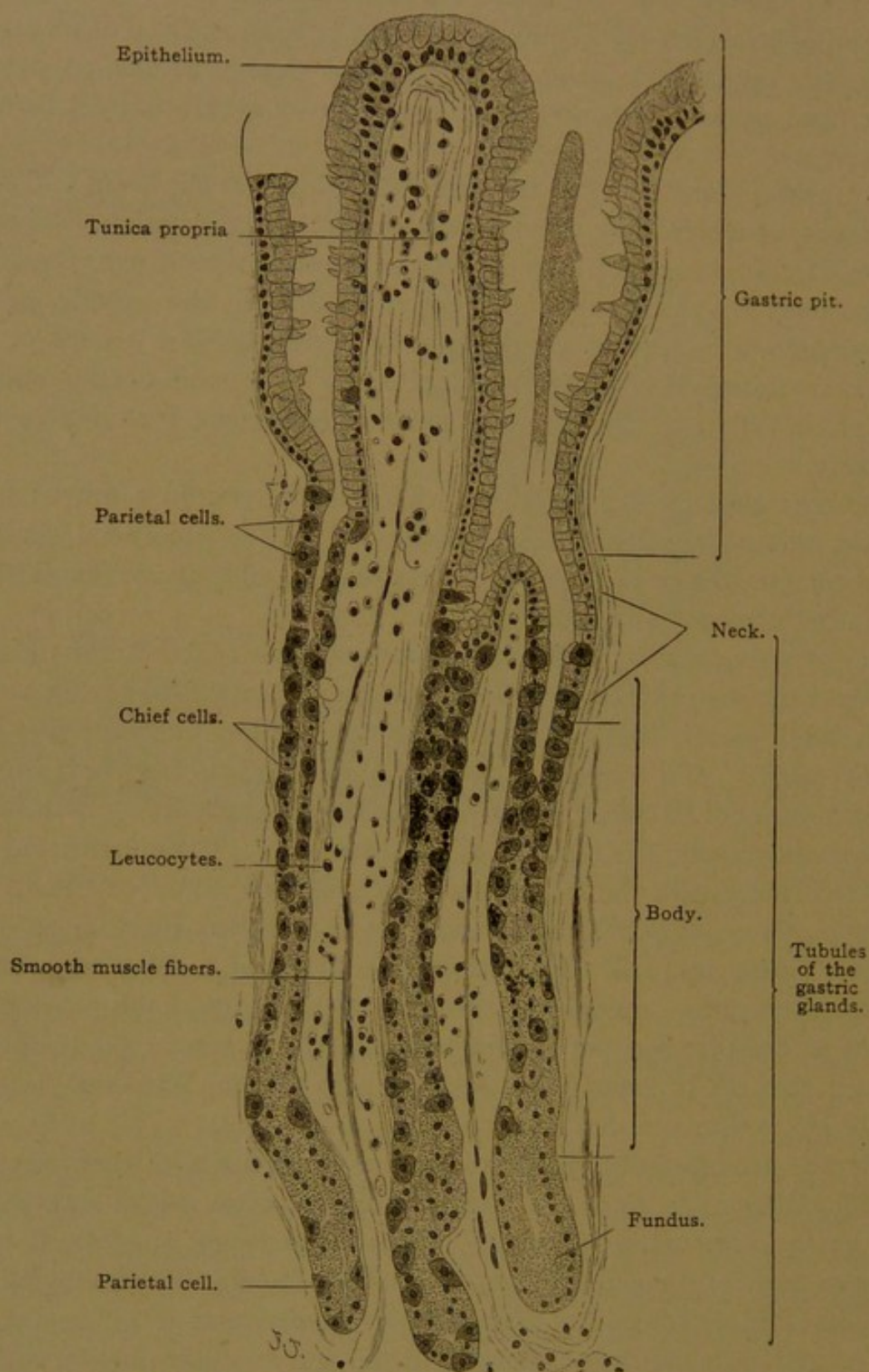


FIG. 245.—VERTICAL SECTION OF THE MUCOUS MEMBRANE OF A HUMAN STOMACH, SHOWING GASTRIC GLANDS (GLANDULÆ GASTRICÆ PROPRIÆ). X 220.

mitotic figures are found. Each tubule is composed of cells of two sorts, *chief cells* and *parietal cells*.

The chief cells usually form the greater part of the tubules. They are

wedge-shaped cells, having a narrow contact with the lumen. In general they have the aspect of serous cells, containing round nuclei and granular protoplasm. The granules, which are coarser toward the lumen, do not respond to mucin stains. They accumulate, and the chief cells enlarge, in the absence of food from the stomach; but during gastric digestion, the cells become small and the granules disappear. They apparently give rise to the pepsin of the gastric juice, and are called *zymogen granules*. After death the chief cells rapidly disintegrate, and the granules are seldom well preserved except in special preparations.

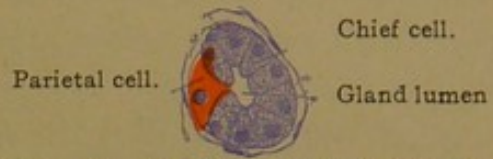

FIG. 246.—TRANSVERSE SECTION OF A HUMAN GASTRIC GLAND. $\times 240$.

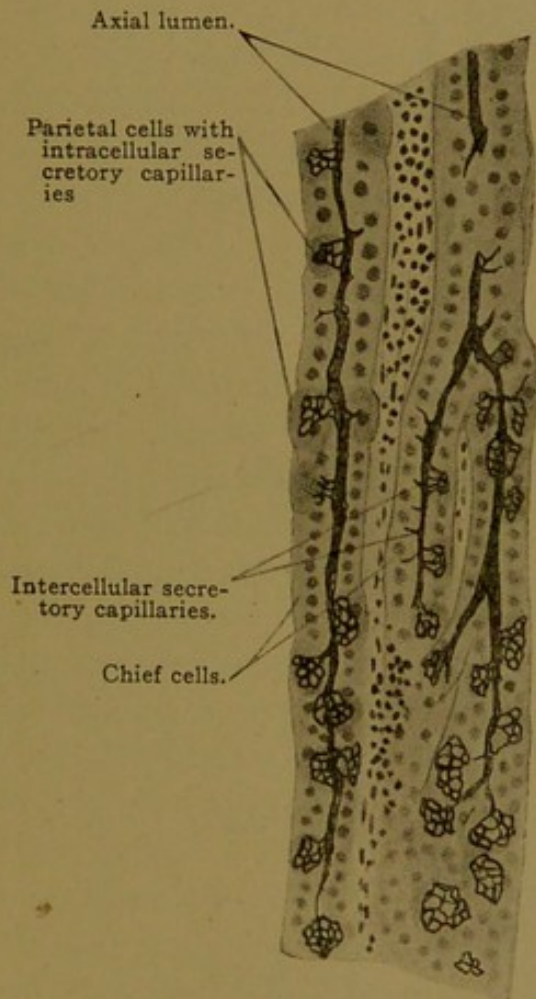


FIG. 247.—GOLGI PREPARATION, SHOWING THE SECRETORY CAPILLARIES IN GASTRIC GLANDS. $\times 230$.

whereas the parietal cells are clear. They are large cells, containing one or occasionally two round nuclei, and are crowded away from the lumen like the cells in the serous crescents (Figs. 245 and 246). They discharge their secretion through secretory capillaries which produce basket-like networks within the protoplasm; thus they differ from the chief cells which have only intercellular secretory capillaries. The secretory capillaries of the parietal cells may be demonstrated by the Golgi method, which produces a precipitate wherever secretion is encountered (Fig. 247). After fasting, the parietal cells are small and their intracellular capillaries have disappeared. Following abundant meals, these cells enlarge and may contain vacuoles due to the rapid formation of secretion. They produce the hydrochloric acid which is found in the gastric juice.

In ordinary preparations they are better preserved than the chief cells, and exhibit a finely granular structure, being deeply stained with the anilin protoplasmic dyes. They differ so markedly from the chief cells that they have been erroneously believed to develop from the surrounding tunica propria. As seen in Fig. 245 they occur chiefly along the body of the tubule, being infrequent at its fundus.

The *pyloric glands* are found near the pylorus, but the area which they occupy is not sharply set off; they pass over into gastric glands through a "transition zone." Pyloric glands have very deep pits, from which short, winding, branched tubules grow out. Their form in the adult is shown in Fig. 248. The cells in the pits are mucous cells, and those in

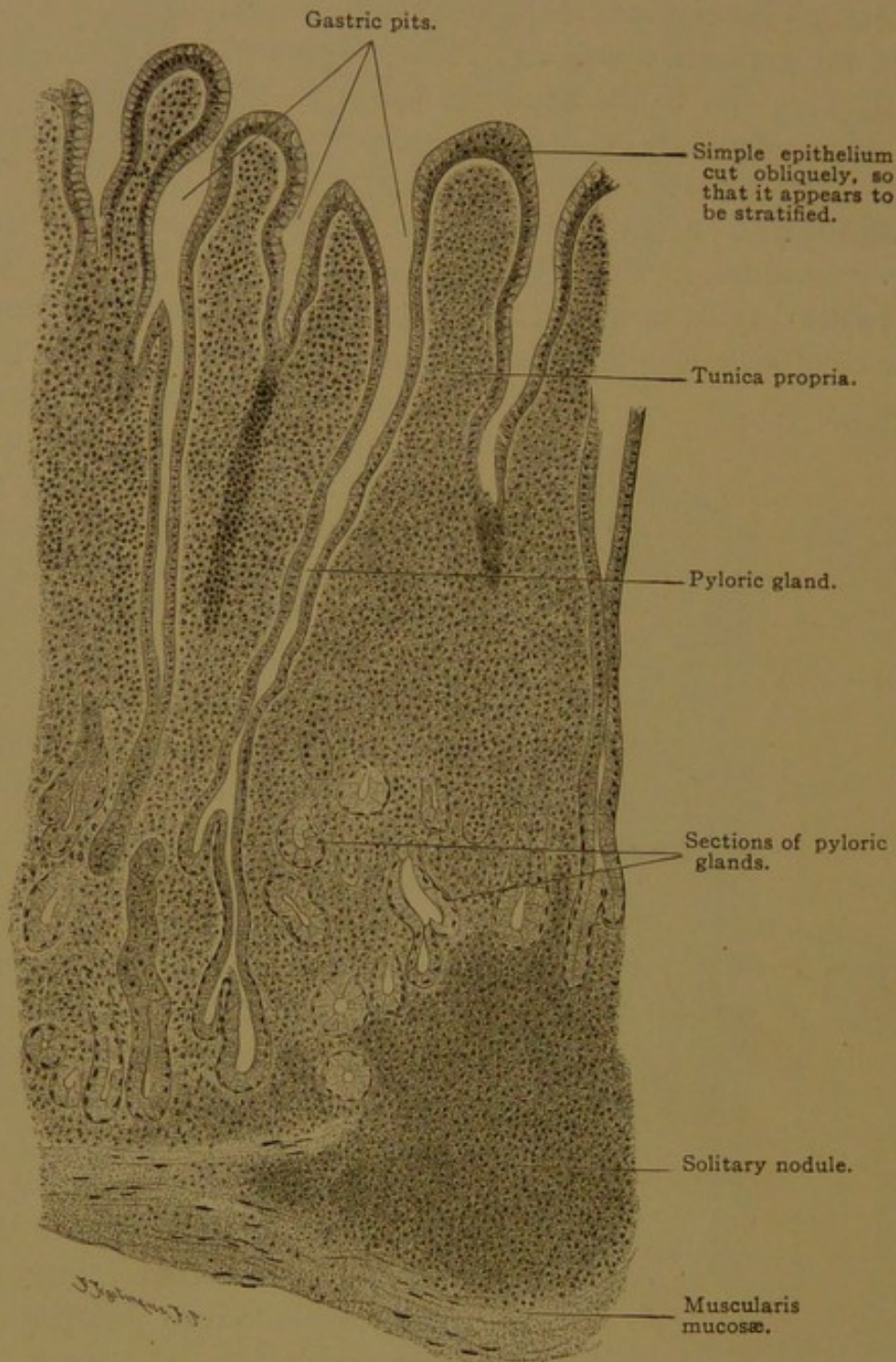


FIG. 248.—VERTICAL SECTION OF HUMAN PYLORIC GLANDS. $\times 90$.

the tubules are also regarded as mucous cells. The latter are columnar, with rounded nuclei in their basal part, and protoplasm which may closely resemble that of the chief cells. Parietal cells are occasionally found, and such cells have been reported in the duodenal glands and in the superficial glands of the œsophagus. Slender dark cells, apparently due to com-

pression, are found in the pyloric glands of the dog. In certain respects the pyloric glands are transitional between gastric and duodenal glands.

The *tunica propria* consists of the small amount of reticular and connective tissue which is found between the closely packed glands and immediately beneath them (Fig. 249). It is sufficient to support the numerous capillaries branching about the glands, the terminal lymphatic vessels and nerves, numerous wandering cells and a few vertical smooth muscle fibers prolonged from the muscularis mucosæ (Fig. 245). The lymphatic

vessels begin blindly near the superficial epithelium and pass between the glands into the submucosa where they spread out and are easily seen; they continue across the muscularis and pass through the mesentery to join the large lymphatic trunks. Solitary nodules occur in the gastric mucosa, especially in the cardiac and pyloric regions (Figs. 243 and 248); they may extend through the muscularis mucosæ into the submucosa. The muscularis mucosæ may

be divided into two or three layers of fibers having different directions. The submucosa contains its plexus of nerves and many vessels, together with groups of fat cells. Its elastic fibers are said to be abundant toward the pylorus.

The muscular coat of the stomach consists of three layers of smooth muscle, an outer longitudinal, middle circular, and inner oblique layer respectively. These layers can be recognized by dissection more readily than by microscopic examination, and were found by Willis in 1674. The middle layer is the one most highly developed. It not only surrounds the body of the stomach, but as the fundus pushes outward, muscle fibers of this layer encircle its apex concentrically. Toward the pylorus, along the antrum, the circular layer gradually thickens, thus forming the *sphincter pylori*; it becomes abruptly thin in the duodenum. There is no sphincter at the cardia, where the circular layer is continuous

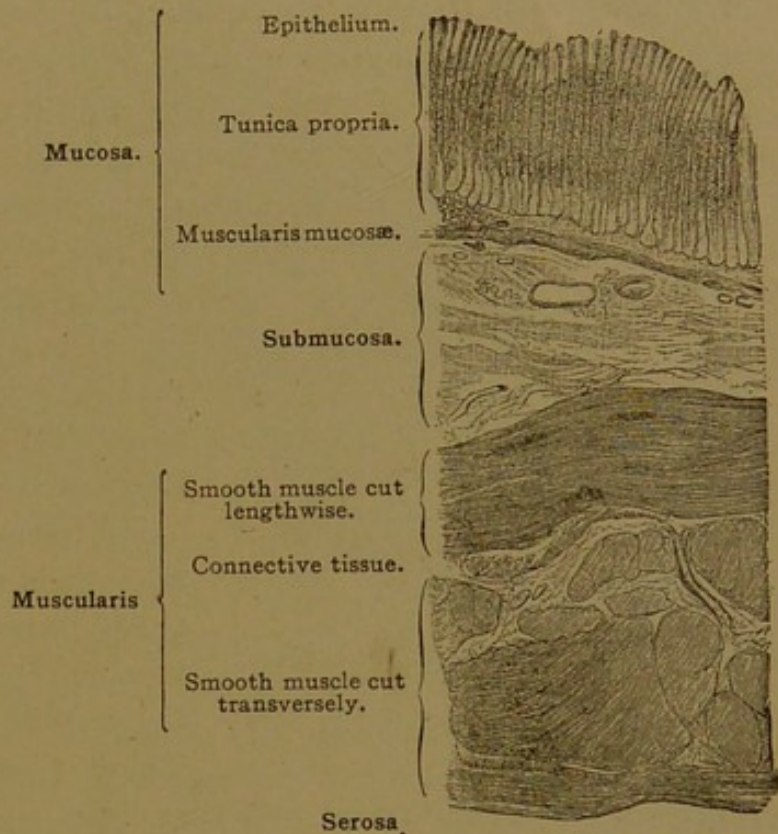


FIG. 249.—VERTICAL SECTION OF THE WALL OF A HUMAN STOMACH. The tunica propria contains glands standing so close together that its tissue is visible only at the base of the glands toward the muscularis mucosæ.

with that of the œsophagus, but elastic tissue in the muscularis is said to be specially abundant and to "contribute to the tonus of the cardiac musculature." The outer longitudinal layer, continuous with the outer layer in the œsophagus and duodenum, is an incomplete layer, being deficient toward the greater curvature. As the body of the stomach bulges outward to form this curvature, the longitudinal fibers apparently become separated into scattered bundles. In the pars pylorica, however, there is a continuous longitudinal layer, and some of its fibers, which become intermingled with those of the sphincter pylori, serve to dilate the pylorus. The innermost layer, composed of oblique fibers, is not represented

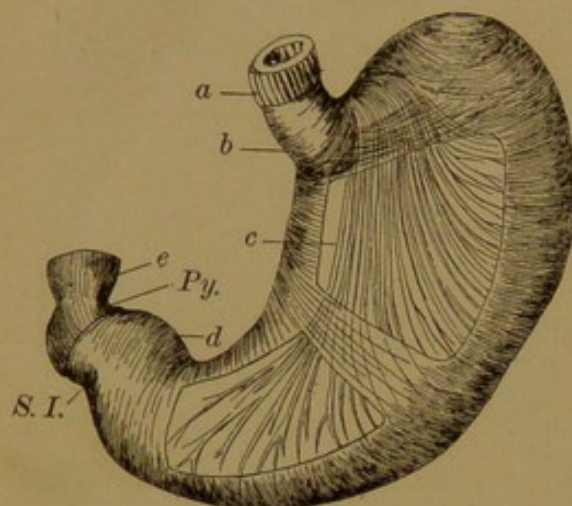


FIG 250.—A DISSECTION OF THE MUSCULATURE OF THE STOMACH. (Spalteholz.)

a and e, Longitudinal layer; b and d, circular layer; c, oblique layer; Py., pylorus; S. I., sulcus intermedius.

in the œsophagus and duodenum, and is said to be absent from the pars pylorica. The peculiar arrangement of its fibers is shown in Fig. 250, in which the outer longitudinal layer has been almost entirely removed, and windows have been cut through the circular layer; the oblique fibers are seen against the submucosa. They form a longitudinal strand parallel with the lesser curvature, and they pass from one side of the stomach to the other across the notch between the œsophagus and fundus.

These fibers are important in the activity of the gastric canal, but they do not produce the canal as some have supposed. From these longitudinal bundles, fibers curve obliquely toward the greater curvature, where, as transverse fibers they cross to the opposite side. Thus the musculature of the stomach is so arranged that it is very difficult to determine the plane of section in a small piece of gastric mucous membrane, which is usually cut obliquely; but the section shown in Fig. 249, with inner and outer layers cut lengthwise and a middle layer cut across, is consistent with a longitudinal section of the *corpus gastrici*.

The *tunica serosa* consists of connective tissue with well-developed elastic nets, and a covering of peritoneal epithelium interrupted only along the curvatures, at the mesenteric attachments. It contains the nerves and vessels which supply the stomach. The right and left vagus trunks descend beside the œsophagus as the main stems in a plexiform network, and then come together along the lesser curvature. From there they send plexiform branches over both sides of the stomach, and the main stems continue into the small intestine. Sympathetic nerves from the celiac plexus pass to the pyloric end of the stomach and join the vagus

plexus. The further distribution of the nerves in myenteric and submucous plexuses is similar to that in the small intestine.

DUODENUM.

The duodenum contains branched mucous glands, the bodies of which are found in the submucosa. These are called *duodenal glands* (Brunner's

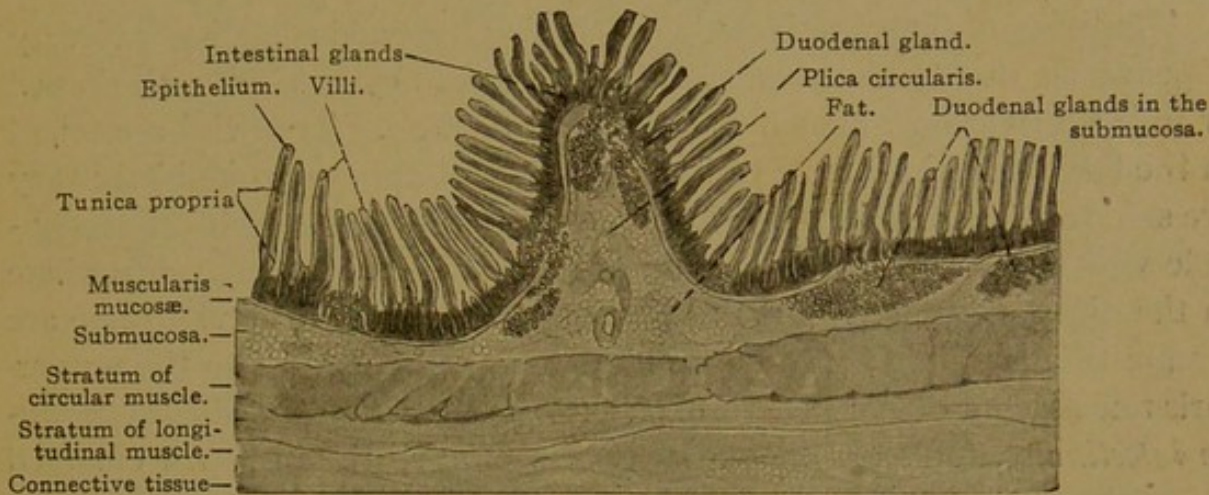


FIG. 251.—LONGITUDINAL SECTION OF THE HUMAN DUODENUM. $\times 16$.

glands) and they occur nowhere else in the small intestine (Fig. 251). Their cells produce a mucus which stains with difficulty, thus contrasting with the mucus of the goblet cells in the tubular glands above them. The nature of their epithelium is shown in Fig. 252, which shows also that a portion of their tubules may lie above the muscularis mucosae, in the tunica propria. As in the pyloric glands, occasional parietal cells have been found, and also the dark cells, due to compression. Secretory capillaries extend out from the lumen between the cells, and the tubules are provided with a structureless basement membrane. The ducts of the duodenal glands may open on the free surface of the epithelium, or into the lower ends of the tubular pits situated in the mucous membrane and known as *intestinal glands*. The duodenal glands are so numerous toward the stomach that the submucosa may be filled with their tubules. They are also abundant near the *duodenal papilla* where the

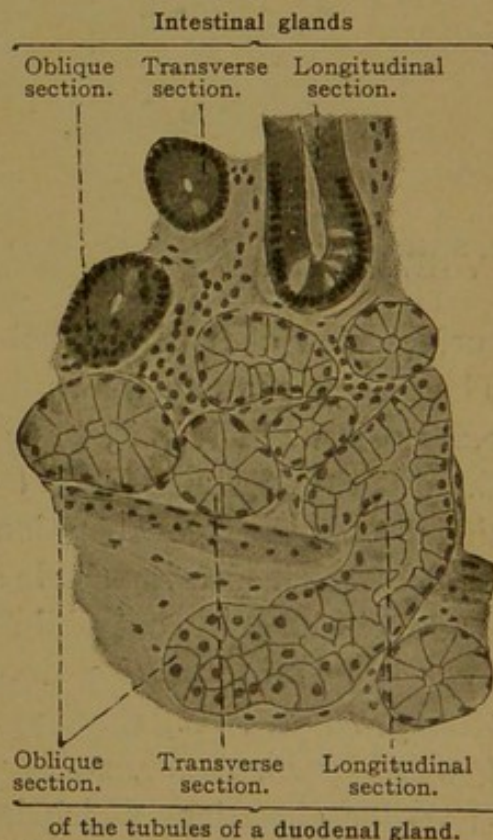


FIG. 252.—FROM A SECTION OF A HUMAN DUODENUM. $\times 240$.

Only the lower half of the mucosa and upper half of the submucosa are sketched.

bile and pancreatic ducts enter the descending portion of the duodenum. Beyond this point they become fewer, and disappear before the end of the duodenum is reached. Except for these glands the duodenum is essentially like the remainder of the small intestine, described in the following section.

JEJUNUM AND ILEUM.

The lining of the small intestine, including the duodenum, has a velvety appearance, due to the presence of innumerable cylindrical, club-shaped or foliate elevations, known as *villi* (hairs or nap). True villi are found in the large intestine of the embryo but they disappear before birth; they are said to occur also in the pyloric end of the stomach, but it is questionable whether these are typical villi or merely irregular folds. Elsewhere in the digestive tube, villi are absent. At the bases of the villi there are simple tubular pits of glandular epithelium, which extend to the muscularis mucosæ but do not penetrate it; these are the *intestinal glands* (*glandulæ intestinales*, formerly known as crypts of Lieberkühn). An enlarged

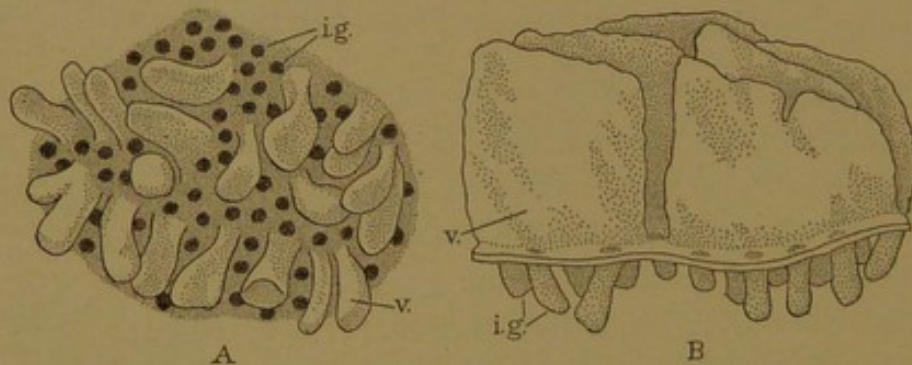


FIG. 253.

A, Surface view of the hardened mucosa of the small intestine (after Koelliker). B, Side view of a wax reconstruction of the epithelium in the human duodenum (Huber). i. g., Intestinal gland; v., villus.

surface view of the hardened mucous membrane is shown in Fig. 253, A. The orifices of the glands appear as round holes; the villi, which are from 0.2–1.0 mm. in height, have fallen over in various directions. Within the duodenum the villi are low leaf-like folds, 0.2–0.5 mm. high, seen in side view in the reconstruction, Fig. 253, B. Their shape cannot be determined from inspecting single sections (cf. Fig. 251).

It will be seen that villi are essentially circumscribed folds, and they have been said to arise through the subdivision of longitudinal ridges (Berry, *Anat. Anz.*, 1900, vol. 17, pp. 242–249). According to Johnson (*Amer. Journ. Anat.*, 1910, vol. 10, pp. 521–561) they develop as low knob-like elevations which increase in height. They may become subdivided, as indicated by bifid villi (Fig. 253).

The small intestine contains other elevations of its lining which are much larger than the villi. These are the circular folds (*plicæ circulares*,

formerly known as Kerkring's *valvulae conniventes*), which are seen conspicuously on opening the intestine. They are thin leaf-like membranes, in places very close together, which, as their name implies, tend to encircle the tube. Sometimes they form short spirals, and they may branch and connect with one another. They begin in the duodenum, and beyond the duodenal papilla they are tall and close together. They are highly developed in the jejunum and form its most characteristic feature. In the ileum they are lower and further apart; and they may come to an end two feet above the colon. The villi correspondingly are taller and

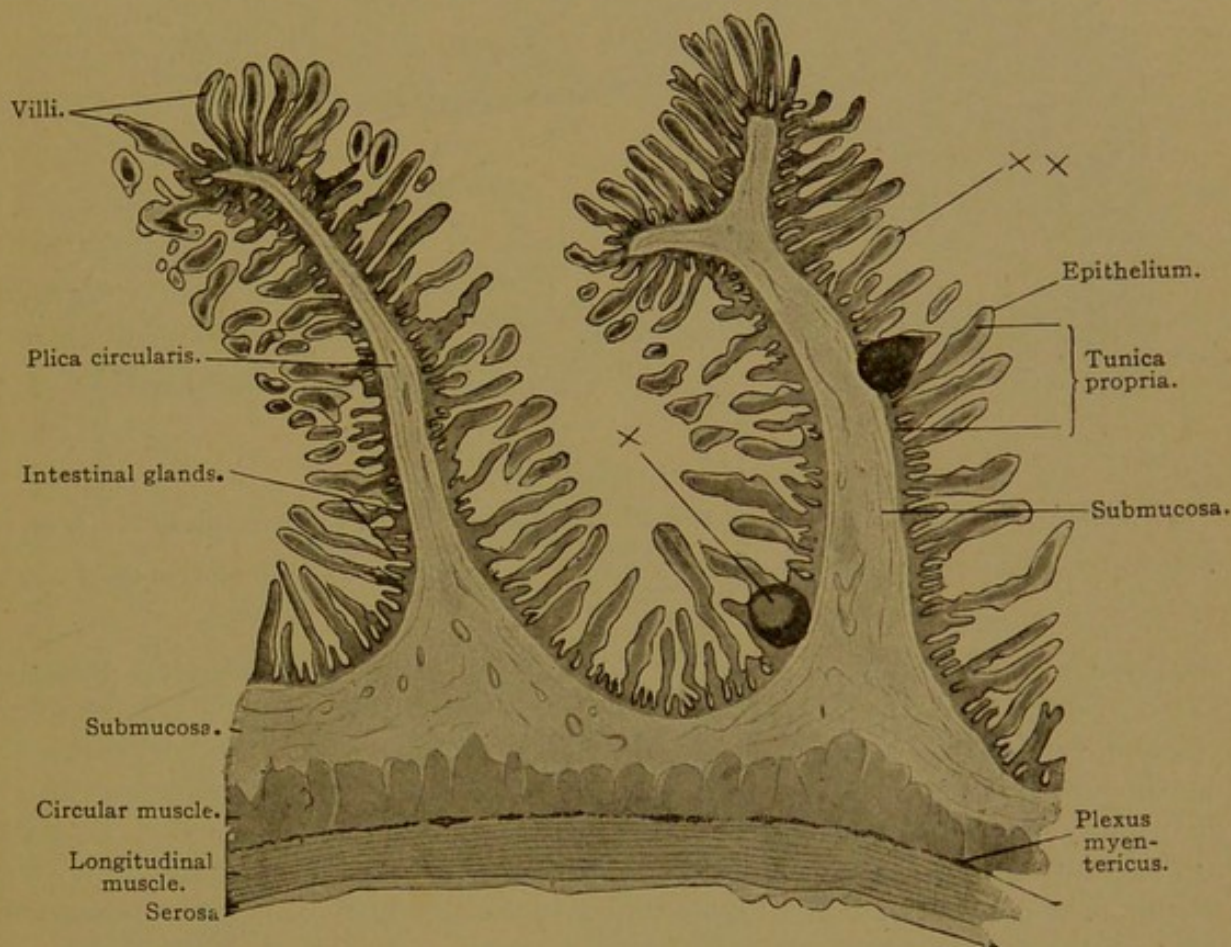


FIG. 254.—VERTICAL LONGITUDINAL SECTION OF THE JEJUNUM OF AN ADULT MAN. $\times 16$.

The plica circularis on the right supports two small solitary nodules, which do not extend into the submucosa; one of them exhibits a germinal center. *x*. The epithelium is slightly loosened from the connective tissue core of many of the villi, so that a clear space, *xx*, exists between the two. The isolated bodies lying near the villi (more numerous to the left of the plicae circulares) are sections of villi that were bent, so that their ends were cut off in sectioning.

more numerous in the jejunum than in the ileum, in the distal part of which they are short and scattered, finally disappearing on the colic surface of the *valve of the colon* (ileo-cæcal valve). Thus few and short villi and scattered plicae indicate that a section of the intestine is from the ileum.

As seen in sections, the *plicae circulares* are elevations of the submucosa (Fig. 254) covered on both sides by the entire mucous membrane—villi, glands and the muscularis mucosæ. A low plica of the duodenum is shown in Fig. 251.

The glands, villi, and plicæ have usually been regarded as permanent structures, serving to increase the secreting and absorbing surfaces of the intestine. In mammals they apparently are not obliterated by the normal distention of the intestine, although the villi may become shorter, the glands shallower, and the plicæ may be partially taken up like the folds of the œsophagus. In the guinea-pig, and to some extent in the rabbit and cat, Heitzmann found that the villi change their shape with the intes-

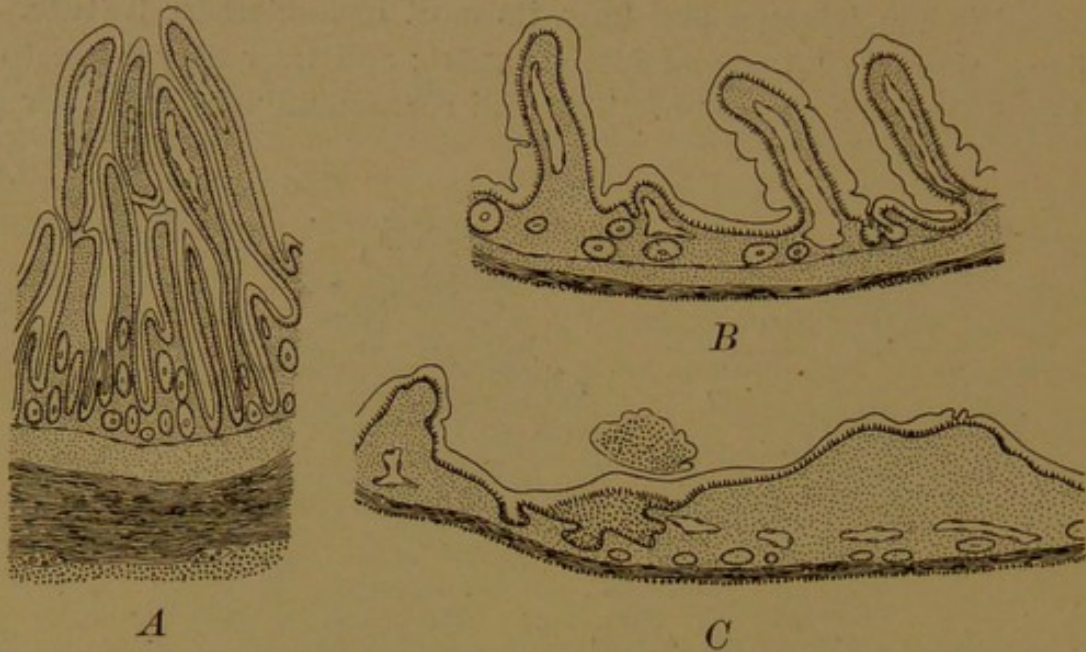


FIG. 255.—EFFECTS OF DISTENTION ON THE SMALL INTESTINE OF THE ADULT GUINEA-PIG. $\times 50$. (Johnson.)

A, Strongly contracted; B, normally distended with food; C, distended with a pressure of 150 cm. of water.

tinal contractions and expansions associated with its physiological activity. Johnson (Amer. Journ. Anat., 1913, vol. 14, pp. 235-250) has shown that in guinea-pigs the villi and glands of the contracted intestine have the form seen in Fig. 255, A; with normal distention due to abundant food, they appear as in B; and with extreme artificial distention, the glands and villi are nearly obliterated as in C. The tube expands to this limit, beyond which additional pressure has no effect until it ruptures. On releasing the pressure, glands and villi return to their normal size. Interesting questions are suggested, as to how the muscle fibers become rearranged in the thin layer when the intestine is distended, and what takes place in the blood and lymphatic vessels. These problems are under investigation.

Finer Structure of the Glands and Villi. At the blind lower end or fundus of the glands, there occur certain cells containing many coarse granules in that part of their protoplasm which is toward the lumen (Fig. 256). These cells were first described by Paneth (Arch. f. mikr. Anat., 1888, vol. 31, pp. 113-191) and are known as *Paneth's cells*. They are found in the glands of the duodenum, jejunum and ileum, but not in those of the large intestine. Although they may be observed with ordinary stains, they are more strikingly demonstrated in iron-hæmatoxylin preparations. Apparently they produce a special secretion, which enters the lumen of the gland in the form of fine granules when the digestion of fat

is taking place, and may perhaps be concerned also with protein digestion, but not with that of carbohydrates (Miram, *Arch. f. mikr. Anat.*, 1912, vol. 79, pp. 105-113). They do not contain mucinogen granules, although goblet cells occur in their immediate vicinity.

A short distance above the fundus, the epithelial cells of the glands exhibit mitotic figures. From this it is inferred that the outer cells, including those of the villi, are renewed from below. The cells near the bottom of the gland have terminal bars, but they are not as distinct as those of the villi. During division, the cell seems to be drawn up from the basement membrane, as if held in position by the

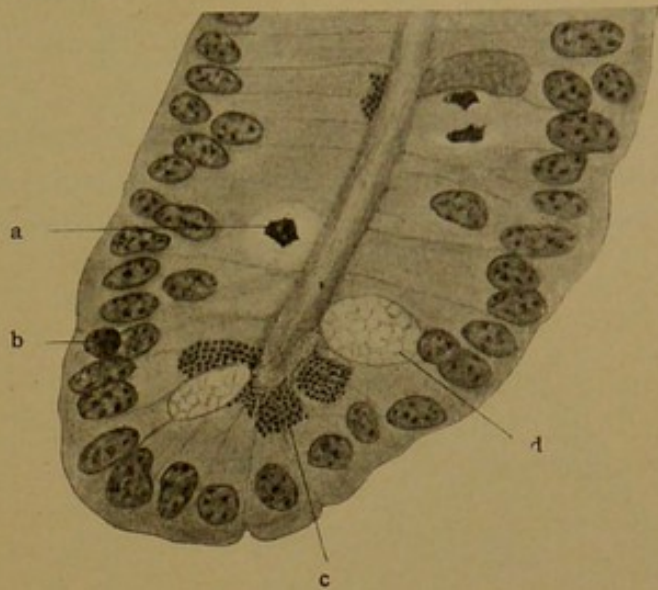


FIG. 256.—THE FUNDUS OF AN INTESTINAL GLAND FROM THE DUODENUM OF A GUINEA-PIG. $\times 480$.
a, Cell in mitosis; b, lymphocyte; c, Paneth's cell; d, goblet cell.

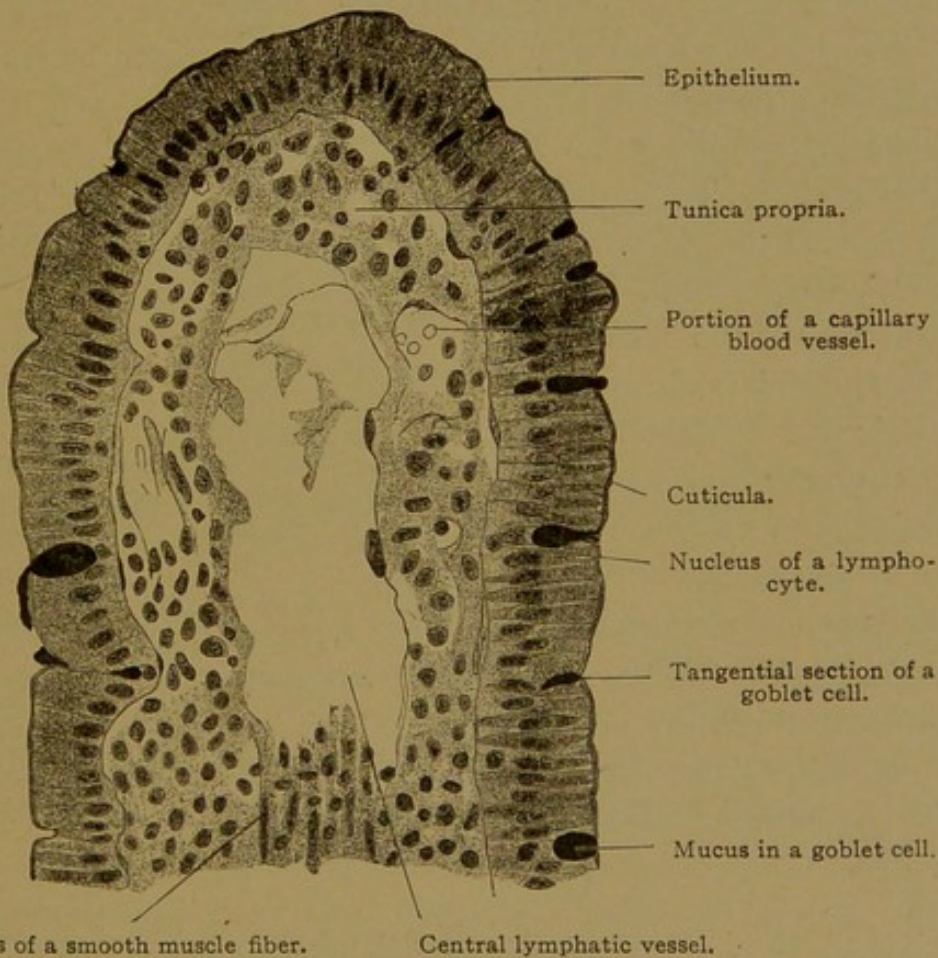


FIG. 257.—LONGITUDINAL SECTION THROUGH THE APEX OF THE VILLUS OF A DOG. $\times 360$.
The goblet cells contain less mucus as they approach the summit of the villus.

terminal bars (Fig. 256, a). The plane of division is at right angles with the long axis of the gland (as shown on the right of Fig. 256), and after

mitosis the nuclei move back to the basal layer. Lymphocytes which have made their way between the epithelial cells (Fig. 256, *b*), are frequently seen, and when near the lumen and over-stained they may be mistaken for mitotic figures.

The sides of the glands and surfaces of the villi are covered with simple columnar epithelium, similar to that shown in Fig. 256. It contains goblet cells separated from one another by cells free from mucus. The

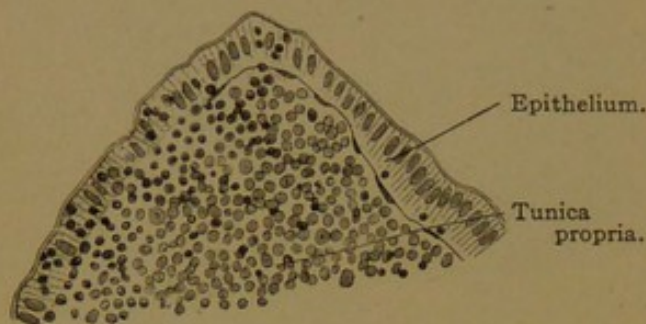


FIG. 258.—FROM A SECTION OF THE SMALL INTESTINE FROM A KITTEN SEVEN DAYS OLD. $\times 250$.

The epithelium on the left contains many wandering leucocytes (lymphocytes). The epithelium on the right contains but three.

cells of the villi are taller than those in the glands, and the goblet cells are somewhat larger, but toward the tip of the villus they become slender and empty (Fig. 257). The top plates or *cuticulæ* become thicker from the fundus of the gland outward to the tips of the villi, and when well developed they

exhibit vertical striations which are considered to be protoplasmic processes lodged in pores. The top-plate of the goblet cells is thin and apparently ruptures to allow the escape of the mucus. Lymphocytes may enter the epithelium in abundance as shown in Fig. 258.

Interest in the villi centers chiefly in their relation to the absorption of nutritive material from the intestinal contents (*chyme*). Fat, chemically changed so that it does not blacken with osmic acid, is conveyed through the cuticula. Within the epithelial cells it forms characteristic fat droplets, which appear in abundance also between the epithelial cells. Lymphocytes ingest the droplets, and may then enter the lymphatic vessel in the central axis of the villus (Fig. 257), but apparently fat is conveyed to the lacteals also through intercellular spaces, without the intervention of leucocytes. Within the lymphatic vessel it forms the milky lymph known as *chyle*.

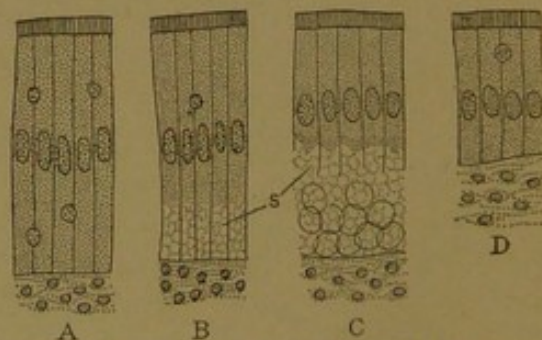


FIG. 259.—STAGES OF INTESTINAL ABSORPTION AS SEEN IN EPITHELIAL CELLS OF VILLI FROM A HEN. (After Mingazzini.)

A and D, The states of repose preceding and following the process. s., Spherules.

In regard to the absorption of protein material, the observations of Pio Mingazzini, which have been confirmed by some and denied by others, are of considerable interest. As shown in Fig. 259, he found that the basal protoplasm of the resting epithelium presented an ordinary appearance (A), but that after absorption had progressed, hyaline spherules appeared in it (B). As these became numerous they were detached from

the cells, forming a reticular mass between them and the tunica propria (C). After the spherules had broken down and had probably been transferred to the blood vessels, the tunica propria entered into its usual relation with the shortened epithelium (D). The basal protoplasm was then restored. According to this interpretation protein absorption is accomplished as a secretory process of the epithelium, the product being eliminated from its basal portion. The spherules accumulate at and near the tips of the villi, in spaces which many authorities describe as due to the artificial retraction of the tunica propria (Fig. 260, a). The spherules have been considered a coagulum of the fluid squeezed from the reticular tissue. In part they may be boundaries of the basal ends of epithelial cells on the distal wall of the villus.

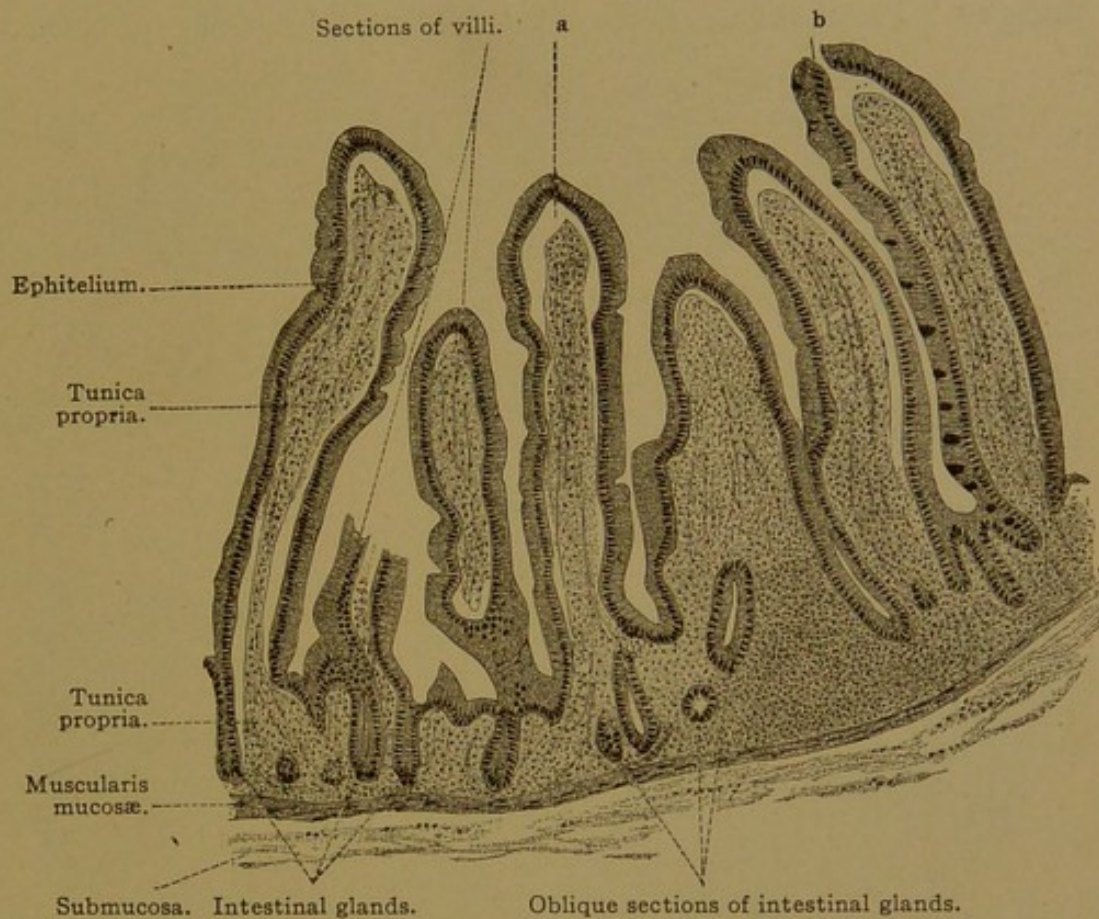


FIG. 260.—VERTICAL SECTION OF THE MUCOUS MEMBRANE OF THE JEJUNUM OF AN ADULT MAN. $\times 80$. The space, a, between the tunica propria and the epithelium of the villus is perhaps the result of the shrinking action of the fixing fluid. At b the epithelium has been artificially ruptured. The goblet cells have been drawn on one side of the villus on the right.

Outer layers of the small intestine. The tunica propria, which forms the cores of the villi and extends between the glands, is a reticular tissue, containing the usual types of free cells and also a large number of plasma cells (see p. 68). Slender strands of smooth muscle extend up and down the villi, being inserted into the reticulum, and by contraction they cause the villi to shorten. The *muscularis mucosæ* consists of an inner circular and an outer longitudinal layer, thus duplicating on a small scale the tunica muscularis. The submucosa is a connective tissue layer, such as has been described in the stomach and œsophagus, and the muscularis is divided into a thick inner circular layer of smooth muscle and a thinner outer longitudinal layer, between which is a thin stratum of intermuscular connective

tissue. The intestine is covered externally by the *tunica serosa*. The distribution of the vessels and nerves in these layers is as follows.

Blood vessels. The arteries pass from the mesentery into the serosa, in which their main branches tend to encircle the intestine. Smaller branches from these pass across the muscle layers to the submucosa, in which they subdivide freely (Fig. 261, A). In crossing the muscle layers they send out branches in the intermuscular connective tissue. These and the arteries of the serosa and submucosa supply the capillary networks found among the muscle fibers. The capillaries are mostly parallel with the muscles. From the submucosa the arteries invade the mucosa, form-

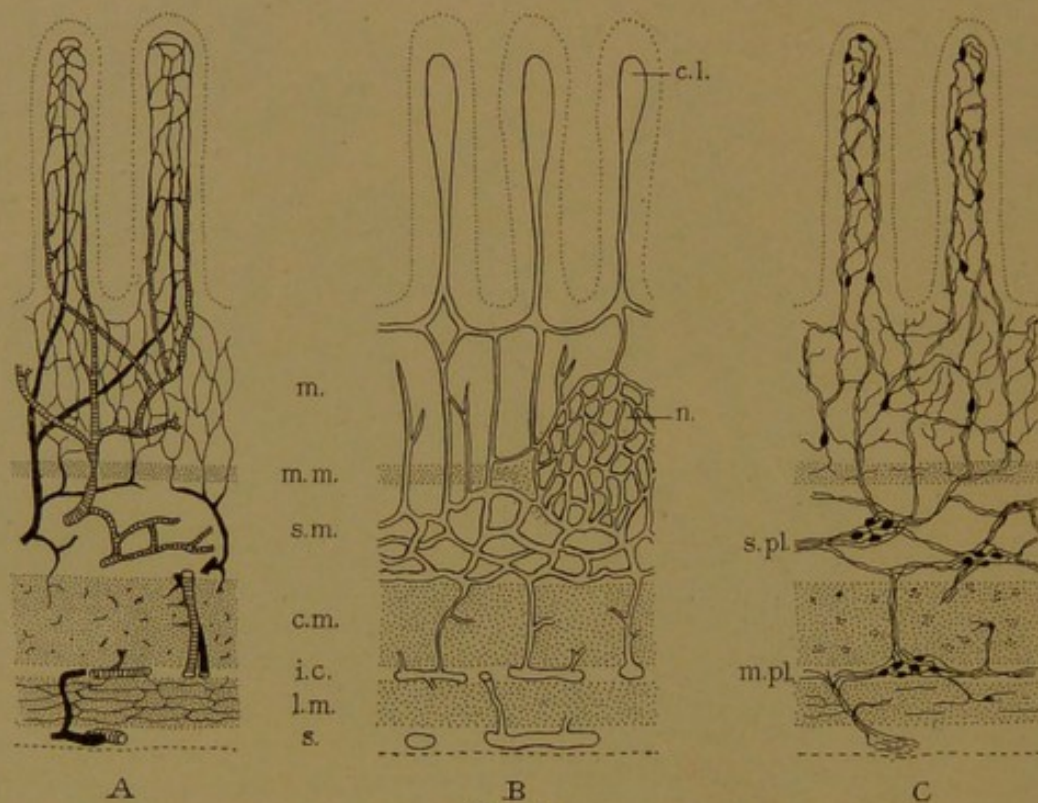


FIG. 261.

A, Diagram of the blood vessels of the small intestine; the arteries appear as coarse black lines; the capillaries as fine ones, and the veins are shaded (after Mall). B, Diagram of the lymphatic vessels (after Mall). C, Diagram of the nerves, based upon Golgi preparations (after Cajal). The layers of the intestine are m., mucosa; m. m., muscularis mucosae; s. m., submucosa; c. m., circular muscle; i. c., intermuscular connective tissue; l. m., longitudinal muscle; s., serosa. c. l., central lymphatic; n., nodule; s. pl., submucous plexus; m. pl., myenteric plexus.

ing an irregular capillary network about the glands, and sending larger terminal branches into the villi. There is usually a single artery for a villus, and it has been described as near the center, with the veins at the periphery (Fig. 261), or sometimes on one side of the villus with the vein on the other. The network of blood vessels in the villi is very abundant as shown in Fig. 262. The veins branch freely in the submucosa and pass out of the intestine beside the arteries. The muscularis mucosae has been described as forming a sphincter for the veins which penetrate it; thus it may control the amount of blood within the villi. No valves occur until the veins enter the tunica muscularis; there they appear, and continue into the collecting veins in the mesentery. They are absent from

the large branches of the portal vein which receive the blood from the intestines.

Lymphatic vessels. The intestinal lymphatics (lacteals) appear as

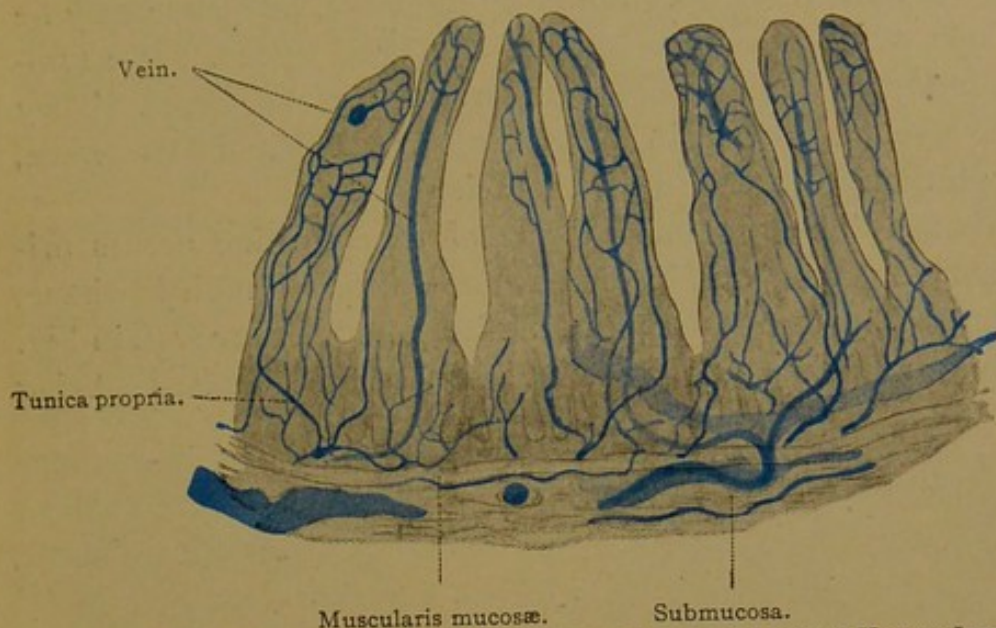


FIG. 262.—VERTICAL SECTION OF THE MUCOUS MEMBRANE OF THE HUMAN JEJUNUM. $\times 50$.
The blood vessels are injected with Berlin blue. The vein of the first villus on the left is cut transversely.

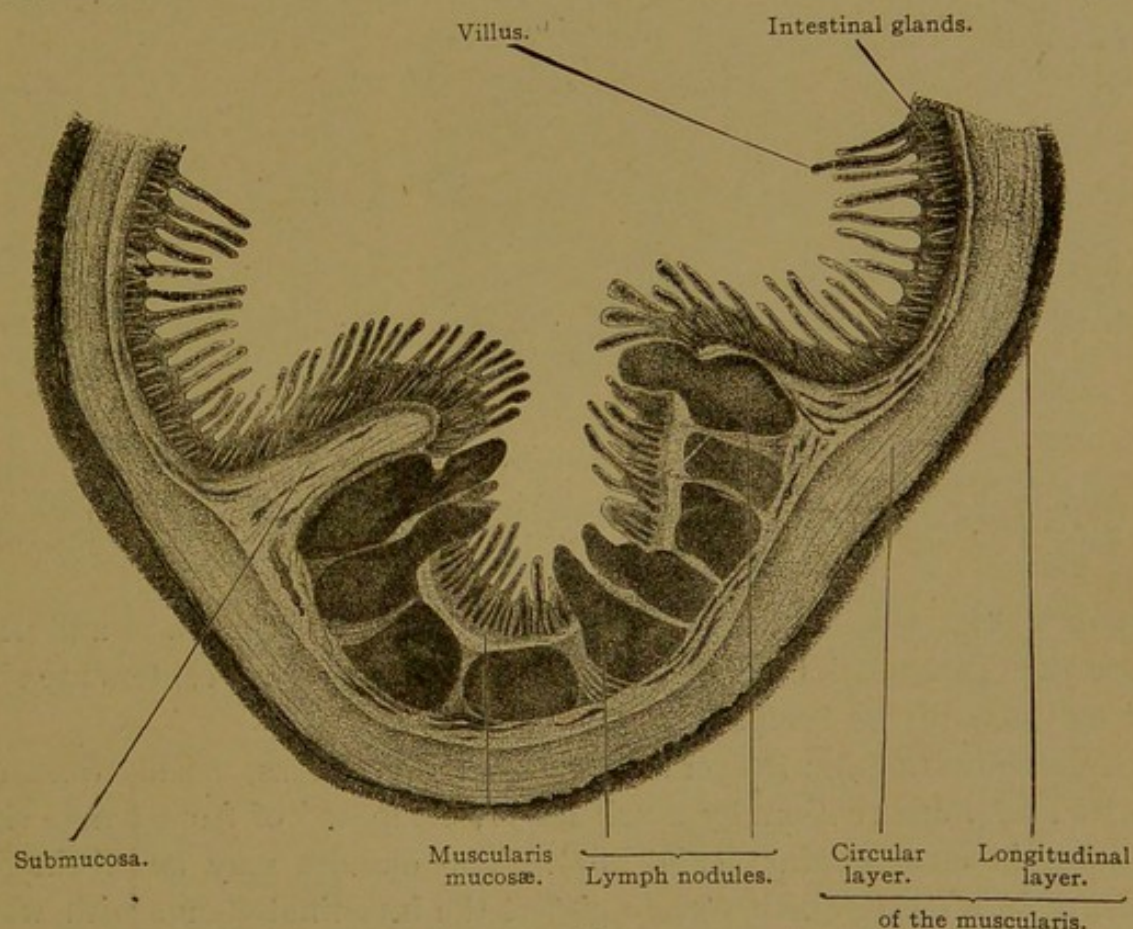


FIG. 263.—TRANSVERSE SECTION OF AGGREGATE NODULES OF THE SMALL INTESTINE OF A CAT.
The crests of four nodules were not within the plane of the section. $\times 10$.

central vessels within the villi (Fig. 261, B). Each villus usually contains a single lacteal ending in a blind dilatation; sometimes there are two or three which form terminal loops. In some stages of digestion the disten-

tion of these lymphatics is very great and their endothelium is easily seen in sections. When collapsed they are hard to distinguish from the surrounding reticulum. Small lateral branches and a spiral prolongation of the central lymphatic have been found by injection, but these may be tissue spaces into which the injected fluid has been forced. The lymphatics branch freely in the submucosa and have numerous valves. They cross the muscle layers, spreading in the intermuscular tissue and the serosa, and pass through the mesentery to the thoracic duct.

Lymphoid tissue. The lymphoid tissue of the intestine occurs primarily in the tunica propria, and in three forms—diffuse lymphoid tissue, solitary nodules, and aggregate nodules. Solitary nodules are seen in Fig. 254. The nodules are surrounded by small vessels, the lymphatics being

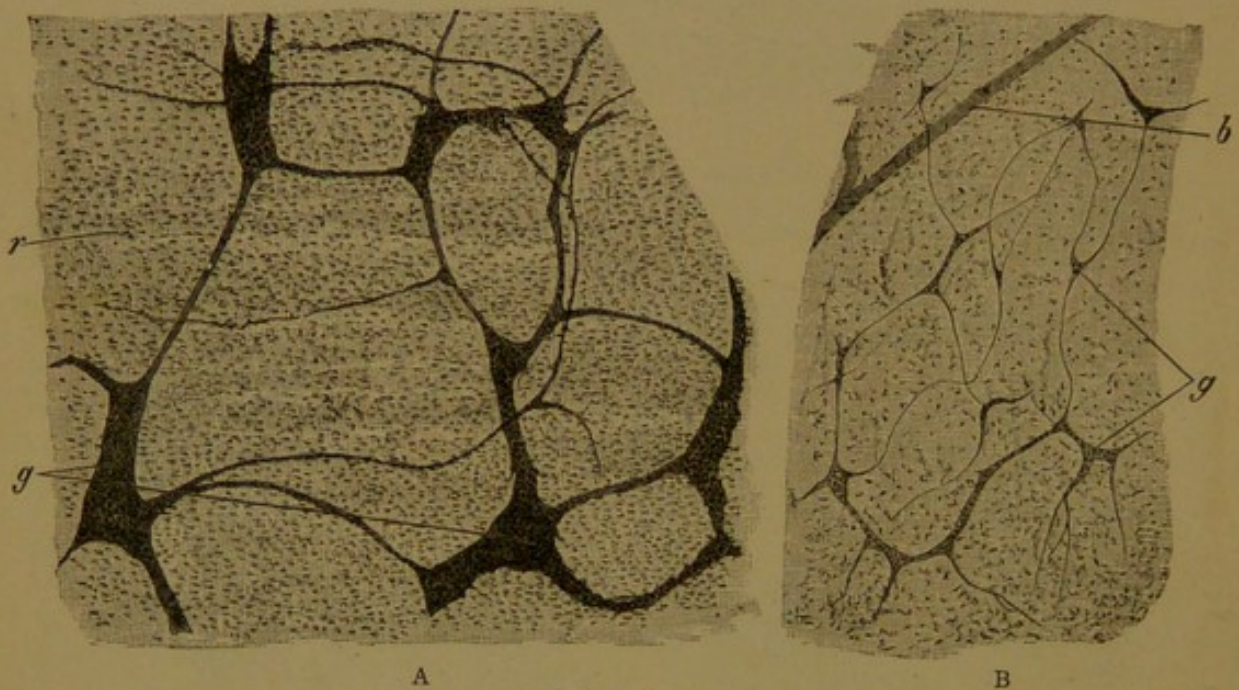


FIG. 264.

A, Surface view of the plexus myentericus of an infant. $\times 50$. g, Groups of nerve cells; r, layer of circular muscle fibers recognized by their rod-shaped nuclei. B, Surface view of the plexus submucosus of the same infant. $\times 50$. g, Groups of nerve cells; b, blood vessel visible through the overlying tissue.

drawn in Fig. 261, B. Blood vessels may make a similar net, and penetrate the outer portion of the nodule. The germinative centers are similar to those in the lymph glands.

Aggregate nodules (Peyer's patches) are oval areas, usually from 1 to 4 cm. long but occasionally much larger, composed of from ten to sixty nodules in close contact (Fig. 263). The nodules may be distinct or blended in a single mass. They distort the intestinal glands with which they are in relation, and immediately above the nodules the villi are partly or wholly obliterated. Thus they appear as dull patches in the lining of the freshly opened intestine, and may be readily seen. There are from fifteen to thirty of them in the human intestine (rarely as many as fifty or sixty) and they occur chiefly in the lower part or the ileum on the side

opposite the mesentery. A few occur in the jejunum and the distal part of the duodenum. In the vermiform process, diffuse aggregate nodules are always present, but they do not occur elsewhere in the large intestine.

Nerves. The small intestine is supplied by prolongations of the vagus nerves, which are joined by branches of the superior mesenteric plexus of the sympathetic system. The latter are regarded as the principal supply. This plexus is ventral to the aorta, and sends branches through the mesentery into the serosa. The manner in which they penetrate the other layers, forming the *myenteric plexus* (Auerbach's plexus) between the circular and longitudinal muscle-layers, and the *submucous plexus* (Meissner's plexus) in the submucosa, is shown in Fig. 261, C. In surface view, obtained by stripping the layers apart, these plexuses are seen in Fig. 264. Their branches supply the smooth muscle fibers. From the submucous plexus the nerves extend into the villi, where nerve cells have been detected by the Golgi method (Fig. 261, C); it has been suspected, however, that some of these "nerve cells" are portions of the reticular tissue. The nerve fibers probably terminate in contact with epithelial cells and provide for local reflex action, whereby the muscles contract in response to stimulation of the epithelium. Most of the intestinal nerves are non-medullated, but they include a few large medullated fibers said to have free endings in the epithelium.

MESENTERY AND PERITONEUM.

The serous membrane which surrounds the intestinal tube and certain other abdominal viscera is a part of the lining of the body cavity. Its general relations are shown in the diagram, Fig. 265. After covering the ventral surface and the sides of the intestinal tube, the two layers of serous membrane come together to form the mesentery and extend to the dorsal body wall; then, separating, they pass laterally as the lining of the abdominal walls and again come together in the mid-ventral line. This serous membrane, or peritoneum, consequently forms a closed sac. It is divisible into the visceral peritoneum which covers the viscera, and parietal peritoneum which lines the body walls. In all cases its free surface is covered with a single layer of flat polygonal cells, resembling endothelium (Fig. 266, B). Although quite flat, the cells have a thin cuticular border which is said to be striated, and the cuticulæ of adjacent cells fit together closely. The lateral walls of these flat cells are connected with one another by proto-

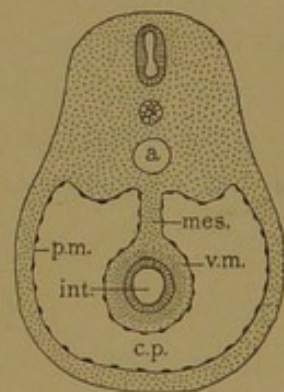


FIG. 265.—DIAGRAM OF A MESENTERY AS SEEN IN CROSS SECTION OF THE ABDOMEN. (After Minot.)
a., Aorta; c. p., cavity of the peritoneum; int., intestine; mes., mesentery; p. m. and v. m., parietal and visceral layers of mesothelium.

plasmic bridges; thus in passing through the epithelium along the intercellular boundaries, one or two intercellular vacuoles would be encountered (Fig. 266, A). Wandering cells pass readily across this epithelium, between the cells, and substances in the peritoneal cavity are taken up into the subserous lymphatics. It has long been thought that there are permanent orifices or "stomata" between the epithelial cells (Fig. 266, B), bounded either by modified protoplasm or by separate small cells, and that lymphatic vessels open directly into the serous cavity through such stomata. This is contrary to recent investigations of the nature of lymphatic

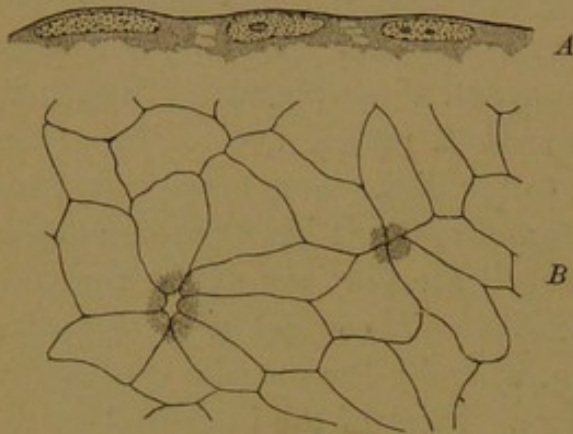


FIG. 266.—SEROUS MEMBRANES.

A, Vertical section of the epithelium (after Heidenhain); B, Surface view, showing two stomata (after Ludwig).

vessels, and the existence of stomata as permanent apertures has been denied. The stomata, so frequently found in a great variety of animals may be shrinkage effects caused by reagents, but their interpretation is not clear. In any case, the transfer of material through the epithelium takes place readily, and the substances or cells which pass through may be taken up freely by the closed lymphatic vessels in the underlying tissue.

In the mesentery, a thin layer of connective tissue with elastic networks and interwoven bundles of white fibers fills the interval between the two epithelial layers. In this connective tissue there are many lymphatic and blood vessels, and nerves to the various organs. Mast cells may be found along the vessels, especially in young animals (Fig. 55, p. 68) and various other forms of wandering cells occur. The connective tissue layer is denser in the parietal than in the visceral peritoneum. In places where the peritoneum is freely movable there is a *subserous layer* of loose fatty tissue, but there is no subserous layer in the intestine.

VERMIFORM PROCESS.

The vermiform process is a "worm-like" prolongation of the cæcum. Although small in size, in structure it more closely resembles the large intestine, of which it is a part, than the small intestine. In embryos of three and one-half to five months it is lined with villi, but with further development the villi flatten out and disappear. Meanwhile the glands, which are of the same type in both small and large intestines, have developed and are increasing in number and in length. Sometimes they pene-

trate the muscularis mucosæ. In the adult (Fig. 267) they are simple tubes, occasionally forked, thus indicating the way in which they multiply in the embryo. As early as the fourth month, lymphoid tissue has been found in the vermiform process, and at birth the lymphoid nodules in the tunica propria are abundant and more or less confluent. The great development of lymphoid tissue is the most important histological feature of the vermiform process in the adult (Fig. 267). It may invade and partly

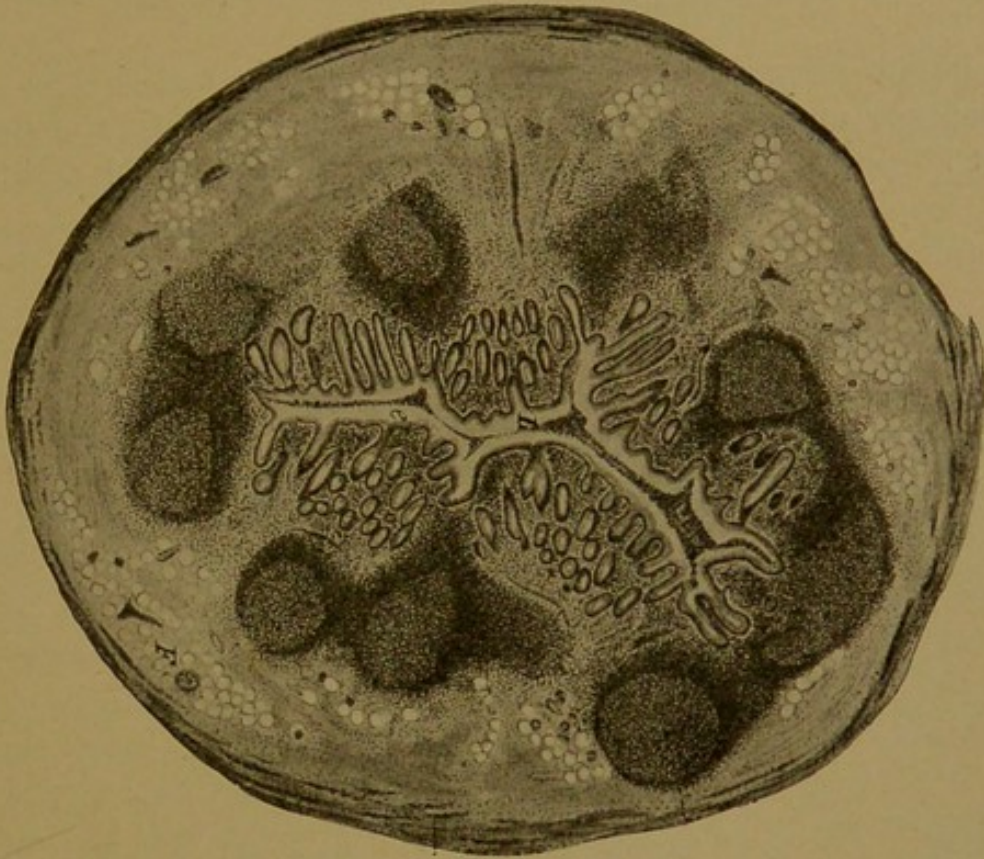


FIG. 267.—TRANSVERSE SECTION OF THE HUMAN VERMIFORM PROCESS. $\times 20$. (Sobotta.) Note the absence of villi and the abundance of nodules. Clear spaces in the submucosa are fat cells. Only a part of the circular layer of the muscularis has been drawn.

break up the muscularis mucosæ, and extend into the submucosa. The latter, together with the inner circular and outer longitudinal muscle layers, and the serosa, are similar to the corresponding layers of the small intestine, already described.

During the fifth month of embryonic life, Stöhr has found an interesting normal form of degeneration in the glands of the vermiform process (*Arch. f. mikr. Anat.*, 1898 vol. 51, pp. 1-55). The tunica propria around them appears to thicken, and the goblet cells in the neck of the degenerating gland, after becoming flattened, produce a solid strand. The strand then ruptures and the detached fundus becomes cystic. Subsequently it shrinks to a small nodule surrounded by dense connective tissue, and ultimately disappears. This degeneration is said to be limited to the fifth and sixth months.

The lumen of the normal vermiform process in the adult, when empty, is thrown into folds, between which are deep pockets; but the normal con-

dition is found in scarcely 50% of individuals over forty years of age (Stöhr). Often the lumen is narrowed or even obliterated. The epithelium with its glands and the lymphoid nodules then disappear, and are replaced by an axial mass of fibrous tissue. This is surrounded by the unaltered submucosa and muscularis; the serosa may show the results of inflammatory conditions.

CÆCUM AND COLON.

The human cæcum and colon contain villi only in the embryo. These villi disappear at about the sixth month. The production of new cells does not keep pace with the expansion of the epithelial tube, and the villi

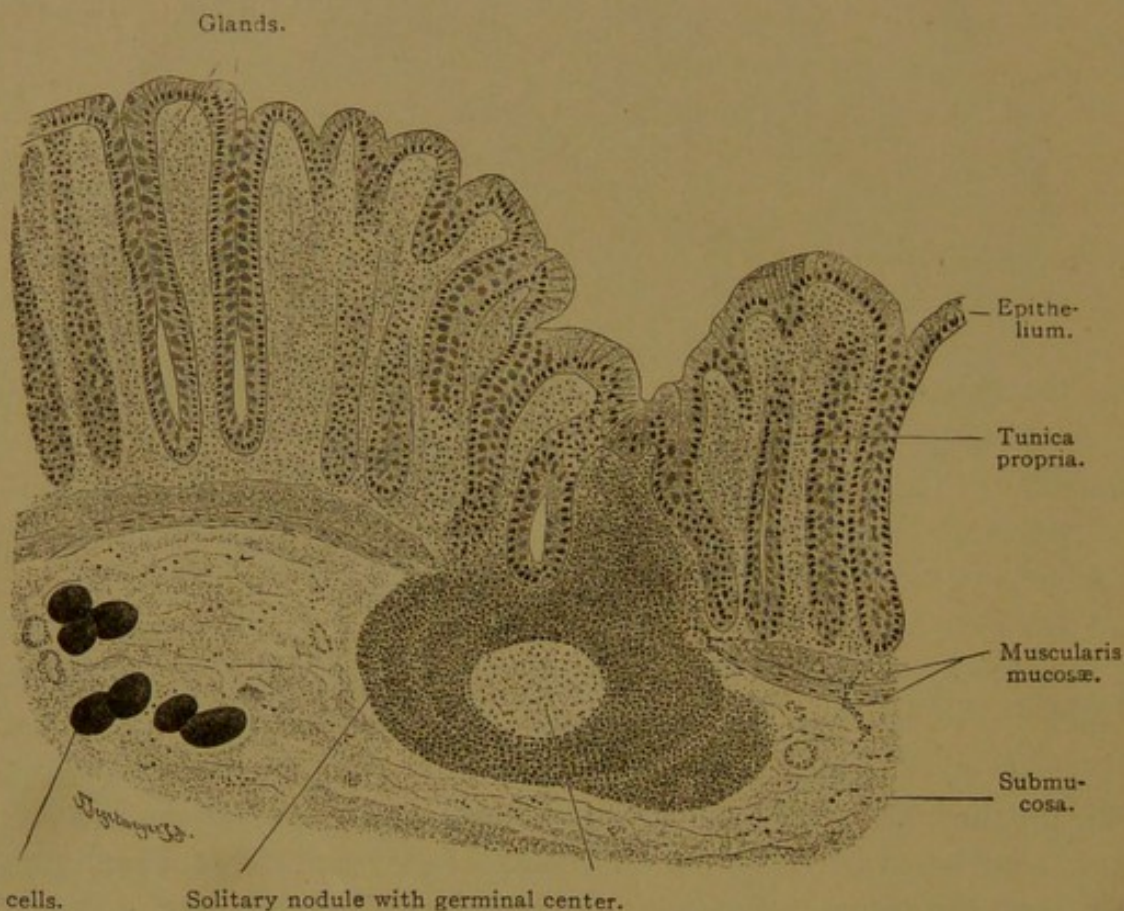


FIG. 268.—VERTICAL SECTION OF THE MUCOUS MEMBRANE OF THE DESCENDING COLON OF AN ADULT MAN. $\times 80$.

The fat has been blackened with osmic acid. Compare the length of the glands with those of the small intestine (Fig. 260), from the same individual and drawn under the same magnification.

therefore gradually flatten and disappear. In the parts of the embryonic intestine distended with secretions and desquamated cells (constituting the *meconium*), the villi disappear earlier than in the contracted portions (Johnson).

After the villi have gone, the mucosa contains only tubular pits or glands, lined with simple columnar epithelium (Fig. 268). These glands are similar to those in the small intestine but are longer—sometimes twice as long (0.4–0.6 mm.). They contain more goblet cells, but cells

of Paneth are absent. Striated cuticular borders appear near the outlets of the glands, and are well developed upon the columnar cells lining the intestinal lumen. Solitary nodules are numerous, especially in the cæcum. They may extend through the muscularis mucosæ and expand in a flask-shaped manner in the submucosa (Fig. 268); in peripheral sections of such a nodule the stalk by which it joins the tunica propria may not be included, and the area of lymphoid tissue may seem to be wholly in the submucosa. The latter is a connective tissue layer like that of the small intestine.

The *tunica muscularis* of the colon and cæcum has a characteristic arrangement not found in the vermiform process. The longitudinal smooth muscle fibers of the outer layer become gathered into three equidistant longitudinal bands or *tæniæ* (Fig. 269); between them the longitudinal fibers form a thin layer which may be interrupted. The *tæniæ* come together at the root of the vermiform process and are continuous with its outer muscle layer. Since the longitudinal muscle layer does not elongate as rapidly as the parts within it, the inner layer of circular smooth muscle, together with the mucosa and submucosa, become thrown into a succession of transverse crescentic folds or *plicæ semilunares*. The horns of the crescents are opposite the *tæniæ*. Between the semilunar folds the wall of the large intestine bulges outward, forming the *haustra* (Lat., buckets) as shown in Fig. 269. The valve of the colon (*valvula coli*) is a pair of folds or *labia*, which resemble the semilunar folds; that is, they include fibers of the circular muscle layer, but the layer of longitudinal fibers passes directly from the ileum to the colon without entering the valves. The serosa of the colon contains lobules of fat which form pendulous projections known as *appendices epiploicæ*.

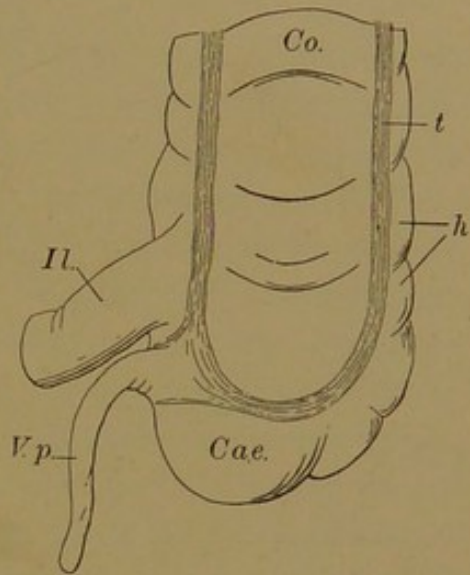


FIG. 269.—VERMIFORM PROCESS (V. p.), CÆCUM (Cae.), AND PARTS OF THE ILEUM (Il.) AND COLON (Co.). (After Sobotta.)
h., Haustrea; t., tænia.

RECTUM.

The rectum is divided into two parts, an upper which extends from the third sacral vertebra to the pelvic diaphragm, and a lower which continues downward to the anus. The lining of the first part is thrown into several folds, the *plicæ transversales recti* (valves of Houston). These are large semilunar folds which usually extend only part way around the rectum, but they have been described in some cases as having a spiral arrangement. The second part of the rectum, the *pars analis recti* (anal canal),

presents on its inner wall a number of longitudinal folds, known as *rectal columns* (columns of Glisson or Morgagni). At their lower extremities the columns unite with one another, thus forming small transverse plicæ

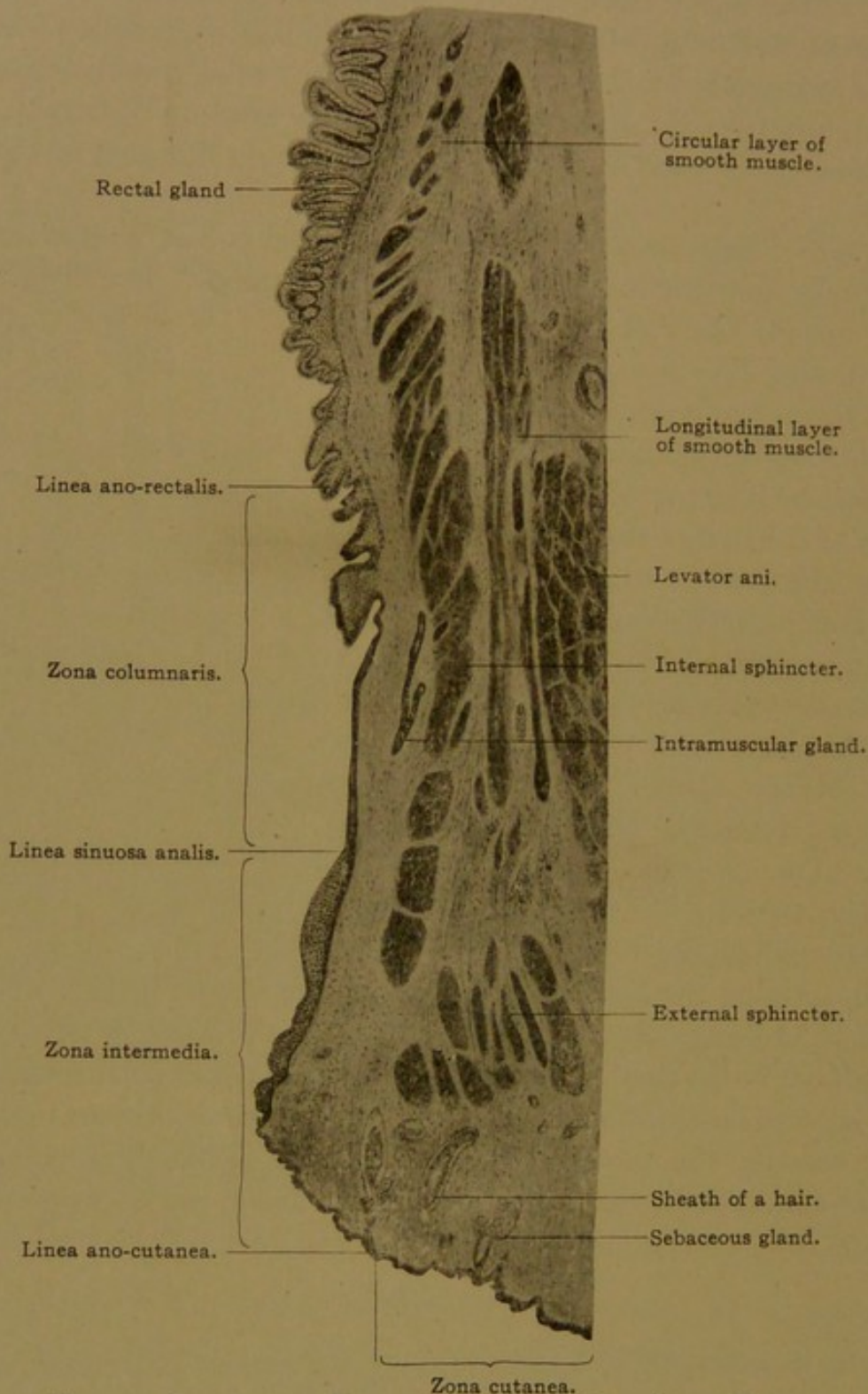


FIG. 270.—LONGITUDINAL SECTION THROUGH THE PARS ANALIS RECTI.
From a human embryo of 187 mm. (about four months). (F. P. Johnson.)

or *anal valves*. The grooves between the columns extend downward behind the valves, forming a series of blind pockets, the *sinus rectales*.

The mucous membrane of the first part of the rectum is similar to that of the colon, but its glands are somewhat longer (0.7 mm.). Soli-

tary nodules are present. The muscularis mucosæ, submucosa, and circular layer of smooth muscle also resemble those of the colon, but the three tæniæ spread out and unite so as to form a continuous layer of longitudinal muscle. In the upper part of the rectum this layer is specially thickened dorsally and ventrally. As the rectum loses its mesentery, the tunica serosa is replaced by adventitious connective tissue.

The pars analis recti is the region of transition from mucous membrane to skin. This transition is not gradual but takes place in three steps, thus forming three distinct superimposed zones. From above downward these are the *zona columnaris*, *zona intermedia*, and *zona cutanea* (Fig. 270). The last, however, does not belong to the *pars analis*, properly speaking, but to the outside skin.

The *zona columnaris* is the region of the rectal columns, but these are not always limited to this zone. They may extend upward into the first part of the rectum for a short distance, and they may also be continuous downward with the so-called *anal skin folds*. In the upper part of the *zona columnaris* the simple columnar epithelium of the superior portion of the rectum becomes two- or three-layered. Its outer cells are columnar, with finely granular protoplasm. The transition takes place gradually at the *linea ano-rectalis*. In the upper part of the zone there are usually a few intestinal glands containing numerous goblet cells, and a few goblet cells are found also in the surface epithelium. In the lower part of the *zona columnaris*, arising from the rectal sinuses, there are a few branched tubular gland-like structures, the *intra-muscular glands* (Fig. 270). There are seldom more than six or eight in any one rectum. The main ducts of these glands extend outward, and usually downward, and penetrate the internal circular muscle (internal sphincter). Here a flask-shaped swelling is usually met with. Extending beyond this ampulla there are several tubular branches which continue through the internal sphincter and end blindly in the intra-muscular connective tissue. Occasionally a tubule is seen piercing the longitudinal muscle layer. Around the terminations of the tubules, which are sometimes swollen, there is a small amount of lymphoid tissue. The epithelium lining the main ducts of these glands consists of several layers of polygonal cells, but the ampullæ and branches are lined with one or two layers of cuboidal cells. Secretory cells are present in the embryo and at birth, but are apparently wanting in the adult.

The transition between the *zona columnaris* and *zona intermedia* is marked by a rather abrupt change in the epithelium, which becomes many layered and squamous. This transition takes place at the level of the anal valves, but between the valves it extends upward on the rectal columns. Thus it follows a zig-zag line, the *linea sinuosa analis* (ano-cutaneous line of Hermann). Within the *zona intermedia* the epithelium, com-

posed of several layers of polygonal cells, is thicker than the epidermis. Dermal papillæ are present, but hairs and sweat glands are absent. In the lower part of this zone there are a few isolated sebaceous glands without hairs, and the epithelium is slightly cornified. Thus it gradually goes over into skin, forming a true *linea ano-cutanea*, but this line is not well marked. It has been defined as the place where the first sheaths of the hairs appear.

The skin immediately surrounding the anus forms the zona cutanea. Sweat glands are absent from the region bordering on the anus, but at a distance of 1.0–1.5 cm. there is an elliptical zone, 1.25–1.5 cm. wide, containing simple tubular coiled glands, the *circum-anal glands* of Gay. These are very similar to sweat glands but are considerably larger.

The outer layers of the pars analis recti include a very vascular tela submucosa, which contains numerous nerves and lamellar corpuscles. The muscularis mucosæ terminates in slender longitudinal bundles which extend for varying distances into the rectal columns (forming the *M. dilatator ani internus* of Rüdinger). The circular layer of the tunica muscularis becomes thickened at its termination, forming the *M. sphincter ani internus*; it extends a little below the *linea sinuosa analis*. Beyond the internal sphincter, which is composed of smooth muscle, striated muscle fibers surround the anus forming the *M. sphincter ani externus*. The outer longitudinal layer of the tunica muscularis ends in relation with connective tissue strands which diverge as they pass downward through the external sphincter, to terminate in the subepithelial tissue of the zona cutanea.

LIVER.

DEVELOPMENT AND GENERAL STRUCTURE.

The liver first appears in human embryos of about 2.5 mm. as a diverticulum of the ventral wall of the fore-gut, near its junction with the yolk-sac. If the embryo is placed in an upright position (Fig. 271, A) the liver is seen to be below the heart, and between the vitelline veins as they pass from the yolk-sac to their cardiac termination. The diverticulum projects into a mass of mesoderm, to which His gave the old anatomical term for diaphragm, namely *septum transversum*. The diaphragm develops in the anterior or upper part of this septum; the lower or posterior part constitutes the ventral mesentery, which extends from the fore-gut to the ventral body wall. The hepatic diverticulum is in the mesenteric part of the septum, although it is always connected with the overlying diaphragmatic shelf.

Very early the liver becomes divided into two parts, (1) the somewhat rounded diverticulum proper, lined with columnar cells with pale proto-

plasm, and (2) a mass of anastomosing cords or trabeculæ, composed of deeply staining cells with round nuclei and abundant granular protoplasm. These two parts are so unlike in appearance that they have been thought to proceed from different germ layers, the trabeculæ being described as formed from mesenchyma in the septum transversum. This opinion is erroneous; the entire structure is entodermal, and the trabeculæ grow out from the diverticulum. They encounter the vitelline veins, which ramify around them, producing the lacunar vessels or sinusoids already described (Fig. 160, p. 167).

In an embryo of 10-12mm. (Fig. 271, B), the hepatic diverticulum has elongated and is connected with the mass of anastomosing trabeculæ at several points. It shows also some detached ducts and round knob-like

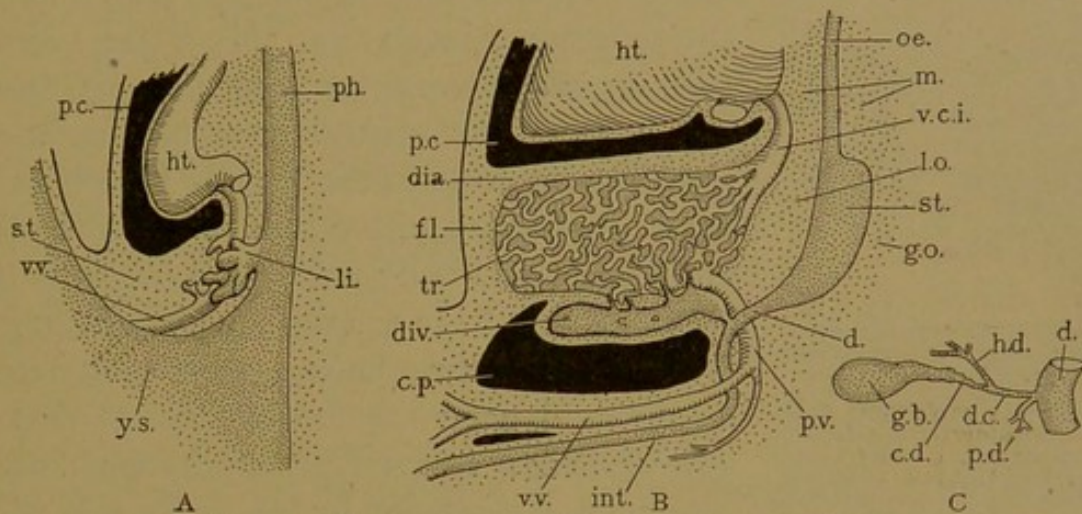


FIG. 271.—DIAGRAMS OF THE DEVELOPMENT OF THE LIVER.

A, From a 4.0-mm. human embryo. B, From a 12-mm. pig. C, The ducts in the human adult. c. d., Cystic duct; c. p., peritoneal cavity; d., duodenum; d. c., ductus choledochus; dia., diaphragm; div., distal end of the diverticulum; f. l., falciform ligament; g. b., gall bladder; g. o., greater omentum; h. d., hepatic duct; ht., heart; int., intestine; li., liver; l. o., lesser omentum; m., mediastinum; oe., oesophagus; p. c., pericardial cavity; p. d., pancreatic duct; ph., pharynx; p. v., portal vein; s. t., septum transversum; st., stomach; tr., trabecula; v. c. i., vena cava inferior; v. v., vitelline vein; y. s., yolk-sac

swellings. The vitelline veins have given rise to the portal vein, which enters the liver from below and breaks up into sinusoids among the trabeculæ. These reunite, and leave the liver above as the *hepatic vein*, which was originally a part of the vitelline veins. In the 10-mm. embryo the circulation of the liver is wholly venous. The trabeculæ consist of cells which are doubtless very active, taking up and transforming material received from the blood, but it may be questioned whether bile is secreted at this stage, since no complete system of ducts has been demonstrated.

In later stages the mass of anastomosing trabeculæ is drained by a system of ducts lined with clear cuboidal or columnar epithelium. These all empty into a single *hepatic duct*, which represents one of the original connections between the trabeculæ and the diverticulum. (In the otter there are said to be as many as seven persistent ducts.) The hepatic duct (Fig. 271, C) is joined by the cystic duct which comes from the tapering pyriform *gall bladder* (*vesica fellea*). The latter is perhaps to be re-

garded as a special subdivision of the original diverticulum, rather than as its expanded terminal portion. In certain mammals, as in the horse and elephant, the gall bladder is lacking. After the hepatic duct has joined the cystic duct, the common bile duct (*ductus choledochus*) thus formed proceeds to the duodenum into which it opens, together with the pancreatic duct, at the *duodenal papilla*. The common bile duct is an elongated portion of the original hepatic diverticulum.

Ligaments of the Liver. At the time of its earliest formation the liver bulges laterally from the ventral mesentery, on both sides, thus forming right and left lobes. The lobes are covered with the peritoneal epithelium.

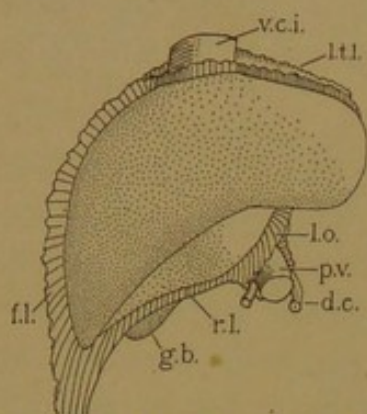


FIG. 272.—THE LEFT SIDE OF AN ADULT LIVER. (Compare with Fig. 271, B.)

d. c., Ductus choledochus; g. b., gall bladder; f. l., falciform ligament; l. o., lesser omentum; l. t. l., left triangular ligament; p. v., portal vein; r. l., round ligament; v. c. i., vena cava inferior.

The mesenchyma beneath this epithelium produces loose connective tissue externally, and a dense fibrous tissue, immediately surrounding the trabeculae, internally; this latter becomes the *capsula fibrosa* (or capsule of Glisson). The part of the ventral mesentery extending from the intestine to the liver is known as the *lesser omentum*, and the part between the liver and the ventral body wall is the *falciform ligament*. These lie in the median plane (Fig. 272). Beneath the liver, the peritoneal cavity comes to extend across the median line so that the gall bladder is covered with peritoneum, except along its attachment to the under side of the liver. On the upper surface of the liver, the

original broad connection with the septum transversum becomes relatively narrow dorso-ventrally, and forms a pair of lateral ligaments which pass from the upper surface of the liver to the diaphragm. They extend across the liver at right angles with the falciform ligament and lesser omentum. The left lateral ligament retains these simple relations and is known as the *left triangular ligament*. The right lateral ligament, except at its tip (the *right triangular ligament*), extends down over the posterior surface of the liver as an extensive area of fusion with the diaphragm; this is the *coronary ligament* (Fig. 275). The significance of this asymmetrical condition will be explained with the veins of the liver.

Development of the veins of the liver. The hepatic trabeculae are always in close relation with the veins which are conveying nutriment to the heart. These are (1) the vitelline veins conveying nutriment from the yolk-sac, (2) the umbilical veins conveying nutriment from the placenta, and (3) the portal vein conveying absorbed food from the intestine. The liver also has important relations with the vena cava inferior.

The *portal vein*, which is the principal afferent vessel of the adult liver, is derived from the vitelline veins. The latter, as they pass from the yolk-sac into the abdominal

cavity, fuse with one another so as to form a single trunk (Fig. 271, B, *v.v.*). On reaching the duodenum, the trunk separates into its components, and they pass into the liver as the right and left vitelline veins (Fig. 273, A). Before entering the liver they anastomose with one another dorsal to the duodenum, as shown in the figure. Thus, with the connections between the right and left veins within the liver, two complete venous rings are formed around the intestine. Branches extend out from these rings, notably the superior mesenteric vein which receives blood from the primary loop of intestine, and the splenic vein which not only drains the spleen but receives the inferior mesenteric vein together with pancreatic and gastric branches. The superior mesenteric vein (Fig. 273, *s.m.v.*) is joined by the splenic (*s.*) to form the *portal vein* (*p.v.*), and the portal vein is a persistent portion of the peri-intestinal rings formed by the vitelline veins. Other parts of the rings atrophy, and as the yolk-sac degenerates and becomes detached, the main vitelline trunk disappears. The portal system of veins is therefore a derivative of the vitelline system; its blood flows through the liver in the vitelline sinusoids.

The formation of the rings as above described takes place with great constancy, and apparently the only variations observed in their atrophy are the two cases described by Begg (Amer. Journ. Anat., 1912, vol. 13, pp. 105-110).

The *umbilical veins* are at first a pair of vessels, but they early unite in the umbilical cord. The single vein thus formed brings the embryonic blood back to the body after its excursion to the placenta. On reaching the body, the vein divides into right and left vessels, which are contained in the ventral body wall, and at first pass directly to the heart; later they anastomose with the vitelline sinusoids in the liver, and the right umbilical vein then atrophies, leaving the left vein to convey the blood to the liver. In Fig. 274, the left vein is larger than the right, and is seen connecting with the hepatic sinusoids. Gradually it shifts from the left side to the median line. It then passes from the umbilical cord to the under surface of the liver along the free edge of the falciform ligament, where, after the umbilical cord has been severed, it degenerates to form the *round ligament of the liver* (Fig. 275). This extends to the *porta* or entrance to the liver, where the portal vein goes in and the hepatic duct comes out. Beyond this point the umbilical vein may be followed as the *ductus venosus* in the embryo, or the ligament of the ductus venosus in the adult, to the vena cava inferior. The ductus venosus may be defined as the channel made by the umbilical vein in passing to the vena cava inferior across the under surface of the liver. It is sometimes completely enfolded by the hepatic trabeculæ, and it communicates with the hepatic sinusoids. It follows the line of attachment of the lesser omentum, and empties into the vena cava inferior.

The *vena cava inferior* apparently does not send much blood into the liver but passes along its dorsal surface. An essential part of this great vein is formed from the hepatic sinusoids. Before the vena cava inferior has developed, the blood in the dorsal body wall flows to the heart through the posterior cardinal veins, one on either side of the aorta. Each posterior cardinal vein shows a ventral subdivision, the right and left subcardinal veins respectively, which are seen in section in Fig. 274. As shown in the figure, the stomach prevents the liver from approaching the dorsal body wall (at the root of the mesentery) on the left, but on the right there is no such obstruction, and the

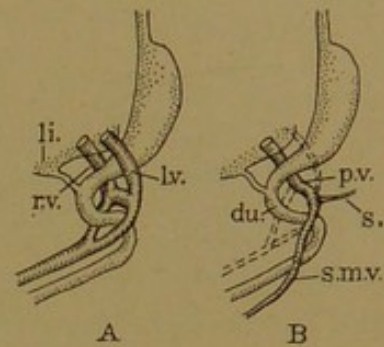


FIG. 273.

The formation of the portal vein, *p.v.*, from the right and left vitelline veins, *r.v.*, and *l.v.*; *du.*, duodenum; *li.*, liver; *s.*, splenic vein; *s.m.v.*, superior mesenteric vein.

liver approaches and fuses with the body wall immediately in front of the right subcardinal vein. This fusion constitutes the coronary ligament (cf. Fig. 275); and across it, the subcardinal vein anastomoses with the hepatic sinusoids. By a rapid enlargement of this anastomosis, the trunk of the vena cava inferior is formed. It drains the posterior cardinal system of veins, and the outlet of the vitelline veins into the heart becomes the terminal portion of the inferior vena cava; the main vessel from the liver, the hepatic vein, is thereafter described as a branch of the vena cava inferior. The development of the posterior part of the vena cava inferior is described in connection with the Wolffian body (p. 309); for a fuller account, see the Amer. Journ. Anat., 1902, vol. 1, pp. 229-244. Occasionally the trunk of the vena cava is entirely surrounded by a band of hepatic tissue, as in Fig. 275.

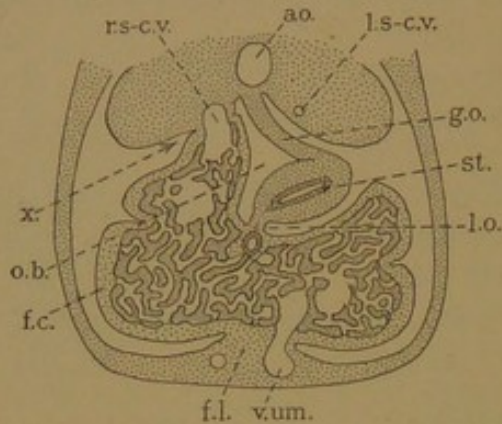


FIG. 274.—CROSS SECTION OF A MAMMALIAN EMBRYO, TO SHOW THE ADHESION, x, BETWEEN THE RIGHT LOBE OF THE LIVER AND THE DORSAL ABDOMINAL WALL.
ao., Aorta; f. c., fibrous capsule and serosa; f. l., falciform ligament; g. o., greater omentum; l. o., lesser omentum; l. s-c. v., left subcardinal vein; o. b., omental bursa; r. s-c. v., right subcardinal vein; st., stomach; v. um., left umbilical vein.

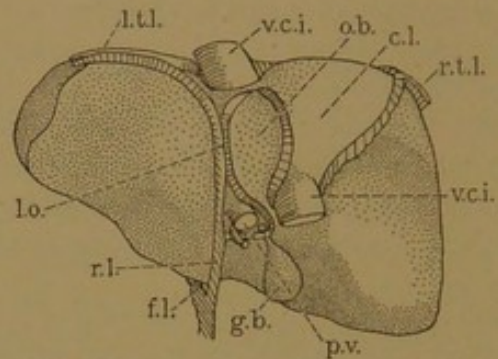


FIG. 275.—DORSAL SURFACE OF THE ADULT LIVER.
c. l., Coronary ligament; f. l., falciform ligament; g. b., gall bladder; l. o., lesser omentum; l. t. l., left triangular ligament; o. b., caudate lobe bounding the omental bursa ventrally; p. v., portal vein; r. l., round ligament; r. t. l., right triangular ligament; v. c. i., vena cava inferior.

Lobes of the liver. The structures already described form the boundaries of the lobes of the liver, which in man are few and not sharply marked out. Right and left lobes have already been mentioned as the lateral halves of the liver; they are not separated from one another by any internal septum or indentation of the surface. The left lobe is relatively small, and has a thin margin. It terminates in the *appendix fibrosa* at the extremity of the left triangular ligament. This appendix represents a portion of the liver from which the hepatic cells have degenerated and disappeared, leaving chiefly the anastomosing ducts. It indicates that in earlier stages the left lobe was more extensively developed. Similar tissue containing aberrant ducts (*vasa aberrantia*) may be found around the vena cava and in some other parts of the liver. The quadrate lobe is marked out by the porta, the round ligament, and the fossa containing the gall bladder. The caudate lobe is bounded by coronary ligament, lesser omentum and porta. The caudate process of this lobe extends to the right lobe over the *foramen epiploicum* (of Winslow) between the vena cava and the porta.

The hepatic artery. The liver in an embryo of 10 mm. has no arteries, but at that stage the hepatic artery can be followed to the porta. Later it

extends through the connective tissue around the gall bladder, so that the cystic branch of the adult appears to be the main vessel in the young embryo. Still later, as the connective tissue which surrounds the structures at the porta gradually extends into the liver around the branches of the hepatic duct and portal vein, the hepatic artery sends branches in with it, and they form capillaries which empty into the adjacent portal sinusoids. Branches of the artery ramify also in the connective tissue capsule around the entire liver. The quantity of blood supplied to the liver by the artery always remains much smaller than that brought in by the portal vein, and it is distributed to the connective tissue. There are no vessels between the hepatic cells other than the "capilliform sinusoids" derived directly from the embryonic lacunæ of the vitelline veins.

MICROSCOPIC STRUCTURE.

Lobules. A section of the embryonic liver, or of the liver at birth, shows great areas of anastomosing trabeculæ, with intervening sinusoids and occasionally a larger vein. In the adult pig the hepatic tissue is arranged in lobulrs bounded by connective tissue (Fig. 276). These subdivisions were

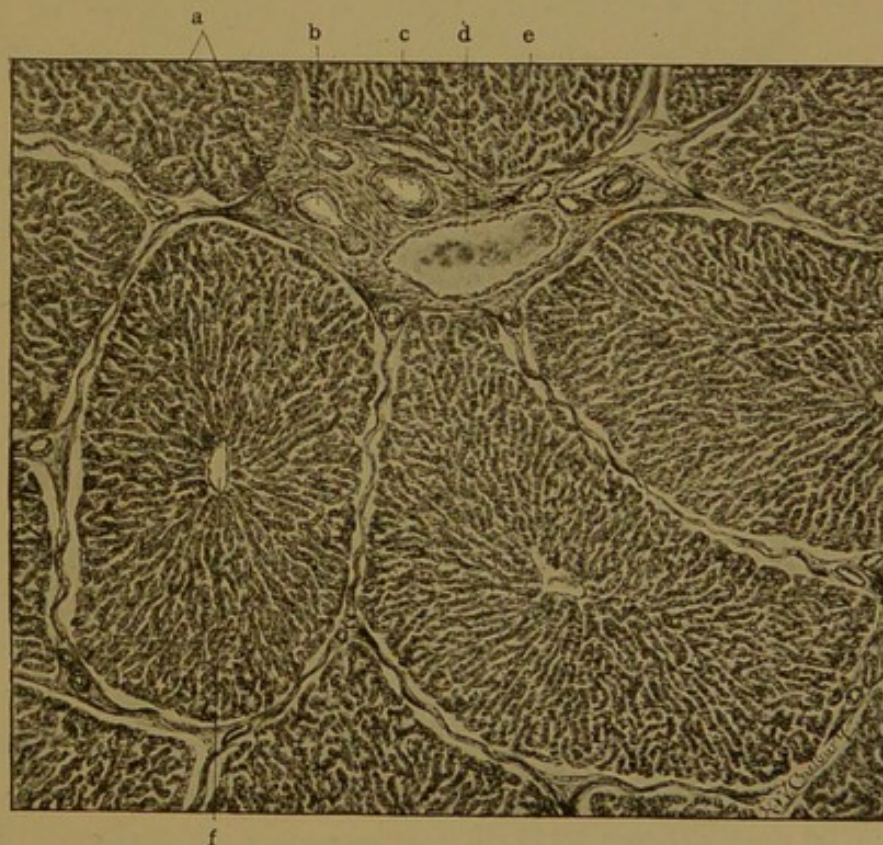


FIG. 276.—LIVER OF A PIG. (Radasch.)

The lobules have artificially shrunk from the interlobular tissue, a; b, bile duct; c, hepatic artery; d, interlobular vein (a branch of the portal); e, trabeculæ; f, central vein.

first recognized in the liver of the pig (Wepfer, 1664), and in 1666 Malpighi made the general statement that the entire liver is composed of a multiplicity of lobules. In the dog Mall finds that the lobules are short cylinders

averaging 0.7 mm. high and 0.7 mm. in diameter, and that the entire liver (of 175 c.c.) contains 480,000 of them (Amer. Journ. Anat., 1906, vol. 5, pp. 227-308). There has been prolonged discussion as to whether the lobules should be regarded as centering about the terminal branches of the portal vein or around those of the hepatic vein, for, although it was frequently stated that they were arranged like a bunch of grapes, there was no unanimity as to what formed the stem. If the human liver is examined (Fig. 277) it is seen that the lobules are not definitely marked out as in the pig, but the liver retains to a greater extent its embryonic appearance. Scattered about through the section, but at quite uniform distances from one another, there are islands of connective tissue containing branches of the portal vein, hepatic artery, and bile duct. The strands of connective

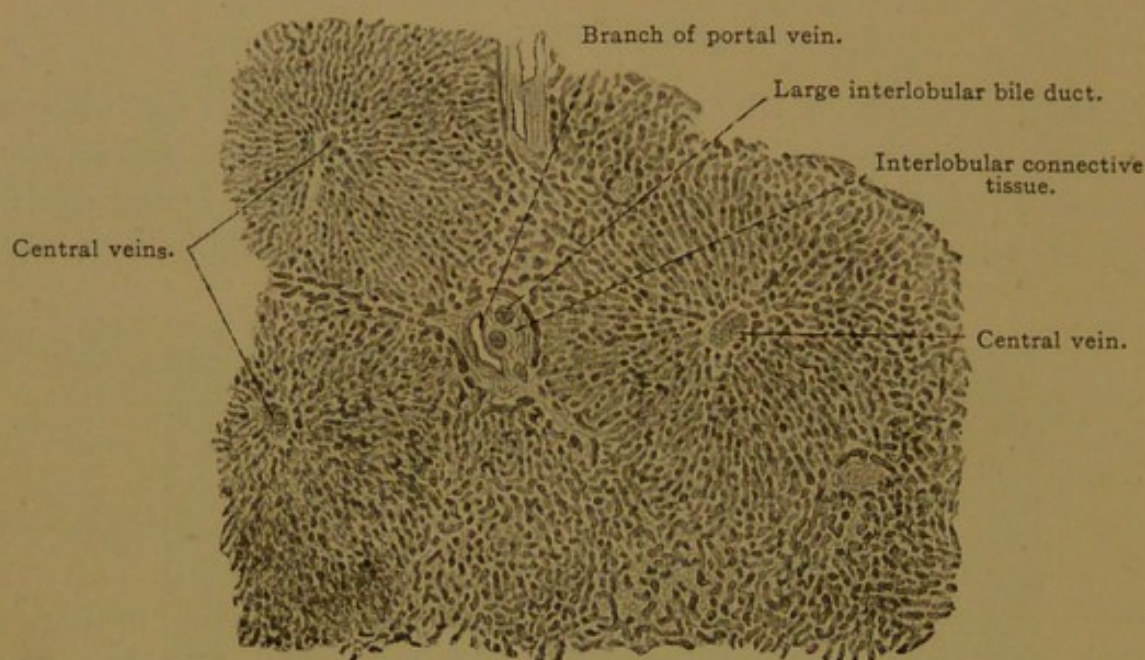


FIG. 277.—FROM A TANGENTIAL SECTION OF THE HUMAN LIVER. $\times 40$.

The three central veins in cross section mark the centers of three lobules, which are not sharply separated, at the periphery, from their neighbors. Below and at the right the lobules are cut obliquely and their boundaries are not seen.

tissue which conduct the portal branches were named *portal canals* by Kiernan (Trans. Roy. Soc. London, 1833, pp. 711-770). If the connective tissue should spread from one canal to another, connecting those nearest together, it would mark out lobules like those in the pig's liver, and this sometimes takes place pathologically in man. Normally the portal canals stand as isolated "boundary stones."

Within each lobule thus marked out there is a central vein or enlarged sinusoid, toward which the capilliform sinusoids between the hepatic trabeculae converge. Occasionally there are two veins, side by side. These *central veins* empty at right angles into *sublobular veins* (Fig. 278), which come together to form the main branches of the *hepatic vein*. All these veins, in contrast with the portal branches, have very little connective tissue around them, and they are not associated with bile ducts or arteries;

thus the hepatic veins are readily distinguished from the portal veins. The flow of the blood (Fig. 279) is from the portal veins (in the portal canals) through the capilliform sinusoids to the central veins, thence

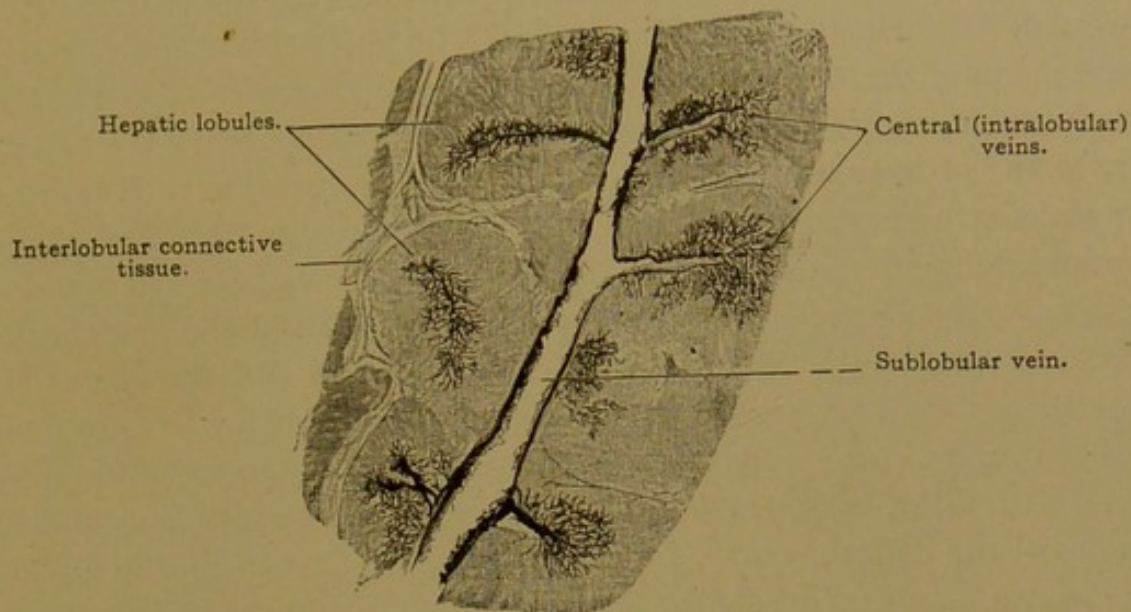


FIG. 278.—FROM A VERTICAL SECTION OF A CAT'S LIVER, INJECTED THROUGH THE VENA CAVA INFERIOR. The central veins and the sublobular vein into which they empty are cut longitudinally. $\times 15$.

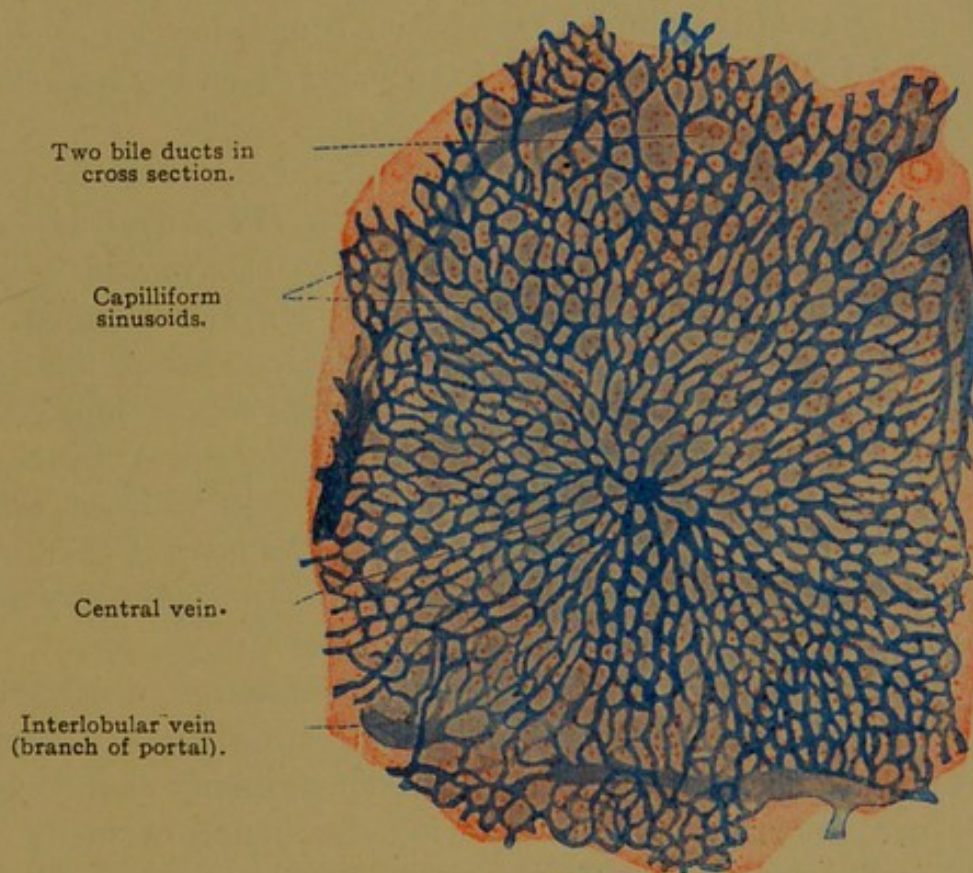


FIG. 279.—FROM A SECTION OF THE HUMAN ADULT LIVER INJECTED THROUGH THE PORTAL VEIN.

through the sublobular veins into the hepatic vein, which empties into the vena cava inferior. The arteries empty through capillaries into the capilliform sinusoids adjacent to the portal canals, and there is some

evidence that the hepatic cells at the periphery of the lobule are better nourished than those in its interior.

The recognition of the lobules above described, as the essential basis of hepatic structure, would have been unquestioned except that, as Kiernan stated, "the essential part of the gland is undoubtedly its duct; vessels it possesses in common with every other organ; and it may be thought that in the above description too much importance is attached to the hepatic veins." If the liver were divided into lobules comparable with those of other glands, the portal canals with their ducts and adjacent afferent vessels would be the *axial* structures, and the efferent central veins would be peripheral. By connecting the five central veins around the portal canal in Fig. 277 (two of the central veins are not labelled and the one at the lower edge of the figure is indistinct), such a *structural unit* or secretory unit would be marked out. It has been proposed to call it a *portal* lobule (from its axial structure), in contrast with the *hepatic lobules*, which surround the branches of the hepatic vein. In the seal it is said that the portal lobules, or units, are bounded by connective tissue, but this must be regarded as very exceptional. However, in attempting to picture the complex relations of the lobules in the liver, the morphologist must regard the portal canals as axial, even though the term lobule is used for areas surrounding the central veins. The bile flows from parts of several hepatic lobules into a single portal canal.

Parenchyma. The parenchyma or essential tissue of the liver is found in the anastomosing trabeculæ of the lobules. The general arrangement of the cells in these trabeculæ is shown in Fig. 280, in which, however, the slender lumens are rendered conspicuous by special treatment. These lumens, or *bile capillaries*, are ordinarily inconspicuous, and the trabeculæ appear on superficial examination as solid cords of cuboidal cells, with abundant granular protoplasm and large round central nuclei. Often the hepatic cells contain two nuclei, and large cells with several nuclei, produced by amitosis, have been reported. The general characteristics of hepatic cells are shown in Fig. 281. They are arranged chiefly in double rows which in certain positions appear single.

The hepatic cells have very delicate cell membranes, which are sometimes said to be absent. Their protoplasm often contains brown pigment, especially toward the central vein. Near the periphery of the lobule the cells may contain fat vacuoles of varying size, found normally in well-nourished individuals. Pathologically the vacuoles may be large and widely distributed. Glycogen (p. 78) occurs in granules and larger masses, especially after abundant meals. In the fasting condition, the cells are relatively small, dark, and obscurely outlined, but during digestion they become larger with a clearer central part and a peripheral zone of coarse granules. In man both conditions may be found in one liver.

The bile, secreted by the hepatic cells, probably through granule formation, frequently contains granules and fat droplets such as are found within the cells. It is eliminated through the bile capillaries.

The *bile capillaries* are minute tubes with continuous cuticular walls, presumably formed by the local modification of the cell membranes of two adjacent hepatic cells. The completed capillary, however, shows no

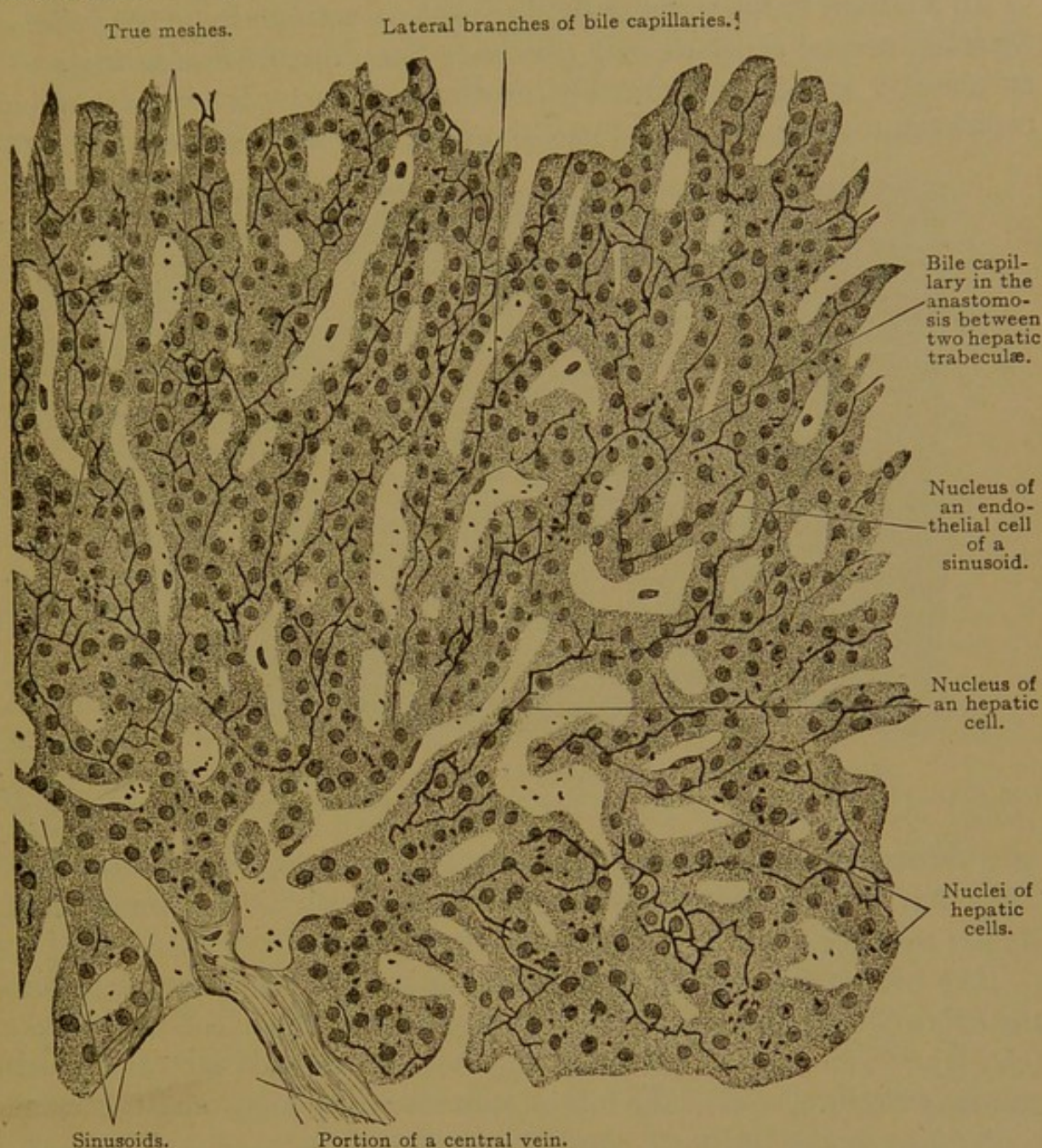


FIG. 280.—FROM A CROSS SECTION OF A HUMAN HEPATIC LOBULE. $\times 300$.
Golgi preparation. The boundaries of the hepatic cells could not be seen. The black dots are precipitates of the silver.

indication of being formed of lateral halves which have fused. Cross sections of the large bile capillaries in the liver of *Necturus* are shown in Fig. 281, and their arrangement in the human liver is indicated in Fig. 280. They extend through the axis of the two-rowed trabeculae of cells, giving off short intercellular branches at right angles. Thus the bile capillaries shown in Fig. 281 between the two sinusoids, may be separate axial

capillaries, or they may be intercellular branches of an axial capillary which is in the plane of the printed page. In some places the bile capillaries completely encircle an hepatic cell, forming "true meshes" (Fig. 280). They may form larger meshes due to the anastomosis of trabeculæ. Occasionally a bile capillary is in relation with three surrounding hepatic cells, or even more, thus resembling the lumen of an ordinary gland-tubule.

In addition to intercellular capillaries there are said to be *intracellular branches*, several of which may penetrate the protoplasm of a single cell and end in knobs, as shown by the Golgi method. Since neighboring capillaries may be free from these branches, they are regarded as tempo-

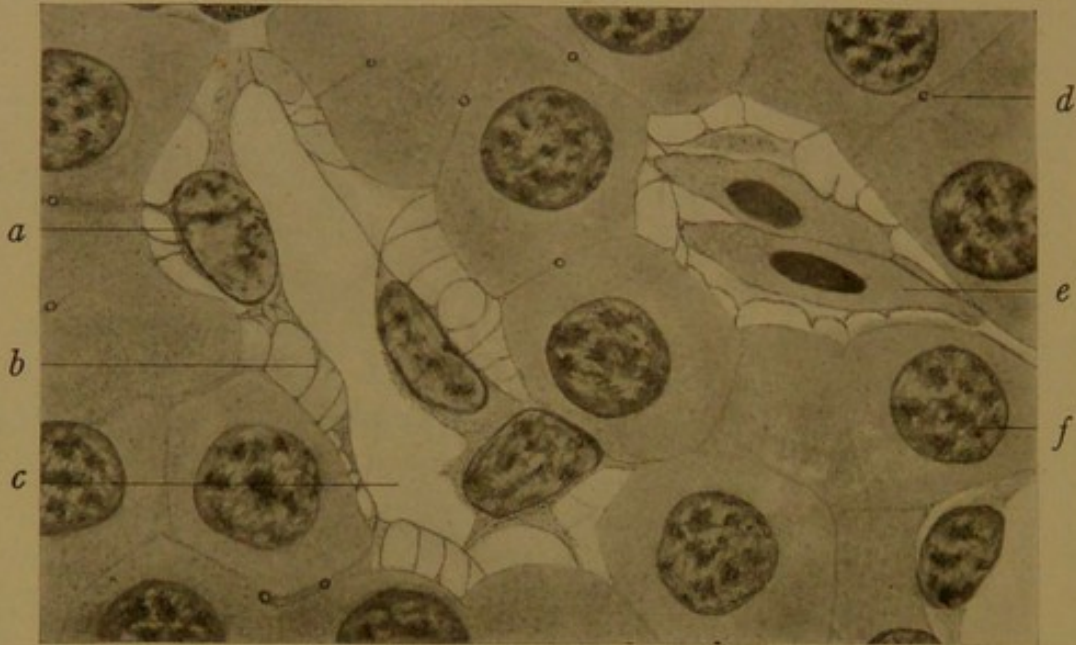


FIG. 281.—SECTION OF THE LIVER OF A SALAMANDER (*Necturus*). $\times 380$.
a, Endothelial cell; b, endothelial reticulum; c, blood vessel; d, bile capillary; e, red corpuscle; f, hepatic cell.

rary phases of functional activity, accompanying the discharge of secretion. They have been reported as forming baskets within the protoplasm, similar to those found in parietal cells of the stomach.

The bile capillaries and their branches are generally separated from the lining of the blood vessels by an appreciable portion of the hepatic cells (cf. Figs. 280 and 281). Pathologically they may extend nearer the vessels and may rupture, so that the bile escapes into the perivascular tissue and is distributed over the body, causing jaundice.

Endothelium and Perivascular Tissue. The endothelium of the capilliform sinusoids which border upon the hepatic trabeculæ is specially modified; it is well shown in the coarse-grained liver of *Necturus* (Fig. 281), but the same form occurs in the human liver. The endothelial cells, which are phagocytic, produce a network of reticular fibers toward the hepatic cells (Fig. 282). The reticulum contains no elastic elements, and the only cell bodies associated with it are those of the endothelium. In the reticular meshwork in the embryo, erythroblasts multiply in great numbers,

and to some extent leucocytes are formed, but in the adult the reticulum is free from cells. The endothelial cells, moreover, do not fit closely together, and are known as the *stellate cells* of *Kupffer*. It is probable that, whereas the blood flows through the capilliform sinusoids toward the central vein, there is a current of tissue fluid in the reticulum taking the reverse direction and passing toward the portal canal. This fluid is the source of the great quantity of lymph which flows from the liver.

According to Schäfer (Quain's Anatomy, 1912, vol. 2) the blood flowing through the sinusoids comes into direct contact with the liver cells. He states that blood corpuscles may occasionally be found normally within the hepatic cells, into which they are readily forced by injections at low pressure; and he describes canaliculi within the protoplasm of the hepatic cells, which communicate with the sinusoidal blood vessels. These canaliculi are presumably secretory channels or canals of the trophospongium, which have been artificially invaded by the injection. At the same time, the reticulum has been compressed and its significance obscured.

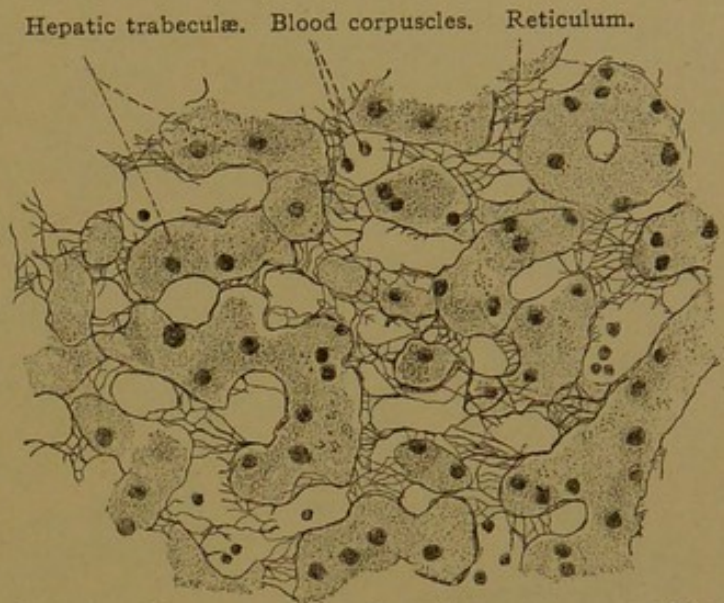


FIG. 282.—SECTION OF THE LIVER PREPARED BY THE BIEL SCHOWSKY METHOD. $\times 300$.

Portal canals. The portal canals are strands of connective tissue extending into the liver from the transverse fissure or porta (which is essentially a hilus). They constitute the interlobular tissue of the liver, and the ducts, arteries, and veins which they contain are often called interlobular. In addition to the structures already considered, the portal canals contain lymphatics and nerves; these and certain features of the ducts require further consideration.

The lymphatic vessels are abundant, forming plexuses around the ducts and blood vessels, and receiving fluid from the perivascular reticulum within the lobules; but no lymphatic vessels enter the lobules. They pass out of the liver at the porta, where lymph glands are found. Certain of the lymphatics in the capsule of the liver drain toward the porta; others enter the diaphragm.

The nerves are chiefly non-medullated fibers from the sympathetic system, but the liver also receives branches from the vagus. These nerves are principally distributed to the blood vessels, but some are said to penetrate the lobules and end in contact with the hepatic cells.

The interlobular ducts are lined with simple columnar or cuboidal epithelium. They anastomose with one another, and have blind pockets; in the larger ducts, there are branched mucous glands. The connection between the ducts and the hepatic trabeculæ is difficult to observe, and it was once thought that the ducts with their ramifications produced the bile, leaving the parenchyma for the function of internal secretion. Through injections, however, or by using the Golgi method, the connections between the bile capillaries and the bile ducts can be readily demonstrated (Fig. 283). They are found at the periphery of the portal canals, and were

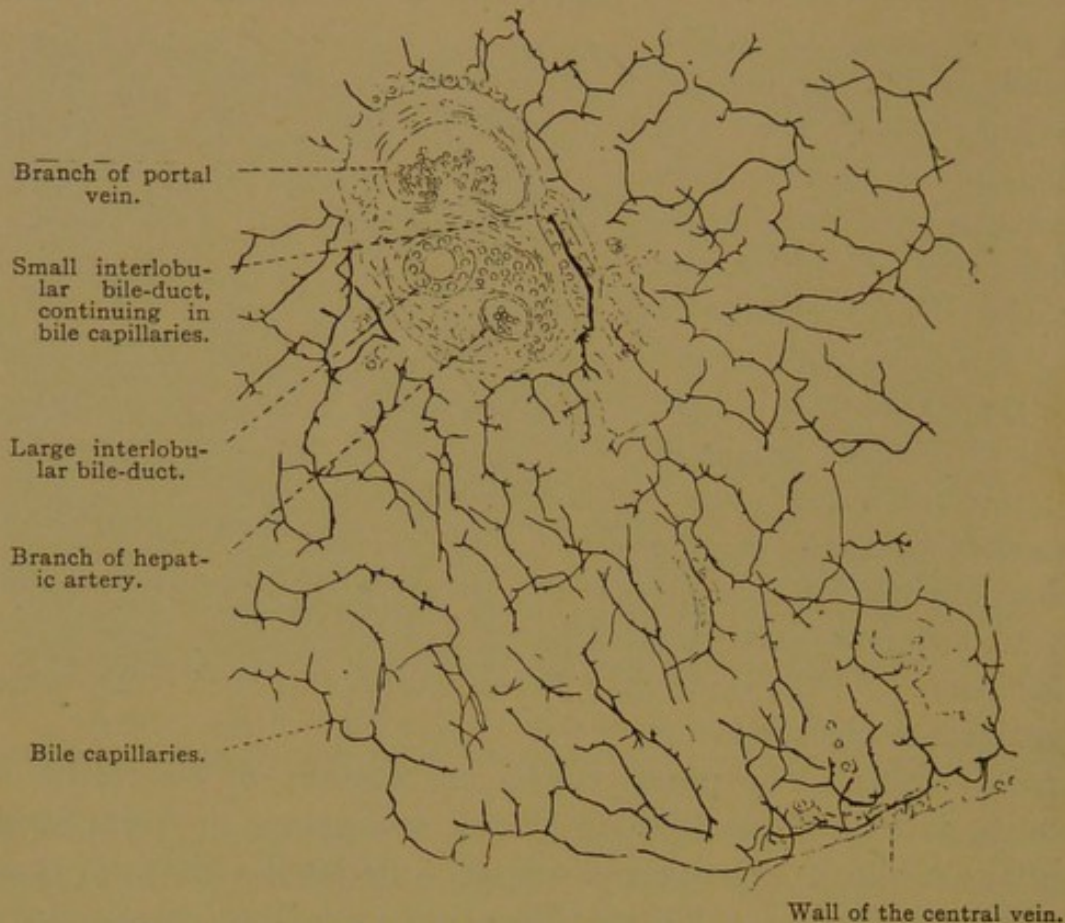


FIG. 283.—GOLGI PREPARATION OF THE LIVER OF A DOG. $\times 240$.

described histologically by Hering (Stricker's Handbuch, Leipzig, 1871). On the side toward the connective tissue these "canals of Hering," or periportal ducts, exhibit a flat or cuboidal epithelium, like that of ordinary ducts; but toward the lobule they are bounded by hepatic cells, or by flat cells interrupted by hepatic cells (Fig. 284). Thus the hepatic trabeculæ are directly inserted into the walls of the ducts, and the bile capillaries connect with the lumen.

The *hepatic*, *cystic* and *common bile ducts* all have a simple columnar epithelium, with occasional goblet cells and branching mucous glands. Around the hepatic duct there is a wide zone formed by the ramifying ducts of these mucous glands, as they extend into the surrounding connective tissue. The connective tissue layer is said to contain many elastic

fibers. It is followed by a tunica muscularis consisting chiefly of circular fibers. These form a sphincter around the common bile duct, at the duodenal papilla. In the cystic duct there are folds of mucous membrane, containing muscle fibers, and forming the "spiral valve."

The *gall bladder* is lined with a folded mucous membrane covered with tall epithelial cells similar to those of the intestine (Fig. 285). They have elongated basal nuclei and secretory granules (mucin) in the outer part of their protoplasm. The free surface is covered with a distinct cuticular border, and terminal bars have been observed.

Goblet cells are absent and glands are infrequent. The muscularis consists of obliquely circular fibers arranged in a plexiform layer. Among them are groups of sympathetic nerve cells which supply the muscle, and medullated fibers which end in the epithelium. The subserous tissue is highly developed and contains large lymphatic vessels.

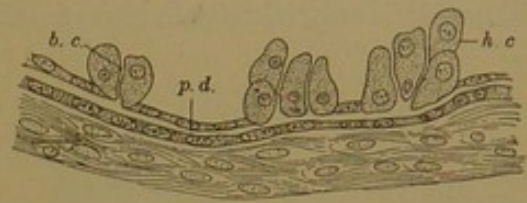


FIG. 284.—THE CONNECTION BETWEEN BILE CAPILLARIES AND BILE DUCTS IN A HUMAN EMBRYO OF FOUR AND A HALF MONTHS. (After Toldt and Zuckerkandl.)

b. c., Bile capillary; h. c., hepatic cell; p. d., periportal duct.

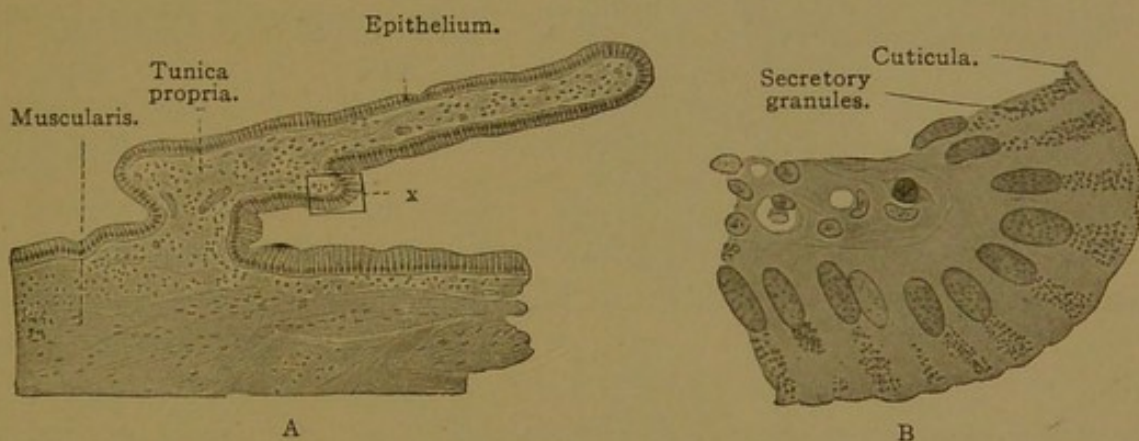


FIG. 285.—FROM A SECTION OF THE GALL BLADDER OF AN ADULT, A. $\times 100$. B, the portion x of A. $\times 560$.

PANCREAS.

Development and General Features. Although the pancreas in the adult is a single gland, it arises in the embryo as two entirely distinct entodermal outgrowths, known as the dorsal and ventral pancreases respectively. The dorsal pancreas grows out from the dorsal wall of the intestinal tube, a little below the level of the common bile duct in most mammals, but a little above it in man. The ventral pancreas grows down from the common bile duct at its junction with the intestinal tube. As seen in Fig. 286, A and B, the ventral pancreas may be more or less bi-lobed. Usually it grows to the right of the intestine and there meets the dorsal pancreas, which approaches it in close relation with the portal vein.

The left lobe of the ventral pancreas sometimes grows around the left side of the intestine and joins the dorsal pancreas, so that the intestine is encircled by pancreatic tissue (annular pancreas); sometimes it grows out beneath the gall bladder where it ends in a cystic enlargement, as has been observed in adult cats (cf. Amer. Journ. Anat., 1912, vol. 12, pp. 389-400). Usually the left lobe is scarcely indicated. As a rather frequent abnormality, accessory pancreases of small size, but sometimes of very typical

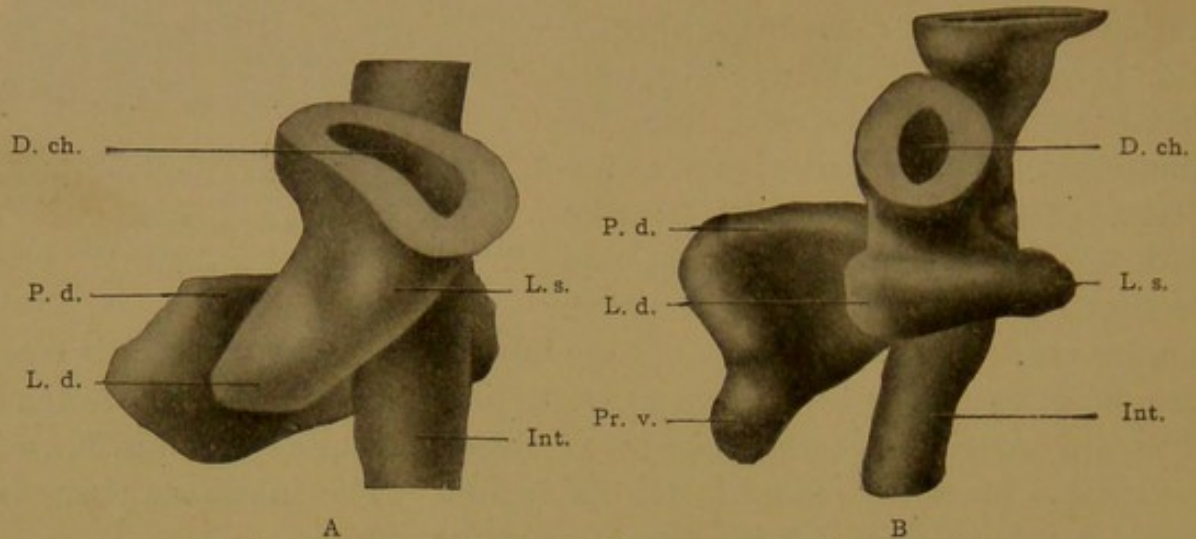


FIG. 286.—MODELS OF THE VENTRAL PANCREAS IN PIG EMBRYOS. $\times 120$. A, 5.1 mm., B, 6.0 mm. D. ch., ductus choledochus; Int., intestine; L. d., right lobe, and L. s., left lobe of the ventral pancreas; P. d., dorsal pancreas; Pr. v., ventral process of the dorsal pancreas.

structure, are found along the intestine, or even in the wall of the stomach, especially at the constriction between its cardiac and pyloric portions. Such glands may or may not extend through the tunica muscularis.

After the dorsal and ventral pancreases have come in contact, they are related to one another as shown in Fig. 287, A. The dorsal pancreas is

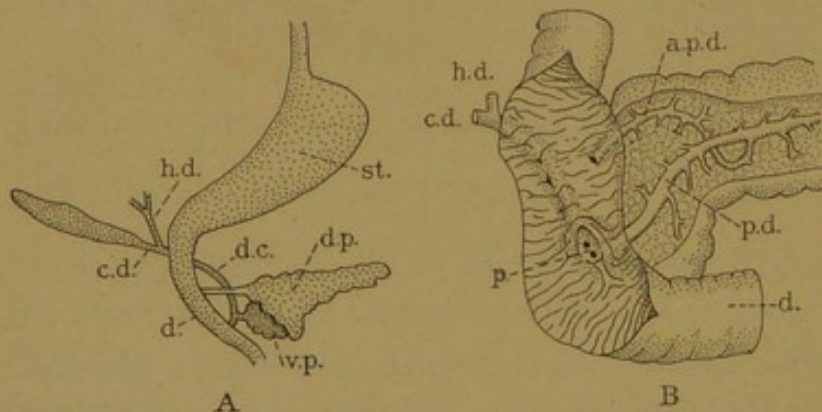


FIG. 287.—A, DIAGRAM OF THE PANCREAS FROM A 15-MM. HUMAN EMBRYO. B, DISSECTION OF THE DUODENUM AND PANCREAS OF AN ADULT. (After Schirmer.)

a. p. d., Accessory pancreatic duct; c. d., cystic duct; d., duodenum; d. c., ductus choledochus; d. p., dorsal pancreas; h. d., hepatic duct; p., duodenal papilla; p. d., pancreatic duct; st., stomach; v. p., ventral pancreas.

much larger than the ventral pancreas, and it grows across the body toward the left until it reaches the spleen. Thus it gives rise to the *body* and *tail* of the pancreas of the adult; and it forms also the ventral part of the *head* of the gland, which fills the concavity in the duodenal loop. In

the adult its duct opens into the duodenum 1-3 cm. above the orifice of the common bile duct, but it has been tapped by an anastomosis with the ventral pancreas. Its outlet persists as the *accessory pancreatic duct*, discovered by Santorini (1775). It is shown in the dissection, Fig. 287, B, but a large

branch ordinarily found descending from it in front of the pancreatic duct, *p. d.*, is not included. In some cases the accessory duct becomes imperious, but it is generally functional, and if the outlet of the main duct were blocked by gall-stones or otherwise, the presence of this accessory duct would be of considerable importance. In some mammals, as in the pig, it is normally the chief duct.

The duct of the ventral pancreas either opens into the duodenum close beside the common bile duct (Fig. 287, B), or it retains its embryonic relation (Fig. 287, A) and opens into the common bile duct near its duodenal orifice. The duct of the ventral pancreas, by an anastomosis with the duct of the dorsal pancreas, becomes the outlet of the main *pancreatic duct*, which was first figured by Wirsung (1642). It will be noted that a large part of the dorsal pancreatic duct, extending through the body and tail, becomes incorporated in this main duct of Wirsung; the ventral pancreas supplies only its outlet.

In the adult no histological distinction has ever been found between the two pancreases, but although alike in structure and close together, there is no general anastomosis between them. Rarely they remain entirely separate. Usually, on injecting the ducts, only one connection is found between the dorsal and ventral pancreases, but in an abnormal case two connections have been observed. Moreover, anastomoses between the smaller ducts and tubules in the separate glands have not been found in human adults. Rings of pancreatic tissue occur in the embryo, and in adult guinea-pigs Bensley has demonstrated a free anastomosis of the ducts (Amer. Journ. Anat., 1911, vol. 12, pp. 297-388); such a condition has not yet been found in man.

Microscopic structure. As a whole the pancreas somewhat resembles the parotid gland. It is divided into lobes and lobules by connective tissue septa containing blood and lymphatic vessels, nerves, and interlobular ducts (Fig. 288). The lobules are composed chiefly of short tubules, or *alveoli*, which in models appear pear-shaped; in sections they are cut at all possible angles. Instead of exhibiting a well-defined lumen, the

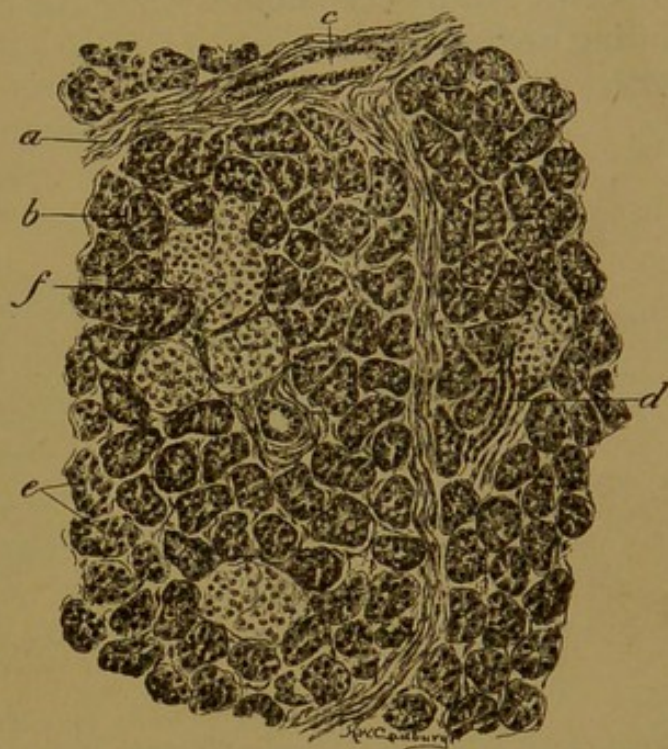


FIG. 288.—SECTION OF HUMAN PANCREAS, SHOWING SEVERAL ISLANDS. (Radasch.)

a, Interlobular connective tissue containing an interlobular duct, c; b, capillary; d, interlobular duct; e, alveoli; f, pancreatic island.

alveoli appear to be clogged with cells, known as *centro-alveolar cells* (or centro-acinal cells). Irregularly distributed among the alveoli there are round areas of paler cells, peculiar to the pancreas (Fig. 288). They may be at the center or periphery of the lobule, or occasionally in the interlobular connective tissue. These important structures were first described in Langerhans' thesis in 1869 (Inaug. Diss., Berlin), and are known as the pancreatic *islands* (islands of Langerhans).

The alveoli are composed chiefly of the secreting *pancreatic cells* (Fig. 289). Toward the lumen their protoplasm contains coarse granules of *zymogen*, which accumulate while the cell is inactive and are eliminated during secretion. Apparently they are transformed into fluid as they

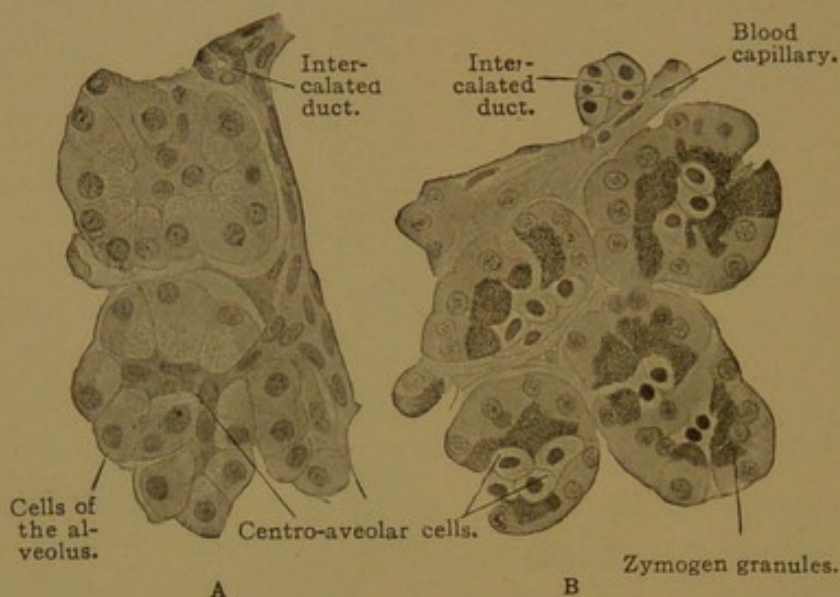


FIG. 289.—FROM SECTIONS OF A HUMAN PANCREAS. $\times 500$.

In section A the granules are wanting, the centro-alveolar cells are flat and dark; in section B the granules are distinct, the centro-alveolar cells are cuboidal and clear.

are discharged, for they are not found free in the intestine. In fresh specimens the granules are refractive and easily seen, but in preserved tissue they are readily destroyed, so that the granular zone appears reticular. The granules are soluble in water, and are darkened by osmic acid. The basal protoplasm of the pancreatic cells is vertically striated. It contains the round nucleus which has coarse masses of chromatin. Within the pancreatic cells there have been found "paranuclei" of unknown nature, thought to be functionally important. After the discharge of secretion the cells become smaller and their boundaries more distinct. The pancreatic cells rest upon basement membranes containing "basket cells."

The centro-alveolar cells may be darker or lighter than the pancreatic cells (Fig. 289), but they are always smaller, and may be readily identified from their central position. They do not contain zymogen granules. The intralobular intercalated ducts, which connect with the alveoli, are very slender, and their walls are formed of flat cells (Fig. 289, A). They

terminate in clusters of alveoli, which often present clover-leaf forms. The centro-alveolar cells have been interpreted as due to the invagination of these ducts into the alveoli, but apparently they do not develop in this way; they are formed as an inner stratum of a two-layered epithelium. The secretory capillaries of the alveoli are shown in Fig. 290. They extend between the centro-alveolar cells to the pancreatic cells, and may be prolonged between the latter, but they do not reach the basement membrane.

The intercalated ducts pass into excretory ducts lined with cuboidal epithelium, without the intervention of secretory ducts such as are found in the salivary glands. The plan of the pancreatic ducts is shown in Fig. 291. The main pancreatic and accessory pancreatic ducts are composed of simple columnar epithelium surrounded by a connective tissue

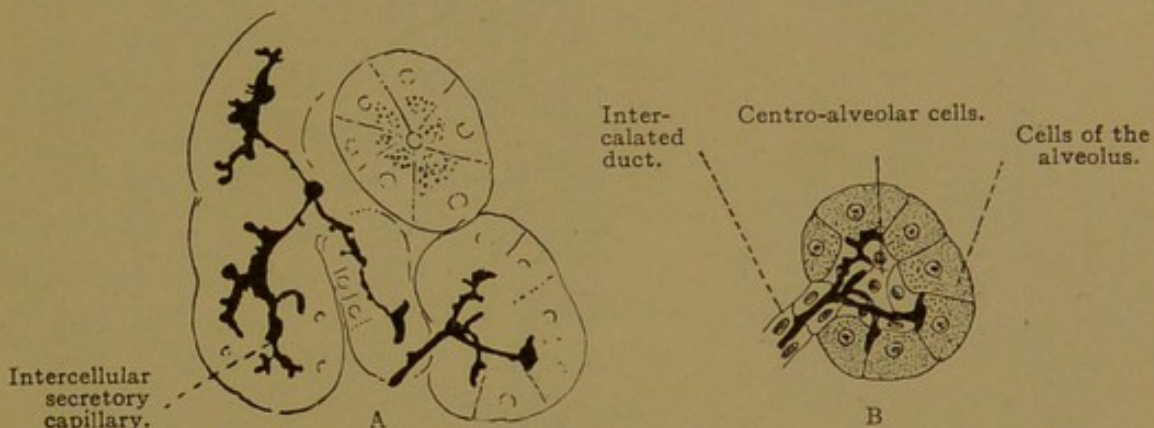


FIG. 290.—A, FROM A SECTION OF THE PANCREAS OF AN ADULT MAN. $\times 320$. B, AN INTERPRETATION OF THE RIGHT LOWER PORTION OF A.

layer, outside of which is a zone of circular smooth muscle fibers. The latter are gathered into sphincters at the major and minor duodenal papillæ, where the ducts open. Occasional goblet cells and small glands resembling mucous glands have been found in the mucosa of the large ducts.

The blood and lymphatic vessels and nerves of the pancreas resemble those of the salivary glands. The capillaries have notably wide meshes so that considerable portions of the alveoli are not in contact with them. The nerves end around the blood vessels, ducts and pancreatic cells. They are chiefly non-medullated sympathetic fibers from the cœliac plexus, associated with scattered nerve cells found within the pancreas. Lamellar corpuscles occur in the connective tissue.

The pancreatic islands are usually not to be found in human embryos under 50 mm. in length. Thus they develop only after the pancreatic glands have come together and attained considerable size. They arise as outgrowths from the smaller ducts, with which they may retain a solid stalk-like connection, or they may become wholly detached. According to Bensley, detached islands in the guinea-pig are infrequent. In the

embryo, as in the adult (Fig. 292), they consist of coiled anastomosing cords of cells, or irregular masses, which are in close relation with the endothelium of dilated capillary blood vessels. The islands are composed of pale cells with very delicate cell walls, and they contain finer granules than those in the pancreatic cells. In fresh preparations Bensley observed that these granules exhibit the Brownian movement, and that colorless spaces occur among them, representing the canals of Holmgren's trophospongium. When preserved by special methods, two forms of island-cells may be distinguished by the staining reactions of their gran-

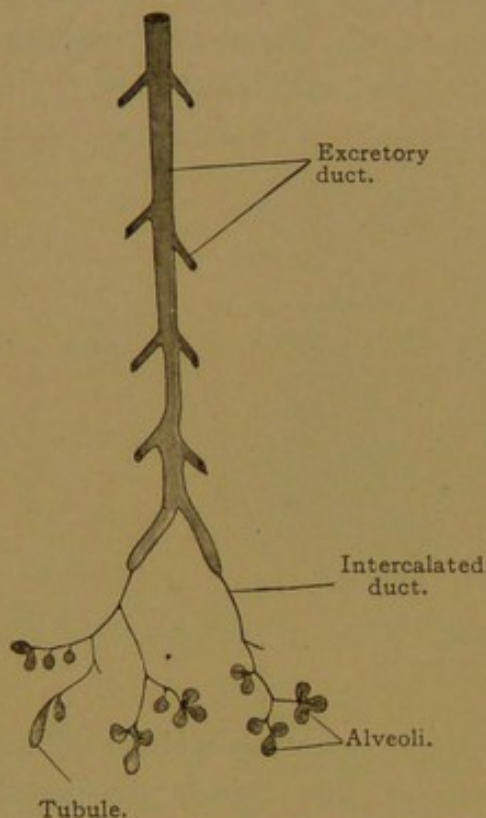


FIG. 291.—DIAGRAM OF THE PANCREAS.

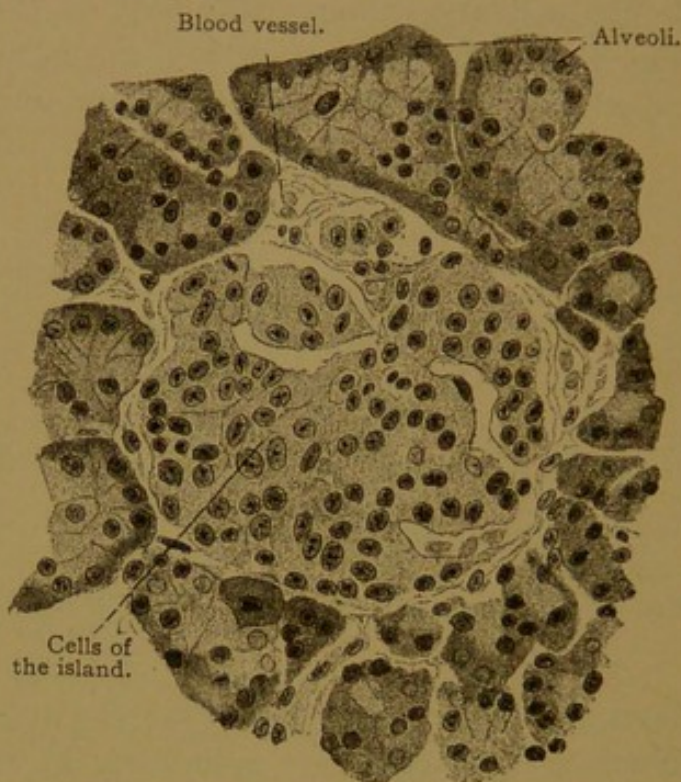


FIG. 292.—AN ISLAND OF THE PANCREAS WITH THE SURROUNDING ALVEOLI, FROM AN ADULT. $\times 400$.

ules. In one type of cell the nucleus is oval, with finely granular chromatin; and in the other it is round, with large chromatin granules. Having neither ducts nor lumen, the islands produce an internal secretion, which is received by the blood vessels. There is evidence that this secretion plays an important part in carbohydrate metabolism. If the pancreas is removed, sugar appears in the urine; but if the ducts of the pancreas are tied, the pancreatic alveoli degenerate, leaving the islands functional, and sugar is not found in the urine. Thus the islands are regarded as physiologically distinct from the remainder of the pancreas.

Morphologically the islands are likewise distinct, and Bensley finds that the possibility of the transformation of alveolar tissue into island tissue, or conversely of island tissue into alveolar tissue, "has not a single well-established fact to support it" (*Amer. Journ. Anat.*, 1911, vol. 12, pp. 297-388). The number of islands, however, is subject to great variation,

there being from 13,000 to 56,000 in the entire pancreas of guinea-pigs (Bensley), the average being twenty-two islands per cubic millimeter. In all stages, both in the guinea-pig and in man, they are usually most numerous in the tail of the pancreas, and least numerous in its head (Opie, Johns Hopkins Hosp. Bull., 1900, vol. 11, pp. 205-209).

RESPIRATORY APPARATUS.

Development. The respiratory apparatus, consisting of the larynx, trachea, bronchi, and lungs, arises as a median ventral outgrowth of the fore-gut, immediately behind the last pharyngeal pouches. It apparently is in no way related to the branchial pouches, but it may correspond with the air-bladder of the bony fishes. At the stage when the lung-bud develops, the fore-gut is laterally flattened, so that its lumen is a dorso-ventral cleft. The lung-bud develops as a pear-shaped swelling, directed downward, on the ventral border of the fore-gut; and this swelling becomes split off, from below upward, to form the trachea, which is at first short but which rapidly elongates. The upper end of the trachea, with the cartilages which develop around it, constitutes the larynx. At the lower end of the trachea, the pyriform dilatation spreads out on either side to form the primary bronchi (Fig. 293, A).

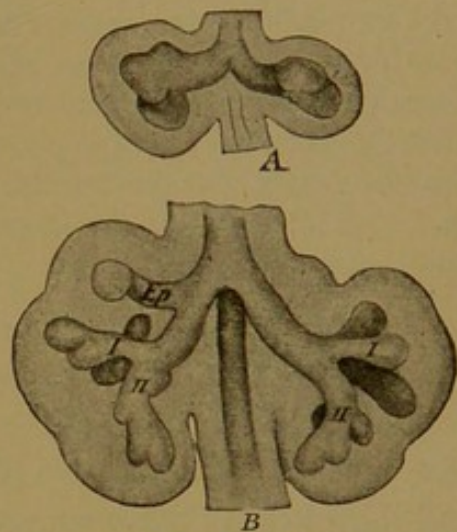


FIG. 293.—RECONSTRUCTIONS OF THE LUNGS OF YOUNG EMBRYOS, SEEN FROM THE VENTRAL SURFACE. (His.)
A, A younger stage than B; ep, apical bronchus; I, II, primary bronchi.

The tracheal and bronchial tubes are lodged in a mass of connective tissue, situated above and behind the pericardial cavity, and since this tissue stands in the middle of the thorax it is known as the *mediastinum*. It is comparable with a broad mesentery. As the bronchi push out laterally they occupy right and left folds bulging from the mediastinum, called by Ravn the *pulmonary wings* (*alae pulmonales*). Into these the bronchi extend and produce branches after the manner of a gland (Fig. 293, B). The pulmonary wings consist of mesenchyma, covered by the epithelium which lines the body cavity. At first they project into the part of the body cavity which connects the peritoneal with the pericardial cavity; later, by the development of the pleuro-pericardial and pleuro-peritoneal membranes respectively (the latter being a part of the diaphragm) the chamber into which the pulmonary wings project is entirely cut off from the rest of the body cavity. On either side, it forms a pleural cavity (see Fig. 169, p. 175). The epithelium and underlying connective tissue covering the pul-

monary wings, constitute the *visceral pleura*; and the similar layers toward the thoracic wall form the *parietal pleura*. These layers are comparable in development and structure with the corresponding layers of the peritoneum. Other subdivisions of the pleura are the mediastinal, pericardial, and diaphragmatic pleuræ. The lung is connected with the mediastinum by a short and broad stem of connective tissue, across which the bronchi, vessels and nerves extend. This is the *root* of the lung, and the vessels enter at the *hilus*.

The branches which are given off by the stem-bronchus within the pulmonary wings, are formed with great regularity, and they have been carefully studied in many mammals. Very early in development, the human lungs become asymmetrical, and at the stage shown in Fig. 293, B, the three lobes of the right lung and the two lobes of the left lung are already indicated. In the pig the asymmetry is greater, since on the right an unpaired lobe proceeds directly from the trachea; in certain animals, as in the seal, the right and left lungs have symmetrical bronchi. Whether the symmetrical condition is the primary one, and how the bronchi of one lung should be homologized with those of the other, are questions which have been much discussed. For the comparative anatomy of the bronchi, see Huntington, Ann. N. Y. Acad. Sci., 1898, vol. 11, pp. 127-148; for their development, especially in the pig, see Flint, Amer. Journ. Anat., 1906, vol. 6, pp. 1-137.

The blood vessels of the lungs are derived from several sources. They include the large pulmonary arteries and veins, which are the principal vessels of the lung, and the small but important bronchial arteries and veins. The pulmonary vessels are shown in Fig. 294, which represents the trachea and right lung of a human embryo, seen from the left side; the left lung has been cut away at *l. br.*

The *pulmonary arteries* develop in connection with the *pulmonary arches*, which are two vessels, one on either side, passing from the ventral aorta to the dorsal aorta. Approximately midway in its course, each of these arches sends a branch to the lung of the corresponding side. Subsequently the trunk of the ventral aorta becomes spirally subdivided by a septum, so that the portion leading to the pulmonary arches is split off from the rest; the way in which its root becomes connected with the right ventricle only, has been described with the development of the heart. As a result of this subdivision, the pulmonary artery leaves the heart and divides into right and left arches, each of which sends a branch to the lung on the same side and then passes on to the dorsal aorta. The connection between the right arch and the right dorsal aorta is soon lost, however, so that the vessel to the right lung (Fig. 294, *r. r.*) appears to be given off from the main pulmonary artery. The left pulmonary arch enlarges, and until birth it forms a great vessel, known as the *ductus arteriosus*, which conveys most of the blood from the pulmonary artery into the aorta. The amount of blood which goes to the inactive lungs may be inferred from the relative size of the vessels shown in the figure. Soon after birth, when respiration

has begun, the ductus arteriosus closes, becoming a fibrous cord, and then the volume of blood going through the pulmonary artery equals that in the aorta. (For further details regarding the development of the pulmonary arteries, see Bremer, Amer. Journ. Anat., 1902, vol. 1, pp. 137-144).

The *pulmonary veins* are at first represented by a capillary plexus around the lung-bud, which receives its blood in part from the pulmonary arteries already described, and in part from branches of the dorsal aorta, some of which persist as the bronchial arteries. The capillary plexus is drained partly by branches of the posterior cardinal or azygos veins, representing the future bronchial veins, and partly by a minute vein which has grown out from the left atrium and is destined to become the great pulmonary veins. At a certain stage these veins, two from each lung, have a common orifice in the left atrium; but in later stages, as the heart enlarges, their short common stem is taken up into the wall of the atrium, so that the four pulmonary veins acquire separate openings. The early stages in the development of the pulmonary veins in the cat have recently been studied by Brown (Anat. Rec., 1913, vol. 7, pp. 299-330).

The small *bronchial arteries*, one or two on each side, are branches of the upper part of the thoracic aorta (Fig. 294); sometimes one of them proceeds from an intercostal artery. The bronchial arteries enter the hilus of the lung and pass into the fibrous tissue in the walls of the bronchi. The main stems branch with the bronchi. They produce capillary networks in the bronchial mucous membrane, and send branches to the peribronchial connective tissue, supplying it with capillaries and becoming the vasa vasorum of the main branches of the pulmonary artery (Miller, Anat. Anz., 1906, vol. 28, pp. 432-436). In some animals Miller finds that the bronchial arteries pass on into the pleura, as in the horse; in others, like the dog, terminal branches of the pulmonary arteries supply the pleura; and in the human lung the pleura receives both pulmonary and bronchial vessels (Amer. Journ. Anat., 1907, vol. 7, pp. 389-407).

The *bronchial veins* are small branches of the azygos vein. They do not receive all the blood from the bronchial arteries, since some capillaries from the latter are drained by the pulmonary veins.

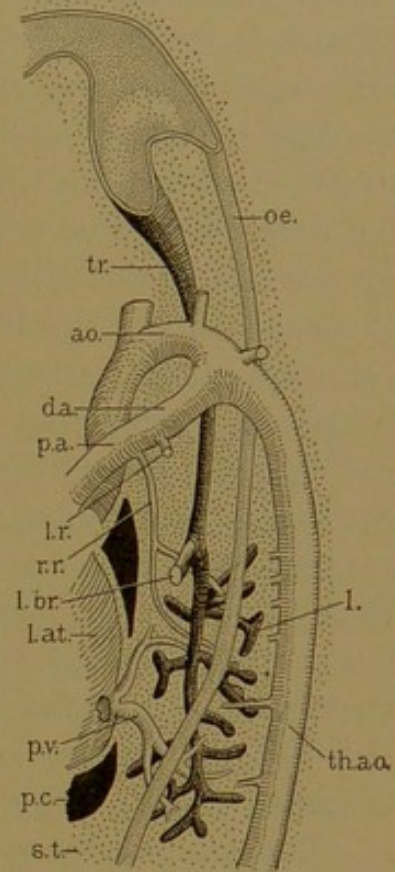


FIG. 294.—RECONSTRUCTION OF A PART OF A HUMAN EMBRYO OF 13.8 MM. (Dr. F. W. Thyng.)

ao., Aorta; d.a., ductus arteriosus; l., entodermal part of the lung; l. at., left atrium; l. br., left bronchus; l. r., left ramus of pulmonary artery; p. a.; r. r., its right ramus; oe., oesophagus; p. c., pericardial cavity; p. v., pulmonary vein; s. t., septum transversum; th. ao., thoracic aorta; tr., trachea.

LARYNX.

The mucous membrane of the larynx is a continuation of that of the pharynx, and accordingly consists of epithelium and tunica propria. A submucosa connects it with the underlying parts. In most places the epithelium appears to be stratified and columnar, but it is said to be pseudo-stratified, with nuclei at several levels (Fig. 38, p. 49). It is difficult to determine whether or not all the cells are in contact with the basement membrane. This type of epithelium, which occurs also in the trachea, is ciliated. The stroke of the cilia is toward the pharynx. A stratified epithelium with squamous, non-ciliated outer cells is found on the vocal folds (true vocal cords), on the anterior surface of the arytaenoid cartilages and on the laryngeal surface of the epiglottis. The distribution of the two sorts of epithelium above the vocal folds is subject to individual variation. The squamous epithelium often occurs in islands. The tunica propria is composed of fibrous connective tissue with many elastic fibers, and beneath the epithelium it forms a basement membrane (*membrana propria*). It includes reticular tissue containing a variable number of lymphocytes, which are gathered in solitary nodules in the wall of the laryngeal ventricle (sinus of Morgagni). Connective tissue papillæ are found chiefly beneath the squamous epithelium. At the free border of the vocal folds and on their under surface, the papillæ unite to form longitudinal ridges. On the laryngeal surface of the epiglottis there are only isolated papillæ, against which rest the short taste buds.

The submucosa contains mixed, branched, tubulo-alveolar glands, measuring from 0.2 to 1.0 mm.; they are abundant in the ventricular folds but are absent from the middle part of the vocal folds. The ventricular folds (false vocal cords) consist of a loose vascular fatty tissue, often containing small bits of elastic cartilage about 1 mm. long, and similar cartilages measuring 2-3.5 mm. are sometimes found in the anterior ends of the vocal folds.

The cartilages of the larynx are mostly of the hyaline variety, resembling those of the ribs. To this class belong the thyreoid, cricoid, the greater part of the arytaenoid, and often the small triticeous cartilages. Elastic cartilage is found in the epiglottis, the cuneiform and corniculate cartilages, the apex and vocal process of the arytaenoids, and generally the median part of the thyreoid. In women this portion is not involved in the ossification (chiefly endochondral) which begins in the thyreoid and cricoid cartilages between the twentieth and thirtieth years. The triticeous cartilages (nodules in the lateral hyothyreoid ligaments, named from their resemblance to grains of wheat) are sometimes composed of fibro-cartilage.

The blood vessels form two or three networks parallel with the surface,

followed by a capillary plexus just beneath the epithelium. The lymphatic vessels similarly form two communicating networks, of which the more superficial consists of smaller vessels and is situated beneath the capillary plexus. The nerves form a deep and a superficial plexus which are associated with microscopic ganglia. Non-medullated fibers end either beneath the epithelium in bulbs and free endings with terminal knobs, or within the epithelium in free ramifications and in taste buds. Below the vocal folds, subepithelial nerve endings and buds are absent, but many intraepithelial fibers occur, which surround individual taste cells. The nerves and vessels of the larynx are numerous, except in the dense elastic tissue of the vocal folds.

TRACHEA AND BRONCHI.

The trachea consists of a mucosa, submucosa, and a fibrous outer layer containing the tracheal cartilages. The general arrangement of the layers is the same as that found in the large bronchi (Fig. 295).

The *mucosa* consists of pseudo-stratified columnar epithelium with cilia proceeding from distinct basal bodies (Fig. 38, p. 49). Exceptionally, the lining of the trachea, toward the œsophagus, has been found to consist of stratified squamous epithelium resting on connective tissue papillæ. Beneath the epithelium there is a broad basement membrane, followed by a layer of reticular tissue containing many lymphocytes, forming a tunica propria. Beneath the reticular tissue there is a layer of coarse longitudinal elastic fibers, which may readily be seen in hæmatoxylin and eosin preparations. This layer may be compared with the muscularis mucosæ of the intestine.

The *submucosa* is a layer of loose fatty connective tissue extending to the perichondrium of the tracheal cartilages. It contains the bodies of the tracheal glands, which include both serous and mucous cells, and are beautiful objects for the study of serous crescents.

The outer layer of the trachea is continuous with the tissue of the mediastinum. It contains abundant blood and lymphatic vessels, and nerves, both medullated and non-medullated. Internally it forms the perichondrium around the succession of C-shaped hyaline cartilages, the free ends of which are toward the œsophagus. In the intervals between these ends there is a layer of transverse smooth muscle fibers, usually accompanied by outer longitudinal fibers. As in the intestine, elastic fibers are abundant among the muscle cells. In old age, the hyaline cartilages show fibrous degenerative changes, and may become partly calcified.

The primary bronchi have the same structure as the trachea, but in their subdivisions changes occur, and the C-shaped rings of cartilage are

replaced by irregular plates found on all sides of the tube (Fig. 295). These diminish in size as the bronchi become smaller, and disappear in those about 1 mm. in diameter. Usually the cartilages are hyaline, but elastic cartilage is said to occur in places. The circular muscle fibers form a layer completely surrounding the tube internal to the cartilages. Branched tubulo-alveolar *bronchial glands* extend further down the tubes than the cartilages. In the larger bronchi they are present in great numbers,

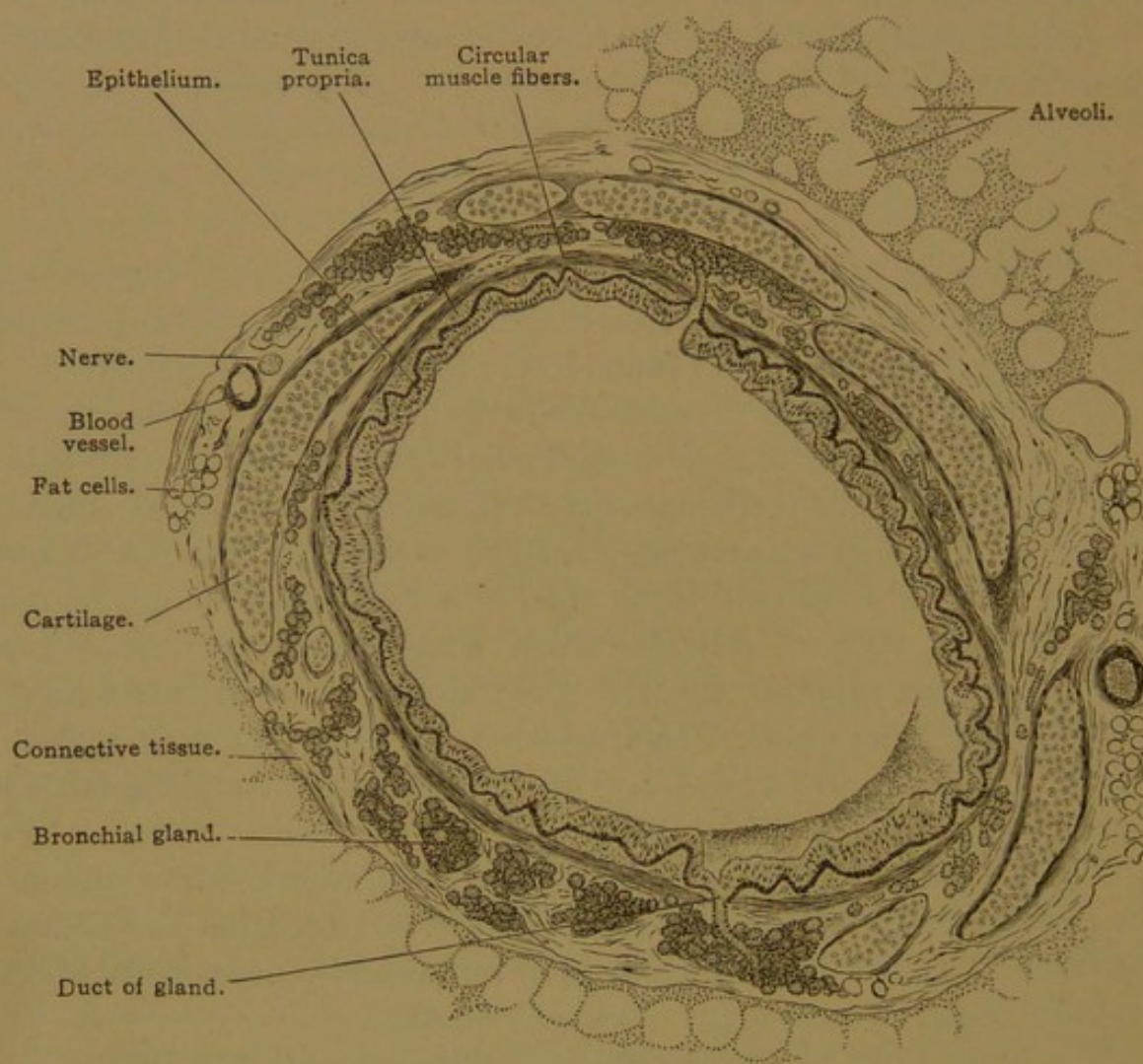


FIG. 295.—CROSS SECTION OF A BRONCHUS 2 MM. IN DIAMETER, FROM A CHILD.

and their bodies lie outside of the muscular layer and project into the spaces between the cartilages. The mucosa is thrown into longitudinal folds; it is covered with ciliated epithelium containing goblet cells and resembling that of the trachea. Lymphocytes are numerous in the tunica propria, sometimes collecting in solitary nodules and wandering into the epithelium.

The small bronchi, 0.5–1.0 mm. in diameter, are known as *bronchioles*. They are free from cartilage and glands, and are lined throughout with ciliated columnar epithelium.

LUNGS.

The arrangement of the ultimate branches of a bronchiole is shown in the diagram, Fig. 296. The *respiratory bronchioles*, 0.5 mm. or less in diameter, at their beginning contain a simple columnar ciliated epithelium. Further in their course the goblet cells disappear, cilia are lost, the cells become cuboidal, and among them are found thin, non-nucleated plates of different sizes. These plates constitute the *respiratory epithelium*. The transition from the cuboidal to the respiratory epithelium occurs irregularly, so that a bronchiole may have cuboidal epithelium on one side and

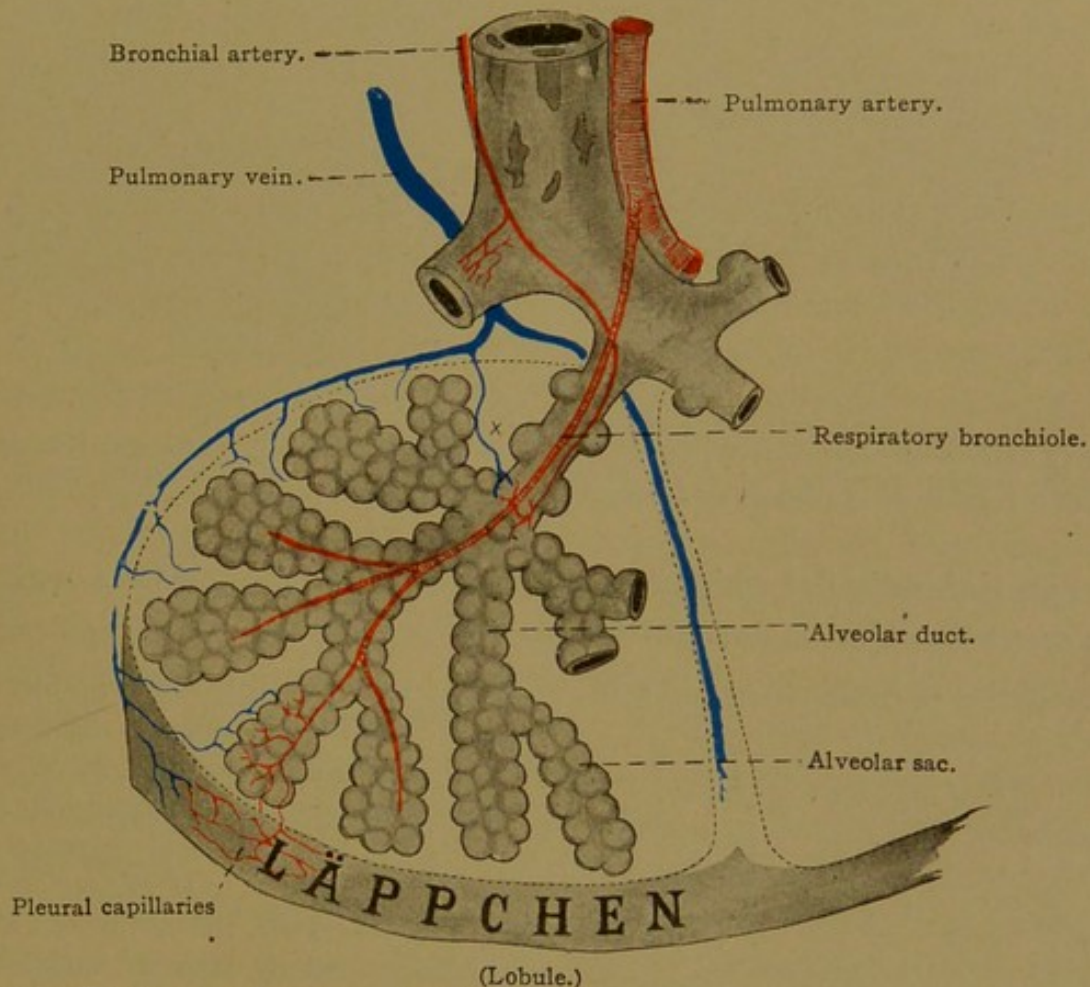


FIG. 296.—DIAGRAM OF A LOBULE OF THE LUNG, SHOWING THE BLOOD VESSELS AND THE TERMINAL BRANCHES OF A BRONCHIOLE.

respiratory epithelium on the other; or one sort of epithelium may form an island in the midst of the other. Hence the respiratory bronchioles contain a mixed epithelium (Fig. 297, A). The respiratory epithelium steadily gains in extent until the cuboidal epithelium has disappeared.

At irregular intervals along the bronchioles the respiratory epithelium forms hemispherical outpocketings or *alveoli*. The *alveolar ducts*, from 1 to 2 mm. long, differ from the respiratory bronchioles in that they contain only the respiratory epithelium and are thickly beset with alveoli. The layer of smooth muscle fibers may be traced to the end of the alveolar ducts, where it terminates. Since the muscles do not extend over the

alveoli, but merely surround the main shaft of the duct, the layer is greatly interrupted, and some consider that it ends in the course of the duct. The respiratory bronchiole may be continued as a single alveolar duct or may divide into two or more. The alveolar ducts branch to produce *alve-*

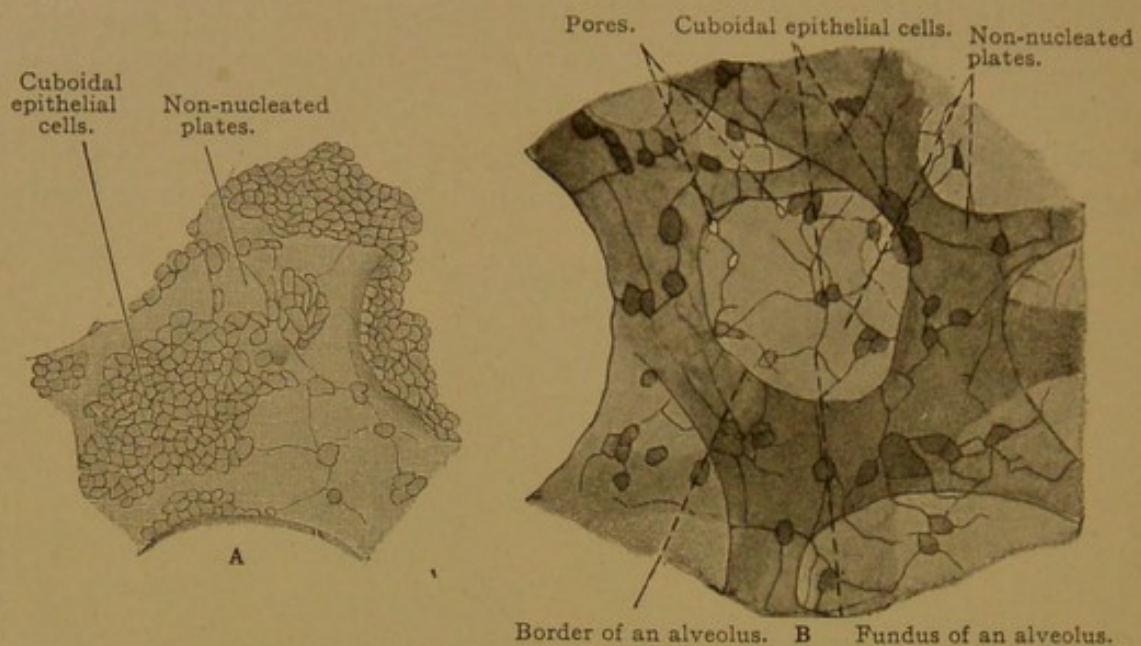


FIG. 297.—FROM SECTIONS OF THE HUMAN LUNG. $\times 240$.

A, Mixed epithelium of a respiratory bronchiole; B, an alveolus sketched with change of focus; the border of the alveolus is shaded; it is covered by the same epithelium as that of the (clear) fundus of the alveolus; the nuclei of the cells are invisible. (Silver nitrate preparation.)

olar sacs (infundibula) which are cavities in the center of clusters of alveoli. The sacs resemble the ducts as shown in Fig. 296.

According to Miller (Arch. f. Anat. u. Entw., 1900, pp. 197-228) who has made careful reconstructions of the terminal branches in the human lung, an *atrium*, or round cavity, should be recognized between the alveolar duct and the alveolar sac. The alveolar duct is said to terminate by opening into 3 to 6 atria, the entrances to which are surrounded by smooth muscle fibers forming "a sort of sphincter"; the atria possess no muscle fibers. Each atrium is connected with two or more alveolar sacs, and is moreover beset with alveoli (Fig. 298).

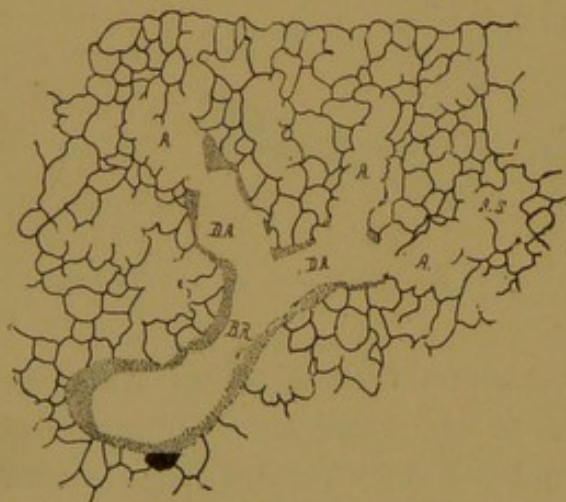


FIG. 298.—CAMERA LUCIDA DRAWING FROM A SECTION OF A CALF'S LUNG. (Miller.)

The stippling indicates smooth muscle and cuboidal epithelium; the lines, respiratory epithelium. B. R., Respiratory bronchiole; D. A., alveolar duct; A., atrium; A. S., alveolar sac.

Stöhr states that the recognition of an atrium between the alveolar duct and alveolar sac seems to him superfluous; "in good casts of the human lung it is not to be distinguished, and in other animals it is inconstant."

In sections, without resort to reconstructions, very little can be found out concerning the relations of the alveoli to the bronchial ramifications. The following structures are all which can easily be identified: (1) alveoli;

(2) spaces bounded by alveoli (alveolar sacs, atria and alveolar ducts, the ducts having muscle fibers in their walls); (3) small bronchioles having scattered alveoli along their walls, and therefore presenting a mixed epithelium (respiratory bronchioles); and (4) bronchioles with no respiratory epithelium.

The study of sections of the adult lung is facilitated by comparison with those from an embryonic lung. Comparable sections, including the pleura, and drawn at the same scale of magnification, are shown in Figs. 300 and 301. In the lung of the embryo of four months, the terminal branches of the bronchioles are found in the centers of lobules, one of which is shown in Fig. 300 (bounded by *b. v.* and *lym.*). The axial bronchioles break up into ramifying tubules lined with cuboidal cells, and at birth the alveoli which are found at the end of these structures are also lined with cuboidal epithelium. The main arteries run with the axial bronchioles in the centers of lobules; and the large veins and lymphatic vessels are at their periphery. This arrangement is retained in the adult (Fig. 296). Deep in the lung, the small bronchi are surrounded by considerable connective tissue, containing arteries, veins and large lymphatic vessels.

After respiration has been established, the alveoli become greatly distended, so that the connective tissue containing the capillary vessels is flattened out in very thin layers. These layers are bounded on either side by the respiratory epithelium of adjacent alveoli (Fig. 301). In producing this epithelium, the cells not only become flattened but they are transformed into thin structureless plates, and those from several cells may fuse to form large plates. In amphibia, nuclei in small amounts of protoplasm are found attached to the basal or connective tissue side of the plates, often associated in groups. In addition to these cells, the alveolar walls contain the endothelial cells of the capillaries, connective tissue cells, wandering cells, and many elastic fibers. These fibers surround the alveoli and encircle their outlets; the alveolar walls are so elastic that in inspiration they may expand to three times the diameter to which they return during expiration (0.1 to 0.3 mm.). Pores have been described leading from one alveolus to another (Fig. 297, B).

The richness of the capillary network in the alveolar walls is seen in injected specimens (Fig. 299). Respiration takes place by the transfer of gases between the blood in these vessels and the air in the alveoli, therefore through the endothelial cells and alveolar plates, together with the trivial amount of connective tissue which may intervene.

The pulmonary and bronchial blood vessels have already been described, and their relations to the lobule of the lung are shown in Fig. 296. The pulmonary arteries are axial vessels within the lobules, breaking up into terminal branches at the atria, and these branches become axial along the alveolar sacs. Each terminal branch has been described as the center of

an ultimate lobule or structural unit. The veins are peripheral both in the units and larger lobules; between the latter they run through connective tissue septa.

The abundant lymphatic vessels are arranged in a superficial set draining into the pleura by way of the interlobular septa; and a deep set draining toward the hilus along the bronchi, accompanying the large vessels. Lymphatics of the deep set do not extend into the lobules; they terminate along the alveolar ducts. Around the larger bronchi and at the root of the lung, lymph glands are numerous. A conspicuous feature of the sections of the lung is the presence of black soot in the tissue around the lymphatic

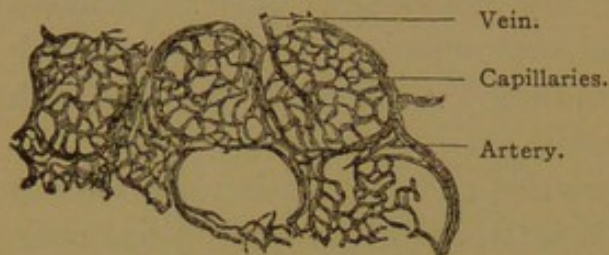


FIG. 299.—FROM A SECTION OF THE LUNG OF A CHILD, INJECTED THROUGH THE PULMONARY ARTERY. $\times 80$.

Of the five alveoli drawn, the three upper ones are fully injected.

vessels. It penetrates the pulmonary epithelium in the smallest bronchioles, apparently passing between the epithelial cells. Some of it is taken up by phagocytes. Having entered the lymphatic vessels it is distributed along their courses. On the surface of the lung it is seen in the interlobular septa, marking out the boundaries

of the lobules. Because of the steady increase in this deposit, the color of the lungs changes from birth until old age.

The nerves of the lung include the pulmonary plexus derived from the sympathetic system. Its fibers enter at the root of the lung and spread around the bronchi and vessels, to which they are chiefly distributed. Small ganglia are found within these plexuses. The vagus also sends branches to the lungs, including medullated and non-medullated fibers, which join the sympathetic plexuses.

PLEURA.

The visceral pleura is a thinner layer than the parietal pleura, and is closely attached to the lung. It is covered with a single layer of flat mesothelial cells, which in the collapsed lung become thicker and shorter. In specimens which have been handled, this layer is often lacking. It rests upon a thin layer of fine-meshed fibrous tissue, beneath which is the coarse subserous layer continuous with the interlobular septa of the lung (Fig. 301). This tissue is highly elastic. In the subserous layer, blood vessels, derived from both pulmonary and bronchial arteries, form an abundant capillary plexus. The superficial lymphatic vessels are very evident, and in relation with them lymphoid tissue is found, and occasionally lymph nodules. Stomata, which have been described, are presumably artificial apertures in the epithelium and are not connected with the lymphatic vessels.

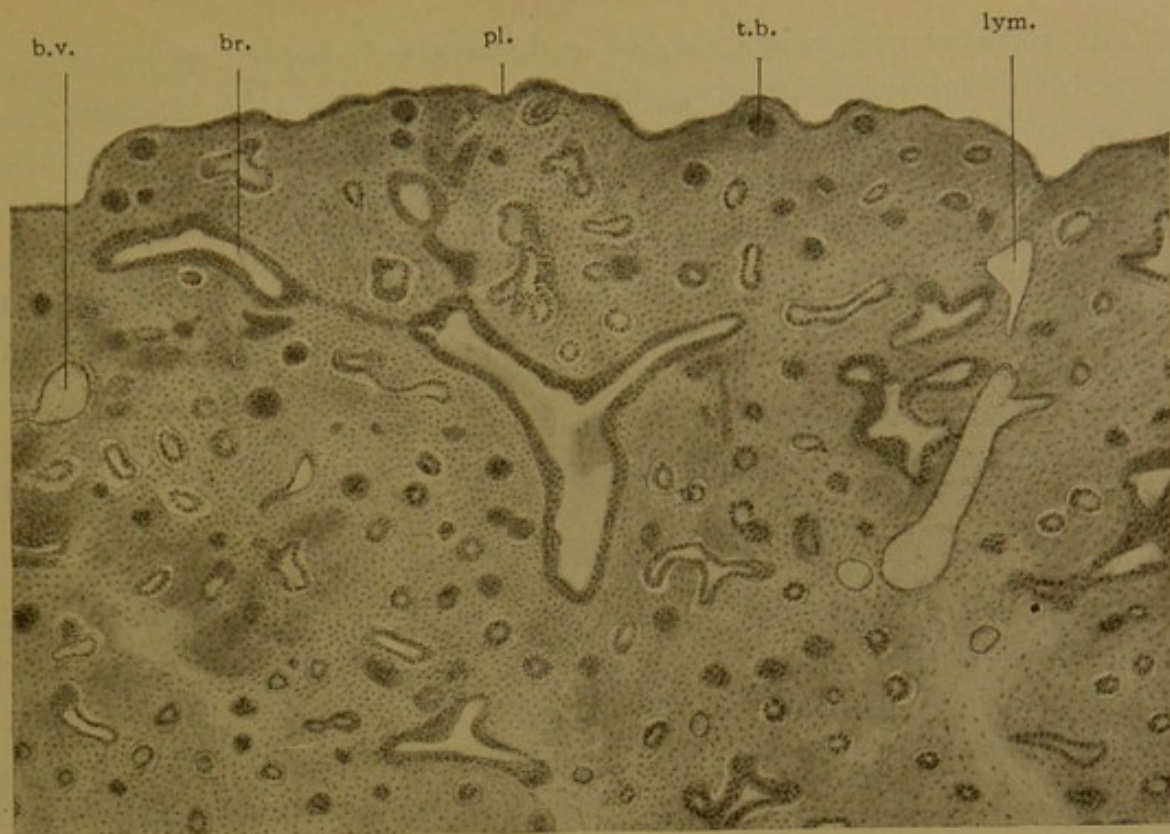


FIG. 300.

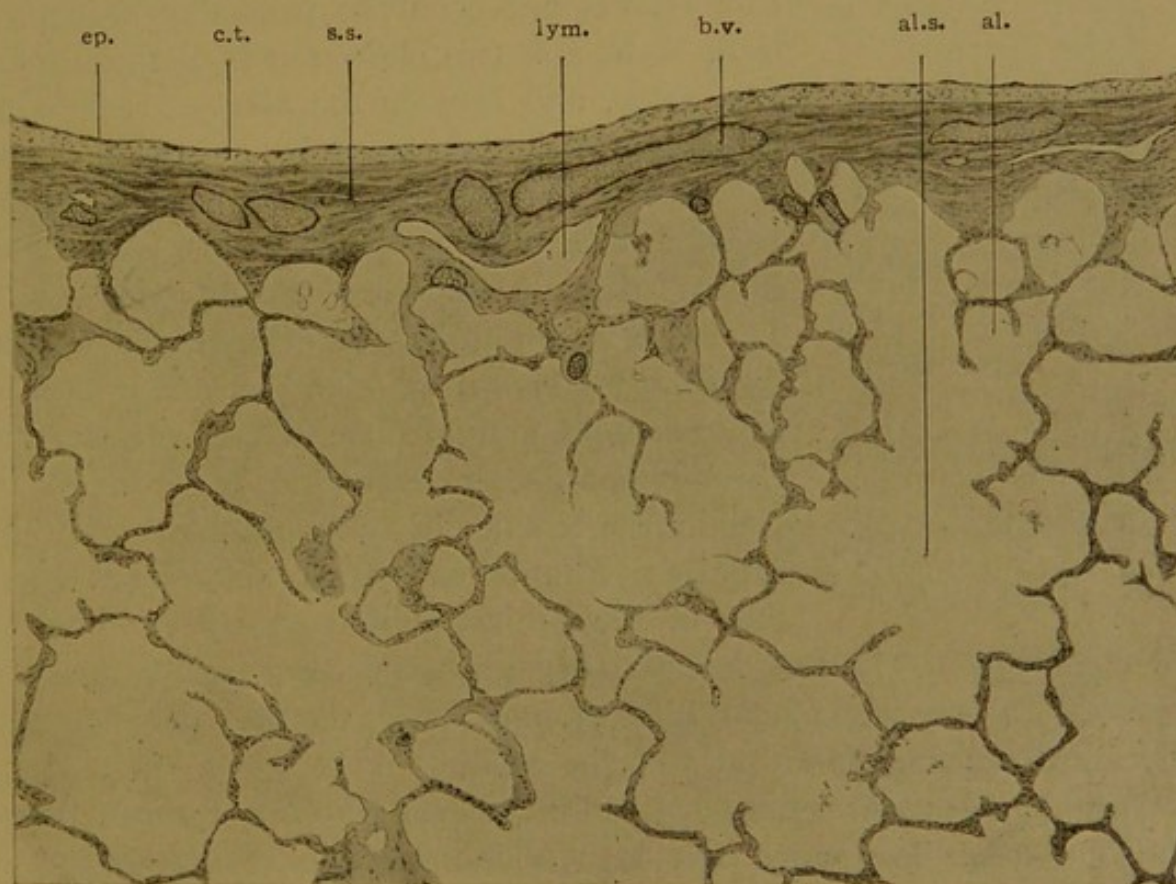


FIG. 301.

FIGS. 300 AND 301.—SECTIONS OF THE LUNG DRAWN ON THE SAME SCALE OF MAGNIFICATION; FIG. 300 FROM A HUMAN EMBRYO OF FOUR MONTHS; FIG. 301, FROM AN ADULT.

al., Alveolus; al. s., alveolar sac; br., bronchiole; b. v., blood vessel; c. t., outer layer of pleural connective tissue; ep., pleural epithelium; lym., lymphatic vessel; pl., pleura; s. s., subserous connective tissue; t. b., terminal branch of the bronchiole.

The parietal pleura is a thicker and less elastic layer. Ventrally and below, toward the pleuro-pericardial membrane, it exhibits folds containing fat (*plicæ adiposæ*); and sometimes it forms vascular elevations resembling synovial villi—the *pleural villi*. Fat may be found in the pleura elsewhere.

The nerves of the pleura are derived from the phrenic, sympathetic and vagus nerves. In the parietal pleura typical lamellar corpuscles may be found, together with the smaller variety, known as the Golgi-Mazzoni corpuscles.

URINARY ORGANS.

WOLFFIAN BODIES AND WOLFFIAN DUCTS.

On the twenty-eighth of November, 1759, Caspar Friedrich Wolff, then in his twenty-sixth year, defended a thesis entitled "*Theoria generationis*," and obtained the degree of doctor of medicine at Halle. In addition to the fundamental principles which this renowned thesis set forth, it included

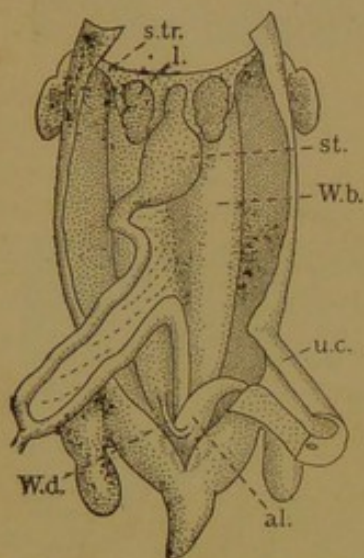


FIG. 302.—DISSECTION OF A HUMAN EMBRYO OF THIRTY-FIVE DAYS. (After Coste.)

al., Bladder; l., lung; st., stomach; s. tr., septum transversum; u. c., umbilical cord; W. b., Wolffian body; W. d., Wolffian duct.

an account of the development of the kidneys in chick embryos. From the diffuse *substantia cellulosa* along the ventral side of the spinal column, beginning on the third day of incubation, Wolff saw two elongated bodies gradually take form, and become the *kidneys*, each being connected with the cloaca by a *ureter*. These structures, however, are not the kidneys of the adult, and they are generally known as *Wolffian bodies*; their ureters are the *Wolffian ducts*. They are large and important organs in human embryos, as shown in Fig. 302. The true or permanent kidneys of mammals arise later, and the Wolffian bodies degenerate, becoming vestigial in the female; in the male, however, they acquire new functions, and are retained as a portion of the genital ducts (namely the duct of

the epididymis). In the embryo they are renal organs built upon the same plan as the permanent kidneys, and moreover in the fishes and amphibia they are the kidneys of the adult.

Still another renal organ develops in embryos, anterior to the Wolffian body, and it has been found that the Wolffian duct is primarily the duct of this anterior kidney or *pronephros*; consequently the Wolffian duct is sometimes called the pronephric duct. The pronephros is the functional kidney in only the lowest of vertebrates (myxinoids). Singularly it has been found that "the human pronephros is by far the best developed within the groups of mammals" (Felix, in Keibel and Mall's Human Embry-

ology, Vol. 2). Except for its duct, it entirely disappears in very young embryos (5 mm.). All the renal organs—pronephros, Wolffian body (or mesonephros), and kidney (or metanephros)—are developed from the nephrotomes. They are all composed of mesodermal tubules, each of which is in close relation with a knot of capillary blood vessels derived from branches of the aorta. Such a knot of vessels is a *glomerulus*, and certain products are eliminated from the glomerulus into the tubules to form the urine.

Development of the Wolffian Body and Wolffian Duct. The general relations of the nephrotome to the mesodermic somites and to the coelomic

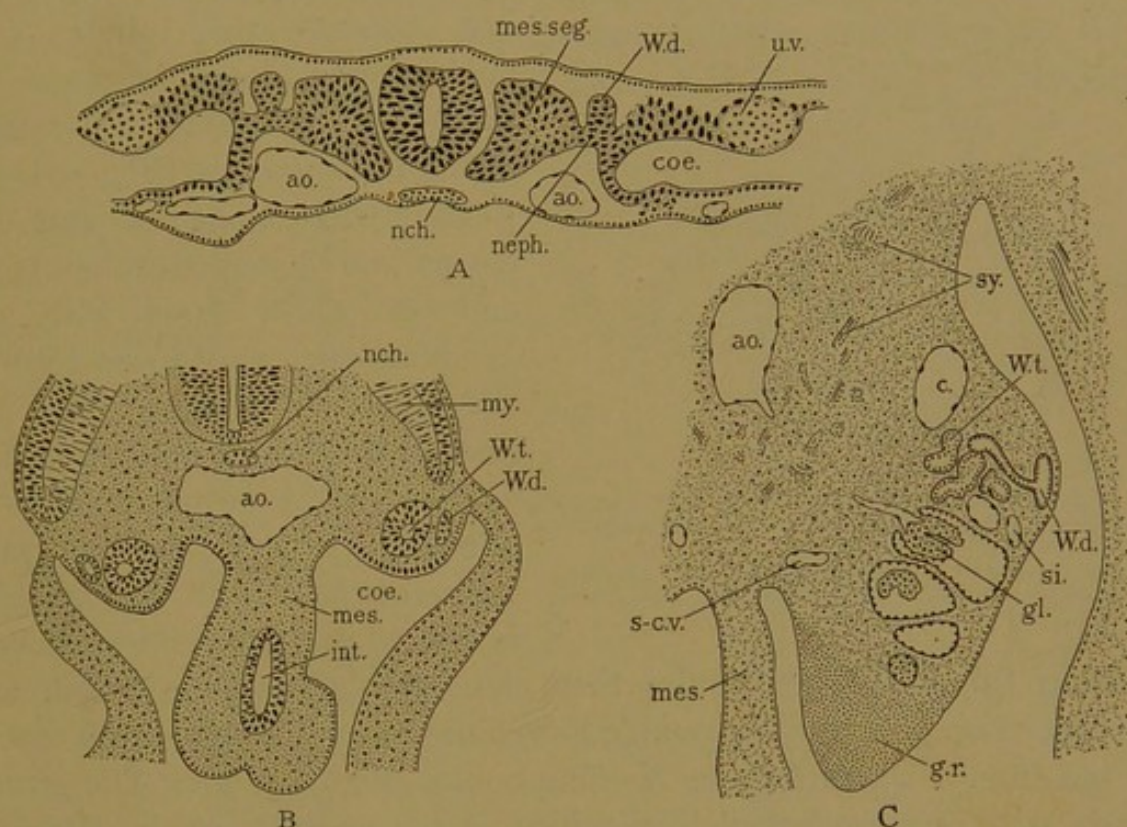


FIG. 303.—A, TRANSVERSE SECTION OF A RABBIT EMBRYO OF NINE DAYS; B, HUMAN EMBRYO, 4 MM.;
C, HUMAN EMBRYO, 10 MM.

ao, Aorta; c., posterior cardinal vein; coe., coelom; gl., glomerulus; g. r., genital ridge; int., intestine; mes., mesentery; mes. seg., mesodermic somite; my., myotome; nch., notochord; neph., nephrotome; s-c. v., subcardinal vein; sl., sinusoid; sy., sympathetic nerves; u. v., umbilical vein; W. d., Wolffian duct; W. t., Wolffian tubule.

epithelium have already been briefly discussed (p. 41). A nephrotome from a young rabbit embryo is seen in section in Fig. 303, A, together with its elevation which contributes to the formation of the Wolffian duct. The nephrotome here shown is from one of the anterior segments and belongs with the pronephros.

In human embryos, according to Felix, pronephric tubules are formed from the seventh to the fourteenth segments, and perhaps from those further forward. The elevations to which these nephrotomes give rise turn posteriorly and unite with one another to form the Wolffian duct. This is at first a solid cord of cells which grows posteriorly in the trough

between the somites and somatic mesoderm. It lies near the ectoderm, but it is now generally agreed that the ectoderm takes no part in its formation. Finally its growing extremity reaches the ventral portion of the cloaca and fuses with it. Later this ventral part of the cloaca becomes cut off to form the bladder, and the Wolffian ducts then empty into the neck of the bladder. The pronephric tubules meanwhile become detached from the coelomic epithelium, but they remain rudimentary and degenerate without having any glomeruli formed in connection with them.

The mesonephric tubules develop from the more posterior nephrotomes, after the Wolffian duct has formed. They acquire openings into the Wolffian duct, but do not contribute to its development. In produc-

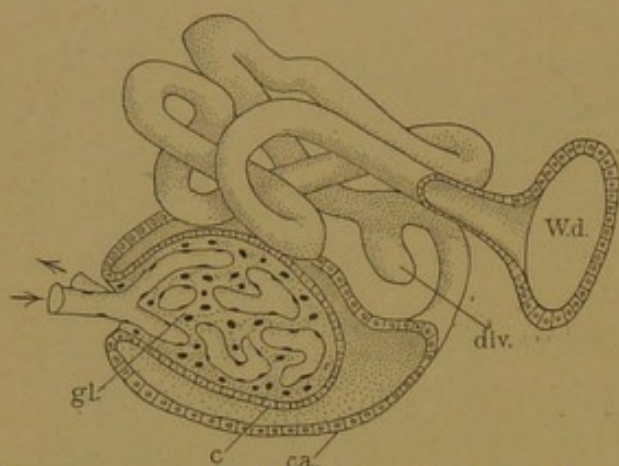


FIG. 304.—RECONSTRUCTION OF A WOLFFIAN TUBULE FROM A HUMAN EMBRYO OF 10.2 MM. (Except the glomerulus, after Kollman.)

c., Inner layer, and c. a., outer layer of the capsule of the glomerulus; div., diverticulum; gl., glomerulus; W. d., Wolffian duct.

ing mesonephric tubules, the nephrotomic tissue becomes detached and separates into masses which form vesicles (Fig. 303, B). Each vesicle elongates and becomes an S-shaped tubule, one end of which fuses with the Wolffian duct and opens into it; the other end remains blind. A knot of capillaries, derived from a branch of the aorta, develops in the distal concavity of the S and becomes a glomerulus; a glomerulus is formed in connection with every

Wolffian tubule. The tubules then elongate and become coiled, and together they produce the rounded swellings on either side of the root of the mesentery, which are the Wolffian bodies (Fig. 303, C). The genital glands arise as mesodermal thickenings on the ventro-medial surface of these bodies.

A single Wolffian tubule is shown in Fig. 304, and the way in which its distal end envelops the glomerulus is clearly indicated. It is said to form the *capsule* of the glomerulus. By passing through the inner layer of this capsule, fluid from the blood vessels enters the tubule and is conveyed through the Wolffian duct to the bladder. The tubules are generally unbranched, and are lined with simple epithelium. The epithelium is in part glandular, and contributes to the formation of the urine. Finally it may be noted that a nephrotome may divide into several vesicles (sometimes perhaps as many as four), and therefore the number of Wolffian tubules is greater than the number of corresponding segments. In man the maximum number is 83 (Felix). The mesonephric tubules also extend forward, so that some segments contain both mesonephric and pronephric tubules.

It is generally believed that the Wolffian bodies of mammalian embryos are active renal organs, producing a form of urine which collects in the allantoic sac. In pig embryos this sac and the Wolffian bodies are both unusually large. MacCallum (Amer. Journ. Anat., 1902, vol. 1, pp. 245-259) notes that the tubules of the Wolffian body in the pig "show a very distinct division into a secretory and a conducting part." In the human embryo, however, the allantois is very small and the Wolffian bodies degenerate early, before the kidney can become functional. Therefore Felix (Keibel and Mall's Human Embryology, vol. 2) regards the question as settled. The Wolffian body "does not function as an excretory organ"; but he adds, "This does not, of course, imply that it may not have been active in another manner unknown to us."

Veins of the Wolffian Body. In determining the arrangement of the large veins of the abdomen, the Wolffian bodies are of fundamental importance. They are supplied by the *posterior cardinal veins* which pass from the tail of the embryo, on either side of the aorta, to the heart.

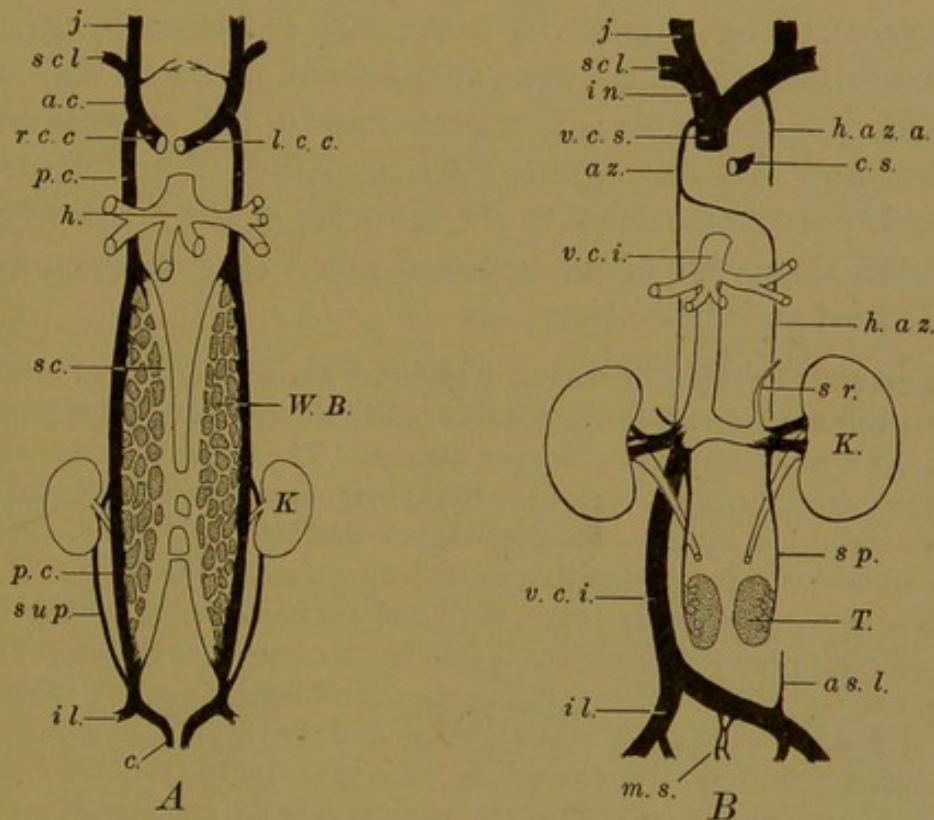


FIG. 305.—THE TRANSFORMATION OF THE POSTERIOR CARDINAL SYSTEM OF VEINS.

a. c., Anterior cardinal; as. l., ascending lumbar; az., azygos; c., caudal; c. s., coronary sinus; h., hepatic; h. a. z., hemiazygos; h. a. z. a., accessory hemiazygos; il., common iliac; in., innominate; j., jugular; K., kidney; l. c. c., left common cardinal; m. s., median sacral; p. c., posterior cardinal; r. c. c., right common cardinal; s. c., subcardinal; scl., subclavian; sp., spermatic; sr., suprarenal; sup., supracardinal; T., testis; v. c. i., vena cava inferior; v. c. s., vena cava superior; W. B., Wolffian body.

Before entering the right atrium of the heart, they are joined by the *anterior cardinal veins* from the head, thus forming the right and left *common cardinal veins*, or "ducts of Cuvier." As each posterior cardinal vein extends along the dorsal side of the Wolffian body, it sends branches in among the tubules, and these unite ventrally on either side in the *subcardinal vein* (Fig. 305, A). Thus each Wolffian body is lodged in a venous loop formed by the posterior cardinal and subcardinal veins, and

such a loop is found in all classes of vertebrates. Venous blood entering the Wolffian body posteriorly flows out from it anteriorly, and circulates among the tubules in lacunar vessels, closely resembling the hepatic sinusoids. This is the "renal portal system." It should be noted, however, that the renal sinusoidal vessels are poorly developed in mammalian embryos.

In sections these veins are readily recognized. The mesonephric arteries pass from the aorta to the glomeruli of the Wolffian body, between the subcardinal vein in front and posterior cardinal vein behind (Fig. 303, C). In places, the subcardinal veins form large anastomoses across the mid-ventral line; the posterior cardinal veins are further apart, and receive intersegmental branches from the dorsal musculature.

As the kidneys grow upward behind the Wolffian bodies, their ureters become encircled by a branch from the posterior cardinal vein (Fig. 305, A). The venous loop around the ureter was described by Hochstetter (Morph. Jahrb., 1893, vol. 20, pp. 543-648), and its dorsal limb, together with secondary anastomoses, has been named the *supracardinal vein* (Huntington and McClure, Anat. Rec., 1907, vol. 1, pp. 29-30). The transformation of these veins into the branches of the inferior vena cava is represented somewhat diagrammatically in Fig. 305, B, and may be briefly described as follows:

The anastomosis between the subcardinal veins becomes a part of the left renal vein. Above this anastomosis the right subcardinal vein connects with the veins of the liver and forms a portion of the vena cava inferior. The left subcardinal vein, above the renal anastomosis, becomes reduced to the left suprarenal vein (Hochstetter). The subcardinal veins below the renal anastomosis are associated with lymphatic vessels to which they apparently give rise; otherwise they disappear.

The posterior cardinal veins above the renal anastomosis, after they have been tapped by the formation of the vena cava inferior, are known as the azygos and hemiazygos veins, and the outlet of the left common cardinal becomes cut off as the coronary sinus (Fig. 305, B, which shows also the formation of the superior vena cava). Below the renal anastomosis the posterior cardinal veins give rise to the genital veins (spermatic or ovarian), and the Wolffian body becomes reduced to an appendage of the genital glands. As the genital glands descend into the pelvis, their veins become elongated; and the corresponding arteries, derived from the mesonephric arteries, are likewise elongated. The supracardinal vein on the right side becomes a part of the vena cava inferior; on the left it is probably represented by the ascending lumbar vein.

The kidneys are supplied by vessels which enter them after they have attained their permanent position. Their arteries and veins consequently pursue a straight course from the aorta and vena cava, respectively, to the hilus of the kidney.

KIDNEY.

Development. The kidney develops after the Wolffian body has been formed. It arises in two parts, one of which is an outgrowth of the Wolffian duct; the other is a mass of dense mesenchyma surrounding this outgrowth, and said to be derived from the posterior nephrotomes. Both

parts are mesodermal. The part derived from the Wolffian duct may be considered first.

Each Wolffian duct, near the place where it enters the cloaca, forms a knob-like outpocketing which elongates rapidly, becoming the *ureter*. The distal end of the outpocketing expands and becomes lobular, thus producing the *pelvis* of the kidney. After the ventral part of the cloaca

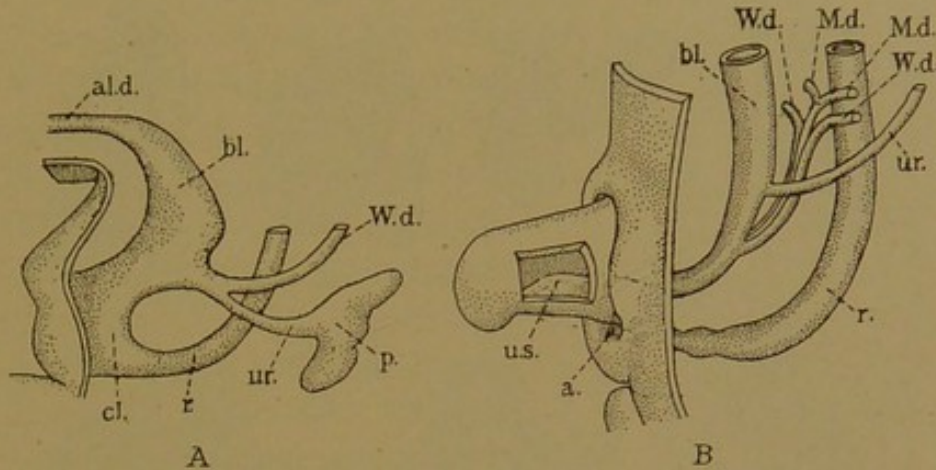


FIG. 306.—THE DEVELOPMENT OF THE RENAL PELVIS AND URETER. (Keibel.)

A, Human embryo of 11.5 mm. (4½ weeks); B, 25 mm. (8½-9 weeks). a., Anus; al. d., allantoic duct; bl., bladder; cl., cloaca; M. d., Müllerian duct; p., pelvis of the kidney; r., rectum; ur., ureter; u. s., urogenital sinus; W. d. Wolffian duct.

has been split off to form the bladder, the ureter and Wolffian duct, on either side, open into it by a common outlet (Fig. 306, A). Later, the terminal portion of each Wolffian duct is taken up into the wall of the expanding bladder, so that the ureters acquire openings separate from

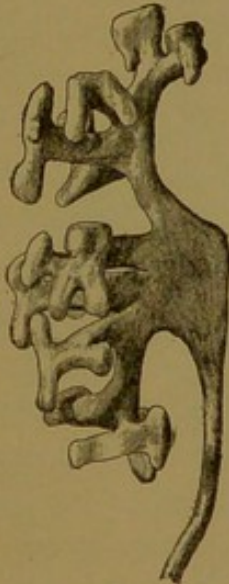

FIG. 307.—RECONSTRUCTION OF THE URETER, RENAL PELVIS, AND ITS BRANCHES IN A 20-MM. HUMAN EMBRYO. (Huber.)

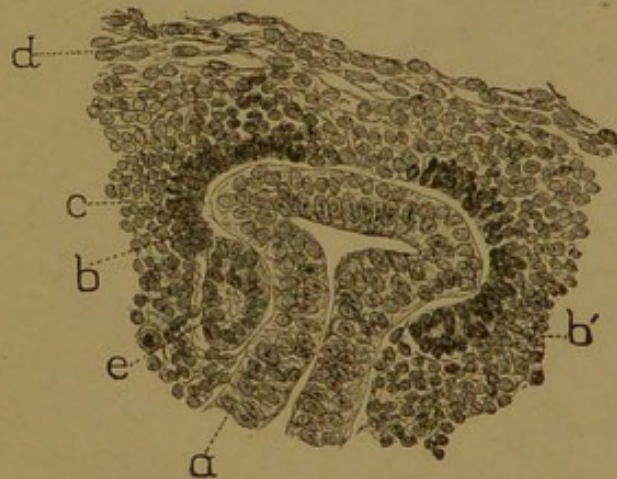


FIG. 308.—FROM A SECTION OF A KIDNEY OF AN 18-MM. HUMAN EMBRYO. $\times 233$. (Huber.)

a., Primary collecting tubule, with dilated extremity; b, b', inner layer, and c., outer layer of dense mesenchyma; d., loose mesenchyma; e., vesicle, the beginning of a renal tubule.

those of the ducts. With further growth the orifices of the Wolffian ducts are carried toward the median line and downward toward the outlet of the bladder (Fig. 306, B), and this position is permanently retained.

Meanwhile the lobes of the renal pelvis have become deeper and formed

pouches known as the *major* and *minor calyces*. In the adult there are usually two major calyces, one at either end of the pelvis, and from these most of the minor calyces grow out; the others spring directly from the main pelvic cavity. There are about eight in all. From the minor calyces the *collecting tubules* grow out. Each tubule has an enlarged extremity

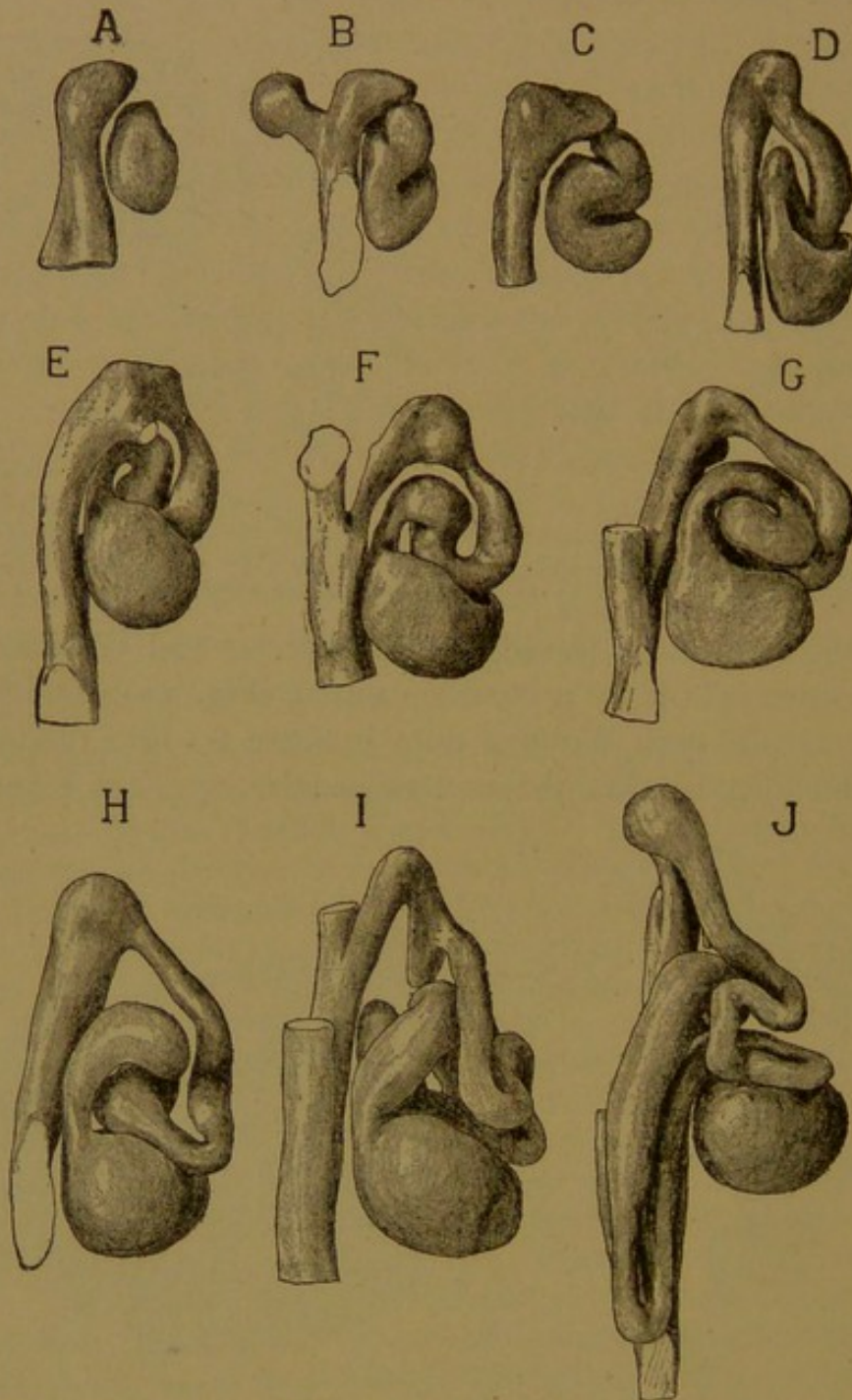


FIG. 309.—MODELS SHOWING SUCCESSIVE STAGES IN THE DEVELOPMENT OF A URINIFEROUS TUBULE INCLUDING THE ASSOCIATED PORTION OF THE COLLECTING TUBULE. (Huber.)
From a human embryo of the seventh month. $\times 160$.

(Fig. 307) which divides into two branches with a U-shaped crotch, like a tuning-fork. The branches subdivide repeatedly in the same manner, so as to make pyramidal masses of straight tubules radiating from the calyces. Thus the renal outgrowth from the Wolffian duct produces the

epithelial lining of the ureter, pelvis, calyces and collecting tubules, including all of their branches.

The second part of the kidney, which consists of dense mesenchyma, becomes subdivided into masses enveloping the enlarged tips of the branching collecting tubules. Some of its cells become arranged so as to form vesicles (Fig. 308), one of which is shown in the reconstruction, Fig. 309, A. The vesicles are at first entirely separate from the collecting tubules. Each vesicle becomes elongated, making an S-shaped tubule (Fig. 309, B, C), and its outer or upper end unites with the collecting tubule (Fig. 309, D). A glomerulus develops in the lower curve of the S, and is gradually enveloped in the terminal part of the tubule, which thus forms its capsule. Between the capsule and the collecting tubule, the renal tubules become greatly convoluted. One of the loops in the coils thus formed elongates downward, lying close beside and parallel with the collecting tubule; this is the *loop of Henle* (Fig. 309, J).

Three tubules of the adult kidney are shown diagrammatically in Fig. 310. Each *capsule* connects with a *proximal convoluted tubule*, which, after extending outward toward the surface of the kidney, turns downward as the *descending limb* of Henle's loop. The descending limb is a straight tubule, the lower portion of which is of small diameter owing to the flatness of the cells in its walls; its lumen is not reduced. This "thin segment," as shown in the diagram, does not form the entire descending limb, but only its lower part. Frequently it passes around the bend into the ascending limb. The tubule, after turning the bend, forms the *ascending limb* of Henle's loop. It returns to the vicinity of the capsule from which it arose, and makes a few coils, thus constituting the *distal convoluted tubule* (intercalated or intermediate tubule). By means of the *junctional tubule* it joins the arched collecting tubule and this passes into

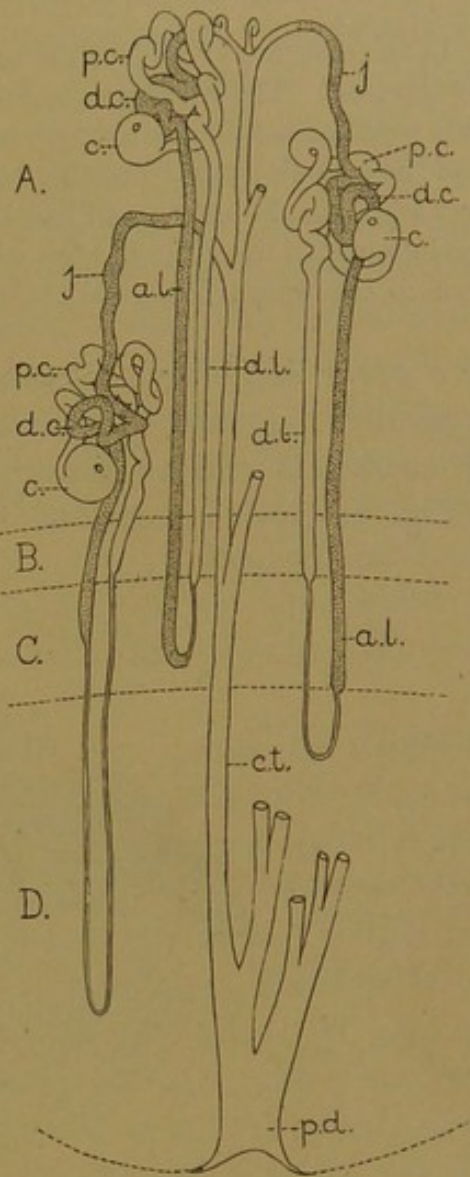


FIG. 310.—DIAGRAM OF THREE URINIFEROUS TUBULES IN RELATION WITH A COLLECTING TUBULE. (Modified from Huber.)

a. l., Ascending limb of Henle's loop; c., capsule; c. t., collecting tubule; d. c., distal convoluted tubule; d. l., descending limb; j., junctional tubule; p. c., proximal convoluted tubule; p. d., papillary duct. A, cortex; B-D, medulla, subdivided into an inner zone (D) and an outer zone (B-C); the latter includes an inner band or stripe (C), and an outer band (B).

the straight descending *collecting tubule*. From the capsule to the collecting tubule no branches occur; and this extent of the tubule represents the part derived from mesenchyma. The collecting tubules receive many branches. Traced toward their outlet in the pelvis they become larger, finally forming the *papillary ducts*.

In the diagram (Fig. 310) the tubules are represented as much coarser than is actually the case. Their true proportions in the rabbit's kidney have been shown by Huber, who, with extraordinary success, has isolated individual tubules, keeping them intact from the capsule to the collecting tubule (*Anat. Rec.*, 1911, vol. 5, pp. 187-194). They are 20-30 mm. in length and less than 0.1 mm. in diameter. Huber's account of the development of the kidney, from which Figs. 307-309 have been taken, is in the supplement to the *Amer. Journ. Anat.*, 1905, vol. 4.

Surface Markings. Before studying sections of the kidney microscopically, the small subdivisions of the organ which may be seen upon its cut surface should be examined. They are shown in transverse section in Fig. 311, but appear equally well when the kidney is divided length-

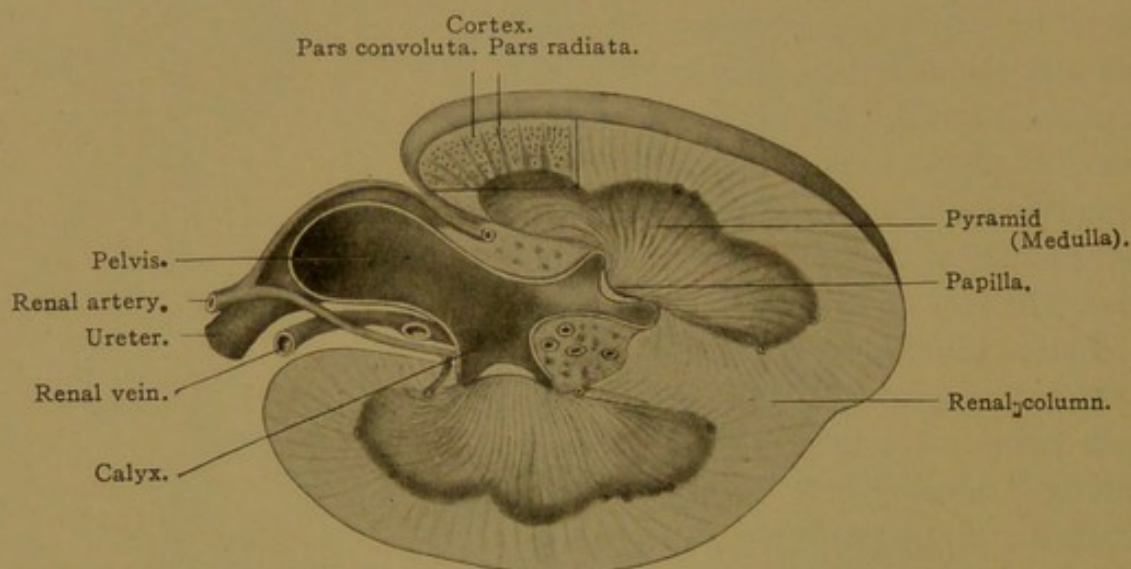


FIG. 311.—THE SURFACE MARKINGS OF THE HUMAN KIDNEY. (After Brödel.)

wise. The ureter opens into the pelvis, which is prolonged into the cup-like calyces, two of which are shown in Fig. 311. Each calyx receives a nipple-like projection of the substance of the kidney, known as a *renal papilla*. Sometimes two of them project into one calyx. They are soft, dark red structures, and it does not appear on inspection that the grayish lining of the calyx is reflected over their outer surface; this is seen in sections. Toward the apex of each papilla there are from 15 to 20 foramina, which are the orifices of as many papillary ducts; through them the urine enters the calyx. The foramina are barely visible without magnification. Each papilla forms the apex of a *renal* (or Malpighian) *pyramid*, described by Malpighi (1666) in his treatise "on the structure of the viscera," which gave the first account of various almost microscopic "corpus-

cles" and surface markings. The base of the pyramid is toward the periphery of the kidney, and may be lobular as in the figure. From two to nine embryonic or primary pyramids are said to fuse to form a pyramid of the adult kidney. In favorable specimens the pyramid is seen to be divided into an inner and an outer zone, and the latter is composed of two concentric bands. The significance of these markings will be considered later. The pyramids collectively constitute the *medulla* of the kidney, a term more fittingly applied to the kidneys of many animals which have but a single pyramid. The base of each pyramid is surrounded by a lighter zone, the *cortex*, which shows radial striations. With low magnification the striations are seen to taper outward. They constitute the processes or pyramids of Ferrein and are known collectively as the *radiate part* of the cortex (*pars radiata*). They consist of straight radial tubules which are continuous with those in the medulla. Consequently they are often called "medullary rays," but being in the cortex they may more properly be designated "cortical rays." Between these rays is the *convoluted part* of the cortex (*pars convoluta*); it may be recognized by the presence of many *renal corpuscles* (Malpighian corpuscles), which are bodies consisting of a glomerulus and its surrounding capsule. They are barely visible without magnification.

Over the outer surface of the kidney, there is a fibrous capsule (*tunica fibrosa*) which may be readily stripped off when normal; and outside of this there is a fatty layer (*capsula adiposa*). The fat surrounds the pelvis and extends into a hollow of the kidney known as the *renal sinus*; this is the excavation which contains the pelvis and its calyces. In this fatty tissue the large blood vessels enter the kidney, passing chiefly over the anterior or ventral surface of the pelvis; having reached the boundary zone between cortex and medulla they enter it, and pursue an arched course, giving off both cortical and medullary branches. In certain places, the cortex dips down to the renal sinus; this occurs between the Malpighian pyramids, and constitutes the *renal columns* (of Bertini); one of them is shown in Fig. 311.

The arrangement of the renal tubules in relation to the cortex and medulla is as follows. The convoluted part of the cortex contains the capsules, and both proximal and distal convoluted tubules. The rays contain the collecting tubules, together with the outer portions of Henle's loops. The medulla contains the larger collecting tubules and the deeper portions of Henle's loops; since these are all straight tubules, the medulla resembles the radiate part of the cortex. Tubules which are connected with capsules deep in the cortex, near the boundary zone, send their Henle's loops much further into the medulla than those from the outer capsules; and in the deeply placed tubules the thin segment of Henle's loop is not limited to the descending limb but extends well up into the

ascending limb. Thus it happens that a broad *inner zone* of the medulla (*i.e.*, toward the papilla) contains only thin segments of renal tubules in addition to the large collecting tubules (Fig. 310, D); and the zone so characterized may be distinguished macroscopically. The papilla contains only collecting tubules, but the loops of Henle turn back at different levels, and therefore the papillary zone entirely free from loops is not well defined. The *outer zone* of the medulla contains both thick and thin seg-

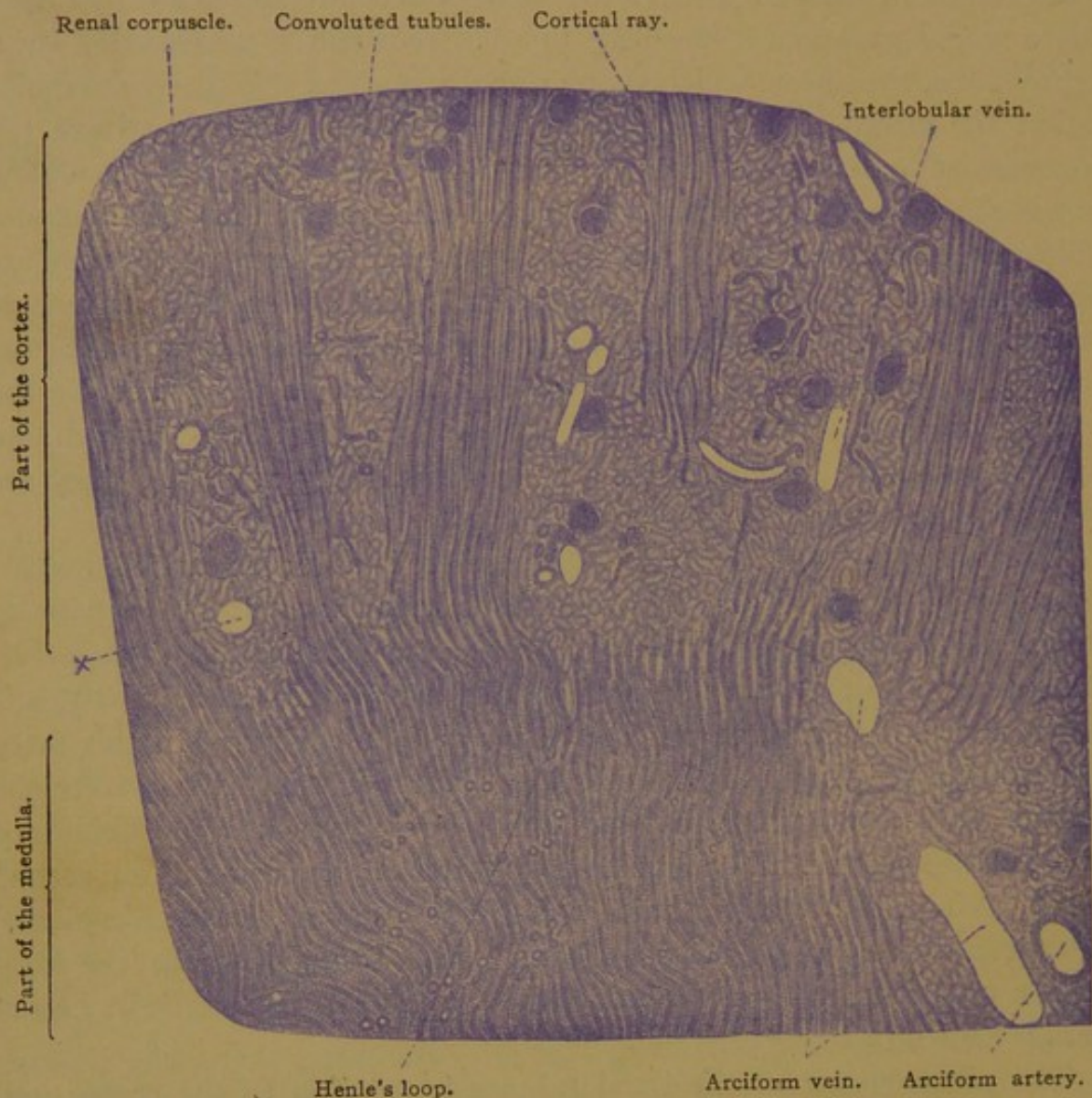


FIG. 312.—PART OF A RADIAL SECTION OF A HUMAN KIDNEY. $\times 5$.
At x a renal corpuscle has dropped out.

ments of Henle's loops, in addition to the collecting tubules. In the descending limbs the change to thin segments occurs at a more or less definite level within this outer zone, thus subdividing it into a narrow outer band, with few thin segments, and an inner band containing many of both sorts. These zones have only recently been recognized (Peter, *Untersuchungen über Bau und Entwicklung der Niere*, Jena, 1909).

The renal tubules which have their capsules close to the medulla are the first to develop; the others are formed successively outward, the young-

est being immediately beneath the capsule. Thus a single section of an embryonic kidney shows various stages in the development of the tubules.

Sections of the Kidney. Since a radial section of the kidney shows both cortex and medulla, it is the form usually made for pathological examinations (Fig. 312). The tubules may be studied to better advantage, however, in tangential sections, one through the cortex and the other through the medulla. The tubules are then seen in cross section. The

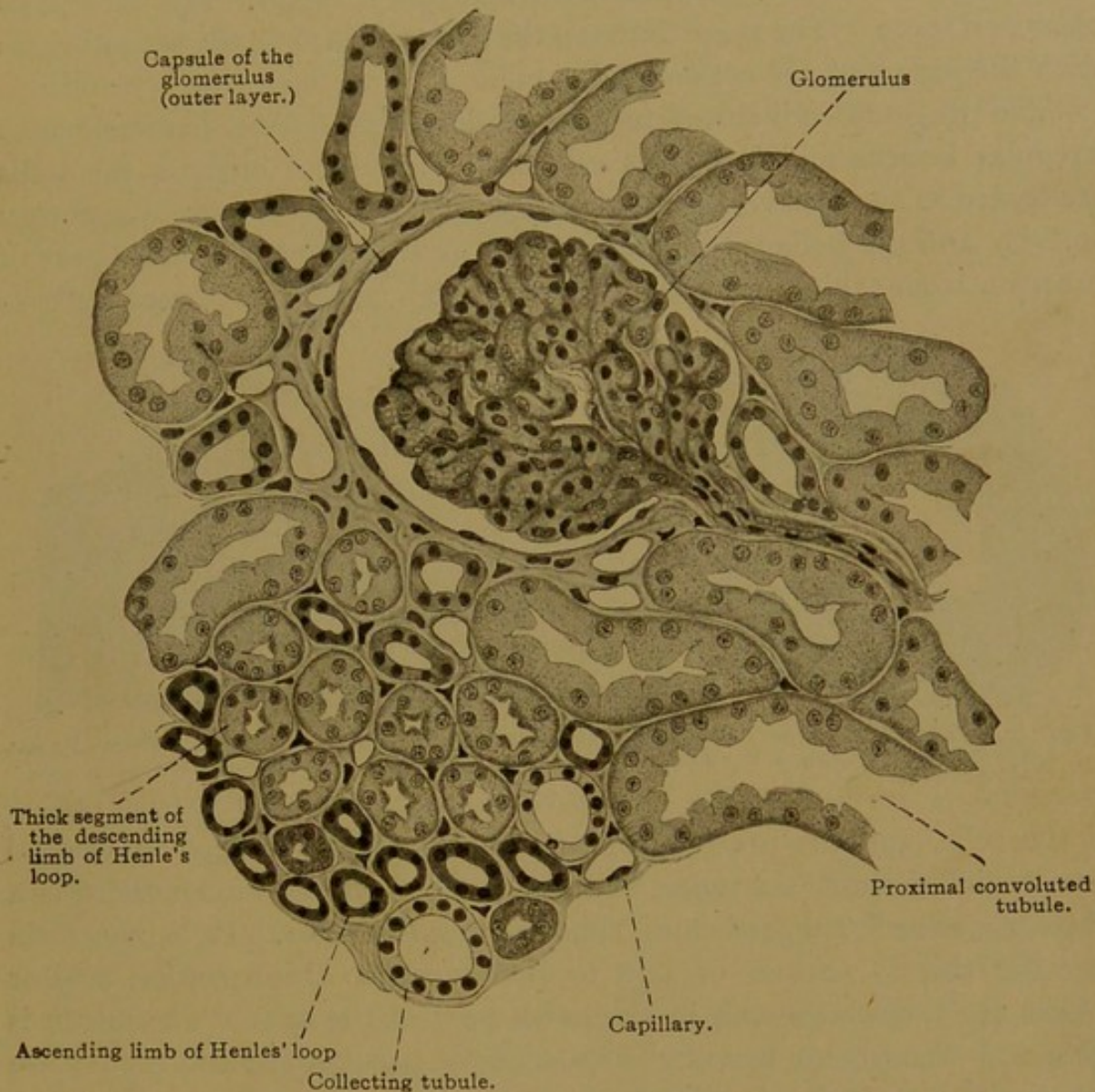


FIG. 313.—TANGENTIAL SECTION OF THE CORTEX OF A HUMAN KIDNEY. $\times 200$. (Schaper.)
The pars radiata is seen in the lower left corner. The line from "capsule of the glomerulus" passes between two distal convoluted tubules.

rays of the cortex appear as islands of circular sections surrounded by the irregular convoluted tubules, among which are the scattered renal corpuscles. The greater part of such an island is shown in the lower portion of Fig. 313. The renal tubules are lined throughout with simple epithelium and their characteristic features will now be considered, beginning with the glomerular capsule.

The glomerular capsule (of Bowman) consists of two layers. Its inner

layer is a flat syncytium blending with the perivascular tissue of the glomerulus, and following its lobulations. The outer layer of the capsule is smooth, and is composed of flat polygonal cells. Terminal bars, which have been found in all other divisions of the renal tubules, have not been demonstrated in the capsule. The flat epithelium of the outer layer changes at the "neck" of the capsule to the low columnar epithelium of the proximal convoluted tubule. The neck may occur in various positions, generally being opposite the aperture through which the vessels enter and leave. The space between the layers of the capsule is continuous with the lumen of the convoluted tubule.

The proximal convoluted tubules are large (40–60 μ in diameter), with irregular lumens and indistinct cell walls. In some animals the walls are folded so as to be vertically plaited. The cells show signs of secretory activity and are believed to excrete urea and pigments; the fluid part of the urine comes chiefly from the glomeruli. The nuclei are toward the base

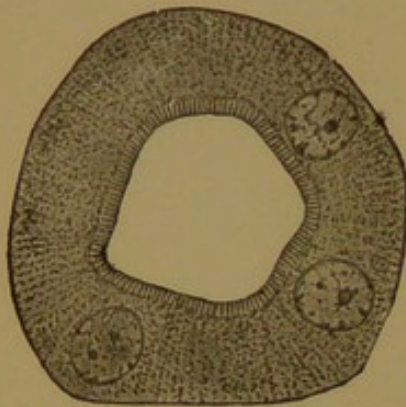


FIG. 314.—CROSS SECTION OF A CONVOLUTED TUBULE FROM A RABBIT. (Szymonowicz.)

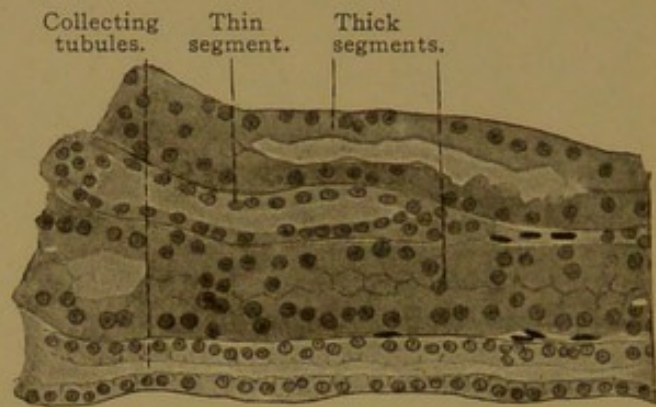


FIG. 315.—TUBULES OF THE PARS RADIATA. FROM A RADIAL SECTION OF A HUMAN KIDNEY. $\times 240$.

of the cells, and the protoplasm contains granules arranged in vertical rows which form basal rods (Fig. 314). Toward the lumen there is a "brush border" suggestive of short non-motile cilia. It is uncertain whether this is normal or due to post-mortem disintegration. Clear spaces are sometimes seen in the outer part of the cells. The lumen is wide and the cells are low after copious urine production; and the reverse is true when the urine is scanty.

The upper segment of the descending limb of Henle's loop is similar in structure to the proximal convoluted tubules. It is a straight tubule, however, and is found in the radiate part of the cortex (Fig. 313).

The upper segments of the ascending limbs are also found in the *pars radiata*. Their protoplasm is less granular than that of the descending limbs, but closely resembles that of the distal convoluted tubules. The latter are typically shown in Fig. 313 (there being one on either side of the label line to the "capsule of the glomerulus"). Huber (*loc. cit.*) describes these tubules as showing "an outer dark zone which is finely striated,

and an inner zone which is lighter, the nuclei being placed at the junction of the two zones." It is probable, from their position, that the distal convoluted tubules in Fig. 313 are parts of the tubule which connects with the glomerulus shown in the figure.

The arched collecting tubules, into which the distal convoluted tubules empty, pass into the collecting tubules of the rays, which are readily identified. They have round and clear-cut lumens; cell walls are distinct (in all but the smallest), and the nuclei are regularly arranged. Thus the collecting tubule resembles an excretory duct.

The structures seen in the radiate part of the cortex are therefore the ascending and descending limbs of Henle's loops, and the collecting tubules;

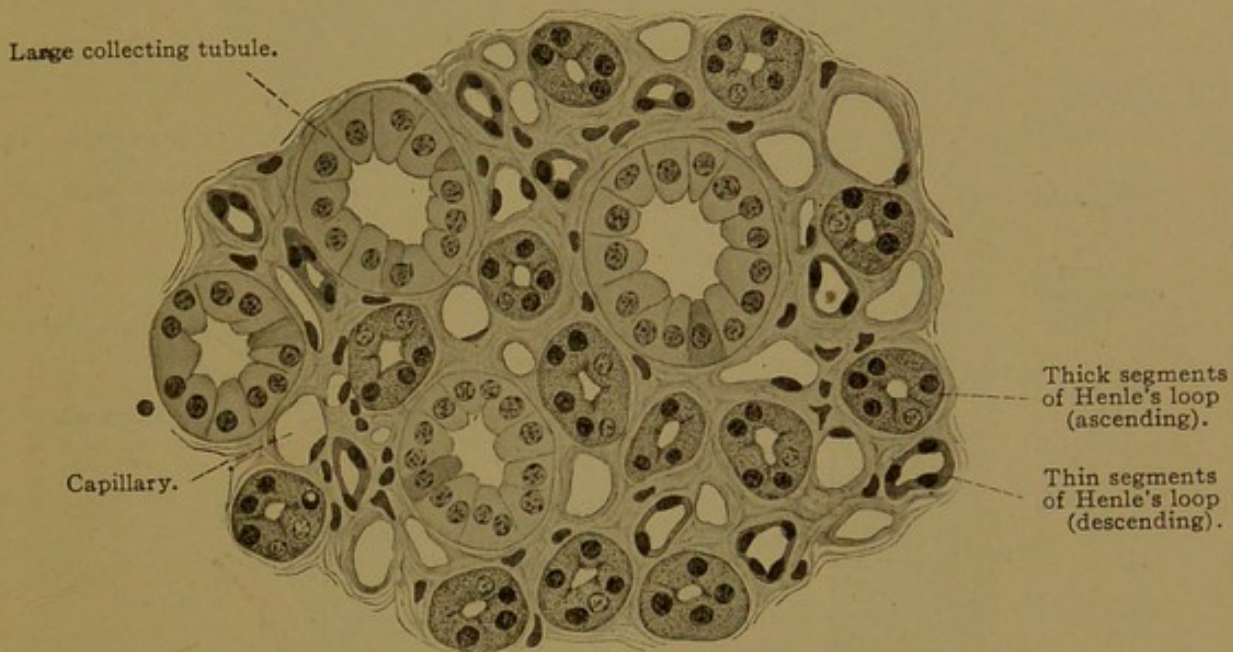


FIG. 316.—TRANSVERSE SECTION THROUGH THE MEDULLA OF A HUMAN KIDNEY. $\times 320$. (Schaper.

they are shown in longitudinal section in Fig. 315. The convoluted part of the cortex contains proximal and distal convoluted tubules and glomerular capsules.

The medulla (Fig. 316) contains the same elements as the rays. The collecting tubules are larger, and their walls are more distinct. Among their columnar cells a few are decidedly darker than the others. The thick segments of Henle's loops are easily distinguished from the thin segments. The latter are slender ($9-16 \mu$ in diameter) but have large lumens. Cell walls are absent, and the cells are so flat that their nuclei cause elevations. The thin segments are generally descending, but they may also ascend, as seen in the inner zone of the medulla; Fig. 315 is from the outer zone, in which most, if not all, of the thin segments are descending. (In comparing Fig. 316 with Fig. 313, it should be noted that the former is more highly magnified, and the thick ascending limbs appear more granular than those tubules of the cortex with which they are continuous.)

Connective tissue. Between the renal tubules there is a small amount of interstitial connective tissue. It is more abundant toward the papillæ and around the vessels and glomeruli than elsewhere. Beneath the

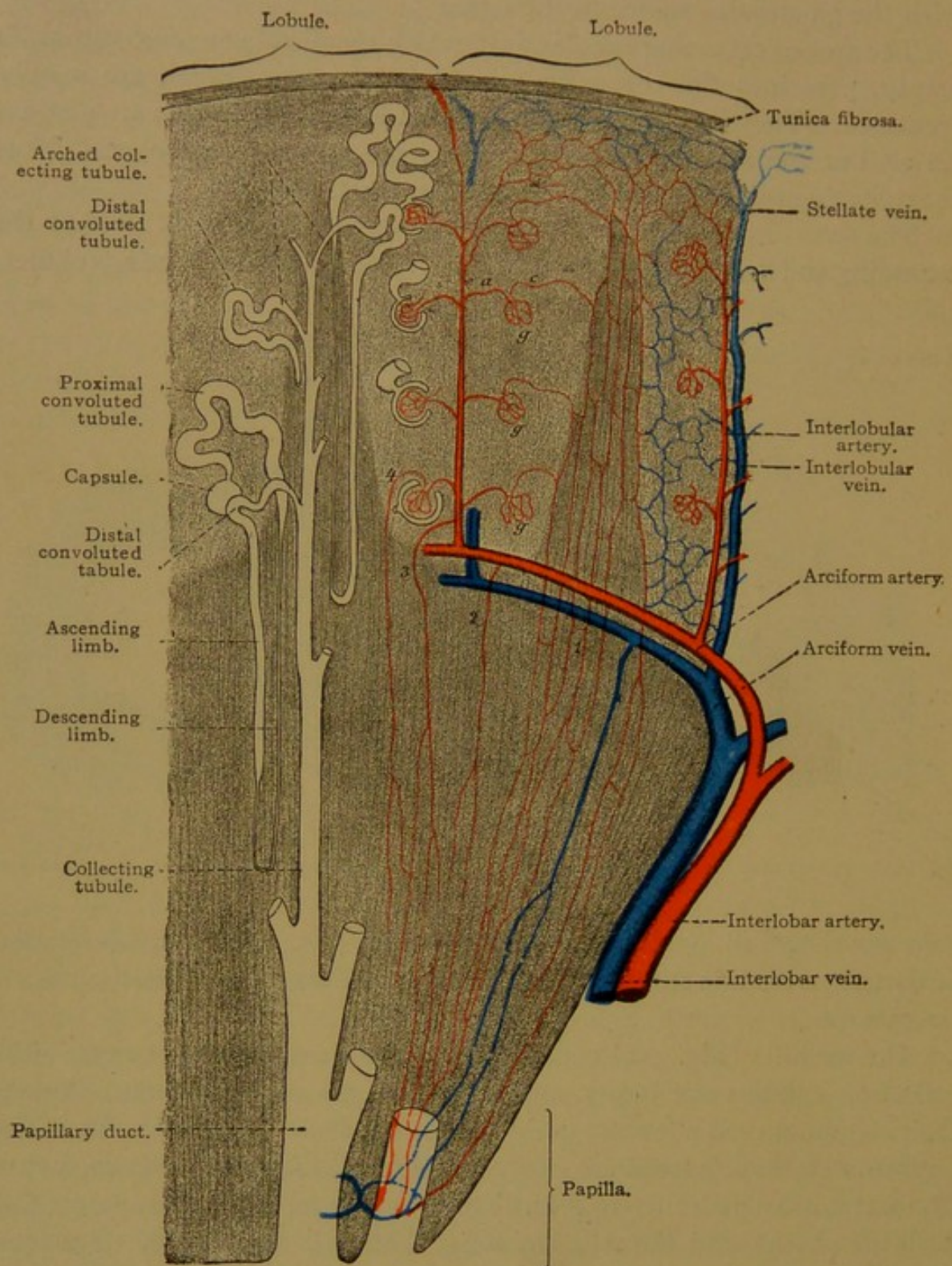


FIG. 317.—DIAGRAM OF THE COURSE OF THE RENAL BLOOD VESSELS.

epithelium of the tubules it forms basement membranes, apparently homogeneous, but actually composed of fine fibrils. The normal amount of interstitial tissue should be carefully studied, since its increase is indicative of an important pathological condition. This tissue is continuous

with that of the fibrous capsule. The latter contains elastic fibers, which increase in abundance with age, and also smooth muscle fibers.

Lobes and lobules. In embryonic life the kidney is divided into *lobes*, bounded by the renal columns, and indicated by grooves upon the outer surface (Fig. 318). The grooves become obliterated during the first year. In the ox similar grooves are permanent; in many mammals as in the cat and rabbit, they never exist, since the kidney has but one lobe, papilla and pyramid. The *lobules* or *structural units* of the kidney are the areas centering around each radiate division of the cortex, by which they are drained (Fig. 317). They are not bounded by connective tissue septa.

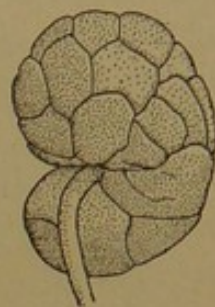


FIG. 318.—KIDNEY OF A CHILD AT BIRTH. (After Hertwig.)

Blood vessels. The kidney has a capillary circulation. The renal artery passes from the aorta to the *hilus*, or notch on the medial border of the kidney. It divides into several branches, most of which pass over the

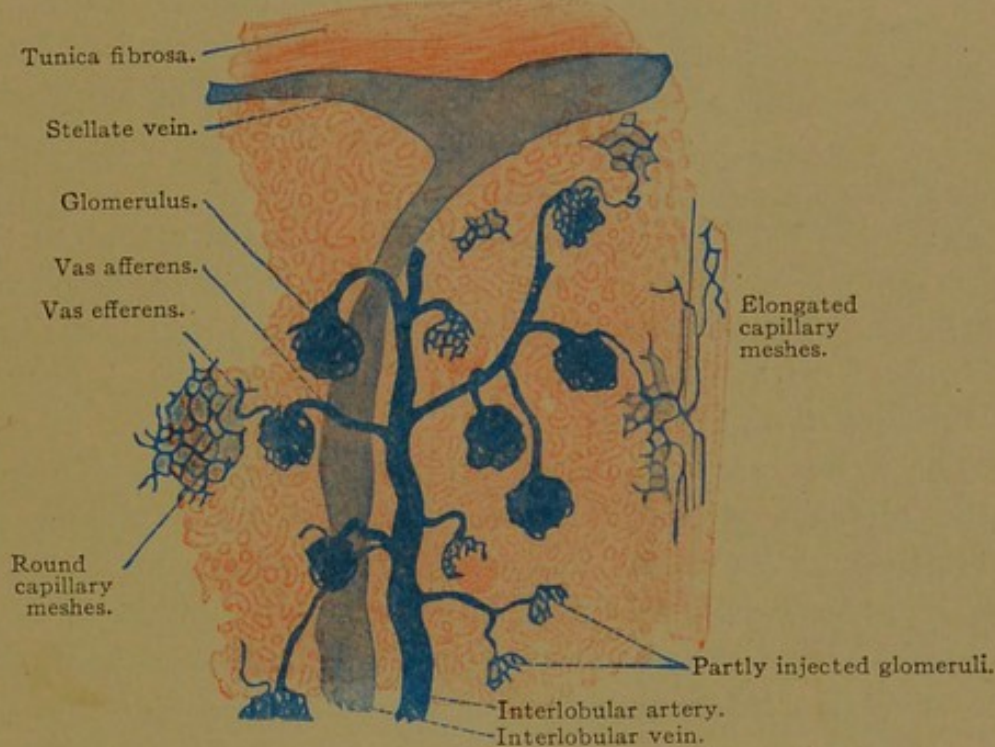


FIG. 319.—FROM A SECTION OF THE INJECTED CORTEX OF AN ADULT HUMAN KIDNEY. $\times 30$.

ventral surface of the pelvis into the fat around the calyces (Fig. 311). Thence, as *interlobar arteries*, they extend to the boundary layer between the cortex and medulla where they are known as *arciform arteries* (Fig. 317). These send *interlobular* arteries through the convoluted part of the cortex and their terminal branches enter the fibrous capsule. It will be noted that the kidney is exceptional in having its arteries at the periphery of its lobules. From the interlobular arteries small stems pass to the *glomeruli*, each of which receives a single twig (Fig. 319). This is resolved into a knot of capillary loops, the endothelium of which seems to blend with the surrounding syncytium and indirectly with the inner layer of the capsule.

The glomerulus often appears lobed, due to the arrangement of its vascular loops. The capillaries unite to form a single efferent vessel which is smaller in diameter than the afferent vessel; thus the pressure within the glomerulus is increased. The entire glomerulus is regarded as arterial. On leaving it, the efferent vessel divides into small branches. These spread among the convoluted and straight tubules of the cortex, and some continue into the medulla. The latter is supplied also by straight branches (*arteriolæ rectæ*) from the interlobular, efferent and arciform arteries, as shown in Fig. 317. The veins of the medulla begin around the papillæ, and as *venulæ rectæ* empty into the arciform veins. The cortical veins are the *interlobular* vessels which are beside the corresponding arteries. They arise from converging veins in the renal capsule, which on surface view form stellate figures (*venæ stellatæ*). The interlobular veins drain the capillaries of the cortex, but have no direct relation with the glomeruli. *Interlobar veins* follow the arteries, passing out from the hilus of the kidney over the ventral surface of the renal pelvis.

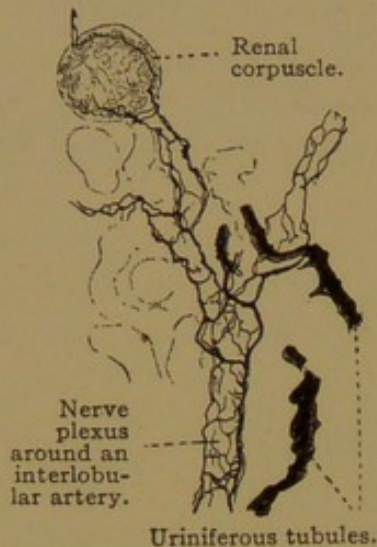


FIG. 320.—FROM THE KIDNEY OF A MOUSE. GOLGI PREPARATION. $\times 180$.

Lymphatic vessels are said to occur within the cortex and to follow the blood vessels out at the hilus. The cortical lymphatics also pass through the tunica fibrosa to connect with a network in the adipose capsule. They proceed to neighboring lymph glands.

The *nerves* are medullated and non-medullated. There is a sympathetic plexus at the hilus associated with small ganglia, and from it interlacing nerves extend into the kidney around the vessels (Fig. 320). Fine branches supply the epithelial cells, especially those of the convoluted tubules. They form plexuses beneath and above the basement membrane, and have free intercellular endings.

RENAL PELVIS AND URETER.

The renal pelvis and ureter both consist of a mucosa (and submucosa), muscularis and adventitia (Fig. 321). The mucosa includes the epithelium and tunica propria, the latter blending with the submucosa. In sections the epithelium resembles that of the moderately contracted bladder (Fig. 322), and its cells when found detached in urine are not distinguishable from bladder cells. The epithelium is stratified but consists of few layers. The basal cells are rounded, those of the middle layer are club shaped or conical with rounded ends, and the outer cells are columnar, cuboidal,

or somewhat flattened. Their lower surface may be indented by the rounded ends of several underlying cells, as is particularly the case in the contracted bladder (Fig. 323). Two nuclei are often found in a superficial cell, and

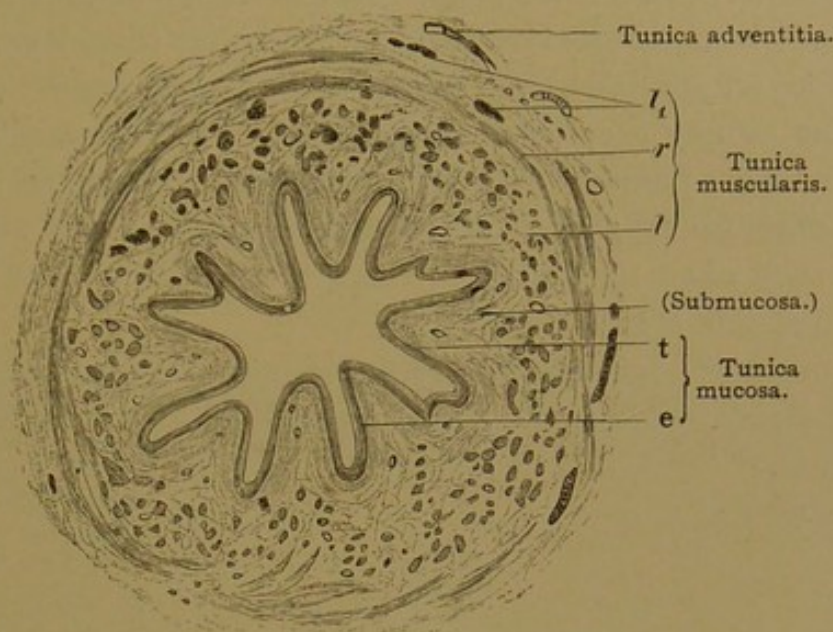


FIG. 321.—TRANSVERSE SECTION OF THE LOWER HALF OF A HUMAN URETER. $\times 15$.
e., Epithelium; t., tunica propria; l, inner longitudinal muscle bundles; r, circular layer of muscle bundles
l₁, outer longitudinal muscle bundles.

in some animals they are known to arise by amitosis. Leucocytes frequently enter the epithelium. In some animals mucous glands have been found extending into the tunica propria, and there are gland-like pockets in man. Some of these have no lumen and it is said that none

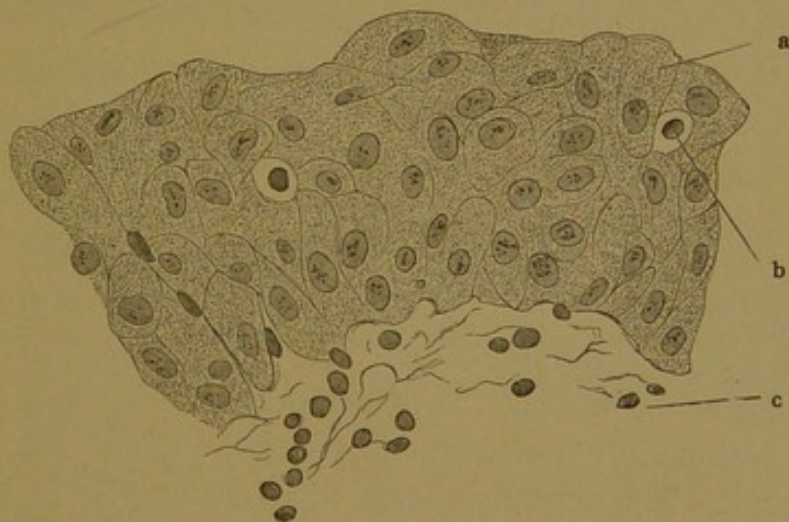

FIG. 322.—VERTICAL SECTION OF THE MUCOUS MEMBRANE OF A HUMAN BLADDER. $\times 560$.
a, Columnar cell with cuticular border; b, lymphocyte; c, tunica propria.

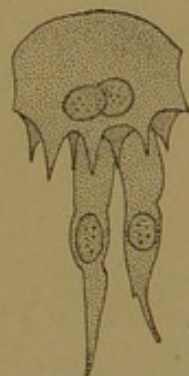


FIG. 323.—A SUPERFICIAL EPITHELIAL CELL AND TWO CLUB-SHAPED CELLS FROM A CONTRACTED BLADDER. (Koelliker.)

are true glands. Capillary blood vessels, which are abundant in the mucosa, are found directly beneath the epithelium and present the deceptive appearance of becoming intra-epithelial. The tunica propria consists of fine connective or reticular tissue, with few elastic fibers. It contains

many cellular elements and some lymphocytes, and passes without a definite boundary into the loose connective tissue of the submucosa.

The tunica muscularis has considerable connective tissue among its smooth muscle bundles. The latter form an inner longitudinal and an outer circular layer. In the lower half of the ureter there is a third, outer longitudinal layer, specially thickened along the last 5 cm. Around the papillæ of the kidney the circular fibers form a "sphincter." The part of the ureter which passes obliquely through the wall of the bladder has only longitudinal fibers, ending in the tunica propria of the bladder. By contracting they open the outlet of the ureter. The adventitia consists of loose fibro-elastic connective tissue.

Lymphatics and blood vessels are numerous. There are sympathetic nerves to the muscles, and free sensory endings in the tunica propria and epithelium.

BLADDER.

The development of the bladder from the ventral part of the cloaca has been described on page 245. Its epithelium is entodermal whereas that of the ureters opening into it is mesodermal. There is however no demarcation between the layers in the adult, since both produce the same sort of "transitional epithelium." (This term, introduced by Henle (*Allg. Anat.*, 1841) as a designation for epithelia which are intermediate between stratified squamous and simple columnar, such as occur at the cardia and elsewhere, is now generally restricted to the peculiar epithelium of the bladder, ureter and renal pelvis.)

The bladder consists of a mucosa, submucosa, muscularis and serosa. The epithelium has been described as two-layered in the distended bladder, the outer cells having terminal bars; in the contracted condition it becomes several-layered and the bars form a net extending into the epithelium. Thus it is not believed that during distention the layers shown in Fig. 322 merely flatten; they are thought to "slip by each other." The columnar cells may, however, become extremely flat. The appearances of the epithelium in the bladder and ureter of the dog under various conditions of distention and contraction have been figured by Harvey (*Anat. Record*, 1909, vol. 3, pp. 296-307). The superficial cells have a cuticular border; they often contain two nuclei, and their darkly granular protoplasm has been considered suggestive of secretory activity. Round or oval pockets extend into the tunica propria (Fig. 324). Some of them have no lumen, or are detached from the epithelium, but others are pits containing a colloid substance. The pits are rudimentary glands. In the adult, branched tubules lined with cylindrical epithelium may sprout from the bottom of the pits, thus forming true glands. Their occurrence is limited to the

fundus, which is the dorsally bulging lowest part of the bladder, and to the neighborhood of the urethral outlet. In the latter position they have been regarded as rudimentary prostatic glands.

The tunica propria sometimes contains solitary nodules. It blends with the submucosa, as in the ureter, and contains lymphatic and blood vessels, the latter extending very close to the epithelium.

The muscularis consists of smooth muscle fibers arranged in three interwoven layers, which are seldom separable in sections. They are an inner longitudinal, middle circular and outer longitudinal layer. The

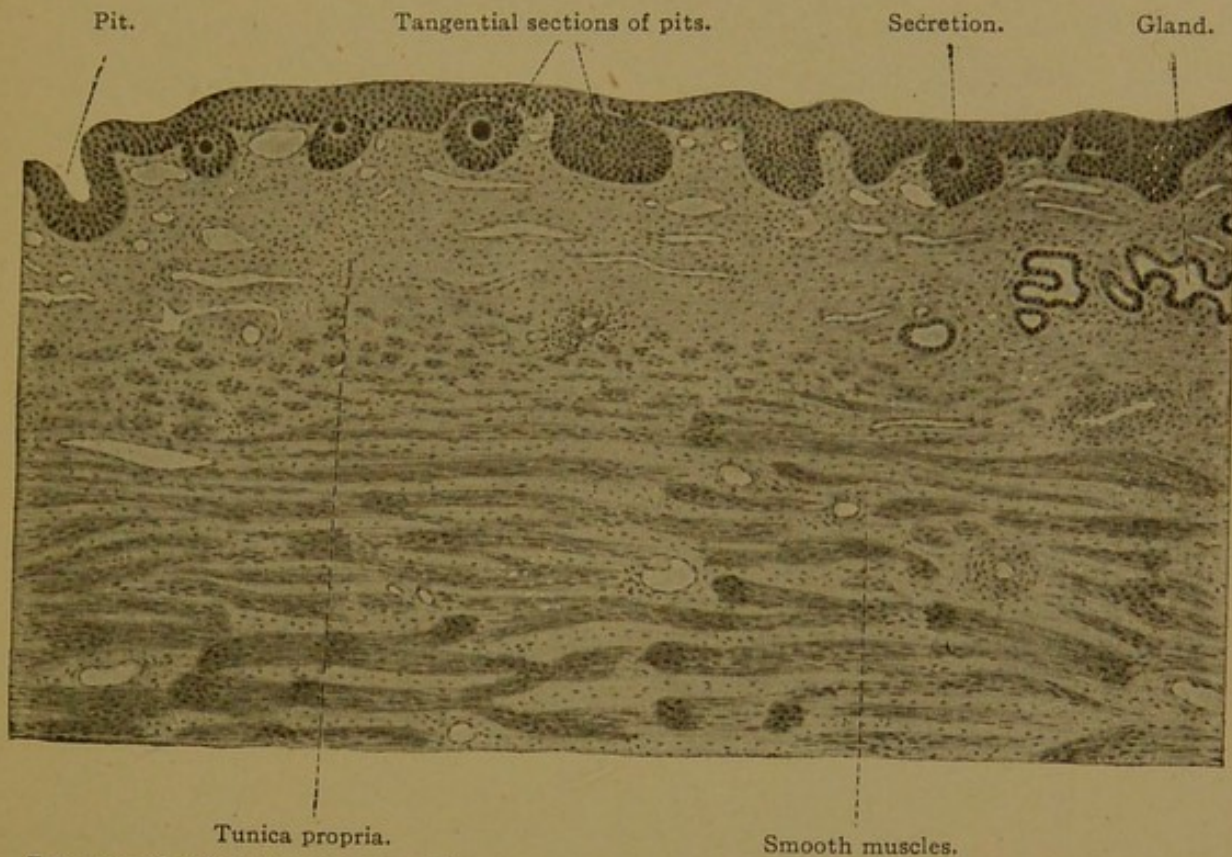


FIG. 324.—SECTION THROUGH THE FUNDUS OF THE URINARY BLADDER OF AN ADULT MAN. $\times 48$.

circular fibers are strengthened at the beginning of the urethra to form the "internal sphincter" of the bladder, a muscle not always distinct.

The serosa is a connective tissue layer covered with mesothelium. In the non-peritoneal part of the bladder it is replaced by an adventitia or fibrous layer.

Non-medullated nerves, with scattered groups of ganglion cells, are found outside the muscles and also among them. Medullated fibers terminate around the ganglion cells; others pass through the ganglia to intra-epithelial sensory endings.

URETHRA (IN THE FEMALE).

The male urethra will be described with the genital organs; only its upper portion is homologous with the urethra of the female. The latter

is exclusively the outlet of the urinary tract. The epithelium has been variously described as stratified, with outer squamous cells, or as pseudostratified, and columnar. It may be of different forms in different individuals. The lumen is irregularly crescentic, with longitudinal folds (Fig. 325). Branched tubular *urethral glands* are found only in small numbers, except near the outlet. Their secretion is mucoid, but is not typical mucus. In the submucosa there are many thin-walled veins con-

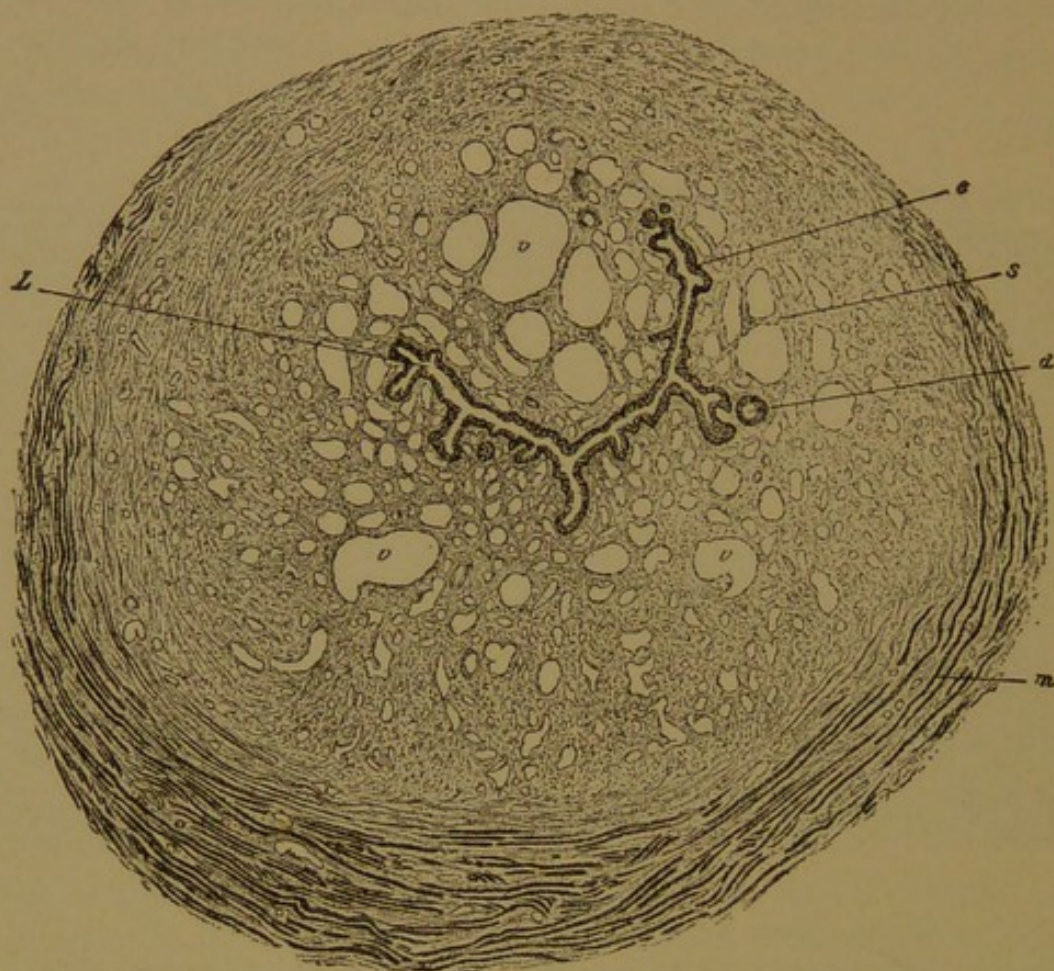


FIG. 325.—CROSS SECTION OF THE FEMALE URETHRA. (Koelliker.)

d., Gland-like diverticulum; e., epithelium; L., lumen of the urethra; m., striated muscle; s., corpus spongiosum, containing venous spaces (v) and smooth muscle.

stituting the *corpus spongiosum*. This is comparable with the upper part of the more highly developed corpus cavernosum urethrae of the male. (Compare with Fig. 349, p. 347.) The muscularis is a thick layer, consisting of inner longitudinal and outer circular smooth muscle fibers, among which the veins extend, and connective tissue with many elastic fibers is abundant. The striated *constrictor urethrae* is outside of the smooth muscle layer, as shown in the figure.

MALE GENITAL ORGANS.

DEVELOPMENT AND GENERAL FEATURES.

The discovery that the Wolffian bodies become a part of the genital system was made by Oken, through dissections and injections of dog embryos (Beiträge, Heft II,

1807). Rathke studied these "Oken's bodies" further, and found more accurately their relation to the epididymis and ductus deferens. Müller (*Bildungsgeschichte der Genitalien*, 1830) wrongly declared that they do not form the epididymis; but he discovered that "at the time when the Wolffian bodies are most highly developed, the germ of the ovary or testis lies on their inner side; and on their outer side, extending even to their upper end, there is a duct which does not connect with the Wolffian bodies—it appears to have arisen from their short and much stouter excretory duct." He saw that this second duct, now known as the *Müllerian duct*, formed a part of the uterine tubes. In fact it forms the entire tubes together with the uterus and vagina; in the male it produces interesting vestigial structures which are constantly present in the adult.

The Müllerian duct arises as an outpocketing of the coelomic epithelium near the anterior end of the Wolffian body. The orifice into the peritoneal cavity becomes surrounded by irregular folds known as *fimbriæ*. As the Müllerian duct grows posteriorly by the elongation of its blind end, it lies in contact with the Wolffian duct as seen in Fig. 326, but the Wolffian duct does not contribute toward its formation. The two Müllerian ducts reach the neck of the bladder side by side, and acquire openings into it between those of the Wolffian ducts. Near the bladder the two Müllerian ducts fuse with one another so that their distal part is represented by a single median tube, on either side of which is a Wolffian duct (Fig. 306, B, page 311). In the female the united portion becomes the *vagina* and *uterus*, and the separate parts are the *uterine* (or Fallopian) *tubes*. In the male the united portion becomes a small blind pocket, the *prostatic utricle*, opening into the prostatic urethra. Each fimbriated extremity becomes transformed into the *appendix testis*, and the remaining portion of the ducts, except for occasional fragments, becomes obliterated. Thus only the two extremities of the Müllerian ducts are ordinarily permanent in the male (Fig. 328).

The *genital glands* in either sex begin as a thickening on the ventromedial border of each Wolffian body (Fig. 326). A section of this *genital ridge* is shown in Fig. 303, C, page 307. The ridge is a dense mass of mesoderm covered by the peritoneal epithelium, which here consists of a syncytium very closely connected with the underlying tissue. According to Felix (Keibel and Mall's *Human Embryology*, vol. 2) *everything* that is later developed within the genital ridge has a common origin from the peritoneal epithelium. The ridge becomes filled with an epithelial mass which then separates from the peritoneal layer. Beneath the peritoneum this mass produces the dense connective tissue capsule which surrounds the testis, called, from its whiteness, the *tunica albuginea*; within the genital ridge it is "quite suddenly" resolved into anastomosing cords with looser tissue between them, and the cords become the tubules of the testis. Allen, in an earlier account (*Amer. Journ. Anat.*, 1904, vol. 3, pp. 89-155), likewise finds that the cells of the peritoneum and the under-

lying mesenchyma appear to form a continuous protoplasmic network, and "the stroma cells are practically identical with the peritoneal cells from which they are originating." But Allen concludes that "the tubules of the testis are formed as solid invaginations of the peritoneum, which later become separated from it, and grow by the activity of their component cells." There is, then, a difference of opinion as to whether the tubules of the testis are formed directly from the stroma within the genital ridge (Felix), or as invaginations from the peritoneal epithelium

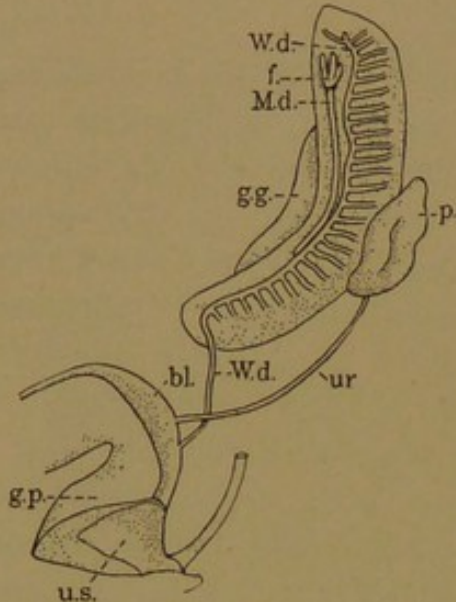


FIG. 326.—FROM A RECONSTRUCTION OF A 13.6-MM. HUMAN EMBRYO. (F. W. Thyng.)

bl., Bladder; f., fimbriae; g. g., genital ridge; g. p., genital papilla; M. d., Müllerian duct; p., peritoneum; r., rectum; ur., ureter; u. s., urogenital sinus; W. d., Wolffian duct.

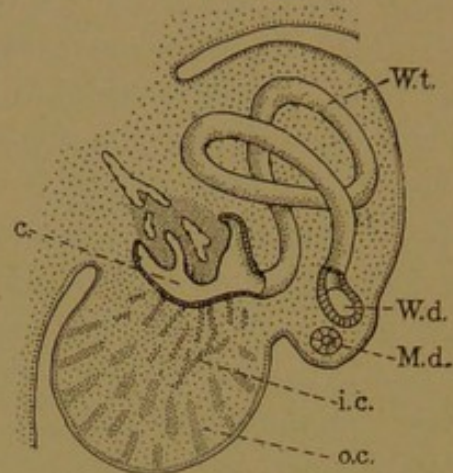


FIG. 327.—DIAGRAM OF THE DEVELOPMENT OF THE TESTIS, BASED UPON FIGURES BY MAC-CALLUM AND B. M. ALLEN.

c., Glomerular capsule; i. c., inner or sex cords; M. d., Müllerian duct; o. c., outer or rete cords; W. d., W. t., Wolffian duct and tubule.

(Allen). A figure of an 11-mm. human embryo published by Felix appears to accord with Allen's interpretation, and such a condition is shown diagrammatically in Fig. 327.

As the cords become detached from the peritoneum, they form arching anastomoses, convex toward the periphery of the ridge; and with further growth they become greatly convoluted. They acquire lumens, and become the *tubuli contorti*, in the walls of which spermatogenesis takes place. The shapes presented by these tubules in the embryo have been carefully modelled by Bremer (Amer. Journ. Anat., 1911, vol. 11, pp. 393-416).

Toward the interior of the genital ridge the cords become more slender and converge toward the Wolffian body. There they are imbedded in a considerable mass of tissue, which in the adult becomes the *mediastinum testis*. The inner ends of the contorted tubules, toward the mediastinum, remain straight, forming the *tubuli recti*; and these, further inward, become thin-walled and anastomose freely, thus constituting the *rete testis* (Fig. 328).

All the tubules thus far considered are produced by the genital ridge. Their inner ends, which form the rete, acquire openings into the capsules of the degenerating Wolffian glomeruli, or sometimes directly into a Wolffian tubule. From ten to fifteen Wolffian tubules thus become connected with the rete testis, and serve to convey the genital products to the Wolffian duct; these tubules are known as the *ductuli efferentes*. In the adult each of them is a greatly convoluted tube which if straightened measures 8 inches (20 cm.). When coiled, it forms a conical mass or *lobule of the epididymis*, with its apex toward the rete, and its base toward

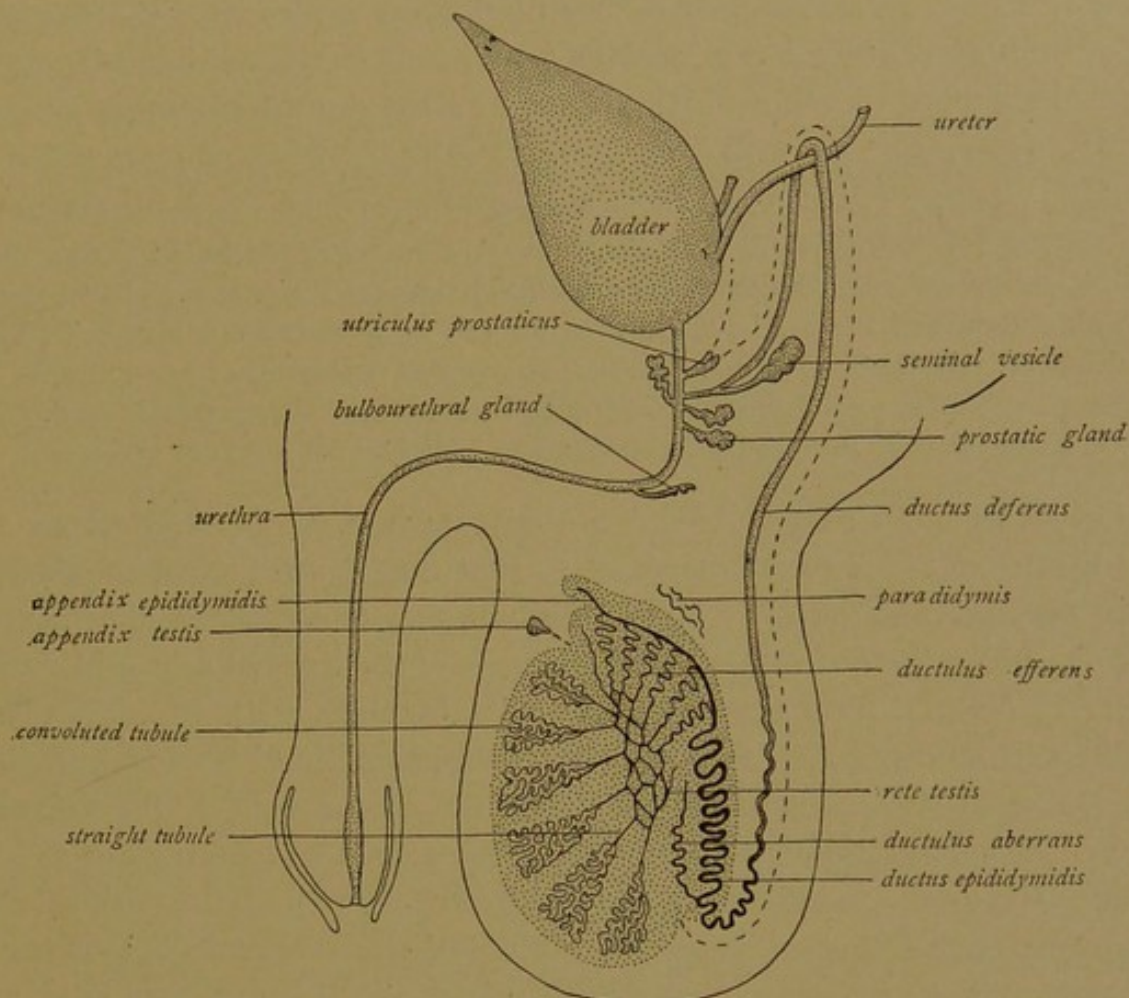


FIG. 328.—DIAGRAM OF THE MALE SEXUAL ORGANS. (Modified from Eberth, after Waldeyer.)
(The course of the Müllerian duct is indicated by dashes.)

the Wolffian duct which it enters (Fig. 328). The Wolffian duct, which passes along the dorsal surface of the testis, is also greatly convoluted so that it measures about 20 feet when straight (6-7 meters). Together with the efferent ducts this coiled mass constitutes the *epididymis* (Gr. ἐπί, upon; δίδυμος, testis). Along the testis the Wolffian duct is called the *ductus epididymidis*, and from the testis toward the urogenital sinus it is named the *ductus deferens*. Near its termination a saccular outgrowth, like a distended gland, develops from each Wolffian duct. It is called the *seminal vesicle*, and that portion of the Wolffian duct between the duct of the vesicle and the urethra is named the *ejaculatory duct*. Thus

the Wolffian duct is arbitrarily divided in the adult into three parts, the ductus epididymidis, ductus deferens, and ductus ejaculatorius.

It has been noted that only 10-15 of the Wolffian tubules persist as efferent ducts; in man, according to Felix, these are the fifty-eighth to seventieth out of a series of eighty-three which develop. Thus a great many degenerate, and certain appendages of the epididymis are explained as persistent remnants. The *appendix epididymidis* may represent a part of the Wolffian duct or an anterior tubule (Fig. 328); its history is still obscure. Other anterior tubules may be retained as *appendages of the rete*. The *paradidymis* is "a functionless remnant of the Wolffian body," situated behind the head or upper end of the epididymis and in front of the cord of veins which accompany the ductus deferens.

Giraldès first described it (Bull. Soc. Anat. Paris, 1857) and Koelliker named it the "organ of Giraldès"; Henle called it the *paraepididymis* (i.e., the organ beside the epididymis), and Waldeyer later shortened the term and changed its meaning. Felix (*loc. cit.*, 1912) contrary to the earlier descriptions, places the paradidymis "between the epididymis and the testis, slightly below the head of the epididymis." Toldt (Verh. Anat. Gesellsch., 1892, pp. 241-242) recognized two forms of paradidymis, but both are behind the epididymis and in front of the veins of the spermatic cord. The precise origin of these tubules from the Wolffian body has not been determined.

Other remains of the Wolffian body, apparently derived from the tubules below those which become efferent ducts, are known as *aberrant ducts* (*ductuli aberrantes*). There may be two or three of them; usually there is said to be but one. It proceeds from the duct of the epididymis, or rarely from the ductus deferens at its junction with the duct of the epididymis, and terminates in a coiled mass, sometimes having branches. The length of the aberrant duct is "4-36 cm., generally 5-8 cm." (Henle).

The External Genital Organs. After the cloacá has been divided into ventral and dorsal portions by the downward growth of the perineal septum, the ventral portion below the outlets of the Wolffian ducts is called the *urogenital sinus*. It receives both urinary and genital products, and in the male it forms all of the urethra below the orifices of the ejaculatory ducts. In the young embryo, the distal part of the urogenital sinus becomes laterally compressed so that it forms an epithelial plate. This plate reaches the external surface of the body along the mid-ventral line of an elevation known as the *genital papilla* (or tubercle). The genital papilla (Fig. 326) becomes very prominent in embryos of both sexes. In the male it continues its development and forms the penis, along the under side of which the urogenital sinus acquires a cleft-like opening (Fig. 329, A). This elongated aperture closes from behind forward, along the line permanently marked by a *raphe* (or seam). In the abnormal cases of *hypospadias*, the urogenital sinus retains a more or less extensive opening on the under side of the penis. A rounded terminal *glans* is early differen-

tiated at the apex of the genital papilla. The epidermis is adherent to it, but later becomes separated by the formation and splitting of an epithelial plate, thus producing the reflection of skin called the *prepuce*. The urogenital sinus becomes secondarily prolonged through the glans so as to form the terminal part and external orifice of the urethra. The entire urethra is divided into three parts: (1) the prostatic portion (*pars prostatica*), which includes the outlet of the bladder together with the upper end of the urogenital sinus, and receives the ejaculatory and prostatic ducts; (2) the membranous part (*pars membranacea*), which is the short dilatable portion traversing the "pelvic diaphragm"; and (3) the long cavernous portion (*pars cavernosa*), which is surrounded by the cavernous vascular tissue.

The *scrotum* develops as a median pouch at the dorsal end of the urogenital raphe. It is continuous above with the pair of large genital folds which tend to encircle the base of the genital papilla, being deficient only below (Fig. 329, A). At the stage when the testis and Wolffian body are

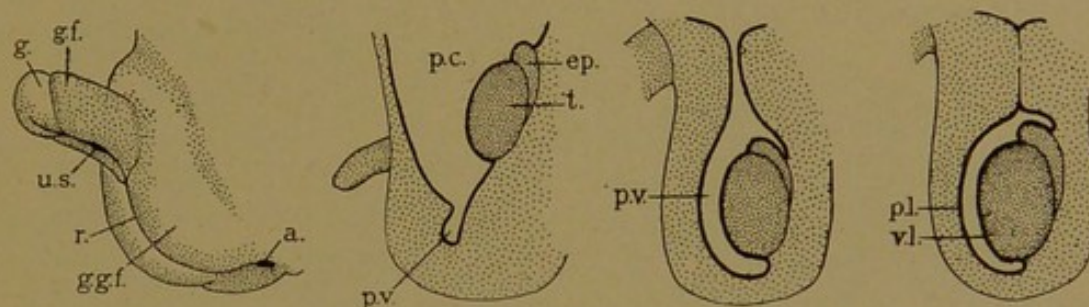


FIG. 329.—A, DIAGRAM OF THE EMBRYONIC EXTERNAL GENITAL ORGANS IN THE MALE; B, C, D, DIAGRAMS OF THE DESCENT OF THE TESTIS. (After Eberth.)

a., Anus; ep., epididymis; g., glans penis; g. f., lesser genital folds; g. g. f., greater genital folds; p. c., peritoneal cavity; p. v., processus vaginalis; r., raphe; t., testis; p. l., parietal layer of the tunica vaginalis; u. s., urogenital sinus; v. l., visceral layer of the tunica vaginalis.

still within the abdomen, lying behind the peritoneum, the peritoneal cavity sends a prolongation, the *processus vaginalis*, over the pubic bone into each half of the scrotum (Fig. 329, B). A large retroperitoneal column of connective tissue, the *gubernaculum testis*, extends from the posterior end of each testis into the depth of the scrotum. For reasons still obscure, such as unequal growth or the shortening of this cord, the testes pass down in front of the pubic bones, into the scrotum (Fig. 329, C). The Wolffian duct becomes bent over the ureter as shown in Fig. 328, and this important relation is found in the adult. Except on its dorsal border, the testis is closely invested by the peritoneum of the processus vaginalis. Later the distal part of the processus becomes separated from the abdominal cavity by the obliteration of its stalk. The part remaining about the testis is the *tunica vaginalis*, having a parietal and a visceral layer as shown in Fig. 329, D. The descent of the testes is completed shortly before birth, except in the occasional cases of "undescended testis."

TESTIS.

Septa, Vessels, and Nerves. The general arrangement of the parts of the testis, as they appear in cross section, is shown in Fig. 330. From the tunica albuginea, small connective tissue septa (*septula testis*) pass to the mediastinum, dividing the testis into "100-200" pyramidal lobules with their apices toward the rete. The tunica albuginea is a dense connective tissue layer, containing numerous elastic fibers which increase in abundance with age. Its outer surface is covered with the visceral layer of the tunica vaginalis. The inner portion of the albuginea is very vascular, forming a distinct layer at birth (the tunica vasculosa).

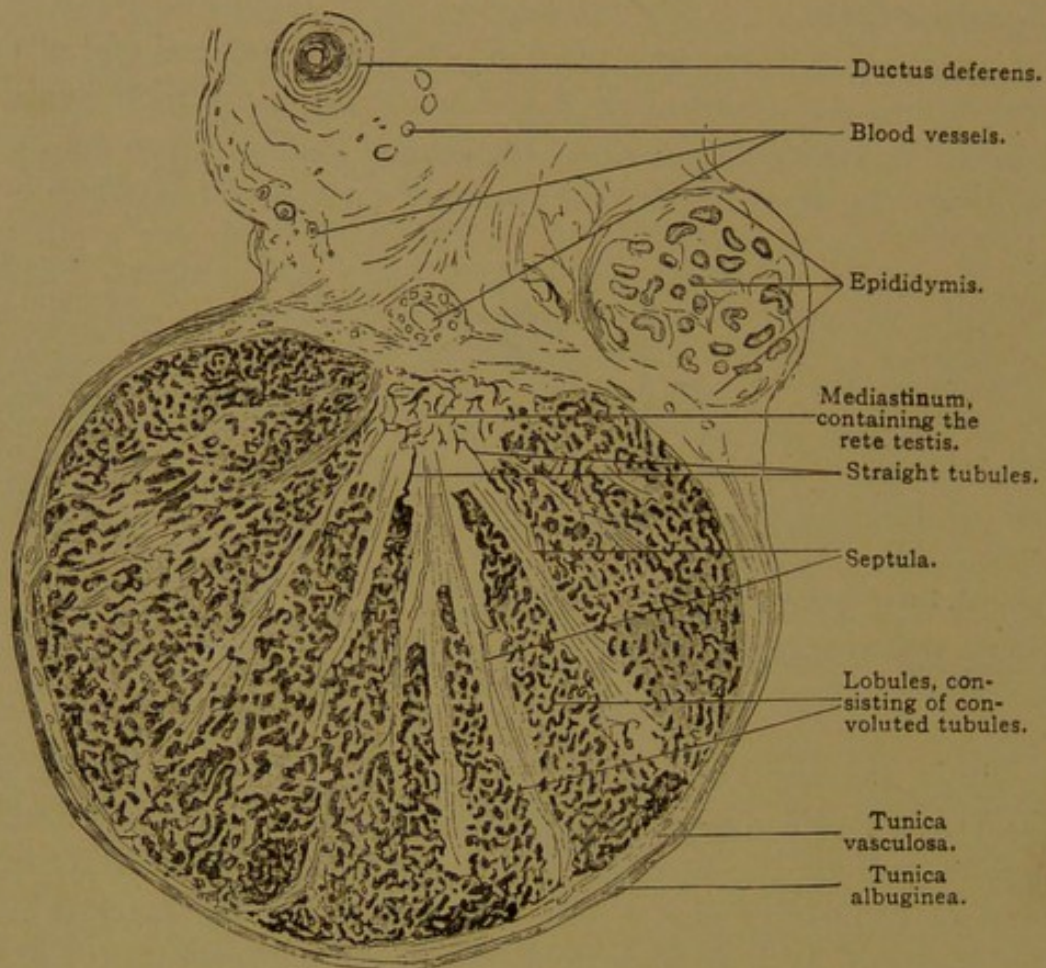


FIG. 330.—CROSS SECTION OF THE TESTIS OF A CHILD AT BIRTH. $\times 10$.

Connective tissue extends from the septula among the convoluted tubules. Immediately surrounding them there is a delicate basement membrane, followed by a layer of closely interwoven elastic fibers and flat cells. In the looser connective tissue between the tubules, there are clumps of *interstitial cells* (Figs. 331 and 335), which arise from mesenchymal cells of the genital ridge. Sometimes they retain protoplasmic processes, but more often they are rounded or polygonal structures in close contact, and without distinct cell boundaries. In their abundant protoplasm there are pigment and other granules, fat droplets, and rod-shaped

crystalloids, the significance of which is unknown. The nature of the granules is discussed by Whitehead (Amer. Journ. Anat., 1912, vol. 14 pp. 63-71).

The interstitial cells, although not intimately related with the vessels, are thought to produce an internal secretion, and certain observations suggest that the sexual instinct is dependent on these cells rather than upon the spermatozoa (*cf.* Whitehead, Anat. Rec., 1908, vol. 2, pp. 177-182). During senile atrophy of the testis, the interstitial cells at first increase; later they are destroyed. At the same time the basement membrane becomes thickened and hyaline, fat droplets accumulate, and the sexual cells disappear from the tubules, leaving the sustentacular cells.

The *arteries* of the testis are branches of the internal spermatic artery, which descends through the spermatic cord, beside the ductus deferens. The branches enter the testis in part through the mediastinum, and in

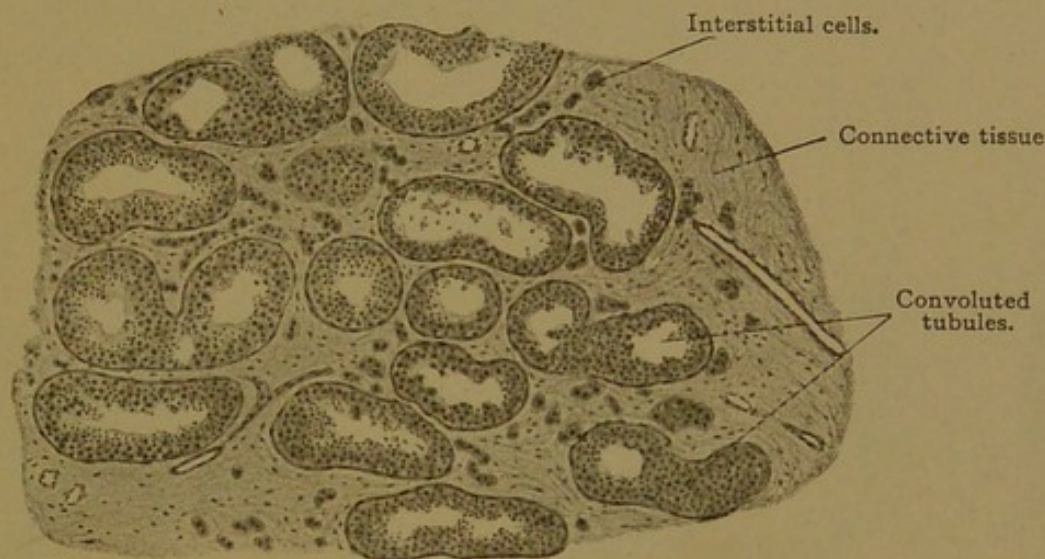

FIG. 331.—FROM A CROSS SECTION OF THE TESTIS OF A MAN TWENTY-TWO YEARS OLD. $\times 50$.

part through the tunica vasculosa. They extend through the septula, and form capillary plexuses around the convoluted tubules. The veins accompany the arteries. Lymphatic vessels are numerous in the tunica albuginea and extend among the tubules. Nerves from the spermatic plexus surround the blood vessels; the presence of intraepithelial endings has not been established with certainty.

Convoluted Tubules. The shape of the tubules of the testis has been repeatedly investigated, but whether blind ends occur has not been established; generally the tubules end in loops. Anastomoses have been recorded, not only between the tubules in a single lobule, but also between adjacent lobules. The extent of the anastomoses among the closely coiled tubules is difficult to determine.

For more than seventy years eminent anatomists have recorded their success or failure in finding blind ends—Krause, Kölliker, Sappey and LaValette St. George state that they exist; Hyrtl, Henle, Mihálovics and Eberth fail to find them. Two

recent papers have dealt with the subject. Bremer (1911) concludes that the tubules may end blindly; Huber and Curtis (1913) state that the seminiferous tubules in the rabbit present no blind ends.

The convoluted tubules are lined with a highly specialized stratified epithelium (Fig. 332). The cells divide and differentiate as they pass from the basal layer outward. Finally each outer cell produces a single

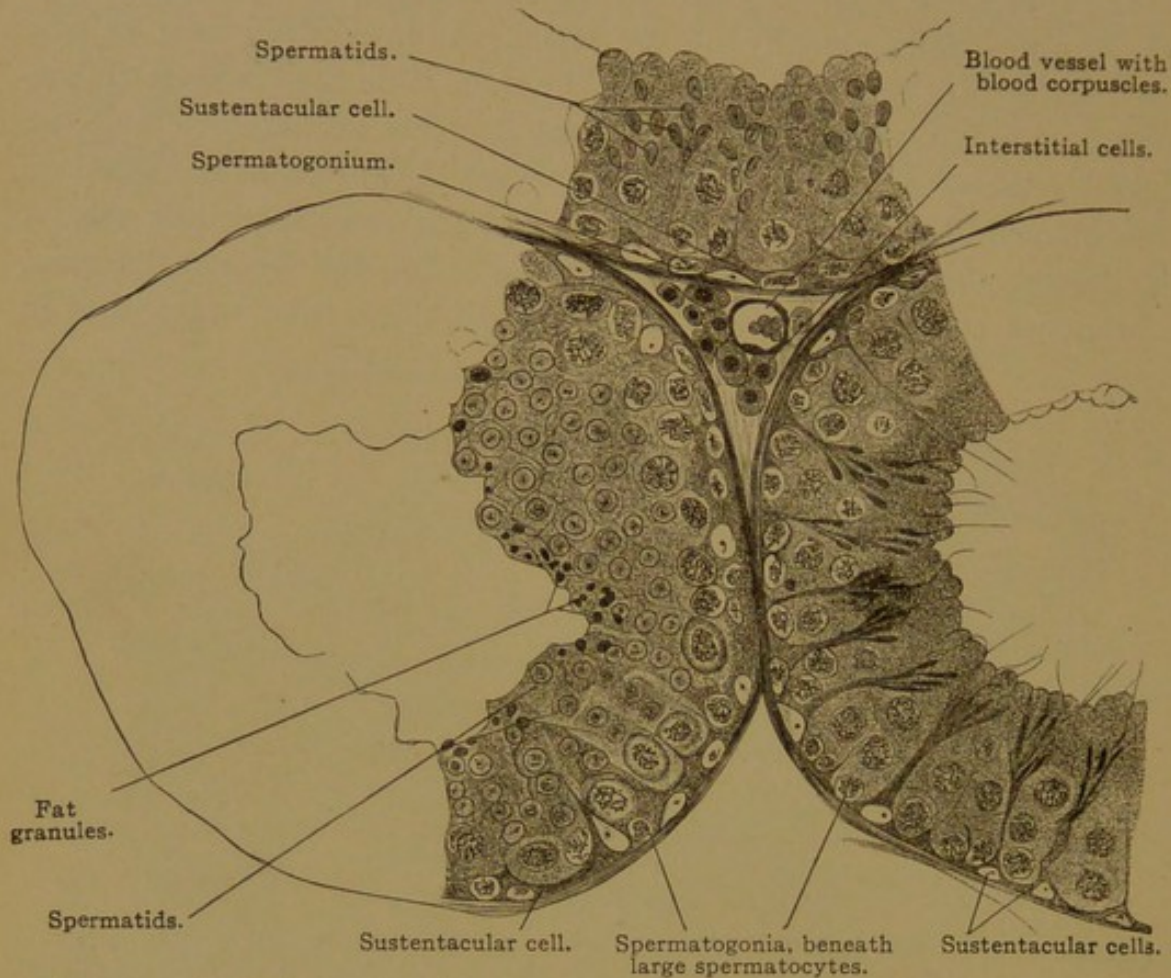


FIG. 332.—CROSS SECTIONS OF SEMINIFEROUS (CONVOLUTED) TUBULES OF A MOUSE. $\times 360$.

large cilium, or flagellum, projecting from the free surface, and becomes detached as a spermatozoon. The process of transformation of the basal cells, or spermatogonia, into spermatozoa is known as *spermatogenesis*. Its cytological features, as observed in the testis of the grasshopper, have already been described (p. 21). Ordinary sections of the human testis present the following characteristics:

Each tubule is composed of cells of two sorts—*sexual cells* and *sustentacular cells*. At birth the cords and developing tubules contain relatively few sexual cells (Fig. 333). These are characterized by their large size, clear protoplasm, and round vesicular nuclei. It is said that they retain a primitive granular arrangement of their mitochondria. These cells multiply by ordinary mitosis, producing the spermatogonia. Thus the sexual cells in various forms eventually far outnumber the sustentacular cells.

The sexual or genital cells are apparently produced from the cords in the testis, relatively late in embryonic development. It was suggested by Nussbaum, however, that the sexual cells are set apart much earlier—"they do not come from any cells that have given up their embryonic character or gone into building any part of the body." In accordance with this idea, it is considered by some authorities that in the segmentation stages, a line of undifferentiated cells is set apart to become the sexual cells, add that from the beginning they are distinct from the somatic cells which form the rest of the body. As stated by Allen (*Journ. Morph.*, 1911, vol. 22, pp. 1-36), the sexual cells do not belong to any one germ layer; they are free to follow their own path in their travels from the place of origin to the genital glands where they finally come to rest. Thus the sexual cells have been reported as distributed somewhat diffusely in the entoderm and mesoderm. (For papers on this subject, see Allen, *Anat. Anz.*, 1906, vol. 29, pp. 217-236.) In a human embryo of 2.6 mm. Felix found seven of these large clear cells, all in the immediate vicinity of the cloaca. Another embryo of 2.5 mm., showed twelve "primary genital cells." But he adds that they all disappear in later stages, and when the genital glands are formed there are no genital cells. At present it has by no means been demonstrated that the mammalian sexual cells are not differentiated products of the testis or ovary, adapted for the special purpose of reproduction.

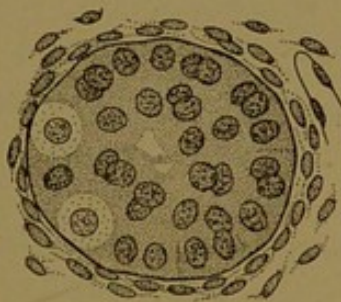

FIG. 333.—CROSS SECTION OF A CONVOLUTED TUBULE OF THE TESTIS AT BIRTH. (Eberth.)

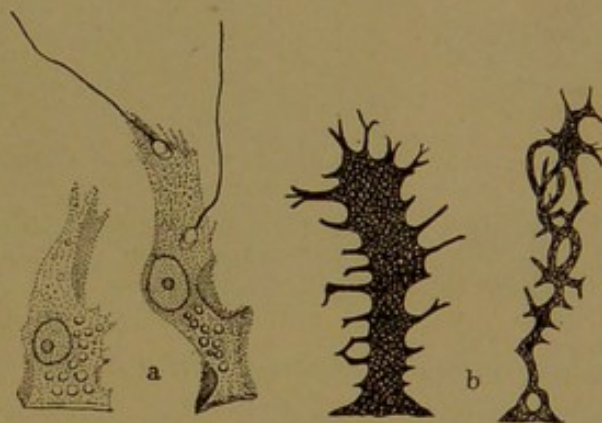


FIG. 334.—SUSTENTACULAR CELLS. a., Isolated (Koelliker); b., Golgi preparations. (Böhm and von Davidoff.)

The sustentacular or supporting cells, often called *Sertoli's cells*, are at first indifferent cells forming a syncytium (Fig. 333). With the increase in the number of spermatogonia, their protoplasm is resolved into a network of strands, molded by the surrounding cells (Fig. 334). Their nuclei are radially compressed into ovoid shapes, and lie in columns of protoplasm extending from the periphery of the tubule toward its lumen. Each nucleus has a distinct nucleolus, apart from which its chromatic material is very scanty. Usually the nuclei are in the lower half of the branching protoplasmic columns, the polygonal bases of which are in contact with one another beneath the spermatogonia. Within the protoplasm fat droplets occur, together with brown granules; crystalloid bodies in pairs may also be found. As seen in Fig. 334, a, the heads of the spermatozoa appear attached to, or imbedded in, the protoplasm of the sustentacular cells, which are supposed to nourish them. The

spermatozoa may be gathered in characteristic clumps at their upper ends (Fig. 332).

In ordinary sections of the testis, the sustentacular cells may be recognized by their distinctive nuclei (Fig. 335). The sexual cells in the basal row are presumably spermatogonia. Above them are the spermatocytes, which are larger; their nuclei usually show spiremes or other indications of cell division. Secondary spermatocytes are further out than the primary spermatocytes; and above them are the spermatids in various stages of transformation into spermatozoa. Since spermatogenesis occurs in "waves," the outer cells in a tubule cut lengthwise form a succession of zones, each of which shows gradations from young spermatids to mature spermatozoa; a single zone is included in Fig. 335. In transverse sections all the superficial cells may be of one stage, which differs from that in the adjoining tubule (Fig. 332).

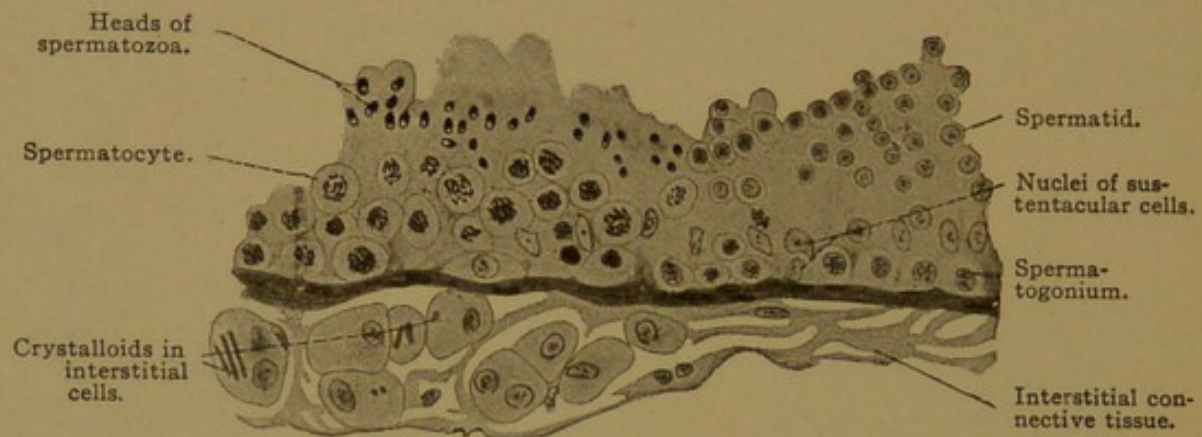

FIG. 335.—FROM A LONGITUDINAL SECTION THROUGH A CONVOLUTED TUBULE OF A HUMAN TESTIS. $\times 360$

Stages in the transformation of a spermatid into a spermatozoon are shown in the diagram Fig. 336. The chromosomes of the spermatid disappear in a dense chromatic network which becomes apparently homogeneous. This deeply staining nucleus passes to one end of the protoplasm of the spermatid. It becomes the essential part of the *head* of the spermatozoon, which in man is a flattened structure, oval on surface view, and pyriform with its apex forward when seen on edge (Fig. 337). The head is at the anterior end of the spermatozoon, which during its development is directed toward the basal layers of the convoluted tubule. The anterior end of the head is probably covered by a thin layer of protoplasm, known as the *galea capitis*. The archoplasm of the spermatid (known as the *idiozome*) is said to leave the centrosome and to enter the protoplasm of the *galea capitis*, where it forms the *perforatorium*. If this exists in man, it is in the form of a cutting edge following the outline of the front of the head; in other animals the *perforatorium* may be a slender spiral or barbed projection, which enables the spermatozoon to penetrate the ovum.

The protoplasm of the spermatid forms an elongated mass at the posterior end of the nucleus. It contains the centrosome which soon divides in two. Of these the anterior forms a disc which becomes adherent to the nuclear membrane. The posterior centrosome also becomes a disc after giving rise to a motile *axial filament*, which grows out from it like a cilium. The disc-like centrosome attached to the anterior end of the filament becomes thin in such a way that its peripheral portion is detached, and as a ring surrounding the filament it passes to the posterior limit of the protoplasm. The protoplasm between the two parts of the posterior centrosome is reduced to a thin layer in which a spiral filament develops, winding about the axial filament. Distal to the centrosome ring, the axial filament, which consists of fine fibrils, is surrounded by a thin membrane, which terminates or becomes very thin near the extremity of the filament. This membrane, which in salamanders forms a conspicuous undulating frill, is thought to be a product of the filament and not an extension of the protoplasm. In man it is inconspicuous, and many of the details here described can be made out only under most favorable conditions. The preceding account

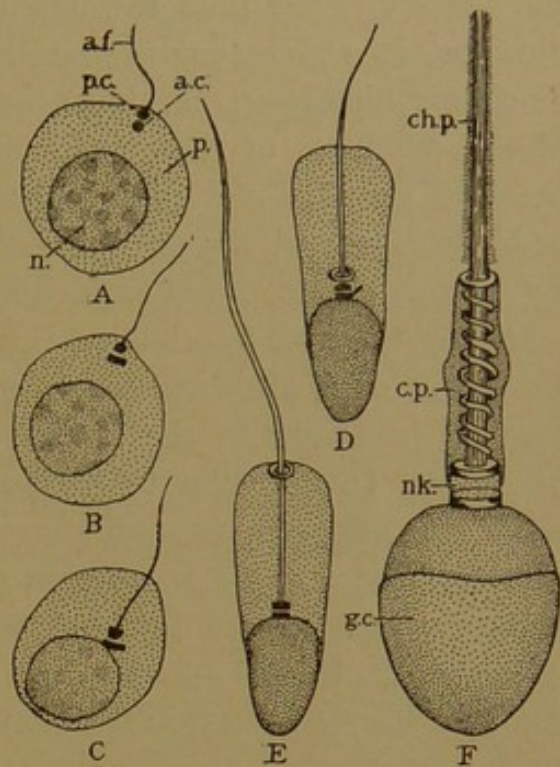


FIG. 336.—DIAGRAMS OF THE DEVELOPMENT OF SPERMATOZOA. (After Meves.)

a. c., anterior centrosome; a. f., axial filament; c. p., connecting piece; ch. p., chief piece; g. c., galea capitis; n., nucleus; nk., neck; p., protoplasm; p. c., posterior centrosome.

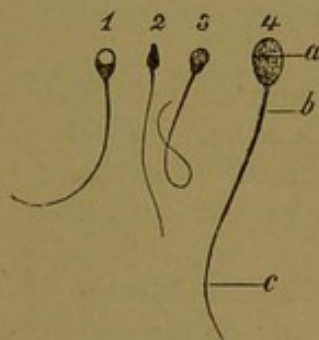


FIG. 337.—SPERMATOZOA: 1, 2, 3, HUMAN 4, FROM A BULL. a, Head; b, connecting piece, and c, chief piece of the tail. 1, 3, and 4, Surface views; 2, side view. $\times 360$

account is based on studies of the guinea-pig (Meves, Arch. f. mikr. Anat., 1909, vol. 73, pp. 751-792).

Mature spermatozoa are divided into three parts—the *head*, *neck*, and *tail*. The head (3-5 μ long and 2-3 μ wide) includes the nucleus, galea capitis and perforatorium. The neck consists of the anterior centrosome and the substance, not traversed by the axial filament, between it and the posterior centrosome. The neck in man is not constricted as in some forms, yet it is a place where the head may become detached. The tail includes three parts, the *connecting piece*, *chief piece* and *end piece*. The connecting piece (6 μ long and scarcely 1 μ wide) consists of protoplasm, axial and spiral filaments, and the two parts of the posterior centrosome. The chief piece (40-60 μ long) is the axial

filament with its surrounding membrane; and the end piece ($10\ \mu$) is a prolongation of the filament. When the spermatozoa become free they float in the albuminous fluid secreted in small quantity by the tubules of the testis. They pass through the straight tubules and rete to the epididymis, in which they accumulate, and where they first become motile. Their motility is greater, however, in the seminal fluid, which is a mixture of the products of the epididymis, seminal vesicles, prostate and bulbourethral glands. By an undulating movement of the tail, the head is propelled forward, always being directed *against* such a current as is made by cilia, at a rate of $\frac{1}{8}$ of an inch in a minute. Water inhibits the motion, which is favored by alkaline fluids; it occurs also in those faintly acid. For three days after death spermatozoa may retain their activity in the seminal passages; in the female urogenital tract they may live a week or more. In addition to normal spermatozoa, giant forms, and some with two heads or two tails occur, but these are probably functionless abnormalities. The production of spermatozoa, beginning at puberty, continues throughout life, but with advancing age the rate diminishes. Since about 60,000 spermatozoa occur in a cubic millimeter of seminal fluid, it has been estimated that 340 billions are produced in a lifetime.

The discovery of spermatozoa was reported to the Royal Society of London, in 1677, by Leeuwenhoek. They were first seen by Dr. Ham, "a man of singular modesty," to whom Leeuwenhoek gives full credit for the discovery in his letters to the Royal Society. He wrote as follows:

"This discerning youth visited me and brought with him, in a small glass vial, seminal fluid from a man who had cohabited with a diseased woman; and he stated that after some minutes when the fluid had become so attenuate that it could be put in a slender glass tube, he had seen living animalcules in it, which he thought were produced by some putrefaction. He added that those animalcules seemed to him to be provided with tails, and that they did not survive the space of twenty-four hours. Moreover he declared that when terebinth had been given to the patient internally, the animalcules appeared to be dead.

"I poured this material in a glass tube and examined it in the presence of Dr. Ham, and saw some live animalcules in it. But when after two or three hours, I examined the material more carefully, by myself, I saw that all the animalcules were dead."

Leeuwenhoek diligently pursued the study of these animalcules, and found them in enormous numbers in the semen of insects, fishes, birds and quadrupeds. He estimated that there were 150,000,000,000 in the milt of one fish, or more than ten times the number of men then living (13,385,000,000 homines in orbe terrarum). Leeuwenhoek believed that the animalcules were of two sexes, and that the egg consisted of a fluid in which they swam about and developed. To some it seemed not unreasonable that new individuals should be enclosed in the spermatozoa, like an insect in its chrysalis, and Dalenpatius (1699) thought that he could observe them. As quoted by Vallisneri, he wrote as follows, illustrating his account with the figure here reproduced (Fig. 338).

"We have seen some animalcules having just the form of tadpoles such as are found in brooks and muddy bogs in the month of May. The tail is four or five times as long as the body. They move with wonderful rapidity and by the strokes of their tails pro-

duce little waves in the substance in which they swim. But who would believe that in these a human body was hidden? Yet we have seen such with our own eyes. For while we were observing them attentively, a large one threw off its surrounding membrane and appeared naked, showing distinctly two legs, thighs, breasts and arms. The cast-off skin, drawn upward, covered the head like a cap, and it was a delightful and incredible sight. Because of the minuteness of the object, the sex could not be distinguished. After the little creature had lost its membrane it soon died."



FIG. 338

This is a gross presentation of the *preformation theory*, according to which the various parts of the adult are represented in the very young embryo. It was held by many who could not verify such observations. An alternative theory is that of *epigenesis*, according to which the body and its parts arise out of formless substance. Descartes (1664) wrote that the source of a new individual "seems to be only a confused mixture of liquors, which, serving to leaven one another, become heated; some of their agitated particles dilate, and press upon the others, gradually disposing them in the way necessary to form organs." Such physico-chemical speculations however, are quite as imaginative as any views of the preformationists. and Descartes's epigenesis was early characterized as "a very lame account of the forming of an animal." Nevertheless, the doctrine of epigenesis, as advocated by Harvey (1651) and Wolff (1759), prevailed over the cruder ideas of preformation. If, however, the spermatozoon can contribute to the production of only one of the myriad forms of animals, even the sex of which is apparently predetermined, it is evident that the spermatozoon must possess a very definite chemical composition, and perhaps a corresponding ultra-microscopic structure. Doubtless there is a preformation no less remarkable than that expressed through the active imagination of Dalenpatius.

Tubuli Recti and the Rete. The large convoluted tubules are $140\ \mu$ in diameter. As they pass toward the epididymis they decrease in size; they receive branches at acute angles and their windings diminish. Sexual cells disappear, leaving only the sustentacular cells in the form of a simple columnar epithelium. This flattens abruptly to form the lining of the straight tubules. Both the straight tubules and the rete are lined with a simple epithelium of low cells. In some places these are very flat, suggesting endothelium; in others they are columnar. The characteristic dilatations of the rete tubules are shown in Fig. 339. They contain spermatozoa and immature sexual cells together with pigment granules and broken down cells.

EPIDIDYMIS.

The *efferent ducts*, which pass from the rete to the duct of the epididymis, are lined with an epithelium in which groups of columnar cells alternate with those which are cuboidal (Figs. 340 and 341). Thus the inner surface of the epithelium has depressions suggesting glands, but the basal surface is free from outpocketings. The epithelium is generally simple, although in the tall parts it may appear two or three layered. The cells contain fat, pigment, and other granules, and produce a secretion which

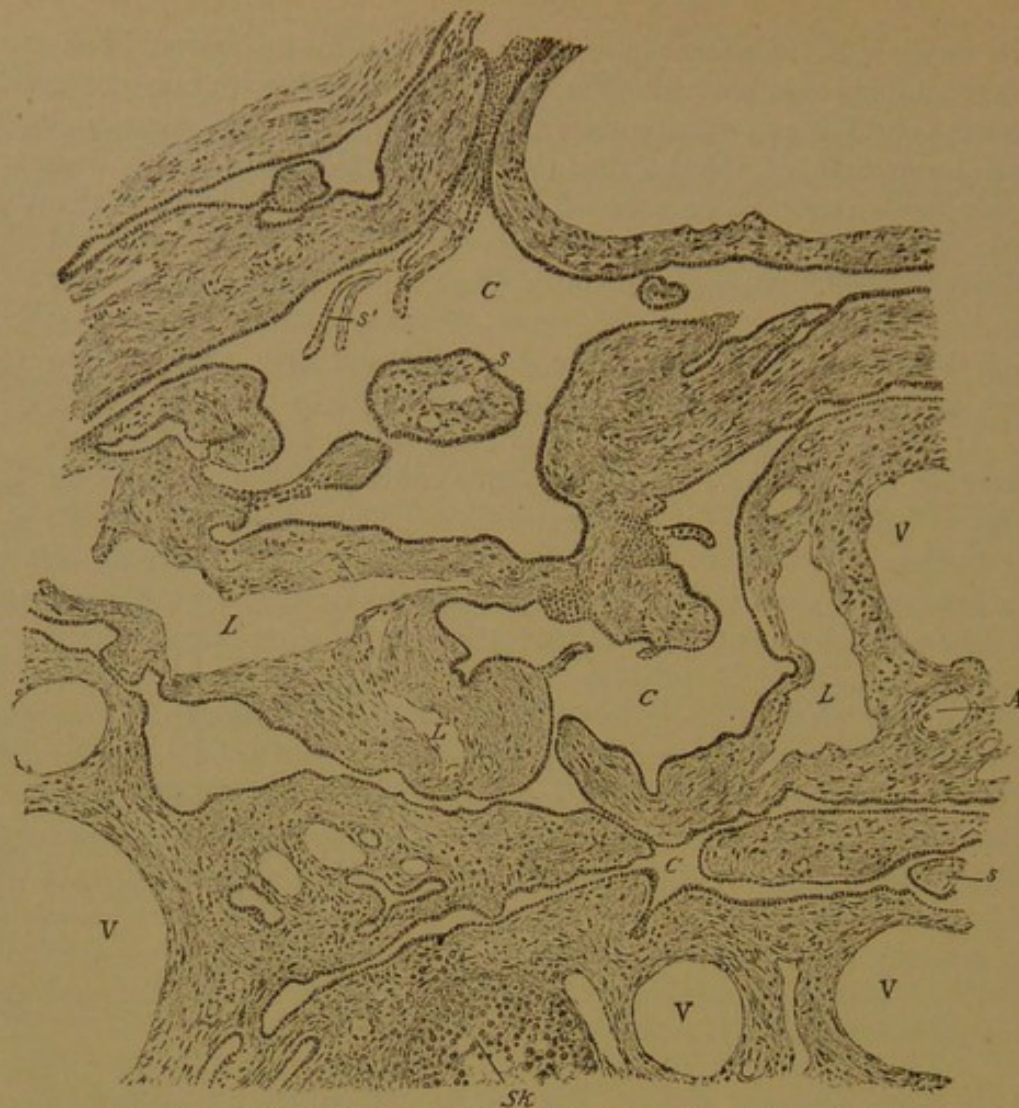

FIG. 339.—SECTION OF THE HUMAN RETE TESTIS. $\times 96$. (Kölliker.)
A, Artery; C, rete tubules; L, lymphatic vessels; s, connective tissue partly surrounded by rete tubules
Sk, part of a convoluted tubule, to the left of which are sections, probably of straight tubules; V, vein.

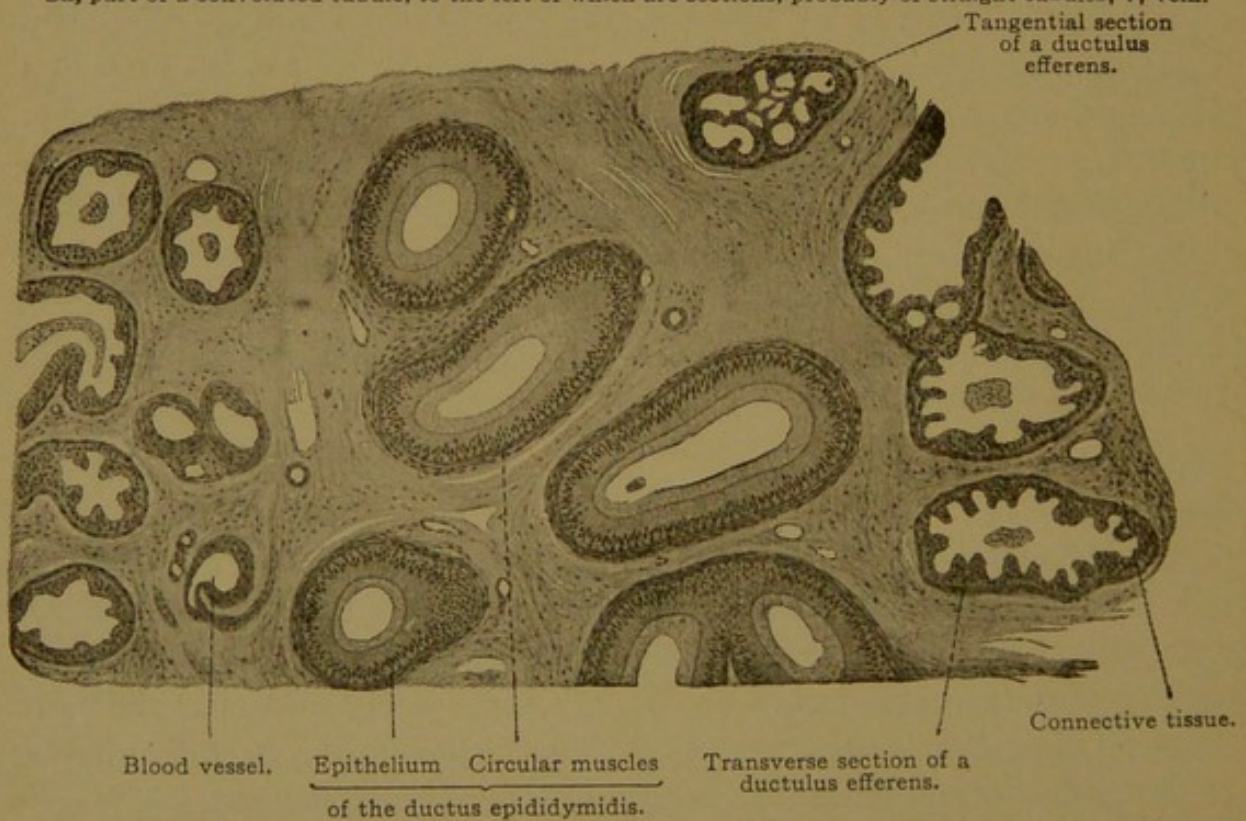


FIG. 340.—FROM A SECTION OF THE HEAD OF A HUMAN EPIDIDYMIS, SHOWING SECTIONS OF THE DUCTUS EPIDIDYMIDIS IN THE CENTER, AND OF DUCTULI EFFERENTES ON THE SIDES. $\times 50$.

may appear in vesicular masses on the surface of the cells. Often the tall cells, and occasionally the short ones, are ciliated. The cilia vibrate so as to produce a current toward the ductus epididymidis. The epithelium rests on a striated basement membrane which is surrounded by a layer of circular smooth muscle fibers, several cells thick. The muscle layer is thickest toward the ductus epididymidis. Among the muscle cells there are elastic fibers, which, like those of the ductus epididymidis and ductus deferens, first appear at puberty. There are no glands in the efferent ducts, but the irregularities in the epithelium are thought to be due to glandular activity. Before puberty and in old age these irregularities are slight.

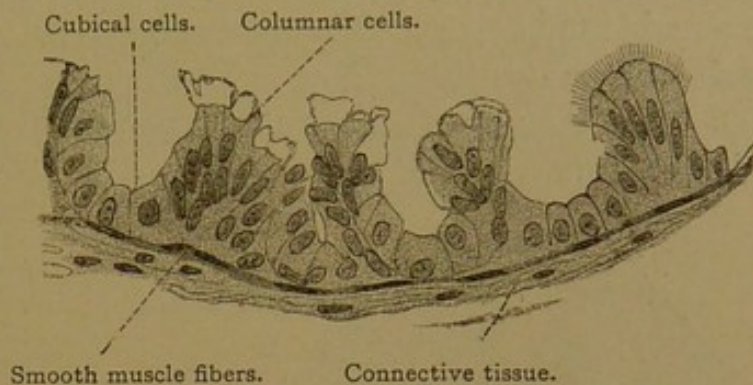


FIG. 341.—TRANSVERSE SECTION OF A DUCTULUS EFFERENS, FROM THE TESTIS OF AN ADULT MAN.

The right-hand end of the illustration is schematic. No cilia could be seen, although those of the epithelium of the epididymis were well preserved. $\times 360$.

The *ductus epididymidis* consists of a two-rowed epithelium with rounded basal cells and tall outer columnar cells. The latter contain secretory granules and sometimes pigment, and have in the middle of their upper surfaces long non-motile hairs, which in sections are usually matted in conical processes (Fig. 41, *b*, p. 51). The epithelium may contain round cavities opening into the lumen or forming closed cysts. The delicate *membrana propria* and thick circular muscle layer complete the wall of the ductus, the convolutions of which occur in a loose connective tissue. Toward the ductus deferens the muscle layer thickens.

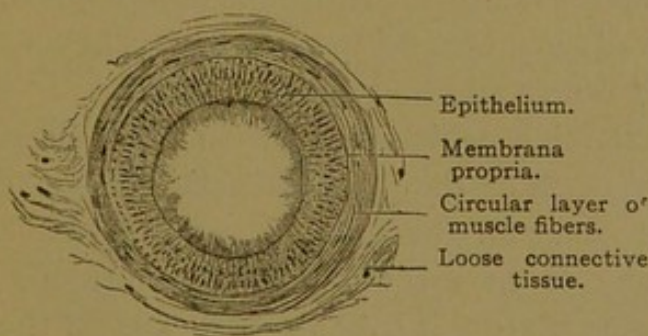


FIG. 342.—TRANSVERSE SECTION OF A HUMAN DUCTUS EPIDIDYMIS. $\times 80$.

There are no glands in the ductus epididymidis, but its cells produce considerable secretion in which the spermatozoa become active.

The blood vessels of the epididymis, which are few in comparison with those of the testis, lie in part so close to the efferent ducts as to cause the *membrana*

propria to bulge toward the epithelium. The nerves, besides perivascular nets, form a thick *plexus myospermaticus* provided with sympathetic ganglia. It is found in the muscle layer, which it supplies, sending fibers also into the mucosa. In the ductus deferens and seminal vesicles this plexus is said to be more highly developed than in the epididymis.

DUCTUS DEFERENS.

The ductus deferens begins as a convoluted tube continuous with the ductus epididymidis; it becomes straight and passes to its termination in the ductus ejaculatorius. Shortly before reaching the prostate it exhibits a spindle-shaped enlargement or *ampulla* about $\frac{1}{2}$ inch long and $\frac{3}{8}$ inch wide (Fig. 344). The ductus deferens consists of a mucosa, muscularis and adventitia. The epithelium is generally in two rows, the tall inner cells producing round masses of secretion. Toward the epididymis it may also have non-motile cilia. Toward the ampulla it may be

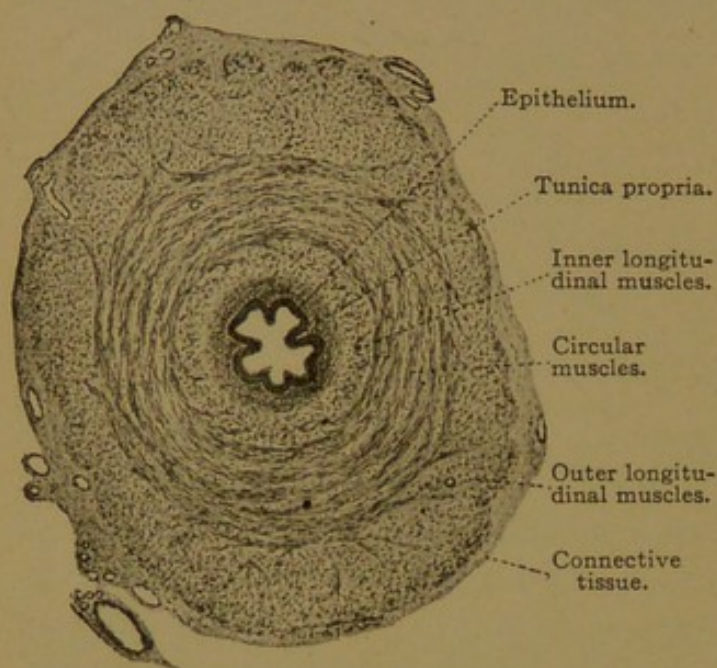


FIG. 343.—CROSS SECTION OF THE HUMAN DUCTUS DEFERENS.
X 24.

several rowed, resembling the epithelium of the bladder. It rests on a connective tissue tunica propria, which is surrounded by the three layers of the muscularis. The inner and outer layers are longitudinal and generally less developed than the middle circular layer. The adventitia is a loose elastic connective tissue, blending with that which forms the *spermatic cord*. The latter contains numerous arteries, veins, lymphatics and nerves, together with the striated muscle

fibers of the cremaster muscle, and the rudiment of the processus vaginalis. The veins are very numerous and constitute the pampiniform plexus (*i.e.*, tendril-like). Their walls are usually provided with a very thick musculature including both circular and longitudinal fibers.

In the ampulla the longitudinal folds, which are low in the ductus deferens, become tall and branched, so that they partly enclose irregular spaces (*diverticula*). Similar folds occur in the seminal vesicles. It is doubtful whether in either place any of the spaces should be considered glands. Around the ampulla the musculature is irregularly arranged; the longitudinal layers separate into strands which terminate toward the ejaculatory ducts.

SEMINAL VESICLES AND EJACULATORY DUCTS.

The seminal vesicles grow out from the ductus deferentes at the prostatic ends of their ampullæ. Each consists of a number of saccular expansions arranged along the main outgrowth, which is irregularly coiled. The

lining of the sacs is honeycombed with folds as shown in Figs. 344 and 345. The epithelium is generally simple or two-layered, the height of the cells varying with the distention of the vesicles by secretion. Granules occur in the cells, which produce a clear gelatinous secretion in sago-like masses. Spermatozoa are generally found in the human vesicles, but except during sexual excitement they are absent from the vesicles of rodents; this and other facts indicate that the function of the organ is primarily glandular. The lumens of the various sexual glands are generally of very large caliber, associated with the storing of secretions. Pigment granules in varying

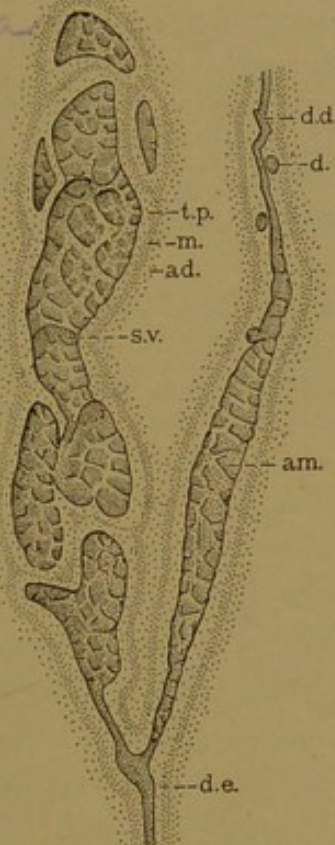


FIG. 344.—SEMINAL VESICLE AND DUCTUS DEFERENS. (This is natural size.) (After Eberth.)
ad., Adventitia; am., ampulla; d., diverticulum; d. d., ductus deferens; d. e., ductus ejaculatorius; m., muscularis; s. v., seminal vesicle; t. p., tunica propria.

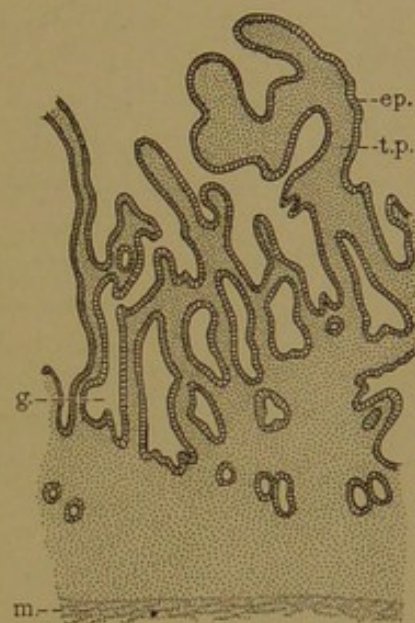


FIG. 345.—VERTICAL SECTION OF THE WALL OF A SEMINAL VESICLE. (After Kölliker.)
ep., Simple epithelium; g., gland-like depression; m., muscularis; t. p., tunica propria.

quantity occur in the epithelial cells and in the underlying connective tissue. They may impart a brownish color to the secretion.

The *ductus ejaculatorii*, along their dorso-median sides, are beset with a series of appendages, which do not project externally but are wholly enclosed in the connective tissue wall of the duct. Some of these appendages show the same structure as the seminal vesicles and therefore might be described as accessory seminal vesicles; others are simply convolutions of alveolo-tubular glands which may be compared with prostate glands. The mucous membrane of the ductus ejaculatorii is like that of the seminal vesicles, except that its folds are not so complicated. Muscle

fibers occur only around the appendages. The wall of the duct itself consists of an inner dense layer of connective tissue with circular strands, and an outer loose layer (adventitia).

APPENDICES AND PARADIDYMIS.

The appendices are frequently called *hydatids*, which is a general term for watery cysts. The *appendix testis* is a small lobule of connective tissue projecting from the groove between the head of the epididymis and the testis (Fig. 346). It is quite constant, having been reported in 90% of the testes examined. The projection is covered with the peritoneum of the tunica vaginalis, which may be thickened around it, or corrugated, suggesting the fimbriated orifice of the uterine tube. The appendix consists of vascular connective tissue and encloses a canal, or fragments of canals, lined with simple columnar epithelium which is sometimes ciliated. It is generally not cystic, and it may be pedunculated, so that the terms "hydatid of Morgagni" and "sessile hydatid," formerly applied to it, are inappropriate. Although its canal has been reported as connecting with the seminal ducts, this is not now believed to be the case; the structure is regarded as the degenerated end of the Müllerian duct.

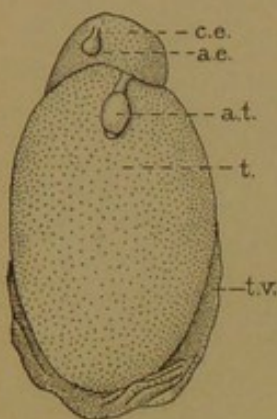


FIG. 346.—FRONT VIEW OF A TESTIS, somewhat reduced. (After Eberth.)

a. e., Appendix epididymidis; a. t., appendix testis; c. e., caput epididymidis; t., testis; t. v., tunica vaginalis.

The *appendix epididymidis* (stalked hydatid) is not always present. Among 105 cases examined by Toldt it was found twenty-nine times. It consists of loose vascular connective tissue covered by the vaginalis, and contains a dilated canal lined with columnar epithelium, sometimes ciliated. The canal generally has no connection with the tubules of the epididymis. It is regarded as a persistence of detached degenerating Wolffian tubules, or possibly of the terminal portion of the Wolffian duct.

The *paradidymis*, according to Toldt (Verh. Anat. Gesellsch., 1892, pp. 241-242), occurs in two forms. The first is found frequently, but by no means regularly, in older embryos and in children. It is a round or elongated structure, conspicuous because of its white color, found on the ventral side of the spermatic cord, either behind the head of the epididymis or higher up. Microscopically it is seen to be a thin, coiled, blind canal, expanded in places, and lined with a simple columnar epithelium. Occasionally there are two to four such structures at varying distances from one another. In later years they all disappear. They never contain spermatozoa.

The second form of paradidymis was found by Toldt in late childhood and in adults, but it does not occur regularly. It is always immediately behind the head of the epididymis and in front of the pampiniform plexus. It consists of a canal, sometimes with saccular dilatations, which is easily followed with the naked eye. The tubule may be closed at both ends, or one end may connect with the epididymis or testis; sometimes one end connects with the testis and the other with the epididymis. These tubules may contain spermatozoa, and they have been said to resemble the efferent ducts in structure. They may be ciliated.

Toldt regards the first form of paradidymis as due to persistent Wolffian tubules, and the second as a late separation of an efferent duct from its connection with the epididymis. He notes that the second form may give rise to cysts of varying size. Other cysts in the vicinity of the epididymis are said to arise from in-pocketings of the tunica vaginalis.

PROSTATE.

The prostate is a group of branched tubulo-alveolar glands, imbedded in a mass of muscular tissue, which stands before the outlet of the bladder. The smooth muscle of the adult prostate forms a quarter of the bulk of the organ, and together with an elastic connective tissue, it unites the numerous glands in a compact mass. The development of these glands up to the time of birth, has been studied by Lowsley (*Amer. Journ. Anat.*, 1912, vol. 13, pp. 299-349). He finds that the prostate includes from fifty-three to seventy-four separate glands (the average number being sixty-three) which are grouped in five lobes. The middle lobe consists of nine to ten large glands growing out from the dorsal side of the urethra, between the bladder and the openings of the ejaculatory ducts. The glands of the posterior lobe grow out from the dorsal wall of the urethra below the ejaculatory ducts; those of the right and left lobes develop from the sides of the prostatic urethra; and those of the anterior lobe proceed from its ventral surface. The anterior lobe is well developed in young embryos, but it "shrinks into insignificance at the twenty-second week." It may persist in the adult, but the great mass of the prostatic glands is at the sides and back of the prostatic urethra. The number of glands apparently becomes reduced. In the adult it is said to be from thirty to fifty.

The glandular epithelium is simple and either cuboidal or columnar. It may appear stratified as it passes over the folds in the walls of the tubules. Near the outlet of the larger ducts the epithelium is like that of the bladder and prostatic urethra. In the prostatic alveoli, of older persons especially, round or oval colloid masses from 0.3 to 1.0 mm. in diameter occur; as seen in sections (Fig. 348) they exhibit concentric layers. Their reactions on treatment with iodine solutions suggest amyloid. These concretions are probably deposited around fragments of cells. Octahedral crystals also occur in the prostatic secretion, which is a thin milky emulsion, faintly acid; it has a characteristic odor, whereas the other constituents of the seminal fluid are said to be odorless.

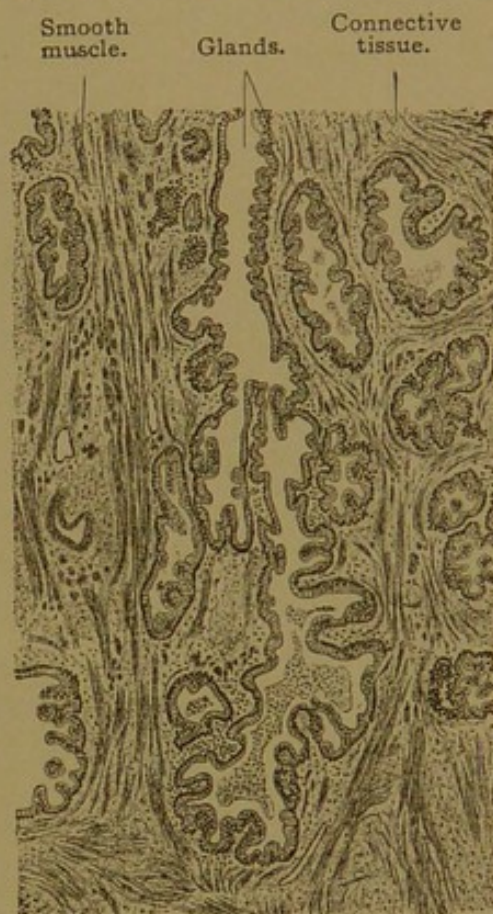

FIG. 347.—FROM A SECTION OF THE PROSTATE OF A MAN TWENTY-THREE YEARS OLD. $\times 50$.

The smooth muscle fibers are found everywhere between the prostatic lobules; toward the urethra they thicken to form the internal sphincter of the bladder. Smooth muscle is also abundant on the surface of the prostate, and it borders upon the striated fibers of the sphincter of the membranous urethra. The prostate is abundantly supplied with blood and lymphatic vessels. The numerous nerves form ganglionated plexuses from which non-medullated fibers pass to the smooth muscles; others of the nerves have free endings; still others, both in the outer and inner

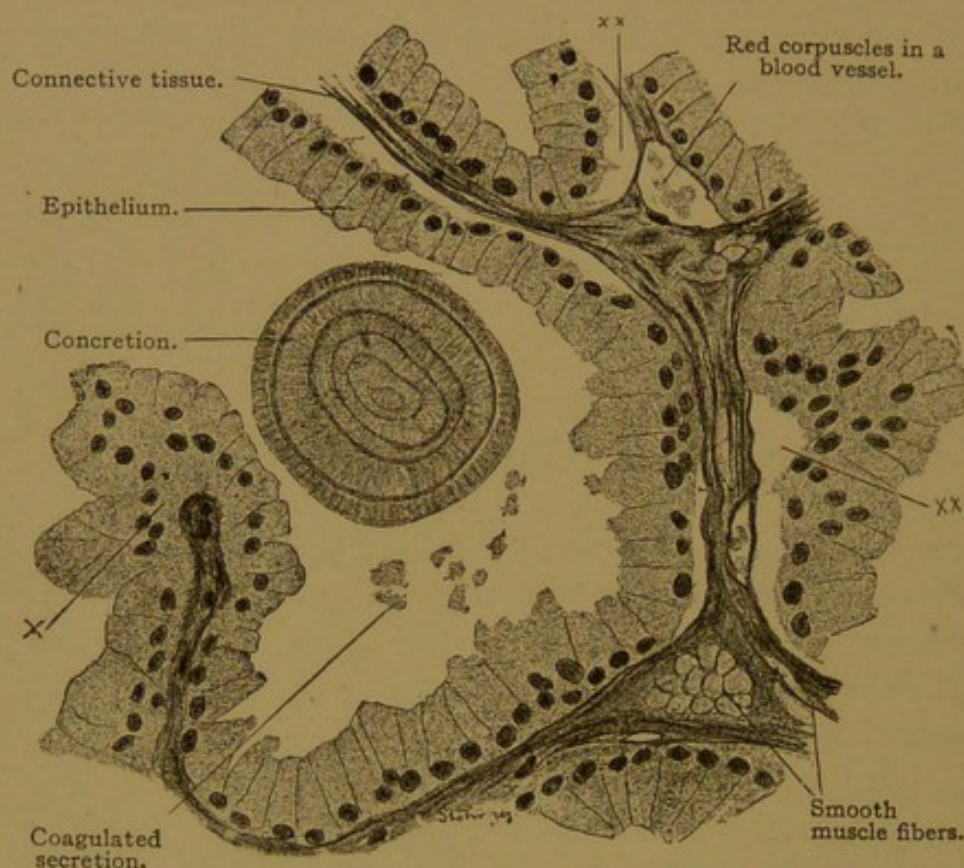


FIG. 348.—FROM A SECTION OF THE PROSTATE OF A MAN TWENTY-THREE YEARS OLD. $\times 360$. The epithelium is cut obliquely at *x*, and has artificially separated from the connective tissue at *xx*.

parts of the gland in dogs and cats, end in cylindrical lamellar corpuscles.

The *utricleus prostaticus* (uterus masculinus, vagina masculina) is a small pocket lined with stratified epithelium, opening into the dorsal wall of the urethra midway between the orifices of the ejaculatory ducts, or a little below them. It is sometimes absent, and is occasionally quite deep. Lowsley failed to find any small prostatic tubules opening into it, such as have been reported as occasionally present. The utricleus prostaticus is the lower end of the Müllerian ducts, which have fused, and it corresponds with the vagina in the female.

URETHRA AND PENIS.

The form of epithelium found in the bladder extends through the prostatic to the membranous part of the urethra. Its outer cells gradu-

ally become elongated and it changes to the simple or few-layered columnar epithelium of the cavernous portion. In the dilatation of the urethra near its distal end, the *fossa navicularis*, the epithelium becomes stratified with its outer cells squamous; the underlying papillæ of the tunica propria become prominent, and the whole is the beginning of the gradual transition from mucous membrane to skin.

Glands. Small groups of mucous cells are scattered along the urethra, and in the cavernous part, especially on the upper wall, they form pockets called *urethral glands* (of Littré). Often these pockets are on the sides of epithelial pits so that the glands are branched. Non-glandular pits

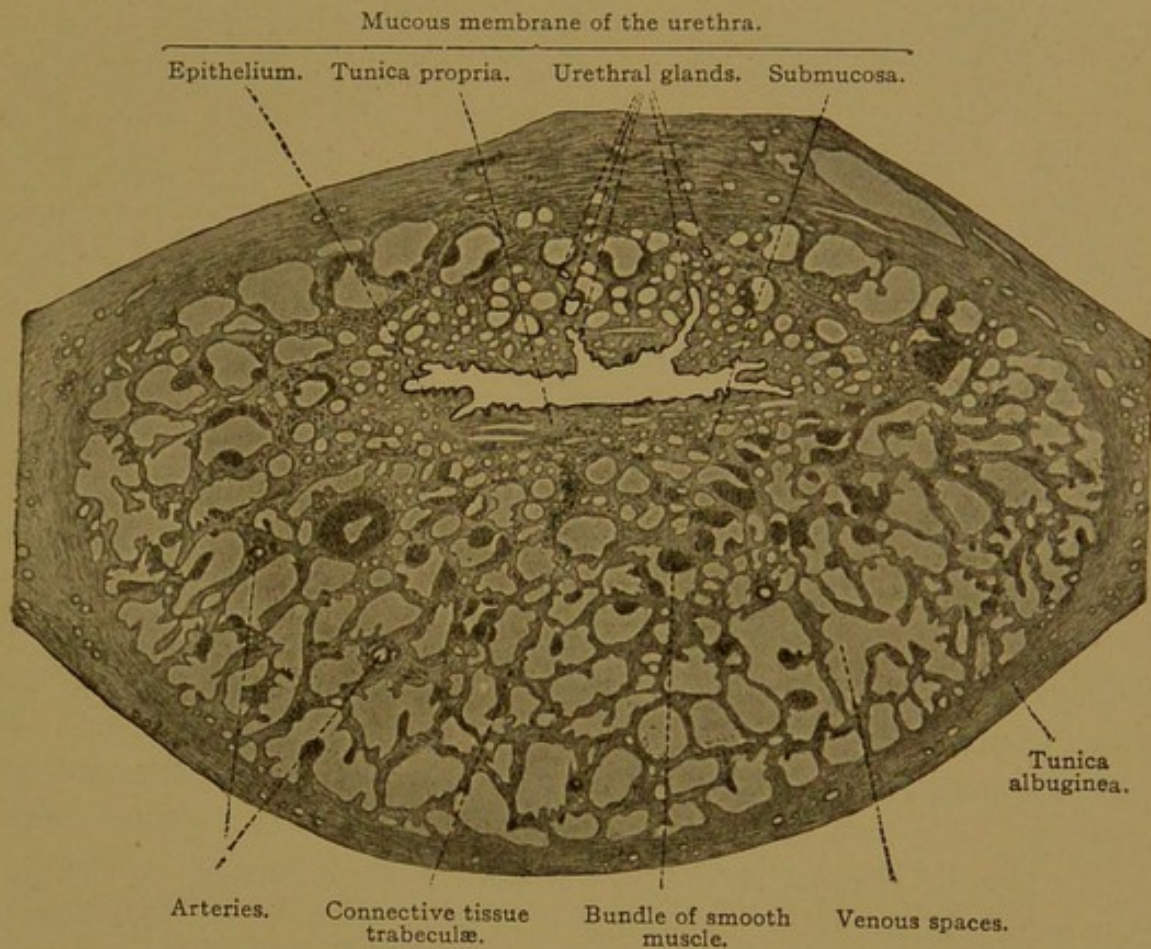


FIG. 349.—TRANSVERSE SECTION OF THE PARS CAVERNOSA URETHRÆ OF MAN. $\times 28$.

also occur, known as *urethral lacunæ*, and the “paraurethral ducts” near the external orifice are large lacunæ of various sorts.

Two glands of considerable importance empty by irregularly dilated ducts, $1\frac{1}{2}$ in. long, into the beginning of the cavernous urethra. The bodies of these *bulbo-urethral glands* (Cowper’s glands) are found one on either side of the membranous urethra, in close relation with striated and smooth muscle fibers. The end pieces, which are partly alveolar and partly tubular, anastomose. They consist of mucous cells, with intercellular secretory capillaries, and produce a clear, glairy mucus, discharged during sexual excitement. The ducts, surrounded by thin rings of smooth

muscles, consist of simple low epithelium. They may connect directly with the end pieces, or a secretory duct may intervene.

The *muscularis* of the prostatic part of the urethra consist of an inner longitudinal and an outer circular layer of smooth muscles. Both layers continue throughout the membranous part; the circular layer ends in the beginning of the cavernous urethra leaving only oblique and longitudinal bundles in its distal part.

Corpus cavernosum urethræ. In the submucosa of the cavernous urethra there are many veins (Fig. 349) which become larger and more numerous in and beyond the muscularis. This vascular tissue which surrounds the urethra is limited by a dense elastic connective tissue layer, the *tunica albuginea*, and the structure which is thus bounded is the *corpus cavernosum urethræ*. Toward the perineum it ends in a round enlargement, the *bulbus urethræ*, and distally it terminates in the *glans penis*. The urethra enters the upper surface of this corpus cavernosum near the bulbus. Branches of the internal pudendal (pudic) artery, namely, the *arteriæ bulbi* and the urethral arteries, penetrate the albuginea, and the former pass the length of the cavernous body and end in the glans. These arteries have particularly thick walls of circular muscle, and in cross sections the intima may be seen to form coarse rounded projections into the lumen. These projections contain longitudinal muscles and subdivisions of the inner

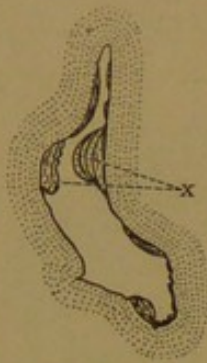

FIG. 350.—CROSS SECTION OF AN ARTERY OF THE BULBUS URETHRÆ, SHOWING THICKENINGS OF THE INTIMA AT X. Elastic tissue stain. (After Eberth.)

circular elastic membrane (Fig. 350). The arteries in the corpus cavernosum produce capillaries found chiefly toward the albuginea. The capillaries empty into thin-walled venous spaces which appear as endothelium-lined clefts in a connective tissue containing many smooth muscle fibers. The cavernous body is permeated with these spaces which, at times of sexual excitement, become distended with blood, reducing the tissue between them to thin trabeculæ. Such distensible vascular tissue is known as *erectile tissue*. Some arteries connect directly with the venous spaces, and such as appear coiled or C-shaped in a collapsed condition are called *arteriæ helicinæ*. The *venæ cavernosæ* have such very thick walls that they resemble arteries. They contain an abundance of inner longitudinal muscle fibers, and since these are not evenly distributed but occur in columns, the lumen of the veins is usually crescentic or stellate in cross section. Emissary veins pass out through the albuginea and empty into the median dorsal vein of the penis.

The *corpora cavernosa penis* are a pair of structures similar to the cavernous body of the urethra, and are found side by side above it (Fig. 351). The septum between them is perforated distally so that they

communicate with one another. Each is surrounded by a very dense albuginea, 1 mm. thick, divisible into an outer longitudinal and an inner circular layer of fibrous tissue. The septum is formed by the median fusion of these layers. The cavernous or erectile tissue of which these corpora are composed is essentially like that around the urethra.

All three cavernous bodies are surrounded by fascia and subcutaneous tissue containing blood vessels, lymphatics and nerves. The lymphatic vessels form a superficial and a deep set, the latter receiving branches from the urethra. The principal sensory nerves are the medullated *dorsal nerves of the penis*. They terminate in many tactile corpuscles in the papillæ beneath the skin, in bulbous and genital corpuscles in the deeper connective tissue, and in lamellar corpuscles found near or in

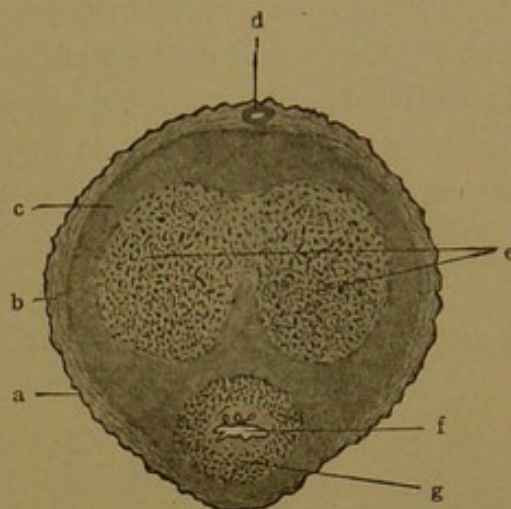


FIG. 351.—CROSS SECTION OF A PENIS.
a., Skin; b., subcutaneous tissue; c., tunica albuginea; d., dorsal vein; e., corpora cavernosa penis; f., urethra; g., corpus cavernosum urethræ. (Bailey.)

the cavernous bodies. Free endings also occur. The sympathetic nerves are from a continuation of the prostatic plexus. They constitute the cavernous plexus, which includes the *major cavernous nerves* accompanying the dorsal nerves of the penis, and the *minor cavernous nerves* which enter the roots of the corpora cavernosa penis. The sympathetic nerves supply the numerous smooth muscles of the trabeculæ and cavernous blood vessels. They are said to be joined by fibers from the lower spinal nerves, the *nervi erigentes*.

FEMALE GENITAL ORGANS.

DEVELOPMENT AND GENERAL FEATURES.

CERTAIN

Although it is ~~possible~~ that sex is determined at the time of the fertilization of the ovum, and that it cannot be modified by subsequent conditions of any sort, the sex of young embryos cannot be recognized. All human embryos of 13 mm. possess a prominent genital papilla; they have both Wolffian and Müllerian ducts, in so far as the latter have developed; and they contain genital ridges which are still in an "indifferent stage"—it cannot be said whether they will become ovaries or testes—(cf. Fig. 326, p. 328). In the female the Müllerian ducts become highly developed, the Wolffian ducts degenerate, and the genital ridges produce ovaries.

The Müllerian Ducts. Before reaching the urogenital sinus, the lower ends of the Müllerian ducts are in contact, being situated between the Wolffian ducts (Fig. 352). The figure here reproduced represents a por-

tion of the genital apparatus shown in Fig. 306, B, p. 311, both being sketched from the beautiful lithographs accompanying Keibel's fundamental account of the development of the human urogenital tract, which students should consult in its original form (Arch. f. Anat. u. Entw., 1896, pp. 55-156). A fusion of the Müllerian ducts begins just above their lower termination and extends downward to the urogenital sinus. Thus the entire ducts form a Y-shaped structure, and the lower part of the stem becomes the vagina. It is at first a solid cord of cells, but those in the center break down and a lumen appears, "first in embryos of 150-200 mm."

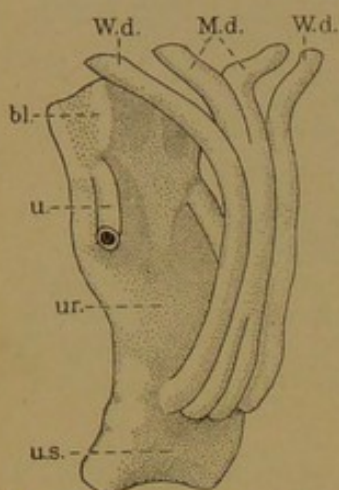


FIG. 352.—RECONSTRUCTION SHOWING THE FUSION OF THE MÜLLERIAN DUCTS. (After Keibel.)

bl., Bladder; M.d., Müllerian duct; u., ureter; ur., urethra; u.s., urogenital sinus; W.d., Wolffian duct.

The lower end of the vagina remains closed by epithelium for some time longer, and as the vagina enlarges, a transverse fold, the *hymen*, is formed at this point. With the breaking down of the central cells, the hymen becomes perforate; it then usually forms a crescentic fold on the dorsal side of the entrance to the vagina (Fig. 353). Its remains permanently mark the orifice of the Müllerian ducts.

Above the vagina the Müllerian ducts form the lining of the uterus, which develops from the upper part of the stem of the Y, and from the inner ends of its arms. This region of junction becomes surrounded by a very thick layer of smooth muscle. The occasional occurrence of a median septum in the uterus or vagina, dividing them into right and left halves, is due to imperfect fusion of the Müllerian ducts.

The outer portions of the Müllerian ducts retain relatively thin walls and become the *uterine* (or Fallopian) *tubes*. Each opens freely through its fimbriated extremity into the abdominal cavity.

The Wolffian Bodies and Wolffian Ducts. In the female these structures become functionless and degenerate. Their principal derivative is a group of blind tubules, which may readily be seen in the translucent mesentery-like membrane extending between the ovary and tube. These tubules were named the "organ of Rosenmüller" after their discoverer, who described them in 1802, and were called the "parovarium" (later corrected to paroöphoron) because of their position beside the ovary; but when it was shown that these tubules were homologous with the epididymis, they were given a corresponding name, and are now known as the *epoöphoron* (ἐπί, upon; ὠφóρος, ovary). The epoöphoron consists of "8 to 20" *transverse ducts*, which begin with blind ends in or near the upper end of the ovary and follow a more or less convoluted course to the *longitudinal duct*, into which they empty (Fig. 353). They are lined with

simple cuboidal or columnar epithelium, sometimes ciliated, and are surrounded with muscle fibers. Occasionally there are detached solid cords in their vicinity, and sometimes the tubes become cystic. Obviously they correspond with the efferent ducts of the testis, and the longitudinal duct, into which they empty, represents the duct of the epididymis. Some of the transverse tubules, or the main duct itself, may extend into soft round nodules of tissue projecting from the mesentery, to which they may be attached by slender pedicles. These *appendices vesiculosæ* correspond with the appendix of the epididymis. Frequently there is a vesicular appendix entirely separate from the epoöphoron, situated near the fimbriated orifice of the uterine tube, and said by Felix to develop around an accessory Müllerian duct. Although accessory ducts have not been found in the male, the relations of this structure to the Müllerian duct suggest a comparison with the appendix testis. Both in the female and the male the appendages have been described as of two sorts, connected with the Müllerian and Wolffian ducts respectively.

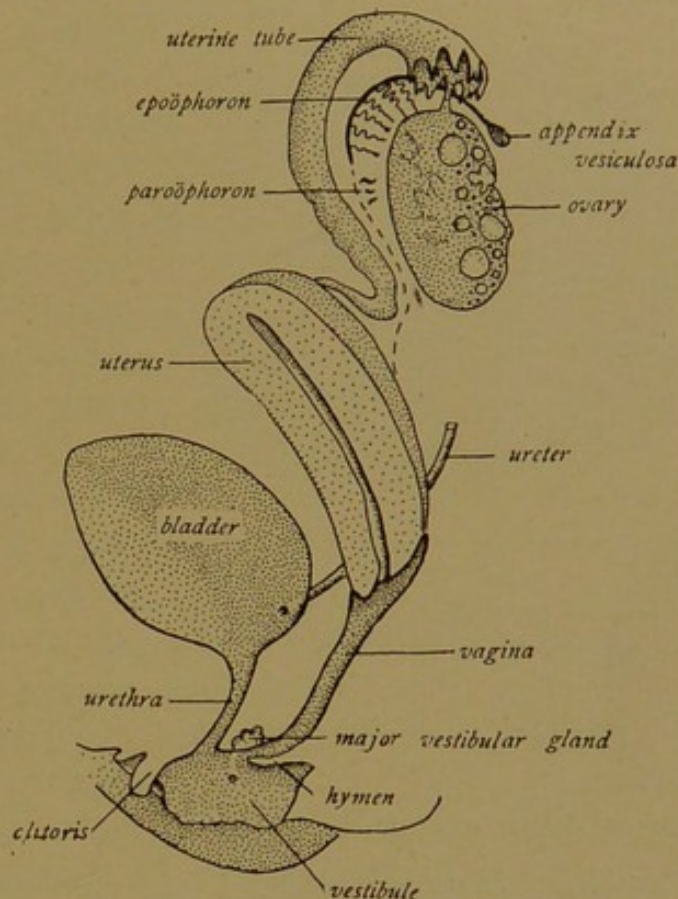


FIG. 353.—DIAGRAM OF THE FEMALE GENITAL ORGANS.

The *paroöphoron* is a remnant of the Wolffian tubules corresponding with the paradidymis. It was first described as nearer the uterus than the epoöphoron, and situated as in the diagram, Fig. 353. The tubules there shown, however, are presumably a part of the epoöphoron; the paroöphoron is now said to be on the opposite side of the ovary (toward the right of the diagram), in relation with the ovarian vessels. It disappears by the fifth year.

The lower end of the Wolffian duct, which corresponds with the ductus deferens, may remain as the *canal of Gärtner*. This canal terminates near the hymen. It may extend upward beside the vagina, and be enclosed in the musculature of the lower part of the uterus; usually it is entirely obliterated.

Development of the Ovary. Like the testis, the ovary is formed from the middle portion of the genital ridge. The peritoneum which covers it gives rise to the mass of cells in its interior, and deep within, the cells become arranged in medullary cords and a *rete ovarii*. These are rudimentary structures. The rete cords do not connect with the Wolffian tubules. They are said to acquire lumens toward birth, so that they are bounded

by simple epithelium; they remain in the adult and may become cystic. Sexual cells disappear from the cords in the central part of the ovary, which becomes filled with vascular connective tissue and forms the *medulla* in the adult. The peripheral part of the ovary, or *cortex*, contains great numbers of sexual cells, which instead of being lodged in tubules as in the testis, are arranged in small groups surrounded by indifferent cells. The entire structures are *primary follicles*, and they are imbedded in a stroma likewise derived from the peritoneum. Felix considers that the

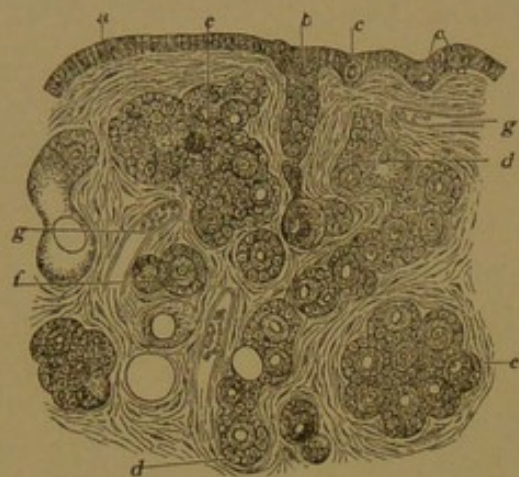


FIG. 354.—SECTION OF THE OVARY AT BIRTH.
(Waldeyer.)

a, Epithelium; b, epithelial cord; c, sexual cell; d, detached cord; e, group of follicles; f, a single primary follicle; g, blood vessel.

follicles develop, for the most part at least, directly from the tissue of the genital ridge, and states that tubes or cords growing in from the peritoneal epithelium, as described by Pflüger, do not exist in the human ovary. Generally it has been said that the primary follicles arise by the subdivision of such cords (Fig. 354).

Ligaments. As the Müllerian ducts come together below, they occupy ridges covered with peritoneum. These ridges coalesce so as to form a partition which crosses the pelvis from side to side and rises upward from its floor. Ventral to

the partition is the bladder, separated from it by the vesico-uterine pouch; dorsal to it is the rectum, separated by the deeper recto-uterine pouch; and within it are the uterus and tubes. In the adult these folds of peritoneum extending laterally from the uterus constitute its *broad ligaments*. The Wolffian bodies and ovaries, which at first occupy vertical ridges on either side of the root of the mesentery, appear to slip down or descend into the interior of the broad ligaments, from the dorsal surfaces of which the ovaries later project.

Above each ovary there is a band of fibrous tissue which extends to the orifice of the tube, and running along this band there is a fimbria known as the *fimbria ovarica*; this arrangement apparently serves to keep the orifice of the tube in close relation with the ovary. Below the ovary, between the laminae of the broad ligament, a cord of fibrous tissue passes from it to the musculature of the uterus, lying just below the uterine tubes; this is the *ovarian ligament*. The *round ligaments* start from the uterine musculature not far from the ends of the ovarian ligaments. They pass downward, one on either side within the broad ligament, and terminate in the folds which correspond with those of the scrotum. The ovarian and round ligaments are believed to be subdivisions of a single structure equivalent to the *gubernaculum testis*.

The External Genital Organs. The urogenital sinus, which receives the urethra and vagina, becomes a shallow space called the *vestibule* (Fig. 353). The genital papilla, with the *glans* at its apex, becomes relatively shorter as the female embryo develops. It forms the *clitoris*, analogous with the penis, and is covered by the lesser genital folds, the *labia minora*. (Compare Fig. 355 with Fig. 329, A, page 331.) The labia form a prepuce for the clitoris but do not unite beneath it to make a raphe; they remain separate, as parts of the lateral boundaries of the vestibule. The larger genital folds, *labia majora*, likewise remain separate. They receive the ends of the round ligaments of the uterus which pass into them over the pubic bones, sometimes accompanied by a prolongation of the peritoneal cavity forming a *processus vaginalis*. In late stages of development the labia majora become large enough to conceal the clitoris and labia minora, which previously project between them.

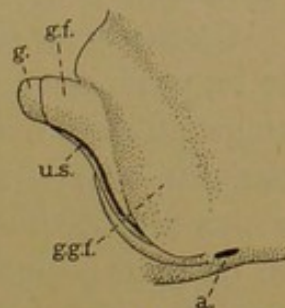


FIG. 355.—DIAGRAM OF THE EXTERNAL GENITAL ORGANS OF A FEMALE EMBRYO.

a., anus; g., glans clitoridis; g. f., lesser genital folds (labia minora); g. g. f., greater genital folds (labia majora); u. s., urogenital sinus (vestibule).

OVARY.

The ovary is an oval body about an inch and a half long, covered by a modified portion of the peritoneum. Along its *hilus* it is attached to a mesentery, the *mesovarium*, which is a subdivision of the broad ligament of the uterus. The epithelium of the mesovarium is continuous with that of the ovary, and its connective tissue joins the mass which forms the ovarian medulla. This tissue, rich in elastic fibers and containing strands of smooth muscle, surrounds the vessels and nerves. The blood vessels are abundant, and they pursue a very tortuous course both in the mesovarium and within the ovary. This is strikingly shown in Clark's injections (Johns Hopkins Hosp. Rep., 1900, vol. 9). They are derived in part from branches of the uterine vessels, but are chiefly the terminations of the ovarian artery and vein. Large stems traverse the medulla and form capillary plexuses around the follicles in the cortex. Thin-walled lymphatic vessels arise in the cortex below the rather dense sub-peritoneal layer (or *tunica albuginea*) and pass out at the hilus. The nerves are chiefly non-medullated sympathetic fibers, derived from the plexus which accompanies the ovarian artery, and distributed to the blood vessels. Ganglion cells have been found near the hilus, and a few medullated fibers occur. It is said that certain fibers end in contact with the cells of the follicles.

The relation of the cortical stroma to the looser tissue of the medulla is so characteristic that sections of the human ovary containing few ova

and no active follicles may be readily identified. Usually a section of the ovary may be recognized as such without magnification, owing to the presence of the large cysts or follicles in which the maturing ova are contained. These extend from the cortex into the medulla, and are numerous even in childhood (Fig. 356).

Growth of the Follicles. It is probable that all the sexual cells which are to be produced in a life-time are present in the ovaries at birth. At that stage, at least, many of those previously formed have already degenerated; and the ovaries contain a great excess of ova, all but a few hundred of which are destined to atrophy within the limits of the genital glands. In so far as the sexual cells have ceased to multiply and have entered upon the growth period, they represent the last generation of oögonia, and are being transformed into primary oöcytes. During this transformation

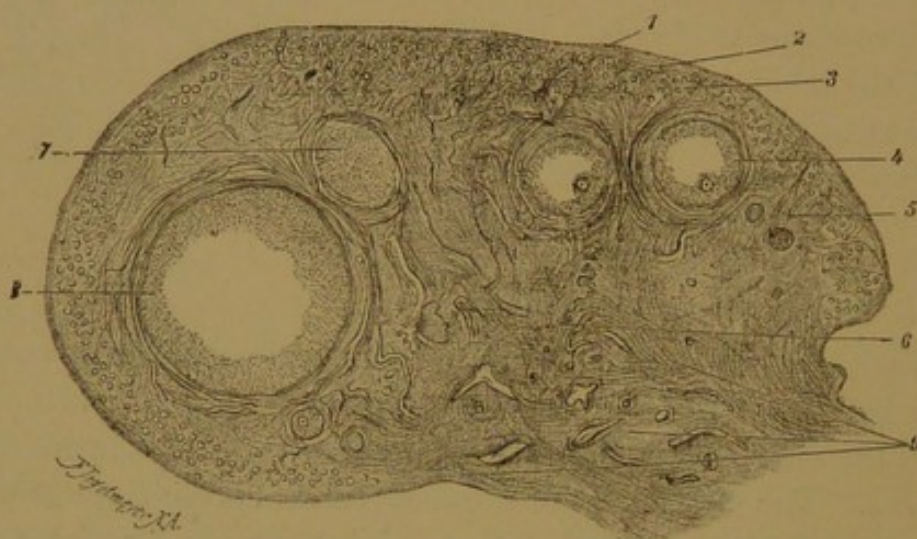

FIG. 356.—CROSS SECTION OF THE OVARY OF A CHILD EIGHT YEARS OLD. $\times 10$.
Germinal epithelium; 2, tunica albuginea; 3, peripheral zone with primary follicles; 4, vesicular follicle; 5, stroma ovarii; 6, medulla; 7, 8, peripheral section of vesicular follicles; 9, hilus, containing large veins.

they increase greatly in size, finally becoming about 0.3 mm. in diameter. These egg cells have already been described in detail (p. 29). They are conspicuous in sections as large, round, deeply staining cells, with round or oval vesicular nuclei, each containing a prominent nucleolus. The cells become so large that frequently they are cut into several sections, and portions of protoplasm without nuclei are to be expected. The larger oöcytes are surrounded by the clear, radially striated *zona pellucida* (Fig. 22, p. 30); their protoplasm may contain the vitelline bodies previously described.

The follicles are composed of the cells which surround the oöcytes. After the groups of egg cells and indifferent cells become subdivided, each oöcyte is typically surrounded by a single layer of flat follicular cells, and this *primary follicle* lies isolated in the stroma of the cortex, beneath the tunica albuginea (Figs. 357 and 358). As the follicle enlarges, the follic-

ular cells become columnar and then stratified (Fig. 358). A crescentic cleft filled with fluid appears in the midst of the stratified epithelium on one side of the follicle, and by the accumulation of fluid, or *liquor folliculi*, this cleft becomes a spherical cavity (Fig. 359). The fluid is regarded by some as a transudate from the blood vessels, which are abundant in the stroma outside of the follicle. Others consider that it is actively secreted by the cells of the follicle, certain of which undergo liquefaction. Spaces containing a stainable fluid, differing from that in the main cavity, may appear in the epithelium (Call-Exner bodies), around which the cells are radially arranged. By the development of the main cavity, the stratified epithelium becomes a relatively thin layer, the *stratum granulosum*, which decreases in width as the follicle enlarges. The oöcyte is on one side of the follicle, contained in a heap of cells known as *cumulus oöphorus* (formerly the *discus proligerus*). This is connected with the wall of the follicle, but in certain sections it may appear completely detached (e.g., in a sec-

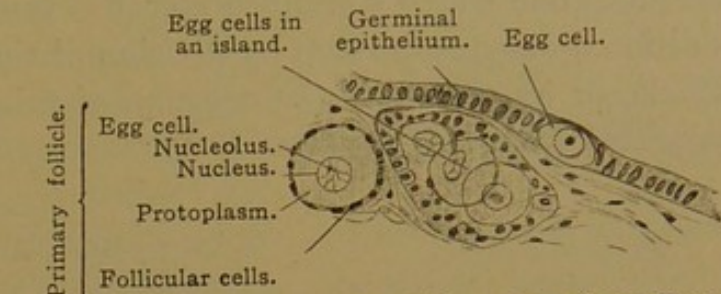


FIG. 357.—FROM A SECTION OF THE OVARY OF A CHILD FOUR WEEKS OLD. $\times 240$.

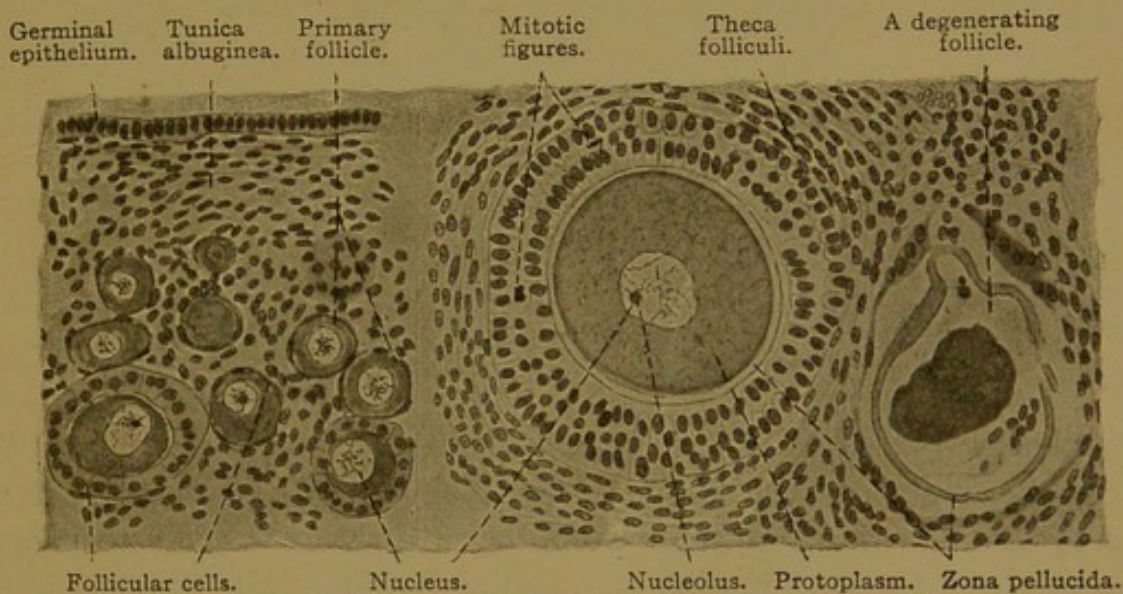


FIG. 358.—FROM A SECTION OF A RABBIT'S OVARY. $\times 240$.

tion at right angles with the plane of the page, near the top of the cumulus in Fig. 359).

Surrounding the follicle, even in early stages, there is a connective tissue sheath, the *theca folliculi* (Fig. 358). This later becomes differentiated into a vascular *tunica interna*, and a fibrous *tunica externa* (Fig. 359). The tunica interna contains many cells with abundant protoplasm. It is separated from the epithelium of the follicle by a delicate *membrana propria*.

In distinction from the solid *primary follicles*, those with cavities are known as *vesicular follicles* (Graafian follicles). They increase in diameter from 0.5 to 12.0 mm., and are then ready to discharge the contained oöcyte. Occasionally a single follicle has two oöcytes, and rarely more. Arnold (Anat. Rec., 1912, vol. 6, pp. 413-422) describes the ovaries of a negress, in which he found forty-three follicles containing four oöcytes or more, including one which contained eleven. It cannot be stated whether the additional oöcytes develop by division of the oögonium within a primary follicle, or by the failure of a group of primitive sexual cells to become separated from one another.

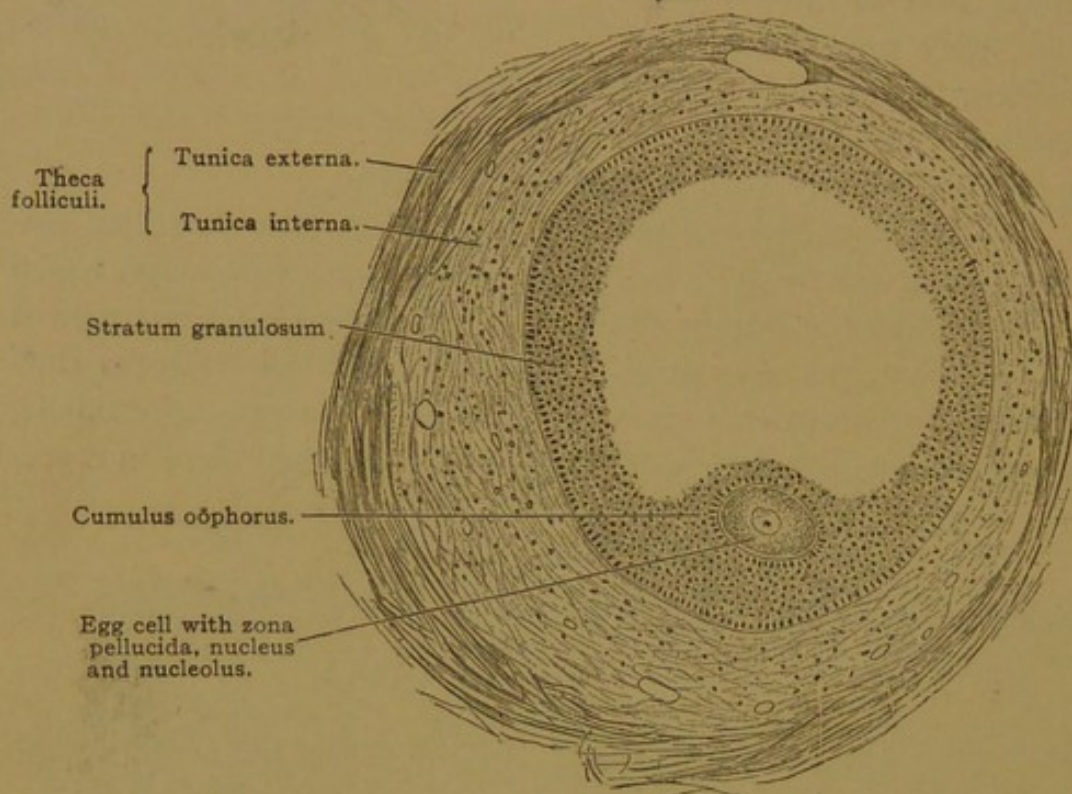


FIG. 359.—SECTION OF A LARGE VESICULAR FOLLICLE OF A CHILD EIGHT YEARS OLD. $\times 90$.
The clear space within the follicle contains the liquor folliculi.

Ovulation and the Corpus Luteum. Around the mature vesicular follicle, the tunica interna becomes very thick and cellular, forming elevations toward the stratum granulosum. At this stage the follicle is large, being about half an inch in diameter, and one surface of it is so close to the ovarian epithelium as to cause it to bulge and then to rupture. Through the opening thus made the liquor folliculi escapes, together with the oöcyte. The latter is said to become detached by the formation of fluid-filled spaces between the cells of the cumulus; it generally carries with it more or less of the innermost layer of the cumulus, and these cells, because of their radial arrangement, are termed the *corona radiata*. As the oöcyte leaves the follicle there is apparently a chance for it to become lost in the abdominal cavity, but the fimbriated orifice of the tube is near at hand, and the stroke of its cilia produces a current toward its entrance. In a guinea-pig

Hensen observed that the fimbriæ were in very active motion, sweeping here and there over the surface of the ovary so powerfully that the effect of ciliary action must have been trivial. The ova, surrounded by the mucoid cells of the follicles, adhered more closely to the fimbriæ than to the smooth surface of the ovary. Except toward the time of ovulation, Hensen found that the fimbriæ were relatively inactive (*Zeitschr. f. Anat. u. Entw.*, 1875, pp. 213-270). The discharge of the ovum from the follicle is known as *ovulation*.

It may be noted that in approaching the peritoneal epithelium, through which the rupture occurs, the follicle must push aside or distend the connective tissue of the tunica albuginea. This is ordinarily a rather weak layer, but it has been suggested (by Reynolds) that in some cases it is more highly developed and acts as an obstruction to ovulation.

After ovulation, blood escapes from the capillaries of the tunica interna and forms a clot within the empty follicle (Fig. 360). This clot is sometimes called the *corpus hæmorrhagicum*. On all sides it is surrounded by the cells of the stratum granulosum, which enlarge and produce a yellow fatty pigment. They form a yellow convoluted zone which may easily

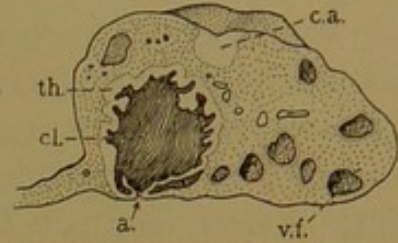


FIG. 360.—OVARY, CUT ACROSS SLIGHTLY REDUCED.

a., Aperture through which the ovum escaped; c. a., corpus albicans; cl., blood clot in a corpus luteum of ovulation; th., theca folliculi; v. f., vesicular follicle. (After Rieffel.)

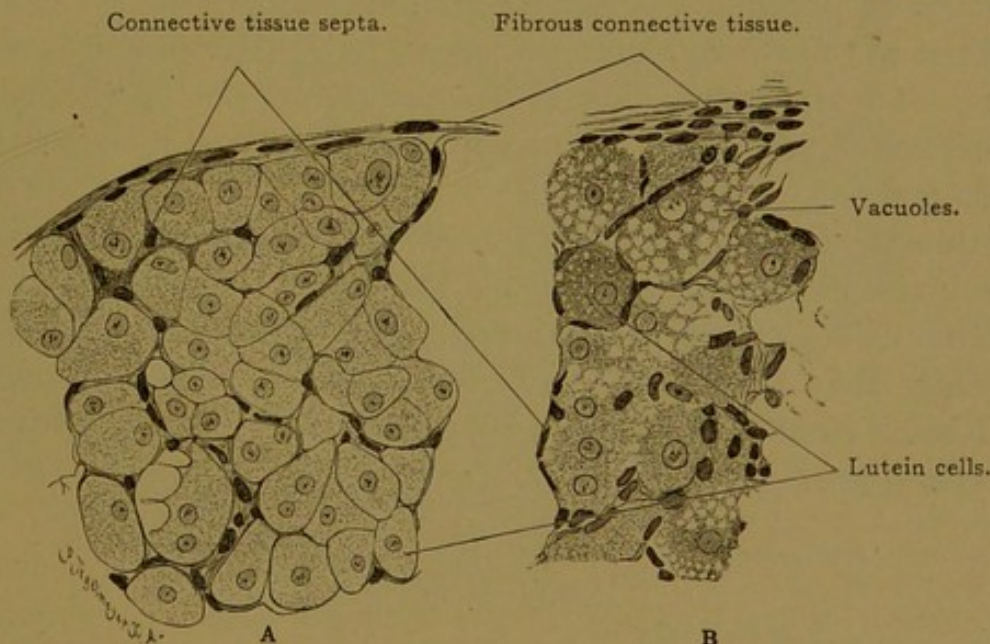


FIG. 361.—A, PORTION OF A CORPUS LUTEUM OF A RABBIT. B, PORTION OF A CORPUS LUTEUM OF A CAT. $\times 260$.

In B the lutein cells have become fatty and contain large and small vacuoles.

be seen without magnification; the entire structure is then known as the *corpus luteum*. Vascular strands of connective tissue extend between the lutein cells (Fig. 361) and enter the central clot. The extravasated blood breaks down into granules and hæmatoidin crystals, and is gradually

absorbed. It is replaced by gelatinous connective tissue which finally contracts into a dense white fibrous nodule, and this scar is known as the *corpus albicans*. Meanwhile the lutein cells undergo hyaline degeneration and become resorbed. The surface of the ovary, which is smooth in childhood, becomes pitted and irregular with the increasing formation of these corpora albicantia.

Provided that pregnancy does not take place, the corpus luteum reaches its maximum development in about two weeks after ovulation, and it becomes reduced to a scar in about two months. If pregnancy occurs, it enlarges further and persists at the height of its development until the fifth or sixth month. Its diameter is then 1.5-3.0 cm., and at the end of pregnancy it is still quite large and yellow. If the corpus luteum is removed, the ovum fails to become attached to the wall of the uterus. There is both experimental and histological evidence that it produces an internal secretion which is probably received by the blood vessels invading it from the theca. In order to distinguish between the corpus luteum of pregnancy and that of unproductive ovulation, the former is called the *true* corpus luteum; the latter is the *corpus luteum spurium*.

Many follicles degenerate at various stages in their evolution without discharging their ova. Leucocytes and cells from the stratum granulosum are said to invade the protoplasm of the oöcytes, in which they disintegrate. The zona pellucida, which surrounds the oöcyte, may become conspicuously folded and persist for some time (Fig. 358). The basement membrane of the stratum granulosum may also thicken and become convoluted. These degenerating or *atretic follicles* are finally reduced to inconspicuous scars. After the menopause the degeneration of the oöcytes becomes general.

Within the stroma of the cortex, *interstitial cells* are found, which resemble lutein cells but are smaller. They have been compared with the interstitial cells of the testis, and are said to contain secretory granules. Apparently they are derived from the thecæ of atretic follicles (Cohn, Arch. f. mikr. Anat., 1903, vol. 62, pp. 745-772; Allen, Amer. Journ. Anat., 1904, vol. 3, pp. 89-153).

UTERINE TUBES.

Each uterine tube is about 5 inches long and extends from its orifice in the abdominal cavity to its outlet in the uterus. It is divided into the fimbriated funnel or *infundibulum*; the *ampulla* or distensible outer two-thirds, the lumen of which is about a quarter of an inch in diameter; the *isthmus* or narrow inner third, not sharply separated from the ampulla; and the *uterine portion* which extends across the musculature of the uterus to the uterine orifice. The wall of the tube is composed of three layers, a

mucosa, muscularis, and serosa (in addition to which a tela submucosa is enumerated in the Basle nomenclature). The mucosa is thrown into thin longitudinal folds, which are low in the isthmus, but tall and branched in the ampulla (Fig. 362). Occasionally the branches anastomose, enclosing a pocket, but glands are absent. The epithelium is chiefly simple columnar, and ciliated, the stroke of the cilia being toward the uterus; but there are areas of non-ciliated cells which are said to produce a mucoïd fluid. The two types of cells are connected by intermediate forms. Mucous cells are absent.

The folds of the mucous membrane are occasionally indented or overhanging, so that in transverse sections detached fragments may appear, suggestive of villi (Fig. 363); but the fact that almost all of the many pro-

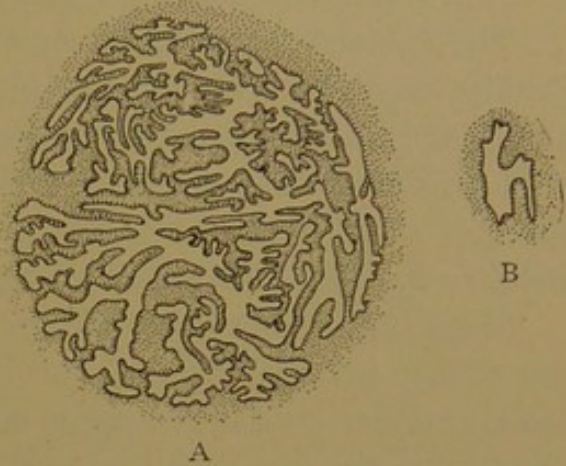


FIG. 362.—THE MUCOSA OF THE UTERINE TUBE. A, Near its FIMBRIATED END; B., NEAR THE UTERUS. (After Orthmann.)

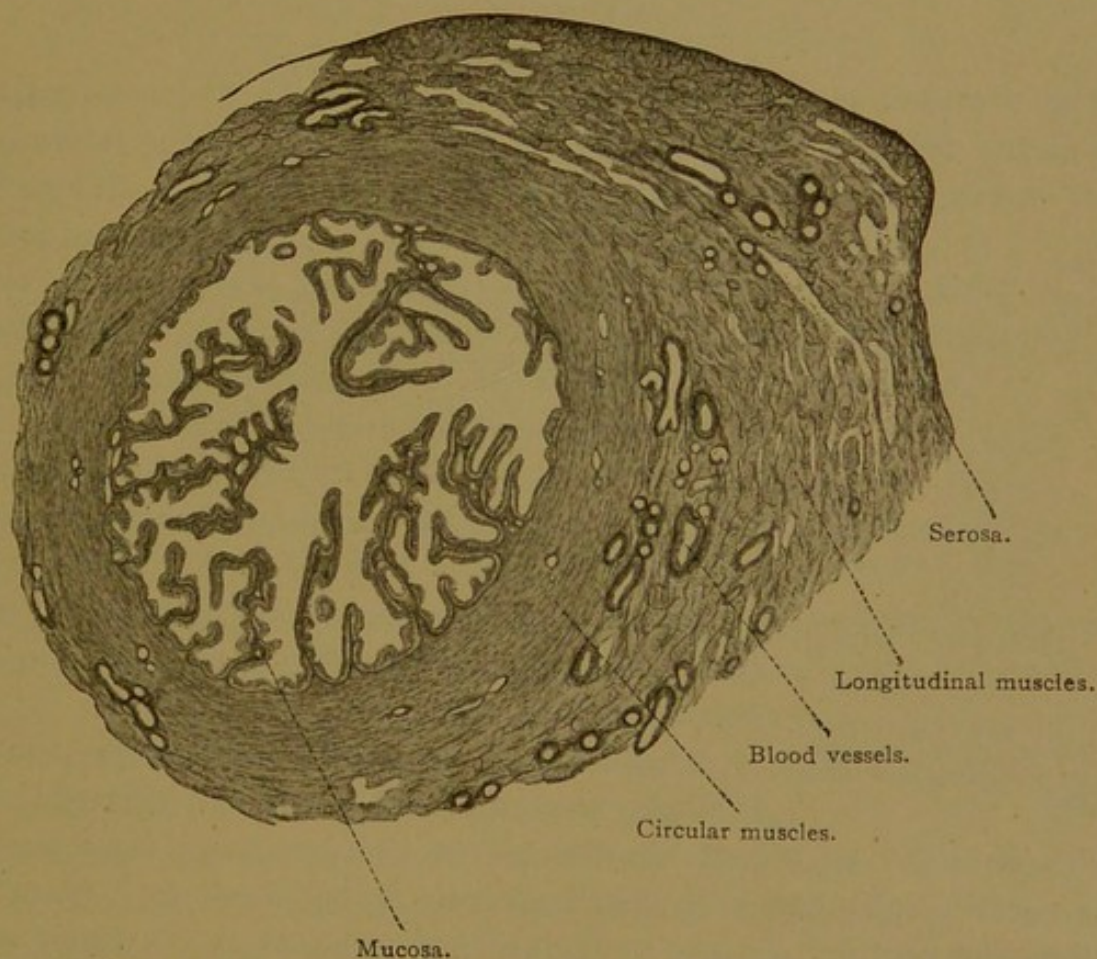


FIG. 363.—CROSS SECTION, NEAR THE AMPULLA, OF A UTERINE TUBE FROM AN ADULT WOMAN.

jections connect with the submucous layers indicates that they are elongated folds. Each of them contains a thin layer of cellular connective tissue, in which there are small arteries and veins running chiefly length-

wise of the tube. Lymphocytes occur in the meshes of the tissue and lymphatic vessels have been reported. Occasionally strands of smooth muscle fibers are found within the folds.

The mucous membrane rests directly upon the tunica muscularis, and Schäfer considers that "the larger part of the muscular layer must probably be regarded as a much thickened muscularis mucosæ." The muscle coat consists of a thick inner circular layer and a thin outer longitudinal layer of smooth muscle fibers, but both layers are resolved into coarse bundles by the abundance of intermuscular connective tissue.

Since the uterine tubes are imbedded in the broad ligaments, they are not closely invested by the peritoneum. There is a considerable layer of loose vascular connective tissue outside of the muscularis, and toward the ovary this tissue may include sections of the tubules of the epoöphoron. It contains the branches of the ovarian and uterine blood vessels which supply the tube. These are accompanied by lymphatic vessels and nerves. The latter innervate the tubal musculature and the mucous membrane.

UTERUS.

The uterus is a pyriform, muscular organ, flattened dorso-ventrally. It is about two and a half inches long, receiving the uterine tubes at its upper end or fundus, and ending below in the vagina. It is divided into

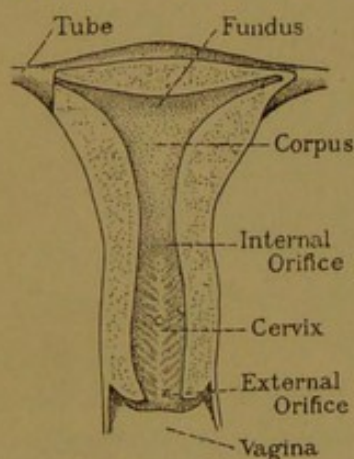


FIG. 364.—THE DORSAL HALF OF A VIRGIN UTERUS. Two-thirds natural size. (After Rieffel).

fundus, corpus and cervix. The corpus and fundus together have a triangular cavity, which opens into the *canal of the cervix* through the *internal orifice*; the canal communicates with the vagina through the *external orifice* of the uterus. The lining of the cervix presents a feather-like arrangement of folds on its dorsal and ventral surfaces; these are the *plicæ palmatæ*. The walls of the uterus consist of a mucosa, muscularis and serosa (constituting the endometrium, myometrium, and perimetrium, respectively).

The uterus is lined with simple columnar epithelium, some areas of which are ciliated. The cilia have been described as difficult to preserve, and their absence from certain cells has been attributed to faulty fixation. According to Gage the uterine cilia are as readily preserved as those which occur elsewhere, and he finds that only one cell among fifteen or twenty is actually ciliated. Mucous cells are absent. The epithelium forms slender tubular pits, the *uterine glands*, but these produce no definite secretion. They are branched tortuous tubes extending through the broad mucosa

(which is 1 mm. thick), and invading to a slight extent the muscular tissue beneath. They have been carefully modelled by Hedblom, whose studies are not yet published; he finds that occasionally they anastomose with one another, and that in their deeper portion they have long horizontal branches, at right angles with the main tube. Sometimes a small group of glands opens into a single depression of the surface epithelium (Fig. 365). In older persons the glands degenerate, losing their connections with the surface and becoming cystic. Each gland is surrounded by a delicate basement membrane, and between them there is an abundant tunica

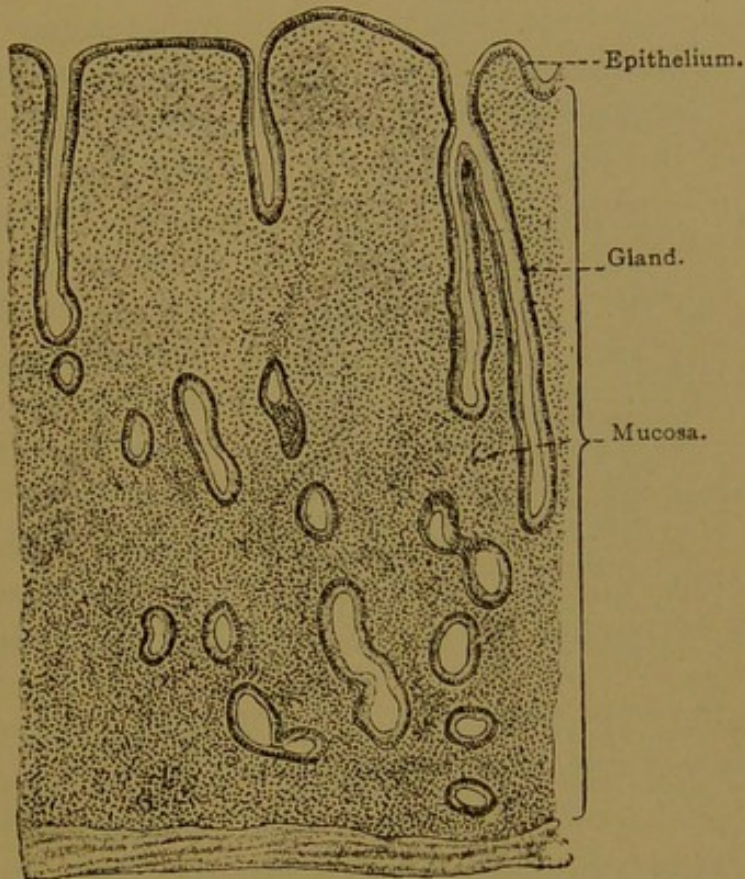


FIG. 365.—MUCOUS MEMBRANE OF THE RESTING UTERUS OF A YOUNG WOMAN. $\times 35$.
(After Böhm and von Davidoff.)

propria, containing many blood vessels. These form capillary networks around the glands and especially beneath the free surface. The propria contains also many lymphocytes, and its lymphatic vessels form a wide-meshed plexus with blind extensions. These structures are supported by a reticular tissue framework containing many nuclei.

The upper and larger part of the cervix of the uterus is likewise lined with simple columnar ciliated epithelium, but its cells are taller than those of the corpus ($60\ \mu$ as compared with $20\ \mu$). Mucous cells occur, especially in the outpocketings of epithelial pits which constitute the branched *cervical glands*. They discharge a secretion which occludes the canal of the cervix during pregnancy. Often they produce macroscopic retention cysts, named "ovules of Naboth," after the Leipzig anatomist who first

described them. Toward the external orifice of the uterus the epithelium becomes stratified and squamous, and rests on connective tissue papillæ. Thus it resembles the lining of the vagina of which it is a continuation, and after the first child-birth it extends further up into the cervix than before.

The musculature of the uterus is a thick investment of interwoven bundles which cannot be subdivided into well-defined layers (Fig. 366). It begins immediately outside the tunica propria, and its inner portion has been regarded as "an immensely hypertrophied muscularis mucosæ."

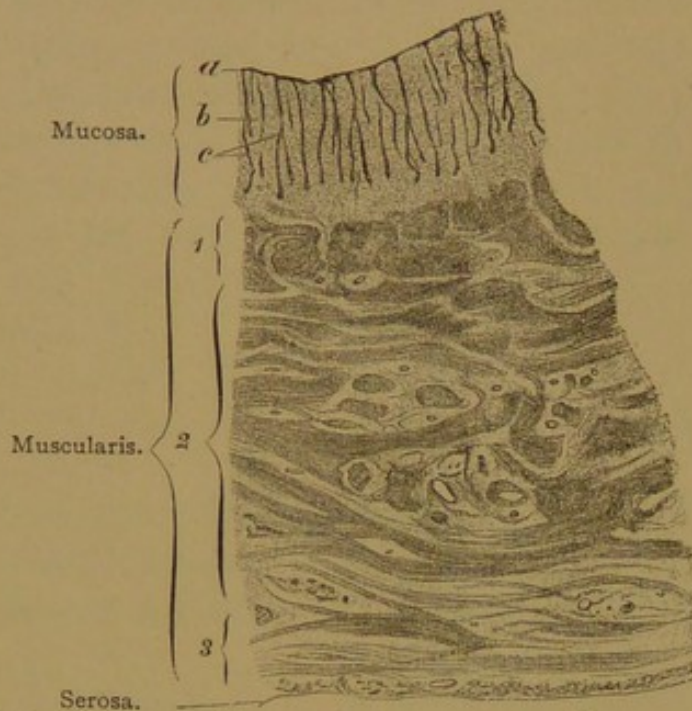


FIG. 366.—FROM A TRANSVERSE SECTION OF THE MIDDLE OF THE UTERUS OF A GIRL FIFTEEN YEARS OLD. $\times 10$.

a, Epithelium; b, tunica propria; c, glands; 1, inner muscular layer; 2, middle muscular layer; 3, outer muscular layer.

Further out there is a zone containing many blood vessels, which according to this interpretation marks the position of the submucosa (Schäfer). According to Henle and Stöhr, these vessels belong with the middle of three muscle layers, which is named, therefore, the "stratum vasculare." It is the thickest of the layers and its fibers are chiefly circular. The innermost layer or "stratum submucosum" (Stöhr) consists principally of longitudinal fibers. The outermost layer or "stra-

tum supravasculare" contains circular fibers internally and longitudinal fibers externally. Some of the latter are continuous with the longitudinal fibers of the uterine tubes; others are said to enter the round ligaments, which contain also some striated fibers; and still others spread into the broad ligaments.

In the cervix the three strata of muscle fibers are found to be very distinct—inner and outer longitudinal, and middle circular. Although the uterus generally contains few elastic fibers, found only in its peripheral layers and running perpendicular to the plane of contraction of the muscles, elastic fibers are abundant in this position in the lower segment of the corpus and vaginal portion of the uterus. During the first half of pregnancy both elastic and muscular fibers increase in size and number; in the second half, the elastic fibers decrease in the musculature, but increase in the perimetrium (Stöhr). The way in which the thick layer of muscles in the resting uterus becomes arranged in the thin layer of

late pregnancy is an unsolved problem, similar to that presented by the musculature of the bladder and intestine during distention.

The serosa covering the dorsal and ventral surfaces of the uterus is in part a well-defined layer, but it blends with the connective tissue of the broad ligaments laterally and below; and this tissue, from its position beside the uterus, is known as the "parametrium." Imbedded in the parametrium the main trunks of the uterine vessels run along the lateral margins of cervix and corpus, both artery and vein showing many kinks and convolutions. The vessels are thus apparently adapted to the future expansion of the uterus, but when it retracts after pregnancy they are said to show more pronounced bendings, as if they had been permanently elongated. The parametrium contains also numerous lymphatic vessels, together with the ganglionated sympathetic *utero-vaginal plexus*. Nerves from this plexus and from the third and fourth sacral nerves supply the uterus.

MENSTRUATION.

Menstruation is the periodic degeneration and removal of the superficial part of the mucosa of the uterus, accompanied by hæmorrhage from the vessels of the tunica propria. Three successive stages may be distinguished, namely (1) the stage of *congestion*, lasting four to five days; (2) the stage of *desquamation* and *hæmorrhage*, four days; and (3) the stage of *regeneration* and *repair*, seven days. Thus the entire process requires about sixteen days, and after an interval of twelve days the cycle begins anew.

For four or five days before the discharge occurs, the thickness of the mucosa increases greatly, due to the congestion of its vessels and the proliferation of the reticular tissue. The glands become wider, longer, and more tortuous, opening between irregular swellings of the superficial epithelium. Red corpuscles pass out between the endothelial cells of the distended veins and capillaries, and form subepithelial masses. This stage of congestion and tumefaction is followed by one of hæmorrhage and desquamation. The epithelium of the surface and outermost parts of the glands becomes reduced to granular débris, or it may be detached in shreds. The underlying vessels rupture and add to the blood which had escaped by diapedesis. In the stage of regeneration, the epithelium spreads from the glands over the exposed reticular tissue, the congestion diminishes, and the mucosa returns to its resting condition. The cervix takes no part in menstruation except that the secretion of its glands may increase during the stage of congestion.

Beginning at puberty (13-15 years) menstruation takes place normally once in 28 days for 33 years, more or less. During pregnancy it is interrupted,

although the time when it should occur may be indicated by slight uterine contractions and finally by those which cause the delivery of the child. Thus the duration of pregnancy is described as ten menstrual cycles. The significance of menstruation is suggested by conditions in those mammals in which sexual seasons are annual or infrequent. In them a period of congestion, accompanied by uterine changes which are sometimes closely comparable with those of menstruation, precedes sexual intercourse and ovulation. Thus in the bitch ovulation takes place when the external bleeding "is almost or quite over," and this is the time of coitus. Domestication in

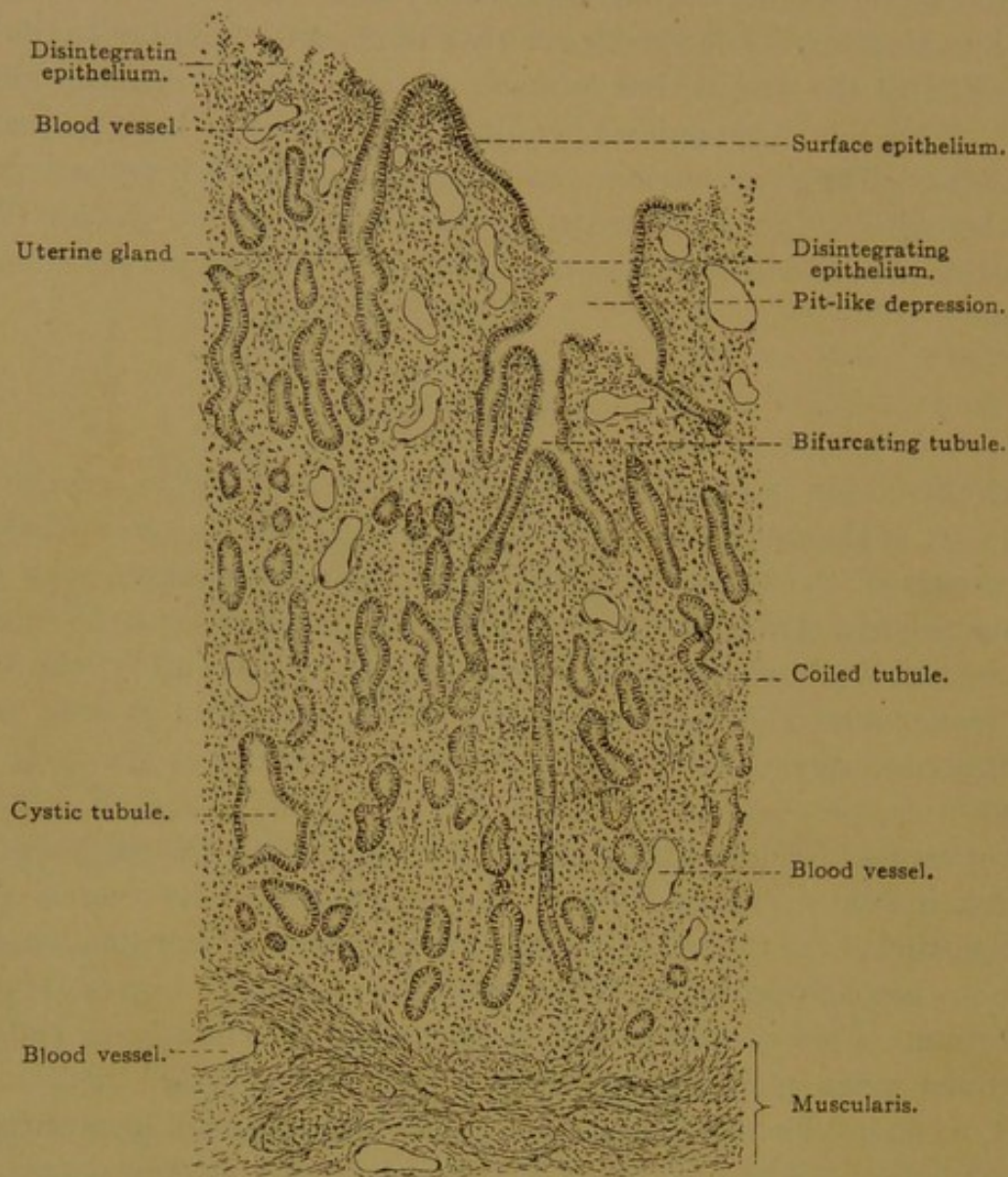


FIG. 367.—MUCOUS MEMBRANE OF A VIRGIN UTERUS DURING THE FIRST DAY OF MENSTRUATION. $\times 30$. (Schaper.)

various animals causes an increased frequency of the congestive cycles, sometimes unaccompanied by ovulation. It is generally accepted that human menstruation may take place without ovulation, and that ovulation may occur between menstrual periods, and also during pregnancy. It may even occur in children before menstruation has begun. Nevertheless ovulation probably occurs usually and normally at the close of menstruation. Coitus is not considered to be a factor in inducing ovulation, but it is said that in the rabbit and ferret, and in pigeons, ovulation may fail to occur in the absence of the male.

The following considerations are also important in establishing the age of young embryos. The time required for spermatozoa to travel to the upper end of the tube, where fertilization takes place, is probably about twenty-four hours. There they may fertilize the ovum at once if ovulation has just occurred. They retain their vitality and are capable of fertilizing the ovum during a period of ten days in the rabbit, and this may be true also of man. Thus it is probable that if coitus has occurred shortly before menstruation, the spermatozoa may remain active in the tube, and fertilize the ovum discharged at the close of the following menstruation.

THE DISCOVERY OF MAMMALIAN OVA.

During the seventeenth century the ovary was called the *testis muliebris*, or *testis fæmineus*. It was believed to produce the mucoid secretion which escapes from the genital orifice, and this was regarded as seminal fluid. The uterine tubes were accordingly the *vasa deferentia mulierum*, serving to convey this fluid to the uterus, where, through a mixture and interaction of the male and female semina, an embryo was produced. Aristotle had argued to the contrary, but his opinion was summarily disposed of by Bartholin, who discussed the ovaries as follows (*Anatomia*, 1666):

"Their function is to produce semen in their own way, which Aristotle, against all reason and observation, has dared to deny to women, contrary to the express teaching of Hippocrates."

The ancient doctrine of Aristotle, expounded in his treatise on the generation of animals, was based upon the familiar facts that menstruation marks the beginning, and ceases at the end, of the child-bearing period; and moreover menstruation is interrupted while the embryo is being formed. Therefore he concluded that the menstruum supplies the substance and material for the new body, which arises like the curd in milk, through the agency of the semen. The semen engenders; the menstruum nourishes. The theory had already been advanced that the semen comes from all parts of the body, and that its particles reproduce the structures from which they are derived. This enticing speculation, revived by Darwin in his theory of pangenesis, was discussed at length and rejected by Aristotle.

Generation, therefore, was considered to result from the mixing of two fluids, and would have remained a barren physico-chemical problem until recent times, if further morphological observations had not been made. The view of Bartholin had at least the merit of definitely associating the ovary with the reproductive function. Vesalius and Fallopius had seen the follicles and corpora lutea; Fallopius described them as "vesicles filled with water or aqueous humor, some limpid and others yellow (*Observationes*, 1588). Many others had observed them, and from their resemblance to the ova of birds they had even been called "ova," when in 1672 a young Dutch physician, Regnerus de Graaf, made his thorough study of the female genital tract.

De Graaf concluded that the "semen muliebres" is not produced by the "testes muliebres," but that the general function of the latter is "to produce and nourish ova, and bring them to maturity." Consequently he proposed to substitute the name *ovary*, and to call the tubes *oviducts*. He declared that the ova escaped from the follicles through minute apertures (in the rabbit admitting a bristle) and made their way through the tubes to the uterus, in which they developed. The abnormal formation of a human embryo within the tube was figured and, to a certain extent, explained. De Graaf studied many mammals, and especially rabbits. He found minute ova in the oviducts and observed the follicles from which they had escaped. In older stages he recorded a general agreement between the number of corpora lutea and embryos.

Since, however, he frequently referred to the entire follicles as ova, his results were not promptly accepted; the diameter of the isthmus of the tube is so small that the entrance of the follicles into the uterus was considered impossible. It was a matter of easy observation to determine more precisely the relation of the ova to the follicles. After many years this was done by Von Baer, an eminent embryologist, whose studies of the chick are regarded as "the most profound, exhaustive and original contribution to embryology which has ever been made" (Minot). This work bears the famous subtitle "*Beobachtung und Reflexion*"—the German expression of Haller's "*Observations suivies de Reflexion*" and De Graaf's "*Cogitationes atque observationes.*" After describing the condition of the ova in the tubes of the bitch, Von Baer writes:

"It remained for me to ascertain the condition of ova in the ovary, for it seemed clearer than day that ova so small as those found in the tubes did not represent Graafian follicles expelled from the ovary; and I did not consider it probable that such solid bodies had been coagulated from the fluid of the vesicles. Now, contemplating the ovaries before making an incision, I clearly distinguished in almost every vesicle, a yellowish-white point unattached to the walls, which swam about freely in the fluid when the vesicle was pressed upon with a probe. Led on by a certain curiosity, rather than moved by hope that with the naked eye I had seen ovules in the ovaries through all the coats of the Graafian follicle, I opened a vesicle, and taking out a point in question on the blade of a knife, I placed it under the microscope. I was overcome with amazement when I saw the ovule, now recognized outside of the tubes, so clearly that a blind man could hardly doubt it. Surely it is strange and unexpected that an object so persistently sought for, and endlessly described as inextricable, in every physiological compendium, could so easily be placed before the eyes" (De ovi genesi, Lipsiae, 1827).

Thus the ova in mammalian ovaries, which had long been believed to exist, were first definitely seen within the follicles one hundred and fifty years after the discovery of the microscopic spermatozoa, the existence of which had never been suspected.

THE DECIDUAL MEMBRANES OF THE UTERUS AND EMBRYO. DEVELOPMENT AND GENERAL FEATURES.

Before describing the mucous membrane of the uterus during pregnancy, it is necessary to consider the membranes which envelop the embryo. Although these are in contact with the lining of the uterus and in part intimately blended with it, they are portions of the embryo itself. The external membrane, toward the uterus, is known as the *chorion*; the inner membrane, toward the embryo, is the *amnion*. Since the embryo receives its nutriment from the wall of the uterus through blood vessels in the chorion, these membranes develop very early and thus provide for rapid growth. They are already present in the youngest human embryos which have yet been obtained.

Of the fertilization and segmentation of the human ovum, which doubtless take place in the upper part of the uterine tube, nothing is known except by inference from lower animals. The four-celled stage has been observed once in a monkey, but the youngest known human embryo is already provided with ectoderm, mesoderm and entoderm, and has entered the uterus. As a purely hypothetical figure, we venture to

present the diagram Fig. 368, A, followed by the diagrams B and C which include many features actually observed.

In Fig. 368, A, a mass of cells (*ect.*) represents the ectoderm which will later cover the body and line the inner membrane or amnion. This ectoderm probably arises in connection with the layer (*tr.*) which covers the entire vesicle and becomes the epithelium of the outer membrane or chorion. The layer in question has been named the *trophoblast* (or *trophoderm*).

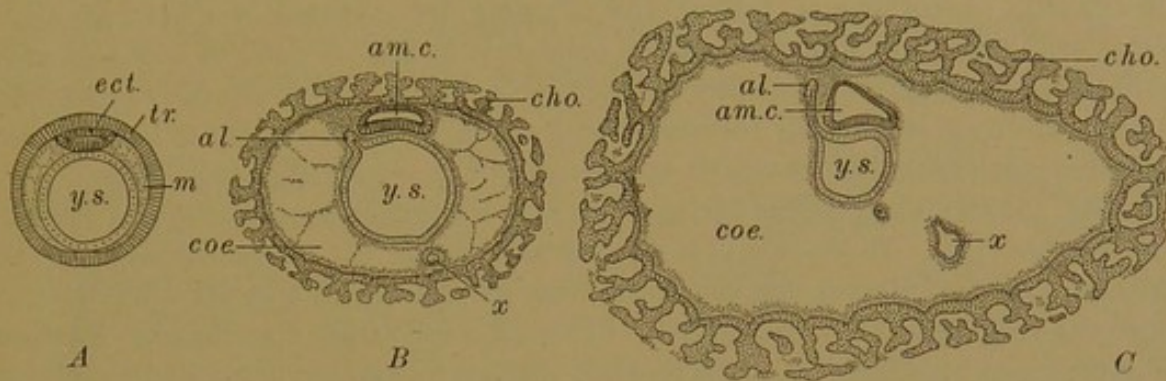


FIG. 368.—DIAGRAMS ILLUSTRATING THE EARLY DEVELOPMENT OF THE HUMAN EMBRYO (A IS HYPOTHETICAL).

al., Allantois; am. c., amniotic cavity; cho., chorion; coe., coelom; ect., ectoderm; m, mesoderm; tr. trophoderm (trophoblast); x, entodermal cyst; y. s., yolk-sac.

The term trophoblast (*i.e.*, nutritive layer) was introduced by Hubrecht to correspond with the terms epiblast, mesoblast and hypoblast, which he used for the other germ layers. Since these are now generally called ectoderm, mesoderm and entoderm, the outer layer should be *trophoderm*, and the substitution of this name is therefore recommended. Trophoderm has, however, been used by Minot for the proliferating part of Hubrecht's trophoblast. It may be noted that a similar difficulty is encountered in His's angioblast which, as a germ layer, should be angioderm. Schäfer applies angioblast logically to the individual cells which become the endothelial lining of vessels. Consistency requires the use of "-derm" for germ layers, leaving "-blast" for formative cells.

In addition to the trophoderm and ectoderm, the hypothetical stage shown in Fig. 368, A, exhibits a yolk-sac completely lined with entoderm. Between the trophoderm and entoderm, the mesoderm has appeared and is separating into somatic and splanchnic layers, with the body cavity between them. The somatic mesoderm is closely applied to the trophoderm, and together they form the chorion; the splanchnic mesoderm is against the entoderm of the yolk-sac, and forms the outer layer of its wall. The early and rapid development of the mesoderm is characteristic of human embryos, as may be inferred from the later stages.

In the diagram Fig. 368, B, the *amniotic cavity* has appeared in the ectoderm. It is believed to arise as a cleft in a solid mass of cells, and not by the coalescence of ectodermal folds as in the chick; however, in the youngest human embryos observed, it is completely formed. The entoderm

shows an outpocketing extending into the mesoderm at the future caudal end of the embryo; this is the *allantois*, which soon becomes a slender tube (Fig. 368, C). The mesoderm in which it is lodged later produces the "body stalk."

The allantois develops very early in human embryos, being present in most if not in all of the specimens thus far obtained. Possibly there is no allantois in the very imperfect embryo described by Bryce and Teacher (Contributions, etc, Glasgow, 1908), and there is uncertainty as to its presence in Peters's embryo (Ueber die Einbettung des menschlichen Eies, Leipzig, 1899); but in other very young specimens it is well defined. According to Keibel, the allantois first appears in chicks of about twenty segments; in rabbits of eleven segments; in pigs of four to five segments; and in the apes and man, before any segments have formed. Its very early appearance in human embryos is probably correlated with the rapid establishment of the placental circulation, for the umbilical vessels are primarily the vessels of the allantois.

In Fig. 368, B and C, the entoderm of the yolk-sac is represented as giving rise to a detached cyst (*x*). There is a cyst of this sort within the chorionic cavity of the somewhat damaged Herzog embryo in the Harvard Collection, and a smaller detached cyst in the very perfect Minot embryo. (These will be further described by the writer in a subsequent publication.) It is possible that such cysts are of regular occurrence, although destined to atrophy. They may be lodged in a strand of mesoderm extending from the lower pole of the yolk-sac downward to the chorion (Grosser, Anat. Hefte, 1913, Abt. I, vol. 47, pp. 653-686), and they may arise as indicated in the diagrams (Fig. 368).

As the body cavity develops between the somatic and splanchnic layers of mesoderm, it is at first bridged by strands of mesenchymal tissue, forming the "magma reticulare." These strands become attenuate and break down, so that the yolk-sac is then suspended in a well-defined "extra-embryonic coelom." This part of the coelom, although within the embryonic membranes, is outside of the body proper of the embryo, as will appear in the following diagrams.

The arrangement of the membranes surrounding human embryos of about 2 mm. is shown in Fig. 369, A. The chorion has become covered with branching elevations or villi, which contain a vascular core of chorionic mesoderm, not shown in the diagram. The body of the embryo is connected with the chorion by the mesodermic body stalk containing the allantois. This has become relatively slender. On one side it is covered by the ectoderm of the amnion. The ectoderm, as in preceding stages, may be divided into two parts. Toward the yolk-sac it is thickened and there it forms the axial medullary tube and gives rise ultimately to the epidermis covering the body. Continuous with this epidermal ectoderm is the thinner portion which lines the amnion, as shown in the figure. The amnion forms a membranous sac attached to the ventral side of the embryo, leaving an aperture through which the yolk-sac projects downward into the extra-embryonic coelom. The coelom now extends between the amnion and chorion, except at the narrow body stalk. The yolk-sac has

given rise to the fore-gut and hind-gut, and the allantois now appears as an appendage of the latter.

In Fig. 369, B, the embryo is represented as rotated so that its head is downward and its ventral side toward the left. It is now connected with the membranes by an *umbilical cord*, the composition of which may be seen by comparing A and B. Its principal constituent is the elongated body stalk, containing the allantois and covered above and on the sides with adherent amnion. Below, the amnion also forms the covering of the cord, but here it is separated from the body stalk by an extension of the body cavity. The yolk stalk passes from the primary loop of intestine through the cavity of the umbilical cord to the yolk-sac, in which it terminates

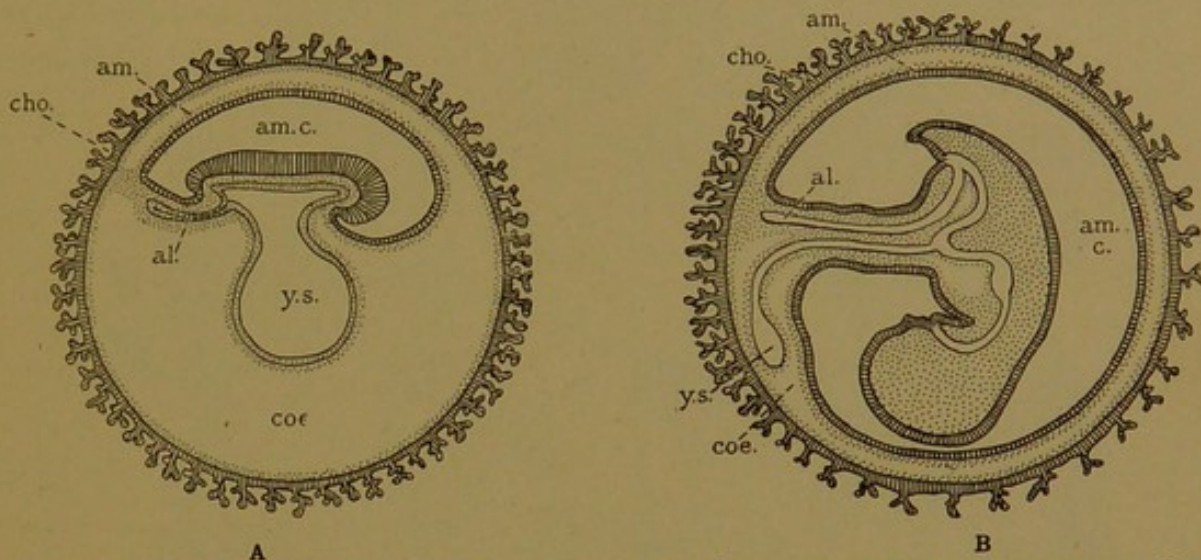


FIG. 369.—DIAGRAMS ILLUSTRATING THE DEVELOPMENT OF THE EMBRYONIC MEMBRANES AND THE FORMATION OF THE UMBILICAL CORD.

al., Allantois; am., amnion; am. c., amniotic cavity; cho., chorion; coe., coelom; y.s., yolk-sac.

This sac is now lodged in its permanent position between the amnion and chorion. Ultimately the parts of the allantois, yolk stalk and body cavity within the cord are obliterated.

The appearance of a human embryo at a stage intermediate between those shown in Fig. 369 is reproduced in Fig. 370. An irregular piece cut out from the chorionic vesicle forms the background of the picture. Around the cut edges of this piece the shaggy chorionic villi are seen, directed toward the wall of the uterus. At the top of the figure is the spherical yolk-sac lodged between chorion and amnion, between which the yolk stalk passes to the distal end of the umbilical cord, which it enters. The amnion is a membranous sac completely enclosing the embryo; in the figure, half of it has been cut away to show the embryo within. The skin of the embryo is continuous with the covering of the umbilical cord, and distally this covering is reflected and becomes continuous with the amnion.

In later stages the umbilical cord is greatly elongated. It contains the umbilical vessels which pass between the embryo and the chorion,

through the persistent body stalk. The amniotic cavity greatly enlarges to accommodate the growing embryo, and the mesoderm of the amnion comes in contact with that of the chorion, to which it adheres more or less firmly. The embryo is bathed in the amniotic fluid (*liquor amnii*) of uncertain derivation, once thought to be sweat from the embryo, and later considered to contain the products of the Wolffian body, and urine from the permanent kidneys. Occasionally toward birth the meconium from

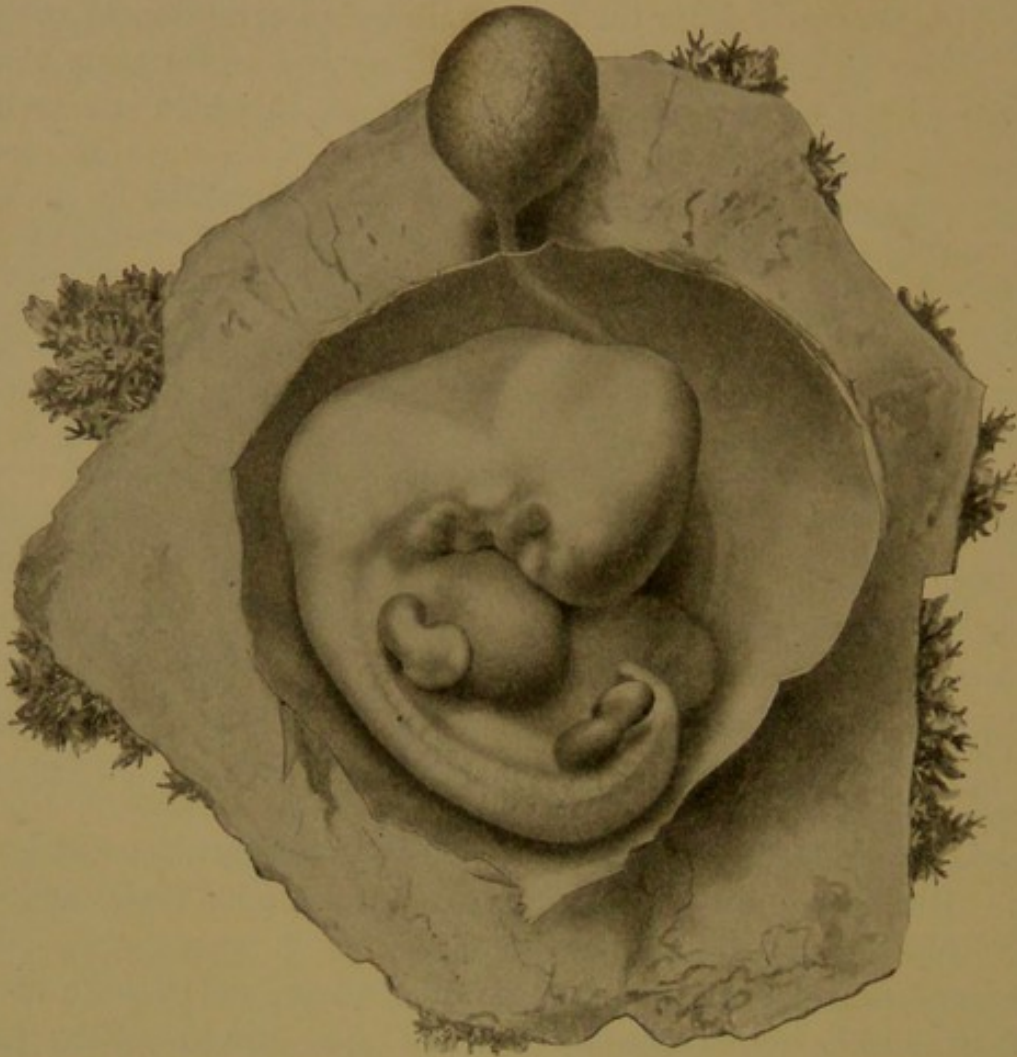


FIG. 370.—A NORMAL HUMAN EMBRYO OF 10.0 MM., REMOVED SURGICALLY WITH THE UTERUS, SIX WEEKS AFTER THE LAST MENSTRUATION.

the intestine mingles with it and discolors it. It is now generally believed to be secreted by the amniotic epithelium.

Relation between the Embryonic Membranes and the Uterus. When the embryo within its chorionic vesicle passes from the tube into the uterus, it is probably in a stage comparable with that shown in Fig. 368 (B or C). By the activity of the proliferating trophoderm, the uterine mucosa is partially destroyed and the chorionic vesicle becomes imbedded in its substance. This process is known as the *implantation* of the ovum. The walls of the vessels in the tunica propria of the uterus are broken down, and the maternal blood flows over and around the chorionic villi, in con-

tact with which it does not clot. Elsewhere in the body, except in reticular tissue, blood clots on escaping from the endothelial tubes. Toward the uterine cavity, however, there is a clot which completes the encapsulation of the chorionic vesicle in the mucosa. The mucous membrane itself later passes entirely around the vesicle as shown in Fig. 371, A.

The greater part of the mucosa of the uterus becomes cast off at the end of pregnancy; thus it forms a *membrana decidua*, which may be subdivided into three parts—(1) the *decidua basalis* (or serotina) on which the implanted chorionic vesicle rests, and which forms the maternal part of the *placenta*; (2) the *decidua capsularis* (or reflexa) which spreads over the part of the vesicle which is toward the uterine cavity; and (3) the *decidua vera*, which lines the remainder of the uterus. These subdivisions of the decidua are indicated in Fig. 371, A.

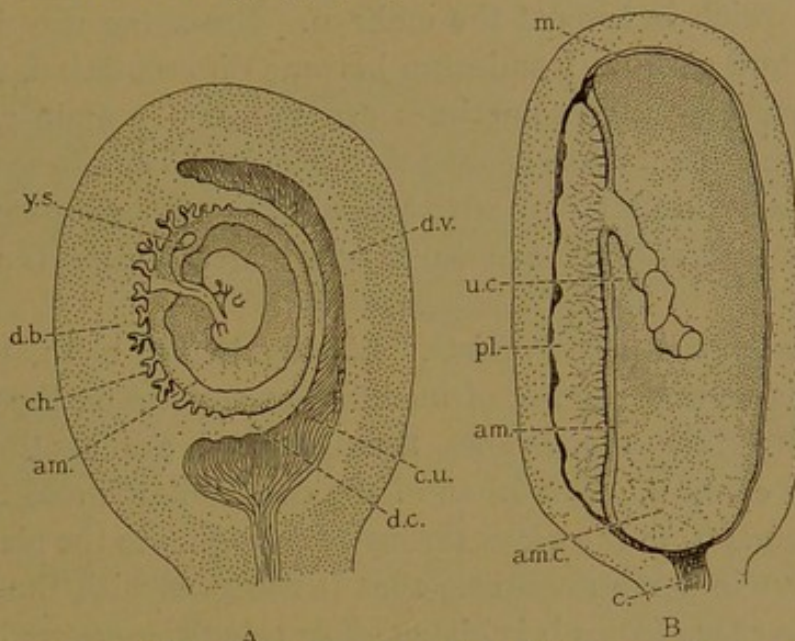


FIG. 371.—THE UTERUS AND DECIDUAL MEMBRANES IN EARLY PREGNANCY, A, AND IN LATE PREGNANCY, B. THE CORD HAS BEEN CUT AND THE EMBRYO REMOVED FROM B.

am., Amnion; am. c., amniotic cavity; c., cervix; ch., chorion; c. u., cavity of the uterus; d. b., decidua basalis; d. c., decidua capsularis; d. v., decidua vera; m., amnion and chorion laeve drawn as one line; pl., placenta; u. c., umbilical cord; y. s., yolk-sac.

Soon after the ovum becomes implanted, the chorion ceases to be uniformly covered with villi. The villi toward the decidua basalis elongate and branch freely, producing the shaggy *chorion frondosum*; this is the embryonic portion of the placenta. As the chorionic vesicle enlarges, the villi directed away from the wall of the uterus, toward the decidua capsularis, become shorter and disappear, so that a large portion of the chorion becomes smooth—the *chorion laeve*. Usually the umbilical cord passes to a nearly central position in the chorion frondosum; rarely it has a "marginal attachment" at the periphery of the frondosum, and it may have a "velamentous insertion" in the adjacent part of the chorion laeve, through which the umbilical vessels then extend to the frondosum.

With the growth of the embryo, which fills and distends the uterine cavity, the decidua capsularis becomes thin, degenerates, and is resorbed,

so that in the last half of pregnancy the chorion laeve rests directly against the decidua vera (Fig. 371, B).

The *placenta* at birth is a discoid mass of spongy vascular tissue, about 7 in. in diameter and 1 in. thick, weighing a pound. It is composed of two parts, the *placenta uterina* and *placenta fetalis*, which in certain lower mammals can be readily separated, but in others, and in man, they cannot be disengaged. The uterine portion, as already stated, is the decidua basalis, and the embryonic or fetal portion is the chorion frondosum. At the margin of the placenta, the chorion frondosum is continuous with the chorion laeve, which is adherent to the decidua vera. Lining the chorionic cavity and spreading from the distal end of the umbilical cord, the amnion forms a complete sac, with a smooth and glistening surface toward the embryo. It is lightly adherent to the chorion laeve and to that surface of the placenta which is toward the embryo. From the way in which the chorion laeve and chorion frondosum become differentiated, the fact that small accessory placentas sometimes occur near the main mass may be readily understood; detached groups of chorionic villi continue their growth, and their vessels communicate with those of the adjacent placenta. Such small accessory structures are known as *succenturiate* (i.e., recruited) *placentas*.

Fate of the Membranes at Birth. Shortly before birth, the cervix of the uterus dilates and the sac of membranes containing the *liquor amnii* bulges into it. The membranes thus exposed are ruptured, and the amniotic fluid escapes. The birth of the child follows, and the umbilical cord then extends from the navel through the vagina to the placenta. The cord is so short in some mammals that it ruptures with the expulsion of the embryo; in other forms it is bitten off or otherwise severed, setting free the embryo. Occasionally the membranes rupture in such a way that the head of the infant remains more or less covered with a cap of amnion and chorion laeve, formerly known as the "caul." After the birth of the child the uterine musculature contracts quite rapidly, and in about half an hour the after-birth is expelled, the sac of membranes being turned inside out in this process. The part from the fundus of the uterus is forced out first, and that from the lower segment of the uterus follows. Thus the amnion and the amniotic surface of the placenta are on the outside of the after-birth. The denuded uterine mucosa is gradually restored to its normal condition. As after menstruation, the epithelium spreads from the glands over the tunica propria.

The entire after-birth, since its delivery follows that of the child, was called the *secunda* or *secundina* by the ancient anatomists. The round flat mass which is its principal part was named the *placenta* by Fallopius, from its fancied resemblance to a pan-cake. Long before this, the membranes enveloping the embryo were known as the chorion, allantois, and amnion, and were described as the outer, middle and inner

layers respectively. These ancient terms are of obscure derivation. *Chorion* (Gr., *χόριον*) is the same as the Latin *corium*, which is applied to the vascular layers of the skin. In its Greek form it is used to designate the vascular *chorioid coat* of the eye, and the *chorioid plexuses* of the brain, but it refers particularly to the vascular embryonic membrane. *Amnion* is derived indirectly from *ἀμνός* (a sheep) and Hyrtl reasonably asks "How came the sheep to have his name enrolled in anatomy?" Whether the amnion was first observed in the sheep, or was so named because of its softness, or for some very different reason, is discussed by the early commentators. The *allantois* was first observed in the lower mammals in which it attains great size. For example, in the sheep and pig it forms an elongated sac filled with fluid and attached like the arms of a "T" to the distal end of the allantoic duct. This duct, which corresponds with the entire human allantois, issues from the ventral abdominal wall and divides into its two branches, as seen indistinctly through the chorion in Fig. 372 (over the body of the embryo). The allantoic sac extends almost the entire length

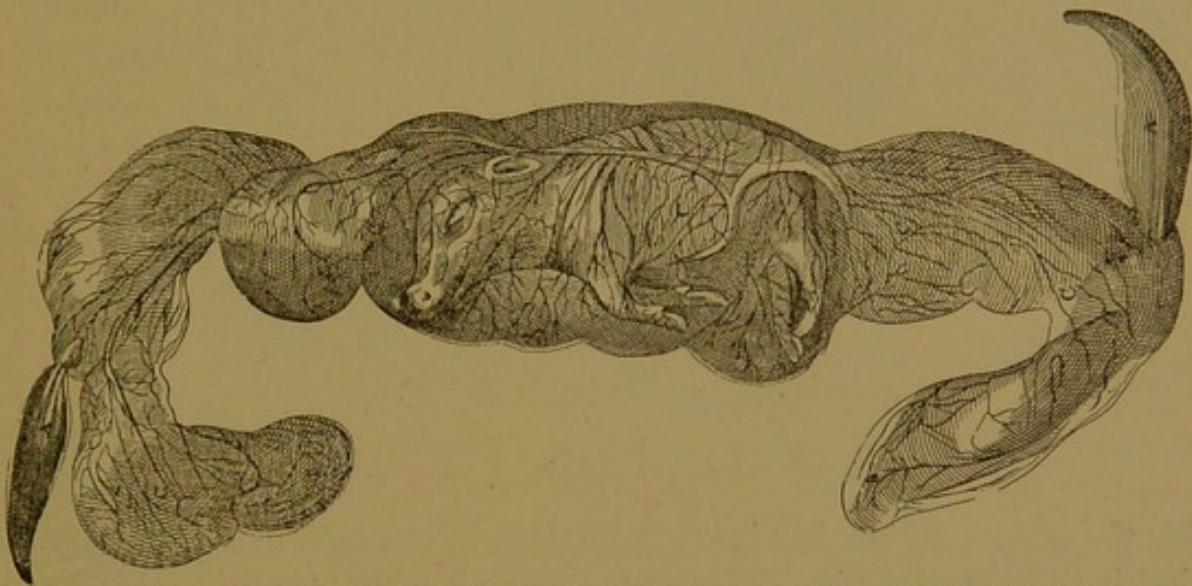


FIG. 372.—A PIG EMBRYO REMOVED FROM THE UTERUS, "SURROUNDED BY ITS THREE MEMBRANES."
(Fabricius ab Aquapendente, 1687.)

of the chorion, and its ends break through the chorionic membrane, projecting freely as the allantoic appendages. In Fig. 372, the one at the right extends upward, and the one at the left, downward. Such an allantois was sought for in man, between the amnion and chorion, where a corresponding structure should be located. Hale (1701) was among those who thought that he found one, but he declared that "most of the ancients allow a human allantois not from their experience of it, but because they took it for granted that men and other animals were alike in their viscera." It was not until 1885 that it was clearly and finally stated that the human allantois was merely a blind tube in the body stalk, never being free or vesicular (His, *Anatomie menschlicher Embryonen*).

As to the appropriateness of the term *allantois* (sausage-like, from the Gr. *ἀλλᾶς* there is difference of opinion. Fabricius (*De formato fœtu*, 1600) one of whose drawings is reproduced in Fig. 372, considers that the word really means "intestinal," or like a sausage *skin*.

DECIDUA VERA, AMNION, AND CHORION LÆVE.

The three structures named above may readily be included in a single vertical section of the wall of the uterus, in the latter part of pregnancy. Care must be taken, however, not to detach the amnion. In Fig. 373 the

amnion is seen on the upper surface of the section, having its simple cuboidal or flat epithelium toward the embryo, and its mesodermic connec-

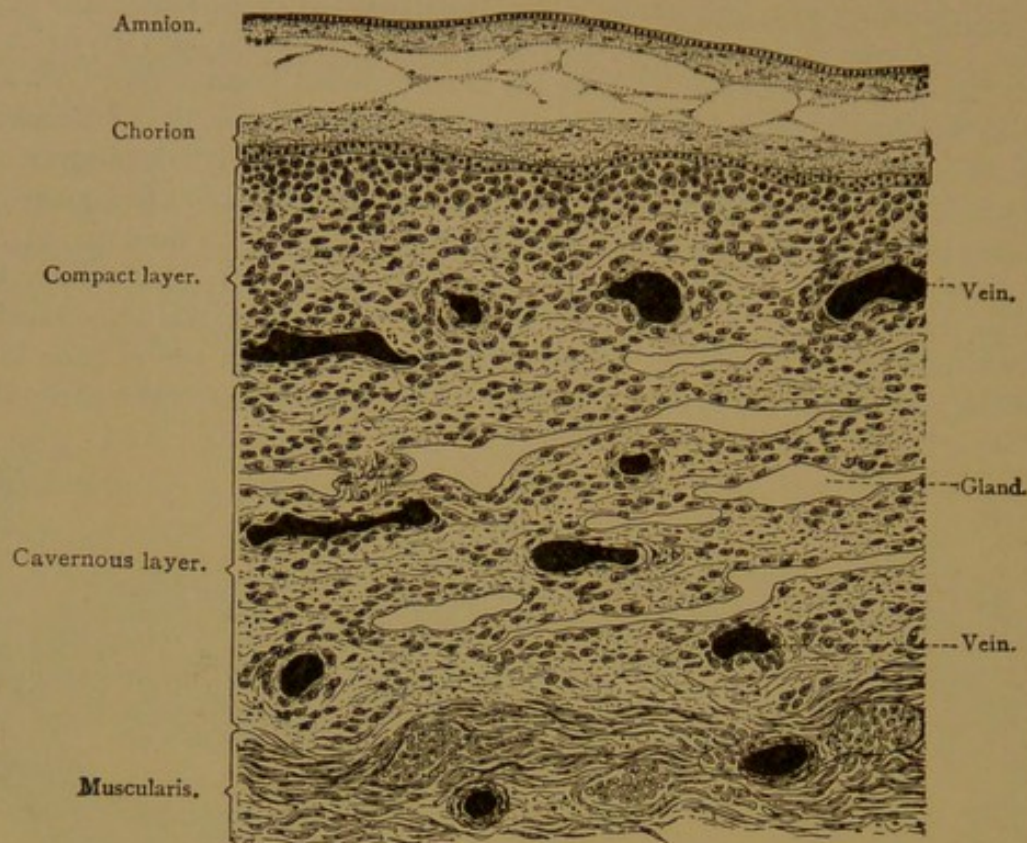


FIG. 373.—VERTICAL SECTION THROUGH THE WALL OF A UTERUS ABOUT SEVEN MONTHS PREGNANT WITH THE MEMBRANES IN SITU. $\times 30$. (Schaper.)

tive tissue toward the chorion. Adhesions in the form of slender strands bind it to the connective tissue of the chorion. The chorionic epithelium

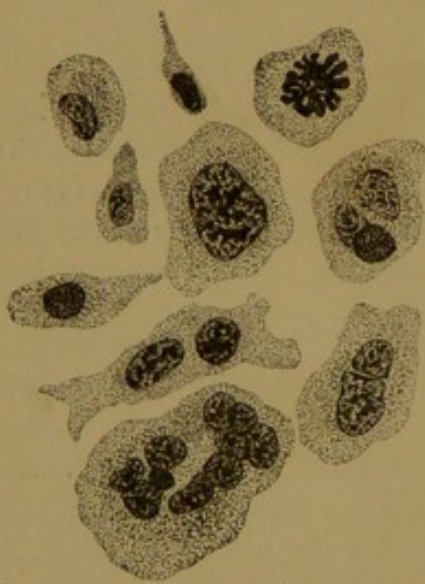

FIG. 374.—DECIDUAL CELLS FROM THE MUCOUS MEMBRANE OF A HUMAN UTERUS ABOUT SEVEN MONTHS PREGNANT. One cell shows a mitotic figure. $\times 250$. (Schaper.)

forms a layer over the surface of the vera; it presents slight irregularities but is without villi. The superficial uterine epithelium has degenerated; it disappeared in an earlier stage. The modified mucosa, or decidua vera, is divisible into a superficial *compact layer* and a deep *cavernous layer*. After the epithelium of the glands in the compact layer had degenerated and was resorbed, the connective tissue came together, obliterating the gland cavities. The compact layer is therefore without glands. The cells of the tunica propria have enlarged, and become *decidual cells* (Fig. 374). These cells, which occur only in pregnancy, are flattened, round, oval or branched structures of large size (0.03

to 0.1 mm.). Usually they contain a single nucleus but often there are two or more, and in giant forms there may be thirty or forty. The

cavernous layer of the mucosa contains slender clefts parallel with the muscularis. These are glands which have been stretched laterally; some of them retain areas of normal epithelium, but in many the epithelium has degenerated, and from some it has wholly disappeared. The connective tissue is but slightly modified. Throughout the decidua, but especially in the superficial portion, the vessels are greatly distended.

PLACENTA.

The chorionic villi, the interlacing branches of which form the fetal portion of the placenta, are shaped as in Fig. 375. The finding of such structures in a uterine discharge or curetting is diagnostic of pregnancy. The villi in the earliest stages are composed entirely of epithelium, but they soon acquire a core of the chorionic mesenchymal tissue, in which are the terminal branches of the umbilical vessels. The epithelium is very early divisible into two layers. The outer layer consists

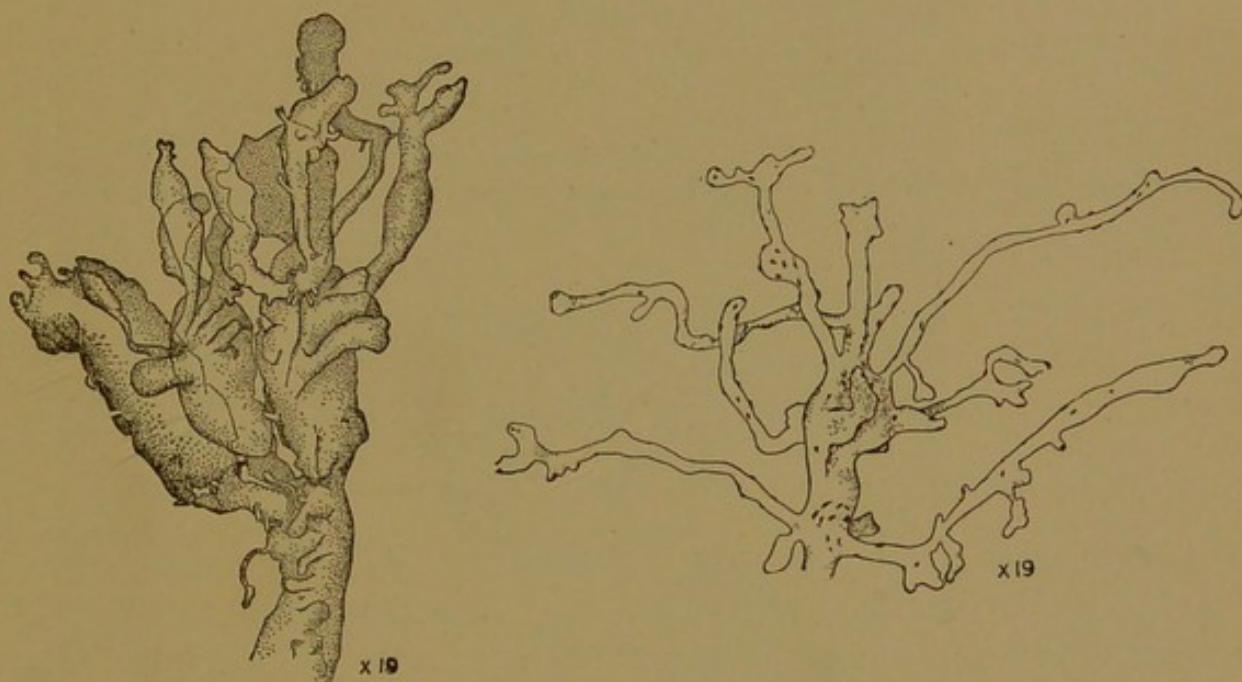


FIG. 375.—ISOLATED TERMINAL BRANCHES OF CHORIONIC VILLI; THAT ON THE LEFT IS FROM AN EMBRYO OF TWELVE WEEKS; ON THE RIGHT, AT FULL TERM. (Minot.)

of densely staining protoplasm, said to contain fat granules and to present a brush border; it has dark, round or flattened nuclei. Since cell boundaries are lacking, this is called the *syncytial layer* (Fig. 376). Mitotic figures are seldom seen in it. Generally its nuclei are in a single layer at varying distances from one another, but they may accumulate in "knots" or "proliferation islands," especially in late stages (Fig. 377). The knots project from the surface of the villi, so that in certain planes of section they appear completely detached and suggest multinucleate giant cells. The syncytial layer perhaps completely invests the villi at first, but later it is interrupted in many places.

The deeper layer of the chorionic epithelium consists of distinct cells with round nuclei and clear protoplasm. Although this is a single layer at the base of young villi, it produces great masses of cells at their tips. These columns or caps of cells in which the villi terminate fuse with one

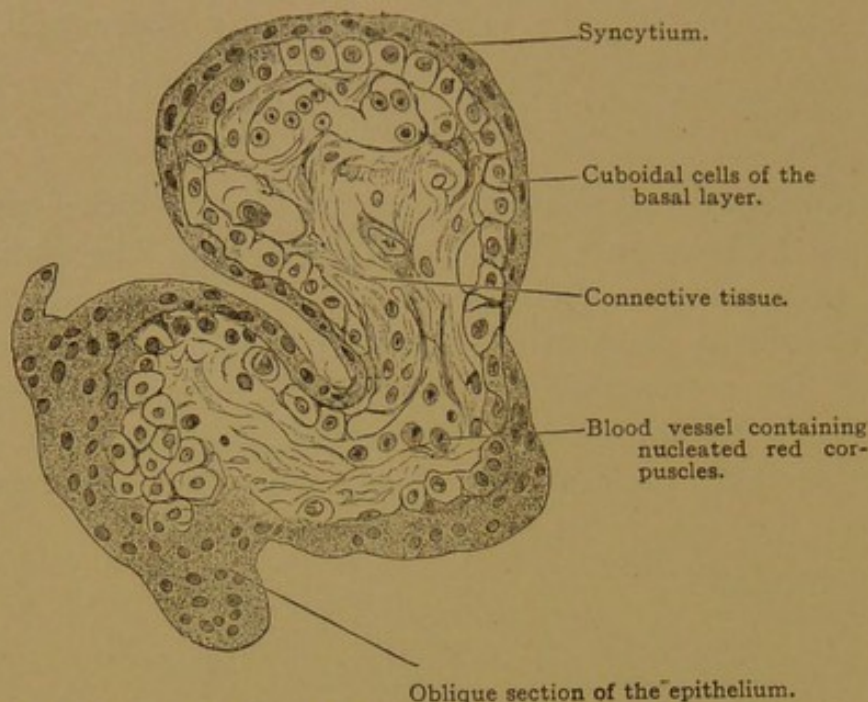


FIG. 376.—CROSS SECTION OF A HUMAN CHORIONIC VILLUS OF THE FOURTH WEEK OF PREGNANCY.

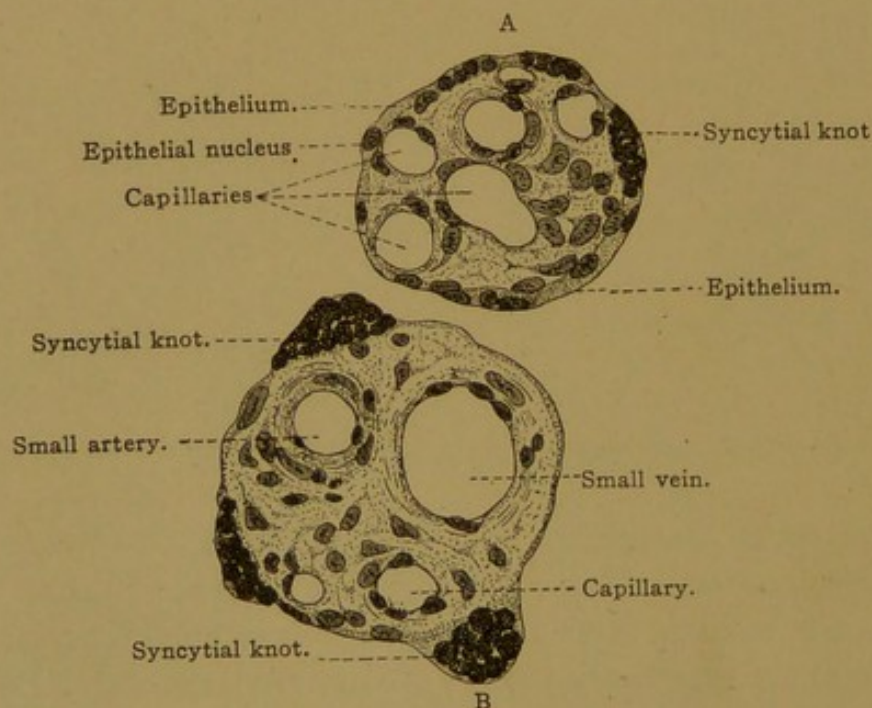


FIG. 377.—CROSS SECTION THROUGH A SMALLER (A) AND A LARGER (B) CHORIONIC VILLUS OF A HUMAN PLACENTA AT THE END OF PREGNANCY. $\times 250$. (Schaper.)

another next the decidua, and the uterine tissue seems to be dissolved as this mass of epithelium proliferates. All the superficial epithelium of the decidua basalis degenerates and disappears, and the underlying parts of the blood vessels in the tunica propria are destroyed. The uterine blood

escapes into the intervillous spaces, bounded by the syncytium, or where this is deficient, by the basal cells. The maternal blood circulates in the intervillous spaces as shown in the diagram Fig. 378, and does not clot. So extraordinary is this, that attempts have been made to detect an endothelial covering for the villi, but without success. (The syncytial layer has been considered endothelial or otherwise of maternal origin, but this view is not accepted.) It is said that the products of the disintegration of the maternal tissue, including hæmoglobin and even entire red corpuscles, are taken up by the syncytium and used for the nutrition of the embryo.

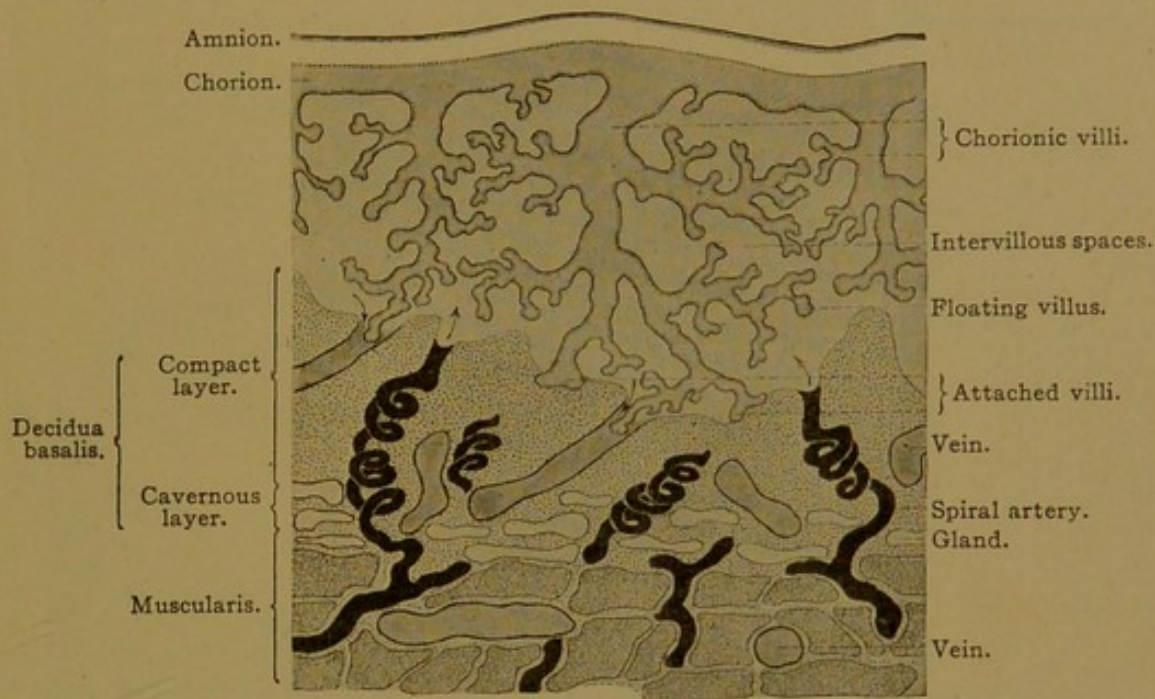


FIG. 378.—DIAGRAM OF THE HUMAN PLACENTA AT THE CLOSE OF PREGNANCY. (Schaper.)

The placenta at birth, being an inch thick, presents in cross section a vast number of the branches of villi cut in various planes. A small fragment is shown in Fig. 379. On the left, there is a section of a large villus, containing fibrous tissue of the loose embryonic type, in some cases forming a thin basement membrane beneath the epithelium. Each villus contains a branch of the umbilical artery which ends in capillaries of very large but varying caliber. They are situated close beneath the epithelial layer, through which nutriment is transferred from the maternal blood in the intervillous spaces to that of the embryo in the vessels of the villi. Maternal and fetal blood never mingle, as may readily be seen in early stages when the embryonic blood contains nucleated red corpuscles.

The two primary layers of the chorionic epithelium are difficult to recognize in many parts of the placenta at birth. Thus in the villi shown in Fig. 377 it is seen that the epithelium is in places hardly distinguishable from the connective tissue. This thin portion may represent the basal

layer and the dark clumps of nuclei scattered over its surface may arise from the syncytium, but the reverse relation of the two types of epithelium to the original layers is sometimes stated. Frequently the villi are covered in part with very conspicuous masses of hyaline material, apparently derived from epithelial degeneration (Fig. 379). Deposits of a substance staining deeply with eosin and resembling the fibrin of blood clots may also be observed. This material is often in the form of layers, with intervals between them, and is known as "canalized fibrin." It is believed to be derived from the blood, but the origin of these deeply staining masses is "not yet fully understood" (Stöhr).

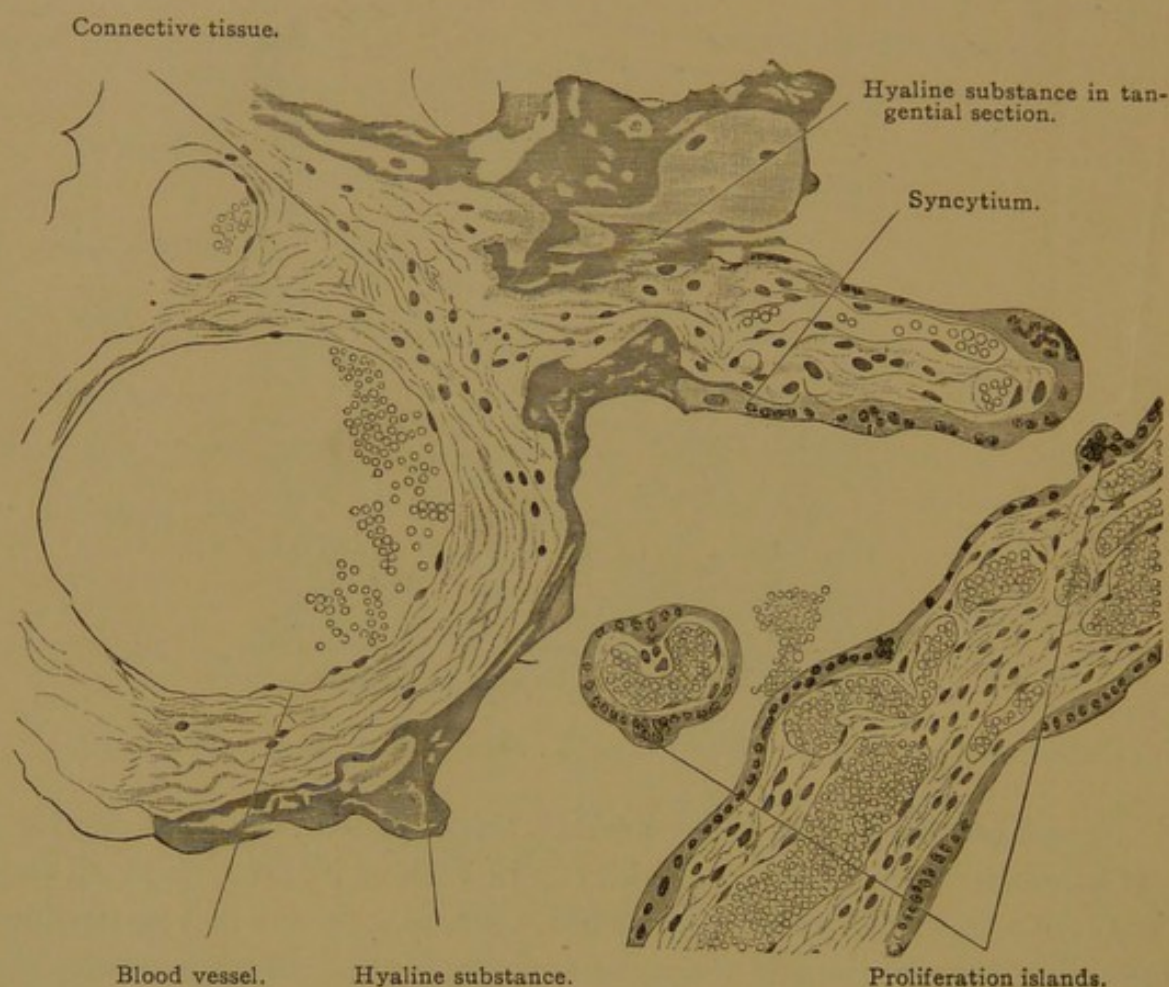


FIG. 379.—FROM A SECTION OF A HUMAN PLACENTA AT TERM. $\times 260$.

The surface of the placenta toward the embryo is covered with amnion, which has remained in place in the section shown in Fig. 380. Sometimes it becomes detached in preparing the specimen. It consists of homogeneous connective tissue toward the chorion, and is covered on its free surface by simple low columnar epithelium, sometimes containing fat droplets and vacuoles. The chorionic membrane is a much thicker layer, consisting of vascular connective tissue, and covered with epithelium continuous with that of the villi. The root of a villus is cut tangentially in Fig. 380. The epithelium at term is often in relation with the hyaline material or "canal-

ized fibrin" which partially replaces it. In Fig. 380, cells of the deeper layer of the chorionic epithelium may still be recognized, but these are often lacking.

Toward the uterine wall the placenta is formed by the decidua basalis, which, like the decidua vera, includes a superficial compact layer and a deeper cavernous layer. The compact layer, which is detached with the placenta at birth, consists of connective tissue, blood vessels, giant cells and decidual cells (Fig. 381). Some of the chorionic villi

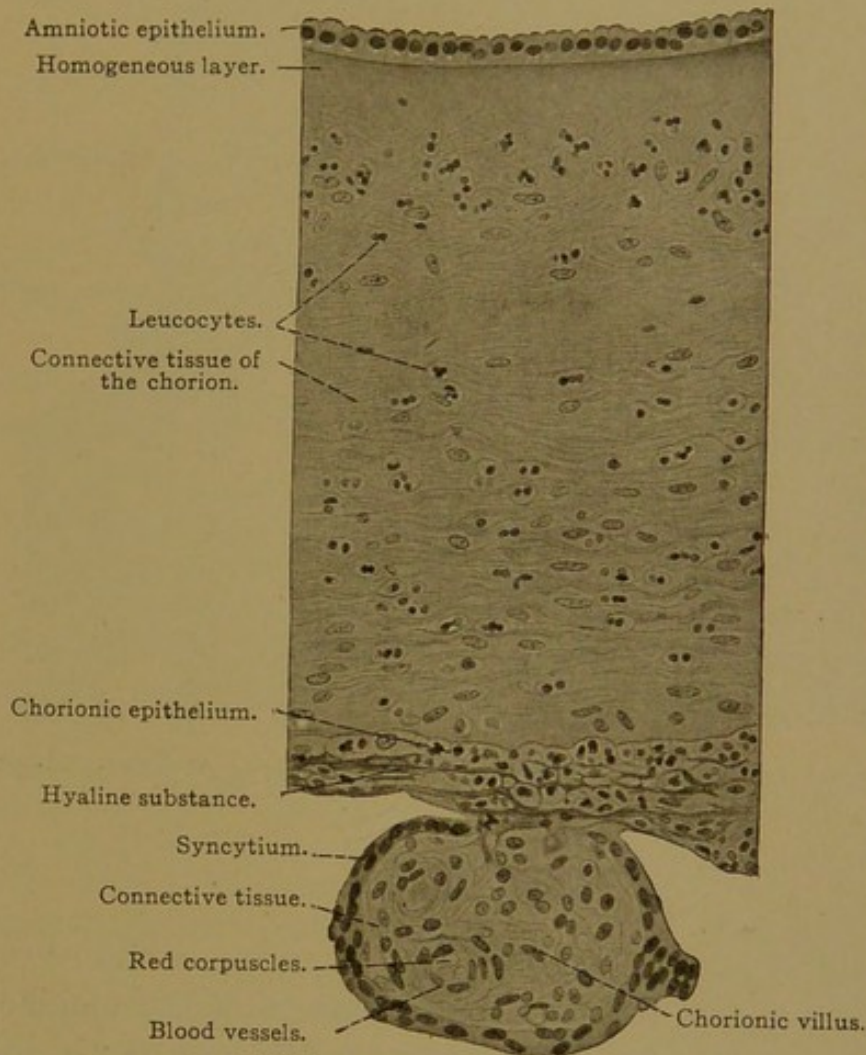


FIG. 380.—FROM A SECTION OF THE HUMAN PLACENTA AT TERM. $\times 200$.

have free endings toward this layer; others are extensively fused with it, forming such masses as shown on the right of Fig. 381.

The decidua basalis extends out among the villi in the form of *septa*, which subdivide the mass of villi into lobes or *cotyledons*. (In the ruminants, the cotyledons are widely separated by areas of smooth chorion, but in man they are closely adjacent, with septa between them.) The septa end before reaching the chorionic membrane, except at the placental margin, where they form an enclosing wall. As the uterine arteries approach the intervillous spaces of the chorion, they pursue a coiled course, so that they may be cut several times in one section (Fig. 378). They pass,

without branching, into the septa of the placenta, and before they empty into the intervillous spaces, their walls are reduced to mere endothelium. The veins which drain the intervillous spaces are not found in the septa, except at the placental margin. They pursue an oblique course downward from the floor of the cotyledons, beginning as large thin-walled tubes, into which free ends of villi may project (Fig. 378).

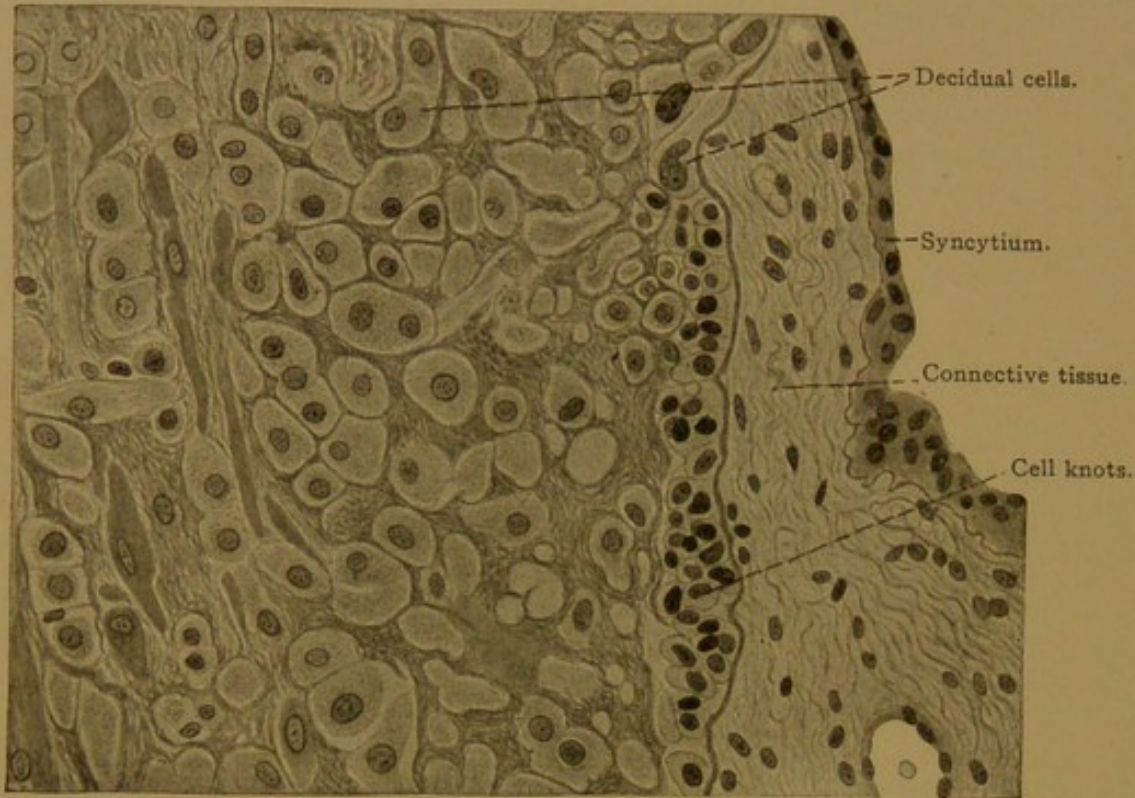


FIG. 381.—FROM A SECTION OF THE HUMAN PLACENTA AT TERM. $\times 260$.

UMBILICAL CORD.

The umbilical cord is a translucent, glistening, white or pearly rope of tissue about 2 feet in length, extending from the umbilicus to the placenta. It consists of mucous tissue (p. 62) covered with epithelium, and contains at birth three large blood vessels, two *umbilical arteries* and one *umbilical vein* (Fig. 382, B). The parallel arteries generally wind around the vein making sometimes forty revolutions. The surface of the cord shows corresponding spiral markings and often irregular protuberances called false knots. (True knots, tied by the intrauterine movements of the embryo, are very rare.) There are no lymphatic vessels or capillaries in the cord, and the large blood vessels do not anastomose. The walls of the arteries contain many muscle fibers but very little elastic tissue, and they are usually found collapsed in sections; their contraction is of interest since nerves have been traced into the cord for only a very short distance. The vein generally remains open.

The *umbilical arteries* arise in young embryos as the main terminal branches into which the dorsal aorta bifurcates. These vessels curve ventrally on either side of the pelvis and pass out through the cord to the chorion; they are equidistant from the allantois which they accompany. In the adult the parts of these vessels near the aorta are known as the common iliac arteries, and the small offshoots from them which

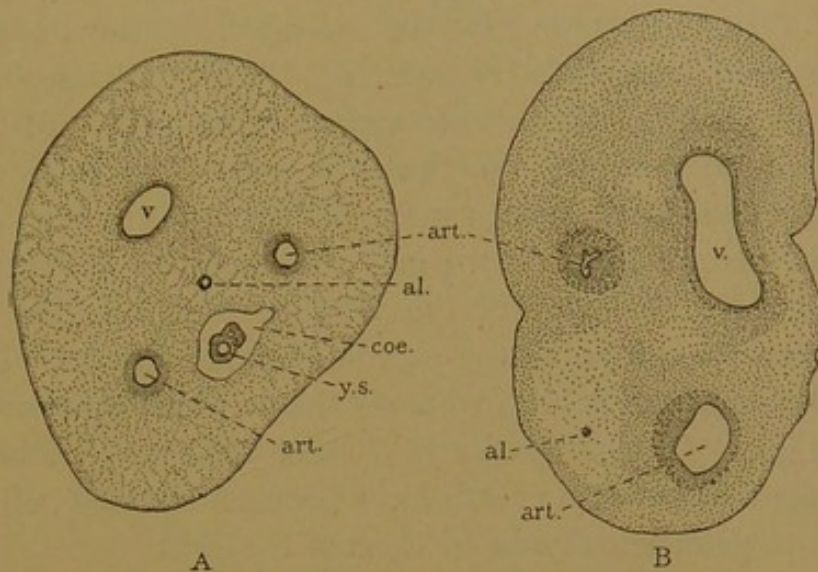


FIG. 382.—CROSS SECTION OF UMBILICAL CORDS.

A, from an embryo of two months, $\times 20$; B, at birth, $\times 3$. al., Allantois; art., artery; coe., coelom; v., vein; y. s., yolk stalk.

have grown down the limbs, have become the external iliac arteries. The distal course of the original vessels may still be followed through the hypogastric arteries (internal iliacs) up on either side of the median line to the navel; toward the navel the vessels have become reduced to slender cords. The *umbilical vein*, within the cord, represents the fusion of a pair. On entering the body it conveys the blood from the placenta, through the persistent left umbilical vein, directly to the under side of the liver, which it crosses as the ductus venosus, and then empties into the vena cava inferior. In the adult, its former course is marked by the round ligament of the liver and the ligament of the ductus venosus.

The *allantois*, which the umbilical vessels accompany, at first extends the entire length of the cord as a slender epithelial tube. Its condition at three months is shown in Fig. 383. At birth, it has become reduced to a very slender, and generally interrupted, solid strand of epithelial cells. That it may retain its continuity is stated by Ahlfeld (Arch. f.

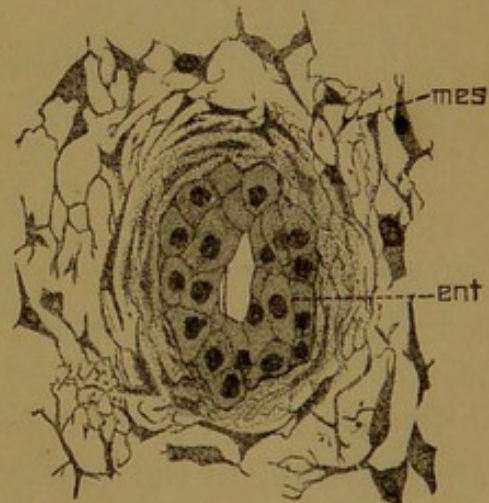


FIG. 383.—CROSS SECTION OF THE ALLANTOIC DUCT, FROM THE UMBILICAL CORD OF A HUMAN EMBRYO OF THREE MONTHS. $\times 340$. (Minot.) Ent., Entodermal epithelium; mes., mesenchyma.

Gynäk., 1876, vol. 10, p. 81). This remnant may be sought for near the body of the embryo, and its tendency to retain its original position equidistant from the umbilical arteries is the best guide for locating it. By the use of Mallory's connective tissue stain, the epithelial cells may be

stained red in contrast with surrounding blue fibrils. Within the body of the embryo the allantois is prolonged to the upper end of the bladder, with which it is continuous; this intra-abdominal part has long been called the *urachus* (i.e., vas urinarium). If it remains pervious at birth, which is abnormal, urine may escape at the umbilicus.

The *yolk stalk*, surrounded by an extension of the body cavity, is found in young umbilical cords (Fig. 382, A). This stalk is a slender strand of mesoderm, containing the entodermal vitelline duct, and the vitelline vessels which accompany it to the yolk-sac. The loop of intestine from which the yolk stalk springs may also extend into the cavity of the cord, and if it has not been drawn into the abdomen at birth, umbilical hernia results. If the cavity of the vitelline duct remains pervious at birth, the intestinal contents may escape at the umbilicus. (Such a condition is known as a fecal fistula, whereas the pervious urachus constitutes a urinary fistula.) Ordinarily the yolk stalk and its vitelline vessels, together with the coelom of the cord, have been obliterated before birth, so that no trace of them remains in sections of the cord.

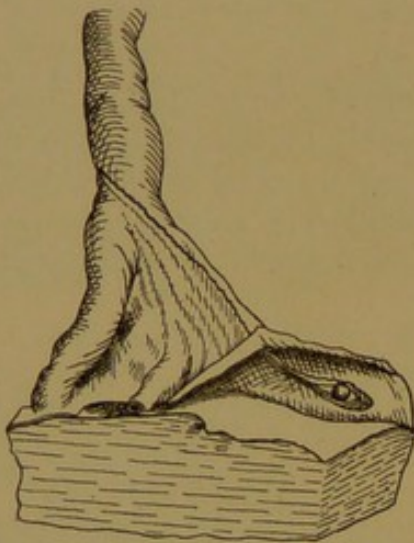


FIG. 384.—YOLK-SAC AND PERSISTENT VITELLINE VESSELS, EXPOSED BY REFLECTING THE AMNION AT THE DISTAL END OF THE CORD. (Lönnerberg.)

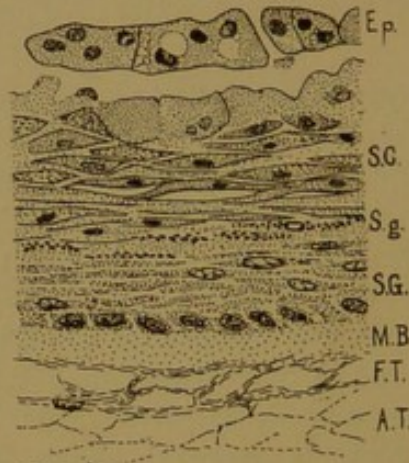


FIG. 385.—PART OF A HUMAN AMNIOTIC VILLUS. $\times 330$.

Ep., Epitrichium; S. C., stratum corneum; S. g., stratum granulosum; S. G., stratum germinativum; M. B., homogeneous layer; F. T., fibrous tissue; A. T., areolar tissue.

The *yolk-sac* may be found with almost every placenta, as a very small cyst adherent to the amnion in the placental area. If the distal end of the cord is gently stretched, a wing-like fold appears (Fig. 384), differing from all others by containing no large vessels; the fold indicates the direction of the yolk-sac, which may be exposed by stripping the amnion from the chorion. It may be beyond the limits of the placenta. Further details will be found in Lönnerberg's admirable *Studien über das Nabelbläschen*, Stockholm, 1901.

Amniotic villi are irregular, flat, opaque spots on the amnion near the distal end of the cord. They are often present and may suggest a diseased

condition. As seen in Fig. 385 they are areas of imperfectly developed skin, and as shown in this case (Lewis, Art. "Umbilical Cord," Buck's Hdb., 2nd ed.) they present all of its fundamental layers. Frequently these cornified areas are less fully developed. They have been compared with the pointed epithelial elevations which cover the surface of the umbilical cord in ruminants, but the latter do not appear as areas of imperfect skin, and probably are entirely different structures. They may appropriately be called villi, but the human "villi" scarcely rise above the surface. Their significance is unknown.

VAGINA AND EXTERNAL GENITAL ORGANS.

The *vagina* consists of a mucosa, submucosa, muscularis and fibrosa. Its epithelium is thick and stratified, its outer cells being squamous and easily detached. It rests upon the papillæ of the tunica propria, and is thrown into coarse folds or *rugæ*. Glands are absent. The tunica propria is a delicate connective tissue with few elastic fibers, containing a variable number of lymphocytes. Occasionally there are solitary nodules, above which numerous lymphocytes wander into the epithelium. The submucosa consists of loose connective tissue with coarse elastic fibers. The muscularis includes an inner circular and a small outer longitudinal layer of smooth muscle. The fibrosa is a firm connective tissue, well supplied with elastic elements. Blood and lymphatic vessels are found in the connective tissue layers, and wide veins form a close network between the muscle bundles. There is a ganglionated plexus of nerves in the fibrosa.

The mucous membrane of the vestibule differs from that of the vagina in possessing glands. The numerous *lesser vestibular glands*, 0.5–3 mm. in diameter, produce mucus; they occur chiefly near the clitoris and the outlet of the urethra. The pair of *large vestibular glands* (Bartholin's) also produce mucus; they correspond with the bulbo-urethral glands in the male and are of similar structure. The hymen consists of fine-fibered, vascular connective tissue covered with mucous membrane. The clitoris is an erectile body, resembling the penis. It includes two small *corpora cavernosa*. The glans clitoridis contains a thick net of veins. It is not, as in the male, at the tip of a corpus cavernosum urethræ which begins as a median bulb in the perineal region; the bulbus in the female exists as a pair of highly vascular bodies, one on either side of the vestibule. Each is called a *bulbus vestibuli*. The labia minora contain sebaceous glands, 0.2–2.0 mm. in size, which are not connected with hair follicles; they first become distinct between the third and sixth years. The labia majora have the structure of skin.

SKIN.

The skin (*cutis*) consists of an ectodermal epithelium, the *epidermis*, and a mesodermal connective tissue, the *corium* (Fig. 386). The ectoderm is at first a single layer but it soon becomes double, the outer cells staining more deeply, and being notably larger than the inner cells. Their

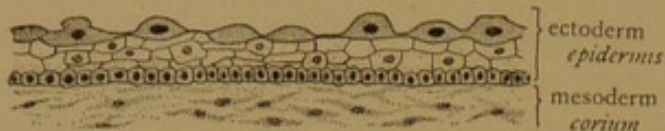

FIG. 386.—SKIN FROM THE OCCIPUT OF AN EMBRYO OF TWO AND ONE-HALF MONTHS. (After Bowen.)

The outer layer of dark cells is the *epitrichium*.

characteristic dome shape is seen in the figure. The outer layer has been named the *epitrichium*, since the hairs which grow up through the underlying epithelium do not

penetrate it, but cause it to be cast off. The *epitrichium* has been found on the umbilical cord and in places on the amnion. It may possibly be related to the chorionic syncytium. The deeper layer of ectoderm becomes stratified, and gives rise to the hairs, nails, and

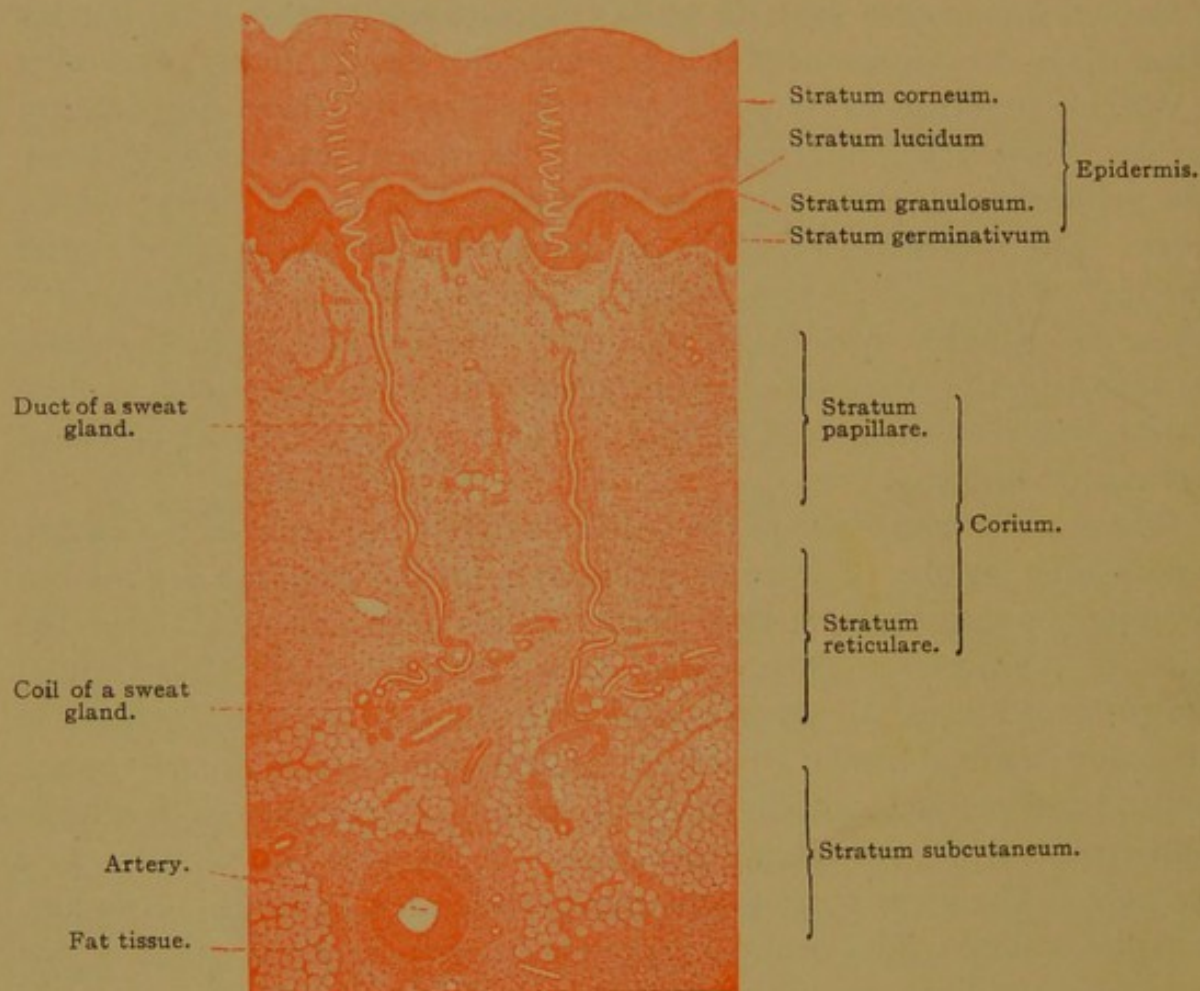


FIG. 387.—VERTICAL SECTION FROM THE SOLE OF THE FOOT OF AN ADULT. $\times 25$.

enamel organs. It also produces two types of glands, the *sebaceous glands* which are usually connected with hairs, and the *sweat glands*. These are widely distributed; locally the ectoderm forms the *mammary glands*, *ceruminous glands* of the ear, *ciliary glands* of the eyelids,

and other special forms. The greater part of the surface of the skin presents many little furrows, the *sulci cutis*, which intersect so that they bound rectangular spaces. On the palms and soles the furrows are parallel for considerable distances, being separated from one another by slender ridges, the *cristæ cutis*, along the summits of which the sweat glands open. The ridges are most highly developed over the pads of tissue at the finger tips, where they present the familiar spiral and concentric patterns. These pads of connective tissue, the *toruli tactiles*, must not be confounded with elevations due to underlying muscles.

In the pentadactylous mammals, each extremity typically presents five digital toruli, at the tips of the fingers or toes; four interdigital toruli, near the metacarpo- or metatarso-phalangeal joints; and two or three proximal cushions—a tibial and an elongated fibular; or a radial and two ulnar, one behind the other. Often the interdigital cushions fuse, as in the paw of the cat and the ball of the human foot, and the one between the thumb and fingers may be suppressed. These toruli are very prominent in the embryo. According to Miss Whipple (Zeitschr. f. Morph. u. Anthr., 1904, vol. 7, pp. 261-368) they are primarily walking pads, with ridges at right angles to the slipping force. Usually they are considered primarily tactile. The extensive literature pertaining to them has been reviewed by Schlagenhaufen (Anat. Hefte, 1906, Abt. II, vol. 15, pp. 628-662).

Corium. The corium is a layer of densely interwoven bundles of connective tissue extending from the epidermis to the fatty, areolar *subcutaneous tissue* (Fig. 387). Toward the epidermis the corium forms *papillæ*, which vary considerably in size and number in different parts of the body. They are tallest (even 0.2 mm. high) and most numerous, often being branched, in the palms and soles. Beneath the epidermal ridges they may occur quite regularly in double rows (Fig. 388), as long since observed by Malpighi. In the skin of the face the papillæ are poorly developed, and in advanced age they may wholly disappear. The papillæ are composed of cellular connective tissue, which forms a *tunica propria*; and each papilla contains a terminal knot of capillary blood vessels, or a tactile corpuscle (Fig. 152, p. 159). The corpuscles are most numerous in the sensitive finger tips, where they may be found in one papilla in every four.

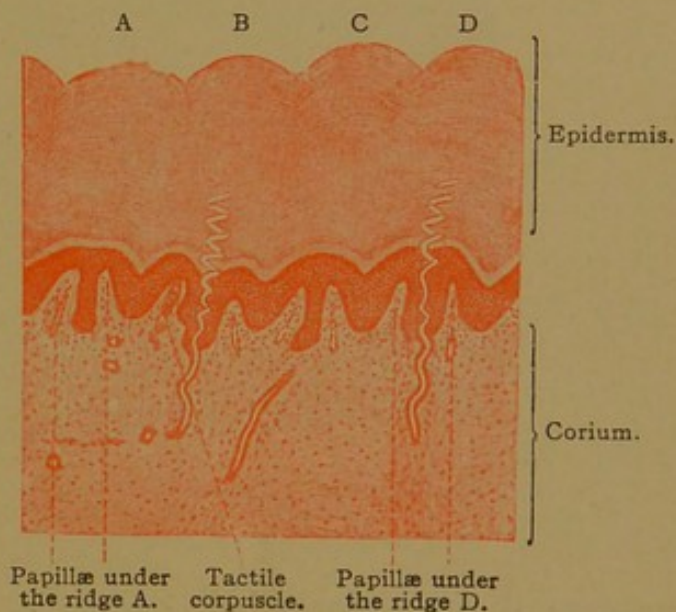


FIG. 388.—VERTICAL SECTION FROM THE SOLE OF THE FOOT OF AN ADULT, SHOWING FOUR RIDGES (A-D) WITH A PAIR OF PAPILLÆ BENEATH EACH. Between the papillæ of D is the duct of a sweat gland. $\times 25$.

The entire corium is somewhat arbitrarily subdivided into an outer *stratum papillare* and an inner *stratum reticulare* (Fig. 387). These layers blend with one another, but the outer portion consist of finer bundles of connective tissue, more closely interwoven than those in the coarse network characteristic of the *stratum reticulare*. Beneath the skin, but inseparable from it, is the *stratum subcutaneum*, which is composed of areolar tissue with large areas of fat cells; where the fat forms a continuous layer, it is known as the *panniculus adiposus*. Finally the bundles of the *stratum subcutaneum* connect more or less intimately with the fascia around the muscles, or, in places, with the periosteum.

The elastic fibers of the corium form evenly distributed networks, which are finer in the *stratum papillare* and coarser in the *stratum reticulare*. There is said to be a subepithelial network, and a layer of

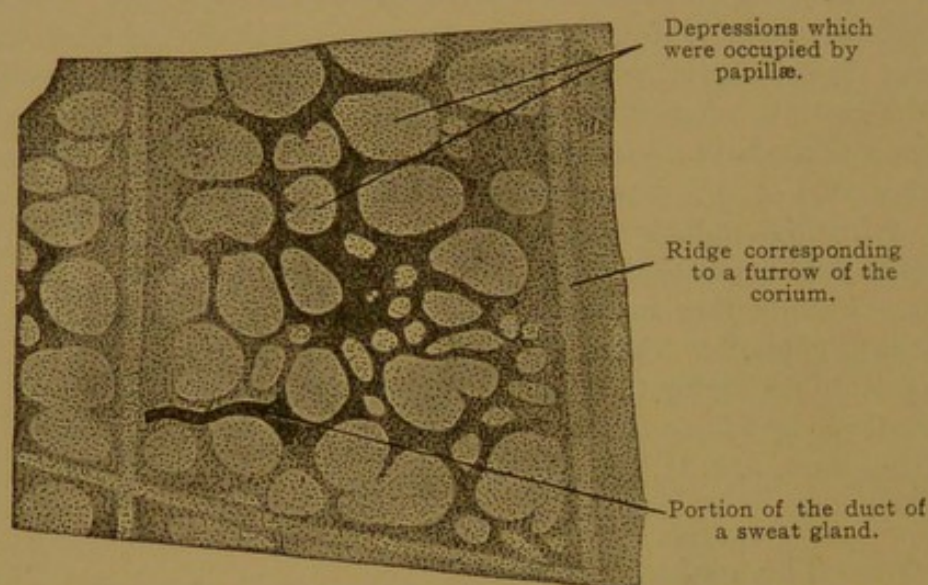


FIG. 389.—EPIDERMIS DETACHED FROM THE DORSUM OF THE HUMAN FOOT, SEEN FROM THE LOWER SURFACE. $\times 120$.

The dark epithelial network between the papillæ is the rete Malpighii.

numerous coarse fibers immediately above the general layer of fascia. In old age a notable decrease in the elastic fibers has been recorded. The muscle fibers of the corium are chiefly the small bundles of smooth muscle attached to the sheaths of the hairs, forming the *arrectores pilorum*. Smooth muscle is diffusely distributed in the nipple, and in the scrotum it forms a layer pervaded by elastic tissue, known as the *tunica dartos*. Striated muscle fibers derived from the muscles of expression terminate in the skin of the face. The vessels and nerves of the corium are described on page 399.

Epidermis. If a piece of skin is boiled, the epidermis may be stripped off, carrying the *tunica propria* with it; and the epidermis itself may be separated into two layers. The outer layer is the *stratum corneum*; the inner is the *stratum germinativum*.

The *stratum germinativum* was formerly called the *stratum mucosum* or *rete Malpighii*. It was first described by Malpighi who recognized its soft or "mucous"

nature, and referred to it as a rete since it forms a network between the papillæ of the corium (Fig. 389). Malpighi considered that the color of the Ethiopian skin was confined to this layer.

The stratum germinativum and stratum corneum are subdivisions of a single thick stratified epithelium. The basal cells, which rest directly upon the papillæ of the corium, constitute a single row of columnar cells, with elongated nuclei and no cell walls (Fig. 390). Through mitotic division these cells multiply and give rise to the outer polygonal cells, but it is noteworthy that mitotic figures are seldom seen. The polygonal cells which form the bulk of the stratum germinativum are connected with one another by slender intercellular bridges (Fig. 43, p. 53), through which fibrils pass from cell to cell. Because of this striking feature, the stratum germinativum was formerly called the stratum spinosum.

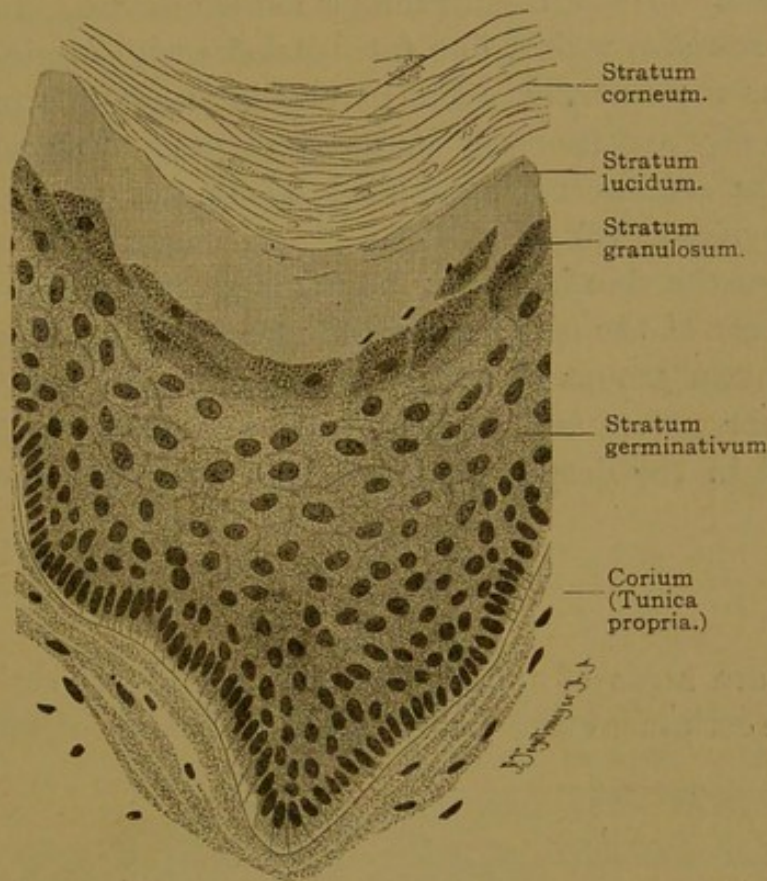


FIG. 390.—THE DEEPER PART OF THE EPIDERMIS, FROM THE SOLE OF THE FOOT OF AN ADULT MAN. $\times 360$.

The transition from the stratum germinativum to the stratum corneum is abrupt. It may be marked by an incomplete layer of coarsely granular cells, such as are highly developed in the skin of the palms and soles, where they form the *stratum granulosum* (Fig. 390). In the stratum corneum the cells acquire a horny exoplasmic membrane; the bridges become short stiff spines; the protoplasm and nucleus are dry and shrunken; and in the outermost cells the nucleus wholly disappears. The cells become flatter toward the surface, from which they are constantly being desquamated.

The process of cornification presents a more elaborate picture in sections of the palms and soles. Outward from the stratum germinativum there is a darkly staining, coarsely granular layer, one or two cells thick, which is followed by a clear, somewhat refractive band in which the cell outlines are indistinct. This layer seems saturated with a dense fluid formed by dissolution of the underlying granules. In hæmatoxylin and eosin specimens, the granular layer or *stratum granulosum* is followed by a pink and then by a bluish band, which are subdivisions of the clear *stratum lucidum*. These are followed by a very thick stratum corneum. Except in the palms and soles, the granulosum is thin and the lucidum is absent. Chemically the coarse granules of the stratum granulosum resemble the horny substance *keratin* (from which they differ by dissolving in caustic potash); they are therefore called *kerato-hyalin* granules. Their diffuse product in the stratum lucidum is named *eleidin*. In the corneum it becomes *pareleidin*, which, like fat, blackens with osmic acid, but the reaction occurs more slowly. The pareleidin is not due to fat entering the skin from oily secretions on its outer surface. Further information regarding these substances is supplied by Pinkus (Keibel and Mall's Human Embryology, vol. 1).

The color of the skin is due to fine pigment granules in and between the lowest layers of the epidermal cells. Underlying cells of the corium sometimes contain groups of finer pigment granules, but such cells are absent from the palms and soles and are infrequent elsewhere. They may be found in the deeply pigmented circum-anal tissue, and in the eyelids.

NAILS.

The nails are areas of modified skin consisting of corium and epithelium. The corium is composed of fibrous and elastic tissue, the bundles

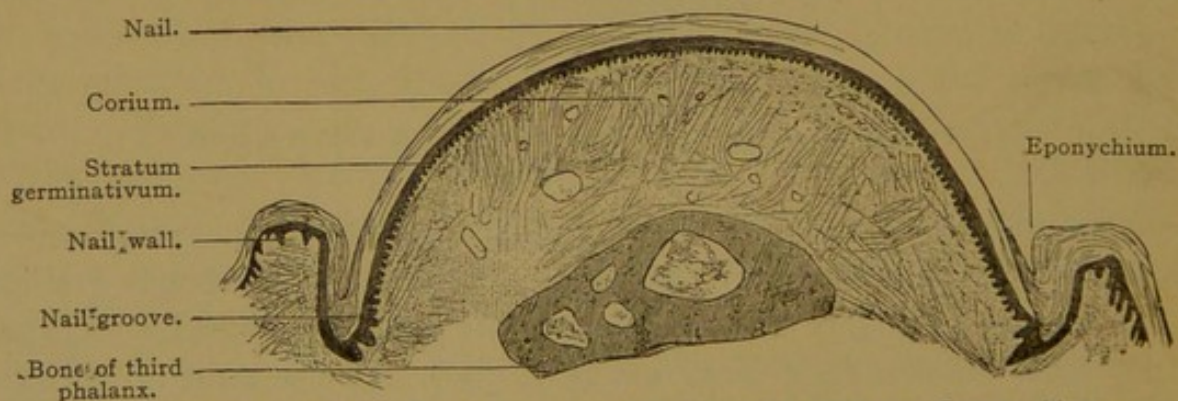


FIG. 391.—DORSAL HALF OF A CROSS SECTION OF THE THIRD PHALANX OF A CHILD. $\times 15$.
The ridges of the nail bed in cross section appear like papillæ.

of which in part extend vertically between the periosteum of the phalanx and the epithelium, and in part run lengthwise of the finger. In place of papillæ, the corium of the nail forms narrow longitudinal ridges, which

are low near the root of the nail but increase in height toward its free distal border; there they abruptly give place to the papillæ of the skin. The epithelium consists of a *stratum germinativum* and a *stratum corneum*. The latter, according to Bowen (Anat. Anz., 1889, vol. 4, pp. 421-450), represents a greatly thickened stratum lucidum, but this opinion requires confirmation. In the embryo the horny substance is entirely covered by a looser layer, the *eponychium*, and this name is applied in the adult to the skin-like tissue which overlaps the root and sides of the nail (Fig. 391). The eponychium is the stratum corneum of the adjoining skin.

It is now generally considered that the cells of the stratum germinativum covering the greater part of the "nail bed" do not produce any of the overlying horny material. This function is reserved for the germinative cells at the root of the nail, beneath the crescentic white area, the *lunula*, and its extension backward under the *nail fold*. The latter is a fold of skin which is deep at the root of the nail, but becomes shallower as it extends forward on either side, bounded by the nail wall (Fig. 391). It is now stated that cornification in the nails takes place without the formation of kerato-hyalin granules, and a fibrillar arrangement of the keratin has been thought to account for the whiteness and opacity of the lunula. The cornified cells of the nail may be separated by placing a fragment in a strong solution of caustic potash and heating to boiling. The cells differ from those in the outer layers of the skin by retaining their nuclei (Fig. 392).

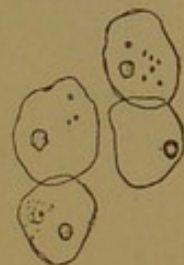


FIG. 392.—CELLS OF A HUMAN NAIL. $\times 240$.

HAIR.

Development. The hairs arise as local thickenings of the epidermis.

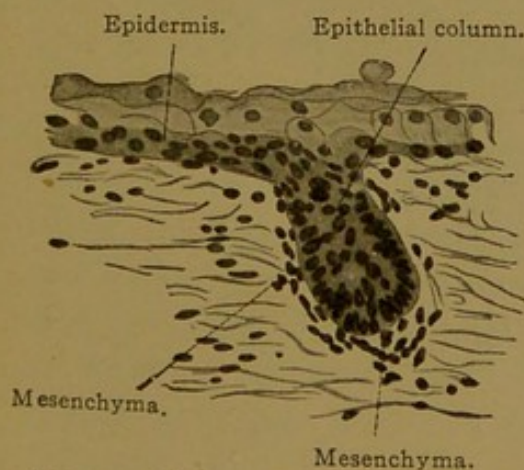


FIG. 393.—VERTICAL SECTION OF THE SKIN OF THE BACK OF A HUMAN EMBRYO OF FIVE MONTHS. $\times 230$.

They soon become round columns of ectodermal cells extending obliquely downward into the corium (Fig. 393). As the columns elongate the terminal portion becomes enlarged, forming the *bulb* of the hair, and a mesodermal *papilla* occupies the center of the bulb. On that side of the epithelial column which from its obliquity may be called the lower surface, there are found two swellings (Figs. 394-396). The upper is to become a *sebaceous gland*, discharging its secretion into the epithelial column; the lower or deeper swelling is called the "epithelial bed," and

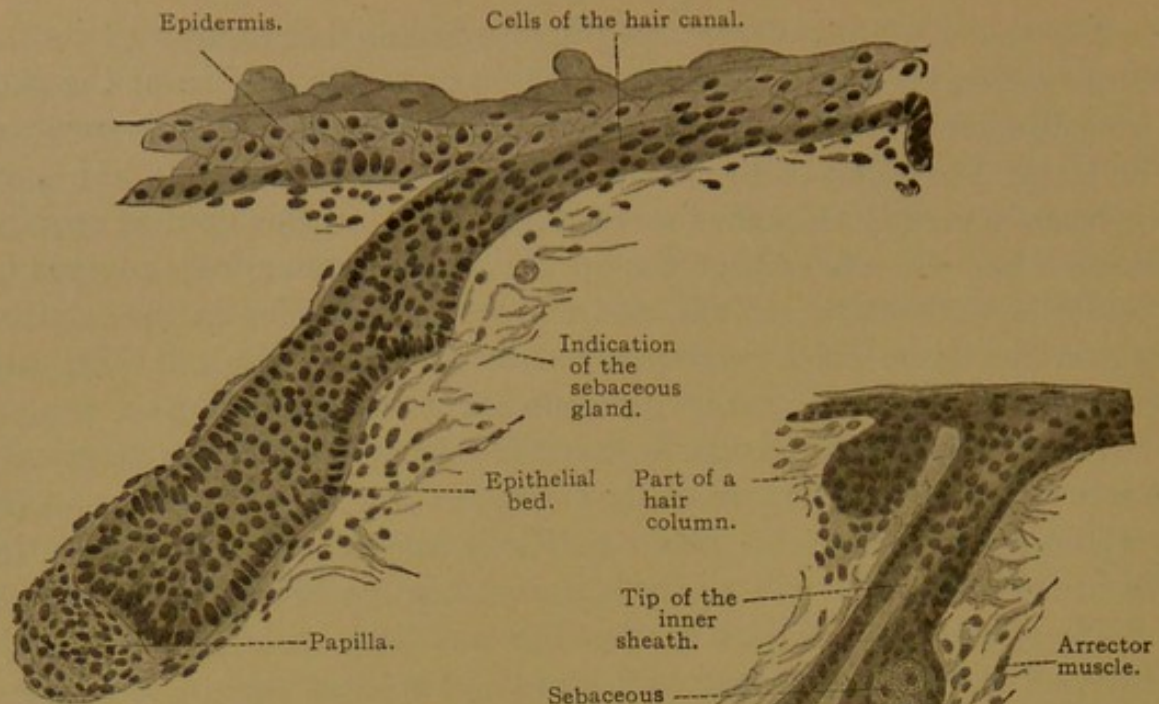


FIG. 394.—VERTICAL SECTION OF THE SKIN OF THE GLUTEAL REGION OF A HUMAN EMBRYO OF FIVE MONTHS. $\times 230$.

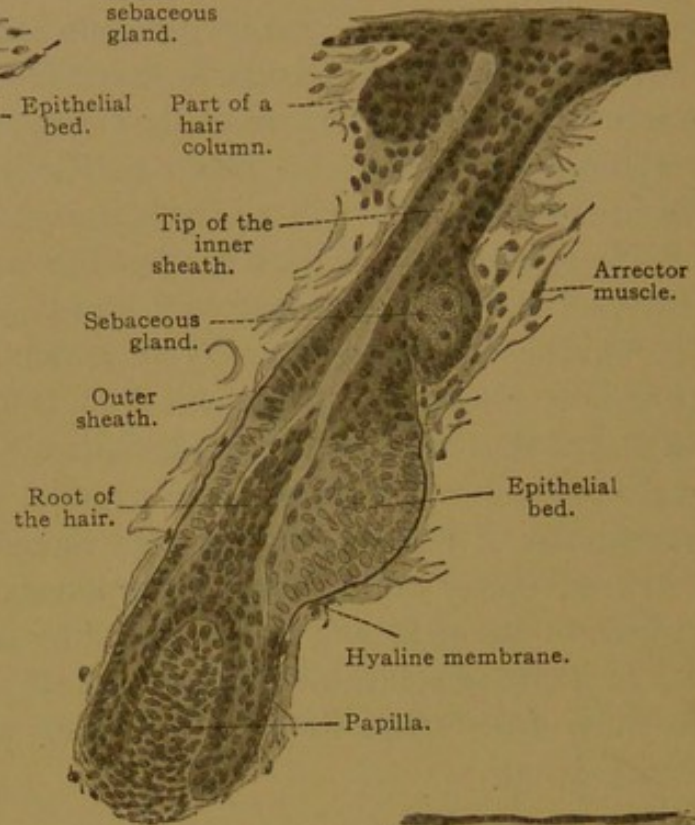


FIG. 395.—VERTICAL SECTION OF THE SKIN OF THE BACK OF A HUMAN EMBRYO OF FIVE AND A HALF MONTHS. $\times 230$.

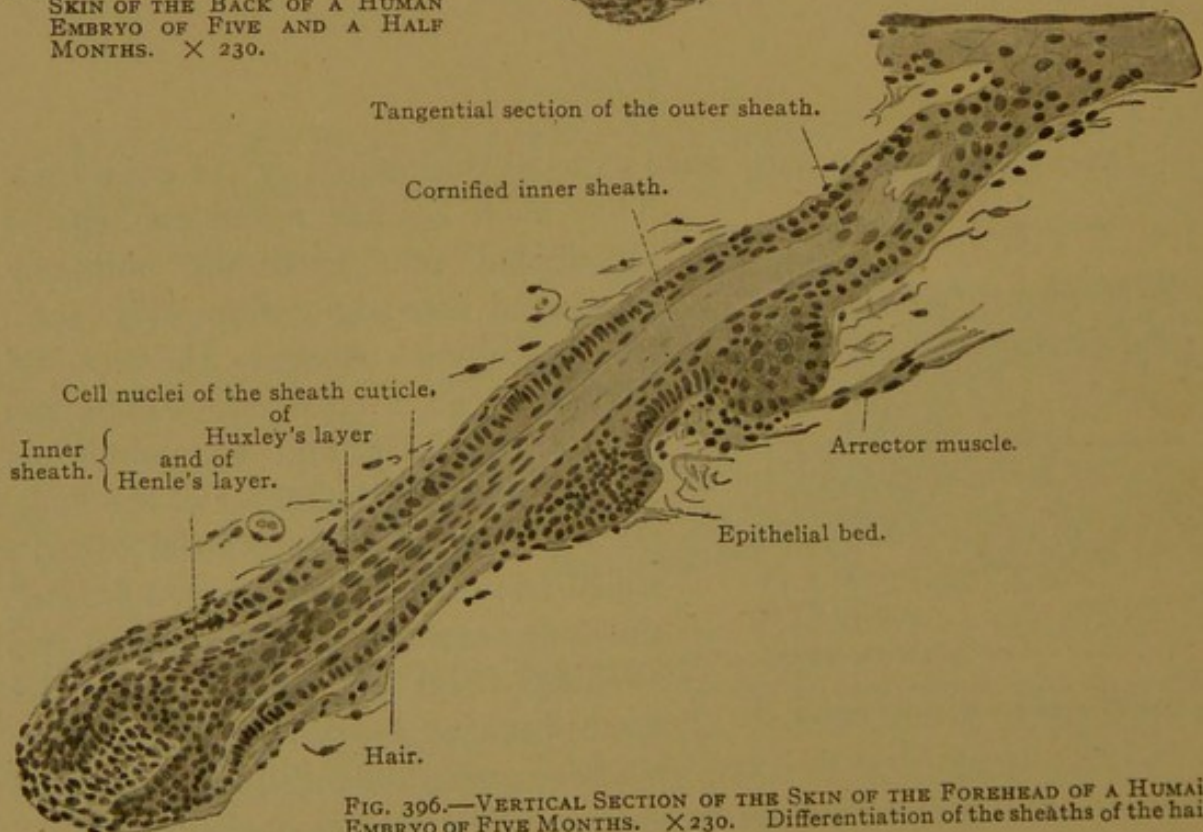


FIG. 396.—VERTICAL SECTION OF THE SKIN OF THE FOREHEAD OF A HUMAN EMBRYO OF FIVE MONTHS. $\times 230$. Differentiation of the sheaths of the hair.

its cells, which increase by mitosis, contribute to the growth of the column. (The lower swelling is often described as the place of insertion of the arrector pili muscle). Beginning near the bulb, the core of the column separates from the peripheral cells; the latter become the *outer sheath* of the hair. The core forms the *inner sheath* and the *shaft* of the hair. The cells of the shaft become cornified just above the bulb, and they are surrounded by the inner sheath as far as the sebaceous gland. Beyond this point the inner sheath degenerates, so that in later stages the distal part of the shaft is immediately surrounded by the outer sheath. As new cells are added to the hair from below, the shaft is pushed toward the surface. The central cells in the outer end of the column degenerate, thus producing a "hair canal" which is prolonged laterally in the epidermis (Fig. 397). The shaft enters the canal, breaks up the overlying epidermis, and projects from the surface of the body. That portion of the hair which remains beneath the epidermis is called its *root*. In addition to the epithelial sheaths, the root in all

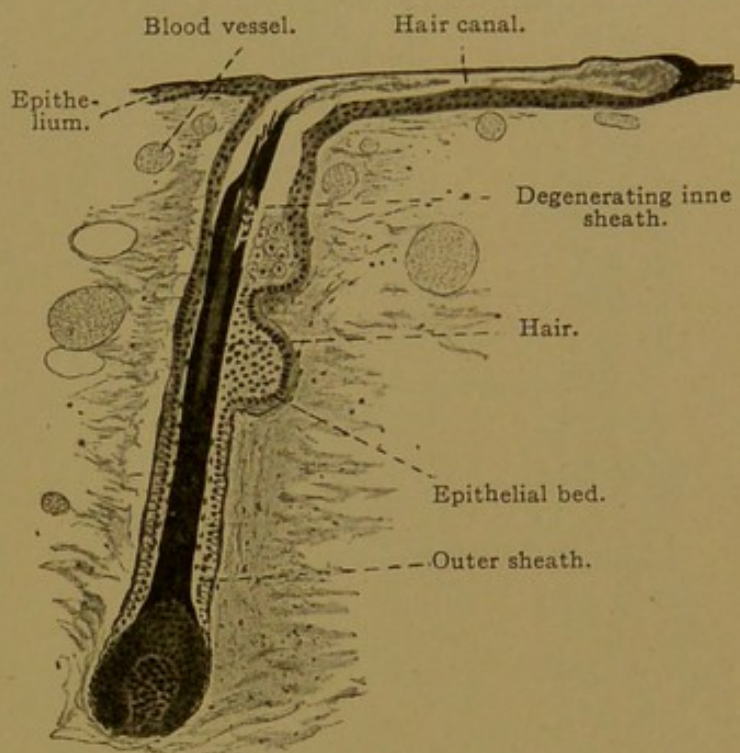


FIG. 397.—VERTICAL SECTION OF THE SKIN OF THE BACK OF A HUMAN EMBRYO OF FIVE AND A HALF MONTHS. $\times 120$.
The staining with iron hæmatoxylin has made the horny parts so black that their details are invisible.

larger hairs possesses a *connective tissue sheath*, derived from the corium. This serves for the insertion of a bundle of smooth muscle fibers, the other end of which is connected with the elastic and fibrous elements in the superficial part of the corium. Since this muscle by contraction causes the hair to stand on end, it is called the *arrector pili*. Its insertion is always below the sebaceous gland and on the lower surface of the hair, as shown in Fig. 398. The hairs which cover the body of the embryo, persisting after birth to a variable extent, are soft and downy, and are known as *lanugo*. Arrector muscles are absent from the lanugo of the nose, cheeks and lips, and also from the eyelashes (cilia) and nasal hairs (vibrissæ).

Adult Structure. The general appearance of hairs in sections of the adult skin is shown in Fig. 398, which includes also the sebaceous glands emptying into the sheaths of the hairs, and sweat glands which are usually

entirely separate structures. Occasionally a sweat gland opens into the sheath of a hair near its outlet. Each hair consists of a papilla, bulb and shaft, together with sheaths around the root, namely an inner and outer epithelial sheath and, external to these, a connective tissue sheath. These structures, together with the arrector pili muscle which is inserted into the connective tissue sheath, are indicated in Fig. 398, but they are

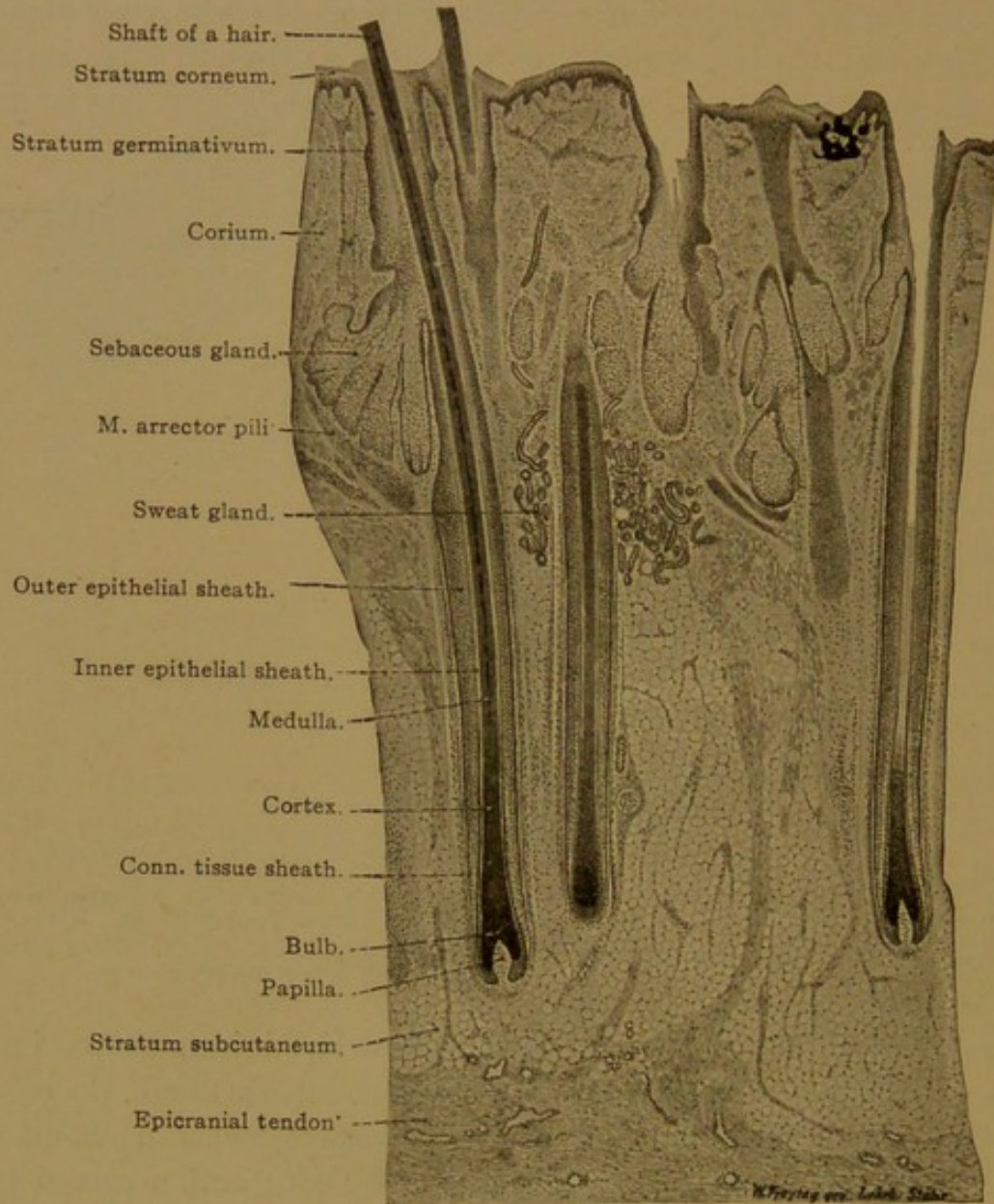


FIG. 398.—THICK SECTION OF THE HUMAN SCALP. $\times 20$.

shown in detail in the longitudinal section, Fig. 399, and in the transverse sections, Figs. 401-405. They may be described as follows:

The *connective tissue sheath*, derived from the corium, is found around the roots of the coarser hairs, but is absent from the lanugo. It may be subdivided into three concentric layers. The outermost consists of loose connective tissue with longitudinal fibers, and contains elastic tissue and numerous vessels and nerves. The middle layer, which is thicker, consists of circular bundles of connective tissue without elastic fibers. The inner

layer, also free from elastic tissue, is sometimes longitudinally fibrous, and sometimes homogeneous. It forms the outer stratum of the *hyaline* (or *vitreous*) *membrane*, and is continuous below with the thin but distinct

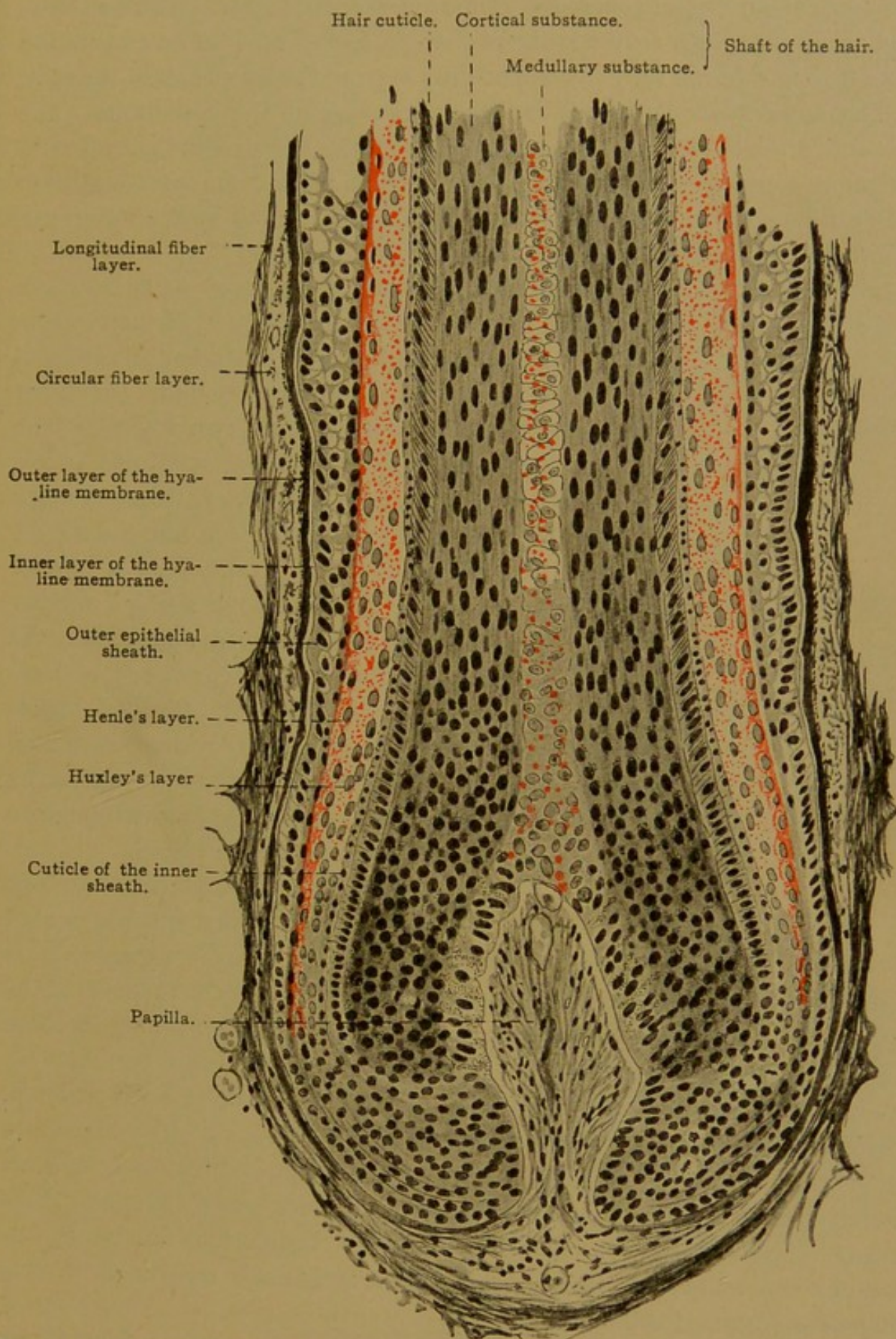


FIG. 399.—LONGITUDINAL SECTION OF THE LOWEST PART OF THE ROOT OF A HAIR. (From a section of the human scalp.) $\times 200$.
The kerato-hyalin granules are colored red.

layer which covers the papilla (Fig. 399). An inner stratum of the hyaline membrane is formed, according to Stöhr, from the epithelial cells of the root sheath. This inner stratum is provided with fine pores, and is always clear and homogeneous. It may unite with the connective tissue stratum so that both may appear as a single membrane. The connective tissue sheath is found fully developed only around the lower half of the root.

The *outer epithelial sheath* is an inpocketing of the epidermis. The stratum corneum extends to the sebaceous gland; the stratum granulosum continues somewhat deeper, but only a thinned stratum germinativum can be followed to the bulb. All of these are included in the outer epithelial sheath (Figs. 401-405, I, II, and 5).

The *inner epithelial sheath* extends from the sebaceous gland to the bulb. It begins as a layer of cornified cells below the termination of the stratum

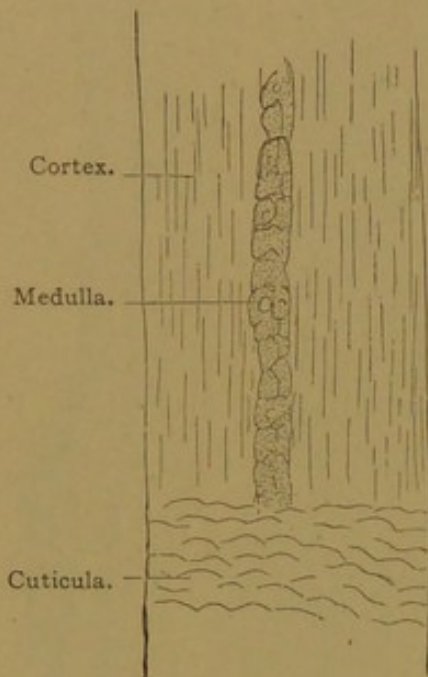


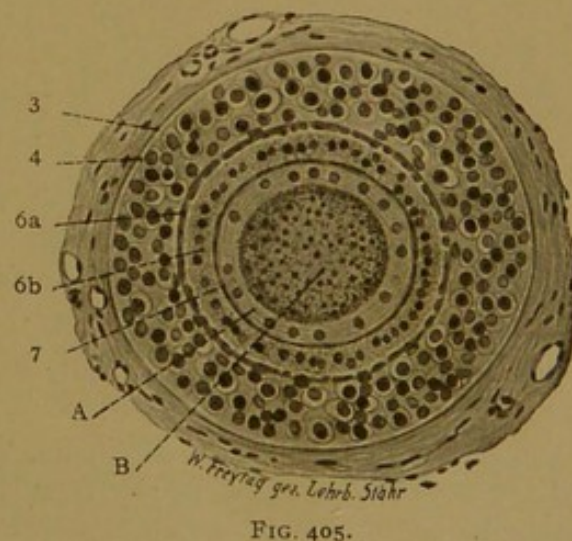
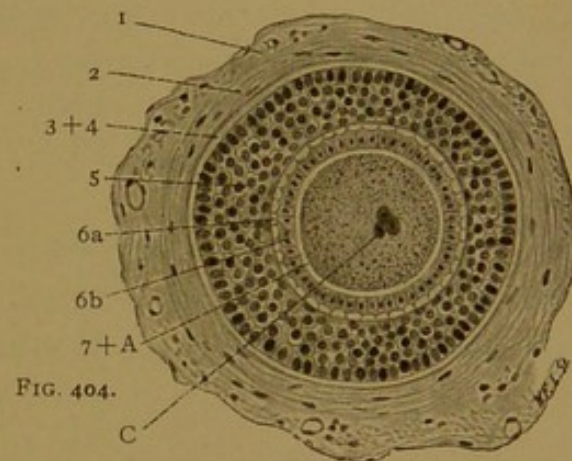
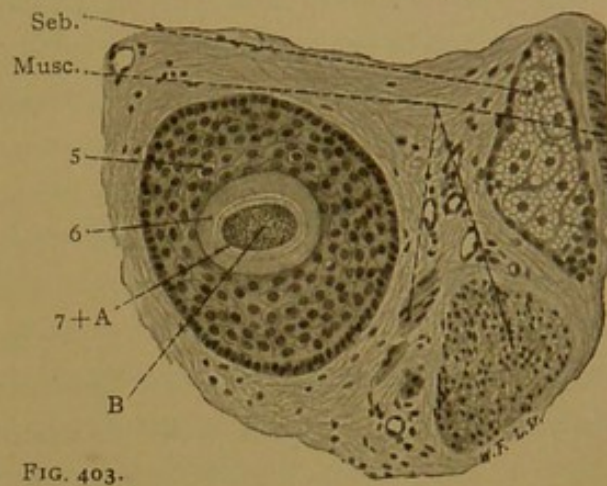
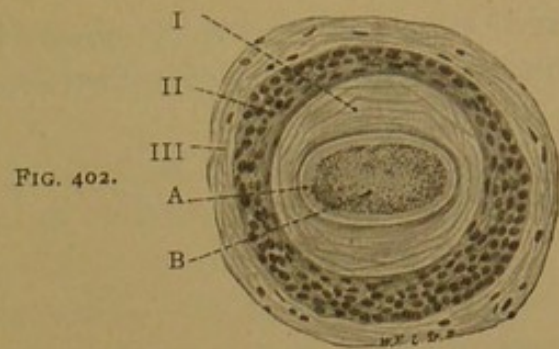
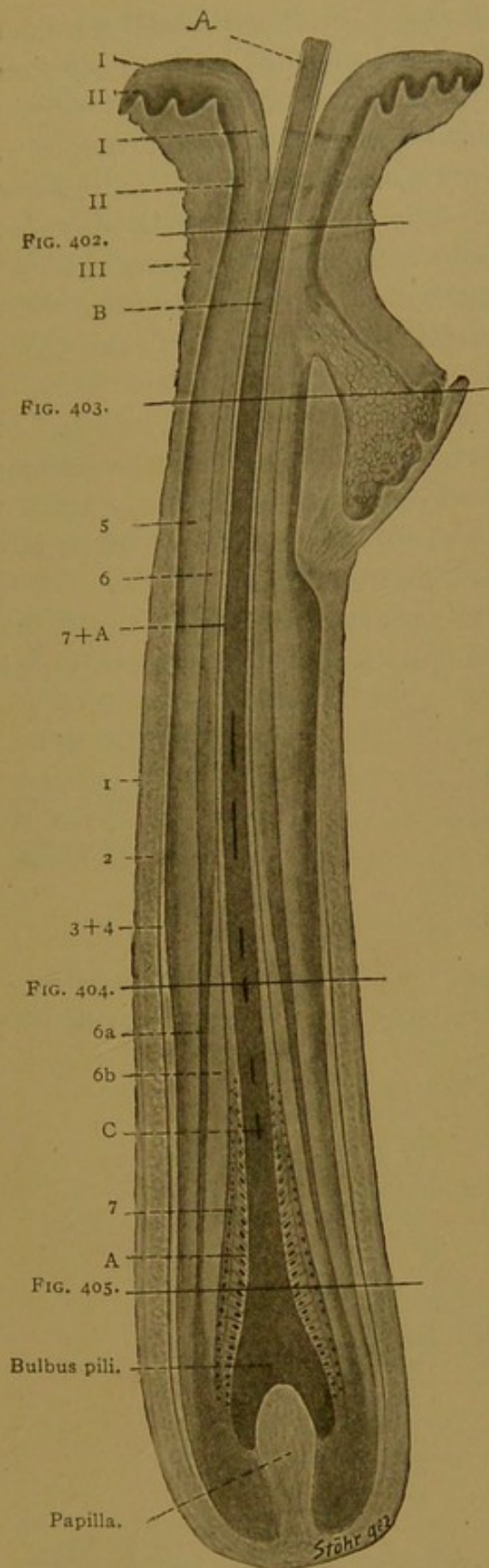
FIG. 400.—PART OF A WHITE HUMAN HAIR. $\times 240$.

granulosum, but it is not a continuation of that layer. Toward the bulb the inner sheath is divisible into two layers. The outer or *Henle's layer* consists of one or two rows of cells with occasional atrophic nuclei; for the most part they are non-nucleated. The inner or *Huxley's layer* is a row of nucleated cells. The inner surface of Huxley's layer is covered by a membrane, the cuticula of the sheath, composed of non-nucleated cornified scales. Traced downward, the elements of the inner epithelial sheath and its cuticula all become nucleated cells, but the layers may be distinguished almost to the neck of the papilla. There they lose their sharp boundaries, but may still be distinguished from the pigmented cells of the bulb. Traced upward, it is

found that kerato-hyalin granules appear in Henle's layer at the level of the papilla, and in Huxley's layer somewhat higher (Fig. 399); still higher these granules disappear and the cells of the inner sheath become cornified.

The *shaft* of the hair is entirely epithelial; it consists of cuticula, cortex and medulla (Fig. 400). The *cuticula*, which covers its surface, is a thin layer formed of transparent scales directed from the center of the shaft outward and upward, thus overlapping like inverted shingles. This arrangement is readily seen in wool and the hairs of various mammals, but is much less evident in human hair. The cuticula is composed of non-nucleated cornified cells.

The greater portion of the shaft is included in the *cortex*. Toward the bulb, the cortex consists of soft round cells; distally these cells become corni-



FIGS. 401-405.—FOUR CROSS SECTIONS OF A HAIR OF THE HEAD ($\times 160$), WITH A DIAGRAMMATIC LONGITUDINAL VIEW FOR ORIENTATION.

A, Cuticula; B, cortex; C, medulla. I, Str. corneum; II, str. germinativum; III, corium. 1-3, Connective-tissue sheath; 1, longitudinal fiber layer; 2, circular fiber layer; 3, conn. tiss. hyaline membrane; 4: epithelial hyaline membrane; 5, outer epithelial sheath; 6, inner epithelial sheath; 6a, Henle's layer, 6b, Huxley's layer; 7, cuticula of the sheath; Musc., arrector pili; Seb., sebaceous gland.

fied, elongated and very closely joined together. Their nuclei are then linear. The cortex of colored hairs contains pigment both in solution and in the form of granules. These granules are partly within the cells, and partly between them. Moreover every fully developed hair contains minute intercellular air-spaces, found within both cortex and medulla. But a *medulla* is lacking in many hairs, and when present, in the thicker hairs, it does not extend their whole length. It consists of cuboidal cells containing kerato-hyalin (Fig. 399), and generally arranged in a double row. Their nuclei are degenerating.

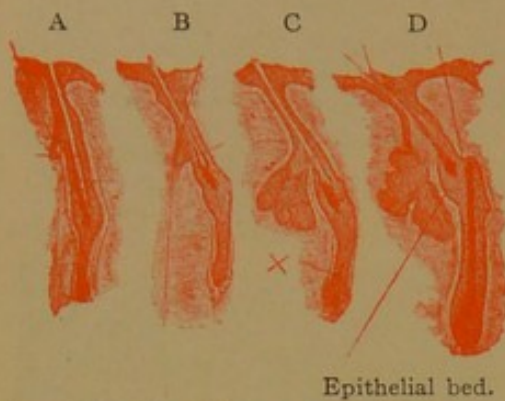


FIG. 406.—FOUR STAGES IN THE SHEDDING OF A HAIR. FROM THE SKIN OF THE NOSE OF A SEVEN AND ONE-HALF MONTHS EMBRYO. $\times 50$.

Parts of A and B are shown enlarged in Figs. 407 and 408.

Growth and Replacement of Hairs. The growth of the shaft, and of the inner epithelial sheath with its cuticula, takes place through continued

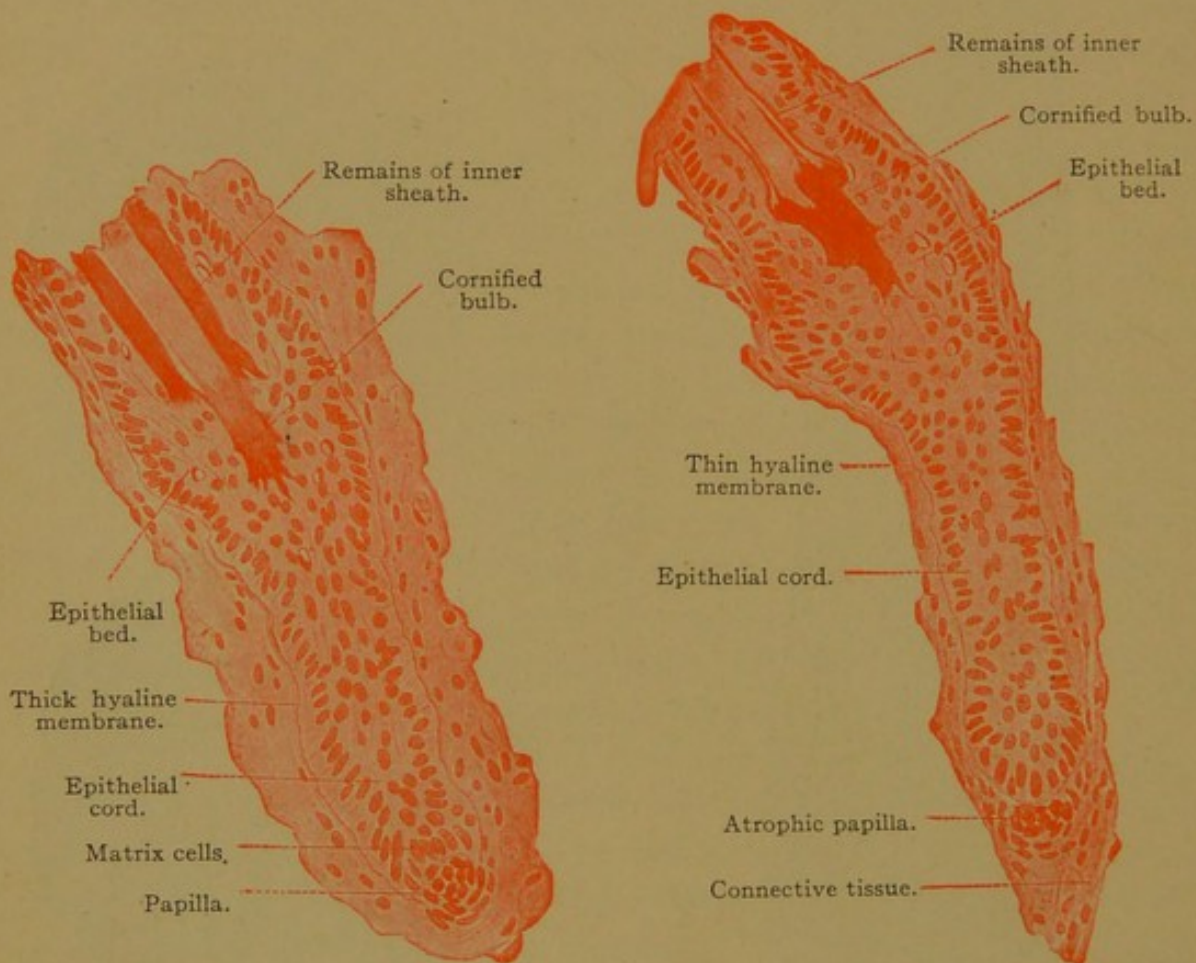


FIG. 407.—LOWER PART OF FIG. 406, A. $\times 230$.

FIG. 408.—LOWER PART OF FIG. 406, B. $\times 230$.

mitotic division of the epithelial *matrix cells* of the bulb of the hair. These become cornified, and are added from below to the cells previously cornified. Accordingly the oldest cells are at the tip of the hair and the young-

est are immediately above the bulb. The outer epithelial sheath grows in a radial direction from the inner surface of the hyaline membrane toward the shaft.

Shortly before and after birth, there is a general shedding of hair, subsequent to which the loss and replacement of individual hairs is constantly taking place. A hair of the scalp is said to last 1600 days, but the duration of other hairs has not been definitely determined. The process of removal begins with a thickening of the hyaline membrane and circular fiber sheath. The matrix cells cease to produce, first the inner epithelial sheath, and then the cuticulæ and shaft. The hollow bulb becomes a solid cornified "club." The matrix cells increase without differentiating into hair cells or sheath cells, and the clubbed hair, with its inner sheath, is forced outward to the level of the orifice of the sebaceous gland, where it may remain for some time (Fig. 406, D). The lower part of the outer epithelial sheath, which has become empty, forms an epithelial strand which shortens and draws the papilla upward; but the connective tissue sheath remains behind, forming the "hair stalk." After some time, the columnar cells of the epithelial bed proliferate, causing the epithelial cord to return to its former depth (Figs. 407 and 408), and a new hair develops in the old sheath upon the old papilla. The new hair in growing toward the surface completes the expulsion of its predecessor, which is dislodged together with cells of the adjacent epithelial bed.

SEBACEOUS GLANDS.

The sebaceous glands are simple, branched or unbranched alveolar structures situated in the superficial layer of the corium and usually ap-

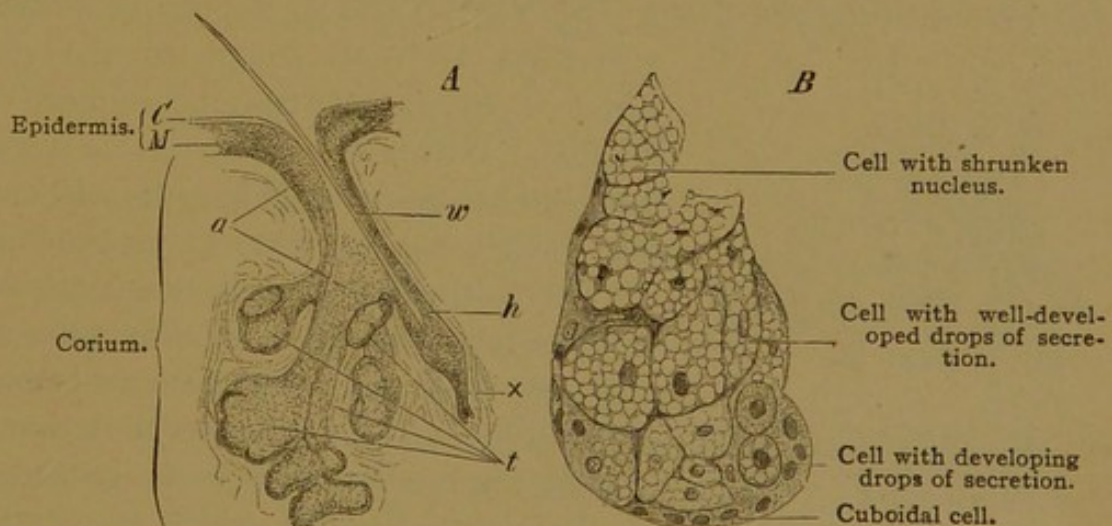


Fig. 409.—A, FROM A VERTICAL SECTION THROUGH THE ALA NASI OF A CHILD. $\times 40$. C, Stratum corneum; M, stratum germinativum; t, sebaceous gland consisting of four sacs, a, duct of the same; w, lanugo hair, about to be shed; h, sheath of the same at the base of which a new hair, x, is forming. B, FROM A VERTICAL SECTION OF THE SKIN OF THE ALA NASI OF AN INFANT. $\times 240$. Sac of a sebaceous gland containing gland cells in various stages of secretion.

pendent to the sheath of a hair (Fig. 398). In connection with the lanugo, a large gland may be associated with a very small hair (Fig. 409), and in

exceptional cases as at the margin of the lip or on the labia minora, they occur independently of hairs. They vary in size from 0.2 to 2.2 mm., the largest being found in the skin of the nose where the ducts are macroscopic. None are found in the palms or soles, where hairs also are absent.

The short duct is a prolongation of the outer epithelial sheath of the hair and is formed of stratified epithelium, the number of layers of which decreases toward the alveoli. The alveoli consist of small cuboidal basal cells, and of large rounded inner cells in all stages of fatty metamorphosis. As the cell becomes full of vacuoles, the nucleus degenerates, and the cell is cast off with its contained secretion. In life the product of the glands is a semi-fluid material, composed of fat and broken-down cells.

Glandulæ præputiales are sebaceous glands without hairs which are sometimes, but not always, found on the glans and præputium penis. The designation "Tyson's glands" is not justified since Tyson described the epithelial pockets $\frac{1}{2}$ to 1 cm. long which regularly occur near the frenulum præputii. Præputial glands and crypts are not found in the embryo. The præputium is united to the outer surface of the glans by an epithelial mass, which often persists after birth and is broken up by the formation of concentric epithelial pearls. Glands and crypts are absent from the præputium and glans of the clitoris.

SWEAT GLANDS.

The *glandulæ sudoriparæ* are long unbranched tubes terminating in a simple coil (described by Oliver Wendell Holmes as resembling a fairy's intestine, Fig. 410). The coil is found in the deep part of the corium or in the subcutaneous tissue (Fig. 387). The duct pursues a straight or

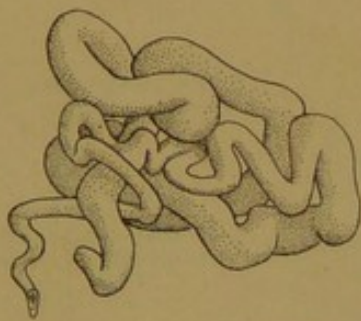


FIG. 410.—MODEL OF THE COILED PART OF A SWEAT GLAND FROM THE SOLE OF THE FOOT. (After Huber.)

somewhat tortuous course to the epidermis which it enters between the connective tissue papillæ. Within the epidermis its spiral windings are pronounced (Fig. 387); it ends in a pore which may be detected macroscopically.

The epithelium of the ducts consists of two or three layers of cuboidal cells; it has an inner cuticula, and an outer basement membrane covered by longitudinal connective tissue fibers. Within the epidermis its walls are made of cells of the strata through which it passes. The secretory portion of the gland (3.0 mm. long according to Huber) forms about three-fourths of the coil, the duct constituting the remainder. The secretory epithelium is a simple layer of cells, varying from low cuboidal to columnar, according to the amount of secretion which they contain. Those filled with secretion present granules, some of which are pigment and

fat. The product is eliminated through intra- and intercellular secretory capillaries. It is ordinarily a fatty fluid for oiling the skin, but it becomes the watery sweat under the influence of the nerves. The gland cells are not destroyed by either form of activity. The secretory tubule is surrounded by a distinct basement membrane, within which there is a row of small longitudinally elongated cells described as muscle fibers. They do not form a complete membrane, and they appear as a continuation of the basal layer of cells of the ducts.

Sweat glands are distributed over the entire skin, except that of the glans and the inner layer of the præputium penis. They are most numerous in the palms and soles. In the axilla there are branched sweat glands and large forms with 30 mm. of coiled tube. They acquire their large size at puberty and have been considered as sexual "odoriferous" glands. In the vicinity of the anus there are also branched sweat glands, together with the large unbranched "circum-anal glands."

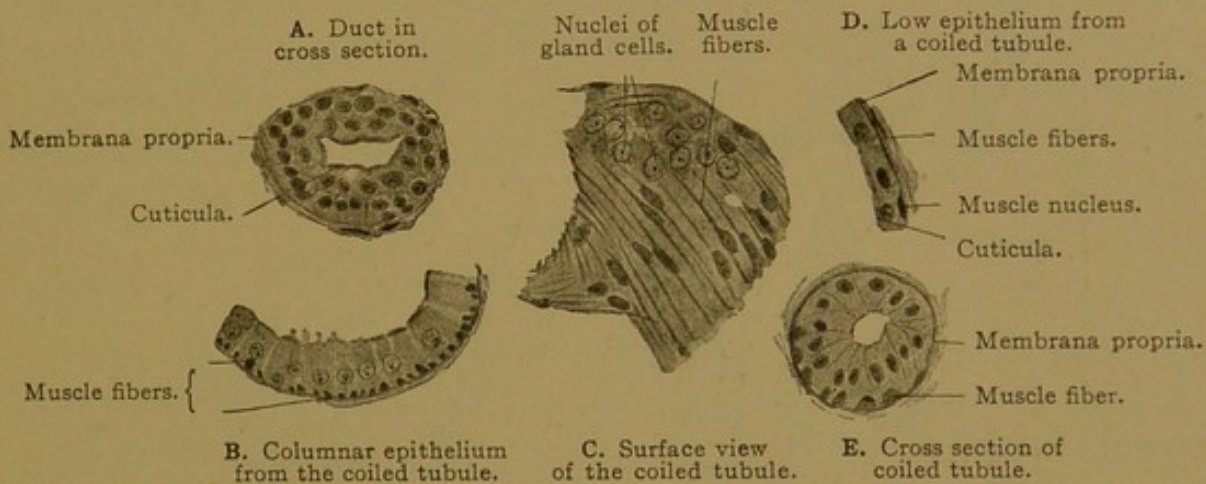


FIG. 411.—A-D, FROM A SECTION OF THE SKIN OF THE AXILLA; E, FROM THE FINGER TIP OF A MAN OF TWENTY-THREE YEARS. $\times 230$. E is not a true cross section.

VESSELS AND NERVES OF THE SKIN.

The arteries proceed from a network above the fascia, and branch as they ascend toward the surface of the skin. Their branches anastomose, forming a *cutaneous plexus* in the lower portion of the corium. From this plexus branches extend to the lobules of fat and to the coils of the sweat glands, about which they form "baskets" of capillaries. Other branches pass to the superficial part of the corium where they again anastomose, forming a *subpapillary plexus*, before sending terminal arteries into the papillæ. The subpapillary plexus sends branches also to the sebaceous glands and hair sheaths, but the papilla of a hair receives an independent artery. The veins which receive the blood from the superficial capillaries form a plexus immediately beneath the papillæ, and sometimes another just below the first and connected with it. The veins from these plexuses accompany the arteries and the ducts of the sweat

glands to the deeper part of the corium, where they branch freely, receiving the veins from the fat lobules and sweat glands. Larger veins continue into the subcutaneous tissue where the main channels receive specific names.

The *lymphatics* form a fine-meshed plexus of narrow vessels beneath

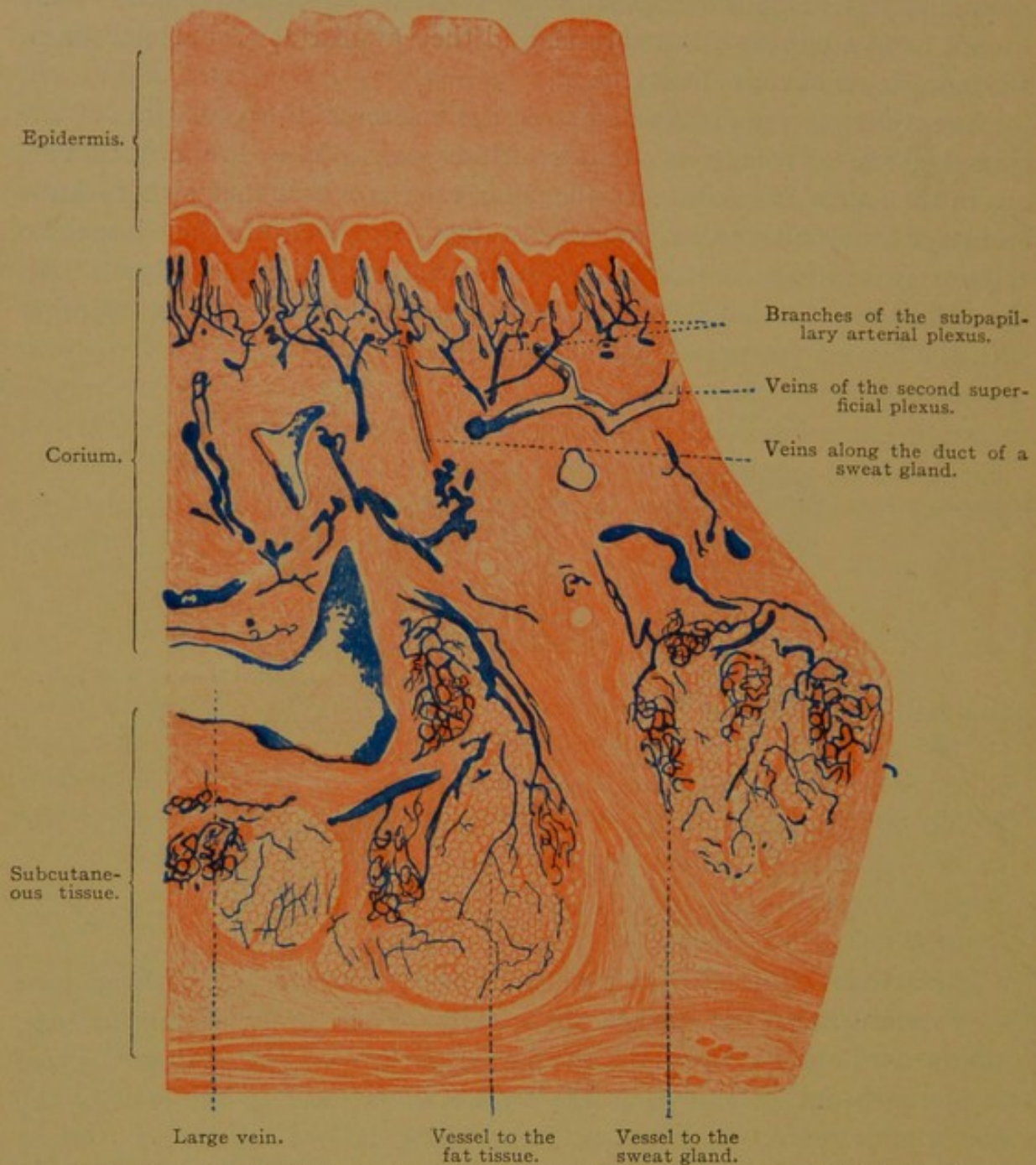


FIG. 412.—PART OF A VERTICAL SECTION OF THE INJECTED SKIN OF THE SOLE OF THE FOOT. $\times 20$.
The veins are not completely filled by the injection.

the subpapillary network of blood vessels, receiving tributary loops from the papillæ. This plexus empties into a wide-meshed subcutaneous plexus. There are lymphatic vessels around the hair sheaths, sebaceous glands, and sweat glands.

The *nerves* form a wide-meshed plexus in the deep subcutaneous tissue, and secondary plexuses as they ascend through the skin. The sympathetic,

non-medullated nerves supply the numerous vessels, the arrector pili muscles, and the sweat glands; an epilamellar plexus outside of the basement membrane sends branches through the membrane to terminate in contact with the gland cells. Medullated sensory nerves end in the various corpuscles already described, and in free terminations, some being intraepithelial. Medullated fibers to the hairs lose their myelin and form elongated free endings with terminal enlargements in contact with the hyaline membrane. (The nerves to the tactile hairs of some animals penetrate the hyaline membrane and terminate in tactile menisci among the cells of the outer epithelial sheath.) Small, round or discoid elevations of the epidermis, visible with the naked eye, occur close to the hairs as they emerge from the skin, being on the side toward which the hairs slope. These "hair discs" (Pinkus) are said to be abundantly supplied with nerves. The corium beneath the nails is rich in medullated nerves, the non-medullated endings of which enter the Golgi-Mazzoni type of lamellar corpuscle (having a large core and few lamellæ), or they form knots which are without capsules. Elsewhere the skin contains tactile corpuscles in its papillæ and lamellar corpuscles in the subcutaneous tissue, together with free endings in the corium and epidermis (as far out as the stratum granulosum).

MAMMARY GLANDS.

In young mammalian embryos generally, the mammary glands are first indicated by a thickened line of ectoderm extending from the axilla to the groin. Later much of the line disappears, leaving a succession of nodular thickenings corresponding with the nipples. In some mammals

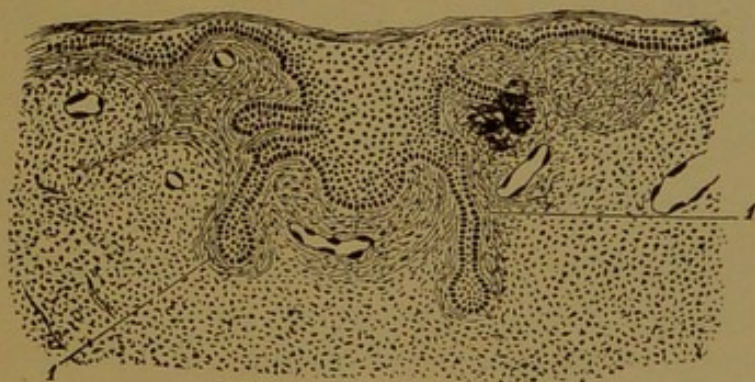


FIG. 413.—SECTION THROUGH THE MAMMARY GLAND OF AN EMBRYO OF 25 CM.
1, Connective tissue of the gland. (After Basch, from McMurrich.)

this row of nipples remains, in others only the inguinal thickenings, and in still others only those toward the axilla. Thus in man there is normally only one nipple on each side, but structures interpreted as accessory nipples are frequent; they are not always situated along the mammary line. In an embryo of 25 cm. (Fig. 413) several solid cords have grown out from

the ectodermal proliferation. There are ultimately from 15 to 20 of these in each breast, and they branch as they extend through the connective tissue. At birth the nipple has become everted, making an elevation, and at that time the glands in either sex may discharge a little milky secretion similar to the *colostrum* which precedes lactation. The glands grow in both sexes until puberty, when those in the male atrophy and only the main ducts persist. In the female enlarged terminal alveoli are scarcely evident until pregnancy. The glands until then are discoid masses of connective tissue and fat cells, showing in sections small scattered groups of duct-like tubes.

Toward the end of pregnancy each of the fifteen or twenty branched glands forms a mammary lobe, and its alveolo-tubular end pieces are

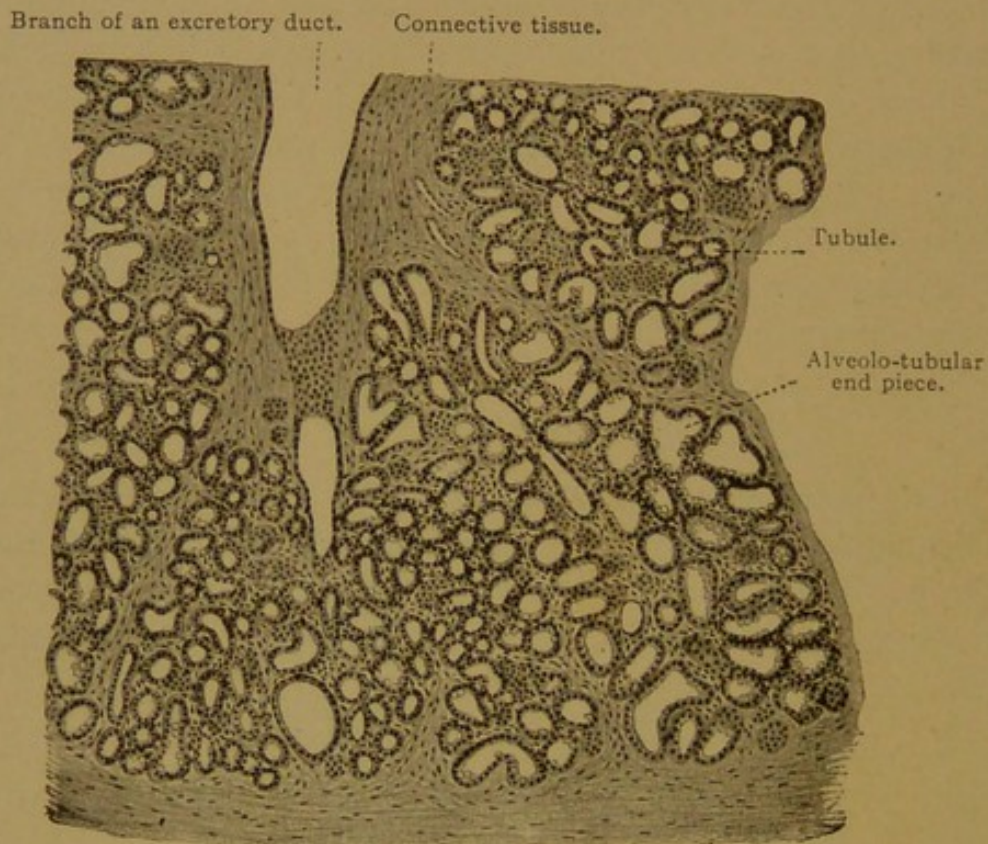


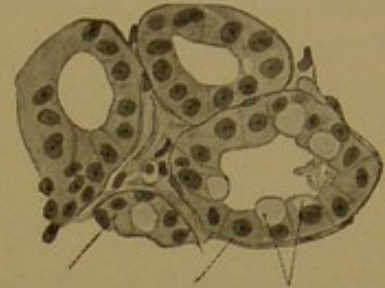
FIG. 414.—SECTION OF A HUMAN MAMMARY GLAND AT THE PERIOD OF LACTATION. $\times 50$.

grouped in lobules. The secretory epithelium is a simple cuboidal or flattened layer, in which fat accumulates at the seventh or eighth month of pregnancy. The fat first appears as small granules at the basal ends of the cells, where it is taken up from the surrounding tissue. It is not produced by the gland cells. Leucocytes, derived from the connective tissue, make their way between the epithelial cells of the alveoli and enter the gland lumen, where some of them degenerate; others receive fat from the gland cells, either in solution, or in drops which are devoured by phagocytic action. These fatty leucocytes grow to considerable size and are called *colostrum corpuscles*. Beneath the alveolar epithelium there are basal or basket cells, which have been compared with the muscle fibers of sweat

glands. A basement membrane separates them from the connective tissue which contains many lymphocytes and eosinophilic cells.

After the birth of the child, the gland cells become larger and are filled with stainable secretory granules and fat droplets; the latter are near the lumen and are often larger than the nucleus (Fig. 415). After two days of lactation, some of the gland cells are flat and empty of secretion. Others are tall and columnar, with a rounded border toward the lumen; often they contain two nuclei. The fat within them is not the result of degeneration as in sebaceous glands, nor a secretion produced by the nucleus; it accumulates through protoplasmic activity, and the cell may be filled several times before it perishes. Transitions between low empty cells and columnar forms occur, but mitoses are absent from the lactating gland. Mitotic divisions are numerous during pregnancy.

Milk consists of fat droplets, 2-5 μ in diameter, floating in a clear fluid which contains nuclein derived from degenerating nuclei, and occasionally a leucocyte or colostrum corpuscle. Free nuclei may be found, and some cells which undoubtedly are to be interpreted as detached from the alveoli of the gland.



Gland cell. Membrana Oil drops.
propria.

FIG. 415.—FROM A SECTION OF
THE MAMMARY GLAND OF A
NURSING WOMAN. $\times 250$.

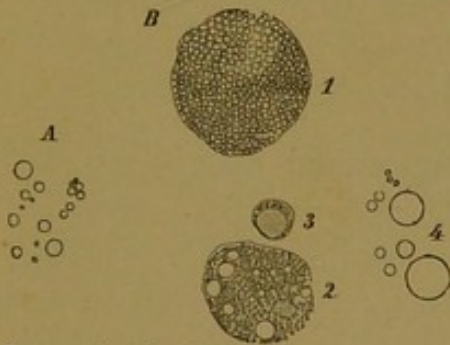


FIG. 416.—A., MILK GLOBULES FROM
HUMAN MILK. $\times 560$. B., ELE-
MENTS OF THE COLOSTRUM OF A
PREGNANT WOMAN. $\times 560$.

1. Cell containing uncolored fat glob-
ules; 2. cell containing minute
colored fat globules; 3. leucocyte;
4. milk globules.

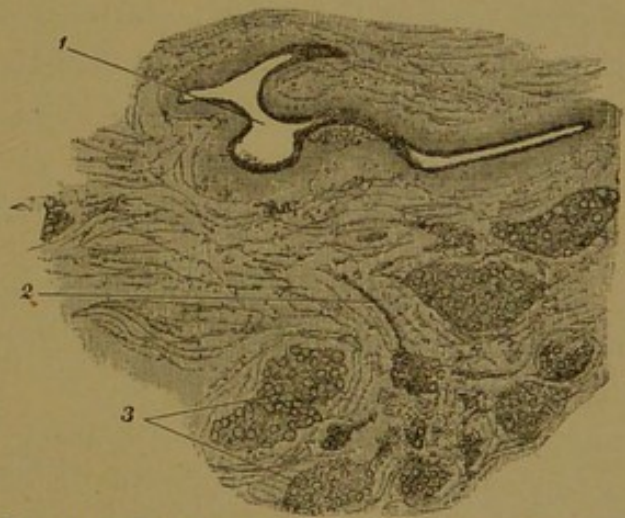


FIG. 417.—FROM A THICK SECTION OF THE
MAMMARY GLAND OF A WOMAN LAST PREGNANT TWO
YEARS BEFORE. $\times 50$.

1. Large excretory duct; 2. small excretory duct; 3.
gland lobules, separated from one another by con-
nective tissue.

At the end of lactation, the connective tissue, which has become greatly reduced owing to the enlargement of the glands, increases in quantity and the leucocytes reappear; as during pregnancy, they form colostrum corpuscles. The lobules become smaller and the alveoli begin to degenerate.

In old persons all the end pieces and lobules have gone and only the ducts remain.

The *ducts* are lined with simple columnar epithelium, surrounded by a basement membrane and generally by circular connective tissue bundles. Toward the nipple each duct forms a considerable spindle-shaped dilatation, the *sinus lactiferus*. The epithelium near the outlet of the ducts is stratified and squamous.

The skin of the nipple, and of the *areola* at its base, contains abundant pigment in the deepest layers of its epidermis. The corium forms tall papillæ and contains smooth muscle fibers, some of which extend vertically through the nipple and others are circularly arranged around the ducts. There are tactile corpuscles in the nipple, and lamellar corpuscles have been found beneath its areola. It is particularly sensitive, and upon irritation becomes rapidly elevated, due both to muscular and vascular activity. There are many sweat and sebaceous glands in the areola, and occasional rudimentary hairs. The *areolar glands* (of Montgomery) are branched tubular glands having a lactiferous sinus and otherwise resembling the constituent mammary glands. Their funnel-shaped outlets are surrounded by large sebaceous glands. The areolar glands are regarded as transitions between sweat glands and mammary glands.

Blood vessels enter the breast from several sources and form capillaries around the alveoli. Lymphatic vessels are found in the areola, around the sinuses, and in the interlobular tissue. The collecting lymphatics pass chiefly toward the axilla; a few penetrate the intercostal spaces toward the sternum. The nerves are mostly those which supply the blood vessels, but fibers are said to extend to the glandular epithelium.

SUPRARENAL GLANDS.

Development and General Features. The suprarenal glands are two flattened masses of cells, without lumen or ducts, situated in the retroperitoneal tissue above the kidneys. They vary considerably in size and shape, but are usually about a quarter of an inch thick and between 1 and 2 inches tall, sometimes being wider and sometimes narrower than their height. The right suprarenal gland is generally described as triangular and the left as crescentic.

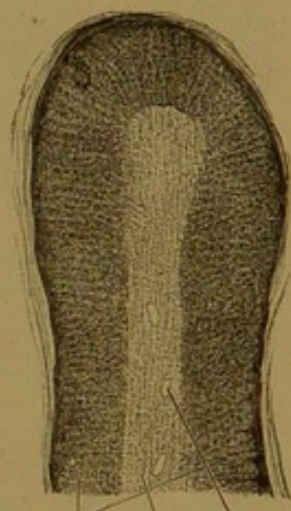The gland resting upon the kidney (*Glandula Reni incumbens*) was first described by Eustachius (Tractatio de Renibus, 1564). It was apparent from the outset that the relation of the suprarenal glands to the kidneys was merely that of juxtaposition, nevertheless most anatomists still find it convenient to describe them with the urinary organs. Certain early writers supposed that they were renal structures and named them "succenturiate kidneys." Bartholin (Anatomia, 1666) perceived the medulla, which he described as a cavity containing a black humor; and he published an extraordinary figure in which the gland resembles a cocoanut cut across with the lid lifted.

In accordance with this conception he named the structures "atrobiliary capsules," and the name *capsule* is still often applied to them. Diemerbroeck (Anatome, 1672), following Wharton, states that "the glands are found at a place where there is a plexus of nerves, to which they are firmly united." In reviewing the various "conjectures" as to their function, he writes, "Wharton thinks that in these capsules a certain juice is removed from the plexus of nerves on which they lie, useless indeed to the nervous system, but which, flowing thence into the veins, may serve some useful purpose." The intimate relation of these glands to the nervous system, and the production of an internal secretion received by the veins, have since been demonstrated; in certain recent works the glands have even been described as parts of the nervous system. Diemerbroeck concludes by hoping that physicians, through many autopsies, may find out to what diseases these glands give rise. In 1855, Addison described the disease, usually fatal, which is thought to depend upon the loss of function of these glands. Their physiological importance has been amply demonstrated, but they still present fundamental problems, both as to function and structure.

A section through a fresh suprarenal gland reveals at once the division into cortex and medulla. The cortex is yellowish, owing to the presence of lipid substance, and the medulla is dark brown, due in part to the large amount of blood which it contains. The color contrast is usually very striking, and it is shown also in unstained sections of tissue preserved in chromic acid solutions (Fig. 418), although the medulla may then be lighter than the cortex. Not only do the cortex and medulla differ in gross appearance, but they are radically different in embryonic origin, and in the sharks they exist as separate organs. In sharks the medulla is represented by groups of chromaffin cells associated with the sympathetic ganglia, and the cortex takes the form of an "interrenal gland," composed of cords of mesodermal cells with a sinusoidal circulation. In human embryos corresponding parts arise separately, but they come together to form a single gland.

The cortex appears first, and is formed from cells which develop as buds of the coelomic epithelium, growing into the mesenchyma on either side of the root of the mesentery, medial to the Wolffian bodies. In embryos of 8-12 mm., the buds or cords have become detached from the peritoneal epithelium (Zuckermandl), and in cross sections they appear as round masses of cells penetrated by a network of slender veins. The cells of these masses rest directly against the vascular endothelium, so that the vessels are described as sinusoids.

Meanwhile cells from the sympathetic ganglia grow ventrally along the medial side of these masses, where they are conspicuous because of their dark stain (Fig. 419). These cells, which give rise to the medulla of



Cortex. Medulla.
FIG. 418.—SECTION OF THE
SUPRARENAL GLAND OF
A CHILD. $\times 15$.

the suprarenal gland, do not appear like nerve cells and may be radically different from them, although always closely associated with the sympathetic ganglia. Because of their affinity for chromium they are known as *chromaffin cells*. They produce the important internal secretion, *adrenalin*, which on injection causes contraction of the musculature of the blood vessels, with consequent rise in blood pressure. The chromaffin cells are not confined to the suprarenal glands, as already stated (p. 152). In embryos of 15–20 mm., strands of chromaffin cells are seen penetrating the cortical portion of the gland, but it is not until much later that they gather in a central mass which constitutes the medulla; even at 190 mm.

the invasion is not complete (Zuckerkindl). As a whole, the gland acquires a relatively very great size in embryos.

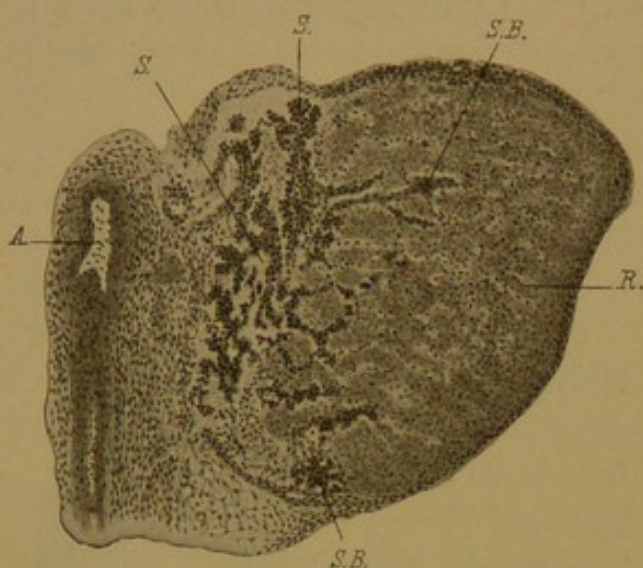


FIG. 419.—SECTION OF THE SUPRARENAL GLAND OF AN EMBRYO OF 17 MM. (Wiesel.)

A, Aorta; R, cortical portion; S, chromaffin tissue, penetrating to form the medulla at S.B. (From McMurrich's *Development of the Human Body*.)

108, pp. 257–280). Such glands usually consist entirely of cortex, but they may contain medullary substance. Isolated *paraganglia*, consisting entirely of medullary substance, are not regarded as suprarenal glands. There is no evidence that accessory suprarenal glands may arise from the coelomic epithelium at a distance from the main glands (Zuckerkindl, Keibel and Mall's *Human Embryology*, vol. 2).

Adult Structure. The cortical substance may be divided into three layers or zones—the *zona glomerulosa*, *zona fasciculata*, and *zona reticularis* (Fig. 420). The *zona glomerulosa*, found just beneath the capsule, is said to develop between the second and third years after birth, “reaching its characteristic structure only in the later years of childhood.” It consists of round masses of cells which in man are much like those of the *zona fasciculata*; in some animals they are distinguished by their columnar shape. The *zona fasciculata* is composed of cords of rounded or cuboidal cells, containing secretory granules and an abundance of fat vacuoles (Fig. 421). There is no lumen within these cords and they are not surrounded by basement membranes. Thin-walled vessels pass between them, sometimes lodged in connective tissue strands proceeding from the capsule. The

cords of the zona fasciculata are perpendicular to the surface; they end below in a network, the zona reticularis. In this deeper portion the cells

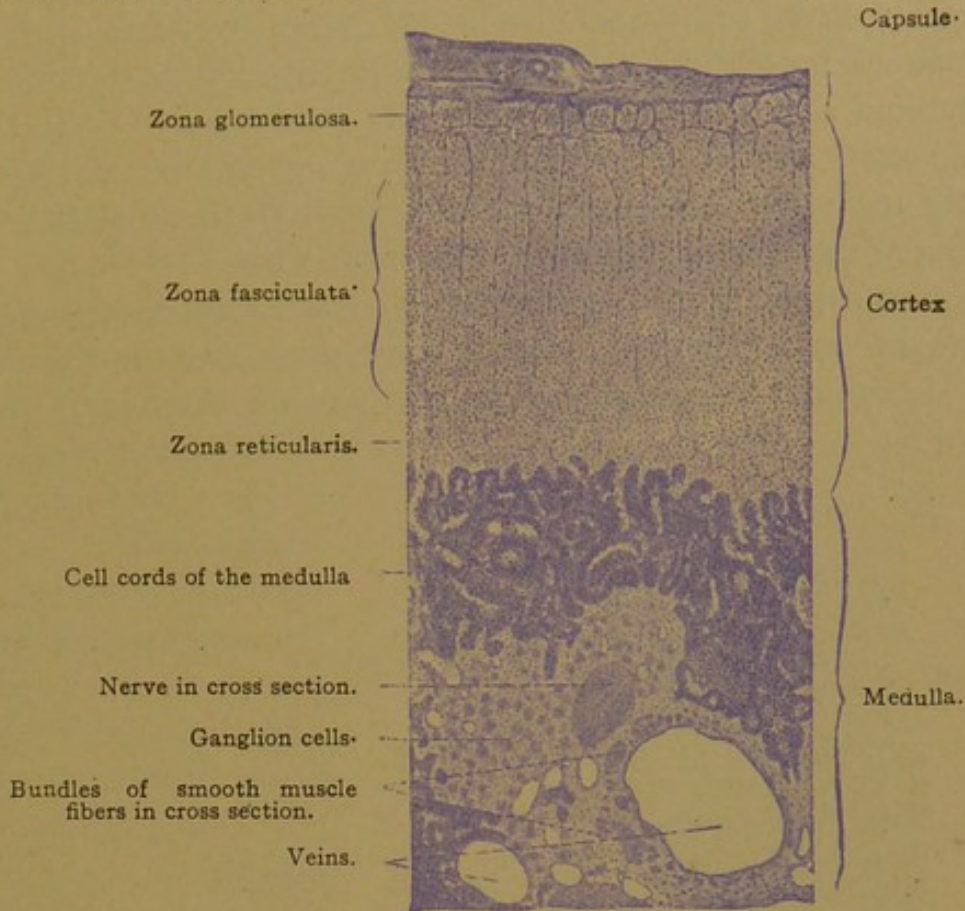


FIG. 420.—SECTION OF A HUMAN SUPRARENAL GLAND. $\times 50$.

become pigmented, so as to form a dark brown band visible without magnification. Fat vacuoles are here smaller or absent, as seen in Fig. 421, which shows also the close relation between the cells and the vascular endothelium. In portions of the suprarenal gland where the medulla is lacking, the zonæ reticulæ of the opposite sides come together, forming the core of the organ.

The medulla is composed of chromaffin cells arranged in strands and masses which unite to form a network, with lacunar veins filling the interstices (Fig. 420). The cells contain an abundant granular protoplasm, but they tend to shrink, even in well-preserved specimens, so that they appear stellate (Fig.

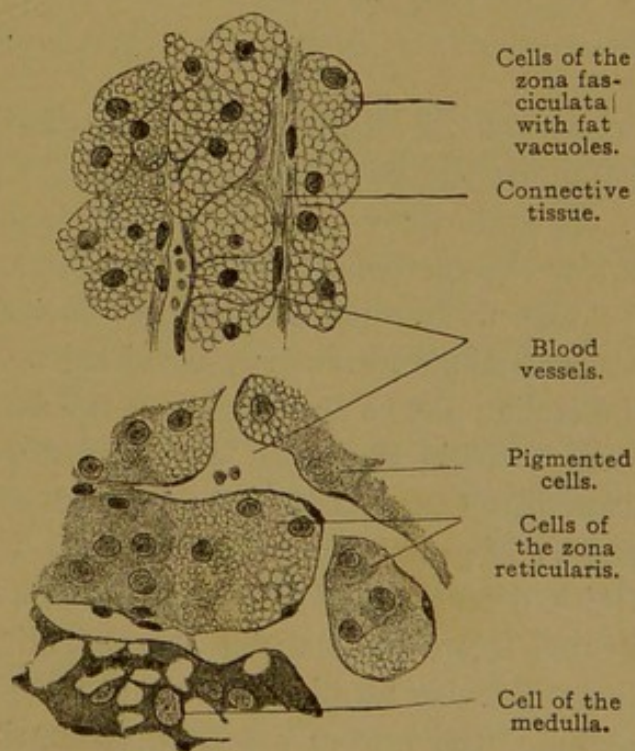


FIG. 421.—FROM A SECTION OF THE SUPRARENAL GLAND OF AN ADULT. $\times 360$.

421). These are the cells which are believed to produce adrenalin; the function of the cortical cells remains unknown.

The capsule of the suprarenal glands is a connective tissue layer, said to contain smooth muscle fibers and small ganglia, in addition to vessels and nerves. Around the blood vessels especially, it contains elastic tissue. The capsule sends slender prolongations into the gland, and elastic tissue occurs in the medulla. The cortex contains very few if any elastic fibers, and its framework appears to consist of reticular tissue.

The arteries supplying the suprarenal glands are from several sources. They divide into many small branches in the capsule, and these penetrate the cortex, forming a long-meshed capillary network (Fig. 422). In the

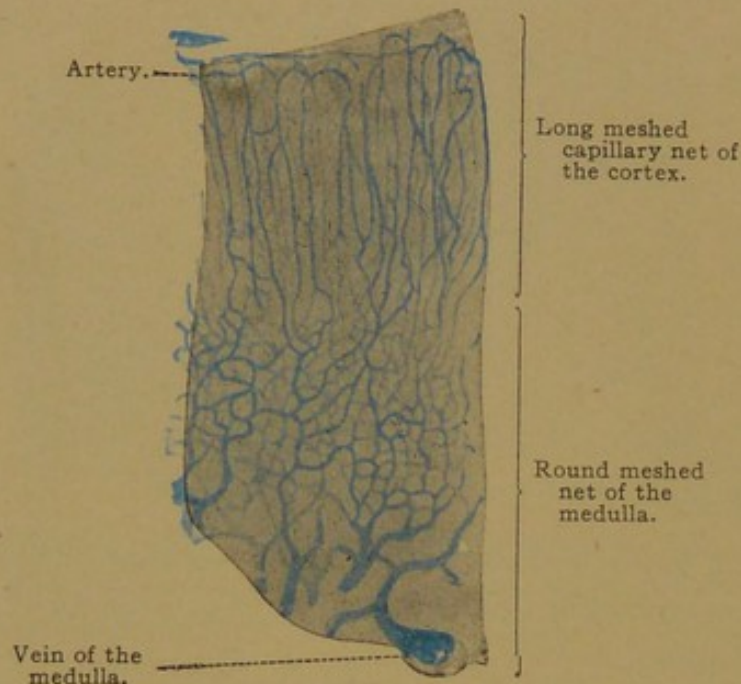


FIG. 422.—FROM A SECTION OF AN INJECTED SUPRARENAL GLAND OF A CHILD. $\times 50$.

medulla the meshes become round and the vessels collect to form veins, the larger of which are accompanied by longitudinal strands of smooth muscle fibers. Some arteries are said to pass directly from the capsule to the medulla, without branching in the cortex. Within the medulla the veins unite to form the *central veins*, which are the main stems of the *suprarenal veins* (Fig. 168, p. 173). They

emerge at the *hilus*; the right empties into the inferior vena cava and the left joins the left renal vein.

Lymphatic vessels have been found in the capsule, where they may drain the cortex, and also in the medulla, emerging at the hilus.

The numerous, mostly non-medullated *nerves*, of which a human suprarenal gland receives about thirty small bundles, proceed chiefly from the celiac plexus and pass with the arteries from the capsule into the medulla. Within the capsule they form a plexus, from which branches descend into the zona glomerulosa and zona fasciculata; there they end on the surface of groups of epithelioid cells, without penetrating between the individual cells. The plexus in the zona reticularis is more abundant, and is formed from fibers which descend directly through the outer zones; its fibers likewise terminate on the outer surface of groups of cells. In the medulla, the nerves are extraordinarily abundant and each cell is surrounded by nerve fibers. Groups of sympathetic ganglion cells are found

here and there in the medulla but only rarely in the cortex. A part of the nerves terminate in the walls of the vessels.

CENTRAL NERVOUS SYSTEM.

SPINAL CORD.

Development and General Features. The formation of the medullary tube, which gives rise to the spinal cord and brain, has already been described (*cf.* Fig. 125, p. 133); in the following section, the differentiation which takes place in its wall will be considered, together with the general features of the spinal cord in the adult.

Very early in development, the cells of the medullary tube form a syncytium. Those nuclei of the syncytium which border upon the lumen

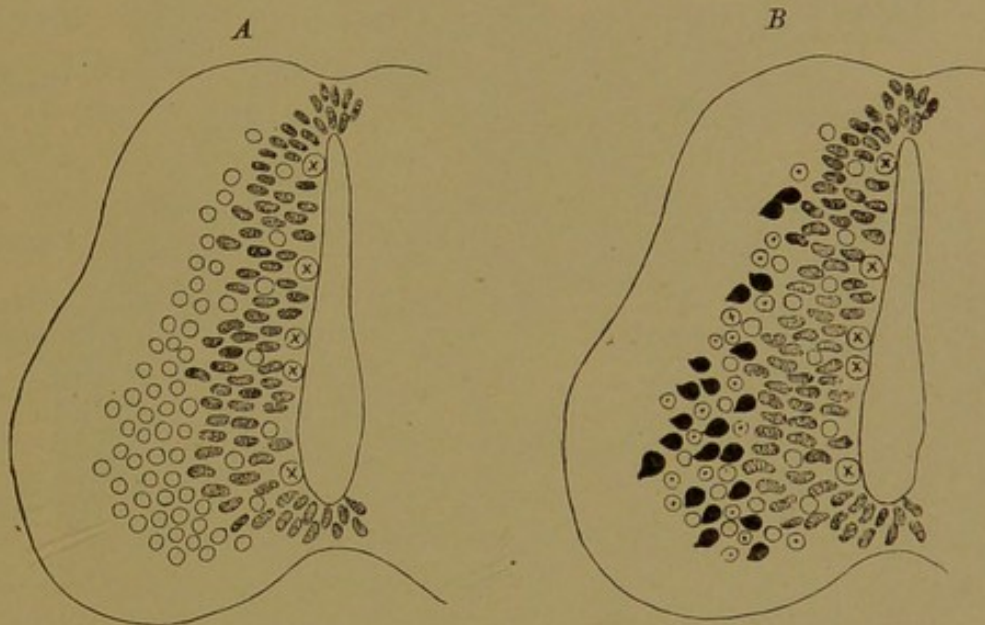


FIG. 423.—DIAGRAMS SHOWING THE DIFFERENTIATION OF THE CELLS IN THE WALL OF THE MEDULLARY TUBE. (Schaper.)

The germinal cells are stippled, and the indifferent cells are empty circles. Circles with dots represent neuroglia cells, and the black cells are neuroblasts. Circles containing an x are germinal cells in mitosis.

of the tube, or *central canal*, divide repeatedly by mitosis, and many of them are forced outward laterally, so that the sides of the tube become greatly thickened. In the floor and roof of the tube a corresponding thickening fails to take place, as shown in Fig. 423.

The lateral walls of the tube very early become divisible into three layers (Fig. 423). The inner layer consists of germinal or proliferating cells and is wide only in the embryo. In the adult it becomes reduced to a single layer of inactive cells, which surround the central canal like a simple epithelium and constitute the *ependyma* (Gr., ἐπένδυμα, a cloak). The middle layer is composed of cells derived from the germinal layer, and in the adult it constitutes the *gray substance* of the cord. Its cells early differentiate into two types—the supporting cells, or *neuroglia*, and the

nerve cells. The processes of the nerve cells, in so far as they are within the limits of the gray substance, are non-medullated. The outer layer is at first entirely free from nuclei, and later it contains only a few cell bodies, belonging with the neuroglia and with the endothelium of vessels which penetrate the cord; it contains no nerve cells. This layer consists of a network of neuroglia fibers through which nerve fibers extend in various directions, but chiefly up and down the cord. As these fibers become medullated, the layer becomes white macroscopically, and it forms the *white substance* of the adult cord. In preparations in which myelin is

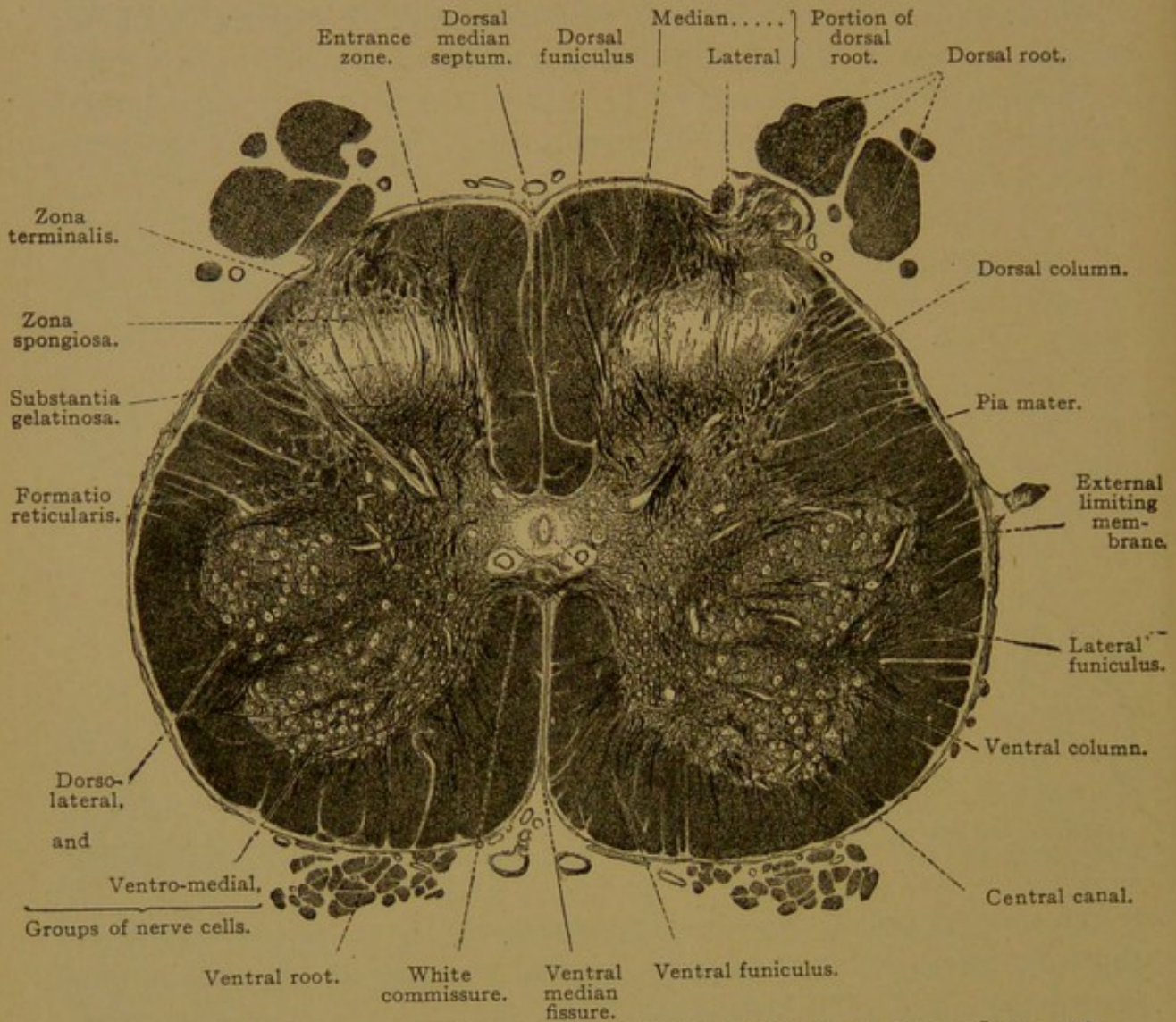


FIG. 424.—CROSS SECTION OF THE LUMBAR ENLARGEMENT OF THE HUMAN SPINAL CORD. $\times 8$.

deeply stained, the white substance appears darker than the gray substance (Fig. 424). From what has been said, it appears that the medullary tube early becomes divisible into inner, middle, and outer layers, which give rise to ependyma, gray substance and white substance respectively.

As the medullary tube enlarges, ventral swellings are formed on either side of the median line (Fig. 423). These later project so far ventrally that the floor of the medullary tube is found at the dorsal end of a *ventral*

median fissure, which is bounded on either side by the bulgings just described. Into each of these two swellings the gray substance projects, forming the ventral "horns" or columns (*columna anterior* or *ventralis*). The term "horn" refers to the appearance in sections, and "column" applies to their true form, taken as a whole. Corresponding with the ventral columns of gray substance, there are two dorsal columns, which arise somewhat later, and cause the gray substance, as seen in sections, to assume the form of a letter H. With many variations this appearance is characteristic of the entire spinal cord in mammals generally. As seen in Fig. 424, there are secondary swellings on the sides of the "H" which are called lateral columns; at certain levels they are ill-defined or absent.

Instead of forming a dorsal median fissure, the medullary tube produces a *dorsal median septum*. The lower or ventral part of the septum is apparently formed by the coalescence of the lateral walls of the medullary tube, thus leaving the ventral portion of the original lumen as the central canal of the adult. Occasionally this small cavity, 0.5-1.0 mm. wide, is entirely obliterated. The dorsal portion of the septum consists of neuroglia fibers extending from the roof of the central canal to the periphery of the cord. Thus in the adult the cord is divided into right and left halves, except for the transverse connections or *commissures* near the central canal. These include a *dorsal commissure*, a *ventral gray commissure*, and a *ventral white commissure*.

The white substance of each half of the cord is subdivided into three longitudinal *funiculi*, each of which includes several smaller bundles or *fasciculi*, otherwise known as "fiber tracts." The funiculi are dorsal, lateral, and ventral respectively, and their boundaries are seen without magnification. The dorsal or sensory roots enter the cord along a groove known as the *dorso-lateral sulcus*, and the ventral or motor roots emerge along the *ventro-lateral sulcus*. All the white substance between these two sulci is included in the lateral funiculus. The dorsal funiculus extends from the dorso-lateral sulcus to the median dorsal septum; and the ventral funiculus extends from the ventro-lateral sulcus to the mid-ventral fissure.

The fasciculi of which each funiculus is composed cannot be studied profitably in normal specimens. They have been followed chiefly by observing the effects of local injury and disease, for if a group of nerve cells is destroyed, all the fibers proceeding from it will degenerate. In this way it has been shown that the fibers of the funiculi are not arranged indiscriminately, but occur in definite tracts, which in some respects are radically different in different animals. Thus the fibers of voluntary motion which descend from the cerebral hemispheres to the motor cells of the cord, forming the *cerebro-spinal fasciculi*, are found in the dorsal fun-

iculi of rodents but in the lateral and ventral funiculi of the human cord. In man most of these fibers, in descending from the brain, cross to the opposite side in the medulla oblongata and complete their descent in the lateral funiculus of the cord, where they form the *lateral cerebro-spinal fasciculus*; they terminate in relation with motor cells on the same side of the cord. A smaller number of these fibers fail to cross in the medulla, and descend in the ventral funiculus as the *ventral cerebro-spinal fasciculus*; these fibers cross to the opposite side in the cord, passing through the ventral commissure, and then terminate in relation with the motor cells. Thus the cerebro-spinal fibers all cross, but the decussation may take place either in the medulla or in the cord.

The fibers which convey tactile stimuli to the brain enter by the dorsal roots and pass into the gray substance of the cord, where they terminate in relation with small cells dorsally placed. Fibers from these cells cross to the opposite side of the cord through the gray commissure, and then enter the white substance of the lateral funiculus in which they ascend to the brain. One of these fibers and a descending fiber of the lateral cerebro-spinal fasciculus are shown in the diagram, Fig. 123, p. 131.

In addition to fibers of the long tracts, such as pass between the spinal cord and the hemispheres, cerebellum and other parts of the brain, the ventral and lateral funiculi contain fibers which emerge from the gray substance of the cord at one level and re-enter it at another, thus placing the cells at different levels in communication. The fibers of these "ground bundles" or *fasciculi proprii* generally remain close to the gray substance. Their entrance and exit along the lateral concavity of the gray substance causes it to be broken up into a *formatio reticularis* (Fig. 424).

The dorsal funiculi in the upper part of the cord are each subdivided into a slender medial *fasciculus gracilis* (column of Goll) and a wider lateral *fasciculus cuneatus* (column of Burdach), which are partially separated from one another by a septum. These fasciculi are composed chiefly of the fibers of "muscle sense," which enter by the dorsal roots and divide into ascending and descending branches. Many of these pass into the gray substance of the cord after traveling varying distances in the dorsal funiculi. Some of the ascending fibers, however, are very long and extend to the medulla oblongata, gradually approaching the median septum in their ascent. The gracile fasciculi are composed of these long ascending fibers, and since they are not segregated in a distinct bundle in the lower portion of the cord, this fasciculus is absent from the lumbar region. In addition to the fibers of muscle sense, the dorsal funiculi contain some fibers of general sensation, a limited number of association fibers, and others.

The description of the fiber tracts in the spinal cord and brain is the subject of special text-books; they are briefly and clearly described by

Villiger (Brain and Spinal Cord, translated by Piersol, 1912). The form of the cord at different levels is considered in works on gross anatomy. In general, the white substance increases toward the brain, since the cervical cord contains the fibers to and from all the lower levels in addition to those for the cervical region itself. In levels which supply the nerves to the upper and lower limbs, there is a general increase in both gray and white substances, producing the *cervical* and *lumbar enlargements*, respectively. The lower end of the cord tapers into the rudimentary *filum terminale*.

Adult Structure. The spinal cord and brain are surrounded by two membranes or *meninges*, of which the outer is dense and fibrous, and is known as the *dura mater*; and the inner is thin and vascular, forming the *pia mater*.

Curiously they are not called membranes, and the term *meninx* (in the singular) is not employed in anatomy. They retain the ancient Arabic designation of "mother of the brain," following, according to Hyrtl, a general Arabian tendency to name things "mothers," "fathers," etc. (The vena cava was the *mater venorum*, and the pupil, the *filia oculi*.) Carrying the figure further, the adjectives of double meaning, *dura* and *pia*, were substituted for dense and thin. In the fifteenth century it was said that these membranes were called *matres* because they produce the membranes surrounding the nerves, the coats of the eye, and the periosteum of the skull, with which they are continuous; but Hyrtl denies that the term has any such significance.

The *dura mater spinalis*, or *dura mater* of the cord, consists of compact fibrous connective tissue with many elastic fibers, flat connective tissue cells and plasma cells. Its inner surface is covered by a layer of flat cells forming a mesenchymal epithelium. It has few nerves and blood vessels. Anteriorly it is continuous with the *dura mater* of the brain at the foramen magnum. It does not fill the vertebral canal, and is not continuous with the vertebral periosteum. Around it externally there is a layer of vascular fatty connective tissue; and internal to it there is a capillary cleft containing a very small amount of fluid. This *subdural space* connects with tissue spaces in the *dura* and with those which extend out in the perineurium of the peripheral nerves. It communicates freely, but probably indirectly, with the lymphatic vessels.

The *pia mater spinalis*, as described by Stöhr, is a two-layered sac. The outer layer is covered on its free outer surface with a simple layer of flat cells, which is lightly connected with the *dura*, and forms the inner wall of the subdural space. The inner layer, or *pia proper*, is a delicate and very vascular connective tissue, closely connected with the spinal cord, into which it sends prolongations accompanying the blood vessels. The arteries of the spinal cord are primarily two pairs, situated as shown in Fig. 125, *E* (p. 133) and in Fig. 424. One pair is ventral to the dorsal roots, and the other is near the mid-ventral fissure; their branches supply both the white and gray substance, and the collecting veins branch freely

in the pia mater. Between the two layers of the pia, as described by Stöhr, there is a wide space filled with *cerebro-spinal fluid* and traversed by many strands and membranes which pass from one layer of the pia to the other. These strands constitute the *arachnoid membrane*, so-called from its cobwebby texture. Often the name is restricted to the subdural membrane (following Henle), so that the spaces between the meshes of the arachnoid are described as subarachnoid. They are preferably termed *arachnoid spaces* and they are of great importance. The fluid which they contain has access to that within the central canal of the cord and the ventricles of the brain, through an aperture in the thin roof of the medulla

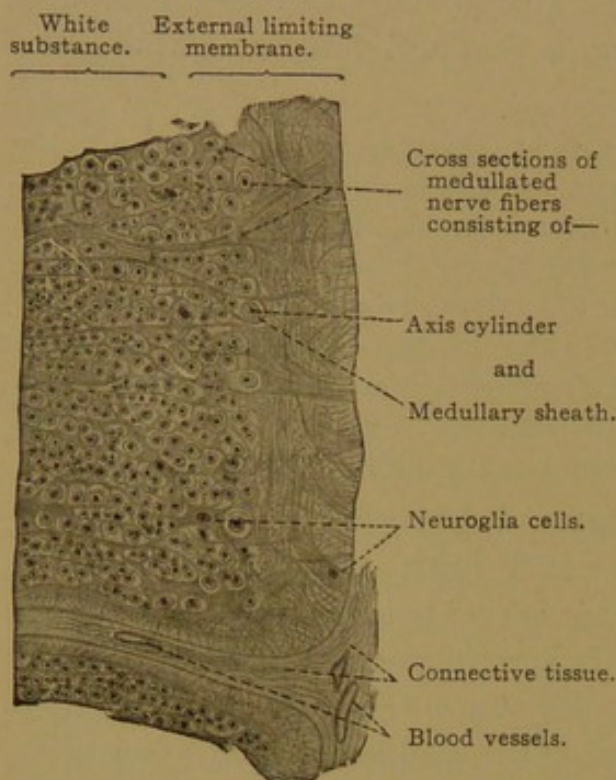


FIG. 425.—FROM A CROSS SECTION OF THE HUMAN SPINAL CORD IN THE REGION OF THE LATERAL FUNICULUS. $\times 180$.

oblongata. Whether the arachnoid spaces open directly into lymphatic vessels may be questioned, but undoubtedly they are freely drained by the lymphatic system.

On either side of the cord, between the successive spinal nerves, there is a frontally placed triangular plate of fibrous connective tissue, which passes from the pia to the dura and serves to support the cord. The succession of these pointed projections, with their bases attached to the pia, constitutes the *denticulate ligament*.

White Substance. The white substance of the cord consists essentially of medullated nerve fibers supported by a network of neu-

roglia. Toward the outer surface, the neuroglia fibers become felted together, forming an external limiting membrane just within the pia mater (Fig. 425); this is an ectodermal tissue, which must be distinguished from the adjacent connective tissue penetrating the cord with the blood vessels. Although in transverse sections the neuroglia fibers appear to be radially arranged (Fig. 425), longitudinal sections show that they extend also up and down the cord (Fig. 426), and in fact they form a diffuse syncytial network. The protoplasm of this network is characterized by the presence of stiff neuroglia fibrils, imbedded in the peripheral exoplasm, and passing freely from one cell territory to another. They are well shown in specimens stained with Mallory's phosphotungstic acid hæmatoxylin, and resemble the myoglia and fibroglia fibrils both in form and staining reaction.

As the nerve fibers which occupy the interstices of the neuroglia network increase in number and acquire myelin sheaths, thus becoming larger, the protoplasm of the neuroglia is compressed into stellate accumulations, often surrounding a nucleus (Fig. 428, A). In Golgi preparations they appear as in Fig. 427, and are described as long rayed, and short rayed or mossy cells. These forms represent clumps of neuroglia fibers, sometimes clogged with precipitate, in the center of which there may or may not be a nucleus.

The *nerve fibers* of the white substance vary in diameter, the coarsest being found in the ventral funiculi and lateral parts of the dorsal funiculi;

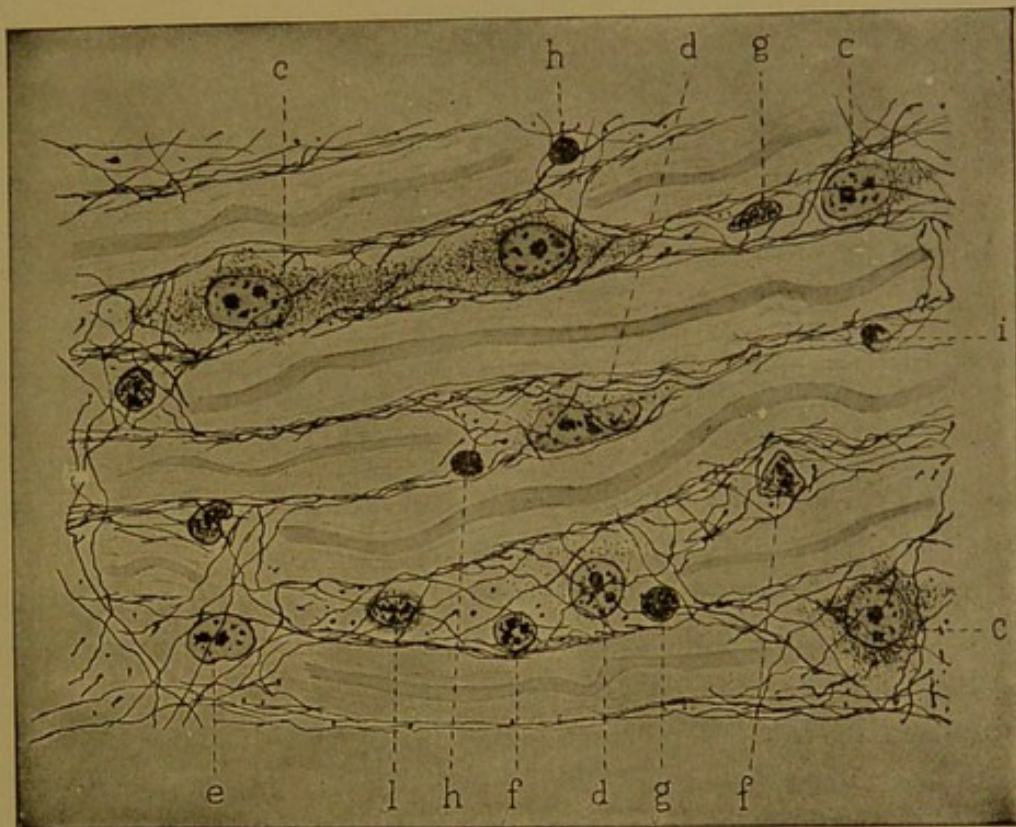


FIG. 426.—NEUROGLIA CELLS AND FIBERS FROM THE SPINAL CORD OF AN ELEPHANT. (Hardesty.)
c-i, Successive stages in the transformation of neuroglia cells, ending with disintegrating nuclei (i); l, a leucocyte. Benda's stain. $\times 940$.

the finest are in the medial parts of the dorsal and lateral funiculi. Elsewhere coarse and fine fibers are intermingled. Their general direction is parallel with the long axis of the cord. Like other nerve fibers they consist of fibrillæ imbedded in neuroplasm. Most of them are medullated, and in cross section the myelin often forms concentric rings. Although a few observers have described nodes, it is generally considered that there are no nodes in the central nervous system. During the development of the myelin, fibers have been found encircled by sheath cells, Fig. 428, B, as described by Hardesty (Amer. Journ. Anat., 1905, vol. 4, p. 329-354). In longitudinal view, these sheath cells are seen in depressions of the myelin, where they greatly resemble the neurolemma cells of peripheral

nerves. With the increase of myelin the sheaths become very slender and can seldom be detected in the adult. It is ordinarily stated that the medullated fibers of the central nervous system are without a neurolemma.

Gray Substance. The gray substance consists of neuroglia, nerve cells, and a confused mass of non-medullated nerve fibers running in all direc-

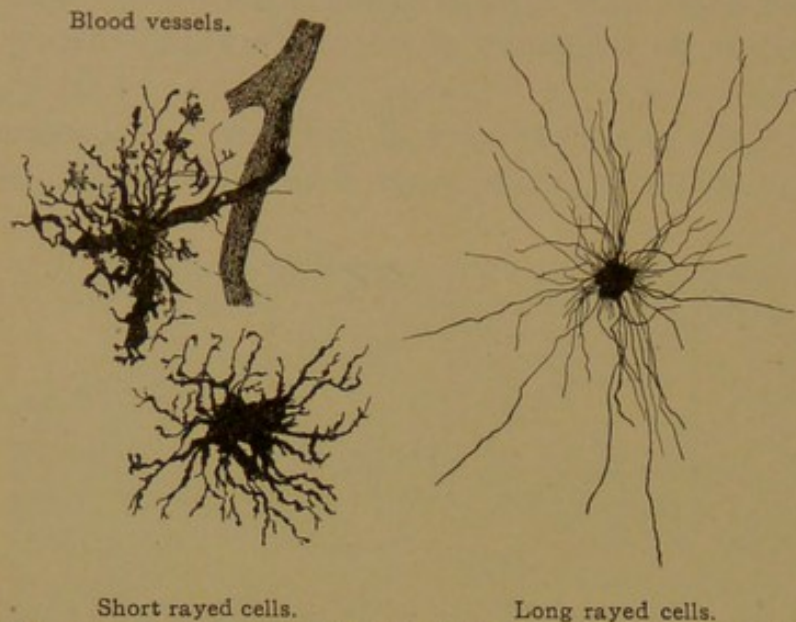


FIG. 427.—NEUROGLIA CELLS FROM THE BRAIN OF AN ADULT MAN. Golgi Method. $\times 280$.

tions. The nerve cells are of three types: (1) large motor cells with processes which enter the peripheral nerves; (2) cells with processes limited to the central nervous system and extending through its white substance from one part to another; and (3) small cells with processes confined to the gray substance. The neurax-

ons of cells of the third type branch freely, and they may cross to the gray substance on the opposite side of the cord.

The motor cells occur in groups in the ventral columns (horns). In the cervical and lumbar enlargements there are two groups, a ventro-medial and a dorso-lateral (Fig. 424), which unite in the upper cervical and thoracic portions of the cord; less well defined are the dorso-medial and ventro-lateral groups. In all of these groups the motor cells are large (67-135 μ in diameter), with round or oval nuclei and prominent nucleoli (Figs. 429 and 430). Their protoplasm appears densely granular in ordinary preparations, but when specially treated it is seen to contain an abundance of neurofibrils;

if preserved in alcohol and stained with methylene blue, the groups of granules known as Nissl's bodies may be demonstrated. As already noted, these are abundant in vigorous cells but become reduced or disappear in various conditions of exhaustion. Granules of brownish

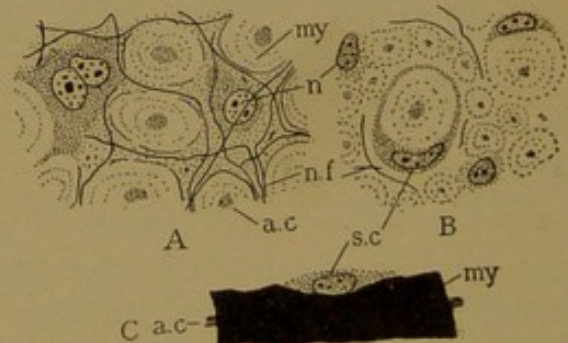


FIG. 428.

- A, Neuroglia cells and nerve fibers from a cross section of the spinal cord of an elephant. B, Neuroglia cells, nerve fibers and sheath cells, from the spinal cord of a pig, 2 weeks after birth. C, Isolated fiber from the cord of 21 cm. pig embryo, stained with osmic acid. (After Hardesty.) a. c., Axis cylinder; my., myelin; n., neuroglia nuclei; n. f., neuroglia fibrils; s. c., sheath cell.

pigment are sometimes conspicuous. All of these features may be observed in the smaller nerve cells, but they are most evident in the large motor cells. The dendrites of the motor cells extend far into the dorsal columns (horns), and they even pass out of the gray substance into the ventral and lateral funiculi. The neuraxon begins as a slender non-medullated fiber at the tip of a clear "implantation cone" and acquires its myelin sheath as it crosses the white layer. Ordinarily it has no collaterals; when present they are very small. None of the neuraxons cross to the opposite side of the cord before entering the motor roots.

The nerve cells of the second type, usually smaller than the motor cells but more abundant, are distributed throughout the gray substance either singly or in groups. Definite groups of nerve cells in the spinal cord and brain are known as *nuclei*, and at the root of the dorsal column (horn) near its junction with the gray commissure, there is the important

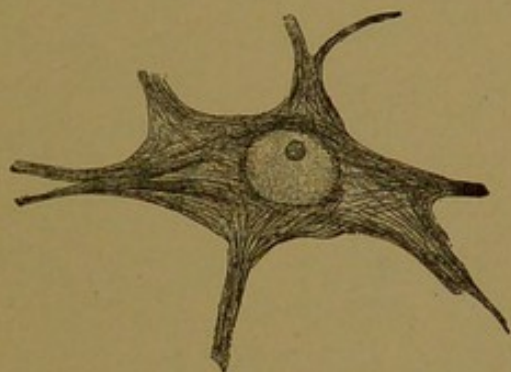


FIG. 429.—NERVE CELL OF THE SPINAL CORD OF A DOG. $\times 600$.

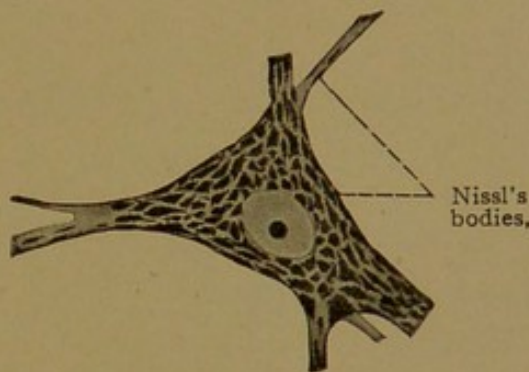


FIG. 430.—NERVE CELL OF THE SPINAL CORD OF A CHILD. $\times 430$.

dorsal nucleus (column of Clarke). It is composed of cells which send their neuraxons into the lateral funiculus, in which they ascend to the cerebellum. The dorsal nucleus is limited to the thoracic portion of the cord, and adjacent parts of the lumbar and cervical regions.

The fibers of the ground bundles are derived from scattered cells of the second type. Their dendrites are long but sparingly branched. The neuraxons give off collaterals in the gray substance, and enter the ventral and lateral funiculi (rarely the dorsal) of the same or opposite side. In the white substance most of them divide into ascending and descending fibers, which send collaterals back into the gray, either singly or in bundles, and the main branches finally terminate like the collaterals. After re-entering the gray substance they ramify freely around the motor cells.

In transverse sections the dorsal column appears capped by the *zona spongiosa* which covers the *substantia gelatinosa* (Fig. 424). The former contains spindle-shaped "marginal cells" which send fibers into the white substance. The *substantia gelatinosa* contains a limited number of very small nerve cells which send processes into the *zona terminalis*

(Fig. 424); it contains also stellate neuroglia cells, the processes of which are said to become transformed into a granular substance.

Ependyma. The ependyma is that part of the neuroglia which lines the central canal. It appears like a simple columnar epithelium, but its cell-like bodies are the ends of strands which primarily extend clear across the spinal cord to the external limiting membrane. A nucleus is generally found in the strand near the central canal, and there may be others further out (Fig. 431). Although in the embryo strands may readily be traced from the central canal to the periphery, in the adult they are generally broken up into stellate cells, or forms retaining a chief

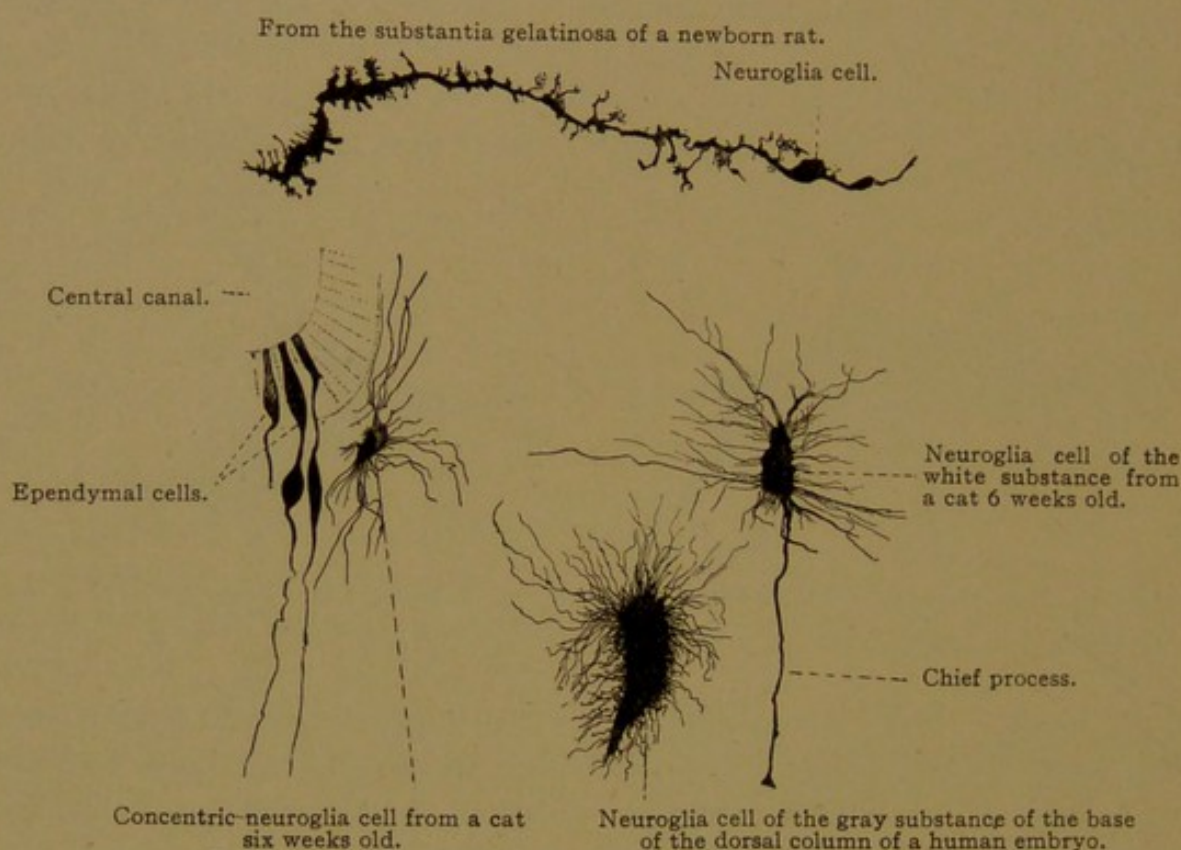


FIG. 431.—NEUROGLIA CELLS FROM THE SPINAL CORD. $\times 280$.

process directed either toward the central canal or the periphery (Fig. 431). All these cells are parts of a general syncytium, as already described.

The ependymal cells at birth, and for sometime afterwards, possess cilia projecting into the central canal, but in the adult these disappear. It is questionable whether or not they are motile. Single bodies have been found at their bases, but not diplosomes.

Surrounding the central canal, outside of the ependymal layer, there is a zone of central gray substance, characterized by concentrically arranged neuroglia cells, one of which is shown in Fig. 431.

BRAIN.

Development and General Features. If a human embryo of 4 mm. is placed in such a position that the spinal portion of the medullary tube is

approximately vertical, the anterior end of the tube, from which the brain develops, is bent as shown in Fig. 432, A. The first portion, beginning at the anterior extremity where the neuropore is still open, passes vertically upward. At the *head-bend* it turns backward and passes to the *neck-bend*, where it curves downward, becoming continuous with the part of the tube which forms the spinal cord. The anterior ascending portion is the *fore-brain* (*prosencephalon*); the part where the head-bend occurs is the *mid-brain* (*mesencephalon*); and the remainder is the *hind-brain* (*rhombencephalon*). These three fundamental parts have become more distinct and exhibit subdivisions in the 10 mm. embryo shown in Fig. 432, B.

Prosencephalon. The fore-brain becomes subdivided into the *telencephalon* anteriorly, and the *diencephalon* posteriorly; the latter connects with the mid-brain. In very early stages the fore-brain produces two lateral outpocketings, one on either side, called the *optic vesicles*. Each expands distally to form the retina of an eye, and its connection with the fore-brain becomes reduced to a slender stalk. In later stages, the depression on the inner wall of the brain which marks the position of the stalk is called the *optic recess*. It is shown in the median sagittal sections of the brain of an embryo of three months and of an adult, in Figs. 433 and 434 respectively.

Telencephalon. The principal derivatives of the telencephalon are a pair of lateral outpocketings which arise somewhat later than the optic vesicles and are known as the cerebral *hemispheres*. Each contains a cavity, or *lateral ventricle*, which opens into the medullary tube through the *interventricular foramen* (foramen of *Monro*). In later stages this foramen is relatively small, and it appears in Figs. 433 and 434 as a darkly shaded cleft in front of the thalamus (th.). As the hemispheres expand, they approach one another in the median line above the brain, being separated by a thin plate of connective tissue. They grow backward, cover-

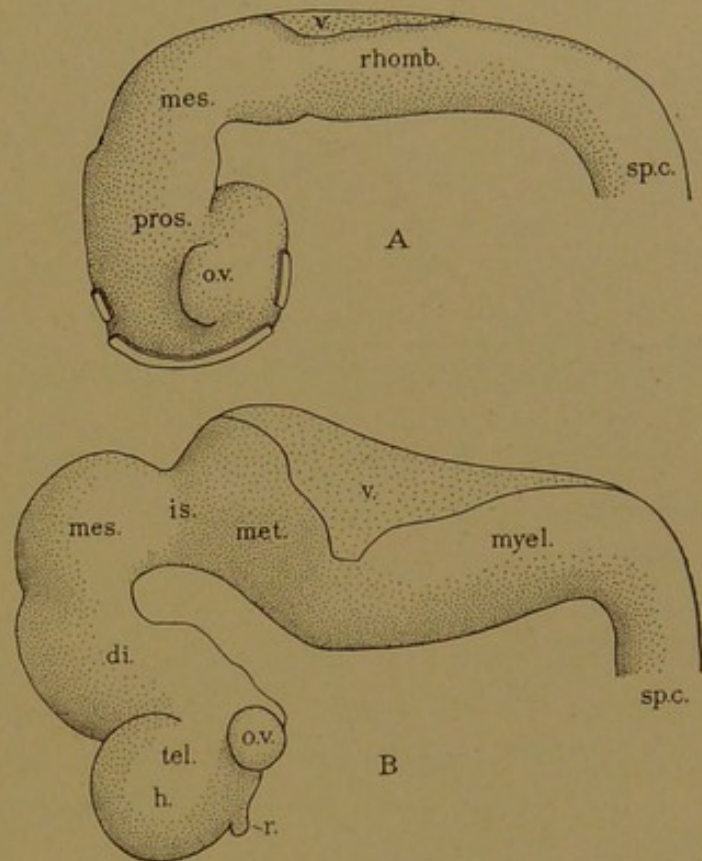


FIG. 432.—A, THE BRAIN OF A 4.0 MM HUMAN EMBRYO (after Bremer); B, THE BRAIN OF A 10.2 MM. EMBRYO (after His).

Except the isthmus, is. the principal subdivisions of the brain are indicated by prefixes of the term *encephalon*; sp. c., spinal cord; h., hemisphere; o. v., optic vesicle; r., rhinencephalon; v., roof of the fourth ventricle.

ing all the hind part of the brain. Their outer walls (constituting the *pallium*, or mantle) become convoluted, forming *gyri*, with intervening

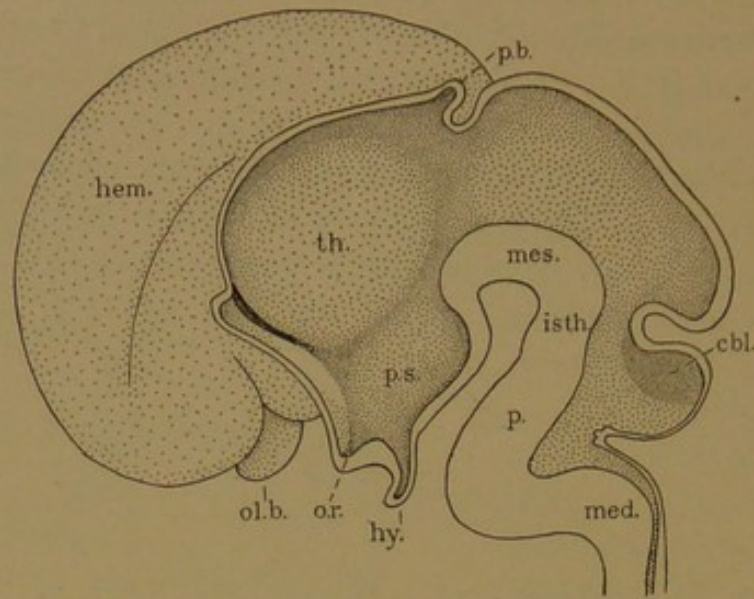


FIG. 433.—SAGITTAL SECTION OF THE BRAIN OF AN EMBRYO OF THREE MONTHS. (After His.)
cbl., Cerebellum; hem., hemisphere; hy., hypophysis (posterior lobe); isth., isthmus; med., medulla oblongata; mes., mesencephalon; ol. b., olfactory bulb; o. r., optic recess; p., pons; p. b., pineal body; p. s., pars subthalamica; th., thalamus.

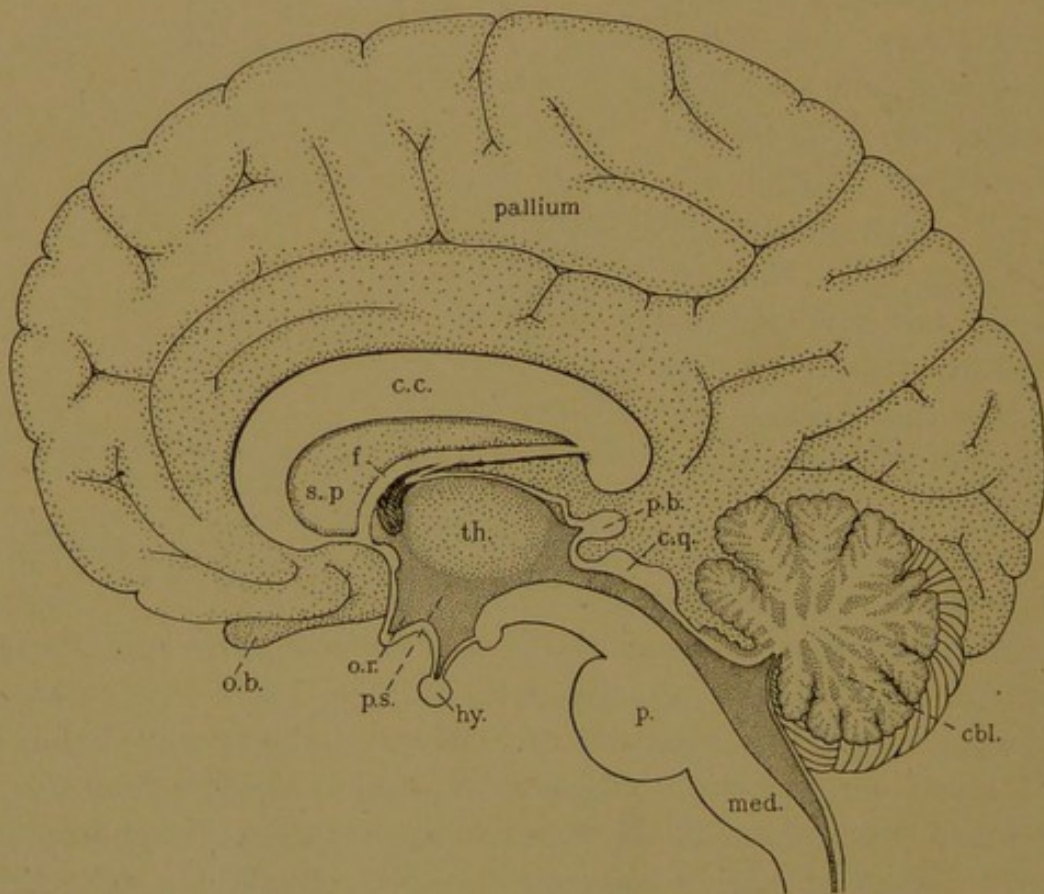


FIG. 434.—MEDIAN SAGITTAL SECTION OF AN ADULT BRAIN.
cbl., Cerebellum; c. c., corpus callosum; c. q., corpora quadrigemina; f., body of the fornix; hy., posterior lobe of the hypophysis; med., medulla oblongata; o. b., olfactory bulb; o. r., optic recess; p., pons; p. b., pineal body; p. s., pars subthalamica; s. p., septum pellucidum; th., thalamus.

sulci, and each hemisphere as a whole is divided into frontal, parietal, occipital and temporal lobes, as described in works on gross anatomy. A

more independent subdivision of the hemisphere is the *olfactory lobe*, which terminates anteriorly in the *olfactory bulb*—an expansion which receives the olfactory nerves. The entire olfactory portion of the brain is called the *rhinencephalon*.

Connecting the hemispheres with one another, there is a great transverse commissure known as the *corpus callosum* (Fig. 434, c.c.). Below this is the arched *body of the fornix* (f), representing a median fusion of two longitudinal bundles of commissural fibers, only small parts of which are included in a median section. Between the corpus callosum and the fornix, there is a thin *septum pellucidum* which consists of two vertical plates with a closed cleft-like cavity between them.

It is probable that the corpus callosum and body of the fornix develop in a thickening of the front wall of the telencephalon, where it crosses the median line. The cavity of the septum pellucidum is, accordingly, a secondary cleft in the thickened wall. A fusion between the adjacent medial walls of the hemispheres, to provide a path for the fibers of the corpus callosum and to account for the cavity in the septum, has been described, but not confirmed.

In addition to the hemispheres with their commissures and olfactory lobes, and the optic vesicles which are not counted as a part of the brain, the telencephalon produces the *pars optica hypothalami*. This "optic portion of the region below the thalamus" includes the optic recess, and in the mid-ventral line it forms a funnel-shaped depression, the *infundibulum*, terminating below in the *posterior lobe of the hypophysis*. (The anterior lobe of the hypophysis is derived from the pharynx.) The median cavity of the telencephalon is a laterally compressed space which forms the front part of the *third ventricle*. The lateral ventricles, which open from it, are counted as the first two.

Diencephalon. In the mid-dorsal line the diencephalon produces a cone-like body, the *corpus pineale*. Laterally, in its thick walls, there is a mass of gray substance called the *thalamus* (bed). External to the thalamus are the great bundles of fibers passing from the hemispheres to the spinal cord. The sensory fibers ascending from the cord terminate in the thalami, where there is a relay of nerve cells to convey the impulses to the hemispheres. The thalami have other connections of equal importance. They come in contact with one another across the cleft-like cavity of the diencephalon (which is a part of the third ventricle) and may fuse, forming the *massa intermedia*. The ventricle surrounds this mass. Beneath the thalamus the diencephalon forms the *pars mammillaria hypothalami*, which is represented on the under surface of the brain by the pair of rounded *mammillary bodies*, one on either side of the median line (Fig. 435, B).

Mesencephalon. The mid-brain remains undivided, and its walls become very thick. Dorsally it forms four rounded elevations, the

corpora quadrigemina (Fig. 435, A). These are arranged in pairs, the anterior pair being known as the *superior colliculi*, and the posterior as the *inferior colliculi*; the former have important relations with the optic tracts, and the latter with the auditory tracts. On the under side of the mid-brain there are two great bundles of fibers, the cerebral peduncles (*pedunculi cerebri*), which diverge as they pass forward from the hind-brain, and swing upward on the sides of the mid-brain to connect with the hemispheres (Fig. 435). Between the cerebral peduncles on the under side of the mid-brain, the oculomotor nerves emerge. They are derived from groups of motor cells situated just beneath the floor of the cavity of the mid-brain. This cavity remains a slender tube and is known as the cerebral aqueduct (*aquæductus cerebri*).

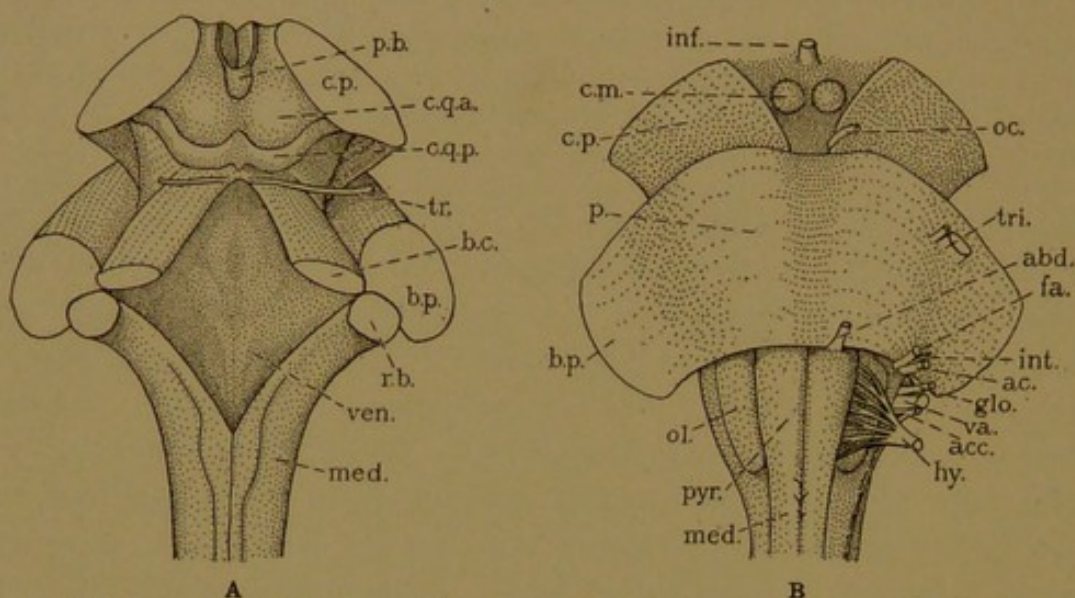


FIG. 435.—A, DORSAL AND B, VENTRAL VIEW OF THE POSTERIOR PART OF THE ADULT BRAIN. THE CEREBELLUM AND ROOF OF THE FOURTH VENTRICLE HAVE BEEN REMOVED FROM A.

b. c., Brachium conjunctivum; b. p., brachium pontis; c. m., corpus mamillare; c. p., cerebral peduncle; c. q. a., and c. q. p., anterior and posterior corpora quadrigemina; inf., infundibulum; med., medulla; ol., olive; p., pons; p. b., pineal body; pyr., pyramid; r. b., restiform body; ven., floor of fourth ventricle. The nerves are—oc., oculomotor; tr., trochlear; tri., trigeminal; abd., abducens; int., intermedius, fa., its facial portion; ac., acoustic; glo., glossopharyngeal; va., vagus, acc., its accessory portion; hy., hypoglossal.

Between the mid-brain and the hind-brain there is a marked constriction, known as the *isthmus* (Fig. 432, B). From the dorsal surface of the isthmus the trochlear nerves make their exit (Fig. 435, A); they are processes of nerve cells situated beneath the floor of the cavity, but they pass to the dorsal surface and cross to the opposite side before emerging.

Rhombencephalon. The rhombencephalon (or hind-brain) receives its name from the diamond shape which it presents when seen from above. This form is established in young embryos and persists in the adult (Fig. 435, A). The roof of the rhombic cavity becomes a thin membrane and is readily torn away, but the sides and especially the floor are greatly thickened. The form of the hind-brain may be imitated, as described by His, by cutting a short slit in the upper side of a piece of rubber tubing

and forcing the ends toward one another; the region with the weakened dorsal wall buckles downward and bulges toward either side. The most prominent part of the embryonic hind-brain, as it buckles downward, becomes the *pons* in the adult. From the dorsal part of the front end of the hind-brain, the *cerebellum* develops, overhanging the thin roof of the posterior portion. Pons and cerebellum are thus both derived from the anterior part of the rhombencephalon, which is set apart as the *metencephalon*; the remainder of the hind-brain is included in the *myelencephalon* (Fig. 432), which becomes the *medulla oblongata* and is continuous with the spinal cord.

Before considering the subdivisions of the hind-brain in further detail, the relation of the principal parts of the adult brain to the primary vesicles may be reviewed in the following table:

Fore-brain.....	{	Telencephalon....	{	Hemisphere: Pallium. Rhinencephalon. Corpus callosum. Optic part of the hypothalamus. Hypophysis (posterior lobe).
		Diencephalon.....	{	Pineal body. Thalamus. Mammillary part of the hypothalamus.
Mid-brain.....	{	Mesencephalon...	{	Corpora quadrigemina. Cerebral peduncles.
Hind-brain.....	{	Isthmus.....	{	Isthmus.
		Metencephalon...	{	Cerebellum. Pons.
		Myelencephalon...	{	Medulla oblongata.

Metencephalon. The pons, as seen from the under side of the brain (Fig. 435, B), appears as a broad bundle of transverse fibers interrupted for the passage of the motor and sensory roots of the trigeminal nerve. The superficial fibers of the pons pass dorsally around the wall of the brain-tube, forming a pair of arms, the *brachia pontis*, which enter the cerebellum. In addition to these large bundles, the cerebellum receives fibers through the *brachia conjunctiva* which extend into it from the isthmus, and also from the *restiform bodies* (i.e., rope-like) which ascend from the posterior part of the hind-brain (Fig. 435, A). Thus on either

side the cerebellum connects with three bundles of fibers, which come together to form its medulla (*corpus medullare*). The medulla is surrounded by the gray cortical substance, and the entire cerebellum is divided into many lobes and lobules.

The cavity of the hind-brain, which is continuous posteriorly with the central canal of the cord, and anteriorly with the cerebral aqueduct, is known as the *fourth ventricle*. It extends upward toward the medulla of the cerebellum, forming a tent-like recess, the apex of which is the *fastigium*.

Myelencephalon. The myelencephalon becomes the *medulla oblongata*, continuous without demarcation with the *medulla spinalis* or spinal cord. The ventral median fissure becomes shallow, but it may be traced to the pons (Fig. 435, B). On either side of its upper portion, there is an elongated swelling, the *pyramid*, corresponding in position with the ventral funiculus of the cord. Each pyramid is bounded laterally by the ventro-lateral groove, from which the motor roots of the hypoglossal nerve emerge; this groove is continuous with the ventro-lateral groove of the cord, from which the motor roots of the spinal nerves proceed. Near the pons the abducent nerve comes out close beside this groove. The dorso-lateral groove of the cord likewise extends to the pons; and in line with the dorsal roots of the cord, the sensory roots of the vagus, glossopharyngeal, acoustic and facial nerves enter this groove. The lateral roots of the accessory, glossopharyngeal and facial nerves emerge just below them. The space between the ventro-lateral and dorso-lateral grooves corresponds with the lateral funiculus of the cord. Toward the upper end of the medulla, it presents a rounded swelling known as the *olive* (Fig. 435, B).

The dorsal funiculus of the upper part of the cord is divided into the medial *gracile* and lateral *cuneate fasciculi*; these may be followed into the medulla where they become broader (Fig. 435, A). Some of their fibers enter the restiform body, and pass to the cerebellum; others pass downward on either side of the central canal and continue beneath the floor of the fourth ventricle to the hemispheres. Where the central canal expands to become the thin-roofed fourth ventricle, all nerve fibers either pass downward into its floor, or turn aside to enter the restiform body.

MEDULLA OBLONGATA.

The study of the medulla oblongata requires full consideration of the fiber tracts of the cord and anterior portion of the brain, which cannot here be taken up; only a few of the most fundamental features of the medulla are to be mentioned. Sections through the lower end of the medulla resemble those of the cord, and the gray substance retains the form of

an H. The fibers from the hemispheres, which descend to the motor cells of the cord, run mostly in the lateral funiculi, as previously stated. They descend from the brain, however, in the ventral funiculi, in which they form the pyramids in the upper part of the medulla (Fig. 437). In the lower part of the medulla they decussate, crossing to the lateral funiculus of the opposite side, as shown in Fig. 436; they appear to cut off the ventral columns (horns) from the remainder of the gray H. Then they descend in the spinal cord as the *lateral cerebro-spinal tract* (also called crossed pyramidal). A few fibers, however, descend in the ventral funiculi of the cord without having crossed in the medulla. Such fibers of the *ventral cerebro-spinal tract* (direct pyramidal) cross to the op-

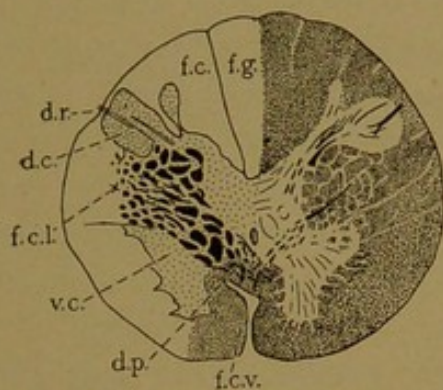


FIG. 436.—SECTION AT THE LEVEL OF THE FIRST CERVICAL NERVE. (After Dejerine.)

The right half of the section shows the effect of Weigert's stain, the myelinated portions being dark; the left half shows the gray substance stippled; the white is blank. f. c., Fasciculus cuneatus; f. c. l., fasciculus cerebro-spinalis lateralis; f. c. v., fasciculus cerebro-spinalis ventralis; f. g., fasciculus gracilis; d. c., dorsal column; d. p., decussation of the pyramids; d. r., dorsal root of first cervical nerve; v. c., ventral column.

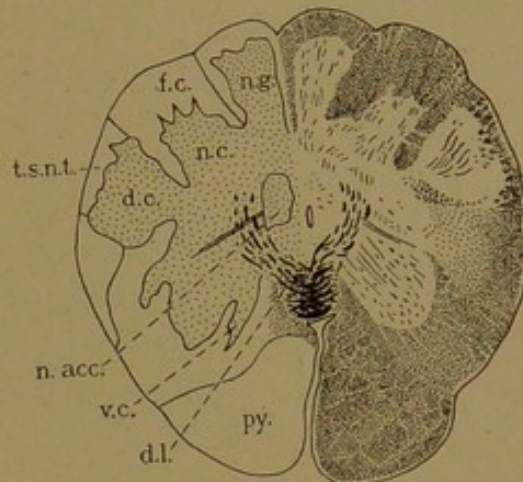


FIG. 437.—SECTION OF THE MEDULLA. (After Dejerine.)

d. c., Dorsal column; d. l., decussation of the lemnisci; f. c., fasciculus cuneatus; n. acc., nucleus of the accessory nerve; n. c., cuneate nucleus; n. g., gracile nucleus; py., pyramid; t. s. n. t., spinal tract of the trigeminal nerve; v. c., ventral column.

posite side in the cord before terminating in contact with the motor cells of the ventral columns.

The fibers in the cerebro-spinal tracts are the neuraxons of the pyramidal cells in the outer layers of the hemispheres, which will be described in a following section. They descend through the internal capsule (which in a layer of white substance lateral to the thalami), thence through the cerebral peduncles, pons, medulla oblongata and spinal cord, without interruption. This motor path from the hemispheres to the voluntary muscles includes, therefore, only two neurones or nerve cells, one from the cortex to the motor cells of the ventral column of the cord, and the other from the ventral column to the end plate on the muscle fiber. Other motor fibers from the hemispheres to the cord terminate in the *red nucleus* deep within the substance of the mid-brain; cells of the red nucleus send neuraxons to the opposite side, and these descend in the lateral funiculi of the cord as the *rubro-spinal tract*. They terminate in relation with

motor cells on the same side, and thus is formed a motor path composed of three neurones. Other tracts to the cord proceed from the cerebellum.

The motor nerves of the medulla oblongata, pons, and mid-brain arise from groups of cells, or nuclei, which are typically near the median line and only a short distance below the floor of the ventricle or cavity. Fig. 438 includes the nucleus of the hypoglossal nerve, which is in this position. The lateral motor roots are further below the ventricle and are more lateral. The *nucleus ambiguus*, which is an elongated structure containing the motor cells of the accessory, vagus and glossopharyngeal nerves, is of

this sort (Fig. 438). These motor nuclei correspond with cell groups in the ventral columns of the cord, and they are similarly in connection with fibers from the pyramidal cells of the hemispheres. In so far as the latter pass to these cerebral nerves, they form the *cortico-bulbar tract*, "bulb" being a general term for the expanded part of the hind-brain. The cortico-bulbar fibers decussate at different levels.

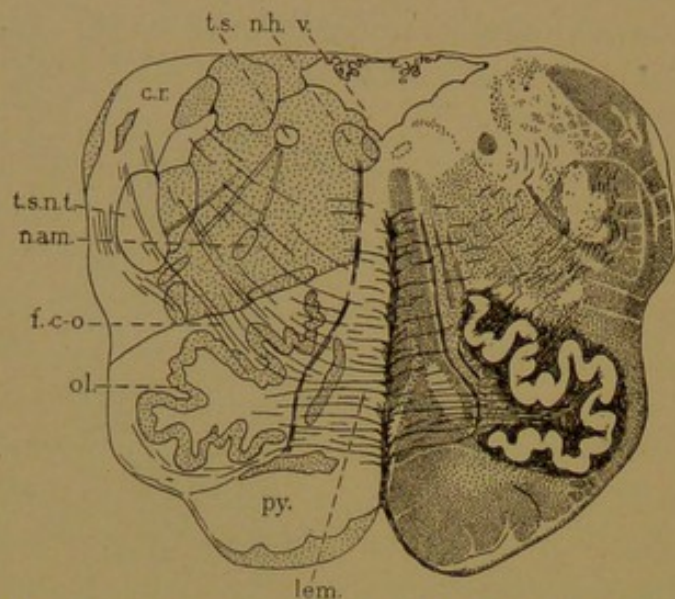


FIG. 438.—SECTION OF THE MEDULLA. (After Dejerine.)

c. r., Corpus restiforme; f. c. o., cerebello-olivary fibers; lem., lemniscus or fillet; n. am., nucleus ambiguus; n. h., nucleus hypoglossi; ol., olive; py., pyramid; t. s., tractus solitarius; t. s. n. t., tractus spinalis nervi trigemini; v., fourth ventricle.

of the descending motor fibers or pyramids, the sensory fibers ascending in the gracile and cuneate fasciculi terminate in relation with groups of cells known as the *gracile* and *cuneate nuclei* respectively (Fig. 437). They appear as additional horns of gray substance. The neuraxons from the cells in these nuclei pass ventrally and decussate beneath the central canal, as shown in Fig. 437. The bundles to which they give rise are known as the *medial lemnisci* or *fillets*. In their course through the upper part of the medulla, they are vertically placed bands of longitudinal fibers, on either side of the median line (Fig. 438). The fillets not only receive fibers of muscle sense through the gracile and cuneate fasciculi, but they are joined by the *spino-thalamic fasciculi* of fibers of cutaneous sense, which pass up the cord in the lateral funiculi. Moreover, they receive accessions from the cerebral sensory nerves. The fibers of the latter enter the medulla and divide into ascending and descending branches, like the dorsal root fibers of the spinal nerves, but the descending fibers are relatively longer. The position of the descending fibers of the trigeminal nerve (*tractus spinalis*

nervi trigemini) is shown in Fig. 438, and the *tractus solitarius*, containing sensory fibers from the vagus and glossopharyngeus, is shown in the same figure. In connection with these bundles of sensory fibers, there are groups of nerve cells forming the *nucleus of the tractus solitarius*, and *nucleus of the spinal tract of the trigeminal nerve*. These correspond with the gracile and cuneate nuclei, and send fibers into the fillets. The fillets continue through the pons and cerebral peduncles to the thalami, in which they terminate. Nerve cells of the thalami convey the impulses received onward to the hemispheres. Thus the sensory tract is composed of three neurones, the first being in the ganglia of the sensory nerves, outside of the central nervous system; the second begins in the gracile and cuneate nuclei, or in the gray substance of the cord in case the impulse travels by the spino-thalamic tract, or in the nuclei associated with central tracts of the sensory cerebral nerves, and in all three cases extends to the thalamus; the third begins in the thalamus and extends to the cerebral cortex.

CEREBELLUM.

The medullated nerve fibers of the restiform bodies, brachia pontis, and brachia conjunctiva come together to form the medulla of the cerebellum, and place the cerebellum in connection with spinal and cerebral nerves and with the hemispheres. The medulla contains several paired nuclei, the largest being the *dentate nuclei*, which have convoluted gray capsules resembling those of the olivary nuclei (shown in Fig. 438).

The restiform bodies include the fibers derived from the dorsal nuclei or columns of Clarke in the spinal cord; these fibers ascend in the lateral funiculi, within which they form the *dorsal spino-cerebellar tract* (of Flechsig). The restiform bodies contain also fibers from certain cells in the gracile and cuneate nuclei, and many fibers from the olivary nuclei, mostly of the opposite side. The brachia pontis contain fibers passing to the cerebellum from the numerous *nuclei pontis*. The latter are in connection with fibers descending from the hemispheres, thus forming cerebro- or cortico-cerebellar tracts. Some fibers pass in the reverse direction. The brachia conjunctiva contain fibers of the *ventral spino-cerebellar tracts* (of Gowers), which arise from central or lateral cells in the gray substance of the cord, and pass through the lateral funiculi to the brachia conjunctiva, through which they turn back to enter the cerebellum. The main part of the brachia conjunctiva consists, however, of fibers passing outward from the cerebellum and its dentate nucleus, to end, after decussating, in the red nuclei of the mid-brain. Thence fibers pass on to the thalami and hemispheres, and also downward to the medulla and spinal cord.

The medulla of the cerebellum extends into the small peripheral lobules, where it is covered by the cortical substance (Fig. 439). The latter consists of three strata—an inner *granular stratum*, which is rust-colored in the fresh condition; a middle *ganglionic stratum*, composed of a single row of large cell bodies; and an outer *gray stratum*.

The inner granular stratum consists of many layers of small cells which

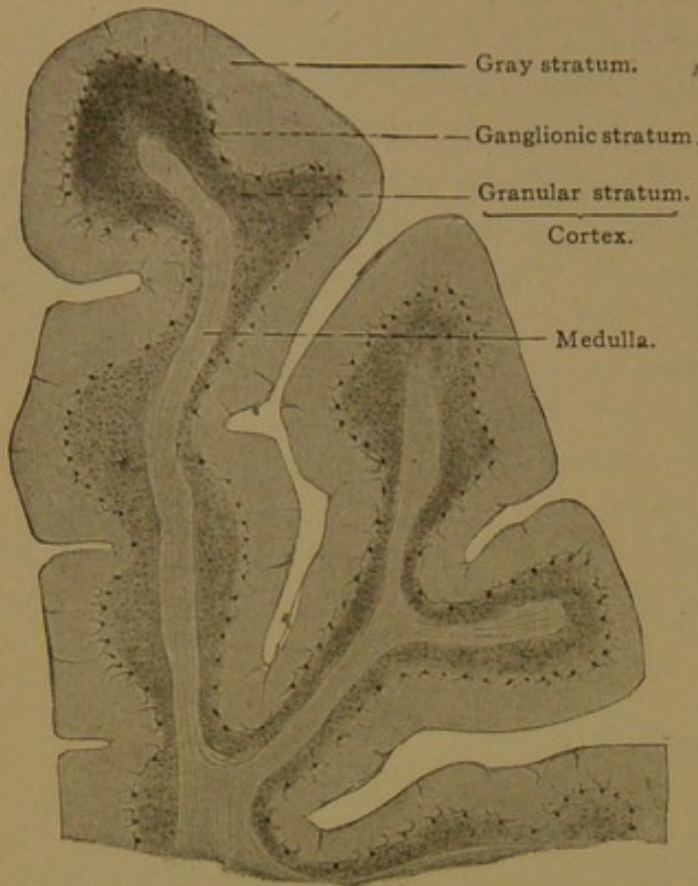


FIG. 439.—FROM A SAGITTAL SECTION OF THE CEREBELLUM OF AN ADULT MAN. X 12.

by ordinary methods show relatively large nuclei and very little protoplasm. With the Golgi method it appears that besides neuroglia cells, two sorts of nerve cells are present, the *small* and *large granule cells*; the former (Fig. 440) are multipolar ganglion cells with short dendrites having claw-like terminations, and slender non-medullated neuraxons which ascend perpendicularly to the gray layer and there divide in T-form into two branches. The branches run lengthwise of the transverse folds or convolutions of the cerebellum and have free unbranched endings. In sagittal sections (Fig. 442) the terminal branches of the neuraxons are cut across. The small granule cells form the bulk of the granular stratum. The less frequent large granule cells (Fig. 442) are more than twice the size of the small ones; their branched dendrites penetrate the gray stratum and their neuraxons, going in the opposite direction, are soon resolved into very numerous branches which ramify throughout the granular stratum.

The granular layer contains also a thick network of medullated fibers which enter it chiefly from the white substance. A part of these fibers end in the "eosin bodies" of the granular stratum, which are heaps of stainable particles found between the small cells (Fig. 441).

by ordinary methods show relatively large nuclei and very little protoplasm. With the Golgi method it appears that besides neuroglia cells, two sorts of nerve cells are present, the *small* and *large granule cells*; the former (Fig. 440) are multipolar ganglion cells with short dendrites having claw-like terminations, and slender non-medullated neuraxons which ascend perpendicularly to the gray layer and there divide in T-form into two branches. The branches run lengthwise of the transverse folds or convolutions of the cerebellum and have free unbranched endings. In sagittal sections (Fig. 442) the

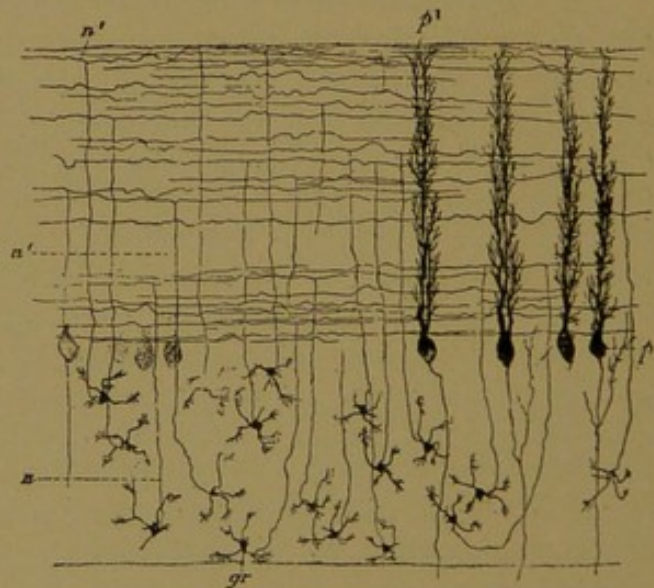


FIG. 440.—DIAGRAM OF A SECTION OF THE CEREBELLUM LENGTHWISE OF THE TRANSVERSE CONVOLUTIONS. GOLGI'S METHOD. (Koelliker.)

gr., Cells of the granular stratum; n. their neuraxons in the granular layer and n', in the gray stratum; p., p', Purkinje's cells. (From Bailey's "Histology.")

Some of the fibers form bundles parallel with the surface, running between the granular and ganglionic strata in the sagittal direction; they send branches into the gray layer. A small portion of the granular stratum is formed by the medullated neuraxons of the cells in the ganglionic layer.

The middle ganglionic stratum consists entirely of a single layer of very large multipolar ganglion cells, called *Purkinje's cells*. Their oval or pear-shaped bodies send two large dendrites into the gray stratum, where they form an extraordinary arborization (Fig. 442) Their many branches do not extend in all directions but are confined to the sagittal plane, that is, to a plane at right angles with the long axes of the convolutions. When the convolutions are cut lengthwise, Purkinje's cells appear as in Fig. 440. The neuraxons arise from the deep surface of the cell bodies, and as medullated fibers they pass through the granular stratum to the white substance. Within the granular layer they produce collateral fibers which branch and in part run back into the ganglionic layer, ending near the bodies of other Purkinje's cells (Fig. 442).

The outer gray stratum, of gray color, contains two sorts of nerve cells, the *large* and the *small cortical cells*. The large cortical or *basket cells* are multipolar ganglion cells, the dendrites of which pass chiefly toward the surface. Their long neuraxons, thin at first but later becoming thicker, run parallel with the surface in the sagittal plane. They send occasional collaterals toward the surface, and at intervals produce fine branches which descend and terminate in baskets around the bodies of Purkinje's cells (Fig. 442), often surrounding also the beginning of their neuraxons.

The small cortical cells, distinguishable from the basket cells since their neuraxons are not in relation with Purkinje's cells, may be divided into two types, connected by intermediate forms. The cell bodies of the first type are nearly or quite as large as those of the basket cells. Their two to five dendrites lie in the sagittal plane like those of Purkinje's cells; the slender neuraxons, 1 mm. long or more, sometimes form loops and are characterized by abundant branches in their proximal parts. The terminal branches are few. Cells of the second type are in general somewhat smaller; their shorter neuraxons branch in the immediate vicinity of the cell bodies. The elements of the first type form the bulk of the relatively numerous small cortical cells, and are found throughout the

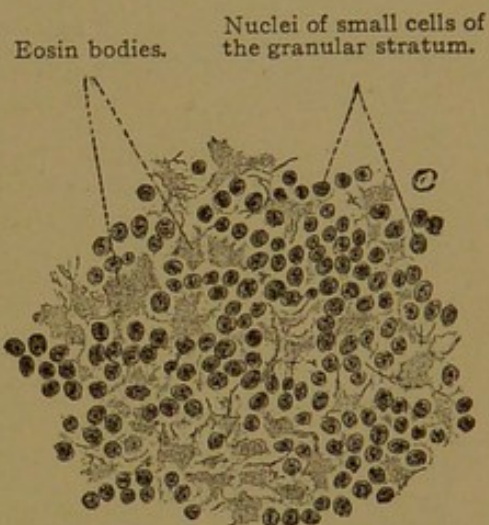


FIG. 441.—FROM A THIN SECTION OF THE CEREBELLUM OF AN ADULT. $\times 400$.

gray stratum, though they are more abundant in its superficial part. The second type likewise appears throughout the gray stratum.

The medullated nerve fibers found in the gray layer are prolongations of those in the granular stratum. In part they proceed toward the surface, where, after losing their myelin, they end in branches among the

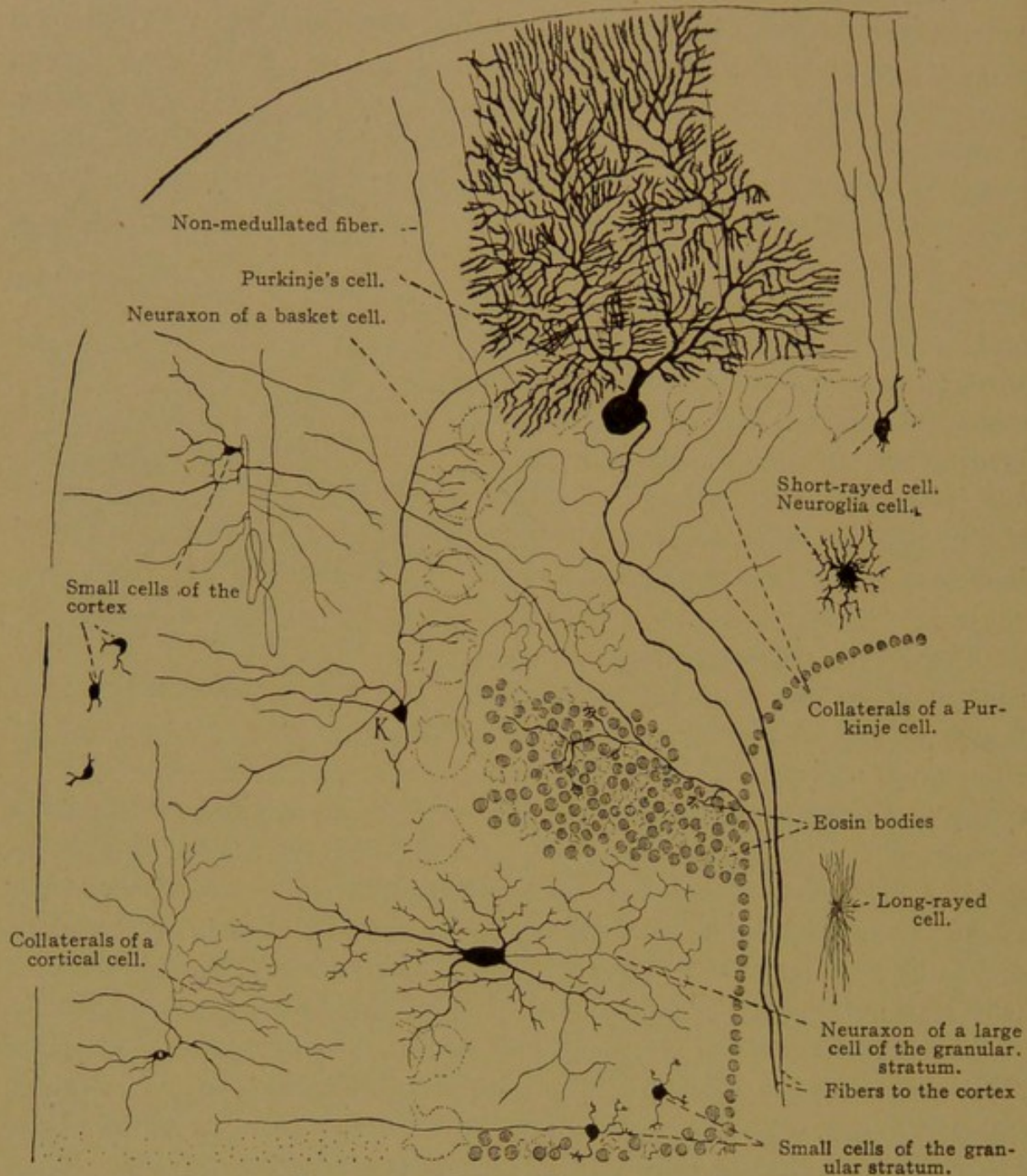


FIG. 442.—DIAGRAM OF A SAGITTAL SECTION OF THE CEREBELLUM.

Except the large granule cell, which is from a kitten, the cells are drawn from Golgi preparations from an adult man. K, large cortical or basket cell.

dendrites of Purkinje's cells; in part they run between the bodies of Purkinje's cells lengthwise of the convolutions.

The neuroglia of the cerebellum consists of short-rayed stellate cells found in all the layers; of long-rayed cells in the white substance; and of peculiar cells with small bodies at the outer boundary of the granular layer

(Fig. 442). These send only a few short processes inward, but many long processes straight out to the free surface, where they end in triangular expansions. In this way a thick peripheral neuroglia layer is produced.

As long as the cerebellar cortex is not fully developed, it presents a series of peculiarities which are lacking in the adult. Thus in embryos and young animals the partly developed gray stratum is covered by a superficial granular layer, the cells of which later become more deeply placed.

HEMISPHERES.

The ascending sensory fibers from the thalamus and the parts below, and the descending motor fibers which pass out of the hemispheres are contained in the *internal capsule*, which is a layer of white substance between the thalamus medially and the basal nuclei of the hemispheres laterally. The path by which these fibers enter and leave the deep white substance of the hemispheres is indicated in Fig. 443. Surrounding the inner white substance is the peripheral layer of gray, which forms the *cerebral cortex*. The cortex is divided into four ill-defined layers—an outer molecular or neuroglia layer; a layer of small pyramidal cells; a layer of large pyramidal cells; and next the white substance, a layer of polymorphous cells. From the pyramidal cells the fibers of the descending motor tract arise. The layers are shown in Figs. 444 and 445.

The *molecular layer*, which in ordinary sections appears finely punctate or reticular, contains besides many neuroglia cells, a network of medullated *tangential fibers*, which are parallel with the surface. Other fibers, as shown by the Golgi method, are partly neuroglia, and partly dendrites of pyramidal cells. The "cells of Retzius" found in this layer have bodies of irregular shape, which send out processes parallel with the surface, and these processes send short branches outward; other processes descend into the deeper layer (Fig. 446). They are probably neuroglia cells.

The *layer of small pyramidal cells* contains a special form of nerve cells, with pyramidal bodies measuring 10–12 μ . Since they taper into a dendritic process, their length cannot be definitely determined. The chief dendrite, after producing small lateral branches, enters the molecular layer

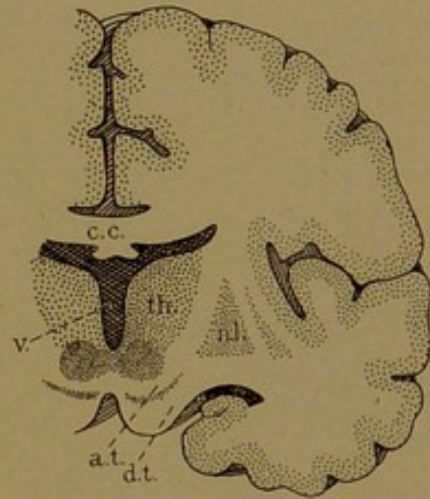


FIG. 443.—TRANSVERSE SECTION OF THE BRAIN. About $\frac{1}{2}$ natural size.

The gray substance is stippled; the white is blank. a. t., Ascending tract, including the fillet; c. c., corpus callosum; d. t., descending tract, leaving the hemisphere to enter the cerebral peduncle; n. l., nucleus lentiformis; th., thalamus; v., third ventricle.

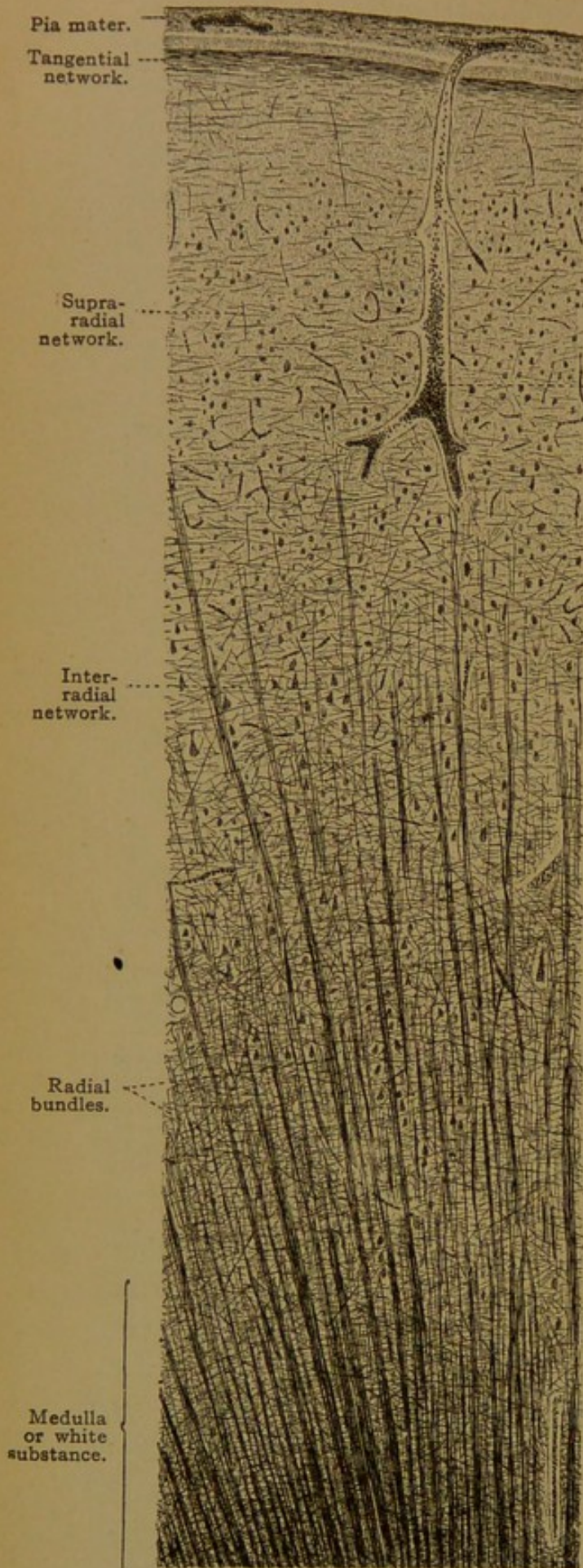


FIG. 444.

Molecular layer.

Layer of small pyramidal cells.

Blood vessel.

Layer of large pyramidal cells.

Layer of polymorphous nerve cells.

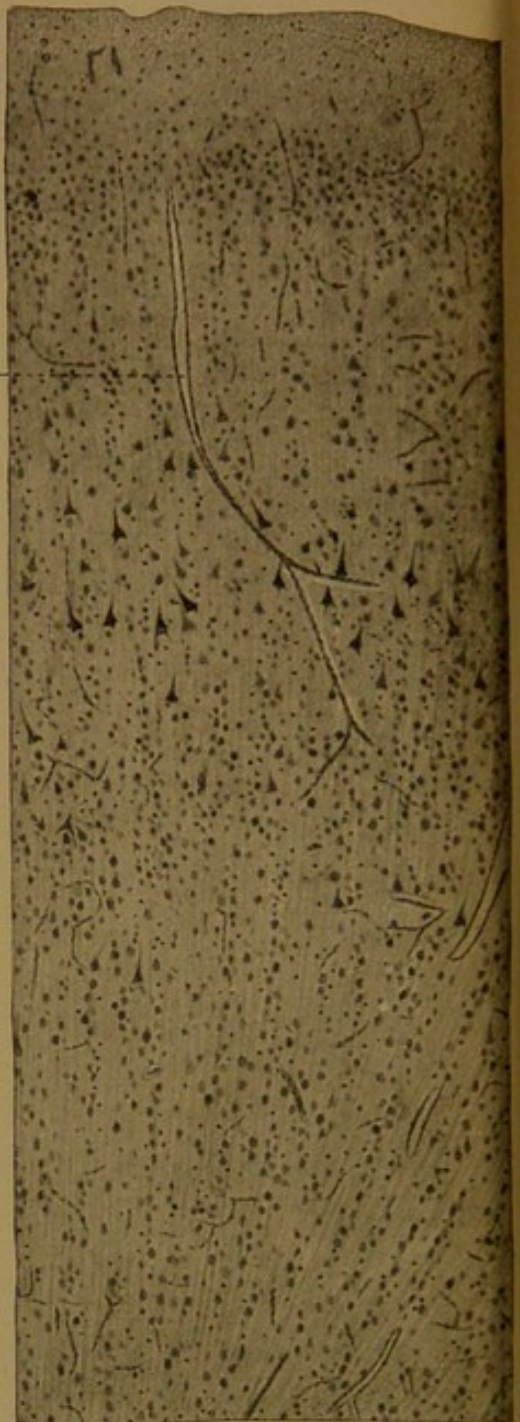


FIG. 445.

FIGS. 444 and 445 are from vertical sections of the cortex (central convolution) of an adult. Fig. 444 is a Weigert preparation; Fig. 445 is from a section stained with hæmatoxylin and eosin. $\times 45$.

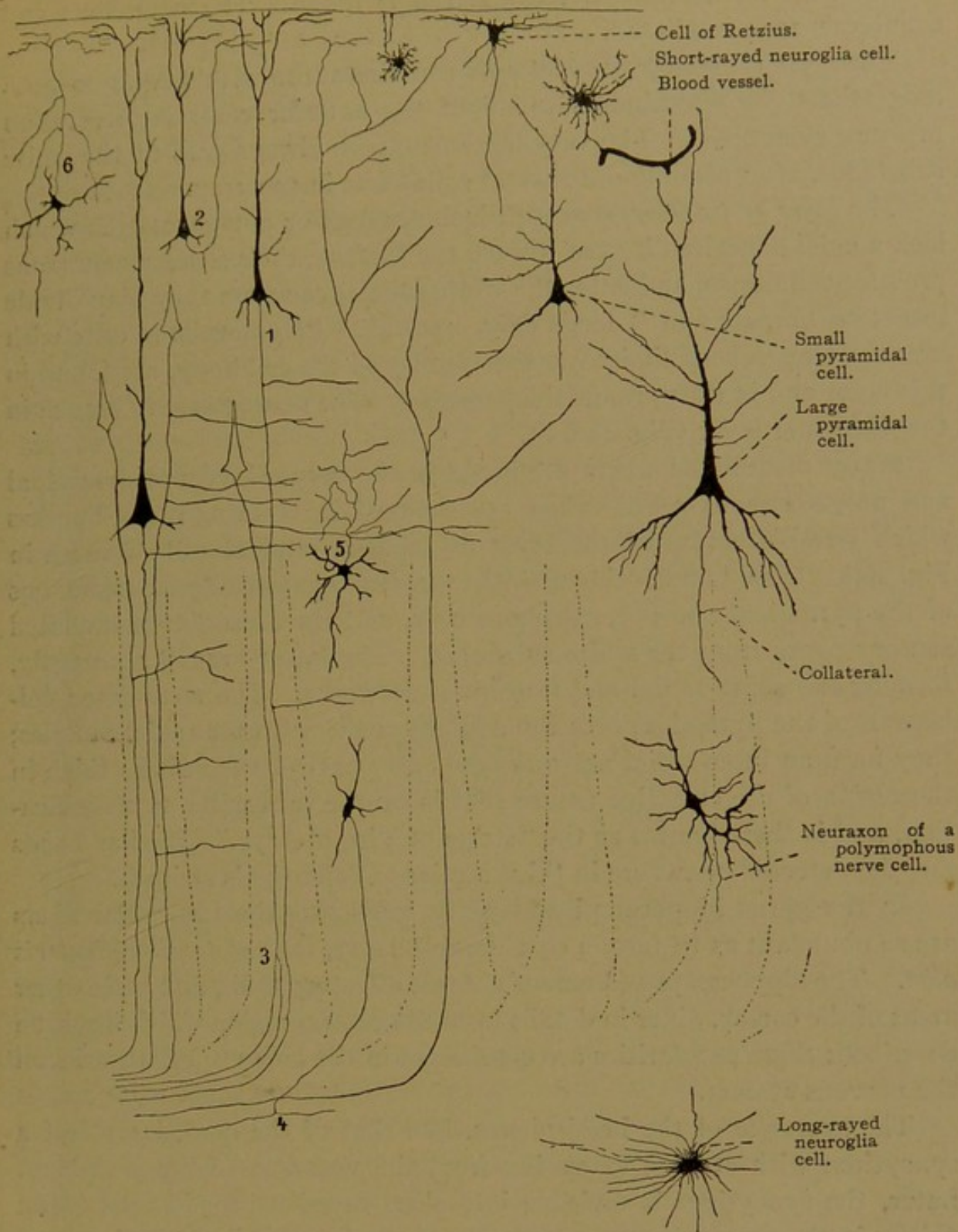


FIG. 446.—DIAGRAM OF THE CEREBRAL CORTEX. The cells on the right are drawn from Golgi preparations of an adult man. $\times 120$. The left portion of the diagram is $\times 60$.

where it arborizes freely; its terminal branches often show small irregular projections. Lesser dendrites proceed from the sides and basal surface of the pyramidal cell body. The neuraxon always arises from the basal surface, and after producing branched collaterals, it generally enters the white substance where it may divide in two (Fig. 446, 3). Sometimes the neuraxon turns toward the molecular layer, joining the tangential fibers;

infrequently an inverted pyramidal cell is found. The neuraxons and collaterals are medullated.

The *layer of large pyramidal cells* contains those with bodies 20-30 μ long (the "giant pyramidal cells" of the anterior central convolution measure even 80 μ). The very large neuraxon always goes to the white substance, after sending out several collaterals in the gray.

The *layer of polymorphous cells* includes oval or polygonal cells which lack a chief dendrite directed toward the surface; their slender neuraxons produce collaterals, and enter the white substance where they may divide into two branches in T-form (Fig. 446, 4). Polymorphous cells with branched neuraxons limited to the vicinity of the cell body, are found in this layer and in the pyramidal layers also. The neuraxon may branch in the molecular layer (Fig. 446, 6).

Many medullated fibers are found in the deeper layers of pyramidal and polymorphous cells. They are grouped in tapering radial bundles which terminate toward the layer of small pyramidal cells, as seen in Fig. 444. The bundles include the descending medullated neuraxons of the pyramidal and polymorphous cells, and the ascending medullated sensory fibers from the white substance. The latter branch repeatedly, forming the supra-radial and tangential networks. The medullated collaterals of the pyramidal cells run at right angles with the radial bundles; they form an inter-radial network, the outer part of which is so thick in the region of the calcarine fissure that it can be seen without magnification, and is there known as the "stripe of Vicq d' Azyr." Similar bands may be detected elsewhere in thick sections (Baillarger's stripes).

In the gyrus hippocampi and gyrus uncinatus the tangential fibers are so abundant as to form a considerable layer, the *substantia reticularis alba*. The hippocampus (Ammon's horn), olfactory bulb, and some other areas of the cortex, differ in details from the central region which has been described; these peculiarities are considered in the larger special works on the nervous system.

The *neuroglia* of the hemispheres, like that of the cord, is at first a syncytium with strands extending from the ventricle to the periphery. Later, the syncytium is divisible into short-rayed neuroglia cells found chiefly in the gray substance, long-rayed cells found chiefly in the white, and ependymal cells lining the ventricles. The ependymal layer is continuous through the aqueduct with that of the fourth ventricle and central canal. In early stages its cells have cilia-like processes which are in part retained in the adult. The short-rayed cells, which are characterized by knotted branching processes, are often in close relation with the blood vessels; they may serve to transfer the nutritive and myelin-forming material from the vessels to the nerve fibers. The outer surface of the cerebral cortex is covered with a feltwork of neuroglia fibers.

HYPOPHYSIS.

The hypophysis (*i.e.*, a *growth beneath* the brain) is a rounded mass, about half an inch wide and a quarter of an inch thick, attached to the tip of the infundibulum, and lodged in the *sella turcica* of the sphenoid bone. Its stalk of attachment to the infundibulum extends through the fibrous membrane fastened to the four posts or corners of the sella, and in removing the brain, the hypophysis is therefore often torn from its stalk and left in the bony excavation. It is now known to be a most important organ of internal secretion, consisting of two parts which are as distinct from one another as the cortex and medulla of the suprarenal gland. The *anterior lobe* is formed from *Rathke's pouch* (Rathke, Arch. f. Anat., Phys., u. wiss. Med., 1838, pp. 482-485) which grows upward from the oral ectoderm and encounters the knob-like *posterior lobe* which is a part of the brain (Fig. 203, p. 216). The anterior lobe then sends up a short process on either side of the posterior lobe, like the thumb and first finger of a hand, and in later stages Cushing ventures to describe the pos-

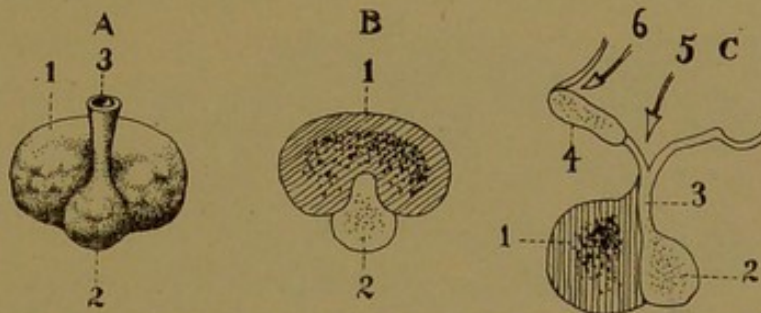


FIG. 447.—DIAGRAMS OF THE HYPOPHYSIS CEREBRI. (From Morris's Anatomy, after Testut.)
A, Posterior surface. B, Transverse section. C, Sagittal section. 1, Anterior lobe; 2, posterior lobe; 3, infundibulum; 4, optic chiasma; 5, infundibular recess; 6, optic recess.

terior lobe as resting in the anterior lobe like a ball in a catcher's glove. The anterior lobe becomes separated from the roof of the mouth by the obliteration of its duct, which is reduced to a slender solid epithelial strand and ruptures in embryos of about 20 mm. A depression marking its former outlet has sometimes been found in the vault of the pharynx, and there may be a canal through the sphenoid bone, the *craniopharyngeal canal*, which follows the course of the former duct. It is said that a small "pharyngeal hypophysis," having the structure of the anterior lobe, is constantly found near the pharyngeal end of this canal, on the under surface of the sphenoid bone.

The posterior surface of both lobes, as they appear in the adult, is shown in Fig. 447, A, and a sagittal section is shown in C; the orientation of the latter may readily be understood by comparing it with the region of the optic recess in Fig. 434.

The hypophysis can hardly be overlooked in examining the brain, and its existence is recorded by the earliest writers. The epiphysis, on the top of the brain, was called

the pineal body from its resemblance to a pine cone, and according to Hyrtl the hypophysis below, being a round structure attached to a stem, was named the "rose hip" by the Mohammedan physician Avicenna (ca. A. D. 1000). Vesalius introduced the name *pituitary gland*. The pituita or phlegm was believed to be excrementitious material, eliminated by the brain and received by the naso-pharynx, and its possible origin by way of the olfactory nerves had been discussed. Vesalius and his followers believed that it was collected by the infundibular funnel and eliminated by the pituitary gland. If the sella turcica of a prepared skull is examined, four grooves may be traced from it, two passing forward to the optic foramina, and two passing backward to the lacerated foramina. Vesalius pictured these four channels as outlets for the pituitary gland, the two latter (which in life are closed by cartilage) being in relation with the naso-pharynx. Bartholin recorded another function of the pituitary gland, namely, "to close the infundibulum lest vital spirits should escape," and finally V. C. Schneider showed conclusively that the pituitary gland is not the source of phlegm. According to Hyrtl this was accomplished in five classic but lengthy books, *De catarrhis*, 1640-1642, and he adds—"No physician and no anatomist should leave this fundamental and learned work unread—if he has time for it."

The *anterior lobe* consists of solid branched epithelial cords, of irregular caliber, connected with one another by frequent anastomoses. Between

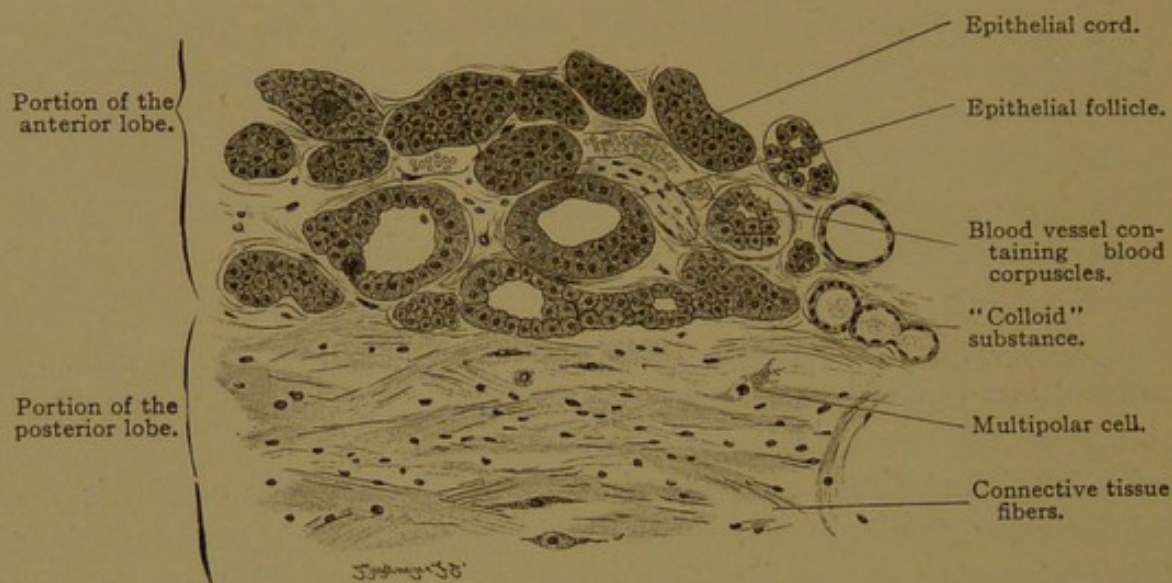


FIG. 448.—PORTION OF A HORIZONTAL SECTION OF A HUMAN HYPOPHYSIS, showing the boundary line between the anterior and the posterior lobes. Two gland follicles on the left each contain a dark epithelial cell. $\times 220$.

the cords and in close relation with them, there are wide lacunar capillaries derived from several arterioles which descend along the stalk of the infundibulum. The wide terminal vessels are arterio-venous connections having a sinusoidal structure. Along their margins, especially in the central part of the lobe, the cords are covered with eosinophilic cells, having round nuclei; the axial cells of the cords are neutrophilic and less granular. Although the nature of the marginal cells has not been fully determined, they are usually described as glandular, and their granules presumably represent an internal secretion which is discharged into the adjacent vessels. At the periphery of the anterior lobe, basophile cells occur.

Like the cortex of the suprarenal gland, the anterior lobe of the hypophysis is the larger part, and has a characteristic epithelial structure, whereas the portion associated with the nervous system is smaller, with less striking morphological characters. Nevertheless the latter, in both cases, produces the more active extracts, and its products are better understood. The anterior lobe of the hypophysis appears to "preside more intimately over skeletal growth;" and overgrowth, acromegaly and gigantism are attributed to its excessive activity. The administration of extracts of the posterior lobe causes a rise in blood pressure, owing to the contraction of the vascular musculature, thus resembling adrenalin in its action. Repeated injections cause emaciation; and deficient secretion, or the removal of the gland, leads to a high tolerance for sugars with the resultant accumulation of fat. "Thus normal activity of the posterior lobe is essential for effective carbohydrate metabolism" (Cushing, *The Pituitary Gland and its Disorders*, 1912).

The *posterior lobe* consists of a mass of neuroglia cells, the *pars nervosa*, and an epithelial investment, the *pars intermedia*. The latter is of special interest since its cells, sometimes ciliated, tend to become arranged in cysts containing a hyaline or colloid secretion. According to Stöhr, these cysts belong with the anterior lobe, and since the two lobes are in contact near the anterior part of the infundibular stalk, it is possible that its elements have grown around and invested the *pars nervosa*, thus producing the *pars intermedia*. Except anteriorly, however, the two lobes of the hypophysis are generally separated by a cleft.

The *pars nervosa* contains ependymal and neuroglia cells, but no nerve cells and only a few nerve fibers. The ependyma lines the cavity which extends downward into the lobe from the infundibulum. According to Tilney, "very often in the human hypophysis the lumen is not only seen to be distended by large masses of colloid, but its walls are evaginated so as to give rise to cysts of varying sizes, all containing colloid" (*Mem. of the Wistar Inst.*, No. 2, 1911). The colloid material is believed to be evidence of a secretion which is eliminated into the third ventricle, and which finds its way into the cerebro-spinal fluid. Possibly it may be given off from the outer surface of the lobe, for the inconstant cavity or lumen is not a typical duct; but the secretion apparently does not enter the blood vessels, which in this lobe are neither abundant nor sinusoidal. Eosinophilic cells are generally absent.

PINEAL BODY.

The pineal body (sometimes called the epiphysis) is a median dorsal outpocketing of the diencephalon (Figs. 434 and 435), terminating in a small nodule composed of neuroglia and round or polygonal epithelial cells. The human pineal body contains no nerves (Kölliker) but below it there is the *commissura habenularum*. A connective tissue capsule sends prolongations into its interior and surrounds groups of epithelial cells, and follicles.

It is generally considered that the pineal body is a functionless rudiment. In lower vertebrates an eye-like structure develops just in front of it, sometimes being found beneath a transparent cornea, but the extent of the visual functions of this organ remains undetermined. The corpus pineale immediately behind this eye may take its place to some extent, and "often shows, as in certain lizards, traces of visual structure" (Kingsley). The unimportant position to which this organ has been relegated, contrasts with the familiar conjecture of Des Cartes that all ideas which proceed from the five senses are perceived in the pineal body as a center, and that from it all nervous impulses irradiate. In man not the slightest function is now assigned to it.

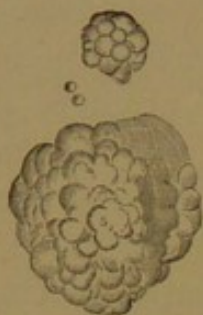

FIG. 449.—ACERVULUS
FROM THE PINEAL
BODY OF A WOMAN
SEVENTY YEARS
OLD. $\times 50$.

Within the pineal body, *acervulus cerebri* or "brain sand" is usually found, consisting of round or mulberry-like concretions, 5 μ to 1 mm. in diameter (Fig. 449). In specimens preserved in glycerin or balsam these concretions show distinct concentric layers. They consist of an organic matrix containing calcium carbonate and magnesium phosphate, and are sometimes surrounded by a thick connective tissue capsule.

Not infrequently, especially in old age, the brain substance contains round or elongated bodies, distinctly stratified, which are colored violet by tincture of iodine and sulphuric acid, and therefore are related to amyloid. These *corpuscula amylacea* are found almost always in the walls of the ventricles, and also in many other places in both gray and white substance, and in the optic nerve. They have a homogeneous capsule with occasional processes, and are evidently neuroglia cells transformed by amyloid infiltration.

MENINGES.

The *dura mater cerebialis* or dura mater of the brain, includes the periosteum of the inner surface of the cranium and consists, therefore, of two lamellæ. The inner is like the dura mater of the cord but contains more elastic fibers; the outer corresponds with the periosteum of the vertebral canal. It contains the same elements as the inner layer, but its fibers run in a different direction. In order that the dura of the brain and cord may be strictly comparable, some anatomists count the vertebral periosteum and the considerable layer of vascular fatty tissue beneath it, as a part of the dura of the cord. In relation with the brain, the dura forms reduplications extending between the cerebellum and the hemispheres, and between the right and left hemispheres. Its two layers separate to enclose large, thin-walled veins, the *sinuses* of the dura. These receive

veins from the substance of the brain, but the arteries of the dura, or *meningeal arteries*, supply the cranial periosteum. The dura has many nerves, some with free endings, and others supplying the musculature of the vessels.

The *arachnoid membrane*, as in the cord, is separated from the dura by a cleft-like sub-dural space. In certain places, especially along the sides of the superior sagittal sinus, there are found *arachnoid villi* (Pachionian bodies or granulations), which project into the cavity of the venous sinus. They are elevations of the arachnoid covered with a thin portion of the dura and venous endothelium, and possibly facilitate the transfer of fluid between the arachnoid (or subarachnoid) spaces and the veins. These spaces contain the cerebro-spinal fluid, and are continuous with the corresponding spaces around the cord. Through apertures in the thin roof of the fourth ventricle, they communicate with the central cavity of the cord and brain.

The pia is a delicate and highly vascular layer, containing arteries which send branches into the cortex from all points on its surface. These cortical arteries arise from the anastomoses between the internal carotid and vertebral arteries at the base of the brain, which produce the arterial circle of Willis. Other branches from these vessels enter the substance of the base of the brain, supplying the basal nuclei, thalamus and internal capsule. Because of the effects of hæmorrhage in relation with the motor and sensory tracts in this region, these small arteries are of very great importance. The vascular membranes which cover the thin portions of the roof of the third and fourth ventricles are in places invaginated into the ventricles, forming the *chorioid plexuses*. These networks of small vessels, covered only by thin membranes, are found in the lateral ventricles, as well as in the third and fourth; their position is described in text-books of gross anatomy. The simple layer of cuboidal epithelium, which covers the plexuses, contains pigment granules and fat droplets, and may perform secretory functions.

EYE.

Development and General Anatomy. The eyes first appear as a pair of *optic vesicles*, which are lateral out-pocketings of the fore-brain (Fig. 451, A). They enlarge rapidly, but their connections with the wall of the brain remain relatively slender, forming the *optic stalks*. The epidermal ectoderm immediately overlying the vesicles thickens and becomes invaginated (Fig. 451, B and C). The invaginated portion is then detached in the form of a vesicle, the inner wall of which is distinctly thicker than the outer; this "lentic vesicle" becomes the lens of the eye. Meanwhile, as seen in B and C, that layer of the optic vesicle which is

toward the epidermis sinks in upon the deeper layer, transforming the vesicle into the *optic cup*. At first the cup is not complete, being deficient on its lower side (Fig. 450). The *arteria centralis retinae* is seen passing through this indentation, which begins on the lower surface of the stalk and extends to the free margin of the cup; the cleft is sometimes called the "chorioid fissure." Distal to the point of entrance of the artery into the optic cup, the edges of the fissure fuse; the artery then appears to perforate the base of the cup, and it retains this relation in the adult. The artery is shown in section in Fig. 451, D.

In a remarkable series of experiments upon tadpoles, Warren Lewis has shown that "the lens is dependent for its origin on the contact influence or stimulus of the optic vesicle." If the optic vesicle is removed, the epithelium in the region of the normal lens does not become thickened or invaginated; but if an optic vesicle is transplanted by detaching it from its stalk and pushing it caudally through the mesenchyma, it will cause the formation of a lens from any portion of the epidermal epithelium which happens to be above it. Moreover, if an area of skin from the abdomen of a frog of one species is grafted over the optic vesicle of another species, a lens may be produced from the grafted epithelium. Thus there is no predetermined area for lens formation, and its development depends upon the presence of the vesicle beneath (Amer. Journ. Anat., 1904, vol. 3, pp. 505-536, 1907, vol. 7, pp. 145-169).

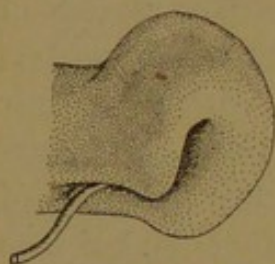


FIG. 450.—OPTIC CUP AND STALK OF A HUMAN EMBRYO OF 6.9 MM. (After Kollmann.)

The two layers of the optic cup, the inner of which is toward the lens, are normally in contact with one another, although in sections they have often become more or less separated. They constitute the *retina*, which includes a thin outer *pigmented layer*, and a thick inner *visual layer*; the latter is composed of several strata of nerve cells and fibers. The stimulus of light is received by tapering projections extending from the outer surface of the visual layer toward the pigmented layer; to reach them the rays of light must traverse the strata of the visual layer. In explanation of the fact that the sensory processes are turned away from the light, it may be said that the outer surface of the skin ordinarily receives stimuli, and that through the infolding which makes the medullary tube and the outpocketing which makes the optic vesicle, the sensory surface of the retina is continuous with the outer surface of the skin. Since in mammals the optic vesicles begin to form before the related portion of the medullary groove has closed, they first appear as depressions in a thickened epidermal ectoderm.

Nerve fibers grow from the inner surface of the visual layer toward the central artery and vein of the retina, around which they pass out of the optic cup (Fig. 451, D). They grow beneath and among the cells of the optic stalk to the brain, which they enter. These fibers, which constitute the *optic nerve*, cause the obliteration of the optic stalk. It is

shown in the figure that the optic nerve at its origin interrupts the retinal layers, producing a "blind spot." The part of the nerve which forms the blind spot, with the vessels in its center, is called the *papilla of the optic nerve*.

The lens (Fig. 451, D) loses its central cavity by the elongation of the cells in its posterior layer. These become the *fibers of the lens*. The anterior layer remains throughout life as a simple epithelium, called the *epithelium of the lens*. The lens becomes covered by an elastic *capsula*

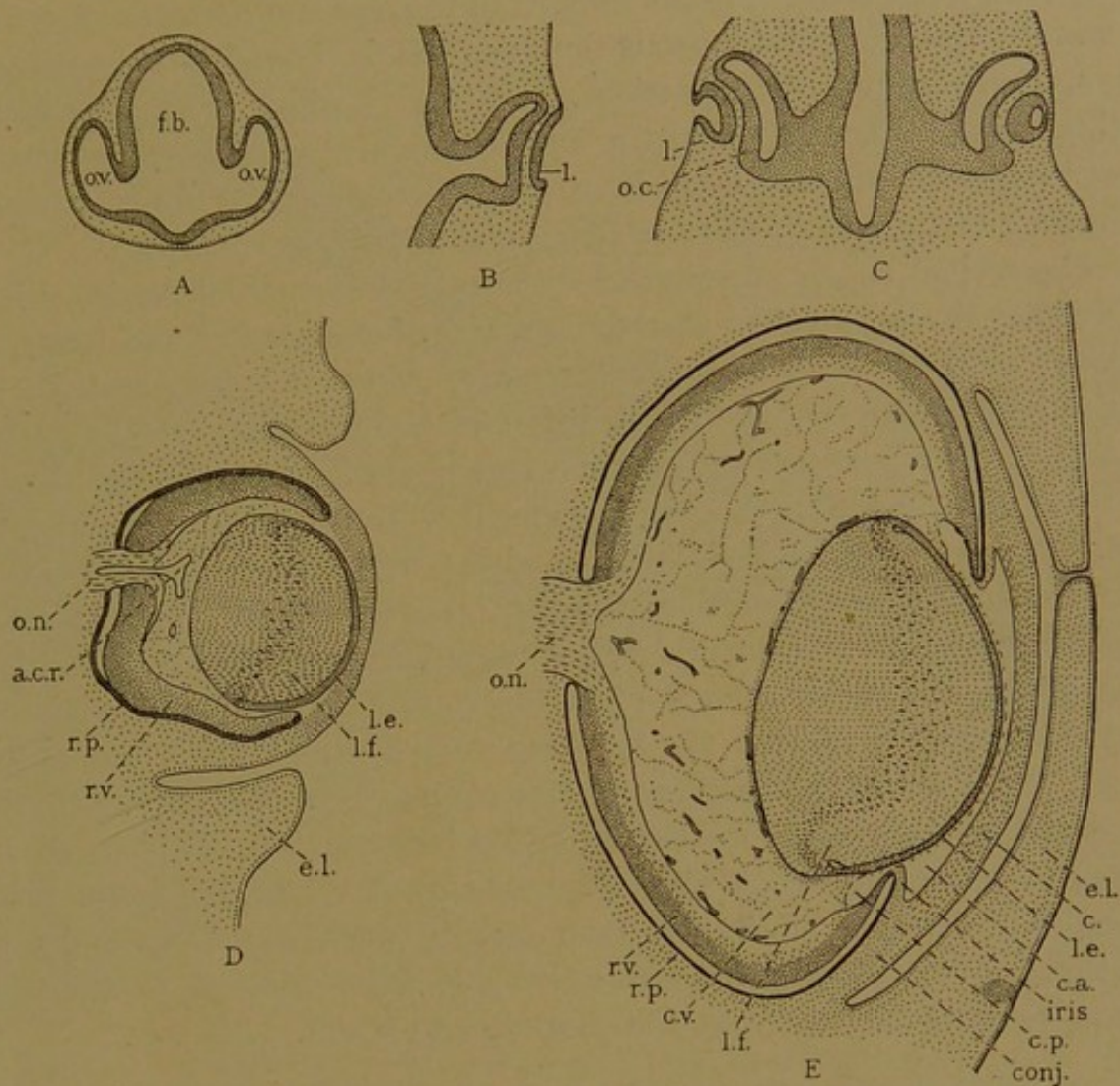


FIG. 451.—SECTIONS OF RABBIT EMBRYOS TO SHOW THE DEVELOPMENT OF THE EYE. A, 9½ days, 3.0 mm.; B, 10½ days, 5.4 mm.; C, 11 days, 5.0 mm.; D, 14 days, 18 hours, 12.0 mm.; E, 20 days, 29 mm.

a. c. r., Arteria centralis retinae; c., cornea; c. a., anterior chamber; conj., conjunctiva; c. p., posterior chamber; c. v., corpus vitreum; e. l., eyelid; f. b., fore-brain; l., lens; l. e., lens epithelium; l. f., lens fibers; o. c., optic cup; o. n., optic nerve; o. v., optic vesicle; r. p., pigmented layer of the retina; r. v., visual layer of the retina.

lentis, and in embryonic life it possesses a *vascular capsule* (Fig. 451, E) containing branches of the central artery. The vascular layer covering the anterior surface of the lens is designated the *pupillary membrane*, and it disappears shortly before birth. Its occasional persistence interferes with vision.

Between the lens and the retina there is a peculiar tissue, mucoid in appearance and resembling mesenchyma in form. Since processes from

the retina and from the lens have been found extending into it, it is considered to be essentially ectodermal. Its blood vessels become obliterated and it forms the *vitreous body* of the adult, consisting of a *stroma* and a *humor*. Extending through it, from the papilla of the optic nerve toward the lens, is the *hyaloid canal*, which in the embryo lodged the *hyaloid artery* (a prolongation of the central artery). Sometimes this artery is represented in the adult by a strand of tissue. The vitreous body is surrounded by a fibrous layer called the hyaloid membrane.

A cavity forms in the tissue in front of the lens and becomes filled with a watery tissue fluid (aqueous humor). It is bounded by a mesenchymal epithelium. The portion of the cavity which is anterior to the retinal cup and lens is called the *anterior chamber of the eye*; the smaller part within the retinal cup but in front of the lens and the fibrous covering of the vitreous body, is the *posterior chamber* (Fig. 451, E, c.p.).

The retinal cup is surrounded by two layers of mesenchymal origin. The inner *tunica vasculosa* corresponds with the pia mater and forms the *chorioid* coat of the eye; the outer *tunica fibrosa* corresponds with the dura mater and forms the *sclera*, into which the muscles of the eye are inserted. The portion of the retinal cup which forms a curtain, circular in front view, between the anterior and posterior chambers, is called the *iris*. It consists of tunica vasculosa with a thin pigmented prolongation of the retina over its posterior surface (Figs. 451, E, and 452). This *pars iridica retinæ* is rudimentary and without visual function. The iris is covered by the mesenchymal epithelium of the chambers. At the attached border of the iris the vascular coat contains important muscle fibers, and is there thickened to form the *ciliary body*. This is also covered by a rudimentary pigmented layer on its inner surface, the *pars ciliaris retinæ*. At the *ora serrata* (Fig. 467) an abrupt thickening of the visual layer of the retina marks the boundary between its ciliary and optic portions. The *pars optica retinæ* extends from the ora to the optic nerve, covered externally by the chorioid and sclera.

As a relatively frequent congenital anomaly, the chorioid fissure fails to close normally and the resulting defect is known as *coloboma*. If the closure has been nearly complete, so that there is merely a notch at the free margin of the optic cup, it appears in the adult as a median ventral cleft in the iris, so that the pupil is shaped like an inverted pear. If the deeper parts of the chorioid fissure fail to unite, there will be a median ventral gap in the optic portion of the retina, which may seriously interfere with vision.

The *cornea* is the tissue in front of the anterior chamber, consisting of a non-vascular mesenchymal tissue, bounded posteriorly by mesenchymal epithelium and anteriorly by the epidermal ectoderm. It is extremely transparent. The epidermal ectoderm extends from the cornea and front of the eye over two folds which form the eyelids. They have met in

Fig. 451, D, and fused temporarily. Externally the lids are covered by skin, and internally by the *conjunctiva palpebrarum*, or conjunctiva of the lids. The latter is continuous with the *conjunctiva bulbi* which forms the opaque vascular "white of the eye." It surrounds the cornea, the epithelium of the two structures being continuous.

The parts of the eye to be examined histologically are therefore the retina, optic nerve, lens, and vitreous body, all of which are ectodermal;

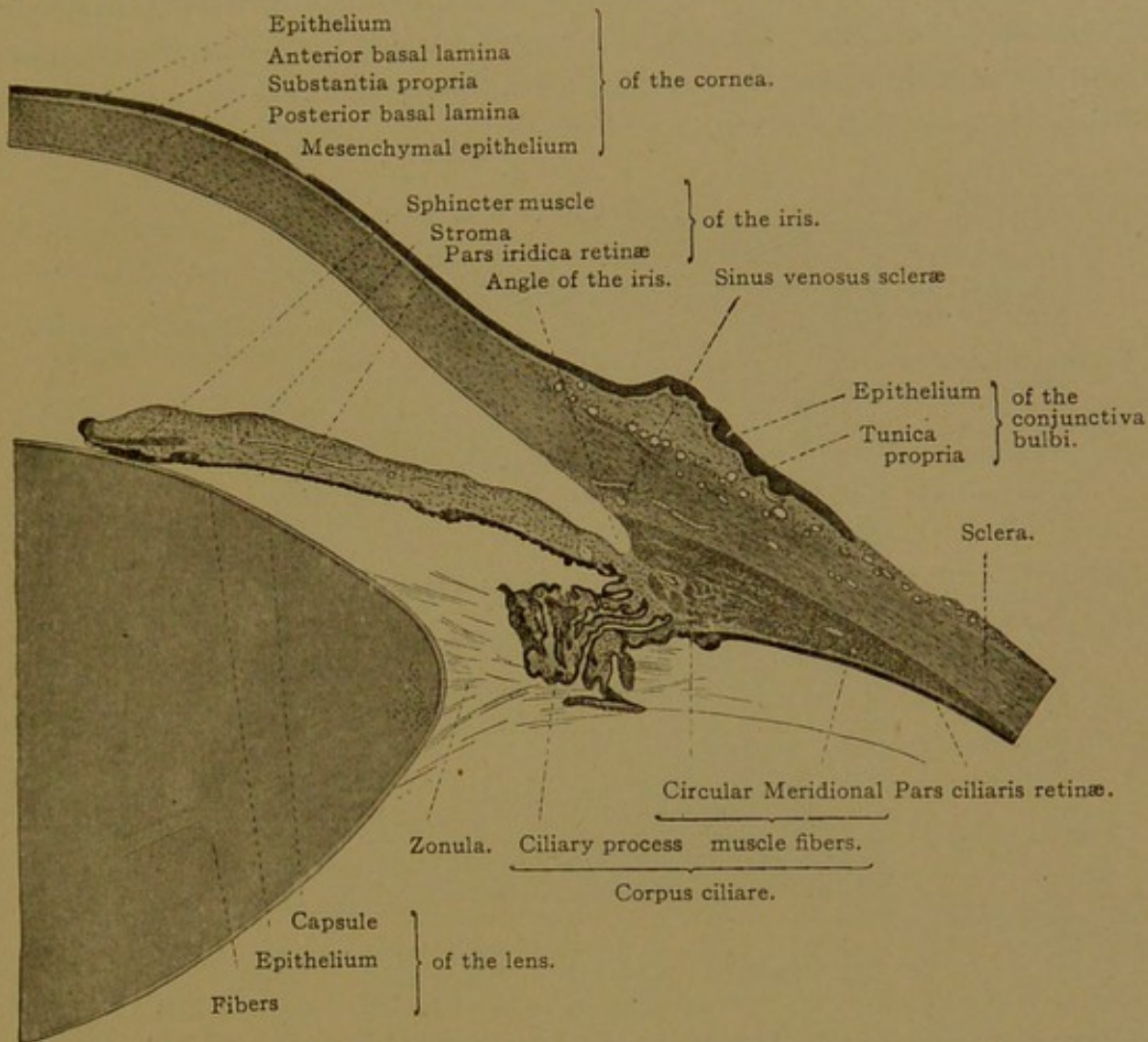


FIG. 452.—MERIDIONAL SECTION OF A PART OF THE EYE. $\times 15$.

The radial fibers of the ciliary muscle cannot be distinguished with this magnification.

then the tunica vasculosa, including the chorioid, the ciliary body, and iris; next the tunica fibrosa, including the sclera and cornea; and finally the accessory structures—the lids, conjunctivæ and glands.

RETINA.

The retina extends from the papilla of the optic nerve to the pupillary border of the iris, and is divisible into three parts; the *pars optica retinae* includes all which is actually connected with the optic nerve and which therefore is sensitive to light. It covers the deeper portion of the optic

cup, ending near the ciliary body in a macroscopic, sharp, irregular line bounding the ora serrata. The *pars ciliaris* and the *pars iridica retinae* are the rudimentary layers covering the ciliary body and iris respectively.

The *pars optica retinae* in a fresh condition is a transparent layer colored reddish by the "visual purple." In sections it presents many layers arranged as seen in Fig. 453, the cells of which are related to one another as in the diagram, Fig. 454. The outer layer of the optic cup forms the *pigmented epithelium* of the retina, which consists of a simple layer of six-sided cells. Toward their outer surface (that next the chorioid, where the nucleus lies) they are poor in pigment, whereas in their inner portion they contain numerous rod-shaped ($1-5\ \mu$ long) brown granules of

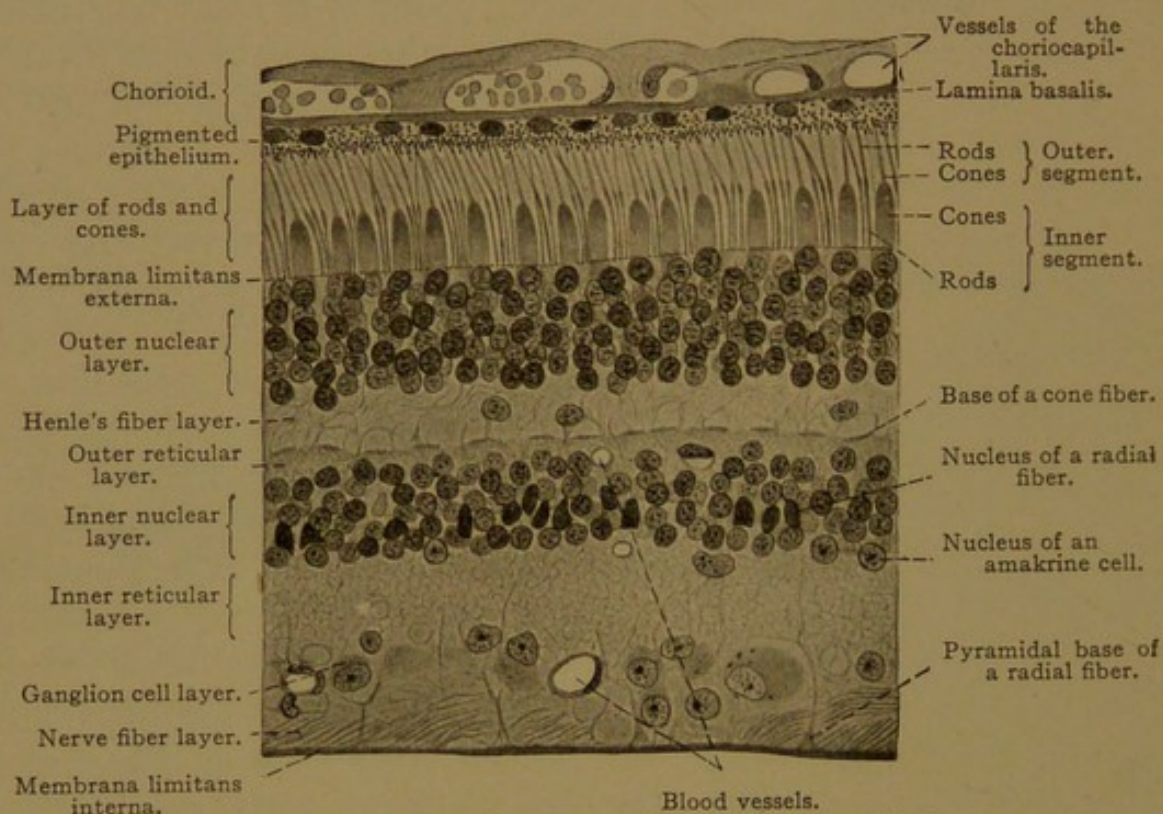


FIG. 453.—VERTICAL SECTION OF A HUMAN RETINA. $\times 36$.

the pigment "fuscin." In albinos the pigment is lacking. From the inner surface of the pigmented epithelium, numerous processes extend between the rods and cones.

The *visual cells*, which are found along the outer surface of the inner retinal layer, are of two sorts, *rod cells* and *cone cells*. In both, the nucleus is found in the inner half of the cell, and the outer non-nucleated half projects through a membrane, the *membrana limitans externa*. This causes the visual cells to appear divided into layers, their nucleated parts beneath the limiting membrane constituting the *outer nuclear layer* (or outer granular layer), and the non-nucleated parts outside of the membrane forming the *layer of rods and cones*.

The rods are four times as numerous as the cones. They are regularly placed so that three or four rods are found between every two cones (Fig

453). The rods are elongated cylinders ($60\ \mu$ long and $2\ \mu$ thick) consisting of a homogeneous outer segment, in which the visual purple is found exclusively, and a finely granular inner segment. In the outer third of the inner segment there is said to be an ellipsoidal, vertically striated structure (which in some lower vertebrates is very distinct). The portion of the rod cells below the limiting membrane is a slender thread, expanding to surround the nucleus which is characterized by from one to three transverse bands. Beneath the nucleus the protoplasm again becomes thread-like, and this basal prolongation of the cell terminates in a small club-shaped enlargement, without processes (Fig. 454).

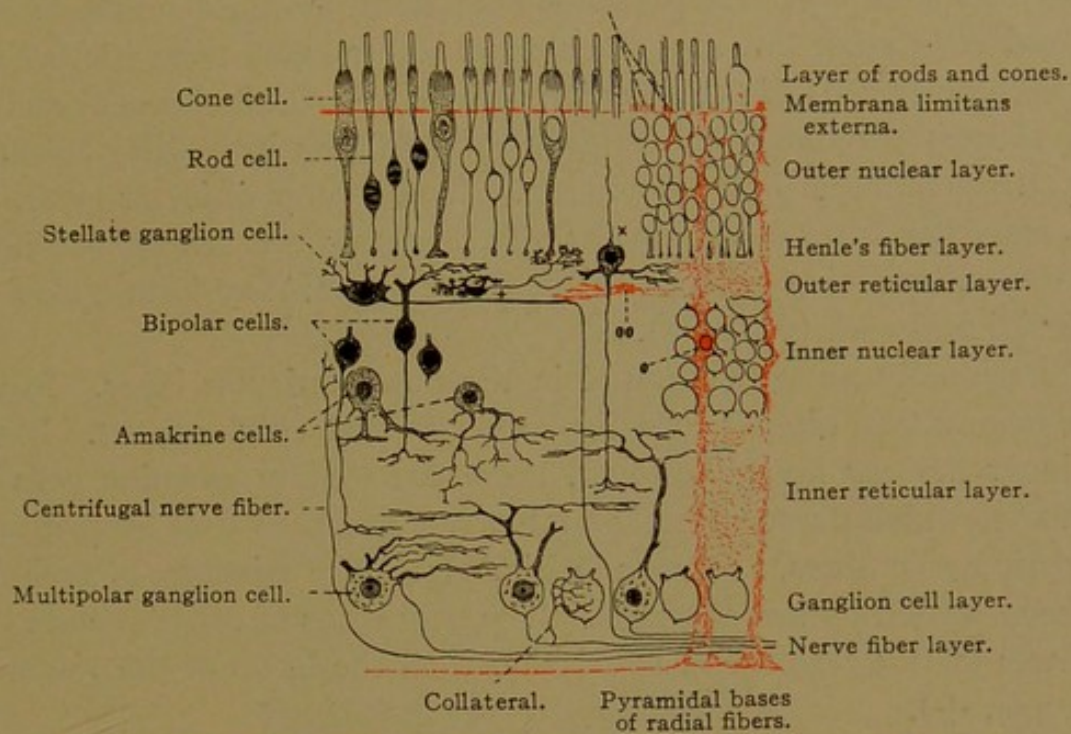


FIG. 454.—DIAGRAM OF HUMAN RETINA. SUPPORTING SUBSTANCE RED.

The cones likewise consist of an outer and an inner segment. The conical outer segments are shorter than those of the rods. The inner segments are thick and somewhat dilated so that the entire cone is flask-shaped. Moreover, the inner segment contains a vertically striated "fiber apparatus." The nuclei of the cone cells are situated just beneath the limiting membrane; below the nuclei the protoplasm forms a fiber, ending in an expanded pyramidal base.

The entire visual cells therefore form three layers of the retina, namely, (1) the *layer of rods and cones*; (2) the *outer nuclear layer*, containing the nuclei of the rod and cone cells; and (3) *Henle's fiber layer*, composed of the basal processes of these cells. The three layers next beneath are formed essentially of superposed parts of the radially arranged bipolar nerve cells, which constitute the *ganglion retinae*. Immediately beneath Henle's fiber layer, dendritic processes of these cells form an *outer reticular layer*, whereas their nuclei are situated in an *inner nuclear layer*, and their centripetal processes, or neuraxons, enter an *inner reticular layer*. There

they terminate in relation with dendrites and cell bodies of large ganglion cells which constitute the *ganglion of the optic nerve*. Cell bodies of this ganglion form the *ganglion cell layer*, and their neuraxons, traveling toward the papilla of the optic nerve, are the principal elements in the *nerve fiber layer*. The latter is separated from the vitreous body by an *internal limiting membrane*. Thus visual stimuli, received by the rods and cones, are transferred by means of the bipolar cells of the ganglion retinae, to the ganglion cells of the optic nerve, through the neuraxons of which they proceed to the brain. These layers may be described in further detail as follows:

Henle's fiber layer contains not only the fiber-like basal ends of the rod and cone cells, but also the slender unbranched dendritic processes of the bipolar cells of the ganglion retinae. Each bipolar cell sends one such process through Henle's layer to terminate in a little thickening near the *membrana limitans externa*. In the outer reticular layer, however, these dendrites of the bipolar cells send out branches which bifurcate repeatedly, becoming reduced to the finest fibrils; they form a close sub-epithelial felt-work (Fig. 454).

Occasionally nuclei are found in the outer reticular layer. Most of these belong with bipolar cells displaced outward (Fig. 454, x). Toward the inner nuclear layer, however, there are stellate ganglion cells with neuraxons which pursue a horizontal course and then turn inward to join the optic nerve fibers, as shown in Fig. 454. The existence of such fibers has been denied by some writers. The neuraxons of other stellate ganglion cells in this region end in relation with the bases of the visual cells (Fig. 454, +).

Toward the inner reticular layer, the inner nuclear layer contains the bodies of ganglion cells, which appear to lack a chief or large process, and are therefore called "amakrine" cells. They send branching fibers into the inner reticular layer, where they interlace with the fine varicose branches of the bipolar cells, and with the ramifications of the dendrites from the *ganglion nervi optici*.

The ganglion cell layer consists of a single row of large multipolar cells containing Nissl's bodies. Certain of these cells because of exceptional size are known as "giant ganglion cells," and they occur at quite regular intervals. "Twin cells" have been found, consisting of two cell bodies united by a short bridge; only one of the pair has a neuraxon.

The nerve fiber layer consists chiefly of the non-medullated neuraxons of the ganglion cells, arranged in plexiform bundles. Occasionally the neuraxons send collaterals back to the ganglion cell layer, where they branch about the cell bodies (Fig. 454). The fiber layer contains also neuraxons which have come out from the brain to terminate in free branches among the cells of the inner nuclear layer.

In addition to the nervous elements, the retina contains blood vessels and a supporting framework of neuroglia cells. The largest vessels are toward the fiber layer (Fig. 453), in which they travel to and from the central vessels in the papilla. The neuroglia framework consists chiefly of *radial* (or Müller's) *fibers*, which are elongated cells extending from the internal to the external limiting membrane. Beyond this membrane they send short processes between the rods and cones, forming "fiber baskets" (Fig. 455). The radial fibers are not isolated cells but are parts of a general syncytium, being connected by a network of processes which penetrate all the layers of the retina (Fig. 454). The external limiting membrane, through which the rods and cones pass, is formed by the coa-

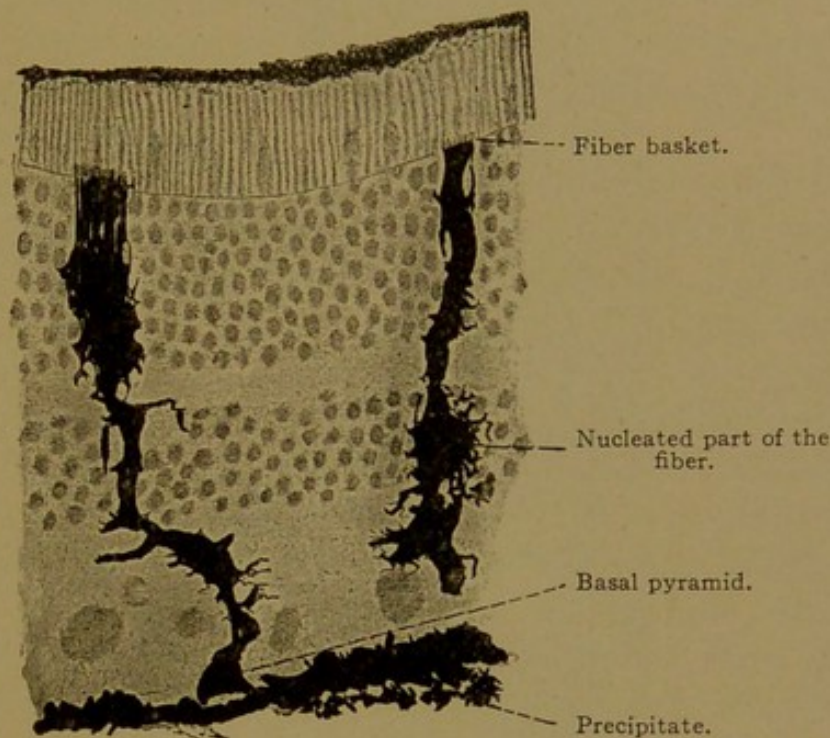


FIG. 455.—GOLGI PREPARATION OF RADIAL FIBERS IN A THICK SECTION OF THE HUMAN RETINA. The fine processes of the fibers in the outer nuclear layer appear as a compact mass. $\times 360$.

lescence of these processes, and the internal limiting membrane is made up of the closely adjacent basal expansions of the radial fibers. The nuclei of the fibers are found in the inner nuclear layer. In addition to the radial fibers there are neuroglia cells with horizontal or tangential branches (Fig. 454, "oo"). As in the central nervous system, some of the stellate groups of fibers do not contain nuclei.

Two modifications of the retina require special description, namely, the *fovea centralis*, which is the region of most acute vision, and the *pars ciliaris*, which is the rudimentary peripheral portion.

Macula lutea and fovea centralis. When vision is centered upon a particular object, the eyes are so directed that the image of the object falls upon the *macula lutea*, or yellow spot of the retina, within which there is a depression, the *fovea centralis*. The macula sends straight slender

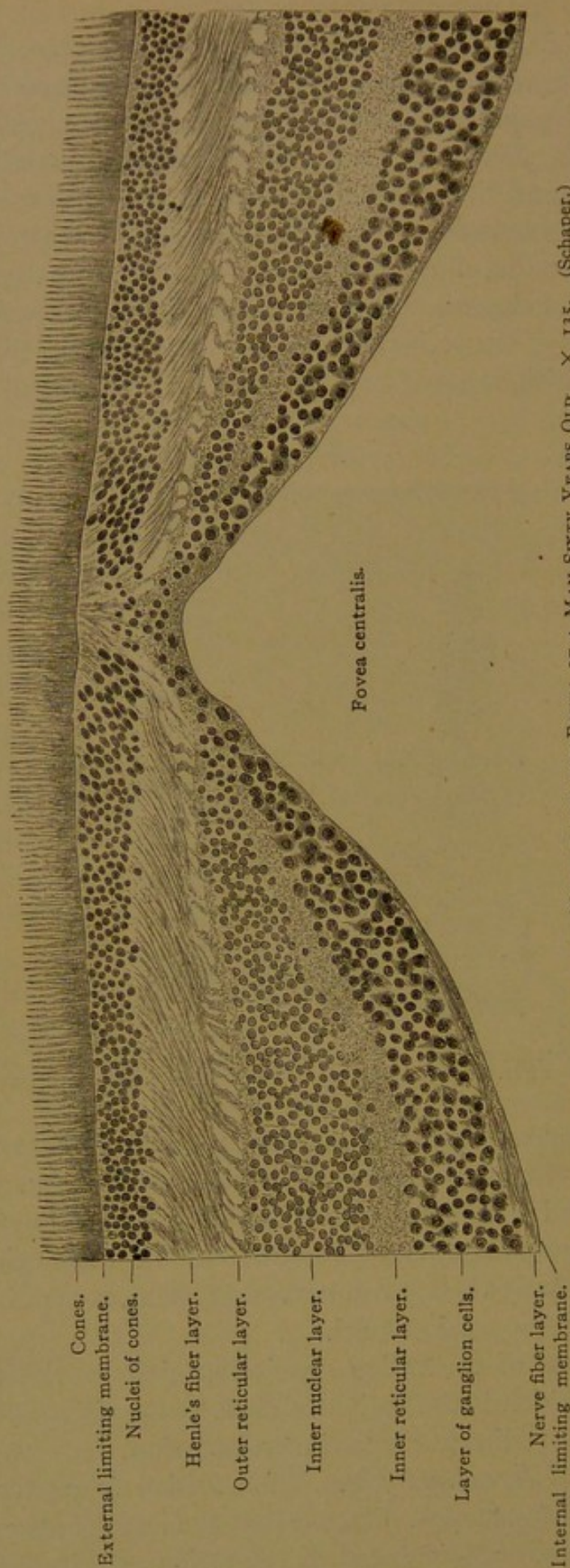


FIG. 456.—HORIZONTAL SECTION THROUGH THE MACULA AND THE FOVEA OF A MAN SIXTY YEARS OLD. $\times 135$. (Schaper.)

The nerve fiber layer, like all the layers, is thicker on the side toward the papilla of the optic nerve than on the opposite side; in the latter situation the nerve fibers are seen in transverse section as minute dots. The section is not through the exact center of the fovea, for there only cone cells are present; no remnants of the confluence of the inner granule and ganglion cell layers are found.

fibers to the papilla of the optic nerve, which is close by on its median side; other coarser optic fibers diverge as they pass the macula, forming an ellipse around it. The retinal layers of the macula are arranged as shown in Fig. 456. At its border the number of rod cells diminishes, and within the macula they are entirely absent. The nuclei of the numerous cone cells, which are here somewhat smaller than elsewhere, form an inner nuclear layer of twice the usual thickness. The basal portions of the cone cells make a broad Henle's fiber layer, and slope away from the fovea. The bipolar cells of the ganglion retinae are so numerous that their nuclei may form nine rows. The ganglion cells of the optic nerve are also abundant. All of these strata become thin toward the fovea, the deepest part of which contains scarcely more than the cone cells. In some individuals the slope of the sides of the fovea is less steep than in the figure; its depth is variable. The macula and fovea are saturated with a yellow pigment soluble in alcohol.

Pars ciliaris retinae. The optic nerve fibers and their ganglion cells disappear before reaching the ora serrata. The cone cells extend further toward the ora than the rods, but the last of them appear to lack outer segments. By the thinning of the reticular layer, the nuclear layers become confluent (Fig. 457). Near the ora serrata large clear spaces normally occur in the outer nuclear layer, and they may extend into the deeper layers (Fig. 457). The radial sustentacular cells form a simple columnar epithelium as the other layers disappear, and they constitute the visual layer of the pars ciliaris. The pigmented epithelium is apparently unmodified as it extends from the optic to the ciliary portion. Along the inner surface of the ciliary part of the retina, the cells of the visual layer produce closely packed horizontal fibers, which form a refractive hyaline membrane.

Zonula ciliaris. Some of the fine homogeneous fibers arising from the pars ciliaris immediately in front of the ora serrata enter the vitreous body, but a much larger number pass between the ciliary processes to the lens. They are attached to the borders of its capsule, overlapping slightly its anterior and posterior surfaces. Thus they form the zonula ciliaris (suspensory ligament) which holds the lens in place (Fig. 452). The zonula is not a continuous layer, nor does it consist of two laminae, one to the anterior and the other to the posterior surface of the lens, with a space between them. It consists rather of numerous bundles, between which and the vitreous body, and among the bundles themselves, there are *zonular spaces* (canals of Petit) which communicate with the posterior chamber.

OPTIC NERVE.

In its intraorbital portion the optic nerve is surrounded by prolongations of the meninges. On the outside is the dural sheath, consisting of

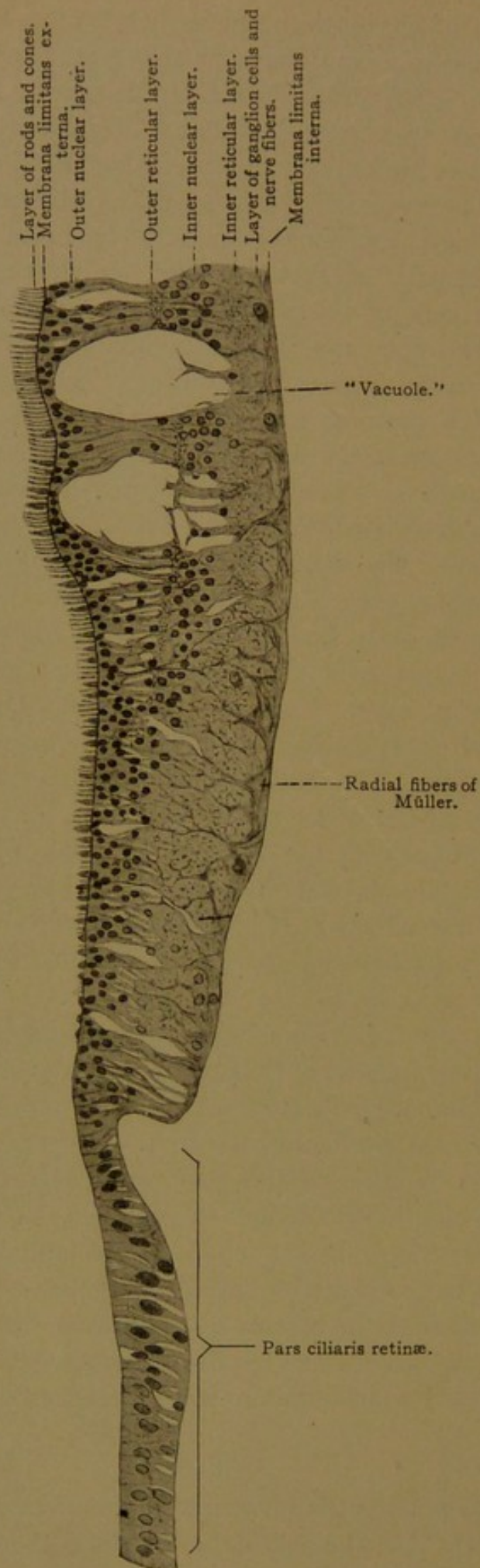


FIG. 457.—MERIDIONAL SECTION OF THE ORA SERRATA AND THE ADJACENT PORTION OF THE PARS CILIARIS RETINÆ OF A MAN THIRTY-SEVEN YEARS OF AGE. $\times 180$ (Schaper.)

dense connective tissue with many elastic fibers. The outer connective tissue bundles tend to be longitudinal and the inner circular. Internally the outer sheath is connected with the arachnoid layer by a few dense strands of tissue, and the arachnoid joins the pial sheath by many branched trabeculæ. The pia surrounds the entire nerve and sends anastomosing septa among the bundles of nerve fibers. The latter are slender and medullated, but without a neurolemma; they are supported by long-rayed *neuroglia cells*, which are found between the individual fibers, but are most numerous at the periphery of the bundles and around the entire nerve. Thus the optic nerve differs from the peripheral nerves, and resembles a cerebral commissure.

At the posterior surface of the eye-ball (or *bulbus oculi*), the dura blends with the sclera. Continuous with both is the dense elastic *lamina cribrosa* which is perforated by the optic nerve fibers. The chorioid and the pia are also in relation with this lamina (Fig. 458). As the optic

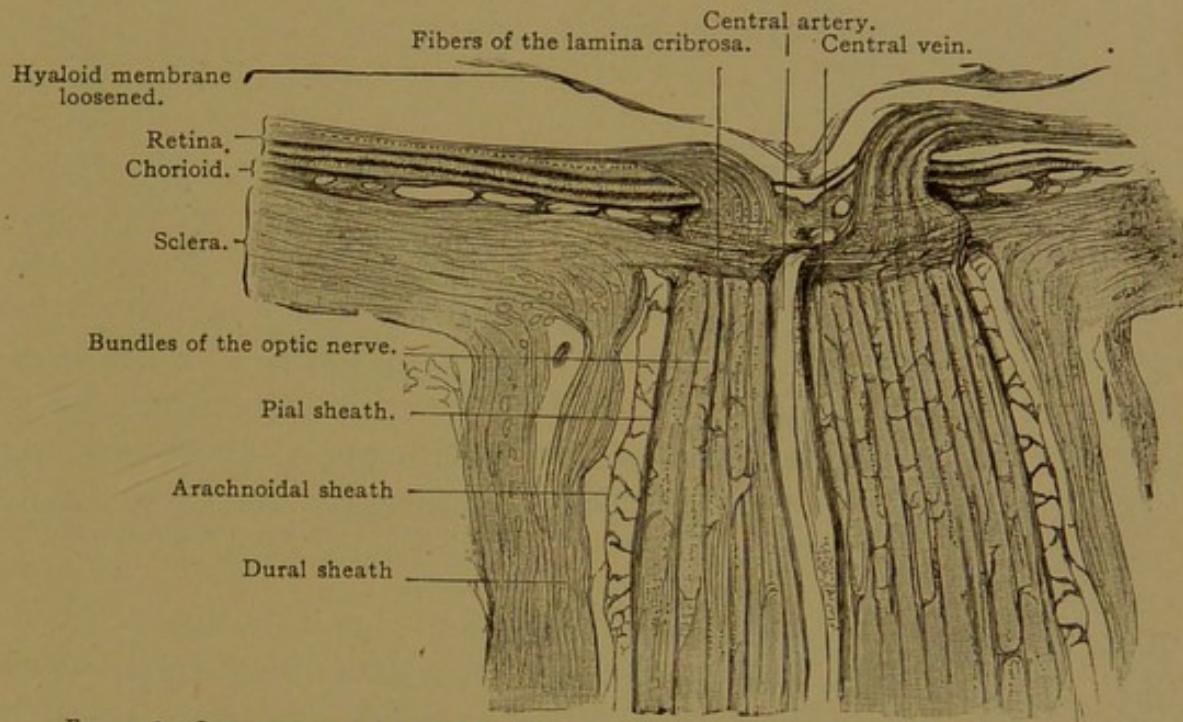


FIG. 458.—LONGITUDINAL SECTION OF THE OPTIC ENTRANCE OF A HUMAN EYE. $\times 15$.

Above the lamina cribrosa is seen the narrowing of the optic nerve, due to its loss of myelin. The central artery and vein have been for the most part cut longitudinally, but above at several points transversely.

nerve penetrates the lamina, its fibers lose their myelin and radiate into the nerve fiber layer of the retina. The central artery and vein of the retina enter the optic nerve in its distal half, and appear at the fundus of the eye in the center of the optic papilla. Their branches spread in the inner layers of the retina, which are covered by the *membrana limitans interna* (Fig. 453).

LENS.

The lens is a biconvex structure having an anterior and a posterior pole, and a vertical equatorial plane. It is enclosed in a thick transparent

elastic *capsule*, 6.5–25 μ thick in front and 2–7 μ thick behind, which is apparently derived from the lens itself. Within the capsule the anterior surface of the lens is formed by the *lens epithelium*, a single layer of cells 2.5 μ thick at the pole, but becoming taller toward the equator. There they are continuous with the elongated *lens fibers* of the posterior layer, which collectively are called the *substantia lentis*.

Originally the fibers multiply throughout the lens, but in later stages the formation of new fibers, as indicated by the presence of mitotic figures, is limited to the region of transition between the lens epithelium and the mass of lens fibers (Figs. 451, E, and 460). When first formed the fibers are short, but they increase in length and become six-sided prisms, somewhat enlarged at one or both ends. The first fibers extend from one surface of the lens to the other. Later these become buried in by the new

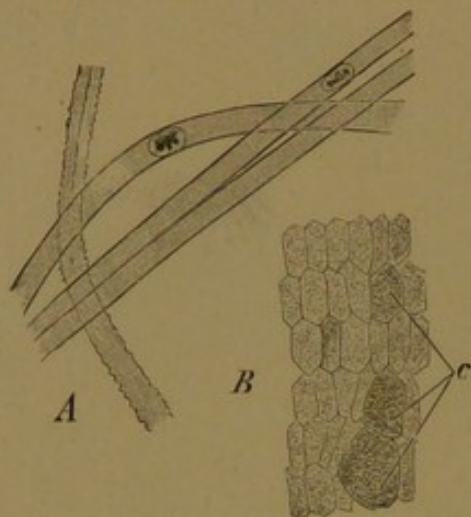


FIG. 459.—LENS FIBERS OF A NEW-BORN INFANT.

A, Isolated lens fibers; three with smooth and one with dentate borders. $\times 240$. B, Human lens fibers cut transversely; c, section through club-shaped ends. $\times 560$.

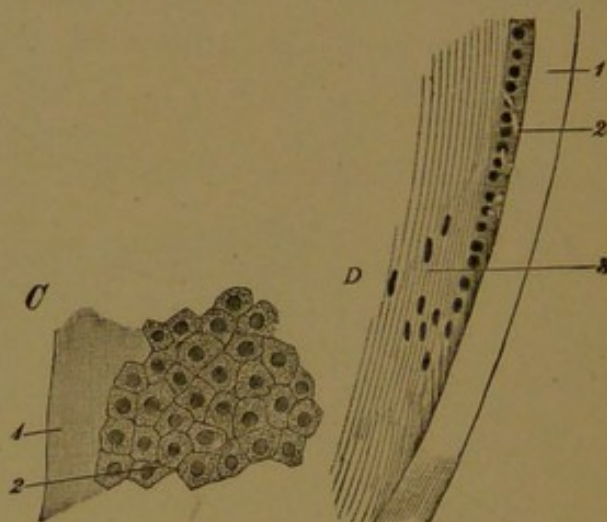


FIG. 460.—CAPSULE AND EPITHELIUM OF A LENS OF ADULT MAN.

C, Tangential section. D, Meridional section across the equator of the lens; 1, capsule; 2, epithelium; 3, lens fibers. $\times 240$.

fibers formed at the periphery, and thus they constitute the *nucelus of the lens*. This is a dense mass of somewhat shrunken fibers, which have lost their nuclei and have acquired wavy or notched margins (Fig. 459). The outer fibers of the *cortical substance* are softer. They have smooth borders, and nuclei which are chiefly in the equatorial plane. Their protoplasm is transformed into a clear fluid substance, said to be chiefly a globulin. The fibers are united to one another by a small amount of cement substance, which is more abundant at the poles, at each of which it forms a "lens star," usually with nine rays.

When the fibers formed at the periphery of the original nucleus elongate so as to cover it in, they do not extend from one pole to the other. Those that reach the anterior pole fall short of the posterior pole, terminating along a *horizontal suture* of cement substance; and conversely those that reach the posterior pole terminate anteriorly along a linear *vertical suture*. As the lens becomes larger, the linear sutures at either pole are replaced by tri-radiate or Y-shaped stars, one of which is inverted.

Lens fibers starting near the center of one star end near the tips of the rays of the other, and vice versa. When the stars become nine-rayed the arrangement of the fibers is very intricate. Without crossing one another, and without any of them being long enough to pass from pole to pole, they cover the lens with even layers. The development of the stars is described by Rabl (Ueber den Bau und Entwicklung der Linse, Leipzig, 1900). As a result of its structure the lens may be separated into concentric lamellæ, but Rabl considers that the meridional segments, or "radial lamellæ," of which the lens contains about two thousand, are its essential subdivisions.

VITREOUS BODY.

The corpus vitreum consists of the fluid *vitreous humor*, together with looser or denser strands of fibrous *stroma* which stretch across it in all directions. Although it is difficult to recognize any definite arrangement in the stroma, certain pathological cases suggest that it is distributed like the septa of an orange. The cells of the vitreous body are round forms, probably leucocytes, and stellate or spindle-shaped connective tissue cells, sometimes degenerating and vacuolated, which invaded the vitreous body with the blood vessels. The latter have atrophied and been resorbed, except for occasional shreds and filaments. Such opacities, which occur normally, are observed when looking at a bright light, and are frequently troublesome to those beginning to use the microscope; because of their erratic motion they are known to physiologists as *muscæ volitantes*. In old age, in eyes otherwise normal, crystals may form in the vitreous humor and float about, "falling like a shower to the bottom of the eye when the eye is held still." Surrounding the vitreous body there is a very resistant thick fibrous layer, which is continuous anteriorly with the hyaloid membrane of the ciliary part of the retina.

TUNICA VASCULOSA.

Chorioid. Between the sclera and the chorioid there is a loose tissue containing many elastic fibers and branched pigment cells, together with flat non-pigmented cells. In separating the sclera from the chorioid, this layer is divided into the *lamina fusca* of the sclera and the *lamina supra-chorioidea*. Internal to the latter is the *lamina vasculosa*, which forms the greater part of the chorioid. It contains many large blood vessels imbedded in a loose elastic connective tissue, some of its cells being branched and pigmented; others without pigment are flat and arranged in layers surrounding the vessels. A thin inner layer of blood vessels, the *lamina choriocapillaris*, consists of a very close network of wide capillaries. The choriocapillaris is separated from the pigmented epithelium of the retina by a structureless elastic lamella which may be $2\ \mu$ thick. This *lamina basalis* shows the imprint of the polygonal retinal cells on its inner surface, and is associated with fine elastic networks toward the choriocapillaris.

Between the vascular lamina and the choriocapillaris, there is a boundary layer consisting of a fine elastic network, generally without pigment. Here in ruminants and horses there are many wavy bundles of connective tissue, which give to the eyes of those animals a metallic luster. Such a layer is known as the *tapetum fibrosum*. The similarly iridescent *tapetum cellulosum* of the carnivora is formed of several layers of flat cells which contain numerous fine crystals.

The *ciliary body* encircles the eye as a muscular band, attached to the inner surface of which there are from 70 to 80 meridional folds, the *ciliary processes* (Fig. 452). The equator of the eye is vertical, like that of the lens, and the meridians are antero-posterior. The processes begin low at the ora serrata and rise gradually to a height of 1 mm., terminating abruptly near the border of the lens. Each process consists of fibrillar connective tissue containing numerous elastic fibers and blood vessels, and is bounded toward the pars ciliaris retinae by a continuation of the

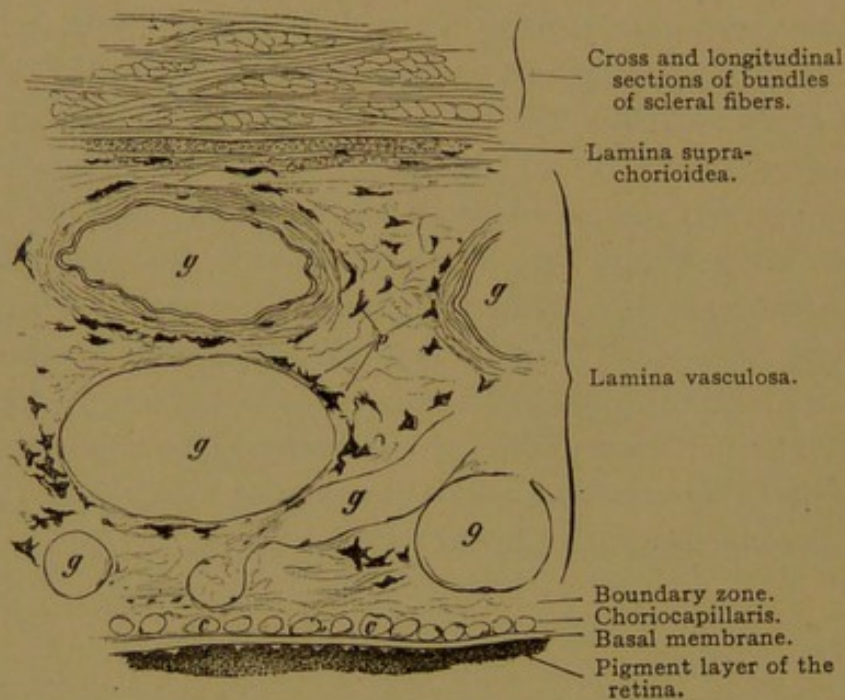


FIG. 461.—VERTICAL SECTION THROUGH A PART OF THE HUMAN SCLERA AND THE ENTIRE THICKNESS OF THE CHOROID. $\times 100$.

g, Large vessels; p, pigment cells; c, cross section of capillaries.

lamina basalis, which is thrown into intersecting folds. The ciliary processes, which are compressible, may serve to prevent the increase of intra-ocular pressure during the contraction of the ciliary muscle; and the fluid within the eye is derived from the vessels which they contain. The *ciliary muscle* is a band of smooth muscle fibers about 3 mm. broad and 0.8 mm. thick anteriorly; it arises beneath the sinus venosus of the sclera and tapers toward the ora serrata (Fig. 425). It consists of three sets of fibers, the *meridional*, *radial*, and *circular*. The meridional fibers (Fig. 452, p. 443) are next to the sclera, grouped in numerous bundles with elastic tissue intermingled. They extend to the smooth part of the choroid, and constitute the *tensor chorioideæ*. The radial fibers are directed to-

ward the center of the eye-ball. They form a middle layer of curving fibers which blend with the meridional fibers externally. The circular fibers, which vary in number in different individuals, form that part of the ciliary muscle which is nearest to the equator of the lens. The contraction of these muscles affects the shape of the lens, which is attached to the adjacent tissue by the zonula.

The *iris* consists of its *stroma* anteriorly, and the *pars iridica retinæ* posteriorly, and is covered by the mesenchymal epithelium of the chambers of the eye. The anterior epithelium is a simple layer of flat polygonal cells (sometimes called "endothelium"). It rests upon a loose network of stellate cells, in part pigmented, resembling the reticulum of a lymph gland. This is followed by the loose connective tissue of the stroma, likewise containing networks of stellate cells, which in blue eyes are not pigmented. The very few elastic fibers are limited to the posterior layers, where they are radially arranged in rela-

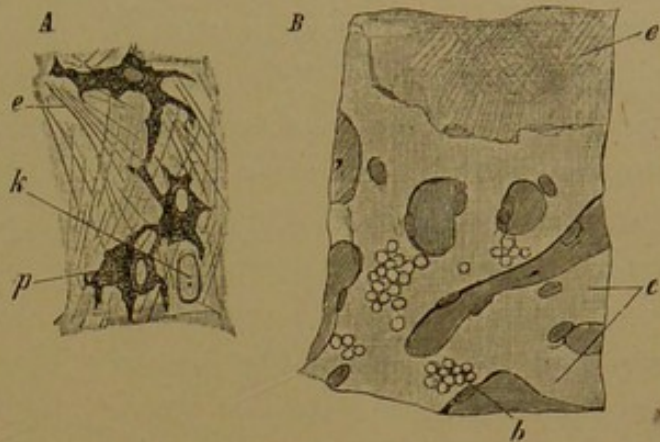


FIG. 462.—A, FROM A TEASED PREPARATION OF A HUMAN CHORIOID. $\times 240$. p, Pigment cells; e, elastic fibers; k, nucleus of a flat non-pigmented cell; the cell body is invisible. B, PORTION OF A HUMAN CHORIOCAPILLARIS AND THE ADHERENT LAMINA BASALIS. $\times 240$. c, Wide capillaries, some of which contain (b) blood-corpuscles; e, lamina basalis, showing a fine "lattice work."

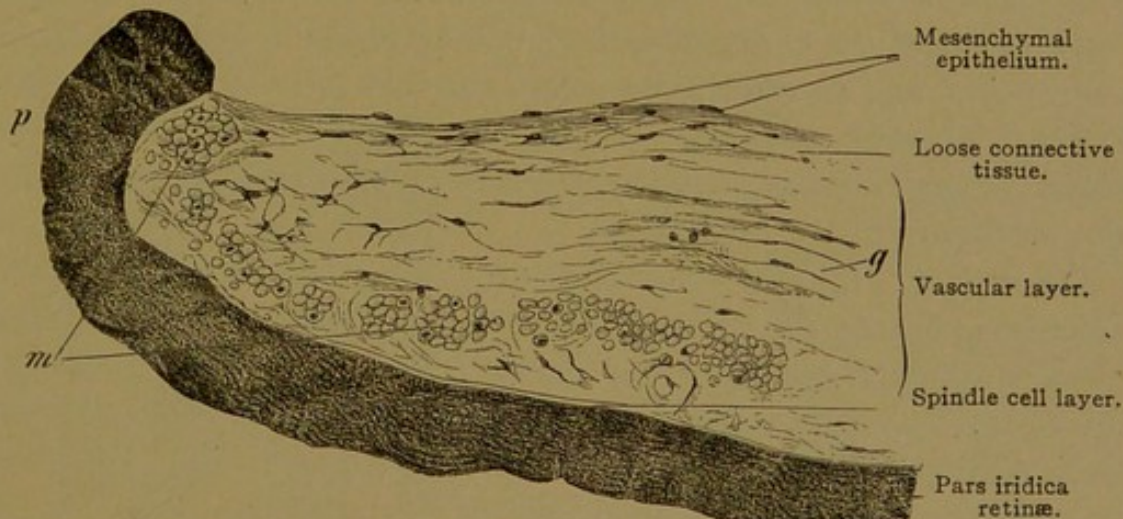


FIG. 463.—VERTICAL SECTION OF THE PUPILLARY PORTION OF A HUMAN IRIS. $\times 100$. About one-fifth of the entire width of the iris is shown. g, Blood vessel, with thick connective tissue sheath; m, sphincter pupillæ muscle cut transversely; p, pupillary border of the iris.

tion to the pupil. The stroma contains numerous radial blood vessels with thick connective tissue coats, but (in man) without musculature or elastic fibers. In the vascular layer, toward the pupillary border of the iris, there is a band of circular smooth muscle fibers, 1 mm. deep; this is the *sphincter pupillæ*. It is invested with many

prolongations of the stromatic network, the polygonal meshes of which are radially elongated. The *dilatator pupillæ* is a peculiar membrane of smooth muscle fibers on the posterior surface of the vascular layer, stretching from the connective tissue between the muscle bundles of the sphincter, to that between the ciliary muscles. Its fibers consist of an anterior contractile portion, and a posterior nucleated and pigmented portion. The anterior parts form a continuous layer, readily seen in radial sections as "Henle's spindle cell layer," which is a clear non-nucleated stripe, 2-5 μ wide (Fig. 463). The nucleated portions of the fibers appear to blend with the pigmented retinal layer of the iris, from which they are derived. These muscles are therefore ectodermal.

The two layers of the optic cup are intimately blended in the thin stratum which forms the posterior layer of the iris. Except in albinos, this *pars iridica retinæ* is deeply pigmented. Posteriorly it is covered by a continuation of the hyaline membrane of the *pars ciliaris*.

TUNICA FIBROSA.

The sclera, toward the chorioid, is bounded by the pigmented *lamina fusca*. This is a loose tissue containing branched pigment cells and flattened connective tissue cells. Except for this boundary layer, the sclera consists of densely interwoven bundles of connective tissue, chiefly meridional and longitudinal. Elastic fibers accompany the bundles, and are especially abundant at the insertions of the ocular muscles. The flat irregular cells of the connective tissue are surrounded by tissue spaces as in the cornea, and anteriorly the cornea and sclera are continuous with one another. The transition, however, is quite abrupt and the boundary is oblique, so that the rim of the cornea is bevelled at the expense of its anterior surface.

The *cornea* (Fig. 464) consists of an outer epithelium, external basal membrane, substantia propria, internal basal membrane, and mesenchymal epithelium bounding the anterior chamber. The corneal epithelium, about 0.03 mm. thick, is stratified and consists of a basal layer of clearly outlined columnar cells followed by three or four rows of cuboidal cells and several layers of flattened superficial cells. The outer cells retain their nuclei. Peripherally the epithelium is continuous with that of the conjunctiva bulbi. The anterior basal membrane (Bowman's) is an almost homogeneous layer, sometimes as much as 0.01 mm. thick. Superficially it connects with the epithelial cells by spines and ridges. Beneath, it blends with the substantia propria, of which it is a modification. Since it is not formed of elastic substance the name "anterior elastic membrane" is not justified.

The substantia propria consists of fine straight fibrils of connective

tissue, bound together in bundles of almost uniform thickness by an interfibrillar substance, perhaps fluid; these bundles are joined to one another by an interfascicular cement, so that they form a succession of

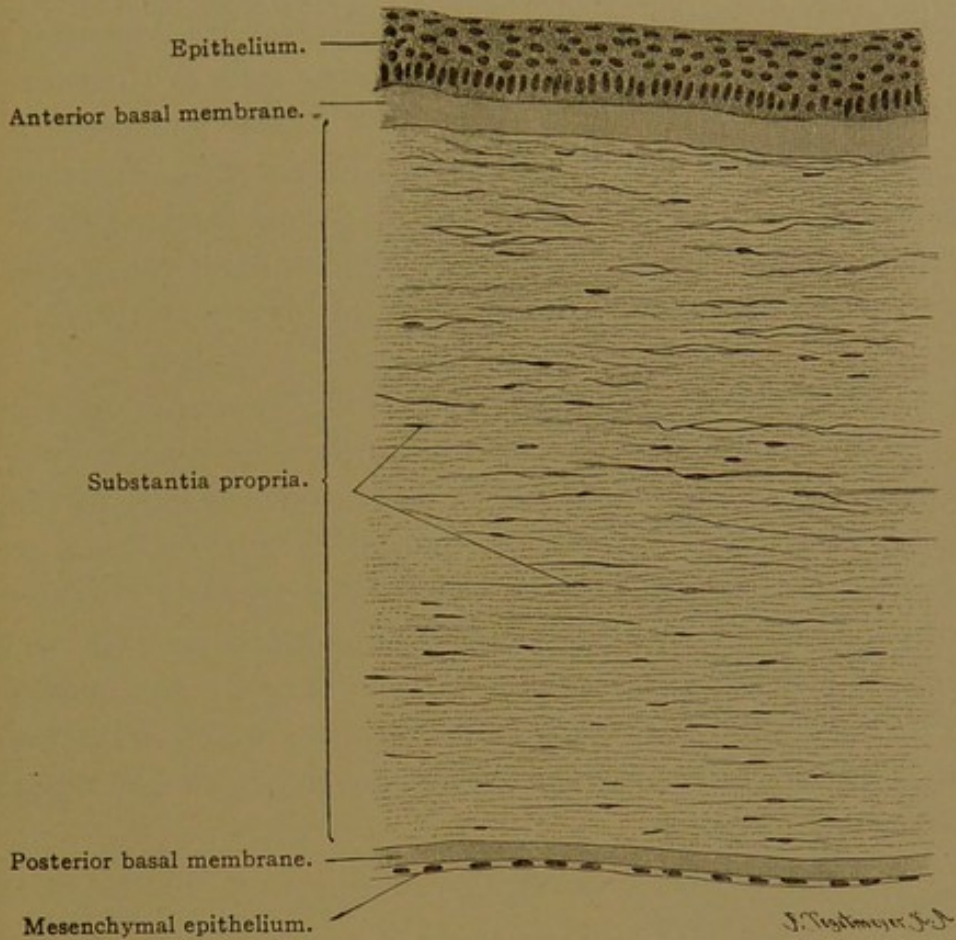
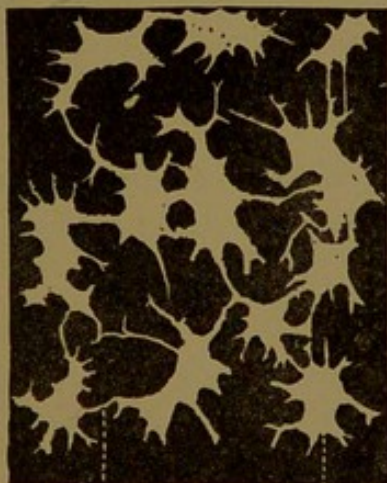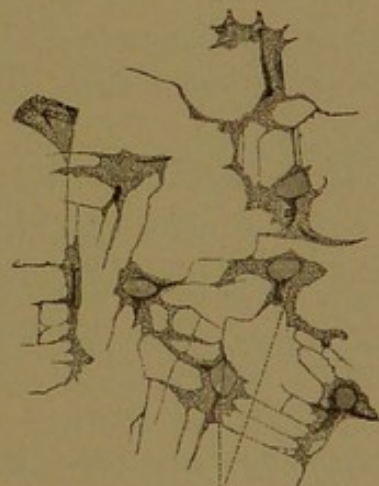


FIG. 464.—VERTICAL SECTION OF A HUMAN CORNEA. $\times 100$.



Corneal canaliculus. Corneal space.

FIG. 465.—CORNEAL SPACES AND CANALICULI (IN WHITE) FROM A HORIZONTAL SECTION OF THE CORNEA OF AN OX. Silver preparation. $\times 240$.



Corneal cells.

FIG. 466.—CORNEAL CELLS FROM A HORIZONTAL SECTION OF THE CORNEA OF A RABBIT. $\times 240$.

superposed flat lamellæ, parallel with the corneal surface. Oblique bundles, the so-called arcuate fibers, are found especially in the anterior layers, where they pass from one lamella to that next above or below.

Numerous tense elastic fibers are found especially in the deeper layers, where they form a fine network over the posterior elastic membrane.

Within the cement substance, there is a system of branched canaliculi, dilated in places to form oval spaces. The latter are between the lamellæ, but the canaliculi extend also among the constituent fiber-bundles. Within the spaces, there are flat stellate anastomosing cells or "corneal corpuscles," the branches of which extend into the canals and tend to unite with those of neighboring cells, at right angles (Fig. 466). The cells and their processes are more or less surrounded by serous fluid. Leucocytes enter the canals, and are normally found in the cornea; if the cornea is inflamed they become abundant. Blood vessels and lymphatic vessels are absent.

The posterior basal or elastic membrane (Descemet's membrane) is a structure clear as glass, 6 μ thick. Its posterior surface is covered by a simple layer of flat polygonal cells (Fig. 464), which form a part of the lining of the anterior chamber. Toward the periphery of the cornea in adults, the posterior surface of the elastic membrane presents rounded elevations, and the posterior epithelium becomes continuous with the anterior epithelium of the iris (Fig. 452). In this "angle," the cornea receives connective tissue prolongations from the iris, which form the *pectinate ligament of the iris*—a structure highly developed in the horse and cow, but rudimentary in man.

BLOOD VESSELS.

The *central vessels of the retina* supply a part of the optic nerve, and the retina; the *ciliary vessels* supply the rest of the eye. These two sets of vessels anastomose with one another only at the entrance of the optic nerve (Fig. 467).

The *ciliary arteries* include (1) the *short posterior ciliary arteries*; (2) the *long posterior ciliary arteries*; and (3) the *anterior ciliary arteries*. The three groups will be considered in turn.

1. After supplying the posterior half of the surface of the sclera, some twenty branches of the short posterior ciliary arteries penetrate the sclera around the optic nerve. They form the capillaries of the lamina choriocapillaris. At the entrance of the optic nerve they anastomose with branches of the central artery of the retina (*c*) and thus form the *circulus arteriosus nervi optici*. At the ora serrata they anastomose with recurrent branches of the long posterior ciliary and the anterior ciliary arteries.

2. The two long posterior ciliary arteries also penetrate the sclera near the optic nerve (Fig. 467, 1). They pass, one on the nasal and the other on the temporal side of the eye, between the chorioid and sclera to the ciliary body. There each artery divides into two branches which follow the ciliary border of the iris, and connect with the corresponding branches from the artery of the opposite side, thus encircling the iris with an arterial ring. This is the *circulus iridis major* (Fig. 467, 2), from which

numerous branches extend to the ciliary processes (3) and to the iris (4). Near the pupillary border of the iris, the arteries form an incomplete ring, the *circulus iridis minor*.

3. The anterior ciliary arteries proceed from those supplying the recti muscles, penetrate the sclera near the cornea, and in part join the *circulus iridis major*, in part supply the ciliary muscle, and in part through recurrent branches, connect with the

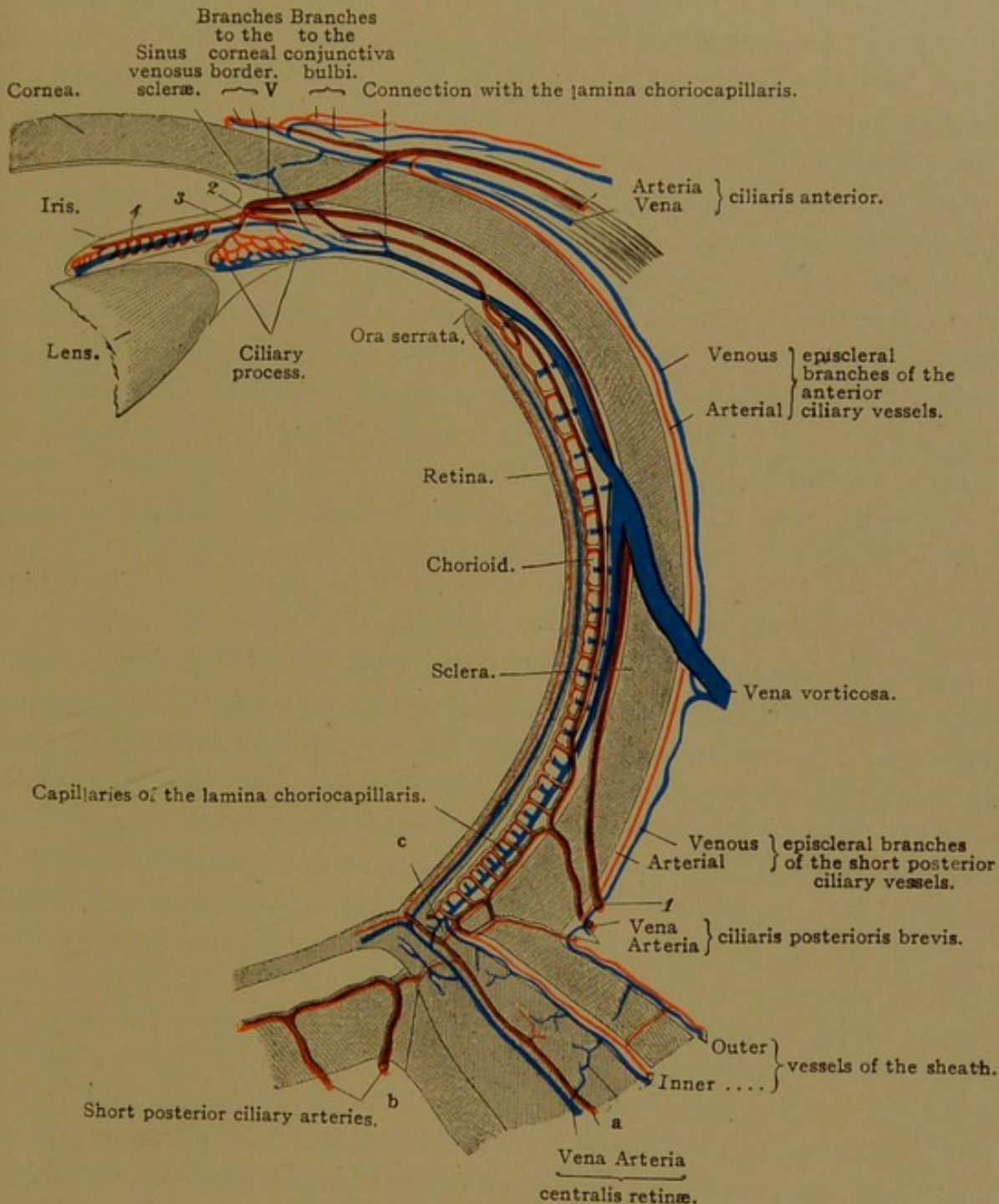


FIG. 467.—BLOOD VESSELS OF THE EYE. (After Leber.)

The retina, optic nerve and tunica fibrosa are stippled; the tunica vasculosa is blank. V, Connection of the anterior ciliary artery with the *circulus iridis major* (2).

lamina choriocapillaris. Before penetrating the sclera, the anterior ciliary arteries give off posterior branches for the anterior half of the sclera, and anterior branches for the conjunctiva bulbi and the corneal border. The cornea itself is without vessels, but at its border, between the anterior lamellæ of the substantia propria, there are terminal loops.

The *veins* generally proceed toward the equator, uniting in four (less often in 5 or 6) *venæ vorticosæ*. These pass directly through the sclera and empty into one of the ophthalmic veins. Besides the *venæ vorticosæ* there are small veins accompanying the short posterior and the anterior ciliary arteries. The short ciliary veins receive branches from the ciliary muscle, the episcleral vessels, the conjunctiva bulbi and the periphery of the cornea. The episcleral veins also connect with the *venæ vorticosæ*. Within the sclera, near the cornea, there is a circular vein, receiving small branches from the capillaries of the ciliary muscle. This *sinus venosus scleræ* (canal of Schlemm) connects with the anterior ciliary veins.

Arteria centralis retinae. The central artery of the retina enters the optic nerve 15–20 mm. from the eye-ball, passes to its center and proceeds to the optic papilla. There it divides into two branches directed upward and downward respectively, and these by further subdivision supply the entire pars optica retinae. Within the optic nerve the artery sends out numerous little branches which anastomose with small vessels that have entered the sheaths from the surrounding fat; and also with branches of the short posterior ciliary arteries (Fig. 467, *b*).

The central vein of the retina receives two main branches at the optic papilla and follows the artery along the axis of the optic nerve.

CHAMBERS AND TISSUE SPACES OF THE EYE.

The eye contains no lymphatic vessels, but is provided with communicating tissue spaces, bounded by loose cells or mesenchymal epithelia. They include the corneal and scleral canaliculi, and the *anterior* and *posterior chambers*; the latter connect with one another through the capillary interval between the lens and iris. The posterior chamber extends into the *zonular spaces*; and there are irregular extensions of the anterior chamber, associated with the pectinate ligament of the iris, called *spaces of the angle of the iris* (spaces of Fontana). The latter are but slightly developed in man. Posteriorly the tissue spaces include the *hyaloid canal* of the vitreous body; the very narrow *perichorioideal space* between the chorioid and sclera; the subdural and arachnoid spaces of the optic sheaths named the *intravaginal spaces*; and finally the *interfascial space* (of Tenon) which surrounds most of the sclera and is prolonged as a supradural space around the optic nerve. These spaces may be filled from the arachnoid space about the brain. They contain a "filtrate from the vessels." The interfascial and perichorioideal spaces hold but little fluid; acting as bursæ, they facilitate the movements of the eye.

NERVES.

Apart from the optic nerve, the eye is supplied by the *short ciliary nerves* from the ciliary ganglion, and the *long ciliary nerves* from the naso-

ciliary branch of the ophthalmic nerve. The ciliary nerves penetrate the sclera near the optic nerve and send branches containing ganglion cells to the vessels of the chorioid. The main stems pass forward between the chorioid and sclera to the ciliary body, where they form a circular ganglionated plexus, the *plexus gangliosus ciliaris*. Its branches extend to the ciliary body, the iris and the cornea, and are described as follows:

The nerves of the ciliary body form a delicate network on its scleral surface; they supply its muscle fibers and those of the vessels with slender motor endings; and between the ciliary muscle bundles they have branched free endings, perhaps sensory.

The medullated nerves of the iris lose their myelin and form plexuses as they pass toward the pupillary margin. A sensory plexus is found just beneath the anterior surface, and motor fibers supply the sphincter, dilator and vascular muscles. The existence of ganglion cells in the human iris is denied.

The nerves of the cornea enter it from the *plexus annularis* in the sclera just outside. The annular plexus also sends fibers into the conjunctiva, where they end in networks, and in bulbous corpuscles (Fig. 154, p. 160) situated in the connective tissue close to the epithelium. Such corpuscles may be found 1 or 2 mm. within the corneal margin. The corneal nerves become non-medullated and form plexuses between the lamellæ throughout the stroma. They extend into the epithelium and there form a very delicate plexus with free intercellular endings.

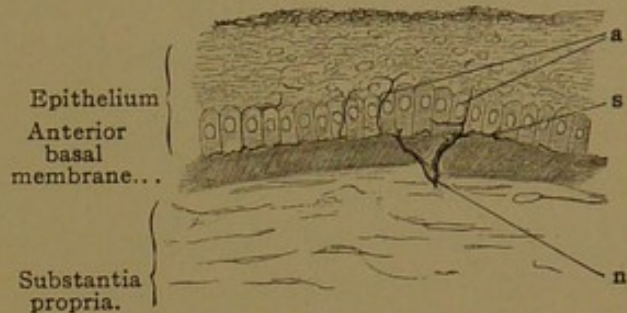


FIG. 468.—FROM A SECTION OF THE HUMAN CORNEA.
X 240.

n, A branching nerve penetrating the anterior basal membrane; s, subepithelial plexus beneath the cylindrical cells; a, fibers of the intraepithelial plexus ascending between the epithelial cells.

EYELIDS.

The eyelids or *palpebræ* (Fig. 469) are covered with thin skin provided with fine lanugo hairs; small sweat glands extend into the corium, which here contains pigmented connective tissue cells. The subcutaneous tissue is very loose, having many elastic fibers and few or no fat cells. Near the edge of the lid there are two or three rows of large hairs, the eyelashes or *cilia*, the oblique roots of which extend deep into the corium. Since they are shed in from 100 to 150 days they occur in various stages of development. They are provided with small sebaceous glands, and the *ciliary glands* (of Moll) open close beside or into their sheaths. The ciliary glands are modified sweat glands, with simpler coils, which may show successive constrictions; "a branching of the tubules has been observed."

The central portion of the eyelids is muscular. Beneath the subcutaneous tissue there are bundles of the striated *orbicularis palpebrarum* extending lengthwise of the lid. A subdivision of this muscle, found behind the roots of the cilia, is called the *musculus ciliaris Riolani*. Posterior to the orbicularis muscle are found the terminal radiations of the tendon of the *levator palpebræ*. A part of these are lost in connective tissue; another part, associated with smooth muscle fibers, are inserted into the upper border of the *tarsus* and form the *superior tarsal muscle*. This occurs in the upper lid, but correspondingly in the lower lid the radiations from the *inferior rectus* muscle contain smooth muscle fibers, forming the *inferior tarsal muscle*.

The inner portion of the lids consists of the conjunctival epithelium and the underlying connective tissue, including the *tarsus*. This is a plate of dense connective tissue which gives firmness to the lid. It begins at the free edges and extends over the adjacent two-thirds of the lid, close to the conjunctiva. Imbedded in its substance in either lid, there are about 30 *tarsal* (or Meibomian) *glands*, which open along the palpebral border. Each of them consists of a wide excretory duct, surrounded on all sides by small acini, which empty into the duct through short stalks. In structure they resemble sebaceous glands. At the upper end of the *tarsus* and partly enclosed in its substance, there are branched tubular *accessory lachrymal glands*. They occur chiefly in the medial (nasal) half of the lid.

The tunica propria of the palpebral conjunctiva contains plasma and lymphoid cells; the latter invade the epithelium, beneath which in some animals they form nodules. The stratified epithelium of the skin gradually changes to that of the conjunctiva, which has several basal layers of cuboidal cells and a superficial layer of short columnar cells. The latter are covered by a thin cuticula, and goblet cells are found among them. The transition from the superficial squamous cells to the columnar form may occur at the posterior edge of the lid, or quite high on the conjunctival surface. Toward the arch where the palpebral conjunctiva becomes continuous with that of the bulb, the epithelium is so folded that in sections it may seem to form glands.

The conjunctiva bulbi is similar to that of the lid. Its outer epithelial cells, however, become squamous toward the cornea and over the exposed portion of the eye, and its basal cells contain pigment. The yellow appearance of the exposed portion, often most pronounced near the medial border of the cornea, and known as *pinguecula*, is said not to be due to fat or to an epithelial pigment; it accompanies a thickening of the connective tissue layer. The tunica propria forms well-marked papillæ near the cornea. Its lymphocytes may form nodules, as many as twenty having been found in the human conjunctiva bulbi. Occasional

mucous glands occur. (It may be noted that the entire anterior covering of the bulb of the eye is named by some the *conjunctiva bulbi*, which accordingly is divided into the *conj. scleræ* and the *conj. corneæ*.)

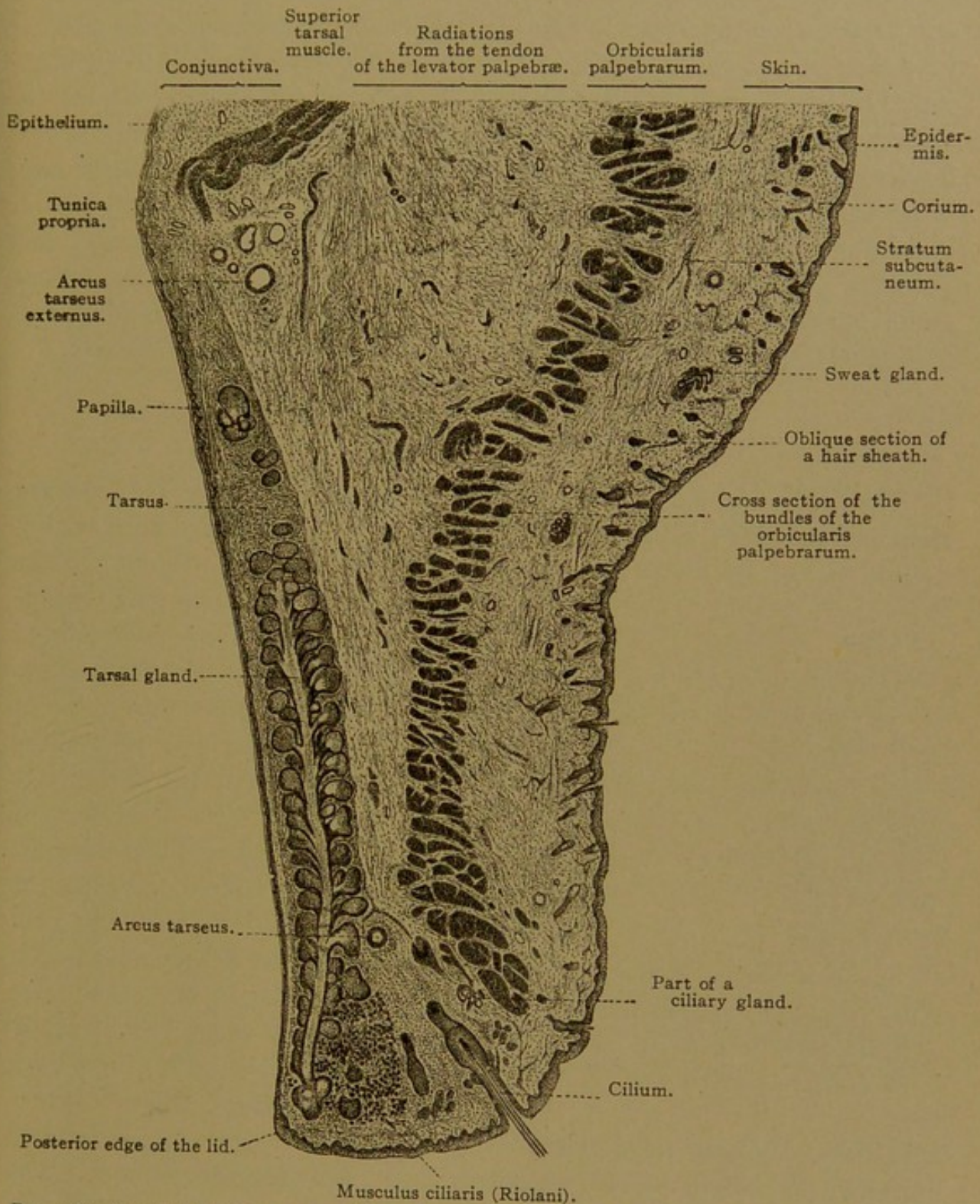


FIG. 469.—SAGITTAL SECTION OF THE UPPER LID OF A CHILD OF SIX MONTHS. The outlet of the tarsal gland was not in the plane of section. $\times 15$.

At the medial angle of the lids there is a thin fold of connective tissue covered with stratified epithelium; this *plica semilunaris* is a rudimentary third lid. The nodular elevation of tissue at the medial angle, the *caruncula lacrimalis*, resembles skin except that a stratum corneum is lacking;

it contains fine hairs, sebaceous and accessory lachrymal glands, and in its middle part, small sweat glands.

The blood vessels of the lids proceed from branches approaching the lateral and medial angles of the eye. They form an arch, the *arcus tarsus externus*, at the upper border of the tarsus, and a second *arcus tarseus* near the free margin of the lid (Fig. 469). They extend also into the conjunctiva bulbi, and near the margin of the cornea they pass inward to unite with the anterior ciliary vessels (Fig. 467). The lymphatic vessels form a close network beneath the palpebral conjunctiva, and a loose one in front of the tarsus. Whether the lymphatic vessels of the conjunctiva bulbi end blindly toward the cornea or connect with the canaliculi, has not been determined. The nerves form a very thick plexus in the tarsus and supply the tarsal glands. There are free endings in the conjunctival epithelium, and bulbous corpuscles in the connective tissue beneath.

LACHRYMAL GLANDS.

The lachrymal glands are groups of compound tubular glands, and are therefore provided with several excretory ducts. These are lined with a double row of epithelial cells, the superficial layer being columnar. The

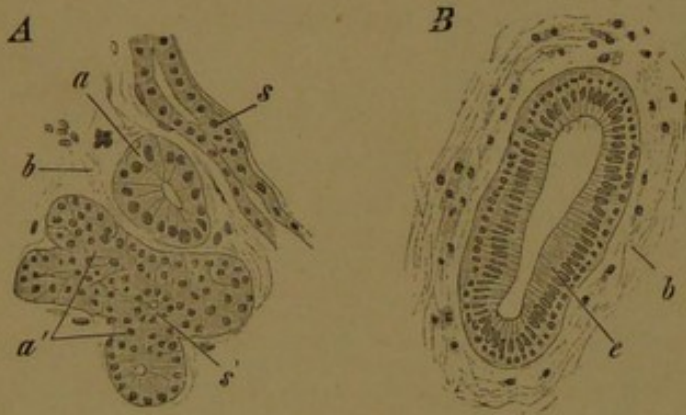


FIG. 470.—FROM A SECTION OF A HUMAN LACHRYMAL GLAND.
X 420.

A, Gland body; a, tubule cut across; a', group of tubules cut obliquely; s, intercalated tubule; s', intercalated tubule in cross section; b, connective tissue. B, cross section of an excretory duct; e, two-rowed cylindrical epithelium; b, connective tissue.

excretory ducts pass gradually into long intercalated ducts with a low epithelium. These terminate in tubules, surrounded by a membrana propria, and containing two sorts of cells. Certain cells are tall when filled with secretion, which occupies the superficial half of the cell; when empty they are shorter. The cells of the other form are low when full of secretion, which gathers in a large round mass, leaving only a

thin basal layer of protoplasm. Intercellular secretory capillaries and secretory granules have been demonstrated. Between the gland cells and the basement membrane there are occasional flat cells, which are a continuation of the deeper layer of the epithelium of the duct. The blood vessels and nerves are similar to those of the oral glands.

At the medial angle of either eye there are two *lachrymal ducts* which have no connection with the lachrymal glands, but serve to convey the secretions which pass across the front of the eye to the *lachrymal sacs*.

From these sacs it passes through the *naso-lachrymal ducts* into the nasal cavity. The lachrymal ducts are lined with stratified squamous epithelium, resting upon a tunica propria containing an abundance of cells and elastic fibers. Externally these ducts are surrounded by striated muscle fibers, chiefly longitudinal. The lachrymal sac, which is provided with small branched tubular glands, and the naso-lachrymal duct are both lined with two-rowed columnar epithelium, surrounded by a lymphoid tunica propria. They are separated from the underlying periosteum by a thick plexus of veins.

EAR.

Development and General Anatomy. The ear is divided into three parts: (1) the *external ear*, which includes the *auricles* projecting from the surface of the body, and the *external acoustic meatus* leading from the surface to the *tympanic membrane*; (2) the *middle ear*, including the tympanic cavity or "drum" and the chain of three bones extending across it; and (3) the *internal ear*, which is a system of epithelial ducts and surrounding tissue spaces, imbedded in the temporal bone, and connected with terminal branches of the acoustic nerve.

On either side of the body, the internal ear first appears as a local thickening of the epidermal ectoderm near that portion of the medullary tube which later becomes the pons. The thickened areas are invaginated as shown in Fig. 471 A and B, and the pockets thus produced become separated from the epidermis in the form of *auditory vesicles* (otocysts). The place where they become detached from the epidermis is marked by a slight elevation on the medial surface of the vesicle, which soon elongates, producing the tubular *endolymphatic duct* (Fig. 471, C). The blind upper end of the duct becomes enlarged to form the *endolymphatic sac*, which, however, is only slightly developed in man; it appears in the models of the embryonic vesicle shown in side view in Fig. 472, A-C. In the adult the endolymphatic duct is a very slender tube, terminating blindly (or perhaps with secondary apertures) just beneath the dura.

In two places the medial and the lateral walls of the upper half of the vesicle approach one another, and after fusing, the epithelial plates thus produced become thin and rupture, so that two *semicircular ducts* are formed (Fig. 472, B and C). The space encircled by each duct may be regarded as a hole through the vesicle. The two ducts are the *superior* and *posterior semicircular ducts* respectively. The third or *lateral semicircular duct* forms soon afterward. In Figs. 471, D and 472, B it is a horizontal shelf-like projection of the vesicle, the center of which is to become perforated so that its rim will become the duct. The portion of the vesicle which receives the terminal openings of the three semicircular ducts is called the

utricle. Since at one of their ends the superior and posterior ducts unite in a single stalk before entering the utricle, there are but five openings for the three ducts (Fig 472, D). Near one end of each duct there is a dilatation or *ampulla*, where nerves terminate.

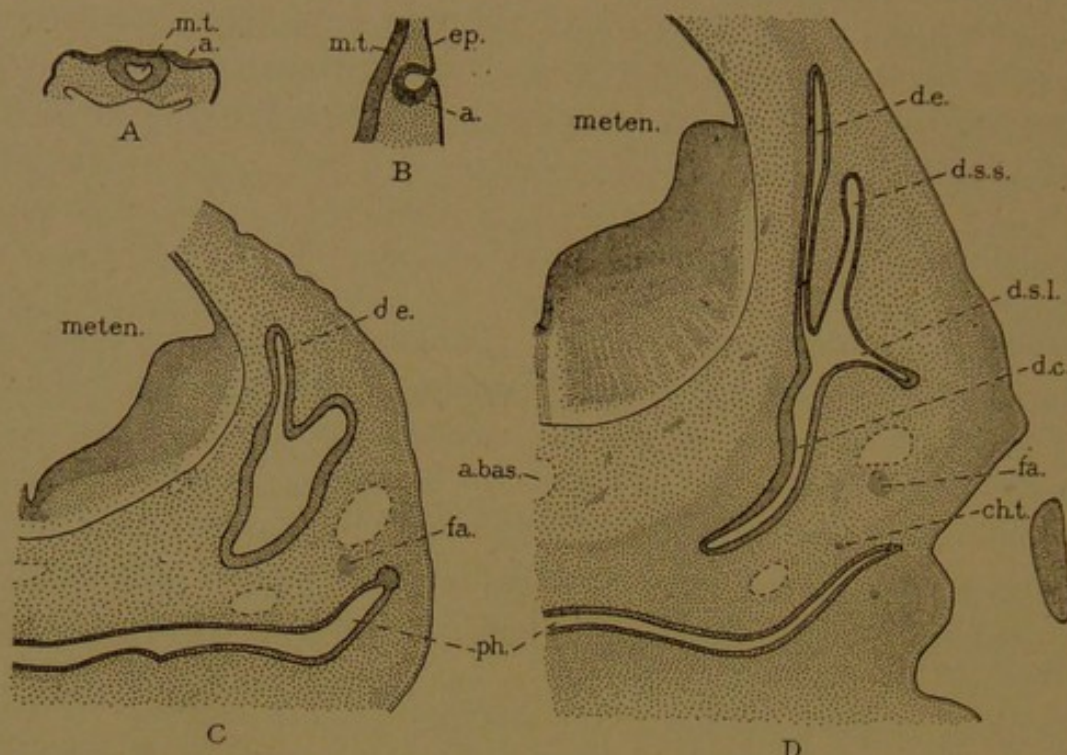


FIG. 471.—SECTIONS OF RABBIT EMBRYOS TO SHOW THE DEVELOPMENT OF THE EAR. $\times 9$. A, 9 days, 3.8 mm.; B, 10 days, 3.4 mm.; C, 12½ days, 7.5 mm.; D, 14 days, 10 mm. a., ectodermal epithelium which forms the membranous internal ear; a. bas., basilar artery; ch. t., chorda tympani; d. c., cochlear duct; d. e., endolymphatic duct; d. s. l., lateral semicircular duct; d. s. s., superior semicircular duct; ep., epidermis; fa., facial nerve; meten., metencephalon; m. t., medullary tube; ph., pharynx.

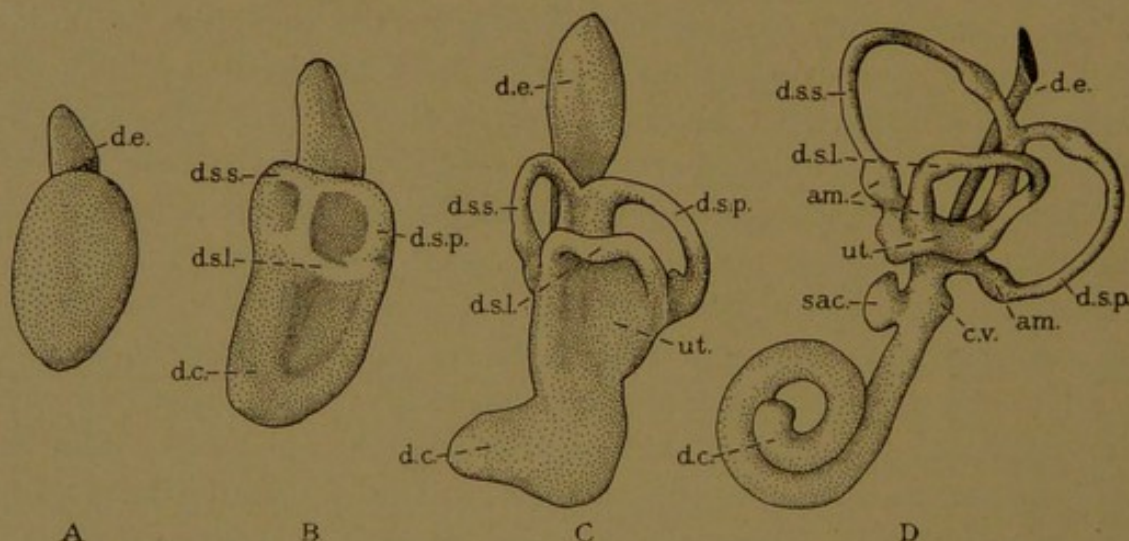


FIG. 472.—LATERAL OR EXTERNAL SURFACES OF MODELS OF THE MEMBRANOUS PORTION OF THE LEFT INTERNAL EAR FROM HUMAN EMBRYOS. Different enlargements. (After His, Jr.)

A, from an embryo of 6.9 mm.; B, 10.2 mm.; C, 13.5 mm.; and D, 22 mm. am., ampulla; c. v., caecum vestibulare of d. c., cochlear duct; d. e., endolymphatic duct; d. s. l., d. s. p., and d. s. s., lateral, posterior, and superior semicircular ducts; sac., saccus; ut., utricle.

While the formation of the semicircular ducts is occurring in the upper part of the auditory vesicle, the lower portion elongates and its end becomes coiled, eventually making two and a half revolutions. The coiled

tube is the *ductus cochlearis*; its distal end is the *cæcum cupulare*, and at its proximal end is the *cæcum vestibulare* (Fig. 472, D, c. v.). A dilated sac formed at its proximal or upper end, opposite the *cæcum vestibulare*, is known as the *sacculus*; in the adult the connection between the *sacculus* and *ductus cochleæ* is relatively narrow, and is called the *ductus reuniens* (Fig. 481). The portion of the original vesicle between the *sacculus* and *utricle*, from which the endolymphatic duct arises, becomes a comparatively slender tube, the *ductus utriculo-saccularis* (Fig. 481).

The ectodermal vesicle thus produces a complex system of connected epithelial ducts, namely the superior, posterior, and lateral semicircular

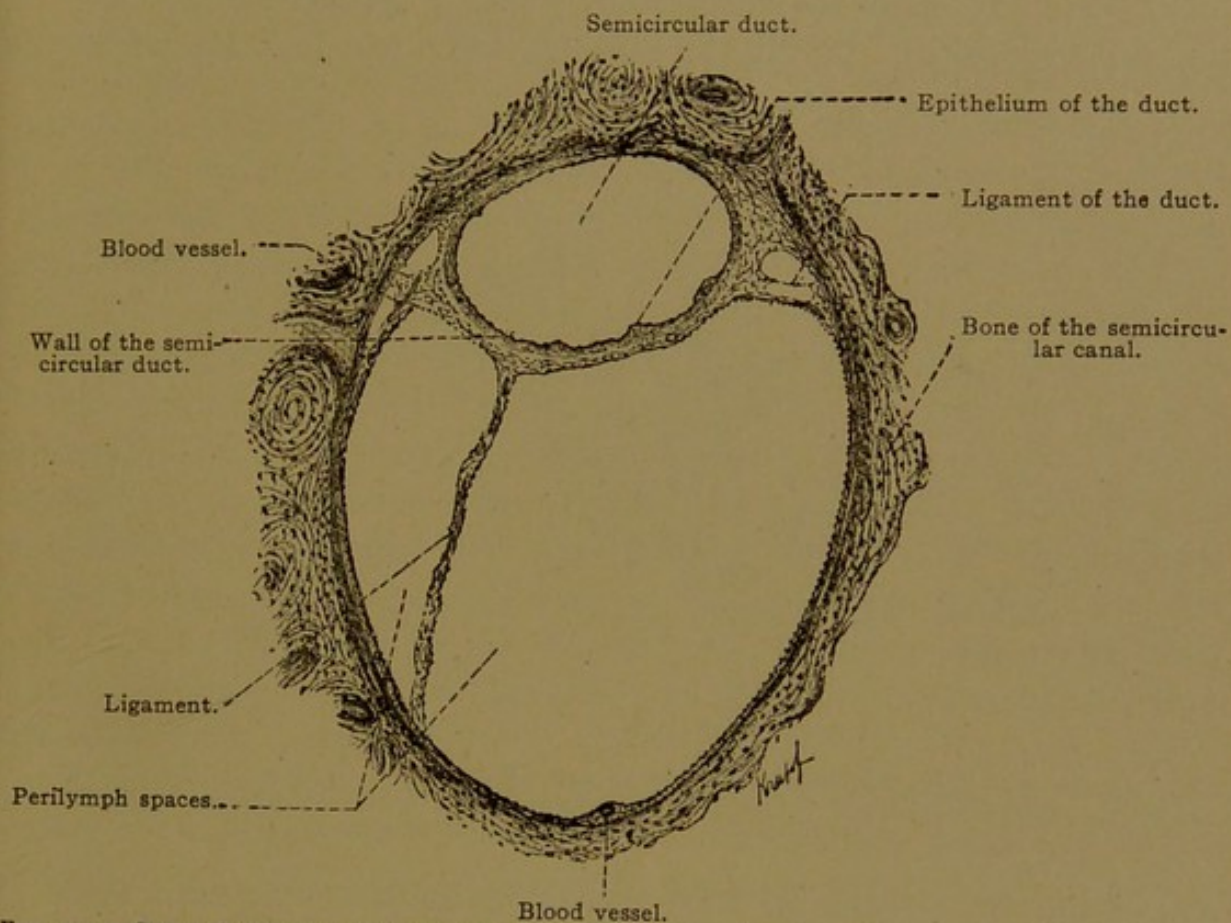


FIG. 473.—CROSS SECTION OF A SEMICIRCULAR DUCT AND THE ADJACENT PERILYMPH SPACES TOGETHER WITH THE SEMICIRCULAR CANAL OF BONE IN WHICH THEY ARE LODGED. From a human adult. $\times 50$. (Böhm and von Davidoff.)

ducts; the utricle, and utriculo-saccular duct with the endolymphatic duct connected with it; the *sacculus*, *ductus reuniens* and *ductus cochleæ*. They all contain a fluid called *endolymph*. The acoustic nerve sends branches between the epithelial cells in certain parts of the ducts. Round areas of neuro-epithelium, in which the nerves terminate, are called *maculæ acusticæ*; there is one in the *sacculus* and another in the utricle. Elongated areas are *cristæ*, and there is one in each of the three ampullæ. The axis, or *modiolus*, about which the cochlear duct is wound, contains the nerves which send terminal fibers to the *spiral organ* of the adjoining epithelium. In this they form a line of terminations along the medial wall of the cochlear duct, following its windings from base to cupola.

The mesenchyma immediately surrounding the entire system of ducts becomes mucoid in appearance, and cavities lined with mesenchymal epithelium are formed within it. They contain a tissue fluid called *perilymph*. Around the semicircular ducts the perilymph spaces are so large that the tissue between them is reduced to strands as shown in Fig. 473; these are sometimes called ligaments. The perilymph spaces around the semicircular ducts are irregularly arranged and communicate with one another at various points; they connect also with the perilymph cavities of the *vestibule*, which is the central part of the internal ear, from which the semicircular, cochlear and endolymphatic ducts proceed outward. All of these structures are surrounded by spaces, connecting with those of the vestibule which enclose the sacculus and utriculus. At the distal

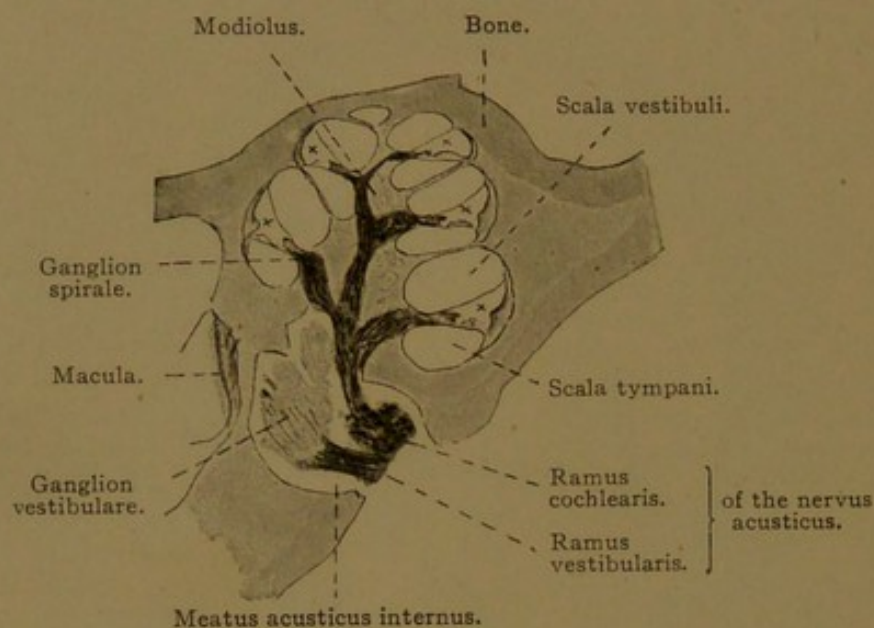


FIG. 474.—HORIZONTAL SECTION OF THE COCHLEA OF A KITTEN. $\times 8$.
The winding ductus cochlearis, x, crossed the plane of section five times. Above it in every case is the *scala vestibuli*, and below it is the *scala tympani*.

end of the endolymphatic duct, the spaces communicate with those of the cerebral arachnoid, and the perilymph mingles with cerebro-spinal fluid.

Around the cochlear duct the perilymph spaces form a single tube. Starting from the vestibule, it ascends to the cupola, following the windings of the cochlear duct, to which it is closely applied. It is known as the *scala vestibuli* (*i.e.*, "staircase of the vestibule," from which it passes out). At the apex of the cochlea it turns and becomes the descending *scala tympani*, which ends blindly at the base of the cochlea, close against the wall of the tympanum. The two scalæ bear a constant relation to the coils of the cochlear duct. If the cochlea is so placed that its apex is upward, the *scala vestibuli* is always found on the upper side of the duct, and the *scala tympani* on the lower side, as shown in Fig. 474. In the body, the apex of the cochlea is directed forward and outward.

The temporal bone develops from the mesenchyma surrounding the

ducts and their perilymph spaces, so that when the *membranous labyrinth* which they form, is removed by maceration, the bone still contains a corresponding arrangement of cavities and canals. These constitute the *bony labyrinth*. Casts of it, made in soft metal, may be seen in all anatomical museums. Instead of subdivisions to correspond with the utriculus, sacculus, and utriculo-saccular duct, the bony labyrinth has a single space, already referred to as the *vestibule*. Into it the semicircular and cochlear canals open, together with the *aquæductus vestibuli* which contains the endolymphatic duct.

The middle ear and external ear arise in connection with the first or spiracular gill cleft. In common with the other clefts, this includes an entodermal pharyngeal outpocketing (Fig. 206, p. 217) and an ectodermal depression (Fig. 205, *sp.*). At an early stage these meet one another and fuse, but later, the primary epithelial connection breaks down, and mesenchyma intervenes. In the adult, however, the two parts are still close together, being separated by only the drum membrane, which is covered on one side with ectoderm and on the other with entoderm.

The ectodermal groove becomes surrounded by several nodular elevations of skin, which coalesce in a definite manner to make the projecting *auricle* (pinna). Its depression deepens, becoming the *external acoustic meatus*, which extends inward to the *tympanic membrane*. The entodermal portion of the spiracular cleft becomes in the adult an elongated outpocketing of the pharynx, known as the *auditory tube* (Eustachian tube). As seen in the section Fig. 475, the tube is separated from the bottom of the meatus by a very thin layer of mesenchyma, which is later included in the drum membrane.

In the mesenchyma behind the spiracular cleft, a chain of three small bones (the *malleus*, *incus*, and *stapes*) develops; it extends from the meatus to the vestibule. The bony wall of the vestibule is deficient at the small oval area where the stapes reaches it, so that the chain of bones comes directly in contact with the fibrous covering of the perilymph space. This area of contact is the *fenestra vestibuli* (*i.e.*, window of the vestibule). When the chain of bones vibrates back and forth, the motion of the stapes is transmitted through the fenestra vestibuli to the perilymph, and waves may pass up the scala vestibuli and down the scala tympani, stimulating the nerves of hearing in the cochlear duct. The blind termination of the scala tympani rests against the lateral wall of the vestibule, where also the bone fails to develop; the round *fenestra cochleæ* is thus produced. Its fibrous membrane may yield somewhat to the perilymph waves, thus relieving tension in the cochlea.

In Fig. 475 the fragments of the chain of bones together with neighboring nerves are imbedded in a mass of mesenchyma. In a later stage the outer end of the auditory tube expands, filling all the space between

the vestibule and the bottom of the meatus. Thus it forms the *tympanic cavity*. It encounters the chain of bones and the chorda tympani, and wraps itself around them so that they lie in its folds or *plicæ*. Thus all structures which extend into the tympanic cavity, or appear to cross it, are covered with a layer of entodermal epithelium derived from the auditory tube. The original contact between the ectoderm and entoderm of the spiracular cleft forms only an insignificant part of the tympanic membrane. The latter becomes greatly enlarged, extending somewhat along the upper surface of the ectodermal auditory meatus. The portion of the malleus lying near it becomes imbedded in its mesenchymal layer,

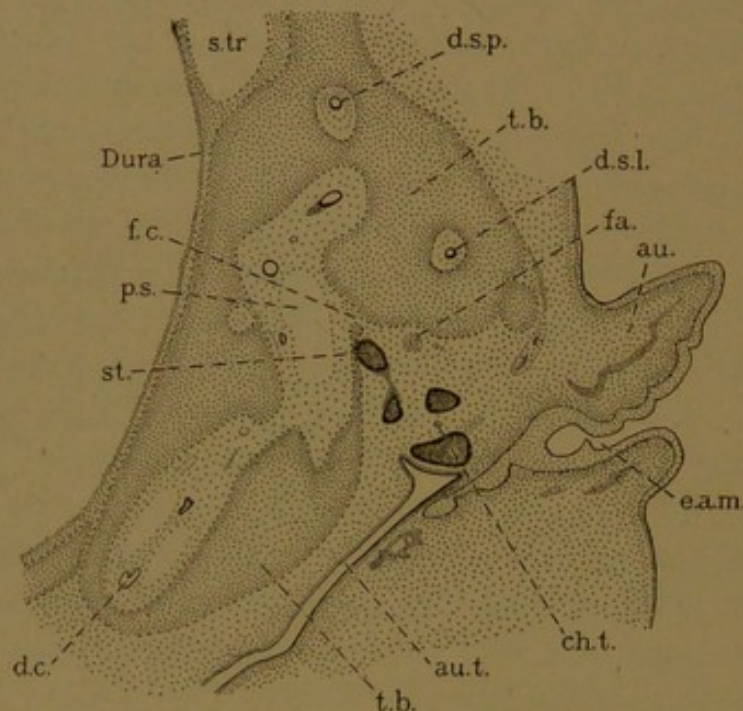


FIG. 475.—HORIZONTAL SECTION THROUGH THE EAR OF A HUMAN EMBRYO OF ABOUT 5 CMS.
 au., Auricle; au.t., auditory tube; ch.t., chorda tympani; d.c., cochlear duct; d.s.l., and d.s.p., lateral and posterior semicircular ducts; e.a.m., external acoustic meatus; fa., facial nerve; f.c., fenestra cochleæ; p.s., perilymphatic space; st., stapes; s.tr., transverse sinus; t.b., temporal bone.

and its inner entodermal layer is made by the expansion of the tympanic cavity. The enlargement of the tympanic cavity continues after birth, when it invades the spaces formed within the mastoid part of the temporal bone.

In spite of these modifications the course of the spiracular cleft is retained in the adult. The ectodermal depression and its surrounding elevations constitute the external ear; the pharyngeal outpocketing persists as the auditory tube and the tympanic cavity of the middle ear. It opens freely into the pharynx and contains air.

SACculus, UTRICULUS, AND SEMICIRCULAR DUCTS.

The walls of all these structures consist of three layers. On the outside there is *connective tissue* with many elastic fibers and occasional pig-

ment cells. This is followed by a narrow *basement membrane* said to form small nodular elevations toward the third and innermost layer, the simple flat *epithelium*. Near the maculæ and cristæ the connective tissue and the basement membrane become thicker, and the epithelial cells are columnar with a cuticular border. In the neuro-epithelium of these areas there are two sorts of cells, sustentacular and hair cells. The *sustentacular* or *fiber cells* extend clear across the epithelium and are somewhat expanded at both ends; they contain oval nuclei. *Hair cells*, which receive the stimuli, are columnar cells limited to the superficial half of the epithelium; they have large spherical nuclei near their rounded basal ends, and a clump of fine agglutinated filaments projecting from their free surface. The nerves lose their myelin as they enter the epithelium and ascend to the bases of the hair cells. There they bend laterally, forming a dense network which appears as a granular layer in ordinary preparations; the granules are optical sections and varicosities. The horizontal fibers terminate like their occasional branches, by ascending between the hair cells, on the sides of which they form pointed free endings. They do not reach the free surface of the epithelium. This surface is covered by a continuation of the cuticula, a "membrana limitans," which is perforated by the hairs. Over the two maculæ there is a soft substance containing very many crystals of calcium carbonate, 1-15 μ long, which are named *otoconia*. (Large "ear stones" of fishes are called otoliths.) Over the cristæ of the semicircular ducts there is a gelatinous substance, transparent in fresh preparations, but coagulated and rendered visible by reagents.

The "ligaments" of the ducts, the thin periosteum of the bony semicircular canals, and the perilymph spaces lined with mesenchymal epithelium are seen in Fig. 473.

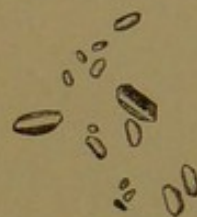

FIG. 476.—OTOCONIA FROM THE SACCULUS OF AN INFANT. $\times 560$.

COCHLEA.

The relation between the ductus cochleæ and the scalæ tympani and vestibuli is shown in Fig. 474. The ductus is triangular in cross section, being bounded on its peripheral surface by the thick periosteum of the bony wall of the cochlea; on its apical surface (toward the cupola) by the *membrana vestibularis* (Reissner's membrane); and on its basal or medial surface by the *lamina spiralis*. These three walls may be described in turn.

The peripheral wall of the cochlear duct is formed by the dense fibrous periosteum attached to the bone, together with a large mass of looser tissue crescentic in cross section, the *ligamentum spirale* (Fig. 477). The spiral ligament is covered by a layer of cuboidal epithelial cells belonging

to the cochlear duct. Close beneath the epithelium there are blood vessels which are said to give rise to the endolymph. The thick plexus which they form is described as a band, the *stria vascularis*, which terminates more or less distinctly with the *vas prominens*. The latter occupies a low elevation of tissue which has its maximum development in the basal coil of the cochlea (Fig. 477).

The apical wall, or *membrana vestibularis*, consists of a thin layer of connective tissue bounded on one side by the mesenchymal epithelium of the scala vestibuli, and on the other by the simple flattened ectodermal epithelium of the cochlear duct.

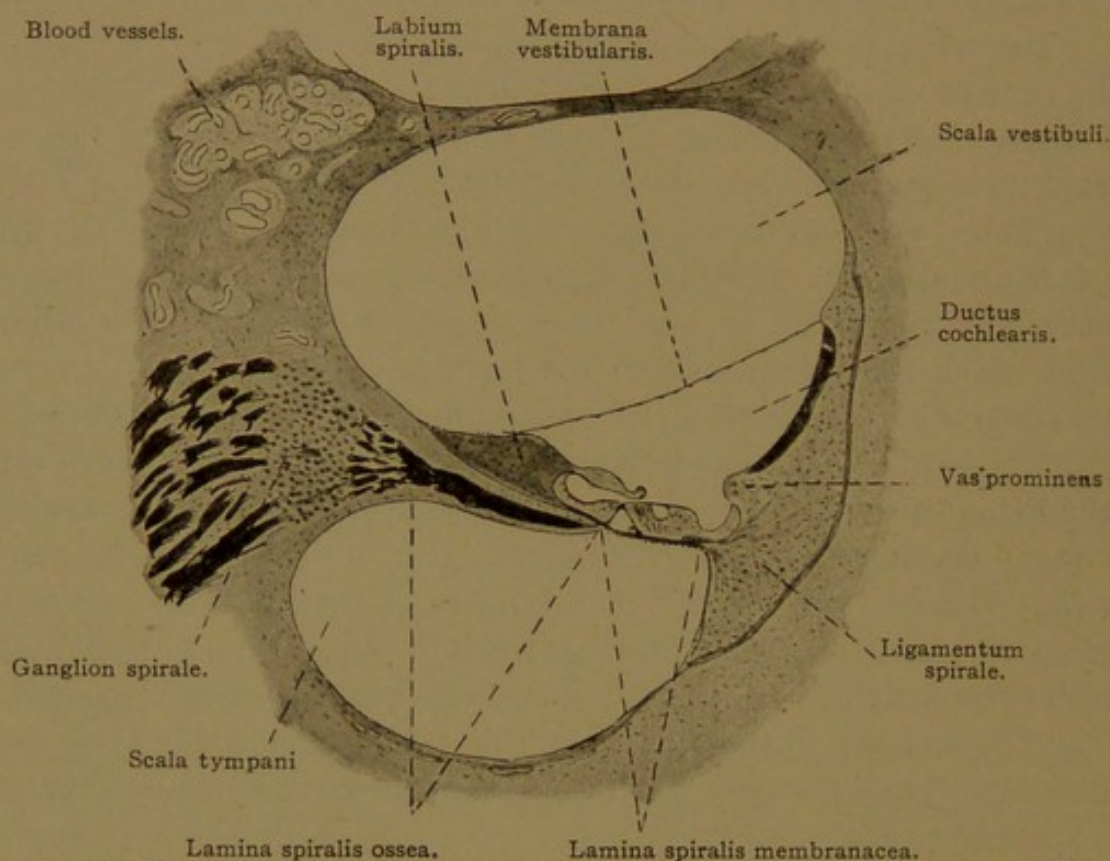


FIG. 477.—THE PORTION OF FIGURE 474 MARKED "SCALA VESTIBULI" AND "SCALA TYMPANI." $\times 50$.

The basal wall or *lamina spiralis* extends outward from the modiolus to the bony wall of the cochlea. Near the modiolus it lies between the two scalæ, but peripherally it is between the cochlear duct and the scala tympani. Toward the modiolus it contains a plate of bone perforated for the passage of vessels and nerves; this part is the *lamina spiralis ossea*. The peripheral portion is the *lamina spiralis membranacea*. Both parts are covered below by the mesenchymal epithelium of the scala tympani, and above by the epithelium of the cochlear duct, including its complex neuro-epithelium known as the *spiral organ* (of Corti).

Where the *membrana vestibularis* meets the osseous spiral lamina, there is an elevation of tough connective tissue called the *limbus spiralis* (Fig. 477). It consists of abundant spindle-shaped cells, and blends below with the periosteum of the spiral lamina. Superficially it produces irregularly

hemispherical papillæ covered with simple flat epithelium, found within the cochlear duct near the vestibular membrane. Further within the cochlear duct the papillæ give place to a single row of flat ridges or plates, directed peripherally. These are "Huschke's auditory teeth" (Fig. 480). Beneath them the limbus terminates abruptly in an overhanging *labium vestibulare*, which projects over an excavation—the *sulcus spiralis* (Fig. 478). The basal wall of the sulcus is the *labium tympanicum*, found at the peripheral edge of the osseous spiral lamina. As the epithelium of the limbus passes over the labium vestibulare into the sulcus, it becomes cuboidal. A remarkable non-nucleated structure projects from the labium

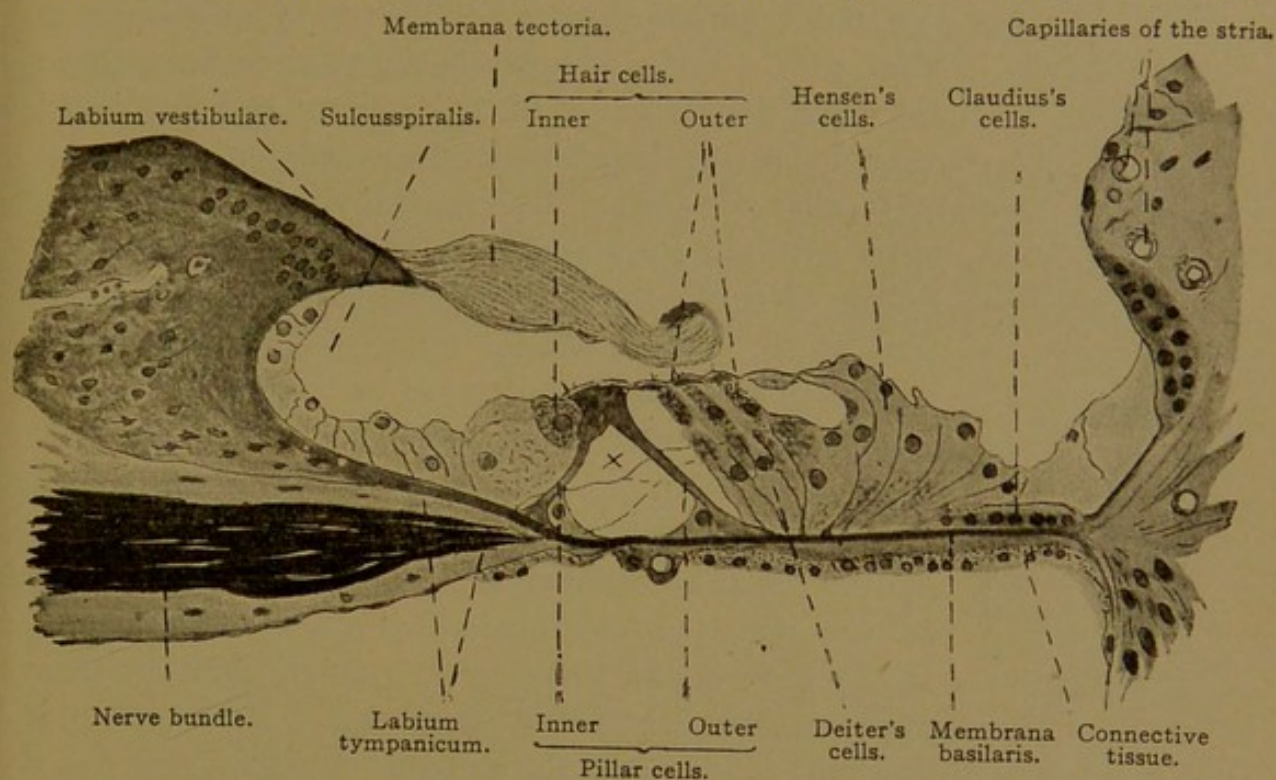


FIG. 478.—PORTION OF FIGURE 477. X 240. x, Intercellular "tunnel" traversed by nerve fibers.

vestibulare over the neuro-epithelium of the membranous spiral lamina. It is called the *membrana tectoria* and is considered to be a cuticular formation of the labial cells to which it is attached. Hardesty describes it as composed of "multitudes of delicate fibers of unequal length, embedded in a transparent matrix of a soft, collagenous semi-solid character, with marked adhesiveness" (Amer. Journ. Anat., 1908, vol. 8, pp. 109-179).

The lamina spiralis membranacea, or lamina basilaris, consists of four layers. The *mesenchymal epithelium* of the scala tympani is followed by a layer of delicate *connective tissue*, prolonged from the periosteum of the scala. Its spindle cells are at right angles with the fibers of the overlying *membrana basilaris*. This membrane, which is beneath the *epithelium* of the cochlear duct, consists of coarse straight fibers extending from the labium tympanicum to the ligamentum spirale. They cause it to appear finely striated (Fig. 479). Peripherally (beyond the bases of the outer pillar cells) the fibers are thicker, and are called "auditory strings"; they are

shortest in the basal part of the cochlea and longest toward the apex, corresponding in length with the basal layer of the cochlear duct. These fibers have been thought to vibrate and assist in conveying sound waves to the nerves, but theories which assume that the basilar membrane is a "vibrating mechanism" are considered untenable by Hardesty; he finds it more probable that the membrana tectoria vibrates and transmits stimuli to the neuro-epithelium.

The epithelial cells covering the basilar layer occur in rows of highly modified forms, which extend up and down the cochlear duct, constituting the *spiral organ* (organ of Corti). Next to the cuboidal epithelium of the sulcus spiralis there is a single row of *inner hair cells* (Fig. 480). These are short columnar cells which do not reach the bottom of the epithelium; each has about forty long stiff hairs on its free surface. The inner hair cells are followed peripherally by two rows of *pillar cells*, the *inner* and *outer*, which extend the whole length of the cochlear duct. As seen in cross section they are in contact above, but are separated below by a triangular intercellular space or "tunnel," which is filled with soft intercellular substance. Thus they rest upon the basilar membrane in \wedge -form. Each pillar cell may be subdivided into a head, a slender body, and an expanded triangular base. The greater portion of each cell has been transformed into a resistant band, at the base of which, within the tunnel, there is a mass of protoplasm containing the nucleus. A protoplasmic

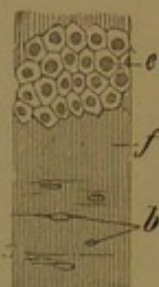


FIG. 479.—SURFACE VIEW OF THE LAMINA SPIRALIS MEMBRANACEA OF A CAT. $\times 240$. Drawn with change of focus.

e, Epithelium (cells of Claudius) of the ductus cochlearis in focus; f, fibers of the membrana basilaris in focus; b, nuclei of the underlying connective tissue.

sheath extends up from the base around the body of the cell. Dark round structures which may be found in the heads of the pillars, and at the foot of the outer ones, are not nuclei, but are "probably of horny nature." The heads of the pillars interlock. Both pillars produce "head-plates" directed outward, and so arranged that the plate from the inner pillar overlies that from the outer pillar (Fig. 480). Moreover, the round head of the outer pillar is fitted into a concavity in the head of the inner pillar, as shown in the figure.

On the peripheral side of the outer pillars there are several rows (usually four) of *outer hair cells* separated from one another by *sustentacular cells* (Deiter's cells). The outer hair cells have shorter hairs than the inner ones, and are characterized by the presence of "Hensen's spiral bodies," one of which occurs in the outer half of each cell. These bodies, shown as dark spots in Fig. 480, probably represent a trophospongium. The centrosomes of the hair cells are always in their upper ends. Like the inner hair cells, the outer ones do not extend to the basilar membrane, thus leaving unoccupied the communicating intercellular spaces between

the deeper portions of the sustentacular cells. These *Nuel's spaces* connect with the tunnel.

Deiter's sustentacular cells are slender bodies, each containing a stiff filament, and having at its free end a cuticular formation referred to as a "phalanx." The phalanges come between the outer hair cells, separating them from one another (Fig. 480), and the inner hair cells are similarly separated by short processes—the inner phalanges, derived from the inner pillars. (The inner phalanges are not shown in the figure.) The phalanges of Deiter's cells connect with one another, forming a trim reticular membrane. As a whole Deiter's cells resemble the pillar cells, but their transformation into stiff fibers has not proceeded so far; the cuticular border is comparable with the head plate.

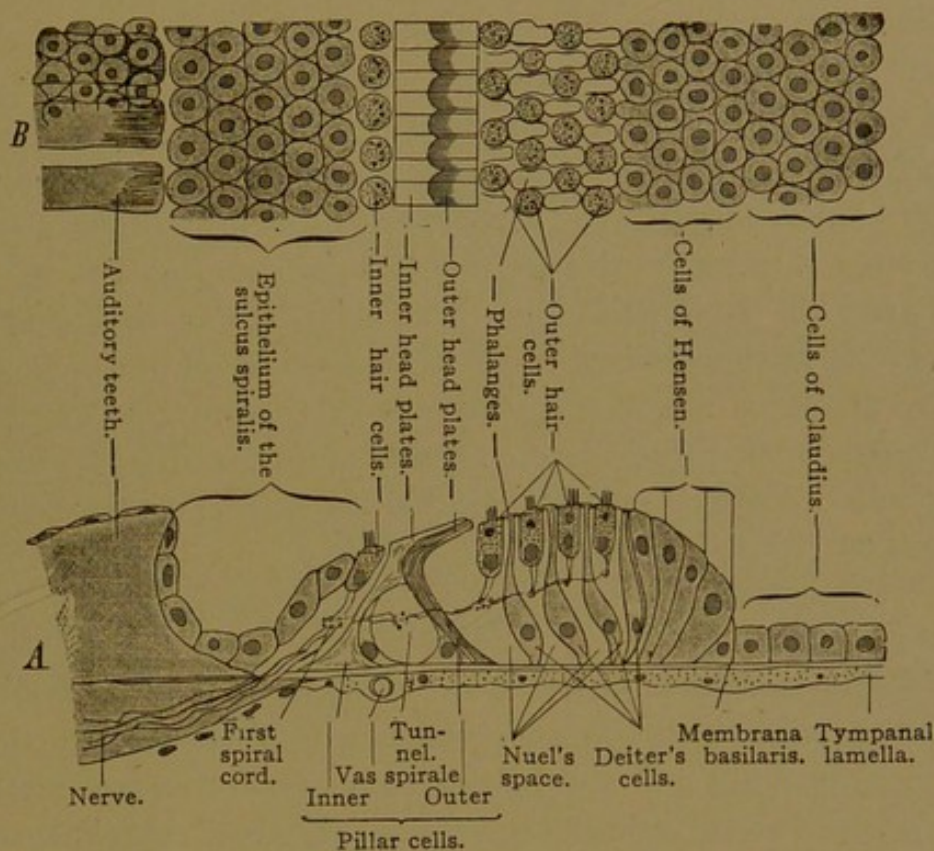


FIG. 480.—DIAGRAM OF THE STRUCTURE OF THE BASAL WALL OF THE DUCT OF THE COCHLEA.

A, View from the side. B, View from the surface. In the latter the free surface is in focus. It is evident that the epithelium of the sulcus spiralis, lying in another plane, as well as the cells of Claudius, can be seen distinctly only by lowering the tube. The membrana tectoria is not drawn. The spiral nerves are indicated by dots.

The most peripheral of the sustentacular or Deiter's cells are followed by elongated columnar cells (cells of Hensen), which gradually shorten, and are succeeded by the low "cells of Claudius" which extend to the limit of the membrana basilaris. In both the columnar and the low forms there are single stiff filaments which are less developed than in the sustentacular cells. The centrosomes of all these cells lie near their free surfaces. Beyond the basilar membrane the epithelium is continued over the ligamentum spirale as a layer of cells with branching basal processes extending deep into the underlying tissue.

NERVES OF THE LABYRINTH.

The *acoustic nerve* is a purely sensory nerve passing between the pons and internal ear through a bony canal, the *internal acoustic meatus*. It is divided into vestibular and cochlear portions (Fig. 474). The *vestibular nerve* proceeds from the *vestibular ganglion* and has four branches—the *utricle nerve* and the *superior, lateral, and posterior ampullary nerves*; according to Streeter (Amer. Journ. Anat., 1906, vol. 6, pp. 139-165) it produces also the branch to the sacculus, usually regarded as derived from the cochlear nerve. If this is true, the cochlear nerve supplies only the spiral organ of Corti. The ganglion of the cochlear nerve is lodged within the modiolus at the root of the lamina spiralis, and is known as the *spiral ganglion* (Figs. 474 and 477). The ganglion cells remain bipolar, like those of embryonic spinal ganglia. They are surrounded by connective tissue capsules; and their neuraxons and single peripheral dendrites receive myelin sheaths not far from the cell bodies.

The peripheral fibers extend through the lamina spiralis ossea, within which they form a wide-meshed plexus, and after losing their myelin they emerge from its outer border in the labium tympanicum through the *foramina nervosa*. In continuing to the spiral organ they curve in the direction of the cochlear windings, thus producing spiral strands. Those nearest the modiolus are on the axial side of the pillar cells; the middle ones are between the pillars, in the tunnel; and the outer ones are beyond the pillar cells. From these bundles, delicate fibers pass to the hair cells, on the sides of which they terminate.

VESSELS OF THE LABYRINTH.

The *internal auditory artery* is a branch of the basilar artery. It arises in connection with branches which are distributed to the under side of the cerebellum and the neighboring cerebral nerves, and passes through the internal acoustic meatus to the ear. It divides into vestibular and cochlear branches (Fig. 481). The *vestibular artery* supplies the vestibular nerve and the upper lateral portion of the sacculus, utricle and semicircular ducts. The *cochlear artery* sends a vestibulo-cochlear branch to the lower and medial portion of the sacculus, utricle, and ducts. This branch also supplies the first third of the first turn of the cochlea. The capillaries formed by the vestibular branches are generally wide meshed, but near the maculae and cristae the meshes are narrower. The terminal portion of the cochlear artery enters the modiolus and forms three or four spirally ascending branches. These give rise to about thirty radial branches distributed to three sets of capillaries (Fig. 482); 1, those to the spiral ganglion; 2, those to the lamina spiralis; and 3, those to the outer walls of the scala and the stria vascularis of the cochlear duct.

The *veins* of the labyrinth form three groups (Fig. 481). 1. The *vena aquæductus vestibuli* receives blood from the semicircular ducts and a part of the utricle. It passes toward the brain in a bony canal along with the ductus endolymphaticus, and empties into the superior petrosal sinus. 2. The *vena aquæductus cochleæ* receives blood from parts of the utricle, sacculus and cochlea; it passes through a bony canal to the internal jugular vein. Within the cochlea it arises, as shown in Fig. 482, from

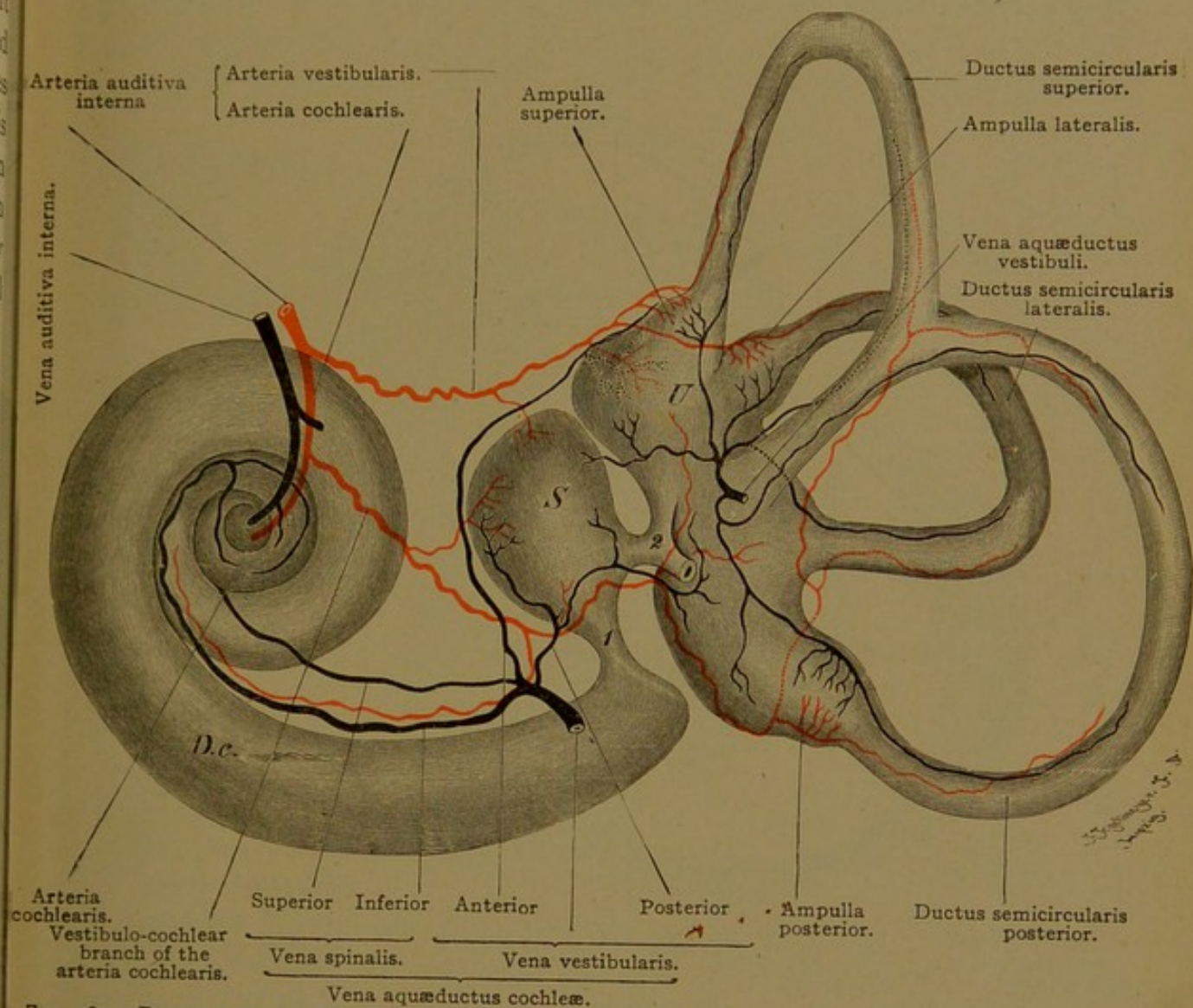


FIG. 481.—DIAGRAM OF THE BLOOD VESSELS OF THE RIGHT HUMAN LABYRINTH. MEDIAL AND POSTERIOR ASPECT. D, c., Ductus cochlearis; S., sacculus; U., utricle; 1, ductus reuniens; 2, ductus utriculo-saccularis. The saccus endolymphaticus is cut off.

small vessels including the *vas prominens* (a) and the *vas spirale* (b). Branches derived from these veins pass toward the modiolus. (There are no vessels in the vestibular membrane of the adult, and the vessels in the wall of the scala tympani are so arranged that only veins occur in the part toward the membranous spiral lamina; thus the latter is not affected by arterial pulsation.) Within the modiolus the veins unite in an *inferior spiral vein*, which receives blood from the basal and a part of the second turns of the cochlea, and a *superior spiral vein* which proceeds from the

apical portion. These two spiral veins unite with vestibular branches to form the vena aquæductus cochleæ (Fig. 481). 3. The *internal auditory vein* arises within the modiolus from the veins of the spiral lamina; these anastomose with the spiral veins (Fig. 482). It receives branches also from the acoustic nerve and from the bones, and empties "in all probability, into the vena spinalis anterior."

Lymphatic spaces within the internal ear are represented by the perilymph spaces, which communicate through the aquæductus cochleæ with

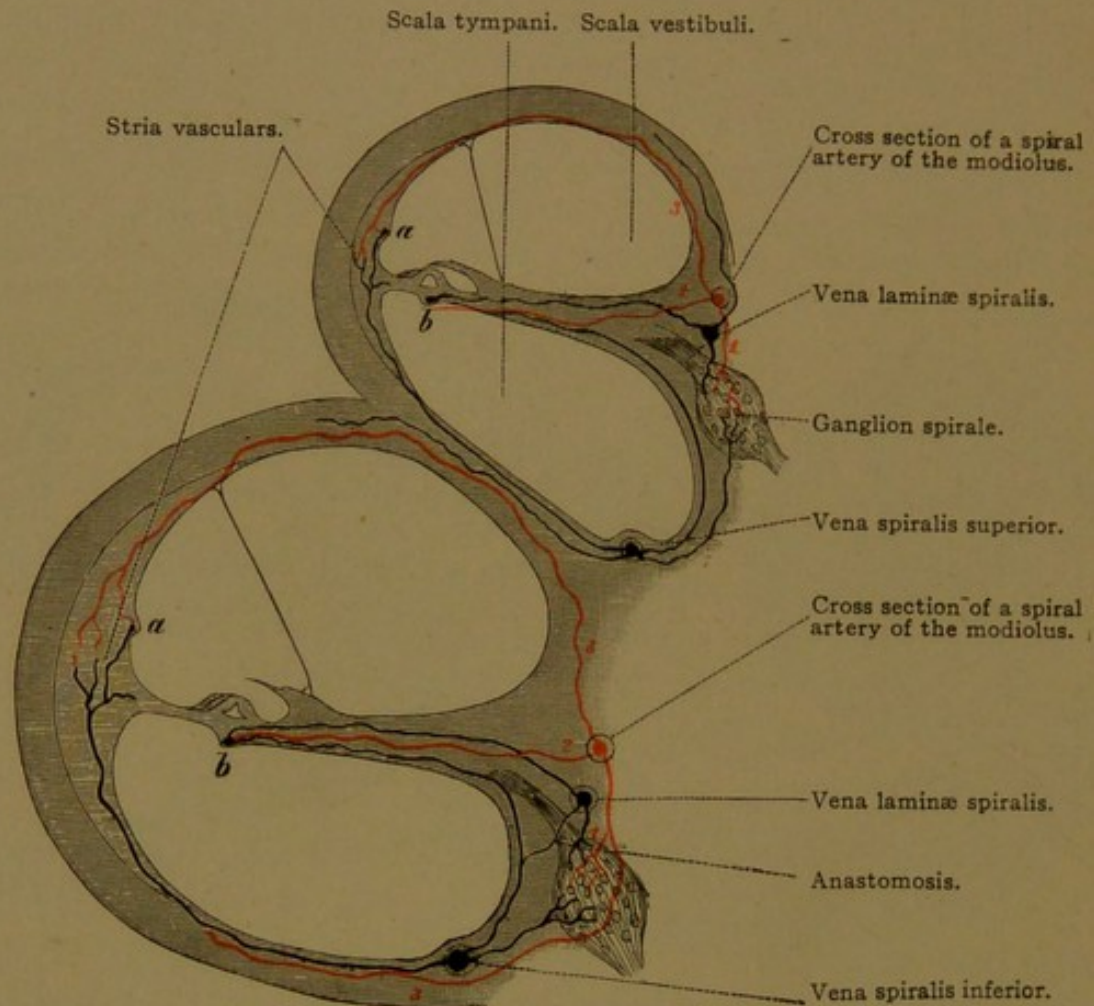


FIG. 482.—DIAGRAM OF A SECTION OF THE FIRST (BASAL) AND SECOND TURNS OF THE COCHLEA.
a, Vas prominens; b, vas spirale.

the arachnoid space; the connecting structure, or "ductus perilymphaticus," is described as a lymphatic vessel. The *saccus endolymphaticus*, which is the dilated distal end of the endolymphatic duct, is in contact with the dura, and there are said to be openings between it and the subdural space. In the internal ear perivascular and perineural spaces are found, and they probably connect with the arachnoid spaces.

MIDDLE EAR.

The *tympanic cavity*, which contains air, is lined with a *mucous membrane* closely connected with the surrounding periosteum. It consists of

a thin layer of connective tissue, covered generally with simple cuboidal epithelium. In places the epithelial cells may be flat, or tall with nuclei in two rows. Cilia are sometimes widely distributed and are usually to be found on the floor of the cavity. In its anterior part, small alveolar mucous glands occur very sparingly. Capillaries form wide-meshed networks in the connective tissue, and lymphatic vessels are found in the periosteum.

The *auditory tube* includes an *osseous part* toward the tympanum, and a *cartilaginous part* toward the pharynx. Its mucosa consists of fibrillar connective tissue, together with a ciliated columnar epithelium which

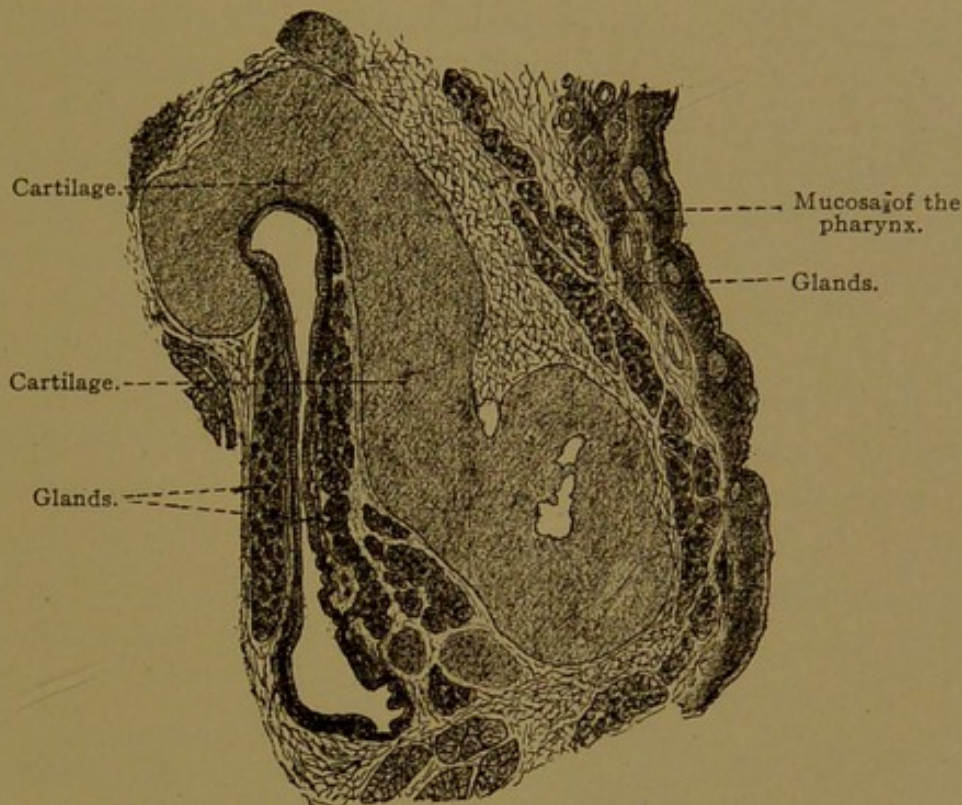


FIG. 483.—CROSS SECTION OF THE CARTILAGINOUS PART OF THE AUDITORY TUBE. $\times 12$.
(Böhm and von Davidoff.)

becomes stratified as it approaches the pharynx. The stroke of the cilia is toward the pharyngeal orifice. In the osseous portion, the mucosa is without glands and very thin; it adheres closely to the surrounding bone. Along its floor there are pockets containing air, the *cellulae pneumaticae*. In the cartilaginous part the mucosa is thicker; near the pharynx it contains many mucous glands (Fig. 483). Lymphocytes are abundant in the surrounding connective tissue, forming nodules near the end of the tube, which blend with the pharyngeal tonsil. The cartilage, which only partly surrounds the auditory tube, is hyaline near its junction with the bone of the osseous portion; it may contain here and there coarse fibers which are not elastic. Toward the pharynx the matrix contains thick nets of elastic tissue, and the cartilage is consequently elastic.

EXTERNAL EAR.

Between the middle ear and the external ear is the *tympanic membrane*, which consists, from without inward, of the following *strata*: the *cutaneum*, *radiatum*, *circulare* and *mucosum* (Fig. 484). The stratum cutaneum is a thin skin without papillæ in its corium, except along the

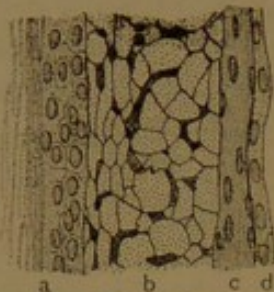

FIG. 484.—CROSS SECTION OF THE MEMBRANA TYMPANI BELOW THE MANUBRIUM. $\times 450$. (After K  lliker.)

a, Stratum cutaneum (showing the corneum and germinativum); b, stratum radiatum, its fibers cut across; c, stratum circulare; d, stratum mucosum.

handle or *manubrium* of the malleus. There it is a thicker layer, containing the vessels and nerves which descend along the manubrium and spread from it radially. In addition to the venous plexus which accompanies the artery in that situation, there is a plexus of veins at the periphery of the membrane, receiving tributaries from both the stratum cutaneum and the less vascular stratum mucosum. The radiate and circular strata consist of compact bundles of fibrous and elastic tissue, arranged so as to suggest tendon. The fibers of the radial layer blend with the perichondrium of the hyaline cartilage covering the manubrium.

Peripherally the fiber layers form a fibro-cartilaginous ring which connects with the surrounding bone. The stratum mucosum is a thin layer of connective tissue covered with a simple non-ciliated flat epithelium

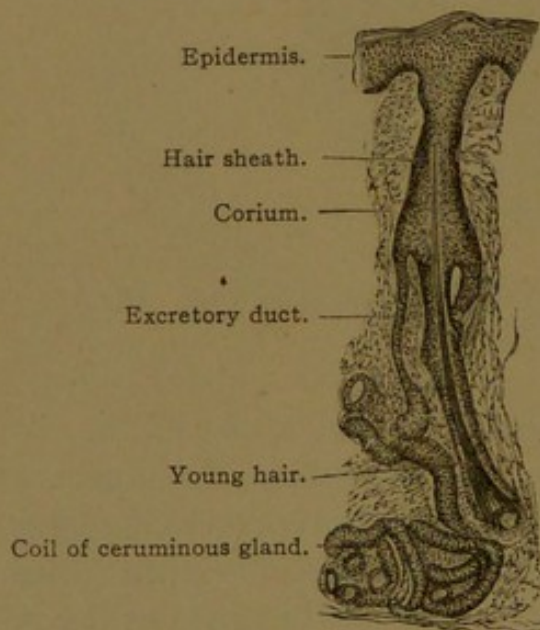


FIG. 485.—FROM A VERTICAL SECTION THROUGH THE SKIN OF THE EXTERNAL AUDITORY MEATUS OF AN INFANT. $\times 50$. The excretory duct opens into the hair follicle.

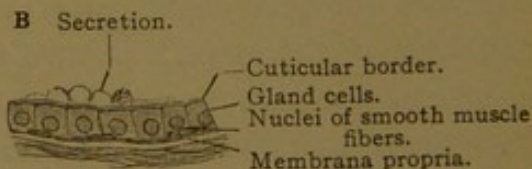
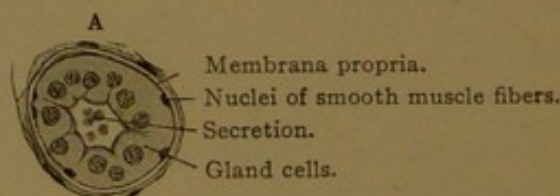


FIG. 486.—TUBES OF THE CERUMINOUS GLANDS. A, Cross section, from an infant; B, longitudinal section, from a boy 12 years old.

continuous with the lining of the tympanic cavity. Peripherally, in children, its cells may be taller and ciliated. As a whole the tympanic membrane is divided into *tense* and *flaccid* portions. The latter is a relatively small upper part in which the fibrous layers are deficient.

The *external acoustic meatus* is lined with skin continuous with the cutaneous layer of the tympanic membrane. In the deep or osseous portion the skin is very thin, without hair or glands except along its upper wall. There and in the outer or cartilaginous part, *ceruminous glands* are abundant. "They are branched tubulo-alveolar glands" (Huber) which in many respects resemble large sweat glands. Their ducts are lined with stratified epithelium. The coils consist of a single layer of secreting cells, general cuboidal, surrounded by smooth muscle fibers and a well-defined basement membrane. They differ from sweat glands in that their coils have a very large lumen, especially in the adult; and their gland cells, often with a distinct cuticular border, contain many pigment granules and fat droplets. Their narrow ducts in adults end on the surface of the skin close beside the hair sheaths; in children they empty into the sheaths (Fig. 485). It has not been shown that the ceruminous glands are more directly concerned in the production of cerumen than the sebaceous glands. The cerumen obviously is an oily rather than a watery secretion, and it contains fatty cells and pigment.

The cartilage of the external acoustic meatus and of the auricle is elastic.

NOSE.

The nasal cavities are formed by the invagination of a pair of epidermal thickenings similar to those which give rise to the lens and auditory vesicle. The pockets thus produced in the embryo are called "nasal pits" (Fig. 205, *n*, p. 216). Their external openings remain as the *nares* of the adult, but temporarily, from the third to the fifth month of embryonic life, they are closed by an epithelial proliferation. Each nasal pit acquires an internal opening, the *choana*, in the roof of the pharynx. The choanæ are at first situated near the front of the mouth, separated from one another by a broad *nasal septum* (Fig. 487). As the latter extends posteriorly, it is joined by the *palate processes* which grow toward it from the sides of the maxillæ. Thus the choanæ recede toward the back of the mouth while the embryonic condition of cleft palate is being removed (Fig. 488). The lateral walls of the nasal cavities produce three curved folds one above another; they are concave below, and in them the *conchæ* (turbinate bones) develop. The nasal mucosa covers these and extends into excavations in the adjacent bones, forming the sphenoid,

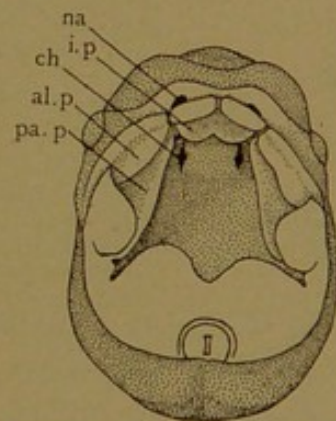


FIG. 487.—THE ROOF OF THE MOUTH OF A HUMAN EMBRYO OF 8 WEEKS. X 4. (After Kollmann.)

na, Nares; ch., choana; al. p., i. p., and pa. p., alveolar, intermaxillary, and palate processes.

maxillary, and frontal sinuses, and the ethmoidal cells. The boundary between the epithelium of the nasal pit and that of the pharynx early disappears, and the extent of each in the adult is uncertain. Presumably the olfactory neuro-epithelium is derived from the nasal pit. In man the olfactory region is limited to the upper third of the nasal septum and nearly the whole of the superior concha (Read). This *regio olfactoria* is covered by a yellowish-brown membrane, which may be distinguished macroscopically from the reddish mucosa of the *regio respiratoria*. The latter includes the remainder of the nose. The two regions may be considered in turn.

The *vestibule*, or cavity of the projecting cartilaginous portion of the nose, is a part of the respiratory region which is lined with a continuation

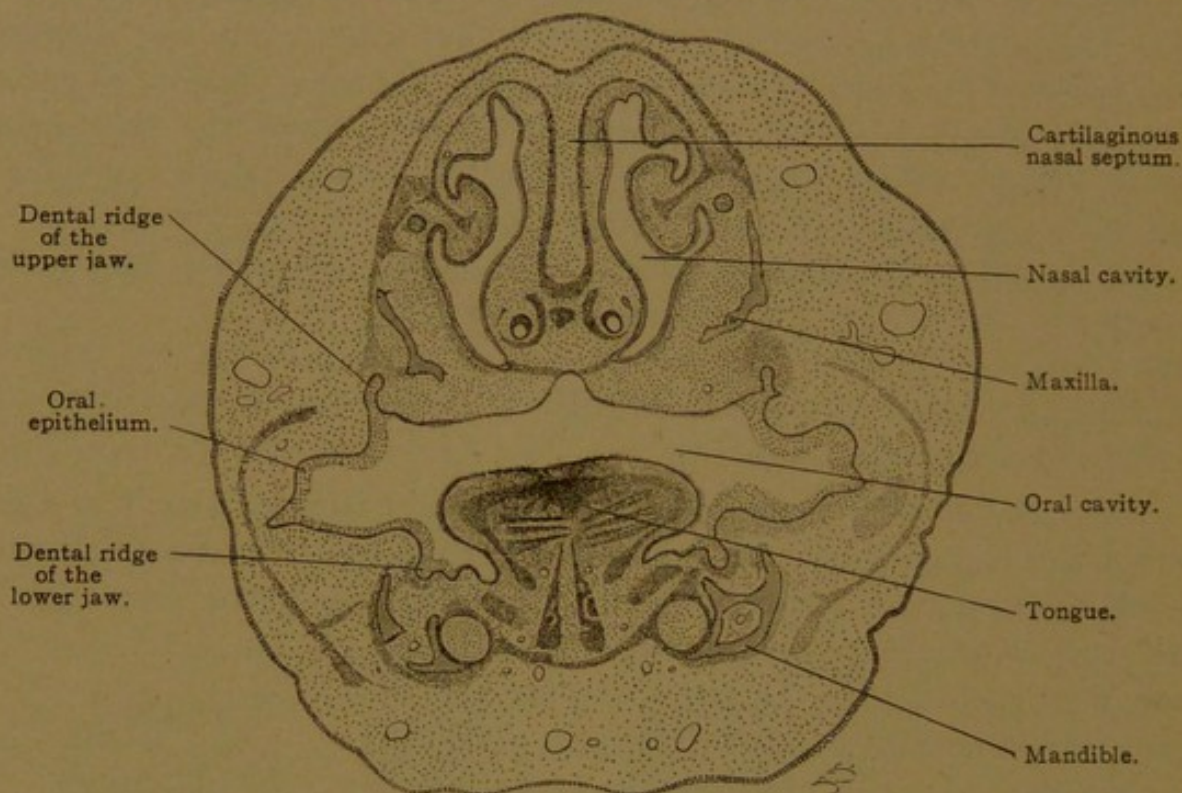


FIG. 488.—FRONTAL SECTION OF THE HEAD OF A 40-MM. SHEEP EMBRYO. $\times 15$.

The palate processes have united with the nasal septum. The conchæ are developing along the lateral walls of the nasal cavity. In the lower part of the nasal septum the vomero-nasal organs are seen as a pair of tubes, each of which is partly surrounded by a crescentic cartilage.

of the skin. Its stratified epithelium has squamous outer cells and rests upon a tunica propria with papillæ. It contains the sheaths of coarse hairs (*vibrissæ*) together with numerous sebaceous glands. The extent of the squamous epithelium is variable; frequently it is found on the middle concha, less often on the inferior concha.

The remainder of the respiratory mucosa consists of a pseudo-stratified epithelium with several rows of nuclei. It may contain few or many goblet cells. The tunica propria is well developed, being even 4 mm. thick on the inferior concha (Fig. 489). It consists of fibrillar tissue with many elastic elements, especially abundant in its deeper layers. Beneath the epithelium, it is thickened to form a homogeneous membrana propria,

perforated with small holes. Lymphocytes are present in variable quantity, sometimes forming solitary nodules and often entering the epithelium in great numbers. Branched alveolo-tubular mixed glands extend into the tunica propria. Their serous portions have intercellular secretory capillaries, and both mucous and serous cells contain a trophospongium. The glands often empty into funnel-shaped depressions, which are macroscopic on the inferior concha, and are lined with the superficial epithelium.

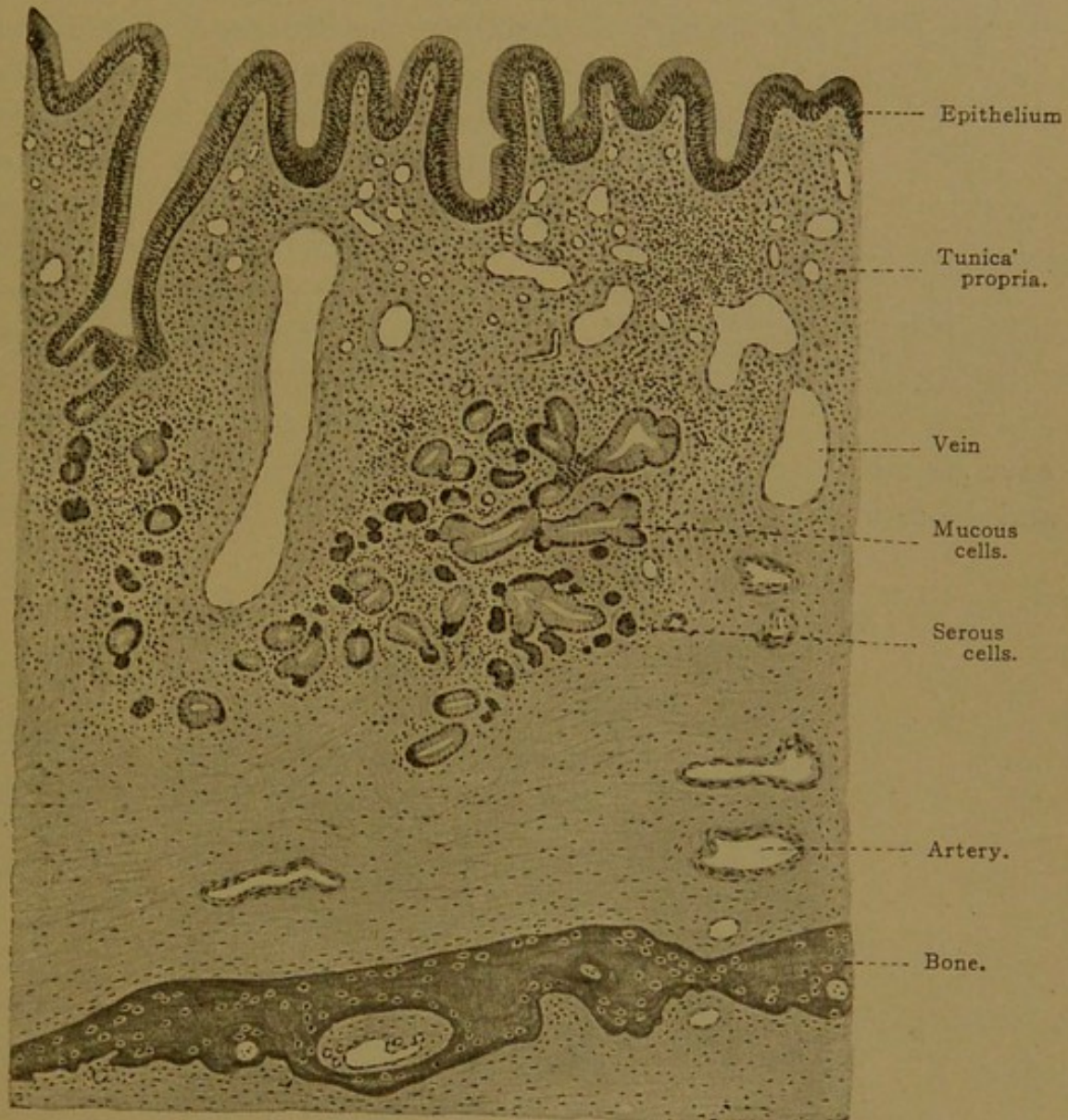


FIG. 489.—VERTICAL SECTION THROUGH THE MUCOSA OF THE INFERIOR CONCHA OF MAN. $\times 48$. On the left is a funnel-shaped depression receiving an excretory duct; near-by on the right is the section of a large vein.

The mucosa of the several paranasal sinuses is thin (-0.02mm.), with less elastic tissue and but few small glands. A pocket which extends into the lower part of the median septum has already been described as the *vomero-nasal organ* (Jacobson's organ). In man it is the rudimentary remnant of an important sense organ, supplied by special branches of the olfactory nerves and by the *nervus terminalis* (cf. p. 141). It is lined with a tall columnar epithelium, and contains, at least in the

cat, "sensory cells apparently identical with those of the olfactory mucosa." In man sensory cells are said to be lacking in the adult and in embryos older than five months.

In the *regio olfactoria* the mucosa includes a tunica propria and an *olfactory epithelium*. The latter consists of *sustentacular cells* and *olfactory cells*. The

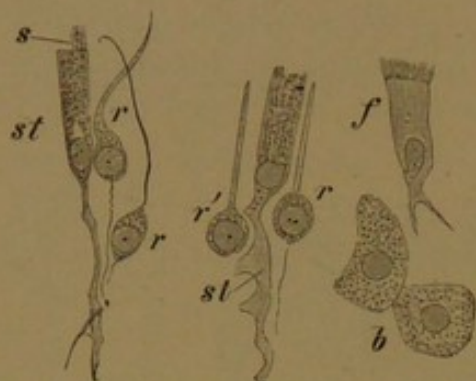


FIG. 490.—ISOLATED CELLS OF THE OLFACTORY MUCOSA OF A RABBIT. $\times 560$.

st, Supporting cells; s, extruded mucus resembling cilia; r, olfactory cells, from r' the lower process has been torn off; f, ciliated cell; b, cells of olfactory glands.

The superficial halves of the sustentacular cells are cylindrical, and contain yellowish pigment, together with small mucoid granules often arranged in vertical rows (Fig. 490). The more slender lower halves have dentate or notched borders, and branched basal ends which unite with those of neighboring cells, thus forming a protoplasmic network. Their nuclei, generally oval, are in one plane and in vertical sections they form a narrow "zone of oval nuclei" (Fig. 491). The olfactory cells generally

have round nuclei containing nucleoli. They occur at different levels and so form a broad "zone of round nuclei." From the protoplasm

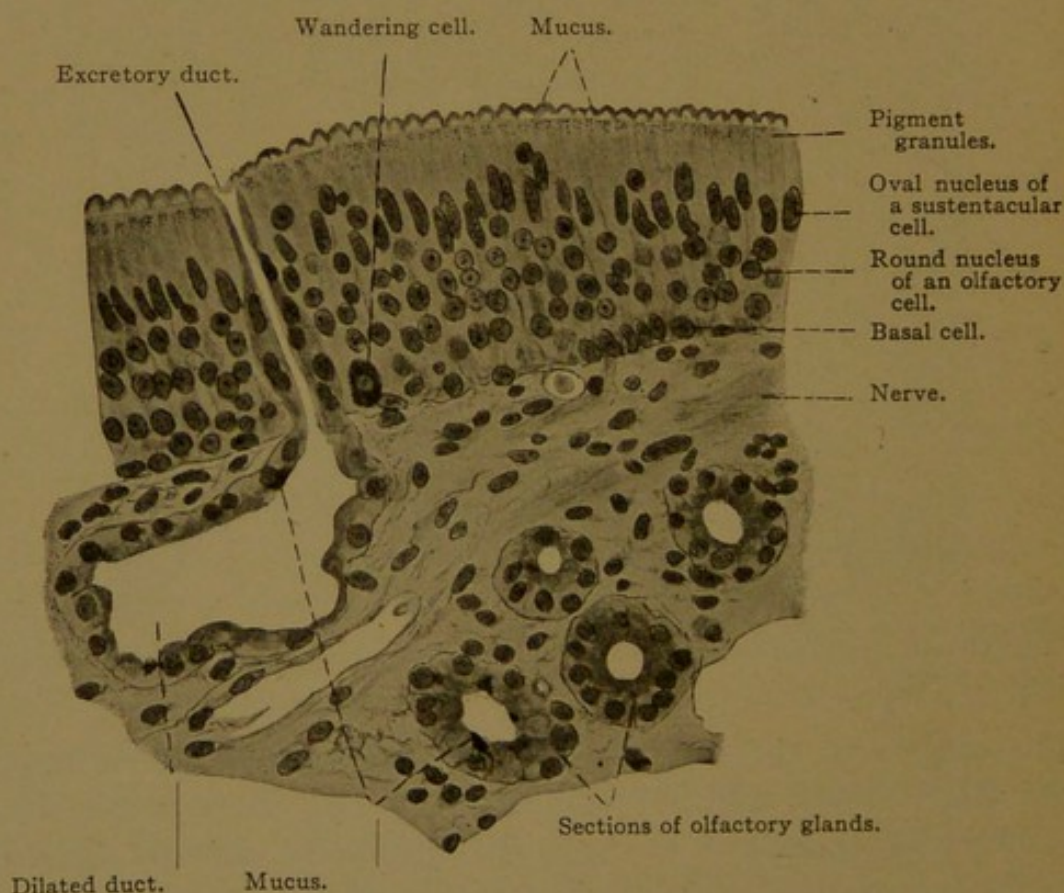


FIG. 491.—VERTICAL SECTION THROUGH THE OLFACTORY REGION OF AN ADULT. $\times 400$.

which is gathered immediately about the nucleus, each olfactory cell sends a slender cylindrical process toward the surface, where it ter-

minates in a variety of ways. It may end in a small knob-like swelling, or in a single slender spine; sometimes the terminal knob sends out a small cluster of divergent olfactory hairs or spines. Basally the olfactory cells pass directly into the axis cylinders of the olfactory nerves (Fig. 492). Thus they are ganglion cells, their basal processes being neuraxons. Cells intermediate between the olfactory and sustentacular forms may be found, and these are doubtless imperfectly developed sensory cells. At the free surface of the olfactory epithelium there are terminal bars, and small projecting strands of mucus, sometimes suggesting cilia (Fig. 490, s).

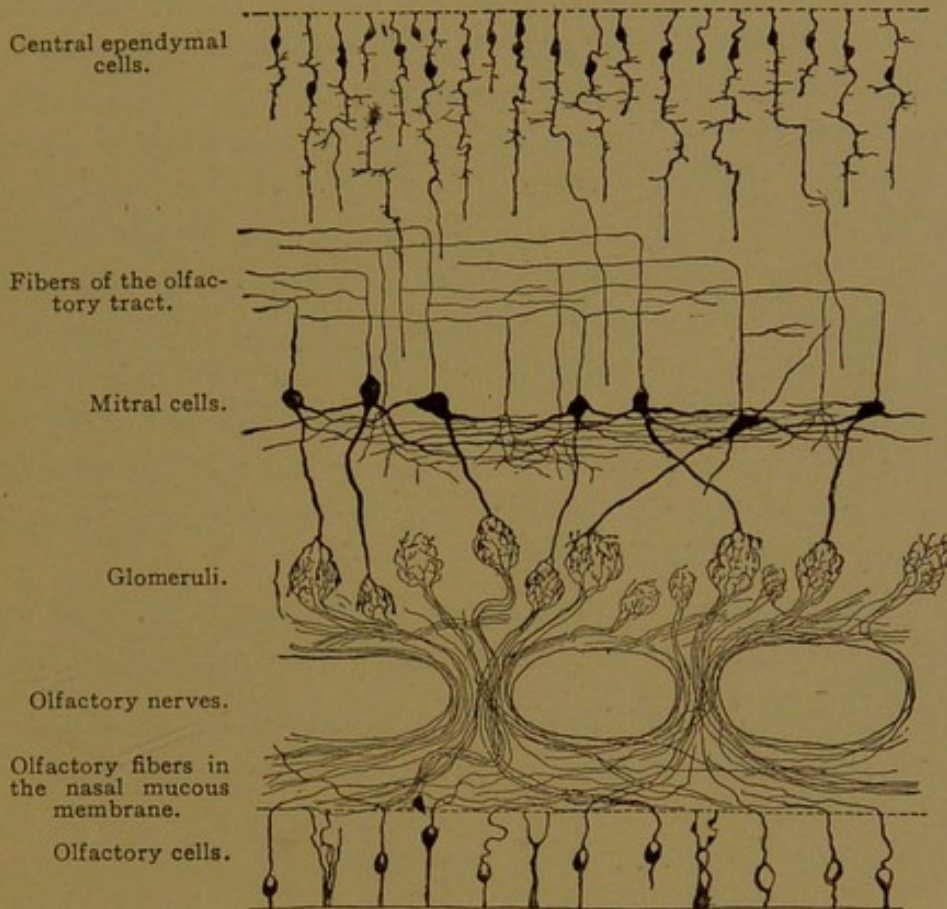


FIG. 492.—CHIEF ELEMENTS OF THE OLFACTORY BULB. (Gordinier, after Van Gehuchten.)

The mucus, which is the product of the sustentacular cells, may appear to form a continuous superficial membrane (Fig. 491). Near the tunica propria there is a network of so-called "basal cells" (Fig. 491).

The tunica propria is composed of fibrous tissue and fine elastic fibers, associated with many connective tissue cells. In some animals (for example, the cat) it forms a structureless membrane next to the epithelium. It surrounds the numerous *olfactory glands* (Bowman's glands). In man these consist of excretory ducts extending through the epithelium, and of branching gland bodies beneath. They have the appearance of serous glands, but sometimes contain mucus, generally in small quantities. They are found not only in the olfactory region, but also in the adjoining part of the respiratory region.

The deeper layers of the tunica propria contain the arteries of the mucous membrane, which send branches toward the epithelium, and form a thick sub-epithelial plexus of capillaries. The veins are very numerous, especially at the inner end of the inferior concha, where the tunica propria resembles cavernous tissue. Lymphatic vessels form a coarse meshed network in the deeper connective tissue. Injections of the arachnoid spaces around the olfactory bulbs follow the perineural sheaths of the olfactory nerves into the nasal mucosa, but these tissue spaces are not lymphatic vessels.

The olfactory nerves, as already stated, are formed of the basal processes of the olfactory epithelial cells, which become non-medullated nerve fibers. This is a primitive type of nervous apparatus (cf. p. 132), such as is not found elsewhere in the human body. After a tangential course beneath the epithelium, the fibers unite in bundles, and pass through the cribriform plate of the ethmoid bone to the olfactory bulb just above it, which they enter. They spread tangentially and branch, finally terminating in the *glomeruli*. The glomeruli are round or oval groups of arborizing fibers, in which the processes of the olfactory cells end in relation with the dendrites of the *mitral cells*. The latter are nerve cells with triangular bodies, which form a characteristic layer of the olfactory bulb, and send their neuraxons through the olfactory tracts to make various connections within the hemispheres.

In addition to the olfactory nerves, the nasal mucous membrane contains medullated branches of the trigeminal nerve, distributed both to the olfactory and respiratory regions.

PART II.

MICROSCOPICAL TECHNIQUE.

I. THE PREPARATION OF MICROSCOPICAL SPECIMENS.

REVISED BY LAWSON G. LOWREY.

The methods of fundamental importance, which are likely to be employed by students who are beginning their histological studies, are here given. Further information may be obtained from "The Microtome Vade Mecum" by A. B. Lee (Blakiston, Philadelphia) and from Mallory and Wright's "Pathological Technique" (Saunders, Philadelphia). The former deals with the subject from the point of view of general biology; the latter is particularly adapted to the needs of medical students.

FRESH TISSUES.

Certain tissues may be studied advantageously in a fresh condition. They are simply spread on a clean glass slide, covered and examined. Desquamated epithelial cells, spermatozoa, blood, and other fluids containing cells, may be treated in this way. But structures such as muscles, tendons, nerves, connective tissue, etc., must first be "teased"—that is, torn into very small fragments or spread into a thin layer with a pair of fine needles.

The "parenchymatous" organs, or other structures which cannot be investigated satisfactorily by the above methods, must be sectioned or macerated. The old methods of making free-hand sections of the object held between pieces of pith, or of making sections with a double bladed knife, have been superseded in most laboratories by the freezing method. This method is often serviceable in histology, and is indispensable in the rapid diagnosis of pathological conditions.

Blocks of tissue not over 5 mm. thick are moistened with water, placed on the carrier of a special form of microtome and frozen by a jet of carbon dioxide proceeding from a tank of the compressed gas. Sections 10 to 15 μ thick may be chiselled from the block of tissue and unrolled by transferring to a dish of 0.6 per cent. sodium chloride solution. They are floated on a slide, covered and examined.

Sections or teased preparations must be kept moist during examination. In order to avoid distortion, they are not mounted in water, but in so-called indifferent fluids, such as the lymph, aqueous humor, serous fluids, amniotic fluid, etc. Of the artificial indifferent media, a 0.6 per cent. solution of sodium chloride in distilled water has been found to cause less distortion than the stronger fluids formerly recommended.

Ringer's Solution. An indifferent fluid which is perhaps more satisfactory than the 0.6 per cent. salt solution is a modification of Ringer's solution adapted to the tissues of warm-blooded animals. It is to be made in large quantities.

Sodium chloride.....	90.0
Potassium chloride.....	4.2
Calcium chloride (anhydrous).....	2.4
Potassium bicarbonate.....	2.0
Distilled water.....	10,000.0

Examination of fresh tissues reveals but little of the fine details of structure. Since the indices of refraction of the different tissue elements have much the same value, outlines are usually dim and there is very little optical differentiation. The method of handling is prone to produce distortion and with many tissues and organs it is difficult to separate their constituent elements. It is generally necessary to employ more complex methods of treatment to gain an adequate idea of the histological details.

One of the simplest methods is to add one or two drops of 1 to 5 per cent. acetic acid solution to the fresh preparation. The nuclei then appear more distinctly. Albuminous granules are dissolved, but fat and myelin are not affected. The white fibers of connective tissue swell and disintegrate, leaving the elastic fibers unaffected.

Nuclei may be rendered distinct by allowing a few drops of stain to act upon the tissue for a few minutes. A 1 per cent. aqueous solution of methylene blue, or a 1 per cent. solution of methyl green in 20 per cent. alcohol, or the hæmatoxylin solutions, may be used.

ISOLATION.

Some tissues cannot properly be separated into their elements in the fresh condition, but may be shaken or teased apart after preliminary treatment. The reagents employed in maceration have the property of softening or removing certain constituents of the tissues, at the same time fixing or hardening other elements. Usually the intercellular portions are softened or removed, while the cellular elements undergo fixation.

Ranvier's Alcohol. This is a mixture of one volume of 95 per cent. alcohol and 2 volumes of distilled water. The cells of small pieces of epithelium (5-10 mm. square) are separable in 24 to 48 hours. They are examined in the same fluid, or washed in water and examined in glycerin.

Nitric Acid and Potassium Chlorate. About 5 gm. of potassium chlorate are dissolved in 20 c.c. of the acid. Muscle cells are separable in one to six hours. Wash thoroughly in water and examine in water or glycerin.

Potassium Hydrate. Muscle cells may be teased apart after immersion for about an hour in a 35 per cent. aqueous solution. They may be examined in the same solution or transferred to a saturated aqueous solution of potassium acetate, which prevents further maceration. The solution of potassium hydrate may also be used for isolating epithelial cells.

Concentrated Sulphuric Acid. The elements of the epidermis, hair and nails may be separated after immersion in this fluid. They should be thoroughly washed in water.

PERMANENT PREPARATIONS.

None of the methods described above yield much information respecting the finer structure of tissues and organs, nor do they yield permanent preparations. For ease of reference, the various steps in the production of a permanent preparation have been grouped under the following five headings.

1. *Fixation.* Under this heading are given formulæ for the best fixing fluids, with directions for their use and for the subsequent handling of the tissue until it is placed in 80 per cent. alcohol, in which tissues may be kept for a considerable time.

2. *Imbedding.* This includes the various steps for preparing the tissues to be sectioned in paraffin or celloidin, starting from 80 per cent. alcohol.

3. *Cutting and handling sections.* Brief directions are given for cutting sections and handling them, until they are ready for staining.

4. *Staining.* Formulæ and directions for the use of stains, and the after treatment until the preparation is in the appropriate clearing fluid.

5. *Clearing and mounting.* The choice of a clearing agent for paraffin and celloidin sections is discussed, together with the methods and media for mounting.

Since each of the fixing, imbedding and staining methods is considered as a unit, each starting where the previous step ends, the student can easily prepare specimens according to any desired possible combination by referring to the directions for the selected fixative, imbedding method, and stain.

1. Fixation.

A good fixative should penetrate and kill tissues quickly; preserve the tissue elements, particularly the nuclei, in the condition in which they are

found at the moment of its action; render structures insoluble, and harden them so that they will not be altered by the various after-steps; and give a certain degree of optical differentiation.

No single compound has yet been found which successfully fulfills all of these conditions, nor are any of the recommended fixatives adequate in all cases or for all special studies. Only the fluids commonly employed, which have proven most useful, are here given.

Small pieces of tissue, preferably less than 1 cm. in thickness, should be dropped into a considerable amount of fluid. The tissue should be handled as little as possible, in order that delicate structures may not be destroyed. For example, contact between the fingers and the peritoneum is sufficient to destroy the thin epithelium.

In order to insure uniform action of the fixing fluid, it is often advisable to place a little absorbent cotton in the bottom of the vessel. Frequent gentle mechanical agitation will serve the same end. Tubular organs should be washed out, or cut open and their contents and any adherent blood washed away, with salt solution. Membranes may be kept flat and smooth by tying them across the end of a short tube or detached bottle neck.

Alcohol. Small or thin pieces of tissue are supported on a little absorbent cotton in absolute alcohol, for 12 to 24 hours, changing after 3 or 4 hours. Large pieces are fixed by successive immersion in 70 per cent., 80 per cent., and 95 per cent. alcohol for 24 hours each.

Alcohol is a valuable dehydrating and hardening agent, but its fixing qualities are inferior, so that it is rarely used alone as a fixative. Small embryos or blocks of tissue obtained in an emergency should be preserved in 10 per cent. formalin, rather than in alcohol.

Bouin's Fluid.

Picric acid, saturated aqueous solution.....	75
Formalin.....	20
Glacial acetic acid.....	5

This fluid is particularly recommended for the fixation of embryos, for which it is unexcelled. Small embryos are fixed in 4 to 6 hours. Larger objects may be fixed 24 to 48 hours or longer. For washing out the fixing fluid, alcohol, first 70 per cent., then 80 per cent., should be employed. Renew the alcohol as often as discolored.

Carnoy's Mixtures.

No. 1—Absolute alcohol.....	6
Chloroform.....	3
Glacial acetic acid.....	1

This is a very rapid fixative, even large pieces being fixed in $\frac{1}{2}$ to 1 hour. Wash in absolute alcohol until the odor of acetic acid is lost, changing every 12 hours, and imbed; or grade through 95 per cent. to 80 per cent. alcohol.

No. 2. Saturate mixture No. 1 with mercuric bichloride (about 20 parts). This is the most rapid and penetrating fixative known, and it affords a very delicate cytological fixation. Immersion for 30 minutes to 1 hour is sufficient even for the larger pieces. Subsequent treatment as with No. 1, except that the crystals of sublimate must be removed from the tissue, either by placing the block in 80 per cent. alcohol and iodine (see Zenker's fluid); or after the block has been cut, by treating the sections with iodine (see p. 497).

Flemming's Fluid.

Osmic acid, 1 % aqueous solution.....	10
Chromic acid, 1 % aqueous solution.....	25
Glacial acetic acid, 1 % aq. solution.....	10
Distilled water.....	55

This solution should be mixed only at the time of using. Only very thin pieces (not over 2 mm. thick) should be used. Fix for 24 hours or longer (sometimes even for weeks). Wash in running water 24 hours. Pass through 50 per cent., 70 per cent. (12 hours in each), to 80 per cent. alcohol.

Formaldehyde. The gas is soluble in water to the extent of 40 per cent., and solutions of this strength are obtainable under the trade names of formalin, formol, and formalose.

For fixing tissues, 10 c.c. of the commercial product are added to 90 c.c. of water. It penetrates very quickly, but specimens may be left in it for a considerable time without apparent harm. Ordinary blocks are sufficiently fixed in from 12 to 24 hours. Transfer directly to 80 per cent. alcohol.

Histologically, its chief use is for the preservation of nervous tissue, the fixation of tissue to be cut with the freezing microtome, and the preservation of embryos. *Small human embryos obtained by practitioners should be put at once into 10 per cent. formalin and forwarded to an embryological laboratory.*

Marchi's Fluid.

Potassium bichromate.....	2.5
Sulphate of sodium.....	1.0
Water.....	100.0
Osmic acid, 1% aqueous solution.....	50.0

Small pieces are fixed for 5 to 8 days in the dark. Wash 24 hours in running water; 50 per cent. and 70 per cent. alcohol (24 hours each); 80 per cent. alcohol. Used for demonstrating degenerated nerve fibers and in making damar mounts of fat and myelin, since the osmium reduced by fat is insoluble in alcohol. Sections must not be treated with xylol, but chloroform should be used instead.

Orth's Fluid.

Potassium bichromate.....	25
Sodium sulphate.....	10
Water.....	1000

At the time of using mix 10 c.c. of formalin with 90 c.c. of the above solution (which is known as Müller's fluid). Small pieces are fixed in about 48 hours. Wash in running water for 12 to 24 hours. Then 50 per cent. alcohol and 70 per cent. alcohol, 12 to 24 hours each; 80 per cent. alcohol. This is useful as a fixative for the central nervous system, and as a general fixative.

Zenker's Fluid.—This is kept in the form of the following stock solution, in preparing which the water is heated and the ingredients are stirred with a glass rod (metal instruments must not be put into this fluid).

Potassium bichromate.....	25
Sodium sulphate.....	10
Mercuric bichloride.....	50
Water.....	1000

At the time of using, add 5 c.c. of glacial acetic acid to 95 c.c. of the above solution. The tissues, which float for a short time, are fixed for 6 to 24 hours, after which they are washed in running water 12 to 24 hours. Then they are transferred to 50 per cent. alcohol for 12 to 24 hours; 70 per cent. alcohol, 12 to 24 hours; 80 per cent. alcohol.

Corrosive sublimate forms crystalline deposits in the tissues, and these must be removed before the preparation is stained. They may be removed by adding enough tincture of iodine to give a port-wine color to the 70 per cent. and 80 per cent. alcohols in which the block of tissue is immersed. More iodine is added as the solution becomes colorless (or nearly so) and the treatment must be continued until the color no longer changes. The tissues are then to be placed in fresh 80 per cent., renewed two or three times in order to remove completely the mercuric iodide. The crystals of sublimate may be removed after the tissue has been sectioned, as described on p. 497.

Zenker's fluid is an excellent fixative, which penetrates easily and does not decrease the staining qualities. It is probably the best "general fixative."

DECALCIFICATION.

Specimens which contain bone or calcareous material cannot be sectioned until they have been decalcified. The tissues are fixed, according to the directions given above, in Zenker's fluid, Orth's fluid, or formaldehyde, and hardened. After several days in 80 per cent. alcohol, they are put into a considerable quantity of 3 to 5 per cent. aqueous solution of nitric acid. This should be renewed at intervals for 3 or 4 days, until the bone can be penetrated easily with a needle. Wash in running water for a day, and return to 80 per cent. alcohol. Imbed in celloidin.

Phloroglucin is sometimes added to the decalcifying fluid to protect the tissue. The following solution has been recommended. It is to be used in the same manner as the aqueous solution of nitric acid.

Phloroglucin.....	1
Nitric acid.....	5
Alcohol, 95%.....	70
Water.....	30

The addition of 1 or 2 per cent. of nitric acid to the 80 per cent. alcohol will decalcify small embryos. The specimen should then be thoroughly washed in fresh 80 per cent., in order to remove the acid.

2. Imbedding.

Most of the fixatives employed are in aqueous solution. After fixation and the removal of the fixative by washing in water or alcohol, as directed, the specimen must not be left in water, but must be dehydrated. Dehydration has a double purpose: (1) to remove the water, which especially favors post-mortem decomposition, and (2) to prepare the tissue for infiltration with the imbedding substance or, in the case of objects to be mounted whole, for infiltration with the mounting medium.

All the fixation methods given above end with placing the block of tissue in 80 per cent. alcohol. Here they may be left until wanted, although immersion for a considerable time causes a gradual loss in staining qualities. Stronger alcohol causes an overhardening, while maceration may occur in weaker alcohols.

Dehydration is accomplished by immersing the specimen in gradually increasing strengths of alcohol. Those commonly employed are 50 per cent., 70 per cent., 80 per cent., 95 per cent. and absolute. The lower grades may be prepared from the ordinary barrel alcohol, of about 95 per cent. strength, as follows:

80 per cent.—425 c.c.	95 per cent. alcohol mixed with	75 c.c. distilled water
70 per cent.—370 c.c.	" " " " " "	130 c.c. " "
50 per cent.—265 c.c.	" " " " " "	235 c.c. " "

The specimen is left in each grade long enough to be saturated. The time required varies from 3 to 24 hours. Objects of average size require about 6 to 12 hours. Prolonged immersion in 95 per cent. or absolute is very injurious to the tissues.

In imbedding, the tissue is surrounded and infiltrated with a firm substance which can be cut into thin sections, supporting and holding firm the fragile tissue. Celloidin, which is solid upon the evaporation of its solvent, and paraffin, which is solid at ordinary temperatures, are the substances used, each having its particular advantages.

Paraffin Imbedding. Specimens cannot be passed directly from alcohol to paraffin, since alcohol dissolves only a very little paraffin and the specimen would not be thoroughly infiltrated. So the specimen must first be passed through some fluid which mixes with absolute alcohol and will dissolve paraffin. Of a host of reagents possessing this property, chloroform is recommended for general use.

After thorough dehydration (12-24 hours in absolute alcohol), the

specimen is passed from absolute to a mixture of equal parts of absolute and chloroform for 2 to 6 hours, and then to pure chloroform for an equal length of time. It is then transferred to a saturated solution of paraffin in chloroform, kept warm by placing on top of the paraffin bath, for 2 to 4 hours, and is then put into melted filtered paraffin.

The melting point of the paraffin used varies with the temperature in which it is to be cut. During the winter, paraffin melting at 50° – 52° C. should be used, while during the summer paraffin with a melting point of 56° – 58° is best. Harder paraffin is required for thin than for thick sections. The melted paraffin should be kept in a paraffin bath or thermostat maintained at a temperature but slightly higher than the melting point of the paraffin.

The specimen should be left in the melted paraffin for the shortest time which will allow thorough infiltration, as heat is very injurious to the tissue. For average specimens, 3 hours is sufficient. Transfer to fresh paraffin at the end of $1\frac{1}{2}$ or 2 hours. At the end of the full time, the specimen is to be imbedded.

The imbedding frame consists of a glass plate and two L-shaped pieces of metal. By sliding the latter back and forth on one another, the size of the enclosed space or box may be varied. Before using the frame, the inner surfaces of the metal pieces and that part of the glass plate on which they rest are rubbed with glycerin. It should form a thin film over the surfaces, but not accumulate in drops. Melted paraffin is poured into the box and the specimen is transferred to it with a spatula. The specimen sinks to the bottom, and may be arranged in any desired position by means of needles warm enough to prevent the paraffin solidifying over their surfaces. The paraffin must be *quickly* cooled by lowering the frame into a basin of cold water so that the water comes up on the sides of the metal pieces. As soon as a resistant film has formed over the surface of the paraffin, the entire frame may be submerged, and in a few minutes the glass plate and metal pieces may be detached from the solid paraffin. The block may be sectioned as soon as it is thoroughly cooled.

When a number of specimens are to be imbedded, a flat dish of suitable size may be used. After a thin layer of glycerin has been coated over the interior, the dish is filled with a sufficient quantity of melted paraffin and the blocks are put into position. The mass is cooled and removed as before, and the large mass is cut into smaller parts, each containing a specimen.

One or several specimens may be imbedded in paper boxes of suitable size. The tabs at the ends may be labelled and the specimens kept in the boxes until wanted; otherwise labels may be scratched in the paraffin with needles.

Paraffin imbedding is to be chosen when very thin sections or serial sections are desired. Material imbedded in paraffin may be kept for years without any apparent deterioration.

Celloidin Imbedding. Thick celloidin is prepared by dissolving 30 gm. of Schering's granular celloidin in 300 c.c. of a mixture of equal parts of ether and absolute alcohol. It has a thick syrupy consistency, and becomes constantly denser by evaporation of the solvent. It should be kept in a tightly closed preserve jar. Thin celloidin is prepared by mixing equal volumes of the thick celloidin and the absolute and ether mixture.

The hardened and dehydrated block of tissue, trimmed to the size and shape desired, is transferred from absolute alcohol to a mixture of equal parts of ether and absolute for 24 hours. From this it is transferred to thin celloidin, in which it remains from 24 hours to a week or longer, and then to thick celloidin for the same length of time. The success of the process depends largely upon the thorough infiltration of the tissue with the celloidin. The time required in the celloidin varies with the penetrability of the tissue and the size of the piece.

After remaining for a sufficient length of time in the thick celloidin, the tissue is taken out with a mass of adherent celloidin and is pressed gently against the roughened surface of a block of vulcanized fiber. As soon as a film has formed upon the surface, the block and attached specimen are dropped into 80 per cent. alcohol, in which the mass becomes firm. It is ready for sectioning in about 6 hours.

In case it is desired to secure sections through the entire thickness of the specimen, the following method is recommended. A sufficient quantity of thick celloidin is poured into a flat dish (or paper box) and the specimen is put into it. The entire mass is hardened as before and then a block of celloidin containing the specimen is cut out. This is trimmed to leave only a thin rim around the specimen. The block is placed for a few moments in the ether-absolute mixture, and then dipped in thick celloidin and pressed against the surface of a fiber block, which has also been dipped in the ether-absolute mixture and in thick celloidin. The mass is allowed to harden somewhat, and then is placed in 80 per cent. alcohol.

The imbedded specimen is kept in 80 per cent. alcohol until wanted for sectioning. Celloidin imbedding is recommended for large objects, or for those from which very thin sections are unnecessary.

RÉSUMÉ OF IMBEDDING METHODS.

Assuming that the tissues have been fixed and carried into 80 per cent. alcohol, the steps in imbedding are as follows:

Paraffin		Celloidin	
95 per cent. alcohol.....	12-24 hr.	95 per cent. alcohol.....	12-24 hr.
Absolute.....	12-24 hr.	Absolute.....	12-24 hr.
Absolute and chloroform, equal parts.	2- 6 hr.	Absolute and ether, equal	
Chloroform.....	2- 6 hr.	parts.....	12-24 hr.
Chloroform saturated with paraffin.	2- 4 hr.	Thin celloidin.....	24 hr. to a week
Melted paraffin.....	2- 4 hr.	Thick celloidin.....	24 hr. to a week
Imbed in fresh melted paraffin and	<i>cool quickly.</i>	Mount on fiber block; harden and preserve in	80 per cent. alcohol.

3. Cutting and Handling Sections.

Paraffin Sections. Two kinds of microtomes are in general use for sectioning objects imbedded in paraffin. In one form, the "precision microtome," the knife is horizontally placed and the object is moved backward and forward on a carrier. In the rotary microtome, the knife is vertically placed and the object is moved up and down, being cut on the down stroke. In both forms, the knife edge is at right angles to the carrier and the object.

For sectioning with the precision microtome, the object is mounted on a fiber block which is then clamped in the microtome; with the rotary form, it is mounted on a special metal disc. Before attaching the imbedded object, superfluous paraffin is cut away, leaving the tissue rising from a broad base and completely surrounded by a thin layer of paraffin. The block should be trimmed so as to give a rectangular or square surface to be cut, and there should be a considerable layer of paraffin between the object and the block or disc to which it is to be attached. The base is placed upon a heated spatula which rests upon the fiber block. When the paraffin is somewhat melted, the spatula is withdrawn and the base is pressed down upon the block, to which it adheres when the paraffin solidifies. In mounting upon the metal disc, the disc is heated, the block pressed upon it and the whole quickly cooled by immersing in water.

If the paraffin on each side of the object is trimmed parallel with the knife edge, the successive sections adhere to one another, forming *ribbons*. As they are taken from the knife, the ribbons are laid in a shallow box. By placing them in order, they may later be attached to the slide in perfect series, one after the other. The first one cut is attached to the upper left hand corner, and the others follow like lines on a printed page. Sections mounted in this way are called *serial sections*. The sections should be from 5 to 10 μ in thickness, but under favorable conditions thinner sections may be secured.

Before they can be stained, paraffin sections must be attached to the slide and the paraffin must be removed. To attach them to a slide, a mixture of equal parts of white of egg and glycerin is used. The white of egg is thoroughly stirred and filtered. An equal volume of glycerin is added, the two thoroughly mixed and a small lump of camphor added as

a preservative. The mixture is kept in a glass-capped bottle, with a glass rod for a dropper.

A drop is placed upon a thoroughly clean slide and rubbed evenly with the finger (freed from oil) over all the area upon which sections may be placed. It should be free from bubbles and should make a very thin layer, just thick enough to allow the finger to glide easily over the surface of the slide. A few drops of water are placed upon it, forming a layer over the albumen deep enough to float the paraffin sections, strips of which are placed upon the water. The shiny side of the ribbon should rest upon the water. The slide is then held for a moment over the flame of an alcohol lamp so that the water is heated. Repeat until the sections become perfectly smooth and flat, but the paraffin must not be melted. The water should not come in contact with the fingers holding the slide. If the albumen layer ends abruptly before reaching the border of the slide, the water will not so readily spread beyond it. After the flattening process, the water is cautiously drained off by a moist sponge held at the corner of the slide. The sections settle down upon the albumen and may be arranged in straight lines with needles applied to the paraffin, but not to the tissues of the sections. The slide is then held vertically in contact with filter paper to drain off any water which may remain, and the portions of the slide which are free from sections are wiped off with a cloth free from lint. The slide is next placed in a drying oven which is not warm enough to melt the paraffin. It is well to let the slides remain over night, but a few hours may be sufficient to dry them thoroughly.

In preparing large numbers of slides, each bearing only one or two sections, fragments of the ribbon containing the desired number of sections are floated in a basin of water warm enough to flatten but not to melt them. Slides rubbed with albumen are dipped into the water beneath the sections, which are held in place with a needle. The slides are drained and dried in the usual way, care being taken to have the sections in the center of the slide. Or the ribbons may be floated on warm water and cut into fragments with a heated knife, proceeding then as before.

To remove the paraffin, the slides are immersed in xylol for about 5 minutes. The slide is then transferred in turn to a mixture of equal parts of xylol and absolute alcohol, then through absolute, 95 per cent., 80 per cent., 70 per cent. and 50 per cent. alcohols, remaining about 1 minute in each, to water. In case the stain is in alcoholic solution, the transfers may be stopped at that grade of alcohol which corresponds to the solvent of the stain.

In case the sectioned tissue was fixed in a fluid containing corrosive sublimate and has not previously been treated with iodine for the removal of mercurial deposits, enough tincture of iodine to give a port-wine color may be added to the 80 per cent. alcohol. The slide is immersed in this

for about a minute and then washed in fresh 80 per cent. to remove the iodine.

All of the reagents and stains to be used for paraffin sections may be kept in a series of tube-like vials, in which the slides may be placed in pairs back to back, being transferred from one vial to another. The vials are kept tightly corked, and the reagents can be used for some time before they must be renewed.

In handling a large number of slides, grooved rectangular boxes are useful. Each reagent is allowed to act, poured out and another substituted.

Celloidin Sections. Objects imbedded in celloidin are cut with either a sliding or a precision microtome, the knife edge meeting the block obliquely. The block and knife are kept wet with 80 per cent. alcohol. Sections are cut 10 to 15 μ in thickness, and are transferred, by means of a camel's-hair brush wet with alcohol, to a dish of 80 per cent. alcohol, in which they remain until wanted for staining.

Celloidin sections are stained in a series of small, shallow staining dishes. The sections are taken from 80 per cent. alcohol and transferred through graded alcohols to water or the solvent of the stain. If deposits of corrosive sublimate are present and were not removed before imbedding, the sections should be treated as directed for paraffin sections. The sections are transferred from dish to dish with bent metal or glass needles. Celloidin sections are not treated with absolute alcohol, since the celloidin would be softened.

The handling of large numbers of celloidin sections is facilitated if they are placed in a perforated cup which fits into another ordinary cup. The ordinary cups contain the various reagents and the sections are transferred from one to another in the perforated cups. The latter may be obtained as "Hobb's Tea Infusers," and lemonade cups are of proper size to receive them.

Wright's Method for Frozen Sections. This method gives permanent preparations which are adequate for most routine purposes in histological examination, and saves much time, labor, skill and expense. The success of the method depends to a considerable extent upon the frozen sections being as thin as good celloidin sections. Special automatic microtomes may now be purchased, or the older form in which the sections are "chiselled" from the block will give good results if properly used.

The tissues are fixed in 10 per cent. formalin for 12 to 24 hours or longer. The piece is then trimmed so that it will present a thickness to be frozen of not over 5 mm. The other dimensions of the block may be as large as the freezing box of the microtome will permit. The block is rinsed in water, placed on the freezing box with a few drops of water beneath it; frozen and cut into sections, which should not be over 10 or 15 μ in thickness.

The sections are floated into water, in which they unroll. Select a good section and spread it smoothly on a slide which has been coated with a thin, even layer of albumen-glycerin. Superfluous water is drained off and the section pressed upon the slide with a piece of smooth blotting paper, by exerting an even but not great pressure with the ball of the thumb. The section will adhere to the slide.

Now quickly cover the section with a small quantity of 95 per cent. alcohol, followed in a few seconds by absolute. Pour from a drop bottle quickly and evenly over the section and adjacent surface of the slide a very thin solution of celloidin dissolved in equal parts of ether and absolute alcohol. Drain off immediately, blow the breath once or twice on the surface of the section and immerse the slide at once in water for a few seconds. The thin film of celloidin thus formed fastens the section to the slide. The solution of celloidin should be almost watery in consistence, and so thin that it will form drops readily without stringing. If it is too thin, it will not hold the section on the slide, while if it is too thick, the layer on the slide will become white when it is immersed in water. The film of celloidin should be so thin as to be almost invisible.

The section may now be stained by any of the usual methods applied to sections affixed to the slide. The thin layer of celloidin offers no obstruction to the staining. After staining, the section is dehydrated by covering with 95 per cent. alcohol for a few seconds. Absolute is now poured on and allowed to remain for a few seconds. This removes most of the celloidin, but, unless the action is unduly prolonged, the section will not be loosened. Clear in xylol.

The microtomes and knives mentioned in this section are described and directions for their use are given in Mallory and Wright's "Pathological Technique." Their use, however, is seldom learned except by personal demonstration in the laboratory.

4. Staining.

The purpose of staining is to differentiate the tissue elements. The staining of tissues is in a measure a micro-chemical color reaction, the differential staining being due to the fact that certain elements take up more of the stain than others.

Stains used in microscopic work may be divided into two general classes according to their chemical properties—(1) *basic* stains, which show especial affinity for the nuclei of cells and are called *nuclear* stains, and (2) *acid* stains, which affect the cytoplasm more readily and are called *cytoplasmic* stains. Certain so-called selective stains (either acid or basic) affect one tissue element especially, or even exclusively. Preparations may therefore be stained with several dyes, each affecting certain tissue

elements only. Certain stains may be applied to the tissue before it is imbedded and sectioned. They are seldom used except in the preparation of embryos.

GENERAL STAINS.

THE STAINING OF SECTIONS.

Hæmatoxylin and Eosin. Hæmatoxylin is a basic dye obtained from logwood, which stains nuclear structures blue. Eosin is an acid anilin dye which stains cytoplasm red. (It is recommended that all anilin dyes used in histological work be those prepared by Grübler in Germany.)

There are many formulæ for the preparation of hæmatoxylin solutions, of which the two following are especially useful.

Alum hæmatoxylin.

Hæmatoxylin crystals.....	1 gm.
Saturated aqueous solution of ammonia alum.....	100 c.c.
Water.....	300 c.c.

Dissolve the hæmatoxylin in a little water with the aid of heat, and add to the remainder of the solution. Put the mixture in a bottle and add a small lump of camphor or thymol to prevent the growth of mould. Stopper the bottle with a loose plug of cotton and set in the light for about 10 days to *ripen*. It changes to a deep blue color during this process of oxidation, after which it is ready for use and is kept tightly stoppered. It deteriorates and must be renewed after a few months. The solution may be ripened immediately by the addition of 2 c.c. of hydrogen peroxide solution, neutralized by a crystal of sodium chloride.

For use after Zenker fixation, the water in the above formula may be omitted.

Delafield's Hæmatoxylin.

Hæmatoxylin crystals.....	4 gm.
Alcohol, 95 per cent.....	25 c.c.
Sat. aq. sol. of ammonia alum.....	400 c.c.

The hæmatoxylin is dissolved in the alcohol and added to the alum solution. This is exposed to the light in an open vessel to ripen for about 4 days and then is filtered. To the filtrate is added:

Methyl alcohol (or 95%).....	100 c.c.
Glycerin.....	100 c.c.

This mixture is exposed to the light in a cotton-plugged bottle for about a week, after which it is again filtered and tightly stoppered. The solution keeps for a considerable time. It may be used in this strength, but preferably it is diluted with one or two volumes of water.

Eosin is sold in two forms, one soluble in water, the other in alcohol. In connection with hæmatoxylin, a $\frac{1}{10}$ to 1 per cent. aqueous solu-

tion may be used, but it is preferable to use a solution made by adding to 95 per cent. alcohol enough of a stock solution, consisting of 5 gm. of eosin dissolved in 300 c.c. of 50 per cent. alcohol, to give a deep yellowish-red color to the alcohol.

Sections are transferred from water to the hæmatoxylin solution for about 5 minutes. They are then washed in several changes of tap water until the sections are deep blue in color. If this change does not occur rapidly, a few drops of ammonium hydrate may be added to the water. They are then examined with the microscope. If the sections are overstained (a condition recognizable in the staining of the cytoplasm as well as the nuclei) the sections are washed in a 0.5 per cent. solution of hydrochloric acid in 70 per cent. alcohol until the section is reddish-brown, usually about 1 minute. Wash in water made alkaline with a few drops of ammonia and re-examine. If the nuclei are not well stained, the sections are returned to the hæmatoxylin solution for 5 to 10 minutes longer, after which they are examined as before.

When the stain is sharply limited to the nuclei and is of satisfactory depth, the sections are washed for 15 to 30 minutes in tap water and then are passed through 50 per cent., 70 per cent., 80 per cent. and 95 per cent. alcohol, remaining about 1 minute in each. Stain in the alcoholic solution of eosin for 1 to 5 minutes. Wash in 95 per cent. until red clouds no longer leave the section.

Paraffin sections are then passed through absolute; absolute and xylol (equal parts); and xylol, in which they remain for about 5 minutes, and are then ready for mounting. Celloidin sections are transferred from 95 per cent. to oil of origanum for about 5 minutes, before mounting.

Eosin and Methylene Blue. This method is highly recommended, especially for tissues fixed in Zenker's fluid and sectioned in paraffin.

Stain the sections for 20 minutes or longer in a 5 or 10 per cent. aqueous solution of eosin. The tissue must be overstained, as the eosin is partially extracted in the subsequent treatment. Wash out the excess of the stain in water.

Stain for 10 to 15 minutes in Unna's alkaline methylene blue (1 gm. of methylene blue and 1 gm. of potassium carbonate dissolved in 100 c.c. of water) diluted 1:3 or 1:5 with water. Wash in water. Differentiate and dehydrate in 95 per cent. alcohol, keeping the section in constant motion so that the decolorization is uniform. When the pink color returns to the section and when, as seen under the microscope, the blue is limited to the nuclei, the section is quickly washed in absolute, passed through absolute and xylol, and put in xylol for about 5 minutes.

Heidenhain's Iron Hæmatoxylin. The best results are obtained with very thin paraffin sections. From water the sections are transferred to a 2-2.5 per cent. aqueous solution of ferric ammonium sulphate for 4 to

8 hours. Wash quickly in water. Stain for 12 to 24 hours in a well-ripened solution consisting of 0.5 gm. hæmatoxylin dissolved in 10 c.c. of absolute alcohol and added to 90 c.c. of water. Wash in water. Differentiate in the iron alum solution, controlling the result under the microscope. The section should be washed in water before each examination. When the stain is limited to the nuclei, and these are sharp, wash in running water for 15 to 30 minutes; 50 per cent.; 70 per cent.; 80 per cent.; 95 per cent.; absolute alcohol; absolute and xylol; xylol.

If a counterstain is desired, add to 95 per cent. alcohol enough of a 1 per cent. solution of Orange G in 50 per cent. alcohol to give a deep orange color. Transfer the section from 95 per cent. to the stain for a few minutes. Wash well in 95 per cent., and pass through absolute, absolute and xylol, to xylol.

Weigert's Iron Hæmatoxylin.

A. Hæmatoxylin crystals.....	1 gm.
Alcohol, 95 per cent.....	100 c.c.
B. Liquor ferri sesquichlorati.....	4 c.c.
Water.....	95 c.c.
Hydrochloric acid.....	1 c.c.

At the time of using, mix equal parts of A and B. Transfer the sections from water to the stain for 2 to 5 minutes. Wash in water. If the section is overstained, add a few drops of hydrochloric acid to the water. To stop the decolorization, dip in water made alkaline with a little ammonia. This is an excellent stain and gives brilliant results. If a counterstain is desired, place sections for about 1 minute in Van Gieson's mixture:

Picric acid, sat. aq. sol.....	100
Acid fuchsin, 1 per cent. aq. sol.....	10

Wash in water; 95 per cent.; absolute; absolute and xylol; xylol. For celloidin sections, 95 per cent.; oil of origanum.

Safranin.

Safranin.....	1 gm.
Absolute alcohol.....	10 c.c.
Anilin water.....	90 c.c.

Anilin water is prepared by shaking up 5 c.c. of anilin oil in 95 c.c. of distilled water and filtering through a wet filter. Dissolve the safranin in the alcohol and add to the anilin water.

Safranin is to be used after fixation in Flemming's fluid. Stain thin paraffin sections for 24 hours; wash in water; decolorize in absolute alcohol, to which has been added hydrochloric acid in the proportion 1:1000, until only the nucleus retains the stain; fresh absolute; absolute and xylol; xylol.

STAINING IN BULK.

Embryos which are to be mounted whole or cut into serial sections are commonly stained before they are imbedded. The time given for the action of the following stains is that required in the preparation of 12-mm. pigs. Larger or smaller objects should, of course, receive a longer or shorter treatment.

Alum cochineal.

Cochineal.....	60 gm.
Potassium alum.....	60 gm.
Water.....	800 c.c.

Boil vigorously for 20 minutes. Cool and filter. Boil the filter paper and contents with more water for the same length of time. Cool and filter. Repeat the boiling and filtering until the powder disappears from the residue. Then put all of the filtrate together, boil for about 20 minutes and make the volume up to 800 c.c.

Stain 12-mm. pigs for about 36 hours. Wash in water for 10 to 15 minutes; 50 per cent. alcohol, 20 to 30 minutes; 70 per cent., 1 hour; 80 per cent. Imbed in paraffin and cut in serial sections.

Counterstaining the sections in the solution of Orange G described with Heidenhain's iron hæmatoxylin will bring out the nerves beautifully. The paraffin is removed in xylol, the sections passed through absolute and xylol, absolute, and 95 per cent. to the stain. Wash in several changes of 95 per cent.; and pass back through absolute, and absolute and xylol, to xylol.

Borax carmine.

Borax.....	20 gm.
Carmine.....	30 gm.
Water.....	500 c.c.

Boil until everything is dissolved. Cool and add 500 c.c. of 70 per cent. alcohol. Let stand 24 hours and filter.

Stain a 12-mm. pig about 36 hours; water 10 to 15 minutes; 0.5 per cent. hydrochloric acid in 70 per cent., 30 minutes to 1 hour; 70 per cent. changed several times, 1 hour; 80 per cent. changed twice. Imbed in paraffin and cut in serial sections. The sections may be counterstained as directed under alum cochineal.

SELECTIVE STAINS.

Mallory's Phosphotungstic Acid Hæmatoxylin.

Hæmatoxylin.....	0.1 gm.
Water.....	80.0 c.c.
10 per cent. aq. sol. of phosphotungstic acid (Merck).....	20.0 c.c.

Dissolve the hæmatoxylin in a little water with the aid of heat; cool, and add to the rest of the solution. If the solution does not stain, it may

be ripened by the addition of 10 c.c. of $\frac{1}{4}$ per cent. aq. sol. of potassium permanganate.

Tissues must be fixed in Zenker's fluid. Sections are transferred from water to $\frac{1}{4}$ per cent. aqueous solution of potassium permanganate for 3 to 5 minutes, washed in water, and put for 5 to 10 minutes in 5 per cent. aqueous solution of oxalic acid. Wash thoroughly in several changes of water, and stain in the hæmatoxylin solution for 12 to 24 hours. Transfer directly to 95 per cent. alcohol for not more than 1 or 2 minutes, followed by absolute for paraffin sections. Clear in xylol, using the filter-paper blotting method for celloidin sections (see p. 508).

Neuroglia, myoglia, and fibroglia fibrils and fibrin are stained blue; collagen fibrils reddish-brown; mitotic figures well shown.

Mallory's Connective Tissue Stain.

Anilin blue soluble in water (Grübler).....	0.5 gm.
Orange G (Grübler).....	2.0 gm.
Phosphomolybdic acid, 1 per cent. aq. solution.....	100.0 c.c.

Paraffin or celloidin sections of material fixed in Zenker's fluid are transferred from water to a 0.2 per cent. aqueous solution of acid fuchsin for 5 to 20 minutes. Transfer directly to the anilin blue solution and stain for 20 minutes or longer. Wash in several changes of 95 per cent. alcohol. Clear celloidin sections in oil of origanum. Paraffin sections are passed through absolute, absolute and xylol, to xylol.

Fibrils of connective and reticular tissue, amyloid, and mucus stain blue; nuclei, cytoplasm, muscle, axis cylinders, and neuroglia fibers stain red; red corpuscles and myelin, yellow.

Weigert's Resorcin-fuchsin. Boil, in an evaporating dish, 2 gm. of fuchsin and 4 gm. of resorcin in 200 c.c. of water. When it is boiling briskly, add 25 c.c. of liquor ferri sesquichlorati. Stir and boil for 5 minutes. Cool and filter. Allow the precipitate to dry; return the filter paper with precipitate to the dry dish; add 200 c.c. of 95 per cent. alcohol and boil, stirring constantly. Fish out the paper. Cool and filter; add alcohol until the volume of 200 c.c. is reached and add 4 c.c. of hydrochloric acid.

From 95 per cent. alcohol the sections, preferably fixed in alcohol or formaldehyde, are transferred to the stain for 20 minutes to an hour. Wash in 95 per cent. Clear in xylol by the blotting method (p. 508).

The elastic fibers are stained a deep purple. The remainder of the tissue should be nearly or quite colorless. If other parts are affected, the sections should be washed in alcohol containing 0.5 per cent. of hydrochloric acid. A light nuclear stain with alum hæmatoxylin after the elastic tissue has been stained will increase the value of the specimen.

Scharlach R. Frozen sections of fresh or formalin fixed material are stained from 15 minutes to over night in a saturated solution of the

dye in 70 per cent. alcohol. The sections are transferred from water to the stain, which has been freshly filtered into a tightly closing vessel. Evaporation of the alcohol causes a precipitation of the staining material. Wash in water, stain the nuclei lightly with alum hæmatoxylin, and mount in glycerin. Fat and lipoids stain red.

Nile Blue. Frozen sections of fresh material or material fixed in formalin for not more than 12 hours are stained for 15 minutes to 2 hours in a saturated aqueous solution of Nile blue (Grübler). Wash in distilled water for 5 minutes or more, and transfer to tap water. If after 5 minutes in the tap water the section does not assume a reddish hue, add a small amount of alkali to the tap water. When the section is reddish, transfer to distilled water. Mount in glycerin or glycerin jelly and examine at once. Neutral fat red; lipoids blue.

Osmic Acid. Fat and myelin in fresh tissues may be blackened in a 1 per cent. aqueous solution of osmic acid. The myelin sheaths of teased nerve fibers may be so treated, the fragments dehydrated, cleared in chloroform, and mounted in chloroform damar. Sections may be prepared from tissues fixed in Marchi's fluid (p. 491), showing the fat blackened by the osmium. Use chloroform to remove paraffin from the sections, and mount in chloroform damar.

Wright's Blood Stain. After 0.5 gm. of sodium bicarbonate has been completely dissolved in 100 c.c. of distilled water, add 1 gm. of Grübler's methylene blue (either the form called BX, Koch's, or Ehrlich's rectified). "The mixture is next to be steamed in an ordinary steam sterilizer at 100° C. for 1 hour, counting the time after steam is up. The heating should not be done in a pressure sterilizer, or in a water bath, or in any other way than as stated." The mixture is then removed from the sterilizer and allowed to cool, the flask being placed in cold water if desired. When cold, it is poured into a large dish or flask. Add to each 100 c.c. of the methylene blue solution, stirring or shaking meanwhile, about 500 c.c. of a 0.1 per cent. solution of Grübler's yellowish eosin soluble in water. The eosin solution should be added until the mixture, losing its blue color, becomes purple, and a scum with yellowish metallic luster forms on the surface, "while on close inspection a finely granular black precipitate appears in suspension." The solution is then filtered and the precipitate allowed to become perfectly dry on the filter paper. The stain is made by dissolving 0.3 gm. of the precipitate in 100 c.c. of *pure* methyl alcohol. The stain need not be filtered, and like the precipitate, it keeps indefinitely. If by evaporation of the alcohol it becomes too concentrated, as shown by the formation of a precipitate when it is used, it should be filtered and a small quantity of methyl alcohol added.

Blood is obtained usually from a needle puncture in the lobule of the ear. A drop of blood is caught in the center of a perfectly clean dry

cover, and another clean dry cover is immediately dropped upon it. The blood should spread between the two cover glasses, forming a film which cannot be too thin. The covers are then drawn rapidly apart (they should slide along one another and not be lifted apart). The blood film dries from exposure to the air, and remains stainable for weeks.

To stain the blood film, the cover glass is to be held in cover-glass forceps with the film side uppermost. The stain is applied as follows:

1. Cover the preparation with a noted quantity of the stain by means of a drop-bottle or medicine dropper.

2. After 1 minute add to the staining fluid on the preparation the same quantity of distilled water, by means of the dropper, and allow the mixture to remain $2\frac{1}{2}$ minutes, not longer. Longer staining may produce a precipitate. The total quantity of diluted fluid on the preparation should not be so much that some runs off. A metallic scum forms when the stain is properly diluted, but the stain should not become transparent.

3. Wash the preparation in tap water for 30 seconds, or until the thinner portions of the film become yellow or pink. Disregard the thick parts, which are blue. The process of decolorizing may be watched through the microscope by placing the cover glass with film side uppermost on a slide.

4. Dry and mount directly in damar.

Silver Nitrate. Intercellular cement spaces and the boundaries of endothelial cells may be blackened by a $\frac{1}{8}$ to 1 per cent. aqueous solution of silver nitrate, which acts chiefly upon free surfaces. The fresh tissue should be kept flat, the mesentery, for example, being tied over a detached bottle neck, while it is immersed in the solution for 1 to 10 minutes. Transfer to distilled water, and expose to direct sunlight. As soon as it becomes brown, usually in 5 to 10 minutes, it is washed in 0.6 per cent. salt solution. If desired, the nuclei may be lightly stained in alum hæmatoxylin. Examine in glycerin, or dehydrate clear in xylol and mount in damar.

Blood vessels may be injected through glass tubes with the silver solution. Sections are made and exposed to the light, and the outlines of the endothelial cells become dark.

5. Clearing and Mounting.

CLEARING.

Before satisfactory permanent preparations can be obtained, the sections or object must be *cleared*. This is accomplished by infiltrating the tissues with substances which, by reason of their high index of refraction, render the tissues more or less transparent. Structures to be studied are previously stained and thus easily rendered prominent.

A variety of reagents with widely different chemical properties are used. Glycerin and acetate of potash are commonly used for frozen sections or teased preparations which, for any reason, cannot be mounted in damar.

The choice of a clearing agent for damar mounts depends chiefly on two factors, the kind of stain employed and the imbedding medium.

Xylol. This is the best clearing agent for use after aniline dyes. It clears only from absolute alcohol, through which celloidin sections cannot be passed, since it dissolves celloidin. However, it can be used for celloidin or other sections dehydrated in 95 per cent. alcohol by the following method. Blot the section on the slide with smooth, soft filter paper and pour on a few drops of xylol. Repeat the blotting, followed by xylol two or three times and the section will be perfectly clear. Paraffin sections attached to the slides are cleared by immersion in a vial of xylol; this has already been mentioned as the last step in the staining processes.

Oleum Origani Cretici. This clears readily from 95 per cent. alcohol without dissolving celloidin and affects aniline colors slowly. Although particularly recommended for clearing after celloidin imbedding, it is useful for all kinds of sections.

Carbol-xylol.

Carbolic acid crystals.....	1
Xylol.....	3

Used for clearing thick sections of the central nervous system after carmine and hæmatoxylin stains. Clears from 95 per cent. alcohol without affecting celloidin, but extracts the basic aniline dyes.

Chloroform. Since osmic acid reduced by fat is soluble in xylol, chloroform is used in cases where permanent mounts of such preparations are desired (as after fixation in Marchi's fluid).

MOUNTING.

Frozen sections which cannot be mounted in damar are mounted in glycerin, potassium acetate or glycerin jelly.

Glycerin Jelly. Soak 7 gm. of gelatin for about 2 hours in 42 c.c. of distilled water. Add 50 gm. of glycerin. Warm, stirring constantly for 10-15 minutes. Filter hot through moistened cotton.

Bring sections on a slide and blot off excess water. Put on a small piece of glycerin jelly and warm gently until it melts. Cover and cool.

Preparations mounted in any of these three substances may be rendered more or less permanent by coating the edges of the cover and adjacent surfaces of the slide with paraffin or wax.

Gum Damar. Of the two substances most commonly employed for permanent mounts, namely, Canada balsam and damar, the latter is preferable, since balsam turns yellow with age.

Colorless pieces of damar are dissolved in xylol and filtered. If the solution is too thin, evaporate to the proper consistence; if too thick, add more xylol. The proper consistence is that of a thin syrup.

A solution in chloroform should be prepared in similar manner for use with osmium preparations.

After paraffin sections have been cleared (3 to 5 minutes), the excess of clearing agent is drained away and the surface of the slide outside the sections is wiped off. The section must not be allowed to become dry. A drop of damar solution is placed at once upon the section and a cover glass is carefully lowered over it. With all preparations, whatever the mounting medium may be, the cover glass should be lowered in the following manner. It is held over the specimen and its left edge is first brought into contact with the slide; a needle held in the left hand holds this edge in position. Another needle held in the right hand with its point beneath the right edge of the cover enables one to have perfect control of the cover glass while it is being lowered. The contact between the cover glass and the mounting medium spreads gradually from left to right as the cover is lowered, expelling the air as it advances. If air bubbles are caught in the medium, the cover may be alternately raised and lowered a little until they escape, but once the cover is flat upon the specimen it should not be lifted. The cover glass should be somewhat larger than the specimen so as to extend beyond it on all sides.

Celloidin sections which have been cleared in oil are floated over the blade of a spatula placed in the oil, and are spread out flat upon it with the aid of a needle. They are then transferred to a clean glass slide, being pulled from the spatula with the needle. They should be moved to the exact center of the slide, if the preparations are to look well, and then the oil is removed by placing two thicknesses of filter paper over the section and pressing upon it quite firmly; at the same time the section is made smooth. A drop of damar is then placed upon the section before it dries, and the cover glass is applied as described in the preceding paragraph.

Damar mounts are then labelled and may be placed in a drying oven with a temperature of 35-40° C. They may be used after a few days, but the damar is not thoroughly hardened for a considerable time.

SLIDES AND COVER GLASSES.

Slides should be of colorless glass with ground edges. For ordinary use, slides measuring 1×3 inches (26×76 mm.) are preferable. Occasionally, as in mounting serial sections, or large sections of the central nervous system, wider slides are needed. Thick slides are preferable to thin ones.

For ordinary use, cover glasses 18–22 mm. square are sufficient. Occasionally, as in mounting serial sections or large specimens, oblong covers may be needed. If possible, no covers ranging outside of 0.15–0.18 mm. in thickness (No. 1 grade) should be used, since thicker covers (No. 2 grade) often prevent the oil immersion lens from being brought into focus. Many valuable sections have been destroyed in attempting to focus through thick cover glasses.

Clean the slides and covers by dipping in alcohol and drying with a soft crash towel or old linen handkerchief. Sometimes it may be necessary to wash them in 10 per cent. nitric acid, followed by a thorough washing in water and then in alcohol. Slides which remain hazy after thorough washing must be discarded.

INJECTIONS.

The courses of blood and lymphatic vessels and of ducts are studied by means of injections. Transparent, deeply colored fluid mixtures, which will harden in the vessels, are used. So-called “warm” injection masses, which contain gelatin, give more perfect results but are more difficult to use than “cold” injection masses.

A tapering glass or metal *cannula* is inserted into the vessel or duct, which is then tied securely around it. From a syringe connected with the cannula by a short rubber tube, the mass is then forced into the vessel. Pressure may also be obtained by having the injection mass in a receptacle which is connected with the cannula by a long flexible tube. The pressure is varied to suit the needs of the moment by raising and lowering the receptacle.

When a warm injection mass is being used, the bottle containing the mass must be placed in a water-bath and kept at a temperature of about 45° C. The organ or animal to be injected must also be placed in a water-bath of the same temperature.

Organs to be injected must be perfectly fresh; they may be left within the body or removed and injected separately. It is advisable to wash out blood vessels with warm salt solution or Ringer's solution before the injection.

It is important that in connecting the end of the tube carrying the injection mass with the cannula inserted into the vessel, no air bubbles be allowed to enter.

COLD INJECTION MASSES.

1. Blue Injection Mass.

Soluble Berlin blue.....	1
Distilled water.....	20

2. **Carminc Injection Mass.** Dissolve 1 gm. of carmine in 1 c.c. of strong ammonia plus a little water; dilute with 20 c.c. of glycerin. Add 1 gm. of common salt dissolved in 30 c.c. of glycerin. To the whole solution add an equal quantity of water.

WARM INJECTION MASSES.

1. **Berlin Blue.** Allow clear sheets of best French gelatin to swell up for 1 or 2 hours in double the quantity of water. Dissolve by warming gently over a water-bath and add, stirring constantly, an equal volume of a warm solution of Berlin blue prepared as directed above. Filter through flannel wrung out in hot water.

2. **Carminc.** This is the best injection mass to use, but it is very difficult to prepare. Dissolve 2 to 4 gm. of the best carmine in the required amount of ammonia. Filter and stir into 10 to 50 gm. of a filtered warm solution of gelatin, prepared over the water-bath as described above. Then add 25 per cent. acetic acid, drop by drop, stirring constantly, until the mass becomes bright red and loses its ammoniacal odor. If too much acetic acid is added a precipitate forms and the mass is spoiled. Filter through warm flannel.

Organs injected with a cold mass are put into 80 alcohol. After a few hours they may be cut into pieces. After injection with a warm mass, the specimen is put into cold water to hasten the solidification of the gelatin, and then transferred to 80 per cent. alcohol. Imbed in celloidin. Thick sections are necessary in order to follow the course of the vessels.

Prepared injection masses for use, cold or warm, are sold by dealers in microscopical supplies.

Many ingenious injection methods have been devised, such as the injection of small living embryos by allowing ink to enter the veins and be distributed through the body by the action of the heart; and vessels have been injected with milk, after which frozen sections were stained with Scharlach R.

SPECIAL METHODS.

The following special methods are included because of their fundamental importance. For the many other special methods which are occasionally of service, reference should be made to the works on technique mentioned at the beginning of this section.

Weigert's Method for Staining Myelin Sheaths. This is a method for the differential staining of the myelin sheath of nerve fibers and is much used in the study of the normal and pathological histology of the central

nervous system. As a result of some chemical reaction between myelin and a chrome salt, the myelin is fixed so that it does not dissolve in alcohol and ether, and at the same time is mordanted so that it stains deeply with hæmatoxylin.

1. Fix in a 10 per cent. aqueous solution of formalin for several days to several weeks, or indefinitely. Use a large quantity of fluid; change at the end of 24 hours and thereafter whenever it becomes cloudy.

2. Cut the tissue into pieces not over 1 cm. thick, and place in a 2.5 per cent. aqueous solution of potassium bichromate renewed each day for 3 or 4 days; then in a 5 per cent. solution renewed each day for 3 to 4 days.

3. Wash in running water for 24 hours (large pieces several days).

4. Transfer the tissues to the following solution (Weigert's second mordant) for 24 to 48 hours.

Acetate of copper.....	5.0 gm.
Acetic acid, 36 per cent. solution.....	5.0 c.c.
Fluorchrom.....	2.5 gm.
Water.....	100.0 c.c.

Boil the fluorchrom and water in a covered dish; turn off the gas and add the acetic acid and then the acetate of copper. Stir until the latter dissolves, and cool.

5. Wash in running water 24 hours or longer.

6. Dehydrate in graded alcohols and imbed in celloidin. Cut sections 20-25 μ thick.

7. Stain sections for 12 to 24 hours in:

Ripened 10 per cent. solution of hæmatoxylin in absolute alcohol.....	10
Saturated aqueous solution of lithium carbonate.....	1
Water.....	90

The hæmatoxylin is kept as a stock solution and combined with the carbonate of lithium and water at the time of using. Beautiful results may also be obtained by staining over-night or longer in Weigert's iron-hæmatoxylin (p. 502).

8. Wash in water.

9. Differentiate in the following solution:

Borax.....	2.0
Potassium ferricyanide.....	2.5
Water.....	100.0

It is advisable to dilute this solution with 1 or 2 volumes of water. After the first staining method, the gray substance of the sections appears yellow; after the iron-hæmatoxylin it is colorless.

10. Wash in running water 4 hours to over-night.

11. 95 per cent. alcohol, 3-5 hours (may be left over-night).

12. Fresh 95 per cent., 5 minutes.

13. Clear in carbol-xylol.

14. Mount in xylol damar.

Pal's Modification of Weigert's Stain. The tissue is fixed, mordanted and imbedded as directed in 1, 2, 3 and 6 above. Sections may be very much thicker.

7. Sections are placed for several hours in a $\frac{1}{2}$ per cent. aqueous solution of chromic acid, or for a longer time in a 2.5 per cent. solution of potassium bichromate. (May be omitted.)

8. Stain for 24 to 48 hours in:

Ripened 10 per cent. solution of hæmatoxylin in absolute alcohol.....	10
Water.....	90

9. Wash in water plus 1 to 3 per cent. of a saturated aqueous solution of lithium carbonate until the sections appear of a uniform deep blue color.

10. Differentiate for 20 seconds to 1 minute in a $\frac{1}{4}$ per cent. aqueous solution of potassium permanganate.

11. Place for a few seconds in the following solution, until the gray substance is colorless or nearly so:

Oxalic acid.....	1
Potassium sulphite.....	1
Water.....	200

12. Wash in water.

Repeat steps 10, 11 and 12 until the differentiation is complete. Then wash 4 hours or longer in running water.

13. 95 per cent. alcohol, 3 to 5 hours.

14. Fresh 95 per cent., 5 minutes.

15. Carbol-xylol. Mount in xylol damar.

Golgi's Method for the Impregnation of Nerve Cells. This method depends on the formation of a fine precipitate in certain tissue elements or in pre-existing spaces when the tissues are treated with a solution of potassium bichromate and then with a solution of silver nitrate or mercuric bichloride. The value of the method lies on the fact that it picks out here and there a cell and stains it with its processes more or less completely. This same fact renders the method very uncertain. Of the several modifications of this stain, only one—the so-called rapid method—is here given.

1. Pieces of fresh tissue about 5 mm. thick are placed for 3 to 8 days in the following solution:

Osmic acid, 1 per cent. solution.....	1 part
Bichromate of potassium, 3.5 per cent. solution.....	4 parts

2. Transfer to a large quantity of 0.75 per cent. solution of silver nitrate for 2 or 3 days.

Keep the tissues in the dark during treatment with both fluids.

The length of time the tissues should remain in the first solution depends on the elements it is desired to impregnate.

For the human cord, the time is approximately as follows: for neuroglia, 2-3 days; nerve cells, 3-5 days; for nerve fibers and collaterals, 5-7 days.

3. Cut sections 50 to 100 μ thick. They may be made free-hand or with a microtome. Blocks may be quickly imbedded by dehydrating for a few minutes in absolute alcohol, and placing in a thick solution of celloidin for about 5 minutes. Harden in 80 per cent.

4. Sections are dehydrated quickly in alcohol.

5. Clear in oil of cloves or bergamot.

6. Mount without a cover glass in xylol damar and dry quickly at 40° C. Protect the sections from the light and dust as much as possible.

If the method is unsuccessful, the specimens may be transferred back to an osmic acid and bichromate mixture containing less osmic acid, and after several days again placed in the silver nitrate solution for 24 to 48 hours.

II. THE EXAMINATION OF MICROSCOPICAL SPECIMENS.

THE MICROSCOPE.

It is unfortunate that the price of a microscope is prohibitive to many medical students, and that some who might purchase instruments at the beginning of their work wait until later. The cost is now so reduced that an increasing proportion of students can enjoy the advantage of having a microscope of their own.

Microscopes of a certain grade are required, and if they cannot be afforded, no instrument should be bought. The necessary equipment, as shown in the figure, is a stand with fine and coarse adjustments ("micrometer screw" and "rack and pinion"), and a large square stage. The more expensive round and mechanical stages are not necessary, and since mechanical stages are detachable, they may be obtained later if desired. There should be an Abbé condenser (with iris diaphragm), a triple revolver, a high and a low eyepiece or ocular, and the following objectives: a 16-mm. ($\frac{2}{3}$ -inch) and a 4-mm. ($\frac{1}{6}$ - or $\frac{1}{8}$ -inch) which must be parfocal; together with a 2-mm. ($\frac{1}{2}$ -inch) oil immersion, for cytological and bacteriological work; and a 48-mm. (2-inch), which is a very low power, for embryological work. The figures indicate the distance of the section from the objective when the specimen is in focus; the higher the power, the nearer the objective is brought to the object. The 2-mm. oil immersion is an expensive objective, and its purchase may be postponed. The 2-inch is a cheap objective which is very useful in obtaining a view of an entire section, and for embryological reconstructions it is essential. It may be noted that microscopes are now being finished more extensively in black enamel than in lacquered brass; the former is not damaged by alcohol and is more desirable. Improvements have also been made in the post and fine adjustment, so that the form shown in the figure, although good, is not the best.

Satisfactory microscopes of American manufacture are now made but all agree that the Zeiss microscopes (German) are the best (and most expensive). If the microscope is purchased by a student unfamiliar with its use, it is well to have the lenses examined by a disinterested microscopist.

For a description of the nature and use of the microscope, the student is referred to the 11th edition of "The Microscope," by Professor S. H. Gage (Comstock Pub. Co., Ithaca, N. Y.).

For the sake of emphasis it may be said that the microscopist works with his right hand upon the fine adjustment and his left hand upon the

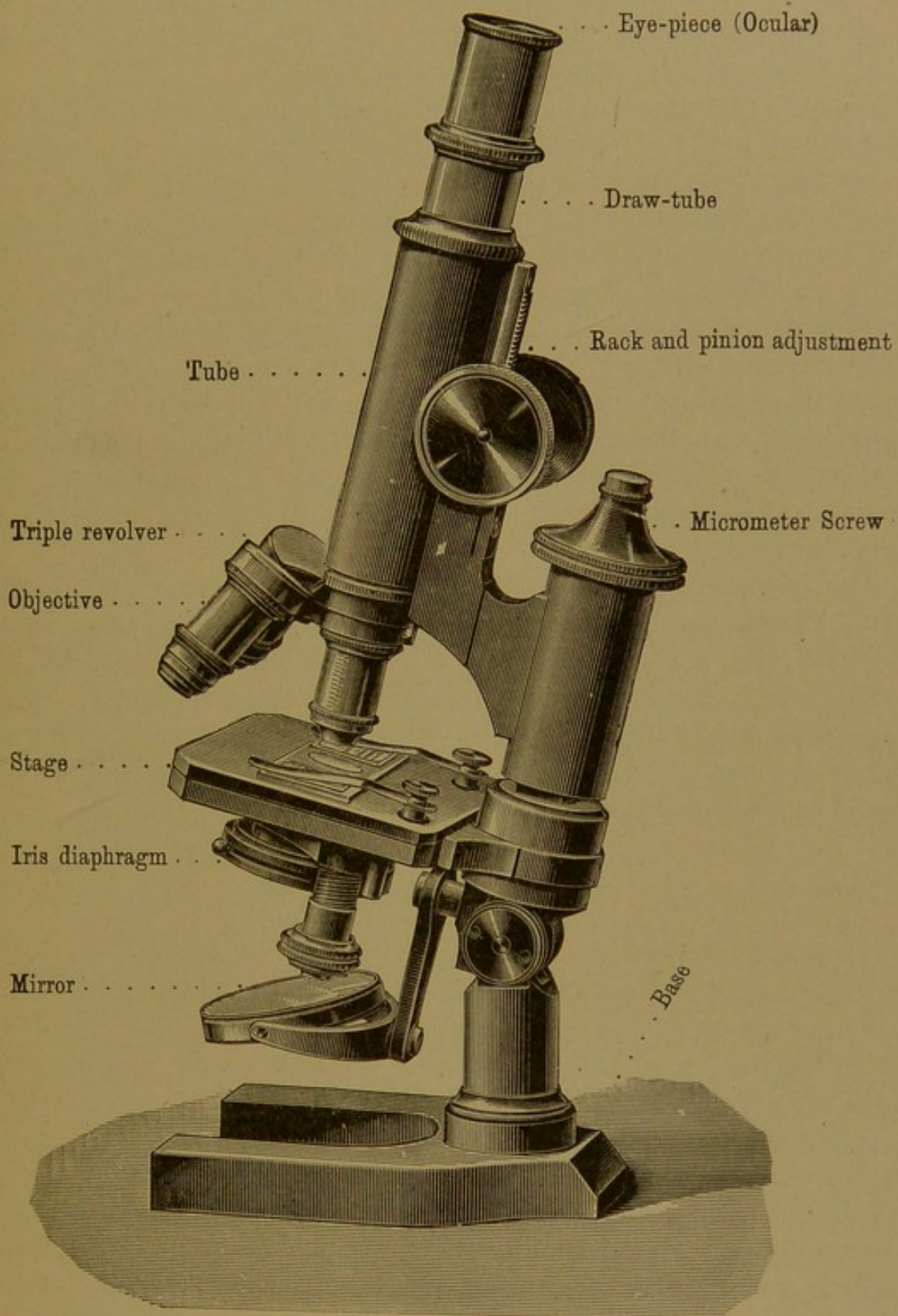


FIG. 493.

slide. As the latter is moved about, bringing different fields into view, the focussing is done with the adjustment and not with the eyes. It is impossible to study even a single field without constantly changing the

focus, and the continuous use of the fine adjustment distinguishes an experienced microscopist from a beginner. Both eyes should be open (as will be natural after becoming accustomed to the instrument). Often one acquires the habit of using only the right or the left eye for microscopic work, but it is better to learn to use both.

Always examine a specimen first with a low power objective and then with a high power. In focussing the microscope, have the objective drawn away from the slide and focus down. This should be done *cautiously*, with a portion of the specimen actually beneath the lens; if there is only cover glass and damar there, the objective will probably be driven down upon the slide. Unless one is sure that stained tissue is in the field, the slide should be moved back and forth as the objective is being lowered.

In working with the Abbé condenser, the flat surface of the mirror should be uppermost, provided that it is used in daylight and the rays falling upon it are therefore parallel; but for the divergent rays of an artificial light near at hand, the concave mirror may be used, and the light may advantageously be made to pass through a blue glass, which lessens the yellow glare.

The objectives must never be scratched. Lens paper or fine linen should be used to wipe them. If they are soiled with damar they should be wiped with a cloth moistened with xylol, but since the lenses are mounted in balsam, xylol must be applied to them cautiously. A microscope of the kind shown in the figure should never be lifted by any part above the stage, lest the fine adjustment be damaged; the pillar should be grasped below the stage.

RECONSTRUCTIONS.

There is an important arrangement of mirrors (Abbé's camera lucida) for drawing the outlines of sections. It is attached to the microscope above the eye-piece, and on looking into it one can see the image of the section beneath the objective apparently spread upon the drawing paper beside the microscope. Thus the pencil point can be seen as it is made to trace the outline on the paper. With a little practice the same result may be obtained more or less perfectly without the camera, by looking into the microscope with one eye and at the same time upon the paper with the other. This possibility was noted by the early microscopists, and it is a useful accomplishment. More satisfactory than the camera lucida is the projection apparatus of Edinger, arranged with an arc light, whereby the image of the section is projected through an inverted microscope upon the drawing paper beneath. With the camera, or projection apparatus, a succession of serial sections may be drawn with the uniform magnification essential for reconstructions. The magnification is deter-

mined by substituting a stage micrometer for the slide of sections. The micrometer is a slide upon which 1 mm., with subdivisions into twentieths or hundredths, has been marked off by scratches in the glass; the subdivisions may be drawn with the camera, under the same conditions as the sections, and the enlargement of the subdivisions may then be measured.

From the camera-drawings of serial sections, *wax reconstructions* of various embryonic organs or small structures in the adult can be built up. If the sections are 10 μ thick and alternate sections have been drawn, magnified 50 diameters, then, on the scale of the drawings, these alternate sections are 1 mm. apart. Wax plates 1 mm. thick are therefore to be made, either by rolling beeswax, or by spreading a weighed amount of melted wax in a pan of hot water. It floats and spreads in an even layer, solidifying as the water cools. The outlines of the drawings are then indented upon the wax plates, and the desired portions are cut out and piled up to make the model. In this way reconstructions like those of the ear (p. 466) may be made. This method was first employed by Born. Further details of the process should be learned from demonstrations in the laboratory.

Graphic reconstructions (first used by His) are generally side views of structures, made from measurements of their transverse sections. Fig. 176, p. 185, is from such a reconstruction. A camera drawing of the side of an embryo (or other structure) is made before it is sectioned. The outline of this drawing is enlarged, and parallel lines, equally spaced, are ruled across it, corresponding in number and direction with the sections into which it was cut. Often only every other section, or every fourth section, is used for the reconstruction, and the number of lines to be ruled across the drawing is correspondingly reduced. Camera drawings of a lateral half of every section to be used in the reconstruction are then made, and across each drawing two lines are ruled. The first follows the median plane of the body; and the second is at right angles with it, being drawn so as to touch the dorsal or ventral surface of some structure to be included in the reconstruction. Provided that the camera drawings and side view have been enlarged to the same extent, the perpendicular distance from the middle of the back to the junction of the two lines is marked off in the side view, on the line corresponding with the section in question. The perpendicular distances from the second line to the dorsal and to the ventral surfaces of all structures to be reconstructed, are also marked off upon the line on the side view. The same is done in the following section, and the points belonging with a given structure are connected from section to section. Thus the outlines of the organs are projected upon the median plane; two dimensions are accurately shown but the third is lost.

Often it is undesirable to attempt to make the magnification of the

sections and of the side view identical; the measurements may be enlarged or reduced as they are transferred for plotting, by means of the draughtsman's *proportional dividers*, an indispensable instrument for this method of reconstruction. The corrections for unequal shrinkage of the sections in paraffin, and other details, can best be explained in the laboratory with the drawings at hand.

In addition to making side views, this method may be used in reconstructing ventral or dorsal views, by plotting outward from the median line.

DRAWINGS.

Since anatomy, both gross and microscopic, is a study of forms and relations, that is of things seen, it finds natural expression in drawing; and the volumes of wood-cuts, copper-plates, and lithographs, together with the cheaper process-drawings and half-tones of the present day, form almost as important a part of anatomical literature as the accompanying text. Often there may be shown in a figure at a glance what pages of writing fail to make clear; and it is significant that the great books of Vesalius, which marked a new era in anatomy, were illustrated by Jean de Calcar, a pupil of Titian. Burggraave believes that Vesalius doubtless supplied preliminary sketches and adds—"Almost all the great anatomists were no less excellent draughtsmen—Scarpa and Cuvier furnish us remarkable examples—and one can hardly imagine an anatomist who is not deeply sensitive to the beauty and harmony of contours and forms." Selenka (1842-1902) drew the ape embryos, which he collected and described, with consummate skill, and "always impressed upon his students the great value of a ready pencil." Robert Hooke (1635-1703) was far less successful with his drawings. In the preface to his fully illustrated microscopical observations, he makes the following explanation of the defects of his plates, and in conclusion sets an example which all students should follow. He says—

"What each of the delineated Subjects are, the descriptions annexed to each will inform, of which I shall here, only once for all, add, that in divers of them the Gravers have pretty well followed my directions and draughts; and that in making of them, I indeavoured (as far as I was able) first to discover the true appearance, and next to make a plain representation of it."

To discover the true appearance of each section and to make a plain representation of it, is by far the best method for beginning the study of histology, and conscientious attempts to represent what is seen invariably lead to deeper and more valuable observations. Thus drawings are unhesitatingly required of all students, and every effort should be

made to acquire some skill in this direction. The problem of the microscopist, who has but little to do with the third dimension, is relatively simple. A few suggestions may be given.

Generally sections are stained in different colors, and the question at once arises how to represent these with the pencil. The accompanying




FIG. 494. DIAGRAMS SHOWING THE WAY IN WHICH THE SHADE VALUES OF THE PRIMARY SECONDARY AND TERTIARY COLORS MAY BE REPRESENTED IN TERMS OF BLACK AND WHITE. (Lee, in Hardesty's "Laboratory Guide;" Blakiston, 1908.)

figures indicate the way in which this is done, the primary colors being shown in the inner ring, and their combinations in the outer rings. Red being a brighter color than blue is to be made lighter. Orange, a combination of the two brightest of the primary colors, should be lighter than

purple—a combination of the darkest—and lighter than pure red since it has the brighter yellow mixed with it. Thus the various colors may be suggested in black and white, and the contrast between blue nuclei and red protoplasm can be carefully preserved in the drawing. This is facilitated by the use of pencils of varying degrees of hardness—"H" and "3 H" for dark structures, and "6 H" for pale areas. Soft pencils, which rub, should not be used.

Before beginning a drawing, the specimen should be carefully looked over, to find the place most worthy of such attention. The time which the drawing is to take must be considered, and a small area may be found which combines features elsewhere scattered about the specimen. The entire field is rarely, if ever, to be drawn; and the figures should not be encumbered with surrounding circles.

The magnification of the drawing is next to be decided upon. The form of a gastric gland and the structure of its cells, for example, cannot profitably be included in a single drawing. General features, such as the forms of glands, should be represented in "low power" sketches. "Low power" as here used does not necessarily refer to the lenses employed, but means that the drawing is on such a scale that the nuclei appear merely as spots, round or elongated as the case may be. Often, however, such a drawing shows features which can be clearly observed only with high power lenses. "High-power drawings" are those which present details of nuclear and protoplasmic structure.

Usually in studying an organ, it is desirable to make a general low-power sketch showing the arrangement of its lobules or layers, and to supplement this by high-power drawings of the most significant cells or tissues. In these, which are the final test of a student's keenness of observation, no details of cellular structure are too minute for careful representation, and "the difficulty of observing them proves not the merit of overlooking them."


Having selected a field and decided upon the magnification, the outlines of the parts should be sketched lightly, with a soft pencil, and corrected until accurate. As finally made, they should be definite clean lines, not pieced out, representing the boundaries of layers, nuclear membranes, cell walls when present, cuticular surfaces, and the like. Having completed the outline, shading should be undertaken, to differentiate substance from empty space, and to indicate the nature of the substance. In high-power drawings protoplasmic texture must be faithfully reproduced—homogeneous, finely granular or coarsely granular; if the granules are not distinct enough to be counted, they should not be readily countable in the drawing. If definite walls are absent from the specimen, they should not be drawn, but the shaded areas of the finished drawing should end abruptly without a bounding line.

Drawings consist, therefore, of two parts—outline, and shaded texture or finish. Ruskin observes that the real refinement of the outline depends on its truly following the contours, and in regard to finish he offers suggestions which may be applied to the drawings of the wall of the medullary tube here reproduced. He states that if we are to “finish” farther, we

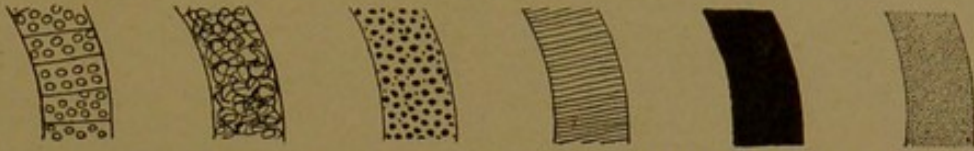

FIG. 495. THE WALL OF THE MEDULLARY TUBE, AS DRAWN BY SIX STUDENTS.

must *know* more or *see* more about the object. These sketches are not finished in any sense but this, that the paper has been covered with lines. A piece of work is more finished than others, not because it is more delicate or more skillful, but simply because it tells more truth. “That which conveys most information, with least inaccuracy, is always the highest finish.”



INDEX

A

Abducent nerve, 141, 424
 Absorbents, 183
 Absorption, intestinal, 264
 Accessory chromosome, 23
 duct of pancreas, 290
 nerve, 142, 424
 Acervulus cerebri, 438
 Acetic acid, 488
 Acidophiles, 197
 Acinus, 58
 Acoustic meatus, external, 481; internal, 477
 nerve, 141, 476
 Adamantoblasts (*ameloblasts*), 103
 Addison, on suprarenal glands, 405
 Adelomorphous cells (*chief cells*), 254
 Adenoid tissue, 207
 Adipose tissue, 72
 Adrenalin, 406
 Aggregate nodules, 268
 Agminated nodules (*aggregate nodules*), 268
 Ahlfeld, on the allantois, 381
 Albumen, for attaching sections to slides, 497
 Alcohol, for fixation, 490
 Allantois, 245, 368, 373, 381
 Allen, on tubules of the testis, 327
 sexual cells, 335
 ovary, 358
 Alum cochineal, 503
 hæmatoxylin, 500
 Alveolar ducts, 301
 sacs, 302
 Alveolus, 58
 of the lungs, 301
 of the pancreas, 291
 of the teeth, 99
 Amakrine cells, 446
 Ameloblasts, 103
 Amianthoid fibers, 80
 Amitosis, 13
 Amnion, 366, 373
 Amniotic cavity, 367
 fluid, 370
 villi, 382
 Amœboid motion, 11
 Amphiaster, 17
 Ampulla, of the ductus deferens, 342
 of the semicircular ducts, 466
 of the uterine tubes, 358
 Ampullary nerves, 476
 Anal canal, 273
 membrane, 247
 Anaphase, 18
 Angioblast (*angioderm*), 43, 367
 Anisotropic substance in muscle, 123
 Annuli fibrosi, 176, 178
 Anterior neuropore, 37
 Anus, 247
 Aorta, 165
 in young embryos, 44
 Aortic arches, 219

Apáthy, on myofibrils, 128
 neurofibrils, 146
 Appendices epiploicæ, 273
 Appendix epididymidis, 300, 344
 fibrosa hepatis, 280
 testis, 327, 344
 vesiculosa, 351
 vermiformis (*processus vermiformis*), 270
 Aponeuroses, 77
 Aquæductus cerebri, 422
 cochleæ, 477
 vestibuli, 469
 Aqueous humor, 442
 Arachnoid membrane, 414, 439
 granulations, 439
 Archoplasm, 6
 Areola, 404
 Areolar glands, 404
 tissue, 65
 Aristotle, on blood vessels, 163
 generation, 365
 Arnold, on ovarian follicles, 356
 Arrector pili, 386, 391
 Arteria centralis retinae, 440, 460
 Arteriæ helicinae, 348
 Arteries, 168
 Arterioles, 168
 Articular cartilage, 92, 97
 discs, 98
 Aschoff, on the atrio-ventricular bundle, 180
 Aselli, on lymphatics, 182
 Association fibers, 132
 Aster, 15
 Atretic follicles, 358
 Atria, of the heart, 175
 of the lungs, 302
 Atrio-ventricular bundle and node, 180
 Attraction sphere, 6
 Auditory nerve (*acoustic nerve*) 141, 476
 teeth, 473
 tube, 217, 469, 479
 vesicle, 465
 Auerbach's plexus, 138, 248, 249
 Auricle, 469
 of the heart, 175
 Automatic system, 139
 Autonomic system, 139
 Avicenna, on the intestine, 247
 hypophysis, 436
 Axial filament, 337
 Axis cylinder, 145
 Axolemma, 156
 Axon, 134
 Azygos veins, 310

B

Badertscher, on eosinophiles, 198
 v. Baer, on ova, 366
 Baldwin, on muscle cells, 122, 124
 tendon, 127, 128
 Balsam, 507

- Bardeen, on the development of muscle, 119
 myelin, 156
 sheath cells of non-medullated nerves, 154
- Bartholin, on the ovary, 365
 suprarenal glands, 404
 pituitary gland, 436
 vestibular glands of Bartholin, 383
- Basal body, 7
- Basement membrane, 53
- Basophile cells, 69
- Begg, on the vitelline veins, 279
- Bell, on the nerves, 134
- Bell, E. T., on the thymus, 224
- Bensley, on the pancreas, 291, 294
- Berlin blue, for injections, 510
- Berry, on intestinal villi, 260
- Bertini, columns of (*renal columns*), 315
- Bichat, on the nervous system, 139
- Bicuspid valve, 176
- Bidder, on bone, 92
- Bile capillaries, 285
 ducts, 278, 288
- Bipolar nerve cells, 143
- Bladder, 324
 development, 245
- Blast, 67, 367
- Blood, 188
 crystals, 194
 destroying organs, 202
 forming organs, 202
 islands, 43
 pigments, 194
 plasma, 188
 plates (or platelets), 188, 199
 red corpuscles, 188
 stains for, 505
 vessels, 163
 white corpuscles, 188, 195
- Blue injection masses, 509
- Body cavity, 36
 stalk, 369
- Bone, 83
 blood vessels, 96
 cartilage replaced by bone, 87
 cells, 84
 compact, 87
 corpuscles, 85
 decalcification, 492
 development, 84
 endochondrial, 90
 growth, 91
 lacunæ, 85
 lamellæ, 92
 marrow, 202
 membrane bones, 83
 nerves, 96
 perichondrial, 90
 spongy, 87
- Borax carmine, 503
- Border fibrils, 64, 114
- Born's method of reconstruction, 517
- Bouin's fluid, 490
- Bowman, on the sarcolemma, 121, 122
- Bowman's capsule (of the renal glomeruli), 317
 glands (*olfactory glands*), 485
 membrane (of the cornea), 456
- Brachium conjunctivum, 423, 427
 pontis, 423, 427
- Brain, 418
 cerebellum, 427
 early development, 37; later development, 418
 hemispheres, 431
 hypophysis, 435
 medulla oblongata, 424
 meninges, 438
 pineal body, 437
 pons, 423
- Branchial arches, 230
 clefts, 216, 217
- Bremer, on development of blood vessels, 43, 186
 pulmonary arteries, 297
 tubules of the testis, 328, 334
- Bridges, intercellular, 53
- Bronchi, 299
- Bronchial arteries, 297
 glands, 300
 veins, 297
- Bronchioles, 300
 respiratory, 301
- Brown, on pulmonary veins, 297
- Brownian movement, 12
- Brunner's glands (*duodenal glands*), 259
- Brush border, 50, 318
- Bryce and Teacher's embryo, 368
- Bulbous corpuscles, 161
- Bulbo-urethral glands, 347
- Bulbus analis, 247
 coli, 246
 urethræ, 348
 vestibuli, 383
- Bullard, on granules in muscle, 124
- Bundle of His, 180
- Burdach, on sympathetic system, 139
 column of, 412
- Bursæ, 77

C

- Cæcum, 246, 272
 cupulare, 467
 vestibulare, 467
- Cajal, on the growth of nerves, 136
- Call-Exner bodies, 355
- Calvert, on lymph glands, 209
- Calyx, renal, 312
- Camera lucida, 516
- Canada balsam, 507
- Canal of Gärtner, 351
 of Schlemm, 460
- Canaliculi, of bone, 85
 of the cornea, 458
- Canalized fibrin, 378
- Capillaries, 164, 167
 bile, 285
 secretory, 57
- Capsula fibrosa hepatis, 278
- Capsule, Bowman's, 317
 of cartilage cells, 78
 Glisson's, 278
 internal, 431
 of joints, 97
 of the kidney, 315
 of the lens, 441, 452
 of the liver, 278
 of the spleen, 214
 Tenon's (*interfascial space*) 460

- Carbol-xylol, 507
 Cardia, 251
 Cardiac ganglion, 182
 glands, of the cesophagus, 248
 of the stomach, 253
 muscle, 113, 128
 plexus, 138
 Cardinal veins, 309
 Carmine, for injections, 510
 Carnoy's mixtures, 390
 Cartilage, 77
 articular, 92, 97
 elastic, 80
 epiphyseal, 91
 fibro-cartilage, 81
 growth, 78, 79
 hyaline, 80
 Caruncula lacrimalis, 463
 Celloidin sections, 498
 imbedding in, 495
 Cells, 1
 amakrine, 446
 amœboid motion, 11
 basket, 292, 402, 429
 basophile, 69
 centro-alveolar (or centro-acinal), 292
 chromaffin, 152, 406
 chief (of gastric glands), 254
 Claudius's, 475
 decidual, 374
 Deiter's (of the cochlea), 474
 differentiation, 9
 division, direct, 13; indirect, 14
 egg, 354
 eosinophilic, 69
 ependymal, 413
 epithelial, 48
 fat, 73
 form, 8
 formation, 12
 germ, 20, 334
 giant, of the bone marrow, 200, 202
 glia (neuroglia), 64, 414, 434
 goblet, 56
 Hensen's (in the cochlea), 475
 Kupffer's (in the liver), 287
 lutein, 358
 mast, 69, 197
 mitral, 486
 mucous, 237
 neuroglia, 64
 olfactory, 484
 Paneth's, 262
 parietal, 255
 pigment, 71, 72
 pillar (of the cochlea), 474
 plasma, 68, 70
 polymorphonuclear, 196
 Purkinje's, 429
 pyramidal, 431
 "resting wandering," 71
 Retzius's, 431
 serous, 237
 Sertoli's, 335
 sexual, 20, 334
 size, 9
 squamous, 49
 tactile, 157
 taste, 235
 Cells, visual, 444
 vital phenomena, 11
 wall or membrane, 7
 Cellulæ pneumaticæ, 479
 Cement (*substantia ossea dentis*), 99, 111
 intercellular, 10
 Central nervous system, 130, 409
 Centro-alveolar cells, 292
 Centrosome, 6, 17, 33
 Cerebellum, 423, 427
 Cerebral hemispheres, 431
 nerves, 139, 424
 Cerebro-spinal fluid, 414
 tracts, 425
 Ceruminous glands, 481
 Cervical glands (of the uterus), 361
 sinus, 217
 Chambers of the eye, 460
 Chief cells (of the stomach), 254
 Chloroform, 507
 Choana, 481
 Chondrioconta, 63, 121
 Chondriosomes, 63
 Chondromucoid, 78
 Chorda dorsalis, 38
 Chordæ tendineæ, 176, 178
 Chordoid tissue, 82
 Choriocapillaris, 453
 Chorioid (coat of the eye), 442, 453
 plexuses, 439
 Chorion, 366, 371, 373
 frondosum, 371, 375
 læve, 371, 373
 villi, 375
 Chromaffin cells, 152, 406
 organs, 152
 Chromatin, 5
 Chromatocytes, 72
 Chromatolysis, 10
 Chromatophores, 71
 Chromosomes, 15, 19
 accessory, 23
 individuality, 20
 number, 19
 Chyle, 264
 Chyme, 264
 Cilia, 7, 50
 (eyelashes), 461
 Ciliary arteries, 458
 body, 454
 glands, 461
 muscle, 454; (of Rioloanus), 462
 nerves, 460
 processes, 454
 Circumanal glands, 276
 Circumvallate papillæ (or vallate), 230, 231
 Cisterna chyli, 183
 Clark, E. F., on amitosis, 13
 E. R., on lymphatics, 184
 J. G., on ovarian vessels, 353
 Clarke, column of, 427
 Claudius's cells, 475
 Clasmatoocytes, 71
 Clearing sections, 506
 Clitoris, 353, 383
 Cloaca, 245
 Cochlea, 471
 scala tympani, 468
 vestibuli, 468

- Cochlear artery, 476
 duct, 467, 471
 nerve, 476
 Cœlom, 36
 extraembryonic, 368
 Cohn, on ameloblasts, 103
 on interstitial cells of the ovary, 358
 Cohnheim's areas, 120
 Coil glands (sweat glands), 398
 Collagen, 62
 Collateral nerve fibres, 131, 144
 Collecting tubules, of the kidney, 312, 319
 Colliculi, 422
 Colloid, 227
 Coloboma, 442
 Colon, 246, 272
 Colostrum, 402
 Column, of Bertini, 315
 of Burdach, 412
 of Clarke, 427
 of Glisson, 274
 of Goll, 412
 of Morgagni, 274
 rectal, 274
 renal, 315
 spinal cord, 411
 Commissural fibers, 132
 Commissures of the spinal cord, 411
 Common bile duct, 278, 288
 Conchæ, 481
 Concretions, prostatic, 345
 Cone cells, 445
 Conical papillæ, 230, 231
 Conjunctiva bulbi, 443, 462
 corneæ, 463
 palpebrarum, 443
 scleræ, 463
 Conklin, on cleavage centrosomes, 34
 Connective tissue, 43, 65
 cells, 67
 fibers, 65
 stains, 504
 Contour lines, in dentine, 108
 in enamel, 105
 Convoluted tubules, of the kidney, 313
 of the testis, 334
 Corium, 384, 385
 Cornea, 442, 456
 Corona radiata, 356
 Coronary ligament, 278
 sinus, 177
 sulcus, 175
 Corpora cavernosa clitoridis, 383
 cavernosa penis, 348
 mamillaria, 421
 quadrigena, 422
 Corpus albicans, 358
 callosum, 421
 cavernosum urethræ,
 hæmorrhagicum, 357
 luteum, 356; luteum spurium, 358
 spongiosum, 326
 Corpuscles, articular, 151
 blood, red, 188; white, 188, 195
 bone, 85
 bulbous (of Krause), 161
 colostrum, 402
 corneal, 458
 cylindrical, 161
 Corpuscles, genital, 161
 Golgi-Mazzoni, 401
 Hassall's, 225
 lamellar, 161
 Malpighian (renal) 315; (splenic), 211
 nerve, 160
 Pacinian, 161
 renal, 315
 salivary, 220
 splenic, 211
 tactile (of Meissner), 160
 thymic, 225
 Corpuscula amygdalacea, 438
 Cortex, 205
 cerebral, 431
 Corti, organ of, 472, 474
 Cotyledons of the placenta, 379
 Councilman, on plasma cells, 70
 Cover glasses, 508
 Cowper, on the stomach, 251
 glands of, 347
 Cranial nerves, 139, 424
 Crenated red corpuscles, 194
 Crescents of serous cells, 237
 Crile, on Nissl's bodies, 3
 Cristæ ampullares, 467
 Crypts of Lieberkühn, 260
 Cumulus oöphorus, 355
 Curran, on the atrio-ventricular bundle, 180
 Cushing, on the hypophysis, 435, 436
 Cuticula, 7, 50
 dentis, 105
 Cutis, 384
 Cuvier, duct of, 309
 Cylindrical corpuscles, 161
 Cystic duct, 288
 Cytoblastema, 12
 Cytogenetic glands, 58
 Cytomorphosis, 9
 Cytoplasm, 2

D

- Dalenpatius, on spermatozoa, 338
 Damar, 507
 Davis, on spermatogenesis, 21-23, 25, 27
 Decalcification, 492
 Decidua basalis, 371
 capsularis, 371
 reflexa, 371
 serotina, 371
 vera, 371, 373
 Decidual cells, 374
 membranes, 366
 Decussation of the lemnisci (sensory), 426
 of the pyramids (motor), 425
 Deiters, on nerve cells, 145
 cells of cochlea, 474
 Dekhuyzen, on red corpuscles, 191
 Delafield's hæmatoxylin, 500
 Demilunes, 237
 Dendrite, 143
 Dental canaliculi, 107
 cavity, 99
 fibers, 107
 groove, 102
 lamina, 100
 papilla, 101, 107
 pulp, 99, 110
 sac, 110

Dentine, 99, 107
 contour lines, 108
 Dermomyotome, 41, 118
 Descartes, on epigenesis, 339
 pineal body, 438
 Descemet's membrane (of the cornea), 458
 Deuteroplasm, 29
 DeWitt, on the atrio-ventricular bundle, 180
 Diaphragm, 174
 Diaphysis, 91
 Diarthrosis, 96
 Diaster, 18
 Diemerbröck, on the suprarenal gland, 405
 Diencephalon, 421
 Digestive tube, 245
 layers, 248
 Dilator muscle of the pupil, 456
 Diplosome, 7
 Discus proligerus, 355
 Dispireme, 18
 Diverticulum ilei, 247
 Downey, on plasma cells, 71
 Drawing of specimens, 518
 Ducts, 56
 aberrant, of epididymis, 330
 aberrant, of the liver, 280
 alveolar, 301
 Bartholin's (*sublingual*), 242
 cochlear, 467, 471
 common bile, 278, 288
 Cuvier's, 309
 cystic, 288
 efferent, 329
 ejaculatory, 329, 343
 endolymphatic, 465
 Gärrelia's, 351
 hepatic, 288
 intercalated, 58, 240, 292
 Müllerian, 327, 349
 perilymphatic, 478
 Santorini's (*accessory pancreatic*), 290
 semicircular, 465, 470
 Stenson's (*parotid*), 238
 thoracic, 183
 utriculo-saccular, 467
 Wharton's (*submaxillary*), 242
 Wirsung's (*pancreatic*), 291
 Wolffian, 306, 307
 Ductuli efferentes, 329
 Ductus arteriosus, 296
 deferens, 329, 342
 epididymidis, 329
 reuniens, 467
 venosus, 279
 Dujardin, on red corpuscles, 191
 Duodenum, 246, 259
 Dura mater cerebri, 438
 spinalis, 413
 Dyads, 24

E

Ear, 465
 external, 480
 internal, 470
 middle, 478
 nerves, 476
 stones, 471
 vessels, 476

v. Ebner, on enamel prisms, 107, 108
 red corpuscles, 191
 Ectoderm, 35, 36
 derivatives, 45
 Efferent ducts (of the testis), 339
 Egg cells, 354
 Ejaculatory ducts, 329, 343
 Elastic cartilage, 80
 fibers, 66
 stain for elastic tissue, 504
 Elastin, 66
 Eleidin, 388
 Embryos, human, earliest stages, 1366
 preservation of, 491; see also *Bouin's fluid*, 490
 Enamel, 99, 104
 organs, 100, 102
 prisms, 104
 pulp, 102
 End bulbs (Krause's), 161
 discs, 149
 organs (of Ruffini), 160
 Endocardium, 178
 Endochondrial bone, 90
 Endolymph, 467
 Endolymphatic duct, 465
 sac, 465, 478
 Endometrium, 360
 Endoneurium, 154
 Endoplasm, 3
 Endosteum, 91
 Endothelium, 43, 46
 Entoderm, 35, 38
 derivatives of, 45
 Entodermal tract, 215
 Eosin, 500
 bodies, 428
 Eosinophiles, 69, 197
 Ependyma, 409, 418
 Epicardium, 178, 181
 Epidermis, 36, 384, 386
 Epididymis, 329, 339
 Epigenesis, 339
 Epiglottis, 230
 Epineurium, 154
 Epiphysis, of bone, 90
 of the brain, 437
 Epithelioid glands, 58
 Epithelium, 42, 46
 basement membrane, 53
 bridges, 53
 cilia, 50
 columnar, 48
 cuboidal, 48
 cuticular border, 50
 differentiation of cells, 50
 false, 47, 98
 glands, 54
 membrana propria, 53
 mesenchymal, 47, 98
 neuro-epithelium, 130
 pseudo-stratified, 50
 simple, 48
 secretion, 54
 stratified, 48
 terminal bars, 52
 transitional, 324
 Epitrichium, 384
 Eponychium, 389

Epoöphoron, 50
 Equational division, 24
 Equatorial plate, 15
 Erasistratus, on lymphatics, 182
 Erectile tissue, 348
 Ehrlich, on mast cells, 69
 Erythroblast, 189, 204
 Erythrocyte, 188, 202
 Eustachian tube, 217, 469
 Eustachius, on lymphatics, 182
 suprarenal gland, 404
 Evans, on development of blood vessels, 166
 perilymphatic blood vessels, 188
 Exoplasm, 3
 External acoustic meatus, 481
 Eye, 439
 blood vessels, 458
 chambers, 442, 460
 cornea, 442
 iris, 442, 455
 lacrimal glands, 462, 464
 lens, 451
 lids, 461
 nerves, 460
 optic nerve, 450
 retina, 443
 tunica fibrosa, 456
 tunica vasculosa, 453
 vitreous body, 453

F

Fabricius, on valves of the veins, 164
 stomach, 251
 allantois, 373
 Facial nerve, 141
 Falciform ligament, 278
 Fallopian tube, 327
 Fallopius, on ovarian follicles, 365
 placenta, 372
 Farmer and Shove, on cell division, 14, 19, 20
 Fascia, 77
 linguæ, 232
 pharyngo-basilaris, 236
 Fasciculus cerebro-spinalis, 411, 425
 cuneatus, 412, 424
 gracilis, 412, 424
 proprius, 412
 rubro-spinalis, 425
 spino-thalamicus, 426
 Fat cells, 73
 crystals, 74
 stains, 504
 Felix, on the pronephros, 306
 Wolffian tubules, 308
 genital glands, 327
 paradidymis, 330
 sexual cells, 335
 Female genital organs, 349
 Fenestra cochleæ, 469
 vestibuli, 469
 Fenestrated cells, 150
 membrane, 66, 170
 Ferrein, pyramids of, (in the kidney), 315
 Fertilization, 32
 Fiber cells (in the internal ear), 471
 layer of Henle, 445
 tracts, 132 (see also *Fasciculi*).

Fibers, elastic, 66
 Müller's (in the retina), 447
 muscle, 113, 116, 126
 nerve, 132
 osteogenic, 84
 Sharpey's (in bone), 92
 white, 62
 Fibrils, in connective tissue fibers, 65
 in muscle fibers, 113
 in smooth muscle, 114
 in striated muscle, 122
 in nerve fibers, 144
 Fibrin, 191
 canalized, 378
 Fibroblasts, 67
 Fibro-cartilage, 81
 Fibroglia, 64
 Filiform papillæ, 230, 231
 Fillets (*lemnisci*), 426
 Fimbria ovarica, 352
 Fixation of tissues, 489
 Flack, on the sino-atrial node, 181
 Flagella, 52
 Flemming, on the origin of white fibers, 63
 Flemming's fluid, 491
 Foliate papillæ, 230, 231
 Follicles, 58
 atretic, 358
 Graafian (vesicular ovarian), 354
 primary ovarian, 352
 thyreoid, 227
 Fontana, spaces of (in the iris), 460
 Foramen apicis dentis, 99
 epiploicum (of Winslow), 280
 interventriculare (of Monro), 419
 interventriculare, of the heart 76
 ovale, 176
 Fore-brain, 419
 Fore-gut, 39, 245
 Formaldehyde, 491
 Formalin, 491
 Fornix, 421
 Fossa of Rosenmüller, 218
 Fovea centralis, 447
 Fresh tissues, examination of, 487
 Frozen sections, 498
 Fungiform papillæ, 230, 231
 Funiculi of the spinal cord, 411

G

Gärtner's duct, 351
 Gage, on glycogen, 78
 Galea capitis, 336
 Galen, on the intestine, 247
 stomach, 251
 Gall bladder, 277, 289
 Ganglia, 113, 147
 cardiac, 182
 cervical, 137
 coeliac, 138
 of the cerebral nerves, 141
 of the sympathetic nerves in the head,
 142
 retinal, 445
 spinal, 134, 147
 spiral, 476
 sympathetic, 137, 142, 150

- Gastric canal, 252
glands, 253
- Gelatin, 62
- Genital corpuscles, 161
organs (female), 349
organs (male), 326
papilla, 330, 353
ridge, 327
- Germ cells, 20, 334
layers, 36; origin of tissues from, 45
- Giant cells, of the bone marrow, 200, 202
- Gill clefts, 216, 219
- Giraldès, organ of, 330
- Glands, 54
anterior lingual, 232
areolar, 404
Bartholin's (*major vestibular*), 383
Bowman's (*olfactory*), 485
bronchial, 300
Brunner's (*duodenal*), 259
buccal, 241
bulbo-urethral, 347
cardiac, 248, 253
ceruminous, 481
cervical, of the uterus, 361
ciliary, 461
circumanal, 276
classification, 56, 59
compound, 57
Cowper's (*bulbo-urethral*), 347
cytogenic, 58
duodenal, 259
ducts, 56, 58
v. Ebner's (*serous lingual*), 238
end-pieces, 56
epithelial, 54
epithelioid, 58
fundus (*gastric*), 253
gastric, 253
intestinal, 259, 260
labial, 241
lachrymal, 462, 464
Lieberkühn's (*intestinal*), 259, 260
lingual, 241
Littré's (*urethral*), 347
lumen, 57
lymph, 205
mammary, 401
Meibomian (*tarsal*), 462
mixed, 241
molar, 241
Moll's (*ciliary*), 461
Montgomery's (*areolar*), 404
mucous, 54, 241
oesophageal, 248
olfactory, 485
oral, 237
palatine, 241
peptic (*gastric*), 253
præputial, 398
pyloric, 256
sebaceous, 237, 397
secretory capillaries, 57
serous, 54, 238
simple, 57
sublingual, 242
submaxillary, 242
sudoriparous, 398
suprarenal, 404
- Glands, sweat, 398
tarsal, 462
tracheal, 299
Tyson's, 398
unicellular, 56
urethral, 326, 347
vestibular, 383
- Glans penis, 330
- Glia cells (*neuroglia*), 64, 414, 434
- Glisson's capsule, 278
columns, 274
- Glomerulus, 307
of the kidney, 313
of olfactory nerves, 486
of Wolffian body, 307
- Glomus caroticum, 229
- Glossopharyngeal nerve, 142, 424
- Glycerin jelly, 507
- Glycogen, 78
- Goblet cells, 56
- Golgi preparations, 145
method, 512
- Golgi-Mazzoni corpuscles, 401
- Goll, column of, 412
- Gower's tract, 427
- Graafian follicles, 356, 365
- Granules, in protoplasm, 3
metachromatic, 70
- Grasshopper, sex determination, 28
spermatogenesis, 21
- Gray matter (*substance*), 416
nerves, 153
rami, 137
- Grégoire and Wygaerts, on cell division, 15
- Gregor, on muscle spindles, 127
- Grosser, on pharyngeal pouches, 219
yolk-sac, 368
- Gubernaculum testis, 331
- Gum damar, 507
- Gums (*gingivæ*), 112
- Gustatory organ (taste-buds), 232, 234

H

- Hæmatoidin, 194
- Hæmatoxylin, 500
- Hæmin, 194
- Hæmoglobin, 188, 194
- Hæmolymp glands, 209
- Hæmolysis, 195
- Hæmosiderin, 194
- Hair, 389
bulb, 389
lanugo, 391
papilla, 389
root, 389, 391
shaft, 394
shedding, 396
- Hair-cells, of the cochlea, 471, 474
- Halban, on muscle fibers, 126
- Hale, on the allantois, 373
- Haller, on epithelium, 46
thymus, 222
- Hammar, on pharyngeal pouches, 218
thymus, 222, 225
- Hardesty, on nervous tissue, 415
membrana tectoria, 473
- Harrison, on the growth of nerves, 135, 146
- Harvey, on epigenesis, 339

- Harvey, R. W., on epithelium of the bladder, 324
- Hassall's corpuscles (*thymic*), 225
- Haustra, 273
- Haversian systems, 94
- Head-bend, 419
- Heart, 174
 - endocardium, 178
 - epicardium, 178, 181
 - myocardium, 178, 179
 - nerves, 181
 - pericardium, 178
 - valves, 176
- Hedblom, on uterine glands, 361
- Heidenhain, on muscle contraction, 124
 - intercalated discs, 129
- Heidenhain's iron hæmatoxylin, 501
- Hemiazygos veins, 310
- Hemispheres, cerebral, 431
- Henle, on collagenous fibers, 62
 - transitional epithelium, 324
 - aberrant ducts, 330
- Henle's fiber layer of the retina, 445
- layer of the hair sheath, 394
- loops in the kidney, 313
- spindle cell layer in the iris, 456
- Hensen, on the number of ova, 29
 - ovulation, 357
- Hensen's cells of the cochlea, 475
 - membrane in striated muscle, 123
- Hepatic arteries, 280
 - cells, 284
 - diverticulum, 276
 - duct, 277, 288
 - lobules, 281
 - trabeculæ, 277
 - veins, 277, 282
- Hertwig, on mesenchyma, 59
 - origin of nerves, 132
- Hertzog's embryo, 368
- Hewson, on the thymus, 222
- Hilus, 205
- Hind-brain, 422
- Hind-gut, 39, 245
- Hippocrates, on the intestine, 247
- His, on endothelia, 46
 - development of nerves, 136
 - allantois, 373
- Hochstetter, on the cardinal veins, 310
- Home, on the stomach, 251
- Hooke, on cells, 8
 - drawing, 518
- Horns of the spinal cord (*columns*), 411
- Houston's valves, 273
- Howship's lacunæ, 86
- Howell, on red corpuscles, 191
 - white corpuscles, 195
- Huber, on the notochord, 38
 - end-discs, 149
 - tubules of the kidney, 314, 318
 - tubules of the testis, 334
 - ceruminous glands, 481
- Hubrecht, on the trophoblast, 367
- Huntington, on lymphatics, 186
 - bronchi, 296
 - supracardinal vein, 310
- Huschke's auditory teeth, 473
- Huxley, on the cuticula dentis, 105
- Huxley's layer of the hair sheath, 394
- Hyaline cartilage, 80
- Hyaloid artery, 442
 - canal, 442
 - membrane, 453
- Hyaloplasm, 4
- Hydatid of Morgagni, 344
 - sessile, 344
 - stalked, 344
- Hymen, 350
- Hypogastric plexus, 139
- Hypoglossal nerve, 142, 424
 - nucleus, 426
- Hypophysis, 435
- Hypospadias, 330
- Hypothalamus, 421
- Hyrtl, on the intestine, 247
 - amnion, 373
 - meninges, 413
 - pituitary gland, 436
- I
- Idiozome, 336
- Ileo-cæcal valve (*valve of the colon*), 261
- Ileum, 246, 260
- Imbedding, 493, 495
- Implantation of the ovum, 370
- Incisures of Lantermann (in myelin sheaths) 155
- Inclusions, 5
- Incus, 469
- Infundibulum of the fore-brain, 421
 - of the lungs, 302
 - of the uterine tubes, 358
- Injections, 509
- Inner cell mass, 35
- Intercalated discs, 129
 - ducts, 58, 240, 292
- Intercellular bridges, 53
 - secretory capillaries, 57
 - substance, 10
- Interfascial space, 460
- Interglobular spaces in dentine, 110
- Intermediate nerve, 141
- Internal acoustic meatus, 477
 - secretions, 58
- Interstitial cells of the ovary, 358
 - cells of the testis, 332
 - granules in sarcoplasm, 124
 - lamellæ of bone, 94
- Interventricular foramen, of the heart, 176
 - of the brain (Monro), 419
- Intestinal absorption, 264
 - glands, 259, 260
 - villi, 260
- Intestine, large, 270
 - small, 246
- Intracellular secretory canals, 57
- Involuntary muscle, 113, 128
- Iris, 442, 455
- Iron hæmatoxylin, 501, 502
- Islands of Langerhans, 292
- Isolation of tissues, 488
- Isotropic substance in muscle, 123
- Isthmus, 422
- J
- Jacobson's organ (*vomero-nasal organ*), 141, 483

- Jejunum, 246, 260
 Johnson, on the rectum, 247, 273
 intestinal villi, 260, 272
 distention of the small intestine, 262
 Johnston, on the nervus terminalis, 141
 Joints, 96
 Jordan, on intercalated discs, 129

K

- Karyokinesis, 14
 Karyolysis, 10
 Karyoplasm, 2
 Karyorrhexis, 10
 Keibel, on the development of the urogenital tract, 350
 allantois, 368
 Keith and Flack, on the sino-atrial node, 181
 Kent, on the atrio-ventricular bundle, 180
 Keratohyalin, 388
 Kerkring's valvulae conniventes, 261
 Kidney, 310
 calyces, 312
 capsule, 315
 columns, 315
 corpuscles, 315
 cortex, 315
 labyrinth (*pars convoluta*), 315
 lobes, 321
 medulla, 315
 medullary rays (*pars radiata*), 315
 pelvis, 311, 322
 pyramids, 314
 vessels and nerves, 321, 322
 zones of the medulla, 316
 Kiernan, on the portal canals, 282
 Kingsbury, on mitochondria, 4
 Kingsley, on the pineal body, 438
 Kling, on lymph glands, 205
 Kölliker, on osteoclasts, 86
 growth of bone, 91
 aorta, 172
 paradidymis, 330
 v. Korff, on dentinal fibers, 108
 Krause's corpuscles, bulbous and cylindrical, 161
 membrane in striated muscle, 123
 Kupffer's stellate endothelial cells, 287

L

- Labia majora, 353, 383
 minora, 353, 383
 Labium tympanicum, 473
 vestibulare, 473
 Labra glenoidalia, 98
 Labyrinth, of the ear, 469
 of the kidney (*pars convoluta*), 315
 Lachrymal glands, 464; accessory, 462
 sac, 464
 Lacteals, 201, 267
 Lactiferous sinus, 404
 Lacunæ, of bone, 85
 of cartilage, 78
 Howship's, 86
 urethral, 347
 Lamellæ of bone, 92
 Lamellar corpuscles, 161

- Lamina choriocapillaris, 453
 cribrosa, 451
 fusca, 453
 spiralis, 471
 suprachorioidea, 453
 Langer, on lymphatics, 186
 Langerhans, cells of in epidermis, 159
 islands of, 292
 Lantermann's incisures, 155
 Lanugo, 391
 Large intestine, 270
 Larynx, 298
 Leeuwenhoek, on the teeth, 105
 red corpuscles, 191
 spermatozoa, 338
 Lens, 439, 451
 Lentic vesicle, 439
 Lesser omentum, 278
 Leucocytes, 188, 195, 199
 Lewis, F. T., on lymphatics, 185
 shape of red corpuscles, 191
 stomach, 252
 vena cava, 280
 ventral pancreas, 290
 amniotic villi, 383
 Lewis, W. H., on muscle, 118
 development of the lens, 440
 Lewis, W. H. and M. R., on the growth of nerve fibers, 146
 Lieberkühn, crypts of (*intestinal glands*), 259, 260
 Ligaments, 77, 97
 denticulate, 414
 hepatic, 278
 ovarian, 352
 pectinate, 458
 suspensory, of lens, 449
 Ligamentum spirale, 471
 Limbus spiralis, 472
 Lingual glands, 232, 241
 tonsil, 218, 222
 Linin, 5
 Lips, 235
 Liquor amnii, 370
 folliculi, 355
 Littré, glands of (urethral glands), 347
 Liver, 276
 artery, 280
 bile capillaries, 285
 capsule, 278
 ducts, 288
 hepatic cells, 284
 ligaments, 278
 lobes, 280
 lobules, 281, 284
 perivascular tissue, 286
 portal canals, 282, 287
 structural units, 284
 veins, 278
 Lode, on the number of spermatozoa, 29
 Loeb, on fertilization, 34
 Long, on maturation, 31, 32
 Lowsley, on the prostate, 345
 Lumen of glands, 57
 Lungs, 301
 alveoli, 301
 atria, 302
 development, 295
 lobules, 304

Lungs, pigment, 304
 pleura, 296, 304
 structural units, 304
 vessels and nerves, 303, 304

Lunula, 389

Lutein cells, 358

Lymph, 201

follicles (*nodules*), 204, 205
 glands, 204
 nodes (*lymph glands*), 204
 nodules, solitary, 207; aggregate, 207
 sacs, 185
 sinuses, 205, 208

Lymphatic vessels, 182
 development, 183, 185
 stomata, 270
 valves, 188

Lymphocytes, 70, 196, 202

Lymphoid tissue, 207

M

MacCallum, on lymphatics, 184
 Wolfian bodies, 309

McClung, on spermatogenesis, 21, 23

McClure, on lymphatics, 186
 supracardinal vein, 310

McCotter, on the nervus terminalis, 141

McGill, on smooth muscle, 114, 116, 118

Macula acustica, 467
 lutea, 447

Magma reticulare, 368

Mall, on reticular tissue, 61
 cartilage, 77
 endocardial connective tissue, 178
 spleen, 212
 lobules of the liver, 281

Malleus, 469

Mallory, on fibroglia, 64

Mallory's connective tissue stain, 504
 phospho-tungstic acid hæmatoxylin, 503

Malpighi, on capillaries, 164
 lobules of the liver, 281
 skin, 386

Malpighian corpuscles (renal), 315; (splenic),
 211
 pyramids, 314

Mammillary bodies, 421

Mammary glands, 401

Marchi's fluid, 491

Mark, on maturation, 31, 32

Marrow, 202

Mascagni, on lymphatics, 183

Mast cells, 69, 197

Maturation, 20

Maurer, on capillaries in epithelium, 53

Maximow, on the centrosome in amitosis, 13
 mast cells, 69
 clasmotocytes, 71
 lymphocytes, 195

Meckel, on the thymus, 222

Meckel's diverticulum, 247

Meconium, 272

Mediastinum, of the testis, 328
 of the thorax, 295

Medulla, 205
 oblongata, 424
 ossium, 202
 spinalis, 409

Medullary groove, 36
 tube, 36, 409

Medullated nerve fibers, 144

Megakaryocytes, 202

Megaloblasts, 189

Meibomian glands (*tarsal glands*), 462

Meigs, on the contraction of smooth muscle,
 117

contraction of striated muscle, 124

Meissner's corpuscles, tactile, 160

plexus, 269

Melanin, 72

Membrana basilaris (of the cochlea), 473

limitans externa (of the retina), 444

limitans interna, 446

propria, 53

vestibularis (of the cochlea), 471

Membrane, Bowman's (of the cornea), 456

Descemet's (of the cornea), 458

hyaloid, 453

pupillary, 451

Reissner's (*membrana vestibularis*), 471

tympanic, 469, 480

Meninges, 413, 438

Menstruation, 363

Merkel, on the origin of white fibers, 63

Mesencephalon, 421

Mesenchyma, 59

Mesenchymal epithelium, 47, 98

tissues, 59

Mesentery, 269

Mesoderm, 35, 39

derivatives, 45

Mesodermic somites, 39, 118

Mesonephros (*Wolffian body*), 307

Mesothelium, 47

Mesovarium, 353

Metachromatic granules, 70

Metaphase, 17

Metencephalon, 423

Methylene blue, 501

Meves, on the origin of white fibers, 63
 fibroglia, 114

spermatozoa, 337

Micron, 9

Microscope, 514

Microtome, 496

Mid-brain, 421

Milk, 403

Miller, on perivascular lymphatics, 188
 pulmonary arteries, 297

lungs, 302

Mingazzini, on intestinal absorption, 264

Minot, on cytomorphosis, 9

mesothelium, 47

sinusoids, 166

blood corpuscles, 195

trophoderm, 367

Miram, on Paneth's cells, 263

Mitochondria, 4, 54, 63, 239

Mitosis, 14

Mitral cells, 486

valve, 176

Mixed glands, 241

Modiolus, 467

Moenkhaus, on fertilization, 34

Moll, glands of (*ciliary glands*), 461

Mononuclear leucocytes, 196

Monophyletic theory of blood formation, 195

Monro, foramen of, 419
 Montgomery's glands (*areolar glands*), 404
 Morgagni, hydatid of (*appendix testis*), 327,
 344
 sinus of (*ventricles of the larynx*), 298
 Morpurgo, on muscle fibers, 126
 Morula, 35
 Motor cells, 132, 134
 endings, 163
 nerves, 134
 plate, 163
 Mounting sections, 507
 Mouth, 215
 Mucins, 62
 Mucous bursæ, 77
 glands, 54, 241
 tissue, 62
 Mucus, 62
 Müller, on the Wolffian bodies, 327
 Müllerian duct, 327, 349
 Müller's fibers, of the retina, 447
 Multipolar ganglion cells, 143
 Muscle, 113
 cardiac, 113, 128
 columns, 120
 contraction, 117, 124
 fibrils, 113, 114, 120
 involuntary, 113
 skeletal, 118
 smooth, 113
 spindles, 127, 159
 striated, 113, 122, 125, 128
 voluntary, 113
 Myelencephalon, 424
 Myelin, 144, 155
 Myelocytes, 202, 203
 Myenteric plexus, 138, 248, 269
 Myoblasts, 114
 Myocardium, 178, 179
 Myofibrils, 113
 Myoglia, 64
 Myometrium, 360
 Myotome, 118

N

Naboth, ovules of, 361
 Nagel on oögenesis, 30
 Nails, 389
 Nares, 481
 Nasal pits, 481
 septum, 481
 Nasolachrymal ducts, 465
 Nasmyth's membrane (*cuticula dentis*), 105
 Neck-bend, 419
 Němec, on mitosis, 14, 18, 19
 Nephrotome, 41
 Nerve cells, 130, 132
 bipolar, 143
 dendrites, 143
 multipolar, 143
 neuraxon, 134, 143
 in spinal ganglia, 134
 in sympathetic ganglia, 150
 unipolar, 143
 Nerve corpuscles, 160
 Nerve endings, free, 157
 motor, 163
 sensory, 157
 tactile menisci, 158

Nerve fibers, 132
 afferent, 132, 134
 association, 132
 axis cylinders, 145
 axolemma, 156
 collateral, 134, 144
 commissural, 132
 efferent, 132, 134
 growth, 135
 incisures, 155
 motor, 132
 neuraxon, 134, 143
 neurofibrils, 144
 neurolemma, 144
 neuroplasm, 156
 nodes of Ranvier, 144, 156
 reflex path, 131
 Remak's fibers, 145
 sensory, 132
 sheath of Schwann, 144
 in the spinal cord, 415
 structure, 153
 Nerves, 153
 automatic, 139
 autonomic, 139
 cerebral, 139
 gray, 153
 medullated, 154
 non-medullated, 153
 spinal, 133
 sympathetic, 137
 visceral, 139
 white, 153
 Nervous system, 130
 central, 130, 409
 peripheral, 130
 sympathetic, 137, 139
 Nervus terminalis, 141, 483
 Neumann's sheath, 109
 Neural crest, 133
 tube (*medullary tube*), 36
 Neuraxon, 134, 143
 Neuroblasts, 134
 Neuro-epithelial cells, 130
 Neurofibrils, 144
 Neuroglia, 64, 114, 434, 451
 Neurokeratin, 155
 Neurolemma, 144
 Neurone, 145
 Neuroplasm, 156
 Neuropores, 37
 Neutrophiles, 199
 Nile blue, 505
 Nissl's bodies, 3, 416
 Nitric acid, 489
 Nodes of Ranvier, 144, 156
 Nodules, aggregate, 207, 268
 solitary, 207
 Nodus thymicus, 218
 Non-medullated nerves, 153
 Normoblasts, 189
 Nose, 481
 Notochord, 38, 83
 Notochordal tissue, 82
 Nuclear membrane, 5
 sap, 5
 Nucleolus, 6
 Nucleus, ambiguous, 426
 of cells, 5

Nucleus cuneatus, 426
 dorsal, 417, 427
 gracilis, 426
 of the nervous system, 417
 pulposus, 38
 pycnotic, 10, 189
 Nuel's spaces, 475
 Nussbaum, on sexual cells, 335
 Nutrient artery, 96

O

Oculomotor nerve, 141, 422
 Odontoblasts, 107
 Odoriferous glands, 399
 Oesophagus, 246, 248
 Oil of origanum, 507
 Oken, on the Wolffian bodies, 326
 Olfactory bulb, 421
 cells, 483
 epithelium, 483
 glands, 485
 nerves, 141, 486
 Olive, 424
 Oöcytes, 28, 354
 Oögenesis, 20, 28
 Oögonia, 28
 Opie, on the islands of the pancreas, 295
 Optic cup, 440
 nerve, 141, 449
 recess, 419
 stalk, 439
 vesicle, 439
 Ora serrata, 442, 449
 Oral plate, 215
 Organ of Corti (*spiral organ*), 472, 474
 of Rosenmüller (*epoöphoron*), 350
 of Zuckerkandl, 152
 Organs, 46
 Orth's fluid, 491
 Osmic acid, 505
 Ossification, 90
 Osteoblast, 84
 Osteoclast, 86
 Osteo-dentine, 110
 Osteogenic fibers, 84
 Otoconia, 476
 Otocyst, 465
 Otoliths, 471
 Ova, discovery of, 365
 maturation, 31
 mature, 28
 number in human female, 29
 Oviduct, 365
 Ovulation, 31, 356
 Ovules of Naboth, 361
 Oxyhæmoglobin, 194
 Oxyphiles, 197

P

Pacchionian bodies (*arachnoid granulations*), 439
 Pacinian corpuscles (*lamellar corpuscles*), 161
 Palate processes, 481
 Palatine glands, 241
 tonsils, 218, 219
 Pallium, 420
 Palpebræ, 461

Pal's modification of Weigert's stain, 512
 Pancreas, 289
 centro-alveolar cells, 292
 dorsal, 289
 islands, 292
 ventral, 289
 Paneth, cells of, 262
 Panniculus adiposus, 386
 Papilla, duodenal, 259, 278
 genital, 330
 of hair, 389
 of the optic nerve, 441
 renal, 314
 Papillæ, of the corium, 385
 of the tongue, 230
 Paradidymis, 330, 344
 Paraffin, imbedding in, 493
 sections, 496
 Paraganglia, 152
 Parametrium, 363
 Paranucleus, 26
 Parathyreoid glands, 218, 228
 Parenchyma, 46
 of the liver, 284
 Parietal cells, 255
 Parker, on cilia, 52
 on the nervous system, 132
 Paroöphoron, 350, 351
 Parotid gland, 238
 Parovarium (*epoöphoron*), 350
 Pavement epithelium, 48
 Pecquet, on lymphatics, 183
 Pectinate ligament, 458
 Peduncles of the cerebrum, 422
 Pelvis of the kidney, 311, 322
 Penicilli, 212
 Penis, 346
 Peptic glands (*gastric glands*), 253
 Perforating fibers, of Sharpey, 92
 Perforatorium, 336
 Pericardial cavity, 174
 Pericardium, 178
 Perichondrial bone, 90
 Perichondrium, 79
 Periodontal membrane, (*alveolar periosteum*), 111
 Perilymph, 468
 Perilymphatic duct, 478
 Perimetrium, 360
 Perimysium, 124
 Perineum, 247
 Perineurium, 154
 Peripheral nerves, syncytial interpretation of, 145
 Peripheral nervous system, 130
 Periosteal lamellæ, 93
 Periosteum, 91, 92
 Peritoneum, 269
 Permanent preparations, 489
 Peter, on the zones of the renal medulla, 316
 Peters's embryo, 368
 Petit, canal of (zonular spaces), 449
 Peyer's patches (*aggregate nodules*), 207, 268
 Pflüger's egg tubes, 352
 Phagocytes, 12, 197
 Pharyngeal pouches, 216, 217
 recess, 218
 tonsil, 218, 222
 Pharynx, 215

- Phospho-tungstic acid hæmatoxylin, 503
 Pia mater, 413, 439
 Pigment cells, 71, 72
 Pillar cells of spiral organ, 474
 Pineal body, 421, 437
 Pinguecula, 462
 Pinkus, on the nervus terminalis, 141
 on the skin, 388
 Pinna, 469
 Pituitary gland (*hypophysis*), 436
 Placenta, 372, 375
 succenturiate, 372
 Plasma, 188, 201
 Plasma cells, 68, 70
 Plates, blood, 188, 199
 Pleura, 296, 304
 Pleural villi, 306
 Plexus annularis, 461
 Auerbach's, 138, 248, 269
 cardiac, 138
 chorioid, 439
 coeliac, 138
 gangliosus ciliaris, 461
 hypogastric, 139
 Meissner's, 269
 myenteric, 138, 248, 269
 pulmonary, 304
 solar, 139
 submucous, 139, 248, 269
 Plica semilunaris of the eyelid, 463
 Plicæ adiposæ, of the pleura, 306
 circulares, of the small intestine, 260, 261
 palmatæ, of the uterus, 360
 semilunares, of the large intestine, 273
 transversales, of the rectum, 273
 villosæ, of the stomach, 252
 Polar bodies, 31
 field, 20
 radiations, 17
 Polykaryocyte, 202
 Polymorphonuclear leucocytes, 196
 Polyphyletic theory of blood formation, 195
 Pons, 423
 Porta hepatis, 279
 Portal canals, 282, 287
 lobules, 284
 vein, 277, 278
 Potassium chlorate, 489
 hydrate, 489
 Præputial glands, 398
 Præpermatid, 22
 Præpermid, 22
 Precartilage, 77
 Predentine, 107
 Preformation theory, 339
 Premyelocytes, 202, 203
 Prenant, on amianthoid fibers, 80
 Prepuce, 331, 398
 Primitive knot, 35
 streak, 35
 Prisms, enamel, 104
 Processus vaginalis, 331
 vermiformis, 270
 Pronephros, 306
 Pronucleus, 32
 Prosencephalon, 419
 Prostate, 345
 Prostatic utricle, 327
 Protoplasm, 2
 Protoplasmic processes, 145
 Protovertebræ (*mesodermic somites*), 39, 118
 Prowazek, on cilia, 51
 Pseudopodia, 7
 Pseudostratified epithelium, 50
 Pulmonary arches, 296
 arteries, 296
 plexus, 304
 veins, 297
 Pulp of teeth, 99, 110
 Pupil, dilatator muscle of, 456
 sphincter muscle of, 455
 Pupillary membrane, 441
 Purkinje's cells, 429
 fibers, 181
 Pycnotic nuclei, 10, 189
 Pyloric glands, 256
 Pylorus, 251
 Pyramidal cells, 431
 tracts, 425
 Pyramids of Ferrein (in the kidney), 315
 of Malpighi (in the kidney), 314
 of the medulla oblongata, 424
- ### R
- Rabl, on the development of the lens, 453
 Radial fibers of the retina, 447
 Rami of spinal nerves, 136, 137
 Ranson, on ganglion cells, 150
 Ranvier, on clasmotocytes, 71
 on lymphatics, 184
 nodes of, 144, 156
 Ranvier's alcohol, 488
 Raphe of the penis, 330
 Rathke, on gill clefts, 219
 on the Wolffian bodies, 327
 Rathke's pouch, 435
 Reconstructions, 516
 Rectal columns, 274
 Rectum, 247, 273
 Red corpuscles, 188
 color, 188
 dimensions, 193
 number, 193
 shape, 191
 Red nucleus, 425
 Reductional division, 24
 Reflex path of spinal cord, 131
 Reflexa (*decidua capsularis*), 371
 Reissner's membrane, 471
 Remak on nerves, 145
 Remak's fibers, 145
 Renal columns, 315
 corpuscles, 315
 lobules, 321
 papilla, 314
 pelvis, 322
 portal system, 310
 pyramids, 314
 tubules, 312-316
 Resorcin-fuchsin, 504
 Respiratory apparatus, 295
 bronchioles, 301
 Restiform body, 423
 Resting wandering cells, 71
 Rete Malpighii (*stratum germinativum*), 386
 ovarî, 351
 testis, 328, 339

Reticular tissue, 26
 Reticulin, 62
 Retina, 443
 cones, 445
 development, 440
 fovea centralis, 447
 macula lutea, 447
 pars ciliaris, 449
 pars iridica, 455, 456
 pars optica, 443
 pigment layer, 440, 444
 rods, 444
 Retzius, cells of, 431
 lines of, 105
 Reynolds, on ovulation, 357
 Rhinencephalon, 421
 Rhombencephalon, 422
 Rhomboidal sinus, 37
 Richards, on mitosis, 14, 18, 19
 Rindfleisch, on red corpuscles, 191
 Ringer's solution, 488
 Riolaris, ciliary muscle of, 462
 Rod cells, 444
 Rollett, on muscle striations, 123
 Röse, on tooth-development, 101
 Rosenmüller, fossa of, 218
 organ of (*epithelion*), 350
 Rouleaux, 191
 Round ligament, of the liver, 272
 of the uterus, 352
 Ruffini's terminal cylinders, 160
 Russel's bodies, in plasma cells, 70
 Ruysch, on epithelia, 46

S

Sabin, on lymphatics, 184, 185
 lymph glands, 224
 Sacculus, 467, 470
 Saccus endolymphaticus, 465, 478
 Safranin, 502
 Salivary corpuscles, 220
 Sappey, on lymphatics, 183
 Sarcolemma, 121
 Sarcomeres, 123
 Sarcoplasm, 124
 Sarcostyles, 120
 Scala media (*cochlear duct*), 467, 471
 tympani, 468
 vestibuli, 468
 Schäfer, on striated muscle, 120, 122, 124
 non-medullated nerve fibers, 153
 development of blood vessels, 166
 shape of red corpuscles, 191
 blood plates, 200
 sinusoids of the liver, 287
 musculature of the uterine tube, 360
 Schaffer, on chordoid tissue, 82
 Scharlach R, 504
 Schlagenhaufen, on the tactile toruli, 385
 Schlemm, canal of (*sinus venosus sclerae*), 460
 Schneider, on the pituitary gland, 430
 Schreger's lines, 106, 109
 Schultze, M., on nerve cells, 130
 white corpuscles, 197
 Schultze, O., on muscle and tendon, 127
 Schulz, on bone, 92
 v. Schumacher, on lamellar corpuscles, 162
 haemolymph glands, 210

Schwann, sheath of, 144
 on striated muscle fibers, 121
 Schweitzer, on the lymphatics of the teeth, 110
 Sclera, 456
 Sclerotome, 118
 Scrotum, 331
 Sebaceous glands, 237, 397
 Secretion, 54
 internal, 58
 Secretory capillaries, 57, 238
 Sections (cutting and handling), 496
 Segmentation of the ovum, 35
 Semicircular canals (*ducts*), 465, 470
 Seminal vesicles, 329, 342
 Sensory decussation, 426
 nerve cells, 132, 134
 endings, 157
 Septa, in glands, 57
 Septula testis, 332
 Septum membranaceum, 177
 pellucidum, 421
 transversum, 276
 Serotina (*decidua basalis*), 371
 Serous glands, 54, 237
 Sertoli's cells, of the testis, 335
 Serum, 201
 Sexual cells, 20, 334
 Sharpey's fibers, 92
 Sigmoid colon, 247
 Silver nitrate, 506
 Silvester, on lymphatics, 185
 Simple epithelium, 48
 Sino-atrial (or sino-auricular) node 181
 Sinus, coronary, 177
 lactiferous, 404
 rectalis, 274
 tonsillaris, 218
 transversus pericardii, 175
 urogenital, 330, 353
 venosus, 177
 sclerae, 460
 Sinuses of the dura mater, 438
 in lymph glands, 205, 208
 in haemolymph glands, 209
 Sinusoids, 166
 Skin, 384
 corium, 384, 385
 epidermis, 384, 386
 hair, 389
 nails, 388
 sebaceous glands, 397
 sweat glands, 398
 vessels and nerves, 399
 Slides and cover glasses, 508
 Small intestine, 246
 blood vessels, 266
 distention of, 262
 duodenum, 246
 glands, 262
 ileum, 246
 jejunum, 246
 lymphatics, 267
 mesentery, 269
 nerves, 269
 villi, 262
 Smreker, on enamel prisms, 107
 Sobotta, on fertilization, 33
 Solar plexus, 139

- Solitary nodules, 207
 - Somatopleure, 36
 - Spermatic cord, 342
 - Spermatid, 22, 26, 336
 - Spermatocytes, 22, 26, 336
 - Spermatogenesis, 21
 - Spermatogonia, 22, 23, 334
 - Spermatozoa, 22, 26, 337
 - discovery of, 338
 - number in man, 29
 - Spermid, 22
 - Spermium, 22
 - Sphincter pylori, 257
 - Spinal cord, 409
 - central canal, 409
 - columns, 411
 - commissures, 411
 - dorsal nucleus, 417
 - ependyma, 418
 - fasciculi, 411
 - funiculi, 411
 - gray substance, 416
 - horns, 411
 - membranes, 413
 - white substance, 414
 - Spinal ganglia, 134
 - nerves, 133
 - Spindle, 17
 - muscle-spindle, 159
 - Spiracle, 216
 - Spiral ganglion, 476
 - organ, 467, 472
 - Spireme, 15
 - Splanchnic nerves, 138
 - Splanchnopleure, 36
 - Spleen, 210
 - capsule, 214
 - cells, 211, 213
 - lobules, 215
 - nodules, 211, 214
 - pulp, 211, 213
 - Spongioplasm, 4
 - Squamous cells, 49
 - Stains, general, 500
 - selective, 503
 - Staining methods, 499
 - Stapes, 469
 - Steele, on intercalated discs, 129
 - Stenson's duct (*parotid duct*), 238
 - Stöhr, on peripheral nerves, 145
 - thymus, 224
 - glands of the vermiform process, 271
 - Stomach, 246, 251
 - glands, 253
 - musculature, 257
 - subdivisions, 251
 - Stratified epithelium, 48
 - Streeter, on the acoustic nerve, 476
 - Striated muscle, 113, 128
 - Stroma, 46
 - Studnička, on dentinal fibers, 108
 - Subarachnoid space, 414, 439
 - Subcardinal veins, 309
 - Subcutaneous tissue, 385
 - Subdural space, 413, 439
 - Sublingual glands, 242
 - Submaxillary glands, 242
 - Substantia adamantina, 99
 - alba, 414
 - Substantia eburnea, 99
 - gelatinosa, 417
 - grisea, 416
 - lentis, 452
 - ossea, 99
 - Sulphuric acid, 489
 - Supracardinal vein, 310
 - Suprarenal gland, 404
 - Supratonsillar fossa, 218
 - Sustentacular cells, of the inner ear, 471, 475
 - of the olfactory epithelium, 484
 - of the taste buds, 235
 - of the testis, 334
 - Sweat glands, 398
 - Sylvius, aqueduct of, 422
 - Sympathetic ganglia, 137, 142, 150
 - ganglionated trunk, 138
 - nervous system, 137, 139
 - Synapsis, 23
 - Synarthrosis, 96
 - Synchondrosis, 91, 96
 - Syncytium, 8
 - Synizesis, 23
 - Synovia, 99
 - Synovial membrane, 98
- T
- Tactile cells, 157
 - menisci, 158
 - Tæniæ coli, 273
 - Tapetum cellulosum, 454
 - fibrosum, 454
 - Tarsal glands, 462
 - Taste buds, 232, 234
 - cells, 235
 - Technique, microscopical, 487
 - Teeth, 99
 - cement, 99, 111
 - dentine, 99, 109
 - enamel, 99, 104
 - pulp, 99, 110
 - Tela submucosa, 220, 248
 - Telencephalon, 419
 - Tendon, 75
 - spindles, 159
 - Tenon's capsule, 460
 - Terminal bars, 52
 - Testis, 332
 - cells, 332, 334
 - convoluted tubules, 334
 - descent of, 331
 - development, 328
 - interstitial cells, 332
 - muliebris, 365
 - rete, 328, 339
 - vessels and nerves, 333
 - Tetrads, 23
 - Thalamus, 421
 - Thebesius, veins of, 179
 - Theca folliculi, 355
 - Thoma, on the development of blood vessels
 - 166
 - Thoracic duct, 183
 - Thrombocytes, 199
 - Thymus, 213, 222
 - Thymic corpuscles, 225
 - Thyreo-glossal duct, 217
 - Thyroid gland, 217, 226

Tilney, on the hypophysis, 437
 Tissues, 35
 Toldt, on gastric glands, 253
 paradidymis, 344
 Tome's fibers, 107
 processes, 104
 Tongue, 230
 Tonsils, lingual, 218, 222
 palatine, 218, 219
 pharyngeal, 218, 222
 Top-plate 50
 Toruli tactiles 385
 Trabeculae, 205
 Trachea, 290
 Tradescantia, cell division in, 14
 Transitional epithelium, 324
 leucocytes, 196
 Triangular ligaments of the liver, 278
 Tricuspid valve, 177
 Trigeminal nerve, 141, 423, 426
 Trochlear nerve, 141, 422
 Trophoblast, 367
 Trophoderm, 367
 Trophospongium, 5
 Tuberculum impar 230
 Tunica albuginea, 327, 349 353
 propria, 220
 Tympanic cavity, 470, 478
 membrane, 469, 480
 Tyson's glands, 398

U

Umbilical arteries, 381
 cord, 369, 380
 veins 279, 381
 Unipolar cells, 143
 Units, structural, of kidney, 321
 of the liver, 284
 of the spleen, 215
 Unna, on plasma cells, 70
 Urachus, 382
 Ureter, 311, 322
 Urethra, female, 325
 male, 346
 Urinary organs, 306
 Uriniferous tubules, 313
 Urogenital sinus, 330, 353
 Uterine tubes, 327, 358
 Uterus, 327, 360
 masculinus, 346
 menstruating, 363
 pregnant, 366
 Utriculus, 466, 470
 prostaticus, 346

V

Vacuoles, 4
 Vagina, 327, 383
 masculina, 346
 Vagus nerve, 142, 424, 426
 Vallate papillae, 230, 231
 Valves, of the colon, 261, 273
 of the heart, 176
 of Houston, 273
 of lymphatic vessels, 188
 of the veins, 164, 174
 Valvulae conniventes (*circular folds*), 261

Vas deferens (*ductus deferens*), 324, 342
 Vasa aberrantia of the liver, 280
 Vasa vasorum, 171
 Vascular tissue, 44, 163
 Veins, 172
 cardinal, 309
 portal, 277, 278
 pulmonary, 297
 umbilical, 279, 381
 vitelline, 44, 278, 279
 Vena cava inferior, 177, 279
 Venae minimae, 179
 Ventral aorta, 165
 Ventricles, of the brain, 419, 421, 424
 of the heart, 175
 Vermiform process, 270
 Vesalius, on blood vessels, 164
 pituitary gland, 436
 Vesica fellea, 277
 Vesicular follicles of the ovary, 354
 supporting tissue, 82
 Vestibule, of the labyrinth, 468
 of the nose, 482
 of the vagina, 353
 Vibrissae, 482
 Villi, amniotic, 382
 chorionic, 375
 intestinal, 260
 pleural, 306
 synovial, 98
 Visual cells, 444
 purple, 444
 Vitelline duct, 245
 veins, 44, 278, 279
 Vitreous body, 442, 453
 humor, 442
 Volkmann's canals, 93
 Vomero-nasal organ, 141, 483

W

Waldeyer, on spermatozoa, 29
 oögenesis, 34
 plasma cells, 68
 Wax reconstructions, 516
 Weidenreich, on pigment cells, 72
 shape of red corpuscles, 191
 white corpuscles, 195
 eosinophiles, 198
 the spleen, 212
 Weigert's iron hæmatoxylin, 502
 method for myelin sheaths, 510
 resorcin-fuchsin, 504
 Wepfer, on the lobules of the liver, 281
 Wharton, on the suprarenal glands, 405
 Wharton's duct (*submaxillary duct*), 242
 jelly, 62
 Whipple, on the tactile toruli, 385
 White corpuscles, 188, 195
 fibers, 62
 nerves, 153
 rami, 137
 substance of the spinal cord, 414
 Wiesel, on the suprarenal gland, 406
 Williams, L. W., on the notochord, 38, 82
 somites of the chick, 118
 Williams, S. R., on anomalous vessels, 166
 Willis, on the intercostal nerve, 136
 stomach, 251

Wilson, on fourth molars, 101
Wilson, E. B., on sex chromosomes, 21, 28
Winslow, foramen of, 280
Wolff, on the kidney (Wolffian body), 306
 epigenesis, 339
Wolffian body, 306, 307
 duct, 41, 306, 307
 tubules, 308
Wright, on blood plates, 200
Wright's blood stain, 505
 method for frozen sections, 498

X

Xylol, 507

Y

Yolk nucleus, 29
 sac, 39, 382
 stalk, 382

Z

Zenker's fluid, 492
Zona columnaris, 247
 pellucida, 29
 radiata, 29
Zonula ciliaris, 449
Zuckerkindl, on chromaffin bodies, 152
 suprarenal glands, 406
 organs of Zuckerkindl, 152
Zymogen granules, 255







