

## **Essentials of pathology and morbid anatomy / by C.E. Armand Semple.**

### **Contributors**

Semple, C. E. Armand 1845-1895.

### **Publication/Creation**

London : Henry Renshaw, 1889 (London : Ballantyne, Hanson.)

### **Persistent URL**

<https://wellcomecollection.org/works/eyhbrybj>

### **License and attribution**

This work has been identified as being free of known restrictions under copyright law, including all related and neighbouring rights and is being made available under the Creative Commons, Public Domain Mark.

You can copy, modify, distribute and perform the work, even for commercial purposes, without asking permission.



Wellcome Collection  
183 Euston Road  
London NW1 2BE UK  
T +44 (0)20 7611 8722  
E [library@wellcomecollection.org](mailto:library@wellcomecollection.org)  
<https://wellcomecollection.org>

RENSHAW'S STUDENTS ESSENTIALS.

---

---

ESSENTIALS  
OF  
PATHOLOGY AND MORBID  
ANATOMY.

ARMAND SEMPLE,  
B.A., M.B. CANTAB., M.R.C.P. LOND,

---

---

4/6





22102065368




Med

K19248









## MR. RENSHAW'S MANUALS.

- Dr. Druitt's Surgeon's Vade Mecum. By STANLEY BOYD, F.R.C.S., Assistant-Surgeon to Charing Cross Hospital. The Twelfth Edition, price 16s.
- Dr. Hooper's Physician's Vade Mecum. By Dr. GUY and Dr. JOHN HARLEY. The Tenth Edition, with wood engravings, price 12s. 6d.
- Dr. Churchill's Theory and Practice of Midwifery. Sixth Edition, with 123 fine wood engravings, price 12s. 6d.
- Dr. Fowler's Medical Vocabulary. Second Edition. Containing an explanation of 16,000 of the terms used in Medicine, &c., price 12s. 6d.
- Dr. Knox's Manual of Human Anatomy. 250 wood engravings, the vessels coloured, price 12s. 6d.
- Dr. Guy and Dr. Ferrier's Principles of Forensic Medicine. Sixth Edition, just published, with 174 wood engravings, price 12s. 6d.
- Dr. Silver's Practical Medicine, with Sketch of Physiology and Therapeutics. Price 5s.
- Dr. Tanner's Index of Diseases, and their Treatment. Third Edition, price 10s. 6d.
- Mr. Lawson on Diseases of the Eye. Fifth Edition, with 98 wood engravings, coloured plate, and copious Formulæ. Price 10s. 6d.
- Dr. Green's Introduction to Pathological Anatomy, with 150 fine wood engravings. Seventh Edition. Price 12s. 6d.
- Dr. Meadows' Manual of Midwifery. Fourth Edition, much enlarged, with 145 wood engravings, price 10s. 6d.
- Mr. Hilles' Essentials of Physiology. Second Edition, enlarged, improved, and illustrated by 141 wood engravings, price 4s. 6d.
- Mr. Fairlie Clarke's Manual of the Practice of Surgery. By ANDREW CLARK, F.R.C.S., Lecturer on Surgery at Middlesex Hospital, and Mem. Court of Exam. Apoth. Soc. Fourth Edition, price 10s. 6d.
- Whitla's Pharmacy, Materia Medica, and Therapeutics. Fifth Edition, price 10s. 6d.
- Meade's Manual for Medical Examination. Fifth Edition, price 5s. 6d.
- Roser's Manual of Surgical Anatomy. Translated by JOHN C. GALTON. 74 wood engravings, price 3s. 6d.
- Milne-Edwards' Manual of Zoology. Translated by Dr. KNOX. Second Edition, enlarged, with 572 wood engravings, price 3s. 6d.
- Dr. Silver's Outlines of Botany. Second Edition, 300 wood engravings, price 5s.
- Dr. Tanner and Dr. Tilbury Fox's Manual of Clinical Medicine. Third Edition, price 4s. 6d.
- Mr. F. O. Ward's Outlines of Human Osteology. Third Edition, price 7s.
- Dr. Thompson on the Physical Examination of the Chest. 26 wood engravings, price 3s. 6d.



Just Published.

# RENSHAW'S STUDENT'S ESSENTIALS.

## QUESTION AND ANSWER SERIES.

Price 4s. 6d. each. Crown 8vo. Each book contains over 1000 Questions and Answers.

THE ADVANTAGE OF QUESTIONS AND ANSWERS.—The usefulness of arranging the subjects in the form of *questions and answers* will be apparent, since the student, in reading the standard works, often is at a loss to discover the important points to be remembered, and is equally puzzled when he attempts to formulate ideas as to the manner in which the *questions could be put in the examination-room*.

### LIST OF VOLUMES.

- No. 1.—Essentials of Physiology.** By H. A. HARE, M.D., Demonstrator of Therapeutics and Instructor in Physical Diagnosis in the Medical Department, and Instructor in Physiology in the Biological Department of the University of Pennsylvania, Physician to the Dispensary for the Diseases of Children and Assistant-Physician to the Nervous Dispensary of the University Hospital; Physician to St. Clement's Dispensary and Hospital; Member of the American Society of Physiologists and of the American Society of Naturalists.
- No. 2.—Essentials of Surgery.** With ninety Illustrations. Containing also, *Surgical Landmarks, Minor and Operative Surgery, and a Complete Description together with full Illustration of the Handkerchief and Roller Bandage.* By EDWARD MARTIN, A.M., M.D., Instructor in Operative Surgery and Lecturer on Minor Surgery, University of Pennsylvania; Surgeon to the Out-patients' Department of the Children's Hospital, and Surgical Registrar of the Philadelphia Hospital.
- No. 3.—Essentials of Anatomy.** Including *Visceral Anatomy*, based upon the last edition of Gray's *Anatomy*. Over three hundred and fifty printed pages, with one hundred and seventeen Illustrations. By CHAS. R. NANCERDE, M.D., Senior Surgeon to Episcopal Hospital; Surgeon to Jefferson College Hospital; formerly Lecturer on Osteology, &c., in Medical University of Pa.; late Professor of General and Orthopedic Surgery in Philadelphia Polyclinic; and Lecturer on Surgery in Dartmouth Medical College, &c. &c.
- No. 4.—Essentials of Medical Chemistry.** Organic and Inorganic, containing also Questions of Medical Physics, Chemical Philosophy, Analytical Processes, Urinalysis, and Toxicology. By LAWRENCE WOLFF, M.D., Demonstrator of Chemistry Jefferson Medical College, Visiting Physician to German Hospital of Philadelphia, Member of Philadelphia College of Pharmacy, &c. &c.
- No. 5.—Essentials of Obstetrics.** By W. EASTERLY ASHTON, M.D., Demonstrator of Clinical Obstetrics in the Jefferson Medical College, and Chief of Clinics for Diseases of Women in the Jefferson Medical Hospital. (Others in Preparation.)

SPECIALLY INTENDED TO ASSIST STUDENTS TO PUT TOGETHER THE KNOWLEDGE THEY HAVE ALREADY ACQUIRED BY ATTENDING LECTURES.

Just Published, price 4s. 6d., crown 8vo.

**Essentials of Pathology and Morbid Anatomy.** By ARMAND SEMPLE, B.A., M.B. Cantab., L.S.A., M.R.C.P. Lond. All contained in 176 pages, and illustrated with 46 fine wood engravings, with large margins for Notes. This is not written in question and answer form, but contains the essence of those facts with which the student must be familiar before going up for examination.

At the present time, when the student is forced by the rapid progress of medical science to imbibe an amount of knowledge which is far too great to permit of any attempt on his part to master it, a book which contains the "essentials" of a science in a concise yet readable form must of necessity be of value.

356 STRAND, LONDON.

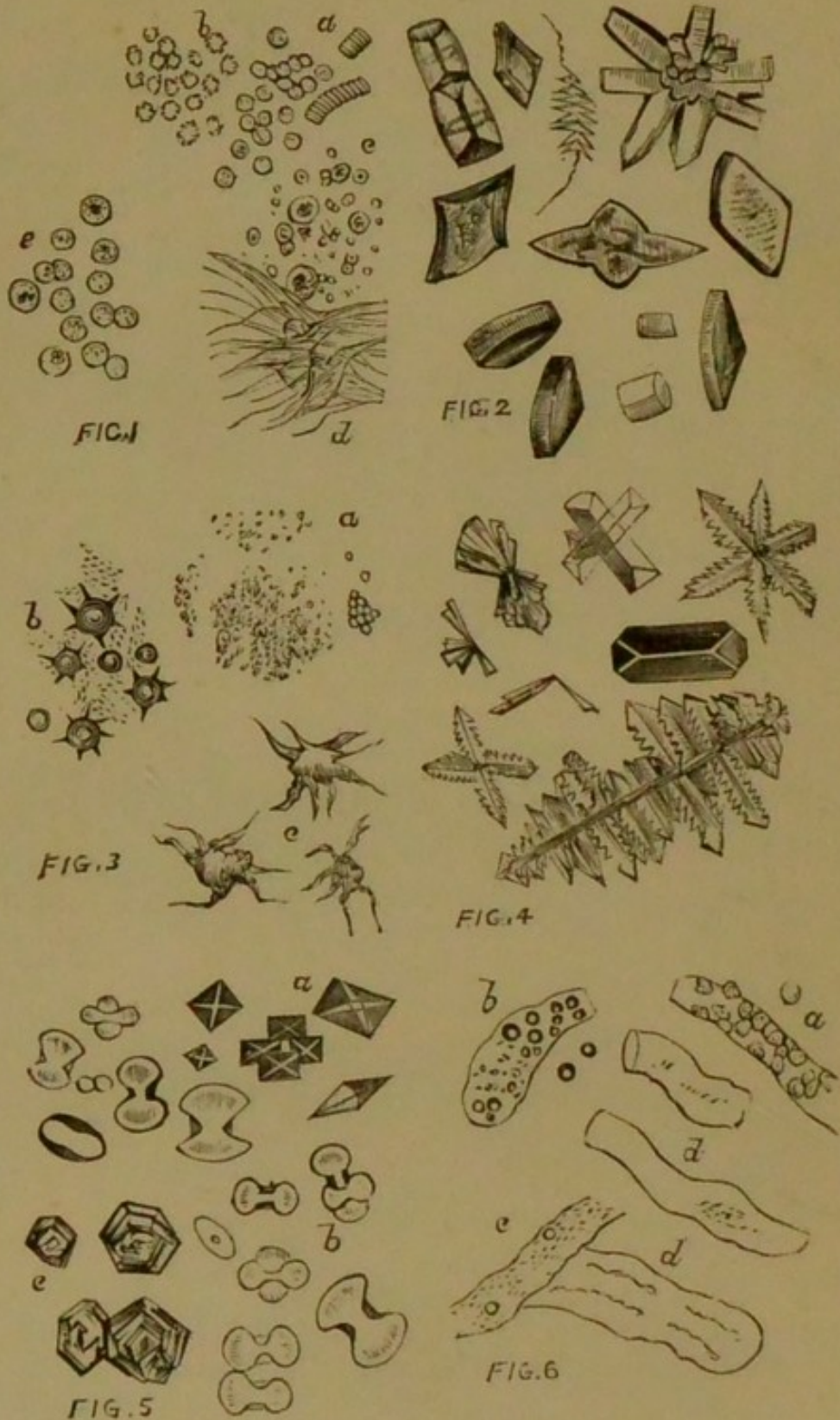
[To face title.



J. B. H. Beatty  
32 Elgin Avenue,  
St Peter's Park, W.

ESSENTIALS  
OF  
PATHOLOGY AND MORBID ANATOMY.





URINARY DEPOSITS, &c.

For explanation of the plate, see back of dedication page, and also pages 108-121.



13300

ESSENTIALS  
OF  
PATHOLOGY AND MORBID  
ANATOMY.

BY

C. E. ARMAND SEMPLE,

B.A., M.B. CANTAB.; L.S.A., M.R.C.P. LOND.;

PHYSICIAN TO THE BLOOMSBURY DISPENSARY; PHYSICIAN TO THE NORTH-EASTERN HOSPITAL FOR CHILDREN, HACKNEY; PHYSICIAN TO THE ROYAL SOCIETY OF MUSICIANS; PROFESSOR OF VOCAL AND AURAL PHYSIOLOGY AND EXAMINER IN ACOUSTICS AT TRINITY COLLEGE, LONDON; LATE MEDICAL CLINICAL ASSISTANT AND SURGICAL REGISTRAR AT THE LONDON HOSPITAL; LATE SENIOR EXAMINER IN ARTS AND MEMBER OF THE COURT OF EXAMINERS AT APOTHECARIES' HALL.

AUTHOR OF "THE VOICE MUSICALLY AND MEDICALLY CONSIDERED," "A MANUAL OF DISEASES OF CHILDREN," "AIDS TO CHEMISTRY," "MEDICINE," "MATERIA MEDICA AND THERAPEUTICS," ETC.

*WITH FORTY-SIX ILLUSTRATIONS.*

HENRY RENSHAW,  
356 STRAND, LONDON.

1889.



840- 11 110 216  
(XQZ)

WELLCOME INSTITUTE LIBRARY	
Coll.	weIMOmec
Call	(2)
No.	4660

TO MY FATHER,  
ROBERT HUNTER SEMPLE,  
M.D., F.R.C.P. LOND.,  
AS A SLIGHT TRIBUTE TO HIS  
SCIENTIFIC ATTAINMENTS AND LABOURS  
IN THE WIDE FIELD OF PATHOLOGICAL INVESTIGATION,  
THIS SMALL WORK IS  
Affectionately Dedicated  
BY  
THE AUTHOR.



## URINARY DEPOSITS, &c.



### EXPLANATION OF PLATE.

Fig. 1.—*a.* Blood discs, as usually seen.  
*b.* Blood discs altered in shape.  
*c.* Tubercle corpuscles.  
*d.* Lung tissue in expectoration.  
*e.* Pus-corpuscles.

Fig. 2.—Uric acid in various forms.

Fig. 3.—*a.* Urate of ammonium.  
*b.* Urate of sodium (rare form).  
*c.* Urate of sodium (rare form).

Fig. 4.—Common forms of ammonio-magnesian phosphates.

Fig. 5.—*a.* Oxalate of calcium (octahedra).  
*b.* Dumb-bell crystals of oxalate of calcium.  
*c.* Cystine.

Fig. 6.—*a.* Epithelial casts.  
*b.* Oily casts.  
*c.* Granular casts.  
*d.* Large and small waxy casts.

## PREFACE.

---

SOME apology may seem necessary for the appearance of another work, and so small a one, upon the subject of Pathology and Morbid Anatomy. I have, however, been led to believe that such a book might be of service to the student, and I have been induced to undertake the somewhat difficult task at the often-repeated request of numerous friends and former pupils.

I have only endeavoured to present an outline of the matter, and must distinctly state that I have no intention of replacing or supplanting the many admirable text-books which are already within reach of the aspirant to pathological knowledge. I can only express a hope that this, my latest effort, may be found useful as an introduction to the subject, or to refresh the memory after more laborious and extensive work has been performed.

Very little space has been devoted to the section on Inflammation, since hundreds of pages might be written upon it, and lengthy description would have been quite beyond the scope of the present undertaking.

The *Bacillus tuberculosis* will not be found under the general heading "Tuberculosis," as I have thought it better described in the section on Bacteria and Bacilli.

The section on Bacteria has been treated at comparative length, since this branch of the subject has of late years acquired very great prominence.



I have thought it advisable to introduce a section on Urinary Pathology, a subject usually omitted from works upon General Pathology, but which nevertheless is regarded of such importance by every examining board in the United Kingdom that a special portion of the examination is given up to its investigation.

In the compilation of the following pages, although I have embodied many of my own observations, I have carefully consulted the most important works on Pathology, and my sincere thanks are due to my numerous medical friends for many hints and much valuable information during the passage of the work through the press.

I must especially thank my publisher for so kindly placing at my disposal the numerous and excellent blocks with which the book is illustrated.

The success which has attended my previous efforts upon subjects in connexion with the training of the medical student lead me to hope that the present volume may also find some small amount of favour, and that it may serve either to awaken in him an interest in an almost illimitable study or to lighten his labours in so wide a field of inquiry.

ARMAND SEMPLE.

8 TORRINGTON SQUARE, W.C.

*February 1889.*



# CONTENTS.

## INFLAMMATION.

Acute Inflammation—Chronic Inflammation—Phlegmonous Inflammation—Inflammatory Effusion—Inflammation of Serous Membranes—Inflammation of Mucous Membranes—Suppuration—Pus—Granulations—Traumatic, Infective, Idiopathic, Specific, Productive, and Interstitial Inflammations . . . . . pp. 1-4

INFLAMMATORY PROCESSES IN THE LUNGS.—Bronchitis—Acute Bronchitis—Chronic Bronchitis—Bronchiectasis—Inflammation of Mucous Membrane—Catarrhal, Croupous, and Diphtheritic Inflammation—Coagulation-Necrosis—Pneumonitis—Acute, Lobar, Plastic, or Croupous Pneumonia—Catarrhal or Lobular (Bronchopneumonia)—Chronic, Interstitial, Cirrhotic, or Fibroid Pneumonia—Pleuritis—Pleurisy with Effusion—Empyema . . . . . pp. 5-9

INFLAMMATORY PROCESSES IN THE HEART.—Pericarditis—Hydropericardium—Pyopericardium—Tubercular Pericarditis—Endocarditis: Acute, Chronic, Papillary—Endocardial Ulcer—Ulcerative Endocarditis—Myocarditis  
pp. 9-12

INFLAMMATION OF BLOOD-VESSELS.—Atheroma—Atheromatous Abscess—Atheromatous Ulcer . . . pp. 12-13



INFLAMMATORY PROCESSES IN THE LIVER.—Hepatic Congestion: Active, Passive, Biliary—Hepatitis (Acute)—Cirrhosis (Chronic or Interstitial Hepatitis)—Hypertrophic or Biliary Cirrhosis—Inflammation of the Biliary Passages: Catarrhal, Plastic or Exudative, and Suppurative . . . . . pp. 13-16

INFLAMMATORY PROCESSES IN THE KIDNEY. — Acute Tubular Nephritis—Chronic Tubular Nephritis (Large White Kidney)—Intertubular Nephritis (Granular or Cirrhotic Kidney)—Pyelitis: Acute and Chronic . . . . . pp. 16-18

INFLAMMATORY PROCESSES IN THE STOMACH.—Congestion of the Stomach—Gastritis: Acute, Subacute, and Chronic—Ulceration of the Stomach—Superficial Erosions—Perforating Ulcers—Chronic Gastric Ulcers—Sloughing Ulcers—Intestinal Lymphatic Structures—Typhoid Fever—Colitis: Acute and Chronic—Peritonitis . . . . . pp. 19-22

INFLAMMATORY PROCESSES IN THE BRAIN AND SPINAL CORD.—Meningitis—Congestion of the Brain—Encephalitis—Abscess of the Brain—Brain Softening: Red Inflammatory; White, Yellow, or Non-inflammatory—Induration of the Brain—Spinal Meningitis—Spinal Myelitis—White Softening of the Cord—Infantile Paralysis—Trismus Nascentium—Grey Degeneration of the Cord: Inflammatory and Non-inflammatory—Sclerosis: Multiple and Lateral—Bulbar Paralysis . . . . . pp. 22-28

SCROFULOUS INFLAMMATION . . . . . p. 28

INFLAMMATION OF BONE . . . . . pp. 28-30

THROMBOSIS AND EMBOLISM.—Sanguineous Apoplexy . . . . . pp. 30-32

### TUBERCULOSIS.

Grey Miliary Tubercle—Crude Yellow Tubercle—Obsolete Tubercle—Pulmonary Tuberculosis—Tubercular Ulceration



of the Intestines—Tubercular Peritonitis—Tuberculosis of the Brain and its Membranes—Tubercular Meningitis—Acute Hydrocephalus. . . . . pp. 32-38

### THE DEGENERATIONS.

LARDACEOUS DEGENERATION.—The Lardaceous Liver—The Lardaceous Kidney—The Lardaceous Spleen—Lardaceous Disease of Lymphatic Glands and of the Alimentary Canal—Corpora Amylacea . . . . . pp. 38-44

FATTY DEGENERATION AND FATTY INFILTRATION.—Fatty Degeneration of Epithelium—Fatty Degeneration of Arteries (Primary and Secondary)—Fatty Infiltration of Muscle—Pseudo-hypertrophic Muscular Paralysis—Fatty Disease of the Heart—Fatty Infiltration of the Liver—The Fatty Kidney . . . . . pp. 44-51

CALCAREOUS DEGENERATION.—Gangrena Senilis—Calcification of Arteries . . . . . pp. 51-53

PIGMENTARY DEGENERATION.—Pigmentation—False Pigmentation—Pigmentation of the Lungs—Brown Induration of the Lung—Pigmentation of the Liver pp. 53-56

MUCOID DEGENERATION . . . . . pp. 56-57

COLLOID DEGENERATION . . . . . pp. 57-58

### THE TUMOURS.

Fibromata : Solid, Soft, and Cavernous Fibroma—Myxomata : Myxo-lipoma, Myxo-sarcoma, Myxo-fibroma, Myxo-chondroma, Myx adenoma—Lipomata—Chondromata—Osteomata : Exostoses, Osteophytes, Cancellous, Compact, Eburnated Osteoma—Lymphomata: Soft and Indurated—Lymphadenoma—Hodgkin's Disease (Adénie)—Lymphangiomas—Sarcomata : Round-celled, Spindle-shaped (Small and Large), Myeloid and Melanotic or Pigmented—Fibro-plastic Tumour—Lipo-sarcoma, Chondro-sarcoma, Osteo-sarcoma, Myxo-sarcoma, Glioma, Lympho-sarcoma,



Alveolar Sarcoma — Epulis — Psammoma — Myomata —  
 Neuromata—Angiomata : Simple or Capillary, Cavernous  
 or Venous—Papillomata : Simple and Venereal—Adeno-  
 mata : Adeno-fibroma, Glandular Hypertrophy, Mucous  
 Polypus, Adeno-myxoma, Adeno-sarcoma—Carcinomata :  
 Acinous Cancer, including Scirrhus, Encephaloid, and  
 Colloid; Epithelial Cancer, including Squamous and  
 Cylindrical-celled Epithelioma—Fungus Hæmatodes  
 pp. 59-85

TERATOMATA . . . . . p. 85

CYSTS.—Unilocular, Multilocular, and Retention Cysts—  
 Exudation Cysts—Extravasation Cysts, &c. . pp. 85-86

#### SEPTICÆMIA.

Septic Intoxication—Septic Infection—Aseptic Traumatic  
 Fever—Simple Inflammatory Fever—Septic Traumatic  
 Fever . . . . . pp. 87-88

#### PYÆMIA.

Abscesses following Infarction—Metastatic Abscesses p. 88

#### HYPERÆMIA.

Active or Arterial—Passive or Capillary—Mechanical or  
 Venous—Collateral Hyperæmia—Mechanical Hyperæmia  
 of the Liver . . . . . pp. 88-90

#### ISCHÆMIA.

Local Anæmia—Hydræmia . . . . . pp. 90-91

#### LEUCOCYTHÆMIA,

Leukæmia or Lymphæmia : Splenic and Lymphatic—Leuco-  
 cytosis . . . . . pp. 91-93

URÆMIA . . . . . pp. 93-94



## SYPHILIS.

Gumma or Syphiloma . . . . . pp. 94-97

## HYPERTROPHY.

Simple, Numerical (Hyperplasia), Spurious . . . pp. 97-98

## ATROPHY.

Simple, Numerical, General, Partial—Necrobiosis—Atrophy  
of Adipose Tissue, of Muscular Fibres, of Glandular  
Organs, of Nerves, of Muscles, of Heart, of Liver, of  
Walls of Air-vesicles, of Bone . . . . . pp. 98-102

NECROSIS OF BONE . . . . . pp. 102-103

CARIES—RAREFYING OSTEITIS . . . . . pp. 103-104

MOLLITIES OSSIUM, OR OSTEOMALACIA . . . . . pp. 104-105

RACHITIS . . . . . pp. 105-106

## PATHOLOGY OF THE URINE.

The Morbid Deposits and Constituents—Uric Acid Diathesis  
—Oxaluria—Phosphaturia—Hæmaturia—Albuminuria—  
Diabetes: Insipidus and Mellitus—Urinary Calculi and  
Concretions—Urinary Tube Casts . . . . . pp. 106-121

## ANIMAL PARASITES.

ENTOZOA.—Cestoda (Tapeworms): *Tænia Solium*, *Tænia*  
*Mediocanellata*, *Bothriocephalus Latus*, *Tænia Echino-*  
*coccus*—Trematoda (Flukes): *Distoma Hepaticum* and  
other forms of *Distoma*, *Bilharzia Hæmatobia*—Nema-  
toda (Round Worms): *Ascaris Lumbricoïdes*, *Ascaris*  
*Vermicularis*, *Ascaris Mystax*, *Trichocephalus Dispar*,  
*Trichina Spiralis*, *Filaria Medinensis*, *Filaria Lentis*,  
*Filaria Sanguinis Hominis*, *Sclerostoma Duodenale*,  
*Strongylus Gigas*, *Strongylus Bronchialis* . . . pp. 121-128



DERMATOZOA—ECTOZOA.—Pediculi: Capitis, Pubis, Corporis—Acarus Scabiei—Comedones . . . pp. 128-130

#### VEGETABLE PARASITES.

BACTERIA OR SCHIZOMYCETÆ (FISSION FUNGI).—Entophytes — Epiphytes — Saprophytes — Pathogenic Parasites — Ptomaines — Bacterium Termo — Saprogenic, Zymogenic, and Chromogenic Bacteria—Micrococci—Zooglœæ — Arthrococci: Streptococcus, Merista, Sarcina, Staphylococcus — Bacilli — Clostridium — Proteus (Spirulina)—Vibrio—Spirillum—Crenothrix—Leptothrix Buccalis—Analytical Table of Bacteria—Methods of Cultivation of Bacteria (Nutrient Gelatine, Agar-agar, Coagulated Blood Serum, Surface of Cut Potato)—Sterilisation—Continued and Plate Cultivations—The Micromillette . . . . . pp. 131-140

PATHOGENIC BACILLI (HUMAN).—Bacillus Anthracis—Bacillus Tuberculosis—Bacillus Lepræ—Bacillus of Glanders (Bacillus Mallei)—Bacillus Typhosus—Bacillus Œdematis Maligni, Diphtheriticus, Syphiliticus, Malariae—Comma-Bacillus, or Cholera Spirillum—Spirillum Finkleri and Obermeieri . . . . . pp. 140-146

BLASTOMYCETÆ (YEAST FUNGI).—Saccharomyces, or Torula Cerevisiæ—Saccharomyces Ellipsoideus, Mycoderma, Albicans (Oidium Albicans, Oidium Lactis)—Parasitic Yeasts on the Skin: Saccharomyces Capillitii, Actinomyces (Ray-Fungus), Actinomycosis, Mycetoma (Madura Foot of India) . . . . . pp. 146-148

HYPOMYCETÆ (MOULDS).—Non-pathogenic or Saprophytic, as Aspergillus Glaucus, Niger, Fumigatus; Penicillium Glaucum; Mucor Mucedo—Pathogenic Fungi on Human Skin: Trichophyton Tonsurans, Achorion Schoenleinii, Microsporon Furfur, Microsporon Audouini pp. 148-154

METHODS FOR RECOGNISING BACTERIA . . . . . p. 154



## LIST OF ILLUSTRATIONS.




	Urinary Deposits, &c. . . . .	<i>Frontispiece</i>
<b>FIG.</b>		<b>PAGE</b>
1.	Cells from a Granulation . . . . .	4
2.	Chronic Atheromatous Change in an Artery . . . . .	12
3.	Intertubular Nephritis in the Acute and Early Stage . . . . .	18
4.	Scrofulous Inflammation of a Bronchus . . . . .	29
5.	Acute Tuberculosis (Grey Tubercle) . . . . .	32
6.	Acute Tuberculosis (Yellow Tubercle) . . . . .	33
7.	Acute Tuberculosis (Yellow Tubercle) . . . . .	34
8.	Miliary Tubercle of the Omentum . . . . .	37
9.	Lardaceous Liver . . . . .	41
10.	Fatty Degeneration of Epithelium . . . . .	45
11.	Fatty Degeneration of Connective Tissue Cells in the Internal Coat of an Artery . . . . .	47
12.	Fatty Infiltration of Muscle . . . . .	48
13.	Fatty Infiltration of the Liver . . . . .	50
14.	Calcified Cartilage . . . . .	52
15.	Cells in various stages of Pigmentary Infiltration . . . . .	54
16.	Collier's Lung, with carbon particles . . . . .	55
17.	Fibrous Tumour . . . . .	59
18.	Hyaline Myxoma . . . . .	61
19.	Adenoid Tissue in Chronic Phthisis . . . . .	65
20.	Lymphadenoma . . . . .	66



FIG.	PAGE
21. Lymphadenoma . . . . .	66
22. Round-celled Sarcoma . . . . .	70
23. Glioma of the Cerebellum . . . . .	70
24. Adenoma of the Mamma . . . . .	71
25. Fully-formed Carcinomatous Tissue . . . . .	77
26. Scirrhus of the Mamma . . . . .	80
27. Scirrhus of the Mamma . . . . .	80
28. Scirrhus (commencing cicatrisation). . . . .	81
29. Adenoid Structure from a Gummy Growth in the Kidney . . . . .	96
30. Trichina Spiralis in its Cyst . . . . .	126
31. Trichina Spiralis removed from its Cyst . . . . .	126
32. Pediculus Capitis (female). . . . .	128
33. Pediculus Pubis . . . . .	128
34. Pediculus Corporis or Vestimenti . . . . .	129
35. Acarus Scabiei (male) . . . . .	130
36. Comedones . . . . .	130
37. Tubercle Bacilli in Phthisical Sputum . . . . .	141
38. Tubercle Bacilli in Alveolus of Human Lung . . . . .	141
39. Bacillus of Glanders . . . . .	143
40. Bacilli of Typhoid Fever . . . . .	144
41. Trichophyton Tonsurans . . . . .	149
42. Trichophyton Tonsurans . . . . .	150
43. Achorion Schoenleinii . . . . .	151
44. Microsporon Furfur . . . . .	152
45. Microsporon Audouini . . . . .	153



# ESSENTIALS OF PATHOLOGY AND MORBID ANATOMY.



## INFLAMMATION (PHLOGOSIS).

FROM the artificial production of inflammation in the lower animals, this process has been found to consist in:—

- (1) **Changes in the Blood-vessels and Circulation.**
- (2) **Exudation of Liquor Sanguinis, and Migration of White Blood-corpuses.**
- (3) **Alterations in the Nutrition of the Inflamed Tissue.**

(1) The first result of inflammation set up by irritation of the mesentery (a transparent tissue) is a **dilatation** of the arteries, followed by the same condition in the veins, and accompanied by an **acceleration** in the blood-flow, lasting for about twelve hours. Then follows a considerable **retardation** in the circulation, the dilatation of the vessels still continuing. During this retardation the leucocytes or white blood-corpuses congregate in the capillaries, and cling to the sides of the vessels.

(2) The blood current passing over the accumulated leucocytes—these by their active movements permeate the vascular walls, and thus enter the surrounding tissues. In their passage button-like elevations appear to spring from the outer walls of the vessel, and these elevations by degrees assume the form of pear-shaped bodies. They then become severed from the wall, and thus complete their passage. The red blood-corpuses at the same time pass through the walls of the blood-vessels, but in



far less number, and chiefly through the walls of the capillaries.

The exudation of liquor sanguinis constitutes the so-called **Inflammatory Effusion**. In this a larger amount of fibrin and albumen is contained than in the transudation of simple mechanical congestion, whilst the phosphates and carbonates are also in excess. The large number of cell structures contained is remarkable, the particular tissue inflamed and the severity of the inflammation occasioning considerable variation in the nature and quality of the effusion.

(3) The nutritive activity of the cellular elements is always increased; cells which ordinarily undergo no change in form or movement send out processes and alter variously in shape. Cell-proliferation is one of the earliest of the nutritive changes.

In **ACUTE INFLAMMATION** the **local symptoms**, when **external**, are pain, swelling, redness, and heat. The pain is produced by the pressure on the nerves by the surrounding swollen textures; the swelling and redness arise, the latter from the increased amount of red blood which the vessels of the part contain, the former from the same cause, and from the exudation of serum, lymph, and leucocytes from the blood; it is further increased by the enlargement and proliferation of these leucocytes, and of the connective-tissue corpuscles and other cellular elements of the inflamed tissue. The heat never exceeds that of the blood, although it is greater than that of the other superficial and unaffected parts.

When **internal**, the symptoms are functional disturbance and pain; the former symptom is indicated in secreting organs by alteration, increase, diminution, or entire suppression of the proper secretions; in other organs there are varying conditions of excitement: in the lungs there is dyspnoea; in the ear and eye, intolerance of light and sound; in the heart, palpitation; in the brain, delirium.

**Modifications** in the inflammatory character. These may be due to (1) The texture; and (2) The condition of the system.

(1) **The Texture.**—**Serous** membranes in acute inflammation become the seat of adhesive inflammation, but very rarely of the suppurative; in the **mucous** membranes inflammation gives rise to the production



of pus, increased flow of mucus, and occasionally lymph, and these membranes are liable to suppuration, ulceration, and softening, but rarely to adhesion of their surfaces. The inflammation of the areolar tissue is termed **phlegmonous**, and induces the secretion of serum, and frequently of lymph and pus, and it very commonly ends in abscess. Among **fibrous** tissues, ligament and tendon are liable to become gangrenous, and cartilage may ulcerate. The parenchyma of organs may be softened by acute, or hardened by chronic inflammation; or the inflammation may end in abscess or in gangrene. Inflammation of the bones terminates in caries and necrosis. The skin resembles the mucous membranes in its liability to suppuration. In inflammation of the **serous** membranes there is acute pain, there is an excess of fibrin in the blood, bleeding and depletory measures are usually well borne, and the blood is buffed and cupped, the heat of surface and muscular debility are increased, the frequency of the pulse is accompanied by hardness, and there is sometimes a tendency to delirium. In the **mucous** membranes, on the contrary, the pain is often slight, bleeding and depletion are not well borne, the fibrin in the blood is not increased, and there is no buffed and cupped appearance of that fluid. A certain doubtful resemblance may be observed, however, between the mucous and serous membranes in the formation of those **false membranes** which occur in diphtheria and some allied diseases of the mucous membrane of the lungs and bowels.

**Terminations.**—(1) Resolution or cure; (2) Metastasis or change of seat; (3) Effusion of serum; (4) Effusion of lymph; (5) Suppuration or formation of pus; (6) Ulceration; (7) Gangrene, mortification, or sphacelus.

The process of **Suppuration** is a frequent result of inflammation, and it may be broadly stated that according to the intensity of the inflammation so is the abundant formation of the pus.

**Pus** is essentially composed of a liquid almost identical with liquor sanguinis, and holding cells suspended in it. This liquid also contains albumen, pyin, chondrin, fatty matters, and inorganic substances. The pus-corpuscles closely resemble the white globules of the blood, but they are somewhat rougher in outline, and contain more nuclei, although some authors believe them to be

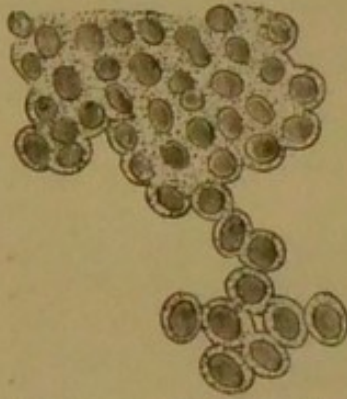


identical. They are spherical, semi-transparent, and vary from  $\frac{1}{2500}$  to  $\frac{1}{3500}$  of an inch in diameter. The addition of acetic acid causes the cells to swell up, increasing their transparency, and rendering the nuclei more visible. The pus-corpuses are derived either from the blood (leucocytes) or from the cells of the inflamed tissue, and the suspending liquid is undoubtedly the liquor sanguinis.

**CHRONIC INFLAMMATION** differs from the acute form in the lower degree of the severity of the irritation occasioning it, and in the duration of its action being in general much more prolonged. The exudation of liquor sanguinis and blood-corpuses is not so abundant, and the tendency is eventually to produce an increase of the connective tissue in the part; the redness is more dusky in tint, the pain is sometimes very slight, and the heat of a mild character—an exception to this is, however, observed in the painful joints of chronic rheumatism. When the internal parts are affected, the secretions are performed languidly, and the quantity of the secretions is diminished. Should the areolar tissue

be the seat, serous effusions are the usual result.

FIG. 1.



*Cells from a Granulation.*

When inflammation is the result of an injury, it is termed **Traumatic**; when it is due to septic influences, as in pyæmia and tuberculosis, it is called **Infective**; when the cause is not apparent, the name of **Idiopathic** is given; and as **Specific** inflammations may be instanced the "rash" of small-pox, the inflammation of the skin and mucous membranes in syphilis, and the inflammation of the intestinal structures in typhoid fever. In those cases in which inflammatory connective tissue is formed, the inflammation is termed **Productive**; and to inflammation of solid organs in which the evidences reside especially in the connective tissue, the term **Interstitial** is applied.

**Granulation Tissue.**—On the floor of a healing ulcer composed of this tissue a number of rounded projections are seen; these are about the size of a pin's head, and are known as **granulations** (Fig. 1).



## INFLAMMATORY PROCESSES IN THE LUNGS.

**BRONCHITIS** (Inflammation of the **Bronchial Mucous Membrane**).—In the **acute** form there is redness of the mucous membrane of the bronchial tubes, which are at the same time soft, thickened, and coated by frothy mucus or muco-purulent fluid.

In the **chronic** form there is an increase of the muscular structure with thickening and striation of the mucous and sub-mucous tissue. The tubes are usually constricted; but occasionally dilatation is produced, a bronchial tube becoming so dilated as to form a pouch, or series of pouches.

In **Bronchiectasis**, or dilatation of the bronchial tubes, the dilatation may be of considerable size and isolated, of a round or irregular shape, surrounded by condensed lung-tissue and connected with one of the larger tubes; or the tubes of a part of one lung may be dilated uniformly, the walls being either thinned or thickened; or, lastly, a large number of minute rounded dilatations of the terminal branches of the bronchi may be present in a lung which is the seat of some morbid condition, as emphysema.

In the **plastic** form there is an exudation of false membrane upon the inflamed mucous surface.

**Microscopically**, the same appearances are presented as in inflammation of any mucous membrane.

Inflammation of mucous membrane is described as occurring in three forms—viz.,

*Catarrhal, Croupous, or Diphtheritic.*

The bronchi are more commonly the seat of the catarrhal form.

**ACUTE CATARRHAL INFLAMMATION.**—The blood-vessels are engorged with blood, and, consequently swollen, the lymph follicles are enlarged from increased cell-formation within them; there is an increased secretion of mucus, showing numerous cells, in part leucocytes and in part originating in pre-existing epithelial cells. In **chronic** catarrh elongation of the cells of the connective tissue takes place, new structures being formed, and the thickness and density of the membrane become increased.

**CROUPOUS AND DIPHTHERITIC INFLAMMATION** are terms applied to inflammations of mucous



membranes and raw surfaces which lead to the formation of a false membrane. The terms croupous and diphtheritic are now more generally considered synonymous. The membrane is sometimes termed **croupous** when it merely involves the epithelium of the mucous membrane, and **diphtheritic** when the mucosa is implicated.

Some authors limit the term **croupous** to false membranes which consist chiefly of coagulated fibrin, and apply the name **diphtheritic** to those false membranes which are composed of tissues that have undergone the so-called **coagulation-necrosis**, that is, in which the epithelium is entirely destroyed, together with more or less of the sub-epithelial tissue. In this case the term croupous is really equivalent to fibrinous.

**Microscopically**, the fibrinous membrane appears like lymph. There is a network of fibrin containing leucocytes, débris, and desquamated epithelial cells, and this membrane is stripped off without difficulty. The diphtheritic membrane is not so easily separated—in fact, sometimes only with great difficulty. It would appear, even accepting the latter view, that in reality the diphtheritic is only an advanced stage of the croupous.

**PNEUMONIA (Pneumonitis).**—Inflammation of the lung substance exists in the three following forms:—

- (1) Acute, Plastic, Lobar, or Croupous.
- (2) Catarrhal or Lobular (Broncho-pneumonia).
- (3) Chronic, Interstitial, Cirrhotic, or Fibroid.

**LOBAR PNEUMONIA**, called **lobar**, because it involves a large tract of the lung; **croupous**, from a fancied resemblance of the histological process to that of croup.—Three stages are described, as follows:—

1st stage: Engorgement, Hyperæmia, Congestion, or Splenisation.

2nd stage: Red Hepatisation or Consolidation.

3rd stage: Grey Hepatisation or Purulent Infiltration.

In the 1st stage, there is great congestion of lung capillaries; the lung is, consequently, redder and larger than usual. On section, the lung yields blood, serum, and froth. The whole organ somewhat resembles the spleen; its sponginess and elasticity are lessened, but it still floats on water, and crepitates under the finger.

In the 2nd stage the spongy character of the lung is lost, the organ becoming hard and solid, resembling liver. The lung is much heavier, and its size is increased; it



sinks in water, and breaks down when pressed by the finger, and, when cut, appears granular.

**Microscopically**, the air vesicles are filled with exudation, consisting of cells variously formed, bound together by coagulated fibrine or plastic lymph, the smaller bronchial tubes being usually blocked by plugs of lymph. The walls of the air vesicles are not thickened by exudation, but they are to some degree swollen by the engorgement of the capillaries.

In the 3rd stage there is diffused suppuration of the pulmonary tissue. The tissue is dirty grey. There are cavities of pus, and pus points start from all parts of the lung on pressure; the lung sinks in water.

**Microscopically**, there is a great proliferation of cells of the surrounding connective tissue and of the epithelial cells lining the air vesicles; in this manner the exudation becomes loosened from the alveolar walls. Further liquefaction of the contents ensues by alterations in the coagulated fibrine, and by the cells of the exudation undergoing fatty degeneration. The mass thus becomes softened, and in a condition to be removed by expectoration or absorption.

Acute lobar pneumonia may end in resolution, or go on to gangrene, or abscess, or may leave unabsorbed deposits, becoming "caseous," and leading to consumption.

In gangrene, a part of the diseased tissue becomes dark in colour, has an intensely fetid odour, and is very friable.

When it ends in abscess, the inflamed portion breaks down into a cavity of an irregular shape, and filled with pus and broken-down lung structure.

**INTERSTITIAL, CIRRHOTIC, OR FIBROID PNEUMONIA.**—In this form, the lymph which is always exuded in pneumonia, and usually thrown off by expectoration, remains in the lung, and degenerates into fibrous tissue and caseous matter. The lung substance is black or dark grey in colour, hard and dense, and permeated by whitish or black bands of fibres, often enveloping old masses of tubercle. It is usually dependent on pre-existing inflammation.

As increase and hardening of the connective tissue take place, the air-cells are diminished in calibre, and are replaced by fibroid growth.

**Microscopically**, the alveolar walls are observed to be considerably thickened by newly formed fibrous tissue, which has replaced the elastic fibres.



This tissue frequently extends inwardly, lessening the cavity of the air vesicles, which are in some cases blocked by epithelial and other cells.

The only indication in some cases of fibroid pneumonia is an increase of connective tissue between the lobules filled with tubercular deposits.

When the growth is fully developed the lung is solid, and hard to the touch; its size is diminished, and on section it appears smooth and shining, and creaks under the knife.

The term cirrhotic is adopted, since the change is regarded as the same which takes place in liver or kidney cirrhosis.

**ACUTE CATARRHAL OR LOBULAR PNEUMONIA (Broncho-pneumonia)** frequently occurs in the lungs of children; it is usually observed in those portions of lung which have become collapsed from bronchitis, single lobules with the small bronchi and the surrounding tissue being usually alone involved, these being red and firm. When cut, the lobules present a smooth, not granular surface, and bloody fluid can be squeezed from them.

In this form the consolidation is limited to single lobules, and disseminated over the lung in variously sized patches.

In plastic or lobar pneumonia the consolidation is massive.

**Microscopically**, the capillaries which surround the air vesicles are dilated and engorged. Enlargement of the epithelial cells of the alveoli takes place, their numbers increase by proliferation, and, in company with serous fluid, effused from the vessels, the cavity of the air-cells becomes filled.

**PLEURITIS (Inflammation of the Pleura).**—(1) The surfaces of the pleura are at first dry from the arrest of the ordinary secretion consequent upon inflammation, and the sub-serous areolar tissue is injected.

(2) Lymph, or serum, is effused, or lymph-flakes mingled with pus, and recent adhesions are to be observed. (Pleurisy with effusion.)

(3) The pleural sac is filled with pus. (Empyema.)

**Microscopically**, the appearances in pleurisy are those of inflammation of any serous membrane. The first event is a dilatation of the capillaries, by which the red-



ness is produced. The epithelium then falls off, the membrane being left roughened and its denuded surface coated by lymph which the dilated blood-vessels exude. The lymph is composed of fine fibres, cells, and nuclei. The cells and nuclei are exuded by the overloaded vessels, or take origin from proliferation of the epithelial cells. The fibres result from the coagulation of the fibrine of the liquor sanguinis. Should the opposite surfaces of the pleura remain touching one another, the cells entangled in fibrine become fusiform (spindle-shaped), and thus form connective tissue; blood-vessels are developed from the inflamed pleural vessels, and the false membrane is said to become organised, leading to adhesions. If a copious fibro-serous effusion exists between the opposed pleural surfaces, union may result by a process affecting the connective tissue of the serous membrane itself. Externally the false membrane is composed of coagulated fibrine, but beneath this is a layer of cells formed by the proliferation of the connective-tissue cells of the sub-epithelial structures; vessels soon permeate the cellular layer, the cells become fusiform, and produce connective tissue. The flakes of fibrine in the fluid by which the sac of the pleura is distended undergo fatty degeneration, soften, and are absorbed in company with the fluid, the opposed surfaces coming in contact and uniting. When suppuration takes place, the pus-cells originate, partly from the exudation of the white blood-corpuscles, and partly from proliferation of the cells of the false membrane and of the connective tissue of the structures in the vicinity. In a microscopic specimen the injected newly formed blood-vessels appear in the midst of material consisting of cells; they vary in size, and look like channels rather than vessels.

## INFLAMMATORY PROCESSES IN THE HEART.

### **PERICARDITIS** (*Inflammation of the Pericardium*).

—In recent cases lymph is observed, of a pale-straw colour, soft, tenacious and firm, and mixed with serum and flakes of fibrine. The surfaces of the serous membrane are shaggy and rough, and present honeycomb depressions; at later periods there are exudations of lymph and fibrin-



ous serosity, causing adhesions between the opposite surfaces which may obliterate the pericardial cavity; where the powers of life are very low, there is considerable serous effusion, constituting dropsy of the pericardium (Hydropericardium). Pus is rarely, but occasionally present (Pyopericardium), and sometimes tubercles are observed (Tubercular Pericarditis).

**Microscopically**, the appearances resemble those of a serous membrane as in pleuritis (p. 8).

**ENDOCARDITIS (Inflammation of the Endocardium).**—The inflammation is usually confined to the valves of the heart.

The valvular inflammation gives rise to deposit of lymph upon or beneath the lining membrane. The valves thus lose their thinness and transparency, they become thick, puckered up, and adherent to one another or to opposite walls of the channel; or they may present warty vegetations or excrescences; or they may be the seat of atheromatous degeneration, or of calcification (deposit of carbonate and phosphate of calcium).

In an early stage the endocardium is reddened and roughened with lymph, vegetations or warty projections being found on the valves, and being most thickly situated on the lines at which the segments of the valves during their closure come into contact with each other—*i.e.*, where they are most exposed to friction. In some cases the valve segments become united, or the valves or chordæ tendineæ are torn and softened. In rare instances perforation of a valve or ulceration of the endocardium may take place. The valves may become opaque, thickened, or contracted. If the inflammation becomes chronic the valves of the heart may become thickened, contracted, atrophied, or ossified.

The endocardium is non-vascular, and consists of a layer of connective tissue, having an internal **endothelial** covering.

When the process is of considerable intensity (acute), the deeper layers of the endocardium become rapidly infiltrated by young cells. The intercellular substance becomes destroyed, and a new tissue is formed, which, as it projects through the superjacent endothelium, produces minute granulations and vegetations upon the surface of the softened valve. The term **papillary** is applied to this form of the disease. The granulations, being roughened and stripped of endothelium, may become



covered by fibrinous caps by inducing coagulation upon themselves.

When the inflammatory process is of moderate intensity, as is usually the case, the granulating valves may become adherent to one another or to an inflamed patch on the cardiac walls, the new tissue undergoing fatty and calcareous degeneration, and becoming more or less organised into a fibrillated structure. Consequently, thickening, rigidity, and shrinking of the valves are produced, leading to their insufficiency (regurgitant disease) and narrowing (stenosis). The vegetations and papillary excrescences are caused by the new tissue continuing to grow after the severity of the process has ceased. If, however, the inflammatory process is very intense—that is, if the cellular infiltration of the deeper layers of the endocardium is very great—an **endocardial ulcer** results, the new tissue breaking down and loss of substance ensuing. The condition itself is then called **ulcerative endocarditis**, in rare cases small quantities of pus being observed in the deeper layers of the endocardium. This condition is very serious, as it frequently gives rise to embolism, and sometimes to pyæmia.

**CHRONIC ENDOCARDITIS** may follow the acute form, or be of a chronic nature from the onset. It is characterised by less rapid and copious cell-infiltration; the intercellular substance suffers far less than in the acute form, but a **fibroid thickening** of the endocardium may result, leading to induration and contraction of the cardiac valves. Occasionally, the valves become the seat of papillary growths (derived from the new tissue), in which fatty and calcareous changes may take place. A long vegetation on a segment of a valve may, by its constant rubbing upon the endocardium (situated beneath it), produce numerous inflammatory granulations.

**MYOCARDITIS**, or inflammation of the substance of the heart, is very rare as an uncomplicated condition, but it may accompany pericarditis. It usually occurs as a general inflammation, immediately situated beneath the endocardium or pericardium.

The muscle is either soft and dark red or hard and dense, and,

**Microscopically**, the transverse striæ of the fibrillæ appear lost, the muscle apparently consisting in the main of fatty and granular matters.



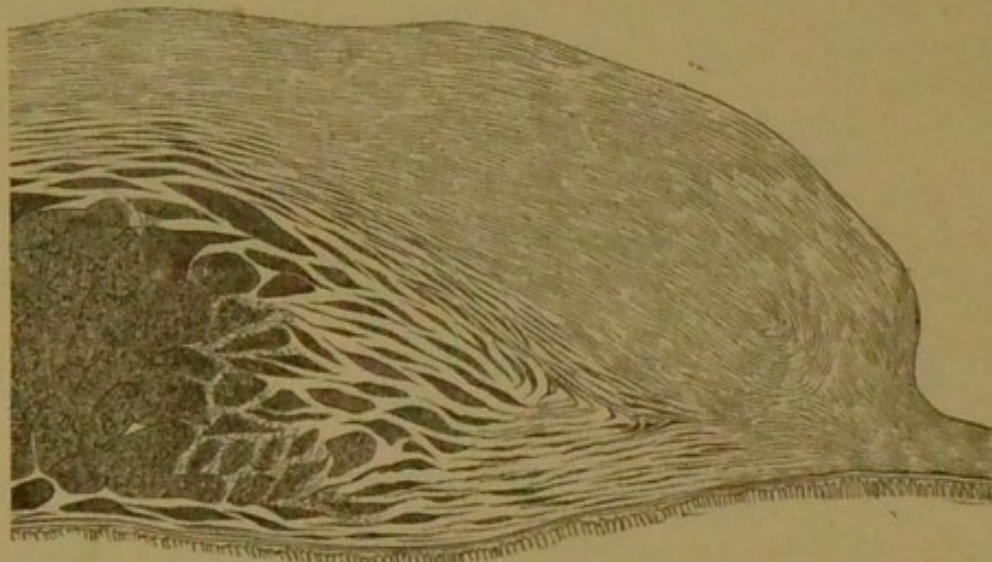
Chronic myocarditis usually results from syphilis. The tissue is dense and hard, from the formation of fibrous tissue between the bundles of the muscular fibres.

### INFLAMMATION OF BLOOD-VESSELS.

Inflammatory changes independently of thrombi are more frequently found in the arteries (Arteritis) than in the veins (Phlebitis), and in the walls of the former vessels they give rise to the so-called

**ATHEROMA.**—Atheromatous changes are found in the deeper layers of the *intima* or inner coat of the arteries. The fibrous and elastic lamellæ of the intima become infiltrated with young cells, and as the number

FIG. 2.



*Chronic Atheromatous Change in an Artery.* The new tissue is seen in the deeper layers of the inner coat, as is also the resulting internal bulging of the vessel. The darker portions show the new tissue, which has become softened and pultaceous. At the lower part of the figure are shown a few of the most internal fibres of the middle coat.  $\times 25$ .

of these cells increases they occasion a swelling beneath the innermost layers of this coat. At first this swelling is soft and flabby, and its lining membrane can be stripped off easily. When the inflammatory process is of great intensity (*acute*), the intercellular substance is



entirely destroyed, the walls of the vessel soften, and dilatation, aneurism, or rupture may follow. The process is, however, usually of much less severity—*i.e.*, more **chronic**—and the term "**atheroma**" is commonly applied to the more **chronic arterial changes** (Fig. 2).

**ATHEROMATOUS ABSCESS.**—When the inflammatory process is of a *chronic* nature, the atheromatous swelling of the intima becomes the seat of retrogressive changes, which commence in the deeper portions of the new tissue. A soft, yellowish, pultaceous substance is thus produced, due to fatty degeneration of the young cells and softening of the intercellular substance.

**ATHEROMATOUS ULCER.**—This is formed when the lining membrane eventually gives way, and the softened matters are carried away by the circulation. Occasionally absorption of the more **fluid** constituents of the morbid tissue takes place, with the formation of cholesterin, and the deeper layers of the inner coat become the seat of a mass of broken-down fibres and cells, cholesterin crystals, and fatty débris. This mass may ultimately become calcified, and result in a **calcareous** plate.

The most chronic forms of the atheromatous process produce but little softening of the new tissue; a fibrillated structure is developed from the cells, and the inner coat of the artery undergoes **fibroid thickening**. The fibroid stroma, however, usually encloses more or less fatty débris.

## INFLAMMATORY PROCESSES IN THE LIVER.

**CONGESTION** of the liver occurs under three forms—*viz.*, (1) **Active**, (2) **Passive**, leading to (3) **Biliary Congestion** (a condition in which the ducts are engorged with bile).

The **Active** form arises from an excessive supply of blood to the organ, resulting from intermittent fever, excess in eating and drinking, or from residence in tropical climates. It may also be caused by morbid materials in the blood, or by the suppression of habitual discharges (catamenial or hæmorrhoidal), or by sedentary habits.

The **Passive** form may occur from obstruction to the



circulation through the portal and hepatic veins, or from obstruction of the blood-flow into the heart, due to dilatation of the heart or valvular disease; from emphysema and other diseases of the lungs, in which the venous blood-flow through the right side of the heart is obstructed; but blows on the side, and intemperance, especially when spirits have been freely indulged in, are common causes of hepatic congestion. It may precede or accompany cirrhosis and other diseases of the liver.

In the first two forms the liver is enlarged, its surface is smooth and dark red, with a hard and prominent margin, and on section blood flows freely. The so-called "nutmeg liver" is the result of long-standing **passive** congestion. Here a section of the liver presents the appearance of a nutmeg—*i.e.*, red spots or patches, which are surrounded by dirty-white or yellowish spaces.

**Microscopically**, in *passive* congestion the hepatic veins are considerably dilated and their walls thickened. The enlarged veins press upon the surrounding parts, and thus the size of the cells in the interior of the lobules is reduced. The colour of the cells is dark yellow, whilst the cells in the exterior are large, fatty, and pale. Occasionally the cells in the centre of the lobules become absorbed, leaving only dark-coloured granular matter.

**ACUTE HEPATITIS** (**Inflammation of the Liver**) presents similar pathological changes to those observed in acute pneumonia.

There is at first great **Congestion** of the capillaries of the liver, with consequent swelling.

Then effusion of **Albumino-Fibrine** or **Plastic Lymph** takes place.

The attack may end in (*a*) **Resolution**, with absorption of the exudate, (*b*) in **Purulent Infiltration**, (*c*) in **Abscess**, (*d*) in **Gangrene**.

**CIRRHOSIS, CHRONIC OR INTERSTITIAL HEPATITIS** is a form of chronic inflammation, resulting in a fibroid hypertrophy of the capsule of Glisson.

In health, the hepatic artery conveys the nutrient blood to the liver, the hepatic duct carries away the bile, the portal vein conveys blood from the viscera to form the bile, and the hepatic vein carries from the liver the waste blood. In cirrhosis there is a **fibroid hypertrophy** of the capsule of Glisson, and, therefore, thickening and



hardening of the liver, the edges of which become rounded, and the surface nodulated (hobnailed). The gland becomes of a light yellow colour, tough and leathery, and its size is much reduced, especially that of the left lobe.

In the early stages of the disease the organ becomes enlarged, but it eventually becomes shrunken, and shuts off the supply of blood by the hepatic artery, producing atrophy and pallor; this contraction of the liver obstructs the circulation through the portal vessels, producing enlargement of the veins upon the surface of the abdomen, and by compression upon the portal vein induces ascites, for, since the blood-stream is thrown back upon the intestines, no absorption takes place, and watery fluid is thrown out into the peritoneum. From pressure upon the hepatic duct the bile-flow is arrested, and this fluid is not properly secreted.

**Microscopically**, the chief portion of the structure is composed of connective tissue, originating from inflammation around the portal canals. The lobules become compressed by the new-formed tissue, the liver cells becoming fatty, or they are absorbed and disappear.

The branches of the hepatic artery are frequently enlarged, and may be seen ramifying in the thickened structure, but the branches of the portal vein are compressed and very often obliterated.

The secreting cells are disintegrated, there is a multiplication of the fat cells, an increase in the colouring matter, and deposit of granular matter, whilst newly-formed connective tissue is seen between the lobules. The tissue first becomes infiltrated with round cells, which eventually, becoming spindle-shaped, form a fibrillated structure. The cells in the outer zone of the lobules are the first to become atrophied, and, in consequence of the new tissue insinuating itself between them, the inter-cellular network is gradually involved.

**HYPERTROPHIC OR BILIARY CIRRHOSIS.**—

The organ is greatly enlarged, and hard and dense. The ascites of ordinary cirrhosis is usually absent, and jaundice is common, in consequence of obstruction of the biliary ducts.

**Microscopically**, the disease appears to have its origin in a chronic inflammation around the smaller biliary ducts, seated between the lobules.

The existence of this form of liver disease is denied by some authors.



**INFLAMMATION OF THE BILIARY PAS-  
SAGES.**—The gall bladder and biliary ducts are liable to the three following forms of inflammation:—

(1) **Catarrhal** Inflammation.—In this form there is an increase of mucous secretion, which becomes viscid or muco-purulent. Occasionally a firm plug of mucus may obstruct, for a time, the cystic or common duct. It is generally preceded by catarrh of the stomach and duodenum.

(2) **Plastic or Exudative** Inflammation.—In this there are **fibrinous** products. Casts of the tubes are found blocking up these channels and causing dilatation.

(3) **Suppurative** Inflammation, in which a thick kind of blood-stained mucus and pus is formed. Ulceration may follow; it is usual to find gall-stones when the gall bladder is ulcerated, but ulceration may be induced by decomposing bile, in the absence of calculi.

## INFLAMMATORY PROCESSES IN THE KIDNEY.

**ACUTE TUBULAR NEPHRITIS** (**Inflammation of the Kidney**).—The kidneys are increased in volume and weight, even to twice their normal size. The surface is smooth, and the capsule readily removable. In early stages the kidney on section is dripping with blood, from which circumstance it has been called the chocolate blood-dripping kidney. The renal substance is sometimes everywhere engorged with blood, but occasionally the cortical portions are everywhere anæmic. There is no alteration of the intertubular stroma. Red points are generally observed upon the surface, and within the cortical portions, being due to minute ecchymoses. A wheatsheaf appearance is sometimes presented, owing to the cones being deeply congested, and the tubes separated at their bases by swollen cortical substance. The kidneys offer considerable resistance to pressure. In later stages they are mottled white and red. The normal weight of each kidney being 3 to 5 ounces, in this disease one kidney may attain to, or even exceed, 8 ounces.

**Microscopically**, the tubuli uriniferi are distended by large granular epithelial cells, mixed with and bound together by blood-corpuscles and fibrine, by which these



channels are partly or entirely blocked up. If recovery does not take place at this period it is stated that the condition of the large white kidney may be established.

**CHRONIC TUBULAR NEPHRITIS, OR LARGE WHITE KIDNEY.**—The kidney is much increased in size; the capsule peels readily. On section, the cortical portion is increased in volume; the surface is smooth and white, marked with blue arborescent veins, or it is of a pale yellow colour, and marked with striations. The pyramids are frequently congested.

**Microscopically**, the renal tubes appear dilated and distended with cells, and with fatty and granular materials, which block up their channels. The intertubular stroma is unaltered. In later stages the tubes lose their lining membrane, and become atrophied.

**INTERTUBULAR NEPHRITIS (THE GRANULAR OR CIRRHOTIC KIDNEY).**—The whole organ is much reduced in size in the advanced stage, but in an early stage its size is often somewhat increased. The capsule is thickened and firmly adherent; when an attempt is made to peel it off, small portions of its tissue adhere to the surface of the gland. The surface is covered with small irregular prominences (granular). In other cases cysts are observed. On section, the cortical portion is found much reduced in size and thickness, the whole structure being coarse and fibrous.

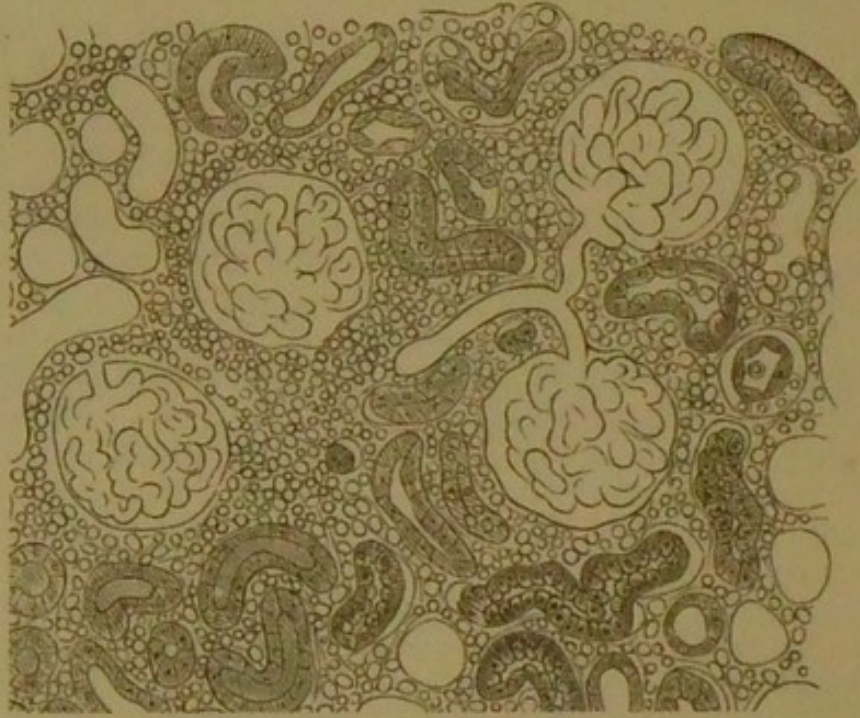
In the earliest stages, the changes are limited to the cortical portion of the kidney, the new growth being usually most abundant around the Malpighian bodies, and at this period the tubes and their epithelial lining are intact; as the disease advances the tubular structures atrophy, and in a very advanced stage calcareous deposits may often be noticed as white streaks between the tubes of the pyramids.

**Microscopically**, in early stages the intertubular connective tissue becomes abnormally vascular, and infiltrated with numerous round cells (Fig. 3). These cells as the disease advances become fusiform, and are converted into fibrous tissue. The newly-formed tissue produces pressure upon the adjoining parts, and hence appear atrophy of the Malpighian bodies and shrinking of the renal tubes, which are often devoid of epithelium. Some pathologists incline to the opinion that the granular kidney is only a modification of the large white variety.



**PYELITIS.**—In the **acute** form there is redness of the lining membrane, which is thickened, ulcerated, or covered by muco-purulent secretion, and there are calculi in the pelvis of the kidney.

FIG. 3.



*Intertubular Nephritis in the Acute and Early Stage.* The figure shows the cellular infiltration of the intertubular tissue.

In an advanced stage of the process the intertubular structure becomes mixed with granular and fatty débris, which result from the degeneration. In a very advanced stage of the process a large amount of fibroid tissue is seen between the tubes of the cortex, with extensive atrophy of the tubes.

In the **chronic** form, when suppuration (suppurative nephritis) has taken place, the kidneys are enlarged and congested, and scattered abscesses are observed, varying from the size of a walnut to that of a hemp-seed. The tubes are crammed with pus-corpuscles and epithelial cells. If the suppuration has resulted from a calculus, the kidney substance will be found destroyed, and its external portions converted into the sac of an abscess which occupies its interior.



## INFLAMMATORY PROCESSES IN THE STOMACH.

**CONGESTION OF THE STOMACH.**—The gastric mucous membrane is of a deep red or purple colour, thickened and covered by tenacious mucus. The vessels are enlarged and filled with blood, the rugæ are very prominent; dark-coloured small round spots are observed chiefly at the pylorus.

**Microscopically**, the vessels are intensely congested, and the coats of the veins are thickened.

**ACUTE GASTRITIS (Inflammation of the Stomach).**—There is unusual and universal redness of the gastric mucous membrane, which is covered by inflammatory patches, especially around the pylorus and cardia. The rugæ are deep red, and numerous brown or soot-black spots, varying in size from a pin's head to a pea, termed "hæmorrhagic erosions," are observed, or the membrane may be softened, ulcerated, or even gangrenous.

**SUB-ACUTE GASTRITIS.**—The stomach is contracted and small. The chief appearances under the **microscope** are those of congestion; the vessels are injected. The gastric tubes are filled with cells, fatty and granular matters, and sometimes with blood.

**CHRONIC GASTRITIS.**—The whole stomach is globular and much thickened, especially at the pylorus, the walls not collapsing on section. If the inflammation is limited to the mucous membrane, this membrane is of a dark or slate-grey colour, the surface being uneven and warty—*i.e.*, *mammillated* and dense.

**Microscopically**, at early periods the gastric tubes are observed to be firmly bound together, the blood-vessels being thickened and enlarged. At later periods fibrous tissue replaces the tubes, and atrophy of the gastric tubes may result from the pressure of the newly-formed fibres. The changes in this form of gastric affection are analogous to those which take place in cirrhotic conditions generally.

**ULCERATION OF THE STOMACH.**—This affection occurs under four well-marked forms:

- (1) **Superficial Erosions** consequent upon the dark



round spots which are frequently observed in congestion and sub-acute gastritis.

(2) **Perforating Ulcers.**—These are circular in shape, and penetrate the coats of the organ, the edges being sharp, as if punched out.

(3) **Chronic Gastric Ulcers.**—In these the edges are usually elevated, and the structures around them are dense and hard, their surfaces being formed by the unperforated coats, or by some other organ, as the liver, to which adhesions have extended; they are most common at pylorus.

(4) **Sloughing Ulcers.**—These may sometimes be found in persons who have previously shown no indication of disease of the stomach, but are much reduced by syphilis or renal disease.

The simple perforating ulcer is rarely smaller than a fourpenny piece or larger than a five-shilling piece. In shape it is generally oval or round, and presents the appearance of a shallow level pit, with a sharp, smooth, vertical edge, as if punched out. The ulcerated space is largest in the mucous membrane, next in the muscular tissue, the shape being that of a funnel or cone; and, if it pass through the peritoneum, the perforation then becomes a mere chink or pin-hole. The areolar tissue and mucous membrane are at times thickened by exudation of lymph, and the surrounding mucous membrane is occasionally inflamed. Perforation occurs in about one case in eight, the fatal result being often averted by adhesion of the bases of the ulcers to the liver, spleen, pancreas, mesentery, or diaphragm.

**INTESTINAL LYMPHATIC STRUCTURES.**—In typhoid fever the local manifestations are chiefly observed in the solitary and agminated glands (Peyer's patches) of the lower third of the ileum, near the ileo-cæcal valve. These normally obscure glands are first swollen and elevated, pale, soft, and rounded at the margins. They rapidly become vascular, the swollen gland becomes abraded, and sloughing and ulceration soon succeed. A whole Peyer's patch may be coated with a discoloured aphthous-looking slough. When the ulcer has advanced, or after the separation of the slough, the surface is rugged and granular. The edges of the ulcers are raised and hard.

Internally the ulcers are ragged with excavations, and



externally they are smooth and rounded. As the base of the ulcer approaches the peritoneum, the inflammation of that membrane increases; when the ulcers are numerous, the patches become confluent, and the outer surface may be covered with plastic lymph. If this covering becomes the seat of ulceration, perforation must ensue, but it is often temporarily delayed by the adhesions of sloughy tissue within the membrane itself, or by the formation of solid lymph upon its external surface.

In cases of recovery, the ulcers heal, contract, cicatrise, and eventually form a depressed smooth surface, which is less vascular and thinner than the surrounding coat.

The mesenteric glands are always much swollen, and more or less inflamed. The spleen is found softened and enlarged, and it sometimes contains little yellowish-white deposits, similar to those found in the diseased glands of the intestines.

**Microscopically**, in a very early stage, there is catarrhal inflammation of the entire mucous membrane of the diseased parts, the lymphatic follicles being enlarged in consequence of their cells being increased in number, and the blood-vessels by which they are surrounded are intensely congested at later stages. The surrounding connective tissue becomes infiltrated with cells, and, by the union of these with the enlarged follicles, a soft medullary mass is formed. In consequence of the cells degenerating, and being absorbed, the follicles may become normal, or, through their bursting, the contents may be discharged.

The characteristic termination is the separation of the dead tissue as a slough, thus forming the **Typhoid Ulcer**. The ulcers which arise in the solitary glands are usually of a spherical shape; those originating from the patches are oval, and their long diameter is in the direction of the gut. The base of the ulcer is smooth and generally formed by the muscular or submucous coat of the intestine, the edges being thin and undermined, and consisting of a fringe of hyperæmic mucous membrane.

**COLITIS, DYSENTERY.**—In the **acute** form there is inflammation either in patches or spread over the whole extent of the mucous membrane of the colon, which is in places black, gangrenous, and softened. The mucous follicles are hard and opaque, or enlarged and transparent.



In the **chronic** form there are ulcers commencing in the solitary glands, which spread and become at last confluent into large ragged patches. The surrounding tissues are much thickened. The lower part of the small intestines, and sometimes the stomach, may present similar appearances, and there is often softening, with swelling and redness of the mesenteric glands. In the *early* stages mucus, blood, and watery lymph are found in the intestines; in *later* stages pus and blood are present.

When the disease has been of long standing, the tissue in the vicinity of the ulcers is almost of the hardness of cartilage. The position of ulcers which have eventually healed is marked by tough cicatrices. Abscess of the liver is observed in the majority of fatal cases of dysentery.

**PERITONITIS (Inflammation of the Peritoneum).**

—The peritoneal vessels are injected; the surface of the serous membrane is covered by coagulable lymph, or flakes of lymph, floating in pus or serum; the intestinal folds are bound by coagulable lymph to each other, or to neighbouring viscera. Plastic lymph is thrown out around the intestines, and this, becoming organised, glues them together and produces obstinate constipation, no peristaltic movements being capable of performance by the firmly-bound intestines.

## INFLAMMATORY PROCESSES IN THE BRAIN AND SPINAL CORD.

**MENINGITIS (Inflammation of the Brain Membranes).**—On post-mortem examination, the vessels of the pia mater are found to be enlarged and engorged with blood, and the arachnoid is opaque, serum and lymph being situated beneath it.

**CONGESTION OF THE BRAIN.**—In the **active** form, the size of the capillaries and the large blood-vessels of the brain and of the pia mater is increased. The puncta cruenta are increased in number, and are larger than usual. The pia mater appears red or rose-coloured, either throughout its entire extent, or in spots. The hue of the grey matter is violet or red. Fluid in excess is contained in the ventricles, and there is enlargement of the choroid plexuses. In the **passive** form, the veins are



usually distended, since the amount of venous blood is increased.

**ENCEPHALITIS, CEREBRITIS** (**Inflammation of the Brain Substance**), may be **general**, when it is especially associated with meningitis, or **local**, in which case it may lead to red softening or to

**ABSCESS OF THE BRAIN.**—This usually results from diseases of the ear, nose, or orbit, or other parts of the skull.

Abscess of the brain may occur in the middle or posterior lobe; the petrous portion of the temporal bone is almost always carious. The dura mater covering it is inflamed, and an abscess is found in a diseased patch of brain, the pus being green and offensive. It is not uncommon to find, in recent cases, a cavity filled with reddish or yellowish fluid, bounded by reddened, softened brain substance; in older cases, encysted pus will be observed—*i.e.*, enclosed in walls formed by connective tissue.

**BRAIN SOFTENING** (**Ramollissement**) may be caused by inflammation or by anæmia, or by long-continued intellectual exertion, and it is most liable to take place between the ages of fifty and eighty.

Two **Varieties** are described—(1) The Red or Inflammatory, and (2) The White, Yellow, or Non-inflammatory.

In **Red or Inflammatory Softening** the brain is soft and pulpy, of a red colour, and often presents numerous blood-points (*puncta vasculosa*).

**Microscopically**, the nerve-tubes are seen broken up and mixed with blood-cells, pus-cells, granular matters, and dark granular fatty bodies like mulberries, called "exudation-corpuscles." The minute arteries are also covered by fatty and granular materials.

In the **White, Yellow, or Non-inflammatory Softening** the brain is soft and pulpy, becoming ultimately of a creamy consistence, white or yellow in colour, and capillary hæmorrhages are sometimes found upon the exterior of the affected part.

To distinguish the softened part from the healthy part of the brain, a stream of water is projected against the organ, the diseased part breaking down under the stream, whilst the healthy is unaffected by it.

**Microscopically**, softened and disintegrated nerve-





fibres, granular matters (resulting from the destruction of the nerve-tissue), the yellow colour being due to the admixture of the fat granules with the colouring matter of the blood, fatty blood-vessels, and fatty cells are observed.

White softening is always the result of imperfect nutrition of the affected part; it is a frequent consequence of the blocking of an artery by a plug (embolism), and it may be caused by the pressure of a tumour or hæmorrhagic clot upon the circulation of the surrounding parts.

**INDURATION OR HARDENING OF THE BRAIN.**—This condition is usually considered to be, and often is, the result of chronic inflammation. The cerebral mass resembles wax or boiled white of egg. Some cases which during life have been regarded as softening of the brain have upon post-mortem examination proved to be really instances of induration.

**SPINAL MENINGITIS.**—The dura-arachnoid is thickened, its vessels congested, and there is effusion of puriform lymph, and serum.

When **Lepto-meningitis**, or inflammation of the pia-arachnoid, is present, there is an irregular appearance of the cord, due to effusion of lymph in the arachnoid space.

When caused by disease of the vertebræ and the structures in their vicinity, the inflammation is localised in portions of the spine; but if due to a general cause, it may extend over the whole extent of the spine, selecting the posterior rather than the anterior aspect.

**SPINAL MYELITIS.**—On post-mortem examination, the affected tissue usually appears much softened; it is often of a creamy consistence. Small extravasations of blood are sometimes seen; in rare cases an abscess forms.

**Microscopically**, broken-down nerve-fibres, blood-cells, granules, and pus-corpuscles are observed. More or less spinal meningitis is always present. Sometimes the cord becomes indurated from fibrinous exudation.

A **Chronic Myelitis** or **White Softening** of the cord is sometimes observed in which the cord is white or of a more or less red or yellowish colour. This may arise from acute myelitis, from gradual pressure upon the substance of the cord from injury, or from failure of nutrition from the vessels becoming degenerated.

**INFANTILE PARALYSIS OR SPINAL PARALYSIS.**—The latest observations of these affections seem



to indicate an inflammation of the anterior cornua of the grey matter of the spinal cord, from which arise the spinal nerves. Atrophy of the large cells takes place, being followed by their subsequent disappearance. Charcot is of opinion that the disease commences with inflammation of the ganglionic cells of the anterior cornua of the grey matter of the spinal cord, which by degrees extends to other situations. The cervical, dorsal, and lumbar portions of the cord may be affected, but the dorsal is the least often implicated. It occasionally happens that the muscles increase in bulk instead of shrinking. In cases which have proved fatal after having lasted for some years, the posterior cornua are found healthy, the anterior cornua being changed and their cells disintegrated. There are flaccidity and atrophy of the muscles, which are to some extent replaced by fat, and the interstitial tissue is hypertrophied; the bones are shorter, the tendons smaller, and there is enlargement of the medullary canal.

The term **Acute Anterior Polio-myelitis** includes the diseases known as Infantile Paralysis and Acute Spinal Paralysis of Adults.

In **TRISMUS NASCENTIUM**, **microscopically**, according to Demme and Rokitansky, the constant anatomical character appears to be proliferation of the connective tissue of the cord, the striking peculiarity being the large area over which it extends. The product is a viscous mass with abundant nuclei, never advancing to a fibre-forming stage. The change is almost exclusively limited to the white medullary substance, the grey matter appearing merely to suffer secondarily. The proliferation is chiefly in the medulla oblongata, crura cerebri, inferior peduncles of the cerebellum, and in the greater part of the spinal cord.

The white substance, then, of the brain and spinal cord is prone to two varieties of grey degeneration—viz., the inflammatory and the non-inflammatory. The grey appearance is due to wasting of the white substance of Schwann, the axis-cylinder of the nerve fibres (itself of a greyish colour) being left untouched.

**The Inflammatory Grey Degeneration** is generally less extensive than the non-inflammatory form. It causes hardness and some reduction in thickness of the parts involved.

**Microscopically**, the external coats of the blood-vessels



appear much thickened; there is an increase in the amount of the connective tissue, with compression and degeneration of the nerve fibres.

**The Non-inflammatory Grey Degeneration** affects the spinal cord more frequently than the preceding form, generally beginning at the lower part and extending upwards. It usually commences at the surface, and, upon making a section of the cord, the posterior columns are seen to be transformed into reddish-grey matter, extending inwards to a variable distance.

**Microscopically**, the amount of connective tissue is considerably increased, a network of fine fibres being formed, by which the nerve fibres are compressed, their degeneration subsequently ensuing. The white substance of Schwann first breaks down, but even late in the disease the axis-cylinder can frequently be made out.

**SCLEROSIS.**—In the discussion of diseases of the nervous system, a good deal of confusion has been created in connexion with that class of lesions in which hardening of the tissues is a distinctive feature. It is a little unfortunate, perhaps, that the word "cirrhosis" has not been more generally applied to such changes; for, practically, the conditions which exist in such diseases as cirrhosis of the liver and sclerosis of the spinal marrow are of a similar nature. In both cases the "hardening" that ensues depends on an overgrowth of the connective tissue of the part, hypertrophy of which destroys the functional powers and the structural integrity of the organ involved, through pressure on the essential elements in each instance. Moreover, there is no common agreement among pathologists in the terminology that is adopted; nor is "sclerosis" commonly used to indicate all lesions in which overgrowth of connective tissue in the nervous system is a characteristic feature. For this reason, therefore, it has seemed desirable to give a brief description in this place of the meaning of "sclerosis" in its application to diseases of the nervous system; and to associate with it an account of the two affections classed as "scleroses"—namely, lateral sclerosis and disseminated sclerosis. Overgrowth of neuroglomatous connective tissue in the posterior columns of the cord is also found in locomotor ataxia, and in the anterior horns of grey matter in progressive muscular paralysis.

The **Pathology** of sclerosis, as already indicated, in-



cludes an account of changes originating in the fine connective-tissue network distributed throughout the nervous structures, and serving as a support for the more important elements—the nerve-cells and nerve-tubules. Under conditions of disease, this connective tissue, or neuroglia, undergoes an increase in bulk, and, as a consequence, the proper nerve elements are subjected to pressure and atrophy, the necessary effects of which are complete destruction of the conducting properties of the nerves, and of the activity of the central cells. According to the position and extent of the induration, so will the symptoms produced differ both in degree and in the parts affected, paralysis being a main result of the changes.

The **Causation** of sclerosis is not always easy to comprehend. In some cases it is undoubtedly a sequel of inflammation extending from the coverings of the cord, &c., and may result from pressure of tumours, curvature, &c. Gout, syphilis, and sexual over-indulgence are likewise credited, probably through the agency of a vitiated blood-supply, with inducing it; and heredity also is regarded by some as an efficient cause. The form of sclerosis affecting the posterior columns of the cord in tabes dorsalis is frequently found in syphilitic subjects.

**MULTIPLE SCLEROSIS.**—This disease is also known under the names of **Disseminated, Cerebro-spinal, and Insular Sclerosis**. It is an affection of which the anatomical characters are overgrowth of the neuroglia, associated with atrophy and degeneration of the essential nerve-elements. It is often found in those who have indulged immoderately in alcoholic liquors, and sometimes it appears to originate from exposure to cold. It is most frequent between the ages of twenty and thirty, but may be encountered in much older or younger subjects.

The morbid growth is most plentiful in the white substance of the brain and cord, and consists of hard round nodules having a greyish translucent appearance. On **microscopical** examination of a section of such a growth the neuroglia is found much increased, its nuclei and fibres being distinct, and the nerve-fibres are atrophied, although their axis-cylinder can generally be made out.

**LATERAL SCLEROSIS.**—In this affection the seat of the lesion is in the antero-lateral columns of the cord.



**BULBAR PARALYSIS, OR GLOSSO-LABIAL-LARYNGEAL PARALYSIS.**—This term is employed when the medulla oblongata and pons Varolii are the seat of the sclerotic change. The medullary matter of nervous tissue is unaffected by carmine, whilst the connective tissue is deeply stained by this substance. The test for sclerosis of such nerve tissue is therefore the action of carmine colouring which imparts to the affected parts a deep-red staining. The disease may thus be recognised without the aid of the microscope.

Thus it may be observed that the anterior cornua of the spinal cord are the seat affected in infantile spinal paralysis, the spinal paralysis of adults, or anterior poliomyelitis, and in progressive muscular atrophy or wasting palsy. The posterior cornua are the seat of change in locomotor ataxia, the lateral columns in lateral sclerosis, and various tracts of the cord in multiple sclerosis.

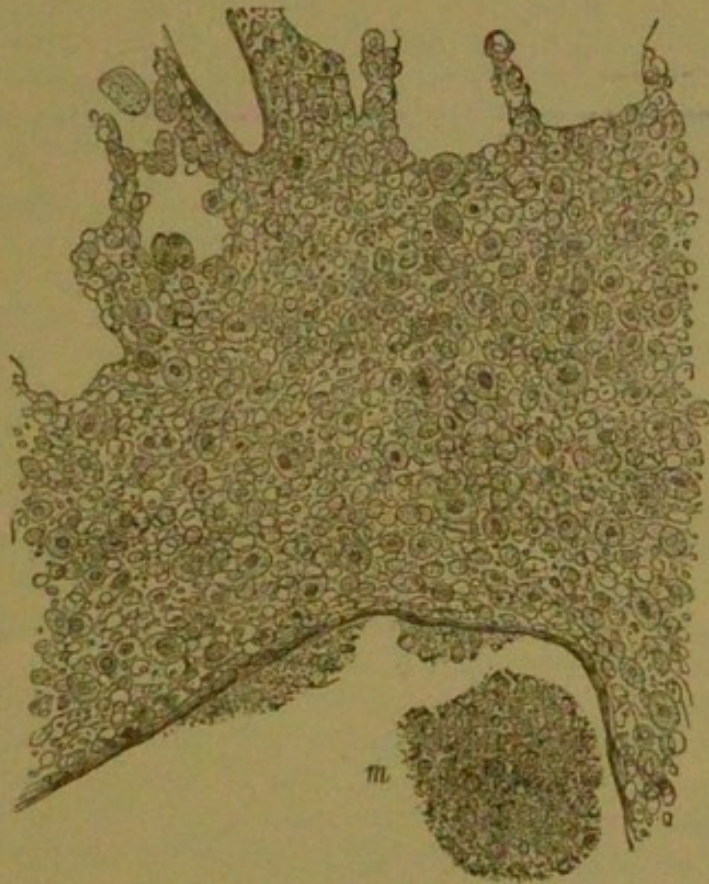**SCROFULOUS INFLAMMATION.**—Injuries which would scarcely affect a healthy subject will produce inflammation in the subject of scrofula. This form is characterised by the abnormal chronicity of its processes. Inflammation in a healthy person leads to absorption of its products, or to suppuration, or to the formation of vascularised connective tissue. In scrofulous inflammation, on the other hand, the absorption of the inflammatory products takes place much less readily; they are prone to infiltrate and accumulate in the tissue, obstruct the circulation by their pressure, and induce retrogressive and caseous changes. No organisation of the new growth ensues in consequence of the slight tendency to the development of new blood-vessels. The cells in this form of inflammation are stated to be *larger* than in those of healthy inflammation; it is common to find giant-cells. The large cells and their infiltration and accumulation are seen in Fig. 4.

**INFLAMMATION OF BONE** is characterised by an increase of medullary tissue and softening of the compact osseous structure. Enlargement and multiplication of the medullary spaces and Haversian canals take place. From those cells containing fat this substance is first removed, a tissue being formed which resembles that found in the medulla during its development—*i.e.*, consisting of many small, round, multinucleated cells, like the so-called "myeloid cells," having a soft, scanty, inter-



cellular substance. The bony lamellæ become gradually absorbed, the calcium salts are removed, the medullary spaces and Haversian canals enlarging and eventually

FIG. 4.



*Scrofulous Inflammation of a Bronchus.* The figure shows a section of a small bronchus in a case of bronchitis associated with marked scrofula, which ended in miliary tuberculosis. Extensive cell infiltration is seen in the deeper structures of the bronchial wall. Most of these cells are larger than those which occur in the less abundant infiltration of healthy inflammation. At the upper part of the figure the walls of the adjacent alveoli are seen invaded by the inflammation. At *m* is observed the cavity of the bronchus in which is contained a little mucus.  $\times 200$ , reduced  $\frac{1}{2}$ .

becoming confluent. The bone becomes very spongy, soft, and vascular; ultimately a fungating mass of granulations may appear beneath the periosteum or the articular cartilage. Pus may accumulate either within the cavities formed in the bone, or it may make its way



to the surface through interference with the vascular supply, loss of vitality (necrosis) of portions of the bone may ensue, or molecular disintegration or death (caries) of the bone may take place in minute portions. When the inflammatory process is of less severity, a compact osseous structure may be formed, which is much denser than the original bone (sclerosis).

### THROMBOSIS AND EMBOLISM.

A **Thrombus** is a coagulum which forms in some part of the vascular system. It usually occurs in one of the heart's cavities, or in a vein, but it may arise in an artery, as is the case with an aneurism. It may be caused by endocarditis, through the roughening of the lining membrane, with which it comes in contact, or it may ensue from the current of blood being retarded. A thrombus may become organised, blood-vessels being developed in it, in which case it is ultimately converted into connective tissue, and adheres closely to the vessel in which it arises; or the thrombus may soften, breaking up into a pulpy mass, which microscopically presents fat globules, altered blood-corpuscles, and granular matters.

An **Embolus** is the term given to that portion of a thrombus, or of an excrescence, which becomes detached from the valves of the heart, and, being driven on by the blood, at last meets with a vessel the calibre of which will not admit of its passage, and in which it therefore becomes fixed.

Foreign matters introduced into the blood induce coagulation on their surface, such as solid metallic bodies, Iron, Mercury, Pus, &c. A clot of fibrine in the blood-vessels tends to increase by addition, layer upon layer.

Thrombosis may be caused by phlebitis (inflammation of a vein), arteritis, and endocarditis from solid exudations from the inner surfaces of the membranes. A film of coagulum being formed upon a roughened and inflamed surface, layer upon layer is deposited, and it in time becomes a thrombus, one portion being attached and the other freely vibrating in the circulating fluid; portions will become detached, and, at length meeting with a vessel the calibre of which will not allow passage, an embolus is formed.

A thrombus may reach from one side of a vessel to the



other, and obstruct the passage of blood from below. Hence pouch-like dilatation and aneurism result. Pus may be formed in the centre of a thrombus, and thus cause pyæmia. When a coagulum has formed in the right side of the heart the pulmonary circulation is most liable to be affected; when the mitral and aortic valves are the seats involved, the cerebral vessels are liable to be obstructed; when those organs the blood of which is returned by the portal vein are affected, the liver may be obstructed.

When the blood-stream is obstructed by an embolus, the functions of the parts thus robbed of their nourishment are destroyed.

Paralysis may occur if a portion of the brain becomes anæmic by the pressure of an embolus. Congestion occurs in the surrounding vessels, and generally hæmorrhage takes place, unless the circulation is carried on through collateral branches, in which case the injury will only be temporary. Softening or suppuration takes place in the structures which are permanently deprived of blood. The brain is most frequently the seat of softening, since the emboli which impede its circulation are derived from the heart. The result of the obstruction is defective nutrition of the particular spot, with softening and abolition of the functions of the parts which are thus robbed of their nutrient blood-supply. In the liver and lungs suppuration is more common, in consequence of the clots by which their vessels are obstructed being as a rule derived from veins obstructed by decomposing blood.

In the **Hæmorrhagic or Sanguineous** form of **Apoplexy** there is effusion of blood from some ruptured artery, and the following is the order of frequency in which the effusion occurs:—First, in the corpora striata and optic thalami; then in the lobes of the cerebrum; then in the pons Varolii (in which case the pupils are contracted); and finally, in other parts of the encephalon. The effused blood dislodges a part of the cerebral substance, and occupies the cavity so produced. If a fatal result does not take place, the serum of the extravasated blood undergoes absorption, contraction and degeneration of the fibrine and red blood-corpuscles take place, the cavity contracts, and ultimately a cicatrix is formed in which the remains of the clot are inclosed.

Thus there is often evidence of a previous attack—viz., a recent clot with circumscribed inflammatory softening



of the surrounding nerve-substance, or there may be an old contracted colourless clot containing blood-crystals, or a small cicatrised cavity containing serum.

## TUBERCLE BACILLI.\*

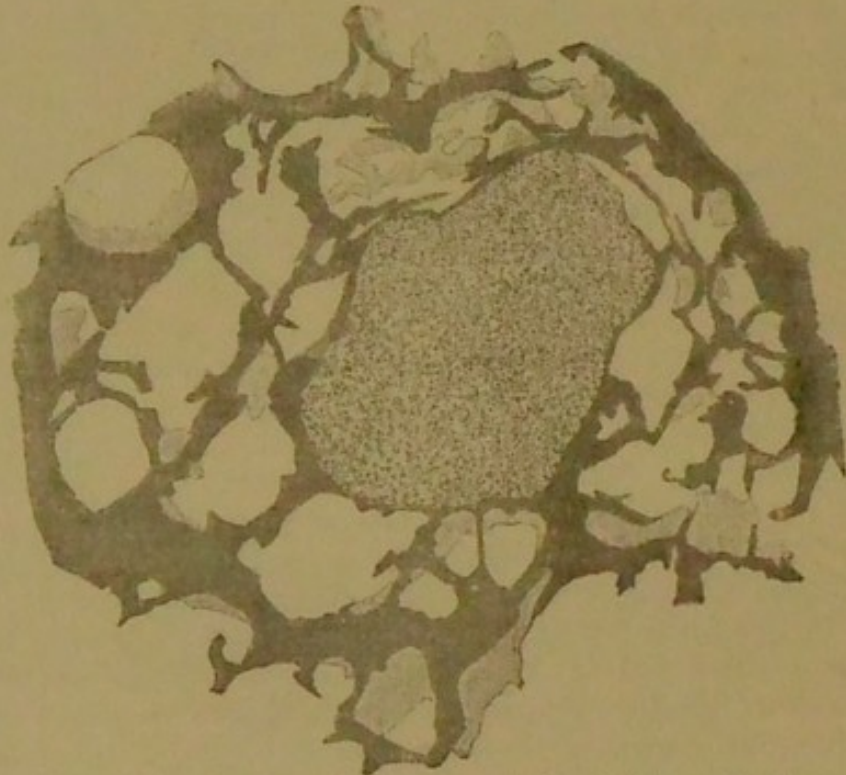
### TUBERCULOSIS.

The term tubercle includes certain morbid products. The affections characterised by the presence of these products are known collectively under the name of **Tuberculosis**—viz., Pulmonary Tuberculosis and Tuberculosis of the Mesentery; but the lungs are the most common seat selected by the tubercular deposit.

Two **Varieties** of tubercle are usually described:

- (1) The **Grey Miliary Tubercle**, or **Grey Granula-**

FIG. 5.



*Acute Tuberculosis.* A firm grey tubercle from the lung. The tubercle is seen situated *between* the alveoli. The appearance of the alveoli is quite normal.  $\times 33$ .

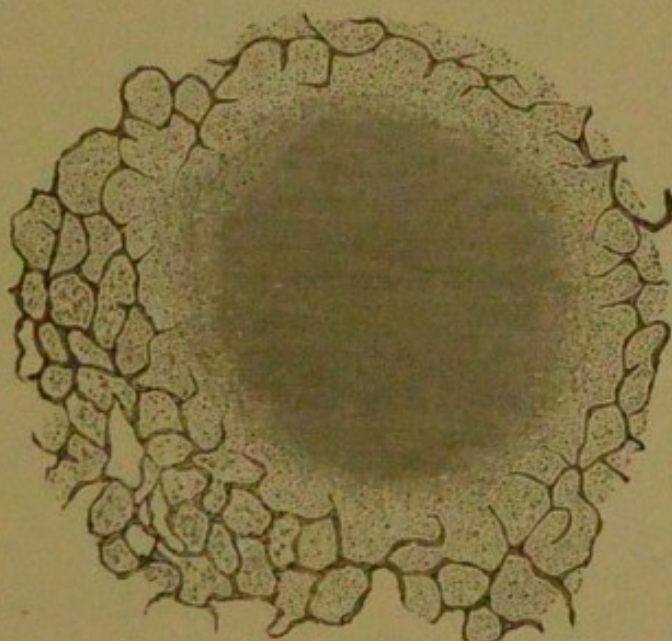
**tion**; of a grey colour, translucent, and varying in size from a millet-seed to a hemp-seed; composed chiefly of albumen, and presenting microscopically a faint cellular organisation (Fig. 5). It may be either hard or soft.

\* For Tubercle Bacilli, see section on Bacteria, page 141.



(2) The **Yellow** or **Crude Tubercle**; larger than the grey, softer, and more irregular in outline, less defined, and often merging insensibly into the surrounding tissue. Many of these yellow tubercles have a greyish-white, translucent margin, which may be moderately firm, while in the centre they are opaque, yellowish, or caseous. This variety of tubercle consists chiefly of albumen and fat, and is about the size of a pea or bean, consisting chiefly of albumen and fat globules. Microscopically, the appearances are shown in Figs. 6 and 7. Occasionally

FIG. 6.



*Acute Tuberculosis.* A yellow tubercle from the lung. At the peripheral portions of the nodule are seen the accumulations within the alveoli; in the centre is the degeneration.  $\times 33$ .

carbonate and phosphate of calcium are deposited in this variety, giving rise to a process called **calcification** or **cretification**, the tubercle being then termed **obsolete**.

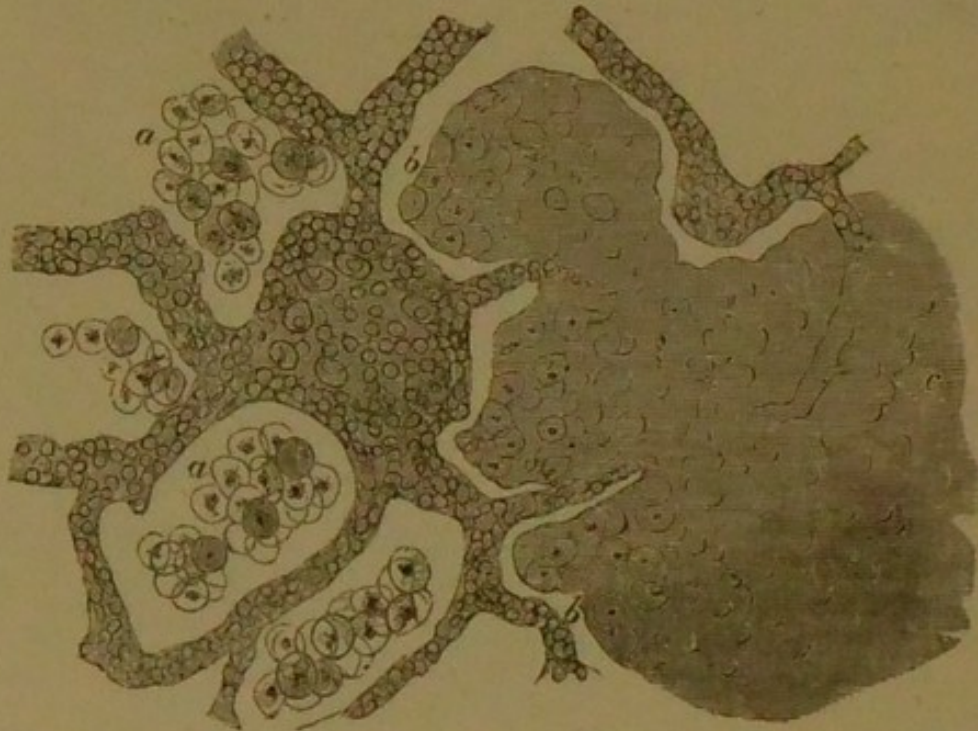
Collections of these tubercles may be found in the liver, spleen, and other parts, and in the peritoneum and cerebral meninges they give rise to tubercular peritonitis and tubercular meningitis respectively.

**Microscopically**, the most characteristic appearance is the large, multinuclear, so-called giant cell, from which numerous branching fibrillary processes extend in all directions, intimately interlacing, and forming a beautiful net-



work or reticulum, the meshwork thus formed being filled with small cells ("lymphoid cells") identical with those of lymphatic or granulation tissue; a third, or large, round, and irregular cell is also observed, which is often pigmented, and contains many nuclei. A collection of such systems constitutes the tubercle as seen by the naked eye; it is, however, only in certain tubercles which have

FIG. 7.



*Acute Tuberculosis.* A small portion of the most external part of a yellow tubercle from the lung. At *a* (most externally) the alveoli are seen to be filled with epithelioid cells. At *b* (more internally) both the walls of the alveoli and their epithelial contents appear in the process of degeneration. At *c* (the central portions) the degeneration has so far advanced that no trace of structure remains. The walls of the alveoli are thickened by a small-celled growth, and at one part is visible a minute mass of this small-celled tissue.

developed slowly that the giant cell is found—*i.e.*, when the "*tubercular process*" is of slight intensity. In more rapidly-developed tubercle the structure is less definite. In this case the lymphoid cells are found, with other cells of various descriptions, according to the tissue affected; thus, in the lungs is found the epithelium of the air-cells.



One or more giant cells may be seen in the interior of the tubercle, the periphery being occupied by the smaller cells.

The most recent view entertained of tubercle is that it is an inflammatory growth of an infective nature, produced by the irritation of particles derived from some morbid focus (most commonly a product of scrofulous inflammation), and conveyed by the vessels and lymphatics.

Virchow considered the tubercular product to be a neoplasm (new growth) due to the proliferation of the connective-tissue cells. Bayle supposed the grey tubercles to remain unchanged for an indefinite period, but the latest microscopical researches seem to show that they eventually become opaque and soften, being infiltrated with fatty and granular matters.

The grey and yellow tubercle may both undergo absorption, the affection being then known as *retrogressive*.

Laennec considered the grey and yellow forms to be the same substance, and that the yellow was merely a progressive stage of the grey. Virchow considers the grey tubercle as the only true tuberculous product, and regards the yellow tubercle as the result of a degenerative change of different morbid products, including the grey tubercle; that it consists chiefly of the products of inflammation, which have undergone a cheesy metamorphosis, and that in some cases the so-called yellow tubercle simply consists of inspissated pus. In the greater number of cases of "chronic pulmonary tuberculosis," the disease is probably only chronic pneumonia supervening upon the production of the grey miliary granulations, and it is supposed that the pneumonia may take place without the granulations, just as the latter are not always followed by the former.

Most authors, then, formerly considered that these varieties were merely stages of the same disease, that the same constitutional affection gave rise to both, and that the crude tubercle must be necessarily preceded by the grey miliary; but some later views of the pathogeny and progress of the disease seem to point to an outgrowth of pre-existing disease of the lung, as in bronchitis, pneumonia, and pleurisy, and phthisis is thought sometimes to attend or follow general diseases, as syphilis and albuminuria.

The more recent theory alluded to supposes that an inflammation, whether pneumonic, pleuritic, or bronchitic



instead of undergoing resolution or its products becoming absorbed and thrown out, leaves unabsorbed deposits which assume a fibroid character, termed cirrhotic, and give rise to yellow and miliary tubercle.

The well-recognised hereditary tendency of phthisis, and the result of every-day experience in private practice in dispensaries, life insurance offices, and hospitals, would seem to point to the earlier views as being more generally applicable.

It may be confidently asserted that whatever may be the relation between the two products known under the name of tubercle, they must both be considered as the expression of a morbid constitutional condition—*i.e.*, they are the manifestation of a tuberculous cachexia.

Tubercle can be easily produced in many of the lower animals, not only by inoculation, but in other ways, and not necessarily by the introduction of tubercle itself, but by other morbid substances.

**TUBERCULAR ULCERATION OF THE INTES-TINES.**—Throughout the ileum, but especially, as in typhoid fever, in the solitary and Peyer's glands and those structures at the lower part of the small intestine and in the cæcum, there are large patches of ulceration at variable intervals, commencing as small, round, discrete ulcers at the upper part of the canal, and becoming confluent below into irregular patches, which extend throughout the entire circumference of the canal.

Each ulcer is of an irregularly circular form, and bounded by a thick, raised, round, and inflammatory border. Internally the margin is irregular and continuous, with coarse granulations, between which are scattered little yellow masses of tuberculous matter firmly adherent to the base of the ulcer. Some of the ulcers may extend to the peritoneal coat, and their existence may be known, before the intestines are opened, by an irregular thickening and a corresponding irregularity of the peritoneum.

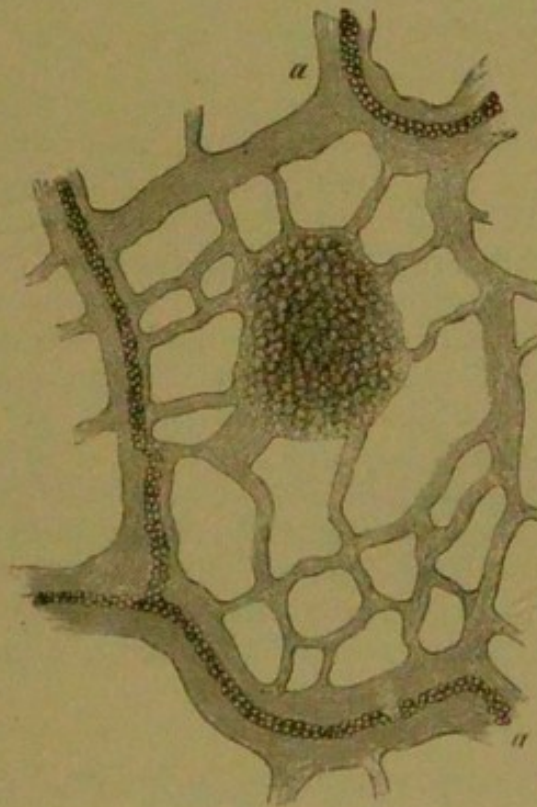
The points of difference between the tubercular ulcer and the typhoid ulcer are the following:—The ulceration in the tubercular ulcer extends transversely round the whole surface of the intestine; the edges and base of the ulcer are thickened and indurated. This form of ulcer very rarely heals, and perforation is also very rare. Some contraction and narrowing of the gut frequently



occur. In the typhoid ulcer, the ulceration rarely extends beyond the confines of the glands; there is no induration or thickening of the base or edges of the ulcer; the edges are thin and undermined. Cicatrisation may take place, or perforation may result.

**TUBERCULAR PERITONITIS.**—In recent cases the peritoneum is found filled with clear serum, and the peritoneal investment of the intestines is studded with miliary tubercles. There is more or less enlargement and hardening of the mesenteric glands. In cases of long standing there is great enlargement of the mesenteric glands, with the formation of hard, matted, nodular

FIG. 8.



*A Miliary Tubercle of the Omentum. a a, Capillary vessels.*

masses, which, when opened, are found softened in the centres (Fig. 8). Tubercular ulceration is also often found in the mucous membrane of the small intestines.

**TUBERCULOSIS OF THE BRAIN AND ITS MEMBRANES.**—In the brain of children a firm, yellow, cheesy tumour may frequently be found, which is called



tubercular. **Microscopically**, there appear to be two varieties of these tuberculous tumours. In one, of which the smaller nodules are usually constituted, a number of miliary tubercles, united together, may be recognised. In the other none of the characters of tubercle can be distinguished, but it seems to take origin in a growth of cells from the neuroglia (connective tissue of the brain or nerve-cement), which towards the centre of the mass become cheesy. Surrounding the tumour is a tissue consisting of cells with considerable vascular supply, the interior and older part showing only firm fibrous tissue.

**TUBERCULAR MENINGITIS.**—Tuberculosis of the pia mater is nearly always present in cases of general tuberculosis, and is of far more common occurrence than that of the brain substance. It is spoken of as **tubercular meningitis**, since it is generally accompanied by inflammation, and is sometimes termed **basilar meningitis**, as it is almost exclusively limited to the membranes at the base of the brain, although tubercular nodules are found in the pia mater, which dips down between the cerebral convolutions, and more particularly in the fissure of Sylvius.

The ventricles of the brain are found distended with limpid or turbid serum, often of considerable amount, in consequence of which the disease is often called **Acute Hydrocephalus**; lymph is observed in various parts of the brain, especially at the base, about the optic commissure, and also between the membranes; the cerebral substance is often softened to a creamy consistence, and the convolutions are flattened. There are usually tubercles in other parts of the body, especially in the mesenteric glands.

## THE DEGENERATIONS.

### LARDACEOUS DEGENERATION.

This process consists in the infiltration of the tissues by a peculiar morbid substance, the exact nature of which is even now not satisfactorily understood. In the opinion of some pathologists this affection is regarded rather as an infiltration than a degeneration. Virchow gave to the new substance the name of



"**Amyloid**," since he supposed it to be analogous to starch. The name **Lardaceous** is employed since the infiltrated organs somewhat resemble bacon (*lardum*).

Hughes Bennett considered it to be an albumen derivative, and therefore termed it **Albuminoid**.

Dickinson, after numerous experiments, considers it to be fibrine deprived of its alkali potash, and he therefore designates it

"**De-alkalised Fibrine**," and from its association with purulent discharges in which the potash is removed he calls the condition "**Depurative Infiltration**."

Budd, however, disputes the last-mentioned theory, and thinks that a substance termed **Distropodextrine** exists normally in the blood, and that this material agrees with the amyloid substance in its most specific characteristics, and that to establish an amyloid infiltration all that is requisite is that this distropodextrine should become insoluble and be deposited in the tissues.

It is never a primary affection, but appears to be allied to certain cachectic states. In chronic diseases of bone, empyema, chronic phthisis, chronic pyelitis, and syphilis, where suppuration is prolonged and profuse, the lardaceous change is most frequently observed. Syphilis appears to take an active part in the causation, apart from the suppuration so often produced by its various lesions. Every tissue and organ may be the seat of the change, but it is most prone to attack the liver, spleen, kidneys, and lymphatic glands. It may, however, be found in the stomach and intestines, in the œsophagus and pharynx, in the supra-renal capsules, in the bladder, prostate, and organs of generation, in the serous membranes, in the membranes of the brain (in which at times it forms small tumours), in the spinal cord, and in muscle. From the mucous membranes, *e.g.*, of the intestines, the exudation of lardaceous matter appears to pass off as a secretion, *viz.*, by diarrhœa and vomiting. It is usual to find several organs simultaneously the seat of the change.

**Microscopically**, the lardaceous material appears first in the walls of the capillaries and small arteries, and then involves the surrounding tissues; both cells and intercellular substance are invaded, and the whole organ may eventually become infiltrated. As the cells become filled with lardaceous substance, they gradually increase in size, their contour becomes less irregular, the nuclei dis-



appear, and the cells themselves become converted into a structureless substance peculiarly translucent and shining. Many of the cells may coalesce, thus losing their distinctive boundaries.

**Macroscopical** or naked-eye appearances: The organs affected by the change are usually increased in size; their absolute weight and specific gravity are increased. The surface is smooth, and the capsule tense. The consistence is somewhat elastic. A glistening, translucent appearance like wax is observed on section, and from this circumstance the terms waxy and vitreous have been applied to the change.

The function and nutrition of the affected organs are gradually impaired, the cells undergo atrophy, and become fatty; the vitality of the cellular elements is diminished, and their functions may be altogether arrested.

When an aqueous solution of **Iodine** (to which some **Iodide of Potassium** is added) is applied to a lardaceous organ, the morbid deposit acquires a deep **reddish-brown** colour. This gradually passes off, and the former appearance is regained. The term amyloid or starchy is clearly untenable, since starch gives a blue colour with iodine.

By cautiously adding some **Sulphuric Acid** after the application of the **Iodine**, a **violet** or **blackish-blue** tint is obtained. Many objections are raised by some authors to this latter test, but the reaction with iodine alone is thoroughly characteristic, and is admitted by all writers. The best test appears, however, to be **Methyl-Aniline**, which gives with the lardaceous material a **deep-violet stain**; this colouring is more permanent than the reddish-brown stain given by iodine.

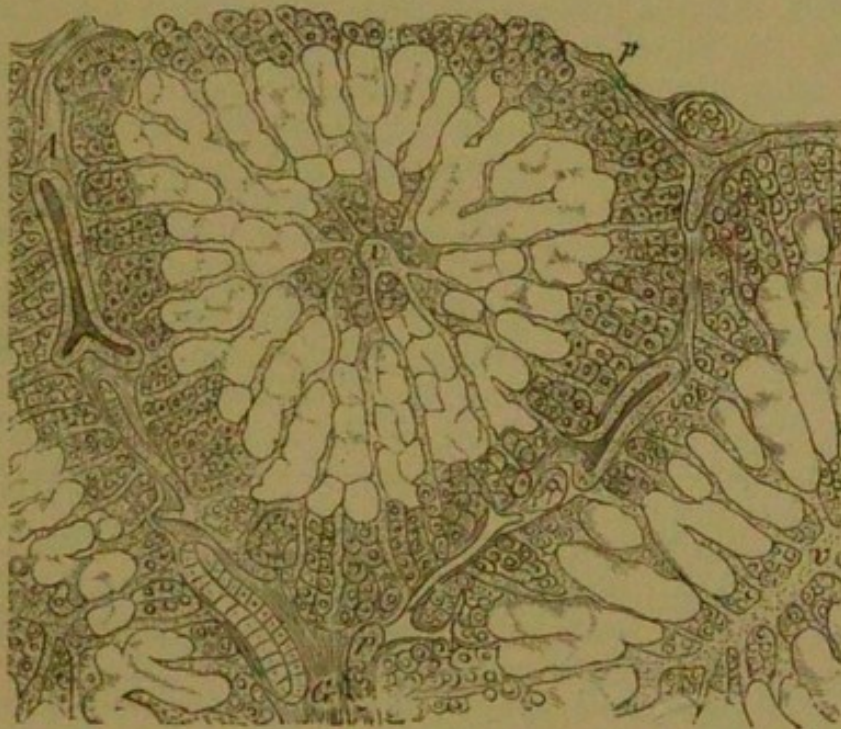
**THE LARDACEOUS LIVER.**—The gland is usually enlarged, heavy, and firm, and the enlargement is *uniform* and sometimes very considerable. The capsule is smooth and tense from distension. Its substance is hard, like wax, and gives a reddish-brown (mahogany) staining when tincture of iodine is applied to the tissue. The disease is always fatal.

It may co-exist with the fatty liver, with cirrhosis, or with syphilitic gummata, and is generally observed in connexion with carious bones, drainages of pus, and phthisis. The spleen is usually similarly affected and enlarged. A section of the organ is dry and bloodless,



and presents a translucent appearance. The structure of the gland is converted into dense matter, and abolition of its functions is occasioned by the destruction of the hepatic cells. The minute vessels, especially the arteries, are first affected, the morbid change then extending to the capillaries, and subsequently invading the proper elements of the implicated texture. The cells in the intermediate or hepatic zone of the lobules are first affected, since the ramifications of the hepatic artery are chiefly distributed to this locality (Fig. 9); eventually the morbid

FIG. 9.



*Lardaceous Liver.* Showing the infiltration of the cells in the intermediate zone of the lobule. *A*, The interlobular artery. *v v*, The hepatic or interlobular veins. *p p*, The portal vessels. *G G*, The biliary ducts.  $\times 300$ .

change spreads towards the centre of the lobules themselves.

**Microscopically**, the cells are extremely coherent, a clear substance is seen replacing their granular contents; the nucleus is obscured, the walls of the smaller blood-vessels being hard and thickened. In fatty degeneration, the fatty change is confined to the peripheral zone.

When the lardaceous and fatty changes co-exist, a



striking appearance is imparted to the lobule, a bold contrast being presented by the waxy translucence of the lardaceous intermediate zone, the normal central tissue, and the whitish opacity of the fatty periphery.

The bile is scanty and thinly fluid. Abdominal dropsy (ascites) is not present, since there is no absolute blockage of the hepatic vessels. The function of the liver is, however, materially impaired in consequence of the swelling of the secreting structure and the prevailing ischæmia (local anæmia), which results from the elastic pressure exerted on the vessels by the over-filled and tense parenchyma.

**THE LARDACEOUS KIDNEY.**—In this condition the kidney substance is infiltrated or replaced by the lardaceous material. The kidney is generally hard and enlarged, the capsule is easily removed. The cut surfaces are smooth, of the consistency of raw bacon (lardum), and translucent like wax. In extreme cases the organ appears as if it were soaked in balsam or glycerine, which had hardened the tissues. The morbid material is first deposited in and around the walls of the vessels, and afterwards it involves the surrounding tissues. Both kidneys are usually affected in about an equal degree.

The disease is usually associated with diarrhœa, carious bones, phthisis, enlarged liver or spleen, syphilis, and drainages of pus.

**Microscopically**, there is usually thickening of the smaller arteries, the Malpighian bodies and their vessels being the first seats of the morbid change, which afterwards implicates the renal tubes.

The appearances are at first chiefly confined to the cortex of the kidney, but as the disease advances the infiltration follows the course of the vessels into the pyramids. In consequence of the thickening and alteration in the quality of the vascular walls, transudation and escape of albumen are favoured, and to this circumstance is attributable the large quantity of albumen which characterises the early stage of the disease. In the last stage of the affection the urine becomes diminished in quantity, since the blood-vessels are no longer able to admit sufficient blood to supply their secretion, and also because the function of the tubules is materially impaired.

In more advanced stages, when iodine solution is applied to the cut surface of the organ, the Malpighian



bodies are made to stand out like mahogany-tinted stars, and when the infiltration has become general the arborescent tracings of the blood-vessels are revealed by the test.

**THE LARDACEOUS SPLEEN.**—Two forms are recognised—viz., (1) that in which the affection is limited to the **Malpighian Corpuscles**, and then termed the **Sago Spleen** (far the most common form), and (2) that in which the **pulp** is chiefly involved. It is probable, however, that the latter is only an advanced stage of the former. In the sago spleen the Malpighian corpuscles become metamorphosed into translucent wax-like bodies resembling boiled sago. The small arteries of the Malpighian corpuscle are first involved, then the lymphatic cells which compose it, until the whole becomes a firm, translucent, pale, glistening mass.

The sago spleen is enlarged, and its density and weight are increased. On section its surface appears smooth and dry and studded with the sago-like bodies, the size of which varies from a millet-seed to a hemp-seed. The characteristic mahogany stain is yielded when iodine solution is applied to the surface.

When the splenic pulp is involved, the increase in the size of the organ is often very considerable; its hardness and firmness are remarkable.

In the **Lymphatic glands** the lardaceous change is very similar to that which occurs in the spleen.

In the **Alimentary canal** the whole tract may be the seat of lardaceous change, leading to impairment of general nutrition and serous diarrhoea, which probably results from the walls of the vessels being more permeable. The **macroscopical** (naked-eye) appearances afford no information, but the application of iodine gives very characteristic results; the whole surface of the intestinal membrane then exhibits numerous reddish-brown points corresponding to the villi, of which the capillaries and arteries are infiltrated with the new material.

**THE CORPORA AMYLACEA**, or "amyloid" bodies, which have been frequently found in the nervous system, especially in old persons, in the prostate, and in other parts, have been thought to be allied to the lardaceous or amyloid material. The only resemblance between them, however, appears to be a certain similarity of their behaviour with iodine and sulphuric acid. The brown



appearance resulting upon the addition of these reagents is probably then only caused by the amount of nitrogenous material they contain.

These bodies are round or oval in shape, being made up of successive concentric layers, and they vary in size from a microscopical granule to a body visible to the naked eye.

It may be mentioned that, whilst lardaceous degeneration is a general change, the production of corpora amylacea is manifestly local in its nature.

These "bodies," especially when occurring in the choroïd plexus of the brain and its lateral ventricles, are prone to calcareous change, then constituting a form of "brain sand," so frequently found in these localities.

### FATTY DEGENERATION AND FATTY INFILTRATION.

In **Fatty degeneration** the normal substance of the tissues is *replaced* by fat; the muscles are especially prone to the change, as is more especially observed in the heart, in which the characters of the muscular fibres are either impaired or lost. The tissues become proportionally softened, and there is a liability to rupture. The affected parts present a yellowish, tawny, fawn-coloured appearance, and the proper function of the structure is impaired.

**Fatty Growth or Infiltration** must not be confounded with fatty degeneration, since infiltration merely consists in an increase of the adipose tissue of the whole or a part of the body, while in degeneration the adipose tissue replaces the normal elements of the affected part.

Thus fatty degeneration may take place in the fibres of the voluntary muscles as a result of protracted disease, and a similar condition of the arterial coats, especially those of the minute cerebral arteries, is not uncommon in middle life and in aged persons; the vessels give way, hæmorrhage occurs, and apoplexy or hemiplegia may result. In the fatty kidney the fat is deposited within the cells of the convoluted tubes; and in the like condition of the liver, fat may replace the hepatic cells. It is stated that cancer may undergo retrogression and cure by a fatty change. Persons of advanced age show fatty degenera-

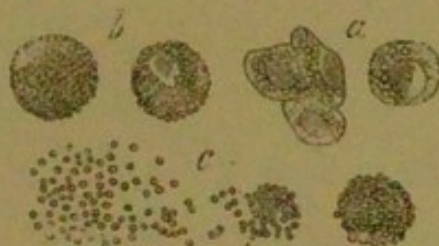


tion around the cornea (*arcus senilis*), but this is not now held as reliable evidence of the fatty change in any other organ.

In the heart, the power of the organ to carry on the circulation is impaired in proportion to the amount of the degeneration.

Fatty degeneration of certain tissues may occur in lean as well as in obese persons. The fatty liver is sometimes met with in persons who have died of phthisis, especially in females, and is also one of the results of alcoholic abuse. In a cell infiltrated with fat, the cell constituents are merely pushed aside and altered in form; they are not destroyed or disorganised; when the cell is completely filled it seems to have lost its nucleus and its protoplasm (Fig. 10, *a*). Upon the re-absorption of the fat, both

FIG. 10.



*Fatty Degeneration of Epithelium.* *a*, Cells containing molecules of fat. *b*, Granular corpuscles; in one the nucleus is still seen. *c*, Disintegrated corpuscles.

these reappear. Tissues infiltrated with fat are increased in weight and volume, but their specific gravity is diminished. They are less elastic and anæmic. When cut they are of a light-yellow colour, and fat accumulates on the knife.

**Microscopically**, fat globules are observed; these are white by reflected light, and black with a sharp outline by transmitted light. They are dissolved by ether. Fatty infiltration may be caused by a deficient consumption of the fat normally produced, or by its over-production. In the system the fat is produced from fatty food, from albuminous substances, and from saccharine and starchy matters. Fat by exudation is destroyed, the red blood-corpuscles being the carriers of the oxygen to the tissues which effect their oxidation, and the presence of fat in any



situation may be said to result from the amount of oxygen to the oxidisable matter being relatively deficient.

In fatty degeneration the nucleus becomes involved, the cell-wall is destroyed, and the cell is thus converted into a mass of granular fat (Fig. 10, *b*).

After the cell-wall and nucleus are destroyed, the fat granules may for some time remain coherent, constituting the so-called "inflammatory" "exudation corpuscles," or "corpuscles of Gluge." These are very commonly found in chronic softening of the brain and other varieties of fatty degeneration (Fig. 10, *c*). At last the corpuscles become disintegrated, liquefaction of the albuminous matter situated between the fat granules takes place, and the fat is distributed to the tissue.

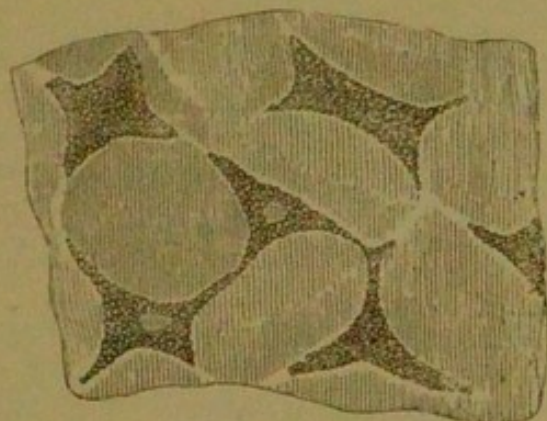
The essential feature of **fatty degeneration** is the destruction of the cells, whereas in **fatty infiltration** the cell within which the fat accumulates remains absolutely intact. Fatty degeneration may lead to caseation (cheesy deposition), to calcification, or to softening, with formation of puriform fluid. A common cause of fatty degeneration is diminished blood-supply. The fatty heart is frequently associated with disease of the coronary arteries; chronic softening of the brain shows an intimate connexion with the obstruction to the circulation following atheromatous disease of the cerebral blood-vessels. Inflammation and mechanical congestion, by interference with the blood-supply, may lead to fatty degeneration; cancers and other rapidly growing tumours may undergo fatty changes in consequence of the rapidity of their growth being disproportionate to the vascular supply. The impaired nutritive activity of tissues resulting from old age is a very common cause of their fatty degeneration. This is well shown in the so-called "arcus senilis"—the white ring formed around the cornea.

**FATTY DEGENERATION OF ARTERIES.**—This may be **primary** or **secondary**. As a secondary process, it is seen in atheroma and those inflammatory affections in which a cellular infiltration of the subendothelial connective tissue precedes the fatty change. As a primary affection, it is a passive process, and may affect both the middle and internal coats, but most commonly the latter. The usual seat is the epithelial and connective-tissue cells of the internal coat. In the earlier stages, the cells being filled with fat, the condition is known by the



presence of small irregular patches of an opaque yellowish-white colour, which project very slightly above the surface of the intima (Fig. 11). These patches might be mistaken for atheroma, but they are generally more superficial, and are readily stripped off from the subjacent layers, the appearance of which is natural. Atheroma affects the deeper structures, and, upon removing the superficial layer, thickening and opacity are observed beneath it. The opaque patches eventually break down, leaving superficial erosions which resemble those so commonly met with upon the mucous membrane of the stomach. Fatty degeneration of the muscular fibres of the middle coat may lead to dilatation, aneurism, and finally rupture of the vessel. The capillaries may also be

FIG. 11.



*Fatty Degeneration of Connective-tissue Cells in the interna coat of an artery. × 300.*

affected by fatty changes; they are most common in the nervous centres, and in Bright's disease of the kidneys, the process commencing in the endothelial cells and involving extensive areas of their walls, rupture often resulting. This result frequently occurs in the smallest blood-vessels of the brain, and in these situations it is an occasional cause of capillary cerebral hæmorrhage.

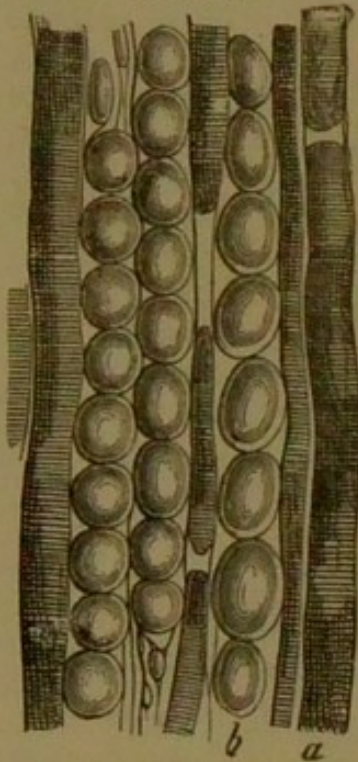
Primary fatty degeneration of the blood-vessels is usually a senile change, and is indicative of the general impairment of vitality common to advanced life.

**FATTY INFILTRATION OF MUSCLE.**—The cells in the connective tissue by which the muscular fasciculi are surrounded become filled with fat, the fat being deposited *between* the fasciculi, which are usually un-



affected, at any rate until in the later stages. The condition is distinguished from true **degeneration** since in

FIG. 12.



*Fatty Infiltration of Muscle.* *a*, Atrophied muscular fibres. *b*, Interstitial fat cells.  $\times 300$ .

this condition the fat originates within the fasciculi, the fasciculus itself eventually perishing in company with the sarcolemma. The fat varies in amount: sometimes single rows of fat are seen alternating with rows of muscular fasciculi; at other times more exists between some fibres than between others; and at all times muscular elements may be found lying amongst the fat, the albuminoid matter of which the fibres is composed being converted into fat (Fig. 12).

In **Pseudo-hypertrophic muscular paralysis**, or Duchenne's paralysis, the muscles of the calf of the leg become overgrown. Upon section, in one case the gastrocnemius resembled a fatty tumour, presenting a mass of greasy fat, with entire absence of muscular redness. **Microscopically**, there appear degenerations both in number and

size of the muscular fibres, with considerable hypertrophy of their connective tissue. The affected part of the muscle is freely covered with fat.

**FATTY DISEASE OF THE HEART.**—Fat is naturally deposited about the heart, and an excess of this substance is called a **fatty infiltration**—*i.e.*, fat accumulates below the pericardium, and is deposited in large quantities upon and between the muscular fibres, constituting a form of local obesity. In this condition the fibrillæ appear healthy, and the functions of the heart do not appear to be much interfered with.

**FATTY DEGENERATION.**—Here the muscular fibres are *replaced* by fat, and the heart appears of a pale-yellow colour and feels soft, greasy, and flabby; it also tears readily. **Microscopically**, the sharp edges and striæ of the muscles are lost, and the tissue appears loaded with



oil. Molecules of fat and oil globules are contained in the sarcolemma. The most frequent seats of the degeneration are the left ventricle, the columnæ carneæ, and the musculi papillares. The degeneration may either be diffuse, as in cases of extreme anæmia, or be more localised and in patches. This condition is usually met with in old or middle-aged persons, and is often associated with other diseases of the heart or the coronary arteries. It is also associated with myocarditis, fevers, and phosphorus poisoning.

#### FATTY INFILTRATION OF THE LIVER.—

Fatty disease of the liver is a frequent accompaniment of pulmonary phthisis and fatty disease of other organs, and has been observed in syphilis, general anæmia, and, after death from typhus fever, variola, and phosphorus poisoning. It frequently results from chronic alcoholism. It is supposed that the fat is absorbed from the tissues, which are undergoing rapid disintegration, and that it becomes deposited in the hepatic cells.

The fatty liver is *uniformly* enlarged, and it feels rather soft and smooth. The edges of the liver are round and greasy to the touch, the whole gland being of a pale-fawn colour.

In the normal condition the liver contains a certain amount of oil, but in this disease **microscopically** the hepatic cells are crammed with oil globules and their nuclei are obscured or disappearing. The specific gravity is diminished. The morbid process commences on the exterior of the lobules, since here the ramifications of the portal vein are distributed; but as the disease advances it extends to their centres. The normal weight of the liver being  $4\frac{1}{2}$  lbs., in this condition it may even exceed 12 lbs.

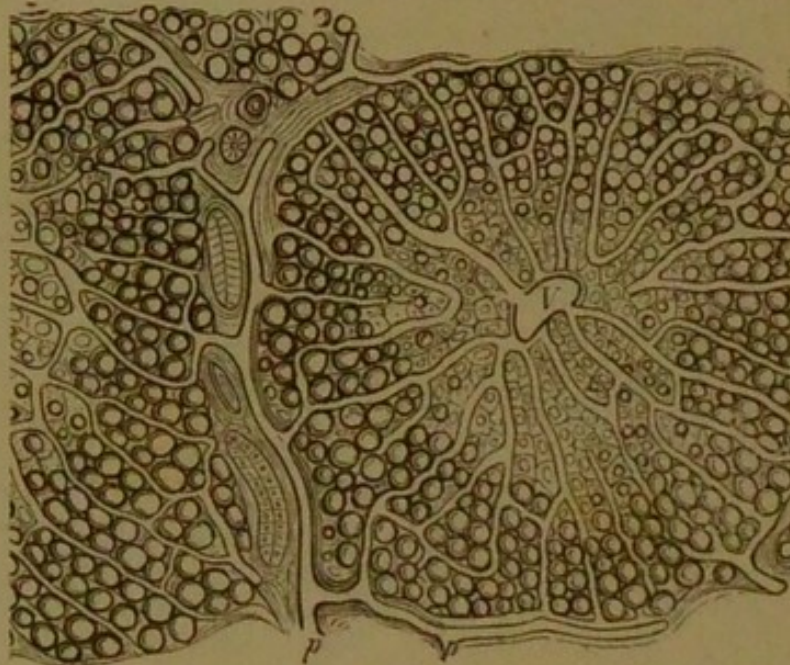
It is a necessarily fatal disease, and may last about two years.

The liver cells are the storehouse of surplus fat. The fat is carried to them by the portal vein, as in the physiological state, and, since the lobule is surrounded by the portal branches, the first evidences of the fatty infiltration are in the periphery—*i.e.*, in the **portal zone** (Fig. 13). By degrees the infiltration approaches the centre of the lobule, until at last it completely fills the lobule, but it is usually limited to the portal zone, or forms a marginal ring upon the extreme outskirts of the lobule.



This fatty infiltration of the liver must be carefully distinguished from **true fatty degeneration**, in which there is impairment of nutrition of the liver cells, these cells

FIG. 13.



*Fatty Infiltration of the Liver (somewhat diagrammatic), showing the accumulation of fat in the external zone of the lobules. V, The hepatic vein. pp, Interlobular portal vessels.*

undergoing a retrogressive change. Fatty degeneration takes place in many structural affections of the liver, such as in cirrhosis and lardaceous degeneration, and is perfectly distinct from fatty infiltration.

Fatty infiltration of the liver may occur either with general obesity, fat accumulating in the organ in common with other parts, or it may be found with general emaciation, the fat being removed from its usual sites and being stored up in the hepatic cells.

**FATTY KIDNEY.**—In this condition the kidney substance is replaced by fat. The incised organ feels greasy, is of a pale-fawn colour, it yields to pressure, and is more or less enlarged. **Microscopically**, oil drops, or globules of fat, are observed in great excess in the epithelial cells of the convoluted tubes and in the capillaries of the Malpighian bodies, the disease being usually confined to the cortex. The weight of one kidney may reach, or even exceed, 14 ounces. The morbid appearances are similar



to those of chronic tubular nephritis (the large white kidney).

This condition can only be determined accurately after death, but if numerous oil-casts are found in clear pale albuminous urine, of low specific gravity, the disease may be suspected. The chief cause is spirit-drinking, but it may occur in cases of phthisis and poisoning by phosphorus, and in connexion with fatty disease of other organs.

### CALCAREOUS DEGENERATION.

This condition is due to the deposition of earthy salts, especially of phosphate of calcium and magnesium, and carbonate of calcium. It is known as calcareous degeneration, calcification, or cretification. It is generally preceded by atheroma, and presents no bony structure (although it was once called ossification), but simply consists of earthy salts. **Gangrena senilis** is often attributable to obstruction to the circulation from calcareous degeneration of the arteries of the lower extremities, and apoplexy and hemiplegia are often occasioned by this degeneration.

The serous membranes may, in rare cases, present plates of bony substance: in old pleurisy the pleura may become so hard and calcareous that it has been removed entire, retaining the form of a solid box; cancer and tubercle may both be the seat of calcareous change, which is also very common in the walls of hydatid cysts.

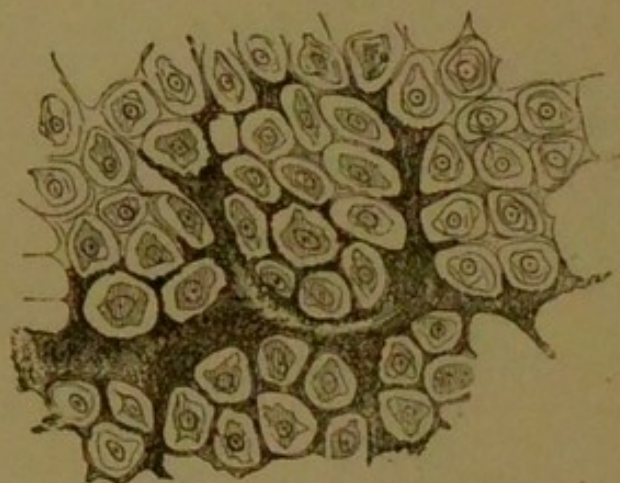
Calcareous infiltration occurs as a physiological process in the choroid plexus, the pineal gland, and in the development of bone (ossification). The essential difference between calcification and ossification, however, is that in the former the tissues are quiescent and simply act as a receptacle for the deposit, the process being a passive one, whereas in the latter there is nutritive activity, increased vascularity, cell proliferation, and a methodical arrangement of parts, the process being active.

**Microscopically**, the calcareous particles are seen both within the cells and the intercellular substance, more frequently in the latter, and appear at first in the form of fine molecules irregularly scattered through the intercellular substance (Fig. 14). When viewed by transmitted light they are recognised by their opacity, irregular



outline, and dark-black appearance. As they increase in number large tracts of tissue may become converted

FIG. 14.



*Calcified Cartilage.* Showing the calcification of the intercellular substance.  $\times 300$ .

into an opaque calcified mass, in which the cells can be no longer distinguished.

When added to calcareous matter, nitric and hydrochloric acids dissolve it, leaving the matrix. Evolution of bubbles of carbonic anhydride indicate the presence of carbonate of calcium.

The causes of calcification may be—

1. Excess of **calcareous salts in the blood**, such as occurs in caries, osteo-malacia, and osseous cancer, in which the blood first takes up the calcium salts, but which, being stopped in their passage through the tissues, are left as a filtrate.

2. **Retardation of the circulation.**—The calcium salts are held in solution by the free carbonic, lactic, volatile fatty, and glycerine-phosphoric acids of the circulating fluids. When these acids are displaced by the formation of new combinations, the calcium salt is precipitated. The localities selected for this form of infiltration are either in tissues not supplied by blood-vessels, or in the spaces between the capillary vessels—*i.e.*, in the extravascular regions. Thus, in the lungs, the interlobular tissue is the seat of the change; in the kidney, the tubuli uriniferi and the intertubular tissue; and in the stomach, the spaces between the glands. Fatty degeneration often precedes the calcareous change.



**CALCIFICATION OF ARTERIES.**—This may be a primary or secondary affection. It constitutes, as a secondary change, one of the terminations of atheroma; as a primary affection, calcification is a senile change, resulting from impairment of nutrition.

It usually occurs in vessels of medium size, and its most common situations are the arteries of the brain and those of the upper and lower extremities.

Its usual seat is in the middle coat, commencing in the muscular fibres. The calcareous particles deposited from the vasa vasorum, first appear within and around the nucleus, gradually increasing in number until the cell is filled. The process may be limited to isolated portions of the muscular coat, with the production of calcareous plates and rings, or the coat is entirely calcified. The external and internal coats may at last participate in the change, and the vessel become calcified throughout. Elasticity and contractility are lost, and the vessel becomes converted into a rigid brittle tube. The external iliacs and the vessels of the lower extremity are frequently found calcified; in the latter case senile gangrene frequently results, and when the process occurs in the cerebral vessels apoplexy is the common termination.

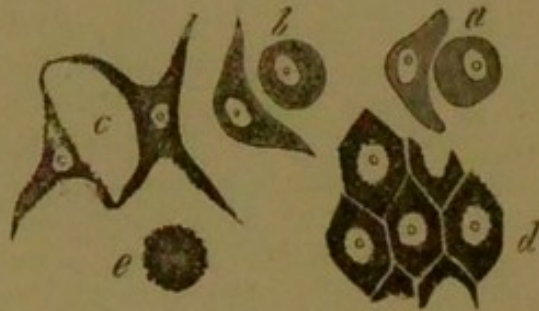
### PIGMENTARY DEGENERATION.

**PIGMENTATION.**—This term implies an abnormal formation of pigment in the tissues. The source of all true pigment is the colouring matter of the blood (hæmoglobin). Many tissues are physiologically the seat of pigment: for example, the skin of the negro and the choroid coat of the eye; here the cells appear to possess a special power of attracting and storing the colouring matters from the blood, which subsequently undergo chemical change and become pigment. Pathologically, pigment usually results from changes in the circulation or in the blood-vessels, the colouring matter escaping and infiltrating the tissues in its vicinity, staining them of a brownish-red or yellowish colour. It stains, however, only the cell-contents, the nucleus and cell-wall being unaffected (Fig. 15). In course of time the hæmoglobin undergoes chemical change, forming granular or crystalline hæmatoidin. It becomes darker and more or less granular, the cells and intercellular substance being filled with



small reddish-brown or black granules. Hæmatoidin contains iron and more carbon than hæmoglobin. It gives the same reaction (green, blue, rose, and yellow colours)

FIG. 15.



*Cells in various stages of Pigmentary Infiltration. a, b, c, from a case of melanosis. d, Pigmented epithelium from the vessels (same specimen), showing the staining of the cell-contents, the nucleus and cell-wall being unaltered. e, Cluster of free pigmented cells.*

with strong mineral acids, as cholepyrrhin, the colouring matter of the bile. Pigmentation is of but slight importance as a morbid process, and the ill-effects which accompany it must be regarded as the results of the conditions upon which the pigment depends rather than due to the pigment itself.

Pigmentation affords evidence of antecedent conditions, and must be considered the result of alteration in the circulation and blood-vessels, colouring matter escaping. An exception to this may be stated in the case of the choroid and the rete mucosum, which are, however, most frequently melanotic (seat of black pigment), since they contain pigment normally, and their cells appear to be endowed with special pigment-selective power. In cerebral hæmorrhage crystals of hæmatoidin may be the only evidence of ruptured capillaries; and in the ovaries, the slight hæmorrhage following the escape of the ovum at each menstrual epoch is denoted by the pigment-formation, constituting the so-called "corpus luteum."

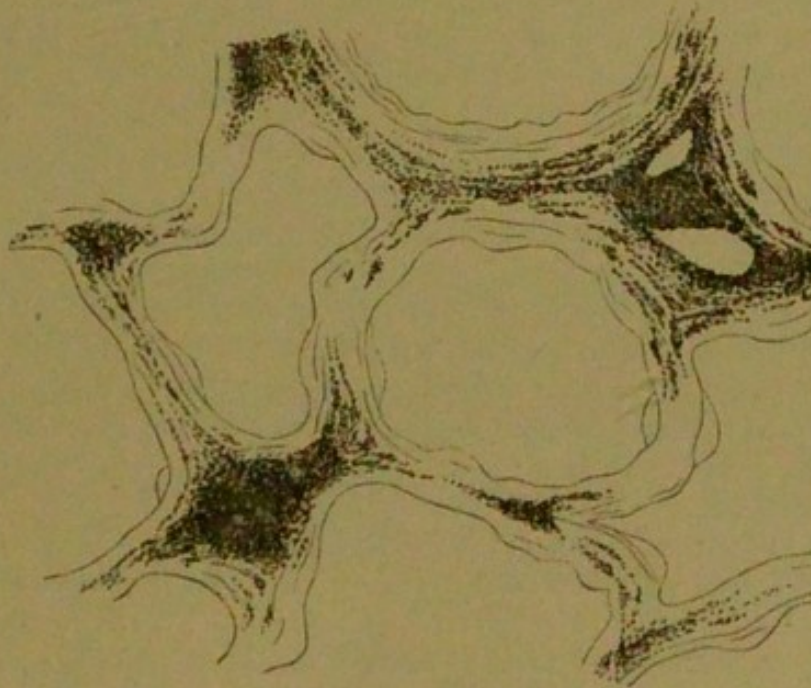
**FALSE PIGMENTATION.**—This term implies discoloration of tissue which is not due to hæmatoidin. It occurs in "jaundice," the yellow staining being due to the colouring matter of the bile. Again, the slaty coloration of the skin, following the internal administration of



silver salts, silver being deposited in the tissues, is another instance; the black colour of gangrenous parts, the sulphuretted hydrogen acting upon the colouring matter of the blood, may be mentioned; and, lastly, the small particles of inhaled carbon always observed in the lungs.

**PIGMENTATION OF THE LUNGS.**—The lungs usually contain pigment, which increases with advancing age. This is chiefly due to the presence of carbon, derived from the atmosphere. Much of this carbon is removed by expectoration, but many particles pass to the air-vessels, and finally find their way to the alveolar walls and interlobular tissue (Fig. 16); in these most of the pulmonary pigment is seen, either lying free amongst the fibres or within the connective-tissue cells. In the case of miners, stonemasons, and grinders, minute particles of coal, iron, and stone enter the bronchi and become de-

FIG. 16.



*Collier's Lung.* In which are seen the carbon-particles in the walls of the alveoli and in the interlobular tissue.

posited chiefly in the interlobular tissue. The lungs of miners are of a uniformly dark colour, and the carbon is most abundant in the interstitial tissue. The black colour of the lungs is not entirely attributable to the presence



of the substances inhaled, but is in part due to the true hæmatoidin pigment, since inflammatory changes occur in the bronchial tubes and the lung tissue, through the irritation of the inhaled particles; thus, an escape of colouring matter is permitted.

Pigment in the lungs is rarely found in a crystalline form, but usually as black, irregular granules. Pigmentation may take place in chronic phthisis, both from the inflammatory action and from obstruction of the vessels; the consolidated nodules may be seen surrounded by lines of pigment. In acute lobar pneumonia the sputum subsequently becomes greyish-black, in consequence of the blood—which in earlier stages has caused the so-called rusty expectoration—becoming changed into pigment. The pigmentary process also plays an important rôle in the condition known as

#### **Brown Induration of the Lung.**

This condition is the result of long-standing mechanical hyperæmia, and generally follows some affection of the mitral valves. Elongation and dilatation of the lung capillaries take place, the walls of the alveoli appearing abnormally tortuous and covered by a multitude of epithelial cells, which are filled with dark-brown pigment. An increase in the interlobular connective tissue follows, large quantities of brownish-black pigment being formed. When these changes are at all advanced, the lungs are mottled with brown or blackish streaks and specks, and present a more or less brownish-red tint.

In the so-called "**Nutmeg liver**" (the result of mechanical congestion) pigmentation of the hepatic cells takes place in the most central portion around the hepatic vein. Thus in each hepatic lobule three zones may be made out: 1. A **central** zone, in which chiefly resides the **pigmentary** change; 2. An **external** zone, the chief seat of the **fatty** change; 3. An **intermediate** zone, in which the **lardaceous** change is chiefly seen.

#### **MUCOID DEGENERATION.**

This process consists in the conversion of the albuminoid constituents of the tissues into **mucin**, by which means they are transformed into a soft, jelly-like substance. This substance (mucin) is identical with that found in the nose and mucous passages, and is the result



of a mucoid degeneration of the secreting cells. The vitreous humour of the eye and a considerable portion of the umbilical cord are both composed of mucin, and nearly all tissues in their foetal state are in the mucoid condition.

This process affects more particularly the intercellular substance of the tissue, although it may also affect the cells. Mucin is closely allied to albumen, since it is only found in alkaline fluids, from which it is precipitated by diluted acetic acid, but differs from it in containing no sulphur, and by its insolubility in excess of the acid, and in not being precipitated by boiling, by tannin, or by perchloride of mercury. It is also distinguished from chondrin and gelatine, which are precipitated by these re-agents. Mucoid degeneration affects principally the connective-tissue substance—viz., cartilage, serous membranes, bone, and fibrinous exudations—especially when occurring in the air-passages—new growths, as sarcoma, chondroma, lipoma, and syphilitic nodes. In bone and cartilage the intercellular substance first becomes fibrillated or broken into shreds, and then becomes converted into mucin. In bone, simultaneously with or previous to the fibrillation, the calcium salts are re-absorbed. The costal and articular cartilages of aged persons are prone to this change, bearing out the common saying, "second childhood."

With regard to the cause of this degeneration nothing is known.

### COLLOID DEGENERATION.

This process consists in a conversion of the albuminoid constituents of cells into **colloid** material. This substance, which is colourless, glistening, and transparent, of the consistence of half-set glue, closely resembles mucin, but it contains sulphur, and is not precipitated by acetic acid. It appears within the cells as small lumps, increasing gradually in size and pushing the nucleus on one side until the cell is entirely filled. The cells thus become destroyed and transformed into colloid masses. The small colloid masses at length coalesce and form larger masses of jelly-like substance; the intercellular substance atrophies and softens, and thus cyst-like cavities are formed, containing within them the



gelatinous material, which subsequently may become liquefied.

Colloid degeneration is most frequently found in enlargement of the thyroid gland, the lymphatic glands, the choroid plexus, and many new formations. The causes and nature of this degeneration are very obscure.

The myxomata (mucous tumours) resemble the umbilical cord in structure, and are composed entirely of a gelatinous substance, yielding mucin; the lipomata, chondromata, sarcomata, and carcinomata, may become the seats of colloid softening. The terms "colloid" and "mucoid," when applied to a new growth, merely indicate certain chemical and physical properties, and throw but little light upon the real nature of the growth.

### THE TUMOURS.

These are classified as follows:—

#### I. *Type of fully developed Connective Tissues.*

<b>Fibroma</b> . . .	<b>Type of fibrous tissue.</b>
<b>Myxoma</b> . . .	" mucous "
<b>Lipoma</b> . . .	" adipose "
<b>Chondroma</b> . . .	" cartilage "
<b>Osteoma</b> . . .	" bone "
<b>Lymphoma</b> . . .	" lymphoid "
<b>Lymphangioma</b> . . .	

#### II. *Type of Embryonic Connective Tissue.*

**Sarcoma** . . . its different varieties.

#### III. *Type of higher Tissues.*

<b>Myoma</b> . . .	<b>Type of muscle.</b>
<b>Neuroma</b> . . .	" nerve.
<b>Angioma</b> . . .	" blood-vessels.

#### IV. *Type of Epithelial Tissues.*

<b>Papilloma</b> . . .	} <b>Papillæ of skin or mucous membrane.</b>
<b>Adenoma</b> . . .	
<b>Carcinoma</b> . . .	} <b>Glands.</b>

#### V. **Mixed Tumours, or Teratomata.**



### FIBROMATA (Fibrous Tumours).

These tumours are growths of mature connective tissue. Both the cell and intercellular substance are in a condition of complete development, and they resemble normal connective tissue. In addition to a constitutional predisposition, the fibrous tumours may result from prolonged irritation, may follow inflammation, and may sometimes be caused by over-nutrition, or they may be due to the blockage of the lymph channels, the tissues becoming gorged by nutritive fluids.

The **varieties** are three in number :


1. The **solid**, or dense, as is seen in aponeurosis and tendon.

2. The **soft** and succulent, as in subcutaneous areolar tissue.

3. A **cavernous** form, the growth being permeated by large cavernous sinuses, having unyielding walls, and being subject to troublesome hæmorrhage if injured.

These tumours may originate from connective tissue in any situation, at first consisting of embryonic tissue, cells being abundant and intercellular substance scanty. As they develop, however, the number of the cells decreases, the intercellular substance becoming increased enormously, fibrillated, and hardened. The cells are very small and spindle-shaped, and hidden amidst the fibres which run irregularly in all directions ; the fibres form the greater portion of the growth, being closely interlaced (Fig. 17), and often concentrically arranged around the

FIG. 17.



*Fibrous Tumour.* × 200.

blood-vessels. The growth of these tumours is gradual and central, and they are always encapsuled. They are



liable to inflammation, hæmorrhage, mucoid, fatty, and calcareous degeneration. They may vary in consistence from the densest dry cicatricial tissue to that of succulent areolar tissue, and may vary in size from the smallest to the most massive growths. They are usually painless and single, unless originating from the skin and sheaths of nerves; harmless, except as to their locality and size. They are benign, and non-recurrent after removal. The dense variety is generally found to spring from the deeper-seated structures, but the soft form usually arises from the mucous surface and the skin, and is liable to become pedunculated.

### MYXOMATA (Mucous Tumours).

These tumours consist of mucous tissue. Mucous tissue is connective tissue, the intercellular substance of which is homogeneous, translucent, and jelly-like, containing much fluid, and yielding mucin.\* It is found physiologically in one form in the vitreous body of the eye, the cells being isolated and roundish, in another form in the umbilical cord, the cells of which are star-shaped or fusiform (spindle-shaped), giving off fine branched prolongations, anastomosing one with another. Pathologically the mucous tumours present the same varieties of cells as those just described. They usually contain one or two distinct nuclei. The cells are ovoid, stellate, fusiform, or spherical. In consequence of the strongly refractive nature of the intercellular substance their contour is very indistinct. The branched cells communicate with one another to form a reticulum (network), the spheroidal cells lying scattered and isolated (Fig. 18). The cells are usually distributed scantily, in which case the growth is translucent, but if the cells are very abundant and packed closely, a whitish brain-like opacity is imparted to the growths. The growth as a whole is gelatinous, soft, and trembling, somewhat translucent, and of a greyish-white or pinkish-white colour. The cut surface yields a mucilaginous, tenacious liquid, in which the cellular elements may be seen.

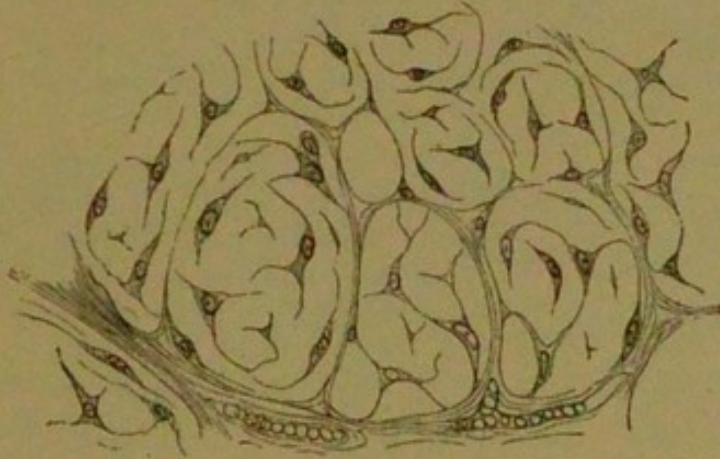
These tumours are usually encapsuled, and are met with in the later periods of life, being most common in

\* See Mucoid Degeneration, p. 56.



subserous and subcutaneous fat, intermuscular and subserous tissue. Growing from the perineurium of nerves, they form one variety of "neuroma," and when spring-

FIG. 18.



*Hyaline Myxoma* (mucous tumour).  $\times 300$ .

ing from the placenta they constitute "uterine hydatids;" occurring in the nasal passages they constitute a form of nasal polypus.

A pure myxoma is uncommon. It is usually combined with lipoma as myxo-lipoma, but myxo-sarcoma, myxo-fibroma, myxo-chondroma, and myx-adenoma are also met with.

Of the secondary changes, rupture of the capillaries, hæmorrhage, and formation of sanguineous cysts is most common. The cells may become the seat of fatty or mucoid degeneration and thus be destroyed, liquefaction of the intercellular substances being a usual accompaniment. The growth may become inflamed, ulcerated, or necrosed.

The myxomata are mostly benign growths, but they may attain enormous dimensions. They rarely recur after complete removal, and probably never reproduce themselves in internal organs. With respect to their malignant tendency, their occasional association with sarcoma must not be overlooked.

### LIPOMATA (Fatty Tumours).

These tumours are growths of adipose tissue—*i.e.*, common connective tissue—the cells of which are infiltrated with fat. A general and diffused infiltration by fat con-



stitutes **obesity**; a fatty tumour or **lipoma** is a localised and circumscribed formation. Lipomata originate wherever fat exists normally, being produced by fatty infiltration of existing connective-tissue cells, but more frequently by proliferation and subsequent infiltration of new connective-tissue cells. Their growth is central, encapsuled, and lobulated, and it increases very slowly at first.

These tumours may become the seat of inflammation or of mucoid and calcareous degeneration. The interstitial fibrous tissue increases in volume and density, or it is accompanied by other forms of connective-tissue growth, forming myxomatous, fibromatous, or chondromatous lipoma.

The cells of the lipomata are larger, and the fat they contain is more fluid than that of normal adipose tissue.

In shape they are round or polygonal, from pressure on one another, and are collected in clusters, forming lobules. The protoplasm and nucleus are so compressed by the fatty contents to the cell periphery that they form a mere enveloping film. Each lobule and aggregation of lobules of which the growth is constituted is thinly invested by connective tissue.

The vascular supply in general arises from one trunk, which is situated centrally, and which pierces the capsule, giving off numerous branches to ramify in the connective-tissue septa between the vesicles and lobules.

Fatty tumours are liable to glide out from the deeper structures, and show themselves under the skin. They may become pedunculated. They are of all sizes, and their form, unless they are bound down by surrounding structures, is irregularly globular.

The lipomata are simple or multiple, benign and painless.

### CHONDROMATA (Cartilaginous Tumours).

These tumours are growths of cartilaginous tissue. Cartilage exists in three forms—1. As cells embedded in a hyaline basis substance (hyaline cartilage); 2. As cells embedded in fibrillated basis substance (fibro-cartilage); 3. As cells embedded in a mucoid basis substance (gelatinoid or mucoid cartilage). To these may be added an osteoid form, the growths leading to ossification. The first



is the most common form, the last is the rarest. Cartilage cells are chiefly round or oval, sometimes fusiform, notably so in fibro-cartilage, or reticulated and star-shaped, as in the cornea. Chondromata occur most commonly in early life, and are supposed to take origin usually from a nidus of immature cartilage—*i.e.*, one which has not matured *pari passu* with the surrounding tissues, and which in some manner has been incited to proliferation. Mixed growths may also occur—*viz.*, fibrous, myxomatous, osteoid, and sarcomatous chondroma.

The greater number of the chondromata arise from bone, especially the shaft of long bones—*viz.*, phalanges and long bones of the extremities; but it is a singular fact that few chondromata arise from cartilage proper.

The growth is slow and central, usually single, and may become very great in size. The intercellular substance may become the seat of ulceration, fibrillation, calcification, or mucoid degeneration, and the cellular elements may become calcified.

The growths are distinctly lobulated, and invested by fibrous tissue in which the nutrient vessels ramify. They are almost always innocent, except those softer varieties which spring from the medulla of bone.

### OSTEOMATA (Bony Tumours).

These are growths of osseous or bony tissue; a variety of connective tissue in which the "bone corpuscles" (cells) are embedded in calcified intercellular substance. Bone is developed originally from cartilage or fibrous membrane, and eventually from periosteum, all these substances being varieties of connective tissue.

Osteomata may be produced by irritation of the periosteum or medulla of bone. They may be divided into two classes.

1. The **Exostoses**; the growth proceeding from the bone or its membranes (homologous osteoma).

2. **Osteophytes**; the growth originating in connective tissue, more or less remote from bone (heterologous osteoma).

**Cancellous** osteomata resemble the spongy tissue of bone.

**Compact** osteomata resemble the compact tissue.

**Eburnated** osteoma is exceedingly dense, and receives



its name on account of its ivory consistence; it contains no cancellous tissue or blood-vessels.

The selected seats of the osteomata are the external and internal tables of the skull. The harder varieties select the periosteum and orbit; the cancellous forms seem to prefer the articular extremities or the medulla of long bones.

**Osteophytes** are found in common connective tissue, tendons, or cartilage, in interstitial connective tissue of muscles in glands or organs, when it results from chronic irritation, and chiefly in the vicinity of diseased bones or joints. They are distinguished from calcareous deposits by showing osseous structure—viz., Haversian canals, blood-vessels, and bone corpuscles.

A compact osteoma, which grows from the surface of a bone, is separated from it by a line of demarcation, but is notwithstanding enveloped by the common periosteum.

The growth is comparatively small in size, central, and slow; it is frequently multiple, and quite innocent.

Sarcomata and carcinomata that have become ossified must not be mistaken for osteomata. These are, of course, malignant, and their true nature will be exhibited in that part of the tumour in which the secondary change has taken place.

### LYMPHOMATA (Lymphoid Tumours).

These tumours are growths of lymphatic or **adenoid** tissue, and may be divided into: 1. **Soft** lymphomata, in which there is a preponderance of **lymph corpuscles**; and 2. **Indurated** lymphomata, with preponderance of **stroma**.

The causes of lymphomata are so numerous and varied that any attempt at enumeration is impossible. If the exciting agent be of a specific character, as the poison of syphilis, scrofula, or small-pox, the resulting growth will exhibit specific features; but, should the agency be indifferent, the lymphatic growth that ensues will constitute a simple hyperplasia.

It should be noticed, however, that many morbid growths that may occur in the lymphatic tissues are not properly lymphomata. For instance, the infectious elements of a cancer may locate themselves in a lymphatic gland, and



produce a growth, possessing the structure and elements of a cancer. This would not constitute a lymphoma, for the reason that the nature of the new-formed tissue is not lymphatic; it would, in reality, be cancer of a lymphatic gland. True growths of lymphatic tissue are, however, observed in many diseases—viz., leucocythæmia, small-pox, syphilis, scarlatina, measles, Bright's disease of the kidneys, and in some cardiac affections

Adenoid tissue has also been found in cases of chronic phthisis (Fig. 19).

**Soft lymphomata** begin with a proliferation of the lymph corpuscles, and possibly a migration of white blood corpuscles. Many of the cells are larger than normal, they are increased in number, and clustered together in a reticulum. The fibres of the reticulum often become attenuated, and sometimes destroyed, in consequence of the pressure of the amassed cells. The growth *en masse* is pultaceous and soft, resembling brain substance in its colour and consistence. On section the surface is uniformly dull and white, yielding a quantity of milky juice containing copious leucocytes.

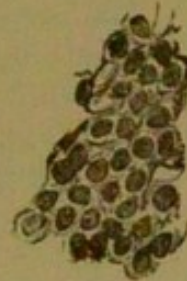**Microscopically**, thin sections exhibit massive collections of lymph-corpuscles, by which the stroma is completely hidden. When shaken with water the corpuscles are dislodged, and a delicate filamentous reticulum is exposed to view.

The growth of the soft lymphoma is rapid. It often becomes very large, and is apt to break through the structure in which it is situated, and thus to infiltrate structures in its vicinity.

The **Indurated lymphomata** are characterised by an entirely opposite condition of matters. The branched cells of the reticulum become large and massive, and encroach upon the interstitial spaces which the lymph corpuscles occupy. Thus these corpuscles decrease both in number and size.

These indurated forms are small in size, slow in development, and feel nodular and hard; they never infiltrate the surrounding structures; on section they exhibit a cartilaginous or fibrous surface, yield no juice, and

FIG. 19.



Adenoid tissue from a lung in a case of chronic phthisis.  $\times 200$ .



**microscopically** present a heavy barred reticulum with few lymph corpuscles. The hard lymphoma sometimes follows the softer form after acute symptoms have subsided.

The most frequent seats of the lymphomata are, the lymphatic glands of the neck, the axilla, the groin, the abdominal and thoracic cavities, but they may be found in the liver, kidneys, spleen, bones, muscles and serous membranes, along the intestinal tract, and in the nasal cavities, in which they form polypi. They are frequently single, occasionally multiple and lobulated. These tumours do not undergo any marked secondary changes, and clinically they are quite innocent.

**Lymphadenoma.**—Occasionally the lymphomata present malignant properties: especially is this the case with the soft, richly cellular, and rapidly growing forms. By these the surrounding structures are rapidly infiltrated, the neighbouring lymphatic glands are involved, and even distant parts infected. These malignant forms correspond to the lympho-sarcomata of Virchow, and to them the term Lymphadenoma has been sometimes applied.

When they occur in the mediastinum they may implicate one or both lungs and establish the so-called "thoracic cancer" (Fig. 20).

FIG. 20.

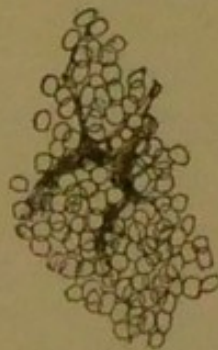
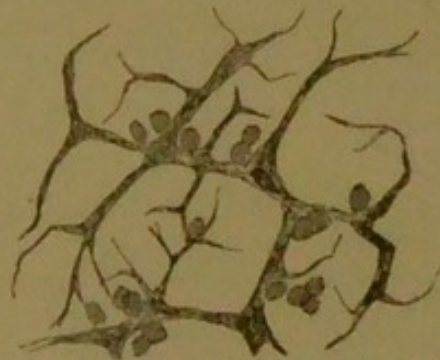


FIG. 21.



*Lymphadenoma.* Fig. 20 represents a thin section of a lymphadenomatous tumour of the mediastinum.

Fig. 21 shows a similar section to Fig. 20, from which most of the cells have been removed by pencilling in order to exhibit the reticulated network. This network is far more marked than that often met with.  $\times 200$ .

**Hodgkin's Disease: Adénie, or Anæmia lymphatica,** is characterised by enlargement of the lymphatic



glands and lymphatic structures and by progressive anæmia. Histologically the new growths are exactly similar to the lymphomata; their course and tendency are, however, somewhat peculiar. They differ from the lymphomata inasmuch as the lymphatic structures are so very universally involved, and in the progressive anæmia, which is attributable to the loss of red blood corpuscles. Hodgkin's disease differs from leukæmia (a disease in which the white blood corpuscles are greatly increased in number), since the number of the white corpuscles is not notably increased.

The lymph glands are usually first affected, the affection eventually spreading to most of the lymphatic structures throughout the body, possibly in the following order—viz., cervical, axillary, inguinal, retro-peritoneal, bronchial, mediastinal, and lastly the mesenteric. With the advance of the growth the capsule yields and the neighbouring glands become fused into a lobulated mass, the adjacent structures ultimately becoming infiltrated. The spleen is notably affected, the growth commencing in the Malpighian bodies, with the production of scattered nodules, which in size vary from a pin's-head to a walnut, are of greyish or yellowish colour, not encapsuled, and somewhat firm. The spleen is somewhat enlarged, sometimes uniformly so, instead of being nodular; its capsule is thickened and frequently adherent to surrounding organs. In a similar manner to the spleen, the liver, kidneys, lungs, subcutaneous connective tissue, and the medulla of bone may become involved.

The growth of adénie may exhibit either the soft or indurated forms of lymphoma. Little is known as to its pathogeny, and it is not infectious.

**Lymphangiomata.**—These tumours consist of lymphatic vessels, which are larger than normal. They are divided into simple and cavernous forms, like those of the angiomas or vascular tumours. The stroma usually contains fat. It is doubtful what share simple dilatation and new formation of lymphatic vessels take in the production of these tumours.

Each variety of dilatation may be acquired or congenital. The latter form is seen in the tongue as makroglossia, in the lip, as makrocheilia, these parts becoming hypertrophied. In the skin, especially of the thorax and thigh, acquired dilatation is not uncommon. Tumours



which are sometimes the size of an orange may be formed in the subcutaneous tissue. The part from which the lymphatic vessels pass to the skin may become the seat of fibroid thickening, and from rupture of a vessel dangerous loss of lymph may result.

### SARCOMATA.

Sarcomatous tumours consist of embryonic connective tissue, and retain that embryonic type throughout the whole of their growth. Amongst them are included the so-called **Fibro-plastic**, **Fibro-nucleated**, **Recurrent-fibroid**, and **Myeloid Tumours**.

Many growths which were formerly described as cancers are now placed under this heading.

**Cells** constitute nearly the whole of the growth, and present great variety of shape, form and colour. The chief **varieties** are the following—viz., (1) The **Round**; (2) the **Fusiform**; (3) the **Myeloid**; and (4) the **Pigmented Cells**. As several of the above-named cells may be present in the same growth, this formation takes its name from the variety which predominates.

Many of the **Round Cells** are identical with white blood-corpuscles or lymphatic cells, whilst others are larger, present an indistinct nucleus with bright nucleoli, and closely resemble the granulation cells. The **Spindle-shaped**, **Fusiform**, or "**Fibro-plastic**" cells are long and narrow, and at each end terminate in a fine prolongation; they usually contain an oval nucleus, with or without nucleoli, and exhibit a higher stage of development than the round cells.

The **Mother** or **Myeloid Cells** are much larger than the two preceding varieties, and are analogous to the cells found in the inflamed medulla of bone. Their shape is very irregular, and they often have numerous offshoots; they contain many round or oval nuclei with bright nucleoli.

All the sarcomata possess an **intercellular** substance (usually very small in amount) and their blood-vessels are very numerous. They always originate from connective tissue, usually common connective tissue, and their growth takes place in two ways—viz., by:

(1) A **central growth**, from multiplication of their own elements:



(2) A **peripheral growth**, by the continuous invasion of their matrix.

The peripheral growth is very characteristic of the sarcomata.

These morbid growths rarely implicate other tissues indiscriminately, but they usually merely displace them, and cause them to atrophy by their pressure. They extend to remote regions of the body by the lymph and blood paths and through their wandering cells, the slender condition of the smaller vessels which supply the growth being especially favourable to the access of blood into the cells. By this channel secondary infection usually takes place, and thus is presented a marked contrast to what takes place in cancer, in which the infecting material is transmitted by the lymphatics.

Amongst the secondary changes the most important is fatty degeneration; but inflammation, hæmorrhage, calcification, ossification, and mucoid degeneration are not uncommon.

Fatty degeneration occurs in the older parts of the growth, producing softening or cyst-like cavities. Hæmorrhage may cause the formation of sanguineous cysts. Calcification and ossification are more liable to arise in tumours connected with bone, pigmentation in those which arise from the eyeball or cutis.

Little is known of the causes of the sarcomata, but it is supposed that extremes of youth and of old age and constitutional syphilis may predispose to, and repeated irritation may excite, these growths.

From the different varieties of the cells, the following **varieties** of sarcoma are known:

(1) **Round-celled Sarcoma**; (2) **Spindle-shaped Sarcoma**, or **Fibro-plastic Tumour**; (3) **Myeloid Sarcoma**; and (4) **Melanotic** or **Pigmented** (dark granular pigment being deposited in the cells). Sarcomata are sometimes combined with fatty, cartilaginous, osseous, and mucous tissue, giving rise to mixed forms, such as **Lipo-Sarcoma**, **Chondro-Sarcoma**, **Osteo-Sarcoma**, and **Myxo-Sarcoma**.

*Clinically*, sarcomatous tumours may be considered as semi-malignant.

*Histologically*, they differ from cancers in the fact that the cells are not grouped in alveoli, but are intimately mixed with the fibrous stroma.

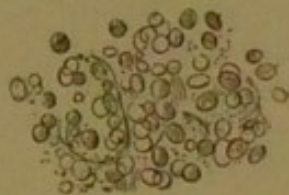

**Round-Celled Sarcoma.**—This form has been called “medullary,” “encephaloid,” or “soft,” sarcoma. It consists chiefly of round cells embedded in fine granular intercellular substance. The fusiform cells and partial fibrillation—so common in highly-developed spindle-shaped sarcoma—are almost entirely absent. In some there is a remarkable likeness to granulation tissue (Fig. 22), the cut surface is reddish-white, and when

FIG. 22.

*Round-celled Sarcoma.* 200.

FIG. 23.

*Glioma.* A thin section of a glioma of the cerebellum.  $\times 200$ .

The cells in glioma are exceedingly small and round, enclosed in a delicate network of intercellular substance, and spring from the sheaths of the cranial nerves.

stance. A somewhat reticulated structure is sometimes presented.

**Lympho-Sarcoma** is a round-celled sarcoma, the matrix of which has developed into a reticulum similar to that of lymphoid tissue. It may commence in lymphatic glands, or in any connective tissue.

It differs from lymphoma in its course being more rapid, and in forming secondary growths by embolism.

**Alveolar Sarcoma** is a rare form of the round celled variety—the cells are large and sharply defined, and contain prominent nuclei and are separated by fibrous

scraped yields a small quantity of almost clear fluid. The blood-vessels are abundant, and from their liability to rupture may give rise to sanguineous cysts.

These tumours may be mistaken for encephaloid cancers, but are recognised by the penetration of the intercellular substance between the individual cells and the absence of alveolar stroma.

**Glioma** is a form of round-celled sarcoma springing from the **neuroglia**, or connective tissue of nerve, and may occur in the grey or white substance of the brain, in the cranial nerves, and in the retina (Fig. 23).

A gliomatous tumour consists of small round cells with a scanty granular, or slightly fibrillated, intercellular sub-



stroma. In some parts the stroma forms small alveoli in which the cells are grouped. It is found chiefly in the skin, bones, and muscles.

**Spindle-shaped Sarcomata.**—These tumours are the most common form of the sarcomata, and include the recurrent fibroid and fibro-plastic growths. They are divided as follows:—

1. The **Small spindle-shaped** sarcoma in which the cells are about  $\frac{1}{1375}$  inch in length, with sometimes an imperfectly fibrillated intercellular substance. This growth is usually of a whitish or pinkish colour, and may grow from the periosteum, fasciæ, and connective tissues generally. It is more frequently encapsuled than other forms of sarcoma, and is very prone to cause infiltration of surrounding structures, and to recur locally after being removed.

2. The **Large spindle-shaped** sarcoma.—In this the cells are larger than in the preceding form, the nuclei and nucleoli very prominent and often multiple. There is less intercellular substance, and all fibrillation is absent. The consistence is much softer than that of the small spindle-shaped variety, the growth is of a pinkish-white colour, often the seat of extensive fatty degeneration, grows rapidly, and is usually very malignant.

**Myeloid Sarcoma.**—This "**myeloid**" tumour usually occurs in connexion with bone, frequently arising in the medullary cavity. It consists of "**myeloid**" cells (large and many nucleated) mixed with many fusiform cells. There is very little intercellular substance, so that the cells are almost in contact. The growth may be so vascular as to occasion distinct pulsation. Springing from the upper and lower alveolar processes it constitutes a form of **Epulis**. When arising from the medullary cavity the compact substance becomes expanded over the growth, producing, on palpation, the so-called "**egg-shell crackling**." The consistence is firmer than in the other forms of sarcoma, and on section presents a uniform succulent appearance of a red, brown, or maroon colour, which is very typical. The myeloid are the least malignant of the sarcomatous tumours.

**Melanoid Sarcoma.**—In this form the cells contain granules of dark-coloured pigment, which are distinct from that of extravasated blood. Most of the formerly styled *melanotic cancers* are, in reality, melanotic sarco-



mata. The eye is the seat usually selected, and, in a less degree, the skin, and the growth usually arises from normally pigmented structure. It is soft and vascular, presenting on section a dark-brown colour, or a mottled, streaked appearance. The cells are generally spindle-shaped, but in some cases they are oval or round. It may occur in almost every organ of the body, and is extremely malignant.

**Psammoma** is a doubtful growth, thought to be sarcomatous in its nature, which springs from the brain-membranes, and is composed of corpora amylacea calcareously infiltrated, and containing a few cells and blood-vessels.

### MYOMATA (Muscular Tumours).

A myoma is a growth of muscular tissue. It is generally accompanied by development of connective tissue, and is seldom purely muscular. It almost always consists of non-striated muscular fibres. The myomata always arise from muscular tissue, especially from the walls of the uterus; in this organ, as they enlarge, they push aside the normal tissue, and protrude into the cavity of the peritoneum or the uterus.

Becoming pedunculated in the latter organ, they form a variety of **uterine polypus**. They may also be found in the prostate, œsophagus, stomach, and intestines. The growth is slow and central, often multiple and encapsuled. The uterine growths, in consequence of the *large* amount of interstitial connective tissue they contain, have been named, although improperly, **uterine fibroids**.

The myomata are especially liable to become calcified, forming in the uterus a hard, stony lump, the so-called **womb-stone**.

2 Exhaustive hæmorrhage sometimes results from the presence of the intra-uterine myomata.

3 Mucoid degeneration sometimes may occur, leading to cyst-like formations in the growth.

The myomata are elastic, pear-shaped, and spheroidal. Their firmness is dependent on the amount and age of the connective tissue. Their colour varies from muscular redness to pinkish or greyish white.

**Microscopically**, spindle-shaped cells, with rod-like



nuclei, appear mixed with, or collected into, fasciculi amongst the connective tissue. These tumours are innocent.

### NEUROMATA (Nerve Tumours).

These tumours are growths of nervous tissue. True neuroma is rarely met with. Although the term "Neuroma" has been given to numerous growths found in connexion with nerves—viz., fibrous, myxomatous, and gummy tumours within the nerve sheath—the neuromata usually consist of ordinary medullated nerve fibres, and therefore their structure resembles that of the cerebro-spinal nerves. With the nerve fibres is associated a certain amount of connective tissue.

Their growth is slow, they seldom become of large size, and they usually exist in single nodules, and they are quite innocent, although very painful. They always spring from pre-existing nerve-tissue either from the spinal or cranial nerves.

### ANGIOMATA (Vascular Tumours).

These tumours are growths consisting of blood-vessels held together by a small amount of connective tissue.

Under this heading are included the various kinds of *nævi*, and aneurism by anastomosis. They are divisible into two varieties:—

1. The **simple or capillary** angiomas; in these the new vessels chiefly resemble normal capillaries. They usually occupy the superficial layers of the cutis, and form the well-known mother's marks (port-wine stains). They are but slightly elevated. They may, however, lie in the submucous or subcutaneous tissue, and give rise to large tumours. In colour they are red (when superficial), violet or purple (when subcutaneous), and are probably always congenital. They are frequently associated with lipomatous, gliomatous, and sarcomatous tumours.

2. The **cavernous or venous** angiomas; in these the blood-passages are wide, tortuous, and freely communicating with one another, as in normal erectile tissue, and similar to the corpus cavernosum of the penis.

The angiomas originate from blood-vessels, and occur chiefly on the skin, and also on the mucous membranes.



Their growth is slow, rarely large, and they are liable to ulceration and hæmorrhage.

They are usually of a bluish hue, and sometimes distinctly pulsate. They usually occur in the skin and subcutaneous tissue, but may be found in the orbit, muscles, liver, spleen, and kidneys.

They may become developed through the dilatation of the vessels in a simple angioma, and may be congenital; it is stated, however, that they may develop in the liver after middle-age, when atrophy of the cells has commenced.

### PAPILLOMATA (Epithelio-Connective Tumours).

In structure these tumours resemble ordinary papillæ, and they spring from the existing papillæ, especially from mucous, serous, or cutaneous surfaces. They may, however, arise *de novo* from the subepithelial connective tissue, as in that of the stomach and larynx.

The **simple papilloma** is usually small and conical, and is composed of a central connective tissue surrounded by epithelium. As in normal papillæ, the vessels of the connective tissue form loops, by ascending to the apex and returning on themselves, or they may form a plexus.

These growths usually owe their origin to some irritation.

Of the secondary changes, hæmorrhage and ulceration are the most common. The hæmorrhage may be so severe as to endanger life, as is not unfrequent in the case with papillary growths of the intestine and bladder.

Papillary growths upon the skin include **horny growths** and **warts**.

Larger and more vascular papillary tumours may occur on cutaneous surfaces—viz., **venereal warts** and **condy-lomata**—which are seen upon the external female and male genital organs and around the anus, and are produced by irritating secretions.

The papillomata *clinically* are innocent growths, but they may prove fatal from prolonged ulceration and hæmorrhage. They may be mistaken (when occurring in the bladder and intestines) for epithelioma. In the papillomata the epithelium is **homologous**, since it is situated



only upon the surface of the papillæ, and never grows within their connective-tissue basis. In epithelioma the epithelium is **heterologous**, and is found at the base of the tumour in the subjacent connective tissue.

It should be remembered, however, that a growth which primarily is a *simple papilloma* may eventually become an *epithelioma*.

### ADENOMATA (Glandular Tumours).

These tumours are growths of gland tissue, and they resemble tubular or racemose glands in consisting of saccules or acini lined by epithelial cells. The acini are separated merely by connective tissue which contains the blood-vessels.

**Adeno-Fibroma** is a term applied to the growth when the connective tissue is greatly in excess of the normal.

The adenomata always take their origin in follicles and glands—viz., in the mammary gland (by far the most common seat), in the mucous follicles of the stomach, intestines, nares, pharynx, uterus and vagina; also in the liver and other organs. They commence either as sacculated or cylindrical offshoots, or as proliferations of the epithelium by which the tubules or acini are lined, and resemble the normal gland structure. The epithelial growth is liable to grow in excess of the connective-tissue groundwork, and to become heaped up in the interior of the spaces until these are transformed into globes or cylinders. The growth usually becomes encapsuled, and when it is distributed equally through the whole gland it forms **glandular hypertrophy**; it is, however, more often confined to certain lobules, which, by their increase in size and by their pressure, cause blockage of ducts, formation of cysts, degeneration, and atrophy. The most common secondary change is fatty degeneration leading to caseation and mucoid softening.

The adenomatous tumours are elastic, firm, and nodular, their outline is ovoid, globular, and distinctly lobulated. In colour they usually resemble that of the tissue from which they arise. Their growth is slow, and seldom becomes of any great size. When found on the mucous membrane these tumours are gelatinous and soft, and they may force their way to the surface, at which they become pendulous and form a variety of **mucous polypus**.



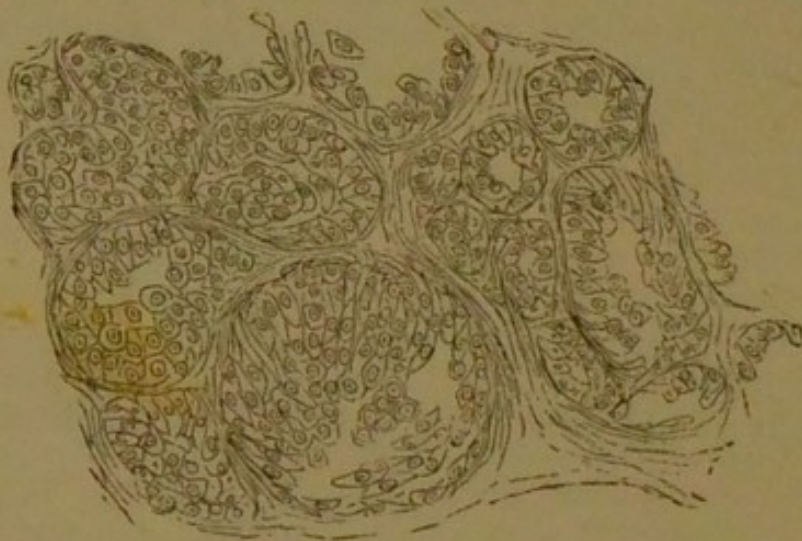On section they appear lobulated, and at times, even to the naked eye, may exhibit their glandular nature in their follicular arrangement; gaps, fissures, and cystic cavities are often present. **Microscopically**, the glandular character is very clearly shown.

The adenoma proper is always an innocent tumour, and is very rare; other growths—viz., fibroma, myxoma, and sarcoma—which affect glandular organs with much greater frequency, are often mistaken for adenoma. The mixed growths are known as **Adeno-fibroma**, **Adeno-myxoma**, and **Adeno-sarcoma**.

It is often very difficult to distinguish between an adenoma and a carcinoma of glandular origin, since in both cases epithelial cells are crowded in spaces formed by connective tissue; and, again, since a sarcomatous insensibly passes into a fibrous tissue, it is in many cases impossible to determine with perfect accuracy the *exact* nature of a tumour-stroma in which gland-tissue is contained.

The **mamma** is by far the most frequent seat of adenoma, or, more correctly, **adeno-fibroma**, since the

FIG. 24.



*Adenoma of the Mamma.* Showing the racemose arrangement of acini or saccules lined with epithelial cells.  $\times 300$ .

mode in which the epithelium is arranged, the proportion of the stroma, the size and number of the spaces, and the number of contained cells, is more or less abnormal.



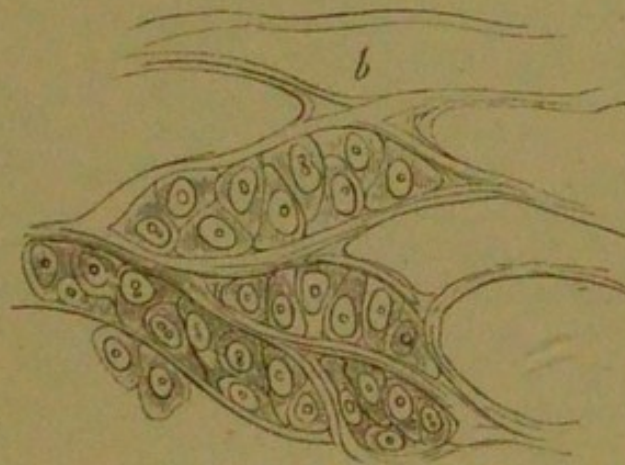
The names of "adenoid" and "chronic mammary" have also been applied to these tumours. Their description corresponds with what has been stated above, and their microscopic appearances are shown in Fig. 24.

### CARCINOMATA (Cancers).

All true cancers are *clinically* highly malignant—*i.e.*, they increase in size by infiltrating with cells and destroying the surrounding tissues, and tend to recur locally after their removal and reproduce themselves in the internal organs and lymphatic glands. Other tumours of different structure may exhibit malignant characters; consequently, the mere recurrence of the affection after surgical removal does not prove it to have been a cancer.

**Microscopically**, all the cancers resemble one another in consisting of variously shaped cells, enveloped in a fibrous stroma **without** intercellular substance (Fig. 25).

FIG. 25.



*Fully-formed Carcinomatous Tissue.* Showing the grouping of the cells in a fibrous stroma destitute of intercellular substance; at *b* a space is seen formed by the fibrous stroma, which is devoid of cell-contents.

The cells are of the epithelial type, are large, and exhibit great diversity of form, being polygonal, round, oval, caudate, or fusiform. They vary in size from  $\frac{1}{100}$  to  $\frac{1}{1000}$  of an inch in diameter, and contain large prominent nuclei inclosing bright nucleoli.

There is no **specific** cancer-cell, since cells exactly



similar to the above are observed in other tissues, normal or morbid, but their general nature, and their distribution in a fibrous stroma, determine their cancerous character. This absence of fibres or of any other material between the cells forms the important distinction between cancerous and many other kinds of tumours. The cancer-cells are contained in hollow spaces formed by connective tissue, and these spaces freely communicate one with another. The character of the cells varies very much, according as they arise from stratified, or columnar epithelium, or from that of acinous glands; those from stratified epithelium may end in cornification, often exhibiting prickle-cells; the outermost cells from columnar epithelium usually retain a cylindrical form; in acinous glands the cells may multiply and their shape become greatly altered by mutual pressure; the cancers are therefore sometimes divided into **squamous**, and **cylindrical-celled epithelioma**, and **acinous cancer**. A juice exudes from the cut surface. The stroma varies in amount in different forms of cancer: if the growth be rapid, the stroma will contain numerous round, or fusiform cells; if it be slow, but few cells are exhibited, and the tissue is fibrous and dense.

Blood-vessels are contained within the stroma, but these never encroach upon the alveoli in which the cells are contained. This fact is important in distinguishing between carcinomata and sarcomata, except some alveolar forms of the latter, and tumours arising from endothelium. Lymphatics also accompany the blood-vessels, and these, communicating with the alveoli, may in a measure account for the tendency of cancer to involve the lymphatic glands. With regard to the development of cancer, many authors consider the epithelial cells to originate only from pre-existing epithelium, whilst others declare that they may originate from the cells of connective tissue, or from migrated white corpuscles. But it appears reasonable to admit that both origins may be correct, and that where the epithelium is the source, the cells are more strictly epithelial, as in epithelioma, and when the connective tissue is the origin, the epithelial characters are less observable, as in encephaloid and scirrhus.

The stroma is partly made up of the connective tissue of the seat of the cancer, and is in part a new growth.



Of the **secondary changes**, fatty degeneration is the most important, and this always occurs in greater or less degree in all the cancerous varieties; it is generally most marked in encephaloid. Hæmorrhage, pigmentation, cancrroid, and colloid degeneration may also occur, but calcification is very rare.

The **varieties** are the following—viz., two chief groups:—

1. **Acinous Cancer**, including as varieties, **Scirrhus Chronic** or **Hard Cancer**, **Encephaloid Medullary Acute** or **Soft Cancer**, **Colloid Alveolar** or **Gelatiniform Cancer**; and

2. **Epithelial Cancer**, including **Squamous** and **Cylindrical-celled Epithelioma**.

**Scirrhus, Chronic, or Hard Cancer.**—This variety is characterised by the chronicity of its growth, and the large amount and density of its stroma, the small size of the spaces (loculi), and the scantiness of the epithelioid elements. The epithelial growth quickly subsides, although at first it may be abundant. The stroma subsequently becomes indurated and contracted, and takes on the character of cicatricial tissue. The central portion of the growth may consist eventually of dense fibrous tissue, epithelial structure being only observed at the circumference. On section, in scirrhus a white glistening surface is presented, with fibrous bands intersecting. The more external portions of the growth are less firm than the central, and upon scraping these they exude a juice abounding in granules, free nuclei, and nucleated cells. The exudation of this juice is very characteristic of cancer. The most common seats of scirrhus are the female breast, the liver, and the alimentary canal, particularly the rectum, pylorus, and œsophagus. It may also be found on the skin.

The elements quickly atrophy and undergo retrogressive changes. In the external portions of the tumour, at which growth is taking place, they are most abundant, but in the central portions they may be nearly altogether wanting.

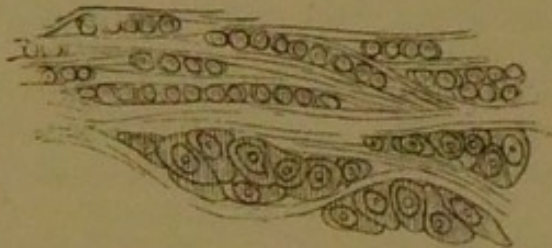
**Scirrhus** presents a well-defined tumour, which is hard, lobular, and uneven, the hardness and unevenness of outline being very characteristic. The growth is frequently depressed in the centre from the contraction of the cicatricial tissue, and this is very typical of scirrhus of the



mamma (breast), in which situation it occasions more or less puckering of the superjacent structures.

The **microscopical** appearances of scirrhus are shown in Figs. 26, 27, and 28.

FIG. 26.

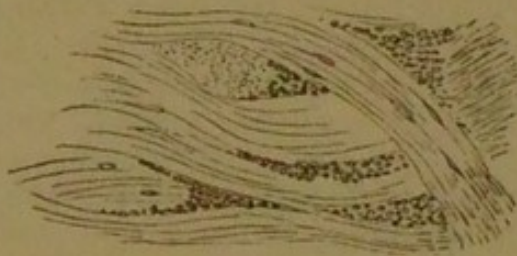

*Scirrhus of the Mamma.* A thin section from the most external portions of the tumour, showing the clusters of small "indifferent" cells; more externally is seen the development of the epithelioid elements within the alveoli of the stroma.  $\times 300$ .

**Encephaloid, Medullary, or Soft Cancer.**— This cancer differs from scirrhus in the greater rapidity of its growth, the smaller amount of its stroma, and its softness of consistence.

**Microscopically,** the greater part of the growth is seen to be formed of nucleated cells of various sizes

FIG. 27.



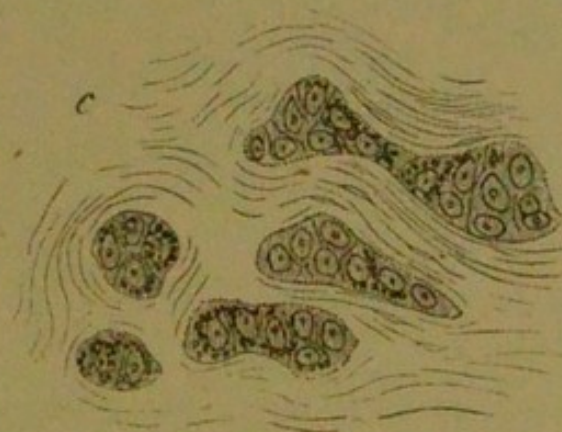
*Scirrhus of the Mamma.* A thin section from the more central portion of the tumour, showing the cicatricial tissue of which the older portions of the growth are constituted.

and shapes, the loculi or spaces in which they are enclosed being composed of thinner and fewer fibres than in scirrhus. The blood-vessels are frequently very numerous. There are all intermediate stages between



scirrhous and encephaloid (scirrho-encephaloid), so that these can hardly be considered as distinct varieties of cancer, their only distinction being the rapidity of their growth, and their physical characters. In encephaloid the epithelial growth is rapid and luxuriant, the cells soon becoming fatty. The stroma in proportion is very

FIG. 28.



*Scirrhous.* Showing commencing cicatrisation, and at the same time the relation of the stroma (c) and the cells in this form of cancer.

small, does not undergo cicatricial contraction, and is less fibrous than in scirrhous. Hæmorrhage readily takes place, from the abundance of the blood-vessels, and the softness and non-resistance of the tissues supporting them. The growth may fungate and bleed, forming the so-called **Fungus Hæmatodes**.

This form of cancer is of brain-like consistence, the central portions being frequently completely diffuent; on section the affected part presents a white pulpy mass, very like brain substance, and it is often stained with extravasated blood, the unaffected parts being soft, pinkish-grey, and translucent.

Encephaloid cancer occurs primarily in the testis and mamma, and it is very commonly met with in internal organs as a secondary growth. Many soft sarcomata were formerly described as encephaloid cancers.

**Colloid, Alveolar, or Gelatiniform Cancer.**—Although this is often described as a distinct variety of cancer, it is probably only one of the preceding forms which have undergone a colloid or mucoid change. The colloid



growth itself may become of great size, is of mucous or gelatinous consistence, and possesses a colourless or slightly yellowish translucency. In colloid cancer the alveoli are large, and more or less spherical, and contain within them a gelatinous or colloid substance, which is translucent, colourless, or yellow, and of a thin mucilaginous consistence. The distinctness and large size of the alveoli is due to their distension by the degeneration-products. It is probable that the colloid change commences in the cells, which are gradually destroyed by the process. Within this colloid substance are contained epithelioid cells, which, in their turn, contain a similar colloid material. The most frequent seats of this variety of cancer are in the peritoneum, the ovary, stomach, and intestines. In the peritoneum the growth is either secondary or it is sarcomatous.

**Microscopically**, the alveolar cavities are seen to contain nucleated cells, which enclose and are intermixed with gelatinous material.

The term alveolar is employed, since the appearance is very like that of a honeycomb.

**Epithelioma (Epithelial Cancer).**—This form differs from the preceding varieties in always growing in connexion with cutaneous or mucous surfaces, and in its epithelial elements bearing a close resemblance to squamous epithelium. The cells are peculiarly arranged, most of them being situated in irregular tubular-shaped lobules. As the cells increase in number they become grouped concentrically, forming globular masses, and as multiplication of the epithelium takes place, the peripheral cells become flattened by the pressure of the surrounding structures, the central cells remaining more or less spherical in shape. Thus are formed the **epithelial nests** or **concentric globes**, so characteristic of epithelioma. The cells may be so closely packed as to become eventually dry and hard like those of the hair and nails; the concentric globes are then of firm consistence and of a yellowish-brown colour. The stroma may be very abundant or almost entirely wanting.

**Microscopically**, then, a section exhibits numerous nests or cells, termed **epithelial nests** or **concentric globes**, the outer cells being flattened in a circular form whilst the inner are round and oval.

The first appearance presented by epithelioma is as a



foul ulcer with indurated edges, or as a subcutaneous nodule which eventually suppurates. On section of the tumour a greyish-white granular surface is presented, with lines of fibrous tissue intersecting. Upon pressing the cut surface turbid fluid exudes, and in general a thick curdy material is yielded, coming out in a worm-like shape resembling sebaceous matter from the cutaneous glands. This material is highly characteristic, and consists of fatty epithelial scales, and upon mixture with water it separates into small visible particles, but does not diffuse like other cancerous juices. The name *cancroid*, which is sometimes given to the growth, denotes its likeness to cancer, and also that it deviates from the true cancerous type.

*Epitheliomata* are developed by a down-growth of the surface-epithelium of certain mucous membranes or of skin into the connective tissue and deeper parts. This form of cancer seems in many cases to be due to some external irritation. It is often found on the lower lip (at the junction of the mucous membrane with the skin), on the prepuce, scrotum (*chimney-sweep's cancer*), the tongue, labia, cheeks, eyelids, the bladder, and in the cervix uteri, in which it constitutes the so-called *cauliflower excrescence*. By its extension any tissue may become involved—viz., muscle, bone, tendon, and lymphatic glands. It is very rare in internal organs.

The malignancy of epithelioma varies with its situation. On the tongue its course is very rapid, the glands are affected early, and death is very speedy. On the skin of the face its course is very chronic, and the glands rarely become affected.

**Cylindrical Epithelioma; Adenoid Cancer.**—These terms are given to certain forms of epithelial cancer which grow from mucous membranes, having columnar or cylindrical epithelium, such as those of the intestines and stomach, and especially the uterus and the rectum. The shape of the epithelial elements and their arrangement in these tumours are precisely similar to the columnar epithelium of the mucous surface on which they are found.

The morbid growths are soft and frequently of gelatinous consistence, and are very liable to become the seat of colloid change. They induce secondary growths in the lymphatic glands, and occasionally in the bones, the



lungs, and the liver, which present the same features as the primary cancer. The distinction between simple adenomata and the adenoid cancers is dependent upon the tissue invaded by the cancers.

Of all the cancers by far the least malignant is epithelioma; here local extension takes place, and the lymphatics may be involved, but reproduction in the internal organs rarely takes place, probably because the size and nature of the epithelial element render them far less liable to be transmitted by the lymph streams and blood than are the cells of the other cancerous varieties. Encephaloid and scirrhus present very different degrees of malignancy; the former being far more rapidly disseminated than the latter, in consequence of its greater rapidity of growth and its greater vascularity; both these forms are reproduced in the lymphatic glands and internal organs.

Colloid, in its degree of malignancy, is somewhat inferior both to encephaloid and scirrhus.

In all cancers the secondary growth is apt to repeat the characters of the primary one. This is most observable in colloid, epithelioma, and encephaloid. In scirrhus, the secondary growths in internal organs are usually different to the primary one; they are vascular and soft, and exhibit the characters of encephaloid. In some cases the different varieties of cancer may replace one another.

The leading differences between **Carcinomata** and **Sarcomata** may be briefly stated as follow:—

Carcinomata usually show a much greater tendency to reproduce themselves in neighbouring lymphatic glands, and this is probably due to the communication between the lymphatic vessels and the alveolar spaces of the cancerous formation. The general dissemination in internal organs, *per contra*, frequently takes place with far less rapidity in carcinoma than in sarcoma, and therefore the course of the cancer is occasionally more protracted than in the sarcoma. This may be due to the fact that in cancer the blood-vessels are contained in the stroma and very seldom enter into contact with the cells of the growth; in the sarcomata they ramify among the cells, and their walls, consisting of thin embryonic tissue, resembling the growth they supply, a rapid dissemination takes place through the medium of the blood. In carcinoma, since the lymph is a very ready medium of



infection, a considerable delay may occur in the reproduction of the growths in internal organs.

### TERATOMATA.

Mere mention of these tumours is sufficient. They are congenital, occurring especially in the region of the sacrum (coccygeal tumours), the neck, and head, at which points double monsters are united; they may, however, be internal. Many of these tumours result from the inclusion and imperfect development of one foetus within another, but others are due to abnormal development of the tissues of one foetus. Their constitution is extremely complex, and in them may be contained all the tissues of the body up to ganglion cells, mixed up in more or less confusion. At birth they may be very large. To this group belong the dermoid cysts.

### CYSTS (Cystic Tumours).

**Cysts** are cavities, regular, with rounded outlines, and which contain a fluid or pultaceous matter separated by a more or less distinct capsule from the surrounding structures. The walls are usually composed of connective tissue, in some cases membranous and distinct, in others not so sharply defined, and at others consisting of the tissue of the organ in which the cyst is situated. The cyst-wall and its contents vary according to the nature and origin of the cyst.

Cysts are divided into (1) **simple**, or **unilocular**, when they contain one chamber (loculus); and (2) **compound**, or **multilocular**, when they contain more than one loculus. The **loculi** of this latter form are sometimes contained one within another, and at other times ranged side by side. They may, or may not, communicate one with another. The prefix **cysto-** is used to designate the cystic nature of a new formation—viz., cysto-sarcoma, cysto-carcinoma.

The secondary changes include an inflammatory process ending in suppuration. Calcification of the walls and contents may take place.

**Cysts** may be **classified** as follows:—

A. **CYSTS** formed by the accumulation of substances within the cavities of pre-existing structures.



(i) **Retention Cysts.**—Resulting from the retention of normal secretions. In these are included:—

(a) *Sebaceous Cysts.*—Formed by the retention of secretions in the sebaceous glands.

(b) *Mucous Cysts.*—Formed by the retention of secretions in the glands of mucous membrane.

(c) *Cysts due to Retention of Secretions in other Parts*—viz., Ranula, from occlusion of the salivary ducts; encysted hydrocele, from occlusion of the tubules of the testes; cysts of the mammary gland, from obstruction of the lacteal ducts; simple and certain compound cysts of the ovary, from dilatation of the Graafian follicles; simple cysts of the kidneys and of the liver.

(ii) **Exudation Cysts.**—Resulting from excessive secretions in cavities not supplied with an excretory duct—viz., bursæ, ganglia, hydroceles, meningoceles, cystic bronchoceles; many cysts of the broad ligaments of the uterus.

(iii) **Extravasation Cysts.**—Resulting from extravasation into closed cavities—viz., hæmatocele, and some other varieties of sanguineous cysts.

**B. CYSTS** the origin of which is independent.

(i) **Cysts from Softening of Tissues.**—Especially common in new formations—viz., chondroma, sarcoma, &c.

(ii) **Cysts from Extravasation into Solid Tissues**—viz., brain, soft new growths.

(iii) **Cysts from Expansion and Fusion of Spaces in Connective Tissue**, such as—

(a) Bursæ, arising from irritation and exudation into the tissues.

(b) Serous cysts in the neck, as hygroma (frequently congenital).

(c) Many compound cysts of the ovary.

(iv) **Cysts formed round Foreign Bodies.**—Extravasated blood, and around parasites.

(v) **Congenital Cysts** include many dermoid cysts. They often appear to be the remains of blighted ova. Their wall possesses, more or less perfectly, the structure of the skin. They contain fatty matter, teeth, bones, &c.



## SEPTICÆMIA and PYÆMIA.

These diseases arise from the absorption and dissemination of substances generally derived from the septic discharge of acute inflammation or from some wound. The two diseases are often associated.

The term **Septicæmia** now comprehends those forms of septic disease which are *unaccompanied* by the development of secondary inflammations.

The term **Pyæmia** now includes cases of septic disease in which secondary or metastatic suppurations are present, and it no longer implies disease resulting from the absorption of pus into the blood. Nearly all instances of both these affections have been due to the existence of a wound to which unpurified air has gained access.

**Septicæmia** includes two varieties—viz., **septic intoxication** and **septic infection**. The former is non-infective and results from absorption of a chemical poison created in some putrefactive process external to the body; the latter is caused by the entrance of specific fungi into the blood and their multiplication in this fluid.

The symptoms of septicæmia in both varieties are fever, and often repeated rigors, vomiting, diarrhœa, delirium passing into stupor or coma, great prostration, and the "typhous" condition, with jaundice and albuminuria. Death occurs in the infective form with a semi-comatose condition; the termination of the non-infective variety being in speedy collapse. The red corpuscles drawn during life, instead of being in rouleaux, run in clumps. The **post-mortem** appearances are early decomposition and feeble rigor mortis. The blood is more clotted than normally, and hypostatic congestion of the lungs and abdominal viscera appears. The spleen is swollen and pulpy, and the mucous membrane of the alimentary canal may be congested.

Serous membranes and raw surfaces absorb readily, whereas granulating surfaces have been shown not to absorb the putrid material. Septic intoxication, therefore, is most apt to take place before the commencement of granulation. Septic infection may take place from the smallest wound, and the presence of a small wound shows the inoculation of a septic poison.



As the result of an injury **fever** may follow from three causes—viz., 1. **Aseptic traumatic fever**, in which the injury is subcutaneous and shielded from decomposition; 2. **Simple inflammatory fever**, inflammation taking place at the injured part without decomposition or infection of the wound; 3. **Septic traumatic fever**, the discharge from a wound undergoing putrefaction, and the chemical products of the putrefaction becoming absorbed. Between this last form and septic intoxication no distinction can be drawn.

In **Pyæmia** the secondary or metastatic abscesses are of two kinds:—

1. They may follow upon infarction, which has been caused by an infective clot lodging in a terminal artery. Embolic abscesses are most frequently found in the lungs, then in the liver, spleen, kidneys, and brain. They may be very numerous, and are surrounded by a zone of hyperæmia.

2. The metastatic abscesses may occur as *diffuse* suppurations in the intermuscular and subcutaneous connective tissues.

### HYPERÆMIA or CONGESTION.

The term denotes an excess of blood in the more or less dilated vessels of a part. The **varieties** of a local hyperæmia are:—

(1) **Active or Arterial Hyperæmia**, in which the arteries are dilated, a greater supply of blood being thus distributed through the parts, and so forming an important element in the commencement of sthenic inflammations.

The immediate cause of this form is diminished arterial resistance pathologically produced by

(a) *Certain agencies having a weakening or paralysing effect upon the involuntary muscle of vessel walls.*

Examples: The hyperæmia of the hands which results from snowballing and is the result of fatigue due to previous prolonged contraction; the sudden removal of pressure, leading to congestion of the abdominal vessels which follows the withdrawal of much ascitic fluid.

(b) *The removal of the vaso-tonic action of the sympathetic, either directly or reflexly—viz., by inhibition.*



**Directly**, as shown in the active congestion in the neck following pressure on the sympathetic by an aneurism; and the action of certain drugs taken internally, such as amyl nitrite, tobacco, and alcohol, which are thought to paralyse the vaso-tonic nerves temporarily and directly. **Reflexly** the process is usually due to stimulation of the sensory nerves, the resulting diminution in tonicity being limited to the locality supplied by the nerve.

**Collateral Hyperæmia** is produced in some other part when anæmia exists in any large part, as in the skin from cold, or the compression of a limb by a bandage. If one kidney is removed, the other receives the main share of the blood of the lost one.

(c) *By excitation of vaso-dilator nerves*, such as the chorda tympani. To this process is referred the hyperæmia that accompanies facial neuralgia, and that of the thyroid gland in cases of exophthalmic goître.

(2) **Passive or Capillary Hyperæmia**.—Here the capillaries are chiefly involved; a condition leading to atrophic and degenerative changes in tissues which may become the seat of asthenic and chronic inflammations.

(3) **Mechanical or Venous Hyperæmia**.—In this form there is no excessive supply of blood, but merely a difficulty in the escape of this fluid—*i.e.*, a retardation of the blood-flow.

The causes of this form are two in number:—

(a) *Those which diminish the force by which the blood ought to be propelled through the veins* (the *vis a tergo*), such as diminished cardiac power and affections of the arteries, as simple atony, fatty, atheromatous, or fibroid changes.

**Hypostatic congestions** may occur if the circulation is much retarded.

(b) *Those which impede directly the return of blood by the veins*, such as the congestion of the chylo-poietic viscera following obstruction to the portal circulation in liver-cirrhosis, and that of the lung in mitral disease. Among the sequelæ of venous hyperæmia are, transudation of serum (œdema and dropsical effusions), hæmorrhage (into the stomach in liver cirrhosis, and into the lung in mitral disease), fibroid induration, thrombosis, and necrosis.

In **mechanical hyperæmia of the liver**, or "**nutmeg liver**," a condition so often resulting from disease of the heart, there is an abundant accumulation of blood in the



hepatic veins which become dilated and thickened; atrophy of the hepatic cells takes place in the central parts of the acini; and an increase of the interlobular connective tissue occurs. The obstruction to the return of blood by the hepatic veins induces pressure and consequent atrophy of the cells in the central parts of the acini, and leads to the production of granular pigments. **Microscopically** the central portions of the acini appear to consist of granules of pigment and broken-down cells. The veins are greatly dilated, and filled with red blood-corpuscles; there also appears thickening of the venous walls, and of the intercellular network by which the central vein is immediately surrounded. In advanced stages of the affection the most central parts of the acini may appear fibrous. At the periphery of the acini is observed the new interlobular growth dipping between the nearly unaltered hepatic cells. This new growth is generally distinctly nucleated, but less so than that observed in cirrhosis of the liver.

In the earlier stages, from the large amount of blood it contains, the liver is frequently much enlarged. A section shows a mottled appearance, the periphery being yellow-white and the centre of the lobules dark-red in colour. Eventually the size of the organ becomes gradually diminished; the cells in the centre of the lobules undergo atrophy from pressure of the contracting interlobular growth, which, as is the case in cirrhosis, tends to obstruct the portal circulation.

Mechanical hyperæmia, or brown induration of the lungs, has already been described under pigmentation of those organs (see page 56).

### ISCHÆMIA, or LOCAL ANÆMIA.

This term denotes a diminution of blood in a part, due to diminished arterial supply. It results from any condition which partially or completely constricts the supplying artery, such as atheroma, calcification, or syphilitic thickening, or any external source of pressure. Thrombosis, embolism, or ligature may occasion entire closure of a vessel. Diminished blood-supply may also result from an increase of natural resistance, due to irritation of the vaso-motor nerves, as takes place from a low temperature



in some nervous affections, as neuralgia, and from the action of such substances as opium and ergot.

Hyperæmia of other parts, and the presence of too little blood in the system resulting from hæmorrhage, may also produce anæmia. The results of anæmia in a part are atrophy, fatty degeneration, and necrosis (death).

**Hydræmia** is a term used to imply a state of blood in which there is a relative excess of water. This excess may be absolute, or it may depend upon a deficiency of solids, or be due to both conditions in combination.

The hydræmic condition is always accompanied by deficiency of albumen in the blood, and is dependent upon this deficiency. It is a constant accompaniment of anæmia, especially when this is due to sudden and profuse hæmorrhage, water being absorbed to restore the volume. The best illustration that can be given is Bright's disease of the kidneys, in which there is a deficiency of water eliminated by the organs, accompanied by excessive loss of the albumen of the blood. Œdema and dropsical effusions frequently go hand in hand with hydræmia, but it is supposed that this condition of blood does not itself occasion the transudation into the areolar tissues or the cavities of the body, but induces them secondarily, by leading to malnutrition of the vascular walls.

### LEUCOCYTHÆMIA.—LEUKÆMIA.— LYMPHÆMIA.

This condition is characterised by the presence of an abnormal proportion of white corpuscles in the blood, a diminution of the red corpuscles, and enlargement of some of the lymphatic organs. In health, the white corpuscles are in the proportion of 1 to 300 of the red, and to constitute this condition the relative number of white cells must be at least 1 to 20 of the red; 1 white to 10 red is very common, and frequently there are as many as 1 to 3.

The **divisions** into **Splenic** and **Lymphatic** were made by Virchow, who associated the former with enlargement of the spleen, and the latter with a similar condition of the lymphatics. The blood becomes of a more opaque and paler appearance than in health. The white globules are sometimes unaltered, but they are frequently more



granular and somewhat larger than those of the healthy condition. This is chiefly noticeable in the splenic form of leukæmia. In the lymphatic variety many of the corpuscles are generally smaller than normal. The red corpuscles may be reduced to one-half or one-quarter the normal proportion; they appear occasionally abnormally soft, and tend to stick together instead of forming rouleaux. The anæmia which is present in leukæmia, and in the majority of cases of splenic enlargement, is due to the diminution in the number and the impairment of the quality of the red corpuscles.

The most satisfactory view of the production of leukæmia is that of Virchow, who thought that the normal transformation of white corpuscles to the red was performed imperfectly, so that not only was the number of white increased, but the number of the red diminished.

Hughes Bennett regards the ductless glands as agents in the production of the corpuscular blood constituents, and considers the red corpuscles to be the free nuclei of the colourless ones, and concludes that in leucocythæmia the blood-producing function is disturbed, and that the white globules, not being transformed into the red, appear in the circulation in morbidly increased quantities. Others think, however, that there is an increased formation of the white corpuscles.

It is questionable whether leucocythæmia can be considered as a special disease, or as merely incidental to certain affections. It should be regarded rather as the pathological element of a cachexia, the essential nature of which is yet to be determined.

The **Spleen** often becomes enormously enlarged, and the enlargement is uniform. The capsule is often thickened. On section the surface is smooth, of a brownish-red or greyish colour, and marked by whitish lines (thickened trabeculæ).

**Microscopically**, the enlargement is seen to be due chiefly to increase of the splenic pulp. The trabecular tissue is also thickened and increased.

In the **Lymphatic Glands** the enlargement is much less in the splenic leukæmia than in those cases where the glands are primarily and chiefly affected.

Extreme development of lymphatic structures sometimes occurs in other parts, the medulla of bone and the follicles of the intestine being most commonly implicated.



During the course of leukæmia a new growth of lymphatic tissue generally occurs in non-lymphatic structures, especially in the liver and kidneys.

In the leukæmic **liver**, the vessels are usually enlarged and distended with white blood-corpuscles. Between the acini are seen accumulations of corpuscles and lymphoid tissue, which extend along the intercellular reticulum into the acini themselves, the lobules sometimes being clearly mapped out by greyish-white interlobular infiltration.

Ultimately, the hepatic cells are compressed, and undergo atrophy, until at last the lobules may be completely replaced by the new growth. Small lymphoid nodules resembling grey tubercles sometimes accompany this infiltration.

The liver becomes greatly increased in size.

In the **kidneys** the changes are similar to those in the liver, and consist of infiltration, together with roundish nodules.

**Leucocytosis.**—This name is given to a condition in which there is a slight and temporary increase in the number of white corpuscles, and which is not necessarily associated with diminution in the number of the red corpuscles. The increase is never so great as in leukæmia; a marked excess of white corpuscles is often observed in many acute febrile maladies, especially when acute swelling of lymphatic structures is present, as in scarlatina, typhoid fever, and septicæmia. There is also an increase after profuse discharges of blood. These are only temporary conditions, and the general health and circulation do not seem to be interfered with by them.

## URÆMIA.

This term denotes an excess of urea in the blood. In the healthy state this substance is present in the blood in very small quantities, but under any circumstances in which the renal functions are impaired, it accumulates in very large quantities, especially in structural affections of both kidneys, or when these organs have been extirpated or the ureters occluded.

The symptoms of uræmic poisoning chiefly relate to the nervous system, consisting of neuralgia, delirium, blindness, coma and convulsions, vomiting and diarrhœa.



There are pallor and puffiness of the face, which are due to anæmia and œdema.

The symptoms indicative of uræmic poisoning have been attributed to the presence of carbonate of ammonium in the blood, to œdema of the brain, and to interference with the processes of nutrition, resulting from the accumulation of waste products in the blood and the tissues.

The facts in connexion with uræmia may be summarised as follows:—It is manifest that the uræmic condition is dependent upon a failure in the proper performance of the functions of the kidneys. That in consequence of this failure, certain matters accumulate in the blood and the tissues, the most important being urea. That the amount of the retained urea, all things being equal, is proportionate to the uræmic poisoning. That when urea is introduced into the blood, under conditions which preclude its elimination, it is followed by uræmic poisoning. Lastly, that the introduction of no other excrementitious matter, as far as is known, is succeeded by like symptoms.

### SYPHILIS.

The lesions which are observed during the course of constitutional syphilis are mainly of an inflammatory nature, but certain peculiarities in the seat, distribution, and anatomical characters of some of them render them perfectly characteristic of this disease. The various lesions are the results of chronic inflammatory processes, induced by the syphilitic poison. The special characteristic lesions are of two kinds—viz., certain fibroid indurations and nodular growths known as **gummata**. These are frequently associated. The fibroid changes generally occur somewhat earlier than the gummy growths. The new tissue at first consists of an embryonic small-celled structure, which eventually becomes more or less fibrillated. The resulting fibroid thickenings are characterised by great irregularity of distribution. They usually occupy small areas, and, when more extensive, they are far denser in some parts than in others. It is, therefore, not their anatomical characters, but the peculiarities in their localisation and distribution, which makes them so characteristic of syphilis. In the capsules of organs the fibroid changes are very characteristic. In the liver and spleen



—their most frequent seat—they produce an irregularly distributed thickening and puckering of the capsule, which is very typical of an advanced stage of syphilis. Dense fibrous septa pass up to the interior of the organs, and these are frequently connected with the thickened portions. The change in the liver is somewhat similar to that occurring in an ordinary cirrhosis. It generally differs in the fact that the new tissue-growth is far less uniform and regular, and that it takes place in certain localities or around certain branches of the portal vein. The new tissue often arises from only two or three centres, a corresponding number of dense fibroid cicatrices being formed in the organ; consequently the liver becomes much more contracted and irregularly puckered than in cirrhosis, and there is little if any obstruction to the portal circulation. From the fibrous septa gummy growths often arise. In congenital syphilis the interstitial change is far more general.

**THE GUMMA, SYPHILOMA, OR SYPHILITIC TUMOUR.**—Gummata, as usually met with, are yellowish-white nodules, of moderately firm consistence, which frequently on section present the appearance of a sliced surface of a horse-chestnut. Their size varies from that of a hemp-seed to a walnut, and they are enveloped by a zone of fibrous-looking translucent tissue, sometimes appearing like a capsule, which is so completely connected with the surrounding structure that enucleation *en masse* is impossible. In the most advanced stages these tumours may become distinctly caseous, in consequence of extensive retrogressive changes.

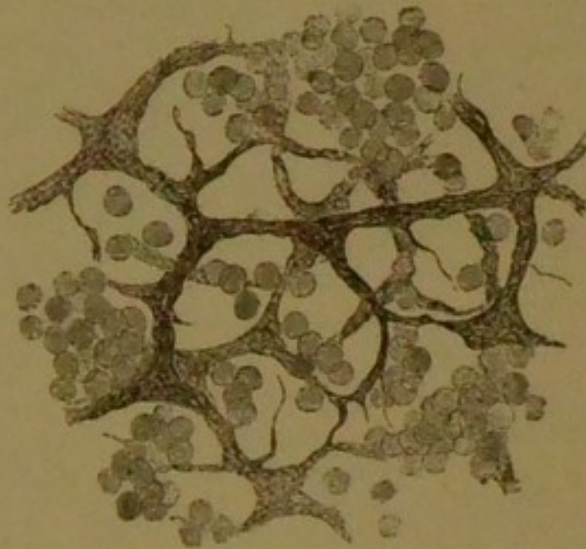**Microscopically,** gummata consist chiefly of atrophied and broken-down cell-products, which are embedded in a completely fibrillated tissue. The central and the external parts of the growth present marked structural differences. The central portions almost entirely consist of fat granules, cholesterine and close-packed granular débris, lying amid which may be a very scanty fibrillated tissue; around this and directly continuous with it is a more completely fibrillated structure. The peripheral parts of the growth, continuous with the surrounding tissue, are composed entirely of small round cells (granulation or "indifferent" cells). The blood-vessels only exist in the external parts of the growth, and are very few. Thus there are three zones. 1. The **external** or **granu-**



**lation-tissue zone**, representing the earliest stage of development. 2. The **intermediate** or **fibrous zone**, or the second stage of the process, the granulative tissue becoming developed into fibrillated structure. 3. The **central** or **amorphous granular zone**, the oldest part of the growth which has undergone retrogressive changes.

In some growths the fibrillation is very distinct; in others the tissue is of a dense and cicatricial nature. Occasionally the growth presents a reticulated structure, holding in its meshes small round cells, as shown in Fig. 29, which represents a gummatous growth in the kidney.

FIG. 29.



*From a Gummy Growth in the Kidney.* Showing the adenoid structure occasionally met with in the intermediate zone of these formations. Within the meshes of the reticulated structure are seen the groups of small round cells.  $\times 200$ .

Thus, in the formation of a gumma, the first process is the production of a granulation tissue, then follows the incomplete development of this new tissue into a fibrillated structure, accompanied by atrophy and degeneration of the young elements. In the centre of the growth the degenerated elements become closely packed, the proliferation and incomplete fibrillation continuing at the circumference. Gummata are observed in the skin and subcutaneous areolar tissue, in the submucous tissue, in bone, muscle, and the connective tissue of organs, especially in the liver, kidney, brain, and testicle. When



seated in the submucous tissue, destruction of the mucous membrane may take place, with the formation of a deep ulcer, as is seen in the pharynx, tongue, larynx, and soft palate. These ulcerating membranes must not, however, be confounded with the superficial ulcerations which result from inflammatory processes in the lymphatic structures and which are also met with in constitutional syphilis.

### HYPERTROPHY.

This term denotes an overgrowth of tissue, and it may be dependent upon an increase in the size or the number of the normal constituent elements.

**Simple Hypertrophy** is the name employed when the process is due to an increase in the **size** of the elements.

**Numerical Hypertrophy** or **Hyperplasia** denotes an increase in the **number** of the elements. When an organ is hypertrophied the whole of the elements of a tissue are increased equally, the various tissues of which the organ is composed maintaining their relative proportions.

**Spurious Hypertrophy** is where no equipoise is maintained, as when certain tissues develop, others remaining quiescent. This last heading includes inflammatory products and various forms of infiltration; here the secreting cells in glandular organs, and the muscular fibres in muscles, frequently waste from the pressure of the adventitious products; and thus an organ, although much enlarged, may be deficient in the normal development of its essential constituents. An hypertrophied organ always increases in size and in weight, but no material change of form, colour, or consistence takes place, since the tissue-elements are distributed evenly in their normal proportions.

This equable growth is not always possible in some situations, and thus a symmetrical development cannot take place. When a muscle is unable to elongate (its bony attachments being at a fixed distance), its development must be lateral, and its normal symmetry is destroyed. The chief causes of hypertrophy are functional activity and increase of nutritive fluids. Functional activity is shown in the general muscular development of the athlete, in the arm of the blacksmith, and in the leg muscles of the ballet dancer.



Hypertrophy of the heart occurs in obstruction of the circulation of the bowels and stomach; in obstruction of a lower portion of the alimentary tract; of the bladder in urethral stricture; when one kidney is disabled the opposite organ becomes enlarged in consequence of the extra work thrown upon it. A bone will even become hypertrophied, and the law of compensation extends to every structure of the body.

An influx of nutritive fluids is of course a result of functional activity, but arterial excitement, venous obstruction, and blockage of the lymph-channels may cause an inundation of the tissues of an affected locality with nutritive fluids, in consequence of which the tissues may become gorged, and thus overgrown.

The functional capacity of an hypertrophied organ generally increases proportionately with the increase of size. In spurious hypertrophy the functional capacity is diminished. True hypertrophy is a beneficial process, since by it an organ is enabled to perform its functions properly, notwithstanding obstacles. When the circulation is obstructed, disastrous results would ensue, if it were not for the compensatory enlargement and increased power of the heart, by which efficient distribution of the blood is ensured.

### ATROPHY.

This term denotes a waste of tissue; it implies a decrease in size and weight of the affected parts, and is dependent upon a decrease in the size or number of the constituent elements.

**Simple Atrophy** is the term used when the process depends upon diminution in **size** of the histological elements (fibres, cells, &c.);

**Numerical Atrophy**, when it depends on diminution in the **number** of the elements.

In the latter form there is destruction of the tissue elements, and thus the size of the tissues is lessened. The name **necrobiosis** is given to the cell-death, which is occurring constantly in the healthy condition of the organism, the old cells being replaced by young and vigorous cells. In this form there is no loss of substance, since new elements are substituted immediately. Simple atrophy always precedes and accompanies numerical



atrophy, and the latter may be considered a more advanced stage of the former.

Atrophy may be **general** when the entire organism is involved, as in general emaciation; or **partial** when it is limited to certain structures. Atrophy is most often observed in the adipose tissue, the secreting cells of the glands, and in nervous and muscular tissues. Connective tissue frequently atrophies; but it often increases as the other elements decrease, and thus occasions an unnatural proportion of the atrophied structures.

In consequence of this increase in the connective tissue elements it sometimes happens that the size of an organ does not diminish at all proportionately to the loss of its proper histological elements. In muscles, the muscular fibres, and in glandular organs, the secreting cells, may become atrophied; but since there is a coincident increase of connective tissue, the size and weight of the muscle or the gland may be retained. In proportion to the loss of these proper constituents the physical properties of the organ are, however, altered, and the functional activity impaired.

In **Adipose tissue**, which is composed of connective tissue, and the cells of which are filled with large fat globules, the atrophic change is manifested by the larger globules breaking up into numberless smaller ones, and by these subsequently disappearing, either partially or entirely. The cell either returns to its primitive form, exhibiting nucleus and protoplasm, or becomes filled with serum. A fat vesicle may be occupied partly by serum and partly by fat.

**Muscular fibres** become pliable and soft, losing their transverse markings: **glandular organs** diminish in size, whilst in **nerves** the medullary substance becomes disintegrated and disappears. As a rule, the size and weight of an atrophied structure are reduced; the structure is dryer and firmer than normal, and usually comparatively bloodless.

The **causes** of atrophy are the following:—

**Functional Inactivity:** as in a part long diseased, in the end of a bone after amputation, in nerves and muscles of paralysed parts, and in the orbit bones after the eyeball has been removed.

**Pressure:** as in atrophy of the bones of the skull due to hydrocephalus, of the kidney in hydronephrosis, in the vertebræ and sternum from aneurismal pressure.



**Excessive violence or use:** as in the testicles in cases of extreme masturbation, or in a muscle which has been strained.

**The Use of Certain Drugs.**—*Ergot*, by constricting the smaller arteries, and thus obstructing the blood supply, may occasion atrophy. *Phosphorus*, by destruction of the red blood-corpuscles, may induce fatty degeneration and atrophy. *Bromine* and *iodine* produce atrophy of the lymphatic glands, and other glandular structures.

As a physiological process, atrophy is observed in parts the purpose of which has been served. At birth the ductus venosus and arteriosus, as also the umbilical cord, disappear. Another instance is the involution of the uterus after childbirth.

Recovery may follow simple atrophy, since under proper conditions of nutrition the tissue returns to its natural state; but cell-death may occur under adverse circumstances. Atrophy affecting a morbid growth is a mode of cure.

**Atrophy of Muscle.**—The muscular fibre in simple atrophy shrinks within the sarcolemma, from which it is held apart by its attachment to the interstitial connective tissue; as the contractile substance decreases the interstitial tissue frequently grows and increases in thickness. Sometimes the cells of the interstitial substance become the seat of fatty infiltration, so that the cavity (produced by the shrinking of the muscular fibres) becomes filled. Thus in atrophy of muscle it should be noted that no fat accumulates *within* the sarcolemma, but outside the sheath of the fibre, and within the interstitial connective tissue.

**Atrophy of the Heart** is evidenced by flabbiness, absence of turgescence, and by thinness of its walls. The weight of the organ is always diminished, but not always the size. In general marasmus, the entire heart is atrophied.

**Brown Atrophy of the Heart** is distinguished by the cardiac tissue being the seat of rusty-brown pigmentation. The actual colour of the pigment is yellow, and it either resides in the contractile substance or forms granular rows between the fibrillæ. The entire heart is affected and its size reduced. It is most frequently observed in senile marasmus, and in the tuberculous and cancerous diatheses.



**Atrophy of the Liver** is of three kinds :

1. **Simple Atrophy.**—This affects only the hepatic cells, no change taking place in the blood-vessels and connective tissue. Reduction in size of the cells results, and they are covered with brown or yellow pigment; the individuality is, however, maintained, the entire liver becomes brown, shrunken, tough, leathery, dry, and anæmic, and relative, although not actual, increase of the connective tissue takes place. This form of atrophy occurs in cases of general marasmus, and results from the same cause.

2. **Red Atrophy** is really a **pigmentary infiltration**, resulting from venous hyperæmia, and occurs when the venous circulation is obstructed by diseases of the lungs and heart. It is most prominent in the centre of the lobule (the zone of the hepatic vein), and it gradually shades off towards the periphery; as it is frequently accompanied by fatty degeneration of the more external portion of the lobule, this structure appears mottled and constitutes the so-called **nutmeg liver**.

This form of atrophied liver is large, tense, and firm, and its surface exhibits arborescent furrows in the course of the hepatic vein and its branches, by which the line of destruction of the hepatic cells is mapped out. On section, the deep red colour, the thickness, and the amplitude of the vessels are remarkable.

**Yellow Atrophy (acute)** is generally considered to consist in a rapid non-inflammatory degeneration, and is thought to result from a specific poison, the nature of which is unknown. In this form the liver is small, flabby, and soft, its capsule wrinkled and rough, and the whole organ is stained a deep yellow colour. There is complete disintegration of the cellular elements, with the production of a mass of stained, granular, and fatty molecules. The blood-vessels are blocked, the connective tissue being swollen and infiltrated. This disease especially affects females, more particularly when pregnant. It is terribly fatal, runs a very rapid course, and commences insidiously. Two substances—viz., leucine and tyrosine—are found in the urine.

**Atrophy of the Walls of the Air-vesicles.** This is a chief change in the lungs in **Vesicular Emphysema**. Atrophous or small-lunged Emphysema is the name given to a form which occurs in old persons, the changes in



the walls of the air-vesicles consisting merely of atrophy of the various structures of which these are composed.

The size of the air-vesicles may not be much increased, but many of these vesicles may have coalesced into one, and the walls are much thinner than normally, the connective tissue, elastic tissue, and blood-vessels having apparently participated in the wasting process. An abnormal amount of pigmentation is generally present. Lungs in this condition are smaller than in the natural state, and upon opening the thorax they rapidly collapse.

**Atrophy of Bone.** This is always accompanied by decrease in weight, but not always by diminished size. There are two forms—viz. :

1. **Concentric Atrophy**, in which the compact and cancellous tissue become absorbed by degrees, the size of the medullary canal diminishing, and the entire bone becoming smaller. This variety is found chiefly in the large bones, in ankylosis of long standing, in dislocations, or in paralysis.

2. **Eccentric Atrophy.** Here the size of the bone is not diminished, but the condition consists in a gradual transformation of the compact tissue into the cancellous. The entire bone becomes very light and brittle, and thus is liable to be fractured with great ease. This is generally found as a senile change, and is usually associated with some fatty degeneration.

### NECROSIS OF BONE.

The term necrosis denotes the death of bone *en masse*—*i.e.*, the structure of the dead portion is still preserved, so that bone tissue can be recognised; as with other structures, when the blood supply is cut off, the bone dies. An entire bone may be necrosed or the process may be confined only to portions of the bone. Interruption to the blood supply may take place in various ways, such as the nutrient arteries being injured by the periosteum becoming detached or injured, or it may result from inflammatory changes. Fragments of broken bone, the vascular connexion of which has been lost, also become the seat of necrosis; the dead portion, when not already parted from the living structure, becomes so in consequence of a granulation tissue being formed between these parts, and this granulation, eventually melting down, leaves the



necrosed part free. This process is generally tedious, and if the situation of the necrosed part is deep, its separation is long delayed; a purulent accumulation, which consists of broken-down tissue *débris*, takes place around the dead part, and by degrees works its way to the surface, through which it discharges itself. It not unfrequently happens that an organising periostitis is established at the same time, and layer upon layer of condensed tissue becomes superadded to the old bone in which the dead part was enclosed.

**Sequestrum** is the name given to the dead part. **Involucrum** is the part that surrounds it. The **Cloacæ** are the openings in the involucrum.

The openings or cloacæ are retained in the new formation, and through these the discharge continues; and this discharge may in time carry with it the sequestrum piece by piece. After the separation of the sequestrum, the cavity and its surrounding parts become gradually altered, and the bone may become, mainly through the agency of the granulation tissue, to a certain extent restored to its normal state.

### CARIES.

This affection of bone corresponds to the ulceration of soft parts, that is to say, caries is a molecular disintegration of bone structure, in which no trace of structure can be distinguished. In necrosis, as has been stated, bone structure can be found. Caries results from inflammation, and it is often accompanied by a so-called

#### **Rarefying Osteitis.**

This is an inflammation of bone in which the medullary spaces are enlarged, and the Haversian canals widened, and often the septa between adjacent spaces are broken down, a system or series of twisting, distended, ramifying passages being produced. This cancellation or rarefaction of bone is produced by the development of a medullary granulation tissue which grows and expands within the vascular canals and the natural meshwork. This granulation tissue bores its way into the bony structure, absorbing during its passage the waste products. Thus a number of winding canals are produced, which extend from the centre to the periphery or circumference.



The infiltration of cells intended for the formation of the granulation tissue becomes fixed, and the meshes of the condensed tissues in the vessels become blocked, and both the cells and the vessels decay.

The bony lamellæ now slowly crumble away, the detritus collecting on the surface and in the meshes of the lamellæ, since it cannot be removed by absorption. The result is an irregular superficial excavation, the base of which is friable and spongy, and is coated and infiltrated with purulent ichorous matter. In this matter is contained the débris of tissue in a state of dissolution. Occasionally the medullary tissue bursts into the carious cavity, protruding like a fungus from its sides and floor. Beneath the floor of the cavity, a layer of condensed tissue sometimes forms, thus separating the dead parts from the living. A superficial osteitis or periostitis may lead to superficial caries, independently of any deep-seated inflammation. In a carious cavity it is common to find necrosed pieces of bone, which are the result of an undermining caries. Carious products when pent up may become caseous, and this is specially the case in the subjects of scrofula.

#### MOLLITIES OSSIUM or OSTEOMALACIA.

This is a rare disease; it occurs only in adults, and notably in pregnant women who have borne many children.

Its chief characteristics are a progressive loss of calcareous salts from the bones, the marrow of which steadily increases, and becomes subsequently converted into a vascular round-celled structure. The whole bone is gradually absorbed, with the exception of a thin layer underneath the periosteum; thus, in extreme cases, the bones become mere shells, they are very light, are cut easily, and bend or break with great facility. Fractures will unite at early stages of the affection, in which on section the Haversian canals and cancelli are found to be enlarged and filled by a gelatinous reddish material. At later stages this material may become yellow and fatty. The nature of osteomalacia is very obscure. It is common in some of the Rhine valleys, in which it is said there are women in existence who have undergone the Cæsarian operation for pelvic deformity on more than one



occasion. In the **osteomalacial pelvis** the weight of the body pushes down the sacrum, the resistance of the femora forcing the acetabula inwards and upwards, and in this manner the two oblique diameters are shortened. Lactic acid has been found both in the bones and in the urine. In this secretion is generally contained an excess of calcium salts which, after removal from the bone, has become eliminated by the kidneys.

### RACHITIS—RICKETS.

This disease apparently owes its origin to defective conditions of hygiene, particularly improper feeding and bad air. It is especially observed in children that have been brought up by hand, and is said to become more severe in the later children of poor families. Probably the absence of fresh food is the chief cause which seriously interferes with the nutrition of a child, and thus produces rickets.

The most remarkable changes are those affecting the growing tissues of bones, especially the epiphyses of long bones and the margins of flat bones. By these changes undue softness and consequent bending or breaking are produced. The accompanying symptoms are general bad health, and frequently enlargement of the spleen and liver, and sometimes of the kidneys and lymphatic glands. The alteration in the bones has been aptly said to consist in an increased preparation for ossification, but incomplete performance of the process. In a ricketty bone the blue transition zone between the bone and the epiphysis is similar to that of health as far as its elements are concerned, but it is much wider, and affects several rows of cells, whilst its outlines towards the bone and towards the cartilage are exceedingly irregular; patches of calcification, or of young bone, may be observed in the transition zone separated from the shaft, and oval accumulations of cartilage cells are found amid secondary areolæ, or filled with red marrow. The deposit of bony laminæ is very slight in amount. An excessive number of osteoblasts form beneath the periosteum, but calcification is very backward. The soft ricketty bone breaks under slight violence, but the fracture is often incomplete. After bending has taken place, Nature may try to support the concave side by throwing out along it



a new bone: and this is frequently seen in the femur and tibia, the bone presenting a flat and somewhat razor-like aspect. The epiphyses often join the shafts early, a dwarfed stature resulting.

The **Ricketty Pelvis**.—There are two varieties. In the first there is shortening of the conjugate diameter only, and it is contracted in those cases in which the child is kept lying, since it is unable to walk. The second form is very similar to the osteomalacial pelvis, and the mechanism of its production is similar.

### THE PATHOLOGY OF THE URINE.

In health the composition of the urine in 1000 parts is, roughly speaking, the following:—

Water	. . . . .	950
Urea	. . . . .	25
Uric acid	. . . . .	1
Fixed salts	{ Chloride of sodium . . . . .	} 14
	{ Salts of ammonium . . . . .	
	{ Alkaline phosphates . . . . .	
	{ Alkaline sulphates . . . . .	
	{ Phosphates of calcium and magnesium . . . . .	
Organic matters	{ Extractive matter . . . . .	} 10
	{ Creatine and creatinine . . . . .	
	{ Colouring matter . . . . .	
		1000

The quantity of urine normally excreted by an adult in twenty-four hours is about one to two pints and a half, or twenty to fifty ounces; but it may exceed this average by the ingestion of large quantities of fluids, as in beer drinkers; in winter; and in individuals of sedentary habits. It is pathologically increased in diabetes and hysteria. It may be below the average in summer, and generally under all conditions by which the amount of perspiration and pulmonary exhalation are increased. It is pathologically diminished in acute febrile diseases, and in all diseases attended by dropsical effusions or watery discharges. The colour of the urine varies physiologically as follows:—



The greater the quantity of urine voided, the lighter, as a rule, is the colour.

Urine voided in the morning is darker than that at other times. The use of certain drugs imparts a peculiar colour to the urine: rhubarb gives *bright yellow*; logwood, *reddish*; senna, *brownish*; santonin, *orange-red* or *golden-yellow*.

Pathologically the urine is rendered pale in anæmia, and in those conditions which produce an increase in the quantity, and it is similarly heightened in colour under those conditions in which the quantity of water eliminated by the kidneys is diminished, while the elimination of the solids remains normal, or is increased.

The presence of bile may render the urine brown, or even black.

The specific gravity of healthy urine varies from 1015 to 1025; but after copious drinking upon an empty stomach the specific gravity may fall as low as 1001, and again it may rise to 1030 after a full meal.

The urine of females is usually slightly lower in specific gravity than that of males, except during pregnancy, at which period the specific gravity is normally about 1030. A rough estimation of the solid matter contained in the urine may be made by multiplying the last two figures of its specific gravity by 2. Supposing the specific gravity to be 1020, and 1000 grains be taken, this amount will possibly contain 40 grains of solid matter. The entire quantity of urine passed during the twenty-four hours should be examined, since the density of this fluid varies at different periods of the day.

The reaction of healthy urine is faintly acid.

The colour of the urine is probably due to at least two colouring matters, *Urobilin* and *Indican*.

The urine may become alkaline by exposure to air after some days, its urea being converted into carbonate of ammonium; or it may be rendered alkaline by remedies, such as carbonate of calcium or magnesium, or its acid condition may be lessened by constant vomiting in certain diseased states of the stomach, or when the urine is loaded with pus.

It may also be alkaline after a full meal, the digestion of food absorbing the gastric juice. Alkaline urine turns yellow turmeric brown.

Acid urine turns blue litmus to a red colour, whereas alkaline urine restores to red litmus its blue colour.



Urea in excess gives urine a high specific gravity (1030—1035). This substance may be detected by adding strong nitric acid or oxalic acid to urine. If kept cool, nitrate or oxalate of urea crystals are formed. The former of these appears in the form of scales, which are composed of numerous rhomboidal plates; the latter also take the form of rhomboidal plates, but the angles are much less acute.

From the preceding table of the composition of the urine it will thus be observed that about one-half of the solid matter of the urine consists of urea.

Now, urea is theoretically formed by the oxidation of uric acid, so when this oxidation does not take place, and there is an excess of uric acid in the system, as occurs in the gouty diathesis, this disease is termed one of *sub-oxidation*.

In considering the pathology of the urine, we may conveniently divide the subject into two sections:—

- (1) **The Morbid Deposits.**
- (2) **The Morbid Constituents.**

### THE MORBID URINARY DEPOSITS.\*

These are the following:—

- |                               |                                 |
|-------------------------------|---------------------------------|
| 1. <b>Urates or Lithates.</b> | 5. <b>Cystine.</b>              |
| 2. <b>Uric Acid.</b>          | 6. <b>Leucine and Tyrosine.</b> |
| 3. <b>Oxalates.</b>           | 7. <b>Pus.</b>                  |
| 4. <b>Phosphates.</b>         | 8. <b>Mucus.</b>                |

**URATES OR LITHATES.**—These usually consist of urate of sodium and ammonium, and are the most common urinary sediments, being occasionally passed by almost everybody. They are found in the course of most fevers, in liver diseases, in rheumatism, and in gastric disturbance, but *per se* they do not indicate anything serious. There are two **varieties**—the pink and the white, the former of which forms the so-called *brick-dust sediment*.

**Tests.**—(1) Lithate of ammonium is soluble in liquor potassæ with evolution of ammonia, but

(2) All lithates are dissolved by heat, and thrown down in the cold.

**Microscopically.**—Lithate of ammonium appears as *feathery amorphous bodies*.

\* See frontispiece.



Lithate of sodium sometimes forms spherical masses, from parts of which very small needle-shaped crystals of uric acid project. The crystals are sometimes of a hedgehog shape.

Lithate of sodium is commonly met with in children's urine in a globular form.

**URIC OR LITHIC ACID.**—An excess of this acid constitutes the *uric acid diathesis*, the leading characters of which are gout, gravel, and dyspepsia, and the urine is always decidedly acid. Uric acid may occur as a deposit (**gravel**), forming the *cayenne-pepper grain* deposit, or as a concretion (**calculus**). The red colour of the grains is adventitious, being acquired from the colouring matter of the urine. The real appearance of uric acid is white. The urine of serpents (which consists almost entirely of uric acid) is white.

**Tests.**—(1) Uric acid is dissolved (without evolution of ammonia) by liquor potassæ and liquor lithiæ, but not by liquor sodæ or liquor ammoniæ.

(2) The formation of the *purpurate of ammonium*, or *murexide*, is as follows:—A few grains of the deposit are placed upon a glass slide, with a drop or two of strong nitric acid, and the whole evaporated to dryness, a substance termed *alloxan* being formed. This alloxan is now exposed to the vapour of ammonia, and the *purple murexide* results.

Uric acid is insoluble in water, but is supposed to be held in solution in the urine by the action of the phosphates.

*Microscopically.*—Uric acid usually appears as a *rhombus with rounded edges* (lozenge-shaped), or as a *dumb-bell with fringed extremities*, always of a yellow or reddish colour, but some crystals are at times halberd-shaped or needle-shaped.

**OXALATE OF CALCIUM.**—The presence of this salt in the urine constitutes the condition known as *oxaluria*. It is not found in healthy urine, but its elements—carbon, oxygen, and calcium—are present, and these give rise to the so-called *mulberry calculus*. Oxaluria often does not indicate anything serious, but is usually associated with dyspepsia and gastric disturbance. It is not unfrequent to find, upon the same microscopic specimen, crystals of oxalate of calcium lying side by side with those of uric acid.



**Tests.**—(1) Oxalates are dissolved by nitric acid, but not by acetic acid, or by liquor potassæ.

(2) They are converted by the blow-pipe into carbonates.

*Microscopically.*—Oxalates present a white deposit, consisting of *square octahedra*, and *dumb-bells* without fringed extremities. The crystals are usually very small.

**PHOSPHATES.**—These form a white deposit, and occur in the urine under three forms, viz.:—

(A) **The Triple or Tribasic Phosphate, or Ammonia-Magnesian-Phosphate**, appearing under the microscope in the form of triangular prisms, with obliquely truncated ends. Frequently the crystals are four-sided, and sometimes peculiar forms are observed in which two prisms appear united.

(B) **The Basic, Bibasic, or Triple Phosphate, with Excess of Ammonia**, microscopically presenting **stellate** crystals, and thus sometimes called the star-shaped phosphate: they after a time assume the prismatic form.

(C) **The Phosphate of Calcium**, occurring as rounded particles, usually clinging to the angles of the triple phosphate.

Upon adding a few drops of liquor ammoniæ to healthy urine it becomes turbid, and deposits the triple salt with phosphate of calcium.

*Phosphaturia* is the name applied to the condition in which the urine contains any considerable excess of phosphates. The presence of a small deposit of phosphates in the urine is always an indication of depression and debility, but a large quantity always shows a waste of tissue, and may be considered as caused by a breaking up of the mind and body.

**Tests.**—(1) Phosphates are precipitated both by heat and by liquor potassæ. They are thus distinguished from white lithates.

(2) They are soluble in acetic and nitric acids. Phosphates are thus distinguished from oxalates, which, although soluble in nitric acid, are *not* dissolved by acetic acid.

**CYSTINE, or CYSTIC OXIDE.**—This is an organic compound of a fawn colour, containing carbon, hydrogen,



and nitrogen, with a large and equal quantity of sulphur and oxygen (26 per cent. of each). It is probably a derivative of albumen, and constitutes a form of urinary calculus, but very rarely occurs as a deposit. The urine containing it usually possesses an odour of sweetbriar. Cystine is often found mixed with uric acid and the urates.

**Test.**—Cystine is soluble in liquor ammoniæ, but is re-precipitated unchanged upon the spontaneous evaporation of the ammoniacal solution.

*Microscopically*, the deposit exhibits *six-sided colourless plates*, which, if very abundant, are aggregated together so as to form superimposed plates.

**LEUCINE and TYROSINE.**—These substances are very rare indeed, but are found in the urine in cases of acute yellow atrophy of the liver.

*Microscopically*, leucine occurs in gland-like masses of leaves or scales, and tyrosine appears as shining, long needles clustered together.

**PUS.**—This occurs as a white deposit, and is a frequent indication of chronic pyelitis, especially when mixed with blood.

**Test.**—Pus forms a glairy or ropy mass with liquor potassæ.

*Microscopically*, the pus-corpuscles are observed. These resemble the white corpuscles of the blood, but are somewhat rougher in outline, and contain more nuclei; but some recent authorities regard them as identical.

**MUCUS.**—This also forms a glairy mass with liquor potassæ, but the microscope shows its true nature.

In perfectly healthy urine a slight cloudy deposit of mucus is occasionally present, and microscopically the epithelial cells are apparent; if they proceed from the bladder they are flat and scaly, if from the urethra, columnar.

## THE MORBID URINARY CONSTITUENTS

are the following :—

1. BLOOD ; 2, BILE ; 3, ALBUMEN ; and 4, SUGAR.

**BLOOD.**—The presence of this substance in the urine is termed **Hæmaturia**.

The **Causes** of hæmaturia are congestion of the kidneys or any part of the urinary organs, either idiopathic, or produced by cantharides, turpentine, &c. The



most frequent cause is a calculus, but a diseased prostate, inflammation of the bladder, or tumours (cancerous and otherwise) in the mucous membrane may cause the presence of blood in the urine. Again, hæmaturia may occur in the course of purpura, typhus, and scarlet fever, or it may be vicarious of menstruation. In the hæmorrhagic diathesis, large quantities of blood may be discharged by the vagina or penis, or by the nose (epistaxis).

**Indications.**—When the blood proceeds from the bladder, it generally follows a flow of urine; when from the kidney, it is intimately mixed with the urine.

**Tests** for blood:—

- (1) Its red colour.
- (2) The heightening of the colour by liquor ammoniæ, a crimson tint being produced.
- (3) The characteristic corpuscles under the microscope.
- (4) The dark bands in the spectrum.
- (5) Its coagulability by heat and nitric acid, throwing down a dirty-brown coagulum.
- (6) The *blue* colour produced with blood by fresh tincture of guaiacum and ozonised ether (the peroxide of hydrogen test).

**BILE.**—This substance gives to the urine a dark-brown colour, varying in the depth of its shade according to the amount of bile present.

Bile may be present in the urine from one of two conditions: either from—

1. *Suppression* of the biliary functions, in which case the blood is charged with the colouring matter of the bile and with cholesterine; or, from
2. *Obstruction* to the bile-flow into the duodenum, in which case the matters generated in the liver itself—viz., the bile acids—appear in the urine.

**Tests.**—(1) A few drops of nitric acid added to the bile-stained urine upon a white porcelain plate produce an *iridescent (rainbow) play of colours*.

(2) If strong sulphuric acid,  $\frac{1}{2}$  drachm, with a small fragment of loaf sugar is added to about 2 drachms of similar urine, *suppression* will be indicated by a *mere browning* of the sugar, whereas *obstruction* will be shown by a scarlet or purple colour at the junction of the two fluids, resulting from the oxidation of the bile acids.

**ALBUMEN.**—The presence of this substance in the urine constitutes



**ALBUMINURIA.**—The most common causes of this condition are cold, scarlatina, and intemperance; but albuminuria may occur during epidemic cholera, diphtheria, pulmonary tuberculosis, articular rheumatism, typhus and typhoid fevers, erysipelas, measles, and pregnancy.

*Applied*  
**Tests.**—(1) Heat and nitric acid will independently coagulate or throw down albumen, but these reagents should be ~~added~~ together, since either, separately, may give a fallacious result. Phosphates, when in excess, are thrown down by heat, but dissolved by nitric acid, and nitric acid may cause a turbidity in urine containing an essential oil, as of copaiba or cubebs. This oil may be separated by ether, and the urine will then have its usual reaction.

(2) Place some urine in a test-tube, incline it gently, and allow a little nitric acid to trickle to the bottom slowly. Three strata will appear if the fluid is albuminous: at the bottom, colourless nitric acid; above this, coagulated albumen; at the top, unaltered urine.

(3) Some nitric acid may be placed at the bottom of a test-tube, and the urine poured gently on the top; at the line of junction of the fluids a white line of albumen will appear.

If the urine is alkaline, heat will not affect the albumen until a drop or two of acetic acid is added; or the presence of a drop or two of nitric acid in the test-tube may, by re-dissolving the albumen, prevent its precipitation upon the subsequent addition of nitric acid.

(4) Picric acid in powder precipitates albumen, a reaction not interfered with by the presence of phosphates or urates. This test is so very delicate that it will detect a minute trace of albumen, irreconisable by the nitric acid or heat method.

**SUGAR.**—When sugar is found in the urine, the condition is known as diabetes mellitus, or glycosuria, since glucose, or grape-sugar, is the variety present.

**DIABETES.**—There are two varieties of this disease described by authors, viz. :—

1. **Diabetes Insipidus, Hysterical, or the Non-Saccharine.**
2. **Diabetes Mellitus, Glycosuria, or the Saccharine.**

**Diabetes Insipidus** occurs in hysterical persons: a

H

X or By pouring the urine into a saturated solution of Picric acid a cloudiness is produced if albumen be present.




very large quantity of almost colourless urine is passed, but its specific gravity is very low (1001-5), and it contains no sugar. It is not a condition of much pathological importance.

**Diabetes Mellitus.**—In this disease a very much larger quantity of urine than normally is passed daily—the normal quantity being 30 to 50 ounces, in some cases there may be as many pints as there are usually ounces.

To estimate the quantity of sugar passed in the twenty-four hours, the sample of urine should be fermented with yeast, the specific gravity being taken before and after fermentation. The difference in the number of degrees represents the number of grains of sugar per ounce.

The pathology of diabetes mellitus is extremely obscure. The disease would appear to be one of mal-assimilation, or suboxidation, or a perversion of the healthy function of the liver.

**Claude Bernard's** view is the following. In health, the portal circulation carries off from the stomach some of the products of digestion, *i.e.*, starchy matters and dextrine (a modification of starch). The latter is carried to the liver, and converted into glucose, hence the origin of the glycogenic function of the liver. Since this glucose is elaborated in the hepatic cells, it receives the name of hepatin. The blood containing the hepatin is conveyed by the hepatic vein into the inferior vena cava, and thence through the right side of the heart to the lungs, and still contains this hepatin or glucose throughout its whole course; but the blood returning from the lungs is found to contain *no* sugar. The assumption is, therefore, that the glucose ( $C_6H_{12}O_6$ ) acquires in the lung more oxygen (O), and is burnt off as carbonic anhydride ( $CO_2$ ) and water ( $H_2O$ ), thus—



In diabetes mellitus this combustion evidently does not take place, and hence the vessels passing from the lungs into the left side of the heart still contain sugar, which is found in the urine.

Another theory supposes diabetes to be a brain disease, since irritation of the fourth ventricle has produced an increase of sugar in the urine.

**Pavy** thinks that the hydrocarbons taken up with the food are normally stored up in the liver, under the form of



glycogen, which is changed into fat, and not into sugar; the fat serving for the formation of bile. When the conditions are abnormal the glycogen is converted into sugar, glycosuria being thus occasioned. It is extremely probable that the greater number of cases of diabetes have a nervous origin; but it must be admitted that some cases may proceed primarily from the digestive organs.

Some hours after the administration of the vapour of nitrite of amyl the urine is found to contain sugar, dilatation of the hepatic vessels being the probable cause of this transient diabetes.


**Tests** for diabetic urine:—

The specific gravity may be from 1025 to 1050. In old persons, however, it may not exceed the limits of health.

(1) (Moore's test.) Equal quantities of liquor potassæ and saccharine urine, when boiled, exhibit a *deep brown coloration*, varying in tint with the amount of sugar present, and due to the formation of *melassic acid*.

(2) (Trommer's test.) Equal quantities of the urine and liquor potassæ, with the addition of just enough of a saturated solution of sulphate of copper to give the mixture a blue colour, precipitate (when boiled) the *suboxide of copper (reddish-brown)*.

Possibly the reactions may be the following: The glucose ( $C_6H_{12}O_6$ ) reduces the black oxide of copper ( $CuO$ ) (thrown down from the sulphate of copper by the liquor potassæ) to the suboxide ( $Cu_2O$ ), sucrose ( $C_{12}H_{22}O_{11}$ ) and oxygen ( $O$ ) being also formed. Thus:—



Pavy's solution consists of caustic potash (1280 grains); neutral tartrate of potassium (640 grains); and sulphate of copper (320 grains); *i.e.*, in the proportions 4, 2, 1.

The suboxide of copper is precipitated of a beautiful bright red by this solution.

Fehling's solution contains sulphate of copper ( $90\frac{1}{2}$  grains); neutral tartrate of potassium (364 grains); solution of caustic soda, specific gravity 1.2 (4 ounces), water being added to make up exactly 6 ounces. One grain of sugar exactly decomposes 200 grains of this solution.

(3) A few grains of the white subnitrate of bismuth are placed in a test-tube, and an equal quantity of urine and liquor potassæ are added, and the mixture boiled at the



bottom. The white subnitrate is reduced to *black* metallic bismuth.

(4) Some German yeast is added to the diabetic urine and the temperature raised to 80° Fahr. Effervescence occurs with discharge of gas, a yellow liquid remains, which smells like beer and yields alcohol by distillation. One part of sugar in 1000 parts of urine of the density of 1030 may be detected by this means.

It may be useful to point out the gradations of the specific gravities of the urine under different circumstances. Thus the specific gravity of

Hysterical urine is . . . . .	1001- 5
Albuminous „ . . . . .	1005-15
Healthy „ . . . . .	1015-25
Saccharine „ . . . . .	1025-50

It should be remembered, however, that in acute Bright's disease the specific gravity may be as high as 1025 or 1030.

## URINARY CALCULI AND CONCRETIONS.

Urinary concretions, when small and numerous, and which pass readily with the urine, constitute *sand or gravel*. When, however, they are too large to be evacuated by the urine, they constitute *calculi*. The chief chemical constituents of urinary calculi are the following, viz.:—Uric acid and urates; cystine (cystic oxide); oxalate of calcium; carbonate of calcium; phosphate of calcium; ammonio-magnesian-phosphate; proteine compounds (fibrine, mucus).

With the above are mixed very small quantities of earthy matters (silica, alumina, &c.). Sometimes the urinary concretion consists entirely of one of these substances; at others, it is composed of several of them, and not unfrequently the concretion is formed of separate layers of the different constituents.

In testing a sandy deposit, it should first be examined microscopically, then the particles should be cleared of impurities, as pus and blood, and washed with distilled



water; large particles should be reduced to powder. In testing calculi, their occasional constitution in layers must be borne in mind. They should be broken to pieces, and some of the powder from each layer carefully analysed.

The best mode of proceeding analytically, is to heat some of the powdered calculus on platinum foil over a spirit lamp. Then if—

- (1) The powder is *entirely consumed*, or only a *very small amount of residue* is left; it may consist of—
  - Uric acid, or urate of ammonium;
  - Cystine;
  - Proteine bodies; or,
- (2) The powder is *incombustible*, or leaves *considerable residue* after being exposed to red heat; it may consist of—
  - Urates with a fixed base (sodium, calcium, magnesium);
  - Oxalate of calcium;
  - Carbonate of calcium;
  - Phosphate of calcium;
  - Ammonio-magnesian-phosphate.

If, when the powder is acted upon by nitric acid and ammonia, a *distinct murexide* reaction is obtained, the concretion is formed of *urate of ammonium* or *uric acid*, and these substances are thus distinguished: uric acid is only slightly soluble in boiling water; whilst urate of ammonium is far more readily soluble, occurs in much larger quantities, and, upon the cooling of the solution, it is again precipitated, and on the addition of liquor potassæ gives off ammonia.

The **Uric acid calculus** is of tolerably frequent occurrence, and is sometimes of considerable size. It is usually of a yellowish, or reddish-brown, colour, with a smooth surface and rather hard.

The **Urate of ammonium calculus** is of rare occurrence. It is generally small, of a loamy lightish colour, and more earthy in consistence than the preceding substance.

If there be *no murexide reaction* and the concretion is *combustible*, it may consist of one of the following:—

The **Cystine calculus**. This is rare. It is of a dull yellow colour; the surface is smooth, and exhibits a glis-



tening crystalline appearance when broken. It is softish, and when reduced to powder communicates a soapiness to the fingers. From the large amount of sulphur contained in it, if this calculus be dissolved in liquor potassæ and a little acetate of lead be added, the solution being then boiled, the mixture becomes *inky* from the precipitation of the black sulphide of lead.

A **calculus** formed of **proteine substances** (fibrine, or blood coagula) is very rare. It is amorphous in appearance; upon burning, it gives off an odour of burnt horn, it swells up on the addition of acetic acid, and is soluble in boiling nitric acid.

**Urates of sodium, calcium, and magnesium** are very seldom found as the only constituents of a calculus, but they are occasionally met with in variable quantities in calculi consisting chiefly of other substances—viz., in the uric acid and urate of ammonium calculi. The powdered calculus is boiled with distilled water, and the solution filtered while hot; if urates are present, they will be found in the filtrate. This is evaporated, the residue being heated to redness, and should it turn moistened turmeric papers *brown*, will indicate *sodium or potassium*. Sodium imparts a *yellow*, potassium, a *violet* tinge to the blowpipe flame. Magnesium and calcium will be found in the residue, as carbonates; these are freely soluble in diluted acids. Upon the addition of phosphate of ammonium and sodium to the solution, the ammonio-magnesian-phosphate and phosphate of calcium are precipitated.

**Oxalate of calcium**, when subjected to strong heat, turns black from the combustion of the organic matter often present, but becomes white again after continued exposure to heat, being converted into caustic lime (hydrate of calcium). If this last substance be dissolved in hydrochloric acid and oxalic acid added, oxalate of calcium is precipitated, which may be recognised by its microscopic appearance. The oxalate of calcium calculus is frequently met with; it is either small, smooth, and pale in colour, or larger, with a nodular, warty surface, and of a dark-brown or black colour (the mulberry calculus). It is common in children.

A **calculus** composed entirely of **carbonate of calcium** is also rare. It is of a whitish grey colour, and chalky appearance.

*Carbonate of calcium* is generally found, in small quan-



tity, as a component of other calculi blended with the earthy phosphates and oxalate of calcium.

A concretion of carbonate of calcium is infusible, and becomes black when burnt, on account of the organic matter which it often contains, but further heating renders it white. It also dissolves in hydrochloric acid *with effervescence*, carbonic anhydride being driven off.

**Basic phosphate of calcium and ammonio-magnesian-phosphate** are generally found together as constituents of urinary calculi. These calculi are usually whitish and often of considerable size. If *phosphate of calcium* is in excess, they are hard and thick; but if the *ammonio-magnesian-phosphate* predominates, they are chalky and soft. They are incombustible, and have been termed *fusible calculi*, since they fuse to a white enamel-like mass after exposure to strong heat; they are soluble in hydrochloric acid *without effervescence*.

These two constituents are separated by adding to the calcined powder diluted hydrochloric acid, and filtering the solution; then adding ammonia and oxalate of ammonium, by which the calcium is precipitated as an oxalate. After filtration, the phosphate of ammonium and magnesium may be obtained by the addition of ammonia in excess. Calculi of *neutral phosphate of calcium* are very rare; they resemble the earthy phosphates.

The composition of urinary calculi is sometimes very complicated. Thus, some consist of uric acid, urates, and earthy phosphates; others of oxalate of calcium and earthy phosphates; and, again, others have been met with, composed of six constituents—viz., uric acid, oxalate of calcium, carbonate of calcium, urate of ammonium, phosphate of calcium, and ammonio-magnesian-phosphate. These may be all mixed together, or disposed in concentric layers.

**Every calculus** usually possesses a nucleus which is formed by foreign bodies, such as blood coagula, mucus, and fibrine, or by sand particles, but sometimes there may be a cavity, instead of a nucleus, the mucus having dried up by which the nucleus was originally formed.

**False, or spurious calculi**, usually contain much silica, which will be detected by fusion with carbonate of sodium or potassium.



## URINARY TUBE CASTS.\*

These are six in number—

(1) **Granular Casts.**—These are dark and granular in appearance; are about  $\frac{1}{700}$ th of an inch in diameter, and are composed of fibrine and disintegrated epithelium; they are produced in tubes, the epithelium of which is undergoing disintegration, and are indicative of “chronic nephritis,” especially the “intertubular” variety (granular kidney). They usually occur in the urine after frequent attacks of gout, and may be found long before any other sign of renal mischief has been exhibited.

(2) **Waxy or Transparent Hyaline Casts.**—These are quite structureless, clear glassy cylinders, and vary in diameter from  $\frac{1}{3000}$ th to  $\frac{1}{800}$ th of an inch. They may easily be overlooked, and are best seen when light is thrown upon them obliquely, or when a drop of a watery weak solution of iodine is added to the microscopic specimen. They are sometimes found in the advanced stages of chronic nephritis, but also occur in acute forms of kidney disease.

(3) **Oily Casts.**—These consist of fibrine, in which are entangled oil globules, and epithelial cells gorged with oil. When persistent and in large numbers they indicate fatty degeneration of the kidney, but even in recent cases a few casts, somewhat oily, may be found.

(4) **Purulent Casts.**—These exhibit pus cells entangled in casts of fibrine, and occur in “suppurative nephritis.”

(5) **Blood or Exudative Casts.**—In these the blood is moulded in the renal tubes. They are observed in cases of strangury and hæmaturia, and in acute diseases of the kidney. When blood or pus cells are entangled in the tube casts, the size of the casts will vary in accordance with the particular part of the kidney in which they were formed, and also with the condition of the lining membrane of the tubes. If the epithelium is detached, the cast will of course be somewhat larger; but if the epithelium is still adherent, it will be small. Whenever inflammation of the pelvis of the kidneys, the ureters, or the bladder is present, the epithelium of these parts may be found in the urine. The cells exhibit a great resemblance to those of cancer and may give rise to an incorrect diagnosis.

(6) **Cellular or Epithelial Casts.**—These are covered

\* See frontispiece.



by the epithelial cells of the tubuli uriniferi. They indicate that the disease is recent, and that the tubes are as yet lined by epithelium. The cells themselves are generally opaque, and granular.

## ANIMAL PARASITES.

### ENTOZOA—VERMES—WORMS.

The worm-shaped or helminthic parasites are arranged in three orders, viz. :—

#### **Cestoda, Trematoda, and Nematoda.**

##### 1. **CESTODA (Tapeworms)**

may be present in two forms—(a) in the immature or larval form; (b) in the matured form.

When sexually mature, these entozoa are found in the small intestines. They are elongated, shaped like a ribbon, and consist of separate segments or joints, male and female reproductive organs being contained in every mature joint. They possess no mouth or alimentary canal, and in all probability exist by absorbing fluids in which they may be immersed. The head is furnished with suckers, and sometimes with hooklets, which enable them to attach themselves to the mucous membrane of the intestines.

New segments take growth at the upper extremity of the worm below the head; the older and lower segments, after their contained ova become mature, separate, and are discharged with the fæces. When a ripe ovum gains entrance into the stomach of any animal suited for its habitation, the investing capsule becomes digested by the gastric juice, and the embryo, termed at this stage the **prosclex**, is set free. The prosclex, by means of its spikelets, perforates the intestinal walls, and reaches some organ fitted for its abode. In this it becomes excluded from the air and enveloped in a cyst, a colony of individuals being produced.

Each of these individuals is termed a **scolex**, and is provided with a head and hooklets, the neck being fixed to a vesicular body containing fluid. Whilst in this condition it possesses no organs of reproduction, and undergoes no further development, unless it is received into the intestinal canal of some warm-blooded animal.



No less than eight varieties of cestoda are found in the human body; only two, however, are common in England—viz., *Tænia solium* and *Tænia mediocanellata*.

**Tænia Solium (the ordinary or Pork Tapeworm)** inhabits the whole track of the intestines, but especially the ileum.

These worms vary in length from 4 to 24 feet, and consist of a number of square-shaped segments. The anterior extremity (head) is exceedingly small—about the size of a pin's head—and is furnished with a double row of hooklets, by which the entozoon attaches itself to the mucous membrane; behind the hooklets are three or four suckers situated round the head (scolex). Each ripe segment or proglottis represents the independent or adult form of the sexual animal, and contains independent female and male organs of generation. In the centre of the segment is a branched organ (the ovisac) which may contain thousands of ripe spherical eggs. To the larval form the name of **cysticercus tæniæ cellulosaë** is given, and it constitutes the measles of the pig (measly pork). The worm is liable to become developed in persons who consume underdone or raw pork.

**Tænia Mediocanellata or Saginata (the Beef Tapeworm)** bears a close resemblance to the *tænia solium*, but it is generally longer, and its segments are more numerous and larger. The head is about three times the size of the *tænia solium*, but it possesses no hooklets. The larval form is termed **cysticercus tæniæ medio-canellatæ**, and infests the flesh of the ox and calf; the worm is therefore apt to be developed in persons who have eaten imperfectly cooked beef and veal.

**Bothriocephalus Latus (the Broad Tapeworm)** is very rare in England, but peculiar to Poland, Russia, and Switzerland. Of all the tapeworms this is the largest which infests the human subject, having sometimes a length of 25 feet, and even more, each foot having 150 segments, and each segment possessing male and female organs. It only possesses a suckorial apparatus in the head, which is club-shaped, with a longitudinal slit, and is destitute of hooklets. The ova are developed in water; it is thought that in the larval state the parasite inhabits the body of some mollusc or fish.

**Tænia Echinococcus.**—The mature worm is rarely longer than a quarter of an inch, and consists of three or



four segments. The head is furnished with hooklets. It has not been found in man, but occurs in the intestines of the dog. In the larval form it constitutes the

**Hydatid**, which occurs in the human being, and especially in the liver.

An **hydatid** consists of a sac lined with a thin bladder or cyst, which is filled with a limpid, colourless fluid, in which float numerous smaller cysts called *acephalocysts*, similar to the cyst lining the sac, and varying in size from that of a pea to a pigeon's egg. These cysts contain the *echinococci*.

**Microscopically**, each **echinococcus** is an oval-shaped animalcule having some thirty or forty minute calcareous hooklets arranged in a circle round its head, which is pointed and furnished with four suckers; when the creature is viewed with the head retracted, the circle of hooks appears like a ring in the centre of the body.

The history of an hydatid is the following:—Diseased offal is thrown to a dog. The animal passes, by the bowels, either in the stream or on the field, segments of the developed worm. These segments are swallowed by sheep and cattle. Eventually the animal by which the segments have been swallowed becomes the food of man, and then the larval tapeworm becomes developed into a bladder-like hydatid.

In the sheep it goes to the brain, producing "staggers;" in the ox it seeks the peritoneal cavity; and in man it selects the liver.

## 2. TREMATODA (Flukes, or Fluke-like Parasites).

The entozoa which belong to this order are minute, flat shaped, generally pointed at each end, and are not divided into segments. They are furnished with two sucking discs, one situated on the abdomen and the other at the mouth. They are devoid of anus, but possess a mouth and a bifurcating alimentary canal, which is hollowed out in the substance of the body, and is surrounded by no peri-visceral cavity. Both male and female organs of reproduction are found in the same individual.

The larvæ have no hooklets, and are never cystic, but are frequently tailed. Flukes chiefly infest the liver and intestines in man and herbivorous animals (liver flukes).

The *fluke* disease is produced in sheep thus:—The ova



pass from the gall-bladder of an infected animal into its intestines, and are voided with the excrement upon the land. A moist situation being found, they are hatched rapidly into circular ciliated embryos, which swim or move about, and before long become fixed to some mollusc, such as a slug or snail; they then alter their condition, and assume the form of a minute bladder-like hydatid, termed a **cercaria-sac**, from which numerous young tailed cercariæ take origin. After a number of transformations, these cercariæ become pupas, which are buried in the body of the snail. In wet weather the infected snail, crawling upon the grass, is eaten by the sheep, in whom the pupa develops into a perfect fluke. When found in the human body, it has possibly been drunk with water or eaten with an aquatic plant, such as watercress.

Nine species of trematoda have been found in man; among which are the following:—

**Distoma Hepaticum, or Fasciola Hepatica**, is rare in man, and it is only found in the gall-bladder and ducts. It is common in the sheep, giving rise to the disease termed the "rot."

**Distoma Crassum** has been found in the human duodenum. **Distoma Lanceolatum** is a very rare form. **Distoma Ophthalmobium** has occurred in an eye affected by cataract. **Distoma Heterophyes** has been found in the intestine of a boy at Cairo.

**Bilharzia Hæmatobia**.—In this form the male and female are separate; the latter is much the larger. It has been discovered in the Cape of Good Hope and in Egypt in the bladder, kidneys, ureters, and mesenteric veins.

Through the irritation it excites, hæmorrhage and inflammation are induced in the organs it inhabits. When the kidneys are the seat of the parasite, a form of hæmaturia is produced; when the intestines are affected, symptoms of dysentery are set up.

The presence of the bilharzia can only be determined on microscopical examination by finding the ova in the urine or in the fæces.

### 3. NEMATODA (Round Worms).

A number of different families are included in this order. The worms are elongated and slender, and devoid



of joints. They possess a mouth, alimentary canal, and an anus.

The majority are parasitic only during part of their existence, and they are unisexual. The following are the most important varieties:—

**Ascaris Lumbricoides (the Common Round Worm).**—This worm varies in length from 6 to 16 inches. Its body is reddish in colour, tapering towards each extremity, and its general appearance closely resembles the ordinary earth-worm. The head is terminated by three distinct and uniform papillæ, which surround the mouth, and are capable of spreading out into a broad circular sucker during the act of suction. Each papilla is furnished internally with microscopic teeth. The posterior extremity of the male is bent round like a hook, the corresponding part of the female being pointed and comparatively slender. The fecundity of this entozoon is remarkable the body of the mature female has been calculated to contain sixty-four millions of eggs at a given time. The ova probably find their way into the alimentary canal by unripe fruits and vegetables, or by impure water. This round worm occupies chiefly the small intestines, but it may present itself in the œsophagus, stomach, and gall-ducts.

**Ascaris Vermicularis—Oxyuris Vermicularis (the Thread or Maw-worm).**—These worms are termed collectively **Ascarides or Oxyurides.**

Ascarides resemble small pieces of thread, often massed together as round balls of considerable size. The male is small in comparison with the female. They are of a pale silver colour, with obtuse and rounded extremities. The females are more numerous than the males, and are recognised by their whiteness and thickness, and by their fine-pointed tail. The head has three papillæ. As these worms exist in large numbers, they set up great irritation at the margin of the anus. They frequently crawl out of the rectum, and may be discovered in the bed and the clothes of the patient; they often occasion vaginitis in the female and irritation of the penis in the male. They infest the large intestines, especially the rectum.

The worm, it is supposed, is admitted into the intestine in the embryonic condition, through eating uncooked or unripe fruits; but water is a more probable vehicle for its introduction.

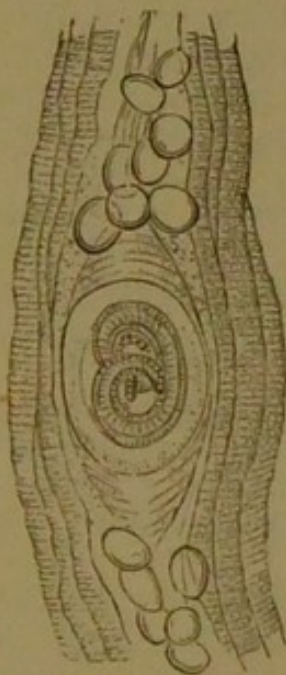


**Trichocephalus Dispar (the Long Thread-worm).**—The male trichocephalus is more slender and shorter than the female. These worms differ from the ordinary thread-worms in the fact that their length is greater, their anterior two-thirds extremely thin, and their posterior third of comparatively large size. They chiefly inhabit the cæcum and colon. They are rare in this country, but common in France.

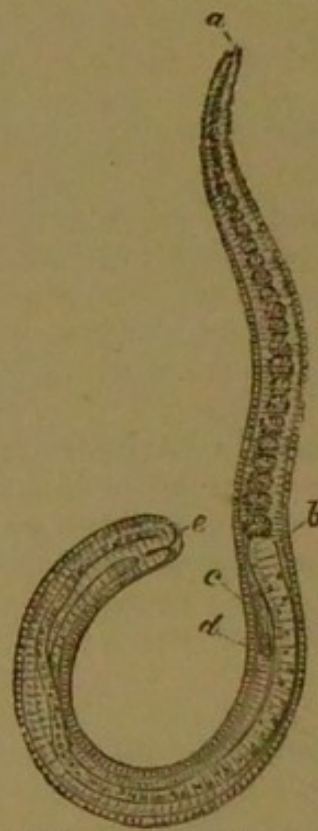**Ascaris Mystax** has been found occasionally in the human subject, but it chiefly occurs in the cat. Its head is spear-shaped.

**Trichina Spiralis.**—This is a very small worm, which

FIG. 31.



*Trichina Spiralis* coiled up within its Cyst, with groups of fatty cells at either end.  $\times 50$ .



*Trichina Spiralis* removed from its Cyst. *a*, The mouth; *b*, Commencement of the alimentary canal; *c* and *d*, Tubular sac, with granular body, extending to *e*, The anal extremity.

may exist in the human body in a free or encysted state, and when mature is only about  $\frac{1}{18}$  inch in length. When encysted, it is seated between the sarco-



lemma of the primitive muscular fibres, the capsule becoming more or less calcified. It is frequently found in the flesh of the pig, and, when raw or insufficiently cooked pork so diseased is eaten, digestion sets free the encysted trichinæ; these then commence to develop, numberless embryos being produced in the intestines, from which they advance to the muscles, setting up violent symptoms until they become enveloped in capsules, in which condition they are harmless. The trichinæ are found in the muscular tissue, each being coiled up within an oval cyst, and appearing to the naked eye as tiny white grains. The colour of the affected muscles is pale reddish grey, speckled with small light points of trichinæ, which exist in all stages of development, lying upon and within the sheaths of the muscular fibres. They have been found in all the voluntary muscles, and have been seen in the heart's substance.

**Microscopically**, the trichina spiralis appears of a spiral form coiled up within the sarcolemma of the muscular fibre (Figs. 30 and 31).

**Filaria Medinensis (the Dranunculus, or Guinea-worm)** is about  $\frac{1}{16}$  inch thick, but may be 6 feet long. The female alone occurs in the human body, and the worm is only found in certain tropical regions.

These filariæ are thought to constitute some of the species of "tank-worms," since they are believed to perforate the skin of persons bathing in the muddy water of tanks. The parasite seems to remain inert in the tissues for about one year, by which time it has become distended with young. It now advances to the surface, and forms a blister, upon the bursting of which its head appears, its young are discharged, and the parent worm is gradually removed.

**Filaria Lentis** has been found in the human eye.

**Filaria Sanguinis Hominis.**—The embryos of a very small nematoid worm have been found in large numbers in the blood, in the urine, and other secretions of persons in India who were suffering from chylous urine and elephantiasis. They only differ from the young of other nematoda in being enveloped in a delicate transparent sheath within which they can be seen to contract.

**Sclerostoma Duodenale** infests the small intestines; it occurs chiefly in Italy and Egypt. Its head is round, and furnished with hooklets. It exists in large numbers



and, by the frequent minute hæmorrhages it occasions, may set up a variety of anæmia, termed Egyptian chlorosis.

**Strongylus Gigas** is rare in the human being.

**Strongylus Bronchialis** has been found in the bronchial glands.

### DERMATOZOA—ECTOZOA.

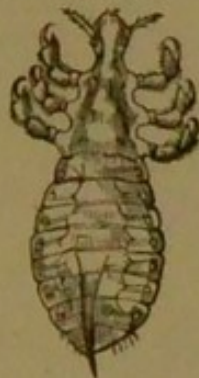These are the animal parasites which are found upon the surface of the skin. They are the following:—

#### PEDICULI (Lice).

Of these there are three varieties, viz.:—

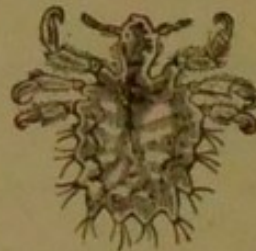**Pediculus capitis**, infesting the head; **Pediculus pubis** (the crab-louse), infesting the privates; and **Pedi-**

FIG. 32.



*Pediculus Capitis* (female),  
found in Phthiriasis capitis.

FIG. 33.



*Pediculus Pubis*, found in  
Phthiriasis pubis.

**culus corporis** or **vestimenti** (the body or garment louse). These parasites occasion a disordered state of the skin, termed **phthiriasis** or **lousiness**.

The **Pediculus Capitis** (Fig. 32) occurs chiefly on the heads (the top and back) of badly nourished and unclean children. The "nits" on the hairs are the deposited eggs of the parasite. It usually causes an eczema or an impetigo by its irritation, but in a healthy subject it may merely excite a pruritus; sometimes it produces a so-called "pruriginous" rash.

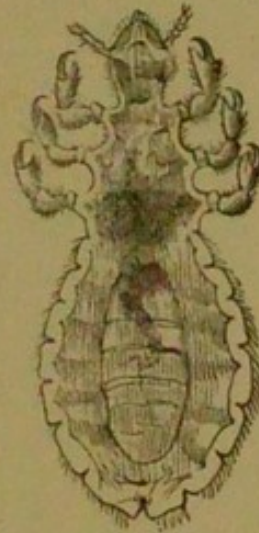The **Pediculus Pubis** (Fig. 33) generally inhabits the inguinal and pubic regions, and clings especially to the hairs close to the skin about the scrotum, mons veneris, and anus, appearing as darkish specks. It grasps the



hair with its forelegs, and is not easily detached. It is found in adults, not in children, and not uncommonly results from impure connexion.

The **Pediculus Corporis or Vestimenti** (Fig. 34) is of a whitish appearance, and may be  $\frac{1}{2}$  line to even 2 lines in length. These pediculi do not *bite*, but are furnished with a proboscis, by which they extract blood, and thus produce a characteristic hæmorrhagic speck on the skin. They are mostly found, with their whitish, shining ova, in the folds of linen next the skin. Some authors consider that the prurigo of old persons is due to pediculi, but this is denied by others. Phthiriasis corporis in the early stages is found about the shoulders, neck, and clavicles, and in chronic cases upon the body as well, but the pediculi themselves infest the clothes, and *not* the body.

FIG. 34.



*Pediculus Corporis or Vestimenti* (female), found in Phthiriasis corporis.

**ACARUS SCABIEI** (the **Itch Insect**).—This is the cause of the disease known as the itch. The disease (scabies) itself depends essentially upon the burrowing of the *acarus scabiei*. The female *acarus* is the more important of the two, since she alone burrows, the male simply wandering over the surface. The female gets beneath the skin, and establishes a cuniculus or furrow, in which she lays her eggs. These furrows or cuniculi may be detected in the skin. At the extremity of each furrow a minute whitish elevation may be observed, which is in reality a thin epidermal layer covering the *acarus* itself. By raising this layer with a penknife, the *acarus* and her ova may be obtained. Although papular, vesicular, and pustular scabies are described, yet the real scabies is only the *acarus* in its burrow. All else is secondary to the irritation occasioned by the parasite. The chief seats of the disease are the thin skin between the fingers, the wrists, forearm, belly, thighs, and especially the upper line of the penis.

When fully grown, the *acarus* has eight legs attached to a round body, and has a projecting head. The four front legs are furnished with suckers, the four hindmost with hairs. The male *acarus* (Fig. 35) is smaller



than the female, which is about  $\frac{1}{60}$  to  $\frac{1}{80}$  inch long. The inner pair of posterior legs are furnished with suckers, and the genital organs are well marked. The young acari have six legs at first; they then cast their skin, and are provided with eight legs. The eggs are about  $\frac{1}{25}$  line broad and  $\frac{1}{11}$  line long.

**COMEDONES, or Grubs.**—These constitute the black specks observed on the face of adolescents and adults;

FIG. 35.

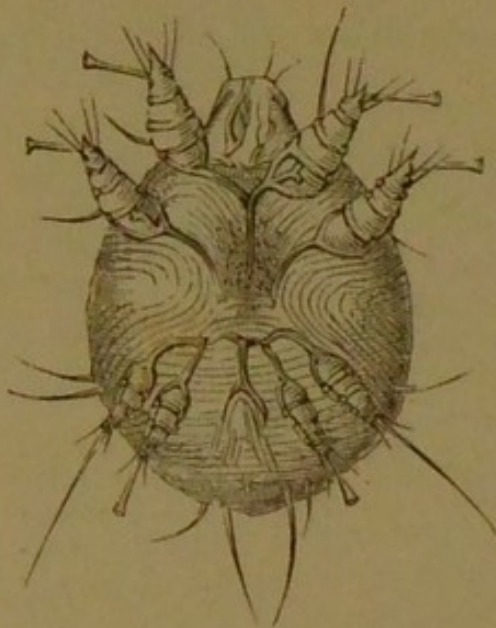
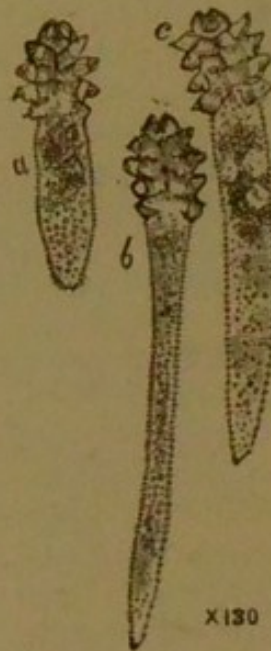*Acarus Scabiei* (male).

FIG. 36.



Comedones, containing a species of acarus (steatozoon, or acarus folliculorum).

they are simply produced by the retention of sebaceous matter. When slight inflammation is excited, the affection termed *acne punctata* is produced. The skin is greasy-looking and thickish. The secretion is retained and inspissated. The dark speck or point is occasioned by the dirt collecting at the apex of each little grub. The sebaceous matter can be squeezed out of each follicle, and is supposed popularly to resemble a little maggot. The mass itself is composed of sebaceous matter, epithelial cells, numerous minute hairs, and one or more of a species of acarus, termed **Steatozoon**, or **Acarus folliculorum** (Fig. 36).



## VEGETABLE PARASITES.

## Bacteria, Bacilli, &amp;c.

For a long time the opinion has been held that there must be some special cause for acute specific diseases, since the poison from which each arises multiplies in a most remarkable manner, a single case possibly causing the death of millions when introduced into a community of persons. Whatever this poison was, it was inappreciable to the senses, and was called the "**contagion**" of the disease. It would seem that the contagium must be some living organism, and this theory is termed the "**contagium vivum**" or **Germ Theory**. A close parallel may be drawn between an infective disease and a fermentation.

The germ theory is the one more generally adopted in the present day. This view considers that the yeast plant (*saccharomyces cerevisiæ*) is the cause of the alcoholic fermentation. It must be provided with food, such as sugar, with nitrogen, and certain inorganic materials; its life-action produces alcohol, carbonic acid, glycerine, and succinic acid. The supposition is that the food-stuffs pass into the cells, by which is taken what is requisite for their own growth and repair, and which throw back the products of their action on to the fluid. In the same manner, then, as the bile-constituents are formed in an hepatic cell, so does a yeast cell form the foregoing substances.

The so-called **Physical Theory** holds that fermentation consists in a "*molecular motion*" which is transmitted by albuminoid particles (ferment) themselves undergoing decomposition, *i.e.*, the seat of "*motor decay*," to unstable organic compounds (fermentable substance).

The conclusion is arrived at, however, that, although this last-named theory may be possible theoretically, evidence seems to demonstrate that the vital theory is true practically, and that *all the processes which are generally recognised as fermentations and putrefaction, are due to the action of vegetable organisms.*

The vegetable organisms connected with diseases in man are fungi (belonging to the group of so-called achlorophyllous thallophytes), and these pathological fungi are the following three kinds:—



1. **Bacteria, or Schizomycetæ, or Fission fungi.**
2. **Blastomycetæ, or Yeast fungi.**
3. **Hyphomycetæ, or Mould fungi.**

The most important are the Bacteria, which include all the organisms by which the infective diseases are considered to be produced. The Schizomycetes are all very small, and many approach the limits of microscopical visibility. They consist of a form of protoplasm called **mycoprotein**, and appear structureless, but they probably possess a cell-membrane. In form they vary very much. The new cells produced by fission sometimes form chains, and sometimes lie side by side, being bound together by a viscid intercellular substance (zooglœa) formed of mycoprotein or of swollen cell-membrane. It has been estimated that in twenty-four hours a single bacterium may give rise to a progeny of over 16,000,000.

Vegetable parasites are termed **Entophytes**, which are capable of living *inside* the body, and **Epiphytes**, which merely grow *on the surface*, just as, with animal parasites, entozoa are distinguished from ectozoa or epizoa. Like epizoa, epiphytes are frequently transplanted mechanically from one individual to another, and in the same manner as the tapeworm may be said to be contagious, so also is the epiphytic disease, ringworm, contagious. **Saprophytes** (saprogenic, or septic species) is the name given to those vegetable parasites which live merely upon the food-substances or waste products of the body without producing any pathological changes. The **Pathogenic** species induce inflammation and necrotic changes at the locality where they grow, as well as serious general diseases.

It is clear that in some species the vitality is sustained by *spores*. The bacillus anthracis, after living in the blood and tissues of cattle in the form of long threads, produces spores which, after leaving the body, maintain their vitality in the soil or the grass until they are able again to enter some animal body. As in the case of the liver fluke, the bacilli-spores of a sheep's carcass dead with anthrax infect the soil, the contagium being thus preserved for the infection of other animals.

#### **SCHIZOMYCETES (Fission Fungi).**

The schizomycetes are most extensively diffused throughout nature; no space, unless it is produced artificially, is free from them; they or their spores are con-



tained in all natural waters. The conditions of growth requisite are moisture and some nitrogenous material serving as food. A certain range of temperature is also needful: although they may retain their vitality, they cannot grow under freezing-point; all the species appear to be destroyed by a temperature of about  $60^{\circ}$  C. In some species the spores are not killed by heating them to the boiling-point, a temperature of  $120^{\circ}$  or  $130^{\circ}$  being necessary for their complete destruction.

Certain species of bacteria live in dead organic matter, and are themselves the direct cause of putrefaction. In their absence the earth would be encumbered by dead carcasses. The fertility of soils is directly attributable to other species, by which ammoniacal substances are converted into nitrates, and in this form absorbed by plants. During putrefaction certain substances termed **ptomaines** (cadaveric alkaloids) are formed; these bear a strong resemblance to vegetable alkaloids, and are poisonous. Bacteria by which putrefaction is set up may be termed **saprogenic** or **septic**. The best-known form, the **bacterium termo**, probably covers many species.

One group of bacteria flourish in organic fluids or solids, such as milk, butter, cheese, and bread, producing chemical changes, called fermentations—*e.g.*, vinegar, produced from sugar by the action of *bacterium aceti*; lactic acid, from milk by *bacterium lactis*; butyric acid, by *bacillus butyricus*; ammonia, from urine by *micrococcus ureæ*. These bacteria are termed fermentative or **zymogenic**. Certain species of bacteria produce coloured substances (red, blue, green, or brown), and have been called **chromogenic**.

Septic bacteria were at one time regarded as the cause of various diseases, but the majority cannot exist in healthy blood or tissues. They may nevertheless live in gangrenous or dead parts, and are liable to be harboured by pus or other morbid products.

With regard to whether the living tissues and blood of healthy persons contain bacteria under ordinary circumstances, the verdict of the large majority of experimenters is to the contrary.

The **Schizomycetes** are classified as follows:—

**Forms of Bacteria.**—Simple forms must be looked upon as single cells. United in various ways, compound forms are produced.



The single-cell form is a *micrococcus*; two-celled form, a *diplococcus*; three or more cells, a *streptococcus*. When numerous cells (colonies) are found connected by an intercellular gelatinous substance, the *zooglœa* or living jelly is produced.

I. The **Single-celled Forms** are unicellular, and multiply by fission. They include—

(a) Cocci or micrococci; (b) Rods of variable shape; (c) Spirals or corkscrew forms; and (d) Degenerative forms.

In some bacteria, cilia or flagella are observed.

II. **Combinations of Single Cells.**—No intervening substance.

(a) Growth in one direction only: producing rosary, thread, or spiral forms. (b) Growth in various directions in a plane, a flat mass or lamina resulting. (c) Growth extending in all three dimensions, solid masses resulting: as *sarcinæ*. (d) Agglomerations or perfectly irregular masses.

III. **Zooglœæ, or Colonies.**—Presence of intercellular gelatinous material, producing the form zooglœa. Rods or cocci may form a zooglœa. Some species may be in turn a micrococcus, a bacillus, a leptothrix, and so on.

Two modes of formation are observed in those varieties which produce spores—viz.:

1. **Endogenous**, in which the spore is formed within the cell-membrane from the protoplasm, as in bacillus anthrax.

2. **External Spore Formation**, in which the cell itself, or one segment of a chain, is converted into a joint-spore or arthrospore.

It has been stated that in micrococci the spores are identical with vegetable cells.

Bacteria by which *endogenous* spores are formed have been termed **Endosporeal Cocci**, or simply **Bacteria**. Those by which *arthrospores* or no spores are formed receive the name of **Arthrococci** or **Arthrobacteria**.

In the so-called **Coccaceæ** two families are recognised according to the presence or absence of endogenous spores. Thus:

A. **Arthrococcaceæ**, in which, according to the different modes of combination of the cells, genera are formed—viz.:

1. *Streptococcus*, the cells forming chains.



2. *Merista*, or *Merismopedia*, the cells forming plates.
3. *Sarcina*, cells forming packets, or "bales."
4. *Micrococcus*, or *Staphylococcus*, in irregular masses or clumps.
5. *Ascococcus*, the cocci being united in gelatinous pellicles.

B. **Endosporal Coccaceæ**: chief genus *Leuconostoc*. *Bacteriaceæ* are divided into the following groups, according to the presence or absence of endogenous spores:—

C. **Spore-forming Bacteriaceæ**, or **Bacilli**.—Rods of all lengths, but sometimes so short as to be indistinguishable from micrococci. Genera are two—

1. *Bacillus*.—Rods not altering in shape during spore-formation, as in bacillus anthracis.
2. *Clostridium*.—Rods altering in shape during spore-formation, or always fusiform (spindle-shaped), as in clostridium butyricum.

D. **Arthro-bacteriaceæ**.—Genera are

1. *Bacterium*, strictly so termed; includes straight rods, forming no spores.
2. *Proteus* (*spirulina*) shows cocci, chains, rods, and threads. In certain stages, motile.

In the spiral bacteria are seen forms with and without spores.

E. **Spiro-bacteriaceæ**.—Rods small and curved, resembling the fragments of a spiral, and known as "*comma-bacilli*." May unite and form corkscrew-like threads. Genera are—

1. *Vibrio*.—The rods enlarge, spores forming in the dilated part.
2. *Spirillum*.—Spores formed without alteration of shape of the rods in some non-pathogenic genera.

F. **Leptotricheæ**.—Early stages, rods or cocci; later stages, thread forms, spiral or straight. Differing from the threads formed by bacillus, &c., since the threads exhibit a distinction between the fore end and the base, at which they are attached. Genera are—

1. *Crenothrix*.—Threads and rods distinctly articulated, and showing a sheath.
2. *Leptothrix*.—Threads articulated or non-articulated, without a sheath. One species occurs in the mouth, and is termed *leptothrix buccalis*.

G. **Cladotricheæ**.—In rods and sheathed threads,



spiral or undulated. Genus is *cladotrichia*; very common in water. One variety has been discovered in the human lachrymal channels.

ANALYTICAL TABLE OF BACTERIA.

Cocci; round or oval cells	{	Arranged in chains . . . . .	Streptococcus (chain-cocci)			
		"    "    fours or small chains . . . . .	Merista (plate-cocci)			
		"    "    eights or small chains . . . . .	Sarcina (packet-cocci)			
		"    "    irregular masses . . . . .	<table border="0" style="display: inline-table; vertical-align: middle;"> <tr> <td>Zooglœa va-rious . . . . .</td> <td rowspan="2" style="font-size: 2em; vertical-align: middle;">{</td> <td rowspan="2">Micrococcus, or Staphylococcus . . . . .</td> <td rowspan="2">(mass cocci)</td> </tr> <tr> <td>Zooglœa in spherical encapsulated masses . . . . .</td> </tr> </table>	Zooglœa va-rious . . . . .	{	Micrococcus, or Staphylococcus . . . . .
Zooglœa va-rious . . . . .	{	Micrococcus, or Staphylococcus . . . . .	(mass cocci)			
Zooglœa in spherical encapsulated masses . . . . .						
Cells; cylindrical rods	{	Longer or shorter threads, without distinction of base or apex	Threads straight or wavy; no endogenous spores . . . . .	Arthro-bacterium		
			Threads straight, wavy, or spiral; motile; no endogenous spores . . . . .	Proteus (spirulina)		
			Threads straight or wavy; formation of endogenous spores . . . . .	Bacillus		
		Threads, showing distinction of base and apex	{	Threads without a sheath . . . . .	Leptothrix	
				Threads with a sheath	{ not ramified } . . . . .	Crenothrix
					{ ramified . . . . .	Cladotrich
Curved or spiral rods	{	Spiral threads, flexible or stiff	Endogenous spores, with alteration of shape . . . . .	Vibrio		
			Endogenous spores or arthro-spores, or none, without alteration of shape . . . . .	Spirillum		

This classification is one of forms only, and how far these forms represent actual species is uncertain.

With reference merely to *pathogenic* bacteria, it would suffice to recognise four principal groups—viz.:

1. **Micrococci.** 2. **Bacilli.** 3. **Spirilla.** 4. **Bacteria.**

The term **Aerobic** has been applied to those bacteria which can only live, or grow where there is access of air; **Anaerobic** to those where air is excluded—*i.e.*, beneath the surface of the fluid or other nutritive medium.

Artificial cultivation is employed to demonstrate certain characters derived from the mode of growth, since the forms of bacteria do not always afford constant distinguishing characters, and the form of numerous apparently different species is identical.

**Cultivation of Bacteria.**—*Nutrient gelatine* is the



medium chiefly employed, the nutrient material being peptonised meat-juice mixed with sufficient gelatine to cause the mixture (prepared with heat) to solidify on cooling; when solid, it again becomes liquid on heating to about 85° F. For use after liquefying, it is poured into test-tubes, which are filled up to one-third and then closed at the top by a plug of cotton wool. The medium is now sterilised—*i.e.*, heated in such a manner as to destroy any living bacteria or spores which may be present in it. This medium is transparent, thus rendering the commencing growth visible.

*Agar-agar*, a vegetable jelly derived from certain species of algæ, and imported from Japan, is employed for some purposes since it bears a higher temperature without liquefying than does nutrient gelatine. It is added to peptonised meat-juice, and the mixture prepared as in the case of the nutrient gelatine. Thus prepared, this jelly remains solid up to a temperature about 100° F. It is quite as transparent as gelatine.

*Coagulated blood serum* is in other cases made use of. This is obtained from fresh blood, and, after being sterilised carefully, is solidified at about 150° F., the test-tube being held obliquely, so as to obtain a sloping surface on the coagulated mass. This is particularly useful for the cultivation of the tubercle-bacillus.

*The surface of a cut potato* is very suitable for certain cultivations. The outside of the potato is sterilised; it is then steamed and cut in half with a sterilised knife.

**Sterilisation.**—This proceeding is absolutely necessary in order to prevent the entrance of organisms so abundant in the air and upon the solid objects employed. It is performed by heating to a temperature much above the boiling-point, 300° F. being the necessary minimum.

The **Method of Cultivation** is the following:—

Suppose a tube of nutrient gelatine is taken, a platinum wire is allowed to touch the material in which the micro-organism is contained, so as to bring away the smallest quantity possible; the tube is then inverted (to avoid the falling in of germs), the wire being made either to touch or being dipped beneath the surface of the gelatine, and then withdrawn. The tube may now be placed in the incubator—*i.e.*, a hot chamber with a self-regulating gas-burner, by which a constant temperature is provided. After a time growth ensues, the gelatine becoming turbid,



or definite masses being formed. By the forms produced different species may be distinguished, regard being had as to whether the growth does or does not liquefy the gelatine, or whether bubbles of gas are evolved or not, and so on. The rapidity of the growth and the temperature at which it takes place are other important features.

**Plate Cultivations.**—The plate method is employed when there is a mixture of organisms. The original tube-cultivation is placed in a fresh tube of gelatine, melted by heat; from this tube a small portion may be introduced into a second tube similarly prepared. The contents of the two tubes are poured separately upon a glass plate, then carefully spread over it, and allowed to solidify. The plates are now placed under a bell glass in a moist chamber. Organisms will be observed to spring as isolated cultivations at different parts of the plate.

Another method of cultivation is to spread a single drop of gelatine on a glass slide, and allow it to solidify. The organism may then be sown in lines or streaks, and its development watched microscopically.

For microscopical examination, cultivation in the so-called "hanging drop" is very useful. A glass slide with a hollow ground in it (forming a shallow cell) is required. Over the hollow is placed a cover glass, the under surface of which is moistened with a drop of nutrient liquid containing a minimal amount of the organism. The edges are rendered air tight by a little vaseline, a moist chamber being thus formed.

**Continued Cultivations.**—A growth having been obtained which consists of one organism only—*i.e.*, a "pure cultivation"—a minute portion can be transplanted on a fresh gelatine tube, and carried on through numerous generations. In this manner any extraneous matter is separated from the organism. The cultivation of the tubercle-bacillus has been carried through thirty-four generations in nearly two years, and even through a much longer series.

The cultivated bacterium has been also introduced into the blood or tissues of a guinea-pig or a mouse. Inoculation may then be made from this animal into the body of another, and then through numerous generations. The identity of some specific diseases has been established by this method.



Two kinds of actions are set up when a pathogenic organism is introduced into the body. The first are *local*, or changes in tissues, including destruction of elements and new growth; the second *general*—viz., fever and cachexia. The most perfect combination of local and general disturbance is seen in tubercle.

The micro-organisms especially attack tissue-cells and migratory leucocytes. A notable increase in the size of elements is extremely characteristic of chronic bacterial inflammations. The spread of bacterial infection is said to be caused partially by the multiplication of the organisms; but considerable areas of change may be found which exhibit very few organisms. Many tubercles without bacilli may be observed in acute tuberculosis of man, other similar tubercles containing them. The majority of bacteria pass easily into the lymphatics, and from them into the lymph-glands. After passing these glands they may reach the blood by the thoracic duct, and in this manner be conveyed to all parts of the body. A special participation of the thoracic duct has been noticed in some cases of acute tuberculosis.

Other forms of bacteria pass into the veins, a coagulum being formed, which is penetrated by the micro-organisms, and, the clot breaking down, these are carried into the circulation and produce pyæmia.

During the circulation of bacteria in the blood they may become arrested at various points with the formation of secondary deposits, thus establishing new foci of disease. A blockage is more likely to occur in the first set of capillaries passed through, as in an ordinary embolism.

In many bacterial diseases the lungs are thus affected, as in pyæmia, glanders, and possibly in some instances of general tuberculosis. When the portal circulation is invaded by bacteria the liver will be the seat of the earliest secondary foci of disease. The synovia of joints appear specially liable to attract wandering germs of disease. Micrococci in considerable numbers have been found in the joints in the suppurative arthritis consequent upon scarlatina. Some of the organisms are eliminated from the system by the urine and fæces in diphtheria and pyæmia, and the micrococci of scarlatina have been traced in the kidneys, the pyæmic distinctly in the urine. *Bacillus tuberculosis* and *bacillus anthrax* have been observed in



the Malpighian tufts. It has clearly been demonstrated, however, that bacteria, whether saprophytic or pathogenic, after introduction into a healthy body, do not become eliminated by any secretion unless a diseased condition of the eliminating organ is present.

As the symbol  $\mu$  (the Greek m), micromillimetre, will be constantly used in succeeding pages, the following may be found useful:—

The micromillimetre,  $\mu = \frac{1}{1000}$  of a millimetre.

The metre is a unit of length, and is equivalent to a little more than 1 yard—viz., 39·37 English inches.

The metre may therefore, for the sake of convenience be considered as equal to 40 inches.

Now, 1000 millimetres are equal to 1 metre; and since

the metre = 40 inches,

and  $\frac{1}{1000}$  of 40 =  $\frac{40}{1000} = \frac{4}{100} = \frac{1}{25}$ ;

therefore, 1 millimetre =  $\frac{1}{25}$  inch.

Again,  $\mu = \frac{1}{1000}$  of a millimetre,

and  $\frac{1}{1000}$  of  $\frac{1}{25} = \frac{1}{25000}$ ;

therefore, the micromillimetre,  $\mu = \frac{1}{25000}$  inch (roughly).

Allowing for the '63 inches added above for the convenience of working, it may be stated that  $\mu$  very nearly equals  $\frac{1}{27000}$  inch.

#### PATHOGENIC BACILLI (HUMAN).

**Bacillus Anthracis.**—This occurs in anthrax or splenic fever in the human subject, known as malignant pustule or wool-sorters' disease. The bacillus is of comparatively large size, and therefore more easily seen than most bacilli. The rods present sharply truncated ends, and are from 3 to 20  $\mu$  long and 1 to 1·2  $\mu$  thick. When they have doubled their length they divide, but, if cultivated at 96° F. in nutrient fluids, they grow out into long, frequently convoluted threads, in which the individual elements can be sharply recognised. Spore-formation commences after a time, the spores being formed from the internal protoplasm of the rods. These bodies are oval, about 2 to 3  $\mu$  long and 1  $\mu$  thick. When exposed



to a hot solution of fuchsine for twenty minutes or more they may be stained red, but they are not stained by aniline dyes with the ordinary processes. A temperature below boiling-point kills the bacillus. On exposure to moist heat at  $212^{\circ}$ , after fifteen minutes the spores are destroyed. Freezing arrests the growth, but does not destroy the vitality. Drying up kills the bacilli, but not the spores.

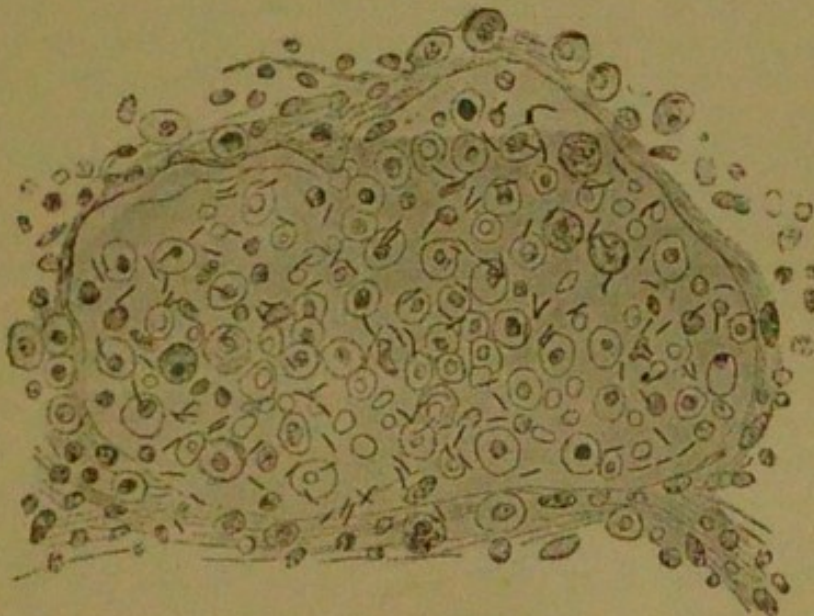
The **Bacillus Tuberculosis** is one of the smallest bacilli. It is a motionless rod, with rounded ends, 2 to  $5\ \mu$  in length—viz., one-third or one-half the diameter of a red blood-corpuscle—and about one-sixth of its length in thickness. When stained with aniline dyes it exhibits at times a beaded structure, with coloured and uncoloured portions alternating. The ends are always coloured. A spore-formation is thought to be present. The beaded bacilli are frequently observed in sputa and in caseous tubercular products. The rods in sputa are often somewhat curved (Figs. 37 and 38).

FIG. 37.



*Tubercle Bacilli*  
In phthisical spu-  
tum.  $\times 300$ .

FIG. 38.



*Tubercle Bacilli in Alveolus of Human Lung.* From a speci-  
men of catarrhal pneumonia.

The tubercle bacillus is cultivated with some diffi-



culty. When tubercular matter is implanted on solidified sterilised blood serum in a shallow cell or tube, the temperature being maintained at  $98.5^{\circ}$  to  $102^{\circ}$ , it commences to grow slowly, and in about ten or fifteen days small whitish scales appear, which increase until a thin whitish layer is formed. Under the microscope this layer is seen to consist of bacilli masses disposed either in curved or spiral lines. Successive generations may be produced, and the organism kept alive even for years, unaltered in mode of growth or in form.

It is unquestionable that the bacillus acts as a foreign body or irritant, with the addition of certain special properties. After their introduction into the body, the bacilli multiply and extend through the surrounding tissues along the ordinary lymph spaces and channels. About the sixth day appear visible tubercles, which at first are composed entirely of abundant *epithelioid* cells. About the tenth day after inoculation appear migratory leucocytes, forming the so-called lymphatic tubercle. The giant cells of phthisis in man seldom contain bacilli, although these are very numerous in the giant cells of some animals. In the caseous masses of human tuberculosis, however, the bacilli are very abundant.

**Tests for the Bacillus Tuberculosis.**—The addition of liquor potassæ to the sputum dissolves other elements but does not affect the tubercle bacilli. These are distinguished from all bacilli, with the exception of that of leprosy, by their action with the aniline colours, say, methyl-violet and fuchsine. If a section is stained of a deep red with fuchsine, and a mineral acid is added, the tubercle bacillus will remain red, although from every other part of the preparation the colour is discharged. If to the stained preparation a solution of methylene-blue be added, this colour will replace the fuchsine in all elements except in the tubercle bacilli.

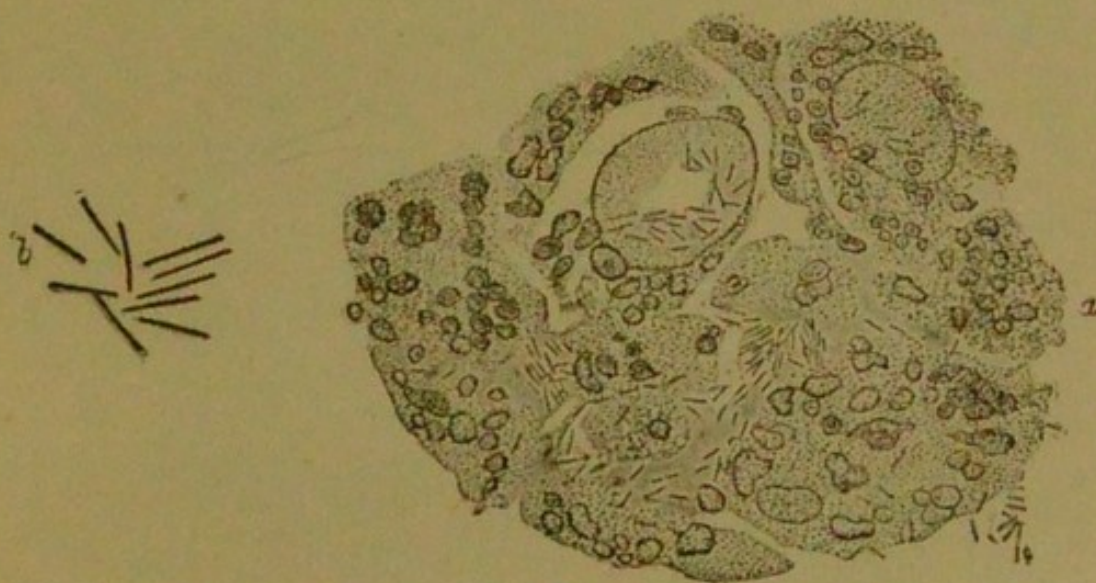At the present day it is believed that the bacillus tuberculosis is the cause of all tuberculous processes, and that its presence, at least in the early stages, must be the essential characteristic of tubercle. The latest investigations tend to show that both in the lungs and in the sputum of every case of phthisis the tubercle bacillus is present, and therefore phthisis must be regarded as a more or less chronic pulmonary tuberculosis. Although it may be stated that without doubt tubercular consolidation of



the lung is the result of an inflammatory process, still it cannot be that this process is not due to simple causes. The tendency to infect both adjacent and distant parts of the lung, and the progressive nature of the inflammation, clearly point to the presence of some continuous irritant. Without speaking too dogmatically, this much may be stated—viz., that a special pathogenic organism considered to be peculiar to phthisis finds its way to the lung mainly by inhalation, and at times by some other route. Some authorities consider such an organism as primary to the lesions of phthisis, and in reality to be the cause of that disease. Others, however, maintain that it is an epiphyte for the generation of which the phthisical soil is especially favourable.

The **Bacillus Lepræ**.—The bacillus of leprosy closely resembles that of tubercle, and is a slender rod 4 to 6  $\mu$

FIG. 39.



*Bacilli of Glanders. a, Section of a nodule.  $\times$  700.  
b, Bacilli coloured with methylene-blue.  $\times$  1500.*

in length and less than 1  $\mu$  thick—i.e., about one-half or three-fourths the diameter of a red blood-corpusele.

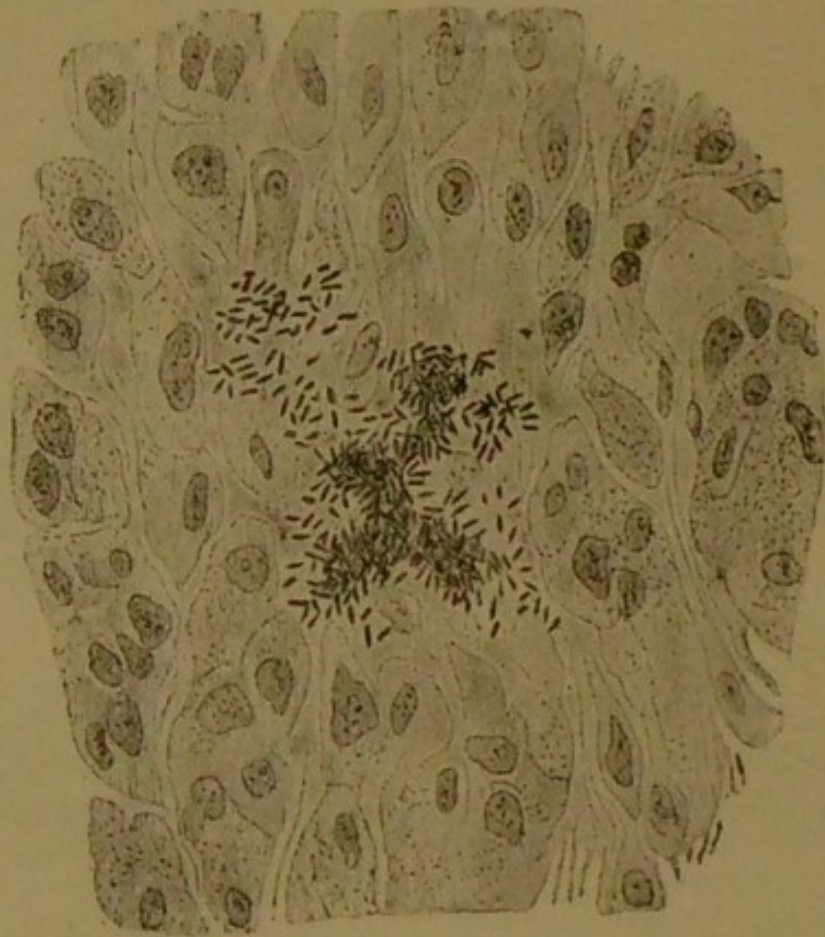
In its reaction with colouring matters it agrees with the bacillus tuberculosis. It exhibits no movements. It occurs in a remarkable number of tissues, and it is stated that, in leprosy skin, almost the larger half of the tissues consists of bacilli and their products.



The **Bacillus of Glanders**, or **Bacillus Mallei**, is about the size of the tubercle bacillus, but is highly motile and thicker (Fig. 39). It forms spores. It has been found both in the human glanders and in that of the horse. When cultivated and inoculated into rabbits, guinea-pigs, horses, and mice it has produced a disease with nodules and ulcers resembling glanders. The proof is complete that the disease is caused by the bacillus, since it has been found in the diseased organs as well as in the blood and urine of these animals. This bacillus may be cultivated on gelatine, agar-agar, or blood serum at about 99° F., but its growth is slow.

The **Bacillus of Typhoid Fever**, or **Bacillus Typhosus** (Fig. 40).—The bacilli typhosi have been found in

FIG. 40.



*Bacilli of Typhoid Fever.* Section of spleen.  $\times 800$ .

Peyer's patches, the mesenteric glands, and spleen in typhoid fever. The bacillus itself is 2 to 3  $\mu$  long, about



one-third of its length in thickness, with rounded ends. It sometimes occurs in very short rods, and is capable of growing into pseudo-filaments. It probably possesses flagella, and is very motile.

Long action of the usual dyes is required, as it takes the stains with difficulty. Its growth on potatoes is very characteristic. No visible growth is apparent after forty-eight hours, the surface having a moist and glistening aspect, but, on touching it with a platinum needle, it appears to be coated with a hard film, which, on examination, is found to be composed of long threads of the bacilli containing spores.

The best temperature is  $90^{\circ}$  to  $104^{\circ}$ , terminal spores being produced in three or four days within these limits. Gelatine is not liquefied by the growth.

The following bacilli have sometimes been found—viz., the **Bacillus Œdematis Maligni**, in progressive gangrene; **Bacillus Diphtheriticus**, in diphtheria; **Bacillus Syphiliticus**, in syphilis; **Bacillus Malariae**, in ague.

The **Comma-Bacillus**, or **Spirillum Cholerae Asiaticæ**, or **Cholera Spirillum**, has been discovered in the intestines of persons affected by Asiatic cholera. It appears in the shape of curved rods, one-half to two-thirds the length of the bacillus tuberculosis, varying from  $0.8$  to  $2 \mu$  in thickness, about one-third to one-sixth of the length, and often united so as to make an S shape.

**Spirillum Finkleri** has been found in the contents of the intestines in cases of "cholera nostras," or English cholera.

**Spirillum Obermeieri** has been found in the blood in cases of relapsing fever. It appears as long, flexible, wavy threads, in spirals of from ten to twenty turns, measuring 16 to 40 inches in length, and exceedingly thin.

It is important to note that, in order to prove a special organism to be the cause of any disease, certain conditions must be fulfilled, and these have been distinctly laid down by Koch as follows:—

1. The micro-organisms must be constantly found in the blood or tissues, or both, of the men (or animals) suffering from the disease.

2. The micro-organism must be made to grow on some medium external to the body, and by successive cultiva-



tions completely separated from all matter belonging to the body from which they came.

3. After being cultivated through several generations the organism must be inoculated into some animal, and in it reproduce the original disease.

4. In the blood or tissues of this animal the same micro-organism must be discovered which was found in the original patient.

In all cases it is not possible that the foregoing conditions can be fulfilled, but analogy with other cases in which complete evidence can be obtained may render the pathogenic nature of such organisms in the highest degree probable.

For some organisms frequently associated with certain diseases—as with bacillus lepræ—no suitable cultivation medium has been found.

### BLASTOMYCETÆ (Yeasts).

These fungi consist of oval or roundish cells, and multiply by simple budding. They possess no mycelium proper, nor, as a rule, do they produce spores. The most important species is the **Saccharomyces**, or **Torula Cerevisiæ** (the common beer-yeast), this being the chief agent in the alcoholic fermentation. It is composed of oval cells, the diameter of which measures 8 to 9  $\mu$ , and which occur either singly or in short chains. To the ferment of wine, frequently observed in ripe fermenting fruits, the name **Saccharomyces Ellipsoideus** is applied. The cells of this are somewhat smaller than those of the *Saccharomyces cerevisiæ*; they occur either singly or in short chains, and measure about 6  $\mu$ .

**Saccharomyces Mycoderma** forms the scum on fermenting beers; it is known as the vinegar plant, and does not ferment sugar. Its cells measure 6 to 7  $\mu$  long by 2 to 3  $\mu$  broad, and form long branched chains. It presents a great similarity to the principal parasitic yeasts of the human body.

The **Saccharomyces Albicans**, the *thrush* parasite, constitutes the white patches in the mouths of children, especially those who have been fed on milk. At one time this was known by the name of *Oidium Albicans*, and considered to be a mould fungus allied to *Oidium Lactis*. The thrush parasite is composed of oval or spherical



cells, sometimes united in long chains, and at other times growing into threads or cylindrical cells ten or twenty times as long as they are thick. The diameter of the small cells may be 3.5 to 5  $\mu$ . The growth of this fungus takes place upon the mucous membrane of the mouth, and occasionally upon that of other portions of the alimentary canal, such as the ileum. It has been stated to have been known to find its way into the circulation and lead to cerebral embolism.

Any fermentative action the *saccharomyces albicans* may possess is exerted, *not upon the tissues*, but upon the contents of the digestive tract.

The **PARASITIC YEASTS** occurring as epiphytes upon the skin are the following:—

**Saccharomyces Capillitii.**—This is usually found amongst the scurf of the scalp (particularly when this is in abundance) and in the condition known as *Seborrhæa Sicca*, or *Pityriasis (dandruff)*. Little oval cells are formed by this yeast fungus which are said to correspond exactly in form and size with the *saccharomyces ellipsoideus* from fermenting fruits.

It must be admitted that the yeasts exert very little, if any, pathogenic effects.

The **Ray-Fungus**, or **Actinomyces.**—This parasitic plant produces the disease called *actinomycosis*. It grows in roundish masses, the size of which varies from grains just visible to those as large as a hemp-seed, having a granular surface and a yellow colour.

**Microscopically**, these masses appear composed of numerous radiating threads with club-shaped diameters somewhat resembling a rosette. Sometimes narrow threads, like hyphæ, are seen, either growing peripherally out of the mass, or forming coils in the central parts. These threads have been thought to be the mycelium of a mould fungus, but they are, in all probability, a form of *cladotrix* or *leptothrix*, belonging to the *schizomycetes*.

The disease called **Actinomycosis** was first seen in cattle, and gives rise to hard tumours, which at one time were described as sarcoma, osteo-sarcoma, lymphoma, &c. The hardened masses consist of embedded nodules, which, when not softened (as they sometimes become), exhibit the structure of typical tubercle, containing epithelioid cells, leucocytes, giant cells, and fibroid tissue. The centre of irritation is the *ray-fungus*, and in the presence



of this alone consists the distinction between these nodules and tubercles.

Actinomycosis is a rare disease in man, and in him the tendency is towards suppuration, large abscesses being formed in the liver, pus burrowing in other parts, as around the jaws, in the walls of the thorax, in the mediastinum, or in front of the vertebræ.

**Mycetoma, or Madura Foot of India,** "the fungus foot of India."—Here the fungus grows in the tissues of the human body. The parasite, called *Chionyphe Carteri*, is usually considered to cause this disease, but some authors regard it as merely a *saprophytic* parasite flourishing in the necrotic tissues. The disease itself consists in a morbid state of the feet and hands, which are enlarged and distorted in consequence of thickening of the skin, caries of the bones being present, and sinuses forming. From the sinuses either yellowish concretions of the size of a millet-seed or dark-brown concretions like gunpowder grains are discharged. In the latter, but not in the former, are found bodies, consisting of a fungous growth, which forms a regular mycelium, in company with black masses which have been compared to the truffle fungus.

### HYPOMYCETÆ (Moulds).

The "moulds" are fungi, and consist of *mycelium* and organs of fructification. The mycelium consists of *filaments* or threads, termed *hyphæ*, which are usually divided into septa, and are frequently branched.

The organs of fructification are composed of cells called *conidia*, or spores, which are sometimes produced by simple "abstriction" (cutting off) of certain parts of the hyphæ.

In some cases the hyphæ are upright and grow into the air, being then termed *conidiophores*.

In the parasitic and pathogenic species of the human body, the conidia are directly formed from the hyphæ of the mycelium.

Amongst the commoner moulds which may occur in certain pathological conditions, and are also found in external nature, are the following:—

The **Non-Pathogenic, or Saprophytic**, which include—

**Aspergillus Glaucus.**—A greyish-blue mould, growing on rotten wood and decaying fruit.



**Aspergillus Niger.**—Sometimes found in the human ear. A similar species of aspergillus has been observed in a wound of the cornea of the eye.

**Aspergillus Fumigatus** has been observed in tubercular, gangrenous, or bronchiectatic cavities: it is, however, merely saprophytic, not producing any disease.

**Penicillium Glaucum.**—A common blue mould, growing on all decaying animal matter in dark and moist localities.

**Mucor Mucedo.**—A white mould, found chiefly on horse-dung.

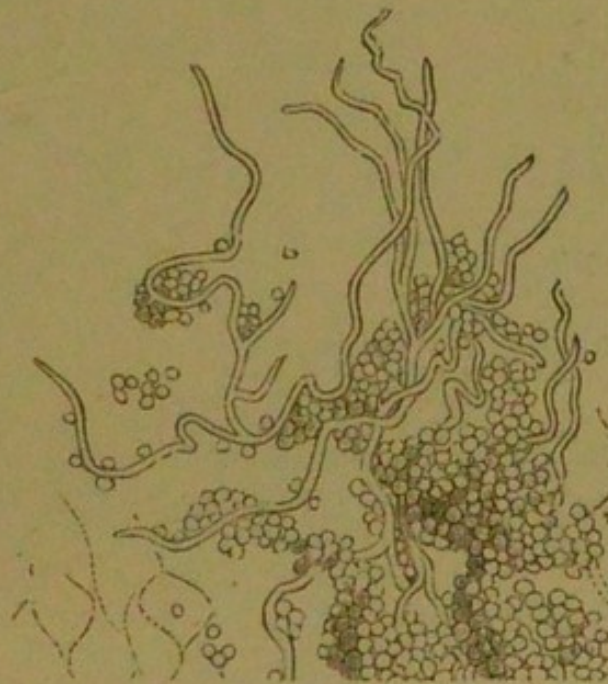**PATHOGENIC FUNGI** occurring on the human skin.—These are the following:—

**Trichophyton Tonsurans; Achorion Schoenleinii;**

**Microsporon Furfur; Microsporon Audouini (?).**

× **Trichophyton Tonsurans.**—This fungus causes the

FIG. 41.



*Trichophyton Tonsurans*: showing an exaggerated form of tinea in a patch of epithelium from the arm of a man who groomed a pony affected with tinea circinata.

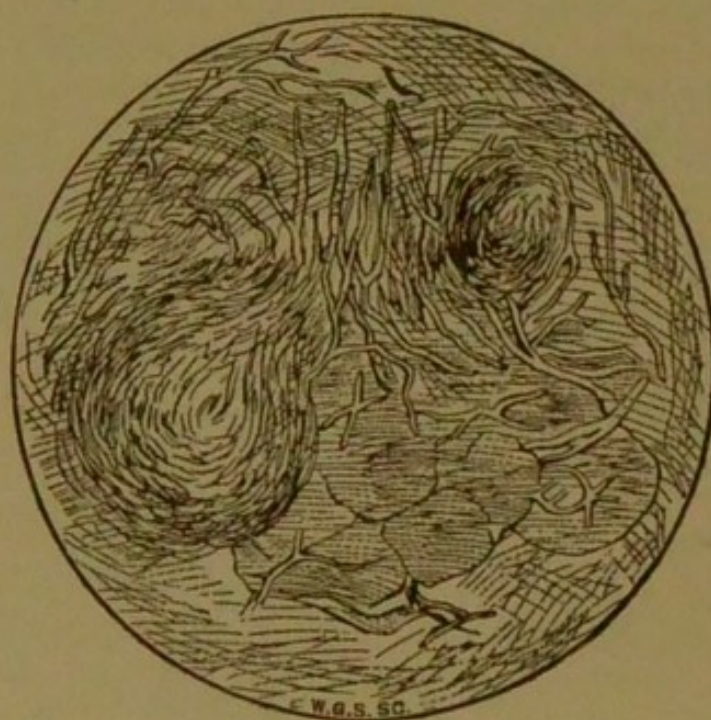
affection known as ringworm of the scalp (*tinea tonsurans*), of the skin (*tinea circinata*), of the beard (*tinea sycosis*, or *tinea barbæ*). The mycelium is composed of

× *Porrigo scutulata*  
*Tinea*  
*Favus*



ramified hyphæ. Upon staining with methylene-blue the central portion takes the colour more deeply than the sheath. At first the growth consists of mycelium only, but eventually the ends of the hyphæ break up into spherical cells, which after separation by abstriction constitute the conidia or spores. These spores are round or oval, about  $\frac{1}{7000}$  of an inch in diameter, being sometimes united in the form of chains, but for the most part isolated (Figs. 41, 42). This fungus has been cultivated, and after inoculation into the human skin produces

FIG. 42.



*Trichophyton Tonsurans*, from a case of Burmese ring-worm (*tinea circinata*).

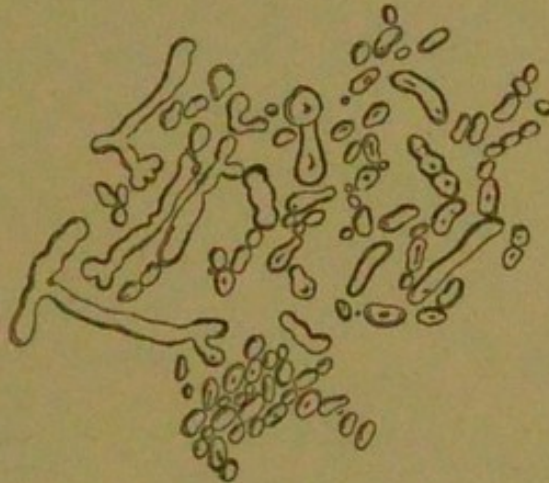upon it the characteristic rings of herpes circinatus or tinea circinata. The mycelium makes its way between the scales of epidermis, either causing their desquamation or elevating them in the form of vesicles. A ring is formed by the outward growth from a centre. A vesicular and sometimes a pustular growth results, according to the amount of inflammation. On the scalp, as soon as the mycelium reaches the hairs, it grows down inside the root-sheath, penetrating the hair-shaft, rendering it



brittle and causing it to break off, thus producing the scaly patches with broken stumps.

**Achorion Schoenleinii.**—This fungus is the cause of the disease known as "favus." The mycelium is composed of hyphæ, forming extremely dense masses of yellowish colour and exhaling a peculiar mouse-like odour. On the scalp it occasions cup-shaped structures surrounding the

FIG. 43.



*Achorion Schoenleinii*, from a case of tinea favosa (commonly called favus).

hairs. This favus growth consists of a mass of mycelium and conidia entangled with granular and fatty matters. This fungus may be said to consist of spores, filaments, sporophores or fibres, and a stroma made up of numerous small free cells. The spores are round or oval,  $\frac{1}{3000}$  inch in diameter, have a slight constriction in their centre, and are mixed with a number of branched tubes, some filled with granular matter and some empty, and which vary from  $\frac{1}{4000}$  to  $\frac{1}{5000}$  inch in diameter. Although it has been stated that in the trichophyton the number of the tubes is smaller and the number of the spores greater than in the achorion, the great distinction between trichophyton and achorion is the production by the latter of conspicuous masses (Fig. 43).

The cultivated fungus, after inoculation, has produced characteristic cases of favus. The mycelium penetrates between the scales of epidermis and occasions a ring of vesicles, but in consequence of the fungus penetrating into the hair-sheath the formation of yellow crusts and

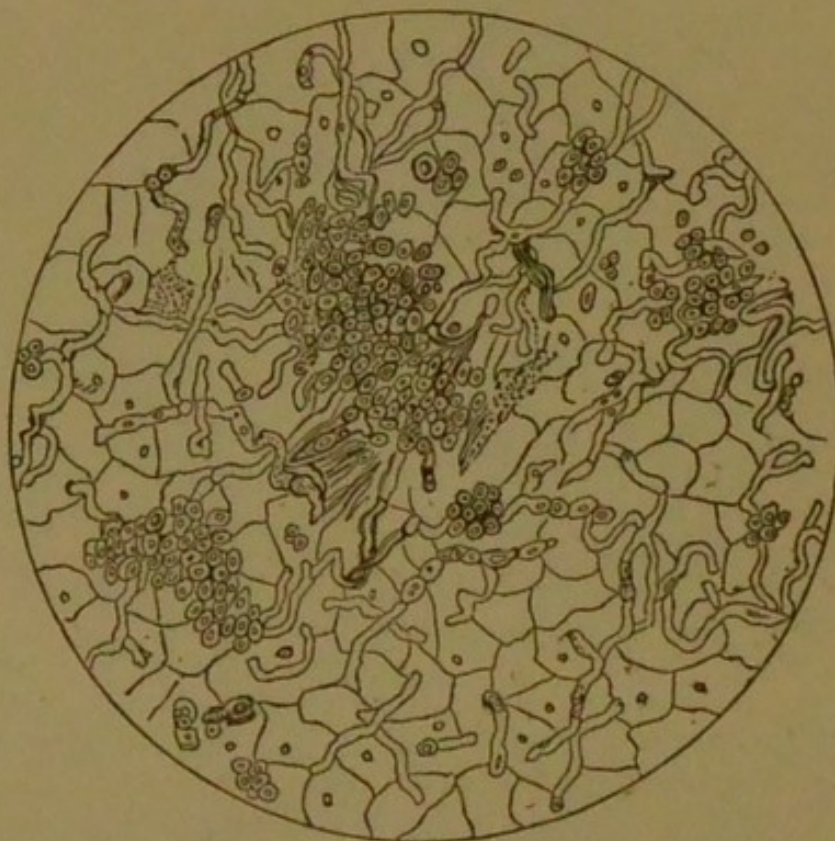

cups is superadded. The hair-shafts also break off. The growth of this fungus into the skin is far more deep than that of the trichophyton.

**Microsporon Furfur.**—This is the fungus of tinea versicolor, chloasma, or pityriasis. It presents marked differences to the foregoing fungi. Ramified hyphæ compose the mycelium; the hyphæ do not, however, break up into conidia, but produce a group of round spore-like bodies by a process of budding (Fig. 44).

The epidermic scales are penetrated by the mycelium, but not deeply, the epidermis assuming a peculiar fawn

FIG. 44.



*Microsporon Furfur*, from a case of tinea versicolor (chloasma or pityriasis versicolor).

colour, and desquamating slowly. The fungus selects the covered parts of the skin, particularly the abdomen, chest, and shoulders, forming the discoloured patches known as pityriasis versicolor.

**Microsporon Audouini.**—This fungus is believed by some authorities to be the cause of tinea decalvans or

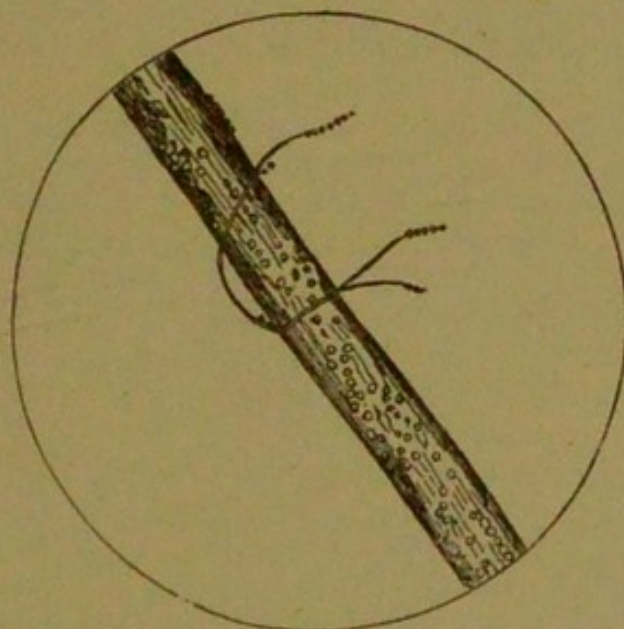


porrigo decalvans, and to lead to the condition sometimes described as alopecia areata or localised baldness.

*Tinea decalvans* presents oval or round patches of baldness, the hair being entirely removed or replaced by fine downy hairs. The skin is quite white, and there is little or no irritation. The skin is at first somewhat reddened and wrinkled. The affection is generally confined to the scalp, but may be seen in the eyebrows, genitals, or beard.

**Microscopically**, in some instances, collections of minute spores are seen. The hair may exhibit bulgings here

FIG. 45.



*Microsporon Audouini*, from a case of tinea decalvans (alopecia areata).

and there due to the presence of abnormal granular matter, which is in part pigmentary, and in part the minute stromal form of the fungus. The spores are from  $\frac{1}{25000}$  to  $\frac{1}{5000}$  of an inch; the filaments being few, wavy, and destitute of granules. The ordinary appearance of the microsporon audouini is shown in Fig. 45. Sometimes the fungus is found in the epithelium at the extending edge of the disease; but it is believed that it frequently lodges behind in the empty follicles, attacks the epithelial structures contained therein, and interferes with the proper re-formation of the hair.



It must, however, be stated that some authorities dispute the existence of the parasitic fungus, and attribute the affection to a diseased condition of the nervous system.

#### METHODS FOR RECOGNISING BACTERIA.

For the proper study of bacteria, a microscope of a power of at least 600 diameters is requisite, and the thinnest cover-glasses that can be obtained must be employed.

The bacteria exhibit a remarkable affinity for colouring matters, and especially for the aniline dyes. The following colours are the most important, viz. :—

**Fuchsine** or **Magenta** (hydrochlorate of rosaniline); **Methyl-violet**, or a variety termed **Gentian-violet**; **Methylene-blue**; and **Eosine** (a red colour, not made from aniline).

The last is employed for staining parts other than bacteria, so as to produce a contrast of colour; for this purpose **Bismarck-brown** is also sometimes employed.

**Eosine** is best dissolved in *water*. The other colours are conveniently kept in saturated alcoholic solutions. For use they should always be much diluted.

Of all the above colouring agents, **methylene-blue** is perhaps the most generally applicable; moulds as well as bacteria are coloured by it.

**Methyl-violet** is a strong purple dye, and acts with greater energy when diluted with aniline water.

**Fuchsine** is a red dye, of which a carbolic acid solution is sometimes used. This solution keeps better than the aniline solution; the carbolic acid exercises the same action in increasing the colouring power of the dye as afforded by aniline.

The colours above mentioned are chiefly employed for staining bacteria, but in order to exhibit the cells or tissues, these may be stained by some contrast colour. If the bacteria are coloured blue, eosine (red) or solution of carmine or picro-carmine may be used as a contrast stain; if they are red, then methylene-blue may be employed.



## INDEX.

- ABSCESS of the brain, 23  
  *carus folliculorum*, 130  
  *scabiei*, 129  
*Achorion Schoenleinii*, 151  
Acinous cancer, 79  
*Actinomyces*, 147  
Actinomycosis, 147  
Actions set up by bacteria, 139  
Active congestion of the liver, 13  
Acute anterior-polio-myelitis, 25  
Adénie, 66  
Adenoid cancer, 83  
  tissue, 65  
Adenomata, 75  
Agar-agar, 137  
Albumen in urine, 112  
Albuminoid degeneration, 39  
Alopecia areata, 153  
Alveolar cancer, 81  
Amyloid bodies, 43  
  degeneration, 39  
Anæmia, local, 90  
  *lymphatica*, 66  
Analytical table of bacteria, 136  
Angiomata, 73  
Animal parasites, the, 121  
*Arcus senilis*, 45  
*Ascaris lumbricoïdes*, 125  
  *mystax*, 126  
  *vermicularis*, 125  
*Ascococcus*, 135  
*Aspergillus fumigatus*, 149  
  *glaucus*, 148  
  *niger*, 149  
Atheroma, 12  
Atheromatous abscess, 13  
  ulcer, 13
- Atrophy, 98  
  general, 99  
  numerical, 98  
  of bone, 102  
  of glandular organs, 99  
  of heart, 100  
  of liver (simple, red, yellow),  
    101  
  of muscle, 100  
  of muscular fibre, 99  
  of nerves, 99  
  of walls of air-vesicles, 101  
  partial, 99  
  simple, 98
- BACILLI, 131  
*Bacillus anthracis* (of malignant  
  pustule), 140  
  *butyricus* (butyric acid), 133  
  *diphtheriticus* (of diphthe-  
  ria), 145  
  *lepræ* (of leprosy), 143  
  *malarie* (of ague), 145  
  *mallei* (of glanders), 144  
  *oedematis maligni* (of pro-  
  gressive gangrene), 145  
  *syphiliticus* (of syphilis),  
    145  
  *tuberculosis* (of tubercle),  
    141  
    tests for, 142  
  *typhosus* (of typhoid fever),  
    144
- Bacteria, 131  
*Bacterium aceti*, 133  
  *lactis*, 133



- Bacterium termo, 133  
 Beef tapeworm, the, 122  
 Bi-basic phosphate, 110  
 Bile in urine, 112  
 Bilharzia hæmatobia, 124  
 Biliary cirrhosis, 15  
   congestion of the liver, 13  
 Bismarck-brown, 154  
 Blastomycetæ, 146  
 Blood in urine, 111  
 Bothriocephalus latus, 122  
 Brain sand, 44  
   softening, 23  
     red, inflammatory, of, 23  
     white, yellow, non-in-  
       flammatory, of, 23  
 Broad tapeworm, the, 122  
 Bronchiectasis, 5  
 Broncho-pneumonia, 8  
 Brown atrophy of the heart, 100  
   induration of the lung, 56  
 Bulbar paralysis, 28  
  
 CALCAREOUS degeneration, 51  
 Calcification, 33  
   of arteries, 53  
 Calculi (urinary), 116  
 Cancers, the, 77  
 Carcinomata, the, 77  
   contrasted with the sarco-  
   mata, 84  
 Caries of bone, 103  
 Catarrhal inflammation, 5  
   pneumonia, 8  
 Cayenne-pepper grain deposit  
   in the urine, 109  
 Cercaria-sac, 124  
 Cerebritis, 23  
 Cerebro-spinal sclerosis, 27  
 Cestoda, 121  
 Chionyphe Carteri, 148  
 Chloasma, 152  
 Cholera spirillum, the, 145  
 Chondromata, 62  
 Cirrhosis of the liver, 14  
 Cirrhotic kidney, the, 17  
   pneumonia, 7  
 Clostridium, 135  
 Coagulation-necrosis, 6  
 Colitis, 21  
   acute, 21  
  
 Colitis, chronic, 22  
 Colloid cancer, 81  
   degeneration, 57  
 Comedones, 130  
 Comma-bacillus, the, 135, 145  
 Common round worm, the, 125  
 Concentric globes in epithelioma,  
   82  
 Condylomata, 74  
 Congestion, 88  
   of the brain, 22  
   of the liver, 13  
   of the lung, 6  
   of the stomach, 19  
 Corpuscles of Gluge, 46  
 Crenothrix, 135  
 Croupous inflammation, 5  
   pneumonia, 6  
 Crude yellow tubercle, 33  
 Cylindrical epithelioma, 83  
 Cysticercus tæniæ cellulosæ, 122  
   tæniæ mediocanellatæ, 122  
 Cystic oxide, 110  
   tumours, 85  
 Cystine, 110  
   calculus, 117  
 Cysts, 85  
  
 DANDRIF, 147  
 De-alkalised fibrine, 39  
 Degenerations, the, 38  
 Dermatozoa, the, 128  
 Diabetes insipidus, 113  
   mellitus, 114  
 Diphtheritic inflammation, 5  
 Diplococcus, a, 134  
 Disseminated sclerosis, 27  
 Distoma crassum, 124  
   hepaticum, 124  
   heterophyes, 124  
   lanceolatum, 124  
   ophthalmobium, 124  
 Distropodextrine, 39  
 Dranunculus, the, 127  
 Duchenne's paralysis, 48  
 Dysentery, 21  
   acute, 21  
   chronic, 22  
  
 ECTOZOA, the, 128  
 Embolism, 30



- Empyema, 8  
 Encephalitis, 23  
 Encephaloid cancer, 80  
 Endocardial ulcer, 11  
 Endocarditis, 10  
     acute, 10  
     chronic, 11  
     papillary, 10  
     ulcerative, 11  
 Entozoa, the, 121  
 Eosine, 154  
 Epithelial cancer, 79  
     nests in epithelioma, 82  
 Epithelio-connective tumours, 74  
 Epithelioma, 82  
 Epulis, 71  
 Exostoses, 63  
 Exudation corpuscles, 46
- FALSE calculi, 119  
     pigmentation, 54  
 Fasciola hepatica, the, 124  
 Fatty degeneration, 44  
     of arteries, 46  
     disease of the heart, 48  
     infiltration, 44  
     of the liver, 45  
     of muscle, 47  
     kidney, the, 50  
 Favus, 151  
 Fibroid pneumonia, 7  
 Fibromata, the, 59  
 Fibro-nucleated tumours, 68  
 Fibro-plastic tumours, 68  
 Filaria lentis, the, 127  
     medinensis, the, 127  
     sanguinis hominis, 127  
 Fission fungi, the, 132  
 Flukes, the, 123  
 Fuchsine, 154  
 Fungus hæmatodes, 81
- GANGRENA senilis, 51  
 Gelatiniform cancer, 81  
 Gentian-violet, 154  
 Giant cells in tubercle, 33  
 Glandular hypertrophy, 75  
     tumours, 75  
 Glioma, 70  
 Glosso-labial-laryngeal paralysis,  
     28
- Gluge, corpuscles of, 46  
 Granular kidney, the, 17  
 Granulations, 4  
 Grey degeneration of the brain  
     25  
     inflammatory, 25  
     non-inflammatory, 26  
     granulation tubercle, 32  
     miliary tubercle, 32  
 Grubs, 130  
 Guinea-worm, the, 127  
 Gummata, 94
- HÆMATURIA, 111  
 Hæmorrhagic apoplexy, 31  
 "Hanging drop," the, 138  
 Hardening of the brain, 24  
 Heart, fatty disease of, 48  
     fatty infiltration of, 48  
     inflammatory processes in  
     the, 9  
 Hepatitis, acute, 14  
     chronic interstitial (cirrho-  
     sis), 14  
 Hodgkin's disease, 66  
 Horny growths, 74  
 Hydatid, an, 123  
 Hydræmia, 91  
 Hydrochlorate of rosaniline  
     154  
 Hydropericardium, 10  
 Hyperæmia, 88  
 Hyperplasia (numerical hyper-  
     trophy), 97  
 Hypertrophic biliary cirrhosis  
     15  
 Hypertrophy, 97  
     numerical, 97  
     simple, 97  
     spurious, 97  
 Hyphæ, 148  
 Hypomycetæ, 148
- INDURATION of the brain, 24  
 Infantile paralysis, 24  
 Infective inflammation, 4  
 Inflammation, 1  
 Inflammatory effusion, 2  
     grey degeneration of the  
     brain and spinal cord, 25



- Inflammatory processes in the  
brain and spinal cord, 22  
in the heart, 9  
in the liver, 13  
in the lungs, 5  
in the stomach, 19  
softening of the brain, 23
- Insular sclerosis, 27
- Interstitial hepatitis, 14  
inflammation, 4  
(intertubular) nephritis, 17  
pneumonia, 7
- Intestinal lymphatic structures, 20  
inflammation and ulceration  
of, 20, 21
- Ischæmia, 90
- Itch insect, the, 129
- LARDACEOUS** degeneration, 38  
disease of lymphatic glands,  
43  
of the alimentary canal,  
43  
kidney, 42  
liver, 40  
spleen, 43
- Large white kidney, the, 17
- Lateral sclerosis, 27
- Leptomeningitis, 24
- Leptothrix, 135  
buccalis, 135
- Leucine, 111
- Leucocythemia, 91  
lymphatic, 91  
splenic, 91
- Leucocytosis, 93
- Leukæmia, 91
- Lipomata, the, 61
- Lithates in the urine, 108
- Lithic acid in the urine, 109
- Liver, congestion of the (active,  
passive, biliary), 13  
nutmeg, 14, 56, 89, 101
- Lobar pneumonia, 6
- Lobular pneumonia, 8
- Local anæmia (ischæmia), 90
- Long thread-worm, the, 126
- Lymphadenoma, 66
- Lymphæmia, 91
- Lymphangiomata, the, 67
- Lymphoid cells, 34
- Lymphomata, the, 64  
indurated, 65  
soft, 65
- MADURA** foot of India, 148
- Magenta, 154
- Makrocheilia, 67
- Makroglossia, 67
- Maw-worm, the, 125
- Medullary cancer, 80
- Melanotic cancers, the, 71
- Merismopedia, 135
- Merista, 135
- Methods for recognising bacteria,  
154  
for the cultivation of bac-  
teria, 136
- Methylene-blue, 154
- Methyl-violet, 154
- Micrococcus, 134  
urææ, 133
- Micromillitre, the  $\mu$ , 140
- Microsporon Audouini, 152  
furfur, 152
- Mollities ossium, 104
- Morbid urinary constituents, 111  
deposits, 108
- Moulds, the, 148
- Mucin, 56
- Mucoid degeneration, 56
- Mucor mucedo, 149
- Mucous polypus, 75
- Mucus in the urine, 111
- Mulberry calculus, 109
- Multiple sclerosis, 27
- Murexide, 109
- Muscular paralysis, pseudo-hy-  
pertrophic, 48  
tumours, the, 72
- Mycelium, 148
- Mycetoma, 148
- Mycoprotein, 132
- Myeloid tumours, the, 68
- Myocarditis, 11
- Myomata, the, 72
- Myxomata, the, 60
- NECROBIOSIS**, 98
- Necrosis of bone, 102



- Nematoda, the, 124  
 Neutral phosphate of calcium calculus, 119  
 Non-inflammatory grey degeneration, 26  
 Numerical hypertrophy, 97  
 Nutmeg liver, the, 14, 56, 89, 101
- OBESITY, 62**  
 Obsolete tubercle, 33  
*Oidium albicans*, 146  
*Oidium lactis*, 146  
 Osteomalacia, 104  
 Osteomalacial pelvis, the, 105  
 Osteomata, the, 63  
 Osteophytes, 64  
 Oxalate of calcium, 109  
     calculus, 118  
*Oxyuris vermicularis*, the, 125
- PAPILLARY endocarditis, 10**  
*Papillomata*, the, 74  
 Parasitic yeasts on the skin, the, 147  
 Parasites, the animal, 121  
     the vegetable, 131  
 Pathogenic bacilli (human), 140  
     fungi on human skin, 149  
     parasites, 132  
 Pathology of the urine, the, 106  
*Pediculi*, 128  
*Pediculus capitis*, 128  
     corporis, 129  
     pubis, 128  
     vestimenti, 129  
*Penicillium glaucum*, 149  
 Pericarditis, 9  
 Peritonitis, 22  
 Phlegmonous inflammation, 3  
 Phlogosis, 1  
 Phosphates in the urine, 110  
 Pigmentary degeneration, 53  
 Pigmentation of the liver, 56  
     of the lungs, 55  
*Pityriasis*, 147  
     versicolor, 152  
 Pleuritis, 8  
 Pneumonitis, 6  
 Pork tapeworm, the, 122  
*Porriigo decalvans*, 153
- Productive inflammation, 4  
*Proscoplex*, 121  
*Proteus*, 135  
*Psammoma*, 72  
 Pseudo-hypertrophic muscular paralysis, 48  
*Ptomaines*, 133  
 "Pure" cultivation, a, 138  
 Pus, 3  
     in the urine, 111  
*Pyæmia*, 87  
*Pyelitis*, 18  
     acute, 18  
     chronic, 18  
*Pyopericardium*, 10
- RACHITIS, 105**  
 Ramollissement of the brain, 23  
 Rarefying osteitis, 103  
*Ray-fungus*, the, 147  
 Red atrophy of the liver, 101  
     softening of the brain, 23  
*Rickets*, 105  
*Ricketty pelvis*, the, 106  
 Round worms, the, 124
- SACCHAROMYCES albicans, 146**  
     capillitii, 147  
     cerevisiæ, 131, 146  
     ellipsoideus, 146  
     mycoderma, 146  
 Sanguineous apoplexy, 31  
 Saprogenic bacteria, 133  
*Saprophytes*, 132  
 Saprophytic moulds, the, 148  
*Sarcomata*, the, 68  
     contrasted with the carcinomata, 84  
*Schizomycetes*, the, 132  
*Scirrhus*, 79  
 Sclerosis, 26  
     cerebro-spinal, 27  
     disseminated, 27  
     insular, 27  
     lateral, 27  
     multiple, 27  
*Sclerostoma duodenale*, 127  
*Scolex*, 121  
 Scrofulous inflammation, 28  
*Seborrhœa sicca*, 147



- Septic bacteria, 133  
     infection, 87  
     intoxication, 87  
 Septicæmia, 87  
 Simple atrophy of the liver, 101  
     hypertrophy, 97  
 Softening of the brain, 23  
 Specific inflammation, 4  
 Spinal meningitis, 24  
     paralysis, 24  
 Spirillum, 135  
     cholerae asiaticæ, 145  
     Finkleri, 145  
     Obermeieri, 145  
 Spirulina, 135  
 Staphylococcus, 135  
 Star-shaped phosphate, 110  
 Steatozoon folliculorum, 130  
 Streptococcus, 134  
 Strongylus bronchialis, 128  
     gigas, 128  
 Sugar in the urine, 113  
 Suppuration, 3  
 Syphilis, 94  
 Syphiloma, 95
- TÆNIA** echinococcus, 122  
     mediocanellata, 122  
     saginata, 122  
     solium, 122  
 Tapeworms, the, 121  
 Teratomata, the, 85  
 Thoracic cancer, 66  
 Thread-worm, the, 125  
 Thrombosis, 30  
 Thrush parasite, the, 146  
 Tinea decalvans, 152  
     versicolor, 152  
 Torula cerevisiæ, 146  
 Trematoda, the, 123  
 Trichina spiralis, 126  
 Trichocephalus dispar, 126  
 Trichophyton tonsurans, 149  
 Triple phosphate, the, 110  
 Trismus nascentium, 25  
 Tubercle bacillus, the, 141
- Tubercular meningitis, 38  
     peritonitis, 37  
     ulceration of the intestines,  
     36  
 Tuberculosis, 32  
     of the brain and its mem-  
     branes, 37  
 Tumours, classification of the, 58  
 Typhoid ulcer, 21
- ULCERATION** of the stomach, 19  
     chronic gastric ulcers, 20  
     perforating ulcers, 20  
     sloughing ulcers, 20  
     superficial erosions, 19  
 Ulcerative endocarditis, 11  
 Uræmia, 93  
 Urates, 108  
 Uric acid, 109  
     calculus, 117  
 Urinary calculi and concretions,  
     116  
     tube casts, 120  
         blood or exudative, 120  
         cellular or epithelial, 120  
         granular, 120  
         oily casts, 120  
         purulent, 120  
         waxy, transparent hya-  
         line, 120  
 Urine, pathology of the, 106  
 Uterine polypus, 72
- VERMES**, the, 121  
 Vibrio, 135
- WHITE** softening of the brain, 23  
     of the cord, 24  
 Womb-stone, 72
- YEAST** plant, the, 131  
 Yeasts, the, 146  
 Yellow atrophy of the liver, 101  
     softening of the brain, 23  
     tubercle, 33
- MOGENIC** bacteria, 133  
 Zooglœa, 134



68







