

Descriptive catalogue of the museum of the Sixth International Otological Congress : held in London, August 8th to 12th, 1899 / Comp. and edited by W. Jobson Horne and Arthur H. Cheatele.

Contributors

Horne, W. Jobson.

Cheatele, Arthur H.

International Otological Congress 1899 : London, England)

Publication/Creation

London : J. & A. Churchill, 1900.

Persistent URL


<https://wellcomecollection.org/works/sem23p39>

License and attribution

Conditions of use: it is possible this item is protected by copyright and/or related rights. You are free to use this item in any way that is permitted by the copyright and related rights legislation that applies to your use. For other uses you need to obtain permission from the rights-holder(s).




Wellcome Collection
183 Euston Road
London NW1 2BE UK
T +44 (0)20 7611 8722
E library@wellcomecollection.org
<https://wellcomecollection.org>






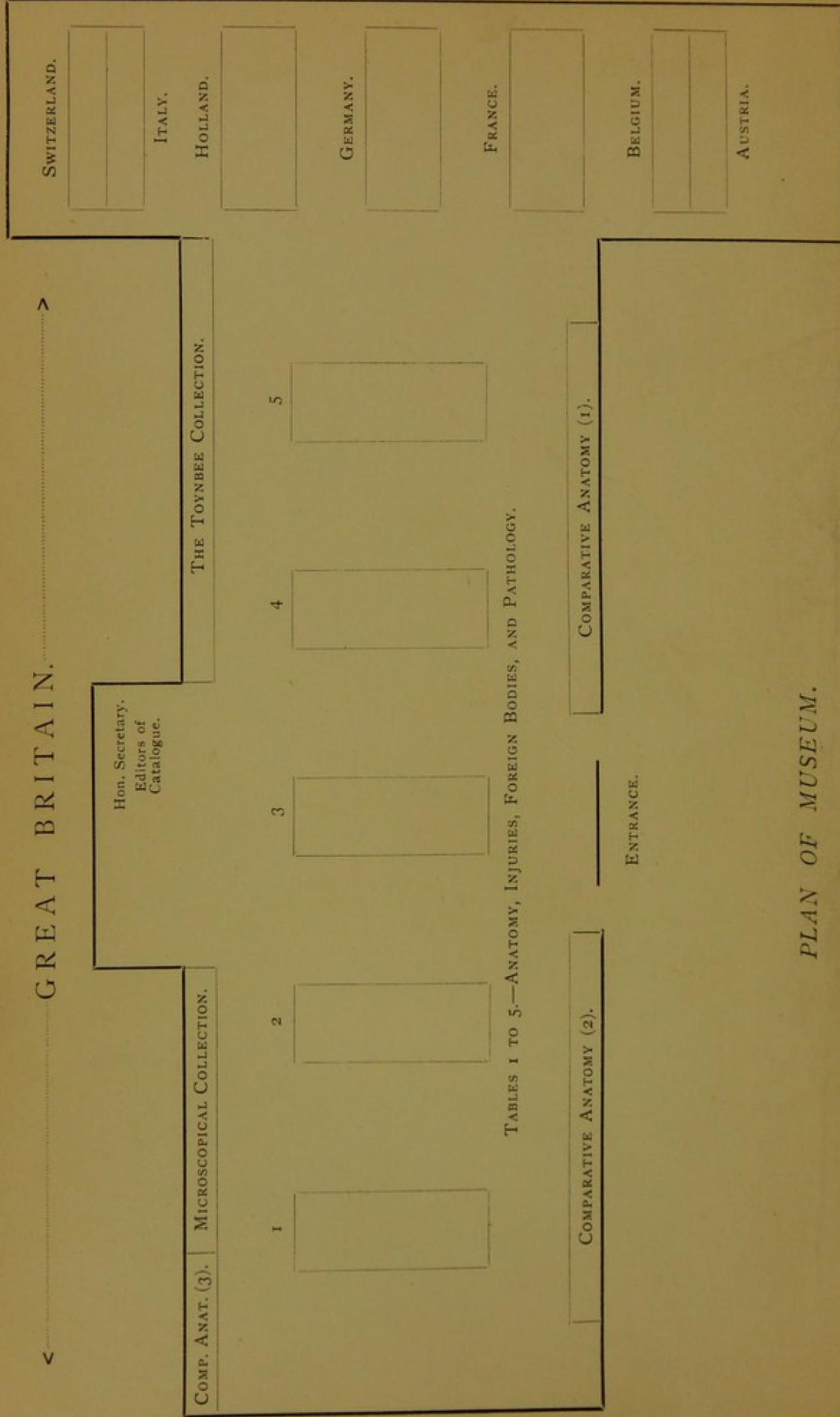
22101906041

Med
K49655





<.....GREAT BRITAIN.....>



PLAN OF MUSEUM.

DESCRIPTIVE CATALOGUE

OF THE

MUSEUM

OF THE

SIXTH INTERNATIONAL OTOLOGICAL CONGRESS

HELD IN

London, August 8th to 12th, 1899.

Compiled and Edited

BY

W. JOBSON HORNE

AND

ARTHUR H. CHEATLE,

Hon. Secretary to the Museum Sub-Committee.

REVISED EDITION.

LONDON:

J. & A. CHURCHILL,

7, GREAT MARLBOROUGH STREET.

1900.

10161

RESERVE CATALOGUE

MUSEUM

SIXTH INTERNATIONAL ZOOLOGICAL
CONGRESS

LONDON 1905

PRINTED BY ADLARD AND SON,
BARTHOLOMEW CLOSE, LONDON, E.C., AND 20, HANOVER SQUARE, W.

12 030 541

WELLCOME INSTITUTE LIBRARY	
Coll.	weIMOmec
Call	
No.	WV

MUSEUM SUB-COMMITTEE.

Chairman :

The PRESIDENT-ELECT, Professor URBAN PRITCHARD, M.D., *ex officio*.

Vice-Chairman :

CHARLES A. BALLANCE, Esq.

Hon. Secretary General : E. CRESSWELL BABER, Esq., *ex officio*.

Hon. Treasurer : A. E. CUMBERBATCH, Esq., *ex officio*.

Members :

H. A. BALLANCE, Esq.
THOMAS BARR, Esq., M.D.
J. W. BARRETT, Esq.
F. W. BENNETT, Esq., M.D.
H. S. BIRKETT, Esq., M.D.
J. MACKENZIE BOOTH, Esq., M.D.
ADOLPH BRONNER, Esq., M.D.
C. E. FITZGERALD, Esq., M.D.
G. T. GUILD, Esq., M.D.
W. H. HARSANT, Esq., M.D.
W. JOBSON HORNE, Esq.
HUGH E. JONES, Esq.
A. BROWN KELLY, Esq.

RICHARD LAKE, Esq.
F. MARSH, Esq.
P. MCBRIDE, Esq., M.D.
W. MILLIGAN, Esq., M.D.
STEPHEN PAGET, Esq.
G. W. RIDLEY, Esq.
A. W. SANDFORD, Esq., M.D.
HERBERT TILLEY, Esq., M.D.
LOGAN TURNER, Esq.
H. SECKER WALKER, Esq.
R. H. WOODS, Esq., M.D.
ARTHUR H. CHEATLE, Esq.,
Hon. Secretary.

CONTRIBUTORS TO THE MUSEUM.

GREAT BRITAIN.

The Council of the Royal College of Surgeons of
England.

Charing Cross Hospital.

Guy's Hospital.

King's College.

London Hospital.

Middlesex Hospital.

St. Bartholomew's Hospital.

St. George's Hospital.

St. Mary's Hospital.

H. A. Ahrens, Esq.

E. Cresswell Baber, Esq.

H. A. Ballance, Esq.

Thomas Barr, Esq., M.D.

F. W. Bennett, Esq., M.D.

W. Bulloch, Esq., M.D.

J. Cameron, Esq.

Arthur H. Cheatle, Esq.

G. Lenthal Cheatle, Esq.

Galbraith Connal, Esq.

Professor Crookshank.

Professor Cunningham, F.R.S.

W. Jobson Horne, Esq.

Jonathan Hutchinson, Esq., F.R.S.

Hugh E. Jones, Esq.

R. D. Joyce, Esq.

Richard Lake, Esq.

Charles G. Lee, Esq.

St. Thomas's Hospital.

University College.

Westminster Hospital.

The University of Cambridge.

Liverpool Eye and Ear Infirmary.

Norwich Hospital.

Royal Albert and Edward Infirmary, Wigan.

University College, Liverpool.

Yorkshire Medical College.

C. A. Moore, Esq., M.D.

D. R. Paterson, Esq., M.D.

L. Hemington Pegler, Esq., M.D.

Professor Urban Pritchard, M.D.

H. E. D. Rolleston, Esq., M.D.

P. de Santi, Esq.

Charles Shears, Esq.

Marmaduke Sheild, Esq.

A. A. Scot-Skirving, Esq.

Professor Charles Stewart, F.R.S.

J. Bland-Sutton, Esq.

StClair Thomson, Esq., M.D.

Herbert Tilley, Esq., M.D.

E. F. Trevelyan, Esq.

Logan Turner, Esq.

H. Secker Walker, Esq.

Wyatt Wingrave, Esq.

Macleod Yearsley, Esq.

AUSTRIA.

Dr. Gustav Alexander.

Dr. Ferdinand Alt.

Dr. Barnick.

Dr. Carl Biehl.

Ludwig Castagna.

Dr. Hugo Frey.

Professor Gruber.

Dr. Victor Hammerschlag.

Stud. Med. Walther Kolmer.

Professor Politzer.

BELGIUM.

Dr. Delie.

| Dr. Charles Delstanche

FRANCE.

Dr. Louis Bar.
Dr. Gellé.

Dr. E. J. Moure.

GERMANY.

Professor Bezold.
Dr. Beckmann.
Dr. Breitung.
Dr. Brieger.
Dr. Gustav Brühl.
Dr. Denker.
Professor Edelman.
Dr. Hermann Gutzmann.
Dr. Arthur Hartmann.
Dr. L. Katz.
Dr. Kirstein.
Dr. Kretschman.
Professor Lucae.
Dr. Noebel.

Dr. Rudolf Panse.
Professor Passow.
Dr. Röpke.
Dr. Rudloff.
Dr. Scheibe.
Dr. Schwendt.
Professor Siebenmann.
Dr. Guido Sonnenkalb.
Dr. William Stern.
Dr. Teichmann.
Dr. Wegener.
Dr. Alfred Wolff.
Dr. Zarniko.

HOLLAND.

Dr. J. D. Boeke.
Professor W. Einthoven.
Professor Guye.
Dr. W. Posthumous Meyjes.
Dr. W. Schutter.

Dr. A. Sikkell.
The late Dr. B. J. Smits.
Dr. P. J. Zaalberg.
Professor H. Zwaardemaker.

ITALY.

Dr. G. d'Ajutolo.
Dr. Cagnola.
Professor Cozzolino.
Professor Dionisio.
Professor Faraci.

Dr. G. Geronzi.
Professor Gradenigo.
Dr. Reicitjes.
Dr. T. della Vedova.

NORWAY.

Professor Uchermann.

SWITZERLAND.

Dr. F. Rohrer.

PREFACE TO THE REVISED EDITION.

IN revising and making some additions to the Descriptive Catalogue used in the Museum of the Sixth International Otological Congress, the original character of the volume has been preserved.

Care has been taken to revise the numerous references that are given, and to eliminate the errors that so easily creep into work of this kind and detract from its value to those engaged in scientific research.

1900.

W. J. H.

A. H. C.

P R E F A C E.

WE are desirous of recording how deeply we stand indebted to the Governing Bodies of Hospitals and Medical Schools, to the Curators of Museums, to our Foreign and British *confrères*, and to numerous friends for their invaluable kindness and assistance in completing a task entrusted to us by the Executive Committee of the Congress.

To make clear our own responsibilities, we must add that we are alone responsible for the arrangement of the Museum and the Catalogue, and for any errors. The arrangement usually followed in museums of a temporary nature has been departed from. The general plan and aims of the Museum are given in the Introduction. In the Catalogue the specimens are described, and not merely named. It is hoped that with this guidance the Museum may be studied as an orderly and complete collection of illustrations of the Comparative Anatomy, Embryology, Anatomy, and Pathology of the special organs with which it deals, and that the Catalogue may be found to be a useful work for future reference.

W. J. H.

A. H. C.

PREFACE TO THE REVISED EDITION.

In revising and adding new chapters to the *Thirteenth Edition* of the *History of the United States*, I have been guided by the same principles which governed the *Twelfth Edition*. The *Twelfth Edition* was published in 1881, and since that time the progress of the nation has been rapid and the changes in its institutions and government have been great. It is therefore necessary to revise the *Twelfth Edition* and to add new chapters to it.

H. A. H.

A. D. 1884

PREFACE.

The *Twelfth Edition* of the *History of the United States* was published in 1881. Since that time the progress of the nation has been rapid and the changes in its institutions and government have been great. It is therefore necessary to revise the *Twelfth Edition* and to add new chapters to it.

The *Twelfth Edition* was published in 1881, and since that time the progress of the nation has been rapid and the changes in its institutions and government have been great. It is therefore necessary to revise the *Twelfth Edition* and to add new chapters to it.

H. A. H.

A. D. 1884

CONTENTS.

	PAGE
GENERAL INTRODUCTION	xiii
GREAT BRITAIN	1—151
COMPARATIVE ANATOMY	1—16
Auditory apparatus	1—13
Olfactory apparatus	14—16
EMBRYOLOGY	16
HUMAN ANATOMY	17—39
Introduction	17
Ear—	
Foetus	19—21
Child	22—25
Adult	25—35
Nose, accessory sinuses, and naso-pharynx—	
Foetus	35—36
Child	36
Adult	36—39
INJURIES AND THEIR RESULTS—	
Ear	39—45
Nose	45—47
FOREIGN BODIES—	
Ear	47—48
Nose—naso-pharynx	48—49

	PAGE
PATHOLOGY	51—151
Introduction	51
Malformations—	
Ear	53—57
Nose, naso-pharynx	57, 58
Anomalies in the distribution of the blood and lymph ...	58
Retrogressive disturbances—atrophy, sclerosis, calcareous de- generation, formation of cysts	59—61
Progressive or formative disturbances of nutrition, hyper- trophy, regeneration	61—64
Inflammation and its consequences	64—112
External ear	64, 65
Middle ear	65—70
Middle ear—extension of inflammation—	
i. <i>Caries and perforation through the walls</i> ...	70—72
ii. <i>Extension to internal ear</i>	72—74
iii. <i>Extension to temporo-maxillary joint</i> ...	75
iv. <i>Perforation through digastric fossa</i> ...	75
v. <i>Extra-dural abscess with localised pachymeningitis</i>	75—77
vi. <i>Lepto-meningitis</i>	77—81
vii. <i>Cerebral abscess</i>	81—91
viii. <i>Cerebral abscess with general lepto-meningitis</i> ...	90, 91
ix. <i>Cerebellar abscess</i>	91—96
x. <i>Thrombosis of sinuses</i>	97—100
xi. <i>Thrombosis of lateral sinus and meningitis</i> ...	100—102
xii. <i>Thrombosis of lateral sinus and temporo-sphenoidal</i> <i>abscess</i>	102, 103
xiii. <i>Thrombosis of lateral sinus, temporo-sphenoidal</i> <i>abscess, and meningitis</i>	103
xiv. <i>Thrombosis of lateral sinus and cerebellar abscess</i>	103—105
xv. <i>Thrombosis of lateral sinus, cerebellar abscess, and</i> <i>meningitis</i>	105
xvi. <i>Hernia cerebri</i>	105
Nose	105—108
Accessory sinuses	108—112
Fauces... ..	112
Specific inflammation	112—119
Ear—	
i. <i>Leprosy</i>	112
ii. <i>Tuberculosis</i>	113
iii. <i>Syphilis</i>	113, 114

Nose, accessory sinuses, and naso-pharynx—		
i. <i>Erysipelas</i>	...	114
ii. <i>Variola</i>	...	114
iii. <i>Tuberculosis</i>	...	114, 115
iv. <i>Lupus</i>	...	115
v. <i>Glanders</i>	...	115, 116
vi. <i>Rhinoscleroma</i>	...	116
vii. <i>Syphilis</i>	...	116, 119
Tumours and new formations		119—148
Ear—		
Epiblastic—		
i. <i>Epithelioma</i>	...	119—121
ii. <i>Adeno-carcinoma</i>	...	122
iii. <i>Rodent ulcer</i>	...	122, 123
Mesoblastic—		
i. <i>Angeioma</i>	...	123
ii. <i>Fibroma</i>	...	123, 124
iii. <i>Exostosis—hyperostosis</i>	...	124
iv. <i>Tumour of doubtful nature</i>	...	125
v. <i>Sarcoma</i>	...	125—128
Nose and accessory sinuses—		
Epiblastic—		
i. <i>Papilloma</i>	...	128, 129
ii. <i>Epithelioma</i>	...	129—132
iii. <i>Rodent ulcer</i>	...	132—133
Mesoblastic—		
i. <i>Angeioma</i>	...	133, 134
ii. <i>Myxoma</i>	...	134
iii. <i>Enchondroma</i>	...	135
iv. <i>Osteoma</i>	...	135—138
v. <i>Sarcoma</i>	...	139—143
Naso-pharynx and pharynx—		
Epiblastic—		
i. <i>Papilloma</i>	...	144
ii. <i>Epithelioma</i>	...	144
Mesoblastic—		
i. <i>Angeio-fibroma</i>	...	144, 145
ii. <i>Fibroma</i>	...	145—147
iii. <i>Sarcoma</i>	...	147, 148
Parasites	...	148
Microscopical specimens	...	148—150

	PAGE
SKIAGRAPHS	150
INSTRUMENTS	150, 151
THE TOYNBEE COLLECTION	153—223
AUSTRIA	225—233
BELGIUM	233—234
FRANCE	235
GERMANY	236—243
HOLLAND	244—248
ITALY	249
NORWAY	249
SWITZERLAND	249
APPENDIX A.—Too Late List	250
APPENDIX B.—Notes and references to the different methods used for preparing and preserving specimens exhibited in the Museum ...	251

INTRODUCTION.

THE general plan of the Museum of the Sixth International Otological Congress being different in so many respects from that usually followed in forming temporary museums in connection with scientific congresses, some observations and account may be permitted, and perhaps usefully given, of how the Museum was organised, the aims of those responsible for it, and the scope and utility of a fully descriptive Catalogue.

THE MUSEUM COMMITTEE.

When the British Organisation Committee in charge of the arrangements for the Congress to be held in London in August of 1899 decided that a Museum should form part of its programme, it referred the carrying out of the matter to a Committee, with Mr. Charles A. Ballance as Chairman, and Mr. Arthur H. Cheatle as Secretary. This Committee commenced work in the autumn of 1898, and invited from all quarters the loan of specimens illustrating the comparative anatomy, embryology, anatomy, injuries, malformations, and diseases of the ear, the nose and its accessory sinuses, and the naso-pharynx; also the loan of instruments and appliances for investigating and treating disease in these regions, and of preparations for teaching and advancing the Science of Otology.

It was considered that the issuing of circulars even widely through the post, and the reproduction of them in the medical journals at home and abroad, would not in itself lead to sufficient response. The Committee therefore decided to ascertain as far as possible what specimens and preparations were in existence and obtainable. For this purpose representatives were elected on to the Committee of all parts of Great Britain and of some of the Colonies, who would acquaint themselves with the specimens in their respective districts, and report to the Museum Committee at its monthly meetings the results of their inquiries, with a view to the loan of such specimens as might be required being obtained.

The Editors of the Catalogue worked through the museums of comparative and morbid anatomy in London, and, with the help so readily given by the Curators, were able to compile a classified list of all the specimens in London bearing upon the subject.

The following foreign representatives kindly undertook to obtain contributions in their respective countries :

Professor POLITZER,	}	Austria.
Professor GRUBER,		
Dr. CHARLES DELSTANCHE, Belgium.		
Dr. E. J. MOURE,	}	France.
Dr. GELLÉ,		
Dr. ARTHUR HARTMANN, Germany.		
Professor GUYE, Holland.		
Professor GRADENIGO, Italy.		
Dr. F. ROHRER, Switzerland.		

Some months previous to the Congress the Secretary-General, Mr. Cresswell Baber, travelled through France, Spain, and Italy, and made known the requirements of the Museum. Two of the Committee, Mr. Jobson Horne and Mr. Richard Lake, visited Germany and Holland, and these two countries sent over representative collections through their respective Otological Societies.

Descriptions for the Catalogue were receivable up to the end of the first week in July, but the time allowed had to be extended ; the specimens themselves could be received up to the day previous to the opening of the Museum.

THE MUSEUM.

The kindness of the Conjoint Boards of the Royal Colleges of Physicians and Surgeons in placing their Examination Hall at the disposal of the Congress very considerably contributed to the success of the Museum. The large rooms on the first floor, well lighted by windows on all sides, lent themselves admirably for the purpose.

Knowing that the time available for arranging the Museum would necessarily be brief, the Committee previously worked out as approximately as possible all details for the furnishing and arranging of the rooms. The studying of specimens, and more particularly of wet specimens, being greatly facilitated by their being placed at a convenient height from the ground, in a good light, and with a background of a suitable colour, all these points received the most careful consideration in designing and arranging the tables and stands. To expedite the moving without breakages or confusion of such a large number of fragile articles from the several museums in London classified lists were prepared, and a system of coloured labels employed ; but however carefully a system for the purpose might have been thought out, it could only have been efficient in experienced and responsible hands, and in this Mr. George, the attendant of the Anatomy Room of the Royal College of Surgeons, rendered valuable services ; so that when possession of the rooms was obtained a week before the opening of the Congress, the work of arranging the museum was most expeditiously carried out.

A plan will be found facing the title-page showing the general arrangement of the rooms. From this it will be seen that the larger room had to be entirely given up to the British section. With the support liberally given by the Council of the Royal

College of Surgeons and the London and Provincial Hospitals in allowing their collections to be freely drawn upon, and with the help of contributions from many private sources, the opportunity was taken of arranging in this section complete series of specimens illustrating the several branches of the science. The arrangement usually followed in temporary museums of grouping specimens under the names of exhibitors has therefore, except in the case of the Toynbee Collection and of private collections received from abroad, been departed from. Such a disjointed arrangement would have defeated the aim of the British section, which was to enable by means of systematic classification the studying of complete series of specimens without having to move about from one part to another of the Museum, or to turn from one part to another of the catalogue. The section contains, exclusive of the Toynbee Collection, nearly a thousand exhibits separately catalogued and described, and as many exhibits contain more than one specimen, the total number of specimens is considerably larger.

The Council of the Royal College of Surgeons has done honour to the memory of Toynbee by lending his collection entire, and by allowing the original catalogue to be reproduced. What modern pathologists and physiologists have done to advance the science of otology may be well seen in the British and Foreign sections; yet the Toynbee Collection and its descriptive catalogue show that minute dissection, together with accurate observation and careful description, is no new thing in otology, and that at its moments of high performance it reached half a century ago an unsurpassed point of distinction. The collection, if viewed only as a memorial of the man who first placed otology on a scientific basis, will always arouse admiration for the diligence of one man, and surprise at the lack of contemporary appreciation of the results of his patient labours. No one ought to predict the opinions of future generations, few men, however, will ever stand higher in the English annals of otology, and still fewer will ever more justly deserve the gratitude of subsequent workers in the science, than Joseph Toynbee.

In the Foreign Section the exhibits have been arranged under the names of the countries from which they have been received. Notwithstanding the difficulties and risks in transporting specimens under glass, extensive collections have been received illustrating all branches of the science; this section, however, will be found to be particularly rich in preparations devised especially for demonstrating the anatomy and diseases of the more minute structures of the ear, affording further proof of the progress made in the modern methods of teaching otology.

The Museum, moreover, has been brought into closer relationship with the work of the Congress by containing the preparations which form the basis of some of the papers communicated, and the theories they advance.

THE CATALOGUE.

The compiling and printing of a catalogue, fully descriptive of a Congress Museum, the contents of which are arriving from all quarters, is necessarily met with difficulties; and these difficulties are considerably increased when a systematic classification of the subjects with which it deals is to be arrived at, and the fullest

latitude of time for forwarding contributions is to be allowed. It was felt, however, that a descriptive catalogue would so materially add to the value of the Museum, that no difficulty ought to be allowed to be insurmountable.

It is hoped that the table of contents will make clear the general arrangement of the sections and sub-sections, and that the Catalogue will be found to be an index in itself.

In the British Section the exhibits are numbered consecutively, and only one series of numbers has been used as in the pagination of the book; where a letter (a, b, c) is placed after a number it is to indicate that the specimen so marked is part of or connected with the previous one. The descriptions of a few contributions which arrived too late to be classified in the body of the Catalogue are given separately in an appendix.

To add to the interest and future value of the Catalogue for reference, clinical accounts have been given wherever received, and also references to the Transactions of Scientific Societies and published accounts of cases.

The source from which each specimen was obtained is given at the foot of the description. In the case of a public hospital or museum, the name of the hospital or museum and the reference to the catalogue of that museum are printed to the left; in the case of a specimen received from a private source the name of the contributor is printed to the right.

In the Toynbee Collection the numbers given are those used in the original catalogue. In the Foreign Section the arrangement of countries is alphabetical, and the series of numbers used are the same as received with the descriptions.

The Catalogue, arranged in this way, it is thought, will be of more than momentary value. So far as it relates to the specimens preserved in the museums in London, it may be regarded as a record of aural pathology coeval with the holding of the Congress. No catalogue, no museum can claim to contain a complete set of illustrations of the pathology of the ear, so many aural conditions being dependent upon changes in the nervous and vascular systems which cannot be demonstrated after death. Every effort, however, has been made to make the Catalogue as complete a synopsis as possible of the several branches of the science with which it deals, and as such it may be useful to many who wish to study the concrete evidence upon which modern otology is based.

COMPARATIVE ANATOMY AND EMBRYOLOGY.

THE specimens contained in this section have been serially arranged to afford by means of dissected preparations a comparative study of the external ear, the auditory apparatus, and the olfactory apparatus in the lower animals.

The kindness of the Council of the Royal College of Surgeons in lending so many specimens from their museum, and the invaluable assistance so readily given by the curator, Professor Charles Stewart, F.R.S., have mainly contributed to the completeness of the section.

The reference numbers and the descriptions that have been followed are those given in the museum copy of the 'Descriptive and Illustrated Catalogue of the Physiological Series of Comparative Anatomy contained in the Museum of the Royal College of Surgeons in London,' Vol. III, Part I, "Nervous System and Organs of Sense." London, 1835. The museum copy of this catalogue has been largely added to, and is partly in manuscript.

COMPARATIVE ANATOMY AND EMBRYOLOGY.

This volume contains the first section of the work, and is devoted to the study of the comparative anatomy of the vertebrate and the invertebrate animals, and the history of the progress of the science.

The second section of the work is devoted to the study of the comparative anatomy of the invertebrate animals, and the history of the progress of the science.

The third section of the work is devoted to the study of the comparative anatomy of the invertebrate animals, and the history of the progress of the science.

COMPARATIVE ANATOMY.

AUDITORY APPARATUS.

EXTERNAL EAR.

1. Head of *Megaderma frons*, showing large and confluent external ears, and leaf-like appendage to nose. O. Thomas, Esq.
R.C.S. Museum, 1607A.
2. Skin of head of *Noctilio leporinus*, showing auricles. J. E. Harting, Esq.
R.C.S. Museum, 1607Aa.
3. Skin of the side of the head and meatus auditorius externus of a young male *Echidna hystrix*.
R.C.S. Museum, 1609A.
4. Right half of the head of *Echidna hystrix*, showing the external auditory passage, with its walls strengthened by imperfect rings and plates of cartilage, with the muscles that open and close its orifice. A bristle has been passed into the Eustachian tube.
R.C.S. Museum, 1609Aa.
5. Auricle of a young *Opossum (Didelphys azaræ)*.
R.C.S. Museum, 1609B.
6. Skull of *Perameles lagotis*, with external ear attached.
R.C.S. Museum, 1609Ba.
7. Pinna of right and left ear of *Phascolarctos koala*. J. Abrahams, Esq.
R.C.S. Museum, 1609Bb.
8. External organ of hearing of adult male *Delphinus tursio*. It is a minute aperture behind the posterior angle of the eye, leading by a dense cartilaginous meatus, buried in subcutaneous fat, to the membrana tympani. The walls of the meatus, thin near the outer skin, get thicker as they pass inwards. The canal is throughout only wide enough to admit the ordinary size of bristle. There is no vestige of a pinna. F. Buckland, Esq.
R.C.S. Museum, 1609C.
9. External ear of *Mymecophaga jubata*.
R.C.S. Museum, 1609D.

10. Skin of side of head of a female African Manis (*Manis longicauda*), showing absence of pinna.
R.C.S. Museum, 1609E.
11. External ear of Grison (*Galictis vittata*), an adult male, pinna very rudimentary.
R.C.S. Museum, 1610A.
12. External ear of an adult male Ferret (*Mustella furo*).
R.C.S. Museum, 1610B.
13. External ear of an adult female *Galidia elegans*.
R.C.S. Museum, 1610C.
14. External ear of adult female *Crossarchus obscurus*.
R.C.S. Museum, 1610D.
15. External ear of adult male Kinkajou (*Cercoleptis caudivolvulus*).
16. External ear of *Genetta tigrina*. St. G. Mivart, Esq.
R.C.S. Museum, 1610F.
17. Skin of the left side of the head of *Mydans meliceps*, showing the rudimentary pinna and the pig-like snout. J. W. Clark, Esq.
R.C.S. Museum, 1610G.
18. Right half of head of Seal (*Phoca vitulina*), showing the long external auditory meatus and its supporting cartilages.
R.C.S. Museum, 1611A.
19. External ear of adult female Potto (*Perodicticus potto*). F. M. Skues, Esq.
R.C.S. Museum, 1612A.
20. External ear of *Arctocebus calabarensis*. (See Huxley's paper, 'Proc. Zool. Soc.,' 1864.)
R.C.S. Museum, 1612B.
21. External ear of adult Viscacha (*Lagostornus trichodactylus*).
R.C.S. Museum, 1614A.
22. External ear of adult female Coypu (*Myopotamus coypus*).
R.C.S. Museum, 1614B.
23. External ear of adult female Javan Porcupine (*Hystrix javanica*).
R.C.S. Museum, 1614C.

24. External ear of Fournier's *Capromys* (*Capromys piloridis*), adult male.
R.C.S. Museum, 1614D.
25. Skin of the head of *Lagidium Cuvieri*, showing the pinnae. S. Epprett,
Esq.
R.C.S. Museum, 1614Da.
26. External ear of *Dolichotis patachonica*.
R.C.S. Museum, 1614E.
27. The cartilages and muscles of the pinna of a Calf (*Bos taurus*). S.
Davey, Esq.
R.C.S. Museum, 1615A.
28. External ear of adult female *Hyomoschus aquaticus*.
R.C.S. Museum, 1616A.
29. The cartilages of the ear of a Horse.
R.C.S. Museum, 1617A.
30. Right pinna of a Horse. There is a mass situated at the base of the
pinna, which probably facilitates its rapid movement in different directions.
Prof. McFadyean.
R.C.S. Museum, 1617B.
31. The fibro-cartilage of the expanded pendent portion of the auricle of an
Elephant; it is remarkable for the notches and perforations of its margin,
all of which are natural.
R.C.S. Museum, 1618A.
32. Cartilage and muscles attached of pinna of right ear of foetal Elephant
(*E. indicus*).
R.C.S. Museum, 1618Aa.
33. External ear of *Hyrax capensis*.
R.C.S. Museum, 1618B.
34. Right external ear of collared Peccary (*Dicotyles tajacu*).
R.C.S. Museum, 1618C.
35. Auricle of *Midas oedipus*.
R.C.S. Museum, 1619A.
36. Auricle of *Cebus capucinus*.
R.C.S. Museum, 1619B.
37. Auricle of an adult male *Lagothrix Humboldtii*.
R.C.S. Museum, 1619C.

38. Auricle of *Cynocephalus babouin*.
R.C.S. Museum, 1619D.
39. Auricle of *Cercocebus fuliginosus*.
R.C.S. Museum, 1619E.
40. Auricle of a young Orang-utan (*Simia satyrus*, Blum.). Mr. Owen.
R.C.S. Museum, 1620A.
41. A similar specimen.
R.C.S. Museum, 1620Aa.
42. Auricle of a young Chimpanzee (*Troglodytes niger*, Geoff.).
R.C.S. Museum, 1620B.
43. Auricle of a Bushwoman.
R.C.S. Museum, 1621A. *Journal of Anat. and Physiol.*, vol. i, p. 189,
1867.
44. Auricle of a man of Malayan or Neptunian race, from Tahiti. The lower
part has been perforated by a pendent ornament.
R.C.S. Museum, 1622A.
45. External ear of a man.
R.C.S. Museum, 1622B.
46. Cartilages of the auricle of a European.
R.C.S. Museum, 1623A.

Crustacea.

AUDITORY APPARATUS.

47. Auditory sac in right first antenna of *Palinurus vulgaris*. Prof. Stewart.
R.C.S. Museum, 1559Aa.
48. The antennules of a Lobster (*Homarus vulgaris*), prepared to show the
auditory sac. Prof. Stewart.
R.C.S. Museum, 1559Aaa.
49. Tympanic membranes on inner and outer sides of proximal extremities of
tibiæ of fore-legs of *Hemiacrida*. Prof. Stewart.
R.C.S. Museum, 1559Ab.
50. Tympanic membrane on fore-legs of *Deinacrida heteracantha*. Prof.
Stewart.
R.C.S. Museum, 1559Ac.
51. Pseudophyllus. Tympanic membranes, protected by a fold of skin, which
leaves two openings on each tibia by which sound waves enter; indicated
on one side by black paper. Prof. Stewart.
R.C.S. Museum, 1559Ad.

52. *Rhomalea gigantea*. A thin transparent patch of cuticle on each side of the first abdominal segment, serves as a tympanic membrane. Prof. Stewart.

R.C.S. Museum, 1559Ae.

53. *Locusta migratoria*. Tympanic membrane—indicated by an arrow—is protected by being depressed below the surface of the first abdominal segment. Prof. Stewart.

R.C.S. Museum, 1559Af.

Cephalopoda.

54. Head of a Cuttle-fish (*Sepia officinalis*, Linn.), prepared to show the organ of hearing. Mr. Owen.

R.C.S. Museum, 1559B.

55. A dissection of the head of *Petromyzon marinus*. The brain, spinal cord, olfactory sac, eyes, and ears are exposed; of the cartilaginous periotic capsules, situated by the sides of the medulla, the left has had its upper half removed to show the membranous labyrinth, the right is entire, showing the auditory apparatus, &c. Prof. Stewart.

R.C.S. Museum, 1559C.

Pisces.

56. Otoliths of the Cod. Sir Astley Cooper.

R.C.S. Museum, 1566A.

57. Membranous labyrinth of Dory (*Zeus faber*). Prof. Stewart.

R.C.S. Museum, 1567A.

58. Otoliths from right and left ears of *Zeus faber*. Prof. Stewart.

R.C.S. Museum, 1567B.

59. Membranous labyrinth of Angler-fish (*Lophius piscatorius*). Prof. Stewart.

R.C.S. Museum, 1567C.

60. Membranous labyrinth of Lump-sucker (*Cyclopterus lumpus*). Prof. Stewart.

R.C.S. Museum, 1567D.

61. Right membranous labyrinth of *Cyclopterus lumpus*, showing the delicate ductus endolymphaticus connecting saccule and utricle, and behind the duct the fine nerve going to the macula neglecta. Prof. Stewart.

R.C.S. Museum, 1567E.

62. Membranous labyrinths of Wolf-fish (*Anarrhichas lupus*). Prof. Stewart.

R.C.S. Museum, 1567F.

63. Otoliths from the right and left ears of *A. lupus*. Prof. Stewart.

R.C.S. Museum, 1567G.

64. Membranous labyrinths of Hake (*Merlucius vulgaris*). Prof. Stewart.
R.C.S. Museum, 1567H.
65. Otoliths from *M. vulgaris*. Prof. Stewart.
R.C.S. Museum, 1567I.
66. Right membranous labyrinth of *M. vulgaris*. Otoliths and parts of walls removed to show maculæ and cristæ acusticæ. Prof. Stewart.
R.C.S. Museum, 1567J.
67. Membranous labyrinths of Coal-fish (*Gadus virens*). Prof. Stewart.
R.C.S. Museum, 1567K.
68. Membranous labyrinths of Grey Mullet (*Mugil chelo*). Prof. Stewart.
R.C.S. Museum, 1567L.
69. Otoliths from right and left labyrinths of *M. chelo*. Prof. Stewart.
R.C.S. Museum, 1567La.
70. Right membranous labyrinth of Halibut (*Hippoglossus vulgaris*). Prof. Stewart.
R.C.S. Museum, 1567M.
71. Left ditto. Prof. Stewart.
R.C.S. Museum, 1567N.
72. *Abramis brama*. The membranous labyrinths, showing the lagena cochleæ to be larger than the sacculus. The sacculi of opposite sides communicated with one another. Prof. Stewart.
R.C.S. Museum, 1567O.
73. Otoliths from right and left labyrinths of *A. brama*. Prof. Stewart.
R.C.S. Museum, 1567P.
74. Portion of skull and spinal column of *A. brama*, showing the chain of four bones on each side (painted red on the left), by which the air-bladder is related to a special prolongation of the membranous labyrinth. Prof. Stewart.
R.C.S. Museum, 1567Q.
75. Three first vertebræ and chains of bones of *A. brama*. Prof. Stewart.
R.C.S. Museum, 1567R.
76. Right membranous labyrinth of *Clupea alosa*; parts of the periotic bones are left to show the chambers in which the bifid anterior terminations of the air-bladder are lodged. Prof. Stewart.
R.C.S. Museum, 1567S.
77. The swim-bladder of a Herring (*Clupea harengus*), showing its connection with the membranous labyrinth. The opening of the swim-bladder behind the anus is marked by a bristle. Prof. Stewart.
R.C.S. Museum, 1567sa.

78. Right side of head of Pike (*Esox lucius*), showing labyrinth, remarkable for special backward directed process of utricle. Prof. Corfield.
R.C.S. Museum, 1567T.
79. Right and left membranous labyrinth of *E. lucius*. Prof. Corfield.
R.C.S. Museum, 1567Ta.
80. Membranous labyrinth of *Sciæna aquila*. Prof. Stewart.
R.C.S. Museum, 1567U.
81. Right and left labyrinths of Sturgeon (*Acipenser sturio*), showing large fusiform and nearly free ductus endolymphaticus lying in front of the common canal; hardly a trace of distinction between sacculus and lagena cochleæ; auditory nerve small. Prof. Stewart.
R.C.S. Museum, 1568A.
82. Membranous labyrinths of *Ceratodus Forsteri*. Prof. Stewart.
R.C.S. Museum, 1568C.
83. Otoliths of *C. Forsteri*. Prof. Stewart.
R.C.S. Museum, 1568D.
84. Dissection displaying the membranous sac of the Skate's ear (*Raia batis*). See MS. Catalogue, 'Nervous System,' No. 673. J. Swan, Esq.
R.C.S. Museum, 1570A.
85. Another preparation of the ear of *Raia batis*, showing the point at which the auditory nerve enters it, and the relation of the auditory branches of the fifth nerve in their passage from the brain to the sense capsule of the ear. See MS. Catalogue, 'Nervous System,' No. 674. Mr. Swan.
R.C.S. Museum, 1570B.
86. Right membranous labyrinth of *R. batis*. Bristle in ductus endolymphaticus, red glass in anterior and green rod in posterior utriculo-sacculine ducts; at the junction of the posterior duct with the saccule is a macula neglecta. The utricle with common canal is divided into two parts, not directly connected together. The anterior division has the anterior and horizontal canals continuous with it, the posterior division the posterior canal. Prof. Stewart.
R.C.S. Museum, 1570C.
87. Right membranous labyrinth of Porbeagle Shark (*Lamna cornubica*), with portion of periotic capsule and skin, &c. The ductus endolymphaticus passes from the saccule upwards through the cartilaginous capsule, becomes tortuous, and opens by a minute orifice on the skin at the top of the head. A bristle is passed through the duct. Prof. Stewart.
R.C.S. Museum, 1574A.

88. Right membranous labyrinth, with nerves attached, of *L. cornubica*. Prof. Stewart.
R.C.S. Museum, 1574Aa.
89. Left membranous labyrinth of *L. cornubica*. Prof. Stewart.
R.C.S. Museum, 1574B.
90. Right membranous labyrinth of a Fox Shark (*Alopias vulpes*), seen from the inner side. Prof. Stewart.
R.C.S. Museum, 1574Ba.
91. Left membranous labyrinth of *A. vulpes*, seen from the outer side. Prof. Stewart.
R.C.S. Museum, 1574Bb.
- 92 & 93. Membranous labyrinths of *Carcharias lamia*. Prof. Stewart.
R.C.S. Museum, 1574C & 1574D.
- 94 & 95. Membranous labyrinths of *Notidanus griseus*. Dr. Günther.
R.C.S. Museum, 1574E & 1574F.
- 96 & 97. Membranous labyrinths of *Læmargus borealis*. W. Cowan, Esq.
R.C.S. Museum, 1574G & 1574H.

Reptilia.

98. Right membranous labyrinth, tympanic cartilage, and columella auris of *Rana Catesbiana*. Prof. Stewart.
R.C.S. Museum, 1575A.
99. Left half of the head of *R. Catesbiana*. The membranous labyrinth is exposed, posterior half of the tympanic membrane and wall removed. A bristle is passed in front of the columella through the Eustachian opening. Prof. Stewart.
R.C.S. Museum, 1575B.
100. Skull of *Pipa americana*; black bristle through the Eustachian tube, a green one through the fenestra ovalis. On the right side the stapes and extra-stapedial are painted blue, the medio-stapedial red. Prof. Stewart.
R.C.S. Museum, 1575C.
101. Head of *P. americana*. The bristle indicates the unpaired opening of the Eustachian tubes and projects behind the right middle stapedial bone. A red rod has been passed through the right nasal openings. Prof. Stewart.
R.C.S. Museum, 1575D.
102. Skull of *Hatteria apunctatus*, showing the fusion of the lesser horn of the hyoid with the extra-stapedial cartilage. F. E. Beddard, Esq.
R.C.S. Museum, 1576A.

103. The posterior part of the roof of the mouth of a Crocodile, showing the posterior nares and the orifices of the Eustachian tubes, into which bristles are inserted.

R.C.S. Museum, 1577A.

104. The occipital region of the head of a Crocodile (*Crocodilus acutus*) dissected from behind to show the Eustachian tubes. Two Eustachian tubes open out of each tympanum; after a somewhat complicated course in the occipital bone, all four open by a single aperture in the roof of the mouth.

R.C.S. Museum, 1577B.

105. Auditory organ of a Turtle (*Chelonia midas*, Linn.).

R.C.S. Museum, 1580A.

106. A preparation similar to 1580A.

R.C.S. Museum, 1580Aa.

107. Preparation of the internal ear of a Turtle.

R.C.S. Museum, 1580B.

108. "Bones of the ear connected with the vestibule and semicircular canals in the Turtle, auditory nerve in the same dividing upon the labyrinth." Sir Astley Cooper.

R.C.S. Museum, 1580C.

109. Dried preparation of part of the head of a Turtle, with columella *in situ*.

R.C.S. Museum, 1580D.

Aves.

110. A section of the head of a Barn Owl (*Strix flammea*), to show organ of hearing.

R.C.S. Museum, 1581A.

111. Skull of a corvine bird; bony labyrinth and columella displayed.

R.C.S. Museum, 1581B.

112. Skull of a Rook (*Corvus frugilegus*); semicircular canals displayed.

R.C.S. Museum, 1581C.

113. Skull of a Goose; semicircular canals displayed.

R.C.S. Museum, 1581D.

Mammalia.

114. A small portion of the tympanum of a young Whalebone Whale (*Balæna mysticetus*, Linn.), including the membrane and the ligament which attaches it to the malleus. Shows the attachment, form, and structure of the membrane.

R.C.S. Museum, 1598A.

115. Dissection of the petrous bone and ossicles of *B. mysticetus*.
R.C.S. Museum, 1598B.
116. The pouch-like membrana tympani of a Rorqual (*Balænoptera borealis*).
R.C.S. Museum, 1598C.
117. A preparation of the human temporal bone, showing the ossicles *in situ*,
the cochlea, &c. J. Swan, Esq.
R.C.S. Museum, 1602A.
118. Tympanic, squamosal, and periotic bones, with ossicula auditûs of a
fœtus. Sir Astley Cooper.
R.C.S. Museum, 1602B.
119. Bony labyrinth of a Fœtus. Sir Astley Cooper.
R.C.S. Museum, 1602C.
120. Fœtal skull, showing membrana tympani on right side, and tympanum
with its contents on left.
R.C.S. Museum, 1602Ba.
121. "Cochlea, separated from the other parts of the labyrinth, beautiful." Sir
Astley Cooper.
R.C.S. Museum, 1602D.
122. "Incus, os orbiculare, and stapes." Sir Astley Cooper.
R.C.S. Museum, 1602E.
123. Stapes, incus, and malleus.
R.C.S. Museum, 1602F.
124. Ossicula auditûs, including os orbiculare of both sides.
R.C.S. Museum, 1602G.
125. Ossicula Auditûs of Mammalia. Prepared by Alban H. G. Doran, Esq.,
F.R.C.S.
R.C.S. Museum.
126. Microphotographs of sections of the cochlea and vestibule in birds and
mammals.

Prof. Urban Pritchard.
127. Model of a section through the cochlea of a cat. × 500 diameters.

Prof. Urban Pritchard.
128. Sections showing the cochlear and vestibular nerves and their central
connections, viz. the corpus trapezoides and the lateral fillet in the orang,
chimpanzee, and man.

Orang Series.

- Lateral cochlear nucleus on one side; vestibular nerve and mesial or ventral cochlear nucleus on other side. Note relation of vestibular nerve to the descending root. 137.
- Same as above, but connections of vestibular nerve with its descending root more clearly seen. 138.
- Lower part of corpus trapezoides. Note on one side highest point of lower olive and the lowest part of superior olive. Observe also relations of superior olive to nucleus of facial nerve. 150.
- Specimen to show fibres of corpus trapezoides. Note lower olives with their peduncles. 166.
- Lateral fillet, with nucleus. In Orang this nucleus is merely a continuation upwards of the lower olive. 221.
- Same as above. 223.
- Lateral fillet entering inferior quadrigeminal body. 253.

Chimpanzee Series.

- A few slides to compare with orang and man.
- Corpus trapezoides with inferior olive. A.
- Lateral fillet. 206A.
- Lateral fillet at level of lower borders of the inferior quadrigeminal bodies. 226.

Human.

- Lateral cochlear nucleus; descending root of vestibular nerve. 33.

Vestibular Nerve.

- Ventral cochlear nucleus on one side.
- Lateral cochlear nucleus on other side. 46.
- The same as above. 48.
- Vestibular nerve penetrating pons on mesial side of the ventral cochlear nucleus and the restiform body. 62.
- Vestibular nerve in its relations to its descending root. 66.

Professor Cunningham.

129. Microphotographs of sections, demonstrating the central connections of the cochlear and vestibular nerves.

(i) *Orang*.—Through the lower part of pons, fibres of corpus trapezoides and the upper olives. V. Section, 166.

(ii) *Orang*.—Through lower part of pons, vestibular nerve and its descending root. V. Section, 150.

(iii) *Orang*.—Through lower part of mesencephalon, segmental part only shown. Inferior quadrigeminal bodies, lateral fillet.

(iv) *Orang*.—Through mesencephalon, lower part.

(v) *Chimpanzee*.—Through upper part of pons. V. Section, 206a.

The photographs are taken by an apparatus designed by the exhibitor, Prof. Cunningham.

OLFACTORY APPARATUS.

130. Dissection of the head of a Sturgeon (*Acipenser sturio*, Linn.), showing the organ of smell on the right side.
R.C.S. Museum, 1527.
131. Longitudinal dorso-ventral section of the head of *Petromyzon marinus*, showing the nasal structures.
R.C.S. Museum, 1527A.
132. Dissection of the nasal sac of the Skate (*Raia batis*) with the olfactory nerve expanded upon it; the involuted surface of the sac answers the same object in extending its dimensions as the presence of turbinated bones in mammalia.
R.C.S. Museum, 1528A.
133. Another preparation showing the same.
R.C.S. Museum, 1528B.
134. Dissection of the head of a Python, showing the brain, olfactory nerve, and organ of smell.
R.C.S. Museum, 1535A.
135. Section of head of Turkey Buzzard (*Cathartes aura*), labelled "olfactory nerve of *Vultur aura*."
R.C.S. Museum, 1540A.
136. Preparation of the head of a Turkey (*Meleagris gallopavo*). This is evidently put up to show by way of contrast the large size of the nerve and organ of smell with vulture. Contrast with specimen 1540A.
R.C.S. Museum, 1540C.
137. Skin from the middle of the upper surface of the head of a young *Platanista gaugetica* (from Calcutta), showing the longitudinal linear single nostril, or "blow-hole." Sir Joseph Fayrer.
R.C.S. Museum, 1544A.
138. "Blow-hole" and nasal sacs of an adult female *Lagenorhynchus*. J. W. Clark, Esq.
R.C.S. Museum, 1544B.
139. Longitudinal section of the head of *Ornithorhynchus paradoxus* (Blum.), showing the organs of smell.
R.C.S. Museum, 1546A.
140. Longitudinal section of the head of *Echidna hystrix* (Cuv.), showing the extremely complicated superior turbinated bone and nasal structures on the right side.
R.C.S. Museum, 1546B.
141. Skin from the end of the nose, showing the openings of the nostrils of (?) *Phochochærus Pallarii*.
R.C.S. Museum, 1546C.

142. Skin from the face, showing the external form of the nose of an old male Baboon (*Cynocephalus anubis*).
R.C.S. Museum, 1546D.
143. Skin of the head of a male Proboscis Monkey (*Lemnopithecus nasalis*), showing the elongated nose.
R.C.S. Museum, 1546E.
144. Skin of the head of Gibbon (*Hylobates leuciscus*).
R.C.S. Museum, 1546F.
145. Injected preparation showing lateral wall of right nasal cavity (human).
R.C.S. Museum, 1550A.
146. Injected preparation showing lateral wall of left nasal cavity (human).
R.C.S. Museum, 1550B.
147. Human septum nasi, injected.
R.C.S. Museum, 1550C.
148. Lateral wall of left nasal cavity (human), injected.
R.C.S. Museum, 1550D.
149. The cartilages of the human nose.
R.C.S. Museum, 1550E.
150. A longitudinal and a transverse vertical section of the head of an infant at birth, showing the organ of Jacobson in the nasal septum. Bristles in the tubes. S. G. Shattock, Esq.
R.C.S. Museum, 1550F.
151. Longitudinal vertical section of the head of a Hare (*Lepus timidus*, Linn.), showing the respective degrees of vascularity and nerve-supply of the nose.
R.C.S. Museum, 1551A.
152. Section of the head of a young Pig (*Lus scrofa*), injected, showing the form of the nasal cavity.
R.C.S. Museum, 1551B.
153. The other section of the same head, showing the septum.
R.C.S. Museum, 1551C.
154. Skin of the head of *Pteropus vampyrus*, showing the nostrils.
R.C.S. Museum, 1551D.
155. Skin of the head of a male *Epomophorus monstrosus*, showing the great development of the nose and lips.
R.C.S. Museum, 1551E.

156. Three sections of the inferior turbinated bone of a Horse (*Equus caballus*, Linn.), showing the cut extremities of the veins of the plexus, subjacent to the pituitary membrane. J. Swan, Esq.
R.C.S. Museum, 1556A.
157. Vertical transverse section of the nasal chambers of a Horse.
R.C.S. Museum, 1556B.
158. Anterior part of the face of a Horse, to show the false nostrils, opening of the lachrymal duct, nasal cartilages, and muscles which move the nostrils and upper lip.
R.C.S. Museum, 1556Ba.
159. Preparation of the left side of the face of an Ass, showing the nostril, false nostril or nasal pouch, &c.
R.C.S. Museum, 1556Bb.
160. Proboscis of Tapir (*Tapirus americanus*), dissected to show the muscles and curious scroll-like extension of the lateral nasal cartilages.
R.C.S. Museum, 1556Bba.
161. Head of a female foetal Elephant (*Elephas africanus*).
R.C.S. Museum, 1556Bc.
162. Vertical section of the anterior part of the head of a young Bladder-nosed Seal (*Cystophora cristata*), showing the subcutaneous air-sac connected with the upper and anterior part of nasal passage in a rudimentary condition.
R.C.S. Museum, 1556C.
163. Air-sac dissected from the skull of an adult male Bladder-nosed Seal.
R.C.S. Museum, 1556D.
164. Portion of the skin forming the outer wall of the same air-sac (1556D), showing its subcutaneous muscular fibres radiating over the sac.
R.C.S. Museum, 1556E.
165. Vertical transverse section of anterior portion of head of a male Bladder-nosed Seal.
R.C.S. Museum, 1556F.
166. Posterior part of specimen 1556F.
R.C.S. Museum, 1556G.
167. Nose of *Nasua rufa*, showing the cartilages. St. George Mivart, Esq.
R.C.S. Museum, 1556H.

EMBRYOLOGY.

168. A series of consecutive sections demonstrating the earlier stages in the development of the auditory and olfactory apparatus of the embryo of the chicken. (See Mic. Coll.)
Jobson Horne, Esq.

HUMAN ANATOMY. INJURIES AND THEIR RESULTS. FOREIGN BODIES.

In the section of Human Anatomy the specimens are arranged not only to show the parts, but also to demonstrate their development, growth, and variations from foetal to adult life. The two main groups, (*a*) ear and (*b*) nose, accessory sinuses, and naso-pharynx, are therefore each subdivided into those of (i) foetal life, (ii) childhood, and (iii) adult life. In these subdivisions the ear specimens are arranged, as far as possible, to show the external, the middle, and internal portions, and the surrounding parts in the order named. In those of the nose the order is the external nose, the cavity of the nose, the accessory sinuses, and the naso-pharynx.

HUMAN ANATOMY.

EAR.

FŒTUS.

- 169. A Fœtus of about the ninth week ; shows auricle.
St. Thos. Hosp. Museum, 254.
- 170. A Fœtus between the second and third month ; shows auricle.
St. Thos. Hosp. Museum, 255.
- 171. A Fœtus of more than three months ; shows auricle.
St. Thos. Hosp. Museum, 256.
- 172. A Fœtus of three and a half months ; shows auricle.
St. Thos. Hosp. Museum, 257.
- 173. A Fœtus at five months ; shows auricle.
St. Thos. Hosp. Museum, 258.
- 174. A Fœtus at six months ; shows auricle.
St. Thos. Hosp. Museum, 261.
- 175. A Fœtus at seventh month ; shows auricle.
St. Thos. Hosp. Museum, 264.
- 176. Auricle of Fœtus, injected.
King's Coll. Museum, 200.
- 177. Four foetal temporal bones dissected. Ages 20 weeks, 22 weeks. 24 weeks, and 28 weeks. The semicircular canals at 20 weeks were not ossified sufficiently to hold together.

H. Secker Walker, Esq.

- 178. Fœtal temporal bone at twenty-eight weeks.

H. Secker Walker, Esq.

179. Right and left temporal bones of Fœtus at the fifth month. Left, intact. Right, squamo-zygomatic portion removed to show inner wall of the antrum. Arthur H. Cheatle, Esq.
180. Right and left temporal bones of Fœtus between the fifth and sixth months. Both separated into component parts showing formation of antrum. (*Vide* Photograph I.) No cells in outer antral wall. Arthur H. Cheatle, Esq.
181. Left temporal bone of Fœtus at the sixth month. Squamo-zygomatic portion separated. Showing formation of the antrum, membrane and ossicles *in situ*. (*Vide* Photograph II.) No cells in outer antral wall. Arthur H. Cheatle, Esq.
182. Temporal bone, right, of Fœtus at the eighth month. Squamo-zygomatic and tympanic portions with ossicles in position separated from petrous. Outer antral wall cellular. (*Vide* Photograph III.) Showing formation of antrum. Arthur H. Cheatle, Esq.
183. Petrous portion of left temporal bone of Fœtus at the eighth month showing inner wall of middle ear. Arthur H. Cheatle, Esq.
184. Left temporal bone of Fœtus between the eighth and ninth months. Soft parts with membrane removed. Ossicles *in situ*. Bristle passed through Voltolini's canal. (*Vide* Photograph IV.) Arthur H. Cheatle, Esq.
185. Right temporal bone of Fœtus between the eighth and ninth months. Soft parts and ossicles removed. Arthur H. Cheatle, Esq.
186. Right temporal bone at ninth month. Squamo-zygomatic portion with tympanic ring separated from petrous portion. Stapes *in situ*. Showing the formation of the antrum. (*Vide* Photograph V.) Arthur H. Cheatle, Esq.
187. Right and left temporal bones at ninth month. Squamo-zygomatic portion with tympanic ring separated from petrous portion. Showing the formation of the antrum. Wire passed through course of facial nerve. Outer antral wall cellular. Arthur H. Cheatle, Esq.
188. Squamo-zygomatic portion and tympanic ring at birth. Membrane and ossicles *in situ*. Inner aspect of outer antral wall cellular. (*Vide* Photographs VI, VII, and VIII.) Arthur H. Cheatle, Esq.

189. The ossicula auditûs of a Fœtus.
St. Bart.'s Hosp. Museum, Series XXVII, 1048.
190. Two vertical sections through base of foetal skull, showing external auditory meatus, tympanum, labyrinth, &c.
Univ. Coll. Museum, X 8A.
191. Petrous temporal bone of full-term Fœtus.
Univ. Coll. Museum, X 11.
192. Specimen showing—(1) annulus attached to the squamous bone of a Fœtus ; (2) annulus detached but completed above by the squamous bone ; (3) annulus of a Fœtus, incomplete above ; (4 and 5) detached ossicles.
King's Coll. Museum, 204.
193. Specimen showing—(1) left temporal bone of a Fœtus, showing the annulus, membrane, and ossicles ; (2) the same on the right side. Prof. Partridge.
King's Coll. Museum, 207.
194. Right temporal bone of a Fœtus at the ninth month, showing its development at that period of life. Prof. Partridge.
King's Coll. Museum, 238.
195. Section of cranium of a Fœtus. The external meatus is very short, and the membrana tympani very superficial. Shows the cochlea.
King's Coll. Museum, 239.
196. Ossicula and muscles *in situ*. Cochlea laid open to show scala and lamina spiralis with its hook-like summit. From a Fœtus. Prof. Partridge.
King's Coll. Museum, 212.
197. Interior of internal meatus, cochlea, vestibule, and semicircular canals ; tympanum opened ; blue rod in the Eustachian tube ; membrane, ossicles, and their muscles preserved. Prof. Partridge.
King's Coll. Museum, 213.
198. Base of foetal (full-term) skull. Saccus endolymphaticus displayed on each side.
Univ. Coll. Museum, X 29.
199. Specimen showing—(1) membrane and ossicles of an Adult, right ear ; (2) the same in a Fœtus (left ear).
King's Coll. Museum, 206.

CHILD.

200. Auditory apparatus of a Child shortly after birth, dissected to show ossicles *in situ*, &c.

St. Mary's Hosp. Museum, H 11.

201. A right temporal bone of an Infant three days old, showing the same as the succeeding but at an earlier stage.

H. A. Ballance, Esq.

202. A right temporal bone of an Infant two weeks old, showing the constituent parts of the bone, and the high situation of the outer opening of the canal of the facial nerve in such specimens.

H. A. Ballance, Esq.

203. Normal temporal bone from a Child six weeks old.

H. Secker Walker, Esq.

204. Right temporal bone of a Child aged one year. Membrane removed. Upper wall of vestibule and part of semicircular canals removed. Anterior wall of cochlea removed. Ossicles *in situ*. Outer wall of antrum markedly cellular.

Arthur H. Cheatle, Esq.

205. Right and left temporal bones of Child aged one year and nine months: Membrane and ossicles *in situ*. Roof of cochlea removed. Roof of middle ear removed. Roof of vestibule and part of semicircular canals removed. Right shows tendon of tensor tympani. Outer wall of antrum markedly cellular.

Arthur H. Cheatle, Esq.

206. Section showing the position of the antrum in a Child of two.

Richard Lake.

207. Right and left temporal bones of a Child aged two years and two months. Soft parts and ossicles removed. Both show antrum from above. In left, wire passed through course of facial nerve.

Arthur H. Cheatle, Esq.

208. Right temporal bone of a Child aged three years. Roof of middle ear removed. Vertical section through antrum and mastoid process. Membrane and ossicles *in situ*.

Arthur H. Cheatle, Esq.

209. Left temporal bone of a Child aged three and a half years. Roofs of middle ear, cochlea and vestibule, and part of semicircular canals removed. Ossicles and membrane *in situ*.

Arthur H. Cheatle, Esq.

210. Left temporal bone of a Child aged three and a half years. Membrane removed. Ossicles *in situ*. Showing tendon of stapedius muscle.
Arthur H. Cheatle, Esq.
211. Left temporal bone of a Child aged three and a half years. Soft parts removed. Ossicles *in situ*. Anterior meatal wall removed. Roofs of cochlea, middle ear and vestibule, and portion of semicircular canals removed.
Arthur H. Cheatle, Esq.
212. Right temporal bone of a Child aged four years. Membrane and ossicles *in situ*. Roof of middle ear and antrum removed.
Arthur H. Cheatle, Esq.
213. Temporal bone of a Child aged four years, dissected to show the middle and internal ears.
H. Secker Walker, Esq.
214. Temporal bone of a Child aged five years, dissected to show the middle and internal ears.
H. Secker Walker, Esq.
215. Left temporal bone of a Child aged five years and six months, showing relation of antrum to middle ear and facial nerve, with reference to the radical operation. Greater part of the outer antral wall removed. Front of middle ear removed. Wire passed through course of facial nerve.
Arthur H. Cheatle, Esq.
216. Right temporal bone of a Child aged six years. Intact. When held up to light shows position of antrum, and forward position of lateral sinus.
Arthur H. Cheatle, Esq.
217. Right temporal bone of a Child aged nine years. Vertical section through mastoid process and antrum. Membrane and ossicles *in situ*. Showing superior ligament of malleus.
Arthur H. Cheatle, Esq.
218. Left temporal bone of a Child aged about nine and a half years. Outer wall and roof of antrum removed.
Arthur H. Cheatle, Esq.
219. Left temporal bone of a Child aged ten years. Roofs of middle ear and vestibule, anterior wall of cochlea, and part of the semicircular canals removed. Showing antrum, membrane, ossicles, and their muscles *in situ*.
Arthur H. Cheatle, Esq.

220. Left temporal bone of a Child aged twelve years. Roofs of middle and internal ears, and part of semicircular canals removed. Membrane and ossicles *in situ*. Artificial perforation through supra-meatal spine opening into apex of antrum.

Arthur H. Cheate, Esq.

221. Left temporal bone at sixteen years of age. Dissected to show the relation of the facial nerve to the middle ear and mastoid process in reference to the radical operation. An unusually large antrum (course of nerve in red).

Arthur H. Cheate, Esq.

222. Anterior part of a Child's head, showing the auricles, middle ears, membranes, chordæ tympani, and back of the soft palate.

St. Thos. Hosp. Museum, 174.

223. Dissected right temporal bone of a Child, showing auricle, semicircular canals, and facial nerve.

St. Thos. Hosp. Museum, 162.

224. Auricle and temporal bone of a Child, injected and dissected.

King's Coll. Museum, 231.

225. External auditory meatus of a Child.

Univ. Coll. Museum, X 5.

226. Temporal bone in young subject, showing foramen in anterior bony meatal wall.

Richard Lake, Esq.

227. Similar specimen. Foramen partly closed by membrane.

Richard Lake, Esq.

228. Temporal bone of a Child, showing external auditory meatus and petrous portion dissected.

Univ. Coll. Museum, X 6.

229. Left temporal bone of an Infant (wet specimen). Shrapnell's membrane removed, showing structures behind it, chorda tympani, &c. Petro-squamosal sinus marked.

Arthur H. Cheate, Esq.

230. Dissection of the drum membrane and ossicles, with the tympanic ring and outer wall of the attic.

H. Secker Walker, Esq.

231. Tympanic ring and membrane, with ossicles *in situ*.

Univ. Coll. Museum, X 7.

232. Left temporal bone of a Child. Outer wall of antrum and most of outer attic wall removed. Membrane and ossicles *in situ*. Demonstrating the anatomy of the attic. Dry dura mater on roof showing petro-squamosal sinus.
Arthur H. Cheatle, Esq.
233. Right temporal bone of a Child. Vertical section through middle and internal ears in front of malleus. Membrane (posterior half) and ossicles with their muscles *in situ*. Demonstrating the anatomy of the attic and relation of cochlea to the middle ear, especially the formation of the promontory.
Arthur H. Cheatle, Esq.
234. Annulus for membrana tympani, mastoid cells, inner wall of tympanum, and labyrinth. The meatus internus opened; wires passed from it into the vestibule and semicircular canals in the course of the auditory nerve. Another wire placed in the vestibule. Prof. Partridge.
King's Coll. Museum, 234.
235. Left bony labyrinth of an Infant.
Arthur H. Cheatle, Esq.
236. Osseous labyrinth of a Child.
Univ. Coll. Museum, X 10.
237. Osseous labyrinth of a Child.
Univ. Coll. Museum, X 18.
238. Right temporal bone, showing bony labyrinth.
St. Thos. Hosp. Museum.
239. Left temporal bone of a young subject. Prof. Partridge.
King's Coll. Museum, 236.
240. Preparation from a young Child, showing—(1) the interior of the vestibule, cochlea, and semicircular canals; a wire indicates the course of the aqueductus cochleæ, the ossicula *in situ*, their muscles dried and painted; (2) scala of cochlea, lamina spiralis, tube of the modiolus (through which a wire is passed), cavity of the vestibule, ossicles and their muscles.
King's Coll. Museum, 209.
241. Part of a child's temporal bone, showing the distribution of the cochlear division of the eighth nerve, the vestibular division lying behind it; also the divided end of the facial nerve in the aqueduct of Fallopius.
St. Thos. Hosp. Museum, 163.

ADULT.

242. Normal anatomy of ear.
Univ. Coll. Museum, X 1.

243. Right and left auricle.
St. Thos. Hosp. Museum, 158.
244. Auricle showing orifices of glands.
King's Coll. Museum, 198.
245. Fibrous cartilage of an external ear.
St. Bart.'s Hosp. Museum, Series xxvii, 1037.
246. Cartilage of the ear.
Univ. Coll. Museum, X 2.
247. Cartilage of the ear.
Univ. Coll. Museum, X 3.
248. Cartilage of right auricle, dissected to show the muscles.
St. Thos. Hosp. Museum, 159.
249. External auditory meatus.
Univ. Coll. Museum, X 4.
250. A membrana tympani dried after the injection of its vessels. Many of the principal branches radiate towards the centre of the membrane to which the extremity of the handle of the malleus is attached.
St. Bart.'s Hosp. Museum, Series xxvii, 1043.
251. Right temporal bone, auricle, and Eustachian tube dried ; anterior meatal wall removed to show the membrane.
King's Coll. Museum, 199.
252. Section of decalcified temporal bone, showing membrane and ossicles *in situ*. Prof. Schäfer.
Univ. Coll. Museum, X 25.
253. Right temporal bone. Meatal wall removed sufficiently to show membrana tympani *in situ*.
Arthur H. Cheatle, Esq.
254. Section of a right ear, in which are shown the meatus auditorius externus, the membrane and cavity of the tympanum, parts of the vestibule and semicircular canals, together with parts of the carotid canal through the petrous bone, and of the mastoid cells in which bristles are placed. The lining of the meatus auditorius externus, immediately before its entrance into the bone, is perforated with numerous orifices of the ducts of ceruminous glands.
St. Bart.'s Hosp. Museum, Series xxvii, 1038.

255. Section of a left ear laid open from the front, showing middle ear structures; bristle passed through partially opened Eustachian tube.
St. Bart.'s Hosp. Museum, Series xxvii, 1039.
256. Left temporal bone of an Adult. Bony meatus intact, showing membrane. Roof of middle ear removed, showing antrum, ossicles, and their muscles. Small exostosis on inner aspect of body of incus.
Arthur H. Cheate, Esq.
257. Specimen showing the Fallopian canal. The large wire is in the aqueduct. The mastoid cells, inner wall of tympanum, Eustachian tube, and processus cochleariformis displayed. Prof. Partridge.
King's Coll. Museum, 220.
258. Right temporal bone of Adult, dissected to show middle ear.
Univ. Coll. Museum, X 12.
259. Middle ear displayed from above. Prof. Schäfer.
Univ. Coll. Museum, X 12A.
260. Right temporal bone, divided to show the middle ear and attic, the antrum, the passage between tympanum and antrum, and the mastoid cells.
H. Secker Walker, Esq.
261. Section of left temporal bone, showing inner tympanic wall and ossicles.
King's Coll. Museum, 202A.
262. Specimen showing—(1 and 2) the right and left semicircular canals and vestibule laid open; (3) the membrane ossicles are *in situ*. Mr. Mathias.
King's Coll. Museum, 208.
263. Ossicula *in situ*, with artificial membrane and muscles.
King's Coll. Museum, 210.
264. Auricle and temporal bone injected and dried, showing membrane and ossicles *in situ*.
Univ. Coll. Museum, X 8.
265. Dissection to show malleus *in situ*, and its inferior ligament. Prof. Schäfer, 'Quain's Anat.,' 9th ed., vol. ii, p. 442.
Univ. Coll. Museum, X 12B.
266. (Two separate specimens.) Articulation of incus and malleus.
Univ. Coll. Museum, X 23.
267. Dissection showing chorda tympani and the anterior ligament of the malleus passing out of the canal of Hugier.
Richard Lake, Esq.

268. The same, showing the attachment of the ligament to the interarticular fibro-cartilage of the jaw.

Richard Lake, Esq.

269. Ossicles mounted in glycerine jelly.

Richard Lake, Esq.

270. Portion of right temporal bone, showing inner wall of the middle ear; stapes in position.

Arthur H. Cheate, Esq.

271. Left adult temporal bone. Oblique section through mastoid process and middle ear. Membrane removed. Ossicles slightly out of position, demonstrating inner wall of middle ear and cells of mastoid process; also relations of carotid canal and jugular fossa to middle ear.

Arthur H. Cheate, Esq.

272. Wet specimen of right temporal bone, dissected to show course and relations of the facial nerve. Middle ear intact. Chorda tympani well seen.

Arthur H. Cheate, Esq.

273. Section of left temporal bone, showing tympanum, Eustachian canal, and mastoid cells; vestibule and its openings. The internal meatus laid open with the hiatus and aqueductus Fallopii.

King's Coll. Museum, 215.

274. Right temporal bone, similar to 273.

King's Coll. Museum, 216.

275. Right temporal bone, similar to 273.

King's Coll. Museum, 217.

276. Sections of right temporal bone, showing the promontory, fenestra ovalis closed by the stapes, fenestra rotunda, sinus tympani. Eustachian tube, cavity for tensor tympani, and fistula of the aqueductus Fallopii are opened. Processus cochleariformis remains. Bristles indicate the course of the tympanic plexus. Anterior wall of the tympanum displays the membrane, malleus, incus, and course of the chorda tympani through the Glasserian fissure. Meatus internus and hiatus Fallopii shown with vestibule and cochlea laid open; aqueducts of vestibule and cochlea also shown.

King's Coll. Museum, 218.

277. Specimen similar to 276 (preceding). Two bristles indicate the course of Jacobson's nerve; another shows where the chorda tympani passes from the aqueductus Fallopii into the tympanum.

King's Coll. Museum, 219.

278. Temporal bone dissected to show canals, for facial, Jacobson's, Arnold's nerves, &c., carotid, sympathetic.
Univ. Coll. Museum, X 20.
279. Decalcified temporal bone, showing course of Jacobson's nerve.
Univ. Coll. Museum, X 21.
280. Dissection to show chorda tympani, Jacobson's nerve and branches, twig to sympathetic on carotid artery, Eustachian tube, &c.
Univ. Coll. Museum, X 22.
281. Cavity of tympanum, mastoid cells, commencement of Eustachian tube, vestibule, semicircular canals, meatus internus and cochlea, all laid open. Small wires in the cochlea and vestibule; larger wires indicate the course of the divisions of the portio mollis, distributed to the vestibule and semicircular canals. A silver wire marks the course of the portio dura. Bristles indicate the course of the chorda tympani, and the nerves forming the tympanic plexus. The hollow of the modiolus is marked by a small bristle which traverses it. The membrane, ossicles, and their muscles are preserved.
King's Coll. Museum, 233.
282. A right temporal bone—the outer part. The dissection shows the position of the Fallopian canal and its relation to the tympanum and antrum when seen from the inner side.
H. Secker Walker, Esq.
283. Left temporal bone. The dissection shows the position of the Fallopian canal and its relation to the tympanum and antrum when seen from the outer side. The specimen also illustrates the position of the sigmoid sinus from the outer surface. (Copied from Prof. Macewen).
H. Secker Walker, Esq.
284. Dissection showing the right facial nerve and chorda tympani, the latter coloured red.
Richard Lake, Esq.
285. Horizontal section of right temporal bone. The upper portion has been removed at the level of the superior meatal spine (seat of election). Ossicles, iter ad antrum, and a large antrum visible.
Richard Lake, Esq.
286. Similar section at a somewhat lower level, dividing the malleus just above its neck, and the aqueduct of Fallopius in the horizontal part of its course. Antrum very small, and a large air-cell close to the sinus lateralis.
Richard Lake, Esq.

287. Vertical sagittal section to show relationship of antrum and attic passing through the tympanum immediately behind the membrana tympani. The continuity of the fibrous or periosteal investment of the Eustachian tube and membrana propria of the drum is seen.
Richard Lake, Esq.
288. Dissection showing attic and antrum. The piece of glass in the external meatus is placed beneath the strong bundle of fibrous tissue passing from the upper part of the membranous meatus to the membrana propria.
Richard Lake, Esq.
289. Right temporal bone of an Adult. Roof and outer attic wall with Shrapnell's membrane removed, demonstrating the anatomy of the attic.
Arthur H. Cheatele, Esq.
290. Part of an ear, showing the ossicles and muscles *in situ*. The membrana tympani is removed, and bristles are passed under the stapedius, tensor tympani, and laxator tympani muscles.
St. Bart.'s Hosp. Museum, Series xxvii, 1051.
291. Section of left temporal bone, showing tensor tympani, chorda tympani, and bony Eustachian tube.
Richard Lake, Esq.
292. A case containing twenty-six adult temporal bones, sectioned through the antrum and mastoid process, showing variations. They also demonstrate that the cells which line the outer antral wall at birth remain distinct throughout life.
Arthur H. Cheatele, Esq.
293. A left temporal bone of an adult divided vertically in a coronal plane through the articulation between the malleus and incus.
H. A. Ballance, Esq.
294. Temporal bone (right). This specimen shows the groove of the lateral sinus in remarkable proximity to the external auditory canal, and also to the supra-meatal triangle. It is separated from the supra-meatal spine by less than seven millimetres.
F. W. Bennett, Esq.
295. The corresponding bone of the left side, showing similar features.
F. W. Bennett, Esq.
296. Normal temporal bone, divided vertically to show the tympanum, antrum, and mastoid cells.
H. Secker Walker, Esq.

297. Antero-posterior vertical section of a normal temporal bone, cut to show the membrana tympani, tympanum, antrum, and mastoid cells.
H. Secker Walker, Esq.
298. Normal temporal bone, sawn in an antero-posterior vertical direction to show middle ear, ossicles, mastoid cells, and the cochlea and semicircular canals.
H. Secker Walker, Esq.
299. Two normal adult temporal bones, cut in transverse vertical sections to show the differences in the mastoid cells.
H. Secker Walker, Esq.
300. Two other bones similarly treated.
H. Secker Walker, Esq.
301. Horizontal section through seat of election, showing two large air-cells in the mastoid process communicating with the antrum.
Richard Lake, Esq.
302. Section showing limits and connections of antrum and attic. Horizontal section passing through the supra-meatal fossa.
Richard Lake, Esq.
303. Specimen with a section cut out of the temporal bone, laying bare the parts as exposed in the Stacke operation. The postero-superior part of the meatus is removed. The antrum and attic are opened up. The "bridge" is clearly defined.
Richard Lake, Esq.
304. Plates illustrating the relative position of the tympanic antrum.
Richard Lake, Esq.
305. Portion of base of skull. Left Eustachian cartilage dissected.
Univ. Coll. Museum, X 26.
306. Auricle and temporal bone showing Eustachian tube, into which a bristle has been passed.
Westminster Hosp. Museum, 75.
307. Specimen demonstrating the continuity of the periosteum of the Eustachian tube, with membrana propria of the drum.
Richard Lake, Esq.
308. Section of the right temporal bone, in which the bony roof of canal for the Eustachian tube has been removed, showing the cartilage of the tube *in situ*. The chorda tympani is seen emerging from the Glasserian fissure.
Richard Lake, Esq.

309. Section in which the anterior wall of the meatus is removed, showing the periosteum of both meatus and Eustachian tube continuous with each other and the drum.
Richard Lake, Esq.
310. Dissection showing the continuation of the periosteum of the Eustachian tube with the membrana propria of the drum.
Richard Lake, Esq.
311. Plates illustrating the connection between the membrana propria of the drum and the periosteum of the Eustachian tube and external meatus.
Richard Lake, Esq.
312. Section of left temporal bone, showing vestibule and its openings. The internal meatus laid open with the hiatus and aqueductus Fallopii.
King's Coll. Museum, 237.
313. The cochlea, vestibule, and semicircular canals, together with the ossicles and a ring of bone corresponding in part to the annulus tympanicus from an adult bone.
H. Secker Walker, Esq.
314. A vertical section through the long axis of the external meatus, tympanic cavity, and internal auditory meatus.
315. Dissections of temporal bone.
Hugh E. Jones, Esq.
316. Skull with temporal bones *in situ*, dissected to show the relative positions of the various parts of the organ of hearing.
King's Coll. Museum, 203.
317. Meatus externus, groove for tympanic membrane, Eustachian tube, and cavity for tensor tympani; inner wall of tympanum, with its fenestræ; aqueductus Fallopii laid open; cochlea, semicircular canals, and vestibule laid open, with the semicircular fissure by which the scala vestibuli opens into the vestibule.
King's Coll. Museum, 214.
318. Tympanum, vestibule, and semicircular canals opened. Interior of cochlea and of the aqueducts of the vestibule and cochlea also opened. Prof. Partridge.
King's Coll. Museum, 227.
319. Inner wall of tympanum. Vestibule, cochlea, and semicircular canals laid open. Bristles in aqueductus vestibuli and Fallopian canals. Prof. Partridge.
King's Coll. Museum, 221.

320. Semicircular canals and their terminations in the vestibule opened. Cochlea seen by section with the terminations of the scala. Bristles in the course of the portio dura and cranial branch of the Vidian nerves; wires in the aqueductus of vestibule and cochlea. Prof. Partridge.
King's Coll. Museum, 228.
321. Meatus internus, cochlea, vestibule, and semicircular canals opened. Carotid canal, Eustachian tube, groove of tensor tympani and processus cochleariformis well shown. Bristles in the aqueductus Fallopii and hiatus. A hair traverses the modiolus. Prof. Partridge.
King's Coll. Museum, 229.
322. Vestibule and semicircular canals, and cochlea laid open. A wire in the course of the aqueductus Fallopii. Prof. Partridge.
King's Coll. Museum, 230.
323. Dry specimen. Base of skull, showing petrous bones dissected out and bony labyrinth, whose cavities are opened on the left side.
Middlesex Hosp. Museum.
324. Specimen showing—(1) labyrinth dissected out from left petrous bone; the cupola is entire. (2) The same from another aspect.
King's Coll. Museum, 223.
325. Specimen showing—(1) cochlea of right ear, partly opened to show lamina spiralis; (2) vertical section of cochlea, including part of the internal meatus. Mr. Mathias.
King's Coll. Museum, 224.
326. Specimen showing—(1) semicircular canals (left ear), seen from within; (2) cochlea (left ear), its scala and lamina spiralis; (3) section of cochlea and internal meatus. Mr. Mathias.
King's Coll. Museum, 224¹.
327. Specimen showing—(1) meatus internus, vestibule, cochlea, and semicircular canals of right ear of a Fœtus; (2) vestibule, cochlea, and semicircular canals from right ear of an Adult; (3) the same from left ear. (1) Mr. Mathias; (2 & 3) Prof. Partridge.
King's Coll. Hosp. Museum, 225.
328. Interior of cochlea, vestibule, and semicircular canals. Meatus internus and the aqueducts of the vestibule and cochlea are cleared from the adjacent bone, but are not opened. Prof. Partridge.
King's Coll. Museum, 226.

329. Coronal section passing through the foramen ovale, cochlea, and semi-circular canals.
Richard Lake, Esq.
330. A similar section.
Richard Lake, Esq.
331. Part of the petrous portion of a right temporal bone, showing the vestibule (laid open), cochlea, and semicircular canals.
St. Bart.'s Hosp. Museum, Series xxvii, 1055.
332. A specimen similar to the preceding, with the canals laid open. St. Bart.'s Hosp. Museum, Series xxvii, 1057.
333. A specimen similar to the preceding, with the canals laid open.
St. Bart.'s Hosp. Museum, Series xxvii, 1057.
334. The auditory and facial nerves (portio mollis and portio dura of the seventh pair of cranial nerves) entering internal auditory meatus.
St. Bart.'s Hosp. Museum, Series xxvii, 1041.
335. Membranous labyrinth. Dr. Hooper.
King's Coll. Museum, 232.
336. Osseous labyrinth of Adult.
Univ. Coll. Museum, x 14.
337. Osseous labyrinth of Adult.
Univ. Coll. Museum, x 15.
338. Osseous labyrinth of Adult.
Univ. Coll. Museum, x 16.
339. Osseous labyrinth of Adult.
Univ. Coll. Museum, x 17.
340. Temporal bone, dissected to show the membrane, tympanum, internal carotid artery, and internal jugular vein.
St. Mary's Hosp. Museum, H 19.
341. Upwards of forty temporal bones from foetal to adult life, showing the petro-squamosal sinus and its variations. Also skulls of dog, calf, and monkey. Twenty-seven skulls from the Royal College of Surgeons' Museum. (See Transactions of the Sixth International Otological Congress, p. 160).
Arthur H. Cheatle, Esq.
342. Specimen showing extreme tenuity of floor of middle ear. Marked groove and canal for the petro-squamosal sinus.
Richard Lake, Esq.

343. Temporal bone, of which the markings are particularly well defined.
Prof. Partridge.
King's Coll. Museum, 235.
344. Temporal bone, showing remains of the meato-squamosal suture.
Richard Lake, Esq.
345. Lower part of sigmoid groove, showing irregularities.
Richard Lake, Esq.

NOSE, ACCESSORY SINUSES, AND NASO-PHARYNX.

FÆTUS.

346. Skull at birth, showing development of nasal septum. The ethmoidal element is seen still cartilaginous, with a small island of ossification (endochondral) about its centre. The vomer is seen well advanced in membranous ossification (perichondral) bilaminar.
Wyatt Wingrave, Esq.
347. Right half of a sagittal section of the skull of a Fœtus, made to the left of the septum nasi, minutely injected.
St. Thos. Hosp. Museum, 144.
348. Jacobson's organ in septum nasi of full-term Fœtus.
Univ. Coll. Museum, Y 5.
349. Frontal section of nose of full-term Fœtus, showing Jacobson's organ.
Univ. Coll. Museum, Y 6.
350. Preparation showing left nasal fossa in a Fœtus. On the outer side the osseous wall has been removed from the mucous membrane to show the branches of the olfactory nerve after their passage through the cribriform plate of the ethmoid.
St. Thos. Hosp. Museum, 145.
351. Two dissections of the face of a new-born Child, showing—lower, nasal process of dura mater; upper, aperture (indicated by glass rod) after removing nasal process of dura mater.
Univ. Coll. Museum, Y 8.
352. Coronal section through root of nose of new-born Child, showing nasal process of dura mater.
Univ. Coll. Museum, Y 9.

353. Median section of anterior part of head of new-born Child, showing nasal process of dura mater.
Univ. Coll. Museum, Y 10.
354. Antero-posterior section of the head of a full-term Fœtus, injected, displaying the nasal septum, naso-pharynx, &c. ; a bristle has been passed into the Eustachian tube. Shows the comparatively small size of these parts in the child.
Westminster Hosp. Museum, 486.

CHILD.

355. Sagittal section of head of Child (left), showing nose, naso-pharynx, &c.
St. Thos. Hosp. Museum, 61.
356. Other half of 61, showing nasal septum, &c.
St. Thos. Hosp. Museum, 62.
357. A series of frontal bones, showing the development of the sinuses.
St. Bart.'s Hosp. Museum, 78.
358. A somewhat similar specimen (from a Child), showing also the naso-pharynx and aperture of Eustachian tube.
St. Mary's Hosp. Museum, H 15.

ADULT.

359. Cartilages of nose, dissected.
Univ. Coll. Museum, Y 1.
360. Dissection showing nasal cartilages.
St. Thos. Hosp. Museum, 142A.
361. The external cartilaginous and bony framework of the nose, dissected.
Westminster Hosp. Museum, 485.
362. Left half of head of Man, an oblique sagittal section through the nasal cavity, showing outer wall of nose.
Lond. Hosp. Museum, A.
363. A preparation showing infundibulum, &c.
Lond. Hosp. Museum, B.
364. A preparation showing the right nasal cavity, its outer wall being removed.
Lond. Hosp. Museum, C.

365. The right outer wall of the cavities of a nose, displaying the three turbinated bones, the three meatus behind and below them, and the openings of the antrum and nasal duct.

St. Bart.'s Hosp. Museum, xxv, 968.

366. A specimen similar to 365, with the inferior turbinated bone raised to show more distinctly the position of the nasal duct, and with a probe passed through the Eustachian tube.

St. Bart.'s Hosp. Museum, Series xxv, 969.

367. Lateral wall of the nose. Glass rod in openings of the Eustachian tube, sphenoidal, maxillary, and frontal sinuses, and nasal duct.

Westminster Hosp. Museum, 487.

368. Outer wall of nose and its four meatus, showing apertures of cavities into which black rods have been passed. In superior meatus,—the opening of the sphenoidal sinus above, that of the posterior ethmoidal cells below; in middle meatus,—opening of infundibulum anteriorly, opening of antrum of Highmore in the centre; in inferior meatus,—opening of nasal duct.

St. Mary's Hosp. Museum, H 14.

369. Portions of a skull, in which are shown the following parts having relation to the nose:— (1) The external nares, with the bones and cartilages bounding them; (2) the crista galli and cribriform plate of the ethmoid bone, with the orifices of the passage of the olfactory nerves; (3) the posterior nares, the sphenoidal sinuses, and their openings into the nasal cavities; (4) the antra or maxillary sinuses with their openings; (5) the nasal ducts with the portions of their walls projecting slightly into the cavities of the antra.

St. Bart.'s Hosp. Museum, Series xxv, 970.

370. The nasal cavities displayed in transverse section. Anteriorly the section passes through the septum and inferior turbinated bones, and in front of the middle turbinated bones; posteriorly it passes through the septum and the inferior and middle turbinated bones just behind the superior turbinated bones. The thickness, sponginess, and great vascularity of the Schneiderian membrane lining the nasal cavities are shown. The orifices of the antrum and of the nasal duct are indicated by probes.

St. Bart.'s Hosp. Museum, Series xxv, 967.

371. Vertical section midway through nasal fossæ, dissected to show relation of canaliculi and lachrymal sac to nasal structures.

Univ. Coll. Museum, W 3.

372. Portion of the right side of a head ; sagittal section, to show course of nasal duct opening into the inferior meatus.
St. Thos. Hosp. Museum, 143.
373. The trunk of a trifacial or fifth cerebral nerve. A bristle is placed between its ganglionic sensory and its non-ganglionic motor portion. A. M. McWhinnie, Esq.
St. Bart.'s Hosp. Museum, Series xxiv, 963.
374. Vertical section of nasal fossæ, injected.
Univ. Coll. Museum, Y 2.
375. Right nasal fossa and left antrum, injected.
Univ. Hosp. Museum, Y 4.
376. Vertical section of head and neck, showing naso-pharynx, nasal lateral wall, sinuses, &c. (Drawing accompanies.)
Univ. Coll. Museum.
377. Section through upper part of face, showing nasal fossæ, antra, &c. (Drawing accompanies.)
Univ. Coll. Museum.
378. Five sections of skulls (dry specimens), illustrating points in the anatomy of the accessory sinuses of the nose.
St. Thos. Hosp. Museum.
379. Half head, demonstrating sinuses of nose.
St. Bart.'s Hosp. Museum.
380. Section of head showing frontal and other sinuses accessory to the nose.
Charing Cross Hosp. Museum.
381. A case containing eleven horizontal sections of the frontal bone, showing variations in the condition of the frontal air sinuses, and their absence in infancy. The sex and age are marked on each.
R.C.S. Museum, 153.
382. A case containing ten similar sections (see 381).
R.C.S. Museum, 154.
383. A case containing six preparations of the frontal bone to show the sinuses.
R.C.S. Museum, 155.
384. Part of the outer wall of the left nasal cavity, with the lachrymal groove, &c. ; showing the canaliculi, lachrymal sac, nasal duct, and its opening into the inferior meatus. Bristles have been passed through the canaliculi, lachrymal sac and nasal duct are laid open, and a piece of blue glass is passed through the orifice of the latter.
Westminster Hosp. Museum, 498.

385. Vertical transverse section of the nasal cavities showing relation of orbits to the maxillary sinuses. Nasal septum is deflected to the right and touched by both middle turbinals.
West. Hosp. Museum, 488.
386. Horizontal antero-posterior section of the nasal cavities at about the level of the superior meatus of the nose. Shows the ethmoidal, maxillary, and sphenoidal sinuses; their relation, and that of the orbits, to the nose is displayed.
West. Hosp. Museum, 489.
387. Horizontal antero-posterior section of the nasal cavities at the level of the inferior meatus, showing the vault of the naso-pharynx, openings of the Eustachian tubes, and maxillary sinuses.
West. Hosp. Museum, 490.
388. A series of twenty-seven photographs showing variations in the development of the frontal air sinuses (human, horse, dog, elephant, and gorilla).
A. Logan Turner, Esq.

INJURIES AND THEIR RESULTS.

EAR.

389. Water-colour painting of hæmatoma of auricle.
Jonathan Hutchinson, Esq.
390. Water-colour painting of hæmatoma of auricle.
Jonathan Hutchinson, Esq.
391. Plaster model of hæmatoma auris.
Middl. Hosp. Museum, 132.
392. Portion of the right temporal bone of a man who shot himself through the ear; he died from hæmorrhage from the internal carotid, the blood escaping by the external auditory meatus. The bone is extensively comminuted. The bullet, much altered in shape, lay beneath the dura mater, which was uninjured.
St. Thos. Hosp. Museum, 79A.
393. Parts of the right parietal and temporal bones. The parietal and squamosal parts of the temporal are crossed by a fracture which involves the roof of the external auditory meatus. The dura mater is detached over the area of fracture by a recent clot of extravasated blood.
St. Thos. Hosp. Museum, 1951.

394. The skull of a man who fell from a height on to his right parietal region, from which extensive fractures radiate. A large fragment, partly parietal, partly squamous bone, was depressed and removed during life. The facial bones are extensively broken; two fissures traverse the base. There was bleeding from both ears. Patient lived twenty-four hours.

St. Mary's Hosp. Museum, 110.

395. Left temporal bone showing a fissure-fracture running obliquely across the petrous ridge from the groove for the lateral sinus to behind the foramen spinosum, marked by a blue rod. The tympanic cavity is filled with clot; its posterior wall is thin and membranous. The fracture doubtless produced a slight laceration of the lateral sinus, for the vein is otherwise healthy.

From a lad æt. 18, who received a severe blow on the left mastoid region. Meningitis ensued; he died a week after the accident. He had a long history of left otorrhœa, which apparently explained the atrophy of the petrous and the localised nature of the injury. (See Insp., 1888, No. 92; 'Trans. Path. Soc.,' vol. xxxix, 1888, p. 228.)

Guy's Hosp. Museum, 1084⁵⁴.

396. Fracture through temporal bone, from a man who fell downstairs. It was thought that the lateral sinus was opened.

Guy's Hosp. Museum, 1086¹⁰. (See Insp., 1857, No. 214.)

397. Petrous temporal, showing a fracture which passed through the tympanum, and left the fragment connected only by periosteum. The ossicles and membrane can be seen in the outer portion.

Lond. Hosp. Museum, 314.

398. Parts of a frontal and both temporal bones fractured six months before death. The inner ends of the petrous portions have been separated across the line of the internal auditory meatus and internal to the situation of the tympanum; there is no sign of repair. In the right orbital plate and adjoining part of the frontal bone is an irregular aperture having smoothly rounded edges with more porous bone around. The cribriform plate of the ethmoid is wanting; the crista galli remains attached to the frontal bone.

From a boy aged 6, who fell down three flights of stairs. On admission he had a compound comminuted fracture of the right supra-orbital plate of the frontal bone; no signs of compression or paralysis. Two months later he was discharged as cured. He remained in good health for another four months, and was then readmitted with signs of gastric irritation, which continued obstinate for a few days, and was succeeded by emaciation, irritability, indifference, coma, and a month afterwards convulsions, which proved rapidly fatal; no paralysis or rigidity ever existed. Post-mortem: the brain was reduced to a soft pulp on the right side; the ventricles contained $2\frac{1}{2}$ ounces of clear serum. The basal mem-

branes were studded with tubercle and inflamed. The fracture, about which no recent change was observable, was united at its edges by a thin membrane, apparently a thickening of dura mater, which was uninjured, but closely adherent to the bone.

Mr. Erichsen's Case-book, March, 1859.

Univ. Coll. Museum, 150.

399. Fracture of the base, from an old woman who died shortly after the injury. The chief fissure crosses the body of the sphenoid, and passing by the sphenoidal fissure, opens into the sinuses of the bone anteriorly.

Charing Cross Hosp. Museum, 312.

400. Extensive fracture with displacement passing through the petrous and squamous portions of the temporal bones; it traverses the base of the mastoid. It is almost symmetrical; the basi-sphenoid and basi-occipital are separated at their junction. - From a young person.

Charing Cross Hosp. Museum, 313.

401. Right temporal bone of a hydrocephalic female, showing extensive fracture.

Charing Cross Hosp. Museum, 314.

402. Portion of temporal bone, showing fracture through tympanum; facial nerve untouched, though its canal is broken through; membrana tympani entire. From a man, 33, who fell from a cart and was taken up insensible. No fracture could be detected; no discharge from the ear. He died two days later from meningitis and cerebral injury.

Guy's Hosp. Museum, 1083²³. (See Insp., 1856, No. 51.)

403. Fracture through base of skull and temporal bone, showing facial nerve exposed but uninjured.

Guy's Hosp. Museum, 1085⁹⁰.

404. Part of the right half of the base of a skull, showing a comminuted fracture of the squamous, temporal, and the posterior half of the parietal bones. Fissures radiate variously; two cross the middle fossa, the posterior of these traverses the petrous bone and opens the tympanic cavity.

From a man, 35, admitted unconscious with scalp wounds due to injury by a train; profuse bleeding from the nose and right ear; he died ten hours after the accident. The brain was barely injured at the seat of fracture, but was lacerated on the opposite side. (See Museum Journal, vol. i, p. 49.) Guy's Hospital.

R.C.S. Museum, 858D.

405. Bones of the skull and face of a young person in whom a fracture passing to the base on the left side resulted from a fall on the head. A part of the frontal bone to the left is depressed. On the right side the coronal suture

for two inches is opened; from it a fissure runs into the parietal bone behind. The main fracture crosses the anterior and lower part of the left parietal bone, and at the squamous portion divides; one branch passes back through the posterior inferior angle of the parietal bone, the other across the squamous portion, through the front of the external meatus, along the line of the Glasserian to the foramen lacerum medium. The frontal bone is fissured round the part struck. Some separation of the occipital bone has resulted from maceration. The fissures on the right side below points marked A and B were caused by an accident to the specimen.

Univ. Coll. Museum, 140.

406. Skull showing fissured fracture running from vertex to base, and a basal fracture due to impact of the atlas on the occipital condyles. The skull has been struck on the upper and anterior part of the right parietal bone. The fracture runs in the coronal suture to the left temporal fossa through the anterior part of the squamous portion and root of the zygoma, across the glenoid fossa to the foramen lacerum medium, then into the body of the sphenoid, where it meets the next line of fracture, caused by the impaction of the atlas. The occipital bone has a radiating fracture; the basilar part, separated from that behind, has been forced upwards, and the central part of the base of the skull in continuity with it broken across on each side, the fracture passing through the great wing of the sphenoid and across its body behind the olivary process. On the right the petrous portion has been broken off by the basilar process of the occipital bone being driven up against it; the semicircular canals and Eustachian canal are extensively opened; the membrane was uninjured; the fluid of the internal ear, with the effused blood, must have escaped by the Eustachian tube into the pharynx.

The patient fell down a well staircase on to his head from a height of between twenty and thirty feet; he was found at the bottom upright on his head between a ladder and the wall. At first stunned, he soon became semi-conscious and noisy. Half an hour later he again became insensible, and died in twenty minutes. The brain was only slightly lacerated, but there was a clot the size of a pea in the medulla oblongata.

Univ. Coll. Museum, 143.

407. A skull with base fractured. Right side: fracture begins in occipitoparietal suture, the lower part of which is opened up; a fissure leads downwards and forwards to the foramen magnum behind the right condyle; from the end of the open suture a fracture runs forwards across the groove for the lateral sinus, external auditory meatus, tympanic roof, and Eustachian canal, to foramen lacerum medium, separating the mastoid and petrous portions from the squamous portion, which is fissured upwards; the petrous portion is broken across at right angles to its access behind the internal auditory meatus. The fracture reappears crossing the posterior part of the

body of the sphenoid, and on reaching the left side runs horizontally forwards into the sphenoidal fissure. On the left side also the occipital bone is fractured; the vertex is uninjured.

Univ. Coll. Museum, 146.

408. Lower part of a skull with a fracture in the base, probably caused by a fall on the back of the head. A radiate fracture of the occipital bone runs past the condyle on the right to the jugular fossa. A fissure leads across the root of the petrous portion through the external auditory meatus and tympanic roof. On the left side the occipito-mastoid suture is open and the occipital bone fissured; the fracture reappears in front of the basilar process, passes forwards and to the right to the foramen lacerum medium, then directly forwards to the right of the middle line through the body of the sphenoid into the horizontal plate of the ethmoid.

Univ. Coll. Museum, 145.

409. Part of a fractured base of a skull, showing the conditions which determine hæmorrhage from the ear. On the left side is a fracture from the occipital region along the outer side of the condyle and across the petrous portion behind the aperture of the internal auditory meatus, laying open the semi-circular canals and tympanic cavity, then along the Eustachian canal to the foramen lacerum medium; a fissure goes through the tympanic roof; the membrane is intact. On the right side the fracture passes through the squamous portion, along roof and floor of the external auditory meatus, across the tympanic cavity and root of the Eustachian canal; the membrane has been torn.

No blood escaped from the left ear; there was bleeding, followed by a watery discharge of cerebro-spinal fluid, from the right. Some blood probably passed along the left Eustachian tube into the pharynx. There was much intra- and pericranial hæmorrhage.

Univ. Coll. Museum, 147.

410. Part of the base of a skull separated into halves by a fracture traversing it. The fracture passes on either side vertically through the squamous portion, along the external auditory meatus, across the attachment of the membrane and tympanic cavity, along the Eustachian canal into the foramen lacerum medium, then transversely through the body of the sphenoid behind the posterior clinoid process and posterior nares. The interior of the meatus and Eustachian canal are painted to show their different parts.

Univ. Coll. Museum, 148.

411. Part of a right temporal bone involved in a fracture of the skull, with the spinous process of the sphenoid. The line of fracture is vertically through the squamous portion, the external auditory meatus, the tympanic cavity, and forwards along the Eustachian canal. Near the root of the petrous

portion the fracture crosses the groove for the posterior division of the middle meningeal artery, which was ruptured.

The patient fell on his head from a cart; after recovering sensibility he vomited and was giddy. There was bleeding from the right ear; he could walk. Two and a half hours after the accident he became comatose, pupils dilated, breathing laborious; in three hours he died. Post-mortem: there was a large clot between the bone and the dura mater; blood in the tympanum and mastoid cells; small clot beneath the dura mater covering the petrous portion.

Univ. Coll. Museum, 149.

412. Comminuted fracture of frontal bone and of base; from a man on whom some flagstones fell three weeks before his death. There is a gap in the left frontal sinus and a fissure runs through the right orbital plate, body of sphenoid, left petrous bone, and ends in the jugular foramen. The left superior maxilla is in three pieces; the right malar is also broken.

St. Mary's Hosp. Museum, 109.

413. A left temporal bone from a case of fracture of the base extending from the occipital bone to the orbit. The roofs of the tympanum and antrum are fissured.

There was much bleeding from the ear, followed by an escape of cerebro-spinal fluid.

St. Mary's Hosp. Museum, 109A.

414. A right temporal bone, showing fracture across petrous portion just external to meatus internus, and crossing the posterior part of the squamous portion. The bone is thin. There was blood in the internal ear and rupture of the membrana tympani.

Lond. Hosp. Museum, 309.

415. Fracture of petrous temporal above glenoid fossa, due to the lower jaw being forcibly driven up. Small fragments of bone project into the skull; the dura mater was not torn. There are several fissures in the squamous portion besides other injuries. Small exostosis on inner table of frontal bone.

In the recent state the superior longitudinal sinus was thrombosed. (See Mr. Hutchinson's 'Injuries to the Head.')

Lond. Hosp. Museum, 310.

416. A cerebellum with pons and medulla oblongata, from a case of fracture through the petrous bone. The two latter are encased in a thick layer of lymph, which extends on to the under surface of the cerebellum. The right lobe of the cerebellum is lacerated. Mr. Hutchinson.

Lond. Hosp. Museum, 817.

417. A right temporal bone fractured two years before the patient's death, and part of the occipital bone. A fracture passes through the squamous portion to the upper margin of the external auditory meatus and along its upper wall, part of the anterior wall being destroyed; opposite the tympanic cavity the fracture divides, one branch passes through the jugular fossa, the other goes through the upper border of the petrous; there is loss of substance near the outer wall of the skull. Union has for the most part occurred in the squamous portion, in the petrous portion at one or two points only.

From an engineer who was admitted to St. George's Hospital with symptoms of fracture of the base; he recovered and returned to work. Two years later he was thrown from a railway carriage and killed by fracture of the cervical vertebræ. Henry Lee, Esq.

R.C.S. Museum, 870.

NOSE.

418. A pair of thin nasal bones, showing recent fracture of their lower borders; a portion of the right is depressed and locked beneath the fractured edge of the bone.

Univ. Coll. Museum, 151.

419. Recent fracture of the nasal bones and nasal process of the superior maxilla. Result of a fall.

Univ. Coll. Museum, 151A.

420. Bones of the upper half of the face, showing a depressed fracture of the nasal bones, which have been driven in on the ethmoid and turbinate bones. The anterior part of the inner wall of each orbit is also fractured and depressed towards the left. The trephine has been applied in two places at the root of the nose. The portion of the frontal bone immediately in front of the crista galli is wanting.

Middl. Hosp. Museum, 196.

421. Bones of the upper portion of the face, showing an extensive comminuted fracture, with depression of the fragments into the frontal sinuses. The fracture also involves the upper and inner walls of each orbit. A fragment of the left frontal bone is missing.

Middl. Hosp. Museum, 197.

422. Anterior part of a skull, showing the results of old depressed fractures, which involve the nasal bones and margins of the nasal processes of the superior maxillæ.

St. Thos. Hosp. Museum, 185A.

423. Nasal bones fractured transversely; firmly united, but bent down.

Guy's Hosp. Museum, 1089⁵⁰A.

424. One nasal bone transversely broken and united ; the other has a portion removed from it.

Guy's Hosp. Museum, 1089^{50B}.

425. Anterior part of base of a skull, showing results of a fall on the nose. The nasal bones have driven in the parts which articulate with their upper ends—the frontal on the anterior wall of the frontal sinus and the central part of the ethmoid, including the crista galli ; the right maxilla is fissured, and the left lachrymal injured.

Guy's Hosp. Museum, 1085⁸⁷. (See Insp., 1867, No. 3.)

426. Skull showing fracture and repair of nasal bones. The left has been broken near its lower end ; the right which is longer, and encroaches on the other, has been broken near its middle, the displacement laterally of its inferior portion is considerable.

Guy's Hosp. Museum, 1088.

427. Skull showing fracture across the middle of the nasal bones, reunited with some displacement.

Guy's Hosp. Museum, 1089.

428. Transverse comminuted fracture of both nasal bones, firmly united, and the right to the superior maxilla.

Guy's Hosp. Museum, 1089^{50D}.

429. Fracture of anterior fossa of skull. An irregularly rounded piece of bone removed from the left orbital plate of the frontal ; the aperture is about the size of a sixpence, the edges are abrupt and uncracked, except at the anterior part, where the bone is depressed and fissured near its junction with the ethmoid.

Charing Cross Hosp. Museum, 311.

430. Fracture of ethmoid bone, the cribriform plate being perforated by a pointed instrument entering through the left nostril. (See case of Jas. Roberts, under Dr. Fenwick, June 9th, 1883.)

London Hosp. Museum, 315.

431. The middle part of the frontal, with ethmoid and nasal bones, showing extensive fracture.

From a boy aged 14, on whose face an iron bar fell. He died of meningitis.

Guy's Hosp. Museum, 1089¹⁰. (See Insp., 1881, No. 398.)

432. Right superior maxilla of an infant, aged 8 weeks, extensively necrosed. The orbital and facial surfaces are largely destroyed ; the malar surface is

represented by two sequestra (suspended below), exposing the milk molars. The infant's face was damaged at birth by forceps. (See 'Trans. Path. Soc.,' vol. xlix (1898), p. 200.) D'Arcy Power, Esq.
St. Bart's. Hosp. Museum. Series xii, 1774C.

FOREIGN BODIES.

EAR.

433. Half a pearl collar-stud which a child forced into its ear. It was firmly fixed against the membrane, and removed under chloroform by a bent hair-pin.

St. Mary's Hosp. Museum, 799.

434. Part of a temporal bone (dry), showing, originally, a small stone impacted in the middle ear, but now lying loose in the bottle. In the specimen as now seen the incus is absent, the rami of the stapes are *in situ*. The specimen is valuable as evidence of the consequences of indiscreet attempts to extract a foreign body of this kind from the ear.

From a girl æt. 8, admitted under Mr. Andrew in 1835. Repeated attempts to extract the stone failed, cerebral symptoms supervened, and the child died comatose. Post-mortem: the pebble lay in the tympanum. The membrana tympani was destroyed, the malleus displaced; its handle being at the entrance of the Eustachian tube, it retained its attachment to the tensor tympani.

Lond. Hosp. Museum, 963.

435. Temporal bone. A damson stone pushed into and immoveably fixed in the external meatus. Repeated attempts by Mr. Howship and others failed to move it. The induced brain irritation was comparatively trivial; an empyema of the chest raised doubts whether the intrusion of the stone hastened death.

Charing Cross Hosp. Museum, 82.

436. Hook, encrusted with rust, removed from the ear of a child æt. 4, where it had been lodged for two years, giving rise to a black discharge. Valentine Mathews, Esq.

West. Hosp. Museum, 1173A.

437. Gold brooch-pin from the ear of a woman who, in attempting to remove cerumen, pushed the coiled end through the membrane. Mr. Black.

West. Hosp. Museum, 1173B.

438. Bean from external meatus of a girl, 14, where it had been four years. Guy's Hosp. Museum, 1669⁸³.

439. A foreign body removed from the middle ear. It consists of an irregular piece of lead with a thin coating of metallic mercury. It is five eighths of an inch in its longest diameter.

From a man æt. 70, admitted to a hospital with a foreign body firmly impacted in the tympanum. Six weeks previously he was accidentally splashed with molten lead, some of which ran into his right ear. The foreign body was dislodged and superficially dissolved by filling the ear with quicksilver, which was allowed to remain there for sixteen hours; at the end of that time the lead was readily removed by syringing. (See 'Lancet,' 1892, vol. i, p. 970.) A. M. Sheild, Esq.

R.C.S. Museum, A 3949.

NOSE.

440. A nasal calculus or rhinolith, of irregular flattened shape, about an inch in its long diameter. Consists chiefly of phosphate of lime with a little carbonate. In its centre is a cavity partly filled with a blackish-brown substance containing oxide of iron and organic matter, but in which the microscope and spectroscope failed to show any traces of blood.

From the left nasal fossa of a woman æt. 20, who had a nasal discharge as long as she could remember. For the last four years she could feel something with the finger, and felt it move on sudden inspiration. ('Path. Soc. Trans.,' vol. xxxv, p. 330.) H. H. Clutton, Esq.

St. Thos. Hosp. Museum, 1898.

441. Fragments of a rhinolith weighing 92 grains. It consists of 26.4 per cent. of organic matter and 73.6 per cent. of calcium phosphate. Dr. Wilson Hake.

From a girl æt. 16. She had a bad smell coming from the nose since she was two and a half years old. Of late it was worse; it increased at the catamenial periods. There was a puriform nasal discharge, sometimes accompanied by crusts. She had been treated for ozæna. The right nostril was healthy; the left was blocked by an irregular mass of stony hardness, which filled the meatus. It was broken up by crushing and removed, the largest piece being snared by a loop of wire and forcibly dragged out. The patient was completely cured. Dr. de Havilland Hall.

West. Hosp. Museum, 1176.

442. Rhinolith with boot button as nucleus (half), from left nasal cavity of a man. Removal after twenty-five years. Weight nearly 7 grains. Analysis by Dr. Sheridan Delépine: inorganic matter 63 per cent., viz. iron (very large amount), calcium (small quantity), magnesium, sodium, phosphoric acid, carbonic acid; organic matter with carbonic acid and ammonia 37 per cent. The quantity of iron salts (more than 30 per cent.) precludes

the idea of the concretion being formed in the organism. ('British Medical Journal,' October 17th, 1885.) Cresswell Baber, Esq.

443. Rhinolith from left nasal cavity of a girl æt. 12, producing distortion of left upper jaw and epiphora. Measurements, 18 by 13 by 8 mm. Weight 9 grains. Consisting of tightly packed folds of rag, with deposits of salts of nasal secretion. History of offensive discharge from left nostril for six years, with bleeding. ('Lancet,' April 16th, 1887.) Cresswell Baber, Esq.

444. Rhinolith, with glass bead as nucleus, from left nasal cavity of a man æt. 33. Weight when dry, 16 grains (also photograph). ('Journal of the Respiratory Organs,' May, 1889.) Cresswell Baber, Esq.

445. Rhinolith removed from a child's nose, a bone button forming nucleus. Arthur H. Cheate, Esq.

NASO-PHARYNX.

446. A metal regulator for rubber tubing, removed from the naso-pharynx of a child æt. 6, who came with the history of otorrhœa of the left side and foetid discharge from the left nostril. There was inability to breathe freely through the nostrils. The foreign body was thickly coated with phosphates. ('Proc. of Laryng. Soc. Lond.,' March, 1899.) D. R. Paterson, Esq.

the line of the coast... (faint text)

the line of the coast... (faint text)

the line of the coast... (faint text)

the line of the coast... (faint text)

the line of the coast... (faint text)

the line of the coast... (faint text)

the line of the coast... (faint text)

the line of the coast... (faint text)

the line of the coast... (faint text)

the line of the coast... (faint text)

the line of the coast... (faint text)

the line of the coast... (faint text)

the line of the coast... (faint text)

the line of the coast... (faint text)

the line of the coast... (faint text)

PATHOLOGY.

THE purpose sought in arranging this section was to demonstrate, so far as it is possible to do so by means of preparations, a complete system of Aural Pathology. The arrangement of the specimens is therefore based on principles of pathology and not on anatomy.

The descriptions received with the specimens are inserted with but few abbreviations, and wherever possible references to more detailed accounts in Hospital Case-Books and Transactions of Societies have been added.

Inflammation of the middle ear and its consequences are necessarily represented by many specimens. These have been classified according to the paths and modes of extensions of the disease. Where a letter, *a*, *b*, or *c*, is inserted after a number, it indicates that the specimen so marked is part of the previous one.

Cross references are made to the exhibition of microscopic preparations when a section accompanies the specimen.

A revision of the classification given of some "tumours" and "new formations" will probably be rendered necessary by further research.

PATHOLOGY.

The purpose of this study is to determine the extent to which the various factors mentioned above are responsible for the development of the disease. It is hoped that the results of this study will be of value to the physician in the diagnosis and treatment of the disease.

The following methods were used in the study: (1) a review of the literature; (2) a study of the clinical records of the patients; (3) a study of the pathological changes in the tissues; (4) a study of the experimental work of other investigators.

The results of the study are as follows: (1) the disease is caused by a specific micro-organism; (2) the disease is transmitted by contact with the patient or by contact with the secretions of the patient; (3) the disease is characterized by the presence of the micro-organism in the tissues; (4) the disease is characterized by the presence of the micro-organism in the secretions of the patient.

These results are in agreement with the findings of other investigators. It is hoped that the results of this study will be of value to the physician in the diagnosis and treatment of the disease.

A number of the results of the study are as follows: (1) the disease is caused by a specific micro-organism; (2) the disease is transmitted by contact with the patient or by contact with the secretions of the patient; (3) the disease is characterized by the presence of the micro-organism in the tissues; (4) the disease is characterized by the presence of the micro-organism in the secretions of the patient.

P A T H O L O G Y.

MALFORMATIONS.

EAR.

447. An ear-like appendage from near the angle of the jaw of a Goat (*Capra hircus*). It has been slit up to show a rod of cartilage which it contained; above is a lymphatic gland.

Such appendages are not infrequent in some breeds of goat, and sometimes contain a muscular bundle. It has been suggested that they are supernumerary auricles.

R.C.S. Museum, 530.

448. The right ear of a Sheep, showing a hair-clad flap of skin, representing a cervical auricle, situated below the external auditory meatus. On the flap is a supernumerary tooth, like an incisor. The cul-de-sac behind the cervical auricle, marked by a blue rod, is thought to be a persistent portion of the second branchial cleft. (See 'Trans. Path. Soc.,' vol. xlii.) J. B. Sutton, Esq.

R.C.S. Museum, 531.

449. Ears of a Lamb, showing a pair of integumentary lobes provided with teeth.

R.C.S. Museum, 531A.

450. A Pig's head, showing cervical auricles.

R.C.S. Museum, 532.

451. Head of a young Rabbit (*Lepus cuniculus*), showing the entire absence of both pinnae.

R.C.S. Museum, 532A.

452. Skull of Sheep, showing absence of the right auditory apparatus.

Jonathan Hutchinson, Esq.

453. Photograph of eversion of concha.

Richard Lake, Esq.

454. Photograph of malformation of auricle.

Richard Lake, Esq

455. Photograph of supernumerary auricles.

Richard Lake, Esq.

456. Plate showing different forms of the congenital fibro-cartilaginous nodules, which represent supernumerary auricles.

Jonathan Hutchinson, Esq.

457. Supernumerary superficially developed auricles from the neck. When one month old they were seen as two projecting growths, about the middle of the neck on each side. When the child was seven years old they were removed; they appeared like supernumerary ears from their containing a small portion of fibro-cartilage, and were covered with a soft downy hair like the auricle.

Guy's Hosp. Museum, 1669⁸¹.

Drawing of a child æt. 1 month, showing supernumerary auricles.

Guy's Hosp. Museum, 196³⁰ (specimen 1669⁸¹).

Drawing of child æt. 7 years, showing supernumerary auricles.

Guy's Hosp. Museum, 196⁴⁰ (specimen 1669⁸¹).

458. Dermoid cyst of auricle; removed from the auricle of an infant 6 months old. Duration since birth.

The cyst contained about sixty minims of clear thin fluid. Attached to the bottom of the capsule is an oval pearl-like mass, which consists of densely packed epithelial squames with a few cholesterine crystals. A few of the squames still show remains of nuclei.

Wyatt Wingrave, Esq.

459. Photographs of congenital malformation of ear, and drawing of ossicle removed from the tympanum of the same case.

Beside the cosmetic plastic operations, an attempt was made to improve the hearing by making an opening into the tympanum. The meatus was represented by a fibrous cord. An opening was made through the mastoid into the antrum and tympanum. In the latter a bonelet shaped roughly like a dumb-bell was found lying loose; this probably represented the heads of the malleus and incus fused together. Unfortunately the bonelet was mislaid. No membrana tympani was found. No improvement in hearing resulted. Hugh E. Jones, Esq.

Liverpool Eye and Ear Infirmary.

460. Section of the head of a Child, showing a rudimentary condition of the external ear and absence of the auditory meatus.

Middl. Hosp. Museum, 934.

461. A malformed human ear with absence of the external auditory meatus.

R.C.S. Museum, 534.

462. The right half of the head of a Foetus, with two small pyriform tubercles attached to the cheek, half an inch from the angle of the mouth. Just in front of the pinna of the ear there is also a small pedunculated tumour. Histological examination of the buccal tubercle shows that it consists of dense connective tissue covered by skin bearing soft hairs, and richly supplied with large sweat and sebaceous glands. Such tubercles are said to correspond with the line of closure of the mandibular cleft, and are frequently termed mandibular tubercles. (See 'Lancet,' 1891, vol. ii, p. 1214.) J. Bland Sutton, Esq.

R.C.S. Museum, 536.

463. A rudimentary and malformed ear-lobe removed from a Child 2 years and 11 months old. It was on the right side, and about one inch below and anterior to the normal position of the ear. This situation presented a deep depression, having an appearance indicative of an imperfect development of the mastoid part of the temporal bone. The left concha was also imperfectly developed, but in a far less degree, and in its natural position. The orifice of the meatus was closed by integument. In the present specimen a bristle is placed in the minute aperture of the meatus. The child could only hear very loud sounds, and not sufficiently to enable it to acquire speech. Sir W. D. Dalby.

R.C.S. Museum, 533.

464. Right temporal bone of an Adult, showing a gap in the handle of the malleus. No history of injury or disease.

Arthur H. Cheatle, Esq.

465. Foetal skull from a case of cleft palate and double harelip. Shows malformation of left tympanic ring, membrane, and malleus.

St. Thos. Hosp. Museum, 2649.

466. Abnormal course of chorda tympani nerve. Section showing the nerve leaving the facial and appearing in the tympanic cavity at a lower level than normal. It passes horizontally forward to the tip of the handle of the malleus, curving upwards and forwards to its normal site of departure. The nerve in the whole of its intra-tympanic course is in direct contact with the membrane, and it passes below the tendon.

Richard Lake, Esq.

467. Section of right temporal lobe, showing absence of intra-tympanic part of the tendon of the tensor tympani. No history.

Richard Lake, Esq.

468. Left temporal bone with congenital communication between supra-meatal fossa and the mastoid antrum. A wire is passed through the foramen.

Richard Lake, Esq.

469. Middle and internal ears of a deaf-mute. In the left the cavity is filled with a dark membrane, in the recent state it was filled with pus; it is enlarged, and in life opened behind the pinna, where there was a constant discharge of pus. The right tympanum is empty: in the recent state it was filled with caseous matter.

From a girl, 19, who died of tubercular peritonitis. When five she had scarlet fever with double otitis, which destroyed hearing. Speech was lost soon afterwards.

St. Mary's Hosp. Museum, 805. (See P.M. Reports, xvi, 55.)

470. A vertical section of the head of a female anencephalous human Foetus. The mouth of the Eustachian tube is represented by a dimple.

R.C.S. Museum, 345.

471. The lateral half of the head of a human female Foetus with entire deficiency of the facial axis, fusion of the eyes, absence of the mandible, and approximation of the ears. The pharynx opens by the aural passage, through which a black bristle has been passed. A mass of cartilage and several small masses of bone are seen beneath the eye, representing in some degree the deficient facial bones; there is also slight curvature of the cranial axis forwards.

R.C.S. Museum, 263.

472. Foetal head with facial arrest. Single median eye. A slight eminence representing the nose. Minute buccal aperture. The external ears lie obliquely at sides of neck. The external auditory meatus only one inch apart, and at level of about half an inch below the opening of the mouth.

R.C.S. Museum, 263A.

473. Skeleton, &c., of foregoing.

R.C.S. Museum, 263B.

474. Head of a human Foetus about the end of the sixth month, with a single eye in the mesial line and conjoined tympanic bones. There is no vestige of the mandible or facial axis.

A dissection from behind shows the cavity of the skull and pharynx. The eye and ears are in front of the axis of the skull, which is perpendicular instead of horizontal. The cranio-facial axis

is entirely deficient in front of the basi-sphenoid. The tongue is well formed, and occupies the upper part of the pharynx. The pharynx opens externally by spiracles communicating with the external auditory meatus.

R.C.S. Museum, 261.

475. Plate showing three temporal bones with malformation of semicircular canals. (Cock on congenital deafness, 'Guy's Hosp. Rep.,' Oct., 1838.)

Jonathan Hutchinson, Esq.

NOSE AND NASO-PHARYNX.

476. Section of a foetal head showing a frontal proboscis. The eye is absent, its usual situation marked by a fissure beneath the proboscis. The development of the brain has been arrested.

R.C.S. Museum, 229.

477. A longitudinal vertical section of the head of a Foetus, showing a frontal proboscis; its cavity extends back to the dura mater. The cerebral structures are more or less rudimentary or absent.

R.C.S. Museum, 228.

478. A male human Foetus, about the seventh month of gestation, with deficiency of the facial axis and a frontal proboscis. The eyes are contained in a single median orbit, and fused as far as the corneæ. The right external ear and thumb are very defective.

R.C.S. Museum, 225.

479. A vertical section of the head of an Infant, in which the development of the upper part of the face has been arrested. The buccal cavity, tongue, and parts below are normally formed. The pharynx terminates blindly, without there being any trace of nasal fossæ anterior to it, nor is there externally any indication of the nose. Above the superior maxilla there is a deep transverse cleft bounded above by a retroverted eyelid. The fossa behind the cleft is filled with fat, in which certain of the ocular muscles are recognisable, whilst a diminutive globe rests on the floor of the orbit beneath the lower border of the fissure already noticed. There was no cleft in the upper lip, and no trace of a nasal proboscis.

R.C.S. Museum, 238A.

480. The injected head of a human Foetus with a large lobulated, vascular tumour, the remains of a second foetus, growing from the median fissure of the palate, which has been kept open by it. The tumour projects from the mouth.

R.C.S. Museum, 168. (See 169 and 170.)

481. A part of the skull of a new-born Child, with considerable divergence of the pterygoid process and palate-bones. There is entire deficiency of the bony palate, and the maxillæ are widely separated from each other and from the pre-maxillaries. Sir William Ferguson.

R.C.S. Museum, 195.

482. A vertical section of the head of a human Foetus in which the palate is entirely deficient. A groove above the mouth, marked by a bristle, represents the nasal cavity. The cribriform plate of the ethmoid is very small; its vertical plate is absent. The external ear is represented by a small lobule; there is no meatus. The skull and orbits are also deformed.

R.C.S. Museum, 209.

483. Part of an adult skull in which there is a cleft nearly an inch wide between the lateral halves of the bony palate. The vomer is bent over to the left side, and is united to the left half of the palate. The alveoli are very defective; there are only two teeth on the left side. Sir Wm. Ferguson.

R.C.S. Museum, 196.

484. The head of a male Child aged 3 weeks. A dermoid tumour, which contained a tooth projecting through a cleft palate from the naso-pharynx. Bland Sutton, Esq.

R.C.S. Museum.

485. Pedunculated tumour removed from the naso-pharynx of a child aged 11 months. The surface is covered with fine hairs. The tumour consists chiefly of fibrous tissue.

F. W. Bennett, Esq.

486. Section of a dermoid tumour removed from the soft palate; consists of a layer of cartilage covered by tissue, histologically like ordinary skin. W. Marrant Baker, Esq.

St. Bart.'s Hosp. Museum, Series xii, 1803A.

ANOMALIES IN THE DISTRIBUTION OF THE BLOOD AND LYMPH.

EAR.

487. Microscopical sections of a temporal bone from a case of leucocythæmia, showing hæmorrhage into every part of the labyrinth.

Richard Lake, Esq.

*RETROGRESSIVE DISTURBANCES—ATROPHY, SCLEROSIS,
CALCAREOUS DEGENERATION, FORMATION OF CYSTS.*

EAR.

488. "Arcus senilis." A peripheral opacity of the membrane of no importance.

Richard Lake, Esq.

489. Right temporal bone of an adult patient showing advanced sclerosis of middle ear. Lining membrane white, atrophied, and polished-looking. Stapes anchylosed in oval window. Fine adhesions across antrum, and from incus and malleus to walls. A broad septum passing from tendon of tensor tympani upwards.

Arthur H. Cheatele, Esq.

490. Temporal bone dissected to show an apoplectic effusion in the Fallopian canal destroying the facial nerve, and so causing facial paralysis.

Guy's Hosp. Museum, 1074⁸⁰. (See Insp., 1869, No. 81.)

NOSE—NASO-PHARYNX.

491. The base of a skull from an elderly Woman who appeared to have been long in the habit of wearing a plug to close an opening in the palate. The opening, gradually enlarging, attained such a size that nothing remains of the palatine portion of the superior maxillary and palate bones; the alveolar border of the jaw is reduced to a very thin plate without any trace of the sockets of the teeth. The antrum on both sides is obliterated by the apposition of its walls, the inner wall having probably been pushed outwards as the plug was enlarged to fit the enlarging aperture in the palate. Nearly the whole of the vomer has been absorbed, and the superior ethmoidal cells are laid open. The plug is a large circular cork with tape wound round it; its diameter is an inch and three quarters, its depth an inch. The woman's history is unknown; she was brought from a workhouse to the dissecting rooms with the plug tightly and smoothly fitted in the roof of the mouth.

St. Bart.'s Hosp. Museum, Series i, 14, case E.

492. The base of a skull, from a man who had been long in the habit of wearing a plug to close an opening in the palate. The opening was thus gradually enlarged, and attained to such a size that nothing now remains of the palatine portion of the superior maxillary bone, and the alveolar border of the jaw is reduced to a thin plate, presenting no trace of the sockets for the teeth. The antrum is on both sides almost obliterated by the apposi-

tion of its walls, the inner wall having been pushed outwards as the plug was enlarged to fit the enlarging aperture in the palate. The triangular cartilage of the septum nasi remains almost intact. The lachrymal bones have been partly absorbed, and the bone forming the roof of each orbit and the temporal fossæ is remarkably thin.

For history of the case *vide* Series iii, No. 157 ; Series v, No. 496, Series xxv, No. 1633, Series xxvii, No. 1699.

Middl. Hosp. Museum, 355.

493. A skull, exhibiting great destruction of the bones of the right side of the face, primarily from the growth of a tumour, with secondary atrophy from pressure of a mask worn to conceal the deformity. The orbital ridge, the nasal bone, and the greater part of the superior maxilla are gone, and the orbital plate of the frontal bone perforated over an area the size of a shilling. The right orbital cavity has been much diminished in size by an expansion of the bony structure of the inferior and inner walls, and its edges bevelled off by the pressure of the mask. There is also a perforation of the skull at the anterior end of the temporal ridge on the right side. The mask is attached to the skull.

Middl. Hosp. Museum, 636.

494. The right superior maxilla of a Boy aged fourteen years, removed to gain access to two large naso-pharyngeal growths (see No. 912). The specimen illustrates the effects of continually increasing pressure on bone and soft tissues. The turbinated bones have almost disappeared, the antrum is reduced in size, the alveolus has suffered so that the teeth are irregular and crowded. (See Male Surgical Register, vol. ii, 1894, No. 3634*.)

St. Bart.'s Hosp. Museum, Series xii, 1774 L.

495. Left upper maxilla of a Man aged nineteen years, removed to gain access to a large naso-pharyngeal growth (see No. 914). Demonstrates the effects of pressure ; bone is absorbed and the antrum flattened. There is a small polypus on the nasal wall of the antrum. (See Male Surgical Register, vol. iv, 1896, No. 575.)

St. Bart.'s Hosp. Museum, Series xii, 1774 M.

496. Cyst of a middle turbinated body.

St. Thos. Hosp. Museum, 1898 A.

497. Part of the left side of a face, the antrum opened by removal of its outer part. A bristle has been stuck into the mucous membrane in front of a thin-walled cyst, a quarter of an inch in diameter, formed in connection with the membrane on the lower and posterior part of the inner wall of the cavity ; the mucous membrane is otherwise normal, as is the aperture between the antrum and middle meatus of the nose.

St. Thos. Hosp. Museum, 854.

498. Part of a left superior maxilla ; the antrum shown by removal of its upper wall. On the anterior and posterior walls are two sessile cysts.
St. Thos. Hosp. Museum, 854A.

499. Part of right side of skull ; outer portion of antrum removed. From the inner antral wall three thin-walled cysts project, two of these have been laid open ; the largest is five eighths of an inch in diameter. "It contained, after many years' immersion in spirit, a turbid fluid in which were numerous masses of a (?) fibrinous material."
St. Thos. Hosp. Museum, 855.

500. Part of the right side of a skull ; cavity of antrum exposed by removal of its anterior and posterior walls. Arising from membrane of anterior wall is a globular cyst, and below it a smaller cyst marked by a bristle. There is a slender club-shaped polypus, one inch long, attached to the lower border of the aperture leading to the middle meatus.
St. Thos. Hosp. Museum, 856.

501. A right superior maxilla, showing the calcified wall of a cyst which in great part fills the antrum. The antral cavity does not appear dilated, except perhaps to a slight extent posteriorly. The cyst walls are continuous with those of the antrum below and to the outer side, but above are separated by a considerable interval from the roof of the cavity. They are very delicate, and perforated by minute apertures. The alveolus of the second premolar opens into the floor of the cyst. The origin of the cyst is uncertain ; perhaps it was inflammatory, and connected with the fang of the second premolar.
R.C.S. Museum, 2197F.

502. Section of cyst of naso-pharyngeal vault. (See Mic. Coll.)
Arthur H. Cheatle, Esq.

*PROGRESSIVE OR FORMATIVE DISTURBANCES OF
NUTRITION—HYPERTROPHY—REGENERATION.*

EAR.

503. A skull exhibiting increased thickness and density of both tables and of the cancellous tissue of all its constituent bones.
St. Bart.'s Hosp. Museum, Series i, 88, case E.
504. A temporal bone showing hyperostosis of the external meatus.
St. Mary's Hosp. Museum, 802.

NOSE.

505. A pendulous lipoma which hung from the extremity of the nose and septum nasi. It is composed of tough fibro-cellular tissue.

Removed from an Italian aged 53; it had been growing since he was nine years old. A similar but smaller tumour was attached to the upper lip. (See Henry Ward Book, vol. vii, p. 8.)

St. Bart.'s Hosp. Museum, Series xii, 1760.

506. A large lobulated growth removed from the nose of an old man, where it had been growing for several years. The surface of the tumour is thickly studded with the orifices of enlarged sebaceous follicles. A cut section is firm and fibrous, but in places contains sebaceous material.

Microscopically the tumour consists of enlarged sebaceous glands held together by fibrous tissue.

Sections are preserved, Series lv, No. 183.

St. Bart.'s Hosp. Museum, Series xii, 1760A.

507. Lipoma nasi.
Univ. Coll. Liverpool.

508. Lipoma, probably malignant, removed from a man aged 20 years, on whose nose it had been growing slowly for twelve months without pain or glandular enlargement. The tumour occupied the whole of the nose from the nasal bones downwards. It was hard, of a dusky red colour, especially at the base, and covered with wart-like nodules. Much hæmorrhage followed the operation. The exposed surface granulated healthily.

St. Bart.'s Hosp. Museum, Series xii, 1761.

509. Skull and facial bones of a female exhibiting spongy hypertrophy or leontiasis. The distinction between the tables and diploë of the cranial bones has disappeared; the section presents a uniformly dry, friable, spongy texture; the smooth internal surface is mostly replaced by a close-set porous structure; the exterior is similarly altered. Owing to increased thickness of its walls the cranial cavity is lessened, the orbital plates of the frontal bone (measuring $\frac{5}{8}$ inch in thickness) stand prominently out, causing the horizontal plate of the ethmoid to appear sunken. The grooves for the vessels, and fossæ for the cerebellum, are exaggerated; the foramen magnum is contracted to a triangular form; the other apertures in the base retain their proper size. No trace remains of the sutures in the vault except the coronal.

In the face the size of the orbits is unaltered, but the mouth is diminished by thickening of the palate, which is rendered almost flat. The malar bones are unaffected.

Univ. Coll. Museum, 5.

510. Left half of a skull, showing uniform spongy thickening—to about $\frac{1}{2}$ inch—of the bones of the vault, but not of the face; the sphenoid is affected. Owing to vacuity between the tables the upper ethmoidal cells, sphenoidal and frontal sinuses are nearly brought into continuity. (See 511.)
St. Thomas's Hosp. Museum, 420.
511. Right half of specimen 510.
The specimen is said to have been obtained from an idiot.
St. Thomas's Hosp. Museum, 422.
512. A skull exhibiting leontiasis ossium. Of the bones seen in the anterior aspect of the face, the left nasal bone and the orbital processes of the malar bones are alone unaffected.
R.C.S. Museum, 1238.
513. Hypertrophy of bones of right side of face; death followed ligature of the carotid artery. Shows hypertrophy of right osseous meatus. (See 'Path. Soc. Trans.,' 1881, vol. xxxii, Mr. Barwell's case.)
Charing Cross Hosp. Museum, 13A.
514. Face of a man for whom a new nose was formed, three months before death, from the integuments of the forehead.
Some years previously the patient cut off his nose while insane. He died with fever shortly after union of the transplanted part was effected. F. C. Skey, Esq.
St. Bart.'s Hosp. Museum, Series xii, 1775.
515. A portion of the bones of the right side of a face, showing in the nasal fossa an overgrown and papillary condition of the whole of the mucous membrane covering the inferior spongy bone. There is a small pointed process of mucous membrane springing from the anterior part of the middle spongy bone, apparently an incipient polypoid growth.
R.C.S. Museum, 3926.
516. A preparation exposing the lower part of the right nasal fossa, showing a papillary condition of the mucous membrane over the inferior spongy bone more advanced than in the preceding specimen (515).
R.C.S. Museum, 3927.
517. Hypertrophy of the mucous membrane. Section of a nose in which the mucous membrane covering the posterior portion of the inferior turbinated bone is thick, soft, and spongy, so that in the recent state it resembled a vascular tumour or polypus projecting in the nasal passage.
St. Bart.'s Hosp. Museum, Series xii, 1762.

518. True hypertrophy of the inferior turbinal.
St. Thos. Hosp. Museum, 1898B.
519. Drawing from section of great hypertrophy of nasal septal tubercle. The mass hid the middle turbinal from view, and reached down to inferior tubercle. Removed with snare. (For section see Mic. Coll. 4.)
Arthur H. Cheate, Esq.
520. A pharynx and naso-pharynx, the posterior wall divided in the middle line. The hypertrophied adenoid tissue is seen on either side of the stretched velum palati. The posterior nares were completely obstructed. Looking into the mouth from behind, the enlarged tonsils are seen. The lymphatic follicles at the root of the tongue are hypertrophied (lingual tonsil). (See 'Surgical Post-mortem Register,' 1894, p. 72.)
St. Bart.'s Hosp. Museum, Series xii, 1806C.
521. Naso-pharynx, soft palate, and tonsils of a Boy æt. 8, who died of general tuberculosis, showing moderate-sized adenoids. Glass rods in the Eustachian tubes. (See 'Post-mortem Reports,' April 12th, 1896.)
St. Mary's Hosp. Museum, 1057A.
522. A mass of post-nasal adenoid tissue removed by operation; almost identical, microscopically, with tonsil.
St. Bart.'s Hosp. Museum, Series xii, 1806B.
523. A set of adenoid masses removed by operation from the naso-pharynx, showing variations.
H. A. Ahrens, Esq.
524. The pharynx of a Child exposed from behind, showing on each side chronic enlargement of the tonsil.
St. Bart.'s Hosp. Museum, Series xii, 1806A.
525. Painting of polypoid overgrowth from the right supra-tonsillar fossa. (For section see Mic. Coll. 5.)
Arthur H. Cheate, Esq.

INFLAMMATION AND ITS CONSEQUENCES.

EXTERNAL EAR.

526. Water-colour painting of tophi.
Jonathan Hutchinson, Esq.
527. Model in wax of tophi in auricles.
Univ. Coll. Museum, 954 B.

528. Keratosis obturans. The contents of this bottle, consisting of laminated epithelial masses, were removed from the ear of a Male. (a) Masses removed three years later. Richard Lake, Esq.

529. Exfoliative dermatitis of external meatus. Richard Lake, Esq.

MIDDLE EAR.

530. Water-colour drawings of the tympanic membrane, showing various pathological conditions. Richard Lake, Esq.

531. Water-colour drawings of the tympanic membrane, showing various pathological conditions. P. Macleod Yearsley, Esq.

532. Blood-clot removed from the ear of a Man who had suffered from offensive otorrhœa for two years. Mr. Black.
West. Hosp. Museum, 1173D.

533. Water-colour painting of large polypus projecting from meatus.
Jonathan Hutchinson, Esq.

534. Water-colour painting of the polypus after removal.
Jonathan Hutchinson, Esq.

535. Microscopical section of an extremely thickened edge of a perforation of old standing. Richard Lake, Esq.

536. Part of a temporal bone. The external meatus is opened from the front and below to expose a long, soft, gelatinous polypus nearly filling it, the base of the polypus is attached to nearly the whole outer surface of the membrane. A bristle is passed under a slender band of false membrane extending from the inner surface of the tympanic membrane, which is much thickened, to the opposite wall of the vestibule.
St. Bart.'s Hosp. Museum, Series xxxiv, 2683.

537. Large aural polypus, removed by avulsion. Microscopically it is inflamed fibrous tissue covered with epithelium. From a man æt. 26; it extended to the edge of the meatus and had probably been growing for many years, as the man had suffered from otorrhœa as long as he could remember.
St. Bart.'s Hosp. Museum, Series xxxiv, 2682B.

538. A polypus, partly smooth, partly nodular and warty, removed from the inside of the external meatus.
St. Bart.'s Hosp. Museum, Series xxxiv, 2681.
539. A small polypus, suspended by the narrow pedicle which appears to have passed through a perforation in the membrane.
St. Bart.'s Hosp. Museum, Series xxxiv, 2682.
540. Small fibrous polypus, removed from the external auditory meatus.
St. Bart.'s Hosp. Museum, Series xxxiv, 2682A.
541. A lobulated aural polypus. Microscopically it mainly consists of loose fibrillar tissue.
St. Bart.'s Hosp. Museum, Series xxxiv, 2685A. (See section in Series i, v, No. 501.)
542. A large polypoid growth, removed through the external meatus from the middle ear of a girl *æt.* 11, who had suffered for years from chronic middle ear disease. The polypus occupied the entire meatus, and appeared externally. It was covered with thick squamous epithelium. (For drawing of ear, see Series i, vii, No. 7. For microscopic specimen, see Series i, v. See 'Female Surgical Register,' vol. v (1895), No. 666.)
St. Bart.'s Hosp. Museum, Series xxxiv, 2685B.
543. Half of a hairy polypus which came through Shrapnell's membrane. (For section, see Mic. Coll. 1.) Arthur H. Cheatle, Esq.
544. Section of hairy polypus which came through Shrapnell's membrane. (See Mic. Coll. 2.) Arthur H. Cheatle, Esq.
545. Section of hairy polypus from middle ear, with drawing. (See Mic. Coll. H. Pegler, Esq.)
546. Left temporal bone of a Child. Perforation in posterior superior segment, exposing stapes and incus joint. Arthur H. Cheatle, Esq.
547. Large perforation in posterior segment. Richard Lake, Esq.
548. Perforation of the posterior segment. Richard Lake, Esq.
549. Perforation of the anterior inferior quadrant. Richard Lake, Esq.

550. A case containing upwards of thirty sets of ossicles (excluding the stapes) removed for chronic middle ear suppuration. Arthur H. Cheatle, Esq.
551. Twenty sets of ossicles (excluding the stapes) which were removed for Ot. Med. Supp. Chron. R. Lake, Esq.
R.C.S. Museum, 3949B.
552. Five specimens of carious ossicles (excluding the stapes) removed through meatus for Ot. Med. Supp. Chron. P. Macleod Yearsley, Esq.
553. Thirteen specimens of ossicles (excluding the stapes) removed by operation for Ot. Med. Supp. Chron. Prof. Urban Pritchard.
554. Malleus and incus exfoliated with some necrosed bone after scarlet fever. Guy's Hosp. Museum, 1669⁸⁴.
555. Complete destruction of membrana tympani, destruction of malleus, stapes bound down by cicatricial tissue, and the mouth of the Eustachian tube completely occluded. Richard Lake, Esq.
556. Section exposing the inner wall of the tympanic cavity. The long process of the malleus is destroyed, and the long process of the incus eroded, the membrane being completely destroyed. Richard Lake, Esq.
557. Left temporal bone. Ot. Med. Supp. Chron., showing erosion of outer attic wall. Perforations through anterior meatal wall. Ossicles and soft parts removed. Arthur H. Cheatle, Esq.
558. Left adult temporal bone. Ot. Med. Supp. Chron. Large loss of inferior segment of membrane. Caries of head of malleus. No perforation in Shrapnell. Arthur H. Cheatle, Esq.
559. Formalin preparation of a left adult temporal bone. Ot. Med. Supp. Chron. Perforation in posterior segment of membrane. A granulation springing from promontory. Loss of articular process of incus. Secondary implication of attic. Thickened tissue shuts off disease from the antrum. Arthur H. Cheatle, Esq.
560. Right adult temporal bone. Ot. Med. Supp. Chron. Complete loss of membrane. Handle of malleus bare. Loss of articular process of incus and stapes. Arthur H. Cheatle, Esq.

561. Right adult temporal bone. Ot. Med. Supp. Chron. Complete loss of membrane. Handle of malleus bare. Both processes of incus lost, small portion of body only remaining. Arthur H. Cheatle, Esq.
562. Left adult temporal bone. Ot. Med. Supp. Chron. Loss of inferior segment of membrane. Loss of articular process of incus. Arthur H. Cheatle, Esq.
563. Right adult temporal bone. Ot. Med. Supp. Chron. Loss of lower segment of membrane. Loss of tip of handle of malleus, articular process of incus, head, and crura of stapes. An adhesion passes from remains of incus to Fallopian canal. Arthur H. Cheatle, Esq.
564. Right adult temporal bone. Ot. Med. Supp. Chron. Large loss of inferior segment of membrane. Malleus adherent to promontory. Posterior remains of membrane adherent to incus. Arthur H. Cheatle, Esq.
565. Caries of the Fallopian canal. From a boy who had facial paralysis; the seventh nerve was exposed in the tympanum. (See P.M. Reports, iv.)
St. Mary's Hosp. Museum, 804.
566. A small sequestrum removed from the external auditory meatus of a boy æt. 2 years, who had suffered for a year with otorrhœa. Mr. Black.
West. Hosp. Museum, 1173C.
567. Right temporal bone of an infant, æt. one month, who died of tuberculous meningitis. Small perforation in Shrapnell's membrane. Middle ear full of pus. Petro-squamosal sinus marked. Lining membrane thick. Sections of lining membrane showing small-cell infiltration of superficial layers and destruction of superficial epithelium in patches. No blood in vessels. No tubercle. Arthur H. Cheatle, Esq.
568. Right temporal bone of a child, æt. one year and four months, who died of general tuberculosis. Ot. Med. Supp. Chron. Small perforation below handle of malleus. Lining membrane thick. Middle ear full of pus. Section of lining membrane showed small-celled infiltration of superficial layers. Arthur H. Cheatle, Esq.
569. Temporal bone of an infant, æt. seven months, who died of general tuberculosis. Ot. Med. Supp. Chron. Large perforation of posterior segment exposing stapes and incus joint. Middle ear full of pus. Lining membrane thick and injected. Also perforation in anterior segment. Arthur H. Cheatle, Esq.

570. Right temporal bone of an infant, æt. one year and eight months, who died of tuberculosis meningitis. Membrane intact and bulging. Middle ear full of pus. Petro-squamosal sinus marked, with opening into lateral sinus. Arthur H. Cheatle, Esq.
571. Right temporal bone of a child, æt. two years and seven months, who died of tuberculous meningitis. Small perforation behind tip of handle of malleus. Lining membrane thick. Middle ear full of pus. Petro-squamosal sinus marked, opening into lateral sinus. Arthur H. Cheatle, Esq.
572. Right adult temporal bone. Ot. Med. Supp. Chron. Healed. Cicatrix posterior segment (cracked in drying) adherent to head of stapes. Loss of articular process of incus. Erosion of posterior meatal wall. A fine membrane attached to upper border of horizontal semicircular canal shuts off meatus from antrum. A peculiar bend in handle of malleus. Caries of the handle below short process, thinning it for some distance. Arthur H. Cheatle, Esq.
573. Left adult temporal bone. Ot. Med. Supp. Chron. Healed. Circular cicatrix in anterior inferior segment. Remainder of membrane white and thickened. Lining membrane thick and white. No adhesions. Arthur H. Cheatle, Esq.
574. Right adult temporal bone. Healed. Ot. Med. Supp. Chron. Perforation posterior segment. Calcareous deposit in anterior segment. Loss of tip of articular process of incus. Membrane adherent to head of stapes, a thickened band passing upwards to the remains of incus. Arthur H. Cheatle, Esq.
575. Left adult temporal bone. Ot. Med. Supp. Chron. Healed. The meatus was full of cerumen and desquamated epithelium. Cicatrix in Shrapnell's membrane, and in the posterior segment, where it is adherent to the head of the stapes and inner wall. The tip of the descending articular process of the incus has been lost. A fine membrane passes from the body of the incus to the outer attic wall. A vertical transverse membrane runs across the middle ear above the tensor tympani to the roof. Arthur H. Cheatle, Esq.
576. Anchylosis of joint of malleus and incus.
St. George's Hosp. Museum, Series xvi, 69A.
577. Anchylosis of malleus and incus, probably due to middle ear disease.
Macleod Yearsley, Esq.
West. Hosp. Museum, 1173E.

578. Specimens showing adhesions of malleus to promontory and membrane to incus.
Richard Lake, Esq.
579. Postero-superior quadrant of membrane, retraction of the handle of malleus. The chorda tympani and long process of the incus are visible through the membrane. The malleus also shows great posterior rotation.
Richard Lake, Esq.
580. Section of the base of a skull, ear dissected to show inflammation of the tympanic cavities. When recent the mucous membrane of the right was vascular and thickened, firm membranous bands crossed it. On the left side the membrane was thickened, the tympanum and mastoid cells filled with a purulent fluid and viscid mucus. Membranous bands crossed the cavity and united the ossicles.
Guy's Hosp. Museum, 1669⁸⁷.

MIDDLE EAR—EXTENSION OF INFLAMMATION.

Note.

The following specimens from No. 581 to No. 708 are grouped to illustrate the consequences of inflammation when the disease has spread by continuity or otherwise from the middle ear to parts beyond. In the great majority of cases in which intra-cranial complication existed, and in which the temporal bone alone has been preserved, the bone is grouped with the specimens illustrating each particular complication or series of complications.

i. Caries and Perforation through the Walls.

581. Temporal bone of child. Extensive caries of petro-mastoid portion and tympanic ring-extension to squamosa. Sequestrum forming.
Hugh E. Jones, Esq.
582. Left temporal bone with evidences of old chronic middle ear suppuration. Great destruction of middle ear, handle of malleus gone, and there is a sinus at the site of an old Schwartze operation. The bottom of the sinus is shut off from the middle ear by firm fibrous tissue.
Richard Lake, Esq.
583. Shows chronic middle ear suppuration with perforation of the outer wall of the tympanic antrum.
St. George's Hosp. Museum, Series xvi, 62⁰.
584. A temporal bone, showing a polypus hanging from the external auditory meatus. The roof of the tympanum shows a small area of necrosis.
Middl. Hosp. Museum, 944.

585. A similar specimen. Dissected by Mr. Bernard Lawson, 1883.
Middl. Hosp. Museum, 945.

586. Left adult temporal bone in part, showing the results of an operation for mastoid disease two years before death. A large opening on the surface leads down to the mastoid antrum. In the deeper parts the bone is compact and smooth, and in the recent state was covered with an unhealthy-looking fibrous membrane. The superficial parts are freshly cut with a chisel. The posterior wall of the meatus has been removed over the greater part of its extent. The cranial surfaces of the bone are healthy.

Patient, æt. 20, had symptoms of mastoid disease, with vomiting and left optic neuritis. The mastoid was trephined. Patient recovered, lost his vomiting and neuritis, but had a persistent otorrhœa. Eighteen months later he returned with a polypus in this ear. It was removed, and he did not come back for further treatment for six months, when he was admitted into the Leeds Infirmary, under Mr. Secker Walker's care, complaining of pain behind the ear, accompanied by œdema of the skin and tenderness over the mastoid. The old cicatrix was reopened and much pus and offensive *débris* found in the antrum. This was removed and the antral walls were noticed to be covered by reddish, fibrous membrane. The bony opening was much enlarged, and the partition between meatus and antrum chipped away. A flap of skin from the back of the ear was transplanted into the opening. The boy died from ether pneumonia on the eighth day after operation.

H. Secker Walker, Esq.

587. Part of a left temporal bone from a child of 5 years. A large natural sinus has formed above and behind the meatus leading down to the antrum, the bone around being marked by inflammatory changes. A small sequestrum, since lost, lay in the sinus.

The child died in the medical ward from some disease unconnected with the ear. The opening on the anterior surface of the meatus was made *post mortem*.

H. Secker Walker, Esq.

588. Right temporal bone from a youth. The patient had been operated on two years before death for right-sided mastoid disease of an extensive character. The disease was quite cured. The temporal bone shows on its outer side an irregular oval opening behind the meatus, divided from this by a pillar of bone which seems to have grown up from below. The two openings lead into a large cavity, whose walls are formed by the compact bone of the anterior and posterior surfaces of the petrous. The whole of the cancellous tissue in the mastoid has disappeared. The anterior part of the cavity is formed by the middle ear, from which the ossicles have disappeared. Two small openings lead into the sigmoid fossa.

Patient was admitted into the Leeds Infirmary suffering from suppurative disease of the left mastoid process. He had been

a patient two years before when the right mastoid was operated on for similar disease, with good result, the disease entirely ceasing, and the large cavity in the temporal becoming dry and lined with epithelium. On the left side there was a subdural abscess over the roof of the antrum. Patient died of septic pneumonia.

H. Secker Walker, Esq.

589. Left temporal bone of a child of three months old. There is considerable absorption of bone in the attic region, and general osteitis over a larger area around squamo-mastoid suture. A portion of bone forming the roof of the antrum is missing.

H. Secker Walker, Esq.

590. Temporal bone showing carious erosions at groove of lateral sinus, also at tegmen antri and outer wall of antrum.

Thos. Barr, Esq.

591. Right temporal bone from young adult. The petrous portion is divided by a horizontal saw cut to expose the antrum and attic. On the external surface the bone appears normal. The inner surface shows extensive caries over the roof of the attic and antrum, the inner surface of the squamous and the bone in the region of the sigmoid groove. Several large perforations exist on the superior surface of the petrous leading into the antrum and mastoid cells, and similar perforations are found on the posterior surface. The malleus and stapes remain in position and the incus has disappeared.

The patient was admitted into the hospital unconscious and died before anything could be done.

H. Secker Walker, Esq.

ii. *Extension to Internal Ear.*

592. Portion of a temporal bone, in which the mastoid cells, tympanum, and parts of the internal ear were filled with thick, purulent, scrofulous matter. A large portion of bone, including a part of one of the semicircular canals, lies loose in a cavity in the petrous bone, and is indicated by a bristle. From a man who was extremely deaf.

R.C.S. Museum, 3949.

593. Sequestrum of osseous labyrinth. (See 'Lancet,' January, 1887.)

Thos. Barr, Esq.

594. A sequestrum consisting of almost the whole of the walls of the bony labyrinth of the left ear, separated from the surrounding portion of the petrous bone by necrosis. The semicircular canals are almost complete, especially the superior transverse vertical canal by which the specimen is

suspended. The cavity of the vestibule is displayed from the front, the termination of the internal auditory meatus can be seen on the back of the specimen. To the left (of the observer) are the cochlea—opened below the apex, with the spiral lamina and the modiolus exposed—and a small portion of the tympanic cavity, with the canal for the tensor tympani. To the right is an irregular portion of the mastoid cells.

Removed from a girl æt. $4\frac{1}{2}$, by an incision immediately behind the left ear. There had been a purulent otorrhœa, with mastoid pain and swelling, for three months previously; these symptoms were sequelæ of scarlet fever. Complete paralysis of the portio dura had existed for about a month. There were no cerebral or meningeal symptoms, and the child's general condition was good. The sequestrum was lying loose in a cavity with bony walls, except at the upper part where there appeared to be dura mater only; it was easily removed and the cavity soon filled up; some return of power in the muscles supplied by the portio dura was noticed a fortnight after the operation. Walter Pye, Esq.

R.C.S. Museum, 3949A.

595. Sequestrum consisting of almost the whole of the petrous portion of a temporal bone. From a child æt. 7. Recovered completely, with loss of hearing and facial paralysis of the same side.

St. George's Hosp. Museum, Series 32B.

596. Large sequestrum successfully removed. ('Med.-Chir. Trans.,' vol. lxi, p. 240.)

St. George's Hosp. Museum, Series xvi, 62.

597. Sequestrum from left temporal bone, consisting of part of the cochlea, vestibule, and semicircular canals. No history.

H. Secker Walker, Esq.

598. A sequestrum from the left temporal bone composed of the cochlea, vestibule and semicircular canals. The aqueduct of Fallopius is contained in the specimen.

Patient was a child of three who had left otorrhœa for four months as a result of scarlet fever. There was mastoid swelling and tenderness. An opening was made behind the ear into the antrum, and the sequestrum found and removed by enlarging the bony opening. The child recovered.

H. Secker Walker, Esq.

599. A temporal bone in which ulceration has extended from the meatus through the greater part of the base of the petrous portion, and has destroyed nearly the entire cavity of the internal ear.

St. Bart.'s Hosp. Museum, Series xxxiv, 2677.

600. Necrosis of right petrous bone, including the parts enclosing the internal and middle ear. A sequestrum lay loose in a smooth-walled cavity.
Lond. Hosp. Museum, 964.

601. Part of a right petrous bone, including the osseous labyrinth, the internal meatus, and part of the apex of the petrous bone; it measures $\frac{7}{8}$ inch from apex to base. Removed by syringing from the ear of a girl with congenital syphilis.
St. Mary's Hosp. Museum, 805A.

602. Shows result of chronic middle ear suppuration; extensive caries; perforation of the roof of the middle ear, opening into the lateral sinus; caries of the labyrinth, and sequestrum. From a girl æt. 16.
St. George's Hosp. Museum, Series xvi, 62D.

603. Right temporal bone from a child æt. 4. External surface normal. On the anterior surface of the petrous the bone situated over the cochlea is absorbed, showing the cochlea as a sequestrum beneath. The hiatus Fallopii is enlarged. On the posterior surface through various openings a sequestrum is visible, composed of internal auditory meatus, vestibule and two semicircular canals. The bone is divided by the saw-cut in an antero-posterior direction through the middle ear. The ossicles have disappeared; the antrum is enlarged and its walls carious. The aqueduct of Fallopius is destroyed at the bend below the horizontal semicircular canal, which appears as part of the sequestrum in the antrum. The posterior wall of the meatus is carious.

Patient, a child æt. 4, admitted into the Leeds Infirmary in March, 1893, under the care of Mr. Nunneley. There was right facial paralysis; profuse otorrhœa. Rigors were frequent. There was no optic neuritis. Convulsions continued; the child became comatose, and rapidly died. Post-mortem: Distension of all the ventricles of the brain. Right cerebellar lobe occupied by a superficially placed abscess.

H. Secker Walker, Esq.

604. A left temporal bone, showing a large, irregular, carious cavity on the superior and posterior surfaces of the petrous portion measuring 1.5 cm. by 1.5 cm. The whole of the structures forming the internal ear have disappeared, and the walls of the cavity are roughened and eroded. Less than .5 cm. of the inner end of the internal auditory meatus remains.
Addenbrooke's Hosp. Museum, Cambridge, 1574.

iii. Extension to Temporo-maxillary Joint.

605. Shows chronic middle ear suppuration. Caries of the middle ear and perforation through the roof and posterior wall of the antrum. Bony floor of meatus and mid ear absorbed, forming a carious cavity, which communicates with temporo-maxillary joint; the condyle almost entirely absorbed.

St. George's Hosp. Museum, Series xvi, 62B.

iv. Perforation through Digastric Fossa.

606. Vertical section through a right temporal bone, showing extensive carious disease of the mastoid cells, with perforation into the digastric fossa. A small opening also exists into the middle cerebral fossa behind the antral roof. A large perforation occurs in the posterior half of the membrana tympani.

The patient, a man of about 60, was admitted into the medical ward of the Leeds Infirmary suffering from empyema and pneumonia. He died very shortly after admission. It was noticed that he had profuse right otorrhœa, with a fluctuating swelling beneath the sterno-mastoid and a second under the deltoid muscle. Post-mortem: the temporal bone showed the lesion above described, and there was a large abscess under the sterno-mastoid and digastric muscles communicating with the mastoid abscess through a carious opening in the digastric groove.

H. Secker Walker, Esq.

v. Extra-dural Abscess with Localised Pachymeningitis.

607. Right adult temporal bone, showing the results of acute mastoiditis. The antrum was opened, and by removal of the posterior meatal wall the middle ear the two cavities were thrown into one. Suppuration was also found in the mastoid cells. Looked at from behind the bony spaces have been absorbed in the lower cells. An extra-dural abscess has also formed on the anterior surface just in front of the genu of the facial nerve, excavating the bone around for an area five-eighths of an inch by three-eighths of an inch. The facial canal is freely opened. There was no facial paralysis.

Patient had pain and otorrhœa for three months following influenza. Almost complete deafness on the right side. A small perforation was visible in Shrapnell's membrane. The ossicles were removed, but there was no abatement in the symptoms. A month later antrectomy was performed. The patient improved rapidly, but on the seventh day died quite suddenly from cardiac failure while sitting up in bed. Post-mortem revealed fatty degeneration of cardiac muscle. Brain membrane and sinuses healthy. The examination also revealed the subdural abscess on the anterior surface of the petrous.

H. Secker Walker, Esq.

608. Part of right side of head. Mastoid process and adjoining part of temporal bone necrosed after destruction by caries, roof of tympanum and posterior wall of antrum towards lateral sinus perforated. The dura mater, covered with granulations on the surface next the disease, is reflected; it is not perforated.

St. Thos. Hosp. Museum, 574.

609. Part of a temporal bone, in which there was disease of the internal ear and adjacent tissues. On the attached surface of the dura mater, covering the diseased part of the petrous bone, is a small irregular growth which has the consistence and general appearance of a fibrinous coagulum. It is firmly fixed to the dura mater, with which it has been reflected from the diseased bone.

From a girl æt. 18, who had long had profuse purulent otorrhœa. On its sudden cessation violent headache and delirium ensued, which were speedily followed by coma and death. Robert Liston, Esq.

R.C.S. Museum, 3950.

610. Portion of a skull, the cavities of the internal ear displayed, and other adjacent parts. The tissues of the internal ear are extensively destroyed by ulceration, and part of the surface of the petrous bone is ulcerated. From that part the dura mater has been reflected, and with it two large growths of the same kind as that described in specimen 609, but connected with its free surface, not, as in that case, with the surface attached to the bone. The tumours are very irregular in form, and about an inch in their chief diameter.

From a man æt. 47, subject to severe and almost constant headache for two or three years. For some days before his death the pain became intense, and was accompanied by great constitutional excitement. Robert Liston, Esq.

R.C.S. Museum, 3951.

611. A specimen similar to the preceding (610), except that the dura mater beneath the growth is so thin and soft that it cannot be detached from the petrous bone; and the growth appears, therefore, to be in part fixed to the bone itself.

From a middle-aged woman, who long laboured under obscure symptoms of disease in the head, with occasional discharge from the ear. Robert Liston, Esq.

R.C.S. Museum, 3952.

612. Skull of a child, with destruction and perforation through roof of the left middle ear; dura mater beginning to slough.

Guy's Hosp. Museum, 1074⁷⁶.

613. Right temporal bone of a man who some years previous had had the antrum opened and an extra-dural abscess in the posterior fossa evacuated by G. Lenthal Cheatle. The result is perfect. No re-formation of bone. The dura mater and cicatricial tissue forming roof and posterior wall of antrum. Caries of incus. Arthur H. Cheatle, Esq.

vi. *Lepto-meningitis.*

614. Right temporal bone of a patient who died of meningitis; perforation in Shrapnell and posterior segment; caries of head of malleus; loss of incus; erosion of outer attic wall. Middle ear opened artificially from above. A large number of minute perforations through posterior antral wall, partly into inner edge of groove for lateral sinus; dura mater over this area ulcerated and perforated. No thrombosis of lateral sinus or cerebellar abscess. Arthur H. Cheatle, Esq.

615. Brain of a boy æt. 12, who died of suppurative otitis media (right side) and suppurative meningitis. The medulla, pons, and crura, with neighbouring parts of the cerebellum and brain, are coated with purulent exudation. At the post-mortem there was extensive suppurative disease of the right middle ear; no perforation of the roof or posterior wall of the tympanum; the dura mater over the upper surface of the right petrous bone and over the external surface external to the internal auditory meatus was healthy and not adherent to the brain, but internal to the meatus it was coated with exudation, which extended as mentioned above. The vessels of the pia mater are greatly injected. (See 'Surgical Male Register,' vol. iv (1897), No. 1894; and 'Surgical Post-mortem Register' (1897), p. 163.)

St. Bart.'s Hosp. Museum, Series xxx., 2453A.

616. Portion of dura mater from a case of scarlet fever; the subjacent petrous bone was carious, and the tympanum full of pus. About the centre of the specimen is an area soft and flocculent on the surface next the bone. When recent it was brownish in colour, the discoloration extended to its arachnoid surface; at two points perforation existed. The arachnoid was slightly inflamed; the brain was normal in appearance.

St. Bart.'s Hosp. Museum, Series xxx, 2457.

617. The cerebral hemispheres showing suppurative meningitis, mainly confined to the vertex. The pus lies in the meshes of the pia arachnoid, and principally in the sulci. The pia mater is congested.

From a woman æt. 35, seized one morning with a left earache, the same afternoon there was a discharge of pus. On admission, three days later, she was drowsy and had left mastoid tenderness, weakness of the left face, and slight nystagmus; discs

normal. Next day she became delirious ; slight proptosis of left eye, weakness of left hand and retraction of head. On trephining the mastoid cells, the bone was found acutely inflamed ; left lateral sinus normal, a needle failed to find pus. She died next day. Post mortem : the middle ear was found to be the origin of the disease without gross lesion of intermediate structures. There was no pus outside the dura mater ; right ear and both lateral sinuses normal. (See Mr. Page's clinical notes (1898), No. 405 ; and Post-mortem Surgical Register, No. 11.)

St. Mary's Hosp. Museum, 727B.

618. Left temporal bone of a child æt. one year, who died of suppurative meningitis. Membrane intact and bulging. Middle ear full of muco-pus containing streptococci and staphylococci. Lining membrane thick and congested looking. Veins from middle ear to petro-squamosal sinus marked. Roof of middle ear was intact.

The child was admitted to the hospital on March 24th, 1899, having been ill, with difficulty of breathing and cough, since March 17th. Pneumonia was found at both bases. Temperature ranging from 102° to 104°. On April 8th twitching of limbs. No rolling or retraction of head. Child did not put hand up to ear, or cry out as if in pain. The temperature came gradually down to normal but shot up on April 10th to 107°, when death occurred. Post-mortem : the base of both lungs solid with abundant deposit of lymph on diaphragmatic pleura. Surface of brain especially on the left side over motor areas covered with pus. Pus also at base of brain. Section of veins from middle ear and of sinus negative bacteriologically. No thrombosis.

Arthur H. Cheate, Esq.

619. Section of the base of the skull, the ear dissected, showing inflammation of the tympanum. When recent the Eustachian tubes were thickened and closed with muco-purulent fluid. Both tympanic cavities were filled with a viscid red fluid, the mucous membrane was red and velvety ; the membrana tympani was vascular and thick. The right side was also affected. The disease probably commenced in the fauces and spread along the Eustachian tubes.

From a child, 3½, who had had cerebral symptoms for three or four days, and died in convulsions.

Guy's Hosp. Museum, 1669⁸⁶.

620. A right temporal bone the seat of acute disease in the mastoid cells and in the cancellous tissue at the apex of the petrous. The bone is sawn in an irregular antero-posterior vertical direction. There is not much coarse osseous disease. A large irregular opening on the outer surface leads in an upward and forward direction into the mastoid cells, from which a quantity of softened cancellous and granulation tissue was removed at the time of

operation. The cancellous tissue in the apex of the petrous has all been absorbed—its place in the recent state being occupied by pus—and the cavity communicates by means of a narrow tunnel with the mastoid cells. Probably septic organisms passed along the tunnel from behind forming the abscess which eventually by producing meningitis caused the death of the patient.

The patient a girl of 25, three weeks prior to admission into the Leeds Infirmary under the care of Mr. Hewetson in October, 1893, had naso-pharyngeal catarrh, followed by double otorrhœa. The left ear soon healed. The discharge from the right ear became profuse and accompanied by severe pain and later paresis of the facial nerve appeared. On admission there was no swelling or redness over the mastoid region but some tenderness on pressure over the meatus. The antrum was opened and found full of pus and granulations. Forty-eight hours afterwards patient was seized with shivering and pain in back and shoulders. Temp. 102.6° . Soon delirium followed with tenderness and fixation of the neck. No papillitis. By the following day the optic discs were becoming swollen, divergent strabismus appeared with contraction of the right pupil, and dilation of the left pupil. Temp. 106.2° . Death occurred four days after operation. Post-mortem appearances, basal and spinal meningitis. The meningitis appeared to have started from an abscess in the apex of the petrous rupturing through the dura mater near the foramen lacerum medium.

H. Secker Walker, Esq.

621. Left adult temporal bone divided by a vertical antero-posterior section. On the outer side is a trephine opening $\frac{3}{8}$ inch in diameter, placed on a level with the external meatus and $\frac{1}{4}$ inch behind its posterior wall. This trephine opening leads into the mastoid cells and indirectly into the antrum. In the squamous portion half a circle of bone has been removed by a large trephine. The inner half of the temporal bone shows absorption of some of the bony trabeculæ. The roof of the antrum is partly absorbed and perforated in several small areas, and similar perforations exist in the sigmoid groove.

Patient a man of forty-three, admitted into the Leeds Infirmary under Mr. Jessop, May 2nd, 1892. Up to six weeks before had been quite well, then a sore throat developed, which was followed in a fortnight by severe and continuous pain in the left ear for ten days; relieved when discharge appeared. Two days before admission had a rigor, followed by free otorrhœa; the next day became delirious, spoke incorrectly, and slipped words and sometimes whole sentences. The following day, May 2nd, had a second rigor and was more delirious, and complained of pain over the right frontal region. If spoken to loudly, became attentive and answered rationally for a few moments. Ear red and rather swollen, skin over mastoid red but not œdematous or swollen. No optic neuritis.

Left temporo-sphenoidal lobe trephined, no abscess found; but on passing the needle backwards and downwards to the roof of the antrum twenty minims of pus were withdrawn. The mastoid process was then trephined, but no pus found; some granulations and pus

found in left middle ear. Patient never regained consciousness, but died on May 4th. Post-mortem: suppurative meningitis around the right frontal lobe, right Sylvian fissure, and upper part of left lateral lobe of cerebellum. There was a collection of pus on roof of antrum under the dura mater. No cerebral or cerebellar abscess was found.

H. Secker Walker, Esq.

622. Section through right petrous bone of a boy *æt.* 18, showing (1) polypus growing from the tympanum, (2) perforation in membrane with bristle passed through it, (3) ossicles destroyed, (4) attic enlarged and tympanic roof destroyed by caries. At the autopsy the meatus was filled with thick pus, there was extensive meningitis on the right side and subdural suppuration. (See Surgical Post-mortem Register (1895), p. 223.)

St. Bart.'s Hosp. Museum, Series xxxiv, 2676F.

623. Posterior half of a left temporal bone from a man *æt.* 24, who died of general suppurative meningitis secondary to ear disease. There are two perforations, each 3 mm. across on the outer surface of the mastoid leading from the antrum. The latter cavity is enlarged. There are also two perforations between the antrum and the lateral sulcus, and one through the roof of the cavity into the middle fossa.

Post mortem an extra-dural abscess was found in the region of the antrum, and the lateral sulcus shows extensive superficial caries. There was no brain abscess.

Addenbrooke's Hosp. Museum, Cambridge, 1576.

624. R. H., *æt.* 22 years. Influenza three months before admission, followed by acute suppurative otitis of left ear. Three weeks before admission there was pain and swelling behind the left ear, and a fortnight later a rigor and vomiting.

Admission, May 12th, 1893. Hard brawny swelling in upper part of posterior triangle of neck; temperature 100.2° ; pulse 120; pupils dilated; no optic neuritis; membrana tympani hidden by swelling of posterior wall of meatus. Diagnosis: ? Bezold's disease. Operation on day of admission. Mastoid opened, sinus traced from cells into posterior fossa of skull. Extra-dural abscess evacuated. Large subperiosteal abscess in posterior triangle of neck opened. These abscesses communicated in some way not discovered at that period. Lotion passed from one to the other. Case did well from May 13th to 30th, and patient began to get up; then suddenly severe facial neuralgia was followed by general symptoms of suppurative meningitis. Trephining and opening the dura in middle and posterior fossa failed to give relief. Post-mortem examination, June 3rd, 1893: purulent meningitis over parietal and frontal lobes and into Sylvian fissure and front part of base. Temporo-sphenoidal lobes free. T-shaped gutter formed by caries in posterior wall of petrous bone; one end of the cross-piece communicated with the mastoid cells, the other with the internal ear by way of the vestibular vein. The vertical portion passed down through the petro-occipital fissure beneath

the sigmoid sinus into the periosteal abscess on the under surface of the occipital bone. From this a sinus burrowed amongst the deep cervical muscles to the front of the spine. The whole of the left parietal lobe of brain breaking down.

Liverpool Eye and Ear Infirmary.

625. Left temporal bone affected by caries due to middle ear disease. A longitudinal section shows that the posterior wall of the tympanum and the mastoid are affected. The inner surface of the mastoid constituting the groove of the lateral sinus is extensively destroyed.

From a man *æt.* 22, who had been deaf in the left ear with occasional discharge for sixteen years. A month before death he was seized with great pain the left side of the head, and became delirious. On admission he was morose and semi-conscious. There were several discharging sinuses over the temporal bone. After a free incision had been made he improved and could answer questions. Then the pain became worse, and death followed. Over the affected bone the dura was thickened and softened. There was an extra-dural abscess and purulent meningitis over the cerebellum and occipital lobes. (See P.M. Reports, xiv, 80.)

St. Mary's Hosp. Museum, 803.

626. Right mastoid from child *æt.* 2, showing perforation in the upper superior quadrant. The tegmen has been removed. Death from meningitis.

Richard Lake, Esq.

627. Right temporal bone of child *æt.* 4. Showing necrosis of the external wall over site of the antrum. In the tube are the ossicles from the same case. The incus exhibits destruction of its long process; the malleus, destruction of its handle. The patient died of meningitis.

Richard Lake, Esq.

628. Right mastoid, perforation of membrane in its inferior part. A sinus in the tegmen has been enlarged to expose the interior of the attic. Death from meningitis.

Richard Lake, Esq.

629. Temporal bone of a patient who died of purulent lepto-meningitis, showing the work of a dental burr, exposure of antrum and attic; also of middle and posterior fossæ of cranium.

Thomas Barr, Esq.

vii.—*Cerebral Abscess.*

630. Left temporal bone, showing perforation. Infection passed from the middle ear and set up extra-dural and temporo-sphenoidal abscess.

Charing Cross Hosp. Museum, 83.

- 630A. Brain of preceding specimen from a girl *æt.* 15½. A large abscess occupies nearly the whole of the left temporo-sphenoidal lobe; it contained one and a half ounces of curdy foetid pus; resulted from middle ear suppuration and subdural abscess (See 'Post-mortem Book' (1886), p. 835.)

Charing Cross Hosp. Museum, 948.

631. Part of the temporal bone of a child who died with a cerebral abscess consequent on necrosis of the mastoid process, which is brown and rough. The periosteum is retracted over the internal surface of the petrous portion, leaving the bone bare. (See 'Male Surgical Register,' vol. v, 1885, No. 482. For Brain see Series xxx, 2486A.)

St. Bart.'s Hosp. Museum, Series i, 226B.

- 631A. Left cerebral hemisphere of preceding specimen, showing an abscess in the temporo-sphenoidal lobe, caused by the extension of inflammation arising from necrosis of the mastoid cells.

The patient, *æt.* 5, was admitted with a mastoid abscess, from which offensive pus was evacuated one month before death. No diffuse meningitis was found post mortem, but there was a localised patch of meningitis corresponding with the diseased bone. The temporal bone is shown in Series i, 226B. (See 'Male Surgical Register,' vol. v, 1885, No. 482.)

St. Bart.'s Hosp. Museum, Series xxx, 2486A.

632. Temporal bone and portion of brain *in situ*, showing temporo-sphenoidal abscess. Hugh E. Jones, Esq.

Univ. Coll. Liverpool.

633. Part of a skull, including the right temporal bone, and the portion of brain resting on it. A bristle is passed through a perforation on the anterior surface of the petrous bone to the internal ear. The dura mater, with lymph in it, is reflected from the diseased bone; there is an aperture in it corresponding to that in the bone. In the substance of the adjacent brain there is a large, irregular cavity.

R.C.S. Museum, 3768.

634. Right temporal bone from a case of cerebral abscess; perpendicular section through auditory meatus exposing the tympanic cavity. Suppuration had occurred in the tympanum, and though the posterior mastoid cells were opened by operation immediately behind the meatus, the inflammation spread to the roof of the tympanum, thence to the dura mater, which is thickened and perforated, and finally to the brain. The lateral sinus is not affected.

St. Bart.'s. Hosp. Museum, Series xxxiv, 2676B.

- 634A. Right hemisphere of brain belonging to preceding specimen with abscess in the temporo-sphenoidal lobe, the result of middle ear suppuration (see

634). The outer wall of the abscess cavity has been cut away to expose more fully the cavity itself. About one inch behind the abscess is a ragged wound in the cerebral substance caused by a trephining operation ineffectually performed two days before death for the relief of symptoms.

From a man *æt.* 29, who had suffered from purulent discharge from both ears for many years. Cerebral abscess was diagnosed and the skull trephined with a view to evacuate the pus; a director was passed through the ragged wound in the direction of the abscess; no pus escaped; two days later the man died; it was found post mortem that the director had entered the abscess, but the brain substance, by closing round the instrument, prevented the detection of the pus. (See 'Male Surgical Register,' vol. iv, 1892, No. 2918; and 'Surgical Post-mortem Register,' for 1892, p. 146.)

St. Bart.'s Hosp. Museum, Series xxx, 2486E.

635. Left temporal bone and left half of brain from a case of chronic suppurative disease of the middle ear.

Female, *æt.* 20. Discharge and deafness two years duration. Fourteen days before admission lost consciousness suddenly for a few hours and vomited freely; discharge from ear ceased; there was redness, swelling and tenderness over left mastoid; mastoid cells and antrum freely opened. Died comatose two days after operation. Caries of mastoid antrum extending to mastoid cells, sigmoid groove, tegmen, and forwards along Eustachian tube to margin of carotid canal. The dura mater over temporal bone was intact, but abscess was discovered on incising superior temporal lobe.

Wyatt Wingrave, Esq.

636. Left temporal bone and brain containing temporo-sphenoidal abscess, from a girl *æt.* 12 years.

The bone shows that the radical post-aural operation has been performed, and that the middle fossa has been trephined (Mr. Burghard). In the roof of the antrum is a carious patch with a sequestrum. The dura mater over this is ulcerated through to the site of the abscess. Patient had discharge from the ear for seven years after measles. Fourteen days before admission pain behind ear. Frequent vomiting for four days with severe frontal headache and tenderness and pain behind ear. On admission: face flushed, tongue furred, drowsy, slight blurring of optic discs, temperature 99.2° , pulse 96. Abscess was evacuated; symptoms of meningitis and death within twenty-four hours; temperature $105\frac{4}{5}^{\circ}$, reaching 110 after death.

Arthur H. Cheatle, Esq.

637. A temporal bone, with perforation through tympanic roof. Patient died of temporo-sphenoidal abscess.

St. George's Hosp. Museum, Series xvi, 62C. (See Brain, Series xvi, 61F.)

- 637A. Abscess from preceding specimen dissected out ; thick wall.
St. George's Hosp. Museum, Series xvi, 61F.
638. A case of middle ear disease, showing the communication between the middle ear and a temporo-sphenoidal abscess.
St. Mary's Hosp. Museum, 803A.
- 638A. Left temporo-sphenoidal lobe of an adult brain, belonging to preceding specimen. A red glass rod marks a small aperture in the antero-lateral border ; this communicated with a subdural abscess, and leads to a cavity in the lobe. Two rods mark another aperture leading to the cavity. The cavity on the deep side of the abscess is the descending cornu of the lateral ventricle, found filled with pus at the autopsy.

From a man, æt. 33, admitted semi-conscious, with retracted head and abdomen, tâche cerebral, pupils dilated and insensitive to light, plantar reflexes gone, left ptosis, and ankle clonus and paresis of right upper and lower limbs. On the third day Mr. Silcock trephined and drew off three ounces of pus ; the patient improved for a day or two, then became comatose. The abscess was perfectly drained. See 803A. (See P. M. Reports, Sept. 18th, 1894.)

St. Mary's Hosp. Museum, 746A.

639. Left temporal bone showing slight development of the mastoid cells. There is a perforation in the posterior meatal wall.

From a man, æt. 28, who was trephined for cerebral abscess. (See Pathological Series, No. 947A.)

King's Coll. Museum, 239¹.

- 639A. Brain belonging to preceding specimen.
King's Coll. Museum, 947A.

640. Temporal bone of following specimen.

- 640A. Portion of temporo-sphenoidal lobe with small abscess. Boy æt. 8 years. Left chronic suppurative otitis of some years' duration.

Nov. 26th, 1898.—Right-sided clonic convulsions, commencing above, on and off eight hours. Discharge had stopped two or three days. Condition improved for ten days ; then tenderness over mastoid.

On admission (Dec. 8th) pulse 80 ; temperature subnormal ; foetid discharge left ear ; no optic neuritis ; no slowness of cerebration ; superficial mastoid abscess opened.

Dec. 10th.—Temperature 104° ; mastoid and sulcus lateralis opened ; sinus apparently normal ; blood examined, no streptococci found (Dr. Grünbaum) ; course of case resembled one of septic thrombosis of lateral sinus or of acute septic absorption (oscillating temperature and rigors), and not of uncomplicated brain abscess.

21st.—On puncturing lateral sinus fluid blood was obtained.

22nd.—Frequent vomiting, diarrhœa, feeble rapid pulse, temperature 103°—death.

Post-mortem.—Small abscess in temporo-sphenoidal lobe burst on removal of brain. Lymph found over roof of tympanum and antrum; post-mortem clot in sinuses; carious patches in roof of antrum and floor of tympanum. Death probably due to septic absorption (probably from bulb of jugular vein) and not to the temporo-sphenoidal abscess. Mr. Chas. Shears.

Liverpool Eye and Ear Inf.

641. Temporo-sphenoidal abscess on the left side, the result of middle ear and mastoid suppuration. The left superior and inferior petrosal sinuses contained a little pus. On anterior and posterior surfaces of the petrous on the left side beneath the dura was a thin layer of pus. Above the attic was a perforation of the dura, through which pus could be made to well up. The bone itself appeared healthy. The middle ear and antrum contained pus. The surface of the brain and meninges appeared quite healthy. There was a small area on the under surface of the left temporal lobe which was depressed below the general surface, and a little pressure exercised here caused pus to well up through a small opening at the side of the area (see specimen). A section of the brain near this spot exposed an abscess cavity which contained a drachm of greenish yellow somewhat flocculent pus. Microscopically examined it contained quite a number of degenerated pus cells, and comparatively few staphylococci and pneumococci. The abscess cavity was well defined, limited by a membrane in course of formation. No general meningitis. There were numerous and exceptionally large abscesses in the peripheral portions of both lungs, and both pleural cavities contained some eight ounces of pus. The peritoneal cavity also contained a few drachms of a dirty puriform fluid. (The abscess in the brain was injected with glycerine jelly, which has unfortunately shrunk.) E. F. Trevelyan, Esq.

Yorkshire Coll. Path. Museum.

642. Left hemisphere of a brain; large abscess cavity in the temporo-sphenoidal lobe, which communicated directly by a small opening in the dura mater, and tympanic roof with the middle ear. The dura was inflamed, and adhered to the softened cerebral substance over an area corresponding to the opening now seen. There was a small extra-dural abscess over the roof of the tympanum.

From a woman, æt. 52, who died of pyæmia. Admitted with a history of facial paralysis, "maniacal" fits, and offensive otorrhœa. After admission there was no facial paralysis, no mastoid tenderness till a few days before death. The fits recurred; the patient was always drowsy and semi-conscious. (See Post-mortem Book, 1712. Mr. Boyd's cases, Sept., 1896.)

Charing Cross Hosp. Museum, 950A.

643. Portion of cerebrum; in the left hemisphere is a cavity, an inch and a half in diameter, which contained pus. The cavity is situated over the fissura Sylvii; its walls are distinct, thin, smooth on both surfaces, and easily

separable from the surrounding brain substance. The patient had left purulent otorrhœa for five weeks before death. He died suddenly. The petrous portion of the temporal bone, over which the abscess was situated, was extensively diseased. The brain between the abscess and the bone was dark and sloughy.

St. Bart.'s Hosp. Museum, Series xxx, 2486.

644. Right hemisphere of the brain of a woman æt. 21. It shows a large abscess cavity in the temporo-sphenoidal lobe, a sequela of otitis media. The lobe was swollen and its convolutions flattened; the lateral sinus was normal. There was localised meningitis over the roof of the tympanum; here the dura mater was grey and sloughing and there was a small communication between the abscess and the middle ear. Formalin-glycerine specimen. (See 'Female Surgical Register,' vol. iii (1896), No. 2290 'Surgical Post-mortem Register' (1896), p. 224.)

St. Bart.'s Hosp. Museum, Series xxx, 2486E.

645. Right hemisphere of brain, with abscess in temporo-sphenoidal lobe (Victor Horsley). Hemispheres flattened. Abscess involving parts of each temporo-sphenoidal convolution, clotted foul mass of cerebral tissues surrounded by ring of œdematous solid tissue. No collection of pus found.

From a female æt. 38, whose ear trouble had originated after influenza four months previously. (See 'Univ. Coll. Running Catalogue' (1891), pp. 66, 74.)

Univ. Coll. Museum, 3486A.

646. W. S—, æt. 23 years, had discharge from ears many years ago, but none lately till second week of present illness. He was ill in bed at home three weeks and in the hospital one week before he came under the writer's care on November 5th. A large superficial mastoid abscess (right), and some of the outer cells of the mastoid had been opened.

Symptoms.—Double optic neuritis. Pupils dilated, vision good, no squint, marked "slowness of cerebration"; occasional delirium, severe pain. Pulse-rate had gradually risen from 70 to 90 and 100, and temperature from 97° to 100°. *Operation.*—After opening the antrum and removing the carious tegmen, the dura over it was found to be sloughing, and a probe passed readily through it into a large abscess in the temporo-sphenoidal lobe. The opening was enlarged and the cavity gently washed out with boric acid solution. The probe could be passed directly upwards 2½ inches without meeting any resistance. The patient died ten days after the brain abscess was opened. Post mortem: the abscess cavity was found to be without definite lining, and the brain around it was much softened. Hugh E. Jones, Esq.

Royal Albert Edward Inf., Wigan.

647. A large temporo-sphenoidal abscess, the result of aural suppuration. H. Secker Walker, Esq.
Yorkshire Coll. Path. Museum.

648. Transverse section of a brain containing a small abscess in the temporo-sphenoidal region, the result of aural suppuration. H. Secker Walker, Esq. Yorkshire Coll. Path. Museum.

649. Dura mater and sinuses of following specimen.

649a. Brain, with abscess of occipital and temporo-sphenoidal lobe.

Case II. June 19th, 1897. Boy, J. T., æt. 7 years. Otorrhœa followed scarlatina within a few months, and post-auricular abscess formed seven weeks before admission. This abscess had been incised one inch and a half behind the auricle, and a small discharging sinus existed at that point. When admitted, the abscess was freely opened up. Alarming hæmorrhage occurred from the mastoid vein, which could only be stopped by plugging the foramen. The patient had the characteristic oscillating temperature of septic thrombosis, but rigors and vomiting were conspicuous by their absence until the last three days, when vomiting was frequent. Third day in hospital: mastoid and lateral sinus opened up, the latter full of suppurating broken-down clot. The bleeding from the sinus and from a bunch of veins over the mastoid was so great that the wound had to be plugged up before the sinus could be thoroughly cleaned out. Fifth day a second attempt was made to clear out the sinus. This time an attempt was made to control the hæmorrhage by trephining over the sinus near the torcular, and pushing in the wall with gauze pledgets. Patient died on tenth day. Post mortem: both lateral sinuses were full of suppurating, broken down clot, through which the fluid blood permeated. About one inch from the torcular on the side away from the original lesion the dura was in a sloughing condition, and in contact with this was one end of a large abscess, which extended through the occipital lobe to the anterior end of the temporo-sphenoidal lobe. Hugh E. Jones, Esq.

Royal Albert Edward Inf., Wigan.

650. Right parietal lobe of a brain containing an abscess the size of a pigeon's egg; the cerebral substance round appears to have been so soft as to have allowed of a ready isolation of the wall.

From a girl, æt. 18, who had otitis media four years before death, she had always been subject to earache. Four months before death, and again two weeks before death, a polypus was removed from the ear. Later she was admitted with an acute attack of otitis (November, 1843); epileptic fits ensued, and she died eleven days after admission from abscesses and softening of the brain.

St. Thos. Hosp. Museum, 1989.

651. Left temporal of a boy, æt. 11 years, who died of temporo-sphenoidal abscess. Membrane almost lost. Caries of head of malleus. Loss of incus and head and crura of stapes. Two perforations per roof of antrum. Erosion of outer attic wall. External opening for petro-squamosal sinus present.

Arthur H. Cheate, Esq.

652. Left temporal bone of a patient who died of temporo-sphenoidal abscess. Anterior meatal wall removed. Perforations in Shrapnell and posterior and anterior segments. Large calcareous plaque in posterior and inferior segments. Caries of head of malleus and body of incus. Caries of posterior meatal wall. Caries with sequestrum of roof of antrum.

Arthur H. Cheatele, Esq.

653. Portion of a left temporal bone, showing necrosis of roof and posterior wall of tympanum. Caries of outer attic wall. Mastoid perforated by operation.

From a lad æt. 17, admitted under Mr. Jacobson, with double otorrhœa and symptoms of meningitis. He became hemiplegic; the following day both mastoids were trephined; some pus was evacuated from a cerebral abscess. Post mortem: abscess in left temporo-sphenoidal lobe, pyæmic abscesses in the lungs. (See Insp., 1889, 210.)

Guy's Hosp. Museum, 1074⁷⁶.

654. A left temporal bone from a case of temporo-sphenoidal abscess. There is a perforation 4 mm. in diameter in the roof of the antrum, through which the infective process spread; around the perforation there is some superficial rarefying osteitis. A recent trephine opening exists above and behind the external auditory meatus.

Addenbrooke's Hosp. Museum, Cambridge, 1576.

655. A right temporal bone of a girl æt. 15, who died of temporo-sphenoidal abscess. There are two minute apertures on the upper surface of the petrous portion leading into the attic, and by these the infection into the cerebrum spread. A recent trephine opening exists in the squamous portion.

The patient during the course of her illness suddenly became comatose and ceased to breathe. She was trephined during artificial respiration, and a large temporo-sphenoidal abscess evacuated, but although the pulse continued to beat, the evacuation of the abscess was not followed by the return of the respiratory movements.

Norwich Hosp. Museum.

656. Left temporal bone from a girl of sixteen, who died from an abscess in the left temporo-sphenoidal lobe. The bone has been sawn in an antero-posterior direction. On the outer surface an opening has been made with the chisel into the antrum and a second lower and posterior into the groove for the sigmoid sinus. On the inner surface the ossicles are seen in position. On the upper surface of the smaller and petrous portion of the bone are seen two small openings through which a bristle has been passed. In the recent state the dura mater was softened in this region and adherent to the cerebrum. The antral cavity is large and very freely communicates with the middle ear. The rest of the mastoid is composed of rather more compact bone than usual.

The patient, *æt.* 16, was admitted into the Leeds Infirmary in December, 1893, under the care of Mr. Secker Walker. There had been continuous double otorrhœa since scarlet fever when ten months old. At the age of seven she had for a period violent headache associated with shivering, but remained well until Dec. 3rd, 1893, when she began to suffer violent pain in both ears, with continuous headache. On Dec. 12th she became unconscious for ten minutes with convulsive movements of right side of face and both eyes; the limbs were not affected. There was some difficulty in articulation before and after the fit. On Dec. 18th delirium and coma, she was then brought to the infirmary. The foregoing history was only obtained after the death of the patient. Temperature was subnormal, with slow pulse, muscles of neck rigid, no muscular twitchings. The left mastoid antrum was opened and cleaned, the tegmen examined for perforations but none could be seen; the lateral sinus was then exposed and aspirated, no disease found. The right mastoid and lateral sinus were opened, but no sinus disease found. The following day the coma continued, but the pulse was stronger. The left cerebellar lobe was trephined and explored, but no abscess was found. The patient died two days later. Post mortem: a large abscess was found in the left temporo-sphenoidal lobe, the lower wall adherent to the dura over the antrum. The abscess had ruptured into the descending cornu of the lateral ventricle. The lateral and third ventricles were distended, the distension being of long standing, as shown by the increased size of the foramen of Monro, and a large club-shaped dilatation of the lining membrane of the third ventricle, which projected below the velum. The other organs in the body were healthy.

H. Secker Walker, Esq.

657. Part of a right temporal bone. The antrum has been opened and the bone external to and continuous with it removed, exposing the dura mater, which is separated from the skull anterior to the opening. The dura is opened over the roof of the antrum. The tympanic roof is sound, but the cavity was filled with granulations.

From a boy *æt.* 10, admitted to North-West London Hospital in a state of hebetude, subnormal temperature (86°), slow pulse (56); no history of vomiting; a puffy swelling in front of the ear. The mastoid was cut down on, the antrum opened, a probe passed on the bone towards the swelling; two ounces of stinking pus escaped. The dura was exposed and one ounce of pus escaped. The roof of the antrum was then found to be destroyed; a probe passed easily into the brain, giving exit to more pus. This natural opening in the dura was enlarged, and four ounces of pus escaped from a temporo-sphenoidal abscess. The pulse rose to 100, the temperature to 102° , and death occurred twenty-four hours later.

St. Mary's Hosp. Museum, 746B.

658. Shows chronic middle ear disease; perforation of the roof of the tympanum through to the lateral sinus, and through outer wall. From a case of death from cerebral abscess.

St. George's Hosp. Museum, Series xvi, 62E.

659. Temporal bone showing carious apertures in roof of middle ear, with operation cavity in the mastoid. Death from temporo-sphenoidal abscess.
Thomas Barr, Esq.
660. Temporal bone from child who died of cerebral abscess, showing trephine opening from which the abscess was partially drained. Pus was seen during life coming down in quantities from roof of tympanum. "Otorrhœa cereb-
bralis."
Thomas Barr, Esq.

viii. *Cerebral Abscess with General Leptomeningitis.*

661. Formalin preparation of temporo-sphenoidal abscess and meningitis. Patient æt. 23. Middle ear full of cheesy pus.
St. George's Hosp. Museum, viii, 61P.
662. A right temporal bone with temporo-sphenoidal lobe of the brain. The antrum has been opened, and a way made into the cranial cavity exposing the dura mater, in which is an opening leading into an abscess. The pus has reached nearly to the lateral ventricle. The lateral sinus contains a little adherent clot.

From a woman æt. 44, who had otorrhœa six years before admission. Till seven weeks before admission the ear gave no trouble except deafness; seven weeks before that time the discharge began again; the day before admission she had a rigor. The antrum was opened, pus and granulations removed; then the subdural space was exposed and pus escaped. Several rigors followed. Two days later a trephine opening was made over the temporo-sphenoidal lobe, but no pus obtained. No improvement followed; temperature rose to 107° ; right facial paralysis set in; patient died on the fourth day. Post-mortem: there was this abscess and general suppurative meningitis, which had likely begun before the operations were done. (See P.M. Records, May 4th, 1895.)

St. Mary's Hosp. Museum, 746C.

663. Coronal section of the left cerebral hemisphere from a man æt. 29, displaying a small temporo-sphenoidal abscess, 1 cm. in diameter, which was secondary to otitis media. The probe above it shows the track made by the trocar at the operation performed for the relief of the disease. This track just misses the abscess cavity. The abscess was too small to cause any localising symptoms. The patient died of suppurative meningitis.

Norwich Hosp. Museum.

664. A right temporal bone, divided in three, showing caries of the tympanum and mastoid. The roof of the tympanum is perforated; a ragged opening communicates between the posterior fossa and the mastoid cells, which are full of cholesteatoma.

From a man *æt.* 30, who had had otorrhœa since childhood. In consequence of severe earache, headache, rigors and vomiting, on which symptoms of cerebral abscess supervened, trephining was performed, an abscess reached and evacuated; but basal meningitis co-existed, and the abscess in the temporo-sphenoidal lobe had already burst into the ventricles. (See 'Med. Soc. Trans.,' 1889-90.) Mr. Sheild.

Charing Cross Hosp. Museum, 83A.

ix. *Cerebellar Abscess.*

665. Right temporal bone and cerebellum from a girl *æt.* 17, who died of a cerebellar abscess secondary to otitis media. A vertical transverse section passing through the middle ear exposes the opening of the antrum. A bristle is passed through the perforation in the posterior wall of the antrum into the posterior fossa. The membrana tympani was destroyed, with the exception of a part of the inferior segments. The middle ear (including the antrum) was full of curdy pus, and the ossicles were carious. The roof of the middle ear and middle fossa natural. In the posterior fossa, at a point one eighth of an inch below the superior petrosal sinus and one third of an inch internal to the commencement of the descending portion of the lateral sinus, is a minute perforation leading to the antrum. The dura matter, opposite the same point, was adherent over an area having a diameter of a quarter of an inch. There was a small ragged perforation in this corresponding to that of the bone. The right cerebellar hemisphere contains an abscess sac, rather larger than a walnut, which contained foul greenish pus. It was covered by a thin layer of brain substance which was perforated at a spot corresponding to the above-mentioned perforations. There was no meningitis anywhere but at this one spot. No cranial nerves appeared to have been affected. There was nothing at all the matter with any other part of the brain or membranes, except a very slight adhesion between the frontal lobes of the cerebrum. The sinuses were perfectly natural.

For two years there had been discharge from the right ear. No pain until twelve days before death, when the discharge became less, and severe headache, paroxysmal, and worse over the right side, was complained of. A week later vomiting set in and persisted up to death, which occurred somewhat suddenly.

W. Jobson Horne.

666. Portion of a left temporal bone, sawn to expose the cavity of the tympanum, in which suppuration has occurred. The posterior mastoid cells were most affected; from them the inflammation spread to the posterior fossa of the skull below the lateral sinus, where the dura mater became involved. In it is a rugged opening, which communicated with an abscess in the semilunar lobe of the cerebellum.

St. Bart.'s Hosp. Museum, Series xxxiv, 2676c.

- 666A. A cerebellum belonging to preceding specimen, with a large abscess on the lateral margin of the left semilunar lobe, a sequela of otitis media. The abscess cavity has been evacuated and hardened in its distended condition.

From a man æt. 26, who had suffered from otorrhœa as long as he could remember. (See 'Surgical Male Register,' vol. ii (1892), No. 2951, and 'Surgical Post-mortem Register' for 1892, p. 141.)

St. Bart.'s Hosp. Museum, Series xxx, 2486F.

667. Abscess of left lobe of cerebellum, following middle ear disease and caries of the petrous portion. Numerous small veins leading from the carious bone to the cranial surface contained coagula. (See 'Medical Post-mortem Book,' 1875, p. 350.)

King's Coll. Museum, 941.

668. Portion of right temporal bone of a lad æt. 16. The dura mater covering the posterior aspect of the petrous was raised by subjacent suppuration from the bone. It is thin, softened, and perforated; its inner surface near the perforation is coated with inflammatory lymph.

L. P. B—, æt. 16, admitted semi-conscious under Dr. Sharkey. Could be roused to answer questions, but was very irritable. History of deafness and occasional otorrhœa for seven years; no headache or mastoid pain. Present illness came on suddenly a week before admission with vomiting, headache, shivering, and sweating; the pain increased and he became delirious. On admission, no paralysis; deep reflexes normal; no mastoid tenderness; no thickening or swelling over the internal jugular vein. The ears were syringed with boracic lotion; a quantity of blood-stained pus came from the right. Each meatus was red and inflamed; the right membrane had two small perforations. Death occurred the day after admission without fit or convulsions; tongue dry and brown; temp. 99°; pulse 84; resp. 30.

St. Thos. Hosp. Museum, 1992.

- 668A. The cerebellum from the preceding case. In the right hemisphere, about a quarter of an inch from upper surface, is an abscess cavity about three quarters of an inch in its chief diameter. It followed suppurative middle ear disease, but there is no recognisable extension of disease that can be traced from the exterior.

St. Thos. Hosp. Museum, 1991.

669. Temporal bone, &c., from the following case (669A), showing the operation openings.

St. Thos. Hosp. Museum, 1992B.

- 669A. Cerebellum, with abscess in anterior part of left hemisphere near the internal auditory meatus, following left otitis media. The external opening in the abscesses, marked by two pieces of glass, was caused in removing the

brain; at that spot the cortex was softened and adherent to the softened dura mater covering the inner part of the posterior surface of the petrous bone. The seventh and eighth nerves were softened and discoloured. The track of the pus-seeker, leading from the trephine opening to the cavity, was recognisable by some hæmorrhage in the brain substance.

From a woman, æt. 21, who had left otorrhœa for some years. Three months before admission a polypus was removed from the left ear, after which she suffered from giddiness, a staggering gait, and a tendency to fall forwards to the left; but these symptoms cleared up. Four days before admission she came again to the out-patient department; her otorrhœa was offensive; another polypus was removed. Next day she had severe headache, vomiting, vertigo. Three days later she was admitted, drowsy, complaining of severe pain in the left side of the head, with vomiting, giddiness, and shivering; temp. 100° ; complete paralysis of the left facial nerve; absolute deafness, offensive otorrhœa; no mastoid tenderness or œdema; pupils and optic discs normal; knee-jerks normal; no abnormal signs elsewhere. The following day she was calling out with the head pain; head slightly retracted and neck stiff; face cyanosed; temp. from 98° to 101° ; pulse 80, full and soft; always lying on right side; still vomiting and giddy; tenderness over the left occipital region. Mr. Ballance decided to clear out the mastoid and explore the cerebellum; the superficial parts of the mastoid were extremely sclerosed; no abscesses were struck in the cerebellum. After the operation patient seemed better; pulse 100, stronger; temp. 101° ; no vomiting. This state lasted two days, then severe headache, vertigo and vomiting returned; rotary nystagmus; slightly retracted head; retention of urine; temp. 97° . An attempt, without anæsthesia, was made to strike pus in the cerebellum through the trephine opening previously made; about two drachms of very fœtid pus were drawn from about the apex of the petrous. Patient died one hour later. No meningitis or thrombosis was found at the autopsy. The various internal organs were healthy.

St. Thos. Hosp. Museum, 1992A.

670. Cerebellum, showing the site of a localised abscess in the left lobe resulting from a fracture which extended transversely through the external auditory meatus and tympanum, as well as through the petrous and mastoid portions of the temporal bone. Pus was also diffused through the temporal bone; the internal auditory meatus, with the seventh pair of nerves, was also implicated in the suppuration. The membrana tympani was entirely destroyed.

From a man, æt. 43, who fell off a mail cart on to his head, fracturing the base of the skull. On admission there was hæmorrhage from the left ear and left nostril; he could answer questions; the pupils were equal; he passed water naturally; the left side of the face was paralysed. Three days after the accident the ear discharge became purulent, and subsequently fœtid, and the patient died a fortnight later. (See 'Male Surgical Register,' vol. ii (1886), No. 3410.)

St. Bart.'s Hosp. Museum, series xxx, 2487A.

671. Abscess of cerebellum.

June 14th, 1895.—R. G., æt. 17 years. Otorrhœa off and on twelve months. Patient was confined to bed at home for two weeks with symptoms of inflammation of the brain. A slight improvement allowed his medical man (Dr. Parker, of Ince), to send him to the hospital to have his ear examined. The symptoms present were slow pulse (64), low temperature (97.6°), retracted abdomen, severe pain in ear and forehead, and giddiness without staggering. Right external meatus was full of granulations. No external sign of mastoid disease. First operation (day of admission): antrum and tympanum laid open. The cavities were full of offensive cheesy material. Inner wall rough, tegmen carious and easily broken away, posterior wall and floor smooth and apparently healthy. During next three days there was no marked change. No localising symptoms appeared. Intellect clear and quick. Exploration of temporo-sphenoidal lobe through roof of antrum gave a negative result. On the sixth day, in hospital, the following symptoms appeared. Temperature rose to 102° , pulse 120, left ptosis, conjugate deviation of eyes to left side, nystagmus; while lying on right side on right arm the patient swings his left arm over constantly, striking the bed-side and locker with his closed fist. If anything, the grip of the right hand is stronger than the left, but both are good; the pain in the head and shouting had increased day by day. He had only been sick twice; urine was passed naturally; bowels had acted once; optic neuritis, and slowness of cerebration were absent. Third operation (sixth day). The dura was first exposed through the posterior wall of the cavity in the mastoid, and a probe passed between the dura and bone in the direction of the internal auditory meatus, but no pus was found there. A disc of bone was then removed from the occipital bone, just behind the posterior border of the mastoid, and on a level with its lower half. A fair-sized hydrocele trocar was used for exploring, and this was introduced four times without pus being found. Death occurred next day. Post mortem: we found that an abscess which had embraced the middle peduncle of the cerebellum had burst on its median aspect, bathing the pons in pus. The inner wall of the cavity, towards the pons, was not more than one sixteenth of an inch in thickness. The parts involved were the flocculus, the amygdala and parts of the quadrate and biventral lobes. The outer half of the affected area was still in a semi-solid condition. Into this solid portion one could follow the track of the trocar. Any direct connection of the abscess with mastoid or internal ear could not be demonstrated. There was no evidence of any other intra-cranial mischief. Hugh E. Jones, Esq.

Royal Albert Edward Inf., Wigan.

672. Abscess in left lobe of cerebellum.

From a woman æt. 26. For five weeks she had vomiting and headache, for a few days before admission she shouted and showed other signs of mental excitement. Admitted a few hours before death, drowsy and unable to answer questions; she vomited; complained of headache, especially of the left side; no paralysis of limbs; pupils, especially the left, dilated. Post-mortem: dura mater

adherent to left petrous temporal; but for the cerebellar abscess the brain was healthy; pus in left lateral sinus. (See Post-mortem Book, p. 314.)

Charing Cross Hosp. Museum, 949.

673. Abscess in right cerebellar hemisphere; its wall formed of soft brain substance. The contents were greenish pus; the surface of the cerebellum was sloughing.

From a man *æt.* 25, who for eleven years had right middle ear disease, latterly with profuse discharge and facial paralysis. Complained of deep-seated pain in the ear and over the side of the head.

St. Mary's Hosp. Museum, 747.

674. A cerebellum, with an irregularly-shaped abscess cavity in its left hemisphere.

From a girl, *æt.* 8, admitted to Guy's Hospital with facial paralysis and an abscess behind the left ear. She had a history of otorrhœa for many months. A foul extra-dural abscess was drained by a trephine opening above the external meatus. Death occurred on the third day after the operation. Post mortem: no general meningitis, a cerebellar abscess, the surrounding brain matter being green and sloughy; the lateral sinus was thrombosed. Guy's Hospital.

R.C.S. Museum, 3768A.

675. Cerebellum, &c., with the fibrous wall of a chronic abscess in the left lobe; from a case of middle ear disease.

St. Mary's Hosp. Museum, 745A.

676. Abscess in left lobe of cerebellum due to middle ear disease.

From a boy who had headache, delirium, retraction of head and abdomen, irregular breathing, the hydrocephalic cry, and *tâche* cerebral. He vomited twice. Temperature reached 102.5° . (See Post-mortem Reports, No. 736 (1890); Dr. Broadbent (1890), No. 80.)

St. Mary's Hosp. Museum, 746.

677. Abscess in the cerebellum.

Charing Cross Hosp. Museum, 950.

678. The left temporal bone of a child of 12 years, dead of cerebellar abscess. The posterior and superior wall of the meatus has been absorbed. Seen from the inner surface, a large cavity exists which contained the sequestrum mounted close to. The bone forming the walls of this cavity has been destroyed and absorbed on the superior and posterior surfaces of the petrous. The malleus remains in position. The sequestrum consists of the whole of the cochlea and vestibule and parts of the three semi-

circular canals. The base of the stapes remains in the fenestra ovalis. The right temporal bone from the same child, divided in an antero-posterior direction. The section shows the mastoid cells to have undergone extensive sclerosis. At the inner end of an enlarged internal auditory meatus lies a small sequestrum. The specimen also shows a discoloured sequestrum, removed by syringing through the meatus during life, composed of parts of the cochlea, vestibule, and canals.

The child, a girl æt. 12, was admitted into the Leeds Infirmary under the care of Mr. Nunneley in November, 1893. There had been double otorrhœa for several years following scarlet fever (?). Complete facial paralysis and deafness were present on each side. The sequestrum was syringed from the right ear, and a polypus removed from the left. The otorrhœa diminished very much. Six months later a second polypus was removed from the left ear. This was followed in four days by attacks of vomiting and headache, the temperature being 101.6° . On the sixth day double papillitis with nystagmus when looking to either side was noted, the pupils were equal and reacted to light, the neck was becoming rigid and painful, vomiting and constipation present. Death occurred fourteen days after the onset of general symptoms. Post mortem: the membranes of the brain appear normal except in posterior fossa on the left side, where lateral lobe of the cerebellum is adherent to the dura mater on the posterior surface of the petrous. At this point the dura is covered with a thin layer of lymph which spreads about $\frac{1}{8}$ inch into the interior of the cerebellum, and is separated by a thin layer of apparently healthy cerebellar tissue from a large abscess cavity in the lateral lobe. The rest of the organs were healthy.

H. Secker Walker, Esq.

679. Section of temporal bone, showing erosions in labyrinthine wall of tympanum, denuded facial nerve in tympanum (which was embedded in granulation tissue) dilated antrum and osteo-sclerosis of mastoid. Death from cerebellar abscess.

Thomas Barr, Esq.

680. Temporal bone from case of cerebellar abscess. Suppurative otitis media, mastoid disease, extra-dural abscess in cerebellar fossa, abscess of lateral lobe of cerebellum connecting with extra-dural abscess. Abscess evacuated through mastoid opening and counter-opening made through occipital bone. Richard Williams, Esq., Hugh E. Jones, Esq.

Liverpool Eye and Ear Inf.

681. Base of skull with rough model of part of cerebellum *in situ* to show how an abscess in the same situation as in specimen 680 can be reached with the least difficulty, viz., through the mastoid and along the posterior wall of the petrous bone, and not by a trephine opening in the occipital bone.

Hugh E. Jones, Esq.

x. *Thrombosis of Sinuses.*

682. Portion of skull with right temporal bone, lateral sinus, and internal jugular vein laid open to show the various conditions which have resulted from a suppurative otitis media. (1) The membrane and some of the ossicles have been destroyed. (2) The attic is enlarged and still contains some pus. (3) The jugular vein is filled and blocked by a dark breaking-down clot, and in a state of phlebitis to its termination. (4) To the left the operation opening can be seen. (5) There is suppurative phlebitis of the lateral sinus, which still contains a portion of clot. (6) The mastoid cells, partially opened up at the operation, still contain pus. (7) The superior petrosal sinus is thrombosed.

At the time of the post-mortem there was no clot at the lower end of the jugular vein, so its putrid contents and those of the lateral sinus passed directly into the right innominate veins and so into the heart, giving rise to septicæmia, and in this case also to pyæmia, as shown by a specimen of the lungs. (See Series xi, No. 1711C; 'Male Surgical Register,' vol. ii (1895), No. 807; and 'Surgical Post-mortem Register' (1895), pp. 73 and 74.)

St. Bart.'s Hosp. Museum, Series xxxiv, 2676E.

683. The right temporal bone of a girl æt. 11, who died of lateral sinus thrombosis and pyæmia. The anterior meatal wall, roof of antrum, and roof of middle ear have been artificially removed. There is a small perforation of Shrapnell's membrane with minute granulation coming through. Part of a granulation polypus was removed at the time of the dissection of the anterior meatal wall. The remainder of the membrane is intact. The attic and antrum are occupied by a mass of blood-stained pus and epithelial debris. The head of the malleus and body of the incus are carious, and there is some ankylosis and obliteration of the joint on the superior and outer aspect. The granulation through Shrapnell's membrane appears to be coming from the remains of the head of the malleus. On looking into the groove for the lateral sinus the bone will be seen whitened, roughened, and minutely perforated at a spot corresponding to the lowermost part of the posterior wall of the antrum, and down to this part a bristle has been passed. From this white spot downwards, when the dura mater is reflected, the outer wall of the lateral sinus reaching from the carious area to the masto-occipital suture is discoloured. Occupying the sinus from the top of the sigmoid groove to the jugular foramen is a firm, brownish-yellow septic thrombus. The mastoid vein is also thrombosed. The thrombosis was found to extend along the jugular vein as far as the sterno-clavicular joint. The dura mater over the middle fossa was healthy.

There had been a purulent discharge from the right ear for one month. No history of scarlet fever or diphtheria. Three days before death the patient vomited, and complained of pains in the ear, head, neck, and chest; she became worse. Two days later,

when taken to hospital, the temperature was 102° , pulse 142, and respirations 40. The child had a rigor; temperature rose to 105° . There was tenderness along the anterior border of the right sterno-mastoid and an ill-defined area of induration; the anterior border of the left sterno-mastoid was also tender. There was no paralysis. The patient died on the following day. Post mortem: the internal jugular vein was found thrombosed from base of skull to its junction with the subclavian. The thrombus was apparently of some standing, since the walls of the vein were thickened and adherent to the surrounding structures. Nothing abnormal was met with in the brain itself, in the other sinuses, or in the temporal bone of the opposite side. Some masses of adenoids occupied the post-nasal space. In the lungs were several small abscesses from the size of a pea to that of a pigeon's egg.

W. Jobson Horne, Esq.

684. Portion of the left temporal bone with the cerebral membranes, from a case of middle ear suppuration. The bone is not necrosed. The small puncture was made during life for exploration; it opens into the groove of the left lateral sinus. The sinus itself was filled with the breaking-down adherent and decolorised clot which is suspended over the membranes. The clot extended as far as the torcular Herophili, and thence into the inferior longitudinal sinus for two inches. In one part in the centre of the clot was a distinct circumscribed collection of pus. The left internal jugular vein was filled with a similar clot down to its opening into the innominate vein.

From a boy *æt.* 13, admitted for otorrhœa following an injury to the left ear three months previously. He was drowsy, but conscious, and had pain on the left side of the head. The temperature rose rapidly, and he had a sudden attack of dyspnœa; he died without symptoms of pyæmia.

St. Bart.'s Hosp. Museum, Series xxxiv, 2676A.

685. Upper half of a left temporal bone. The section is in an oblique plane, passing through the middle of the tympanum and antrum; the latter is enlarged, and was closed externally by a cicatricial membrane. The aperture between antrum and tympanum is only a little larger than normal. Only the upper part of the tympanic membrane remained. The ossicles were normal; the sinus was damaged in preparing the specimen. The aqueduct of Fallopius and posterior extremity of the external semicircular canal are seen in section.

From a pale, thin youth *æt.* 16, admitted with a temperature of 103.6° , and very ill. He had several rigors before admission; had a purulent discharge from the right ear. Septic thrombosis of the lateral sinus was diagnosed; the antrum was opened, the sinus exposed, opened, cleared out and plugged. For four days he did well; on the fifth he had a rigor; a few days later he complained of pain in the chest; a left-sided pneumonia was found. Five weeks after admission he died. The opening in the right lateral sinus had

granulated up. There was gangrenous broncho-pneumonia, and an empyema which had been drained, on the left side. The patient had been operated on three years before his death by Mr. Lane for disease of the left temporal bone, which is here shown. (See P.M. Records, May 15th, 1895.)

St. Mary's Hosp. Museum, 801C.

686. Left temporal bone and jugular vein of a child *æt.* 4 years, who died from the sequelæ of acute suppurative otitis media. The bone has been opened up to expose the various parts—(1) The meatus, the middle ear and attic are filled with pus, and the structures in the tympanic cavity disorganised; the suppuration has extended into the labyrinth. (2) From the labyrinth the process has passed into the mastoid cells, as indicated by a bristle. The antrum was opened by operation during life. (3) The jugular vein down to its end, the innominate vein and the superior vena cava show the characteristic appearances of phlebitis, the vessel wall being roughened and covered by fibrinous clot over the whole circumference. (4) The lateral sinus is thrombosed; a red glass rod has been passed from it into the jugular vein. (5) The superior petrosal sinus is also thrombosed. The clinical symptoms were those of septicæmia and pyæmia. (See 'Male Surgical Register,' vol. iii (1893), No. 1058; and 'Surgical Post-mortem Register' (1893), p. 81.)

St. Bart.'s Hosp. Museum, Series xxxiv, 2676D.

687. Thrombosis of the left lateral sinus, petrosal and cavernous sinuses and of the left ophthalmic vein, secondary to chronic middle ear suppuration.

From a patient *æt.* 22, of unsound mind. She had epileptic attacks, ptosis of the left eye, and dilatation of the pupil. There was pain in the left ear.

St. George's Hosp. Museum, Series viii, 32B.

688. Photograph of bone and portion of dura mater with lateral sinuses.

A girl, M. C—, *æt.* 6 years, had otorrhœa for nine months. Fourteen days before admission had vomiting, rigors, stiffness and swelling of neck and over mastoid. Was admitted into hospital on the day on which she was first seen, and the mastoid antrum and tympanum were thoroughly cleared out. On the third day the lateral sinus was exposed and septic clot removed, and at the same operation the internal jugular vein was tied. Marked improvement, lasting four days, followed; then the symptoms recurred, and the patient died on the seventh day. Post mortem: patches of ulceration were found in the opposite lateral sinus. Hugh E. Jones, Esq.

Royal Albert Edward Inf., Wigan.

689. Left temporal bone, showing caries connected with disease of the internal ear; there is a large opening on the superior surface of the petrous bone

communicating with another in the lateral sulcus, and connected with caries of the mastoid cells. The disease appeared to extend from the posterior wall of the external meatus.

From a man æt. 52, admitted under Dr. Gull with headache, pyrexia, &c.; this continued, with occasional rigors, followed by pain and stiffness in the neck. Discharge from left ear and deafness. Death twenty-five days after the accession of the symptoms. Extending from the diseased bone was phlebitis of the lateral sinus, reaching to the jugular vein and producing pleuro-pneumonia. No affection of the brain beyond the discoloration of the membranes.

Guy's Hosp. Museum, 1669⁹¹.

690. Right temporal bone from a lad æt. 16. Perforation into roof of external meatus, lateral sinus exposed by operation through wall of skull. Tegmen removed showing sinus communicating with lateral sinus and the antrum. The sigmoid groove is superficially necrosed. Death from pyæmia, the operation on the sinus being insufficient.

Richard Lake, Esq.

691. Temporal bone from patient who died from otitic sinus thrombosis.

Thomas Barr, Esq.

692. Right temporal bone from a patient who died of pyæmia. Extensive caries through roof of middle ear, and through the apex of the antrum into the groove for the lateral sinus. A large carious cavity involving the whole of the lower half of groove, and extending well under the antrum.

Arthur H. Cheatle, Esq.

693. A left temporal bone of a young woman who died of lateral sinus pyæmia, and upon whom an inefficient mastoid operation for the relief of the condition was performed. The ossicles are present but carious, and about one third of the membrana tympani can be seen. There are two openings on the upper surface of the petrous portion, one .5 cm. in diameter in the roof of the attic, and the other oval in shape and 1 cm. long in the roof of the antrum. The posterior wall of the latter cavity presents a ragged opening 1.5 cm. across, the interior of the antrum thus communicating freely with the lateral sulcus. The brain was healthy.

H. A. Ballance, Esq.

694. Temporal bone, showing caries of posterior wall of mastoid. This case was a typical one of septic thrombosis of lateral sinus; operation on sinus failed to arrest extension of disease; death.

Chas. Shears, Esq.
Liverpool Eye and Ear Inf.

xi. *Thrombosis of Lateral Sinus and Meningitis.*

695. Formalin preparation of the right temporal bone of a boy æt. 19, who died of lateral sinus thrombosis and meningitis. The anterior meatal wall has been removed. The posterior meatal wall is eroded. Shrapnell's

membrane is perforated and the incus lost. There is considerable destruction of the outer attic wall up to the roof of the middle ear. In the middle fossa can be seen some localised pachymeningitis over the roof of the middle ear, which is an irregular carious area and perforated. In the posterior fossa, immediately beneath the superior petrosal sinus in the neighbourhood of the saccus-endolymphaticus, and stretching across the lateral sinus, is an abscess sac indicated by a white rod. The incision through the abscess shows that its walls are between the layers of the dura mater. The abscess has perforated in two directions; there is a perforation (through which a bristle passes) into the posterior fossa causing posterior lepto-meningitis, and on opening the lateral sinus it was found that the abscess had perforated its wall, causing septic thrombosis of the sinus from that point downwards. On reflecting the dura mater from the internal auditory meatus, into which a glass rod has been passed, pus was found surrounding the seventh and eighth nerves. The labyrinth as seen through the bone looked yellow. The roof of the labyrinth has been sawn off and the internal ear can be seen, occupied throughout its entire extent with dark brown pus. The dura mater has been stripped from above downwards to the aqueductus vestibuli, and it can be seen that pus has emerged along the aqueductus to the site of the saccus-endolymphaticus. Infection has spread from the middle ear to the labyrinth, *viâ* the oval window.

There had been discharge from the right ear and deafness since infancy. The patient had been in his usual health, which he regarded as good, up to thirteen days before death, when he felt giddy, perspired profusely in the night, and awoke with a bad headache. He became drowsy and slept badly. On the fourth day after the onset of the symptoms the temperature was 103.5° , the headache persisted, and pain was complained of in the back. The deafness increased, and during the night of the fifth day he vomited three times. Herpes developed on the upper lip and chin. He was fully conscious and rational; the head was retracted and the neck somewhat rigid; the face and arms at times twitched. The pulse was 100, regular, full volume, low tension, and slightly dicrotic. The respirations 40 and tranquil; no facial paresis. The urine was 1013 sp. gr., and contained a cloud of albumen. On the ninth day patient had a rigor lasting ten minutes, temperature rising to 105.4° . The ear continued to discharge freely. The following day the antrum was explored, and also the lateral sinus. The temperature fell to 97° , and he passed a fairly good night. On the eleventh day patient had another rigor, temperature rising to 104.6° . On the fourteenth day of the illness the pulse was 184, temp. 105.6° , and death occurred. Temperature in the rectum immediately after death was 108° . Post mortem: a slight amount of meningitis was found over the pons and medulla, more marked over right than left side, and the serous fluid beneath the tentorium was increased. In the neighbourhood of the mastoid cells on the right side beneath the dura mater, and almost surrounding the lateral sinus, was a collection of pus—about three quarters of a drachm. No pus was found beneath

the dura mater over the middle ear. In the lungs there was some old tubercle at both apices; at the right apex there was one small cavity containing pus. Bacterioscopic examination of the pus from the middle and internal ear yielded diplococci, staphylococci and some streptococci. (*V. Trans. VI Internat. Otolog. Congr.*, p. 392.)

W. Jobson Horne.

696. Dura mater covered with pus, caused by inflammation and suppuration of sinuses. The dura is spread out to show the inner surface, of which the part forming the right subarachnoid space is coated with thick pus; the pus does not pass below the lateral sinus. The lateral and longitudinal sinuses are laid open to show their contents.

From a man æt. 20, who had been ailing for six months, for the latter half of which he had discharge from the right ear. He had an abscess over the mastoid bone, convulsions, partial paralysis; he became unconscious, and died. Post mortem: the middle ear was full of sanious matter and the membrane perforated. A small canal containing a vein was discovered, which made a direct communication between the tympanum and the lateral sinus. (See '*Path. Soc. Trans.*,' vol. xv, p. 26.)

St. George's Hosp. Museum, Series viii, 33A.

697. A right temporal bone. The antrum and mastoid cells have been opened. The dura over the tympanic roof was raised by an extra-dural abscess, sloughy and perforated, as marked by a bristle. A second bristle shows where the dura lining the groove of the lateral sinus was also detached. Pus had entered the lateral sinus by a second perforation.

From a woman æt. 20, with a history of otorrhœa for four years. A week before admission she noticed a swelling behind the right ear. It increased for three days, when a large discharge of pus came from the ear. A few days later rigors set in, and the patient was sent to the hospital. The antrum and mastoid cells were first opened. Next day the patient became unconscious and moribund before anything further could be done. After death the base of the brain was found covered with a subarachnoid collection of pus, chiefly on the under surface of the cerebellum and right temporo-sphenoidal lobe. (See Post-mortem Records, April 27th, 1893.)

St. Mary's Hosp. Museum, 801D.

xii. *Thrombosis of Lateral Sinus and Temporo-Sphenoidal Abscess.*

698. Two sections of temporal bone, showing erosion at groove of lateral sinus; also dilated antrum and osteo-sclerosis of mastoid. It was from a case of cerebral abscess with complete occlusion of left lateral sinus.

Thomas Barr, Esq.

699. Temporal bone showing caries communicating with the internal ear. The roof of the tympanum is destroyed; when recent, the cavity, the vestibule, and semicircular canals contained a cream-like fluid.

From a woman æt. 23, who had right otorrhœa and more or less deafness since infancy. A fortnight before death she complained of headache; this continued till it was clear the brain was seriously involved. She died with marked cerebral symptoms. Post mortem: the inferior part of the right middle lobe was filled with purulent fluid. This was connected with disease of dura mater and lateral sinus, situated over a carious temporal bone. There was a polypoid growth in the auditory canal. (See 'Guy's Hosp. Reports,' Series iii, vol. iii, p. 279.)

Guy's Hosp. Museum, 1669⁹².

xiii. *Thrombosis of Lateral Sinus, Temporo-Sphenoidal Abscess, and Meningitis.*

700. Right temporal bone of a patient who died with meningitis. Thrombosis of lateral sinus and temporo-sphenoidal abscess.

The patient brought to hospital almost *in extremis*. Extensive operation exposing middle and posterior fossæ by G. Lenthal Cheate. The dura mater shows extensive pachymeningitis in middle and posterior fossæ. An abscess cavity lies behind the jaw, pus having come through anterior bony meatal wall (Huschke's Foramen.)

Arthur H. Cheate, Esq.

xiv. *Thrombosis of Lateral Sinus and Cerebellar Abscess.*

701. Cerebellum containing a large abscess in the right lateral lobe, secondary to right middle ear disease.

The patient, æt. 10 years, had right otorrhœa for nine weeks, was drowsy, answering questions rather slowly but correctly. Complained of headache and tenderness on moving the head from side to side. No external signs of mastoid disease. There was a history of frequent vomiting. Paresis of the left arm and leg, and slightly (?) of the left side of the face. Knee reflexes absent. Pupils dilated, hardly react to light. Double optic neuritis, with many hæmorrhages in the right fundus. Urine passed involuntarily. Constipation marked. Pulse and respirations very slow, the latter irregular. Temperature varied between 98° and 99°. The patient died before operation could be commenced. Post-mortem showed mastoid disease, right cerebellar abscess, with thrombus in the lateral sinus. The brain abscess was not visibly connected with the bone disease.

H. Secker Walker, Esq.

702. The temporal bones from a boy æt. 7 years. The right shows a good result of the post-aural radical operation two and a half years after its performance. A recent infection of the left middle ear led to lateral sinus thrombosis and cerebellar abscess; death resulting in spite of thorough operation.

P. de Santi, Esq.

703. Right temporal bone with cerebellum containing an abscess, from a woman æt. 53. Large fungating wound below ear. Loss of inferior and

anterior bony meatal walls. Extensive caries and perforation of posterior bony meatal wall to within half inch of orifice. Caries of articular process of incus and handle of malleus. Middle ear opened artificially from above and found full of inspissated pus and cholesteatoma. Perforation through apex of antrum to posterior fossa internal to sigmoid groove. The caries extended under the middle ear, all cavities communicating with one another and with the fungating wound in neck. Thrombosis of lateral sinus. Discharge from ear since childhood. Dull aching pain in ear five months, worse at night. Abscess below and behind ear eight days.

On admission.—Throbbing pain behind ear; facial paresis, rigors. Temp. 99.8° . The sinus was exposed, found thrombosed, incised, cleared out, and internal jugular ligatured and divided. The external jugular thrombosed and ligatured. Did well for twenty days. Headache, vomiting, drowsiness and irregular temperature. Death in spite of exploration of cerebrum and cerebellum.

Arthur H. Cheate, Esq.

704. Abscesses of the left lobe of the cerebellum, following middle ear and mastoid suppuration; from a boy, *æt.* 10. There was an abscess in the lateral sinus communicating with that in the mastoid bone. The cerebellar abscess did not communicate with that in the lateral sinus, but their walls lay close together. (See Medical Post-mortem Book (1874), p. 239.)

King's College Museum, 940.

705. Right adult temporal bone divided into two by a vertical saw, cut through the middle ear and antrum. On the outer surface an oval opening has been chiselled, leading anteriorly into the mastoid antrum, and posteriorly by a larger opening into the sigmoid groove. The antrum is enlarged, the malleus is carious, the incus and stapes have disappeared.

Four weeks before admission into the Leeds Infirmary, under the care of Mr. Walker, the patient was seized with pain in the right ear, followed by otorrhœa; the membrane was incised to enlarge a small perforation. The pain increased and the temperature rose. The mastoid was opened, not much disease appeared, and liquid was easily syringed through the meatus from behind. The sigmoid sinus was then exposed, its walls appeared white and quite healthy; it was not incised. The patient gradually sank and died in a few days. Post mortem: a cerebellar abscess was found on the right side abutting on the lateral sinus, which was filled with pus from the torcular herophili to the internal jugular vein. Neither the phlebitis nor cerebellar abscess had given rise to symptoms sufficient for diagnosis during treatment.

H. Secker Walker, Esq.

706. Left temporal bone of a boy *æt.* 11 years, who died of cerebellar abscess and thrombosis of the lateral sinus. The anterior meatal wall is removed, showing a granulation coming through Shrapnell's membrane. Perforation through roof and posterior wall of antrum. Pachymeningitis in

both situations. Discharge from ear one month. Ten days ago fell down, and complained of headache and earache. Temperature 99° ; pulse 66; respiration 24. No vomiting or giddiness. Coherent, general headache. No oedema over mastoid. Rather drowsy, but easily roused. Death fourth day, with temp. 104° . Abscess in cerebellum size of chestnut. Thrombosis and pus in lateral sinus. Arthur H. Cheatele, Esq.

xv. *Thrombosis of Lateral Sinus, Cerebellar Abscess, and Meningitis.*

707. Section through right temporal bone, exposing mastoid cells and tympanum. The membrana tympani is destroyed. Tympanum and mastoid cells are filled with pus. At the junction of the posterior surface of the petrous with the mastoid bone there is a small opening, marked by a piece of wire, through which pus passed from the mastoid cells to the under surface of the dura mater, where a small collection was found. There was also an abscess in the right half of the cerebellum, and the right lateral sinus contained a thrombus.

From a girl æt. 16, who was attacked with earache and otorrhœa seven days before her death, which was due to meningitis. A year previously she had a similar attack of earache, which was relieved by a profuse discharge of pus from the ear. (See Hope Ward Book, vol. vii, p. 455.)

St. Bart.'s Hosp. Museum, Series xxxiv, 2676.

xvi. *Hernia Cerebri.*

708. Mushroom-shaped hernia cerebri. The convex superficial part is separated by a groove from the part by which the protrusion was attached. The microscope shows brain matter infiltrated by inflammatory cells.

From a boy æt. 9, who began to have otorrhœa and to lose his sight eight months before admission. He had a sinus discharging behind the left ear, in which he was totally deaf; double optic neuritis, from which he was nearly blind; and weakness and some wasting of the right face and limbs. He was trephined over the back part of the left temporo-sphenoidal lobe and over the cerebellum, but no pus was found. A month later the hernia formed. It increased in size for some months, and was then removed by Pacquelin's cautery. It returned. (See Register, No. 562, 1890.)

St. Mary's Hosp. Museum, 725.

NOSE.

709. Perforation of the septum nasi. A large oval hole is seen in the cartilaginous portion of the septum. The bony portion is not affected. The specimen was removed from a man æt. 80, who died from carcinoma of the rectum. The origin is presumably a simple ulceration. (See 'Male Surgical Register, vol. iii (1894), No. 98; 'Surgical Post-mortem Register' (1894), p. 6; 'Proceedings of Laryngological Society' (1895), February 13th.)

St. Bart.'s Hosp. Museum, Series xii. 1763A.

710. Nasal fossæ showing necrosis of fore part of septum.

From a negress æt. 21, who died of septicæmia following symptoms of acute rhinitis.

St. Mary's Hosp. Museum, 1055.

711. Polypus with distinct delicate pedicle growing from the septum of the nose at junction of cartilaginous septum with vomer.

C. A. Moore, Esq.

712. Part of right side of a skull, showing nasal fossæ. The middle turbinal has been raised to display a small sessile mucous polypus on the outer wall of the middle meatus in front of and below the antral opening. A piece of whale bone has been passed into an unusually large ethmoidal cell, which forms a low eminence in the lateral boundaries of the fossa, and has been artificially opened from below.

St. Thos. Hosp. Museum, 1902.

713. Part of a head, showing the nasal fossæ from below, with a large gelatinous polypus attached to the anterior part of the left middle spongy bone, and to the mucous membrane below the orifice of the antrum; it extends the whole length of the floor of the nostril and through the posterior nares. It has exactly adapted its form to that of the parts round it.

R.C.S. Museum, 3936.

714. A preparation of the bones of the face and cranium surrounding the right nasal fossa. A pyriform, gelatinous polypus projects into the anterior part of the fossa, springing by a broad pedicle from its outer wall anterior to the middle spongy bone. The mucous membrane covering that bone is hypertrophied. The cavity of the antrum appears normal.

R.C.S. Museum, 3936A.

715. Part of the left side of a head. A flattened mucous polypus, measuring $1\frac{1}{2}$ inches from before backwards, fills the anterior half of the middle meatus, to the roof of which it is attached. Similar smaller growths project from the lower border of the superior turbinal bone.

St. Thos. Hosp. Museum, 1901.

716. Sections of a nose, exhibiting on each side large, soft polypi suspended from the mucous membrane, covering the inferior and middle spongy bones. One polypus of smaller size is situated in the frontal sinus.

St. Bart.'s Hosp. Museum, Series xii, 1764.

717. Part of a skull with the palate removed. The nasal fossæ are nearly filled with polypi growing from their outer and upper walls. The membrane over the lower border of the left inferior turbinal is prominent and deeply corrugated, an early condition of the disease.

St. Thos. Hosp. Museum, 1900.

718. Polypi of the nose; one attached to the os unguis, the other to the turbinated bone.

Guy's Hosp. Museum, 1662.

719. A section of a nose and palate, showing a polypus in the upper fossa of the nose. From a man æt. 40, a dissecting-room subject.

Middl. Hosp. Museum, 1151.

720. Nasal polypus.

St. George's Hosp. Museum, Series xvi, 51E.

721. A large lobed polypus of soft texture, which was extracted from the nose. A portion of it which hung into the fauces is opaque, apparently from the thickening of its investing membrane; the rest is soft and more nearly transparent.

It was removed from a young lady in whom obscure signs of its existence had long been observed. It was attached to the mucous membrane of the nose by the narrow portion by which it is now suspended. The larger part of it lay in and projected from the posterior aperture of the nostrils, through which also the whole mass was extracted by seizing the portion which was hanging in the fauces.

St. Bart.'s Hosp. Museum, Series xii, 1768.

722. Large nasal polypus containing several cysts. It occupied the post-nasal space, and a red nipple-like process of it extended below the level of the uvula for about one inch. Patient was a female æt. 45, who suffered from temporary attacks of deafness and difficulty of breathing at night.

Herbert Tilley, Esq.

723. Numerous polypi removed from the nose. They are of soft texture, semi-transparent or gelatinous in aspect, and several of them were attached to the mucous membrane of the nose by long, narrow pedicles.

St. Bart.'s Hosp. Museum, Series xii, 1765.

724. Several polypi removed from the nose by Mr. Heath. In the middle of the large mass the turbinate bone is seen, a piece of blue glass marking its position. Other parts of the turbinates are also present.

Univ. Coll. Museum, 1382A.

725. Polypi removed from the nose. They are of firm, semi-transparent texture, and with the one which is suspended a large portion of the inferior spongy bone is connected.

St. Bart.'s Hosp. Museum, Series xii, 1766.

726. Two polypi, like those last described, attached by narrow pedicles to the inferior surface of the body of the sphenoid bone.

St. Bart.'s Hosp. Museum, Series xii, 1767.

727. A large naso-pharyngeal polypus removed by avulsion from a girl. It consists of myxomatous tissue with a little fibrous tissue. A microscopic section is preserved in Series lv, No. 186, St. B. H.
St. Bart.'s Hosp. Museum, Series xii, 1769A.
728. A large, oval, slightly lobulated, polypoid growth, measuring $2\frac{1}{2}$ inches by $1\frac{1}{2}$ inches, from the naso-pharynx. The thin mucous membrane covering it has been in great part removed by ulceration. The section of the tumour shows a firm, almost homogeneous opaque substance, in places indistinctly fibrous, scattered through which are a few cysts. When fresh there was a rounded projection from the lowest part of a dark red colour, the surface of which was ulcerated. From a woman æt. 43. The tumour was attached to the posterior nares, protruded into the pharynx, impeding respiration, deglutition, and speech. Removed by Mr. Liston by ligature.
Univ. Coll. Museum, 1383.
729. A myxomatous naso-pharyngeal polypus, about three inches in length, with a base nearly an inch in breadth. The part which occupied the right nasal passage is firmer and whiter, and is somewhat constricted off from the remainder of the polypus. The growth was removed by avulsion from a woman æt. 33, in whom it had been growing for three years. (See 'Female Surgical Register,' vol. v (1886), No. 2743.*)
St. Bart.'s Hosp. Museum, Series xii, 1768B.
730. A large, deeply-lobed polypus, which was extracted through the fauces. The patient was an elderly lady. She had long observed the disease, and had herself removed portions of the polypus by seizing it with pincers whenever she could force it towards the cavity of the mouth, and cutting it with scissors. The part which was thus cut presents a cicatrised surface.
St. Bart.'s Hosp. Museum, Series xii, 1769.
731. A large, lobed, naso-pharyngeal polypus removed from a girl. It is composed of soft fibrous mucous tissue.
St. Bart.'s Hosp. Museum, Series xii, 1768A.

ACCESSORY SINUSES.

732. A right superior maxilla (from a subject in the dissecting-room); the orbital plate has been removed to open the antrum, within which is a long pyriform polypus, resembling in its general characters those found in the nasal cavity. It is attached by a narrow pedicle to the posterior part of the inner wall.
Univ. Coll. Museum, 1384.
733. Empyema of left antrum.
St. George's Hosp. Museum, Series xvi, 45 and 46.

734. Right superior maxilla ; piece of whalebone passed through a perforation made during life in the anterior wall of the antrum above the second bicuspid tooth, the fang of which projects into the cavity. Considerable deficiency in the antral walls posteriorly, the lowest part of the loss apparently due to disease. The cavity contained a quantity of dark brown, foetid fluid ; the mucous membrane of the posterior part was sloughing, and floated in shreds in the contained fluid.

St. Thos. Hosp. Museum, 853.

735. The antrum Highmori laid open. The lining membrane is greatly thickened, the opening into the middle meatus of the nose is widely dilated, and the mucous membrane of the middle meatus greatly thickened. The antrum contained a fair amount of pus, which has been washed out. The superior maxilla had to be removed to get access to a polypoid growth filling the nasal cavity and naso-pharynx. This growth was extremely vascular, and the patient's life had been endangered through repeated hæmorrhages ; microscopically it consisted of a fibrous stroma, intersected by innumerable vascular spaces and capillaries. Patient's age 21 years. (See Male Surgical Register, vol. iv (1894), No. 722.)

St. Bart.'s Hosp. Museum, Series xii, 1774A.

736. Right upper maxilla with antrum Highmori, which had been the seat of an empyema. The antrum is enlarged, its lining is generally thickened, and posteriorly is a polypoid mass. The first molar tooth was removed to evacuate the pus ; the anterior alveolar plate is partially necrosed and destroyed. A blue glass rod shows the communication between antrum and fang cavity.

The patient, a boy æt. 11 years, had a severe attack of toothache, followed by swelling of the right cheek, discharge from the right ear, and severe constitutional disturbance ; also purulent discharge from the right nostril and posterior nares. The antrum was opened from the alveolus, but symptoms persisted, rigors became frequent, the inflammation spread over the face and neck ; the boy died within two months of the onset of the toothache. A post-mortem revealed meningitis, suppurative thrombosis of the cavernous sinuses, gangrenous cellulitis of left orbit, necrosis of the right lower maxilla, and abscesses in the lungs. (See Male Surgical Register, vol. v (1894), No. 2790 ; Surgical Post-mortem Register (1894), p. 157.)

St. Bart.'s Hosp. Museum, Series xii, 1774B.

737. Superior maxillæ and adjacent bones, removed after death from a lad æt. 18, who suffered from phosphorous necrosis. The following bones were denuded of periosteum and dead. On the right side : the whole of the upper maxilla, the molar, external and internal angular processes of the frontal, and that part of it in contact with the lachrymal and nasal bones, except at the base ; all the internal pterygoid plate and the front part of the external pterygoid plate of the sphenoid ; also a narrow strip of the orbital

plate of the greater wing adjacent to the malar; all the palate bone; the inferior spongy bone and the back part of the middle one; the os planum of the ethmoid, which, however, was whiter than the other bones. On the left side: the whole of the upper maxilla with all the teeth, the orbital surface, the back part, however, being less stained; that part of the malar bone adjacent to the superior maxilla; all the palate bone except the orbital process; the inferior spongy bone; the lachrymal, which was less stained above than below; the nasal bone, except at the base; the os planum of the ethmoid, which was whiter than the other bone; the vomer, except a strip in the middle third of the right side, which was still covered; below it was quite separated from the crest of the maxilla and the palate bones, and from the perpendicular plate of the ethmoid behind. In some parts the surface of the bones has a worm-eaten appearance, and in others is coated with a rough deposit of new bone.

St. Bart.'s Hosp. Museum, Series i, 230.

738. The greater part of the two superior maxillary bones in a state of necrosis, removed from a man æt. 34.

St. Bart.'s Hosp. Museum, Series i, 231.

739. Gangrenous stomatitis of the superior maxillæ, involving the antra; blood-clot in right antrum.

Charing Cross Hosp. Museum, 685B.

740. Anterior part of the skull of a man who died of arachnitis after removal of an ivory exostosis from the frontal sinus. About eighteen months previously a similar exostosis was removed from the left frontal sinus without ill results. The operation was repeated for a growth on the right side; the dura mater was injured, and fatal arachnitis followed. The exostosis was lobulated and appeared to spring from the nasal processes of the frontal bone. The frontal sinuses were much enlarged, and in parts their bony walls were deficient. A small portion of the exostosis is shown *in situ*. The lacerated dura mater is preserved, with flakes of lymph on the arachnoid lining.

Lond. Hosp. Museum, 308.

741. Bones of face, showing caries of antrum of Highmore and frontal sinus.

After an attempted extraction of the first upper molar tooth an orbital abscess formed and was opened. Purulent discharge from the nose; antrum opened; subperiosteal abscess in roof of orbit and frontal sinus also opened; coma; abscess found and drained in frontal lobe; death. Post mortem: thick walled abscess in frontal lobe with softening of brain tissue around, reaching anterior horn of the lateral ventricle.

Royal Albert Edward Inf., Wigan.

- 741A. Abscess in the frontal lobe from preceding case.

Royal Albert Edward Inf., Wigan.

742. Part of the anterior and middle lobes of the left hemisphere of a cerebrum. Near its lower part is a small circumscribed abscess with a well-defined wall. Its internal surface is nearly smooth; its walls are from half a line to a line in thickness, they are partly separated from the subjacent brain substance, with which they appear to have been very intimately united. The dura mater is thickened and firmly adherent to the surface of the brain over the abscess.

From a girl *æt.* 24. Three years before death she was stunned and her nasal bones broken by a blow on the face; previously she had been healthy. Her lower jaw began slowly to close from the time of the accident, she was never after able to depress it more than a quarter of an inch. For four months she was delirious. Two abscesses formed at the side of the face and throat. After the delirium ceased her left eye became inflamed and perished, though timely and actively treated. For more than six months before death she had acute headache; for the last three months she was often incoherent and wandering; in the last fortnight she lost all power of voluntary motion. Besides this abscess there was one beneath the pia mater on the right side, the lateral ventricles were distended with thick, foetid, greenish-yellow pus, and their internal surfaces were diseased. The dura mater was thickened but not ulcerated. There was extensive ulceration of the inner table of the upper part of the skull. (See specimens 1263 and 3766, R.C.S. Museum.)

R.C.S. Museum, 3767.

743. Portions of brain, skull, and cerebral membranes exhibiting a hernia cerebri. The front of the preparation shows a vertical section of the protrusion and of the part of the brain from which it has arisen. In the centre of the protruded brain, which consists of medullary substance, the vessels have given way and blood is effused in it. The portions of the skull and of the membranes of the brain surrounding the base of the protrusion were included in the section, to show how the protrusion has occurred through the openings formed by ulceration in the dura mater and pia mater, and through the aperture in the bone.

St. Bart.'s Hosp. Museum, Series xxx, 2525.

- 743A. Section of the protruded brain of preceding specimen. The deep groove intervening between the outer part of the protrusion and the portion of brain from which it has arisen was occupied by the bone and by the membranes of the brain.

From a boy *æt.* 13, who sustained an extensive fracture of the frontal bone, several pieces of which were removed without injury to the dura mater. The hernia began on the fifth day after the injury and increased without disturbance of the intellect or other remarkable symptoms till the tenth day, when it was cut off; it consisted of healthy cortical and medullary substance. For ten days the protrusion was restrained by firm pressure; insensibility ensuing, the pressure was removed, whereupon the protrusion progressed and the patient died of brain softening twenty-seven days after receiving the

injury. (See Mr. Stanley's article in the 'Medico-Chirurgical Transactions' (1817), vol. viii, p. 22.)

St. Bart.'s Hosp. Museum, Series xxx, 2526.

744. Hydrorrhœa. A preparation exposing the cavity of the left antrum. Two gelatinous growths cover the lower part of the outer wall; they spring respectively from the anterior and posterior walls.

From a lady æt. 50. For nearly two years before death, except the last month, a clear watery fluid dropped almost constantly from the left nostril. About six months before the commencement of the discharge she received a heavy blow over the left frontal sinus. A drop of the discharge would fall on the lip every five or six seconds, and the quantity was always increased by mental distress or straining. Its specific gravity varied from 1010 at first to 1004 later, it contained a little over one per cent. of solid matter, chiefly chloride of sodium. Sulphate of zinc was given internally and by the nasal douche; after two months of this treatment the discharge ceased. A month later, after exposure to cold, during a period of great distress, she was seized with acute meningitis and died in three days. Besides the meningitis no morbid condition could be detected outside the left antrum; in that cavity were traces of collapsed and degenerated polypi as well as the two shown. (See 'Trans. Clin. Soc.,' vol. xii (1869), p. 43.) Sir James Paget.

R.C.S. Museum, 3944.

FAUCES.

745. Enlarged tonsil, showing follicular tonsillitis; removed, mostly with the finger nail, under cocaine.

St. Mary's Hosp. Museum, 1058B.

746. A tongue with the soft palate and its arches; exhibits an enlarged right tonsil with deep and ragged ulceration.

St. Bart.'s Hosp. Museum, Series xii, 1805.

SPECIFIC INFLAMMATION.

Leprosy.

EAR.

747. Model of the face and ear of a man with tubercular leprosy. The nodules, clustered on the supra-orbital, malar, and mental eminences, have the average size of a pea. The lobule of the ear is enlarged. The face is dusky and purplish.

St. Mary's Hosp. Museum, 481B.

748. Leprosy of ear.

Univ. Coll. Museum, 6292B

Tuberculosis.

749. Right temporal bone of an infant who died of general tuberculosis. Tuberculosis of middle ear. A perforation in the posterior segment of membrane. Lining membrane thick and nodular. Ossicles intact. Middle ear contained cheesy pus. Sections of the lining membrane show tuberculosis. (*Vide* specimens in Microscopical Collection 941, the latter showing tubercle bacilli.) Arthur H. Cheatele, Esq.
750. Left temporal bone of a child who died of general tuberculosis. Tuberculosis of middle ear. Complete loss of membrane. Middle ear was full of brown pus. Handle, short process, and neck of malleus lost. Descending articular process of incus lost. Necrosis of tympanic ring. Perforations through floor of middle ear. Stapes in position. Caries of promontory above and around the round window. Arthur H. Cheatele, Esq.
751. Right temporal bone of an infant who died of general tuberculosis. Tuberculosis of middle ear. The antrum was opened during life, caries of the middle ear roof found at the operation, exposing roughened dura mater. Disease extended until death occurred. The line of extension can be seen, the affected bone being porous and white. The Fallopian canal carious, the facial nerve destroyed. The promontory rough and carious. Both the fenestræ irregularly enlarged, the disease having invaded the labyrinth. Sections of exposed dura mater of middle fossa showed tuberculous disease. Wire passed through Fallopian canal. Arthur H. Cheatele, Esq.
752. Left temporal bone of a child who died of tuberculosis, tympanum acutely inflamed. When recent the cavity was filled with a puriform mucus, and the mastoid cells with a viscid fluid. Membranous bands united the incus and stapes; the mucous membrane of the tympanum and Eustachian tube was red and thick. The other ear was somewhat similarly affected.
From a child, æt. $3\frac{1}{2}$; the hearing was not observed to be affected during life.
Guy's Hosp. Museum, 1669⁸⁵.
753. The base of a skull, from a young subject, exhibiting extensive ulceration through a part of the parietal and temporal bones, the effects of tuberculous disease.
St. Bart.'s Hosp. Museum, Series i, 133A (Case F).

Syphilis.

754. Right half of a skull. Irregular ulceration has destroyed great parts of the outer table of the frontal and temporal bones, and parts of the entire thickness of the mastoid part of the latter, in which is a large opening; the petrous temporal is also deeply ulcerated, the internal ear laid open, and the roof of the tympanum destroyed. In all these situations, portions of

bone, after being separated by necrosis, lie loose; at the posterior inferior angle of the parietal bone a scale-like portion only of the internal plate, about two inches long, has been detached. The whole skull is thickened; the diploë is in many cases converted into compact substance.

Univ. Coll. Museum, 605.

755. Syphilitic middle ear disease, showing thickening and destruction of bones.

St. Mary's Hosp. Museum, 805B.

NOSE.—ACCESSORY SINUSES AND NASO-PHARYNX.

Erysipelas.

756. Portions of the left frontal bone from the same case as following specimen. Bristles have been passed into small openings with ragged, uneven edges, in the outer table, and in the horizontal and orbital plates; these result from ulceration. The lining membrane of the frontal sinuses is thick and velvety.

St. Bart.'s Hosp. Museum, Series xxx, 2486D.

- 756A. The anterior half of the lateral hemispheres of a brain, from preceding case. Beneath the left frontal convolutions the brain substance has been excavated by a large abscess; a part of the wall has been removed to show the cavity. The cavity extends backwards towards the lateral ventricle, with which it now communicates, the thin partition having been broken since the specimen was removed from the body. There is also marked bulging of the left frontal convolutions on the inner aspect of the hemisphere, accompanied by a corresponding depression of the right hemisphere.

From a man, æt. 25, admitted with erysipelas of the left side of the forehead. The inflammation spread to the frontal bones, thence to the frontal sinuses, causing a localised necrosis of the horizontal and orbital plates (see No. 2486D), and spreading through the former to the dura mater and brain. (See Male Surgical Register, vol. iv, (1890), No. 582.)

St. Bart.'s Hosp. Museum, Series xxx, 2486C.

Variola.

757. Nose, naso-pharynx, pharynx, and larynx, from a case of small-pox. King's Coll. Museum, 1386.

Tuberculosis.

758. A small growth removed by operation from the septum nasi of a girl æt. 10 years, which microscopically proved to be tuberculous (Lupus nasi). She had had suppurating tuberculous glands in the neck, and seven years before admission the nose became swollen, and a "polypus" was removed. On admission nasal respiration through the right nostril was difficult;

there was a yellow discharge, and on the septum a mass of granulations. (See Histological Records, xii, 1763B; Female Surgical Register, vol. iv (1897), No. 568.)

St. Bart.'s Hosp. Museum, Series xii, 1763B.

Lupus.

759. Model in wax of lupus of face and nose.
King's Coll. Museum.

760. Skull, showing destruction of bones of the face by lupus.
Univ. Coll. Museum, 702B.

Glanders.

761. Three wax models by M. Baretta, Hôpital St. Louis, Paris. Chronic farcy. Model of a woman's face. The upper lip is almost destroyed by ulceration, which has extended to the nose and hard palate; the appearance resembles severe syphilitic ulceration.

St. Mary's Hosp. Museum, 481A.

762. Septum nasi of a man affected with glanders. The mucous membrane is thickened, presents groups of minute circular ulcers, apparently originating in the glands.

St. Thos. Hosp. Museum, 1899.

763. Upper jaw, nose, septum, and adjacent parts from a case of human glanders. Certain of the lesions shown probably depend upon tertiary syphilis, from which the patient also suffered. Externally the nose and upper lip show extensive ulceration and scabbing, giving the surface a blackened and eroded appearance. The ulceration extends into the nostrils and is seen on the septum nasi. The latter is perforated behind, probably as the result of syphilis, and part of the necrosed vomer lies in the perforation. The mucous membrane of the septum shows several yellowish-white glanders nodules, and the left antrum, which has been laid open, presents similar appearances. It would appear that in this case recent glanders lesions have been superposed on old lesions of tertiary syphilis.

From a man æt. 37 years, who had contracted syphilis sixteen years before his death. Ten days before admission his left eyelid swelled; it grew worse, and an inflammatory condition resembling erysipelas spread over the face. On admission there were pustules over the nose, and there was great constitutional disturbance. The skin of the nose became gangrenous; there was a discharge from the nostrils. The patient died four days after admission. No source of infection could be traced. (See Surgical Post-mortem Register (1897), p. 239; Male Surgical Register, vol. iv, (1897), No. 2991; 'Transactions of the Pathological Society,' vol. xlix, (1898), p. 20.)

St. Bart.'s Hosp. Museum, Series xii, 1763C.

764. Portion of the septum nasi of a horse, exhibiting pustules and ulcers of the piuitary membrane. Each separate ulcer is small and circular; but on the posterior part of each surface of the septum there is a large extent of ulceration of an irregular form, probably the result of the coalescence of many small ulcers.

The disease was produced by inoculation with matter taken from an abscess in the arm of a man who was believed to have been infected by glanders. Previous to inoculation the horse was healthy.

St. Bart.'s Hosp. Museum, Series xii, 1763.

Rhino-scleroma.

765. Model of lower part of face of a person suffering from rhino-scleroma. The upper lip is swollen and projecting. Its upper surface is rough as if from ulceration, on its lower surface the small veins are dilated.

St. Mary's Hosp. Museum, 481C.

Syphilis.

766. Part of the right half of the head of a man, the subject of syphilis. The nasal septum is removed to show extensive destruction due to ulceration of the soft parts and necrosis of bone. The inferior turbinal and the inner with parts of the anterior and posterior walls of the antrum are wanting; the lachrymal is exposed and detached from all its connections save above. The skin of the face is destroyed over the lachrymal sac and along the course of the lachrymal duct.

St. Thos. Hosp. Museum, 565.

767. Anterior part of skull, showing effects of syphilis; palate is perforated and vomer partly destroyed.

St. Thos. Hosp. Museum, 566.

768. A skull exhibiting the effects of syphilis. The palate, septum nasi, and the lateral boundaries of the nose are destroyed by ulceration, extending as high as the middle turbinated bones. The outer table of nearly all the upper part of the skull is tuberculated and extensively ulcerated, and in several places the ulceration has penetrated the inner table.

St. Bart.'s Hosp. Museum, Series i, 311 (Case F).

769. Portion of the base of a skull exhibiting syphilitic ulceration of the palate and the front of the alveolar process; also of the left malar bone.

St. Bart.'s Hosp. Museum, Series i, 328 (Case F).

770. Ethmoid bone. The right lateral mass is partially, the vertical plate almost entirely destroyed by syphilis.

St. Mary's Hosp. Museum, 293.

771. Sequestrum due to syphilis, involving much of the frontal and right nasal bones, the nasal and part of the alveolar process of the superior maxilla. The frontal is thickened, and its margin as if worm-eaten. Removed at the Lock Hospital from a woman, who lived some years afterwards.

St. Mary's Hosp. Museum, 310.

- 771A. Skull of the person from whom the above (310) sequestrum was removed. The bones bounding the gap are thickened, the frontal sinuses opened. The ethmoid, nasal and upper maxillary bones are more or less destroyed.

St. Mary's Hosp. Museum, 311.

- 771B. Wax model of the face of the patient from whom the two preceding specimens (771, 771A) were obtained.

St. Mary's Hosp. Museum, 312.

772. Syphilitic ulceration of the skull and bones of face, from a middle-aged woman. Interior of nose destroyed.

Charing Cross Hosp. Museum, 125.

773. The bones of a face and portions of adjacent bones. The external table of the frontal is irregularly ulcerated, parts are more deeply affected; on each side the lower part of the frontal sinus is opened into. Areas of bone unaltered in appearance, remain scattered over the ulcerated surface. Nothing remains of the nasal bones, and, after considerable destruction of their surfaces, the nasal processes of the superior maxillary bones, with the front of the hard palate and adjoining portion of the alveolar border, have been almost completely separated after necrosis, being connected only by two slender pedicles near the inner margins of the orbits with the bone around. From a female, doubtless suffering from syphilis, who had taken much mercury.

Univ. Coll. Museum, 594.

774. Part of a skull, &c., from a case of syphilis. The calvaria was very dense and thick. There was some basal meningitis. Parts of the palate process of the superior maxilla and the vomer have been removed after necrosis.

Univ. Coll. Museum, 603A.

775. A skull in which large portions of the superior maxillary and palate bones and the whole of the vomer are destroyed. From a man, 24, who died of syphilis.

R.C.S. Museum, 1421.

776. An upper jaw, showing the effects of tertiary syphilis. The inner wall of the antrum has disappeared, the result of necrosis of the bony portions. The mucous lining of the antrum and of the floor of the mouth is shaggy and in parts thickened.

Univ. Coll. Museum, 597A.

777. Syphilitic caries of frontal bone of a child *æt.* 11, who died of meningitis secondary to disease of the nose and frontal bone. Part of the crista galli has disappeared; on either side of it is an area of bare bone, roughened and almost symmetrically eroded, but extending further on the left side. The mucous membrane of the nose and frontal sinuses was thick, vascular, and easily detached.

Charing Cross Hosp. Museum, 127.

778. A skull-cap, exhibiting extensive syphilitic ulceration of its outer table, parts of which are tuberculated; the inner table is very vascular and less extensively ulcerated. The frontal sinuses, especially the left, are involved. The ulcers are distinct, large, and round; some of them, especially one on the frontal bone, show that they commenced in an annular form, an ulcerated groove forming round a portion of diseased bone, which portion was subsequently removed by the widening of the groove.

St. Bart.'s Hosp. Museum, Series i, 320 (Case F).

779. Skull of a young adult, showing extensive effects of syphilis. Areas of frontal and parietal bones irregularly ulcerated; in places the outer table is undermined, in others there is a raised edge of new bone. Deep ulcer at junction of basilar process of the occipital bone and body of sphenoid. Base of vomer is superficially ulcerated, and exhibits some new bony deposit. These parts have probably corresponded with ulcers of the pharynx. Above the angular process of the frontal bone on the right side is a slightly depressed circular area, with compact osseous tissue, not smooth like the surface of the bone around, forming its base; in the centre of this is a small, irregular, smooth-edged aperture, the opening apparently of a more deeply ulcerated space in the diploë.

Univ. Coll. Museum, 583.

780. Syphilitic caries of frontal bone, with thickening round the carious area. The left frontal sinus is opened, and the septum between the two sinuses partially destroyed.

St. Mary's Hosp. Museum, 313.

781. Portion of a skull, with syphilitic ulceration of the frontal bone extending into the frontal sinuses and through the inner table of the skull.

St. Bart.'s Hosp. Museum, Series i, 326 (Case F).

782. A frontal bone, exhibiting ulceration of its outer table penetrating to the frontal sinus. The border of the ulcer is surrounded by an unequal ring of new bone. Probably the result of syphilis.

St. Bart.'s Hosp. Museum, Series i, 325 (Case F).

783. Complete necrosis of frontal bone. Patient, male, *æt.* 53. Frontal symptoms commenced twenty years ago. He suffered from corneal opacities, ulceration of the corneæ, and loss of vision. The frontal bone was

easily removed *en bloc*, exposing the pulsating dura mater covered with pus; there was perforation of the hard palate and communication between the cranial and orbital cavities.

783A Photographs of preceding case of complete frontal necrosis.

A. A. Scot Skirving, Esq., and J. Cameron, Esq.

784. A skull, in which, in the course of syphilitic disease, there occurred necrosis of several large portions of the frontal and parietal bones. Many of the sequestra were completely separated, and the surface of the diploë and inner table exposed by their removal seems to have healed smoothly; but many other portions in which the ulceration extends through both tables are only partially detached. The portions of skull which remain behind those that have suffered necrosis appear quite healthy; they were not even increased in vascularity.

St. Bart.'s Hosp. Museum, Series i, 333 (Case F).

785. A skull, with syphilitic necrosis and ulceration of a portion of the left parietal bone. The dead bone has been in part removed. The frontal bone is tuberculated and vascular.

St. Bart.'s Hosp. Museum, Series i, 337 (Case F).

TUMOURS.

EAR (EPIBLASTIC).

Epithelioma.

786. Tumour of auricle. A rapidly-growing pigmented (? malignant) papilloma following an injury. From a woman æt. 54. Richard Lake, Esq.

787. Papillary epithelioma of auricle.
Univ. Coll., Liverpool.

788. Epithelioma of auricle.

Patient a man æt. 57. Growth first noticed as a wart nine months before he sought advice at the Eye and Ear Infirmary; when seen the growth occupied site of tragus and concha; it measured $\frac{1}{2}$ inch by $\frac{1}{4}$ inch, was surrounded by thickened edges, and ulcerated on surface. No glandular enlargements. Chas. G. Lee, Esq.

Liverpool Eye and Ear Inf.

788A. Photograph of patient after excision of growth.

789. Epithelioma of auricle.
Univ. Coll., Liverpool.

790. Epithelioma of auricle.
St. George's Hosp. Museum, Series xvi, 68B.

791. Epithelioma of auricle.

St. George's Hosp. Museum, Series xvi, 67A.

792. The pinna of a right ear affected with an epitheliomatous ulcer, the size of a shilling, which has destroyed the lower end of the helix and the adjacent part of the lobule. Its margin is rolled, sinuous, and slightly raised, whilst its thickened base is smooth and depressed. Histologically it is a squamous-celled epithelioma.

Removed by operation from a man æt. 67, who had first noticed two small crusts on the skin of the lower part of the ear two years previously. These became detached and left a discharging sore, which extended and excavated the surrounding tissues. The lymphatic glands were not affected. Dr. Lediard.

R.C.S. Museum, 3960c.

793. Portion of the pinna of a left ear showing an ulcerated new growth on its internal surface; it has extensively infiltrated the substance of the organ, and a part of the helix is destroyed by ulceration. Histologically it is a squamous-celled epithelioma.

Removed by operation from a mariner æt. 67, who first noticed a sore on the ear two years previously. The ulcer gradually increased in size; there was no enlargement of the lymphatic glands. J. H. Targett, Esq.

R.C.S. Museum, 3960d.

794. Part of the pinna of a right ear affected with epithelioma, which forms a rounded, oblong growth, much ulcerated anteriorly.

From a man æt. 48. The disease was of four years' duration, having grown slowly at first, but more rapidly before it was removed. Richard Quain, Esq., 1865.

R.C.S. Museum, 3961.

795. An external ear, the seat of epithelioma, which occupies the whole thickness of more than half the auricle, projecting on its internal and external surfaces, and having only the upper and anterior borders and the lobule free. It forms a flat, lobed, and fissured growth, the overhanging margins of which are in part sinuous, and have everted the adjacent skin of the auricle. The middle of the posterior border of the auricle is, with part of the cancer, destroyed by ulceration. The general texture of the cancer is soft, shreddy, and very vascular; the microscopic structure is well marked, according to the type of epithelioma.

A small superficial ulcer, with a scab, had existed on the outer surface of the ear for six years, the scab being frequently detached and removed. The growth here shown had been in progress of increase and ulceration for six months before it was removed. The patient was a strong man 76 years old.

St. Bart.'s Hosp. Museum, Series xxxiv, 2670.

796. Epithelioma of the external ear.

St. Bart.'s Hosp. Museum, Series xxxiv, 2670A.

797. Epithelioma of the right pinna, occupying a large portion of the external surface of the auricle, including the concha and anti-helix, but it does not penetrate through its whole thickness. The growth forms an irregular sprouting mass, which is, in parts, coloured black with blood. Microscopically it is typical epithelioma.

From a man æt. 62, who noticed a small pimple on his ear 18 months before the operation. The growth remained quiescent for 15 months and then rapidly increased in size and began to ulcerate. (See Male Surgical Register, vol. ii (1886), No. 2692.)

St. Bart.'s Hosp. Museum, Series xxxiv, 2670B.

798. Epithelioma of auricle, invading the external canal and completely occupying its lumen.

From a woman æt. 45. Removed by Mr. Treves in 1885.

Lond. Hosp. Museum, 968.

799. Epithelioma of auricle.

Lond. Hosp. Museum, 968B.

800. Epithelioma of auricle

St. George's Hosp. Museum, Series xvi, 68A.

801. Left side of the face of a woman æt. 60, showing a mass of epithelial cancer surrounding and involving the eyelid, extending inwards over the bridge of the nose and downwards to within one inch of the lips. The borders are elevated, everted, and sinuous; the surface is deeply ulcerated. Some of the hair of the eyebrow can be seen on the upper part, above which the frontal bone is bare from previous destruction of part of the disease by caustics. At one spot the disease is more recent, it has perforated the bone and invaded the dura mater. The lower part of the ear and the skin adjacent to the external meatus are affected.

From a hawker accustomed to carry heavy loads on her head. For three years she observed a small spot, like a mole, on the hair line on the left side of her forehead. Six months before death it began to grow rapidly and to bleed freely. It was destroyed with chloride of zinc; but it recurred round the eyelid, and a hardened gland was formed in front of the external auditory meatus. This was incised and the wound became cancerous. Death was due to repeated hæmorrhages. (See MSS. Notes, vol. iii, p. 126.) Dr. H. A. Lediard.

R.C.S. Museum, 485.

802. Carcinoma of temporal bone. (See Insp., 1862, No. 149.)

Guy's Hosp. Museum, 1081¹⁰.

Adeno-carcinoma.

803. Half of a tumour of meatus, with part of auricle removed from young adult, with photographs of patient and ossicles (caries of handle of malleus). Patient suffered also from chronic middle ear suppuration, for which the radical post-aural operation was performed. Adeno-carcinoma. (*Vide* Mic. Coll., 943.) 'Transactions of Sixth International Otological Congress,' 1899, p. 294. Arthur H. Cheatele, Esq.

804. An external ear, with the adjacent integuments, which are involved in a morbid growth. In the recent state the tumour was as large as an orange, and extended from the mastoid process to the ramus of the jaw; the pinna was surrounded by it, and it passed into the auditory meatus. Its surface had ulcerated; in the lower part a sinus existed, discharging foul pus. A section of the growth has a gland-like aspect.

Microscopically it may be described as a tubular epithelioma which probably originated from sebaceous glands. It was composed of rounded, cylindrical, and irregular masses of small epithelium, intersected by narrow bands of connective tissue. The cells, especially in the intra-cranial growth, were undergoing degeneration. (See following specimen.)

R.C.S. Museum, 3960A.

- 804A. The left half of the skull from the preceding case, bisected vertically. Occupying nearly the whole of the base of the middle fossa, and springing from the superior aspect of the petrous portion, is a rounded tumour two inches in diameter; its surface is finely nodulated, the nodules being formed by numerous cysts filled with colloid substance. The intra-cranial growth was continuous with that in the skin through the tympanum. There is a trephine opening in the squamous portion.

From a man æt. 61, who was first seen in December, 1886, for a tumour behind the ear. It was excised (see 804). He first noticed a small lump behind the ear three years before. A local recurrence in the skin was removed three months after the first operation. After February, 1888, there was again evidence of recurrence in the scar, and the patient presented symptoms of aphasia. There was no paralysis or visual defect. An intra-cranial tumour being diagnosed, trephining was performed, but the growth could not be removed. Three days later the patient died comatose. (See 'Trans. Clin. Soc., vol. xxi (1888), p. 172.) J. Bland Sutton, Esq.

R.C.S. Museum, 3960B.

Rodent Ulcer.

805. Rodent ulcer which has destroyed the auricle and deeply excavated the temporal bone.

St. George's Hosp. Museum, Series xvi, 62N.

806. Portion of the left side of the skull and soft parts of a man who died of

rodent ulcer. The anterior part of the ear is destroyed and the external meatus exposed. The scalp is eaten away over a large area; parts of the frontal and parietal bones are destroyed, and the dura mater thickened. The malar bone is laid bare.

Westminster Hosp. Museum, 1258.

EAR (MESOBLASTIC).

Angioma.

807. A section through an external ear injected. It is occupied by a nævoid growth which has much shrunk from its original dimensions.

From a girl æt. 22. A small florid nævus, situated at the back of the upper border of the left pinna, had existed since birth. Five months before its removal amenorrhœa ensued, without any apparent cause, and the nævus at once began to spread and grow darker in colour, and soon occupied the whole ear. The nævus was excised, except a small piece which subsequently increased and was removed. The catamenia had not then reappeared.

R.C.S. Museum, 3960.

808. Left external ear and surrounding integuments showing a cirroid aneurism.

From a woman æt. 23, in whom it was congenital; it was at first quite small, giving rise to no trouble till she was thirteen, when its increasing size brought her to the hospital. Ligature of vessels by Mr. Pye was ineffectual, as was pressure of a circular pad by Mr. Norton. Mr. Pepper removed the parts on account of hæmorrhage, tying the right external carotid and left internal carotid. Operation was followed by right hemiplegia and aphasia; the former cleared up, the latter was persistent. (*Vide* Mr. Pepper (1897), Clinical Notes, No. 1311.)

St. Mary's Hosp. Museum, 715A.

Fibroma.

809. Fibroma from lobule of left ear. From a woman æt. 29; some years previously she had her ears pierced for earrings, which she had discontinued for five or six years. Two years previously a tumour began to grow from the edges of the aperture on either side of the left ear; at time of admission it was the size of a hazel nut. There was a growth on each side of the lobule; it was cut off, and on section the two growths were found to be continuous by the hole made by the ear piercer. On the right side were two small nodules the size of a millet seed. (See drawing 224³⁸.)

Guy's Hosp. Museum, 1669⁸⁰.

810. A tumour growing from the lobe of the ear.

Middl. Hosp. Museum, 935.

811. Fibrous growth removed from the auricle of a child of eleven months.

Guy's Hosp. Museum, 1669⁷³.

812. Fibrous growth removed from the pinna of a right ear.
Guy's Hosp. Museum, 1669⁷⁶.

813. Fibroma of lobule.
Univ. Coll., Liverpool.

Exostosis and Hyperostosis.

814. Thirteen skulls showing hyperostosis and exostosis of the meatus.
R.C.S. Museum, 285, 294, 729, 749C, 765K, 765N, 765V, 765W, 765Z,
870, 875, 893, 895.

815. Three specimens of exostosis of meatus removed by operation.
1. Exostosis removed from external meatus with galvano-caustic snare.
2. Exostosis removed from external meatus with dental burr after dissecting forwards the auricle and cartilaginous meatus.
3. Exostosis removed from external meatus with cold steel wire loop.
Thomas Barr, Esq.

816. Four specimens of exostosis of meatus removed by operation.
1. Ivory exostosis removed by Pritchard's trephine and dental engine.
2. Hyperostosis removed by chisel and trephine.
3. Half a pedunculated exostosis removed by dental stump forceps.
4. Whole pedunculated exostosis removed by stump forceps.
Prof. Urban Pritchard.

817. Solitary pedunculated exostosis from anterior wall of right auditory meatus of a lady æt. 26.
Cresswell Baber, Esq.

818. Three specimens of pedunculated exostosis removed by operation.
1. Pedunculated exostosis removed from posterior wall of meatus. Cut in half.
2. Pedunculated exostosis removed from inferior meatal wall. Patient also suffered with chronic otitis media suppurativa.
3. Pedunculated exostosis removed from inferior meatal wall.
Arthur H. Cheatle, Esq.

819. A pedunculated exostosis from the right external meatus of a man æt. 45.
P. Macleod Yearsley, Esq.

820. 1. Aural exostosis; fragments of tumour. It grew from the anterior wall and completely occluded the external meatus.
2. Hyperostosis of external meatus.
Richard Lake, Esq.

821. Left temporal bone from an adult, showing the presence of an exostosis growing from the posterior wall of the middle ear.
H. Secker Walker, Esq.

Tumour of doubtful nature.

822. Petrous portion of a left temporal bone. From the orifice of the internal meatus projects a growth, partly solid, partly cystic, over which the fibres of the auditory nerve are stretched. The bone is absorbed round the mass, and the cerebral substance was depressed by it.

From a woman æt. 54, who was insane for years. She was deaf on the affected side, and suffered severe pain over the whole of that side of the head.

St. Bart.'s Hosp. Museum, Series xxxiv, 2686.

Sarcoma.

823. Photograph of patient and section of spindle-celled sarcoma from the external auditory meatus.

Girl æt. 6. Death nine months after first coming under observation. (Section, in Mic. Coll.) (V. 'Trans. VI Internat. Otolog. Congr.,' p. 295.) Galbraith Connal, Esq.

824. Lower part of a skull with the facial bones and some adjacent soft parts. Occupying the left orbit and overlapping its margin is a lobulated mass of firm sarcomatous substance. On the right side a similar growth, arising apparently from the periosteum, fills the temporal and zygomatic fossæ, surrounds the ear, and spreads inwards beneath the base of the skull to the margin of the foramen magnum; the zygoma and malar bone are embedded in the growth. The skin round the ear is covered with close set, prominent, warty growths. A small oval mass of similar tumour substance has grown from the dura mater, with which it has been detached from the base of the petrous temporal; the surface of the latter, corresponding with the seat of the tumour, is deeply and irregularly pitted.

The patient, a delicate girl, had a tumour removed from the orbit by Mr. Quain; it had existed only two months, and was believed to be malignant. Microscopically it proved to be an "unequivocal specimen of fibro-plastic growth," or a large spindle-celled sarcoma. A fortnight later a second growth appeared beneath the upper eyelid, and grew so rapidly that it was removed two months afterwards. Microscopically it was similar to the first growth. A third tumour afterwards appeared below the outer canthus; it was removed and found to reach the bottom of the orbit. All this time the child grew fat and hearty. Some weeks later, with the growth of the tumour here shown, she began to lose flesh, grew weaker, and died.

Univ. Coll. Hosp., 659.

825. A left temporal bone infiltrated with malignant disease. (Ligature of common carotid artery for hæmorrhage from ear.) The cavity of the ear and adjacent bone is invaded with sarcomatous growth. All traces of the middle and internal ear are lost. The growth had absorbed the wall of the carotid canal in the temporal bone, and produced ulceration of the arterial wall, three quarters of an inch from its entrance into the cranial cavity.

The ulcerated opening in the artery is shown in the specimen half an inch from the upper end of the blood-vessel, and at this point the growth completely surrounds the artery. There was considerable breaking down of the bony structures, and the condyle of the jaw was exposed. The ligature on the common carotid can be seen; that on the internal carotid was applied at the post-mortem.

Clinical Notes.—Patient a male æt. 40. Admitted under Mr. Hewitson's care into the Leeds Infirmary, August 27th, 1887. Had had left otorrhœa for fifteen years, and recently a purulent discharge from the nose and mouth. On August 31st, and again on September 8th, Mr. Hewitson removed some polypi from the external auditory meatus, and on the second occasion some pieces of necrosed bone. On September 25th, at 9.30 p.m., patient lost a large quantity of blood from the ear, and at 10 p.m. a second profuse attack occurred. Under cocaine injection, Mr. Littlewood ligatured the common carotid artery, and then transfused sixteen ounces of saline solution. The patient died sixteen hours later. H. Secker Walker, Esq.

Yorkshire Coll. Path. Museum.

826. Left temporal bone from a child, with photographs. Sarcoma originated in the middle ear. Spread outwards behind ear and into middle and posterior fossæ. G. Lenthal Cheatle's case. (See 'Transactions of British Medical Association,' 1898.)
Arthur H. Cheatle, Esq.
827. Spindle-celled sarcoma of the middle ear.
St. George's Hosp. Museum, Series xvi, 66A.
828. Sarcoma of temporal bone.
Guy's Hosp. Museum, 1081¹⁵.
829. Sarcoma of left temporal region, growing into the posterior fossa.
From a girl æt. 10½, a tuberculous subject; some necrosed bone had been removed from the site of the tumour behind the ear. (See Insp., 1881, No. 341.)
Guy's Hosp. Museum, 1073²⁵.
830. A petrous bone, invaded by a sarcoma originating in the cerebellum. (See Insp., 1885, No. 228.)
Guy's Hosp. Museum, 1576⁵⁵.
831. The base of a skull, in which a tumour of nearly oval form, two and a half inches in its longitudinal, and one and a half in its transverse diameter, and an inch in depth, is attached by a narrow base to the dura mater covering the posterior and inner part of the right petrous bone. The tumour is composed of a firm, pale, "caseous" substance, and is invested with a thin, tough membrane. Looking vertically upon it, it completely conceals the foramen magnum, and fills nearly half the right posterior

fossa of the skull. The bone beneath and for a distance in front of the tumour is superficially ulcerated.

From a woman *æt.* 32 when admitted to the workhouse of St. Leonard's, Shoreditch. Four years previously she received a severe blow behind the right ear, which stunned her for several minutes, since when she had never been free from uneasy head sensations, and occasionally severe headache, which was relieved by nothing but bloodletting. She became depressed, sometimes suddenly giddy, and obliged to hold on to something to avoid falling. These symptoms increased; at length she felt occasional weakness and numbness of the right arm and leg, which after a time became constant. As she was helpless she was brought to the workhouse. On admission the loss of voluntary power over the right arm and leg was almost complete. She complained also of numbness of the right side of the body, more so of the right side of the face, which she would rub violently with her left hand. The mouth was drawn to the left and speech slightly impaired. The right eye was motionless, it appeared smaller and more deeply sunk in the orbit than the left; its pupil was dilated and scarcely affected by light, and the right upper eyelid was lower than the left. By the loss of the consentaneous movements of the eyes sight was affected, so that, except when looking straight forwards at a distant object, vision was confused; she closed the left eye with the left hand in order to see better. Her mental faculties were little, if at all, impaired. For a time local bleeding and counter-irritation seemed to be beneficial; after ten weeks in the workhouse she was seized with a severe epileptic paroxysm, became insensible, and was violently convulsed on the left side. After being freely bled she recovered from this state, but had now completely lost both sight and hearing, and the paralysis of the right side was more complete; her mental faculties remained good. A fortnight later she had another seizure, which was fatal. Post-mortem: fluid was found in all the tissue of the pia mater, and its vessels were nearly empty. The brain substance was pale; the ventricles contained six or seven ounces of fluid. The olfactory and optic nerves, and all those on the left side, appeared healthy; but the third and all the following nerves of the right side had a dusky red colour, from fulness of the vessels of their neurilemma. The right side of the tentorium was much elevated. The tumour was deeply embedded in, but not adherent to, the right lobe of the cerebellum; it was loosely attached to the bone and dura mater, and pressed considerably on the right side of the pons and medulla oblongata, the adjacent substance of which, as of the cerebellum, had a dusky red hue. The trunk of the facial and auditory nerves of the right side could not be found; they were more than any others implicated by the tumour.

R.C.S. Museum, 3863.

832. Part of the right side of a skull, of which almost the whole of the mastoid and petrous portions of the temporal bone, with part of the occipital below the groove of the lateral sinus, have been destroyed by a tumour growing within the skull; the floor of the external auditory meatus has also been

destroyed. The cancellous tissue thus exposed is scarcely altered in appearance; the external table of the bones round the edge of the opening, which is bevelled from its inner aspect, is perforated by roundish apertures about one twentieth of an inch in diameter.

From a man 20 years old; the first symptoms were pain in, and discharge from, the right ear. After two years a slight puffiness appeared behind the ear, accompanied by giddiness, unsteadiness in walking, and occipital pain; the symptoms increased, and the sight of the right eye was gradually lost. Fluctuation was felt in the swelling behind the ear; it was punctured, but only a little blood escaped. Finally the swelling began to pulsate, and the common carotid artery was tied by Mr. Syme, causing cessation of pulsation. The symptoms were relieved by the operation, but on the tenth day the pulsation returned and a swelling appeared in the ear. The patient became gradually weaker, and at last comatose, and died three months after the appearance of the external swelling, and one month after the ligature of the carotid, both sight and hearing having been lost on the right side.

After death a tumour was found to have destroyed the right half of the base of the skull, half the sphenoid bone (with the optic nerve), and the petrous portion of the temporal with the mastoid process. The tumour extended down the neck, including the internal carotid artery. The dura mater was destroyed; the right lobe of the cerebellum, which was gelatinous in substance and of a pale straw colour, contained a cavity about as large as an almond, and filled with clear fluid.

Univ. Coll. Museum, 699.

833. Malignant cerebral tumour; from a boy 12 years of age. Originated in the middle ear, and extended into the temporo-sphenoidal lobe, finally giving rise to symptoms simulating those of temporo-sphenoidal abscess. (See 'British Medical Journal,' 1897, vol. ii.)

Two photographs and two micro-photographs of above.

Thomas Barr, Esq.

NOSE AND ACCESSORY SINUSES (EPIBLASTIC).

Papilloma.

834. Papilloma of the nasal septum. The tumour growing from the nasal septum resembled a typical cauliflower mass, and measured $6\frac{1}{2}$ inches in circumference. It weighed $1\frac{1}{4}$ ounces. Several small accessory growths are seen springing from the mucous membrane of the septum. The patient was a male æt. 52 years.

Logan Turner, Esq.

835. A growth from the septum nasi; a simple papilloma. From a man, æt. 80, removed with scissors from the left side of the septum. It protruded from the nostril, had been growing five years, and caused nasal stenosis. On the opposite side of the external nose was a small rodent ulcer. P. de Santi, Esq.

Westminster Hosp. Museum, 1175C.

836. Warty growth, partly ulcerated, removed from the nasal septum of a woman æt. 50.

St. George's Hosp. Museum, Series xvi, 52A.

Epithelioma.

837. Portion of the integuments of a nose, exhibiting an oval ulcerated growth; the edge is thick, raised, undermined, and the base is deeply excavated. Histologically it is a squamous-celled epithelioma with very numerous cell-nests.

From a man æt. 70. The sore was first noticed ten years previously on the bridge of the nose, on the site of an old gunshot injury. The lymphatic glands were not enlarged. F. S. Eve, Esq.

R.C.S. Museum, 3948A.

838. Section of an epithelioma removed from the septum nasi. It has replaced the triangular cartilage; in the recent state it formed a prominent swelling in both nostrils. A piece of vomer is seen in the right lower corner, behind the attachment of the lateral cartilage remains. A secondary growth in the lower jaw is suspended below.

From a man æt. 47, admitted with enlarged nose and thickened septum, first noticed six months before. The tumour was excised, but recurred at intervals of a year, locally and in the submaxillary region. (See Surgical Reports, Mr. Davies-Colley, No. 80, 1887; for drawing see 199^{84A}.)

Guy's Hosp. Museum, 1666⁷⁵.

839. Carcinomatous tumours in the nasal cavities, particularly in the sphenoidal cells; they have invaded the left middle fossa of the skull.

From a patient æt. 40, under Dr Bright in 1827. (See 4, Green Insp. Book, p. 128.)

Guy's Hosp. Museum, 1666⁷⁰.

840. Cancer of the right nasal cavity, extending to the middle fossa of the skull. Eyelid, near the inner canthus, also involved. Disease supposed to have commenced in the maxillary antrum.

From a woman, under Mr. B. Cooper, in 1827. (See 4, Green Insp. Book, p. 127.)

Guy's Hosp. Museum, 1666⁸⁰.

841. Carcinoma originating in the base of the nose; it involves the greater part of the ethmoid and body of the sphenoid, also the nasal and palatine processes of the superior maxilla. The antra are healthy. The sphenoidal sinus contained a little pus. The olfactory nerves traversing the tumour were healthy.

St. George's Hosp. Museum, Series xvi, 53C.

842. Anterior part of right half of a head; the antrum distended with a large tumour, microscopically a carcinoma. It has destroyed the anterior and

inner antral walls; fills the right nasal cavity and distends the nostril; a small portion projects through the skin over its most prominent part. It has displaced the nasal septum to the left, and fills the right posterior naris. There is no displacement of the palate.

St. Thos. Hosp. Museum, 870.

843. Carcinoma, removed after death from the face. It appeared to begin in the maxillary antrum, had entered the orbit and perforated the cribriform plate; it had also destroyed some of the facial bones.

Taken from a woman in 1826. (See 1, Green Insp. Book, p. 14.)
Guy's Hosp. Museum, 1666.

844. Epithelioma of maxillary antrum. The left antrum in a foul state, communicating with the nares and mouth. The upper angle of the facial part of the maxilla is converted into dry, soft, cancerous tissue.

From a man æt. 40. Acetic acid injection was tried without avail. He lay in a dying state for two or three weeks, expectorating large quantities of offensive matter. (See Insp., 1867, No. 48. Microscope drawing preserved.)

Guy's Hosp. Museum, 1087⁵.

845. The base of a skull, with portions of the facial bones, in which extensive destruction has been caused by malignant disease originating in the antrum. The left superior maxilla and malar bone, with considerable parts of the right maxilla, among the facial bones, and the pterygoid processes of the sphenoid on the right side, and almost the whole of the ethmoid and lower part of the frontal bone, among the bones of the skull, have disappeared. The floor of the frontal sinus is wholly wanting on the right side; and by the destruction of the cribriform plate of the ethmoid a considerable opening exists into the cranial cavity. The portions of the bones affected have an open, reticular surface, showing them to have been infiltrated by the morbid growth. But on the lower surface of the remains of the left orbital plate of the frontal bone, and in one situation within the opened sinus, a layer of new osseous substance has been formed.

Univ. Coll. Museum, 700.

846. Sections of a skull, with the brain *in situ*. The antrum is occupied by a large and tolerably firm growth, which has extended upwards into the orbit and inwards so as to fill the nostril on the right side. The growth extends along the inferior meatus from the anterior nares, where it is ulcerating nearly as far as the choanæ. Microscopically the growth is a spheroidal-celled carcinoma.

The specimen was obtained from the body of a woman æt. 64, who died from epistaxis. The tumour had only been observed for two months before her death. The patient had well-marked diplopia. J. A. Gray, Esq.

St. Bart.'s Hosp. Museum, Series xii, 1772A.

847. Epithelioma of upper jaw.
Charing Cross Hosp. Museum, 700A.
848. Epithelioma of superior maxilla.
Westminster Hosp. Museum.
849. A skull, which has been the seat of a cancerous growth. The frontal bone is very extensively ulcerated, and is also perforated on the right side. It presents a coarse, spongy appearance, from the formation of a quantity of porous new bone. The parts involved are the right half of the frontal bone completely, and the anterior aspect of the left half of the lachrymal bones, the vomer, and the nasal processes of the superior maxillæ. The upper and part of the inner wall of each orbit is seen to be also affected.
Middl. Hosp. Museum, 621.
850. The bones of the face, with the adjoining parts of those forming the skull. In consequence of some malignant (probably epitheliomatous) disease, commencing in the soft parts, the alveolar portion of the left superior maxilla has been wholly destroyed, and the antrum, after complete destruction of its floor, opens by a wide triangular aperture into the mouth; the neighbouring margin of the palatine process has for a part of its thickness been removed (anteriorly for the whole of it), its cancellous tissue being opened by the inward spread of the disease. The lower jaw is also much affected.
Univ. Coll. Museum, 702.
851. The alveolar portions of two superior maxillary bones with a large tumour, which involved the hard and soft palates and projected upwards into the nose. The section of the tumour is firm and indistinctly alveolar or reticulated; the surface projecting into the mouth presents several patches of ulceration. Microscopically the tumour was a tubular or gland-like carcinoma, its appearance was suggestive of its origin from mucous follicles.
Removed by operation from a woman. Twenty-one months before, a lump was first noticed on the hard palate; six months later a tumour was removed, but soon recurred. (See 'Brit. Med. Journ.,' vol. i, 1887, p. 395.) F. Bowreman Jessett, Esq.
R.C.S. Museum, 2222A.
852. Carcinoma of antrum. Section shows a remarkably vacuolated appearance. Ziegler calls this growth "cylindroma carcinomatodes." Thoma, in his 'General Pathology,' figures an exactly similar growth from the antrum as hyaline degeneration of a round-celled carcinoma. This specimen was shown at the Pathological Society of London on April 4th, 1899, and the title "vacuolated carcinoma" suggested. (*Vide* 'Brit. Med. Journ.,' April 8th, 1899.)
From a man æt. 32. Symptoms of the growth had been

noticed for fifteen months. The upper jaw was removed by Mr. H. W. Allingham at St. George's Hospital. (See *Mic. Coll.* 951.)
H. D. Rolleston, Esq.

853. Epithelioma of face, attached to malar bone. The malar bone, zygoma, and roof of the maxillary antrum were destroyed, and the antrum laid open into the ulcer, though its lining membrane was healthy. The sphenoid was ulcerated through just above the optic foramen. (See '*Med.-Chir. Trans.*,' vol. xxi, p. 69.) Cæsar Hawkins, Esq.
St. George's Hosp. Museum, Series xvi, 17D.

Rodent Ulcer.

854. A head and face with a rodent ulcer, which has destroyed the greater portion of the integuments and bones of the face. The ulceration extends upwards to the scalp and backwards to near the tragus; on the right side its margin slopes downwards to the angle of the mouth, but on the left the integuments covering the alveolar portion of the lower jaw are destroyed. The lower lip is intact, being the only portion of the oval orifice undermined, while the upper are gradually shelved. The frontal bone is perforated by rounded patches of superficial ulceration with irregularly eroded bases. Both eyes, the nasal, ethmoid, and the left superior maxillary bones are completely destroyed; the right superior maxilla remains, though its orbital plate has disappeared. The orbital, nasal, and oral cavities are thrown into one, with irregularly ulcerated walls, at the bottom of which the tongue and behind the naso-pharynx are exposed to view. Sections of the undermined margins, examined in 1883, showed that the corium and subcutaneous tissue were infiltrated by a new growth of epithelium, consisting of irregularly scattered and anastomosing columns and masses of very small epithelial cells, but chiefly of nuclei of epithelial cells. A few cell-masses contained rounded groups or whorls of cells, which were not cornified. The epithelial covering of the skin at the margin was unaffected, the infiltration having extended gradually beneath it.

From an insane woman æt. 52. The disease began in 1869 as a "tubercle" on the forehead; this became the seat of ulceration, which extended to the inner canthus. The sight of the left eye was lost in 1874, and in 1875 the right eye and the nasal bones were destroyed. She died in November, 1879. Wm. Orange, Esq.

R.C.S. Museum, 2265.

855. Rodent ulcer of the face, showing extensive destruction of the right side. From a man æt. 70. ('*Path. Soc. Trans.*,' vol. iii, p. 192.)
St. George's Hosp. Museum, Series xvi, 16A.
856. Extensive loss of nasal and other structures due to rodent ulcer. Floor of right orbit, greater part of superior maxilla, nasal bones and part of

lower jaw, with the soft parts, are destroyed; posterior wall of right antrum, part of malar bone, of right superior alveolus, posterior part of hard palate, posterior nares, right middle turbinal, left middle and inferior turbinals, and part of left superior maxilla, the tongue and lower jaw, all lie exposed on the floor of the ulcer. The disease probably commenced above the mouth and either on the side of the nose or at the inner angle of the orbit.

Lond. Hosp. Museum, 1006.

857. A skull, showing very extensive destruction of the bones of the face, the result of rodent ulcer. There has been ulceration of the frontal bone extending into the frontal sinuses and also into the cranial cavity through the ethmoid bone. A great part of the superior maxilla on the left side, with both the nasal and lachrymal bones, have disappeared.

Middl. Hosp. Museum, 620.

858. The anterior half of the head of a man, from whom the right superior maxilla and surrounding parts, including the right eyeball, were removed on account of rodent ulcer. The patient lived several months after the operation. C. Moore, Esq.

Middl. Hosp. Museum, 38.

NOSE AND ACCESSORY SINUSES (MESOBLASTIC).

Angeioma.

859. Bones of the face and part of the skull from Case 860. The sawn surface of the malar bone is smoothly healed, and a layer of porous osseous substance has been formed on the other sawn and broken surfaces, as well as on the bone around them.

Univ. Coll. Museum, 685.

860. A large tumour of the pterygo-maxillary fossa, removed with the upper jaw. It includes the whole of the left upper maxilla except a narrow strip of its palatine process, and small portions of its nasal and malar processes, the whole of the lower part of the palate bone, and the lower portion of both pterygoid plates of the sphenoid and the inferior turbinated (see 859). A piece of whale-bone passed beneath the infra-orbital nerve in its canal. The tumour, measuring about three inches antero-posteriorly, has grown from the posterior surface of the maxilla and filled the speno-maxillary and lower part of the temporal fossæ, has passed backwards under cover of the ramus of the inferior maxilla, so that its under side projected in the pharynx; a portion has grown forwards from the anterior part of the tumour beneath the hard palate into the mouth. The posterior half of the tumour is deeply cleft into lobes. On its inner aspect a portion has

been cut away; the divided surface has a uniformly open, cavernous structure, like that of the corpus spongiosum penis, the meshes of which are nowhere occupied by a solid substance, and probably allowed of the circulation of blood through them. The tumour was everywhere bounded by a dense layer of fibrous tissue. The cavity of the antrum is entirely unaffected.

Removed from a man æt. 21. The tumour was $3\frac{1}{2}$ years in progress, first appearing as a projection into the pharynx and posterior nares. Frequently a severe hæmorrhage occurred from it (two or three pints at a time); there was little pain. Portions were ligatured on three occasions, the entire mass, with the upper maxilla, &c., being finally removed by Mr. Liston. The patient recovered rapidly from the operation, but died three months later from erysipelas of the head and face. (See 'Lancet,' vol. i, (1841-42), p. 67; and vol. ii, (1844), p. 123.)

Univ. Coll. Museum, 684.

Myxoma.

861. The left half of a vertical section of the face and base of the skull. Occupying the nasal fossa, and expanding and separating the bones of the face is a large myxomatous tumour, which appeared to have originated within the septum of the nose. It is incorporated with the frontal nasal and with the superior maxillary bone, and with the base of the cranium from the lower part of the body and right internal pterygoid process of the sphenoid forwards. The crista galli is involved, but not the cribriform plate or air-cells of the ethmoid. The orbits are much encroached upon. The tumour in the recent state consisted of a framework composed partly of spongy bone and partly of a delicate fibrous stroma, enclosing cavities filled with a transparent glairy viscid fluid, having the character of mucin.

From a man æt. 22, who died during the performance of an operation for the removal of the tumour (1864). The tumour began to grow in 1857, after an injury to the nose from a fall on the ice. (Reported in 'Path. Soc. Trans.,' vol. xix, p. 332, where will be found drawings and an account of the microscopical structure.)
C. H. Moore, Esq.

Middl. Hosp. Museum, 539.

862. The right side of a child's head, in which the nasal passages are completely filled by lobulated polypoid growths from the mucous membrane. The section of one of the largest growths displays a pale, pinkish, and obscurely fibrous texture, firmer and less transparent than that of the common gelatinous polypi. The growth of these polypi was very rapid. They proved fatal by suffocating the child, filling the nasal passages and pressing down the soft palate so as to obstruct the fauces.

St. Bart.'s Hosp. Museum, Series xii, 1770.

Enchondroma.

863. Small enchondroma, removed from the septum nasi. Presented by Mr. Spencer.
Westminster Hosp. Museum, 1175B.
864. Section of a large enchondroma, removed from the face; supposed to have sprung from the maxillary antrum; only a part was removed.
From a man æt. 24, admitted under Mr. Morgan in 1824. The growth had commenced nine years before in the right nostril, involving the superior maxilla, vomer, and malar bone. It returned after removal, growing slowly till his death, seven years afterwards, when it had reached a great size and caused great disfigurement. (See 'Guy's Hosp. Reports,' Series i, vol. i, p. 403; vol. vii, p. 491.)
Guy's Hosp. Museum, 1666³².
865. Drawing of preceding tumour.
Guy's Hosp. Museum, 4⁵⁰.
866. Cartilaginous tumour of skull and face. Cæsar Hawkins, Esq.
St. George's Hosp. Museum, Series xvii, 13D.

Osteoma.

867. Antrum of Highmore, involved in a diffuse osseous growth.
Middl. Hosp. Museum, 531.
868. A dense osseous tumour, involving the whole of the left superior maxillary bone. From a boy æt. 9. (See Abernethy Ward Book, vol. i, p. 344.)
St. Bart.'s Hosp. Museum, Series i, 400.
869. Osteoma of left superior maxilla; the bone is divided in two. Removed by Mr. Bloxam from a man æt. 25, admitted suffering from pain in the left upper jaw, which had been swollen for eleven years; the swelling was attributed to an injury received eight months previously. The swelling had been painful for four years. Pain extended from inner angle of left orbit upwards and outwards to the temporal muscle of the same side. On admission the tumour was of dense, bony hardness, with a smooth surface; skin freely moveable over it. The superior maxilla was completely excised; the tumour was found to be an osteoma, consisting of tissue having the structure of normal bone, but somewhat denser than ordinary cancellous tissue. Patient made a good recovery. (See Surgical Reports of Mr. Bloxam's cases, 1890.)
Charing Cross Hosp. Museum, 146A.

870. Lower part of skull, having a rounded, bony growth on each superior maxilla; the antra are obliterated and the nasal fossæ encroached on; frontal and ethmoid sinuses also obliterated. Microscopically the growth consists of two kinds of bony matter; one firm and compact, in which are Haversian canals with concentric laminæ; the other spongy and soft, of granular structure, with numerous osseous corpuscles having no definite order.

From a Billingsgate fishwoman, long known for her hideous appearance. Two large swellings had grown under the orbits in the fore part of the cheeks, between which the nose appeared wedged, and the nostrils were closed. Each eye projected from its socket. She was seized with a fit, seemingly apoplectic, was brought to the hospital and died almost immediately. (See 'Surgical Essays,' by Cooper and Travers, part i, p. 171.)

St. Thos. Hosp. Museum, 610.

871. Sections of the bones of a face, showing an osseous growth filling the maxillary sinuses. The sections through the sinuses show a small cavity in each, indicating, as the disease of the adjacent bones also does, that their obliteration is the consequence, not of the growth of tumours into them, but of the thickening of their walls. The new bone by which they are increased in thickness is hard, nearly solid, and heavy; it is almost all found on their inner surfaces; only a few small similar growths spring from their outer surfaces, and project on the face and into one of the orbits. The septum nasi and spongy bones are similarly thickened, enlarged, and very dense in their texture.

St. Bart.'s Hosp. Museum, Series i, 397.

872. Right superior maxilla; antrum expanded by a globular fibrous tumour. Inferiorly the tumour has perforated the palatine process; it has protruded the anterior antral wall; it projected into the fauces posteriorly, and reached the septum nasi internally. Its most intimate bony connection is the anterior antral wall.

St. Thos. Hosp. Museum, 859.

- 872A. A slice of the preceding tumour, dried, and showing osseous portions. The bone is arranged in winding trabeculæ, apparently corresponding with the arrangement of the fibrous fasciculæ of the growth.

From a boy æt. 17. The tumour was noticed only ten months before its removal by Mr. Solly, when the face began to swell and get painful. The boy left the hospital with very slight deformity, and was in perfect health five years after the operation.

St. Thos. Hosp. Museum, 860.

873. A skull, with the osseous part of a large tumour connected with the bones of the right side of the face. The tumour originated in the antrum, was five years in progress, and in its growth destroyed all the right orbit

except its roof, and involved or destroyed the whole of the right malar, palate, and superior maxillary bones. The part which has remained after maceration consists of an oval mass of light cancellous bone, about five inches in its chief diameter, and very slightly connected with the remaining bones of the face. At its lowest part it preserves somewhat of the form of the alveolar border of the upper jaw, some teeth remain implanted in it. A part of the frontal bone above the right temple is thin and perforated by several small apertures, apparently in consequence of a tumour growing from the dura mater.

R.C.S. Museum, 1712.

874. Large exostosis, growing from outer surface of left frontal bone. Mr. Stanley Boyd.

Charing Cross Hosp. Museum, 144.

875. Exostosis of frontal sinus and of orbit.

Guy's Hosp. Museum, 1073¹⁵.

876. Tumour, probably ossified enchondroma of frontal sinus, encroaching on the orbit. From a man *æt.* 72, a dissecting-room subject.

Charing Cross Hosp. Museum, 149.

877. A diffused osteoma, which has grown into the frontal sinus. From a young woman *æt.* 20, who was admitted to the hospital with protrusion of the left eye, due to the projection of the osseous growth at the upper and inner angle of the orbit. The protrusion of the eye had been first observed three years previously. A portion of the growth was with difficulty sawn off, with the hope of producing necrosis and separation of the whole mass, but the patient died of meningitis.

St. Bart.'s Hosp. Museum, Series i, 396.

878. The bones of a face, with bony tumours. The masses are nearly as hard and heavy as ivory, and apparently consist of close cancellous tissue resembling true bone.

From a man *æt.* 60, who believed that the disease began eighteen years before his death, in consequence of repeated blows received in fighting. During the growth of the bones he suffered much pain in the face, eyes, and head. The eyes projected; the right eye, after suppuration and sloughing of the cornea, shrivelled; the left was accidentally burst by a blow while it was projecting and turgid with inflammation. He died suddenly with apoplexy; during his last two years he at times showed symptoms of insanity. All the cranial bones were thick and hard, and their sutures obliterated. The integuments of the face were greatly attenuated; the periosteal covering of the growths was dense and vascular. The growths probably began in the superior maxilla.

R.C.S. Museum, 1606.

879. A superior maxillary bone, in which the cavity of the antrum is completely filled by a growth of porous or very finely cancellated bone. The external surface of the maxillary bone is superficially tuberculated and porous, and its walls are changed into bone of the same texture as that which occupies the antrum. The disease is attended with a general but irregular enlargement of the maxillary bone, its alveolar portion alone retains a nearly natural form. The palate bone is healthy.

From a girl æt. 15. Enlargement of the nasal process of the inferior maxillary bone had been observed for eight months, and was still increasing. The general health appeared good, and the disease was painless. The upper jaw was removed, and ten days later the patient died with erysipelas. The case is related in Mr. Stanley's treatise on 'Diseases of Bones,' p. 297.

St. Bart's Hosp. Museum, Series i, 398.

880. Portions of a superior maxillary bone, diseased, as in the specimen preceding (879), and which separated after necrosis. The portions, before division, formed a nearly spherical mass of hard, heavy, and finely cancellous bone.

From a man æt. 37. A smooth prominence of the nasal process of the right superior maxillary bone had been noticed for two years; it was not increasing, and he was admitted into the hospital with what appeared to be necrosis of the alveolar portion of the jaw and suppuration around it. After four months this mass of bone, which occupied the position of the antrum, completely separated and was removed. The cavity, which remained opening widely into both the mouth and nose, gradually contracted, or was filled up, and the man recovered perfectly.

St. Bart.'s Hosp. Museum, Series i, 399.

881. The greater part of a right superior maxilla, with contiguous portions of the pterygoid plates, the malar and the palate bones. The antrum is quite filled by a dense bony mass; the hard palate is of more than twice its normal thickness. Before maceration the interstices of the bony mass were found to be filled with myeloid cells. It may be considered either an ossified myeloid tumour or a bony overgrowth.

From a girl æt. 21, in whom the swelling had existed as long as she could remember, and had grown very slowly. The bone was removed entire, except a small part in the hard palate on the left side. Fourteen months after the operation this portion had not increased in size, and the patient suffered from no inconvenience, except that she could not use both eyes simultaneously, the right eye having sunk to a lower level than the left since the floor of the orbit had been removed. (See 'Trans. Path. Soc.,' vol. xxx, 1879, p. 358.) Branford Edwards, Esq.

R.C.S. Museum, 425.

Sarcoma.

882. Sarcoma of nose.

- 882A. The opposite side from the same patient. Along the superior margin of the middle turbinated body is a polypus, of cauliflower appearance, attached by a long pedicle. The free margin of the middle turbinated body presents a large vesicle.

St. George's Hosp. Museum, Series xvi, 54B.

883. The left side of a head, with a large malignant polypus of the nasal cavities, and other similar tumours attached to adjacent parts; they all appear to be pale and soft, but compact and smooth on their cut surfaces; they are in no part ulcerated. The nasal cavities on both sides are filled; the septum is bent outwards by the portion on its left side, and a large lobulated mass adhering to its right side and to the basilar process of the occipital bone, fills the right nasal cavities and the sphenoidal sinuses, and projects into the pharynx. Another large tumour, continuous with that in the sphenoidal sinuses, rises through the bone and dura mater under the anterior lobe of the left hemisphere of the cerebrum; other small tumours of the same kind are attached to adjacent parts of the dura mater. Other tumours, again, or parts of those seen within the nose, have protruded the eye, everted the lower lid, and formed an enormous swelling in the temporal and temporo-maxillary fossæ. The frontal sinuses and antrum are free from the disease, but the latter is much compressed.

From a man æt. 20. Eight years before death he first had signs of a cold, which continued and increased for two years. Three years after it began a polypus appeared in the nose, and an imperfect attempt was made to extract it. After this the disease shown in the specimen gradually made progress. He had scarcely any signs of cerebral affection from the tumour within the skull.

R.C.S. Museum, 3947.

884. Round-celled sarcoma of left superior maxilla; appears as polypoid mass in left nostril and as alveolar tumour in the mouth; displaces the eye upwards. There was a similar mass in the right lung. From a child, æt. 3½.

Guy's Hosp. Museum, 1091¹².

885. Portions of superior maxillary bones, symmetrically involved in a new growth, involving mainly their alveolar portions. The nasal fossa is blocked by large polypoid outgrowths of the tumour. Microscopically it is a spheroidal-celled sarcoma.

Removed by Sir W. MacCormac from a woman æt. 54, admitted February, 1884. Her mother died at 52 with carcinoma of the breast. Two years before admission a lump appeared in the left nostril and was removed; a year afterwards it recurred, accompanied by foul discharge, and six and a half months before admission

several polypi were again removed; one was noted as very firm, the others were regarded as ordinary mucous polypi; shortly after this, thickening of the alveolar margin led to her being admitted. G. H. Makins, Esq., 'Path. Soc. Trans.,' vol. xxxvii.

St. Thos. Hosp. Museum, 869.

886. Superior maxilla, removed by Mr. Hancock on account of a large fibrous tumour which was attached to the pterygoid processes of the sphenoid bone. It extended into the antrum, destroying its posterior wall, into both nasal cavities and into the posterior palatine canal. The patient was able to leave the hospital in a fortnight.

Charing Cross Hosp. Museum, 692.

887. Part of the right side of a face, in which the antrum and other nasal cavities and passages are completely filled by a soft medullary tumour, which also projects with an extensive sloughing surface through the skin of the cheek and through the anterior part of the gum and of the hard palate.

[Microscopically, a spindle-celled sarcoma with some round cells.]

St. Bart.'s Hosp. Museum, Series xii, 1771.

888. The left side of a face, with a soft medullary tumour, filling the antrum and thence extending into the nostrils and cavities of the mouth and orbit. The parts of the tumour exposed are broken and flocculent, as if sloughing. J. H. B. Williams, Esq.

[Microscopically, a mixed-celled sarcoma.]

St. Bart.'s Hosp. Museum, Series xii, 1772.

889. The central portion of a head, showing a medullary tumour, probably originating from the walls of the right antrum. The greater part of the tumour was soft, pale, and homogeneous; the surface of its section is like that of brain. (See two following specimens.)

R.C.S. Museum, 2250.

- 889A. The right side of the head (see 889 and 889B). The facial bones, except the lower jaw, have disappeared, being replaced by medullary growth. The bones of the base of the cranium, the adjoining vertebræ, and the lower jaw are soft, and infiltrated by the growth.

R.C.S. Museum, 2250A.

- 889B. The left side of a head, showing the nasal cavities occupied by a large medullary tumour. The uvula and soft palate are thickened by infiltration with medullary matter.

From a woman æt. 55, an upholstress. She is stated to have felt uneasy sensations in her face for three years; but the tumour did not appear externally till ten months before her death; after that time it grew rapidly.

R.C.S. Museum, 2250B.

890. The base of a skull, dried, showing complete destruction of the nasal bone and right superior maxilla by a tumour. The right malar bone is also partly destroyed, and the surface of the part remaining is roughened from ulceration; this change is also seen in the left nasal bone and adjacent part of the superior maxilla. The hard palate has almost disappeared.
Middl. Hosp. Museum, 619.
891. Part of the right superior maxilla, and two large tumours which occupied the cavity of the antrum (possibly sarcomata). Removed from a boy æt. 14, who made a good recovery. A. Shaw, Esq.
Middl. Hosp. Museum, 614.
892. Anterior part of a left superior maxilla, from the antrum of which has grown a slightly lobulated globular tumour, of which a part occupies the portion of the antrum shown; between the latter part and the larger mass which projects anteriorly, portions of the anterior wall of the antrum remain unaltered, either in form or thickness; but this wall is for the most part wanting, the two parts of the tumour being continuous through its defects. It appears to have perforated the hard palate and grown into the mouth. It is most probably a fibro-sarcoma.
Univ. Coll. Museum, 658.
893. Anterior part of the right side of a head; a large tumour of the superior maxilla probably arising in the antrum. The growth has caused deformity in every direction; filled the right nasal fossa (the septum has been turned downwards in dissection); depressed the arch of the palate on the right side; formed a prominence on the front and side of the face; it fills the zygomatic fossa and encroaches on the orbit. Microscopically, a round-celled sarcoma.
St. Thos. Hosp. Museum, 861.
894. Head of a man æt. 20, posterior part removed. Face is deformed from the growth of a large spindle-celled sarcoma, probably arising in the left maxillary antrum. A portion projects from the mouth; in it are two teeth showing the protrusion has occurred from the palatine side of the antrum. The left eye is closed; there is widespread convexity over the left side of the skull. The divided surface shows the growth to have extended beyond the parts shown, especially on the right side, where the bone has been destroyed and replaced by growth; similar destruction of bone is elsewhere indicated by the eminences in the left middle and anterior fossæ. The angle of the mouth and left nostril are much displaced downwards. The patient died in full possession of his senses except sight.
St. Thos. Hosp. Museum, 862.
895. Anterior part of right half of skull; superior maxilla involved in large tumour, probably arising in antrum, consisting of spindle-celled tissue mixed with cartilage, the deeper part of the growth having undergone calcification or bony transformation. The tumour projects into the orbit, mouth,

nose, and sphenoidal sinus, fills the zygomatic fossa, and protrudes from the cheek.

St. Thos. Hosp. Museum, 863.

896. Mixed-celled sarcoma of antrum projecting into orbit, mouth, nose, and face. (See Post-mortem Book, 1841; Case Book (1841), p. 133.)

St. George's Hosp. Museum, Series ii, 53A.

897. Sarcoma of antrum in a child; perforating the anterior wall, invading the orbit, mouth, and nose, and destroying the cribriform plate of the ethmoid.

St. George's Hosp. Museum, Series xvi, 53B.

898. Ossifying sarcoma of upper jaw. It appeared one year before removal, with pain and discomfort attributed to a gumboil and toothache in the last molar on that side. Five months later the bone began to enlarge, with pain in the nostril and ear and headache. The palate became sore and ulcerated. Mr. Heath removed the jaw, June 16th, 1886. The tumour was found to be an osseous sarcoma, but there were no Haversian canals, the appearances were rather those of calcification of the matrix than true ossification. The cells are round and spindle-shaped. The matrix is mainly hyaline, but in parts fibrillated. From a woman æt. 36.

Univ. Coll. Museum, 659A.

899. Anterior half of a skull wanting the calvarium. There is an extensive, ossifying, sarcomatous growth, which recurred after removal of the left upper maxilla for similar disease. It projects widely in all directions.

St. Thos. Hosp. Museum, 864.

900. Sarcoma of superior maxilla invading orbit and adjacent part of cranium.

Lond. Hosp. Museum, 675.

901. Sarcoma of Superior maxilla.

Lond. Hosp. Museum, 676.

902. Sarcoma of antrum.

Lond. Hosp. Museum, 672.

903. Section of a large tumour formed in the face of a lad 16 years old. The greater part of it occupies the situation of the superior maxillary bones which are completely absorbed. Above the tumour has extruded through the left side of the base of the skull into its cavity, where it forms a large projection in the situation of the anterior lobes of the cerebrum; below, it is united to the soft palate; in front, it protrudes, distends the left nostril, and has caused the ulceration of a part of the integuments of the face. The outer surface of the tumour is nodulated; its interior, shown by the section, is formed of close-set nodules and masses of cartilage, partially and irregularly ossified, and in some parts intersected by layers of a softer, probably

fibrous, tissue. A portion of its external surface projecting below the left nostril has sloughed.

- 903A. The other half of tumour No. 903. This portion extends into the cavity of the left orbit, and has elongated and compressed the left optic nerve, pushing it to the outer wall of the orbit. The tumour presents the same partially ossified cartilaginous structure as the preceding. The tumour was of very slow growth. (See Mr. Stanley's treatise on 'Diseases of the Bone,' pl. xvii, fig. 3.)

St. Bart.'s Hosp. Museum, Series vii, 1773 and 1774.

904. Part of the skull of a man about 40 years old, who had a large malignant tumour of the face. The tumour appears to have originated at the nasal process of the left superior maxillary bone and at the left nasal bone, on which there is a projecting growth of bony processes and plates. The tumour, extending from its centre, produced absorption of the inner and lower part of the left orbit, the inner and anterior part of the right orbit, the septum of the nose, the turbinated bones, and the middle and posterior parts of the palate. To a slight degree also it destroyed the left cribriform plate of the ethmoid bone, and the adjacent part of the upper wall of the orbit. At nearly all the parts of the bones upon which the tumour encroached there is a thin everted border of bone.

St. Bart.'s Hosp. Museum, Series i, 544.

905. Portion of the base of a skull with the pharynx, larynx, &c. Projecting into the left nasal fossa and corresponding side of the pharynx is a low, ulcerating, morbid growth; the left posterior naris is quite blocked by it, but little of it can be seen from the mouth; the soft palate is much depressed. The growth extends deeply among the structures of the neck, the external carotid being quite surrounded; the course of the internal carotid has been displayed as far as the base of the skull.

Univ. Coll. Museum, 1383A.

906. Part of the facial region of a skull, showing destruction of bones by the extension of a malignant tumour, said to have originated in the orbit. Left nasal bone, nasal process of superior maxilla, ethmoid, and bones forming inner wall of orbit have disappeared. The growth has invaded the frontal sinus and extruded into the cranium through its posterior wall. Inner wall of antrum in part destroyed. New bone deposited on superciliary ridge. No actual disease of the bones. Mr. Holthouse.

Westminster Hosp. Museum, 263.

907. Melanotic nasal polypus. Hugh E. Jones, Esq.
Univ. Coll., Liverpool.

908. Melanotic sarcoma of nose.

St. George's Hosp. Museum, Series xvi, 54c.

NASO-PHARYNX AND PHARYNX (EPIBLASTIC).

Papilloma.

909. A papillomatous hypertrophied tonsil, removed by operation from a woman. (For microscope section see Histological Records, xii, 1807D.)
St. Bart.'s Hosp. Museum, Series xii, 1807D.
910. Papilloma removed from a tonsil. W. Jobson Horne, Esq.

Epithelioma.

911. Left half of a skull with pharynx, tongue, &c. Left side of soft palate and pharynx is destroyed and replaced by a deeply excavated ulcer, with raised irregular margins, which extends to the base of the skull. From the seat of ulceration growth had extended to the middle fossa and left sphenoidal fissure, and to the left inferior turbinated bone and antrum of Highmore. A mass of enlarged glands is cut through on the left side of the neck.

From a man æt. 45, who had had syphilis, admitted for fainting fits and facial paralysis. He noticed occlusion of the left nostril six months previous to admission. A month later there was hæmorrhage from the right nostril, and persistent headache on the left side. After two months there was difficulty in opening the mouth and swelling in the left side of the neck. Three weeks before admission the right side of the neck began to swell, there was difficulty in protruding the tongue, and fainting fits. On admission he had pains in the neck, difficulty in speaking, and giddiness; lower jaw retracted and pulled to the left; wasting of left temporal and masseter muscles; wasting of left side of tongue, which was pulled to the left; left internal strabismus and anæsthesia of left cornea; anæsthesia of left side of face generally; swellings on each side of the tongue. (See 'P.M. Reports,' March 12th, 1896.)

St. Mary's Hosp. Museum, 1058A.

(MESOBLASTIC.)

Angio-fibroma.

912. The two halves of a large naso-pharyngeal polypus removed from a man æt. 19, by operation, after removal of the upper jaw and splitting of the palate. The polypus consists of soft, cellular, fibrous tissue, and was excessively vascular. The enormous number of blood-vessels is well shown, the patent openings of the vessels being very evident. The tumour after removal measured $2\frac{1}{2}$ by $1\frac{1}{2}$ inches, had a well-defined capsule and was elastic to the touch. On section, numerous vessels and sinuses were seen, one large enough to admit the tip of the little finger. The patient had suffered from nasal obstruction, but had never had epistaxis. (See Male Surgical Register, vol. iv (1894), No. 1893; also 'Lancet,' vol. ii (1895), p. 913.)

St. Bart.'s Hosp. Museum, Series xii, 1770E.

913. Two large polypoid masses removed by operation from the naso-pharynx of a boy æt. 14. To obtain access to the growth the right superior maxilla had to be removed. The two polypi appeared to be attached to the periosteum of the sphenoid bone. The growths had been diagnosed on clinical grounds as sarcomatous. There had been very frequent epistaxis and pain and swelling in the face; the right nostril was completely obstructed. After removal the growths were shown to be angio-fibromata.

A microscopic specimen is preserved in the Histological Records, xii, 1770C. The vascularity of the growth is well seen on examining the surface of the section. The superior maxilla is preserved, No. 1774L, St. B. H. (See Male Surgical Register, vol. ii (1894), No. 3634*; and 'Lancet,' vol. ii (1895), p. 913.)

St. Bart.'s Hosp. Museum, Series xii, 1770C.

914. A large polypoid mass weighing four ounces, removed by operation from the naso-pharynx of a man æt. 19. To obtain access to the growth the left superior maxilla had to be removed. The tumour was attached to the base of the skull. Microscopically the growth proved to be an angio-fibroma. The vascularity is well shown on section in the lower part of the specimen, the surface of the section being riddled with little holes—the openings of the vessels. The superior maxilla is shown in this series, No. 1774M, and microscopic sections in the Histological Records, xii, 1770D. (See Male Surgical Register, vol. iv (1896), No. 575; also 'Lancet,' vol. ii (1895), p. 913.)

St. Bart.'s Hosp. Museum, Series xii, 1770D.

Fibroma.

915. Part of the base of a skull with the nasal fossæ, palate, ear, &c., showing an irregular, lobulated polypus occupying the upper part of the pharynx, and extending forwards into both nares, laterally occupying the position of the left tonsil, passing into the auditory canal and appearing at the external auditory meatus.

From a female child, æt. 5, who was much emaciated and died partly from asphyxia and partly from inanition. Portions of the growth were removed by Mr. Quain with polypus forceps at different times to give relief. Microscopically it consists of irregular wavy fibres, of different lengths, intersecting each other in all directions, with fusiform cells. The child was quite well two months before her death. See Mr. Quain's Female Case Book, 1851, p. 122.

Univ. Coll. Hosp. 1383B.

916. Naso-pharyngeal tumour, bisected; of oval shape, and two inches in its chief diameter; base of attachment comparatively small; its investing mucous membrane ulcerated in places.

W. S—, æt. 14, admitted under Mr. Clutton, May, 1886. Dyspnoea and dysphagia eighteen months previously. Tumour not adherent

to soft palate or posterior wall of pharynx; projected below border of soft palate which it bulged downwards. Attached to basi-occipital; it was removed with piano wire, passed through left nostril and adjusted by a finger in the pharynx attached to an ecraseur. The basilar process was then scraped. The growth was a soft fibroma. Recurrence took place, and in July masses of new growth were removed with the sharp spoon, the basilar process and sphenoidal sinuses being effectively cleared. The second growth was more cellular than the first. No further growth occurred and the patient was well six years later. H. H. Clutton, Esq., 'Lancet,' 1888, vol. ii, p. 1059.

St. Thos. Hosp. Museum, 1913.

917. A large lobed naso-pharyngeal polypus measuring two inches in breadth and nearly three inches in length.

Removed by avulsion from a man *æt.* 65, in whom it had been growing for the preceding fourteen years.

St. Bart.'s Hosp. Museum, Series xii, 1770B.

918. Polypoid growth removed from the tonsil; consists of a larger and a smaller portion, each crescentic in shape. The two portions are attached by a narrow bridge of tissue. Microscopically the growth is a soft fibroma.

From a man *æt.* 25, who said he had repeatedly suffered from sore throat for ten years. The swelling gave him no inconvenience, and he did not know how long it had been growing. (See Male Surgical Register, vol. iii (1886), No. 360.)

St. Bart.'s Hosp. Museum, Series xii, 1807A.

919. A tonsil to which is attached a polypus half an inch long.

The whole was removed by operation for chronic enlargement from a patient *æt.* 17. Alex. G. R. Foulerton, Esq.

St. Bart.'s Hosp. Museum, Series xii, 1807B.

920. Portion of the right tonsil with a fibrous polypus projecting from one of its follicles; the affected portion of tonsil was shelled out of its bed.

From a woman *æt.* 42. The tumour was observed four weeks before its removal, it is uncertain how long it had been present. Formalin glycerine specimen. (For microscopic specimen see Histological Records, xii, 1807B.) H. T. Butlin, Esq.

St. Bart.'s Hosp. Museum, Series xii, 1807B i.

921. A small fibrous tumour removed from the soft palate.

St. Bart.'s Hosp. Museum, Series xii, 1802.

922. Section of a boy's head with a largely lobed tumour apparently of fibro-cellular structure, in the soft palate. The tumour grew slowly. The boy was suddenly suffocated.

922A. Drawing of 922.

St. Bart.'s Hosp. Museum, Series xii, 1803.

Sarcoma.

923. A tumour removed from a man æt. 40. It had existed eighteen months; it began in the right tonsil and grew into the fauces. More than a year before its appearance a considerable portion of the enlarged right tonsil had been excised. In general character and structure it resembles the tissue of the tonsils.

[Microscopically, round-celled sarcoma.]

St. Bart.'s Hosp. Museum, Series xii, 1807.

924. A tonsil uniformly enlarged by a growth which infiltrates the muscles; removed by operation and found microscopically to be a round-celled sarcoma. (See Female Surgical Register, vol. v (1894), No. 786.)

St. Bart.'s Hosp. Museum, Series xii, 1807c.

925. A large naso-pharyngeal polypus, 2 inches in its long diameter by $1\frac{1}{2}$ inches breadth. Its cut surface is firm and fibrous, and its base of attachment broad and very vascular. The tumour grew from the bones at the base of the skull, and was removed through an opening made in the roof of the mouth. The patient was a boy æt. 14, and made a good recovery. Microscopically the growth was found to consist of sarcomatous cells mixed with a good deal of loose connective tissue. Thos. Smith, Esq.

St. Bart.'s Hosp. Museum, Series xii, 1770A.

926. Part of sphenoid and adjacent bones, showing a mass of sarcoma, which probably commenced in the body of the sphenoid, and has passed up into the skull and down into the nares. The left Gasserian ganglion is embedded in a mass of growth which extends on the posterior aspect of the petrous bone, and involved the fourth, sixth, and eighth nerves on that side. The right Gasserian ganglion is invaded by a smaller mass, which involves the third nerve on that side.

The patient had paralysis of the nerves involved. At an early stage the cervical glands were enlarged, which led to a correct conjecture as to seat of the primary disease.

Lond. Hosp. Museum, 843.

927. Sarcoma of naso-pharynx invading the neck and brain. (See Insp., 1885, No. 117.)

Guy's Hosp. Museum, 1666¹⁵.

928. Fore part of left hemisphere of a brain, cortex cut away to show the cavity of an abscess; the cyst is mostly on the orbital aspect where its wall is thin.

From a boy æt. 18, admitted with a sloughing naso-pharyngeal polypoid sarcoma. It was removed, but he had a convulsion at the

end of the operation, remained comatose, and died. (See Insp., 1882, No. 78.)

Guy's Hosp. Museum, 1565⁹¹.

PARASITES.

929. A series of cultures in tubes illustrating the more common varieties of pathogenic organism met with in diseases of the ear and nose.

Wm. Bulloch, Esq., and G. Lenthal Cheatle, Esq.

930. Microscopical preparations of aspergillus from the external meatus :—
i, *Aspergillus niger* ; ii, *A. fumigatus*. Prof. Urban Pritchard.

MICROSCOPICAL SPECIMENS.

EMBRYOLOGY.

931. A series of consecutive sections demonstrating the earlier embryonic stages in the development of the head (auditory and olfactory apparatus) of the chicken. Jobson Horne, Esq.

PATHOLOGY.

ANOMALIES IN THE DISTRIBUTION OF THE BLOOD AND LYMPH.

EAR.

932. Sections through a temporal bone from a case of leucocythæmia, showing hæmorrhage into every part of the labyrinth. Richard Lake, Esq.

RETROGRESSIVE DISTURBANCES—FORMATION OF CYSTS.

NOSE.

933. Section showing formation of cysts in nasal polypus. Jobson Horne, Esq.

NASO-PHARYNX.

934. Section of a cyst removed from the naso-pharyngeal vault. Arthur H. Cheatle, Esq.

PROGRESSIVE OR FORMATIVE DISTURBANCES OF NUTRITION—HYPERTROPHY. REGENERATION.

NOSE.

935. Section showing hypertrophy of the nasal-septal tubercle. (See No. 519.) Arthur H. Cheatle, Esq.

PHARYNX.

936. Section of polypoid overgrowth from supra-tonsillar fossa. Arthur H. Cheatle, Esq.

INFLAMMATION AND ITS CONSEQUENCES.

EAR.

937. Section of a thickened edge of a perforation in membrana tympani.
Richard Lake, Esq.
938. Section of a granulation which came through Shrapnell's membrane.
Fine hairs in interior and projecting from surface; no follicles. (See
No. 543.) Arthur H. Cheate, Esq.
939. A section from a similar granulation. Arthur H. Cheate, Esq.
940. A section of a hairy polypus. H. Pegler, Esq.

SPECIFIC INFLAMMATION.

EAR.

941. Two sections of tuberculous lining membrane of the middle ear; i, stained
with logwood, rubin and orange; ii, stained with fuchsine and methylene
blue, showing bacilli. (See No. 749.) Arthur H. Cheate, Esq.

TUMOURS.

EAR—EPIBLASTIC.

942. Section of papilloma of external meatus. Arthur H. Cheate, Esq.
943. Section of adeno-carcinoma of meatus. (See No. 803.)
Arthur H. Cheate, Esq.
944. Section of epithelioma (squamous) from auricle. The growth commenced
at tip of helix. Wyatt Wingrave, Esq.
945. Section of epithelioma (alveolar) from external auditory meatus. From a
man æt. 54; history of chronic discharge becoming hæmorrhagic; stenosis
of meatus; fungations. Wyatt Wingrave, Esq.

MESOBLASTIC.

946. Section of a pedunculated exostosis removed from the external auditory
meatus.
947. Section of a round-celled sarcoma which grew rapidly from the middle
ear of a girl æt. 11 years; first appeared as granulations in meatus, and the
post-aural operation was performed; fungation through wound; death six
weeks later from asthenia. Wyatt Wingrave, Esq.
948. Section of a sarcoma of the ear. (See No. 823.)
Galbraith Connal, Esq.

NOSE (ACCESSORY SINUSES, NASO-PHARYNX, AND PHARYNX)—EPIBLASTIC.

949. Sections of epithelial tumours of nasal septum.
 Papillomata :—i, squamous ; ii, columnar ; iii, vascular.
 Adenoma :—i, vestibular ; ii, Schneiderian.
 Epithelioma :—i, squamous ; ii, alveolar.
 Wyatt Wingrave, Esq.
950. Section of mucous adenoma of nose. Jobson Horne, Esq.
951. Section of vacuolated carcinoma of antrum of Highmore ; absorption of bone. (See No. 852.) H. D. Rolleston, Esq.
952. Section of squamous-celled carcinoma of antrum of Highmore.
 Jobson Horne, Esq.
953. Section of epithelioma extending to antrum of Highmore.
 Jobson Horne, Esq.

MESOBLASTIC.

- Sections of mesoblastic tumours of nasal septum :—i, Myxoma (polypus) ;
 ii, enchondroma ; iii, fibroma ; iv, fibro-angioma ; v, sarcoma (round-,
 spindle-, and giant-celled, alveolar). Wyatt Wingrave, Esq.
955. Section of a highly vascular nasal polypus. Jobson Horne, Esq.
956. Section of a sarcoma of nose. Galbraith Connal, Esq.
957. Section of a fibro-angioma of naso-pharynx. Jobson Horne, Esq.

SKIAGRAPHS.


958. Skiagraph of portion of temporal bone, with band of metal in the Fallopian canal.
 Richard Lake, Esq.
959. Skiagraph, taken by F. H. Low, Esq., of foreign body (coiled silver wire tube) in antrum of Highmore.
 Arthur H. Cheatle, Esq.
960. Skiagraph showing a bullet in front of the second cervical vertebra (attempted suicide by shooting into the mouth) ; patient quite well.
 Thomas Barr, Esq.

INSTRUMENTS.

961. An adaptable nozzle for ear syringe for washing out the attic or lateral cavities.
 Prof. Urban Pritchard.
962. Continuous syringe for the removal of cerumen, &c., from the ear, or for irrigation of any cavity.
 Richard Lake, Esq.

963. Attic curette, for removal of the incus, granulations, &c.
Richard Lake, Esq.
 964. Cryer's skull-cutter, adapted for the removal of the outer attic wall.
Arthur H. Cheatele, Esq.
 965. Mastoid gouges with handle.
Richard Lake, Esq.
 966. Linen retractor for auricle and soft part of meatus for use during tympano-mastoid operations.
Hugh E. Jones, Esq.
 967. Curette for removal of polypoid masses from beneath the middle turbinate bone.
Richard Lake, Esq.
 968. Large drill for opening the anterior wall of the maxillary sinus in the radical treatment of chronic empyema of that cavity.
Cresswell Baber, Esq.
-

969. An Egyptian votive tablet, carved in wood, from a patient after recovery from some ear disease. Date probably 600 B.C., XXVIth Dynasty. There is a somewhat similar tablet carved in limestone in the British Museum.
Lent by Prof. Crookshank from his collection of Egyptian antiquities.



CATALOGUE
OF
PREPARATIONS OF THE DISEASES OF THE EAR

PREPARED AND DESCRIBED BY

JOSEPH TOYNBEE, F.R.S.

THE COLLECTION KINDLY LENT BY

The Council of the Royal College of Surgeons of England.

SERIES I.—THE EXTERNAL EAR.

1. A model of the external ear of a child, in which there was no meatus externus. (See 'Medical Times and Gazette,' No. 311, June 17, 1856.)

SERIES II.—MEATUS EXTERNUS.

ABNORMAL CONTENTS.

I. ACCUMULATION OF CERUMEN, AND ITS EFFECTS.

- 2A. Various specimens of cerumen, some of them containing a large quantity of hair.
- 3A. Mass of cerumen filling the external meatus, and moulded upon the surface of membrana tympani.
4. Portions of cerumen, presenting casts of the external surface of the membrana tympani.
5. A large mass, presenting a cast of membrana tympani.
6. Masses of cerumen with hair and epidermis.
7. Osseous meatus dilated by cerumen.
8. Meatus dilated by cerumen. (See No. 160.)
9. Meatus dilated by cerumen. Membrana tympani ossified. Auditory nerve and membranous vestibule atrophied. *History*.—Male, æt. 79. Could not hear a shout; had been deaf 40 years. (See No. 160.)
10. Left ear. Cerumen in external meatus; absorption of part of the anterior wall. Membrana tympani thick and white.

11. Osseous meatus, diseased from presence of cerumen. Membrana tympani thick and white; it is flat and connected to inner wall of tympanum by firm membranous bands.
12. The meatus was full of cerumen and epidermis. The anterior osseous wall is thin and perforated by orifices, one as large as a pea. The lower wall is rough, and presents a worm-eaten appearance. The membrana tympani is dull; the dermoid layer at the upper part is detached from the surface of the radiating fibrous layer, and there is a space between them; it is connected by membranous bands to the inner wall of the tympanum.
13. Meatus dilated from cerumen; osseous wall partly absorbed; posteriorly communicating with mastoid cells, inferiorly with the jugular fossa; cerumen projected into the mastoid cells.
14. Posterior wall of meatus rough, and dilated by cerumen; membrana tympani concave and uneven.
15. Meatus dilated from cerumen; inferior wall partly absorbed. Membrana tympani very concave, the cartilaginous ring exposed from the dilation of the meatus.
16. Right ear. From a male, æt. 80. Deaf 12 years. The meatus slightly dilated at its aperture; stapes ankylosed.
17. Left ear, from preceding case. Meatus dilated from cerumen; portion of posterior wall absorbed; stapes partially ankylosed.
18. Meatus dilated by cerumen; walls much thinned.

2. FOREIGN BODIES.

19. Meatus dilated by cotton wool and epidermis; aperture into mastoid cells; membrana tympani atrophied; malleus partly destroyed; stapes ankylosed; labyrinth very thick and opaque.
20. From a male, æt. 88. Very deaf. Meatus dilated and diseased from cotton wool and epidermis.
21. Portions of lint removed from the ear in a case in which the membrana tympani was perforated.
22. A piece of paper which had been in the meatus for six months.
23. A fragment of slate pencil, which was in contact with the membrana tympani.
24. Some husks of rye-seeds, removed from the meatus of a petrous bone; otherwise healthy.

3. EPIDERMIS.

25. Epidermis, forming a complete cast of meatus externus and membrana tympani.
26. A similar cast.
27. A similar cast.
28. Thickened epidermis from the meatus.
29. Very thick, discoloured ditto.
30. Portions of thickened epidermis.

- 31. A portion of ditto.
- 33. Very thick epidermis from ditto.
- 34. Meatus, containing diseased epidermis attached to thickened membrana tympani.

B.—EFFECTS OF INFLAMMATION.

I. DERMOID LAYER, THICK AND CONGESTED.

- 38. Dermoid layer, thick and congested.

C.—POLYPI.

I. FIBRO-GELATINOUS.

- 41. Two large fibro-gelatinous polypi, with small roots.

D.—MOLLUSCOUS TUMOURS AND THEIR EFFECT ON THE BONE.

- 45. Small molluscosus tumour, causing destruction of upper third of membrana tympani.
- 46. Molluscosus tumour *in situ*.
- 47. Right ear. A molluscosus tumour has caused absorption of upper wall of meatus, and also of the superior wall of the tympanum, so that the dura mater is in contact with it. (See No. 50.)
- 48. Absorption of the posterior wall of meatus to a slight extent from the presence of a molluscosus tumour.
- 49. The same disease of greater extent, the cancellous structure being exposed.
- 51. Absorption of posterior wall near to membrana tympani, by ditto.
- 52. The meatus contained three molluscosus tumours, one at the lower part of the orifice, a second in the substance of the superior osseous wall, near the membrana tympani, the contents of which projected into the tympanic cavity; a third in the lower part of the posterior wall between the circular cartilage of the membrana tympani and its sulcus. (Right ear. See No. 629.)
- 53. The outer part of the meatus contained cerumen, the inner half was occupied by a molluscosus tumour which had caused considerable dilation of the meatus. This tumour had caused the whole of the long process of the malleus to disappear by absorption, and had pressed the membrana tympani (which remained entire) inwards, so that its inner surface was in contact with the whole outer surface of the incus. The head of the malleus remains firmly attached to the incus. At the lower wall of the meatus the tumour had caused absorption of the bone near to the membrana tympani, and had produced an aperture into the tympanic cavity. The stapes was fixed more firmly than natural. The semicircular canals contained a large quantity of otoconie. (John Brown, æt. 87, 1850.)
- 54. Osseous wall of meatus partly absorbed at lower and inferior part from presence of molluscosus tumour.
- 55. A small molluscosus tumour has caused absorption of the bone at the upper wall of the meatus. The membranous labyrinth was thick. *History.*—

- Male æt. 72. Could hear a very loud voice with this ear. Deaf for many years, but much worse about four years before his death.
56. A molluscous tumour, as large as a hazel-nut, occupied the whole of the posterior part of the meatus, and projected into the mastoid cells and tympanic cavity. It had also caused absorption of the superior wall of the tympanum, producing atrophy of the dura mater, which was but slightly adherent to the bone. Inferiorly in the meatus it had caused absorption of the lower wall, near to the membrana tympani, so that the inferior margin of that membrane was unattached, and in the tympanic cavity it had produced absorption of the lower wall, and the fossa jugularis was laid open; anteriorly it had produced an orifice in the osseous lamina, separating the cavitas tympani from the carotid canal. The superior half of the membrana tympani was entirely destroyed, and the remaining part was very thick, and had fallen in. *History*.—R. Wood, æt. 66. Acute pain in right ear, from which there was profuse discharge. He died of apoplexy.
57. Portion of the contents of the above tumour.
58. Meatus greatly enlarged by a molluscous tumour, which penetrated to the cerebral cavity and caused death by abscess in the middle lobe of the brain. (See 'Trans. Path. Soc.,' vol. xi, p. 2, 1860.)
59. Molluscous tumour in external meatus extending into cranial cavity, and filling the tympanum, causing death by abscess in the cerebellum. From a woman, æt. 24, who had had discharge from the ear for five years. Case of M. W. (See 'Med.-Chir. Trans.,' vol. xlv, p. 55.)
- 59A. A small sebaceous tumour, extending from meatus into tympanic cavity. (See 'Med.-Chir. Trans.,' vol. xlv, p. 67. Case 14, 1861.)

C.—OSSEOUS WALLS.

1. LOWER WALL PARTLY DEFICIENT.

60. A small orifice in inferior wall of meatus.
61. The inferior wall of meatus incompletely developed.
62. The inferior wall of meatus incompletely developed.
63. A small orifice in inferior wall of meatus near membrana tympani.
64. An orifice of considerable size near the membrana tympani.
65. Osseous wall of meatus deficient at lower and inner part; the jugular vein was in contact with its lining membrane. Bands of adhesion in tympanum.

2. MEATUS DILATED.

66. Meatus dilated, especially at upper and outer part; superior wall of the tympanum imperfect.
67. Meatus dilated, chiefly at anterior part; superior wall of tympanum imperfect.
68. Meatus dilated, chiefly at upper and anterior part; superior wall of tympanum imperfect.
69. Meatus externus very large.

3. MEATUS CONTRACTED.

70. The anterior and posterior surface of the lower wall of the meatus present a bulging, by which the calibre of the tube is diminished.
72. Meatus contracted near the membrana tympani by bulging of the anterior and inferior walls. The layer of bone between the mastoid cells and lateral sinus very thin.
73. Meatus narrowed by hypertrophy of anterior and inferior walls.
74. Meatus externus contained dark purulent matter. Its osseous walls are in so highly diseased and thickened a state that the passage is almost obliterated. The inferior wall is dark in colour, rough, and carious. The membrana tympani is reduced to a dense mass of fibrous tissue, about one third of its natural size. The cavitas tympani is much diminished in size by the enlargement of its osseous walls and thickening of its lining membrane. The ossicula, however, still retain their position. The dura mater was attenuated and firmly adherent to the superior wall of the tympanum, and more particularly to that portion of the bone which formed the upper boundary of the meatus. The lateral sinus, also, was very firmly attached to the bone answering to the mastoid cells. The carotid canal is much narrowed by the increased thickness of its parietes, especially of the lower wall, which partakes of the thickening of the adjacent wall of the meatus. The coats of the internal carotid artery, at the point of constriction, are greatly attenuated, the external tunic having almost disappeared, and the internal one become of an opaque whiteness, hard and brittle. The internal carotid artery of the right side has undergone a similar change, though to a less extent. (Right ear. See No. 844.)
75. Stricture of the meatus from bulging of the inferior osseous wall. Membrana tympani greatly hypertrophied, white and opaque.
76. Meatus very small, about half the natural size.
77. The opposite ear, presenting a similar narrowing of the meatus.
78. Meatus much narrowed by bulging of the lower wall.
79. Meatus contracted near the membrana tympani by bulging of the inferior and posterior walls. (See No. 86.)
80. Meatus flattened and contracted; lower wall partly deficient.
81. Meatus contracted by bulging inwards of the anterior wall; membrana tympani red, thick, and tense.

4. MEATUS CONTAINING BONY GROWTHS.

82. Meatus contracted to about half its natural size by bony growth, chiefly from the posterior surface; surrounding bone exceedingly dense. Superior wall of tympanum imperfect.
83. Meatus contracted by bony growth from the posterior wall.
84. Meatus contracted by bony growth from inferior and posterior wall; osseous substance very dense.
85. From a man æt. 57. Meatus contracted by a bony growth at the posterior part.

86. Meatus greatly contracted by bony growths from anterior and posterior walls. Membrana tympani very concave, of a dark leaden hue. The tympanum contains numerous adhesions, connecting the malleus and membrana tympani to the promontory. (See No. 79.)
- 87 & 88. In each meatus there is a bony growth from the lower half of the posterior wall.
89. From a man æt. 59. A bony growth at the lower part of the meatus.
91. Meatus greatly contracted by a bony protuberance from the posterior wall.
92. Meatus contracted by bony growth from the posterior wall. Cavitas tympani contains broad bands of adhesion.

5. OSSEOUS WALLS PARTLY ABSORBED FROM INFLAMMATION.

94. From a patient who died from smallpox. Mucous membrane of tympanum congested; chronic inflammation of fibrous layers of membrana tympani and of osseous meatus. The meatus contained a large mass of cerumen. The fibrous laminæ of the membrana tympani have undergone ulceration. They have entirely disappeared in the upper third of the membrane; the mucous layer, having fallen inwards, has become attached to the promontory and stapes, and formed a septum, dividing the tympanic cavity into two, which had no communication with each other. The lower one was continuous with the Eustachian tube, the upper one with the meatus externus. The long process of the incus had been absorbed; the body remained attached to the malleus; the upper wall of the tympanum was very thin and of a dark colour, a considerable quantity of blood which filled the posterior portion of the tympanic cavity was distinctly seen through it. A portion of the upper wall of the meatus externus, close to the ulcerated portion of the membrana tympani, has been absorbed.
95. Left ear. The membrana tympani is very thick and white, especially at its circumference; it is more flat than natural. The lining membrane of the meatus is red and soft, and the epidermis very thick. The upper and posterior osseous wall of the meatus close to the membrana tympani presents an orifice about the size of a small pea, so that at this point the circumference of the membrana tympani is free and has no attachment to the bone. The stapes is fixed more firmly than natural. The tympanum contains mucus, its lining membrane is thickened. (Right ear.—See No. 453.)
97. Left ear. Lower wall of the meatus is partially absorbed. Stapes more fixed than natural. (Right ear. See No. 564.)
98. Meatus externus was full of cerumen; the upper and posterior wall, at its inner extremity, has been removed, apparently by absorption, and it no longer gives attachment at this part to the membrana tympani. The inferior third of the membrana tympani is white and thick like parchment. To this part is attached the inferior extremity of the long process of the malleus. The upper two-thirds of the fibrous laminæ have been entirely destroyed, leaving the mucous lamina alone persistent. This mucous lamina is concave, extremely thin and transparent, and gives attachment

to the incus and malleus; its upper and posterior part is adherent by a firm membranous band to the stapes and promontory. The head of the malleus is firmly ankylosed to the upper wall of the tympanic cavity; it is also immoveably attached to the body of the incus by means of dense ligamentous fibres. The posterior cricoid process of the incus has been entirely absorbed, its long process is disconnected from the stapes. The stapes is connected more firmly than natural to the circumference of the fenestra ovalis. Posterior to the incus, where the osseous wall of the meatus has been absorbed, there is a thin septum of mucous membrane, which separates the cavity of the mastoid cells from that of the meatus. The tensor tympani muscle is atrophied. The carotid canal is one third less than natural, and the internal carotid artery is not quite half the size of that on the opposite side. The upper wall of the tympanum is thicker than natural, and its cerebral surface has lost its smooth aspect. The Eustachian tube is healthy. (Left ear. See No. 343. Carotid artery. See No. 699.) *History*.—Male æt. 60. Was able to hear the click of the nail. Period of deafness unknown.

99. The lower wall of the meatus is rough, partly absorbed, and appears to have been inflamed. Lower wall of tympanum imperfect.

100. Meatus was filled with cerumen and epidermis. The bone forming the posterior wall was rough and partly absorbed. *History*.—Male æt. 68. He had a discharge from the ear some time since, and portions of dead bone came away.

6. OSSEOUS WALLS CARIOUS.

101. The meatus, at the lower and posterior part, presents a rough carious excavation, about three lines in each diameter. (See No. 110.)

102. A thin lamina of dead bone, from the meatus of a child æt. 5 years.

103. Portions of dead bone, from the meatus after chronic inflammation, in a child æt. 5 years. Discharge had existed from a month after birth, and the exfoliation of the bone was preceded by the formation of a polypus. The removal of the bone was followed by complete recovery.

105. A portion of dead bone from the meatus.

SERIES III.—MEMBRANA TYMPANI.

A.—EPIDERMOID LAMINA.

107. The epidermoid lamina of membrana tympani thick and opaque. The stapes partially ankylosed. Otoconie more abundant than natural. (See No. 190.)

108. A mass of thickened epidermis, nearly the size of a bean, removed from the surface of the membrana tympani. The patient (æt. 21) was deaf, and affected with noise in the head and giddiness; the removal of the mass of epidermis was followed by entire recovery.

- 109. The epidermoid and dermoid layers of the membrana tympani much thicker than natural. The dermoid layer vascular and soft.
- 110. The epidermoid and dermoid layers of membrana tympani thicker than natural. (See No. 101.)
- 111 & 111A. Epidermoid lamina thick, with general thickening of the membrana tympani.

B.—DERMOID LAMINA.

- 112. Dermoid lamina of membrana tympani thick.
- 114. A small growth (? polypoid) from the surface of the dermoid lamina of the membrana tympani. The membrane is adherent to the promontory; mucous membrane of tympanum thick.

C.—RADIATE FIBROUS LAMINA.

- 116. Radiate fibrous lamina thickened. The stapes was firmly attached to circumference of fenestra ovalis by thickening and solidification of the connecting membrane. (See No. 514.)
- 117. The opposite ear, presenting similar disease. (See No. 515.)
- 118. Radiate fibrous lamina very thick.
- 119. Radiate fibrous lamina very thick.

D.—CIRCULAR FIBROUS LAMINA.

- 120. Circular fibrous lamina thick and white. The incus was ankylosed to stapes. (See No. 643.)
- 121. Circular fibrous lamina thickened. There was a small quantity of mucus covering the inner portion of the meatus, the membrane was softened. The tympanic cavity contained mucous and rhomboid crystals. *History.*—Male æt. 23. Died from smallpox on the thirteenth day. Was delirious several days; not deaf.
- 122. Circular fibrous lamina thick, white, and dense, causing the membrane to be more rigid than natural.

E.—BOTH FIBROUS LAMINÆ.

- 124. Both fibrous laminæ thickened, especially the radiate.
- 125. Both fibrous laminæ very thick.
- 126. Both fibrous laminæ slightly thickened.
- 128. The membrana tympani is fallen in, so as to lie nearly flat against the promontory; fibrous laminæ inflamed and thickened. Mucous membrane of tympanum thick; cavity full of yellow mucus.
- 129. Degeneration of the fibrous laminæ after ulceration. Membrana tympani concave, very thick and yellow like cartilage; there is a large orifice anteriorly. The canalis caroticus is contracted.

130. Membrana tympani yellow and very concave. Anteriorly to the malleus the fibrous laminæ have been destroyed, and the mucous lamina is exposed over a surface three quarters of a line in diameter. The bone at the superior part of the membrana tympani has been absorbed over a surface about a line in diameter, and the mucous membrane of the tympanum is exposed. The tympanic cavity is full of bands of adhesion. The carotid canal is contracted.
132. Fibrous laminæ ulcerated over a circular spot about a line in diameter in the anterior portion of the membrane. Mucous lamina persistent.
133. A small orifice in fibrous laminæ at posterior part of membrana tympani. Mucous lamina persistent.
134. Right ear. The fibrous laminæ of the posterior and superior third of the membrana tympani are destroyed, the mucous lamina remaining; this portion is very concave, and adheres to the stapes. The posterior and inferior two thirds of the membrane are very thick and white. The carotid canal contracted to half its natural size. (See No. 134A.)
- 134A. Left ear. In the same state as the former specimen. The inferior extremity of the long process of the incus is absorbed, and the stapes is firmly attached to the membrana tympani.
135. Right ear. Membrana tympani more concave than natural; the posterior half is extremely thin; the fibrous coats apparently having been destroyed by ulceration, the mucous lamina only remains; it is extremely thin and flaccid, and its inner surface is adherent to the inferior extremity of the long process of the incus. The anterior half of the membrana tympani is thick and white like cartilage, especially at its circumference; near to the handle of the malleus it is very vascular, the vessels being large and tortuous. The superior osseous wall of the tympanum is very much thicker than natural, and it presents towards the cavity of the skull an exostosis about a line in depth, and four or five lines in circumference. The stapes is attached to the fenestra ovalis much more firmly than natural. *History.*—Male æt. 62. Hard of hearing for many years; about three years before his death became much more deaf after a violent cold, so that he required to be spoken to in a loud voice. Could hear the click of the nail. (Left ear. See No. 161.)
136. Fibrous laminæ of membrana tympani ulcerated at posterior and superior part; mucous lamina remaining.
137. Membrana tympani of a man æt. 65. It is concave and thick; at the posterior part, close to the handle of the malleus, there is an orifice of oval shape, about a line in its longest diameter. The remaining portion of the membrane is white and thick like parchment, and tense. The meatus contained cerumen. The mucous membrane of the tympanum is thicker than natural.
138. Right ear. Meatus very red and soft, especially at the inner third. The membrana tympani consists only of some delicate fibres lined by mucous membrane; it is fallen in (with the malleus) so as to be in contact with the

promontory. The head of the stapes, disconnected from the incus, pushed out the membrana tympani and formed a slight projection. By the falling in of the membrana tympani, what was the cavity of the tympanum now formed part of the meatus. *History*.—Male æt. 53. Thirty-seven years before his death he had an attack of fever, which caused deafness in the right ear. Thirteen years ago, after another attack of fever, he became deaf in the left ear also. With the right ear he could hear a loud voice at a distance of two feet. On the left side he required a loud voice close to the ear.

F.—MUCOUS LAMINA.

141. Membrana tympani of a boy æt. 5 years, who died from scarlet fever. Deaf. The membrane was vascular, the mucous lamina thick. The tympanum was completely filled with mucus. (See Nos. 315 and 639.)
142. Membrana tympani of a girl æt. 10 years, who died from smallpox on the twenty-second day after the appearance of the eruption. Deafness originated from the attack of smallpox; she heard well previously. Her mother was deaf. Left ear. The membrana tympani is white, but the surface reflects the light and is smooth. The mucous lamina is very thick and white. It is three or four times as thick as the membrana tympani itself when in a natural state. There is a small space, about a line and a half in diameter, towards the centre of the membrane, which is less thick. The tympanic cavity was completely full of thick and very tenacious mucus: this mucus consists of very large corpuscles, composed of a membranous envelope enclosing distinct rounded granules. Some of the cells are full of granules, others contain only a few. The mastoid cells contained blood; mixed with the blood discs were granules and fine transparent scales or lamellæ. The mucous membrane of the tympanum was very thick. It partially concealed the ossicles, binding them together more firmly than natural. The epithelial cells covering this thick mucous membrane were globular, and they stood out from the surface like the vesicles of the leaves of the ice plant.
144. Left membrana tympani of a boy æt. 21 months, who died of fever. The mucous lamina is very thick. The tympanic cavity is nearly filled with thick white mucus, and its lining membrane is very thick, red, and soft. The internal auditory meatus was very large. (See No. 233.)
145. Membrana tympani of a woman æt. 20, who died from typhus fever; was very deaf for five days before death. Left ear. The membrana tympani is thicker, softer, and whiter than natural. The mucous membrane of the tympanum was very thick, and firmly encircled the stapes, which is almost concealed. The fossa fenestræ rotundæ was concealed by it. The blood-vessels of the cochlea were distended with blood. The stapes was fixed more firmly than natural in the fenestra ovalis, owing to rigidity of the connecting membrane. (See Nos. 296 and 741, Membranous ankylosis.)

146. Membrana tympani of a woman æt. 50, who died from pneumonia. The mucous lamina is thick; the tympanum contained bands of adhesion.
147. Membrana tympani. Mucous lamina thick.
148. Membrana tympani. Ossific matter deposited on its inner surface.

G.—ALL THE LAMINÆ.

150. From a man æt. 74, who died from apoplexy, having been deaf some years. Right ear. The membrana tympani is white, thick, concave; bands envelop the ossicula. The base of stapes is enlarged and fixed more firmly than natural to fenestra ovalis. (See Nos. 176, 734, 735, and 739.)
151. From a man, æt. 76. Deaf for thirty-six years; probable cause, the noise of cannon during naval engagements; could hear the click of the nail. Right ear. Membrana tympani very thick, its structure being converted into a yellow, irregular mass, nearly as hard as bone. It is fallen in, so as to be barely in contact with the promontory.
153. Left ear. All the laminæ of membrana tympani thick.
155. Membrana tympani. All the laminæ thick and adherent to each other.
156. Membrana tympani. All the laminæ thick.
158. Membrana tympani. Anterior and inferior part thick and white.
160. Membrana tympani of a man æt. 74. Deaf for forty years; could not hear a shout. It is thick like cartilage. At the lower part there is a large calcareous patch. Anteriorly there is an orifice about a line in diameter. (See No. 8.)

H.—CALCAREOUS.

161. Left ear. (See Nos. 135 & 516.) A crescent-shaped calcareous deposit in the membrana tympani. The inferior extremity of the long process of the incus was much atrophied, and the articulation between it and the stapes much larger than natural. Stapes partially ankylosed, its base thicker than natural, and the lower border projected into the cavity of the vestibule, the crura of the bone appearing to have been pressed down or drawn downwards by bands of adhesion.
162. From a man æt. 70. The membrana tympani contains a small white deposit at its upper and posterior portion.
163. From a man æt. 70. Deaf. Right ear. The membrana tympani contains a crescentic calcareous deposit near its lower border. Stapes partially ankylosed. The membranous labyrinth was of a dark colour, as if blood had been effused and partly absorbed. The vessels of the modiolus of the cochlea were distended; the lamina spiralis was of a dark colour, and covered by a dark soft substance.
164. Membrana tympani calcareous in parts.
165. Membrana tympani contains a large calcareous deposit anteriorly, the

posterior part destroyed. The edges of the orifice are adherent to the stapes.

- 166. The membrana tympani contains a calcareous deposit.
- 167, 168. Small calcareous deposits in the membrana tympani.
- 169. Membrana tympani containing two large oval deposits of calcareous matter in its anterior and posterior portions respectively. At its lower part the fibrous laminæ are destroyed over a circular spot about a line and a half in diameter.
- 170. Right ear, in the same state.
- 172. Membrana tympani deficient posteriorly, the anterior part with calcareous deposits. From a man æt. 60.
- 173. Membrana tympani calcareous with an orifice, and adherent to promontory.
- 174. Membrana tympani calcareous with an orifice, and adherent to the stapes.
- 175. Membrana tympani calcareous with an orifice.

I.—CONCAVE, ATROPHIED, AND RELAXED.

- 176. Left ear. The membrana tympani is more concave than natural; its surface has somewhat the aspect of ground glass, having numerous white spots upon it, which are produced by thickened epidermis. The incus and stapes are connected together and to the promontory by bands of adhesion. The base of the stapes is expanded, and it projects somewhat into the vestibule. (See Nos. 150 and 739.)
- 177. From a man æt. 70. Hard of hearing for seven or eight years. Right ear. Membrana tympani very concave. Stapes partially ankylosed. Cochlea contains abundant pigment. (See No. 215.)
- 178 & 179. From a man æt. 75. Relaxation of membrana tympani. Each meatus contained several hairs. The epidermoid layer of each membrana tympani was thick and opaque, presenting the aspect of ground glass. Instead of presenting the usual convexity posterior to the malleus, each membrana tympani at the part had a lax and shrivelled aspect. When the tympanic cavity was distended with air by means of a blowpipe this portion assumed its natural convex aspect, but returned to its former state as soon as the pressure was removed. When pressed by a probe, it felt quite flaccid, and had the appearance of silver-paper. Each carotid canal was slightly contracted.
- 180. Malleus partly detached from membrana tympani. From a man æt. 46. Not deaf. Left ear. The membrana tympani is of normal thickness, but more flat than natural. The inferior third of the long process of the malleus is detached from the membrana tympani, and projects into the cavity of the tympanum.
- 181. From a man æt. 72. Became deaf about five years before his death, with giddiness. Suffered much from noises in the ears, especially on the right side. Twelve months before his death he required to be spoken to in a distinct voice near to him. Right ear. Membrana tympani much

more concave than natural, the lower extremity of the handle of the malleus being much drawn inwards. Upon looking at the internal surface it is observed to have the shape of a funnel. The lower extremity of the long process of the malleus is detached from the membrane, and projects into the cavity of the tympanum. Membranous bands fill the greater part of the tympanum surrounding the ossicles, and somewhat impeding their motions. One, which is very broad and strong, connects the membrana tympani to the promontory. The cochlea contains much black pigment. The membranous labyrinth is congested. (See No. 182.)

182. Left ear. The membrana tympani, like that of the right ear, is very concave, and the inferior extremity of the long process of the malleus is partly detached from it, *i.e.* only a few scattered fibres connect them. Some of the fibres of the radiate lamina are very much atrophied, and others appear to have been ruptured. These changes are no doubt to be attributed to the drawing in of the membrana tympani and malleus by the membranous bands which connect them to the promontory. The circular fibres have also been ruptured in parts. (See No. 181.)
183. From a man æt. 85. Right ear. The membrana tympani is delicate and atrophied, except at the part around the malleus, which was yellow and thick.
184. Left ear. The membrana tympani is very thin, flat, and seems to have lost its attachment to the malleus, which projects into the tympanic cavity. This atrophied condition is probably the result of inflammation of the fibrous layers.

K.—CONNECTED BY BANDS TO THE INNER WALL OF TYMPANUM.

185. Right ear. Membrana tympani thickened, and connected by bands to the promontory.
186. Left ear. Membrana tympani thickened, very concave, and adherent to the promontory.
187. From a man æt. 55, deaf in left ear. Right ear. Membrana tympani healthy in structure, adherent by a broad band to the promontory.
188. Left ear. Membrana tympani flat, and much thicker than natural; it is firmly adherent to promontory.
189. Membrana tympani thick and opaque; at the anterior part is a narrow elongated band of calcareous matter. It is connected to the inner wall of tympanum by numerous bands.
190. Membrana tympani more concave than natural, tense, its inner surface connected to the promontory by strong bands of adhesion; ossicula rigid. (See No. 107.)
191. From a man æt. 65, deaf for thirty years, the deafness commencing in right ear about ten months after an injury, occasioned to it by the report of a cannon. Could only hear a very loud voice; subject to noises in the

head. Right ear. Membrana tympani very thick, white, and opaque, especially at the posterior part; it is fallen in and adherent to the promontory, the tympanic cavity being nearly obliterated. Stapes partially ankylosed. Lamina spiralis of the cochlea very thick.

- 192, 192A. Membrana tympani connected to promontory by membranous bands.
- 193. Membrana tympani concave, thick, and white, connected by bands to the promontory.
- 194. Membrana tympani connected by a broad membrane to stapes and promontory, very concave.
- 195. Membrana tympani adherent to promontory.
- 197. Membrana tympani united by a thick, white, membranous band to the promontory.
- 198. Membrana tympani partly destroyed, fallen in, connected by bands to stapes and promontory.
- 199. Membrana tympani connected by thin bands to promontory.
- 200. Membrana tympani adherent by bands to promontory.
- 201. Membrana tympani adherent by a broad band to promontory.
- 202. Membrana tympani adherent by a broad band to stapes and canal for portio dura nerve.
- 203. Membrana tympani adherent by bands to inner wall of tympanum.
- 204. Membrana tympani and incus adherent by bands to promontory.
- 205. Membrana tympani fallen in, connected to inner wall of tympanum by numerous firm bands of adhesion.
- 206. Membrana tympani perforated, and adherent to stapes and promontory.

*L.—FALLEN IN AND ADHERENT TO THE INNER WALL OF
TYMPANUM.*

- 210. From a man æt. 59, deaf. Died from pneumonia. Right ear. Membrana tympani nearly destroyed by ulceration; a portion at the posterior part is fallen in, and adheres to the stapes and promontory. Mucous membrane of the tympanum very thick; it was covered with purulent matter. The osseous walls of the tympanum are thick and soft, while to the upper one the dura mater adhered very firmly. From the extension of the disease the carotid canal is diminished in size. The internal carotid artery was so contracted, that on being opened at the point of contact with the wall of the tympanum it was found wrinkled up, and presenting the appearance of an old ulcer of the intestines.
- 211. Left ear. Membrana tympani greatly thinned by disease; it is fallen in, and is in contact with the inner wall of the tympanum in nearly the whole of its extent. Carotid canal contracted.
- 212. From a woman æt. 64. Died from pneumonia. Right ear.—Membrana tympani very concave externally; it is thick, white, and cartilaginous, and firmly adherent to the inner wall of the tympanum. The mucous membrane

of the tympanum is very thick, with small patches of yellow scrofulous matter adhering firmly to its surface. The incus, the crura of the stapes, and the greater part of the malleus have disappeared, and the membranous labyrinth is very much atrophied.

213. Left ear. The upper half of the membrana tympani has been destroyed; the remaining portion is very thick and opaque, and firmly adherent to the inner wall of the tympanum. The mucous membrane of the tympanum is but slightly thicker than natural. The malleus and incus have both disappeared, and the stapes is adherent at its cervix to the remnant of the membrana tympani. In the bands of adhesion which connect the membrana tympani with the inner wall of the tympanum, small yellow masses of scrofulous matter, of a caseous consistence, are interspersed. The membranous labyrinth is atrophied.
214. Right ear. The membrana tympani has been partially destroyed; some cellular tissue and a few fibres only remain. These fibres were attached to the malleus externally, and to the promontory internally; the lower part of the tympanic cavity has thus been obliterated. The upper part of the tympanum and the mastoid cells contain a dark, thick matter, like coagulated blood, which was visible through the upper osseous wall of the tympanum, which is translucent. The mucous membrane of the tympanum is thick and of a dark colour. The vestibular cavity is in a diseased state, the membranous labyrinth atrophied. The dark matter in the tympanum was visible through the base of the stapes. *History*.—Male æt. 40. Died from smallpox. Deaf; he could hear when spoken to in an ordinary tone near to his bed. He had had scarlet fever when a child, since which time he had been somewhat dull of hearing, but he was considerably worse during the attack of smallpox; he died on the eleventh day after the appearance of the eruption. (See No. 316.)
215. Left ear. Membrana tympani very concave and thick, adherent to inner wall of tympanum. Mucous membrane of tympanum very thick, covered with mucus. The fluid of the labyrinth and cochlea opaque; otoconie very abundant. (Right ear. See No. 177.)
- 216 & 217. Membrana tympani partially destroyed by ulceration, fallen in and adherent to the inner wall of the tympanum. The membrane of the fenestra rotunda greatly thickened and of dark colour. On the right side the stapes partially ankylosed. (See 'Transactions of the Pathological Society,' 1852-3, vol. iv, p. 251.)
218. Membrana tympani very concave. Inner surface in contact with promontory.
219. Membrana tympani adherent to inner wall of tympanum, containing a thick white deposit at upper and posterior part.
220. Membrana tympani and malleus in contact with stapes.
221. From a man æt. 71. Right ear. Membrana tympani fallen in and adherent to the promontory. Left ear healthy.
222. From a man æt. 72. Left ear. The meatus was full of cerumen. The

lower part of the membrana tympani is destroyed; the surface of the promontory is seen covered only by a delicate membrane. The inferior extremities of the malleus and incus are nearly in contact with, and are attached to, the promontory. The lower extremity of the incus is detached from the stapes, and the neck of the latter projects towards the external meatus. The tympanic cavity is filled by thick mucous membrane. The lower osseous wall of the tympanum is imperfect.

223. Membrana tympani anterior half destroyed; posterior half adherent to promontory.
224. Membrana tympani absent, excepting a part of the mucous layer, which is in contact with the promontory.

M.—PERFORATED.

227. Membrana tympani nearly destroyed; portions of its mucous layer adherent to stapes and promontory.
228. From a female æt. 16. Died from fever after seven weeks' illness. She was in a certain degree deaf from the commencement of the attack. Right ear. The meatus externus contained a large quantity of purulent secretion, and the lining membrane was soft and ulcerated. The membrana tympani is destroyed, except a small portion at posterior and inferior borders. The mucous membrane of the tympanum is thick, soft, and ulcerated, the long process of the malleus has been partly absorbed. The tympanic cavity contains a thick, white matter; the mastoid cells are filled with a dense mucus. The dura mater is very loosely connected to the upper wall of the tympanum, and the periosteum of the fossa parotidea is very easily separable from the bone. The mucous membrane of the Eustachian tube was healthy.
229. Right ear. Membrana tympani entirely destroyed, except a small thick white strip, about half a line in width, remaining at its circumference. The inner surface of the remnant at the point to which the malleus is attached is bound to the inner wall of the tympanum by firm bands of adhesion, which entirely conceal the stapes. The long process of the malleus has partially disappeared, but the processus brevis is firmly adherent to the remnant of the membrana tympani. The internal part of the head of the malleus presents an exostosis of nearly equal size with the head of that bone. The surface of the malleus and incus is rough, and they are surrounded by caseous matter. The upper wall of the tympanum is dark and infiltrated with fluid. The tensor tympani muscle is atrophied to half its natural size. *History*.—Male æt. 53. Died of pneumonia. He had become deaf after a scrofulous disease when young, and continued so during the rest of his life.
230. Membrana tympani; orifice in centre, the margin of which is adherent to the stapes. The outer part of the membrane is white and thick.
231. Membrana tympani, larger part absent; the remnant, much thickened, is adherent to the promontory. *History*.—Female æt. 50. Had been deaf for many years.

232. The membrana tympani of a child æt. 18 months, who died of measles. It was thick and red, the red appearance being due to the congested mucous layer. There are two small perforations at the lower part. The tympanum contained yellow tenacious muco-purulent fluid, its mucous membrane thick and red.
233. Right membrana tympani of a boy æt. 21 months, who died from fever. Inner surface thick; in the central part was an orifice in the mucous and fibrous coats, which was covered by thick epidermis. This epidermis having been removed, mucus escaped from the tympanic cavity. The tympanum was nearly filled by thick white mucus, and its lining membrane was very thick, red, and soft. (See Nos. 144 and 317.)
234. From a man æt. 61. Right ear. The fibrous layers of the membrana tympani, at its posterior half, have been entirely destroyed. The mucous layer has fallen inwards, and is attached to the stapes and long process of the incus. The canalis caroticus is slightly contracted. (Left ear. See No. 787.)
235. Membrana tympani, perforated at lower and anterior part. The upper portion, with the long process of the malleus, is adherent to the promontory. The tympanum and mastoid cells contain numerous bands of adhesion.
237. Left ear. The central portion of the membrana tympani (about the extent of a pea) was very thin and concave, and broke down on being touched. The circumference, to the depth of three quarters of a line above and half a line below, remained, and the upper part was adherent by a broad band to the inner wall of the tympanum. The long process of the malleus is absent.
238. From a man deaf for a long time. Right ear. The meatus was full of cerumen; the surface of the bone, at the posterior part, is rough, and presents small depressions. Membrana tympani opaque, very concave; at the superior and posterior part is an orifice, which communicates with the tympanic cavity; the inner surface is adherent to the promontory by a broad band.
239. Left ear. Meatus in same condition as that of right ear. Membrana tympani partly destroyed, and adherent to incus and stapes. The handle of the malleus is absorbed.
- 240 & 241. From a man æt. 64. In each membrana tympani there is a circular orifice, three quarters of a line in diameter, between the malleus and the posterior part of its circumference. This orifice was covered by the epidermoid layer, which was complete.
242. From a man æt. 72. Membrana tympani not much thicker than natural, but at its anterior part there is an orifice about a line and a half long by three quarters of a line broad. Near the posterior border are two very small deposits of calcareous matter.
- 243 & 244. From a man æt. 80. Deafness for many years, first occasioned by a cannonade. The membrana tympani in each ear is thick and white at superior part; lower part destroyed.

245. From a man æt. 70. Very hard of hearing. Left ear. The inferior and posterior portions of the membrana tympani destroyed; the superior part to which the malleus is still adherent is thick, fallen inwards, and adherent to the promontory. Mucous membrane of tympanum thick. Stapes disconnected from the incus.
246. From a man æt. 70. Left ear. The posterior third of the membrana tympani is destroyed, exposing the incus, stapes, and chorda tympani nerve. The anterior two thirds of the membrane is thick and white. Right ear healthy.
247. Membrana tympani perforated at superior and posterior part; margins not thickened.
248. Membrana tympani thick and opaque; it presents an orifice a line in diameter at the anterior part; the mucous membrane of the tympanum is thick and red.
250. The greater part of the membrana tympani destroyed; the margins of the orifice connected to the stapes.
251. Membrana tympani partially destroyed, adherent to promontory.
252. Membrana tympani partially destroyed; adhesions in the tympanum.
253. The membrana tympani presents two orifices at the posterior part.
254. Membrana tympani presenting an orifice at the central part; the mucous layer thick.
255. Membrana tympani presenting an orifice in the lower part; the end of the long process of the malleus has disappeared.
256. Membrana tympani adherent to promontory; mucous membrane of tympanum very thick.
257. Membrana tympani thick and adherent to stapes.
258. Membrana tympani adherent to promontory.
- 258, 258A. From a woman æt. 60. Died from bronchitis. She had been deaf for several years; the deafness had come on gradually. There were repeated accumulations of wax in the ears, the removal of which afforded partial relief. Each meatus contained a large quantity of cerumen. Membrana tympani white, concave, the short process of malleus very prominent. The mucous membrane of the tympanum is thickened, and numerous bands of adhesion connect the membrana tympani with the inner wall of the tympanum and the ossicula with each other.
260. From a woman æt. 40. Died from uterine disease. Right ear. Membrana tympani white, thick, and more concave than natural. Mucous membrane of tympanum very thick, and also white. The tympanum and mastoid cells contained a white, glairy fluid.
- 263 & 264. Membrana tympani adherent to the promontory; mucous membrane of tympanum thick.
- 266 & 267. From a man æt. 60. The membrana tympani in each ear presents an orifice.

SERIES IV.—CAVITAS TYMPANI.

A.—ABNORMAL CONTENTS.

1. MUCUS AND EPITHELIUM.

270. Mucus removed from the tympanum of a woman æt. 22, who was deaf.
(See No. 334.)
271. Mucus that escaped from the tympanum through an orifice in the membrana tympani.
272. Another specimen of tympanic mucus from the same cause.
273. Thick, dark-coloured mucus from the tympanum.
274. Mucus from the tympanum.
- 275 & 276. Cavitas tympani distended with mucus.
277. The tympanum contains a mass of epithelium cells, which occupies the larger part of it.
278. The tympanum contains an accumulation of epithelium.

2. LYMPH AND BLOOD.

279. The tympanum nearly full of firm lymph.
280. Right ear. The tympanum contains a mass of soft, pale substance, which surrounds the stapes, and partly conceals the other ossicles. *History*.—Male æt. 79. Deaf for four or five years; the deafness came on slowly from cold. The right ear was the worst. He could hear the click of the nail. He suffered from a feeling as of stopping up on the right side of the head, and from noise like the ticking of a clock; was worse during the cold. The membrana tympani, on examination, was seen to be white, concave, and thick. The act of blowing the nose was accompanied with a feeling of cracking and bursting in the ears.
- 280A. Right ear. The meatus contained purulent fluid and thickened epidermis. The membrana tympani is fallen in to the promontory, of a dark colour, and thick. The anterior part of the tympanum is filled with a firm mass, resembling a partially decolourised clot: the posterior part is filled with a clot of comparatively recent blood, which appears to extend into the mastoid cells. The malleus and incus are freely moveable; the base of the stapes is somewhat less moveable than natural. *History*.—Male æt. 79. At times, when a boy, was hard of hearing, which he attributed to bathing; for fifty years had been decidedly deaf; it varied much, being worse during a cold. He could only hear a loud voice; had a beating noise in his head. Died from cancer of the liver. (Left ear, see No. 701A.)

3. SCROFULOUS MATTER.

- 281, 282. From a girl æt. $2\frac{1}{2}$, who died from phthisis. Right ear. Membrana tympani entirely destroyed by ulceration; the tympanum contained some scrofulous matter, although the lining membrane is so swollen as nearly to fill the cavity. Left ear. Membrana tympani thick, white, and

soft; the mucous membrane of the tympanum very thick and red. The tympanum is nearly filled with a mucus so dense as to be almost solid. Examined by the microscope, this substance was found to be mucus in combination with scrofulous matter.

283. From a girl æt. 9, who died from diseased hip and phthisis. Left ear. The mucous membrane of the tympanum is thick, soft, and ulcerated. The tympanum contains scrofulous matter. The stapes is entirely concealed. Right ear healthy.

284, 285. The tympanum of each ear is distended with scrofulous matter.

4. CALCAREOUS MATTER.

286. The tympanum contains calcareous matter, deposited chiefly upon its inferior and posterior walls.

287. The incus dislocated and impacted in the mastoid cells, and surrounded by calcareous matter.

287A. Meatus dilated by cerumen; tympanum nearly full of coagulated blood and cholesterine; Eustachian tube occluded. From a man æt. 33, partly hemiplegic four years. Two small, hard, semi-transparent masses were found in the cerebrum. (See 'Trans. Path. Soc.,' vol. xi, p. 222, 1860.)

287B. Cholesterine from the tympanum of the above.

B.—MUCOUS MEMBRANE THICK.

288. Mucous membrane of tympanum very thick.

289, 289A. From a child æt. 7, who died with tubercles in nearly all the organs of the body. Right ear. Strong bands of adhesion between the membrana tympani and incus. In both ears the mucous membrane of the tympanum is thick, soft, and vascular, so as nearly to conceal the stapes, and filling the greater part of the cavity, which latter also contained mucus and scrofulous matter.

290. Mucous membrane of the tympanum very thick; incus and stapes partially concealed.

291. From a woman æt. 62. Died of gangrene. Deaf in the left ear. Right ear. The membrana tympani is unusually concave; its internal surface about the centre is not more than a quarter of a line from the promontory. The membrane is also, in parts, rather opaque, especially at the circumference, and its internal layer is white and slightly thickened. The mucous membrane of the tympanum is rather thicker and more vascular than natural, and is also very tough. A firm band of adhesion connects the cervix of the malleus with the long process of the incus, and another membranous band connects the anterior surface of the long process of the incus with the promontory and with the stapes, which latter bone it completely envelops. The tensor tympani muscle is of diminished size. (Left ear, see No. 805.)

292, 293. From a child æt. 6 months, who died of pneumonia. The membrana

tympani of each ear is white, and contains red vessels of twice or thrice their natural dimensions. The mucous membrane of the tympanum is so thick as nearly to fill the tympanic cavity. The stapes and incus are almost concealed. The tympanum contains a white, muco-purulent matter, which is thick and tenacious, and distends the mastoid cells. (Note.—This thick condition of the mucous membrane illustrates one possible mode of formation of bands of adhesion, for the mucous membrane of the promontory is here in contact with the membrana tympani and malleus.)

- 294, 295. From a boy æt. 3, who died from scarlatina. In each ear the membrana tympani is thick, and of a reddish-white hue. The mucous membrane of the tympanum is so much thickened as nearly to fill the cavity, but is not ulcerated.
296. Mucous membrane of tympanum thick; ossicula partly concealed. (For *History*, &c., see No. 145.)
297. Female æt. 25. Died of pleuritis. Right ear. Membrana tympani more concave than natural. The mucous membrane of tympanum very red, thick, and soft. The dark colour of the mucous membrane of the tympanum is distinctly observable through the membrana tympani.
298. At the inferior and anterior part of the membrana tympani is an orifice about half a line in diameter, with thick margins. The mucous membrane of the tympanum is thick; the tympanic cavity contains a considerable quantity of mucus.
299. Mucous membrane of tympanum very thick, the stapes concealed.
300. Membrana tympani and mucous membrane of tympanum thick, the stapes surrounded by thickened membrane.
301. Membrana tympani and mucous membrane of tympanum thick.
302. Mucous membrane of tympanum thick around the stapes.
303. Membrana tympani and mucous membrane of tympanum thick. Adhesions between the membrana tympani and incus.
304. Mucous membrane of tympanum very thick.
305. A portion of thickened mucous membrane of the tympanum; from a boy æt. $3\frac{1}{2}$, who died of dysentery. (See No. 640.)
306. A portion of thickened mucous membrane of the tympanum; from a woman æt. 20, who died from typhus fever; deaf five days before her death. (See Nos. 145 and 755.)
307. A portion of the mucous membrane of the tympanum rather thicker than natural.

C.—MUCOUS MEMBRANE—EFFECTS OF SCROFULOUS INFLAMMATION.

308. From a child who died of enteritis. A degree of deafness had been perceived. Right ear. Membrana tympani white. The tympanum was quite full of a white purulent mass, consisting of oleaginous globules and scrofulous granular matter. The mucous membrane is thick and very

vascular. The head of the malleus is rough and disjoined from the incus ; the tendon of the tensor tympani muscle is ulcerated and reduced to a fine thread. The incus and stapes are concealed by the thickness of the membrane. The mastoid cells are filled with pus.

- 308A. Left ear. In the same general state as the right. The vascularity of the mucous membrane was imparted to the osseous wall of the tympanum and to the membrana tympani, which is crowded with vessels.
309. Mucous membrane of the tympanum thick, from scrofula.
310. Mucous membrane of the tympanum thick, from scrofula.
311. Mucous membrane of the tympanum thick, from scrofula ; bands of adhesion uniting the ossicula.

D.—EFFECTS OF MEASLES.

312. From a male infant *æt.* 9 months, who died from measles. Left ear. The membrana tympani presents a large orifice at the posterior part. There is ulceration of the mucous membrane of the tympanum, and the incus is disconnected from its attachments, and lies free in the tympanic cavity, which contains pus. The stapes is completely concealed by the thick mucous membrane. (See No. 333.)
313. From a male child *æt.* 2 years, who died from measles. Right ear. Membrana tympani thick and white. The mucous membrane of the tympanum is inflamed and thickened. The tympanum contained mucus.
314. Left ear. The tympanum is in the same condition as that of the right ear. (No. 313.)

E.—EFFECTS OF SCARLATINA.

315. From a boy *æt.* 5, who died from scarlatina. The tympanum was completely filled with mucus ; the mucous membrane thick and vascular. (See Nos. 141 and 639.)
316. A portion of greatly thickened mucous membrane from the tympanum of a man, deaf since scarlatina in early life. (See No. 214.)
317. Portion of thickened mucous membrane of the tympanum from a boy *æt.* 21 months, who died from fever. (See No. 233.)
318. Mucous membrane of the tympanum, thick from smallpox.

F.—MUCOUS MEMBRANE—EFFECTS OF ACUTE INFLAMMATION.

319. Dermoid meatus, membrana tympani, and mucous membrane of tympanum of a red colour, and containing numerous vessels distended with blood. Bands of adhesion in tympanum and mastoid cells. *History.*—Male *æt.* 22. Three weeks before death complained of pains in right ear,

as if a foreign body were there. The pain became very severe. Died of fever after a week's illness. Ulceration of ileum.

320. Mucous membrane of tympanum in a state of acute inflammation.
321. Mucous membrane of tympanum (acutely) inflamed, of a deep red colour, and thick.
322. Mucous membrane of the tympanum and mastoid cells, of red colour and thick.
323. Mucous membrane of the tympanum, of a pale red colour.
324. Mucous membrane of tympanum, inflamed. The tympanum contains numerous bands of adhesion of a deep red colour. Membrana tympani perforated at anterior and lower part.
325. Membrana tympani and lower two thirds of malleus destroyed. Mucous membrane of tympanum ulcerated. Cavity filled with soft membranous bands and offensive purulent matter. Upper wall of the tympanum of a green colour.
326. From a woman æt. 38, who died of dropsy. Deaf. Right ear. The membrana tympani is rather dull towards the posterior and superior part, and a round, fleshy-looking substance is visible beyond it. The membrane is also much more concave than natural, and at its central region there is a round portion, about a line in diameter, which is white. The surface is smooth and shining, and the white appearance evidently arises from the presence of some substance near its internal surface. The tympanum is nearly filled by a firm gelatinous-looking substance of a red hue, and which is the mucous membrane of the tympanum in a highly tumefied condition. This is the substance which was seen through the membrana tympani, the inner surface of which being in contact with the mucous membrane covering the promontory explains the peculiar appearance of its central region. The handle of the malleus is also in contact with the mucous membrane of the promontory; a small quantity of mucus existed in the tympanic cavity. The membrana tympani appears to be drawn inwards, at its upper and posterior part, by adhesions, which connect it firmly with the inner wall of the tympanum.
- 329, 330. From a child æt. $2\frac{1}{2}$, who died from consumption. In each ear the membrana tympani is thick and soft and of a white colour. The mucous membrane of the tympanum is thick and soft, and the tympanic cavity full of muco-purulent matter.
- 331, 332. From a child æt. 1, who died from hydrocephalus; it was scrofulous. The mucous membrane of the tympanum in each ear is red, and swollen to four or five times its natural thickness. The cavity is full of yellowish-white mucus, which to the naked eye wears the appearance of pus, except that it is more tenacious. The osseous walls of the tympanum are red, and the lower wall which separates it from the jugular vein is dark-coloured. The mastoid cells are nearly filled by the thickened lining membrane. The membrana tympani of the left ear presents a large ulcerated orifice about its centre.

333. Right ear. From an infant æt. 9 months, who died from measles. The mucous membrane of the tympanum is red, soft, and pulpy.
334. From a woman æt. 22, deaf. Died from diseased heart. Right ear. Membrana tympani much more concave than natural; its circumference, for the extent of half a line, is white and thick. It is adherent to the inner wall of the tympanum by firm membranous bands. The mucous membrane of the tympanum and mastoid cells is much thicker and softer than natural. (See No. 270.)
- 336, 337. From a child who died from scrofula. The mucous membrane of the tympanum in each ear is very thick.

H.—CONTAINING MEMBRANOUS BANDS OF ADHESION.

340. From a man æt. 67, who died of gangrena senilis. Left ear. The meatus externus contained a collection of cerumen lying in contact with the membrana tympani, which is more concave than natural. The whole of the inner surface of the long process of the malleus is connected by a strong band of adhesion to the stapes and the inner wall of the tympanum. The stapes is entirely hidden, and the mucous membrane covering the ossicula and lining the mastoid cells is very much thickened. (Right ear. See No. 761.)
341. From a man æt. 44, who died of a diseased bladder. He had been growing gradually deaf during many years. The Eustachian tube was pervious. Right ear. The meatus contained a large quantity of cerumen. Membrana tympani white, shining, and concave. The mucous membrane of the tympanum is thick, and bands of adhesion connect the stapes, malleus, and incus to the membrana tympani.
342. From a man æt. 70. Died of disease of the heart. Hard of hearing. Right ear. Membrana tympani dull like lead, but not much thicker than natural; the tympanum completely full of cellulo-fibrous tissue, which connects the ossicles and the membrana tympani to the promontory.
343. Left ear. The meatus contained cerumen. Membrana tympani soft, flaccid, and as if sodden; it is of a leaden hue, the handle of the malleus being scarcely visible; at its circumference, for the breadth of a line, there is a band of a darker colour than the central part; this is produced by thickening of the mucous lamina. The mucous membrane of tympanum is slightly thicker than natural; the posterior and superior part of the cavity is full of a firm, membranous, cellular tissue, apparently organised lymph, which surrounds the upper part of the malleus and incus, connecting them together and to the stapes. (See No. 98.)
344. From a man æt. 76. Right ear. The membrana tympani is concave, and the inferior extremity of the malleus is detached from it and projects into the cavity of the tympanum. Numerous firm bands of adhesion connect the malleus and other ossicles to the inner wall of the tympanum. The canal for the superior petrosal nerve is as large as a crow's quill.

- 345, 346. Right ear. Membrana tympani thick and concave. Numerous bands of adhesion connect the ossicles to the tympanic walls and to the membrana tympani. Ossicles not so moveable as natural. Left ear. Membrana tympani destroyed, except a narrow portion posteriorly; the ossicula remain, and are connected to each other and to the tympanic walls by broad bands of adhesion. The tympanum contained secretion of black colour. *History*.—Male æt. 70. Had been deaf in the left ear since the battle of Trafalgar; for three weeks after the battle was almost entirely deaf, but afterwards became better. During the four years preceding his death became more deaf; subject to noises of a tinkling character in the left ear during a cold. Could hear a watch on pressure over the right ear; with the left could hear the click of the finger-nails.
- 347, 348. Right ear. Membrana tympani: lower two thirds destroyed; the lower margin of the upper third is connected to the thick mucous membrane of the tympanum, which shuts off the mastoid cells from the tympanic cavity. The mastoid cells were full of a dark-coloured serous fluid, epithelium, and cholesterine. Mucous membrane of tympanum very thick. Labyrinth healthy. Left ear. In the same state as the right ear, except that the fluid in the mastoid cells was transparent. The stapes was fixed. The mastoid cells were separated from the tympanic cavity by a distinct band between the inner wall of the tympanum and the upper part of the membrana tympani. *History*.—Male æt. 67. Had been deaf for thirty or forty years after a naval engagement; was subject to roaring noises in both ears, which sometimes ceased for a day or two. At times there had been discharge from both ears. Up to about two years before his death he could hear the click of the finger-nails with each ear, but before he died he became unable to hear the voice.
349. A portion of some bands of adhesion removed from the tympanum of a man æt. 84.
350. The same, treated with acetic acid.
- 351, 352. Bands of adhesion connecting the malleus to the incus and promontory. Superior wall of the tympanum partly deficient.
353. Bands of adhesion connecting the malleus to the stapes and promontory.
- 354, 355. Bands of adhesion connecting the stapes to the inner wall of the tympanum.
- 356, 357. Bands of adhesion connecting the membrana tympani, malleus, and incus to the inner wall of the tympanum.
358. A broad band of adhesion connecting the incus to the membrana tympani.
359. Bands of adhesion connecting the incus to the membrana tympani, and also to the stapes and inner wall of the tympanum.
360. All the ossicula connected to each other, and to the inner wall of the tympanum by numerous bands of adhesion.
361. Base of the stapes entirely surrounded by delicate bands of adhesion.

- 362. Bands of adhesion connecting the malleus and incus to the tendon of the tensor tympani muscle.
- 363. A broad band of adhesion between the long processes of the malleus and incus, which are considerably approximated.
- 364. Incus and stapes connected to each other and to the walls of the tympanum by bands of adhesion. The stapes entirely embedded in them.
- 365. All the ossicula connected together, and to the walls of the tympanum by bands of adhesion.
- 366. Malleus adherent by bands to the incus, and to the inner and upper wall of the tympanum; broad bands of adhesion in the mastoid cells.
- 367. Membrana tympani connected by a band of adhesion to the incus; also the tendon of the stapedius muscle to the promontory.
- 368. Bands of adhesion connecting the incus and stapes to the inner and superior wall of the tympanum.
- 369. The membrana tympani and all the ossicula connected together, and to the inner and posterior walls of the tympanum by bands of adhesion.
- 370. Bands of adhesion connecting the membrana tympani to the malleus, incus, and stapes; the stapes connected to the adjacent portions of the tympanic wall, especially to the promontory.
- 371, 372. Membrana tympani connected by bands of adhesion to the ossicula and promontory.
- 373. Thick bands of adhesion enveloping all the ossicula and connecting the membrana tympani to the promontory.
- 374, 375. Bands of adhesion connecting the membrana tympani to the long process of the incus.
- 376. Bands of adhesion connecting the membrana tympani to the incus, and the incus and stapes to the walls of the tympanum.
- 377. Bands of adhesion connecting the membrana tympani and malleus to the long process of incus and promontory. The membrana tympani is more concave than natural.
- 378. Bands of adhesion connecting the malleus to the superior and internal walls of the tympanum. Membrana tympani very concave, being almost in contact with the promontory.
- 379. Malleus connected by bands of adhesion to the long process of the incus and to the tendon of the tensor tympani muscle.
- 380. Broad bands of adhesion connecting the malleus to the superior and inner wall of the tympanum, and the long process of the incus to the posterior margin of the membrana tympani.
- 381—385. Bands of adhesion connecting all the ossicula together, and to the inner wall of the tympanum.
- 386—389. Bands of adhesion connecting the incus and stapes to the inner wall of the tympanum.
- 390—394. Bands of adhesion surrounding the stapes, and attaching it to the inner wall of the tympanum.
- 397, 398. From a girl æt. 11, who died from phthisis. Right ear. Membrana

tympani opaque and very concave. At its posterior part is an orifice of a line in diameter, through which the fenestra ovalis is seen. The margins of this orifice are smooth and defined; the upper one is attached to the neck of the stapes. The mucous membrane of the tympanum is slightly thickened; the cavity contains a small quantity of mucus, which the microscope shows to be composed of epithelial corpuscles. The posterior portion of the membrana tympani is attached by fine adhesions to the stapes and inner wall of the tympanum. The upper third of the long process of the incus has disappeared, and it is no longer attached to the stapes. Left ear. Membrana tympani opaque and thick, and more concave than natural. At its posterior part a defined portion of the membrane, to the extent of two lines in length and one in breadth, is much thicker, and quite white, probably in the first stage of calcareous degeneration. The surrounding portion of the membrane has an increased vascularity. The mucous membrane of the tympanum is thick and soft, and exhibits innumerable large vessels distended with blood. The tympanum contains muco-purulent fluid. The stapes is almost entirely concealed in the thick, soft, and vascular membrane. In this case the right ear presents traces of former disease, from which it had, to a certain extent, recovered. The left ear was in a state of active disease at the time of death. *History*.—The patient was in the hospital for six weeks previous to death, and was not supposed to be deaf until a few days preceding that event, when she complained of great pain in the left ear accompanied with deafness. No doubt, however, can exist that she was deaf in the right ear during a considerable period, though the deafness was not detected until the left ear became diseased.

399. Bands of adhesion extending across the tympanum; stapes firmly fixed.
 400A. A mass of membranous bands in the posterior part of the tympanic cavity, connecting the incus and stapes to the tympanic walls. From a man æt. 80, deaf.

I.—CANAL FOR THE PORTIO DURA NERVE IMPERFECT.

401. The osseous wall of the canal for the portio dura nerve is deficient for a narrow space, about three quarters of a line in length, in the upper part of its course around the tympanum, the neurilemma of the nerve being in contact with the tympanic mucous membrane.
 402. The osseous walls of the canal are entirely wanting throughout the greater part of its course around the tympanum.
 403. The canal is deficient at the superior and inferior thirds.
 404. The canal is deficient at the inferior two thirds.
 405. The osseous walls of the canal are deficient for a space of about a line and a half above the fenestra ovalis and at the inferior fourth.
 406. The osseous walls of the canal are wanting superiorly and inferiorly; in the central part of its course the nerve is separated from the tympanic mucous membrane by a very thin and translucent lamina of bone.

- 407. The canal is deficient at the superior third.
- 408. The canal is deficient at the superior and inferior portions.
- 409. The canal is deficient at the middle third.

K.—SUPERIOR OSSEOUS WALL HYPERTROPHIED.

- 410, 410A. From a man æt. 85, who had been deaf for many years. Right ear. The meatus externus contained a large mass of hardened epidermis, pressing on the membrana tympani, which is opaque. The tympanum contained muco-purulent fluid. The superior wall of the tympanum is greatly hypertrophied, being more than half an inch in thickness. The canal for the carotid artery is greatly contracted. Left ear. The superior wall of the tympanum is similarly hypertrophied. The canal for the carotid artery is contracted to a less degree.

L.—SUPERIOR OSSEOUS WALL EXPANDED.

411. The tympanic cavity is so expanded that its superior and posterior walls are so thin as to be translucent.

M.—SUPERIOR WALL PARTLY DEFICIENT, THE MUCOUS MEMBRANE OF THE TYMPANUM BEING MORE OR LESS IN CONTACT WITH THE DURA MATER.

412. Orifice in the roof of the tympanum, about three lines in length by one and a half in breadth, exposing the head of the malleus. The mucous membrane of the tympanum is nearly continuous across the orifice. The membrana tympani is partly destroyed, and adherent to the promontory. Bands of adhesion connect the malleus and stapes to the inner wall of the tympanum.
- 412A. A very small orifice in the roof of the tympanum, which is generally thin and translucent.
413. Several small orifices in the roof of the tympanum; the mucous membrane of the tympanum continues across them.
414. A large orifice in the roof of the tympanum above the attachment of the posterior crus of the incus, and a smaller one corresponding with the commencement of the Eustachian tube.
415. The bone partially deficient over a large part of the roof of the tympanum; the mucous membrane continuous.
- 416, 417. Several small orifices in the roof of the tympanum; the bone, to a great extent, translucent.
418. A large part of the roof of the tympanum deficient; several small orifices in the plate of bone forming the roof of the mastoid cells.
419. An orifice of square form, and about four lines in diameter, in the posterior portion of the roof of the tympanum; it is traversed at right angles by

narrow bands of bone. There are several small orifices in other portions of the bone.

420. The larger portion of the upper wall of the tympanum is absent; numerous small osseous laminae, arranged perpendicularly, are observed, which project into the cerebral cavity slightly above the level of the surrounding bone. This orifice is three quarters of an inch long and half an inch broad; a crescent-shaped band of bone, about half a line in diameter, divides it into an outer larger and an inner smaller portion. In this case the prominence of the vertical laminae of bone affords evidence that the defective state of the tympanic wall is the result of arrest of development, and has not been produced by pressure of the brain, as supposed by some pathologists. The crescentic band of bone, which is so well marked in this specimen, may be less distinctly observed in many others, especially in Nos. 421, 422, and 423.
421. A large irregular orifice, involving the larger part of the roof of the tympanum; a crescentic band of bone, passing in a direction inwards and forwards, divides it into two nearly equal parts.
422. The larger portion of the roof of the tympanum is deficient; numerous vertical laminae of bone occupy the posterior portion of the orifice.
423. Roof of the tympanum very thin, and in parts deficient; at the external and posterior part there is a large orifice, across which the mucous membrane is continuous.
424. Roof of the tympanum deficient for a space nearly an inch in length, and about a line in breadth, extending from within outwards and backwards. Anteriorly to the tympanum, and near the junction of the squamous with the petrous portion of the temporal bone, there is a depression extending into the cancellous structure, about three lines in length by one in breadth.
- 425—429. Roof of the tympanum deficient to a slight extent, the mucous membrane continuous.
- 430—432. A small orifice in the posterior portion of the roof of the tympanum.
- 433—450. Orifices of considerable size in the roof of the tympanum, which is generally thin and translucent.
451. Upper wall of the tympanum defective.

N.—THE INFERIOR OSSEOUS WALL DEFICIENT, THE MUCOUS MEMBRANE OF THE TYMPANUM BEING MORE OR LESS IN CONTACT WITH THE OUTER SURFACE OF THE JUGULAR VEIN.

453. Right ear. Membrana tympani flatter and much thicker than natural; the lower half is white, like parchment; the mucous membrane lining the tympanum is thick, especially the portion surrounding the ossicula; the cavity contained mucus. The layer of bone between the jugular vein and the tympanum is incomplete. The stapes is fixed more firmly than natural in the fenestra ovalis. From a man æt. 54. (See No. 95.)

454. From a man æt. 60. The lower wall of the tympanum is formed by a membrane, in which a small plate of bone is deposited. The membrana tympani was very concave.
455. The lower wall of the tympanum is formed partly by a very thin and translucent plate of bone, and partly by a membrane. It presents an orifice of oval shape, and about a line in length.
456. The lower wall of the tympanum is very thin, and presents an irregular triangular orifice, about a line and a half in diameter.
457. The larger portion of the lower wall of the tympanum consists of membrane only.
458. The lower wall of the tympanum is very thin and translucent; for a space, about the size of a small pea, it consists of a layer of membrane containing a little osseous deposit.
459. The lower wall of the tympanum is very thin and translucent, and perforated by many minute orifices.
460. Lower wall of the tympanum translucent, and presenting a small oval orifice.
461. An orifice in the lower wall of the tympanum of the size of a small pea, with two or three minute orifices around it. The lower wall of the meatus externus also presents an orifice about the size of a mustard seed.
462. The larger portion of the lower wall of the tympanum is deficient.
463. The lower wall of the tympanum is entirely absent, except a very thin lamina of bone at the inner angle.
464. Bony floor of tympanum imperfect. Minute apertures traverse it, into which bristles are inserted.
- 466—468. The lower wall of the tympanum is perfect, but exceedingly thin and translucent.
469. Lower wall of the tympanum imperfect in several places.
470. Lower wall of the tympanum presenting several minute orifices.
- 471—476. The lower wall of the tympanum consists, in part, of membrane only.
- 477—480. The lower wall of the tympanum is deficient in parts.
482. There is an orifice in the layer of bone between the lateral sinus and the mastoid cells, which allows of a communication between the two cavities.

SERIES V.—THE EUSTACHIAN TUBE.

A.—DILATED.

484. Eustachian tube very large; there is an orifice, the size of a small pea, between it and the canal for the internal carotid artery, so rendering that canal continuous with the cavity of the tympanum.

B.—STRICTURE.

485. Stricture of the Eustachian tube; the mucous membrane covered by dense fibrous tissue.

486. Left ear. The central portion of the membrana tympani is white and thick; the lateral portions are extremely soft and attenuated. The tympanum and mastoid cells were filled with white, thick mucus, and no air was discoverable in them. The mucous membrane of the tympanum was thicker than natural. The internal portion of the Eustachian tube, for the length of half an inch, is healthy; but at about that distance from the tympanum there is a sudden constriction, and for the length of about a line and a half the tube is so contracted, that even when the anterior wall was removed it was with difficulty that a bristle could be introduced into the opening. The cause of the stricture appears to be an enlargement of the external and internal walls of the tube. The external osseous wall is at this part twice its natural thickness and somewhat rough; the internal wall is forced outwards by dilation of the carotid canal. The mucous membrane of the tube was healthy. *History*.—Male æt. 45; died of phthisis; had become gradually deaf in the left ear for six or seven years. (See 'Monthly Journal of Medical Science,' August, 1850.)
488. Eustachian tube impervious at its entrance into the tympanic cavity. Membrana tympani very thick.
490. Right ear. Eustachian tube obstructed by a bulging of the anterior bony wall. Membrana tympani concave, posterior part very thin, and composed of very delicate cellular tissue. The left ear was in a similar condition. *History*.—Male æt. 66. Had been deaf for forty-two years, having first become so from the firing of a piece of ordnance. He was at first rendered entirely deaf, but after some weeks he began to improve, and continued to improve for some twenty years. Since then he has become worse, and two years before his death he required to be spoken to in a loud voice. He suffered from "noises like a din."
- 490A. Right ear. Eustachian tube contracted so much by extension upwards of its lower osseous wall that an ordinary pin could only just be made to pass through it. This constricted portion was about one third inch in length; on both sides the tube was as large as, or rather larger than usual. The tympanic cavity contained more mucus than natural, and it was very fluid. The mucous membrane was very vascular; membrana tympani more concave externally than natural, flaccid, of a leaden hue, and very shining. Meatus externus natural. From a man æt. 80, who died of serous apoplexy. He was so deaf on the right side as to require to be spoken to loud. The left ear was only slightly deaf. His deafness varied.
- 490B. Left temporal bone of the same patient. A slight bulging inwards of the anterior bony wall of the Eustachian tube. (See 'Trans. Path. Soc.,' vol. xi, p. 221 [1860]).

C.—OBSTRUCTED BY FIBRIN:

491. Eustachian tube and tympanic cavity full of dense fibrin.

SERIES VI.—THE OSSICULA.

A.—ANKYLOSIS OF THE STAPES TO THE FENESTRA OVALIS.

- 492, 493. From a man æt. 64, who died from asthma. The stapes of each ear is ankylosed by bony union to the circumference of the fenestra ovalis. The ears are in other respects healthy.
494. From a man æt. 52, who died from dropsy. He was deaf. Right ear. The membrana tympani is smooth externally, but opaque from thickening of its mucous layer. The mucous membrane of the tympanum is very thick, and the stapes is completely ankylosed to the margin of the fenestra ovalis.
495. From a woman æt. 36, insane. Deaf, especially in the right ear; died from consumption. Right ear. Membrana tympani; posterior two thirds destroyed by ulceration; what remains is in a state of ossific degeneration, the seat of the bony deposit being in the fibrous laminæ of the membrane. The mucous membrane of the tympanum is so much thickened that the stapes scarcely projects from the fenestra ovalis, to the margin of which it is firmly ankylosed. The disease has extended from the tympanum to the carotid canal, the internal wall of which is much thickened, and its calibre reduced to a third less than the natural size. The external wall of the carotid canal is also deficient in more than one place, leaving at those points the mucous membrane of the tympanum in contact with the external surface of the internal carotid artery. The membranous labyrinth is much atrophied, and its peculiar fluids deficient in quantity. The base of the stapes is seen projecting into the cavity of the vestibule, being three or four times its natural thickness and perfectly white.
496. From a woman æt. 34, who died after an attack of fever, which lasted six weeks. She was insane; so deaf that she could not hear a shout. She had had several attacks of fever. Left ear. Mucous membrane of the tympanum thick. Only a small portion of the crura of the stapes was seen, the larger portion being hidden in the cavity of the vestibule. The base of the stapes is completely ankylosed to the fenestra ovalis. In both ears the labyrinthine humour were very deficient.
- 497, 498. From a man æt. 36, who died from phthisis. He was deaf in both ears, but especially in the right. The stapes in each ear is partially ankylosed to the fenestra ovalis. In the right ear the fluids in the vestibule are much diminished in quantity.
499. From a man æt. 64, who died from pneumonia. He had been deaf in the left ear from childhood, having had a scrofulous affection of the ear. Left ear. The membrana tympani is almost entirely destroyed; a fragment remains posteriorly, which is fallen in and adherent to the promontory, and a small portion is still attached to the long process of the malleus. The tympanum contained a small quantity of pus; its mucous membrane is dark-coloured and much thickened. The stapes is fixed more firmly than natural

in the fenestra ovalis. The carotid canal is slightly contracted. The right ear was healthy.

500. From a woman æt. 48, who died from cancer. She was not very deaf, The stapes in each ear was almost completely concealed by the thickened mucous membrane of the tympanum, and by bands of adhesion.

501. Stapes partially ankylosed.

502, 503. From a man æt. about 50. Deaf. Right ear. The meatus externus was white and deprived of cerumen. Membrana tympani and mucous membrane of the tympanum healthy. The base of the stapes is expanded, and projects into the cavity of the vestibule, so as to form within it an oval protuberance, which is smooth, of an opaque white colour, and firmly adherent to the vestibular parietes. The walls of the vestibule are perfectly healthy, and may be distinguished from the base of the stapes by their difference of colour. The crura of the stapes are disconnected from the base. Left ear. Meatus externus dry and deprived of cerumen. Stapes completely and firmly ankylosed to the margin of the fenestra ovalis; it is entire. (See 'Medico-Chirurgical Transactions,' vol. xxiv.)

504, 505. From a woman æt. 79, who died from gangrena senilis. She had been deaf for several years; the disease commenced by a succession of attacks of earache. Right ear. The membrana tympani is white and thicker than ordinary parchment, to which it bears a great resemblance. The mucous membrane of the tympanum is thick; the base of the stapes is firmly ankylosed. Left ear. In the same state. (See 'Monthly Journal of Medical Science,' March, 1849, p. 569.)

506. Stapes firmly ankylosed, a broad band of adhesion occupying the posterior part of the tympanum, and covering the fenestra rotunda. (See No. 733.)

507, 508. Base of the stapes expanded; bands of adhesion in the tympanum; mucous membrane thick.

509. Stapes ankylosed. Tympanum containing numerous bands of adhesion.

511. From a woman æt. 87. Deaf during a few years preceding death. Right ear. The meatus externus was dry and contained no cerumen. The membrana tympani was more concave and tense than natural, the fibrous laminae white and slightly thickened. The stapes is fixed more firmly than natural to the margin of the fenestra ovalis. The tympanum contains numerous bands of adhesion, connecting the ossicula, and especially the stapes, firmly to the inner wall of the tympanum. The left ear was in a similar condition. (See 'Monthly Journal of Medical Science,' February, 1849, p. 523, Mrs. L—.)

512. Right ear. Stapes completely ankylosed, the surface articulating with the os orbiculare more flat than natural. The malleus connected to the incus by bands of adhesion, tensor tympani muscle atrophied. The membrane of the fenestra rotunda is thickened. The cochlea had a deep red colour, the cochlearis muscle (Todd and Bowman) was larger than natural. (See No. 746.) In the left ear the stapes was also completely ankylosed, and the

membranous vestibule thickened. (See No. 724.) *History*.—Male æt. 48. Deaf for about five years before death; could hear a shout on the right side, no sound at all on the left. The deafness commenced during a very severe ulceration of the throat after syphilis.

513. From a man æt. 50, who died from hæmoptysis. Left ear. Membrana tympani whiter and thicker than natural, the thickening depending on hypertrophy of the mucous lamina. The stapes was surrounded by bands, and was adherent to the margin of the fenestra ovalis more firmly than natural.

514, 515. From a man æt. 80. Very deaf. In each ear the stapes is firmly attached to the margin of the fenestra ovalis by means of thickening and solidification of the connecting membrane. The crura of the stapes are much atrophied. (See Nos. 116 and 117.)

516. Stapes firmly attached to the margin of the fenestra ovalis, so that some force was required to move it. Upon examining the cavity of the vestibule, the base of the stapes is observed to be thicker than natural, and the lower border projects into the vestibule, the crura of the bone appearing to have been pressed down or drawn downwards by the bands of adhesion which connect it to the inner wall of the tympanum. Deaf. (See Nos. 135 and 161.)

517, 518. From a man æt. 65. Right ear. The meatus externus was distended by cotton wool; the lining membrane was more vascular than natural. The stapes adhered to the margin of the fenestra ovalis more firmly than natural, so that, upon being withdrawn, a small portion of it remained in contact with the margin of the fenestra. Left ear. The meatus externus was distended by cerumen. The stapes was much smaller than natural, the space between the crura being one third less than natural; the base also is diminished in size. The fenestra ovalis is smaller than that of the right side, being partially obliterated by a deposit of bone.

518A. The stapedes from the above case.

519. Left ear. The external meatus was full of cerumen. Membrana tympani very concave, the epidermoid and fibrous laminæ thick and opaque. The ossicula are less moveable than natural. The mucous membrane of the tympanum is thick, and bands of adhesion connect the ossicula. The base of the stapes is so firmly fixed in the fenestra ovalis, that when the malleus is pressed inwards it is scarcely moved. The membranous labyrinth is somewhat atrophied. The right ear was in a similar condition. *History*.—Male æt. 78. Deaf for thirty-eight years, after a fall upon his head from a height of ten feet, which produced insensibility for two hours. The right ear has been useless ever since the accident, the left ear has not varied much. He hears with the left ear the click of the finger-nails; suffers from noise in the head, and a cracking when he turns his head quickly.

520. Stapes partially ankylosed.

521. Stapes partially ankylosed, chiefly at the posterior and inferior border.

522, 523. Stapes partially ankylosed. In the right ear numerous bands of

adhesion connect all the ossicula to the walls of tympanum. In the left ear a few delicate bands extend between the crura of the stapes and the superior wall of the tympanum. *History*.—Male æt. 85. Had been deaf for five or six years. The deafness commenced during a cold, and was worse when he had a cold: he required speaking to loudly near him. Cerumen was removed from the meatus.

- 524, 525. Stapes ankylosed to the fenestra ovalis. In the right ear the membrana tympani is perforated, and the posterior margin is adherent to the wall of the tympanum. The crura of the stapes are detached from the base. In the left ear the ossicula are connected together by bands of adhesion, which extend into the mastoid cells.
- 526, 527. From a man æt. 73. The base of the stapes ankylosed to the fenestra ovalis; the crura connected by delicate bands to the promontory.
- 528, 529. Right ear. Meatus externus very large, full of cerumen. Membrana tympani opaque, thick, and flat. The mucous membrane of the tympanum much thicker than natural, and a large part of the cavity filled by bands of adhesion, which connect the ossicula together and to the walls of the tympanum. The mucous membrane was red. The stapes was fixed to the fenestra ovalis more firmly than natural, and its base, as seen from the vestibule, is thicker and whiter than natural. The membranous vestibule contained a larger quantity of otoconie than natural; it formed at the posterior and superior part an irregular patch nearly half a line in diameter. Left ear. The epidermoid and fibrous laminae of the membrana tympani are somewhat thickened. The mucous membrane of the tympanum is hypertrophied, and the stapes is firmly fixed in the fenestra ovalis. *History*.—Male æt. 87. Ten or eleven years before death deafness came on without any assignable cause. It was not worse during a cold, but was so in thick weather. He suffered from occasional giddiness and rumbling noises in both ears, especially at night. He was able to hear the click of the finger-nails with each ear.
530. From a man æt. 63. Left ear. The stapes is much more firmly attached to the margin of the fenestra ovalis than natural. The membrana tympani and ossicles are more fixed than usual. The right ear was healthy.
- 531, 532. From a man æt. 67. Right ear. Meatus full of cerumen and epidermis. Membrana tympani more rigid than natural, scarcely moving when the tensor tympani is drawn. The stapes is fixed. Left ear. The stapes is more fixed than natural.
533. From a man æt. 77. Right ear. Stapes ankylosed. Bands of adhesion between the malleus and incus.
534. From a man æt. 80. Right ear. The meatus contained cerumen. Stapes completely fixed. In the left ear the stapes was firmly fixed by rigid membrane. The meatus also contained cerumen.
535. From a man æt. 65. Left ear. Stapes completely ankylosed. The otoconie was more abundant than natural. (Right ear. See No. 730.)

536. From a man æt. 70. The base of the stapes is somewhat expanded and white; it adhered to the fenestra ovalis more firmly than natural.
537. Membrana tympani partly destroyed, fallen in to the promontory. Stapes completely ankylosed.
- 538, 539. Right ear. The membranous meatus was so thin that at the posterior part its presence could hardly be detected, and the bone at first sight appeared denuded. Membrana tympani quite transparent, more concave than natural; the bright spot is not triangular but elongated. There was a line of pigment-cells extending along the posterior part of the upper half of the handle of the malleus. The tensor tympani muscle was not more atrophied than is usual in extreme old age; and when it was drawn in the direction of its course, the membrana tympani moved nearer to the promontory than usual. The mucous membrane of the tympanum was not thicker than natural, but several bands of adhesion connected the posterior part of the stapes and the long process of the incus to the margin of the mastoid cells. The malleus and incus were in a normal state, except that the orbicular process was perhaps slightly expanded. The chief deviation from the normal state was observable in the stapes: the articular process, like that of the incus, was perhaps slightly flattened: the outer half of the anterior crus had its usual translucent appearance, but the inner half is white like enamel, the line of separation between the healthy and diseased parts being very defined. Near to the point which is usually attached to the base the anterior crus was observed to have a free extremity, which was separated from the base itself by a thick, soft, whitish tissue. The base projected slightly into the cavity of the vestibule, and was somewhat rounded. Left ear. The petrous bone is very light. The wall of the mastoid cells, to which the sterno-mastoid muscle was attached, is so thin as to be translucent; and upon tearing from its surface the fibres of the muscle portions of the bone as thin as paper were removed, and the cavity of the cells was exposed. The membranous meatus was so atrophied that it could not, at the posterior part, be detected; the epidermis at that point covered the bone. Membrana tympani more concave than natural; instead of the usual triangular spot there was a narrow bright line around the anterior three-fourths of the membrane, which corresponds with the change of direction from the flat part near the circumference to the concave part at the centre. The malleus was rather more moveable than usual, and the membrana tympani perhaps rather more relaxed. The upper wall of the tympanum was very thin, and in parts the bone was absent: the tensor tympani muscle was large, strong, and natural. The mucous membrane of the tympanum was rather thicker than natural, the malleus and incus normal. The crura of the stapes were only connected to the base through the medium of a thick membrane. The free extremities of the crura were rounded, and had not the appearance of a recent fracture. The base of the stapes was larger and thicker than natural, and projected slightly into the cavity of the vestibule. It was white like enamel, and the bone forming the inner wall of the vestibule had, near to

the base of the stapes, undergone a similar change. There was a very faint line, which indicated the point of distinction between the two parts.
History.—J. C—, æt. 86. At the age of forty dulness of hearing gradually came on and increased until the age of sixty, when he was obliged to have recourse to a speaking-trumpet. By means of this trumpet he could hear a loud voice.

540, 541. Right ear. The meatus contained cerumen. The membrana tympani was less moveable than natural, and became more and more rigid as it was pressed inwards, until it felt like a piece of solid bone. The tensor tympani muscle was atrophied. The stapes was firmly fixed to the fenestra ovalis; the base, seen in the vestibule, was white like ivory; the posterior half of the base was expanded and projected into the vestibule; the anterior half was on a level with its walls. The membrane of the fenestra rotunda was much thickened; the membranous vestibule was atrophied. The fluid of the cochlea was more opaque than natural, and floating in it were observed rounded globules of the size of peas, and blood discs. In the cochlea was a large quantity of black pigment. The nerve was somewhat atrophied.
 Left ear. In the same state as the right ear, except that the base of the stapes did not bulge into the cavity of the vestibule, but the line around its circumference was perceptible. The cochlea did not contain so much black pigment; the membrane of the fenestra rotunda was not so thick. The membrana tympani was more concave than natural. (See No. 756.)
History.—Male æt. 84. Was wounded in the head at Trafalgar in 1805. Two days afterwards he felt very deaf, and a permanent deafness gradually ensued. For twelve years preceding his death, in 1852, he had been so deaf that he could only hear a shout close to the left ear.

542, 543. From a man æt. 68. Right ear. The stapes is so firmly attached to the fenestra ovalis that it requires considerable pressure to move it. The base is somewhat expanded. Left ear. The stapes is less firmly fixed.

544, 545. From a man æt. 63. Entirely deaf in the right ear. Could only hear a shout with the left ear. Right ear. Membrana tympani destroyed, except a very narrow strip at the upper and posterior part, to which the body of the malleus is attached. The long process of the malleus is absent, the head articulates with the incus; the inferior extremity of the incus is absent so that it does not articulate with the stapes. Mucous membrane of the tympanum thick, concealing the ossicula. The base of the stapes projects slightly into the cavity of the vestibule. Left ear. The membrana tympani, with the exception of a small portion anteriorly, about a line in diameter, is of a yellowish-white colour, very thick and quite hard; the upper half is firmly adherent to the promontory. The tympanum is nearly full of the same calcareous matter into which the membrana tympani is converted. The malleus and incus are firmly pressed against and fixed to the promontory. The stapes is completely ankylosed.

546. From a man æt. 71. Right ear.—The membrana tympani contains a

- crescentic deposit of calcareous matter near its inferior and anterior border. Stapes completely ankylosed.
- 548, 549. From a man æt. 71. Right ear. Stapes more fixed than natural. Left ear. Stapes fixed; lower wall of tympanum imperfect.
- 550, 551. From a man æt. 69. Right ear. The tympanum contains numerous bands of adhesion. The stapes was more fixed than natural. Left ear. Stapes partly fixed; base expanded. The cochlea contained an excess of pigment.
- 552, 553. From a man æt. 76, who had been becoming slowly dull of hearing for a long time. Right ear. Membrana tympani white like parchment, and more concave than natural. The stapes is so fixed that when the base is pressed upon it can only just be made to move. Bands of adhesion of considerable firmness connect the ossicula with various parts of the tympanum. Left ear. In the same state as the right, except that there are only two or three delicate threads of adhesion connecting the stapes to the canal for the portio dura nerve.
554. From a man æt. 77. Deaf in the right ear. Right ear. Membrana tympani mottled; transparent in one or two parts, but white and leaden at others. Tympanum filled by mucus. Stapes ankylosed.
- 555, 556. From a man æt. 71. Right ear. The meatus contained pus. The anterior part of the membrana tympani is absent, the posterior part is disorganised, fallen in, and attached to the promontory. The upper part of the tympanum was full of thick membrane and dark purulent matter. The malleus is drawn inwards to the promontory; its lower part is absent. The incus is disarticulated from the stapes and pressed upwards. Stapes firmly fixed. Left ear. A dark-coloured matter resembling blood occupied the tympanum, and was also found on the floor of the fossa auditoria interna. The stapes is fixed. The tympanum contains bands of adhesion.
- 557, 558. From a man æt. 80, deaf. In each ear the fibrous layers of the membrana tympani are very thick and yellow; the membrana tympani is very concave. The tympanum is full of thick mucous membrane and mucus. In the left ear the stapes is ankylosed.
- 559, 560. From a man æt. 68. In each ear the base of the stapes is fixed much more firmly than natural; the tympanum contains bands of adhesion, and the membrana tympani and malleus, on being pressed, moved much less than usual.
561. From a man æt. 71. The stapes is more fixed than natural. The malleus and incus are connected by a broad firm band of adhesion.
- 562, 563. From a man æt. 63. The stapes is ankylosed in each ear; otherwise healthy.
564. From a man æt. 80. Right ear. Stapes more fixed than natural. The lower wall of the meatus was partially absorbed. (See No. 97.)
- 565, 566. From a man æt. 74, deaf. In each ear the Eustachian tube was much larger than natural, and the base of the stapes projected into the cavity of the vestibule.

- 567, 568. Right ear. The fibrous laminae of the membrana tympani are much thickened. Bands of adhesion connect the membrana tympani, ossicles, and promontory. The base of the stapes is expanded, and more fixed than natural. Left ear. Membrana tympani thickened; bands of adhesion in the tympanum. Base of the stapes white, expanded, and ankylosed. The meatus externus on each side is partly absorbed from the presence of cerumen. *History*.—Male æt. 77. He first became deaf forty-two years before his death, when, being somewhat deaf from a cold, he was engaged in a naval action, after which the deafness was much increased. Since that time it had become worse, being increased by colds. He suffered from noises in both ears. He felt cracking in them when he blew his nose. Two years before his death he could hear the click of the finger-nails with each ear, but could hardly distinguish the voice with the left ear.
569. Left ear. Membrana tympani much thicker, more opaque and rigid than natural; the mucous membrane of the tympanum thick. The chain of bones is almost as fixed as if it consisted of but one, having two fixed extremities. The base of the stapes is firmly ankylosed. Upon looking at the base of the stapes from the cavity of the vestibule it is observed to have its natural colour, but the adjacent wall of the vestibule is white and thick, and projects, in the form of two curved lines, into the vestibule, one above and one below, the lower one being the larger. *History*.—Male æt. 74. Forty-five years ago he was rendered very deaf by the report of a cannon. He remained so for fourteen days; the left ear then partially recovered, but he has never heard with the right ear since. He could only hear a loud voice close to the left ear. Had sometimes "terrible noises." Was worse during a cold.
- 570, 571. Right ear. The meatus contained cerumen. Membrana tympani thick, white, concave, tense; its inner surface is firmly adherent to the long process of the incus. The stapes is firmly fixed by membranous ankylosis. The mucous membrane of the tympanum is much thicker than natural; bands of adhesion occupy the tympanic cavity. Left ear. In the same condition as the right ear, but the stapes is less firmly fixed. *History*.—Male æt. 71. Became deaf six or seven years before his death, after a cold. He requires speaking to in a loud voice; can hear the click of the finger-nails with each ear. After coughing or sneezing the left ear opens, and he hears better for ten minutes or a quarter of an hour, then it closes again; has sometimes singing in the ears.
- 572, 573. Right ear. The meatus contained cerumen. The membrana tympani is large, opaque, concave, and less tense than natural; the concavity is produced by the falling in of the central three fourths of the membrane; the external fifth is flat, and on the usual plane. The stapes is rigid. Left ear. Membrana tympani very concave, the central part drawn in to the shape of a trumpet. Upon drawing the tensor tympani muscle the membrana tympani moves, but less than usual, and the stapes is not in the least affected. The base of the stapes is firmly fixed to the fenestra ovalis, so that upon

making a section a portion of its base was removed with the wall of the vestibule. *History*.—Male æt. 77. Deaf for twenty years; cause assigned, a cold; was worse during a cold. Could hear a loud voice with the right ear; on the left side required shouting into the ear.

- 574, 575. Right ear. The meatus contained hard cerumen. The stapes not so moveable as natural; the membrane around the base apparently rigid. Left ear. Meatus distended, and partially absorbed by the presence of hard cerumen. The stapes was not so moveable as natural, although the membrana tympani and incus moved as freely as usual, the orbicular process moving over the head of the stapes without that bone participating in the motion. The anterior two thirds of the base of the stapes on its vestibular aspect is surrounded and partly concealed by a narrow ring of bone, which has an appearance like ivory. *History*.—Male æt. 80. Twenty years ago he became dull of hearing during a cold; had not become worse during the six years preceding his death. He required to be spoken to in a loud voice near him; heard about equally well with each ear.
576. Right ear. The base of the stapes was so firmly fixed in the fenestra ovalis that it required considerable pressure to move it. The other parts of the organ were healthy. The left ear was in the same state. *History*.—Male æt. 71. Became deaf in the left ear forty years ago from cold. Can just hear the click of the finger-nails with it. Had been deaf in the right ear about fifteen years; could only just hear a shout. Was subject to a roaring noise in the head.
- 577, 578. Right ear. Membrana tympani opaque, especially in parts. The handle of the malleus was fixed, so that pressure upon it by means of a probe scarcely moved it. The stapes was firmly ankylosed by bone to the fenestra ovalis; the central part of the base is of the natural appearance and thickness, but the portion at the circumference is as white as ivory, and projects into the vestibule further than natural. The inner surface of the vestibule, for the space of a quarter of a line around the base of the stapes, is also of an ivory whiteness. The membrane of the fenestra rotunda is rather thicker than natural. Left ear. Membrana tympani opaque, mottled; malleus nearly fixed. The base of the stapes is firmly ankylosed by bone to the fenestra ovalis. The surface of the bone looking towards the base is completely buried in a mass of ivory-like matter, which also extends a full line around it and projects into the vestibule. The tensor tympani muscle was atrophied. The membranous labyrinth was atrophied. The nerve filaments on the surface of the lamina spiralis were not distinct, and appeared to be undergoing fatty degeneration. *History*.—Male æt. 79. Had been deaf since being engaged in a naval action, thirty-two years before his death. He was entirely deaf for six weeks, recovering partially after that time. Two years before his death he required shouting into the right ear, and could hear nothing with the left.

580. From a man who was very deaf. Left ear. Stapes ankylosed. (See No. 711.)
581. Right ear. The posterior half of the membrana tympani is absent; the remaining portion is thick, white, and tense; at the centre of it there is a portion about half a line in diameter, in which the epidermoid, dermoid, and mucous laminæ only remain: around the margin it is degenerated into earthy matter. The mucous membrane of the tympanum was not thicker than natural, nor was there any discharge. The long process of the incus is absent. The crura of the stapes are absent: the base is partially ankylosed and expanded. The membranous labyrinth was atrophied. The left ear was in a similar state. *History*.—Male æt. 80. Had been absolutely deaf for sixteen years before his death. The cause assigned was thunder on the coast of Guinea.
582. Right ear. Membrana tympani, the fibrous layers are cartilaginous at the external part. Bands of adhesion connect the body of the incus to the mastoid cells, and the stapes to the surrounding bone. The base of the stapes is more fixed than natural, being ankylosed apparently by thickening, and increased tenseness of the capsular ligament. The perilymph of the labyrinth and cochlea was turbid and of a red colour. The mucous membrane of the faucial extremity of the Eustachian tube was thick and congested. *History*.—Male æt. 75. Became deaf during a cold about seven years before his death, and was always much worse when he had a cold. Two years before his death he required to be spoken to in a loud voice; he could hear the click of the finger-nails with each ear. He was not subject to noises in the ears or head.
583. Left ear. Meatus distended by cotton wool. Membrana tympani tense. Malleus so fixed that upon being touched it felt quite rigid. The stapes firmly ankylosed. The otoconie is very abundant, and besides it there are crystals of carbonate of lime, which form almost a shell within the vestibule. The right ear was in a similar condition. *History*.—Male æt. 64. Had been more or less deaf for fifty years. For eighteen months at least before his death he had been quite unable to distinguish a single word.
- 584, 585. Right ear. Stapes not so movable as natural. Left ear. Stapes partially ankylosed; surrounded by membranous bands. Cochlea congested. *History*.—Male æt. 68. Two years before his death he was able to hear a watch only upon contact with the ear. He had suffered from noises in the head, which were relieved by the removal of cerumen from each meatus. The affection of the ears was attributed to his having fallen overboard, while at sea, many years previously.
- 586, 587. From a man who was deaf. In each ear the stapes is ankylosed; a band of adhesion connects the handle of the malleus to the long process of the incus.
- 588, 589. From a woman æt. 26, who died from acute tuberculosis: she was deaf. Right ear. The membrana tympani contains two patches of calcareous deposit. The stapes is firmly united to the fenestra ovalis by

membranous ankylosis. Bands of adhesion connect the handle of the malleus to the head of the stapes, and the crura of the stapes to the promontory. Left ear. The base of the stapes is expanded, and firmly ankylosed. There is a deposit of a calcareous matter at the superior and anterior part of the membrana tympani. The long process of the incus is connected to the malleus and the membrana tympani by a broad band of adhesion.

- 590, 591. The stapes is partially ankylosed in each ear. In the right ear the crura have been broken from the base. *History*.—Male æt. 82. Had been deaf for six or seven years; had become so gradually after a cold: was worse during a cold. Had constant noises in the ears, and a rattling sound when he yawned or sneezed. Two years before his death, he required to be spoken to in a loud voice near him; he could hear the click of the nail with each ear; the right ear was the worse.
592. Right ear. The membrana tympani is fallen in, so that the long process of the malleus is in contact with the promontory: it is also connected to the promontory by bands of adhesion. There appears to have been ulceration of the fibrous laminae, and the remaining fibres have fallen inwards. The membrana tympani is thick and white, and contains a calcareous deposit anteriorly. The inferior extremity of the incus is in contact with it, and projects at the posterior part. The stapes is firmly ankylosed. The membrane of the fenestra rotunda is very thick. In the left ear the stapes was partially ankylosed, and the chain of bones rigid. *History*.—Male æt. 67. Had been very deaf for fifteen years, since an attack of scarlatina. About a year before his death he could only distinguish the loudest voice close to either ear. Suffered from singing noise in the head.
- 593, 594. From a man æt. 68, who was very deaf. Right ear. Membrana tympani very concave at the central part; it is also very thin and transparent, except at the circumference, which is occupied by a narrow white band of great thickness. The lower third of the handle of the malleus is separated from the membrana tympani. The mucous membrane of the tympanum was thick and red, the mastoid cells full of mucus. Stapes firmly ankylosed. Left ear. The larger part of the membrana tympani destroyed; stapes ankylosed.
- 595, 596. Right ear. Membrana tympani large, concave, opaque, the incus and malleus partly ankylosed, drawn in, and pressing on the stapes, which is also partly ankylosed. Left ear. Membrana tympani thick and opaque; there is an orifice at the central part about the size of a pea. The incus and malleus are drawn in and connected by bands of adhesion. The stapes is completely ankylosed. *History*.—Male æt. 83. Had been deaf in the left ear since childhood; the deafness was at first accompanied with a discharge. For several years he had been deaf in the right ear also. About a year before his death he was only able to hear a loud voice close to either ear.
- 597, 598. Right ear. Membrana tympani large, white and thin. Chain of

bones rigid; the stapes firmly ankylosed by membrane. Bands of adhesion surround the stapes. Tensor tympani muscle atrophied. Left ear. The fibres of the membrana tympani are separated in parts, as if there had been an orifice. In other respects it presents the same condition as the right ear. *History*.—Male æt. 78. He first became deaf after a cannonade at sea at the age of thirty-four. For six months he was quite unable to hear, but afterwards partly recovered. He was much worse during a cold. About three years before his death he was able to hear a click of the finger-nails with the right ear, but not with the left.

599, 600. In each ear the membrana tympani is concave and in parts opaque. The chain of bones is more rigid than natural, the stapes firmly fixed to the fenestra ovalis. In the right ear the ossicula are connected together by bands of adhesion. *History*.—Male æt. 75. Had been deaf for ten or twelve years, after a bad cold in the head. He was confined to his bed for some time, and never heard with the right ear since. At the same time he became as deaf in the left ear as he was two years before his death, when he could only hear a shout close to the ear. He suffered from a buzzing in the head.

601, 602. In each ear the membrana tympani is opaque, and the stapes is firmly ankylosed to the fenestra ovalis, a result which seems to be caused by an expansion of the base. *History*.—Male æt. 89. Had been growing gradually deaf for twenty-five years. The deafness was worse during a cold, but did not commence from one. He never had pain in the ears, but had ringing noises in them at times. Four years before his death he was able to hear the click of the finger-nails well with the right ear, and, on pressure, with the left.

603. Base of the stapes expanded. From the right ear of a man æt. 80, who had been slowly growing deaf for about twenty-two years. He had a rumbling noise in the head. There was an orifice in the membrana tympani. He required to be spoken to loudly, and could just hear the click of the finger-nails.

604. Stapes surrounded by thickened membrane. It was more firmly fixed than natural, and there were bands of adhesion in the tympanum. From a man æt. 66.

604A. Stapes partially ankylosed to the fenestra ovalis by rigidity of the connecting membrane.

605. Stapes fixed more firmly than natural. The mucous membrane of the tympanum very thick.

606. A stapes, the base of which was adherent to the fenestra ovalis.

607. Stapes ankylosed; base completely hidden by thick bands of adhesion.

608. Stapes ankylosed.

609. Deaf and dumb; stapes ankylosed.

610, 611. Stapes ankylosed by rigid membrane.

612. From a man æt. 30, who died from injury to the spine. Partially deaf as long as he could remember. Right ear.—The mucous membrane of the

tympanum and the membrana fenestræ rotundæ are thickened. The stapes is connected to the tympanic walls by bands of adhesion; it extends further than usual into the vestibule, so that but small portions of its crura are visible. Its base is expanded and adherent to the margin of the fenestra ovalis, with which there is a partial inter-ossification. The membrane lining the vestibule was much thickened. The superior semicircular canal was unusually prolonged and ovate in form. The left ear was in a similar condition.

613. Stapes completely ankylosed. A large deposit of calcareous matter occupies the anterior portion of the membrana tympani.
- 614, 615. Stapes attached to fenestra ovalis more firmly than natural; the crura have separated from the base.
616. Ankylosis of the lower margin of the base of the stapes to the fenestra ovalis. The lower wall of the tympanum is translucent and perforated.
617. Stapes adherent by bands to the fossa fenestra ovalis.
- 618, 619. Stapes partially ankylosed to the fenestra ovalis; base denser than natural.
- 620, 621. Stapes ankylosed. Membrana tympani thick, and containing calcareous deposit. *History*.—Male æt. 78. Had been becoming gradually deaf for six or seven years, and had been very deaf so as to require shouting to, for two or three years. Worse during a cold.
622. From a man æt. 68. Left ear. Stapes fixed more firmly than natural. In the right ear the stapes was completely ankylosed.
623. From a man æt. 67. Deaf, but only to a moderate degree. Right ear. Stapes partially ankylosed; the cartilage surrounding the base seemed to be expanded. Numerous bands of adhesion connected together various points of the tympanum. The malleus was very firmly fixed, the membrana tympani more concave than natural. The left ear was in a similar state.
624. From a woman who died of acute tuberculosis. Right ear. Stapes ankylosed. Membrana tympani slightly opaque and concave.
625. From a woman æt. 68, who died from pericarditis. Left ear. Stapes partially ankylosed. In the vestibule the quantity of otoconie was much larger than natural. A band of adhesion connects the long process of the malleus to the incus. (See No. 723.) In the right ear the stapes was firmly ankylosed. The tympanum contained mucus.
- 626, 627. From a man æt. 44, deaf. The base of the stapes in each ear is expanded. The mucous membrane of the tympanum thick.
- 627A. Stapes ankylosed.

B.—DISEASES OF THE MALLEUS.

628. A small exostosis grows from the inner surface of the neck of the malleus, which is adherent to the internal wall of the tympanum. The fenestra rotunda is covered by bands of adhesion, which also almost entirely conceal the stapes.

- 628A. Malleus and incus ankylosed together.
- 628B. Exostosis in the tympanum, surrounding the neck of the stapes, apparently a morbid development of the malleus and incus, which were not to be distinguished. From a man æt. 80, requiring a loud voice.
629. From a man æt. 76. Right ear. The handle of the malleus more curved than natural. Sulcus lateralis rough. (Left ear. See No. 52.)
630. From a man æt. 72. The membrana tympani is very concave. Broad bands of adhesion, which completely cover the incus, connect all the ossicula to the inner wall of the tympanum. The inferior extremity of the malleus has been fractured, and is partially separated from the long process.
631. The handle of the malleus carious. From a youth æt. 10. Effect of scarlatina.
632. Caries of malleus and incus from scarlatina.

C.—DISEASES OF THE INCUS.

633. The short process of the incus and a portion of the mastoid cells carious.
634. Membrana tympani very thick, almost resembling bone. Incus partly absorbed; os orbiculare absent.
635. From a woman æt. 50, blind and insane; deaf in the left ear. Right ear. The incus disconnected from the os orbiculare, the latter being attached to the stapes.
636. From a man æt. 19, who died of apoplexy. He was deaf in the left ear. Left ear. The membrana tympani contains calcareous deposit. Both processes of the incus are partially absorbed. The mucous membrane of the tympanum was very thick. The right ear was healthy.
637. From a man æt. 67. Right ear. Incus and stapes.
638. Portion of the incus removed six months after an attack of scarlatina.
639. From a boy æt. 5, who died from scarlatina. Left ear. The os orbiculare is separated from the incus and attached to the stapes, which is fixed to the fenestra ovalis more firmly than natural. The tympanum contained mucus; lymph was also effused, and bands of adhesion between the membrana tympani and the inner wall of the tympanum were in process of formation. (Right ear. See Nos. 315 and 141.)
- 640, 641. From a boy æt. 3½, who died from dysentery. The incus extended more posteriorly towards the mastoid cells than usual, and was disconnected from the stapes. The os orbiculare was absent. The neck of the stapes was covered by thick mucous membrane, and there was no appearance of an articular surface for the incus. The membrana tympani was of a dark leaden hue, and much flatter than natural. (See No. 305.)
642. The incus from the left ear of the preceding case. (See No. 654.)
643. The incus and stapes from the left ear of a man æt. 79, who died from disease of the brain; he was dull of hearing. The stapes was firmly ankylosed to the incus. (See No. 120.)

644. Three specimens of the incus affected with caries; in one the larger part of the body of the bone is destroyed; in the other two the surface is roughened.
- 644A. An incus with the long process absent. No history.

D.—DISEASES OF THE STAPES.

645. The incus and stapes from the right ear of a man æt. 65. The os orbiculare was disconnected from the incus and firmly ankylosed to the stapes.
646. From a man æt. 60, who died from apoplexy; he was partially deaf in both ears. Left ear. The base of the stapes is expanded. The fibrous and mucous laminae of the membrana tympani are thickened and opaque. The mucous membrane of the tympanum was thick; the tympanum contained bands of adhesion and caseous matter.
647. The stapes from the right ear of a woman æt. 26, who died from pneumonia; slightly deaf at times. It is larger than natural.
- 649, 649A. From a man æt. 66. The base of the stapes in each ear is slightly expanded, so that it could not be easily withdrawn from the fenestra ovalis. The membrana tympani in each ear was thickened; the mucous membrane of the tympanum was healthy.
650. The stapes from each ear of a man æt. 80, who had been deaf for twenty years, since a severe cold. He could hear the watch on contact with each ear; was worse during a cold. The base of each stapes is thicker than natural. Right ear. Bands of adhesion surrounded the stapes and incus, and the former was more fixed than natural to the fenestra ovalis; its crura were atrophied. Left ear. Stapes partially ankylosed; one of the crura was separated from the base in the attempt to detach it, which was not effected till the vestibule was laid open. Each meatus contained cerumen.
651. In each ear the base of the stapes is expanded, thick and dense, and adhered to the fenestra ovalis with considerable firmness. The fluid in each vestibule was deficient in quantity, and in the right ear large blood-vessels were observed to ramify in the periosteum. *History.*—Male æt. 78. Had been deaf for about twelve years, occasioned by hammering in an iron foundry. He could hear the click of the finger-nails; required to be spoken to in a loud voice; was worse during a cold. Had a ringing noise in the ears, especially the left when he shook his head.
653. Base of stapes hypertrophied.
654. Neck of stapes covered with thick mucous membrane, with no articulating surface for the incus. (See Nos. 641 and 642.)
655. The stapes of the right ear in the same case as the preceding, in a similar condition. (See No. 640.)
656. The crura of the stapes detached from the base, which was left adhering to the fenestra ovalis.
657. Stapes from a tympanic cavity having carious walls. Crura hypertrophied.

658. A stapes surrounded by thickened mucous membrane and by bands of adhesion.
659. Stapes; investing membrane thickened.
660. Mucous membrane of the tympanum thick and attached to the stapes.
- 661, 662. Stapes resting upon and adherent to the promontory.
663. Stapes entirely surrounded by firm bands of adhesion.
664. Stapes ankylosed; the posterior extremity of the base projects more than natural into the vestibule.
665. A stapes greatly hypertrophied, the space between the crura being very much diminished.
666. A stapes smaller than natural. The base and crura are disproportionately thick, the neck partly carious.
667. A stapes, the crura connected by false membrane.

SERIES VII.—MASTOID CELLS.

A.—HYPERTROPHIED.

- 680—683. Specimens of the mastoid cells, remarkably large.
684. Mastoid cells very large, the external plate of the mastoid process so thin as to be translucent.

B.—ATROPHIED.

- 685, 686. Mastoid process small and dense, presenting very little cellular structure.

C.—CONTAINING CHOLESTERINE.

687. From a man *æt.* 50. Left ear. The mastoid cells are separated from the tympanum by a broad false membrane, and the anterior portion is lined by a thick membrane of dark colour, the surface of which is covered by a shining metallic-looking substance, which under the microscope was found to consist of crystals of cholesterine. The membrana tympani is destroyed except a small semicircular portion at the upper and posterior part. Bands of adhesion connect the malleus and stapes to the inner wall of the tympanum.
688. Cholesterine from the foregoing case.
- 689, 690. From a man *æt.* 64. Right ear. Membrana tympani very concave, white like parchment, and thick. The tympanum contained some mucoserous fluid, with numerous bands of adhesion; the mucous membrane was thick. The mastoid cells were hollowed out, and contained muco-serous fluid of a dark greenish colour, and containing crystals of cholesterine. Blood was effused around the auditory nerve at the floor of the internal meatus. The cochlea was also full of a dark coloured fluid. Left ear. In the same state, but the stapes was also ankylosed.
- 690A. Cholesterine from the foregoing case.

D.—MUCOUS MEMBRANE THICK.

691. From a woman æt. 60, who died from fever. Not deaf. Left ear. A portion of very thick mucous membrane from the mastoid cells. The membrana tympani was perforated.

E.—CONTAINING BANDS OF ADHESION.

- 692, 693. Firm bands of adhesion occupying the mastoid cells.

F.—CARIOUS.

694. Two portions of carious bone from the mastoid cells.
 695. Two large portions of carious bone from the mastoid process.
 696. A small necrosed portion of the mastoid process syringed from the ear of a boy æt. 6, twelve months after scarlatina.

SERIES VIII.—CAROTID CANAL.*A.—CONTINUOUS WITH THE EUSTACHIAN TUBE.*

697. Showing the relations of the carotid canal to the tympanum.
 697A. The layer of bone between the carotid canal and the Eustachian tube deficient for a space of a line and a half horizontally by a third of a line vertically.

B.—CONTRACTED.

- 698, 698A. Right ear. Osseous meatus dilated by cerumen, the lower wall partly absorbed. Membrana tympani very opaque, thick, and more concave than natural. Superior wall of tympanum partly deficient. The tympanum contained a little thin mucus and several bands of adhesion. Stapes much more firmly fixed than natural, though not entirely immovable; the entire chain of bones unnaturally rigid. The membranous vestibule was rather thick and opaque. Left ear. Osseous meatus also dilated by cerumen. Membrana tympani concave, covered with exceedingly thick epidermis; the fibrous laminæ are also thick. The roof of the tympanum was so thin as to be translucent; it was deficient in parts. Numerous bands of adhesion in the mastoid cells. The stapes was almost immovable from rigidity of its connecting membrane. In each ear the carotid canal is contracted.
 698B. The internal carotid arteries from the preceding case. Each artery contains a calcareous deposit in its inner coat, and presents a puckered appearance about the middle of its course through the petrous bone. *History.*—Male æt. 76. Had been dull of hearing for thirty years. For twenty years he could only hear a loud voice close to the right ear.

699. The internal carotid artery. It was less than half the size of that of the opposite ear. (See No. 98.)
- 699A. A large, sharp, bony growth in the lateral sinus, and smaller growths of a similar character in the carotid canal.
- 700, 701. From a man æt. 26, who died from a syphilitic disease of the cranial bones, pericranium, and dura mater. He was deaf, especially in the right ear. The deafness was much increased during an attack of erysipelas. The whole surface of the cranium was rough. The carotid canal in each ear is greatly contracted at the lower part, so as to present a shape nearly resembling that of a balloon. The contraction is caused by projection of the lateral walls, and occupies the angle and part of the horizontal portion of the canal. Right ear. Membrana tympani very soft and opaque. Mucous membrane of tympanum thicker and more vascular than natural. A band of false membrane, nearly half an inch in length and half a line in breadth, extends from the mastoid cells to the neck of the stapes. This band is soft and very vascular. Bands of adhesion also connect the stapes with the walls of the tympanum. The entire petrous portion partakes of the disease with which the skull generally was affected. Left ear. Membrana tympani very thin and soft. The mucous membrane of the tympanum is very vascular and rather thick. Large vascular and soft bands of adhesion connected the membrana tympani and ossicula with the internal walls of the tympanum and with the stapes. The mastoid cells contained a quantity of mucus, and also some smooth portions of bone lying in the cavity and attached to the mucous membrane.
- 701A. Left ear. There is a small bony growth, about the size of a mustard seed, on the internal wall of the carotid canal, in the situation of the angle. The membrana tympani is fallen in, and adherent to the internal wall of the tympanum throughout nearly its entire extent; the handle of the malleus and the neck of the stapes are seen as projections at the bottom of the meatus. The mucous membrane of the tympanum is much thickened around the heads of the malleus and incus, which are movable. The base of the stapes is fixed. (Right ear. See No. 280A.)
- 702, 703. Carotid canal contracted by bulging of the lateral walls. Membrana tympani containing a deposit of osseous matter.
704. From a man æt. 40. The carotid canal slightly contracted.
705. The horizontal portion of the carotid canal is much contracted, the contraction being produced by the presence of a rounded protuberance of the bone at the inner and outer surface of the lower half of the canal. The membrana tympani thick, opaque, and more concave than natural.
- 706—710A. Specimens showing contraction of the carotid canal. In each case the contraction is produced by more or less protuberance of the lower portion of the lateral walls in the angular and horizontal portions of the canal.

SERIES IX.—INTERNAL EAR.

A.—VESTIBULE AND SEMICIRCULAR CANALS.

711. From a man who was very deaf. Right ear. The tympanum and vestibule were full of blood. (Left ear. See No. 580.)
- 712, 713. From a man æt. 20. Subject to epilepsy. Exostoses of small size grow from the posterior surface of each petrous bone, and from the upper surface of each meatus internus. The meatus internus of the left ear is reduced to one half its natural size.
714. The fenestra ovalis is surrounded by an exostosis or additional deposit of bony matter, the margin being thickened and of a pearly white colour. The lower wall of the tympanum is deficient in nearly half its extent.
- 715, 716. An exostosis in each tympanic cavity, partially filling up the fenestra ovalis, so that it is no longer oval, but of a triangular shape, and its size is reduced by a full third.
- 717, 718. An exostosis in each tympanic cavity, partially filling up the fenestra ovalis.
- 718A. Exostosis in the tympanic cavity, slightly diminishing the fenestra ovalis; the floor of the tympanum partly deficient.
719. Exostosis in the tympanic cavity surrounding and diminishing the fenestra ovalis. Floor of the tympanum deficient to a small extent.
720. Exostosis in the tympanic cavity diminishing the fenestra ovalis; the floor of the tympanum imperfect; the external meatus very large.
721. Exostosis in the tympanic cavity around the anterior part of the fenestra ovalis. The anterior wall of the external meatus diseased.
722. Fenestra ovalis diminished and rendered irregular in form by an exostosis in the tympanic cavity.
723. Otoconie more abundant than natural. (See No. 625.)
724. Left ear. A portion of the membranous vestibule thickened. The stapes was ankylosed, the mucous membrane of the tympanum thick, and the cochlearis muscle hypertrophied. Deaf. (See Nos. 512, 747, and 763.)
- 727, 728. The osseous superior semicircular canal deficient at its upper part, the cavity of the canal being open for an extent of about three lines.
729. From a man æt. 64. Right ear. The upper wall of the tympanum and of the superior semicircular canal imperfect. The left ear was well formed and healthy.
730. From a man æt. 65. Right ear. The upper wall of the superior semicircular canal is deficient for the extent of about a line. (Left ear. See No. 535.)
- 731, 732. From a man æt. 92. Right ear. The posterior semicircular canal is incomplete, its posterior wall being deficient for an extent of about three lines. Stapes ankylosed. Left ear. Stapes ankylosed. The membranous labyrinth and cochlea contained black pigment.

733. Left ear. Membranous semicircular canal atrophied. The membrana tympani was white and collapsed; the tensor tympani muscle atrophied. (See No. 506.)
734. Membranous semicircular canals from a man æt. 74, who had been deaf some years. (See No. 150.)
735. The cochlea from the same case, containing pigment cells. (See Nos. 739, 740.)
736. Semicircular canal distended with otoconie. Deaf and dumb.
737. Portion of a semicircular canal with its ampulla hypertrophied.
- 737A. Otoconie in excess in the semicircular canals. From a young woman deaf and dumb.
- 737B. The same. From the same case.

B.—COCHLEA.

738. Cochlea containing coagulated blood.
- 739, 740. Left ear. Portions of the cochlea containing pigment cells. (See Nos. 176, 734, and 735.)
741. Cochlea containing pigment. (See Nos. 145 and 296.)
743. Two specimens of the cochlea containing an excess of pigment-cells.
744. Cochlea containing black pigment.
745. Cochlea containing black pigment.
746. A portion of the cochlearis muscle enlarged. From a man æt. 48, deaf. (See No. 512.)
747. A portion of the cochlearis muscle enlarged. From the same case as the preceding. (See No. 724.)
748. Cochlearis muscle enlarged. From the same case.
749. The scala vestibuli at and near its entrance into the cavity of the vestibule is much smaller than natural. The stapes is surrounded by bands of adhesion.
750. A large portion of the cochlea necrosed. It was discharged during life from the ear of a man æt. about 55. The disease of the ear appeared to originate in an attack of erysipelas of the head. There were no symptoms of affection of the brain.
- 751, 752. In each ear the cochlea was in a state of degeneration, the lamina spiralis presenting dark patches under the microscope as if from old effusion of blood. No deviation from the healthy state was observed in the vestibule. The membrana tympani thin, white, relaxed, concave at the central part, the margin for the width of three quarters of a line having its normal outline. The ossicula rather less mobile than natural. Numerous bands of adhesion occupy the mastoid cells. *History.*—Male æt. 65. Thirty-three years before death he fell on his head (he was a sailor), and has been deaf ever since. His hearing power varied somewhat, being worse during a cold. He could never distinguish words, but could sometimes hear the sound of a loud voice. He suffered from headache and giddiness.

C.—*FENESTRA ROTUNDA.*

755. The membrane of the fenestra rotunda thickened. From a woman æt. 30, who died from fever, having been very deaf for five days previous to death. There was a considerable quantity of mucus in the tympanum; it was white, and consisted of circular cells covered by fine granules. The mucous membrane of the tympanum was so thick that the stapes and incus were entirely concealed. It was red and pulpy, and so firmly adherent to the membrane of the fenestra rotunda that they could not be separated. (See No. 306.)
756. The membrane of the fenestra rotunda thick and dark-coloured. The stapes was ankylosed. (See No. 541.)
- 757, 758. In each ear the membrana fenestræ rotundæ is thick and opaque. The ossicles are connected by bands of adhesion. *History.*—Male æt. 73. Had been growing deaf for six or seven years; sometimes, as during a cold, had a humming noise in the ears, not in the head; also at times a pain running up in the left ear. He could hear the watch with pressure.
- 759, 760. Right ear. The membrane of the fenestra rotunda is ossified, and covered in its cochlear aspect by a deposit of osseous matter. The vestibule and cochlea contained a sanguineous fluid, and their blood-vessels were greatly distended with blood. The base of the stapes is ankylosed to the fenestra ovalis, and projects farther into the vestibule than natural; a bony growth from the wall of the vestibule is attached to and fixes the base of the stapes. Mucous membrane of the tympanum thicker than natural. Membrana tympani opaque and concave. In the meatus externus, midway between the membrana tympani and the orifice, there is a bulging of the posterior osseous wall. Left ear. Vestibule and cochlea full of bloody serum. Membrane of the fenestra rotunda ossified, and covered with a deposit of osseous matter occupying the termination of the cochlea and extending into the vestibule. The bone forming the floor of the internal auditory meatus atrophied. Portio mollis nerve not seen. Stapes ankylosed. The membrana tympani and mucous membrane of the tympanum thick and vascular. The posterior wall of the meatus externus presents an osseous bulging. *History.*—Male æt. 56. Insane; so deaf that it was impossible to make him hear. Deafness hereditary, and also insanity on both father's and mother's side. It is not known whether he was born deaf; indeed, it is said that he was able to read, but a sister was born deaf.
761. From a man æt. 67, who died from gangrena senilis. Right ear. The fenestra rotunda is entirely concealed by a false membrane, which is firmly attached to the entire circumference of the fossa fenestræ rotundæ. (Left ear. See No. 340.)
762. Left ear. At the lower part of the tympanic cavity there is a false membrane, in length about a line and a half, which completely conceals the fenestra rotunda. The false membrane is firm, and of a white colour. Bands of adhesion connect the stapes to the tympanic walls. *History.*—

From a woman æt. 26, who died fourteen days after childbirth. She was very deaf in the right ear, and slightly so in the left. She had scarlatina when a child, and from that time had always a discharge from the right ear. The osseous walls of the right tympanum were diseased, and that portion which corresponds with the carotid canal was carious and perforated with small holes. (Right ear. See No. 843.)

763. Left ear. A false membrane covering the fenestra rotunda. Stapes ankylosed. Deaf. (See No. 512.)
764. A false membrane completely covering the fenestra rotunda, being attached to the margin of its fossa. The stapes connected by bands of adhesion to the tympanic walls.
765. Mucous membrane of the tympanum thick, nearly burying the stapes. Fenestra rotunda entirely concealed.
766. Membrana fenestræ rotundæ adherent by bands to the fossa fenestræ rotundæ.
767. Membrana fenestræ rotundæ partially covered by a false membrane.
768. Membrana fenestræ rotundæ completely covered by a false membrane, which also connects the stapes to the walls of the tympanum.
769. Membrana fenestræ rotundæ entirely concealed by bands of adhesion.
770. A smooth, transparent false membrane covering the fossa fenestræ ovalis.
- 770A. Membrane of fenestra rotunda thickened, stapes ankylosed. From a man æt. 83, deaf.

D.—AUDITORY NERVE AND MEMBRANOUS LABYRINTH.

771. (See 'Transactions of Pathological Society,' 1850-51, p. 49.) Left ear. From a man æt. 60, partially deaf. A tumour of white colour and about the size of a small bean occupies the internal auditory meatus, and projects about a line beyond its posterior border. It is of conical shape, the small end being at the anterior part of the meatus; its texture was firm posteriorly, and upon being cut into presented little but cellular tissue; anteriorly it was softer. It is attached to a portion of the nerve supplying the vestibule, the fibres of which pass through its anterior half. Under the microscope the tumour presented nerve tubes, parallel fibres, and nucleated cells. The right ear was healthy.
- 772, 773. From a woman who died from serous apoplexy, with aneurism of the basilar artery. She was quite deaf. Each auditory nerve atrophied. Dr. Van der Byl, under whose care the patient was, states "there was no pressure on the root of the nerve, but it seems probable that one of the small branches of the basilar artery to supply the internal ear was pressed upon, and in this way the nutrition of the organ may have been interfered with."
- 776, 777. From a woman æt. 70: had been hard of hearing during many years. Latterly it was with the greatest difficulty that the voice could be heard through a speaking-trumpet. Each petrous bone was of a dark plum-colour and somewhat expanded. Upon making a section each portion, instead of

possessing the usual hard and rock-like properties of this bone, was so soft that its exterior could be cut with a strong knife. The only part that retained the aspect and density of the healthy petrous bone was that portion which directly surrounds the vestibule, cochlea, and semicircular canals. Right ear. Membrana tympani thicker and whiter than natural; the surface of the incus is rough, parts of its outer layer having been absorbed; the stapes partly ankylosed. The auditory nerve atrophied, and less white than natural; the membranous labyrinth atrophied.

778, 779. From a man æt. 73, deaf for fourteen years. Right ear entirely useless. Left ear required shouting into the ear. Suffered from noises in the head. In each ear the membranous labyrinth was atrophied. Stapes partially ankylosed. Membrana tympani thickened and opaque.

780, 781. From a man æt. 74, who had been deaf for twenty years, occasioned by falling into the sea. For fourteen years he had only been able to hear a shout. In each ear the vestibule was full of aqueous fluid, but the membranous labyrinth was atrophied. Membrana tympani rather opaque; mucous membrane of tympanum rather thicker than natural; bands of adhesion surround the ossicula.

782, 783. From a man æt. 97, who had become gradually deaf many years ago. He was entirely deaf on the left side; could hear a loud voice close to the right ear. In each ear the membranous labyrinth appeared to be atrophied. Right ear. Pus was effused among the muscles surrounding the styloid process, and some was contained in the meatus externus, the tissues of which, however, were themselves healthy. Membrana tympani thickened and opaque. Stapes more rigid than natural. Bands of adhesion in mastoid cells. Left ear. Meatus externus large. Bands in mastoid cells.

784, 785. From a man æt. 62, who had been deaf for twenty years. He required speaking to in a loud voice close to the head. Was worse during a cold. Right ear. Membrana tympani healthy, except a slight thickening at the point to which the extremity of the long process of the malleus is attached. Stapes ankylosed by thickening of the connecting membrane. Membranous vestibule much atrophied; there was no vestige of otoconie. Left ear. Membrana tympani quite red, arising from the effusion of serum of a dark red colour in the tympanum; it is very concave, the handle of the malleus being almost in contact with the promontory. Stapes partially ankylosed. The membranous labyrinth was so much atrophied that its presence was scarcely to be detected, it having become one with the periosteal lamina. The otoconie was absent. On the tympanic surface of the lamina spiralis of the cochlea external to the denticulate processes are dark granules, which are aggregated into a thick band beyond them. Beyond this thick band are transparent cells. The nerves distributed over the lamina spiralis appeared to be diseased, as they did not present any traces of the fine tubercles, but in their place were granules of various sizes.

E.—MEATUS INTERNUS.

787. The basilar process of the occipital bone and the inner surface of the petrous bone present numerous depressions, with sharp margins, as if the bone had been ulcerated. The roof of the tympanum is imperfect, the meatus internus larger than natural. (See No. 234.)
- 788, 789. The meatus internus very large.
790. The meatus internus very large.
791. A large exostosis with a rough protuberance, surrounding the upper part of the orifice of the meatus internus. Also a rough triangular exostosis on the upper part of the petrous bone near its junction with the squamous portion.
792. An exostosis surrounding and diminishing the size of the meatus internus.
- 793, 794. The inner and posterior portion of each petrous bone, especially of the right, absorbed by the pressure of a tumour arising from the cerebellum. Each meatus externus rough.

SERIES X.—DISEASE EXTENDING FROM THE EAR TO THE BRAIN.*A.—EXTERNAL MEATUS.*

798. Caries of the external meatus extending to the middle cerebral cavity and lateral sinus; upper wall of the tympanum healthy.
800. From a woman æt. 16, who had had pain and discharge in the left ear for seven months, and died three days after the accession of acute cerebral symptoms. Left ear. The dura mater forming the posterior wall of the lateral sinus, where it is situated in the temporal bone, was of a dark colour and soft; the sinus contained at its upper part a firm coagulum of dark-coloured fibrin; at its lower part it was filled by dark pus. The anterior wall of the sinus was but loosely attached to the sulcus lateralis. The tympanic cavity contained a considerable quantity of scrofulous matter, which, by its pressure on the posterior wall of the meatus, had produced a carious orifice in the bone. The membrana tympani was thick and soft, and on its outer surface were two dark-coloured polypi. (See 'Pathological Society's Transactions,' vol. v, 1853-4, p. 273.)
801. There is a small orifice, about half a line in diameter, between the anterior wall of the meatus externus, near its outlet, and the cranial cavity. On the internal surface the bone, about the junction of the anterior wall of the petrous portion with the squamous portion of the temporal bone, is deeply excavated over a space the size of a horse-bean; for half this extent there remains only the thin and translucent external plate.
802. The meatus externus is rough, and the cancellous texture partially

exposed, especially at the posterior and inferior walls. The lateral sinus is also rough, and presents, in a portion of its extent, a deep branching fissure.

802A. The external surface of the temporal bone has been destroyed, apparently by malignant disease, over a space extending from the root of the zygoma to the articulations of the parietal and occipital bones; the cranial cavity is exposed in nearly the entire course of the lateral sinus. The ulceration extends deeply into the petrous bone, forming a large cavity, bounded internally at the lower part by the internal wall of the tympanum; the promontory, stapes, and fossa of the fenestra rotunda remaining unaffected by the disease.

802B. From a girl æt. $3\frac{1}{2}$. *History*.—From the age of five months an offensive creamy discharge had issued from the left ear. The child complained of itching, but not of pain. About six weeks before death the discharge ceased, violent pain came on in the ear, and an abscess formed behind the ear, at the bottom of which the surface of the squamous and mastoid bone was felt to be carious. She was delirious and very restless. Left ear. The lateral ventricles contained about half an ounce of perfectly clear serum; the cerebrum was otherwise healthy, as was also the dura mater covering the upper part of the petrous bone. Upon the removal of the tentorium the left hemisphere of the cerebellum was observed to be much softer than natural, and the portion in contact with the posterior surface of the pars petrosa was dark-coloured and very soft, and upon gently drawing it backwards it was found to be applied against two orifices in the posterior part of the lateral sinus, and it was separated from the cavity of the sinus by the thickened arachnoid and pia mater. A considerable vessel in the pia mater opposite the orifice was distended by a firm and dark coagulum, half an inch in length. The anterior membranous wall of the lateral sinus was absent; the bone forming the sulcus lateralis in the mastoid process was carious, and the sinus full of a dark-coloured coagulum and purulent matter; pus was also found in the jugular vein. The ear. The dermis lining the whole of the external meatus was soft, tumefied, and of a dark colour; its surface was denuded of epidermis; beneath it posteriorly was purulent matter which separated it from the carious bone. The membrana tympani was absent, but there was no more appearance of disease in the tympanic cavity than might have been produced by the affection of the meatus. The bone was carious anteriorly as far as the root of the zygoma; posteriorly and superiorly the caries extended nearly to the margin of the parietal bone. In some parts the external table only was affected; in others it extended to the diploe, and thence to the external table. Upon holding the bone up to the light small orifices may be observed through the bone, so that its external surface, viz. that part which was covered by the membranous meatus, was directly continuous with the lateral sinus.

802C. Necrosis of meatus and tympanum. Membrana tympani thickened, not perforated. Ossicula all *in situ*. A small carious orifice from tympanum

into the external semicircular canal. Labyrinth full of purulent matter. Pus at the base of the brain. Pons Varolii soft and ulcerated. *History*.—A healthy man æt. 26; had discharge from ear for four or five years; severe symptoms twelve days before death. Membranous meatus not ulcerated; two small polypi attached to it. (See 'Med. Times and Gazette,' 1855, vol. i, p. 510.)

B.—*TYMPANIC CAVITY.*

- 803, 803A. From a youth æt. 19, who died from scarlet fever after an illness of five weeks. In each ear the membrana tympani had lost all its central portion by ulceration. The mucous membrane of the tympanum was thick and ulcerated; a sero-purulent matter pervaded both it and the mastoid cells. The ossicula were rough. The dura mater was not adherent to the upper and posterior parts of the petrous bone, the coats of the internal carotid artery were very much thickened and dark-coloured, and the walls of the jugular vein corresponding to the floor of the tympanum are thin, soft, and easily detached from the bone.
804. Superior wall of the tympanum absorbed. Mucous membrane of the tympanum thick.
805. Left ear. From a woman æt. 62, who died from gangrene; deaf in the left ear. Membrana tympani white and very concave; around the point of attachment of the malleus the blood-vessels are enlarged and distended with blood. The tympanum is three parts filled with a thick, tenacious white mucus, which was partly the cause of the white appearance of the membrana tympani. The mucous membrane of the tympanum was thick and very vascular, and that portion of it which covers the body of the incus was red, the vessels being greatly distended with blood. The upper wall of the tympanum is very thin and almost transparent; the blood-vessels contained in it are distended with blood, and are continuous with the vascular mucous lining of the tympanum and the dura mater, which latter was also more vascular than natural. The tensor tympani muscle was atrophied, and no effect was produced on the membrana tympani by pulling it. (Right ear, see No. 291.)
806. Left ear. Membrana tympani destroyed by ulceration, except a small band at its posterior and superior region, to which the malleus is attached. Mucous membrane of tympanum very thick and diseased, and the bone forming the upper wall of the tympanum is also diseased in its entire thickness, the cranial surface of the bone being rough and very vascular. The dura mater which covers this part is in some places very thin, and in others presents large orifices. *History*.—Male æt. 22, died from phthisis: he was deaf in the left ear, and when a child had a scrofulous affection of that ear with discharge. In the right ear there was incipient calcareous degeneration of the membrana tympani, thickened mucous mem-

brane of the tympanum, with bands of adhesion and partial ankylosis of the stapes.

807. Left ear. The dura mater covering the upper surface of the petrous bone was more vascular than natural, and on its free surface was a patch of blood. The upper wall of the tympanum was of a dark colour, and the thick mucous membrane was seen beneath it. The tympanic mucous membrane was very thick and of a dark purple colour, its vessels being distended. The upper part of the tympanum was filled by this thick membrane, so that scrofulous matter and pus were retained in the tympanic cavity by it. The stapes was disarticulated from the incus; the ossicles were concealed by the thick mucous membrane. The lower osseous wall is also thin and of a red colour: it presented an orifice which allowed a communication between the tympanum and the jugular fossa. *Membrana tympani destroyed. History.*—Boy æt. 4. Had suffered from discharge in the left ear since his first year; the ear was tender, but pain had not been complained of. Convulsions and hemiplegia occurred two months before death. There was a large deposit of tubercles surrounded by pulpy matter in the left cerebral hemisphere. (See 'Medical Times and Gazette,' 1855, vol xxi, p. 107.)
- 808, 809. Right ear. The lower half of the *membrana tympani* is destroyed, and the inferior half of the upper part is attached to the promontory, so that the upper portion of the cavity of the tympanum and that of the mastoid cells was closed, and the matter there secreted had no exit. The tympanic mucous membrane was thick and ulcerated in parts. The mastoid cells presented a large cavity full of pus. On this side the dura mater was much congested. In the sulcus lateralis was a portion of necrosed bone about three quarters of an inch long and half an inch broad. Between this and the dura mater was a considerable quantity of pus, which communicated with superficial abscesses behind the ear. An abscess was found in the substance of the middle lobe of the cerebrum. In the left ear the lower two thirds of the *membrana tympani* were absent, but the upper part was not adherent to the promontory, so that there was ample room for the egress of discharge from the tympanum. The tympanic mucous membrane was thick, but not otherwise diseased; the bone was healthy. *History.*—From a youth æt. 12, who had an attack of scarlatina two years before death, since which he had a discharge from each ear. Acute symptoms, affecting the left ear, supervened on February 13th, 1854, and he died on March 16th. (See 'Medical Times and Gazette,' 1855, p. 306.)
810. From a girl æt. 10 years, who died with acute cerebral symptoms of short duration. She had formerly had a discharge from the right ear, but that had ceased, though deafness remained. Right ear. The whole of the petrous bone, and of the dura mater covering it, was of a deep red colour from the distension of the vessels. The upper wall of the tympanum was of a black colour and very thin; the tympanic cavity was full of scrofulous matter, dark in parts and in others white. The malleus was drawn inwards so as to touch the promontory, and shut off the upper part of the tympanum from the

lower, and to confine the matter. (See 'Medical Times and Gazette,' 1855, p. 52.)

811. Right ear. The whole of the upper wall of the tympanum destroyed by caries, the tympanic cavity communicating with that of the cerebrum by an aperture measuring three quarters of an inch in length, and a third of an inch in breadth. The mastoid cells contain scrofulous matter. The periosteum was detached from the exterior, and the dura mater from the interior of the squamous bone, and separated by dark-coloured pus. The dura mater on the right side was gangrenous over a large surface; the middle lobe of the cerebrum was in a state of suppuration. *History*.—Female æt. 18, of scrofulous diathesis. She had been deaf in the right ear for two years; the deafness was preceded by discharge. She died after nine days' illness, death being preceded by epileptic fits. There was a very foetid odour about the ear, but no discharge. (See 'Medical Times and Gazette,' 1855, p. 106.)
812. Right ear. External meatus. Dermis extremely congested, and of a light pink colour. Membrana tympani of a dark red colour and thick; it presents two perforations of small size, one at the anterior and upper part, and a second smaller, not larger than a pin's head, at the anterior and lower part. The tympanum contained pus and blood, the pus being chiefly at the upper part, the blood at the lower. There is an ulcerated orifice, about a line and a half in length by a line in breadth, in the plate of bone that separates the tympanum from the fossa jugularis. There is an irregular oval orifice, about two lines in length, in the posterior osseous wall of the fossa jugularis, by which it communicates with the cavity of the cranium. The walls of the jugular fossa are stained with blood. *History*.—From a soldier who returned from the Crimea after fever in November, 1855. At that time he had an abscess in the right side of the neck, with discharge from the ear; both became well, but he then became slightly jaundiced, vomited, and had a sharp attack of fever. He died on 12th December, 1855, having been delirious for some hours. The day before and night just preceding his death there was a good deal of bleeding from the ear, amounting to about three or four ounces. He was deaf after the fever in the Crimea. All the viscera, except the spleen, which was large, were normal.
813. The upper part of the membranous meatus externus, near the point of attachment of the membrana tympani, was thick, red, and soft; the membrana tympani was absent, the whole of it having been destroyed by ulceration, with the exception of a small portion of the upper part to which the ossicula are attached. The tympanum contained a considerable quantity of thick caseous matter, consisting of granules, epithelium, and oil globules. The mucous membrane of the tympanum is very thick, soft, and of a deep red colour; the lower wall of the tympanum is rough and carious, and there are several small orifices in this wall, which allow of a communication between this cavity and that of the jugular fossa. The handle of the malleus has been destroyed by caries, the long process of the incus is rough and carious, and part of its substance has been destroyed; the portion which

remains is adherent to the stapes. The dura mater was disconnected from that part of the surface of the petrous bone which forms the upper wall of the tympanum; the superior surface of this portion of the dura mater was adherent to the arachnoid membrane. Serum was effused beneath the arachnoid and in the lateral ventricles. *History*.—From a boy *æt.* 3, who died during whooping-cough. There was discharge from the left ear for eighteen months previously; it came on slowly without pain, but now and then it ceased, when there was great pain in the ear, which disappeared on the return of the discharge. The discharge was usually thick and white.

814. There is a large aperture in the squamous bone, and the petrous and mastoid bones are converted into a white cheesy-looking mass. The basilar process of the occipital and sphenoid, and the whole of the malar bone, were in a similar condition. A cavity was found in front of the ear, and another beneath the temporal muscles; both contained a soft cheesy substance. The ventricles contained three ounces of bloody serum; the arachnoid was much injected, and between it and the pia mater was a layer of yellow pus extending along the base of the brain. In the middle lobe of the brain was an abscess, containing upwards of an ounce of very foetid greenish pus, and a second abscess existed in the middle of the posterior lobe. The softened bone consisted of cells of various forms, some few only having distinct nuclei; there was also interspersed among the cells granular matter. *History*.—Male *æt.* 25. Subject for five years to a discharge from the right ear with occasional pain. A year before his death an abscess broke behind the ear, and discharged at times. About a fortnight before his death he suffered from severe pain in the head and vomiting, and had paralysis of the right portio dura nerve. (See 'Medical Times and Gazette,' 1855, p. 589.)

815. From a youth *æt.* 19, strumous. About nineteen months before his death he was knocked down and struck on the right side of his head. Deafness and pain soon supervened, followed by swelling, with sloughing and ulceration, to such an extent that a large chasm formed around the ear, leaving that organ completely isolated. No brain symptoms occurred. The brain appeared perfectly healthy, except at the lower part of the right hemisphere, which was pulpy and very soft. The softening was caused by the upward pressure of a soft scrofulous-looking mass, springing from the dura mater covering the petrous bone. This mass pressed upon the bone below, and appeared as though inclined to force its way downwards through the temporal bone at the junction of the squamous with the petrous portion, a great part of the latter being completely absorbed. Some new bone had formed at the inner side, and the whole of the exterior was occupied by a sloughy mass and carious bone, the surrounding parts being very hypertrophied. No vestige of meatus or mastoid cells could be discovered; the lateral sinus was filled by a coagulum. (See 'Medical Times and Gazette,' 1855, p. 588.)

816. From a woman *æt.* 35. *History*.—After a severe cold a year previously,

pain began in the right ear accompanied by tumefaction of the right side of the face. Six months ago a red growth (supposed to be a polypus) was removed from the meatus. Since then there has been at times considerable bleeding from the ear. After this the pain in the ear increased, a red tumour occupied the meatus, and the parts surrounding the ear were swollen. The left portio dura nerve was paralysed. She died in about three months with symptoms of cerebral congestion. A large mass of reddish-white colour extended from the posterior part of the mastoid process to the body of the malar bone. It was of different degrees of consistence; anteriorly it was hard and firm like the pancreas, posteriorly it was softer and deeper towards the styloid process; it contained a white creamy fluid; it contained also spiculæ of bone. The mastoid process was involved in the disease, and consisted of some detached masses of bone in the middle of a portion of the tumour. The osseous meatus had wholly disappeared; the remains of the membranous meatus could scarcely be distinguished. The only remains of the tympanic cavity were some portions of the mucous membrane having a dark livid hue; its blood-vessels were distended, and small red growths were attached to parts of it. There was no remnant of the bony tympanic cavity. The whole of the squamous bone, from an inch below the squamous suture, and the whole of the outer part of the petrous bone had been destroyed, so that the apex of the petrous bone had no connection with the squamous. The tumour had advanced inwards to the cavities of the cerebrum and cerebellum, through the aperture formed by the destruction of the squamous and petrous bones. In the middle cerebral fossa was a reddish-white tumour, about the size of a small pear; it consisted of two portions, one of which was continuous with the external tumour, while the upper portion seemed to be an independent growth from the free surface of the dura mater. It was adherent to the lower surface of the posterior cerebral lobe, which was softened to the extent of half an inch. The harder portions of the tumour consisted of very delicate fibres and nucleated cells, while the softer parts and the creamy fluid were almost wholly composed of nucleated cells, some being circular, others fusiform, and others angular. (See 'Medical Times and Gazette,' 1855, p. 587.)

817. Upper wall of the tympanum diseased; orifice.

817A. Caries of the upper and inner walls of the tympanum.

817B. Necrosis of superior wall of tympanum. The specimen shows the necrosed mass with new bone formed around. The ossicula are all wanting except the base of the stapes. From a female æt. 20, who had had discharge from the ear from infancy, with formation of polypi. Death from abscess in the cerebellum.

817C. The central part of the petrous bone destroyed by necrosis. Abscess in cerebellum. From a man æt. 25, who had had discharge from the ears for nine years. (See 'Trans. Path. Soc.,' vol. xii, p. 13 [1861].)

C.—MASTOID CELLS.

818, 819. From a girl æt. 10 months, subject to scrofulous glands. *History*.—

When first seen there was a considerable abscess behind the left ear, and discharge from the meatus. The membrana tympani was absent, the mucous membrane of the tympanum thick and red. At the bottom of the abscess dead bone could be felt. There had been a discharge from the right ear at the age of three months; this lasted six or seven weeks and then disappeared. At five months of age discharge took place from the left ear, and after it had continued for a month an abscess formed behind the ear. She had frequently suffered from great pain in the left side of the head. The symptoms of cerebral irritation increased, and she died in a few days. Left ear. The bone above and posterior to the meatus externus over the space of a sixpence was denuded; it was rough, black, and soft; the external table had been removed. Upon making a vertical section of the bone through the horizontal portion of the cells the walls of the latter were observed in a state of disease, and the cavity contained purulent matter. The outer wall of this portion of the cells was carious throughout. The membrana tympani had been wholly removed by ulceration, as also were parts of the tympanic mucous membrane; the small portions remaining were thick, soft, and of a livid colour. The long process of the malleus had disappeared; the remnant was partially disconnected from the incus, as was the incus from the stapes. The inner surface of the carious bone is of a dark colour, and is itself carious; it presents numerous small depressions. The dura mater, thick, soft, and red, was separated from the carious bone by a transparent fluid. Right ear. Affected by the same disease, but in an incipient state; the meatus was soft and red, the membrana tympani thick, white, and concave. The mucous membrane lining the tympanum and mastoid cells was thick and red, and there was a collection of mucus. (See 'Medical Times and Gazette,' 1855, p. 154.)

821. From a man who died in St. George's Hospital in 1847. Disease of the mucous membrane of the tympanum and mastoid cells; caries of its inner wall; suppuration in the lateral sinus produced by the inflammation of the mastoid cells. Secondary abscess. The case is recorded in the Register of St. George's Hospital for 1847, No. 289. (Post-mortem Book, No. 42.)

822. From a man æt. 50, deaf in the left ear. When young he had scrofulous disease of the left mastoid process, followed by caries. Left ear. A fossa exists at the upper and anterior part of the mastoid process, near to the external meatus; it is nearly large enough to admit a horse-bean. This fossa was lined by the integuments which adhered firmly to it. The lower half of the membrana tympani was absent, having apparently been destroyed by ulceration; the upper half is directed very obliquely inwards, and is adherent to the promontory. The ossicles remain, but the incus and stapes are disconnected. Attached to the anterior part of the long process of the

malleus, near its inferior extremity, is an exostosis, measuring three quarters of a line in length, which passes outwards and somewhat backwards and downwards. The lamina of bone which forms the sulcus lateralis is much thickened. The right ear was healthy.

823. From a girl *æt.* 12, who died twenty-two days after receiving a violent blow on the head. An abscess formed beneath the temporal muscle, discharge took place from the left ear, and coma supervened upon symptoms of cerebral irritation. Left ear. The pericranium was separated from the squamous bone by purulent matter; the dura mater lining the squamous bone and covering the upper wall of the tympanum was thicker than natural, and but slightly adherent to the bone; the arachnoid and a portion of the cerebral matter were attached to this part of the dura mater. In the middle cerebral lobe was an abscess containing four ounces of pus. The petrous bone was diseased. The membranous meatus was thicker than natural; its free surface was smooth and presented no signs of ulceration. The superior and posterior walls of the osseous meatus were rough; this rough appearance was produced by a deposit of new bone, which was also found to extend on the outer surface of the squamous bone above the meatus for a space measuring half an inch in its vertical and an inch in its antero-posterior diameter. The posterior two thirds of the membrana tympani were absent; the mucous membrane of the tympanum was healthy, but in the passage to the mastoid cells there was a collection of pus and scrofulous matter which had not been freely discharged on account of the small size of the aperture leading into the tympanum, contracted as it was by the thick mucous membrane. The upper wall of the tympanum was in a diseased state; the surface next to the dura mater was composed of a very fine scale of dead bone, about six lines long and four broad; this was perforated by small orifices, and posteriorly it was eaten away in parts. Beneath this portion of dead bone was a layer of new bone, which formed the upper wall of the tympanum, and it was continued upwards and outwards on the inner surface of the squamous bone to its upper margin; the old bone underneath and adjacent to this new bone was worm-eaten, and had been the seat of the disease, being about half an inch in breadth. In this case there can be no doubt that disease in the horizontal portion of the mastoid cells commenced in early childhood, the squamous bone and dura mater being affected, but not to such an extent as to endanger life. As the bone was developed new bone was deposited on each side of the diseased squamous bone, and it is probable the patient might have lived many years if the disease had not been re-excited by the blow. (See 'Medical Times and Gazette,' 1855, p. 155.)

823A. Portion of brain and dura mater from the inner surface of the squamous bone, from the preceding case.

824. From a boy *æt.* 13, who died, after six weeks' illness, with symptoms of cerebral disease, pain in the right temporal region, with discharge and impaired hearing in the right ear. *Autopsy.*—The ventricles of the brain

were enormously distended with transparent serous fluid, amounting to at least half a pint. The venæ Galeni were flattened, and contained no blood, having been obstructed by the pressure of the underlying disease. A few transparent and very minute granulations were scattered over the arachnoid at the base of the brain. The inferior surface of the right lobe of the cerebellum was attached to the dura mater by slight adhesions. This lobe was the seat of three distinct abscesses, and the central part of it was almost entirely converted into pus. The left lobe and other parts of the cerebellum were free from disease. On examining the interior of the skull a yellow spot about the size of a pea was discovered over the petrous portion of the right temporal bone. The dura mater was here separated from the bone by a thin layer of pus lying upon the carious bone, but there was no trace of inflammation or other disease in the cerebral aspect of the membrane. Over this space the bone was destroyed in its whole thickness, so that on lightly scraping it with a scalpel the cavity of the tympanum was brought into view. This cavity was filled with opaque lymph of a reddish-yellow colour, but on removing this the bones and muscular apparatus of the ear were seen to be still in place. The membrana tympani was slightly thickened and opaque. (See 'Med. Times and Gaz.,' 1855, p. 405.)

825. From a child æt. 13 months. *History*.—At the age of six weeks a discharge was observed to flow from the right ear, which continued with short intermissions. About two months before her death, an abscess formed at the back of the ear, which discharged into the meatus. She died in convulsions after febrile symptoms of a fortnight's duration. *Autopsy*.—The part of the sterno-mastoid muscle attached to the mastoid process was discoloured. The membranous meatus was much thickened, and of a dark purple colour. The posterior part of the osseous meatus was carious, and the bone continuous with and above it for a space the size of a fourpenny piece was also carious, this being the portion of bone which bounds externally the horizontal mastoid space. The periosteum covering this carious bone was thick and soft in parts and ulcerated in others; internally there is also a portion of necrosed bone about one half the size of that externally; and upon a section the inner surface is found to be part of the necrosed portion of bone which is seen externally, where it covers the tympanic cavity and extends above it. The outer surface of the dura mater, which was in contact with the dead bone, was soft, spongy, and of a dark colour, and partly filled the superficial cavity formed by the necrosed bone. In immediate contact with the bone, however, was a soft, pulpy tissue. The membrana tympani was absent, the mucous membrane of the tympanum ulcerated, and the ossicles carious.

- 826, 827. From a man æt. 73, who had been deaf some years. Could only hear a loud voice near to the left ear. Right ear. Membrana tympani in parts transparent, in parts thick and white like cartilage. The chain of bones fixed, the head of the malleus being ankylosed to the upper wall of the tympanum; when it was freed the ossicles moved freely. Left ear.

Membrana tympani: all the laminae perforated except the epidermis; adherent to stapes and incus. In each ear the cancellous bone entering into the formation of the mastoid process was soft and dark-coloured.

828. Osseous wall of the lateral sinus carious and perforated by numerous orifices, which communicated with the mastoid cells. The surrounding bone was thick, rough, and vascular. The mucous membrane of the tympanum was very thick, and in contact with the membrana tympani, which was white and thick.

829. From a man æt. 29. *History*.—Had been subject to diabetes. The fatal illness commenced with a pain in the head, chiefly referred to the right mastoid process. The pain increased, and was attended with a purulent discharge from the ear. Drowsiness, giddiness, and stupor supervened. Six weeks previous to death an abscess was opened behind the right ear, from which a large quantity of pus was discharged. Right ear. The external meatus contained muco-purulent discharge; it was inflamed and tumefied. The membrana tympani was entire, but of a dull leaden hue, and much softer than natural. The tympanum contained much purulent matter, and its lining membrane was vascular, thick, and flocculent. The incus had disappeared; the stapes was *in situ*, but was surrounded by bands of adhesion. The osseous walls of the tympanum were healthy. The mastoid cells were full of purulent matter; the bony laminae dividing the cells were externally carious, large portions of them having been destroyed. The whole of the posterior wall of the mastoid cells, usually forming the sulcus lateralis, is destroyed, and in its place is an orifice measuring an inch and a quarter from above downwards, and more than half an inch in breadth. This orifice in reality corresponds exactly with the sulcus lateralis as situated in the temporal bone, with the exception of half an inch before it reaches the fossa jugularis. A circular orifice about the size of a pea existed at the posterior part of the mastoid process, which communicated with the aperture just mentioned on one hand, and with the abscess behind the ear on the other. The membranous lateral sinus was much attenuated, and beneath it was a large quantity of pus.

830. From a woman æt. 31, who died comatose four weeks after an attack of scarlatina, since which there had been a discharge from the left ear. *Autopsy*.—An abscess was found in the left lobe of the cerebellum of the size of a walnut. It reached to the surface, and thus came in contact with a large quantity of pus, bounded by the diseased and distended walls of the lateral sinus; the latter contained pus and blood. There was an opening through the membrana tympani, which had a regular shape, and its size was one third of the whole diameter of the membrane. The upper wall of the tympanum was healthy, and not even discoloured. The portion of the mastoid cells posterior to the incus contained some pus and blood mixed together; this extended down as far as the mastoid process. The portion of the lateral sulcus, about an inch long and half an inch broad, which forms the posterior boundary of this part of the mastoid cells, was of a dark

leaden colour. The canals in this portion of the bone were also distended with black matter. The blood-vessels between the lateral sinus and the mastoid cells were distended with dark pus and blood.

831. The right petrous bone of a child who died with discharge from the ear after scarlatina. The mastoid cells are inflamed, and the plate of bone forming their external boundary is carious.
832. A portion of carious bone, about the size of a hazel-nut, from the mastoid cells.
833. Mastoid cells distended with scrofulous matter ; upper wall of tympanum diseased ; dura mater greatly thickened.
834. Scrofulous matter from the preceding case.
835. From a woman æt. 20, who was deaf in the left ear, and had long been subject to intense earache, with occasional foetid discharge from the meatus. About a month before death an abscess formed just above the left collar-bone, which continued to discharge large quantities of matter. She suffered from great disturbance of the heart's action, delirium, erysipelas, and coma. *Autopsy.*—A large abscess existed at the root of the neck on the left side, communicating with and extending through the whole of the carotid sheath ; the internal jugular vein was full of matter, and a clot containing pus globules extended into the vena cava. The lungs contained purulent infiltration. The cerebrum was healthy ; the arachnoid near the tentorium was smeared over with pus. The tentorium, covering the left lobe of the cerebellum, was much inflamed, thickened, and had matter between it and the arachnoid covering that lobe of the cerebellum ; and immediately beneath this, on cutting into the cerebellum, a circumscribed abscess, about the size of a walnut, was discovered. The part of the cerebellum in contact with the cranial bones was healthy. Petrous bone. The external meatus contained pus. The glandular and periosteal portions of the membranous meatus were much softer than natural, and they adhered but slightly to the surface of the bone. The bone forming the upper and outer half of the tube was found to present numerous foramina for the transmission of blood-vessels ; they were much larger than natural, and some of them were surrounded by delicate layers of new bone. The lateral sinus was of a dark brown colour ; the dura mater forming its posterior wall was entire. The sinus was full of coagulated blood, mixed with purulent matter. The dura mater constituting its anterior wall, and which was in contact with the surface of bone forming the sulcus lateralis, was very thick and soft ; portions of it were destroyed by ulceration, and the bone was exposed. The bone forming the sulcus lateralis was of a dark colour, and covered by masses of lymph and pus ; its surface was rough, presenting throughout numerous orifices and tortuous grooves, this appearance being produced by the almost complete disappearance of the internal table of the skull, which, excepting two scales, each measuring about two lines in diameter, had been destroyed by caries. A carious orifice exists between the cavity of the cerebellum and the mastoid cells. The bone forming the jugular fossa is

also carious. There is an orifice in the posterior part of the membrana tympani. The tympanic mucous membrane was much thicker than natural, and in the upper osseous wall was a carious orifice that would allow the passage of a small pin. The mastoid cells at their upper part formed a cavity about the size of a horse-bean; it contained pus. This cavity communicated posteriorly with the lateral sulcus by means of an orifice three lines in diameter; anteriorly the orifice into the tympanic cavity was not more than two lines in diameter, and it was placed above the level of the floor of the cavity containing the pus. (See 'Medical Times and Gazette,' 1855, p. 228.)

836. Bony wall of the lateral sinus, rough and covered with a thin irregular deposit of new bone.

837. Lateral sinus distended with dark coagulum, the dura mater around it inflamed and thickened.

838. From a child æt. 11 months, subject to much privation and very weakly. *History*.—There had been a discharge from the right ear since birth. At the age of three months there were redness and swelling of the ear, with purulent discharge and tenderness over the mastoid process. At the age of seven months paralysis occurred on the left side of the face, the soft parts around the ear became sloughy, and the mastoid process offered no resistance on pressure. *Autopsy*.—The dura mater was very thin; the convex surface of the brain was greatly congested, patches of dark-coloured blood were scattered over its hemispheres, especially on its right side, where in one or two places they extended to the depth of three or four lines into the substance of the brain. The cerebral veins were distended by coagula. At the surface of the posterior part of the middle lobe on the right side was a small abscess, the size of a pea. The dura mater covering the petrous portion of the right temporal bone was separated from it by pus, and it was very much thickened. Temporal bone. The part of the squamous portion between the root of the zygomatic process and the mastoid process has been entirely destroyed, and the larger part of the mastoid process has also disappeared; an aperture, an inch in length and three quarters of an inch in depth, has thus been formed. The petrous portion is detached, and it is carious both on its superior and posterior surfaces. The small remaining part of the mastoid cells contained scrofulous matter. (See 'Medical Times and Gazette,' 1855, p. 154.)

839. Necrosis of mastoid cells producing meningitis.

D.—THE LABYRINTH.

841. A portion of necrosed bone from the vestibule in the preceding case.

SERIES XI.—DISEASE EXTENDING FROM THE EAR TO THE CAROTID CANAL.

843. From a woman æt. 26, who died fourteen days after childbirth. She was very deaf in the right ear, and slightly so in the left. She had scarlatina when a child, and from that time had always a discharge from the right ear. Right ear. Membrana tympani destroyed; the tendon of the tensor tympani muscle had disappeared. The malleus and incus were in contact, and the connecting ligaments were soft, and so relaxed as scarcely to hold the bones together. The incus and the stapes were disconnected. The mucous membrane of the tympanum was thick, white, and soft, and in several places ulcerated; a thick discharge was diffused over it. The stapes was nearly concealed. The osseous walls of the tympanum were diseased, and that portion which corresponded with the carotid canal was carious and perforated with small holes, through which the external surface of the carotid artery was covered with purulent matter from the tympanum. The coat of the artery was thick and red, and there was a slight contraction of the carotid canal. (Left ear. See No. 762.)
845. Acute caries of the left temporal bone, preceded by a severe blow on the left side of the head two years before. Ulceration of the internal carotid artery; hæmorrhage. (See 'Med.-Chir. Trans.,' vol. xliii, p. 217 [1860]).

VARIOUS SPECIMENS.

846. From a man æt. 46, who died from a malignant disease of the central region of the left middle lobe of the brain. A tumour attached to the dura mater pressed upon the brain at the point indicated. Left ear. The upper surface of the petrous portion of the temporal bone is dark-coloured and roughened, presenting slight elevations. The mastoid cells are diseased, and the mucous membrane of the tympanic cavity was thickened, partaking of the disease of the bone.
847. Partial absorption of the upper surface of the petrous bone from the pressure of the tumour of the cerebrum.
- 847 A. Part of a petrous bone showing absorption in consequence of the presence of sebaceous tumour in the meatus externus. From a patient æt. 67. (See 'Med.-Chir. Trans.,' vol. xlv, p. 63 [1861].)
- 848, 849. From a woman æt. 26, of scrofulous diathesis, who had been subject to a discharge from the right ear since an attack of measles when a child. For twelve or sixteen months she had suffered from headaches and attacks of giddiness. Twenty-three days before death acute pain came on in the ear, and she died comatose. *Autopsy.*—An abscess occupied the whole of the upper part of the right cerebral hemisphere. The substance of the surrounding brain was healthy. Lymph was effused on the dura mater

covering the petrous bone, and a portion of it was detached from the bone. The membrana tympani was absent; the tympanic mucous membrane and that of the mastoid cells was thick and soft, and it was covered by a large quantity of caseous scrofulous matter. The upper tympanic wall was of a dark colour, extremely thin, and perforated by numerous blood-vessels. The dura mater covering the upper part of the petrous bone and lining the squamous bone was very thick and detached from the bone, and a large quantity of purulent matter was deposited between the dura mater and the arachnoid. The arachnoid was highly congested. In some parts the pus had passed through the dura mater, and was in contact with the bone. The outer surface of the dura mater forming the lateral sinus is rough where it is in contact with the inflamed bone; the internal surface of the sinus had portions of fibrin adhering to it.

850. The surface of the bone forming the wall of the lateral sinus is rough, and as if slightly worm-eaten. The membrana tympani is fallen inwards, and is in contact with the promontory. The mastoid cells contain scrofulous matter.

851. From a man æt. 35, subject to severe pain in the right ear for many years. Five weeks before his death a large polypus was removed from the external meatus. He died comatose, having suffered from great pain in the back of the head and neck, and loss of control over the limbs. *Autopsy.*—There was an abscess in the right lobe of the cerebellum large enough to hold a pigeon's egg. The contents were very foetid, the walls were firm and lined with false membrane, but were very thin where the cerebellum rested on the aquæductus vestibuli of the temporal bone. At this spot there was a small ulcerated opening in the dura mater communicating with a carious portion of the temporal bone. Temporal bone. The membrana tympani was very much thickened; it presented an orifice at its anterior part, and had two small polypi attached to its superior and inner part. Upon separating the membranous from the osseous meatus, the latter, near to the membrana tympani, was darker and rougher than natural, and had evidently been subject to inflammation, which had penetrated into the mastoid cells and thence to the sulcus lateralis which bounds them internally. The upper part of the sulcus lateralis is carious over a space about three lines in diameter, and there are orifices which were filled by coagulated fibrin. The dura mater in this locality was softened, but the disease had not penetrated to the cavity of the lateral sinus. The dura mater adjacent to the fossa jugularis was soft and partially destroyed by ulceration; the bone beneath it was found to be carious, and to form part of the posterior wall of the inner extremity of the mastoid cells. (See 'Transactions of the Pathological Society,' 1850-51, vol. iii, p. 179.)

852, 853. From a woman æt. 33, who died after an illness of several years' duration, of which the symptoms were violent pain in the head, followed by delirium and loss of power in the limbs, chiefly of the right side, but varying very greatly in amount. She was able at times to rise from her bed

until within a few days of her death. There was discharge from the left ear, which was sometimes very profuse, as much as a tablespoonful escaping in the course of a few minutes, sometimes very slight or absent. The discharge generally relieved the severity of the symptoms. *Autopsy*.—Dura mater healthy. Vessels of pia mater, especially the veins, very full of blood. The brain seemed firmly compressed by the dura mater. On removing it from the skull, pus exuded from the external portion of left middle lobe; and, on a careful examination, it was found that the substance of the brain was adherent, together with the dura mater and other membranes, to the bone, over a space about the size of a sixpence, constituting the roof of the mastoid cells on the left side. The bone was carious at this part, and allowed a communication between the mastoid cells and the cavity of the cranium; but the substance of the brain having given way during its removal, owing to its adhesion to this portion of the bone, it is not possible to say whether there was an actual communication between the ear and the abscess within the brain. A large part of the middle and posterior lobes of the cerebrum, on the left side, were occupied by an abscess, containing about two ounces of green-coloured pus, contained in a firm membranous sac, which was easily torn out from the surrounding cerebral tissue. The brain substance around the abscess was softened and broken down for the extent of two or three lines in all directions; but internally the softening extended farther, and involved the whole of the left corpus striatum, which was entirely disintegrated. The left lateral ventricle contained no excessive amount of fluid, but the right lateral ventricle was distended with about three ounces of clear pale serum. The substance of the brain on both sides was firmer than natural, and presented many bloody points, most numerous on the right side. The anterior boundary of the abscess was situated about two inches behind the fissure of Sylvius, and the posterior boundary about one inch and a half in front of the termination of the posterior lobes. The cerebellum and pons Varolii were healthy. Left ear. The superior bony wall of the tympanum is much thickened; and internally, opposite the horizontal portion of the mastoid cells, is an orifice about one third of an inch in diameter. This orifice allowed of a communication between the middle cerebral cavity and that of the tympanum. There is a large aperture in the membrana tympani. From the large quantity of matter which sometimes escaped from the external meatus, it may be supposed that the contents of an abscess in the cerebrum situated above the aperture in the bone passed through the tympanic cavity. Right ear healthy, with the exception of an excess of pigment in the cochlea.

- 855, 856. From a man æt. 77, deaf. Right ear. The meatus contained a small quantity of cerumen. Membrana tympani somewhat opaque, concave, its inner surface nearly touching the promontory; the mucous membrane of the tympanum is thick, and the cavity contains a quantity of fibro-cellular tissue, which occupies the whole of the upper part, and connects the body of the malleus to the inner wall of the tympanum, concealing the stapes.

A membranous band connects the malleus to the promontory. The stapes is firmly ankylosed to the fenestra ovalis. The membranous vestibule is much atrophied, and the vestibular portion of the auditory nerve is shrivelled to half its usual size. The cochlear nerve is healthy. Left ear. Meatus externus full of hard [cerumen; membrana tympani hazy. The tympanic cavity is of its natural size, but it contains fibrinous matter. The stapes is completely ankylosed.

... of the ...
... of the ...
... of the ...
... of the ...
... of the ...
... of the ...

... of the ...
... of the ...
... of the ...
... of the ...
... of the ...
... of the ...

... of the ...
... of the ...
... of the ...
... of the ...
... of the ...
... of the ...

... of the ...
... of the ...
... of the ...
... of the ...
... of the ...
... of the ...

... of the ...
... of the ...
... of the ...
... of the ...
... of the ...
... of the ...

... of the ...
... of the ...
... of the ...
... of the ...
... of the ...
... of the ...

FOREIGN CONTRIBUTIONS.

AUSTRIA.

RECEIVED FROM VIENNA THROUGH PROF. ADAM POLITZER.

Prof. ADAM POLITZER.

SERIES I.—*Anatomical and Pathological Preparations of the Ear.*
Normal Tympanic Membrane.

1. Outer surface, infant.
- 1A. Outer surface, adult.
- 2, 3. Inner surface.
4. Inner surface, with malleus, incus, and stapes.
- 5, 6. The external bony meatus in connection with the tympanic membrane.
- 7, 8. Frontal section through the outer attic and Prussak's cavity.
- 9, 10. Chalk deposit in the tympanic membrane.
- 11, 12. Perforation of the tympanic membrane.
13. Double perforation.
- 14—17. Chalk deposit in and perforation of the membrane.
- 18, 19. Topographical preparations of the ear: (1) infant; (2) adult.
- 21—31A. Tympanic cavity and labyrinth, opened from above.
- 32—34B. Frontal section through the tympanic cavity and the labyrinth.
- 35—38C. Tympanic cavity, opened from below.
- 39—41. Topographical preparations of the auricle, external meatus, tympanic cavity, and labyrinth.
- 42—45. Tympanic cavity opened from behind.
46. Mastoid process opened, showing sinus. The "saccus endolymphaticus" also opened.
47. Mastoid process, mastoid antrum, and sinus laid open.
48. Perforation in tympanic membrane.
49. Tympanic membrane destroyed.
50. Destruction of tympanic membrane and long process of incus.
51. Tympanic membrane adherent to the promontory.
52. Perforation in Shrapnell's membrane. Tympanic membrane adherent to head of stapes.
53. Double perforation in tympanic membrane.
54. Perforation in tympanic membrane, with calcareous deposit.
55. Excavations in a temporal bone, due to cholesteatoma. An exostosis of the external auditory meatus.

SERIES II.—*Specimens of the Labyrinth, Tympanic Cavity, and Tympanic Membrane.*

- 1—3. Membranous semicircular canals and ampullæ, prepared *in situ* from the petrous bone.
- 4—6. Cochlea prepared from petrous bone (adult).
- 7—10. Cochlea and semicircular canals prepared *in situ*.
- 11, 12. Section through the vestibule and utricle.
13. Section through the cochlea.
14. Section through the vestibule, utricle, and the inferior ampulla.
- 15—19. Sections through the pyramid, showing cochlea, vestibule, utricle, and the branch of the eighth nerve to the vestibule and cochlea.
20. Politzer's pedunculated bodies in mastoid antrum.
- 21, 22. Inner wall of tympanic cavity with the stapedius muscle.
- 23—26. Frontal section through the tympanic cavity, showing superior ligament of the malleus.
- 27, 28. Sections through outer attic and Prussak's cavity.
- 29, 30. Sections through outer attic in a case of acute inflammatory exudation into this cavity.
- 31—33. Topographical sections through the middle ear and labyrinth (infant).
34. Inner surface of tympanic membrane with chorda tympani.
35. The same in an infant.
- 36—50. Different pathological changes in tympanic membrane.

SERIES III.—*Fifteen Anatomical and Pathological Specimens of the Ear.*

- 1—5. Topographical preparations of the ear, showing all the parts of the organ minutely.
- 6—10. Specimens of cases of healed suppuration of middle ear, showing perforations and chalk deposits in tympanic membrane and adhesions of drum to inner wall of tympanic cavity.
- 11—15. Topographical preparations of the organ of hearing.

SERIES IV.—*Anatomical and Pathological Specimens.*

1. Half of a skull, showing the outer and inner surface of the tympanic membrane, the situation of the Eustachian tube, the tympanic cavity, the labyrinth, the auditory nerve, and the carotid artery.
2. Preparation showing the external ear, the middle ear, Eustachian tube, and labyrinth *in situ*.
- 3, 4. Symmetrical fissures in a temporal bone.
5. Fistula between external meatus and tympanic cavity. An exostosis near the fistula.

PREPARATIONS OF DIFFERENT VARIETIES OF MASTOID PROCESS.

1. Ten different specimens of mastoid processes containing air-cells.
2. Ten different specimens of cancellous and solid mastoid processes.

3. Ten different specimens combining 1 and 2.
4. A series of different preparations of the ear.
5. A similar series.

SERIES V.—*Anatomical Sections, the details of which can be seen by a magnifying glass. Used by Prof. Politzer for teaching purposes.*

- a. Pathological changes in outer attic.
- b. „ „ in middle ear and in the niche of the oval window.
- c. Cases of middle ear sclerosis.
- d. Normal labyrinth.
- e. Pathological changes in labyrinth.

SERIES VI.—*Normal and Pathological Microscopical Specimens.*

PLASTER MODELS OF THE EAR.

1. Showing the different pathological changes of the tympanic membrane.
Modelled by Prof. Politzer.
2. Inner surface of tympanic membrane with malleus and incus.
(a) The original wax model by Prof. Politzer.
(b) A copy in plaster.
3. The labyrinth.
(a) The original wax model by Prof. Politzer.
(b) A copy in plaster.

Plaster Models made by Dr. Henning, of Vienna, of Pathological Changes in the Auricle.

Prof. POLITZER.

1. "Perichondritis sclerosa" of the auricle.
2. Epithelioma of the auricle.
3. Hæmatoma of the auricle.
4. Congenital deformity of the auricle.
5. Keloid of the auricle.
6. Angioma in the temporal region.
7. Lupus vulgaris of the auricle.
8. Atheroma of the auricle.
9. Carcinoma of the auricle.
10. Sarcoma of the temporal bone.
11. Dermoid cyst of the auricle.

DRAWINGS.

For Instruction in the Otological Clinic in Vienna.

- 1, 2. Two original drawings for Prof. Politzer's 'Atlas' (Wandt. zur Anatomie des Gehörorgans).

- 3, 4. Two oil pictures showing the different pathological changes of the tympanic membrane (magnified).
5. Section through the malleus, outer attic, and Prussak's cavity.
6. Bony occlusion of the oval window by bony proliferation of the labyrinthine capsule.
7. Epithelioma of temporal bone and othæmatoma auris.
8. Inner surface of tympanic membrane, after a drawing by Prof. Politzer.
- 9—12. Carbon and pencil drawings representing pathological changes in the drum. Freehand designs by Prof. Politzer during his lectures in his clinic.
- 13—18. Water-colour drawings of the pathological appearances of the tympanic membrane, painted from nature by Prof. Politzer. A part of the original drawings for his 'Atlas der Beleuchtungsbilder des Trommelfells.'
13. Normal tympanic membrane.
Exostosis of external meatus (9—12).
Hyperæmia and hæmorrhage.
14. Retraction of the tympanic membrane.
15. Perforations of the tympanic membrane.
16. Perforations and granulations of tympanic membrane and tympanic cavity.
17. Cicatrices of tympanic membrane.
18. Adhesions of tympanic membrane to inner wall of tympanic cavity.
- 19—22. Chromolithographic copies from Prof. Politzer's 'Atlas der Beleuchtungsbilder des Trommelfells,' Wien, 1897.
- 23—25. Pen-and-ink drawings showing pathological changes of the tympanic membrane, taken from anatomical specimens. Original drawings for illustration of Prof. Politzer's 'Atlas der Beleuchtungsbilder des Trommelfells,' 1897.
26. Original pen drawings for Prof. Politzer's 'Primary Affection of the Labyrinthine Capsule' (sclerosis of the middle ear).

INSTRUMENTS.

A collection of instruments used in Prof. Politzer's clinic.

Prof. JOSEPH GRUBER.

I. Wax Models.

- 1, 2. Deformity of the auricle.
3. Deformity of the auricle. Defect of the external meatus.
4. Congenital aural fistula causing retro-auricular abscess.
5. Coloboma of the auricle.
6. Anomalous congenital junction of the antitragus with the crista helices; diminished fossa of the concha.

7. Anteversion of both auricles.
8. Macrosia with anteversion of the auricle.
9. Appendix in front of auricle.
10. Appendices in front of auricle.
11. Appendix and simple molluscous tumour in front of auricle.
12. Congenital enlargement of the tragus.
13. Congenital double tragus.
14. Marked spina helix.
15. Frozen auricle ; gangrene.
- 16—20. Lupus of the auricle.
21. Sarcoma of the ear, nine months after the beginning of the disease.
2. Carcinoma of the ear.

II. *Drawings.*

1. Traumatic othæmatoma, untreated.
2. Othæmatoma in sane patient.
3. Othæmatoma in sane female patient.
4. Othæmatoma in patient of weak mind.
5. Othæmatoma of both sides in patient of weak mind.
6. Othæmatoma cured by surgical treatment ; suppuration.
7. Cavernous tumour in region of the auricle.
8. Cavernous tumour of the auricle.
9. Polypus from the middle ear.
10. Chronic erysipelas of the lobule.
11. Chronic erysipelas with resulting hypertrophy.

III.

1. Skull demonstrating the cavities.
2. Temporal bone demonstrating the organs of hearing.
3. Human organ of hearing.

Dr. FERDINAND ALT.

1. Appearances of the membrane from caisson workmen.
2. Hæmorrhage into the bulla (dog).
3. Hæmorrhage into the cochlea (guinea-pig).
4. Hæmorrhage into the semicircular canals (guinea-pig).
5. Necrosis of the spinal cord (dog).
6. Heart, with gas bubbles in the coronary vessels (dog).
7. Recompression room.
8. Microscopical preparation of the medulla oblongata in a case of leukæmia.

Dr. VICTOR HAMMERSCHLAG.

Drawings.

1. Section through the cochlea of a guinea-pig embryo 36 mm. long.
2. Section through the cochlea of a guinea-pig embryo 10 cm. long.
3. Organ of Corti from the first turn of the cochlea, from a guinea-pig embryo 10 cm. long.
4. Organ of Corti from the second turn of the cochlea, from a guinea-pig embryo 10 cm. long.
5. Organ of Corti from the third turn of the cochlea, from a guinea-pig embryo 10 cm. long.
6. Organ of Corti from the fourth turn of the cochlea, from a guinea-pig embryo 10 cm. long.
7. Section through the cochlea of a twelve days old cat.
8. Section through the vestibule of a guinea-pig one day old.

Dr. GUSTAV ALEXANDER.

A Collection of Eighteen Macroscopical Preparations of the Membranous Labyrinth. (Human.)

1. Duct and saccus endolymphaticus. Chrom. and hydrochlor. acid prep.
2. Membranous labyrinth, prepared from the under surface of the petrous portion. Chrom. and hydrochlor. acid prep.
3. Contents of the vestibule. Chrom. and hydrochlor. acid prep.
4. Superior part of labyrinth. Osmic prep.
5. Recess of the utricle, anterior and external ampullæ, showing the branching of the superior acoustic nerve. Chrom. and hydrochlor. acid prep.
6. Ductus endolymphaticus, canal of utricle and saccule, saccule ductus reuniens, cæcum of vestibule. Chrom. and hydrochlor. acid prep.
7. Internal auditory canal. Osmic prep.
8. Horizontal section through the labyrinth. Chrom. and hydrochlor. acid prep.
9. Inferior part of labyrinth, saccule, ductus reuniens, aqueduct of cochlea. Chrom. and hydrochlor. acid prep.
10. Topography of the saccule in the vestibule. Chrom. and hydrochlor. acid prep.
11. Topographical preparation of the aqueduct of the cochlea. Chrom. and hydrochlor. acid prep.
12. Membrana spiralis of the basal turn of the cochlea. Osmic prep.
13. Membranous labyrinth prepared from the under surface of petrous portion. Chrom. and hydrochlor. acid prep.
14. Ditto. Osmic prep.
15. Ditto. Chrom. and hydrochlor. acid prep.

16. Oval sacculæ *in situ*, seen from above. Chrom. and hydrochlor. acid prep.
17. Canal of the utricle and sacculæ. Chrom. and hydrochlor. acid prep.
18. Ditto.
19. Case of persistence of the stapedial artery in a man.
20. Collection of ossicles from double monsters.

Dr. HUGO FREY.

Microscopical Preparations of the Roots and Ganglia of the Auditory Nerve.

- 1, 2. Roots and ganglia of the auditory nerve in the medulla oblongata—man. After Weigert-Pal's method.
- 3, 4. Ditto.
- 5, 6. Roots, ganglia, and ganglion cells of the auditory nerve in the medulla oblongata—man. After Van Gieson's method.
- 7, 8. Section through the medulla oblongata in the region of the acoustic ganglia, showing ganglion cells and their structure—rabbit. After Nissl's method.
9. Diagram of the roots of the auditory nerve—man.
10. Diagram of the roots and ganglia of the auditory nerve—man.
11. Diagram of the ganglion cells of the acoustic ganglia—rabbit.

Dr. C. BIEHL.

1. Otogenous thrombophlebitis of the left sinus sigmoideus; other thrombic masses in right sigmoideus, and also in left inferior petrosal sinus, and in the antrum of the same side. The several thrombic masses are plainly shown. The preparation is fully described in the 'Monatsschrift für Ohrenheilkunde,' 1899, No. 1.
2. Squamous epithelioma of the left antrum of Highmore, involving the nasal cavities and the pterygo-palatine fossa and interior of the skull. A putrefying abscess in left temporal lobe. The preparation is from an old soldier æt. 46, who in the middle of August, 1898, had the last upper molar on the left side extracted. The pain continued. At the beginning of September a swelling of the left cheek appeared, and a putrid discharge from the nose ensued. The opening of the maxillary sinus afforded him little relief; death occurred on November 18th.

Dr. BARNICK (Graz).

PLATE I.—*Fractures of the Petrous Portion of the Temporal Bone.*

1. Longitudinal fracture of the right petrous portion, medial fracture.
2. Ditto.
3. Cross-fracture of the same, lateral fracture.
4. Cross-fracture of the pyramidal process of left petrous portion in the region of the vestibule, lateral fracture.

PLATE II.—*Tuberculosis of the Auditory Canal.*

1. Tuberculous infiltration of the mucous membrane of the Eustachian tube.
2. Protrusion from the tympanic cavity of a wide granulation of a tuberculous character.
3. Incipient erosion of the sheath of the horizontal semicircular canal.
4. Double perforation of the right membrana tympani from a tuberculous patient æt. 28.
5. Treble perforation of the left membrana tympani of a tuberculous patient æt. 13.

WALTHER KOLMER (Heidelberg).

Microscopical Preparations of the Labyrinth.

1. Cochlea of cat. Fixed during life in warm osmic acid. Staining with Heidenhain's hæmatoxylin and fuchsin.
2. Cochlea of guinea-pig. Fixed during life in warm concentrated sublimate solution. Decalcification during twenty-four hours in 2 per cent. nitric acid, with a few drops of dichloride of platinum. Three days. Staining with Heidenhain's hæmatoxylin and eosin.
3. Same as 2. Staining with hæmatoxylin and Biondi's triple stain.
4. Same as 2. Staining with hæmatoxylin only.
5. Same as 2. Staining with Nissl's methyl blue ganglion-cell stain.
6. Same as 4, but with various concentrated iron solutions.
7. Cochlea of guinea-pig. Hardened with osmium. Staining as in 1.
8. Ditto. Unstained.
9. Ditto. Stained as 3.
10. Cochlea and utriculus of cat. Fumigation with osmic acid for ten minutes; then Flemming's solution, twenty-four hours. Decalcification in 3 per cent. nitric acid. Staining with Heidenhain's ferrous hæmatoxylin. Epithelium in utriculus unusually well preserved. Macula with hairs.
11. Cochlea of guinea-pig. Sublimate and osmium vapour. Heidenhain's hæmatoxylin and fuchsin.
12. Well-preserved organ of Corti.
13. Surface preparation of the detached lamina spiralis ossea and membranacea. Osmic acid, glycerine. Cat.
14. Nervus cochlearis and ganglia of guinea-pig. Osmic acid, hæmalum, eosin.
15. As 13. Dog.
16. Utriculus of monkey. Sublimate hæmatoxylin.
17. Cochlea of cat. Hardening and acid decalcification. Picro-nitric acid. Staining with Weigert's solution for elastic vessels. Negative result. On the other hand, connective tissue stained.
18. Cochlea of cat. Hardening as in 17. Staining with Delafield's hæma-

toxylin with Biondi-Heidenhain's triple stain. The pillar cells here show three distinct portions—protoplasm and nucleus at the base, a fibrilline cuticular substance, and more strongly prominent yellow-stained head.

19. Cochlea of monkey. Heidenhain's hæmatoxylin.
20. Cochlea of 35-cm. calf fœtus. Hardening with Klemberg's picro-sulphuric acid. Staining with hæmalum.

LUDWIG CASTAGNA (Vienna).

Models of the Ear.

1. Semicircular canal. After Prof. S. Exner.
2. Otoliths. After Prof. S. Exner.
3. Middle ear. After Prof. S. Exner.
4. A sterilising apparatus. After Dr. Victor Hammerschlag.
5. An ear and nose syringe, with spray attachment. After Dr. Beer.

BELGIUM.

Dr. DELSTANCHE (Brussels).

1. Raréfacteur, modèle primitif (avec deux soupapes métalliques, l'une à la partie inférieure du corps de la pompe, l'autre dans le piston.
2. Raréfacteur à double effet, modèle ancien et lourd (avec soupapes en bandruche).
3. Idem, moins lourd.
4. Idem, léger, modèle définitif (avec soupapes coniques, en métal).
5. Masseur du tympan, trois modèles : A, B, et C.
6. Masseur à combinaisons. Masseur identique aux précédents, mais à l'extrémité inférieure duquel s'adapte un tube métallique en forme d'Y, dont les branches obliques renferment chacune une soupape, se soulevant, l'une de dehors en dedans, l'autre de dedans en dehors.
7. Seringue à parajet pour oreille.
8. Cuvette à irrigation de l'oreille, à deux compartiments.
9. Injecteur-aspirateur, premier modèle (avec pompe constituée par une boîte métallique dont le couvercle est formé d'un feuillet de gomme fortement tendu, sur lequel agit le bouton d'un levier.
10. Injecteur-aspirateur, second modèle (avec corps de pompe métallique, à piston). Injecteur à répétition, muni d'un tube en gomme qui du corps de pompe aboutit au récipient contenant de liquide à injecter. Sert particulièrement au nettoyage de l'attique.
11. Canules à injection rétronasale ; trois modèles, avec jet dirigé soit en avant, soit en arrière, soit en haut. Manœuvre au moyen d'un appareil à double ballon.
12. Petits instruments montés sur tige formant angle obtus avec le manche. Série de quinze modèles variés.

13. Adénotome à coulisse, avec cinq espèces de mors. Premier modèle employé par l'auteur pour extraire le tissu adénoïde.
14. Adénotome à cuvette. Deux modèles.
15. Racleur de la mugueuse pharyngienne à cuvette. Sert à compléter l'élimination du tissu adénoïde et à enlever les granulations.
16. Obturateur du conduit.
17. Porte-ouate spiroïde : deux modèles—1° pour le nez, 2° pour l'oreille.
18. Pince à coulisse, pour l'extraction des polypes et corps étrangers de l'oreille ; trois espèces de mors.
19. Idem, modèle plus grand, pour le nez.
20. Etrangleur, pour polypes de l'oreille.
21. Idem, pour polypes du nez.
22. Etrangleur automatique. L'anse formée par un ressort de montre, se développe d'elle-même.
23. Etrangleur galvanique ; pour polypes du nez.
24. Extracteur du marteau.
25. Extracteur de l'enclume.
26. Sécateur du manche du marteau.
27. Explorateur latéral, pour le conduit et la caisse.
28. Sonde flexible à mandrin caché.
29. Miroir reflecteur dental. Sa tige de support se fixe entre les dents.
30. Abaisse-langue ; deux modèles—en métal, en celluloïd.
31. Pince fixatrice en baleine, pour empêcher le déplacement de la sonde abouchée à la trompe d'Eustache.
32. Spéculum fixe du nez.
33. Dilatateur profond du nez.
34. Seringue à vaseline.
35. Redresseur de la cloison nasale, avec plaques variées.
36. Attelles externes du nez. S'applique des deux cotés du nez, en vue de maintenir le redressement de la cloison, obtenu par l'appareil précédent.
37. Attelles internes du nez. Remplacent dans les fosses nasales les plaques métalliques du redresseur.
38. Dilateur forcé des fosses nasales.
39. Ecarteur à érignes. Se maintient en place de lui-même.
40. Mentonnière à élastiques, pour corriger l'habitude de respirer par la bouche.

Dr. DELIE (Ypres).

1. Une gouge pour les crêtes de la cloison du nez.
2. Râcles pour le curettage de l'attique.
3. Couteau pour l'ablation des polypes fibreux du pharynx nasal.

FRANCE.

Dr. GELLÉ (Paris).

Instruments.

Dr. E. J. MOURE (Bordeaux).

1. Des sécrétions croûteuses moulées venant des sinus sphénoïdaux.
2. Un flacon contenant une série d'éperons de la cloison enlevés avec mon ostéotome.
3. Une amygdale linguale enlevée avec l'anse froide.
4. Une partie du corps du sphénoïde nécrosé enlevé sur un malade.
5. Une exostose du conduit auditif enlevée par les voies naturelles avec la gouge.
6. Une série de coupes des fosses nasales montrant les rapports des diverses cavités accessoires entre elles, avec les méats ou les cornets des fosses nasales. Dans ces coupes, deux sont antéro-postérieures, une autre transversale, et dans cette dernière se trouve un sinus maxillaire excessivement vaste s'étendant en arrière de l'orbite et presque jusqu'à la partie supérieure de cette région.
7. Les autres pièces comprennent : deux coupes du rocher, montrant l'absence à peu près complète de l'antre et l'impossibilité où on aurait été dans ce cas, de pratiquer la trépanation sans tomber dans le sinus latéral tellement les apophyses mastoïdes étaient minuscules, le sinus était au contraire très développé. Ces deux pièces sont très intéressantes à cause de cette disposition anatomique tout à fait spéciale.
8. Une dernière pièce est le rocher d'une malade morte d'un abcès encéphalique ouvert dans le ventricule latéral, à laquelle j'avais pratiqué la mise en communication de l'antre et de la caisse et ouvert la fosse cérébrale pour vider un abcès extra-dural. Dans cette pièce on voit que la partie inférieure de la caisse était complètement défoncée et en rapport avec l'articulation temporo-maxillaire qui se trouvait ainsi ouverte en haut. D'un autre côté le golfe de la veine jugulaire était tellement profond que si le processus ulcéreux avait pu continuer à évoluer il n'y a pas de doute que cette région eût été ouverte par le pus. La malade, en état de puerpéralité succomba 48 heures après la première intervention qui avait été faite malheureusement un peu trop tardivement. L'observation a du reste été publiée dans un de mes travaux (sur trois cas de complications intracrâniennes d'origine otique).

Dr. LOUIS BAR (Nice).

Quelques préparations histologiques d'otomycose et d'aspergillus.

GERMANY.

CONTRIBUTIONS RECEIVED FROM THE GERMAN OTOLOGICAL SOCIETY THROUGH
DR. ARTHUR HARTMANN OF BERLIN.

EDITORS OF 'ARCHIVES OF OTOLOGY,' 'ZEITSCHRIFT FÜR OHRENHEILKUNDE,'
Plates of the recent yearly volumes.

Dr. HUGO BECKMAN (Berlin).

1. Four adenotomes of different sizes.
2. Nasal speculum.
3. Nasal scissors.
4. Nasal scissors for middle turbinal.
5. Nasal saw with spring blade.
6. Polypus snares.
7. Pliable cannula for maxillary antrum and frontal sinuses.

Prof. BEZOLD and Prof. EDELMANN (Munich).

Prof. Bezold's continuous scale for testing the sensitiveness of the ear for sound, consisting of the following :

1. Tuning-fork No. 1, from 15—24 vibrations per second (C_2 — G_2).
2. „ No. 2, from 24—36 „ „ (G_2 — D_1) ; note produced without being weighted C.
3. „ „ from 36—55 vibrations per second (D_1 — A_1) ; without weight G.
4. „ „ from 55—90 vibrations per second (A_1 — $F\sharp$) ; without weight c.
5. „ „ from 90—155 vibrations per second ($F\sharp$ — $D\sharp$) ; without weight g.
6. „ „ from $D\sharp$ —a, without weight c^1 .
7. „ „ from a— $d\sharp^1$, „ g^1 .
8. „ „ from $d\sharp^1$ — a^1 , „ c^2 .
9. „ „ from a^1 — $d\sharp^2$, „ g^2 .
10. „ „ from $d\sharp^2$ — a^2 , „ c^3 .
11. Large whistle, note-range c^2 — a^3 .
12. Small „ „ a^3 — a^4 .
13. Galton „ of the latest construction, note-range g^5 to beyond the upper hearing limit.
14. Drumstick for sounding tuning-forks Nos. 6 to 10.
15. Tuning-fork No. 11, g^3 (1550 vibrations).
16. „ No. 12, c^4 (2069 „).
17. „ No. 13, g^4 (3100 „).
18. „ No. 14, c^5 (4139 „).

Dr. MAX BREITUNG (Coburg).

1. Electro-motor air-pump for the treatment of chronic progressive deafness.
2. Hand air pump for the same object, for practitioners who have no electric apparatus, and for patients who, after receiving medical treatment, have been advised to continue the treatment themselves.
3. "Excelsior" inhalation apparatus for inhalation of ammonia or ether, or both combined.
4. A case of various instruments.

Dr. OSCAR BRIEGER (Breslau).

1. Collection of stereoscopic microscopical photographs taken with the stereoscopic microscope of Zeiss-Greenough, and showing alterations in the ossicles.
2. Collection of drawings of microscopic preparations. The drawings have been executed with the same colours as have been used for staining the preparations. The illustrations of this volume are mainly to show changes of the pharyngeal tonsil, polypi of the ear, tuberculosis of the nose and of the ear, etc.
3. Apparatus for procuring sterile water. The sterilisation is effected by means of a Berkefeld filter, through which warm water is poured by means of Meyer's shower-bath. The pressure undergoes through this filtration by no means inconsiderable diminution. The filter is enclosed in a syringe-formed hood, which ends in a mouth-piece composed of platin-iridium, and which can be made red-hot for sterilisation. From this mouth-piece, when inserted in the external meatus, there flows sterilised water.
4. Double lamp for simultaneously transilluminating both frontal sinuses. By the employment of this lamp a comparison of the translucency of both frontal sinuses is possible.

Dr. GUSTAV BRÜHL (Berlin).

- I. Four pictures representing the human organ of hearing :
 1. The auricle.
 2. The temporal bone.
 3. „ with tympanic membrane and cerebrum.
 4. Petrous bone, ossicles, nerves, vessels, Eustachian tube, and labyrinth.
- II. Atlas, the human organ of hearing.
- III. Four X ray photographs :
 1. Temporal bone of a child, the labyrinth filled with quicksilver.
 2. „ of an ape.
 3. Middle ear cavity filled with quicksilver.
 4. A half-skull ; accessory cavities filled with quicksilver.

IV. Transparent preparations of bone filled with mercury :

1. Petrous bone of an infant.
2. „ of a child (aqueductus cochleæ).
3. Temporal bone of an adult (carotid artery, jugular vein, transverse sinus, seventh nerve, chorda tympani, aqueductus cochleæ, and vestibuli).
4. Temporal bone of an adult ; from the tip of mastoid process, the whole pneumatic system and labyrinth injected.
5. A quarter-skull ; nasal accessory cavities injected.

Bone preparations (by Porter Seifert, Anat. Institut) :

1. Temporal bone ; labyrinth, Fallopian canal, transverse sinus chiselled out.
2. A half-skull, with accessory cavities, and like 1.

Dr. DENKER (Hagen).

1. Lithographic plates of corrosion specimens and of sections of bones of the organ of hearing in mammals.
2. Naso-pharyngeal scissors for removing adenoid growths.

Dr. HERMANN GUTZMANN (Berlin).

Apparatus to demonstrate the movements of the soft palate and upper air-passages during speech.

Dr. ARTHUR HARTMANN (Berlin).

I. *Preparations.*

1. Glass plate with series of sections through nose of (a) man, (b) dog, (c) fox, (d) cat, (e) guinea-pig, (f) rabbit, (g) hedgehog, (h) rat, (i) mouse.
2. Four glass plates with series of sections through nose of fox.
3. Three glass plates with series of sections (vertical) through human organ of hearing.*
 A glass plate with series of sections (vertical) through human organ of hearing.
 A glass plate with series of sections (horizontal) through human organ of hearing.
4. Four skulls exhibiting different forms of frontal sinuses :
 a. Large common frontal sinus without a septum, and with only one infundibulum.
 b. Small frontal sinuses.
 c. Frontal sinus developed only on one side.
 d. „ of a deformed skull.
5. Two specimens showing hyperostosis of the external auditory meatus.
6. Specimens showing congenital defect of external auditory meatus :
 a. Infant ; b. adult ; c. plaster model of the shape of the auricle.

* The sections through the human organs of hearing are prepared by Dr. Zarniko of Hamburg.

II. *Photographs.*

1. Three wall charts of the frontal sinuses :
 - a.* Frontal sinus without frontal cells.
 - b.* „ „ with „
 - c.* Indirect formation of frontal sinuses.
2. Three wall charts showing deviation of septum :
 - a, b.* Deviation with a horizontal bend.
 - c.* „ „ with vertical bend and crista.
3. Vertical section through tympanic cavity (through the drum and malleus).
4. Two stands of diapositives.

III. *Instruments.*

1. Case for operation on tonsils.
2. „ „ on adenoid proliferations.
3. „ containing handle and accessories for nose operations : *a.* Saw, half-toothed ; *b.* saw, whole-toothed ; *c.* straight long curette for sphenoid sinus ; *d.* straight short curette ; *e.* straight short curette, bent upwards for ethmoidal cells and maxillary sinus.
4. Case containing three drills for opening the maxillary antrum through the alveolar process or through the anterior wall of the antrum.
5. Cannulæ for irrigating the frontal sinuses and maxillary antrum.
6. Conchotomes and sharp nasal forceps of different forms.
7. Case containing snares, accessories for ear and nose.
8. Galvano-caustic holder, with slides and different cauterisers.
9. Head-strap for fixing the needle in electrolysis in the nose.
10. Aseptic pocket case, for examining ear and nose.
11. Case for small ear instruments, holder and accessories.
12. „ „ holder and three accessories.
13. Universal holder for accessories, with adjustable angular setting.
14. Forceps for fixing and dividing the auditory meatus in the radical operation.
15. Double hooklets for extracting the membranous wall of the auditory meatus in the radical operation.
16. Three-cornered ear bandages.
17. Glass dish with concavity for receiving fluids when syringing the ear.
18. Case of tuning-forks.
19. Five different aural forceps.
20. Case containing instruments for mastoid operation.
21. Sterilised dressings for mastoid operation, in case.
22. Rolled strips for the ear with woven edge :
 - a.* Sterilised.
 - b.* Prepared with nophosen.
 - c.* With iodoform.
23. Automatic stopper for ethyl chloride.

Dr. L. KATZ (Berlin).

1. Stereoscopic views of the complicated anatomical relations of the region of the foramen rotundum, specially of the membrane of the round window. The specimens give views from without and from within. In the latter are seen the convexly bent kidney-shaped membrane at the entrance to the aquæductus cochleæ and at the beginning of the lamina spiral ossea, also the ligamentum spirale in its bow-shaped course from without inwards. In the former a clear view is obtained of the recessus sub fenestra rotunda (previously described by Katz), which is separated from the true fenestra rotunda by a more or less prominent bony wall. This recess is here unusually long (circ. 1 cm.), and runs in a horizontal direction from behind forwards, beneath the cochlea to the junction of the median labyrinthine wall and the floor of the tympanum.
2. A number of stereoscopic views of the whole *transparent* labyrinth, tympanum, tympanic membrane, etc., which present to the student most instructive pictures of this very complicated region. For a description of exhibitor's method of rendering bone transparent see 'Archiv f. Ohrenheilk.,' vol. xxxvii.
3. Microscopic specimens of the organ of Corti, which demonstrate clearly the most minute details of the epithelial structures of the papilla spiralis with its fine nerves.
4. Macroscopic specimens—the labyrinthine wall, shown under a Zeiss binocular "Praeparier" microscope.
5. Instruments for operating on nose and ear :
 - a. Curette for adenoid vegetations in naso-pharynx.
 - b. Curettes, moveable or fixed as desired, for nasal operations, particularly the posterior end of the inferior turbinated body.
 - c. Probes with crown-shaped ends for the application of chromic acid or nitrate of silver to nose and ear.
 - d. Moveable caustic carrier (a small plate) for the nose.
 - e. Protected chisel for removing the outer wall of the attic.

For a description of these instruments see 'Berlin. klin. Wochenschrift,' 1899, No. 5.

Dr. KIRSTEIN (Berlin).

Tongue depressor for examination of the larynx.

Dr. KRETSCHMAN (Magdeburg).

1. Two forceps for extirpation of tonsils.
2. Incus hook.
3. Three drills for opening the recessus hypotympanicus.
4. A sterilisable aural syringe.

Prof. Dr. LUCAE (Berlin).

1. A tuning-fork (c) of 128 vibrations, with hammer apparatus for obtaining an uniform strength of stroke.
2. A tuning-fork (c⁴) of 2048 vibrations, with similar hammer apparatus. Both instruments, as has been proved by experiments on adults, have a normal audible period of 50 to 55 sec. by air conduction; and the tuning-fork (c) a hearing period of 18 to 20 sec. by bone conduction (mastoid process). Naturally in other instruments, made after these models, the normal hearing period must be defined empirically.*
3. A new modification of spring pressure-probe ("federnde Drucksonde") for mobilising the conducting apparatus of the organ of hearing. To facilitate the movements of the spring rod, this works now in a frame in place of the former small tube. An arrangement is attached to the spiral spring in the handle whereby the strength of the pressure-probe can be increased at will from 100 to 300 grammes.

Dr. NOEBEL (Zittau).

1. An apparatus for massage to be worked by hand; for treatment of tinnitus aurium in chronic middle-ear catarrh.
2. Three knives for removal of adenoid growths.
3. An aseptic spatula with shield, for the examination of infectious throat affections.
4. Three pairs of scissors (modification of Beckman's); one pair bent at the edge, two pairs bent on the flat, for resection of the posterior part of the mid-concha.
5. Sharp spoon for scraping the anterior wall of the sphenoid.

Dr. RUDOLF PANSE (Dresden).

1. Wood model of ossicles, 20 times enlarged: for memoranda on diseases.
2. Horizontal, frontal, and sagittal sections in region of stapes, with drawings.
3. Diseased malleus and incus in natural position.
4. Twelve representations of the drum in water-colours: 25 × 33 cm. Topographical in water-colours.
5. Microscopical specimens for study without magnification:
 - (1) Interior of cochlea.
 - (2) Labyrinthine necrosis.
 - (3) „ „ suppuration.
 - (4) „ „ „
 - (5) „ „ „
6. Comparative anatomy:

The organs of hearing of—(1) man, (2) calf, (3) pigeon, (4) bullfinch, (5) turtle, (6) carp, (7) flounder, (8) pike.

* For further information see 'Verhandl. der Deutsch. otol. Gesellschaft,' Hamburg, 1899.

7. Glass model of semicircular canals for studying the fluid streams.
8. Corrosion specimens, with accompanying water-colour drawings.
9. Saw section, accompanied with water-colour enlargement.

Prof. PASSOW (Heidelberg).

- I. A collection of stereoscopic photograms showing—
 - a.* Diseases of the external ear, and abnormal positions of the auricle.
 - b.* Phases of the radical operation and plastic, after Passow.
 - c.* Phases of the operation for closing a retro-auricular opening after radical operation by Passow.
- II. *a.* A pharyngeal tonsillotome, by Schütz.
b. Its modification as used in the Heidelberg Eye Clinic.
- III. A number of hypertrophied pharyngeal tonsils removed with the instrument II. *b* (without anæsthetic).

Dr. RUDLOFF (Wiesbaden).

1. Sagittal section through the head (intended to illustrate the operation for adenoid vegetations).
2. Macroscopical specimens, illustrating the relation existing between the lateral wall of Rosenmüller's fossa and the carotid artery.
3. Casts showing the varying dimensions of Rosenmüller's fossa, and the relation between Rosenmüller's fossa and the pharyngeal orifice of the Eustachian tube.
4. Macroscopical specimen showing a portion of adenoid growth in connection with a piece of the cartilage surrounding the pharyngeal orifice of the Eustachian tube.
5. Two microscopical specimens exhibiting a portion of adenoid growth in connection with a piece of the cartilage surrounding the pharyngeal orifice of the Eustachian tube.
6. Four curettes.

Dr. SCHEIBE (Munich).

Drawings of histological sections of diseased petrous bones.

Dr. A. SCHWENDT (Basel).

Photographs showing the length of sound-waves of the highest pitched sounds.

Prof. SIEBENMANN (Basel).

Atlas—Corrosion preparations of the human ear.

Atlas—The blood-vessels in the labyrinth of the human ear.

Dr. G. SONNENKALB (Chemnitz).

A set of rotating cylindrical burrs and vulcanite obturators (with holder for introducing) for perforation of the maxillary antrum.

Dr. WILLIAM STERN (Breslau).

"Tonvariator." A bottle apparatus for producing continuous blow-sound changes.

Dr. TEICHMANN (Berlin).

Sketch for hearing tests.

Dr. WEGENER (Hanover).

Aural vibratory massage apparatus.

Dr. ALFRED WOLFF (Berlin).

Two tonsil guillotines, after Mackenzie, of aseptic construction, which can be entirely taken to pieces for thoroughly cleansing.

(a) Tonsil guillotine, after Lucae-Baginsky, of aseptic construction ; also detachable.

Dr. ZARNIKO (Hamburg).

Instruments :

1. Fixing hooks for operation on the mastoid process.
2. Fixable nose-wedges for chiselling operations in the nose.

Dr. ODO BETZ (Heilbronn, Württemberg).

Plaster Models of Sections of Skull exhibiting the Topographical Anatomy of the Upper Air-passages.

1. Alto-relievo of a direct medial sagittal section.
2. Model 1, with middle and inferior turbinal bodies removed.
3. Sagittal section of the left side of the skull.
4. Sagittal excision of the sphenoid sinus of model 3.
5. Frontal section including the air cavities of the skull and the trachea.
6. Frontal section showing the air cavities of the skull and buccal cavity.

Dr. MAX SCHEIER (Berlin).

1. Skiagraph of the head during different periods of life, from birth upwards.
2. Skiagraphs of gunshot wounds of the head :
 - a. Wound of the olfactory nerve.
 - b. Wound of the Gasserian ganglion.
3. Skiagraphs of the head to show topographically the accessory cavities of the nose :
 - a. Cavities not injected.
 - b. The same head with the cavities filled with red-lead. One photograph taken externally, the other taken by illumination from the middle line.
4. Skiagraphs of a living and of a dead new-born child showing the labyrinth, which is uninjected, very plainly.

HOLLAND.

CONTRIBUTIONS RECEIVED FROM THE DUTCH OTO-RHINO-LARYNGOLOGICAL SOCIETY THROUGH PROF. A. A. G. GUYE.

Prof. A. A. G. GUYE (Amsterdam).

1. A forceps for removing foreign bodies from the ear, nose, &c.
2. A curette for removing adenoid vegetations (in two sizes, *a* and *b*).
3. A tampon holder for the post-nasal space.
4. A conical probe to make the tampons with.
5. A conical tube for syringing and insufflating Highmore's antrum.
6. A menthol insufflator (modification of Hartmann's) adapted for catheterism of the Eustachian tube, for politzerisation and for insufflation of Highmore's antrum (with filtration of the air through cotton wool).
7. A contra-respirator.
8. India-rubber rings to keep open the nostrils and prevent the aspiration of the plica vestibuli.

Dr. W. SCHUTTER (Groningen).

1. Self-retaining three-bladed nostril dilator. The pressure of the blades on the wall of the nostril is regulated by screw movement, so the instrument holds firmly without occasioning pain.
2. Perforated Nélaton bougie used as a tube for spraying the nasal and post-nasal cavities. It is to be fixed on a simple pumping apparatus.

Dr. W. POSTHUMUS MEYJES (Amsterdam).

1. A cannula for washing out the frontal sinus.
2. Files for enlarging the nasal end of the ductus naso-frontalis.
3. A gold antrum tube with valve on artificial piece, showing its application.
4. *a.* Silver-gilt antrum tube with valve.
b. Fitting cannula for washing out the antrum.

Dr. P. J. ZAALBERG (Amsterdam).

1. A forceps for the ear (Gruenwald's forceps, reduced size).
2. A retracting hook to hold open the wound during the operation of the sinus frontalis.

Dr. A. SIKKEL (The Hague).

Plaster Casts of the Superior Maxilla, taken from cases of Chronic Obstruction of the Nose (adenoid vegetations of the naso-pharynx).

The plaster casts show the peculiar deviations to which Körner in 1891 has called particular attention. These abnormalities differ according to whether the obstruction exists only during the first or also still during the second dentition.

In the first case we find a high position of the hard palate ; the whole superior maxilla has lagged behind in the period of development, the cross-dimension has shortened, the dimension from before backwards has lengthened.

In the second phase of disturbance of development there are, further, the following deviations:—The hard palate takes a much higher position, and the alveolar edges approach each other still more ; the jaw seems to be compressed. A sharp bend arises in the median line. Both the middle incisors, which in normal circumstances point backwards with their lingual surfaces, make an angle and turn the aforementioned surfaces to each other. The transverse intersection of the jaw shows a pointed bow-shape, whilst otherwise it is lowly vaulted.

In obstructions of the nose resulting from other causes we also find abnormalities of the upper jaw, but of another kind ; only in adenoid vegetations we meet with the above-mentioned bend of the alveolar edges and the V-shaped position of the median incisors. While the accompanying plaster casts show distinctly the known deviations, there is still another phenomenon of which nothing is said in the several communications on this subject.

In 1895 Rosenberg published a paper in which he was able to record several observations as to the frequent want of the lateral incisors, or of their being met with in an atrophic state.

Among the accompanying casts there are several (7, 6, 4) in which the want of one lateral incisor and the considerable atrophy of the other are noticeable. The disturbance of the development of both the outer incisors and sometimes of the canines (1, 3, 5, 14, &c.) is an abnormality of which the author did not find any description in the literature concerning the malformation of the superior maxilla.

Though this collection of plaster casts is certainly insufficient to justify a definite conclusion on the subject, they yet may be useful in fixing the attention on the above-mentioned peculiar disturbances in the process of development.

When the number of observations increases it will perhaps be possible to find a certain relation between the disappearance of the outer incisors and the canine teeth, and the space limitation in the upper jaw in adenoid vegetations.

The late Dr. B. J. SMITS (Holland).

Chin Bandage.

It is composed of three parts :

- a. The headpiece with its drawing ribbons.
- b. The cap, keeping the whole on the right place.
- c. The chin shoe with fixed ribbons in which are two conducting eyes.

In putting on the apparatus the cap is brought backwards to the head and the shoe under the chin, the ribbons being drawn so as to obtain pressure on the chin. Even with very strong pressure the mouth, if necessary, can be opened, which is one of the best merits of the chin bandage, and is due to the elastic working of the whole, every part of the apparatus working together. In taking off the bandage only the drawing ribbons are loosened ; the others are for adjustment. The chin bandage has a weight of about 40 grammes, and can be washed without discolouring even the silk stitching.

Prof. W. EINTHOVEN (Leyden).

Stereoscopic Instantaneous Photograph of the Cavum Pharyngonasale of a Man while swallowing, sucking, and speaking.

The man was operated on for carcinoma of the orbital cavity. The back wall of the pharynx, the mouth of the Eustachian tube, the recessus pharyngeus (Rosenmülleri), and the upper surface of the soft palate can be seen.

- | | | |
|------|--------------------|---|
| I. | <i>Photograph.</i> | At rest, the soft palate hanging down. |
| II. | " | At rest, the soft palate raised. |
| III. | " | In the act of pronouncing the (Dutch) letter A. |
| IV. | " | In the act of sucking. |
| V a | " | In the act of swallowing, 1st phase. |
| V b. | " | In the act of swallowing, 2nd " |
| V c. | " | In the act of swallowing, 3rd " |
| V d. | " | In the act of swallowing, 4th " |
| V e. | " | In the act of swallowing, 5th " |

Dr. J. D. BOEKE (Alkmaar).

Apparatus for Microscopical Investigation of the Phonograms of Vowel Sounds, made in following the author's indications in the Physiological Laboratory of the Utrecht University.

The method is fully described by the author in the 'Proceedings of the Royal Society of Edinburgh,' 1897-8, p. 88. It consists in measuring microscopically the transverse diameter of the impressions on the surface of the phonograph cylinder on different (generally equidistant) parts of the period, and in inferring from the measurements the depth of the impression on the same spot; or, in other words, in deriving from them the curve of the sound which produced the impression.

The depths of the impressions are easily, by means of a formula, deduced from its measured transverse diameters.

The apparatus is placed, when in use, upon a firmly fixed table before a window with a northern aspect. The axis of the mandrel on which the cylinder of the phonograph is placed carries a drum, the outside of which is divided into 360 equal parts.

This disc can be rotated by means of the worm of a screw over perfectly equal distances of $\frac{1}{360}^{\circ}$. In this way any full period of a vocal sound is measured at 40 equal distant points of the trace that the vibrations of the air have left in the surface of a phonograph.

The cylinder placed in this moment under the microscope contains—

1. Whistle vibrations.
2. The open Italian vocal sound "a" (key-word "Apeldoorn").
3. The short vocal sound a (key-word "Apeldoorn").
4. The vocals a, e, i, o, u, y, sung by the author on the tone a'.

	Horizontal scale.	Circumference scale.
1. Whistle	4.25 cm.	200°
2. Open Italian "a" (key-word "Apeldoorn")	4.4	51°
3. Short "a" (key-word "Apeldoorn")	4.5	274°
4. "a"	5.8	275°
"e"	6.25	110°
"i"	6.8	290°
"o"	7.25	190°
"u"	7.7	150°
"y"	8.1	144°

The apparatus will be demonstrated to the visitors of the Museum by the Vice-Chairman of the Dutch Oto-rhino-laryngological Society, Dr. Moll.

L. Hermann. Phonophotographische Untersuchungen I. Pflüger's 'Archiv für die gesammte Physiologie,' vol. xlvii (1890), p. 42.

J. D. Boeke. Mikroskopische Phonogrammstudien. Pflüger's 'Arch. f. d. ges. Phys.,' vol. 1 (1891), p. 297.

J. D. Boeke. 'Proceedings of the Royal Society of Edinburgh,' 1897-8, p. 88.

Prof. H. ZWAARDEMAKER (Utrecht).

Measuring Apparatus for the Movements in Speech.

The whole apparatus is suspended from a steel band round the forehead, which can be widened or narrowed at will. A horseshoe-shaped band of aluminium is firmly fixed in front to the chin-bone by a small brass rod, ending in a small wheel or caster to allow the skin to move freely; at the sides, to the angles of the jaw by a piece of caoutchouc firmly enclosing the same. A brass rod underneath the chin-bone keeps the jaw-band in position, and because it can be shortened or lengthened at will keeps the caoutchouc firmly fixed to the angles of the jaw.

To prevent the jaw-band from falling, a spiral spring connects the front of the jaw-band to a cylindrical air-cushion—a sort of bellows with a spiral spring inside—which works in a vertical direction, and communicates by an india-rubber tube with a Marey's tympanum. With this contrivance it is possible to trace any up or down movement of the lower jaw on the blackened cylinder of a kymograph.

Strictly speaking, this part of the apparatus suffices for the study of the jaw movements; but to give the apparatus greater firmness it is desirable, if not necessary, that the lip-movement recorder should be put on. This is a cylindrical air-cushion, resting on the upper lip, attached to the head-band by two stout leaden wires, and partly screened by an aluminium plate, the edge of which presses against the lower part of the bridge of the nose. Moreover to the aluminium plate is attached a sort of nostril dilator, which is inserted into the nose before the lip recorder is adjusted by means of the leaden wires. A brass tube projecting air-tight into the air-cushion is connected by an india-rubber tube with a second Marey's tympanum.

The movements of the lower lip are recorded by two little india-rubber balls, resting in brass cups and connected by an india-rubber piece which communicates

with a third Marey's tympanum by india-rubber tubing. These little balls may be raised or lowered, drawn backwards or pressed closer against the lower lip at will.

For recording the working of the tongue muscles a wooden knob or button pressing against the muscular part of the lower jaw rests on a tympanum, which in its turn communicates with a fourth Marey's tympanum, the writing lever of which records in the usual manner the slightest contraction or slackening of the tongue muscles on the smoked paper of the cylinder.

Olfactometers.

If the air before being inhaled is allowed to pass through a tube lined with a scented material, the odour, whatever it is, will be distinctly perceptible. The odour will seem faint or powerful according to the nature of the material in use; moreover the degrees of intensity will depend on the length of the tube. It is on this principle that olfactometry should be grounded. In all our olfactometers, whatever their form may be, the essential part consists of two tubes fitting into each other. The outer one is lined or impregnated with scented material, and made to slide up and down over the inner one, of which one end remains free and is bent to fit the nostril. Our tubes not being thick enough to fill an ordinary nostril, care must be taken, when experimenting, to place it in the anterior half.

The olfactometers shown in the Museum are—

1. Simple olfactometer as described in the text-books of our science, the outer tube lined with—
 - a.* Caoutchouc.
 - b.* Ammoniacum gutta-percha.
2. Clinical series of four olfactometers as shown at the "Association of German Naturalists and Physicians" of 1898, in Düsseldorf, by Dr. C. Reuter (constructed by him in the Physiological Laboratory of Utrecht in February of that year—*vide* 'Monatsschrift f. Ohrenheilk.,' 1899, No. 1).
3. Standard olfactometer for clinical use (in making observations on partial anosmia—*vide* Zwaardemaker u. Reuter, "Qualitative Riechmessung," 'Archiv f. Laryngologie,' Bd. iv, H. 1).
4. Standard olfactometer for physiological and accurate clinical observations, allowing the embedding of the porous outer tube with synthetically prepared, chemically perfectly known substances (solved in liquid paraffin).

The mode of inhaling the air through the nose is registered on the blackened cylinder of a kymograph by means of air-transport, and the inner tube is cleaned immediately after every experiment by a stream of common sand and air ('Onderzoekingen van het Physiol. Laboratorium der Utrechtsche Hoogeschool,' Serie v, vol. i, p. 172).

Literature on olfactometers:

- a.* 'Lancet,' Juni 29, 1889, p. 1300.
- b.* Zwaardemaker, 'Die Physiologie des Geruchs,' Leipzig, 1895.

ITALY.

Contributions received through Prof. G. Gradenigo, of Turin.

Prof. GRADENIGO (Turin).

Collection de l' Archivio Italiano di Otologia, Rinologia, e Laringologia, vols. i—viii.

Écarteur du pavillon et du conduit dans l'opération radicale sur l'oreille moyenne.

Photographies pour démontrer une nouvelle méthode optique de détermination acoumétrique.

Dr. G. D'AJUTOLO (Bologna).

Appareil d'irrigation pour la cavité orale.

Dr. T. DELLA VEDOVA (Milan).

Photographies.

Pharyngoscope électrique.

Instruments.

Prof. I. DIONISIO (Turin).

Cannule-tampon pour les hémorragies du nez.

Prof. G. FARACI (Palermo).

Pince ostéotome pour la résection de la paroi externe de l'épitympan.

Instrument pour scarifications de la paroi postérieure du pharynx.

NORWAY.

Prof. UCHERMANN (Christiania).

1. Cotton-wool holder with curette for the ear.
2. Cotton-wool holder for the pharynx.
3. Two instruments for excising adenoid growths.

SWITZERLAND.

Dr. H. ROHRER (Zurich).

A large series of paintings illustrating the comparative anatomy, embryology anatomy, and pathology of the organ of hearing.

APPENDIX A.

TOO LATE LIST.

INJURIES AND THEIR RESULTS.

- (P. 39.) A photograph of the head of a statue showing the result of a hæmatoma of auricle in a Roman boxer. Gladiatorer Sedato (Ferene Diocleziane).
StClair Thomson, Esq.

FOREIGN BODIES.

EAR (p. 48).

Pebble removed, by detaching the auricle, from the ear of a boy aged 14 years, who had been deaf for six years. A. Marmaduke Sheild, Esq.

Head of a shawl pin removed by syringing from an insane lady aged 47. Buzzing, singing, etc., in the head, with rotatory giddiness had been complained of. A. Marmaduke Sheild, Esq.

PATHOLOGY.

EAR (p. 67).

A malleus with loss of half of handle removed for ot. med. supp. chron. Perforation of inferior segments. Cure. A. Marmaduke Sheild, Esq.

(P. 75.) *Extra-dural abscess with localised pachymeningitis.*

Formalin preparation of the right temporal bone, from the same patient as No. 559. Death resulted from extra-dural abscess and convulsions. The anterior meatal wall has been artificially opened. The posterior segment of the membrana tympani and the greater part of Shrapnell's membrane are destroyed, and the incus lost. In the middle fossa the dura mater covering the petrous bone is apparently natural on its upper or cerebral surface, but has been reflected to show a patch of localised pachymeningitis on its under surface, corresponding to the roof of the middle ear. At this spot the dura mater was separated from the bone by a thin layer of foetid pus, and the bone itself is necrosed. In the posterior fossa the dura mater and sinuses are natural.

The patient, a newsvendor æt. 32, had been sleepless for some nights, and for five days preceding his death had complained of headache and general malaise. When examined two days before death the pulse was 64 and the temperature 100°. An hour before death he suddenly became convulsed. The convulsions commenced with twitchings on the left, and to this side the head was turned. The pulse rose rapidly to 140, and temperature to 101°. The convulsions became general and lasted fifteen minutes. The patient

became quite unconscious, and died in a second attack of convulsions. Post mortem the membranes of the brain were somewhat opaque, the superficial and deep vessels were considerably congested. No definite meningitis. No evidence of a suppurating focus in brain. The post-nasal space contained remnants of adenoids. At the base of the right lung were some old adhesions, and more recent ones over the middle lobe. Both lungs were very oedematous, and the right lower lobe was friable.

W. Jobson Horne, Esq.

(P 124.) *EAR. TUMOURS.*

Pedunculated exostosis removed by the chisel after detaching auricle.

A. Marmaduke Sheild, Esq.

APPENDIX B.

Notes and References to the Different Methods used for Preparing and Preserving Specimens exhibited in the Museum.

'On the Mode of Removing the Ears for Investigation, and their Dissection.' Appendix B to a Descriptive Catalogue of Preparations illustrative of the Diseases of the Ear in the museum of Joseph Toynbee, F.R.S. London, John Churchill, 1857.

'Die anatomische und histologische Zergliederung des menschlichen Gebörorgans im normalen und kranken Zustande,' von Dr. Adam Politzer. Stuttgart, Ferdinand Enke, 1889. Translated by George Stone. Published by Baillière, Tindall, and Cox, London, 1892.

"Formalin Methods for the Preservation of Museum Specimens." Prof. Kanthack. 'St. Bartholomew's Hospital Journal,' 1897, p. 43.

Stereoscopic Views of the Entire Labyrinth, Tympanum, Tympanic Membrane, etc., rendered transparent to present to the student instructive views of this very complicated region. Dr. L. Katz, Berlin.

For a description of the method used by Dr. Katz for rendering the bone transparent see 'Archiv für Ohrenheilkunde,' Bd. xxxvii.

"A Method of Demonstrating the Appearances of the Labyrinth in its natural position in the bone by first injecting the labyrinth with mercury, and then rendering the bone transparent by a slight modification of the method described by Katz ('Archiv für Ohrenheilkunde,' Bd. xxxiv)," by Dr. Gustav Brühl. 'Anatomischer Anzeiger,' Bd. xiii, No. 3, 1897.

"New Methods of Demonstrating the Cavities of the Nose and Ear by injecting the Accessory Cavities with Mercury, and rendering the Bone Transparent," by Dr. Gustav Brühl. 'Anatomischer Anzeiger,' Bd. xiv, No. 9, 1898.



