

Dental surgery for medical practitioners and students of medicine.

Contributors

Barrett, Ashley William.

Publication/Creation

London : Lewis, 1897.

Persistent URL

<https://wellcomecollection.org/works/m5qanqvc>

License and attribution

This work has been identified as being free of known restrictions under copyright law, including all related and neighbouring rights and is being made available under the Creative Commons, Public Domain Mark.

You can copy, modify, distribute and perform the work, even for commercial purposes, without asking permission.



Wellcome Collection
183 Euston Road
London NW1 2BE UK
T +44 (0)20 7611 8722
E library@wellcomecollection.org
<https://wellcomecollection.org>

DENTAL SURGERY



A. W. BARRETT

914



22102168783

H. H. G. GRATTAN,
MEDICAL BOOKSELLER
BY APPOINTMENT
TO
GUYS AND ST. THOMAS'S
HOSPITALS.
THE TABAG BOOK STORE
17, THE BOROUGH,
LONDON BRIDGE

Med

K48627

3/6

1/

LEWIS'S PRACTICAL SERIES.

DENTAL SURGERY.

LEWIS'S PRACTICAL SERIES.

In Crown 8vo Volumes, Illustrated.

-
- ON THE TREATMENT OF PULMONARY CONSUMPTION. A PRACTICAL MANUAL. By V. D. HARRIS, M.D. (Lond.), F.R.C.P., Physician to the City of London Hospital for Diseases of the Chest, and E. C. BEALE, M.A., M.B. (Cantab.), F.R.C.P., Physician to the City of London Hospital for Diseases of the Chest. 10s. 6d.
- THE SURGICAL DISEASES OF CHILDREN. By D'ARCY POWER, M.A., M.B. (Oxon.), F.R.C.S. (Eng.), Surgeon to the Victoria Hospital for Children. 10s. 6d.
- DISEASES OF THE NOSE AND THROAT. By F. DE HAVILLAND HALL, M.D., F.R.C.P. (Lond.), Physician to Out-Patients at the Westminster Hospital. 10s. 6d.
- PUBLIC HEALTH LABORATORY WORK. By HENRY R. KENWOOD, M.B., D.P.H., F.C.S., Instructor in the Hygienic Laboratory, University College, &c. Second Edition, 10s. 6d.
- MEDICAL MICROSCOPY. By FRANK J. WETHERED, M.D., F.R.C.P., Medical Registrar to the Middlesex Hospital. 9s.
- MEDICAL ELECTRICITY. By H. LEWIS JONES, M.A., M.D., F.R.C.P., Medical Officer in Charge of the Electrical Department in St. Bartholomew's Hospital. Second Edition, 10s. 6d.
- HYGIENE AND PUBLIC HEALTH. By LOUIS C. PARKES, M.D., D.P.H. (Lond. Univ.), Lecturer on Public Health at St. George's Hospital Medical School. Fourth Edition, 10s. 6d.
- A PRACTICAL TEXTBOOK OF THE DISEASES OF WOMEN. By ARTHUR H. N. LEWERS, M.D., M.R.C.P., Obstetric Physician to the London Hospital. Fourth Edition, 10s. 6d.
- ANÆSTHETICS, THEIR USES AND ADMINISTRATION. By DUDLEY W. BUXTON, M.D., B.S., Administrator of Anæsthetics in University College Hospital. Second Edition, 5s.
- MANUAL OF OPHTHALMIC PRACTICE. By C. HIGGENS, F.R.C.S., Ophthalmic Surgeon to Guy's Hospital. 6s.
- ON FEVERS, THEIR HISTORY, ETIOLOGY, DIAGNOSIS, PROGNOSIS, AND TREATMENT. By A. COLLIE, M.D. 8s. 6d.
- HANDBOOK OF DISEASES OF THE EAR. By URBAN PRITCHARD, M.D. (Edin.), F.R.C.S. (Eng.), Professor of Aural Surgery at King's College. Third Edition, 6s.
- A PRACTICAL TREATISE ON DISEASES OF THE KIDNEYS AND URINARY DERANGEMENTS. By C. H. RALFE, M.A., M.D., F.R.C.P., Physician to the London Hospital. 10s. 6d.
- DENTAL SURGERY. By ASHLEY W. BARRETT, M.B., M.R.C.S., L.D.S., Dental Surgeon to the London Hospital. Third Edition.
- BODILY DEFORMITIES AND THEIR TREATMENT. By H. A. REEVES, F.R.C.S. (Edin.), Senior Assistant Surgeon to the London Hospital. 8s. 6d.
-

LONDON: H. K. LEWIS, 136 GOWER STREET, W.C.

DENTAL SURGERY

FOR

MEDICAL PRACTITIONERS

AND

STUDENTS OF MEDICINE

BY

A. W. BARRETT, M.B. (LOND.), M.R.C.S., L.D.S.E.

CONSULTING DENTAL SURGEON TO THE LONDON HOSPITAL, AND LATE
LECTURER ON DENTAL SURGERY IN THE MEDICAL SCHOOL;
EXAMINER IN DENTAL SURGERY TO THE ROYAL
COLLEGE OF SURGEONS, ENGLAND

THIRD EDITION

WITH ILLUSTRATIONS

LONDON

H. K. LEWIS, 136 GOWER STREET, W.C.

1897

PRINTED BY
H. K. LEWIS, 136 GOWER STREET,
LONDON, W.C.



WELLCOME INSTITUTE LIBRARY	
Coll.	welMomec
Call	
No.	WU

TO MY UNCLE

H. J. BARRETT, M.R.C.S.,

FOR MANY YEARS


DENTAL SURGEON TO THE LONDON HOSPITAL, I DEDICATE

THIS SMALL HANDBOOK, IN THE BELIEF

THAT FOR WHAT IT MAY

CONTAIN OF VALUE I AM MOSTLY INDEBTED TO HIS

ADVICE AND EXAMPLE



PREFACE TO THE THIRD EDITION.

HAVING stated as concisely as possible what for many years I have been teaching to medical students in the Dental Department of the London Hospital, I venture to hope that this small book may also prove useful to the busy medical practitioner, too much occupied perhaps to study larger and more exhaustive works on Dental Surgery.

To such matters as the insertion of gold fillings, the pivoting of mineral crowns, and to others which fall only within the scope of the dental specialist, passing reference only is made. My aim throughout has been to give upon dental matters just so much practical information as may suffice the medical student or practitioner in the work of his profession.

To my brothers, S. and F. Barrett, my thanks are due for their assistance in revising the proof sheets.

It only remains to add that in accordance with the suggestions of critics of a former edition the subjects of dental caries, plastic fillings, &c., have been reconsidered; and also drawings of various teeth, as an aid to their extraction, have been inserted.

A. W. BARRETT.

7 Cavendish Place,
Cavendish Square, W.

THE LIFE OF THE REV. J. C. SPENCER

He was born at Northampton, Mass., on the 10th of May, 1802. His father, John Spencer, was a farmer, and his mother, Mary (née) Spencer, was a daughter of a farmer. He was educated at the Northampton Academy, and at the Northampton Theological Seminary. He was ordained as a minister of the Gospel in 1825, and has since that time been engaged in the pastoral charge of the Northampton Church.

He was married to Miss Mary (née) Spencer, daughter of a farmer, on the 10th of May, 1826. They have three children, viz. John, Mary, and Elizabeth. He has been engaged in the pastoral charge of the Northampton Church for many years, and has been very successful in his ministry. He has also been engaged in the pastoral charge of other churches, and has been very successful in his ministry.

He has also been engaged in the pastoral charge of other churches, and has been very successful in his ministry. He has also been engaged in the pastoral charge of other churches, and has been very successful in his ministry. He has also been engaged in the pastoral charge of other churches, and has been very successful in his ministry.

He has also been engaged in the pastoral charge of other churches, and has been very successful in his ministry. He has also been engaged in the pastoral charge of other churches, and has been very successful in his ministry.

CONTENTS.

CHAPTER I.

THE TEETH GENERALLY.

	PAGE
The two Dentitions—General characters of a Tooth—Structure of a Tooth	1

CHAPTER II.

THE FIRST DENTITION.

Eruption of Temporary Teeth—Lancing the Gums—Absorption of Temporary Fangs—Relative positions of Temporary and Per- manent Teeth—Irrregularity among Permanent Teeth caused by unduly retained Temporary Teeth—Decay among Temporary Teeth—Protrusion of Fangs of Temporary Teeth through the Gum—When to extract Temporary Teeth	7
--	---

CHAPTER III.

THE SECOND DENTITION.

Eruption of Permanent Teeth—Eruption of Wisdom Teeth—To dis- tinguish Temporary from Permanent Teeth	15
---	----

CHAPTER IV.

ABNORMALITIES IN DEVELOPMENT OF PERMANENT
TEETH.

	PAGE
Retarded Eruption—Supernumerary Teeth—Odontomes and Abortive Teeth—Dilacerated and Geminated Teeth—General developmental irregularity with Honeycombed and Syphilitic Teeth	19

CHAPTER V.

IRREGULARITY IN THE POSITIONS OF PERMANENT
TEETH.

Causes of Irregularity in Positions of Teeth—Treatment of Irregularity by Extraction. Symmetrical Extraction—Treatment of Irregularity by Regulating Frame—Irregularities for which no Treatment is needed—Classification and Treatment of Dental Irregularities—Modelling	27
--	----

CHAPTER VI.

DENTAL CARIES.

Eburnation—Penetrating and Superficial Decay—Micro-organisms of Decay—Defective Calcification—Acid state of Oral Fluids—Diminished Vitality—Comparative tendency of Teeth to Decay—Caries in its first stage—Gutta-percha and Amalgam fillings—Use of Arsenic—Caries in its second stage—Periodontitis, Acute and Chronic—Caries in its third stage—Closure of the Jaws—Fistulous opening through Cheek—Summary of Remedial Measures—List of Instruments and Materials required	48
---	----

CHAPTER VII.

TOOTHACHE.

	PAGE
From Local Cause; as from odontalgia, tension in pulp-cavity, periodontitis, or irritation of stumps—From Constitutional Causes	81

CHAPTER VIII.

Tartar—Pyorrhœa Alveolaris—Absorption of Alveolar Process . .	86
---	----

CHAPTER IX.

INJURIES TO THE TEETH.

Wearing down of the Teeth from Friction of Mastication—Hunter's Denuding Process—Fracture and Dislocation of a Tooth from Violence	89
--	----

CHAPTER X.

PREPARATION OF THE MOUTH FOR, AND THE WEARING
OF ARTIFICIAL TEETH.

Motives for Wearing Frames—Concerning removal of Decayed Teeth and Stumps—Partial Frames and Modes of Supporting them—Pivotted Teeth—Complete Frames and Modes of Sup- porting them—Concerning the Wearing and Cleansing of Frames—The Process of "Crown and Bridge Work"	92
---	----

CHAPTER XI.

ANÆSTHETICS, GENERAL AND LOCAL.

Nitrous Oxide—Chloroform—Ether—"Gas" and Ether—Alcohol	PAGE
Chloroform Ether—Cocaine—Ether Spray	111

CHAPTER XII.

FRACTURES OF THE MAXILLÆ.

Mechanical Treatment	121
--------------------------------	-----

CHAPTER XIII.

EXTRACTION OF TEETH.

Conditions necessitating Extraction—General directions as to the positions of Operator and Patient—Concerning the application of forceps—As to the Extraction of the Tooth—Accidents during Extraction—Instruments needed for Extraction—Forceps, their general characters and various forms—The Elevator, its description and mode of using	126
--	-----

DENTAL SURGERY.

CHAPTER I.

THE TEETH GENERALLY.

THE TWO DENTITIONS. GENERAL CHARACTERS OF A TOOTH.

STRUCTURE OF A TOOTH.

The two dentitions.—The teeth in man are designed for the biting and mastication of food. They are of two sets, respectively named the *first* and *second dentitions*. The former appear and depart in early childhood, and are also called *temporary*, *deciduous* or *milk* teeth. The latter begin to be erupted at the age of six, last until a late period of life and are called *permanent*.

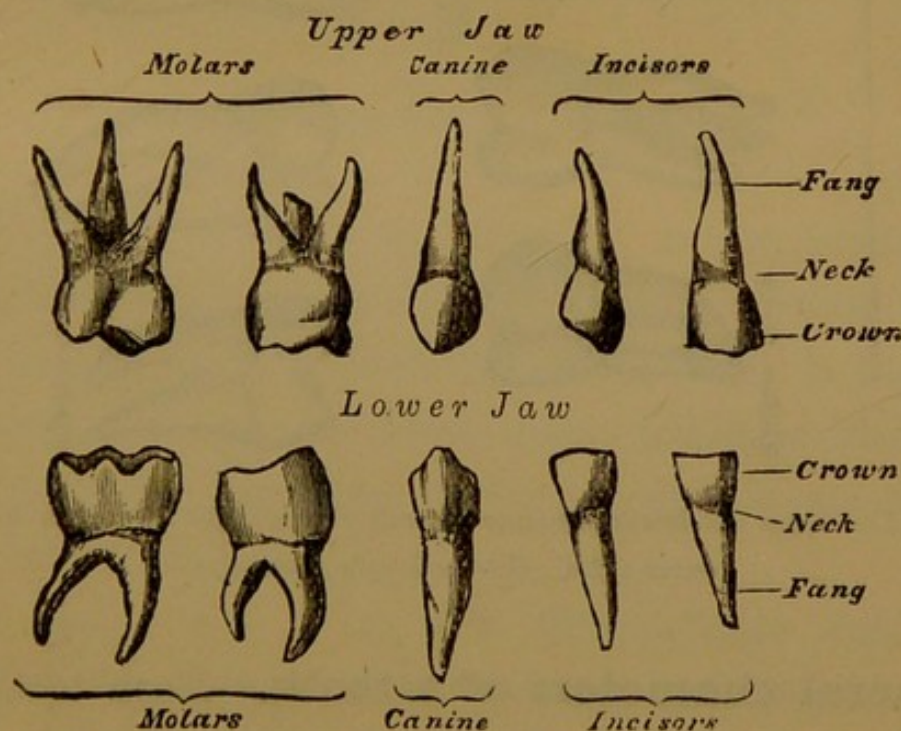


FIG. 1.—The upper and lower temporary or milk teeth on right side, seen from their outer sides. (From Gray's *Anatomy*).

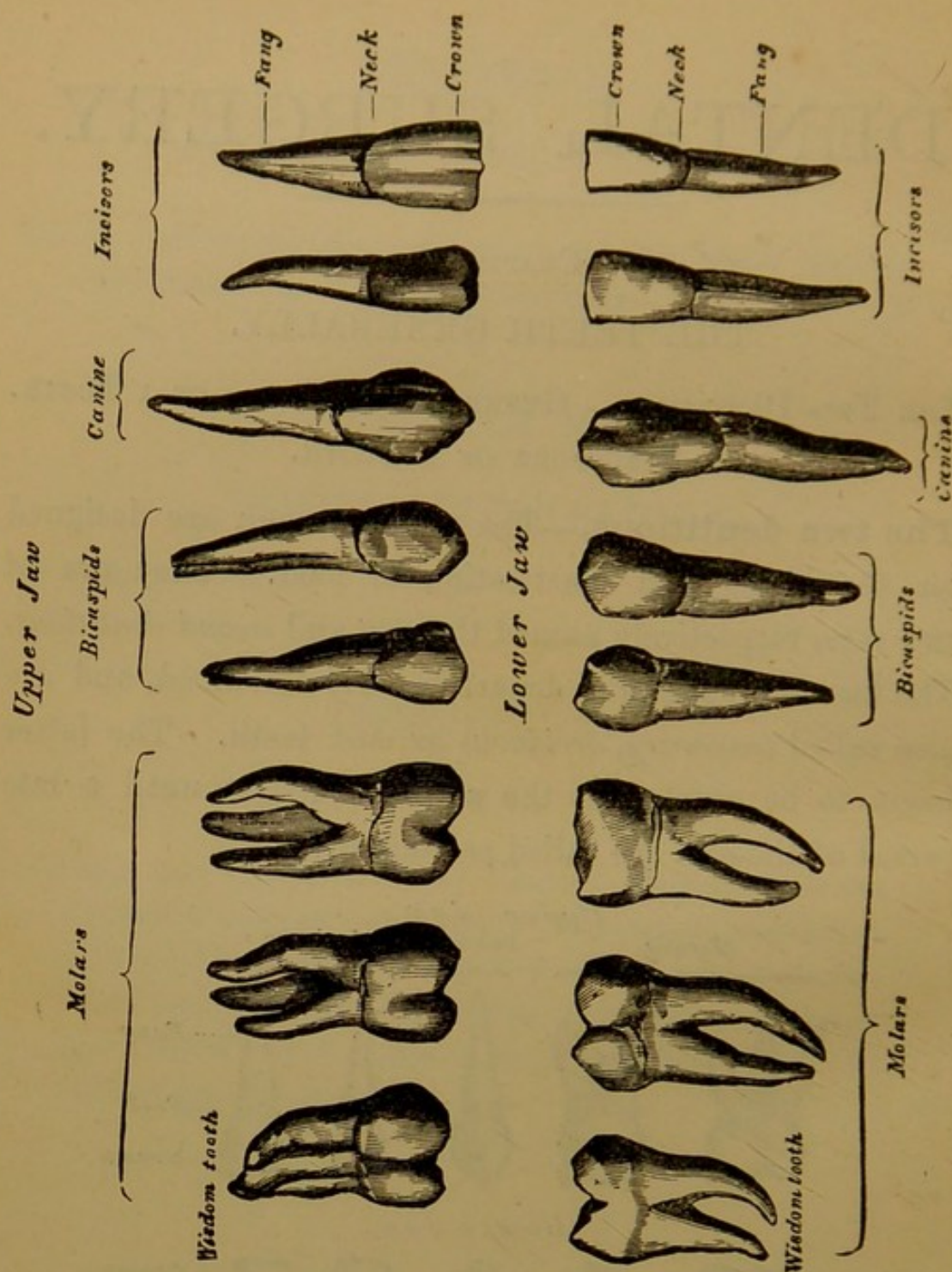


FIG. 2.—The upper and lower permanent teeth of the right side, seen from their outer sides. (From Gray's *Anatomy*).

General characters of a tooth.—Each tooth consists of three portions; the *crown*, projecting above the gum; the *fang*, entirely concealed within the alveolar

process; and the *neck*, the constricted portion between the crown and the fang.

The fangs of the teeth are firmly implanted in bony sockets which are lined with dense fibro-vascular tissue, the fibres of which pass directly from the bony wall into the cementum of the fang. Thus a tooth is slung by what may be termed an alveolar-dental ligament and pressure being put upon its crown is not transmitted to the injury of the nutrient vessels entering the end of its fang.

Structure.—On making a vertical section of a tooth,

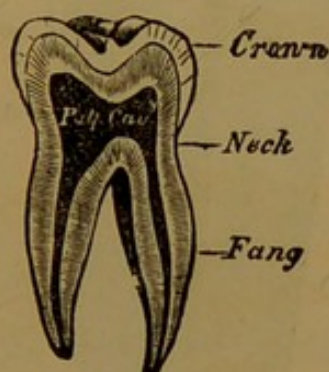


FIG. 3.—Vertical Section of a Molar Tooth.

its crown will be seen to contain a cavity, continuous with a canal running down each fang and opening at the end of the latter by a small aperture. This is the *pulp cavity* and contains the *dental pulp*, which is also prolonged into each fang and passes out of the end thereof by the *apical foramen*.

The *dental pulp* is a soft fibro-cellular structure, plentifully supplied with blood vessels and nerves, which enter at the apical foramina. It fills the pulp cavity, and is prolonged into each fang down the fang canals.

Its outer surface is covered with a layer of *odontoblastic* cells, and is throughout in close contact with the inner walls of the pulp cavity. These odontoblastic cells are of the nature of *cylindrical epithelium*, and their special function is to effect calcification of the dentine, which process proceeds from without inwards. From the outer

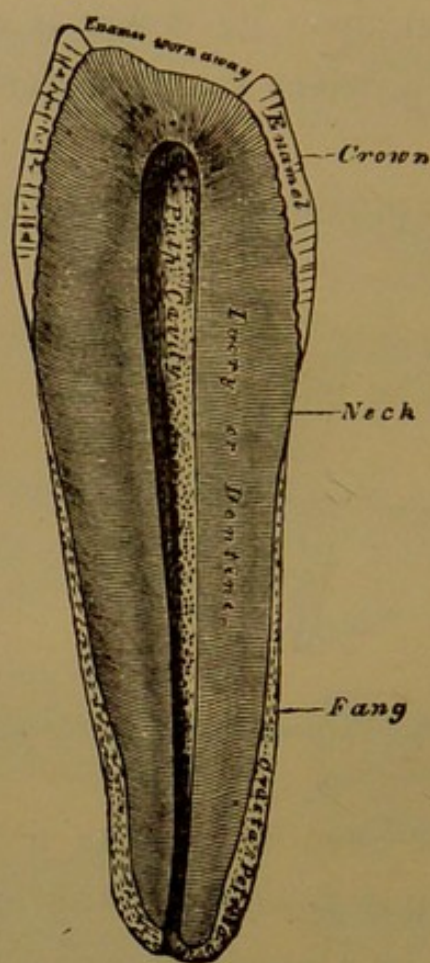


FIG. 4.—Vertical Section of a Bicuspid Tooth. (Magnified).

surface of this odontoblastic layer many fine filaments arise and these are continued into the *dentinal tubules*. Thus sensation is communicated to the hard ivory of the tooth, and thus may be explained the extreme pain occasionally suffered by a patient whose tooth is being

cut or drilled by an operator. Such pain does not, as is sometimes supposed, of necessity imply that the walls of the pulp cavity have been penetrated, or that the dental pulp has been exposed.

The solid structure of the tooth, which also forms the walls enclosing the dental pulp and its fang prolongations, is composed of three structures, *Dentine*, *Enamel* and *Cementum*.

Dentine is the material of which the crown and fangs of a tooth are mainly composed. It is built up of a multitude of minute parallel tubes, the *dentinal tubuli*, and of a dense homogeneous structure, the *intertubular substance*. The tubuli are in diameter $\frac{1}{4500}$ of an inch. They run more or less parallel to each other from the pulp cavity, into which they open, towards the outer part of the tooth, where they terminate just beneath the enamel or cementum covering. As before said these tubuli contain highly sensitive prolongations from the dental pulp.

Enamel forms the hard covering to the crown of the tooth. It is thickest on the grinding surface, until worn down by friction of mastication, and thinnest towards the neck of the tooth, where it terminates. It is built up of six-sided rods, placed parallel to each other, and each about $\frac{1}{3500}$ of an inch in diameter. Unlike the dentine it does not contain sensitive prolongations from the pulp, and when compared with dentine as to its chemical composition it is found to contain in proportion to its lime salts very much less organic matter, or gelatine.

Enamel contains—96 per cent. earthy matter, 4 per cent. organic matter.

Dentine contains—70 per cent. earthy matter, 30 per cent. organic matter.

Cementum or *crusta petrosa* forms a thin covering to the fangs, and in structure and composition much resembles bone.

CHAPTER II.

THE FIRST DENTITION.

ERUPTION OF TEMPORARY TEETH. LANCING THE GUMS.

ABSORPTION OF TEMPORARY FANGS. RELATIVE POSITIONS OF TEMPORARY AND PERMANENT TEETH. IRREGULARITY AMONG PERMANENT TEETH CAUSED BY UNDULY RETAINED TEMPORARY TEETH. DECAY AMONG TEMPORARY TEETH. PROTRUSION OF FANGS OF TEMPORARY TEETH THROUGH THE GUM. WHEN TO EXTRACT TEMPORARY TEETH.

Eruption of temporary teeth.—The temporary or milk teeth are twenty in number, and their eruption usually begins and ends between the ages of six months and two and a half years. These are smaller and more blue in colour than the permanent teeth, and their fangs are more divergent. Reference may be made to a drawing in Chapter I. (fig. 1) concerning their various forms. The following table gives the order and usual times of cutting of the members of this series.

The 2 Lower Central Incisors, about 6th month.

„ 2 Upper	„	„	„ 8th	„
„ 2 Lower Lateral	„	„	„ 10th	„
„ 2 Upper	„	„	„ 12th	„
„ 4 First Molar	„ 16th	„
„ 4 Canines	„ 20th	„
„ 4 Second Molars	„ 30th	„

Lancing the gums.—Among the most healthy children more or less trouble is usually caused when cutting the temporary teeth. The child then suffers not infrequently from diarrhœa and febrile symptoms, or a troublesome cough with convulsive seizures may be induced. On looking into the mouth the site of the erupting tooth may then be indicated by a protrusion of the gum, and relief may be afforded by incising this freely with a well pro-

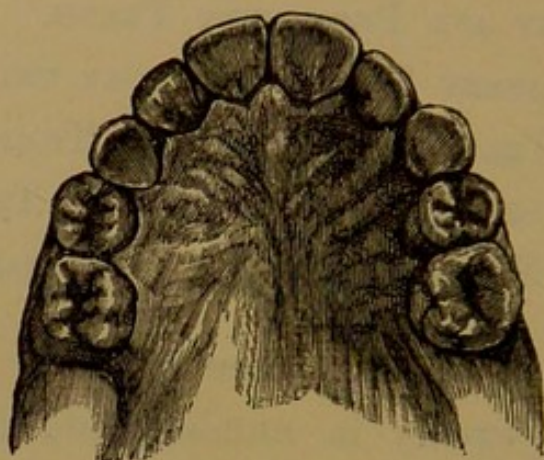


FIG. 5.—A model of an upper jaw at the age of three years, showing the ten upper temporary teeth.

Two Temporary Central Incisors.

" " Lateral "

" " Canines.

" " First Molars.

" " Second Molars.

tected lancet. Such an operation is, however, I think rarely called for. As a rule the symptoms abate in a few hours, and it should be performed only when the mucous membrane of the mouth is in a healthy condition, and when also it is quite evident to the sense of touch that the cutting edge of the new tooth is bound down by the tense and fibrous gum.

Absorption of temporary fangs.—At the age of

four years absorption of the fangs of the temporary teeth commences, and those of the incisors are first attacked. This process, in its nature purely vital and in no way mechanical, is brought about by the action of the *absorptive papilla*, a mass of multi-nucleated cells that lies closely behind and eats into each temporary fang, intervening between the latter and the crown of the permanent tooth which is to succeed it. The erosion of the fangs of a temporary tooth proceeds usually upon that surface which is nearest to the crown of the tooth that is to replace it, and thus we find among temporary incisors and

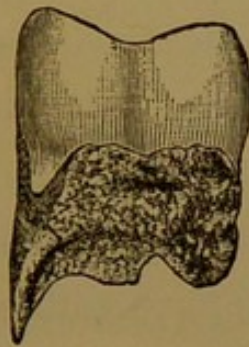


FIG. 6.—The crown of a temporary molar, the fangs of which have become almost entirely absorbed. (Enlarged).

canines the posterior portion of the fang is first removed, and thus a chisel-like edge is imparted. Among temporary molars, the roots of which embrace the growing bicuspid crowns, the absorptive papilla first attacks the inner and adjacent fang surfaces. The eroded surface, when examined through a low power, is found to be pitted, with an outline thus rendered uneven, and in some of the depressions a large multi-nucleated cell may be observed. There can be no doubt that erosion of temporary fangs is thus effected, and that pressure of the advancing perman-

ent tooth does not serve as the mechanical cause thereof, since between the two bodies the absorptive papilla intervenes. Yet the presence of a growing tooth is essential to development of this cellular structure, and when any permanent tooth happens to be undeveloped we usually find that its corresponding temporary one continues firmly implanted, and with its fangs non-eroded by any absorptive papilla.

Relative positions of temporary and permanent teeth.—*Behind* the fang of each temporary incisor and canine, and deeply seated in the maxilla, is placed its growing permanent successor; while *underneath* each temporary molar, and embraced within its widely diverging fangs, is the crown of the bicuspid that is to take its place. A knowledge of the latter fact is of value when it becomes necessary to extract a temporary molar. The forceps should then be applied with caution and not thrust deeply into the alveolus, lest the permanent be taken out with the temporary tooth.

Irregularity among permanent teeth caused by unduly retained temporary teeth.—It is not often necessary to extract a temporary tooth to make room for its permanent successor, since the rapid development of the jaw, and consequent expansion of the alveolar arch that occurs during childhood, tends to permit permanent teeth to fall into their normal situations, although at the time of, and shortly after their eruption, they may have been crowded out of line. It becomes, however, most necessary to take out a temporary tooth or its decayed fang which is so unduly retained that its growing perma-

nent successor is being diverted from its normal direction (see fig. 7). The fixity of such persistent temporary teeth shows that the action of the absorptive papillæ upon their fangs is but slight, and the need for their prompt removal is greater when the irregularity happens among upper front teeth. It will then be observed that if a permanent upper incisor or canine is so diverted from its proper line of growth that, in place of biting *in front* of the lower teeth when the jaws are approximated, it closes

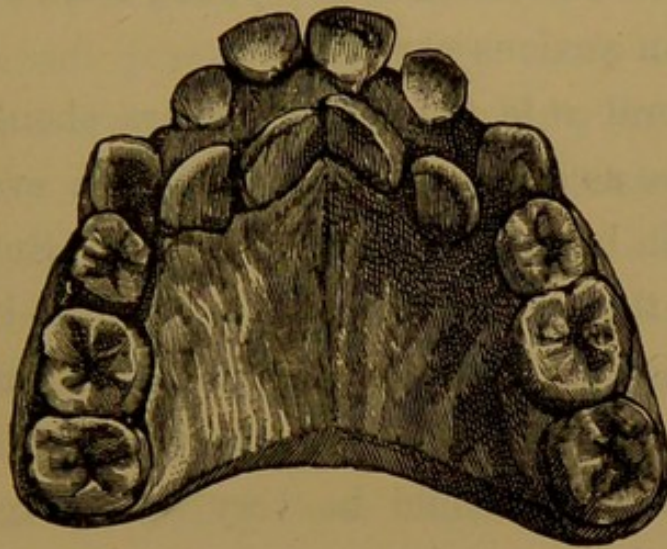


FIG. 7.—Diagram from a cast of the upper jaw of a neglected mouth in a child aged nine. The four permanent incisors have erupted, so that they bite within and behind the lower teeth when the mouth is closed. The four temporary are unduly retained with their fangs but slightly absorbed.

behind them, a deformity has become established which can be cured only by the *regulating plate* of the Dental Surgeon. To obviate this necessity be careful to extract any temporary incisor or canine which is obviously diverting a growing permanent tooth.

Decay among temporary teeth.—The temporary molars are prone to early and rapid decay. Their dental pulps are large, highly sensitive, and apt, as the result of

caries, to take on a process of destructive inflammation, thus becoming rapidly devitalized and decomposed. The treatment, however, of decay, with its sequelæ among temporary and permanent teeth, must be referred to later on. Suffice it now to say that a badly developed and carious set of permanent teeth does in no way necessarily occur in a mouth which may have been conspicuous by the faulty character of its milk teeth. It is well to bear this in mind in order that a more hopeful prognosis concerning the future condition of a young child's mouth may be given to an anxious parent.

As a general rule temporary molars should never be extracted save as a last resource, and when every attempt to relieve pain by other means has failed. Small cavities occurring in them should if possible be filled before decay has encroached greatly upon their walls, and in so doing it is well to avoid causing pain to the child. Carious dentine and enamel should be very lightly removed, and for the stopping of the cavity, such a material as gutta-percha gently warmed over a candle flame, or cotton-wool that has been dipped into a solution of gum mastic in alcohol, answers admirably. Decay when more advanced, with death of the dental pulp resulting, may necessitate other treatment; but it should always be remembered that a broken down temporary molar, if only it be not causing pain, is better than none at all, and may be invaluable to the child for the mastication of its food and the due nutrition of its body. As a means of preventing decay among temporary teeth the tooth-brush is valuable. This should be earnestly impressed upon the

parent, and the young patient should be taught to cleanse the teeth twice daily with a soft brush dipped in warm water and lightly wiped across a tablet of toilet soap.

Protrusion of fangs of temporary teeth through gum.—A condition attending frequently the shedding of milk teeth needs recognition. It is not unusual to find, as the result of absorption of the posterior surfaces of their fangs, that the sharp ragged ends so resulting have ulcerated through the gum and have wounded the lip or cheek. The laceration and inflammation of the soft parts is apt to be more severe when it results from a lower than when caused by an upper fang, owing to the greater mobility of the tissues around the former. Moreover, pressure from below, exerted by the growing permanent tooth, tends to extrude these sharpened temporary fangs, but the trouble of course ceases as soon as the latter are removed. A little difficulty is sometimes met with in extracting these fragments, but with the aid of a scalpel the gum adherent to them may be divided, and with fine forceps their extraction may be then easily effected. This condition should be carefully noted, lest it be wrongly attributed to necrosis and exfoliation of a portion of the maxilla.

Generally, concerning conditions under which temporary teeth should be extracted.—Speaking generally, the operator should aim, as far as may be, at enabling a child to retain its milk-teeth in order that food may be efficiently masticated and digested, but he should not be deterred from removing them when necessary by the old-fashioned notion that in so doing an irregularity

among the permanent series would be caused. The constant growth and expansion of the maxillæ during childhood act, as before remarked, in the opposite direction, and tend to prevent overcrowding and overlapping of the permanent set. The chief conditions under which temporary teeth should be extracted may thus be expressed concisely:—

1. When their undue retention is causing irregularity in the permanent series.
2. When from advanced decay the masticatory power, sleep, and health of the child are impaired.
3. When their sharpened fang ends have cut through alveolar process and gum.
4. When a decayed temporary molar is causing such severe inflammatory action within the maxilla that there seems likelihood of injury resulting to the permanent tooth developing beneath it.

CHAPTER III.

THE SECOND DENTITION.

ERUPTION OF PERMANENT TEETH. ERUPTION OF WISDOM TEETH. TO DISTINGUISH TEMPORARY FROM PERMANENT TEETH.

Eruption of the permanent series.—The order and times of eruption of the permanent teeth are usually as follows :—

The 4	First (or six-year-old) Molars	at about the 6th year.
" 2	Lower Central Incisors	" " 7th "
" 2	Upper " "	" " 8th "
" 4	Lateral Incisors	" " 9th "
" 4	First Bicuspids	" " 10th "
" 4	Second "	" " 11th "
" 4	Canines	" " 12th "
" 4	Second Molars	" " 13th "
" 4	Third Molars (or wisdom teeth)	" " 20th "

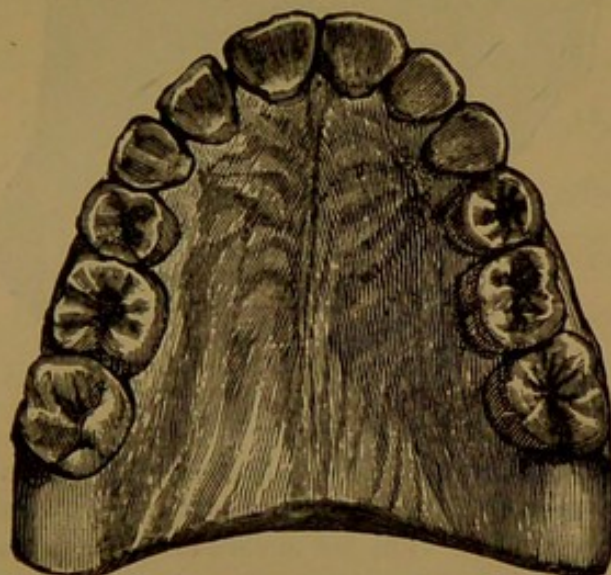


FIG. 8.—A model of an upper jaw at the age of seven years, showing the ten before-mentioned temporary teeth, and also the recently erupted first permanent (or six-year-old) molars. The following teeth are presented :—

Two Temporary Central Incisors.
" " Lateral "
" " Canines.
" " 1st Molars.
" " 2nd Molars.
" Permanent 1st (or six-year-old) Molars.

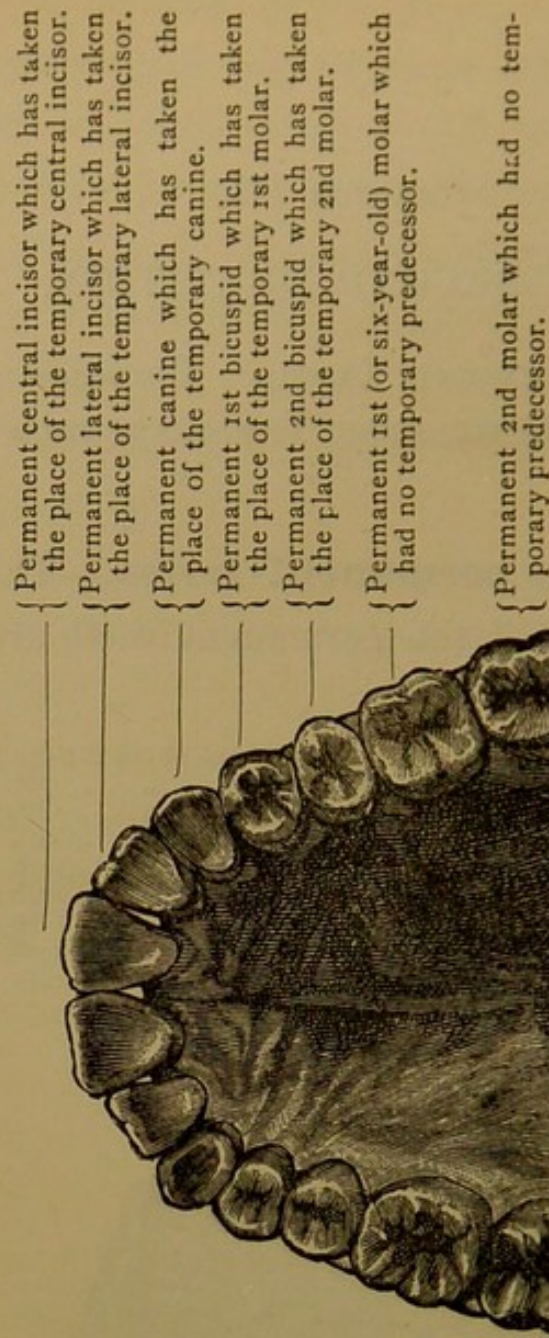


FIG. 9.—A model of an upper jaw at the age of thirteen years, showing the fourteen upper permanent teeth. All the before-mentioned temporary teeth have been replaced by their ten corresponding permanent ones, and also the 1st and 2nd permanent molars have been cut. The 3rd molars (or wisdom teeth) have not as yet been erupted. There are here present:—

Two Permanent Central Incisors.

"	"	Lateral	"
"	"	Canines.	
"	"	1st Bicuspids.	
"	"	2nd	"
"	"	1st (or six-year-old) Molars.	
"	"	2nd Molars.	

As a rule but little local or general disturbance attends the eruption of the permanent teeth. They grow up *behind*, and then advance into the places of, their temporary predecessors, which in due course through action of the absorptive papillæ become loosened and are shed. Thus the process is quietly effected without attracting much notice.

Eruption of wisdom teeth.—The cutting of the lower wisdom tooth is often, however, attended with a good deal of suffering. A flap of gum is lifted up by its growing crown, and between this last and the upper third molar the soft parts are liable to be bruised during mastication. Relief may at times be given by incising the constricting tissue, and by touching the incised surface lightly with nitrate of silver. Usually the pain and inflammation subside in the course of a few days, and the treatment of such cases may generally be limited to the use of hot fomentations inside the mouth. If, however, the erupting lower wisdom tooth be impacted between the base of the coronoid process and the back of the lower second molar, its cutting may be delayed for months. It then remains partially erupted and almost concealed by bruised and ulcerated gum tissue. In this condition the patient, if he be in weak health, may suffer greatly from suppurative action at the back of the mouth, and among the masticatory muscles of the affected side. To give relief a wisdom tooth, either upper or lower, should be removed, and as it is usually a most difficult task to extract the lower third molar thus impacted, the operator will do well to sacrifice the corresponding upper

tooth, which fortunately proves to be as a rule of easy removal. Thus I have often relieved the trouble with as much certainty as though the lower tooth itself had been extracted. To aid the operator in getting access to the tooth, and to overcome the closure of the mouth resulting from effusion around the temporo-maxillary articulation of the affected side, the assistance of "gas" or chloroform and of a powerful mouth opener are sometimes needed.

To distinguish temporary from permanent teeth.—The need for this is very evident. If the operator be not versed in the characteristic features of the two series, he may very readily extract a permanent canine, bicuspid, or six-year-old molar in the belief that he is taking out a temporary eye-tooth or molar. Fortunately, as a rule, it is an easy matter to tell at a glance to which series any tooth may be assigned. The permanent teeth are larger and yellower than those of the temporary series, with cusps and cutting edges more accentuated and serrated, although, after they have been cut a year or two, the serrations in the cutting edges of lower permanent incisors become worn out through friction of mastication. The student should compare bicuspid with temporary molars, and note that the former are larger, and that their two prominent cusps are wanting in the latter. He may distinguish a permanent first, or six-year-old molar, from a second temporary molar by its larger size, and the greater prominence of its cusps.

CHAPTER IV.

ABNORMALITIES IN DEVELOPMENT OF
PERMANENT TEETH.

RETARDED ERUPTION. SUPERNUMERARY TEETH. ODONTOMES AND ABORTIVE TEETH. DILACERATED AND GEMINATED TEETH. GENERAL DEVELOPMENTAL IRREGULARITY WITH HONEYCOMBED AND SYPHILITIC TEETH.

Retarded eruption.—The cutting of a permanent tooth may be delayed long after the normal time, or its absence may continue through life. This condition may be assigned to one or more of the following three causes.

1. The progress of inflammatory action, or development of a morbid growth, in the immediate neighbourhood of the encysted and growing tooth. Thus the latter is pressed upon, and its nutrition being impaired, its development ceases. In illustration of this, reference may be made to a case which came under the care of the late Mr. Maunder at the London Hospital. A girl, aged 14, was admitted with a large myeloid growth connected with the left side of the lower jaw, and rapidly developing within its substance. It was also noticed that the lower left 2nd bicuspid tooth was absent, and from the history it was evident that it had never been cut. A large portion of the inferior maxilla was removed with the contained growth, and on dissecting this the missing bicuspid was

seen to be deeply embedded, and partially developed within it. Here it may fairly be thought that the growth of the tumour prevented development of the tooth. There is reason to believe that long continued and severe inflammatory action around the fang of a temporary may impair the development of the permanent tooth which should replace it, and thus a motive is supplied for the judicious removal of temporary teeth that are causing trouble of this nature.

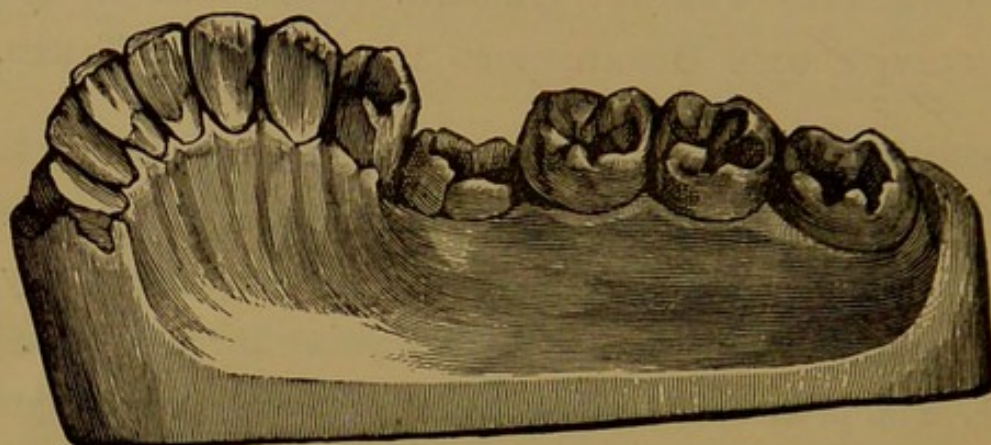


FIG. 10.—Diagram of a model of the right side of a lower jaw, aged 36. All the lower permanent teeth are erupted with the exception of the 2nd bicuspid. The 2nd temporary molar is retained and prevents the bicuspid from being cut. The drawing also shows the difference in level between the temporary and permanent series.

2. The undue retention of a temporary tooth owing, as before spoken of, to the absence or ineffectiveness of its Absorptive Papilla. Thus, by a mechanical cause, the growth of the permanent tooth may be restrained, and it may remain locked within the maxilla, unable to find its way to the surface. The annexed drawing from the mouth of an adult illustrates this condition very fairly.

3. The crowding together of permanent teeth sometimes

prevents eruption of some member of the series, as when a lower wisdom tooth is impacted between the base of the coronoid process and the back of the lower 2nd molar, thus remaining partially erupted throughout life.

Concerning treatment of these cases of tardy eruption not much can be said. The only practical suggestions to be made are these. When a decayed temporary tooth is causing much alveolar inflammation, and there seems likelihood of its injuring the underlying permanent tooth

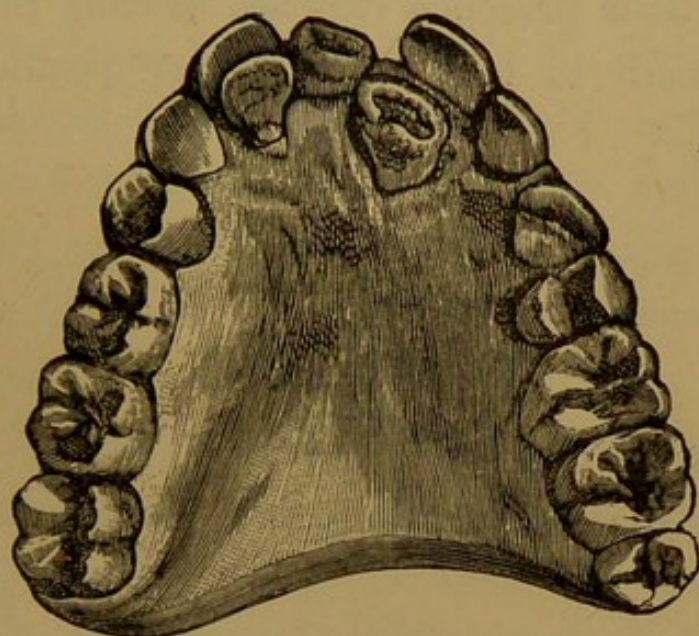


FIG. 11.—From a model of a mouth, aged 13. In the front of the mouth are two supernumerary teeth, which are displacing permanent incisors from their rightful positions.

by interference with its development, it is well to extract the source of trouble. When it would seem that a retained temporary tooth is preventing the cutting of its permanent successor the former may be removed, but this should be done with much caution, lest the gap so created be never filled up by the growth of any member of the permanent series.

Supernumerary teeth.—The permanent dentition

normal to the human mouth is 8 incisors, 4 canines, 8 bicuspid, 12 molars. If teeth appear in any part of the mouth in excess of these, such may be termed *supernumerary*. These when present are usually found in the front of the mouth, in the neighbourhood of the upper permanent incisors, among which by their presence they may cause a good deal of irregularity. They are generally more or less conical, with stunted fangs and imperfectly developed crowns. As a rule it is well to extract them, if by their presence they are causing the normally developed teeth to take up improper positions in the dental arch.



FIG 12.—From a malformed central incisor (size of nature)

Odontomes and abortive teeth.—A tooth though normally placed in the series may be irregular in form. Annexed is a drawing of a permanent central incisor, or of what corresponded therewith, which was removed on account of its deformity from a patient in the dental department of the London Hospital.

An ODONTOME may be regarded as a tooth, the development of which has become perverted in greater or less degree. Its occurrence is infrequent, and it may remain buried in the maxilla for a long period. At length its presence may be manifested by inflammation and slough-

ing of the soft tissues covering it, and there may then be evident to the eye and sense of touch a fibro-elastic or hard calcified growth filling the place of an absent molar. It then becomes necessary to make a differential diagnosis between an odontome, a chronic abscess, cystic disease of the jaw, and simple or malignant new growths in or on the maxilla. An odontome may be diagnosed if there be found in the situation of a missing tooth, an irregular mass of dental structure such as dentine or enamel, or if on making an exploratory puncture in a softer growth, the latter be found to contain within it a glairy gelatinous fluid in which is contained an imperfectly developed tooth. The existence of a chronic dental abscess may be inferred if the history connects the condition with long standing inflammation in the neighbourhood of a carious tooth containing a decomposed pulp. The rapidity of growth, and the age of the patient, the sensation on manipulating the tumour, its size and position, the evidence that the microscope may give as to its minute anatomy, and the general history of the case may all inform us as to the nature of the growth if it be simple or malignant.

Treatment, if an odontome be recognised, should be expectant in character. If it be causing no trouble it should be left alone. If the gum over it be bruised by an upper tooth the latter may be extracted, and if the odontome be loose it should be removed. If this be then examined it may be found to be an hypertrophied mass of intermixed dentine and enamel, showing but slight resemblance to a tooth; or its crown may be of fair shape with its fangs monstrously distorted; or it may take the

form of an abortive tooth enclosed within a fibrous sac containing a glairy gelatinous fluid.

Dilacerated teeth.—As the result of developmental irregularity, or of pressure on the soft tooth germ, the long axis of a tooth may be bent at an angle near its neck, when it is said to be *dilacerated*.

Geminated teeth.—Two adjacent teeth may be *geminated*, or united by their adjacent surfaces, the union being sometimes so complete that they have but one common pulp cavity.

General developmental irregularity.—Hitherto we have regarded only such abnormalities as are limited



FIG. 13.—Two lower temporary incisors united by cementum on their adjacent sides.

to one, or possibly two, of the teeth. Certain conditions, however, exist which so profoundly modify the developmental process in the growing child as to produce what are known as *Strumous* or *Syphilitic* teeth.

Strumous, or *Honeycombed Teeth*, are generally ascribed to overdosing a child with calomel in its infancy, but by some they are considered to be indicative of a strumous diathesis. They are dark yellow in colour and deeply pitted or ridged transversely upon their surfaces, as though the deposition of enamel had been injuriously affected during development of the organs. A careful

examination with a very fine steel probe will reveal many interstitial cracks and fissures, penetrating through enamel and into the dentine beneath. These apertures admit micro-organisms into the body of the tooth, and hence such honeycombed teeth are prone to fall early victims to decay. A further examination of a mouth thus impressed will probably suggest that the interruption to normal development, of whatever nature it may have been, endured only until the infant had reached a certain period of its life. Thus we may find an imperfect development only of such portions of the various teeth as had until then become developed, while in such parts as were subsequently formed a normal growth may be traced. On looking at the upper teeth of such patients it is very usual to find the lower halves of the crowns of central incisors and 1st molars imperfectly calcified, while not more than one-third of the lateral incisors and one-fourth of the canines show this defect, and the bicuspid and 2nd molars are quite free from blemish. The varying periods at which dental calcification commences serves to account for this condition.

Syphilitic or Specific Teeth.—These, the result of inheritance of the syphilitic taint, show the following well marked characteristics :—one crescentic notch in the middle of the cutting edges of the upper and lower permanent incisors ; also these teeth are separated from each other, are of dark colour, and of peg-top shape. The development of bicuspid and molars is also modified, but the central notch of the incisors is most typical of the diathesis. The temporary teeth of children with syphilitic parentage present

no peculiar traits. The annexed two diagrams are from drawings by Mr. Hutchinson, and show the features of

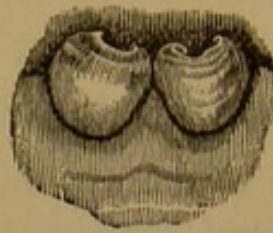


FIG. 14.—Syphilitic Incisors.

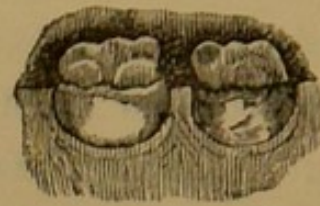

FIG. 15.—Honeycombed Incisors.

typically marked honeycombed and syphilitic permanent upper central incisor teeth.

CHAPTER V.

IRREGULARITY IN THE POSITIONS OF PERMANENT TEETH.

CAUSES OF IRREGULARITY IN POSITIONS OF TEETH. TREATMENT OF IRREGULARITY BY EXTRACTION. SYMMETRICAL EXTRACTION. TREATMENT OF IRREGULARITY BY REGULATING FRAME. IRREGULARITIES FOR WHICH NO TREATMENT IS NEEDED. CLASSIFICATION AND TREATMENT OF DENTAL IRREGULARITIES. MODELLING.

Causes of irregularity in positions of teeth.—

The normal and well formed dental arch possesses an equable curvature. It is not pointed in front, nor is it compressed laterally. Now it is not to be doubted that the varied influences of what is termed civilization tend to disturb this harmony, and stunted jaws with overlapping teeth are greatly on the increase. This is to be proved by comparing skulls of an early date, or from savage tribes, with those that obtain in the present day. The reasons for this degenerative change are complex. In all probability we may ascribe it to the following:—

1. The improvement in the quality and preparation of food, whereby less work is thrown upon the masticating apparatus. Diminished use has here, as in other instances, brought about lessened growth. Hence the jaw

bones, being rendered smaller, induce overlapping and displacement among the contained teeth.

2. To the influence of sexual selection, whereby civilized man, consciously or unconsciously, prefers in his partner the dwarfed maxilla which realizes his ideal of beauty. The process of *heredity* then comes into play, and helps to perpetuate the deformity.

3. To the amenities of civilization, whereby the physically defective, and those less completely developed, are preserved and enabled to marry. In earlier days, with a keener struggle for existence, when a strong body was of more value than a cultivated mind, the survivors possessed wide and strong jaw bones, affording ample space for the dental organs implanted in them. Among aboriginal tribes of to-day, where the conditions of life are so severe as to compel the weaker members to go to the wall, we rarely meet with cases of overcrowding of the teeth.

In the normal upper maxilla a line drawn between first molars of opposite sides is equal to one from either first molar to the space between the central incisors (see fig. 16).

Irregularities in positions of teeth are so varied that an altogether satisfactory method of classifying them is somewhat difficult. The common and typical deformities are therefore hereafter described, and it must be noted that any one may co-exist with other forms. Irregular and overlapping teeth, when occurring in the front of the upper jaw, are more unsightly than when they are found in the lower, but it is always desirable that teeth should be evenly arranged in the maxillæ. Behind projections

food collects, and escaping the cleansing action of the tooth brush, will certainly decompose, thus favouring the attack of caries.

For the curing of irregularity we have two methods of treatment, which may be applied singly or combined; we may extract teeth to give additional room, or we may employ a regulating plate to force the teeth outwards, and so enlarge the dental arch.

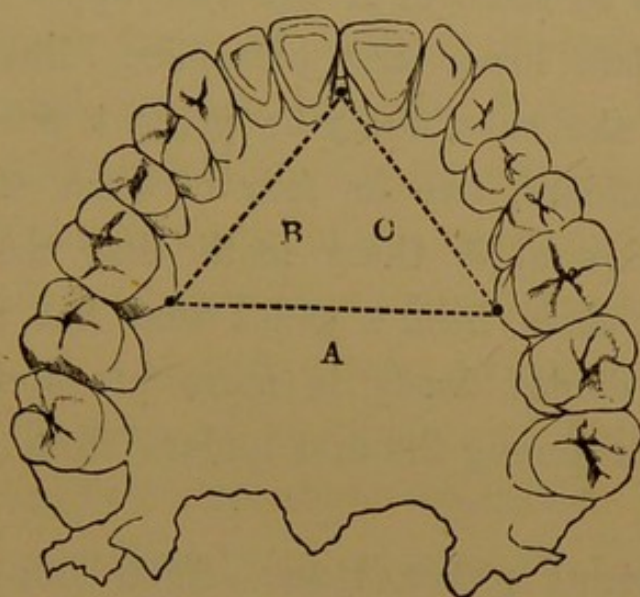


FIG. 16.—An upper maxilla with a normal dental arch. An equilateral triangle (ABC) may be drawn with its angles touching the right and left first molars and the central incisors. In a malformed maxilla, if a triangle be thus constructed, the side A will be longer or shorter than those marked B and C.

Treatment of irregularity by extraction.—If extraction be practised these points should be noted. Front teeth, and especially canines, should if possible be spared, since the loss of two upper eye teeth is apt to alter the appearance of the face by the absorption of alveolar process that follows their extraction, and the consequent sinking in of the angle of the mouth. The canines, moreover, have more value for purposes of mastication than other

front teeth, since they are less liable to decay, and are more firmly implanted in the alveolar sockets. Before deciding which teeth may best be spared, careful examination of the mouth with the assistance of a fine probe and mouth mirror should be made, and those showing most marked decay should by preference be sacrificed.

If all bicuspid and molars be well developed and free from decay, the best and speediest mode of curing irregularity may be by removal of the two upper and possibly also of the two lower first bicuspid. But if as is more likely to be the case, decay be present among the first permanent molars, two or four of these should be extracted. It is upon these teeth that the choice will probably fall, since, from a cause that has not yet been ascertained, dental decay is more prevalent and commences earlier among the first molars than among other teeth.

Symmetrical extraction.—Such extraction should be practised symmetrically. If an upper molar or bicuspid on one side be removed, then also the corresponding tooth on the other side of the mouth should be taken out. If of the four first molars, or of the four first bicuspid, two only, an upper on the right and a lower on the left, be decayed, or if three of the series be carious and the other sound, then extraction should be completed as regards all four corresponding teeth. Thus, from a timely and judicious symmetrical extraction, will often follow a natural and symmetrical regulation of the crowded front teeth, and the forces tending to bring this about are the continuous pressure exerted upon the dental arches by the

lips and muscles of the face and the tongue, and the pressure exerted upon bicuspid during the process of mastication.

If then it be advisable to part with four first molars the extraction may be performed at about the twelfth year, when the four second or twelve-year-old molars are just erupting. The latter then advance, and in two years time the spaces resulting from extraction are nearly obliterated. Although the removal of four decayed first molars may hardly serve of itself to materially alter the positions of much overlapping front teeth, yet the additional room thus gained in the mouth cannot but be salutary, since the increase of the irregularity, from the pressing forward of erupting and advancing back teeth, is certainly arrested. Also the more perfect cleansing and polishing of the sides of bicuspid and molars, which is rendered practicable by the slight separation that ensues among them, conduces very greatly to their ultimate preservation from caries.

More space will however be given to crowded front teeth by symmetrical extraction of the four first molars if the operation be delayed until about the fourteenth year when the four second molars have grown to their full height and are in complete contact as to their grinding surfaces, the upper with the lower. The first molars may be then removed and the second molars will not as before advance to the same extent to fill their places. Thus space will be created and maintained for the backward travelling of the eight bicuspid, and so relief will be given to the crowded incisors and canines. It may be seen that the

upper bicuspid impinge on the lower by a series of inclined planes, and thus the sloping surface forming the back half of the grinding surface of the lower second bicuspid meets an anterior inclined plane on the upper second bicuspid. When food is masticated between these teeth the upper one is forced backward into the space before filled by the first molar—this allows the second lower bicuspid to fall back and it is compelled to do so through the pressure of the upper first bicuspid—and the latter in turn yields to the force of the lower first bicuspid. We see therefore that if in a crowded mouth symmetrical extraction of four first molars be by judicious filling delayed until the fourteenth or fifteenth year more relief to overcrowding will be given than if the extractions be performed earlier, before the complete eruption of the twelve-year-old molars.

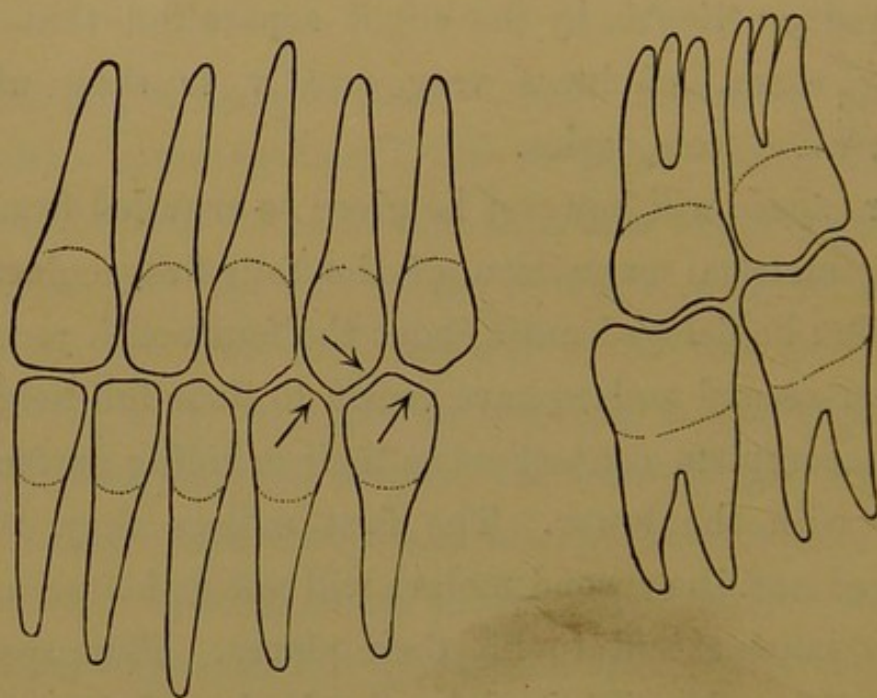


FIG. 17.—The arrows show the direction in which the four bicuspid will frequently move after symmetrical extraction of four 1st molars. (From Smale and Colyer's *Diseases and Injuries of the Teeth*. Longmans & Co.)

Treatment of irregularity by use of regulating frame.—This is usually made of vulcanite or gold, and is constructed by the dentist to a plaster model of the jaw with its irregular teeth. Such a plate carries springy gold wires which looping over the outstanding teeth serve to draw them back into line, and if needed it may contain small wooden pegs to press upon the posterior surfaces of back-standing teeth. Thus by forcing these outwards the dental arch is expanded, and increased room is obtained for the reduction of any irregularity.

During the wearing of all regulating plates great cleanliness should be observed; the teeth being brushed with soap and water each morning and evening, and the plate

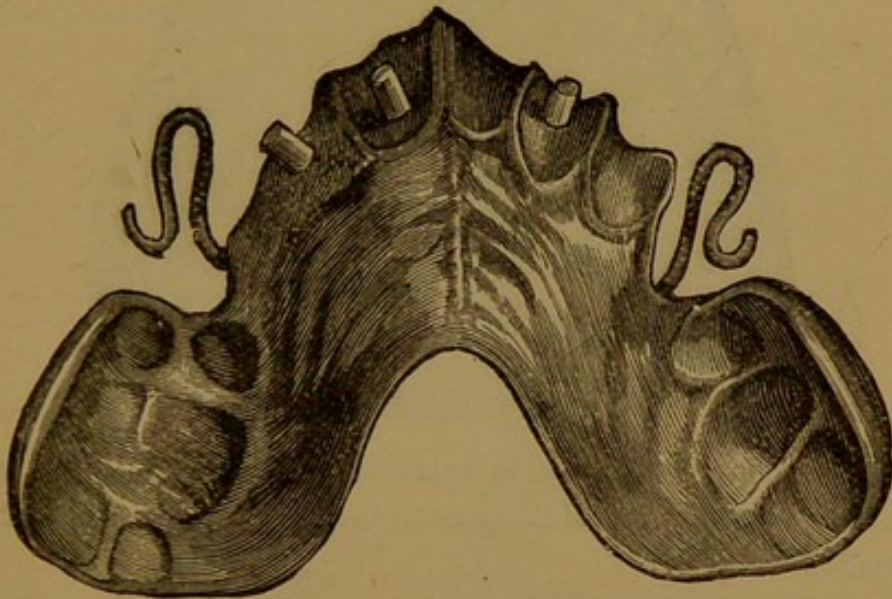


FIG. 18.—Vulcanite regulating plate for treatment of an irregularity among upper front teeth, showing the gold wires and wooden pegs referred to. Such a plate may be worn for three months. It fits closely to the palate, and on each side overlaps the bicuspid and molar teeth as shown in the drawing. The upper, or palatine surface of the plate is here shown. The two springy gold wire loops fit over and draw back the projecting canines, and the three wooden pegs of hickory wood, which are replaced each week by longer ones, impinge upon the backstanding incisors. Thus the latter are forced forward during mastication by the pressure of the lower jaw upon the plate.

being taken from the mouth after every meal to be brushed in like manner on both surfaces. If this be done a regulating plate may be safely worn for several months, but if it be omitted the acid produced by decomposition of food and saliva will eventually soften and erode the crowns of the teeth.

Irregularities for which no treatment is needed.—These form a large proportion of the cases for which the doctor or the dentist is consulted. They

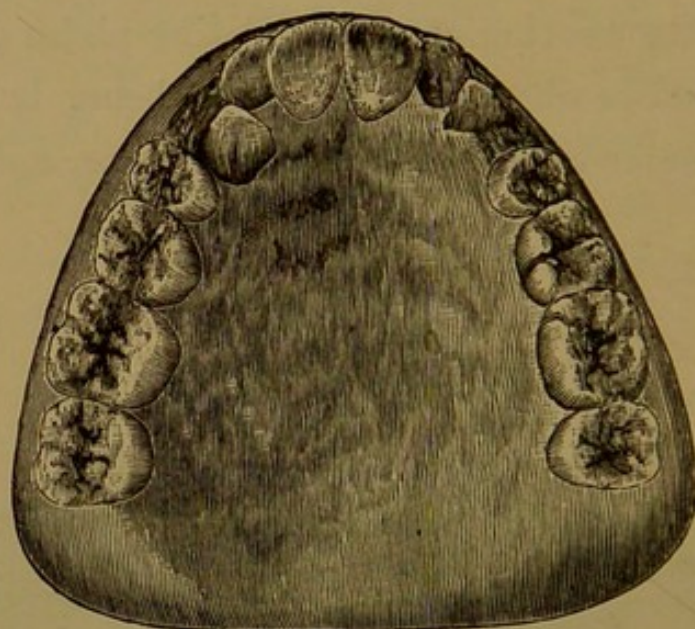


FIG. 19.—An upper maxilla aged 13 years with a backstanding and underhung right canine. The latter is said to be *underhung* since the corresponding lower tooth bites in front of it.

occur usually in children of less than twelve years in age, whose permanent canines are as yet uncut. A slight overlapping or twisting of permanent incisors is observed, and the parents are anxious as to the future regularity of the child's mouth. Here the prognosis is hopeful. Such cases if left to themselves frequently improve greatly, and the additional room given by the growing jaw permits

the teeth to fall into more even line. The pressure of the tongue within, and of the lips without, help to bring this about. In such cases an expectant treatment should be

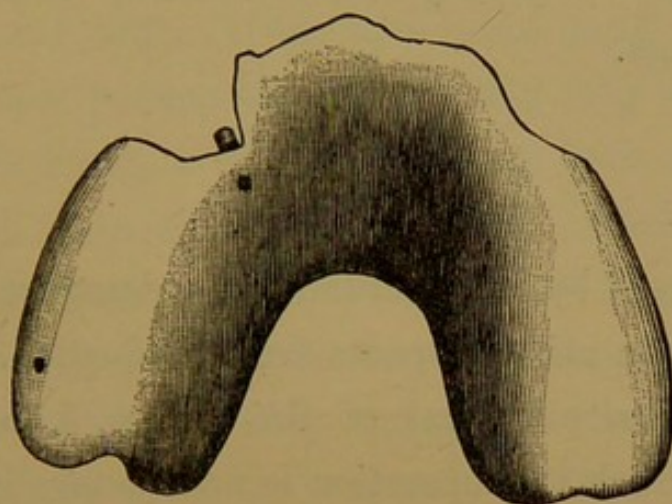


FIG. 20.—Vulcanite regulating plate applied to the mouth illustrated in fig. 19. The lingual surface of the plate is shown, and also the hickory peg that pressed upon the backstanding canine.

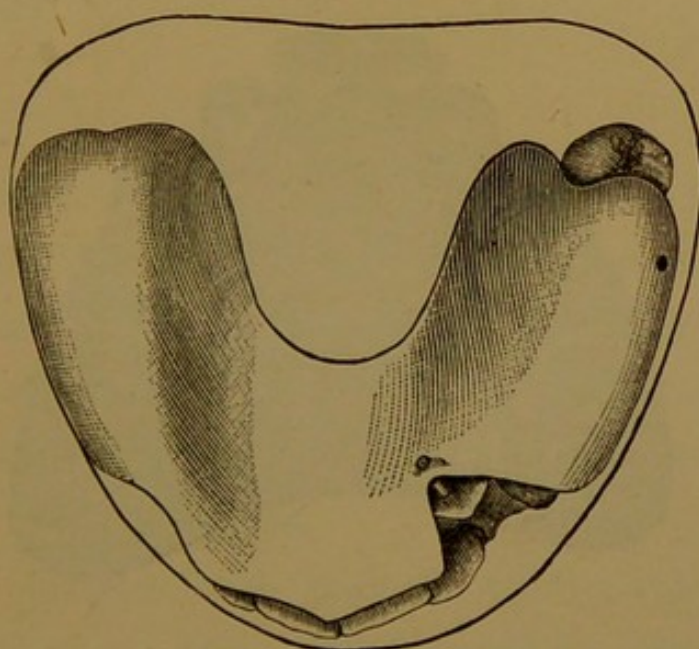


FIG. 21.—The mode of applying the regulating plate. It will be seen that the peg raises the plate from the palate about $\frac{1}{20}$ of an inch on each occasion that it is changed. The closure of the lower jaw bites the plate up to the palate, and so pushes forward the canine. By "*capping*" the back teeth the bite is raised, and the lower incisor sufficiently removed from contact with the front of the upper canine to allow movement of the latter in the desired direction.

adopted, and resort to extraction or the regulating plate should be delayed as long as is prudent.

Classification of irregularities.—The irregularities most often met with may be conveniently arranged under three headings.

GROUP A.

Those caused by undue retention of temporary teeth in maxillæ that in other respects are well formed.

An irregularity typical of the group A is shown in figure 22. Such malformation is not generally so extensive, but is more often limited to one upper incisor or a canine. The result of undue retention of the upper temporary tooth is that its permanent successor becomes

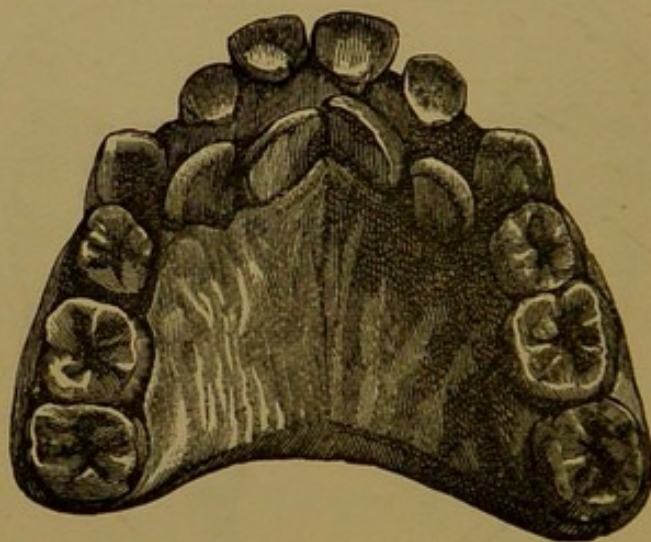


FIG. 22.—Four underhung upper incisors with retained corresponding milk teeth.

After removal of the temporary incisors a regulating plate was worn for six weeks. Thus the backstanding permanent teeth were forced forward and were made to bite in front of the lower incisors. The plate was discarded when this condition was reached, and a fairly regular mouth was then effected by the natural force of mastication.

underhung, and bites behind the lower tooth when the jaws are closed. This of course might have been prevented by judicious removal of the obstructing milk tooth at an earlier period of life, when it became evident that harm was being done. If the case come under observation when the upper permanent tooth, being fully erupted, has become underhung, a regulating plate with wooden pegs (see fig. 18) must be employed. The vulcanite curves over the upper molars and bicuspid, and by thus keeping the jaws slightly apart, relieves interdigitation of upper and lower front teeth. Thus the obstacle to the advance of the misplaced tooth is removed. When it has been forced in front of its lower antagonist the frame may be discarded, since the closure of the jaws prevents a relapse, and tends to induce a symmetrical arrangement of the dental organs.

GROUP B.

Irregularities characteristic of group B take varied forms. They have this in common, that they do not seem to be caused by overcrowding, but are due rather to an error in the direction in which the misplaced tooth has erupted. The development of the maxillæ themselves in these cases is not impaired.

Thus an incisor tooth may be partly rotated on its long axis (*vide* fig. 23). This should be treated with a regulating plate constructed to draw back the projecting margin by the aid of a gold wire, and with a wooden peg to push out the posterior side of the tooth. A few years back it was not unusual to forcibly turn such teeth into

proper position with the aid of forceps. This course is not to be recommended, as the disruption that it causes to

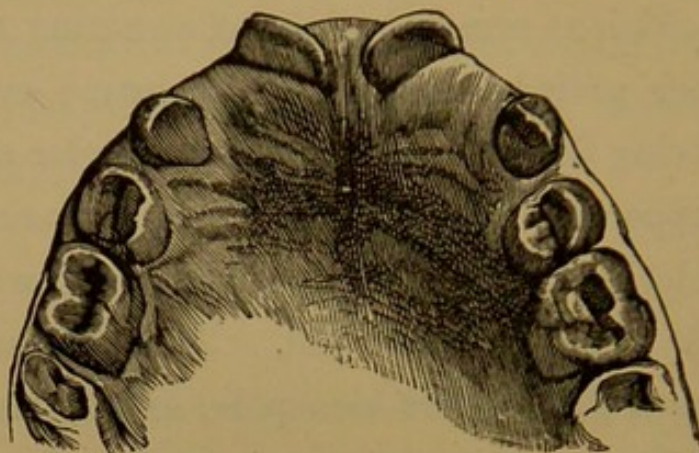


FIG. 23.—Model of upper jaw with rotated incisors

the nerves and vessels entering the tooth at the end of its fang is very liable to induce death and early loss of the organ. If however this operation of *Immediate Torsion* as it is termed be performed it should be done within eighteen months of eruption of the tooth while the opening at its fang end is large, so that the nutrient vessels there entering may escape undue compression.

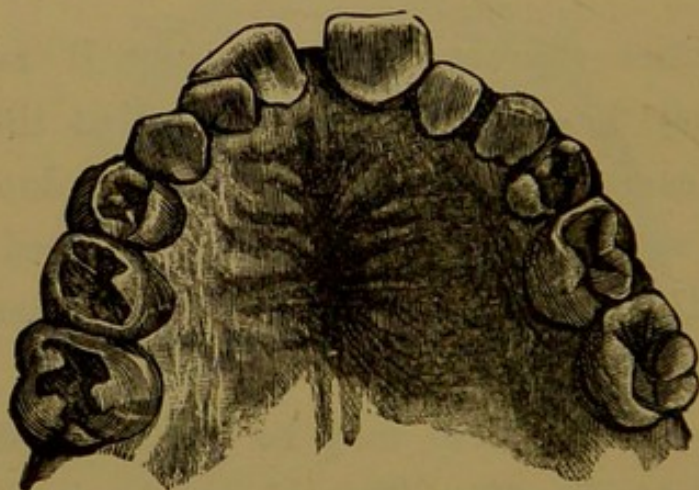


FIG. 24.—Model of upper teeth with widely spaced and divergent incisors.

Again, as characteristic of group B, may be instanced those cases in which upper incisor teeth are widely spaced and divergent (*vide* fig. 24). Such cases are best treated

by the dental surgeon, who if the contact of the lower teeth do not present an obstacle, may draw together divergent centrals by placing round their necks a thin elastic band. It must be noted that such treatment needs close watching, and the band must be prevented from forcing itself up the necks of the teeth beneath the gum by attaching to it one or more gold wire loops, which may be hooked over the cutting edges of the teeth that are being operated upon. If this be neglected the latter will certainly be loosened and will probably be lost.

GROUP C.

Here we find more extensive departures from a normal dental arrangement. Since this overcrowding and projection of the teeth are due to malformations in the maxillæ themselves these cases are less amenable to treatment. Much, however, may often be done to increase the symmetry of the face. We may for convenience divide irregularities of this class under four headings.

1. Those in which the antero-posterior development of the upper maxillary arch, as compared with that of the lower is too great. Hence results projecting upper teeth, the prominence of which in these cases is not caused by pressure on their back surfaces of the lower front teeth (*vide* fig. 25). Treatment usually comprises removal of two upper bicuspids or of two first molars, and the use of a regulating frame to draw back by the aid of elastic wire loops the prominent upper front teeth. The plate must be worn for a year or so, and it must not be dis-

continued until the teeth have become firmly fixed in their new and improved positions.

2. Those in which the antero-posterior development of the upper maxillary arch, as compared with that of the

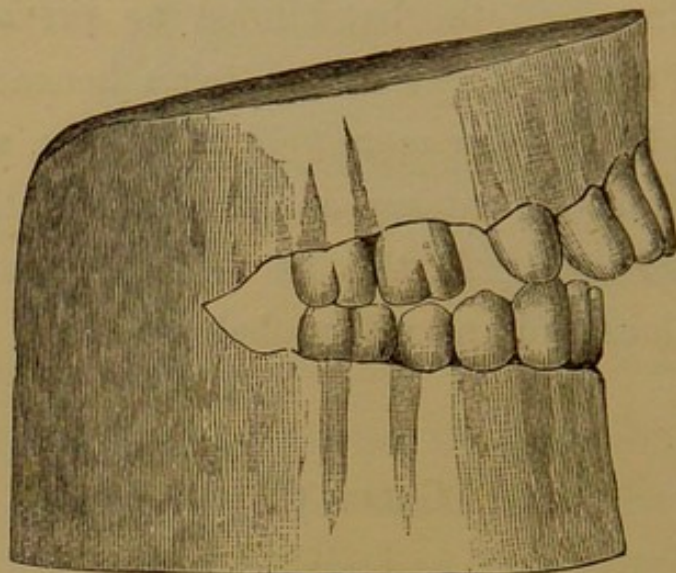


FIG. 25.—Side view of model of upper and lower front teeth. The upper incisors project considerably in front, and beyond the lower teeth, thus greatly marring the symmetry of the face. Here the length of the upper maxilla is disproportionate to that of the lower.

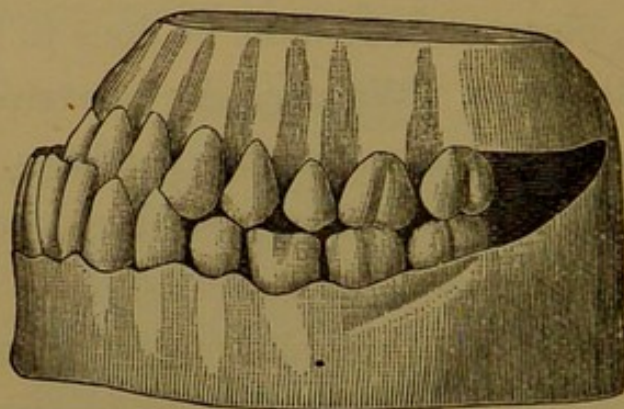


FIG. 26.—Model of underhung upper incisors.

lower, is too little. Hence results projecting lower teeth, which bite in front of the underhung upper incisors (*vide* fig. 26).

Projection of the lower jaw is often inherited, though frequently it develops itself in middle life, when the masti-

cators have been lost, and the individual has acquired the habit of protruding the lower jaw in order that food may be triturated between the upper and lower front teeth. Although very unsightly, we can do little to relieve the condition. Slight irregularities of this nature have been cured by placing small wedges of india-rubber between all the upper incisors, canines and bicuspid. Thus the

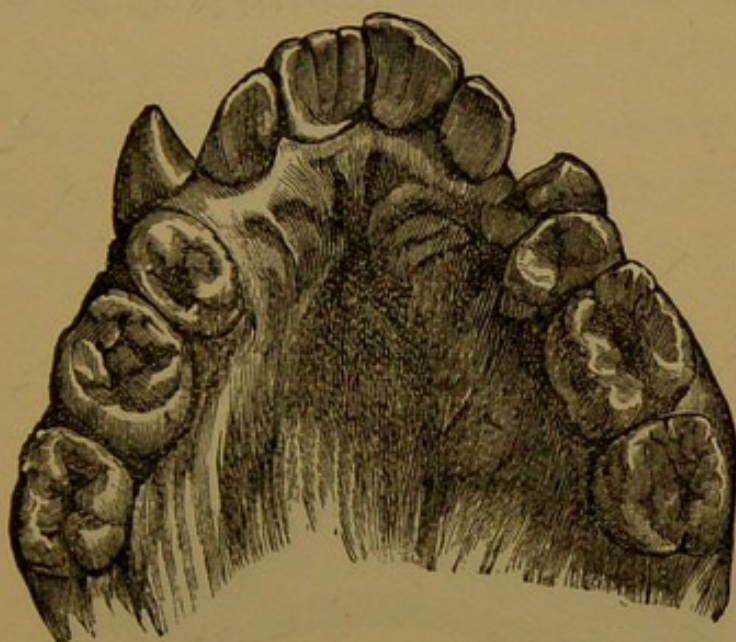


FIG. 27.—Model of a narrow upper jaw, aged 14 years. The canines are projecting but these were subsequently, by a regulating plate, drawn backwards and inwards into the spaces caused by the removal of first bicuspid. At the same time the four incisors were pushed slightly outwards by wooden pegs connected with the frame. The model was taken a month after removal of the two first bicuspid.

upper arch has become expanded, and its teeth, being separated, have been induced to close in the normal way, over and in front of their lower antagonists. Taking into consideration, however, the painful nature of this treatment, with the uncertainty of bringing about a good result, I would prefer, as a rule, to leave these cases undisturbed.

3. Those in which the transverse development of the upper, and often, also, of the lower maxilla is too little. Here we meet with what is termed the *V shaped arch*, illustrated in figures 27 and 28. The teeth are seen to be arranged along two more or less straight lines, which meet at the line of contact of the two central incisors. The space afforded to the dental organs is manifestly insufficient. Hence results overlapping of the central

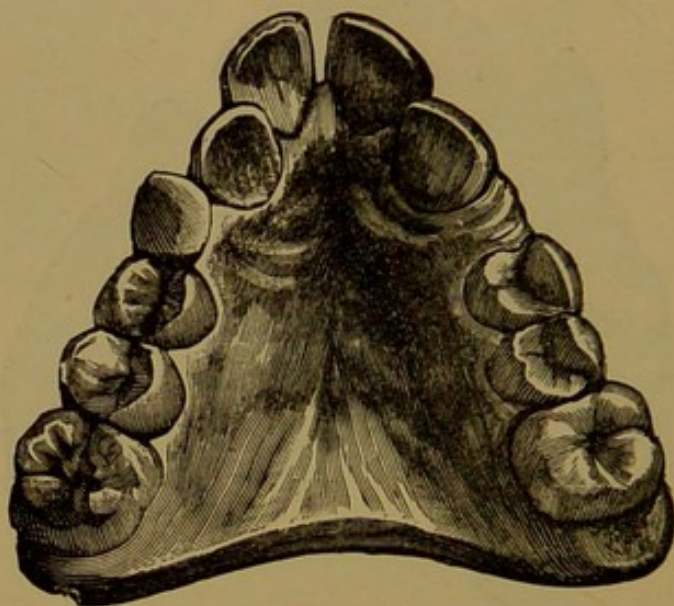


FIG. 28.—Model of a V shaped upper jaw, aged 11 years. This co-existed with a vaulted palate, and idiocy of a congenital nature. The drawing scarcely indicates the extent to which vaulting of the palate was carried.

incisors, displacement or twisting of lateral incisors, displacement of bicuspid, which may be extruded towards the palate, or projection of the canines as in figure 27. This latter is a very common form of irregularity, and no doubt is favoured by the late eruption of the eye-teeth, which on being cut are apt to find their sites filled up by the approximation of lateral incisors and first bicuspid. The V shaped arch is frequently associated with a palate more or less deeply vaulted, and a deformity of this

nature is, in the opinion of Dr. Langdon Down, often combined with congenital idiocy (*Transactions of Odontological Society*, 1871).

Much may be done to improve these V shaped arches. By extraction we may relieve overcrowding, and afford space for an improved arrangement of the teeth. As before said, first bicuspid or first molars may be removed, and in selecting the teeth which can best be spared the operator must use his own judgment. If the molars be decayed, he will of course prefer to sacrifice these, and sometimes he will do well, if overcrowding be extreme, to

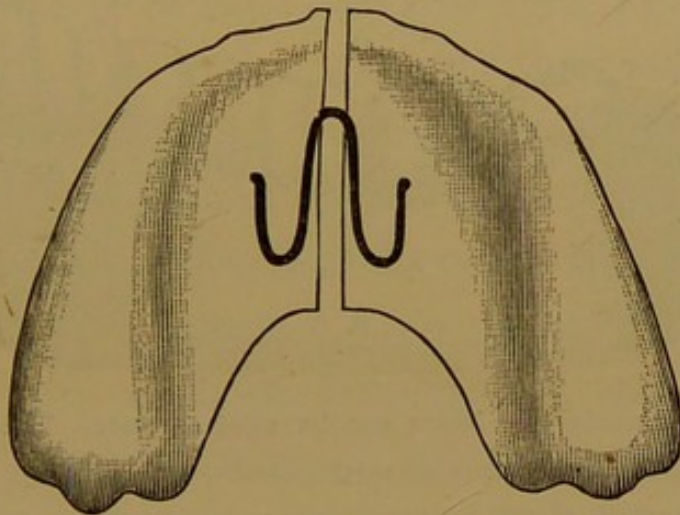


FIG. 29.—Dr. Coffin's expansion plate for widening upper maxillary arch, the dark line represents a tempered steel spring, the force of which is increased by pulling the halves of the frame slightly asunder.

part also with the first bicuspid. By employing a vulcanite regulating plate (*vide* fig. 18), he may draw in outstanding teeth, and also push out those that stand behind their proper positions. Also by the use of a plate, such as was designed by Dr. Coffin (*vide* fig. 29), much may be effected as regards widening or expanding the dental arch. Such a plate must be worn for several months, and its pressure upon the sides of the alveolar

arch may be increased by stretching apart the two portions of which the frame consists.

4. Those in which the developmental irregularity would seem chiefly to be located in the lower maxilla. Here we find the front of the lower maxillary arch, with its contained incisors and canines, on a higher level than the back portion thereof, which supports the molars and bicuspid (*vide* fig. 30). The result of this is that the edges of the lower front teeth bite forcibly against the back of the necks of the upper incisors. The latter are thus loosened and caused to project.

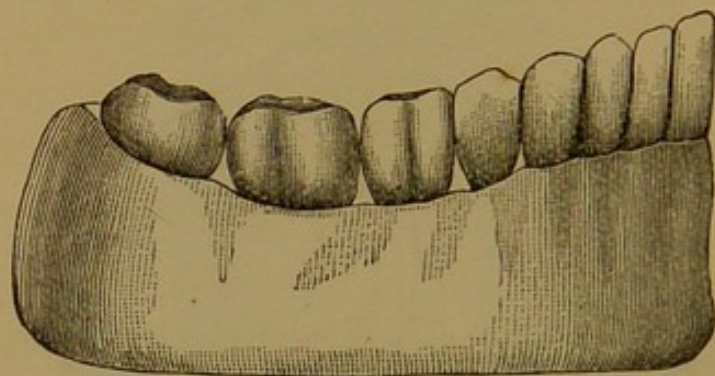


FIG. 30.—From a model of a lower maxilla, aged 40 years. The maxilla curves upward in front, thus raising its front teeth considerably above its lower bicuspid and molars. The result of this is that the upper front teeth are deeply indented and worn away, as regards the posterior surface of their fangs. They are, moreover, much loosened and so pushed forward as to lie in an almost horizontal position. A gold plate capping the lower molars is now worn and thus, the bite being raised, the upper front teeth are preserved.

In a pronounced case of this nature lately under treatment, the only plan that proved successful in preventing loss of the two upper central incisors was to adapt a thin gold plate to the grinding surfaces of the lower masticating teeth. Thus the lower front teeth were kept out of reach of the upper ones, which they were rapidly destroying. Before the wearing of this plate, which served

only to prevent increase in the irregularity and in no way tended to reduce it, a prolonged but quite unsuccessful attempt to improve the positions of the upper and lower teeth had been made. The four first bicuspidis had been removed; the lower incisors had been slightly shortened by filing away a little from their cutting edges; the lower incisors with the lower canines had been drawn back by a vulcanite regulating plate; this being effected, the projecting upper incisors and canines were then drawn in by the continuous and gentle contraction of an elastic band passed round the back of the head, and attached to each end of a narrow gold band that impinged upon the front surfaces of the six projecting upper front teeth. By this prolonged treatment the irregularity was almost entirely cured, but on discontinuing the apparatus the case unfortunately relapsed into something much like its first condition, through the renewed pressure upon the backs of the upper front teeth of the edges of the lower ones. From this it may be inferred that malformations of this nature are not very amenable to treatment.

In conclusion, the subject of this chapter may thus be summarised. In treating irregularities the practitioner must rely upon the growth of the jaws with judicious extraction when necessary, and failing these he must refer his young patient to the dentist that a plate may be made and worn. The following is a convenient and comprehensive classification of dental irregularities, in accordance with the foregoing.

A. Those occurring in normal maxillæ, but caused by undue retention of temporary teeth.

B. Those occurring in normal maxillæ, but due to some local interference with the due direction of eruption of the permanent teeth.

C. Those occurring in maxillæ so malformed that space is not afforded for the due arrangement of the dental arches. These last may be thus classified:—

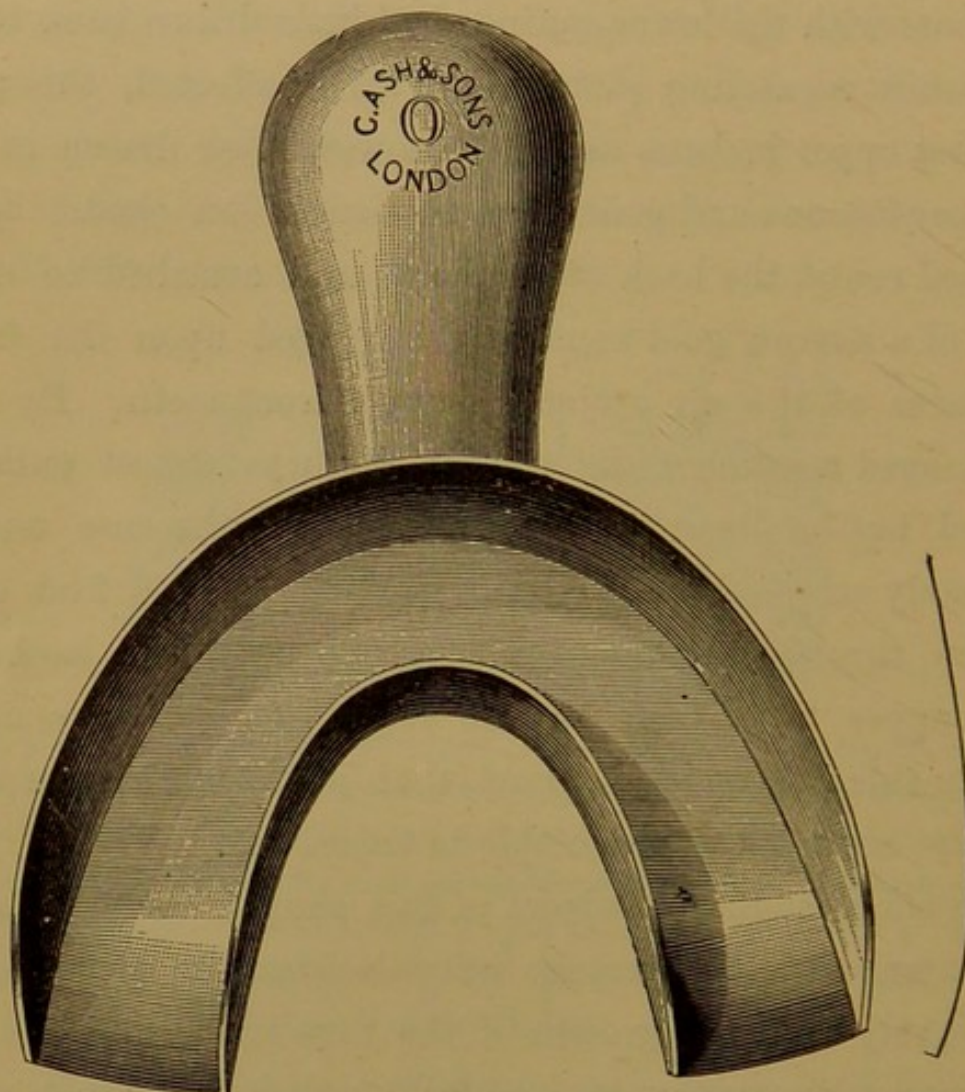


FIG. 31.—A pewter tray to hold softened wax for modelling purposes.

1. Those in which the upper jaw is too long in comparison with the lower.

2. Those in which the upper jaw is too short, added to which may also be abnormal length or protrusion of the lower jaw.

3. Those in which the jaws are too narrow.

4. Those in which the front portion of the body of the lower jaw curves upward, so that the lower incisors are much higher than the lower molars.

Modelling.—In connection with this subject, reference may be made to the modelling of mouths of which a record is desired. A tray such as shown in fig. 31 is filled with beeswax, or modelling composition, well softened in warm water. The wax should be such as is sold under the name of modeller's wax, and the water should never be too much heated. The wax and tray should then be pressed firmly and steadily against the teeth of which a model is desired. After an interval of a minute they should be removed, and into the impressions of this matrix Plaster of Paris, rendered fairly fluent by admixture with much water, should be poured. After an hour the mass of plaster, which has now set hard, may be placed in hot water, and the wax thus again softened may be peeled off. The model may then be trimmed up with a knife and dried for an hour or two before the fire. For the purpose indicated wax is more useful than Plaster of Paris; an impression is more easily taken with it, and it is quite accurate enough for the purpose.

CHAPTER VI.

DENTAL CARIES.

EBURNATION. PENETRATING AND SUPERFICIAL DECAY. MICRO-ORGANISMS CAUSING DECAY. DEFECTIVE CALCIFICATION. ACID STATE OF ORAL FLUIDS. COMPARATIVE TENDENCY OF TEETH TO DECAY. CARIES IN ITS FIRST STAGE. GUTTA-PERCHA AND AMALGAM FILLINGS. USE OF ARSENIC. CARIES IN ITS SECOND STAGE. PERIODONTITIS, ACUTE AND CHRONIC. CARIES IN ITS THIRD STAGE. CLOSURE OF THE JAWS. FISTULOUS OPENING THROUGH CHEEK. SUMMARY OF REMEDIAL MEASURES. LIST OF INSTRUMENTS AND MATERIALS REQUIRED.

DENTAL CARIES consists in a progressive destruction, softening, and wearing away of the hard tissues of a tooth. In its early stage it affects only a small circumscribed portion of a tooth-crown, and commences always in some open crack, or in some defective patch of enamel. It tends to increase with more or less rapidity, to invade the deeper lying healthy tissue, and it extends always from without inwards, towards the pulp cavity. Caries never originates within the substance of the dentine. The cavity of decay has always, from its very commencement, an orifice through which food, saliva, and micro-organisms may gain access to the interior of the tooth.

Natural arrest of decay.—If measures be not taken to arrest the disease, entire destruction of the tooth usually results, but occasionally the latter assumes a state of *eburnation*, and the morbid action ceases. The surface of dentine is then found to be polished, black, and very hard, and in this condition the tooth may be retained usefully for years.

Upon the causes and nature of decay much light has of late years been thrown by the work of Professor Wedl and others, still our knowledge is as yet far from complete. It is convenient to consider the appearance and nature of caries before discussing its causes.

Dental decay presents itself under two aspects, occurring either as penetrating or superficial caries.

Penetrating caries makes itself evident at the bottom and sides of some natural fissure, such as is often found between the cusps of a molar or bicuspid, in the middle of the outer surface of a molar, or at the back of an upper incisor. Thence it spreads in all directions throughout the dentine, which is often greatly softened before the enamel overlying it is much affected. Of the two tissues, dentine is found to be far the more prone to soften down; enamel is harder and more resistant. If a tooth thus affected be examined with an excavator, we find a small irregularly shaped hole in the enamel, which being chipped away with the instrument, reveals a larger cavity in the dentine, which has become softened, leathery, and brownish in colour. On removing this diseased tissue a hard substratum of white healthy dentine is reached.

Superficial caries attacks the surface of the crown, usually near the neck in proximity to the gum. In its early stage the enamel presents a white chalky appearance, it is found to be soft and friable, and decay of this nature extends rapidly throughout the tooth, the enamel softening down as rapidly as, and proving not more resistant than the dentine underlying it.

Between these two forms of decay there is essentially little difference. Their symptoms and treatment are similar, and the occurrence of either is determined by the nature of the developmental defect which the tooth exhibits. If it be homogeneous and solidly constructed it does not decay. Penetrating caries is favoured if it be built up of nodulated masses of dentine and enamel, which, though themselves well calcified, are yet so imperfectly united to each other at their surfaces of contact that fissures exist into which micro-organisms may find entrance. Superficial caries attacks the sides of a tooth whose tissues throughout are more or less porous and badly constructed. The former may be likened to the damage suffered by a well-built house whose roof is slightly defective, the latter to the sapping of walls and foundations that weather produces in a structure whose bricks and mortar are alike imperfect. Since it is easier to repair a roof than to rebuild a house, it may be inferred that penetrating caries is more easily arrested by the dental art than superficial decay.

A close examination of a decaying tooth shows that the enamel over and around the cavity has lost translucency, has become whitish in colour and chalky on cutting with

the excavator, while the soft underlying dentine is easily flaked off with the instrument. The decayed tissue will then be found to consist mainly of organic matter, stained brown or black by degenerative changes. The phosphate and carbonate of lime which formerly gave hardness to it

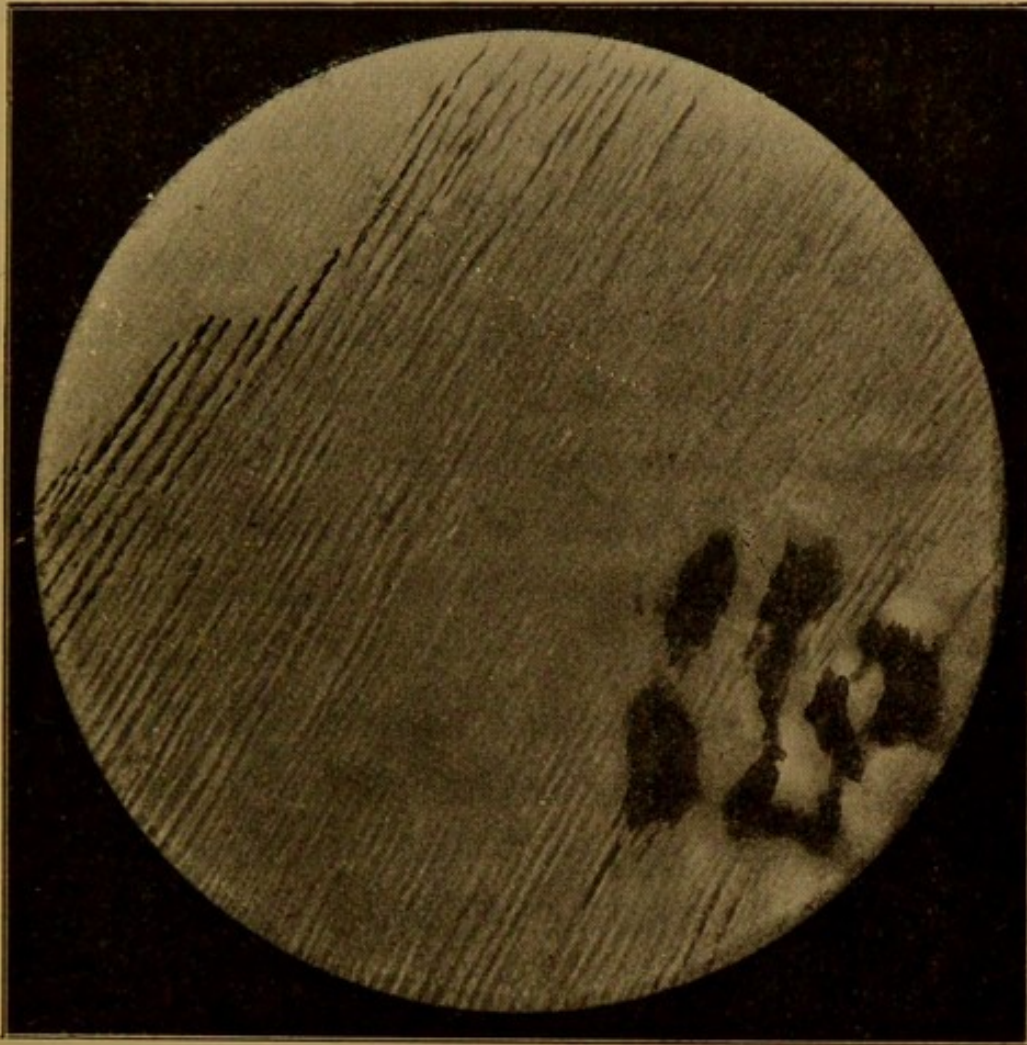


FIG. 32.—From a photomicrograph of a section of carious dentine (both by the author). An objective of $\frac{1}{2}$ was first employed and the negative subsequently four times enlarged. The drawing shows that the section has been made parallel with the dentinal tubules, which are more or less filled and distended by an invasion of the micrococci productive of decay. Towards the upper part the dentine is seen to be free from micro-organisms, in the centre the tubes are to be found filled with them, while in the lower part of the picture it will be noticed that they have massed themselves into spaces which they have excavated in the dentine.

have been dissolved out. In addition to this softening of enamel and decalcification of dentine, the progress of decay is attended by the growth of a micro-organism, the micrococci of which intrude themselves into the dentinal tubules and proliferate within them.

The connection between the growth of a cryptogam and the progress of decay is now established. The micro-organism is probably present in most mouths but when it invades the dentinal tubules it finds a soil wherein it grows luxuriantly. It then plays the part of a ferment, changing the starchy and saccharine particles of food around it into lactic and acetic acids which dissolve out the lime salts from a tooth. It grows moreover at the expense of the organic matter contained in the dentine and thus minute liquifaction foci will be formed around masses of proliferating micro-cocci, and may be discerned under a low microscopic power.

The conditions which favour the invasion of the dentinal tubules by the micro-organisms and the destructive growth thereof within the tooth may be thus expressed :—

- (1). The defective calcification of the tooth.
- (2). Acid condition of the oral fluids.

DEFECTIVE CALCIFICATION is shown, as before said, by an imperfect consolidation of the tooth with a porous condition of its enamel and dentine—and this defect lies at the bottom of the matter. The deeply fissured and porous tooth is open to the attacks of enemies which a tooth well built can successfully resist. It permits the entrance of acid saliva, of food which subsequently ferments, and of Bacteria that favour fermentation. It is certain that

among more civilised races, such as the inhabitants of European countries, imperfectly developed and decaying teeth are greatly on the increase. Few mouths can now be found which do not exhibit dental caries, and closer scrutiny of young teeth, immediately after their eruption, shows that defects in development and calcification are widespread. The evidence whereof is to be found in the deep fissures between cusps, and soft patches at the sides of crowns, which the mouth mirror and fine excavator so often reveal. Among aboriginal and savage races, as the Zulus and Caribs, imperfect calcification and decay are rare. From this it must be inferred that the influences of civilisation are prejudicial to the well being of our teeth. Many reasons have been given for this unfortunate result. It has been ascribed to the deleterious influence of iced drinks and of sweet foods. The true explanation is probably to be found in that survival only of the physically strong, which is permitted to the savage by the severity of his struggle for existence; while among more cultivated races the weaker members are preserved, and are allowed to transmit and extend their developmental defects among their posterity.

An acid condition of oral fluids is frequently met with, associated with a secretion of mucus of a peculiarly adhesive nature. Thus the necks of the teeth are not readily cleansed from agents which tend to damage them. This condition is often met with among strumous young people of either sex, and it is apt to be associated with widespread and devastating decay. Among those who fail to use the tooth brush, and this omission is

almost universal among our working classes, we may see *débris* of food adherent to the crowns, and this, by its fermentation produces an acid solvent of the tooth structure around the neck of the tooth. It is convenient here to note that the tooth brush should be a soft one, should be used twice daily, and to aid its action warm water, with a mixture of soap and chalk, should be employed.

Comparative tendency of teeth to decay.—The tendency to caries shown by various teeth differs greatly. Those most liable to it are the four six-year-old molars, and of all decayed teeth extracted by the operator, about one-third will belong to this series. Those least liable to this disease are the four lower incisors and two lower canines, and their comparative immunity from caries is due to their more perfect calcification, whereby micro-organisms are better excluded from their interiors.

With the condition of the health generally the tendency to decay naturally varies, and so our efforts to combat the latter should be both general and local in their nature. The local treatment of a carious tooth should have a double aim; firstly to relieve the toothache which is usually the exciting cause of our patient's visit; secondly, to preserve the tooth usefully and to retard or prevent the extension of caries. It is evident that the insertion of gold fillings, sometimes the most successful way of effecting this last, is as much outside the work of a medical practitioner as is the making of plates for artificial teeth. Still much remains that a doctor may do for his dental patient.

In speaking of the symptoms and treatment of caries

we may conveniently divide the process into three stages.

Each of these conditions presents well-marked and unvarying characters, and familiarity with them is the more necessary since treatment that serves to relieve pain in the first stage would, if adopted in the second, make matters very much worse.

Caries in its first stage.—SYMPTOMS.—The first stage of caries endures until the dental pulp, or any portion of it has become gangrenous. The patient generally complains of severe intermittent pain, increased and induced by cold water, hot fluids, the sucking of air from the carious cavity by the tongue, and the pressure of food within it during mastication. Frequently the carious and aching tooth cannot be exactly indicated by the sufferer. Pain, as he says, flies round the teeth, so that he hardly knows which is in fault. Careful examination with the aid of a mouth-mirror, and an excavator carrying a small dressing of absorbent wool, will usually reveal a cavity of moderate size in some tooth around which pain seems to centre. Our examination shows :—1. The tooth is not discoloured, therefore it contains no dead and decomposed dental pulp, such as might stain the dentine. 2. Pain is not complained of when moderate pressure is made upon a sound portion of its crown with a strong blunt pointed excavator, and the absence of such pain shows that the tissues outside and embracing its fangs are in a normal condition. Guard, however, against being deceived by the starting and flinching in which a nervous patient will indulge at the moment of contact of the excavator with the tooth. A good plan is to test other teeth near the

suspected and carious one *before* coming to the latter. 3. Most acute and darting pain is felt when the edge of the excavator is inserted into the decayed dentine in the floor of the cavity, or when the dressing of wool is wiped across its surface. Be it remembered that this should be very cautiously and gently conducted, the walls and floor of the cavity being stroked rather than cut with the instrument, since intense pain may readily be caused, and the dental pulp, if not exposed by the progress of decay, may be thus accidentally laid bare. 4. The crucial test to ascertain if the nerve be still alive and sensitive, *i.e.*, if the caries be still in its first stage, may now be applied. Inject from the nozzle of a small syringe three or four drops of cold water into the cavity in the tooth. This will cause severe though momentary pain, but before inflicting it the patient should be cautioned that what is about to be done will probably produce this result. These four conditions then : the absence of discoloration, the absence of tenderness on pressing the crown of the tooth, the sensitiveness of the decayed dentine, and the pain caused by injecting cold water, go to show that the nerve is alive, and in a normal though perhaps irritated condition, and that the first stage of caries still continues.

TREATMENT.—*The cavity small and nerve not exposed, or exposed by only a small opening through the wall of the pulp cavity.*—Carefully examine the bottom of the cavity to learn if the nerve be exposed, which, if such be the case, may be seen as a bleeding highly sensitive spot. If this be not evident, or if the point of exposure be very minute and the cavity of moderate size, a filling may be inserted.

Before doing this all particles of food should be washed from the cavity by syringing with *warm* water, and its walls and floor should be dried by gently wiping with a dressing of absorbent cotton-wool upon the end of an excavator. The overhanging margins of enamel should be carefully cut down with files and enamel cutters. A sharp excavator should then be carried round the walls of the cavity, undercutting them slightly, that the filling may not fall out, and removing the softened dentine until the underlying hard tooth structure is reached. In so doing care must be taken to cause but little pain, and not to expose the dental pulp. To avoid this, operate chiefly on the edges of the cavity, leaving untouched on its floor some of the carious tissue. While thus excavating and shaping up the cavity the tooth should be kept dry by the aid of a mouth napkin, used as directed in a subsequent paragraph of this Chapter.

The filling may consist of wool with carbolic acid, wool with solution of mastic, gutta-percha, or amalgam.

1. *Wool with carbolic acid* may be used if the walls of the cavity be very sensitive, if the nerve be exposed by a minute puncture, or if the tooth be aching at the time of treatment. It may remain in for a day or two, and then be replaced by a similar dressing; after which if tenderness be lessened, a wool and mastic, or gutta-percha filling, may be inserted. In applying the carbolic dressing the cutting end of an excavator should be rotated within a small piece of cotton-wool held between the thumb and fingers. The wool is thus rolled into a compact plug, the end of which may be dipped into a phial containing wool

already saturated with carbolic acid. Thus only a small quantity of the latter is absorbed by the dressing, and indeed a larger application is undesirable, as it is apt to excoriate the gums and cheek. Care should be taken that the plug is not inserted with so much force as to cause pain by pressure upon a nerve possibly exposed; and sometimes when the application of carbolic acid fails to soothe an aching dental pulp relief may be readily obtained by the substitution for it of thymol or eucalyptin.

2. The *wool and mastic* plug may be inserted when the cavity has only slight tenderness. In applying it, the end of an excavator should be armed as before with a little cotton-wool, which may be dipped into a strong solution of gum mastic in alcohol, after which a little dry wool should be wrapped around the plug. This may be introduced into the cavity, which has previously been washed out and dried, and may be allowed to remain for a few days, after which it is apt to acquire an offensive odour and should be changed.

3. *Gutta-percha* as a filling may be used under such conditions of the tooth and cavity as make a wool and mastic plug possible, and it is more durable and less absorbent of the fluids of the mouth than the last. The gutta-percha, having been warmed over a spirit lamp, should be inserted while soft, and while only so hot that it may be applied to the back of the operator's hand without causing any pain. If the cavity be kept thoroughly dry while being filled, and if such a stopping be in contact all round with hard walls, it may endure for years. Be it remembered that the durability of any stopping is chiefly

proportionate to its hardness and its faculty for excluding moisture. Gutta-percha is most useful in that its low conductivity protects a nerve sensitive to thermal changes.

4. *Amalgam* is more durable than gutta-percha. It may be used when the nerve is well protected, and the tooth not sensitive. A pellet of "Sullivan's Cement" (*see after*) should be heated over the lamp until globules of mercury ooze from its surface. It should then be crushed in the pliers, and worked in the hand into a plastic bolus, from which superfluous mercury may be squeezed through a piece of linen cloth. The filling being inserted in a perfectly dry cavity sets in three hours, and since in setting it does not greatly contract, we obtain hereby a fairly water-tight plug. As this material is apt to blacken on the surface and stain the tooth, its use should be confined to the back of the mouth, and it should never be inserted in any of the front teeth. Also the high conducting power of this metal filling renders it undesirable when the dental pulp is nearly approached, and but slightly protected from thermal changes.

In this connection reference to gold and oxychloride fillings is purposely omitted, such materials having no value save in the hands of those trained to their use.

The cavity large and nerve exposed.—Under these circumstances it may be impracticable to retain even a soft or temporary filling in the tooth, either on account of its extreme sensitiveness and constant aching, or from the absence of such adjacent teeth, or overhanging walls to the cavity, as would prevent the plug from coming out during mastication. Frequently under these conditions

extraction is the best course to adopt, but the health of the patient or other causes may prohibit this. The employment of arsenic is then indicated and should be thus effected. Equal parts of yellow soap and arsenious acid are to be well worked into a bolus, of which a pellet, as large as the head of a good sized pin, should be carried on an excavator into the bottom of the washed and dried cavity, as near as possible to the point of exposure of the pulp. The pellet may be held *in situ* by a plug of wool, which should be removed after 24 hours, and replaced with a wool and mastic filling. One application of arsenic generally suffices to devitalize a dental pulp, but sometimes a second and smaller piece may be introduced into the tooth after two or three days, if it be found still sensitive to cold water from the syringe. The pain caused by the action of arsenic on a pulp is generally severe for three hours, and commences within half an hour of its application. After six hours the pain has generally quite departed, and the condition of the tooth so changed that the patient no longer dreads to inhale a deep breath of cold air, or to brush the teeth with cold water. Thus, at the expense of a temporary increase in such toothache as he may have already long suffered, complete relief may be gained, and the tooth, though its existence be not prolonged, will no longer remain a constant source of pain. In applying arsenic, guard against allowing the soft pellet to be squeezed out of the cavity, while the wool plug is being introduced, so that it is brought into contact with the surrounding gum. Thus much painful ulceration may be caused, and no beneficial action upon the aching

dental pulp result. Guard also against using a pellet larger than the head of a good sized pin; and avoid its use altogether if decay has so far advanced that both walls, or the floor of the pulp cavity, are perforated so that the caustic should exert its destructive influence upon the socket on the opposite side of the tooth. After thus devitalizing the dental pulp it is best, in the absence of facilities for carrying antiseptic dressings into the fangs, to leave the cavity open, or at any rate filled only with a readily removable plug of wool and mastic.

Caries in its second stage.—SYMPTOMS.—The second stage of dental caries is reached when the dental pulp, or any portion of it, becomes gangrenous, *i.e.*, dead and decomposing. Such a condition usually results from decay when it is allowed to go on unchecked by natural or artificial means. The natural limination to this morbid process is of the nature of *eburnation*, before referred to; the artificial measures include the process of excavating and filling the cavity.

As a consequence then of advancing caries the pulp becomes irritated, aches and at last takes on a process of destructive inflammation, by which after several hours of severe pain its vitality is destroyed; or this last condition may be reached more gradually and without any attack of severe pain. Here it may be noted that the vitality of a dental pulp may depart without any pre-existent decay, and as the result of a generally depressed condition of the health; or again it may be destroyed by a violent blow upon the tooth; also by the action of arsenious acid employed as before mentioned. The pulp having lost vitality

will in a few weeks become putrescent, evolving the usual gaseous products of decomposition. The pulp cavity and the canals down each fang are now charged with a dark, viscid, fetid substance, from which gas is constantly escaping by any opening that may exist through the wall of the pulp cavity. This opening is usually found at the bottom of the original cavity of decay, and results from the softening and destructive action of disease upon the dentine, or it may have been made artificially by the excavator of the operator.

In the absence of certain special antiseptic measures, which it is not here useful to discuss, the death of the pulp, whether it come from the advance of caries, from depressed state of general health, from traumatic cause, or from arsenical action, induces putrefactive change within the pulp cavity. So long as the evolved gas can escape freely into the mouth no special symptoms, beyond occasionally a disagreeable odour of the breath, result. If, however, there be no such opening through the wall of the pulp cavity, or if one that has been made be plugged up by a particle of food, or by a filling of any kind inserted by the operator, we find at once, or within a few hours, a special and characteristic set of symptoms induced. The septic gas now collects within the pulp cavity, where it is pent up unable readily to escape, and it may cause very severe toothache within half an hour of the plugging up of the hole, if there be a small portion of the pulp still alive in one of the fangs.

To *tension* within the pulp cavity thus produced, and thus suddenly applied to a dental nerve of which the upper

part was gangrenous while the lower half was alive and sensitive, must be attributed the severe pain which has been observed within twenty minutes of the closure of an opening leading into the pulp chamber whence a discharge was escaping from a semi-devitalized pulp. The opinion as to the mode in which such pain was induced, which always occurred within a short time of the aperture being blocked by particles of food, was confirmed when the tooth was subsequently removed. On splitting it open the deeper lying parts of its nerve tissues were found to be perfectly healthy, those nearer the surface being gangrenous.

If, however, the pulp be entirely gangrenous throughout, the gaseous products of putrefaction, when pent up within the pulp chamber and fang canals and unable to escape into the mouth, serve to force out some of the softened and decomposed nerve tissue through the openings at the fang extremities into the socket of the tooth. The extrusion of such septic particles into proximity with the healthy membrane lining the socket serves in most cases to induce more or less severe periodontitis, the cause of which, when it is localized around one tooth, is almost invariably such as has been indicated, and it is a tooth producing this condition which is popularly said to have "caught a cold."

Periodontitis then is in almost all cases preceded by the death and putrefaction of the *whole of the pulp*, and the extrusion of putrescent particles through the openings at the ends of the fangs. My own experience induces me to believe that periodontitis very rarely results from exten-

sion of inflammation from an inflamed pulp within a tooth to the healthy tissue outside its fangs, and I have never yet met with periodontitis, attended with alveolar abscess, around the fangs of teeth containing vital nerves. On opening the pulp cavities of such teeth as were causing periodontitis, their pulps have always been found to be in a decomposed state, and it is not evident how inflammatory action can extend, as has been asserted, from a tissue which is itself already dead.

We find further evidence in support of the cause here assigned for the production of periodontitis, localised around one tooth, in the fact that the condition may be almost invariably relieved in a few hours by drilling through the walls of the pulp chamber, and so allowing the gas to escape into the mouth rather than through the fang ends. If the opening so made be accidentally or intentionally closed in the course of a day or two, the gas which collects within the pulp cavity will again force its way into the socket through the openings of the fangs, and thus acute periodontitis may be once more set up. It may be noted that the rheumatic diathesis, mercurial treatment, or a traumatic cause, may produce sub-acute inflammatory change within the maxillary socket, but this may be distinguished from periodontitis arising from putrefactive change within a pulp cavity. The latter is at first localised beneath one tooth, which is tender to pressure, often much decayed, and with pus escaping around its neck if the inflammation in the neighbourhood of its fangs have proceeded to the production of an alveolar abscess.

Periodontitis, thus caused by a process of putrescent inoculation, may be acute or chronic.

Acute Periodontitis.—The evidence of this is:—

1. Dull, aching, continuous pain around a tooth, which is usually much decayed. It must be noted, as has already been observed, that the pulp may die and decompose within a tooth that is in no way affected by caries ; so the presence of a cavity is not invariable, and acute periodontitis may occur around the teeth of old persons, or of those in feeble health, or as a sequence to some injury that has devitalized a dental pulp.
2. The tooth is slightly raised from its socket, and so stands above the level of its neighbours, and to the patient feels “longer” than others. This comes from the swelling of the tissues inside the socket, whereby the conical fangs are slightly lifted out. From the same cause the tooth is rather loosened, and may be rocked readily from side to side.
3. It is very tender on pressure and tapping, and this results from the communication of the force through the tooth to the highly sensitive and inflamed tissues around its fangs. In applying this test it is well to tap other teeth before the suspected one, so that the element of nervousness may be excluded.
4. Our crucial test is to inject cold water with a syringe into the carious cavity, which of course, as the nerve is quite dead, causes no pain. On cutting the decayed dentine very lightly with a sharp excavator there is also no pain produced, since there is no longer sensation in the tooth. If the instrument be used at all forcibly the patient will complain, but this comes from pressure of the tooth into its inflamed

socket, and cannot be mistaken for the acute pain caused by cutting the dentine of a tooth affected by caries in its first stage. 5. Around the fangs and within the socket a collection of pus soon forms, which discharges around the neck of the tooth, and with the formation of this alveolar abscess, as it is termed, relief from pain is generally experienced.

The pain and inflammation may now subside, and the tooth may become fairly firm again, but while it remains in the mouth it is likely to cause again similar trouble, or to act as a source of chronic periodontitis.

As a rule it is best to extract the tooth causing such mischief; but relief may usually be given in an hour or two by opening into the pulp chamber, through its walls at any part, with an excavator or sharp drill. By so doing the imprisoned gas, generated by the putrefaction that is going on within the tooth, is permitted to escape freely into the mouth, and is no longer compelled to leak from the fang ends. The opening should be free, and kept patent by a filling of dry cotton wool *loosely* inserted and changed daily, the object in so doing being to exclude food which otherwise might plug up the recently made opening into the pulp cavity, and to provide also a filling more or less pervious to escape of gas and fluid from the interior of the tooth. This treatment should be applied to such teeth as it may not be desirable to extract, and relief from pain may be almost certainly promised. The decayed temporary molars of children may be so treated (*vide ante* Chapter II.), also among adults we may thus relieve inflammation around a tooth which may be valu-

able for appearance or mastication. Extraction or opening into the pulp cavity, affords the only means of relieving acute periodontitis, and a slight consideration of the cause leading up to this condition will serve to convince of the absolute inutility of applying escharotics or counter-irritants to the gum overlying the affected part. A popular impression is apt to prevail as to the undesirability of extracting a tooth around the fang of which acute inflammatory action, or an alveolar abscess, is existing. This it may be said is quite erroneous. With the removal of the tooth that is causing periodontitis, whether the latter be attended with the formation of matter or not, the pain and swelling in and around the alveolar structures will soon subside, and, if extraction be deemed desirable, the operation should be effected without any delay. Not infrequently a good deal of dull aching pain with a sense of tension and throbbing within the socket will follow the removal of the tooth. This may endure for two or three days unless relief be given by occasionally raising from the site of extraction with a point of an excavator the firm blood-clot beneath which sanguineo-purulent fluid is apt to collect, and be pent up within the inflamed socket. This is a point of some importance, and the patient if unable to obtain medical assistance daily, should be instructed to perform the operation for himself, using for the purpose the point of a pair of scissors, or the end of a sharpened quill. It is also very desirable in this case to wash out the socket twice daily with a $2\frac{1}{2}$ per cent. solution of carbolic acid.

Chronic Periodontitis.—The inflammatory action

set up around the fangs may take a chronic form, though the cause is the same whether the periodontitis be acute or chronic, and relief may be given by similar treatment in both cases. The gaseous products of decomposition from the interior of the tooth leaking through the fang ends, with the purulent secretion that forms around it within its socket, escape through a sinus which usually opens through the outer alveolar plate and the gum covering it. The orifice of such sinus is marked by a small papilla, or *gum-boil* as it is termed, from which pus may be often found escaping in small quantities. The gum-boil may at times be found on the palatine mucous membrane over the inner fang of an upper molar, but as a rule it is placed on the outer surface of the gum. This condition may endure for several years, the gum-boil alternately coming and going, and the tooth slightly loosened in its socket and occasionally tender on pressure. An alteration in the colour of a tooth containing a decomposed pulp is generally evident in the course of a few weeks from the time at which the latter became devitalized. The coffee-coloured fluid within the pulp chamber fills the dentinal tubules, stains the dentine, and its dark tint is apparent through the semi-translucent enamel. If then any tooth in the neighbourhood of which there is a gum-boil, and which is a little loose, and occasionally rather tender, shows on examination by daylight a darker tint than its neighbours we may safely conclude that its contained pulp is decomposed, and that a condition of chronic periodontitis is established around its fangs. In such a condition we often find a tooth contain-

ing a large stopping under which the pulp has died and decomposed, or in which the pulp at the time of stopping was devitalized by the operator with the aid of arsenic. It should be noted, however, that if certain special anti-septic precautions be taken after the use of the latter there is little fear that putrefactive changes within the tooth, and chronic periodontitis around its fangs, will be the sequel to its stopping. Such a mishap may generally be attributed to the neglect of such precautions, or to the imperfect manner in which they have been carried out. It is not unusual to find a tooth, that has long caused periodontitis, becoming eventually quiet and ceasing to trouble. Frequently, however, such teeth become gradually loosened and are shed, or by becoming a source of pain their extraction is necessitated. Then their fangs are found to be rough and partly eroded towards their extremities, around which also are adherent shreds of fibrous exudation.

Chronic or sub-acute periodontitis may be relieved by drilling or excavating an opening through the walls of the pulp chamber, or through the stopping as the case may be. Such a hole may be minute, and may be drilled through the outer side of the fang on a level with the edge of the gum, an operation to which the name of *rhizodontropy* has been given. Thus a vent is afforded to the imprisoned gas, the irritation within the socket is usually allayed, and the gum-boil disappears and is absent so long as the opening into the pulp chamber remains patent. By a careful introduction of carbolic acid into the fangs, if access can be obtained thereto, the putrefactive change

may be partially arrested ; but such an operation can at the best be only imperfectly performed unless the special appliances of the dentist be at hand, and the dentinal tubules, charged as they are with fetid organic matter, remain inaccessible to the agents and instruments of the operator. If the pulp has but recently died and decomposed, these measures should be adopted, and have great value, but if the staining of the tooth shows that the septic change is of long standing they cannot be expected to prevent further putrefactive change within the tooth. Care should be taken when introducing carbolyzed wool into a fetid fang lest any decomposed organic matter be driven by a piston-like action through the opening at the fang end. Such a mishap has frequently resulted in the treatment, which was designed to relieve chronic periodontitis, becoming in itself a cause of acute inflammatory action within the socket.

The symptoms of caries in its second stage with its frequent sequelæ, acute and chronic periodontitis, have thus been discussed at some length. Its treatment differs from that of caries in the first stage in this respect, that while the last is benefitted by filling up the cavity, the former demands that all stopping be removed, and that none be inserted. If the second stage of caries exist the operator should remove the tooth, or should establish and maintain a free opening through the walls of the pulp cavity by which putrefactive products may escape into the mouth. To remove discomfort a loose filling of carbolyzed wool may be placed in the tooth, and changed daily.

Caries in its third stage.—If decay advance unchecked the crown of the tooth disappears, leaving sharp spiculæ of enamel that are apt, unless filed down, to excoriate the cheek or tongue. With the disappearance of the crown decay may be said to have reached its third stage, and naught now remains of the tooth save the fangs, the dentine of which has become carious and softened, and which contain the debris of dead and decomposed nerve tissue. Such stumps may remain for years without causing any trouble, but frequently they set up a condition of chronic inflammation, as the result of which they may become rough, eroded, and more or less enlarged, or *exostosed* as it is termed. Moreover, by an exudation around them of inflammatory lymph, they may be glued into their sockets so tightly that their extraction becomes at times no easy task. The difficulties occasionally met with in the removal of such stumps arise from three causes; (1) the glueing of the fang into its socket which prevents ready introduction of the blades of forceps; (2) the hollow condition of the interior of the fang, which induces its walls to collapse when the instrument is forcibly closed upon it; (3) the exostosed condition of its surface, which is often caused by chronic periodontitis, and by which it is firmly rivetted as it were into the maxilla. Pain, when it is caused by decaying stumps, is of a neuralgic nature, not located around its exciting cause, but intermittent and flying over the side of the face and head, and it is increased by hunger, fatigue, or other depressing causes. As to the propriety of removing such fangs there can be no question. With their removal the

neuralgic trouble will vanish, and it may be confidently stated that facial neuralgia has generally a dental cause. Stumps, if quiet, may be disregarded, since they may be of certain use in masticating food; but, if it be thought desirable that artificial teeth should be worn, it is generally well to extract such stumps as are causing any local or nervous irritation, before taking the models to which frames are to be constructed.

It should be noted that chronic inflammatory action or irritation, when produced by any of the six lower molars or their fangs, is apt to prove the cause of the two following well marked conditions, which, though they may be caused by other teeth, are not often associated with disease of any but the lower molars.

1. Closure of the jaws.—This rarely results from irritation other than that caused by a second or third lower molar, and more often comes from the latter than the former tooth. Inflammatory exudation, slowly organized into fibrous bands, may have formed around the temporo-maxillary articulation on the affected side, and by its gradual contraction may so reduce the opening into the mouth between the incisor teeth that the introduction of solid food becomes almost impossible. Under these circumstances the patient should be well anæsthetised, and the mouth forcibly opened with the aid of a powerful screw gag, placed between the bicuspid teeth. Pressure should bear upon these rather than upon the incisors, since the latter may be broken or dislocated by the required force. The ligamentous adhesions around the articulation being thus stretched, the

dental cause of the mischief may be searched for, and should be entirely removed. For the after treatment of such cases a daily separation of the teeth should be gently and gradually effected with the aid of the screw gag, and will serve to restore in a week or two the original mobility of the jaw.

2. Fistulous opening through the cheek.—This rarely proceeds from any but the lower molars, and of these the first molar is more apt than the second or third to prove the cause. It may be apprehended when the cheek over-lying the seat of periodontitis, whether this be acute or chronic, is found to become glazed, reddened, and adherent to subjacent structures. No time should then be lost in extracting the tooth or stumps that appear to be causing mischief, and thus by timely action the disfigurement may be averted. The fistulous opening when once established may remain for years a channel through which purulent fluid, secreted around the diseased fangs, occasionally escapes. After a time the discharge may cease by natural causes, but the extraction of the stump, which may be glued into its socket and therefore difficult of removal, will at once cure the condition, if this be not so far advanced that necrosis of a portion of the maxilla has been induced. If the latter exist the healing must of course be delayed until the dead structure has been thrown off or removed, but always an unsightly pucker in the face will mark the site of the old fistulous opening.

Summary of remedial measures advocated in this chapter for the relief of Caries and its results.—A resumé of this nature may be useful, and it

should be remembered that the treatment here advocated is limited to such as in the author's opinion may be exercised by a medical practitioner for his patient's good. The remedial measures suggested are as follows:—

1. *Use of arsenic.*—This, if wisely employed, may prevent the need for very many difficult and undesirable extractions. For the few precautions required the earlier portion of this chapter may be consulted (*see* p. 60).

2. *Rhizodontropy and opening of pulp cavity.*—Herein we have a speedy method of relieving pain. The cases in which such treatment is appropriate and the manner of effecting this are referred to in this chapter elsewhere. The operation, when it relieves pain, does so by lessening tension within the pulp cavity whereby some sensitive nerve fibre may have been compressed, or else by affording an exit for pus that has collected within and around the fangs (*see* pp. 69 and 70).

3. *Filling the cavity with:*—(1) Wool and carbolic acid; (2) Wool and mastic; (3) Gutta-percha; (4) Amalgam (*see* pp. 57-59).

These operations are described elsewhere in this chapter.

4. *Extraction with the aid, if required, of an anæsthetic and the mouth opener.*—This is the heroic remedy, to be resorted to only when other treatment fails, and it should be noted that in removing an upper grinder we also deprive its lower antagonist of the opportunity for being useful. To the subject of extraction a chapter is devoted elsewhere.

Summary of instruments and materials.—An operator should provide himself with the following:—



FIG. 33.—An Excavator



FIG. 34.—Enamel Cutter for use in upper jaw




FIG. 35.—Enamel Cutter for use in lower jaw



FIG. 36 —Dividing file for separating teeth at back of mouth and for other purposes. The edge is more or less knife-shaped.



FIG. 37.—A file for smoothing down metal stoppings and rough edges of enamel.



FIG. 38.—Tweezers



FIG. 39 —A Bur, or rose-headed drill.

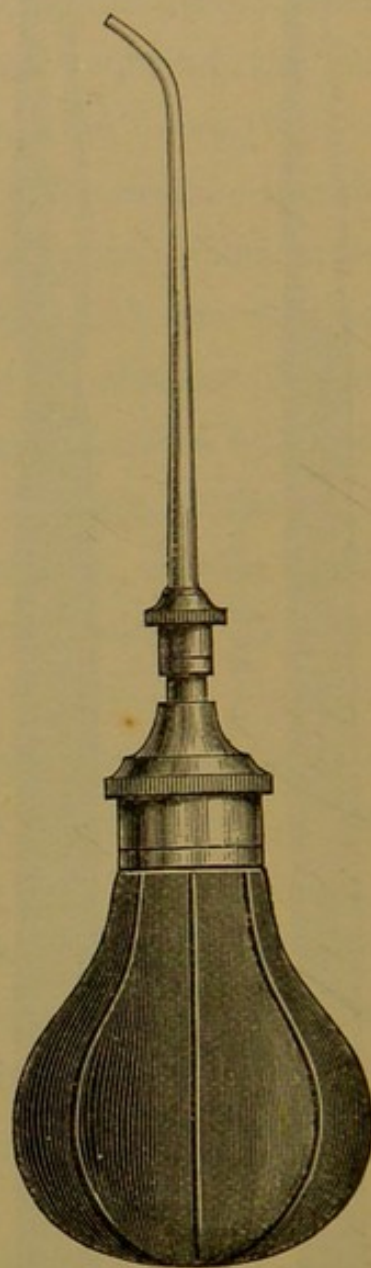


FIG. 40.—A syringe—seven inches long.

1. One dozen *Excavators*, of various sizes. In figure 33 an instrument of this nature is illustrated. The cutting ends of these instruments should vary considerably as to length, size and direction.

2. Three *Enamel Cutters*, to be used for breaking down hard enamel around the margins of a cavity. These should be strong and of hard temper. One, shaped as in figure 34, and two (a right and left) as in figure 35 should be purchased.

3. Four *Files*.—Two being flat sided, as in fig. 36; and two being flat on one side and round on the other, as in fig. 37.

4. A pair of *Tweezers* for carrying amalgam stoppings or dressings of wool into a cavity. Illustrated in fig. 38.

5. Six *Burs* of various sizes, to be used in opening up a cavity on grinding surface of molar, as in penetrating decay, preparatory to filling it (*vide* fig. 39).

6. A *Syringe*, from which warm water can be injected into a cavity for the purpose of cleansing it (*vide* fig. 40).

7. Two *Pluggers*. They should be shaped as in figs 41 and 42, which are of the sizes as used. Their flat and rounded ends are very useful in moulding plastic stoppings.

8. A *Spirit Lamp* of usual shape, to be used in warming gutta-percha or amalgam, or for raising the temperature of the mouth mirror that it may not be clouded by the breath.

9. A *Mouth Mirror*, as shewn in fig. 43. This is useful in throwing light upon and reflecting obscure cavities. It should be warmed over the lamp before being used.

10. A pair of *Pliers and Cutting Nippers*, as in fig. 44.



FIG. 41.—Amalgam or gutta-percha plugger.



FIG. 42.—Amalgam or gutta-percha plugger.

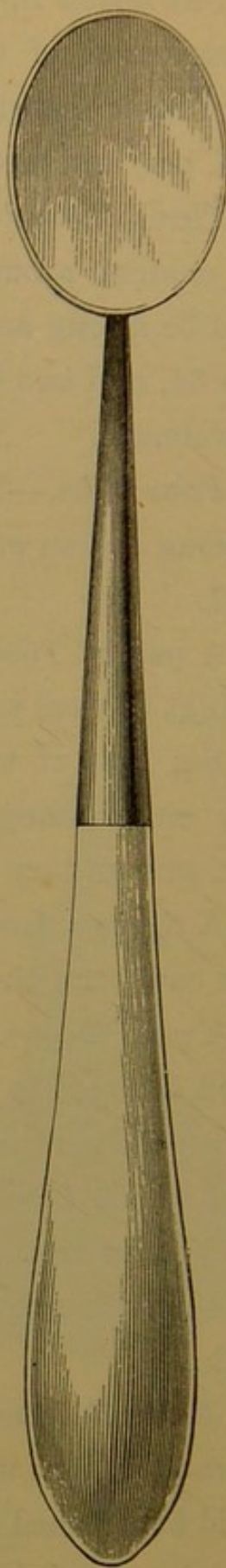


FIG. 43.—A mouth mirror.

These will prove useful for a variety of purposes, and are convenient for adjusting wires or bands connected with artificial teeth.

11. One dozen *Mouth Napkins*. These should be of soft, well washed linen, and each about 8 by 5 inches. In operating upon a lower tooth one may be twisted loosely into a rope, and being placed under the tongue and carried round behind and on the outer side of the tooth, it serves, when held firmly *in situ* by the thumb and fingers of the left hand, to exclude saliva by closing the orifices of the sub-maxillary glands. In operating upon an upper

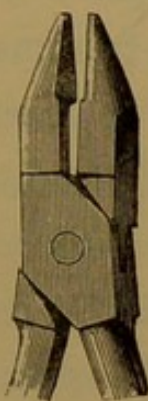


FIG. 44.—Pliers and cutting nippers. The handles are not included in the sketch.

tooth the opening of the parotid gland may be similarly closed.

12. *Absorbent Wool*. This is useful when drying cavities preparatory to filling them; also it is of service in carrying applications of carbolic acid, and with the aid of mastic solution it makes a serviceable temporary filling.

13. *Carbolic Acid*. It is convenient to place in a small phial a little absorbent wool, and on this to pour a few drops of carbolic acid. Then, if an excavator be armed with a wool plug, the latter may be lightly carried into

the phial, and as small a quantity of the drug as may be desired can be collected for conveyance to the tooth.

14. *A Solution of Gum-Mastic in Alcohol.* If a plug of absorbent wool be dipped into this, and if a little more dry wool be then wrapped around the saturated plug, a very useful temporary filling may be obtained.

15. *Arsenious Paste.* Made by mixing equal parts of oxide of arsenic (arsenious acid) with yellow soap. There is nothing gained by adding morphia to this. A piece, the size of a large pin's head, placed in contact with an exposed dental pulp, and there retained by any temporary filling, soon serves to deprive the tooth of all sensation (*see p. 60 concerning this treatment*).

16. *Gutta-percha.* As ordinarily sold it *may* be used, but two preparations of this, known as *Hill's* and *Jacob's* fillings, are prepared. These are specially soft and plastic.

17. *Amalgam.* Various forms of this are sold by the manufacturers of dental appliances. That known as "Sullivan's cement" is very useful. It is readily employed, lasts well in the mouth, and the process of manipulating it is described in an earlier part of this chapter (*see p. 59*). At a pinch an amalgam filling may be extemporised by mixing mercury with silver filings, and rubbing them in the hand until a stiff paste is produced. The plastic material thus produced becomes extremely hard in about four hours. In the mouth it blackens from oxidation in a few days, and therefore, as with *Sullivan's cement*, it should never be inserted in a front tooth.

CHAPTER VII.

TOOTHACHE.

FROM LOCAL CAUSE ; AS FROM ODONTALGIA, TENSION IN
PULP-CAVITY, PERIODONTITIS, OR IRRITATION OF STUMPS.
FROM CONSTITUTIONAL CAUSES.

PAIN in and around a tooth is so prominent a feature in connection with dental cases that an attempt at classifying its causes and treatment may be useful. The nature of toothache varies with the condition of the dental pulp. It takes these forms, when its cause is local.

1. **Odontalgia**, or that which accompanies the first stage of decay (*see* Chap. VI.). This varies in severity, is intermittent, and at times comes on in sharp paroxysms. It is located usually in the aching tooth, but if a lower wisdom tooth be affected, it may fly up into the neighbourhood of the ear. It is increased and induced by hot and cold fluids, cold air, pungent or sweet food, and pressure of particles into the carious cavity during mastication ; while its cause is always to be found in some tooth of which the crown is more or less damaged by decay or mechanical violence, and of which the dental pulp is in a vital, highly sensitive, and irritated condition.

The treatment of odontalgia must vary with the local condition producing it. If decay be not far advanced, and the nerve not exposed, or exposed by only a small aper-

ture, the cavity should be syringed out with warm water, and should be plugged with a dressing of wool and carbolic acid (*see* Chap. VI.). Thus the irritated pulp is soothed, and protected by a non-conductor from thermal and other influences. The wool may be changed daily, or may be replaced in a few days by a filling of gutta-percha, or amalgam. Should the cavity be large and the pulp freely exposed it will probably be necessary to destroy the latter with the aid of arsenic (*see* p. 60), or to extract the tooth.

2. Pain caused by tension in the pulp cavity.—

Such pain is most intense, constant, of several hours in duration, and located strictly within the affected tooth. This will usually be found to contain *semi-gangrenous* nerve tissue; that portion of the latter situated within the fang canals being still vital and sensitive, while that occupying the pulp chamber has lost vitality, is gangrenous and evolving gaseous products of putrefaction. These, pent up within the sealed pulp chamber, unable to discharge themselves into the mouth, produce, by their increasing pressure on the nerve filaments still retaining sensibility, the intense pain that accompanies this condition, which may endure for five or six hours, until the vitality of the whole of the nerve has been destroyed. This onset of severe pain may result from any increase of tension within a sealed pulp cavity containing sensitive nerve filaments, and such tension may come from *acute inflammation of the pulp* or from a partial death of the nerve. It may also be caused by filling a carious cavity through which a partly dead nerve has for some time discharged.

The tooth thus affected is very sensitive to warm water, which probably adds to the pain by increasing the tension. Cold water on the contrary gives great relief. To gentle tapping or pressure the tooth is not tender, since as yet no periodontitis exists within its socket. Relief may be instantaneously afforded by opening with drill or excavator into the pulp chamber through the floor of the carious cavity which generally exists, and by so doing the tension within the tooth is at once relieved. The opening should be kept patent by a plug of cotton wool, *loosely* inserted and changed daily. From what is said in the chapter upon *caries* (see p. 63) it may readily be understood that the death and subsequent putrefaction of the *whole* of the dental pulp thus brought about, may, in the course of a few weeks, produce a condition of periodontitis within the alveolar socket.

3. Pain caused by acute periodontitis.—Such pain is constant, as distinguished from the intermittent pain of odontalgia. It is at first dull, but becomes more severe as the inflammation increases, and endures often until a discharge of pus takes place, which wells up around the neck of the tooth from the alveolar abscess that may have formed within the socket around its fangs. With the formation of matter a sensation of throbbing is experienced within the maxilla, and considerable swelling of the soft parts around the seat of mischief is then noticeable. The tissues around the tooth become very tender when it is pressed into its socket, or is lightly tapped, moreover the tooth becomes raised from its socket, and so loosened that its crown may at times be readily moved to

and fro, but it is not sensitive to hot or cold fluids. Its pulp cavity and fang canals contain almost invariably throughout their entire length dead and decomposed nerve tissue, from which septic particles are extruded into the alveolar sockets through the orifices at the ends of the fangs. A tooth thus circumstanced is usually found to be much decayed, but, as before mentioned, periodontitis may be induced by the action of one in which the pulp has lost its vitality from causes other than caries, as from a blow, or from general ill-health. To relieve the pain of periodontitis the pulp cavity should be opened with a drill or an excavator, so that the pent up gas may escape, or, if the mischief be far advanced, the tooth should be extracted. The latter operation, as before said, may be performed at any stage of the disease; indeed, the more severe the inflammatory action may be, the more needful it becomes to extract the tooth.

4. Pain caused by Dead Teeth and Stumps.—

This is variable in degree, becoming more severe when the general health is disturbed, and after bodily fatigue and want of food. It flies up the side of the face, into the neighbourhood of the ear, or downwards to the shoulder or arm. There may in almost all cases be found the stumps of decayed teeth, which should be completely removed if the neuralgic symptoms are persistent, and it may be noted that most cases of what is termed *face-ague* and *tic douloureux* have, as their exciting cause, a dental condition such as that described.

5. Pain caused by periodontitis affecting the sockets of several adjacent teeth.— Such pain will

be more or less continuous and diffused along the maxilla. The patient will complain that the teeth are "too long" and may at first get relief by biting them into their sockets from which inflammatory effusion has slightly raised them. This condition of periosteal congestion and inflammation affecting the sockets of several adjacent teeth may be induced by varied causes. It may be due to prolonged use of mercury or iodide of potassium, or to exposure to phosphorous fumes. It may have a syphilitic or rheumatic origin. It may be due to pyorrhœa alveolaris, or to the chilling action of exposure to a cold wind. Again it may without apparent cause attack a patient whose nutrition has become impaired. Diagnosis must be made between these varied forms of alveolar periosteal trouble as a preliminary to the application of treatment, and it may be added that a rubefacient applied to the gum over the affected region, or the application thereto of capsicum plasters, will often be of service.

CHAPTER VIII.

TARTAR. PYORRHOEA ALVEOLARIS. ABSORPTION OF ALVEOLAR PROCESS.

Tartar or Salivary Calculus.—This earthy deposit from the saliva, consisting of lime salts and organic matter, is found to collect around the teeth under these circumstances.

1. At the back of the lower incisors and canines, a part of the mouth always escaping that friction from the tooth brush and from the passage of food during mastication, which tends to polish the surface of the teeth and to prevent lodgment thereon of calcareous particles.

2. Upon and around any masticating tooth which from decay has become tender to pressure and change of temperature, and so has become disused. Thus, if a patient be unable to eat on one side of the mouth, the outer surfaces of molars and bicuspidis on that side will shortly become coated with deposit. Its occurrence there may be accounted for, as in the previous case, by the absence of the cleansing influence of friction.

3. Towards middle life upon the necks of teeth which from absorption of alveolar process and gum are becoming exposed, and probably in such cases the growth of the deposit is but a sequence to the absorption and in no manner its cause.

The formation of tartar is undesirable since it is apt to induce an irritated state of the gums and to form a lodgment for particles of food. Being porous and absorbent it retains decomposing organic matter which may give an unpleasant odour to the breath. Its removal is easily effected by scaling it from the surface of the tooth with a strong excavator. It should be noted that a mass of tartar is seen, when a vertical section thereof is made *in situ*, to be triangular in form, the apex being directed towards the cutting edge of the tooth, and the base towards and in contact with the gum. In the removal of this deposit, therefore, it is necessary to insert the instrument beneath its base, and then to raise it from below upwards.

Tartar, when freshly and rapidly deposited, is of a light brown colour, but in the mouth of a smoker it becomes blackened. In the mouths of young people, who do not use the tooth-brush with due care, a greenish deposit is apt to collect around the necks of the upper incisors and canines. Our knowledge as to the character of this is as yet insufficient, but it may be of a vegetable nature, the growth of which is favoured by the warmth, moisture, and light in this part of the mouth.

Pyorrhœa Alveolaris.—To this condition the name of *Rigg's Disease* is also given, from the name of an operator by whom attention was drawn to it. It is characterised by a condition of chronic inflammation of the gum, which, becoming tumid and separated from the necks of the teeth, forms a *cul-de-sac* around them, in which collects debris of decomposing food and purulent secretion. The margins of the bony sockets become absorbed, and the

necks of the teeth being unsupported, these are rendered so loose that their removal is necessary. Much smarting pain is often complained of, and the affection is apt to attack adults otherwise healthy and below middle age. In two cases lately under treatment the patients were in complete general health, but extraction of the teeth around which the disease extended was the only measure that afforded relief. Something may be hoped for by the careful removal of the tartar which is apt to form upon the exposed necks. A weak solution of sulphate of copper should be painted daily with a fine camel hair brush into the sulcus around the teeth and the bodily health meanwhile must be maintained by all possible means.

Absorption of alveolar process.—This frequently occurs to the front walls of the sockets of outstanding teeth, such as the canines, on which the friction of the tooth-brush falls most severely. It is also a change which normally attends advancing years, and its incidence is felt most by those whose anxieties, or whose manner of living, have specially tended to wear out their frames. It is also met with, as before remarked, in association with *Pyorrhœa Alveolaris* or Rigg's Disease.

The shedding of teeth by the aged is due to this wasting of the alveolar sockets, and in proportion to the vitality of the individual will this senile change be deferred.

CHAPTER IX.

INJURIES TO THE TEETH.

WEARING DOWN OF THE TEETH FROM FRICTION OF MASTICATION. HUNTER'S DENUDING PROCESS. FRACTURE AND DISLOCATION OF A TOOTH FROM VIOLENCE.

Attrition.—Towards middle life the cutting edges of incisors, and the grinding surfaces of masticating teeth, show signs of wearing down, and the rapidity of such action is dependent upon the density of the tooth structure, and upon the nature of the food. Among savage races, who live mostly on coarse badly prepared materials, we see such extensive attrition that pulp cavities would be speedily opened, did not a development of secondary dentine, or a calcification of the pulp occur.

Hunter's Denuding Process.—It is also not unusual to find among middle aged persons a deep horizontal well polished groove, reaching almost into the pulp chamber, across the outer surfaces of the necks of incisor, canine, and bicuspid teeth. This condition, to which the name of *Hunter's denuding process* has been applied, results from the friction of the tooth-brush upon the soft cementum of the neck of the tooth, which has become exposed by recession of the gums. From this latter condition, which is to be regarded as a senile change, the necks of the teeth are towards middle life frequently laid bare.

Their less durable structures are then liable to be damaged by the brush, aided by the solvent action of acid fluids within the mouth.

The surface tenderness which is often associated with this action may be relieved by a frequent application of Eau de Cologne upon wool: but if there be a deep cup-shaped cavity in the grinding surface of a molar, or a groove upon the neck of an incisor opening almost into its pulp-chamber, it may become necessary to insert a metal filling in order to prevent further and more serious damage to the tooth. Moreover, all rapidly cutting tooth-powders, such as charcoal or pumice powder, should be at once discontinued, and a soft brush be used with soap and chalk. These last only should be employed in all cases, and if used twice daily will be quite effective in keeping the teeth well polished.

Fracture of a Tooth.—One or more teeth may be fractured by a blow acting directly on the damaged organs, or indirectly through the sudden closure of the lower teeth upon the upper, as when a heavy fall is sustained upon the chin in the hunting field. The rough fractured surface may be smoothed down with a fine file if the damage be but slight, and surface tenderness may be relieved by an application of Eau de Cologne or nitrate of silver. If the pulp cavity be broken into, it may be necessary to destroy the nerve with arsenic and subsequently to fill the tooth, or to file it down to a level with the gum; or to extract its fang preparatory to the insertion of a plate carrying an artificial tooth.

Dislocation of a Tooth.—This may happen to an

incisor tooth from a blow. The tooth should be washed gently in warm carbolized water, and should be replaced in its socket. It should then be held *in situ* by gutta-percha moulded around, and frequently it will become again tightly fixed. The violence to which it has been subjected, even if the dislocation be but partial, generally destroys its dental-pulp, which by subsequent decomposition is liable to induce periodontitis in the course of a few months.

The process of REPLANTATION should be adopted only in dealing with a healthy upper front tooth which has been driven by violence from its socket. Although in many cases it has proved successful, its result is as a rule unsatisfactory. By some operators it has been extended to the treatment of teeth which have induced chronic periodontitis, and in such cases a tooth, after its removal and the disinfection and filling of its pulp cavity and fangs, has been replaced in the socket whence it was removed. The statistics of this latter operation suffice to condemn it, and more than a parting reference to it is not needed.

CHAPTER X.

PREPARATION OF THE MOUTH FOR, AND THE WEARING OF, ARTIFICIAL TEETH.

MOTIVES FOR WEARING FRAMES. CONCERNING REMOVAL OF DECAYED TEETH AND STUMPS. PARTIAL FRAMES AND MODES OF SUPPORTING THEM. PIVOTTED TEETH. COMPLETE FRAMES AND MODES OF SUPPORTING THEM. CONCERNING THE WEARING AND CLEANSING OF FRAMES. THE PROCESS OF "CROWN AND BRIDGE WORK."

A GENERAL knowledge of the manner in which the use and appearance of the mouth may be restored after the loss of teeth, cannot be otherwise than useful to the medical practitioner. Although the mechanical processes do not fall within the scope of his work, yet, speaking generally, the subject is one on which his advice is often asked, and of which the broad outlines may usefully be stated.

Reasons for wearing frames.—For various reasons it becomes at times needful to replace missing teeth with artificial ones. They may be worn for the sake of appearance, and to prevent lisping during speech, as when an artificial incisor is adopted; to restore or increase power of mastication, as when molars and bicusps are inserted; or to serve as props when all the back teeth of one or both jaws have been lost. Thus they prevent the lower jaw from approximating too closely to the upper,

and so directly tend to preserve the upper front teeth, which would otherwise be bitten out and loosened by the increased pressure exerted upon their back surfaces through the lower incisors and canines. Moreover, by keeping the jaws apart to the normal distance, they prevent that protrusion of the inferior maxilla, and raising of the chin towards the nose, which characterises the aged.

Concerning removal of decayed teeth and stumps.—After deciding from any of the foregoing reasons that frames should be worn, it is sometimes desirable that any greatly decayed or very loose teeth, or tender stumps should be removed; and after such extractions an interval of a day to six months should elapse before models of the mouth are obtained to which frames can be made. The wax or Plaster of Paris impression should indeed not be taken until absorption of the alveolar process is well advanced or completed. Only a short delay, however, need occur if before their removal the extracted teeth have been very loose, since already much of their sockets has disappeared; and if there be *necessity for immediate* wearing of artificial teeth, the impressions may be taken within a week or so of the operation. In this case a temporary frame may at once be made, to be replaced by one of a more permanent character at the end of a year or so, when the alveolar ridge has settled down somewhat to its ultimate level.

It may be observed that modern treatment tends rather in the direction of *not* extracting teeth and stumps. The following reasons may be given for their preservation:—

1. The retention of teeth and stumps tends to prevent

absorption of alveolar process, whereby the form of the mouth is altered, and the fitting of a plate eventually impaired.

2. The fangs of decayed teeth, if they be fairly sound and firmly implanted, may be of the greatest use in supporting a pin from a gold plate in a manner to be described (*vide* fig. 48).

3. The avoidance of the operation usually consists with the patients wish.

As reasons for extracting decayed teeth and stumps the following may be mentioned:—

1. They may be causing, or threatening to cause, pain or inflammation, the occurrence of which might be prejudicial to the use of artificial teeth.

2. Their retention in any considerable numbers may impart a disagreeable odour to the breath.

To summarize the foregoing, I would add that decayed teeth should be filled, firm and healthy stumps should be filed down to a level with the gums, and loose and unhealthy stumps should be removed.

Having thus prepared the mouth, a decision must be arrived at, subject to the advice of the dental attendant, concerning the character of the frames to be worn. These may be classified as partial and complete. They are partial when the patient still possesses some of his own natural teeth, by which the artificial ones may be supported (*vide* fig. 48). They are complete when the patient has lost all his own teeth, and in such case the frames must be retained by atmospheric pressure or springs (*vide post*).

Partial frames and the modes of supporting them. The choice between gold and vulcanite as a base on which the teeth are to be mounted.—

The ivory base of former days, and the human teeth, are now never employed. Concerning the respective merits of gold and vulcanite, it may be said that the former is stronger, and takes up less room in the mouth than the latter. For larger frames vulcanite is, however, very useful. It is lighter than gold, it may be made to fit the mouth with more exactness, and when of fair thickness it is strong enough for most work. For partial frames it is usually best to employ gold, since it provides us with a thin and strong base. For suction plates vulcanite is most useful, since it is sufficiently strong, and is lighter than gold. With vulcanite better suction can be obtained, since being plastic while the frame is in course of construction, it can be made to fit with more exactness. The two materials may, however, in many cases be combined, and thus can be obtained a frame which unites the advantages of each. It may be observed that both vulcanite, and the 18-carat gold of which plates are usually made, are quite unalterable by the fluids of the mouth. It was once asserted that the vermilion, employed to give the reddish colour to vulcanite, was capable of causing mercurial symptoms by absorption into the system. Further investigation, however, showed that the assertion was not based on fact.

The teeth, as now used, are made of well-fired mineral substances. Projecting from the posterior surface of each tooth are two platinum pins, by which it is affixed to the gold or vulcanite base (*vide* figs. 46 and 47).

Partial plates are supported, and kept in position, by aid of one or more of the following:—clasps, pins, atmospheric pressure, or the pressure of lips and tongue.

1. *Clasps* are such as are shown in fig. 48. Doubtless they are at times quite necessary adjuncts to a plate, but



FIG. 45.—An upper central incisor of mineral material (anterior view).



FIG. 46.—The same (posterior view) showing the two platinum pins.



FIG. 47.—The same (lateral view) showing one pin.

they should be sparingly employed, and as loose as is consistent with its comfortable wearing. By abrading enamel at the necks of the teeth, and by retaining particles of food and mucus, they favour the progress of caries.

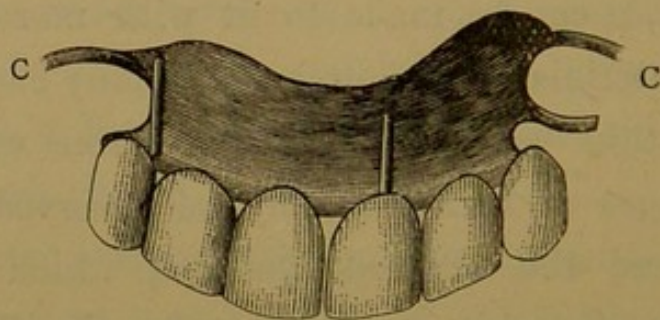


FIG. 48.—Upper or palatine surface of a small gold plate carrying six upper front teeth. The two gold pins fit into tubes, let into canine and incisor fangs. C. C. Are gold clasps which embrace bicuspid teeth. Such a plate is perfectly firm, and can readily be removed for cleansing purposes by the patient.

Clasps should therefore be so placed on a frame as not to be in contact with the necks of the teeth, and they should be as near to the grinding surfaces of those teeth which they embrace as is consistent with secure retention of the plate.

2. *Pins* are such as are shown in fig. 48. One or more of such project from, and are attached to, the under surface of the plate, and fitting accurately into gold tubes which are inserted into and fixed within healthy stumps (*vide* fig. 52), they form an admirable means of supporting a

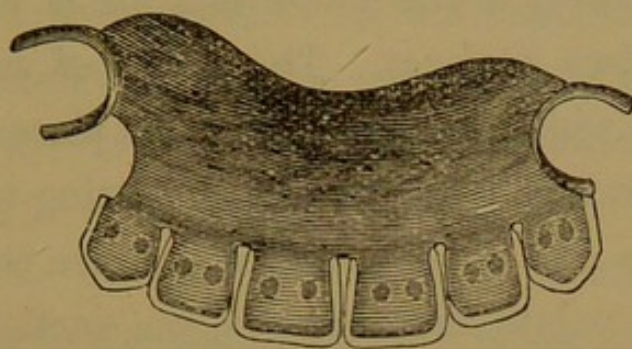


FIG. 49.—Under or lingual surface of last drawn plate.



FIG. 50.—The tube of gold or platinum, half an inch long, firmly inserted into the root.



FIG. 51.—The pin of gold or platinum fitting the tube accurately. The pin is attached to the under surface of the plate. It may, if required, support the crown of a mineral tooth pivotted upon the fang.

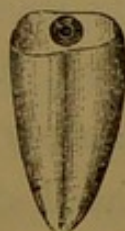

FIG. 52.—The fang of the upper canine, cut down to the level of the gum. Its nerve canal has been drilled out and into this has been inserted a tube half an inch long. The tube is held securely *in situ* by packing around it a plastic amalgam stopping which soon hardens.

frame. If the pin be roughened in the least degree with a file or pliers, it may be made to fit as tightly as desired within its tube, from which it can be readily withdrawn when the patient desires to cleanse the frame.

3. *Atmospheric pressure or suction* is obtained when a plate fits so closely to the palate that air is excluded from between the two surfaces. The degree of suction, or the firmness with which a plate holds in its place is dependent upon the following:—1st, its accurate fitting to the various palatine rugæ and the depressions between them; 2nd, to the extent of palate thus covered, the suctional force increasing in proportion thereto; 3rd, the extent to which

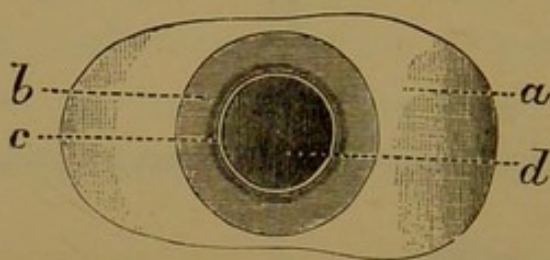


FIG. 53.—Section of fang with tube inserted. *a*. Surface of dentine. *b*. Amalgam. *c*. Edge of tube. *d*. Opening of tube. (Enlarged about four times).

the plate may be moved during mastication without intromission of air beneath it. Thus if a plate rest on hard and projecting stumps, or if it cover only a small portion of the front of a deep or V-shaped palate, it will permit leakage when moved to the least degree in any direction, and so, losing its suction, will drop into the mouth. If, on the contrary, it covers closely a fairly large surface of palate, if it do not rest on hard stumps, and if the mucous membrane be so soft that the edges of the plate may to a slight degree embed themselves within it, we shall obtain a sufficiency of suction to support a plate with comfort.

It should be observed that many plates, which when first worn possess but little suction, are found to keep up well enough after a week or two. Here the palate has adapted itself to the frame.

4. *The pressure of lips and tongue on the plate.*—This no doubt is an important factor in the support of many old and ill-fitting frames. In the course of years the clasps and pins, which formerly held the plate securely, become useless, owing to the loss of teeth or stumps to which they were attached. Suction of the plate to the palate also departs, owing to the shrinkage of alveolar process which



FIG. 54.—A canine fang prepared for pivoting and carrying within it a gold tube half an inch long. The tube is firmly cemented into the fang by an amalgam stopping.

attends the shedding of teeth, and the advance of age. Then it is no uncommon thing to find the frame held in position by the unconscious action of the tongue and lips, and so automatic does this become, that a patient may be totally unaware of the condition and of the means by which he is enabled to wear his plate.

Pivotted teeth.—In connection with the subject of partial frames reference may be made to the *pivoting* of teeth. This is generally employed to replace one of the upper front teeth, lost by decay or accident. The broken crown is cut to a level with the gum; into the fang is in-

served a gold tube (*vide* fig. 50); and on to the surface of the fang, is adapted an artificial crown (*vide* fig. 55), with a gold pin attached thereto which fits into the tube inserted in the fang (*vide* fig. 54). The resulting tooth (*vide* fig. 56) looks extremely well, and if inflammation occur around the root it may be relieved by withdrawing the crown and pin from the fang and tube.



FIG. 55.—Side view of mineral tooth, with its attached pin of gold, for pivoting on to above fang.

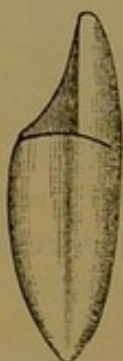

FIG. 56.—Side view of above mineral tooth pivotted on to above canine fang.

Complete frames and the modes of supporting them.—When all the teeth are lost plates must rely for support upon *suction*, or the use of *springs*.

Suction is obtained by means such as were mentioned before in connection with partial frames. Our best cases occur among those who possess prominent upper and lower alveolar processes, which, as well as the hard palate, are covered with a soft spongy mucous membrane. In such cases good-fitting vulcanite frames, carried well over the

outer alveolar plate and behind the tuberosities of the upper maxilla to prevent leakage during slight movement, are found to answer admirably (*vide* figs. 57 and 58).

So great may be suctional power resulting from the air pressure in some of these cases that a weight of a pound or more may be supported by the upper frame without detaching it, although if the plate be tilted forward by

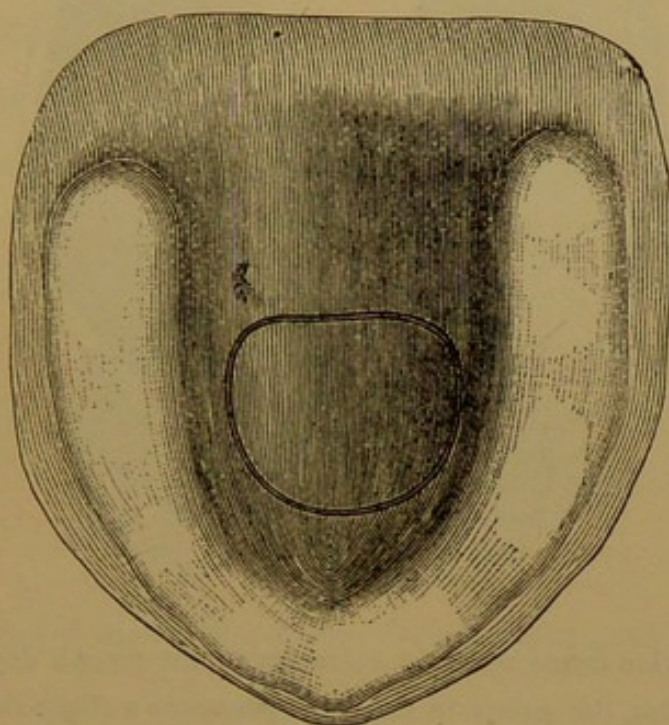


FIG. 57.—Model of an upper maxilla for which a suction plate was made. The gum was soft and spongy and the alveolar process was very prominent and well rounded. This is typical of a maxilla specially well fitted for the use of a suction frame.

pressure upon its front teeth, it may easily be detached from the palate. The fixity of a lower suction frame is, as may be imagined, less than that of the upper, but even here in many cases a considerable degree of adhesion is obtained. As time goes on, however shrinkage of the maxilla and absorption of alveolar process tends to lessen the security of these plates, but it is not unusual to meet

with patients who have worn their upper and lower suction frames without alteration and with comfort for a period of fifteen or twenty years. It must be added that if the work is executed within a short time of any extensive removal of teeth, and while the resulting alveolar absorption is in active progress, it will be necessary to remake or remodel

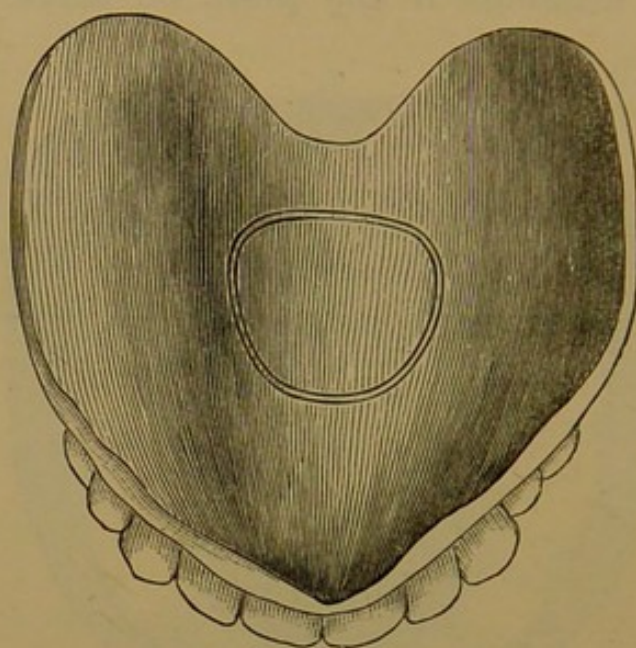


FIG. 58.—A suction frame made in vulcanite to the mouth depicted in fig. 57. It will be seen that the palate is deep and possesses a slight ridge enclosing an ovoid space, also that the vulcanite curves well over the alveolar process and round the maxillary tuberosities. This may be regarded as typical of the well shaped suction frame. A natural appearance is given to the teeth by mounting them irregularly on the vulcanite base.

these suction frames at the expiration of a year or so. This should be clearly explained to the patient who wishes that there should be only a short interval between the extraction and the making of his new frames.

Two methods are at times employed to assist the adhesion of suction plates. It is obvious that the best result is obtained when the whole of the frame is closely applied

to the mucous surface. This condition depends solely upon the accuracy of the impression and plaster model cast therein. If, however, from any cause air is not entirely excluded from between the plate and the palate, then it may be useful to aim at producing a vacuum over one portion at least of the palate. By the use of a *ridge*, or of a *suction disc*, this may be achieved.

1. The ridge is a projection from the palatine surface of a vulcanite plate. Its section is in size about that of a large hog's bristle, and it encloses an area about equal to that of a halfpenny. The ridge soon embeds itself into

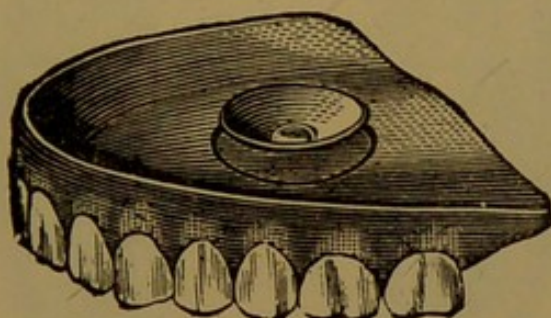


FIG. 59.—A suction disc applied to an ill-fitting upper frame.

the mucous membrane, and air being sucked out of the enclosed space by the patient, and being unable readily to re-enter, a vacuum is there produced. This device is drawn in fig. 58, and though useful in keeping up a well fitting frame, it is not of value to one that fits imperfectly.

2. The suction chamber consists of a small elastic india-rubber cup affixed to the palatine surface of the frame (*vide* fig. 59), which it attaches to the palate, much as the well-known railway reading lamp is applied to a carriage window. As before remarked it is a quite needless adjunct to a well-fitting plate, and is specially objectionable, since

it tends to produce and maintain an irritable state of the mucous membrane with which it is in contact.

Springs are used to keep upper and lower complete frames in position when from any cause suction is unable to effect this, (*vide* figs. 60, 61, 62). Although organic

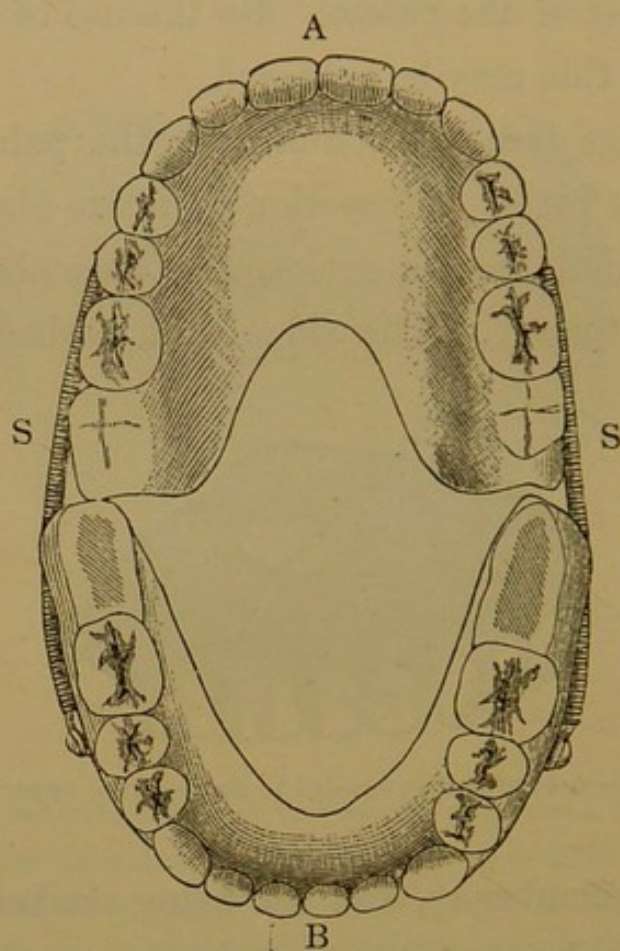


FIG. 60.—Upper and lower frames with springs attached. The springs are each $2\frac{1}{2}$ inches long, and about the thickness of a very thin slate pencil. They are made of 16-carat gold wire wound spirally, and the ends of each are attached to swivels upon the frames. In the drawing, A is the upper frame, B the lower, and S S the springs.

matter will collect within them, they may be kept in a cleanly condition if the frames are placed throughout the night in a weak solution of Carbolate of Soda. They are liable, however, to wound or irritate the inside of the cheeks, unless they are skilfully attached, and of the proper length.

Under favourable conditions, however, they form a secure and convenient mode of supporting frames, and they prevent the annoyance of any untimely dropping of the upper plate.

Concerning the wearing and cleansing of frames.—When frames can be worn throughout the day

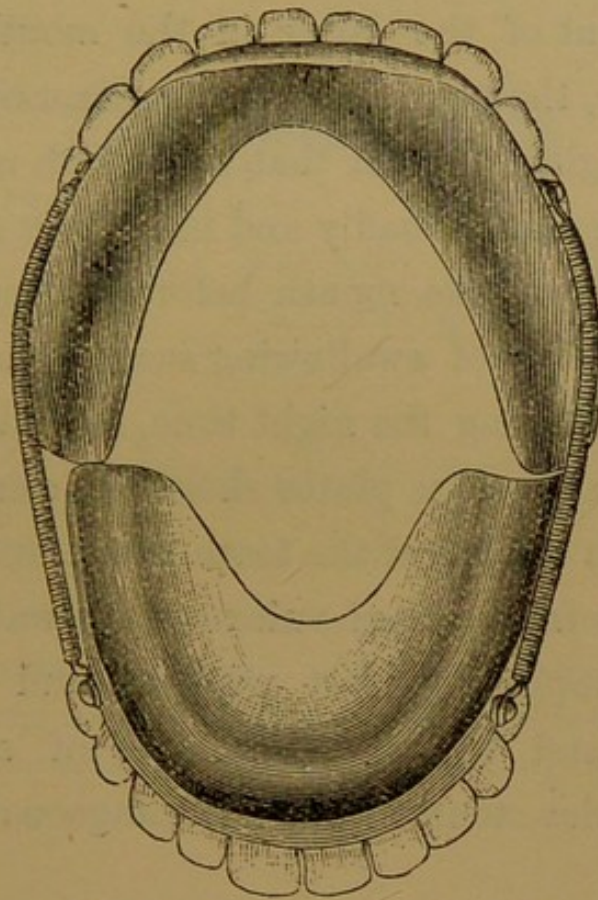


FIG. 61.—Under or palatine side of above frames.

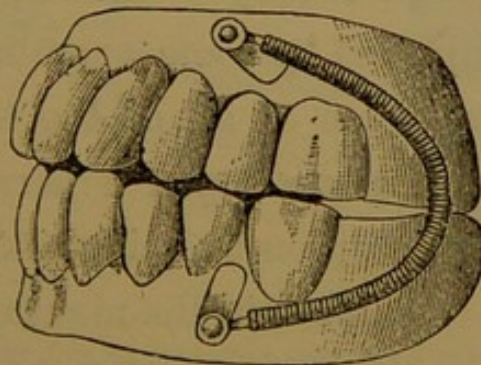


FIG. 62—The upper and lower frames in above two diagrams placed in articulation with each other.

and night with comfort and safety, they should usually be so employed. Thus the patient becomes more readily accustomed to them, and finds them of greater service for purposes of speaking and mastication. Also he may thus prevent the shifting of his own moveable teeth, which sometimes happens when the wearing of frames is intermitted, and which may oppose a considerable obstacle to the replacement of the latter in the mouth. In many cases, however, the wearer prefers to discontinue their use during the night in order that the mouth may be rested, Partial frames that fit badly and insecurely should invariably be taken from the mouth before the patient retires, and the possibility of swallowing such, if he insist upon wearing them during the night time, should be impressed upon him. In all cases plates should be cleansed at least once daily with the aid of the tooth-brush, soap, and warm water. If the frame be of vulcanite the water should not be of high temperature, lest warping and alteration in form result, and the occasional use of a little finely powdered pumice stone will be advantageous for cleansing purposes.

Concerning frames supported by the process of "crown and bridge work."—This is a system which has lately been employed by some operators. It consists in a replacement of some or all of the teeth by mineral crowns, which are supported upon a narrow bar of gold. The latter is held in position by being attached to various teeth and stumps remaining in the mouth, and it is generally intended that artificial teeth thus constructed should be worn permanently, and without removal, by the

patient. In figs. 63 and 64 is shown a partial frame of bridge work supplying three teeth to a mouth in which they were deficient.

In figs. 65, 66 and 67 is shown an entire upper range of mineral teeth so attached to two upper molars, and the fangs of two incisors, that its removal by the patient is impracticable.

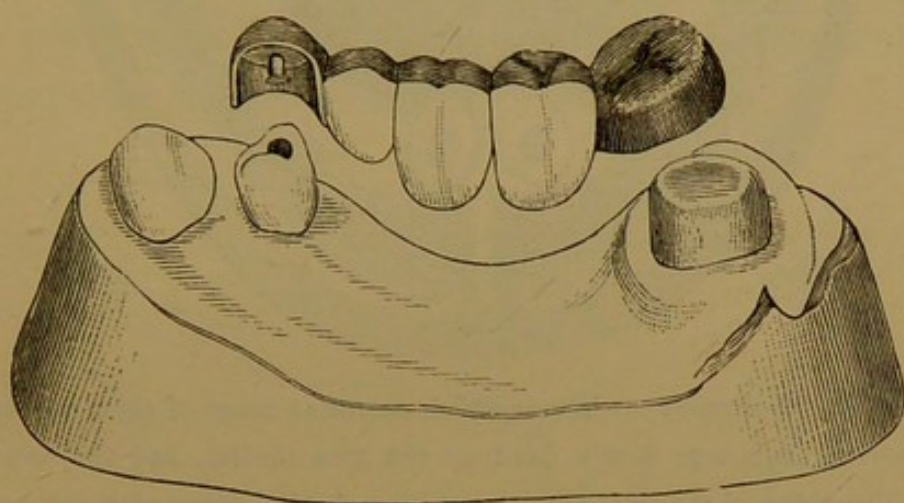


FIG. 63.—The frame carrying three mineral teeth is supported and held *in situ* by the patient's molar and bicuspid teeth. The molar is so ground with a corundum stone that its sides are parallel, and it is then tightly embraced with a gold collar and cap; the bicuspid is drilled into, and a gold stud projecting from the plate is firmly anchored within it.

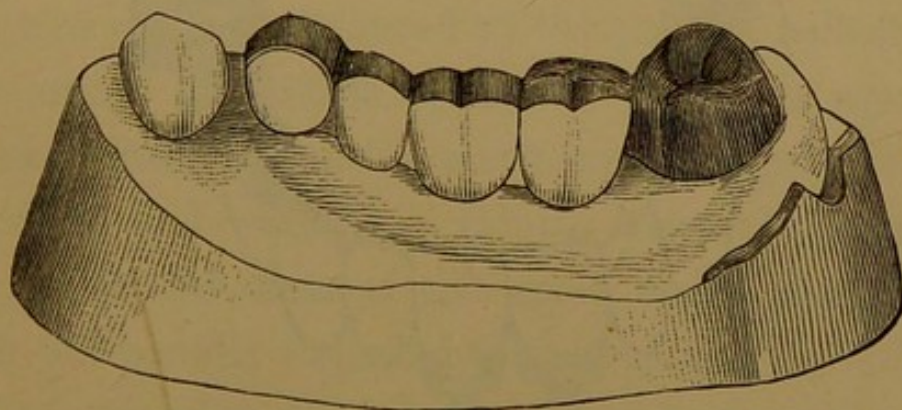


FIG. 64.—A model of the side of the above mouth with the above frame fixed *in situ*, the molar being capped and the bicuspid pierced by a projecting stud on the frame.

The accompanying drawings (from Evan's *Artificial Crown and Bridge Work*) of two cases in which artificial

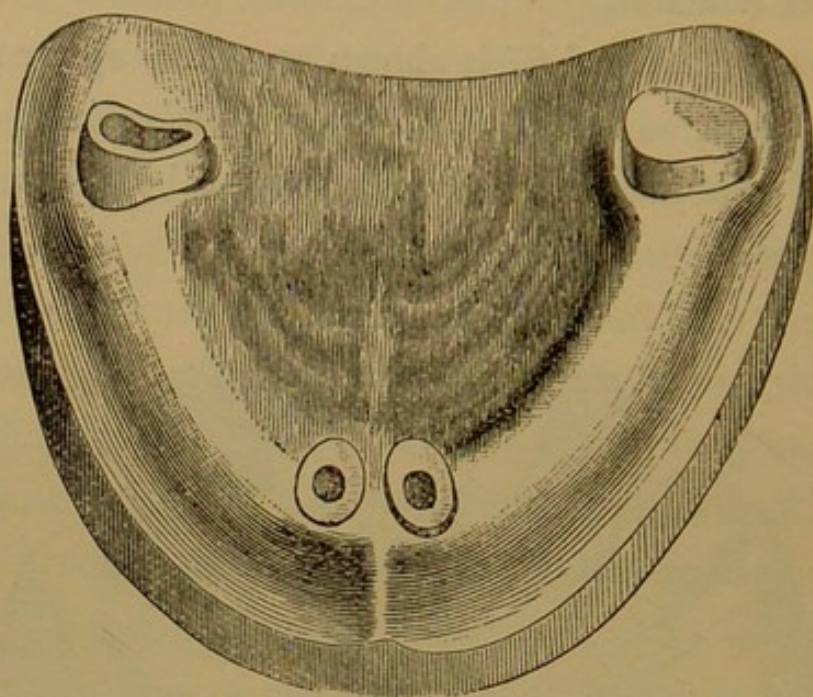


FIG. 65.—Model of an upper jaw to which an entire range of teeth was attached. The supporting bar was firmly fixed to the two molars, and the two incisor stumps. The sides of the molars were cut to a parallel form with the corundum wheel, and to these teeth the bar was attached by gold collars tightly embracing them. In the two incisor stumps tubes were inserted for reception of pins projecting from the bar.

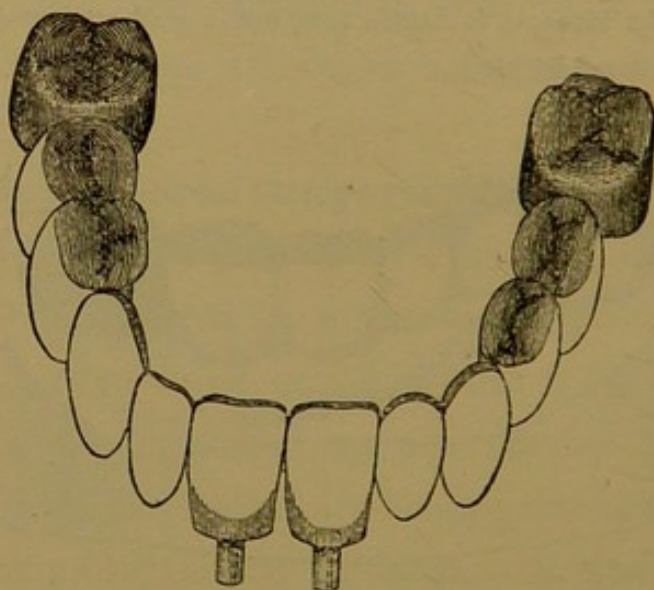


FIG. 66.—A frame, carrying all the upper teeth, which was attached to the mouth drawn in fig. 65 by gold bands around the molars, and pins which fitted into the two incisors

teeth were thus inserted by the process of *bridge work* serve fairly for its illustration. Although ingenuity is needed to execute such work, the objections that may be urged against it are very weighty.

In its favour it is asserted :—

1. That the wearing of a frame is dispensed with.
2. That it is firmly fixed in the mouth, when the work is skilfully performed.

The following objections to this system, are urged by most operators in this country.

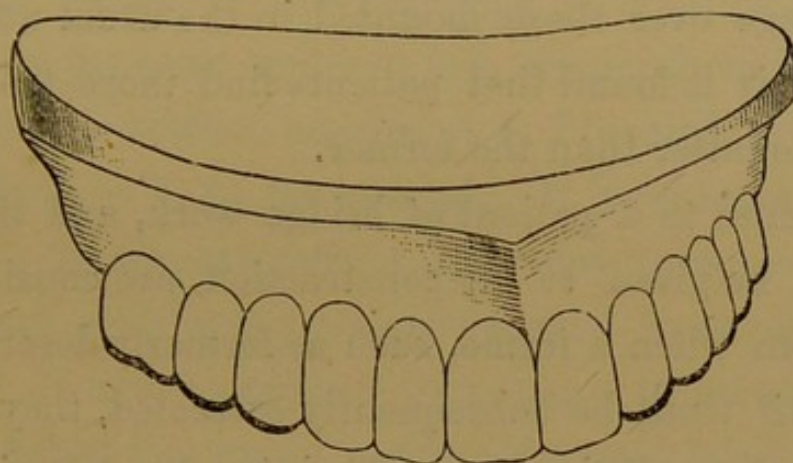


FIG. 67.—Model of the frame in fig. 66, attached to the mouth drawn in fig. 65, and so firmly affixed that its removal by the patient was impossible.

1. The apparatus being permanently attached in the mouth, and not to be removed by the patient, collects and retains mucus and *débris* of food. This can never be effectually removed from the many interstices of the work by brushing and washing. Hence, frequently results a sore and irritated state of the gums, and a disagreeable odour is of necessity imparted to the breath.

2. The apparatus derives no support from atmospheric pressure or suction. It depends entirely upon the preservation of a few fangs or cut teeth, one or more of which

may at any time become tender and inflamed. This result is favoured by the undue stress and pressure to which they are exposed, and by the very painful process of drilling to which teeth, perfectly sound and free from decay, are in many of these cases subjected. If this occur the operator may be called upon to remove one or more stumps to which the apparatus may be attached, and this is then rendered no longer serviceable to the patient.

In conclusion, it may be said concerning the system of bridge work, that teeth thus inserted have in appearance no advantage over those mounted in the usual way upon plates, nor is it found that patients find more trouble in wearing the latter than the former.

The expense to a patient of bridge work, and the time that must be given to its construction, are considerably greater than when a frame, such as formerly described, is made, and if teeth be subsequently extracted, they can be speedily, and at little cost, added to the latter. The opinion here expressed, should, however, be taken as being condemnatory only of such bridges as attempt the replacement of several teeth by the means mentioned. The placing of gold and porcelain crowns upon teeth decayed beyond useful stopping, is a perfectly legitimate and valuable operation.

CHAPTER XI.

ANÆSTHETICS, GENERAL AND LOCAL.

NITROUS OXIDE. CHLOROFORM. ETHER. "GAS" AND
ETHER. ALCOHOL CHLOROFORM AND ETHER. COCAINE.
ETHER SPRAY.

Nitrous oxide is now supplied in a liquid form, condensed by pressure under a low temperature into strong wrought iron bottles, whence it is liberated into the bag from which it is to be inhaled. It is an anæsthetic well suited for minor extractions, and may in some cases be re-inspired with safety when a second tooth is to be removed. It may be applied to patients of all ages, but is very suitable for young healthy persons fairly free from nervousness. It has great value when anæsthesia is needed by one whose heart is enfeebled from age or ill-health, and then should be greatly preferred to chloroform, since it acts as a stimulant to the weak organ, while the latter tends to depress its action. Nervous, hysterical girls will frequently not take "gas" well, and for such, chloroform should be used, which will usually be found quite safe and efficient. A *sine quâ non* in the employment of nitrous oxide is a free and full expansion of the chest during inspiration, and this the highly strung nervous patient is frequently quite unable to effect. Among unfavourable subjects may be included those with marked

alcoholic habit. It should not be given to those who suffer from Bright's disease or an atheromatous condition of the arterial walls, since by increasing the heart's action and the tension within the blood vessels, the liability of rupturing the latter with resulting cerebral hæmorrhage is incurred.

Its anæsthetic action is due *primarily* to a special toxic action that it exerts upon the nervous system, and *second-*

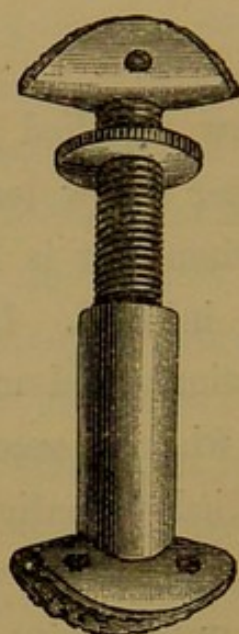


FIG. 68.—A telescopic gag, or mouth prop, for use during inhalation of nitrous oxide. It should be carefully adjusted before the inhalation between upper and lower bicuspid or canines, or between such teeth as are not readily loosened by spasmodic closure of the jaws. The string attached should be twelve inches long.

arily to its asphyxiating influence. The latter is probably caused by an increase in the amount of carbonic acid gas and the substitution of nitrous oxide for oxygen in the blood. Cyanosis is often very apparent within one minute of applying the mask, and taken by itself need excite no alarm.

Nitrous oxide may be breathed until slight blueness of

the face and commencing stertor indicate that the right degree of insensibility has been attained. The latter, if the mask fit so accurately that no air be introduced with the inhaled gas, is usually arrived at within 50 to 80 seconds from the commencement of inhalation. Owing to the speedy return of consciousness the extraction should of course be performed as rapidly as possible after withdrawing the mask, and great care needs then to be taken lest the tooth slip from the grasp of the forceps into the air passages of the patient, and lest a like accident occur with the prop that has been used to keep the jaws apart. To prevent the last mishap a short piece of thin twine should always be attached to the gag, which should be of a telescopic or sliding pattern in order that it may retain its position during movements of the jaws (*see* fig. 68).

In the administration of "gas" these points should be studied:—

1. The patient should be able to breathe freely. To obtain this the operator must insist upon the removal of all impediments thereto, the existence of which a patient will frequently disclaim. The head also should not be thrown backwards, nor flexed in the opposite direction. The patient should be so placed that the feet if violently extended cannot come in contact with the wall or other fixed point of resistance. No objection need be raised to the administration of gas two hours from a moderate meal, but it should not follow too speedily upon a heavy dinner.

2. The apparatus employed should be of modern description, and in good working order. *The mouth-prop*

should be not too long (it is well to possess three sizes thereof), and so placed as to cause no dislocation of any loose incisors, nor to hamper the operator in the use of his forceps. Note further that the string attached to the prop be neither rotten nor frayed.

The mask should be of celluloid, and so transparent that any slipping of the prop may be at once observed. Its rubber air pad should be inflated with the operator's breath immediately before use, so that it may be sufficiently warm not to distress a nervous patient. Its ingress and egress valves should work easily without regurgitation and it should be remembered that celluloid is highly inflammable.

The air-bag should not be filled from the iron bottle within the patient's sight, nor should it be so tensely filled as to cause an explosive rush of gas into the patient's face at the moment of opening the stop-cock. It should rest during inhalation in the lap of the patient, and being thus under the administrator's eye, it may be kept about three parts charged. A *supplemental bag*, as it is termed, whereby gas may be expired and again inspired with a view to economy, should not be used. This addition is unsanitary and does not favour rapid anæsthesia.

The gas bottles should be small, should be duplex, and should both be connected up with the air bag, so that if one be exhausted, the other may be drawn from without delay. Their screw plugs should be loosened, so that they may work smoothly during the operation. In first starting these screw plugs, it is well to direct the neck of the bottle away from the operator or surrounding persons. If

the plug be then blown out, as has happened, no harm will result.

3. During administration, see that the mask fits so closely as to allow no admission of air, which is apt to enter at the sides of the nose or in the neighbourhood of a thick beard. Leakage should be prevented by a careful adjustment of the mask, rather than by a too vigorous pressure thereof upon the face. As a general rule the administrator should be content to give gas once only on any one occasion. A second administration sometimes causes much excitement in a patient who could with comfort endure one inhalation. If it be wished to prolong the usual period of unconsciousness, the mask may be lifted up after the patient has taken six or eight full breaths of gas, or when he shows signs of anæsthetization, so that air alone may be once inhaled, and this may be repeated after three or four more gas breathings have been taken. A smoother and speedier anæsthetization may be produced in a nervous patient if the administrator will count aloud monotonously, and impress the patient with the need of carefully attending thereto, and of recording the exact number counted.

4. During, and immediately after the operation, all care should be taken lest the extracted tooth, or blood clots, or the mouth prop be drawn by a vigorous inspiratory effort into the patient's larynx. The former accident may be prevented by keeping the tooth, after removal by forceps or elevator and until it is clear of the mouth always under the eye of the operator and within the grasp of his forceps or fingers. For the removal of blood it suffices to wash

the mouth out while the head is turned well to one side. The string attached to the prop should prevent it from falling into the throat.

5. The operator should secure the presence of a qualified assistant, to whom the administration of the gas, as a general rule should be entrusted; and the possible occurrence of erotic delusions among female patients should be noted and guarded against.

Chloroform is useful when many teeth have to be extracted, or when from nervousness and absence of deep breathing, or from the hysterical tendency, gas is contra-indicated. In a word, with a weak heart use gas rather than chloroform, and for a nervous hysterical female employ chloroform rather than gas. The patient should fast for five hours before taking it. It should be administered by pouring it frequently in small quantities upon a wire frame covered with flannel, and fitting loosely over the patient's face.

Inhalation should be rapid, and although we do not desire to push anæsthesia into its profound stage, yet an effort should be made to bring the patient quickly through the stage of excitement. As soon as this is attained, the mouth should be forcibly opened by a screw gag placed between the upper and lower bicuspid teeth. The gag may be held by an assistant between the bicuspids, on the side remote from the operation, while the operation is completed. Thus the sense of pain may be dulled or entirely removed and we avoid causing that nausea and prostration which generally follow upon a large use of chloroform. A mouth opener should be employed such as is shown below (Fig. 69).

I have met with no untoward symptoms in thus giving chloroform in appropriate cases. The points to note in connection therewith are these:—

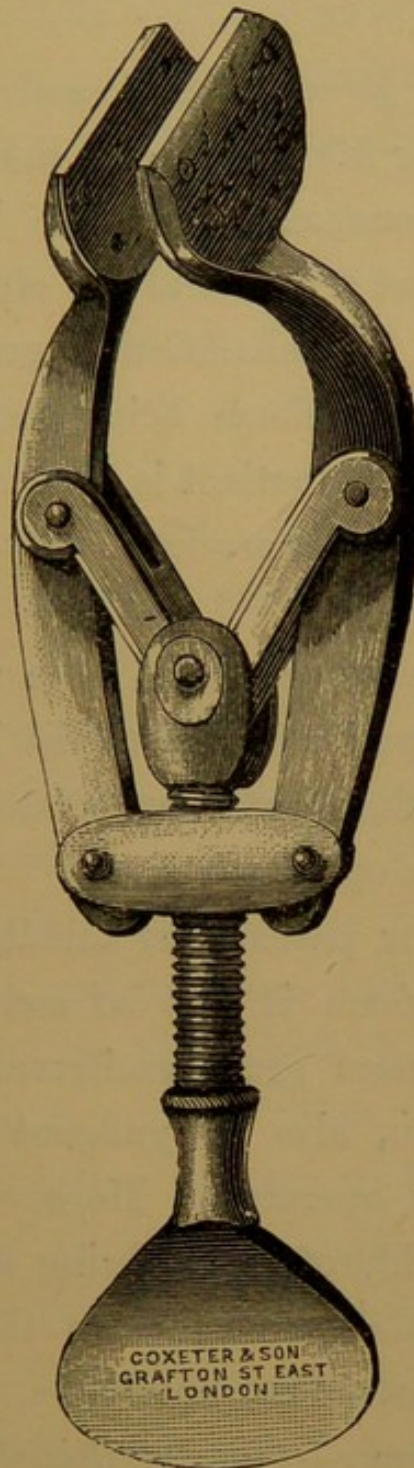


FIG. 69.—A mouth opener and gag to be used with the administration of chloroform or ether.

1. It is very suitable for nervous, highly strung patients

with no special cardiac irregularity, and in dental operations on children it answers better than gas, if given in small quantity.

2. It should be taken after an absolute fast of five or six hours.

3. It should be given quickly, and after stertor has continued for ten or fifteen seconds the mouth should be opened and the operation completed. The administrator should guard against a too timid use of the anæsthetic. If this be practised the inhalation is greatly prolonged, a larger amount of chloroform being required to produce unconsciousness. The patient is then saturated with the drug, and suffers the more from subsequent prostration and nausea.

4. Blood should be prevented from accumulating, and flowing down the patient's throat, the head being turned freely to one side, the mouth opened and the clot removed by a free use of the operator's finger.

Ether is used for patients of middle age, but though safer than chloroform is not so convenient for dental purposes. It causes great excitement, salivation, and bronchial irritation, also its pungent vapour is apt to inconvenience the operator. Moreover, as it requires longer time than chloroform to bring about unconsciousness, it saturates a patient more thoroughly, and he recovers consciousness less rapidly.

Gas and Ether.—This combination is frequently given and has much to recommend it. The gas is inhaled until stertor commences. The mask is then removed and one inspiration of air permitted, to be followed immediately

by the use of ether. Thus the patient escapes the inconveniences attending the early stage of etherization.

Alcohol Chloroform and Ether in proportions of alcohol 1 part, chloroform 2 parts, and ether 3 parts. This also is frequently used for prolonged dental operations and is perhaps more convenient and safer than most other anæsthetics. It should be freshly prepared and freely administered.

Cocaine is used for production of local anæsthesia during extraction. A fresh solution of a quarter of a grain of the hydrochlorate of cocaine in four minims of water is hypodermically injected on each side of the tooth to be removed. The needle is thrust in deeply between the gum and the alveolar process; regurgitation of the fluid is prevented, as far as may be, by application of the finger to the orifice from which the needle has been withdrawn; and after a lapse of ten minutes the tooth may be removed. As to whether the pain of extraction is thus materially lessened, opinions differ. It is certain, however, that at times, much nausea and cardiac disturbance have resulted, and on the whole I do not think that cocaine thus used has much value for large extractions. The scope of its action appears to be limited chiefly to dulling sensibility in mucous surfaces, and a solution painted over the back of the tongue and palate of a nervous sensitive patient will enable one to introduce into the mouth with less discomfort wax or plaster for modelling purposes. A quarter of a grain of the alkaloid may be placed in a sensitive cavity about to be excavated, and being there retained for ten minutes by a loose plug of

cotton-wool, will sometimes lessen the pain of the operation. The salt acts with more certainty upon softened leathery dentine than upon that which is hard and undecayed. If applied to the gum around a loose stump it lessens the pain of its removal.

The ether spray was formerly used to relieve pain, and without doubt the freezing of the gum prevented sensation during the application of the forceps. The pain, however, of subsequent efforts to extract the tooth was not diminished, and the projection of the cold spray upon a sensitive dental pulp caused so much suffering that the process has fallen into disfavour.

CHAPTER XII.

MECHANICAL TREATMENT OF FRACTURES OF
THE MAXILLÆ.

IF the fracture be in the body of the lower jaw, an impression should be taken, and a plaster cast made of the teeth and alveolar process thereof. In doing this it will be convenient to use two half trays for the right and left

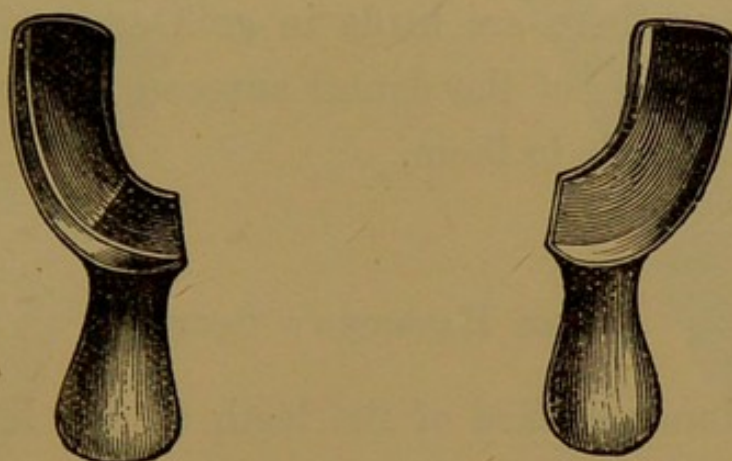


FIG. 70.—Two half-trays for taking separate impressions of the fragments of a broken lower jaw.

sides respectively and to fill them with the softest variety of *Hind's Modelling Composition*, well softened in warm water, or in the absence of modelling composition ordinary wax may be used. An impression should also be taken and a plaster cast made of the upper teeth. The two separate casts of the lower jaw should be pared away to the line of the fracture or fractures, and the teeth then remaining in the lower models should be adjusted, or as it

is termed "articulated," with the teeth in the upper model. The casts of the lower fragments should then be waxed together *in situ* with equal parts of wax and resin, melted together and rolled out into thin sticks, and upon the base of the models of the lower fragments Plaster of Paris should be poured so as to solidly unite them. Thus will be obtained a replica of the lower jaw as it was before fracture, and in the position to which we wish to reduce it with the aid of our splint.

There are two forms of lower splint, *Hammond's* and the *Interdental* which may commend themselves to the general practitioner. Others exist which are at times of value, but as these are made in gold and vulcanite, and need the services of the dental surgeon, no further reference will be made to them.

THE HAMMOND'S SPLINT.

To the inner surface of the teeth on the lower model, made as before directed, a piece of silver or galvanised iron wire, of about the thickness of thin copper bell-wire, should be carefully bent and adjusted with pliers. This should be fitted to lie close against the lingual surfaces of the necks of the teeth, and its ends should curve round behind the molars, and passing forwards in close contact with the necks of these and of the lower bicuspid, should overlap each other by half an inch in front of the lower incisors. The two ends should now be united with soft or pewter solder, which can readily be done with the aid of a spirit flame if the wires are scraped and dipped previously

into a saturated solution of Zinc Chloride. The wire splint thus joined being placed over and around the teeth in the mouth, the fragments of the lower jaw are restored to their proper positions and silver suture wires are threaded between the teeth and twisted up so as to connect the outer and inner wires, thus keeping the fragments firmly in

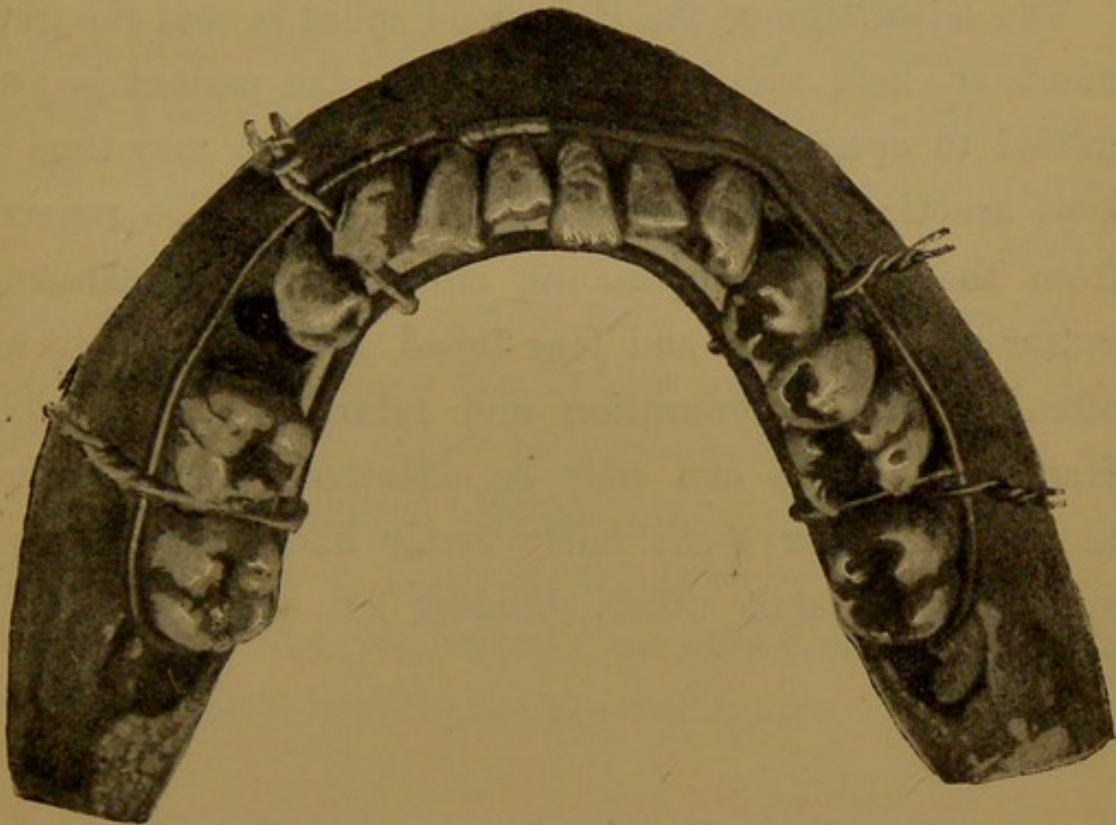


FIG. 71.—Hammond's Splint applied to a broken lower jaw showing the mode of threading the suture wires.

position. The application of the suture wire needs comment. This should be threaded between two adjacent molars or bicuspid from without inwards, first *over* the outer splint-wire, then *under* the inner one, and it should return again between the same two teeth, first *over* the inner splint-wire and then *under* the outer one. The two free ends of the suture-wire are tightly twisted up, cut

short, and their sharp ends tucked in so as not to wound the cheek. It is well where practicable to lead the suture wire back as it entered, between the same two teeth, but this is not essential. In some cases it will prove more useful to affix the splint by carrying the suture-wire around a molar or bicuspid, entering in front thereof and emerging behind it, or *vice versa*.

The advantage of the Hammond splint is that the fragments are held well in position while the patient is permitted to open and close the mouth, which may thus be kept aseptic by frequent washings. He is also relieved from the pressure upon the chin of the old-fashioned gutter-percha splint and four-tailed bandage, which too often favoured suppuration and retarded repair. The Hammond splint can only be effectively applied when there are a few teeth fairly firmly fixed and in close apposition to each other, standing on each side of the fracture.

THE GUTTA-PERCHA INTERDENTAL SPLINT.

The preliminary steps in regard to modelling the lower fragments, and articulating upon the upper model the the cast of the broken lower jaw, are such as were described in connection with the Hammond's splint. Upon the teeth of the lower model thus built up, a roll of warm gutta-percha is pressed, and into this the upper model is indented so that the gutta-percha shall be about $\frac{1}{2}$ inch thick in front, between the edges of the upper and lower incisors. Through this part of the splint a hole of

about $\frac{1}{2}$ inch in diameter may be made with a warmed instrument, so that liquid food and aseptic mouth washes may be subsequently introduced into the mouth. The splint is then inserted and placed in position upon the upper teeth, and the lower teeth with the lower fragments should be drawn into it and kept in position with an ordinary four-tailed bandage. This interdental splint may be used when the lower jaw is nearly or quite edentulous or when the remaining teeth are so loose or so separated from each other that a Hammond's splint cannot be employed. An opportunity for cleansing the mouth and feeding the patient is afforded if such an interdental splint be used in conjunction with the customary four-tailed bandage, although the troublesome pressure of the latter upon the chin cannot be here escaped.

If the upper or lower alveolar process be fractured as may happen from a blow in the front of the mouth a modification of the Hammond's or interdental splint will doubtless suggest itself to the practitioner.

CHAPTER XIII.

EXTRACTION OF TEETH AND STUMPS.

CONDITIONS NECESSITATING EXTRACTION. GENERAL DIRECTIONS AS TO THE POSITION OF OPERATOR AND PATIENT. CONCERNING THE APPLICATION OF FORCEPS. AS TO THE EXTRACTION OF THE TOOTH. ACCIDENTS DURING EXTRACTION. INSTRUMENTS NEEDED FOR EXTRACTION. FORCEPS, THEIR GENERAL CHARACTERS AND VARIOUS FORMS. THE ELEVATOR, ITS DESCRIPTION AND MODE OF USING.

Conditions necessitating extraction.—Attention to some practical points in connection with this subject is necessary to the medical practitioner, who is likely to be more often called upon to use the forceps than to perform other dental operations. Extraction may be necessary to relieve irregularity and overcrowding among teeth of young patients. It may afford speedy relief to the severe pain of an aching pulp, exposed by decay or fracture of the tooth. It is necessary to extract a diseased lower wisdom tooth, which is causing closure of the jaws through contraction and rigidity, induced around the temporo-maxillary articulation. To cure a fistulous opening through the cheek, or prevent its occurrence when threatened, nothing will suffice but complete removal of the decayed lower molar which will probably prove to be the

cause of mischief. It may be required to take out a loose temporary tooth, the fangs of which, sharpened by partial absorption, are ulcerating through the gum and excoriating the cheek or lip. Extraction may be needed by a decayed molar whose ragged edges are threatening to produce malignant disease of the tongue; or for the cure of epulis some stump, underlying the tumour, may need removal. As teeth become loosened by the absorption of alveolar process and recession of gums which accompany other senile changes, extraction will from time to time be required to prevent them from proving a hindrance to mastication.

General directions as to the position of operator and patient.—The foregoing are frequent conditions under which the use of forceps is indicated, though doubtless from time to time their employment will be required from other causes. To apply them effectively it is necessary to place the patient in a solidly made chair with the back sufficiently low and so cushioned that, if the removal of an upper tooth be required, the head may be readily thrown back and supported. The head and hand of the operator should never be allowed to intercept the light which should fall directly upon the tooth. When an upper tooth on either side is to be extracted, he should stand with feet well separated by the *right hand* of his patient; he should stand immediately *behind* the latter and leaning over his head when about to take out a lower tooth on the right side; and when extracting any lower tooth on the left side, the operator should place himself by the *left side* of his patient. The attitude of the operator

should be easy and unconstrained, so that his power may be exerted to the best advantage. With this in view the operating arm should be held fairly close to the side, that its movements may be well regulated and under control; the head of the patient raised or lowered; the chin thrown

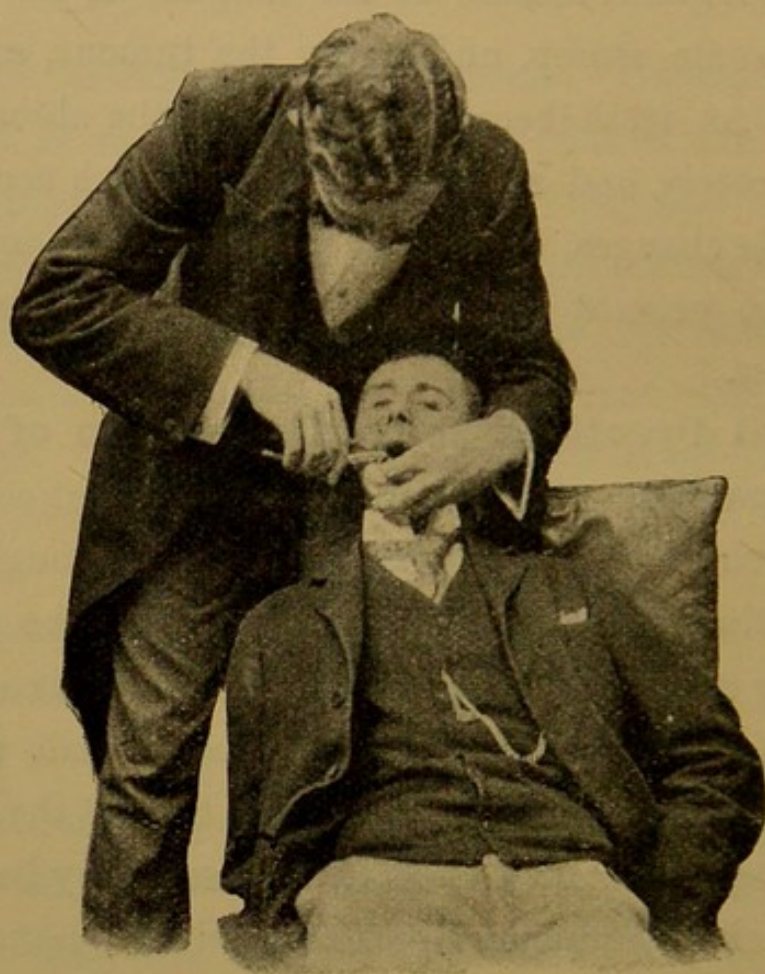

FIG. 72.—Position of operator when about to take out a tooth on the right side of the lower jaw.

upwards or depressed; and the head always so turned towards the operator that his forceps may have easy access to the tooth. If it be an upper tooth that is to be extracted his left hand must be used to steady the upper maxilla during application of the forceps, and to aid the extraction by providing an opposing force to the traction.

of the instrument. To effect this he should firmly grasp with fingers and thumb the alveolar process on both sides of the tooth he is about to remove. If the tooth be in the lower jaw the left hand should be used to prevent all rocking and depression of the inferior maxilla by rigidly securing and supporting it between the fingers and thumb.



FIG. 73.—Position of operator when about to take out a tooth on left side of the lower jaw.

In regard to the position of the patient these three points should specially be studied :—

1. The seat of the chair should be low rather than high ; thus the operator may the better exert his force.

2. The patient's head should be well turned towards the operator's arm. This needs attention since the tendency is to avert the face.

3. The maxilla, whether it be the upper or lower from which the tooth is to be drawn, should be well secured by the operator's left hand.

Concerning the application of forceps.—The operator should determine to insert their blades as deeply into the socket, and as far up the fang, as is practicable. An exception to this holds good when the removal of a temporary molar is demanded, since the crown of the underlying permanent bicuspid may be grasped if the instrument be used too vigorously. To secure a good application these points should be noted.

1. The tooth should be grasped VERY LIGHTLY between the blades that they may travel readily up its fang, and to obtain this let the thumb be pressed between the handles, close to the joint. Thus, the operator may inform himself of the amount of force with which he is gripping the tooth.

2. The forceps should be driven freely home. In so doing there should be no sparing of effort. There should be two or three vigorous thrusts. A gentle pushing movement is here of no avail, and the operator must resolve to drive the blades of his instrument well below the margin of the socket. If upper forceps be used they should be so held that the ends of their handles may rest against the palm of the hand, and thus they may the more vigorously be driven home.

3. While doing this see that the instrument receive the slightest possible rotation to and fro on its long axis. This should hardly amount to more than a tremulous movement, but it suffices to convince the operator that

the blades are not gripping the neck of the tooth so tightly as to prevent them from travelling up it. Moreover, it enables the sharp ends of the blades to cut their way through any fibrous structure opposing their advance. This applies to all teeth other than the upper 1st and 2nd molars, and the lower 1st, 2nd, and 3rd molars. In these cases the tang at the ends of the blades prevents this slight rotatory movement.

4. The long axis of the blades of the forceps should be continuous with or in the same direction as the long axis of the tooth. If this be disregarded their edges may impinge upon a neighbouring tooth, which by its resistance may greatly hamper the operator during extraction. This precaution is very necessary when an upper bicuspid has to be removed.

5. The eye of the operator should be fixed upon the tooth, and it should never be lost sight of throughout the operation. Take all care that it be never hidden by blood or the patient's tongue, by the operator's hand or forceps, or be obscured by the head of an onlooker.

Extraction may now be proceeded with. The tooth should be firmly and securely grasped by the forceps, and care should be taken that they do not slip around the tooth while the effort is being made. This mishap, which proves a serious hindrance, results from the use of an instrument whose handles are too thin and flexible, or whose blades do not close sufficiently. Power should be applied in the following directions, the second and third of which are designed to loosen the tooth in its socket, and so should rather precede the effort of *traction*.

1. *Traction*, whereby the tooth is drawn straight out of its socket.

2. *Torsion*, by which the tooth, being quickly rotated on its long axis alternately in each direction for about $\frac{1}{32}$ of a circle, becomes loosened from its surroundings. This movement produces a separation of the fang from its membranous connections, and also tends to expand and dilate the socket. It should be always applied to Incisors, Canines, or Bicuspids, since their fangs are more or less cylindrical; but in the extraction of two or three fanged teeth, as are molars, this movement of Torsion is of course not applicable.

3. *Rocking*.—By this is meant a vigorous inward and outward movement of the crown. This should be always employed when dealing with molars, but to all other teeth it should be sparingly used.

To sum up the foregoing:—In extracting Incisors, Canines, and Bicuspids, apply Traction, Torsion, with if necessary a little Rocking, and remember that force in the latter direction has a great tendency to break the tooth. In extracting Molars use Traction and Rocking only, and it matters not whether the tooth be first rocked inwards or outwards.

Mishaps in extraction.—A. *The tooth to which forceps are applied may break.*—This accident usually results from one of the following causes:—

1. The long continued progress of decay may have entirely softened the dentine of which its fangs are composed. Added to this may be a glueing of the latter into their sockets by inflammatory exudation. These

conditions prevent the blades of forceps from travelling down, and favour the collapsing of the walls of the stumps as soon as pressure is brought to bear upon them. In such cases it is well to commence by using the elevator to partially dislodge them, and the forceps may then complete their removal. In this state is often found a carious lower molar with which a fistulous opening through the face is connected.

2. The fangs may be considerably curved and clinging tenaciously to septa of bone, or to fangs of neighbouring teeth.

3. The fangs, as the result of chronic inflammatory action, may have become enlarged or exostosed, and so rivetted into the alveolar process.

4. The dentine may become, as the result of senile changes, almost as brittle as glass, and on this account it is well to be on one's guard when dealing with the teeth of elderly persons.

From any of the above causes a tooth or stump may break, and blame in many cases is not to be attributed to the operator if it do so. He should always, before applying forceps, ascertain the mobility of the tooth in its socket by rocking it *lightly* to and fro, with a strong excavator resting against one side, and the first finger of the left hand against the opposite side of its crown. More lateral mobility may be thus shown than if the attempt be made to rock the tooth with an excavator resting on its grinding surface, whereby its conical fangs are tightly pressed into its conical socket. If fracture occur during extraction, he should wipe away with a

plug of absorbent wool on the end of an excavator any blood which may conceal the surface of the stump, and then attempt its removal with a finer or narrower instrument. If he now fail after a reasonable attempt, let him desist, since a prolonged operation serves but to exhaust his patient, and prevents his own success in any subsequent attempt. If, as the result of the fracture, there be apparent a vital and intensely sensitive exposed dental pulp, this may be removed as completely as possible by passing down the fang a finely barbed nerve extractor (*vide* fig. 74). The stump, if it cannot be removed, may now be allowed to remain, with the probability that it will now give no more trouble, since the nerve which was previously aching has been removed, and being healthy and free from septic change it is not likely to set up periodontitis. If the motive for the attempted extraction be the relief of periodontitis, this condition will be relieved by the complete opening of the fang canals, and the free escape thus given to imprisoned gas, by the breaking off of the crown of the tooth. The patient may be further consoled by an assurance that after a year or two the progress of absorption both of fang and alveolar process will probably render the removal of the broken stump comparatively easy.

B. *While extracting a lower molar an upper incisor may be broken by the back of the forceps.*—This results from the sudden parting of the tooth from its socket after a prolonged effort has somewhat exhausted the muscular power of the operator. Guard against this by keeping the operating arm well under control, and by intently watch-

ing for the moment when the tooth is about to sever connection with its socket.

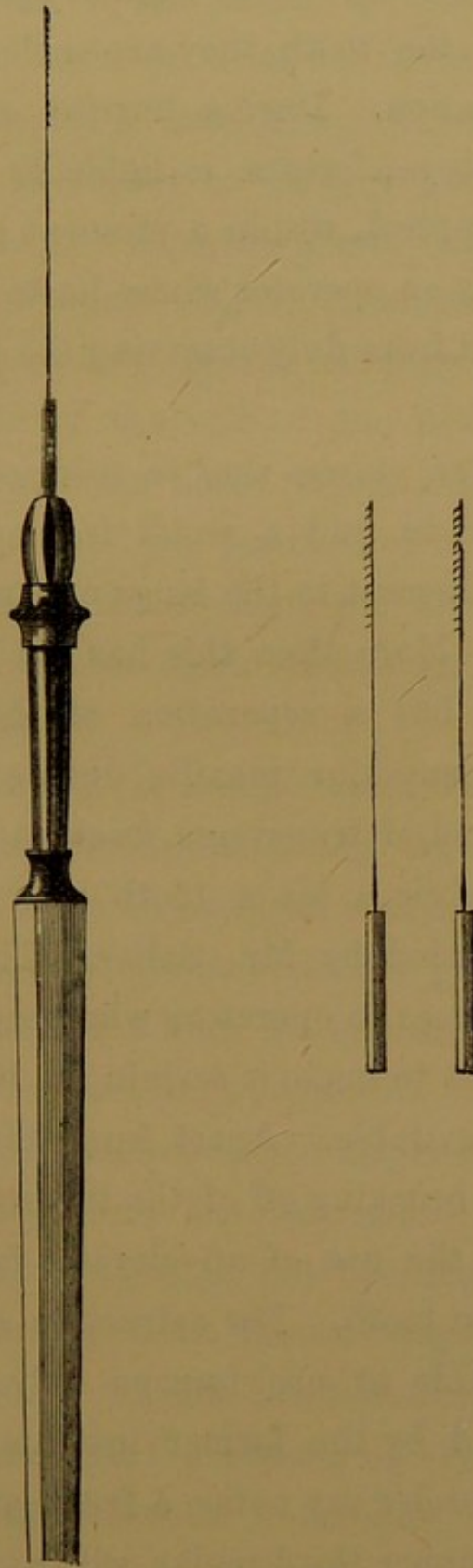


FIG. 74.—Barbed nerve extractors, and a holder for the same, with which a dental pulp may be removed from the fangs of a broken tooth

C. *A tooth may be taken out other than that which it was designed to extract.*—This can result only from want of care, and should be guarded against by closely watching the forceps and the tooth they are enclosing, throughout the whole operation. During hurried extractions under nitrous oxide this misfortune is liable to occur, when the instrument is applied, within a moment of the removal of the face-piece, by an operator whose haste and nervousness may prevent him from duly observing the parts with which he is dealing.

D. *The alveolar process may be fractured*, and indeed it is very common to find a small fragment of the outer alveolar plate adherent to the fangs of a molar after it has been removed. More than this has not happened within my experience, but a separation of the intermaxillary bone from the superior maxilla during removal of an upper incisor, and of transverse fracture of the ramus of the lower jaw while a lower tooth was being extracted, have been recorded by Mr. Salter. The accidents occurred in both cases to operators who possessed such skill and knowledge as to make it certain the like may in some conditions be inevitable. Apart from this, however, must be regarded the breaking off of the tuberosity of the upper maxilla during the use of an elevator for the removal of an upper wisdom tooth. For extraction of this last, it is generally desirable to use forceps only. The powerful leverage afforded by the former instrument served in a case that came under my notice a few years since to break away, with the upper third molar which was extracted, a mass of spongy bone in size as large as a walnut.

E. *The gum may be lacerated* during removal of a lower second, or third molar, through its occasionally strong adhesion to the neck of the tooth. If this be the case a scalpel should be used to divide it before the molar is entirely withdrawn from its socket. It may be remarked that it is never necessary to employ the scalpel before extracting in order to "lance the gums" as it is termed.

F. *The tongue or cheek may be punctured*, and a large blood vessel thus opened, by the slipping of an elevator. The firm pressure of the end of the first finger of the operating hand upon the blade within one quarter of an inch of its extremity, at the moment of introduction, and then, as it is being thrust into the alveolus, upon the tooth to be taken out, or upon its fulcrum, will suffice to prevent this mishap.

G. *The extracted tooth or stump may slip from the grasp of the instrument* and passing into the trachea may cause much trouble. This is an accident which those operating upon an anæsthetised patient should guard against by folding a mouth-napkin within the mouth behind the teeth or stumps that are about to be removed.

H. The fang of a much decayed upper bicuspid may be forced by the forceps into the antrum. This can only occur if the operator, through not opening the blades of his forceps sufficiently wide, thrust directly against the surface of the stump. If this accident occur, the opening into the antrum through the bottom of the socket should be cautiously enlarged with a trochar, or by a large coarsely cut inverted-pear shaped bur driven in the dental engine. The buried stump may then be withdrawn

with a wire loop, or a pair of long fine pliers, or may be ejected by vigorously injecting into the antral cavity a stream of warm water, which enters and escapes through the opening at the bottom of socket.

I. *Persistent hæmorrhage after extraction*, or coming on within a few hours of the operation, may need prompt attention. The firm blood clot, which may then be found concealing the bleeding socket and its neighbouring teeth, should be vigorously wiped away with a plug of wool on an excavator. A strip of dry lint, $\frac{1}{4}$ of an inch wide and about six inches long, should then be plugged into the socket, being condensed tightly and carried down *completely to its bottom* with the aid of an excavator. It will be observed that the blood escapes from this situation, where the vessels that supply the pulp are torn across. Over the plug should be applied a compress of lint, and on this the jaws should be kept tightly closed for a few hours with the aid of a four-tailed bandage. In this way the bleeding may with certainty be controlled, and though the compress may be changed daily, the plug within the socket should remain undisturbed for three or four days. In arresting hæmorrhage under these circumstances, dry lint will be found more effective than Matico leaf, and it is not necessary or desirable to employ any styptic such as Tinct. Ferri Perchlor.

J. Severe painful inflammation within the gum and socket may follow an extraction. This happens more often after removal of a lower than of an upper tooth, since gravity favours the lodgement within the former of particles, septic and otherwise. A more probable cause of

the trouble is the use of unclean forceps by the operator and the introduction thereby of micro-organisms. Forceps and elevators immediately after use should stand for an hour in a saturated solution of Carbolate of Soda, and should then be well brushed with a tooth-brush, soap and water. They should then be *gently* warmed over a gas flame to expel water from within their joints, into which Carbolate of Soda, since it is somewhat hygroscopic, should not be allowed to enter.

Instruments needed for extraction.—These comprise nine pairs of forceps and three elevators.

The forceps should have these characters. Their handles should be strong, unyielding, and quite without spring, which tends to prevent an operator from judging accurately of the amount of pressure he is applying to a tooth. They should be so rigid that all the force that an operator may apply shall be transmitted directly to the tooth, and not in part wasted by uselessly bending the handles of the instrument. Their joints should be strong and without any play. If this occur after considerable use, it should be remedied by carefully tightening up the central rivetted screw. A loose joint causes much inconvenience during extraction, and while wrenching the fangs from their sockets, since it allows the blades to slide to and fro over the sides of the tooth. Care should be taken that water, when cleansing the forceps, does not enter the joint, and the latter should be occasionally oiled that it may work freely and without any rigidity. The blades should be well tempered, being neither so soft as to bend or splay out at their edges, nor so hard as to chip or fly.

Their cutting ends should be kept well sharpened by occasionally touching their outer edges upon an oil-stone, sharpening them as a carpenter would his chisel. The space between the blades towards the joint, should be wide enough to enable them to close firmly upon the neck of a tooth without coming in contact with its crown.

The stock of forceps should consist of the following.

1. *One pair upper incisor and canine forceps.*—These should be seven inches long from end of the blade to that of handles. The cutting edges of the blades when closed

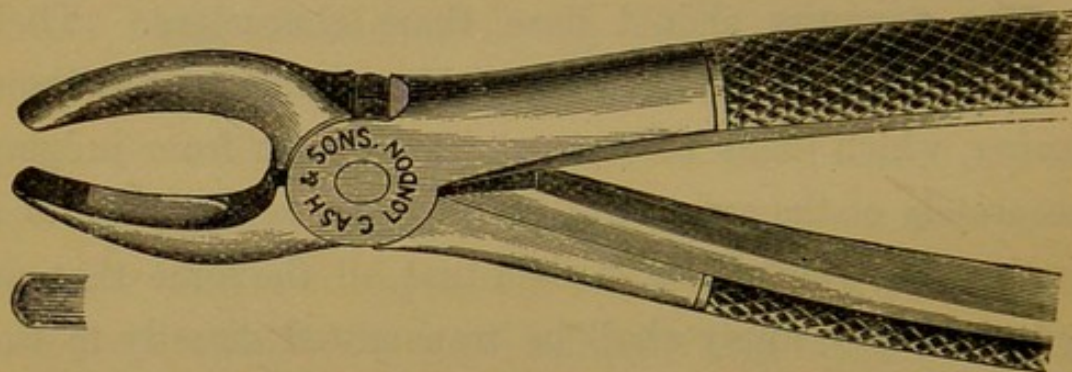


FIG. 75.—Upper incisor and canine forceps available for either side.

should be in contact. The handles and blades should be continued in the same line. Remember in their application to *thrust* them well up the neck of the tooth. Ensure this by grasping the latter lightly, regulating the pressure by firmly pressing the ball of the thumb of the operating hand into the space between the handles. Also, while forcing them up within the socket, give them a slight tremulous movement, or one of partial rotation upon their long axis, amounting to about $\frac{1}{32}$ of a circle in each direction, so that the sharp cutting edges of their blades shall sever the membranous connections between the fang

and its socket. Extraction will be performed by steady continuous traction, increasing gradually in amount, during which the fang, being firmly and cautiously grasped, may be slightly rotated to-and-fro on its long axis. Any rocking movement in an antero-posterior direction is, as before mentioned, generally undesirable. Efforts in this direction should at any rate be applied with much circumspection, and only when traction with rotation does not promise to produce the desired result. The operation should not be hurried, and if the fang show signs of giving

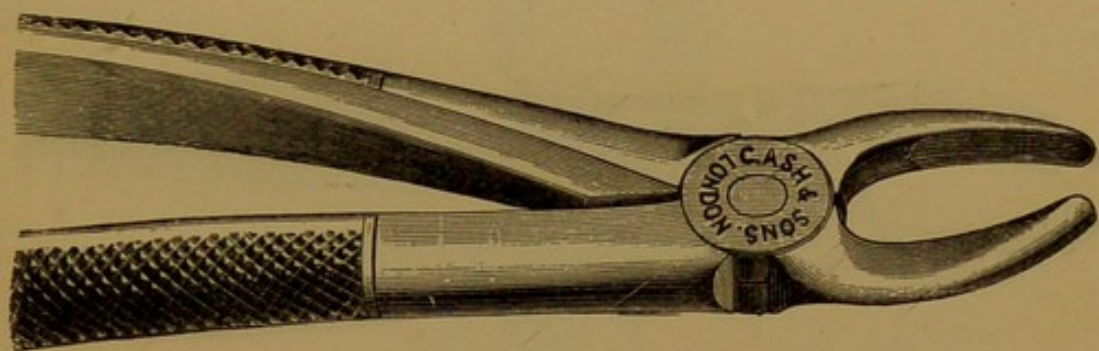


FIG. 76.—Upper bicuspid forceps available for either side.

way the grasp of the instrument should be relaxed, and it should be thrust more deeply into the socket. What is applicable to these forceps may be held to apply equally to those intended for the removal of lower front teeth, and of upper and lower canines and bicuspid, though in the extraction of bicuspid a rocking movement from and to the median line is admissible.

2. *One pair upper bicuspid forceps.*—These should be seven inches long from end of the blades to that of the handle. The cutting edges of the blades when closed should be in contact. The blades and the handles should

be nearly in the same straight line. Over-much curvature in this direction is not needed and it tends to interfere with any to-and-fro rotation of the tooth on its long axis during extraction. These forceps should never be used for extraction of upper molars the fangs of which are still united.

3. *One pair of forceps for upper right 1st and 2nd molars.*—The handles of molar forceps should be longer and stronger than is generally the case. The tang projecting from one blade is thrust up between the two outer fangs, and the neck of the tooth being rigidly grasped, well

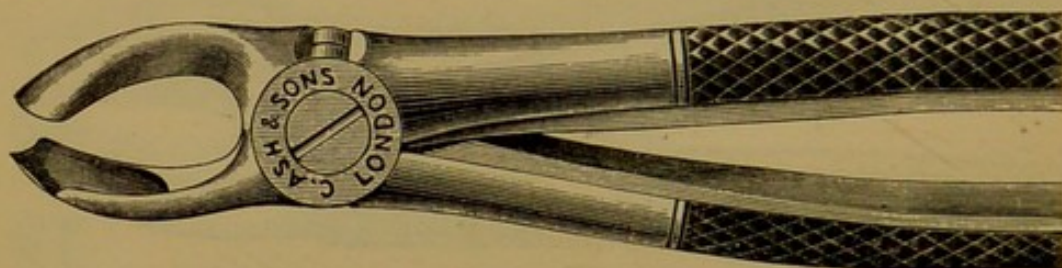


FIG. 77.—Forceps for upper right molars.

within the socket, should be steadily rocked inwards and outwards, while forcible traction is being exercised. No movement of rotation is admissible during extraction of upper and lower molars, owing to the arrangement of their fangs. These forceps should be only very slightly curved—as a rule their overmuch curvature lessens their efficiency. They should be seven inches in length from the end of the blades to that of the handles.

4. *One pair of forceps for upper left 1st and 2nd molars.*—What has been said of forceps for upper right molars applies equally to those used on the upper left side.

5. *One pair of forceps for upper wisdom teeth.*—These resemble upper molar forceps save that they possess no

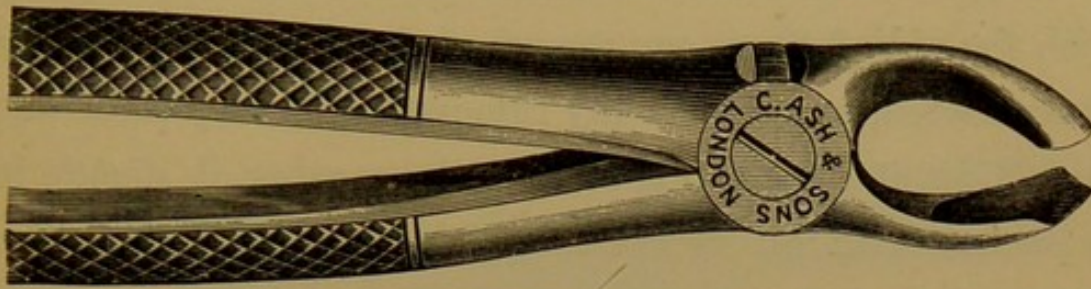


FIG. 78.—Forceps for upper left molars.

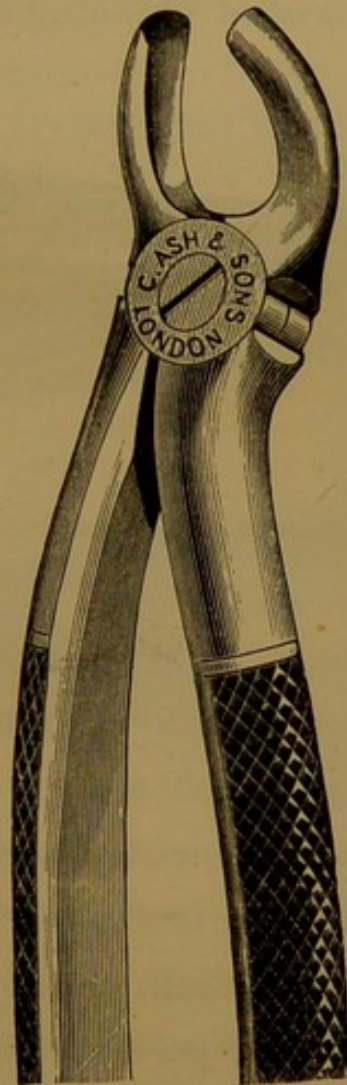


FIG. 79.—Upper wisdom forceps, available for either side.

tang on their outer blades to pass in between outer fangs, and that their handles and blades are well curved for

better access to the tooth. Their blades should be short, and set close to the joint so that they may be *quite* unyielding, and their handles also should be very strong. With the aid of these an upper wisdom tooth, if not too firmly rooted, may be readily removed. If very rigid and unyielding, it is well to commence by moving it *slightly* in its socket with an elevator, which should be thrust in between it and the second molar. The use of the elevator in this situation requires considerable care, owing to the liability thus encountered of breaking away the tuberosity

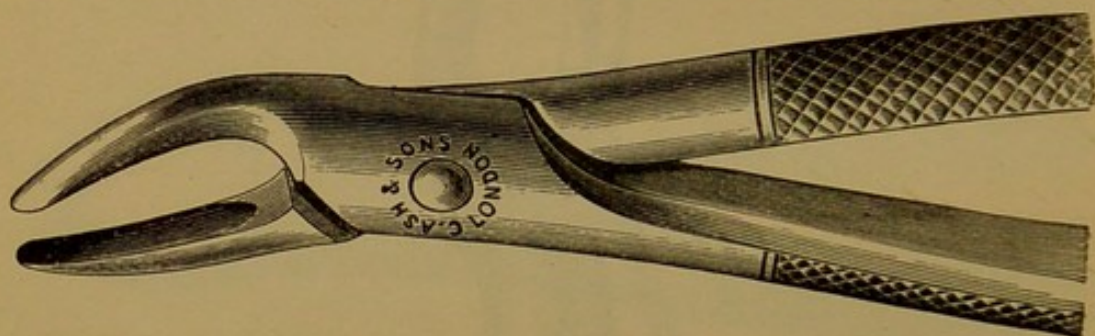


FIG. 80.—Read's forceps for extraction of upper stumps.

of the superior maxilla, and the extraction of the tooth is to be completed with forceps. The upper wisdom tooth possesses usually fangs which are conjoined, stunted, and conical. So that the movement of slight rotation to-and-fro on the long axis of the tooth may be here very effectively applied during extraction.

6. *One pair of Read's forceps.*—These should be strongly made, with joint and connecting pin of large size.

7. *One pair of cutting forceps for separating the stumps of an upper molar.*—These are effective in dealing with very difficult upper molar stumps. Extraction of these be-

comes fairly easy if the strong diverging fangs are first separated, and are then separately removed with Read's forceps. To make this separation, a hole of good size should be drilled through the stump in the floor of what

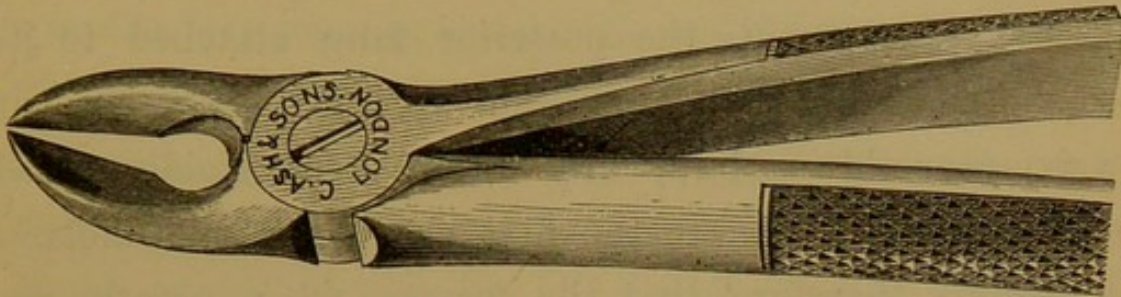


FIG. 81.—Forceps for separating the three fangs of an upper molar, decayed below the level of the gum.

was its pulp cavity, between the three fangs. Into this one blade of the separating forceps should then be thrust and their cutting blade, being passed up the side of the

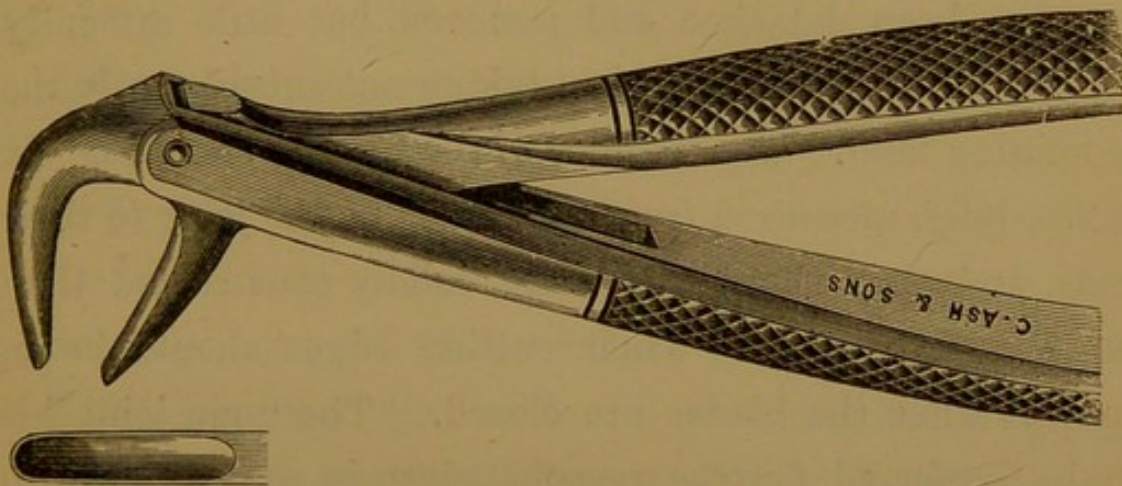


FIG. 82.—Forceps for lower incisors, lower canines, lower bicuspid, lower molars greatly decayed, or lower stumps, for use on either side of the mouth. The width of the blades is also shown.

stump, should be strongly closed into the depressions between the fangs, which thus may be disunited.

8. *One pair of lower single-bladed forceps.*—These are of

much service in the extraction of greatly decayed lower molars, which threaten to be fractured if grasped by the ordinary lower molar forceps. With the single-bladed forceps, one fang, usually the anterior, may be grasped deeply in the alveolus and removed separately, or as often happens, with the posterior fang attached to it. It should be noted that the second permanent, or twelve-year-old molars, are often more rigidly fixed in the maxilla than are the first or six-year-old molars. It follows, therefore, that the former, when greatly decayed, are more liable than the latter to fracture when the ordinary molar or double forceps (to be spoken of later on) are applied to them. For extraction therefore of very carious second permanent molars, the *lower bicuspid*, or, as they are sometimes termed, *single* forceps (see fig. 82), are of considerable value. When one fang has been detached and removed, but little difficulty will usually be encountered in taking out subsequently the remaining fang. The handles of the forceps should be six inches long, measured from the centre of the joint to their ends, and they should be more solidly constructed than those usually made. Their cutting edges should be in contact when the blades are closed. The "pin joint" is to be preferred for the reasons given in connection with the lower molar forceps next described.

9. *One pair of lower molar forceps (for use on either side of the mouth).*—The handles of these should be very strong and inflexible. Measured from the centre of the joint to their ends they should be six inches long. Each blade presents a projecting tang which should be inserted be-

tween the two fangs of the tooth. If this be fairly solid and resisting these forceps should be used in preference to the *lower bicuspid* forceps, since they afford a more secure and complete grasp of the tooth. The "pin joint" is here advantageous, if it be very strongly constructed, since it occupies less room in the mouth and lessens the liability of impinging upon the upper teeth during extraction. As the long axis of lower molar teeth is frequently directed upwards and somewhat inwards, the operator should guard against depressing the handle of the forceps too




FIG. 83.—Lower molar forceps for either side of the mouth. The width of the blades is also shown.

freely, by doing which he may at any time readily break off the crown of the tooth. If the lower molar be at all tilted inwards, he should aim at lifting it upwards and inwards at the time he is engaged in rocking it alternately inwards and but slightly outwards.

The elevator should be strong and unyielding. An operator should possess one *straight* and two *curved* elevators.

The straight elevator should be $5\frac{1}{2}$ inches from end to end.

The handle should possess a smooth broad end, that the palm of the hand may not be injured when using it forcibly. The blade should be two inches long; and, for its lower inch, it should be flat on one side, convex on the other, and one quarter of an inch wide. Its extremity should possess a sharp cutting edge, and be neither

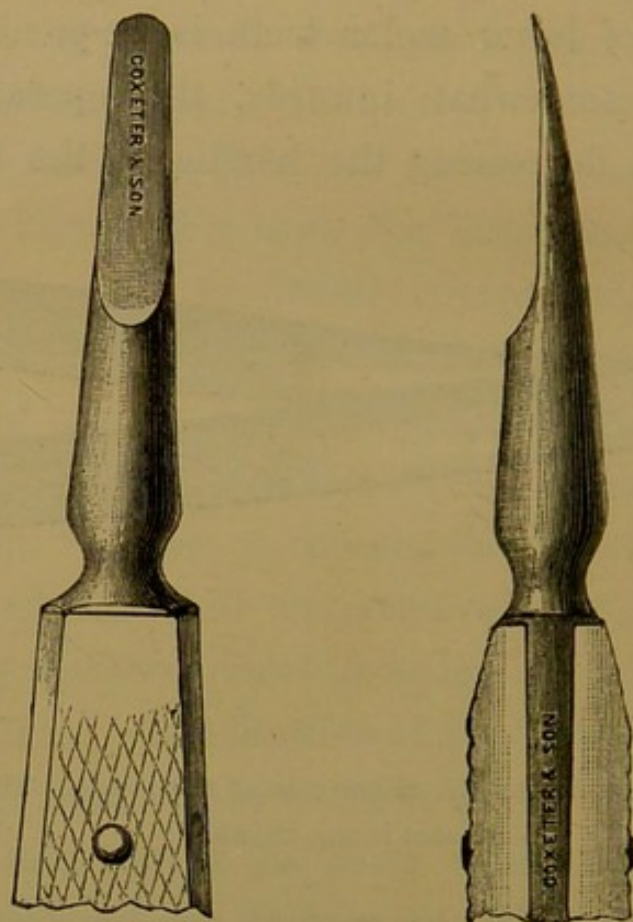


FIG. 84.—Diagrams of straight elevator—front and side views. The drawing shows the exact size of the blade, and the handle should be $3\frac{1}{2}$ inches long.

pointed nor flat, but gently rounded. All spear and spoon shaped straight elevators are to be avoided; also, the instrument should be straight throughout, without curve or bend of any nature.

This instrument is of great value for extraction of lower wisdom teeth, and of firmly implanted stumps. The

straight elevator can be employed only when there is a vacant space immediately adjacent to the tooth for removal of which it is to be used; and for extraction of upper wisdom teeth it is rarely to be used, owing to the

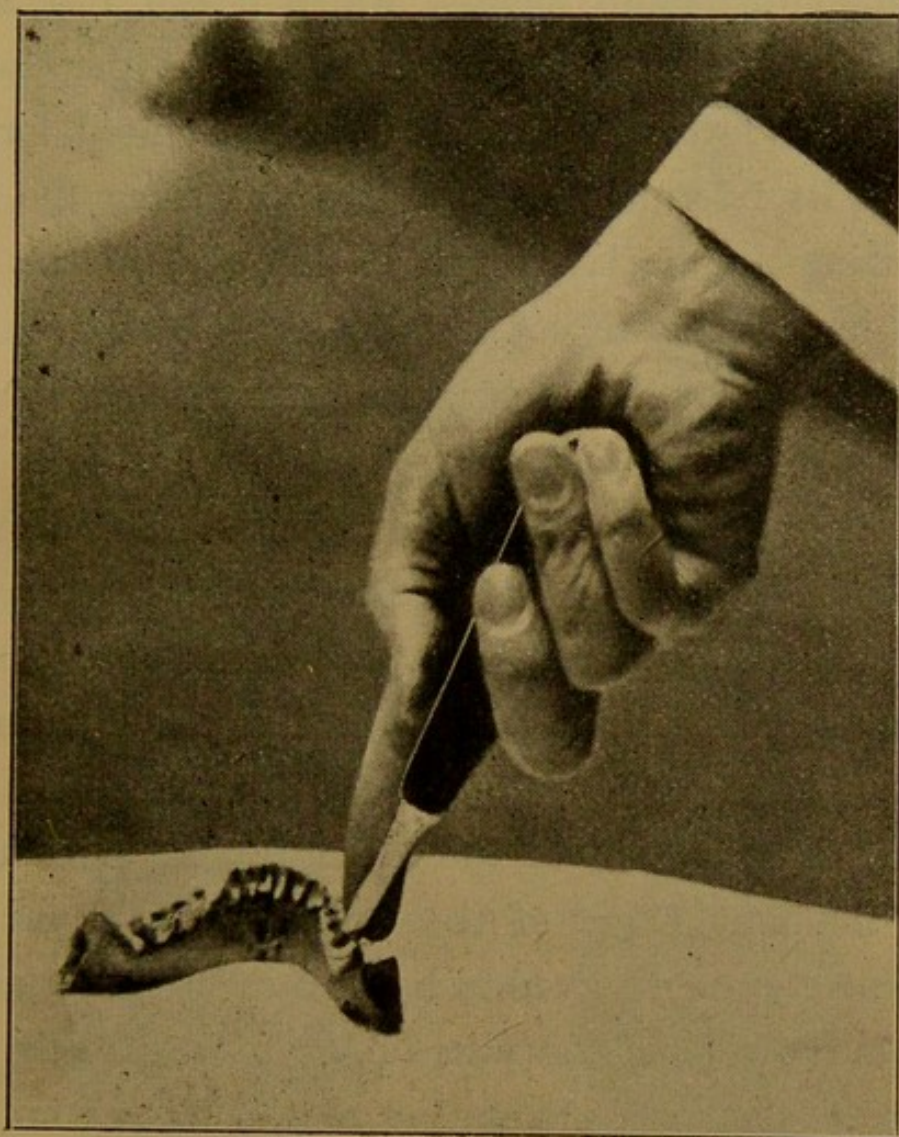


FIG. 85.—Showing the mode of applying an elevator in the extraction of a lower right wisdom tooth and of guarding the end of its blade.

liability of fracturing the tuberosity of the upper maxilla. It should be thrust forcibly into the alveolus, alongside and *in front of* the tooth or stump on which it is to operate, with its flat face adjacent to the latter, and its

convex side in contact with the fulcrum. Its point should be directed during insertion downwards and inwards, so that the long axis of the instrument is about half way between the horizontal and the perpendicular. The elevator can be used effectively only if there be some strong, firmly implanted tooth, against which it can rest, as on a fulcrum; and if it be remembered that the elevator is used as a lever of the first order, the need for this rigidity in its fulcrum must be apparent, since the pressure bearing on the latter will be the sum of the force applied by the operator's hand, and of the resistance offered by the tooth which is being extracted. Usually it will be found needful that the fulcrum should be in front of the tooth that is to be taken out, but this can hardly be laid down as a rule. Be it noted, however, that the edge of the outer alveolar plate never offers a useful fulcrum, the bony socket being far too yielding for this purpose.

During the insertion of the blade into the alveolus, the end of the first finger of the operating hand must be pressed firmly upon it, within half an inch of its end and also upon the side of the fulcrum, or of the tooth to be extracted. Thus any puncturing of the tongue or cheek may be quite prevented in the event of a slip, a by-no-means unusual event, since the force needed to insert the instrument is frequently very great. After the insertion of the blade its handle should be carried forward towards the median line. At the same time the instrument should be slightly rotated on its long axis, so that the lower edge of its blade may tend to lift up and loosen the stump from

its socket. During these operations the eye should be fixed intently upon the fulcrum, which may, if care be not taken, readily start from its position. Thus used, the

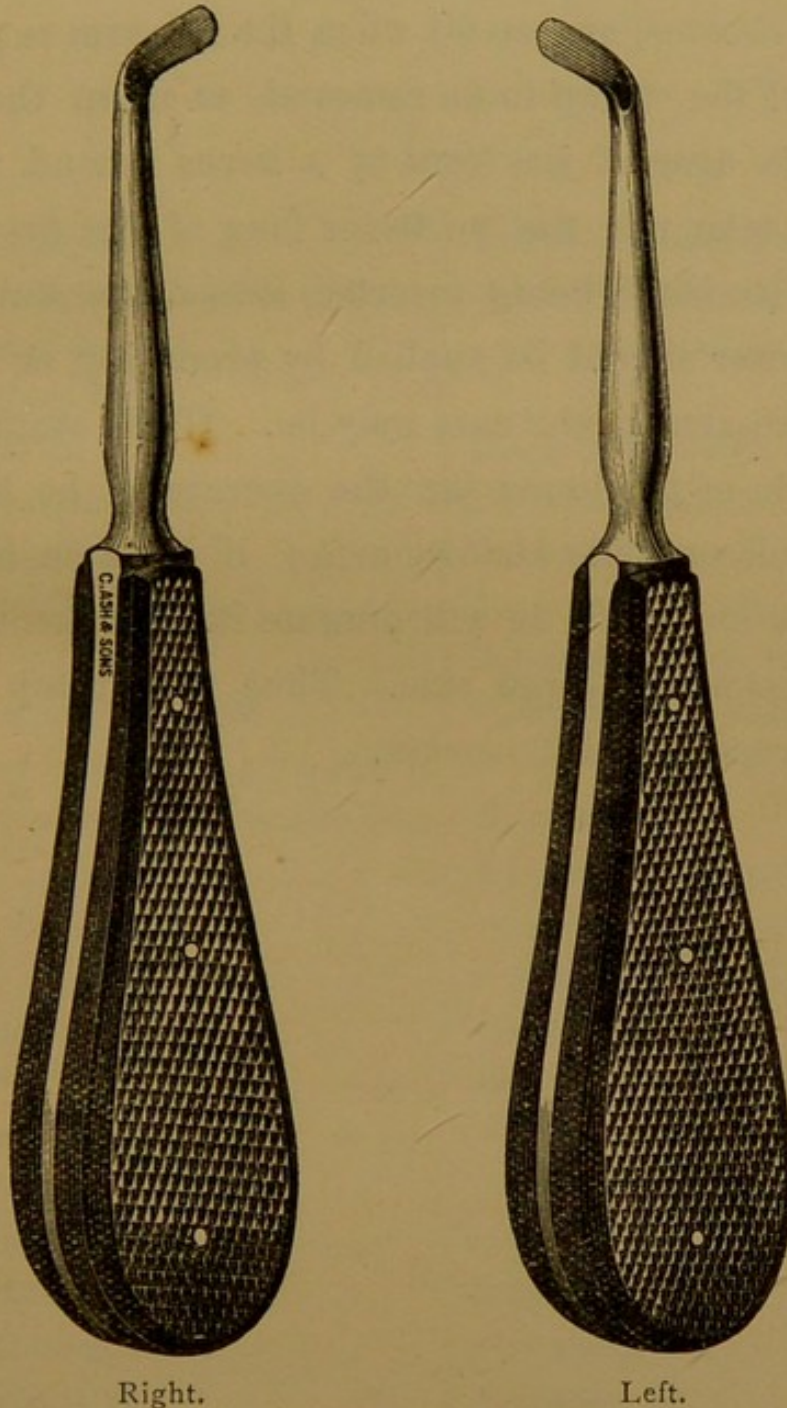


FIG. 86.—Curved Elevators.

elevator serves to raise and slightly detach a tooth, but for the completion of its extraction, which is thus rendered an easy task, the forceps may be required. For the removal

of *lower* wisdom teeth the elevator is very serviceable. Being thrust freely into the alveolar process between the second and third molars, the latter may often readily and safely be tilted backwards out of its socket.

Curved elevators are useful when the fulcrum is placed at the *back* of the stump to be removed, as when the instrument rests against the front of a lower second molar in order to take out the posterior fang of the first double tooth. The blade being inserted *behind* the stump to be moved, power should be applied by pronating or supinating the fore-arm as the case may be. If the stump be on the left side of the lower jaw the operator if he be right-handed, will supinate his fore-arm; if it be on the right side of the lower jaw he will pronate it. To facilitate this the handles are of large size. Thus the stump may be readily turned out of its socket.

INDEX.

- Abortive teeth, 22
- Absorption of alveolar process, 88
- Absorption of fangs, 8
- Absorptive papilla, 9
- Acid saliva, 53
- Amalgam stopping, 80
- Arsenic, use of, 60
- Artificial teeth, clasps and pins for, 96
 - — cleansing of, 105
 - — of vulcanite or gold, 95
 - — preparation of mouth for, 93
- Attrition of teeth, 89

- Calcification, defective, 46
- Caries, 48
 - causes of, 52
- Caries in its first stage, 55
 - — second stage, 61
 - — third stage, 71
 - penetrating, 49
 - superficial, 50
- Cementum, 6
- Chloroform, 116
 - mouth opener, for use with, 117
- Closure of the jaws, 72
- Cocaine, 119
- Coffin's regulating plate, 43
- Crown and bridge work, 106
 - — objections to, 109

- Death of the nerve, 61
- Dentinal tubuli, 5
- Dentine, 5
- Destroying the nerve, 60
- Dilacerated teeth, 24
- Dislocation of a tooth, 90

- Eburnation, 49
- Elevator, the curved, 151
 - the mode of using, 149
 - the straight, 147
- Enamel, 5
- Eruption of permanent teeth, 15
 - of temporary teeth, 7
 - of wisdom tooth, 17
 - retarded, 19
- Ether, 118
 - spray, 120
- Exostosis, 71
- Extraction, accidents during, 132
 - of nerves, 134
 - of stumps, motives for, 93
 - of teeth, 126
 - the cause of hæmorrhage, 138

- Fistulous opening through cheek, 73
Forceps, their characters, 139
— their varieties, 140
Fracture of a tooth, 90
— of jaw, 121
- Gangrene of the nerve, 61
Gemminated teeth, 24
Gum-boil, 68
Gutta-percha stopping, 58
- Hammond's splint, 122
Hunter's denuding process, 89
- Interdental splint, 124
Irregular teeth, causes of, 27
— — classification of, 36
— — treatment by extraction, 30
- Lancing the gums, 8
- Micro-organisms causing caries, 51
Modelling, 47
Mouth opener, 117
- Nerve exposed, 59
Neuralgia, 81
Nitrous oxide, 111
— — gag for, 112
- Odontalgia, 81
Odontoblastic cell, 4
Odontomes, 22
- Periodontitis, acute, 65
— chronic, 67
Pivotted teeth, 99
Protrusion of fangs, 13
Pulp cavity, 3
Pyorrhœa Alveolaris, 87
- Regulating plates, 33
Replantation of a tooth, 91
Rhizodontropy, 69
Ridge for suction frame, 102
Rigg's disease, 87
Rotation of teeth, 38
- Salivary calculus, 86
Springs for frames, 104
Stopping the tooth, 58
Strumous teeth, 26
Stump in antrum, 137
Suction disc, 103
— frames, 101
Supernumerary teeth, 21
Symmetrical extraction, 30
Syphilitic teeth, 25
- Tartar, 86
Temporary teeth, 1
Tension in pulp cavity, 82
Tooth powder, 90
- V-shaped arch, 42
Wool stopping, 57





A. C. ABBOTT, M.D.

First Assistant Laboratory of Hygiene, University of Pennsylvania.

THE PRINCIPLES OF BACTERIOLOGY: A Practical Manual for Students and Physicians. Third Edition, with 98 Illustrations, 17 being coloured, 12s. 6d. *nett.*

[Now ready.]

JAMES ANDERSON, M.D., F.R.C.P.

Late Assistant Physician to the London Hospital, &c.

NOTES ON MEDICAL NURSING; from the Lectures given to the Probationers at the London Hospital. Edited by E. F. LAMPORT, Associate of the Sanitary Institute. With an Introductory Biographical Notice by the late SIR ANDREW CLARK, BART. Second Edition, crown 8vo, 2s. 6d.

E. CRESSWELL BABER, M.B. LOND.

Surgeon to the Brighton and Sussex Throat and Ear Hospital.

A GUIDE TO THE EXAMINATION OF THE NOSE WITH REMARKS ON THE DIAGNOSIS OF DISEASES OF THE NASAL CAVITIES. With Illustrations, small 8vo, 5s. 6d.

FANCOURT BARNES, M.D., M.R.C.P.

Physician to the Chelsea Hospital; Obstetric Physician to the Great Northern Hospital, &c.

A GERMAN-ENGLISH DICTIONARY OF WORDS AND TERMS USED IN MEDICINE AND ITS COGNATE SCIENCES. Square 12mo, Roxburgh binding, 9s.

H. CHARLTON BASTIAN, M.A., M.D., F.R.S.

Examiner in Medicine at the Royal College of Physicians; Physician to University College Hospital, etc.

I.

PARALYSES: CEREBRAL, BULBAR, AND SPINAL. A Manual of Diagnosis for Students and Practitioners. With numerous Illustrations, 8vo, 12s. 6d.

II.

VARIOUS FORMS OF HYSTERICAL OR FUNCTIONAL PARALYSIS. Demy 8vo, 7s. 6d.

RUBERT BOYCE, M.B., M.R.C.S.

Professor of Pathology in University College, Liverpool.

A TEXTBOOK OF MORBID HISTOLOGY FOR STUDENTS AND PRACTITIONERS. Royal 8vo, with 130 coloured figures, 31s. 6d.

CHARLES H. BURNETT, A.M., M.D.

Clinical Professor of Otology in the Woman's Medical College of Pennsylvania; Aural Surgeon to the Presbyterian Hospital, Philadelphia.

SYSTEM OF DISEASES OF THE EAR, NOSE AND THROAT. By 45 Eminent American, British, Canadian and Spanish Authors. Edited by CHARLES H. BURNETT. With Illustrations, in two imperial 8vo vols., 48s. *nett*.

HARRY CAMPBELL, M.D., B.S. LOND., M.R.C.P.

Physician to the North-West London Hospital.

I.
THE CAUSATION OF DISEASE. An exposition of the ultimate factors which induce it. Demy 8vo, 12s. 6d.

II.
FLUSHING AND MORBID BLUSHING, THEIR PATHOLOGY AND TREATMENT. With plates and wood engravings, royal 8vo, 10s. 6d.

III.
DIFFERENCES IN THE NERVOUS ORGANISATION OF MAN AND WOMAN, PHYSIOLOGICAL AND PATHOLOGICAL. Royal 8vo, 15s.

IV.
HEADACHE AND OTHER MORBID CEPHALIC SENSATIONS. Royal 8vo, 12s. 6d.

R. E. CARRINGTON, M.D., F.R.C.P.

NOTES ON PATHOLOGY. With an Introductory Chapter by J. F. GOODHART, M.D., F.R.C.P., Physician to Guy's Hospital. Edited by H. E. CROOK, M.D. Lond., F.R.C.S. Eng., and G. MACKESON, L.R.C.P., M.R.C.S. Cr. 8vo, 3s.

ALFRED H. CARTER, M.D. LOND., F.R.C.P.

Senior Physician to the Queen's Hospital; Professor of Therapeutics, Mason College, Birmingham, &c.

ELEMENTS OF PRACTICAL MEDICINE. Seventh Edition, crown 8vo, 10s. [Now ready.]

FRANCIS HENRY CHAMPNEYS, M.A., M.B. OXON., F.R.C.P.

Physician-Accoucheur and Lecturer on Obstetric Medicine at St. Bartholomew's Hospital, &c.

LECTURES ON PAINFUL MENSTRUATION.

Royal 8vo, 7s. 6d.

W. BRUCE CLARKE, M.A., M.B. OXON., F.R.C.S.

Assistant Surgeon to, and Senior Demonstrator of Anatomy and Operative Surgery at St. Bartholomew's Hospital, &c.

THE DIAGNOSIS AND TREATMENT OF DISEASES OF THE KIDNEY AMENABLE TO DIRECT SURGICAL INTERFERENCE. Illustrations, demy 8vo, 7s. 6d.

WALTER S. COLMAN, M.D., M.R.C.P.

Assistant Physician to the National Hospital for the Paralysed and Epileptic, &c.

SECTION CUTTING AND STAINING: A Practical Introduction to Histological Methods for Students and Practitioners. Second Edition, with Illustrations, crown 8vo, 3s. 6d.

W. H. CORFIELD, M.A., M.D. OXON., F.R.C.P. LOND.

Professor of Hygiene and Public Health in University College, London.

I.

DWELLING HOUSES: their Sanitary Construction and Arrangements. Third Edition, with Illustrations, crown 8vo., 3s. 6d.

II.

DISEASE AND DEFECTIVE HOUSE SANITATION. With Illustrations, crown 8vo, 2s.

SIDNEY COUPLAND, M.D., F.R.C.P.

Physician to the Middlesex Hospital, and Lecturer on Practical Medicine in the Medical School, etc.

NOTES ON THE CLINICAL EXAMINATION OF THE BLOOD AND EXCRETA. Third Edition, 12mo, 1s. 6d.

H. RADCLIFFE CROCKER, M.D. LOND., B.S., F.R.C.P.

Physician for Diseases of the Skin in University College Hospital.

DISEASES OF THE SKIN: THEIR DESCRIPTION, PATHOLOGY, DIAGNOSIS, AND TREATMENT. Second Edition, with Illustrations, 8vo, 24s.

EDGAR M. CROOKSHANK, M.B.

Professor of Comparative Pathology and Bacteriology, King's College,
London.

I.

A TEXT-BOOK OF BACTERIOLOGY: Including the
Etiology and Prevention of Infective Diseases, and a
short account of Yeasts and Moulds, Hæmatozoa, and Psoro-
sperms. Fourth Edition, illustrated with 22 coloured plates and
273 illustrations in the text, med. 8vo, 21s. *nett.* [Now ready.

II.

HISTORY AND PATHOLOGY OF VACCINATION.
2 vols., royal 8vo, coloured plates, 20s. *nett.*

HEBERT DAVIES, M.D., F.R.C.P.

Late Consulting Physician to the London Hospital, etc.

**THE MECHANISM OF THE CIRCULATION OF
THE BLOOD THROUGH ORGANICALLY DIS-
EASED HEARTS.** Edited by ARTHUR TEMPLER DAVIES, B.A.,
M.D. Cantab., M.R.C.P. Crown 8vo, 3s. 6d.

HENRY DAVIS, M.R.C.S. ENG.

Teacher and Administrator of Anæsthetics at St. Mary's Hospital, and Anæ-
sthetist at the Dental Hospital of London.

**GUIDE TO THE ADMINISTRATION OF ANÆS-
THETICS.** Second Edition, fcap. 8vo, 2s. 6d.

DR. A. DÜHRSEN.

Privat Docent in Midwifery and Gynæcology in the University of Berlin.

**A MANUAL OF GYNÆCOLOGICAL PRACTICE FOR
STUDENTS AND PRACTITIONERS.** Translated and
Edited from the fourth German edition, by JOHN W. TAYLOR,
F.R.C.S., Surgeon to the Birmingham and Midland Hospital for
Women, &c.; and FREDERICK EDGE, M.D. LOND., M.R.C.P.,
F.R.C.S., Surgeon to the Wolverhampton and District Hospital
for Women. With 120 Illustrations, cr. 8vo, 6s. [Now ready.

W. SOLTAU FENWICK, M.D., B.S. LOND., M.R.C.P.

Assistant Physician to the Evelina Hospital for Sick Children, &c.

THE DYSPEPSIA OF PHTHISIS: Its Varieties and Treatment, including a Description of Certain Forms of Dyspepsia associated with the Tubercular Diathesis. Demy 8vo, 6s.

J. MILNER FOTHERGILL, M.D.

I.
INDIGESTION AND BILIOUSNESS. Second Edition, post 8vo, 7s. 6d.

II.
GOUT IN ITS PROTEAN ASPECTS. Post 8vo, 7s. 6d.

III.
THE TOWN DWELLER: HIS NEEDS AND HIS WANTS. Post 8vo, 3s. 6d.

ERNEST FUCHS.

Professor of Ophthalmology in the University of Vienna.

TEXTBOOK OF OPHTHALMOLOGY. Translated from the Second German Edition by A. DUANE, M.D., Assistant Surgeon, Ophthalmic and Aural Institute, New York. Large 8vo, with 190 Illustrations, 21s.

PROFESSOR DR. PAUL FÜRBRINGER.

Director of the Friedrichshain Hospital, Berlin, &c.

TEXTBOOK OF DISEASES OF THE KIDNEYS AND GENITO-URINARY ORGANS. Translated by W. H. GILBERT, M.D., Physician in Baden-Baden, &c. Vol. I., demy 8vo, 7s. 6d.

SIR DOUGLAS GALTON, K.C.B., HON. D.C.L., LL.D., F.R.S.,
Formerly Secretary Railway Department Board of Trade; Assistant Inspector-General of Fortifications, &c.

HEALTHY HOSPITALS. OBSERVATIONS ON SOME POINTS CONNECTED WITH HOSPITAL CONSTRUCTION. With Illustrations, 8vo, 10s. 6d.

JOHN HENRY GARRETT, M.D.

Licentiate in Sanitary Science and Diplomate in Public Health, Universities of Durham and Cambridge, &c.

THE ACTION OF WATER ON LEAD: being an inquiry into the cause and mode of the action and its prevention. Crown 8vo, 4s. 6d.

ALFRED W. GERRARD, F.C.S.

Examiner to the Pharmaceutical Society.

ELEMENTS OF MATERIA MEDICA AND PHARMACY. With the New Official Remedies, 1890. Crown 8vo, 8s. 6d.

JAMES F. GOODHART, M.D. ABERD., F.R.C.P.

Physician to Guy's Hospital, and Consulting Physician to the Evelina Hospital for Sick Children.

ON COMMON NEUROSES; OR THE NEUROTIC ELEMENT IN DISEASE AND ITS RATIONAL TREATMENT. Second Edition, crown 8vo, 3s. 6d.

JOHN GORHAM, M.R.C.S.

TOOTH EXTRACTION: A manual on the proper mode of extracting teeth. Fourth edition, fcap. 8vo, 1s. 6d.

GEORGE M. GOULD, A.M., M.D.

I.

THE STUDENT'S MEDICAL DICTIONARY: Including all the words and phrases generally used in Medicine, with their proper pronunciation and definitions. 8vo, 14s. *nett.* [Now ready.]

II.

A POCKET MEDICAL DICTIONARY, giving the Pronunciation and Definition of about 12,000 of the Principal Words used in Medicine and the Collateral Sciences. 32mo, 4s. *nett.*

LANDON C. GRAY, M.D.

Professor of Nervous and Mental Diseases in the New York Polyclinic, &c.

A TREATISE ON NERVOUS AND MENTAL DISEASES FOR STUDENTS AND PRACTITIONERS OF MEDICINE. With 168 Illustrations, 8vo, 21s.

DR. JOSEF GRUBER.

Professor of Otology in the University of Vienna, &c.

A TEXT-BOOK OF THE DISEASES OF THE EAR. Translated from the German, and Edited by EDWARD LAW, M.D., C.M. EDIN., M.R.C.S. ENG., Surgeon to the London Throat Hospital for Diseases of the Throat, Nose and Ear; and COLEMAN JEWELL, M.B. LOND., M.R.C.S. ENG. Second edition, with 165 Illustrations, and 70 coloured figures, royal 8vo, 28s.

BERKELEY HILL, M.B. LOND., F.R.C.S.

Professor of Clinical Surgery in University College;

AND

ARTHUR COOPER, L.R.C.P., M.R.C.S.

Surgeon to the Westminster General Dispensary, &c.

SYPHILIS AND LOCAL CONTAGIOUS DISORDERS. Second Edition, entirely re-written, royal 8vo, 18s.

NORMAN KERR, M.D., F.L.S.

President of the Society for the Study of Inebriety; Consulting Physician,
Dalrymple Home for Inebriates, etc.

INEBRIETY: ITS ETIOLOGY, PATHOLOGY, TREATMENT, AND JURISPRUDENCE. Third Edition, 8vo, 21s.

F. CHARLES LARKIN, F.R.C.S. ENG.

Surgeon to the Stanley Hospital,

AND

RANDLE LEIGH, M.B., B.SC. LOND.

Senior Demonstrator of Physiology in University College, Liverpool.

OUTLINES OF PRACTICAL PHYSIOLOGICAL CHEMISTRY. Second Edition, with Illustrations, crown 8vo, 2s. 6d. *nett.*

J. WICKHAM LEGG, F.R.C.P.

Formerly Assistant Physician to Saint Bartholomew's Hospital, and Lecturer on Pathological Anatomy in the Medical School.

A GUIDE TO THE EXAMINATION OF THE URINE. Seventh Edition, edited and revised by H. LEWIS JONES, M.D., Medical Officer in charge of the Electrical Department in St. Bartholomew's Hospital. With Illustrations, fcap. 8vo, 3s. 6d.

LEWIS'S POCKET MEDICAL VOCABULARY.

Second Edition, 32mo, limp roan, 3s. 6d.

WILLIAM THOMPSON LUSK, A.M., M.D.

Professor of Obstetrics and Diseases of Women in the Bellevue Hospital Medical College, &c.

THE SCIENCE AND ART OF MIDWIFERY. Fourth Edition, rewritten, with numerous Illustrations, 8vo, 18s.

LEWIS'S PRACTICAL SERIES.

In Crown 8vo Volumes, with Illustrations.

THE TREATMENT OF PULMONARY CONSUMPTION.

By VINCENT D. HARRIS, M.D. Lond., F.R.C.P., Physician to the City of London Hospital for Diseases of the Chest, etc., and E. CLIFFORD BEALE, M.A., M.B., Cantab., F.R.C.P., Physician to the City of London Hospital for Diseases of the Chest, etc. 10s. 6d. [Now ready.]

THE SURGICAL DISEASES OF CHILDREN AND THEIR

TREATMENT BY MODERN METHODS. By D'ARCY POWER, M.A., M.B. Oxon., F.R.C.S. Eng., Demonstrator of Operative Surgery at St. Bartholomew's Hospital, &c. 10s. 6d.

DISEASES OF THE NOSE AND THROAT.

By F. de HAVILLAND HALL, M.D., F.R.C.P. Lond., Physician in Charge of the Throat Department at the Westminster Hospital, &c. 10s. 6d.

PUBLIC HEALTH LABORATORY WORK.

By H. R. KENWOOD, M.B., D.P.H., F.C.S., Instructor in the Hygienic Laboratory, University College, &c. Second Edition, 10s. 6d.

MEDICAL MICROSCOPY.

By FRANK J. WETHERED, M.D., M.R.C.P., Medical Registrar to the Middlesex Hospital. 9s.

MEDICAL ELECTRICITY.

By H. LEWIS JONES, M.A., M.D., F.R.C.P., Medical Officer, Electrical Department, St. Bartholomew's Hospital. Second Edition, 10s. 6d.

HYGIENE AND PUBLIC HEALTH.

By LOUIS C. PARKES, M.D., D.P.H. Lond. Univ., Lecturer on Public Health at St. George's Hospital, etc. Fourth Edition, 10s. 6d.

MANUAL OF OPHTHALMIC PRACTICE.

By C. HIGGINS, F.R.C.S., Lecturer on Ophthalmology at Guy's Hospital Medical School, &c. Illustrations, 6s.

A PRACTICAL TEXTBOOK OF THE DISEASES OF

WOMEN. By ARTHUR H. N. LEWERS, M.D. Lond., M.R.C.P., Obstetric Physician to the London Hospital. Fourth Edition, 10s. 6d.

ANÆSTHETICS, THEIR USES AND ADMINISTRATION.

By DUDLEY W. BUXTON, M.D., B.S., M.R.C.P., Administrator of Anæsthetics at University College Hospital, etc. Second Edition, 5s.

ON FEVERS: THEIR HISTORY, ETIOLOGY, DIAGNOSIS,

PROGNOSIS, AND TREATMENT. By A. COLLIE, M.D. 8s. 6d.

HANDBOOK OF DISEASES OF THE EAR.

By URBAN PRITCHARD, M.D. (Edin.), F.R.C.S., Professor of Aural Surgery at King's College, London, etc. Third Edition, 6s.

A PRACTICAL TREATISE ON DISEASES OF THE KID-

NEYS AND URINARY DERANGEMENTS. By C. H. RALFE, M.A., M.D. Cantab., F.R.C.P., Physician to the London Hospital. 10s. 6d.

DENTAL SURGERY FOR GENERAL PRACTITIONERS

AND STUDENTS OF MEDICINE. By ASHLEY W. BARRETT, M.B. Lond., M.R.C.S., L.D.S., Dental Surgeon to the London Hospital. Third Edition. [Just ready.]

BODILY DEFORMITIES AND THEIR TREATMENT.

By H. A. REEVES, F.R.C.S. Ed., Senior Assistant Surgeon and Teacher of Practical Surgery at the London Hospital. 8s. 6d.

JEFFERY A. MARSTON, M.D., C.B., F.R.C.S., M.R.C.P. LOND.
Surgeon General Medical Staff (Retired).

NOTES ON TYPHOID FEVER: Tropical Life and
its Sequelæ. Crown 8vo, 3s. 6d.

WILLIAM MARTINDALE, F.C.S.

AND

W. WYNN WESTCOTT, M.B. LOND.

THE EXTRA PHARMACOPŒIA, with Medical Refer-
ences, and a Therapeutic Index of Diseases and Symptoms.
Eighth Edition, limp roan, med. 24mo, 9s.

A. STANFORD MORTON, M.B., F.R.C.S. ENG.

Assistant Surgeon to the Moorfields Ophthalmic Hospital, &c.

REFRACTION OF THE EYE: Its Diagnosis, and the
Correction of its Errors. Fifth Edition, small 8vo, 3s. 6d.

C. W. MANSELL MOULLIN, M.A., M.D. OXON., F.R.C.S. ENG.

Surgeon and Lecturer on Physiology at the London Hospital, &c.

I.

**SPRAINS; THEIR CONSEQUENCES AND TREAT-
MENT.** Second Edition, crown 8vo, 4s. 6d.

II.

ENLARGEMENT OF THE PROSTATE: its Treat-
ment and Radical Cure. With plates, 8vo, 6s.

WILLIAM MURRAY, M.D., F.R.C.P. LOND.

I.

ROUGH NOTES ON REMEDIES. Crown 8vo, 3s. 6d.

II.

**ILLUSTRATIONS OF THE INDUCTIVE METHOD
IN MEDICINE.** Crown 8vo, 3s. 6d.

WILLIAM MURRELL, M.D., F.R.C.P.

Lecturer on Materia Medica and Therapeutics at Westminster Hospital.

I.

**MASSOTHERAPEUTICS; OR MASSAGE AS A
MODE OF TREATMENT.** Fifth Edition, crown 8vo,
4s. 6d.

II.

WHAT TO DO IN CASES OF POISONING. Eighth
Edition, royal 32mo, 3s. 6d. [*Just ready.*]

G. OLIVER, M.D., F.R.C.P.

I.

PULSE-GAUGING: A Clinical Study of Radial Measurement and Pulse Pressure. Illustrations, fcap. 8vo, 3s. 6d.

II.

ON BEDSIDE URINE TESTING: a Clinical Guide to the Observation of Urine in the course of Work. Fourth Edition, fcap. 8vo, 3s. 6d.

III.

THE HARROGATE WATERS: Data Chemical and Therapeutical, with notes on the Climate of Harrogate. Crown 8vo, with Map of the Wells, 3s. 6d.

DR. A. ONODI.

Lecturer on Rhino-Laryngology in the University of Budapest.

THE ANATOMY OF THE NASAL CAVITY, AND ITS ACCESSORY SINUSES. An Atlas for Practitioners and Students, translated by ST CLAIR THOMSON, M.D. LOND., F.R.C.S. ENG., M.R.C.P. LOND. Plates, small 4to, 6s. *nett*.

WILLIAM OSLER, M.D., F.R.C.P. LOND.

Professor of Medicine, Johns Hopkins University, &c.

ON CHOREA AND CHOREIFORM AFFECTIONS. Large 8vo, 5s.

LOUIS C. PARKES, M.D. LOND., D.P.H.

Lecturer on Public Health at St. George's Hospital, &c.

INFECTIOUS DISEASES, NOTIFICATION AND PREVENTION. Fcap. 8vo, cloth, 2s. 6d, roan, 4s. 6d.

R. DOUGLAS POWELL, M.D., F.R.C.P.,

Physician Extra-ordinary to H.M. the Queen; Physician to the Middlesex Hospital; Consulting Physician to the Hospital for Consumption and Diseases of the Chest at Brompton.

DISEASES OF THE LUNGS AND PLEURÆ INCLUDING CONSUMPTION. Fourth Edition, with coloured plates and wood-engravings, 8vo, 18s.

DR. THEODOR PUSCHMANN.

Public Professor in Ordinary at the University of Vienna,

HISTORY OF MEDICAL EDUCATION FROM THE MOST REMOTE TO THE MOST RECENT TIMES. Translated by EVAN H. HARE, M.A. (OXON.), F.R.C.S. (ENG.), F.S.A. Demy 8vo, 21s.

SAMUEL RIDEAL, D.SC. (LOND.), F.I.C., F.C.S., F.G.S.
Fellow of University College, London.

I.
PRACTICAL ORGANIC CHEMISTRY. The detection and properties of some of the more important organic compounds. 12mo, 2s. 6d.

II.
PRACTICAL CHEMISTRY FOR MEDICAL STUDENTS, Required at the First Examination of the Conjoint Examining Board in England. Fcap. 8vo, 2s.

J. JAMES RIDGE, M.D., B.S., B.A., B.SC. LOND.
Medical Officer of Health, Enfield.

ALCOHOL AND PUBLIC HEALTH. Second Edition, Crown 8vo, 2s.

SYDNEY RINGER, M.D., F.R.S.

Holme Professor of Clinical Medicine in University College; Physician to University College Hospital.

A HANDBOOK OF THERAPEUTICS. Thirteenth Edition, 8vo. [*In preparation.*]

FREDERICK T. ROBERTS, M.D., B.SC., F.R.C.P.

Professor of the Principles and Practice of Medicine in University College; Physician to University College Hospital, &c.

I.
THE THEORY AND PRACTICE OF MEDICINE. Ninth Edition, with Illustrations, large 8vo, 21s.

II.
THE OFFICINAL MATERIA MEDICA. Second Edit., entirely rewritten in accordance with the latest British Pharmacopœia, with the Additions made in 1890, fcap. 8vo, 7s. 6d.

H. D. ROLLESTON, M.D., F.R.C.P.

Fellow of St. John's College, Cambridge; Assistant Physician and Lecturer on Pathology, St. George's Hospital, London;

AND

A. A. KANTHACK, M.D., M.R.C.P.

Lecturer on Pathology, St. Bartholomew's Hospital, London.

PRACTICAL MORBID ANATOMY. Crown 8vo, 6s.
[CAMBRIDGE NATURAL SCIENCE MANUALS.]

ROBSON ROOSE, M.D., F.R.C.P. EDIN.

I.
GOUT, AND ITS RELATIONS TO DISEASES OF THE LIVER AND KIDNEYS. Seventh Edition, crown 8vo, 4s. 6d.

II.
NERVE PROSTRATION AND OTHER FUNCTIONAL DISORDERS OF DAILY LIFE. Second Edition, demy 8vo, 18s.

WILLIAM ROSE, B.S., M.B. LOND., F.R.C.S.

Professor of Surgery in King's College, London, and Surgeon to King's College Hospital, &c.

ON HARELIP AND CLEFT PALATE. Demy 8vo, with Illustrations, 6s.

BERNARD ROTH, F.R.C.S.

Fellow of the Medical Society of London.

THE TREATMENT OF LATERAL CURVATURE OF THE SPINE. Demy 8vo, with Photographic and other Illustrations, 5s.

DR. G. SCHIMMELBUSCH.

Privat-docent and Assistant Surgeon in Prof. v. Bergmann's University Clinic at Berlin.

THE ASEPTIC TREATMENT OF WOUNDS.

Translated from the Second German Edition by A. T. RAKE, M.B., B.S. LOND., F.R.C.S. ENG., Registrar and Pathologist to the East London Hospital for Children. With Illustrations, crown 8vo, 5s. [Now ready.]

G. E. SHUTTLEWORTH, B.A., M.D.

Late Medical Superintendent, Royal Albert Asylum for Idiots and Imbeciles of the Northern Counties, Lancaster, &c.

MENTALLY-DEFICIENT CHILDREN: THEIR TREATMENT AND TRAINING. With Illustrations, crown 8vo, 4s.

ALEXANDER J. C. SKENE, M.D.

Professor of Gynæcology in the Long Island College Hospital, Brooklyn.

TREATISE ON THE DISEASES OF WOMEN.

Second Edition, with 251 engravings and 9 chromo-lithographs, medium 8vo, 28s.

E. HUGH SNELL, M.D., B.SC., LOND.

Diplomate in Public Health of the University of Cambridge; London County Council Medical Officer to the Blackwall Tunnel.

COMPRESSED AIR ILLNESS, OR SO-CALLED CAISSON DISEASE. Demy 8vo. [Just ready.]

JOHN KENT SPENDER, M.D. LOND.

Physician to the Royal Mineral Water Hospital, Bath.

THE EARLY SYMPTOMS AND THE EARLY TREATMENT OF OSTEO-ARTHRITIS, commonly called Rheumatoid Arthritis. With special reference to the Bath Thermal Waters. Small 8vo, 2s. 6d.

JAMES STOCKEN, L.D.S. ENG.

Pereira Prizeman for Materia Medica; Late Dental Surgeon to the National Dental Hospital.

DENTAL MATERIA MEDICA AND THERAPEUTICS. Fourth edition, revised by LESLIE M. STOCKEN, L.R.C.P., M.R.C.S., L.D.S.; and J. O. BUTCHER, L.D.S. ENG., Assistant Dental Surgeon to Guy's Hospital. Fcap. 8vo, 4s.

ADOLF STRÜMPPELL.

Professor and Director of the Medical Clinique at Erlangen.

A TEXT-BOOK OF MEDICINE FOR STUDENTS AND PRACTITIONERS. Second edition translated by Dr. H. F. VICKERY and Dr. P. C. KNAPP, with Editorial Notes by Dr. F. C. SHATTUCK, Visiting Physician to the Massachusetts General Hospital, &c. With 119 Illustrations, imp. 8vo, 28s.

JUKES DE STYRAP, M.R.C.P.I.

Physician-Extraordinary to the Salop Infirmary; Consulting Physician to the South Salop and Montgomeryshire Infirmaries, etc.

I.

THE YOUNG PRACTITIONER: With practical hints and instructive suggestions, as subsidiary aids, for his guidance on entering into private practice. Demy 8vo, 7s. 6d. *nett.*

II.

A CODE OF MEDICAL ETHICS: With general and special rules for the guidance of the faculty and the public in the complex relations of professional life. Fourth Edition, demy 8vo, 3s. 6d. *nett.*

III.

MEDICO-CHIRURGICAL TARIFFS. Fifth edition, fcap. 4to, 2s. *nett.*

IV.

THE YOUNG PRACTITIONER: HIS CODE AND TARIFF. Being the above three works in one volume. Demy 8vo, 10s. 6d. *nett.*

C. W. SUCKLING, M.D. LOND., M.R.C.P.

Professor of Materia Medica and Therapeutics at the Queen's College, Physician to the Queen's Hospital, Birmingham, etc.

I.

ON THE DIAGNOSIS OF DISEASES OF THE BRAIN, SPINAL CORD, AND NERVES. With Illustrations, crown 8vo, 8s. 6d.

II.

ON THE TREATMENT OF DISEASES OF THE NERVOUS SYSTEM. Crown 8vo, 7s. 6d.

JOHN BLAND SUTTON, F.R.C.S.

Lecturer on Comparative Anatomy, and Assistant Surgeon to the Middlesex Hospital.

LIGAMENTS: THEIR NATURE AND MORPHOLOGY. Second Edition, wood engravings, post 8vo.

[In preparation.]

HENRY R. SWANZY, A.M., M.B., F.R.C.S.I.

Examiner in Ophthalmic Surgery in the Royal University of Ireland; Surgeon to the National Eye and Ear Infirmary, Dublin, etc.

A HANDBOOK OF DISEASES OF THE EYE AND THEIR TREATMENT. Fifth Edition, Illustrated with Wood Engravings, Colour Tests, etc., large post 8vo, 10s. 6d.

ALBERT TAYLOR.

Associate Sanitary Institute; Chief Sanitary Inspector to the Vestry of St. George, Hanover Square, etc.

THE SANITARY INSPECTOR'S HANDBOOK.

Cr. 8vo, with Illustrations, 5s.

E. G. WHITTLE, M.D. LOND., F.R.C.S. ENG.

Senior Surgeon to the Royal Alexandra Hospital for Sick Children, Brighton.

CONGESTIVE NEURASTHENIA, OR INSOMNIA AND NERVE DEPRESSION. Crown 8vo, 3s. 6d.

SIR JOHN WILLIAMS, M.D., F.R.C.P.

Professor of Midwifery in University College, London, &c.

CANCER OF THE UTERUS: BEING THE HARVEIAN LECTURES FOR 1886. Illustrated with Lithographic Plates, royal 8vo, 10s. 6d.

E. T. WILSON, M.B. OXON., F.R.C.P. LOND.

Physician to the Cheltenham General Hospital, &c.

DISINFECTANTS AND ANTISEPTICS: HOW TO USE THEM. In Packets of one doz. price 1s., by post 1s. 1d.

[Just thoroughly revised.]

BERTRAM C. A. WINDLE, D.SC., M.D., M.A. DUBL.

Professor of Anatomy in Mason College, Birmingham, &c.

A HANDBOOK OF SURFACE ANATOMY AND LANDMARKS. Second Edition, revised with the collaboration of T. MANNERS-SMITH, M.A., M.R.C.S., Lecturer on Osteology, Mason College, Birmingham. Illustrations, post 8vo, 3s. 6d.

[Now ready.]

OSWALD ZIEMSEN, M.D.

Knight of the Iron Cross, and of the Prussian Order of the Crown.

THE TREATMENT OF CONSTITUTIONAL SYPHILIS. Post 8vo, 3s. 6d.

LEWIS'S DIET CHARTS. A Suggestive set of Diet Tables for the use of Physicians, for handing to Patients after Consultation, modified to suit Individual Requirements; for Albuminuria, Anæmia and Debility, Constipation, Diabetes, Diarrhœa, Dyspepsia, Eczema, Fevers, Gall Stones, Gout and Gravel, Heart Disease (chronic), Nervous Diseases, Obesity, Phthisis, Rheumatism (chronic); and Blank Chart for other diseases. 5s. per packet of 100 charts, post free.

A special leaflet on the Diet and Treatment of Infants is sold separately. 12, 1s.; 100, 7s. 6d., post free.

LEWIS'S FOUR-HOUR TEMPERATURE CHART.

Meets the requirements of a chart on which the temperature and other observations can be recorded at intervals of four hours. Each chart will last a week. 20, 1s.; 50, 2s.; 100, 3s. 6d.; 500, 14s.; 1000, 25s.

CHART FOR RECORDING THE EXAMINATION OF URINE.

Designed for the use of medical men, analysts and others making examinations of the urine of patients, affording a convenient method of recording the results of the examination. 10, 1s.; 100, 7s. 6d.; 250, 15s.; 500, 25s.; 1000, 40s.

CLINICAL CHARTS FOR TEMPERATURE OBSERVATIONS, ETC.

Arranged by W. RIGDEN, M.R.C.S. 12, 1s.; 100, 7s.; 250, 15s.; 500, 28s.; 1000, 50s.

Each Chart is arranged for four weeks, and is ruled at the back for making notes of cases; they are convenient in size, and are suitable both for hospital and private cases.

LEWIS'S CLINICAL CHART, SPECIALLY DESIGNED FOR USE WITH THE VISITING LIST. This Temperature Chart is arranged for four weeks, and measures 6 × 3 inches. 12, 6d.; 25, 1s.; 100, 3s. 6d.; 500, 16s. 6d.; 1000, 30s.

LEWIS'S NURSING CHART. Printed on both sides. 20, 1s.; 50, 2s.; 100, 3s. 6d.; 500, 14s.; 1000, 25s.

* * MR. LEWIS is in constant communication with the leading publishing firms in America and has transactions with them for the sale of his publications in that country. Advantageous arrangements are made in the interests of Authors for the publishing of their works in the United States.

MR. LEWIS's publications can be procured of any Bookseller in any part of the world.

Complete Catalogue of Publications post free on application.

Printed by H. K. Lewis, Gower Street, London, W.C.



