

## **An elementary treatise on human anatomy / by Joseph Leidy.**

### **Contributors**

Leidy, Joseph, 1823-1891.

### **Publication/Creation**

London : Smith, Elder, 1889.

### **Persistent URL**

<https://wellcomecollection.org/works/dy78d9mf>

### **License and attribution**


This work has been identified as being free of known restrictions under copyright law, including all related and neighbouring rights and is being made available under the Creative Commons, Public Domain Mark.

You can copy, modify, distribute and perform the work, even for commercial purposes, without asking permission.



Wellcome Collection  
183 Euston Road  
London NW1 2BE UK  
T +44 (0)20 7611 8722  
E [library@wellcomecollection.org](mailto:library@wellcomecollection.org)  
<https://wellcomecollection.org>









22101687206

Med  
K7878



116 F

76 Presented to the Library  
by Ernest Hart  
AN



ELEMENTARY TREATISE  
ON  
HUMAN ANATOMY.



BY

JOSEPH LEIDY, M.D., LL.D.,

PROFESSOR OF HUMAN AND COMPARATIVE ANATOMY AND ZOOLOGY IN THE UNIVERSITY OF  
PENNSYLVANIA, PRESIDENT OF THE ACADEMY OF NATURAL SCIENCES, AND  
OF THE FACULTY OF THE WAGNER FREE INSTITUTE OF  
SCIENCES, PHILADELPHIA.

---

SECOND EDITION, REWRITTEN.

WITH FOUR HUNDRED AND NINETY-FIVE ILLUSTRATIONS.

---

LONDON:  
SMITH, ELDER & CO., 15 WATERLOO PLACE.  
1889.

25 117 866

RECEIVED

CANCELLED

WELLCOME INSTITUTE LIBRARY	
Coll.	weIMOmec
Call	
No.	QS





## PREFACE.

---

TWENTY-EIGHT years have passed since the publication of a former edition of the present work, entitled "An Elementary Treatise on Human Anatomy," and it is at the repeated solicitation of medical students, who have been pupils of the author, that another edition has now been prepared. With the excellent and admirably illustrated text-books on the same subject from the English press, such a work may seem to be inferior and superfluous; but the experience of the author as a teacher leads him to believe that our students generally desire, if they do not require, such a treatise as he has attempted to provide them. With the view of facilitating the study of anatomy and its commitment to memory, in the employment of the multitude of necessary technical terms, as a rule, one name for an organ or part is used, and that one selected which is simplest and most expressive of its character. The name, also, as far as may be permitted, is rendered into English. Many phrases in common use as names have been curtailed of what have appeared unnecessary portions, and sometimes the adjective portion of the phrase has been retained, in preference to the substantive portion, where, for various reasons, it has seemed more appropriate. Where names of persons are applied to parts they are generally avoided, and others in all respects better adapted to the purpose are used. Some further attempts have been made to improve the nomenclature, and it is hoped that the experiment may prove successful in helping the student in acquiring a knowledge of the subject. While the author regards with favor the proposed improvement in anatomical nomenclature of able authorities, he has not followed them completely, in

apprehension that, with the prevalent nomenclature, a radical change would confuse rather than facilitate the study of anatomy.

The present edition of the book has been entirely rewritten, and, though the author has taken due precaution to avoid palpable errors and omissions, he nevertheless asks indulgence for such as may have escaped his notice.



# CONTENTS.

## CHAPTER I.

	PAGE
INTRODUCTION . . . . .	25
Man as related to the other Vertebrate Mammals . . . . .	25
Anatomy, General, Special, Systematic, Surgical, etc. . . . .	26
Proximate Physical Elements and Tissues of the Human Body . . . . .	27
Ultimate Physical Elements of the Human Body . . . . .	28, 29

## CHAPTER II.

GENERAL ANATOMY OF THE SKELETON . . . . .	32
The Bones Classified . . . . .	33
Structural and Chemical Elements of the Bones . . . . .	33
The Periosteum . . . . .	41
The Marrow . . . . .	42
Vessels and Nerves of the Bones . . . . .	43
Development and Growth of the Bones . . . . .	44
Articulations of Joints of the Skeleton . . . . .	50
Of the Relative Position of the Different Structures entering into the Com- position of Articulations . . . . .	52

## CHAPTER III.

SPECIAL ANATOMY OF THE SKELETON . . . . .	54
The Vertebral Column.—The Vertebrae . . . . .	54
The Sacrum . . . . .	62
The Coccyx . . . . .	63
The Vertebral Column viewed entire . . . . .	64
Development and Growth of the Vertebral Column . . . . .	69
Articulations of the Vertebral Column . . . . .	71
Movements of the Vertebral Column . . . . .	79
The Ribs . . . . .	80
The Sternum . . . . .	82
Articulations of the Ribs . . . . .	85
The Thorax . . . . .	87
The Skull . . . . .	89
The Occipital Bone . . . . .	90
The Sphenoid Bone . . . . .	93
The Parietal Bones . . . . .	101
The Frontal Bone . . . . .	102
The Ethmoid Bone . . . . .	106
The Temporal Bones . . . . .	109
The Maxillæ . . . . .	118

	PAGE
The Palate Bones . . . . .	122
The Turbinal Bones . . . . .	124
The Lachrymal Bones . . . . .	125
The Nasal Bones . . . . .	126
The Vomer . . . . .	127
The Malar Bones . . . . .	128
The Mandible . . . . .	129
The Entire Skull . . . . .	133
The Sutures of the Skull . . . . .	134
Supernumerary or Sutural Bones . . . . .	137
The Interior of the Cranium . . . . .	137
The Lateral Region of the Skull . . . . .	141
The Base of the Skull . . . . .	143
The Face . . . . .	144
The Orbits . . . . .	145
The Nasal Cavities . . . . .	146
Development and Growth of the Skull . . . . .	149
Variations of the Skull . . . . .	151
Mechanical Construction of the Skull . . . . .	153
Articulation of the Lower Jaw . . . . .	155
The Hyoid Bone . . . . .	156
Bones of the Upper Limbs . . . . .	157
The Scapula . . . . .	158
The Clavicle . . . . .	162
The Humerus . . . . .	163
The Ulna . . . . .	167
The Radius . . . . .	169
The Hand . . . . .	171
The Carpus . . . . .	171
The Metacarpus . . . . .	174
The Digits . . . . .	177
The Articulations of the Upper Limbs . . . . .	178
The Sterno-Clavicular Articulation . . . . .	178
The Scapulo-Clavicular Articulation . . . . .	179
The Shoulder-Joint . . . . .	179
The Elbow-Joint . . . . .	181
The Radio-Ulnar Articulation . . . . .	182
The Articulations of the Hand . . . . .	183
The Wrist-Joint . . . . .	184
The Intercarpal and Carpo-Metacarpal Articulations . . . . .	185
The Metacarpo-Phalangeal and Phalangeal Articulations . . . . .	186
The Bones of the Lower Limbs . . . . .	187
The Hip Bones . . . . .	187
The Pelvis . . . . .	192
The Articulations of the Pelvis . . . . .	195
The Femur . . . . .	196
The Patella . . . . .	200
The Hip-Joint . . . . .	200
The Bones of the Leg . . . . .	202
The Tibia . . . . .	202
The Fibula . . . . .	204
The Knee-Joint . . . . .	206
Articulations of the Tibia and Fibula . . . . .	210



	PAGE
Bones of the Foot . . . . .	211
The Tarsus . . . . .	211
The Metatarsus . . . . .	215
The Foot . . . . .	217
Ossification of the Bones of the Foot . . . . .	218
The Ankle-Joint . . . . .	218
Articulations of the Tarsus . . . . .	219

## CHAPTER IV.

THE CONNECTIVE TISSUES . . . . .	223
Fibro-Connective Tissue . . . . .	223
Areolar Tissue . . . . .	225
Elastic Tissue . . . . .	227
Adipose Tissue . . . . .	228
The Cartilages . . . . .	230
Cartilage . . . . .	230
Fibro-Cartilage . . . . .	234
Elastic Cartilage . . . . .	235
Fasciæ . . . . .	235

## CHAPTER V.

THE MUSCULAR SYSTEM . . . . .	237
General Remarks on the Head . . . . .	237
The Unstriped or Involuntary Muscles . . . . .	238
The Striped or Voluntary Muscles . . . . .	239
The Cardiac Muscular Tissue . . . . .	243
Muscles and Fascia of the Cranial Vault . . . . .	246
The Auricular Muscles . . . . .	248
Muscles of the Face . . . . .	248
Muscles of the Eyelids and Eyebrows . . . . .	248
Muscles of the Nose . . . . .	250
Muscles of the Mouth, Lips, and Cheeks . . . . .	251
Muscles of Mastication . . . . .	254
Muscles and Fasciæ of the Neck . . . . .	256
Supra- and Infra-Hyoid Muscles . . . . .	260
Lateral Cervical Muscles . . . . .	263
Prevertebral Muscles of the Neck . . . . .	264
Postvertebral Muscles of the Neck . . . . .	265
Muscles of the Thorax . . . . .	266
The Diaphragm . . . . .	267
Muscles and Fasciæ of the Abdomen . . . . .	270
Fasciæ of the Pelvis . . . . .	279
Fasciæ and Muscles of the Back of the Trunk . . . . .	280
Superficial Muscles of the Back . . . . .	281
Deep Muscles of the Back . . . . .	285
Fasciæ and Muscles of the Upper Limb . . . . .	290
Muscles of the Breast and Shoulder . . . . .	291
Muscles of the Back and Shoulder . . . . .	293
Muscles of the Shoulder . . . . .	293
Muscles of the Arm . . . . .	296
Fasciæ and Muscles of the Forearm and Hand . . . . .	300

	PAGE
Fasciæ of the Forearm . . . . .	300
Fasciæ of the Hand . . . . .	301
Muscles of the Front and Inner Part of the Forearm . . . . .	302
Muscles of the Outer and Back Part of the Forearm . . . . .	307
Muscles of the Hand . . . . .	312
Muscles of the Thumb . . . . .	313
Muscles of the Little Finger . . . . .	314
Fasciæ and Muscles of the Lower Limb . . . . .	315
Muscles of the Front and Outer Part of the Thigh . . . . .	318
Muscles on the Inner Fore Part of the Thigh . . . . .	321
Muscles of the Buttock . . . . .	324
Muscles of the Back of the Thigh . . . . .	328
Fasciæ of the Leg and Foot . . . . .	330
Muscles of the Inner Fore Part of the Leg and Back of the Foot . . . . .	333
Muscles on the Outer Part of the Leg . . . . .	335
Muscles on the Back of the Leg . . . . .	336
Muscles of the Foot . . . . .	341

## CHAPTER VI.

GENERAL COMPOSITION OF THE SKIN, THE MUCOUS MEMBRANES, THE GLANDS, THE LUNGS, THE SEROUS AND SYNOVIAL MEMBRANES, AND THE LINING OF THE VASCULAR SYSTEM . . . . .	345
General Remarks . . . . .	345
Epithelial Tissue . . . . .	345
Serous Membranes . . . . .	351
Synovial Membranes . . . . .	353
Serum.—Synovia . . . . .	355
Mucous Membranes . . . . .	355
Mucus . . . . .	358
The Glandular System . . . . .	358

## CHAPTER VII.

THE NECK, THORAX, AND ABDOMEN . . . . .	363
The Neck . . . . .	363
The Thorax . . . . .	363
The Abdomen . . . . .	366
The Peritoneum . . . . .	368

## CHAPTER VIII.

THE ALIMENTARY APPARATUS . . . . .	376
The Mouth . . . . .	377
The Glands of the Mouth . . . . .	380
The Tonsils . . . . .	381
Muscles of the Palate . . . . .	381
The Tongue . . . . .	383
Muscles of the Tongue . . . . .	386
The Salivary Glands . . . . .	389
The Saliva . . . . .	393
The Teeth . . . . .	393
The Permanent Teeth . . . . .	394



	PAGE
The Temporary Teeth . . . . .	399
Structure of the Teeth . . . . .	401
The Pharynx . . . . .	410
Muscles of the Pharynx . . . . .	411
The Œsophagus . . . . .	414
The Organs of Digestion . . . . .	416
The Stomach . . . . .	416
The Small Intestine . . . . .	424
The Large Intestine . . . . .	432
The Gastric Juice . . . . .	440
The Intestinal Juices . . . . .	440
The Pancreas . . . . .	440
The Pancreatic Juice . . . . .	442
The Liver . . . . .	442
Structure of the Liver . . . . .	446
The Bile . . . . .	452

## CHAPTER IX.

THE VASCULAR SYSTEM . . . . .	453
The Blood-Vessels . . . . .	453
The Arteries . . . . .	453
The Veins . . . . .	458
The Capillaries . . . . .	460
The Blood . . . . .	463
The Heart . . . . .	467
Structure of the Heart . . . . .	474
Vessels and Nerves of the Heart . . . . .	476
Relative Position of Important Parts of the Heart to the Anterior Wall of the Chest . . . . .	477
The Aorta . . . . .	477
The Arch of the Aorta . . . . .	479
Branches of the Aorta . . . . .	479
The Innominate Artery . . . . .	480
The Common Carotid Arteries . . . . .	480
The Subclavian Arteries . . . . .	482
The Internal Carotid Artery . . . . .	483
The Ophthalmic Artery . . . . .	485
The External Carotid Artery . . . . .	487
The Subclavian Artery . . . . .	496
The Axillary Artery . . . . .	502
The Brachial Artery . . . . .	504
The Radial Artery . . . . .	507
The Ulnar Artery . . . . .	511
The Descending Thoracic Aorta . . . . .	514
The Branches of the Descending Thoracic Aorta . . . . .	515
The Abdominal Aorta . . . . .	517
The Branches of the Abdominal Aorta . . . . .	518
The Common Iliac Arteries . . . . .	525
The Internal Iliac Artery . . . . .	526
The External Iliac Artery . . . . .	532
The Femoral Artery . . . . .	533
The Popliteal Artery . . . . .	537

	PAGE
The Anterior Tibial Artery . . . . .	539
The Dorsal Pedal Artery . . . . .	541
The Posterior Tibial Artery . . . . .	542
The Plantar Arteries . . . . .	544
The Veins of the Heart . . . . .	546
The Superior Cava . . . . .	548
The Innominate Veins . . . . .	548
Veins of the Head and Neck . . . . .	550
The Internal Jugular Vein . . . . .	550
Veins of the Cranium . . . . .	556
Sinuses of the Dura . . . . .	556
The Ophthalmic Vein . . . . .	559
Veins of the Brain . . . . .	560
The Diploic Veins . . . . .	561
The Emissary Veins . . . . .	562
Veins of the Upper Limbs . . . . .	562
The Inferior Cava . . . . .	565
The Azygos and Hemiazygos Veins . . . . .	566
Veins of the Spine . . . . .	568
Branches of the Inferior Cava . . . . .	569
Veins of the Pelvis and Lower Limbs . . . . .	570
The Portal System of Veins . . . . .	574
The Vascular System of the Fœtus . . . . .	576
The Lymphatic System . . . . .	579
The Lymph . . . . .	584
The Chief Trunks of the Lymphatics . . . . .	585
The Thoracic Duct . . . . .	585
The Right Lymphatic Duct . . . . .	586
Lymphatics of the Lower Limbs . . . . .	586
Lymphatics of the Pelvis and Abdomen . . . . .	588
Lymphatics of the Thorax . . . . .	591
Lymphatics of the Upper Limbs . . . . .	592
Lymphatics of the Head and Neck . . . . .	594

## CHAPTER X.

THE RESPIRATORY APPARATUS AND LARYNX . . . . .	597
The Lungs . . . . .	598
The Trachea . . . . .	602
Structure of the Lungs . . . . .	605
The Larynx . . . . .	608
Cartilages of the Larynx . . . . .	608
Ligaments and Articulations of the Larynx . . . . .	612
Muscles of the Larynx . . . . .	615
The Interior of the Larynx . . . . .	617

## CHAPTER XI.

THE URINARY ORGANS . . . . .	621
The Kidneys . . . . .	621
The Ureters . . . . .	627
The Urinary Bladder . . . . .	629



## CHAPTER XII.

	PAGE
THE MALE REPRODUCTIVE APPARATUS . . . . .	634
The Penis . . . . .	634
The Prostate . . . . .	639
The Urethra . . . . .	640
The Testicles . . . . .	643
The Semen . . . . .	653

## CHAPTER XIII.

THE FEMALE REPRODUCTIVE APPARATUS . . . . .	654
General Description . . . . .	654
The Vulva . . . . .	654
The Clitoris . . . . .	655
The Nymphæ . . . . .	657
The Urethra . . . . .	658
The Vagina . . . . .	659
The Uterus . . . . .	661
The Oviducts . . . . .	666
The Ovaries . . . . .	667
The Mammæ . . . . .	672
The Milk . . . . .	675
The Perineum . . . . .	675
Muscles and Fasciæ of the Perineum . . . . .	676

## CHAPTER XIV.

GLAND-LIKE ORGANS WHOSE FUNCTION IS OBSCURE OR UNKNOWN . . . . .	680
The Spleen . . . . .	680
The Thyroid Body . . . . .	683
The Thymus . . . . .	685
The Suprarenal Bodies . . . . .	686
The Carotid Gland . . . . .	688
The Coccygeal Gland . . . . .	688

## CHAPTER XV.

THE NERVOUS SYSTEM . . . . .	689
The Nerves and Nerve-Substance in General . . . . .	689
The Nerve-Fibres . . . . .	691
The Nerve-Cells . . . . .	695
The Nerves . . . . .	697
The Ganglia . . . . .	700
The Cerebro-Spinal Axis . . . . .	703
The Spinal Cord . . . . .	703
Origin of the Spinal Nerves . . . . .	711
The Brain . . . . .	713
The Medulla Oblongata . . . . .	716
The Fourth Ventricle . . . . .	719
The Interior of the Oblongata . . . . .	722
The Pons . . . . .	726
The Cerebellum . . . . .	728



	PAGE
The Cerebrum . . . . .	734
The Cerebral Crura, etc. . . . .	747
The Lateral Ventricles . . . . .	749
The Fifth Ventricle . . . . .	751
The Corpora Striata . . . . .	751
The Fornix . . . . .	752
The Hippocampus . . . . .	754
The Third Ventricle . . . . .	757
The Thalamus . . . . .	757
The Commissures . . . . .	759
The Optic Tract . . . . .	759
The Optic Commissure . . . . .	760
The Quadrigeminal Body . . . . .	761
The Pineal Body . . . . .	762
The Pituitary Body . . . . .	763
The Gray Cortex.—The White Matter . . . . .	763
The Fibres of the Cerebrum . . . . .	765
The Brain of the Embryo . . . . .	767
The Choroid Telæ and Plexuses . . . . .	768
The Ependyma . . . . .	769
Membranes of the Cerebro-Spinal Axis . . . . .	769
Membranes of the Brain . . . . .	770
The Dura Mater . . . . .	770
The Pia Mater . . . . .	771
The Arachnoid . . . . .	772
Pacchionian Bodies . . . . .	772
Membranes of the Spinal Cord.—The Dura, the Pia . . . . .	773
The Arachnoid . . . . .	774
Blood-Vessels of the Spinal Axis . . . . .	775
The Nerves of the Brain . . . . .	778
Origin of the Cerebral Nerves . . . . .	778
The Olfactory, or First Pair of Nerves . . . . .	778
The Optic, or Second Pair of Nerves . . . . .	778
The Oculo-Motor, or Third Pair of Nerves . . . . .	779
The Trochlear, or Fourth Pair of Nerves . . . . .	779
The Trifacial, or Fifth Pair of Nerves . . . . .	779
The Abducent, or Sixth Pair of Nerves . . . . .	779
The Facial, or Seventh Pair of Nerves . . . . .	779
The Auditory, or Eighth Pair of Nerves . . . . .	780
The Glosso-Pharyngeal, or Ninth Pair of Nerves . . . . .	780
The Pneumogastric, or Tenth Pair of Nerves . . . . .	780
The Accessory, or Eleventh Pair of Nerves . . . . .	780
The Hypoglossal, or Twelfth Pair of Nerves . . . . .	780
Distribution of the Nerves of the Brain . . . . .	781
Distribution of the Third Nerve . . . . .	781
Distribution of Fourth and Fifth Nerves . . . . .	782
The Semilunar Ganglion . . . . .	782
The Ophthalmic Nerve . . . . .	783
The Lachrymal Nerve, etc. . . . .	783
The Ophthalmic Ganglion . . . . .	785
The Superior Maxillary Nerve . . . . .	786
The Spheno-Palatine Ganglion . . . . .	788
The Inferior Maxillary Nerve . . . . .	790



	PAGE
The Otic Ganglion . . . . .	793
The Submaxillary Ganglion . . . . .	794
The Abducent Nerve . . . . .	794
The Facial Nerve . . . . .	794
The Auditory Nerve . . . . .	798
The Glosso-Pharyngeal Nerves . . . . .	798
The Vagus Nerves . . . . .	800
The Accessory Nerve . . . . .	805
The Hypoglossal Nerve . . . . .	805
Distribution of the Spinal Nerves . . . . .	806
The Posterior Spinal Nerves . . . . .	807
The Anterior Spinal Nerves . . . . .	808
The Cervical Plexus . . . . .	809
The Brachial Plexus.—Nerves of the Arms and Hands . . . . .	812
The Anterior Thoracic Nerves . . . . .	821
The Anterior Lumbar, Sacral, and Coccygeal Nerves.—The Lumbar Plexus . . . . .	823
The Sacral Plexus . . . . .	828
The Coccygeal Plexus . . . . .	835
The Sympathetic Nerves . . . . .	835
The Cervical Portion of the Sympathetic.—The First Cervical Ganglion . . . . .	836
The Carotid Plexus . . . . .	838
The Second and Third Cervical Ganglia . . . . .	839
The Cardiac Plexus . . . . .	840
The Thoracic Portion of the Sympathetic . . . . .	841
The Solar Plexus . . . . .	843
The Sympathetic Nerve, Lumbar and Sacral Portions . . . . .	842, 844, 845
The Hypogastric Plexus . . . . .	845

## CHAPTER XVI.

ORGANS OF SPECIAL SENSE . . . . .	847
The Nose . . . . .	847
The Eyes and their Appendages . . . . .	854
The Eyebrow and Eyelids . . . . .	854
The Conjunctiva . . . . .	857
The Lachrymal Apparatus . . . . .	859
The Muscles of the Eyeball . . . . .	860
The Eyeball . . . . .	862
The Sclerotica . . . . .	863
The Cornea . . . . .	864
The Choroidea . . . . .	866
The Iris . . . . .	870
The Retina . . . . .	873
The Vitreum . . . . .	881
The Lens . . . . .	882
The Aqueous Humor . . . . .	884
The Ear.—The External Ear . . . . .	884
The Middle Ear . . . . .	890
The Tympanum . . . . .	890
The Tympanic Membrane . . . . .	894
The Eustachian Tube . . . . .	894
The Ear Ossicles . . . . .	895

	PAGE
Articulation and Connection of the Ear Ossicles . . . . .	897
Muscles of the Tympanum . . . . .	898
The Lining Mucous Membrane of the Tympanum . . . . .	899
Vessels and Nerves of the Tympanum . . . . .	900
The Labyrinth . . . . .	903
The Osseous Labyrinth . . . . .	904
The Membranous Labyrinth . . . . .	908
The Skin . . . . .	915
The Nails . . . . .	922
The Sebaceous Glands . . . . .	928
The Sweat-Glands . . . . .	929

## CHAPTER XVII.

ANATOMY OF THE GROIN IN RELATION TO HERNIA . . . . .	931
Inguinal Hernia . . . . .	931
Femoral Hernia . . . . .	933
INDEX . . . . .	935



## LIST OF ILLUSTRATIONS.

---

[Those marked with an asterisk are original, mostly by the author or by Dr. Schmidt. The names opposite the others indicate the authorities from which they have been obtained.]

FIG.

- 1 The organic cell.\*
- 2 Longitudinal section of the proximal extremity of the femur.\*
- 3 Horizontal section of the condyles of the femur.\*
- 4 Vertical section of the calcaneum.\*
- 5 Transverse section of the shaft of a phalanx.\*
- 6 Transverse section of bone from the shaft of the femur.\*
- 7 Thin plate from the ethmoid bone.\*
- 8 Portion of the compact substance of the parietal bone.\*
- 9 Femur at about the sixteenth year of life.\*
- 10 The vertebral column. *Morton.*
- 11 Side view of a dorsal vertebra. *Wilson.*
- 12 Upper view of a cervical vertebra. *Ibid.*
- 13 Upper view of the atlas. *Ibid.*
- 14 Side view of the axis. *Ibid.*
- 15 Side view of a thoracic vertebra. *Ibid.*
- 16 Side view of a lumbar vertebra. *Ibid.*
- 17 Front view of the sacrum. *Ibid.*
- 18 Back view of the sacrum. *Ibid.*
- 19 Back view of the coccyx. *Morton.*
- 20 Development of the vertebræ. *Sharpey & Quain.*
- 21 Development of the epiphyses to the vertebræ. *Ibid.*
- 22 Upper view of a lumbar vertebra. *Ibid.*
- 23 Vertical section of two lumbar vertebræ. *Ibid.*
- 24 Portion of the occipital bone, with the atlas and axis. *Wilson.*
- 25 Three thoracic vertebræ, with costal articulations. *Ibid.*
- 26 Portion of the cranium and of the atlas and axis. *Ibid.*
- 27 Centra of three thoracic vertebræ. *Ibid.*
- 28 Three arches removed from thoracic vertebræ. *Ibid.*
- 29 Portion of the occipital bone, with the atlas and axis, front view. *Ibid.*
- 30 Portion of the occipital bone and of the three upper cervical vertebræ. *Ibid.*
- 31 Part of the skull, the atlas, and the axis, from behind. *Ibid.*
- 32 Front view of the thorax. *Ibid.*
- 33 Front view of the thorax. *Ibid.*
- 34 Anterior view of three thoracic vertebræ, with the costal articulations. *Ibid.*
- 35 Posterior view of four thoracic vertebræ, with the costal articulations. *Ibid.*
- 36 External view of the occipital bone. *Ibid.*
- 37 Internal view of the occipital bone. *Ibid.*
- 38 Front view of the sphenoid bone. *Ibid.*
- 39 Upper view of the sphenoid bone.\*



## FIG.

- 40 Inferior view of the intermediate portion of the sphenoid at birth.\*
- 41 Outer view of left parietal bone. *Wilson.*
- 42 Inner view of left parietal bone. *Ibid.*
- 43 External view of frontal bone. *Ibid.*
- 44 Internal view of frontal bone. *Ibid.*
- 45 Upper view of the ethmoid bone.\*
- 46 Left side view of the ethmoid bone.\*
- 47 Inner view of the right ectethmoid.\*
- 48 External view of the temporal bone, right side.\*
- 49 Internal view of the temporal bone, left side.\*
- 50 Inferior view of the temporal bone, left side.\*
- 51 Temporal bone near the time of birth.\*
- 52 Temporal bone, the three pieces separated.\*
- 53 Temporal bone with portion of the petro-squamosal suture retained.\*
- 54 Maxilla, left side, outer view.\*
- 55 Maxilla, left side, inner view.\*
- 56 Posterior view, right palate bone. *Wilson.*
- 57 Exterior view, right palate bone. *Ibid.*
- 58 External view, right turbinal bone. *Horner.*
- 59 External view, right lachrymal bone. *Wilson.*
- 60 Anterior view, left nasal bone. *Ibid.*
- 61 The vomer, left side. *Ibid.*
- 62 Outer view, right malar bone. *Ibid.*
- 63 The mandible. *Ibid.*
- 64 The skull.\*
- 65 Internal view of the base of the cranium.\*
- 66 Right side of a portion of the face and cranium.\*
- 67 External view of the base of the skull, right side.\*
- 68 Left side of face, outer walls of orbit and antrum removed.\*
- 69 Vertical section of the face.\*
- 70 Outer wall of right nasal cavity.\*
- 71 The cranium, antero-posterior section.\*
- 72 The cranium, horizontal section.\*
- 73 The cranium, transverse section through the front.\*
- 74 The cranium, transverse section in advance of the middle.\*
- 75 The cranium, transverse section through the middle.\*
- 76 The cranium, transverse section posterior to the middle.\*
- 77 Articulation of the lower jaw, vertical section. *Wilson.*
- 78 External view of the temporo-mandibular articulation. *Ibid.*
- 79 The hyoid bone. *Ibid.*
- 80 The scapula, left side, posterior view. *Ibid.*
- 81 The scapula, left side, anterior view. *Ibid.*
- 82 The right clavicle. *Ibid.*
- 83 The left humerus. *Ibid.*
- 84 The left ulna and radius. *Ibid.*
- 85 Bones of the carpus. *Ibid.*
- 86 The left hand. *Ibid.*
- 87 Sterno-clavicular, costo-clavicular, and costo-sternal articulations. *Ibid.*
- 88 Scapulo-clavicular and scapulo-humeral articulations. *Ibid.*
- 89 Right elbow-joint, antero-internally viewed. *Ibid.*
- 90 Right elbow-joint, externally viewed. *Ibid.*
- 91 Ligaments of the wrist and hand. *Ibid.*
- 92 Left hip-bone, inner view.\*



## FIG.

- 93 Left hip-bone, outer view. *Wilson.*
- 94 Female pelvis, front view. *Ibid.*
- 95 Ligaments of the pelvis and hip-joint. *Ibid.*
- 96 Ligaments of the pelvis and hip-joint. *Ibid.*
- 97 Right femur. *Ibid.*
- 98 Right patella. *Ibid.*
- 99 Ligaments of the hip. *Ibid.*
- 100 Left tibia and fibula. *Ibid.*
- 101 Right tibia and fibula, posterior view. *Ibid.*
- 102 Right knee-joint, front view. *Ibid.*
- 103 Right knee-joint laid open. *Ibid.*
- 104 Longitudinal section of knee-joint. *Ibid.*
- 105 Right foot, dorsal surface. *Ibid.*
- 106 Left foot, plantar surface. *Ibid.*
- 107 External view of ankle-joint. *Ibid.*
- 108 Internal view of ankle-joint. *Ibid.*
- 109 Posterior view of ankle-joint and of inferior tibio-fibular articulations. *Ibid.*
- 110 Ligaments of the sole of the foot. *Ibid.*
- 111 Bundles of fibro-connective tissue from a ligament.\*
- 112 Fibro-connective tissue from the heart and from the dura.\*
- 113 Fibro-connective tissue pertaining to the synovial sheath of the flexor tendons of the wrist.\*
- 114 Areolar tissue from the axilla.\*
- 115 Arrangement of fibro-connective tissue in the external coat of blood-vessels.\*
- 116 Elastic tissue.\*
- 117 Elastic tissue from pulmonary artery of the horse. *Kölliker.*
- 118 Elastic tissue from carotid artery of the horse. *Ibid.*
- 119 Adipose tissue, with connective tissue.\*
- 120 Cartilage.\*
- 121 Articular cartilage, vertical section.\*
- 122 Section of costal cartilage.\*
- 123 Section of costal cartilage.\*
- 124 Elastic cartilage from the auricle of the ear.\*
- 125 Unstriated muscle-fibres.\*
- 126 Section of the ulno-carpal flexor.\*
- 127 Structure of striped muscle.\*
- 128 Transverse section of the brachial biceps. *Frey.*
- 129 Transverse section of a fascicle of the cremaster.\*
- 130 Muscle-fibrils from the axolotl. *Kölliker.*
- 131 Muscle-fibre from a salamander.\*
- 132 Striated muscle-tissue from the walls of the heart.\*
- 133 Plexus of non-medullated nerve-fibres. *Frey.*
- 134 A motorial end-plate. *Ibid.*
- 135 Muscles of the head and neck. *Sappey.*
- 136 The temporal muscle. *Bonamy & Beau.*
- 137 Interior part of the left side of the face. *Jamain.*
- 138 Front view of the muscles of the neck. *Wilson.*
- 139 Deep muscles, front of the neck. *Sappey.*
- 140 Inferior view of the diaphragm. *Wilson.*
- 141 Muscles of the front of the thorax and abdomen. *Ibid.*
- 142 Left side of abdomen. *Ibid.*
- 143 The inguinal canal.\*
- 144 Muscles of the back. *Wilson.*



FIG.

- 145 Deep muscles of the back. *Wilson.*
- 146 Muscles of the front of the trunk. *Ibid.*
- 147 Muscles of the back of the scapula. *Bonamy & Beau.*
- 148 Muscles of the front of the scapula. *Ibid.*
- 149 The deltoid muscle. *Ibid.*
- 150 Muscles, fore part of the arm. *Wilson.*
- 151 The brachial triceps. *Ibid.*
- 152 Superficial muscles, front of the forearm. *Ibid.*
- 153 Deep muscles, front of the forearm. *Ibid.*
- 154 Metacarpal bone, phalanges, tendons, and ligaments. *Sharpey & Quain.*
- 155 Muscles, back of the forearm. *Wilson.*
- 156 Deep muscles, back of the forearm. *Ibid.*
- 157 Muscles, palmar surface of the hand. *Ibid.*
- 158 Femoral fascia.\*
- 159 Muscles of the thigh, front and outer. *Wilson.*
- 160 Muscles of the buttock. *Ibid.*
- 161 Muscles, back of buttock and thigh. *Ibid.*
- 162 Muscles, front of leg and dorsum of foot. *Ibid.*
- 163 Superficial muscles, back of leg. *Ibid.*
- 164 Deep muscles, back of leg. *Ibid.*
- 165 Muscles, sole of foot. *Ibid.*
- 166 Deep muscles, sole of foot. *Ibid.*
- 167 Relative position of anatomical elements in serous and mucous membranes, glands, lungs, and skin.\*
- 168 Pavement epithelium.\*
- 169 Mucous membrane of small intestine, vertical section.\*
- 170 Columnar epithelium.\*
- 171 Vertical section of bronchial mucous membrane.\*
- 172 Columnar epithelium.\*
- 173 Polyhedral epithelium.\*
- 174 Section of submaxillary gland. *Frey.*
- 175 Stratified epithelium, corneal conjunctiva.\*
- 176 Epithelium of urinary bladder.\*
- 177 Squamous epithelium.\*
- 178 The relations of the pleura illustrated.\*
- 179 Peritoneal surface of the diaphragm.\*
- 180 Simple tubular glands.\*
- 181 Simple follicular gland.\*
- 182 Compound tubular gland.\*
- 183 Compound follicular gland.\*
- 184 Simple tubular gland convoluted.\*
- 185 Gland of complex form.\*
- 186 Gland of complex form.\*
- 187 Gland of complex character.\*
- 188 A racemose gland.\*
- 189 Posterior mediastinum and lungs. *Sappey.*
- 190 Abdominal cavity and viscera. *Wilson.*
- 191 Vertical section of abdomen; apparent arrangement of the course of the peritoneum.\*
- 192 Course of the peritoneum in the foetus.\*
- 193 The abdominal viscera.\*
- 194 Section of mouth, nose, pharynx, and larynx. *Sappey.*
- 195 A follicular lymphoid gland. *Kölliker.*



- FIG.  
 196 Muscles of the palate. *Bonamy & Beau.*  
 197 Dorsum of the tongue. *Sappey.*  
 198 Papillæ of taste.\*  
 199 Side view of muscles of tongue. *Bonamy & Beau.*  
 200 Section of the submaxillary gland. *Frey.*  
 201 Permanent teeth, exterior view.\*  
 202 Permanent teeth, lateral view.\*  
 203 Molar teeth, triturating surface.\*  
 204 Temporary teeth.\*  
 205 Vertical section of a molar tooth.\*  
 206 Vertical section, fang of a canine tooth.\*  
 207 Section of dentine.\*  
 208 Crown of a canine tooth.\*  
 209 Three enamel columns.\*  
 210 Section of enamel.\*  
 211 Development of the teeth. *After Goodsir, Kölliker.*  
 212 Development of the teeth in the pig. *Frey.*  
 213 Vertical section of the germ of a molar. *Ibid.*  
 214 Muscles of the pharynx, posterior view. *Wilson.*  
 215 Muscles of the pharynx, side view. *Ibid.*  
 216 The abdominal viscera. *Ibid.*  
 217 Mucous membrane of the stomach. *Sappey.*  
 218 Mammillæ of mucous membrane of the stomach. *Ibid.*  
 219 Gastric glands in mucous membrane.\*  
 220 A gastric gland.\*  
 221 Cardiac gastric gland of the dog.\*  
 222 Bottom of a gastric gland.\*  
 223 Columnar epithelium.\*  
 224 Columnar epithelium from an intestinal villus. *Frey.*  
 225 Portion of mucous membrane from the jejunum.\*  
 226 Portion of mucous membrane from the ileum.\*  
 227 Structure of mucous membrane from the ileum.\*  
 228 Portion of the duodenum. *Sappey.*  
 229 Vertical section of the duodenum.\*  
 230 Portion of mucous membrane, upper part of the ileum. *Sappey.*  
 231 Portion of the ileum, from without; agminated glands. *Ibid.*  
 232 The abdominal viscera. *Ibid.*  
 233 The cæcum and ileo-colic valve. *Morton.*  
 234 Mucous membrane of the colon.\*  
 235 Viscera, upper part of the abdomen. *Sappey.*  
 236 The liver, inferior surface.\*  
 237 Portions of the liver of the hog. *After Kiernan, Kölliker.*  
 238 Portions of the liver of the hog. *Ibid.*  
 239 Lobules from the liver of the rabbit. *Kölliker.*  
 240 Hepatic cells.\*  
 241 Transverse section of a hepatic lobule.\*  
 242 Commencement of bile-ducts in the canaliculi.\*  
 243 Transverse section of the wall of an artery.\*  
 244 A small branching artery. *Frey.*  
 245 Elastic tissue, middle coat of popliteal artery. *Kölliker.*  
 246 Unstriated muscular fibres, from the middle coat of an artery. *Ibid.*  
 247 Endothelium of the blood-vessels.\*  
 248 Transverse section of the wall of the aorta. *Kölliker.*



FIG.

- 249 Valves of veins. *Morton.*  
 250 Structure of a capillary vessel.\*  
 251 Artery passing into the capillary structure. *Kölliker.*  
 252 Red blood-corpuscles.\*  
 253 White blood-corpuscles. *Frey.*  
 254 White blood-corpuscles. *Ibid.*  
 255 Front view of the heart.\*  
 256 The heart, anterior portion of ventricles removed.\*  
 257 The aorta. *Bourcery.*  
 258 Left common carotid; external and internal carotids. *Ibid.*  
 259 Arteries of the interior of the cranium. *Ibid.*  
 260 External carotid and its branches. *Ibid.*  
 261 Internal maxillary artery. *Ibid.*  
 262 Arteries of the interior of the cranium. *Ibid.*  
 263 The axillary artery.\*  
 264 Axillary and brachial arteries.\*  
 265 Arteries of the forearm. *Bourcery.*  
 266 Arteries of the palmar surface of the hand. *Ibid.*  
 267 Arteries of the palmar surface of the hand. *Ibid.*  
 268 The aorta. *Ibid.*  
 269 The cœliac artery. *Wilson.*  
 270 Superior mesenteric artery. *Jamain.*  
 271 Inferior mesenteric artery. *Ibid.*  
 272 The pelvis and its viscera and arteries. *Ibid.*  
 273 The perineum, internal pudic artery. *Bourcery.*  
 274 Arteries of the front of the thigh. *Jamain.*  
 275 Arteries of the back of the thigh. *Ibid.*  
 276 Arteries of the front of the leg. *Ibid.*  
 277 Arteries of the back of the leg. *Ibid.*  
 278 Arteries of the sole of the foot. *Ibid.*  
 279 Veins of the heart, posterior view.\*  
 280 Veins of the thorax and abdomen. *Bourcery.*  
 281 Veins of the head and neck. *Ibid.*  
 282 Sinuses at the base of the cranium.\*  
 283 Vertical section of skull; veins of the dura.\*  
 284 Superficial veins of the upper limb.\*  
 285 Veins of the thorax and abdomen. *Bourcery.*  
 286 Superficial veins of the back of the leg. *Ibid.*  
 287 Superficial veins of the inner part of lower extremity. *Ibid.*  
 288 The portal system.\*  
 289 The foetal circulation.\*  
 290 Lymphatic vessels in the skin of the ear. *Sappey.*  
 291 A lymphatic vessel and its valves.\*  
 292 Endothelium of a commencing lymphatic.\*  
 293 Lymphatic gland and vessels.\*  
 294 Lymphatic gland, small, in section. *Frey.*  
 295 Follicle from the cortex of a lymphatic gland. *Ibid.*  
 296 Lymph-corpuscles. *Ibid.*  
 297 Lymph-corpuscles. *Ibid.*  
 298 The great lymphatic trunks. *Bourcery.*  
 299 Lymphatics of the head and neck. *Ibid.*  
 300 The lungs, anterior view. *Sappey.*  
 301 The lungs, posterior view. *Ibid.*



## FIG.

- 302 Portion of the exterior surface of an inflated lung.\*  
 303 Larynx, trachea, and bronchi. *Richardson*.  
 304 Primary lobules of the lungs.\*  
 305 Primary lobules of the lungs. *Kölliker*.  
 306 Section of lung-tissue.\*  
 307 Capillary nets of the air-cells. *Kölliker*.  
 308 The larynx, front view. *Sappey*.  
 309 The larynx, back view. *Ibid*.  
 310 The larynx, muscles of.\*  
 311 The vocal membrane.\*  
 312 Inner view of the larynx. *Sappey*.  
 313 The kidney, longitudinal section.\*  
 314 Uriniferous tubules.\*  
 315 Structure of the kidneys.\*  
 316 Epithelium of the ureter.\*  
 317 Male pelvis and its contents. *Wilson*.  
 318 Part of the bladder and penis. *Ibid*.  
 319 Vertical section of bladder and penis.\*  
 320 Transverse section of penis. *Weber*.  
 321 Part of the bladder and penis, the urethra laid open from above. *Wilson*.  
 322 Transverse section of the testicle. *Kölliker*.  
 323 Testicle, with the vaginal tunic laid open. *Quain & Sharpey*.  
 324 Testicle deprived of its tunics. *After Arnold, Kölliker*.  
 325 Portion of a seminiferous tubule. *Kölliker*.  
 326 Posterior view of the fundus of the bladder. *Cruveilhier*.  
 327 Spermatozoa. *Kölliker*.  
 328 Section of female pelvis. *Schmidt*.  
 329 Female organs of generation. *Sappey*.  
 330 External organs of generation.\*  
 331 Virgin uterus at maturity.\*  
 332 Uterus which has given childbirth.\*  
 333 Muscle-fibre cells of the uterus. *Kölliker*.  
 334 Ovary, parovarium, and oviduct, left side.\*  
 335 Transverse section of an ovary. *Kölliker*.  
 336 Section of an ovary of the rabbit. *Frey*.  
 337 Human ovum. *Kölliker*.  
 338 Two corpora lutea. *Ibid*.  
 339 Milk-duct and lobules of the mammary gland.\*  
 340 Alveolus of the mammary gland.\*  
 341 Corpuscles observed in milk. *Kölliker*.  
 342 View of the perineum. *Bourcery*.  
 343 Diagram of the termination of a capillary vessel in the splenic pulp.\*  
 344 Small branch of the splenic artery, with lymphoid nodules, from the dog  
*Kölliker*.  
 345 Portion of the thyroid body, in section. *Ibid*.  
 346 One lobe of the thymus laid open. *Ibid*.  
 347 Section of a lobule of the thymus body.\*  
 348 Section of the cortical substance of a suprarenal body. *Kölliker*.  
 349 Cells from a suprarenal body. *Ibid*.  
 350 Structure of nerve-fibres.\*  
 351 A medullated nerve-fibre.\*  
 352 Mode of branching of a medullated nerve-fibre.\*  
 353 Portion of a sympathetic nerve. *Frey*.



FIG.

- 354 Nerve-cells from the brain. *Frey.*  
 355 Transverse section of the small sciatic nerve of a calf. *Kölliker.*  
 356 The anastomosis and branching of nerves.\*  
 357 Diagram of a spinal ganglion and its connections. *Frey.*  
 358 Diagram of a ganglion of the sympathetic nerve. *Ibid.*  
 359 Nerve-cells from the semilunar ganglion of the trigeminal nerve. *Kölliker.*  
 360 Medullated nerve-fibres of the white matter of the cerebrum.\*  
 361 The spinal cord with the oblongata. *Sappey.*  
 362 Transverse sections of the spinal cord.\*  
 363 Transverse section of the lumbar enlargement of the spinal cord.\*  
 364 Transverse section of a portion of the spinal cord at the entrance of the anterior root of a nerve.\*  
 365 Diagram of sections of the spinal cord.\*  
 366 Diagram of origin of a spinal nerve.\*  
 367 Base of the brain. *After Hirschfeld, Sappey.*  
 368 Fore part of the pons and oblongata. *Ibid.*  
 369 View back of the pons and oblongata. *Ibid.*  
 370 Posterior part of oblongata and floor of fourth ventricle.\*  
 371 Horizontal section of the oblongata at the upper part of the decussation of the pyramids.\*  
 372 Horizontal section of the oblongata.\*  
 373 Fore part of the pons and oblongata. *Sappey.*  
 374 Section across the pons.\*  
 375 Section across the upper part of the pons.\*  
 376 Right hemisphere of the cerebellum.\*  
 377 Vertical section of the cortex of the cerebellum.\*  
 378 Section of the brain along the great longitudinal fissure. *After Hirschfeld, Sappey.*  
 379 Left hemisphere of the cerebrum of a white man, outer view.\*  
 380 Left hemisphere of the cerebrum of a negro male, outer view.\*  
 381 Under surface of the frontal lobe of the left cerebral hemisphere.\*  
 382 Right hemisphere of the cerebrum of a white man, inner view.\*  
 383 Right hemisphere of the cerebrum of a negro male, inner view.\*  
 384 Sections across the cerebral crura and quadrigeminal body.\*  
 385 Transverse section of the cerebrum on a level with the callosum.\*  
 386 Transverse section of the cerebral hemispheres, the callosum removed, and the lateral ventricles exposed.\*  
 387 Section of the left cerebral hemisphere.\*  
 388 Transverse vertical section of the right hemisphere of the cerebrum.\*  
 389 Transverse vertical section of the left hemisphere of the cerebrum.\*  
 390 Striata, thalami, quadrigeminal body, and cerebellum. *Hirschfeld, Sappey.*  
 391 Horizontal section through the right hemisphere of the cerebrum.\*  
 392 Vertical section through the deeper portion of the cerebral cortex.\*  
 393 Ependyma of the ventricles. *Kölliker.*  
 394 Horizontal section of the spinal cord, showing the general mode of the distribution of the arteries.\*  
 395 Section across a cerebral convolution, showing the arterial arrangement.\*  
 396 Horizontal section of the oblongata; distribution of the arteries.\*  
 397 Oculo-motor and abducent nerve. *After Hirschfeld, Sappey.*  
 398 Trifacial nerve. *Ibid.*  
 399 The ophthalmic ganglion; outer part of the right orbit removed. *Ibid.*  
 400 Superior maxillary nerve; the external wall of the left orbit and of the maxilla removed. *Ibid.*



FIG.

- 401 View of the sphenopalatine ganglion, the outer wall of the left nasal cavity, and the olfactory nerve. *After Hirschfeld, Sappey.*
- 402 Distribution of the inferior maxillary nerve. *Ibid.*
- 403 The otic ganglion and its connections.\*
- 404 The facial nerve. *After Hirschfeld, Sappey.*
- 405 The last four cerebral nerves, the facial nerve, the sympathetic, and the upper two cervical nerves. *Ibid.*
- 406 The vagus nerve. *Ibid.*
- 407 The cervical and brachial plexuses.\*
- 408 The brachial plexus. *After Hirschfeld, Sappey.*
- 409 Cutaneous nerves of the upper extremity. *Ibid.*
- 410 Cutaneous nerves of the upper extremity. *Ibid.*
- 411 Musculo-cutaneous, median, ulnar, and musculo-spiral nerves. *Ibid.*
- 412 Musculo-cutaneous, median, ulnar, and musculo-spiral nerves. *Ibid.*
- 413 Lumbar, sacral, and coccygeal plexuses.\*
- 414 Cutaneous nerves of the front of the thigh. *After Hirschfeld, Sappey.*
- 415 Lumbar plexus and its branches. *Ibid.*
- 416 Peroneal nerve and its branches. *Ibid.*
- 417 Popliteal nerve. *Ibid.*
- 418 The sympathetic, vagus, and other nerves. *Ibid.*
- 419 The sympathetic, lumbar, and sacral portions. *Ibid.*
- 420 Outer wall of left nasal cavity. *Sappey.*
- 421 Portion of the nose. *Ibid.*
- 422 Cartilages of the nose. *Ibid.*
- 423 Vertical section of the nasal mucous membrane. *Kölliker.*
- 424 Nerves of the partition of the nose. *Sappey.*
- 425 Nerves of the outer wall of the nasal cavity. *Ibid.*
- 426 Left eyebrow and lachrymal gland, inner surface. *Ibid.*
- 427 Nerve end-bulbs, from the conjunctiva. *Frey.*
- 428 The left eye, with a portion of the eyelids removed; lachrymal canals and sac. *Sappey.*
- 429 Muscles of the eye. *Morton.*
- 430 Vertical section of the eyeball. *Sappey.*
- 431 The choroidea and iris. *Ibid.*
- 432 Veins of the choroidea and iris. *Ibid.*
- 433 View, from behind, of the anterior half of the eyeball. *Ibid.*
- 434 The same view, with the lens and retina removed. *Ibid.*
- 435 Segment of the choroidea and iris, inner surface. *Ibid.*
- 436 Section through the ciliary region of the eye. *Frey.*
- 437 Pigment-cells of the uvea. *Kölliker.*
- 438 Arteries of the iris. *Sappey.*
- 439 Vessels of the ciliary body and iris. *Kölliker.*
- 440 Eyeball, with sclerotica, cornea, choroidea, and iris removed. *Sappey.*
- 441 Retina, seen on its posterior inner surface. *Ibid.*
- 442 Vertical sections of the retina. *Frey.*
- 443 Rod and cone layer of the retina.\*
- 444 Rod and cone from the retina.\*
- 445 Diagram of the arrangement of the structural elements of the retina. *Frey.*
- 446 Vertical section through one side of the yellow spot and central fovea.\*
- 447 The crystalline lens. *Sappey.*
- 448 Crystalline lens, breaking up into segments. *Ibid.*
- 449 Segment of the crystalline lens. *Ibid.*
- 450 Crystalline lens of the adult, showing the arrangement of the fibres. *Kölliker.*



## FIG.

- 451 Fibres of the crystalline lens.\*  
 452 Diagram of the blood-vessels of the eye. *Frey*.  
 453 The pinna. *Sappey*.  
 454 General view of the ear, laid open from the front. *Ibid*.  
 455 Section through the skin of the auditory meatus. *Kölliker*.  
 456 Section across the pyramid of the left temporal bone.\*  
 457 Cavity of the tympanum. *Sappey*.  
 458 Ear ossicles. *Ibid*.  
 459 Cribriform plate of the left internal auditory meatus.\*  
 460 Internal ear laid open. *Sappey*.  
 461 Nerves of the vestibule and semicircular canals. *Ibid*.  
 462 Distribution of the cochlear nerve. *Ibid*.  
 463 The right labyrinth.\*  
 464 Interior of the vestibule, superior and posterior semicircular canals.\*  
 465 The cochlea, laid open; its summit turned upward. *Sappey*.  
 466 The cochlea, laid open and viewed from its summit. *Ibid*.  
 467 The membranous labyrinth.\*  
 468 Diagram of a cross-section of a semicircular canal.\*  
 469 Diagram of acoustic epithelium.\*  
 470 Otolites.\*  
 471 Diagram of a cross-section of the acoustic crest of an ampulla.\*  
 472 Diagram of a cross-section of one of the turns of the cochlea.\*  
 473 Diagram of a vertical section of the skin of the forefinger.\*  
 474 Two tactile papillæ. *Frey*.  
 475 Pacinian corpuscles.\*  
 476 Diagram of the epidermis, with a tactile papilla.\*  
 477 Corrugated or furrowed cells from the epidermal rete. *Frey*.  
 478 Scurf from the leg.\*  
 479 Fragment of dandruff from the head.\*  
 480 Cells from the epidermal rete.\*  
 481 Bed of the nail. *Sappey*.  
 482 Under surface of the nail. *Ibid*.  
 483 Vertical section of the end of a finger. *Ibid*.  
 484 Transverse section through the nail and its bed. *Kölliker*.  
 485 Cells of the nail. *Ibid*.  
 486 Hair-follicle. *Ibid*.  
 487 Section of the skin of the scalp, with a hair-follicle.\*  
 488 Portion of a hair from the outer part of the thigh.\*  
 489 Portion of the shaft of a light hair. *Kölliker*.  
 490 Diagram of the structure of the root of a hair and its follicle.\*  
 491 Diagram of the structure of a transverse section of a hair with its follicle.\*  
 492 Sebaceous glands opening into the mouth of a hair-follicle. *Todd & Bowman*.  
 493 A large sebaceous gland from the nose. *Kölliker*.  
 494 Sebaceous matter, from one of the sebaceous glands of the nose.\*  
 495 Structure of the sebaceous glands. *Kölliker*.



AN  
ELEMENTARY TREATISE  
ON  
HUMAN ANATOMY.

---

CHAPTER I.

INTRODUCTION.

**Anatomy** is the name given to a knowledge of the structure of organized bodies, which are distinguished as plants and animals. **Human anatomy**, the subject of the present work, applies to the description of the structure of the human body.

**Man** is an **animal**, and belongs to the principal division of the animal kingdom named the **vertebrates**,<sup>1</sup> primarily distinguished from other principal divisions by the possession of an internal skeleton with a median axis, which is usually divided into transverse segments called **vertebræ**. These and other parts of the skeleton mostly consist of bones, with cartilages and ligaments. The vertebral axis or column, more familiarly known as the spine, is enclosed within the trunk of the body and tapers away in the tail. To its opposite extremity is appended the skull, usually composed of bones. The spine and skull contain the spinal cord and brain, from which emanate the nerves, in pairs, distributed to the muscles, the skin, and the organs of special sense. Within the trunk of the body are contained, for the most part, the alimentary, respiratory, and genito-urinary apparatus, and the chief organs of the circulation of the blood.

Among vertebrates man belongs to the class of **mammals**, of which the primary distinctive character is the possession of **mammæ**, or milk-glands, important organs in the female sex, but rudimentary in the male. Highest of mammals is the order of the **primates**, to which belong both man and monkeys, whose primary distinction is the possession of thumbs; that is to say, the first digits opposed to the others, in one or both pair of limbs, adapting them as organs of prehension, or instruments for taking hold of things.

---

<sup>1</sup> Vertebrata.



Man is distinguished among primates as a separate genus, strikingly characterized from the rest, and indeed from all other vertebrates, by the habitually erect position of the body, which is supported alone by the pelvic limbs, used in progression, while the pectoral limbs, entirely relieved from this office, are devoted to prehension. Thus, under the most favorable conditions, man is endowed with instruments which give him capabilities far exceeding those of other animals.

While the anatomy of man, in the kind, number, and construction of the organs, nearly accords with that of the higher monkeys, as exemplified in the gorilla, orang, chimpanzee, and gibbon, it is more or less varied, as it is also among these, in accordance with requirements related to differences in the habits and conditions of each.

Naturalists generally regard all the observed kinds of man, or the genus **homo**, as of one species, distinguishing them as varieties. The most striking of these are the white, Mongolian, and negro; the others being less obviously marked. All, under ordinary circumstances, retain their distinctive marks, which are perpetuated from generation to generation, and only through sexual intermixture do they produce hybrid offspring of intermediate character. The varieties, or races as they are also called, are mainly distinguished by differences in the color of the skin, the character of the hair, exact conformation of the features and skull, degree of development of the brain, and in the less evident variation of other parts. Independent of these differences, the anatomy of the races of men is so nearly alike that for the ordinary purposes of the physician and surgeon it may be regarded as identical.

**Descriptive or special anatomy** applies to the description of the distinct parts or organs of the human body, or that of any other animal, examined as relates to their shape, position, connections, structure, and other characters. When organs of the same kind are investigated in consecutive order, as the bones, the muscles, etc., the study is called **systematic anatomy**; and when they are examined in their relative position in particular regions, it is **topographical** or **regional anatomy**, often also called **surgical anatomy** from its importance in the operations of surgery. An account of the origin and development of the animal and its organs constitutes **embryology**. To the knowledge of the materials of structure or the tissues is applied the name of **histology** or **general anatomy**.

Animals, and likewise plants, except the simplest forms, are composed of distinct parts or **organs**, which are instruments adapted to the various purposes of life. The organs are composed of different materials, which in many cases resemble artificial woven fabrics, and are hence in general called the **tissues**.

The tissues of the human body may be classified according to their general character under the following principal groups, though it must be understood that while some are clearly distinct, they mostly com-



prise widely different varieties, and in some cases they more or less gradate into one another :

Corpuscular tissue. Of the blood and lymph; of the solid lymphatic structures; of the spleen; and of the red marrow of the bones.

Epithelial tissue. Epithelium of mucous membranes and glandular structures; the epidermis and its appendages; and endothelium.

Connective tissue. Fibro-connective tissue; elastic tissue; adipose tissue; and the neuroglia.

Cartilaginous tissue. Cartilage and its varieties.

Osseous tissue. Bone.

Muscular tissue. Muscle or flesh, striated and unstriated.

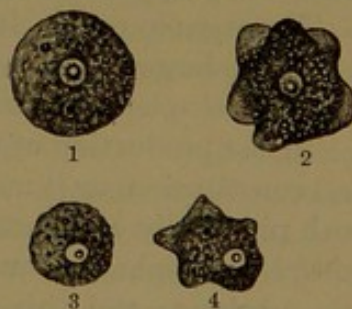
Nervous tissue. Nerve-cells and nerve-fibres.

In most of the organs a single tissue predominates and is characteristic of the organ, as thus the bones are mainly composed of osseous tissue and the muscles of muscular tissue, though both contain proportions of several other tissues. In organs composed of two or more principal tissues, each of these as a rule maintains its continuity; thus, in the walls of the blood-vessels and the intestines, the like tissues are continuous throughout. The different tissues are composed of characteristic particles or units, which are called their **structural elements**. These exhibit much variety of form and structure, both physically and chemically, but all are derived, through more or less transformation, from a common structural element, which from the universality of its existence as the basis of structure of organized bodies, both plant and animal, is named the **organic cell**. The primitive or typical form of this element is a sphere, and is exemplified by a colorless blood-corpuscle, a resting amoeba, a protococcus, or the primitive ovum, or egg, of animals.

In the corpuscular and epithelial tissues, and to a variable degree in most others, the organic cell retains so much of its original character that it is readily recognized as the structural element of the tissue at all times. In the production of some of the tissues the cell undergoes more or less transformation which proportionately obscures its original condition, but mostly the cell character of the structural element may readily be detected. In some of the tissues the cells become greatly elongated and assume the form of fibres, rods, or tubes, and become otherwise altered in both physical and chemical composition, as exemplified in fibro-connective and muscular tissue, in capillary vessels, and in nerve-fibres.

The cellular elements of solid tissues are connected together by an intervening, homogeneous, cementing substance. This **intercellular**

FIG. 1.



THE ORGANIC CELL. 1, 2, a parasitic amoeba of the cockroach, magnified 160 diameters. 1, in the quiescent state; 2, in movement. 3, 4, a colorless blood-corpuscle, 800 diameters. 3, quiescent; 4, in movement.



**substance** is usually in so small a quantity as to be inconspicuous, but sometimes, as strikingly observed in cartilage, is comparatively abundant, when the cells appear embedded in a matrix. It is acted on by certain reagents differently from the cells; and thus the application of silver nitrate to an endothelium, by staining the cement, distinctly outlines the cells.

The simplest of animals, the protozoa, are single-celled organisms,—that is to say, consist essentially of single or isolated cells,—and such, likewise, is the case with the circulating corpuscles of the blood and lymph of higher animals. All plants and animals, with the exception of the simplest kinds or unicellular forms, are built up of aggregations of similar cells or structural elements derived from the transformation of cells, and being thus composed are distinguished as **organized bodies**, the highest forms of which consist of almost incalculable aggregations of organic cells.

The organic cell, now recognized as the common physical element of organization or of the structure of plants and animals, is in general microscopic. In a few plants it is sufficiently large to be distinguished by the unaided eye, as exemplified in the houseleek (*Sempervivum*) and eel-grass (*Vallisneria*); and rarely it reaches a large size, as in *Chara*, in which it grows to an inch or more in length. Commonly it is otherwise, as in the lowest plants exemplified by the fission-fungi, *Schizomycetes*, to which belong the bacteria. The forms are of such exceeding minuteness as to be recognizable only through the aid of the highest powers of the microscope. In man and other animals of his class the cells rarely exceed one three-hundredth of an inch, and more commonly they approach only a tenth of that size.

The organic cell in its primitive condition, or prior to any change it may undergo in the production of different tissues, is composed of a peculiar complex chemical substance distinguished as **protoplasm**.

In the production of the tissues the cell may retain its original form and constitution, or it may undergo transformation to a variable degree, both physically and chemically. The cell almost constantly contains a conspicuous spherical or oval body among the contents, which is named the **nucleus**, and this also is composed of a variety of protoplasm. Many, if not most, cells, in advancing to maturity, in the production of the various tissues, acquire a membranous investment called the **cell-wall**, which is due to a partial solidification or coagulation of the superficial protoplasm; and through this wall, in the solid tissues, the contiguous cells become more or less firmly united together. The cell-wall was formerly regarded as an essential constituent of the organic cell; but it has been ascertained that in young and growing cells, and in many others, at least in their more active state, no such envelope exists, though some of the authorities consider it to be present in a condition of extreme tenuity. As examples, it appears to be absent in the colorless blood- and lymph-corpuscles, the secreting cells of the



liver, and nerve-cells; on the other hand, it is very evident in adipose cells, and in the mature egg it is called the vitelline membrane.

One of the simplest of animal organisms, the *amœba*, exemplifies an isolated organic cell, which in its ordinary condition is a tiny particle of fluent and contractile protoplasm with an internal nucleus, and with no membranous covering. In this state the microscopic bit of jelly moves about from place to place, seizes and swallows solid food and digests it and rejects the waste matter, respire, and reproduces itself. Under certain circumstances the *amœba* becomes quiescent, assumes a spherical form, and acquires a membranous investment. In this the encysted or resting condition the *amœba* is a nucleated cell with a cell-wall. Most mature vegetal structures exemplify the cell-structure, in which each cell is enclosed in a membranous wall, as seen in the section of the leaf of a plant.

**Protoplasm**, the material of composition in the production, development, and growth of organized bodies, has been distinguished as the common physical basis of organization. It is a transparent jelly, which in its qualities, both physical and chemical, resembles albumen, as exemplified by the white of eggs. It is more or less viscid, and contains a large proportion of water; which liquid it also readily imbibes, but appears ordinarily not to be soluble in it. It is homogeneous, but commonly exhibits a finely granular aspect, though the granules seem not to be essential to its constitution; and when they are sufficiently large to show the action of reagents, they mostly prove to have a different chemical composition. The granules often appear as fat-molecules or more or less conspicuous oil-globules, and these at times may completely replace the protoplasm, as in the production of the cells of adipose tissue. In vegetal cells the granules often appear as drops of oil, starch-grains, and other substances, and sometimes in the form of crystals.

Recent observations would appear to indicate that the protoplasm, notwithstanding its diffuent character, is not actually homogeneous, but consists of a more tenacious fibrillar, reticular, or spongy basis, with the interstices occupied by a more liquid or fluent material; and it has been explained that the ordinary granular aspect of protoplasm is due to the optical section of the fibrillar material. In addition to this general constitution, the protoplasm often encloses true granules of variable size and constitution. There often, also, appear in it clear globules, or spherical spaces filled with liquid, and named vacuoles.

The most remarkable physiological character of living protoplasm in its active state is its quality of motility, exhibited in contraction and extension, as strikingly observed in the movements of the *amœba*, and only in a less obvious manner in the colorless blood-corpuscles.

The **nucleus** of the organic cell, a most constant element though not always persistent, is a spherical or oval body, which usually occupies a position at or near the centre of the protoplasmic mass. Generally



single, sometimes several occupy the same cell. The white blood-corpuscles often contain two or three nuclei, and the giant-cells of the bone-marrow contain many. The nucleus is ordinarily defined by a thin membranous wall, and appears also to have a similar constitution to the surrounding protoplasm; consisting of a reticular structure with a more fluent material, and named the **nucleoplasm**.

Within the nucleus there is very constantly to be seen a clear and highly refractive spherule, the **nucleolus**, regarded as a central accumulation of the reticular nucleoplasm. Not unfrequently several nucleoli are contained within the nucleus.

Though the nucleus exhibits a constitution similar to that of the surrounding cell protoplasm, it is not identical in chemical composition; for dilute acids, which commonly dissolve the latter, do not act in the same manner on the nucleus. Further, certain reagents, as hæmatoxylin, stain it more intensely, and while gold chloride colors the cell protoplasm, it does not affect the nucleus in this way.

From the phenomena observed in cell production and reproduction, the nucleus appears to be the starting-point of the action which results in the division and multiplication of the cell. In mature structures the cell contents exhibit a great variety in physical and chemical constitution, and the nucleus ordinarily appears of uniform character and inert; and only in the reproduction of the cell does it appear as an active agent.

In the production and development of the tissues through cells, these are commonly multiplied or reproduced through the division or segmentation of a pre-existing cell. The original cell, exemplified by the primitive egg of animals, divides into two, and these then divide each into two, and in the same manner the multiplication proceeds until the whole are produced in the development of the animal, and subsequently throughout its life in the renewal of the cell elements of its structure.

The reproduction of the cell commences with a series of remarkable changes in the nucleus, the phenomena of which have been named **karyokinesis**; and the progress of research appears to indicate that the process is essentially the same in both plants and animals. In this wonderful process the nucleus, as it were, seems to awake from its resting condition, and gradually assumes the appearance of a tangled **skein** of contorted threads embedded in a clearer matrix, from which the nuclear wall has melted away, but which still remains distinct from the surrounding cell protoplasm. The nuclear skein then changes to the form of a **rosette**, and this, by the breaking of the peripheral threads, to that of a **star**. This afterwards becomes successively barrel-shaped, and then more elongated and spindle-shaped. The **spindle** next divides at the equator into two portions, which separate and recede from each other towards the poles of the nucleus, where they gradually acquire the form of the resting nucleus from



which they started. With the division of the nuclear skein its matrix is constricted, and finally the nucleus is completely divided. At the same time the surrounding cell protoplasm likewise undergoes constriction and division, and thus ultimately two cells are produced, each with its nucleus. In the further reproduction of cells the same steps are repeated, and the process may start in the new pair of nuclei before the complete separation of their cells. The new cells produced by segmentation are often called the **daughter-cells**, in contradistinction to that from which they are derived, which is named the **mother-cell**. The former are smaller than the latter, but quickly grow to the mature size, when the act of karyokinesis may be repeated and new cells formed, and finally they may remain without further change, or they may undergo more or less transformation in the production of the various tissues.

It is generally admitted as the result of all observation that all cells are derived from pre-existing cells, and hence the axiom, "*omnis cellula e cellulis*." The primitive germ of plants and the primitive ovum of animals is a single cell, and from this are derived all the cells which, unchanged or variably metamorphosed, compose the structural elements of the tissues and organs of all plants and animals.

The simplest and minutest living bodies are unicellular organisms, as exemplified by an amœba among animals, and these exhibit in a wonderful manner all the phenomena which distinguish life in the most complex organisms, plants, and animals. These consist of an aggregation of similar cell elements with similar qualities, each in a measure acting independently but in concert with one another. In the course of development from the cell which constitutes the primitive ovum, in the production of the various tissues and organs the cells become widely differentiated in shape, chemical and physical composition, and qualities. Certain cells become comparatively inert and subserve mechanical purposes, as in the structural elements of cartilages, bones, and connective tissues; others become special agents of motor power, as in the muscles; others active chemical agents, as in the glandular organs; others as the subtle agents of nerve power; and some as superlative in the power of reproduction for the maintenance of the species.



## CHAPTER II.

### GENERAL ANATOMY OF THE SKELETON.

The **skeleton** is the hard framework of the body, to which it conforms in general shape and construction and gives stability. It affords a basis of support to the softer structures, forms cases for the protection of delicate and important organs, gives attachment to muscles, and provides levers of movement. The parts of which it consists are the **bones**, with a few **cartilages**, all connected together by ligaments. The bones are closely invested with a fibrous membrane, the **periosteum**, except on their articular surfaces, where **cartilage** or **fibrocartilage** is substituted. They are everywhere pervaded by blood-vessels, and the cavities of their interior structure are occupied by the **marrow** or **medulla**. When the softer adherent parts are removed, the dry bones are in the most convenient condition for ordinary study.

The number of bones in the skeleton depends upon what we may regard as such, for the number of pieces varies at different periods of life, and each is not in all cases viewed as a distinct bone by the anatomist. Some pieces are single and distinct bones from their earliest appearance to the end of life, but most named bones are derived from a variable number of pieces, which are produced at different periods before and after birth, and successively unite at different times before they are complete. Even after maturity many bones regarded as distinct become ankylosed, and in this way, in advanced age, the entire skull, with the exception of the mandible, may become a single bone.

The bones which are more persistent as single pieces, and which are named and described as such, are as follows:

	Bones.
For the spine, including 24 vertebræ, the sacrum and coccyx, together with	
12 pairs of ribs and the sternum . . . . .	51
For the skull, 22, together with the hyoid and 6 ear ossicles . . . . .	29
For the upper limbs, in each 34 . . . . .	68
For the lower limbs, in each 33 . . . . .	66
	214

The number of distinct osseous pieces at the time of birth is 278; at the age of twenty-five years, regarded as maturity, 224; the whole number at all periods, approximatively, 668; and in advanced old age normally reduced to 194.

The bones are mostly in pairs, as those of the limbs, the ribs, and



most of those of the skull; the others are single and symmetrical, or consist of like halves, as those of the vertebral column, the sternum, the hyoid, and several of the skull.

The bones exhibit a great variety in size, shape, and proportions, though most are referable to a few general forms, which are usually distinguished as long, short, and broad, while others are of a mixed character, and mostly irregular. The **long bones**, like most of those of the limbs, have the length conspicuously exceeding the other measurements. They commonly possess a cylindroid or primitive **shaft** or **body**, with expanded extremities, of which that nearest the spine, or central axis of the skeleton, is the **proximal**, and the other the **distal extremity**. The **short bones**, exemplified by those of the wrist and ankle, differ little in their diameters. The **broad bones**, as those of the cranial vault, the scapula, and the hip, are conspicuously broad. **Irregular bones**, partaking of the characters of the others, are exemplified by the sphenoid bone and the vertebræ.

Any projection of a bone is a **process** or an **apophysis**. If it has an articular surface, mostly smooth, it is an **articular process**; and this, usually from its relative position and rounded shape, is often called a **head**. A pair of similar processes on the same plane are termed **condyles**. An obtuse prominence is a **tubercle** or a **tuberosity**. A long, tapering process is a **spine** or a **spinous process**, though the same term is sometimes applied to a tuberosity. A thickened border of a bone is a **crest**; a slight elevation extended along a surface, a **line**; and a more prominent one, a **ridge**. A hole is named by the anatomist a **foramen**, the plural of which is **foramina**. The prolongation of a foramen is a **canal**; and a more conspicuous passage-way is a **meatus**. A broad, depressed surface is a **fossa**; and a cavity with diminished outlet is a **sinus**, though this name is also applied to some of the larger vascular channels in the interior spongy structure of bones.

Bones in the fresh condition, freed from the softer attachments, are dull white, or in the infant bluish white, and in the aged yellowish white, with more or less of a reddish hue where they are most porous and spongy, as at the extremities of the long bones; and young bones appear proportionately more red, from their greater degree of vascularity than in the adult. After maceration, in the ordinary dried state, bones are opaque, dull yellowish white; exposure to light renders them more or less chalky white; and prolonged absence of light causes them gradually to become dull yellow to brownish.

Except the teeth, bones are the hardest parts of vertebrate animals, and they possess considerable tenacity and elasticity. These qualities in some degree vary with age, younger bones being more tough and elastic, while older ones are harder and more brittle. Fresh bones, together with their softer constituents, are solid, and have nearly twice the specific gravity of water. Ordinary dry bones are not only much



lighter, but vary in this respect in proportion to their spongy character and the air they contain. Some are so light as to float on water, while others quickly sink. The substance of bones is **bone** or **osseous tissue**,<sup>1</sup> and compact portions have a specific gravity of about 1·9.

Bones deprived of their soft matters in common are composed of about one-third by weight of a peculiar tough animal substance, the **bone-cartilage**<sup>2</sup> or **ossein**,<sup>3</sup> and two-thirds of a chalk-like substance, the **bone-earth** or **ossiterra**. According to Berzelius, the composition of adult bone is as follows:

Bone-cartilage . . . . .	33·30
Calcium phosphate . . . . .	51·04
Calcium carbonate . . . . .	11·30
Calcium fluoride . . . . .	2·00
Magnesium phosphate . . . . .	1·16
Sodium chloride and soda . . . . .	1·20
	<hr/> 100·00

The exact proportions of the ossiterra and ossein vary under different circumstances, as those of age, sex, and condition of vigor and health; they also vary in different bones of the same individual, and even in the compact and spongy substance of the same bone. It has been generally stated that with age the proportion of bone-earth increases, while the bone-cartilage diminishes; but it would appear from the recent researches of Sappey and Nélaton that the change is not very great; the increase of the former from childhood to adult age scarcely amounting to three per centum, while there is nearly the same amount of decrease in old age. The difference in the proportions of the two substances is very much greater in different bones of the same individual, amounting nearly to eighteen per centum. Thus, according to a table of analyses given by the authorities just named, the following differences were observed:

	Bone-earth.	Bone-cartilage.
Humerus . . . . .	69·25	30·75
Radius . . . . .	68·68	31·32
Femur . . . . .	68·61	31·36
Tibia . . . . .	68·42	31·58
Clavicle . . . . .	67·51	32·29
Scapula . . . . .	65·38	34·62
Ribs . . . . .	64·57	35·43
Hip . . . . .	59·97	40·03
Vertebrae . . . . .	54·25	45·75
Sternum . . . . .	51·43	48·57

<sup>1</sup> Tela ossea.

<sup>2</sup> Cartilage of bone; organic or animal matter, substance, or part of bone.

<sup>3</sup> Osseine; osteine.



From this table it will be seen that the long bones of the limbs contain the largest quantity of bone-earth, and the vertebræ and sternum the least. The bones of the shoulder most nearly correspond in composition with the analysis of bone given by Berzelius; the proportions of the bone-cartilage and bone-earth being about one-third of the former and two-thirds of the latter, while in the sternum the proportions of the two substances are nearly half and half.

To the bone-cartilage bones mainly owe their tenacity and elasticity; to the bone-earth they owe their hardness, rigidity, and stability.

When bones are burned without free access of air the bone-cartilage is charred, and they become black and brittle, and in this condition form bone-black, or animal charcoal, as employed in the arts. When burned with free access of air, the bone-cartilage is consumed, while the bone-earth remains chalk-white and exceedingly friable, but still retains the original shape and size of the bones. Bone-earth is employed in the arts, and it is the chief source of phosphorus.

When bones are subjected to the action of diluted muriatic acid the bone-earth is dissolved, while the bone-cartilage remains intact, tough, and flexible, and still retains the original shape and size of the bones. The bone-cartilage when torn exhibits a laminated and fibrous structure. Though insoluble in water at ordinary temperatures, by boiling it is resolved into gelatin, and hence bones are one of the sources of glue. Bones used as food by carnivorous animals in like manner have the bone-cartilage dissolved by the gastric juice, while the bone-earth, for the most part, reduced to powder, is voided with the excrement.

The bones are constructed of an exterior layer of more **compact substance** of variable thickness, with an interior looser structure of the same material, named the **spongy** or **cancellated substance**. (Figs. 2, 3, 4.) The compact substance is in greater proportion where most strength and protection are required, as in the shaft of long bones, in those of the skull, and in the processes and arches of the vertebræ; while the spongy substance predominates where extent of surface is important for articulation and support, as in the extremities of long bones and the bodies or centra of the vertebræ.

The short bones are composed of a mass of spongy substance, with a thin and mostly uniform exterior layer of compact substance. The broad bones consist of two chief layers of compact substance, with an intervening layer of spongy substance. In those of the cranial vault the latter is stronger than elsewhere, and is named the **diploe**. In thin bones, and in parts of others in the like condition, it is absent, in which cases the distinction of two layers of compact substance does not exist. In the vertebræ the more massive centrum or body is constructed like the short bones, while the arches and processes are mainly composed of the compact substance. In the long bones of the limbs the shaft encloses a large central cavity, which is occupied by a soft marrow and is thence called the **medullary cavity**. At the middle of the



shaft the wall of the cavity is composed of compact substance, and is very thick, but gradually thins away towards the extremities and is in great measure replaced by spongy substance. The extremities of these bones are almost wholly composed of the latter, defined by a thin layer of compact substance. Approaching the central medullary cavity, the spongy substance becomes more cavernous and finely reticular, and in this condition forms a delicate trellis for the support of the marrow and its vessels.

The presence of the spongy substance in the construction of the bones is accompanied by a proportionate increase in bulk, without corresponding augmentation of weight or reduction of strength. The extension of surface is adapted to the requirements of attachment for the soft parts and to the articulations, in which the bones in their expanded condition are least liable to displacement or dislocation. An incidental advantage of the presence of the spongy substance in the extremities of the long bones of the limbs and in the vertebral centra lies in its quality to reduce the force of shocks. With the addition of elastic plates of cartilage in the articulations, the skeleton in its construction exhibits an admirable provision to neutralize or greatly weaken concussions from blows or falls, which otherwise might prove to be more or less injurious to the nerve-centres and other delicate organs it encloses.

The exterior surface of bones, besides exhibiting variable marks of the attachment and impression of the contiguous soft parts, in general presents a more or less smooth or a finely-striated and porous aspect. The articular surfaces are most uniformly smooth and devoid of visible porosity. The numerous foramina of the surface are continuous with vascular canals which pervade the osseous structure, and are in general distinguishable as of three kinds,—1, those which are minute, or scarcely visible without magnifying, and give to the bones, when not thoroughly clean, a finely-punctate appearance, for the transmission of minute blood-vessels; 2, larger and more conspicuous foramina, especially numerous at the ends of the long bones of the limbs, and on the more massive portions of others, for the passage of larger vessels; and, 3, usually a single well-marked foramen near the middle of the shaft of the long bones, and one or several near the centre of the broad ones, for the principal medullary blood-vessels.

The compact substance of bones is laminar and fibrous. When bones are exposed to the weather, the compact substance not unfrequently exhibits a disposition to break up into its constituent laminae and fibres; in the shaft of long bones separating concentrically, and in the broad bones from the more extended surfaces. On the interior of the bones the compact substance resolves itself into the condition of the spongy substance by the apparent separation of the constituent laminae and fibres. Thus, in a long bone, as the compact substance of the shaft thins away towards the extremities it appears to do so by



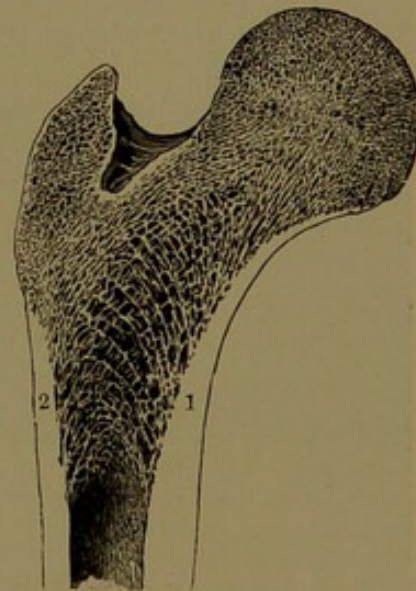
successively giving off thin plates and fibres, which contribute to form the spongy substance.

The spongy substance of bones is composed of thin plates and bars or fibres, intersecting one another, and including intervals, which are occupied with marrow. In certain positions it is traversed by narrow, irregular channels, which are occupied by vessels, mostly veins, communicating with the exterior by some of the more conspicuous foramina of the surface. In the broad bones of the cranial vault these channels are usually well marked, and are called the **diploic sinuses**. In the vertebral centra similar channels diverge from foramina communicating between the vertebral canal and the sides of the bones.

The spongy substance is arranged on a more or less definite plan, which, though varying in different bones, is always alike in the same bone. The general arrangement is such as to contribute to the strength of the bones in the direction they habitually require to resist the greatest pressure. Thus, in a longitudinal section of the proximal extremity of the femur, as in Fig. 2, it may be observed that as the thick, compact substance of the shaft thins away it appears to do so by successively giving off thin, arching plates and fibres, which intersect one another. Those from the inner side of the shaft ascend to the great trochanter and the upper part of the neck and head of the bone, while the opposite ones, springing from the outer side of the shaft, ascend to the inner part of the neck and head. The arrangement strengthens and sustains the head and neck of the bone in their connection with the shaft, and enables them better to bear the weight of the upper part of the body. Similar arrangements contributing to the strength of the bones and rendering them able to resist pressure are seen in a transverse section of the condyles of the femur, as represented in Fig. 3, and in a vertical section of the calcaneum, as in Fig. 4. A section across one of the tabular bones of the cranial vault resembles in construction the extended arches which support the roof of a railway-station. The short intervening columns of the spongy substance between the compact layers are further sustained by short transverse bars. Everywhere, indeed, in the construction of the bones we find an arrangement of the spongy substance favorable to the greatest degree of resistance.

The hollow columnar condition of the long bones of the limbs,

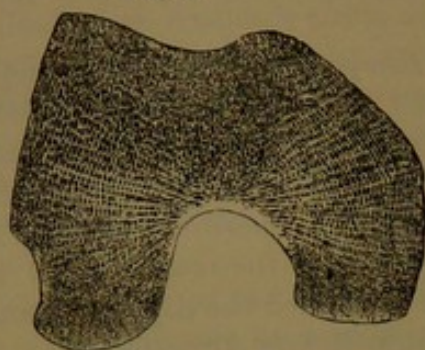
FIG. 2.



LONGITUDINAL SECTION OF THE PROXIMAL EXTREMITY OF THE FEMUR, exhibiting the arrangement of the spongy substance. 1, 2, positions in which the compact substance appears to resolve itself into a series of arching fibres.

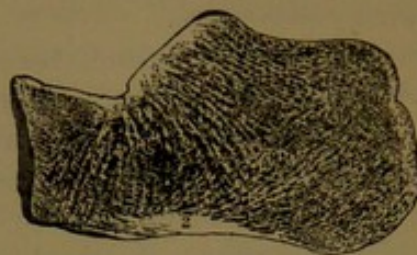


FIG. 3.



HORIZONTAL SECTION OF THE CONDYLES OF THE FEMUR, exhibiting the arrangement of the spongy substance.

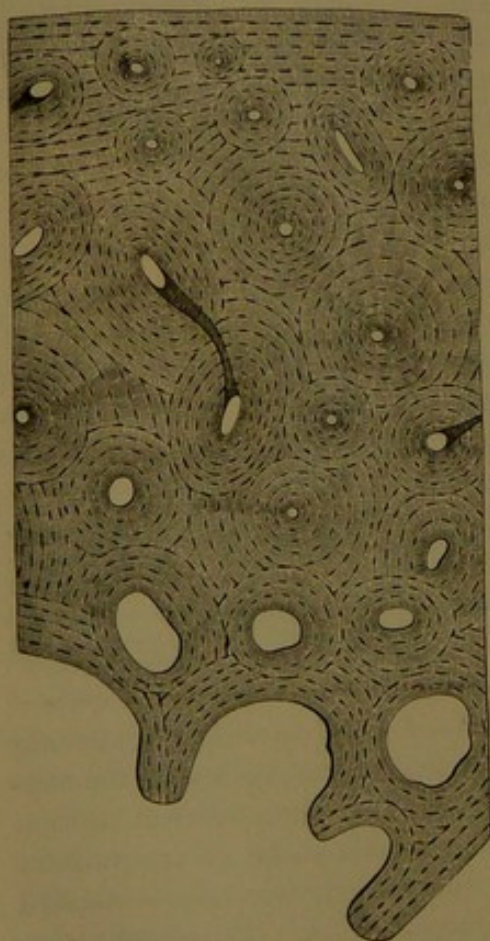
FIG. 4.



VERTICAL SECTION, ANTERO-POSTERIORLY, OF THE CALCANEUM, exhibiting the arrangement of the spongy substance. 1, accumulation of compact substance below the articulation of the astragalus, from which start off numerous radiating fibres; 2, nucleus of compact substance, sending off numerous arching fibres.

while it proportionately increases their bulk to an extent which is most favorable for support and the attachment of the soft parts, at the same

FIG. 5.



TRANSVERSE SECTION OF THE SHAFT OF A PHALANX, moderately magnified. The upper part of the figure corresponds with the exterior surface of the bone; the lower part, with the interior spongy substance.

time renders them lighter and very much stronger, for it is abundantly proved that a hollow column is capable of sustaining a far greater weight than a solid rod of the same amount of material. Advantage is taken of the principle in the same manner in grasses, in which we observe the slender hollow stems supporting heavy heads of grain. In birds the bones are proportionately more hollow than in the other classes of vertebrates, and in them the spaces are occupied by air, which renders the skeleton specifically lighter, and, therefore, more readily sustained in flight.


The structure of bone or osseous tissue may be studied by making thin sections prepared for the microscope. The appearance of a transverse section from the compact substance of the shaft of a long bone is represented in Fig. 5.

The compact substance is traversed by fine tubes, which are named from their chief function the **vascular canals** (*Haversian canals*)<sup>1</sup>. These

<sup>1</sup> Canaliculi vasculares; medullary canals.



mostly pursue a longitudinal course in the long bones, but are joined by many shorter transverse or more or less oblique canals, altogether forming a plexus. The osseous tissue for the most part appears in concentric laminae<sup>1</sup> surrounding the vascular canals, each of which, together with its series of enveloping laminae, forms a cylindrical rod.<sup>2</sup> The rods are collected in a close bundle, with the intervals occupied by interrupted laminae,<sup>3</sup> and the whole together are surrounded by osseous laminae,<sup>4</sup> which are arranged conformably to the surface of the bone. The superficial or subperiosteal laminae are traversed directly by many vascular canals,<sup>5</sup> which are not separately surrounded by concentric laminae like those more deeply situated. The vascular canals, as observed in the transverse section of the bone, commonly appear as circular or oval apertures of variable size. Those towards the exterior are



TRANSVERSE SECTION OF BONE FROM THE SHAFT OF THE FEMUR, highly magnified. The large circular orifices are transverse sections of the vascular canals, surrounded by concentric layers of osseous substance. Between the latter are seen the lenticular excavations or lacunae intercommunicating by means of canaliculi.

the smaller, and commonly range from one two-hundredth of an inch to about one-fifth that diameter, while those towards the interior become larger, and irregularly merge into the more conspicuous medullary spaces<sup>6</sup> contiguous to the main medullary cavity. On the exterior surface of the bones the vascular canals open by funnel-like apertures, and in like manner communicate with the marrow-spaces within. The canals are occupied by blood-vessels, invested with delicate connective tissue, continuous with those of the periosteum externally and of the marrow internally. The canals, except the larger ones, have generally been regarded as transmitting single vessels, which together form the capillary plexus of the osseous tissue; but

<sup>1</sup> L. ossium; Haversian lamellae; secondary or special lamellae. <sup>2</sup> Haversian system.

<sup>3</sup> Primary, fundamental, interstitial, interlamellar, ground, or intermediate lamellae. <sup>4</sup> Peripheric lamellae. <sup>5</sup> Canals of Volkmann. <sup>6</sup> Haversian spaces.



some of the later observers describe them as each containing an artery, a vein, lymphatics, and nerves, together invested with connective tissue.<sup>1</sup>

Thin bones like the lachrymal, and the equally thin parts of others, as in the ethmoid, contain few or no vascular canals, and are composed of laminae of osseous tissue arranged conformably to the investing periosteum.\* The plates and fibres also, which enter into the construction of the spongy substance, are for the

FIG 7.



THIN PLATE FROM THE ETHMOID BONE, without preparation; highly magnified. Two planes of lacunae visible, but one only in focus.

most part devoid of vascular canals, and consist of laminae and fibres of osseous tissue, arranged conformably to the medullary spaces they enclose.

Situated in the laminae of osseous tissue, and less frequently between them, there are numerous little cavities or **lacunae**,<sup>2</sup> from which radiate a multitude of minute tubes or **canaliculi**. In the transverse section of the compact substance of a long bone they appear arranged in circular rows concentric with the vascular canals, and conformably with the laminae of osseous tissue. In the longitudinal section they are arranged in a corresponding manner. The lacunae are generally

of uniform size, and are oval, lenticular in shape, several times longer than wide, and of least thickness. They range from 0.018 to 0.05 mm. in length, 0.006 to 0.0135 mm. in width, and 0.0045 to 0.009 mm. in thickness. The canaliculi proceeding from the lacunae in all directions perforate the osseous tissue, branch in their course, and freely communicate with one another, and with the contiguous vascular canals, the medullary spaces, and the free surfaces of the bones.

In thin sections of bone viewed beneath the microscope by transmitted light, the lacunae and their canaliculi appear as black spots with black radiating lines on a translucent ground, while by reflected light they appear chalk-white on a less white ground. In fresh bones the lacunae are each occupied by a soft, nucleated mass of protoplasm or cell, the **bone-corpuscle** or **osteoblast**,<sup>3</sup> from which delicate processes extend into the canaliculi.

The laminae of osseous tissue, after the solution of the bone-earth, viewed with the microscope, exhibit a reticular structure, due to interlacing fibres of generally uniform size. The fibres consist of bundles

<sup>1</sup> Kölliker describes the vessels as forming a net-work of wide canals. Sappey says each vascular canal encloses a capillary. Klein observes that each Haversian canal contains a blood-vessel, one or two lymphatics, and, according to its size, a greater or lesser amount of connective tissue. Schäfer (Quain's "Anatomy," 9th ed.) figures as the contents of a Haversian canal an artery, a vein, lymphatics, and nerves enveloped in connective tissue.

<sup>2</sup> L. ossium; bone-corpuscles; corpuscula ossea, radiata, or chalicophora; corpuscles of Purkinje; osteoplasts.

<sup>3</sup> Bone-cell.



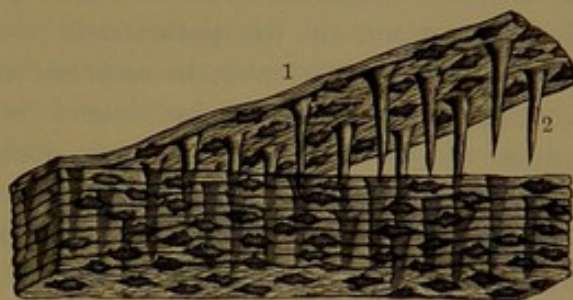
of fibrillæ, which resemble those of fibro-connective tissue. The intervals of the fibres are occupied by a homogeneous or indistinctly granular matrix. Associated with the osseous structure there is also more or less elastic tissue mingled with fibro-connective tissue.

The bone-earth consists of exceedingly minute granules, which are deposited in the fibrous matrix of the osseous lamellæ, and also in or among the constituent fibrillæ of the fibres.

In the compact substance of the bones, especially in the long bones of the limbs and in the broad ones of the cranium, the osseous laminae give off at right angles numerous tapering, **perforating fibres**,<sup>1</sup> which penetrate the subjacent laminae, nailing them together.

From the free communication of the vascular canals of the osseous substance with one another and with the lacunæ through their canaliculi, nutritive matter is readily conveyed throughout every part of the most compact structure of the bones.

FIG. 8.



PORTION OF THE COMPACT SUBSTANCE OF THE PARIETAL BONE, softened in acid, and with one of the laminae, 1, lifted to exhibit the perforating fibres, 2; magnified.

#### PERIOSTEUM.

The **periosteum** is a fibrous membrane which invests the free surfaces of the bones except at the point of tendinous and ligamentous attachment, and on the articular surfaces where cartilage is substituted. It is in general thicker on the larger bones, especially those of the limbs, and is thickest approaching the extremities of these. It is thinner on the surface of the cranial vault than at the base of the skull, and is thinnest in the various sinuses of the same. It adheres most tightly to uneven and the more porous surfaces, and is most readily detached from compact even surfaces. In the removal of the cranial vault in post-mortem examinations of the brain, the vault is torn from its lining periosteum, which remains as an integral part of the dura. At the base of the cranial cavity it for the most part adheres more closely to the bones, especially along the lines of the sutures and at the outlets of the foramina. It appears as a more distinct, dense, tough membrane in young growing bones, and is then readily detached as such; but after maturity it becomes more intimately associated with the osseous structure, is more attenuated, and cannot be easily separated from the bones without laceration or the destruction of its integrity. It is pearly or bluish white, and when thick is more or less tendinous and

<sup>1</sup> Fibres of Sharpey.



glistening in appearance. When thin it is translucent, and permits the color of the bone to be seen through it.

The periosteum is composed of an intertexture of fibro-connective tissue bundles, which on the long bones in general pursue a longitudinal direction, especially where it is thickest, and in other bones also extend in one direction more than another. Where tendons and ligaments are attached to the bones there is an interchange of bundles with the periosteum, and thus the structures appear more or less blended. The deeper portion of the periosteum mainly consists of denser fibrous bundles, which resemble in appearance the fibres of elastic tissue. In young, growing bones the deeper layer of the periosteum contains numerous nucleated cells, which occupy the intervals of the fibrous bundles. This is the bone-producing or **osteogenic layer** of the periosteum, the cells of which are the **osteoplasts**. By its continued production and conversion into bone the bones grow in thickness. Mingled with the predominant fibrous element of structure of the periosteum there is a considerable amount of elastic tissue.

Numerous blood-vessels from the neighboring trunks, arteries with their accompanying veins, are distributed in the periosteum, forming together a copious plexus investing the bones. From the plexus the smallest branches everywhere enter the orifices of the vascular canals of the surface of the bones. Lymphatics form numerous cleft-like spaces among the fibrous elements of structure of the periosteum, communicating with those of the vascular canals of the bones, and joining trunks, which pursue the course of the larger blood-vessels. Fine nerves also are distributed through the periosteum, mainly following the arteries into the bones.

The periosteum, besides forming a nidus of growth for the bones and a support to their nutritive vessels, serves as an intermediate attachment of the softer organs, as the ligaments, tendons, muscles, vessels, nerves, membranes, etc. Removal of the periosteum results in necrosis or death of the subjacent bone, apparently by cutting off the supply of blood through the destruction of the vessels. The membrane is said to possess the quality of producing osseous tissue, so that if it be not destroyed the surface of bone may be regenerated.

#### THE MARROW.

The hollow shaft of the long bones of the limbs and the interstices of the spongy substance of bones generally are filled with a soft material, the **marrow** or **medulla**, which also extends into the larger vascular canals of the compact substance. The marrow, as commonly observed, appears of two kinds,—that occupying the medullary cavity of the limb bones and extending into the spongy substance of the extremities, which is a soft, yellow fat; and that occupying the spongy substance of the vertebræ, ribs, sternum, and the bones of the skull,



which is a soft, red pulp. At birth the bones contain only red marrow, but in approaching maturity that of the shaft of the long bones of the limbs becomes the yellow fat, which also extends into the spongy substance of the extremities. In the advance of age the yellow, fat marrow more or less invades all the bones.

The **yellow marrow** is a delicate fat or adipose tissue, essentially the same as that elsewhere in the body, but differing in the small proportion of connective tissue associated with it, and consequently in its more homogeneous appearance and less consistent character. It consists of groups of fat-cells included in the meshes of a delicate, connective-tissue membrane, associated with an abundant plexus of capillary blood-vessels. The investing membrane of the mass of marrow in the medullary cavity has been viewed as a lining to the latter under the name of the **endosteum**.

The **red marrow** owes its distinctive color mainly to its nutritive blood-vessels, independently of which it consists of a soft, cellular protoplasm. This is for the most part composed of rounded **marrow-cells**, which resemble the colorless blood-corpuscles, but are generally larger, more translucent, and have a larger nucleus. Mingled with them are smaller nucleated cells of a reddish hue, which are regarded as in a transition stage from the former to the condition of red blood-corpuscles, of which the red marrow is supposed to be one of the sources. There also occur in the red marrow a third kind of cells, remarkable for their comparatively large size and many nuclei. They are irregular, flattened spheroidal masses of protoplasm of very variable size, and contain from several to several dozen nuclei. They usually lie directly in contact with the osseous tissue, of which they are supposed to be active absorbents, whence they have been named **osteoclasts**.<sup>1</sup>

#### VESSELS AND NERVES OF THE BONES.

The bones are abundantly supplied with blood-vessels, which are generally small branches derived from the neighboring larger ones. The arteries, with their companion veins, single or in pairs, for the most part ramify in the periosteum, and in this membrane together form a fine net-work or plexus over the surface of the bone. From the plexus the smallest arteries and veins penetrate and traverse the vascular channels of the osseous structure, and in the interior freely communicate with the vessels of the marrow. Larger arteries, together with their companion veins, more directly enter the spongy portions of the bones, and are especially distributed to the marrow. The vessels which extend to the articulating surfaces do not penetrate the investing cartilages. The long bones of the limbs have commonly a single principal medullary artery, which with a companion vein traverses the walls of the medullary cavity of the shaft near its middle through a

---

<sup>1</sup> Myeloplaxes ; giant-cells.



long oblique canal. Entering the medullary cavity, the artery divides into an ascending and a descending branch, and these with the accompanying veins are distributed on and within the marrow. The vessels freely anastomose with those of the vascular canals of the compact wall of the medullary cavity and with those of the spongy substance. In the broad bones of the cranium the chief vessels are the meningeal arteries and accompanying veins in pairs, which traverse channels on the inner surface of the bones next the periosteal layer of the dura. In the broad bones, as the scapula and the hip-bone, one or two principal medullary arteries with accompanying veins enter corresponding foramina on the broad surfaces, nearly centrally, and are especially destined to the spongy substance within. In the spongy substance of the bones many of the veins unite in trunks, which are conspicuous for their size, and they pursue an independent course in corresponding channels of the spongy substance, and emerge from the larger foramina of the surface of the bones. In the bones of the cranium these veins are especially conspicuous and tortuous, and are named the **diploic sinuses**. They emerge from some of the larger foramina of the surface, and communicate with the veins of the scalp and with the sinuses and veins of the dura. In the vertebral centra similar veins pursue a course fore and aft, and communicate with the exterior by one or more of the larger foramina at the sides, and by a central pair behind, with the superficial veins.

Lymphatics traverse the vascular canals of bones in company with the blood-vessels, and are continuous with those of the periosteum and with those of the marrow.

Fine nerves accompany the blood-vessels of the bones, extending into the marrow, but they have not been detected terminating in the osseous tissue.

In the ordinary healthy condition the bones, including their periosteum and articular cartilages and the marrow, are insensible to impressions of pain, but become more or less sensitive in pathological conditions.

#### DEVELOPMENT AND GROWTH OF THE BONES.

The development or production of the completely formed bones and their growth proceed together. Most of the bones originate in a matrix of cartilage, but the frontal and parietal bones, the squamosa of the temporals, and the upper division of the supra-occipital, together with the bones of the face, except the turbinal bones, proceed from fibro-connective tissue. Both the latter and the cartilage are derived from the soft cellular structure of the middle layer<sup>1</sup> of the germinal membrane<sup>2</sup> of the egg. The transformation of the matrix

<sup>1</sup> Mesoderm.


<sup>2</sup> Blastoderm.



into bone or osseous tissue is termed **ossification**, and the point at which this commences is named the **centre of ossification**.<sup>1</sup> The centres vary in number from a single one in bones of the simplest form to two, three, or more in those of complex form. Thus, as examples, the patella and parietal bones have a single centre, the frontal bone and the phalanges have two centres, the vertebræ generally seven centres, the sphenoid bone fourteen centres, and the sacrum thirty-eight centres. Ossification begins in the skeleton in the sixth week of foetal life, and subsequently it occurs in the different bones, both before and after birth, at different times, to nearly adult age. The centres which first appear in the principal part or parts of a bone are distinguished as **primary**, and those which follow in accessory parts of many bones are termed **secondary**. In the long bones the principal part or shaft which grows from the primary centre is named the **diaphysis**, and the accessory parts of different bones which grow from secondary centres are named **epiphyses**. The latter are connected with the diaphysis, or principal parts of a bone, by cartilage, and each grows separately until it has reached its full size before it co-ossifies or ankyloses with the rest. For example, in the development and growth of the femur, or thigh-bone, the shaft or diaphysis grows from the primary centre of ossification, which makes its first appearance in the foetus in the sixth week. A secondary centre appears in the epiphysis of the lower extremity at birth; another for the head of the bone during the first year; then one for the great trochanter in the third year; and finally one for the small trochanter about the ninth year or later. Each part grows from its own centre until it reaches mature size, after which it coalesces with the contiguous part; and it is not until about the twenty-fifth year that all are completed and thoroughly united in one bone.

After the primary centres of ossification appear, the process of ossification advances with rapidity, so that at birth the principal parts of most bones are well produced, at which time the skeleton exhibits about two hundred and seventy-eight pieces, as follows:

FIG. 9.



FEMUR, from an individual about sixteen years of age, exhibiting the diaphysis (1) distinct from the epiphyses (2, 3, 4, 5).

<sup>1</sup> Punctum ossificationis.



For the skull, including 8 ear ossicles and the hyoid bone . . . . .	45
For the vertebral column, ribs, and sternum . . . . .	125
For the upper limbs . . . . .	48
For the lower limbs . . . . .	60

The diaphyses of the long bones, and the half arches of the vertebræ, produced in solid moulds of cartilage, ossify throughout at an early period,—between the third and fourth months of fœtal life. They continue to grow in length at the ends by the incessant production of cartilage, which ossifies as fast as it is produced. At the same time they grow in thickness, but this increase is due to the production of successive layers of osseous tissue from the periosteum. In the mean while the cartilages of the epiphyses grow in all directions, but their centres of ossification do not appear until birth, and subsequently to the ninth year or later. Once started, the centres grow in all directions, but more quickly towards the diaphysis or principal part of the bone, so that they soon come to be separated only by a thin layer of cartilage, from which both diaphysis and epiphyses continue to grow until they have attained their full size, when they become ankylosed by the ossification of the intervening plate. The time of ankylosis differs not only in different bones but in different parts of the same bone, nor does it accord with the order of appearance of the ossific centres in the epiphyses. On the contrary, the order of ankylosis is often reversed, as in the case of most of the larger long bones of the limbs. It would appear in these that the union in order of time is related to the direction in which the medullary nutritious arteries enter the bones. After ankylosis of the epiphyses, the long bones cease to grow in length. The skeleton is completed by the ankylosis of all parts of its respective bones about the twenty-fifth year, at which time it commonly consists of two hundred and twenty-four distinct pieces or bones.<sup>1</sup> Subsequently the bones continue slightly to increase in thickness or bulk to thirty or forty years. In extreme old age, especially through ankylosis of the bones of the skull, the number of distinct pieces of the skeleton is reduced to one hundred and ninety-four.<sup>2</sup>

During the time the diaphysis of a bone grows in thickness from the periosteum the original cartilage bone undergoes partial absorption and is converted into spongy substance, and this then disappears in the production of the medullary cavity. Step by step, as the shaft of the bone grows, its interior is resolved into spongy substance, and this disappears in degree proportioned to the enlargement of the medullary cavity. The spongy substance of epiphyses and of the broad and other bones is produced in the same manner as in the

<sup>1</sup> In this enumeration the sphenoid and occipital are regarded as one, the ear ossicles as six, the styloids as two, the hyoid as five, and the sternum as three pieces.

<sup>2</sup> The skull and styloids together as one; mandible, hyoid, sternum, and coccyx each as one.



diaphysis of a long bone. In the production of the spongy substance by the removal of osseous tissue, the remaining osteoplasts of the latter are probably the source of the marrow-cells of the red marrow, and these by transformation may become the adipose cells of the yellow marrow. With the advance of age the medullary cavity of the limb bones enlarges with the proportionate reduction of its walls at the expense of both the spongy and the compact substance.

The broad bones, whether produced in membrane, as those of the cranial vault, or in cartilage, as the scapula and the ilium, grow in breadth by the continuous production and ossification of their respective matrices at the borders, and all grow in thickness, as in the diaphyses of long bones, by the production of successive layers of osseous tissue from the periosteum. The centres of ossification of the bones of the cranial vault make their appearance during the third month of fetal life. They commence as an osseous net, from which rays extend in all directions towards the border of the bone; additional intervening rays being produced as the former grow and diverge. At birth the bones appear as thin osseous plates, with a prominent centre, from which rays extend to the border, where they project in points. The prominent centre accords with that of ossification, and the rays indicate the direction in which the ossification proceeds. As the bones continue to grow in breadth by addition at the borders, they grow in thickness from the periosteum. As they increase in thickness the original osseous plate is converted into spongy substance, and thus the bones come to be composed of the exterior compact layers with the intervening diploe. The continued growth of the bones and the proportionate production of spongy substance and compact layers proceed in the same manner as in the growth of the shaft of a long bone. The short bones, like those of the carpus and tarsus and the patella and the bodies of the vertebræ, grow essentially in the same manner as the epiphyses of long bones.

That the chief bones of the limbs grow in the manner indicated was long ago proved by the famous experiments of Hale, Duhamel, and Hunter. In these experiments holes were bored at a certain distance apart in the shaft of a long bone of a young animal, and metallic shot were introduced into the holes. Subsequently, after the animal had grown and was killed, it was found that although the bone had increased in length the shot remained the original distance apart. In another case, in which shot were introduced near the end of a shaft and in the contiguous epiphysis, these were afterwards found to be removed a greater distance from each other. Further, in an experiment in which a fine wire was made to encircle the shaft of a growing bone, it was subsequently found within the medullary cavity.



## DEVELOPMENT AND GROWTH OF BONE OR OSSEOUS TISSUE.

The bones, except most of those of the skull, originate in form as corresponding cartilages, which are derived from the common cellular structure of the mesoblast of the egg. At first the cartilages are soft, but gradually acquire the consistence as well as the structure of ordinary cartilage. They are invested with a vascular, incipient connective-tissue membrane, the **perichondrium**, which, after the production of a subjacent lamina of bone or osseous tissue, assumes the name of the **periosteum**.

**Ossification**, or the production of bone or osseous tissue, is a complicated process. As exemplified in the long bones of the limbs, it commences at the middle of the shaft or diaphysis and proceeds towards the extremities, which, with few exceptions, remain cartilaginous until birth, when the centres of ossification of the epiphyses begin to make their appearance. In the first stage of ossification, at the centre of the diaphysis, the cartilage-cells become enlarged and separated to a greater extent than elsewhere by an increase of the intervening matrix. Molecules of bone-earth, consisting of calcareous salts, are deposited in the matrix, rendering it harder, granular, and more opaque; this action being distinguished as **calcification**. At the same time the neighboring cartilage-cells become enlarged, flattened, and arranged in longitudinal rows or columns, which generally radiate from the centre of ossification towards the ends of the diaphysis. Calcification extends into the matrix between the cell columns, which thus become enclosed in spaces, termed the **primary areolæ**. Simultaneously a lamina of bone is produced from the vascular perichondrium, which chiefly consists of incipient connective tissue and protoplasmic cells, named **osteoblasts**. These, in the subsequent production of the osseous laminae, become enclosed by them, and thus form the **bone-corpuscles** contained in **lacunæ**. From the function of the deeper portion of the perichondrium, or periosteum, in producing osseous tissue, it is distinguished as the **osteogenic layer or tissue**.<sup>1</sup>

In the next stage of ossification, through absorption of the osseous lamina at one or more points, the vascular osteogenic tissue is extended by development to the centre of the calcified cartilage. With this extension the matrix of the latter is partially absorbed, and the primary areolæ break up, two or more together, into the larger **medullary spaces**,<sup>2</sup> which are filled with embryonic marrow, consisting of branching connective-tissue cells and osteoblasts, and penetrated axially by a capillary vessel, which is blind or looped at the extremity.

Calcification advances in the matrix of the cartilage towards the ends of the diaphysis, and the cell columns continue to be enclosed in primary areolæ, while the osteogenic tissue incessantly follows, and

<sup>1</sup> Osteoblastic layer or tissue.

<sup>2</sup> Secondary areolæ.



the latter are resolved into medullary spaces. As ossification proceeds, the medullary spaces first formed still enlarge by absorption; but finally their walls, remaining from the original calcified cartilage matrix, begin to thicken by the production of osseous laminæ from the marrow. As successive laminæ are formed, the medullary spaces are contracted into a central vascular canal,<sup>1</sup> with its contained vessels and a little incipient connective tissue, with a few osteoblasts. Between the concentric laminæ many of the latter are included as bone-corpuscles contained in lacunæ.

The **osteogenic layer** of the perichondrium and periosteum, concerned in the production of successive laminæ of osseous tissue at the periphery of the diaphysis of the long bones, is composed of narrow connective-tissue bundles, named **osteogenic fibres**, and nucleated, granular, protoplasmic cells, the **osteoblasts**, together embedded in a homogeneous ground substance and pervaded with blood-vessels. Ossification occurs in the osteogenic layer by the production of a net-work of osseous tissue, in which molecules of bone-earth are deposited in and between the osteogenic fibres, and enclose the osteoblasts as bone-corpuscles. In the advancement of ossification the meshes of the net-work, forming medullary spaces, become contracted into vascular canals, in the same manner as above described in the production of bone in cartilage.

The early-formed osseous tissue differs from that of maturity in its more reticular and less regularly laminated character, and for a long time even the shafts of the long bones are rather spongy than compact in their texture. They acquire a more obvious laminar condition during the year after birth, when a series of concentric laminæ are produced from the periosteum. The vessels from the latter penetrating the laminæ are at first not enclosed by series of concentric laminæ, but these are subsequently produced as in the medullary spaces.

The bones of the skull, excluding the occipital, except the upper division of its supraoccipital division, the petrosal division of the temporals, the sphenoid, the ethmoid, and the turbinated bones, originate in fibro-connective tissue, and grow from the osteogenic layer of the periosteum in the same manner as the principal parts of other bones of the skeleton.

In the ossification of epiphyses, vessels are previously developed in the cartilage extending from those of the ossified principal part of the bones. The vessels are associated with osteoblasts, which together occupy canals of the cartilage produced by absorption. The subsequent steps of ossification are the same as in the production of osseous tissue in the cartilaginous diaphysis of a long bone.

In the absorption of bone, occurring at every step in the development and growth of the bones, in the production of the spongy sub-

---

<sup>1</sup> Haversian canal.



stance and the medullary cavity, and the continued increase of these through life, an important agent appears to be large multinucleated cells, which from their function have been named **osteoclasts**.<sup>1</sup> They are commonly observed occupying shallow recesses of the medullary cavity and spaces, directly in contact with the osseous tissue. They differ greatly in size, and are usually irregularly spheroidal and flattened, though often variable in outline. They consist of granular protoplasm, and contain from several to a dozen or more nuclei. They frequently present a thickened border next the surface of contact with the osseous tissue, and this border is represented as being striated like that of the free extremity of the intestinal epithelial cells. The osteoclasts are probably derived from osteoblasts, with which they are associated, and they probably, after fulfilling their function, revert to the same.

#### ARTICULATIONS OR JOINTS OF THE SKELETON.

The **articulations** or **joints**<sup>2</sup> of the skeleton exhibit a gradation of union from those which are immovable to such as possess motion in all directions.

The most **immovable articulations**<sup>3</sup> are those which exist between the bones of the skull, constituting what are called the **sutures**.<sup>4</sup> Many of the sutures are formed through indentations of the contiguous margins of the bones, which are mutually adapted to one another, often in a somewhat dovetailed manner. From their toothed appearance they are called **dentated** or **serrated sutures**.<sup>5</sup> Examples of them are seen in the union of the frontal, parietal, and occipital bones. In other sutures the contiguous borders of bones are bevelled off and mutually coadapted, as observed in the union of the sphenoid and temporal bones with the parietal. Such, from their scale-like arrangement, are called **squamous sutures**.<sup>6</sup> In some sutures,<sup>7</sup> plane borders of contiguous bones, slightly roughened, are coadapted, as in the union of the maxillary bones. Occasionally the border of one bone is grooved to receive the sharpened edge of another,<sup>8</sup> as in the articulation of the vomer with the sphenoid bone.

The next form of articulation possesses more or less flexibility without allowing other motion. Such a joint is called a **symphysis**,<sup>9</sup> and is formed by the union of broad surfaces of contiguous bones through means of an intervening plate of fibro-cartilage. Examples of this mode of junction are presented in the union of the bones of the pelvis, the centra of the vertebræ, and the pieces of the sternum.

<sup>1</sup> Myeloplaxes; giant-cells.

<sup>3</sup> Synarthroses.

<sup>5</sup> S. dentatæ; s. serratæ.

<sup>7</sup> Harmonia; harmony; false suture.

<sup>9</sup> Amphiarthrosis.

<sup>2</sup> Arthroses.

<sup>4</sup> Suture.

<sup>6</sup> S. squamosæ.

<sup>8</sup> Schindylesis.



In the **movable articulations**<sup>1</sup> the bones have their opposed surfaces invested with cartilage, and their union is preserved by means of ligaments, which enclose the joints. Muscles or their tendons, which in many instances more or less surround these joints, very much contribute to the firmness of their union, and thus to prevent dislocation. To facilitate movement, they are lined with **synovial membrane**, which secretes a lubricating liquid, named the **synovia**.

Of the movable articulations there are several varieties, which exhibit different degrees of mobility.

In some instances the movements are exceedingly limited, amounting only to a slight degree of gliding of the opposed surfaces upon each other, as instanced in most of the joints of the carpus and tarsus, and those of the articular processes of the vertebræ.

In other cases the joints are restricted to a hinge-like motion,<sup>2</sup> as observed in the elbow- and knee-joints, and those of the fingers and toes.<sup>3</sup> The hinge-like movement, together with a motion towards either side, is observed in the wrist- and ankle-joints.

Occasionally joints admit only of a rotary motion, as in the two radio-ulnar articulations and those between the atlas and the axis.

The most movable articulations are the ball-and-socket joints,<sup>4</sup> in which the head of one bone fits into a more or less deep cup-shaped concavity of the contiguous bone. Examples of such joints are presented in the shoulder and hip. The movements of these joints are those of flexion and extension, abduction and adduction, circumduction and rotation.

Of the different movements of the articulations, **flexion** is that in which one or more bones of a joint are made to describe an angle with others, in moving either backward or forward. Thus, the bending of the bones of the forearm forward is the flexion of the forearm upon the arm; the bending of the leg backward is its flexion upon the thigh. **Extension** is the opposite movement to flexion, in which the bones are generally brought into a line with one another. Thus, the bending of the forearm backward after it has been flexed, so as to bring it on the same line with the arm, is the extension of the forearm.

**Abduction** is that movement in which a bone is directed outwardly from another, or from the body; and **adduction** is the opposite movement, in which a bone is directed inwardly. Thus, the movement by which the thumb is moved outwardly from the fingers is abduction, and that by which it is made to approach them is adduction.

**Circumduction** is the motion made by a bone when its head acts as a pivot and the distal end is made to describe a circle. This character of movement is best exemplified with the humerus and glenoid cavity

<sup>1</sup> Diarthroses; diarthrodial articulations.

<sup>3</sup> Ginglymoid joints.

<sup>2</sup> Ginglymus; ginglymoideus.

<sup>4</sup> Enarthroses.



of the scapula. **Rotation** is the motion made by a bone when it rolls on its axis, as in the movements of the radius upon the ulna.

#### OF THE RELATIVE POSITION OF THE DIFFERENT STRUCTURES ENTERING INTO THE COMPOSITION OF ARTICULATIONS.

The bones articulating by suture are continuously associated by intervening fibro-cartilage, which is apt to ossify after the bones have reached maturity. The fibrous periosteum in all cases passes over the sutures, resembling in this position the capsular ligaments of movable joints. In symphyses an intervening plate of fibro-cartilage intimately connects the surfaces of the contiguous bones; and they are surrounded with bands of fibrous tissue, corresponding with the capsular ligaments of movable articulations.

In movable joints the opposed surfaces of the bones are invested with a layer of cartilage, which from its position is called **articular cartilage**.<sup>1</sup> When the cartilage covers a depressed or concave surface, it usually becomes thicker towards the borders, so as to deepen the concavity; but if it invests a head, condyle, or other articular prominence, it becomes thinner towards the margins.

The ligaments surrounding movable joints are of two kinds,—the **capsular**<sup>2</sup> and the **band-like ligaments**.<sup>3</sup> The former are cylindrical sacs, including by their extremities the borders of the articular surfaces of bones, where they become continuous with the periosteum of the latter, and frequently with the contiguous tendons of muscles. They vary in thickness, are composed of an intertexture of bundles of fibrous tissue, and are highly flexible and slightly extensible. In many positions, broad tendons of muscles, passing over joints, assume their place, as in the case of the tendon of the quadriceps extensor muscle of the thigh and the extensor tendons on the backs of the phalangeal articulations. The band-like ligaments are accessory to the capsular ligaments, contributing to the strength of joints in particular positions. They are strong bundles of parallel bundles of fibrous tissue, quite flexible, but entirely inextensible. They constitute the numerous lateral ligaments of the joints.

The **synovial membranes** belong to the class of serous membranes. They line the interior of capsular ligaments, and in the adult are reflected upon the border of the articular cartilages; but in infancy they invest the entire cavity of joints. They secrete a viscid, albuminoid liquid resembling the white of eggs, and called the **synovia**, which lubricates the surfaces of joints, and, by lessening friction, facilitates motion.

The synovial membranes, like the serous, are composed of a layer of connective tissue, in which blood-vessels are distributed, and are invested on the free surface with an endothelium. Their inner surface

<sup>1</sup> Diarthrodial cartilage.

<sup>2</sup> Capsulæ articulares.

<sup>3</sup> Funicular ligaments.



is smooth, and they possess no glands. At the borders of joints they are frequently thrown into folds and processes, containing connective tissue, fat, and an occasional isolated cartilage-cell. These **synovial fringes**<sup>1</sup> apparently act as cushions to fill up interspaces; though, from their greater vascularity as compared with other portions of the membrane, they are no doubt especially active in the production of synovia.

Concave articular surfaces are frequently rendered deeper by the provision of a band of fibro-cartilage tipping or surrounding their margin, as in the case of the glenoid cavity of the shoulder and the acetabulum of the hip-joint. Occasionally joints are partially or completely divided into two parts by the introduction of an interarticular fibro-cartilaginous disk, as in the case of the articulation of the lower jaw and the knee-joint.

In some instances bones are connected by ligaments totally different from the ordinary ones; being composed of an elastic material, such as the elastic ligaments which conjoin the vertebral arches; and such also is the nature of the nuchal ligament which sustains the head of quadrupeds.

The various structures which have been mentioned as entering into the composition of the articulations consist of bones, cartilages, fibro-cartilages, ligaments, and synovial membranes. The constitution of bones or of the osseous tissue has been described, but a consideration of the tissues composing the remaining structures is deferred at present, on account of their entering into the constitution of many other organs. The structure of the cartilages and fibro-cartilages will be found under their appropriate head; the structure of ligaments in the description of the fibro-connective and elastic tissues; and the structure of synovial membranes in the account of the serous membranes.

---

<sup>1</sup> Synovial glands of Havers; Haversian glands; glandulæ articulares; synovial fimbriæ.



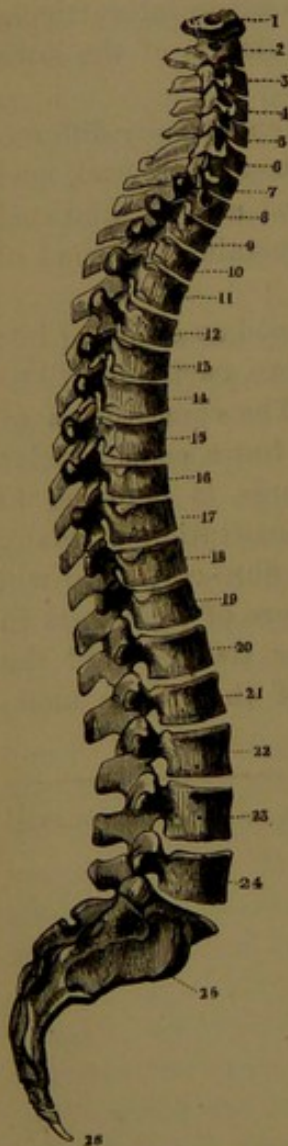
# CHAPTER III.

## SPECIAL ANATOMY OF THE SKELETON.

### THE VERTEBRAL COLUMN.

The vertebral column,<sup>1</sup> more familiarly known as the **spine**, **spinal column**, or **backbone**, is the axis of the skeleton, and as such is a peculiar characteristic of the highest division of the animal kingdom, which is thence named the *vertebrata*. It is composed of a series of articulated segments, in general distinguished as **vertebræ**.<sup>2</sup> In the human skeleton there are thirty-three or four of these segments, and of them twenty-four remain permanently distinct bones, and are those which are especially regarded as the **vertebræ**, and hence called the **true vertebræ**. The succeeding five segments approaching maturity ankylose into a single bone, which is named the **sacrum**; and the remaining four or five segments, exhibiting a rudimentary condition of the others, in the advance of age commonly ankylose into one or two pieces, which together are named the **coccyx**, representing the tail of other vertebrates.

FIG. 10.



THE VERTEBRAL COLUMN, lateral view; exhibiting the curvatures. 1 to 24, true vertebræ; 25, 26, false vertebræ; 1 to 7, cervical vertebræ; 8 to 19, dorsal vertebræ; 20 to 24, lumbar vertebræ; 25, sacrum; 26, coccyx.

#### THE VERTEBRÆ.

The twenty-four vertebræ form a continuous series extending from the skull to the sacrum, and they successively increase in size. They are nearly alike, and consist of similar parts variously modified in different positions to serve special purposes. Each in general is composed of an anterior massive part, named the **centrum** or **body**, and a posterior part, the **arch**; and between the two is a large aperture, the **spinal foramen**, which, with the others, contributes to form the spinal canal. From the arch are given off seven processes, of which four are **articular**, and the others consist of a pair of **transverse processes** and a **spinous process**.

<sup>1</sup> Columna vertebralis, or spinalis; spina dorsi; rachis. <sup>2</sup> Spondyli; backbones.

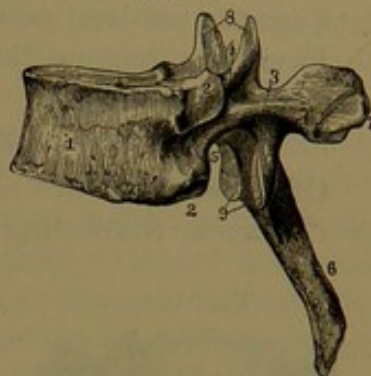


The **centrum** or **body**,<sup>1</sup> at the fore part of the vertebra, is a thick disk, placed horizontally, with its front and sides somewhat narrowed towards the middle, and its back somewhat concave transversely, where it contributes to form the spinal foramen. Above and below it presents broad articular surfaces, mostly nearly flat, but with a slightly elevated rim and a somewhat projecting margin at the sides and in front. The surface of the centrum in front and laterally is more or less conspicuously porous, and that behind exhibits a central pair of larger foramina for the passage of veins from the interior. The **arch**<sup>2</sup> of the vertebra joins the back of the centrum by strong, rounded **pedicles**, behind which it is formed by a pair of deeper shelving **laminæ**, which converge to the spinous process, and in the series overlap one another and present an imbricated appearance. The upper borders of the laminæ behind and the lower borders in front are roughened for the attachment of elastic ligaments, which occupy the intervals of the vertebral arches. A deep, rounded notch beneath the pedicles and commonly a shallow one above are the **intervertebral notches**.<sup>3</sup> These form between the adjacent vertebræ large round or oval holes, the **intervertebral foramina**, through which the spinal nerves emerge. The **spinal foramen**, enclosed by the centrum and arch, varies in size and shape in different positions, being larger and triangular in the upper and lower vertebræ of the series, and smaller and circular in those intermediate.

Of the seven processes of the vertebral arch in general, the most conspicuous is the **spinous process**,<sup>4</sup> from which the vertebral column has received its common name of the spine. It projects backward in the median line at the conjunction of the laminæ of the arch, and varies in size and shape in the different vertebræ.

Four **articular processes**<sup>5</sup> spring from the union of the pedicles and laminæ of the arch,—a pair of **prearticular processes**<sup>6</sup> above and a pair of **postarticular processes**<sup>7</sup> below. They are provided with smooth, articular facets, which are invested with cartilage; those of the prearticular processes looking obliquely backward and upward, and those of the postarticular processes in the opposite direction. The

FIG. 11.



SIDE VIEW OF A DORSAL VERTEBRA. 1, centrum; 2, articular facets for ribs; 3, arch; 4, 5, intervertebral notches; 6, spinous process; 7, transverse process; 8, pre- and 9, postarticular processes.

<sup>1</sup> Corpus.<sup>2</sup> Arcus; neural arch.<sup>3</sup> Incisura vertebrales.<sup>4</sup> Processus spinosus; neural spine.<sup>5</sup> P. articulares; oblique processes; zygapophyses.<sup>6</sup> Superior or anterior articular processes; prezygapophyses; preaxial zygapophyses.<sup>7</sup> Inferior or posterior articular processes; postzygapophyses; postaxial zygapophyses.



pre- and postarticular processes of adjacent vertebræ movably articulate with one another. The **transverse processes**,<sup>1</sup> of variable size and shape, project outward from the arch, one on each side, from between the pre- and postarticular processes.

From the regions they occupy the vertebræ are named cervical, thoracic, and lumbar.

#### CERVICAL VERTEBRÆ.

Of these there are seven, and they form together the bony axis of the neck, connecting the skull with the thorax. They are the smallest and most delicately constructed of the vertebræ. The first two depart most from the ordinary condition of these bones; being specially adapted to the articulation and movements of the skull. The others are more like one another and the rest of the series.

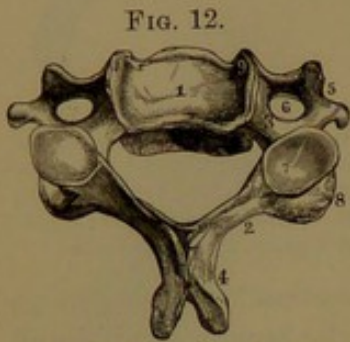


FIG. 12.  
UPPER VIEW OF A CERVICAL VERTEBRA, from the middle of the series. 1, centrum; 2, lamina; 3, pedicle; 4, spinous process; 5, transverse and costal processes; 6, foramen for the vertebral artery; 7, prearticular process; 8, postarticular process; 9, elevated lateral border of the centrum.

The **centrum** of the cervical vertebræ generally is transversely half oval, with the flat or slightly concave part next the spinal foramen. It is but feebly narrowed towards the middle, and the margins of the articular surfaces scarcely project. The upper surface by elevation of its lateral borders is rendered transversely concave, and the lower surface by extension downward mainly of its front border, but in a less degree also by the back

border, is rendered fore and aft concave. By this arrangement of the articular faces the centra interlock, and are thus less liable to dislocation; an important provision where the vertebral column is narrowest.

The **arch** of the cervical vertebræ is about as broad as in the largest vertebræ, but is much shallower than elsewhere. Its **pedicles** extend outward and backward, and the **laminæ** are comparatively long and narrow. The **spinal foramen** is larger than in the thoracic, but smaller than in the lumbar vertebræ. It is triangular with rounded angles, with the base-line transversely forward, and with the width greater from side to side than fore and aft. The **spinous process** varies; usually small and forked at the end in the intermediate vertebræ, it is large and strong in the second and last, and is obsolete in the first one.

The **pre- and postarticular processes** generally form the ends of short, vertical, cylindroid columns, which are situated at the conjunction of the pedicles and laminæ. The articular facets are flat, circular, and oblique; those above looking upward and backward, and those below in the opposite direction. The **transverse processes**

<sup>1</sup> Diapophyses.

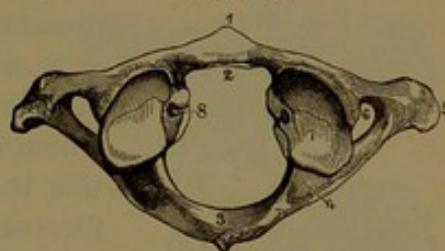


are small and weak, and generally spring from the articular columns, from which they are directed outward and forward, and end in a little tubercle.

Additional elements of the cervical vertebræ are the **costal processes**, which proceed outward from the sides of the centrum in advance of the transverse processes. Near the end they join the latter by an isthmus, and thus enclose between them the **vertebral foramen**, a circular aperture, which, except in the last cervical vertebra, accommodates the vertebral artery in its ascent through the neck. A groove between the processes directed outward from the upper intervertebral notch accommodates the cervical nerves. The costal process is commonly described as part of the transverse process, but it is rather to be viewed as homologous with the ribs. In the last cervical vertebra it originates as a separate piece, and occasionally it remains permanently distinct and variably developed as a movable cervical rib.

The **first cervical vertebra** immediately articulates with and sustains the skull, and is named the **atlas**. It differs remarkably from all other vertebræ in having no centrum, the position of which is occupied by the odontoid process ascending from the centrum of the second vertebra. It appears as a large ring, and is of greater breadth than any other of the cervical vertebræ. Its most massive portions form short columns,<sup>1</sup> one on each side ending in the pre- and postarticular processes. The articular columns are joined in front by a transverse bridge, the **anterior arch**,<sup>2</sup> which is rendered prominent in front by a conical median eminence,<sup>3</sup> and is provided behind with a circular articular facet, invested with cartilage, for movement against the odontoid process. From the back of the columns springs the **posterior arch**,<sup>4</sup> which is double the extent of the former, and surrounds the spinal foramen back of the odontoid process. It is thickened towards the middle, and is variably produced behind in a tubercle or rudimental spinous process. From the outer side of the articular columns arise the conjoined transverse and costal processes, with their enclosed vertebral foramen. On the inner part of the columns is a tubercle for the attachment of the transverse ligament, which confines the odontoid process in place. The **prearticular processes**<sup>5</sup> form deeply-concave facets for the occipital condyles. The

FIG. 13.



UPPER VIEW OF THE ATLAS. 1, anterior arch; 2, articular facet for the odontoid process; 3, posterior arch; 4, groove for the vertebral artery; 5, transverse process; 6, vertebral foramen; 7, prearticular process; 8, tubercle for the transverse ligament.

<sup>1</sup> Massæ laterales.<sup>2</sup> Arcus anterior.<sup>3</sup> Tuberculum anterius.<sup>4</sup> Arcus posterior.<sup>5</sup> Fossæ articulares.



facets are variably constricted, elliptical in outline, and have their long diameter convergent forward and their transverse diameter inclining inward and downward. The **postarticular processes** have large circular facets, which look obliquely downward and inward, are nearly straight fore and aft, and slightly concave transversely.

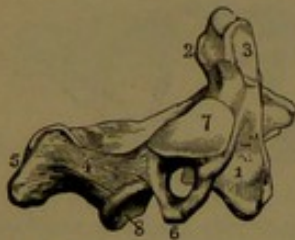
The articular columns of the atlas, together with the prearticular processes of the axis, hold a more advanced position than the corresponding columns of the succeeding vertebræ. From the greater breadth of the atlas the vertebral foramen holds a more external position than in the other cervical vertebræ. From the foramen a variably deep groove winds backward and inward, behind the prearticular process, for the passage of the vertebral artery and first spinal nerve. The groove is sometimes bridged over on one or both sides of the atlas, and is thus converted into a foramen. A less marked groove crossing the atlas behind the postarticular processes forms part of the intervertebral foramen for the second spinal nerve.

The **second cervical vertebra**, named the **axis**,<sup>1</sup> is remarkable for its nipple-shaped eminence, the **odontoid process**,<sup>2</sup> which ascends from the centrum within the ring of the atlas, and serves as a pivot around which the latter moves in the rotation or turning of the head. The centrum is longer than in the succeeding vertebræ, and its lower

part is constructed as in them. In front it presents a median ridge expanding below, and on each side of this it is depressed. The odontoid process is slightly thickened towards the end, which is distinguished as the **head**, and below this it is slightly narrowed as the **neck**. The former in front presents an articular facet, which is invested with cartilage, and is adapted to that on the anterior arch of the atlas; and the neck behind exhibits another facet, which is slightly grooved for the play of the transverse ligament. The sides and back of the head are impressed by the attachment of the lateral odontoid ligaments, and the summit is variably roughened

or smooth for the attachment of the middle ligament. The arch is thicker and stronger than in the succeeding cervical vertebræ, and the spinal foramen is of more uniform diameters. The spinous process is large and robust, nearly square or slightly tapering, sloping and depressed at the sides, ridged above, channelled beneath, and notched at the end. The prearticular processes project outward from the sides of the centrum, and are joined behind by the pedicles of the arch. Their variably circular facets incline more or less outward and downward, in which direction they are nearly straight, but fore and aft

FIG. 14.



SIDE VIEW OF THE AXIS. 1, centrum; 2, odontoid process; 3, articular facet; 4, arch; 5, spinous process; 6, transverse process, with the vertebral foramen; 7, 8, pre- and postarticular processes.

<sup>1</sup> Epistropheus.

<sup>2</sup> Processus odontoides, or dentatus; dens.

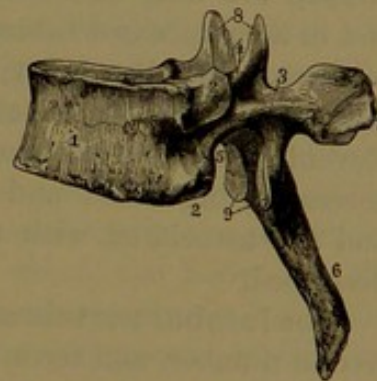


are slightly convex. The postarticular processes conform to those of the succeeding vertebræ. The costal processes proceed outwardly from the fore part of the prearticular processes, and are joined behind by the transverse process, which springs from the usual position. The vertebral foramen ascends beneath the prearticular process, and opens outwardly from it.

The succeeding four cervical vertebræ especially accord with the general description of these as above given. In the **seventh cervical vertebra**<sup>1</sup> the spinous process departs from the more common character, and assumes the condition of that of the first thoracic vertebra, being long, strong, directed obliquely downward, tapering, and ending in a thick tubercle. From its rather abrupt transition of form and prominence the position of the vertebra to which it belongs is readily distinguished in the living body. The vertebral foramen is smaller than in the preceding vertebræ, and does not transmit the vertebral artery.

The **thoracic vertebræ**,<sup>2</sup> twelve in number, support the ribs and enter into the construction of the thorax. The **centrum** in horizontal outline is transversely reniform, but in the third to the sixth of the series varies from this shape, in the greater fore and aft extent, and in appearing more cordiform or trilateral. The articular margins are more prominent than in the preceding vertebræ, and become more so in the lower part of the series; and the intervening portion of the centrum also becomes more conspicuously narrowed towards the middle, especially at the sides. The principal distinctive character of the thoracic vertebræ is the **costal articular facets**,<sup>3</sup> which are mostly half-oval, smooth impressions, situated laterally at the junction of the centrum and arch. One is placed at the upper, the other at the lower corner of the centrum, so that between adjacent vertebræ a contiguous pair of facets form a pit for the articulation of the head of a rib. The first vertebra possesses a complete circular facet for the articulation of the corresponding rib, besides the usual half-oval facet for part of the second rib. The last two vertebræ possess each a single complete facet for the corresponding ribs, placed nearly midway on the conjunction of the arch and centrum. The **arch** is deeper and stronger than in the cervical vertebræ, but its laminae, succeeding

FIG. 15.



SIDE VIEW OF A THORACIC VERTEBRA. 1, centrum; 2, articular facets for ribs; 3, arch; 4, 5, intervertebral notches; 6, spinous process; 7, transverse process; 8, pre- 9, post-articular processes.

<sup>1</sup> V. prominens.

<sup>2</sup> Dorsal vertebræ; v. dorsales; v. dorsi. The term dorsal applied to these vertebræ is objectionable, as they are not more dorsal than those in other parts of the trunk.

<sup>3</sup> Fossæ costales.

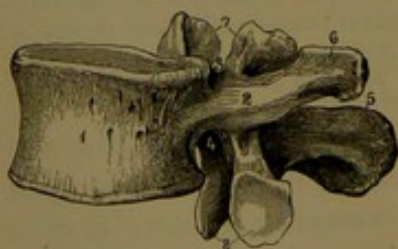

those of the first vertebra, become considerably shorter or of less transverse extent. The **spinal foramen** is smaller than in the cervical or lumbar vertebræ, and, though of much less transverse width, is wider fore and aft than in the former. It is mostly circular and of uniform diameters, but in the first to the fourth vertebra passes from transversely triangular oval to transversely oval and circular.

The **spinous process** is long, pyramidal, tapering, directed obliquely downward, and mostly ends in a narrow tubercle with a descending point. It is longest, most tapering, and most inclined along the middle of the series. The first one inclines much less than that immediately succeeding it, and ends in a thick tubercle like that of the last cervical vertebra. The lowest three or four are shorter, less inclined, and end in larger tubercles, successively increasing, and with the last one disposed to divide into two. The **articular processes** are nearly vertical disks; the upper ones projecting above the junction of the laminae and pedicles, and separated by a deep wide notch; the lower ones directed downward from the laminae below the root of the transverse processes. The **articular facets** are circular and flat, the upper ones looking backward with a slight upward inclination, and the lower ones looking in an opposite direction. The **transverse processes** are long and robust, directed outward and backward. They end in a compressed tuberosity, in front of which is an oval or circular, concave, **articular facet**,<sup>1</sup> which is invested with cartilage for articulation with the tubercle of the ribs. The transverse processes of the eleventh vertebra are much reduced, and do not articulate with the corresponding ribs; and those of the twelfth are almost obsolete, and are associated with two additional processes to be subsequently described.

The **lumbar vertebræ**,<sup>2</sup> the largest and most robust of the series, are five in number, and form together the bony axis of the loins, extending from the thorax to the pelvis. The **centrum** has the same shape, especially of that of the lower thoracic vertebræ, but is slightly more prominent at the articular margins, and more conspicuously narrowed in the intermediate position. The **arch** is proportionately of less depth than in most of the preceding vertebræ, so that wide intervals are left between the laminae of the contiguous vertebræ, not existing elsewhere, except between the upper cervicals. The **spinal foramen** is larger than in other vertebræ, being about as wide transversely as that of the cervicals, but wider fore and aft. As in the latter,

FIG. 16.



SIDE VIEW OF A LUMBAR VERTEBRA.  
1, centrum; 2, side of the arch; 3, 4, intervertebral notches; 5, spinous process; 6, transverse process; 7, pre-  
8, postarticular processes.

<sup>1</sup> Fossa transversalis.

<sup>2</sup> V. lumborum.



it is also triangular, but of more equal proportions and rounded in front instead of being straight. The **spinous process** is a broad vertical plate, thin at its upper border but thickening below, directed backward, with slight inclination downward, and ending in an elliptical tubercle. In the first and last vertebræ it is a little shorter and of less depth than in the others, and the tubercle of the first one is thicker and triangular, and is mostly notched below. The **articular processes** together, between contiguous vertebræ, form conspicuous eminences in the interval of the spinous and transverse processes. The **prearticular processes** ascend from between the pedicles and laminae, and are separated by a wide, deep notch above the latter. Their articular facets are vertically nearly straight, transversely concave, and look towards each other. The **postarticular processes** descend from the junction of the laminae and spinous process, and are separated by a deep notch below the latter. They are received between the prearticular processes of the adjacent vertebræ, and have narrower and transversely convex facets, which look outward to those of the former. The **transverse processes** are long, narrow, flattened, and commonly tapering, but sometimes expanded at the ends, and are directed outward with a slight bend backward. In the series they successively increase in length to the third or fourth, and then again diminish.

On the back part of the prearticular processes of the first and second lumbar vertebræ there projects an elliptical tubercle, named the **metapophysis**.<sup>1</sup> Less well produced it exists in a similar position in the last thoracic vertebra, and further in a successively more rudimentary condition in the other lumbar. In some animals, as the rabbit, the metapophyses are long, conspicuous processes, and in the armadillos serve to support the osseous buckler which covers the body. In the same vertebræ a less prominent process, the **anapophysis**,<sup>2</sup> occupies the angle between the former and the transverse process, which likewise is better represented in some other animals, as, for example, in the cat and the dog.

**Structure of the vertebræ.** The vertebral centra are composed of spongy substance with a thin covering of compact substance; and the principal plates and fibres of the former are for the most part arranged vertically, and are intersected by others. The vertebral arches and their processes contain a less proportion of spongy substance. The centra are traversed by large channels, for veins, especially conspicuous in the thoracic and lumbar vertebræ. The channels ordinarily commence in pairs at the corresponding foramina of the posterior surface of the centra, whence they advance a short distance and then diverge to open at the sides of the centra.

<sup>1</sup> Mammillary process; processus mammillaris; posterior superior tubercle.

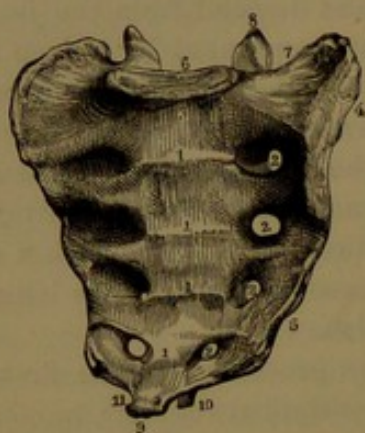
<sup>2</sup> Accessory process; p. accessorius; inferior posterior tubercle.



## SACRUM.

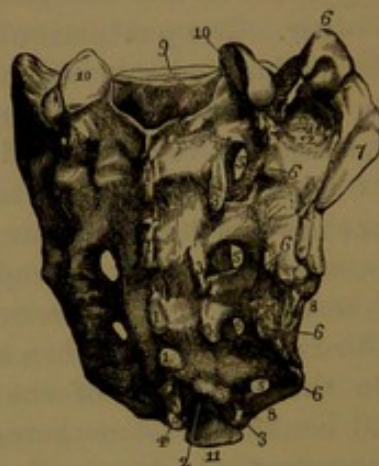
The **sacrum**<sup>1</sup> is a large, curved, pyramidal bone, situated at the lower part of the vertebral column, and wedged between the hip-bones, with which it forms the pelvis. In childhood it consists of five distinct pieces, the **sacral vertebræ**, but these approaching maturity become completely ankylosed into a single bone, which affords a firm basis of articulation to the hip-bones. The existence of a sacrum, which in different animals consists of a variable number of ankylosed vertebræ, is correlated with the presence of pelvic limbs, and

FIG. 17.



FRONT VIEW OF THE SACRUM. 1, transverse ridges, indicating the original separation of the bone into five segments; 2, sacral foramina; 3, promontory; 4, articular surface for the hip-bone; 5, sacral border of the sacro-sciatic notch; 6, base of the sacrum, with its articular surface for the last lumbar vertebra; 7, wing of the sacrum; 8, prearticular process; 9, apex of the sacrum, with its articular surface for the coccyx; 10, cornu of the last vertebral arch; 11, notch for the last sacral nerve.

FIG. 18.



BACK VIEW OF THE SACRUM. 1, rudimentary spinous processes; 2, 2, sacral canal; 3, 3, rudimentary articular processes; 4, cornu; 5, sacral foramina; 6, 6, rudimentary transverse processes; 7, articular surface for the hip-bone; 8, sacral border of the sacro-sciatic notches; 9, articular surface for the last lumbar vertebra; 10, prearticular processes for the latter bone; 11, apex of the sacrum; 12, rough surface on the wing of the sacrum, for the sacro-iliac ligaments.

when these are absent, or are disconnected with the vertebral column, isolated vertebræ form an uninterrupted series from the skull, or cervical region, to the end of the tail, as exemplified in cetaceans, snakes, and fishes.

The sacrum is a very variable bone in its proportions, degree of curvature, and in other respects. The vertebral segments of which it is composed successively decrease in size and in degree of development. Its upper part, or **base**, is widest and thickest, and articulates with the last lumbar vertebra. It tapers below to the **apex**, which articulates with the coccyx. Its sides form strong processes, named the **wings**, which articulate with the hip-bones.

<sup>1</sup> Os sacrum; os latum.



The sacrum differs but little in length and breadth, though commonly the latter dimension is the greater. It is directed obliquely backward from the vertebral column above, so that its base is placed considerably in advance of the position of its apex. The median projecting portion of its base is the **promontory** of the sacrum, forming with the contiguous portion of the centrum of the last lumbar vertebra the conspicuous **sacro-vertebral angle**, which overhangs the cavity of the pelvis.

The anterior broadest surface of the sacrum is variably concave and smooth, and forms the posterior part of the cavity of the pelvis. Its median portion is formed by the vertebral centra, and exhibits a series of four transverse ridges, which indicate the original lines of separation. On each side are the four large **anterior sacral foramina**, which communicate inwardly with the sacral canal, and are directed outwardly in large grooves on the sacral wing.

The posterior surface of the sacrum, of less width than the anterior, is convex and very uneven. Its median portion is composed of the arches of the sacral vertebræ co-ossified in a usually continuous plate, at the upper and lower parts of which are large notches communicating with the sacral canal. The **upper sacral notch**<sup>1</sup> is wide, and is closed in the recent condition by the last pair of elastic ligaments. The **lower sacral notch**<sup>2</sup> is narrower, is usually produced by imperfection of the arch of the last sacral vertebra, and in the recent state is closed by a fibrous membrane. Frequently this notch is extended upward by a similar imperfection in one or more of the arches of the sacral vertebræ above.

Between the sacral notches extend a series of median tubercles as **spinous processes**, which are very variably produced in different specimens. The upper three or four are often more or less united in a broken ridge, and often those of the lower one or two sacral vertebræ appear as a pair of tubercles for each, very variably produced,—sometimes to a greater degree than the upper ones, and sometimes scarcely at all. The open arch of the last sacral vertebra leaves the pedicles as a pair of downward-projecting hook-like processes,<sup>3</sup> the **cornua**, beneath which the notch forms part of the intervertebral foramen for the exit of the last sacral nerve.

On each side of the sacrum are the **posterior sacral foramina**, smaller than the anterior, situated directly opposite, and, like them, communicating inwardly with the sacral canal. Internally the foramina are skirted by feeble processes, rudimentary of the articular processes of the preceding vertebræ. Above the foramina, at the sides of the upper sacral notch, is a pair of well-produced articular processes, which articulate with those of the last lumbar vertebra. External to the position of the posterior sacral foramina is an irregular tuber-

<sup>1</sup> Hiatus sacralis.

<sup>2</sup> Incisura sacro-coccygea.

<sup>3</sup> Cornua sacralia.



cular ridge, which seems to correspond with the extremities of the transverse processes of the vertebræ.

The **base** of the sacrum, directed upward and forward, presents a median, transversely elliptical, flat surface for articulation with the centrum of the last lumbar vertebra. Laterally the base expands outwardly on the sacral wing in a quadrate smooth surface, which contributes to the upper division of the pelvis. Behind the base are the pre-articular processes of the sacrum, separated by the sacral notch.

The **apex** of the sacrum ends in a transverse elliptical articular facet for the coccyx.

The **wings**<sup>1</sup> of the sacrum appear as strong, lateral, pyramidal processes, with the base directed upward and forward, and thence tapering downward. The most prominent part of the base behind forms a tuberos prominence which represents the transverse process of the first sacral vertebra. At the fore part of the wing outwardly is the **iliac articular surface**,<sup>2</sup> a vertical, uneven plane of irregular reniform outline. It usually extends upon the upper two sacral vertebræ, but sometimes reaches a little way on the third vertebra. Behind and below the articular surface is a more uneven surface, which gives attachment to the strong posterior sacro-iliac and sacro-sciatic ligaments.

The **sacral canal**<sup>3</sup> is the continuation of the vertebral canal through the sacrum, in which it follows the curvature of the bone. It is triangular, widest transversely, and narrows in its descent. It communicates laterally by apertures which open into the anterior and posterior sacral foramina for the transmission of the corresponding nerves.

The sacrum accords in structure with the vertebræ above.

In the female the sacrum is commonly shorter and broader in proportion to its length, and usually is less curved, than in the male.

Occasionally the sacrum is composed of six vertebral segments, including five pairs of sacral foramina. Commonly the additional segment is the first coccygeal vertebra, which in its coalescence with the sacrum more or less conforms in its development to the usual condition of the last sacral vertebra. Less frequently the increase is due to the ankylosis of the last lumbar vertebra, which also is variably modified to conform to the ordinary condition of the first sacral vertebra. In such cases the modification may be confined to one side, while the other retains more or less of its usual condition. Sometimes the co-ossification of the lumbar vertebra with the sacrum is lateral only, while the centra remain unankylosed. Rarely the number of sacral vertebræ is reduced to four, in which condition there is an equivalent accession either to the lumbar or the coccygeal series.

<sup>1</sup> Lateral portions; partes laterales; alæ.

<sup>2</sup> Auricular surface; facies auricularis.

<sup>3</sup> Canalis sacralis.



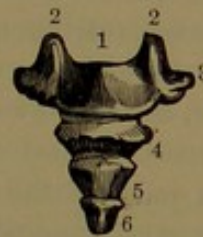The posterior portion of the sacrum is very variable in the degree of production of the arches and processes of the sacral vertebræ. Frequently intervals occur between the laminæ of the segments, especially between those of the first and second sacral vertebræ. This condition is often accompanied by deficient union between the laminæ of each arch and imperfect development of the spinous process. The notch at the lower end of the sacral canal is variably extended, sometimes even the entire length of the sacrum.

### COC CYX.

The **coccyx**<sup>1</sup> succeeds the sacrum, and continues its triangle and curvature downward and forward. It is composed of four or five segments or **coccygeal vertebræ**, which are homologous with the caudal or tail vertebræ of other animals, and differ from the preceding vertebræ of the series in being reduced to the most rudimentary condition.

The first coccygeal vertebra is best developed, and nearly conforms to the last one of the sacrum. It consists of a centrum, of flattened cylindrical shape, with lateral, wing-like, blunt-pointed processes. Between these and the contiguous margin of the sacrum on each side is a notch, which in the recent state is converted by the sacro-sciatic ligament into a foramen for the passage of the fifth sacral nerve. From behind the centrum ascend a pair of processes, the **cornua**,<sup>2</sup> which represent the pedicles of a vertebral arch. These join corresponding descending processes of the sacrum, and with them enclose the intervertebral foramina for the fifth sacral nerves. The remaining coccygeal vertebræ are rudimentary centra, successively decreasing in size. The second coccygeal vertebra commonly possesses a short, blunt, lateral process, between which and the first vertebra is a notch. This is converted by the sacro-sciatic ligament into an intervertebral foramen for the passage of the last spinal nerve. The fifth coccygeal vertebra, when distinguishable, is a little nodule of bone, which in early youth becomes united with the fourth vertebra. The union of the coccygeal vertebræ is very variable. Commonly after adult age the lower two or three are ankylosed, while the first remains separate, or this may be united with the second, and the others be united in another piece. Sometimes the first vertebra is united with the sacrum, and the other vertebræ are joined in two or in a single piece. Late in life all the coccygeal vertebræ may be ankylosed together, and sometimes with the sacrum.

FIG. 19.



POSTERIOR VIEW OF THE COCCYX. 1, first segment; 2, 2, the cornua; 3, transverse process; 4, 5, 6, lower three coccygeal vertebræ.

<sup>1</sup> Os coccygis; ossa coccygis; cauda, rump-bone; crupper-bone. <sup>2</sup> C. coccygea.



## THE VERTEBRAL COLUMN VIEWED ENTIRE.

The vertebral column, or spine, is an upright, flexuose pillar, in which the vertebræ form the shaft, and the sacrum, with the coccyx, forms the base. From the atlas as the capital, the shaft gradually enlarges to its base, which is a curved wedge firmly inserted between the hip-bones. It is the central pillar of support to the skeleton; upon it rests the skull; its sides sustain the ribs with the sternum, to which are suspended the upper limbs; and through the sacrum it transmits the weight of the body to the lower limbs.

The average length of the spine is estimated to be about twenty-eight inches in the male and a couple of inches less in the female. From this size it commonly deviates but little, the difference of stature among persons depending mainly on variation in the length of the lower limbs. At birth it is proportionately longer in consequence of the relatively short growth of the limbs. Its gradual growth continues until about twenty-five years.

In a side view the spine presents a succession of curves alternating in direction, and due to difference in thickness between the front and back part of the centra of the vertebræ and the intervertebral disks; most conspicuously observed in the lumbar region, especially in the last lumbar vertebra and the adjacent intervertebral disks. The curves, named from their position, are the **cervical, thoracic, lumbar, and sacro-coccygeal**, of which the first and third are convex in front and concave behind, and the others are the reverse. The upper three curves gently merge in one another, but the last one is more abrupt, its point of departure being the **sacro-vertebral angle**, which is formed by the centrum of the last lumbar vertebra and the promontory of the sacrum. The upper curves are in a measure proportioned in degree with one another, and ordinarily increase or decrease together. They are influenced by habit, and thus become more pronounced in persons whose occupation retains them habitually in a bent position, as in the miner, and are less conspicuously marked in those habitually erect, as in the soldier. At birth they are slight, augment as the child learns to stand and walk, and gradually increase to maturity. Subsequently, uninfluenced by special occupations, they continue with little or no obvious change until late in life, when with the advance of years they slowly increase, and thus contribute to the diminution of stature of old age.

The curves of the spine contribute to its elasticity, and thus render it less liable to injuries than if it were straight; the direction of the curves also in the thorax and pelvis contributes to the capacity of their cavities. More or less lateral curvature with the convexity directed towards the right, frequently observed in the thoracic region, is attributed to more habitual use of the right upper limb.

In the front view of the spine the vertebræ are observed to have their greatest width at the transverse processes. The atlas is about



equal in width with the first thoracic vertebra, and these are the widest of the series except the lumbar vertebræ. The axis undergoes an abrupt decrease in width, and with the succeeding two cervical vertebræ is the narrowest of the series except the lowest two thoracic vertebræ. The lower cervical vertebræ successively increase, and the first thoracic vertebra undergoes a more abrupt enlargement to the width of the atlas. The other thoracic vertebræ gradually diminish in width to the last, which is the narrowest of all the vertebræ. The first lumbar vertebra abruptly increases to nearly the width of the atlas, and the others successively increase to the third, the widest of the vertebræ, and then again slightly diminish to the last one. The sacrum at its base, with an abrupt increase, is nearly half the width more than the widest portion of the spine above, and it thence, with the coccyx, rapidly tapers to the end of the column. The centra of the vertebræ from that of the axis gradually become broader to that of the first or second thoracic vertebra, then diminish to that of the fourth, and thence again increase in breadth to the promontory of the sacrum. In the side view the centra of the cervical vertebræ are of nearly uniform width to the last, while those of the thoracic vertebræ successively increase, and those of the lumbar vertebræ remain nearly uniform. The articular processes, from the lower pair of the axis to those of the sacrum, form a continuous ridge, extending on each side of the spine along the line of junction of the pedicles and laminae of the arches. Immediately in advance of the ridge are situated the intervertebral foramina, and behind the ridge is the vertebral groove. In front of the cervical portion of the ridge are the transverse and costal processes, with the included vertebral foramen, through which ascends the vertebral artery. From the ridge of the thoracic vertebræ project the transverse processes, together forming a curve conforming to that of the vertebræ. From the last thoracic vertebra to the sacrum the adjoining articular processes and metapophyses produce a row of conspicuous eminences, situated behind the bases of the transverse processes. The articular processes of the atlas, together with the upper pair of the axis, form on each side a short column, which is situated in advance of the position of the articular ridge below, and is immediately devoted to the support of the skull.

The intervertebral foramina appear at the sides of the spine, from the axis to the sacrum, as a row of large round or oval apertures, formed by the apposition of adjacent intervertebral notches, of which the upper are the larger in the cervical region, while the lower are the larger in the thoracic and lumbar regions. Above and below they are formed by the contiguous pedicles, in front by the centra and intervertebral disks, and behind by the conjoined articular processes and their capsular ligaments.

The **vertebral grooves**, for the lodgement of the extensor muscles of the back of the trunk, extend along the spine on each side of the



spinous processes outwardly to the articular processes. In the cervical region they are shallow; in the thoracic region they are deep, and extend farther outwardly to the ends of the transverse processes; in the lumbar region they are narrower and shallower, and are defined outwardly by the articular eminences; and on the sacrum they become more shallow and tapering, and are defined by the articular rudiments skirting the sacral foramina. An additional groove external to the principal ones, in the lumbo-sacral region, is formed between the articular eminences and the ends of the transverse processes.

The bottoms of the vertebral grooves are formed by the laminae of the vertebral arches, which are closely fitted and imbricated in the lower part of the cervical and in the thoracic region, except between the last two vertebrae of the latter. The laminae of these and of the lumbar vertebrae, together with their postarticular processes, form a series of quadrate plates which are directed downward, and are received into square grooves formed by the contiguous prearticular processes. Considerable intervals occur between the laminae, which in the recent state are closed by elastic ligaments. This arrangement, while it permits a considerable degree of flexion and extension of the spine in the lumbar region, closely restricts any lateral motion. The intervals between the laminae of the intermediate cervical vertebrae increase or decrease with the flexion and extension of the neck, and in the recent condition are occupied, like all similar intervals, with elastic ligaments. Large intervals also exist between the arches of the axis and the atlas, and between the latter and the occipital bone, and these in the recent state are occupied by loose membranous ligaments, which are pierced laterally by the first and second pair of intervertebral foramina.

The spinous processes form a continuous crest from the axis to the sacrum. The crest approaches the surface of the body, so that the ends of the processes may be felt along a median groove of the back of the trunk and the prominence of the sacrum; but in the neck the processes mostly are deeply situated between the lateral muscles. Absent in the atlas, the spinous process is large in the axis; then abruptly reduced in the three or four succeeding vertebrae, it again becomes large and prominent in the last one. Together the cervical spinous processes form a deep curve with the concavity behind; those of the axis and last vertebra forming the ends of the curve. The slope backward of the laminae and articular processes of the cervical vertebrae, the shortness of the intermediate spinous processes, and the channelled condition beneath of that of the axis, all favor the extension of the head. The spinous process of the first thoracic vertebra is nearly like that of the last cervical vertebra in form and direction. Those following are more tapering, abruptly incline more downward, successively increase in this disposition, and become closely applied to one another in an imbricated manner. Below the middle of the series they become successively less inclined and more separated towards



the ends, and in the last two are directed nearly horizontally backward. In the lumbar region the deep laminar spinous processes are directed horizontally backward, and are separated by well-marked intervals. On the sacrum the crest of the spinous processes gradually subsides.

The spinal canal, formed by the succession of the spinal foramina, extends from the occipital foramen, where it communicates with the cavity of the cranium, to the second coccygeal vertebra. Its lower extremity is closed by the posterior sacro-coccygeal ligament, which occupies the notch behind the lowest sacral vertebrae and the corresponding interval of the adjacent coccygeal vertebra. The canal in front is formed by the vertebral centra and intervertebral disks connected throughout by the common posterior vertebral ligament, and behind by the vertebral arches and intervening elastic ligaments. At the sides it communicates with the exterior by thirty-one pairs of intervertebral foramina for the transmission of the spinal nerves and blood-vessels. It is most capacious in the lumbar region, nearly as large in the neck, less in the thoracic region, and least in the sacrum, where it tapers to the lower end. In the neck it is trilaterally prismatic, becomes cylindrical in the thoracic region, and is again trilaterally prismatic in the lumbar region and sacrum, tapering away in the latter. In the neck it is much wider transversely than fore and aft, and is flat in front; in the lumbar region it is of greater fore and aft extent, and rounded in front; and in the sacrum it is more of the relative proportions and shape of that in the neck.

The first and second pair of intervertebral foramina open behind the articular processes between the occipital bone and atlas and between the latter and the axis. Those succeeding to the sacrum open in advance of the articular processes. Those of the sacrum open in a corresponding position into the recesses of the sacral foramina, except the last pair, which open between the cornua of the sacrum and coccyx. The last pair, at the end of the spinal canal, open outwardly between the first and second coccygeal vertebrae and the sacro-sciatic ligament.

#### DEVELOPMENT AND GROWTH OF THE VERTEBRAL COLUMN.

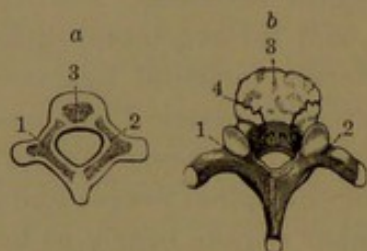
In the embryo, ossification of the vertebrae commences in corresponding cartilaginous segments, which are developed around the notochordal axis of the embryo. In different positions of the column it occurs from the eighth week to three and a half months, proceeding generally from three principal centres for each vertebra,—one for the main portion of the centrum, and one for each half of the arch, including a small contiguous portion of the centrum. At birth all the vertebrae except the atlas and the axis consist of three osseous pieces, which accord with the original centres. As growth proceeds, the laminae of the arches for the most part coalesce before the end of the first year. Those of the upper cervical vertebrae unite from the second to the third



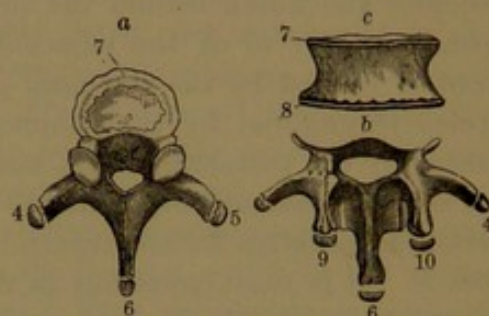
or fourth year. The processes are exogenous growths from the arch, which for some time remains connected with the main part of the centrum by the **neuro-central suture**, which is obliterated from the fourth to the sixth year. The vertebræ gradually assume and nearly reach their complete shape and proportions about puberty, subsequently to which they acquire a number of epiphyses. A pair of these appear on the articular surfaces of the centrum in the form of a marginal zone,

FIG. 21.

FIG. 20.



DEVELOPMENT OF THE VERTEBRÆ. *a*, vertebra of a fœtus, in a cartilaginous condition, with three centres of ossification; 1, 2, lateral pieces; 3, the centrum; *b*, vertebra of an infant. The lateral pieces, 1, 2, are co-ossified in the spinous process, and join the body, 3, at the sutures, 4. The ends of the transverse and spinous processes yet in a cartilaginous state.



DEVELOPMENT OF THE EPIPHYSES TO THE VERTEBRÆ. *a*, thoracic vertebra, with the epiphyses 4, 5, to the transverse processes; 6, to the spinous process; and 7, to the centrum; *b*, arch with its processes; and *c*, centrum of a lumbar vertebra; 4, 5, epiphyses of the transverse processes; 6, of the spinous process; 7, 8, of the centrum; 9, 10, epiphyses of the metapophyses.

attached to the latter by cartilage, from which the centrum continues to grow. Small epiphyses also appear at the ends of the spinous and transverse processes of the thoracic and lumbar vertebræ, and likewise to the metapophyses of the latter. The different epiphyses make their appearance up to eighteen years, and unite with the chief part of the vertebra from that time up to twenty-five years.

The atlas at birth consists of two lateral portions, corresponding with the half-arches of the succeeding vertebræ, united by the anterior arch in the condition of cartilage, in which one or two ossific centres appear in the course of the second year. Ankylosis of the lateral portions behind occurs about the fourth year, and with the anterior arch from the sixth to the eighth year.

The axis at birth commonly consists of four osseous pieces,—one for the lower part of the centrum, one for the upper part, with the odontoid process, and two for the half-arches. The odontoid process originates in a pair of ossific centres, which coalesce, and later an additional centre appears in the summit and speedily unites with the rest. The pieces all coalesce by the fifth or sixth year. As in the other vertebræ, an epiphysis is added to the lower articular surface of the centrum.

In the seventh cervical vertebra the costal processes are produced from separate centres, and they ankylose with the chief part of the



vertebra from the fourth to the sixth year. Rarely one or both remain separate and become larger than usual, thus forming cervical ribs. An epiphysis also appears on the end of the spinous process, as in the succeeding vertebræ.

In the sacrum each vertebral segment commences with three primary centres of ossification, as in the vertebræ above. Later an additional pair of centres appear in the lateral portions of the upper three or four segments. At birth the sacrum commonly consists of five osseous pieces for each of the upper three segments, and three for each of the other two segments. The pieces of each segment coalesce to form the sacral vertebræ from the second to the sixth year. As in the vertebræ above, epiphyseal zones make their appearance on the articular surfaces of each centrum subsequent to puberty. The sacral vertebræ commence to ankylose through their lateral portions about the tenth year, then unite through their arches, and finally through their centra approaching adult age. Near the latter period a thin epiphyseal plate appears in the position of the articular surface for the hip-bone, and another on the margin of the sacrum below. Small epiphyses also appear on the tips of the two or three upper spinous processes. The complete fusion of all the pieces of the sacrum may extend to twenty-five years or later.

The coccyx does not commence to ossify until after birth; a single centre appearing successively in each segment at variable periods up to near puberty, after which epiphyseal zones appear on the articular surfaces, as on the centra of the vertebræ above. The coccygeal vertebræ usually coalesce successively from below upward, the last two uniting shortly after puberty. Commonly the lower three or four become ankylosed before middle age, while the union of these with the first coccygeal vertebra, and of this with the sacrum, occurs at variable periods late in life.

#### ARTICULATIONS OF THE VERTEBRAL COLUMN.

The articulations of the vertebral column are formed between the centra, the laminae, the articular processes, and the spinous processes, and others between the vertebral column and the skull.

The **intervertebral ligaments**<sup>1</sup> or **disks** are fibro-cartilaginous, and occupy the intervals of the vertebral centra, including those of the sacrum and coccyx. They bind the vertebræ closely and tenaciously together, and give to the spine a remarkable degree of flexibility and elasticity, combined with great strength. The first is placed between the axis and third cervical vertebra, and they continue in uninterrupted series to the interval between the last lumbar vertebra and the sacrum, and then occupy the intervals of the latter and the coccyx and the pieces of this.

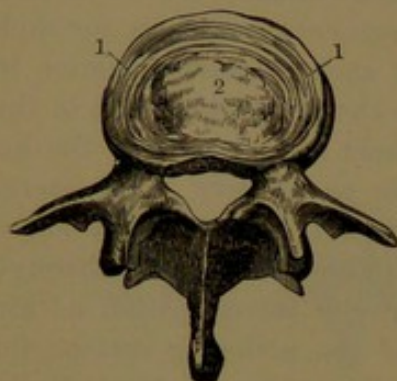
---

<sup>1</sup> Intervertebral fibro-cartilages, or substance; l. intervertebralia; fibro-cartilages intervertebrales.



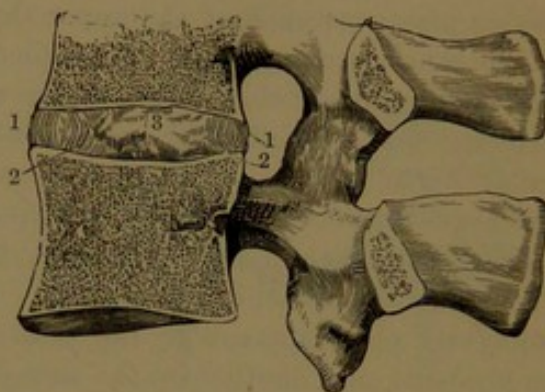
The **disks** conform in shape to the articular surfaces of the vertebral centra. They are largest and thickest in the loin, where they are nearly one-third the depth of the centra they unite. They are thinnest between the centra of the third and seventh thoracic vertebrae, above which they gradually increase. They are thicker in front or behind in accordance with the convexity of the spinal curves, which

FIG. 22.



UPPER VIEW OF A LUMBAR VERTEBRA, with a horizontal section of an intervertebral ligament. 1, concentric layers of fibrous tissue; 2, pulpy fibro-cartilage.

FIG. 23.



VERTICAL SECTION OF TWO LUMBAR VERTEBRÆ, with the intervening intervertebral ligament. The intervening articular processes, enveloped by a capsular ligament, are also represented. 1, 1, concentric layers of fibrous tissue, curving outwardly; 2, 2, concentric layers curving inwardly; 3, pulpy fibro-cartilage in the middle.

they in a measure contribute to produce. They are also thicker centrally in conformity with the depression of the articular surfaces of the centra they unite.

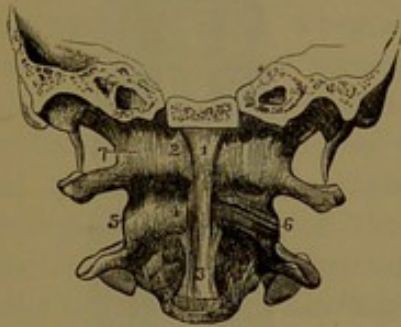
The disks are of complex structure, and are immediately connected with the articular surfaces of the centra through thin plates of cartilage. They are composed of numerous concentric bands, enclosing a central mass of pulpy fibro-cartilage. The bands are closely applied together, and in a horizontal section of the disks appear as a broad, dense zone of concentric parallel rings; in a vertical section as a series of parallel upright layers, with the more superficial ones slightly bent outwardly and the deeper ones inwardly. In a fore and aft section of fresh vertebrae, the central pulp projects from the cut surface, apparently as if squeezed out through contraction of the exterior bands, or as if relieved from pressure to which it had been subjected before the section was made. In a horizontal section of the disks the central pulp commonly rises in parts and sinks elsewhere, and exhibits a more or less irregular aspect. The concentric bands consist of bundles of fibres arranged obliquely and parallel with one another between the vertebrae, alternating or crossing in their direction in the successive layers. The superficial bands are composed of bundles of ordinary fibro-connective tissue, but the deeper and much greater part of the bands is composed of similar bundles of more elastic character. The



concentric bands and their constituent bundles of fibres are associated with an intertexture of connective tissue and elastic fibres, in which are embedded cartilage-corpuscles, especially among the deeper bands. These corpuscles occur singly or in groups, and often in rows of variable length. The intervertebral pulp is soft, but is very tenacious. It chiefly consists of an intertexture of fibro-elastic bundles with embedded cartilage-corpuscles like those situated among the surrounding bands. After adult age it commonly exhibits a lacerated, ragged, and more or less fissured appearance, and when placed in water swells and assumes an irregular villous aspect.

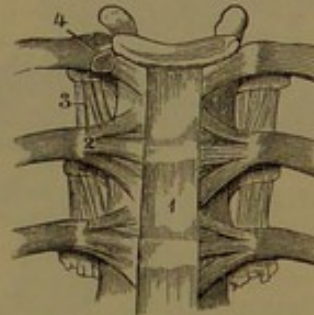
The **anterior vertebral ligament**<sup>1</sup> is a strong, thin, fibrous band, situated in front of the vertebral column, and extending from the occipital bone the entire length of the latter. Starting in a narrow portion or cord<sup>2</sup> from beneath the basilar process and connected in front

FIG. 24.



PORTION OF THE OCCIPITAL BONE, WITH THE ATLAS AND AXIS, front view. 1, origin of the anterior vertebral ligament from the basilar process; 2, anterior atlanto-occipital ligament on each side of the former; 3, widening of the anterior vertebral ligament from the axis; 4, anterior atlanto-axial ligament; 5, 6, 7, capsular ligaments of the articular processes.

FIG. 25.



THREE THORACIC VERTEBRÆ, with the articulations of the ribs, viewed in front. 1, portion of the anterior vertebral ligament; 2, radiating costo-central ligament; 3, anterior costo-transverse ligament; 4, articulation of the head of the rib, laid open, and exhibiting the interarticular ligament separating two synovial cavities.

with the eminence of the atlas and the median ridge of the axis, it thence expands and is attached to the front of all the centra of the vertebræ and intervertebral ligaments to the end of the coccyx. On the lumbar vertebræ it spreads over half their width; on the thoracic vertebræ it is proportionately narrower and thicker; and it spreads more laterally on the cervical vertebræ. On the sacrum it merges into the periosteum and again becomes more distinct, extending from the former to the end of the coccyx as the **anterior sacro-coccygeal ligament**.<sup>3</sup> In its course it adheres most closely to the intervertebral disks and the contiguous margins of the centra, and least so at the intermediate narrowed portions of the latter, where the interval is occupied by

<sup>1</sup> Ligamentum commune vertebrale anticum; l. longitudinale ant.; anterior common ligament.

<sup>2</sup> L. occipitale anterius medium; l. atlanto-occipitale superfic.

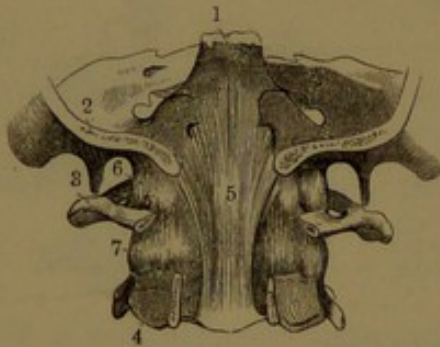
<sup>3</sup> L. sacro-coccygeum anticum.



looser connective tissue. Its lateral borders merge into the periosteum of the vertebræ. On the lumbar vertebræ it is intimately associated with the tendinous origin of the diaphragm, with which it may be said to interchange bundles of fibres. The ligament is composed of parallel bundles extending variable lengths, the more superficial to the extent of three or four or more vertebræ, the deepest to the extent of a contiguous pair. The surface presents a glistening white appearance, divided by many short fissures, which give passage to vessels and are occupied with looser connective tissue.

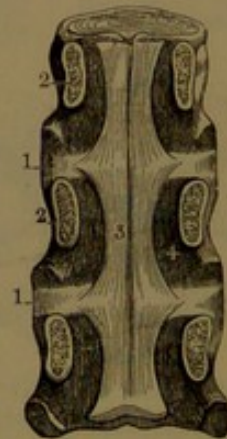
The **posterior vertebral ligament**<sup>1</sup> is a strong fibrous band, situated at the fore part of the spinal canal, and extending from the occipital bone the entire length of the latter. Commencing in an expansion<sup>2</sup> from the inner surface of the basilar process, where it is

FIG. 26.



PORTION OF THE CRANIUM AND OF THE ATLAS AND AXIS, viewed from behind; the posterior portions of the occipital and two last bones removed. 1, declivity of the sphenoid bone; 2, occipital bone; 3, atlas; 4, axis; 5, origin of the posterior vertebral ligament from the basilar process; 6, 7, capsular ligaments of the articular processes.

FIG. 27.



CENTRA OF THREE THORACIC VERTEBRÆ, connected by the intervertebral ligaments, viewed from behind; the vertebral arches having been removed. 1, intervertebral ligaments; 2, pedicles of the vertebral arches; 3, portion of the posterior vertebral ligament, exhibiting its lateral festooned borders, 4.

closely connected superficially with the dura, it descends through the occipital foramen and behind the odontoid process to be attached to the centrum of the axis, and thence to all the succeeding vertebral centra and intervertebral disks. It is widest at the latter, to which and to the contiguous margins of the centra it most closely adheres; and it successively narrows in the intervals towards the middle of the centra, an arrangement which gives it laterally festooned borders. These are continuous with the periosteum of the sides of the spinal canal and of the intervertebral foramen, and are adherent to the an-

<sup>1</sup> L. commune vertebrale posticum; l. longitudinale post.; posterior common ligament.

<sup>2</sup> L. latum epistrophei; apparatus ligamentosus colli; membrana ligamentosa; occipito-axoid or posterior occipito-axial ligament.



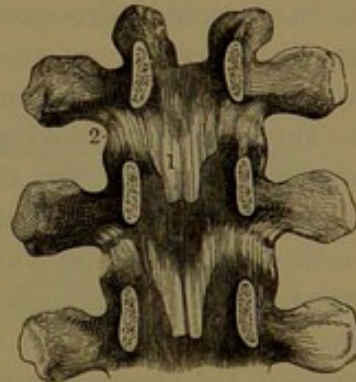
terior longitudinal spinal veins, which are united by transverse veins crossing the centra beneath the ligament. Superficially, the latter is connected with the dura of the spinal cord by loose connective tissue. The ligament is composed of longitudinal bundles of fibrous tissue containing a large proportion of elastic tissue, which gives it a yellowish appearance and a high degree of elasticity compared with the anterior vertebral ligament.

The **elastic or yellow ligaments**<sup>1</sup> are situated at the back of the spinal canal, where they appear in pairs between the laminae of contiguous vertebrae, the intervals of which they fill so as to render the back of the canal even throughout. They are attached to the lower fore part of the laminae above, and to the upper border and adjacent back part of the laminae below, extending from the median line outwardly to the capsular ligaments of the articular processes. They are widest in the cervical region, and become narrower below; and they are nearly as deep in front as the intervening surfaces of the laminae. Behind they are scarcely exposed, except in those positions in which the laminae do not entirely close the intervening spaces, as in the lower part of the thoracic and in the lumbar region to the sacrum. The ligaments are composed of longitudinal bundles of elastic tissue. The first pair occupies the interval between the laminae of the axis and of the third cervical vertebra; the last pair, the interval between those of the last lumbar vertebra and the sacrum.

The **articular ligaments**<sup>2</sup> are fibrous capsules enclosing the articulations, which are formed by the articular processes of contiguous vertebrae. The opposed surfaces of the processes are invested with cartilage, and the capsular ligaments are attached around the adjacent borders. Those of the neck are comparatively loose, while those of the thorax and loin are close.

The **nuchal ligament**<sup>3</sup> forms a median, triangular, membranous partition between the muscles at the back of the neck. Below it is continuous with the supraspinous ligament, and extends between the ends of the spinous processes of the cervical vertebrae and the occipital crest and protuberance. It is a loose intertexture of bundles of fibro-connective tissue with elastic tissue. The bundles, for the most part, start from the end of the prominent spinous process of the last cervical vertebra, and thence proceed in a radiant manner to the ends of the

FIG. 28.



THREE ARCHES REMOVED FROM AS MANY THORACIC VERTEBRÆ, viewed in front, and exhibiting, 1, the elastic ligaments; and 2, the capsular ligaments of the articular processes.

<sup>1</sup> L. flava; l. subflava; l. intercruralia; l. arcuum.

<sup>2</sup> L. capsularia processum articularium; l. c. p. obliquorum.

<sup>3</sup> L. nuchæ.



spinous processes above and to the occipital crest and protuberance. The bundles to the latter are longitudinal and form the thickened border of the ligament. In quadrupeds the nuchal ligament is composed of elastic tissue, and is adapted to sustain the skull, which in such animals is suspended from the spine. In those with a large head, sometimes loaded with heavy appendages, as in the stag with its antlers and the elephant with its huge tusks, it forms a powerful and most efficient instrument in supporting the weight and in removing all strain from the muscles.

The **supraspinous ligament**<sup>1</sup> is a narrow and not very distinct cord, composed of longitudinal bundles of fibres connecting the summits of the spinous processes, and extending continuously from the last cervical vertebra to the sacrum. In the intervals of the spinous processes it is continuous with the **interspinous ligaments**,<sup>2</sup> which are thin membranes extended between the contiguous margins of the spinous processes. In the loin these ligaments are deep and strong; in the thorax short and thin; and in the neck feebly produced and continuous with the nuchal ligament. The **intertransverse ligaments**<sup>3</sup> are thin membranous bands extended between the transverse processes of the lumbar vertebræ, and are less well produced between those of the thoracic vertebræ.

Adapted to the movements of the head, the articulations of the skull with the atlas and the latter with the axis are modified from those of the spine in general.

The **anterior atlanto-occipital ligament**<sup>4</sup> is a loose fibrous membrane, extended between the anterior border of the occipital foramen and the anterior arch of the atlas. In front it is connected with the anterior vertebral ligament, and at the sides with the articular ligaments.

The **anterior atlanto-axial ligament**,<sup>5</sup> similar to the former, connects the anterior arch of the atlas with the front of the centrum of the axis. In the same manner it is connected with the anterior vertebral ligament and the contiguous articular ligaments.

The **posterior atlanto-occipital ligament**<sup>6</sup> is a broad, loose membrane connecting the margin of the occipital foramen back of the condyles with the posterior arch of the atlas. In front it is closely adherent to the dura, and just behind the prearticular processes of the latter contributes to form the foramen for the transmission of

<sup>1</sup> L. supraspinale; l. longitudinale posterius; l. apicum.

<sup>2</sup> L. interspinale; membranæ interspinales.

<sup>3</sup> L. intertransversalia.

<sup>4</sup> L. atlanto-occipitale anticum; l. obturatorium atlanto-occipitale anticum; anterior occipito-atlantal or occipito-atloid ligament or ligaments.

<sup>5</sup> L. atlanto-axiale anticum; l. obt. atlanto-epistrophicum anticum; ant. atlo-axoid ligament or ligaments.

<sup>6</sup> L. atlanto-occipitale posticum; l. obt. atl. oc. post.; posterior occipito-atlantal or occipito-atloid ligament.

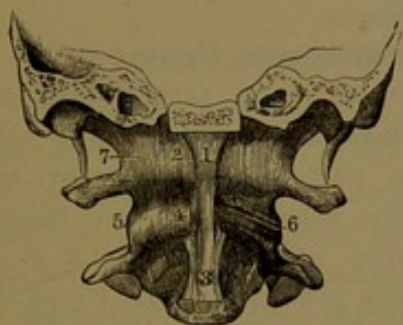


the vertebral artery into the cranial cavity, and for the passage of the first spinal nerve.

The **posterior atlanto-axial ligament**,<sup>1</sup> a similar membrane to the former, connects the contiguous arches of the atlas and axis, between the articular processes, behind which it contributes to form the intervertebral foramina for the second pair of spinal nerves.

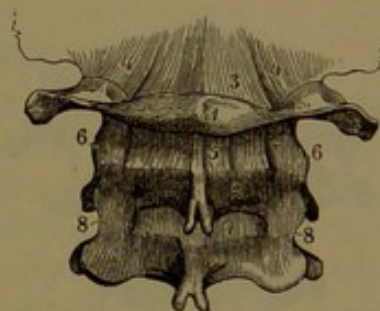
The **atlanto-occipital articulations**, formed between the occipital condyles and the prearticular processes of the atlas, are enclosed by loose **capsular ligaments** in accordance with the movements of flexion and extension of the head. They are reinforced and much

FIG. 29.



PORTION OF THE OCCIPITAL BONE, WITH THE ATLAS AND AXIS, front view. 1, origin of the anterior vertebral ligament; 2, anterior atlanto-occipital ligament on each side of the former; 3, widening portion of the anterior vertebral ligament; 4, anterior atlanto-axial ligament; 5, 6, 7, capsular ligaments of the articular processes.

FIG. 30.



PORTION OF THE OCCIPITAL BONE AND THE UPPER THREE CERVICAL VERTEBRÆ. 1, atlas; 2, axis; 3, posterior atlanto-occipital ligament; 4, capsular ligaments of the occipital condyles and articular processes of the atlas; 5, posterior atlanto-axial ligament; 6, capsular ligaments of the articular processes between the atlas and axis; 7, first pair of elastic ligaments; 8, capsular ligaments of the articular processes between the second and third cervical vertebrae.

strengthened by lateral portions of the posterior vertebral ligament, extending from the sides behind the centrum of the axis to the inner fore part of the occipital condyles. In the flexion and extension of the head the ligaments are put on the stretch in an opposite direction to that of the movement.

The **atlanto-axial articulations**, formed between the contiguous articular processes of the atlas and axis, are, like the former, enclosed by loose **capsular ligaments** in accordance with the rotary movements of the head. They are reinforced by a strong **internal lateral ligament**,<sup>2</sup> which is attached below to the upper part behind of the side of the centrum of the axis, and above to the articular column of the atlas behind the tubercle of attachment of the transverse ligament. When the head is turned to one side the ligaments of both articulations are put on the stretch in opposite directions. In the ordinary position, with the face directed forward, the opposed facets of the

<sup>1</sup> L. atlanto-axiale posticum; 1. obt. atlanto-epistrophicum post.; posterior atlanto-axoid ligament.

<sup>2</sup> Accessory atlanto-axial ligament.

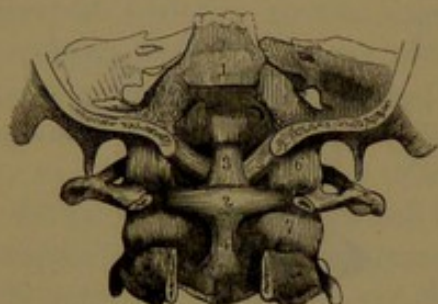


atlanto-axial articulations are in contact only along the middle transversely, and diverge in front and behind. In rotation the facets above and below become about half displaced, and the atlas with the head descends slightly from the highest level, which it occupies when the face is directed straight forward. Thus it appears that a man is actually taller when looking directly in front than when his head is turned to either side.

In the articulation of the skull with the atlas and with the axis the odontoid process is embraced by the transverse ligament, and is connected with the skull by the odontoid ligaments, which are included

between the position of the anterior atlanto-occipital and posterior vertebral ligaments.

FIG. 31.



PART OF THE SKULL, THE ATLAS, AND AXIS, viewed from behind; the posterior portions removed. 1, upper extremity of the posterior vertebral ligament; 2, transverse ligament, with its two appendices, 3 and 4; 5, lateral odontoid ligaments; 6, 7, capsular ligaments of the articular processes.

The **transverse ligament**<sup>1</sup> is a strong fibrous band attached by expanded ends to the tubercles at the inner fore part of the articular columns of the atlas, and passes behind the odontoid process, where it is of considerably greater depth. From the middle of its upper border a band<sup>2</sup> ascends to be attached to the inner surface of the basilar process at the margin of the occipital foramen, and from the lower border a shorter band<sup>3</sup> descends to be attached to the centrum of the axis in conjunction with

the posterior vertebral ligament. The accessory bands give to the ligament the form of a cross, whence, also, its name of the **cruciform ligament**.

The **odonto-atlantal articulation**, formed between the front of the odontoid process and the anterior arch of the atlas, is a synovial joint enclosed by a strong capsular ligament, attached around the opposed articular facets, which are covered with cartilage.

The **odonto-transverse articulation** is a synovial joint enclosed by a thin capsular ligament, situated between the odontoid process and the transverse ligament. Occasionally another synovial joint occupies a position between the transverse ligament and the posterior vertebral ligament.

The **lateral odontoid ligaments**<sup>4</sup> are two strong, thick cords, which spring together from the back and sides of the summit of the

<sup>1</sup> L. transversale atlantis; l. cruciatum; l. c. epistrophei.

<sup>2</sup> Appendix superior.

<sup>3</sup> A. inferior.

<sup>4</sup> Alar odontoid ligaments; check or moderator ligaments; l. alaria dentis; l. a. magna; l. lateralia.



odontoid process, and diverge outward and slightly upward to be attached to the inner borders of the occipital condyles. These check or limit the lateral movements of the head.

The **middle odontoid ligament**<sup>1</sup> is a loose fibrous bundle ascending from the fore part of the summit of the odontoid process to the anterior margin of the occipital foramen between the position of the lateral odontoid ligaments.

The **posterior sacro-coccygeal ligament** is a strong fibrous membrane closing the lower end of the spinal canal. It extends between the sides of the notch produced by imperfect development of the arches of the lower one or two sacral vertebræ, and thence between the cornua of the sacrum and coccyx to the second segment of the latter.

#### MOVEMENTS OF THE VERTEBRAL COLUMN.

The jointed or segmented condition of the spine or vertebral column, and the mode of union of its segments or vertebræ, admirably adapt it for its purposes. While the vertebræ are firmly and tenaciously bound together, the entire spine exhibits a remarkable degree of flexibility, which is only restricted within limits necessary to preserve the integrity of the important organ it encloses, the spinal cord. With the exception of the atlas, adapted to the special movements of the head, any pair of vertebræ alone exhibits comparatively but little motion, but this increases in proportion with the number of vertebræ included in the act, so that the whole spine is capable of movement in any direction, but mainly forward and backward, and more or less restricted in degree. The cervical and lumbar regions exhibit most flexibility, the thoracic region least, except the sacrum, which is immovably fixed. A feeble rotary or twisting movement is obvious in the spine, but is greatly restricted by the imbrication of the arches and interlocking of the articular processes of the vertebræ, and from the condition of attachment of the intervertebral disks and other ligaments. In flexion of the spine the elastic ligaments are stretched, and the laminæ of the arches become more separated. In extension the laminæ become more imbricated, and thus tend to restrict the movement.

The movements of the head on the spine are those of flexion and extension, or bending forward and backward, and those of rotation, or turning from side to side. The former is due to the occipital condyles rocking in a cup formed by the prearticular processes of the atlas. The movement is facilitated by the comparative looseness of the ligaments between the atlas and occipital bone, and is restricted when the ligaments are stretched. Further flexion and extension of the head are due to bending of all the cervical vertebræ. Lateral bending of the head, as when it is directed towards the shoulder, is also produced by

<sup>1</sup> L. rectum medium; l. medium dentis anticum; l. suspensorium dentis; l. apicis dentis.



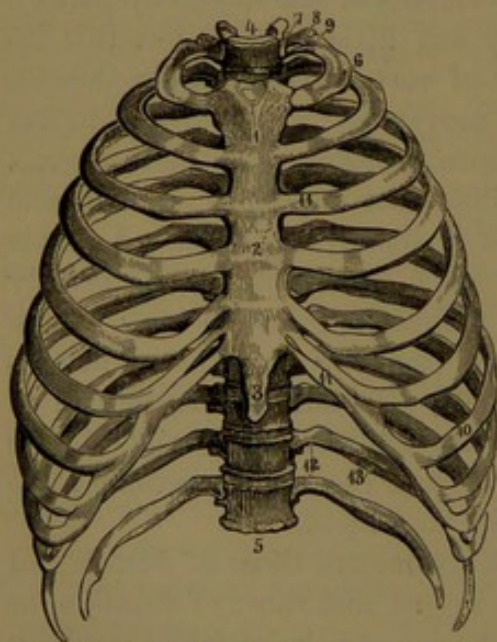
the flexion of all the cervical vertebræ together. In turning the head the motion is due to rotation of the atlas upon the axis, which remains fixed, the odontoid process and the prearticular processes being equally the fixed surfaces on which the movement of the atlas occurs. The motion is also facilitated by the looseness of the ligaments connecting the atlas and axis, and is restricted by these and the odontoid ligaments when put on the stretch.

### THE RIBS.

The **ribs**<sup>1</sup> are a series of twelve arching bones on each side of the thorax, articulating with the thoracic vertebræ, and extended through prolongations, the **costal cartilages**. The upper seven ribs by means of the latter join the sternum, whence they are distinguished as the **sternal ribs**,<sup>2</sup> while the others are the **asternal ribs**.<sup>3</sup> Of the latter, each of the upper three by means of its cartilage joins the cartilage above, while the remaining two have their cartilages free, and are thence more movable, and are called the **floating ribs**.<sup>4</sup>

The ribs successively increase in length from the first to the seventh or eighth, and then successively decrease to the last, which is a rudiment

FIG. 32.



FRONT VIEW OF THE THORAX. 1, 2, 3, the three pieces of the sternum; 4, 5, the thoracic vertebræ; 6, the first rib; 7, its head; 8, neck; 9, tubercle; 10, the seventh rib; 11, costal cartilages; 12, the floating ribs; 13, groove for the intercostal blood-vessels.

of the others. The intermediate ribs are generally the broader and most nearly alike. The vertebral extremity or **head**<sup>5</sup> of the rib commonly presents a pair of articular facets, which slant up and down from an intermediate ridge for the attachment of an interarticular ligament, while the facets articulate with those of the centra of a contiguous pair of vertebræ. From the head extends the slightly-narrowed **neck**,<sup>6</sup> defined outwardly behind by an eminence, the **tubercle**.<sup>7</sup> The neck is smooth in front and roughened behind for ligamentous attachment. The tubercle is roughened outwardly for the posterior costo-transverse ligament, and inwardly presents a small, smooth facet, which articulates with the end of the transverse process of the lower of the two vertebræ with which the head is connected. The **shaft** or **body**<sup>8</sup> of the rib, beyond

<sup>1</sup> Costæ; pleurapophyses. <sup>2</sup> True ribs; costæ veræ. <sup>3</sup> False ribs; costæ spuræ.

<sup>4</sup> C. fluctuantes. <sup>5</sup> Capitulum. <sup>6</sup> Collum. <sup>7</sup> Tuberculum. <sup>8</sup> Corpus.



the neck, is cylindrical, compressed from within outwardly, nearly flat on the exterior surface, and convex on the inner surface, thickest and of least depth behind, and becoming deeper and thinner in front. The upper border is thick and rounded, but becomes narrower in advance. The lower border is thin and for the most part sharp, and its posterior two-thirds are more downwardly extended, and in this position bound a groove<sup>1</sup> along the inner surface for the accommodation of the intercostal vessels and nerve. The anterior extremity of the rib, commonly after slightly narrowing, again widens a little and thickens at the end, where it presents an elliptical pit for junction with the costal cartilage. At the back part of the shaft behind is an oblique ridge, named the **angle**, at which the rib, from its outward direction, is somewhat abruptly bent forward and also downward in its further course. The rib also has a slight twist in its axis, so that the posterior surface behind the angle looks downward, and that in advance of the latter is directed in front a little upward. The angle is absent in the first and last ribs, commences near the tubercle in the second rib, and successively increases in distance from the latter to the eleventh rib.

The first rib, most unlike the others, is nearly flat, with the broad surfaces directed up and down, and with its narrow borders directed inward and outward. The head is small and rounded, and has but a single facet, which articulates with the centrum of the first thoracic vertebra. The neck is slender, and is marked above by a feeble groove for the last cervical nerve. The tubercle occupies the outer border, and is thick and prominent. The shaft curves from the tubercle outward, forward, and inward to a thickened end, but has no downward bend in its course. In strongly-marked specimens the upper surface of the shaft, in advance of the middle, is crossed obliquely by two shallow impressions, which accommodate the subclavian blood-vessels in their course over the rib. A slight ridge separates the impressions, and is variably more prominent inwardly, where it gives attachment to the anterior scalenus muscle.

The second rib conforms more to the common character, but its broad surfaces are directed obliquely upward and downward, and its borders are directed outward and inward. The angle is slight, and the shaft is not twisted, and near the middle is usually roughened for the attachment of the great serratus muscle. The eleventh and twelfth ribs, less well developed than the others, have a single articular facet to the head, to articulate with the centrum of the corresponding thoracic vertebrae, and they possess no tubercle.

Occasionally a rudimental thirteenth rib exists, on one or both sides, articulating with the first lumbar vertebra, in the usual position of the transverse processes. More rarely it is found in the neck, when

---

<sup>1</sup> Sulcus costalis.



it substitutes the usual costal process. In neither case does its presence accord with an additional vertebra to the series.

The ribs are composed of a thin, compact layer enclosing a uniform spongy substance.

In the development of the ribs a primary centre of ossification appears in the shaft about the seventh week of foetal life. Centres for epiphyses to the head and tubercle appear after puberty, and ankylose with the rest of the bone from the twentieth to the twenty-fifth year.

The **costal cartilages**<sup>1</sup> are prolongations of the ribs, and are directly continuous without forming an articulation with them. They successively increase in length from the first to the seventh, and thence decrease to the last one. Their direction is generally convergent to the sternum, the first descending a little, while the second and third are nearly horizontal, and the others successively become more ascending to the last two, which continue in the direction of the corresponding ribs. The first costal cartilage is continuous with the sternum, but those which follow, to the seventh inclusive, are narrowed at the ends and form a blunt, angular point, which movably articulates with the sternum. The ends of the succeeding three cartilages are tapering and turn upward, each to be attached by ligamentous bands to the cartilage above. The remaining two cartilages are tapering and free. In the intervals of the cartilages, from the fifth or sixth to the eighth or ninth, a wide process projects from each and articulates with the other.

In youth the costal cartilages are white, flexible, and elastic; after middle age they appear yellowish, harder, and more rigid. As life advances they are prone to partial ossification, though this rarely, if ever, occurs completely, even in the most advanced age. The ossification is mostly superficial, and especially affects the first cartilage. The disposition to ossification is less in the female, and occurs later.

#### THE STERNUM.

The **sternum** or **breast-bone**<sup>2</sup> is situated in front of the thorax, retained in its position through its connection with the upper seven pairs of costal cartilages. It is a moderately thick and comparatively light plate, slightly curved in the length, and slanting, with its anterior surface looking obliquely forward and upward. Before complete coalescence of all its parts, which occurs late in life, it consists of three pieces, named the presternum, the mesosternum, and the xiphisternum or ensiform process.

The **presternum**<sup>3</sup> is broadest and thickest above, where it is extended laterally to unite with the first pair of costal cartilages and to articulate with the clavicles; and is narrowed below to articulate

<sup>1</sup> Cartilagines costarum; hæmapophyses.

<sup>2</sup> Os xiphoides; scutum pectoris; hæmal spine.

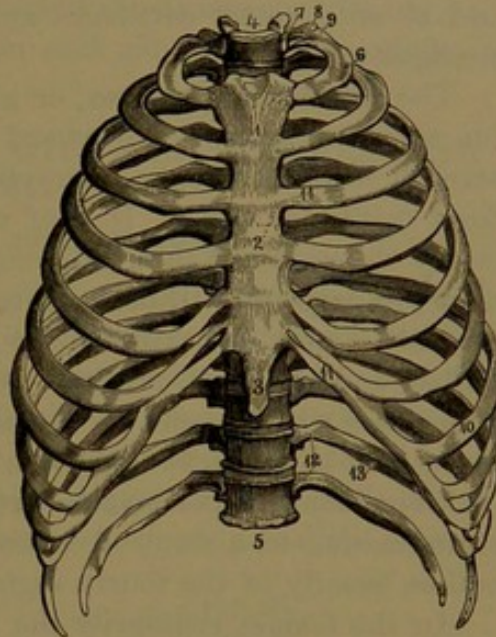
<sup>3</sup> Manubrium.



with the mesosternum and the second pair of costal cartilages. The anterior surface presents a slight median prominence expanding outwardly above, and is slightly concave at the sides; the posterior surface is slightly concave and even. The upper border forms a median transverse concavity, the **interclavicular notch**,<sup>1</sup> which is rounded fore and aft. On each side of this is the **clavicular notch**<sup>2</sup> for articulation with the clavicle. It is an elliptical concavity, inclining outwardly, and is nearly flat or slightly convex fore and aft. From its outer extremity a triangular, rough depression extends downward for union with the first costal cartilage. The margin below is acute, and converges to the inferior angle, which is truncated to form part of the notch for articulation with the second costal cartilage. The inferior extremity—somewhat thickened, and usually slightly prominent in front—ends in a horizontal, roughened surface for articulation with the mesosternum.

The **mesosternum**<sup>3</sup> is the intermediate, longest piece of the sternum, and is a flat plate of nearly uniform thickness. The anterior surface not unfrequently exhibits three slight transverse lines, indicating the early separation of the piece into four segments, which are commonly feebly depressed towards the centre. The posterior surface is evenly flat. In the outline of shape the mesosternum is very variable, and is commonly somewhat rectangular or elliptical, and frequently more or less widened at the lower third, so as to appear clavate. The upper extremity, often a little thickened, is adapted to articulate with the presternum, and on each side has the corresponding angle truncated to form part of the notch for articulating with the second costal cartilage. The lower extremity is usually more or less narrowed and rounded, and ends in a transverse pit, which articulates with the ensiform process. The lateral borders are thick and scalloped, presenting a series of vertically concave articular notches, separated by mostly longer concave notches. The former, together with the

FIG. 33.



FRONT VIEW OF THE THORAX. 1, 2, 3, the three pieces of the sternum; 4, 5, the thoracic vertebrae; 6, the first rib; 7, its head; 8, neck; 9, tubercle; 10, the seventh rib; 11, costal cartilages; 12, the floating ribs; 13, groove for the intercostal blood-vessels.

<sup>1</sup> Incisura semilunaris; i. jugularis.

<sup>3</sup> Body; corpus sterni; gladiolus.

<sup>2</sup> I. clavicularis.



contiguous articular surfaces of the presternum and ensiform process, articulate with the costal cartilages from the second to the seventh inclusive, and the intervening notches correspond with the fore part of the intercostal spaces. The articular notches for the sixth and seventh costal cartilages and the ensiform process are in close contiguity.

The **ensiform process**, or **xiphisternum**,<sup>1</sup> the smallest piece of the sternum, projects downward from the mesosternum between the seventh costal cartilages, occupying a somewhat deeper level than the front surface of these. It is of very variable form, and is more commonly observed as a thin, flat, tongue-shaped plate, ending in a cartilaginous prolongation. Differing greatly in the proportion of length and breadth, it may be narrow and pointed, or ensiform, discoid and entire, forked or perforated, straight or curved. Its upper, thicker border articulates with the end of the mesosternum, and on each side of this forms part of the articular notch for the seventh costal cartilage.

Occasionally a perforation appears in the lower part of the mesosternum, due to a want of coalescence of the lateral centres of ossification, usually of the fourth segment.

In the female, ordinarily the presternum is proportionately wider, and the mesosternum longer and narrower, than in the male.

The sternum is composed of light, spongy substance, with a thin layer of compact substance. Its nutritious foramina, larger on the inner surface, are for the most part inconspicuous. It is invested with a much thicker periosteum than usual in other bones.

The course of development and growth of the sternum is very variable. Ossification commences in the presternum about the sixth month of foetal life, commonly from a single centre, frequently from a pair, and occasionally from three or more centres. Ordinarily when a pair occurs the centres are near together, one larger and placed on a little higher level than the other. In the mesosternum there may be a series of three or four centres, or there may be double the number, in pairs, opposite the intercostal spaces, side by side, or arranged in the same manner as the presternal pair. The upper ones appear about the seventh month of foetal life, and the others follow in succession up to the ninth or tenth year. The lateral centres quickly coalesce, but the resulting four segments remain a long time separated. They successively ankylose from below upward, and the upper piece frequently does not unite with the rest until the twenty-fifth year or later. The ensiform process commences ossification from three to six or more years after birth, usually from a single centre at the base, but occasionally from a pair. At twenty years it is still in great part cartilaginous, nor does it completely ossify before the thirtieth or fortieth

---

<sup>1</sup> Metasternum; hyposternum; processus xiphoides or ensiformis; ensiform or xiphoid appendix; cartilago ensiformis.



year. It commonly ankyloses with the mesosternum after fifty, but sometimes much earlier. The mesosternum unites with the presternum at a still later period, though occasionally the union occurs even long previously, and sometimes it remains permanently separated.

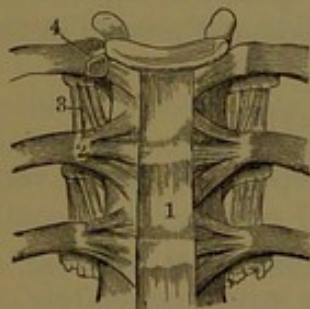
Rarely a pair of osseous nodules, named the **episternal bones**,<sup>1</sup> are found attached to the sternum, one on each side of the interclavicular notch.

## ARTICULATIONS OF THE RIBS WITH THE VERTEBRÆ AND STERNUM.

### COSTO-VERTEBRAL ARTICULATIONS.

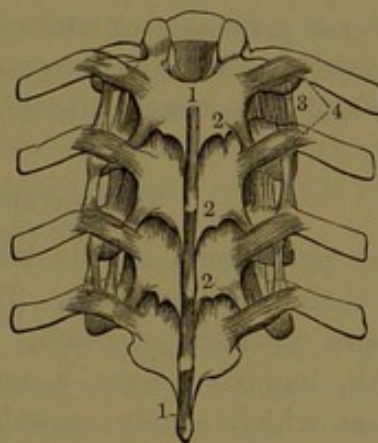
**Costo-central articulations.** These are formed between the heads of the ribs and the centra of the thoracic vertebræ. Each articulation, except the first and the last two, is formed by the head of the rib in conjunction with the centra of two adjacent vertebræ. The articulation is enclosed by a capsular ligament, and is divided into two synovial cavities by an **interarticular ligament**, which is a horizontal band of short fibres passing between the ridge on the head of

FIG. 34.



ANTERIOR VIEW OF THREE THORACIC VERTEBRÆ AND THEIR ARTICULATION WITH THE RIBS. 1, portion of the anterior vertebral ligament; 2, anterior costo-central ligament; 3, anterior costo-transverse ligament; 4, articulation of the head of the rib laid open, exhibiting the cavity divided into two by an interarticular ligament.

FIG. 35.



POSTERIOR VIEW OF FOUR THORACIC VERTEBRÆ AND THEIR ARTICULATION WITH THE RIBS. 1, supraspinous ligament; 2, elastic ligament, seen just below the edge of the vertebral laminae; 3, anterior costo-transverse ligaments; 4, posterior costo-transverse ligaments.

the rib and the contiguous intervertebral disk. The articulation in front is strengthened by the **anterior costo-central ligament**,<sup>2</sup> which consists of three bands radiating from the front of the head of the rib to the sides of the adjoining pair of vertebræ and intervening disk.

As the first and last two ribs articulate each with a single vertebral

<sup>1</sup> Ossa suprasternalia; episternal granules.

<sup>2</sup> Anterior costo-vertebral ligament; stellate or radiate ligament; ligamenta costo-vertebralia radiata; 1. capituli costarum.



centrum, the joint has a single synovial cavity, and its anterior costo-central ligament consists of but two bands, of which one joins the vertebral centrum with which the rib articulates, and the other joins the centrum above.

**Costo-transverse articulations.** A joint with a synovial cavity is formed between the articular facet of the tubercle of the ribs and that of the transverse processes of the thoracic vertebræ, and is enclosed by a **capsular ligament**. The articulation is greatly strengthened by three additional ligaments, as follows:

The **posterior costo-transverse ligament**<sup>1</sup> is a well-marked band which extends from the end of the transverse process to the rib just outside of its tubercle. The **middle costo-transverse ligament**<sup>2</sup> consists of short bundles of fibres which unite the posterior surface of the neck of the rib to the front of the contiguous transverse process. The **anterior costo-transverse ligament**<sup>3</sup> is a membranous band extended from the upper border of the neck of the rib obliquely outward to the lower margin of the transverse process above. Its inner edge is thickened and free, and outwardly it is continuous with the intercostal fascia.

No synovial articulation exists between the last two ribs and the transverse processes of the corresponding vertebræ. In these, also, the posterior and middle costo-transverse ligaments together form a longer and looser band, allowing greater freedom of motion in the ribs.

#### COSTO-STERNAL ARTICULATIONS.

The periosteum of the ribs extended upon the costal cartilages forms their perichondrium. The first costal cartilage is a continuous structure with the sternum. The succeeding costal cartilages to the seventh, inclusive, form a series of joints with the margin of the sternum, which nearly resemble the costo-central articulations. The second costo-sternal articulation, enclosed by its capsular ligament, has two synovial cavities separated by an interarticular ligament. The succeeding articulation commonly has a similar arrangement, while the others have a single cavity or none, in which latter case the end of the costal cartilage is connected with the sternum by a stout interarticular ligament. Each costo-sternal articulation is especially strengthened by the **anterior costo-sternal ligament**,<sup>4</sup> which consists of fibrous bundles radiating from the end of the costal cartilage upon the front

<sup>1</sup> L. costo-transversarium posticum; l. transversarium externum costarium; l. cervicis costæ externum.

<sup>2</sup> Interosseous costo-transverse ligament; l. costo-transversarium intermedium; l. colli costæ.

<sup>3</sup> Superior or long costo-transverse lig.; l. costo-transversarium anticum or inferium; l. trans. internum costarum.

<sup>4</sup> L. costo-sternale radiatum; l. sterno-costale anticum.



of the sternum, where the fibres interlace with those of the ligaments above and below and on the opposite side, and with the tendinous fibres of origin of the pectoral muscles. The **posterior costo-sternal ligament**<sup>1</sup> is the corresponding portion of the capsular ligament, consisting of fibrous bundles, which reinforce the extension over the joint of the contiguous periosteum.

The **costo-xiphoid ligament**<sup>2</sup> is a variable and mostly thin fibrous band, which extends obliquely in front between the ends of the sixth and seventh costal cartilages to the side of the ensiform process.

**Intercostal articulations.** The intervening processes of the costal cartilages, from the fifth or sixth to the eighth or ninth, form joints with nearly flat, articular surfaces enclosed by thin capsular ligaments. The ends of the asternal costal cartilages, except the last two, are each joined to the cartilage above by short intervening bundles of fibres, the **intercostal ligaments**.

#### STERNAL ARTICULATIONS.

Prior to ankylosis the presternum joins the mesosternum by an intervening plate of cartilage, which sometimes exhibits a central fissure. The articulation is enclosed by longitudinal fibrous bundles, short in front, but greatly reinforced behind by others extending the whole length of the sternum. The ensiform process is joined to the mesosternum in like manner with the preceding articulation.

The numerous ligaments connected with the sternum, together with the tendinous attachments and the periosteum, form a fibrous sheath to the bone unequalled elsewhere in the skeleton.

#### THE THORAX.

The **thorax**, or **chest**, is a conical bony cage, composed of the thoracic vertebræ, the ribs with their cartilages, and the sternum. It is compressed fore and aft, so as to be widest from side to side, a condition the reverse of what we observe in many animals, and one which makes it easy for us to lie at rest on the back, while it is inconvenient for them. The thorax rapidly increases in dimension from the first rib to the third or fourth, then more gradually to the eighth or ninth, after which it slightly decreases. Its circumference where greatest, covered with the soft parts, averages about thirty-two inches, and in well-developed subjects reaches three feet, but in feeble ones only twenty-nine inches. It is deepest behind, where it measures about a foot, and decreases in advancing to the sternum, where it is about half the depth. The transverse diameter, greatest at the eighth or ninth rib, is within an inch of the posterior depth, and the fore and aft diameter, greatest at the end of the ensiform process, is nearly a fourth less than the former (Sappey).

<sup>1</sup> L. sterno-costale posticum.

<sup>2</sup> L. costo-xiphoidea.



The **back** of the thorax is vertical, moderately convex from above downward, and flattened from side to side. It is divided by a prominent median ridge formed of the spinous processes of the thoracic vertebræ, and is laterally defined by the angles of the ribs, which successively extend more outwardly from above downward. The interval on each side of the median ridge forms a depressed space, which is occupied by the extensor muscles of the back. The space is divided by the series of transverse processes, the ends of which project to about the level of the angles of the ribs.

The **sides** of the thorax are most prominently convex, both from above downward and from before backward. The lower border reaches about on a level with the third lumbar vertebra.

The **front** of the thorax is flattened, and slopes downward and forward. It is formed by the sternum, the costal cartilages, and the anterior extremities of the upper eight or nine ribs. As the ribs incline forward and downward, their anterior ends are placed on a considerably lower level than the heads. The anterior end of the sixth rib is about on a level with the head of the last rib. The upper border of the sternum is on a level with that of the third thoracic vertebra, and its end with the last thoracic vertebra.

The **cavity of the thorax**<sup>1</sup> in front and laterally conforms to the outside, but behind it is modified by the projection forward of the bodies of the thoracic vertebræ, which form a partial partition between the two sides of the cavity. The projection reduces the median space occupied by the heart, and at the same time, together with the backward extension of the ribs to their angles, it produces the capacious **dorsal recesses**, at the sides of the spine, which are occupied by the posterior portions of the lungs. The projection of the spine diminishes to nearly one-half the median fore and aft extent of the cavity compared with what the thorax is externally; while, on the other hand, the transverse diameters within and without differ only in the thickness of the side walls of the thorax. With the antero-posterior compression of the thorax and the advancement of the vertebral column this assumes a nearly central position, which is most favorable in maintaining the equilibrium of the body in the erect condition.

The horizontal plane of the cavity of the thorax is transversely reniform. The **superior aperture** is on an inclined plane, directed forward, and is twice the width or more from side to side than it is fore and aft. It is formed by the first thoracic vertebra, the first pair of ribs with their cartilages, and the presternum. Through it pass the trachea and œsophagus and the great blood-vessels of the neck and upper limbs, and it is partially occupied by the apices of the pleuræ, into which the lungs extend. The **inferior aperture** has its plane interrupted by three deep, angular notches. Of these the front or ab-

---

<sup>1</sup> Cavum thoracis.



**dominal** notch is the widest and deepest, and is formed on each side by the costal cartilages from the seventh to the last, and has projecting into it the ensiform process. The posterior or **lumbar notches** are formed on each side by the last thoracic vertebra and the last rib. The **intercostal spaces** are formed by the intervals of the ribs with their cartilages, closed in front by the sternum, and below this by the union of the former, except in the last two, which are open. Behind, they are closed by the adjacent vertebræ, from between which the intervertebral foramina open into the spaces. The upper intercostal spaces are widest and the middle ones narrowest, especially laterally, and mostly they are widest in front.

In the female the thorax is proportionately longer, narrower, transversely more circular, and vertically more oval, than in the male. Tight lacing reduces the breadth of the thorax, especially towards the base, and it diminishes the intercostal spaces,—in extreme cases the contiguous margins of the ribs being more or less brought into contact and the inferior lateral margin of the thorax nearer the crest of the ilium.

**Movements of the thorax.** The chief movement of the thorax, as in breathing, consists in partial rotation of the ribs on their axis, up and down, where they articulate with the vertebræ, facilitated by somewhat similar motion in the costo-sternal articulations. In the movement the ribs are alternately raised and depressed from their fore part. When lifted, the ribs approach a more horizontal position, and the capacity of the chest is proportionately increased, and in the depression the reverse condition follows. The sternum is lifted with the ribs, and at the same time projected below, thus contributing to the enlargement of the thoracic cavity. In old age the costo-vertebral articulations become less movable, the costal cartilages rigid, and the costo-sternal articulations obliterated, in which condition the thorax is less dilatable, and respiration is mainly carried on through the diaphragm.

#### THE SKULL.

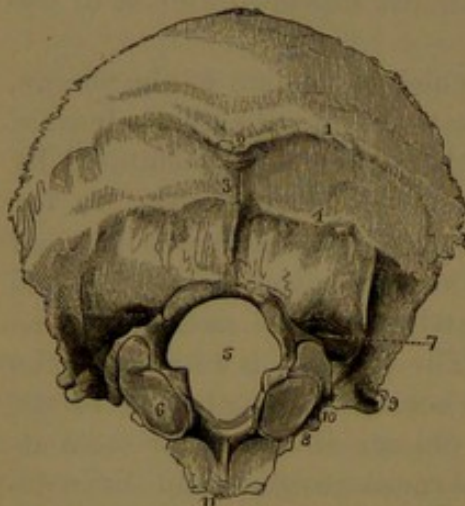
The **skull** includes all the bones of the head, and articulates with the vertebral column by means of the occipital bone. It consists of two chief parts,—the **cranium**, which contains the brain; and the **face**, which with the former contains the orbits or eye-sockets and the nasal cavities, and below is formed by the jaws, which include the cavity of the mouth. The cranium is composed of eight bones, of which four are single and symmetrical,—the occipital, sphenoid, ethmoid, and frontal,—and the others are in pairs,—the parietal and temporal bones. The face is composed of fourteen bones, of which two only are single,—the vomer and the mandible,—and the others are in pairs,—the maxillary, palate, malar, nasal, turbinal, and lachrymal bones. The hyoid, a single, symmetrical bone, situated in the neck, is included in the account of the skull.



## THE OCCIPITAL BONE.

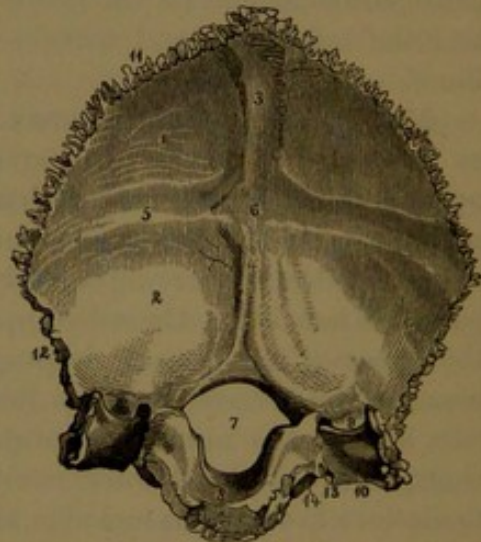
The **occipital bone**<sup>1</sup> occupies the back part of the cranium, between the parietals above and the temporals below, and it extends forward in the middle of the base of the cranium to the sphenoid bone, with which it is commonly ankylosed at adult age. It is irregularly quadrate in outline, convex externally and concave internally; and it consists of an anterior inferior, narrow, and comparatively thickened and spongy portion, the **basilar process**, and a posterior, broad, shell-like portion, the **occipital plate**. Between the two portions is the **occipital foramen**, through which the cavity of the cranium communicates with the spinal canal; and at the sides of the foramen are the **condyles**, which form movable articulations with the prearticular processes of the atlas or first vertebra.

FIG. 36.



EXTERNAL VIEW OF THE OCCIPITAL BONE. 1, superior curved line; 2, external occipital protuberance; 3, occipital crest; 4, inferior curved line; 5, occipital foramen; 6, condyle; 7, fossa behind the condyle, into which a venous foramen frequently opens; 8, position of condylar foramen; 9, jugular process; 10, notch contributing to form the jugular foramen; 11, basilar process.

FIG. 37.



INTERNAL VIEW OF THE OCCIPITAL BONE. 1, fossa for the cerebrum; 2, fossa for the cerebellum; 3, groove for the longitudinal sinus; 4, ridge for the attachment of the cerebellar falx; 5, groove for the lateral sinus; 6, internal occipital protuberance; 7, occipital foramen; 8, basilar process; 9, 10, groove for the lateral sinus, descending on the jugular process to the jugular notch; 11, border for the parietal bone; 12, border for the temporal bone; 13, position at which the ninth, tenth, and eleventh cerebral nerves pass through the jugular foramen; 14, condylar foramen.

The **basilar process**<sup>2</sup> projects in advance of the occipital foramen obliquely forward and upward to near the centre of the base of the skull, where it joins the body of the sphenoid bone. It is irregularly quadrate in outline, but narrows and becomes thicker forward. Its posterior lower border is thinnest, and is notched to form the anterior

<sup>1</sup> Os occipitis.<sup>2</sup> Pars basilaris; basioccipital bone; basis; corpus.



margin of the occipital foramen. Its anterior extremity ends in a quadrate rough surface, which, previous to ankylosis, is connected with the sphenoid bone by cartilage. The lateral borders of the process join the pyramid of the temporal bone. The **lower surface** is transversely convex, and is sometimes and variably produced in a feeble median ridge,<sup>1</sup> which gives attachment to the pharynx. On each side, the surface is marked by the attachment of the prerecti muscles. The **upper surface** forms a smooth concave gutter, the **basilar groove**,<sup>2</sup> which slopes downward to the occipital foramen, and accommodates the medulla oblongata. At the lateral margins it is marked by a shallow furrow for the infrapetrosal sinus.

The **occipital plate**<sup>3</sup> encloses the back part of the cranial cavity in the interval of the parietal bones and the mastoid portion of the temporals. The upper borders<sup>4</sup> from the **lateral angles** converge to the **superior angle**, and are remarkably jagged for sutural union with the parietal bones; the lower borders,<sup>5</sup> converging downward and forward, are less rugged than the former, and articulate with the mastoid portion of the temporal bones. The **external surface** is convex, and forms the prominent back part of the skull. Near its centre it presents a variably produced and roughened eminence, the **occipital protuberance**,<sup>6</sup> from which descends to the occipital foramen a slight ridge, the **occipital crest**,<sup>7</sup> both giving attachment to the nuchal ligament. From the protuberance another ridge, the **superior curved line**,<sup>8</sup> arches outwardly on each side to the lateral angle, dividing the surface into two portions, of which the upper is more prominent and evenly convex, and is covered by the scalp. The lower portion is further divided by the **inferior curved line**,<sup>9</sup> which runs nearly parallel with the former. The curved lines and surfaces below them give attachment to muscles of the neck, the impressions of which are commonly most marked in vigorous muscular subjects.

The **internal surface** of the occipital plate is divided into four shallow concave recesses, of which the lower and larger are the **cerebellar fossæ**, for the reception of the hemispheres of the cerebellum; and the upper are the **cerebral fossæ**, for the accommodation of the hemispheres of the cerebrum. The fossæ are defined by a median fore and aft and a horizontal ridge, which together form the **occipital cross**, and produce at their conjunction the **internal occipital protuberance**.<sup>10</sup> To the upper arm of the cross is attached the cerebral falx, and it is impressed, usually to one side, with a groove,<sup>11</sup> which

<sup>1</sup> Crista basilaris; pharyngeal tubercle.

<sup>3</sup> Supraoccipital; occipital portion; squama.

<sup>5</sup> Margo mastoideus. <sup>6</sup> External oc. post.

<sup>8</sup> Linea semicircularis superior.

<sup>10</sup> Eminentia cruciata.

<sup>2</sup> Sulcus basilaris.

<sup>4</sup> Margo lambdoideus.

<sup>7</sup> Crista occipitalis externa.

<sup>9</sup> L. s. inferior.

<sup>11</sup> Sulcus sagittalis.



accommodates the posterior extremity of the great longitudinal sinus. To the horizontal arms of the cross, which are nearly on a level with the external superior curved lines, is attached the tentorium; and they are impressed with a groove for the lateral sinus, usually larger on one side than on the other, and varying in size in accordance with the sinus. The lower arm of the cross is an acute ridge, the **internal occipital crest**, which gives attachment to the cerebellar falx.

The **occipital foramen**,<sup>1</sup> situated at the lowest level of the bone, is a large oval hole, with its rather greater diameter fore and aft, and with its margin somewhat thickened for ligamentous attachment with the atlas. Through it the medulla oblongata is continuous with the spinal cord, and it also transmits the vertebral arteries and spinal accessory nerves.

The **condyles**<sup>2</sup> are placed beneath, at the sides of the anterior half of the occipital foramen, and are a pair of articular processes, which are invested with cartilage and adapted to the prearticular processes of the atlas. They are irregular elliptical eminences, convergent forward, separated in front by a wide notch in advance of the occipital foramen, and behind by the greater width of the latter. They are sometimes more or less constricted near the middle,—a condition remaining in the line of, and indicating the original separation of the basilar portion from, the rest of the bone. The articulating surface is convex fore and aft, but forms an inclined plane looking downward and outward. On the deeper, inner side of the condyles, bordering the occipital foramen, there is usually a variable, roughened ridge, which gives attachment to the lateral odontoid ligaments.

Piercing the base of the condyles above the middle is a short canal, the **condylar foramen**,<sup>3</sup> which is directed from within the cranial cavity forward and outward for the passage of the hypoglossal nerve. Back of the condyles is a variable fossa,<sup>4</sup> into which there commonly opens on one or both sides of the bone a foramen<sup>5</sup> for the passage of a vein between the lateral sinus and the veins of the scalp. To the outer side of the position of the condyles is the **jugular notch**,<sup>6</sup> which forms the back part of the jugular foramen, situated between the occipital and temporal bones. Projecting outwardly from the notch is the **jugular process**,<sup>7</sup> ending in a usually quadrate, roughened facet, which is covered with cartilage and joins the pyramid of the temporal bone. Beneath the process is a transverse ridge,<sup>8</sup> which gives attachment to the lateral rectus muscle; and above, it is grooved<sup>9</sup> for the accommodation of the lateral sinus as it terminates at the jugular foramen.

At birth the occipital bone consists of four pieces, which are united

<sup>1</sup> F. occipitalis; f. magnum.

<sup>2</sup> Anterior condyloid foramen.

<sup>3</sup> Posterior condyloid foramen.

<sup>4</sup> P. jugularis; paroccipital process.

<sup>5</sup> Processus condyloideus.

<sup>6</sup> Fossa condyloidea.

<sup>7</sup> Incisura jugularis.

<sup>8</sup> Jugular eminence. <sup>9</sup> Sulcus transversus.



by cartilage. The pieces are named the **basioccipital**, in front; the **exoccipitals**, at the sides of the occipital foramen; and the **supraoccipital**, behind.

The **basioccipital** comprises the basilar process, together with the fore part of the condyles and condylar foramina, both of which are divided by the suture. The **exoccipitals**<sup>1</sup> comprise the parts behind the former to the outer side of the occipital foramen, and include the back part of the condyles and condylar foramina. The **supraoccipital** comprises the occipital plate, bounding the occipital foramen behind. A transverse fissure extending a short distance inward from the lateral angles indicates an earlier separation of the supraoccipital into two pieces, of which the upper one originates in fibrous membrane, while the lower one, together with the other pieces of the occipital bone, originates in cartilage. The upper piece of the supraoccipital occasionally remains separate even at maturity, when it is united with the lower by suture. In some animals, as the rabbit, it remains permanently distinct, as the interparietal bone. The upper angle of the supraoccipital is also divided by a fissure, and this, with the transverse fissures, indicates the origin of the supraoccipital from four ossific centres. The occipital bone commences to ossify about the seventh week of foetal life. The supraoccipital ankyloses with the exoccipitals variably from the third to the sixth year, and then with the basioccipital during the latter part of the same time.

#### THE SPHENOID BONE.

The **sphenoid bone**<sup>2</sup> extends across the base of the skull in advance of its middle, and is situated between the occipital and temporals behind, the ethmoid and frontal in front, and the parietals above. It articulates with all the other bones of the cranium, and with five of those of the face; and it contributes to form the cranial cavity, the orbits, the nasal cavities, and the temporal, zygomatic, and sphenomaxillary fossæ. It consists of a central, more massive portion, the **body**, and four pairs of conspicuous processes: the **small** and **great wings** and the **ento-** and **ectopterygoid processes**.

The **body** is irregularly cuboidal, and is usually before adult age firmly ankylosed with the basilar process of the occipital bone, from which, in prepared specimens for study, it is commonly found separated by the saw. Before ankylosis it presents a posterior, vertical, quadrate or oval, rugged surface, which is connected with the basilar process by cartilage.

The upper surface of the body is within the cranial cavity, and extends from the basilar process to the cribriform plate of the ethmoid bone. Behind its middle is a deep hollow, the **sella**,<sup>3</sup> which lodges

<sup>1</sup> Lateral occipitals; condylar portions.

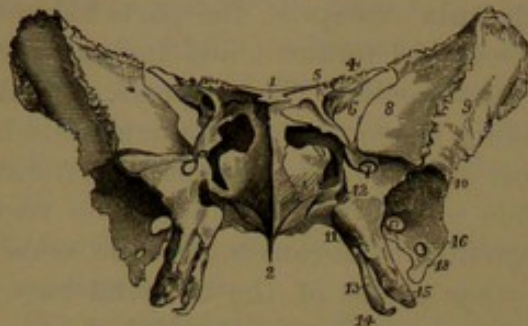
<sup>2</sup> Os sphenoides.

<sup>3</sup> S. turcica; pituitary fossa; ephippium; fossa hypophyseos.



the pituitary body. The back of the sella is formed by an oblique, overhanging, quadrate plate, the **clivus**,<sup>1</sup> the posterior surface of which extends the slope of the basilar groove. The upper thick-

FIG. 38.



FRONT VIEW OF THE SPHENOID BONE. 1, ethmoidal process; 2, sphenoidal crest and rostrum for joining the nasal plate of the ethmoid bone and the vomer; 3, entrance of the sphenoidal sinuses; 4, small wing; 5, optic foramen piercing its base; 6, sphenoidal foramen; 7, rotund foramen; 8, orbital surface of the great wing; 9, temporal surface of the same; 10, ridge separating the temporal and zygomatic surfaces; 11, vaginal process; 12, pterygoid canal; 13, entopterygoid process; 14, hamular process; 15, ectopterygoid process; 16, angular process; 17, oval foramen; 18, spinous foramen.

The side of the body slants downward and outward from the sella into the mesocranial fossa, and is crossed fore and aft by the **carotid groove**,<sup>4</sup> which accommodates the internal carotid artery. The groove pursues a sigmoid course, is scarcely marked along the middle, is deepest behind, where it ascends on the lingule, and terminates in front in a notch between the olivary and preclinoid processes. The **lingule**<sup>5</sup> is a short scroll-like process, which projects from the posterior part of the body on each side, and skirts internally the lacerate foramen.

A usually slight and variable eminence, sometimes present on the side of the sella, is the **mesoclinoid process**.<sup>6</sup> In advance of the olivary process and optic groove a broad and nearly flat or slightly depressed surface is continuous outward on the small wings. It commonly exhibits a slight median elevation, and is variably extended in a projection, the **ethmoidal process**,<sup>7</sup> which articulates with the ethmoidal cribriform plate.

The front of the sphenoidal body is directed towards the nasal cavities, and is divided by a vertical, median, carinate ridge, the **sphenoidal crest**,<sup>8</sup> which joins the ethmoidal nasal plate in the formation of the

enlarged border of the clivus is transversely concave, and at each end is produced in a variable tubercle, the **postclinoid process**,<sup>2</sup> which is commonly extended behind in a short spine, and gives attachment to the tentorium. Below the sides of the clivus is a process directed outwardly to articulate with the end of the temporal pyramid, and grooved above to accommodate the abducent nerve. In advance of the sella is a variable, obtuse eminence, the **olivary process**,<sup>3</sup> which is usually more or less defined in front by the equally variable **optic groove**, which leads outwardly to the optic foramina.

<sup>1</sup> C. Blumenbachii; dorsum sellæ or ehippii.

<sup>2</sup> Posterior c. p.

<sup>3</sup> Tuberculum sellæ. <sup>4</sup> Sulcus caroticus; impressio carotica; cavernous groove.

<sup>5</sup> Lingula sphenoidalis.

<sup>6</sup> Middle c. p.

<sup>7</sup> Spina ethmoidalis.

<sup>8</sup> Crista sphenoidalis.

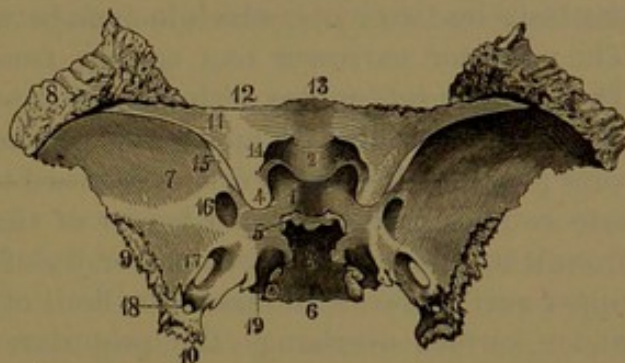


partition of the nose. The surface on each side of the crest is a variable, shallow, quadrate recess, which forms the back part of the roof of the corresponding nasal cavity. About the middle of the recess is a variable, large, irregular hole, which communicates with the sphenoidal sinus. To the outer side of the recess the surface articulates with the ectethmoid and the orbital process of the palate bone. The apposition of the former partially reduces the size of the opening of the **sphenoidal sinuses**. These are two variably large and mostly unequal cavities within the fore part of the sphenoidal body. They are separated by a partition, the **sphenoidal septum**, of which the sphenoidal crest is an extension. The partition is more or less unsymmetrical, and produces the same condition in the sinuses. The septum not only deviates to one or the other side, but often varies from the vertical fore and aft direction. Occasionally there are one or two additional, incomplete partitions. The sinuses occupy the fore part of the body to the complete exclusion of

the spongy substance, which occupies the back part. They increase in size with the advance of age at the expense of the spongy substance, but never to such an extent as entirely to obliterate the latter.

The inferior surface of the sphenoidal body looks downward into the nasal cavities, and extends from these into the guttural region, where it is continuous with the under surface of the basilar process. Its fore part is produced into a median keel-like ridge, the **rostrum**,<sup>1</sup> which is wide and low behind and becomes deeper and narrow in front, and is received in the upper grooved border of the vomer. The rostrum is continuous with the sphenoidal crest, but is usually defined from it by a notch, which remains from an original separation of the body into two parts. The triangular space at the sides of the rostrum, defined outwardly from the root of the great wing by a groove, exhibits a low convex prominence, which forms the bottom of the corresponding sphenoidal sinus. The eminence widens forward, and its surface turns up in front to the entrance of the sinus. In infancy it appears as a

FIG. 39.



UPPER VIEW OF THE SPHENOID BONE. 1, sella; 2, olivary process; 3, clivus; 4, preclinoid process; 5, postclinoid process; 6, posterior border of the body; 7, cerebral surface of the great wing; 8, articular surface for the frontal bone; 9, articular border for the temporal bone; 10, spinous process; 11, small wing; 12, border articulating with the orbital plate of the frontal bone; 13, border joining the ethmoid bone; 14, optic foramen; 15, sphenoidal foramen; 16, rotund foramen; 17, oval foramen; 18, spinous foramen; 19, groove on the lingule for the internal carotid artery.

<sup>1</sup> R. sphenoidale; processus azygos.



distinct bone, the **spheno-turbinal**,<sup>1</sup> which is a hollow cone, and subsequently ankyloses with the rest of the sphenoid to form the sphenoidal sinuses. Sometimes, shortly before adult age, it may be found as a separate piece articulating with the body of the sphenoid bone.

The **small wings**<sup>2</sup> are a pair of nearly horizontal, sabre-like plates, which extend outwardly from the fore part of the body, and are separated from the great wings by the **sphenoidal fissure**. In the articulated skull they project into the cavity of the cranium, where they are received in the sylvian fissure of the brain. They are connected with the body by two roots, which include between them the optic foramen. The posterior narrower root springs from below the olivary process. The anterior root unites with that of the opposite side in a continuous plate, which forms the upper part of the body in advance of the olivary process. The wing tapers outward to a point which nearly comes into contact with the upper border of the great wing, but is separated from it by the outer or open extremity of the sphenoidal fissure. The upper surface forms the posterior limit of the precranial fossa, and the under surface overhangs the posterior extremity of the orbit, the sphenoidal foramen, and the anterior inner part of the mesocranial fossa. The anterior thin margin is serrated for articulation with the orbital plate of the frontal bone. The posterior margin is transversely concave, and forms the dividing line between the pre- and mesocranial fossæ. It is thicker and rounded inwardly, and thins away to a sharp edge outwardly. Its inner end is prolonged backward in a variable compressed knob, the **preclinoid process**,<sup>3</sup> which is separated from the olivary process by a rounded notch terminating the carotid groove. The preclinoid process is sometimes united with the mesoclinoid process, when the notch is converted into a foramen; and occasionally, also, it is united with the postclinoid process.

The **great wings**<sup>4</sup> spring from the sides of the body, and are thence extended outward, forward, and upward, but also give off a large **angular process** directed horizontally backward. They present three principal surfaces. Of these the **internal or cerebral surface**<sup>5</sup> contributes to form the mesocranial fossa. It is crescentic in outline, concave, and marked by cerebral impressions. The **external surface** is crossed below its middle by a ridge<sup>6</sup> dividing it into two portions, of which the upper is the **temporal surface**,<sup>7</sup> looking outward and forming part of the temporal fossa; and the lower is the **zygomatic surface**,<sup>8</sup> looking downward and forming part of the zygomatic fossa. The **anterior surface** in great part is formed by a vertical, quadrate

<sup>1</sup> Ossiculum Bertini; cornu sphenoidale; pyramid of Wistar.

<sup>2</sup> Alæ parvæ, minores, or orbitales; orbitosphenoids; apophyses of Ingrassias.

<sup>3</sup> Anterior c. p.

<sup>4</sup> Alæ magnæ; alisphenoids.

<sup>5</sup> Superficies cerebralis.

<sup>6</sup> Crista alæ magnæ.

<sup>7</sup> Superficies temporalis.

<sup>8</sup> S. zygomatica.



plane, the **orbital surface**,<sup>1</sup> which looks forward and inward, and forms the back part of the outer wall of the orbit. Its anterior margin is serrated, and joins the malar bone; its posterior margin is the outer and lower border of the sphenoidal foramen; its upper margin joins the orbital plate of the frontal bone; and its lower margin is the upper border of the speno-maxillary foramen. Below the orbital surface inwardly a variable smaller surface<sup>2</sup> forms part of the speno-maxillary fossa. The **angular process**<sup>3</sup> of the great wing is received in the notch between the squama and pyramid of the temporal bone. From its apex a variable pointed process, the **sphenoidal spine**,<sup>4</sup> is directed downward, and abuts against the entoglenoid tubercle of the temporal bone.

The posterior border of the great wing, extending from its summit to the end of the angular process, is semicircular, bevelled outward above and inward below, and is serrated for articulation with the squama of the temporal bone. A crescentic, roughened area at the upper part of the wing, included between its three chief surfaces, articulates with the frontal bone; and the summit is bevelled inwardly to articulate with the contiguous angle of the parietal bone.

The **pterygoid processes**,<sup>5</sup> two on each side, the **ento-** and **ectopterygoid processes**, descend nearly vertically, with a slight inclination forward, from beneath the great wing where it joins the body. They consist of a pair of plates conjoined above in front and separated below by a deep angular cleft, the **pterygoid notch**.<sup>6</sup> The **entopterygoid process**<sup>7</sup> is long and narrow, and terminates below in the **hamular process**,<sup>8</sup> a narrow bar bent backward and outward into a hook, through which passes the tendon of the palatal tensor muscle. The inner surface of the entopterygoid process forms the lateral boundary of the postnasal orifice. The **ectopterygoid process**<sup>9</sup> is a shorter and wider plate than the former, from the conjunction of which it diverges backward and outward. Its posterior border is thin and irregular, and is often variably produced into one or two angular points. The outer surface forms the inner wall of the zygomatic fossa, and gives attachment to the external pterygoid muscle. Through the divergence of the ecto- from the entopterygoid process behind is formed an angular niche, the **pterygoid fossa**.<sup>10</sup> This in the articulated skull is completed by the closure of the pterygoid notch through the pyramidal process of the palate-bone. The fossa is mainly occupied by the internal pterygoid muscle. To its inner side the root of the entopterygoid process presents an elliptical concave

<sup>1</sup> S. orbitalis.<sup>2</sup> S. speno-maxillaris.<sup>3</sup> Processus angularis.<sup>4</sup> Spina sphenoidalis or angularis.<sup>5</sup> Processus pterygoidei.<sup>6</sup> Incisura pterygoidea.<sup>7</sup> Internal pt. process or plate.<sup>8</sup> Hamulus pterygoideus; processus uncinatus.<sup>9</sup> External pterygoid process or plate.<sup>10</sup> Fossa pterygoidea.



depression,<sup>1</sup> from which arises the palatal tensor muscle. Sometimes a groove descends from the depression to the hamular process, indicating the course of the muscle. In front of the conjunction of the pterygoid processes, extending to the great wing and body, is the **spheno-maxillary surface**, which is triangular, and forms the posterior wall of the spheno-maxillary fossa. The borders of the processes, at the sides of the pterygoid notch, are roughened to articulate with the pyramidal process of the palate-bone. From the inner side of the root of the entopterygoid process projects the **vaginal process**,<sup>2</sup> a narrow ledge, extending inwardly beneath the sphenoidal body to articulate with the vomer.

Many important foramina for the passage of nerves and blood-vessels perforate the sphenoid bone on each side. The **optic foramen**<sup>3</sup> is a short, cylindrical canal, which is directed from the cranial cavity, at the side of the body, forward and outward through the base of the small wing to the orbit. It transmits the optic nerve and ophthalmic artery.

The **sphenoidal foramen**,<sup>4</sup> the largest of the apertures in the separated bone, appears as the club-shaped **sphenoidal fissure** between the small and great wings. It is variably elliptical near the body, and tapers to its outer extremity, where it is closed by the articulation of the frontal bone with both wings. It communicates between the mesocranial fossa and the orbit, and gives passage to the oculo-motor, trochlear, ophthalmic, and abducent nerves, and the ophthalmic vein.

The **rotund foramen**<sup>5</sup> is a short, cylindrical canal, which pierces the great wing a little way behind the inner extremity of the sphenoidal foramen. It is directed forward from the mesocranial fossa, and opens below the latter on the spheno-maxillary surface. It gives passage to the supramaxillary nerve.

The **oval foramen**,<sup>6</sup> next in size to the sphenoidal, is an elliptical hole in the inner side of the angular process, about half an inch behind and a little outward from the rotund foramen. It opens downward from the mesocranial fossa, behind and outward from the pterygoid processes. It transmits the roots of the inframaxillary nerve.

The **spinous foramen**,<sup>7</sup> smaller than any of the preceding, perforates vertically the apex of the angular process, and transmits the great meningeal vessels.

The **pterygoid canal**<sup>8</sup> is a narrow passage fore and aft through the root of the pterygoid processes. It commences on the sphenoid-

<sup>1</sup> Fossa scaphoidea or navicularis.

<sup>2</sup> Processus vaginalis.

<sup>3</sup> F. opticum.

<sup>4</sup> F. sphenoidale; f. lacerum anterius; f. orbitale superior.

<sup>5</sup> F. rotundum; canalis rotundus, or maxillaris superior.

<sup>6</sup> F. ovale.

<sup>7</sup> F. spinosum.

<sup>8</sup> Vidian foramen; canalis pterygoideus; c. Vidianus; c. recurrens.



maxillary surface, inward and behind the exit of the rotund foramen, and opens posteriorly beneath the lingule, contiguous to the lacerate foramen. It transmits the pterygoid nerve and vessels.

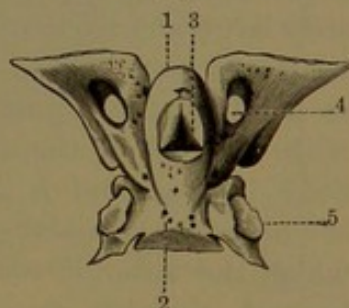
The **pterygo-palatine canal**,<sup>1</sup> smaller than the former, is formed by a groove beneath the vaginal process, closed below by apposition of the sphenoidal process of the palate-bone. It runs fore and aft from the speno-maxillary fossa to the roof of the postnasal orifice, and transmits the pterygo-palatine vessels and the pharyngeal nerve of the speno-palatine ganglion.

Occasionally a fine canal,<sup>2</sup> for the small superficial petrosal nerve, pierces the angular process near the spinous foramen; but commonly the nerve traverses the speno-petrosal suture.

At birth the sphenoid bone consists of three pieces, which are united by cartilage, one consisting of the body with the small wings, and the others each consisting of the great wing and the pterygoid processes of the same side. The bone is developed from seven pairs of ossific centres, which, with the exception of one pair, make their appearance in the third and fourth months of foetal life. The centres are as follows: a pair which subsequently coalesce in a single piece, forming the posterior part of the body, and named the **basisphenoid**; a second pair for the **lingules**; a third pair which unite to form the fore part of the body, named the **presphenoid**; a fourth pair for the great wings with the ectopterygoid processes, named the **alisphenoids**; a fifth for the small wings, termed the **orbitosphenoids**; a sixth for the entopterygoid processes, distinguished as the **pterygoids**; and a seventh pair, which originate after birth, named the **spheno-turbinals**, and subsequently becoming the sphenoidal sinuses.

The first ossific centres appear in the alisphenoids near the rotund foramen, and thence grow outward in the great wing and downward in the ectopterygoid process. The entopterygoid processes originate from independent centres, and subsequently coalesce with the former near the middle of foetal life. In some animals they remain separated as the pterygoid bones. The orbitosphenoids commence to ossify after the alisphenoids, the centres making their appearance as V-like islets embracing the optic foramen outwardly, whence they grow in the same direction. Next in order four centres appear in a transverse row, of which the intermediate pair quickly unite as the basisphenoid, and

FIG. 40.



INFERIOR VIEW OF THE INTER-MEDIATE PORTION OF THE SPHENOID BONE AT BIRTH, CONSISTING OF THE BODY AND SMALL WINGS. 1, the presphenoid; 2, the basisphenoid; 3, pit between the former occupied with cartilage; 4, orbitosphenoid with optic foramen; 5, the lingule with the articulation of the great wing.

<sup>1</sup> Canalis or sulcus pterygo-palatinus.

<sup>2</sup> Canalis innominatus.



the others, as the lingules, soon coalesce with it. Then follow two centres for the presphenoid, appearing as islets at the inner side of the optic foramina. Growing around these, they join the orbitosphenoids, and subsequently coalesce with each other. In the seventh month the basisphenoid and presphenoid ankylose; but in monkeys they remain separated until long after birth, and in many lower mammals even to a still later period.

Of the three pieces of the sphenoid at birth, that consisting of the body and small wings is composed of the basisphenoid, lingules, presphenoid, and orbitosphenoids, all ankylosed. The lateral pieces, consisting each of the great wing and pterygoid processes connected with it, are composed of the corresponding alisphenoid and pterygoid united together. The body is solid, but exhibits a variable number of conspicuous nutritious foramina. The basisphenoidal portion is cylindroid, and includes the sella; but the clivus is yet cartilaginous, and remains in this condition for some time after birth. The lingules are proportionately large, and are more conspicuous than later. They are directed backward in a hook-like process, which sustains the internal carotid artery as it enters the cranium. Laterally, they are connected by cartilage with the root of the alisphenoids. The presphenoidal portion of the body is oval, and is obliquely ankylosed with the upper fore part of the basisphenoidal portion and laterally with the small wings, of which the anterior roots are separated by a deep notch. The body beneath presents an obtuse prominence, in which is a trilateral pit tapering upward and backward into the sella. The pit is occupied by cartilage remaining from that originally connecting the basi- and presphenoids, and finally disappearing after birth. The prominence continues to grow, and gradually becomes a conspicuous elliptical process of spongy structure. Shortly after birth the great wings ankylose with the lingules, and later form an additional union with the fore part of the body.

In infancy the **spheno-turbinals**<sup>1</sup> appear as hollow cones, which occupy the angular intervals beneath the small wings and at the sides of the inferior median process of the body. In front they articulate with the ethmoid bone, and later become ankylosed with it, in which condition, when the ethmoid bone is separated from the others, the spheno-turbinals project from it behind as a pair of conical processes. The spheno-turbinals subsequently coalesce with the adjacent surfaces of the sphenoidal body, and by further growth and partial absorption of the contiguous parts they become the walls of the sphenoidal sinuses. The median process of the body becomes the partition separating the latter, while it also forms the rostrum beneath and the sphenoidal crest in front.

---

<sup>1</sup> *Cornua sphenoidalia*; *ossiculi Bertini*; *cornets of Bertin*; *sphenoidal spongy bones*; *pyramids of Wistar*.



## PARIETAL BONES.

The **parietal bone**<sup>1</sup> joins its fellow in the median line, and with it forms the top and sides of the cranium. It is a square plate of nearly uniform thickness, presenting for examination two broad surfaces with four borders and angles.

The **external surface**, looking outward and upward, is convex, comparatively even, but more elevated centrally in the **parietal eminence**,<sup>2</sup> which is especially conspicuous in infancy. Near the middle

FIG. 41.

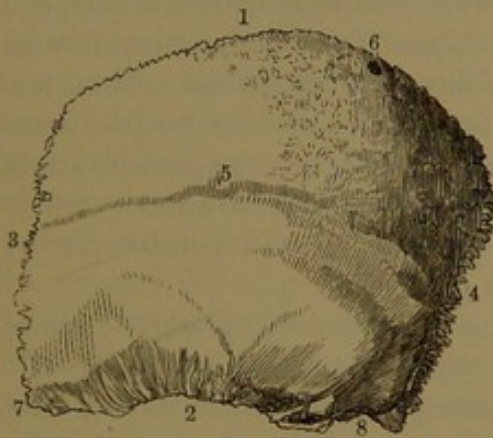
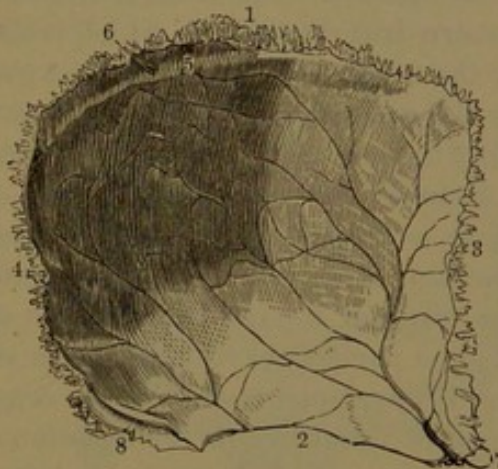


FIG. 42.



OUTER VIEW OF THE LEFT PARIETAL BONE. 1, upper border; 2, bevelled lower border, which articulates with the squama of the temporal bone; 3, anterior border, joining the frontal bone; 4, occipital border; 5, temporal ridge; 6, venous foramen; 7, prolonged anterior inferior angle joining the summit of the great wing of the sphenoid bone; 8, posterior inferior angle articulating with the mastoid portion of the temporal bone.

INNER VIEW OF THE LEFT PARIETAL BONE. 1-4, borders corresponding with same numbers in former figure; 5, groove for the longitudinal sinus, and, communicating with it, a venous foramen; 6; 7, 8, anterior and posterior inferior angles; the groove on the latter accommodates the lateral sinus. The arborescent lines on the inner concave surface of the bone indicate grooves for the great meningeal vessels.

it is crossed fore and aft by a variably distinct arching line, the **temporal ridge**, which marks the upper boundary of the temporal fossa and gives attachment to the temporal fascia. The surface<sup>3</sup> below forms part of the temporal fossa, and that above is covered by the epicranial aponeurosis.

The **internal surface** is concave and marked with shallow impressions, conforming to the convolutions of the brain. It also exhibits arborescent channels, which accommodate the great meningeal vessels; one principal branch ascending from the lower anterior angle, and another from near the middle of the lower border. The commencement of the former branch is sometimes for a short distance converted into a complete canal. Along the upper border of the bone

<sup>1</sup> Os parietale.<sup>2</sup> Tuber parietale.<sup>3</sup> Planum temporale.



is a shallow groove for the longitudinal sinus, the groove being more obvious in the conjoined bones.

The **superior border** of the parietal is thick, straight, and strongly dentated for articulation with the opposite bone. The **anterior border**, also nearly straight and strongly dentated, is slightly bevelled, outwardly above and inwardly below, to accord with the contiguous border of the frontal bone. The **posterior border**, less regular in its course, is deeply dentated to articulate with the occipital bone. The **inferior border**, for the most part thinner than the others, consists of three portions. The intermediate portion is arched and deeply bevelled outwardly to a sharp edge, which is overlapped by the temporal squama. The front portion is formed by the somewhat prolonged **antero-inferior angle**, which is also bevelled outwardly and overlapped by the summit of the sphenoidal great wing. The back portion, formed by the **postero-inferior angle**, is thick and dentated for articulation with the mastoid portion of the temporal bone, and its inner surface is grooved for the lateral sinus. Near the **postero-superior angle** there is frequently a small aperture, the **parietal foramen**,<sup>1</sup> which communicates with the diploe, and often, also, with the interior of the cranium, for the transmission of a vein.

The parietal in its production is one of the purely membrane bones, and is developed from a single centre, which appears about the seventh week of foetal life in the position of the parietal eminence. At birth the bone appears as a simple plate, most prominent and thickest at the centre, whence the osseous fibres radiate to the borders, where many of them project in spicules.

#### THE FRONTAL BONE.

The **frontal bone**<sup>2</sup> occupies the fore part of the cranium, and consists of a frontal plate, which forms the basis of the forehead, and a pair of orbital plates, which extend horizontally backward from the lower part of the former over the orbits.

The **frontal plate**<sup>3</sup> externally is, for the most part, evenly convex and smooth, and is covered with the skin of the forehead. On each side it exhibits a slightly greater prominence, the **frontal eminence**,<sup>4</sup> variable in different individuals, and most conspicuous in infancy, when it is commonly a striking feature. The bone, also, occasionally exhibits a slight median elevation, which corresponds with its early separation into two, and traces of the original suture sometimes remain at the lower part. Below, the surface terminates on each side in a curved ridge, the **supraorbital arch**,<sup>5</sup> which becomes more narrow and prominent outwardly, and forms the upper border of the orbital entrance. The

<sup>1</sup> Foramen parietale.

<sup>2</sup> Os frontis; o. sincipitis.

<sup>3</sup> Frontal portion; pars frontalis, perpendicularis, or ascendens.

<sup>4</sup> Tuber frontale.

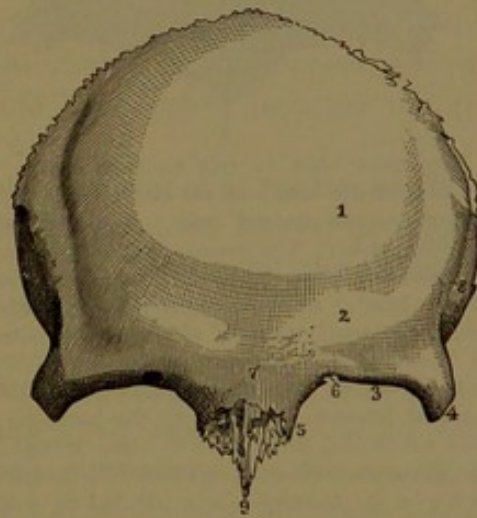
<sup>5</sup> Orbital arch; margo supraorbitalis.



arch terminates in the **internal** and **external angular processes**, of which the former is little produced, is thin, extends backward, and articulates with the lachrymal bone; while the latter is thick and prominent, and is serrated at the end to articulate with the malar bone. The interval of the internal angular processes is a serrated, crescentic surface, the **nasal notch**, which articulates with the nasal and maxillary bones. From its middle behind there projects downward and forward a narrow process of variable length, the **nasal spine**,<sup>2</sup> which articulates with the ethmoid nasal plate behind and with the nasal bones in front. From each side of the spine is reflected outwardly a scroll-like plate, the **nasal ala**,<sup>3</sup> which contributes to form the anterior slope of the roof of the nasal cavity and contiguous portion of the frontal sinus; it articulates in front with the nasal bones, and outward and behind with the maxillary and ethmoid bones. From the external angular process the **temporal ridge** curves upward and backward, defining the fore part of the temporal fossa from the surface of the forehead, and giving attachment to the temporal fascia. Above the supraorbital arch is an obtuse curved eminence, the **superciliary ridge**,<sup>4</sup> for the eyebrow, variably prominent, and gradually subsiding outwardly. Its prominence is due to the projection of a cavity, the frontal sinus, within the bone. The ridges of the two sides conjoin just above the nasal notch in a flat or slightly-depressed median eminence, named the **glabella**,<sup>5</sup> corresponding with the smooth surface between the eyebrows. Near the middle of the supraorbital arch, mostly inwardly, is an aperture or a notch converted into one by a ligament, the **supraorbital foramen**,<sup>6</sup> for the passage of corresponding vessels and nerve. Opening into the foramen, or near it, there is commonly to be observed a smaller one for the passage of a vein from the diploe.

The internal surface of the frontal plate is deeply concave, and everywhere marked with impressions and ridges, conforming to the

FIG. 43.



EXTERNAL VIEW OF THE FRONTAL BONE. 1, position of the frontal eminence; 2, superciliary ridge; 3, supraorbital arch; 4, 5, external and internal angular processes; 6, supraorbital notch or foramen; 7, glabella; 8, temporal ridge; 9, nasal spine.

<sup>1</sup> Margo nasalis.

<sup>3</sup> Ala spinæ nasalis.

<sup>5</sup> Nasal eminence or boss; inferior or middle frontal eminence or boss.

<sup>6</sup> Incisura or foramen supraorbitale; supraorbital notch.

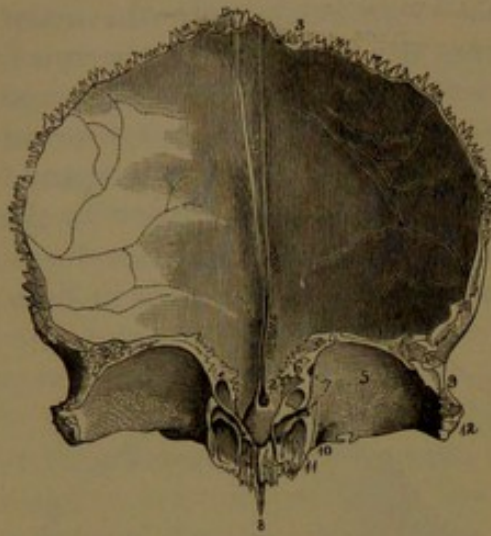
<sup>2</sup> Processus nasalis; spina nasalis.

<sup>4</sup> Arcus superciliaris.



convoluted surface of the cerebrum. In the median line is a groove,<sup>1</sup>

FIG. 44.



INTERNAL VIEW OF THE FRONTAL BONE. 1, groove for the longitudinal sinus, narrowing below on the frontal crest; 2, in the ethmoidal notch; 3, superior dentated border, articulating with the parietal bones; 4, posterior border of the orbital plate 5, which joins the small wing of the sphenoid bone; 6, irregular inner border of the same plate which covers the upper part of the ethmoidal sinuses; 7, points to the position of the ethmoidal foramina; 8, nasal spine; 9, thick rough border articulating with the great wing of the sphenoid bone; 10, refers to the black spot, which indicates the position of a fossa for the pulley of the trochlearis muscle; to its outer side is the supraorbital notch; 11, internal angular process, and entrance to the frontal sinus; 12, external angular process.

wide and feebly marked above, and becoming narrower and more distinct below, where it is defined by elevated margins which unite in the **frontal crest**,<sup>2</sup> a variably prominent, narrow ridge, descending and ending at the ethmoidal notch. The groove lodges the fore part of the longitudinal sinus, and its margins and frontal crest give attachment to the cerebral falx. Below the frontal crest is a little groove, which, by apposition with the ethmoid bone, is converted into a blind pit<sup>3</sup> or a short canal, giving passage to a vein from the nose to the longitudinal sinus. The posterior border of the frontal plate is thick and strongly serrated, is slightly bevelled inwardly above, and to a greater degree outwardly at the sides, for articulation with the parietal bones. Below, the border widens to a triangular rough surface, which articulates with the great wing of the sphenoid bone.

The **orbital plates**<sup>4</sup> extend, in a vaulted manner, horizontally from the supraorbital arches to the small

wings of the sphenoid bone, with which they form the roofs of the orbits. They are much thinner than the frontal plate, and are separated by a rectangular interval, the **ethmoidal notch**,<sup>5</sup> which is occupied by the cribriform plate of the ethmoid bone. The upper surface is convex, and deeply marked by impressions of cerebral convolutions, while the inferior surface is concave and even, and forms the upper boundary of the orbital cavity. A deeper recess,<sup>6</sup> within the external angular process, lodges the lachrymal gland; and a small, shallow pit<sup>7</sup> situated above the internal angular process accommodates the pulley of the trochlearis muscle. The outer border of the orbital plate articulates with the great wing of the sphenoid bone, and the posterior

<sup>1</sup> Sulcus sagittalis.

<sup>3</sup> Foramen cœcum.

<sup>5</sup> Incisura ethmoidalis.

<sup>2</sup> Crista frontalis.

<sup>4</sup> Plana orbitalia; partes orbitales.

<sup>6</sup> Fossa lachrymalis.

<sup>7</sup> Fossa trochlearis.



border with the small wing, completing the sphenoidal foramen outwardly. The inner border below exhibits a number of shallow recesses, which, by articulation with the ectethmoid, complete the contiguous ethmoidal sinuses. Crossing this border transversely are two grooves, which, by apposition of the ethmoid bone, form the **pre- and post-ethmoidal foramina**. At the fore part of the same border is the outlet of the frontal sinus, a large cavity which occupies the interior of the bone, extending outwardly above the supraorbital arch within the position of the superciliary ridge. The **frontal sinuses** are of variable size, and increase with the advance of age. They extend upward and outward in the frontal plate, and backward in the orbital plates, and are separated by a mostly unsymmetrical partition. They often differ in size on the two sides, and are occasionally subdivided by one or two partial partitions. The outlet of each sinus, named the **infundibulum**, descends within the internal angular process, and, in the articulated frontal with the ethmoid bone, opens into the middle nasal meatus.

The frontal plate of the frontal bone consists of a nearly uniform layer of spongy substance, enclosed by the compact layers, of which the external is the thicker, while the orbital plates and the walls of the frontal sinuses consist mainly of compact substance.

The frontal bone is produced in fibro-connective tissue, and is developed from two centres, which make their appearance about the seventh week of foetal life, one on each side above the supraorbital arch, whence ossification extends upward in the frontal plate and backward in the orbital plate. At birth the bone consists of two pieces, corresponding with the halves of the frontal at maturity, connected in the median line, but separated by a wide membranous interval at the upper adjacent angles. The frontal eminences are conspicuous, but the superciliary ridges and frontal sinuses do not yet appear. Ankylosis of the two pieces occurs during the first year, commencing at the glabella and proceeding upward, but the union is not completed until about the end of the second year or later. Sometimes the pieces remain permanently distinct, united by suture, representing the normal condition in some animals in which there are two frontals.

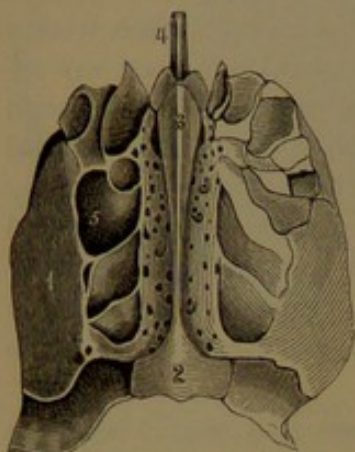
The frontal sinuses begin to make their appearance about the second or third year, and are produced by the gradual absorption of spongy substance, commencing in the internal angular processes and proceeding upward. Later they enlarge by expansion forward, giving rise to the superciliary ridges. They continue to increase even after maturity, extending upward and outward along the supraorbital arch and backward within the orbital plates. Rarely they remain small or altogether undeveloped. They reach a greater degree of development in the male than in the female.



## THE ETHMOID BONE.

The **ethmoid bone**<sup>1</sup> is situated at the fore part of the cranium, in advance of the sphenoid and beneath the frontal bone. It occupies the face between the orbits, and chiefly enters into the construction of the

FIG. 45.



UPPER VIEW OF THE ETHMOID BONE. 1, orbital plate of the ectethmoid; 2, posterior imperforate extremity of the cribriform plate; 3, ethmoidal crest; on each side the olfactory fossa with foramina of the cribriform plate, and in advance the alar processes; 4, anterior extremity of the nasal plate; 5, ethmoidal sinuses.

upper part of the nasal cavities, and only a small portion contributes to the cranial cavity. It is a light, cuboidal bone, and consists of a median vertical plate, named the **mesethmoid**, which is connected by a narrow horizontal portion, the **cribriform plate**, with a pair of lateral cellular masses, named the **ectethmoids**.

The **mesethmoid**,<sup>2</sup> for the most part, enters into the partition of the nose as the nasal plate, while the smaller portion projects into the cranial cavity as the ethmoidal crest.

The **nasal plate**<sup>3</sup> occupies a median position in the upper part of the nasal partition, of which it forms about one-third. It is broad, thin, and smooth except at the upper part, where it is marked by descending and divergent grooves, which proceed from the inner series of foramina of the cribriform plate for the olfactory nerves. The fore part is extended in a triangle, of which the upper border articulates with the

frontal nasal spine, sometimes reaching the nasal bones, and the lower, somewhat thickened border, joins the septal cartilage. The posterior border is thin, and articulates with the sphenoidal crest, while the lower border articulates with the vomer.

The **ethmoidal crest**<sup>4</sup> projects from the middle of the cribriform plate into the cranium, and gives attachment to the anterior extremity of the cerebral falx. It is most prominent in front, where it forms a knob of variable shape and size, and thence slants away behind in a narrow ridge. From its fore part project two little wing-like or **alar processes**,<sup>5</sup> which rest against the frontal bone and partially include a narrow pit, the **cæcal foramen**.<sup>6</sup>

The **cribriform plate**<sup>7</sup> extends from the base of the ethmoidal crest on each side to join the ectethmoids, occupying the ethmoidal notch of the frontal bone, and articulating with the inner borders of its orbital plates. Its lower surface is directed into the nasal cavities, and

<sup>1</sup> Os ethmoides.<sup>2</sup> Median ethmoid; prefrontal.<sup>3</sup> Lamina perpendicularis.<sup>4</sup> Crista ethmoidalis; crista galli.<sup>5</sup> Processus alares.<sup>6</sup> F. cæcum.<sup>7</sup> Lamina cribrosa.



forms the middle portion of their roof on each side of the nasal plate. Its upper surface is directed into the cranial cavity, and is depressed on each side of the crest to form the **olfactory fossa**, which accommodates the olfactory bulb. Within the fossa the plate is pierced with numerous foramina, which communicate with the nasal cavity on each side and transmit the olfactory nerves. A larger aperture at the fore part of the fossa gives passage to the nasal branch of the ophthalmic nerve. The posterior extremity of the plate, less depressed and mostly imperforate, articulates with the ethmoidal process of the sphenoid bone.

The **ectethmoids**,<sup>1</sup> or **lateral masses** of the ethmoid bone, are separated from the nasal plate by a narrow fore and aft passage at the upper part of the nasal cavities. They are of rectangular shape, and enclose a number of irregular vacuities, the **ethmoidal sinuses**,<sup>2</sup> which are separated into an anterior and a posterior group. In the recent condition they are lined with mucous membrane, and communicate with the nasal cavities, of which they are accessory chambers. In the separated bone they are more or less exposed along the borders, especially in front and outwardly above. Articulated, they are closed in front by the apposition of the lachrymal and maxillary bones, above by the orbital plates of the frontal bone, behind by the sphenoid and palate bones, and below by the maxillæ. Outwardly the ectethmoid is defined by the smooth, rectangular **orbital plate**,<sup>3</sup> which forms the greater part of the inner wall of the orbit; articulating in front with the lachrymal bone, behind with the sphenoid and palate bone, above with the frontal, and below with the maxilla. Inwardly the ectethmoid presents a convex, uneven, and rough surface<sup>4</sup> directed in the nasal cavity towards the nasal plate. For more than half its length behind it is divided by a deep passage, the **superior nasal meatus**, which slants downward and backward, and is overhung by a thin curving plate, the **supraturbinal**,<sup>5</sup> of the nose. Into the meatus the posterior ethmoidal sinuses open by several apertures. Not unfrequently above the former there is a shorter channel extending to the back part of the bone.

The lower part of the ectethmoid forms a conspicuous scroll, the **mesoturbinal**,<sup>6</sup> of the nose, extending fore and aft, and overhanging the **middle nasal meatus**. The anterior extremity is rounded and free; the posterior is tapering and attached at the end to the palate bone. The surface directed inwardly is convex and rough; that outwardly is concave, and forms the upper part of the middle meatus; and

<sup>1</sup> Lateral ethmoids; ethmo-turbinals; labyrinthi; prefrontals.

<sup>2</sup> Cellulæ ethmoidales.

<sup>3</sup> Os planum; ectethmoid; lamina papyracea.

<sup>4</sup> Lamina concharum.

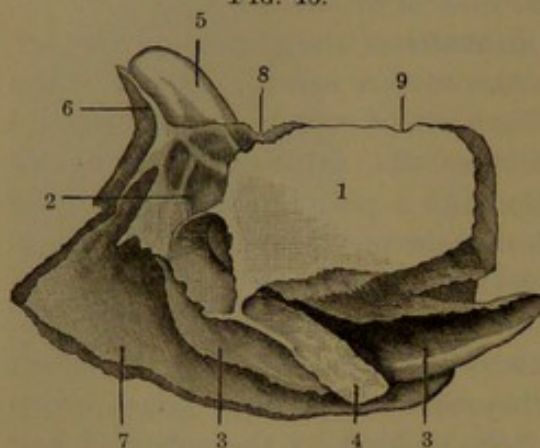
<sup>5</sup> Superior turbinated bone; sup. spongy bone; os turbinatum or spongiosum sup.; ectoturbinal; concha superior; c. Morgagniana.

<sup>6</sup> Middle turbinated bone; middle spongy bone; os turbinatum or spongiosum medium; endoturbinal; concha media.



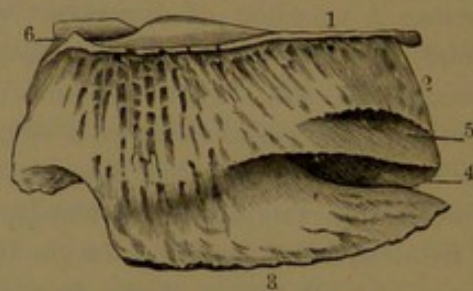
the lower free border is everted, variably thickened, spongy, and rough. The upper part of the internal surface of the ectethmoid is perforated by numerous fine canals, which descend from the outer series of foramina of the cribriform plate. The canals transmit the olfactory nerves to the inner surfaces of the upper and middle turbinals, and are commonly more or less incomplete or open inwardly in their course. The fore part of the ectethmoid extends in advance of the middle turbinal,

FIG. 46.



LEFT SIDE VIEW OF THE ETHMOID BONE. 1, orbital plate; 2, anterior ethmoidal sinuses; 3, the mesoturbinal; 4, uncinat process; 5, ethmoidal crest; 6, alar process; 7, nasal plate; 8, 9, position of the pre- and postethmoidal foramina.

FIG. 47.



INNER VIEW OF THE RIGHT ECTETHMOID. 1, cribriform plate; 2, the supraturbinal; 3, mesoturbinal; 4, supranasal meatus; 5, a shorter meatus occasionally present; 6, part of the coecal pit.

and encloses the anterior ethmoidal sinuses. Above, it joins the frontal nasal spine, and thence outwardly articulates with the nasal process of the maxilla and with the lachrymal bone. From the lower part of the ectethmoid, in the outer part of the middle meatus, a narrow plate, the **uncinate process**,<sup>1</sup> descends to join the ethmoidal process of the turbinal bone, the two serving to reduce the aperture of the maxillary antrum.

In the articulated bone the frontal sinus communicates by a passage, the **infundibulum**, with the anterior ethmoidal sinuses, and with these opens by two or three apertures into the middle nasal meatus.

The nasal plate of the ethmoid bone is frequently unsymmetrical, being more or less bent to either side. The turbinals, also, are frequently unsymmetrically developed on the two sides, and mostly in a degree proportioned to one another.

According to Sappey, the ethmoid bone is developed from four centres of ossification, one for each ectethmoid and two for the mesethmoid. The ectethmoid commences ossification about the middle of foetal life, starting centrally, and proceeding in the production of the sinuses, orbital plate, and turbinals. Ossification commences in the mesethmoid, after birth, from a pair of centres which appear in

<sup>1</sup> P. uncinatus or hamatus; naso-turbinal.

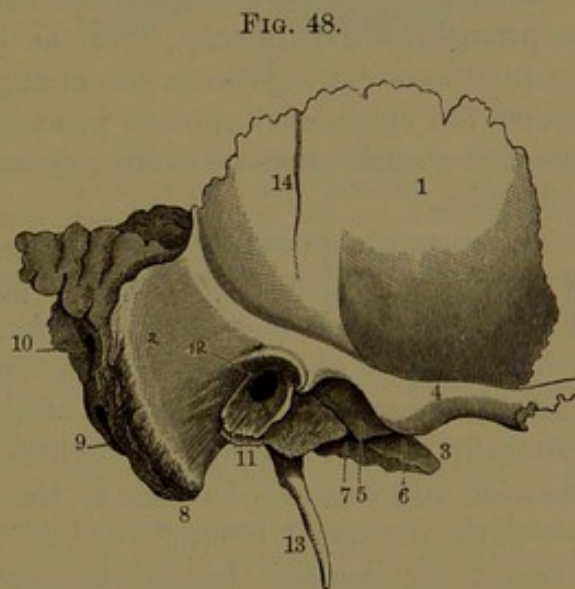


the fore part of the crest. The centres speedily unite, and ossification thence extends in the crest and cribriform plate, and subsequently into the nasal plate. The ectethmoids unite with the mesethmoid through the cribriform plate towards the end of the first year after birth. Unlike the frontal and sphenoidal sinuses, the ethmoidal sinuses are directly produced, and not formed through the subsequent absorption of spongy substance as in the former.

### THE TEMPORAL BONES.

The temporal bone<sup>1</sup> contains within its interior the chief portion of the organ of hearing; and with it the lower jaw articulates. It occupies the lower part of the side of the cranium, and extends inwardly to near its centre. It is enclosed by the sphenoid bone in front, the occipital behind, and the parietal above. For convenience of study and reference it is divided into the squamous, mastoid, and petrous portions, though these do not accord with the original separation of the bone into pieces, as will be subsequently described.

The **squamous portion**<sup>2</sup> is the outer fore part of the bone, and is defined behind from the mastoid portion by a ridge curving from in front of the ear backward and upward. It mainly consists of an irregular oval or nearly circular upright scale-like plate, the **squama**, which, along the greater part of its free border, is deeply bevelled away inwardly to a thin, sharp edge, and overlaps the con-



EXTERNAL VIEW OF THE TEMPORAL BONE OF THE RIGHT SIDE. 1, squama; 2, mastoid portion; 3, apex of the petrous portion; 4, zygomatic process; 5, glenoid fossa; 6, pre-glenoid tubercle; 7, glenoid fissure; 8, mastoid process; 9, back part of digastric fossa; 10, mastoid foramen; 11, tympanic plate forming the vaginal and auditory processes; 12, auditory meatus; 13, styloid process; 14, slight impression of the deep temporal artery.

tiguous bevelled borders of the parietal and sphenoid bones. The outer surface, a nearly vertical plane, forms part of the temporal fossa. The inner surface within the bevelled border is concave, and strongly impressed by the contiguous cerebral convolutions. Running nearly parallel with the anterior and upper border is a groove for the great meningeal vessels. From the lower part of the squama outwardly projects the **zygomatic process**,<sup>3</sup> a horizontal bar, which springs by a broad base

<sup>1</sup> Os temporis, temporum, or temporale.

<sup>2</sup> Pars squamosa.

<sup>3</sup> Processus zygomaticus; p. jugalis.



from above the articulation of the mandible, thence curves outward and forward, and ends in a slightly expanded and serrated extremity, which articulates with the malar bone. From the upper border of the zygomatic process a ridge curves backward and upward over the ear-passage, defining the squama from the mastoid portion of the bone.

Beneath the squama, and extending outwardly under the base of the zygomatic process, is the articulation for the lower jaw, consisting of the glenoid fossa and articular eminence. The **glenoid fossa**<sup>1</sup> is a transverse, elliptical concavity, which is defined behind by the **glenoid fissure**.<sup>2</sup> The **articular eminence**<sup>3</sup> in front of the former is a transverse ridge, variably thick and convex fore and aft, and slightly concave to straight from side to side. Its outer, somewhat more prominent extremity is the **preglenoid tubercle**. The outer back part of the glenoid fossa is extended on a variable, flattened conical process, the **postglenoid tubercle**; and the inner extremity of the fossa is also prolonged on a process, the **entoglenoid tubercle**, which abuts against the sphenoidal spinous process. In advance of the articular eminence a small surface, looking downward, forms part of the zygomatic fossa.

The **mastoid portion**<sup>4</sup> of the temporal bone is situated behind the squama, from which it is separated at the upper border by a notch, which receives the adjacent angle of the parietal bone. It is prolonged downward in a conspicuous nipple-shaped prominence, the **mastoid process**,<sup>5</sup> from which the portion of the bone is named. The process is laterally compressed, and is roughened behind and at the point for muscular attachment. Inward to the process is a deep fore and aft groove, the **digastric fossa**,<sup>6</sup> which gives origin to the digastric muscle. Between the fossa and the inner border of the bone is a narrow furrow,<sup>7</sup> which is traversed by the occipital artery.

Internally, the mastoid portion extends from behind the position of the petrous portion, where it is concave, and for the most part occupied by a variably deep groove, which accommodates the lateral sinus. The free border is thick and rough, and articulates with the parietal bone above and the occipital bone behind and below. Near or at the posterior border, the bone is pierced by a short canal, the **mastoid foramen**,<sup>8</sup> which communicates from the exterior with the groove for the lateral sinus, and transmits a vein.

The **petrous portion**<sup>9</sup> of the temporal bone, internal to the others, appears as a prostrate, three-sided **pyramid**, with its base directed

<sup>1</sup> Fossa or cavitas glenoidalis; fossa articularis; f. mandibularis.

<sup>2</sup> Glaserian fissure.

<sup>4</sup> Pars mastoidea; p. mammillaris.

<sup>6</sup> F. digastrica; incisura mastoidea.

<sup>8</sup> F. mastoideum.

<sup>3</sup> Tuberculum articulare.

<sup>5</sup> Processus mastoideus.

<sup>7</sup> Sulcus arteriæ occipitalis.

<sup>9</sup> Pars petrosa.



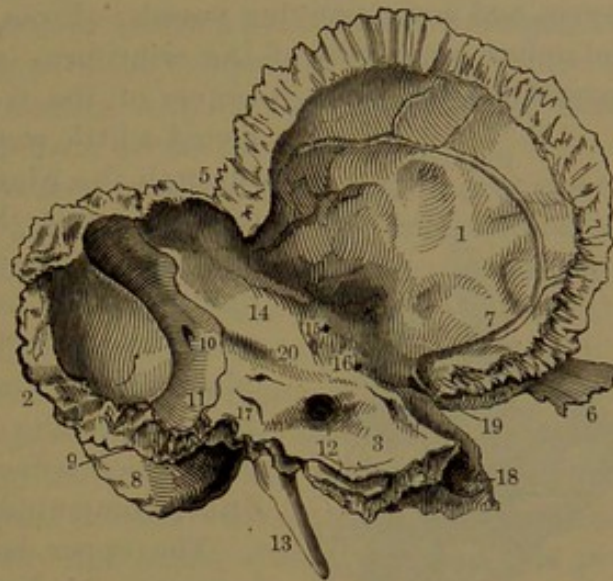
outward, and its apex obliquely forward and inward, received in the angular notch between the sphenoid and occipital bones. It contains within it the greater part of the organ of hearing, including the tympanum and labyrinth. Of the three surfaces of the pyramid, two look into the cranium, while the third looks downward in the base of the skull.

The **anterior surface** of the pyramid is an irregular slope, directed into the mesocranial fossa. Above its middle outwardly is an eminence,<sup>1</sup> which, together with the adjacent inner depression, indicates the position, within the bone, of the labyrinth. In advance of the eminence the surface is formed by a plate, named the **tympanic tegmen**,<sup>2</sup> which is the roof of the tympanum. It is usually more or less defined from the squama by a fissure remaining as part of the petro-squamosal suture; and is further

defined at its inner extremity by a narrow groove, which proceeds from the notch between the apex of the pyramid and squama outward to an opening, or **hiatus**,<sup>3</sup> of the facial canal, for the transmission of the greater petrosal nerve. On the inner end of the tegmen is another little groove, which ends in a fine canal, communicating with the tympanum, for the passage of the small petrosal nerve. From beneath the inner extremity of the tegmen a bar or ridge dips into the glenoid fissure, between the glenoid fossa and tympanic plate.

The **posterior surface** of the pyramid is smaller than the former, and slopes more steeply into the posterianal fossa; and is outwardly defined by the groove of the lateral sinus. A little inward from the centre is the **internal auditory meatus**,<sup>4</sup> a short, wide canal, about a third

FIG. 49.



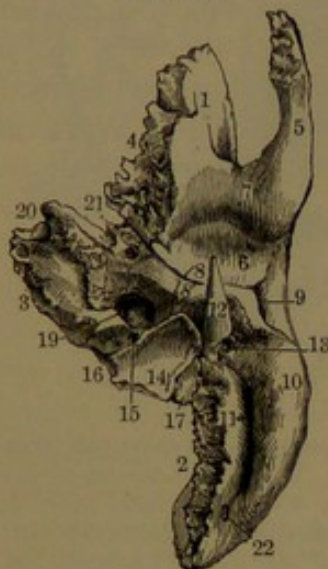
INTERNAL VIEW OF THE TEMPORAL BONE OF THE LEFT SIDE. 1, squamous portion; 2, posterior border of the mastoid portion articulating with the occipital bone; 3, petrous portion; 4, bevelled edge, which overlaps the lower edge of the parietal bone; 5, notch between the squama and the mastoid portion, articulating with the posterior inferior angle of the parietal bone; 6, end of the zygomatic process; 7, groove for the great meningeal vessels; 8, mastoid process; 9, digastric fossa; 10, mastoid foramen opening into the groove 11, for the lateral sinus; 12, internal auditory meatus; 13, styloid process; 14, prominence produced by the supra-semicircular canal of the labyrinth; 15, tegmen; 16, position of hiatus of the facial canal; 17, cleft which communicates with the aqueduct of the vestibule; 18, termination of the carotid canal; 19, eustachian tube; 20, groove of the suprapetrosal sinus.

<sup>1</sup> Eminentia arcuata.<sup>2</sup> Tegmen tympani; tegmentum.<sup>3</sup> H. Fallopii; h. canalis facialis.<sup>4</sup> Meatus auditorius internus; porus acusticus.



of an inch deep, proceeding outwardly, and closed at bottom by the **cribriform lamina**,<sup>1</sup> which is a perforated plate separating it from the labyrinth. The meatus gives passage to the facial and auditory nerves and accompanying vessels. From the bottom of the meatus, at the upper inner part of the cribriform lamina, commences the **facial canal**<sup>2</sup> for the further course of the facial nerve. The canal is di-

FIG. 50.



INFERIOR VIEW OF THE LEFT TEMPORAL BONE. 1, squamous portion; 2, mastoid portion; 3, petrous portion; 4, border articulating with the great wing of the sphenoid bone; 5, zygomatic process; 6, glenoid fossa; 7, articular eminence; 8, glenoid fissure; 9, auditory meatus; 10, mastoid process; 11, digastric fossa; 12, styloid process; 13, stylo-mastoid foramen; 14, jugular fossa; 15, pit which communicates with the aqueduct of the cochlea; 16, position between which and the occipital bone the ninth, tenth, and eleventh cerebral nerves escape from the cavity of the cranium; 17, articular process; 18, vaginal process; 19, 20, entrance and exit of the carotid canal; 21, eustachian tube; 22, mastoid foramen.

rected a little way forward, and communicates through the **hiatus** with the anterior surface of the pyramid, thence turns abruptly outward, and proceeds backward in the inner wall of the tympanum to its back wall, in which it descends to the stylo-mastoid foramen, the outlet of the canal. Outwardly from the meatus is a variable arching eminence, and below it a cleft, from which a fine canal, the **vestibular aqueduct**,<sup>3</sup> communicates with the labyrinth.

The upper border of the pyramid is the longest, and is for the most part acute. It gives attachment to the tentorium, and is commonly marked in its course by a groove for the supra-petrous sinus, while its inner extremity is depressed for the passage of the trifacial nerve. The posterior border is irregular and notched, and articulates with the occipital bone. The anterior is shortest, and, together with the adjacent border of the squama, forms a notch which receives the sphenoidal angular process.

The **inferior surface** of the pyramid is very uneven, and presents many points of interest. At its outer fore part is the **tympanic plate**,<sup>4</sup> which forms the floor of the auditory meatus, the tympanum, and the Eustachian tube. The plate presents a broad concave surface towards the articulation of the lower jaw, and is defined above from the glenoid fossa by the **glenoid fissure**.<sup>5</sup> Below it extends in an acute, jagged, and somewhat flexuose ridge, named the **vaginal process**,<sup>6</sup> from its partially ensheathing the styloid process. The outer, thicker portion of the plate is upwardly involute, and forms

the bottom and sides of the auditory meatus; and at the entrance of this it is produced in an everted, rough, crescentoid lip, which is named

<sup>1</sup> L. cribrosa.<sup>3</sup> Aquæductus vestibuli.<sup>5</sup> Fissure of Glaser; fissura petro-tympanica et petro-squamosa.<sup>2</sup> Canalis facialis; c. Fallopii.<sup>4</sup> Os tympanica.<sup>6</sup> P. vaginalis.



the **auditory process**,<sup>1</sup> and gives attachment to the auricle. The inner, narrowed extremity of the plate closes the bottom of the tympanum and eustachian tube.

About the middle of the glenoid fissure a pair of short passages, the **glenoid canals**, communicate with the tympanum, the outer one being occupied by a process of the malleus with its ligament, and the inner one<sup>2</sup> transmits the tympanic branch of the facial nerve.

From behind the vaginal process projects the **styloid process**,<sup>3</sup> a variably long, tapering spine, directed downward, forward, and inward. Before adult age it is connected with the temporal bone by cartilage, joined to a short pedestal,<sup>4</sup> which occupies a pit embraced by the vaginal process. It is sometimes an inch or more in length, and is connected at the point with the stylo-hyoid ligament.

Between the base of the styloid process and the mastoid process is the **stylo-mastoid foramen**,<sup>5</sup> the outlet of the facial canal. Behind the inner extremity of the vaginal process is the entrance of the **carotid canal**,<sup>6</sup> which ascends vertically and bends abruptly inward, and proceeds to the apex of the pyramid, whence it opens upward into the cranial cavity. The inner fore part of the canal is frequently more or less imperfect, and in the recent condition is completed by fibrous membrane. The canal transmits the internal carotid artery and carotid plexus of the sympathetic nerve.

Externally and behind the carotid canal is the **jugular fossa**,<sup>7</sup> which is variable in size on the two sides of the skull in accordance with the difference in the size of the jugular vein it accommodates. Sometimes it appears as a shallow groove descending from a notch at the back border of the pyramid, and from this it varies to a deeply vaulted recess. To the inner side of the fossa, behind and above the entrance of the carotid canal, is an irregular and less conspicuous groove,<sup>8</sup> which forms part of the jugular foramen giving passage to the ninth, tenth, and eleventh cerebral nerves. Opening into the commencement of this groove at the posterior border of the pyramid is a pyramidal pit, from which a fine canal, the **cochlear aqueduct**,<sup>9</sup> proceeds to the labyrinth. Externally from the jugular fossa there is a commonly quadrate facet, which is joined by cartilage to the jugular process of the occipital bone.

In the partition between the carotid canal and jugular fossa a fine canal ascends to the tympanum for the passage of the tympanic nerve. In the course of the carotid canal there are several small foramina communicating with the tympanum for the transmission of vessels and nerves. From the jugular fossa a fine canal is directed outwardly

<sup>1</sup> P. auditorius.

<sup>2</sup> Canal of Huguier.

<sup>3</sup> P. styloideus; stylo-hyal bone

<sup>4</sup> Tympano-hyal bone. <sup>5</sup> F. stylo-mastoideum. <sup>6</sup> Canalis caroticus.

<sup>7</sup> F. jugularis; incisura jugularis lateralis.

<sup>8</sup> Incisura jugularis medialis.

<sup>9</sup> Aquæductus cochleæ.



to open in the fissure back of the auditory meatus for the transmission of the auricular branch of the vagus. Beneath the apex of the pyramid and the horizontal portion of the carotid canal is a quadrate, rough surface, which gives attachment to the pharynx; and behind this is a rougher space, which articulates with the basilar process of the occipital bone.

In the notch between the apex of the pyramid and the squama is the orifice of the osseous portion of the **eustachian tube**,<sup>1</sup> which communicates outwardly with the tympanum. It is formed above by the tegmen of the pyramid and below by the tympanic plate.

The **auditory meatus**,<sup>2</sup> or outer passage of the ear, is situated in a deep archway between the glenoid fossa and mastoid process. It is a short, wide canal, which in the prepared bone opens inwardly into the cavity of the tympanum. Its roof is formed by the **auditory plate**, which extends from beneath the squama inward to the tympanum, and its floor and sides are formed by the **tympanic plate**, the outer lip of which is the **auditory process**.

A more particular description of the parts of the temporal bone relating to the ear, including the tympanum, labyrinth, and mastoid sinuses, will be given in the account of the organ of hearing.

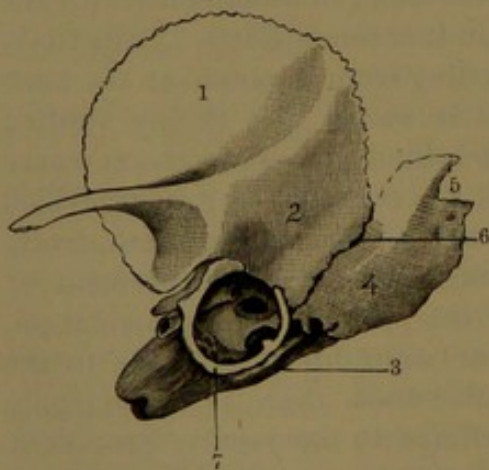
The squama of the temporal bone is chiefly composed of compact substance. The mastoid portion of the bone is thicker than the former,

and pervaded throughout with spongy substance, which, however, for the most part, is empty or contributes to the vacuities of the mastoid sinuses. The petrous portion of the bone, thus named from its supposed comparative hardness, contains the labyrinth, to which it forms a dense wall of compact substance. It also contributes to form the tympanic cavity; but its apex is occupied with spongy substance filled with marrow.

Near the period of birth the temporal bone consists of three distinct osseous pieces, which are named the **squamosal**, **petrosal**, and **tympanal**. Usually at birth these are partially ankylosed, but

are readily separated from one another. In many animals they remain in part or all permanently separated, or become variously united. Thus, in the hog the squamosal and petrosal coalesce and the tym-

FIG. 51.



TEMPORAL BONE NEAR THE TIME OF BIRTH. 1, squamosal; 2, its mastoid portion; 3, petrosal; 4, its mastoid portion; 5, notch remaining from the early separation into two parts; 6, petro-squamosal suture; 7, tympanal or tympanic ring.

<sup>1</sup> Tuba.

<sup>2</sup> External auditory meatus; m. auditorius externus.

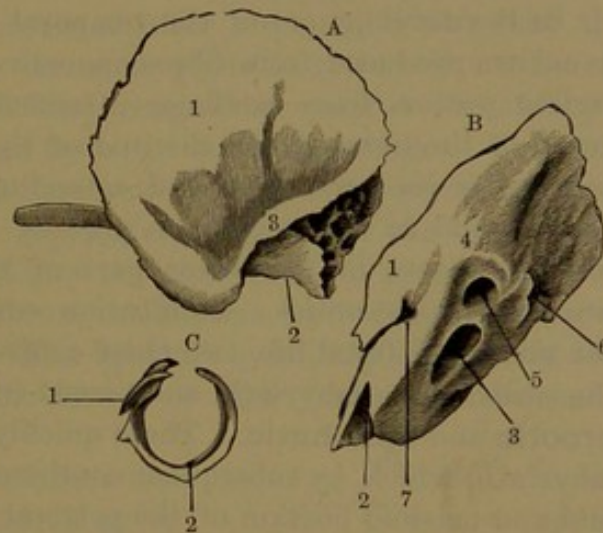


panal remains separate, and in the horse the latter two unite and the former remains distinct. The mastoid portion of the mature bone is an outgrowth from both the squamosal and the petrosal, and is comparatively but little produced at birth.

The **squamosal**<sup>1</sup> is a nearly circular upright plate, which joins the petrosal by the **petro-squamosal suture**. This descends externally behind the position of the ear from the upper notch between the squamosal and petrosal, and internally extends from the upper to the lower notch between the same. The zygomatic process projects obliquely forward, with almost no curvature. The articulation of the mandible deviates but little from the general vertical plane of the squamosal, and it is a shallow concavity, with scarcely any distinction of glenoid fossa and articular eminence. The mastoid portion of the squamosal appears as a triangular plate, which outwardly closes the upper part of the tympanum. Below, it forms the upper margin of the entrance of the latter, to which is attached the tympanic membrane. Internally, it is separated from the upright plate of the squamosal by a slanting shelf, which supports the contiguous border of the tympanic tegmen. Below the shelf is a smooth surface, which forms part of the tympanic cavity; and above and behind this is a cellular surface, which forms part of the mastoid antrum.

The **petrosal**<sup>2</sup> displays the labyrinth, already of mature size and bounded by compact walls, partially embedded in more spongy substance, from which it may be easily excavated. The supra-semicircular canal is especially conspicuous, and includes a considerable recess,<sup>3</sup> which subsequently is, for the most part, filled up. The tympanic tegmen appears as a distinct triangular plate projecting from the petrosal, and resting by its outer border on the shelf of the squamosal. The cavity of the tympanum and mastoid antrum are well

FIG. 52.



THE THREE PIECES OF THE TEMPORAL BONE SEPARATED. A. Inner view of the right squamosal. 1, its squama; 2, mastoid portion; 3, shelf of support for the tympanic tegmen. B. Upper view of the right petrosal. 1, its tegmen; 2, carotid canal; 3, internal auditory meatus; 4, supra-semicircular canal; 5, recess included by the canal; 6, similar recess of the post-semicircular canal; 7, hiatus of the facial canal. C. Tympanal. 1, glenoid canals; 2, groove for the tympanic membrane.

<sup>1</sup> Os squamosum; pars squamosa; p. squamo-zygomatica.

<sup>2</sup> Os petrosum; pars petrosa; p. petro-mastoidea; periotic bone.

<sup>3</sup> Fossa arcuata; periotic fenestra.



produced. The mastoid portion of the petrosal is connected in front with that of the squamosal, and is often already partially ankylosed with it. Its upper border usually exhibits a notch, which remains from the original separation of the petrosal into two parts. The mastoid process is yet undeveloped.

The **tympantal**<sup>1</sup> at birth is a slender osseous ring, incomplete for a short extent above, and is commonly ankylosed at the ends with the extremities of the tympanic margin of the mastoid portion of the squamosal. It slants in a plane from the ends downward and inward, and is suturally connected along the back and lower border with the petrosal. It is grooved along its inner border for the insertion of the tympanic membrane; and its anterior crus is also obliquely grooved internally to form part of the **glenoid canals**, for the accommodation of the long process of the malleus and the tympanic nerve. At this period the osseous auditory meatus is undeveloped, and its tympanic orifice is on a plane almost continuous inwardly from the outer surface of the squamosal.

In the development of the temporal bone, the squamosal and tympanal are produced from fibro-connective tissue, and the petrosal and styloid process from cartilage. Ossification commences in the squamosal of the foetus about the end of the second month, a centre appearing at its lower part and extending in the squama, the mastoid portion, and in the zygomatic process. In the third month an ossific centre appears in the lower part of the tympanal, and grows towards the extremities. Ossification commences in the petrosal near the middle of foetal life, two chief centres appearing and extending in the walls of the labyrinth, and named from their relative positions the **prootic** and **opisthotic**. These quickly coalesce to form the osseous labyrinth, which, by subsequent continuous growth, produces the pyramid and mastoid portion of the petrosal. The prootic gives rise to all that part of the pyramid which is visible within the cranium except the portion contiguous to and forming the jugular fossa; the opisthotic to all that part visible beneath the cranium, including the jugular fossa. The mastoid portion is produced subsequent to the ossification of the labyrinth by outgrowth from the post- and ecto-semicircular canals. The production from the post-semicircular canal first makes its appearance as an elliptical islet<sup>2</sup> in the cartilage which occupies the interval between the squamosal and the occipital and parietal bones. Later the outgrowth from the ecto-semicircular canal appears as a quadrate islet between the former islet and the squamosal. The two islets quickly unite, and thus establish the mastoid portion of the petrosal; and it is

---

<sup>1</sup> Os tympanicum; pars tympanica; tympanic ring.

<sup>2</sup> Epiotic; regarded by Prof. Huxley as a distinct ossific centre; but according to my observations in the human temporal bone, a continuous outgrowth from the opisthotic.



from that part which forms the quadrate islet, together with the mastoid portion of the squamosal, that the mastoid process is subsequently developed.

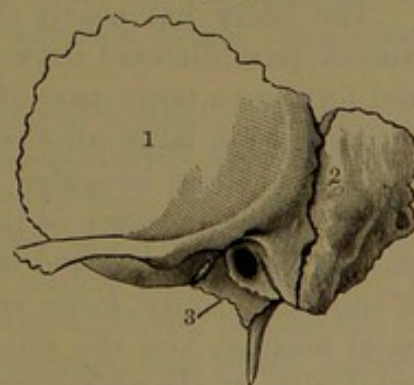
The squamosal and petrosal commonly begin to ankylose shortly before the time of birth, commencing in the external portion of the petro-squamosal suture, which, in this position, is commonly obliterated in the course of the first year. Occasionally traces of this part of the suture remain as short, irregular chinks, and rarely as a continuous fissure which descends from the notch behind the squamosal above to the end of the mastoid process, as represented in Fig. 53. Such a specimen indicates that the anterior third of the mastoid portion of the mature temporal bone pertains to the squamosal, while the remainder belongs to the petrosal. The mastoid process, scarcely marked at birth, becomes more or less conspicuous only after a year or more. The mastoid antrum is produced at birth, but the contiguous mastoid sinuses undergo little development until much later, on the approach of puberty and subsequently.

The auditory meatus is produced after birth, at which time the tympanic orifice is nearly on the same plane as the outer surface of the temporal bone. In the development of the meatus the auditory plate is gradually differentiated from the mastoid portion of the squamosal, and at the same time the tympanic ring grows outwardly. The sides of the ring grow most rapidly and expand at the outer ends, which conjoin to form the auditory process, leaving a central aperture in the tympanal closed by fibrous membrane, and directed towards the mandibular articulation. The aperture gradually diminishes, and commonly disappears about the fourth or fifth year, but occasionally is not completely obliterated.

The styloid process commences to ossify after birth, but remains in great part in a cartilaginous condition until after puberty, and usually does not ankylose with the petrosal until approaching middle age or later.

In the mature temporal bone, to the **squamosal** belongs the so-called squamous portion, with the anterior third of the mastoid portion, and the auditory plate, which forms the roof of the auditory meatus; to the **petrosal** belongs the petrous portion, with the posterior two-thirds of the mastoid portion, excluding the tympanic plate, which belongs to the **tympanal**. The styloid process is a distinct element from the other osseous pieces of the temporal bone; and as the **stylo-hyal** remains permanently separated in many lower animals.

FIG. 53.



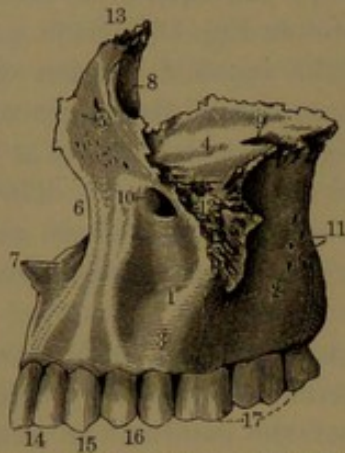
ADULT TEMPORAL BONE, with the external portion of the petro-squamosal suture permanently retained, from a specimen in the museum of the University. 1, squamosal; 2, petrosal; 3, tympanal.



## THE MAXILLÆ.

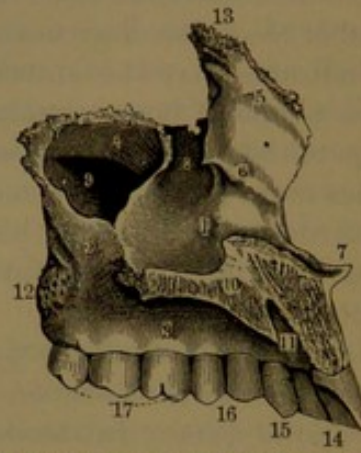
The **maxillæ**, or **maxillary bones**,<sup>1</sup> are the largest of the face, except the lower jaw, and form together the upper jaw, besides contributing to form the nasal cavities and the orbits. Each **maxilla** consists of a hollow portion, the **body**, with four other portions, named the **malar**, **alveolar**, **palate**, and **nasal processes**.

FIG. 54.



MAXILLA OF THE LEFT SIDE, outer view. 1, body; 2, tuberosity; 3, alveolar process; 4, orbital plate; 5, nasal process; 6, nasal notch; 7, nasal spine; 8, lachrymal groove; 9, entrance of the infraorbital canal; 10, infraorbital foramen; 11, orifices of the posterior dental canals; 12, malar process; 13, articulation for the internal angular process of the frontal bone; 14, incisor teeth; 15, canine tooth; 16, premolar teeth; 17, molar teeth.

FIG. 55.



MAXILLA OF THE LEFT SIDE, inner view. 1, nasal surface of the body; 2, surface for the palate bone; 3, alveolar process; 4, orbital plate; 5, nasal process; 6, ridge for the articulation of the turbinal bone; 7, nasal spine; 8, lachrymal groove; 9, antrum; 10, palate process; 11, incisive foramen; 12, tuberosity; 13, articular extremity for the internal angular process of the frontal bone; 14, incisor teeth; 15, canine tooth; 16, premolar teeth; 17, molar teeth.

The **body** has nearly the shape of a short half-cylinder, with the convex part directed outward and the plane surface directed inward, and forming a large part of the outer wall of the nasal cavity. It is occupied by a large air-chamber, the **antrum**,<sup>2</sup> which opens into the latter by a large, irregular aperture, much reduced in the articulated bone by the apposition of the ethmoid, palate, and turbinal bones. The smooth surface below and in front of the aperture, curving to the floor of the nasal cavity, forms the greater portion outwardly of the inferior nasal meatus; and the roughened surface behind articulates with the nasal plate of the palate bone.

From the outer part of the body projects a stout pyramidal offset, the **malar process**,<sup>3</sup> which terminates in an oblique, triangular, rough

<sup>1</sup> Superior maxillary bones; supermaxillary bones; superior maxillæ; upper jaw bones; ossa maxillaria; o. maxillæ.

<sup>2</sup> A. maxillare; a. of Highmore; a. Highmorianum; maxillary sinus; supermaxillary cavity.

<sup>3</sup> Processus malaris; p. jugalis; p. zygomaticus; p. zygomatico-orbitalis.



surface for articulation with the malar bone. The fore part of the body extending outwardly on the malar process is variably depressed, forming the **canine fossa**,<sup>1</sup> above which is the **infraorbital foramen**.<sup>2</sup> The back part of the body is swollen, and its convex surface, continuous outwardly with the posterior concave surface of the malar process, forms the anterior boundary of the zygomatic fossa, while its upper inner corner forms that of the sphenomaxillary fossa. The portion below the latter extending to the back end of the alveolar process is the **maxillary tuberosity**,<sup>3</sup> which is impressed with a rough area or pit articulating with the pyramidal process of the palate bone. From above the tuberosity a groove descends inwardly to form part of the posterior palatine canal. Near the centre of the posterior surface there are usually two small foramina of the **posterior dental canals**,<sup>4</sup> which descend in the outer wall of the antrum and transmit the posterior dental vessels and nerves. The upper part of the body is the **orbital plate**,<sup>5</sup> forming the floor of the orbit and the roof of the antrum. It is triangular and variably concave or nearly flat, and slopes more or less outward. Inwardly, it articulates with the ethmoid and lachrymal bones; at the apex behind, with the orbital process of the palate bone; and at the fore part outwardly, with the malar bone. In front it is defined by a portion of the infraorbital margin, within which may sometimes be seen the impression of the origin of the inferior oblique muscle of the eye. Its posterior outer border is a wide, obtusely rounded notch, which forms the lower margin of the sphenomaxillary foramen. From this a groove communicates with the **infraorbital canal**,<sup>6</sup> which proceeds forward through the orbital plate and descends to its outlet, the **infraorbital foramen**. The fore part of the canal projects from the roof of the antrum, and gives off the **anterior dental canal**,<sup>7</sup> which descends in the anterior wall of the antrum, and gives passage to the anterior dental vessels and nerve.

The **alveolar process**<sup>8</sup> occupies the inferior border of the maxilla, and with its fellow forms a strong arch with slightly divergent or nearly parallel sides; but occasionally slightly convergent, so that the arch assumes a horseshoe shape. It is the thickest and most spongy portion of the bone, and is pierced with a series of conical pits, the **alveoli**, or sockets for the teeth. The posterior two-thirds of the process are beneath the body, and form the floor of the antrum, into which, usually, the bottoms of some of the molar alveoli project. The anterior part of the process is below the fore part of the nasal cavity, projecting more or less obliquely downward and forward. The external or facial surface of the alveolar process, especially in advance, is marked by

<sup>1</sup> F. canina; f. maxillaris.<sup>2</sup> F. infraorbitale.<sup>3</sup> Tuberositas maxillæ.<sup>4</sup> Canales alveolares posteriores.<sup>5</sup> Planum orbitale.<sup>6</sup> Canalis infraorbitalis.<sup>7</sup> C. alveolaris anterior.<sup>8</sup> P. alveolaris; p. dentalis.



vertical prominences due to the projection of the alveoli. That of the canine alveolus, usually the most prominent, separates the **canine fossa** from a shallow depression, the **incisive fossa**,<sup>1</sup> situated in front of the incisive alveoli. The two fossæ are variable, usually slight, but sometimes conspicuous, and to some extent are proportioned with the prominence of the canine and contiguous pair of alveoli. The internal surface of the alveolar process, rough and porous, contributes to form the vaulted hard palate, or roof of the mouth. The anterior extremity ends in a thick, flat, and roughened border, which articulates with that of the opposite bone. Above the extremity is the **nasal notch**, which curves from the median line outward and upward to the nasal process, and forms the lateral and lower boundary of the entrance to the nasal cavity. Its margin above is thin, but below it forms a thicker acute ridge, which rises above the level of the floor of the nasal cavity. The inner end of the ridge projects forward in a pointed process, which joins that of the opposite side to form the **nasal spine**.<sup>2</sup> From this another ridge extends backward, and articulates with that of the opposite side to form the **incisive crest**,<sup>3</sup> which articulates behind with the end of the vomer, and is grooved above for the accommodation of the cartilage of the nasal septum.

The **palate process**<sup>4</sup> is a strong horizontal plate, which extends in a shelf-like manner from the base of the alveolar border inward and about two-thirds the way back. Its inner border is produced in a rising ridge, which is roughened, and articulates with that of the opposite maxilla to form the **nasal crest**.<sup>5</sup> This articulates above with the vomer, and forms the lower border of the nasal partition. The upper surface of the process forms part of the floor of the nasal cavity, is depressed below the level of the nasal notch, and is transversely concave and smooth. The lower surface is flat, rough, and porous, and forms part of the palate or roof of the mouth. The posterior border is transverse and straight, and is serrated for articulation with the palate plate of the palate bone. At the fore part of the palate process, contiguous to the incisive crest, is the **anterior palatine canal**,<sup>6</sup> which descends from the nasal cavity and joins its fellow in the intermediate suture of the maxillæ, to end in the **incisive foramen**<sup>7</sup> of the palate, a short distance behind the incisor alveoli.

The **nasal process**<sup>8</sup> ascends from the fore part of the maxilla, above the anterior nasal notch, and ends in a thickened serrated extremity, which articulates with the internal angular process of the frontal

<sup>1</sup> F. incisiva; f. myrtiformis.

<sup>2</sup> Spina nasalis anterior.

<sup>3</sup> Crista incisiva.

<sup>4</sup> P. palatinus.

<sup>5</sup> Crista nasalis.

<sup>6</sup> Incisor foramen or canal; canalis incisivus; foramen of Stenson.

<sup>7</sup> F. incisivum; f. palatinum anterior; anterior palatine canal.

<sup>8</sup> P. nasalis, or frontalis.



bone. Its inner anterior border, thick above and narrow below, is roughened to articulate with the nasal bone. Its outer surface forms part of the side of the nose in front of the orbit, and is longitudinally grooved behind to form part of the lachrymal fossa and the nasal duct descending from it. The inner surface forms part of the outer wall of the nasal cavity, and is defined below by a fore and aft ridge, the **turbinal crest**,<sup>1</sup> for the attachment of the turbinal bone. The posterior surface is irregular, and articulates with the ectethmoid, so as to close in front the ethmoidal sinuses. The outer border defining this surface is a narrow ridge, which articulates with the lachrymal bone.

The maxilla, with the exception of the alveolar process, which is largely composed of spongy substance, consists mainly of plates of compact substance.

The maxilla commences ossification about the seventh week of foetal life from several points; according to Sappey, five; but these quickly coalesce, and are not regarded as distinct ossific centres. That part of the bone which subsequently contains the incisor teeth is considered to be independent of the rest, from the fact that in the other animals it ordinarily remains as a permanently distinct bone, which is named the **premaxilla**.<sup>2</sup> One of the most remarkable differences in the skull of man from that of all other animals is the apparent absence of the latter; and even in those most nearly allied to him, as the monkeys, it remains to maturity as a completely distinct and conspicuous bone containing the incisor teeth. It originates in the human embryo from a distinct centre, but so quickly coalesces with the maxilla that its independent existence is scarcely recognized. At birth and later, even to adult age, a fissure is observed on the palate process, directed outward from the incisive foramen to the alveolar border, indicating the original separation of the premaxilla, but no trace of such a separation is visible on the facial surface as it is seen in other animals. The abnormal condition of harelip is at times associated with a separate premaxilla. At birth the alveolar border of the maxilla is occupied by a series of receptacles enclosing the developing teeth. The antrum, already of considerable size, begins to appear near the middle of foetal life. The infraorbital canal is open by a fissure along its inner side.

After birth the alveolar process is gradually developed, and acquires its mature condition in conformity with the development and protrusion of the teeth. With the loss of the latter it is proportionately reduced, and finally may appear as a narrow arched ridge projecting comparatively little below the level of the palate process, as is commonly observed in old age.

---

<sup>1</sup> Crista turbinalis.

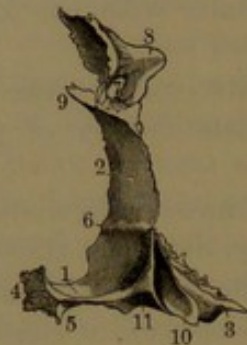<sup>2</sup> Premaxillary, intermaxillary, or incisive bone; os incisivum.



## THE PALATE BONES.

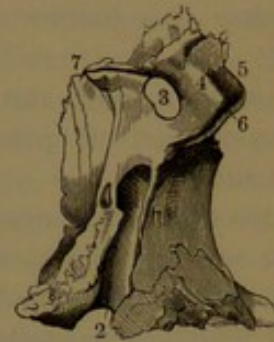The **palate bones**<sup>1</sup> are situated behind the maxillæ, between these and the sphenoid bone. They enter into the construction of the hard palate, the nasal cavities, the orbits, and the spheno-maxillary and pterygoid fossæ. Each bone consists of an inferior palate plate, an external nasal plate, and three conspicuous processes.

FIG. 56.



POSTERIOR VIEW OF THE RIGHT PALATE BONE. 1, palate plate; 2, nasal plate; 3, pyramidal process; 4, articular border for the left palate bone; 5, posterior nasal spine; 6, turbinal crest; 7, sphenopalatine notch, between 8, the orbital, and 9, the sphenoidal process; 10, groove for the entopterygoid process of the sphenoid bone; 11, position of the posterior palatine canal.

FIG. 57.



EXTERIOR VIEW OF THE RIGHT PALATE BONE. 1, rough surface articulating with the maxilla, and diminishing the aperture of the antrum; 2, posterior palatine canal; completed by the maxilla; 3, sphenopalatine notch; 4, 5, 6, orbital process; 4, surface directed towards the sphenomaxillary fossa; 5, orbital surface; 6, maxillary border; 7, sphenoidal process; 8, pyramidal process.

The **palate plate**<sup>2</sup> is horizontal and nearly square, and serves to extend the floor of the nasal cavity and the hard palate behind the palate process of the maxilla. The anterior border, slightly thickened, is serrated to articulate with the latter process. The posterior border is concave and sharp, forms the inferior margin of the posterior nasal orifice, and gives attachment to the soft palate. The internal border is constructed like that of the palate process of the maxilla, and, with that of the opposite side, extends the nasal crest for articulation with the vomer. The crest behind is produced in a pointed process, the **posterior nasal spine**,<sup>3</sup> to which the uvula is attached. The upper surface of the palate plate extends the floor of the nasal cavity, and is transversely concave and smooth. The lower surface extends the hard palate, and is for the most part occupied by a broad, shallow groove, which curves inward and forward from the posterior palatine canal, and is usually defined behind by a variable ridge for the attachment of the palatal tensor muscle.

The **nasal plate**,<sup>4</sup> thinner and longer than the palate plate, ascends

<sup>1</sup> Ossa palati; o. palatina.

<sup>2</sup> Pars palatina; horizontal plate; pars horizontalis.

<sup>3</sup> Spina nasalis postica.

<sup>4</sup> Pars nasalis; p. perpendicularis; p. ascendens; vertical plate.



from this at the outer back part of the nasal cavity, and has its external, slightly roughened surface articulating with the maxilla. It contributes in this position to reduce the aperture of the antrum. Its fore part, extended below in an angle, terminates in a thin, irregular margin, which is partially received in a fissure of the inferior border of the aperture. The posterior concave border, thin and irregular, articulates with the anterior border of the entopterygoid process. Outward from the posterior border is a smooth surface, which extends above on the sphenoidal and orbital processes and forms the inner boundary of the sphenomaxillary fossa, and continues below in a groove, which, by apposition with the maxilla, forms the **posterior palatine canal**, for the transmission of the corresponding vessels and nerve.

The internal surface is smooth, and is crossed near the middle by a ridge, the **turbinal crest**,<sup>1</sup> with which the posterior extremity of the turbinal bone articulates. A similar but less marked ridge<sup>2</sup> at the upper border of the plate articulates with the nasal mesoturbinal, which belongs to the ethmoid bone.

From the upper border of the nasal plate proceed the sphenoidal and orbital processes, separated by a circular notch, which by apposition of the processes to the sphenoid bone is converted into the **spheno-palatine foramen**.<sup>3</sup> This communicates between the back part of the upper nasal meatus and the sphenomaxillary fossa, and transmits the posterior nasal vessels and nerves.

The **sphenoidal process**,<sup>4</sup> the posterior and smaller, is a little plate, of which the upper border is expanded and applied to the under part of the body of the sphenoid bone within the fore part of the root of the entopterygoid process. Its external surface forms part of the inner boundary of the sphenomaxillary fossa, and its internal surface part of the outer wall of the nasal cavity. The upper border applied to a narrow groove beneath the vaginal process of the sphenoid bone forms with it the **pterygo-palatine canal**.<sup>5</sup>

The **orbital process**,<sup>6</sup> situated in advance of the former, is not only much larger but more elevated, and projects more outwardly, expands above, and commonly encloses a considerable cavity. It presents six faces, of which three articulate with contiguous faces of the ectethmoid, sphenoid, and maxilla. Of the others, the **nasal surface** is directed into the upper nasal meatus, the **orbital surface** forms the posterior angle of the floor of the orbit, and the **spheno-maxillary surface** contributes to the corresponding fossa. The latter two surfaces are defined by a smooth border, which forms the inner part of the inferior margin of the sphenomaxillary foramen. The cavity of

<sup>1</sup> Crista turbinalis; inferior turbinal crest.

<sup>2</sup> C. ethmoidalis; superior turbinal crest.

<sup>3</sup> F. spheno-palatinum.

<sup>4</sup> P. sphenoidalis.

<sup>5</sup> Canalis pterygo-palatinus.

<sup>6</sup> P. orbitalis.



the process, of variable extent, commonly communicates with the posterior ethmoidal sinuses, and occasionally with the sphenoidal sinus. Sometimes an additional recess back of the main cavity opens backward into the latter.

The **pyramidal process**<sup>1</sup> projects backward and outward from the nasal plate, extending to its conjunction with the palate plate, and is the thickest portion of the bone. Its outer surface, extending backward and outward from that of the nasal plate, is triangular and rough, and articulates with the inner back part of the maxillary tuberosity. Between it and the nasal plate is the deep groove which forms part of the posterior palatine canal, descending to the under surface of the palate plate. The posterior surface is triangular, with the apex continuous upward into the posterior border of the nasal plate. It is divided into three vertical grooves, of which the outer and inner are divergent and roughened to articulate with the lower extremities of the sphenoid pterygoid processes, while the intermediate smooth one occupies the notch between the latter and completes the pterygoid fossa. The base of the process forms an irregular, oblique ridge, of which the outer end extends beneath the ectopterygoid process of the sphenoid, and the inner end extends under the palate plate and gives attachment to the palatal tensor muscle. About the middle of the ridge, behind the exit of the posterior palatine canal, are usually from one to three small **palatine canals**,<sup>2</sup> which descend through the anterior border of the pyramidal process from the speno-maxillary fossa.

The palate bone is composed of thin plates of compact substance, except the pyramidal process, which contains some spongy substance. It is developed from a single centre, which makes its appearance, near the end of the second month of foetal life, at the conjunction of the nasal and palate plates.

#### THE TURBINAL BONES.

The **turbinal bone**<sup>3</sup> projects along the outer wall of the nasal cavity below the position of the ethmoid bone and overhangs the inferior nasal meatus. It is an elongated, elliptical, scroll-like plate, slightly narrowed and rounded in front, and tapering to a point behind. The inner surface is convex, irregularly pitted, grooved, and porous. The outer surface, for the most part composing the roof of the inferior nasal meatus, is concave and less rough than the former. The lower free border, the thickest portion of the bone, is obtuse, everted, spongy, and rough. The upper border is attached the entire length of the bone, and gives off three processes. Its fore part slants downward,

<sup>1</sup> Pterygoid process; tuberosity; apophysis pterygoideus.

<sup>2</sup> Posterior and external, small palatine canals.

<sup>3</sup> Inferior turbinated bone; os turbinatum inferius; spongy bone; os spongiosum; concha inferior; maxillo-turbinal.



and articulates with the turbinal crest of the maxilla; and its back part, also slanting downward, articulates with the turbinal crest of the palate-bone. In an intermediate position, two thin processes ascend, or a thin plate dividing into two. Of these the anterior, **lachrymal process**,<sup>1</sup> articulates with the maxilla and the lachrymal bones, and forms with them the nasal duct. The posterior, **ethmoidal process**,<sup>2</sup> joins the uncinate process of the ethmoid bone, and with it partially closes the irregular aperture of the antrum. From between the former a thin, angular or semicircular plate, the **maxillary process**,<sup>3</sup> curves inward and downward, and is inserted into a notch at the lower part of the aperture of the antrum, between the maxilla and the nasal plate of the palate bone.

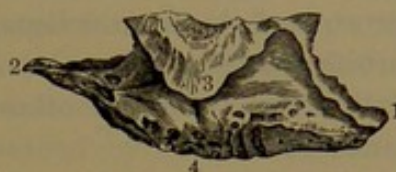The turbinal bone originates in a cartilaginous matrix, the only one of the face that does so. It is developed from a single centre of ossification, which does not make its appearance until several months after birth. The turbinals are often unequally produced, and are frequently otherwise unsymmetrical.

#### THE LACHRYMAL BONES.

The **lachrymal bone**<sup>4</sup> is the smallest of those of the face, and is a thin, upright, quadrate plate situated at the fore part of the inner wall of the orbit. Externally, it is divided by a sharp descending **crest**<sup>5</sup> into two surfaces, of which the usually larger, posterior one, the **orbital surface**, is rectangular, and occupies the same plane as the orbital surface of the ethmoid bone; while the anterior surface forms a groove,<sup>6</sup> which joins that of the nasal process of the maxilla to complete the lachrymal fossa. A descending process from the groove unites with the turbinal bone and maxilla to form the nasal duct; and a hook-like process<sup>7</sup> from the bottom of the crest forms the outer edge of the entrance of the latter.

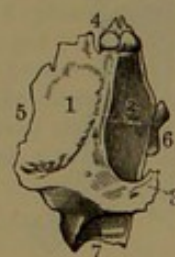The internal surface of the lachrymal bone is applied to the ectethmoid in advance of the orbital plate, and in this position completes the anterior ethmoidal sinuses. The extension of the same sur-

FIG. 58.



EXTERNAL VIEW OF THE RIGHT TURBINAL BONE. 1, anterior extremity articulating with the maxilla; 2, posterior extremity articulating with the palate bone; 3, hook-like plate articulating with the lower border of the maxillary antrum. Above are the lachrymal and ethmoidal processes; 4, inferior obtuse border.

FIG. 59.



EXTERNAL VIEW OF THE RIGHT LACHRYMAL BONE. 1, orbital surface; 2, lachrymal groove; 3, small process bounding the latter inferiorly; 4, frontal border; 5, ethmoidal border; 6, maxillary border; 7, process articulating with the turbinal bone.

<sup>1</sup> P. lachrymalis; p. nasalis.

<sup>2</sup> P. ethmoidalis.

<sup>3</sup> P. auricularis; p. maxillaris. <sup>4</sup> Os lachrymale; os unguis; unguiform bone.

<sup>5</sup> Crista lachrymalis.

<sup>6</sup> Sulcus lachrymalis.

<sup>7</sup> Hamulus lachrymalis.



face on the descending process of the nasal duct forms part of the outer wall of the middle nasal meatus.

The anterior border of the lachrymal bone articulates with the nasal process of the maxilla; its superior border, with the internal angular process of the frontal bone; its posterior and inferior borders, with the orbital plates of the ethmoid and maxillary bones. The inner surface articulates with the ethmoid; and the descending process, with the turbinal bone.

The lachrymal bone is variable, especially in its proportions; and sometimes it is perforated or imperfectly ossified; and occasionally the hook-like process is separate or may be absent. It is a thin plate of compact substance, and is produced from a single centre, which appears about the end of the second month of foetal life.

#### THE NASAL BONES.

The **nasal bones**<sup>1</sup> articulate with each other and with the nasal processes of the maxillæ to form the bridge of the nose. They vary considerably in size and shape in different races and individuals, and are commonly larger and best produced in the white race. They vary not only in size but in proportions, in the degree of prominence and curvature, and in being more or less fan-shaped to nearly rectangular. They project downward and forward from the nasal notch of the frontal bone, and form the upper part of the anterior nasal orifice.

The nasal bone is commonly thickest and narrowest at the upper extremity, and becomes gradually wider and thinner in its descent; but sometimes, especially in the lower races, it becomes narrower in the upper third of its descent and then widens to the lower border. It presents two principal surfaces, defined by four borders.

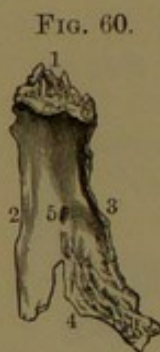

FIG. 60.  
ANTERIOR VIEW OF  
THE LEFT NASAL BONE.  
1, frontal border; 2,  
nasal border; 3, max-  
illary border; 4, lower  
border; 5, nasal fora-  
men.

The **anterior surface** slants downward and forward and also laterally from the inner border, is for the most part concave longitudinally, but becomes convex below, and is convex transversely. Near the centre is a small aperture, the **nasal foramen**, which transmits a little vein descending from the interior. The **posterior surface** above is narrow and rough, and with the upper strongly serrated border of the bone articulates with the nasal notch of the frontal bone. The surface widens below, where

it is smooth and concave, and forms the anterior slope of the roof of the nasal cavity. It is marked by a groove, which is occupied by a branch of the nasal nerve. The internal border above is nearly as thick as the bone is wide in the same position, but after about a third

<sup>1</sup> Ossa nasalia; o. nasi.



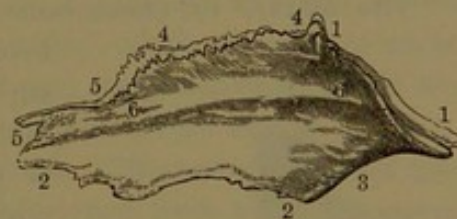
of the length gradually tapers below to a point. It forms a somewhat uneven plane, which conforms to its fellow so as to interlock with it, and projects behind in a slightly roughened ridge, which articulates with the nasal spine of the frontal bone. The external longest border, mostly thin and outwardly bevelled and roughened, articulates with the overlapping edge of the nasal process of the maxilla. The inferior, thin, expanded border is sometimes entire and curved to accord with the nasal notch below, and sometimes is divided by one or two clefts of variable depth.

The nasal bone is mainly composed of compact substance, but usually contains a small quantity of spongy substance in its thicker upper part. It originates in a single ossific centre, which appears about the end of the second month of foetal life.

#### THE VOMER.

The **vomer**,<sup>1</sup> a single bone, is a thin, vertical, irregularly lozenge-shaped plate, which occupies the back lower portion of the nasal partition. Its sides are smooth, and contribute to form the inner wall of the nasal cavities. Of the four borders the longer ones extend forward, while the shorter ones are directed backward. The **posterior border** curves from above downward and forward, and forms the dividing line between the posterior nasal orifices. It is thick and notched at the upper extremity, and becomes thin and sharp below. The **superior border**, about as long as the former, is expanded, and includes an angular gutter from which the sides project in a pair of semi-elliptical ledges, the **alæ**.<sup>2</sup> These articulate with the under surface of the sphenoidal body and embrace the rostrum, and by their edges join those of the vaginal processes of the sphenoid bone and the sphenoidal processes of the palate bones. The **anterior border**, about twice the length of either of the former, slants downward and forward, and for two-thirds of its extent articulates with the contiguous border of the ethmoidal nasal plate. It is commonly cleft to a variable depth, and encloses a prolongation of the septal cartilage extending to the sphenoidal rostrum. The **inferior border**, nearly as long as the former, is horizontal, and articulates with the nasal crest of the maxillæ and palate bones. The anterior angle of the

FIG. 61.



LEFT SIDE OF THE VOMER. 1, broad groove receiving the rostrum of the sphenoid bone; 2, inferior border articulating with the palate plates of the maxillæ and palate bones; 3, posterior border, the dividing line of the posterior nasal orifices; 4, grooved border receiving a narrow slip of cartilage, situated between the vomer and the nasal plate of the ethmoid bone; 5, border for the cartilaginous septum of the nose; 6, nasal surface.

<sup>1</sup> Os vomeris.

<sup>2</sup> Alæ vomeris.



vomer is truncated, and articulates with the back part of the incisive crest of the maxillæ. The vomer is a plate of compact substance.

The bone is frequently unsymmetrical and variably bent from the median position to one or the other side, and especially is it irregular in its articulation with the ethmoidal nasal plate, the union commonly projecting into one nasal cavity more than into the other.

At birth the vomer is proportionately longer and wider, and consists of two thin plates, which are united along the lower border, and include the contiguous portion of the septal cartilage of the nose. In the subsequent growth of the bone it is mainly produced below, while the plates above form the sides of the cleft of the anterior border of the mature bone and expand as the alæ of its superior border. The vomer originates in two ossific centres, about the sixth month of foetal life, appearing in the perichondrium at the sides of the septal cartilage and quickly coalescing beneath.

#### THE MALAR BONES.

The **malar bones** occupy the prominent part of the cheeks, and contribute to form the orbits and the temporal and zygomatic fossæ.

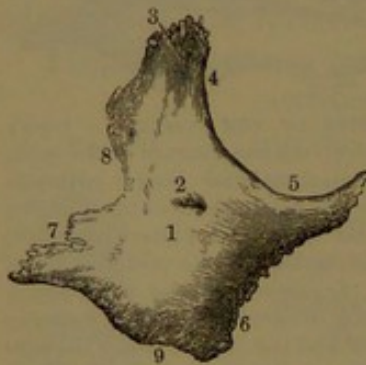
The malar,<sup>1</sup> or cheek-bone, terminates at its lower fore part in a

broad, triangular, rough surface, which is supported upon and articulates with the malar process of the maxilla. Behind, it is prolonged in the **zygomatic process**, which ends in a serrated border slanting downward and backward, and articulating with the corresponding process of the temporal bone. From about its middle the bone is extended upward in the **frontal process**, which forms the outer boundary between the orbit and temporal fossa, and ends in a strongly-serrated extremity, which articulates with the external angular process of the frontal bone.

The external or **facial surface** of the malar bone is vertical, quadrilateral, and variably convex, and forms the basis of the promi-

nence of the cheek. Its lower front, or **maxillary border**, curves outward and downward at the articulation of the bone with the malar process of the maxilla. The lower back, or **zygomatic border**, is convex, contributes more than half to the length of the zygomatic arch, and is roughened for the attachment of the masseter muscle. The upper front, or **orbital border**, is a smooth, obtuse arching ridge, forming about one-third of the circumference of the orbital entrance.

FIG. 62.



OUTER VIEW OF THE RIGHT MALAR BONE. 1, external or facial surface; 2, malar foramen; 3, frontal process; 4, 5, orbital border; 6, maxillary border; 7, zygomatic process; 8, temporal border; 9, zygomatic border.

<sup>1</sup> Os malare; os malæ; os jugale; os zygomaticum; os jugamentum.



The upper back, or **temporal border**, is a sigmoid ridge, which extends from the end of the frontal process to the end of the zygomatic process, forms the anterior boundary of the temporal fossa, and gives attachment to the temporal fascia.

From the orbital border of the bone a curved triangular or crescentic process, directed backward and inward, is the **orbital plate**,<sup>1</sup> which separates the orbit from the temporal fossa. Its inner surface is concave, and forms part of the outer wall and floor of the orbit; its outer surface forms the adjacent portion of the temporal and zygomatic fossæ. Its lower border internally joins the orbital plate of the maxilla, and externally the posterior border of the malar process of the same bone. Its upper border articulates with the orbital plate of the frontal bone, and its back border with the great wing of the sphenoid bone. Commonly, a small portion of the border, between the articulation with the latter and the maxilla, forms the outer extremity of the spheno-maxillary foramen. The posterior, or **temporal surface**, of the malar bone curves from the back of the orbital plate outward and backward within the zygomatic process, forming the anterior boundary of the temporal and zygomatic fossæ.

The orbital surface of the orbital plate commonly exhibits several foramina, the entrance of the **malar canals**,<sup>2</sup> which terminate variably in one or two apertures on the facial and temporal surfaces of the bone, and transmit the branches of the temporo-malar nerve.

The malar bone is variably prominent in different races, and also in individuals of the same race. It is developed from a single centre, which appears about the end of the second month of foetal life.

#### THE MANDIBLE.

The **mandible**, lower jaw, or **inferior maxillary bone**,<sup>3</sup> forms the basis of the lower prominent part of the face, of which it is the largest and strongest piece. It is the only movable bone of the skull, is separated from all others of the face by the intervening teeth, and articulates with the temporal bones of the cranium. It consists of two lateral portions, which are separate pieces in early infancy, and which, in many animals, remain permanently in this condition, as, for example, in the dog, cat, and sheep.

The horizontal thicker portion of the mandible containing the teeth is named the **body**, and the posterior portion on each side extending upward is the **ramus**. In other animals it is usual to distinguish each half of the jaw under the latter name.

The **body** is deepest at its fore part, and slightly decreases behind, is produced above in the **alveolar process**, and is defined below by a

<sup>1</sup> Pars orbitalis; orbital process.

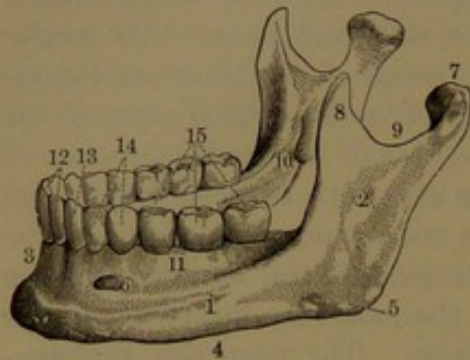
<sup>2</sup> Canales zygomatiko-faciales et temporales.

<sup>3</sup> Mandibula; os maxillare inferius; inferior maxilla.



thick, rounded border, named the **base**. It projects in front in a triangular eminence, the **mental protuberance**,<sup>1</sup> which is of variable prominence and breadth, and forms the basis of the chin, giving to it its variety of shape, narrow or broad, rounded or square. A slight

FIG. 63.



MANDIBLE. 1, body; 2, ramus; 3, symphysis; 4, base; 5, angle; 6, mental foramen; 7, condyle; 8, coronoid process; 9, mandibular notch; 10, mental foramen; 11, alveolar process; 12, incisor teeth; 13, canine tooth; 14, premolars; 15, molars.

ridge ascending from the protuberance is named the **symphysis**,<sup>2</sup> as indicating the position and original character of union of the two halves of the bone.

The **external surface** of the body, for the most part vertical on the alveolar process, thence inclines slightly forward and outward to the base. Commonly a little over an inch from the symphysis, and nearer the base than the upper border, is the **mental foramen**,<sup>3</sup> which opens upward and outward from the dental canal. The **base** is commonly somewhat everted at the chin, and in a less degree laterally; is convex

in its course, and of nearly uniform thickness to the position below the second molar tooth, whence it narrows into the inferior border of the ramus. Above the base, usually below the second molar tooth, an **oblique ridge**<sup>4</sup> rises from the outer surface of the body and curves backward and upward into the anterior border of the ramus. The internal surface of the body, behind the position of the mental protuberance, exhibits a variable process, the **mental tubercle**,<sup>5</sup> which is more or less distinctly divided into four portions, for attachment of the genio-glossal and genio-hyoid muscles. The tubercle is sometimes replaced by a group of roughened impressions, or presents other modifications. Outwardly from it there is usually a slight depression, sometimes conspicuously deepened, the **sublingual fossa**, which accommodates the sublingual gland. Below the fossa, on the everted base, is an oval, rough impression for the insertion of the digastric muscle. Below the position of the molar teeth is a conspicuous ridge, which divides the internal surface obliquely; and gives attachment to the mylo-hyoid muscle, whence its name of the **mylo-hyoid ridge**. Its fore part, less prominent, descends below the sublingual fossa to the mental tubercle. The surface above the ridge is smooth and invested with the mucous membrane of the gums. Below its more prominent

<sup>1</sup> Protuberantia mentalis; tuberculum mentale externum; spina mentalis externa; mental prominence; mental process.

<sup>2</sup> S. mandibule.

<sup>3</sup> F. mentale; f. maxillare ant.

<sup>4</sup> Linea obliqua; external oblique line.

<sup>5</sup> Spina mentalis interna; mental spines; genial tubercles.



part is an elongated depression, the **submaxillary fossa**, which partially lodges the submaxillary gland.

The **alveolar process**<sup>1</sup> of the jaw forms a thick, horizontal arch, into which the teeth are inserted, and nearly conforms to the arch above. Its fore part is vertical, and the lateral portions occupy a position extending backward and inward along the sides of the body. The external surface in advance is variably marked by the projection of the alveoli, though usually to a less degree than in the upper jaw. On each side of the symphysis it is variably, and mostly slightly, depressed as the **incisive fossa**.<sup>2</sup>

The **ramus**<sup>3</sup> is a quadrilateral plate, thinner than the body, ascending more or less obliquely backward, and diverging from the line of the alveolar process. It divides above into the coronoid and condyloid processes, which are separated by a large semicircular interval, the **mandibular notch**.<sup>4</sup> The conjunction of the posterior and inferior borders of the ramus forms the so-called **angle of the jaw**,<sup>5</sup> is convex, and usually projects more or less downward, and is everted. Occasionally it is simply rounded, and does not project downward, and sometimes it is nearly or quite straight, or even slightly inverted. The **external surface** of the ramus is a broad, vertical, slightly depressed, and uneven plane, more or less ridged on the angle, and for the most part serves to give attachment to the masseter muscle. The **internal surface** exhibits a central depression, communicating below with the **dental foramen**,<sup>6</sup> the commencement of the dental canal, bounded inwardly by a sharp-notched border, the fore part of which is produced in a thin, tongue-like process. From the notch a groove proceeds towards the submaxillary fossa, serving to lodge the mylo-hyoid vessels and nerve. Behind the groove, the surface extending to the angle is usually more or less strongly ridged for the attachment of the internal pterygoid muscle.

The **dental canal**<sup>7</sup> descends obliquely within the lower part of the ramus, and thence proceeds forward within the body, beneath the alveoli, and gives an outward fork to the mental foramen, while a smaller one ends in the incisive alveoli. It gives passage to the inferior dental vessels and nerve, branches of which traverse short passages communicating with the bottoms of the alveoli.

The **coronoid process**,<sup>8</sup> of variable size and proportions, is a flattened conical eminence, ascending and slightly divergent from the fore part of the ramus, and usually curving more or less backward. Its anterior convex border continues that of the ramus, forming a

<sup>1</sup> Alveolar border; limbus alveolaris; jüga alveolaria.

<sup>2</sup> Fossa mentalis.

<sup>3</sup> R. adscendens; r. perpendicularis.

<sup>4</sup> Sigmoid, or semilunar notch; incisura mandibularis, sigmoidea, or semilunaris.

<sup>5</sup> Angulus mandibulæ.

<sup>6</sup> Inferior dental foramen.

<sup>7</sup> Inferior dental canal; canalis maxillaris, or alveolaris inf.

<sup>8</sup> Processus coronoideus.



strongly sigmoid ridge descending to the body outside the alveolar process. Its posterior concave border forms part of the mandibular notch. A ridge from the inner surface descends to the inner margin of the alveolar process, and defines an anterior triangular grooved area, which descends to the last molar, and opens externally to it. The lower part of the ridge gives attachment to the pterygo-maxillary ligament and buccinator muscle. The outer surface of the coronoid process, continuous with that of the ramus, gives attachment to the temporal and masseter muscles. The anterior border and internal surface also give attachment to the temporal muscle.

The **condyloid process**,<sup>1</sup> stouter and commonly shorter than the former, ascends from the back part of the ramus and ends in a transverse, elliptical knob, the **condyle**,<sup>2</sup> which is convex, and invested with cartilage, and articulates with the glenoid fossa of the temporal bone. Its transverse, longer axis inclines from without slightly downward and backward. From the condyle, the process narrows in the **neck**, which is compressed from before backward, and is strengthened by three buttress-like ridges, of which two descend from the extremities of the condyle and converge to the posterior sigmoid border of the ramus, and the third descends from the outer fore part of the condyle to the border of the mandibular notch. The inner fore part of the neck presents a roughened, shallow fossa, into which the external pterygoid muscle is inserted.

The mandible is composed of thick layers of compact substance enclosing a strong layer of spongy substance, which predominates in the body, and has excavated in it the alveoli for the teeth. The dental canal, for the most part, lies next the posterior compact layer.

At birth the mandible consists of two pieces, which are united at the symphysis by cartilage. At this period the body appears proportionately shallow and thick, in consequence of the absence of the alveolar process, which is subsequently produced in accordance with the development of the teeth. It is chiefly occupied by a capacious hollow divided into receptacles, which contain the developing teeth. The ramus ascends more obliquely than subsequently after the protrusion of the teeth. Two dental canals commence on its inner surface, of which the upper and larger proceeds as an open groove beneath the position of the molar teeth, and communicates with the mental foramen, while the other is closed along its course, and proceeds beneath the former. The larger canal accommodates the vessels and nerves of the temporary teeth, while the smaller one accommodates those of the succeeding teeth.

The pieces of the mandible commence ossification in the sixth or seventh week of fetal life, and each is reputed to start in several points, which, however, quickly coalesce, so that each is regarded as being de-

<sup>1</sup> P. condyloideus.

<sup>2</sup> Condylus.



rived from a single ossific centre. Ossification occurs in the perichondrium, investing a slender rod of cartilage, the **tympano-mandibular cartilage**,<sup>1</sup> which extends from the malleus of the ear along the course of the mandible, but subsequently atrophies and disappears. The two pieces of the mandible ankylose during the first year after birth, and leave but little trace of the original separation.

In the advance of age with the loss of the teeth the alveolar process disappears, and the fore part of the mandible is proportionately reduced in depth and is surmounted by a narrow ridge, which occupies the former position of the process.

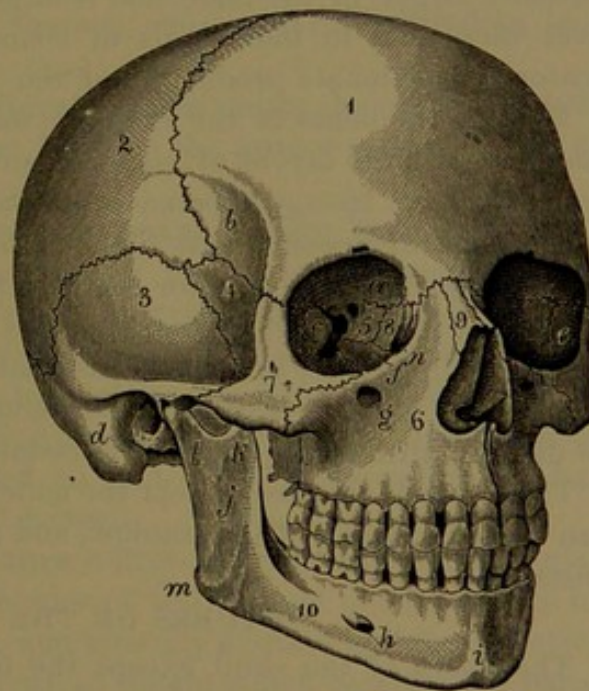
#### THE ENTIRE SKULL.

The skull differs remarkably from other chief parts of the skeleton in the fact that all the bones are immovably articulated together, with the exception of the mandible.

Its upper part, the **cranium**, is commonly ovoid, with the narrower extremity forward, but it varies to a more oval or spheroidal form. Its anterior extremity is the **forehead**, its posterior broader extremity the **occiput**, its highest part the **crown** or **vertex**, and its under part the **base**. The **face**, exclusive of the forehead, is placed beneath the anterior half of the cranium, from which it projects in front to a variable degree.

The cranium conforms in general shape to that of the brain it contains, but the exterior surface does not in all positions accord with the interior surface, which appears closely moulded to the brain. Its walls not only vary in thickness according to the age and sex, but ordinarily at maturity it varies considerably in different individuals, and often most notably in different races, being generally thicker in the barbarous or lowest races. Commonly in the

FIG. 64.



THE SKULL, SEEN PARTLY IN FRONT AND ON THE RIGHT SIDE. 1, frontal bone; 2, parietal bone; 3, temporal bone, its squamous portion; 4, sphenoid bone, temporal surface of its great wing; 5, ethmoid bone, its orbital surface; 6, maxilla; 7, malar bone; 8, lacrimal bone; 9, nasal bone; 10, mandible; a, orbital plate of the frontal bone; b, temporal surface; c, orbital surface of the great wing of the sphenoid bone; d, mastoid portion of the temporal bone; e, orbital surface of the malar bone; f, orbital plate of the maxilla; g, infraorbital foramen; h, mental foramen; i, symphysis; j, ramus; k, coronoid process; l, condyloid process; m, angle; n, lacrimal fossa.

<sup>1</sup> Cartilage of Meckel.



white race it ranges from one-sixth to one-fourth of an inch, and not unfrequently in the negro reaches double these measurements. It also varies in different positions, independent of ridges and processes, and is, for the greatest extent, thickest and most uniform at the upper part, and thinnest in parts protected by muscular masses, as in the temples and lower part of the occiput, where it often is scarcely half a line in thickness.

The upper portion of the cranium, divided horizontally about the middle, is called the **vault**,<sup>1</sup> while the lower portion is distinguished as the **base of the cranium**. On each side of the cranium is the broad depression called the **temporal fossa**, defined below by the zygoma.

The face, conjoined with the cranium, consists of a series of receptacles: the orbits for the eyes and their accessory parts, the nasal cavities with their accessory sinuses, and the cavity of the mouth. It varies in proportionate size and prominence in comparison with the cranium; is usually larger in the male, and is largest and most projecting in the lower races and in individuals of coarse habits, due mainly to the greater proportionate production of the jaws.

Most of the bones of the cranium, except in the thinner parts, are composed of two layers of compact substance, with an intervening layer of strong, spongy substance, named the **diploe**, and it is upon the variable thickness of this that the different thickness of the bones mainly depends. The exterior compact layer is generally thicker than the interior layer, which is less tenacious than the former, and from its comparatively greater brittleness has been distinguished as the **vitreous layer**. The diploe is traversed by irregular branching channels, named the **diploic sinuses**, which accommodate veins.

The bones of the face, except the mandible, are mostly much thinner than those generally of the cranium, and are nearly destitute of spongy substance.

#### SUTURES OF THE SKULL.

The bones of the skull, except the mandible, are articulated by a mode of union called **suture**, in which the contiguous borders of the bones are more or less uneven, roughened, or jagged, and mutually adapted so as to produce the closest connection short of actual coalescence. The sutures vary in character from those in which the borders are slightly roughened to those in which the borders are jagged with irregular, tooth-like processes, whence they are called **dentate sutures**. In some of the sutures the contiguous borders of the bones are bevelled to a thin edge, and mutually overlap, whence they are called **squamous sutures**, from the resemblance to the usual arrangement of the scales of a fish. In a few instances the suture is formed by the edge of one bone fitting into the groove of the border of the adjacent bone.

---

<sup>1</sup> Calvaria; skull-cap.



The different sutures are appropriately named from the bones they unite, but the most conspicuous ones and a few others have, besides, special names.

The sutures of the cranial vault are the most conspicuous, on account of their long, tortuous course and strongly dentate character. Their tortuous condition is, however, mainly confined to the exterior of the cranium, and their course within is much less winding.

The **coronal**<sup>1</sup> or **fronto-parietal suture** crosses the fore part of the cranium between the summits of the great wings of the sphenoid bone, and unites the frontal with the parietal bones. It is more deeply indented laterally than above; and it is slightly bevelled in such a manner that the frontal rests on the parietals above, and supports them at the sides.

The **lambdoid**<sup>2</sup> or **occipito-parietal suture** crosses the back part of the cranium between the mastoid portions of the temporal bones, and unites the occipital with the parietal bones. It is the most intricate of the sutures, is deeply dentate, and wonderfully winding in its course.

The **sagittal**<sup>3</sup> or **interparietal suture** unites the parietal bones in the median line of the cranium between the former sutures. It is also remarkably tortuous in its course.

The **squamous** or **squamo-parietal suture** is formed by the deeply-bevelled contiguous borders of the temporal squama and the parietal bone, in which the former externally overlaps the latter.

The **squamo-sphenoid suture** continues in the circle of the preceding suture to the cranium beneath, and is formed between the temporal squama and the great wing of the sphenoid bone. The contiguous borders are somewhat bevelled, so that the former overlaps the latter above, and is overlapped by it below.

The **parieto-mastoid suture** unites the postero-inferior angle of the parietal with the upper border of the mastoid portion of the temporal bone. It is short, thick, and strongly dentate, and forms between the latter and the squama a grooved notch, which receives the parietal angle.

The **occipito-mastoid suture**, likewise thick and dentate, descends in a curve from the former, and is extended in the base of the skull to the jugular foramen. It is sometimes traversed by the mastoid foramen.

At the side of the cranium, in the fore part of the temporal fossa, the **spheno-parietal**, **spheno-frontal**, and **spheno-malar sutures** are continuous in succession, and descend in a curve from the summit of the sphenoidal great wing to the spheno-maxillary fissure. The contiguous borders are bevelled in such a way that the sphenoid overlaps the parietal and frontal bones.

In the base of the cranium are the **transverse spheno-frontal**

<sup>1</sup> Sutura coronalis.

<sup>2</sup> S. lambdoidea.

<sup>3</sup> S. sagittalis.



**sutures**, uniting the sphenoidal small wings with the frontal orbital plates; and between them is the **spheno-ethmoid suture**.

The **spheno-occipital** or **basilar suture** is formed by the broad, roughened contiguous surfaces united by a thin plate of cartilage, which usually ossifies near adult age.

The **petro-sphenoid** and **petro-occipital sutures** are continuous around the apex of the temporal pyramid; and the former in the macerated skull exhibits a large, irregular aperture, the **lacerate foramen**,<sup>1</sup> which, in the recent state, is closed beneath by cartilage.

Occasionally the pair of frontal bones as they appear at birth remain permanently separated, and are united by the **frontal suture**, which is strongly dentated, and continues in the median line from the sagittal suture to the root of the nose.

The sutures of the face mostly partake of the serrated character, but are generally less intricate than those of the cranium.

The **transverse facial suture** crosses the face in the line of union with the cranium, and unites the frontal bone with the nasal, maxillary, and malar bones. The **middle** and **transverse palate sutures** cross each other in the hard palate.

During the growth of the skull the sutures gradually become more intricate, and the bones more closely knit together. Commonly at maturity they are separable with moderate force, but they gradually become more intimately and firmly united. With the advance of life, but in no regular order, they become more or less ankylosed and inseparably united. Frequently late in life many or most of the sutures are obliterated, and occasionally in very old age all may disappear, so that the skull, exclusive of the mandible, may actually form but a single bone.

The time of commencement and order of succession of disappearance of the sutures are very variable. In those of the cranium they are in some measure related with the cessation of growth of the brain. With the exception of the ankylosis of the occipital with the sphenoid bone, and sometimes with the temporal bone at an earlier period, it usually does not commence until after thirty years. In the cranium the coalescence of the bones mostly commences in the interior, so that the sutures may appear completely obliterated in this position and yet remain open on the exterior. Succeeding the comparatively early union of the occipital with the sphenoid bone, and not unfrequently with the mastoid portion of the temporal bone, commonly the earliest to ankylose are the parietals at their back part, followed by their union with the lower part of the frontal bone, and later with the occipital bone. The squamous suture is usually the latest to be obliterated; and when the frontal suture is retained to maturity it is one of the most permanent. Occasionally the parietals ankylose completely at the sagittal suture in youth, consequent on which the brain meets an ob-

<sup>1</sup> Foramen lacerum; f. l. medium.



stacle to its further growth in the transverse direction and grows proportionately fore and aft, and thus gives rise to an unusual elongated condition of the cranium. In the same manner the premature ankylosis of other bones produces other modifications from the ordinary shape of the latter. More or less complete ankylosis of the cranium occurs in youth in idiots, while the process is greatly retarded or is prevented in hydrocephalus.

The intervals of the sutures are occupied by connective or cartilaginous tissue, and when the bone-earth is removed by macerating the recent skull in muriatic acid, the contiguous bones appear to be continuous in structure.

#### SUPERNUMERARY BONES OF THE SKULL.

Frequently there occur in the course of the sutures, especially those of the cranial vault, little islet-like bones, which are of variable size and shape, and in no regular position, though occasionally a pair show some disposition to symmetry on the two sides of the skull. These **sutural bones**<sup>1</sup> are usually single, but sometimes there are several, isolated or together in a row. In hydrocephalic skulls they are often numerous and large. Ordinarily they are most frequently found in the lambdoid suture. They originate in distinct centres of ossification, but have no special signification. Sometimes a sutural bone,<sup>2</sup> or a pair, replaces to a variable extent the summit of the occipital bone. Rarely, also, the upper division of the supraoccipital of the embryo remains permanently separated, and connected by suture with the rest of the bone. This condition appears to have been a more frequent one in some of the tribes of the South American people. The isolated portion of the supraoccipital corresponds with the interparietal bone of some of the lower animals, as in the rabbit. Of greater rarity is a supernumerary bone<sup>3</sup> occupying the former position of the anterior fontanel.

#### INTERIOR OF THE CRANIUM.

The **interior of the cranium** conforms to the brain with its membranes. Its upper part, or vault, forms one great concavity, which is occupied by the cerebrum, and its lower part, or base, is divided into three compartments, the **pre-, meso-, and postcranial** fossæ. The internal surface of the cranial cavity, except in the postcranial fossæ, everywhere exhibits shallow impressions and low ridges, which conform to the convolutions and fissures of the cerebrum. Besides these, arborescent channels ascend from the fossæ and spread upon the sides and top of the cranial vault, for the accommodation of the meningeal blood-vessels. In many skulls, especially those of old people, there are often to be observed irregular pits, which look like the results

<sup>1</sup> Ossa suturarum, intercalaria, triquetra, rapho-geminata, or Wormiana; Wormian bones.

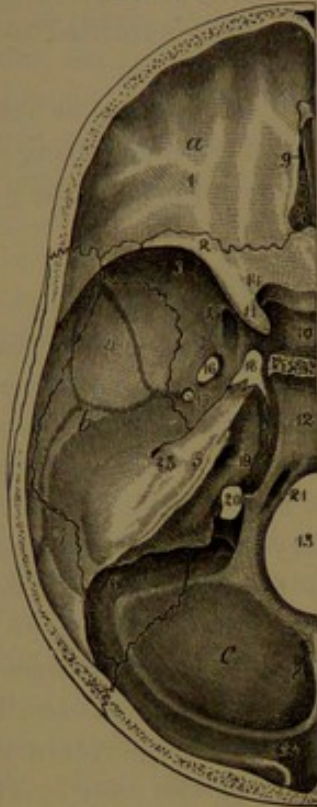
<sup>2</sup> Epactal bone.

<sup>3</sup> Os antiepileptium.



of disease. They vary in number, depth, and position, and are more commonly found near the course of the sutures of the vault. They are produced by granular growths, named **Pacchionian bodies**, which proceed from the membranes of the brain, and are regarded as morbid productions.

FIG. 65.



INTERNAL VIEW OF THE BASE OF THE CRANIUM OF THE LEFT SIDE. *a, b, c*, pre-, meso-, and postcranial fossæ; 1, orbital plate of the frontal bone; 2, small wing of the sphenoid bone; 3, great wing of the same; 4, squamous portion of the temporal bone; 5, petrous portion of the same; 6, mastoid portion; 7, parietal bone; 8, occipital bone; 9, olfactory fossa and ethmoidal crest; 10, sella; 11, pre-clinoïd process; 12, basilar groove; 13, occipital foramen; 14, optic foramen; 15, rotund foramen; 16, oval foramen; 17, spinous foramen and groove from it, indicating the course of the great meningeal vessels; 18, lacerate foramen; 19, internal auditory meatus; 20, jugular foramen; 21, condylar foramen; 22, commencement of the groove for the lateral sinus. The course of the groove is observed along the horizontal limb of the occipital cross, the postero-inferior angle of the parietal bone, the mastoid portion of the temporal, and the jugular process of the occipital, terminating at the jugular foramen.

Along the median line of the cranial vault is observed a shallow groove for the accommodation of the longitudinal sinus of the dura. Commencing narrowly at the frontal crest, it gradually widens as it proceeds backward to the internal occipital protuberance, where it becomes continuous usually with one or the other of the grooves, for the lateral sinuses, passing along the horizontal limbs of the occipital cross.

The three pairs of cranial fossæ widen in a divergent manner from near the centre of the base of the cranium or the position of the sella, and they expand above in the cranial vault. From in front they become successively deeper and more capacious.

The **precranial fossæ**, most elevated in position, are occupied by the frontal lobes of the cerebrum. Their basis is formed by the orbital plates of the frontal bone, with the intervening cribriform plate of the ethmoid bone, bounded behind by the small wings of the sphenoid bone. They are convex on the orbital plates, which are deeply impressed by the cerebral convolutions; and in the intermediate position they form a variably deep concavity, which is divided by the ethmoidal crest. On each side of the latter is the **olfactory fossa**, for the lodgement of the olfactory bulb, a fore and aft elongated, narrow depression floored by the ethmoidal cribriform plate. Opening laterally into the olfactory fossa are the little **pre- and postethmoidal canals**, communicating with the orbit between the ethmoid and frontal bones. Between

the ethmoidal crest in front and the bottom of the frontal crest is a



blind pit<sup>1</sup> or a canal, which communicates below with the nasal cavities, and transmits a vein from the latter to the commencement of the longitudinal sinus.

The **mesocranial fossæ** are deeply concave, occupy a much lower level than the former, and receive the spheno-temporal lobes of the cerebrum. They are narrowest inward where they communicate through the sella, and they expand outwardly to the parietal region. In front they are defined by the concave, posterior edges of the sphenoidal small wings, and between these by the anterior margin of the optic groove. Behind they are defined by the upper borders of the temporal pyramids, and between these by the clivus. Each fossa is formed by the under surface of the sphenoidal small wing, the cerebral surface of the great wing, the inferior parietal angle, the anterior surface of the temporal pyramid, and the inner surface of the squama. Most of the important foramina of the sphenoid bone communicate with it: the optic, sphenoidal, rotund, oval, and spinous foramina. At its inner part, in the macerated skull, is a large, irregular hole, the **lacerate foramen**,<sup>2</sup> situated between the fore part of the apex of the temporal pyramid and the sphenoidal body. In the recent state the hole is closed below by cartilage, and is occupied above by the internal carotid artery as it enters the cranium from the carotid canal. It is usually extended outwardly by the incomplete condition of the bony canal, which in the recent state is made complete by fibrous membrane. The canal opens inwardly and forward into the lacerate foramen, and ascends at the side of the sella, on the lingule in front. Beneath the lingule the pterygoid canal opens backward into the lacerate foramen.

The groove for the great meningeal vessels starts from the spinous foramen in the apex of the sphenoidal angular process, and turns outward to the temporal squama, on which it ascends nearly parallel with the anterior border and divides into two main branches. Of these, one continues in the same course to the back of the squama, whence it ascends and ramifies on the back part of the parietal bone to its upper border; while the other branch leaves the squama, crosses the summit of the sphenoidal great wing to the adjoining angle of the parietal bone, and ascends and ramifies on the fore part of this as in the former.

The **postcranial fossæ**, more capacious and on a lower level than the preceding, expand outward and backward from the clivus, and accommodate the cerebellum, the pons, and the medulla oblongata. Each is defined in front by the upper border of the temporal pyramid and behind by the horizontal limb of the occipital cross, and is formed by the posterior surface of the pyramid and inner surface of the mastoid portion of the temporal bone and the inner surface of the occipital

<sup>1</sup> Foramen cœcum.

<sup>2</sup> F. lacerum medius.



bone below the horizontal limb of the occipital cross. The two fossæ conjoin in front on the **basilar groove**, which slopes from the clivus, near the centre of the cranial cavity, downward and backward to the occipital foramen. The inclined surface of the groove is nearly flat and variably roughened above, and is wider, concave, and smooth below. It gives support to the pons and medulla oblongata. The occipital foramen occupies a central position between the two fossæ, and on each side of it is the condylar foramen for the passage of the hypoglossal nerve. Behind and on each side of the occipital foramen are the **cerebellar fossæ**, for the accommodation of the cerebellar hemispheres, separated by the occipital crest. At the outer fore part each postcranial fossa is crossed by the continuous masto- and petro-occipital sutures, of which the latter is interrupted by a large aperture, the **jugular foramen**. This is formed by contiguous notches of the temporal pyramid and occipital bone, and is partially divided by an angular process of the former. In the recent condition the division is completed by a fibrous band, and the inner portion is further divided by another band, so that three distinct passages are formed in the jugular foramen. The outer passage, usually the largest, is the outlet of the lateral sinus, and accords in size with it and with the jugular vein which commences in it. The middle passage transmits the glossopharyngeal, vagus, and accessory nerves, and the inner passage the infrapetrosal sinus. Into the latter passage opens the pyramidal pit of the cochlear aqueduct.

At the back boundary of each postcranial fossa is the groove for the lateral sinus, which commonly varies more or less on the two sides, one being proportioned to the other. The larger one alone is commonly continuous with the groove for the longitudinal sinus, which is deflected to one side of the internal occipital protuberance to join it. The groove for the lateral sinus, after proceeding along the horizontal limb of the occipital cross, sweeps in a curve forward and downward on the mastoid portion of the temporal bone, and thence turns inward and forward across the occipital jugular process to terminate in the outer passage of the jugular foramen, with which it is related in size. It is deepest in its course on the temporal bone, and in this position communicates with the mastoid foramen. Near its termination it often communicates with a postcondylar foramen. These foramina are very variable in size, are proportioned with one another and with the jugular foramen, and frequently one or both may be absent on either or both sides.

In a skull under observation, the groove of the left lateral sinus and the corresponding passage of the jugular foramen are as large as the last joint of the index finger, while on the right side the groove is about the size of a wheat straw and discharges through the mastoid foramen, while the usual passage of the jugular foramen is only sufficient for the transmission of a small vein.



## LATERAL REGION OF THE SKULL.

The **lateral region** or **side** of the skull has a general triangular outline; the lines of the base and face being more nearly straight, while the line of the vault is convex. It is composed above and behind by the cranium, and in front beneath by the face. Centrally, it exhibits a broad recess, the temporal fossa, which is occupied by the temporal muscle, and forms the basis of the temple. Below, the fossa is defined by the zygoma, and behind this is the passage of the ear, or auditory meatus. Posterior to this again is the mastoid process, a peculiar feature of the human skull. From the zygoma there extends inwardly, behind the maxilla, a deep recess, the zygomatic fossa, and at the inner corner of this is a vertical, wedge-shaped cavity, the sphenomaxillary fossa.

The **temporal fossa**, broad and shallow above, narrows and deepens inwardly as it approaches below to open into the zygomatic fossa. It is defined above by the temporal ridge, which ascends from the frontal external angular process, curves backward across the side of the frontal bone and the parietal to its posterior fourth, whence it descends to the back of the temporal squama, and turns forward to the root of the zygomatic process. It is formed by the lateral surfaces of the frontal bone, the sphenoidal great wing, the parietal bone, and the temporal squama.

The **zygoma** is the narrow, horizontal arch which extends from the temporal bone in front of the auditory meatus to the malar bone. It is formed by the conjunction of the zygomatic processes of the two bones, joined by an oblique serrated suture. The anterior abutment of the arch extends the entire depth of the malar bone between its frontal and maxillary articulations. It encloses an ovoid aperture, defined inwardly by the **infratemporal ridge**, which proceeds from the root of the temporal zygomatic process across the lower part of the squama, and thence across the sphenoidal great wing to the sphenomaxillary foramen. The aperture of the zygoma receives near its centre the tip of the coronoid process of the mandible.

The **zygomatic fossa** is the irregular cuboidal space below the temporal fossa, extending more inwardly in the base of the cranium. It is bounded in front by the tuber of the maxilla; above by the aperture of the zygoma, the under surface of the sphenoidal great wing, and the contiguous under surface of the temporal squama in advance of the articular eminence; outward by the zygoma; and inward by the ectopterygoid process. It is occupied by the coronoid process of the mandible, the pterygoid muscles, the internal maxillary blood-vessels, and the inframaxillary nerve.

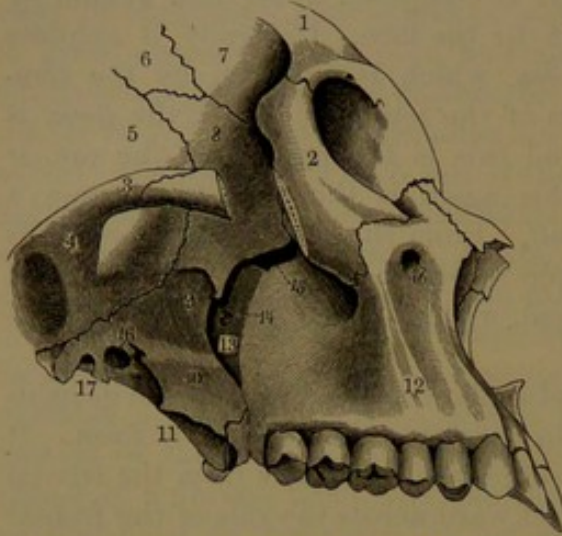
The **spheno-maxillary fossa** is a vertical, wedge-shaped cavity at the fore, inner, and upper corner of the zygomatic fossa, into which it opens outwardly. Its upper **wider part**<sup>1</sup> is situated below the

<sup>1</sup> Spheno-maxillary fossa.



apex of the orbit into which it opens, and is thence extended outward as the spheno-maxillary foramen. Its lower part<sup>1</sup> tapers downward

FIG. 66.



VIEW OF THE RIGHT SIDE OF A PORTION OF THE FACE AND CRANIUM. 1, frontal bone; 2, malar bone, a portion of its zygomatic process removed; 3, zygomatic process of the temporal bone; 4, articular eminence, and back of it the glenoid fossa; 5, squamous portion of the temporal bone; 6, anterior inferior angle of the parietal bone; 7, temporal surface of the frontal bone; 8, temporal surface of the great wing of the sphenoid bone; 9, inferior surface of the great wing; 10, ectopterygoid process; 11, entopterygoid process; 12, maxilla; 13, sphenomaxillary fossa; 14, sphenopalatine foramen; 15, sphenomaxillary foramen; 16, oval foramen; 17, spinous foramen; 18, infraorbital foramen. Figures 5-8 occupy the fore part of the temporal fossa; the space between 9, 10, and 14, 15, is the zygomatic fossa.

occupied by the sphenopalatine ganglion and the nerves connected with it, together with the termination of the internal maxillary artery.

The **sphenomaxillary foramen**<sup>2</sup> is a long elliptical aperture, which extends nearly horizontally outward from the sphenomaxillary fossa along the upper fore part of the zygomatic fossa, from which it opens into the orbit. It is defined above by the lower acute border of the orbital surface of the sphenoidal great wing, and below by the posterior margin of the maxillary orbital plate and palate orbital process. The inner extremity is formed by a notch between the sphenoidal body and great wing, and the outer extremity by the malar bone or the conjunction of the sphenoid with the maxilla. The foramen represents the large and free communication between the orbit and the zygomatic and temporal fossæ in other orders of mammals.

into the posterior palatine canal. It is bounded in front by the tuber of the maxilla and the palate orbital process; behind by the triangular surface in front of the pterygoid processes, and the surface thence extended outwardly below the orbital surface of the great sphenoidal wing; and internally by the upper part of the palate bone, which separates it from the nasal cavity.

Communicating with the fossa are the following: the **rotund foramen**, behind and about midway above; the **pterygoid canal**, below and internal to the former; and the **pterygo-palatine canal**, still more inwardly. On the inner wall above is the **sphenopalatine foramen**, which opens into the nasal cavity. Below, the fossa tapers into the **postpalatine canal** and communicates with several smaller canals. The fossa is chiefly oc-

<sup>1</sup> Pterygo-maxillary fossa.

<sup>2</sup> Sphenomaxillary fissure; foramen orbitalis inferius.

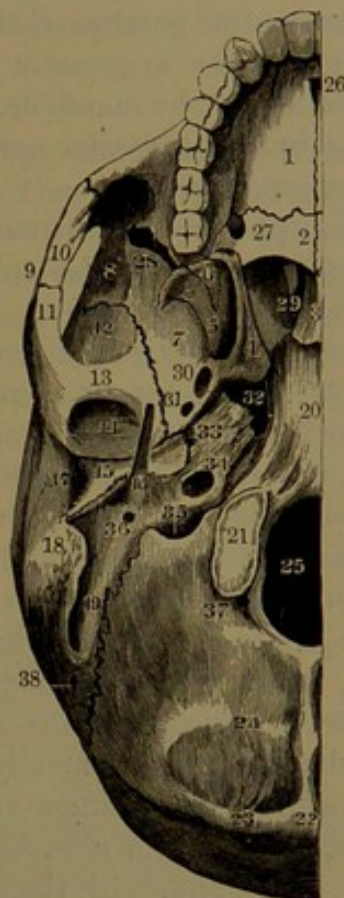

## BASE OF THE SKULL.

The **inferior region** or **base** of the skull is ovoid in outline with the narrowed extremity formed by the chin, and the broader extremity by the occipital protuberance and superior semicircular line. Laterally it is bounded by the jaws, malar bone, zygoma, and mastoid process. It is divided into the palatine, guttural, and occipital regions.

The **palatine** or **oral region** is embraced by the jaws with the teeth, and is bounded above by the palate. It is chiefly occupied by the tongue and muscular floor of the mouth, together with the submaxillary and sublingual glands. It varies greatly in depth in accordance with the presence or absence of the teeth; in the former case being about two and a half inches and in the latter less than an inch. The **palate**, or roof of the mouth, is formed by the alveolar processes of the maxillæ and the palate plates of the latter and of the palate bones. It is strongly vaulted, and is divided by the middle and transverse palate sutures. The surface is, for the most part, roughened and porous, but is smoother and grooved on the palate bones and contiguous portion of the maxillæ. In the back corner on each side is the **posterior palatine canal**, which descends from the speno-maxillary fossa between the palate bone and maxilla, and opens on a smooth grooved surface, dividing into several branches on the palate. Near it, behind and outwardly, are the foramina of several smaller palatine canals descending from the same fossa through the palate pyramidal process. At the fore part of the middle palate

FIG. 67.



EXTERNAL VIEW OF THE BASE OF THE SKULL, RIGHT SIDE. 1, palate plate of the maxilla; 2, palate plate of the palate bone; 3, vomer; 4, 5, ento- and ectopterygoid processes; 6, pyramidal process of the palate bone; 5, 6, occupy the pterygoid fossa; 7, under part of the great wing of the sphenoid bone, forming part of the zygomatic fossa; 8, temporal surface of the great wing of the sphenoid bone; 9, zygoma; 10, zygomatic process of the malar bone; 11, zygomatic process of the temporal bone; 12, squamous portion of the temporal bone; 13, articular eminence; 14, glenoid fossa; 15, tympanic plate; 16, styloid process; 17, auditory meatus; 18, mastoid process; 19, digastric fossa; 20, conjunction of the basilar process and body of the sphenoid bone; 21, occipital condyle; 22, occipital protuberance, and crest leading from it downward; 23, 24, superior and inferior semicircular lines; 25, occipital foramen; 26, incisive foramen; 27, posterior palatine foramen; 28, speno-maxillary foramen; 29, posterior naris; 30, oval foramen; 31, spinous foramen; 32, lacerate foramen; 33, eustachian tube; 34, entrance of the carotid canal; 35, jugular foramen; 36, stylo-mastoid foramen; 37, pit with a posterior condylar foramen; 38, mastoid foramen.



suture is the **incisive foramen**, which is formed above by the conjunction of the naso-palatine canals descending one from each nasal cavity.

The **guttural region**, or the region of the pharynx or throat, occupies the central portion of the base of the skull, and laterally communicates with the zygomatic fossa, and behind this is bounded by the articulation of the mandible. It communicates in front with the nasal cavities by the posterior nares, and is limited behind by the occipital foramen and condyles.

The upper median portion of the region is formed by the basilar process united with the sphenoidal body. Its surface is a slightly prominent quadrate plane, roughened on the basilar process for the attachment of the prerecti muscles and the pharynx. To its outer side is the lacerate foramen, continuous before and behind with the petro-sphenoid and petro-occipital sutures, all of which, in the recent condition, are closed by fibro-cartilage. Below the petro-sphenoid suture is an oblique groove, which accommodates the cartilaginous portion of the eustachian tube, and communicates outwardly with its osseous portion. In advance of the groove are the oval and spinous foramina of the sphenoid bone, and behind it is the entrance of the carotid canal. Immediately behind this is the jugular foramen, which, in the view from below, exhibits in its outer portion a variably large and deep, dome-like fossa, mainly formed by the temporal pyramid. The fossa receives the commencement of the jugular vein, and has opening into it behind, from above, the lateral sinus. It accords in size with these vessels, and, with them, differs in a proportionate degree on the two sides of the skull. The inner portion of the foramen, separated from the former as before described, transmits the accompanying nerves, and the infrapetrosal sinus which ends in the jugular vein. To the inner side of the jugular foramen is the exit of the condylar foramen for the hypoglossal nerve.

The **occipital region** includes the occipital foramen, condyles, jugular processes, and surface extending to the occipital protuberance and superior semicircular line. To its outer side is the mastoid process, with the digastric fossa and groove for the occipital artery, the stylo-mastoid foramen or exit of the facial canal, and the styloid process. The mastoid process is a marked feature of the human skull, while the jugular process is a rudiment of the conspicuous paroccipital process of many lower mammals, as in the hog and horse.

#### THE FACE.

The **face** includes the fore part of the cranium, or forehead, with the bones of the face. It is occupied by the orbits and nasal cavities, all situated beneath the forehead, and is formed below by the jaws. Of variable oval outline, its length extends from the top of the forehead to the chin, and its breadth between the malar bones. Near its centre is the **nasal aperture**, which is inverted cordiform, and gives attach-



ment by its margin to the nose. Above the aperture is the prominent bridge of the nose, formed by the nasal bones and nasal processes of the maxillæ. On each side is the orbit, and outwardly from this the prominence of the cheek formed by the malar bone.

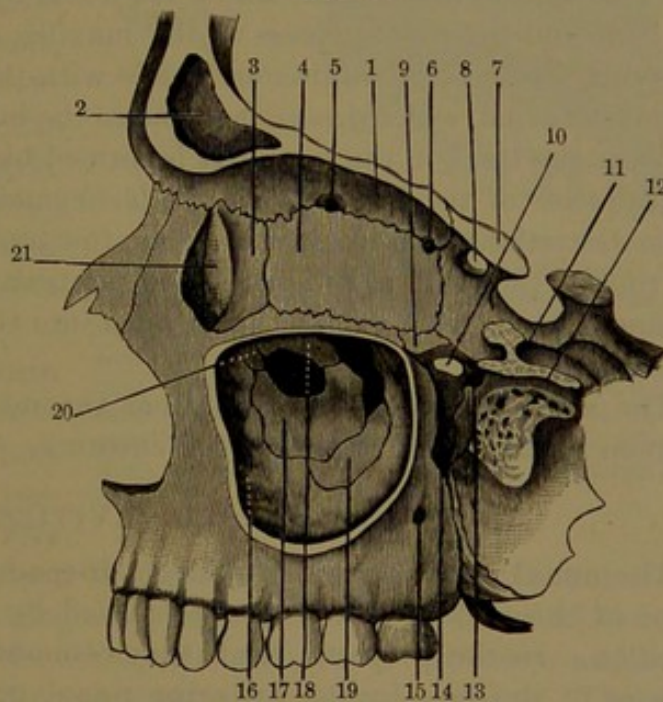
### THE ORBITS.

The **orbits**, or eye-sockets, are four-sided pyramidal cavities, directed fore and aft, and with the apex behind. They are separated by the breadth of the ethmoid bone, in great measure forming their inner walls, which are parallel, while the outer walls are divergent. The entrance of the orbit is transversely quadrate, wider than high, and with rounded angles. It inclines slightly and variably from within outward and downward, with its plane vertical, and directed forward and slightly outward. It is formed

above by the supra-orbital ridge of the frontal bone, inward and below by the maxilla, and outward and below by the malar bone. The roof is vaulted, and is mainly formed by the frontal orbital plate, but receives a small addition at the apex from the under part of the sphenoidal small wing. The floor, less concave, variably slants from within outward and downward, and is mainly formed by the orbital plate of the maxilla, with a portion of the malar bone and the orbital process of the palate bone. The inner wall, nearly vertical, inclines somewhat outwardly behind to the

floor, forming with it a continuous curve. It is mainly formed by the ethmoid and lachrymal bones, but receives a contribution from the sphenoidal body behind and the nasal process of the maxilla in front. The outer wall is also nearly vertical,—a plane behind on the orbital surface of the sphenoidal great wing, and concave in front on the malar bone.

FIG. 68.



LEFT SIDE OF FACE, WITH THE OUTER WALLS OF THE ORBIT AND ANTRUM REMOVED. 1, frontal orbital plate; 2, frontal sinus; 3, lachrymal bone; 4, ethmoid bone; 5, 6, ethmoidal foramina; 7, sphenoid bone; 8, optic foramen; 9, palate bone; 10, sphenopalatine foramen; 11, rotund foramen; 12, pterygoid canal; 13, pterygo-palatine canal; 14, termination of the sphenomaxillary fossa in the posterior palatine canal; 15, posterior dental canal; 16, inner wall of antrum formed by the maxilla; 17, turbinal bone; 18, uncinate process of the ethmoid; 19, palate bone; 20, descending process of the lachrymal, behind which is the opening of the antrum into the nasal cavity; 21, lachrymal fossa.



Opening into the apex or back end of the orbit is the optic foramen, which is situated nearest the conjunction of the roof and inner wall. External to it is the large **sphenoidal foramen**, which ascends from the sphenomaxillary fossa between the inner and the outer wall of the orbit, and curves outward between the latter and the roof. In the floor, at the bottom of the outer wall, is the sphenomaxillary foramen, which communicates with the sphenomaxillary and zygomatic fossæ.

The separation of the orbit from the temporal and zygomatic fossæ by a complete wall is a characteristic of man and the order to which he belongs, and is, for the most part, absent in other animals. The sphenomaxillary foramen is the contracted representative of the free communication existing in the latter between the orbit and temporal fossa, as exemplified in the dog.

At the fore part of the inner wall of the orbit is a half-cylindrical niche, the **lachrymal fossa**, which is formed by grooves of the lachrymal bone and the nasal process of the maxilla, and accommodates the lachrymal sac. It is continuous below with the **nasal duct**, a short cylindrical canal, which descends to end in the inferior nasal meatus, and conducts the tears to the nose. It is formed by the conjunction of the nasal process of the maxilla with the lachrymal and turbinal bones.

In the ethmo-frontal suture, along the junction of the inner wall and roof of the orbit, are the **pre-** and **postethmoidal foramina**, the entrance of two short canals, which open into the olfactory fossa of the cranial cavity.

The axis of the orbit passes from the middle of the sphenoidal foramen to the centre of the orbital entrance.

#### THE NASAL CAVITIES.

The **nasal cavities** are two large air-spaces, which occupy the interior of the middle of the face, separated by a vertical fore and aft partition. In the prepared skull they communicate with the exterior in front of the face by the **anterior nasal orifice**, and behind with the guttural region by a pair of orifices, the **posterior nares**. They are of greatest extent fore and aft along the roof, are about as deep as they are long at the lower part or floor, and are little over half an inch where widest, between the partition and outer wall. Each cavity communicates with a number of accessory air-chambers, named the maxillary antrum, and the frontal, ethmoidal, and sphenoidal sinuses.

The **anterior nasal orifice** is inverted cordiform, and is roofed over by the bridge of the nose, which is composed of the nasal bones and the nasal processes of the maxillæ; and at the sides is formed by the conjunction of the nasal notches of the latter. The border of the orifice is acute, and beneath is extended in a pointed process, the **nasal spine**, which gives attachment to the fore part of the nasal septum and column, separating the nostrils. In the negro the lower border of the orifice is obtusely rounded off to the alveolar surface,



constituting a race distinction, which also finds its counterpart in other species of our order.

The **posterior nares**, or **nasal orifices**, are vertically rectangular, and have their plane directed backward with a slight inclination downward into the guttural region; and they are separated by the posterior border of the vomer. Each naris is bounded outwardly by the entopterygoid process of the sphenoid bone, and below, is defined by the curved edge of the palate plate of the palate bone, which unites with its fellow, in the palate spine, for the attachment of the uvula. Above, it is bounded by the ala of the vomer, connected with the vaginal process of the sphenoid bone.

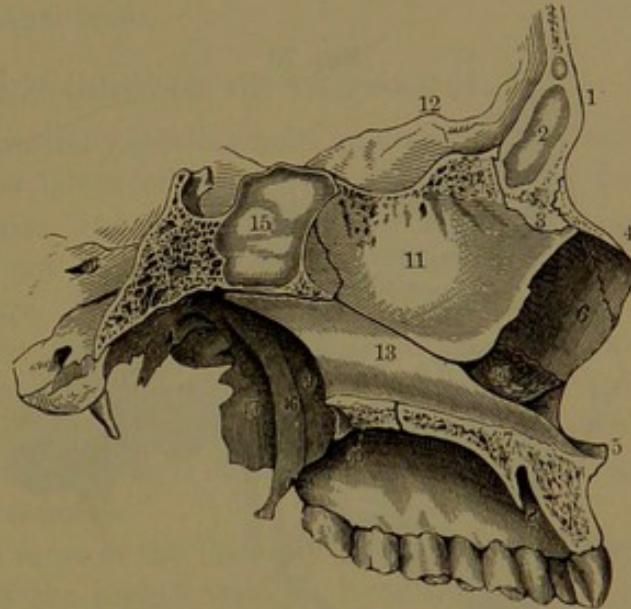
The **nasal septum** separates the nasal cavities in the median line, extending from the posterior nares to the fore

part of the former, where it presents a deep angular notch, which accommodates the cartilaginous portion of the partition of the nose. It is formed above by the ethmoidal nasal plate, and below and behind by the vomer, which alone separates the posterior nares. The notch in front for the septal cartilage is formed above by the ethmoidal nasal plate, and below by the vomer and the incisive crest of the maxillæ. From its back angle a canal is extended between the anterior grooved border of the vomer and the adjacent border of the ethmoidal nasal plate to the sphenoid body. The canal is occupied by a prolongation of the nasal septal cartilage.

The nasal septum forms the inner wall of each nasal cavity, and is normally median and vertical in position, but is frequently more or less bent unsymmetrically to one or the other side.

The roof of each nasal cavity, the greater part of its length, forms a groove or narrow space, which extends from in front of the nose to the sphenoid bone, and then turns abruptly down to the bottom of the latter, where it expands to the width of the cavity; and in this manner extends to the posterior naris. It is formed in succession by the nasal

FIG. 69.



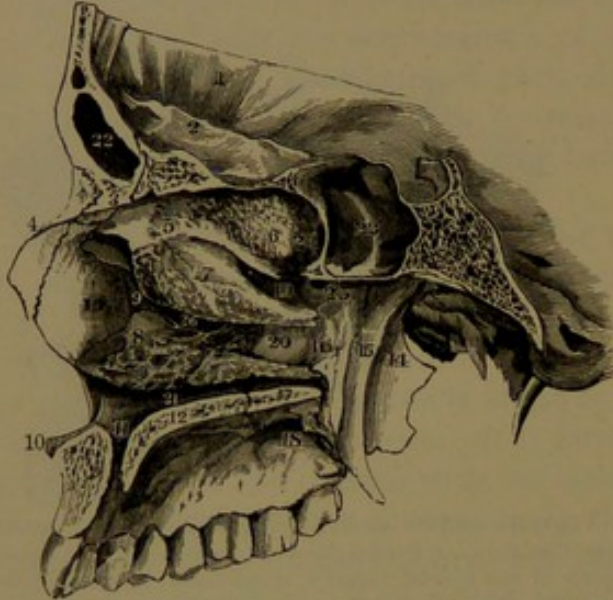VERTICAL SECTION OF THE FACE, exhibiting the osseous nasal septum. 1, frontal bone; 2, frontal sinus; 3, nasal spine of the frontal bone; 4, nasal bone; 5, nasal spine of the maxilla; 6, nasal process of the same bone; 7, border of the palate plate of the same; 8, incisive foramen; 9, left posterior naris; 10, palate plate of the palate bone; 11, nasal plate of the ethmoid bone; 12, ethmoidal crest; 13, vomer; 14, left turbinal bone; 15, sphenoidal sinus; 16, entopterygoid process; 17, ectopterygoid process.



bone, the frontal nasal ala, the ethmoidal cribriform plate, the sphenoid body, and the ala of the vomer with the sphenoidal vaginal process.

The floor of each nasal cavity, depressed below the level of the anterior nasal orifice, is horizontal, nearly flat fore and aft, moderately concave transversely, and smooth. It is formed by the palate plates

FIG. 70.



VIEW OF THE OUTER WALL OF THE RIGHT NASAL CAVITY. 1, frontal bone; 2, its orbital plate; 3, its nasal spine; 4, nasal bone; 5, ethmoid bone; 6, supraturbinal; 7, mesoturbinal; 8, turbinal bone; 9, descending process of the lachrymal bone, within the position of which is the nasal duct; 10, nasal spine of the maxilla; 11, naso-palatine canal; 12, palate plate of the maxilla; 13, nasal process of the latter; 14, ectopterygoid process; 15, entopterygoid process; 16, nasal plate of the palate bone; 17, its palate plate; 18, posterior palatine foramen; 19, superior meatus of the nose; 20, middle meatus; 21, inferior meatus; 22, frontal sinus; 23, sphenoidal sinus; 24, its communication with the upper back part of the nasal cavity; 25, sphenopalatine foramen; 26, orifice of the antrum.

latter at the upper back part of the nasal cavity. The **mesoturbinal**, a process hanging from the ectethmoid, extends along the middle of the nasal cavity above the **middle meatus**. The **infra-turbinal**, a distinct bone, extends along the lower third of the nasal cavity overhanging the **inferior meatus**. Not unfrequently above the supraturbinal there is a smaller one overhanging a shallow recess.

Of the sinuses communicating with the nasal cavity, the sphenoidal sinus opens by a circular orifice directed forward into the upper back part behind the contiguous portion of the ectethmoid. The posterior ethmoidal sinuses open by one or several orifices into the superior meatus. The frontal sinus and the anterior ethmoidal sinuses open by a common passage, the **infundibulum**, into the fore part of

of the maxillæ and palate bones. At its fore part, between the nasal and incisive crests, is the naso-palatine canal, which descends to join its fellow in the intermediate suture and end in the incisive foramen.

The outer wall is the most extensive and complex portion of the nasal cavity, and is formed by the maxilla and palate bone, the ectethmoid and turbinal bone, and the nasal, lachrymal, and sphenoid bones. It exhibits three fore and aft horizontal projections, named **turbinals**, which successively increase in length and overhang equally long passages, or **meatuses**. The **supraturbinal**, a process of the ectethmoid, overhangs the **superior meatus**, which extends about half the length of the



the middle meatus. The maxillary antrum, mainly formed by the maxilla, at the inner part receives contributions from the palate, ethmoid, lachrymal, and turbinal bones. It communicates with the middle meatus, in the macerated skull, usually by two apertures, separated by the union of the uncinatè process of the ethmoid with the ethmoidal process of the turbinal bone.

#### DEVELOPMENT AND GROWTH OF THE SKULL.

The skull originates in a partially cartilaginous and a partially fibro-connective tissue basis. The bones of the base of the cranium, together with the turbinal bones, are derived from cartilage. The ear ossicles and the hyoid bone, not included with the description of the skull, also originate in cartilage. The bones of the vault of the cranium, including the squamosals, the tympanals, the upper division of the supraoccipitals, and the pterygoids, together with all the bones of the face except the turbinals, are produced from fibro-connective tissue. Even those which originate in cartilage subsequently grow in thickness from their periosteal investment.

Ossification commences in most of the bones of the skull, as already mentioned, from the sixth to the eighth week of fœtal life, but in a few instances does not occur until near the middle of the latter period, as in the ectethmoids and petrosals, or even until after birth, as in the mesethmoid and turbinal bones.

At birth the chief tabular bones of the cranium consist of simple plates with conspicuous central prominences, the frontal, parietal, and occipital eminences, from which radiating fibres proceed to the borders and project in spicules. The borders do not interlock with one another in the manner soon after produced, but one parietal bone overlaps the other, and both of these overlap the frontals and occipital bone. This condition renders the skull more yielding under pressure, and is advantageous in birth in facilitating the passage of the head of the child through the less yielding pelvis of the mother.

The fibrous appearance observed on the surface of young bones indicates the chief direction of the nutritive blood-vessels, which determine the lines of ossification or deposition of the bone-earth in the production of the bones. In the subsequent growth of the bones the compact layers are produced from the periosteum, while the original osseous layer and many of those superadded by the periosteum are resolved into the intervening diploe. The early radiated and more porous and spongy appearance of the bones gradually disappears, and the surface becomes more compact and smooth; and the eminences of the bones of the cranial vault or of other centres of ossification become gradually suppressed or less obvious.

In the tabular bones of the cranium, at or near the time of birth, from less advanced ossification at points most remote from the centres, there appear certain membranous spaces, which are named the **fonta-**



**nels.** Of these the largest and most conspicuous is the **anterior fontanel**, situated at the top of the vertex, at the intersection of the coronal with the frontal and sagittal sutures. It is lozenge-shaped, with the sides convex inwardly, and with the anterior angle prolonged. It enlarges for some time subsequent to birth, and during life pulsation is perceptible in it, due to the action of the arteries of the brain. It gradually diminishes from the continued growth of the borders of the bones, and usually disappears two or three years after birth. The **posterior fontanel** is a triangular space at the intersection of the sagittal and lambdoid sutures prior to the last month of foetal life, but is commonly closed at birth, and its position indicated by the contiguous angles of the parietal bones overlapping the summit of the occipital bone. The **lateral fontanels** are similar spaces to the preceding, one in front, between the parietal, frontal, temporal, and sphenoid bones; the other behind, between the parietal, occipital, and temporal bones. These commonly disappear during the year after birth. The anterior and posterior fontanels serve as important means during birth to determine by the touch the relative position of the head of the child to the pelvis of the mother.

At birth the skull is much larger in proportion to the rest of the skeleton than at maturity. The cranium is also much larger in proportion to the face; indeed, while it is half a dozen times larger than the latter in the infant, it is scarcely more than double the size in the adult. There is also a greater disproportion in the breadth of the cranium, the forehead being relatively narrower. The widest part of the cranium in the infant is at the parietal eminences, and the highest point at the fore part of the parietal bones. In the adult the widest part is usually in a more advanced and lower position, and the highest point at the summit of the frontal bone. In infancy the upper part of the cranium, together with the brain, grows more rapidly than the base. The forehead at first is more nearly vertical in front, and the frontal eminences are commonly a conspicuous feature of childhood. Later, from more rapid growth in advance, with the production of the superciliary ridges and the frontal sinuses, the forehead appears more receding and the frontal eminences less marked.

As previously indicated, the face at birth is remarkably small in proportion to the cranium compared with that of the adult. It is also short in comparison with the breadth, and is not prominent from want of development of the teeth and alveolar processes. The upper portion, including the orbits, is proportionately better developed than the others. In the middle portion, of the accessory cavities of the nose only the maxillary antra and the ethmoidal sinuses are produced. From the little development of the former the outer part of the floor of the orbits rests on the alveolar border, and is but slightly above the level of the floor of the nasal cavities. The alveolar borders of the jaws are thick, and exhibit rows of rounded eminences, corresponding to the



recesses of the dental sacs and their contained teeth. The body of the mandible is but little produced below the recesses of the teeth, and the rami are very oblique. The temporal and zygomatic fossæ are proportionately very small. The temporal ridge, scarcely produced, with the temporal fossa, extends but a little way on the parietal bone, occupying only its anterior inferior angle and a small portion of the surface contiguous to the squamosa of the temporal bone. The guttural region, the pterygoid fossæ, and the palatine region are comparatively small and shallow, the latter being scarce a fourth the depth it is after the production of the teeth and alveolar processes.

The skull continues to grow more or less obviously, and its features become more distinctly marked to maturity. The period at which it ceases to grow is in some measure variable, and not very evident. Ordinarily after adult age it slowly increases to thirty or forty years, and even later under certain circumstances, as, for instance, the continued growth of the brain promoted by the active exercise of its functions. Commonly the bones commence to ankylose from thirty to forty-five years, but sometimes the process is delayed to fifty or sixty years. Later than this the bones are commonly found to be ankylosed and the sutures more or less obliterated, though even to the latest period of life the lines of original separation often remain more or less visible. In very old age, eighty or later, but sometimes earlier, the bones of the cranium and face are found to be so completely ankylosed as to form, with the exception of the mandible, but a single piece.

After maturity, with the advance of life, the diploe becomes more open, and its venous channels more capacious, and the various sinuses also gradually become enlarged. In very old age the walls of the cranium become thinner and more brittle, and the cerebral impressions more or less effaced, but the vascular grooves become more marked, and the diploic sinuses more freely communicate with one another. With the loss of the teeth, whether prematurely by disease or accident, or as usual in the advance of life, the alveolar processes of the jaws disappear, and the face is much reduced in length or depth, thus reverting to the condition of infancy. With the reduction of the fore part of the mandible the rami gradually assume a more oblique position, which is also a reversion to the infantile condition. As the arch of the body of the mandible is considerably larger than the arches of the alveolar processes, with the disappearance of these the mandible is drawn up in front of their former position, and thus approximates the prominent chin to the nose, a feature so characteristic of the aged face.

#### VARIATIONS OF THE SKULL.

Sexual differences appear in many skulls, but others show every grade of intermediate variation, so that there is no certainty in their distinction. Generally the skull of the female is smaller and of more delicate construction, with its processes, ridges, and muscular attach-



ments less produced, and with its surfaces more even and smooth. The cranium is proportionately less elevated, more regularly rounded or oval, with thinner walls, less prominent superciliary ridges, and less expanded sinuses. The face is smaller in proportion to the cranium, with narrower and less prominent jaws.

The skull in different races and peoples exhibits certain well-marked peculiarities, but they are of inconstant character, and between extreme differences every shade of variation is to be found. The cranium varies considerably in shape, size, proportions, and capacity. The face also varies in size and proportions, whether viewed separately or in relation with the cranium. The cranium is comparatively long or short, broad or narrow, low or high, and is more or less conspicuously oval, spheroid, square, conical, and roof-like on top. The face is comparatively small and receding, large and protruding, broad or narrow, long or short, and centrally depressed or prominent. The capacity of the normal adult cranium ranges from sixty to one hundred and ten cubic inches; and the average in all races is estimated at eighty-five cubic inches.

The comparatively long cranium is named **dolichocephalic**; the short cranium, **brachycephalic**. The more protruding face is named **prognathous**; the least protruding, **orthognathous**; and the broad face, **eurygnathous**.

Generally the skull of the white race is dolichocephalic and orthognathous, though in some people, as the Danes, the brachycephalic form prevails. The English are commonly dolichocephalic, and this form is prevalent in the United States. The Germans exhibit both forms and every intermediate variety. The cranial capacity is ordinarily highest in the white race, especially in its more intellectual representatives. The face in the white race is mostly comparatively small, narrow, and orthognathous. Frequently it is more or less conspicuously prominent mesially and centrally. In the Mongolian race generally the skull is brachycephalic and prognathous, and the face is eurygnathous and centrally depressed. The Esquimaux pertaining to this race are among the most dolichocephalic of people. In the negro race the skull is dolichocephalic and prognathous, and the cranial capacity small. In the Australian these conditions reach their extreme.

The difference in the angle which is produced by variation in the proportion and relative position of the cranium and face has been regarded as an index of that difference. Distinguished as the facial angle, it is ascertained by drawing a horizontal line from the anterior nasal spine to the auditory meatus, and a second line, to intersect the former, from the glabella to the upper alveolar process. In the white race the facial angle commonly ranges from  $70^{\circ}$  to  $85^{\circ}$ ; in the Mongolian race, from  $65^{\circ}$  to  $80^{\circ}$ ; and in the negro race, from  $60^{\circ}$  to  $75^{\circ}$ . In idiots it is considerably lower.

The skulls of most monkeys, compared with the skull of man, exhibit a very great proportionate reduction in the cranium, with an increase of



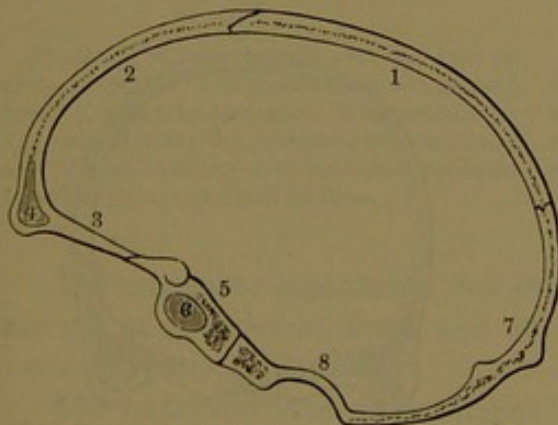
the face, so that the facial angle is reduced in a corresponding degree. In most other animals of man's class the proportionate reduction of the cranium to the face is observed to go on, often with an increase of the latter, so that in the lower orders the face assumes a position almost entirely in advance of the cranium. The human skull, in comparison with that of other animals generally, is especially remarkable for the great proportionate capacity of the cranium and the smallness of the face, especially of the jaws, and of the recesses and attachment of muscles related to the movements of the mandible.

A want of complete symmetry in the shape of the skull is of frequent occurrence. Deformity is readily induced in the cranium during its growth from continued pressure in certain positions, and thus the occiput is observed to become permanently flattened on one side from the sleeping infant habitually lying in that manner. Remarkable deformities of the skull, the result of pressure to the head in infancy, produced by the application of splints and bandages, are exemplified in the ancient Peruvians and in the Flathead Indians.

#### MECHANICAL CONSTRUCTION OF THE SKULL.

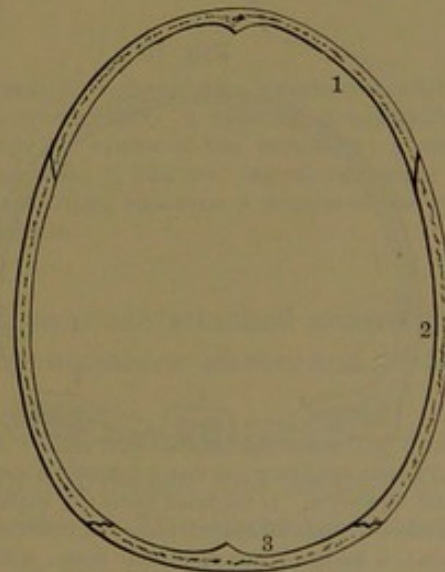
The mechanical construction of the skull is in all respects admirably adapted to its various purposes. The ovoid shape of the cranium, with its narrower extremity directed in the position most liable to shock or accident, insures the protection of the large and delicate brain to the greatest degree. The conspicuously greater

FIG. 71.



ANTERO-POSTERIOR SECTION OF THE CRANIUM, exhibiting the mode by which the connection of the different bones contributes to preserve its integrity. 1, parietal bone; 2, frontal bone; 3, its orbital plate; 4, frontal sinus; 5, body of sphenoid bone; 6, sphenoidal sinus; 7, occipital bone; 8, marginal thickening of the occipital foramen.

FIG. 72.



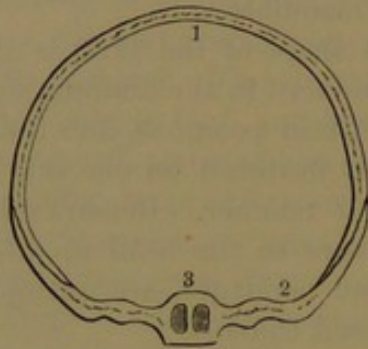
HORIZONTAL SECTION OF THE CRANIUM. 1, frontal bone; 2, parietal bone; 3, occipital bone.

projection of the different eminences in the infantile cranium is a further security against injuries from blows at a time when the brain



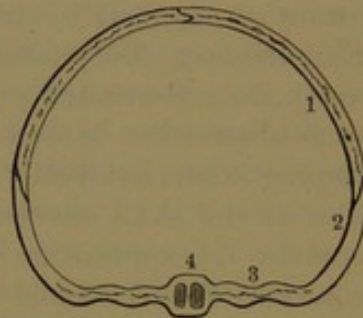
is proportionately larger, and more soft and delicate, than later. Before ankylosis of the bones of the skull they are everywhere so intimately and fitly articulated that no ordinary violence is sufficient to derange or displace them. Sections made through the cranium in any direction, as illustrated in Figs. 71-76, exhibit the varied modes of junction of the borders of the bones, which contribute to main-

FIG. 73.



TRANSVERSE SECTION THROUGH THE FRONT OF THE CRANIUM. 1, transverse arch formed by the frontal bone; 2, great wing of the sphenoid bone, including or overlapping the abutments of the frontal arch; 3, body of the sphenoid bone, with its sinuses.

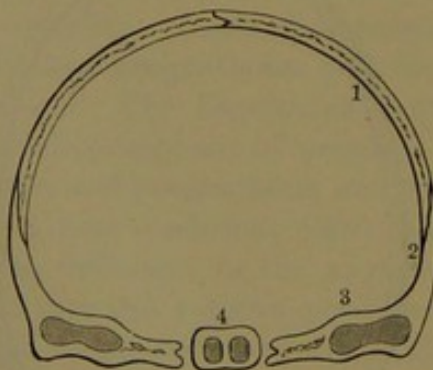
FIG. 74.



TRANSVERSE SECTION IN ADVANCE OF THE MIDDLE OF THE CRANIUM. 1, parietal bone forming with its fellow an arch; 2, great wing of the sphenoid bone; 3, horizontal portion of the wing; 4, body, with the sphenoidal sinuses.

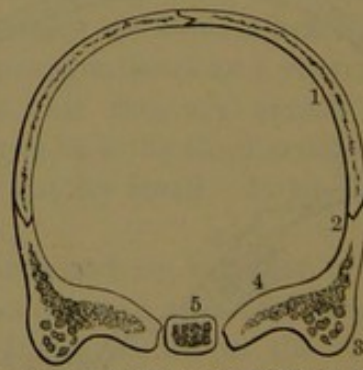
tain the integrity of the whole. The face is a wedge-like segment of a cylinder inserted beneath the narrower extremity of the cranium, against which it is strongly stayed by the orbital and zygomatic arches, the pterygoid processes, and the rami of the mandible. The middle of

FIG. 75.



TRANSVERSE SECTION THROUGH THE MIDDLE OF THE CRANIUM. 1, parietal bone; 2, squamous portion of the temporal bone; 3, petrous portion; 4, body of the sphenoid bone, with the sphenoidal sinuses.

FIG. 76.



TRANSVERSE SECTION POSTERIOR TO THE MIDDLE OF THE CRANIUM. 1, back part of the parietal bones; 2, mastoid portion of the temporal bone; 3, mastoid process with the sinuses; 4, petrous portion of the temporal; 5, sphenoidal body, or the basilar process.

the face is remarkable for its lightness combined with strength. The bridge of the nose, the entrances of the orbits, and the zygomatic arches are all constructed on mechanical principles, giving strength

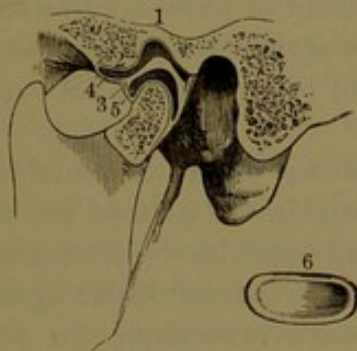


and protection to the parts. The jaws are strong arches, in which the teeth are securely implanted. The upper jaw, like the nether millstone in purpose, is stationary and firmly fixed, and is maintained in position by the stays of the face above mentioned. The mandible, the only movable bone of the skull, through its extension backward to articulate with the temporal bones, becomes a most powerful lever, and, under the action of the muscles of mastication, performs the part of the moving millstone in the trituration of the food.

### ARTICULATION OF THE LOWER JAW.

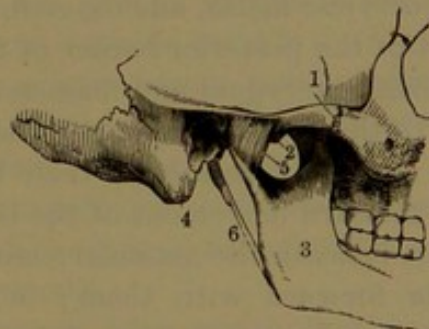
The **articulation of the lower jaw**,<sup>1</sup> or of the mandible, is formed between the condyle of this bone and the glenoid fossa and articular eminence of the temporal bone. The opposed surfaces are invested with cartilage, and the joint is enclosed by a capsular ligament strengthened by lateral ligaments, and is divided by an interarticular ligament into two synovial lined cavities.

FIG. 77.



VERTICAL SECTION OF THE ARTICULATION OF THE LOWER JAW. 1, is placed above the glenoid fossa; 2, articular eminence; 3, interarticular ligament dividing the joint into two cavities, 4 and 5; 6, an interarticular ligament separated from the joint, to exhibit its form.

FIG. 78.



EXTERNAL VIEW OF THE TEMPORO-MANDIBULAR ARTICULATION. 1, zygoma; 2, preglenoid tubercle; 3, ramus of the mandible; 4, mastoid process; 5, external lateral ligament; 6, stylo-maxillary ligament, a process of the cervical fascia.

The **capsular ligament**<sup>2</sup> is a loose fibrous sac attached around the margin of the glenoid fossa and articular eminence above, and to the neck of the mandible below.

The **external lateral ligament**<sup>3</sup> is a thin, flat band extending from the outer part of the preglenoid tubercle downward and backward to the outer part of the neck of the mandible. The **internal lateral ligament**<sup>4</sup> is a thin band descending from the entoglenoid tubercle to the inner side of the neck of the mandible.

<sup>1</sup> Temporo-maxillary articulation.

<sup>2</sup> L. capsulare.

<sup>3</sup> Ligamentum maxillare externum; l. accessorium laterale.

<sup>4</sup> L. accessorium mediale.



The **interarticular ligament**<sup>1</sup> is an oval disk of fibro-cartilage within the articulation, coextensive with the temporal articular surface, and dividing the joint horizontally into two compartments. In fore and aft section it is sigmoid, and is thickest in the position of the glenoid fossa, so as to render the transition from the concavity of the joint behind to the convexity in front much less abrupt below the disk than it is above. It is chiefly composed of an intertexture of horizontal, fibrous bundles, which become more concentric at the thickened circumference, where it is intimately connected with the capsular and lateral ligaments. Occasionally it is perforated, when the two cavities of the joint communicate. Several accessory ligaments are connected with the mandible, independent of the articulation described,—the spheno-maxillary and the stylo-maxillary ligaments.

The **spheno-maxillary ligament**<sup>2</sup> is a long, thin band, narrow above, where it is attached to the sphenoid spinous process, and widening below, where it is attached to the inner border of the dental foramen. It descends between the pterygoid muscles, and has intervening between it and the ramus of the mandible the internal maxillary vessels and the auriculo-temporal and inferior dental nerves.

The **stylo-maxillary ligament**<sup>3</sup> is a band of fibres connected with the cervical fascia, and extending from the styloid process to the lower part of the posterior border of the ramus of the mandible, between the internal pterygoid and masseter muscles.

In the ordinary opening and closing of the mouth the condyles of the lower jaw rotate on their long axis within the glenoid fossæ. In the forward movement of the lower jaw the condyles descend from the fossæ beneath the articular eminences, and the interarticular ligaments glide forward with them; in the backward movement the reverse occurs. In mastication the same movements take place alternately on each side.

#### THE HYOID BONE.

The **hyoid bone**<sup>4</sup> is situated in the neck, at the root of the tongue, to which it gives attachment. It is a horizontal arch, which usually, until about the middle of life, is composed of five osseous pieces, named the body, the greater cornua, and the small cornua.

The **body**,<sup>5</sup> or **basihyal**, is the middle front piece, to which the cornua are united laterally by cartilage. It is a transverse bar of variable proportionate length and depth, is bowed with the convexity forward, and has obliquely truncated ends directed upward, outward, and backward. The anterior surface, convex and uneven, is directed forward

<sup>1</sup> I. fibro-cartilage; cartilago interarticularis; meniscus; operculum cartilagineum.

<sup>2</sup> Internal lateral ligament; l. laterale internum.

<sup>3</sup> L. stylo-maxillare; l. stylo-myloideum.

<sup>4</sup> Os hyoides; os linguae; tongue-bone.

<sup>5</sup> Basis.



and upward. It is divided by a transverse ridge and a variable median prominence into four somewhat depressed areas, which give attachment to muscles. The posterior surface is deeply and evenly concave, and is directed backward and downward. The upper border, nearly straight across, is concave behind. The lower border, variably concave for the most part, turns up convexly at the sides to the articulation of the greater cornua.

The **greater cornua**,<sup>1</sup> or **thyrohyals**, longer than the body, are directed backward from the ends on a level with the upper border. They are slightly curved or nearly straight, club-shaped, flattened obliquely from above downward, tapering behind, and end in a rounded knob.

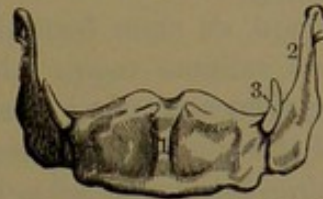
The **small cornua**,<sup>2</sup> or **ceratohyals**, articulate in front of the union of the greater cornua with the body, and are directed obliquely upward and backward, to be connected with the stylo-hyoid ligament. They are conical, of variable length,—from a line or two in youth to half an inch or more approaching the middle of life,—and are often more or less cartilaginous.

Ossification commences in the body and greater cornua in the last month of foetal life; in the small cornua at variable periods during the first to several years after birth. The greater cornua mostly become ankylosed with the body after forty or fifty years; and sometimes in old age the small cornua also co-ossify with the rest of the bone.

The hyoid bone, together with its connections with the temporal bone, represents the complicated branchial arches of fishes, and is very variably developed in other classes of animals.

The **stylo-hyoid ligament** is a long, slender, mostly feeble cord of fibro-connective tissue, which extends between the styloid process of the temporal bone and the small cornu of the hyoid bone. Occasionally it is itself more or less ossified, and in this condition late in life may be ankylosed with either the styloid process or the hyoid bone, and sometimes with both. In some animals, as the dog, it is replaced by a distinct bone, the *epihyal*.

FIG. 79.



THE HYOID BONE. 1, body; 2, greater cornu; 3, small cornu.

## BONES OF THE UPPER LIMBS.

The upper limbs, suspended from the upper part of the thorax, at the sides of the trunk, consist each of the shoulder, the arm, the forearm, and the hand. The bones of the shoulder are the scapula and clavicle, which, with those of the opposite side, form the shoulder-girdle. The arm has a single bone, the humerus; the forearm has two bones, the radius and the ulna; and the hand is composed of three parts, the

<sup>1</sup> C. majora.

<sup>2</sup> C. minora; cornicula.

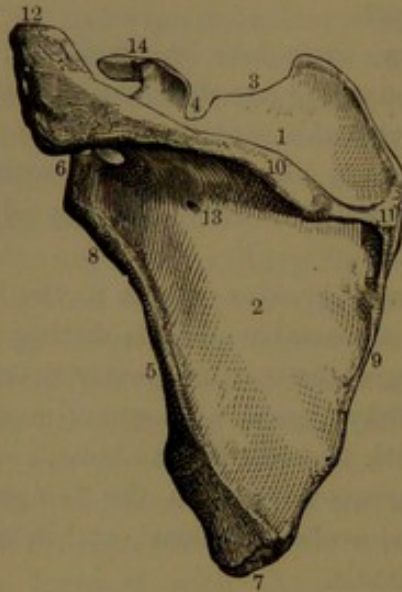


carpus, with eight bones, the metacarpus, with five bones, and the digits, of which there are five, each of three bones or phalanges, except the first, which has two phalanges, and in addition two sesamoid bones.

### SCAPULA.

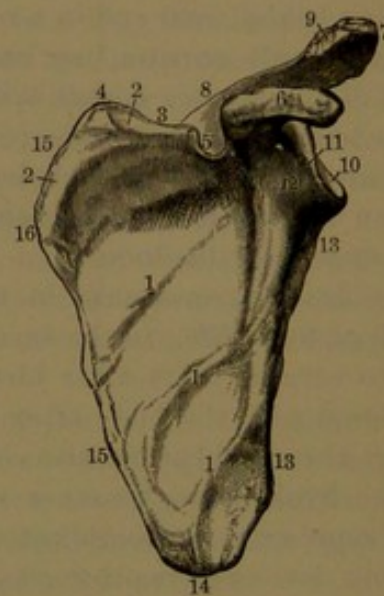
The **scapula**,<sup>1</sup> or **shoulder-blade**, is placed at the upper back part of the thorax, extending from the position of the second to the seventh rib. It consists of a broad, thin, triangular plate, with thickened borders, the **body**, from which spring two conspicuous processes, named the **spine** and the **coracoid process**.

FIG. 80.



THE SCAPULA OF THE LEFT SIDE, posterior view. 1, supraspinous fossa; 2, infraspinous fossa; 3, superior border; 4, coracoid notch; 5, inferior border; 6, glenoid cavity; 7, inferior angle; 8, neck of the scapula; 9, posterior border or base; 10, spine; 11, its triangular commencement, upon which the tendon of the trapezius muscle moves; 12, acromion; 13, one of the nutritious foramina; 14, coracoid process.

FIG. 81.



ANTERIOR VIEW OF THE SCAPULA. 1, ridges crossing the subscapular fossa; 2, attachment of the serratus muscle; 3, superior border; 4, superior angle; 5, coracoid notch; 6, coracoid process; 7, acromion; 8, spine of the scapula; 9, articular surface for the clavicle; 10, glenoid cavity; 11, elevated margin of the same; 12, neck; 13, inferior border; 14, inferior angle; 15, base; 16, position at which the spine commences.

The **anterior surface**,<sup>2</sup> directed towards the ribs, presents a broad, uneven concavity, the **subscapular fossa**,<sup>3</sup> which is occupied by the subscapular muscle. The deepest part of the fossa corresponds with the position behind, of the spine of the scapula, and is named the **subscapular angle**. At the outer border of the fossa is a thick convex ridge, descending from the neck to the inferior angle; and the fossa is also crossed by several narrow ridges,<sup>4</sup> converging towards the neck,

<sup>1</sup> Scapulum; omoplata; blade-bone.

<sup>3</sup> F. subscapularis.

<sup>2</sup> Venter.

<sup>4</sup> Costæ scapulares.



for the attachment of tendinous intersections of the muscle occupying it. At the superior and inferior angles are narrow, flattened surfaces, conjoined by a variable ridge along the vertebral border, for the attachment of the great serratus muscle.

The **posterior surface**<sup>1</sup> of the scapula is divided near its upper third by the spine into two recesses, of which the upper, smaller one is the **supraspinous fossa**,<sup>2</sup> and the lower one is the **infraspinous fossa**,<sup>3</sup> both being occupied by corresponding muscles. The infraspinous fossa is bulging at the middle, and most depressed along the outer border, which forms a prominent obtuse ridge, descending from the neck to the inferior angle of the bone, and giving attachment to an aponeurosis separating the infraspinous from the teres muscles. Outwardly from the ridge above, is a narrow grooved surface for the origin of the small teres muscle, and below, a wider convex surface for the origin of the greater teres muscle.

Of the three borders of the scapula, the **superior border** is shortest, and has springing from its outer part the coracoid process. Its inner two-thirds are thin, and slant downward and outward from the superior angle to the root of the coracoid process, where it ends in a semicircular notch,<sup>4</sup> which is converted by a transverse ligament<sup>5</sup> into the **coracoid foramen**<sup>6</sup> for the passage of the suprascapular nerve. Sometimes the ligament is replaced by a bridge of bone. The **internal or vertebral border**, also called the **base**, is the longest, and extends between the superior and inferior angles. It is convex and somewhat wavy in its course, and is abruptly directed more outward above the position of the spine. It is slightly thickened, and gives attachment to the scapular elevator and rhomboid muscles. The **external or axillary border** is the thickest part of the bone except the head, which it serves to sustain in a bracket-like manner. It is formed by the prominent ridges at the outer part of the subscapular and infraspinous fossæ, which descend from the front and back of the neck to the inferior angle. From it projects a narrow intermediate ridge, which gives attachment to an aponeurosis separating the subscapular from the teres muscles. The upper extremity of the ridge beneath the glenoid fossa is thick and roughened, and gives origin to the long head of the brachial triceps muscle.

Of the angles of the scapula, the **superior angle**, formed by the conjunction of the superior and vertebral borders, is thin, smooth, rounded angular, and slightly prolonged upward. The **inferior angle**, formed by the conjunction of the axillary and vertebral borders, is thick, roughened, and rounded angular. The external angle expands upward and outward into the **head**, the thickest part of the bone,

<sup>1</sup> Dorsum.

<sup>2</sup> F. supraspinata.

<sup>3</sup> F. infraspinata.

<sup>4</sup> Coracoid notch; incisura coracoidea; i. semilunaris.

<sup>5</sup> Ligamentum coracoideum.

<sup>6</sup> F. coracoideum.



terminating in the **glenoid cavity**,<sup>1</sup> which forms the upper and inner articulating surface of the shoulder-joint. The cavity is a vertical, ovoid, shallow, concave fossa, invested with cartilage, and is directed outward with an inclination forward and slightly upward. The narrow extremity above forms a low tuberosity, which gives origin to the long head of the brachial biceps muscle. The prominent margin gives attachment to the glenoid ligament. Within the position of the head, the narrower portion of the bone is the **neck**,<sup>2</sup> defined by the scapular notch between the head and spine behind and the coracoid notch above.

The **coracoid process**<sup>3</sup> springs by a broad base from the upper part of the head, curves upward, forward, and outward, and terminates in a compressed rounded end above the front of the shoulder-joint. Its upper fore part is unevenly convex, and at the base inwardly presents a broad, low tuberosity, which gives attachment to the coraco-clavicular ligament. Its lower fore part forms with the front of the neck a groove, which is directed outward and upward from the subscapular fossa, and serves to conduct the subscapular muscle to its insertion.

The **spine** is a thick, triangular shelf projecting behind the body between the supraspinous and infraspinous fossæ. It springs by a wide base stretching from the vertebral border to about the middle of the neck, and thence extends backward and upward, and is prolonged outward and forward to form the acromion. Its upper surface extends outward beneath the acromion, and forms part of the supraspinous fossa; and its under surface forms the upper part of the infraspinous fossa. The anterior border is thick and rounded, curves backward, outward, and upward, and expands in the inferior surface of the acromion. Between it and the head, at the back of the neck, is the **scapular notch**, through which the supraspinous and infraspinous fossæ communicate. The posterior border is the longest, and is obvious as a ridge, which may be felt beneath the skin, and extends from the vertebral border of the scapula outwardly to the top of the shoulder. It presents a bowed surface of varying breadth; starting at the vertebral border in a triangle, it narrows outwardly, then expands, narrows again, and once more expands upon the acromion. The tendon of the trapezius muscle glides over its triangle, and is then inserted along its upper lip; and from the lower lip arises the deltoid muscle. The **acromion**<sup>4</sup> is prolonged from the spine upward and forward, overhangs the back of the shoulder-joint, and ends at the top of the shoulder, whence the name. It is elliptical, flattened from above downward, and contributes by its upper convex surface, which is subcutaneous, to the rounded

<sup>1</sup> Fossa glenoidea; cavitas glenoidea; acetabulum humeri; omocotyle.

<sup>2</sup> Cervix.

<sup>3</sup> Processus coracoideus; p. uncinatus.

<sup>4</sup> Akron, the top or summit; *omos*, the shoulder; acromion process.



form of the shoulder; while the lower surface is contiguous to the shoulder-joint. The outer roughened border gives attachment to the deltoid muscle, extending from the lower lip of the spine; and its anterior extremity gives attachment to the coraco-acromial ligament. Just within the latter it exhibits a flat, elliptical facet, directed inward and upward, for articulation with the clavicle.

The scapula, for the most part, is a comparatively thin bone, is thicker at the borders, and thickest at the head and processes, where it is composed of a proportionate quantity of spongy substance. In the position of the supraspinous and infraspinous fossæ it consists of a plate of compact substance so thin as to be translucent, and in prepared specimens, from contraction in drying, it often appears broken in these parts. Occasionally, also, the ossification is incomplete in this position, leaving one or more apertures, which in the recent condition are closed by the periosteum. Among the nutritious foramina, several, conspicuous for their size, are to be observed at the base of the spine.

Ossification commences in the scapula, in the latter part of the second month of foetal life, from a principal centre appearing in the body and thence extending into the spine. At birth the chief part of the bone is ossified, but the coracoid process, the acromion, the base and inferior angle, and the margin of the glenoid cavity are yet cartilaginous. Ossification occurs in the coracoid process during the first year after birth, and continues until about puberty, when the process ankyloses with the body; contributing a small portion to the upper extremity of the glenoid cavity. At the same time ossification begins in the acromion, usually from two centres, which speedily unite, when the epiphysis continues to increase till maturity, and then coalesces with the spine. Between sixteen and eighteen years, epiphyses appear at the inferior angle, along the base, in the tuberosity of the coracoid process, and at the upper part of the glenoid cavity, all of which unite with the rest of the bone between twenty-two and twenty-five years, when the scapula is rendered complete.

The coracoid process represents a permanently distinct and well-developed bone in other classes of animals than our own, as, for instance, in birds, in which, like the clavicle, it extends between and articulates with both scapula and sternum. In the hoofed mammals, as, for example, the ox, the process is rudimental. The cartilage and epiphyses of the base of the immature scapula represent the more largely developed cartilaginous or partially ossified suprascapula of many lower animals, such as lizards and amphibians.

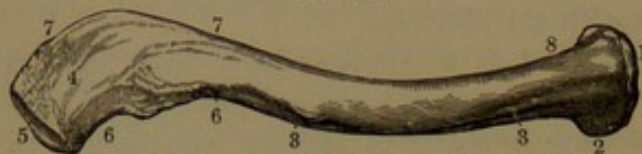
Rarely, the completely ossified epiphysis of the acromion remains permanently separated, and is united with the spine by a ligament.



## CLAVICLE.

The **clavicle**,<sup>1</sup> or **collar-bone**, is placed at the upper part in front of the thorax, and extends nearly horizontally from the sternum out-

FIG. 82.



CLAVICLE OF THE RIGHT SIDE, upper view. 1, sternal end; 2, portion which joins the cartilage of the first rib; 3, anterior convexity and line of attachment of the greater pectoral muscle; 4, upper surface of the acromial end; 5, its articular surface; 6, anterior concavity, giving attachment to the deltoid muscle; 7, posterior convexity, giving attachment to the trapezius muscle; 8, position of origin of the sterno-mastoid muscle.

ward over the first rib to the acromion of the scapula. It is a long bone of irregular cylindroid form and sigmoid curvature, in which the sternal extremity is convex forward and the acromial extremity is convex backward, while the concavities are reversed.

**The sternal extremity**

is trilateral, and ends in a vertical, uneven, articular surface, which is variably rounded triangular, with the base upward and the apex directed downward and backward; and with the greater width in the same direction. For the most part, the surface is somewhat depressed, looks inward, and is connected with the sternum by an intervening fibro-cartilage; while the lower fore part is convex, and articulates with the first costal cartilage. The **acromial extremity** curves outward and backward, is cylindroid and flattened from above downward, and is widest fore and aft. It is defined in front and behind by narrow borders, which are more or less roughened, and afford attachment to the deltoid and trapezius muscles. It ends in a variable transverse oval facet, which is directed outward; with a slight inclination forward and downward, and articulates with the extremity of the acromion.

The **upper surface** of the clavicle, partly subcutaneous, along the inner two-thirds is convex and directed both upward and forward, and at the outer third is variably flattened, sometimes convex and sometimes depressed, and is directed upward. At its inner part, in front, it is impressed by the attachment of the greater pectoral muscle, and at the outer part, in front, by the deltoid muscle, and behind, by the trapezius muscle. The **inferior surface**, at the inner two-thirds, is directed obliquely downward and backward, and at the outer third is directed downward. Along the middle it is feebly depressed or grooved for the attachment of the subclavius muscle, and is defined in front by the inferior prominent border of the bone, to which is attached the subclavian fascia. Beneath the sternal extremity it exhibits a variable, irregular, elliptical, roughened impression for the attachment of the costo-clavicular ligament; and beneath the acromial extremity an equally variable, oblique, roughened ridge for the attachment of the coraco-clavicular ligament.

<sup>1</sup> Clavicula.



The clavicle has nearly the same construction as the long bones of the limbs generally, but does not possess the distinct central medullary cavity. It is composed within of coarse, spongy substance, commonly with traces of a narrow, irregular medullary cavity along the middle back part. The compact substance predominates along the posterior part of the bone, and is comparatively thin in front, except in the outer concavity. One or two medullary nutritious foramina occupy the posterior concavity, with the canals directed outwardly and communicating with the interior.

In the female the clavicle is usually more slender, less curved, and less marked by muscular and ligamentous attachments. In men habituated to the most active muscular exercise, the clavicle is generally shorter, more robust and curved, and more strongly marked by the muscular and ligamentous attachments.

It is a remarkable fact that ossification begins in the clavicle earlier than in any other bone of the skeleton. It commences in the shaft about the sixth week of foetal life, and an epiphysis makes its appearance at the sternal extremity from the eighteenth to the twentieth year, and ankyloses with the shaft a few years subsequently. The clavicle is the only medium of articulation of the upper limb with the rest of the skeleton. In those animals, of our class, in which the fore limbs are used alone for locomotion and support, the clavicle is absent, as instanced in the horse, ox, and elephant. It is a most important means in maintaining an outward position to the shoulder-joint, so as to give the widest range of movement to the limb.

#### THE HUMERUS.

The **humerus**, or **arm-bone**,<sup>1</sup> is directed downward from the scapula, with a slight inward inclination, at the side of the thorax. It is nearly straight, but has a slight curvature forward at the lower extremity. The shaft is trilateral, cylindroid above, more compressed fore and aft and laterally expanded below, and exhibits three surfaces separated by three borders. Its upper extremity is expanded and thickest, and terminates obliquely, at an angle of about forty-five degrees, in the **head**.<sup>2</sup> This is a smooth, hemispherical, articular eminence, which is directed inward, upward, and backward, and partially overhangs the back of the shaft, which projects behind in a bracket-like manner to sustain it. The contracted union of the shaft with the head is the **neck**,<sup>3</sup> which in front and outward appears as a shallow groove separating the head from a pair of conspicuous tuberosities, also separated from each other by the commencement of the **bicipital groove**. The **small tuberosity**<sup>4</sup> is situated below the front of the head, and is an obtuse process impressed inwardly above, with a facet for the

<sup>1</sup> Os humeri; o. brachii; o. brachiale.


<sup>2</sup> Caput.

<sup>3</sup> Cervix; collum.

<sup>4</sup> Lesser tuberosity; tuberculum minus.



insertion of the subscapular muscle. The **greater tuberosity**<sup>1</sup> is situated below the outer part of the head on a level with the former, but rises a little higher in front, and is thrice the size. It is a broad, convex process impressed above with three facets, in succession for the insertion of the supraspinous, infraspinous, and small teres muscles.



HUMERUS OF THE LEFT SIDE, viewed in front. 1, shaft; 2, head; 3, neck; 4, greater tuberosity; 5, small tuberosity; 6, bicipital groove; 7, 8, ridges bounding the latter and giving attachment to muscles; 9, position of insertion of the deltoid muscle; 10, principal nutritious foramen; 11, capitulum for the radius; 12, trochlea for the ulna; 13, 14, external and internal epicondyles; 15, 16, supracondylar ridges; 17, fossa for the coronoid process of the ulna.

of the external head of the brachial triceps muscle. Below this it is crossed by a slight oblique depression, the **musculo-spiral groove**, which descends from within on the posterior surface to the antero-external surface, and indicates the course of the superior profunda vessels and musculo-spiral nerve. Below the groove the border becomes gradually more prominent, and forms the external **supracondylar ridge**, which is roughened, and gives origin to the long supinator and long

The surgeon finds it convenient to apply the name of **neck**<sup>2</sup> to the narrowed portion of the shaft below the head and tuberosities, where the bone is often accidentally fractured, while the accident is rare in the position of the neck as distinguished by the anatomist.

The **internal border**<sup>3</sup> of the shaft descends from the small tuberosity to the internal epicondyle, and separates the antero-internal surface from the posterior surface. Its upper third<sup>4</sup> is obtuse, and forms the inner boundary of the bicipital groove, at the lower part of which it is roughened for the insertion of the latissimus and greater teres muscles. The lower two-thirds are more prominent and narrow; about the middle the shaft is roughened for the insertion of the coraco-brachial muscle, and below forms the internal **supracondylar ridge**, which descends and curves to the end of the epicondyle.

The **external border**<sup>5</sup> descends from the back part of the great tuberosity to the external epicondyle, and separates the antero-external surface from the posterior surface. Its upper half is obtuse, and, for the most part, is somewhat roughened for the origin

<sup>1</sup> Tuberculum majus.

<sup>2</sup> Angulus medialis.

<sup>3</sup> Angulus lateralis.

<sup>4</sup> Collum chirurgicum.

<sup>5</sup> Spina tuberculi minoris.



radio-carpal extensor muscles. The **anterior border**<sup>1</sup> starts from the fore part of the greater tuberosity, and descends in front of the shaft to its lower extremity. Its upper part<sup>2</sup> forms the anterior boundary of the bicipital groove, at the lower portion of which it is produced in a rough ridge<sup>3</sup> for the insertion of the greater pectoral muscle. Below this, to about the middle of the shaft, it forms the anterior limit of a superficial triangular rough eminence, which is situated on the antero-external surface and gives insertion to the deltoid muscle. From this the border proceeds as the median convex prominence of the front of the shaft to its lower extremity.

The **anterior surface**, at its upper part, presents the **bicipital groove**,<sup>4</sup> so named from its being occupied by the longer tendon of the brachial biceps muscle. The groove commences between the tuberosities, descends for several inches along the shaft, and is bounded externally and internally by roughened borders, the **bicipital ridges**, which receive the insertion of the greater pectoral, latissimus, and teres muscles. In the recent condition it is invested with fibro-cartilage, and lined with a prolongation of the synovial membrane of the shoulder-joint. The outer portion of the surface of the shaft at its upper third is smooth, and is covered by the deltoid muscle. The surface on each side of the deltoid insertion, and below this extending to the distal extremity of the bone, is covered by the brachialis muscle. The **posterior surface** of the shaft above is half cylindrical, converges outwardly below to the musculo-spiral groove, and is occupied by the long head of the brachial triceps muscle. Outwardly, from the latter groove, the surface gradually widens to the distal extremity in a flattened triangle, which gives attachment to the internal head of the brachial triceps muscle.

The distal extremity of the humerus is the widest portion of the bone, and the thinnest fore and aft; and it ends in a broad articular surface supported on two processes, the capitulum and the trochlea.

The **capitulum**,<sup>5</sup> or radial head, is the outer process, and articulates with a circular concavity on the head of the radius. The articular surface occupies its anterior and inferior aspect, and is continuous inwardly with that of the trochlea, from which it is defined by a groove.

The **trochlea**<sup>6</sup> articulates with the ulna, and is a transverse cylinder widely and deeply grooved like a pulley-wheel, with the inner side more expanded. It is directed downward, with an oblique inclination from behind forward and from without inward. The articular surface extends fore and aft between two fossæ situated immediately above at

<sup>1</sup> Angulus anterior.

<sup>2</sup> Spina tuberculi.

<sup>3</sup> Anterior bicipital ridge; pectoral ridge.

<sup>4</sup> Sulcus bicipitalis; s. intertubercularis; semicanalis humeri.

<sup>5</sup> Capitellum; eminentia capitata; tuberculum; small head; humeral condyle.

<sup>6</sup> Rotula; pulley.



the front and back of the shaft. The anterior or **coronoid fossa**<sup>1</sup> is a trilateral concave recess, which receives the apex of the coronoid process of the ulna in extreme flexure of the forearm. The posterior or **olecranon fossa**,<sup>2</sup> a much larger recess, like the former receives the summit of the olecranon in extension of the forearm. The fossæ at bottom are separated by a thin, translucent plate, which occasionally is perforated. In the recent condition they are lined by extensions of the synovial membrane of the elbow-joint, and their upper margins give attachment to the capsular ligament. Above the capitulum in front there is usually a slight depression,<sup>3</sup> which accommodates the border of the head of the radius in extreme flexion of the forearm.

Above the trochlea inwardly is a prominent tuberosity, the **internal epicondyle**,<sup>4</sup> continuous with the internal supracondylar ridge, and impressed by the attachment of the internal lateral ligament of the elbow-joint. Its back part is commonly impressed with a feeble groove,<sup>5</sup> which indicates the course of the ulnar nerve. Above the capitulum outwardly is a less prominent tuberosity, the **external epicondyle**,<sup>6</sup> which is continuous with the external supracondylar ridge, and is impressed by the attachment of the external lateral ligament of the elbow-joint.

The humerus is constructed like other long bones of the limbs generally, the shaft being occupied by a large medullary cavity, with thick compact walls thinning away towards the extremities of the bone, which are composed of spongy substance with a thin investment of compact substance. The principal medullary nutritious foramen is commonly situated at the lower third of the humerus on the internal border, and has the canal directed downward. Sometimes a second foramen occupies a higher position on or near the same border.

Ossification commences in the humerus towards the end of the second month of foetal life, the chief centre appearing near the middle of the shaft, which alone is ossified at birth. A centre starts in the head near the middle of the first year or later, and another starts in the greater tuberosity at the end of the second year or early part of the third. About the same time a centre appears in the capitulum, and others follow in the small tuberosity and internal epicondyle in the fourth or fifth year. The centres of the head and tuberosities coalesce about the latter period and grow into a large epiphysis, which, though the first to ossify, is the last to ankylose with the shaft, occurring, as it does, in the female about the twenty-second year, and in the male

<sup>1</sup> F. anterior major; fossa supratrochlearis anterior.

<sup>2</sup> F. olecrani; f. posterior; fossa supratrochlearis posterior; sinus maximus.

<sup>3</sup> Fossa anterior minor.

<sup>4</sup> Internal condyle; condylus flexorius; epicondylus medialis; epitrochlea; internal tuberosity.

<sup>5</sup> Sulcus ulnaris.

<sup>6</sup> External condyle; epicondyle; epicondylus lateralis; nodus externus; external tuberosity; condylus extensorius.



approaching the twenty-fifth year. A centre does not appear in the trochlea until about the twelfth year, and that of the external epicondyle the following year. The centres of the capitulum, trochlea, and external epicondyle unite about the sixteenth year, and shortly after ankylose with the shaft; to which, also, the centre of the internal epicondyle ankyloses a year later.

#### THE ULNA.

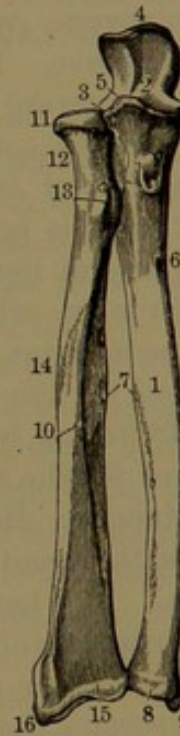
The **ulna**<sup>1</sup> is the inner, more posterior, and longer bone of the forearm. It is trilaterally prismatic, with the upper extremity the larger, and articulating with the humerus and radius, with which it forms the elbow-joint, whence it gradually tapers to the lower extremity, where it also articulates with the radius and forms part of the wrist-joint. It is not quite straight, but from the upper extremity is slightly bent forward to near its middle, whence it pursues a straighter course to the lower extremity, which is slightly bent outwardly.

The **upper extremity** terminates in two conspicuous eminences, the olecranon and coronoid process, separated by the sigmoid fossa.

The **olecranon**,<sup>2</sup> situated at the upper back part of the ulna, forms the prominence of the elbow. It is a thick, strong process, ascending from the back of the shaft above the position of the coronoid process, and curving forward at the summit, which, in the extended condition of the forearm, is received into the olecranon fossa of the humerus. Its posterior surface converges downward and forms a triangle, which is flattened, convex, and subcutaneous. The anterior surface forms the upper division of the sigmoid fossa. The upper surface is trilateral and convex, gives attachment to the brachial triceps muscle contiguous to the posterior surface, and is covered with a synovial bursa next the summit.

The **coronoid process**<sup>3</sup> is a broad pyramidal eminence, which is directed forward from the shaft in advance

FIG. 84.



THE TWO BONES OF THE RIGHT FOREARM, viewed in front; the ulna to the right and the radius to the left of the figure. 1, shaft of the ulna; 2, sigmoid fossa; 3, articulation of the head of the radius with the ulna; 4, olecranon; 5, coronoid process; 6, nutritious foramen; 7, sharp ridges of both bones of the forearm for the attachment of the interosseous membrane; 8, head of the ulna; 9, styloid process; 10, shaft of the radius; 11, head of the same; 12, neck; 13, tuberosity; 14, roughened attachment of the terete pronator muscle; 15, carpal extremity of the bone; 16, its styloid process.

<sup>1</sup> Cubitus; *focile majus*; *canna major*.

<sup>2</sup> Olecranon process; *processus anconæus*.

<sup>3</sup> *Processus coronoideus*.



of the position of the olecranon, and curves upward at the apex. Its upper surface forms the lower division of the sigmoid fossa; and its anterior surface slopes downward, and at the base inwardly exhibits a rough area<sup>1</sup> for the attachment of the brachialis muscle.

The **sigmoid fossa**<sup>2</sup> is formed between the olecranon and coronoid process, and conforms to the trochlea of the humerus, with which it articulates. It is semicircular fore and aft, and is divided into two articular facets by a slight transverse ridge extending between a pair of notches. The upper or **olecranon facet** is directed forward, is somewhat cordiform, broader than long, transversely convex, and vertically concave. The lower or **coronoid facet** is horizontal, irregularly transverse oval, inwardly concave, outwardly convex, and fore and aft concave. From the coronoid facet, another, the **radial facet**,<sup>3</sup> extends downward on the outer side of the base of the coronoid process. It is fore and aft irregularly oval and concave, and articulates with the lateral border of the head of the radius. Internally, the sigmoid fossa is bordered by a ridge, which gives attachment to the internal lateral ligament of the elbow-joint, and at its thickened fore part affords an origin to the superficial digital flexor muscle. Elsewhere the margins, contiguous to the sigmoid fossa, are more or less roughened for the attachment of the capsular ligament, and the borders in front and behind the radial articular facet are in like manner roughened for the attachment of the orbicular ligament.

The tapering **distal extremity** of the ulna expands in a rounded eminence, the **head**,<sup>4</sup> from the inner side of which projects the **styloid process**.<sup>5</sup> The head exhibits a smooth convex surface,<sup>6</sup> which is directed outward and forward for articulation with the radius; and is continued beneath, where it is opposed to an interarticular ligament, which separates the head from the cavity of the wrist-joint. Between the articular surface and the base of the styloid process is a pit for the insertion of the ligament. The styloid process is a nipple-shaped prominence, which extends a little lower than the head, and gives attachment to the internal lateral ligament of the wrist. Between it and the head behind is a groove, descending from the back of the shaft, for the passage of the tendon of the ulno-carpal flexor.

The prismatic shaft of the ulna presents three, for the most part, flattened surfaces, defined by three more or less prominent borders.

The **internal border** descends from the inner side of the coronoid process to the fore part of the styloid process, and separates the internal from the anterior surface. For the greater part of its length it is

<sup>1</sup> *Tuberositas ulnæ*; tubercle of the ulna.

<sup>2</sup> *Fossa sigmoidea*; greater sigmoid cavity; *f. sigmoidea major*; *f. semilunaris major*.

<sup>3</sup> Lesser or small sigmoid cavity; *fossa sigmoidea minor*; *incisura semilunaris*; *sinus lunatus*.

<sup>4</sup> *Capitulum*.

<sup>5</sup> *Processus styloideus*.

<sup>6</sup> *Circumferentia articularis*.



obtusely rounded and smooth, and gives attachment to the deep digital flexor muscle; its lower fourth forms the inner limit of a superficial roughened ridge, which gives attachment to the quadrate pronator muscle. The **external border** descends from the back of the radial articular facet to the fore part of the head, separates the anterior from the posterior surface, and gives attachment to the interosseous membrane, which extends between the ulna and radius. Its upper three-fourths are prominent and acute, especially along the middle of the shaft, but the lower part is rounded and scarcely defined. The posterior border descends from the outer margin of the olecranon to the back of the styloid process, and separates the internal from the posterior surface. Its upper three-fourths are acute, and the lower obtuse and scarcely defined.

The **anterior surface** of the ulna, rounded in front above and flattened or slightly depressed along the middle, gives attachment to the deep digital flexor. At its upper part, outwardly, it is concave, and gives attachment to the short supinator muscle; and at its lower fourth is rounded, and marked by a superficial rough ridge, for the attachment of the quadrate pronator. The **internal surface**, slightly concave at its commencement, but slightly convex the greater part of its length and becoming more narrow and rounded below, for its upper three-fourths gives attachment to the deep digital flexor muscle, and is subcutaneous at the lower fourth. The **posterior surface**, at its upper third, presents a triangular concave area, which gives attachment to the anconeus muscle. Below this it is divided by a longitudinal ridge, the narrower area next the posterior border accommodating the ulnocarpal extensor muscle, and the broader depressed one next the external border accommodating the extensor muscles of the thumb.

The ulna has the usual construction of other long bones. Its chief medullary nutritious foramen is situated at the upper third of the anterior surface of the shaft, and has the canal directed upward. Ossification begins near the middle of the shaft about the end of the second month of foetal life. A centre for the lower epiphysis appears about the fifth year, and another for an epiphysis of the extremity of the olecranon about the tenth year; the former uniting with the shaft about the sixteenth year, and the latter about the twentieth year.

#### THE RADIUS.

The **radius**<sup>1</sup> lies to the outer side of the ulna, parallel with it; is more forward, shorter, and articulates with it at both extremities. It is cylindroid, and in greater part trilaterally prismatic, is slightly bowed forward and inward, is smallest at the upper extremity, where it articulates with the humerus, and is largest at the lower extremity,

---

<sup>1</sup> Focile minus; canna minor.



where it articulates with the carpus, and contributes largely to the construction of the wrist-joint.

The upper extremity ends in the **head**,<sup>1</sup> which is a horizontal, circular disk, with a smooth surface above and around the edge, in the recent state invested with cartilage. The upper surface is concave, and articulates with the capitulum of the humerus, and the marginal surface,<sup>2</sup> widest within, articulates with the radial facet of the ulna, and also moves on the orbicular ligament, embracing the head.

Below the head, the contracted cylindrical commencement of the shaft forms the **neck**.<sup>3</sup> Beneath this, inwardly and forward, is a rounded eminence, the **tuberosity**,<sup>4</sup> the back of which is impressed by the insertion of the tendon of the biceps muscle, and is more convex in front, where a synovial bursa is interposed.

The **inner border** of the shaft is prominently acute along the middle of the bone, and gives attachment to the interosseous membrane, and separates the anterior and posterior surfaces. The **outer border**, or **surface**, of the shaft is convex, and for the most part undefined from the anterior and posterior surfaces. Extending from about its middle upward is an oval rough impression, for the insertion of the terete pronator muscle. Its upper third, extending around the front and back, is embraced by the short supinator muscle. On the **anterior surface** an **oblique line** descends from the tuberosity to the middle of the outer border, and gives attachment to the superficial digital flexor. The surface below the ridge to the lowest fourth of the shaft is convex outwardly and depressed inwardly, and affords attachment to the deep digital flexor. Its lowest part is wider and flatter, and gives attachment to the quadrate pronator muscle. The **posterior surface** above forms part of that embraced by the short supinator; along the middle is depressed inwardly, for the attachment of the extensor muscles of the thumb; and below is covered with the extensor tendons directed to the grooves at the lower extremity.

The lower extremity of the radius is the broadest part of the bone, and about as thick as the head; is narrowest outwardly, and is quadrilateral; and terminates in the carpal articular surface and styloid process.

The **carpal articular surface**, directed downward, is concave and triangular, widest transversely, and with its apex extended on the styloid process. It articulates with the scaphoid and semilunar bones of the carpus, and is inwardly defined by a ridge from the **ulnar articular surface**.<sup>5</sup> This is a concave facet on the inner side of the radius for articulation with the head of the ulna; and the ridge between the two surfaces gives attachment to the interarticular ligament, which separates the radio-carpal from the radio-ulnar articulation.

<sup>1</sup> Capitulum.

<sup>2</sup> Circumferentia articularis.

<sup>3</sup> Collum.

<sup>4</sup> Bicipital tuberosity; tuberositas.

<sup>5</sup> Sigmoid cavity; sinus lunatus.



The **styloid process**<sup>1</sup> is a pyramidal downward projection at the outer part of the shaft, which gives attachment at its base to the tendon of the long supinator, and by its apex to the external lateral ligament of the wrist; and outwardly is grooved for the tendons of the extensor muscles of the thumb.

The front of the distal extremity of the radius is defined from the carpal articular facet by a ridge, which gives attachment to the capsular ligament of the wrist. Behind it is prominent, and is traversed by three descending grooves, of which the outer broadest one gives passage to the tendons of the radio-carpal extensors, the inner one to the digital extensor tendons, and the intermediate narrowest one to the tendon of the second pollical extensor.

The radius is constructed like the ulna, and its chief medullary nutritious foramen holds a corresponding position and course. Ossification, likewise, commences as in the ulna. A centre appears for an epiphysis of the distal extremity about the end of the second year, and one for the head in the fifth year. The latter ankyloses with the shaft about the eighteenth year, and the former in the twentieth year.

#### THE HAND.

The **hand**<sup>2</sup> consists of the carpus, the metacarpus, and five digits.

#### THE CARPUS.

The **carpus**,<sup>3</sup> or **wrist**, is composed of eight small bones closely articulated together and ranged in two transverse rows, the upper row articulating with the bones of the forearm, the lower row with the metacarpus. Mostly named from some supposed resemblance, those of the first or upper row, from the outer or radial side inwardly, are the scaphoid, lunar, cuneiform, and pisiform bones, and those of the second or lower row in the same order are the trapezium, trapezoid, magnum, and unciform bones. In common, their posterior or dorsal surface and their anterior or palmar surface is somewhat roughened for ligamentous attachment, while the other surfaces are articular and smooth, and in the recent state are invested with cartilage. The superior articular surfaces are generally convex, the inferior ones concave, and the opposed lateral ones mostly flat.

The **scaphoid bone**,<sup>4</sup> the largest of the first row of the carpus, occupies its outer side. It is somewhat boat-shaped, as expressed by the name, and has its length directed obliquely from behind, forward, downward, and outward. Its narrow end in front forms a blunt tuberosity, to which the anterior annular and external lateral ligaments of the wrist are attached. Its posterior higher and wider extremity ex-

<sup>1</sup> Processus styloideus.

<sup>2</sup> Manus.

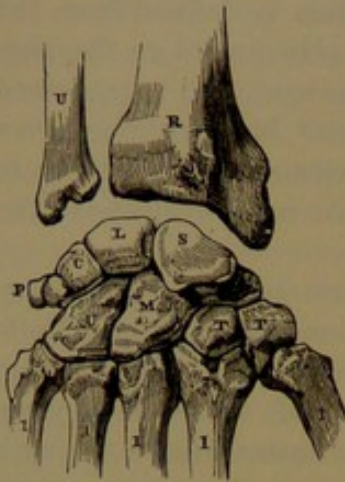
<sup>3</sup> Ossa carpi.

<sup>4</sup> Os scaphoideum; os naviculare.



hibits a trilateral convex facet, directed upward, backward, and outward to articulate with the radius. Inwardly, it has a flat, crescentic facet for the lunar bone, and below the latter a longer concave facet for the magnum. Beneath its anterior extremity it presents a convex surface divided into two facets for the trapezium and trapezoid bones.

FIG. 85.



BONES OF THE CARPUS, and those with which they articulate; right hand, posterior view. Of the upper bones U is the lower end of the ulna, and R is the lower end of the radius. Of the bones of the carpus, in the first row, S is the scaphoid, L the lunar, C the cuneiform, and P the pisiform bone; and in the second row, T T are the trapezium and trapezoid, M the magnum, and U the unciform bones. 1, the metacarpal bones.

The **lunar bone**,<sup>1</sup> succeeding the former inwardly, is crescentic fore and aft, thickest above, and convex where it articulates with the radius, and concave below, and divided into two facets for articulation with the magnum and unciform bones. Outwardly it has a flat crescentic facet for the scaphoid, and inwardly a quadrate facet for the cuneiform bone.

The **cuneiform bone**,<sup>2</sup> next the preceding inwardly, is nearly as large. It is wedge-like, with the base presenting a quadrate facet, which articulates with the lunar bone, and with the apex blunt and forming a tubercle, at the inner border of the wrist, giving attachment to the internal lateral ligament. Upward and backward it presents a convex facet, which enters into the wrist-joint, and is separated from the head of the ulna by the interarticular

ligament. Below and outward it presents the longest facet, which is sinuous, and articulates with the unciform bone. In front of its apex it presents an oval facet, which articulates with the pisiform bone.

The **pisiform bone**,<sup>3</sup> the smallest of the carpus, is oval, and possesses a single oval facet, which articulates in front of the apex of the cuneiform bone.

The **trapezium**,<sup>4</sup> the first bone outwardly of the second row of the carpus, is intermediate to the scaphoid and first metacarpal bone. It is of irregular shape, has its thicker part upward at the outer side of the wrist, and its narrower part directed between the bases of the first and second metacarpal bones. Its fore part presents a laterally compressed tubercle, which affords attachment to the anterior annular ligament, and borders a deep groove within for the tendon of the ulno-

<sup>1</sup> Semilunar bone; os semilunare; os lunare; os lunatum.

<sup>2</sup> Os cuneiforme; os pyramidale; os triangulare; os triquetrum.

<sup>3</sup> Os pisiforme; os orbiculare; os rotundum; os subrotundum.

<sup>4</sup> Os multangulum majus; os rhomboides.



carpal flexor. Upward and inward it presents a concave facet, which articulates with the scaphoid; and below this a surface divided into two facets, which articulate with the trapezoid and second metacarpal bone. Outward and downward it presents its most considerable facet, which is convex fore and aft and concave from side to side, and articulates with the first metacarpal bone.

The **trapezoid bone**,<sup>1</sup> succeeding the former, is the smallest of the second row, and is wedge-like, with its broad extremity forming the dorsal, and its narrow extremity the palmar surface. Its upper surface presents a small quadrate facet for the scaphoid bone; its outer surface, a larger convex facet for the trapezium; its inner surface, a concave facet for the magnum; and its lower surface forms a large facet, fore and aft concave and transversely convex, for articulation with the second metacarpal bone.

The **magnum**,<sup>2</sup> the third bone of the second row, and the largest of the carpus, has an irregular quadrate base below, supporting a rounded head which occupies the centre of the wrist in a concavity formed by the scaphoid and lunar bones. The palmar and dorsal surfaces are large, and occupy the middle of the wrist. The superior convex surface articulates with the scaphoid and lunar bones. The inferior surface of the base is divided into three facets, of which the middle, longer one articulates with the middle metacarpal bone, and the others articulate with the adjacent metacarpals. The inner surface at the base articulates with the trapezoid bone, and above with the scaphoid bone. The outer surface articulates with the cuneiform bone, and is roughened below at the fore part for the attachment of an interosseous ligament.

The **unciform bone**,<sup>3</sup> the second in size, and the last of the second row of the carpus, is remarkable for its conspicuous hook-like process, which is directed forward, and gives attachment to the anterior annular ligament. The dorsal and palmar surfaces are large, and the latter contributes considerably to the anterior concavity of the carpus. The upper part of the bone presents a sinuous surface, which articulates with the lunar and cuneiform bones; its outer surface articulates with the magnum; and the broad base presents two facets, which articulate with the fourth and fifth metacarpal bones.

The bones of the carpus are composed of spongy substance invested with a thin layer of compact substance, which on the dorsal and palmar surfaces exhibits variable, more or less conspicuous nutritious foramina communicating with the interior. At birth they are all in a cartilaginous condition, and each is subsequently ossified from a single centre. Ossification commences in the magnum in the first year, in the unci-

<sup>1</sup> Os trapezoides; os multangulum minus; os pyramidale; os trapezium minus.

<sup>2</sup> Os magnum; os capitatum; capitate bone.

<sup>3</sup> Os unciforme; os hamatum; os cuneiforme.



form in the early part of the second year, in the cuneiform in the third year, in the lunar and trapezium in the fourth or fifth year, in the scaphoid and trapezoid in the sixth year, and in the pisiform from the eighth to the twelfth year.

The carpus, composed of the associated bones above described, forms the basis of the wrist. Its dorsal surface is transversely convex, and its palmar surface is concave. The sides of the concavity are formed externally by the tubercles of the scaphoid and trapezium; internally by the pisiform bone and the hook-like process of the unciform bone. The lateral prominences thus produced give attachment to the anterior annular ligament, which converts the concavity of the carpus into a canal for the passage of the tendons of the flexor muscles accompanied by the median nerve. The upper part of the carpus, composed of the bones of the first row, exclusive of the pisiform bone, is convex, and forms the lower part of the radio-carpal articulation, or wrist-joint. The pisiform holds an advanced position, and is excluded from the joint. The intermediate articulation of the two rows of carpal bones is hinge-like; the first row forming a median concavity, which receives a median convex prominence of the second row, produced by the magnum and unciform bone. The lower border of the carpus forms an uneven, transverse plane articulating with the metacarpus.

#### THE METACARPUS.

The **metacarpus**<sup>1</sup> consists of five bones in a transverse row, extending from the carpus to the digits, and forming the basis of the palm and back of the hand. The **metacarpal bones**<sup>2</sup> are numbered from the outer or radial side, and are designated by number or from the digit appended to each. They are of different lengths, and are slightly bowed with the concavity forward, and their expanded extremities are most produced in front, so as to contribute to the concavity of the palm. Their upper or carpal extremity is also named the **base**,<sup>3</sup> and their lower or digital extremity the **head**.<sup>4</sup> The first metacarpal bone, or that of the thumb, is most unlike the others, is more divergent from the carpus, and has its anterior surface directed inwardly towards the others. The metacarpal bones of the fingers are slightly divergent from the carpus, where they articulate with each other, and they are alike except at the base, which varies in each case.

The metacarpal bones of the fingers are proportionately of more slender proportions than that of the thumb; are longer, have a narrower more cylindrical shaft, and a thicker and more prominent convex head. The shaft is somewhat prismatic and expanded towards the extremities. The **posterior surface** exhibits at the base a narrow ridge, gradually expanding below to the width of the shaft in a nearly flat, triangular

<sup>1</sup> Middle-hand bones.

<sup>3</sup> Basis.

<sup>2</sup> Ossa metacarpi.

<sup>4</sup> Capitulum; caput; condylus.

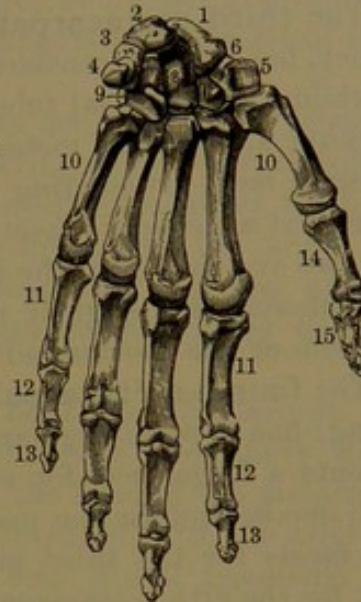


area, which is covered by the expanded extensor tendons as they proceed to the fingers. From the ridge and triangular area the surface slopes away on each side, and is slightly depressed to accommodate the dorsal interosseous muscles. The **anterior surface** presents a slight median ridge, from which the sides incline to the lateral borders for the accommodation of the palmar interosseous muscles. The **base** is irregularly cuboidal, is tuberos and roughened for ligamentous and tendinous attachments, and is furnished with smooth facets, which articulate with the carpus and adjoining metacarpal bones. The **head** is quadrate, depressed at the sides and in front, and ends in a spheroidal eminence which articulates with the first phalanx. The articulating surface is narrow and square behind, widens forward beneath and in front, and in this position is prolonged on a pair of lateral tubercles, upon which the lateral ligaments play in the flexion of the fingers. Behind the lateral depressions of the head is another pair of less prominent tubercles, which give attachment to the lateral ligaments.

The **first metacarpal bone**,<sup>1</sup> or that of the thumb, is shorter and broader than the others, and of more robust proportions. The shaft is fore and aft compressed cylindrical, and more prominent laterally than in the others. Its posterior surface is flattened convex, the anterior surface demi-cylindroid, and slightly more prominent in the median line. The base above presents a large, transversely oval facet, convex from side to side, and slightly concave fore and aft, for articulation with the trapezium. The head is less prominently convex than in the other metacarpals, and is proportionately less thick compared with its width.

The **second metacarpal bone** is the longest of the series, and is otherwise slightly larger than the succeeding ones. The base is divided above by a notch into two lateral angular portions, which are received in corresponding intervals of the trapezium, trapezoid, and magnum. The notch forms the chief carpal facet, is fore and aft convex and transversely concave, and articulates with the trapezoid bone, while the smaller lateral facets articulate with the trapezium and mag-

FIG. 86.



THE LEFT HAND, viewed in front, or on the palmar surface. 1, scaphoid bone; 2, semilunar; 3, cuneiform; 4, pisiform; 5, trapezium; 6, groove in the latter; 7, trapezoid; 8, magnum; 9, unciform; 10, the five metacarpal bones; 11, first row of phalanges of the fingers; 12, second row; 13, last row; 14, 15, phalanges of the thumb.

<sup>1</sup> Os metacarpi pollicis.



num. Another facet on the inner side articulates with the base of the third metacarpal bone. A transverse tubercle in front of the base is the point of insertion of the tendon of the radio-carpal flexor, and a more depressed one, outward and behind, receives the tendon of the longer radio-carpal extensor.

The **third metacarpal bone**, a little shorter and smaller than the former, has its base considerably narrower in front than behind, where it exhibits a pyramidal tubercle<sup>1</sup> fitting into an angular interval of the magnum and second metacarpal bone. The upper surface forms a quadrate facet articulating with the magnum; the outer side presents a fore and aft concave facet for the second metacarpal; and the inner side two oval facets for the fourth metacarpal bone. Below the pyramidal tubercle is a slightly roughened prominence, which receives the insertion of the shorter radio-carpal extensor.

The **fourth metacarpal bone**, shorter and smaller than the preceding, has a more regular quadrate base, the upper part of which presents a large facet for articulation with the unciform bone, and a small one behind for the magnum. On the outer side it presents two oval facets for the third metacarpal, and on the inner side a concave facet for the fifth metacarpal bone.

The **fifth metacarpal bone**, the shortest except that of the thumb, and otherwise the smallest, has the back of the shaft with but one sloping side from the triangular area. The base exhibits a carpal facet, fore and aft convex and transversely concave, for articulation with the unciform bone, and a smaller facet on the outer side for the fourth metacarpal bone. On the inner side it exhibits a low tuberosity, which receives the tendon of insertion of the ulno-carpal flexor.

The metacarpal bones have the same general construction as the larger long bones, and like them include a medullary cavity, which is shortest in the metacarpal bone of the thumb. Usually, a principal medullary nutritious foramen is to be observed in a position related with that in which it exists in larger bones. In the metacarpal of the thumb it occupies the inner side of the shaft below the middle, and is directed downward. In the other metacarpals it usually occupies the outer side of the shaft above the middle, and is directed upward. Not unfrequently, in the second metacarpal, it occupies a position on the inner side, but directed upward.

The shaft of the metacarpals commences ossification near the end of the second month of foetal life, and is ossified throughout at birth. Epiphyses are formed for the base of the first metacarpal and for the head of the other metacarpals from the third to the fifth year, and ankylose with the shaft about adult age.

---

<sup>1</sup> Apophysis pyramidalis; processus styloideus.



## THE DIGITS.

The **digits**<sup>1</sup> succeed the metacarpal bones, with which they articulate, and consist of the **thumb**, or **pollex**,<sup>2</sup> and **fingers**, the latter being named, in order, the **index**,<sup>3</sup> **middle**,<sup>4</sup> **ring**,<sup>5</sup> and **little fingers**.<sup>6</sup> The thumb consists of two bones or phalanges, and in addition includes two little ones named sesamoid bones: the fingers each consist of three phalanges.

The **phalanges**,<sup>7</sup> or **joints**, of the digits are long bones, generally demi-cylindroid, slightly bent forward, tapering below, convex behind, and flattened in front. They end in expanded extremities, most produced forward and laterally, and with the upper one the larger, and named the **base**. In each digit they successively decrease, and are named numerically; and the last one, from its supporting the nail, is also called the **ungual phalanx**.

The **first phalanx**<sup>8</sup> is the longest and otherwise the largest. Its base is transversely rounded rectangular; it is nearly flat above, with a shallow, concave facet for articulating with the head of the metacarpal bone, and forms an obtuse, somewhat roughened, ridge at the sides and front for the attachment of the anterior and lateral ligaments and tendons of the interosseous muscles. The lower extremity is a transverse cylinder, grooved like a pulley, and thus forms a **trochlea** for articulating with the second phalanx. The articular surface is narrow and half oval behind, expands to the width of the trochlea beneath, and ascends higher in front, where it is defined by a transverse, concave margin. At the sides is a slight depression, above and behind which is a tubercle for the attachment of a lateral ligament.

The first phalanx of the thumb is not bent forward, but is even slightly concave in the length behind, instead of convex as in the fingers; and the fore part of the shaft is less expanded and more obtuse at the lateral borders.

The **second phalanx**<sup>9</sup> of the fingers has a transverse oval base ascending from the sides to the middle, and has its articulating surface conforming to the trochlea of the first phalanx, with a pair of shallow concavities separated by a median fore and aft ridge. The shaft and lower extremity are like those of the first phalanx, except that in the former the lateral borders are more strongly impressed for the attachment of the corresponding tendon of the superficial digital flexor.

The **last**, or **ungual phalanx**,<sup>10</sup> has its base like that of the second phalanx of the fingers, but is flat in front to a level with the fore part of the shaft, and roughened for the insertion of the corresponding

<sup>1</sup> Digiti; dactyli.<sup>2</sup> D. secundus; d. index.<sup>3</sup> D. annularis; d. quartus.<sup>4</sup> Nodi; internodia; articuli; condyli.<sup>5</sup> Mescondylus.<sup>6</sup> Digitus primus.<sup>7</sup> D. medius; d. tertius; d. impudicus.<sup>8</sup> D. parvus; d. minimus; d. quintus.<sup>9</sup> Procondylus.<sup>10</sup> Metacondylus.



tendon of the flexor muscle. The shaft is proportionately more tapering than in the other phalanges, is less prominent at the lateral borders, and ends in a discoid expansion<sup>1</sup> with a wide horseshoe-shaped roughness on the front surface.

The phalanges of the middle finger are successively longer than those of the other fingers; those of the index and ring fingers differ but slightly; and those of the little finger are shortest. The first phalanx of the thumb is proportionately the most robust, but is no longer than that of the little finger; the ungual phalanx is the most robust and the longest.

The phalanges have the same construction as other long bones, even to the possession of a medullary cavity. The medullary nutritious foramen, frequently not distinct among other foramina, is commonly situated at the outer border of the front surface, and is directed downward. The development and completion of the phalanges are the same as in the first metacarpal bone.

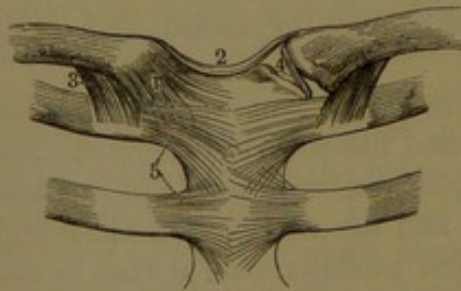
The **sesamoid bones**<sup>2</sup> are two nodules of oval shape with a smooth facet which articulates with the anterior tubercle on each side in front of the metacarpal bone of the thumb.

### ARTICULATIONS OF THE UPPER LIMBS.

The upper limb articulates with the rest of the skeleton only through the sternal extremity of the clavicle, and in such animals as do not possess the latter, as, for example, the horse, it has no ligamentous union with the former.

#### THE STERNO-CLAVICULAR ARTICULATION.

FIG. 87.



STERNO-CLAVICULAR, COSTO-CLAVICULAR, AND COSTO-STERNAL ARTICULATIONS. 1, capsular ligament of the sternoclavicular articulation; 2, interclavicular ligament; 3, costoclavicular ligament; 4, interarticular fibro-cartilage; 5, anterior costo-sternal ligaments.

This is formed by the sternal end of the clavicle in union with the upper lateral angle of the sternum and the contiguous portion of the first costal cartilage. The opposed surfaces of the bones are invested with cartilage, and a disk of fibro-cartilage is interposed, dividing the joint into two synovial cavities. The **interarticular fibro-cartilage**<sup>3</sup> is thickest at the margin, especially above and behind, where it is attached to the clavicle; and below is attached to the junction of the sternum and costal cartilage, and elsewhere

to the enclosing ligaments. A loose **capsular ligament** envelops the joint, connected with the margins of the articular surfaces, and

<sup>1</sup> Tuberositas unguicularis.

<sup>3</sup> Cartilago interarticularis; c. meniscoidea.

<sup>2</sup> Ossa sesamoidea.



strengthened by accessory bands. The two stronger of these are the **anterior** and **posterior sterno-clavicular ligaments**, passing between the bones.

A variable and weaker band, the **interclavicular ligament**,<sup>1</sup> is extended between the clavicles at the upper border of the sternum, to which it is connected. Additional strength is given to the articulation by the **costo-clavicular ligament**,<sup>2</sup> a short, strong band, which ascends from the costal cartilage obliquely outward to the usually well-marked impression beneath the sternal extremity of the clavicle.

The sterno-clavicular articulation is the centre of movement of the upper limb on the trunk, and admits of motion in all directions. The upward and forward movements are limited by the costo-clavicular ligament; the downward and backward movements, by the clavicle coming into contact with the first rib.

#### THE SCAPULO-CLAVICULAR ARTICULATION.

The outer end of the clavicle articulates with the end of the acromion of the scapula, the joint having a synovial cavity enclosed by a capsular ligament, of which two stronger bands passing between the bones above and below form the **superior** and **inferior acromio-clavicular ligaments**. The joint sometimes includes a partial or complete **interarticular fibro-cartilage**. It exhibits limited motion, consisting of gliding of the clavicle on the acromion, and a backward and forward rotation of the scapula.

The articulation of the two bones is greatly strengthened and the motion restrained by the **coraco-clavicular ligament**.<sup>3</sup> This consists of two bands, which ascend from the tuberosity at the root of the coracoid process of the scapula to the rough, oblique impression on the under surface of the acromial end of the clavicle. The bands widen and diverge in their ascent, are united outwardly, and include an angular space inwardly. The ligament especially limits the forward and backward movements of the scapula on the clavicle.

#### THE SHOULDER-JOINT.

This is a ball-and-socket joint, and remarkable for its great range of movement in every direction. It has for its basis the shallow glenoid cavity of the scapula, upon which moves the large hemispherical head of the humerus. The articular surfaces of both bones are invested with cartilage, which becomes thicker from the centre to the circumference in the glenoid cavity, and does the reverse on the head of the humerus. The glenoid cavity is further deepened by the **glenoid ligament**, a prismatic fibro-cartilaginous band attached around the margin of the glenoid cavity and continuous above with the tendon of origin of the longer head of the brachial biceps muscle. The joint is

<sup>1</sup> L. interclaviculare.

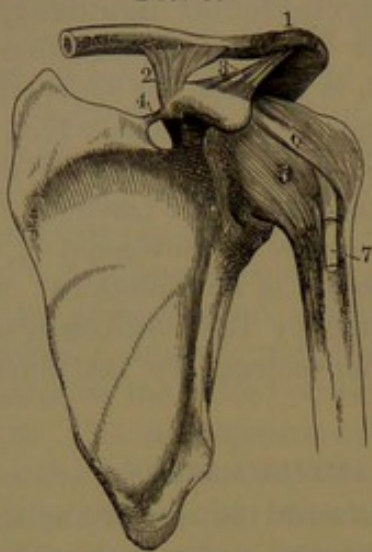
<sup>2</sup> Rhomboid ligament.

<sup>3</sup> L. coraco-claviculare internum et externum; conoid and trapezoid ligaments.



enclosed by a long, loose capsular ligament, attached above to the neck of the scapula adjacent to the glenoid cavity, and below to the neck and

FIG. 88.



SCAPULO-CLAVICULAR AND SCAPULO-HUMERAL ARTICULATIONS. 1, acromio-clavicular articulation, surrounded by its capsular ligament; 2, coraco-clavicular ligament; 3, coraco-acromial ligament; 4, coracoid ligament converting the notch into a foramen; 5, capsular ligament of the shoulder-joint; 6, coraco-humeral ligament; 7, tendon of the brachial biceps muscle.

of the glenoid cavity, descends through the upper part of the joint, and emerges from an aperture of the capsular ligament into the bicipital groove of the humerus. The synovial membrane lines the capsular ligament, invests the glenoid ligament, is reflected in a tubular sheath on the biceps tendon within the joint, and is thence prolonged upon it down the bicipital groove. A synovial bursa between the tendon of the subscapular muscle and the capsular ligament commonly communicates with the synovial cavity of the joint, and sometimes a second one between the infraspinous muscle and the capsular ligament. Greater security is given to the shoulder-joint by the coraco-acromial arch forming the upper part of the shoulder, and composed of the acromion united to the coracoid process by the **coraco-acromial ligament**,<sup>1</sup> which is a strong triangular band attached by its base to the outer border of the coracoid process, and by its apex to the end of the acromion. Between the arch and the supraspinous muscle is placed a synovial bursa.<sup>2</sup>

Motion in the shoulder-joint is limited when the limb is raised from the greater tuberosity coming into contact with the acromion, any further elevation being due to movement in the sterno-clavicular articulation.

<sup>1</sup> L. triangulare; l. triquetrum.

<sup>2</sup> Subacromial bursa.

tuberosities of the humerus. It is thickest above, and is strengthened in this position by the **coraco-humeral ligament**, a broad band, which descends from the outer border of the coracoid process to the front of the greater tuberosity of the humerus. The looseness of the capsular ligament is such that when the surrounding muscles are detached the head of the humerus falls an inch from its articulation with the glenoid cavity. When the limb is in the usual position of rest, the ligament forms a fold at the axillary border of the joint. It is greatly strengthened by the muscles in contact with it, the supraspinous above, the infraspinous and small teres behind, the subscapular in front, and the long head of the triceps beneath. The joint is further strengthened by the tendon of the longer head of the biceps, which starts from the summit



## THE ELBOW-JOINT.

The articulation of the elbow is hinge-like, and in the flexion and extension of the forearm the bones of the latter move upon the humerus; the ulna, with its sigmoid fossa, on the trochlea, and the head of the radius on the capitulum. The ulna moves only in this manner, but in the pronation and supination of the hand, the head of the radius rotates both on the capitulum of the humerus and the radial facet of the ulna. The articular cavity between the humerus and the radius and ulna communicates with that between the latter bones. There is no direct ligamentous attachment between the humerus and radius, but the capsular and external lateral ligaments from the former are connected with the orbicular ligament, which embraces the head of the radius and retains it in position without interfering with its movement of rotation.

The **orbicular ligament**<sup>1</sup> is a strong fibrous band, which passes transversely around and beneath the border of the head of the radius, and is fixed by its ends to the ulna in front and behind the radial articular facet.

The **capsular ligament**<sup>2</sup> of the elbow-joint is attached to the humerus, in front and behind, between the epicondyles, and includes the coronoid and olecranon fossæ; and below it is attached to the coronoid process and olecranon bordering the sigmoid cavity of the ulna, and to the orbicular ligament enclosing the head of the radius. The anterior portion<sup>3</sup> of the ligament is stronger than the posterior portion,<sup>4</sup> and it is reinforced by strong lateral ligaments. The synovial membrane of the joint lines the capsular ligament, invests the coronoid and olecranon fossæ, and extends into the radio-ulnar articulation, where it lines the orbicular ligament to the neck of the radius.

The **internal lateral ligament**<sup>5</sup> is a broad triangular band, with its narrower extremity connected with the fore part of the internal epicondyle, and with its fibres radiating below to be fixed along the inner side of the olecranon and coronoid process.

The **external lateral ligament**<sup>6</sup> is a shorter and narrower band, fixed above to the fore part of the external epicondyle, and radiating below to become continuous with the orbicular ligament surrounding the head of the radius, and to be attached behind to the outer part of the ulna.

In extension of the forearm the fore part of the internal lateral ligament is put on the stretch while the back part is relaxed, and in flexion the condition of the ligament is reversed.

<sup>1</sup> L. orbiculare, annulare, or coronarium.

<sup>2</sup> Membrana sacciformis.

<sup>3</sup> Anterior ligament; l. rectum anticum.

<sup>4</sup> Posterior ligament; l. rectum posticum; l. cubiti posticum.

<sup>5</sup> L. laterale internum.

<sup>6</sup> L. laterale externum; l. brachio-radiale.

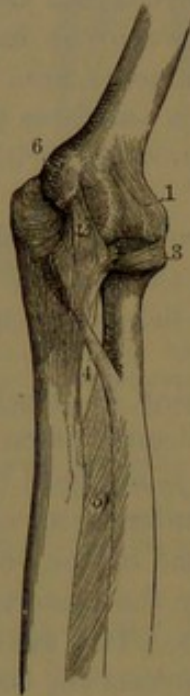

## THE RADIO-ULNAR ARTICULATION.

The **superior radio-ulnar articulation**, formed between the head of the radius and the contiguous radial articular facet of the ulna, forms part with the elbow-joint, as already described.

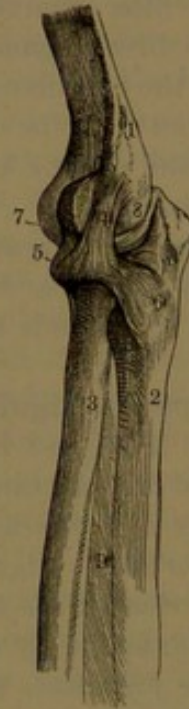The **inferior radio-ulnar articulation**, formed between the ulnar articular surface of the lower extremity of the radius and the head of the ulna, is completely separated from the cavity of the wrist-joint by

FIG. 89.



THE ELBOW-JOINT, LEFT side, viewed antero-internally. 1, the capsular ligament in front; 2, internal lateral ligament; 3, orbicular ligament; 4, oblique ligament; 5, interosseous membrane; 6, internal epicondyle.

FIG. 90.



THE SAME ELBOW-JOINT, viewed externally. 1, external supracondylar ridge of the humerus; 2, ulna; 3, radius; 4, external lateral ligament; 5, 6, orbicular ligament; 7, 8, capsular ligament; 9, interosseous membrane.

a **triangular fibro-cartilage**. This is attached by its apex to the pit beneath the head of the ulna at the root of the styloid process, and by its base to the ridge defining the ulnar articular surface of the radius from the carpal articular surface. The joint is enclosed by a loose **capsular ligament**, which is attached to the roughened borders contiguous to the articular surfaces of the ulna and radius, and to that of the triangular fibro-cartilage. It is strengthened in front and behind by narrow, thin, oblique bands, forming the **anterior** and **posterior ligaments**. It is lined with a synovial membrane, which is usually separate from that of the wrist-joint.

The wide interval of the bones of the forearm is occupied by the **interosseous membrane**,<sup>1</sup> a thin aponeurosis, which is mainly composed of bundles of fibres descending obliquely from the acute inner

<sup>1</sup> Interosseous ligament; membrana interossea; l. interosseum.



border of the radius to the contiguous border of the ulna. While contributing strength to the union of the two bones, by its broad surfaces it affords attachment to the deeper flexor and extensor muscles of the forearm. Above the membrane is a large opening, which permits the play of the tuberosity of the radius in the rotation of the bone on the ulna. The lower margin of the opening formed by the interosseous membrane is commonly reinforced by a narrow band, the **oblique ligament**,<sup>1</sup> which descends from the base of the coronoid process of the ulna to the radius below its tuberosity. Beneath the oblique ligament an aperture in the interosseous membrane gives passage to the posterior interosseous vessels; and another aperture at the lower extremity of the membrane transmits the anterior interosseous vessels to the back of the forearm.

In rotation of the radius it moves on the capitulum of the humerus and on the upper radial articular surface and the head of the ulna, while the latter two bones remain passive. The hand accompanies the movement of the radius, the palm alternately assuming a backward and a forward position, or, in the flexed condition of the forearm, a downward and an upward position. The motion in which the palm is turned downward or backward is called pronation, and is produced by the rotation of the radius inwardly and obliquely across the ulna. The reverse motion, in which the palm is turned forward or upward, is that of supination, and is produced by the rotation of the radius outwardly when it assumes its usual position parallel with the ulna.

#### ARTICULATIONS OF THE HAND.

The **hand**<sup>2</sup> in the ordinary position occupies the same plane as the forearm, and retains this in the rotation of the radius, but in the movement of the wrist-joint may assume a nearly right angle forward or backward, and may bend to a less degree laterally. The dorsal surface of the hand is slightly convex, the palmar surface concave, and becomes so in greater degree in flexion of the fingers. The fore part of the metacarpus forms the basis of the palm or hollow of the hand. The interspaces of the metacarpus, named interosseal, are occupied by the interosseous muscles. When the fingers are flexed and the hand closed, as in the fist, the heads of the metacarpal bones and contiguous bases of the phalanges are rendered prominent as the knuckles, the position of which accords with a flexure or crease at the anterior third of the palm. The fingers may be flexed to nearly a right angle with the metacarpus, but extended only to the same plane; and when extended they are readily moved laterally or from and to one another. The joints or phalanges of the fingers are readily flexed and extended in the same manner as these are on the metacarpus, but have no lateral movement. From the construction of the carpo-metacarpal articulation of the first digit, in

<sup>1</sup> Round ligament; l. obliquum; l. teres; l. cubito-radiale teres; chorda transversalis, transversa, or obliqua.

<sup>2</sup> Manus.



its movements it is rendered readily opposable to the other digits, and is thus distinguished as the thumb, which gives to the hand its quality as a prehensile organ.

All the articulations, including the lower extremities of the bones of the forearm, the carpus, and the base of the metacarpus, appear to

be invested with a common capsular ligament, which is, nevertheless, composed of a number of distinct capsules, more or less blended on account of their proximity to one another.

#### THE WRIST-JOINT.

This is formed by the **radio-carpal articulation**, consisting above of the concave articular surface of the radius continuous with the triangular fibro-cartilage inwardly, and below by the scaphoid, lunar, and cuneiform bones, which together present a continuous convex articular surface. The joint is closed from the radio-ulnar articulation by the intervening fibro-cartilage, and from the intercarpal articulation by short interosseous ligaments between the carpal bones. It is invested with a strong capsular ligament lined by synovial membrane. The capsular ligament is regarded as consisting of the anterior and posterior and two lateral ligaments.

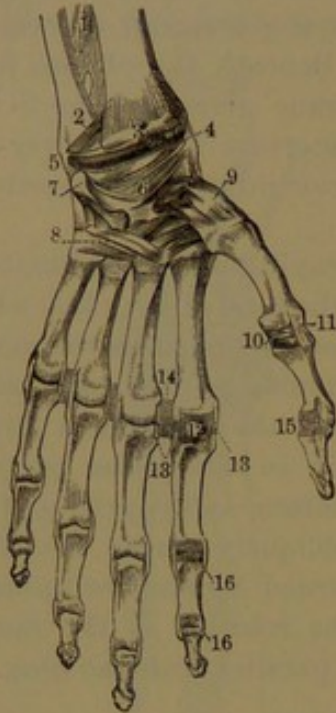
The **external lateral ligament** is a short, thick, half-conoid band, attached by its apex to the styloid process of the radius, and by the base to the outer tuberosity portion of the scaphoid bone, partially extending to the ridge of the trapezium and the anterior annular ligament.

The **internal lateral ligament** is a rounded cord, longer and narrower than the former, attached above to the styloid process of the ulna, and below to the tuberosity inner portion of the cuneiform bone, partially extending to the

pisiform bone and the anterior annular ligament.

The **anterior ligament** is thick and strong, and consists of ob-

FIG. 91.



**LIGAMENTS OF THE WRIST AND HAND, anterior view.** 1, lower part of the interosseous membrane; 2, lower radio-ulnar articulation enclosed by a capsular ligament; 3, fore part of the radio-carpal joint enclosed by a capsular ligament; 4, external lateral ligament of the wrist; 5, internal lateral ligament; 6, palmar portion of the capsular ligament of the carpus; 7, pisiform bone with its capsular ligament; 8, palmar portion of the capsular ligament connecting the carpus with the base of the metacarpus; 9, capsular ligament of the trapezium and metacarpal bone of the thumb; 10, anterior ligament of the metacarpophalangeal articulation of the thumb; 11, external lateral ligament of the same; 12, anterior ligament of the corresponding joint of the index finger, represented as removed in the other fingers; 13, lateral ligaments of the same articulation; 14, transverse ligament connecting the heads of the contiguous metacarpal bones; 15, 16, anterior and lateral ligaments of the phalangeal articulations.



liquely intersecting membranous bands, attached above to the anterior marginal ridge and styloid process of the radius, and fibro-cartilage connecting this with the ulna, and below to the palmar surface of the carpus, mainly to the bones of the first row. The **posterior ligament**, of less strength than the former, likewise consists of intersecting membranous bands, attached above to the posterior marginal ridge of the radius, and the fibro-cartilage connecting this with the ulna, and below to the dorsal surface of the carpus, especially to the bones of the first row.

The radio-carpal articulation permits flexion and extension, abduction and adduction, and also circumduction, but not rotation.

#### THE INTERCARPAL AND CARPO-METACARPAL ARTICULATIONS.

The carpal bones, together with the bases of the metacarpal bones, in their articulation together include three distinct synovial cavities, and occasionally a fourth.

The **principal articular cavity** is formed between the two rows of carpal bones, and between these and the metacarpal bones, exclusive of the pisiform bone and the first metacarpal bone. From between the two rows of carpal bones the cavity extends upward between the scaphoid and lunar bone, and between this and the cuneiform bone; downward between the carpal bones of the second row to the interval between this and the metacarpal bones; and thence downward between the bases of these. The cavity is closed above from the wrist-joint by two short **interosseous ligaments**, connecting the upper contiguous portions of the scaphoid and lunar bone, and of this and the cuneiform bone; and below by three **interosseous ligaments**, connecting the contiguous metacarpal bones. Of three other **interosseous ligaments**, connecting the carpal bones of the second row, a small one is situated between the lower part of the trapezium and trapezoid; a second between the back part of the trapezoid and magnum; and the third and largest in the interval in front of the latter and the unciform bone, and connected with the contiguous portion of the fourth metacarpal bone. Sometimes an interosseous ligament connects the median ridge of the unciform bone below with the contiguous ridge of the fifth metacarpal bone, and separates the cavity between these two bones from the principal one. The joint is invested with a capsular ligament lined throughout with synovial membrane. The capsular ligament is composed of short bands, which pass in different directions between the adjoining bones of the carpus and metacarpus in front and behind, where the bands are named the **palmar** and **dorsal ligaments**. Thus they are extended transversely between the bones of each row of the carpus, and between the bases of those of the metacarpus, and longitudinally and obliquely between the two rows of carpal and the metacarpal bones. The transverse ligaments are stronger than the others, and the dorsal ligaments are also generally stronger than the palmar ligaments. **Lateral ligaments**, continuous with those of the



wrist-joint, occupy the sides of the carpus; the internal extending from the cuneiform to the unciform bone, partially to its unciform process and to the base of the last metacarpal bone; the external, from the scaphoid to the trapezium, and partially extended to the base of the first metacarpal bone.

The pisiform bone forms an independent articulation with the cuneiform bone, the opposed surfaces being invested with cartilage, and the joint enclosed with a thin, loose capsular ligament. This is strengthened by a dorsal and a palmar band, and the articulation is further secured by the partial attachment of the internal lateral ligament of the wrist to the pisiform bone and annular ligament; and by two additional bands extending from the pisiform bone to the process of the unciform bone and to the base of the fifth metacarpal bone.

The metacarpal bone of the thumb likewise forms an independent articulation with the trapezium; the joint being enclosed in a loose capsular ligament extended between the roughened adjacent surfaces of the two bones, and lined by synovial membrane.

The articulation between the two rows of carpal bones admits of considerable motion, contributing to the capability of flexion and extension of the hand. The movements of the other articulations of the carpal bones with each other and with the metacarpus are of a very limited character, except that between the trapezium and the first metacarpal bone, which especially provides for the flexion and extension and abduction and adduction of the thumb.

#### THE METACARPO-PHALANGEAL AND THE PHALANGEAL ARTICULATIONS.

The articulation between the fingers and the metacarpus is formed between the head of the metacarpal bones and the base of the first phalanges. The opposed surfaces of the bones are invested with cartilage, and each joint is enclosed in a capsular ligament lined with synovial membrane, and greatly strengthened fore and aft by the closely-applied flexor and extensor tendons, and laterally by the attachment of the tendons of the interosseous muscles.

The **lateral ligaments** are strong rounded bands, one on each side, attached above to the posterior tubercle of the head of the metacarpal bone, and below to the ridge at the side of the base of the first phalanx. In flexion of the joint they move on the anterior articular tubercles, and become tightly stretched. The **anterior ligament** is a fibro-cartilaginous band intimately connected with the former, and grooved in front for the passage of the flexor tendons to the phalanges. It is thin above, where it is connected with the metacarpal bone, and gradually thickens below to its attachment with the base of the phalanx. The posterior portion of the capsular ligament is a thin layer of connective tissue, and is mainly substituted by the adjacent extensor tendon passing over the joint. The synovial membrane lining the cap-



sule is reflected upward in front between the articular tubercles of the head of the metacarpal bone. The anterior ligaments of the metacarpo-phalangeal articulations are united in the intervals by strong bands, the **transverse ligaments**.

The movements in the metacarpo-phalangeal articulations are those of flexion and extension and abduction and adduction of the fingers.

The articulations between the phalanges are formed by the trochlea of the bones above with the paired concave surface of the bones below, and are provided with ligaments closely according with those of the metacarpo-phalangeal articulations. The phalangeal articulations are hinge-like joints, and admit only of flexion and extension.

### BONES OF THE LOWER LIMBS.

The lower limbs, succeeding the bottom of the trunk, consist each of the thigh, the leg, and the foot. The hip-bone, which together with its fellow and the sacrum forms the pelvis, is an element of the lower limb. The thigh has a single bone, the femur; and another, the patella, occupies the front of the knee. The leg has two bones, the tibia and fibula; and the foot is composed of three parts, corresponding with those of the hand: the tarsus with seven bones; the metatarsus of five bones; and the five digits, each with three phalanges, except the first, which, like the thumb, has two phalanges, and in addition a pair of sesamoid bones.

#### THE HIP BONES.

The **hip, haunch, or innominate bone**<sup>1</sup> forms part of the pelvis, and holds the same relation to the lower limbs that the scapula does to the upper limb. It is immovably articulated with the sacrum behind and with its fellow in front, and just in advance of its middle outwardly it forms the socket of the hip-joint. It is a large, broad, thick bone, constricted at the middle, and in shape has the outline of a figure of eight. It is usually described in three parts, named the ilium, ischium, and pubis, corresponding with the separation of the bone in infancy into three principal portions, which subsequently become completely ankylosed.

The **ilium**<sup>2</sup> is the upper and largest portion of the hip-bone, and is situated below the lateral wall of the abdomen. It is a broad plate, which inclines from the rest of the bone upward, outward, and backward, and terminates above in an expanded and thickened border, the **crest**.<sup>3</sup> This is subcutaneous, and produces the prominence of the hip. It is semicircular and sigmoid in its course, curving inward at the fore part and outward at the back part. It is rounded, and is roughened for the attachment of the abdominal and erector spinal muscles. It is thicker at the extremities, and especially back of the

<sup>1</sup> Os innominatum, coxæ, anonymum, or pelvis lateralis; pelvic bone.

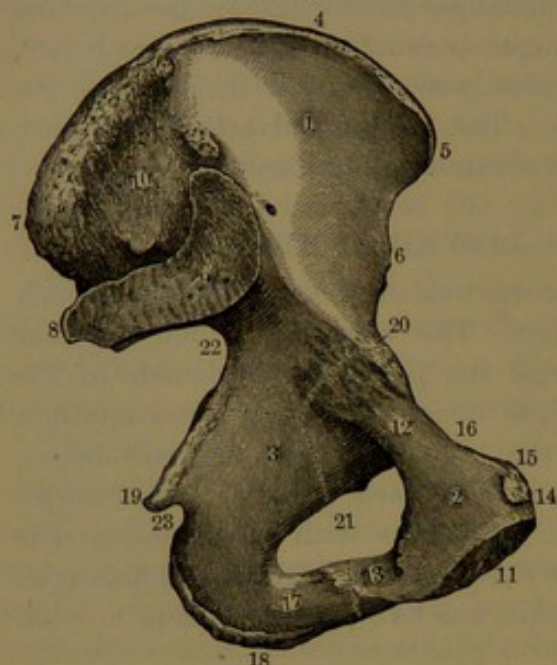
<sup>2</sup> Os ilium, ilei, or ilion; haunch or hip-bone.

<sup>3</sup> Crista ilei.



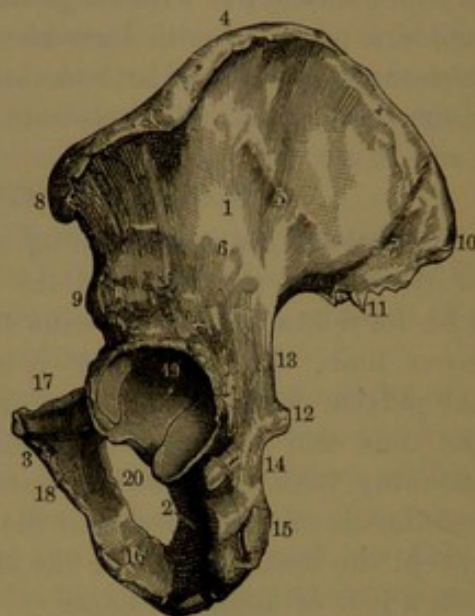
anterior fourth, where it forms a variable angular prominence directed outward. The projecting ends of the crest and a similar pair of processes below, separated from the former by a notch, are named the **iliac spines**,<sup>1</sup> of which the anterior are more prominent and tuberosus than the posterior. The **anterior superior spine**<sup>2</sup> gives

FIG. 92.



INNER VIEW OF THE LEFT HIP-BONE. The dotted line indicates its division into three parts: 1, the ilium, 2, the pubis, and 3, the ischium. (1, iliac fossa:) 4, crest of the ilium; 5, 6, anterior superior and inferior spines; 7, 8, posterior superior and inferior spines; 9, articular surface for the sacrum; 10, rough surface for the attachment of ligaments. (2, body of the pubis:) 11, symphysis; 12, horizontal, and 13, descending ramus; 14, pubic crest; 15, pubic spine; 16, pectineal line. (3, plane of the ischium:) 17, ramus of the ischium; 18, tuberosity; 19, spine of the ischium; 20, ilio-pubic eminence; 21, obturator foramen; 22, great sciatic notch; 23, small sciatic notch.

FIG. 93.



OUTER VIEW OF THE LEFT HIP-BONE. 1, ilium; 2, ischium; 3, pubis. (1, dorsal surface of the ilium:) 4, crest of the ilium; 5, 6, 7, middle, inferior, and superior curved lines; 8, 9, anterior superior and inferior spines; 10, 11, posterior superior and inferior spines. (2, body of the ischium:) 12, spine of the ischium; 13, great sciatic notch; 14, small sciatic notch; 15, tuberosity of the ischium; 16, ramus of the ischium. (3, body of the pubis:) 17, horizontal ramus of the pubis; 18, descending ramus; 19, acetabulum; 20, obturator foramen.

attachment to Poupart's ligament and the sartorius tendon; the **anterior inferior spine**<sup>3</sup> to the ilio-femoral ligament and femoral rectus tendon; and the corresponding posterior spines to the posterior sacro-iliac and great sacro-sciatic ligaments. Below the anterior inferior spine, extending over the acetabulum to the pubis, is a concave notch, which accommodates the ilio-psoas muscle; and below the **posterior inferior spine**<sup>4</sup> is a deep concavity, the **great sciatic notch**,<sup>5</sup> which extends to the spine of the ischium.

The inner surface of the ilium is divided into three unequal portions. Of these the upper anterior is the **iliac fossa**, a broad, smooth,

<sup>1</sup> Spinous processes.<sup>2</sup> Anterior superior spinous process.<sup>3</sup> Ant. inferior sp. pr.<sup>4</sup> Post. inf. sp. process.<sup>5</sup> Incisura ischiadica major.



shallow concavity, which forms the lateral wall of the upper part of the pelvis. It commences above at the iliac crest, and converges below to the notch within the position of the anterior inferior spine. The back portion of the inner surface is an irregular vertical plane, at the fore part of which is the **sacral articular surface**,<sup>1</sup> reniform in outline and uneven. Behind the articular surface, the area extending to the iliac crest is more uneven, and gives attachment to the posterior sacro-iliac ligament. The third and smallest portion of the inner surface of the ilium forms part of the pelvic cavity, and is separated from the iliac fossa by a ridge, which is part of the ilio-pectineal line.

The **outer surface**, or **dorsum**, of the ilium looks obliquely outward, backward, and downward, and forms the basis of attachment of the buttock. It is bent in the course of the crest, and is crossed by three feebly-marked lines,<sup>2</sup> which define the spaces of attachment of the gluteus muscles. The **superior curved line**<sup>3</sup> is the shortest, and proceeds from about the posterior fourth of the iliac crest backward and downward to the great sciatic notch. The **middle curved line**, the longest and usually best marked, proceeds from near the anterior part of the iliac crest to the upper part of the great sciatic notch. The **inferior curved line** proceeds from the notch between the anterior iliac spines to the fore part of the great sciatic notch. To the outer side of the anterior inferior spine a shallow groove curves backward above the acetabulum for the attachment of a tendon of the femoral rectus muscle.

The **ischium**<sup>4</sup> occupies a position beneath the ilium and pubis, and is hook-shaped, with the thicker portion, or **body**, behind, and the narrower portion, or **ramus**, turning up in front to join the descending ramus of the pubis. The body above joins the ilium and pubis in the construction of the acetabulum, and below the latter is produced in a conspicuous prominence, the **tuberosity**.<sup>5</sup> This presents outwardly an uneven convex surface, elliptical in outline, widest above and behind, and tapering beneath to the ramus. The upper part of the surface exhibits two impressions, of which the higher and more anterior gives origin to the semimembranosus muscle, and the succeeding one to the semitendinosus and femoral biceps muscles. The lower part of the tuberosity gives origin to the great adductor muscle, and its inner prominent lip affords attachment to the great sacro-sciatic ligament.

Internally, the body of the ischium presents a deep vertical plane, bent a little forward behind, and forming the chief part of the lateral wall of the pelvic cavity. From its back, inner border, near the middle, projects a compressed angular process, the **ischial spine**,<sup>6</sup> which forms

<sup>1</sup> Auricular surface.

<sup>2</sup> Lineæ arcuatæ.

<sup>3</sup> L. arcuata externa; l. semicircularis.

<sup>4</sup> Os ischii; o. coxendicis; o. sedentarium; seat-bone; hip-bone; knuckle-bone; pin-bone; chance-bone.

<sup>5</sup> Tuberositas, or tuber ischii.

<sup>6</sup> Spina ischii.



the lower limit of the great sciatic notch, and gives attachment to the small sacro-sciatic ligament. Below the spine, between it and the ischial tuberosity, is a concavity, the **small sciatic notch**,<sup>1</sup> which is transversely convex and slightly grooved for the play of the tendon of the internal obturator muscle.

The back of the ischium above the tuberosity is a convex surface behind the acetabulum and bordering the great sciatic notch. The outer surface of the ischium below the acetabulum extends to the lower end of the tuberosity, and borders the lower part of the obturator foramen.

The **ramus of the ischium**<sup>2</sup> is a flattened bar, ascending obliquely forward from the tuberosity to join the descending ramus of the pubis. Its outer or back border is acute, and contributes to form the obturator foramen. Its inner or front border is thickened, and more or less everted and roughened, for the attachment of the crus of the cavernous body of the penis.

The **pubis**<sup>3</sup> occupies a position in advance of the ilium and in advance of and above the ischium, and articulates with its fellow in the symphysis. It is the smallest of the three portions of the hip-bone, and consists of a broader intermediate body, with a horizontal and a descending ramus. The **body** is a thick quadrate plate, slanting from above downward and backward. Its posterior surface looks backward and upward, is smooth, and forms part of the anterior wall of the pelvic cavity. The anterior surface looks downward and outward, is depressed, and gives origin to muscles. The upper border is thickened and convex, and is everted so as to form a transverse obtuse ridge, the **pubic crest**,<sup>4</sup> the inner end of which, with the anterior border of the pubis, forms the **pubic angle**, and the outer, more prominent end forms the **pubic spine**.<sup>5</sup> The inner border of the pubis is thick, roughened, and somewhat projecting behind. Internally it exhibits a vertical, elliptical articular facet, which is uneven, and is united with that of the opposite pubis by fibro-cartilage, together forming the **pubic symphysis**.<sup>6</sup>

The **horizontal ramus**<sup>7</sup> proceeds directly outward from the body to join the ilium and ischium, with which it contributes to form the acetabulum. It is prismatic, and expands outwardly to its junction with the ilium, with which it forms the **ilio-pubic eminence**,<sup>8</sup> a conspicuous convex prominence above the fore part of the acetabulum. The upper surface of the ramus forms a transversely concave triangle, with the pubic spine as its apex and the ilio-pubic eminence as its base. It slopes from behind downward and forward, and is bounded in front

<sup>1</sup> Incisura ischiadica minor.

<sup>3</sup> Os pubis; o. pectinis; pubic bone; share-bone.

<sup>5</sup> Tuberculum pubis.

<sup>6</sup> S. pubis.

<sup>8</sup> Tuberculum ilio-pubicum; ilio-pectineal eminence.

<sup>2</sup> Ramus ascendens.

<sup>4</sup> Crista pubis; pecten.

<sup>7</sup> Body of the pubis.



by an obtuse ridge, which proceeds from the pubic spine to the anterior border of the acetabulum; and behind is defined by a more acute ridge, the **pectineal line**,<sup>1</sup> which proceeds from the pubic spine outward and backward to become continuous with a ridge of the ilium, forming together the **ilio-pectineal line**.<sup>2</sup> The posterior surface of the ramus below the pectineal line forms part of the pelvic cavity. The inferior surface forms the upper part of the obturator foramen, and is outwardly grooved obliquely for the accommodation of the obturator vessels and nerve.

The **descending ramus**<sup>3</sup> of the pubis, shorter than the other, is prolonged from the body downward and outward to join the ascending ramus of the ischium, to which it conforms in shape. The outer border of the pubis between its rami is narrow, and forms the upper anterior portion of the obturator foramen.

The **acetabulum**,<sup>4</sup> or socket of the hip-joint, is situated at the outer part of the hip-bone, in the thickest portion of which it appears as a large hemispherical excavation, looking outward, downward, and forward. It is bounded by a prominent acute border, which is interrupted at its inner part by the **cotyloid notch**<sup>5</sup> communicating with an irregular fossa<sup>6</sup> at the bottom of the acetabulum. The surface of the latter extending to the notch and embracing the fossa is smooth, and is invested with cartilage. The fossa accommodates a cushion of connective and adipose tissue, and the sides of the communicating notch give attachment to the round ligament of the hip-joint. The upper outer portion of the acetabulum, comprising two-fifths, is formed by the ilium, the lower portion about the same extent by the ischium, and the remaining front portion by the pubis. Before ankylosis of the three pieces of the hip-bone, their conjunction in the acetabulum appears as a triradiate fissure occupied by cartilage, but in the mature bone the fissure is commonly completely obliterated.

Traces of the original separation of the three pieces of the hip-bone are frequently to be observed as slightly roughened lines crossing the ilio-pubic eminence, and internally at the conjunction of the ilium, ischium, and pubis.

At the fore part of the hip-bone is a large opening, the **obturator foramen**,<sup>7</sup> which is formed by the pubis and ischium. In the male it is obliquely ovoid, with the broader pole upward and forward between the rami of the pubis, and the narrow pole directed to the lower end of the ischial tuberosity. In the female the foramen commonly appears proportionately shorter and wider and more triangular in shape, with the base of the triangle between the rami of the pubis.

In accordance with the ordinary sexual differences, the hip-bone

<sup>1</sup> Linea pectinea; l. arcuata.

<sup>2</sup> Linea ilio-pectinea.

<sup>3</sup> Ramus of the pubis.

<sup>4</sup> Cotyloid cavity; cotyle.

<sup>5</sup> Incisura acetabuli.

<sup>6</sup> Fossa acetabuli.

<sup>7</sup> F. obturatorium, or obturatum; f. ovale.



of the female is of more delicate proportions, less thick and strong, and less marked by muscular attachments than in the male. In addition it presents other differences peculiar but variable. Commonly, the ilium is of greater proportionate breadth but less depth, more extended outwardly, with the iliac fossa more shallow, and the great sciatic notch wider. The body of the ischium is shorter, its inner surface more vertical, its spine less bent forward, and the ramus narrower, flatter, and more tapering. The body of the pubis is of less depth but greater width; the horizontal ramus is longer and narrower, and the descending ramus more tapering. The obturator foramen is shorter and is wider above, so as to assume a triangular shape with rounded angles. The acetabulum is further removed outwardly from the position of the symphysis.

The hip-bone is the thickest of the broad bones, and like the others is composed of interior spongy substance invested with plates of compact substance. At the central part of the iliac fossa the bone is thinnest, and in this position is frequently devoid of spongy substance and is translucent. It is likewise thin at the bottom of the acetabulum. It is most conspicuously porous and roughened contiguous to the iliac crest, the margin of the acetabulum, and the pubic symphysis. More conspicuous nutritious foramina are observed in these positions, but several of the largest are commonly to be seen at the back part of the iliac fossa, on the dorsum of the ilium and on the inner surface of the body of the ischium.

The hip-bone is developed from three primary centres, of which that of the ilium appears about the end of the second month of the foetus, that of the ischium in the third month, and that of the pubis in the fourth month. At birth the three pieces are conjoined by cartilage in the position of the acetabulum, and the ramus of the ischium is united in the same manner to the descending ramus of the pubis. The pieces continue to grow until about the eighth year, when the ramus of the ischium becomes ankylosed with the descending ramus of the pubis; but all remain connected in the acetabulum through a triradiate cartilage. This commences to ossify, about puberty, in three points which, together with the three chief pieces of the bone, become ankylosed about the eighteenth year. After puberty osseous epiphyses make their appearance in the cartilaginous crest of the ilium, on the anterior superior and inferior iliac spines, the ischial tuberosity, and on the pubic symphysis and spine, and these coalesce with the rest of the bone from about the time of adult age to twenty-five years.

#### THE PELVIS.

The hip bones, together with the sacrum, including the coccyx, compose the **pelvis**,<sup>1</sup> which forms the basin-like lower portion of the trunk.

---

<sup>1</sup> Gr. *pelus*, a basin.



In the erect position of the body the pelvis is bent obliquely backward from the vertebral column above, so that the crest of the pubis descends nearly to a level with the end of the sacrum. It is divided into two parts by a prominent rim, named the **brim of the pelvis**,<sup>1</sup> which is formed on each side by the ilio-pectineal line continued behind the crest of the pubis and by the curved ridge and promontory of the sacrum. The upper part<sup>2</sup> is formed by the ilia, and includes the widest space of the pelvis, which pertains to the abdominal cavity. The lower

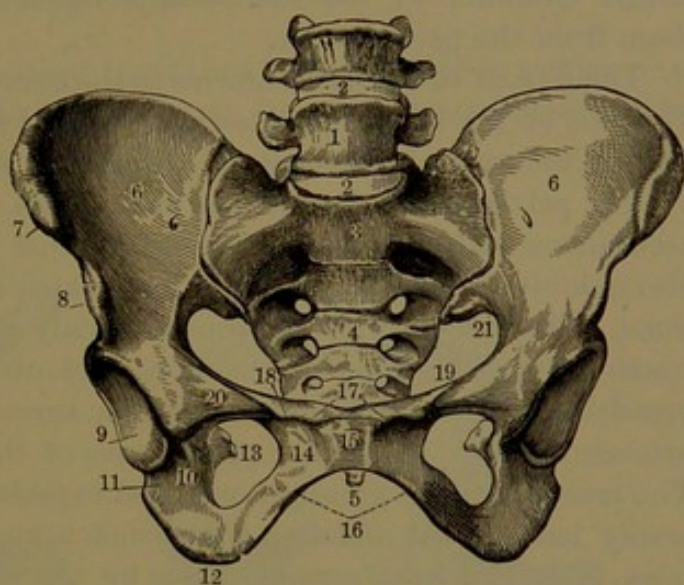
part is distinguished as the **true pelvis**,<sup>3</sup> and encloses the **cavity of the pelvis**. It is a complete bony girdle, formed by the sacrum and coccyx, the ischium and pubis, and a small portion of the ilium. The upper extremity of the pelvic cavity, corresponding with the brim, is the **inlet**, or **superior strait**;<sup>4</sup> the lower extremity is the **outlet**, or **inferior strait**.<sup>5</sup>

In consequence of the curvature of the sacrum and coccyx, the pelvic cavity appears as a curved cylinder, slightly narrowed to-

wards the outlet. It is longest behind, and shortest at the pubic symphysis. Its lateral wall is deep and vertical, and constitutes the **plane of the ischium** of the obstetrician. It extends from the ilio-pectineal line to the end of the ischial tuberosity, and is mainly formed by the body of the ischium with small portions of the ilium and pubis.

The pelvic inlet is cordiform, with the notched base conforming with the base of the sacrum, and the rounded apex with the pubes. Its transverse diameter is greater than that fore and aft, and its plane inclines forward and downward at an angle of about sixty degrees.

FIG. 94.



FRONT VIEW OF A FEMALE PELVIS. 1, last lumbar vertebra; 2, intervertebral ligaments; 3, sacrum, the figure being placed below its promontory; 4, transverse lines indicating the original separation of the sacrum into five vertebral segments; 5, end of the coccyx; 6, iliac fossa; 7, 8, anterior superior and inferior spines; 9, acetabulum; 10, cotyloid notch; 11, body of the ischium; 12, tuberosity of the ischium; 13, spine of the ischium, seen through the obturator foramen; 14, body of the pubis; 15, symphysis of the pubes; 16, arch of the pubes; 17, crest of the pubes; 18, spine of the pubis; 19, pectineal line; 20, ilio-pubic eminence; 21, great sacro-sciatic notch.

<sup>1</sup> Linea innominata; l. terminalis; labrum pelvis.

<sup>2</sup> Superior, greater, or false pelvis.

<sup>3</sup> Pelvis vera; p. minor; inferior pelvis.

<sup>4</sup> Apertura pelvis superior; angustia abdominalis.

<sup>5</sup> A. p. inferior; exitus pelvis; angustia perinealis.



The outlet, rather smaller than the inlet, when completed by the great sacro-sciatic ligaments, has the same shape, with the notched base formed by the coccyx and the apex by the pubic symphysis. Its fore part is the **pubic arch**,<sup>1</sup> the base of which extends between the ischial tuberosities; and the sides are formed by the conjoined rami of the pubes and ischia. On each side of the outlet is the deep **sacro-sciatic notch**,<sup>2</sup> formed in front by the ischium, above by the ilium, and behind by the sacrum and coccyx. It is converted into the great and small sciatic foramina by the sacro-sciatic ligaments, which also separate them from the pelvic outlet.

The axis of the pelvis conforms to the curvature of the pelvic cavity. The axis of the inlet is directed upward and forward to the umbilicus; that of the outlet is directed downward and forward.

The pelvis of the female not only differs from that of the male in accordance with the usual difference in other parts of the skeleton, but also exhibits important modifications which relate to the sexual functions. The female pelvis is proportionately larger, but of more delicate construction. It is proportionately, and often absolutely, of greater breadth, and is of less depth. The ilia spread more laterally, so as to produce greater breadth or prominence of the hips than in the male. The true pelvis has greater horizontal capacity, less depth, and is commonly less curved and less contracted approaching the outlet. The inlet is larger, less intruded upon by the sacral promontory, and is more circular or transversely oval. The outlet is likewise larger, with the ischial tuberosities less convergent, and with the pubic arch wider, lower, more truly arched, and with the sides more everted.

In the male the sides of the pubic arch are much stouter than in the female, and are strongly ridged at the anterior border for the attachment of the crura of the penis. In the female they are narrower, more flattened, and less ridged for the attachment of the clitoris.

Great variability exists in the size and conformation of the pelvis in different individuals, as well as sexes. Several dried and usually well-proportioned male and female pelvises exhibit the following range of measurements:

	Male.	Female.
Breadth of pelvis at iliac crests . . . . .	10 to 11 $\frac{5}{8}$ in.	9 $\frac{1}{4}$ to 11 $\frac{3}{4}$ in.
Fore and aft diameter of inlet . . . . .	4 " 4 $\frac{1}{4}$ "	4 $\frac{1}{8}$ " 5 "
Transverse diameter of inlet . . . . .	4 $\frac{5}{8}$ " 5 $\frac{1}{8}$ "	5 $\frac{1}{4}$ " 5 $\frac{3}{4}$ "
Oblique diameter of inlet . . . . .	5 " 5 "	5 $\frac{1}{8}$ " 5 $\frac{1}{2}$ "
Depth of pelvic cavity behind . . . . .	4 $\frac{1}{2}$ " 4 $\frac{3}{4}$ "	4 $\frac{1}{4}$ " 4 $\frac{3}{4}$ "
Depth of pelvic cavity laterally . . . . .	4 $\frac{1}{4}$ " 4 $\frac{5}{8}$ "	3 $\frac{1}{2}$ " 3 $\frac{3}{4}$ "
Depth of pelvic cavity in front . . . . .	1 $\frac{3}{4}$ " 2 "	1 $\frac{5}{8}$ " 1 $\frac{7}{8}$ "
Fore and aft diameter of outlet . . . . .	3 $\frac{1}{2}$ " 4 $\frac{1}{2}$ "	3 $\frac{1}{2}$ " 5 "
Transverse diameter of outlet . . . . .	3 $\frac{1}{8}$ " 4 "	3 $\frac{3}{4}$ " 5 "

<sup>1</sup> Arcus pubis.

<sup>2</sup> Incisura sacro-ischiadica.



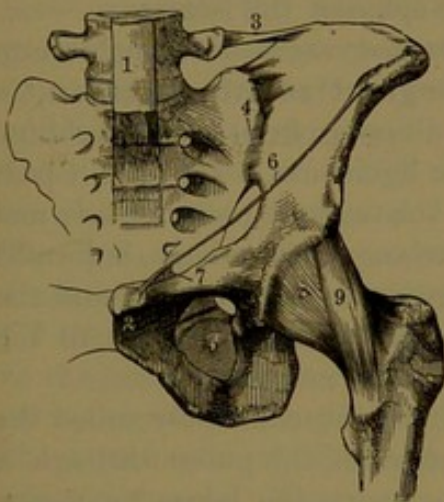
## ARTICULATIONS OF THE PELVIS.

The hip bones are immovably articulated with the sacrum and with each other, forming the sacro-iliac articulation on each side behind, and the pubic articulation in front.

The **sacro-iliac articulation** or **symphysis** is formed by the lateral articular surface of the sacrum with the corresponding surface of the ilium, each being covered by a thin plate of fibro-cartilage. The articulation is enclosed by ligamentous bands, which form the sacro-iliac ligaments.

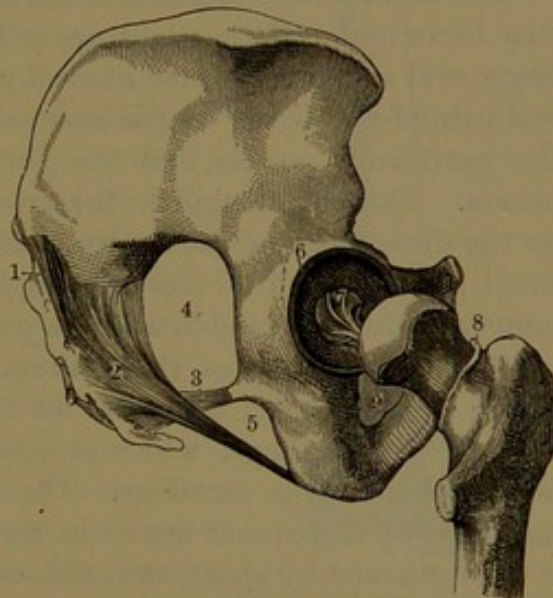
The **anterior sacro-iliac ligament**<sup>1</sup> is thin, and is composed of short fibrous bands, which pass between the contiguous bones in front of the articulation.

FIG. 95.



LIGAMENTS OF THE PELVIS AND HIP-JOINT. 1, lower part of the anterior vertebral ligament; 2, pubic symphysis; 3, ilio-lumbar ligament; 4, sacro-iliac symphysis, with the anterior sacro-iliac ligament; 5, obturator membrane; 6, edge of the tendon of the external oblique muscle of the abdomen, named Poupart's ligament; 7, extension of the latter along the pectineal line named Gimbernat's ligament; 8, capsular ligament of the hip-joint; 9, ilio-femoral ligament.

FIG. 96.



LIGAMENTS OF THE PELVIS AND HIP-JOINT. 1, posterior sacro-iliac ligament; 2, great sacro-sciatic ligament; 3, small sacro-sciatic ligament; 4, great sciatic foramen; 5, small sciatic foramen; 6, cotyloid ligament surrounding the border of the acetabulum; 7, round ligament; 8, cut edge of the capsular ligament; 9, obturator membrane.

The **posterior sacro-iliac ligament**,<sup>2</sup> much thicker and stronger than the former, is composed of numerous fibrous bands, which pass between the contiguous bones in the deep interval behind the articulation. Several of the bands extend between the iliac crest and the irregular surface behind the sacrum, and others descend obliquely from the posterior iliac spines to the latter.

<sup>1</sup> L. sacro-iliacum anterius; l. pelvis anticum.

<sup>2</sup> L. sacro-iliacum posterius; l. sacro-iliacum longum et breve; l. ilio-sacrale interosseum.



The sacro-iliac articulation is further greatly strengthened by the ilio-lumbar and sacro-sciatic ligaments.

The **ilio-lumbar ligament**<sup>1</sup> is a strong band which proceeds from the end of the transverse process of the last lumbar vertebra to the contiguous portion of the crest of the ilium, the base of the sacrum, and the anterior sacro-iliac ligament.

The **great sacro-sciatic ligament**<sup>2</sup> springs by a broad expansion from the posterior inferior iliac spine and the margin below of the sacrum and coccyx, and thence converges to a strong band, which descends obliquely outward to be attached by a narrow expansion along the inner lip of the ischial tuberosity to the pubic arch.

The **small sacro-sciatic ligament**<sup>3</sup> springs in advance of the former in close connection with it from the margin of the sacrum and coccyx, and thence converges to a strong band, which proceeds outward and forward to be inserted into the spine of the ischium.

The sacro-sciatic ligaments convert the deep sacro-sciatic notch into two foramina. Of these the upper is the **great sciatic foramen**,<sup>4</sup> a large, oval aperture, formed above by the ilium, in front by the ischium, and behind and below by the sacro-sciatic ligaments. Through it pass the piriformis muscle, and the gluteal, sciatic, and pudic vessels and nerves. The **small sciatic foramen**,<sup>5</sup> triangular in shape, is formed by the divergence of the sacro-sciatic ligaments from behind and the small sciatic notch of the ischium in front. It gives passage to the internal obturator tendon and the pudic vessels and nerves.

The **articulation of the pubes**. This joint, commonly called the **pubic symphysis**,<sup>6</sup> is formed by the union of the pubes through a disk of fibro-cartilage, which is connected with the bones by means of a lamina of true cartilage. The disk has a disposition to divide, as indicated by a frequent fissure in its upper back part. The symphysis is strengthened by short, thin fibrous bands passing between the pubes, and named the **pre-, post-, supra-, and subpubic ligaments**, the last being the strongest, and rounding off the summit of the pubic arch.

The **obturator membrane**<sup>7</sup> closes the obturator foramen, except at its upper outer part, where it leaves a considerable aperture for the passage of the obturator vessels and nerve. It resembles the interosseous membrane of the forearm, and like it affords an attachment to muscles.

#### THE FEMUR.

The **femur, or thigh-bone**,<sup>8</sup> is the largest and longest bone of the skeleton, and the only one of the thigh. In the erect position of the

<sup>1</sup> L. ileo-lumbale.

<sup>2</sup> L. sacro-ischiaticum majus; l. sacro-tuberosum; l. pelvis posticum magnum.

<sup>3</sup> L. sacro-ischiaticum minus or internum; l. sacro-spinosum; l. pelvis posticum parvum.

<sup>4</sup> F. ischiadicum.

<sup>5</sup> F. i. minus.

<sup>6</sup> Synchondrosis pubis.

<sup>7</sup> Membrana obturatoria.

<sup>8</sup> Os femoris.



body it inclines from its articulation with the hip-bone inward and slightly backward to the knee.

The **shaft**<sup>1</sup> is a cylindrical column slightly bent, with the convexity forward, and moderately expanded at the extremities. The upper extremity terminates in the neck, surmounted by the head, and in two conspicuous processes, the trochanters. The lower extremity, more expanded, ends in a pair of large articular eminences, the condyles.

The intermediate portion of the shaft, narrowest and most cylindrical, is produced behind in a conspicuous roughened ridge, the **linea aspera**,<sup>2</sup> along the sides, or lips, of which the vasti muscles are attached, and between them the adductor muscles. The projection of the linea aspera and the slight flattening of the shaft in front give to this portion of the bone a somewhat prismatic form, the sides of which are completely covered by the crureus and vasti muscles. The linea aspera forks above and below in a pair of diverging, less prominent ridges. Of the upper ones, the outer ridge ascends to the great trochanter, and for several inches of its course is conspicuously roughened for the attachment of the tendon of the great gluteus muscle. The upper inner ridge ascends in advance of the position of the small trochanter, and marks the attachment of the internal vastus muscle. Between the two upper ridges, a less conspicuous one below the small trochanter gives attachment to the pectineus muscle. The lower ridges from the linea aspera diverge and descend to the condyles, whence they are named the supra-condyloid ridges. They include a triangular flat surface, which forms the **anterior wall**<sup>3</sup> of the popliteal space. The outer ridge is the more prominent, and the inner one is partially interrupted by a shallow impression which accommodates the femoral artery.

The **neck of the femur** extends from the proximal extremity of the bone obliquely upward, inward, and a little forward. It is about as long as it is broad, cylindrical, slightly compressed from before backward, and narrowed towards the middle. It is widely expanded

FIG. 97.



FEMUR OF THE RIGHT SIDE, front view. 1, the shaft; 2, head; 3, neck; 4, great trochanter; 5, anterior inter-trochanteric ridge; 6, small trochanter; 7, external, and 8, internal condyles; 9, external epicondyle; 10, groove for the popliteal tendon; 11, internal epicondyle.

<sup>1</sup> Body.<sup>2</sup> Crista femoris.<sup>3</sup> Floor; planum popliteum.



at the base, where it joins the shaft, extending between the trochanters. It is shortest above and in front, and is longest below. The posterior surface is somewhat flattened, and is commonly crossed horizontally by a feeble groove, which accommodates the tendon of the external obturator muscle.

The **head**<sup>1</sup> forms the greater part of a sphere which terminates the neck, and is the highest part of the bone. Its surface, most extensive above, in the recent state is covered with cartilage. Below and behind its centre is a little pit,<sup>2</sup> which gives attachment to the round ligament.

The **great trochanter**<sup>3</sup> is the stout, irregular quadrate eminence which terminates the shaft outside the base of the neck. Its upper posterior angle is its most projecting point, or summit, and curves inward and backward, so as to overhang the **trochanteric fossa**,<sup>4</sup> which is a deep pit, behind the trochanter, for the insertion of the tendon of the internal obturator muscle. The outer surface of the trochanter is prominent, convex and uneven, is impressed at its fore part by the insertion of the small gluteus, and from the summit along its middle by the middle gluteus. Behind the latter it is smooth, for the play over it of the great gluteus. The upper border forms a rough ridge, which curves forward and inward above the neck to its fore part, where it forms a more prominent eminence, the **femoral tubercle**. In advance of the summit the ridge is impressed by the insertions of the pyriformis, external obturator, and geminus muscles. The posterior border of the trochanter is a thick ridge which forms the upper extremity of the posterior inter-trochanteric line.

The **small trochanter**<sup>5</sup> is a conical eminence, situated behind the shaft below the neck. Its roughened summit, directed inward, gives insertion to the psoas muscle.

In front of the femur the shaft is defined from the neck by a low, roughened ridge, the **anterior inter-trochanteric line**,<sup>6</sup> which descends obliquely from the femoral tubercle to the bottom of the neck, in advance of the small trochanter. The line gives attachment to the capsular ligament of the hip-joint, and to the upper extremity of the conjoined crureus and internal vastus muscles.

Behind the femur the shaft is defined from the neck by the **posterior inter-trochanteric line**,<sup>7</sup> a thick, prominent, and smooth ridge, which curves from the summit of the great trochanter downward and inward to the small trochanter.

The lower extremity of the femur, more expanded than the upper, terminates in a pair of large articular eminences, the **condyles**, which,

<sup>1</sup> Caput femoris.

<sup>4</sup> F. trochanterica; digital fossa.

<sup>6</sup> Linea intertrochanterica anterior; l. obliqua femoris; spiral line.

<sup>7</sup> L. i. posterior; crista intertrochanterica.

<sup>2</sup> Fossa capitis.

<sup>5</sup> T. minor.

<sup>3</sup> T. major.



in the normal position, are on the same level, but when the femur is perpendicular the **internal condyle**<sup>1</sup> appears longest, or extends lowest. The **external condyle**<sup>2</sup> is the wider, and more prominent in front, and the internal condyle is more prominent internally. The condyles project most behind, and are there separated by a deep, square notch, the **inter-condyloid fossa**,<sup>3</sup> the sides of which are impressed by the attachment of the crucial ligaments of the knee-joint. Below and behind, the condyles form the smooth, convex **tibial articular surfaces**, which inwardly incline towards each other. In front they unite with the **trochlea**,<sup>4</sup> which is a broadly-grooved articular surface, on which the patella moves upward and downward in the extension and flexion of the leg. The trochlea is placed between the condyles, but extends more on the external condyle, both vertically and transversely. The remote lateral surfaces of the condyles are convex and conspicuously porous, and are produced into a more central prominence, the **epicondyle**,<sup>5</sup> which is impressed by the attachment of the lateral ligaments of the knee. Below the outer epicondyle is a fossa, which is prolonged in a groove to the back of the condyle. In the recent state the fossa gives origin to the tendon of the popliteus muscle, and the groove, invested with cartilage, accommodates the continuation of the tendon. Above the inner epicondyle is a roughened tubercle, which forms the lower extremity of the corresponding supracondyloid ridge, and gives insertion to the tendon of the great adductor muscle. Above the condyles behind are the roughened impressions which give origin to the heads of the gastrocnemius muscle.

The chief medullary nutritious foramen is commonly situated on the linea aspera, about the upper third of the bone, from which the canal is directed very obliquely upward to open into the medullary cavity. Occasionally a second foramen is situated about the middle of the linea aspera.

The shaft of the femur is completely enveloped in the muscles of the thigh, and the head and neck are deeply situated. The great trochanter is covered by the aponeurosis of the great gluteus muscle, and forms the most prominent part of the hip. The condyles at the sides of the knee are subcutaneous, and the inner is the more prominent. The trochlea is covered by the patella, but becomes covered by the extensor muscles when the limb is flexed.

Ossification commences in the shaft of the femur in the seventh week of the embryo. A centre also appears for the lower epiphysis before birth, and another for that of the head during the first year subsequently. Centres further appear in the trochanters,—about the fourth year in the great one, and about puberty in the small one. The

<sup>1</sup> Condylus internus or medialis.

<sup>2</sup> Condylus externus or lateralis.

<sup>3</sup> F. intercondyloidea.

<sup>4</sup> Fossa patellæ; f. intercondyloidea anterior.

<sup>5</sup> Tubercle.

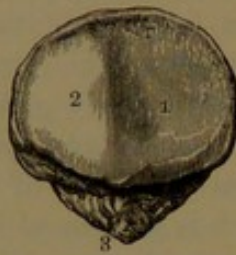

small trochanter fuses with the shaft about the seventeenth year, and the great trochanter a year later. The epiphysis of the head ankyloses with the shaft about the eighteenth year, and that of the distal extremity near adult age.

#### THE PATELLA.

The **patella**, or **knee-pan**,<sup>1</sup> is a chestnut-shaped bone, situated in front of the knee-joint, which it contributes to form. The upper border, or **base**, is thick, and is impressed by the attachment of the tendon of

FIG. 98.



PATELLA OF THE RIGHT SIDE, posterior view. 1, 2, articular facet for the trochlea of the femur; 3, apex of the bone roughened for the attachment of its ligament.

the quadriceps extensor. The lower border is prolonged in an obtuse angular process, the **apex**, which gives attachment to the strong ligament of the patella. The anterior surface is convex and longitudinally striate, for the attachment of the extension of the quadriceps tendon. The posterior surface, except on the apex, forms a transversely oval articular facet, which conforms to the trochlea of the femur, its outer portion being the more extensive. The base, apex, lateral borders, and anterior surface of the patella are embedded in the tendon of the quadriceps extensor, of which the patellar ligament is a continuation. The

articular facet is invested with cartilage. The bone is composed of uniform spongy substance, with a thin layer of compact substance, especially perforated in front for the passage of nutrient vessels.

At birth the patella is in a cartilaginous state, and it does not commence to ossify until the third year. It commonly is developed from a single centre.

#### THE HIP-JOINT.

The hip-joint, formed between the acetabulum and the head of the femur, is a ball-and-socket joint, and is one of the most movable and strongest of the articulations. The opposed articular surfaces of the bones are invested with cartilage, which is thicker centrally on the head of the femur, and thinnest at the circumference, and exhibits the reverse condition in the acetabulum.

The acetabulum is rendered deeper and is somewhat contracted at the mouth by the **cotyloid ligament**, which is a prismatic fibro-cartilaginous band attached around its margin. The ligament bridges over the cotyloid notch, where it is reinforced by additional fibres;<sup>2</sup> and it converts the notch into a foramen, which communicates with the joint, and transmits nutrient vessels. The fossa at the bottom of the ace-

<sup>1</sup> Rotula; knee-cap; os scutiforme, disciforme, or sesamoideum magnum; olecranon mobile.

<sup>2</sup> Transverse ligament.



tabulum, extending to the cotyloid notch, is occupied by a cushion of connective with adipose tissue, invested by the lining synovial membrane of the joint.

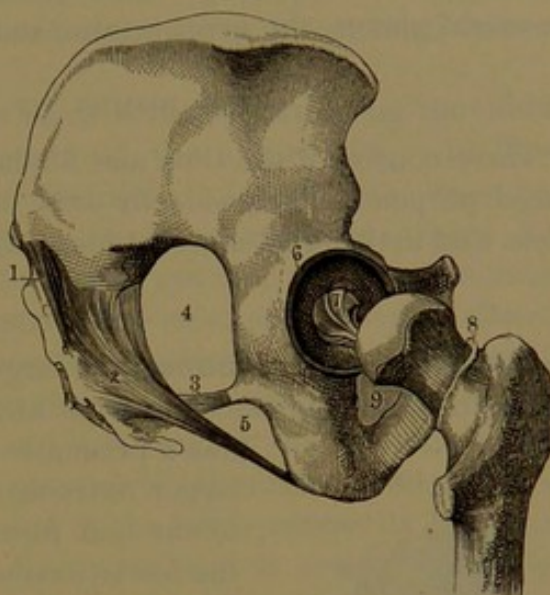
The **capsular ligament** is a dense, membranous, cylindrical capsule, enclosing the joint. Above, it is attached around the margin of the osseous acetabulum, enclosing the cotyloid ligament, and leaving this free, except at the cotyloid notch, where it is connected with it, and with the contiguous border of the obturator foramen. Extending downward and enclosing the neck of the femur, it is attached below to the anterior inter-trochanteric line, the root of the great trochanter at its fore part, and to the back of the neck below its middle. It is much thicker at the upper and fore part of the joint, where the greatest strength is required, and is longer and thin and loose at its lower part. It is chiefly composed of longitudinal fibre-bundles, with others both oblique and transverse, and is reinforced by a stout accessory band, the **ilio-femoral ligament**, which extends from the anterior inferior iliac spine to the anterior inter-trochanteric line.

The **round ligament**<sup>1</sup> is a strong fibrous cord, which is attached to the pit on the head of the femur, proceeds inwardly, and expands to be attached to the sides of the cotyloid notch. It is enveloped in a sheath of the synovial membrane extending from the cushion at the bottom of the acetabulum. The round ligament checks the outward rotation of the femur, and also its adduction in the flexed position of the thigh.

The synovial membrane of the hip-joint, starting from the margin of the articular cartilage of the head of the femur, invests the neck, and thence lines the capsular ligament, invests the cotyloid ligament and the cushion of the acetabulum, and sheathes the round ligament.

The hip-joint is closely enveloped with muscles. In front are the psoas and iliacus, with a synovial bursa between them and the capsular

FIG. 99.



LIGAMENTS OF THE HIP. 1, portion of the posterior sacro-iliac ligament; 2, the great sacro-sciatic ligament; 3, the small sacro-sciatic ligament; 4, the great sciatic foramen; 5, the small sciatic foramen; 6, the cotyloid ligament surrounding the acetabulum; 7, the round ligament; 8, attachment of the capsular ligament of the hip-joint to the neck of the femur; 9, obturator membrane.

<sup>1</sup> Ligamentum teres.



ligament; above are the femoral rectus and small gluteus; behind, the pyriformis, external obturator, geminus, and quadrate femoral muscles.

The arteries of the joint are furnished by the obturator, sciatic, internal circumflex, and gluteal arteries. The nerves are derived from the sacral plexus, the great sciatic, and the obturator nerves.

#### THE BONES OF THE LEG.

These consist of the tibia and fibula, which in the erect position are placed perpendicularly side by side, extending from the knee to the ankle, and articulated almost immovably together.

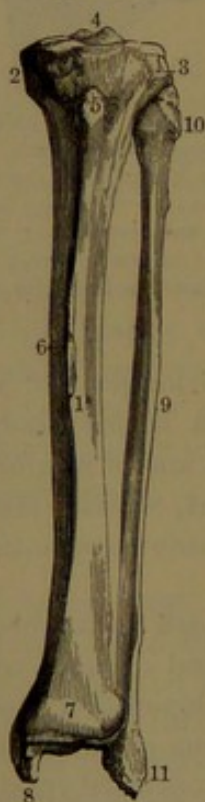
#### THE TIBIA.

The **tibia**, or **shin-bone**,<sup>1</sup> the larger of the leg bones, and next in size to the femur, is placed in front and at the inner side of the leg. It has a prismatic columnar shaft, with the upper, larger extremity or head articulating with the femur and forming part of the knee-joint, and the lower extremity articulating with the foot at the ankle-joint.

The **shaft** is trilateral prismatic and straight, expands above in the head, and gradually narrows below to the lower fourth, where it enlarges to the distal extremity. Its three surfaces are defined by as many borders.

The **anterior border**, called the **crest** or **shin**,<sup>2</sup> commences near the head in the **tubercle**, whence it descends as a prominent, acute, flexuose ridge to the lower fourth of the shaft, where it subsides in a smooth, convex surface extending to the position of the instep. The ridge curves outwardly above and inwardly below; and it serves to give attachment to the deep crural fascia. The **tubercle**<sup>3</sup> is an oblong, obtuse eminence terminating the crest above. Its lower part is roughened for the attachment of the patellar ligament; and its upper portion is impressed with a smooth facet, which accommodates a bursa intervening between the tubercle and the ligament. The **internal border** of the shaft, obtuse and less prominent than the former, defines the internal from the posterior surface. Its upper expanded extremity gives attachment to the internal lateral ligament of the knee-joint, and its lower extremity subsides in a con-

FIG. 100.



TIBIA AND FIBULA OF THE LEFT LEG. 1, shaft of the tibia; 2, 3, tuberosities; 4, spine; 5, tubercle; 6, crest or shin; 7, lower extremity of the bone; 8, internal malleolus; 9, shaft of the fibula; 10, its head; 11, external malleolus.

<sup>1</sup> Focile majus; canna major. <sup>2</sup> Crista; spina. <sup>3</sup> Tuberculum; tuberositas; spina.



tinuous convex surface common to the outer side and back of the shaft. The **external border** separates the external from the posterior surface of the shaft. It forms an acute ridge,<sup>1</sup> less prominent than that of the crest, and subsiding at the extremities. It gives attachment to the interosseous membrane, which is extended between the tibia and fibula.

The **internal surface** of the shaft is nearly flat along the middle, and wider and transversely convex at the extremities. Its lower fourth is continuous in front to the instep. It is, for the most part, subcutaneous, except at the upper, broader extremity, where it is covered by the tendons of the sartorius, gracilis, and semitendinosus muscles. The **external surface**, for the most part above, is directed outwardly, and is depressed along the posterior border approaching the middle. Its lower part is continuous in front with the external surface descending to the instep, and is covered by the extensor tendons. Its upper part gives origin to the anterior tibial muscle. The **posterior surface** is transversely convex, and at the lower extremity is continuous with the external surface. Its upper part is crossed by a slight ridge, the **popliteal line**,<sup>2</sup> which descends obliquely from the fibular articulation to the inner border, and defines a triangular space above, for the attachment of the popliteus muscle. Along the middle of the surface is an obtuse ridge, which defines the attachment inwardly of the long hallucal flexor, and outwardly of the posterior tibial muscle. The lower part of the surface is covered by the long digital flexor, long pollical flexor, and posterior tibial muscles.

The **upper extremity**, or **head**,<sup>3</sup> of the tibia appears as a horizontal, transverse oval disk projecting laterally and behind. It has a thick, porous border, and its convex lateral prominences form the **tuberosities**.<sup>4</sup> Above these are two smooth fore and aft oval facets, which articulate with the condyles of the femur. The inner somewhat narrower facet is a shallow concavity, while the outer one is slightly concave centrally and nearly flat or convex approaching the outer border. They are separated by an irregular tract, which widens in front, and back of the middle is elevated in an eminence called the **spine**.<sup>5</sup> This is notched, and its more prominent sides form the most elevated portion of the contiguous articular facets, and give attachment to the ends of the semilunar cartilages. In front and behind the spine is a rough impression for the attachment of the ends of the crucial ligaments and semilunar cartilages. The front of the head forms a flattened, porous, triangular surface extending to the tubercle. Behind the head the tuberosities are separated by a wide, shallow depression, the **popliteal notch**,<sup>6</sup> which is impressed by the posterior

<sup>1</sup> Crista interossea.

<sup>2</sup> Linea poplitea; l. obliqua.

<sup>3</sup> Caput tibiæ.

<sup>4</sup> Condylæ tibiæ. <sup>5</sup> Spinous process; spina media; eminentia intercondyloidea.

<sup>6</sup> Incisura poplitea.



crucial ligament. Behind the inner tuberosity is a transverse depression, which gives attachment to the tendon of the semimembranosus muscle. Below the back of the outer tuberosity is a smooth, flat, and nearly circular facet, looking downward and outward, for the articulation of the fibula.

The **lower extremity** of the tibia, much the smaller, from nearly cylindrical becomes quadrilateral, and on the inner side is prolonged in a strong, compressed mammillary process, the **internal malleolus**.<sup>1</sup> Below, it forms a smooth, concave, quadrate surface, with a slight fore and aft ridge, for articulating with the astragalus. The articular surface is narrower inwardly, and is there extended downward on the malleolus to articulate with the inner side of the astragalus. The front surface ends in an obtuse ridge bordering the ankle, and depressed at the margin for the attachment of the capsular ligament. The back surface ends in a similar ridge, which is slightly grooved for the tendon of the long hallucal flexor. The outer surface forms a rough depression, to which is attached the interosseous ligament connecting it with the fibula, and the depression is bounded in front and behind by ridges, which give attachment to the corresponding tibio-fibular ligaments. The lower part of the depression is sometimes smooth, and in the recent state covered with cartilage, for articulation of the fibula. The inner surface of the tibia is prolonged on the malleolus, and is there prominently convex and subcutaneous. The malleolus has a thick-ridged border for ligamentous attachment; and behind, it is grooved for the tendons of the posterior tibial and long digital flexor muscles. Its apex outwardly presents a depression, for the attachment of the internal lateral ligament of the ankle-joint.

The principal medullary nutritious foramen is usually found at the upper third of the tibia below the popliteal line, with its canal directed downward. It is larger than the corresponding foramen of any other bone.

The shaft of the tibia commences to ossify about the seventh week of embryonic life. The centre of the epiphysis of the head appears about birth, and that for the lower extremity of the tibia in the second year. An ossific centre sometimes appears for the tibial tubercle. The inferior epiphysis ankyloses with the shaft about the eighteenth year, and that of the head about maturity.

#### THE FIBULA.

The **fibula**<sup>2</sup> is a slender bone nearly as long as the tibia, with which it articulates at the outer side of the leg. It is slightly bent, with the convexity backward and outward, and its upper extremity or head is less advanced in position than the lower extremity. The head articulates with that of the tibia behind and below the outer tuberosity,

<sup>1</sup> Malleolus internus; m. medialis; inner ankle-bone.

<sup>2</sup> Os perone; peroneum; peroneal bone; splint- or splinter-bone.




and does not enter into the formation of the knee-joint. The lower extremity articulates with that of the tibia externally, and is prolonged below it in a conspicuous process, the **external malleolus**, or outer ankle, which contributes to form the ankle-joint.

The shaft of the fibula is half cylindroid and prismatic, and presents three chief borders and surfaces. The **anterior border**, for the most part acutely prominent and obtusely rounded in front of the head, descends from this to the fore part of the external malleolus. The **external border**, least prominent, is obtusely rounded above, and becomes acute below. Commencing at the outer side of the head, about the middle of the shaft it turns behind inward and descends to the back of the external malleolus. The **internal border**, for the most part prominently acute, but especially along the middle of the shaft, is obtusely rounded at the extremities.

The **internal surface**, most flattened and depressed the greater part of its extent, is crossed very obliquely by the **interosseous ridge**,<sup>1</sup> which gives attachment to the interosseous membrane extending between the fibula and tibia. The ridge commences above as the upper part of the anterior border of the shaft, and below is continuous as the lower part of the internal border. The depressed surface behind the ridge above gives attachment to the posterior tibial muscle, and the narrower depressed surface in front and below gives attachment to the extensors of the toes. The **external surface** of the shaft is convex, and at the upper half is continuous with the posterior surface, but is defined from it below by the more prominent portion of the external border. It is for the most part covered by and gives origin to the peronei muscles. Its lower extremity exhibits a flattened, triangular space, which is subcutaneous, and is defined behind by a line descending from the anterior border to the end of the external malleolus. The **posterior surface** of the shaft above, continuous with the external surface, gives attachment to the soleus muscle, and its lower part, directed inward, gives origin to the long hallucal flexor.

The **head**<sup>2</sup> of the fibula is rounded quadrate, and presents above

FIG. 101.



TIBIA AND FIBULA OF THE RIGHT LEG, posterior view. 1, 2, articular surfaces for the condyles of the femur separated by the tibial spine; 3, the inner tuberosity; 4, surface occupied by the popliteal muscle defined by the popliteal line, 5; 6, nutritious foramen; 7, surface covered by the flexors of the toes; 8, internal malleolus; 9, grooves for tendons; 10, interosseous ridge; 11, head; 12, subcutaneous surface at the lower part of the bone; 13, external malleolus; 14, groove for tendons.

<sup>1</sup> Crista interossea.

<sup>2</sup> Capitulum.



an oval, flat facet, in the recent state invested with cartilage, for articulating with the tibia. The border of the head is obtusely rounded for attachment of the tibio-fibular ligaments, and externally and behind it is produced in a conical eminence, the **styloid process**,<sup>1</sup> which gives attachment to the external lateral ligaments of the knee and the tendon of the femoral biceps muscle.

The **external malleolus**<sup>2</sup> is longer and more prominent than the internal malleolus, and forms the outer boundary of the ankle-joint. Externally, it is convex and subcutaneous, and is continuous with the triangular space of the external surface of the shaft. Internally, it presents a triangular smooth facet, which is covered with cartilage, and articulates with the outer side of the astragalus. Behind the facet is a concave fossa extending to the apex of the malleolus, which gives attachment to the external lateral ligament of the ankle. Behind, the malleolus is marked by a shallow groove for the tendons of the peronei muscles. Above the malleolus internally is a roughened surface for articulation with the tibia; sometimes partially smooth and covered with cartilage.

The foramen for the principal medullary artery is situated on the posterior surface of the shaft above the middle, its canal being directed upward.

The head of the fibula is prominent at the outer back part of the knee; the shaft is enveloped by muscles, except over the triangular surface below extending on the external malleolus, which is also prominently subcutaneous.

In the ossification of the fibula a centre appears in the shaft in the seventh week of the foetus; rather later than in the tibia. A centre for a lower epiphysis appears in the second year after birth, and another for an upper epiphysis in the third or fourth year. The lower epiphysis ankyloses with the shaft about the twenty-first year, and the upper one about the twenty-fourth year.

#### THE KNEE-JOINT.

This is the largest and most complicated articulation of the body, and moves as a hinge-joint. The articular surfaces of the bones are those of the femur, the tibia, and the patella. A continuous plate of cartilage invests the condyles and trochlear surface of the femur, and separate plates for each of the articular surfaces of the head of the tibia and of the patella. The head of the fibula does not enter into the construction of the knee-joint, though it affords attachment to the external lateral ligament of the latter. The surrounding ligaments of the knee-joint are reinforced by a superficial fibrous covering, derived from the contiguous tendons and fascia.

The function of an anterior ligament to the knee-joint is performed

---

<sup>1</sup> Processus styloideus.

<sup>2</sup> M. externus; m. lateralis; outer ankle-bone; coronoid process.



by the common tendon of the quadriceps extensor muscle, which is inserted into the base of the patella, thence envelops this bone, except its articular surface, and forms the **patellar ligament**.<sup>1</sup> This is a strong, flattened cylindrical band, which is composed of longitudinal fibrous bundles, and descends from the apex of the patella, to be inserted into the lower part of the tibial tubercle. Between the upper part of the latter and the ligament there is interposed a synovial bursa, which does not communicate with the knee-joint.

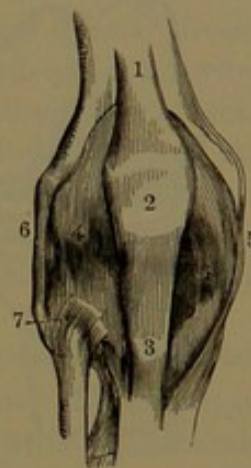
Interposed between the articular surfaces of the femoral condyles and those of the tibia are two fibro-cartilages, which are named, from their shape, the **semilunar cartilages**.<sup>2</sup> These are crescentic, and thin away from their exterior border to a sharp interior edge, which, together with the upper and lower surfaces, is free and smooth, and conforms to the articular surfaces of the femur and tibia. Their thick exterior border is attached to the contiguous part within of the capsular and lateral ligaments. Their extremities assume a distinctly fibrous character, and are firmly attached in the interval between the articular surfaces of the tibia, and they are conjoined in front by a variable band, the **transverse ligament**.

The **external semilunar cartilage**<sup>3</sup> forms nearly a circle, and is of greater width than the internal; and its extremities are fixed in front and behind the tibial spine, between the ends of the internal cartilage. The anterior extremity is continuous with the anterior crucial ligament, and the posterior extremity is fixed to the inner tuberosity of the tibia in front and behind the attachment of the posterior crucial ligament. The external semilunar cartilage externally is grooved by the passage over it of the tendon of the popliteal muscle.

The **internal semilunar cartilage**,<sup>4</sup> nearly semicircular, by its anterior, narrower extremity is attached in front of the inner articular surface of the tibia, and by its posterior extremity back of the tibial spine, between the attachment of the external cartilage and the posterior crucial ligament.

The **crucial ligaments**<sup>5</sup> are two strong fibrous cords, which cross

FIG. 102.



FRONT VIEW OF THE RIGHT KNEE-JOINT. 1, tendon of the quadriceps extensor muscle; 2, patella; 3, ligament of the patella, or tendinous insertion of the muscle just mentioned; 4, capsular ligament; 5, 6, internal and external lateral ligaments; 7, superior tibio-fibular articulation.

<sup>1</sup> Ligamentum patellæ.

<sup>2</sup> Cartilagine semilunares; c. lunatæ; c. falcatæ or falciformes; fibro-cartilages; menisci.

<sup>4</sup> Meniscus medialis.

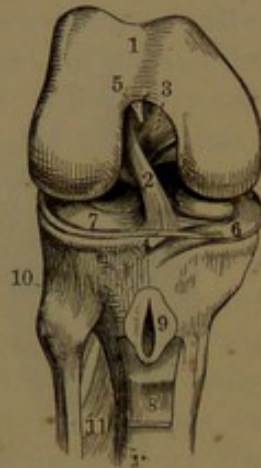
<sup>3</sup> Meniscus lateralis.

<sup>5</sup> L. cruciata, interossea, or obliqua.



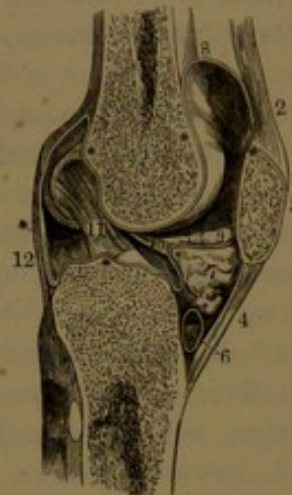
each other near the centre of the cavity of the knee-joint, and connect the femur and tibia. They are extended between the sides of the intercondylar fossa of the former, and the tibia in front and behind its spine.

FIG. 103.



THE RIGHT KNEE-JOINT, laid open from the front. 1, articular surface of the femur; 2, 3, crucial ligaments; 4, insertion of the anterior ligament into the tibia; 5, attachment of the suspensory ligament to the femur; 6, 7, internal and external semilunar cartilages; 8, ligament of the patella turned down, so as to exhibit the synovial bursa; 9; 10, superior tibio-fibular articulation; 11, interosseous membrane.

FIG. 104.



LONGITUDINAL SECTION OF THE KNEE-JOINT. 1, femur; 2, tendon of the quadriceps extensor; 3, patella; 4, ligament of the patella; 5, tibia; 6, synovial bursa; 7, cushion of fat occupying the angular interval between the patella and head of the tibia; \* \* \* \* \* reflections of the synovial membrane; 8, pouch of this membrane extending upward between the tendon of the quadriceps extensor and the front of the femur; 9, the outer alar fold of the synovial membrane; 10, suspensory ligament; 11, crucial ligament; 12, posterior ligament.

The **anterior crucial ligament**,<sup>1</sup> the smaller one, is attached to the inner back part of the external condyle, and descends outward and forward to be attached to the depression in front of the tibial spine.

The **posterior crucial ligament**<sup>2</sup> is attached to the outer fore part of the internal condyle, and descends backward to the inner side of the former ligament, to be attached behind the tibial spine.

The **internal lateral ligament**<sup>3</sup> is a long band, thicker behind, and is situated nearer the back of the joint. It is attached above to the inner epicondyle of the femur, and below to the inner side of the shaft and tuberosity of the tibia for several inches. It is intimately connected with the internal semilunar cartilage.

The **external lateral ligament**<sup>4</sup> consists of a short band of fibres, reinforcing the capsular ligament, and extending from the lower part of the outer epicondyle to the styloid process of the fibula. The tendon of the popliteal muscle passes beneath it. The **accessory lateral liga-**

<sup>1</sup> External crucial ligament; l. cruciatum anticum.

<sup>2</sup> Internal crucial ligament; l. cruc. posticum or medium.

<sup>3</sup> L. laterale internum.

<sup>4</sup> L. laterale externum breve.



**ment**<sup>1</sup> is a strong round cord, attached above to the outer epicondyle of the femur, and below to the outer part of the head of the fibula. It divides the tendon of insertion of the femoral biceps into two parts.

The **capsular ligament** of the knee-joint in front is mainly substituted by the tendon of the quadriceps extensor, together with the patella and its ligament. In the intervals of these and the lateral ligaments it is thin, and is formed by membranous offsets<sup>2</sup> from the tendon of the quadriceps, which extend downward and backward, to be attached to the condyles of the femur, the semilunar cartilages, the lateral ligaments, and the heads of the tibia and fibula. These lateral offsets are intimately blended with the investing femoral fascia. The inner offset is continuous with the edge of the patellar ligament; but the outer offset passes behind the ligament, to be attached to the head of the tibia.

The posterior portion of the capsular ligament, usually described as distinct under the name of the **posterior ligament**,<sup>3</sup> is a strong membranous intertexture enclosing the back of the joint in the interval of the lateral ligaments. It is connected to the femur above the condyles and intercondylar fossa, and below to the head of the tibia, and is intimately connected with the semilunar cartilages. It is reinforced by a strong fasciculus derived from the tendon of the semimembranosus muscle, proceeding from the inner tuberosity of the tibia to the capsule covering the external condyle of the femur.

The interval at the fore part of the knee-joint, between the head of the tibia and the patellar ligament, is occupied by a cushion of connective and adipose tissue. From this a narrow fibrous band, the **suspensory ligament**,<sup>4</sup> proceeds upward and backward, to be fixed to the fore part of the intercondylar fossa.

The synovial membrane of the knee-joint is remarkable for its extent and complexity. Excepting the articular surfaces of the bones, it invests all parts of the cavity, including the crucial ligaments and semilunar cartilages. From the capsular ligament behind it is reflected upon the crucial ligaments, and with them forms a partial partition, separating the sides of the cavity of the joint. At the upper part of the latter, in front, it forms a large, loosely-attached pouch, which, in the extended condition of the leg, reaches several inches above the patella and femoral trochlea, beneath the tendon of the quadriceps extensor, on the shaft of the femur. The pouch, being attached by connective tissue to the contiguous structures, is drawn down in the flexion of the leg. The suberureus muscle is inserted into the pouch. At the lower part of the joint the synovial membrane does not extend below

<sup>1</sup> L. laterale externum longum; l. accessorium laterale.

<sup>2</sup> L. patellare laterale et mediale.

<sup>3</sup> L. posticum Winslowi; l. popliteum or obliquum.

<sup>4</sup> L. mucosum or adiposum; l. suspensorium marsupii; l. plicæ synov. patellaris.



the level of the articular surfaces of the head of the tibia. In this position in front it invests the connective-tissue cushion and its suspensory ligament. From this the membrane is reflected on each side in a pair of conspicuous falcate and irregularly-fringed processes, the **alar folds**,<sup>1</sup> which extend upward on the capsular ligament at the sides of the patella, sometimes encircling it. Frequently a pair of semilunar folds extend from the same point horizontally to the sides of the joint. The inner surface of the knee-cushion and the pouch above the femoral trochlea are more or less conspicuously villous, and often to a remarkable degree. From the back of the joint the synovial membrane extends into a groove between the external tuberosity of the tibia and head of the fibula, and is thence reflected on the tendon of the popliteus muscle, which occupies the groove.

The ordinary motion of the knee-joint is hinge-like, as in flexion and extension of the leg. In the flexed or partially-flexed condition of the leg the joint allows of some rotation, inwardly through the action of the popliteal muscle, outwardly by the femoral biceps. The semilunar cartilages adjust the inequalities of the femur and tibia, and facilitate the movements between these bones. Incidentally they are of service in moderating the jar produced in jumping or falling on the feet. The crucial ligaments, while firmly uniting the femur and tibia, serve also to restrict the movements of the bones in different directions. The patella gives leverage to the quadriceps muscle in its action on the tibia, and further protects the knee-joint. In extreme extension of the leg, the fore part of the condyles of the femur is in contact with the semilunar cartilages and head of the tibia; in extreme flexion, the back part. In the act of flexion the tibia and semilunar cartilages together glide back on the condyles of the femur. In extension, the patellar ligament and posterior crucial ligament are relaxed, while the other chief ligaments are rendered tense; in flexion, the former are put on the stretch, and the latter are relaxed.

#### ARTICULATIONS OF THE TIBIA AND FIBULA.

The tibia and fibula are articulated together almost immovably, are connected at the extremities by synovial joints, and in the intermediate position by an interosseous membrane, which also serves to give attachment to the muscles of the leg.

The **upper tibio-fibular articulation**<sup>2</sup> is formed between the flattened, oval articular surfaces of the head of the fibula and external tuberosity of the tibia. It is enclosed by a capsular ligament, reinforced by oblique bands, which are the upper **anterior** and **posterior tibio-fibular ligaments**.<sup>3</sup> The synovial membrane of the joint

<sup>1</sup> Alar ligaments; lig. alaria externum and internum or minus and majus; processus aliformes marsupium patellare.

<sup>2</sup> Superior peroneo-tibial articulation.

<sup>3</sup> L. capituli fibulae ant. et post.



usually communicates with that of the knee-joint, through the groove for the popliteal tendon, above and behind the head of the fibula.

The **lower tibio-fibular articulation**<sup>1</sup> is formed between the lower extremities of the tibia and fibula. The opposed surfaces of the bones, for the most part roughened, are connected by short intervening fibres, which form the **interosseous ligament**. They are smooth at their lower border, and invested with cartilage continuous with that of the ankle-joint. Strong flat bands descend obliquely from the eminences in front and behind the tibia to the external malleolus, forming the lower **anterior** and **posterior tibio-fibular ligaments**.<sup>2</sup> The latter is much stronger than the former, and is inserted into the fossa within the malleolus, as well as into its back part. The synovial cavity of the joint ascends as a narrow cleft from the ankle-joint to the attachment of the interosseous ligament.

The **interosseous membrane**<sup>3</sup> is a strong, bluish-white aponeurosis, extended between the contiguous borders of the tibia and fibula, and is composed mainly of parallel fibres, descending obliquely from the tibia to the fibula, a few crossing in the opposite direction. At its upper part is a large opening for the transmission of the anterior tibial vessels, and its lower part is continuous with the interosseous ligament of the corresponding tibio-fibular articulation.

#### THE FOOT.

The foot consists of three divisions: the tarsus, the metatarsus, and five digits.

#### THE TARSUS.

The **tarsus** forms the back part of the foot and the instep, and consists of seven bones,—the astragalus, calcaneum, scaphoid, cuboid, and three cuneiform bones.

The **astragalus**, or **ankle-bone**,<sup>4</sup> is the uppermost bone of the tarsus, the second in size, and the only one of the foot which articulates with the bones of the leg. It rests beneath on the calcaneum, and articulates in front with the scaphoid bone. Its long axis is fore and aft, and it is of less height than transverse breadth. Its posterior portion, or **body**, is irregularly quadrate, and is embraced above and at the sides by the tibia and fibula, with which it forms the ankle-joint. The upper articular surface, for the tibia, is fore and aft convex and feebly grooved, and is transversely nearly straight. Articular surfaces also extend downward upon the sides for the malleoli, the depth on the outer side being more than double that on the inner side.

<sup>1</sup> Inferior peroneo-tibial articulation.

<sup>2</sup> L. malleoli lateralis, anterior and posterior.

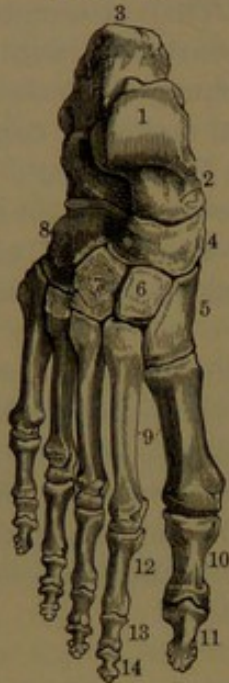<sup>3</sup> Membrana interossea; ligamentum interosseum.

<sup>4</sup> Talus; os tessera or balista; sling-bone; huckle-bone.



Beneath the body is an articular surface for the calcaneum, concave obliquely from behind forward and outward, and nearly straight in the opposite direction. In advance of the body a conspicuous process is the **head**, which is separated from

FIG. 105.



DORSAL SURFACE OF THE RIGHT FOOT. 1, body of the astragalus; 2, its head; 3, calcaneum; 4, scaphoid bone; 5, 6, 7, ento-, meso-, and ectocuneiform bones; 8, cuboid bone; 9, metatarsal bones; 10, 11, phalanges of the great toe; 12, 13, 14, phalanges of the other toes.

the former by a somewhat narrowed and roughened portion, the **neck**. The front of the head presents a convex articular surface for the scaphoid bone, and continuous with it beneath is a narrower articular facet for the sustentacle of the calcaneum. Beneath the body a groove,<sup>1</sup> widening outwardly in a fossa, separates the two calcanean articular surfaces, and accommodates the intertarsal ligament, which connects the astragalus with the calcaneum. The posterior extremity of the body forms a transverse ridge, which is grooved for the passage of the tendon of the long hallucal flexor. The inner side of the body, extending forward and upward on the head, exhibits a roughened porous surface for ligamentous attachment.

The **calcaneum**, or **heel-bone**,<sup>2</sup> the largest bone of the tarsus, forms the posterior extremity of the foot, at its fore part above supports the astragalus, and in front articulates with the cuboid bone. It is irregularly oblong, with its long axis fore and aft, and its depth, for the most part, greater than its width.

The posterior half of the bone forms its **tuberosity**,<sup>3</sup> which projects behind the ankle-joint and forms the prominence of the heel. The tuberosity is laterally compressed, cylindroid and quadrilateral, and terminates in a thickened convex knob, which is roughened below for the insertion of the tendon of Achilles, while it is sloped off above and smooth for the reception of a bursa intervening between the tendon and the bone. Beneath, the tuberosity is produced into a pair of eminences, the **internal** and **external tubercles**,<sup>4</sup> of which the former is much larger than the latter. The upper part of the tuberosity is narrowest, is convex transversely, and concave fore and aft, and corresponds with the interval between the ankle-joint and the Achilles tendon.

The calcaneum above, in advance of its tuberosity, presents a large

<sup>1</sup> Sulcus tali; s. interarticularis.

<sup>3</sup> Tuberositas; tuber calcis.

<sup>2</sup> Os calcis; calcaneus; calcar pedis.

<sup>4</sup> Tuberosities.



fossa partially resting on a process, the **sustentacle**,<sup>1</sup> which overhangs the inner side of the bone. The fossa exhibits two articular facets, separated by a roughened tract, which descends obliquely on the sustentacle and widens on the fore part of the bone.<sup>2</sup> The posterior larger facet slopes in front of the tuberosity downward, forward, and outward, is convex in its descent, and nearly flat transversely, and articulates with the under part of the body of the astragalus. The anterior facet, longer and much narrower, slopes in the same direction on the sustentacle, is concave in its descent, and flat transversely, and articulates with the under part of the head of the astragalus. The tract<sup>3</sup> separating the facets corresponds with that of the astragalus, and accommodates the strong intertarsal ligament connecting the two bones.

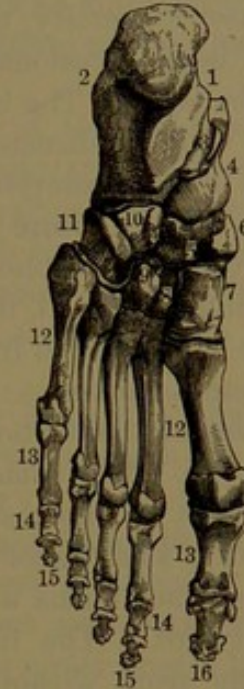The anterior extremity of the calcaneum in front presents a vertical, trilateral facet, which articulates with the cuboid bone. It is concave from above downward, and convex transversely.

The outer surface of the calcaneum forms an uneven vertical plane, which, for the most part, is subcutaneous. The inner surface, less of a plane vertically than the former, between the tuberosity and the sustentacle, forms a deep **concavity**,<sup>4</sup> which is directed obliquely downward and forward, and accommodates the flexor tendons, vessels, and nerves in their course from the back of the leg to the sole. At the fore part of the concavity, beneath the sustentacle, is a curved groove, which gives passage to the tendon of the long hallucal flexor.

The inferior part of the calcaneum forms a thick, transversely convex ridge, which converges from the tubercles beneath the tuberosity to an **anterior tubercle**, which gives attachment to the long plantar ligament.

The **scaphoid bone**<sup>5</sup> occupies the inner part of the tarsus in front

FIG. 106.



SOLE OF THE LEFT FOOT. 1, concavity of the calcaneum; 2, outer face of the same; 3, groove for the tendon of the long hallucal flexor; 4, head of the astragalus; 5, scaphoid bone; 6, its tuberosity; 7, 8, 9, ento-, meso-, and ectocuneiform bones; 10, cuboid bone; 11, its groove for the tendon of the long peroneal muscle; 12, metatarsal bones; 13, first row of phalanges; 14, second row; 15, third row; 16, last phalanx of the great toe.

<sup>1</sup> Sustentaculum tali; processus lateralis; lateral or lesser process.

<sup>2</sup> Greater process.

<sup>3</sup> Sulcus calcanei; s. interarticularis.

<sup>4</sup> Sinuosity. <sup>5</sup> Os scaphoideum or scaphoides; os naviculare; navicular bone.



of the astragalus and with the cuneiform bones in front of it. It is transversely ovoid in outline, with a posterior, elliptical concave articular surface for the head of the astragalus, and a convex articular surface in front divided into three facets for the cuneiform bones. The upper and lower surfaces are roughened for ligamentous attachment. The outer extremity, usually roughened for attachment to the adjacent cuboid bone, occasionally, also, exhibits a small facet for articulating with the latter. The inner extremity is formed by a thickened **tuberosity**, which is directed downward, and receives the insertion of the tendon of the posterior tibial muscle.

The **cuboid bone**<sup>1</sup> occupies the outer fore part of the tarsus, externally to the scaphoid and cuneiform bones, and in advance of the calcaneum. Behind, it presents a vertical, trilateral articular surface for the latter, and in front another, divided into two facets for the outer two metatarsal bones. The inner surface is broad and uneven, and at its upper middle portion presents an articular facet for the ectocuneiform bone. The remaining roughened portion of the surface gives attachment to interosseous ligaments. Sometimes its upper portion presents a small facet for articulation with the scaphoid bone. The upper surface forms a roughened plane inclining downward, forward, and outward. The inferior surface, broad and uneven, is crossed obliquely from without inward and forward by a ridge-like **tuberosity**,<sup>2</sup> which is more prominent and smooth at the outer extremity. In advance of the tuberosity is a **groove**,<sup>3</sup> which accommodates the tendon of the long peroneal muscle, while a patella-like thickening of the tendon plays on the smooth prominence of the tuberosity. Behind the tubercle the surface is depressed, and gives attachment to ligaments. The outer shortest border of the bone presents a notch, which is the commencement of the groove beneath.

The **cuneiform bones**, named from their wedge shape, form a transverse row at the inner fore part of the tarsus, in which they occupy the most advanced position, and articulate with the inner four metatarsal bones. Their upper surface, roughened planes, contributes to form the convex back of the instep. Their posterior border forms a transverse curved line; their anterior border an irregular line, most forward with the entocuneiform and least with the mesocuneiform bone.

The **entocuneiform bone**,<sup>4</sup> the largest of the series, is the most advanced in position of the tarsal bones. The narrow border of the wedge is directed upward, and the base downward, where it forms a thick, convex **tuberosity**, which is situated at the inner border of the tarsus and gives insertion to the tendons of the tibial muscles. The

<sup>1</sup> Os cuboideum or cuboides.

<sup>2</sup> Tuberositas cuboidei.

<sup>3</sup> Sulcus peronei.

<sup>4</sup> Internal cuneiform bone; os cuneiforme internum or primum.



upper surface looks inwardly, and the lower surface is directed outwardly in the sole. The posterior surface presents a trilateral concave facet, which articulates with the scaphoid bone; the anterior surface a large reniform facet, convex from above downward and nearly straight transversely, for articulating with the first metatarsal bone. The surface just beneath the upper outer border exhibits an elliptical articular facet divided into two portions for the mesocuneiform and second metatarsal bones.

The **mesocuneiform bone**,<sup>1</sup> the smallest of the series and less advanced in position, has its nearly square base upward, and its narrow border downward in the sole. The opposite sides are uneven, and exhibit smooth facets above for articulation with the contiguous cuneiform bones. The anterior and posterior surfaces exhibit triangular vertical facets for articulation behind with the scaphoid bone, and in front with the second metatarsal bone.

The **ectocuneiform bone**<sup>2</sup> resembles the former in shape and relative position of the wedge. Its base above presents an oblong rectangular plane, and the lower narrow border of the bone forms in the sole a thick fore and aft ridge for tendinous and ligamentous attachment. Behind, the bone presents a quadrate, vertical articular surface for the scaphoid bone. A similar surface in front articulates with the third metatarsal bone, and is continuous at the upper angles laterally with small facets for the adjoining metatarsal bones. The lateral surfaces of the bone are broad, uneven planes, which present an articular facet at their upper back portion for the contiguous cuboid and mesocuneiform bones.

#### THE METATARSUS.

The five bones of the metatarsus are arranged in a row parallel with one another, and are distinguished by number according to their position from within outward. They have the same general construction as the metacarpal bones, with a trilateral shaft, in each case a different base, and a quadrate hemispheroidal head, impressed at the sides by the attachment of lateral ligaments.

The first metatarsal bone, shorter than the others, is much more thick or robust. It extends farthest forward, but not so far back as the others. It is much longer and thicker than the corresponding metacarpal bone. Its shaft is trilateral cylindroid, and is less compressed laterally than in the other metatarsals. Its most prominent borders are below, external and internal. The upper and outer surfaces are transversely convex and more continuous; the lower surface is more flattened and inclines inwardly. The base forms the larger extremity, is vertically oval, and presents behind a reniform, somewhat concave,

---

<sup>1</sup> Middle cuneiform bone; *os cuneiforme medium* or *secundum*.

<sup>2</sup> External cun. bone; *os cun. externum* or *tertium*.



articular surface for the scaphoid bone. Its lower extremity outwardly is produced in a tuberosity, which receives the insertion of the tendon of the long peroneal muscle. The head is square hemispherical, with its convex articular surface in front for the first phalanx. Below, the articular surface presents a median ridge, and on each side a prolongation for the play of the sesamoid bones.

The remaining four metatarsal bones, larger and of much more slender proportions than the first one, are also more nearly like one another. They slightly and successively decrease in length, and extend farther back, but not so far forward as the first one. In comparison with the corresponding metacarpal bones, they are of more nearly the same length, more slender, and have the shaft more tapering, and ending in a smaller, laterally compressed head. They are thickest at the base, and the shaft narrows forward to within a short distance of the head. The more prominent borders of the shaft are above and below, and the lateral surfaces are flattened for the accommodation of the interosseous muscles. The base is larger than the head, and deepest vertically except in the last one, in which the greater diameter is transverse. Beneath, it is produced in a roughened tubercle for ligamentous attachment. The head is quadrate, deeper than wide, and with a convex articular surface notched beneath.

The second and third metatarsals are more nearly alike than they are to the succeeding ones, which also more nearly resemble each other. The base is unlike in all, but the rest of the bone is the same, except that in the former two the shaft is more uniform, and in the latter it is more spread outwardly approaching the base.

The second metatarsal has a triangular base, with an articular facet behind for the mesocuneiform bone, another at the upper angle on the inner side for the entocuneiform bone, and a pair on the outer side, each usually subdivided, for articulating with the contiguous borders of the ectocuneiform and third metatarsal bones.

The third metatarsal has a more quadrate base, with a large facet behind for the ectocuneiform bone, and usually two small ones on the inner side, and a considerable one on the outer side, for the contiguous metatarsals.

The fourth metatarsal also has a quadrate base, with a facet behind for the cuboid bone, and lateral ones nearly as large, the inner for the ectocuneiform and third metatarsal, and the outer for the last metatarsal.

The fifth metatarsal has a transversely ovoid base, with the narrow extremity produced in a roughened **tuberosity**, which is directed outward and upward, and affords insertion to the short peroneal tendon. Internal to the tuberosity is a flat facet for articulation with the cuboid bone, and continuous with it on the inner side another facet for the contiguous metatarsal bone.



## THE DIGITS.

The digits of the foot are constructed like those of the hand, the first one of two phalanges, with a pair of sesamoid bones, the others each of three phalanges. The digits of the foot, or toes, are distinguished by number in succession. The phalanges in general conform to those of the hand, but are less well developed.

The phalanges of the **first** or **great toe**, or **hallux**, differ but slightly in length from those of the thumb, but are otherwise of much more robust proportion. The phalanges of the other toes are much smaller than those of the fingers. Those of the first row have their shaft of less proportionate width to their depth, so that they appear more narrowed between the extremities. In the succeeding rows the shaft of the phalanges is generally so little produced as to appear but little more than a constriction between the extremities. This is especially the case in the outer two toes; and sometimes in the **fifth**, or **little toe**, the two phalanges are ankylosed.

The **sesamoid bones** consist of a pair of little oval bones, which are placed beneath the head of the first metatarsal bone, with which they articulate, and enter into the formation of the first joint of the great toe. They are embedded in the tendons of the short hallucal flexor, but their articular surface is invested with cartilage. Occasionally smaller sesamoid bones are found in a corresponding position of the other toes. They also occur in other positions in the tendons. Thus, not unfrequently one is found in the long peroneal tendon where it plays over the tuberosity of the cuboid bone, and another in the tendon of the posterior tibial muscle near its insertion.

## THE FOOT.

The foot is placed at a right angle to the leg, with which it articulates at the posterior third to form the ankle-joint, and thence projects behind to form the heel. It is narrowest in the latter position, highest at the ankle-joint, and thence spreads laterally and slants off to the toes.

The **dorsum**, or back of the foot, is convex, and inclines chiefly forward and outward from in front of the ankle-joint, or **instep**, which corresponds with the fore part of the tarsus. The **plantar surface**, or **sole**, extends the entire length and breadth of the foot, and is concave or arched. The extremities of the arch and its outer part, formed successively by the calcaneum, cuboid, last metatarsal bone, and phalanges, nearly reach a level, or rest on the ground. The inner part of the arch is open, and forms the **hollow of the foot**. A large, irregular, funnel-like passage, the **tarsal sinus**, traverses the tarsus from the outer side inward and backward, between the astragalus and calcaneum. Its fore part communicates, between the two latter and the scaphoid and cuboid bones, with the sole. It is occupied by the intertarsal liga-



ment. A large interval in the sole, between the sustentacle of the calcaneum and the scaphoid, leaves exposed a portion of the anterior articular surface of the head of the scaphoid bone, and is closed by the inferior calcaneo-scaphoid ligament.

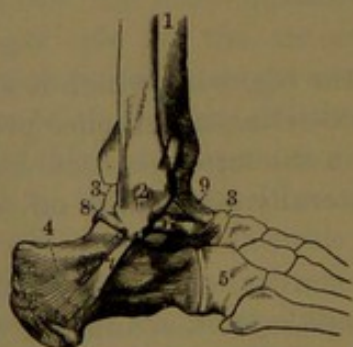
#### OSSIFICATION OF THE BONES OF THE FOOT.

In the development of the bones of the foot, the centres of ossification make their appearance at different periods. A centre appears in the calcaneum about the sixth month of foetal life, and one appears for an epiphysis to the extremity of the tuberosity not until about the ninth year subsequently. A centre for the astragalus appears about the seventh month; one for the cuboid about the time of birth; for the ectocuneiform in the first year; for the entocuneiform in the third year; and for the mesocuneiform and scaphoid about the fourth year. The epiphysis of the calcaneum coalesces about the sixteenth year. The metatarsals and phalanges accord in their development with the corresponding bones of the hand, though the ossification and coalescence of epiphyses may occur a little later.

#### ANKLE-JOINT.

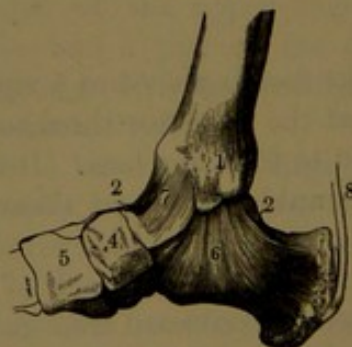
The **ankle-joint**,<sup>1</sup> or **ankle**, is formed by the distal ends of the tibia and fibula, embracing the upper and lateral articular surfaces of the body of the astragalus. It is a hinge-joint, which only permits of flexion and extension of the foot on the leg. It is enclosed by a capsular ligament, reinforced by strong lateral ligaments.

FIG. 107.



EXTERNAL VIEW OF THE RIGHT ANKLE-JOINT. 1, tibia; 2, external malleolus of the fibula; 3, astragalus; 4, calcaneum; 5, cuboid bone; 6, 7, 8, three bands of the external lateral ligament; 9, front of the capsular ligament.

FIG. 108.



INTERNAL VIEW OF THE ANKLE-JOINT. 1, internal malleolus of the tibia; 2, astragalus; 3, calcaneum; 4, scaphoid bone; 5, internal cuneiform bone; 6, internal lateral ligament; 7, capsular ligament; 8, Achilles tendon.

The fore part<sup>2</sup> of the capsular ligament is a broad, thin membrane, attached above to the lip of the articular surfaces of the tibia and fibula, and below to the neck of the astragalus. It is loose in the

<sup>1</sup> *Articulatio pedis*; a. talo-cruralis.

<sup>2</sup> Anterior or tibio-tarsal ligament.



flexed condition of the foot, and is rendered tense when this is extended. It is greatly strengthened by the tendons of the digital extensors, the anterior tibial and third peroneal muscles, which lie in front of it. The back part<sup>1</sup> of the ligament is a short membrane extending between the contiguous borders of the articular surfaces of the tibia and fibula above and the ridge of the astragalus below.

The **internal lateral ligament**<sup>2</sup> is a strong, triangular, membranous band, the fibres of which descend and radiate from the border of the internal malleolus to the inner side of the astragalus, the sustentacle of the calcaneum, and the scaphoid bone. It is crossed by the tendons of the posterior tibial and long digital flexor muscles.

The **external lateral ligament**<sup>3</sup> consists of three widely-divergent bands,<sup>4</sup> which proceed from the apex and fossa of the external malleolus: one in advance to the neck of the astragalus, the second behind to the posterior ridge of the latter, and the third obliquely downward and backward to the outer side of the calcaneum near its middle.

The synovial membrane, besides investing the ankle-joint in the usual manner, gives an offset to the inferior tibio-fibular articulation.

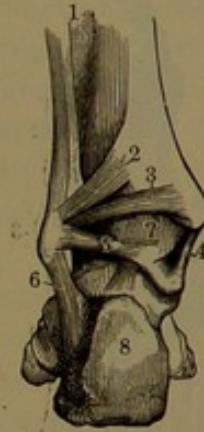
#### ARTICULATIONS OF THE TARSUS.

The astragalus forms with the rest of the tarsus two distinct joints, separated by the intertarsal ligament, and distinguished from the bones which enter into their formation, as the astragalo-calcanean and astragalo-calcaneo-scaphoid articulations. Each forms a distinct synovial cavity.

The **intertarsal ligament**<sup>5</sup> forms a broad, thick partition occupying the tarsal sinus, and consists of fibrous bundles, which extend between the contiguous grooves of the astragalus and calcaneum and connect the two bones firmly together.

The **astragalo-calcanean articulation**,<sup>6</sup> situated behind the intertarsal ligament, is formed by the concave articular facet of the body of the astragalus and the convex facet of the calcaneum below and behind. From the position of the intertarsal ligament in front it is

FIG. 109.



POSTERIOR VIEW OF THE INFERIOR TIBIO-FIBULAR AND ANKLE-JOINTS. 1, interosseous membrane; 2, 3, two bands of the posterior tibio-fibular ligament; 4, internal lateral ligament of the ankle-joint; 5, 6, posterior and middle bands of the external lateral ligament; 7, capsular ligament of the ankle-joint; 8, calcaneum.

<sup>1</sup> Posterior ligament.

<sup>2</sup> Internal lateral or deltoid lig.; 1. calcaneo-tibiale.

<sup>3</sup> External lateral l.

<sup>4</sup> L. fibulare tali ant., post., et calcanei.

<sup>5</sup> L. intertarseum; 1. talo-calcaneum interosseum.

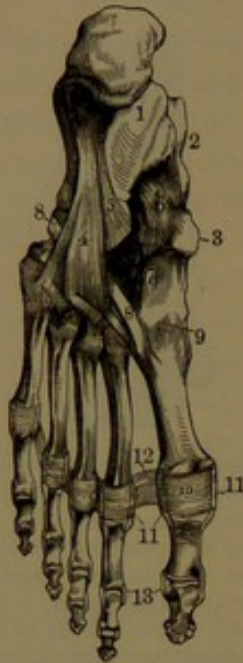<sup>6</sup> Art. talo-calcanea.



enclosed by a short capsular ligament behind, and is strengthened at the sides by the lateral ligaments of the ankle.

The **astragalo-calcaneo-scaphoid articulation**<sup>1</sup> is a ball-and-socket joint, of which the ball is formed by the head of the astragalus

FIG. 110.



**LIGAMENTS OF THE SOLE OF THE FOOT.** 1, calcaneum; 2, astragalus; 3, scaphoid bone; 4, long plantar ligament; 5, inferior calcaneo-cuboid ligament; 6, inferior calcaneo-scaphoid ligament; 7, plantar ligaments between the cuneiform bones and base of the metatarsus; 8, tendon of the long peroneal muscle passing through a groove of the cuboid bone above the long plantar ligament to be inserted into the first metatarsal bone; 9, capsular ligament between the latter and the internal cuneiform bone; 10, plantar ligament, having the same relationship with the metatarso-phalangeal and phalangeal articulations that the anterior ligament has with the corresponding joints of the fingers; 11, lateral ligaments; 12, transverse ligament; 13, lateral ligaments of the phalangeal articulations.

**ment**,<sup>6</sup> a broad, strong band which extends from the anterior tubercle beneath the calcaneum to the contiguous under surface and tuberosity of the cuboid bone.

and the socket by the sustentacle of the calcaneum behind, the scaphoid in front, and the **inferior calcaneo-scaphoid ligament**<sup>2</sup> beneath. The latter is a thick, dense membrane, partially fibro-cartilaginous, and rarely partially ossified, bridging over the interval between the inner border of the sustentacle of the calcaneum and the under part of the scaphoid bone. It articulates with the under part of the head of the astragalus, and is internally connected with the internal lateral ligament of the ankle. The tendon of the posterior tibial muscle passes over it beneath. The **external calcaneo-scaphoid ligament**<sup>3</sup> consists of interosseous bundles passing obliquely between the inner border of the anterior extremity of the calcaneum and the contiguous outer border of the scaphoid bone. The upper part of the articulation is closed by the **astragalo-scaphoid ligament**,<sup>4</sup> a thin membrane which passes between the neck of the astragalus and the upper surface of the scaphoid bone.

The **calcaneo-cuboid articulation** is formed between the fore part of the calcaneum and the cuboid bone, and has a synovial cavity enclosed by a capsular ligament reinforced by the following:

The **superior calcaneo-cuboid ligament**,<sup>5</sup> a thin, narrow band passing between the contiguous surfaces above of the calcaneum and cuboid bone.

The **inferior calcaneo-cuboid liga-**

<sup>1</sup> Art. talo-cal. scaphoidea; a. communis.

<sup>3</sup> Superior cal.-scaph. lig.

<sup>5</sup> L. calcaneo-cuboideum dorsale.

<sup>2</sup> Internal calcaneo-scaphoid ligament.

<sup>4</sup> L. talo-scaphoideum.

<sup>6</sup> Short calcaneo-cuboid ligament.



The **internal calcaneo-cuboid ligament**,<sup>1</sup> a thick, strong band, springs from the fossa at the inner fore part of the calcaneum, and proceeds forward to be attached to the inner side of the cuboid bone.

Accessory to this articulation is the **long plantar ligament**,<sup>2</sup> a strong, fibrous band which proceeds from the ridge beneath the calcaneum, extending from its posterior tubercles to the anterior tubercle, and thence passing forward and expanding, it is attached to the tuberosity of the cuboid bone and the bases of the intermediate three metatarsal bones. Crossing over the groove of the cuboid bone, it forms with it a canal for the passage of the long peroneal tendon.

The calcaneo-cuboid articulation allows of slight rotary motion.

**Articulations of the five smaller metatarsal bones with one another and with the metatarsal bones.**

The opposed articular surfaces of the scaphoid and cuneiform bones, those between the latter and between the ectocuneiform and cuboid bone, have a common synovial cavity. This communicates between the meso- and ectocuneiform bones with the cavity between the latter and the second and third metatarsal bones, extending also between these and likewise between the third and fourth metatarsal bones. A distinct synovial cavity is formed between the cuboid and outer two metatarsal bones, extending also between the latter. A third cavity is also formed between the entocuneiform and first metatarsal bones. The three articulations are enclosed by ligaments, which are distinguished according to their position as dorsal, plantar, and interosseous ligaments. The **dorsal and plantar ligaments** are short bands which connect the adjacent bones, and generally accord with them in number and relative direction. Thus, they proceed from the scaphoid to the cuneiform bones, from these to the inner three metatarsals, and from the cuboid to the outer two metatarsals. Others pass transversely between the cuneiform bones, between the outer of these and the cuboid, and between the bases of the metatarsal bones. The **interosseous ligaments** consist of short fibres connecting the adjoining surfaces in the intervals of the bones. Of these a strong one unites the contiguous surfaces of the scaphoid and cuboid bones; others in the same manner occupy the intervals, and unite the cuneiform bones with each other and with the cuboid bone; a third set consists of a strong one connecting the entocuneiform and second metatarsal, and one passing from each side of the ectocuneiform to the latter and the third metatarsal bone; and a fourth set consists of those between and uniting the bases of the metatarsal bones.

The heads of the metatarsal bones are loosely conjoined by the **transverse metatarsal ligament**, a band which extends across the sole, and is connected with the plantar portion of the capsular ligaments of the metatarso-phalangeal articulations.

<sup>1</sup> Interosseous calcaneo-cuboid ligament.

<sup>2</sup> Long calcaneo-cuboid ligament.



The metatarso-phalangeal and the phalangeal articulations of the toes have the same construction as those of the fingers.

The articulation of the astragalus with the calcaneum allows a limited rotary motion. That formed by these bones, together with the scaphoid and cuboid bone, permits the fore part of the foot to be moved downward and inward or upward and outward, as in the inversion and eversion of the sole. The articulations between the smaller tarsal bones and the metatarsal bones are more or less restricted to gliding motion, which is most marked with the first and last metatarsal bones. The movements of the toe-joints are like those of the fingers.



## CHAPTER IV.

### THE CONNECTIVE TISSUES.

THE body is largely composed of parts which serve to connect, support, and protect other parts, and are chiefly composed of an exceedingly tenacious fibrous material, named from its structure and function the fibro-connective tissue. It is the essential constituent of most ligaments, the tendons, aponeuroses, and fasciæ, the periosteum and perichondrium, the dura and sclerotica, the outer tunic and sheath of blood-vessels, the sheath of nerves, the submucous and subserous tissues, the areolar and parenchymatous tissues, the albuginea, and the dermis. All these, together with the elastic ligaments, are commonly distinguished as **connective tissues**.

#### FIBRO-CONNECTIVE TISSUE.

The **fibro-connective tissue**,<sup>1</sup> or simply the **fibrous tissue**, when viewed through the microscope is seen to be composed of narrow bundles of exceedingly fine filaments or fibres, which are transparent and homogeneous, simple or unbranched, running parallel, and ranging from the  $\frac{1}{2000}$  to the  $\frac{1}{1000}$  of a millimetre in thickness. The filaments are held together by a transparent homogeneous cement or matrix not distinctly separable from them. The bundles are of variable size, and may be associated in variable larger bundles, which may divide and mutually intersect one another. The bundles are also united by a homogeneous matrix, and the larger bundles in addition may be connected by smaller ones. They may be arranged parallel with one another, as in tendons, aponeuroses, and band-like ligaments, or they may intersect one another in different directions, as in fasciæ, the dermis, and other fibrous structures. The bundles of fibres exhibit a waving or undulating course, which is due to slight contraction, and disappears with the same degree of extension. This condition gives rise to the appearance of alternate dark and light striæ across tendons, which is obliterated on slight stretching. The fibro-connective tissue, on the application of acetic acid, swells, becomes more translucent, and to a great extent loses its fibrous appearance. When the ordinary connective tissues are boiled in water the fibro-connective tissue is almost entirely resolved into gelatin, and hence is said to be a col-

---

<sup>1</sup> Fibrous or fibrillar connective tissue; white fibrous tissue; connective tissue.



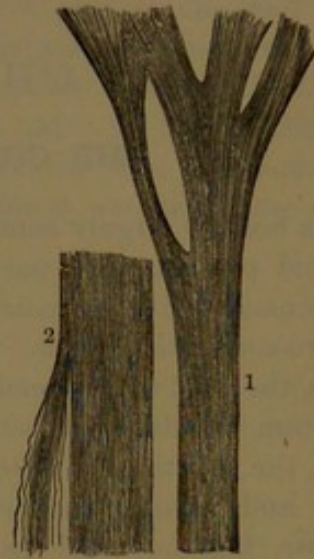
lagenous substance. These tissues are the source of glue, and are the basis of jellies and soups.

FIG. 111.



BUNDLES OF FIBRO-CONNECTIVE TISSUE FROM A LIGAMENT, partially unravelled into their constituent fibres.

FIG. 112.



FIBRO-CONNECTIVE TISSUE. 1, from a tendinous cord of the right ventricle of the heart; 2, from a portion of the dura.

In the various connective tissues above named, besides the chief element described, they contain more or less **elastic tissue**.<sup>1</sup> This is obscured by the presence of the predominant tissue, but when a specimen prepared for the microscope is submitted to acetic acid, this renders the elastic tissue distinctly visible. It appears as well-defined fibres of variable thickness, generally comparatively coarse, and never so fine as the filaments of fibro-connective tissue. The fibres also anastomose in a reticular manner, and the broken extremities appear more or less curled and blunt at the ends. The elastic tissue occupies the intervals of the fibro-connective-tissue bundles, sometimes embracing them in nets, and occasionally turning spirally around them.

A constant structural element of the fibro-connective tissues is the so-called **connective-tissue corpuscle**. This is ordinarily a flattened cell or thin plate, often with one or several thin offsets from the broad surfaces, and dividing irregularly at the borders into branching processes. The corpuscles occupy the intervals of the connective-tissue bundles, and conjoin by their branches. In sections of the tissue they appear as elongated, spindle-shaped branching bodies, or in an opposite direction as irregular stellate bodies. On free surfaces of connective-tissue structures, as exemplified on tendons and aponeuroses, the flattened connective-tissue corpuscles do not branch, but conjoin by their contiguous margins in the manner of endothelial cells. The corpus-

<sup>1</sup> Yellow elastic tissue.

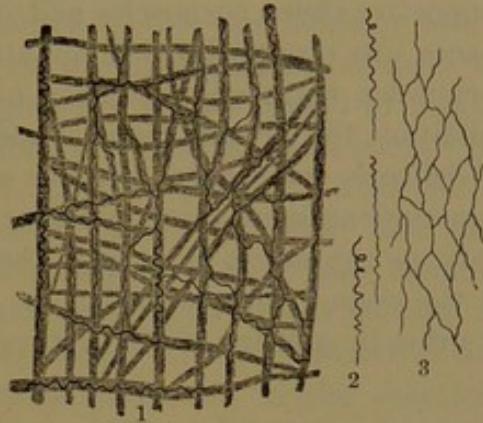


cles are composed for the most part of a clear protoplasm with a central more granular mass and a large oval nucleus.

Other cells are observed in the connective tissues whose character is not very obvious, except certain smaller ones which are endowed with amœboid movement and are evidently migratory colorless blood-corpuscles.

Blood-vessels, lymphatics, and nerves occur in all the connective tissues, but in very different proportions, being few and small in ligaments, tendons, and fasciæ, while they are numerous in the periosteum and dura, and are all in greater abundance in the submucous tissue and dermis. Generally, however, they simply pass through and are supported by the connective tissue, and are destined to supply other parts, while in their course they furnish a few small ones to the fibro-connective-tissue structure.

FIG. 113.



FIBRO-CONNECTIVE TISSUE from beneath the annular ligament of the wrist, and pertaining to the synovial sheath of the flexor tendons. Treated with acetic acid. The darker lines, 1, 2, 3, exhibit fibres of the mingled elastic tissue.

#### AREOLAR TISSUE.

The loosest condition of fibro-connective tissue constitutes the **areolar tissue**,<sup>1</sup> which is named from the circumstance that its component bundles intersect one another and include a multitude of freely communicating clefts or areolæ. Of this character are the entire superficial fascia investing the body beneath the skin, together with its attachment to the latter and to the deep fascia; the submucous and subserous tissues; the sheaths of blood-vessels and their attachments; similar envelopes of the lymphatics, together with accumulations of the same material in various recesses and intervals of the muscles and other organs; the sheaths of nerves and the connecting material of their fibres; the connecting material of the muscles, of their fleshy bundles, and of their sheaths, together with contiguous parts; and the parenchyma of organs, such as that which associates the lobules and follicles of glands and the lobules and air-cells of the lungs. Thus the areolar tissue is widely distributed, and generally serves to hold parts together, to contribute to their strength, to convey and support the principal vessels and nerves, and at the same time to permit of limited movement among all the parts concerned.

<sup>1</sup> Connective tissue; cellular tissue; tela cellulosa or cellularis; reticulated, filamentous, laminated, or porous tissue; cellular or reticular substance.



The fibro-connective-tissue bundles of the areolar tissue vary greatly in size, and interlace in every direction. The density or laxity of the areolar tissue mainly depends on the size of its constituent bundles and the closeness with which they are associated. They are mingled with variable proportions of fine, reticular fibres of elastic tissue, with connective-tissue corpuscles and other corpuscles. The cleft-like interspaces are occupied by lymphatic moisture, in which a few lymph-corpuscles move about. They are readily inflated with air, in which condition the areolar tissue appears white and fleecy, and composed of delicate, transparent vesicles of variable size. It is from the free communication of these interspaces that liquids so readily pervade the body, as the serum of dropsy, the extravasation of blood from injuries to the vessels, the pervasion of pus in abscesses, and the infiltration of urine in rupture of the urethra. The areolar tissue is the chief seat

FIG. 114.



AREOLAR TISSUE FROM THE AXILLA, exhibiting its composition of bundles of fibro-connective tissue, among which are groups of fat-cells.

FIG. 115.



DIAGRAM OF THE ARRANGEMENT OF THE FIBRO-CONNECTIVE TISSUE IN THE EXTERNAL COAT OF BLOOD-VESSELS.

of accumulations of adipose tissue or fat, with the disappearance of which it collapses or becomes more compact. From its constituent material and arrangement, it is endowed with considerable tenacity and extensibility, which admirably adapt it for the union of parts without interfering with their movements or variable changes in size.

The vessels and nerves of the various connective tissues are almost entirely those which traverse and are supported by these tissues in their course to other parts.

The fibro-connective tissue is the most tenacious of all organic tissues, and is admirably adapted to the purposes of holding parts together and protecting them, and of communicating muscular power to parts to be moved. Advantage has been taken of its qualities in the arts,



and thus the dermis, or connective-tissue layer of the skin of animals, forms that most important material, leather, and the similar layer of the intestines forms the strongest of cords, called catgut. Our early ancestors also found tendons and raw hide the best materials for bow-strings and for cords to bind things together.

Flexible at all times, the connective tissues are more or less extensible and inextensible according to the arrangement of their constituent bundles. The band-like ligaments are composed of compact parallel bundles, which are inextensible, and thus hold the bones firmly together and prevent them from being pulled apart. Tendons and aponeuroses, likewise, are composed of parallel bundles, and under ordinary conditions are perfectly inextensible, so that they communicate the power of their muscles to the parts to be moved without any loss which would occur in stretching them. In the connective-tissue layers of the hollow viscera, in the blood-vessels, in the sheaths of muscles, and in capsular ligaments, the diagonal intersection of the widely-spread bundles of fibro-connective tissue, while permitting limited extensibility and expansion, preserves the integrity of the parts.


#### ELASTIC TISSUE.

Besides the variable proportions of **elastic tissue** which enter into the composition of the different connective tissues indicated, it enters largely into the walls of the blood- and lymphatic vessels, especially the arteries, in the ligaments of the larynx, the vocal cords, and in the submucous tracheal and bronchial tissue, and it almost wholly composes the vertebral elastic ligaments. In four-footed mammals it forms the nuchal ligament, which is intended to sustain the head and thus economize muscular power. In animals in which the head is unusually large or weighted with great antlers, or tusks, as in the elk and elephant, the ligament, composed of compact elastic tissue, is of huge proportions. In man, in whom the head is balanced on the spine, the same ligament is reduced to the condition of a mere partition of fibro-connective tissue between the muscles at the sides of the back of the neck.

In the large herbivorous quadrupeds, a thick, strong membrane of elastic tissue aids in the support of the pendent abdomen; in man it is represented only by the deeper layer of the superficial fascia.

As its name implies, the tissue is highly elastic, approaching in this respect india-rubber. It is buff-yellow in color, and opaque.

FIG. 116.

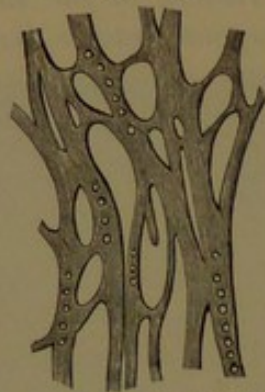


ELASTIC TISSUE, from the elastic ligaments of the vertebral arches, consisting of coarse anastomosing fibres; magnified.



In the yellow ligaments of the vertebræ, in which the elastic tissue is presented in its purest condition, it is composed of longitudinal parallel fibres in bundles, collected into variably larger prismatic bundles united by ordinary fibro-connective tissue, which also penetrates among the fibres of the elastic tissue. These fibres are comparatively coarse, tolerably uniform, about  $\frac{1}{1300}$  of a millimetre in diameter, prismatic, nearly straight or flexuose, and mutually forking and intersecting in their course. From the latter condition the tissue in longitudinal section appears reticular, with the meshes as narrow lanceolate fissures. The fibres are transparent and homogeneous. When broken they curl at the extremities and end abruptly, indicating a degree of fragility, though they are highly flexible and extensible. In some structures the elastic nets are composed of fine fibres with wide intervals. In the

FIG. 117.



ELASTIC TISSUE, from the middle coat of the pulmonary artery of the horse; highly magnified.

FIG. 118.



ELASTIC TISSUE, from the middle coat of the carotid artery of the horse; highly magnified.

vocal membrane and in most areolar tissues the fibres are exceedingly fine. In other parts the fibres are larger and broader, and the intervals proportionately small, so that the tissue may appear to be a homogeneous membrane with rounded apertures, as in the fenestrated membrane of blood-vessels.

The blood-vessels of elastic tissue, in its purest condition, as in the yellow vertebral ligaments, are comparatively few. They run in the interstitial connective tissue, and communicate with capillaries between the smaller bundles of the elastic tissue. Lymphatic vessels pursue the same course.

#### ADIPOSE OR FAT TISSUE.

The **adipose** or **fat tissue** is an important, though not an essential, structural element of the body; nor does it alone form any distinct or separate organ. Its quantity is very variable, and is more or less related with differences of age, sex, habit, health, and other conditions. Commonly most abundant in the infant and the mature female, in the emaciation of disease or through starvation it may disappear almost completely; and sometimes in a condition of apparent



health it may accumulate to such a degree as to be regarded as a disease in itself. It is usually associated with the looser forms of fibro-connective tissue and the blood-vessels, and accompanies these in their distribution through other organs.

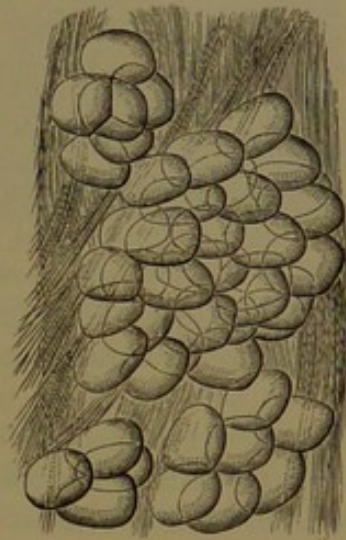
The adipose tissue commonly forms a considerable and continuous layer<sup>1</sup> immediately beneath the skin, for the most part occupying the more superficial layer of the superficial fascia, and thence extending into the meshes of the deeper part of the dermis. In this position it is most abundant in the infant and mature female, giving to them their characteristic rounded symmetry of shape. Ordinarily it accumulates most beneath the skin of the breast, the abdomen, and the buttocks. In the palms of the hands and soles of the feet it serves as an elastic cushion to moderate the influence of pressure on the important parts beneath, and in these positions it is most persistent, and is even retained in ordinary emaciation. It also occupies the intervals of muscles, the hollows of the temples, cheeks, and other similar places; and it fills the interspaces of the eyeball with its muscles and other important organs of the orbit. Its disappearance in emaciation gives rise to the sunken temples, cheeks, and eyes so characteristic of many diseases.

Adipose tissue also collects along the course of the blood-vessels and nerves, and is often conspicuous along those of the heart and intestines. It often accumulates to a considerable degree between the folds of the peritoneum, around the intestines and the kidneys, and in a great measure in these positions contributes to produce the protuberant abdomen of corpulent persons. It likewise fills up the intervals around the articulations, and occupies the interior of some of the synovial fringes; it also forms the soft, yellow marrow of the bones.

The adipose tissue in the living body is usually a pale yellow, soft substance, varying in consistence and tenacity in proportion to the fibro-connective tissue with which it is associated. It is most consistent in the subcutaneous fat, and is softest in the yellow marrow of the bones. In the dead body, with the reduction of the temperature it becomes solidified and harder.

The adipose tissue is composed of little vesicles filled with an oil or liquid fat, and these vesicles are collected in little groups sustained by

FIG. 119.



ADIPOSE TISSUE, WITH CONNECTIVE TISSUE, from the superficial fascia of the abdomen; highly magnified. The groups of fat-vesicles are observed contained in the meshes of connective tissue.

<sup>1</sup> Panniculus adiposus.



bundles of fibro-connective tissue and blood-vessels. The groups of vesicles are collected into larger and larger masses, which present a more or less lobulated appearance, and are supported in the meshes of a fibro-connective-tissue matrix.

The fat-vesicles are spherical or oval cells, usually rendered more or less polyhedral by mutual pressure, and commonly range from the  $\frac{1}{800}$  to the  $\frac{1}{300}$  of an inch in diameter.

The fat-cell consists of a delicate, transparent, homogeneous, membranous wall, distended with a single clear globule of homogeneous oil or liquid fat. Ordinarily, nothing further is visible in the structure of the fat-cell, but it has been shown that in each cell the oil-globule is enveloped by an exceedingly delicate film of protoplasm, next the wall. To one side of the cell a flattened, elliptical nucleus is embedded in the protoplasm.

In emaciation from disease or starvation, the oil-globule of the fat-cell undergoes diminution, and may entirely disappear, and be substituted by a serous liquid.

The fat-cells are derived from cells of protoplasm, and may be produced by the transformation of lymphoid cells, connective-tissue corpuscles, and the marrow-cells of bones.

The adipose tissue is richly supplied with blood-vessels, the capillaries of which form a delicate, reticular sponge, enclosing in its meshes single fat-cells or groups of several cells. Nerves pass through adipose tissue in their course to other parts, but appear not to be distributed to its structure.

#### THE CARTILAGES.

The cartilages, or gristles, are of three kinds,—those composed of pure cartilage; and the fibro-cartilages and elastic cartilages, which are composed of variable proportions of the former tissue with fibro-connective or elastic tissue.

#### CARTILAGE.

**Cartilage**, true or hyaline cartilage, is a dense, bluish-white, or sometimes yellowish-white, pearly substance, of less hardness than bone. Apparently homogeneous and opaque, or slightly translucent, it is elastic and highly flexible, but inextensible, and, though of firm consistence, is less tenacious than fibro-connective tissue. Easily cut, in thin slices it is translucent or transparent, more or less opalescent, and to the naked eye homogeneous. Like the fibro-connective tissue, when dried it is exceedingly hard, yellow, and translucent, but readily imbibes water, and resumes its original condition.

The physical properties of cartilage render it well adapted to its purposes. It enters mostly into the construction of the skeleton, and in all the more movable joints invests the free surfaces of the bones, providing them with an elastic covering which facilitates motion and moderates the force of concussion. It also composes the costal cartilages,



which, without diminishing the strength of the framework of the chest, contribute to its elasticity and security. It further forms the principal cartilages of the larynx, except the epiglottis, those of the windpipe and of the nose, to all of which it gives the necessary firmness to retain the passages they enclose at all times freely open to currents of air.

The skeleton commences in the embryo, chiefly in the condition of cartilage, and in the subsequent growth of the bones the osseous tissue is largely preceded by the production of cartilage. Those cartilages which are converted into bones are distinguished as **temporary cartilages**, while those which remain unchanged are the **permanent cartilages**, though even some of these in later life undergo conversion into bone, as exemplified by the cartilages of the larynx. The ensiform cartilage of the adult is the remaining unossified portion of the last segment of the sternum.

The true cartilages, except those of the movable joints, which are distinguished as **articular cartilages**, are invested with a membrane, the **perichondrium**, which in structure and function accords with the periosteum of the bones.

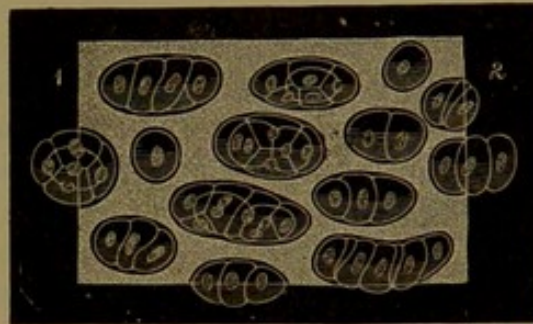
When bones are macerated in dilute muriatic acid and the earthy constituents are dissolved, the articular cartilages are readily detached, and in this condition, when closely bent, are easily broken, with perpendicular edges, which show a distinctly striated condition in the same direction, apparently indicating a fibrous constitution. In pathological specimens these cartilages are also frequently seen more or less resolved into a fibrous condition.

Under the microscope thin sections of cartilage present a uniform hyaline matrix, in which are embedded scattered cells, sometimes single, but mostly in groups of two or more, often up to a dozen, or even a greater number.

In the articular cartilages the matrix appears slightly clouded and obscurely granular. In the costal cartilages, some portions more than others, especially in advanced age, present a more or less finely fibrillar condition of the matrix.

The cells of cartilage, called **cartilage-corpuscles**, when single are spherical or oval, or nearly so; when in pairs each is half oval or ovoid, apparently as if resulting from the division of an original single oval cell. When the groups consist of three or more cells they are usually arranged in rows or columns, and the intermediate cells are more or less discoid. If the group consists of four or more together they

FIG. 120.



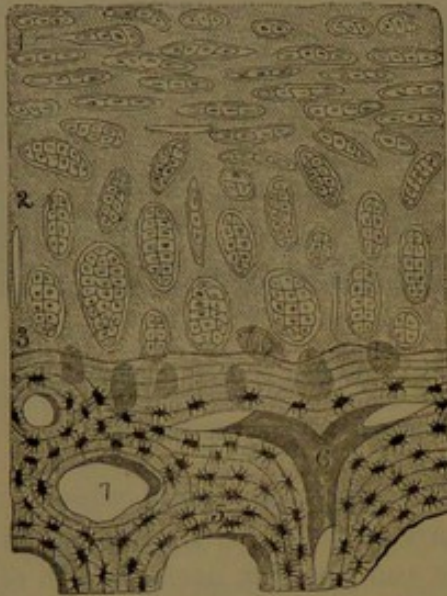
CARTILAGE; section through the thickness of the oval cartilage of the nose. 1, towards the exterior; 2, towards the interior surface; highly magnified. It exhibits groups of cartilage-cells embedded in a homogeneous or faintly granular matrix.



appear as corresponding segments of a spheroid or ovoid. The shape of the groups and of the cells composing them is evidently that which is due to multiplication by division of originally single, spherical or oval cells.

In the articular cartilages the groups or columns of cells in the deepest part are arranged more or less perpendicularly to the surface of bone beneath. At a higher level they are irregularly oblique in

FIG. 121.

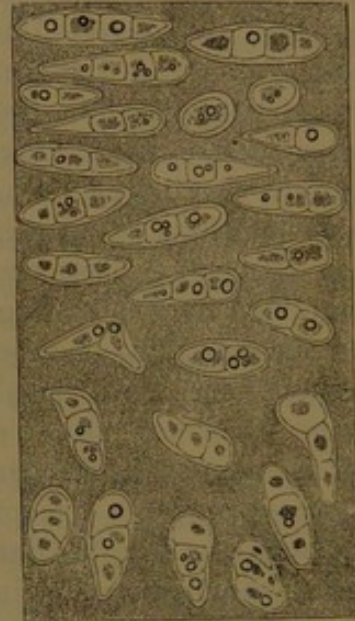


VERTICAL SECTION OF ARTICULAR CARTILAGE from the carpal surface of the radius. 1, 2, 3, articular cartilage; below this is a portion of the bone, 5, 6, 7. 1, exterior portion of the cartilage, exhibiting the groups of cells lying parallel to the slightly irregular free surface; 2, 3, the cells arranged vertically in the deeper part of the cartilage; 4, groups of cells obscured by osseous deposit; 5, structure of the bone, exhibiting the concentric laminae and lacunae; 6, a vascular canal; 7, a marrow areola of the spongy substance of the bone. The specimen is highly magnified, but the depth of the articular cartilage is proportionately reduced, so as to exhibit the relation of all the parts without making too large a figure.

lages the cells are larger, and the groups in general have a variably radiated arrangement from the interior, and gradually become parallel with the surface and flattened in the same direction as they approach the latter.

The cartilage-corpuscle consists of translucent protoplasm, faintly granular, defined by a transparent, homogeneous wall, which is blended with the cartilage matrix, and commonly is scarcely to be distinguished from it. It contains a spherical nucleus, and not unfrequently one or several little oil-globules. The nucleus contains a clear nucleoplasm, together with one or several nucleoli.

FIG. 122.



SECTION OF COSTAL CARTILAGE. The upper part is towards the exterior surface, where the groups of cells are arranged parallel to it; the lower part is towards the interior, where the groups are arranged vertically to the free surfaces; highly magnified.

relation with the former; and approaching the free surface of the cartilage they become horizontal or parallel with the latter, and also flattened, as if influenced by pressure during their production and growth. In the costal carti-



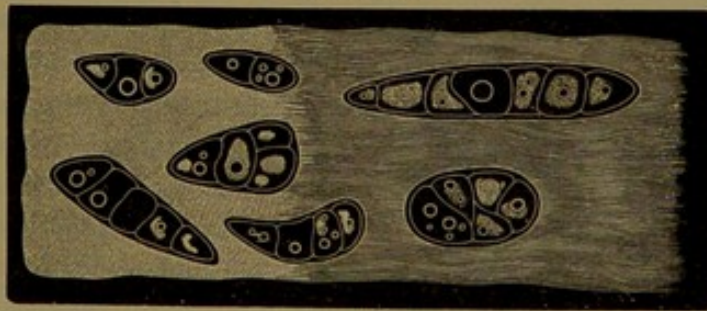By the imbibition of water or other liquids, or by the action of electricity, the protoplasm of the cartilage-corpuscle shrinks from its wall into an irregular mass, enclosing the nucleus.

The **articular cartilages** are thin plates which invest the articular surfaces of bones, the structures of the two being continuous. The osseous structure extends into the cartilage in a multitude of minute irregular points and ridges, and molecules of bone-earth extend still farther into the cartilage and envelop the deepest stratum of cartilage-corpuscles. On articular eminences the cartilages are thickest centrally, and thin away at the periphery, and in articular cavities the reverse condition exists. The free surface of these cartilages is devoid of any especial investment, but at the margin it becomes continuous with the fibro-connective tissue of the adjacent synovial membrane, and many of the contiguous cartilage-corpuscles are provided with branching processes, and appear to be transitional in character with the neighboring connective-tissue corpuscles. The articular cartilages are devoid of vessels, but dilated capillary loops of the subjacent bone reach their attached surface, and a zone of fine capillaries from the vessels of the adjacent synovial membrane surround their circumference.

The articular cartilages retain their character through life, and, together with the cartilages of the nose, are alone deserving the distinction of being called permanent cartilages.

The costal cartilages, which are the thickest examples of cartilage, besides their perichondrium furnished with nutrient blood-vessels are pervaded by a few narrow canals, mostly longitudinal, which give

FIG. 123.



SECTION OF COSTAL CARTILAGE, crossing the free surfaces, but taken from near the centre. To the left, which was towards the exterior surface, the groups of corpuscles are embedded in a homogeneous matrix; towards the right, the matrix has assumed a decidedly fibrous character. Specimen from an adult of about forty years of age.

passage to similar vessels, but these do not farther enter the cartilaginous tissue. These cartilages in the advance of life undergo change, becoming more rigid and hard from the deposit of bone-earth in the matrix. The deposit takes place irregularly, occurring earlier and most abundantly contiguous to the osseous connections of the cartilages. The process of deposit, called **calcification**, rarely extends completely throughout the cartilages.

The cartilages of the larynx towards the middle of life undergo



change, and gradually become more or less completely ossified. The change occurs later in the female.

When cartilages are fractured in life they usually become reunited by fibro-connective tissue, which often is subsequently converted into bone.

The true cartilages yield chondrin on long boiling, a material having different chemical reactions from gelatin.

#### FIBRO-CARTILAGE.

**Fibro-cartilage** is composed chiefly of fibro-connective tissue, with a small and variable proportion of embedded cartilage-corpuscles. Like true cartilage, it possesses great firmness and elasticity without extensibility, but is more flexible and tenacious. It cuts with more resistance, and presents a compact fibrous structure. The fibro-cartilages are as follows :

1. The **interarticular fibro-cartilages**. These occur in the articulations of the mandible, clavicle, wrist, and knee. They occupy the interval of the articular cartilages, and conform to their opposed surfaces. They are plates, thinning towards the centre, with the surfaces free and smooth, and the peripheral border attached to the capsular ligament, whence the contiguous synovial membrane is reflected on the margin of the free surfaces. In the joints of the mandible and clavicle they are disks; in the wrist-joint the fibro-cartilage is triangular; and in the knee-joint there are two, named from their shape the semilunar cartilages.

These fibro-cartilages are mainly composed of bundles of fibro-connective tissue, interlacing and compactly felted together, without interstices such as exist in ligaments and tendons. On the free surfaces the structure assumes more the character of true cartilage. The cartilage-corpuscles are comparatively few, and scattered among the fibro-connective-tissue bundles, often single, but more frequently in pairs, having the appearance of being derived through the division of originally single cells. They possess the same character as those of true cartilage.

The interarticular cartilages not only adapt but aid in maintaining the apposition of the articular cartilages, moderate pressure upon them, and facilitate the gliding movement of the joints.

2. The **connecting fibro-cartilages** unite the opposed articular surfaces of the vertebral centra and of the pubes, giving the articulations limited flexibility. They are the intervertebral and the interpubic disks, and are immediately continuous with thin plates of true cartilage investing the bones. The intervertebral disks mainly consist of numerous concentric layers of fibro-connective-tissue bundles, the interior of which gradually merge into a central tenacious pulp. With the fibro-connective-tissue bundles are associated scattered cartilage-corpuscles, which are more abundant in the interior layers approaching the central pulp. The corpuscles, usually in groups of two



or three or more, exhibit a concentric laminar structure, and many are provided with long branching processes. The central pulp consists of a reticular cell-structure in a soft fibrous matrix, probably derived from the cells of the chorda dorsalis of the embryo. It frequently occupies an exceedingly irregular space, with an interior lacerated villous surface, resembling the subcutaneous synovial bursæ, like that upon the patella. The disk of the pubic symphysis approximates in structure the intervertebral disks.

3. The **circumferential fibro-cartilages** consist of bands which extend the margin of articular cavities, serving to increase their depth, as in the glenoid ligament surrounding the glenoid cavity and the cotyloid ligament surrounding the acetabulum.

4. The **investing fibro-cartilages** consist of thin layers, lining grooves of the bones which give passage to tendons.

5. The **palpebral cartilages**, or **tarsi**, serve to preserve the form of the eyelids, and consist almost entirely of closely-compacted bundles of fibro-connective tissue.

The fibro-cartilages are devoid of vessels beyond their attached surfaces. Like the connective tissues, they yield gelatin on boiling, indicating the great predominance of the fibro-connective tissue.

#### ELASTIC CARTILAGE.

**Elastic cartilage**, in appearance more nearly resembling true cartilage than the former, is intermediate in tenacity and flexibility, and is represented by the auricular cartilage, that of the eustachian tube, the epiglottic cartilage, and the cornicles of the larynx.

It is composed of a matrix of elastic tissue embedded in a more homogeneous or faintly granular substance, mingled with numerous cartilage-corpuscles. The fibres of elastic tissue are closely felted, and freely anastomose with one another. The cartilage-corpuscles, commonly in pairs, are scattered irregularly among the matrix of elastic fibrous tissue, and are each enveloped with a clearer layer of the homogeneous substance. The elastic cartilages are invested with a vascular perichondrium.

All the cartilages appear to be devoid of nerves, as they are of vessels. They are totally insensible.

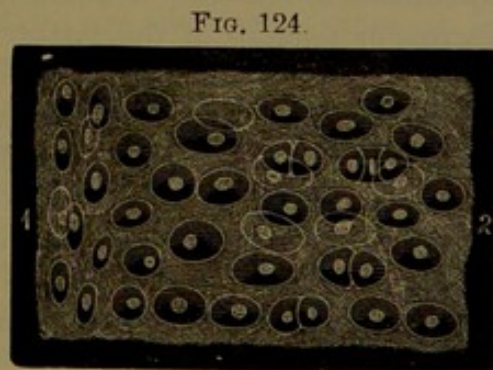


FIG. 124.  
SECTION OF ELASTIC CARTILAGE FROM THE AURICLE OF THE EAR. The cells are seen embedded in a fibrous matrix. 1, exterior surface, where the cells are parallel to it; 2, towards the middle. Highly magnified.

#### FASCLE.

A **fascia** is a membrane of variable texture, more or less compact or loose, and composed of interwoven bundles of fibro-connective



tissue. The fasciæ form a covering or investment for the muscles and other organs, serving to protect and retain them together, give them attachment, and at the same time support and convey vessels and nerves to them.

The principal fasciæ, named from their relative position the superficial and the deep, succeed each other beneath the skin, and invest the body like additional integuments.

The **superficial fascia** is a membrane of loose fibrous structure, situated immediately beneath the skin, and connecting it with the deeper parts. It varies in thickness, compactness, and distinctness in different positions. For the most part it consists of two closely-united layers, of which the more superficial<sup>1</sup> is of looser texture and serves as the matrix of the subcutaneous fat. With the disappearance of the latter, as in lean persons, it becomes more distinctly membranous. The deeper layer of the superficial fascia is more compact, and contains the principal superficial vessels, especially veins, and the trunks of the cutaneous nerves. It is comparatively free from fat, but also becomes more or less pervaded with this material in obesity. In certain positions, as the eyelids, lips, anus, penis, and scrotum, the superficial fascia is always destitute of fat; but in the palms of the hands and soles of the feet it is constantly present.

The **deep fascia** is usually a more dense and strong layer of fibro-connective tissue, closely enveloping the muscles and forming a nearly continuous covering to the body beneath the superficial fascia, to which it is attached. It is also tightly attached to subcutaneous processes and borders of bones where it is continuous with their periosteum. It varies greatly in thickness and strength in different positions, and in many assumes more or less the character of an **aponeurosis**,<sup>2</sup> affording partial attachment to muscles, or actually becoming continuous with the aponeurosis or tendons of the latter. From the inner surface of the deep fascia, laminæ extend between the muscles and become attached to contiguous bony borders, forming the so-called **intermuscular partitions**, which also afford attachment to muscles. When the latter are not attached to the fascia this is adherent by loose connective tissue, which does not interfere with the muscular movements. In the vicinity of some of the joints the deep fascia is strengthened by transverse bands which arch over bony grooves, attached to their borders, and convert them into canals for the passage of tendons. Such bands constitute the annular and vaginal ligaments.

---

<sup>1</sup> Panniculus adiposus.

<sup>2</sup> Aponeurosis of investment.



## CHAPTER V.

### THE MUSCULAR SYSTEM.

THE **muscles** are the chief organs of motion in all the higher forms of animal life, and for this power depend on a peculiar substance composed of special fibres, which are the essential element of structure of the **muscular tissue**. In the living condition the **muscle-fibres** possess the quality of shrinking or contracting, and perhaps also of actively elongating or expanding, under a variety of causes or stimuli which may impress them. Thus, the muscles contract under mechanical irritation, chemical agency, the electric current, and extremes of temperature. Ordinarily, in the living animal they display their motive power under impressions which proceed directly from the nervous system. A single muscle-fibre is an independent motor power, and may act alone or in concert with others; and it is therefore to be physiologically regarded as a muscle, as much as any of the collections of muscle-fibres which are commonly distinguished and specially named as muscles.

All the more obvious movements in the higher animals are produced by muscles, as those of locomotion and prehension, and those concerned in the functions of the alimentary apparatus, the circulation and the respiration, and others. Many of the muscles, like those of locomotion, prehension, and respiration, are ordinarily more or less under the control of the animal and act intentionally, or through the will or volition, and are hence called voluntary muscles, though they may act under other stimuli, and in many cases do so habitually, as in those of respiration. Other muscles are beyond the control of the will, as those of the circulatory and digestive apparatus, and are thence called the involuntary muscles. The two kinds of muscles not only differ in the ordinary mode in which they are excited to activity, but also differ in anatomical characters.

The muscular tissue is one of the most important characteristics of the higher animals in contradistinction to plants. The latter derive all the material of their composition directly from the air, water, and soil, in which they are incessantly enveloped, and are therefore in general stationary in position. The animal derives its chief materials directly or indirectly from the plant, and hence the necessity of motors to enable it to apply to the latter as occasion requires. The muscular tissue is familiarly known as the flesh, or meat, of animals, and it is



the substance which on the whole furnishes the most important food of man, as it contains in the least bulk and in the most assimilable condition the greatest amount of material of which his body is composed.

The muscles vary greatly in size, and are ordinarily proportioned to the work or movement to be performed, and are so intimately related with their activity that they increase or decrease with the latter. Thus exercise enlarges the muscles, and inactivity reduces them.

The smallest muscles are microscopic, and may consist of a single muscle-fibre; the larger ones consist of bundles of muscle-fibres, which bundles may be isolated, arranged in layers, or collected into larger and larger bundles. The various muscles, ordinarily distinguished as such, vary greatly in size, form, and distinctness, and they more or less conform to the position they occupy. Thus, on the limbs they appear distinct and mostly of elongated forms, on the chest and abdomen in broad layers, and in the walls of the hollow viscera and vessels as concentric laminae.

The voluntary muscles are especially characterized by the regular transverse, striped condition of their fibres, whence they are called **striped muscle-fibres**, or **striped muscles**, while in the involuntary muscles generally the fibres exhibit no such stripes, and are distinguished as **unstriped muscle-fibres** or **unstriped muscles**. The heart, though an involuntary muscle, is composed of striped muscle-fibres; but these are otherwise peculiar, and will be described as the cardiac muscular tissue.

#### THE UNSTRIPED OR INVOLUNTARY MUSCLES.

The **unstriped** or **involuntary muscles**<sup>1</sup> in general form component layers of the walls of the hollow viscera, as the stomach and intestines, the urinary bladder, and the uterus; and likewise in the blood-vessels, the air-passages, and in glandular ducts. They also enter into the construction of the skin, the iris, and other parts to be described hereafter.

**Unstriped muscle-fibres**<sup>2</sup> constitute the simplest kind of muscular tissue. Each fibre is a variably elongated, fusiform, nucleated cell, straight or slightly flexuose, rounded prismatic and often flattened, and tapering at the ends. The fibres exhibit a more or less distinctly longitudinal striated appearance, and are composed of a corresponding fibrillar sarcoous substance, which is enclosed by a delicate and closely-adherent sheath, the **sarcolemma**, which is homogeneous and elastic. The nucleus of each fibre is commonly central and elliptical.

The unstriped muscle-fibres differ greatly in length and proportionate width in different organs and parts. They are longest and thickest in the muscular coat of the bowels, and are shortest and pro-

---

<sup>1</sup> Muscle of organic life.

<sup>2</sup> Smooth muscles or muscle-cells or fibres; contractile fibre-cells.



portionately wider in the coats of the blood-vessels, in which they are sometimes divided or irregular at the ends. They are collected into smaller or larger bundles, and these again in many positions form con-

FIG. 125.



UNSTRIATED MUSCLE-FIBRES. 1, from the small intestine; 2, from the middle coat of an artery; 3, from a vein.

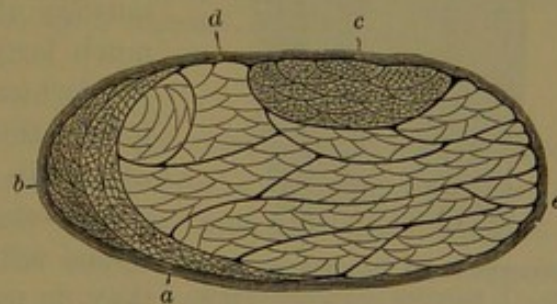
tinuous layers. The fibres of a bundle are imbricated, and adhere together by a cementing substance like that which unites the epithelial and endothelial cells. The bundles of muscle-fibres are sheathed and united by ordinary connective tissue.

#### THE STRIPED OR VOLUNTARY MUSCLES.

The **striped** or **voluntary muscles** generally form distinct fleshy masses, which are mostly attached to the bones and other parts by means of fibrous structures, named aponeuroses and tendons. They vary greatly in size, proportions, and shape. Thus, there are long and short muscles, broad and narrow, thick and thin, cylindrical, band-like, fusiform, triangular, rhomboid, square, and circular muscles. The sartorius muscle is nearly two feet in length; the stapedius about one-fourth of an inch. The attachments of the muscles are the points from which and on which they act; the commonly more fixed point, generally that nearest the axis of the body, is called the **origin**, while the opposite point, or that commonly moved by the muscle, is the **insertion**. The terms are relative, for the muscle may act from either extremity; and only in a few instances, as in some of those of the face, do they act invariably from the fixed bony attachment upon the movable soft parts.

In the construction of the fleshy mass of the muscle, called its **belly**, the muscle-fibres are collected into smaller and larger bundles, called **primary** and **secondary bundles**, or **fascicles**.<sup>1</sup> These may be collected into

FIG. 126.



TRANSVERSE SECTION OF THE LOWER END OF THE ULNOCARPAL FLEXOR, magnified. *a*, section of tendon appearing as two crescents, composed of prismatic bundles of fibrous tissue; *b*, a secondary bundle of crescentic shape, consisting of primary bundles of muscle-fibres; *c*, a flattened cylindrical secondary bundle, consisting of primary bundles of muscle-fibres; *d*, secondary and primary bundles in outline; *e*, sheath of the muscle, composed of fibro-connective tissue.

<sup>1</sup> Fasciculi; lacerti.



still larger ones, producing coarse-looking muscles, as exemplified by the great gluteal muscle.

The muscle-fibres are generally parallel with one another in the same fascicle, and the fascicles pursue the same course or are more or less convergent. Commonly, they proceed in the same direction as the muscle, straight or convergent; but in many cases they pursue a more or less slanting course across the general direction of the muscle. In some of the longest muscles, as the sartorius and gracilis, the fleshy fascicles run parallel with one another throughout their entire length. In others, comparatively short fascicles proceed obliquely from opposite sides of the tendon of origin and converge to that of insertion, producing an appearance like a feather, whence the name of **penniform muscle**,<sup>1</sup> as exemplified by the femoral rectus. In some the fascicles proceed in the same way from one side of a tendon to another, producing a **semipenniform muscle**,<sup>2</sup> as the semimembranosus muscle.

The tissue of the voluntary muscles, as well as some others, is composed of **striped muscle-fibres**.<sup>3</sup> These commonly consist of narrow,




FIG. 127.  
STRUCTURE OF THE STRIPED MUSCLES. 1, fascicles composed of prismatic, striped muscle-fibres, terminating below in tapering ends; 2, cut extremities of the fibres; 3, investing fibro-connective tissue of diagonally crossing filaments; 4, commencing tendinous bundles.

straight columns, which are variably prismatic, with rounded borders and tapering extremities. Exceptionally, in the muscles of the tongue and face, many of them branch at their insertion into the mucous membrane and skin. In the same muscle, generally, they approximate some uniformity, though many present considerable difference in size, which is especially the case in different parts of the body. In the muscles of the limbs and trunk they are much larger than in those of the face; in the former ranging from  $\frac{1}{750}$  to  $\frac{1}{400}$  of an inch in thickness, in the latter from  $\frac{1}{2400}$  to  $\frac{1}{750}$  of an inch. They are usually longest in the longest muscles, but are not proportioned with the size of these. Commonly they do not exceed an inch or two, and in the shortest muscles accord with these in length. In the construction of the fleshy belly of a muscle they are collected in prismatic fascicles, and they terminate among themselves by conical ends; and when at-

tached to tendons they terminate among the connective-tissue bundles composing these.

<sup>1</sup> M. penniformis, bipenniformis, or pennatus.

<sup>2</sup> M. semipenniformis, penniformis, or semipennatus.

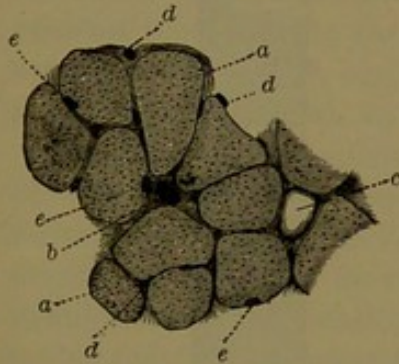
<sup>3</sup> Striped or striated muscles.



Under the microscope the fresh muscular tissue appears translucent, with a faint, yellowish tinge, which in quantity gives the usual so-called flesh-color to the muscles. The fibres are regularly marked by transverse stripes alternately wider and darker and narrower and lighter, very uniform in the same muscle, but varying in different muscles. With higher power of the microscope the lighter stripes appear divided by a fine line. In muscular tissue from a recently-killed animal, the fibres may be observed in motion, at one moment becoming shorter and wider, and at the next moment proportionately longer and narrower, while the stripes undergo corresponding changes.


The striped muscle-fibre is composed of a soft substance, the **sarcous matter**,<sup>1</sup> enclosed in a hyaline sheath, the **sarcolemma**.<sup>2</sup> To the sarcous matter, arranged in disks, are due the characteristic transverse stripes of the muscle-fibre. After death it assumes a longitudinally striated appearance, with a finely-granular aspect. When the

FIG. 128.



TRANSVERSE SECTION OF THE BRACHIAL BICEPS. *a*, muscle-fibres with intervals occupied by connective tissue; *b*, blood-vessel; *c*, fat-cell; *d*, capillaries; *e*, nuclei of the muscle-fibres.

FIG. 129.



TRANSVERSE SECTION OF A FASCICLE OF THE CREMASTER, exhibiting the prismatic form of the muscle-fibres; highly magnified.

muscular tissue is hardened by alcohol or other liquid, the sarcous matter may be torn into filaments, distinguished as the primitive **muscle-fibrils**.<sup>3</sup> These are of extreme fineness, and composed each of a single row of particles, named the **sarcous elements**,<sup>4</sup> the regular arrangement of which gives rise to the equally regular transverse stripes of the muscle-fibre. The sarcous elements are conjoined by a more translucent cementing substance, to which are due the lighter, narrower stripes<sup>5</sup> of the fibre, as well as of the intervals of the fibrils. When muscular tissue has been submitted to the action of the gastric juice or hydrochloric acid, the sarcous matter is disposed to break into disks, apparently indicating the fibrillar condition to be of relative character. The sarcolemma is a delicate, homogeneous, elastic membrane intimately connected with the sarcous matter, and in the recent fibre

<sup>1</sup> Myoline.<sup>2</sup> Myolemma; primitive sheath.<sup>3</sup> Muscular fibrillæ.<sup>4</sup> Rods; caskets.<sup>5</sup> Interstitial disks.

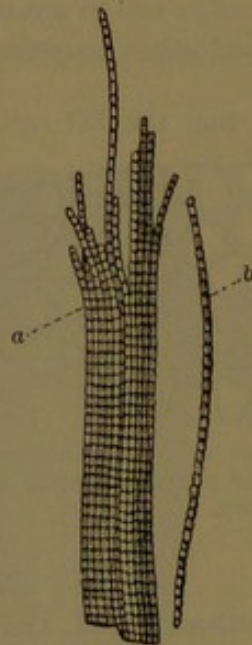


not distinguishable from it, but becomes distinctly visible under the action of certain reagents. It is reputed to give off delicate partitions<sup>1</sup> separating the **sarcous disks**<sup>2</sup> from one another, and giving rise to the fine line which divides the lighter transverse stripes of the muscle-fibre into two parts.<sup>3</sup>

Flattened oval nuclei lie here and there embedded in the surface of the sarcous matter immediately beneath the sarcolemma. Ordinarily they are not seen, but are brought distinctly into view by the application of acetic acid, which renders the muscular tissue more translucent. The nuclei contain a granular or finely-reticular nucleoplasm, with one or two clear nucleoli. In young persons the muscular nuclei are more numerous.

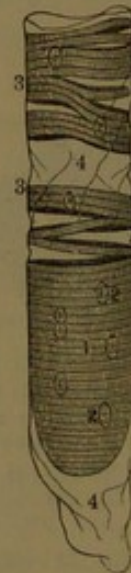The transverse striped condition of the muscle-fibres is a well-

FIG. 130.



FIBRILS FROM A MUSCLE-FIBRE OF THE AXOLOTL, an amphibian; highly magnified. *a*, bundle of fibrils; *b*, an isolated fibril.

FIG. 131.



A MUSCLE-FIBRE OF A SALAMANDER, an amphibian, which had been long kept in weak alcohol. 1, sarcous matter; 2, nuclei; 3, sarcous matter split into disks; 4, the sarcolemma.

marked character of voluntary muscles in man and all other vertebrate animals. It is, however, not restricted to the voluntary muscles, for it is also a character of the muscles of the pharynx and larynx and those of the ear, the muscular coat of the œsophagus, and the heart.

The belly of the striped muscles is enveloped in a loose sheath of fibro-connective tissue, from which partitions extend between and envelop the component muscular fascicles, constituting the **perimysium**. More delicate partitions also extend between and envelop the muscle-fibres, forming the **endomysium**. Both serve to convey and support

<sup>1</sup> Krause's membranes.

<sup>2</sup> Contractile disks.

<sup>3</sup> Lateral disks.



the vessels and nerves of the muscles. They contain some mingled elastic tissue, which is most abundant in the perimysium enveloping the fleshy belly.

It has not been satisfactorily determined in what manner the muscle-fibres end in the tendons to which they may be attached. They are generally regarded as terminating abruptly in obliquely truncated, rounded, or tapering extremities where the sarcolemma and intervening connective tissue merge into and among the connective-tissue bundles of the tendon.

The **tendons**, or sinews,<sup>1</sup> by which the striped muscles are mostly connected with the bones and other parts from which they have their origin and into which they are inserted, vary in character; some consisting of the shortest fibro-connective-tissue attachment of the muscular belly, while others form broad, membranous expansions, called **aponeuroses**,<sup>2</sup> and others form flattened cylindrical cords of various lengths, which are viewed as the most characteristic tendons. These are dense, white, and shining, very flexible, but inextensible and of the greatest tenacity. In their attachment with the muscular belly they usually commence in the interior or upon the exterior surface as an aponeurotic expansion, in which the fleshy fascicles terminate.

The tendons and aponeuroses of muscles are composed of prismatic fibro-connective-tissue bundles, which run in the same direction as the former throughout, but do not continue separate, as they frequently intersect one another by a mutual interchange of bundles. The tendon-bundles consist of smaller ones, collected into larger ones, and are all united together by lower connective tissue, which also forms a compact sheath for the tendon continuous with that of the muscular belly. The sheath of the tendon, and its extensions between the tendon-bundles, accommodate the vessels and nerves of the tendon.

The names of muscles are commonly derived from some prominent character, as office, shape, position, attachment, course, and number of heads or points of origin.

To preserve the position of narrow tendons in their course, they frequently traverse grooves on the bones, converted into canals by means of ligaments. To facilitate the movement of the tendons in such canals, they are lined by synovial membrane, which is also reflected upon and invests the tendons. Likewise, for the same purpose, when muscles pass over prominences usually a synovial bursa is introduced between them.

#### THE CARDIAC MUSCULAR TISSUE.

The heart is composed of muscular tissue, which is of much more compact character than that of the voluntary muscles. The muscle-fibres, instead of being collected into primary and secondary fascicles

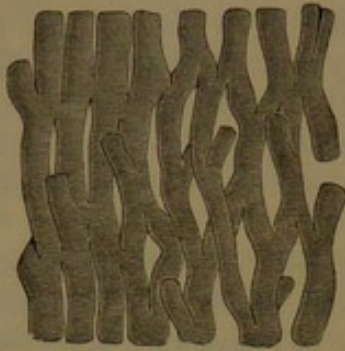<sup>1</sup> Leaders; thews; tendo; tenon.

<sup>2</sup> Expansio nervosa.



associated and enveloped by connective tissue, are more uniformly conjoined, and are generally arranged in concentric layers, which surround the cavities of the heart, and in part project into the interior in numerous, variably-sized, smooth columns.

FIG. 132.



STRIATED MUSCULAR TISSUE OF THE HEART, highly magnified.

The muscle-fibres are transversely striped like those of the voluntary muscles, but otherwise present important differences. They are less translucent, less distinct, and much narrower; being from a fourth to a third the diameter of those of the voluntary muscles. They are irregularly prismatic and mutually

conformable, with the intervals occupied by connective tissue traversed by the capillary blood-vessels and nerves. They seem to be destitute of a distinct sarcolemma, and consist alone of sarcous matter, which is longitudinally striated, as well as transversely striped. The fibres are transversely segmented; each segment being a short columnar muscle-cell, two or three times longer than broad, and containing a central nucleus. The muscle-cells are united with one another at the sides by narrower, oblique branches or offsets, and thus the muscle-fibres are brought into intimate relationship by anastomosis, and exhibit a condition in the cardiac muscular tissue not found elsewhere.

**Vessels and nerves of the muscles.** The muscles are highly vascular, in accordance with the activity of these organs. The arteries, always accompanied by veins, a single one for each, enter the muscles at various points between the larger fascicles, and usually on the inner side. Branching and penetrating between the fascicles, the finer vessels enter the primitive fascicles, and terminate in capillaries running between the muscle-fibres, in general parallel with the latter, and frequently joined by transverse vessels crossing the fibres. In their course the vessels are supported by the connective-tissue sheaths and partitions, which are also furnished with capillaries supplied from the same source.

Lymphatic vessels appear not to exist in the interior of muscles, though they are abundant in the connective-tissue sheath.

The nerves of the voluntary muscles are of considerable size, and generally enter them in company with the vessels. Passing between the fascicles they divide, and frequently make an interchange of bundles of nerve-fibres, producing a plexus. A number of such plexuses in a muscle give off narrower bundles of nerve-fibres and form finer plexuses, from which single nerve-fibres penetrate between the muscle-fibres and divide into branches distributed to the latter.

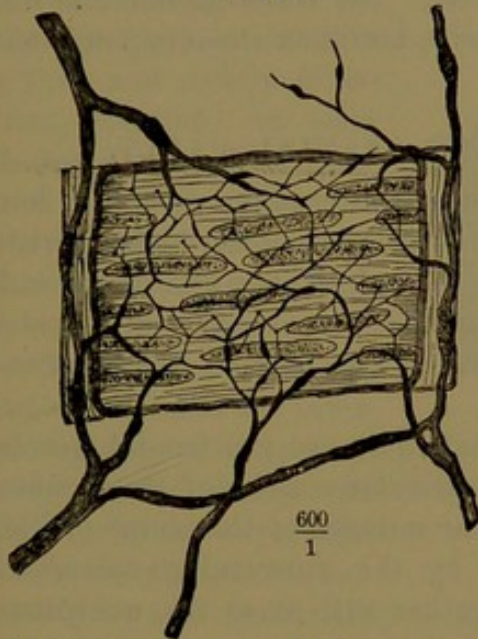
Tendons and aponeuroses are but slightly vascular. The chief vessels and capillaries traverse the connective tissue between the fibrous bundles,



generally parallel with these and joined by transverse vessels, as in the capillaries of the muscular tissue, but much fewer and smaller. Lymphatics are abundant in the connective-tissue sheath of tendons, and also penetrate the intervals of the tendon-bundles. Nerves are few in the tendons, and traverse the intervals of the fibrous bundles.

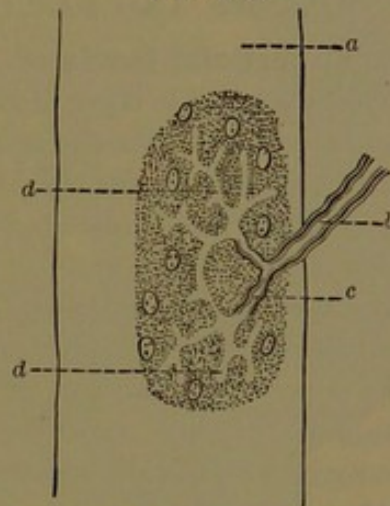
**Termination of the nerves of the muscles.** The nerves of the unstripped or involuntary muscles consist, for the most part, of non-medullated fibres, which proceed from the sympathetic system, and contain but few medullated fibres. Frequently branching in their course,

FIG. 133.



PLEXUS OF NON-MEDULLATED NERVE-FIBRES, distributed to the muscular coat of a small artery, in the frog. After Arnold.

FIG. 134.



A MOTORIAL END-PLATE, in a muscle-fibre, *a*, of a lizard; *b*, a medullated nerve-fibre dividing into two branches, *c*; *d*, the axial fibre ramifying in the motorial end-plate.

they end in intricate plexuses among the fascicles, or between the layers of muscle-fibres. From the plexuses proceed numerous fibres, which fork, and are resolved into fine fibrils running between the muscle-fibres. In the mesenteric plexus of the muscular coat of the bowels, at the anastomosis of the nerve-fibres, little groups of ganglion cells occur. The exact mode of termination of the nerve-fibres in their relation with the unstripped muscle-fibres has not been satisfactorily ascertained.

In the striped voluntary muscles the nerves are chiefly composed of medullated fibres, of which the chief funicles run parallel with and between the fleshy fascicles. Among these the funicles frequently branch, anastomose, and form plexuses, from which single nerve-fibres proceed, in their course fork at the nodes, and after dividing several times in the same manner give a branch to each muscle-fibre. As the branch enters the latter its neurilemma ceases by becoming continuous with the sarcolemma, beneath which the nerve-fibre ends in a peculiar



structure, named the **motorial end-plate**.<sup>1</sup> This consists of an elliptical, granular disk situated immediately beneath the sarcolemma, and resting on the sarcous substance. Scattered through the disk are a number of oval nuclei. The nerve-fibre after entering the muscle-fibre forks into two or more widely-divergent branches, which after a short course lose their medullary sheath, while the axial fibre ramifies in the motorial disk. The further relationship of the latter with the sarcous substance has not been satisfactorily determined.

In the cardiac muscular tissue the nerves, chiefly consisting of non-medullated nerve-fibres, terminate in gangliated plexuses similar to those in the muscular walls of the bowels. The terminal nerve-fibrils from the plexuses end in the muscle-cells, but in a manner not positively determined.

#### MUSCLES AND FASCIA OF THE CRANIAL VAULT.

The **superficial fascia** of the vault of the cranium is a thin but compact, inextensible layer of connective tissue intimately blended with the skin above, and closely adherent to the epicranial aponeurosis and muscles beneath. Next the skin it includes a dense layer of adipose tissue, in which are embedded the roots of the hairs of the scalp enclosed in their follicles.

The superficial muscles of the cranial vault are the frontal muscle of the forehead, the occipital and post-auricular muscles of the occiput, and the supra-auricular and pre-auricular muscles of the temple. The frontal and occipital muscles, united by the intervening epicranial aponeurosis, are usually described together with it as the **occipito-frontal muscle**.<sup>2</sup>

The **frontal muscle**<sup>3</sup> is a thin, pale, fleshy lamina, which occupies the side of the forehead, joining its fellow in the median line below; but divergent and narrowing in a curved line outwardly above, where it reaches the posterior border of the frontal bone. It is connected by its upper margin with the epicranial aponeurosis, whence the fleshy fibres descend, for the most part to end by intersecting the palpebral orbicular and superciliary muscles within the eyebrow, and by a slip which intersects the nasal pyramidal muscle on the glabella.

The **occipital muscle**,<sup>4</sup> less than half the length of the former, but rather wider and redder, arises tendinously from the outer two-thirds or less of the superior curved line of the occipital bone and the ridge of the temporal mastoid continuous with it, and ascends to terminate in a convex line in the epicranial aponeurosis.

The **epicranial aponeurosis**<sup>5</sup> is common to both sides of the

<sup>1</sup> Terminal plate; neural eminence.

<sup>2</sup> *Musculus occipito-frontalis*; *m. epicranius*; *m. cranii cutaneus*.

<sup>3</sup> *M. frontalis*; *m. epicranius frontalis*.

<sup>4</sup> *M. occipitalis*; *m. epicranius occipitalis*.

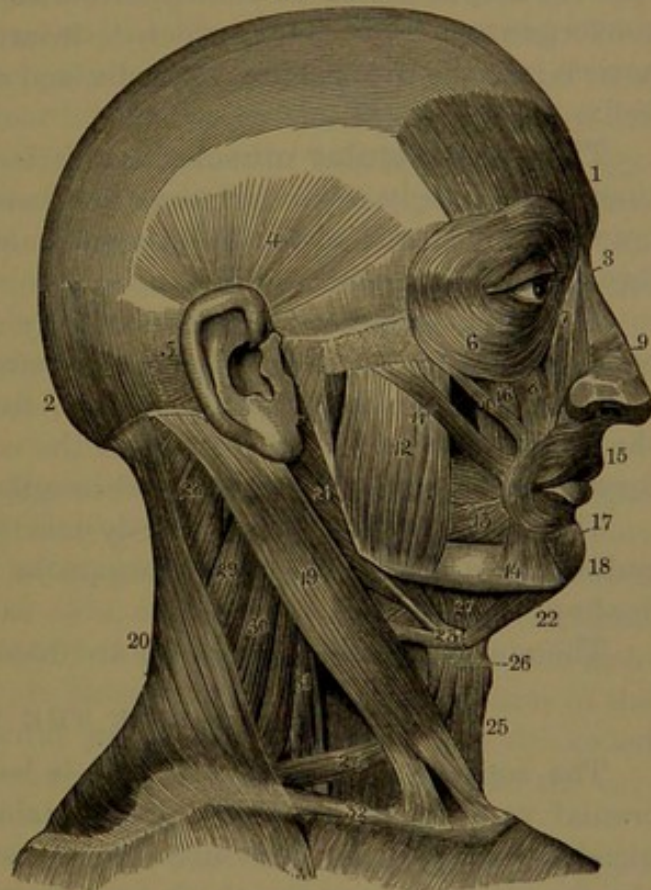
<sup>5</sup> *A. epicrania*; occipito-frontal aponeurosis; *galea aponeurotica*.



cranial vault, extends forward in the angular interval of the frontal muscles, and backward between the occipital muscles, where it is attached to the occipital protuberance and adjacent portions of the superior curved line. Between the frontal and occipital muscles it is most distinctly aponeurotic, especially the occipital portion, and is chiefly composed of longitudinal fibres, of which those from the muscles in front intersect those from behind somewhat obliquely. In the temple the aponeurosis is thinner and of looser texture, is connected with the auricular muscles, and is attached below to the zygoma. At the fore part it exhibits a thin, and mostly indistinct, stratum<sup>1</sup> of pale fleshy fibres, which proceed obliquely from the vicinity of the ear towards the frontal and palpebral orbicular muscles.

The frontal and occipital muscles and the intervening epicranial aponeurosis adhere closely and tightly to the superficial fascia and skin above, and loosely by thin extensible connective tissue to the periosteum beneath. The skin of the cranial vault, together with the subjacent superficial fascia and the epicranial aponeurosis with its muscles beneath, constitutes the scalp, which is readily detached from the skull, while its different layers are separated with difficulty. By the alternate action of the frontal and occipital muscles the scalp is moved forward and backward, though in most persons this action in great measure appears to be confined to the frontal muscles,

FIG. 135.



MUSCLES OF THE HEAD AND NECK. 1, 2, occipito-frontal muscle; 1, its frontal belly; 2, its occipital belly; 3, nasal pyramidal muscle; 4, supra- and 5, post-auricular muscles; 6, palpebral orbicular muscle; 7, naso-labial elevator; 8, supra-labial elevator; 9, nasal compressor; 10, 11, zygomatic muscles; 12, masseter; 13, buccinator; 14, oral-angle depressor; 15, oral sphincter muscle; 16, oral-angle elevator; 17, 18, infra-labial depressor; 19, sterno-mastoid muscle; 20, trapezius; 21, posterior belly of the digastric and the stylo-hyoid muscle; 22, anterior belly of the former; 23, loop of fibrous tissue attaching the tendon of the digastric muscle to the hyoid bone; 24, omo-hyoid muscle; 25, sterno-hyoid; 26, sterno-thyroid, seen to the outer side and behind the anterior part of the omo-hyoid; 27, mylo-hyoid; 28, splenius; 29, scapular elevator; 30, 31, middle and anterior scalenus muscles; 32, clavicle.

<sup>1</sup> M. epicranius temporalis; superficial temporal muscle.



which elevate the eyebrows and throw the skin of the forehead into transverse wrinkles. The frontal and occipital muscles are supplied by the facial nerve.

In bald persons the frontal muscles frequently appear prominent and distinctly outlined through the skin of the forehead.

#### THE AURICULAR MUSCLES.

The **supra-auricular muscle**<sup>1</sup> is a broad, thin, pale, fan-shaped lamina occupying the upper part of the temple. It arises from the epicranial aponeurosis at the upper border of the latter, descends, and converges to a thin tendon, which is inserted at the inner part of the auricle into the fore part of the helix and the prominence of the anti-helix.

The **pre-auricular muscle**<sup>2</sup> is a little, pale, fleshy slip, often indistinct, and scarcely separated from the former. It arises from the epicranial aponeurosis above the zygoma, and is inserted into the lower fore part of the helix.

The **post-auricular muscle**<sup>3</sup> usually consists of two well-marked bands, of redder hue than the former, situated inwardly back of the ear. They arise, one above the other, from the mastoid portion of the temporal bone near the origin of the occipital muscle, and proceed forward and outward to be inserted into the concha of the auricle.

The auricular muscles are mostly inactive, and may be regarded as rudiments of similar important organs in the rabbit, the cat, and the donkey.

The muscles of the tympanum are described with the ear.

#### MUSCLES OF THE FACE.

The superficial fascia of the face is less distinct than that of the cranial vault, is of looser texture, contains more or less fat, and is blended with adjacent structures. It invests the superficial muscles of the face, extends over the cheek and parotid gland, and, involving the platysma muscle, is continuous with the corresponding fascia of the neck. In the eyelids and free border of the lips it blends with the skin, and in these positions is always free from fat. In the hollow of the cheek it usually contains a considerable accumulation of soft fat, extending outward and backward in the interval between the buccinator muscle and the ramus of the lower jaw.

#### MUSCLES OF THE EYELIDS AND EYEBROWS.

The **palpebral orbicular muscle**<sup>4</sup> forms a broad, thin, fleshy zone in front of the orbit immediately beneath the skin. It consists of two

<sup>1</sup> *M. auricularis superior*; *m. attollens aurem*, *auriculam*, or *auriculæ*.

<sup>2</sup> *M. aur. ant.*; *m. attrahens aurem*, etc.

<sup>3</sup> *M. aur. post.*; *m. retrahens aurem*, etc.

<sup>4</sup> *M. orbicularis palpebrarum* or *oculi*; *sphincter palp. or oculi*; *m. orb. latus*.



portions, which, though continuous in other respects, both anatomically and physiologically exhibit striking differences. The central or **palpebral portion**<sup>1</sup> enters into the construction of the eyelids, and is thinner and paler than the rest of the muscle, and adheres to the adjacent thin skin always completely devoid of interposed fat so common elsewhere. It arises from the upper and lower margin of the internal palpebral ligament, and thence spreads outwardly in the upper and the lower eyelid, the fibres intersecting one another externally and forming a series of concentric loops attached to the external palpebral ligament. The peripheral or **orbital portion** of the muscle extends beneath the eyebrow, on the cheek below, and on the fore part of the temple. It is thicker and redder than the palpebral portion, and is separated from the skin in the usual manner by the superficial fascia with fat. It arises narrowly from the inner extremity of the internal palpebral ligament, the inner part of the supraorbital ridge, the length of the nasal process, and the infraorbital margin of the maxilla; and thence extends around the orbit, forming a zone of fibres arranged in concentric circles. The upper border is intersected by the frontal and superciliary muscles; the outer border is attached to the temporal portion of the epicranial aponeurosis, and the lower border to the fascia of the cheek.

The **internal palpebral ligament**<sup>2</sup> is seen in life as a whitish spot at the inner corner of the opening of the eyelids, and is rendered more prominent by stretching the latter outwardly. It is a transverse fibrous cord immediately beneath the skin, attaching the eyelids to the nasal process of the maxilla in front of the lachrymal sac, and to the lachrymal crest behind the sac. It forks outwardly, and terminates in the palpebral tarsi. The **external palpebral ligament** is a thickened portion of the fibrous membrane, which attaches the tarsi to the surrounding margin of the orbit.

The **palpebral tensor**<sup>3</sup> is a little fleshy slip situated at the inner part of the orbit behind the internal palpebral ligament, and is continuous with the orbicular muscle. It arises from the crest and adjacent orbital surface of the lachrymal bone, crosses the lachrymal sac forward and outward, and divides into two portions, which cover the lachrymal canals, and near the puncta are inserted into the palpebral tarsi.

The **palpebral elevator**<sup>4</sup> of the upper eyelid is a long, thin, fan-like muscle, which occupies the upper part of the orbit. It arises by its narrow extremity tendinously from beneath the small wing of the sphenoid bone in front of the optic foramen, proceeds forward beneath the roof of the orbit, and thence emerges in a broad, thin aponeurosis, which descends to be inserted into the upper border of the

<sup>1</sup> M. ciliaris or palpebralis.

<sup>3</sup> M. tensor tarsi; muscle of Horner.

<sup>2</sup> Tendo oculi.

<sup>4</sup> M. levator palpebræ superioris.



tarsus of the upper eyelid immediately behind and connected with the supra-palpebral ligament.

The **superciliary muscle**<sup>1</sup> is a fleshy slip lying on the inner part of the superciliary ridge of the frontal bone under the palpebral orbicular muscle. It arises from the inner end of the ridge, and ascends obliquely outward to the conjoined border of the palpebral orbicular and frontal muscles which it intersects, and is inserted into the skin of the eyebrow.

The palpebral orbicular muscle entirely displays its action in the voluntary and forcible closure of the eyelids. Ordinarily the palpebral portion alone incessantly acts in closing the eyelids momentarily, especially the upper one, in winking. The palpebral tensor retains the lachrymal puncta in contact with the eyeball, so as to facilitate the absorption of the tears. The palpebral elevator raises the upper eyelid, and draws it backward beneath the fore part of the orbit. The superciliary muscles of the two sides draw the eyebrows downward and towards each other, and produce vertical wrinkles on the glabella, as in frowning.

#### MUSCLES OF THE NOSE.

These consist of the pyramidal, compressor, dilator, depressor, and naso-labial elevator muscles.

The **nasal pyramidal muscle**<sup>2</sup> is a little fleshy slip at the side of the root of the nose, in contact with its fellow or separated by a narrow interval widening below. It starts from the aponeurosis of the compressor muscle on the bridge of the nose, and from the adjacent part of the nasal bone, and thence ascends to the glabella, where it intersects a slip of the frontal muscle, than which it is redder in hue.

The **nasal compressor**<sup>3</sup> is a thin, pale, fleshy, triangular muscle, occupying the side of the nose above the wing. It is of variable development and distinctness, and arises narrowly from the maxilla at the side of the nasal orifice, ascends forward, expands on the side of the nose, and terminates in a thin aponeurosis, which is continuous with that of the opposite side across the bridge of the nose. The aponeurosis is tightly connected with the adjacent skin, but loosely with the subjacent bridge of the nose, so that the former together readily move from side to side on the latter. Above, the aponeurosis is connected with the pyramidal muscle, and below with the upper border of the wing and the tip of the nose.

The **nasal dilator**,<sup>4</sup> variably produced and mostly indistinct, con-

<sup>1</sup> *M. superciliaris*; *m. corrugator supercilii*.

<sup>2</sup> *M. pyramidalis nasi*; *m. dorsalis narium*; *m. procerus nasi*.

<sup>3</sup> *M. compressor nasi* or *nari*; *m. c. narium major*; *m. triangularis nasi*; *m. transversus nasi*; *m. attrahens nasi*; *m. constrictor alæ nasi*.

<sup>4</sup> *M. dilatator naris*; *m. dil. naris posterior*; *m. levator proprius alæ nasi posterior*.



sists of a layer of pale fleshy fibres involved in the connective and adipose tissue and adjacent skin of the wing of the nose. The fibres spring from the groove at the back of the wing, and curve forward and downward to end in the skin at the margin of the nostril. Another and less distinct layer has been described as the **anterior dilator**,<sup>1</sup> occupying the side of the end of the nose between the skin and the oval cartilage. Its fibres curve from the margin of the nostril upward and forward to end in the skin at the tip of the nose.

The **naso-labial elevator**<sup>2</sup> lies beneath the skin along the side of the nose at the inner part of the orbit, extending to the upper lip. It arises narrowly from the nasal process of the maxilla, between the nasal pyramidal and the palpebral orbicular muscle, descends and crosses the outer part of the compressor and the inner part of the supra-labial elevator, and is inserted into the posterior border of the nasal wing, and in union with the latter muscle into the skin of the upper lip, at the upper part of the oral sphincter.

The **nasal depressor**<sup>3</sup> is a thin, fleshy layer, which lies under the upper lip next the lining mucous membrane. It arises from the incisive fossa to the canine alveolus of the maxilla, and ascends and curves forward to be inserted into the lower border of the nasal septum and the posterior border of the nostril, extending outwardly behind the nasal wing. In the latter position it is continuous with the origin of the nasal compressor, and is intersected by the insertion of the naso-labial elevator, which together with the oral sphincter covers it.

#### MUSCLES OF THE MOUTH, LIPS, AND CHEEK.

The **oral sphincter**<sup>4</sup> is an elliptical muscle surrounding the orifice of the mouth, and forming the fleshy basis of the lips. It is intersected at the corners, or angles, of the mouth by a number of other muscles, chiefly the buccinators, of which the fibres that arise from the maxilla proceed to the lower lip, while those from the mandible pass to the upper lip. At the free border of the oral orifice the sphincter consists of a rounded fasciculus<sup>5</sup> of fibres, forming an uninterrupted ring, which is covered by the thin skin where it merges into the lining mucous membrane of the lips. The exterior and deeper portion<sup>6</sup> of

<sup>1</sup> M. dil. naris anterior; m. lev. prop. alæ nasi anterior.

<sup>2</sup> M. levator labii superioris alæque nasi; common elevator of the lip and nose; elevator of the upper lip and wing of the nose; superficial common elevator of the wing of the nose and of the upper lip; m. pyramidalis; m. pyr. narium; caput angulare of the m. quadratus labii superioris.

<sup>3</sup> M. depressor alæ nasi; m. depressor labii superioris alæque nasi; m. dep. labii sup.; m. myrtiformis; m. nasalis; m. lateralis nasi; m. dilatator narium; m. dil. pinne; m. fixator labii sup.; labio-nasal depressor.

<sup>4</sup> Sphincter oris; m. orbicularis oris; m. constrictor labiorum; m. c. prolabii superioris et inferioris; oral orbicular muscle.

<sup>5</sup> Pars marginalis, or labialis.

<sup>6</sup> Facial part.



the sphincter is covered externally by fibres of other muscles converging to the mouth, and by the skin with an intervening layer of connective and adipose tissue, and internally is covered by the lining mucous membrane and labial glands. At the oral angle it decussates with the buccinator behind the other converging muscles, which consist of the elevator and depressor of the oral angle and the zygomatic muscle. In the upper lip it<sup>1</sup> arises from the inferior border of the nasal septum, where it is closely connected with the nasal depressor, and thence turns backward, downward, and outward to the oral angle, producing in the divergence of the lateral portions the conspicuous median groove of the upper lip. The muscle is also reinforced on each side by a pair of narrow slips,<sup>2</sup> of which one arises from the incisive fossa of the maxilla, and the other from the mandible below the canine tooth, and both proceed outwardly to the oral angle.

The **supra-labial elevator**<sup>3</sup> is a quadrate muscle situated below the orbit, partially covered by the palpebral orbicular muscle, and partially subcutaneous. It arises immediately below the infraorbital margin from the maxilla and malar bone, and descends inwardly, and is joined by the naso-labial elevator to be inserted, in union with it, into the skin of the upper lip and the adjacent portion of the oral sphincter.

The **oral angle elevator**<sup>4</sup> is a triangular muscle lying beneath the preceding. It arises obliquely across the upper part of the canine fossa of the maxilla, below the infraorbital foramen, and descends outwardly to the oral angle, where it decussates with the other more superficial muscles converging to the same point. Its inner border is contiguous to, and sometimes continuous with, the upper border of the oral sphincter.

The **zygomatic muscle**<sup>5</sup> is a fleshy band embedded in the subcutaneous connective and adipose tissue of the cheek. It arises tendinously from the outer surface of the malar zygomatic process, and descends obliquely forward and inward to the oral angle, where it decussates with the preceding and other converging muscles.

The **lesser zygomatic muscle**<sup>6</sup> is a variable and inconstant fascicle, occupying a similar position of the cheek in advance of the former muscle. It arises in front of this from the malar bone, or partially from

<sup>1</sup> *M. nasalis labii superioris*; depressor septi mobilis narium; depressor apicis narium; *m. naso-labialis*.

<sup>2</sup> *Musculi incisivi*; *m. accessorii orbicularis*.

<sup>3</sup> *M. levator labii superioris proprius* or major; superior labial elevator; elevator of the upper lip; *m. incisorius*; caput infraorbitale of the *m. quadratus labii superioris*.

<sup>4</sup> *M. levator anguli oris*; elevator of the angle of the mouth; *m. caninus*; *m. levator labiorum communis*.

<sup>5</sup> *M. zygomaticus major*; greater zygomatic muscle.

<sup>6</sup> *M. zygomaticus minor*; caput zygomaticum of the *m. quadratus labii superioris*.



this and the adjacent border of the palpebral orbicular muscle, and descends obliquely inward and joins the outer border of the supralabial elevator, to be inserted with it into the skin of the upper lip and oral sphincter.

The **infra-labial elevator**<sup>1</sup> is a small fleshy layer situated under the mucous membrane lining the lower lip. It arises from the incisive fossa of the mandible, descends and widens and terminates in the lower border of the oral sphincter and adjacent portion of the skin of the chin.

The **infra-labial depressor**<sup>2</sup> is a rhombic plane of fleshy fibres at the side of the chin, for the most part subcutaneous, and mingled with connective tissue and fat, in which are embedded the roots of the hairs of the beard. It arises from the outer side of the base of the mandible, between the mental protuberance and the mental foramen, and ascends inwardly, to be inserted into the skin of the lower lip, decussating with the subjacent portion of the oral sphincter and with its fellow of the opposite side.

The **oral angle depressor**<sup>3</sup> is a subcutaneous triangular muscle occupying the side of the chin behind the former, and partially covering it. It arises from the outer part of the base of the mandible, at the side of the chin, and partially is continuous from behind with the platysma muscle, whence it ascends and converges to the oral angle, where it decussates with the oral angle elevator and other muscles converging to the same point.

The **buccinator**<sup>4</sup> occupies the deep part of the cheek next the lining membrane of the mouth. It is a broad, quadrilateral muscle, extended between the outside of the jaws, from the corner of the mouth backward, within the ramus of the mandible to the pharynx. It arises from the base of the molar portion of the alveolar processes of both jaws, and behind from the pterygo-maxillary ligament, and thence proceeds forward to the angle of the mouth, where it joins the oral sphincter, within the position of the other muscles which converge to the same point. From their origin, the muscular fibres, for the most part, are convergent towards the oral angle, where they decussate, those from above passing into the lower lip, and those from below into the upper lip, while others above and below pass into each corresponding lip without decussation. Externally the buccinator is closely invested with a thin layer of the deep fascia, covered by the superficial fascia with an accumulation of soft, adipose tissue, which separates the muscle in front from the skin and platysma muscle, and behind from the

<sup>1</sup> M. levator labii inferioris; elevator of the lower lip; m. levator menti; m. mentalis; m. incisivus inferioris.

<sup>2</sup> M. depressor labii inferioris; depressor of the lower lip; m. quadratis menti.

<sup>3</sup> M. depressor anguli oris; depressor of the angle of the mouth; m. triangularis menti; m. depressor labiorum communis; m. pyramidalis menti.

<sup>4</sup> Muscle of the cheek; trumpeter muscle.



ramus of the mandible. Opposite the second upper molar tooth it is perforated by the parotid duct, around which the contiguous fibres decussate.

The **pterygo-maxillary ligament** is a narrow tendinous intersection between the buccinator and the superior constrictor of the pharynx, extended between the lower extremity of the sphenoidal entopterygoid process and the posterior extremity of the mylo-hyoid ridge of the mandible.

#### THE MUSCLES OF MASTICATION.

These consist of the temporal, masseter, external pterygoid, and internal pterygoid muscles.

The **temporal muscle**,<sup>1</sup> the largest of the muscles of mastication, is fan-shaped, and occupies the entire extent of the temporal fossa, enclosed by the temporal fascia. It arises from the surface of the temporal fossa, extending to the infratemporal crest, and from the upper inner moiety of the temporal fascia, whence the fleshy fascicles descend and converge to an interior aponeurosis, which narrows into a thick, flat tendon, passing through the zygomatic fossa to be inserted into the apex, front border, and inner surface of the coronoid process of the mandible. Its lower fore part is contiguous to the masseter muscle, and usually intimately connected with it. Internally the insertion is separated from the buccinator and pterygoid muscles by an accumulation of areolar and adipose tissue extending backward from the cheek.

The **temporal fascia**<sup>2</sup> is a bluish-white, shining aponeurosis, covering the temporal muscle and outwardly closing the temporal fossa, to the circumference of which it is attached. Its upper part gives origin to the outer fleshy fascicles of the temporal muscle, but is separated below from the latter by a variable quantity of loose areolar tissue and fat. Approaching the zygoma, it divides into two layers, which are attached to the inner and outer surface of the former, and include between them a layer of connective tissue and fat. Its external surface is invested by the temporal portion of the epicranial aponeurosis, between which and the superficial fascia are the supra-auricular and pre-auricular muscles.

The **masseter**<sup>3</sup> occupies the back part of the cheek below the zygoma on the outer side of the ramus of the lower jaw. It is a thick quadrilateral muscle, consisting of two portions. The superficial, larger, quadrate portion arises tendinously from the anterior two-thirds of the lower border of the zygoma, descends with an inclination backward, and is inserted into the outer surface of the lower half and angle of the ramus of the mandible. The deeper, triangular

<sup>1</sup> M. temporalis; m. crotaphites.

<sup>2</sup> Fascia temporalis.

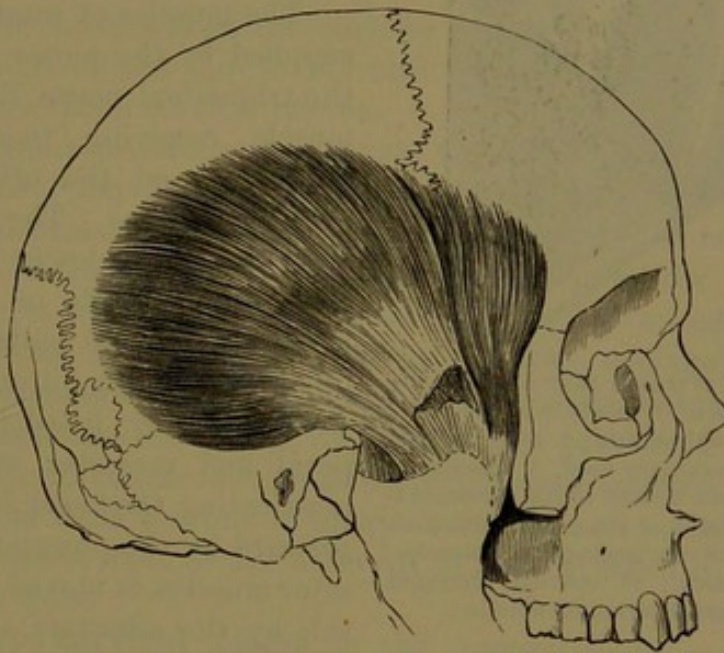
<sup>3</sup> M. massetericus; m. manducatorius; m. mandibularis externus.



portion, partially visible behind the former, arises from the posterior third of the lower border and the whole of the internal surface of the zygoma, descends and joins the other portion, and is inserted into the upper half of the outer surface of the ramus of the mandible.

The masseter muscle is partially subcutaneous, but is overlapped behind by the parotid gland, crossed above by the parotid duct, and covered below by the platysma muscle. It is separated in front from the buccinator by an accumulation of areolar and adipose tissue occupying a hollow outside the latter, and extending backward within the position of the ramus of the lower jaw.

FIG. 136.



VIEW OF THE TEMPORAL MUSCLE. The temporal fascia and zygoma removed.

The **external pterygoid muscle**<sup>1</sup> is a pyramidal fleshy mass, occupying the upper part of the zygomatic fossa. It arises from the under surface of the great wing and the outer surface of the ectopterygoid process of the sphenoid bone, converges backward and outward, and is inserted into the front of the neck of the lower jaw and the capsular ligament and fibro-cartilage of the articulation. At its origin it is divided by a fissure, which receives the internal maxillary vessels in their usual course on the outer side of the lower portion of the muscle. Internally it is in contact with the internal pterygoid muscle, the sphenomaxillary ligament, and the inferior dental vessels and nerve; externally with the insertion of the temporal muscle into the coronoid process of the mandible.

The **internal pterygoid muscle**<sup>2</sup> is quadrilateral, and is situated on the inner side of the ramus of the lower jaw, nearly in like manner

<sup>1</sup> M. pterygoideus externus, or minor.

<sup>2</sup> M. pterygoideus internus, or major.



with the masseter on the outside. It arises in the pterygoid fossa, tendinously and fleshy, from the inner surface of the ectopterygoid process and the pyramidal process of the palate bone, descends backward and outward, and is inserted into the lower back part of the

inner surface of the ramus and angle of the lower jaw. Between it and the ramus are the sphenomaxillary ligament and the inferior dental nerve and vessels; internally it is in contact with the palatal tensor and the superior constrictor of the pharynx.

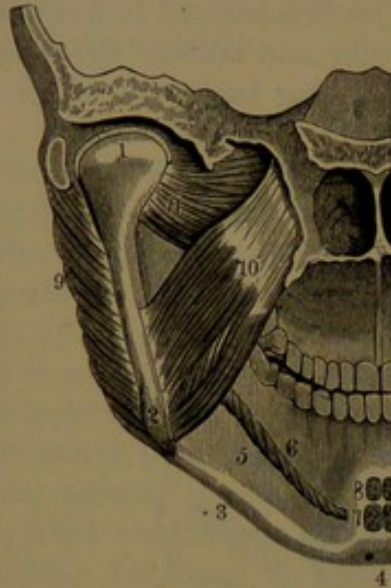
The muscles of mastication are supplied by the motor division of the trigeminal nerve, the temporal muscle receiving two or three branches, and the other muscles each usually one. The muscles are elevators of the lower jaw, and in the ordinary state of rest retain the lower teeth in contact with the upper teeth. In biting, the lower jaw is mainly lifted by the temporal and masseter muscles. In masticating, the lower jaw is drawn forward by the pterygoid and masseter muscles, is moved from side to side by the alternate action of the

former on opposite sides, and is drawn backward by the temporal muscles.

#### MUSCLES AND FASCIAE OF THE NECK.

The *platysma*<sup>1</sup> is a thin, broad, pale muscle, situated immediately beneath the skin at the side of the neck, extending from the chest and shoulder to the face. It consists of a stratum of fleshy fibres, lying between the superficial and the deep fascia; arising from the latter over the pectoral, deltoid, and latissimus muscles; ascending obliquely inward over the clavicle and acromion and the side of the neck to the lower jaw and angle of the mouth. The anterior portion of the muscle is inserted into the base of the mandible at the side of the chin, extending from the symphysis along the line of origin of the infralabial and oral angle depressors. Behind this position the muscle passes over the base and angle of the jaw, and proceeds forward on the masseter and buccinator muscles to end in the oral angle and posterior portion of its depressor. The anterior fibres beneath the chin decussate with those

FIG. 137.



VIEW OF THE INTERIOR PART OF THE LEFT SIDE OF THE FACE. 1, condyle of the lower jaw; 2, angle of the jaw; 3, base; 4, symphysis; 5, submaxillary fossa; 6, attachment of the mylo-hyoid muscle to the corresponding ridge; 7, origin of the genio-hyoid muscles; 8, origin of the genio-glossal muscles; 9, masseter muscle; 10, internal pterygoid muscle; 11, external pterygoid muscle.

<sup>1</sup> *Platysma myoides*; m. subcutaneus colli or cervicis.



of the opposite muscle and become fixed in front of the symphysis and mental protuberance of the mandible. Commonly, a few more or less detached fibres at the upper border of the muscle proceed nearly transversely across the cheek to the oral angle. These have been regarded as distinct under the name of the **risorius** or laughing muscle. It is variable and sometimes absent.

The platysma is separated from the parts beneath by the deep cervical fascia. It covers the acromio-clavicular attachment of the trapezius and the greater extent of the sterno-mastoid muscle, crossing the direction of their fibres. It also covers the supra-hyoid and part of the infra-hyoid muscles, the submaxillary gland, and the triangular space which includes the termination of the carotid artery and its divisions. On the face it covers the muscles and parotid gland, extending from the angle of the jaw to the oral angle. It is supplied by the facial and superficial cervical nerves.

The platysma probably plays a part in preventing undue pressure through contraction of the skin of the neck on the parts beneath. It may aid in depressing the mandible and in opening the mouth. The portion named the risorius, by drawing the corner of the mouth outward, produces the appearance of smiling. In advanced age, after loss of the teeth and alveolar borders of the jaws, and the consequent elevation of the mandible, the anterior borders of the platysma muscles produce conspicuous folds of the skin at the fore part of the neck. The muscle represents the more extensive subcutaneous stratum, named the panniculus carnosus, present in many mammals, and producing movements of the skin such as are observed in a horse when it shakes the flies from its sides.

The **deep cervical fascia** is the connective-tissue membrane which invests all the deeper parts of the neck subjacent to the superficial fascia and platysma, variably produced and distinct in different positions. It is more or less firmly fixed to the contiguous hard parts, and sheathes all the softer parts, varying in thickness, texture, and strength among these. At the back of the neck it is superficially attached to the occipital protuberance, nuchal ligament, and spinous processes below; thence it affords a thin investment to the trapezius muscle, from the outer border of which it extends across the posterior cervical triangle attached below to the clavicle. Sheathing the sterno-mastoid muscle, attached to the mastoid process, the clavicle and sternum, it proceeds across the anterior cervical triangle to the median line of the neck, where it becomes continuous with the fascia of the other side, and above is fixed to the base of the mandible. Beneath the sterno-mastoid muscle it forms a loose sheath to the great cervical blood-vessels and accompanying nerves, and is continuous inwardly with the more compact membrane which invests the pharynx and œsophagus, the trachea and larynx, and the muscles in front of the latter; and outwardly with the equally compact layer which invests



the splenius and scalenus muscles, the brachial plexus of nerves and subclavian vessels, and is fixed to the first rib. It encloses the submaxillary and parotid glands, invests the digastric, stylo-hyoid, and mylo-hyoid muscles, is fixed to the hyoid bone, mandible, and zygoma, and is continuous with the fascia of the masseter and pterygoid muscles. It is reinforced by a thin aponeurotic band, named the **stylo-maxillary ligament**, which descends from the styloid process of the temporal bone to the inner part of the angle of the mandible, and is thence extended as a thinner expansion between the parotid and submaxillary glands to the contiguous part of the sheath of the great cervical vessels. A distinct portion of the fascia encloses the posterior belly of the omo-hyoid muscle and its intermediate tendon, which is attached by the same means to the contiguous part of the sheath of the great cervical vessels, is thence extended and fixed to the inner side of the clavicle, and serves to retain the muscle in its position. In the posterior cervical triangle, along the course of the great vessels, the fascia forms a loose envelope to the cervical lymphatic glands, mingled with more or less fat, and continuous below with the areolar connective tissue of the axilla. Similar portions of connective tissue, with fat and lymphatic glands, occupy the vicinity of the salivary glands and the fossæ at the bottom of the neck.

The **sterno-mastoid muscle**<sup>1</sup> is the largest and most conspicuous of the muscles of the neck, and extends obliquely from the fore part of the chest to the head, back of the ear. It consists of a flattened, cylindroid belly, expanding at the extremities, and arising by separate heads from the sternum and clavicle. The **sternal head**,<sup>2</sup> narrow and rounded, arises by a flattened tendon from the upper front part of the sternum close to its fellow, and thence ascends obliquely backward and outward at the side of the neck. The **clavicular head**,<sup>3</sup> of variable width, arises partially tendinous and fleshy from the upper border, usually of the inner third of the clavicle, whence it ascends nearly vertically and unites with the former head. The common belly, continuing in the direction of the latter, is inserted tendinously into the temporal mastoid process, extending from its apex upward and backward and along the outer half of the superior curved line of the occipital bone. The angular interval of the two heads, situated above the sterno-clavicular articulation, is variable in size, and is closed by the apposition of the two layers of the fascia ensheathing the muscle. The clavicular head is also variable in extent, sometimes being as narrow as the sternal head, and sometimes widening outwardly nearly to the insertion of the trapezius. Occasionally it remains distinct, and

---

<sup>1</sup> M. sterno-cleido-mastoideus; sterno-cleido-mastoid m.; m. mastoideus colli; m. nutator capitis.

<sup>2</sup> Caput sternale; m. sterno-mastoideus; m. nutator capitis int. or ant.

<sup>3</sup> C. claviculare; m. cleido-mastoideus; m. nutator capitis ext. or post.



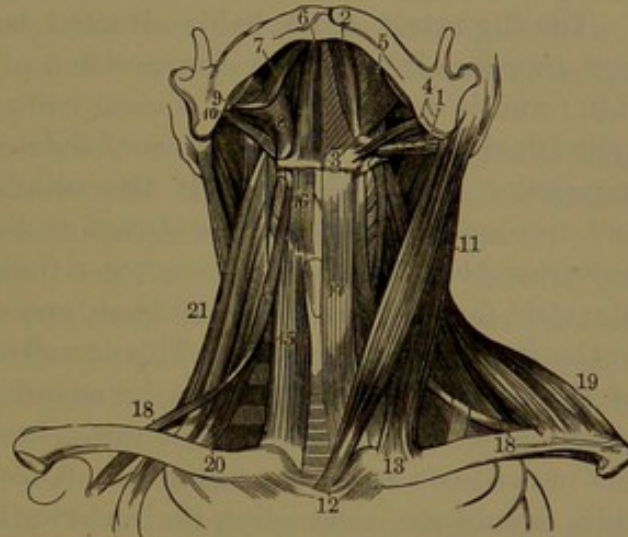
ascends behind the sternal head to be inserted into the apex of the mastoid process.

The sterno-mastoid muscle is covered the greater part of its extent along the middle by the platysma, and is also crossed by the external jugular vein, the superficial cervical, and the great auricular nerve. Its lower portion rests on the sterno-hyoid and sterno-thyroid muscles, and crosses the omo-hyoid; and above it is in contact with the scaleni, scapular elevator, splenius, and digastric muscles. About the middle of the neck it crosses the great cervical blood-vessels contained within their sheath. The accessory nerve pierces its upper third within, and is its main source of supply; other nerves being derived from the cervical plexus.

In action the sterno-mastoid muscle may flex the head towards the shoulder of the same side, or it may turn the head with the face directed towards the opposite side. Ordinarily, both muscles maintain the erect position of the head with the face directed forward, and in greater action bend the head backward with the face directed upward. Most authorities assert that the two muscles acting together bow the head forward, but this appears to be an error in the view that their insertion is posterior to the articulation of the skull with the vertebral column.

The course of the sterno-mastoid divides the quadrilateral space at the side of the neck into two triangles, which are important in their surgical relations. The anterior cervical triangle is defined in front by the median line of the neck, behind by the anterior border of the sterno-mastoid, and above by the base of the lower jaw. The posterior cervical triangle is defined in front by the posterior border of the sterno-mastoid, behind by the anterior border of the trapezius, and below by the clavicle.

FIG. 138.



FRONT VIEW OF THE MUSCLES OF THE NECK. 1, posterior, and 2, anterior belly of the digastric; 3, its intermediate tendon attached to the hyoid bone and passing through the insertion of the stylo-hyoid muscle, 4; 5, mylo-hyoid; 6, genio-hyoid; 7, stylo-glossal; 8, hyo-glossal; 9, styloid process; 10, stylo-pharyngeal; 11, sterno-mastoid; 12, its sternal origin; 13, its clavicular origin; 14, sterno-hyoid; 15, sterno-thyroid; 16, thyro-hyoid; 17, 18, omo-hyoid; 19, trapezius; 20, anterior scalenus; 21, middle scalenus muscle.



## SUPRA- AND INFRA-HYOID MUSCLES.

Of these, the digastric, stylo-hyoid, mylo-hyoid, and genio-hyoid muscles are situated above the hyoid bone, with which they are connected, while the sterno-hyoid, sterno-thyroid, thyro-hyoid, and omohyoid are situated below it.

The **digastric muscle**<sup>1</sup> is situated behind and beneath the lower jaw, curving from within the position of the mastoid process to the chin; and it consists of two conical bellies, united by an intermediate cylindrical tendon. The anterior, shorter belly arises from a rough impression within the base of the mandible, close to the symphysis, and descends backward and outward to the intermediate tendon. The posterior belly, longer and narrower than the former, arises from the digastric fossa of the temporal bone, and descends forward and inward to the intermediate tendon. This usually passes through a perforation of the stylo-hyoid muscle, and in advance is connected with the side of the hyoid bone by an aponeurotic band, which serves to maintain the curved course of the digastric. An extension of the band forms a thin membrane, connecting the anterior belly of the muscle with that of the opposite side, between the chin and hyoid bone. The anterior belly is in contact above with the mylo-hyoid muscle, and below and outwardly with the submaxillary gland. The posterior belly outwardly crosses the course of the external and internal carotid arteries, the internal jugular vein, and the accompanying nerves. It is for the most part covered by the mastoid process, the sterno-mastoid and splenius muscles, and the parotid gland.

The **stylo-hyoid muscle**<sup>2</sup> is a slender fleshy fascicle, situated above the posterior belly of the digastric. It arises by a narrow tendon from behind the outer part of the styloid process, near its base, and descends in company with the digastric muscle to be inserted into the hyoid bone at the junction of the body and greater cornu. Usually it is perforated near its insertion by the digastric tendon, but not unfrequently is inserted to the outside of the latter without being perforated. The muscle is sometimes feebly produced, and occasionally is absent. Its relations are the same as those of the contiguous belly of the digastric muscle.

The **mylo-hyoid muscle**<sup>3</sup> is a flat, triangular, fleshy layer, situated within the position of the lower jaw, and forming with its fellow a muscular floor or diaphragm to the cavity of the mouth. It arises, partially fleshy and tendinous, from the mylo-hyoid ridge of the mandible, extending from the symphysis to the last molar tooth, whence the fibres proceed obliquely inward and downward; the posterior, longer, to be inserted into the body of the hyoid bone; the

<sup>1</sup> M. digastricus; m. biventer mandibulæ, or maxillæ inferioris.

<sup>2</sup> M. stylo-hyoideus.      <sup>3</sup> M. mylo-hyoideus; m. transversus mandibulæ.



others becoming successively shorter and ending in a median fibrous raphe extending from the hyoid bone to the symphysis of the chin. The upper surface of the muscle is in contact with the genio-hyoid, hyo-glossal, and stylo-glossal muscles, the lingual gland, and the hypo-gastric and lingual nerves. The lower surface is in contact with the anterior belly of the digastric muscle, and with the submaxillary gland. The posterior border is free, and has the duct of the latter gland turning over it. The inner part of the muscle is sometimes more or less deficient.

Between the mylo-hyoid muscle above, with the mandible outwardly, and the digastric muscle with the stylo-hyoid muscle below, there is a triangular recess, which lodges the submaxillary gland.

The **genio-hyoid muscle**<sup>1</sup> is a fleshy band situated beneath the tongue, in contact with its fellow immediately above the inner part of the mylo-hyoid muscle. It arises tendinously from the lower division of the mental tubercle, and descends backward to be inserted tendinous and fleshy into the front of the body of the hyoid bone. It is in contact above with the genio-glossal muscle.

The **sterno-hyoid muscle**<sup>2</sup> is a thin, fleshy band, situated immediately beneath the skin along the side of the trachea and larynx. It arises, partially tendinous and fleshy, behind the sternal extremity of the clavicle and the contiguous portion of the sternum, and ascends inwardly to be inserted into the lower border of the hyoid bone. The muscles of the two sides are widely separated at their origin, but approach near together as they ascend at the sides of the trachea, and diverge slightly at the sides of the larynx, allowing the beak of the latter to project between them.

The **sterno-thyroid muscle**<sup>3</sup> lies behind the preceding, than which it is considerably wider and extends more outwardly. It arises, partially tendinous and fleshy, from behind the first costal cartilage and the middle of the presternum, extending variably more or less outward to the end of the former, or inward to the median line of the latter, and ascends at the side of the trachea to be inserted into the oblique ridge at the side of the thyroid cartilage. Behind, the muscle is in contact with the innominate vein, the common carotid artery, the trachea, and the thyroid gland.

The **thyro-hyoid muscle**,<sup>4</sup> situated at the side of the larynx, appears like a continuation of the preceding muscle. It arises from the oblique ridge of the thyroid cartilage, and ascends to be inserted into the lower border of the body and greater cornu of the hyoid bone. It rests against the thyroid cartilage and thyro-hyoid membrane, and is covered by the sterno-hyoid and omo-hyoid muscles.

<sup>1</sup> M. genio-hyoideus.

<sup>2</sup> M. sterno-hyoideus; m. sterno-cleido-hyoideus; m. cleido-hyoideus.

<sup>3</sup> M. sterno-thyroideus.

<sup>4</sup> M. thyro-hyoideus.



The **omo-hyoid muscle**<sup>1</sup> is a long, narrow band, extending from the shoulder across the neck, beneath the sterno-mastoid muscle, up to the hyoid bone. It consists of two fleshy bellies with an intermediate flat tendon, which crosses the carotid artery and jugular vein and adheres closely to their sheath. The posterior belly arises from the upper border of the scapula at the coracoid foramen, and thence proceeds nearly horizontally forward from beneath the trapezius and behind the sterno-mastoid muscle, where it joins the intermediate tendon. From this the anterior belly turns upward and forward at an obtuse angle, and ascends at the outer border of the sterno-hyoid muscle to be inserted immediately to its outer side into the inferior border of the hyoid bone. The deep cervical fascia investing the posterior belly of the muscle, with a firmer extension of the same on the tendon, is attached below to the first costal cartilage and inner surface of the clavicle, and serves to maintain the angular course of the muscle.

In its course the omo-hyoid muscle crosses the scalenus muscles, the axillary plexus, and the great cervical blood-vessels, and at its upper part lies on the sterno-thyroid and thyro-hyoid muscles. It is subject to frequent variation. The posterior belly arises variably from any part of the superior border of the scapula, including the coracoid foramen; the intermediate tendon varies in length, is sometimes partial, and occasionally absent; and the anterior belly is often more or less blended with the sterno-hyoid muscle.

Most of the infra-hyoid muscles receive their motor nerves chiefly from the descending cervical branch of the hypoglossal nerve; the thyro-hyoid muscle receiving a direct branch of the latter.

The infra-hyoid muscles are depressors of the hyoid bone and larynx and other parts adherent to them. They act in swallowing, succeeding the action of the supra-hyoid and other muscles in lifting the same parts. The omo-hyoid muscles in some degree serve to maintain the median position of the parts in front of the neck, the larynx and pharynx, and the trachea and œsophagus, which together are very movable on the cervical vertebræ.

#### MUSCLES OF THE TONGUE.

See *The Alimentary Apparatus*.

#### MUSCLES OF THE PALATE.

See *The Alimentary Apparatus*.

#### MUSCLES OF THE PHARYNX.

See *The Alimentary Apparatus*.

#### MUSCLES OF THE PERINEUM.

See *The Perineum*.

---

<sup>1</sup> M. omo-hyoideus; m. coraco-hyoideus; m. costo-hyoideus; m. scapulo-hyoideus.



## LATERAL CERVICAL MUSCLES.

The scaleni muscles form a group at the lower part of the side of the neck, extending to the upper two ribs, behind the sterno-mastoid muscle and the clavicle.

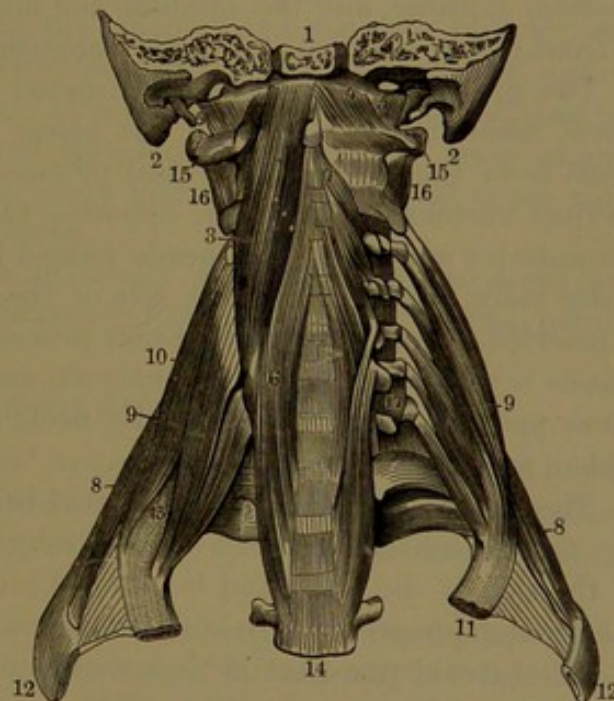
The **anterior scalenus**,<sup>1</sup> situated in front of the others, arises tendinously by four narrow heads from the ends of the costal processes of the third to the sixth cervical vertebra, inclusively. The heads unite in a fleshy belly, which descends outwardly, and is inserted tendinously into the first rib, in advance of the impression for the subclavian artery. Its lower part is immediately behind the clavicle, and in front of the insertion is crossed by the subclavian vein, and above by the omo-hyoid muscle. The phrenic nerve descends in front of it; and behind, it is in relation with the brachial plexus of nerves, the subclavian artery, and the apex of the pleura.

The **middle scalenus**,<sup>2</sup> the largest of the series, is situated behind the preceding. It arises tendinously by six narrow heads from the ends of the transverse processes of all the cervical vertebræ except the atlas. The heads unite in a fleshy belly, which descends outwardly, and is inserted into the first rib from its tubercle to the impression for the subclavian artery.

The brachial plexus of nerves and the subclavian artery pass outwardly between the anterior and middle scalenus muscles.

The **posterior scalenus**,<sup>3</sup> the smallest of the series, is situated behind the lower part. It arises tendinously by two or three narrow heads from the transverse processes of the corresponding lower cer-

FIG. 139.



DEEP MUSCLES OF THE FRONT OF THE NECK. 1, basilar process; 2, mastoid process; 3, greater pre-rectus muscle; 4, small pre-rectus; 5, lateral pre-rectus; 6, long cervical muscle; 7, atlantal muscle; 8, posterior scalenus; 9, anterior scalenus; 10, middle scalenus; 11, 12, first and second ribs; 13, position at which the subclavian artery and brachial plexus of nerves pass over the first rib, between the anterior and middle scalenus muscles; 14, third thoracic vertebra; 15, atlas; 16, 17, intertransverse muscles.

<sup>1</sup> M. scalenus anticus; m. s. prior, or primus; anterior scalene muscle.

<sup>2</sup> M. scalenus medius; m. s. secundus; middle scalene muscle.

<sup>3</sup> M. scalenus posticus; m. s. tertius; posterior scalene muscle.



vical vertebræ, and descends to be inserted into the second rib external to its angle.

The scaleni muscles are variable in the number of heads and in other respects. Sometimes a slip of the anterior scalenus joins the middle scalenus, descending behind the subclavian artery. The posterior scalenus is also at times continuous with the middle scalenus, and occasionally it is altogether absent.

The scaleni acting from the vertebræ are elevators of the upper ribs, and thus assist in the movement of inspiration. Acting from the ribs, they act as flexors of the neck, and bend the head forward. They are supplied by the adjacent cervical nerves.

#### PREVERTEBRAL MUSCLES OF THE NECK.

The prevertebral muscles consist of the greater, small, and lateral pre-recti muscles, and the atlantal and long cervical muscles, situated in front of the cervical and upper thoracic vertebræ.

The **greater pre-rectus**<sup>1</sup> is situated in front of the cervical vertebræ, ascending to the head. It arises tendinously by four narrow heads from the ends of the costal processes of the third to the sixth cervical vertebra, inclusively, opposite the same points of origin of the anterior scalenus. The heads ascend inwardly, and unite in a flat, fleshy belly, which lies at the side of the centra of the vertebræ, and is inserted into the occipital basilar process. The front surface of the muscle is in contact with the pharynx, and supports the sympathetic nerve and the great vessels of the neck, enclosed in their sheath together with the vagus nerve.

The **small pre-rectus**<sup>2</sup> is situated behind the upper extremity of the former muscle. It is a short, fleshy layer, which arises in front of the side of the atlas, and is inserted into the basilar process behind the greater pre-rectus. Behind it is the occipito-atlantal articulation.

The **lateral pre-rectus**<sup>3</sup> is a short muscle situated outwardly from the former. It arises in front of the costal process of the atlas, and ascends to be inserted into the occipital jugular process. Behind it is the vertebral artery, and in front the internal jugular vein.

The **atlantal muscle**<sup>4</sup> arises by three narrow heads tendinously from the costal processes of the third, fourth, and fifth cervical vertebræ, ascends obliquely inward, and is inserted into the anterior tubercle of the atlas.

<sup>1</sup> M. rectus capitis anticus major; m. longus capitis; great anterior straight muscle of the head; larger anterior straight muscle; m. r. c. internus major; m. trachelo-basilaris major.

<sup>2</sup> M. rec. cap. ant. minor; m. r. c. internus minor; smaller anterior straight muscle; m. trachelo-basilaris major.

<sup>3</sup> M. rectus capitis lateralis.

<sup>4</sup> M. longus atlantis; superior oblique portion of the m. longus colli; m. obliquus colli superior.



The **long cervical muscle**<sup>1</sup> arises, tendinously and fleshy, from the sides of the centra of the lower two cervical and the upper two or three thoracic vertebræ, and divides into two portions; of which the inner ascends to be inserted into the sides of the centra of the second, third, and fourth cervical vertebræ, and the outer, smaller portion ascends to be inserted tendinously into the costal processes of the fifth and sixth cervical vertebræ. This and the preceding muscle are commonly described as one, under the name of the **longus colli**.

In front of the prevertebral muscles are the pharynx and œsophagus, the sympathetic nerve, and the great vessels of the neck contained within their sheath.

The **prevertebral fascia** is a thin connective-tissue membrane, investing the front of the cervical vertebræ and the prevertebral muscles, attached to the basilar process above, and extending to the third thoracic vertebra below. On each side it is continuous with the deep cervical fascia investing the splenius and scalenus muscles, and with the sheaths of the cervical and subclavian blood-vessels, and of the brachial plexus of nerves. It is remarkably free from fat; and has attached to it the pharynx and œsophagus by means of loose connective tissue, which allows the ready gliding movement of these parts in deglutition and other functions.

The prevertebral muscles generally are flexors of the head and neck. They are supplied by branches from the adjacent cervical nerves.

#### POSTVERTEBRAL MUSCLES OF THE NECK.

The **greater post-rectus**<sup>2</sup> arises tendinously from the end of the spinous process of the axis, ascends outwardly, gradually expanding, and is inserted into and below the outer part of the inferior curved line of the occipital bone.

The **small post-rectus**<sup>3</sup> arises tendinously from the median tubercle of the atlas, ascends and expands, and is inserted into and below the inner part of the same line as the preceding muscle.

The **supra-oblique muscle**<sup>4</sup> arises tendinously from the end of the transverse process of the atlas, and ascends backward to be inserted outwardly between the curved lines of the occipital bone.

The **infra-oblique muscle**,<sup>5</sup> larger than any of the preceding, arises tendinously from the end of the spinous process of the axis, and ascends outwardly to be inserted into the end of the transverse process of the atlas.

<sup>1</sup> *M. longus colli*; inferior oblique and vertical portions of the longus colli.

<sup>2</sup> *M. rectus capitis posticus major, superficialis, or inferior*; longer straight muscle; *m. axoido-occipitalis*.

<sup>3</sup> *M. r. c. p. minor or profundus*; smaller straight muscle; *m. atlo-occipitalis*.

<sup>4</sup> *M. obliquus capitis superior or minor*; superior oblique m.

<sup>5</sup> *M. o. c. inferior or major*; inferior oblique m.; *m. axo-atloideus*.



## MUSCLES OF THE THORAX.

The muscles of the thoracic wall, independent of those especially concerned in the movements of the upper limbs, are the intercostals, subcostals, sterno-costal muscle, and costal elevators.

The **intercostal muscles**<sup>1</sup> occupy the corresponding spaces of the ribs in pairs, and are composed of short, oblique fleshy fascicles extended between the contiguous borders of the ribs, alternating in direction in each pair of muscles. The eleven intercostal spaces of each side of the thorax are consequently occupied by twenty-two intercostal muscles.

The **external intercostal muscle**<sup>2</sup> starts behind in the position of the tubercle of the ribs, and extends to the anterior extremity of the latter. Its fleshy fascicles, mingled with tendinous fibres, descend from the margin of the rib above obliquely forward to the contiguous border of the rib below. In advance of the position at which the muscle ceases, the remainder of the intercostal space is occupied by a thin aponeurosis, the fibres of which pursue the same course as those of the muscle. In the upper three or four intercostal spaces the muscle does not reach the fore end of the ribs, and in the last two it extends between the costal cartilages.

The **internal intercostal muscle**,<sup>3</sup> thinner than the former, and with its fascicles pursuing an opposite direction, arises from the inner surface of the rib above, within the position of the subcostal groove, and is inserted into the inner portion of the upper border of the rib below. It starts in front with the commencement of the intercostal space, and extends behind to about the angle of the ribs, whence a thin aponeurosis continues to the termination of the space and becomes continuous with the anterior costo-transverse ligament. In the lower two spaces the muscles are continuous with the internal oblique muscle of the abdomen. Between the intercostal muscles are the corresponding vessels and nerve. Internally they are lined by the pleura; externally they are attached to adjacent muscles, the pectorals, abdominal oblique, serrati, rhomboid, and latissimus, by loose, extensible connective tissue.

The **subcostal muscles**<sup>4</sup> are dependencies of the internal intercostals, and consist of small and variable fascicles extended between the inner surfaces of two or three adjacent ribs in the vicinity of the angle, and covered by the pleura. They are very inconstant, and when present are best produced on the lower ribs.

The **sterno-costal muscle**<sup>5</sup> is placed within the thorax behind the costal cartilages. Thin and variable in extent, it arises by a short aponeurosis from the inner surface laterally of the lower part of the mesosternum and ensiform process, and spreads outwardly and

<sup>1</sup> M. intercostales.

<sup>3</sup> M. intercostalis internus.

<sup>5</sup> M. triangularis sterni; m. sterno-costalis.

<sup>2</sup> M. intercostalis externus.

<sup>4</sup> M. subcostales; m. infracostales.



upward into four or five slips, which are inserted into the outer part of the costal cartilages from the sixth to the third or second inclusive. Its lower part, nearly horizontal, is continuous with the series of slips pertaining to the origin of the abdominal transversalis muscle. The pleura covers its inner surface, and the mammary vessels lie between it and the costal cartilages.

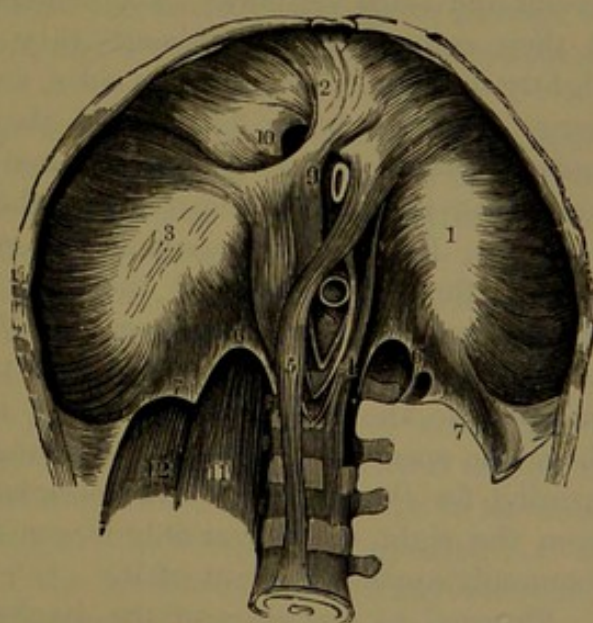
The **costal elevators**<sup>1</sup> are little fan-shaped muscles, each of which arises from the end of the vertebral transverse process above a rib, and descends and expands to be inserted into the back of the next rib below, between the tubercle and angle. The lower ones are commonly prolonged by additional slips to the second rib below. They lie against the external intercostal muscles, and are covered by the longissimus and ilio-costalis muscles. Above they lie in series with the middle and posterior scalenus muscles, and below with the lumbar intertransverse muscles.

The action of the intercostal and other muscles above described is a matter of dispute. It is probable that they may act in concert in respiration in raising the ribs and expanding the chest, and in depressing the ribs and contracting the chest, as predetermined by the alternate action of other muscles.

#### THE DIAPHRAGM.

The **diaphragm**,<sup>2</sup> a most important, extensive, and beautiful muscle, makes a complete partition between the cavities of the thorax and abdomen, and appears as a dome-like roof of the latter, projecting high up into the former. It rises higher on the right side, where it ordinarily reaches a level with the junction of the fifth costal cartilage and sternum, while on the left side it reaches a level with a corresponding junction of the sixth cartilage. It consists of a peripheral muscular layer attached around the inferior border of the thorax, and ascending to a central tendinous layer.

FIG. 140.



INFERIOR VIEW OF THE DIAPHRAGM. 1, 2, 3, the three lobes of the central tendon, surrounded by the fleshy fascicles derived from the inferior margin of the thorax, the crura, 4, 5, and the arcuate ligaments, 6, 7; 8, aortic opening; 9, oesophageal opening; 10, caval opening; 11, psoas muscle; 12, quadratus lumbae muscle.

The **central tendon**<sup>3</sup> occupies the highest part of the diaphragm,

<sup>1</sup> M. levatores costarum; m. supracostales.

<sup>2</sup> Diaphragma; midriff; musculus phrenicus.

<sup>3</sup> Centrum tendineum; c. phrenicum; cordiform tendon; trefoil tendon.



and appears as a broad, glistening aponeurosis. It has nearly the form in outline of the entire diaphragm, or of the lower opening of the thorax, but, being somewhat indented at the fore part on each side, it is trilobed. The lateral portions, or lobes,<sup>1</sup> diverge backward and downward on each side of the vertebral column, and include a deep notch behind, in front of the latter; while the intermediate lobe is anterior and directed forward towards the sternum. The lobes are oval; the right one being the largest and the left the smallest. The tendon is composed of bands which run in different directions, straight and curved, and intersect one another, and then radiate in arching fibres to the surrounding muscular layer. The latter may be conveniently described as consisting of a vertebral and a costo-sternal portion, which are, however, continuous, and together enclose the central tendon.

The **vertebral portion**<sup>2</sup> of the diaphragm in greater part forms a pair of fleshy bellies named the **crura**, or **pillars**.<sup>3</sup> These occupy the sides of the lumbar vertebræ, from which they arise by tendons closely connected with the anterior vertebral ligament. The **right crus**, variably longer and larger than the other, usually arises from the centra and intervening ligaments of the second, third, and fourth lumbar vertebræ; and the **left crus**, from the corresponding points of the second and third vertebræ. The tendons of origin are close together at their commencement, whence they pass from behind the aorta, slightly divergent, ascend at its sides, and for the most part gradually merge into the fleshy fascicles of the crura, while a small portion continues to ascend at their inner margin, and forms a narrow arch across the front of the aorta, over the position of the last thoracic vertebra. By this arrangement the crura leave between them an opening for the passage of the aorta. The fleshy fascicles of the crura ascend, diverge, arch forward, and spread laterally to terminate in the posterior notch of the central tendon of the diaphragm. In their course, the innermost fascicles of the crura decussate in front of the aortic opening, and thence diverging, leave between them another opening for the passage of the œsophagus. The decussating fascicle from the right crus is variably larger than that of the left crus, and commonly ascends in front of it.

External to the crura of the diaphragm are two narrow, arching fibrous bands, the **arcuate ligaments**,<sup>4</sup> from the upper part of which a fleshy layer ascends to the posterior border of the central tendon, continuous inwardly with the crura and outwardly with the costo-sternal portion of the diaphragm.

The **internal arcuate ligament**<sup>5</sup> arches outwardly from the side of the first lumbar centrum, or occasionally from the second, to the

<sup>1</sup> Alæ.

<sup>2</sup> Portio vertebralis; p. lumbalis; lesser or lower muscle.

<sup>3</sup> Capita; appendices.

<sup>4</sup> Ligamenta arcuata.

<sup>5</sup> L. arcuatum internum; arcus internus.



end of the transverse process of the latter. The **external arcuate ligament**<sup>1</sup> in like manner arches from the end of the same transverse process outwardly to the lower border of the last rib. The arcuate ligaments below are continuous with the psoas and lumbar fasciæ.

The **costo-sternal portion**<sup>2</sup> of the diaphragm arises by fleshy slips from the inner surface of the lower six costal cartilages, alternating with intervening slips of the abdominal transversalis muscle, and from the inside of the ensiform process of the sternum. From this origin it ascends in a continuous vaulted layer, and terminates along the anterior and lateral borders of the central tendon. The slips to the lateral lobes of the tendon are longest, and those to the middle lobe decrease in advance. Those proceeding from the sternum are shortest, and usually are somewhat separated from the rest by a narrow interval on each side, which is occupied by connective tissue, and closed by the apposition of the pleura above and the peritoneum below.

The **aortic opening**<sup>3</sup> of the diaphragm is a long, elliptical aperture, opening into the abdomen obliquely in front of the upper three lumbar and last thoracic vertebræ. It is bounded behind by the centra of these vertebræ and by the anterior vertebral ligament, at the sides by the tendinous origin of the crura of the diaphragm, and at its upper extremity by the fibrous arch uniting the crura across the position of the last thoracic vertebra. Besides the aorta, it also gives passage to the thoracic duct, the azygos vein, and occasionally the left sympathetic nerve.

The **œsophageal opening**<sup>4</sup> is likewise an oblique, elliptical aperture, and is situated above, in advance, and a little to the left of the position of the aortic opening. It is formed by the separation of the fleshy fascicles, which diverge from the crura of the opposite sides, and again converge, after passing the opening, to end in the central tendon; at the bottom of the posterior notch of which, the opening is situated. It transmits the œsophagus with the vagus nerves.

The **caval opening**,<sup>5</sup> for the passage of the inferior cava, occupies a higher position than the preceding openings, in the central tendon at the junction behind of the right and middle lobes, a little in advance and to the right of the position of the œsophageal opening. It is quadrate, due to the direction of the tendinous bands which surround it; and it is closely attached to the wall of the inferior cava.

Besides the foregoing, the right crus transmits the corresponding sympathetic and splanchnic nerves; and the left crus the left splanchnic nerves and the hemiazygos vein.

The diaphragm is deeply vaulted, being convex above and concave

<sup>1</sup> L. a. externum; arcus externus.

<sup>2</sup> Portio costo-sternalis; greater or inferior muscle.

<sup>3</sup> Foramen aorticum; hiatus aorticus.

<sup>4</sup> Foramen œsophageum; hiatus œsophageus.

<sup>5</sup> F. quadratum; f. venæ cavæ.



below. On the right side it rises nearly an inch higher than on the left. In forced expiration it ascends on the right to a level in front with the fourth costal cartilage; at the side with the fifth, sixth, and seventh ribs; and behind with the eighth rib. On the left it usually ascends the breadth of one or two ribs lower. In forced inspiration it descends from one to two inches, and its slope nearly accords with a line from the ensiform process to the tenth rib. At its circumference the diaphragm is highest behind the sternum; but centrally, where the heart rests upon it, it is on a slightly lower level than on each side.

The diaphragm by its upper surface is tightly adherent to the pericardium, and on each side is invested with the pleura; and beneath it is covered by the peritoneum. On its right side, above, rests the right lung, and beneath it is in contact with the liver; on its left side rest the heart and the left lung, and it is in contact beneath with the greater extremity of the stomach, the spleen, and the left kidney.

The diaphragm is supplied by the phrenic nerves and the phrenic plexus of the sympathetic. It is the chief muscle of respiration. In its movements the central tendon appears to maintain a nearly fixed position, on account of its firm attachment to the pericardium and mediastinal folds, and the connection of these with the summit of the chest. With contraction of the muscular portion of the diaphragm the capacity of the chest proportionately increases, and produces inspiration of air into the lungs, while the abdominal viscera are pressed downward, and the abdomen is rendered protuberant. In relaxation of the diaphragm the abdominal muscles below contract, press the viscera upward, reduce the capacity of the chest, and cause expiration. In all expulsive actions of the lungs and bowels, the contraction of the diaphragm promotes the effects, as exemplified in coughing and vomiting, in the discharge of the urine and fæces, and in childbirth.

#### MUSCLES AND FASCLE OF THE ABDOMEN.

The muscles of the exterior wall of the abdomen consist of six on each side, occupying the interval between the vertebral column and the median line in front of the abdomen, and extending from the thorax to the pelvis. Three of them, named from the principal direction of their fleshy fibres the external oblique, internal oblique, and transversalis muscles, are of great comparative breadth, each for the most part occupying the extent of the space above indicated. Their fleshy bellies at the sides of the abdomen terminate in front in aponeuroses, which unite in the median line to form the linea alba, extending from the end of the sternum to the symphysis of the pubes. The other three muscles on each side are longitudinal and comparatively narrow, two of them, the rectus and pyramidalis muscles, being situated in front, ensheathed by the aponeuroses of the broad muscles, and the third one, the quadratus lumborum muscle, situated at the side of the loins behind.



The **superficial fascia of the abdomen**<sup>1</sup> is part of that which everywhere invests the body, and is of the same general character, consisting of two layers, of which the subcutaneous layer is thicker, of looser texture, and is the position of the usual variable accumulation of subcutaneous fat. The deeper, thinner, and more distinctly membranous layer, comparatively free from fat, is strongest in front of the abdomen, and adheres to the subjacent aponeuroses by loose connective tissue. It adheres most tightly to the linea alba, around the umbilicus, to the pubic symphysis, and in the inguinal region, after passing over Poupart's ligament, to the fascia lata immediately beneath. Around the external abdominal ring it is loosely attached, and in this position the subcutaneous layer becomes free from fat, and the two unite in a single membrane, which descends upon the spermatic cord, undergoes a change of structure through the association of unstriated muscular fibres, and thus forms the **dartos tunic** of the scrotum. From the groin and front of the pubis the deeper layer of the superficial fascia becomes continuous with that of the penis. From the connection of the fascia to the lower end of the linea alba and the pubic symphysis, considerable bundles of connective and elastic tissue descend and form the **suspensory ligament of the penis**.

In large herbivorous quadrupeds the deeper layer<sup>2</sup> of the superficial fascia of the abdomen is a thick membrane, composed of yellow elastic tissue, admirably adapted to sustain the weight of the abdominal contents.

Subjacent to the superficial fascia a thin connective-tissue layer invests the fleshy belly of the external oblique muscle, continuous in front with the outer border of its aponeurosis. It corresponds with the deep fascia in other parts of the body.

The **external oblique muscle**<sup>3</sup> is the largest and most superficial of the broad muscles of the abdomen. It is an irregularly quadrilateral layer, with its fleshy belly occupying the side and its aponeurosis the front of the abdomen. It arises by eight angular points from the outer surface and lower borders of the inferior eight ribs, in an oblique line extending downward and backward. The upper points are near the anterior ends of the ribs, while those succeeding are farther back, and the lowest one is attached to the end of the last costal cartilage. The upper five points successively enlarge and include between them similar points of the great serratus muscle, while the lower three points diminish and include similar points of the latissimus muscle. The fleshy fascicles descend from their origin obliquely forward, and for the most part terminate in the aponeurosis; those behind, from the lower ribs, descending less obliquely to be inserted into the outer lip of the iliac crest. The aponeurosis unites with its

<sup>1</sup> Fascia superficialis abdominis.

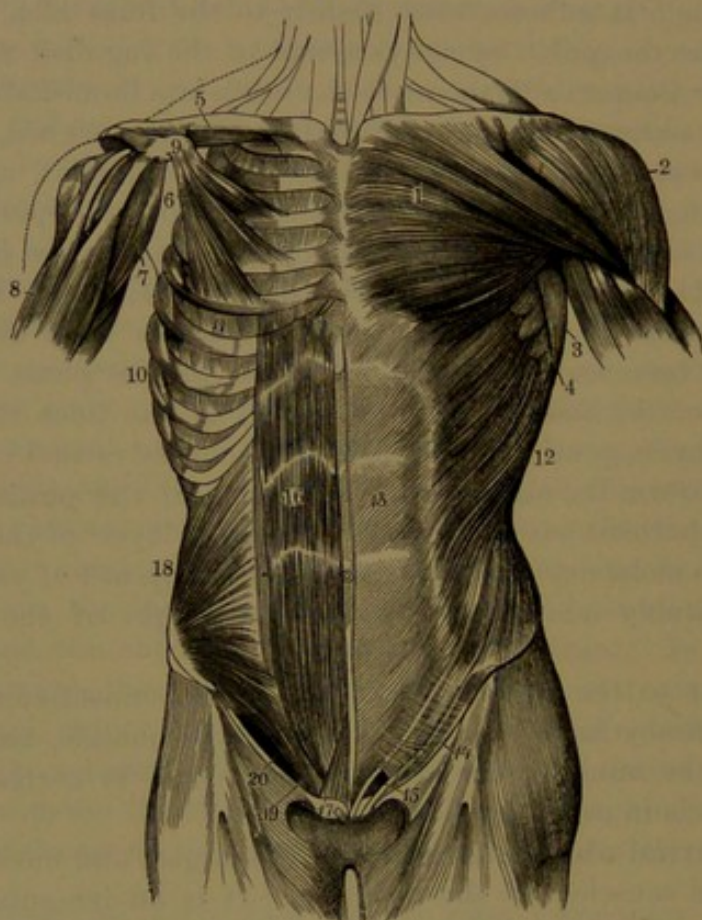
<sup>2</sup> Tunica abdominalis.

<sup>3</sup> Descending oblique muscle; m. obliquus abdominis externus or descendens; great oblique muscle.



fellow in the median line of the abdomen, extending from the ensiform process of the sternum to the symphysis of the pubes, and contributes to form the linea alba. From this position, for the greater part of its length, it spreads outwardly for three or four inches, and at the lower part widens to the anterior superior iliac spine, whence it narrows to

FIG. 141.



MUSCLES OF THE FRONT OF THE THORAX AND ABDOMEN. 1, greater pectoral muscle; 2, deltoid muscle; 3, latissimus; 4, great serratus; 5, subclavius muscle; 6, small pectoral muscle; 7, coracobrachial muscle; 8, brachial biceps; 9, coracoid process of the scapula; 10, origin of the great serratus muscle; 11, intercostal muscles; 12, external oblique muscle of the abdomen; 13, its aponeurosis; 14, lower border of the latter, named Poupart's ligament; 15, external abdominal ring, the lower extremity of the inguinal canal; 16, abdominal rectus muscle; 17, pyramidal muscle; 18, internal oblique muscle; 19, conjoined tendon of the internal oblique and transversalis muscles; 20, position of the inguinal canal below the arching edges of the preceding two muscles.

the pubis. Its fibres pursue the same course as the fleshy fascicles of the muscle, cross at the linea alba, and interlace with those of the opposite aponeurosis. A denser portion of the aponeurosis, starting about an inch above the anterior superior iliac spine and partially from this, in its descent separates from the rest of the aponeurosis above and converges into a narrower band, named **Poupart's ligament**,<sup>1</sup>

<sup>1</sup> Lig. Pouparti, Fallopiæ, or Vesalii; l. iliopubicum; crural arch; arcus cruralis.



which is inserted into the pubic spine, and is thence extended outwardly along the pectineal line for about three-fourths of an inch. This extension of the insertion is named **Gimbernati's ligament**,<sup>1</sup> and terminates outwardly in a concave free margin, forming the inner boundary of the femoral ring, which will be subsequently described. The interval, produced by the separation of Poupart's ligament from the upper portion of the external oblique aponeurosis, widens in its approach to the pubis, and at the upper part is occupied by a thin connective-tissue membrane. The lower part of the interval forms the **external abdominal ring**,<sup>2</sup> the inferior or outer end of the inguinal canal, which transmits the spermatic cord in the male and the round ligament of the uterus in the female. The ring is situated immediately above the body of the pubis, and is obliquely oval, with the long diameter conforming to the direction of the separation of the aponeurosis producing it. In the male it is about an inch long and half as wide, and in the female is much smaller. The sides of the ring are distinguished as its columns,<sup>3</sup> the **external column**<sup>4</sup> being formed by Poupart's ligament, and the **internal column**<sup>5</sup> by that portion of the external oblique aponeurosis which is inserted into the pubic symphysis. Some tendinous fibres curving from the groin to the linea alba are named the **intercolumnar fibres**,<sup>6</sup> and serve to maintain the conjunction above of the two portions of the aponeurosis which form the columns of the ring. A delicate connective-tissue membrane, the **spermatic fascia**,<sup>7</sup> springs from the margin of the external abdominal ring, and is thence prolonged downward as an investment to the spermatic cord. Poupart's ligament in its course curves downward in the line of the groin, and is connected below with the deep femoral fascia of the thigh. From its insertion and that of Gimbernati's ligament behind, a portion of the fibres form the **triangular ligament**,<sup>8</sup> a variable aponeurotic expansion, which curves inwardly beneath the spermatic cord and behind the position of the external abdominal ring, and becomes closely united with the fore part of the sheath of the rectus muscle.

The **internal oblique muscle**<sup>9</sup> lies within the position of the preceding muscle, in contact with it, and is smaller and thinner. It arises fleshy from the lumbar fascia in the angle between the crest of the ilium and the outer border of the dorsal extensor muscle, tendinously from the middle lip of the anterior two-thirds of the iliac crest, and fleshy from the outer half of Poupart's ligament. From this origin the fleshy

<sup>1</sup> L. Gimbernati.

<sup>2</sup> Annulus abdominalis externus; a. inguinalis ext.

<sup>3</sup> Pillars; crura.

<sup>4</sup> Inferior column or pillar; crus inferius.

<sup>5</sup> Superior column or pillar; crus superius.

<sup>6</sup> Fibrae intercolumnares; f. collaterales.

<sup>7</sup> External spermatic fascia; intercolumnar fascia.

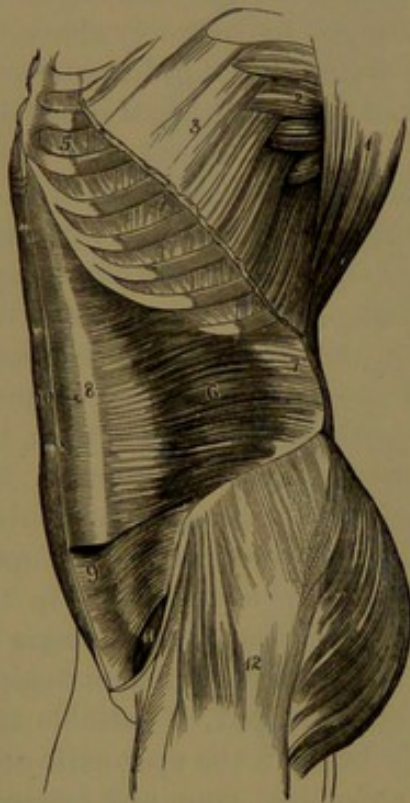
<sup>8</sup> Lig. triangulare or inguinale internum; l. Gimbernati reflexum; ligament of Colles.

<sup>9</sup> M. obliquus internus or ascendens; m. o. abdominis int. or asc.; petit oblique.



fibres mostly ascend obliquely forward and inward, but gradually become less inclined below; those from the anterior superior iliac spine proceeding horizontally forward, and those from Poupart's ligament arching forward and downward. The upper more posterior fascicles are inserted into the inferior margins of the lower three or four costal cartilages in the same plane as the internal intercostal muscles, while the others terminate in an aponeurosis which extends from the lower margin of the thorax to the pubis and unites with its fellow in the linea alba. Along the upper three-fourths of the outer edge of the

FIG. 142.



VIEW OF THE LEFT SIDE OF THE ABDOMEN. 1, portion of the latissimus muscle; 2, origin of the great serratus; 3, origin of the external oblique; 4, external intercostals; 5, internal intercostals; 6, transversalis muscle; 7, its aponeurotic origin; 8, its aponeurosis in front; 9, lower part of the internal oblique muscle; 10, abdominal rectus of the right side; 11, position of the inguinal canal between the arched border of the internal oblique and transversalis muscles and Poupart's ligament: the figure rests on the transversalis fascia; 12, the vaginal tensor muscle.

rectus muscle the aponeurosis divides into two laminae, of which one proceeds in front and the other behind the rectus to the linea alba, and thus enclose the muscle in a sheath. The anterior lamina of the aponeurosis, a short distance from its commencement above, gradually widens below, and blends with the external oblique aponeurosis as it proceeds to the linea alba. Below the point of division the aponeurosis remains in great part free from that of the external oblique muscle, and behind joins that of the transversalis muscle to form the **conjoined tendon**, which extends to the linea alba, and below is inserted into the crest and pectineal line of the pubis.

The **transversalis muscle**<sup>1</sup> succeeds the former, and is next the abdominal cavity. It arises fleshy from the inner surface of the lower six costal cartilages, alternating with contiguous points of origin of the diaphragm; from the lumbar fascia in a line descending from near the end of the last rib to the iliac crest; from the inner lip of the crest in advance; and

from the outer third of Poupart's ligament. From this extensive origin the muscular fascicles, for the most part, proceed horizontally forward and inward, while the lowest arch inward and downward,

<sup>1</sup> M. transversalis abdominis.



and all terminate in a broad aponeurosis, which extends to the linea alba from the sternum to the pubis. The aponeurosis widens outwardly below its middle, and to a greater extent than do the aponeuroses in front, but narrows above to a greater degree, so that at the upper extremity the fleshy fibres of the muscle approach the linea alba nearer than in any other position of the broad muscles. The upper three-fourths of the aponeurosis after a short course unite with the posterior lamina of the internal oblique aponeurosis, though to a gradually lessening extent above, and the united aponeuroses proceed behind the rectus muscle to the linea alba. About midway between the umbilicus and pubis the united aponeuroses thin away and terminate in a more or less defined crescentic border,<sup>1</sup> which is continuous with the subjacent transversalis fascia. The lower fourth of the transversalis aponeurosis proceeds in front of the rectus, and unites with that of the internal oblique muscle to form the **conjoined tendon**, which extends to the linea alba, and is also inserted into the crest and pectineal line of the pubis immediately behind the insertion of Poupart's and Gimbernat's ligaments. The lowest fleshy fascicles of the internal oblique and transversalis muscles are more or less blended, and usually thinner, paler, and less regular than elsewhere, and they arch from Poupart's ligament over the spermatic cord to end in the conjoined tendon. Approaching the pubis, the outer border of the latter is less compact, and is continuous with the adjacent transversalis fascia.

The **rectus muscle**<sup>2</sup> extends along the front of the abdomen, enclosed in a sheath formed by the aponeuroses of the broad muscles, and separated from its fellow by the linea alba. It arises from the crest and symphysis of the pubes by a flat tendon, from which the fleshy belly gradually widens to near the position of the umbilicus, and then proceeds of more uniform width to the front of the thorax, where it becomes wider and thinner, and is inserted tendinously into the fifth, sixth, and seventh costal cartilages, and sometimes into the ensiform process of the sternum. In its course the muscular belly is interrupted commonly by three short **tendinous intersections**,<sup>3</sup> which are transverse, variably bent, angular or zigzag, and sometimes interrupted. Usually one is situated below the end of the ensiform process, another on a level with the umbilicus, and the third in an intermediate position. Sometimes there is another, mostly incomplete, below the umbilicus. They are chiefly confined to the superficial part of the muscle, and are intimately connected with the fore part of its sheath. As observed through the aponeuroses in front of the muscle, they are known as the **lineæ transversæ**.

The **pyramidal muscle**<sup>4</sup> is a triangular fleshy slip, situated in front

<sup>1</sup> Linea or plica semilunaris.

<sup>2</sup> M. rectus abdominis; straight muscle of the abdomen.

<sup>3</sup> Inscriptiones tendineæ.

<sup>4</sup> M. pyramidalis abdominis.



of the origin of the abdominal rectus, and included within the same aponeuroses. It arises from the body and symphysis of the pubes, and ascends for two or three inches to be inserted into the linea alba. It is variable in size, and is frequently absent on one or both sides.

The **cremaster** is a thin plane of fleshy fibres, invested with connective tissue, sheathing the fore part of the spermatic cord, and extending from the inguinal canal to the testicle. The muscle is attached to Poupart's ligament outwardly below the origin of the lowest fibres of the internal oblique muscle, and inwardly is attached to the pectineal line of the pubis. The fibres of the cremaster form on the spermatic cord a series of loops, the lowest of which reach and expand upon the testicle. In the female usually a few small corresponding fibres accompany the round ligament.

The **linea alba**, as expressed by the name, is a conspicuous white fibrous structure in the median line of the abdomen, extending from the ensiform process of the sternum to the symphysis of the pubes. It is produced by the intersection of the fibrous bundles of the aponeuroses of the broad muscles, passing from side to side of the abdomen. It gradually widens from its commencement, and approaching the umbilicus reaches three-fourths of an inch or more, but below the latter rapidly decreases, and becomes a narrow partition, separating the recti muscles. The **umbilicus** is a cicatrix in the linea alba remaining from the original connection of the umbilical cord.

Along the outer limit of the rectus, the bellies of the muscles on each side glimmering through the aponeuroses give rise to the appearance of another, though less conspicuous, white line, which follows the curvature below of the rectus muscle, and is called the **linea semilunaris**. The tendinous intersections of the rectus, in like manner seen through the aponeuroses, give rise to the **lineæ transversæ**, extending between the linea alba and linea semilunaris. The surfaces corresponding with the fleshy bellies of the muscles, as defined by the different lines indicated, are variably prominent, proportioned to the development of the muscles generally, and in powerfully muscular men become more or less evident even on the exterior of the body.

The **quadrate lumbar muscle**<sup>1</sup> is situated at the back of the abdominal cavity, ascending obliquely from the crest of the ilium to the last rib, at the side of the lumbar vertebræ. It is a flat, rectangular muscle, a little wider below, and is enclosed in a sheath formed by the anterior two layers of the lumbar fascia. It arises partially tendinous and fleshy from the ilio-lumbar ligament and adjacent portion behind of the iliac crest, and ascends to be inserted tendinously into the lower border of the last rib for half its length, and into the ends of the transverse processes of the upper three or four lumbar vertebræ. Commonly, in addition slips arise tendinously from the

<sup>1</sup> M. quadratus lumborum; m. scalenus lumborum; m. ilio-lumbalis.

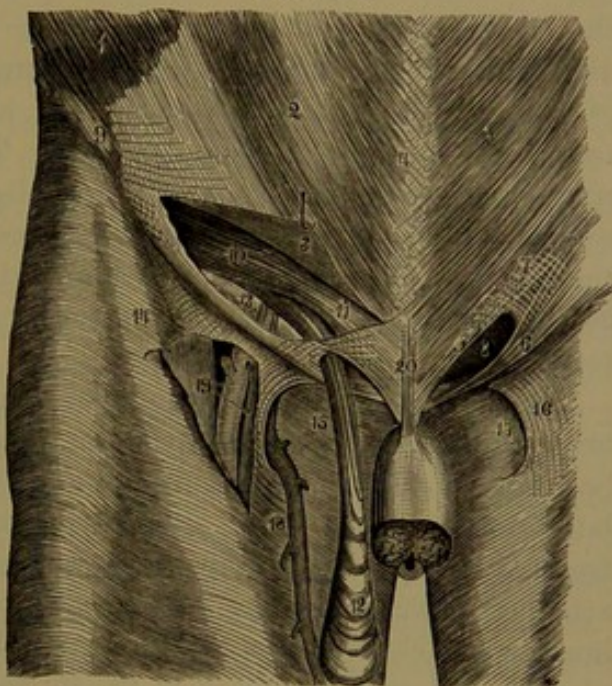


upper border of the transverse processes of the lower two or three lumbar vertebræ, and join the muscle in front, to be inserted with it into the last rib.

The **transversalis fascia**<sup>1</sup> is part of the general connective-tissue investment of the abdominal cavity attaching the peritoneal lining to the muscular walls of the latter. It is very thin the greater part of its extent, and above is continuous with the connective-tissue layer attaching the peritoneum to the diaphragm. Behind, it is continuous with the anterior layer of the lumbar fascia, and below is attached along the crest of the ilium, and is thence continuous with the iliac fascia investing the iliac muscle. It is thickest at the lower front part of the abdomen, where it comes into contact with the posterior surface of the rectus muscle, and is continuous above with the termination behind of the aponeurotic sheath of the latter. In this position the epigastric vessels ascend through the fascia to the rectus muscle. In the inguinal region it is strongest, somewhat aponeurotic, and is attached to Poupart's ligament, the triangular ligament, and the conjoined tendon.

The **inguinal canal**<sup>2</sup> occupies the inguinal region or groin, and, though not a distinct canal as the name would seem to indicate, is the passage which transmits the spermatic cord, or round ligament, through the abdominal wall. It is situated above and parallel with Poupart's ligament, and is about an inch and a half long. It commences at the **internal abdominal ring**, situated about midway in the groin, and terminates below at the **external abdominal ring**. It is bounded in front by

FIG. 143.



VIEW OF THE INGUINAL CANAL. 1, portion of the external oblique muscle; 2, its aponeurosis; 3, portion of the latter raised up, exposing the inguinal canal; 4, linea alba; 5, internal column, and 6, external column; 7, intercolumnar fibres; 8, external abdominal ring; 9, anterior superior iliac spine; 10, arching border of the internal oblique and transversalis muscles; 11, conjoined tendon of the latter muscles; 12, fibres of the cremaster muscle descending on the spermatic cord; 13, rests on the transversalis fascia; to its right are the epigastric vessels crossing the course of the inguinal canal; 14, iliac portion of the fascia lata; 15, pubic portion; 16, falciform process; 17, saphenous opening; 18, saphenous vein joining the femoral vein through the saphenous opening; 19, the femoral artery and vein exposed by raising the portion of fascia which forms the falciform process; 20, suspensory ligament of the penis.

<sup>1</sup> F. transversalis.

<sup>2</sup> Canalis inguinalis.



the external oblique aponeurosis; behind by the transversalis fascia, the triangular ligament, and the conjoined tendon of the internal oblique and transversalis muscles; above by the lower arching border of the latter muscles; and beneath by Poupart's ligament and its attachment to the transversalis fascia.

The **internal abdominal ring**<sup>1</sup> is that point in the transversalis fascia, about midway in the groin, at which the chief constituents of the spermatic cord converge, and thence emerge from the abdomen through the inguinal canal. Though not a distinct opening in the transversalis fascia, it is conveniently regarded as such; and from it the transversalis fascia is prolonged on the cord as a thin investment distinguished as the **infundibuliform fascia**.<sup>2</sup> The inner margin of the ring is usually better defined by a slight thickening of the transversalis fascia in this position. The peritoneum covering the ring commonly exhibits a variably slight depression, from the outside of which a filament may sometimes be observed extending upon the cord. The depression and filament are the remains of the foetal communication between the peritoneum and the vaginal tunic of the testicle.

The **lumbar fascia** is the name commonly applied to three membranous layers, which ensheathe the dorsal extensor and quadrate lumbar muscles and afford origin to the transversalis, internal oblique, and latissimus muscles. The **anterior layer** is the thinnest, and lies in front of the quadrate lumbar muscle next the abdominal cavity. It is attached inwardly to the fore part of the transverse processes of the lumbar vertebræ, above to the external arcuate ligament of the diaphragm, below to the front of the ilio-lumbar ligament and iliac crest, and outwardly joins the posterior layer of the lumbar fascia. The **middle layer**, thicker than the former and somewhat aponeurotic, lies behind the quadrate lumbar muscle, and together with the anterior layer ensheathes the muscle. It is attached inwardly to the ends of the transverse processes of the lumbar vertebræ, above to the last rib, below to the ilio-lumbar ligament and iliac crest, and outwardly joins the posterior layer of the lumbar fascia. The **posterior layer** is subcutaneous, and is a strong aponeurosis which gives origin to the latissimus muscle, and is attached to the ends of the spinous processes of the lumbar vertebræ and sacrum and to the back part of the crest of the ilium. Behind, it closely embraces the dorsal extensor muscle, and joined outwardly by the middle layer of the fascia, includes the latter in a sheath. Proceeding farther it is joined by the anterior layer of the fascia, and on a line descending from the end of the last rib to the iliac crest gives partial origin to the transversalis and internal oblique muscles. Considerable connective-tissue layers occupy the

<sup>1</sup> Annulus abdominalis internus; upper or posterior abdominal ring; apertura interna canalis inguinalis.

<sup>2</sup> Processus vaginalis.



intervals of the broad muscles of the abdomen, continuous behind with the lumbar fascia, and in the inguinal region with the transversalis fascia.

#### PSOAS MUSCLE.

See *Muscles of the Lower Limb*.

The abdominal muscles are supplied by the inferior intercostal, the ilio-hypogastric, and the ilio-inguinal nerves. Together they compress the abdominal viscera, and assist in expiration, in the expulsion of the contents of the stomach, intestines, and urinary bladder, and also in the birth of the child.

#### FASCIÆ OF THE PELVIS.

The **pelvic fascia**<sup>1</sup> is a thin membrane lining the cavity of the pelvis. It is continuous with the iliac and transversalis fasciæ, and is attached to the brim of the pelvis and the surface immediately below, extending along the origin of the internal obturator muscle. From the latter it continues back over the pyriformis muscle and sacral plexus of nerves, behind the internal iliac vessels, to be attached to the front of the sacrum. It passes beneath the obturator vessels in their course from the pelvis, and is attached forward to the lower part of the pubic symphysis. Descending on the inner surface of the internal obturator muscle, it forms a thickened, curved, tendinous line, which extends from the pubic symphysis to the spine of the ischium, gives attachment to the anal elevator muscle, and divides into two layers, the obturator and recto-vesical fasciæ. Internally it is covered by the peritoneum.

The **obturator fascia**<sup>2</sup> is a continuation of the pelvic fascia, descending on the lower part of the internal obturator muscle, and is attached to the pubic arch, the ischial tuberosity, and the great sciatic ligament. By a strong process, extended across the pubic arch within, it is continuous with that of the opposite side;—the process constituting the posterior layer of the triangular ligament of the pubes.<sup>3</sup> From its upper border extends the **anal fascia**,<sup>4</sup> a thin layer which invests the outer surface of the anal elevator and sphincter muscles.

The obturator fascia encloses the pudic vessels and nerve in their course. The interval of the obturator fascia and anal elevator is a considerable space, widening below, and named, from its position between the ischium and rectum, the **ischio-rectal fossa**, which is occupied by areolar tissue, with more or less fat. The disappearance of this fat in emaciation produces the sinking of the perineum around the anus.

The **recto-vesical fascia**,<sup>5</sup> the inner division of the pelvic fascia, descends on the inner surface of the anal elevator muscle to the side

<sup>1</sup> F. pelvica.

<sup>2</sup> F. obturatoria.

<sup>3</sup> Posterior or superior layer of the deep perineal fascia.

<sup>4</sup> Ischio-rectal fascia.

<sup>5</sup> Visceral layer of the pelvic fascia.



of the prostate, the bladder, and the rectum. The fascia divides at the side of the prostate into two layers, which closely invest it, together with the prostatic plexus of veins, and unite with the layers of the opposite side. An extension of the inferior or posterior layer extends backward and invests the seminal vesicles, the vasa deferentia, and the fundus of the bladder, including the vesical plexus of veins. Extensions of the recto-vesical fascia upward invest the bladder and rectum, being thickest where these organs are not covered by the peritoneum. The fasciæ of the two sides unite between the bladder and rectum, and a thin investment is prolonged below on the latter to the anus within the insertion of the anal elevator muscle. A narrow process of the fascia proceeding from the pubis below the symphysis to the upper part of the prostate and neck of the bladder is named the **anterior vesical ligament**.<sup>1</sup> Between the ligaments of the two sides the fascia is thin, and depressed in a hollow. The extension of the attachment of the fascia from the side of the prostate to the side of the fundus of the bladder constitutes the **lateral vesical ligament**.<sup>2</sup>

#### THE FASCIÆ AND MUSCLES OF THE BACK OF THE TRUNK.

The **superficial fascia** of the back of the trunk forms a considerable connective-tissue layer, with a continuous subcutaneous stratum of adipose tissue, which varies with the condition of the body. The **deep fascia** is a thin, compact, connective-tissue membrane, investing the superficial muscles, and continuous with similar thinner intervening septa. It adheres tightly in the median line to the occipital protuberance, the nuchal ligament, and the spinous processes of the vertebral column, outwardly above to the superior curved line of the occipital bone extending to the mastoid process, below to the crest of the ilium, and also along the spine and acromion of the scapula to the clavicle. At the outer border of the trapezius and latissimus muscles it is continuous with the deep cervical fascia, and with that of the axilla and of the abdomen.

The muscles of the back of the trunk consist of a more superficial set, mostly broad, and extending outwardly from the spinous processes of the vertebral column to be connected with the upper limb, and a deeper, more numerous set, mostly longitudinal, and occupying the grooved area on each side of the vertebral column; in the thoracic region reaching outward to the angles of the ribs. In the superficial set they form two layers, of which the first contains the trapezius and latissimus muscles, and the second contains the scapular elevator and rhomboid muscles. In the deeper set they form three layers, as follows: 1, the splenius, supraserratus, and infraserratus muscles; 2, the dorsal extensor, longissimus, ilio-costalis, spinalis, ascending cervical, cervical

<sup>1</sup> Anterior true ligament of the bladder; pubo-prostatic ligament.

<sup>2</sup> Lateral true ligament of the bladder.



transversalis, trachelo-mastoid, and complexus muscles; 3, the semispinalis, multifidus, spinal rotator, interspinal, intertransverse, greater post-rectus, small post-rectus, supraoblique and infraoblique muscles.

#### SUPERFICIAL MUSCLES OF THE BACK.

The **trapezius**<sup>1</sup> is a large triangular muscle lying immediately beneath the skin at the back of the neck and thorax, extending outwardly to the shoulder. It is a broad, thick, fleshy layer, arising by a narrow, thin aponeurosis from the occipital protuberance and inner third of the superior curved line, from the nuchal ligament, and from the ends of the spinous process of the last cervical and all the thoracic vertebræ with their supraspinous ligament. From this extensive origin the fleshy fascicles converge outwardly and are inserted tendinously; the uppermost fascicles descending and turning forward in the neck to be inserted into the posterior border of the outer third of the clavicle; the succeeding fascicles gradually becoming more horizontal, and proceeding outward to be inserted into the inner margin of the acromion and into the upper lip of the posterior border of the spine of the scapula; while the inferior fascicles ascend and end in a flat, firm tendon, which glides on the triangular surface at the commencement of the scapular spine, and is then inserted into the latter. The aponeurosis of origin extends the width of its attachment to the occipital bone, and in this position is of looser texture, lacks the usual tendinous appearance, and is tightly attached to the adjacent skin. Narrowing along the nuchal ligament, it widens at the bottom of the neck, forming with that of the other side an elliptical patch, between the position of the shoulders extending from the sixth cervical to the third thoracic vertebra. Thence it narrows along the thorax, but slightly widens again towards the lower end. It is chiefly composed of transverse tendinous fibres, which are in part continuous between the two muscles at their attachment to the nuchal ligament and in the intervals below of the spinous processes.

The trapezius is variable in its origin, especially in the number of its attachments to the thoracic vertebræ; and its occipital attachment may be reduced or may even be entirely wanting. It covers the splenius, complexus, scapular elevator, rhomboid, and supraspinatus muscles, and portions of the infraspinatus and latissimus muscles.

The trapezius is supplied by the accessorius nerve, which, after being joined by branches from the third and fourth cervical nerves, enters the muscle beneath its outer border, near the clavicle; and it also directly receives branches from the latter nerves.

In the complete action of the trapezius the shoulder, and with it the upper limb, is drawn directly backward. Different portions acting

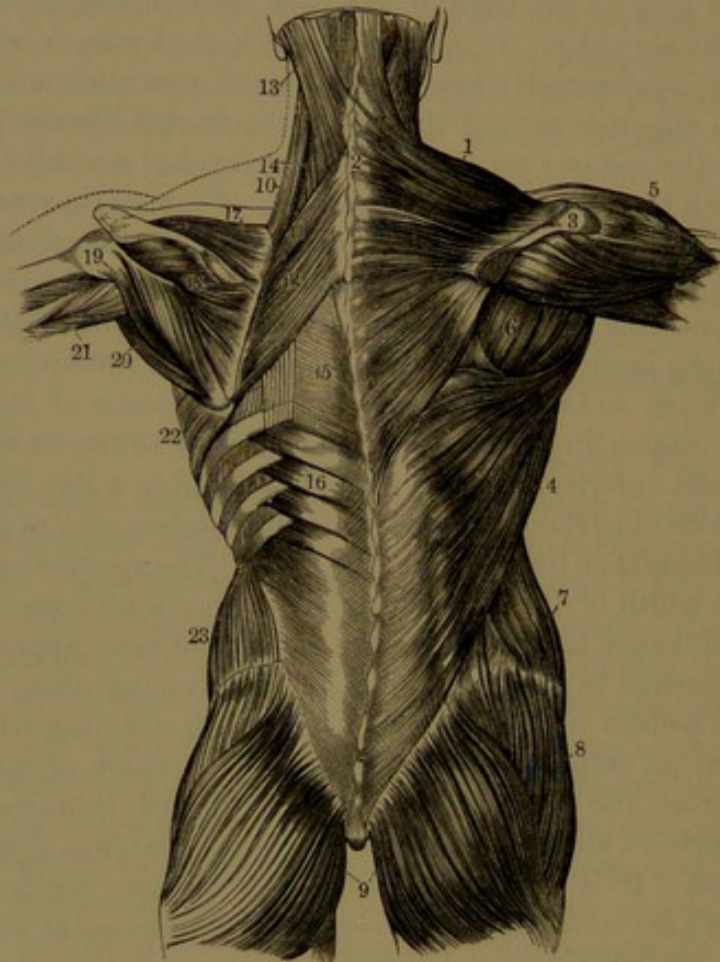
<sup>1</sup> M. trapezius; m. cucullaris.



alone or in concert with other muscles may elevate or depress the shoulder, and at the same time draw it backward.

The *latissimus*,<sup>1</sup> as expressed by the name, is one of the broadest of muscles. It lies immediately beneath the skin, and occupies the

FIG. 144.



MUSCLES OF THE BACK. 1, 2, trapezius; 3, the acromion; 4, latissimus; 5, deltoid muscle; 6, infraspinatus, and to its outer side the teres muscles; 7, external oblique muscle of the abdomen; 8, middle gluteus; 9, great gluteus muscle; 10, scapular elevator; 11, 12, rhomboid muscles; 13, 14, splenius; 15, aponeurosis extending from the supra- to the infraserratus muscle, 16; 17, supraspinatus; 18, infraspinatus muscle; 19, lesser teres, and 20, greater teres muscle; 21, brachial triceps; 22, great serratus muscle; 23, internal oblique muscle of the abdomen.

back from about the middle of the thorax down to the hip, and extends outward and upward along the side of the former and back of the axilla to the arm. It arises by a broad, thin aponeurosis from the supraspinous ligament and ends of the spinous processes usually of the lower five or six thoracic vertebræ, of the lumbar vertebræ, and of the sacrum, and from the outer lip of the crest of the ilium behind the insertion of the external oblique muscle of the abdomen; and is reinforced by

<sup>1</sup> *M. latissimus dorsi*; *m. anitensor* or *aniscalptor*.



fleshy slips from the lower three ribs, alternating with similar slips of the latter muscle. From this extended origin the fleshy fascicles generally converge outwardly in a narrower and proportionately thick band-like portion, ascending behind the axilla and terminating in a thin, flat tendon, which is inserted into the inner ridge of the bicipital groove of the humerus. The uppermost fascicles from their origin first incline downward, the next proceed horizontally, and the greater number which follow become successively longer and more ascending to the outermost ones from the crest of the ilium, which are nearly vertical in their course. The slips from the ribs in succession join the outer portion of the muscle in front. As the muscle is about to ascend behind the axilla its upper border passes over the inferior angle of the scapula, from which it frequently receives an accessory slip. The muscle then winds outward, forward, and upward round the lower part of the greater teres muscle, and in front of this ascends to its insertion. The aponeurosis of origin is narrowest and thinnest above, and becomes stronger and widens outwardly to the iliac crest below, and then narrows again in the sacro-iliac interval. It corresponds with the posterior layer of the lumbar fascia, and tightly embraces the dorsal extensor muscle in the loin, where it is continuous outwardly in front with the middle layer of the lumbar fascia. The tendon of insertion, scarcely an inch and a half wide, is adherent below to that of the teres muscle, but is free from this again, and has a synovial bursa interposed previous to its insertion into the bicipital ridge, along which it extends a little higher than the insertion of the teres tendon.

The latissimus is subcutaneous throughout, except at its origin from the thoracic vertebræ, where it is covered by the trapezius, and at its insertion, where it is covered in front by the axillary vessels and nerves. It rests above on the greater teres muscle, and below it covers the infraserratus muscle, the vertebral aponeurosis, the ribs, and the intercostal muscles.

Between the adjacent borders of the latissimus and trapezius and the base of the scapula is a triangular interval, which is enlarged by raising the upper limb, and is occupied by part of the greater rhomboid muscle and portions of two ribs with the intervening intercostal muscle. The position is a favorable one for auscultation.

The latissimus muscle is supplied by the long subscapular nerve of the brachial plexus. It draws the upper limb downward and backward, and by rotating the arm inward directs the palm of the hand backward.

The **small rhomboid muscle**<sup>1</sup> is a narrow, fleshy fascicle situated at the lower part of the neck, under the trapezius. It arises by a short aponeurosis from the lower extremity of the nuchal ligament and the ends of the spinous processes of the last cervical and first

<sup>1</sup> *M. rhomboideus minor, or superior; lesser rhomboid m.*



thoracic vertebræ, and proceeds outward and downward, to be inserted tendinously into the base of the scapula, opposite the commencement of its spine.

The **greater rhomboid muscle**<sup>1</sup> is a broad, fleshy layer situated under the trapezius, immediately below the former, from which it is separated by a fissure occupied with connective tissue. It arises by a thin aponeurosis from the supraspinous ligament and spinous processes of the upper four or five thoracic vertebræ, and proceeds outward and downward, to be inserted into the base of the scapula below the commencement of its spine. The greater part of the insertion is into a narrow tendinous arch of variable extent, but usually reaching from the position of the scapular spine to the inferior angle, the interval between the arch and base of the scapula being occupied by a thin connective-tissue layer.

Internally the rhomboid muscles cover the supraserratus muscle, and are partially in contact with the dorsal extensor muscle, the ribs, and the intercostal muscles. They are supplied by branches from the fifth cervical nerve. In action they draw the scapula backward and upward.

The **supraserratus**<sup>2</sup> is a thin, flat quadrilateral muscle situated on the upper part of the thorax, under the rhomboid muscles. It arises by a thin aponeurosis, intimately united with that of the latter, from the spinous processes of the last cervical and upper two or three thoracic vertebræ, and descends outwardly, to be inserted by fleshy angular slips into the upper border of the second, third, fourth, and fifth ribs a little beyond their angle. Internally it is in contact with the splenius, dorsal extensor, and intercostal muscles and the ribs.

The **infraserratus**,<sup>3</sup> larger than the former, is situated at the lower part of the thorax, under the latissimus. It arises by a thin aponeurosis, in common with that of the latter, from the supraspinous ligament and spinous processes of the lower two thoracic and upper two or three lumbar vertebræ, ascends obliquely outward, and is inserted by wide, fleshy, angular slips into the four lower ribs a little beyond their angle. Internally the muscle is in contact with the dorsal extensor muscle.

The supra- and infraserratus muscles are supplied by the contiguous intercostal nerves. From the direction of these muscles they are antagonistic, the one aiding in the elevation, the other in the depression, of the ribs; in respiration.

The **scapular elevator**<sup>4</sup> is situated at the side of the neck, beneath the trapezius and sterno-mastoid muscles, covered in the interval

<sup>1</sup> *M. rhomboideus major, or inferior.*

<sup>2</sup> *M. serratus superior posticus; posterior superior serrate m.*

<sup>3</sup> *M. serratus inferior posticus; posterior inferior serrate m.*

<sup>4</sup> *M. levator scapulæ; m. levator anguli scapulæ; m. patientiæ; elevator muscle of the scapular angle.*



of these by the skin. It is a thick muscle, which arises tendinously by four narrow heads from the transverse processes of as many of the upper cervical vertebræ, and descends obliquely backward to be inserted into the base of the scapula between the superior angle and commencement of its spine. It descends along the outer border of the splenius and greater rhomboid muscles, in contact in front and beneath with the middle scalenus, cervical transversalis, cervical ascending, and supraserratus muscles, and behind with the splenius and trapezius muscles. The scapular elevator is supplied by branches from the third and fourth cervical nerves, and sometimes from the fifth.

The **vertebral fascia** is a delicate aponeurotic layer enclosing the dorsal extensor and other muscles which occupy the vertebral groove in the thoracic region. It is attached inwardly to the spinous processes of the thoracic vertebræ, and outwardly to the angles of the ribs, is continuous below with the aponeurosis of the infraserratus and latissimus muscles, and extends above beneath the supraserratus muscle to blend with the deep cervical fascia.

#### DEEP MUSCLES OF THE BACK.

The **dorsal extensor**<sup>1</sup> extends along the side of the spine from the back of the pelvis to the neck, occupying the vertebral groove, and reaching outwardly to the angles of the ribs. From its division, accessories, and numerous attachments, it is very complex in character. Starting in a pointed manner behind the pelvis, it forms a thick, fleshy mass in the loin, and thence ascends and tapers away on the chest, but is continued by accessory slips to the neck and head. It arises mainly by a strong, longitudinally fasciculated aponeurosis, which covers the back of the muscle, and is attached to the spinous processes of the sacrum, lumbar, and lower two or three thoracic vertebræ, to the inner posterior part of the crest of the ilium, and to the lateral border below and end of the sacrum. From the anterior face of the aponeurosis numerous fleshy fascicles, together with others from the contiguous rough inner surface of the ilium, ascend and form in the loin the prominently convex mass which is sheathed by the lumbar fascia. Approaching the thorax the muscle divides into two portions, the longissimus and ilio-costalis, lying close together and continuing upward.

The **longissimus**,<sup>2</sup> the larger and longer portion of the dorsal extensor, lies to the inner side, and is inserted by fleshy fascicles into the back of the transverse processes and the anapophyses of the lumbar vertebræ, and the adjacent middle layer of the lumbar fascia in front of the muscle, and by long, thin tendons, which proceed upward to be inserted into the ends of the transverse processes of the thoracic vertebræ, and

<sup>1</sup> *M. erector spinæ; m. extensor dorsi communis; m. extensor trunci; m. sacro-spinalis; m. opisthothenar.*

<sup>2</sup> *M. longissimus dorsi.*



by accompanying fleshy slips inserted into the ribs between the tubercle and angle, except two, three, or more of the upper ones.

The **ilio-costalis**,<sup>1</sup> or smaller and outer portion of the dorsal extensor, ascends obliquely outward, and is resolved into a half-dozen fleshy slips, which are inserted by as many tendons in succession into the angles of the lower six ribs.

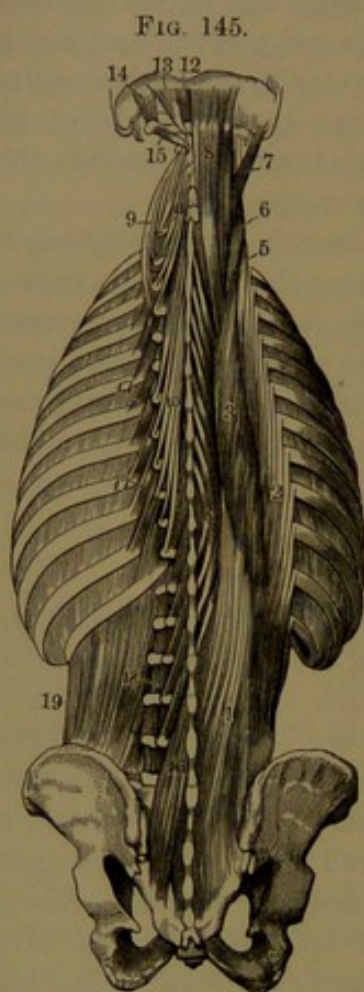


FIG. 145.  
DEEP MUSCLES OF THE BACK. 1, 2, 3, 4, 5, 6, the dorsal extensor muscle. 1, origin from the ilium, sacrum, lumbar and lower thoracic vertebræ; 2, insertion into the ribs, named the ilio-costalis muscle; 3, insertion, named the longissimus; 4, offset, named the spinalis muscle; 5, 6, prolongations to the neck, named the cervical ascending and transversalis muscles; 7, trachelo-mastoid muscle; 8, complexus; 9, cervical transversalis muscle; 10, 11, semispinalis muscle; 12, 13, small and greater post-recti; 14, 15, supra- and infraoblique muscles; 16, multifidus; 17, costal elevators; 18, inter-transverse muscles; 19, quadratus lumbar muscle.

The **ilio-costalis accessory**<sup>2</sup> consists of half a dozen fleshy slips, which arise by flat tendons from the ribs beneath and internal to the insertion of the ilio-costalis tendons, and ascend in series with the latter to be inserted by narrow tendons into the angles of the upper six ribs.

The longissimus rests on the multifidus and semispinalis muscles, the transverse processes of the lumbar vertebræ, the middle layer of the lumbar fascia, the ends of the transverse processes of the thoracic vertebræ, and the ribs. The ilio-costalis lies against the outer side of the former, covering its lateral insertions, and also rests on the middle layer of the lumbar fascia and ribs. The ilio-costalis accessory lies on the ribs, and appears as a continuation of the ilio-costalis muscle.

The **spinalis**<sup>3</sup> is a slender accessory portion of the longissimus, lying between it and the ends of the adjacent spinous processes. Closely connected with the aponeurosis of the dorsal extensor, it usually arises by three or four tendinous slips from the spinous processes of the contiguous lumbar and thoracic vertebræ, uniting in a small fleshy belly, and terminating in from four to nine tendinous slips, which ascend and are inserted into as many of the spinous processes of the thoracic vertebræ above. It lies on the semispinalis muscle beneath, and is also closely connected with it.

<sup>1</sup> M. ilio-costalis, sacro-lumbalis, s. lumbaris, or lumbo-costalis.

<sup>2</sup> M. accessorius ad ilio-costalem or ad sacro-lumbalem.

<sup>3</sup> M. spinalis dorsi.



The **cervical transversalis**,<sup>1</sup> usually united with the longissimus, appears as its continuation into the neck. With a flat, fleshy belly, lying between the longissimus to the outer side below and the splenius to the inner side above, it commonly arises by as many narrow tendons from the ends of the transverse processes of the upper four to six thoracic vertebræ, and ascends to be inserted by similar tendons into the transverse processes of the intermediate five cervical vertebræ.

The **cervical ascending muscle**,<sup>2</sup> situated to the outer side of the former, consists of four or five fleshy slips arranged in continuous series with those of the ilio-costalis accessory muscle, of which it may be regarded as an extension into the neck. It arises by tendons from the angles of the upper four or five ribs internal to the insertion of the ilio-costalis accessory tendons, and ascends to be inserted by slender tendons into the transverse processes of the lower three or four cervical vertebræ, usually excepting the last one.

The **trachelo-mastoid muscle**,<sup>3</sup> regarded as an accessory of the longissimus to the head, lies to the inner side and above the cervical transversalis. It is a thin, flat muscle at the side of the neck, lying between the splenius and complexus. Very variable in the extent of its origin, it commonly arises by four or more tendons connected with those of the cervical transversalis, from the ends of the transverse processes of the upper three or four thoracic vertebræ, except the first and second, and from the articular processes of the lower three or four cervical vertebræ. Ascending outwardly, it is inserted into the posterior border of the mastoid process beneath the splenius and sterno-mastoid muscles.

The **splenius**<sup>4</sup> is a broad muscle extending from the upper part of the thorax, around the back and side of the neck, beneath the trapezius. It arises tendinously from the lower half of the nuchal ligament and from the spinous processes of the last cervical and upper six thoracic vertebræ. Ascending obliquely outward it divides into two portions, the capito- and cervico-splenius. The **capito-splenius**,<sup>5</sup> wider and thicker than the other portion, continues to the head, and is inserted into the lower part of the mastoid process, and thence backward into the outer part of the superior curved line of the occipital bone beneath the sterno-mastoid insertion. The **cervico-splenius**<sup>6</sup> winding forward is inserted into the costal processes of the upper two to four cervical vertebræ.

The splenius rests against the spinalis, longissimus, semispinalis, complexus, cervical transversalis, and trachelo-mastoid muscles. Below it is covered by the rhomboid and supraserratus muscles, and above by the trapezius and sterno-mastoid. At the upper back part of the neck

<sup>1</sup> M. transversalis cervicis.

<sup>2</sup> M. cervicalis ascendens or descendens.

<sup>3</sup> M. trachelo-mastoideus; m. complexus parvus.

<sup>4</sup> M. splenius.

<sup>5</sup> M. splenius capitis.

<sup>6</sup> M. splenius colli or cervicis.



it is separated from its fellow by a large triangular space, in which the complexus is visible.

The **complexus**,<sup>1</sup> a broad, thick muscle, situated partly beneath the former at the back of the neck, arises by tendinous slips from the transverse processes, usually of the last cervical to the sixth thoracic vertebra, and from the articular processes and their capsular ligaments of the next three or four cervical vertebræ above. Ascending the neck the muscle becomes narrower, and is inserted into the inner impressed surface between the curved lines of the occipital bone. The upper part of the muscle is crossed by an irregular and incomplete tendinous intersection. An inner portion of the muscle next the nuchal ligament is interrupted by a narrow tendinous band, giving it the appearance of a distinct muscle, which is often described as such, with the name of the **biventer**.<sup>2</sup> It is sometimes connected by a slip with the spinous processes of the last cervical and first thoracic vertebræ.

The complexus covers the cervical semispinalis and the post-recti and oblique muscles and the deep cervical artery. It is covered by the trapezius, trachelo-mastoid, cervical transversalis, and splenius muscles.

The **semispinalis**<sup>3</sup> occupies the vertebral groove in the neck and thorax beneath the complexus and longissimus. It consists of a fleshy layer of oblique fascicles with tendinous attachments, extending from transverse and articular processes to the neighboring spinous processes, usually across four or five to six vertebræ. It consists of two portions, variably distinct and very variable in the number of their attachments. The **cervical semispinalis**,<sup>4</sup> the upper, thicker portion, arises tendinous and fleshy from the transverse processes commonly of the upper four thoracic vertebræ and the articular processes of the lower three or four cervical vertebræ, and ascends inwardly to be inserted into the spinous processes of the latter from the fifth to the second, the fascicle attached to the axis being the largest. The **thoracic semispinalis**,<sup>5</sup> a thinner stratum than the former, arises by narrow tendinous slips from the transverse processes of the thoracic vertebræ, commonly from the fifth or sixth to the tenth, and ascends inwardly to be inserted by half a dozen tendons into the spinous processes of the lower two cervical and the upper four to six thoracic vertebræ.

The semispinalis rests on the multifidus muscle, covered by the complexus, splenius, longissimus, and spinalis muscles. Lying on the cervical semispinalis are the deep cervical artery and the posterior cervical plexus of nerves.

The **multifidus**<sup>6</sup> occupies the bottom of the vertebral groove at

<sup>1</sup> M. complexus; m. c. magnus; m. trachelo-occipitalis; m. semispinalis capitis.

<sup>2</sup> M. biventer cervicis; m. digastricus cervicalis.

<sup>3</sup> M. semispinalis.

<sup>4</sup> M. semispinalis cervicis.

<sup>5</sup> M. semispinalis dorsi.

<sup>6</sup> M. multifidus spinæ.



the side of the spine from the sacrum to the axis, beneath the dorsal extensor and semispinalis muscles. More largely produced towards the lower part of the spine, it is thinnest in the thoracic region. It consists of numerous comparatively short, fleshy fascicles, which arise from the back of the sacrum, the posterior extremity of the iliac crest, and the posterior sacro-iliac ligament, from the articular and accessory processes of the lumbar vertebræ, from the transverse processes of the thoracic vertebræ, and from the articular processes of the lower four cervical vertebræ. Ascending obliquely across the vertebral groove, they are inserted into the laminae and the sides of the spinous processes of from one to three of the vertebræ above. The deepest and shortest fascicles extend between the adjacent vertebræ, others pass to the second above, and the superficial and longest reach to the third or fourth.

The **spinal rotators**<sup>1</sup> are a series of eleven little muscles on the sides of the thoracic vertebræ beneath the multifidus. Each arises from the upper border of a transverse process, and proceeds obliquely inward to be inserted into the lower border of the lamina of the vertebral arch above extending to the base of the spinous process. The first of the series occupies the space between the upper two thoracic vertebræ, and the last the space between the lower two.

The **interspinous muscles**<sup>2</sup> occupy the intervals of the spinous processes in pairs, pertaining to the two sides of the body, and consist of short, fleshy fascicles extended between the processes. In the neck, from the axis downward, they are short, narrow fascicles between the ends of the spinous processes. In the thorax they for the most part do not appear, except a few fleshy fibres in one or two of the upper and lower spaces; and in the loins there are four pairs, consisting of thin laminae separated by the interspinous ligament.

The **intertransverse muscles**<sup>3</sup> occupy the intervals of the transverse processes, are best developed in the neck, and least in the thorax. In the neck they are little columnar bundles, a pair for each interval of the vertebræ; one<sup>4</sup> between the transverse and the other<sup>5</sup> between the costal processes. The vertebral artery ascends, and the anterior cervical nerves pass outwardly, between them. In the thorax they appear as small, fleshy fascicles<sup>6</sup> in the lower three or four spaces, and are undeveloped in the upper spaces. In the loins there are four pairs, of which one<sup>7</sup> forms a thin lamina extended between the transverse processes, and the other<sup>8</sup> is a narrow fascicle extended between the metapophyses and anapophyses.

<sup>1</sup> M. rotatores dorsi.

<sup>2</sup> M. interspinales.

<sup>3</sup> M. intertransversales or intertransversarii.

<sup>4</sup> M. intertransversalis cervicis.

<sup>5</sup> M. int. cervicis posticus.

<sup>6</sup> M. intertransversales dorsi.

<sup>7</sup> M. intertransversalis lumborum.

<sup>8</sup> M. interarticularis lumborum; m. interaccessorius; m. interobliquus.



The **coccygeal extensor**<sup>1</sup> is a small, fleshy fascicle, occasionally found extending from behind the lower extremity of the sacrum to the coccyx, apparently a rudiment of the extensor of the caudal vertebrae, or of the tail, in lower animals.

All the deeper muscles of the back above described which act on the vertebral column and the head are supplied by the posterior branches of the spinal nerves. They extend the vertebral column and the head, but do not necessarily act together. Acting on one side alone they produce lateral bending of the spine.

#### FASCIAE AND MUSCLES OF THE UPPER LIMB.

The **superficial fascia** of the upper limb is of loose texture, and invests it throughout. Its more superficial layer is more or less pervaded with adipose tissue, and between it and the deeper layer are contained the superficial veins and lymphatics, and the cutaneous nerves. In the hand it is intimately connected with the skin, and not separable from it.

The **deep fascia** of the upper limb extends from that of the front and back of the chest. Attached to the sternum, along the clavicle, the acromion, the spine and the base of the scapula, it invests the muscles of the shoulder and unites them closely together. It forms a thin and closely-adherent investment to the pectoral, deltoid, trapezius, and latissimus muscles. Behind the deltoid it becomes stronger, and thence extending over the infraspinatus and lesser teres muscles, assumes an aponeurotic appearance. In the armpit it forms a layer, the **axillary fascia**, which is extended across the axilla in a concave manner, attached in front to the fascia investing the axillary border formed by the pectoral muscles, behind to that of the border formed by the latissimus and greater teres muscles, and below to that of the serratus muscle. In the arm the deep fascia is loosely attached to the muscles it invests. In front, on the flexor muscles, it is thin; behind, investing the brachial triceps, it is thicker, and becomes stronger approaching the elbow. It is chiefly composed of transverse fibres, intersected by longitudinal and some oblique fibres. It forms on each side the intermuscular septum, attached along the supracondyloid ridges. The **external intermuscular septum** extends from the corresponding epicondyle to the insertion of the deltoid tendon, from which it receives some fibres. The **internal intermuscular septum**, stronger than the former, extends from the corresponding epicondyle to the insertion of the coraco-brachial muscle. At the elbow the deep fascia is attached to all the contiguous bony processes, and is continuous with their periosteum and the adjacent ligaments, and further receives fibres from the tendons of the brachial biceps and triceps muscles.

---

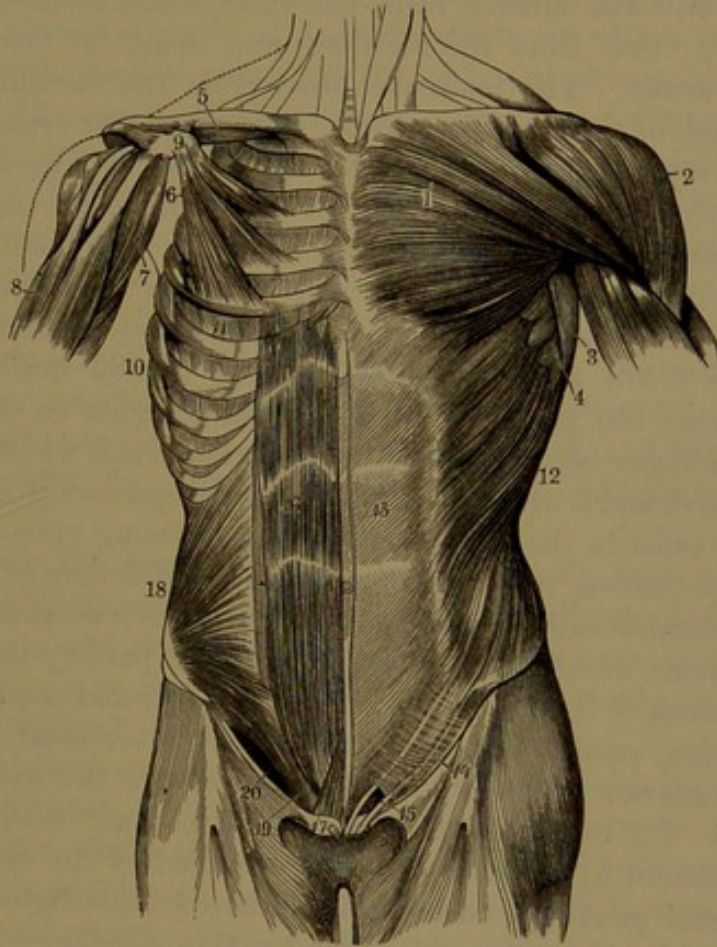
<sup>1</sup> M. extensor coccygis; m. sacro-coccygeus posticus.



## MUSCLES OF THE BREAST AND SHOULDER.

The **greater pectoral muscle**<sup>1</sup> is a large, thick, triangular, fleshy layer situated immediately beneath the skin at the side of the breast, extending outwardly to the shoulder. It arises from the inner half of the front of the clavicle, the front of the sternum, and of the costal cartilages articulating with the latter, and by a slip from the sheath of

FIG. 146.



MUSCLES OF THE FRONT OF THE TRUNK; on the left side are seen the superficial muscles, on the right the deeper ones. 1, greater pectoral muscle; 2, deltoid; 3, latissimus; 4, great serratus; 5, subclavian; 6, small pectoral; 7, coraco-brachial; 8, brachial biceps; 9, coracoid process; 10, great serratus muscle; 11, intercostals; 12, external oblique; 13, its aponeurosis; 14, Poupart's ligament; 15, external abdominal ring; the figure rests upon the falciform process of the fascia lata bounding the saphenous opening externally; 16, abdominal rectus muscle of the right side, exposed by removing the front of its sheath, which remains on the left side; 17, pyramidal muscle; 18, internal oblique; 19, conjoined tendon of the internal oblique and transversalis muscles; 20, position of the inguinal canal below the arching edges of the muscles just named.

the abdominal rectus. From its broad origin, the muscle converges outwardly, and approaching its insertion becomes twisted, so that the lower fleshy fascicles pass behind the upper ones, and together end in a broad tendon, which is doubled on itself, and is thus inserted into

<sup>1</sup> M. pectoralis major.



the outer ridge of the bicipital groove of the humerus. In the ordinary position of the upper limb at rest, suspended at the side of the body, the fascicles of the upper portion of the muscle descend obliquely outward and end in the fore part of the tendon of insertion, while the middle ones pursue a more horizontal course, and with the lower ascending ones pass behind the former and end in the back part of the tendon of insertion. When the limb is raised, the upper fascicles of the muscle proceed horizontally outward, and the others become successively more obliquely ascending.

The origin of the muscle from the clavicle and costal cartilages is mainly fleshy; that from the sternum and sheath of the abdominal rectus aponeurotic. The tendinous fibres from the sternum are intersected by those of the opposite muscle. The clavicular origin is usually more or less separated from the rest of the muscle by a fissure occupied by the investing fascia. In the origin from the costal cartilages, the first, or the seventh of these, or both, may be excluded, and sometimes also the slip from the sheath of the abdominal rectus is wanting.

The anterior portion of the tendon of insertion is the thicker, and gives offsets below to the insertion of the deltoid muscle and the brachial fascia; the posterior portion extends higher on the humerus, and from its upper border gives off a thin expansion, which covers the bicipital groove and is attached to the capsular ligament of the shoulder-joint. The twist in the muscle occasions a doubling upon itself at the outer part, producing the thick anterior rounded border of the armpit.

The pectoral muscle is subcutaneous, but is covered at its upper part by the platysma muscle, and at the lower fore part by the mammary gland. Internally it is in contact with the ribs and costal cartilages, the subclavian, small pectoral, serratus, and intercostal muscles. It forms the anterior wall of the axilla, and covers the axillary vessels and nerves. Its upper outer border is in contact with the deltoid muscle, separated by a narrow interval occupied by the cephalic vein.

The **small pectoral muscle**<sup>1</sup> is situated immediately under the former. It is triangular, and arises by thin aponeurotic slips from the external surface of the third, fourth, and fifth ribs, near their cartilages, ascends outwardly and converges to a flat tendon, which is inserted into the front border of the coracoid process of the scapula. Its anterior surface is in contact with the greater pectoral muscle; its posterior surface with the ribs, intercostal and serratus muscles, and is next the axillary space with its chief vessels and nerves.

The **subclavian muscle**<sup>2</sup> is a narrow one situated below the clavicle, under the greater pectoral muscle. It arises by a short tendon from the first costal cartilage, contiguous to the costo-clavicular ligament, and proceeds upward and outward to be inserted into the shallow-

<sup>1</sup> M. pectoralis minor; lesser pectoral muscle; m. coraco-pectoralis; m. serratus anterior; m. s. a. minor.

<sup>2</sup> M. subclavius.



grooved under surface of the clavicle, extending to the coraco-clavicular ligament.

The muscle crosses above the axillary vessels and nerves as these proceed over the first rib. It is closely invested with a strong, thin, aponeurotic membrane, the **costo-coracoid fascia**,<sup>1</sup> extending from the costal cartilage to the root of the coracoid process of the scapula, and attached in front and behind the muscle to the clavicle.

The **great serratus**<sup>2</sup> is a broad, quadrilateral muscle, occupying the side of the chest at the inner part of the axilla. It arises from the outer surface of the eight upper ribs, by fleshy slips commencing at their fore part in a series of angular points, of which the lower five alternate with similar points of the external oblique muscle of the abdomen. The muscle, from its broad origin, proceeds backward, converges, and becomes proportionately thicker, and is inserted along the front border of the base of the scapula. The first two slips appear as a separate portion of the muscle, and proceed from the upper two ribs directly backward to be attached to the flat surface in front of the superior angle of the scapula. The third slip from the second rib expands behind and becomes thinner, and with the next slip is attached along the greater part of the base of the scapula. The remaining slips together present a fan-like appearance, and converge to be attached to the flat surface in front of the inferior angle of the scapula.

Sometimes the serratus is reinforced by a slip from the ninth rib, and rarely, also, from the tenth rib. Occasionally the first slip has no attachment to the first rib. Sometimes the muscle is more or less divided into two or three distinct portions, and rarely it is defective from the absence of one or more slips.

By its internal surface the serratus is in contact with the ribs and intercostal muscles, and with part of the supraserratus muscle. Its external surface forms the inner wall of the axilla, is in contact behind with the subscapular and latissimus muscles, in front is covered above by the pectoral muscles, and below is subcutaneous. It is supplied by the posterior thoracic nerve.

#### MUSCLES OF THE BACK AND SHOULDER.

The trapezius, latissimus, rhomboid, and scapular elevator, all appropriate muscles of the upper limb, are described with those of the back of the trunk.

#### MUSCLES OF THE SHOULDER.

The supra- and infraspinatus muscles, occupying the back of the scapula, are enclosed by like-named fasciæ attached to the margins of the corresponding fossæ. The fasciæ are strongest internally where

<sup>1</sup> Lig. costo-coracoideum; l. bicornis; clavicular fascia; bifid ligament.

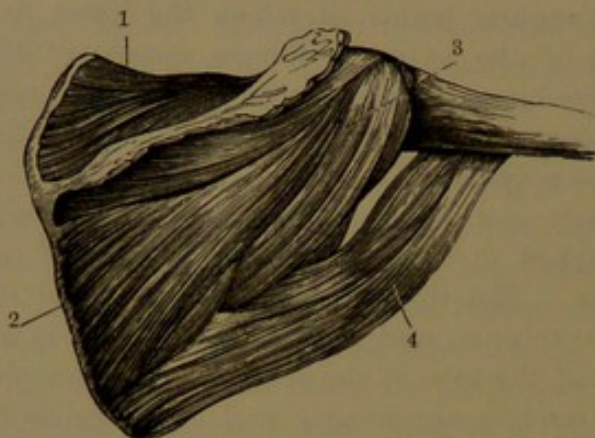
<sup>2</sup> M. serratus magnus; m. serratus anticus; m. ser. ant. major; great serrated muscle.



they give partial origin to the muscles, and become thinner and of looser texture towards the shoulder-joint. The infraspinatus fascia is especially strong and aponeurotic at its lower part, where it is immediately subjacent to the skin and superficial fascia of the back.

The **supraspinatus muscle**,<sup>1</sup> occupying the supraspinous fossa, arises from about two-thirds of its surface next the base of the scapula and from the contiguous portion of the investing fascia. The fascicles converge to a tendon which proceeds outward beneath the acromion,

FIG. 147.



MUSCLES ON THE BACK OF THE SCAPULA. 1, supraspinatus muscle; 2, infraspinatus muscle; 3, lesser teres muscle; 4, greater teres muscle.

over the shoulder-joint, closely adherent to the capsular ligament and the tendon of the infraspinatus muscle, and is inserted into the upper division of the greater tuberosity of the humerus. It is covered by the trapezius muscle and the acromion.

The **infraspinatus**<sup>2</sup> is a thick, triangular muscle, occupying the greater part of the infraspinous fossa. Its fascicles arise from about two-thirds of

the surface of the latter next the base, and from the contiguous portion of the investing fascia, and converge outward and upward to a tendon, which proceeding from within the fleshy belly covers the back of the shoulder-joint, adherent to the capsular ligament, and is inserted into the middle division of the greater tuberosity of the humerus. Partially subcutaneous, it is covered by the deltoid and trapezius above and by the latissimus at the lower scapular angle. A small bursa is sometimes placed between its tendon and the capsular ligament of the shoulder-joint.

The supra- and infraspinatus muscles are supplied by the supra-scapular nerve of the brachial plexus.

The **lesser teres muscle**<sup>3</sup> lies along the outer border of the infraspinatus muscle, with which it is closely connected. It arises from the grooved surface behind the axillary border of the scapula and from the adjacent tendinous septa between it, the infraspinatus, and the greater teres muscles, and ascends outwardly to a tendon which crosses the back of the shoulder-joint below the infraspinatus muscle, and is

<sup>1</sup> M. supraspinatus; m. suprascapularis; m. superscapularis superior.

<sup>2</sup> M. infraspinatus; m. superscapularis inferior.

<sup>3</sup> M. teres minor; lesser terete muscle.



inserted into the lower division of the greater tuberosity of the humerus; and by a few fleshy fibres is extended to the bone a short distance below. It is covered above by the deltoid muscle, is partially subcutaneous below and behind, and in front is in contact with the long head of the brachial triceps muscle.

The **greater teres**<sup>1</sup> lies externally to the preceding, and contributes with the latissimus to form the posterior border of the axilla. It arises from the dorsal surface of the expanded inferior angle of the scapula and from the tendinous septum between it and the lesser teres and infraspinatus muscles, and ascends outwardly to end in a broad, flat tendon, which is inserted into the posterior bicipital ridge of the humerus, in front of the tendon of the latissimus. Partially adhering to the latter, the two tendons are separated close to their insertion by an intervening bursa. In its ascent it diverges from the lesser teres, and is separated from it by the long head of the triceps. Its posterior surface, partially subcutaneous, is covered below by the latissimus, which twists obliquely around its outer border to its front.

The **subscapular muscle**<sup>2</sup> occupies the corresponding fossa, and forms the posterior wall of the axilla; and is invested with a thin fascia, which separates it from

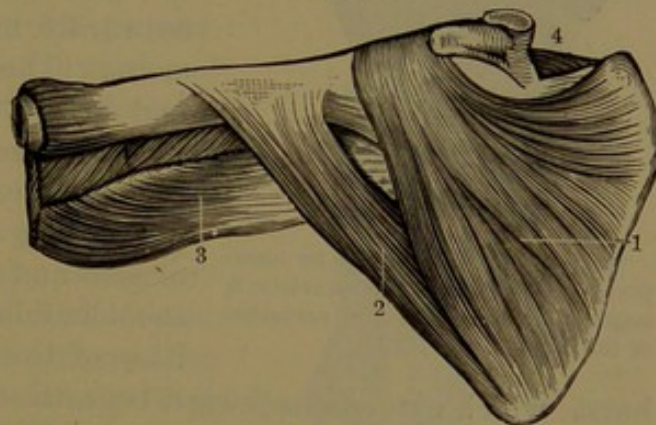


FIG. 148.

MUSCLES ON THE FRONT OF THE SCAPULA. 1, subscapular muscle; 2, greater teres muscle; 3, upper part of the brachial triceps; 4, supraspinatus muscle.

other structures of the armpit and from the great serratus muscle. It arises by large fleshy fascicles and tendinous fibres from the basal two-thirds of the surface of the subscapular fossa, and converges outward and upward to a broad tendon, which passes in front of the shoulder-joint closely adherent to the capsular ligament, and is inserted into the small tuberosity of the humerus, extending a little way down the bone. Between its posterior surface and upper border outwardly and the neck and coracoid process of the scapula a bursa is interposed, usually communicating with the cavity of the shoulder-joint. Near its insertion it is crossed in front by the conjoined heads of the coraco-brachialis and brachial biceps muscles, usually having a bursa intervening.

The subscapular and greater teres muscles are supplied by the subscapular nerves; the lesser teres by the circumflex nerve.

The subscapular muscle rotates the humerus inward; the supra-

<sup>1</sup> M. teres major; greater terete muscle; m. scapulo-humeralis.

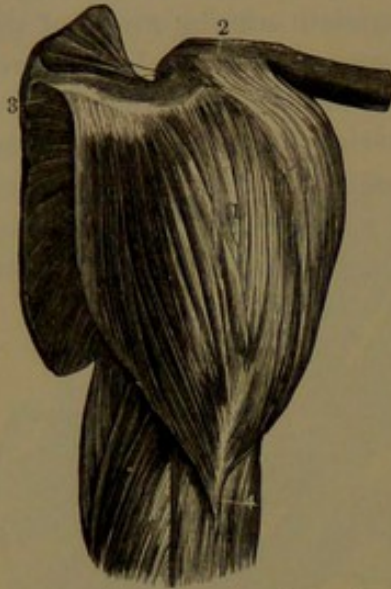
<sup>2</sup> M. subscapularis.



and infraspinatus and the lesser teres muscles outward. The tendons of insertion of all together strongly reinforce the capsular ligament of the shoulder-joint. The greater teres muscle draws the humerus downward and inward.

The **deltoid muscle**,<sup>1</sup> large, powerful, and of triangular shape, forms the rounded prominence of the shoulder. It arises tendinously from

FIG. 149.



THE DELTOID MUSCLE. 1, its insertion; 2, its origin from the clavicle; 3, origin from the spine and acromion of the scapula.

the outer third below of the clavicle, the outer border of the acromion, and the inferior margin of the spine of the scapula. Composed of coarse bundles of fascicles with a penniform arrangement intersected with tendinous bands, the bundles converge to a tendon which partially faces the muscle beneath, and is inserted into the angular roughness outwardly near the middle of the humerus. The external surface of the deltoid muscle is subcutaneous, and its anterior border is contiguous to the greater pectoral muscle, with the cephalic vein lying along the interval. Between the muscle and the tendons embracing the shoulder-joint inserted into the tuberosities of the humerus there is a large

bursa, which extends backward beneath the acromion. The deltoid muscle covers the coracoid process and the coraco-acromial ligament, the origins of the biceps, coraco-brachialis, and long and outer heads of the triceps, and the insertions of the supra- and infraspinatus, lesser teres, and subscapular muscles.

The deltoid muscle is supplied by the circumflex nerve. It raises the upper limb from the body, and with other muscles may assist in drawing it forward or backward.

#### MUSCLES OF THE ARM.

The **brachial biceps**<sup>2</sup> occupies the fore part of the arm, where it forms a conspicuous prominence when the forearm is flexed. It is a long fusiform muscle arising by two heads, distinguished as long and short, though the difference in this respect is trifling. The **longer head** arises by a slender tendon from the top of the glenoid cavity of the scapula, where it is continuous with the glenoid ligament. The tendon passes outwardly within the capsule of the shoulder-joint,

<sup>1</sup> M. deltoideus or deltiformis; m. supra-acromio-humeralis; m. attollens humeri.

<sup>2</sup> M. biceps flexor cubiti; m. biceps brachii; m. flexor radii; scapulo-radial muscle.



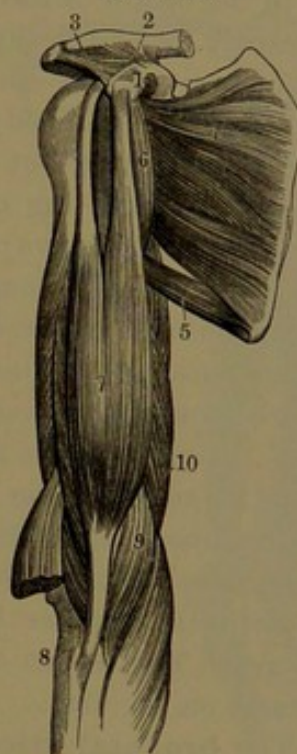
where it is sheathed by the lining synovial membrane; thence emerging from the joint between the tuberosities of the humerus, it descends in the bicipital groove, and terminates in a fleshy belly. This descends the arm, and is joined by the shorter head of the muscle, which arises in union with the coraco-brachialis muscle by a short, flat tendon from the coracoid process of the scapula. The common belly, convex in front and flat behind, tapers below and ends above the elbow in a thick tendon, which passes over the elbow-joint backward, in the pit between the long supinator and terete pronator, and winds outward upon the tuberosity of the radius to be inserted into its back part. Between the fore part of the tuberosity and the tendon a bursa is introduced. With the rotation of the radius inward the tendon becomes more wound upon the tuberosity, and when the bone is rotated outward the tendon becomes unwound. Opposite the elbow the tendon gives off an aponeurotic process, which proceeds downward and inward, and merges in the deep fascia of the forearm over the origin of the muscles from the inner epicondyle.

The greater part of the biceps is subcutaneous, its upper extremity being covered by the greater pectoral and deltoid muscles. It rests successively on the shoulder-joint, the subscapular, greater teres, latissimus, and brachialis muscles; with its inner border related to the coraco-brachialis muscle, the brachial vessels, and the median nerve, and its outer border to the deltoid and long supinator muscles. The aponeurotic offset from the tendon of insertion crosses the brachial vessels and the median nerve.

The biceps frequently exhibits variation from the usual arrangement. It sometimes has a third head arising from the humerus, related with the brachialis or coraco-brachialis muscle, and joining the coracoid portion of the biceps and its aponeurotic offset from the tendon of insertion.

The **coraco-brachialis muscle**<sup>1</sup> is situated at the upper part of the arm to the inner side and behind the biceps. It arises partially tendinous and fleshy in conjunction with the tendon of the shorter head of the biceps from the end of the coracoid process of the scapula.

FIG. 150.



MUSCLES OF THE FORE PART OF THE ARM. 1, coracoid process of the scapula; 2, coraco-clavicular ligament; 3, coraco-acromial ligament; 4, subscapular muscle; 5, greater teres muscle; 6, coraco-brachialis muscle; 7, brachial biceps; 8, its insertion into the tuberosity of the radius; 9, brachialis muscle; 10, brachial triceps.

<sup>1</sup> M. coraco-brachialis; m. coraco-humeralis.



Descending, it is inserted tendinously, and to a small degree fleshy, into a narrow, roughened impression near the middle of the humerus, between the origin of the brachialis and the triceps muscle. It is commonly pierced by the musculo-cutaneous nerve, and its inner border is in contact with the brachial vessels. It is occasionally divided into two muscles, as in apes. Not unfrequently some of its fibres join those of the brachialis muscle.

The **brachialis**<sup>1</sup> is situated at the lower fore part of the arm beneath the biceps muscle. It arises from the front surface of the humerus, commencing in a pair of angular points embracing the deltoid insertion, reaching to near the elbow, to the inner intermuscular septum, and to the origin of the long supinator and longer carpo-radial extensor outwardly. The fleshy fascicles, descending somewhat convergent, pass in front of the elbow-joint closely adherent to the capsular ligament, and are inserted by a short, thick tendon into the fore part of the coronoid process of the ulna. The muscle lies immediately behind the biceps, projecting on both sides. It supports the brachial vessels and the median nerve; and the musculo-spiral nerve lies on its outer side covered by the long supinator muscle.

The biceps, coraco-brachialis, and brachialis muscles are supplied by the musculo-cutaneous nerve, but the last, also, usually receives a branch from the musculo-spiral nerve.

If the palm of the hand is turned downward, the first action of the biceps by rotating the radius outward is to turn the palm upward; a continuance of the action flexes the forearm on the arm, and a further action is to raise the limb at the shoulder. The coraco-brachialis muscle, with the shorter head of the biceps, draws the arm inward and upward. The action of the brachialis muscle is simply flexion of the forearm on the arm.

The **brachial triceps**<sup>2</sup> occupies the back of the arm, extending the whole length of the posterior surface of the humerus. Its upper tapering part is divided into three portions or heads, whence its name; and its lower demi-cylindrical part is faced behind for more than half its length by an aponeurosis, which is joined by another within the muscle, and forms with it the tendon of insertion. The **middle** or **long head**<sup>3</sup> arises tendinous from the roughened impression of the neck of the scapula below the glenoid cavity, descends in close connection with the capsule of the shoulder-joint, and at the inner back part of the humerus between the other two heads of the muscle, to end in the upper extremity of the tendon of insertion extending a short distance along its inner border. The **external head**,<sup>4</sup> little shorter than the former,

<sup>1</sup> M. brachialis; m. brachialis anticus or internus; m. brachii internus; m. humero-cubitalis.

<sup>2</sup> M. triceps extensor cubiti; m. triceps brachii; m. brachialis externus or posterior.

<sup>3</sup> M. anconeus longus.

<sup>4</sup> M. anconeus externus; m. vastus externus.

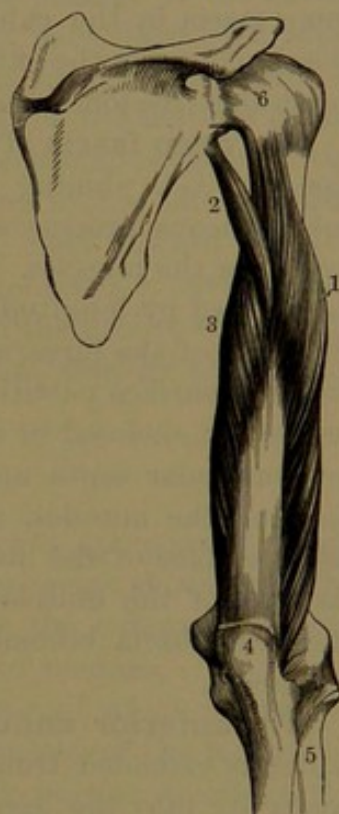

arises tendinous and fleshy from the outer back part of the humerus, commencing pointedly below the greater tuberosity and extending to the musculo-spiral groove near the middle of the bone, whence the fibres descend obliquely to terminate along the outer part of the tendon of insertion. The **internal** or **short head**<sup>1</sup> arises, for the most part, fleshy from the surface of the humerus below the musculo-spiral groove, commencing pointedly below the insertion of the tendon of the greater teres muscle, and on each side from the intermuscular septum, reaching to near the elbow, and it descends obliquely to terminate in the tendon of insertion, with a few fibres reaching the olecranon. The tendon of insertion of the triceps, composed of the posterior aponeurotic facing joined by the layer from within the muscle, converges to be inserted into the back portion of the upper surface of the olecranon extending along its outer border, where it is continuous with the fascia covering the anconeus muscle. In advance of the insertion into the olecranon, a small bursa intervenes between the tendon and the elbow-joint. The musculo-spiral groove of the humerus separates the external and internal heads of the triceps, and with them forms a canal traversed by the superior profunda blood-vessels and the musculo-spiral nerve.

A short distance above the elbow, on each side, there is usually a fleshy fascicle, an offset from the triceps, distinguished as the **sub-anconeus**.<sup>2</sup> It arises from the back of the humerus, and descends to be inserted into the capsular ligament of the elbow-joint.

The **anconeus**.<sup>3</sup> is situated at the outer back part of the elbow, and appears to be a continuation of the triceps, with which it is sometimes continuous. Small and triangular, it arises tendinous from the back of the outer epicondyle of the humerus, and its fleshy fascicles diverge backward and downward to be inserted into the outer side of the olecranon and the depressed surface of the ulna extending several inches downward. Subcutaneously it is invested with a strong fascia, which is continuous with the insertion of the tendon of the triceps. Its deep surface is contiguous to the elbow-joint, the radial orbicular ligament, and the short supinator muscle.

FIG. 151.



VIEW OF THE BRACHIAL TRI-CEPS ON THE BACK OF THE RIGHT ARM. 1, external head; 2, long head; 3, short head; 4, insertion of the muscle into the olecranon of the ulna; 5, radius; 6, capsular ligament of the shoulder-joint.

<sup>1</sup> M. anconeus internus or brevis; m. vastus internus.

<sup>2</sup> M. subanconeus.

<sup>3</sup> M. anconeus; m. anc. parvus or quartus.



The triceps and anconeus are supplied by the musculo-spiral nerve. Together they are the extensors of the forearm on the arm. The long head of the triceps will also draw the upper limb downward towards the scapula.

#### FASCIÆ AND MUSCLES OF THE FOREARM AND HAND.

##### FASCIÆ OF THE FOREARM.

The **superficial fascia** of the forearm, continuous with that of the arm, is a well-marked, loose connective-tissue layer, which involves the subcutaneous fat and the superficial veins, and connects the skin with the deep fascia and subcutaneous bony surfaces. The extension of the same fascia in the palm of the hand is of firmer texture, and more closely connects the skin and subjacent fat to the deep fascia, allowing much less freedom of movement of the skin.

The **deep fascia** of the forearm,<sup>1</sup> likewise continuous with that of the arm, is a shining bluish-white aponeurosis firmly attached to the subcutaneous processes and borders of the bones of the forearm and investing the muscles. It is composed of transverse and oblique fibres, intersected by longitudinal fibres. It is stronger on the back than on the front of the forearm, and is thickest approaching the wrist. From its inner surface partitions extend between the muscles, so that each is separately enclosed in a sheath. In the upper part of the forearm the intermuscular septa appear superficially as more distinct white lines defining the muscles, and their opposed surfaces, together with the inner surface of the investing fascia, give origin to many of the fleshy fascicles of the muscles. Approaching the wrist in front and behind the deep fascia becomes denser, and is continuous with the annular ligaments.

The **anterior annular ligament**<sup>2</sup> is a strong, wide, fibrous band, which is extended transversely across the carpus, converting its deep concavity into the carpal canal for the passage of the flexor tendons of the fingers. It is attached on the one side to the pisiform bone and the unciform process of the unciform bone, and on the other side to the tuberosity of the scaphoid bone and the fore part of the trapezium. Above, it is continuous with the deep fascia of the forearm, and partially receives the insertion of the tendons of the long palmar and ulno-carpal flexor muscles. Below, it is continuous with the palmar fascia, and gives partial origin to the small muscles of the thumb and little finger. Beneath it proceed the tendons of the superficial and deep digital and long pollical flexors and the median nerve, all together enveloped in one large and much-folded synovial sheath, which extends a short distance above and below the ligament into the forearm and the palm of the hand. Two prolongations of the sheath extend upon the tendons of the long pollical flexor and of the little finger to their insertion.

<sup>1</sup> F. antebrachialis.

<sup>2</sup> L. annulare or transversum anterius; l. commune or carpi volare.



At the outer attachment of the annular ligament with the scaphoid bone and the trapezium it converts the groove of the latter into a distinct canal, lined by a synovial sheath, for the passage of the tendon of the radio-carpal flexor.

The **posterior annular ligament**<sup>1</sup> appears as a reinforcement of the deep fascia of the forearm through fibrous bundles which extend in a broad band obliquely across from the outer side of the radius to the inner side of the ulna and carpus. Below, it is continuous with the deep fascia on the back of the hand. In its course across the wrist it is attached to the ridges at the back of the radius and ulna, and converts the intervening grooves into canals for the passage of the extensor tendons. It forms six distinct passage-ways, each lined by a separate synovial sheath. These are from without inwardly, as follows: 1, on the outer side of the radial styloid process for the tendons of the first and second pollical extensors; 2, behind the styloid process for the tendons of the radio-carpal extensors; 3, inward to the latter behind the radius for the third pollical extensor; 4, next inward for the tendons of the common digital and indicial extensors; 5, between the radius and ulna for the minimal extensor; 6, in the groove behind the ulna for the ulno-carpal extensor. The synovial sheaths accompany the tendons to their destination.

#### FASCIAE OF THE HAND.

The **dorsal fascia**<sup>2</sup> of the hand is a delicate aponeurotic membrane, chiefly composed of transverse fibres, continuous above with the posterior annular ligament, and extending over the extensor tendons to the fingers, where it blends with the expanded tendons.

The **palmar fascia**<sup>3</sup> consists of three portions, of which the lateral are thin connective-tissue layers investing the muscles of the ball of the thumb and those of the little finger. The middle portion, to which the name is especially applied, is a strong, triangular aponeurosis, extended across the hollow of the hand between the annular ligament and the roots of the fingers. It is chiefly composed of longitudinal bundles of fibres, which radiate mainly from the tendon of the long palmar muscle and partly from the front of the annular ligament. As it expands it becomes thinner, and approaching the fingers divides into four processes, each of which divides into two others, which are attached to the sides of the first phalanx and the contiguous ligaments of the articulation. Between the primary processes the digital vessels and nerves and the tendons of the lumbrical muscles issue, and in the intervals of the secondary processes the flexor tendons pass to the fingers. At the division of the palmar fascia it is intersected by transverse bundles of fibres, forming the **superficial transverse ligament**. On each side

<sup>1</sup> L. annulare or transversum posterius; 1. commune or carpi dorsale.

<sup>2</sup> F. dorsalis manus.

<sup>3</sup> F. palmaris; aponeurosis palmaris.



it is connected by a thin septum with the **interosseous fascia**, a thin membrane investing the interosseous muscles and fixed to the intervening metacarpal bones. Superficially the palmar fascia is connected by numerous short bands to the subjacent skin. It covers the superficial palmar arch and digital vessels, the digital nerves, and the flexor tendons with the lumbrical muscles.

#### MUSCLES OF THE FRONT AND INNER PART OF THE FOREARM.

Eight muscles occupy the inner front part of the forearm, five of which are superficial and the others more deeply situated. The former consist of the **terete pronator**, the **radio-carpal flexor**, the **long palmar muscle**, the **ulno-carpal flexor**, and the **superficial digital flexor**. These are all intimately connected at their origin from the inner epicondyle of the humerus, to which they are attached by a common tendon. The deeper muscles are the **deep digital flexor**, the **long pollical flexor**, and the **quadrate pronator**.

The **terete pronator**<sup>1</sup> crosses obliquely the upper part of the front of the forearm from the inner side of the elbow. It arises tendinous and fleshy by two heads, of which the larger comes from the fore part of the inner epicondyle of the humerus, the contiguous deep fascia, and the intermuscular septum between it and the radio-carpal flexor; and the smaller head, a thin fascicle, comes from the inner side of the coronoid process of the ulna and joins the former. The common belly proceeds outward and downward and ends in a flat tendon, which turns over the radius and is inserted into the rough impression about the middle of its outer surface. The muscle is, for the most part, subcutaneous, but is covered at its insertion by the long supinator, and is crossed by the radial vessels and nerve. It forms the inner boundary of the angular depression in front of the elbow, in which are the brachial vessels, the median nerve, and biceps tendon. The ulnar vessels pass beneath it, and the median nerve passes between its two heads. It overlies the brachialis muscle and the radial origin of the superficial digital flexor. The coronoid head of the muscle is especially liable to variation, and is sometimes absent.

The **quadrate pronator**<sup>2</sup> is situated at the lower part of the forearm beneath the flexors, and extends across the front of the bones and interosseous membrane just above the wrist. A flat muscle, it arises from the anterior surface of the ulna at its lower part, and passes almost directly outward and a little downward to be inserted into the fore part of the radius, reaching its outer border. Its fascicles are partially transverse and oblique, and some of them arise from an aponeurotic fascia which invests the muscle. Lying immediately on it are the long pollical, deep digital, and ulno-carpal flexors, and the radial blood-vessels.

<sup>1</sup> M. pronator teres; m. pr. radii teres; round pronator m.; m. epitrochlo-radialis.

<sup>2</sup> M. pronator quadratus; m. cubito-radialis.

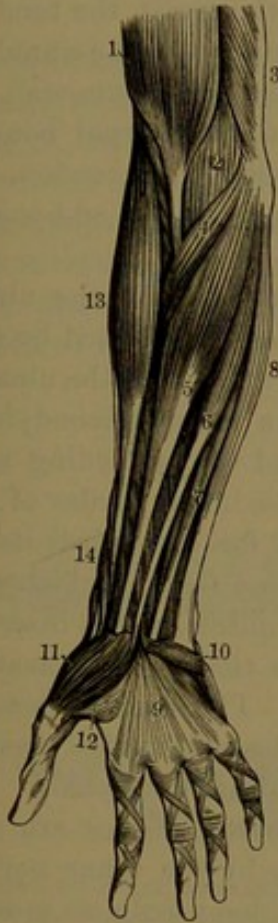


The quadrate pronator is sometimes more or less distinctly divided into two muscles, and sometimes it extends more upward or downward.

The pronator muscles, whose action is indicated by the name, are supplied by the median nerve.

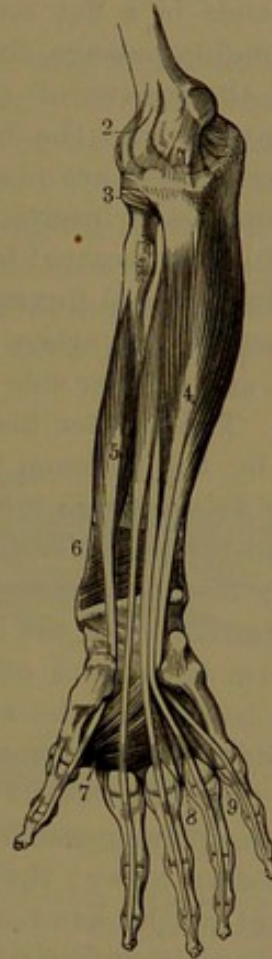
The **long palmar muscle**<sup>1</sup> is subcutaneous, and lies between the radio-carpal and ulno-carpal flexors, resting on the superficial digital flexor. It arises from the inner epicondyle of the humerus by the

FIG. 152.



**SUPERFICIAL MUSCLES OF THE FRONT OF THE FOREARM.** 1, lower part of the brachial biceps; 2, brachialis; 3, lower part of the brachial triceps; 4, terete pronator; 5, radio-carpal flexor; 6, long palmar muscle; 7, superficial digital flexor; 8, ulno-carpal flexor; 9, palmar fascia; 10, short palmar muscle; 11, pollical abductor; 12, short pollical flexor; 13, long supinator; 14, pollical extensors. The crossing and transverse bands on the fingers are the vaginal ligaments enclosing the flexor tendons.

FIG. 153.



**DEEP MUSCLES OF THE FRONT OF THE FOREARM.** 1, internal lateral ligament of the elbow-joint; 2, capsular ligament of the same; 3, orbicular ligament enclosing the head of the radius; 4, deep digital flexor; 5, long pollical flexor; 6, quadrate pronator; 7, pollical adductor; 8, 9, interosseous muscles.

common tendon and from the adjoining intermuscular septa, from which the small fusiform belly descends and terminates in a long, slender tendon, reaching the wrist; partially inserted into the fore part of the annular ligament, and par-

<sup>1</sup> M. palmaris longus; m. epitrochlo-palmaris; m. palmaris minimus.



tially ending in reinforcing the median palmar fascia. The tendon sometimes gives an offset which affords attachment to the small muscles of the thumb. The median nerve lies to the inner side of the tendon, near the wrist. The muscle is frequently absent, and when present is subject to variations of form and attachment.

The **radio-carpal flexor**<sup>1</sup> is a fusiform muscle lying subcutaneously between the former and the terete pronator, resting on the superficial digital flexor. It arises from the inner epicondyle of the humerus by the common tendon, and from the contiguous investing fascia and intermuscular septa, and descends to about the middle of the forearm, where it ends in a flat tendon. Reaching the wrist, the tendon proceeds through a passage, formed by the outer part of the annular ligament and the groove of the trapezium, lined by a synovial sheath, and is inserted into the base of the second metacarpal bone. The radial blood-vessels are placed to the outer side of its tendon. Sometimes it is partially inserted into the annular ligament, and sometimes into the third metacarpal bone.

The **ulno-carpal flexor**<sup>2</sup> lies subcutaneously along the ulnar side of the forearm. It arises by two heads closely connected by a tendinous arch at the inner side of the elbow, beneath which the ulnar nerve descends. The shorter head arises from the inner epicondyle of the humerus by the common tendon of this and the preceding muscles; the other arises by an aponeurosis from the inner border of the olecranon and the posterior border of the ulna for two-thirds its length. The fleshy fascicles descend and terminate in a tendon which occupies the anterior border of the lower half of the muscle, and is inserted into the pisiform bone, with offsets extending to the fifth metacarpal and unciform bones and the annular ligament. The muscle rests on the deep digital flexor, with the ulnar nerve descending between them, and with the ulnar vessels descending beneath its lower half.

The long palmar and the radio-carpal flexor muscles are supplied by the median nerve; the ulno-carpal flexor by the ulnar nerve. All are flexors of the hand at the wrist; the long palmar muscle also renders the palmar fascia tense.

The **superficial digital flexor**<sup>3</sup> is the largest muscle of the superficial group, and lies beneath the others. It arises with them from the inner epicondyle of the humerus by the common tendon, from the adjacent intermuscular septa, the internal lateral ligament of the elbow-joint, the inner side of the coronoid process of the ulna, and from the oblique line of the radius extending from its tuberosity to the insertion of the terete pronator. The fleshy fascicles descend and form a wide and

<sup>1</sup> M. flexor carpi-radialis; m. radialis internus or anterior; m. palmaris magnus.

<sup>2</sup> M. flexor carpi-ulnaris; m. ulnaris internus; m. cubito-carpian; m. cubitalis internus.

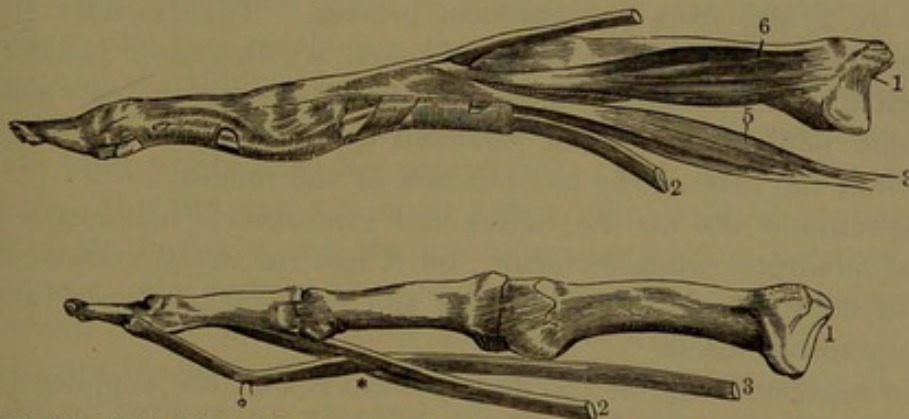
<sup>3</sup> M. flexor sublimis digitorum; m. flexor perforatus; superficial flexor muscle of the fingers.



thick flattened belly, which about the middle of the forearm divides into four parts, terminating in tendons. These proceed to the wrist, pass beneath the annular ligament in pairs, one in front of the other, and diverge in the palm of the hand, the front pair to the middle and ring fingers, the back pair to the index and little fingers, all being finally inserted into the middle of the second phalanges. In front of the first phalanges the tendons are split to give passage to the accompanying tendons of the deep digital flexor, around which the divided tendons are closely folded and again united behind, when they are once more separated to be inserted in the lateral borders of the second phalanges.

The superficial digital flexor rests on the deep digital and long pollical flexors, and covers the median nerve and ulnar blood-vessels. In the palm of the hand its tendons are covered by the median palmar fascia, crossed by the superficial palmar arch of vessels, and lie in front of the accompanying tendons of the deep digital flexor. The radial origin is sometimes wanting, which is also the case with the tendon to the little finger, ordinarily the smallest. The muscle is occasionally subdivided so that each tendon of insertion has a distinct belly.

FIG. 154.



METACARPAL BONE AND PHALANGES OF THE FINGERS, WITH THEIR TENDONS AND LIGAMENTS. In the upper figure the flexor tendons are retained in position by the vaginal ligaments, composed of transverse and obliquely crossing bands; in the lower figure the flexor tendons are freed from the vaginal ligaments. 1, metacarpal bone; 2, tendon of the superficial digital flexor; 3, tendon of the deep digital flexor, passing through a cleft (\*) of the former; 4, tendon of the common digital extensor; 5, a lumbrical muscle, inserted into the extensor tendon; 6, an interosseous muscle, also inserted into the latter.

The **deep digital flexor**,<sup>1</sup> another large, thick muscle, lies beneath the former and the ulno-carpal flexor, at the inner fore part of the forearm. It arises from the ulnar attachment of the aponeurosis of the ulno-carpal flexor, from the inner and anterior surface of the ulna, commencing on each side of the insertion of the brachialis and reaching to within a short distance of the quadrate pronator, and

<sup>1</sup> M. flexor profundus digitorum; m. flexor perforans; deep flexor muscle of the fingers.



from the contiguous half of the interosseous membrane. The descending fleshy fascicles form a belly, dividing about the middle of the forearm into three or sometimes four parts, from which proceed four flat tendons facing the front of the muscle. The first tendon, intended for the index finger, is distinct from the others, which are more or less divided, or fasciculate, and interjoin to the wrist. Here the tendons pass in company with and behind those of the superficial digital flexor beneath the annular ligament into the palm of the hand, and thence diverge to the fingers, where they pass through the slits of the superficial tendons and proceed to be inserted into the bases of the last phalanges.

The deep digital flexor is covered by the ulno-carpal and superficial digital flexors, with the ulnar vessels and nerve intervening, lies between the ulno-carpal and long pollical flexors, and rests on the radius, interosseous membrane, and quadratus pronator. In the palm of the hand its tendons rest on the pollical adductor and the interosseous muscles, with the deep palmar arch of vessels intervening.

The **long pollical flexor**<sup>1</sup> lies at the radial side of the former muscle. It arises from the anterior surface of the radius, commencing below the tuberosity and oblique line and reaching nearly to the quadratus pronator, from the adjacent part of the interosseous membrane, and commonly by a slip from the coronoid process. The fascicles descend obliquely and terminate in a flat tendon, which passes beneath the outer part of the annular ligament, thence between the two heads of the short pollical flexor and sesamoid bones, and proceeds to be inserted into the base of the last phalanx of the thumb.

The muscle lies on the radius and interosseous membrane above and the quadratus pronator below; on it rest the radial vessels; and it is covered by the superficial digital and radio-carpal flexors and the long supinator muscle.

The superficial digital and long pollical flexors are supplied by the median nerve, the deep digital flexor by the latter and the ulnar nerve. The action of these muscles is indicated by the name, and produces the closed fist, and further continued flexes the hand.

The tendons of the superficial and deep digital and long pollical flexors and the median nerve pass together through the **carpal canal**, which is formed by the deep concavity of the carpus bridged across by the anterior annular ligament. In the flexion and extension of the hand the tendons move freely up and down in the canal, and glide upon one another. They are enveloped in a complex folded synovial sheath, which invests each tendon and the nerve and lines the canal, reaching above to the radio-carpal articulation and below to the carpometacarpal articulations.

In front of the digits the flexor tendons are closely confined in

---

<sup>1</sup> M. flexor longus pollicis; long flexor muscle of the thumb.



canals, which maintain their position, but permit ready upward and downward motion in the flexion and extension of the fingers and thumb. These **digital canals** are formed by **vaginal ligaments**,<sup>1</sup> which are strong fibrous bands arching over the tendons and firmly fixed to the roughened lateral borders of the phalanges. Opposite the joints thinner membranes<sup>2</sup> strengthened by obliquely decussating bands<sup>3</sup> occupy the intervals of the former ligaments and complete the canals. The latter are lined by a synovial sheath, which is reflected on and invests each tendon. The sheath forms little folds<sup>4</sup> between the tendons and the phalanges; some of them consisting of slender bands<sup>5</sup> extended between the tendons and the front of the phalanges, and others<sup>6</sup> short and broad, between the insertion of the tendons and the phalanges immediately above.

The synovial sheaths of the tendon of the long pollical flexor and those of the little finger are prolonged from the carpal canal into their respective digital canals.

#### MUSCLES OF THE OUTER AND BACK PART OF THE FOREARM.

Twelve muscles form the mass at the outer and back part of the forearm, and consist of extensors and supinators arranged in two layers. The superficial layer is composed of the anconeus, already described, the long supinator, two radio-carpal, the ulno-carpal, the digital, and the minimal extensors; the deep layer is composed of the short supinator, three pollical extensors, and the indicial extensor.

The **long supinator**<sup>7</sup> lies superficially along the outer part of the forearm. It arises from the outer part of the external supracondylar ridge of the humerus and the intermuscular septum between it and the triceps. Its fascicles descend and form a thin belly, ending about the middle of the forearm in a flat tendon, which proceeds to be inserted into the base of the styloid process of the radius. It lies on the longer radio-carpal extensor, the short supinator, the terete pronator, and the superficial digital flexor, and covers the radial vessels and nerve. In the arm it is in contact internally with the brachialis muscle, having the musculo-spiral nerve interposed; and at the elbow forms the outer boundary of the angular depression in front. Near the wrist it is crossed outwardly by the tendons of the first and second pollical extensors.

The **short supinator**<sup>8</sup> lies beneath the long supinator and superficial extensors folded around the upper outer part of the radius. It arises tendinously from the back of the outer epicondyle of the humerus, from the external lateral and orbicular ligaments of the elbow,

<sup>1</sup> Ligamenta vaginalia or transversa.

<sup>2</sup> L. vaginalia.

<sup>3</sup> L. cruciata.

<sup>4</sup> Vincula accessoria tendinum.

<sup>5</sup> Ligamenta longa.

<sup>6</sup> L. brevia.

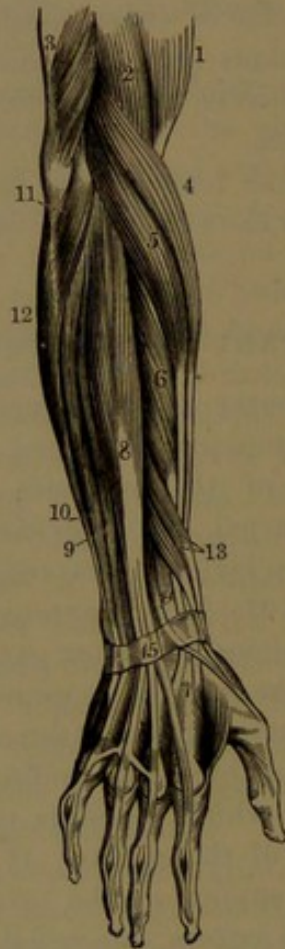
<sup>7</sup> M. supinator longus; m. brachio-radialis; m. supinator radii longus.

<sup>8</sup> M. supinator brevis; m. supinator radii brevis.



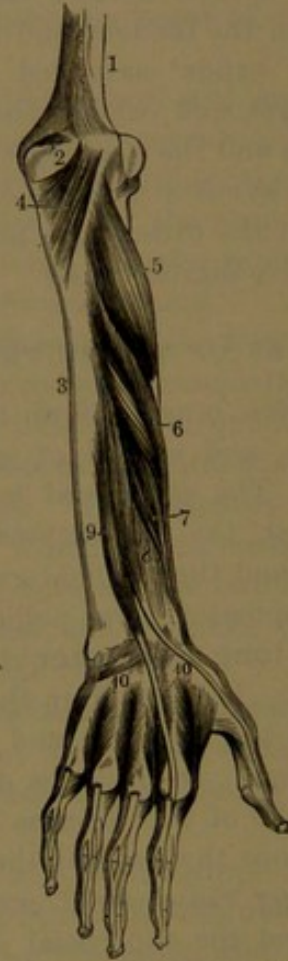
from the depression of the ulna below the radial articulation extending a short distance down the outer border of the bone, and from the investing aponeurosis, which also springs from the tendon of origin of the muscle. The fleshy fascicles descend from the back of the elbow obliquely outward, winding around the radius, into the outer part of which they are inserted, extending from the fore part of the neck and behind and below the tuberosity to the insertion of the terete pronator.

FIG. 155.



MUSCLES OF THE BACK OF THE FOREARM. 1, brachial biceps; 2, brachialis; 3, brachial triiceps; 4, long supinator; 5, longer radio-carpal extensor; 6, shorter radio-carpal extensor; 7, insertion of the tendons of the last two muscles; 8, common digital extensor; 9, minimal extensor; 10, ulno-carpal extensor; 11, anconeus; 12, ulno-carpal flexor; 13, first and second pollical extensors; 14, third pollical extensor; 15, posterior annular ligament.

FIG. 156.



DEEP MUSCLES ON THE BACK OF THE FOREARM. 1, humerus; 2, olecranon; 3, ulna; 4, anconeus; 5, short supinator; 6, first pollical extensor; 7, second pollical extensor; 8, third pollical extensor; 9, indicial extensor; 10, the dorsal interosseous muscles between the metacarpal bones.

The muscle covers the outer back part of the elbow-joint, as well as the upper part of the radius; and

it is pierced by the posterior interosseous nerve.

The **longer radio-carpal extensor**,<sup>1</sup> subcutaneous behind and partially covered by the long supinator, arises below it from the external

<sup>1</sup> M. extensor carpi-radialis longior; m. ext. radialis longus; m. ext. radialis externus longus.



supracondylar ridge of the humerus and the intermuscular septum. The fleshy belly descends to about the middle of the forearm, where it ends in a flat tendon, which runs along the outer border of the radius and through a canal behind the styloid process, and thence across the carpus to be inserted into the outer part of the base of the second metacarpal bone.

The **shorter radio-carpal extensor**,<sup>1</sup> partially covered by and thicker than the former, arises tendinously in common with the succeeding extensors from the outer epicondyle of the humerus, from the adjacent intermuscular septa, and from the investing fascia. Its fleshy belly descends and ends in a tendon, which accompanies that of the longer muscle, closely adherent, but diverges from it, after passing through the canal behind the styloid process of the radius, and crosses the carpus to be inserted into the outer side of the base of the third metacarpal bone.

Passing side by side through the canal behind the styloid process of the radius, the tendons of the radio-carpal extensors are invested with a synovial sheath. Approaching the wrist they are crossed outwardly by the three pollical extensors. The longer radio-carpal extensor partly covers the elbow-joint, the shorter muscle, and the wrist-joint; the shorter radio-carpal extensor partly covers in succession the short supinator, the terete pronator, the radius, and the wrist-joint.

The **ulno-carpal extensor**<sup>2</sup> lies subcutaneously at the inner side of all the other extensors. It arises in common with these from the outer epicondyle of the humerus, from the posterior border of the ulna several inches below the anconeus, and from the investing fascia. Descending, it ends in a tendon which runs through the canal behind the styloid process of the ulna, and thence crosses the carpus to be inserted inwardly into the base of the last metacarpal bone. Internally the muscle lies on the ulna in contact with the deep extensors.

The longer radio-carpal extensor is supplied from the trunk of the musculo-spiral nerve, the shorter radio-carpal, and the ulno-carpal extensors by its posterior interosseous divisions. They are extensors of the hand on the forearm. One or other of the radio-carpal extensors is sometimes divided and partially inserted into the succeeding metacarpal bone. Sometimes the ulno-carpal extensor gives an offset to the extensor tendons of the little finger, and not unfrequently one to the minimal adductor muscle.

The **digital extensor**<sup>3</sup> lies subcutaneously at the back of the forearm, between the radio-carpal and the ulno-carpal extensors. It arises

<sup>1</sup> M. extensor carpi-radialis brevior; m. ext. radialis brevis; m. radialis externus brevis.

<sup>2</sup> M. extensor carpi-ulnaris; m. ulnaris externus; m. cubitalis externus.

<sup>3</sup> M. extensor digitorum communis.



from the outer epicondyle of the humerus in common with the other extensors, from the investing deep fascia, and from the adjacent intermuscular septa. Below the middle of the forearm its belly terminates in three tendons, which descend together and pass under the annular ligament back of the radius, and thence diverge on the wrist and back of the hand; the third tendon dividing, so that four tendons proceed to the digits, extending to the last phalanges. On the back of the hand the tendons become more flattened, the intermediate pair lying on the corresponding metacarpal bones, while the first one crosses obliquely the second interosseous space, and the fourth one usually lies close to the third, and rather abruptly diverges across the lower part of the last interosseous space to the little finger. On the back of the hand the tendons are connected by a thin intervening aponeurosis, which at several points is strengthened by oblique bands. The strongest of these extends from the third tendon obliquely downward across the lower part of the intervening space to the second tendon, and another extends in a nearly similar position from the fourth to the third tendon. A thinner band may also extend transversely or nearly so from the first to the second tendon, but is often scarcely produced. At the metacarpo-phalangeal articulations the tendons become narrower and thicker, and furnish thin lateral offsets to the contiguous capsular ligaments, reinforcing them in this position and serving as posterior ligaments to the joints. From these the tendons spread over the first phalanges, and are joined at the sides by broad, triangular expansions from the insertion of the adjacent interosseous and lumbrical muscles. The median thicker portion of each tendon is inserted into the base of the second phalanx, and serves as a posterior ligament to the contiguous phalangeal articulation. The lateral portions of the tendon then converge upon the back of the second phalanx, and are inserted together into the base of the terminal phalanx, and serve as a posterior ligament to the second phalangeal articulation.

To the thumb there are three extensor muscles, which lie beneath the superficial layer of extensors in the forearm, crossing obliquely downward from the ulnar to the radial side.

The **first pollical extensor**,<sup>1</sup> the external and largest, arises from the posterior surface of the ulna and radius and the intervening interosseous membrane below the insertion of the short supinator. Descending obliquely outward, it terminates in a tendon which passes through a canal on the outer side of the styloid process of the radius and then over the wrist to be inserted into the base of the metacarpal bone of the thumb. The tendon is not unfrequently divided, and is partly inserted into the trapezium; or it may afford an attachment to the small muscles of the thumb.

---

<sup>1</sup> M. extensor metacarpi pollicis; metacarpal extensor of the thumb; m. abductor longus pollicis.



The **second pollical extensor**,<sup>1</sup> the smallest of the series, lies to the inner side of the preceding. It arises from the posterior surface of the radius and contiguous portion of the interosseous membrane below the preceding muscle, which it accompanies. Terminating in a tendon, this passes through the same groove as the former muscle, crosses the wrist, and proceeds along the back of the first metacarpal bone to be inserted into the base of the first phalanx of the thumb.

The **third pollical extensor**<sup>2</sup> lies to the inner side of the preceding, and partly covers it. It arises from the ulna and interosseous membrane just below the first extensor, and pursues the same course, but diverges from it. Terminating in a tendon, this passes alone through a different canal from that of the former muscles at the back of the radius; thence crosses the carpus, and joins the tendon of the second extensor, but continues along the first phalanx to be inserted into the base of the terminal phalanx of the thumb.

The first and second pollical extensors are covered by the digital and minimal extensors, and are crossed by the posterior interosseous vessels and nerve. Together they proceed outward and downward across the tendons of the radio-carpal extensors and long supinator, and at the wrist the radial vessels. The third pollical extensor crosses the tendons of the radio-carpal extensors, separated from the other pollical extensors by a triangular space, which in the extreme extension of the thumb appears as a superficial depression at the outer back part of the wrist, and which at bottom contains the radial blood-vessels.

The second pollical extensor is sometimes absent, or appears fused with the first or with the third one.

The **indical extensor**,<sup>3</sup> a narrow muscle placed to the inner side of the last described, arises below and partly beneath it from the ulna and contiguous interosseous membrane. Descending, it terminates in a tendon which accompanies the tendons of the digital extensor through the canal at the back of the radius, and thence proceeds along the ulnar side of the first tendon of the latter to the index finger, where it becomes part of the common tendon.

The **minimal extensor**,<sup>4</sup> another slender muscle, is placed along the inner side of the digital extensor, with which it is commonly closely connected. Arising in common with the latter muscle and from the adjacent intermuscular septa, it ends in a tendon, which passes through a canal behind the lower radio-ulnar articulation, and thence crosses the wrist to the back of the hand, and proceeds to the little finger. The tendon is usually divided into two parts, of which one is joined

<sup>1</sup> M. extensor primi internodii pollicis; first phalangeal extensor of the thumb; short extensor of the thumb; extensor brevis pollicis or minor.

<sup>2</sup> M. extensor secundi internodii pollicis; second phalangeal extensor; long extensor of the thumb; extensor pollicis longus or major.

<sup>3</sup> M. extensor indicis; m. indicatorius; indicator muscle.

<sup>4</sup> M. extensor minimi digiti; proper extensor muscle of the little finger.



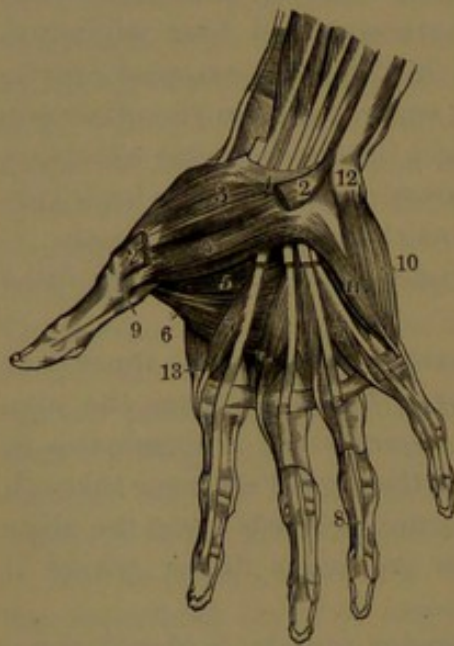
at the metacarpo-phalangeal articulation by an offset from the fourth tendon of the digital extensor, and both are subsequently joined by the latter to form the common tendon of the little finger. Sometimes the muscle has an additional tendon terminating in that of the adjoining finger, and rarely it is absent.

The extensors of the thumb and fingers are supplied by the posterior interosseous branch of the musculo-spiral nerve.

The arrangement of the extensor tendons on the back of the thumb is similar to that on the fingers. On the back of the metacarpo-phalangeal articulation the capsular ligament is reinforced by offsets from the extensor tendons. On the first phalanx the tendons of the extensors are joined at the sides by triangular expansions derived from the insertion of the small muscles of the thumb.

#### MUSCLES OF THE HAND.

The hand, besides containing the tendons of the muscles of the forearm in their course to the fingers, has also many small muscles, which for the most part occupy the palm. They consist of the short palmar and lumbrical muscles, those of the thumb and of the little finger, and the interosseous muscles.



MUSCLES OF THE PALMAR SURFACE OF THE HAND. 1, anterior annular ligament; 2, origin and insertion of the pollical abductor; 3, pollical opponens; 4, 5, two bellies of the short pollical flexor; 6, pollical adductor; 7, lumbrical muscles; 8, tendons of the deep digital flexor passing through the slits of the superficial tendons; 9, tendon of the long pollical flexor, passing from between the bellies of the short flexor; 10, minimal abductor; 11, minimal flexor; 12, pisiform bone; 13, first interosseous muscle.

The **short palmar muscle**<sup>1</sup> consists of a thin subcutaneous layer of fleshy fascicles at the inner part of the palm resting on the muscles of the little finger. It arises from the inner margin of the median palmar fascia and the annular ligament, and passes directly inward to be inserted into the skin along the inner border of the palm. The ulnar vessels pass beneath the muscle. It is supplied by the ulnar nerve.

The **lumbrical muscles**<sup>2</sup> are four worm-like fascicles, which lie in the intervals of the flexor tendons in the hollow of the palm. They arise from the tendons of the deep digital flexor, commencing beneath the annular ligament, thence extend downward and proceed to the radial side of the metacarpo-phalangeal articulations, where

they end in tendons expanding in triangular aponeuroses, which termi-

<sup>1</sup> M. palmaris brevis; m. p. cutaneus.

<sup>2</sup> M. lumbricales; m. fidicinales.



nate by joining and reinforcing the extensor tendons on the back of the first phalanges of the fingers. The outer two muscles arise from the radial side of the corresponding two tendons; the inner two from the contiguous sides of the corresponding three tendons.

The number of these muscles is occasionally diminished or increased, and sometimes their insertion is variable. They are supplied by the median and ulnar nerves.

#### MUSCLES OF THE THUMB.

Four muscles occupy the **ball of the thumb**,<sup>1</sup>—the pollical abductor, opponens, short flexor, and adductor.

The **pollical abductor**<sup>2</sup> is a flat muscle, the most superficial of the group. It arises from the ridge of the trapezium and the annular ligament, and passes downward and outward to be inserted by a flat tendon into the outer part of the base of the first phalanx of the thumb.

The **pollical opponens**,<sup>3</sup> larger than the former and lying partially beneath it, arises from the same parts, from which its fascicles diverge outward and downward to be inserted into the outer border and contiguous palmar surface of the metacarpal bone its whole length.

The **short pollical flexor**,<sup>4</sup> the largest muscle of the group, is placed to the inner side of the former partially covered by the abductor. It consists of two portions, separated by an interval traversed by the tendon of the long flexor. The anterior more superficial portion arises from the annular ligament and trapezium, the deeper portion from the trapezoid, magnum, and adjacent part of the second and third metacarpal bones. The two portions unite behind the long flexor tendon, and descend to be inserted into the outer and inner part of the base of the first phalanx, involving the contiguous sesamoid bones; the outer portion joining with the abductor, the inner with the adductor.

The **pollical adductor**,<sup>5</sup> a triangular muscle, is the most deeply seated of the group. It arises from the ridge in front of the middle metacarpal bone, and proceeds outward to be inserted tendinously, in conjunction with the inner portion of the short flexor, into the base of the first phalanx of the thumb. It covers the outer two interosseous spaces invested behind by an aponeurosis; its anterior surface is in contact with the short pollical flexor, the tendons of the deep digital flexor, and the lumbrical muscles.

The pollical abductor, opponens, and anterior portion of the short flexor are supplied by the median nerve; the deeper portion of the latter muscle and the adductor are supplied by the ulnar nerve.

<sup>1</sup> Thenar eminence.

<sup>3</sup> M. opponens pollicis.

<sup>5</sup> M. adductor pollicis.

<sup>2</sup> M. abductor pollicis.

<sup>4</sup> M. flexor brevis pollicis.



## MUSCLES OF THE LITTLE FINGER.

The prominence<sup>1</sup> at the inner part of the palm is formed by the short muscles of the little finger, consisting of the minimal abductor, flexor, and adductor.

The **minimal abductor**,<sup>2</sup> the most superficial of the group, arises from the pisiform bone and the tendon of insertion of the ulno-carpal flexor, and descends to be inserted tendinously into the ulnar side of the base of the first phalanx of the little finger, and by a slip into the adjacent extensor tendon. Sometimes a second head springs from the annular ligament or some other contiguous point.

The **minimal flexor**,<sup>3</sup> placed at the radial side of the former, arises from the hook of the unciform bone and from the annular ligament, and descends to be inserted in common with the abductor into the first phalanx. At its origin a narrow angular interval, between it and the abductor, gives passage to the ulnar communicating vessels and accompanying nerve. Often the muscle is but feebly produced, and occasionally it is absent, in which case the abductor is larger than usual.

The **minimal adductor**<sup>4</sup> lies beneath the preceding muscles, arises from the same points as the flexor, and is inserted along the ulnar border of the last metacarpal bone.

All the muscles of the above group are supplied by the ulnar nerve.

**Interosseous muscles.**<sup>5</sup> These occupy the intervals of the metacarpal bones; four on the dorsal aspect of the hand, and three on the palmar aspect.

The **dorsal interosseous muscles**<sup>6</sup> are double-headed and peniform, and arise from adjacent sides of the metacarpals, between which they are placed, but especially from the side of that of the finger into which each muscle is inserted. Each terminates in a tendon, which is inserted into the side of the base of the first phalanx and into the contiguous extensor tendon on the back of the finger. The first dorsal interosseous muscle<sup>7</sup> is the largest; its outer head from the proximal half of the first metacarpal and its inner head from the length of the second; and is inserted into the radial side of the index finger. The angular interval between its two heads, wider than in the other muscles, gives passage to the radial vessels between the back and palm of the hand. The second and third muscles are inserted on the two sides of the middle finger, and the fourth one on the ulnar side of the ring-finger.

The **palmar interosseous muscles**<sup>8</sup> arise from one side of the

<sup>1</sup> Hypothenar eminence.

<sup>2</sup> M. abductor minimi digiti.

<sup>3</sup> M. flexor brevis minimi digiti.

<sup>4</sup> M. adductor minimi digiti; m. adductor ossis metacarpi minimi digiti; m. opponens digiti minimi.

<sup>6</sup> M. interossei externi or bicipites.

<sup>5</sup> M. interossei.

<sup>8</sup> M. interossei interni.

<sup>7</sup> M. abductor indicis.



palmar aspect of their respective metacarpal bones, and are inserted on the same side into the first phalanges and extensor tendons in the manner of the dorsal muscles. The first palmar interosseous muscle pertains to the ulnar side of the index finger, and the others to the radial side of the ring and little fingers.

Viewing the axis of the middle finger as a line of departure and approach, the dorsal interosseous muscles act as abductors to the fingers, while the palmar interosseous muscles act as adductors. Together with the corresponding muscles of the thumb and little finger, each digit has its abductor and adductor, as well as its flexor and extensor.

The interosseous muscles are supplied by the deep palmar branch of the ulnar nerve.

#### FASCIAE AND MUSCLES OF THE LOWER LIMB.

The **superficial fascia** of the lower limb is like that elsewhere, and in general consists of two layers variably distinct in different positions; the deeper more compact and membranous in appearance, the subcutaneous of looser texture and including the usual adipose tissue occupying this layer. Over the gluteal region its two layers are less distinct; but the fascia is thick, and includes the largest accumulation of adipose tissue contributing to the prominence of the buttock. In the sole of the foot it is also thick and mixed with adipose tissue, which here serves as a cushion to alleviate the effect of pressure on the important parts above. It is continuous with the superficial fascia of the abdomen and loins. Between its layers it contains the superficial veins, and in the groin the lymphatic glands. Its deeper layer adheres to Poupart's ligament, and internally is continuous with the dartos tunic of the scrotum and with the superficial perineal fascia. Below Poupart's ligament, it covers the saphenous opening of the deep fascia, in which position it is traversed by many small blood-vessels and lymphatics, which pass out and in through the opening, whence the name of **cribriform fascia** given to this portion of the superficial fascia. Subcutaneous bursæ are found in it over the patella, the heel, and the phalangeal articulations.

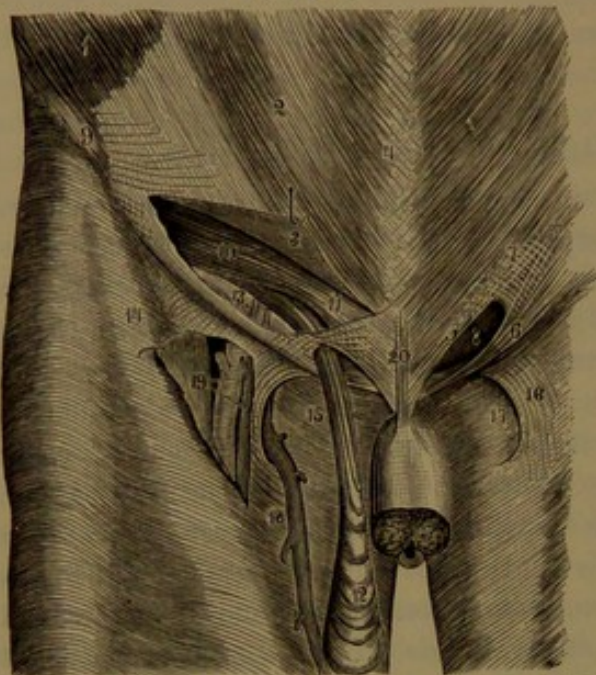
The **deep fascia of the thigh**,<sup>1</sup> named the **femoral fascia**, or more commonly the **fascia lata**, is a bluish-white aponeurotic membrane, chiefly composed of longitudinal fibres intersected by transverse and oblique fibres. It forms a continuous sheath to the thigh, varying in thickness in different positions; is for the most part movably attached to the muscles beneath by loose connective tissue; and by means of partitions extending from its inner surface furnishes each muscle with a separate sheath. The fascia is tightly attached above to the crest of the ilium, the back of the sacrum and coccyx, to Pou-

<sup>1</sup> Fascia femoris.



part's ligament, the body and arch of the pubis, the tuberosity of the ischium, and the great sciatic ligament. Below, it is attached to all the bony prominences about the knee-joint, the condyles of the femur, the heads of the tibia and fibula, and the patella. The thickest portion starts from the fore part of the crest of the ilium in a broad band, named the **ilio-tibial band**,<sup>1</sup> which descends along the outer part of the thigh to be attached to the head of the tibia. From over the great trochanter it is reinforced by the upper portion of the tendon of insertion of the great gluteal muscle, and lower receives the insertion of a

FIG. 158.



VIEW OF THE FEMORAL FASCIA. 1, external oblique muscle; 2, its aponeurosis; 3, portion of the latter raised up, exposing the inguinal canal; 4, linea alba; 5, internal column; 6, external column formed by Poupart's ligament; 7, intercolumnar fibres; 8, external abdominal ring, the termination of the inguinal canal; 9, anterior superior spine of the ilium; 10, arching lower border of the internal oblique and transversalis muscles; 11, conjoined tendon of the latter; 12, fibres of the cremaster descending on the spermatic cord from below the muscles just named; 13, rests on the transversalis fascia; to its right are the epigastric vessels crossing the course of the inguinal canal; 14, iliac portion of the femoral fascia; 15, pubic portion; 16, falci-form process; 17, saphenous opening; 18, saphenous vein joining the femoral vein through the saphenous opening; 19, the femoral artery and vein exposed by raising the iliac portion of fascia which forms the falci-form process; 20, suspensory ligament of the penis.

external thicker septum separates the external vastus in front from the short head of the femoral biceps behind, and gives partial origin to these muscles. The internal septum separates the internal vastus from

special muscle, the fascial tensor. The thinnest portion of the fascia is at the inner and upper part of the thigh, where it invests the adductor muscles. Approaching the knee, it is of intermediate thickness, receives here reinforcements from the neighboring tendons, and contributes to form the capsule of the joint. Behind the knee it passes between the flexor muscles on each side over the popliteal space, and is thence continuous below with the deep fascia of the leg. Covering the great gluteal muscle, it is thin and closely adheres to the latter, but is thick in advance, where it covers the middle gluteal muscle and gives partial origin to it. Of the partitions extending between the muscles, the chief are the **external and internal intermuscular septa**,<sup>2</sup> attached along the linea aspera and thence along the supracondylar ridges. The

<sup>1</sup> Fascia lata.<sup>2</sup> Ligamenta intermuscularia.



the adductors, with the aponeurotic attachment of which it becomes blended.

In front of the thigh below Poupart's ligament is the **saphenous opening**,<sup>1</sup> an aperture in the femoral fascia, through which the internal saphenous vein enters to join the femoral vein. The opening is externally defined by a semicircular edge of the fascia which extends outwardly in front of the femoral vessels and over the sartorius muscle towards the ilium, whence it is named the **iliac portion**,<sup>2</sup> and is attached along Poupart's ligament. From the inner part of the opening the femoral fascia, here named the **pubic portion**,<sup>3</sup> extends outwardly behind the femoral vessels attached to the pectineal line of the pubis, and becomes continuous with the ilio-psoas fascia. The semicircular edge of the iliac portion of the femoral fascia, named the **falciform process**,<sup>4</sup> at its upper extremity<sup>5</sup> is continuous with Gimbernat's ligament, and at its lower extremity with the pubic portion of the fascia, between the conjunction of the internal saphenous and femoral vein. The lower extremity is most sharply defined, and the middle portion least, where it is continuous with the cribriform fascia, which occupies the saphenous opening.

The **ilio-psoas fascia**<sup>6</sup> invests the femoral flexor, consisting of the iliac and psoas muscles, which occupy the back part of the abdominal cavity. Attached along the iliac crest and Poupart's ligament, it is here continuous with the transversalis fascia, than which it is stronger. Its most compact and strongest part extends below from the iliac crest inwardly to the brim of the pelvis, where it is tightly fixed, and in this position receives the expanded insertion of the tendon of the small psoas muscle when it exists. A thinner portion of the fascia extends upward on the psoas, attached inwardly to the lumbar vertebræ and sacrum, outwardly continuous with the anterior layer of the lumbar fascia, and above with the internal arcuate ligament of the diaphragm. In the groin the ilio-psoas fascia, connected outwardly with the transversalis fascia and Poupart's ligament, is prolonged beneath the latter, on the muscle it invests, into the thigh behind the femoral blood-vessels. In this position it is continuous inwardly with the pubic portion of the femoral fascia, and outwardly with the iliac portion of the latter, and is further connected with an intermuscular septum extending between the psoas and pectineus to the ilio-pubic eminence and the capsule of the hip-joint. The peritoneum covers the ilio-psoas fascia, but is separated from the iliac portion by a considerable quantity of loose areolar tissue usually associated with more or less fat. The external iliac vessels lie upon the ilio-psoas fascia, but the lumbar plexus of nerves lies behind it.

<sup>1</sup> Fovea ovalis.

<sup>2</sup> Sartorial fascia.

<sup>3</sup> Pectineal fascia.

<sup>4</sup> Processus falciformis.

<sup>5</sup> Hay's ligament; femoral ligament.

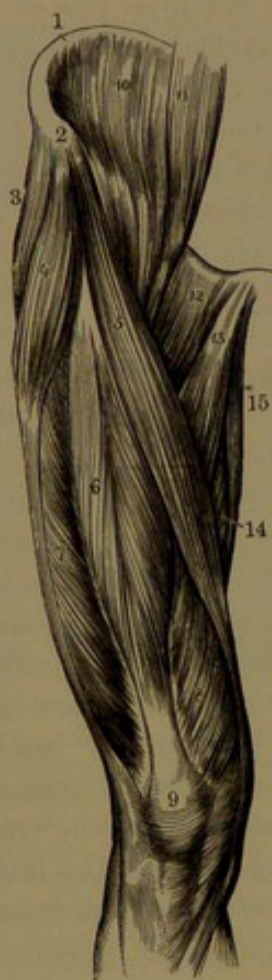<sup>6</sup> F. iliaca or lumbo-iliaca.



## MUSCLES OF THE FRONT AND OUTER PART OF THE THIGH.

The **fascial tensor**<sup>1</sup> is a short, flat muscle at the outer part of the thigh, enclosed in a sheath of the femoral fascia. It arises tendinous from the outer border of the anterior superior spine and contiguous portion of the crest of the ilium, between the origin of the sartorius and middle gluteal muscles, and descends about one-fourth way on the outer side of the thigh, where it ends in the femoral fascia, which it reinforces, and in conjunction with it is extended as the ilio-tibial band to

FIG. 159.



MUSCLES OF THE FRONT AND OUTER PART OF THE THIGH. 1, crest of the ilium; 2, anterior superior iliac spine; 3, middle gluteal muscle; 4, fascial tensor; 5, sartorius; 6, femoral rectus; 7, external vastus; 8, internal vastus; 9, insertion of the quadriceps into the patella; 10, iliac muscle; 11, psoas muscle; 12, pectineus; 13, long adductor; 14, great adductor; 15, gracilis.

the head of the tibia. It diverges from the origin of the sartorius, with the femoral rectus lying between, and rests on the latter, the middle gluteal, and external vastus muscles.

The **sartorius**,<sup>2</sup> the longest muscle of the body, is ribbon-like and remarkable for the great length of its fleshy fascicles, which extend parallel throughout. It is subcutaneous the entire length, and pursues a half-spiral course from the hip to the knee, crossing in front of the thigh from the outer to the inner side. It arises tendinous from the anterior superior iliac spine and the contiguous margin of the notch below, and thence descends obliquely across the front of the thigh to the inner side. Continuing to the knee behind the inner condyle of the femur, it terminates in a tendon which curves forward and expands in an aponeurosis inserted into the upper part of the inner surface of the tibia near the tubercle. An offset from the tendon above reinforces the capsule of the knee-joint, and another below reinforces the fascia of the leg. In its course in succession it lies on the iliac muscle, the rectus, the femoral vessels, the pectineus, the long and great adductors, the internal vastus, the gracilis, and the inner side of the knee-joint. The tendon of insertion covers those of the gracilis and semitendinosus, but is separated from them by a prolongation of the bursa which is interposed between the same tendons and the internal lateral ligament of the knee.

At the upper part of the thigh the muscle forms the outer boundary

<sup>1</sup> M. tensor vaginæ femoris; m. t. fasciæ latæ; m. fascialis.

<sup>2</sup> M. ilio-pretibialis.



of the space named **Scarpa's triangle**, which is traversed through the middle by the femoral vessels.

The fleshy mass forming the front and outer part of the thigh is mainly composed of the **quadriceps muscle**,<sup>1</sup> named from its consisting of four portions or heads terminating in a common tendon, in which is embedded the patella, and is thence extended to be inserted into the tubercle of the tibia. Of the four portions of the quadriceps, the femoral rectus appears as a distinct muscle isolated from the rest except at its insertion, while the others, named the external vastus, internal vastus, and crureus, are closely connected and envelop the femur from the trochanters to the condyles, leaving little more than the linea aspera projecting behind for the attachment of other muscles.

The **femoral rectus**<sup>2</sup> lies in an intermediate position in front of the other portions of the quadriceps. It is fusiform, and arises by two short, stout tendons, of which one springs from the anterior inferior spine of the ilium, while the other curves forward from the impression above and behind the acetabulum. Below the upper margin of the latter the tendons unite in one, which descends and expands in an aponeurosis in front of the muscle, whose fascicles pennately arranged terminate in a posterior aponeurosis, which narrows into a flattened cylindrical tendon proceeding to be inserted into the base of the patella.

The **external vastus**,<sup>3</sup> the largest portion of the quadriceps, occupies the outer part of the thigh, and is for the most part subcutaneous and covered by the thickest portion of the femoral fascia. It arises by a broad aponeurosis, which faces the greater part of the muscle externally, and springs from the upper part of the anterior intertrochanteric ridge of the femur, from the front and outer part of the base of the great trochanter, from behind the rough insertion of the great gluteal muscle, and from the outer lip of the linea aspera. The large mass of fleshy fascicles from this aponeurosis, with additional ones from the surface of the femur immediately beneath the attachment of the latter, from the tendon of insertion of the great gluteal muscle, and from the external intermuscular septum adjoining the short head of the biceps, descend obliquely forward and end in the aponeurosis of insertion. This occupies the deep surface and anterior border of the lower half of the muscle; and it descends and converges into a thicker, flat tendon, which partially passes behind that of the rectus, blends with it and other portions of the common tendon of the quadriceps, and is inserted into the outer part of the base of the patella. A few superficial fascicles join the outer border of the tendon of the rectus, and the deeper portion of the muscle is to a greater or less extent connected with the crureus.

The **internal vastus** and **crureus** are so intimately connected that

<sup>1</sup> M. quadriceps extensor cruris.

<sup>2</sup> M. rectus femoris.

<sup>3</sup> M. vastus externus; m. extensor cruris externus.



they may be regarded as one of the chief divisions of the quadriceps. The former occupies the inner side of the thigh, for the most part subcutaneous and covered by the deep fascia; the latter, the front and outer part of the femur, covered by the rectus and external vastus. They are partially separated by a narrow interval extending in a line from near the small trochanter to the inner side of the patella.

The **internal vastus**<sup>1</sup> arises by an aponeurosis, facing it internally, attached to the femur in a line directed from near the small trochanter to the linea aspera, and along the inner lip of the latter and its inner branch directed to the internal epicondyle, and by numerous fleshy fascicles from the femur beneath the origin of the aponeurosis and from the tendons of insertion of the long and great adductors. The fascicles in general descend forward and outward and terminate in an aponeurosis, which is common to it and the crureus, and descends and converges to be inserted into the inner side of the patella, partly passing under the rectus tendon and blending with it. The fleshy fascicles descend lower than in the external vastus, so as to give a more fleshy covering to the inner side of the knee.

The **crureus**<sup>2</sup> arises fleshy from the upper two-thirds of the front surface of the femur, commencing below the intertrochanteric ridge, and extending on the outer surface beneath the origin of the external vastus and from the external intermuscular septum adjoining the short head of the biceps. The fleshy fascicles descend, those externally and below being directed more forward, and all terminate in a superficial aponeurosis, which is common to the crureus and internal vastus, and converges and descends beneath the tendon of the rectus to form the deeper portion of the common tendon inserted into the base of the patella.

The inner surface of the femur beneath the internal vastus, except along its line of origin, and the lower third of the front surface beneath the crureus, except at the origin of the subcrureus, are free from muscular attachment.

The **subcrureus**<sup>3</sup> is a fleshy band arising from the lower fore part or the femur beneath the crureus, usually more to the outer side. It descends and terminates on the synovial pouch, which is prolonged from the knee-joint upward beneath the tendon of the quadriceps. It is of variable size, and appears like a detached fascicle of the crureus; from which it is sometimes not distinct. Occasionally it is double, and consists of two lateral portions.

The common tendon of the quadriceps is inserted into the base of the patella, extending upon its sides. The more superficial fibres descend upon the anterior surface of the bone closely adherent to it, and join the ligament of the patella, which is to be regarded as the final insertion of the quadriceps into the tubercle of the tibia. A

<sup>1</sup> M. vastus internus; m. extensor cruris internus.

<sup>2</sup> M. crureus or cruralis.

<sup>3</sup> M. subcrureus or subcruralis; m. articularis genu.



thin expansion from the tendon on each side joins the femoral fascia, and with this is closely connected with the capsular ligament of the knee-joint, and is attached to the head of the tibia.

The fascial tensor is supplied by the superior gluteal nerve; the sartorius and quadriceps by the crural nerve. The quadriceps is the extensor of the leg upon the thigh; the rectus may assist in the flexion of the lower limb. The fascial tensor, besides the action indicated by the name, may assist in the rotation inwardly of the lower limb. The sartorius may assist in the latter movement, or may assist in the flexion of the thigh on the body and of the leg on the thigh. It has been considered to be the chief agent in producing the position assumed by the tailor when sitting at work, whence the name.

#### MUSCLES ON THE INNER FORE PART OF THE THIGH.

The inner side of the thigh is occupied by three adductors, together with the pectineus and gracilis muscles. They form the basis of the triangular space which is traversed by the femoral blood-vessels.

The **gracilis**<sup>1</sup> lies superficially along the inner side of the thigh, and is a long ribbon-like muscle, which arises by an aponeurosis from the pubis along the anterior border of the lower part of the symphysis and the descending ramus. Descending, it tapers below and ends in a narrow tendon, which passes to the inner side of the knee, turns forward, and expands to be inserted into the tibia near its tubercle and beneath the insertion of the tendon of the sartorius. Covered by the femoral fascia, the muscle rests against the short and great adductors. Its tendon crosses the internal lateral ligament of the knee, with a synovial bursa interposed.

The **femoral flexor**, or **ilio-psoas muscle**,<sup>2</sup> in greater part, is situated within the abdomen, and consists of two portions, usually described as the psoas and iliac muscles, the former occupying the side of the loin, the latter the iliac fossa of the hip, uniting and emerging from beneath the femoral arch to be inserted into the femur.

The **psoas muscle**<sup>3</sup> is the large fusiform belly situated at the side of the lumbar vertebræ, from which it arises by five slips attached to the contiguous prominent borders of the centra and intervertebral disks and to intervening thin tendinous arches, which span the constrictions of the centra and give passage to the lumbar vessels and communicating branches of the sympathetic with the lumbar nerves. The first attachment starts from the contiguous borders of the last thoracic and first lumbar vertebræ; the last attachment from the corresponding borders of the lower two lumbar vertebræ. The muscle descends, crosses the brim of the pelvis, and converges to a tendon,

<sup>1</sup> *M. gracilis*; *m. rectus internus*; *m. sub-pubio-pretibialis*

<sup>2</sup> *M. ilio-psoas*; *m. flexor femoris*.

<sup>3</sup> *M. psoas magnus* or *major*; *m. lumbaris* or *m. l. internus*.



which commences within the fleshy belly and appears at its outer side, where it receives the fascicles of the iliac muscle, then emerges beneath the femoral arch, and proceeds to be inserted into the small trochanter of the femur.

The **iliac muscle**<sup>1</sup> is fan-shaped, and arises chiefly from the inner margin of the iliac crest with the adjacent two-thirds of the surface of the iliac fossa reaching to the anterior iliac spines, and by a few fascicles from the ilio-lumbar ligament and contiguous portion of the ala of the sacrum. The fleshy fascicles descend and converge, for the most part to terminate with the psoas tendon of insertion into the small trochanter, some of the outermost fascicles descending to be inserted into the oblique line extending from the latter to the linea aspera.

The psoas commences under the external arcuate ligament of the diaphragm, and rests against the lumbar vertebræ, the quadratus lumbæ muscle, the inner portion of the iliac muscle, and the brim of the pelvis. The iliac muscle rests on the ilium, the origin of the femoral rectus, and the hip-joint, from the capsule of which it usually derives a few fibres. The common tendon passes along the groove between the anterior inferior iliac spine and the ilio-pubic eminence; and between it and the capsule of the hip-joint is a large synovial bursa, which sometimes communicates with the cavity of the joint. The external iliac vessels rest against the inner border of the psoas along the brim of the pelvis, but lie in front of the muscle as they become the femoral vessels. The lumbar plexus of nerves is embedded in the psoas, and its branches emerge at different points of the muscle; the ilio-inguinal and external cutaneous nerves cross over the iliac, and the crural nerve descends in a groove between the latter and the psoas muscle.

The ilio-psoas muscle is the flexor of the hip-joint, or it bends the lower limb on the body or the body on the thigh. It also rotates the limb outwardly, and thus widens the basis of support of the body, which it further contributes to maintain in the erect position. The psoas is supplied by small branches from the lumbar plexus, the iliac muscle by branches of the crural nerve.

More frequently than otherwise, on one or both sides of the body, there exists a muscle, named the **small psoas**.<sup>2</sup> It commonly arises from the contiguous prominent margins of the centra of the last thoracic and first lumbar vertebræ and intervening disk, proceeds outwardly, and after a short distance terminates in a long, flat tendon, which descends in front and on the inner side of the psoas to the brim of the pelvis, to which it is fixed, expanding in the corresponding attachment of the ilio-psoas fascia.

The **pectineus muscle**,<sup>3</sup> flat and quadrate, is situated at the upper

<sup>1</sup> M. iliacus, or m. i. internus.

<sup>3</sup> M. pectineus or pectinalis.

<sup>2</sup> M. psoas parvus or minor.



inner part of the thigh. It arises from the pubis attached to the line extending from the pubic spine to the ilio-pubic eminence, and descends outward and backward to be inserted tendinously into the femur behind the small trochanter and into the contiguous portion of the line directed to the linea aspera. It is placed between the psoas outwardly and the long adductor inwardly, and rests on the external obturator and small adductor muscles. In front it is covered with the femoral fascia, and has the femoral vessels lying upon it.

The **long adductor**,<sup>1</sup> a flat, triangular muscle, lies in the same plane to the inner side of the former. It arises tendinous from the front of the body of the pubis near the angle, descends backward and outward, expanding in its course, and is inserted by a wide, thin tendon into the middle third of the linea aspera, where it is united with the aponeurosis of origin of the internal vastus and the insertion of the great adductor. It rests behind against the small and great adductors, and is covered in front by the femoral fascia, the sartorius, and the gracilis. The femoral vessels rest upon it, and the femoral profunda vessels pass behind it.

The **short adductor**,<sup>2</sup> concealed by the pectineus and long adductor, arises partially tendinous and fleshy from the front of the body and descending ramus of the pubis beneath the former, descends obliquely backward and outward, and is inserted by a wide, thin tendon into the upper part of the linea aspera immediately behind the attachment of the pectineus above and the long adductor below. It rests on the external obturator and great adductor muscles, and has the femoral profunda vessels crossing it in front.

The **great adductor**<sup>3</sup> is a large, triangular muscle forming a partition between the other muscles on the front and back of the thigh. It arises partially tendinous and fleshy from the descending ramus of the pubis beneath the former muscle, and from the ramus and outer and lower fore part of the tuberosity of the ischium. From this origin the coarse, fleshy fascicles diverge outward and downward, successively increasing in length; the upper, shortest, passing almost horizontally outward, the lowest, longest, descending almost vertically, and they terminate in a broad aponeurosis, which is inserted into the great part of the length of the femur, commencing within the insertion of the great gluteal, and below that of the quadratus femoral muscle extending along the linea aspera and the supracondylar ridge to the inner epicondyle. The longest fascicles from the ischial tuberosity form the inner limit of the muscle, and terminate in a thickened, tendon-like border to the aponeurosis of insertion, descending to be fixed to the inner epicondyle of the femur. The aponeurosis along the course of

<sup>1</sup> M. adductor longus; caput longum tricipitis.

<sup>2</sup> M. adductor brevis; caput breve tricipitis.

<sup>3</sup> M. adductor magnus; caput magnum tricipitis.



its attachment to the *linea aspera* is interrupted by three or four apertures, with arching fibres springing from the bone, for the passage of the perforating vessels. Another and larger aperture at the lower third of the aponeurosis is the inferior extremity of a passage, called Hunter's canal, for the transmission of the femoral vessels between the fore and back part of the thigh.

The great adductor is in contact behind with the great gluteal and the flexor muscles, internally with the gracilis, and in front with the short and long adductors and the internal vastus. The femoral profunda vessels descend in front of its insertion into the *linea aspera*, and the sciatic nerve descends behind the muscle.

**Hunter's canal** is situated about the middle of the thigh beneath the sartorius muscle. It is several inches in length, and descends with a slight inclination backward and outward close to the femur. Its posterior wall is formed by the aponeurosis of the great adductor inserted into the *linea aspera*, its outer wall by the connection of the internal vastus with the latter, and its anterior wall by an aponeurosis of transverse fibres springing from the internal vastus and extended inwardly in front of the femoral vessels to the aponeuroses of the long and great adductors.

All the muscles of the group above described are supplied by the obturator nerve. The pectineus also receives a branch from the crural nerve, while that from the former is inconstant. The great adductor also receives a branch from the great sciatic nerve. All the muscles are adductors, but assist in other actions: thus, the pectineus and long and short adductors assist in flexion of the thigh, the inner portion of the great adductor assists in its extension, and the gracilis assists in flexion of the leg.

#### MUSCLES OF THE BUTTOCK.

The thick, rounded prominence of the buttock is composed of the three gluteal muscles. Covered by them are the rotators of the thigh, consisting of the internal obturator and pyriform muscles arising from within the pelvis, and the external obturator, geminus, and quadrate femoral muscles arising from its exterior.

The **great gluteal muscle**,<sup>1</sup> the most superficial and the largest of those of the buttock, is a thick, quadrate, and coarsely-fasciculated mass. It arises partly tendinous and fleshy from a small surface at the outer part of the posterior extremity of the crest of the ilium and the superior curved line below, from the side behind of the lower extremity of the sacrum and of the coccyx, from the great sacro-sciatic ligament, and from the lumbar fascia investing the dorsal extensor in the interval of the sacrum and ilium. From this origin the fascicles proceed obliquely outward and downward, and terminate in a thick

<sup>1</sup> *M. gluteus magnus or maximus.*

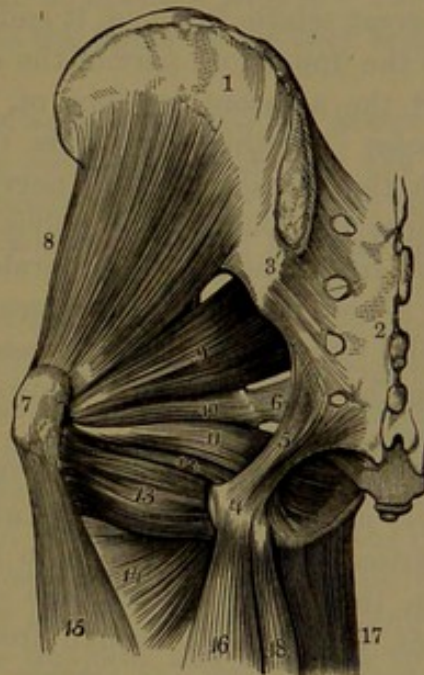


aponeurosis, the upper part of which passes over the great trochanter and merges in the femoral fascia at the outer side of the thigh, while the lower portion converges to be inserted into the roughened line behind the femur, extending from the base of the great trochanter to the linea aspera. The muscle, in great part, rests on the middle gluteal, and its lower portion forming the fold of the buttock covers the small rotators, the ischial tuberosity, the origin of the femoral flexors, and the great trochanter. It also covers the sciatic, pudic, and gluteal vessels and nerves as these emerge from the pelvis. Between the fascial termination and the great trochanter a large multilocular synovial bursa is interposed, or sometimes several smaller ones, and another intervenes between it and the upper part of the external vastus muscle.

The **middle gluteal muscle**,<sup>1</sup> broad, thick, and fan-shaped, is partly situated beneath the former, but in greater part in advance, and covered by a thick portion of the femoral fascia. It arises from the outer margin of the iliac crest and from the sickle-shaped surface below and between the superior and middle curved lines, and from the investing fascia in front. The fleshy fascicles in descending terminate in a strong, flattened tendon, which is inserted into an oblique impression along the outer back border of the great trochanter. A small synovial bursa intervenes between the tendon and the upper part of the latter. The muscle covers the small gluteal, and at its anterior border is usually more or less united with it, and in this position is overlapped by the fascial tensor. The posterior border is in contact with the piriform muscle. The deep branches of the gluteal vessels and the superior gluteal nerve run beneath it.

The **small gluteal muscle**<sup>2</sup> is fan-shaped and situated beneath the preceding muscle. It arises from the dorsum of the ilium between the middle and inferior curved lines, including the upper border of the

FIG. 160.



MUSCLES OF THE BUTTOCK. 1, ilium; 2, sacrum; 3, posterior sacro-iliac ligament; 4, tuberosity of the ischium; 5, great sacro-sciatic ligament; 6, small sacro-sciatic ligament; 7, great trochanter; 8, small gluteal muscle; 9, piriform muscle; 10, 12, geminus muscle, including between its two bellies the termination, 11, of the internal obturator muscle; 13, quadratus femoral muscle; 14, upper part of the great adductor; 15, external vastus muscle; 16, femoral biceps; 17, gracilis; 18, semitendinosus muscle.

<sup>1</sup> M. gluteus medius.

<sup>2</sup> M. gluteus minimus or tertius.



great sciatic foramen, whence it converges and descends to terminate in a superficial aponeurosis narrowing to a strong tendon, which is inserted into an impression at the fore part of the base of the great trochanter. The muscle covers the lower part of the ilium and the upper part of the hip-joint, from the capsule of which its tendon receives a strong fibrous offset. The deep gluteal vessels and superior gluteal nerve cross its surface.

The **pyriform muscle**<sup>1</sup> is situated partly within the back of the pelvis and partly without at the back of the hip-joint. Flat and triangular, it arises in front of the sacrum from the intermediate three segments outside the position of the sacral foramina, slightly from the iliac margin of the great sciatic foramen, and the front surface of the great sacro-sciatic ligament. Converging and passing outward through the great sciatic foramen, it ends in a rounded tendon which is inserted into the upper fore part of the great trochanter, more or less conjoined with the adjacent tendons of the internal obturator and geminus muscles. Within the pelvis the muscle looks towards the rectum, with the sacral plexus of nerves and the internal iliac vessels lying against it. Outside the pelvis it lies on the ilium and over the hip-joint, from which it is separated by the tendon of the small gluteal, and is here covered by the great gluteal muscle. At the upper border of the muscle the gluteal vessels and superior gluteal nerve emerge from the pelvis, and at the lower border the sciatic and internal pudic vessels and nerves.

The **internal obturator muscle**<sup>2</sup> is mainly situated within the pelvis at the front and side, and partly outside behind the hip-joint. It arises within the pelvis, in front and above the obturator foramen, from the contiguous surface of the ramus of the ischium and the pubis, behind the foramen from the upper part of the plane of the ischium and adjacent surface of the ilium extending to the great sciatic foramen, and from the inner surface of the obturator membrane except its lower portion. The fleshy fascicles converge downward and backward, and the muscle emerges from the pelvis through the small sciatic foramen, and ends in a narrow, flat tendon, which is joined by the geminus muscle, and with it is inserted into the fore part of the upper border of the great trochanter. The tendon commences within the muscle in four or five slips uniting in a folded aponeurosis, which plays on the groove at the fore part of the small sciatic foramen. The groove is invested with fibro-cartilage and furnished with a synovial bursa, which is reflected on the folded aponeurosis. Within the pelvis the muscle is covered by the obturator portion of the pelvic fascia, which separates it from the anal elevator, and its lower part is crossed by the pudic vessels and nerve. Outside the

<sup>1</sup> M. pyriformis or pyramidalis; m. iliacus externus.

<sup>2</sup> M. obturator internus.



pelvis its tendon lies on the capsular ligament of the hip-joint, usually with a synovial bursa interposed; is crossed by the sciatic vessels and nerves, and is covered by the great gluteal muscle.

The **geminus muscle**<sup>1</sup> is situated at the back of the hip-joint, embracing the terminal portion of the internal obturator muscle. It consists of a pair of small fleshy bellies conjoined by an aponeurosis under the tendon of the latter, and inserted conjointly with it into the great trochanter. The upper belly,<sup>2</sup> placed above the internal obturator, arises from the back of the spine of the ischium, and proceeds outward to blend with the upper part of the obturator tendon and be inserted with it. The lower belly,<sup>3</sup> larger than the former and placed below the obturator, arises from the upper back part of the tuberosity of the ischium, and in the same manner proceeds outwardly to join the lower part of the obturator tendon and be inserted with it. The two bellies may be separated, and sometimes the upper one is very small or is absent.

The geminus muscle is placed between the pyriform above and the femoral quadrate muscle below, in contact in front with the capsular ligament of the hip-joint, and crossed behind by the same vessels and nerves as the internal obturator, where it is also covered by the great gluteal muscle.

The **external obturator muscle**<sup>4</sup> is situated at the fore part of the pelvis extending outward behind the hip-joint, and is concealed in front by the heads of the muscles at the inner part of the thigh. It arises from the outer surface of the conjoined rami of the ischium and pubis, from the body of the latter contiguous to the obturator foramen, and from the outer surface of the anterior half of the obturator membrane. The fleshy fascicles converge and proceed outward between the acetabulum and tuberosity of the ischium, and terminate in a tendon which passes behind the hip-joint and the neck of the femur to be inserted into the fossa at the base of the great trochanter. The muscle is in contact with the ilio-psoas, pectineus, and great adductor muscles, and approaching its insertion is covered behind by the femoral quadrate muscle.

The **femoral quadrate muscle**<sup>5</sup> is situated at the back of the hip-joint, covered by the lower border of the great gluteal muscle. It arises along the outer border of the tuberosity of the ischium, and proceeds horizontally outward to be inserted into a line of the femur descending a short distance from the posterior intertrochanteric ridge. It is placed immediately below the geminus muscle, and its lower border reaches the upper border of the great adductor. In front of

<sup>1</sup> M. gemini or gemelli; m. marsupialis; m. ischio-spini-trochanterius; geminus muscle.

<sup>2</sup> M. geminus or gemellus superior.

<sup>3</sup> M. geminus or gemellus inferior.

<sup>4</sup> M. obturator externus; external obturator muscle.

<sup>5</sup> M. quadratus femoris.



it is the tendon of the external obturator, the small trochanter, and the hip-joint, and behind, it is crossed by the sciatic nerves and vessels.

The great gluteal muscle is supplied by the inferior gluteal nerve; the middle and small gluteal, and fascial tensor muscles by the superior gluteal nerve. The pyriform, internal obturator, geminus, and quadrate femoral muscles are supplied by branches from the sacral plexus; and the external obturator muscle by the obturator nerve.

The great gluteal muscle is remarkable for its large size in comparison with that of quadrupeds, and is related with the erect condition of the body. It is the principal extensor of the hip, and by its agency the lower limb is brought into the line of the body. Its most powerful action is to extend the trunk when this is bent forward; but in the erect condition the body maintains its position chiefly through tension of the ligaments, while it is balanced with the centre of gravity slightly behind a vertical plane passing through the middle of the hip-joint. The upper part of the muscle may assist in abduction of the thigh, while the lower part acts as an adductor and as a rotator outwardly. Through the connection of the muscle with the thickest portion of the femoral fascia extended to the tibia, it also serves to steady the knee in standing. The middle and small gluteal muscles are powerful abductors of the thigh aided by the fascial tensor, and together they rotate the limb inwardly. They come especially into action in walking, in the support of the body on one limb, and in the rotation of the pelvis on the two limbs alternately. The fascial tensor, from its mode of termination in the thickest portion of the femoral fascia extended to the tibia, aids the great gluteal in steadying the knee when standing. The pyriform, internal obturator and geminus, external obturator, and quadrate femoral muscles are all rotators of the lower limb outward, in which they may be assisted by the lower portion of the small gluteal muscle. They also act together as abductors of the thigh; but the latter two may aid in adduction and the last one in flexion.

#### MUSCLES OF THE BACK OF THE THIGH.

The fleshy mass at the back of the thigh is composed of three flexors of the leg,—the femoral biceps, semitendinosus, and semimembranosus muscles.

The **femoral biceps**<sup>1</sup> is situated at the outer side of the fleshy mass at the back of the thigh, and consists of two portions or heads. The **long head**<sup>2</sup> is fusiform, and arises by a strong tendon in common with the semitendinosus from the lower impression behind the ischial tuberosity, whence its fleshy fascicles descend and terminate in an aponeurosis at the lower back part of the muscle. The **short head**,<sup>3</sup> lying beneath the lower part of the former, is lozenge-shaped, and

<sup>1</sup> M. biceps flexor cruris; m. flexor cruris externus or fibularis; m. biceps femoris.

<sup>2</sup> Caput longum bicipitis.

<sup>3</sup> C. brevi bicipitis.

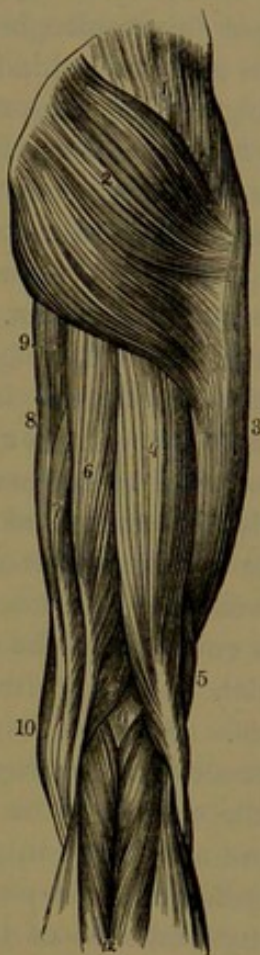

arises from the outer margin of the linea aspera and greater part of the outer supracondylar ridge and adjacent intermuscular septum, whence the fascicles descend obliquely outward and terminate in the posterior aponeurosis. This narrows into a strong tendon, which is inserted into the outer part of the head of the fibula, dividing into two portions, which embrace the external lateral ligament of the knee-joint, giving an offset forward to the outer tuberosity of the tibia and a thinner expansion downward to the deep fascia of the leg.

The upper part of the biceps is covered by the great gluteal muscle, but elsewhere is subcutaneous. It rests against the semimembranosus, great adductor, and external vastus, and covers the great sciatic nerve. Its inner border is in contact with the semitendinosus and semimembranosus, and its lower extremity forms the outer boundary of the popliteal space. A bursa is commonly interposed between its tendon and the external lateral ligament of the knee, and sometimes another between the origin of the long head and that of the semimembranosus.

The **semitendinosus**<sup>1</sup> is situated at the inner side of the former, and arises from the ischial tuberosity, and from the tendon common to it and the biceps for about three inches, whence its fusiform belly descends and gradually diverges from the biceps, and below the middle of the thigh terminates in a long, narrow tendon. This proceeds along the inner side of the popliteal space, resting on the semimembranosus, to the knee, where it turns forward around the inner tuberosity of the tibia and expands to be inserted into the latter near its tubercle, below the insertion of the gracilis and beneath that of the sartorius, giving an expansion downward to the deep fascia of the leg. A synovial bursa is interposed between the three tendons just indicated and the internal lateral ligament of the knee-joint. The belly of the

FIG. 161.



MUSCLES OF THE BACK OF THE RIGHT BUTTOCK AND THIGH. 1, middle gluteal muscle; 2, great gluteal muscle; 3, external vastus, covered by the femoral fascia; 4, long head of the femoral biceps; 5, its short head; 6, semitendinosus, and 7, semimembranosus muscles; 8, gracilis; 9, inner border of the great adductor; 10, lower extremity of the sartorius; 11, popliteal space; 12, gastrocnemius.

<sup>1</sup> M. semitendinosus; m. ischio-pretibialis.



muscle is commonly crossed about its middle by a thin tendinous intersection.

The muscle is covered at its origin by the great gluteal, and elsewhere is subcutaneous. By its deep surface it is in contact with the semimembranosus, great adductor, and inner head of the gastrocnemius muscles.

The **semimembranosus**<sup>1</sup> is situated at the inner side of the preceding muscles, between them and the great adductor. It arises from the upper impression behind the ischial tuberosity by a strong tendon, which is grooved behind to accommodate the common tendon of the adjacent flexors. The tendon descends and expands in an aponeurosis, from which the fleshy fascicles of the muscle proceed obliquely downward and inward and terminate in another aponeurosis, which faces the muscle inwardly, and narrows into a stout tendon descending at the inner side of the knee to be inserted into the back part of the inner tuberosity of the tibia. From the tendon of insertion proceed three considerable offsets, of which one extends to the groove of the tibia beneath the internal lateral ligament of the knee-joint; the second reinforces the capsular ligament of the latter, and is directed upward and outward to be inserted into the outer condyle of the femur; and the third descends and expands as the popliteal fascia.

The semimembranosus rests against the great adductor, with the great sciatic nerve descending behind along its outer border. Its upper part is covered by the conjoined biceps and semitendinosus, the latter of which lies on it its whole length; and below it is partially subcutaneous. Between its tendon of insertion and the inner head of the gastrocnemius is a large synovial bursa, which commonly communicates with the cavity of the knee-joint. Another bursa intervenes between the tendon and the upper margin of the inner tuberosity of the tibia.

The femoral biceps, semimembranosus, and semitendinosus are supplied by branches of the great sciatic nerve. They are flexors of the leg upon the thigh, and when the lower limbs are fixed in position they are extensors of the trunk and sustain the pelvis on the thighs. When the knee is bent, the biceps slightly rotates the leg outward; the other muscles in the opposite direction.

The flexors of the thigh are also called the hamstring muscles; the tendon of insertion of the biceps being the outer hamstring, while those of the semitendinosus and semimembranosus, together with those of the sartorius and gracilis, are called the inner hamstrings.

#### FASCIÆ OF THE LEG AND FOOT.

The **deep fascia of the leg**, or the **crural fascia**,<sup>2</sup> is an aponeurotic membrane investing the muscles of the leg, to which it is loosely attached, except where some of them have partial origin from its inner

<sup>1</sup> M. semimembranosus; m. ischio-popliti-tibialis.

<sup>2</sup> F. cruralis.



surface. It is tightly attached to all the subcutaneous prominences and borders of the bones, as the heads of the tibia and fibula, the malleoli, and the front and inner borders of the shaft of the tibia, where it is continuous with the periosteum. At the knee it is continuous with the femoral fascia, and is reinforced on the inner side by expansions from the tendons of the sartorius, gracilis, and semitendinosus muscles, and on the outer side by an expansion from the tendon of the femoral biceps muscle. It becomes stronger approaching the ankle-joint, and is continuous with the corresponding fascia of the foot. The fascia is thickest and most aponeurotic in appearance at the fore part of the leg, where it invests the anterior tibialis and long digital extensor muscles, to several of which it gives partial origin above by its inner surface. It is thinnest behind, where it invests the muscles of the calf and crosses the popliteal space. In the latter position it is strengthened by transverse fibres binding the two sides together, and is perforated by the external saphenous vein as it passes forward to join the popliteal vein. On the outer side of the leg it is of intermediate thickness, and invests the peroneal muscles, to which it gives partial origin. In this position, also, it is connected by strong intermuscular septa with the fibula, of which one septum separates the peroneal muscles from those of the front, and the other from those of the back of the leg. Besides other septa extending from the inner surface of the fascia between the muscles, a broad one, extended between the bones at the back of the leg, separates the posterior tibialis and long digital and hallucal flexor muscles from those of the calf.

In front and at the sides of the ankle-joint the deep fascia of the leg and foot are reinforced by bands of fibres forming the annular ligaments.

The **deep fascia at the back of the foot**, or the **dorsal fascia**,<sup>1</sup> is a thin membrane extending from the crural fascia over the extensor tendons to the toes. Thin laminae of the same extend between the latter tendons and the short digital extensor, and also beneath this muscle.

The **plantar fascia**,<sup>2</sup> or **deep fascia of the sole of the foot**, consists of three portions, which unite in intermuscular septa penetrating the sole between the median muscles of the latter and those of the great toe at the inner part and those of the little toe at the outer part of the foot. The inner portion<sup>3</sup> of the plantar fascia, thinner and of looser texture than the other portions, invests the muscles of the great toe, and is connected with the bones along the inner border of the foot, where it is continuous with the dorsal fascia and internal annular ligament. The outer portion<sup>4</sup> of the fascia invests the muscles of the little toe, and is connected with the bones along the outer border of the foot, where it is also continuous with the dorsal fascia. It is for the most part thin, but forms a thick, aponeurotic band, extending between

<sup>1</sup> Aponeurosis dorsalis pedis.

<sup>3</sup> A. plantaris interna.

<sup>2</sup> Aponeurosis plantaris.

<sup>4</sup> A. plantaris externa.



the outer tubercle of the calcaneum and the prominent base of the fifth metatarsal bone, giving partial origin to the minimal abductor. The **middle portion**<sup>1</sup> of the plantar fascia is a strong, dense, white, fan-shaped aponeurosis, chiefly composed of longitudinal radiating fibrous bundles starting from the inner tubercle of the calcaneum and expanding at the fore part of the metatarsus, where it divides into five processes. Each of these divides into two slips, between which the flexor tendons proceed to the toes; and the slips are fixed to each side of the base of the first phalanges and contiguous portion of the transverse metatarsal ligament. The processes of the fascia are intersected by numerous transverse fibres, which serve to strengthen their connection and give them attachment to the adjacent skin. Between the processes the digital vessels and nerves and the tendons of the lumbrical and interosseous muscles pass. On each side, the median plantar fascia joins the lateral portions in the formation of the intermuscular septa, which give partial origin to the contiguous muscles. With these septa are connected thinner ones, which extend horizontally between the muscles. The upper surface of the median plantar fascia gives partial origin behind to the short digital flexor.

The **anterior annular ligament**,<sup>2</sup> situated in front of the ankle-joint and on the back of the foot, is a thickened portion of the crural fascia continuous with the dorsal fascia of the foot. Attached externally to the upper fore part of the calcaneum, it is directed inwardly and divides into two variable, divergent bands, of which the upper, thicker, and more constant proceeds to be attached to the fore part of the internal malleolus, while the other is attached to the inner side of the tarsus, where it is continuous with the plantar fascia. The outer extremity of the ligament forms a passage for the tendons of the long digital extensor and anterior peroneal muscles, provided with a synovial sheath. The inner bands of the ligament form two separate passages for the tendons of the hallucal extensor and anterior tibialis, each provided with a synovial sheath. The anterior tibial vessels and nerve descend beneath the ligament between the position of the long digital extensor tendons and that of the hallucal extensor.

Above the anterior annular ligament a variably broad and strong band<sup>3</sup> of the crural fascia extends obliquely downward from the fibula to the tibia, and serves to confine the tendons before they turn forward to the foot.

The **internal annular ligament**<sup>4</sup> extends from the internal malleolus downward and backward to the inner side of the calcaneum and astragalus, and in its course bridges over several bony grooves and converts them into canals, through which the flexor tendons proceed

<sup>1</sup> Aponeurosis plantaris media.

<sup>2</sup> Ligamentum annulare anterius; l. cruciatum.

<sup>3</sup> L. transversum.

<sup>4</sup> L. annulare internum; l. laciniatum int.



to the sole of the foot. Above, it is continuous with the crural fascia, especially with the intermuscular septum separating the deeper muscles from those of the calf. Below, it is continuous with the plantar fascia, and gives partial origin to the hallucal abductor. Of two canals formed by it behind the internal malleolus, each provided with a synovial sheath, one gives passage to the tendon of the posterior tibialis, and the other to that of the long digital flexor. Then succeeds a space occupied by the posterior tibial vessels and nerve; and then another canal, provided with a synovial sheath, for the passage of the tendon of the long hallucal flexor. This canal is formed by the annular ligament bridging over successive and continuous grooves of the tibia, astragalus, and calcaneum.

The **external annular ligament**,<sup>1</sup> of less strength than the preceding, extends from the end of the outer malleolus to the outer side of the calcaneum, and confines the tendons of the long and short peroneal muscles, both in the same canal, which is provided with a synovial sheath.

#### MUSCLES OF THE INNER FORE PART OF THE LEG AND BACK OF THE FOOT.

The fore part of the leg is occupied in the interval of the tibia and fibula with four muscles, from which tendons proceed to the back of the foot and toes. The muscles are the anterior tibialis, long digital extensor, anterior peroneal, and hallucal extensor. The short digital extensor is placed on the back of the foot.

The **anterior tibialis**<sup>2</sup> is subcutaneous, and rests on the tibia. It is a fusiform muscle, and arises beneath the outer tuberosity of the tibia from the external surface of the shaft for two-thirds its length, from the adjacent portion of the interosseous membrane, from the investing fascia, and from the intermuscular septum between it outwardly and the long digital extensor. The fascicles descend and terminate in a tendon, which appears in front of the muscle at the lower third of the leg, passes through the inner canal of the annular ligament in front of the tibia, and proceeds on the back of the foot to be inserted into the inner and lower part of the entocuneiform bone and the contiguous portion of the base of the first metatarsal bone. The muscle lies in contact outwardly with the long digital and hallucal extensors, with the anterior tibial vessels and nerve between them. Its tendon passes over the ankle-joint and the inner surface of the tarsus.

The **long digital extensor**<sup>3</sup> is a flat, semipenniform muscle, which lies to the outer side of the former next the fibula. It is also subcutaneous, and arises from the outer tuberosity of the tibia, the head of the fibula and its anterior surface for about three-fourths of its length,

<sup>1</sup> L. annulare externum; l. laciniatum ext.

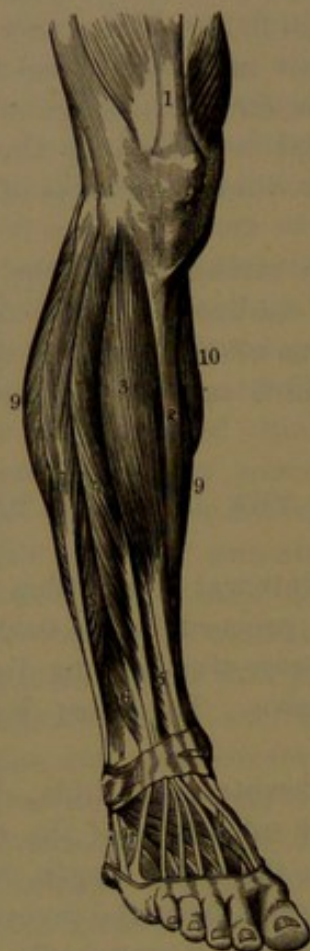
<sup>2</sup> M. tibialis anticus; anterior tibial muscle; m. hippicus.

<sup>3</sup> M. extensor longus digitorum pedis; m. ext. digitorum communis longus.



from the adjacent portion of the interosseous membrane above, from the intermuscular septa between it and the anterior tibialis and peroneal muscles, and from the investing fascia. Its fascicles descend obliquely forward and terminate in three tendons, and later, by the division of

FIG. 162.



MUSCLES OF THE FRONT OF THE LEG AND BACK OF THE FOOT. 1, tendon of the femoral rectus; 2, subcutaneous inner surface of the tibia; 3, anterior tibialis muscle; 4, long digital extensor; 5, hallucal extensor; 6, anterior peroneal muscle; 7, long peroneal muscle; 8, short peroneal muscle; 9, borders of the soleus; 10, border of the inner belly of the gastrocnemius; 11, short digital extensor, beneath the tendons of the long extensor.

them. It arises from the middle half of the deeper part of the anterior surface of the fibula and the adjacent portion of the interosseous membrane, descends the leg, becoming superficial below, and terminates at its fore part in a tendon which passes through a distinct canal

the outer one, in four, which pass beneath the outer part of the anterior annular ligament to the back of the foot, where they diverge to the lesser toes, on which they terminate in the same manner as do the extensor tendons of the fingers. The muscle lies in contact outwardly with the peroneal muscles. Its tendons cross the ankle-joint, and on the back of the foot spread over the short digital extensor.

The **anterior peroneal muscle**<sup>1</sup> is placed below the former, and appears as a continuation of it, arising from the remainder of the shaft of the fibula, the contiguous portion of the interosseous membrane, and the intermuscular septum outwardly between it and the short peroneal muscle. Its fleshy fascicles continue the course of those of the preceding muscle, and terminate at its fore part in a tendon which descends beneath the annular ligament in company with those of the long digital extensor, and diverges from them to be inserted into the base of the last metatarsal bone. The muscle is variable, is sometimes much larger, and extends higher, and is sometimes much smaller, and occasionally absent.

The **hallucal extensor**<sup>2</sup> is a thin triangular muscle situated between the anterior tibialis and long digital extensor, and for the most part concealed by

<sup>1</sup> M. peroneus tertius or anticus.

<sup>2</sup> M. extensor proprius pollicis pedis; m. ext. proprius hallucis; m. ext. hallucis longus.



of the anterior annular ligament between the tendons of the anterior tibialis and long digital extensor, and proceeds along the inner side of the back of the foot to be inserted into the base of the terminal phalanx of the great toe. In the leg the muscle is in contact inwardly with the anterior tibialis and the anterior tibial vessels, and outwardly with the long digital extensor.

The **short digital extensor**<sup>1</sup> lies on the back of the foot, and is a broad, thin muscle, which consists of four penniform bellies, on the same plane, arising together tendinously from the outer fore part of the calcaneum and the contiguous portion of the anterior annular ligament. Directed forward and inward, the bellies terminate in as many tendons, of which the first proceeds to the great toe and joins that of the hallucal extensor in its insertion into the terminal phalanx, while the others proceed in the same manner to the succeeding three toes and join the corresponding tendons of the long digital extensor. The muscle lies somewhat obliquely on the tarsus and metatarsus, beneath the tendons of the long digital extensor and anterior peroneal muscles. Its inner division crosses the dorsal pedal vessels and the anterior tibial nerve.

All the above muscles are supplied by the anterior tibial nerve. The anterior tibialis and anterior peroneal muscles are flexors of the foot; the action of the others is indicated by the names.

#### MUSCLES ON THE OUTER PART OF THE LEG.

Two muscles, the long and short peroneal, occupy the outer part of the leg, covering the fibula, and placed between the muscles of the front and back of the leg.

The **long peroneal muscle**,<sup>2</sup> the larger and more superficial, arises from the head and upper two-thirds of the outer surface of the fibula, from the intermuscular septa between it and the muscles in front and behind the leg, and from the investing fascia. Its fleshy fascicles descend and converge to a long tendon appearing at the lower outer part of the muscle, and thence passing through the canal of the external annular ligament behind the outer malleolus, where it turns forward and downward to the outer side of the calcaneum and cuboid bone, bound to the former by the fore part of the external annular ligament. It then turns inward beneath the cuboid bone, through the canal between it and the long plantar ligament, and proceeds obliquely forward across the sole of the foot to be inserted into the outer part of the base of the first metatarsal bone. Thus the tendon makes two turns in its course, and at the second exhibits a fibro-cartilaginous thickening, which plays on the tubercle of the cuboid bone. Rarely, in this position, it contains an osseous nucleus, a little sesamoid bone.

---

<sup>1</sup> M. extensor brevis digitorum pedis; pedal muscle.

<sup>2</sup> M. peroneus longus; m. p. l. lateralis.



In the canal behind the external malleolus the tendon is accompanied by that of the short peroneal muscle, both being enveloped in a synovial sheath, which extends on the long peroneal tendon in the canal at the outer side of the calcaneum. Another synovial sheath envelops the tendon in the canal beneath the cuboid bone.

In the leg the long peroneal muscle is subcutaneous; its upper part lying between the long digital extensor in front and the soleus and long hallucal flexor behind; and its lower part lies behind on the short peroneal muscle. Near its origin above, it is interrupted for a short distance in its attachment to the fibula for the passage of the peroneal nerve beneath the muscle.

The **short peroneal muscle**<sup>1</sup> lies beneath the preceding, and arises from the lower two-thirds of the outer surface of the fibula and the intermuscular septum on each side. Descending, it terminates in a tendon which runs in front of that of the long peroneal, and accompanies it through the canal behind the external malleolus. Thence it turns forward and downward on the outer side of the calcaneum, to which it is bound by the external annular ligament in a separate canal above that of the long peroneal tendon, and proceeds to be inserted into the dorsal surface of the projection of the base of the fifth metatarsal bone. The synovial sheath investing the tendons of both peroneal muscles behind the outer malleolus is extended in a separate process upon that of the short peroneal in the canal on the outer side of the calcaneum.

The muscle in front is in contact with the long digital extensor and anterior peroneal; behind, with the long peroneal and the long hallucal flexor.

The long and short peroneal muscles are supplied by the musculocutaneous branch of the peroneal nerve. They are extensors of the foot. The three peroneal muscles and the extensors of the toes together extend and evert the foot.

#### MUSCLES ON THE BACK OF THE LEG.

The muscles of the back of the leg consist of a superficial and a deep group. The former compose the calf of the leg, which is one of the striking characters of the human muscular apparatus, and is related with the erect position and mode of progression of man. The chief muscles, the gastrocnemius and the soleus, with the former divided into two portions or heads, terminate in a common tendon, whence they are also regarded as one muscle, with the name of the **sural triceps**.<sup>2</sup> The remaining muscle, the plantaris, is very small, and appears to be a mere rudimental representative of a more important muscle in some lower animals. The muscles of the deep group in-

<sup>1</sup> M. peroneus brevis; m. p. b. lateralis.

<sup>2</sup> M. triceps suræ; m. extensor pedis.



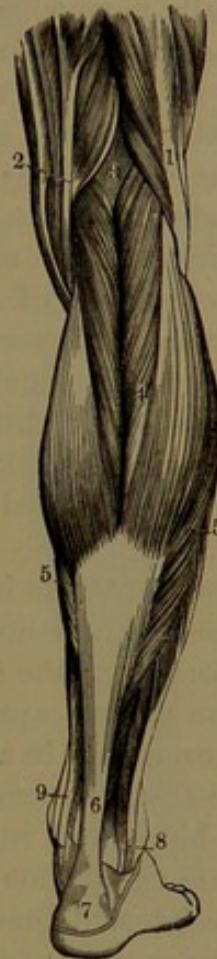vested with a layer of fascia beneath the former, are the popliteus, the posterior tibialis, and the long digital and hallucal flexors.

The **gastrocnemius**,<sup>1</sup> the subcutaneous muscle of the calf, is composed of a pair of elliptical fleshy bellies or heads arising tendinously from the rough impressions behind the femur above the condyles, over which they converge and descend side by side to terminate in the aponeurosis of insertion. The tendons of origin expand in superficial aponeuroses behind the bellies, from which the fleshy fascicles spread obliquely forward and downward and terminate in the aponeurosis of insertion which faces the bellies together in front. The descending aponeurosis leaves the bellies, about the middle of the leg, gradually narrows, thickens, and unites with that of the soleus muscle to form the common tendon, named the **tendon of Achilles**. The inner head is the larger, arises by a thicker tendon, and descends lower; the outer head also partially arises from the contiguous portion of the capsular ligament of the knee-joint.

The gastrocnemius covers the plantaris, popliteus, and soleus muscles. Its heads proceed backward and downward from between the hamstring muscles and from the lateral boundaries of the lower part of the popliteal space. Approaching each other, they conceal the popliteal vessels and nerve. The outer head covers the origin of the plantaris, which lies to its inner side between it and the capsule of the knee; and is crossed externally by the biceps, with the peroneal nerve passing between them. Beneath the inner head and the inner condyle of the femur a synovial bursa is interposed, commonly communicating with the cavity of the knee-joint; and externally it is crossed by the tendons of the semimembranosus and semitendinosus muscles.

The **soleus**, situated under or in front of the former, is a broad, flat muscle, named from its resemblance in outline to a sole-fish. It arises tendinously from behind the head of the fibula and the upper

FIG. 163.



SUPERFICIAL MUSCLES ON THE BACK OF THE RIGHT LEG. 1, femoral biceps; 2, tendons of the semitendinosus, semimembranosus, gracilis, and sartorius; 3, popliteal space; 4, gastrocnemius; 5, soleus; 6, tendon of Achilles; 7, calcaneum; 8, tendons of the long and short peroneal muscles passing behind the outer ankle; 9, tendon of the posterior tibialis muscle and long digital flexor passing behind the inner ankle.

<sup>1</sup> M. gemellus suræ.



third of its shaft, from the oblique line of the tibia below the popliteus, and from the middle third of the inner back border of that bone, with a few fascicles from a tendinous arch which spans the popliteal vessels and nerve between the bones. The fleshy fascicles descend obliquely backward and converge to an aponeurosis facing the muscle behind, gradually narrowing, becoming thicker, and uniting with that of the gastrocnemius to form the deeper part of the tendon of Achilles. The fleshy fascicles are numerous and short, and continue to terminate in the latter within a short distance of the heel.

The soleus rests against the posterior tibialis and the long digital and hallucal flexors, with the posterior tibial vessels and nerve descending between them and covered by the deep fascia.

The **tendon of Achilles**,<sup>1</sup> the thickest of all tendons, is formed by the union of the terminal aponeuroses of the gastrocnemius and soleus. Broad at its commencement, it narrows to a flattened cylindrical cord, which again slightly expands on the heel, and is inserted into the middle of the back surface of the tuberosity of the calcaneum. A bursa is interposed between the tendon and the upper part of the latter.

The **plantaris** is a small fusiform muscle, two or three inches long, situated at the inner side beneath the outer head of the gastrocnemius. It arises from the femur beneath the latter, and from the contiguous portion of the capsule of the knee-joint, on the back of which it lies, and terminates in a long, slender tendon which descends obliquely between the gastrocnemius and soleus to the inner margin of the tendon of Achilles, and runs along this to the heel. It ends variably, sometimes in the tendon of Achilles, the adjacent portion of the deep fascia, or the internal annular ligament. The muscle is frequently absent.

The muscles of the calf are supplied by branches from the popliteal nerve. They lift the heel and raise the body on the toes as in walking. The gastrocnemius may also act as a flexor of the leg.

The **popliteus**, a flat, triangular muscle, is situated below the back of the knee-joint, covered by the gastrocnemius. It arises by a rounded tendon from the lower part of the grooved surface on the outer side of the external condyle of the femur, under the capsular and external lateral ligaments of the knee-joint, and partly, also, from the capsule. Turning around the groove behind the outer tuberosity of the tibia, between it and the head of the fibula, the fleshy fascicles thence diverge, and are inserted into the inner two-thirds of the triangular surface at the upper back part of the tibia and into an investing fascia. The tendon of origin lies between the external lateral ligament and the contiguous semilunar cartilage of the knee invested by the synovial membrane, which is prolonged from the joint upon the tendon behind the outer tuberosity of the tibia. The fascia investing the

---

<sup>1</sup> Tendo Achillis.



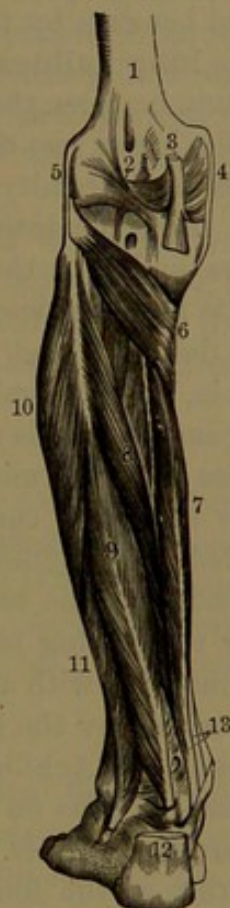muscle and attached to the contiguous bony margins is a thin aponeurosis, mainly an expansion derived from the tendon of insertion of the semimembranosus.

The popliteus is supplied by a branch from the popliteal nerve. It is the only muscle which operates on the knee-joint alone, and rotates the leg inwardly in flexion, in which latter it also assists. In the extended condition of the leg the tendon of origin lies below the groove of the femur, and occupies it only when the leg is flexed.

The remaining three muscles extend down the leg, below the former, into the foot, and are closely invested by a deep layer of the femoral fascia which separates them from the soleus and is attached to the adjacent bony boundaries.

The **long digital flexor**,<sup>1</sup> the innermost of the group of deep longitudinal muscles, lies on the tibia. It arises from the intermediate half of the posterior surface of the tibia commencing below the popliteus, and partially from a thin aponeurosis covering the posterior tibialis and attached to the inner border of the fibula. The fleshy fascicles pass obliquely downward and converge to a posterior tendon, which descends and passes through a canal behind the inner malleolus. Thence directed obliquely forward and outward beneath the arch of the calcaneum into the sole of the foot, it divides into four tendons, which diverge to the lesser toes and proceed to be inserted into the bases of their terminal phalanges. Behind the inner malleolus the tendon is accompanied by that of the posterior tibialis, but through a separate canal invested with a distinct synovial sheath. Before dividing the tendon receives a strong offset from the contiguous tendon of the long hallucal flexor, then expands, and is further reinforced by the insertion of the accessory flexor of the sole of the foot. Opposite the first phalanges each tendon passes through a slit in the

FIG. 164.



DEEP MUSCLES OF THE BACK OF THE LEG. 1, femur; 2, posterior portion of the capsular ligament; 3, tendon of the semimembranosus muscle inserted into the head of the tibia, and giving an offset to the capsular ligament; 4, 5, internal and external lateral ligaments; 6, popliteus muscle; 7, long digital flexor; 8, posterior tibialis; 9, long hallucal flexor; 10, 11, long and short peroneal muscles; 12, tendon of Achilles; 13, tendons of the long digital flexor and posterior tibialis muscles, just before passing beneath the internal annular ligament.

<sup>1</sup> M. longus digitorum pedis; m. digitorum communis longus; m. flexor perforans; long or common flexor of the toes.



corresponding tendon of the short digital flexor, which also occupies the sole of the foot.

In the leg the long digital flexor lies on the tibia and the posterior tibialis muscle, which it crosses below. Above, it is covered by the soleus, and below is subcutaneous. The posterior tibial vessels and nerve descend on it, covered by the investing fascia. In the foot its tendon crosses beneath that of the long hallucal flexor, and it is covered beneath by the hallucal abductor and short digital flexor.

The **long hallucal flexor**,<sup>1</sup> the largest muscle of the group, lies on the fibula between the peroneal and posterior tibialis muscles. It arises from the lower two-thirds of the posterior surface of the fibula, except its inferior extremity, from the lower portion of the interosseous membrane, from the intermuscular septum between it and the peroneal muscles, and from the aponeurosis covering the posterior tibialis muscle. Its fascicles descend obliquely and converge to a posterior tendon, which descends and passes through a canal behind the lower end of the tibia, the astragalus, and beneath the sustentacle of the calcaneum, and thence proceeds along the inner side of the sole to be inserted into the base of the terminal phalanx of the great toe. The canal traversed by the tendon is completed by the internal annular ligament, and is provided with a synovial sheath. In the sole, as it passes forward above the tendon of the long digital flexor, it commonly gives the latter a strong reinforcing offset. In the great toe it is enclosed in a digital canal invested with a synovial sheath. In the leg the muscle is in great part covered by the soleus, but is subcutaneous outside the position of the tendon of Achilles, and is in contact externally with the peroneal muscles. It rests on the fibula and posterior tibialis muscle, and covers the peroneal vessels. Behind the ankle-joint the tendon is separated from that of the long digital flexor by an interval occupied by the posterior tibial vessels and nerve. In the foot it is covered by the hallucal adductor, and proceeds between the heads of the short hallucal flexor. The offset to the long digital flexor is variable in size, and sometimes joins the tendons after the division of the chief one.

The **posterior tibialis**,<sup>2</sup> placed between and beneath the two preceding muscles, arises from the posterior surface of the tibia, from the popliteal line to about its middle, beneath the origin of the long digital flexor, from the inner surface of the fibula, and from the posterior surface of the interosseous membrane, except its lower portion, and by a few fascicles from the investing fascia. The fleshy fascicles pass obliquely downward, and converge to a tendon which descends along the inner back border of the muscle, and passes through a canal behind the internal malleolus. Thence the tendon is directed forward through

---

<sup>1</sup> *M. flexor longus pollicis pedis*; *m. flexor hallucis longus*; long flexor of the great toe.

<sup>2</sup> *M. tibialis posticus*; *m. nauticus*.



a canal over the internal lateral ligament of the ankle-joint and the internal calcaneo-scaphoid ligament, and is inserted into the prominence beneath of the scaphoid and entocuneiform bones, giving offsets to the other cuneiform bones, the cuboid bone, and the bases of the intermediate metatarsal bones.

In the leg the posterior tibialis muscle lies on the interosseous membrane of the fibula and tibia. Its lower part crosses the tibia obliquely beneath the long digital flexor, with its tendon passing from in front to the inner side of the tendon of the latter, enclosed in a separate canal behind the internal malleolus, and invested with a synovial sheath, which extends into the canal at the inner side of the ankle and communicates with the calcaneo-scaphoid articulation.

The above muscles are supplied by branches of the posterior tibial nerve. The long digital and hallucal flexors, as indicated, are flexors of the toes, but continuing their action become extensors of the foot. The posterior tibialis, with the peroneal muscles, is also an extensor of the foot.

#### MUSCLES OF THE FOOT.

On the back of the foot, besides the tendons continued from the muscles on the fore part of the leg, there are the short digital extensor and four dorsal interosseous muscles. In the sole there are numerous muscles, besides the tendons of the long flexors, forming groups, as those of the middle of the sole, those of the great toe and of the little toe, and the three plantar interosseous muscles.

The **short digital extensor**. See page 335.

**Median plantar muscles.** The **short digital flexor**<sup>1</sup> occupies the middle of the sole, covered by the plantar fascia. It arises in a pointed manner from the fore part of the inner tubercle of the calcaneum, from the plantar fascia, and from the intermuscular septum on each side. Expanding forward, it divides into four portions, terminating in as many tendons, which diverge and proceed to the lesser toes to be inserted into the second phalanges, each tendon being split for the passage of the corresponding tendon of the long digital flexor.

The arrangement of the tendons of the short and long digital flexors, their relation with the attachment of other muscles, and their confinement in digital canals, are the same as in the flexor tendons of the fingers already described.

The **accessory flexor**<sup>2</sup> is covered by the preceding. It arises by two heads, of which the inner larger one comes from the inner concave surface of the calcaneum and contiguous portion of the calcaneo-scaphoid ligament, while the outer one springs tendinously from the calcaneum in front of its inner tubercle and from the long plantar ligament. Advancing, the two heads unite, and the muscle proceeds

<sup>1</sup> M. flexor brevis digitorum; m. flexor perforatus; short flexor of the toes.

<sup>2</sup> M. flexor accessorius; caro quadrata Sylvii; massa carnea Jacobi Sylvii.

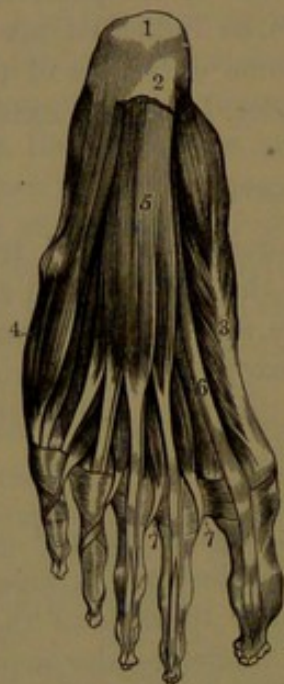

to be inserted into the upper surface and outer border of the tendon of the long digital flexor. The outer head is sometimes absent.

The **lumbrical muscles**,<sup>1</sup> like those of the hand, have similar relations and connections. They arise from the tendons of the long digital flexor: the outer three from the contiguous sides of the tendons; the inner one from the inner side of the corresponding tendon. Proceeding forward, they terminate in narrow tendons, which expand and join the extensor tendons on the back of the toes at the inner side of the first phalanges.

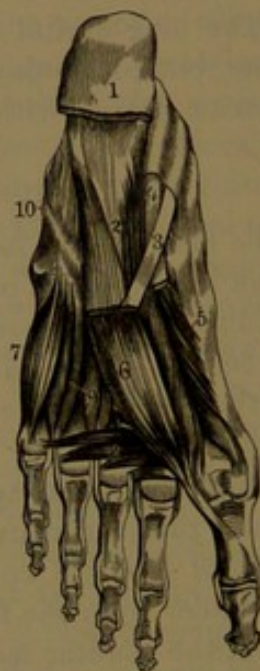**Muscles of the great toe.** Of these there are four, mainly forming the fleshy prominence on the inner side of the sole.

FIG. 165.



MUSCLES OF THE SOLE OF THE FOOT. 1, calcaneum; 2, posterior extremity of the plantar fascia; 3, hallucal abductor; 4, minimal abductor; 5, short digital flexor; 6, tendon of the long hallucal flexor; 7, insertion of the lumbrical muscles, which are seen to the right of the tendons of the short digital flexor.

FIG. 166.



DEEP MUSCLES OF THE SOLE. 1, attachment of the plantar fascia and short digital flexor; 2, accessory flexor; 3, tendon of the long digital flexor; 4, tendon of the long hallucal flexor; 5, two heads of the short hallucal flexor; 6, hallucal adductor; 7, minimal flexor; 8, hallucal transversalis muscle; 9, interosseous muscles; 10, course of the tendon of the long peroneal muscle, seen through the long plantar ligament.

The **hallucal abductor**<sup>2</sup> lies superficially along the inner border of the sole. It arises from the inner tubercle of the calcaneum, the internal annular ligament of the ankle, the intermuscular septum between it and the short digital flexor, and from the investing plantar fascia. The fascicles advance and converge to a tendon which proceeds

<sup>1</sup> M. lumbricales.

<sup>2</sup> M. abductor pollicis pedis; m. abductor hallucis; abductor muscle of the great toe.



forward, is joined by the contiguous head of the short digital flexor, and is inserted into the inner part of the base of the first phalanx of the great toe. Its deep surface is in contact with the tendons of the posterior tibialis and long flexor muscles, and with the plantar vessels and nerves.

The **short hallucal flexor**<sup>1</sup> lies at the inner side of the metatarsus, covered by the preceding muscle. It arises by a tendinous process from the inner border of the cuboid bone and by an offset from the posterior tibialis tendon inserted into the adjacent portion of the ectocuneiform bone. It forms two muscular bellies, which proceed together and terminate in tendons, of which the inner joins that of the hallucal abductor and the outer one the hallucal adductor to be inserted into the sides of the base of the first phalanx of the great toe. The sesamoid bones are embedded in the tendons of insertion, and play on the lateral articular surfaces of the head of the metatarsal bone. The tendon of the long hallucal flexor lies between the two portions of the short flexor.

The **hallucal adductor**<sup>2</sup> lies beneath the metatarsus to the outer side of the former. It arises from the bases of the intermediate metatarsal bones and from the long plantar ligament sheathing the long peroneal tendon, and proceeds obliquely forward and inward to unite with the outer tendon of the short hallucal flexor in its insertion into the first phalanx of the great toe.

The **hallucal transverse muscle**<sup>3</sup> is placed at the fore part of the metatarsus above the flexor tendons. It arises by fleshy fascicles from the inferior metatarso-phalangeal ligaments of the outer three toes and from the transverse metatarsal ligament, and proceeds directly inward to be inserted tendinously, in conjunction with the hallucal adductor, into the base of the first phalanx of the great toe. The fascicle from the little toe is sometimes absent.

**Muscles of the little toe.** Of these there are two, lying along the inner side of the sole of the foot.

The **minimal abductor**<sup>4</sup> is subcutaneous at the outer part of the sole. It arises from the outer tubercle of the calcaneum and from the bone in advance of both tubercles, from the adjacent intermuscular septum, and from a strong band of investing fascia extended from the calcaneum to the base of the last metatarsal bone. Thence the fascicles advance and converge to a tendon, which glides over a smooth depression beneath the base of the last metatarsal bone, and proceeds to be inserted into the outer part of the base of the first phalanx of

<sup>1</sup> M. flexor brevis pollicis pedis; m. flexor brevis hallucis; short flexor muscle of the great toe.

<sup>2</sup> M. adductor pollicis pedis; m. adductor hallucis; adductor muscle of the great toe.

<sup>3</sup> M. transversus pedis; caput breve or transversum adductoris hallucis.

<sup>4</sup> M. abductor minimi digiti; m. abductor digiti quinti.



the little toe. The deep surface of the muscle lies in contact with the outer head of the accessory flexor, the minimal flexor, the long plantar ligament, and the long peroneal tendon.

The **minimal flexor**<sup>1</sup> lies at the outer part of the metatarsus above the preceding. It arises tendinously from the base of the fifth metatarsal bone and the adjacent portion of the long plantar ligament, and proceeds forward to be inserted by a tendon into the outer part of the base of the first phalanx of the little toe. Not unfrequently some of its fascicles are inserted into the outer fore part of the metatarsal bone.

The **interosseous muscles**<sup>2</sup> accord in number, relative position, and attachments with those of the hand.

The **dorsal interosseous muscles**<sup>3</sup> are penniform, and occupy the intervals of the metatarsal bones on the back of the foot. Each arises from the adjacent sides of the metatarsal bones, and proceeds forward, terminating in a tendon, which is inserted into the base of the first phalanx and into the extensor tendon on the back of the latter. The first two are inserted on each side of the second toe, the others on the outer side of the third and fourth toes. At the proximal end of each muscle is an angular interval, which gives passage to the communicating blood-vessels.

The **plantar interosseous muscles**<sup>4</sup> arise from the lower and inner surfaces of the third, fourth, and fifth metatarsal bones, and are inserted in the same manner as the preceding muscles into the first phalanges and the extensor tendons on the inner side of the corresponding toes.

Of the muscles of the sole of the foot, the short digital flexor, the hallucal abductor and short flexor, and the inner two lumbrical muscles are supplied by the internal plantar nerve; all the others, including the interossei, are supplied by the external plantar nerve.

---

<sup>1</sup> *M. flexor brevis minimi digiti*; *m. flexor brevis digiti quinti*.

<sup>2</sup> *M. interossea pedis*.

<sup>3</sup> *M. i. dorsales*.

<sup>4</sup> *M. i. plantares*.



## CHAPTER VI.

### GENERAL COMPOSITION OF THE SKIN, THE MUCOUS MEMBRANES, THE GLANDS, THE LUNGS, THE SEROUS AND SYNOVIAL MEMBRANES, AND THE LINING OF THE VASCULAR SYSTEM.

MANY parts of the body are composed of similar anatomical elements, arranged in the same relative position. They are chiefly the skin, the mucous membranes, the glands, the lungs, the serous and synovial membranes, and the lining of the vascular system. The anatomical elements are a cellular structure, of one or more layers, resting on a basis which is commonly composed of fibro-connective tissue, with blood-vessels, lymphatics, and nerves.

The cellular structure is composed of distinct cells united by a cementing substance, and is in some cases directly supplied with nerve-fibrils. In most parts it is named the epithelium, in others is distinguished as the endothelium, and in the skin is the epidermis. The basis of support of the cellular structure in mucous membranes is distinguished as the **mucosa**, in the skin as the **corium**, in glands and other parts as the **membrana propria**, and in serous and allied membranes as the **serosa**. It is variable in thickness and strength, and ordinarily consists of fibro-connective tissue defined by a delicate and apparently homogeneous layer, the **basement membrane**, which is composed of thin plates or flattened cells. To the supporting basis generally the blood-vessels are distributed, ending in capillary nets beneath the basement membrane; and in the same position commence the lymphatics. Nerves, also, ordinarily terminate in this basis, but in some cases, as in the conjunctiva and the skin, extend into the cellular structure.

#### EPITHELIAL TISSUE.

The **epithelial tissue**, or **epithelium**, is the distinct cellular structure which forms the free surface of mucous, serous, and synovial membranes and of the skin, the essential glandular substance, and the lining of the vascular system, including the capillaries. Com-

FIG. 167.



DIAGRAM EXHIBITING THE RELATIVE POSITION OF THE COMMON ANATOMICAL ELEMENTS OF SEROUS AND MUCOUS MEMBRANES, THE GLANDS, THE LUNGS, AND THE SKIN. 1, cellular layer; 2, basement membrane; 3, fibro-connective-tissue layer, with blood-vessels, 4.



monly, in its more restricted sense, the term **epithelium** is applied to the superficial cell-structure of the mucous membranes, including the lining of the air-cells of the lungs and that of the recesses of glands. The corresponding layer of the serous and synovial membranes and of the vascular system is often distinguished as the **endothelium**; while that of the skin is named the **epidermis**.

The **epithelium**, in general, is composed exclusively of cells, in one, several, or many layers, and closely joined together by a cementing substance. Blood-vessels never enter the cell-structure, but terminate in capillary nets beneath the epithelium. In some cases nerves, as finely-beaded ultimate nerve-fibrils, are distributed among the cells, as exemplified in the conjunctiva of the eye.

When an epithelium consists of a single characteristic cell-layer it is called a **simple epithelium**, and when of several or many layers it is a **stratified epithelium**.

The **epithelial cells**<sup>1</sup> differ greatly in shape, structure, and composition in different epithelia, and often, likewise, in the same epithelium.

Of the simple epithelia there are several kinds, distinguished as the pavement, the columnar, and the polyhedral epithelium.

The **pavement epithelium**<sup>2</sup> is the most common kind, and is exemplified by that of the air-cells of the lungs and nearly all the endothelia. It is composed of clear, thin plates, or flat, scale-like cells, cemented together at the edges. Ordinarily their limits are very obscure, but become distinctly defined by black lines through the action of a solution of silver nitrate.

FIG. 168.



PAVEMENT EPITHELIUM, from a serous membrane, highly magnified, and seen to consist of flat, six-sided, nucleated cells.

In the endothelium of serous membranes the cells are, for the most part, hexagonal with straight outlines; in that of the vascular system they are mostly elongated, lozenge-shaped with sinuous outlines, or lanceolate with more even outlines. The cells have a central round or oval nucleus, from which they thin away to the edge; so that in profile section the cells appear narrow fusiform. The remaining contents are small in quantity, mostly homogeneous, and sometimes finely granular.

The simple **columnar epithelium**<sup>3</sup> is exemplified by that of the entire alimentary canal from the termination of the œsophagus, that of the nasal cavities and adjacent part of the pharynx, of the air-passages, of many ducts and recesses of glands, of the urethra, and of the uterus and oviducts. It is composed of a single layer of six-sided columnar

<sup>1</sup> Epithelia.

<sup>2</sup> Tessellated, squamous, or scaly epithelium.

<sup>3</sup> Cylinder epithelium.

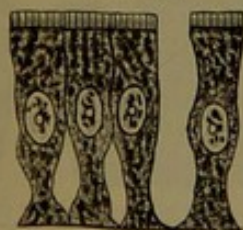

cells, standing upright on the surface of support and closely conjoined. Viewed laterally, they present a palisade-like arrangement, and seen on the free extremities they have a six-sided alveolate appearance. The cells are comparatively soft, and the hexahedral form is due to mutual pressure, so that when isolated they are disposed to assume a more cylindrical shape. They differ in exact form, dimensions, and structure in different positions, and also vary more or less in the same position. They are mostly much longer than the thickness, but in some of the narrower glandular ducts are so short as to appear cubical in the side view. In many positions they are of uniform thickness, but vary with the form of the surface on which they stand, so that in a tube they will be wider at the bot-

tom of the cell than at the free end, so as to conform to the curvature of the tube. More commonly, columnar cells taper at their lower or attached extremity, and the intervals between them are occupied by immature cells, which conform in shape to the latter. The sides of the cells are even, but sometimes are rendered more or less uneven by irregular processes; and the tapering extremity may be pointed at the end, or variably expanded, or divided into diverging processes.

The columnar cells have a large, central, commonly oval nucleus, which in the narrower forms produces a bulging at the middle of the cell. They are provided with a delicate wall, which is usually thicker at the free extremity and thinnest at the bottom. The contents, enclosing the nucleus, consist of a soft protoplasm with a clouded or faintly granular appearance, sometimes mingled with more distinct granules.

COLUMNAR EPITHELIUM, from the mucous membrane of the small intestine.



In the intestinal epithelium the free extremity of the columnar cells is defined by a conspicuous thickening of the wall, forming a terminal plate, which is vertically finely striated. The striæ are considered either to be minute pores, or lines of separation between solid rods of which it is supposed the plate is composed.

A remarkable variety is the **ciliated columnar epithelium**, in

FIG. 169.

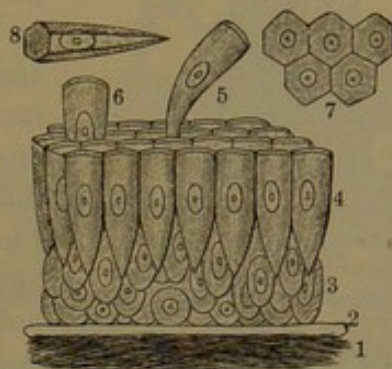


DIAGRAM OF A VERTICAL SECTION OF MUCOUS MEMBRANE OF THE SMALL INTESTINE, highly magnified. 1, fibro-connective-tissue layer, in which the blood-vessels are distributed; 2, basement membrane; 3, young nucleated cells; 4, layer of columnar cells; 5, 6, cells in the act of being shed or thrown off; 7, free ends of the columnar cells, exhibiting their six-sided form; 8, a single columnar cell, exhibiting its prismatic form.



which the cells, instead of the terminal plate as in those last described, are provided with a tuft of exceedingly fine hair-like processes, named

FIG. 171.

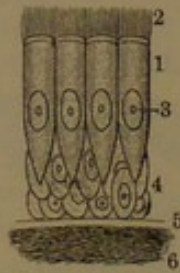


DIAGRAM OF A VERTICAL SECTION OF THE BRONCHIAL MUCOUS MEMBRANE, highly magnified. 1, columnar ciliated epithelial cells; 2, cilia; 3, nuclei; 4, young cells; 5, basement membrane; 6, fibro-connective-tissue layer.

**cilia**,<sup>1</sup> from their resemblance, in the ordinary view of the cells under the microscope, to an eyelash. The cilia, during life and for some time after death, exhibit an incessant and rapid vibratory motion, and serve to sweep secretions from surfaces. They are found in most classes of animals, in which they often serve the most important functions, and in many of the lowest forms are the chief organs of locomotion. The ciliated epithelium, in man and his class, lines the nasal cavities and communicating sinuses, the contiguous portion of the pharynx, eustachian tube,

and tympanum, the larynx and succeeding air-passages, the ventricles of the brain in part and the central canal of the spinal cord, the epididymis, the uterus, and the oviducts.

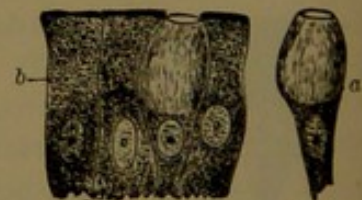In the trachea the ciliated columnar cells are about  $\frac{1}{500}$  of an inch long, and their cilia about  $\frac{1}{10}$  the length of the cell; in the epididymis the cells, about the same length, have their cilia more than half that of the cell.

Certain columnar cells, found in the smaller ducts of the salivary glands and tubules of the kidney, enlarge downward or towards their base, and to a variable extent from the latter position present a longitudinally striated appearance, which appears to be due to the cell being divided into a tuft of rod-like processes.

In the columnar epithelium there often occur, here and there among the others, usually isolated cells, which, from their form, have been called **goblet-cells**.<sup>2</sup> They appear as the product of transformation of the ordinary cells, with the upper part of the cell expanded by an ovoid mass of clear mucus, devoid of the terminal covering, and with the granular protoplasm and nucleus confined to the lower part of the cell.

A simple **polyhedral epithelium**<sup>3</sup> forms the essential cell-structure of many glands, occupying their commencing follicles or alveoli, as in the salivary, lachrymal, peptic, duodenal, and mammary glands and the pancreas. From its usual position, the polyhedral epithelium, even when not simple, as in the sebaceous glands and tes-

FIG. 172.



COLUMNAR EPITHELIUM, from an intestinal villus. a, goblet cells; b, ordinary columnar cells.

<sup>1</sup> Cils; vibrillæ.

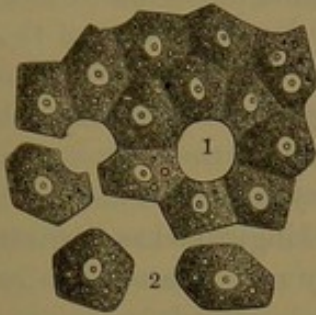
<sup>3</sup> Spheroidal epithelium.

<sup>2</sup> Chalice or beaker cells.



ticle, or having other relations, as in the liver, is also called **glandular epithelium**.<sup>1</sup> It commonly consists of soft, polyhedral cells, of which

FIG. 173.

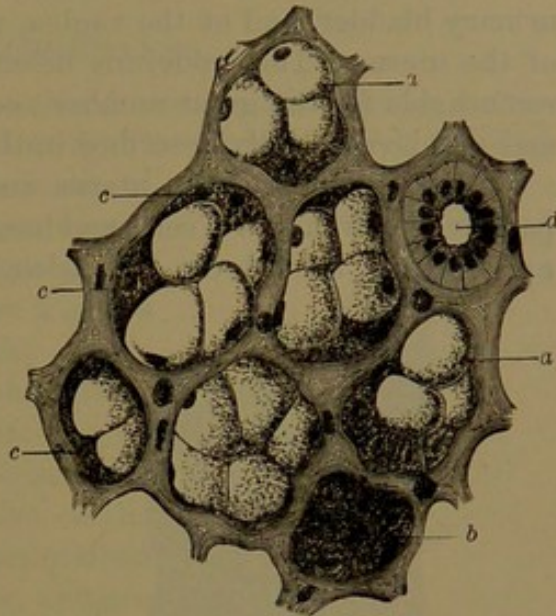


POLYHEDRAL EPITHELIUM, exemplified by secreting cells of the liver. The arrangement is ideal. 1, space occupied by a blood-vessel; 2, isolated cells.

the form is mainly due to surrounding pressure, so that when isolated they assume a more spheroidal shape. They are ordinarily composed of a soft, granular protoplasm, with a central nucleus, and no definite cell-wall; and the protoplasm contains the peculiar materials which are secreted by the glands. A more particular description of the glandular epithelium will be given in the special account of the glands.

While there is no well-marked separation between the simple and

FIG. 174.



SECTION OF THE SUBMAXILLARY GLAND. Alveoli of connective tissue containing the secretory cells, —a polyhedral epithelium. a, cells containing mucus; b, cells with granular protoplasm; c, crescentic parietal cells; d, duct with striated columnar epithelial cells.

FIG. 175.

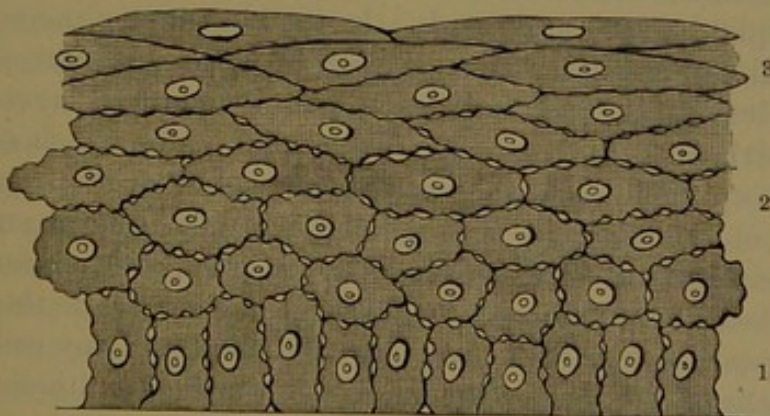


DIAGRAM OF STRATIFIED EPITHELIUM OF THE CORNEAL CONJUNCTIVA, highly magnified. 1, deep layer of columnar cells; 2, layers of polyhedral cells; 3, broader cells at the surface. Between the deeper cell layers the intercellular channels are observed.

the **stratified epithelium**, and one may be said to merge into the other, the latter is distinguished as containing more than several, and

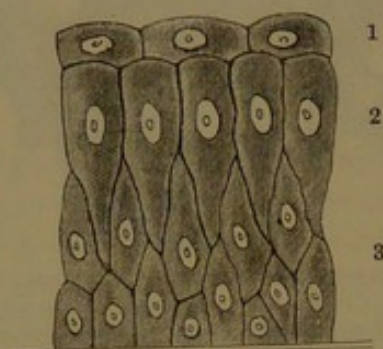
<sup>1</sup> Secretory or secreting cells.



usually many, distinct layers of cells, which greatly differ from one another in shape, in size, and often in composition. The stratified epithelia of mucous membranes are those of the conjunctiva of the eye, of the mouth, lower part of the pharynx, and œsophagus, of the ureters and urinary bladder, and of the vagina, with the lower portion of the neck of the uterus. The epidermis belongs to the stratified epithelium, is remarkable for the great number and variety of its constituent layers, and will be especially described in the account of the skin.

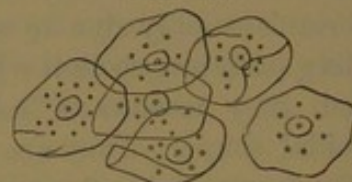
The epithelium of the uterus and urinary bladder consists of comparatively few layers of cells, and has been distinguished as **transitional epithelium**, though the transition is really not greater than in those

FIG. 176.



EPITHELIUM OF THE URINARY BLADDER, highly magnified. 1, superficial layer of flattened polyhedral cells; 2, columnar cells; 3, deep layers of irregular polyhedral cells.

FIG. 177.



SQUAMOUS EPITHELIUM, consisting of nucleated cells, as broad plates or scales. Scraped from the inside of the mouth, and highly magnified.

epithelia which consist of more numerous layers. It will be more particularly described in an account of the urinary organs.

Generally in the stratified epithelium the deepest layer is of columnar form, while that which immediately follows consists of polyhedral cells of equal breadth and depth. In the next layers the cells are also polyhedral, but are successively larger, of greater breadth and proportionately less depth, and finally merge into superficial layers of **squamous epithelium**, consisting of broad, flat scales, which do not, as in pavement epithelium, conjoin at the edges, but overlap one another. The cells of the different layers differ not only in form and size, but also in constitution. The deeper cells consist of soft, granular masses of protoplasm, containing a large, distinct nucleus, while the superficial scales appear as clear corneous plates, with scarcely any contents.

The cells of the deeper layers of the stratified epithelium are not closely applied to one another throughout, but are minutely ridged, and the ridges conjoin so as to leave intercellular channels communicating with one another among the cells. Later researches would indicate the existence of a similar arrangement in the simple columnar epithelium.

The deepest cells of the stratified epithelium incessantly multiply through division, and as the new cells grow they compress and push



away those previously formed. As the older cells are successively shifted towards the surface of the epithelium they undergo transformation, and finally become the superficial scales, which are shed or removed by abrasion, while other cells are produced beneath.

## SEROUS MEMBRANES.

The **serous membranes**<sup>1</sup> line closed cavities of the body, and are thence reflected upon and invest the organ or organs contained within the cavities. The lining membrane is named its **parietal portion**, and the other the **reflected** or **visceral portion**. Together the two portions of the membrane form a closed sac, with its cavity exterior to the organ, which, as it were, is thrust from behind from the parietal portion of the sac into the reflected portion. The opposed free surfaces of the two portions of the membrane, on the interior of the sac, are always maintained in contact, are smooth and shining, and are moistened by a thin liquid, the **serum**. This resembles the serum of blood, and is derived from the membrane, which it lubricates, and thus facilitates the movements of the parts on each other. The serous membranes are attached to the subjacent parts by areolar tissue, named the **subserous tissue**, which varies in the firmness of its connection in different positions, and in some cases is more or less prone to the accumulation of fat. The serous membranes are thin, colorless, and transparent, permitting the subjacent structures to shine through. They are moderately strong, extensible, and elastic, so that they do not wrinkle in the ordinary contraction of the parts with which they are connected.

The most extensive of the serous membranes is the peritoneum, lining the abdomen and reflected upon the contained viscera. The many attachments of the latter, by means of the doublings or folds of the membrane passing from the walls of the cavity, are usually called ligaments, though some are called by special names, as the mesentery and mesocolon. Other folds extend between the contiguous viscera, such as the small and great omenta. The pleuræ are serous membranes, of which one lines the cavity of the chest on each side, and is thence reflected on and closely invests the corresponding lung. The fibrous bag, the pericardium, enclosing the heart, is lined by the serous pericardium, and is thence reflected on and invests the heart. The

FIG. 178.

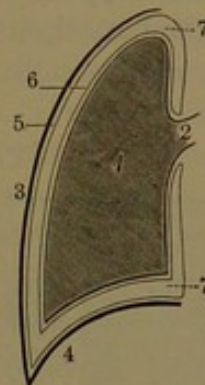


DIAGRAM EXHIBITING THE RELATION OF A SEROUS MEMBRANE, THE PLEURA, TO THE ORGAN IT INVESTS AND THE CAVITY IT LINES. 1, lung; 2, root of the lung, which is the only attached portion of the organ; 3, side of the thorax; 4, diaphragm; 5, parietal pleura; 6, pulmonary or reflected pleura; 7, cavity of the pleura.

<sup>1</sup> Membranæ serosæ.



scrotum on each side is lined by a serous membrane, the vaginal tunic, which thence invests the corresponding testicle.

The serous membranes are composed of a distinct cellular layer, the **endothelium**, which occupies the free surface and rests on the **serosa**, a thin connective-tissue layer defined from the former by a delicate basement membrane.

The **endothelium**<sup>1</sup> consists of a simple layer of pavement epithelium, thin, clear, polygonal plates, which are flattened, nucleated cells: the nucleus being thicker than the cell beyond its periphery, in profile the latter appears narrowly fusiform. The cells of the endothelium are united at their edges by a cement which has the same refractive power as the cells, so that they seem to be continuous, but become

distinctly defined by silver nitrate, which blackens the cement. The cells are mostly hexagonal, but variable. The nucleus, also rendered more visible by certain reagents, as carmine or hæmatoxylin solution, is usually round and central. The prolonged action of silver nitrate renders the protoplasmic contents of the cells more evident, and gives to them a finely granular aspect.

The endothelial cells of the same membrane are not uniform; as in many positions patches of larger cells alternate with those of

FIG. 179.




DIAGRAM OF A PORTION OF THE PERITONEAL SURFACE OF THE DIAPHRAGM. 1, 1, tendinous bundles covered by a pavement endothelium of polygonal cells; 2, interval over a lymph-channel covered with smaller cells; 3, pseudostomata, apparent openings filled with intercellular cement; 4, stomata, or openings surrounded by granular cells.

smaller size. The larger cell-areas generally lie on fibro-connective-tissue bundles of the serosa, while the smaller cells occupy the intervals of the latter over lymphatic clefts and vessels. There occurs here and there between the cells an appearance of angular apertures, called **pseudostomata**, filled with intercellular cement. In the smaller cell-areas of the pleuræ and the peritoneum, especially where this invests the diaphragm, and in the great omentum, there appear true openings, or **stomata**. These are surrounded by a circle of thicker and more granular cells, and communicate between the cavity of the serous membrane and the subjacent lymphatic spaces and vessels of the serosa and subserous tissue.

In the growth and extension of some of the folds of the peritoneum,

<sup>1</sup> Serous epithelium.



as in the omenta, the layers become very thin and are pierced by innumerable holes,<sup>1</sup> as if torn through distention. In these cases the endothelium becomes folded around the reticular bands of the subjacent tissues, including the serosa, the subserous tissue, with vessels, and often more or less fat.

The **serosa** is a delicate intertexture of fibro-connective tissue with elastic fibres, defined from the endothelium by a thin basement membrane, and continuous beneath with the subserous tissue.

The capillary blood-vessels of serous membranes form a wide-meshed net, in the serosa and subserous tissue, communicating with numerous branches of the nearest arteries and veins of the subjacent structures or of the vessels passing between the folds of the membrane. The largest arterial branches and accompanying veins, in many positions, especially in the folds of the peritoneum, traverse tracts of lymphoid tissue, which is most marked in youth, and in the advance of life becomes more or less transformed into fat. Lymphatics are abundant in the serous membranes, commencing in plexuses of the serosa and subserous tissue, and thence pursuing the course of the blood-vessels. The nerves, except those which follow the chief vessels, are comparatively few, and end in fine plexuses of the subserous tissue and the serosa.

#### SYNOVIAL MEMBRANES.

The **synovial membranes** are of the nature of the serous membranes, and have the same function, that of lubricating surfaces which habitually move upon each other, as in the joints of the skeleton and in the grooves which give passage to tendons. They furnish a liquid, named **synovia**, which is much more viscid than the liquid of the serous membranes, resembles in its composition and qualities the white of egg, and is well adapted to the purpose of reducing friction and facilitating motion. Its employment in the animal is like that of the lubricating oil in machinery. The synovial membranes are distinguished as articular, and as synovial bursæ, and sheaths.

The **articular synovial membrane**<sup>2</sup> occupies the movable joints of the skeleton. It closely and evenly lines the interior surface of the capsular ligament, and is thence reflected on the borders of the articular cartilages, but does not extend over them. In like manner in the joints with interarticular cartilages it is reflected to the surfaces of these, but does not entirely cover them. In many of the joints commonly a fold of the synovial membrane projects into the cavity around the periphery of the articulation. The **synovial folds**<sup>3</sup> are strength-

<sup>1</sup> Fenestrated membrane.

Capsula synovialis.

<sup>3</sup> Plicæ synoviales, vasculosæ, or adiposæ; ligamenta mucosa; Haversian fringes; glands of Havers.



ened by connective tissue, and their thin free border is usually fringed with numerous irregular villous processes.<sup>1</sup> The larger folds, like those of the knee-joint, contain considerable fat, and in a measure serve as cushions. In the foetus the synovial membrane lines the joints throughout, but subsequently becomes obliterated on the opposed articular cartilages, apparently as if from the friction to which they are subjected.

The **synovial bursa**<sup>2</sup> is a simple pouch, in certain positions interposed between surfaces which move upon each other, to alleviate friction. The pouch is closed and flattened, and is attached by its exterior to the adjacent moving parts, while its interior opposed surfaces are in contact and lubricated with synovia. It is generally situated between a muscle or its tendon, and a bone or the exterior of a joint, and sometimes between two muscles or tendons. Those contiguous to joints frequently communicate with them, so that the bursa appears to be a continuation of the synovial membrane of the articulation. Others, named from their position **subcutaneous bursæ**, are placed immediately beneath the skin over bony prominences, as on the elbow and knuckles, on the patella and malleoli, and on the heel. These differ from the former in their less distinct character, and in the more or less irregular condition of the interior surfaces, which give them the appearance of a lacerated cleft in the surrounding fibro-connective tissue.

The **synovial sheath**<sup>3</sup> lines bony and ligamentous canals, and invests the tendons traversing the latter; and is intended to facilitate the movement of the tendons in the canals. The sheath lines the passage, to which it is closely adherent, and is thence reflected on the tendon or tendons, which it closely invests; and the intervening surfaces lie in contact, and are lubricated with synovia. The canals of the fingers and toes, formed by the phalanges and the vaginal ligaments, enclosing the flexor tendons, are occupied by such a sheath. The carpal canal is lined by a synovial sheath, which is complexly folded as it invests the numerous tendons which pass through the canal.

The synovial membrane is composed of a basis of fibro-connective tissue intimately associated with the similar tissue of the capsular ligament or other subjacent parts. The free surface consists of an endothelium like that of serous membranes, but commonly is not so distinctly obvious; is variously described, and as a continuous complete layer has been disputed. At the margin of the articular synovial membrane its cells appear to merge into the condition of connective-tissue corpuscles.

<sup>1</sup> Villi synoviales; glandulæ articulares, mucilagines, or Haversii.

<sup>2</sup> Bursa mucosa or synovialis.

<sup>3</sup> Vagina synovialis; vaginal synovial membrane.



## SERUM.

**Serum** is a slightly viscid, straw-colored liquid, which in small quantity moistens the smooth, free surfaces of the serous membranes; and only occurs in the serous cavities in conspicuous quantities as a result of disease. It serves to facilitate the movement of the opposed surfaces of the organs and cavity containing them. In composition it resembles the blood-liquor.

## SYNOVIA.

**Synovia**, the lubricating liquid of the joints and other synovial cavities, is amber-colored or colorless, more viscid than serum, and usually occurs in greater quantity. In composition it resembles serum, with a proportion of mingled mucin.

## MUCOUS MEMBRANES.

The **mucous membranes**<sup>1</sup> line passages and cavities which communicate with the exterior of the body, where they become continuous with the skin. They constitute the lining of the alimentary, respiratory, urinary, and generative apparatus, together with that of the ducts of glands which open upon it. Habitually subjected to the contact of various matters, such as the food and air and the different glandular secretions and excretions, they are protected from undue irritation by a viscid liquid, the **mucus**, which bathes their surface.

Mucous membranes are attached to subjacent parts by a layer of fibro-connective tissue, distinguished as the **submucous layer**,<sup>2</sup> differing in thickness and density in different positions. The attachment of the mucous membrane is variable in degree, in some cases being close and firm, as in that of the nasal cavities, on the dorsum of the tongue, in the air-passages, and in the uterus. In other cases, and especially in organs subject to considerable change of capacity, as in the stomach, intestines, and bladder, it is comparatively loosely attached, and to some extent permits some shifting of the connected surfaces. Thus, in the contraction of the stomach or bladder, the mucous membrane is thrown into folds, which are again obliterated in expansion of the organs. In the small intestine, for the greater part of its length, the mucous membrane forms numerous permanent folds, the **connivent valves**,<sup>3</sup> which are not affected by changes of capacity of the canal. In some positions the mucous membrane is provided with a multitude of minute processes, as exemplified by the papillæ of the tongue and the villi of the small intestine. Generally also the mucous membranes are furnished with numerous minute glands, which are embedded in the thickness of the membrane, and open by their ducts on the free surface.

<sup>1</sup> Membrana mucosa.<sup>2</sup> Submucosa.<sup>3</sup> Valvulæ conniventes.



The mucous membranes are mostly thicker than the serous membranes, less elastic, and less transparent. They vary from gray and various shades of pink to bright red. The latter colors are due to the vascularity, which may be more or less obscured by the character of the epithelium of the membrane. In some they are habitually bright red, as in the nose, mouth, and pharynx; variably pale or darker red in the stomach and intestines, according as these organs are more active or quiescent; and nearly or quite colorless and transparent, as in the conjunctiva in front of the eyeball.

The mucous membranes are composed of a cellular layer, the **epithelium**, supported by the **mucosa**.

The **epithelium** varies greatly in different mucous membranes. In the mouth and throat, on the conjunctiva of the eye (see page 349), and in the vagina, it is a stratified epithelium, consisting of many layers of cells of different forms and constitution. The deepest is a single layer of comparatively short columnar cells, which is followed by layers of polyhedral cells, which become successively of greater relative breadth, while the superficial layers consist of broad, flat cells, or scales, often distinguished as a squamous epithelium. In the mucous membrane of the urinary bladder (see page 350) the epithelium is also stratified, but consists of comparatively few layers of cells, of which the superficial layer is not reduced to the condition of thin scales. The air-cells of the lungs are lined by a simple or single layer of pavement epithelial cells. In most other mucous membranes the epithelium consists of a single, superficial layer of comparatively long, six-sided, columnar cells, often with one or two strata of young cells occupying the intervals at the bottom of the usually tapering columnar cells of the surface. In the gastro-intestinal mucous membrane the columnar epithelium is of plain character (see page 347), but in that of the nasal and air-passages, in the cavity of the uterus and oviducts, and in some other positions, it is ciliated (see page 348).

In mucous membranes with the ordinary stratified epithelium, in which the superficial strata are squamous epithelium, the mucus of the surface is mainly derived from minute racemose glands embedded in the mucous membrane. In those with the columnar epithelium much of the mucus appears to be derived from some of the columnar cells, scattered here and there, undergoing transformation into the condition of **goblet-cells** (see page 348). It is probable that the columnar epithelium is incessantly shed, through successive transformation of the cells into goblet-cells, which are displaced to give room or place to newly-developed cells. In the ordinary stratified epithelium the squamous layers are incessantly shed, while new layers of this kind are due to transformation of the deeper polyhedral layers of cells.

The **mucosa**, or **membrana propria**, variable in thickness, distinctness, and composition in different mucous membranes and other related structures, in general consists of an interlacement of fibro-con-



nective tissue, defined by a thin, apparently homogeneous layer, named the **basement membrane**, and situated next the epithelium. The fibro-connective tissue contains nets of capillary blood-vessels and lymphatics and terminal plexuses of nerves. It is often mingled with some elastic tissue, which is especially abundant in the mucosa of the air-passages. The basement membrane, sometimes scarcely distinguishable from the fibro-connective-tissue layer of the mucosa, appears to be composed of broad, flat cells or plates like those of the serous endothelium. In other cases the cells appear not to be connected by their edges continuously, but through branching processes, and in this condition are barely distinguishable from contiguous connective-tissue corpuscles. In some of the mucous membranes the fibro-connective tissue of the mucosa is substituted to a variable degree, and notably in that of the stomach and intestines, by **lymphoid** or **adenoid tissue**,<sup>1</sup> which also enters largely into the construction of the lymphatic glands. This tissue consists of a reticular structure of branching, radiated connective-tissue cells, which may more or less merge into the ordinary condition of fibro-connective tissue, with the interspaces filled with lymph or lymphoid corpuscles. In most mucous membranes the mucosa is defined from the submucous fibro-connective-tissue layer by a **muscularis mucosa**, a thin stratum of unstriated muscle-fibres, generally circular in their direction; but in the well-developed layer of the gastro-intestinal mucous membrane, in most positions, the circular stratum is succeeded by a longitudinal stratum.

The mucosa generally contains numerous minute glands, whose ducts open on the surface of the mucous membrane. In the gastric and intestinal mucous membrane, and that of the uterus, the glands are tubular, and densely packed in the mucosa. In other mucous membranes they are racemose glands, variable in number and size in different positions, and when large extend from the mucosa into the submucous tissue. Besides the more extended lymphoid tissue entering into the composition of the mucosa, in some of the mucous membranes accumulations of the same structure occur, as **lymphoid nodules**, as exemplified in the solitary and agminated glands of the intestines.

The mucous membranes are abundantly supplied with blood-vessels. Arteries and veins form plexuses in the submucous fibro-connective-tissue layer, whence branches communicate with the capillary nets of the mucosa, including those enveloping the numerous glands of the latter. Lymphatics are also numerous, and commence in lymphatic spaces and capillary nets of the mucosa, whence larger vessels, provided with valves, proceed into the submucous layer in company with the blood-vessels. Nerves terminate in gangliated plexuses of the submucous layer, and thence extend into finer plexuses of the mucosa.

---

<sup>1</sup> Cytogenic tissue.



## MUCUS.

**Mucus**<sup>1</sup> is a viscid liquid, which covers the surface of all mucous membranes in variable quantity, and is produced or secreted by the epithelium, and often also by glands discharging on the surfaces of these membranes. It is tasteless and odorless, transparent and colorless, or more or less clouded, and whitish or yellowish. It consists of a clear, homogeneous liquid, mingled with variable proportions of mucous corpuscles and cast-off epithelial cells. The **mucous corpuscles** are small granular cells, and resemble the colorless blood-corpuscles and lymph-corpuscles. In most cases mucus also occurs mingled with other secretions, as the saliva, pancreatic juice, bile, and urine. It is a solution of a peculiar nitrogenized substance, **mucin**, with some extractive and fatty matters and salts.

## THE GLANDULAR SYSTEM.

The name of gland has been applied to many organs of very different character, though it is probable that they were originally supposed to possess similar functions. Thus, the salivary glands, which produce saliva, the liver, which produces bile, the kidneys, which eliminate urine, the thyroid, thymus, and suprarenal bodies, whose office is obscure, the pituitary and pineal bodies of the brain, and the rounded ones in the course of the lymphatic vessels, have all been and yet continue to be called glands.

A true **gland**<sup>2</sup> is commonly regarded to be a distinct organ, which elaborates or separates from the blood a peculiar liquid, and discharges it by a duct on the surface of the mucous membranes or skin. The

FIG. 180.

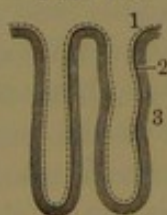



DIAGRAM OF TWO SIMPLE TUBULAR GLANDS. The dotted line 1, the epithelium or secreting cells; 2, the basement membrane; 3, the fibro-connective tissue in which the blood-vessels are distributed.

FIG. 181.



SIMPLE FOLLICULAR GLAND. References as in the preceding figure.

liquid discharged is called a **secretion**, and the act of producing it is called by the same name, or if it

is rejected from the body as useless or harmful, as in the case of urine, it is distinguished as an **excretion**.

The mucous and serous membranes, in their essential structure and function, closely resemble glands, and these produce the liquids which habitually bathe their surfaces, the mucus and serum, likewise known as secretions.

<sup>1</sup> Myxa; mycus; pituita; blenna.

<sup>2</sup> Glans; glandula; aden.



The larger glands are more or less visibly isolated, and are invested with a fibro-connective envelope continuous with the matrix of the gland. The small glands, which are very numerous, are generally embedded in the submucous tissue of mucous membranes and in the dermis or subcutaneous connective tissue.

In general structure the glands consist of a tube, or **duct**, which is simple or branched, defined by a **membrana propria** lined by an **epithelium**, and sustained by a **matrix** of fibro-connective tissue with blood-vessels, lymphatics, and nerves. Difference in the structure of most glands chiefly depends on the extent and arrangement of the constituent tubes and the character of the epithelium. The tubes may be simple or branched, of variable length, straight, tortuous, or convoluted, and commencing in the tubular form, or in that of a club-shaped or more distinct rounded polyhedral sac, called a **follicle**, or an **alveolus**.<sup>1</sup> A gland consisting of a single tube of variable length and arrangement is called a **simple gland**, while those which have their duct more or less branched are called **compound glands**. In the latter all the branches or tubes are likewise named ducts, and the terminal tube or outlet is the principal duct. When the ducts com-

\* FIG. 182

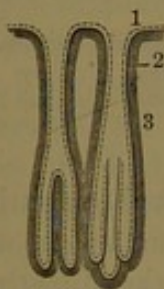


FIG. 183.

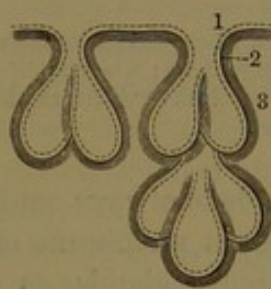


FIG. 184.

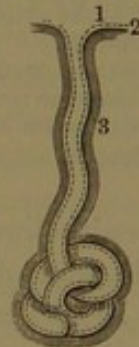

Fig. 182. COMPOUND TUBULAR GLAND. References as in Fig. 180.

Fig. 183. COMPOUND FOLLICULAR GLANDS. References as before.

Fig. 184. A SIMPLE TUBULAR GLAND CONVOLUTED. Same references.

mence in the tubular form and so continue throughout the glands are named **tubular glands**, and when they commence in follicles they are distinguished as **follicular glands**. The distinction is not always well marked, for the commencing tubes of a gland may be variably expanded, and thus the two kinds of glands may merge into one another. Many of the compound follicular glands in the arrangement of their branching ducts and commencing follicles resemble a bunch of grapes, whence from the word *raceme*, meaning a bunch or cluster, they are called **racemose glands**; and a large gland of this kind differs from a small one, just as a large cluster of grapes is composed of a number of small ones. The likeness is more complete to a bunch of raisins; for the follicles of the racemose glands are

<sup>1</sup> Folliculus; sacculus.



compressed together in the least possible space, but are more or less separated by the matrix of connective tissue with blood-vessels. The compound glands are more or less subdivided into small portions distinguished as **lobules**,<sup>1</sup> and more or less distinct collections of these form larger divisions, or **lobes**. The lobules consist of groups of follicles or the commencing tubes of the racemose gland connected together by the ducts and the connective-tissue matrix with the blood-vessels.

FIG. 185.

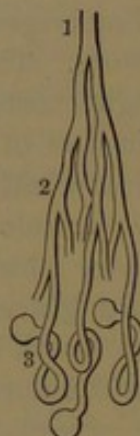


FIG. 186.

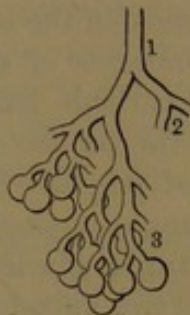
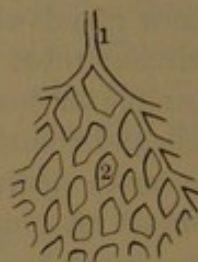
FIG. 187.



*Fig. 185.* GLAND OF COMPLEX FORM; the tubes branching and the commencing ones convoluted and dilated at the extremities. 1, main tube or duct; 2, branches; 3, convoluted portions dilated at the extremities.

*Fig. 186.* GLAND OF COMPLEX FORM, whose arrangement resembles that of a bunch of grapes. 1, duct; 2, branches commencing in follicles; 3, branch of another lobule.

*Fig. 187.* GLAND OF COMPLEX CHARACTER, in which the tubes anastomose, and thus form a network. 1, duct; 2, net-work of tubes.

The epithelium of glands is always continuous at the mouth of the duct with that of the mucous membrane or other surface on which it opens. In the simple tubular glands, as those of the intestines, the lining epithelium throughout is columnar, and not different in appearance from that of the mucous membrane, with which it is continuous. In the gastric tubular glands, both simple and compound, the epithelium is likewise columnar, but in some of them larger polyhedral cells are intermingled or occupy the deeper recesses. In the racemose glands the follicles are occupied by a layer of polyhedral cells, which usually fill the follicles, and are regarded as the peculiar **glandular epithelium**, or **secreting cells**. The larger ducts are lined by a distinct columnar epithelium, which in the smallest ones, directly communicating with the follicles, is of a transitional character. The principal ducts of the large racemose glands are lined with mucous membrane, commonly with a columnar epithelium continuous with that of the smaller ducts, and with that of the mucous membrane on which they open.

The **membrana propria** of the glandular ducts and their commencing tubes and follicles, of variable thickness and distinctness, is

<sup>1</sup> Lobuli; acini.



usually composed of a delicate, limiting basement membrane, apparently homogeneous or consisting of flat cells, and strengthened with more or less connective tissue, which in some cases, as in the sebaceous glands of the skin, appears alone to be present. In the coiled tube of the sweat-glands it is distinguished by containing a thin stratum of longitudinal, unstriated muscular fibres.

The more essential glandular structure is embedded in a connective-tissue matrix traversed by blood-vessels, which communicate with capillary nets enclosing the glandular tubes and follicles, and separated from their epithelium by the *membrana propria*.

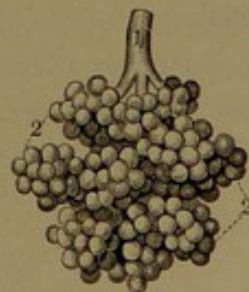The glands are richly supplied with blood-vessels, lymphatics, and nerves, which, for the most part, accompany one another in the course of the ducts, the blood-vessels to communicate with capillary nets, and the lymphatics with interspaces of the connective-tissue matrix between the tubes and follicles of the glands. In the salivary glands it is stated that the nerves have been traced to be in direct connection with the secreting cells.

The numerous true glands of the intestines, with few exceptions, are simple tubular glands, and many of the gastric glands are of the same character, while others more or less divided are compound tubular glands. The glands of the nasal mucous membrane and uterus are also simple tubular glands. Many of these tubular glands by expansion in a club-like manner approximate the more distinct follicular glands. The sweat-glands in general are simple tubular glands, and are remarkable for the great length of their tube, which is coiled into a mass in the body of the gland, whence they are sometimes distinguished as **convoluted glands**.

To the largest compound follicular or racemose glands belong the pancreas, the salivary, lachrymal, and mammary glands. The smallest are very numerous, and are, for the most part, embedded in the sub-mucous tissue and dermis. These are the mucous glands of the mouth, pharynx, cesophagus, trachea, and bronchi, the duodenal glands, the prostate and suburethral glands, the palpebral glands, and the sebaceous glands of the skin.

The testicles are compound tubular glands, remarkable for the great and very conspicuous length and convoluted condition of their branching tubular structure. The commencing tubules possess few branches of great length closely convoluted into elongated, pyramidal lobules. The *membrana propria*, defined by a basement membrane of flat cells, is lined by a stratified polyhedral epithelium, while the larger ducts, also greatly convoluted, are

FIG. 188.



A RACEMOSE GLAND. 1, duct; 2, lobules composed of the divisions of the ducts, commencing in follicles.



lined by a ciliated columnar epithelium, and the main duct, or vas deferens, is lined by mucous membrane with a plain columnar epithelium.

The kidneys are compound tubular glands of peculiar character, especially in the arrangement of their constituent tubes and blood-vessels. Their numerous long, branching tubes commence each in a spherical sac, which is doubly reflected around a tuft of capillary blood-vessels and is lined by a pavement epithelium. The constituent lobules and lobes of the kidney are compactly united; and the larger tubes abruptly end, on the summits of the lobes, in the divisions of a common receptacle, the pelvis of the kidney narrowing to the ureter, which corresponds with the principal duct of glands in general.

The liver, a huge glandular organ, is also peculiar, especially in the arrangement of its secretory cells and their relation with the ducts. The substance of the liver is composed of little polyhedral lobules<sup>1</sup> compactly united together, and in some animals, as, for example, the hog, much more distinct than in man. The lobules are composed of the secretory cells, a polyhedral epithelium, arranged in a sponge-like intertexture, with the interspaces occupied by a corresponding arrangement of the capillary blood-vessels. The ducts commence in an intertexture of canaliculi, the **biliary capillaries**,<sup>2</sup> which run among and between the secretory cells, and communicate in the intervals of the lobules with larger passages, the **interlobular ducts**. These anastomose with one another and converge into the main ducts, which in their course from the liver accompany the chief vessels which supply the organ. The biliary capillaries are variously regarded as tubes of homogeneous membrana propria or as mere intercellular passages. The smallest ducts in which the latter open have a pavement epithelium, which gradually assumes the columnar form in the larger ducts. The largest ducts are lined by a distinct mucous membrane with a columnar epithelium, and provided with numerous minute racemose glands.

---

<sup>1</sup> Acini.

<sup>2</sup> Pori biliarii; radicles of the bile-ducts.



## CHAPTER VII.

### THE NECK, THORAX, AND ABDOMEN.

#### THE NECK.

THE **neck**<sup>1</sup> forms the short, thick, cylindrical column uniting the head with the chest. In front, it is bounded above by the floor of the mouth, defined by the base of the mandible, and below by the breast, from which it is defined by the upper border of the sternum and the clavicles. Behind, it extends on the lower part of the occiput, and is continuous with the back of the chest below. At the sides, it extends from the ear to the shoulder. Near its middle in front, in the adult male, is a conspicuous prominence, Adam's apple,<sup>2</sup> produced by the projection of the larynx, which is not prominent in the female nor in the boy before puberty. Immediately above the larynx is the hyoid bone, which may be readily felt externally. At the bottom of the neck, immediately above the sternum, is a depression, the **jugular fossa**, within which is the trachea as it descends from the neck into the chest. Farther out, above the clavicle, is another depression, the **supraclavicular fossa**, within which lie the axillary blood-vessels and nerves as they escape from the chest into the armpit.

The bony axis of the neck is formed by the cervical vertebræ, which are enclosed behind and laterally by a thick mass of muscles. In front of the vertebræ in succession from above are the pharynx and œsophagus; in advance of these the mouth, tongue, hyoid bone, larynx, and trachea, with the thyroid gland and the supra- and infrahyoid muscles; and at the sides of all these are the great cervical blood-vessels, lymphatics and nerves, and the sterno-mastoid muscle. The skin of the neck, thinner in front, is loosely attached by the superficial fascia to the deep fascia and subjacent parts, and is readily raised in folds. A thin, superficial muscle, the platysma, occupies the sides of the neck, and in aged people by its anterior border forms with the skin a conspicuous fold descending from the chin.

#### THE THORAX.

The **thorax**, or **chest**,<sup>3</sup> comprises the upper part of the trunk of the body below the neck, and consists of the skeleton chest with its appropriate muscles covered by the skin. With the intercostal spaces

<sup>1</sup> Collum; cervix.

<sup>2</sup> Pomum Adami; nodus gutturis.

<sup>3</sup> Pectus; bosom; breast.



occupied by the corresponding muscles its front part is mainly covered by the pectoral muscles, extending outwardly along the clavicle to the arm and forming the thick anterior border of the axilla, or armpit. In the median line, between the greater pectoral muscles, it is slightly depressed, as the **sternal groove**, in which the sternum is subcutaneous. The groove expands below, and over the ensiform process, between the seventh costal cartilages, is still more depressed, as the **infrasternal fossa**, or **pit of the stomach**.<sup>1</sup> To the outer side of the pectorals the ribs are covered by the great serratus muscle, and below, in front and at the side, are covered by the abdominal rectus and external oblique muscles. Behind the chest are the dorsal extensors, the supra- and infraserratus, the rhomboid, trapezius, and latissimus muscles. The latter, as it ascends, lies on the great serratus, and with the greater teres muscle forms the posterior border of the axilla.

The interior of the chest forms the thoracic cavity and the upper part of the abdominal cavity, the two being separated by the diaphragm, which, from its deeply-vaulted character, rises high up in the chest; on a level with the junction of the fifth costal cartilage and rib on the right, and of the sixth on the left side.

The **thoracic cavity**<sup>2</sup> is chiefly occupied by the lungs and heart, the former on each side invested with a membrane, the pleura, and the latter intermediate, and enclosed in a membranous pouch, the pericardium, situated between the two pleuræ. The parietal portions of the latter, where contiguous, form a fore and aft partition to the thoracic cavity, called the **mediastinum**,<sup>3</sup> while the different spaces it includes are distinguished as the anterior, middle, posterior, and superior mediastina.

The **anterior mediastinum**<sup>4</sup> is formed by the two pleuræ reflected from the front of the pericardium to the back of the sternum. Its upper half is narrow where the pleuræ nearly come into contact, but it is wider below where the left pleura recedes from its fellow, and leaves a space which is bounded behind by the pericardium and in front by the sternum, with the fifth, sixth, and a portion of the seventh costal cartilages of the left side, and the sternal triangular muscle.

The **middle mediastinum**<sup>5</sup> is the capacious central portion of the whole mediastinum, containing the heart with the ascending portion of the aorta, the trunk of the pulmonary artery, and the lower half of the superior cava, all included in the pericardium, together with the phrenic nerves, arch of the azygos vein, and roots of the lungs, with the bronchial lymphatic glands.

The **posterior mediastinum**,<sup>6</sup> produced by the reflection of the

<sup>1</sup> Scrobiculus cordis; antecardium.

<sup>3</sup> Septum or dissepimentum thoracis.

<sup>4</sup> Cavum mediastini anterius; m. pectorale.

<sup>6</sup> C. mediastini posterius; m. dorsale.

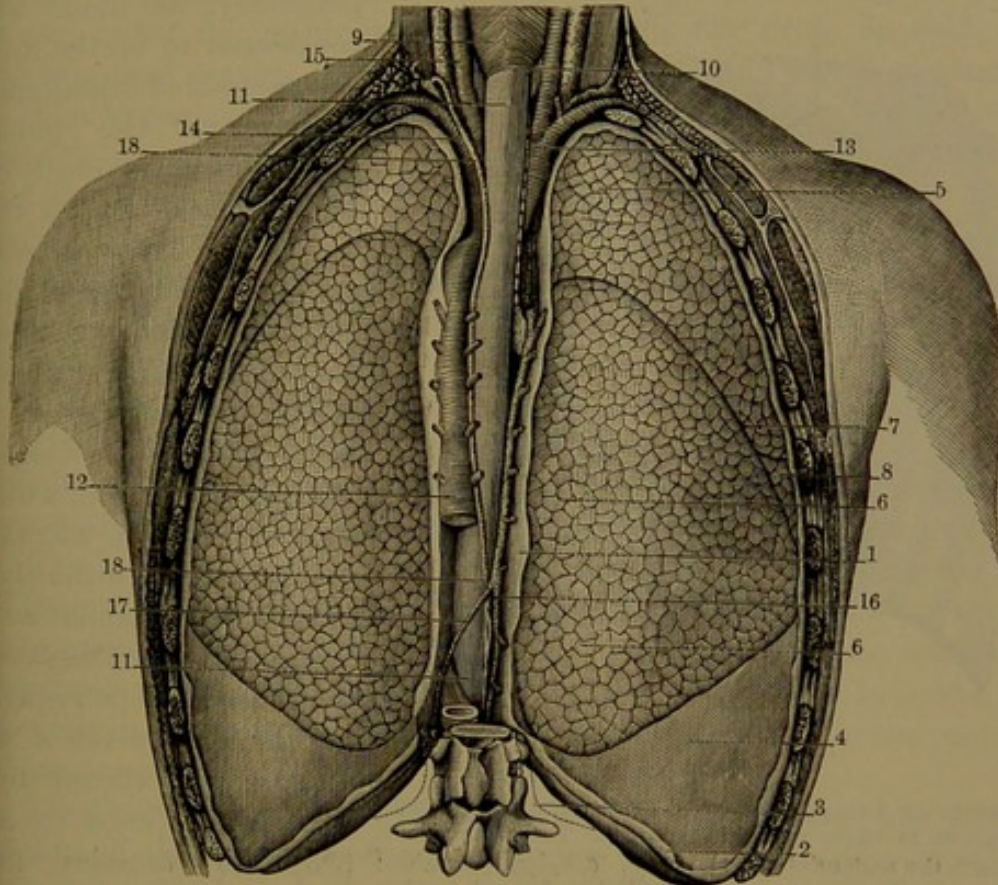
<sup>2</sup> Cavum thoracis.

<sup>5</sup> C. mediastini medium.



pleuræ from the pericardium backward to the sides of the spine, from the fourth thoracic vertebra downward, contains the descending portion of the thoracic aorta, the œsophagus with the vagus nerves, the azygos and hemiazygos veins, the thoracic duct, and the posterior mediastinal lymphatic glands.

FIG. 189.



VIEW OF THE POSTERIOR MEDIASTINUM, and of the lungs. 1, posterior mediastinum, bounded laterally by the pleuræ; 2, lower border of the costal pleura; 3, outline indicating the lower limit of the pleural cavity; 4, pleura covering the diaphragm; 5, upper lobe of the right lung; 6, lower lobe; 7, fissure separating the lobes; 8, middle lobe; 9, pharynx; 10, its lower limit; 11, œsophagus; 12, thoracic aorta, giving off intercostal arteries; 13, innominate artery, dividing into the right common carotid and subclavian arteries; 14, left subclavian artery; 15, left common carotid artery and the accompanying internal jugular vein; 16, azygos vein; 17, hemiazygos vein; 18, thoracic duct.

The **superior mediastinum**<sup>1</sup> is the space between the pleuræ from above the pericardium, on a level with the lower part of the presternum and fourth thoracic vertebra, extending through the upper aperture of the thorax into the root of the neck. It contains the trachea, the œsophagus, the transverse portion of the aortic arch, with the innominate and left carotid and subclavian arteries, the innominate veins and upper portion of the superior cava, the phrenic, vagus, left recurrent laryngeal and cardiac nerves, the cardiac lymphatic glands, and remains of the thymus gland.

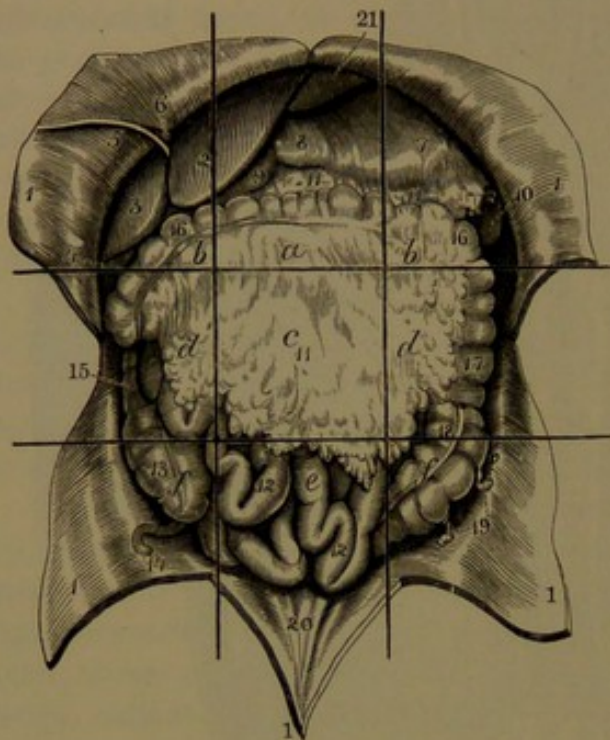
<sup>1</sup> C. mediastini superius.



## THE ABDOMEN.

The **abdomen**, or **belly**,<sup>1</sup> is that portion of the trunk of the body included between the chest and pelvis, enclosing a large cavity which contains the digestive and urinary organs and part of those of the

FIG. 190.



CAVITY OF THE ABDOMEN LAID OPEN, WITH THE VISCERA RETAINED IN THEIR RELATIVE POSITION. The straight lines indicate the regions of the abdomen. *a*, epigastric region; *b*, hypochondriac regions; *c*, umbilical region; *d*, lumbar regions; *e*, hypogastric region; *f*, iliac regions. 1, flaps of the abdominal wall turned aside; 2, 3, left and right lobes of the liver; 4, fundus of the gall-bladder; 5, round ligament of the liver; 6, part of the suspensory ligament of the liver; 7, 8, stomach; 9, commencement of the duodenum; 10, spleen; 11, great omentum; 12, small intestine; 13, caecum; 14, vermiform appendix; 15, ascending colon; 16, transverse colon; 17, descending colon; 18, sigmoid flexure; 19, epiploic appendages; 20, folds indicating the course of the remains of the urachus and umbilical arteries; 21, diaphragm.

generative apparatus. Superficially, its limits are considered to be the inferior margin of the thorax above, and the pubis, groin, and iliac crest on each side below; but the abdominal cavity considerably exceeds these limits, as it includes the pelvic cavity and ascends within the chest, where it is bounded by the deeply-vaulted diaphragm, which separates it from the thoracic cavity. In the skeleton it corresponds with the great vacuity between the thorax and pelvis with the lumbar vertebræ behind. Its surrounding wall is composed of appropriate muscles and fasciæ, together with the skin. Near its centre in front is the **umbilicus**, or **navel**, the cicatrix remaining from the attachment of the umbilical cord of the fœtus. It is somewhat variable in exact position, but is always

below the middle line between the pit of the stomach and the pubes, and generally slightly above the level of the iliac crests.

(For a description of the muscles of the abdominal walls, see page 270.)

For convenient reference in speaking of the position of the abdominal viscera, the cavity of the abdomen is divided into regions. This is done by drawing two parallel lines on a level with the lowest lateral

<sup>1</sup> Venter; gaster; paunch.



margin of the thorax and the highest point of the iliac crest on each side, while two other lines are drawn to intersect the former ascending vertically from the middle of the groin on each side. The lines thus divide the abdomen into nine regions, of which the intermediate three, from above downward, are the **epigastric**,<sup>1</sup> **umbilical**,<sup>2</sup> and **hypogastric**<sup>3</sup> regions, and the others are the **right** and **left hypochondriac**,<sup>4</sup> **lumbar**,<sup>5</sup> and **iliac**<sup>6</sup> regions. The position within the pubes is also called the **pubic region**, that within the groin on each side the **inguinal region**, and that within the pelvis the **pelvic region**.

The hypochondriac, epigastric, and hypogastric regions are often more briefly named each as the **hypochondrium**, the **epigastrium**, and the **hypogastrium**. Most of the viscera are more or less movable, and therefore variable in exact position according to the movements to which they are subjected in respiration, the passage of the contents of the bowels, or otherwise, but ordinarily they occupy the regions as follows:

The stomach occupies the left hypochondriac and epigastric regions.

The duodenum occupies the epigastric and umbilical regions, and the remainder of the small intestine and mesentery occupy the umbilical, hypogastric, and adjacent portions of the lumbar and iliac regions.

The head of the colon occupies the right iliac region, and the rest of the gut ascends through the right lumbar into the right hypochondriac region; thence arches through the umbilical into the left hypochondriac region, and descends through the left lumbar into the left iliac region, where it forms its sigmoid flexure and ends in the rectum, which occupies the back part of the pelvic cavity.

The liver occupies the right hypochondriac, epigastric, and a little portion of the left hypochondriac region. The gall-bladder is in the epigastric region.

The pancreas occupies the epigastric extending into the left hypochondriac region.

The spleen lies in the left hypochondriac region and slightly in the epigastric region.

The kidneys occupy the lumbar regions, with adjacent portions of the umbilical, epigastric, and hypochondriac regions.

The suprarenal bodies are in the epigastric region.

The urinary bladder occupies the fore part of the pelvic cavity, and in the distended condition rises into the hypogastric region.

The uterus and vagina occupy a position between the bladder and rectum in the pelvic cavity.

<sup>1</sup> Regio epigastrica, cardiaca, or stomachica.

<sup>2</sup> R. umbilicalis, gastrica, or mesogastrica; mesogastrium.

<sup>3</sup> R. hypogastrica; venter parvus or imus.

<sup>4</sup> R. hypochondriaca or subcartilaginea.

<sup>5</sup> R. lumbaris or lumbalis; lumbi; lendis; loins; flanks; reins.

<sup>6</sup> R. iliaca.



## THE PERITONEUM.

The cavity of the abdomen is lined throughout by a serous membrane, the **peritoneum**,<sup>1</sup> which is reflected from behind and above upon the different viscera, so as to give them an investment and attach them by folds, which serve to retain them in position and give passage to their vessels and nerves.

The peritoneum is the most extensive of the serous membranes, and

FIG. 191.

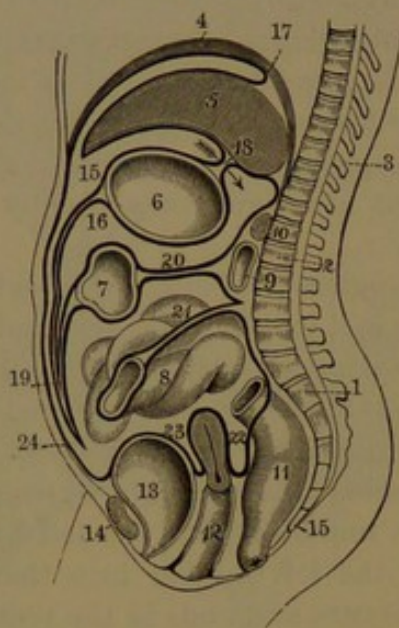


DIAGRAM OF THE APPARENT ARRANGEMENT OF THE COURSE OF THE PERITONEUM IN A VERTICAL SECTION OF THE ABDOMEN, the peritoneum represented by the thick, black line. 1, upper segment of the sacrum; 2, first lumbar vertebra; 3, thoracic vertebrae; 4, diaphragm; 5, liver; 6, stomach; 7, transverse colon; 8, small intestine; 9, duodenum; 10, pancreas; 11, rectum; 12, vagina and uterus; 13, urinary bladder; 14, pubis; 15, greater cavity of the peritoneum; 16, lesser cavity; 17, section of a lateral ligament of the liver; 18, gastro-hepatic omentum: the arrow indicates the communication, at the right border of the latter, of the great and lesser cavities of the peritoneum; 19, great omentum; 20, transverse mesocolon; 21, mesentery; 22, recto-uterine pouch; 23, vesico-uterine pouch; 24, portion of peritoneum lining the anterior wall of the abdomen.

is a strong, uncolored, transparent membrane attached to the subjacent structures by areolar tissue. Its free surface is smooth, moist, and shining, and is provided with a pavement epithelium. The **parietal portion**,<sup>2</sup> or that lining the abdominal cavity, is thickest, and is closely attached to adjacent fasciæ and muscles, more especially along the linea alba and to the diaphragm, and adhering most tightly to the tendinous portion of the latter. The **visceral portion**<sup>3</sup> affords a more or less complete investment to the organs to which it closely and evenly adheres, forming their serous coat.

Like other serous membranes, the peritoneum forms a closed sac, but is rendered much more complex in its arrangement from the many foldings produced by its reflection upon the viscera it invests. In tracing its extension in any direction, its continuity everywhere is obvious. Thus proceeding from the anterior wall of the abdomen outwardly, it reaches the ascending and de-

<sup>1</sup> Membrana abdominis.

<sup>2</sup> Lamina parietalis or externa.

<sup>3</sup> L. visceralis or interna.



the cæcum and the vermiform appendix, and in the left iliac region the sigmoid flexure of the colon, forming its broad fold, the **mesocolon**. Descending from the mesentery and colon on each side, the peritoneum enters the pelvis, invests the upper part of the rectum, and is thence reflected on the bladder, forming between them the **recto-vesical pouch**. From the summit of the bladder it is reflected to the front of the abdomen, producing, in the pubic and inguinal regions, slight folds on the remains of the urachus and on the umbilical arteries of the fœtus. In the female the peritoneum is reflected from the rectum to the upper part of the vagina and thence over the uterus, from which it proceeds to the bladder. It thus forms two pouches, the **recto-uterine** and the **vesico-uterine**; and between the sides of the uterus and the sides of the pelvic cavity it forms two additional folds, the broad ligaments of the uterus.

Above the mesentery the peritoneum forms the transverse mesocolon, a broad fold which encloses the transverse colon and is continuous on each side with the ascending and descending mesocolon, below with the mesentery, and above with the great omentum.

Following the extension of the peritoneum from the front of the upper part of the abdomen, it spreads over the vault of the diaphragm, and thence descends and invests the liver, stomach, and spleen, and forms between them their ligaments. From the transverse fissure of the liver it descends, as the **small omentum**, to the small curvature of the stomach, whence it completely invests the organ and departs from its great curvature as the **great omentum**. This descends like an apron in front of the bowels, doubles on itself, and ascends to join the transverse colon and mesocolon, on which it continues upward to the pancreas, where its layers separate, one to go to the posterior border of the liver, the other to turn downward and become continuous with the upper layer of the mesocolon. From the fundus of the stomach the peritoneum proceeds as the gastro-splenic omentum to the hilus of the spleen, and thence is continuous with the investment of this organ.

The peritoneum forms the following processes, folds, or doublings of the membrane, which serve as attachments for the viscera, and often as convenient means for the passage of the vessels and nerves to and from the organs:

- The suspensory, coronary, and lateral ligaments of the liver.
- The hepatico-renal and hepatico-colic ligaments.
- The phrenico-splenic, phrenico-gastric, and phrenico-colic ligaments.
- The small and great omentum.
- The mesentery, mesocolon, and mesorectum.
- The recto-vesical folds of the male.
- The recto-uterine and vesico-uterine folds and the broad ligaments of the uterus.
- The suspensory ligaments of the bladder.



The **suspensory ligament**<sup>1</sup> of the liver is a strong fold of the peritoneum, which extends from the median line of the diaphragm to the liver, between the right and left lobes, and thence descending is attached along the linea alba to the umbilicus. It is widest at the anterior notch of the liver, and thence diminishes in a falciform manner towards the posterior notch, in front of which its two layers diverge as the fore part of the coronary ligament. The anterior portion also narrows in its descent to the umbilicus, and encloses in its free border the round ligament. The right layer of the upper portion of the suspensory ligament is reflected from the corresponding side of the diaphragm to the upper surface of the right lobe of the liver, and in like manner the left layer is reflected from the diaphragm to the left lobe. The usual position of the ligament is not vertical, but oblique, its left side lying on the left lobe of the liver, and its right side in contact with the diaphragm and front wall of the abdomen, with the free border of the descending portion directed to the right.

The lateral ligaments are transverse folds of peritoneum attaching the posterior border of the liver to the diaphragm. The **right lateral ligament**<sup>2</sup> forms a short attachment to the right lobe, its two layers starting from the right and diverging inwardly from each other, the upper layer reflected from the upper surface of the diaphragm to that of the liver, and continuous with the fore part of the coronary ligament; and the lower layer reflected from the ascending portion of the diaphragm to the under surface of the liver, and forming the lower part of the coronary ligament. In the interval of the two layers, widening from the right to the posterior notch of the liver, the surface of the right lobe is devoid of the serous coat, and is attached to the adjacent part of the diaphragm by connective tissue. The **left lateral ligament**,<sup>3</sup> of greater length than the former, is a close peritoneal fold, attaching the posterior border of the left lobe of the liver to the diaphragm, extending from the posterior notch of the former outwardly in front of the termination of the œsophagus. It is continuous inwardly with the coronary ligament. Its length permits more mobility to the left lobe than to any other portion of the liver.

The **coronary ligament**<sup>4</sup> is not a distinct structure, and is variously described. It may be regarded as the attachment of the liver to the diaphragm by the diverging portions of the suspensory ligament and the intermediate portions of the lateral ligaments, including the intervening connective-tissue attachment of the two organs.

The **hepatico-renal ligament**<sup>5</sup> is a narrow fold, which starts beneath the liver on the right of the caudate lobe, and descends in front of the right suprarenal body to the upper extremity of the corresponding kidney.

<sup>1</sup> Ligamentum suspensorium; broad or falciform ligament.

<sup>2</sup> L. triangulare dextrum.

<sup>4</sup> L. coronarium; l. c. dextrum et sinistrum.

<sup>3</sup> L. t. sinistrum.

<sup>5</sup> Ligamentum hepatico-renale.



The **hepatico-colic ligament**<sup>1</sup> is also a narrow, crescentic fold, which descends from the back of the liver on the right of the gall-bladder to the hepatic flexure of the colon.

The **phrenico-splenic ligament**<sup>2</sup> is a short, triangular fold, descending from the diaphragm to the upper end of the spleen.

The **phrenico-gastric ligament**<sup>3</sup> is also a short, triangular fold, which descends from the diaphragm on the left of the œsophagus to the fundus of the stomach.

The **phrenico-colic ligament**<sup>4</sup> is a narrow, strong fold, which descends from the diaphragm below the spleen to the splenic flexure of the colon.

The **small omentum**, or **gastro-hepatic omentum**,<sup>5</sup> is a thin, transparent doubling of the peritoneum, extending between the transverse fissure of the liver and the small curvature of the stomach, reaching from the cardia to the pylorus. On the right it forms a free border, which extends between the transverse fissure of the liver and the commencement of the duodenum, and encloses the vessels ascending to the former, with the accompanying ducts and nerves. Behind it, above, lies the caudate lobe of the liver; and on the left a fold of it descends from the œsophagus to the pancreas. Between its layers the coronary blood-vessels and accompanying lymphatics and nerves run along the small curvature of the stomach. The free border of the small omentum is the anterior boundary of the **omental foramen**,<sup>6</sup> bounded behind by the inferior cava, above by the caudate lobe of the liver, and below by the duodenum. The foramen will admit the finger, and through it the greater portion of the peritoneal sac communicates and is continuous with the smaller portion, the **omental sac**. This extends behind the stomach into the great omentum, is bounded in front by the small omentum and its extension on the posterior wall of the stomach, below by the doubling of the great omentum, and behind by the ascending layer of the latter, continuous above with the posterior layer of the small omentum.

The **gastro-splenic omentum**<sup>7</sup> is a doubling of the peritoneum, extending from the fundus of the stomach to the hilus of the spleen, continuous above with the phrenico-gastric ligament, and below with the great omentum. It encloses the short gastric vessels.

The **great omentum**, or **gastro-colic omentum**,<sup>8</sup> is a broad, double fold of the peritoneum, which falls from the great curvature of the stomach in front of the intestines to the lower part of the cavity; occasionally a little way below the umbilicus, and sometimes even into the pelvic cavity. It extends lower on the left than on the right, and

<sup>1</sup> L. hepatico-colicum.

<sup>2</sup> L. phrenico-splenicum.

<sup>3</sup> L. phrenico-gastricum.

<sup>4</sup> L. pleuro-colicum or costo-colicum.

<sup>5</sup> O. minus or gastro-hepaticum; small epiploon.

<sup>6</sup> Foramen of Winslow; f. Duverneyi or omenti minoris.

<sup>7</sup> Ligamentum gastro-lienale.

<sup>8</sup> O. majus or gastro-colicum; great epiploon.



in fat than in lean people, and is further varied by the elevation or depression of the stomach. It is squarish, thin, more or less cribriform, and variably loaded with an irregular net-work of dull-yellow fat. At the fundus of the stomach it is continuous with the gastro-splenic omentum, and terminates below in an irregular border. It consists of four layers in great part confluent or blended together, and encloses a space, the omental sac. Two of the layers descend from the greater curvature of the stomach and quickly unite in a single lamina, which continues to the lower border of the omentum, then doubles on itself, and ascends behind, blends with the descending portion, and again separates to become attached to the transverse colon. From this it goes backward attached to the mesocolon, and ascends in front of the pancreas, where it divides into the two original layers, of which one continues upward to the posterior border of the liver, while the other turns downward and becomes continuous with the upper layer of the transverse mesocolon. The great omentum thus forms the

**omental sac**,<sup>1</sup> the cavity of which lies between its descending and ascending portions, and between the transverse colon and mesocolon behind, and the back of the stomach in front, and communicates by the omental foramen with the greater pouch of the peritoneum. Prior to birth the omental sac is entire and its interior free; and in this condition, when inflated, the omentum appears as a large, thin, transparent pouch protruding from between the stomach and the transverse colon. Subsequently, the cavity of the sac below the position of the colon becomes in great part obliterated, and the omentum in its growth becomes proportionately much attenuated

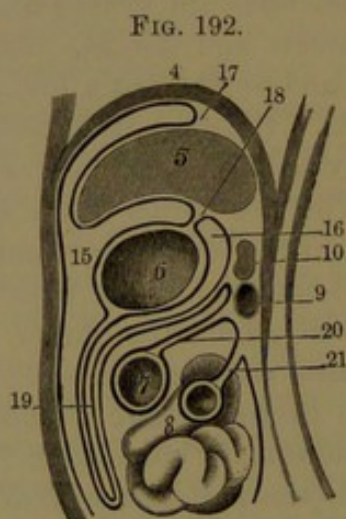


DIAGRAM OF THE COURSE OF THE PERITONEUM IN THE FŒTUS. 4, diaphragm; 5, liver; 6, stomach; 7, transverse colon; 8, small intestine; 9, duodenum; 10, pancreas; 15, greater cavity of the peritoneum; 16, lesser cavity; 17, right or left lateral ligament; 18, gastro-hepatic omentum; 19, great omentum; 20, transverse mesocolon; 21, mesentery.

and is rendered cribriform from the production of innumerable holes in the membrane. In the early part of foetal life the ascending portion of the omentum is free from the transverse colon and mesocolon, and ascends over them to the position of the pancreas, where it divides into the two component layers as before described. The great omentum contains more or less fat, which is proportioned in quantity with the condition of the person; and is especially collected along the course of the vessels, giving to the omentum a striking reticular ap-

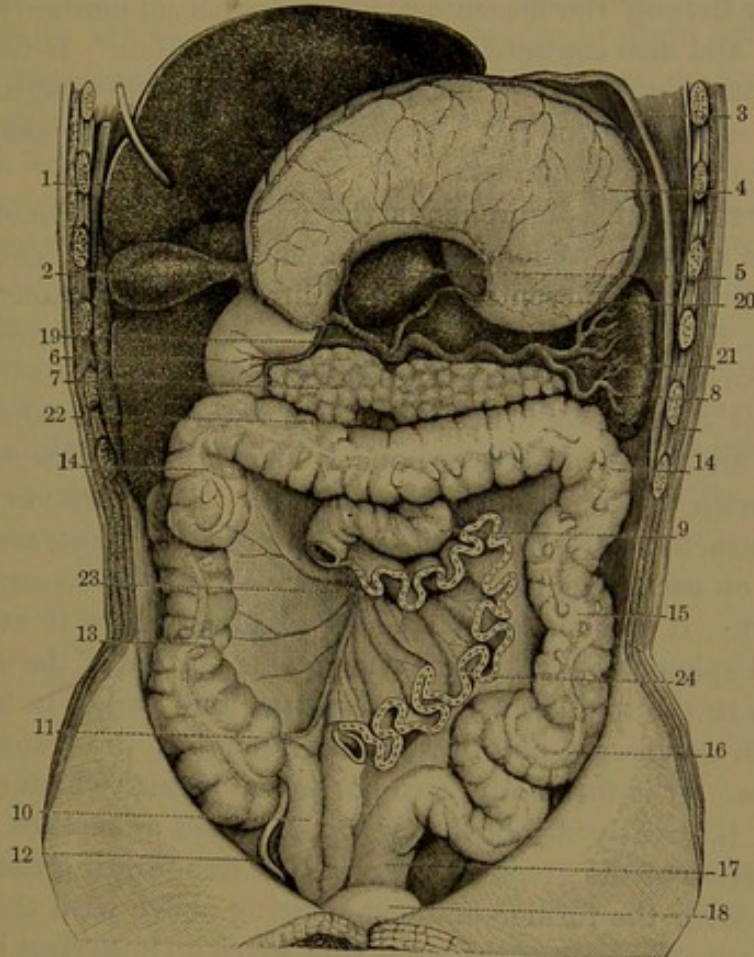
<sup>1</sup> Bursa omenti minoris.



pearance. When in large quantity it forms irregular, knotted ridges pendent from the omentum. The lower portion of the latter is a common element of inguinal hernia.

While there are lymphatic vessels in the great omentum, it contains no glands, except along its attachment to the great curvature of the stomach.

FIG. 193.



VIEW OF THE ABDOMINAL VISCERA; with the greater part of the small intestine removed, and the liver and stomach turned upward. 1, under surface of the liver; 2, gall-bladder; 3, diaphragm; 4, stomach, posterior surface; 5, caudate lobe of the liver; 6, duodenum; 7, pancreas; 8, spleen; 9, jejunum; 10, ileum; 11, cæcum; 12, vermiform appendix; 13, ascending colon; 14, 14, transverse colon; 15, descending colon; 16, sigmoid flexure; 17, rectum; 18, urinary bladder; 19, hepatic artery, giving off pyloric, hepatic, pancreatico-duodenal, and right gastro-epiploic branches; 20, gastric artery to small curvature of the stomach; 21, splenic artery; 22, superior mesenteric vessels; 23, 24, cut edge of the mesentery between the divided ends of the jejunum and ileum.

The **mesentery**<sup>1</sup> is the most extensive and strongest of the peritoneal folds, and encloses and suspends the entire small intestine, except the duodenum. Its upper border, called the **root of the mesentery**,<sup>2</sup> about six inches long, is attached obliquely across the spine in front of the great vessels, from the left of the second lumbar vertebra to the right sacro-iliac articulation. From the root it rapidly expands down-

<sup>1</sup> Mesenterium.

<sup>2</sup> Radix mesenterii.



ward and forward in a fan-like and ruffled manner, and at its distal border encloses the whole length of the jejunum and ileum, while at its widest part it is from four to six inches. It is continuous above with the transverse mesocolon, on each side with the ascending and descending portions of the latter, and below extends towards the promontory of the sacrum. It consists of two layers directed right and left and united by a considerable layer of areolar tissue, which is traversed by the superior mesenteric blood-vessels, numerous lymphatics, and nerves, and also contains many lymphatic glands. It further contains a variable quantity of fat proportioned to the condition of the individual, sometimes in fat persons causing the mesentery to be a half-inch or more in thickness.

The **mesocolon** comprehends the peritoneal attachment of the colon to the adjacent abdominal wall, almost completely encircles the small intestine and mesentery, and is inwardly continuous with the root of the latter. The **ascending mesocolon**<sup>1</sup> is commonly very short, and incompletely invests the corresponding portion of the colon, which is not covered by it behind. It invests the commencement of the cæcum and its vermiform appendix, and furnishes this with a fold connected with the inner side of the former. The **transverse mesocolon**<sup>2</sup> is attached across the abdomen opposite the pancreas, inclining downward on each side, and completely invests the transverse colon at its fore part. It is shortest at the extremities, where it attaches the hepatic and splenic flexures to the contiguous portion of the diaphragm, and widens to the middle, where it is about four inches in length, and permits free downward and upward movement of the transverse arch of the colon. It is formed by two peritoneal layers, which enclose the latter, and is greatly strengthened by the close adherence of the ascending portion of the great omentum. The **descending mesocolon**,<sup>3</sup> continuous with the former and commencing above with the phrenicocolic ligament, like that of the right side, gives an imperfect investment to the descending colon. In the left iliac region the mesocolon from extreme shortness above gradually extends in a broad fold, which conforms to and completely invests the sigmoid flexure of the colon. Between the layers of the mesocolon and their attachments are the colic and sigmoid branches of the superior and inferior mesenteric blood-vessels, together with their accompanying lymphatic vessels and numerous glands and nerves of the colon.

The broad mesocolon of the sigmoid flexure of the colon gradually subsides below into the **mesorectum**, which is short, directed obliquely to the right, and attaches the rectum to the front of the sacrum. It almost completely invests the commencement of the rectum, but in its farther descent gradually retires from behind, covering the rectum at the sides and in front, and finally only in the latter position, near

<sup>1</sup> M. ascendens or dextrum.    <sup>2</sup> M. transversum.    <sup>3</sup> M. descendens or sinistrum.



the middle of its length, whence it is reflected on the bladder. In this manner is formed the **recto-vesical pouch**, bounded laterally by the lunate **recto-vesical folds**.<sup>1</sup> Between the layers of the mesorectum the superior hemorrhoidal blood-vessels, with the accompanying lymphatics and nerves, pursue their course associated with lymphatic glands and more or less fat.

From the posterior surface of the bladder the peritoneum ascends to the summit, and thence to the front of the pelvis and anterior abdominal wall. Within the latter it produces three slight folds, the **suspensory ligaments of the bladder**,<sup>2</sup> which ascend and converge from the pubic and inguinal regions to the umbilicus.

In the female the lower extension of the mesorectum is reflected to the contiguous upper part of the vagina and the uterus, forming the **recto-uterine pouch**,<sup>3</sup> defined laterally by the lunate **recto-uterine folds**.<sup>4</sup> Covering the uterus, the peritoneum produces on each side a fold, the **broad ligament of the uterus**, directed to the side of the pelvic cavity. From the front of the organ it is reflected upon the bladder, forming the **vesico-uterine pouch**, of less depth than the former, and defined laterally by lunate **vesico-uterine folds**.

---

<sup>1</sup> Plicæ recto-vesicales or semi-lunares Douglasii.

<sup>2</sup> Ligamenta suspensoria vesicæ.

<sup>3</sup> Recto-vaginal pouch ; pouch of Douglas.

<sup>4</sup> Plicæ recto-uterinæ

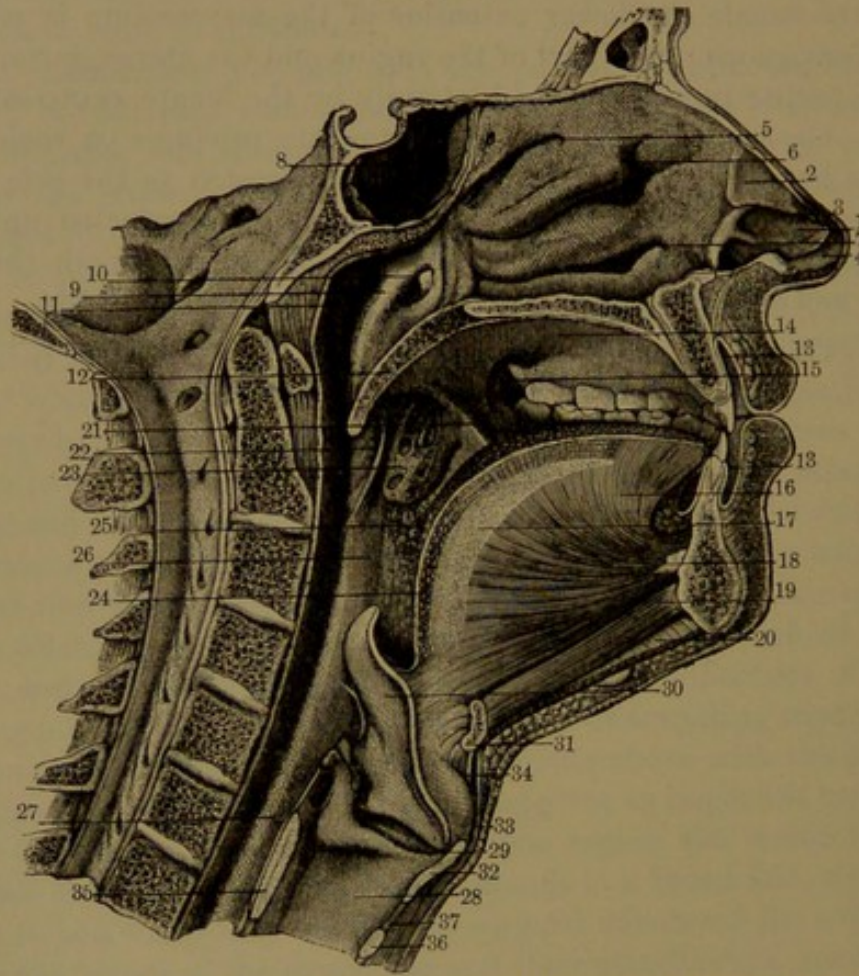


## CHAPTER VIII.

### THE ALIMENTARY APPARATUS.

THIS consists of the alimentary canal, about thirty feet in length, or between five and six times that of the body, extending from the mouth

FIG. 194.



VERTICAL SECTION, ANTERO-POSTERIORLY, EXPOSING THE CAVITIES OF THE NOSE, MOUTH, PHARYNX, AND LARYNX. 1, oval cartilage of the left nostril; 2, triangular cartilage; 3, separation between the two; 4, prolongation of the oval cartilage along the column of the nose; 5, superior meatus of the nose; 6, middle meatus; 7, inferior meatus; 8, sphenoidal sinus; 9, arch bounding the eustachian tube; 10, orifice of the latter; 11, lateral recess of the pharynx; 12, soft palate, ending below in the uvula; 13, vestibule of the mouth between the lips and jaws; 14, roof of the mouth, or hard palate; 15, communication of the cavity of the mouth with the vestibule; 16, tongue; 17, fibrous partition in the median line of the latter; 18, genio-glossal muscle; 19, genio-hyoid muscle; 20, mylo-hyoid muscle; 21, anterior pillar of the palate; 22, posterior pillar of the palate; 23, tonsil; 24, glands of the tongue; 25, floor of the fauces; 26, 27, pharynx; 28, cavity of the larynx; 29, ventricle of the larynx; 30, epiglottis; 31, hyoid bone; 32, 33, thyroid cartilage; 34, thyro-hyoid membrane; 35, 36, cricoid cartilage; 37, vocal membrane.

to the anus. The first portion consists of the mouth, with the organs of mastication, including the teeth, with the jaws and muscles which



act on the latter, the tongue, and the salivary glands. The second portion consists of the pharynx and œsophagus, as the organs of swallowing; and the third portion consists of the stomach and intestines, with the pancreas and liver, as the organs of digestion, contained within the abdomen.

### THE MOUTH.

The **mouth**<sup>1</sup> is included by the lips, cheeks, palate, and floor, and opens behind by a passage named the fauces into the pharynx, or throat. The **cavity of the mouth**<sup>2</sup> is lined throughout by mucous membrane, except upon the teeth, which, when closed together, divide the cavity into two portions, the outer one being called the **vestibule**.<sup>3</sup> The cavity within the position of the lower jaw is occupied by the tongue, attached to the floor of the mouth.

The **lips**<sup>4</sup> enclose the **orifice of the mouth**,<sup>5</sup> and their union forms the **angles**, or **corners**,<sup>6</sup> of the mouth. They are formed by the oral sphincter and other muscles converging to the orifice, covered by the skin outwardly, merging into the oral mucous membrane inwardly. The thin, bright-red skin at the border of the lips adheres directly to the oral sphincter by a layer of connective tissue free from fat. It is furnished with numerous minute vascular papillæ, which are embedded in the investing epithelium; and some of the papillæ are provided with tactile corpuscles. Embedded in the submucous connective-tissue layer of the lining mucous membrane are the **labial glands**,<sup>7</sup> which form an almost continuous layer, and produce a more or less uneven condition of the inner surface of the lips that may be felt by the tip of the tongue. They are rounded, polyhedral, racemose glands, of a pinkish color, secrete mucus, and by their ducts open on the surface of the mucous membrane.

Between the lips and the jaws, in the median line, the mucous membrane forms a little fold, the **labial frænum**,<sup>8</sup> which connects the lip with the gum; the upper one being more produced.

The **cheeks**<sup>9</sup> have a nearly similar composition to the lips, the fore part having for its basis the buccinator and contiguous muscles, and the back part the ramus of the mandible with its muscles, all covered by the skin and lined by the oral mucous membrane. Between the buccinator and the skin, and extending backward between the former and the ramus of the mandible, the space is commonly occupied by more or less soft adipose tissue, the disappearance of which in emaciation produces the "hollow cheek." Numerous small **buccal glands**,<sup>10</sup>

<sup>1</sup> Os; stoma.

<sup>2</sup> Vestibulum.

<sup>3</sup> Orificium, apertura, rima, or hiatus oris.

<sup>4</sup> Commissures; commissura labiorum.

<sup>5</sup> Glandulæ labiales.

<sup>6</sup> Genæ; malæ.

<sup>7</sup> Cavum oris; spatium oris.

<sup>8</sup> Labia.

<sup>9</sup> Frænulum labii.

<sup>10</sup> Glandulæ buccales.



like the labial glands, are embedded in the submucous areolar tissue of the cheek.

Forming the inner boundary of the vestibule of the mouth are the arching alveolar borders of the jaws supporting the teeth. These borders are closely invested with a smooth, dense, and highly-vascular mucous membrane, forming the **gums**.<sup>1</sup> They are attached by firm connective tissue to the periosteum of the subjacent bones. Around the neck of each tooth the gum forms a narrow doubling, or collar, free from the tooth.

The **palate**, or **roof of the mouth**,<sup>2</sup> comprises two portions, the hard and soft palate. The **hard palate**,<sup>3</sup> included within the arch of the upper jaw, has for its foundation the inner surface of the alveolar border and the palate plates of the maxillæ and palate bones. It is deeply vaulted, but is much reduced in old age by the loss of the teeth and alveolar border. It is invested with a firm mucous membrane, continuous with the adjacent gum, and is attached by a dense connective tissue to the subjacent periosteum, along the alveolar border and the median line of the palate. The intermediate subjacent space on each side is occupied by a compact layer of racemose glands embedded in connective tissue closely adherent to the periosteum. The glandular layer increases in thickness behind, and extends into the soft palate. The free surface of the mucous membrane is transversely rugose at its fore part, is smooth behind, and is divided by a feeble median ridge, or raphé, ending in a little papilla beneath the incisive foramen immediately behind the interval of the middle incisors. Many minute apertures, the orifices of the **palatine glands**,<sup>4</sup> are scattered over the surface, the larger and more numerous being situated near the commencement of the soft palate.

The **soft palate**<sup>5</sup> is a movable flap, which extends from the hard palate obliquely downward and backward between the mouth and posterior nares into the pharynx. The lower surface is concave and smooth, and is divided in the median line by a continuation of the raphé of the hard palate. The upper surface is convex and somewhat more prominent along the middle. The posterior free border is prolonged into a median, blunt, conical process, the **uvula**,<sup>6</sup> and it curves outward on each side in the formation of the posterior pillar of the palate.

The soft palate is invested with mucous membrane, continuous below with that of the hard palate and sides of the fauces, and above with that of the posterior nares. Its foundation is an aponeurotic and

<sup>1</sup> *Gingivæ*; *carnicula*.

<sup>2</sup> *Palatum durum*.

<sup>3</sup> *Palatum molle*, mobile, or *pendulum*; *velum palati*, *palatinum*, *pendulum palati*, or *staphylinum*; *claustrum palati*; veil of the palate.

<sup>4</sup> *Glandulæ palatinæ*.

<sup>5</sup> *Uva*; *uvigera*; *staphyle*; *columella*, or *columna oris*; *sublingua*; *palate*.

<sup>6</sup> *Palatum*; *fossa palatina*.



partially fleshy layer, beneath the upper surface, pertaining to the palatine muscles, attached to the palate plates of the palate bones. Below the aponeurosis is a thick extension of the glandular layer of the hard palate, continuous on the two sides and thinning away behind. A thinner layer of the same kind of glands occupies the upper part of the soft palate. The uvula is formed by the uvular muscles extending from above the palatine aponeurosis, enclosed by a softer prolongation of the mucous membrane of the soft palate.

The soft palate on each side joins the triangular niche of the fauces, in which is lodged the tonsil, and is defined in front and behind by the **pillars of the palate**.<sup>1</sup> The **anterior pillar** is a fold of mucous membrane enclosing the palato-glossal muscle, starting from the base of the uvula and curving from beneath the soft palate outward, downward, and forward to the side of the tongue, which it joins about its posterior third. The **posterior pillar**, in like manner, starts from the uvula and curves outward as the posterior border of the soft palate, and continues downward to the side of the pharynx. It encloses the palato-pharyngeal muscle, and is more prominent than the former.

The wedge-shaped space across the mouth between the niches for the tonsils constitutes the **fauces**, or passage-way, from the mouth into the pharynx, its floor being formed by the posterior third of the tongue. The anterior pillars of the palate together form the **anterior palatine arch**, or the **isthmus of the fauces**,<sup>2</sup> through which may be seen the tonsil on each side, the uvula above, and behind the **posterior palatine arch**,<sup>3</sup> formed by the posterior pillars of the palate.

The arteries of the palate are the superior palatine of the internal maxillary artery and the inferior palatine of the facial artery. The veins from the superior palatine join the pterygoid plexus, and with those of the tonsil join the inferior palatine of the facial vein. The lymphatics proceed to the side of the fauces, and join the glands at the side of the hyoid bone and styloid muscles. The nerves are the palatine and naso-palatine branches of the sphenopalatine ganglion.

The **floor of the mouth** is mainly formed by the muscles included within the arch of the mandible, the mylo-hyoid, the genio-hyoid, and the digastric muscles, together with the attachment of those of the tongue, which lies on the floor. Its free surface in the mouth is covered by the mucous membrane continuous with the lower gum and reflected from the mandible to the under part of the sides and tip of the tongue. In the median line it forms a narrow fold, the **lingual frænum**,<sup>4</sup> extended between the symphysis of the mandible and the under part of the tip of the tongue. Beneath the sides of the latter it covers

<sup>1</sup> Half arches of the palate.

<sup>3</sup> Arcus palatinus posticus.

<sup>2</sup> Arcus palatinus anticus.

<sup>4</sup> Frænulum or vinculum linguae.

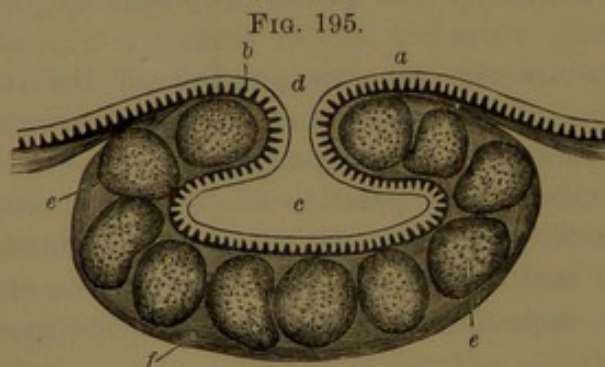


the sublingual gland, the position of which is indicated by a ridge, between the mandible and the attachment of the tongue.

The **mucous membrane** lining the cavity of the mouth, for the most part bright red, varies in thickness and firmness in different positions. It is thicker on the lips and cheeks than on the floor, the soft palate, and the palatine arches, and is firmer on the gums and hard palate than elsewhere; the difference being mainly due to the greater or less density of the subjacent connective-tissue layer. It is provided with a stratified epithelium, of which the deepest layer consists of columnar cells, the succeeding layers of larger polyhedral cells, while the more superficial layers form a squamous epithelium of broad, flat scales overlapping at the borders. The squamous epithelium varies in thickness in different positions, and proportioned with its thickness the mucous membrane appears less red and more or less white. The subjacent mucosa is well marked, and is everywhere provided with minute conical papillæ, which are mostly buried in the deeper part of the epithelium. At the borders of the gums and on the rugose fore part of the hard palate they are more numerous, larger, and more or less prominent. The papillæ are processes of the mucous membrane supplied with nerves, and each with a looped capillary blood-vessel.

#### THE GLANDS OF THE MOUTH.

Besides the special salivary glands, whose ducts open into the cavity of the mouth, there are numerous small racemose glands, which



SECTION OF A FOLLICULAR LYMPHOID GLAND. *a*, oral mucous membrane continued into the follicular gland; *b*, papillæ; *c*, cavity of the follicle; *d*, mouth of the follicle; *e*, nodules of lymphoid tissue; *f*, connective-tissue layer: highly magnified.

are situated in most positions embedded in the sub-mucous layer of connective tissue of the lining mucous membrane and secrete mucus. They constitute the labial and buccal glands, and many of those of the palate and tongue. Associated with the latter, and found also in a similar position of the pharynx, are numerous glands, which may be distinguished as

**follicular lymphoid glands.** The simple form of these, as represented in the adjoining figure, consists of a flask-like follicle or crypt, which is formed by an inflection of the mucous membrane surrounded by a connective-tissue layer, in which are embedded numerous rounded nodules of lymphoid tissue. These glands are commonly more or less conspicuous at the posterior third of the tongue, where their orifices are distinctly visible, and they give to the surface an uneven appearance. The tonsils are compound glands of the same character.



## THE TONSILS.

The **tonsil**<sup>1</sup> is a flattened, oval body, which occupies the niche at the side of the fauces between the anterior and posterior pillars of the palate. It is of variable size, often as a result of disease which causes more or less enlargement, but normally is about two-thirds of an inch long, scarcely half an inch broad, and of less thickness. It is placed with its length upright, with its free, broad surface directed inward, and its outer surface resting against the superior constrictor of the pharynx, to which it is attached by connective tissue. Its inner surface, projecting into the fauces, presents a somewhat honey-combed aspect, due to a number of variably-sized shallow recesses, or crypts, into which open smaller ones. The crypts are lined throughout by a continuation of the oral mucous membrane, and have thick walls of connective tissue, in which are embedded numerous nodular masses of lymphoid tissue.

The tonsil externally lies near the internal carotid artery; and in relation with the outside of the neck it is placed just within the position of the angle of the lower jaw.

The tonsils are supplied by the dorsal branch of the lingual artery, the inferior palatine and tonsillar branches of the facial, and the superior palatine branch of the internal maxillary artery. The veins form the tonsillar plexus, which joins the inferior palatine branch of the facial vein. The lymphatics are abundant, and join the deep cervical glands.

## MUSCLES OF THE PALATE.

The **palato-glossal muscle**<sup>2</sup> is a small, fleshy fascicle within the anterior pillar of the palate. It arises within the lower surface of the soft palate, united with the muscle of the opposite side, and descends to the side of the tongue, where it blends with the stylo-glossal muscle.

The **palato-pharyngeal muscle**,<sup>3</sup> in the same manner, occupies the posterior pillar of the palate. It is a long, fleshy fascicle, which arises within the soft palate in an expanded manner on both sides of the aponeurosis of the palatal tensor and connected with the opposite muscle. Descending to the side of the pharynx at the inner side of the middle constrictor, it expands and unites with the stylo-pharyngeal muscle, to be inserted with it. It receives a narrow slip, which descends from the lower end of the eustachian tube and has been described as a separate muscle.<sup>4</sup>

<sup>1</sup> Tonsilla; amygdala; glandula colli; almond of the throat.

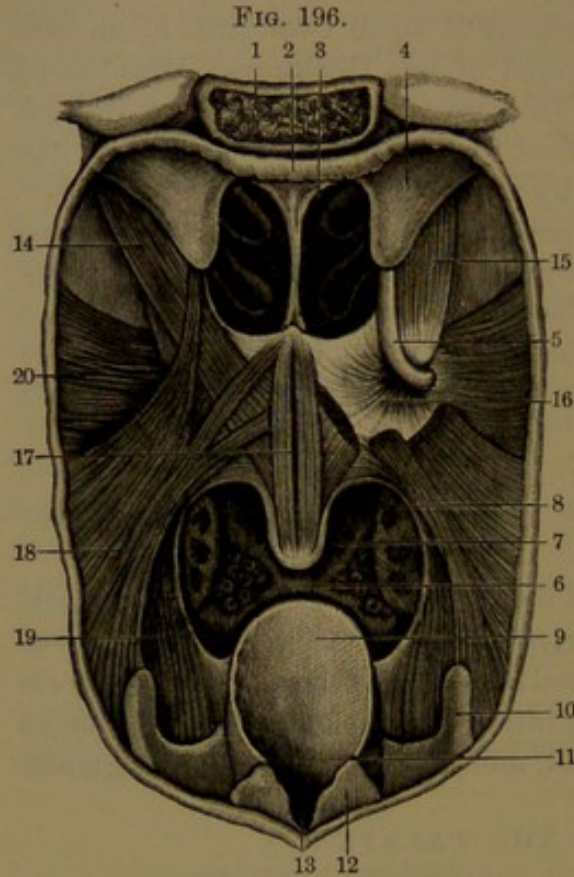
<sup>2</sup> M. palato-glossus, glosso-palatinus, or glosso-staphylinus; m. constrictor isthmi faucium.

<sup>3</sup> M. palato-pharyngeus or pharyngo-palatinus; m. thyreo-palatinus; m. constrictor isthmi faucium posterior superior.

<sup>4</sup> M. salpingo-pharyngeus; m. levator pharyngis internus.



The **palatal elevator**<sup>1</sup> is a columnar muscle placed in the wall of the pharynx, at the outer side of the posterior nares. It arises tendinously from beneath the apex of the temporal pyramid and the contiguous part of the eustachian tube. Descending obliquely forward and inward at the side of the pharynx, it enters the soft palate and expands above the aponeurosis of the palatal tensor, to which it is attached in advance, and joins its fellow in the median line. The muscle lies in contact externally with the palatal tensor and superior constrictor; and internally with the mucous membrane of the pharynx.



**MUSCLES OF THE PALATE.** The pharynx laid open and viewed from behind. 1, basilar process; 2, roof of the pharynx; 3, posterior nasal orifice; 4, cartilaginous eustachian tube; 5, entopterygoid process, ending in a hook; 6, the fauces; 7, uvula; 8, tonsil; 9, epiglottis; 10, thyroid cartilage; 11, aryteno-epiglottic fold; 12, arytenoid cartilage; 13, notch between the arytenoid cartilages; 14, palatal elevator muscle; 15, palatal tensor; 16, expansion of its tendon of insertion in the soft palate; 17, uvular muscle; 18, palato-pharyngeal muscle; 19, stylo-pharyngeal muscle; 20, superior constrictor of the pharynx.

goid process and the superior constrictor of the pharynx. In the soft palate its aponeurosis is beneath the insertion of the palatal elevator and the uvular muscle.

The **uvular muscle**,<sup>3</sup> together with that of the opposite side,

<sup>1</sup> *M. levator palati*; *m. l. p. mollis*; *m. peristaphylinus internus*; *m. petrostaphylinus*; *m. petro-salpingo-staphylinus*.

<sup>2</sup> *M. tensor palati*; *m. circumflexus palati*; *m. peristaphylinus externus*; *m. pterygo-staphylinus*; *m. spheno-salpingo-staphylinus*.

<sup>3</sup> *M. uvulae*; *m. azygos uvulae*; *m. palato-staphylinus*.



forms the fleshy interior of the uvula. It arises from the posterior nasal spine and the contiguous aponeurosis, and, closely connected with its fellow, descends at the back of the soft palate into the uvula.

The palato-glossal and palato-pharyngeal muscles are probably supplied by the adjacent pharyngeal plexus of nerves. The palatal tensor receives a branch from the otic ganglion, and the palatal elevator and uvular muscles from the petrosal branch of the vidian nerve.

### THE TONGUE.

The **tongue**<sup>1</sup> is a muscular organ covered with an extension of the oral mucous membrane, and provided with conspicuous papillæ which are the chief organs of taste. Ordinarily at rest, it occupies the space within the position of the mandible and the teeth on the floor of the mouth. The free portion, called the **body**, is bounded by the rounded **sides** and **tip**, which are often somewhat impressed by contact with the teeth. Its posterior part attached to the hyoid bone is the **root**; and it is also attached its entire length beneath by means of the genio-glossal muscles to the mental tubercle of the mandible. The upper surface, **dorsum**, or **back of the tongue**, is convex, and is marked by a slight median furrow, the **raphé**, which indicates the bilateral symmetry of the organ. The raphé usually ceases behind in a pit, the **cæcal foramen**, situated about an inch from the root of the tongue.

The mucous membrane beneath the sides and tip of the tongue is like that elsewhere in the mouth, and is comparatively loosely attached to the subjacent muscular structure. It is sufficiently thin to see through it, on each side, the ranine vein, which runs forward below the tip, and has close to it externally the ranine artery. To the outer side of the position of these vessels there is not unfrequently a narrow, irregular, and somewhat fringed fold of the membrane; and in the median line under the tip of the tongue is the more distinct fold, or **lingual frænum**.

The **dorsum**, or **back**, of the tongue, on the anterior two-thirds of its surface, is velvety, or covered with a white fur, which is due to numerous little eminences, named from their function the **papillæ of taste**.<sup>2</sup> Of these, visible to the naked eye, there may be distinguished three kinds, different in size and shape, and named the circumvallate, fungiform, and conical papillæ. They are generally beset with others which are minute, and are like those found everywhere in the oral mucous membrane concealed beneath the epithelium. Simple in their character, the larger ones are regarded as compound papillæ. Besides the foregoing, some little folds of the mucous membrane, described as the **foliate papillæ**,<sup>3</sup> are situated on the side of the tongue immediately in advance of the termination of the anterior pillar of the palate.

<sup>1</sup> Lingua; glossa; glotta.

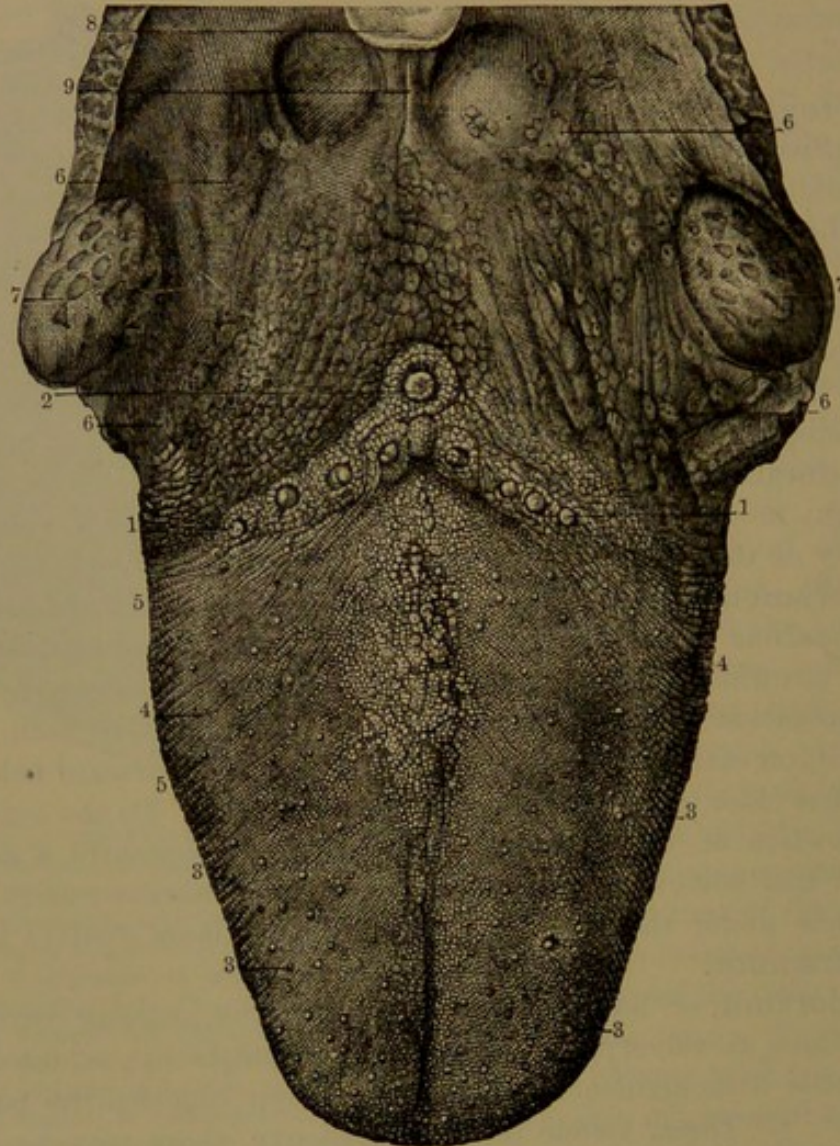
<sup>2</sup> P. gustatoriae.

<sup>3</sup> P. foliatæ.



The **circumvallate papillæ**,<sup>1</sup> the largest kind, are few, usually about nine, but often one to three more or less. They form an angular series at the limit of the papillary layer behind. Each has the shape of a reversed, truncated cone, and occupies a corresponding pit of the mucous membrane surrounded by a thick, prominent ring, which gives

FIG. 197.



VIEW OF THE DORSUM OF THE TONGUE. 1, 2, V-like row of the circumvallate papillæ; 3, fungiform papillæ; 4, 5, conical papillæ; 6, 6, floor of the fauces, with numerous lymphoid follicular glands; 7, tonsils; 8, summit of the epiglottis; 9, the middle glosso-epiglottic frænum, with depressions on each side bounded externally by the lateral fræna.

the papilla the appearance of being enclosed by a wall, and hence its name. The top of the papilla is rounded and beset with many minute, simple papillæ concealed beneath a thick, stratified epithelium, which is thinner on the sides of the papilla. The surrounding wall has a similar construction.

<sup>1</sup> P. circumvallatæ, vallatæ, maximæ, truncatæ, calyciformes, mucosæ, or lenticulares.



The **fungiform papillæ**,<sup>1</sup> smaller than the former, are scattered over the dorsum of the tongue, and are more numerous approaching the lateral borders, and especially the tip. They are rendered conspicuous by their redder color contrasted with the more or less whitish appearance of the conical papillæ occupying the intervals of the former. They are rounded eminences narrowed at their attachment, resembling a young mushroom, whence the name. They are covered with minute simple papillæ covered by a smooth, stratified epithelium.

FIG. 198.

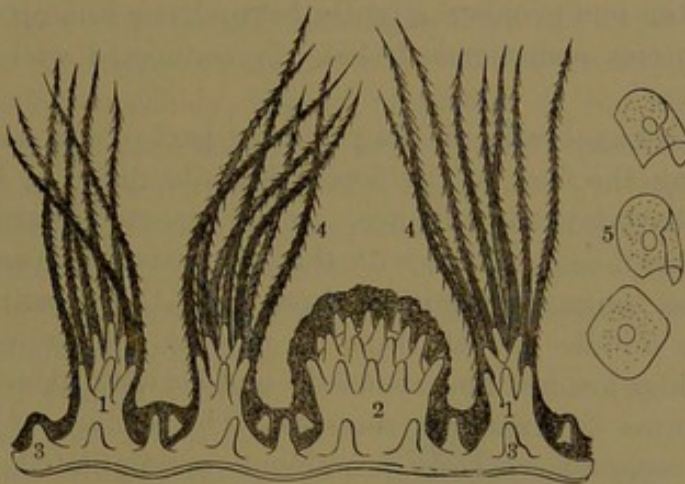


DIAGRAM OF THE PAPILLÆ OF TASTE. 1, conical papillæ; 2, fungiform papilla; 3, simple papillæ, which also surmount the former; 4, epithelial hair-like processes; 5, isolated squamous epithelial cells forming the latter: highly magnified.

The **conical papillæ**,<sup>2</sup> the smallest and most numerous, densely crowd the space unoccupied by the former. They are generally arranged in oblique lines diverging on each side forward from the raphé, but gradually become more transverse towards the tip of the tongue. They vary in size, and are largest and more slender towards the lateral borders of the tongue. Many are small, and merge into the character of the simple papillæ. They are conical or cylindro-conical, and mostly terminate in a group of simple papillæ, from which the epithelium extends in long, hair-like processes, which give to each conical papilla the appearance of a pencil or small brush. It is especially these processes, varying in degree of production, which give to the back of the tongue its whitish, velvety, or furred appearance.

The papillæ of taste have the compound structure of the simple papillæ, and contain nets of capillary vessels with a loop for each simple papilla they possess. The fungiform and circumvallate papillæ also receive numerous medullated nerve-fibres.

Embedded in the epithelium at the base of the circumvallate, the foliate, and many of the fungiform papillæ, there occur peculiar micro-

<sup>1</sup> P. fungiformes, clavatæ, capitatæ, mediæ, or semilenticulares.

<sup>2</sup> P. conicæ, filiformes, minimæ, pyramidales, or villosæ.



scopic bodies, named **taste-buds**.<sup>1</sup> These are ranged in rows, and consist of ovoidal masses of cells, which are placed perpendicularly in the epithelium resting on the basement membrane, with the narrower extremity reaching the free surface of the epithelium. The adjacent portion of the latter forms a special cover for each bud, consisting of a layer of flat, fusiform scales overlapping at the edges and arranged parallel with those composing the bud. The outer cells of the taste-bud are likewise fusiform, slightly flattened, and provided with a large central, oval nucleus. The interior cells, named **gustatory cells**, are similar, but are much more slender, and have filamentous ends, of which the outer one projects slightly beyond the summit of the bud, and the inner one, sometimes divided, is connected with a terminal nerve-fibril.

The mucous membrane at the posterior part of the dorsum of the tongue, forming the floor of the fauces, is quite different in character from the papillary layer in advance. It is connected laterally with the niche of the tonsil and behind with the epiglottis, between which and the root of the tongue it produces three folds, the **glosso-epiglottic fræna**. The middle one of these is narrow and prominent, while those at the sides are low and rounded; and between them the root of the tongue forms two shallow recesses. The surface of the mucous membrane presents a variably prominent mammillated appearance, with a central aperture to each mammilla. The submucous connective tissue, mingled with lymphoid tissue, forms a considerable layer, containing numerous small racemose glands and simple lymphoid follicular glands, which produce the mammillated appearance of the contiguous surface of the tongue. The lymphoid glands, like the tonsils, are liable to enlargement, giving a more conspicuous mammillary condition of the surface of the tongue, each mammilla also presenting an enlarged central aperture. The racemose glands are like those of the lips and palate, and extend between the contiguous bundles of muscular fibres, while their ducts open on the surface of the mucous membrane between the lymphoid glands and also into their recesses. They exist elsewhere in the tongue, as around the circumvallate papillæ and also the cæcal foramen, into which their ducts open; others are beneath the sides of the tongue, and a considerable group under the tip close to the ranine blood-vessels.

#### MUSCLES OF THE TONGUE.

The **genio-glossal muscle**<sup>2</sup> forms with its fellow the chief part of the middle of the tongue. It arises tendinously from the mental tubercle of the mandible, whence its fleshy fascicles diverge in a fan-like manner upward and backward to be inserted into the upper part of the body of the hyoid bone, above which some extend backward to the side of the pharynx, but in great part enter the tongue and extend

<sup>1</sup> Taste-goblets.

<sup>2</sup> M. genio-glossus; m. genio-hyo-glossus.



forward to the tip. Internally, it is in contact with the muscle of the opposite side, but is separated behind and below by the fibrous septum of the tongue. Externally, it is in contact with the infralingual, hyo-glossal, and stylo-glossal muscles, the lingual vessels, the hypo-glossal and gustatory nerves, and the sublingual gland. Its anterior border occupies the lingual frænum, and its posterior lower border is in contact with the genio-hyoid muscle.

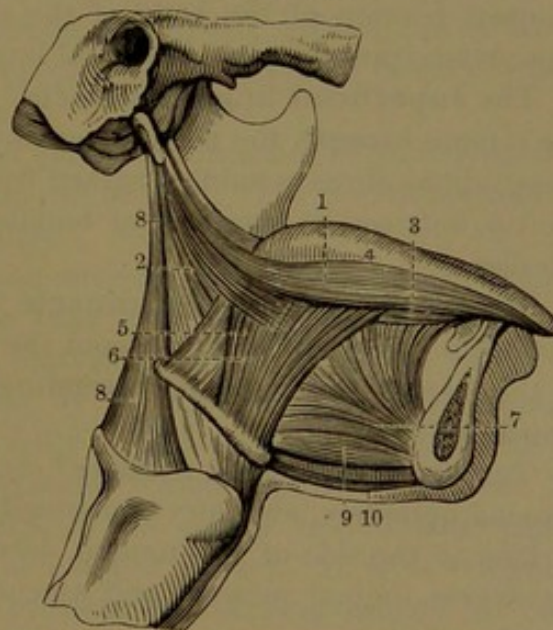
The **hyo-glossal muscle**<sup>1</sup> lies to the outer side of the former. Flat and quadrate, it arises from the side of the body and cornua of the hyoid bone, and ascends to the side of the tongue, where it extends towards the tip. The portion ascending from the hyoid body expands at the side of the tongue to the outer side of that from the cornua. Its different portions, variably distinct according to the attachment and direction of its fascicles, have been described as separate muscles.<sup>2</sup> Internally, it is in contact with the infralingual and genio-glossal muscles, the middle constrictor of the pharynx, and the lingual vessels and the glosso-pharyngeal nerve. Externally, it is connected with the stylo-glossal and palato-glossal muscles, and is in contact with the stylo-hyoid and digastric muscles, and with the lingual vessels, the sublingual gland, and the duct of the submaxillary gland.

The **infralingual muscle**<sup>3</sup> is a longitudinal, fusiform, fleshy bundle extending from the hyoid bone to the tip of the tongue, between the upper part of the genio-glossal and hyo-glossal muscles. At the root of the tongue its fibres are intercalated with those of the stylo-glossal and genio-glossal muscles and of the middle constrictor of the pharynx.

The **stylo-glossal muscle**<sup>4</sup>, the shortest and smallest of those from the styloid process, arises tendinously from the fore part near its end, and from the stylo-maxillary liga-

ment. Descending, it curves forward, and terminates in the lateral

FIG. 199.



SIDE VIEW OF THE MUSCLES OF THE TONGUE. 1, 2, stylo-glossal muscle; 3, infralingual muscle; 4, dorsum of the tongue; 5, 6, hyo-glossal muscle; 7, genio-glossal muscle; 8, stylo-pharyngeal muscle; 9, genio-hyoid muscle; 10, mylo-hyoid muscle.

<sup>1</sup> M. hyo-glossus; m. basio-cerato-chondro-glossus.

<sup>2</sup> M. basio-glossus, cerato-glossus, and chondro-glossus.

<sup>3</sup> M. lingualis; m. lingualis inferior, or lingualis longitudinalis inferior.

<sup>4</sup> M. stylo-glossus.



border of the tongue, with its fibres decussating with those of the hyo-glossal muscle. It is in contact internally with the superior constrictor of the pharynx, the tonsil, and the hyo-glossal muscle; externally with the parotid gland, the internal pterygoid muscle, the sublingual gland, and the mucous membrane of the tongue.

The fleshy portion of the body of the tongue above is very compactly composed of interlacing bundles of fibres of the different muscles which enter into the construction of the organ; but the lower portion is formed alone by the chief muscles, the bundles of which in this position do not interlace, but are distinct and easily separable, as in the voluntary muscles generally. The intervals of the interlacing bundles of muscular fibres are occupied by delicate connective with adipose tissue. The muscles of the two sides of the tongue are separated below by a distinct fibro-connective tissue, **septum**, extending from the hyoid bone to the tip, and fading away above in the more compact muscular structure. Between the hyo-glossal and genio-glossal muscles, and extending on each side of the infralingual muscle, is another fibro-connective tissue layer, attached behind to the hyoid bone.

Besides the former muscles, others, which intersect them in the more compact portion of the body of the tongue, are distinguished as the superficial, transverse, and vertical lingual muscles.

The **superficial lingual muscle**<sup>1</sup> forms a stratum on each side of the tongue beneath the mucous membrane of the dorsum, consisting of longitudinal fibres running forward from the root and curving towards the tip, between the ascending bundles of the genio- and hyo-glossal muscles.

The **transverse lingual muscle**,<sup>2</sup> beneath the former, consists of numerous fibres, which curve from the septum of the tongue outwardly to the border, between the ascending bundles of the genio- and hyo-glossal muscles.

The **vertical lingual muscle**<sup>3</sup> consists of bundles of fibres, which descend obliquely, and curve outwardly from the dorsum to the under surface of the side of the tongue, decussating with the superficial and transverse lingual muscles and ascending bundles of the genio-glossal muscles.

The arteries of the tongue are chiefly branches of the lingual, but it is also supplied by branches of the facial and ascending pharyngeal arteries. Its veins terminate in the facial and internal jugular veins. The main lymphatics follow the ranine vein, and, after passing through one or two little lymphatic glands at the side of the hyo-glossal muscle, end in the deep cervical glands. The nerves are the gustatory branch of the trigeminal nerve, which supplies the mucous membrane and

<sup>1</sup> M. superficialis linguae; m. longitudinalis superior; m. chondro-glossus.

<sup>2</sup> M. transversus linguae; m. transversalis.

<sup>3</sup> M. verticalis linguae.



papillæ of taste at the fore part and side of the tongue; the lingual branch of the glosso-pharyngeal nerve, which sends filaments to the mucous membrane at the posterior part of the tongue, and especially to the circumvallate papillæ; and the hypoglossal nerve, which is distributed to the muscles.

### THE SALIVARY GLANDS.

The glands which secrete the saliva consist of three on each side of the face, named the sublingual, submaxillary, and parotid glands. They are distinctly lobulated, racemose glands; are of a dull, pinkish-white color, and are attached to the contiguous parts by areolar tissue.

The **sublingual gland**,<sup>1</sup> the smallest of the salivary glands, lies along the floor of the mouth, extending from the lingual frænum backward, and producing a ridge of the mucous membrane between the tongue and lower gum. It is elongated elliptical, flattened parallel with the mandible, and is about an inch and a half long. It rests below on the mylo-hyoid, and inwardly on the genio-glossal muscle, with the lingual nerve and submaxillary duct between them. Its anterior extremity is close to its fellow, and behind it is joined by a process of the submaxillary gland. Its lobules are loosely united, and it has a variable number of ducts,<sup>2</sup> commonly from a dozen to twenty, which open along the ridge of the mouth.

The arteries of the sublingual gland are branches of the submental and lingual, and its veins join the ranine vein. The nerves are numerous, and derived from the gustatory.

The **submaxillary gland**,<sup>3</sup> the second in size of the salivary glands, lies partly within and below the base of the mandible in advance of the angle, covered by the skin, platysma, and fascia of the neck. It occupies a hollow, formed within by the mylo-hyoid and hyo-glossal muscles, below by the anterior belly of the digastric muscle, and behind by the stylo-maxillary ligament, which separates it from the parotid gland. The facial artery, in its course to the face, passes through a channel in its back and upper border. It is of irregular, rounded, massive shape, with a prolongation turning around the back border of the mylo-hyoid muscle, and often another directed upward and backward.

The **submaxillary duct**,<sup>4</sup> about two inches long, leaves the gland on the inner side, passes back around the posterior border of the mylo-hyoid muscle, accompanied by a process of the gland, and runs forward above the muscle, below and to the inner side of the sublingual gland to the lingual frænum. Here it ends by a narrowed orifice on a

<sup>1</sup> Glandula sublingualis.

<sup>2</sup> Ductus Rivini.

<sup>3</sup> Gl. submaxillaris, maxillaris, or angularis.

<sup>4</sup> Duct of Wharton; ductus Whartonianus.



little papilla beneath the tip of the tongue. The duct is a line or more thick, and has a comparatively thin wall.

The arteries and veins are branches of the facial, submental, and lingual. The nerves are numerous, and mainly derived from the gustatory nerve, including those from the submaxillary ganglion; and others are from the sympathetic on the facial artery.

The **parotid gland**,<sup>1</sup> the largest of the salivary glands, is situated at the side of the face, in advance of the ear. It occupies the deep interval between the ramus of the mandible and the mastoid process, extending inward to the styloid process and its muscles, and from the zygoma to the angle of the jaw. Its fore part spreads and thins away on the masseter muscle, and its back part rests on the sterno-mastoid muscle, and fills the space between the articulation of the jaw and the mastoid process. Below and behind it is in contact with the digastric muscle, and in front extends between the pterygoid muscles. Its shape conforms to the space it occupies, and it is a little convex externally, and covered by the skin, fascia, and partially by the platysma muscle. Its lobules are smaller than in the other glands, and are more closely united by the interlobular connective tissue.

The **parotid duct**,<sup>2</sup> emerging from the fore part of the gland, proceeds across the masseter muscle, closely adherent to it, parallel with the zygoma, and about the breadth of a finger below. Turning over the anterior border of the masseter inwardly, it pierces the buccinator, and continues a short distance obliquely forward next the mucous membrane of the cheek, and opens by a contracted orifice, on a little papilla, into the vestibule of the mouth, opposite the second upper molar tooth. Its length is about two and a half inches, its diameter scarcely the eighth of an inch, and its wall is thicker than that of the submaxillary duct.

A small detached portion of the gland, or an accessory gland<sup>3</sup> of variable size, usually lies on the masseter in advance of the main gland, below the zygoma; and by its duct joins the main duct.

Ascending through the parotid gland, behind the ramus of the jaw, is the external carotid artery, which divides within it into the temporal and internal maxillary arteries, the former emerging from the gland above, the latter from within, behind the neck of the mandible. From the back of the gland emerges the posterior auricular artery, and from its fore part the transverse facial artery. More superficially the temporal vein enters the gland, and is joined by the internal maxillary to form the temporo-maxillary vein. This divides into two branches, of which one joining the posterior auricular vein forms the external jugular vein, emerging from the lower part of the gland, while the other branch also passes from the latter to join the facial artery. The

<sup>1</sup> Glandula parotis or parotidea.

<sup>2</sup> Duct of Steno or Stenon; ductus Stenonianus.

<sup>3</sup> Gl. socia parotidis.



facial nerve enters the gland behind and divides within it into branches, which emerge from the fore part. Branches of the great auricular nerve also pierce the gland.

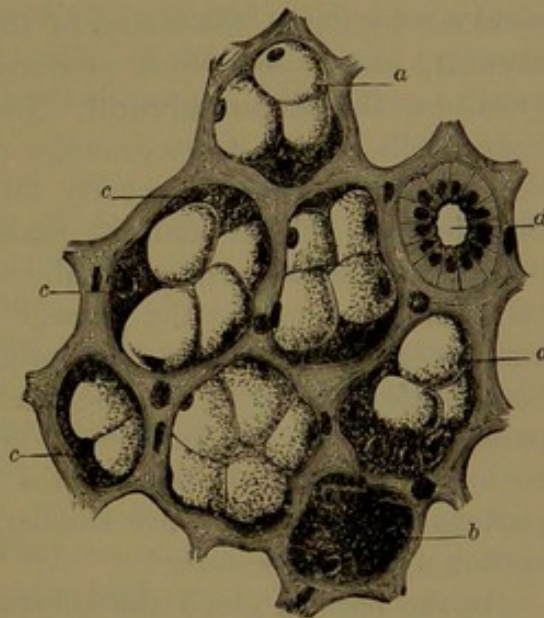
The arteries which supply the parotid gland come directly from the external carotid, and from contiguous branches to other parts. The veins correspond with them. The lymphatics join the deep and superficial ones of the neck. One or two lymphatic glands lie on the surface of the parotid, and often one or two are embedded in its substance. The nerves are derived from the sympathetic on the external carotid artery, and also from the facial, auriculo-temporal, and great auricular nerves.

The salivary glands are compound racemose glands, possessing a common structure, though each exhibits certain important differences. They consist of a close aggregation of polyhedral lobes and lobules, the latter of which consist of a similar aggregation of smaller ones, composed of the peculiar gland-substance. The lobes and lobules are invested with and held together by fibro-connective tissue, which also supports the vessels, nerves, and ducts of the gland. The principal duct divides and subdivides, and furnishes each lobe and lobule with a branch, the branches, for convenience, being called the lobar ducts. These communicate within each lobule with the intralobar duct, which ramifies and finally enters into communication with the alveoli or follicles containing the secreting cells of the gland.

The lobar ducts are lined with a layer of columnar epithelial cells, longitudinally striated, and with an oval nucleus in the outer part of the cells. The epithelium includes a relatively large passage, and rests on a thin basement membrane, sustained by fibro-connective tissue proportioned in quantity with the size of the duct. In the largest ducts, including the principal one, unstriated muscular fibres enter into the construction of the wall.

The larger intralobar ducts<sup>1</sup> have a relatively smaller passage, and are lined by a layer of columnar cells, remarkable for their strongly

FIG. 200.



SECTION OF THE SUBMAXILLARY GLAND. Alveoli of connective tissue containing the secretory cells, —a polyhedral epithelium. a, cells containing mucus; b, cells with granular protoplasm; c, crescentic parietal cells; d, duct with striated columnar epithelial cells.

<sup>1</sup> Salivary tubes of Pflüger.



striated condition, which is most obvious along the inner or deeper part of the cells and gives them the appearance of a short brush. Their nucleus is spherical or oval, and nearly central. The smaller intralobar ducts<sup>1</sup> become successively narrower, and the epithelial cells shorter, polyhedral, and clear, and then more flattened as they join the alveoli. The epithelium of the intralobar ducts rests on a membrana propria consisting of a delicate basement membrane sustained by fibro-connective tissue, gradually decreasing with the division of the ducts.

The **alveoli**,<sup>2</sup> which directly communicate with the latter, are relatively wider branching tubes of variable length, lined by the secreting cells. These rest on a delicate membrana propria continuous with that of the intralobar ducts, and united with the least proportion of fibro-connective tissue between the alveoli, and sustaining the capillary blood-vessels of the latter. The alveoli are of two kinds, those which yield a ropy liquid, the mucus of the saliva, hence called the **mucous alveoli**, and those which produce a more watery secretion, distinguished as the **serous alveoli**. The serous alveoli are lined with polyhedral cells, with a dense granular protoplasm, and a peripheral spherical nucleus. The cells nearly fill the alveoli, and during secretion they become thicker and the passage of the alveoli narrower. The mucous alveoli have a greater calibre than the former, the lining mucous cells being longer and the passage larger. The cells are transparent, and contain a soft, obscurely granular protoplasm, with a compressed basal nucleus. During secretion the cells swell and become more transparent, from the production of mucus in the protoplasm. At the bottom of the alveoli, beneath the former cells, are others, called the **parietal cells**,<sup>3</sup> which are smaller, granular, and polyhedral, but in section appear crescentic.

In the parotid gland the substance is composed entirely of serous alveoli, and therefore secretes pure saliva. The sublingual gland contains only mucous alveoli, and is therefore a mucous gland. The submaxillary gland consists of lobules of serous alveoli, and smaller ones of mucous alveoli, besides others in which the two kinds of alveoli are intermingled.

The alveoli of the salivary glands are surrounded by close nets of capillary blood-vessels, and between them and the alveoli are lymph-spaces, which communicate with plexuses of lymphatic vessels traversing the interlobular connective tissue. The nerves, consisting of medullated fibres, also form a plexus in the latter, and associated with them are minute ganglia.

---

<sup>1</sup> Intermediary or terminal ducts.

<sup>2</sup> Acini.

<sup>3</sup> Crescents of Gianuzzi.



## SALIVA.

**Saliva** is the mixed secretion of the various glands whose ducts open into the mouth, and is a glairy and usually more or less frothy and turbid liquid. Under the microscope, independently of remains of food and cryptogamous growths, it is observed to contain epithelial scales, salivary corpuscles, and fine granules. Its reaction in health is alkaline, especially when the secretion is abundant. The materials detected in it are chiefly mucin, with small quantities of globulin and serum-albumin. It also contains a minute proportion of a substance named ptyalin, which, though it has not been satisfactorily isolated, manifests its power as a ferment, by which the saliva converts starch into sugar.

Parotid saliva is a clear, limpid liquid without viscosity. It contains globulin and some other forms of albumin, but little or no mucin. Ptyalin is indicated by its powerful action on starch. It also contains calcium carbonate and potassium sulpho-cyanide. It is free of corpuscles.

Submaxillary saliva is viscid, and contains mucin, abundance of corpuscles, and amorphous particles of proteid material. Ptyalin is also indicated by greater activity on starch than in the former. It is also more alkaline than parotid saliva.

The epithelial scales of the saliva, single and in little groups, are portions of the detached epithelium of the mucous membrane in all parts of the mouth. They are transparent, polygonal plates, with a clear, circular, or oval central nucleus.

The salivary corpuscles are pale, spherical bodies, resembling the colorless corpuscles of the blood. They contain one or several nuclei and numerous fine granules, which under high power of the microscope are observed to be in an incessant state of agitation or of molecular movement. They resemble the mucous corpuscles of the mucous membranes generally, and with them are probably to be regarded as lymph-corpuscles modified by the condition in which they are found.

## THE TEETH.

Man, and most other animals of his class, in the course of life are provided with two different sets of teeth, of which the first that make their appearance in infancy are called the **temporary**, or **milk teeth**, and those which displace and succeed them from childhood to maturity are distinguished as the **permanent teeth**. To the first set there are twenty teeth, ten in each jaw, and to the second set thirty-two teeth, sixteen in each jaw. The teeth form an unbroken row above and below, and on each side they form a series of several different kinds, which are named incisors, canines, premolars, and molars. In zoology, in defining the chief characters of mammalia, it is usual to



indicate the number and kind of teeth of each lateral series in a formula. Thus, the dental formula of man and his nearest relatives, the higher apes, is expressed as follows:

$$\text{Permanent teeth} \dots \text{in. } \frac{2}{2} \text{ ca. } \frac{1}{1} \text{ premol. } \frac{2}{2} \text{ mol. } \frac{3}{3} = 16 \times 2 = 32.$$

$$\text{Temporary teeth} \dots \text{in. } \frac{2}{2} \text{ ca. } \frac{1}{1} \text{ mol. } \frac{2}{2} = 10 \times 2 = 20.$$

A tooth consists of two principal parts, that displayed in the living mouth, white and glistening, and projecting from the red gums at the border of the jaws, named the **crown**,<sup>1</sup> and another part implanted in the socket, or alveolus, and named the **fang**, or **root**.<sup>2</sup> The place of union of the crown and fang, scarcely constricted and embraced by the edge of the gum, is called the **neck**.

The crown is of various shapes in the different teeth: in the incisors being chisel-like and adapted to cutting; in the canines, conical-pointed and fitted for piercing; and in the premolars and molars cuboidal and provided with tubercles,<sup>3</sup> and suited to crushing the food. The fangs are from one to three in the different teeth, and are long, conical processes by which the teeth are firmly implanted in the sockets, to which they are attached by thin, vascular, connective tissue continuous with the periosteum of the alveoli and the submucous tissue of the gum. The tapering shape of the fangs accurately fitting their sockets is favorable to the diffusion of pressure communicated through the teeth, while it is entirely removed from the point of the fang at which the vessels and nerves enter the latter.

#### THE PERMANENT TEETH.

The teeth in both jaws form unbroken arches, a condition which is peculiar to man among existing animals of the same class. The lower teeth are vertical, though the molars have a slight inward inclination. The upper teeth are, for the most part, vertical, though the molars have a slight outward inclination, and the front teeth, chiefly the incisors, project obliquely to a variable degree in different individuals and races. The arches formed by the teeth are nearly of equal extent, but the upper is slightly the larger, and includes the lower one within its outer limit. They start on the same line behind, but the upper arch extends laterally a little to the outside of the lower arch and overlaps it in front from the oblique projection of the incisors. When the mouth is closed, while the upper incisors overlap the lower ones and adjacent sides of the canines, the other teeth above and below alternate, so that the point of the upper canine occupies the angle between the lower canine and first premolar, the first upper premolar the angle between the lower ones, and so on to the last upper molar,

<sup>1</sup> Corona.

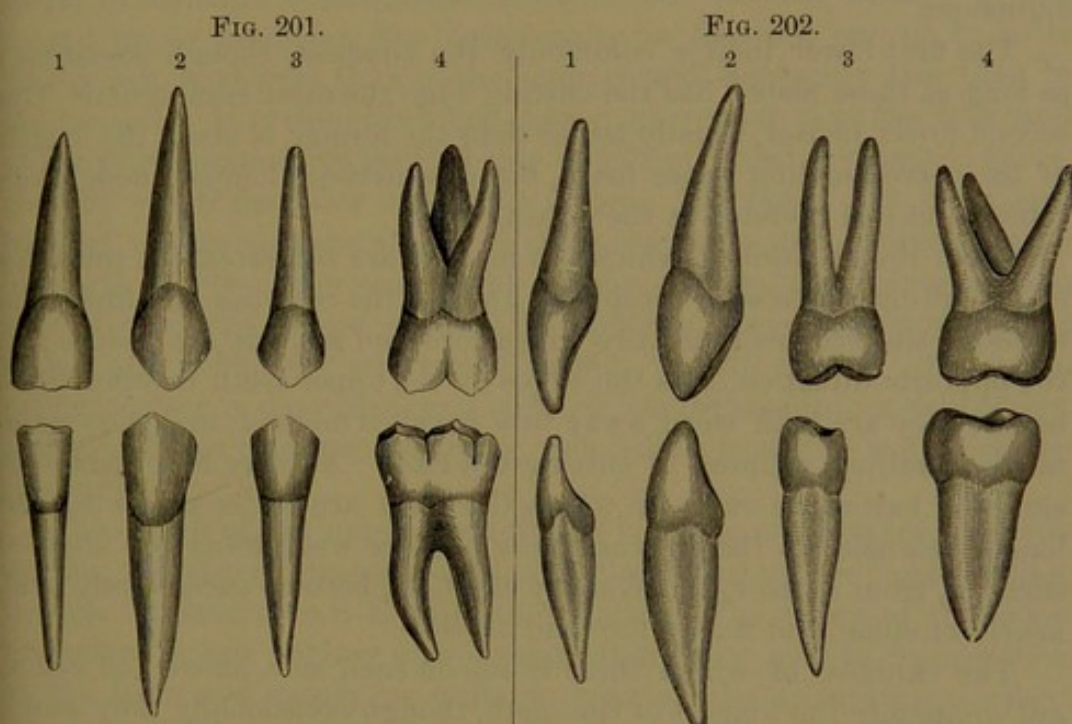
<sup>2</sup> Radix.

<sup>3</sup> Cusps; lobes.



which is in contact alone with the last lower molar. In the movement of the jaw bringing the condyles on the articular eminences, the lower molars are shifted past the last upper ones, on the upper molars and premolars in advance; and the edges of the lower incisors are pushed in advance of those above.

The **incisors**,<sup>1</sup> two on each side above and below, have a single, long, conical fang, usually straight and compressed at the sides, most in the lower teeth and least in the upper first tooth. The crown, as long as, or a little longer than, in all the other teeth except the canines, is wedge-shaped and slightly gouge-like, longer than broad, widest at the biting edge, and narrowing to the base, where it is thicker than wide. The front surface is convex but flattened mesially towards the biting



UPPER AND LOWER PERMANENT TEETH, EXTERIOR VIEW. 1, first incisors; 2, canines; 3, first premolars; 4, middle molars.

LATERAL VIEW of the same teeth as in the preceding figure.

edge, and is conical in outline, with rounded apex next the fang. The posterior surface curves backward to the prominently convex base, is variably concave, and sometimes in the upper teeth slightly ridged. The biting edge, the thinnest part of the crown, is transversely somewhat convex or nearly straight and variably tuberculate. The sides of the crown are curved triangular in outline, and convex but flattened towards the base.

The upper incisors are of more robust proportions than the lower, and have a broader and more gouge-like crown; the posterior surface being more concave and defined by more prominent, lateral borders, and sometimes marked by from two to four slight longitudinal folds

<sup>1</sup> Dentes incisives, incisores, or primores.



or ridges. The cutting edge is more rounded transversely, especially at the outer corner, and is also more variably tuberculate.

The lower incisors are more slender, and have a narrower crown with a straighter cutting edge, which is pretty uniformly divided into three little tubercles. The fang is strongly compressed laterally and sometimes feebly grooved.

The first upper incisor is commonly the longest, is the largest in other respects, and has the fang scarcely compressed. The crown has the edge variably tuberculated, sometimes slightly, and at other times distinctly divided into from three to five little eminences. The second upper incisor, also the second in size, is a reduced likeness of the former, but has the more rounded cutting edge divided into three or four little eminences.

The first lower incisor, commonly the smallest, though sometimes as long as those above, has the cutting edge the most rectangular. The second lower incisor, usually larger than the former, is about the length of the corresponding upper tooth, but is sometimes longer, though less robust and less rounded at the cutting edge.

From the attrition to which the incisors are subjected, the tubercles of the biting edges soon disappear, and as the wearing continues the edges of the crowns gradually widen fore and aft, but are reduced in the opposite direction. As the edges of the upper teeth overlap those below, they are both worn away in a bevelled manner, and thus maintain a condition adapted to cutting the food. As may be observed in skulls of barbarous races, in whom the teeth are better preserved and longer retained, as the crowns of the incisors wear away the abraded surfaces, from narrow, transversely elliptical, become successively oval, nearly circular, and finally fore and aft oval.

The canines,<sup>1</sup> of which there is one on each side above and below, are commonly the longest of the teeth, though occasionally they do not exceed the first upper incisor. The fang is usually longer and more robust, is straight, and is laterally compressed, especially in the lower ones, in which it is also sometimes feebly grooved. The crown is ovoid with the length greatest, and with the thickness from without inward as great as, or even slightly exceeding, the breadth. It is commonly longer and thicker than that of the incisors, except the first upper one, than which it is slightly shorter and of less breadth. The base in section is oval, with the longer diameter from without inward, and the biting extremity tapers to a conical point. The outer surface, more convex than in the incisors, is rhombic-ovate in outline, rounded next the fang, and angular towards the point. The inner surface slopes inward from the latter to the thick, convex base, and on each side is depressed between a low median ridge and the lateral prominent border.

<sup>1</sup> Cuspid teeth; dentes cuspidati, canini, angulares, laniarii, oculares, or mordentes; eye teeth and stomach teeth.



The point of the crown, about a third of the length, is produced in an angular ridge, which extends from the summit on each side to the greatest width of the crown, and separates the outer and inner surfaces.

As the point of the upper canine and adjacent incisor overlap the point of the lower canine, the latter is worn outwardly and the former inwardly. Both become blunted, and by the time the incisors are worn square at the biting border the canines are reduced nearly to the same level.

The **premolars**,<sup>1</sup> two on each side above and below, are shorter than the canines, but in other measurements differ but little. They are commonly nearly of the same size, and mostly have a single fang, laterally compressed and variably grooved, especially in the upper teeth, in which it is sometimes more or less divided, usually in the second upper premolar, but occasionally in the first one or in both. The crown is shorter than in the canines, and commonly also than in the incisors. It is somewhat keg-shaped, narrowest next the fang, and at the biting extremity divided into a pair of broad, pyramidal tubercles,<sup>2</sup> of which the outer one is the larger. The outer and inner surfaces of the crown have about the same convexity and outline reduced in length like the outer one of the canines. From the points of each pair of tubercles ridges proceed in opposite directions, encircle the crown, and define the triturating surface from the sides. The triturating surface is depressed, and more or less divided into a pair of lateral pits by an intermediate ridge proceeding from the points of the tubercles.

The crown of the upper premolars is laterally compressed, the triturating surface is quadrate oval, and the tubercles are nearly alike, though the inner one is slightly the smaller. The crown of the lower premolars is but slightly compressed laterally, is oval in cross-section at the base, and nearly or quite circular at the triturating surface. The tubercles are nearly alike, though usually the inner one of the first premolar is less developed than in the others, and is sometimes reduced to the condition of a thick basal ridge to the outer tubercle, conjoined to the point of the latter by an intermediate ridge.

The outer tubercle of the premolar crown is homologous with the greater part of the canine crown, while the inner tubercle is homologous with the inner basal ridge of the latter.

The **molars**,<sup>3</sup> of which there are three on each side above and below, are the largest of the teeth, and are variable in size and form, especially the last one, which, from its not making its appearance until near maturity, is commonly called the "wisdom tooth."<sup>4</sup> The lower molars are a little the larger, and together occupy as much space as

<sup>1</sup> Small molars; bicuspid teeth; *dentes bicuspidati*.

<sup>2</sup> Cusps; lobes.

<sup>3</sup> *Dentes molares, multicuspidati*, or *maxillares*; true or large molars; grinders.

<sup>4</sup> *Dens sapientiae*; *d. serotinus*.

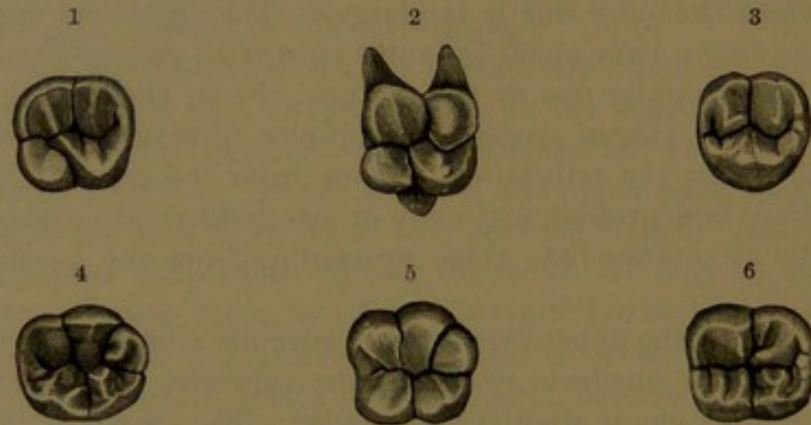


the upper ones together with half the adjacent premolar. The molars of each series usually exhibit successively a slight reduction in size, but sometimes the second is the largest, and rarely they successively increase.

The crown of the upper molars is cuboidal or rhombic, with rounded sides, and about two-thirds the length of the breadth, the diameters of which are nearly equal. Thickest about the middle, it diminishes to the base and to the triturating surface, which is composed of four, or three, pyramidal tubercles with angular-ridged borders, which define the triturating surface from the sides of the crown.

Commonly there are four tubercles occupying the corners of the triturating surface of the crown of the first and second molars, and three tubercles in the last molar; but frequently there are also only three to the second molar. In the crown with four tubercles, the antero-internal is the largest, and is usually extended so as to join the

FIG. 203.



TRITURATING SURFACE OF MOLAR TEETH. 1, first upper molar, right side; 2, view of another specimen; 3, second upper molar, right side; 4, first lower molar, right side; 5, view of another specimen; 6, second lower molar, right side.

postero-external tubercle, while the others are extended at the fore and back part of the crown to join both the former. This arrangement gives to the triturating surface the appearance of a winding, sigmoid ridge, with the enclosed intervals or valleys opening at the outer and inner sides of the crown. The sides of the tubercles sloping from their angular summits into the valleys are variably marked by lesser ridges. In the crown with three tubercles it is less square, more narrowed inwardly, and usually wider from without inward than fore and aft. Two of the tubercles are external, and nearly equal, while the third is internal and much larger than the others, which it joins by its angular ridged summit at the fore and back part of the crown.

In the molar of three tubercles these are homologous with the outer pair and antero-internal one in the molar of four tubercles, of which the postero-internal is undeveloped or rudimentary in the tri-tuberculate crown.



The crown of the lower molars, about the same length and transverse breadth as in the upper teeth, is wider fore and aft. Commonly, in the first and second molars the triturating surface is formed by five tubercles, like those of the upper teeth, differing little in size, and arranged in an outer row of three and an inner row of two. In the last molar there are usually four tubercles, occupying the corners of the crown, and this is also frequently the condition in the second molar. Occasionally all the lower molars exhibit five tubercles.

The upper molars have three fangs, of which two are external, vertical, or slightly divergent, and straight or somewhat bent; and the third internal, thicker, and longer than the former, and directed upward and inward, often grooved, and sometimes forked at the end. In the last molar the fangs are commonly more or less confluent, and often united in a single cone with variable traces of division.

The lower molars have a pair of broad fangs placed one behind the other and grooved, usually parallel and somewhat bent, or straight and slightly divergent. In the last of the series the two fangs are often more or less confluent.

The wisdom tooth is exceedingly variable in its condition of development, and often differs on the two sides of the jaws, as it does also in different individuals. Its size or degree of development is related with the size of the jaws.

From attrition the tubercles of the premolars and molars are gradually worn away, so that finally the triturating surfaces of the teeth become flat, or slightly excavated in the lower teeth, and proportionately prominent in the upper ones. With the obliteration of the tubercles little islets of dentine appear, and with the further wear of the teeth the latter widen and become confluent, and ultimately the triturating surface exhibits a broad expanse of dentine bordered with enamel. In the wear of the crown beyond the middle of its length it gradually diminishes in breadth, as is the case likewise with the canines and incisors.

Ordinarily the crowns of the teeth of each jaw near their biting border and triturating surface are in close contact with one another throughout the series, but are separated by considerable angular intervals approaching the fangs. As the crowns are worn away they maintain their close apposition, and form together a continuous triturating surface, while the intervals next the fangs are narrowed as well as shortened.

#### THE TEMPORARY TEETH.

Of the ten **temporary teeth**<sup>1</sup> in each jaw, the series of five on each side of the median line consists of two **incisors**, a **canine**, and two **molars**, or the same number and kind of the former two as in

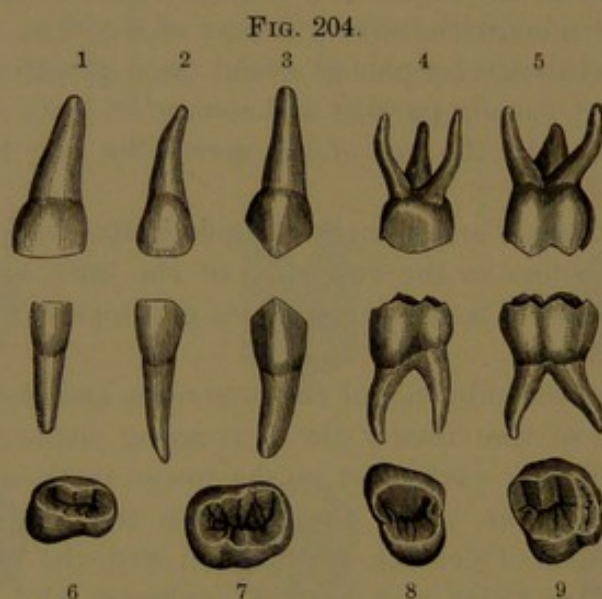
---

<sup>1</sup> Milk teeth; deciduous teeth; dentes lactei, caduci, or temporarii.



the permanent set, with no premolars and one molar less. They are smaller than the permanent teeth, but are broader in proportion to their length.

The incisors and canines have the same proportions among themselves as in the permanent set, which they also resemble in form, but have their crown in general proportionately broader, and do not have the fangs laterally compressed. The crown of the first upper incisor is of greater breadth than the length, which is about equal to the thickness at base. The crown of the second upper incisor has the length and breadth about equal and the thickness somewhat less. In the lower incisors the length of the crown exceeds the breadth, especially in the second one, and the thickness is least. The fang of the first upper



THE TEMPORARY TEETH OF ONE SIDE. 1, 2, upper and lower incisors; 3, upper and lower canine; 4, 5, upper and lower molars; 6, 7, triturating surface of the lower molars; 8, 9, triturating surface of the upper molars.

incisor is thicker fore and aft than from side to side, but in the others is more uniform.

The crown of the upper canine, larger than that of the incisors, has an equal breadth and a less thickness. The crown of the lower canine is longer and narrower than that of the upper one, and has the thickness nearly equal to the breadth.

The molars are constructed on the plan of the permanent ones, but have a proportionately shorter crown and smaller fangs, of which they possess the same number above and below as in the permanent teeth, but differ strikingly in their greater divergence from one another.

The crown of the first upper molar variably approximates both in size and form an upper premolar, which it often resembles, with the outer tubercle pushed, as it were, partially in advance of the inner one. In other instances the outer tubercle presents more or less disposition to the production of two accessory tubercles, and in this way approaches



more nearly the condition of the second molar. The latter ordinarily approximates in size and shape an upper permanent molar, with the four tubercles disposed to assume the arrangement of an S-like ridge, but with the summits more contracted. The crown of the second lower molar approximates in size and form the five tuberculate permanent lower molars, but is more contracted at the triturating surface. The crown of the first lower molar is a reduced representative of the second one.

The first upper molar has its crown horizontally half oval or trilateral and convex inwardly. The triturating surface is formed by three tubercles, of which the inner one is largest, most distinct, and demiconical. The outer pair are but feebly separated, and of these the posterior is the smaller and least distinct. A ridge in front connects the anterior with the inner tubercle, and is sometimes so much produced as to form an accessory tubercle.

The second upper molar, considerably larger than the former, has a more quadrate crown, which is nearly like that of the permanent upper molars. The triturating surface is formed in the same manner as in the latter, but is frequently varied from a less proportionate development of the postero-internal lobe and a variably greater production of the anterior ridge of the crown, which may appear as an accessory tubercle.

The first lower molar has a horizontally ovoid crown, widest behind, and considerably narrowed in front approaching the triturating surface, which is obscurely divided into four tubercles. Of these the posterior pair are much the smaller, especially the inner one. The ridged summit of the outer tubercles, at the front and back of the crown, curves inwardly to the inner tubercles. The second lower molar, also considerably larger than the former, likewise resembles the lower permanent molars in the shape and construction of its crown.

#### STRUCTURE OF THE TEETH.

The teeth contain a soft substance, the dental pulp, and the pulp cavity occupying the central portion of the crown nearly conforms to this in shape, and tapers in each fang into a canal which opens by a small orifice at the point of the latter. The cavity in the incisors is extended towards each corner of the crown, in the canine towards the summit, and in the premolars and molars towards the tubercles. When two fangs are confluent a separate canal occupies each. The pulp cavity is largest in the young tooth, and gradually decreases with the advance of life.

The **dental pulp**<sup>1</sup> is a soft, red, highly vascular and sensitive substance, the basis of which is formed by numerous nucleated cells, which divide into fine filaments and freely interlace together. The peripheral

---

<sup>1</sup> Pulpa dentis.



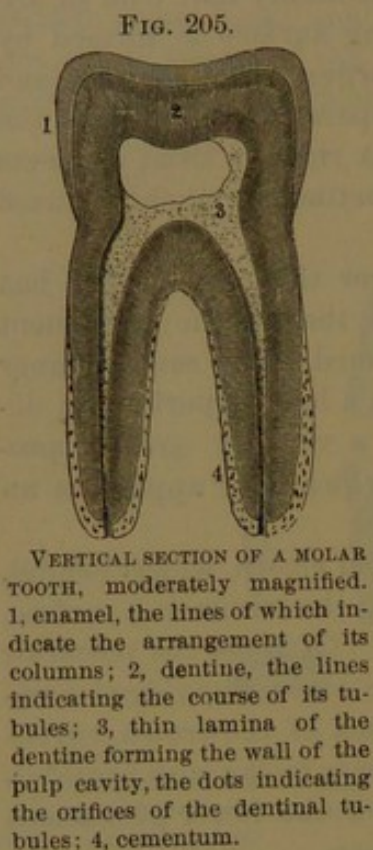
portion consists of a layer of nucleated columnar cells, named the **odontoplasts**. These divide into filaments at their inner extremity, and interlace with the other cells; and at their outer extremity they give off one or more filaments, which penetrate the dentinal tubules. The capillary blood-vessels of the pulp form a close net beneath the odontoplasts, and non-medullated nerve-fibrils extend from the pulp between the latter towards the tooth.

The arteries of the dental pulp are derived from the dental branches of the internal maxillary artery, and the veins are corresponding companions. The nerves are derived from the dental branches of the superior and inferior maxillary divisions of the trigeminal nerve.

The hard substance of the teeth is composed of three different tissues, dentine, enamel, and cementum.

The **dentine**, or **ivory**,<sup>1</sup> forms the chief bulk of a tooth, and is an apparently homogeneous, yellowish-white substance more dense than bone. It resembles the latter in chemical composition, but contains a greater proportion of bone-earth, amounting to nearly three-fourths of the whole. The bone-earth, 72 per cent., consists of calcium phosphate, 66.7, calcium carbonate, 3.3, magnesium phosphate and other salts, including calcium fluoride, 2. The bone-cartilage, 28 per cent., like that of bones, is resolved into gelatin by boiling.

Sections of dentine prepared for the microscope and viewed by transmitted light



VERTICAL SECTION OF A MOLAR TOOTH, moderately magnified. 1, enamel, the lines of which indicate the arrangement of its columns; 2, dentine, the lines indicating the course of its tubules; 3, thin lamina of the dentine forming the wall of the pulp cavity, the dots indicating the orifices of the dentinal tubules; 4, cementum.

exhibit numerous fine, black, parallel lines traversing a translucent matrix; the black lines being due to tubules filled with air. By reflected light the lines appear white on a dark ground. The **dentinal tubules**<sup>2</sup> commence on the surface of the pulp cavity, where their orifices come into contact with the dental pulp, and thence they radiate everywhere through the dentine to its exterior surface. They pursue a generally parallel undulating course with two or three gentle curvatures, and also run in an extended or open spiral. Largest at their commencement in the pulp cavity, they slightly diverge and repeatedly fork as they proceed outwardly, taper and end in the finest branches at the periphery of the dentine. They are of nearly uniform diameter, and are separated from one another about two or three times their thickness. From their sides emanate innumerable minute twigs, which diverge into the intertubular substance, where they imperceptibly end.

<sup>1</sup> Tooth-bone; proper tooth-substance.

<sup>2</sup> Canaliculi dentium; calcigerous tubes.



The tubules have a relatively thick wall<sup>1</sup> distinct from the intertubular dentine, appearing in cross-section as a ring surrounding the orifices. They contain homogeneous soft filaments projecting from the odontoplasts of the dental pulp. The terminal tubules mostly end in the peripheral layer of dentine,<sup>2</sup> where they communicate with narrow, irregular intervals occupied by soft substance, apparently uncalcified dentine. The intervals are limited by botryoidal walls composed of minute globules of dentine, whence they are called **interglobular spaces**. Many of the dentinal tubules traverse these spaces and enter the adjacent enamel or cementum.

The dentinal tubules at their commencement measure about  $\frac{1}{4500}$  of an inch in thickness.

When the bone-earth has been removed from teeth the dentinal cartilage is separable into laminae parallel with the surfaces of the pulp cavity, indicating its mode of original production. In sections

FIG. 206.




Fig. 206. VERTICAL SECTION OF THE FANG OF A CANINE TOOTH, exhibiting the structure of the dentine and cement. 1, inner extremities of the dentinal tubules; 2, outer extremities of the tubules, terminating in interspaces at the boundary of the dentine; 3, cementum; 4, lacunae like those of bone. Highly magnified.

FIG. 207.

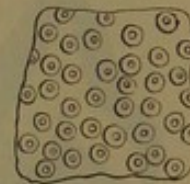

Fig. 207. SECTION OF DENTINE, cutting across the direction of its tubules, very much magnified. The tubules are seen to have thick walls, distinct from the intertubular substance.

of teeth prepared for the microscope, variable lines are often observed conforming with the direction of the laminae indicated. These lines<sup>3</sup> exhibit interglobular spaces like those of the periphery of the dentine, but of greater capacity and apparently of like nature.

The **enamel**<sup>4</sup> forms the glistening white, exposed surface of the teeth, and it is not only the hardest part of the latter, but of all organic tissues, and is therefore admirably adapted to prevent rapid wearing of the teeth. Where these are most exposed to attrition it is about one-sixteenth of an inch thick, and towards the bottom of the crown it thins away to a sharp circular edge at the neck of the tooth.

The enamel contains the smallest proportion of bone-cartilage, amounting to about 3.5 per cent., while all the rest is bone-earth, consisting of calcium phosphate, 89.8; calcium carbonate, 4.4; magnesium phosphate and other salts, including a trace of calcium fluoride, 1.3 per cent.

<sup>1</sup> Dentinal sheath.

<sup>2</sup> Granular layer.

<sup>3</sup> Incremental lines.

<sup>4</sup> Substantia vitrea, adamantina, or filamentosa; crusta adamantina.



The enamel is very brittle, and is very liable to crack, even during life, from undue pressure or the application of extreme cold. In prepared specimens of teeth it is also readily cracked through drying or violence. The broken edge exhibits a vertical fibrous appearance, due to the enamel being composed of narrow columns, which are applied by one end to the dentine in shallow impressions of the surface, and by the other end form the free surface of the crown. The columns are six-sided, and closely united by a small proportion of homogeneous cementing substance. They are slightly flexuose and divergent in their course, and have others interposed in the intervals towards the free surface. In the unworn teeth the columns are invested on the surface of the enamel with a thin, homogeneous layer, called the **cuticle**, which, through treatment with silver nitrate, exhibits the outlines of non-nucleated epithelial cells. The diameter of the enamel columns is about  $\frac{1}{5000}$  of an inch.

At the attached surface of the enamel irregular intervals extend from the dentine a variable distance outwardly among the enamel columns.

FIG. 208.

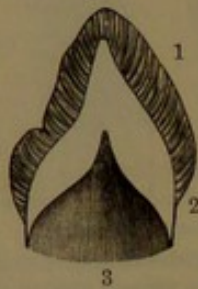

Fig. 208. CROWN OF A CANINE TOOTH, fore and aft section, the fang undeveloped. 1, layer of enamel; 2, dentine; 3, pulp cavity. Magnified two diameters.

FIG. 209.

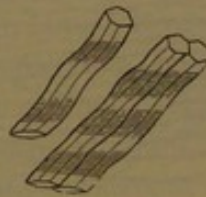


Fig. 209. THREE ENAMEL COLUMNS, highly magnified; exhibiting the six-sided prismatic and waving character.

FIG. 210.

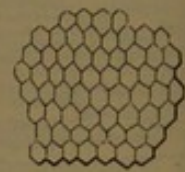


Fig. 210. SECTION OF ENAMEL, highly magnified, at right angles to the course of its columns; exhibiting the six-sided character of the latter.

In thin sections of the teeth the enamel exhibits alternate light and darker stripes extending through its thickness, and narrow, concentric, brownish-colored lines. The enamel columns are also crossed by alternate darker and lighter shadings.

The **cementum**<sup>1</sup> occurs in small proportion in the human teeth, but is largely produced and is an important factor in the teeth of many large herbivorous animals, as the ox, the horse, and the elephant. It consists of osseous tissue with little modification of structure, and forms a thin layer to the exterior surface of the dentine of the fangs. It gradually thickens towards the end of the latter, and increases with the advance of age, when it often forms accumulations at the end of the fangs, obstructing the entrance to the pulp cavity. It is laminated, and contains branching corpuscles like those of ordinary bone, but larger and less regular. When the cementum is thicker than usual

<sup>1</sup> Cement; crusta petrosa; crusta ostoides radialis; cortical substance.



it may also contain vascular canals. In the temporary teeth the cementum is thinner and its corpuscles fewer.

In old teeth the surface of the pulp cavity is formed of a variably thick layer of a substance different from dentine, and partaking of the character of this and of bone, whence its name of **osteo-dentine**. It occurs after adult age, and in much worn molar teeth is sometimes observed extending to the centre of the triturating surface. It is derived from the calcification of the remains of the dental pulp, which sometimes occurs to such an extent as to obliterate the pulp cavity.

The development of the teeth commences in the embryo about the seventh week. At this time the border of the jaws is covered by a

FIG. 211.

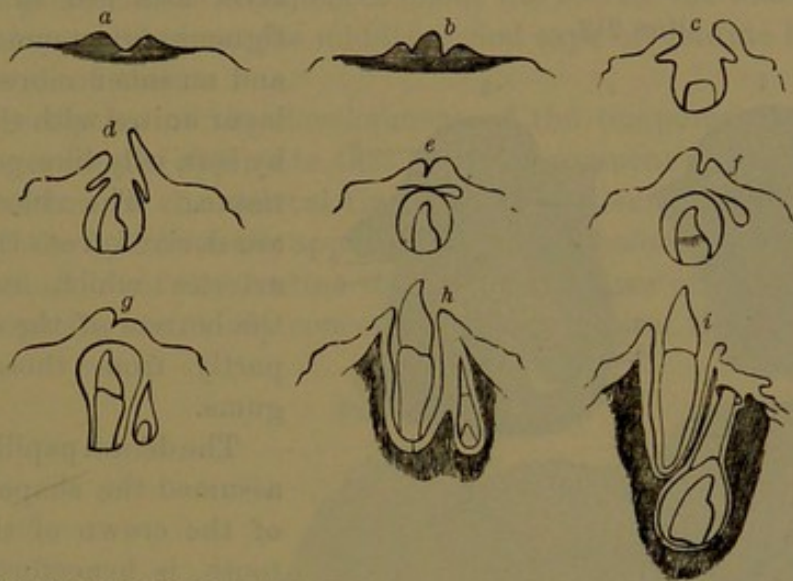


DIAGRAM OF THE MODE OF DEVELOPMENT OF THE TEETH. *a*, section across the dental groove; *b*, dental papilla developed in the latter; *c*, the groove deepened and processes forming which ultimately close it; *d*, the papilla become the dental pulp and the groove becoming closed; *e*, dental sac containing a dental pulp, which is the rudiment of the crown of a temporary incisor; the cavity above is reserved for a permanent incisor; *f*, the crown of the temporary incisor fully formed, and the reserved cavity for the permanent tooth moving backward; *g*, fang of the temporary incisor produced, and origin of the dental papilla of the future permanent tooth; *h*, eruption of the temporary incisor, and the alveoli produced for both teeth; *i*, the temporary incisor occupying its functional position, and the crown of the permanent incisor developed.

thick layer of epithelium, of which the deeper portion<sup>1</sup> occupies a groove<sup>2</sup> in the subepithelial embryonic connective tissue. An increased growth of the epithelium gives rise to the **enamel-germs**<sup>3</sup> of the temporary teeth, which appear as flask-shaped accumulations of cells occupying corresponding recesses of the jaws and attached by their neck to the epithelium at the edge of the latter. With the appearance of the enamel-germs a vascular eminence, the **dental papilla**, projecting into them, is developed from the subepithelial connective tissue at the bottom of the recess occupied by each germ. The dental papilla assumes the shape of the future crown, and is covered by the enamel-germ inserted upon it, cup-like in form, and now separated by the ob-

<sup>1</sup> Common enamel-germ.

<sup>2</sup> Primitive dental groove.

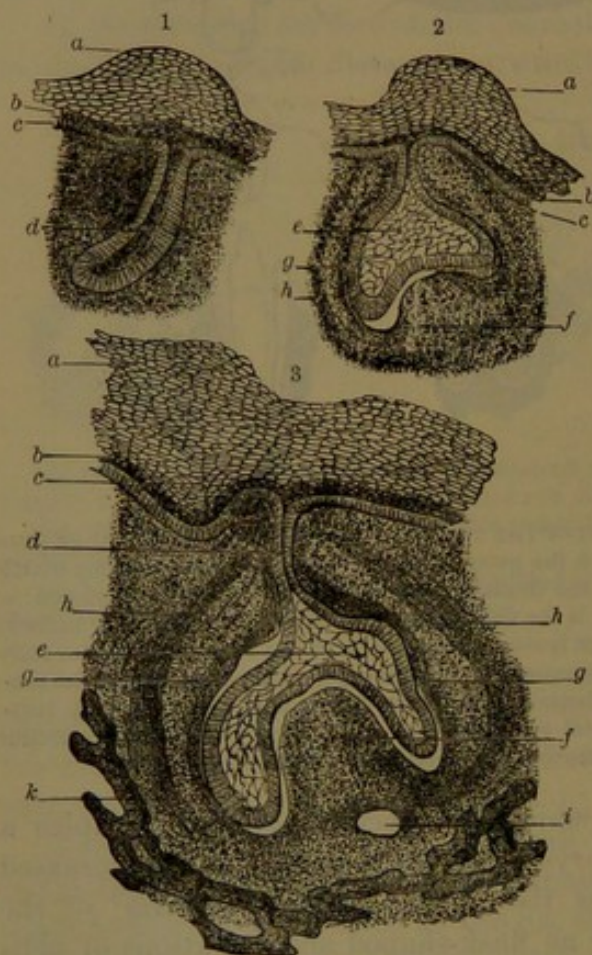
<sup>3</sup> Special enamel-germs.



literation of its neck from the epithelium at the edge of the jaws. The dental papilla and enamel-germ together form the **tooth-germ**, during the production of which it becomes enclosed in a vascular membrane, the **dental sac**, continuous with the papilla of the tooth-germ, and developed from the subepithelial connective tissue of the recess occupied by the latter. The bony jaws first appear as an open gutter containing the dental sacs with their enclosed tooth-germs. The gutter soon becomes divided into compartments with narrowed openings, through which the dental sacs adhere to the gum. The alveoli are formed at a later period, in accordance with the production of the fangs of the teeth and the growth of the alveolar border of the jaws.

The dental sacs consist of an outer vascular fibro-connective-tissue

FIG. 212.



DEVELOPMENT OF TEETH IN THE FIG. 1, 2, sections fore and aft of the maxilla with tooth-germs from a young embryo; 3, from an older embryo. *a*, epithelium of the gum; *b*, deeper layer; *c*, deepest layer of columnar cells; *d*, enamel-germ, and later, *e*, enamel organ connected by a stem with the gum; *f*, dental papilla; *g*, inner, and *h*, outer, layers of the dental sac; *i*, section of a vessel; *k*, osseous structure of the jaw.

layer attached to the contiguous periosteum and gum, and an inner more vascular layer united with the former by soft, jelly-like, connective tissue. The blood-vessels are derived from the dental arteries which run along the bottom of the sacs, and partly from those of the gums.

The dental papilla, having assumed the shape and size of the crown of the future tooth, is henceforth distinguished as the **dental pulp**. After its production it begins to harden or calcify, and is thus converted into dentine, while at the same time the enamel is produced from the enamel-germ or organ on its exterior. Calcification commences in the appearance of little, thin shells of dentine on the prominent points of the dental pulp, corresponding in number with those points. Thus there is one for the incisors and canine, two for the premolars, and from three to five for the molars.

The little shells expand at the edges, and where there are more than one, as in the molars, they become confluent. Continuing to grow

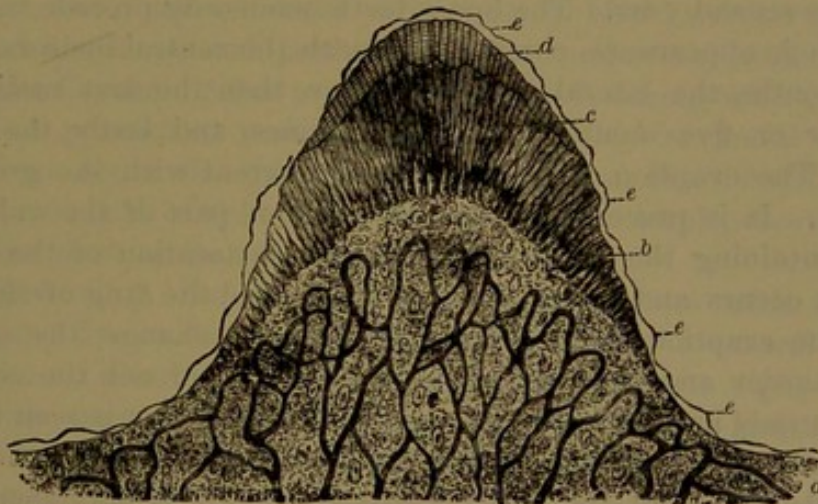


around the edge of the shell, this also grows in thickness by the calcification of the pulp, which proportionately decreases. While the dental shells grow, in like manner the enamel extends step by step with them, and also increases in thickness. After the crown is completed the pulp becomes slightly narrowed at the neck, and then grows in length in a tapering manner to form the basis of the fangs. Where there are more than one of these to a tooth the pulp divides at the base of the crown, and then each portion grows in the manner of that of the single-fanged teeth. Step by step with the elongation of the pulp the calcification extends in length and thickness in the production of the fang, and finally, in the complete tooth, the pulp is reduced to the condition usually observed occupying the pulp cavity. Calcification of the temporary teeth commences about the end of the fourth month of the embryo, and about the middle period caps of dentine have been formed on all of them.

The description of the development of the temporary teeth from the tooth-germs also applies to that of the permanent teeth.

**Production of the dental tissues.** The description of the dental pulp of the mature teeth applies to the same before its calcification. In the production of the dentine the peripheral layer of columnar cells, the odontoplasts, are chiefly concerned. These project from their outer

FIG. 213.



VERTICAL SECTION OF THE GERM OF A MOLAR TOOTH. *a*, vascular papilla; *b*, odontoplasts; *c*, dentine pervaded with tubules; *d*, enamel; *e*, cuticle.

extremity filamentous processes, around which the matrix of the dentine is formed by the calcification of an intervening homogeneous substance, probably derived from the odontoplasts. As the calcification proceeds from without inwardly the body of the odontoplasts recedes, leaving extensions as the dentinal filaments, which occupy the dentinal tubules. In this recession of the odontoplasts they probably continue to grow, but probably also are succeeded by others produced successively in the dental pulp. The calcification occurs in minute



spherical nodules, and in positions in which the process is incomplete the so-called interglobular spaces occur.

The cells of the enamel-germ, at first soft and rounded polyhedral, multiply by division, and then undergo transformation, after which it is called the **enamel organ**.<sup>1</sup> The central cells become stellate, retaining their central nucleus and anastomosing by their rays, the intervals of which are occupied by a clear, jelly-like liquid. The cells next the dental pulp form a close layer<sup>2</sup> of six-sided columns, while those on the inner surface of the dental sac form a pavement of six-sided blocks. Into the enamel organ project numerous processes of the dental sac, minute papillæ resembling those of the oral mucous membrane. The columnar cells of the enamel organ by calcification form the enamel columns, and as the process proceeds the cells either grow or else are succeeded by the production of others. The enamel organ gradually disappears, and its outer layer of pavement-cells is supposed to be the source of the cuticle of the tooth. The cementum is formed from the connective-tissue investment of the fang, as in the production of bone from the periosteum.

**Eruption of the temporary teeth.** At birth the crowns of the temporary teeth enclosed within their sacs occupy compartments within the jaw, with somewhat narrowed apertures, through which the sacs adhere to the gum. The eruption, or cutting, of the teeth commences from six to nine months after birth, and is usually completed at the end of the second year. The lower teeth commonly precede the upper ones in their appearance, commencing with the central incisors. After a few months the lateral incisors appear, then the first molars, and after four or five months more the canines, and lastly the second molars. The eruption of the teeth is concurrent with the growth of the fangs. It is preceded by an absorption of part of the wall of the cavity containing the tooth, after which a restoration of the osseous structure occurs and forms the alveolus around the fang of the tooth. Before the eruption, the gum undergoes some change, the edge becoming harder and sharper, but as the teeth approach the edge this becomes tumid and purplish, and a whitish spot or line is seen through the vascular gum, soon followed by the emergence of the tooth.

**Development of the permanent teeth.** Ten permanent teeth in each jaw succeed the temporary teeth, and three others are added farther back on each side above and below. The former appear towards the end of the fourth month of the embryo as enamel-germs springing from the neck of those of the temporary teeth. They grow within the jaw as club-shaped bodies behind the position of the germs of the temporary teeth, and subsequently pursue the same course of development as the latter. The new germs in like manner become enclosed in dental sacs, which adhere by a narrow neck to the back of the temporary

<sup>1</sup> Organon adamantinæ.

<sup>2</sup> Membrana adamantinæ.



dental sacs. As the permanent dental sacs with their germs continue to grow they recede more deeply in the jaw, but retain their connection with the gum by a long pedicle,<sup>1</sup> which previously formed the neck of attachment to the temporary dental sac, and originally was the neck of the enamel-germ. The upper permanent teeth are developed in recesses above and behind the upper temporary teeth, and the lower permanent teeth below and behind the lower temporary teeth. The recesses are separated from the alveoli of the temporary teeth, and each communicates by a canal<sup>2</sup> for the pedicle of the dental sac, which opens at the edge of the jaw behind the corresponding temporary tooth. The permanent teeth are separated from the temporary teeth by a thin osseous partition, which, as well as the fang of the contiguous temporary tooth, is absorbed when the former is about to protrude. As this occurs the temporary tooth is shed and the permanent tooth takes its place. The absorption of the fangs of the temporary teeth appears not to be the result of direct pressure, but occurs through the agency of absorbing cells or osteoclasts in contact with the fangs.

The additional permanent teeth, which are the three permanent molars, have no predecessors, but are developed in succession in the jaws back of the other teeth. The epithelial production at the border of the jaws, from which were developed the enamel-germs of the temporary teeth, is persistent back of the latter, and about the fifteenth week of the embryo gives origin to the enamel-germ of the first permanent molar. Long after, about seven months subsequent to birth, another germ appears, that for the second permanent molar, projecting back from the neck of the former. After another long period, during which the first and second permanent molars have considerably advanced in their development, about the third year, a third germ, that of the wisdom tooth, appears back of the others. The subsequent development of these teeth is the same as that described in the others.

Calcification in the permanent teeth commences with the first molars about five or six months after birth; with the central incisors a little later; the lateral incisors and canines about eight or nine months; the premolars two years or more; the second molars five or six years; and the wisdom teeth about twelve years.

The eruption of the permanent teeth usually occurs in the following order, the lower preceding the upper ones:

First molars . . . . .	6 years.
Central incisors . . . . .	7 "
Lateral " . . . . .	8 "
First premolars . . . . .	9 "
Second " . . . . .	10 "
Canines . . . . .	12 "
Second molars . . . . .	12 to 13 years.
Third " . . . . .	17 " 25 "

<sup>1</sup> Gubernaculum dentis.

<sup>2</sup> Iter dentium.



About the sixth year, previous to shedding the temporary incisors, the jaws contain the greatest number of teeth. At that time, besides the temporary teeth, the crowns of all the permanent teeth are produced, except those of the wisdom teeth.

#### THE PHARYNX.

The **pharynx**,<sup>1</sup> or throat, is a musculo-membranous pouch, situated back of the nasal cavities, mouth, and larynx, extending from the base of the skull to the lower part of the latter, and to the sixth cervical vertebra. It is about five inches long, the upper two-thirds being half cylindrical, from one and a half to two inches wide in different positions, and mostly less fore and aft, except opposite the mouth. From the hyoid bone it narrows in a funnel-like manner to its termination, where it is narrowest. It lies behind against the cervical vertebræ and prevertebral muscles, attached to them by loose connective tissue, which permits easy movement of the pharynx. Opening into its fore part in succession from above downward are the posterior nares, the fauces, and the opening of the larynx. Projecting into it obliquely downward and backward is the soft palate, with the uvula, which, in the act of swallowing, is drawn upward, so as to separate the upper from the lower part of the pharynx, and thus prevent the egress of the food through the nares. On each side of the latter it communicates with the eustachian tube.

Above, the pharynx is attached to the occipital basilar process between the prerecti muscles, and on each side to the under part of the apex of the temporal pyramid. Thence it is attached in front, in succession, to the entopterygoid process, the pterygo-maxillary ligament, the inside of the mandible, and the sides of the tongue, hyoid bone, thyroid and cricoid cartilages. It is also connected above with the soft palate and styloid process. From its basilar attachment it extends forward to the sphenoidal body, and thence is prolonged in a recess outward to the apex of the temporal pyramid. Below the soft palate, the floor of the fauces forms its anterior sloping surface, and below this, the posterior surface of the larynx within the embrace of the thyroid cartilage.

The wall of the pharynx is about a tenth of an inch thick, and is externally invested by the **pharyngeal fascia**, a thin connective-tissue layer, loosely connected with the contiguous parts, the prevertebral fascia behind, and the sheaths of the principal cervical vessels and nerves at the sides of the neck. The succeeding coat of the pharynx is muscular, and consists of three pairs of constrictors, together with the stylo- and palato-pharyngeal muscles.

Succeeding the muscular coat within is a fibro-connective-tissue layer, thin and inconspicuous below, but strong above, where it, together with

---

<sup>1</sup> Gula; ingluvies; pharus.



the pharyngeal fascia, supplies the deficiency of the muscular layer and attaches the pharynx to the base of the skull; a more compact band extending between the prerecti muscles to the basilar process.

The lining mucous membrane of the pharynx, continuous with that of the different communicating cavities, is variably red and highly vascular throughout. From opposite the fauces downward to the œsophagus it is like that of the mouth, both as regards its minute papillæ and its stratified epithelium. Its upper part, to the base of the uvula, is furnished like that of the nose with a ciliated columnar epithelium. Numerous racemose mucous glands, the **pharyngeal glands**, are found everywhere in the submucous tissue, the ducts of which open on the surface of the mucous membrane. Follicular lymphoid glands are also numerous, and give the surface of the pharynx a more or less slightly mammillated aspect. A patch of these bodies extends between the orifices of the eustachian tubes across the back of the pharynx.

The arteries of the pharynx are derived from the pharyngeal, inferior palatine, pterygo-palatine, and thyroid arteries. The veins form the pharyngeal plexus, which joins the internal jugular through the pharyngeal vein. The nerves are derived from the glosso-pharyngeal, the pharyngeal branch of the vagus, and branches from the first cervical ganglion of the sympathetic.

#### MUSCLES OF THE PHARYNX.

The muscular layer of the wall of the pharynx is composed of three pairs of laminar muscles, the **constrictors**, whose fibres pursue a generally transverse direction; and two pairs of longitudinal muscles, the **elevators of the pharynx**,—the stylo-pharyngeal and the palato-pharyngeal muscles. The constrictors arise at the side of the mouth, the tongue, the hyoid bone, and the pharynx, thence pass to the back of the pharynx, overlapping from below upward, and terminate at the median line in a narrow, tendinous raphé, and partially by continuity through the fibres of the muscles of the two sides.

The **superior constrictor**,<sup>1</sup> a thin, pale, quadrilateral muscle, occupies the upper part of the pharynx. It arises from the lower third of the entopterygoid process, including its hook, from the pterygo-maxillary ligament or tendinous intersection of the buccinator muscle, from the posterior extremity of the alveolar process of the mandible, and from the side of the tongue in connection with the genio-glossal muscle. From this origin the fibres pass around the side to the back of the pharynx, and unite in a median, aponeurotic raphé, common to this and the opposite muscle. The raphé is prolonged above to be attached to the basilar process, and the upper part of the muscle curves to it from beneath the palatal elevator and the eustachian tube. The upper

<sup>1</sup> M. constrictor pharyngis superior.



margin of the muscle is attached to the base of the skull by the pharyngeal fascia.

The **middle constrictor**,<sup>1</sup> thicker and darker than the former, is a fan-shaped muscle, and occupies the middle portion of the pharynx. It arises from the cornua of the hyoid bone and from the stylo-hyoid ligament, whence it widely spreads on the side and back of the pharynx, and terminates in the median raphé, with many of its fibres joining

FIG. 214.

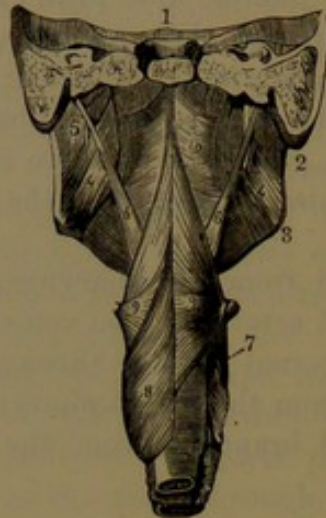
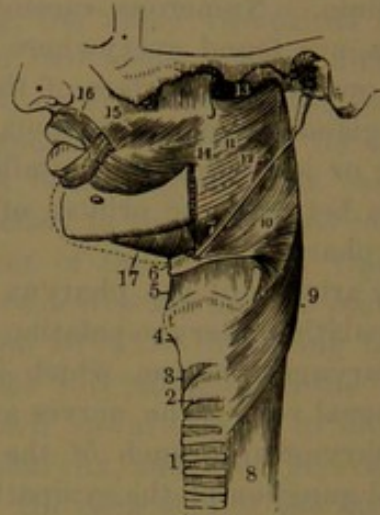


FIG. 215.



*Fig. 214. POSTERIOR VIEW OF THE MUSCLES OF THE PHARYNX.* 1, section of the base of the skull in advance of the cervical vertebræ; 2, 3, posterior border and angle of the lower jaw; 4, internal pterygoid muscle; 5, styloid process giving attachment to 6, the stylo-pharyngeal muscle; 7, larynx; 8, inferior constrictor of the pharynx; 9, middle constrictor; 10, superior constrictor.

*Fig. 215. SIDE VIEW OF THE MUSCLES OF THE PHARYNX.* 1, trachea; 2, cricoid cartilage; 3, vocal membrane; 4, thyroid cartilage; 5, thyro-hyoid membrane; 6, hyoid bone; 7, stylo-hyoid ligament; 8, œsophagus; 9, inferior constrictor of the pharynx; 10, middle constrictor; 11, superior constrictor; 12, position at which the stylo-pharyngeal muscle passes into the interval between the superior and middle constrictors; 13, upper extremity of the pharynx; 14, pterygo-maxillary ligament; 15, buccinator muscle; 16, oral sphincter; 17, mylo-hyoid muscle.

those of the opposite muscle. Its upper part ascends behind the superior constrictor, with which it becomes more or less blended, while the lower part descends within the inferior constrictor, with which it in like manner becomes somewhat blended.

The **inferior constrictor**,<sup>2</sup> the thickest and broadest of the three muscles, occupies the lower part of the pharynx. It arises from the side of the larynx, and passes around the side to the back of the pharynx, where it unites with its fellow in the median line, the fibres of one passing among those of the other. The lower fibres, nearly horizontal in their course, are in continuous series with those of the transverse muscular layer of the œsophagus; the upper ones becoming

<sup>1</sup> M. constrictor pharyngis medius; m. hyo-pharyngeus; m. cerato- and chondro-pharyngeus.

<sup>2</sup> M. c. pharyngis inferior; m. crico-thyro-pharyngeus; m. thyreo- and crico-pharyngeus.



successively more ascending overlap those of the middle constrictor. At the origin of the muscle from the side of the larynx it is attached to the upper border and lateral oblique line of the thyroid cartilage, and to the side of the cricoid cartilage above and below the crico-thyroid muscle; often also to a tendinous arch spanning the latter. Commonly some of its fibres are continuous with those of the sterno-thyroid and crico-thyroid muscles.

The constrictors of the pharynx rest against the cervical vertebræ and prevertebral muscles, separated from these and the prevertebral fascia by the investing pharyngeal fascia. To the outer side of the constrictors lie the carotid vessels, the internal jugular vein, and the sympathetic and vagus nerves. At the outer side of the superior constrictor descends the stylo-pharyngeal muscle, which enters the wall of the pharynx between the former and the middle constrictor. The palato-pharyngeal muscle descends to the inner side of the superior constrictor, with the tonsil resting on the latter in advance of the former. The middle constrictor is separated from the superior constrictor by the lower expanded portion of the stylo-pharyngeal muscle. The inferior constrictor is in contact at its fore part externally with the sterno-thyroid muscle and the thyroid body.

The **palato-pharyngeal muscle** is described in the account of the muscles of the soft palate. See page 381.

The **stylo-pharyngeal muscle**,<sup>1</sup> the longest and largest of the three styloid muscles, lies behind and to the inner side of them. It arises tendinously from the inner side of the base of the styloid process, and descends obliquely to the outer side of the pharynx, which it enters between the superior and middle constrictors. Joined by the palato-glossal muscle it spreads beneath the lining membrane of the pharynx, within the middle and inferior constrictors, extending to the larynx, where many of its fibres are inserted into the posterior border of the thyroid cartilage. It is in contact externally with the stylo-glossal muscle, the external carotid artery, the parotid gland, and the middle and inferior constrictors. Internally it is in contact with the internal carotid artery, the internal jugular vein, the superior constrictor and palato-pharyngeal muscles, and the mucous membrane of the pharynx.

The constrictors of the pharynx are supplied by the pharyngeal plexus of nerves; the inferior constrictor, in addition, by the superior laryngeal nerve. The stylo-pharyngeal muscle is supplied by a branch of the glosso-pharyngeal nerve.

The muscles of the pharynx are invested externally by the pharyngeal fascia, which extends above the superior constrictor to the base of the skull, and is continuous from the former with the buccal fascia investing the buccinator muscle.

The muscles of the soft palate and pharynx, together with those of

---

<sup>1</sup> M. stylo-pharyngeus; m. levator or dilatator pharyngis.



the tongue and others attached to the hyoid bone, form the mechanism of swallowing. The first step of the process is effected through the muscles of the tongue, by which this organ presses the food against the palate and forces it backward into the fauces. The hyoid bone, with the larynx and the pharynx, are at the same time raised by their appropriate elevators. The food passing through the fauces into the pharynx, the soft palate is lifted and the posterior pillars approximated, while the uvula closes the interval, and thus shuts the communication with the posterior nares. The orifice of the larynx is also closed by apposition with the epiglottis; and an inclined plane is formed over the latter, down which the food is pressed into the œsophagus by the successive contraction of the constrictors of the pharynx.

#### THE ŒSOPHAGUS.

The **œsophagus**, or **gullet**,<sup>1</sup> is a musculo-membranous tube descending from the pharynx through the lower part of the neck and back part of the thorax into the abdomen, where it expands in the stomach. It commences opposite the sixth cervical vertebra, and follows the course of the spine to about the tenth thoracic vertebra, where it passes through an aperture of the diaphragm. It is from nine to ten inches long, and is the narrowest portion of the alimentary canal, for the most part being less than an inch in diameter. Inflated, it is cylindrical, but gradually expanding below to the œsophageal orifice of the diaphragm, where it is slightly constricted, and then widely expanded into the stomach. It is narrowest in the first few inches of the course; and in the condition of rest is collapsed fore and aft throughout, and scarcely three-fourths of an inch wide. It follows the flexures of the corresponding portion of the spine; besides which, starting from the median line in the neck, it inclines slightly to the left, then to the fifth thoracic vertebra gradually again assumes a median position, and once more deviates to the left and forward to reach the œsophageal orifice of the diaphragm.

In the neck and upper part of the chest the œsophagus adheres to the spine and prevertebral muscles by loose connective tissue, but lower passes in front of the aorta. In the neck it lies behind the trachea, slightly more to the left side, with the inferior laryngeal nerve ascending between them on each side, and here, also, lying in contact with the sheath of the carotid artery. In the thorax it is successively covered by the lower part of the trachea, the adjacent portion of the left bronchus, and the pericardium. At first placed to the right of the aorta, it afterwards passes in front, inclining to the left, to reach the œsophageal orifice; and the azygos vein lies behind and to its right. Placed between the pleuræ, it is in contact with both; and the thoracic duct ascending on the vertebræ from right to left lies beneath it. The vagus nerves

---

<sup>1</sup> Gula; fistula ventriculi.



descend in its fibro-connective sheath and form a plexus around it, the chief trunk of the left one passing down in front, that of the right passing down behind. The wall of the œsophagus, slightly thicker than that of the pharynx, in its collapsed condition is scarcely two lines thick. Besides an investing sheath of loose fibro-connective tissue with elastic fibres, attached to the adjacent parts, it is composed of three coats.

The **external, muscular coat** consists of an outer longitudinal and an inner circular layer, an arrangement which prevails through the whole of the alimentary canal; but the coat is thicker than elsewhere, excepting at the pyloric orifice of the stomach and the lower extremity of the large intestine. The longitudinal layer commences in three bands, of which one in front is attached to the median ridge behind the cricoid cartilage, and the others are continuous laterally with the inferior constrictors of the pharynx. The circular layer at its commencement is continuous with the latter muscles, but is separated by the lateral bands of the longitudinal layer. At the termination of the œsophagus both layers are continuous with those of the stomach.

The muscular coat is of a darker red color at the upper part of the œsophagus, where it consists of striped muscle-fibres; but it becomes paler below, and the latter are gradually replaced by unstriped fibres, which occur almost alone in the lower part.

The **middle, fibrous, or submucous coat** is a layer of fibro-connective tissue, much thinner than the former, and unites it loosely with the internal coat. It contains the chief vessels of the latter and the œsophageal glands.

The **internal coat, the lining mucous membrane**, is of firm texture, and in the condition of rest is thrown into fine longitudinal folds, which disappear with the distention of the œsophagus. It is pale red at its commencement, but becomes, for the greater part of its extent, gray or nearly white. It is provided with a stratified epithelium like that of the mouth and pharynx, and, as in these, is also furnished with minute papillæ, fewer and smaller, and likewise embedded beneath the epithelium. The mucosa is defined by a deeper muscularis mucosæ, consisting of a thin stratum of longitudinal, unstriped muscle-fibres, incomplete at the upper part of the œsophagus, but continuous in its lower part.

The **œsophageal glands** are minute racemose glands embedded in the submucous fibrous coat, generally scattered, and most numerous in the lower part of the œsophagus. They open by long, slanting ducts upon the surface of the mucous membrane.

The blood-vessels of the œsophagus generally pursue a longitudinal course, and are connected with three systems of capillaries, of which one pertains to the mucous membrane, a second to the œsophageal glands, and a third to the muscular coat. Lymphatics are found especially in the mucous and submucous coats. The nerves form a gangliated plexus between the layers of the muscular coat as elsewhere in the alimentary canal, but the nerve-cells and groups are both larger,



and are associated with many medullated nerve-fibres derived from the vagus nerves.

The arteries are branches of the inferior thyroid, the bronchial, the aorta, and the coronary artery. The veins form a plexus in the fibrous coat, and join the inferior thyroid, pericardiac, azygos, and gastric coronary veins. The nerves are mainly derived from the vagus, but some fine branches also come from the thoracic portion of the sympathetic nerve.

#### THE ORGANS OF DIGESTION.

The succeeding portions of the alimentary apparatus, consisting of the organs concerned chiefly in the digestion of the food, are contained in the abdomen. They are the stomach, small intestine, and large intestine as continuations of the alimentary canal, and two glands, the pancreas and liver, which discharge their secretions into the small intestine.

#### THE STOMACH.

The **stomach**,<sup>1</sup> the most capacious portion of the alimentary canal, the principal receptacle of the food, in which it undergoes the most active digestion, is situated in the upper part of the abdominal cavity, in the left hypochondrium and epigastrium. On the right it is connected with the œsophagus, which opens into it shortly after passing through the œsophageal orifice of the diaphragm. The communication, called the **cardiac orifice**, or the **cardia**,<sup>2</sup> is circular, and opens downward from the stomach like an inverted funnel. On the left and in a lower and more advanced position the stomach joins the duodenum, the circular communication being named the **pyloric orifice**, or the **pylorus**.<sup>3</sup>

The stomach is a curved conical pouch with a hemispherical base, the **fundus**,<sup>4</sup> which is directed to the left side as the **cardiac extremity**,<sup>5</sup> while the narrower portion to the right is the **pyloric extremity**.<sup>6</sup> It is situated with its long axis very oblique, extending from the left hypochondrium downward and to the right in the epigastrium, verging on the right hypochondrium. Its **small curvature**<sup>7</sup> is the superior border between the cardia and pylorus, three or four inches long, concave, and looking upward, backward, and to the right. The **greater curvature**,<sup>8</sup> much longer than the former, is convex, and looks in the opposite direction, downward, forward, and to the left. The fundus extends two or three inches to the left of the œsophagus, and lies in contact with the spleen behind and the diaphragm above and in front. The pyloric end lies beneath the liver, and curves upward from right to left and backward, producing a

<sup>1</sup> Stomachus; ventriculus; gaster.

<sup>2</sup> (Esophageal orifice; upper or left orifice; os ventriculi, ostium œsophageum.

<sup>3</sup> Intestinal orifice; lower or right orifice; ostium duodenale.

<sup>4</sup> Cul-de-sac; great tuberosity.

<sup>5</sup> Cardiac or splenic end.

<sup>6</sup> Pars pylorica.

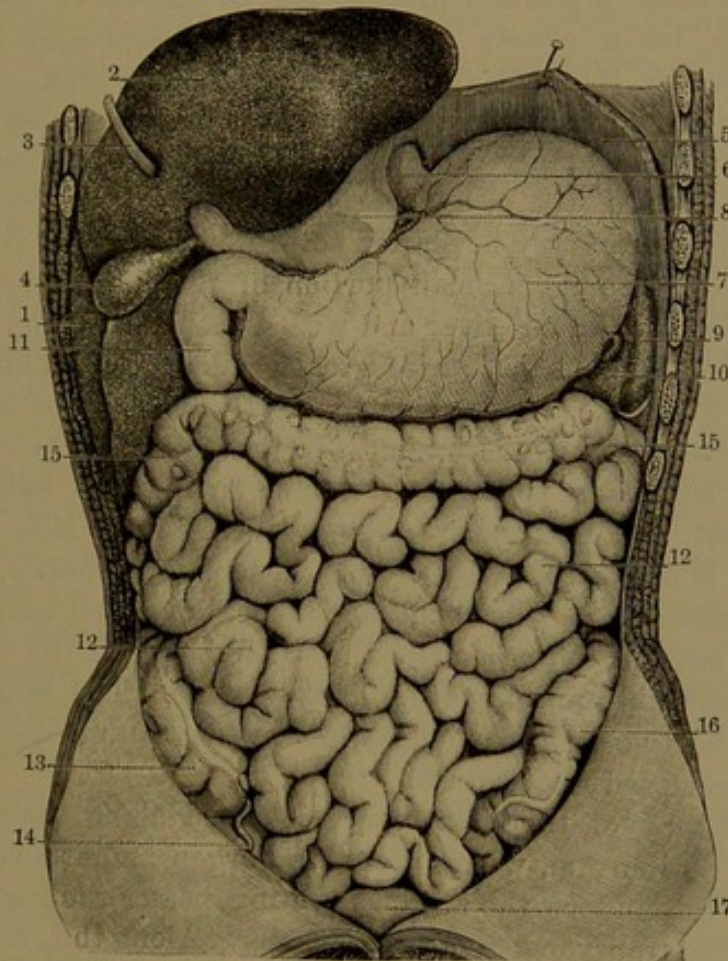
<sup>7</sup> Curvatura inferior.

<sup>8</sup> C. superior.



bulge, named the **pyloric antrum**,<sup>1</sup> situated to the right and below the pylorus. The latter is indicated by a slight external constriction, and is a circular orifice directed backward into the duodenum and provided with a sphincter and valve. Occasionally, the pyloric extremity of the stomach is slightly constricted an inch or two from the pylorus.

FIG. 216.



VIEW OF THE ABDOMINAL VISCERA; the liver raised to show its under surface, and the great omentum removed. 1, upper surface of the liver; 2, under surface; 3, round ligament; 4, gall-bladder; 5, diaphragm; 6, œsophagus; 7, stomach; 8, gastro-hepatic omentum; 9, spleen; 10, gastro-splenic omentum; 11, descending portion of the duodenum; 12, small intestine, jejunum, and ileum; 13, cæcum; 14, vermiform appendix; 15, transverse colon; 16, sigmoid flexure; 17, urinary bladder.

The anterior and posterior surfaces of the stomach are free, smooth, and convex, the former looking variably forward and upward, the latter in the opposite direction. The anterior surface is in contact with the diaphragm, the under surface of the liver, and the front of the abdominal wall in the epigastrium, from which this is called the **pit of the stomach**.<sup>2</sup> The posterior surface lies on the transverse mesocolon, above the transverse colon; and behind the former are the pancreas, spleen, left kidney, and suprarenal body, the great vessels in front of the spine, and the crura of the diaphragm.

<sup>1</sup> Antrum pylori or pyloricum; lesser cul-de-sac; lesser tuberosity.

<sup>2</sup> Scrobiculus cordis; procardium; anticardium.



The exact position of the stomach is variable, and is influenced by its state of distention and that of the intestines, and also by the respiration; falling and rising with the action of the diaphragm and the abdominal muscles below. With the expansion in taking food, its greater curvature rises and is directed more forward, while the anterior surface is directed upward and the posterior surface more downward. The cardia is fixed in position in front and to the left of the last thoracic vertebra, being closely attached to the œsophageal orifice of the diaphragm by the reflection of the peritoneum from one to the other. The pyloric extremity, on the other hand, is very movable. When the stomach is empty the pylorus occupies nearly a median position in the vicinity of the last thoracic vertebra, but in the distended condition of the organ may be shifted several inches to the right. The empty stomach occupies a small portion of the left hypochondrium beneath the left lobe of the liver and with the spleen behind it.<sup>1</sup>

The size of the stomach varies greatly under many different conditions, and, while it may sometimes have the capacity of a gallon or more, it is occasionally reduced almost to the calibre of the small intestine. It is commonly smaller in women, in persons habitually insufficiently fed, and to a much greater degree in the sick after long fasting; and is larger in habitually big feeders. Ordinarily, in a moderately distended state, it is about ten inches long, and nearly half as wide where largest; often a little the wider between the curvatures, and with a capacity approximating half a gallon. The same stomach empty may be two or three inches less in length and one or two in width, and collapsed fore and aft.

The curvatures of the stomach are attached along their course by folds of the peritoneum, which invest the organ and attach it to adjacent parts. From along the small curvature passes the gastro-hepatic omentum to the transverse fissure of the liver. Along the greater curvature is appended the great omentum, continuous on the fundus with the gastro-splenic omentum, attached also to the spleen; and at the left of the cardia is a small fold, the gastro-phrenic ligament, extended between the œsophagus and diaphragm. Between the layers of the omenta the principal vessels and nerves of the stomach run along its curvatures.

The wall of the stomach varies in thickness with the size of the organ, being thinnest in the large or distended state, and it also varies in different positions, becoming gradually thicker as the capacity decreases from the fundus to the pylorus.

In the cardiac extremity it is much thinner than that of the œsophagus; at the middle it is about a line or more, decreasing to less than half a line in the fundus, and increasing towards the pylorus to two or

---

<sup>1</sup> From the proximity of the stomach to the heart, separated only by the left lobe of the liver and the diaphragm, the pain of gastralgia, often accompanied with palpitation, is commonly referred to the heart.



three lines. The weight of the stomach is estimated at four and a half ounces in the male, and less in the female.

Four different coats compose the wall of the stomach, closely united, and named in succession from without the serous, muscular, fibrous, and mucous coats.

The external, **serous coat**,<sup>1</sup> derived from the peritoneum, is a thin, uniform, smooth, transparent, and elastic layer, closely investing the stomach, except a narrow space along the curvatures, which is traversed by the chief vessels of the organ, between the layers of the omenta.

The **muscular coat**<sup>2</sup> is the thickest, and is that upon which the varying thickness of the wall of the stomach chiefly depends. The decrease in size of the stomach is due to contraction of the muscular coat, and hence this is proportioned in thickness to the size of the organ and to the thickness of the wall in different positions. It is of a reddish-brown color, visible through the serous coat, and is composed of comparatively long, unstriped muscle-fibres, which are arranged in three layers, named from the direction of the latter the longitudinal, circular, and oblique layers. The external **longitudinal layer** is continuous with that of the œsophagus, from which the fibres spread upon the stomach, mostly along the curvatures, and especially the short one, where they are best marked. Upon the front and back surfaces they are thinly diffused, and become indistinct approaching the pyloric extremity, where they again appear more evident, and form a continuous layer, proceeding to the pylorus and duodenum. The **circular layer**, most uniformly continuous upon the stomach, consists of thin rings with narrow intervals encircling the course of the organ from the fundus to the pylorus, gradually becoming smaller and thicker approaching the latter, where they accumulate in a stout annular bundle, which is the **pyloric sphincter**.<sup>3</sup> At its commencement the circular layer is continuous with that of the œsophagus to the right of the cardia, whence it spreads over the fundus, gradually extending from left to right. The **oblique layer** of muscular fibres, less complete or extensive than the former, is best produced on the fundus, to the left of the cardia, where it is continuous with the circular layer of the œsophagus, and thence spreads on the front and back of the stomach within the circular layer, with which its fibres become continuous approaching the greater curvature.

The **fibrous, or submucous, coat**<sup>4</sup> of the stomach is a considerable, compact, extensible layer of areolar tissue, composed of a basis of fibro-connective-tissue bundles intersecting one another and mingled with elastic fibres. Besides contributing to the strength of the organ, it gives especial support to the less tenacious mucous membrane, and contains extensive plexuses of the chief arteries, veins, and lymphatics,

<sup>1</sup> Tunica serosa.

<sup>2</sup> T. musculosa; stratum musculare.

<sup>3</sup> Musculus sphincter pylori.

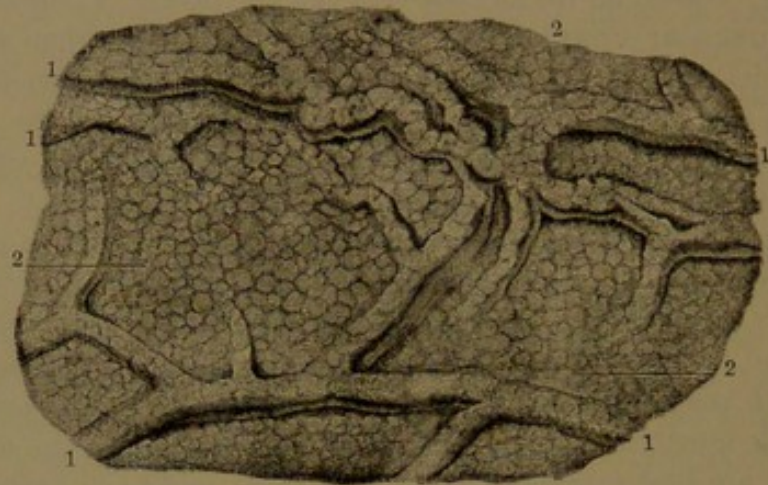
<sup>4</sup> Fibrous coat; tunica fibrosa, nervosa, or nervea.



directly connected with the vessels of the latter, and associated with a gangliated plexus of nerves.

The lining **mucous membrane**<sup>1</sup> of the stomach, comparatively thick, is a moderately firm, inelastic layer, quickly changing color and softening after death. During digestion it is more or less rose-red, but in the empty state of the stomach is gray or yellowish gray. In the fresh condition after death it is usually reddish, but soon becomes paler.

FIG. 217.



SURFACE OF THE MUCOUS MEMBRANE OF THE STOMACH. 1, rugæ; 2, mammillated surface.

It presents a closely- and finely-mammillated appearance, which is especially well marked in the pyloric extremity, but becomes indistinct in the aged, and is also effaced by softening after death.

As the mucous membrane, together with its submucous basis, is possessed of little elasticity, in the contraction of the muscular coat and consequent decrease of the stomach it is thrown into numerous wrinkles or **rugæ**,<sup>2</sup> which are obliterated with the expansion of the organ. The rugæ are most marked along the greater curvature and in the pyloric extremity, and generally pursue a longitudinal and more or less tortuous and reticular course. In advanced life they often appear stained along their course, so that this is evident after their obliteration through distention of the organ.

The **pyloric valve**<sup>3</sup> is a thick, annular fold of the mucous membrane with the submucous coat investing the pyloric sphincter. It encloses a circular orifice, usually central, but sometimes more or less eccentric. In the dried preparation, the valve appears as a circular diaphragm with a circular orifice.

The mucous membrane consists of the epithelium and the mucosa with the gastric glands and its muscularis mucosæ.

The **epithelium** of the stomach consists of a single layer of six-sided columnar cells, commencing abruptly at the cardia, spreading

<sup>1</sup> Tunica mucosa.

<sup>2</sup> Plicæ.

<sup>3</sup> Valvula pylori.

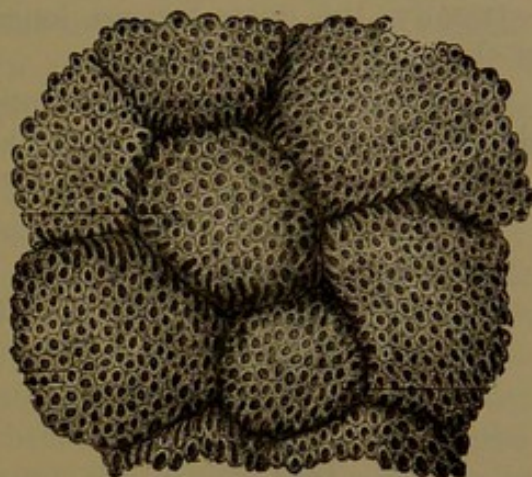


throughout to the pylorus, and extending into the mouths and ducts of the gastric glands. The cells have a delicate wall and protoplasmic contents, appearing more or less granular in the deeper part and clearer in the outer part. An oval nucleus occupies their deeper part. During digestion they become more clear, and many pass more or less into the condition of mucus-secreting goblet-cells. They are supported on a basement membrane of flat cells, from which branching processes ascend among the columnar cells and descend into the mucosa. Between their often narrower attached extremities the intervals are occupied by smaller, immature cells of round or oval outline.

The **mucosa** consists of a small proportion of fibro-connective-tissue matrix, in which are closely embedded the gastric glands vertically arranged, and with their ducts opening upon the free surface of the mucous membrane, to which they give a minutely cribriform appearance.

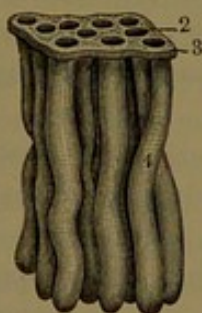
The **gastric glands** are tubular, and are proportioned in length

FIG. 218.



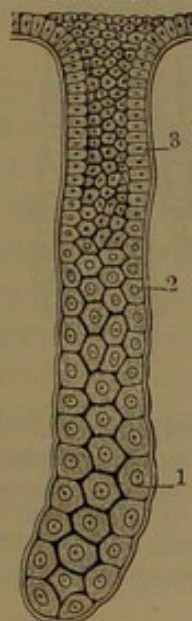
MAMMILLÆ OF THE MUCOUS MEMBRANE OF THE STOMACH, moderately magnified, exhibiting the orifices of the gastric glands.

FIG. 219.



SMALL PORTION OF THE MUCOUS MEMBRANE OF THE STOMACH, WITH THE GASTRIC GLANDS. 1, the glands; 2, orifices of the glands; 3, epithelium of the mucous membrane: moderately magnified.

FIG. 220.



A GASTRIC GLAND, highly magnified. 1, large polyhedral cells at the bottom of the gland, gradually merging 2 into the columnar cells 3, at the upper part of the gland.

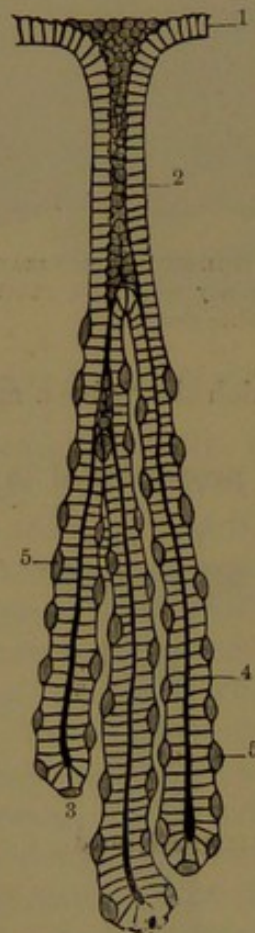
to the thickness of the mucous membrane, being shortest in the fundus and longest in the pyloric extremity. They further present important differences, which have led to their being distinguished as the cardiac or peptic glands and the pyloric glands.



The **cardiac glands**<sup>1</sup> have comparatively short ducts, generally from one-third to one-sixth of the length of a gland, abruptly narrowing below, and communicating generally with two or three slender flask-shaped tubules, which are nearly straight or slightly tortuous, and end in round, expanded, and more or less curved extremities. Approaching the cardia, the ducts are relatively shorter and the communicating tubules longer. Approaching the pyloric extremity, the ducts become longer and approximate the character of the pyloric glands.

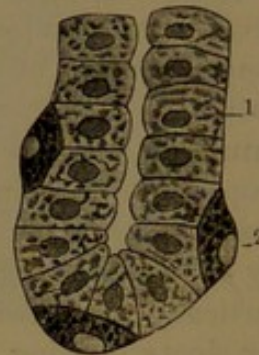
The **pyloric glands** have comparatively long ducts, a half or more the length of a whole gland, and likewise abruptly narrowed below and

FIG. 221.



A CARDIAC GASTRIC GLAND OF THE DOG, highly magnified. 1, columnar epithelium of the mucous membrane of the stomach; 2, columnar epithelium of the mucous membrane of the duct; 3, tubules of the gland; 4, columnar epithelium; 5, parietal or peptic cells.

FIG. 222.



BOTTOM OF A GASTRIC GLAND, highly magnified. 1, columnar cells; 2, parietal cells.

communicating with two or three tubules. These are also slender flask-shaped, and are more or less tortuous or convoluted and have a more capacious passage than in the former.

The ducts of the gastric glands are lined with an extension of the columnar epithelium, the cells of which become proportionately smaller in the narrowed bottom part of the ducts. In the tubules of the pyloric glands the lining cells<sup>2</sup> are also columnar, but shorter, thicker, more opaque, and proportionate in size with the enlargement of the tubules towards their expanded terminations. In

the tubules of the cardiac glands the lining epithelium is of the same general character, but in addition they contain scattered, isolated cells,

<sup>1</sup> Peptic glands; fundus or oxyntic glands.

<sup>2</sup> Principal or central cells.



named from their relative position **parietal cells**.<sup>1</sup> These are situated beneath the lining epithelium on the *membrana propria*, which they often cause to bulge more or less externally. They are compressed spheroidal and somewhat polygonal, more opaque and granular than the columnar cells, and contain a clear, central, compressed-spherical or oval nucleus.

Beneath the gastric glands the mucosa is a thin fibro-connective-tissue layer, which is succeeded by the *muscularis mucosæ* of variable thickness in different positions. In some positions it consists of a single layer of longitudinal unstriated muscle-fibres, in others of an outer longitudinal and an inner circular layer, and again with an additional inner longitudinal layer. Many bundles of the muscle-fibres ascend in the mucosa and pass between the gastric glands.

The stomach is a very vascular organ, more especially its mucous membrane. Its arteries are derived from the coronary, right and left gastro-epiploic, short gastric, and pyloric arteries, all derived from the *cœliac axis*. From along the curvatures the arteries diverge in front and behind the stomach, and enter between the serous and muscular coats, whence they penetrate the latter and ramify and inosculate in the submucous coat, in which they form an extensive retiform plexus. From this numerous small arteries proceed to the mucous membrane, ramifying and anastomosing in the mucosa, and terminating in fine capillary nets surrounding the tubules and ducts of the gastric glands, and finally in a coarser net around the mouths of the latter. From these nets veins pass through the mucosa and join an extensive plexus of the submucous coat, from which emanate the companion veins of the arteries terminating in the splenic and superior mesenteric veins, and directly also into the portal vein.

Lymphatics are very numerous in the mucous membrane of the stomach, commencing as a plexus of lacunar spaces among the tubules of the gastric glands, many of which, as well as the contiguous capillary blood-vessels, they enclose. Near the free surface of the membrane, lymphatic vessels commence in loops and club-like expansions, and descend to the bottom of the mucosa, where they join a fine plexus of vessels which communicates with a coarser plexus in the submucous coat. In the latter plexus the vessels are provided with valves, and from it proceed vessels, which pass through the muscular coat, and thence follow the arteries and veins in their course along the curvatures of the stomach, where they traverse lymphatic glands.

A capillary system of blood-vessels also pertains to the muscular coat of the stomach, and still a third to the serous coat, both of which communicate with the contiguous arteries and veins.

The nerves of the stomach are derived from the terminal branches of the *vagus nerves*, and from branches of the sympathetic accompan-

---

<sup>1</sup> Peptic cells; superadded or oxyntic cells.



ing the arteries from the solar plexus. The nerves form gangliated plexuses between the layers of the muscular coat and in the submucous coat.

#### THE SMALL INTESTINE.

The **small intestine**, or **gut**,<sup>1</sup> is a long, cylindrical tube, extending from the pylorus of the stomach to the large intestine. It is of variable length, ordinarily in the adult about twenty feet, but ranging between fifteen and twenty-five feet or more. (In a well-proportioned muscular man, of six feet and about forty years of age, the small intestine, detached from the mesentery, measured twenty-six feet three inches, and the large intestine measured six feet nine inches; in all, thirty-three feet.) It occupies the middle and lower portions of the abdomen, and is suspended from the spine by the mesentery in numerous coils movable in any direction. It is surrounded by the large intestine except below, and is covered by the great omentum, which separates it from the front wall of the abdomen. It is regarded as consisting of three portions, named the duodenum, jejunum, and ileum, which, though merging into one another, in the main present certain differences.

The **duodenum**<sup>2</sup> is the shortest and least variable in length, the widest, and most fixed portion of the small intestine; from eight to ten inches long, and varying between one and a half to two inches wide. It forms an arch with its convexity directed to the right, and embracing the head of the pancreas in its concavity to the left. From the pylorus it passes upward, backward, and to the right beneath the liver, descends in front of the right kidney, and then makes a sigmoid curve inwardly across the spine, and merges in the jejunum to the left of the second lumbar vertebra.

The **ascending portion** of the duodenum, about two inches long, is free and movable, and invested with the peritoneum of the gastro-hepatic omentum. It is in contact in front and above with the liver and neck of the gall-bladder, and behind with the bile-duct, the hepatic artery, and the portal vein. The **descending portion**, about three inches long, and the most expanded, turns abruptly downward from the neck of the gall-bladder, in front of the right kidney and its vessels, as low as the third lumbar vertebra. It is firmly attached inwardly to the head of the pancreas, and is covered only on its anterior surface by the peritoneum, in front of which are the hepatic flexure of the colon and the mesocolon. The bile and pancreatic ducts enter its inner side a little below the middle. The **transverse portion**, the longest and narrowest of the duodenum, curves inward and upward across the spine from the third lumbar vertebra on the right to the second on the left, where it becomes the jejunum. Behind, it rests on the aorta, inferior cava, and crura of the diaphragm; above, it is in

<sup>1</sup> Intestinum tenue, or gracile; enteron; small bowel.

<sup>2</sup> Ventriculus succenturiatus.



contact with the pancreas, and thence is crossed in front by the superior mesenteric blood-vessels. It lies behind the root of the transverse mesocolon, and receives no peritoneal investment except at its termination.

The small intestine succeeding the duodenum is suspended by the mesentery, which furnishes it with a complete investment throughout. Its upper third or two-fifths comprise the **jejunum**, while the remainder is the **ileum**.<sup>1</sup> Narrower and more uniformly cylindrical than the duodenum, it nevertheless gradually decreases, so that while the upper portion of the jejunum is from one and a quarter to one and a half inches in diameter the lower portion of the ileum is from a quarter to half an inch less. The jejunum is situated more deeply, higher, and to the left, while the ileum is more superficial, lower, and to the right. The former is mainly confined to the umbilical and left lumbar and iliac regions, while the latter occupies part of the umbilical, the right lumbar and iliac, hypogastric, and pelvic regions. From the latter the ileum ascends obliquely to the right over the corresponding psoas muscle, and terminates on the inner side of the large intestine, which commences in the right iliac region. The mobility of the jejunum and ileum renders their coils liable to incessant change in position according to their variable distention, or that of the stomach, large intestine, and bladder; and they are further influenced by the respiratory movements. While the jejunum gradually merges into the ileum, in general it presents a darker appearance, has a thicker wall, and feels considerably thicker when seized between the finger and thumb, due mainly to the numerous interior folds or connivent valves which are included in the pressure.

The wall of the small intestine is thinner than that of any other part of the alimentary canal, and, like that of the stomach, is composed of four coats, except that the external or serous coat is deficient on the greater part of the descending portion and on the transverse portion of the duodenum. To the jejunum and ileum it provides a continuous and close investment, leaving only a narrow interval along the attachment of the mesentery, where the vessels and nerves pass to and from the intestine.

The **muscular coat**, thinner than that of the stomach, and becoming thinner on the ileum than on the jejunum, consists of two layers, an outer longitudinal and an inner circular. The longitudinal layer is continuous but very thin, and is best produced along the distal border, or that opposite the attachment of the mesentery. The circular layer is thicker and more distinct, especially on the jejunum.

The **fibrous, or submucous, coat**<sup>2</sup> is like that of the stomach, but is thinner and more closely connected with the mucous coat. It contains the larger plexuses of blood-vessels and lymphatics directly

<sup>1</sup> Ileum; *intestinum circumvolutum*.

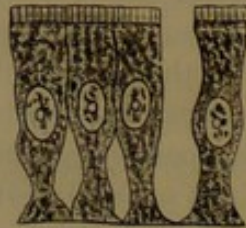<sup>2</sup> Submucosa.



connected with those of the latter, and also serves as a bed for many of its glands.

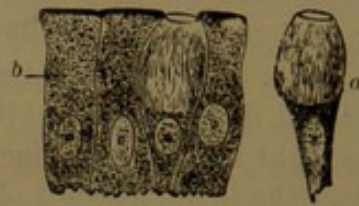
The lining **mucous membrane** has a soft, velvety appearance, due to its surface being closely covered with little processes, the **villi**, which stand up like the pile of velvet. It is very vascular, though ordinarily it is pale red, and becomes still paler, passing to gray in the ileum. From near its commencement, and for more than half the length of the intestine, it is provided with numerous transverse folds, named the **connivent valves**. It consists of the epithelium and the mucosa with numerous glands and its muscularis mucosæ.

FIG. 223.



COLUMNAR EPITHELIUM, from the mucous membrane of the small intestine: highly magnified.

FIG. 224.



COLUMNAR EPITHELIUM, from an intestinal villus. *a*, goblet-cells; *b*, columnar cells: highly magnified.

The **epithelium** consists of a single uniform layer of columnar cells, like those of the stomach, but peculiar in that each cell terminates in a thick plate, which is vertically striate; the striæ seeming to be due either to fine pores or to a division of the plate into minute rods. Among the columnar cells many are to be observed in the condition of mucus-secreting goblet-cells.

The mucosa consists of a basis of ordinary fibro-connective tissue with lymphoid tissue defined by basement membrane of the usual constitution. In it are embedded the enteric glands, and it is defined from the submucous coat by the muscularis mucosæ. This in some positions consists of a single layer of longitudinal unstriated muscle-fibres, but in others of an additional inner, thin, circular layer.

The **connivent valves** (*valvulae conniventes*)<sup>1</sup> are narrow folds of the intestinal mucous membrane strengthened by processes of the submucous coat. They are crescentic, and generally encircle the intestine from one-half to about three-fourths way round, and lie backward, so that where they are numerous and close together they present a somewhat imbricate appearance. They are widest along the middle, and taper at the extremities. The longest measure about two and a half inches by one-fourth of an inch wide, and where most numerous are separated about their own width. They commence with the descending portion of the duodenum, become most numerous and largest in the transverse portion and in the upper portion of the jejunum, whence they continue into the ileum, gradually decreasing both in

<sup>1</sup> Valves of Kerkring; v. c. Kerkringii; plicæ conniventes.

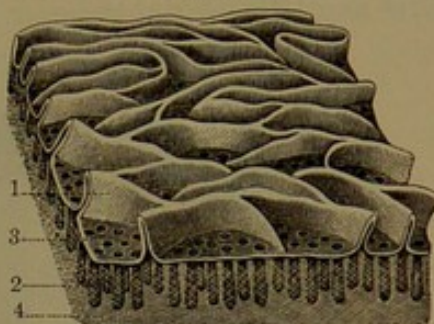


number and size, and finally disappear in the lower portion of the latter, where the mucous membrane is comparatively even. Unlike the rugæ of the stomach, they are permanent and not affected by the contraction or expansion of the intestine, nor are they active during life, as the muscular coat of the latter does not enter into their composition. In dried preparations they project straight inward from the wall of the intestine as narrow, crescentic partitions. Their presence retards the passage of the food, and greatly increases the extent of surface for absorption. It is a remarkable fact that they are peculiar to man, even in the higher apes existing only in a rudimentary condition.

The mucous membrane of the connivent valves is the same as elsewhere in the small intestine, being provided with villi and both enteric and solitary glands.


The villi<sup>1</sup> thickly cover the surface of the mucous membrane from the pyloric valve to the ileo-colic valve. It is estimated that in the

FIG. 225.



SMALL PORTION OF THE MUCOUS MEMBRANE FROM THE UPPER PART OF THE JEJUNUM, moderately magnified. 1, villi, resembling connivent valves in miniature; 2, enteric glands; their orifices, 3, opening on the free surface of the mucous membrane; 4, fibro-connective tissue of the mucosa.

FIG. 226.



PORTION OF THE MUCOUS MEMBRANE FROM THE ILEUM, moderately magnified, exhibiting the villi on its free surface, and between them the orifices of the enteric glands. 1, portion of an agminated gland; 2, a solitary gland; 3, the mucosa.

upper part of the intestine there are from ten to eighteen in the space of a square millimetre, and eight to fourteen in the same space in the ileum, amounting in all to about four millions. They are generally conical, finger-like, and tongue-like in shape, and vary in proportionate length and breadth. They commonly range from one-fiftieth to one-twenty-fifth of an inch in length. They are of greatest breadth in the duodenum and the commencement of the jejunum, where many appear laminar, like minute connivent valves, more or less flexuose, intertwining, and often dividing and joining one another. Lower in the jejunum they become slightly longer and relatively much narrower.

<sup>1</sup> Villi intestinorum; intestinal villousities.



The villi are processes of mucous membrane, composed of a matrix of fibro-connective and lymphoid tissue containing vessels, and covered by the common intestinal epithelium. Each villus contains beneath the basement membrane a net of fine capillary vessels, supplied by an artery ascending from the mucosa and terminating in a vein descending to the venous plexus of the latter. Each also contains centrally usually a single cylindrical or clavate lacteal of much greater calibre

FIG. 227.

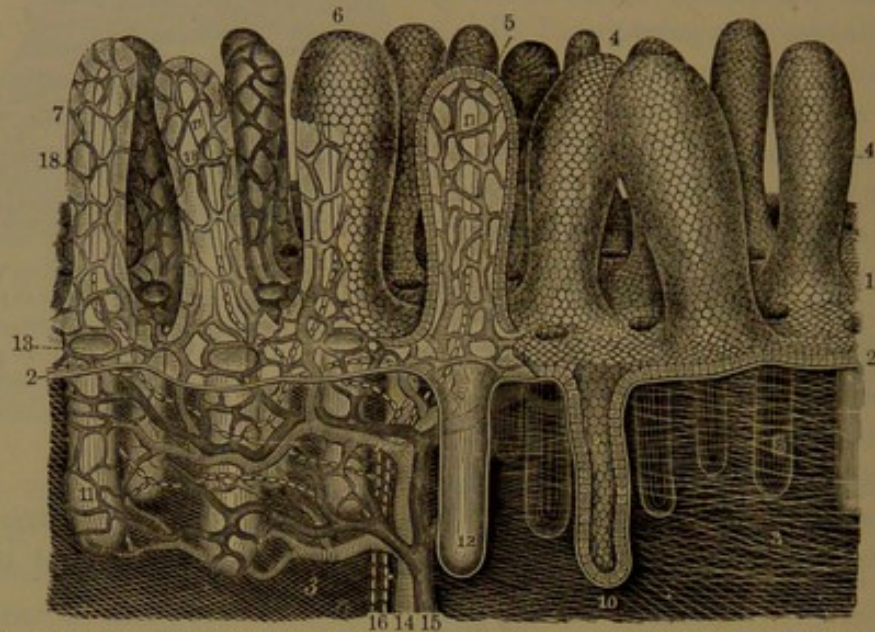


DIAGRAM OF THE STRUCTURE OF THE MUCOUS MEMBRANE OF THE ILEUM, highly magnified. 1, epithelium forming the free surface of the mucous membrane; 2, basement membrane; 3, the mucosa, composed of fibro-connective-tissue; 4, villi covered with epithelium; 5, a villus deprived of one-half of its epithelium, and exhibiting through its basement layer the blood-vessels; 6, a villus partially deprived of its epithelium; 7, villi totally deprived of their epithelium, but retaining their basement membrane; 8, enteric glands embedded in the mucosa; 9, orifices of the enteric glands opening on the free surface of the mucous membrane between the villi; 10, section of an enteric gland, with its epithelial lining; 11, enteric glands stripped of the latter, but retaining their basement membrane; 12, one of the glands in section, without its epithelium; 13, capillaries surrounding the orifices of the enteric glands; 14, an artery; 15, a vein; 16, lymphatics or lacteals; 17, commencement of the latter within the villi; 18, capillary blood-vessels of the villi.

than the surrounding blood-capillaries. It commences in a blind extremity below the top of the villus, and descends to the lymphatic plexus beneath. The broader villi contain two or more lacteals uniting in loops or plexuses. Accompanying each lacteal are some ascending unstriped muscle-fibres, which at their upper ends radiate to the basement membrane of the villus.

**Glands of the small intestine.** The bodies commonly named as such are the enteric, the duodenal, the solitary, and the agminated glands.


The **enteric, or tubular, glands**<sup>1</sup> are minute and very numerous,

<sup>1</sup> Glandulæ entericæ, mucosæ, or Lieberkühnii; crypts, follicles, or glands of Lieberkühn; cryptæ minimæ or mucosæ.



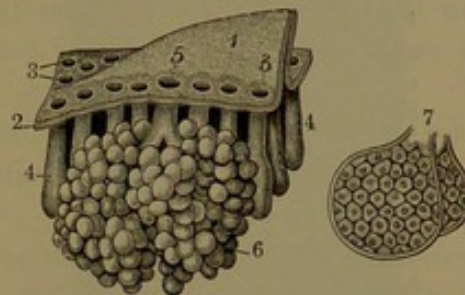
and are embedded vertically in the mucosa of the intestinal mucous membrane. They are simple, cylindrical, slightly flask-shaped tubes, closed at the bottom, and opening on the surface of the mucous membrane in the intervals of the villi. They are related in size with the thickness of the mucous membrane, and are uniform in any particular position. They are longest in the duodenum and shortest in the ileum, and usually range from one-sixty-sixth to one-fiftieth of an inch long. Their wall consists of a membrana propria lined with a columnar epithelium like that of the intestine generally.

FIG. 228.



PORTION OF THE DUODENUM, viewed from without, natural size. 1, thickness of the duodenum; 2, 3, longitudinal and transverse layers of the muscular coat; 4, fibrous coat; 5, exterior of the mucous membrane with the duodenal glands.

FIG. 229.



A VERTICAL SECTION OF THE DUODENUM, highly magnified. 1, a fold-like villus; 2, epithelium of the mucous membrane; 3, orifices of the tubular enteric glands, 4; 5, orifice of a duodenal racemose gland, 6; 7, two follicles of the latter, more highly magnified, exhibiting the secretory cells lining their internal surface.

The **duodenal glands**<sup>1</sup> are little spheroidal, racemose glands embedded in the submucous coat of the duodenum, with their ducts ascending between the enteric glands and opening on the surface with them between the villi. They are largest and most numerous in the ascending portion of the duodenum, where they form a more or less continuous patch, decrease in number and size in the descending portion, and disappear in the transverse portion. They are variable both in number and size in different persons, and usually range from one-hundredth to one-twenty-fifth of an inch in diameter. They are best exposed to view from the outside by dissecting away the serous and muscular coats.

The **solitary glands**<sup>2</sup> are soft, white, spheroidal, or ovoidal bodies scattered here and there, alone as the name indicates, over the inner surface of the small intestine. They usually range from one-fiftieth to one-tenth of an inch, and are rather more numerous in the ileum. They are partially embedded in the submucous coat, protrude through the

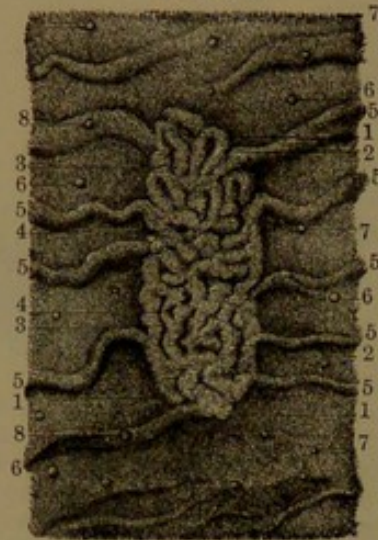
<sup>1</sup> Glands of Brunner; glandulæ Brunnerianæ or conglomeratæ intestinorum.

<sup>2</sup> Glandulæ solitariae or sporacles.



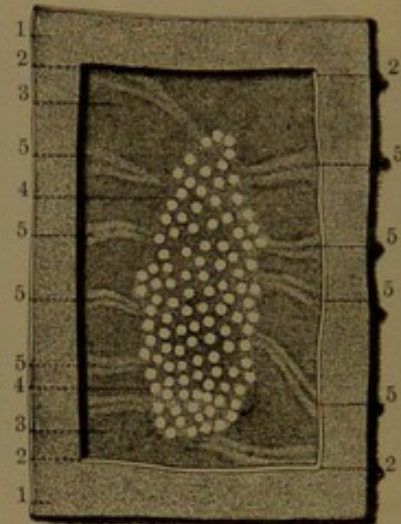
muscularis mucosæ into the mucosa, and cause the investing epithelium to project above the general level of the mucous membrane. They are surrounded by enteric glands, and frequently have villi upon them. Each consists of an egg-shaped nodule of lymphoid tissue,—that is to say, a matrix of stellate connective-tissue corpuscles with the interspaces occupied with lymphoid corpuscles. Though considered and named **follicles**, they are not actually separated from the adjacent lymphoid tissue of the mucosa, but are defined by a surrounding

FIG. 230.



PORTION OF THE MUCOUS MEMBRANE FROM THE UPPER PART OF THE ILEUM, exhibiting the appearance presented to the naked eye when the specimen is floated in water. 1, 2, 3, 4, an agminated gland; 5, connivent valves; the short lines everywhere covering the surface of the mucous membrane, including the valves and the gland, represent villi; 6, 7, 8, solitary glands.

FIG. 231.



PORTION OF THE ILEUM, viewed from without; the serous and muscular coats removed over the position of an agminated gland. 1, exterior surface of the ileum; 2, cut edge of the serous and muscular coats; 3, exterior surface of the mucous membrane and fibrous coat; 4, an agminated gland, exhibiting its nodules of lymphoid tissue; 5, position of connivent valves.

plexus of capillary blood-vessels and lymphatics, from which finer capillaries extend into the interior of the nodules.

The **agminated glands**, or **glands of Peyer**,<sup>1</sup> are patches of lymphoid nodules like the solitary glands, and for the most part occupy the ileum. They are commonly elliptical, of very variable size, and situated opposite the attachment of the mesentery in a single row, with their length parallel to that of the intestine. They number generally from twenty to thirty or more, and range from half an inch to three or four inches in length, by half an inch to three-fourths in width, while a few of the smallest are only two or three lines broad. They are ordinarily largest and nearer together in the lower part of the ileum, and are fewer in the upper part of the intestine, being smallest and often circular in the jejunum. They are more or less sharply or obscurely de-

<sup>1</sup> Glandulæ agminatæ; g. mucosæ coagminatæ; g. Peyeri, Peyerianæ, or sociæ Peyeri; aggregate glands; patches or plaques of Peyer.



finer, slightly or scarcely prominent, and usually even and not crossed by connivent valves. The mucous membrane continuous over them is thinner and more tightly adherent to the subjacent parts than elsewhere, and is usually provided with fewer villi. Sometimes the glands appear more prominent and better defined, and the mucous membrane covering them is tortuously plicated and more villous than usual. Connivent valves approaching the glands usually cease at their border. The constituent lymph-nodules lie on the same plane, and, like the solitary glands, are partially embedded in the submucous coat, and protrude through the muscularis mucosæ into the mucosa, but not to the extent of the solitary glands, which commonly appear more prominent than the nodules of the agminated glands. The latter have the same constitution as the former, and in the intervals they merge into the more diffused lymphoid tissue of the mucosa, which in these positions also include some of the enteric glands surrounding the nodules. The latter are defined by plexuses of capillary blood-vessels, from which finer capillaries extend into the interior of the nodules. Plexuses of lymphatics likewise surround them.

In the position occupied by the agminated glands the submucous coat is denser than elsewhere, and is more closely connected with the mucosa, so that when air is forced into the submucous coat of the intestine it meets with greater resistance to its entrance beneath the glands.

Both the agminated and solitary glands are best developed during growth and maturity, but after middle life are less well marked, and in old age become more or less atrophied. They are remarkable for their susceptibility to disease, especially in typhoid fever, in which they become greatly enlarged, and are very liable to ulceration, often extending through and perforating the intestine.<sup>1</sup>

The **arteries** of the small intestine are chiefly derived from the superior mesenteric, and the commencement of the duodenum receives branches from the gastro-duodenal branch of the hepatic artery. The branches of the superior mesenteric artery reach the intestine along the attachment of the mesentery, diverging in front and behind, and entering between the serous and muscular coats. Penetrating the latter, they ramify freely in the submucous coat, and inosculate around the intestine in a plexus. From this, branches proceed to the mucous membrane, and end in the capillaries of its mucosa, of the villi, and of the various glands. Branches also proceed to the capillaries of the muscular coat and to those beneath the serous coat. The corresponding **veins** return from the capillary plexuses to the large venous plexus of

---

<sup>1</sup> In a young soldier who died in Satterlee Hospital in 1862, in whom the agminated glands were well produced, comparatively even, and the lymph-nodules unusually distinct, in a gland an inch and a quarter long and half an inch wide there were counted about two hundred and sixty nodules.



the submucous coat, whence veins accompany the arteries finally to empty in the superior mesenteric vein.

The **lymphatics** form plexuses of vessels in the mucosa between and around the enteric glands, receive the lacteals from the villi, communicate with plexuses around the lymph-nodules forming the solitary and agminated glands, and unite with a plexus of coarser vessels in the submucous coat. Plexuses also exist in the muscular coat and beneath the serous coat. From the different plexuses the chief vessels proceed to the mesenteric border and conjoin to form the lacteal vessels traversing the mesentery.

The **nerves** of the small intestine are derived from the superior mesenteric plexus emanating from the solar plexus of the sympathetics united with branches from the vagus nerves. Accompanying the superior mesenteric artery and its divisions the plexus is expended in branches diverging to the intestine. Entering the muscular coat, they form an extensive gangliated plexus<sup>1</sup> between the longitudinal and circular layers; the fibres of the plexus being mostly non-medullated. From the plexus proceed branches to the submucous coat, in which they form another gangliated plexus,<sup>2</sup> and from both, fine branches pass to the mucosa, the two layers of the muscular coat, and beneath the serous coat, to form still finer plexuses.

#### THE LARGE INTESTINE.

The **large intestine**,<sup>3</sup> as expressed by the name, is the larger continuation of the canal succeeding the small intestine, and extending from the termination of the ileum to the anus. Of variable length, it is usually from five to six feet; and is also of variable diameter in different persons and in different parts of the intestine, varying from an inch and a half to two or three inches in the largest portion. It comprises two divisions, the colon and the rectum, the former occupying the abdomen, the latter the pelvis.

The **colon**<sup>4</sup> is largest at its commencement, and decreases, often somewhat irregularly, to its termination in the rectum. It is not an even cylindrical tube like the small intestine, but presents three rows of pouches separated by constrictions of the wall, which are produced by narrow folds projecting into the intestine, and caused by three equidistant bands running along the colon from its commencement to the rectum. It nearly surrounds the small intestine at the boundaries of the abdomen, and is attached to the posterior wall of the latter by a fold of the peritoneum named the mesocolon. It commences in the right iliac region, ascends through the lumbar to the right hypo-

<sup>1</sup> Plexus of Auerbach; p. myentericus.

<sup>2</sup> Plexus of Meisner.

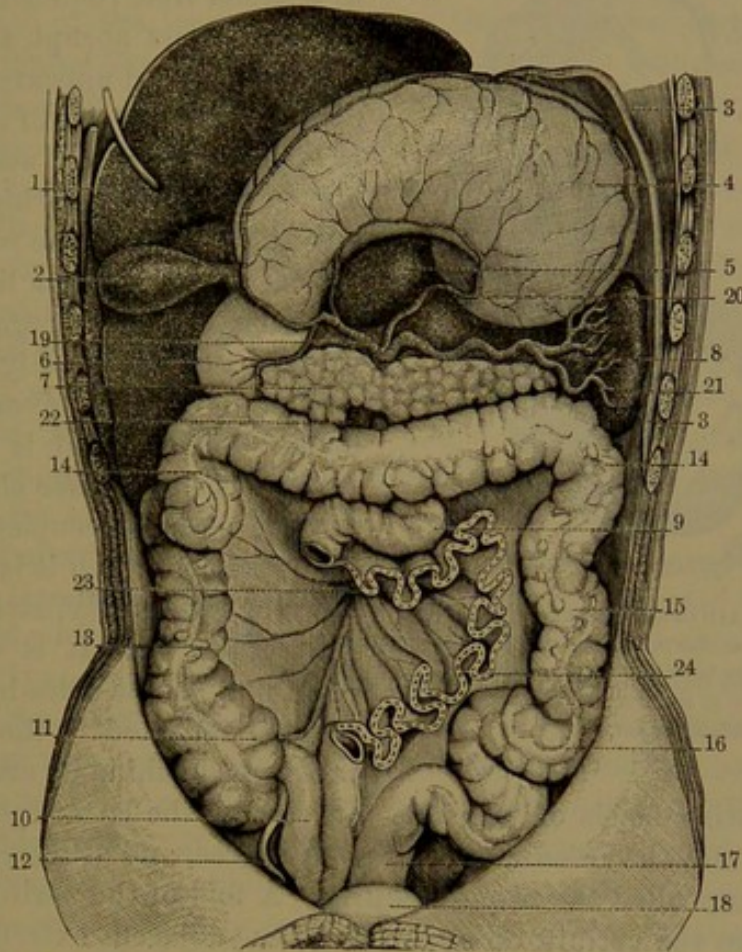
<sup>3</sup> Intestinum crassum, amplum, or plenum.

<sup>4</sup> Colum; intestinum majus, grande, cellulatum, or laxum.



chondriac region beneath the liver; thence curves across to the left hypochondriac region beneath the spleen, and descends through the lumbar to the left iliac region, where it produces a loose S-like fold, and

FIG. 232.



VIEW OF THE ABDOMINAL VISCERA; with the greater part of the small intestine removed, and the liver and stomach turned upward. 1, under surface of the liver; 2, gall-bladder; 3, diaphragm; 4, stomach, posterior surface; 5, caudate lobe of the liver; 6, duodenum; 7, pancreas; 8, spleen; 9, jejunum; 10, ileum; 11, caecum; 12, vermiform appendix; 13, ascending colon; 14, 14, transverse colon; 15, descending colon; 16, sigmoid flexure; 17, rectum; 18, urinary bladder; 19, hepatic artery, giving off pyloric, hepatic, pancreatico-duodenal, and right gastro-epiploic branches; 20, coronary artery to small curvature of the stomach; 21, splenic artery; 22, superior mesenteric vessels; 23, 24, cut edge of the mesentery between the divided ends of the jejunum and ileum.

ends in the rectum, at the border of the pelvis, in front of the left sacro-iliac articulation.

The head of the colon,<sup>1</sup> below the entrance of the ileum, is called the caecum, and the remainder is divided into the ascending, transverse, and descending, and the sigmoid flexure of the colon.

The **caecum**,<sup>2</sup> the broadest portion of the colon, is a capacious sac two or three inches in length and as wide as the greater length. It is pouched, like the rest of the colon, and at its inner back part is extended in a cone, which is abruptly prolonged into a **vermiform**

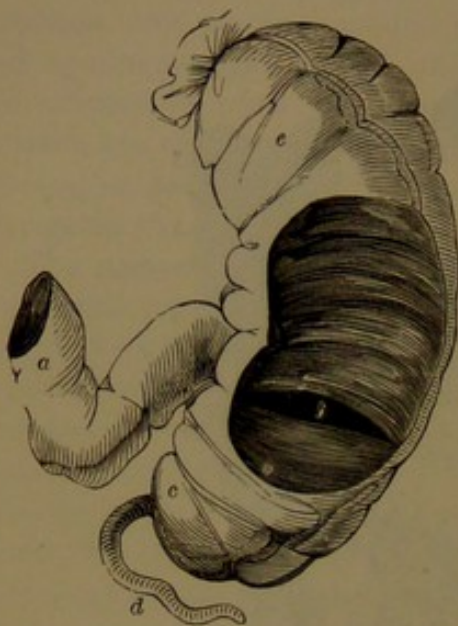
<sup>1</sup> Caput coli; initium or saccus intestini crassi, or coli.

<sup>2</sup> The blind gut.



appendix.<sup>1</sup> This is usually from three to six inches long, about the

FIG. 233.



THE CÆCUM LAID OPEN, TO EXPOSE THE ILEO-COLIC VALVE. *a*, Termination of the ileum; *b*, slit-like orifice between the two folds of the ileo-colic valve; *c*, cæcum; *d*, vermiform appendix; *e*, ascending colon.

thickness of a goose-quill, commonly turns upward, and after a variable flexuose course terminates in a blind, free, rounded end. At birth it is less abrupt at its commencement, and appears more evidently a continuation of the cæcum. It is peculiar to man and some of his nearest allies, the higher apes, but exists also in the wombat, an animal at the opposite limit of the same class. It is regarded as a rudiment of the greatly elongated cæcum of most herbivorous mammals. Sometimes it is short, and rarely it is altogether absent.

The cæcum occupies the right iliac fossa, to which it is closely, or more or less loosely, attached. In the former case it is covered in front and on the sides by the peritoneum reflected to the fossa, and is attached behind by areolar tissue

to the investing fascia of the iliac muscle; in the latter case the peritoneum invests the cæcum to a greater degree, and attaches it behind by a doubling called the **mesocæcum**. A fold of the peritoneum also extends from the vermiform appendix to the adjacent extremity of the cæcum, serving to retain it in a more fixed position.

The ileum, ascending from right to left and backward across the psoas muscle, joins the colon on the inner side above the cæcum. The communication with the colon is guarded by the **ileo-colic valve**,<sup>2</sup> which is composed of two crescentic membranous segments, directed from the ileum into the colon, one above the other. Their convex attached border corresponds with the junction of the latter, whence they converge within the colon, and terminate with their concave free edge directed obliquely to the right and forward. Their extremities unite in a tapering fold,<sup>3</sup> which extends for some distance in front and behind round the interior of the colon. The upper segment of the valve is horizontal, and the lower is larger, and slopes from its free edge downward into the ileum. The aperture of the valve is horizontal,

<sup>1</sup> A. or appendicula vermiformis or vermicularis; appendix cæci; additamentum coli; vermicular process; digital appendix.

<sup>2</sup> Ileo-cæcal valve; valvula coli, cæci, ilei, Bauhini, Fallopii, Tulpii, or Varolii; operculum ilei.

<sup>3</sup> Frenum or retinaculum Morgagni.



curving fore and aft, and looking into the colon obliquely to the right and forward. It varies with the condition of the valve, being elliptical if this is relaxed and is narrowed to a fissure or is closed if the valve is stretched. It ordinarily appears like a button-hole, with the anterior corner rounded and the posterior corner, more to the right, acute. The termination of the ileum, included by the convergent segments of the valve, is funnel-like, the surfaces of the segments being concave, while on the side next the colon they are correspondingly convex.

The **ascending colon**<sup>1</sup> proceeds from the position of the ileo-colic valve through the adjacent lumbar into the right hypochondriac region beneath the liver and to the right of the gall-bladder, where it turns abruptly forward and to the left to become the transverse colon. It lies against the quadrate lumbar muscle and right kidney, to which it is attached by areolar tissue and by the peritoneum, which covers it in front and at the sides, and is thence reflected to the abdominal wall. Sometimes the latter membrane invests it more completely, and forms a narrow mesocolon, giving it some mobility. In front of the ascending colon are the abdominal wall and the convolutions of the ileum.

The **transverse colon**,<sup>2</sup> the longest and most movable portion of the large intestine, produces a broad coil curving forward from the left to the right hypochondrium, whence it is also called the **arch of the colon**. It commonly crosses the upper part of the umbilical region, but often descends to the umbilicus and sometimes much lower. Its extremities are deeply tucked in in the hypochondriac regions, where they form with the ascending and descending colon the **hepatic**<sup>3</sup> and **splenic flexures**.<sup>4</sup> It is suspended from the posterior abdominal wall by the transverse mesocolon, a broad duplicature of the peritoneum, which almost completely invests it. The splenic flexure is further maintained by a fold of the same, the **phreno-colic ligament**,<sup>5</sup> which extends with a free curved border from the colon to the diaphragm in the vicinity of the tenth rib. The transverse colon lies beneath the liver, stomach, and spleen, resting behind on the transverse mesocolon and below on the small intestine, with the great omentum and the abdominal wall in front.

The **descending colon**,<sup>6</sup> more deeply situated than the ascending colon, passes down through the left hypochondriac and lumbar regions to the sigmoid flexure. It is closely attached to the left crus of the diaphragm and kidney by areolar tissue and by the peritoneum covering it in front and thence reflected on the sides to the wall of the abdomen. It is concealed in front by convolutions of the jejunum.

The **sigmoid flexure**<sup>7</sup> is the narrowest portion of the colon, and occupies the left iliac fossa, commencing from the descending colon at

<sup>1</sup> Colon ascendens or dextrum; right lumbar colon.

<sup>2</sup> C. transversum.

<sup>4</sup> F. secunda, sinistra, or lienalis.

<sup>6</sup> C. descendens or sinistrum.

<sup>3</sup> Flexura prima, dextra, or hepatica coli.

<sup>5</sup> Costo-colic or pleuro-colic ligament.

<sup>7</sup> Flexura sigmoidea or iliaca.



the iliac crest and terminating in the rectum at the left sacro-iliac articulation. It pursues an S-like curve, whence its name, and is attached to the iliac fossa by a wide peritoneal fold, which allows of free movement. It lies within the front wall of the abdomen, covered by a few coils of the jejunum; and when the bladder is empty for the most part falls into the pelvis.

The wall of the colon is thicker than that of the small intestine, and becomes slightly thicker as it becomes narrower in approaching the termination. It possesses the same number and kinds of coats as the stomach and small intestine.


The **serous coat** is of the usual character, but is peculiar in that it has attached here and there along its course little long-necked pouches, the **epiploic appendages**,<sup>1</sup> which are processes of the membrane, and are disposed to accumulate fat within them. It does not invest the colon so completely as in the small intestine, being especially deficient along the back of the ascending and descending portions.

The **muscular coat**, like that of the small intestine, consists of two layers, but the fibres of the external layer are, for the most part, collected into three bands, about the third of an inch wide, which start from the base of the vermiform appendix, and thence extend nearly equidistant from one another along the colon to its termination, where they widen and become a continuous longitudinal layer on the rectum. From the commencement of the bands the longitudinal fibres are also extended as a continuous layer on the vermiform appendix. In the intervals of the bands of the colon the wall is provided with a very thin layer of longitudinal fibres. The internal muscular layer is thin, and consists of circular fibres, which are more numerous in the constrictions of the intestine. When the longitudinal bands are cut at the constrictions, these are obliterated.

The **fibrous coat** of the colon is thicker than that of the small intestine, but is otherwise like it.

The **mucous membrane** is dull white, slightly thicker and firmer

FIG. 234.



SECTION OF THE MUCOUS MEMBRANE OF THE COLON. 1, free surface exhibiting the orifices of the colic glands, 2; 3, mucosa: moderately magnified.

than that of the small intestine. It becomes slightly and irregularly rugose in the relaxed or empty condition, and smooth in the expanded condition. It has the same structure as that of the small intestine, but is entirely devoid of villi, and the **tubular, or colic, glands**<sup>2</sup> are longer and relatively more numerous than the enteric glands. The mouths of the glands opening on the surface of the membrane give it a minutely cribriform appearance. Solitary glands are in like manner scattered over the surface, but are less prominent than in the small

<sup>1</sup> Appendices epiploicæ; omentula.

<sup>2</sup> Crypts of Lieberkühn.



intestine. They are most numerous in the cæcum, and especially in the vermiform appendix, where they form a continuous layer as in the agminated glands of the ileum.

The ileo-colic valve is composed of doublings of the mucous membrane strengthened by extensions of the submucous coat and with muscular fibres from the circular layer of the adjacent muscular coat; the longitudinal layer continuing uninterruptedly across the position of the valve. The mucous membrane of the valve on the side of the ileum is covered with villi as elsewhere in the small intestine, but is devoid of them on the opposite side directed into the colon.

The muscularis mucosæ consists of an outer longitudinal and an inner circular layer, and occasionally sends fibres between the colic glands.

The distribution and arrangement of the blood-vessels and capillaries in the coats of the colon are the same as in the stomach. The arrangement of the nerves is the same as in the small intestine, except that the gangliated plexuses<sup>1</sup> possess larger ganglia.

The **arteries** of the colon are the colic and sigmoid branches of the superior and inferior mesenterics, which approach and enter the colon from the mesocolon, in the same manner as the arteries enter the wall of the small intestine. The **veins** correspond with the arteries, and join the inferior and superior mesenteric branches of the portal system. The **lymphatics** are numerous, and emerging from the colon enter glands along the attachment of the mesocolon. The **nerves** are derived from the superior and inferior mesenteric plexuses of the sympathetic, accompanying the corresponding arteries.

The **rectum**,<sup>2</sup> the terminal division of the large intestine, occupies the back part of the pelvis behind the urinary bladder in the male; with the uterus and vagina intervening in the female. From its commencement in the sigmoid flexure, at the brim of the pelvis in front of the left sacro-iliac articulation, it curves downward to the right, and applies itself to the middle of the sacrum, and then follows the curve of this and the coccyx, and continues in the same direction below the latter to near the perineal centre, when it makes another curve backward to the anus. It is not sacculated like the colon, but is club-shaped, narrowest at its commencement and gradually widening to near its termination, where it is most expanded, and then abruptly narrows to the anus, which is a dilatable aperture enclosed by the anal sphincter. It is about seven or eight inches long, but of very variable calibre, in some measure due to habit of the person. In those in whom it is habitually empty it is more contracted; in those who are costive or who habitually restrain the passage of the contents it becomes more or less expanded. Commonly, it measures about one and a half inches at its narrowest part, and from two and a half to three inches at its widest part.

<sup>1</sup> Plexuses of Auerbach and of Meisner.

<sup>2</sup> Intestinum rectum.



Commonly, the rectum exhibits a few variable and partial constrictions, apparently like those of the colon; usually two to the right and an intermediate one to the left. They correspond with crescentic folds projecting into the intestine and varying in exact position, number, and width. When there are three of these folds, the first is high up to the right and the least produced; the second is lower and to the left; while the third is about on the level of the base of the bladder, mostly the largest, and is situated to the right extending in front. Sometimes there are four folds, and sometimes they are reduced to two or one, and rarely none exist. These **rectal folds**<sup>1</sup> are permanent even in excessive distention of the bowel. They probably serve to aid in retaining the contents of the rectum.

The upper portion of the rectum is invested by the peritoneum, which forms a duplicature, the **mesorectum**, attaching it behind to the pelvis. Lower, the peritoneum covers the rectum only at the sides and in front, and finally only in the latter position, whence, in the male, it is reflected on the bladder, which in the distended condition comes into contact with the rectum, but otherwise portions of the small intestine or the sigmoid flexure of the colon fall into the pelvis between them. In the female, in a similar manner, the peritoneum is reflected to the uterus, which intervenes between the rectum and bladder. Below the position at which the peritoneum ceases on the rectum, this is connected to the surrounding parts by areolar tissue, which in approaching the anus becomes more or less loaded with fat. Behind, it is attached to the sacrum and coccyx, and on each side of these to the coccygeal and anal elevator muscles; and in front, in the male, it is attached to the fundus of the bladder, the seminal vesicles, and the prostate gland; and in the female to the vagina. Approaching the anus, it is connected with the anal elevator muscles, and finally is embraced by the anal sphincter.

The wall of the rectum is considerably thicker than that of the colon, and is composed of an extension of the same coats. The **serous coat** is less complete, only forming an investment for its upper part and producing the mesorectum, and thence extending a short distance downward on the sides and farther in front. Where it ceases, the rectum below is invested with a layer of fibro-connective tissue, the rectal fascia, in which the main blood-vessels ramify, and which is connected with the surrounding parts.

The **muscular coat** is comparatively thick, and gradually increases and becomes redder approaching the anus. The external longitudinal layer is thick, and spreads uniformly around the rectum, and at the lower extremity continues between the sphincters, thinning away to the skin at the verge of the anus. The internal circular layer gradually augments approaching the anus, where it is a couple of lines thick,

---

<sup>1</sup> Valves of the rectum.



and forms the **internal sphincter**, within the position of the anal sphincter.

The **fibrous coat** is well produced, and adheres most tightly to the mucous membrane and rather loosely to the muscular coat.

The **mucous membrane** is thicker and firmer than that of the colon, and assumes a red color, which becomes of a deeper hue towards the anus. In the contracted condition of the rectum it is more or less irregularly rugose, the rugæ being supported by the submucosa, as in the stomach, and they are likewise effaced in distention of the bowel. At the lower extremity it is produced in longitudinal folds, the **rectal columns**,<sup>1</sup> shorter or longer, and united in festoons<sup>2</sup> at the verge of the anus. The columns are supported by bundles of longitudinal muscular fibres of the submucous coat, connected below with the termination of the longitudinal layer of the muscular coat below the internal sphincter.

The structure of the coats of the rectum, the glands of the mucous membrane, and the supply and arrangement of the vessels and nerves, are the same as in the colon.

The **arteries** of the rectum are the superior hemorrhoidal branch of the inferior mesenteric artery, the middle hemorrhoidals of the internal iliac arteries, and the inferior hemorrhoidals of the pudic arteries. After entering beneath the serous coat and into the rectal fascia below, the branches penetrate the muscular coat, furnishing it in their course, and enter the submucous coat, in which they ramify and inosculate, forming a plexus extending to the anus. The lower branches, after penetrating the muscular coat, mostly descend longitudinally. The **veins** are very numerous, and closely inosculate in the submucous coat, forming the hemorrhoidal plexus, from which the main veins pursue the course of the arteries, partly conveying the blood through the lower hemorrhoidal veins into the pudic and internal iliac veins and partly by the superior hemorrhoidal vein into the inferior mesenteric vein. The **lymphatics** enter glands behind the rectum and into those of the loins. The **nerves** are numerous, partly derived from the inferior mesenteric and hypogastric plexuses and partly from the sacral plexuses.

The **anus**, the terminal orifice of the alimentary canal, is closed by the action of the anal sphincter muscle, which surrounds it. It is invested with the skin continuous with the mucous membrane, puckered in the contracted condition. The skin is thin, reddish brown, devoid of subcutaneous fat, and furnished with papillæ and sebaceous glands.

For the muscles of the anus, see the Perineum.

<sup>1</sup> Columnæ rectæ Morgagnii.

<sup>2</sup> Valvulæ semilunares Morgagnii.



## GASTRIC JUICE.

The **gastric juice**,<sup>1</sup> derived from the epithelium and glands of the mucous membrane of the stomach, is a clear, viscid liquid with a peculiar odor and acid taste. It is a solution chiefly of a ferment, **pepsin**, with ordinarily free hydrochloric acid, and mineral salts. It is especially a powerful solvent of the proteids.

## INTESTINAL JUICES.

The **intestinal juices**,<sup>2</sup> derived from the epithelium and glands of the mucous membrane of the small and large intestines, are usually clear, viscid liquids, with albumin and mucin, and are alkaline in reaction. Our knowledge of them is very obscure.

## THE PANCREAS.

The **pancreas**<sup>3</sup> is a reddish, cream-colored gland closely connected to the duodenum, into which its duct opens and pours its secretion. It lies behind the stomach, across the spine, resting against the great blood-vessels in front of the latter and the crura of the diaphragm. Its right extremity, the largest portion, named the **head**,<sup>4</sup> occupies the concavity of the duodenum, to which it is closely attached. The remaining portion, the **body**,<sup>5</sup> extends to the left, for some distance of nearly uniform depth, and then diminishes to the blunt end, or **tail**,<sup>6</sup> which usually is in contact with the spleen. Sometimes the body is narrowest where it leaves the head, and widens to the tail.

The pancreas conforms in shape to the space it occupies between adjacent organs, and is an elongated, irregular, fore and aft flattened prismatic body, which has been likened to a dog's tongue in shape. It commonly measures about six to eight inches long, from an inch to an inch and a half in depth, and from one-half to three-fourths of an inch thick, and is estimated to weigh from two to three and a half ounces.

The anterior surface, covered by the upper layer of the transverse mesocolon, lies in contact with the stomach. The posterior surface is attached by areolar tissue to the inferior cava, aorta, portal vein, superior mesenteric vessels, and the crura of the diaphragm, and by its left extremity to the corresponding kidney and suprarenal body. The upper border is grooved to accommodate the splenic vein, and along it, above, runs the corresponding artery. The lower border to the right rests on the transverse colon, and to the left on the junction of the duodenum and jejunum. The superior mesenteric vessels descend behind the pancreas,

<sup>1</sup> Succus gastricus.

<sup>2</sup> Succus entericus or intestinalis.

<sup>3</sup> Pancratiū; glandula salivalis abdominis; sweetbread.

<sup>4</sup> Caput pancreatis, pancreas parvum; lesser pancreas.

<sup>5</sup> Corpus pancreatis.

<sup>6</sup> Cauda pancreatis.



more or less embedded in its substance, and emerge forward between it and the termination of the duodenum. The bile-duct descends behind the head of the pancreas, usually in a groove or canal of the latter between it and the duodenum.

The **pancreatic duct**<sup>1</sup> extends along the interior of the gland from left to right, nearer its anterior surface and lower border, receives many branches in its course, bends a little downward in the head, from which it receives its largest branch,<sup>2</sup> and then emerges from the gland.

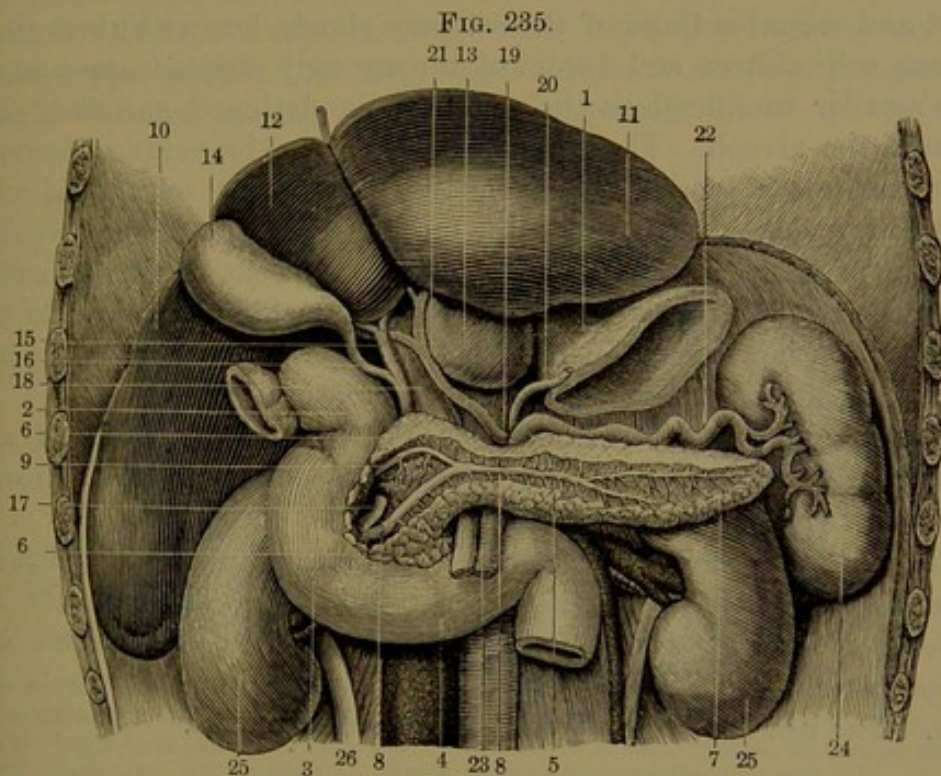


FIG. 235.  
VISCERA OF THE UPPER PART OF THE ABDOMEN; the stomach removed and the liver raised to show its under surface. 1, oesophagus with cardiac extremity of the stomach; 2, commencement of the duodenum; 3, descending portion; 4, transverse portion; 5, line passing over the commencement of the jejunum to the pancreas; 6, 6, head of the pancreas; 7, tail of the pancreas; 8, 8, principal duct; 9, accessory duct; 10, right lobe of the liver; 11, left lobe; 12, quadrate lobe; 13, caudate lobe; 14, gall-bladder; 15, hepatic duct; 16, cystic duct; 17, common bile-duct; 18, portal vein; 19, coeliac axis; 20, coronary artery; 21, hepatic artery; 22, splenic artery; 23, superior mesenteric artery and vein; 24, spleen; 25, kidney; 26, ureter.

Joining the left side of the bile-duct, together they descend obliquely through the wall of the duodenum, behind and to the inner side, and open into the gut by a common orifice on the summit of a papilla, usually about four inches from the pylorus.

Sometimes the pancreatic and biliary ducts open separately into the duodenum, and occasionally the branch from the head of the pancreas opens independently into the latter some distance from the main duct.

The pancreas is a large, much-lobulated, compound racemose gland, in general construction resembling the salivary glands. It is less con-

<sup>1</sup> Ductus pancreatus or Wirsungianus; duct of Wirsung.

<sup>2</sup> D. Santorini.



sistent than the latter, and its numerous angular lobules are less compactly associated. It is invested with a thin connective-tissue capsule, by which it adheres to adjacent parts, and from which partitions extend between and unite the lobules and their lesser divisions, and serve to sustain the blood-vessels and ducts of the organ. The main duct is provided with a fibro-connective-tissue coat lined by a thin, smooth membrane furnished with a columnar epithelium. The smaller ducts have the same composition, with more delicate coats and the cells of the epithelium becoming shorter. The intralobular ducts are likewise nearly similar, and resemble those of the salivary glands, but with their short columnar cells clearer and devoid of the strongly striated appearance. In the smaller ramifications the cells become flattened, and thus continue into the alveoli. These are relatively large, branching, flexuose, or even convoluted gland-tubules, lined by stout, blunt, pyramidal cells, with the narrower extremity next the lumen, or passage, of the alveolus.

When the gland is stimulated to activity the cells swell, and subsequently the granular portion of their contents diminishes while the clearer portion increases. In rest the former enlarges at the expense of the latter, but on the whole the cells increase in size.

The capillary blood-vessels form close nets around the alveoli, and the lymphatics commence in clefts of the fibro-connective tissue around and among them, as in the salivary glands.

The pancreas receives its **arteries** from many branches, which are derived from the splenic and pancreatico-duodenal branches of the hepatic and superior mesenteric. The **veins** join the splenic and superior mesenteric. The **lymphatics** join the lumbar vessels and glands. The **nerves** are derived from the solar plexus.

#### PANCREATIC JUICE.

The **pancreatic juice**,<sup>1</sup> the secretion of the pancreas, is a clear, colorless, and viscid liquid, strongly alkaline, and at a low temperature gelatinizes. It is a solution principally of albumin, with a substance resembling casein and called alkali-albumin, and a number of salts, among which sodium carbonate predominates. It is a powerful food-solvent; dissolves the proteids, saponifies fats, and converts starch into sugar.

#### THE LIVER.

The **liver**<sup>2</sup> is the largest of glandular organs, and the most bulky of the abdominal viscera. It occupies the greater part of the right hypochondrium, and extends through the upper part of the epigastrium a little way into the left hypochondrium. It closely conforms in shape to the space it fills, and is attached by folds of the peritoneum to the diaphragm, but elsewhere is free, and has a smooth, shining surface,

<sup>1</sup> Succus pancreaticus.

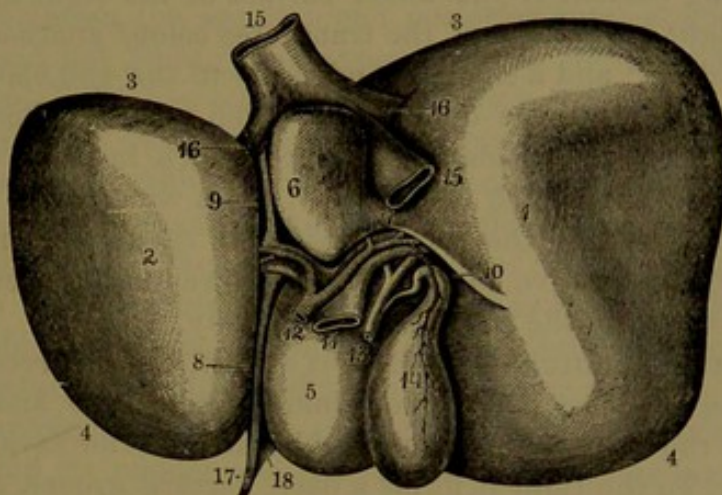
<sup>2</sup> Hepar; jecur; glandula hepatica or biliaria.



due to the serous coat with which it is invested. It is half-ovoidal in shape, with the upper surface convex and closely applied to the diaphragm, and the under surface irregularly slightly concave, and resting on the stomach, duodenum, transverse colon, and right kidney. The posterior border to the right is the thickest part, and is convex; the anterior border is acute; and the left border is the thinnest part and acute.

The liver is of firm consistence, but rather friable, due to the relatively small proportion of connective tissue which enters into its composition. It is of a deep reddish-brown color, but variable, and often mottled with purple. In fatty degeneration it assumes a yellow-clay color. Variable in size, it commonly measures about ten to twelve

FIG. 236.



INFERIOR SURFACE OF THE LIVER. 1, right lobe; 2, left lobe; 3, posterior margin; 4, anterior margin; 5, quadrate lobe; 6, caudate lobe; 7, isthmus, or caudate process, connecting the latter with the right lobe; 8, 9, longitudinal fissure; 10, transverse fissure; 11, portal vein; 12, hepatic artery; 13, common bile-duct formed by the union of the hepatic and cystic ducts; 14, gall-bladder; 15, inferior cava; 16, hepatic veins; 17, round ligament; 18, anterior part of the suspensory ligament.

inches broad, six or seven inches fore and aft, and from two and a half to three and a half inches where thickest to the right behind, and diminishing to a few lines approaching the left border. Its ordinary weight is from three to four pounds; about a sixth to a fifth less in the female. Its specific gravity is 1.06, but may be more in lean and less in fat persons.

The liver is divided into two unequal portions, which, though continuous in structure, are distinguished as the right and left lobes, separated by notches in the anterior and posterior borders, by the suspensory ligament above, and the longitudinal fissure below.

The **right lobe**,<sup>1</sup> much the larger, occupies the right hypochondrium, reaching higher in the thorax and lower in the abdomen than the left lobe, which is not more than a fifth or less the size of the

<sup>1</sup> Lobus dexter; large, or colic lobe.



former. Its upper, smooth, and prominently convex surface is accurately adapted to the diaphragm, and equally conforms to the base of the right lung, from which it is separated by the latter. Its under surface, irregularly and slightly concave, has attached to it in a fossa<sup>1</sup> the gall-bladder, which extends fore and aft, with its fundus usually projecting a little beyond the anterior border of the liver, where this is commonly slightly emarginate. The fossa for the gall-bladder divides the under surface of the right lobe into two unequal portions, of which the smaller, to the right of the fossa, is named the **quadrate lobe**.<sup>2</sup> It reaches the anterior border of the liver, is bounded on the left by the longitudinal fissure, and behind by the transverse fissure. Its smooth under surface lies over the pyloric end of the stomach and the commencement of the duodenum, and is slightly impressed by them. The remaining portion of the under surface of the right lobe exhibits in front a slight impression of the transverse colon,<sup>3</sup> another behind of the right kidney,<sup>4</sup> and a small one adjacent to the gall-bladder of the descending portion of the duodenum.<sup>5</sup> The posterior border of the right lobe presents a considerable surface, which includes the greater part of the posterior notch of the liver, and a wide patch tapering to the right, destitute of the serous coat and closely adherent to the diaphragm by connective tissue. At the lower left corner is a small surface impressed by the right suprarenal body.

The **posterior notch** of the liver is a wide, concave recess between the right and left lobes, mainly pertaining to the former, and embracing the crura of the diaphragm, together with the inferior cava, aorta, and œsophagus. To the right it forms a deep, vertical groove, occupied by the inferior cava, which is closely attached to the liver, and receives from it the hepatic veins as they emerge from the organ. Sometimes the hepatic substance extends partially or completely around the cava, enclosing it in a canal. To the left of the caval groove the notch is occupied by a somewhat detached portion of the right lobe, named the **caudate lobe**.<sup>6</sup> It is of quadrate form, and extends beneath the liver, is bounded on the left by the longitudinal fissure, and in front below by the transverse fissure, between which and the caval groove it is connected by an isthmus<sup>7</sup> with the under surface of the right lobe. It is smooth and invested with the serous coat, and by its posterior surface is applied to the crura of the diaphragm in front of the aorta. Behind its upper left corner the œsophagus joins the stomach.

<sup>1</sup> Fossa or impressio vesicalis.

<sup>2</sup> Lobus quadratus, anterior, anonymus, innominatus, or accessorius.

<sup>3</sup> Faciecula or impressio colica.      <sup>4</sup> F. or i. renalis.      <sup>5</sup> F. or i. duodenalis.

<sup>6</sup> Lobus caudatus, Spigelii, Eustachii, posterior, or posticus papillaris; tuberculum papillare; Spigelian, small, duodenal, or pancreatic lobe; posterior portal eminence.

<sup>7</sup> Caudate lobe; eminentia caudata, longitudinalis, or radiata.



The **left lobe**<sup>1</sup> of the liver, variable in size, comparatively thin and rounded triangular, occupies the upper part of the epigastrium, reaching a little way into the left hypochondrium. It lies beneath the heart, separated by the diaphragm, through which its upper convex surface is somewhat impressed by the former. Its lower surface is impressed by the fore part of the cardiac extremity of the stomach, and its posterior border to the right forms part of the posterior notch of the liver, and is next the termination of the œsophagus.

The **anterior notch**<sup>2</sup> of the liver is a deep angular incision in the front border between the right and left lobes, continuous beneath with the longitudinal fissure. It is situated several inches to the right of the ensiform process of the sternum, and receives the attachment of the suspensory ligament.

The **longitudinal fissure**<sup>3</sup> is a deep furrow beneath the liver, extending between the anterior and posterior notches, and separating the right and left lobes. The anterior longer portion,<sup>4</sup> between the quadrate and left lobes, is often crossed by a bridge<sup>5</sup> of hepatic substance uniting the two. It is traversed by a fibrous cord, named the **round ligament**,<sup>6</sup> which is the remnant of the obliterated umbilical vein of the foetus, ascending from the umbilicus and connected behind with the portal vein. The posterior portion<sup>7</sup> of the same fissure, between the caudate and left lobes, is traversed by a narrower cord,<sup>8</sup> remaining from the obliterated ductus venosus of the foetus, connected in front with the portal vein and behind with the inferior cava.

The **transverse fissure**,<sup>9</sup> another deep furrow, starts from the former behind its middle, and proceeds directly to the right, between the quadrate and caudate lobes, and then commonly bends forward and ends near the centre of the right lobe. It is the chief portal of the liver, giving passage to the portal vein and the hepatic artery, hepatic duct, lymphatics, and nerves of the organ.

The ligaments of the liver consist mainly of folds or reflections of the peritoneum attaching it to the adjacent parts. For a description of the ligaments, see page 370.

The liver above, conforming to the vault of the diaphragm, rises on the right to a level with the junction of the fifth costal cartilage with

<sup>1</sup> Lobus sinister.

<sup>2</sup> Incisura umbilicalis or interlobularis.

<sup>3</sup> Fossa longitudinalis or umbilicalis; sulcus antero-posterior jecoris, umbilicalis jecoris, or sinister; great or horizontal fissure.

<sup>4</sup> Umbilical fissure; fossa longitudinalis sinistra anterior; fossa pro ligamento terete or vena umbilicale.

<sup>5</sup> Pons or isthmus hepatis.

<sup>6</sup> Ligamentum teres, umbilicale hepatis, or chordæ venæ umbilicalis.

<sup>7</sup> Fissure of the ductus venosus; fossa longitudinalis sinistra posterior; fossa pro ligamento or ductu venoso.

<sup>8</sup> Ligamentum venosum.

<sup>9</sup> Fossa transversa; porta or hilus hepatis; sulcus intermedius.



the sternum; on the left to a level with the junction of the sixth costal cartilage and sternum. On the right side it is under cover of the ribs from the seventh to the eleventh, and in front under the costal cartilages from the sixth to the ninth, and the ensiform process. It descends a short distance below the ribs, costal cartilages, and ensiform process, where it is covered by the anterior abdominal wall. The thin edge of the base of the right lung, descending between the diaphragm and its attachment to the ribs, intervenes between the surface of the chest and the mass of the liver. The front border of the right lobe of the liver from the anterior notch slopes downward and outward, following the line of the lower ribs; that of the left lobe from the notch curves upward and backward to the left of the termination of the œsophagus.

The position of the liver is liable to change under different conditions. It is affected by the position of the body; descending an inch or more below the margin of the chest in the upright position, and retiring an inch or more above in the recumbent position. In respiration it falls and rises with the movements of the chest, varying in degree with the extent of inspiration and expiration and the position of the body, whether erect or lying down. It is further affected by the condition of the bowels, whether full or empty, and in like manner by the presence of abdominal tumors and disease of the lungs or heart. Tight-lacing in females forces it below the ribs permanently, sometimes to such a degree that it nearly reaches the iliac crest and becomes impressed by the ribs

#### STRUCTURE OF THE LIVER.

The liver is closely and evenly invested with a transparent membranous covering, which consists of a serous and a fibrous coat. The external **serous coat** is derived from the peritoneum, and is a thin, transparent layer which everywhere invests the organ, except along the posterior border of the right lobe, in the posterior notch, and in the fossa for the gall-bladder. The **fibrous coat** is a thin fibro-connective-tissue layer, inseparably connected with the former and with that of the hepatic substance. It is thicker where the organ is devoid of the serous coat, and especially in the fissures of the liver, where it is continuous with the sheath of the blood-vessels.

The **liver**, or **hepatic substance**, besides its larger vessels and ducts, is chiefly composed of small, polyhedral masses, or **lobules**,<sup>1</sup> compactly united together. The lobules, about the one-tenth of an inch in diameter, on the surface of the liver give to it a uniformly maculated appearance, and on torn surfaces a coarsely granular aspect. In some animals, notably the hog, the lobules are more distinctly

---

<sup>1</sup> Acini.



marked from the greater proportion of connective tissue which defines and connects them together. In the tree-rat (*Capromys*) of Cuba the liver is subdivided into numerous lobules, which lie close together but are quite detached, and are conjoined by the larger branches of the blood-vessels and duct. It represents the common form of the liver of most vertebrates in an unravelled condition.

The hepatic lobules are composed of a sponge-like intertexture of the secretory cells of the liver, the interspaces of which are occupied by a similar sponge-like arrangement of capillary blood-vessels. In their relation with the larger blood-vessels, the lobules are closely

FIG. 237.

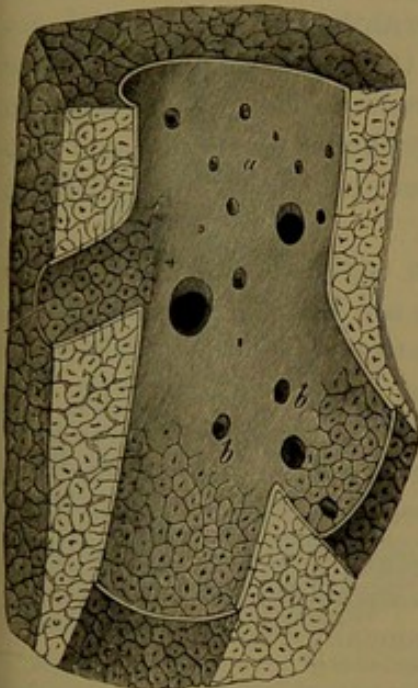


FIG. 238.

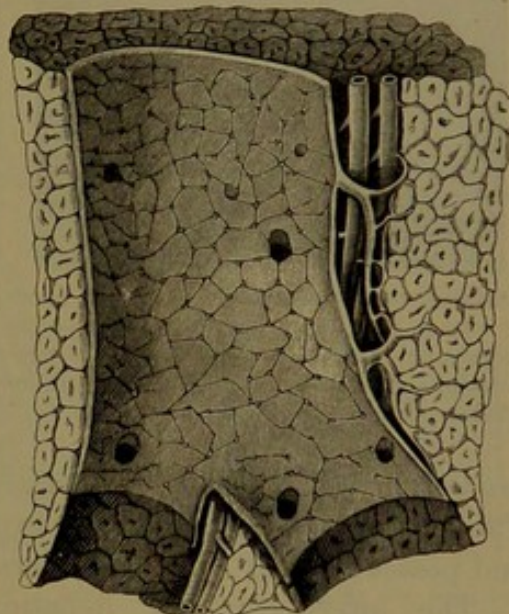


Fig. 237. PORTION OF THE LIVER OF THE HOG, exhibiting the lobular structure and the section of a hepatic vein, somewhat magnified. *a*, Large branch of the hepatic vein; the orifices belong to other branches; *b*, branches exhibiting through their thin walls the outlines of the lobules; the dots in the centre of the latter are orifices of the intralobular veins commencing within the lobules.

Fig. 238. PORTION OF THE LIVER OF THE HOG, exhibiting the lobular structure. The large vessel is a branch of the portal vein, the outlines of the lobules being seen through its transparent wall. The orifices, large and small, seen in the portal vein, are fine branches sent between the lobules. The two vessels lying to the left of the portal vein are branches of the hepatic artery and duct.

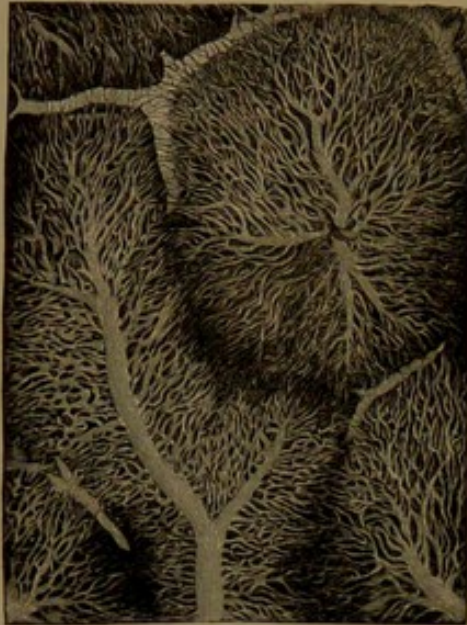adherent to their exterior; and in the smaller vessels, in which the walls are translucent, the outlines of the lobules are visible through them.

In the relationship of the blood-vessels of the liver, those which enter the transverse fissure, the portal vein, and hepatic artery, accompanied by the hepatic duct, ramify together in a generally ascending and diverging manner, and terminate in branches at the periphery of the lobules. The hepatic veins in general pursue a course at right angles to the other vessels, and converge to emerge at the posterior



notch of the liver. The general arrangement of the former vessels in relation to the latter is comparable to a group of three upright trees with their boughs spreading in all directions, and intermingled with those of another tree which had fallen upon them.

FIG. 239.



SECTION OF SEVERAL LOBULES OF THE LIVER OF THE RABBIT, the vessels injected, and the preparation magnified. The capillaries communicate with the interlobular and intralobular veins.

are polyhedral, and range from about  $\frac{1}{1000}$  to  $\frac{1}{800}$  of an inch in diameter. They are composed of granular protoplasm, without a distinct cell-wall, and possess a clear central nucleus, or occasionally two nuclei.

The intertexture of hepatic cells is accompanied by a similar arrangement of fine tubes, the **bile canaliculi**,<sup>1</sup> which are regarded by some observers as formed of a homogeneous membrane, and by others as being simple intercellular passages. The canaliculi at the periphery of the lobules open into or become continuous with the **bile** or **hepatic** ducts, commencing between the lobules.

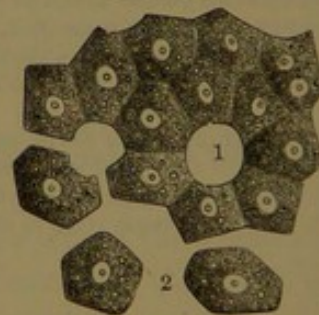
The liver differs from all other organs of the body in the fact that, besides receiving blood through an artery, it also does so in addition by a much larger vessel, the **portal vein**, which derives its blood from the veins of the stomach, intestines,

The portal veins terminate in the intervals of the hepatic lobules, as the **interlobular veins**, which directly communicate with the capillaries within the lobules. The hepatic veins, on the other hand, commence in each lobule as an **intralobular vein**, which receives the capillaries of the latter and proceeds through its axis, to open at the base of the lobule into a larger branch of the hepatic veins.

The capillaries of the hepatic lobules are but little smaller than the contiguous columns of hepatic cells, of which only one or two form the thickness of a column.

The **hepatic cells**, which form the secretory substance of the liver,

FIG. 240.



HEPATIC OR SECRETING CELLS OF THE LIVER. The arrangement is ideal. 1, space occupied by a capillary blood-vessel; 2, isolated cells: highly magnified.

<sup>1</sup> Pori biliarii; tubuli biliferi; bile capillaries.



pancreas, and spleen. The **hepatic artery**, besides being smaller than the portal vein, which it accompanies, is also very small in proportion to the size of the organ it supplies; and is the remaining portion of that artery after giving off a large branch, the gastro-duodenal artery. The hepatic artery and portal vein ascend together, enclosed in the right border of the small omentum, the former lying in front of the latter vessel, and both divide into a right and a left branch, which enter the transverse fissure of the liver, and are distributed through the

FIG. 241.

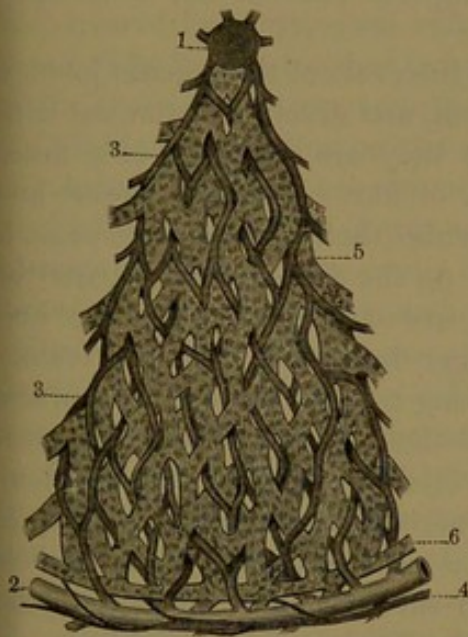
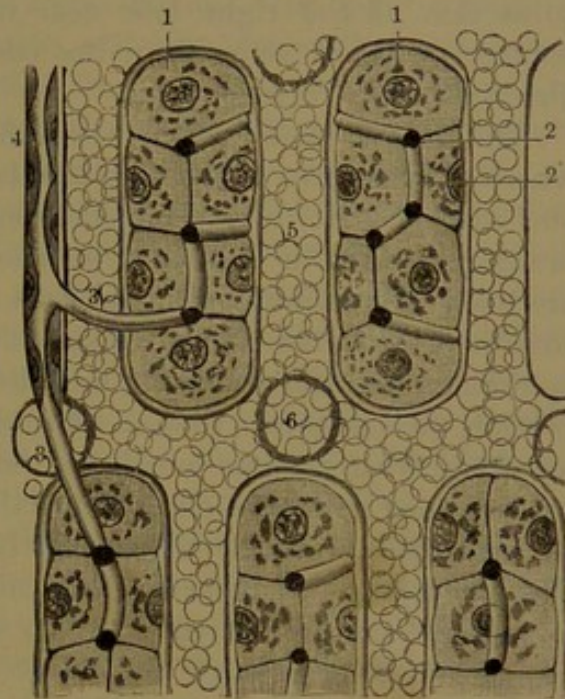


FIG. 242.



*Fig. 241.* DIAGRAM OF A TRANSVERSE SECTION OF A HEPATIC LOBULE, exhibiting the relative position of the vessels and intertexture of hepatic cells. 1, intralobular hepatic vein; 2, interlobular portal vein; 3, capillaries; 4, hepatic artery; 5, hepatic cells; 6, commencement of a bile-duct.

*Fig. 242.* DIAGRAM OF THE COMMENCEMENT OF THE BILE-DUCTS IN THE CANALICULI. 1, hepatic cells; 2, biliary canaliculi; 3, biliary canaliculi ending in a bile-duct; 4; 5, capillaries with blood-corpuscles; 6, orifices of others.

corresponding lobes of the liver. The **hepatic duct** pursues the same course as the hepatic artery and portal vein, and its right and left branches emerge from the liver in the transverse fissure, where they unite at an obtuse angle in a trunk, which descends in front of the vein and to the right of the artery. The duct, smaller than the latter vessel, about an inch and a half long and about one-sixth of an inch wide, is joined by the cystic duct from the gall-bladder, to form the common **bile-duct**.<sup>1</sup>

The portal vein, hepatic artery, and hepatic duct, in their distribution throughout the liver, occupy corresponding passages in its substance, called the **portal canals**, and they are together invested with

<sup>1</sup> Ductus communis choledochus.



a thin connective-tissue sheath,<sup>1</sup> which also includes the accompanying lymphatics and nerves.

The hepatic artery mainly supplies the walls of the vessels and ducts and the nerves of the portal canals, while its blood is returned through the capillaries of the hepatic lobules into the hepatic veins.

The hepatic veins, which pursue an independent course from the other vessels of the liver, have no connective-tissue sheath, and by their thin wall adhere intimately to the hepatic substance they traverse. Of the three trunks, commonly one proceeds from the right, another from the left, and the third from the quadrate lobe, though the latter often joins that of the right lobe near its termination. Besides these a number of small veins from the contiguous part of the liver open directly into the inferior cava.

The hepatic ducts<sup>2</sup> commence in the intervals of the hepatic lobules, where they receive the biliary canaliculi, and freely anastomose with one another. At their commencement they are composed of a membrana propria with a small proportion of fibro-connective tissue, and are lined by flattened epithelial cells, while their lumen, or passage, is continuous with the biliary canaliculi. As the ducts become larger the epithelium becomes columnar, and they are sustained by a greater proportion of connective tissue. The larger ducts, including the trunks, are lined with mucous membrane having a columnar epithelium, and are provided with a vascular connective-tissue coat, and an outer layer of unstriated muscular fibres, mostly circular in their arrangement. The ducts are also furnished with numerous minute glands, which in a measure are proportioned to the size of the ducts. The smallest glands consist of a single follicle or of several, while the larger ones have the usual arrangement of racemose glands.

The lymphatics of the liver are exceedingly numerous. Within the lobules of the liver they commence as cleft-like spaces between the hepatic cells and capillary blood-vessels, the spaces being limited by flat, branching connective-tissue corpuscles. The spaces communicate with nets of lymphatic vessels between and around the lobules, and these nets communicate with larger plexuses of the portal canals, in which they surround the blood-vessels and ducts, while the larger lymphatic vessels traverse their connective-tissue sheath and emerge at the transverse fissure of the liver. Lymphatics also pursue the course of the hepatic veins, on which they form plexuses communicating with those between the lobules of the liver. A subserous plexus also exists at the surface of the liver; the vessels from the upper surface passing through the ligaments of the liver to join the thoracic lymphatics, while those of the under surface join the deep lymphatics emerging at the transverse fissure.

---

<sup>1</sup> Capsule of Glisson; capsula communis Glissoni.

<sup>2</sup> Interlobular ducts; pori biliarii.



The nerves of the liver are derived partly from the cœliac plexus and partly from the vagus nerves, especially the left one. They enter the liver upon the hepatic artery and accompany it in its distribution, but their mode of termination has not been satisfactorily determined.

The **gall-bladder**<sup>1</sup> is a pyriform, membranous pouch, a receptacle for gall or bile, occupying a fossa beneath the right lobe of the liver. It is situated obliquely fore and aft with its **fundus** directed forward, downward, and to the right, and usually projecting a little beyond the anterior border of the liver, while the **neck** is directed in the opposite direction to the transverse fissure. Its upper surface is attached to the liver by areolar tissue, and its under surface and fundus are covered by peritoneum reflected from the adjacent surface of the liver. The fundus touches the front abdominal wall below the margin of the thorax about opposite the tip of the tenth costal cartilage, and the bladder rests below on the commencement of the transverse colon, and behind this on the commencement of the duodenum. The neck gradually narrows and forms an abrupt sigmoid curvature, and turns downward to end in the cystic duct. The gall-bladder is three or four inches long by about an inch and a half where widest, and has a capacity of an ounce to an ounce and a half or more. The **cystic duct**<sup>2</sup> is about an inch and a half long, and descends to the left backward and unites with the hepatic duct to form the bile-duct.

The **common bile-duct**,<sup>3</sup> nearly three inches long and two or three lines wide, continues in the course of the hepatic duct, descending in the small omentum in front of the portal vein and to the right of the hepatic artery. Passing downward behind the transverse portion of the duodenum and the head of the pancreas, a groove or canal of which it occupies, it reaches the inner side of the descending portion of the duodenum. Here it is joined on the left by the pancreatic duct, and the two, side by side, pass obliquely downward through the wall of the duodenum and open by a common orifice on its inner surface at the summit of a low papilla, situated near the lower bend of the gut, about four inches from the pylorus. In passing through the wall of the duodenum the hepatic duct is somewhat narrowed and its orifice is constricted, and not unfrequently opens separately from that of the pancreatic duct.

The gall-bladder, besides its incomplete serous investment of the peritoneum, is provided with a strong fibrous coat lined by mucous membrane.

The **fibrous coat** is composed of interlacing fibro-connective tissue bundles with elastic fibres, and in its exterior part is intermingled with

<sup>1</sup> Vesicula fellea; cystis fellea or choledochus.

<sup>2</sup> Ductus cysticus.

<sup>3</sup> Common bile-duct; ductus choledochus or communis choledochus; d. hepatico-cysticus.



unstripped muscular fibres mostly pursuing a longitudinal direction. The larger vessels of the gall-bladder ramify and form plexuses in the fibrous coat, and it also contains a gangliated plexus of nerves.

The **mucous membrane**, colored by the bile, presents a minutely honey-combed appearance, due to intersecting folds of the membrane. It has a columnar epithelium, and is furnished with glands like those of the hepatic ducts, but smaller, fewer, and more scattered. Its *membrana propria* contains a fine plexus of capillary blood-vessels, which extend into the folds on the surface of the mucous membrane and communicate with the vascular plexuses of the fibrous coat.

In the sigmoid flexure of the neck of the gall-bladder extending into the cystic duct, the lining membrane is thrown into a series of oblique crescentic folds, partially continuous, and together presenting the appearance of a spiral valve.<sup>1</sup> In the structure of its wall the cystic duct resembles that of the gall-bladder, but has a greater proportion of muscular fibres, mainly arranged circularly.

The gall-bladder is supplied by the cystic artery from the right branch of the hepatic artery. The cystic vein joins the portal vein. The lymphatics follow the cystic duct, and join the lumbar lymphatics. The nerves are derived from the hepatic plexus.

The common bile-duct has the same construction as the hepatic duct, but its racemose glands are few and small.

#### BILE.

The **bile** or **gall**,<sup>2</sup> the secretion of the liver, is a clear, yellow liquid of bitter taste and alkaline reaction. In the gall-bladder it becomes mingled with mucus, is brown, thicker, and more alkaline. It is readily decomposed, and on exposure to air becomes green. In herbivorous animals it is ordinarily green, and in carnivorous animals yellow.

Bile is a complex material, and its chief essential constituents are the glycocholate and taurocholate of sodium, with bilirubin, dissolved in water. Besides these, it contains ordinary fatty acids combined with alkalies, lecithin, cholesterin, and mineral matters, mainly sodium chloride, etc. Glycocholic and taurocholic acids are compounds of carbon, hydrogen, oxygen, and nitrogen, and the latter contains in addition sulphur. To the pigment bilirubin the yellow color of the bile is due.

The quantity of the bile secreted by the liver is very large, and is estimated to approximate the weight of the organ itself in twenty-four hours.

<sup>1</sup> Valvulus spiralis Heisteri.

<sup>2</sup> Bilis; fel; cholos.



## CHAPTER IX.

### THE VASCULAR SYSTEM.

#### THE BLOOD-VESSELS.

The **blood-vessels** are branching membranous tubes by which the blood is conveyed throughout the body. They consist of three kinds,—the **arteries**, which commence in the heart and distribute the blood to all parts of the body; the **veins**, by which the blood is returned to the heart; and the **capillaries**, intermediate to the other vessels, and occupying the various tissues of the body, which they supply with nutritive material.

#### ARTERIES.

The **arteries**<sup>1</sup> are comparatively thick-walled vessels, which commence at the heart in two great trunks,—the aorta, by which the blood is distributed to all the organs of the body, and the pulmonary artery, by which it is in the same manner distributed to the lungs. The chief arterial trunks occupy the cavity of the thorax and abdomen, whence large branches proceed to the head and limbs, along the lines of flexure and contiguous to the bones, in which position they are least liable to extension and injury. They commonly pursue a tolerably direct and straight course, continuing in the line of the trunk, and giving off successive branches at variable distances and of various sizes, or they fork into two or more branches of equal or unequal sizes. The branches may come off at any angle, but this is mostly acute at their origin. The arteries continue of uniform size until they branch, when they are in a measure reduced, but not proportionately, for the combined capacity of the branches is commonly greater than that of the trunk from which they spring, except in the case of the origin of the iliac arteries from the aorta. From this circumstance it follows that with the division of the arteries there is a successive increase in the capacity of the whole, the result of which is the reduction in the rapidity of the blood-current as it proceeds in its course. Arteries sometimes pursue a more or less tortuous course, as in the face and uterus, the condition being favorable in permitting the vessels to follow the changes of movement in the parts without undue stretching. In other positions they may be tortuous, but the reason is not so obvious as in the case of the splenic artery.

---

<sup>1</sup> Arteriæ.



In their course arteries frequently join one another, **inosculate**, or **anastomose**, freely communicating, a condition which becomes more common as the vessels are reduced in size, though frequently occurring with larger arteries, as those of the brain, of the stomach and intestines, and of the hand and foot. The arrangement is of advantage in preventing an interruption in the flow of blood from accidental pressure on one or more vessels.

The arteries possess considerable tenacity, and are highly elastic, being extensile and contractile both in length and in width. During life they are also highly contractile, due to their muscularity. Their wall is thick and firm enough to prevent complete collapse when empty, a condition the reverse of that of the veins.

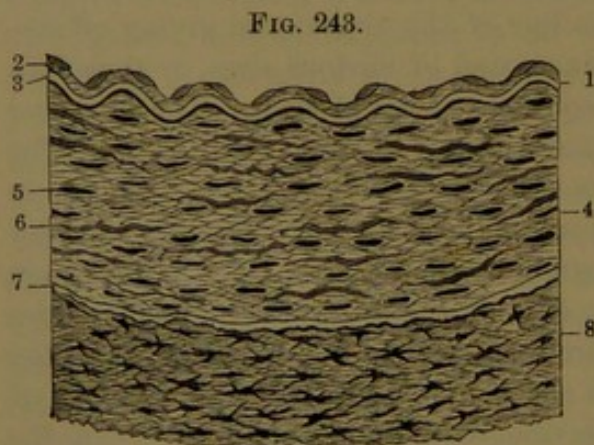
In most positions the arteries are enclosed in a sheath of areolar tissue loosely attached to them, and usually in company with one or two veins and a nerve. Some of the arteries, as those of the brain and of the bones, are devoid of a sheath.

The inner surface of the arteries is smooth and shining, but when empty, from the contracted condition of the vessels, it is minutely wrinkled longitudinally.

**Structure of the arteries.** The wall of the arteries consists of three chief layers, or tunics, of different constitution, intimately connected together, and named the external, middle, and internal tunics, or the tunica adventitia, media, and intima.

The **external tunic**, or **adventitia**,<sup>1</sup> on which the strength of the arteries mainly depends, is mostly thickest in the larger vessels, but compared with the other tunics is relatively thicker in the smallest

ones. It is composed of interlacing bundles of fibro-connective tissue associated with reticular longitudinal fibres of elastic tissue. The latter are more conspicuous in the larger arteries, and are most numerous and thickest approaching the middle tunic, but are absent in the smallest arteries. Generally the fibro-connective-tissue bundles intersect one another diagonally around the vessels in closely-united layers, the outer of which are of looser texture



TRANSVERSE SECTION OF THE WALL OF AN ARTERY. 1, internal tunic; 2, endangium; 3, elastic layer; 4, middle tunic of muscle-fibres with nuclei; 5; 6, elastic fibres; 7, elastic limiting membrane; 8, external tunic of fibro-connective tissue with branching corpuscles: highly magnified.

and become more or less blended with the sheath of the blood-

<sup>1</sup> T. externa or cellularis; vagina cellularis.



vessels. In the meshes of the connective-tissue bundles there are numerous branching connective-tissue corpuscles, and also many lymphatic spaces.

The **middle tunic** or **media**<sup>1</sup> of the arteries is the thickest layer, and in the larger vessels forms the main portion of the wall, but in the smaller ones is thicker in proportion with their calibre. It is chiefly composed of muscular fibres, whence it is also called the **muscular coat**, and in it resides the contractile power of the arteries. It is of a translucent, pale reddish-yellow tint, and is readily broken. When hardened in alcohol it assumes an opaque, clay-yellow color, and is easily torn into transverse annular shreds. It consists of comparatively short, fusiform, unstriated muscle-fibres transversely arranged, and forming laminae proportioned in number with the thickness of the tunic, and in the smallest arteries is reduced to a single lamina. The muscular laminae variably alternate with fenestrated elastic membranes and nets of elastic fibres, which connect the latter through the former. In the smaller arteries the proportion of the elastic tissue is much reduced, while the muscular tissue is relatively greater than in the larger arteries, and hence they possess proportionately greater contractility. In some of the larger vessels, as the carotid and mesenteric arteries, the elastic tissue is in greater quantity than usual, and forms a considerable portion of the media. A small proportion of fibro-connective tissue accompanies the elastic tissue in the larger arteries, and increases in the largest trunks. Mostly, also, in the latter, the media is outwardly defined by fenestrated

elastic membrane,<sup>2</sup> as in the carotid, mesenteric, renal, hepatic, and femoral arteries. Further, the media of the larger arteries contains some small bundles of both oblique and longitudinal muscle-fibres.

The muscle-fibres of the arteries are fusiform cells, rarely exceeding one-twelfth to one-eighth of a millimetre in length; and they are most regular and uniform in the small vessels. They are faintly striated longitudinally, and contain a central, elongated elliptical nucleus.

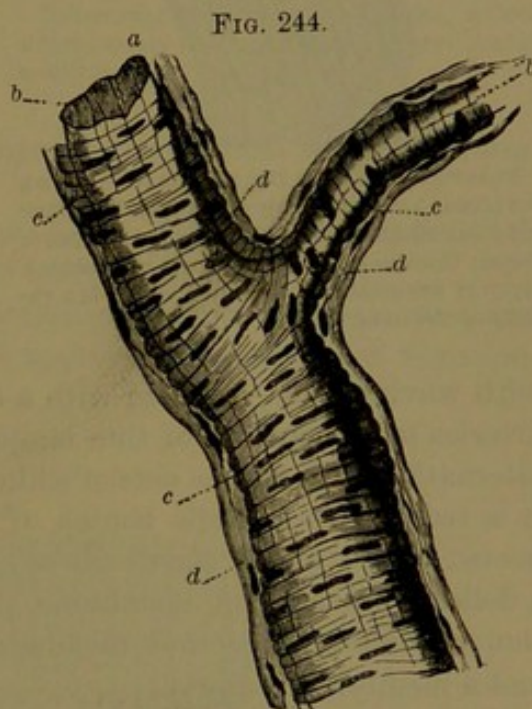


FIG. 244.  
A SMALL BRANCHING ARTERY, highly magnified. *a, b*, elastic layer of the internal tunic or intima; *c*, middle tunic or media of transverse nucleated muscle-fibres; *d*, external tunic or adventitia of fibro-connective tissue.

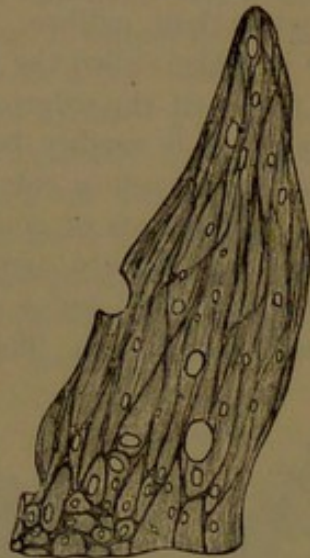
<sup>1</sup> Tunica elastica.

<sup>2</sup> External elastic membrane of Henle.



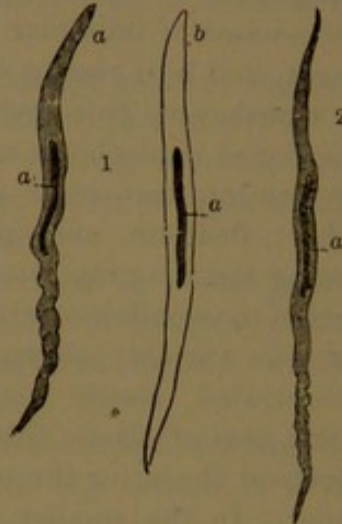
The **internal tunic** or **intima**<sup>1</sup> of the arteries is the thinnest of the series. It is quite distinct from the media, and in transverse sections, prepared for the microscope, appears as a narrow, bright band,

FIG. 245.



ELASTIC TISSUE FROM THE MIDDLE COAT OF THE POPLITEAL ARTERY, highly magnified. The dark reticular lines indicate a narrow net of elastic tissue; the other part of the figure represents a layer of fenestrated membrane, which is a variety of the same tissue.

FIG. 246.



UNSTRIATED MUSCULAR FIBRES FROM THE MIDDLE COAT OF THE ARTERIES, highly magnified. 1, from the popliteal artery: *a*, without, and *b*, treated with acetic acid; 2, from a branch of the anterior tibial artery: *a*, pointing to the centre in the figures, indicates the nucleus.

with waving folds, invested with a delicate endothelium. In the large arteries it is composed of thin laminae of fenestrated elastic membrane, alternating with fibrous nets of a like character. In the smallest arteries it is reduced to a single lamina of elastic membrane, outwardly connected with a net of elastic fibres. The intima is defined inwardly by a delicate transparent membrane, the **endangium**, which in constitution resembles the serous membranes, and consists of an endothelium and a membrana propria.

The **endothelium** is a single stratum of clear, transparent pavement cells, for the most part elongated lozenge-shaped, or fusiform, with sinuous margins, and a central nucleus, and arranged with the length parallel to that of the vessel. In the larger vessels the cells appear of greater proportionate width, but being elastic they, as well as the more elongated forms of the smaller vessels, are variable according to the contraction or expansion of the arteries. The **membrana propria** consists of longitudinal, interlacing fibro-connective tissue, with branching corpuscles, and is related in thickness to the size of the vessels, but is absent in the smallest ones.

The aorta differs slightly in some respects from the other large arteries. Its external tunic is relatively thin. The middle tunic con-

<sup>1</sup> Tunica glabra.

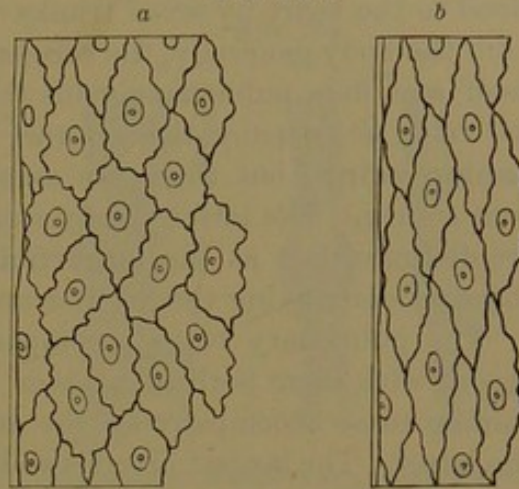


tains between the muscular laminae elastic layers, in horizontal or oblique patches, consisting of laminae of fenestrated elastic membrane and nets of fine elastic fibres. In the arch of the aorta a limited interior portion of the middle tunic differs from the rest in the circumstance that the muscular fibres are arranged in longitudinal or oblique bundles, alternating with bundles of longitudinal elastic fibres and intervening nets of finer fibres of the same kind. The fibres of the muscular bundles subsequently assume the usual transverse course, and the elastic fibres gradually merge into the usual fenestrated membranes. The outer part of the middle tunic also contains groups of longitudinal muscular fibres, especially near the external tunic.

The muscle-cells of the aorta are short, flattened prismatic, fusiform, and vary considerably in their breadth.

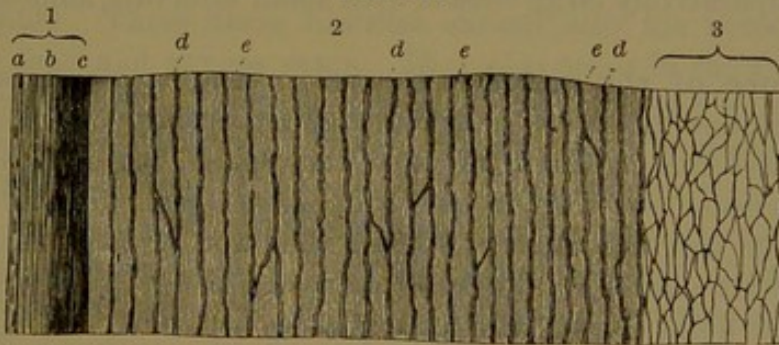
The internal tunic of the aorta is thicker than in other arteries, and is reinforced by the addition of an appreciable quantity of fibro-con-

FIG. 247.



ENDOTHELIUM OF THE BLOOD-VESSELS. *a*, from a large artery; *b*, from a small artery: highly magnified.

FIG. 248.



TRANSVERSE SECTION OF THE WALLS OF THE AORTA, treated with acetic acid, and magnified. 1, internal tunic: *a*, endothelium and membrana propria; *b*, *c*, layers of elastic tissue. 2, middle tunic: *d*, layers of elastic tissue; *e*, muscular tissue. 3, external tunic, composed of fibrous connective tissue and fine nets of elastic tissue.

nective tissue. In the ascending portion and arch of the aorta it is distinctly laminated, the laminae consisting of elastic fibres with intervening connective tissue. The membrana propria of fibro-connective tissue is well produced, and in the ascending portion and arch of the aorta is thicker than elsewhere.



## VEINS.

The **veins**<sup>1</sup> are comparatively thin-walled vessels, which return the blood to the heart by seven trunks: the superior cava and inferior cava from the body generally, the coronary sinus from the walls of the heart itself, and four pulmonary veins from the lungs. For the most part the veins accompany the arteries, whence they are called the **companion veins**,<sup>2</sup> but there are many others which pursue an independent course. The latter chiefly run immediately beneath the skin, and are distinguished as the **superficial** or **subcutaneous veins**, while those accompanying the arteries are distinguished as **deep veins**.

The pulmonary veins accompany the corresponding arteries, and accord with them both in number and capacity. The other veins, including those accompanying the arteries, are of greater capacity than the latter. The largest arteries and their largest branches have a single companion vein, but the medium-sized and smaller branches commonly have two companion veins, though there are exceptions to the rule.

The veins of the brain and those of the spinal canal and the hepatic veins pursue a different course from the arteries; and the veins of the head and face in most instances but partially accompany the corresponding arteries.

The inosculation or anastomosis of veins is much more frequent than in arteries, even among those of large size, as is notably the case with the superficial veins, which indeed form a conspicuous subcutaneous net-work over the whole body. The smaller ones exhibit the same disposition to frequent inosculation, and in some positions form close nets of comparatively large vessels with small intervals, named **venous plexuses**.

**Structure of the veins.** The veins have a thinner wall than the arteries, and therefore commonly appear collapsed when empty, while the arteries in the same condition remain more open. They, however, possess considerable strength, and proportioned to the thickness of their wall are more tenacious than the arteries. In general the superficial veins have a thicker wall than the deep ones, and those of the lower limbs than of the upper limbs.

Many veins are provided with **valves**, which usually consist of a pair of crescentic membranous flaps placed opposite each other, with their convex border attached to the sides of the vein, and their free concave border directed in the course of the flow of the blood. Opposite each flap the vein is dilated, forming a pouch, with the mouth directed forward, so that in a reflux of the blood the two pouches are distended and the flaps brought into contact so as to close the passage. In some of the smaller veins valves occur of a single flap, and in some of the larger veins a single flap is placed over the mouth of some of the smaller branches.

<sup>1</sup> Vena; phlebs.

<sup>2</sup> Venæ comites or satellites.



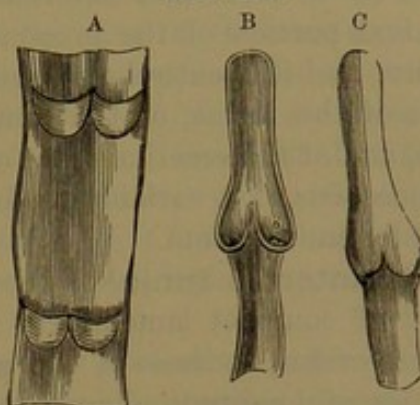
Many of the veins have no valves, nor do they usually occur in those under a line in diameter. They are most numerous in the veins of the limbs, especially the lower ones. They are absent in the pulmonary veins, in the superior and inferior cava, in the veins of the cavity of the cranium and spinal canal, in the hepatic, renal, spermatic, ovarian, and uterine veins, in those of the bones, and generally in those of the portal system. Except in the jugular veins, few or none occur in those of the head and neck, the azygos, hemiazygos, and intercostal veins.

The veins in general, like the arteries, have their wall composed of three tunics, but less distinctly separable than in the latter.

The **external tunic**<sup>1</sup> of the veins is often thicker than the media, from which it is usually not distinctly defined. It ordinarily consists of a compact interlacement of fibro-connective-tissue bundles, associated with nets of longitudinal elastic fibres. In some of the larger veins it contains muscular fibres, as in the inferior cava, in which they pursue a longitudinal course, and form a net-work at the inner part of the tunic. These fibres likewise extend into the renal, spermatic, external iliac, and azygos veins. They also occur in the trunks of the hepatic veins, and that of the portal vein, whence they extend into the splenic and mesenteric veins. They likewise exist in the axillary vein.

The **middle tunic**<sup>2</sup> of the veins is much thinner than that of the arteries, and is less distinctly separable from the external. It presents considerable variability in the different veins. Commonly it is mainly composed of unstriated muscular tissue, for the most part arranged in transverse bands, and not in continuous laminae, as in the arteries. The bands are separated by a notable proportion of fibro-connective tissue with nets of elastic fibres. In many veins the outermost bands pursue a longitudinal course, as in the superior and inferior cavæ, the azygos, hepatic, renal, spermatic, and axillary veins. In others the outer and inner bands are longitudinal, and the intermediate ones transverse, as in the external iliac, femoral, and popliteal veins, branches of the mesenteric, and the umbilical veins. In the veins of the gravid uterus the muscular tissue is well developed, with the fibres all pursuing a longitudinal course.

FIG. 249.



DIAGRAMS EXHIBITING THE ARRANGEMENT OF THE VALVES OF VEINS. A, vein laid open, showing the valves in pairs; B, longitudinal section of a vein, indicating the mode in which the valves, by apposition of their free edges, close its passage. The dilated condition of the wall behind the valves is also seen. C, vein distended, showing how it is expanded opposite the position of the valves.

<sup>1</sup> Tunica adventitia.

<sup>2</sup> Tunica media.



In many of the larger veins the middle coat is less produced than usual, especially in muscular tissue, but this is compensated in increased muscularity of the external coat.

In the internal and external jugular and subclavian veins, and the terminal portion of the innominate veins, the muscular tissue is deficient; and it is entirely absent in the veins of the bones and muscles, those of the retina, of the brain and spinal cord, the sinuses of the dura, and of the erectile tissue of the penis. In these veins mostly the wall consists of a variably-produced stratum of fibro-connective tissue lined by endothelium.

The **internal tunic**<sup>1</sup> of the veins is a thin, elastic membrane, composed of compact lamelliform net-works of longitudinal elastic fibres. In some veins, as those of the gravid uterus, these are associated with bundles of longitudinal muscular fibres. The **endangium**, like that of the arteries, consists of the endothelium, and commonly a subjacent stratum of fibro-connective tissue. The latter, usually thinner than in the arteries, is better marked in some of the medium-sized veins than in the larger ones. In some of the veins, as those of the bones, it is altogether absent. The endothelium consists of short, spindle-shaped plates with sinuous margins.

The **valves of the veins** consist of an extension of the internal coat, with muscular fibres from the middle coat invested with the endangium.

#### THE CAPILLARIES.

The **capillaries**, as expressed by the name, are fine, hair-like blood-vessels, which occupy the various tissues composing the organs of the body. The ultimate branches of the arteries terminate in them, and the corresponding branches of the veins commence in them. They in general form a closed reticular system of tubes, from which the tissues imbibe their materials of growth, repair and action, and to which they yield their waste materials. The greater the vital activity of a tissue or organ, the greater is its supply of capillary blood-vessels. Commonly very numerous, they vary greatly in number in different tissues, and in some, as the cartilages, epithelium, and epidermis, do not exist at all. They are always minute vessels, and only to be seen and studied by the microscope. When viewed in this manner in any transparent tissue of a living animal, as in the web of a frog's foot or the mesentery of a salamander, they appear as a net-work of transparent tubes, through which the blood rapidly flows, its clear liquor in contact with the sides of the vessels and the corpuscles aggregated in a central column and moving with greater rapidity than the surrounding blood-liquor. The capillaries are of pretty uniform size in the same tissue, and in this respect differ from the arteries, which undergo constant reduction as they divide. In different tissues they vary considerably in size, but,

---

<sup>1</sup> Tunica intima.



as the capillaries are both elastic and contractile, the same vessels may differ under different conditions. The size of the capillaries when filled with blood is estimated to be from  $\frac{1}{4000}$  to  $\frac{1}{2000}$  of an inch in diameter, but there are many both smaller and larger.

The capillary nets vary greatly in the size of their meshes, and hence in the number of the vessels in a given space. The net-work is very close in the lungs and in the choroid coat of the eye. It is also comparatively close in the muscular and adipose tissues, in the dermis, in most mucous membranes, in glands, and in the gray substance of the brain and spinal cord. On the other hand, it has wide meshes, and consequently few vessels, in tendons, aponeuroses, ligaments, fasciæ, and similar structures.

The arrangement of the capillary nets is accommodated to that of the tissues to which they pertain. Thus, in the muscles, nerves, tendons, and aponeuroses they generally conform to the direction of the

FIG. 250.

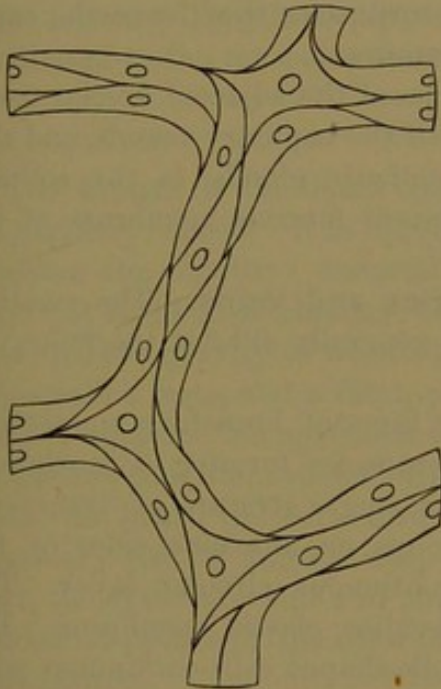
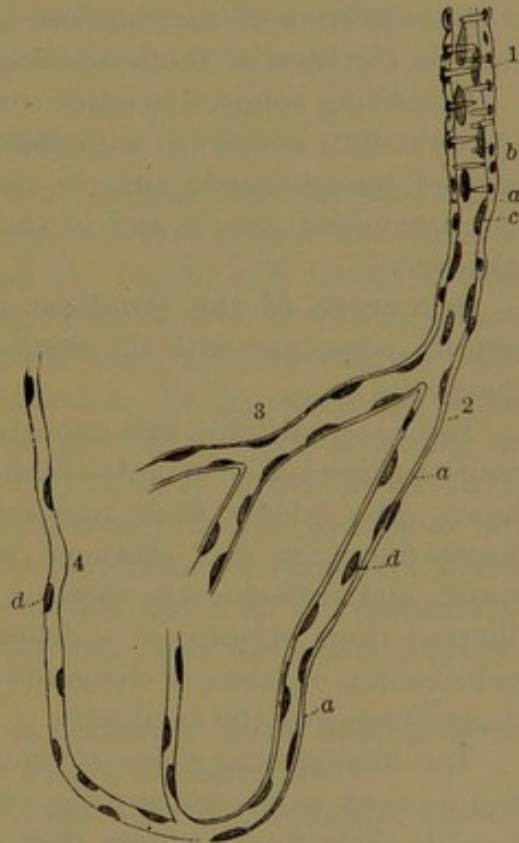


DIAGRAM OF THE STRUCTURE OF A CAPILLARY BLOOD-VESSEL: highly magnified.

bundles and fibres of those tissues, running in greater part parallel with them and producing long, narrow meshes. In the lungs they form little bag-like nets with rounded polygonal meshes; in adipose tissue they form a sponge with polygonal meshes enclosing the fat-vesicles; and in the papillæ of the skin or the villi of the intestine they form loops extending from the subjacent nets.

FIG. 251.



A SMALL ARTERY gradually passing into the structure of the capillary vessels. 1, artery with transverse muscular fibres; *a*, hyaline membrane; *b*, nuclei of transverse muscle-fibres; *c*, nuclei of the internal tunic or intima; 2, 3, 4, capillaries apparently composed of structureless membrane (*a*) with scattered nuclei (*d*): highly magnified.



In youth the tissues contain relatively more capillaries, or are more vascular, than in advanced age.

The wall of the capillaries is a delicate, elastic, transparent, and apparently homogeneous membrane, which by treatment with silver nitrate is shown to have a cellular constitution like the endothelium of the arteries and veins, with which it is continuous. The cells form a single layer, joined at their margin by a cement which is stained black by the silver nitrate, while the cells remain uncolored. Thus darkly outlined, the cells are spindle-shaped plates, with even or slightly sinuous margins, though a few at the intersection of the capillaries are radiate, with two or three points. The cells are arranged longitudinally in the course of the vessels, and there are commonly two or three to the circumference of each. The cells contain a central oval nucleus, which is rendered visible by staining with infusion of logwood or carmine.

In inflammation, from distention of the capillaries, the cement of the cells yields at certain points, leaving small openings, the so-called **stomata**, through which blood-corpuscles escape. It is observed that in the migration of the colorless blood-corpuscles they leave the capillaries in the lines of the cementing substance.

Branching connective-tissue corpuscles of the adjacent areolar tissue are intimately connected with the wall of the capillary vessels, and this is most conspicuously seen in the lymphatic glands, in the solitary and agminated glands, and in the adjacent mucous membrane of the intestine.

**Structure of the smallest arteries and veins.** The smallest arteries connected with the capillaries generally exhibit the following characters:

The external tunic first appears as a layer of branching connective-tissue corpuscles, or of unbranching corpuscles forming a continuous layer. The middle tunic appears as a single stratum of transverse muscle-fibres, at first arranged in groups on alternate sides of the vessel, and subsequently forming a continuous circular layer. The internal tunic appears as a delicate, hyaline elastic membrane. The endothelium consists of elongated spindle-shaped cells continuous with those composing the capillaries.

The commencing veins communicating with the capillaries in general proceed to accompany the corresponding arteries, than which, as usual in their future course, they are wider and have a thinner wall and are more capacious. Their external tunic at first is like that of the terminal arteries, but as they become larger it becomes thicker by the addition of bundles of fibro-connective tissue. A thin internal tunic occurs composed of a net-work of fine longitudinal elastic fibres. The endothelium is composed of shorter and wider spindle-shaped cells than in either the capillaries or the smallest arteries. At first there is no muscular tunic, but as the vein enlarges this makes its appearance as a single stratum of transverse muscle-fibres.



The walls of arteries and veins are themselves provided with blood-vessels, both arteries and veins, which are readily visible ramifying in the external tunic of the large trunks, but require the aid of the microscope to see them in the smaller ones. The **vessel arteries**<sup>1</sup> are derived from neighboring arterial branches, and the **vessel veins** likewise end in neighboring venous branches. A net-work of capillaries in the external tunic occupies the usual position between the vessel arteries and veins. The middle and internal tunics of the arteries and veins have generally been regarded as destitute of vessels, but some recent authorities assert the existence of capillaries in the middle tunic. In some of the larger animals of man's class, as the ox and the whale, the capillaries are quite evident in the middle tunic of the aorta.

Lymphatics are numerous in the external tunic of the blood-vessels, appearing as lymphatic spaces in the smaller trunks and as plexuses of vessels in the larger ones. In the latter, also, lymphatics occur in the middle tunic.

Arteries and veins are also supplied with nerves,<sup>2</sup> to a greater extent in the former. They form plexuses in the external tunic, and are thence distributed to the muscular tissue, chiefly of the middle tunic.

#### THE BLOOD.

The **blood**<sup>3</sup> is the liquid contents of the heart, the arteries, veins, and capillary vessels. It is highly complex in composition, and directly furnishes the nutritive material to all the organs and tissues of the body. It is thickish, clammy, and somewhat heavier than water, having a specific gravity of about 1.055. It has a slightly alkaline reaction, a saline taste, and a faint, peculiar odor. To the naked eye, when fresh, it appears homogeneous, and opaque red to black, according to the various conditions under which it may be seen. From the left cavities of the heart, the aorta and its numerous branches, and from the pulmonary veins it appears deep bright red; from the right side of the heart, the systemic veins and their branches, and from the pulmonary arteries it appears of the color of claret wine or of the ordinary black-heart cherry.

\* The amount of blood in the body is ordinarily about equal to from one-twelfth to one-tenth of the entire weight of the latter.

When the blood is examined by means of the microscope, spread in a thin layer upon a plate of glass, or while it is circulating in the capillary vessels, it is observed to consist of a clear, colorless liquid, the **plasma**, or **blood-liquor**,<sup>4</sup> containing a great number of minute, round particles, the **blood-corpuscles**,<sup>5</sup> which, for the most part, are colored and give to the blood its characteristic red color.

<sup>1</sup> Vasa vasorum.

<sup>2</sup> Vaso-motor nerves.

<sup>3</sup> Sanguis; hæma; cruor; gore.

<sup>4</sup> Liquor sanguinis; hæmatoplasma; plastic or coagulable lymph.

<sup>5</sup> Blood-globules, vesicles, or disks; corpuscula or globuli sanguinis.

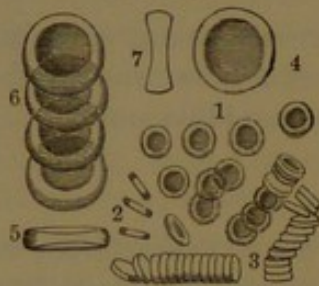


Ordinarily, when blood is drawn from the vessels, it quickly solidifies or coagulates into a mass, the **blood-clot**,<sup>1</sup> which subsequently by contraction squeezes out a pale yellow liquid, the **serum**, in which the clot, reduced in size and retaining the original color of the blood, remains floating. The coagulation is due to the solidification of one of the constituents of the blood, the **fibrin**, which in the change entangles the blood-corpuscles.

The blood-corpuscles are of the character of cells, and they are so minute and numerous that a drop of blood, about a line in diameter, may contain about 50,000,000. They are of two kinds, the red and the white or colorless corpuscles, of which the former very greatly predominate, while the latter are more variable, and are commonly about one to five hundred or more of the red corpuscles.

The red corpuscles, which are so characteristic of the blood, are

FIG. 252



RED BLOOD-CORPUSCLES, highly magnified. 1, corpuscles seen on their broad surface; 2, seen on their edge; 3, rolls of corpuscles, indicating the manner in which they are frequently observed to arrange themselves. The remaining figures more highly magnified: 4, corpuscle seen on its broad surface; 5, seen on its edge; 6, a series of corpuscles; 7, a corpuscle in section, indicating its biconcave discoidal form.

circular, biconcave disks, with a thick, rounded border, and resemble in shape the common biscuit, with us known as a cracker. They appear of remarkable uniformity, measuring about  $\frac{1}{3200}$  of an inch in breadth with about one-fourth that thickness; and the far greater proportion range between  $\frac{1}{3100}$  to  $\frac{1}{3300}$  of an inch. They also appear to be perfectly homogeneous, without evident distinction of cell-wall and contents, and have no nucleus. Isolated, they seem of a pale yellow hue, and it is only in mass that they exhibit a distinctly red color. They are quite elastic, and readily change their shape under pressure and resume their

original form when it is removed. In water they quickly assume a globular form, lose their color, and become very indistinct. Through evaporation and inspissation of the surrounding plasma the corpuscles become contracted, tuberculate, and more or less stellate; and solutions of salt, sugar, etc., produce similar effects. When a fresh portion of blood is examined beneath the microscope, the red corpuscles exhibit a remarkable tendency to arrange themselves together in piles, like rolls of coin, and these more or less intersect one another.

The red corpuscles exhibit no difference in persons of different age, sex, or race. They are characteristic of the blood of all vertebrates, with the sole exception of the lowest recognized representative, the headless fish or lancelet, in which they are absent. In all mammals they have the same shape and composition as in man, with the remark-

<sup>1</sup> Crassamentum; cruor; thrombus.

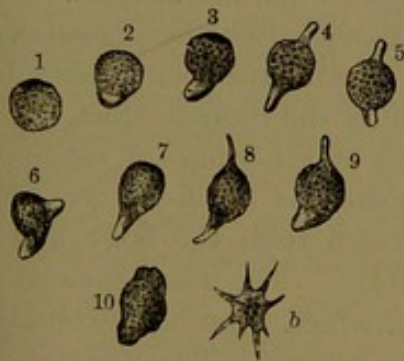


able exception of one small family, that of the camel, in which they are oval disks and are provided with a nucleus. In all other classes of vertebrates, except the lowest fishes, exemplified by the lampreys, they are, as in the camel, oval, nucleated disks.

The red blood-corpuscles are not proportioned in size with the animal. No difference is observed in their size in the different races of man, but they are notably smaller in monkeys. Among mammals they are largest in the elephant, but in all our large domestic animals they are smaller than in man, while those of the mouse are intermediate in size. They are remarkably large in the amphibia, exemplified by the frog; but especially in the proteus and siren, and above all in the amphiuma, of our Southern States, in which the corpuscles are visible with the naked eye, and measure ten times the diameter of those of man.

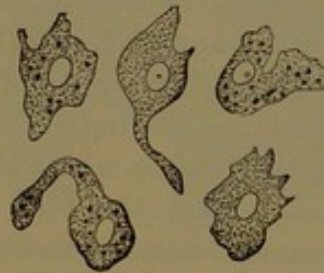
The **white** or **colorless corpuscles**<sup>1</sup> are comparatively few, and from their having no color are not readily recognized among the multitude of red corpuscles with which they are mingled. They are larger than the latter, about  $\frac{1}{2700}$  of an inch in diameter, and when at rest are spherical. They are composed of a mass of finely granular and reticular protoplasm, mingled with a few coarser granules, and contain from one to three nuclei, usually not distinct, but brought more clearly into view by certain reagents, as acetic acid. They often also contain one or more conspicuous vacuoles or clear globules, which

FIG. 253.



WHITE OR COLORLESS CORPUSCLES OF THE BLOOD, highly magnified. 1, corpuscle at rest; 2-10, in movement, exhibiting projections of the protoplasm called pseudopods; b, one which has assumed a stellate shape.

FIG. 254.



THE SAME CORPUSCLES, more highly magnified, and observed at the temperature of the body, exhibiting the changes of shape in movement.

are inconstant, and may appear and disappear. They swell up in water and become clearer, and in this condition, under high power of the microscope, granules in their interior may be observed exhibiting more, or less lively vibratory motion.

When fresh blood, maintained at or near the temperature of the body, is examined, the white corpuscles are noticed to change both their shape and position. The movement from place to place is slow, and the change of shape exceedingly varied. From its resemblance

<sup>1</sup> White globules; pale or lymph corpuscles; leucocytes.



to that of the microscopic animal, *amœba*, which is as simple in structure as the white corpuscle, it is called **amœboid movement**. Through this the corpuscle projects portions of its protoplasm in any direction, and apparently at will again retracts them. In its movements it is also observed to take into its interior, minute particles with which it may meet, as fine granules of carbon, carmine, milk-globules, starch, etc. Through the power of amœboid movement, the white corpuscles may be seen wandering from the blood-vessels, passing out between the tissue elements of their wall, into the interstices of neighboring tissues. Observed in this way, the corpuscles have been distinguished as **migratory cells**.

The white corpuscles of the blood, which are identical with lymph-corpuscles, are derived from the lymph, which is incessantly poured into the blood by the trunks of the lymphatics. They are commonly regarded as the source of the red corpuscles, a view which appears to be confirmed by many observations, but is considered as not yet satisfactorily demonstrated. In the production of the red from the white corpuscle, the nucleus of the latter is gradually transformed into the former, while the surrounding protoplasm disappears. The production of the earliest red corpuscles in the embryo occurs in the same manner.

Besides the ordinary solid constituents of the normal blood, as above described, others have been indicated of an obscure character. They appear as round, colorless disks,<sup>1</sup> smaller than the red corpuscles, homogeneous or finely granular, and without a distinct nucleus.

Blood also at times, especially immediately after the digestion of much fat food, contains fine oil-molecules, which have been absorbed by the intestine, and conveyed into the blood by the thoracic duct.

The **blood-liquor** or **plasma** consists of a permanent liquid, the serum, and of certain materials distinguished as fibrin-factors, which spontaneously unite when blood is withdrawn from the body, and by their union form the solid substance fibrin. The fibrin-factors are fibrinogen and fibrino-plastin, the latter of which is probably contained in the colorless corpuscles as well as in the plasma. The union of the fibrin-factors is supposed to be due to the action of another material, the fibrin-ferment, which does not exist in the circulating blood, but is supposed to be formed after the blood has been withdrawn by the breaking down of some of the colorless corpuscles.

**Fibrin** freed from the blood-corpuscles is a yellowish-white stringy substance, which under the microscope presents an indistinct fibrillar structure. It is a proteid compound, readily dissolved in the gastric and pancreatic juices.

**Serum** is the amber-colored liquid of the blood-plasma after the separation of the fibrin. It has an alkaline reaction and coagulates by heat. \*It is an albuminous solution with salts, fatty matters, sugar, etc.

---

<sup>1</sup> Hæmatoblasts; blood-plates or plaques.

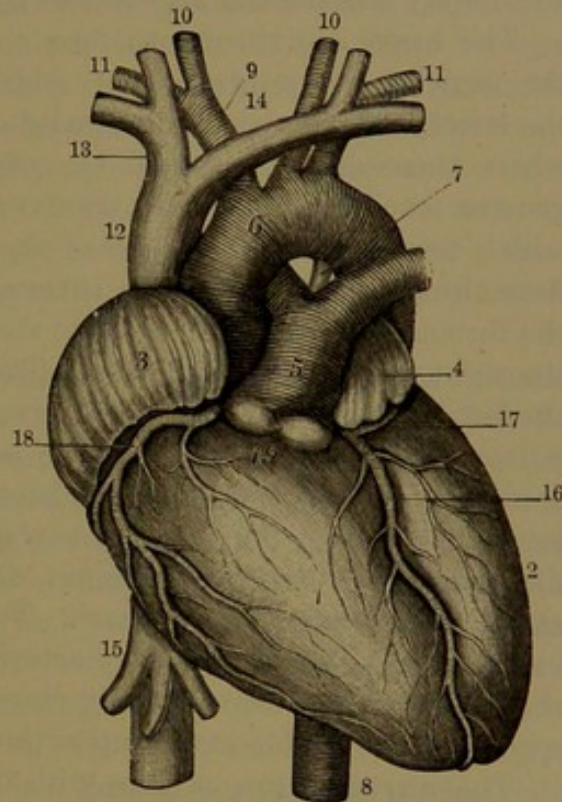


The blood also contains gases, which are readily evolved by the air-pump. They consist of carbonic acid, oxygen, and nitrogen. The red corpuscles contain a coloring-matter named **hæmoglobin**, a proteid of very complex character and having a strong affinity for oxygen. It is readily soluble in water, and under certain circumstances may be crystallized.

## THE HEART.

The **heart**<sup>1</sup> is a hollow, muscular organ, in whose walls resides the power which produces the circulation of the blood. It occupies a nearly central position in the cavity of the thorax, placed behind the sternum, between the second and sixth intercostal spaces, with about two-thirds of its mass to the left side and the other third to the right of the median line. Enclosed in a pouch, called the **pericardium**, it rests on the diaphragm, and is embraced at the sides by the lungs enclosed in the pleuræ. It is blunt conical in shape, and is obliquely inclined, with its base directed upward, backward, and to the right, and its apex downward, forward, and to the left. By its base it is attached, through means of its great blood-vessels, to the front of the spine, in the space between the fourth and ninth thoracic vertebræ. Elsewhere it is entirely free, projecting forward within the pericardium, with its apex opposite the interval of the fourth and fifth costal cartilages, a short distance below and to the inner side of the left nipple, where its impulse is felt during life. The posterior surface is flattened, and rests on the central tendon of the diaphragm, with the pericardium intervening, and tightly attached to the latter. The anterior

FIG. 255.



FRONT VIEW OF THE HEART AND GREAT BLOOD-VESSELS. 1, right ventricle; 2, left ventricle; 3, right auricle; 4, left auricle; 5, pulmonary artery, dividing into the right and left branches; 6, arch of the aorta; 7, remains of the ductus arteriosus; 8, descending aorta; 9, innominate artery; 10, common carotid arteries; 11, subclavian arteries; 12, superior cava; 13, right innominate vein, formed by the union of the right internal jugular and subclavian veins; 14, left innominate or transverse vein, formed like the preceding; 15, inferior cava, with the hepatic veins; 16, left coronary artery; 17, branch to the left auriculo-ventricular groove; 18, right coronary artery; 19, valvular sinuses of the pulmonary artery.

<sup>1</sup> Cor; cardia.



surface is convex, and looks obliquely forward and upward towards the sternum and costal cartilages, from which it is separated by the pericardium and pleuræ. The lungs also project over it in front, especially during inspiration, in which condition there remains a narrow, uncovered interval, widening below to a triangular space of nearly two square inches, to the right of the apex. The right border<sup>1</sup> is the longer and narrower, is rounded angular, and directed obliquely downward. The left border<sup>2</sup> is convex, and directed obliquely upward.

The exact position of the heart is affected by several circumstances: thus, when a person is lying on the left side or on the breast it comes more into contact with the front of the chest; and in breathing it alternately recedes and approaches the latter.

The heart is divided into four compartments or chambers, named the auricles and ventricles, of which the former communicate with the latter. The division is indicated on the exterior by grooves, except where these are interrupted by vessels. The **auriculo-ventricular groove** encircles the heart transversely, and separates the auricles, which form the basal portion of the heart, from the ventricles, which form the apical portion. The **interventricular groove** descends from the former in front and behind to the right of the apex, and separates the right from the left ventricle. The fore part of this groove is nearer the left border of the heart, and the right ventricle forms the greater portion of the front surface of the latter; the back part of the groove is nearer the right border of the heart, and the left ventricle forms the greater portion of the posterior surface of the heart. The **interauricular groove**, in the same manner, separates the right and left auricles at the basal portion of the heart. The grooves accommodate the chief nutritive vessels, the coronary arteries and veins, the lymphatics, and the nerves of the heart, usually associated with more or less fat, which spreads to a variable extent upon the adjacent surfaces.

The **auricles** are cavities with thin, fleshy walls adequate to their purpose, that of sending the blood into the adjoining ventricles. Each consists of a more capacious portion, the **atrium**,<sup>3</sup> and of a prolongation, the **auricular appendix**. The atria are separated by a partition, the **auricular septum**,<sup>4</sup> communicate with the ventricles, each by a large aperture, the **auriculo-ventricular orifice**,<sup>5</sup> and while that of the right auricle receives the two great systemic veins, the superior and inferior cava, that of the left auricle receives the four pulmonary veins.

The **right auricle**<sup>6</sup> occupies the right side of the base of the heart projecting in front, in contact inwardly with its fellow behind, and with the aorta in advance of this. It is the thinnest-walled cavity of the

<sup>1</sup> Margo acutus.

<sup>3</sup> Sinus venosus.

<sup>5</sup> Ostium atrio-ventriculare.

<sup>2</sup> Margo obtusus.

<sup>4</sup> Septum auricularum.

<sup>6</sup> Auricula dextra; atrium dextrum.



heart, being scarcely a line in thickness. The atrium is quadrate, and for the most part internally, except on the anterior wall, is smooth. Communicating with it are the superior and inferior cava, the coronary sinus, and the right auriculo-ventricular orifice.

The superior cava returns the blood from the upper part of the body and descends to open into the upper fore part of the atrium, with its orifice directed downward and forward, so that the entering current of blood is directed to the auriculo-ventricular orifice. The inferior cava, larger than the former, returns the blood from the lower part of the body, and ascends to open in the lowest part of the atrium, with its orifice directed upward and inward. Between the openings of the two veins the right wall of the atrium is produced into a slightly obtuse angle,<sup>1</sup> more evident in some lower animals than in man. In front of the opening of the inferior cava is the **right auriculo-ventricular orifice**, communicating with the corresponding ventricle, oval in shape, and about an inch in diameter. Between the two openings at the inner side is the smaller orifice of the coronary sinus, which returns the blood from the coronary veins of the heart. It is protected by a semi-lunar valve,<sup>2</sup> which is formed by a fold of the lining membrane or endocardium.

The posterior wall of the atrium to the left forms the **auricular septum**. Near its lower part to the left of the orifice of the inferior cava is a depression, the **oval fossa**,<sup>3</sup> which indicates the position during foetal life of the **oval foramen**,<sup>4</sup> communicating with both auricles. The margin of the fossa, prominent above and at the sides, is the **oval annulus**.<sup>5</sup> The bottom of the fossa is thin and translucent, and is formed by what was originally a valve<sup>6</sup> to the oval foramen. Not unfrequently a little cleft is found beneath the annulus above, remaining as part of the latter opening.

In front of the orifice of the inferior cava, and partly covering it, is the **eustachian valve**.<sup>7</sup> This is a thin, crescentic fold of the endocardium, which is attached along the anterior margin of the cava and is prolonged at the left extremity to the fore part of the oval annulus. It is variable in condition, commonly more or less perforated or cribriform, wide or narrow, and sometimes nearly or quite obsolete. Before birth it is well produced, and then serves to direct the entering current of blood of the inferior cava through the oval foramen into the left auricle.

A variable number of apertures<sup>8</sup> of little veins<sup>9</sup> of the heart open on different portions of the inner surface of the right auricle.

The **auricular appendix**, prolonged from the atrium forward,

<sup>1</sup> Tuberculum Loweri.

<sup>3</sup> Fossa or fovea ovalis; vestigium foraminis ovalis.

<sup>4</sup> F. ovale; f. Botalli.

<sup>5</sup> Annulus ovalis.

<sup>7</sup> Valvula Eustachii; v. foraminis ovalis anterior.

<sup>8</sup> Foramina Thebesii.

<sup>2</sup> Valvula Thebesii.

<sup>6</sup> Valvula foraminis ovalis.

<sup>9</sup> Venæ minimæ cordis.



curves to the left around the right side of the commencement of the aorta. It is pyramidal, with irregular dentated borders. Internally, its sides are provided with prominent fleshy fascicles, mostly vertical and reticulated; while others extend on the anterior wall of the atrium, parallel with one another, like the teeth of a comb, whence the name of **pectinate muscles**<sup>1</sup> applied to them.

The **left auricle**<sup>2</sup> occupies the left of the base of the heart in great part behind, is somewhat smaller than the right one, and has slightly thicker walls, being about a line and a half in thickness. The **atrium** is rounded cuboidal in shape, and is in contact with its fellow behind on the right, and with the aorta and pulmonary artery in advance. Internally it is smooth throughout, and on the auricular septum presents a lunated depression defined by a slight ridge, indicating the former position of the oval foramen. At its back part it receives on each side a pair of pulmonary veins, the left pair sometimes uniting in a single vessel. At its lower fore part is the **left auriculo-ventricular orifice**, like that of the right side, but slightly smaller. The **auricular appendix** extends from the left of the atrium and curves forward to the right around the commencement of the pulmonary artery. It springs more abruptly from the atrium than that of the left side, is longer, narrower, and more dentated, and the **pectinate muscles** are confined to its interior alone.

The **ventricles**<sup>3</sup> form the more massive portion of the heart towards the apex, and are cavities with walls of a thickness proportioned to the distance they are required to send the blood. They are separated by a thick partition, the **ventricular septum**.<sup>4</sup> They communicate with the auricles by the auriculo-ventricular orifices, through which they receive the blood, and also with the chief arterial trunks: the right ventricle with the pulmonary artery, by which the blood is conveyed to the lungs, and the left ventricle with the aorta, by which the blood is distributed throughout the body. The auriculo-ventricular orifices are provided with valves, which prevent the reflux of the blood into the auricles, and the arterial orifices are provided with others of different construction, which prevent the reflux of the blood from the vessels into the heart.

The **right ventricle**<sup>5</sup> occupies the chief portion of the front surface of the heart, the right border, and a smaller portion of the back surface. It is pyramidal in shape, convex in front, flattened behind, and concave to the inner side, where it embraces the left ventricle. With its base joined to the corresponding auricle, its apex ceases a little short of that of the left ventricle, which forms the point of the heart. The upper anterior angle is prolonged obliquely upward and to the

<sup>1</sup> Musculi pectinati.

<sup>3</sup> Ventriculi.

<sup>5</sup> Ventrículus dexter, anterior, pulmonalis, or primus.

<sup>2</sup> Auricula sinistra.

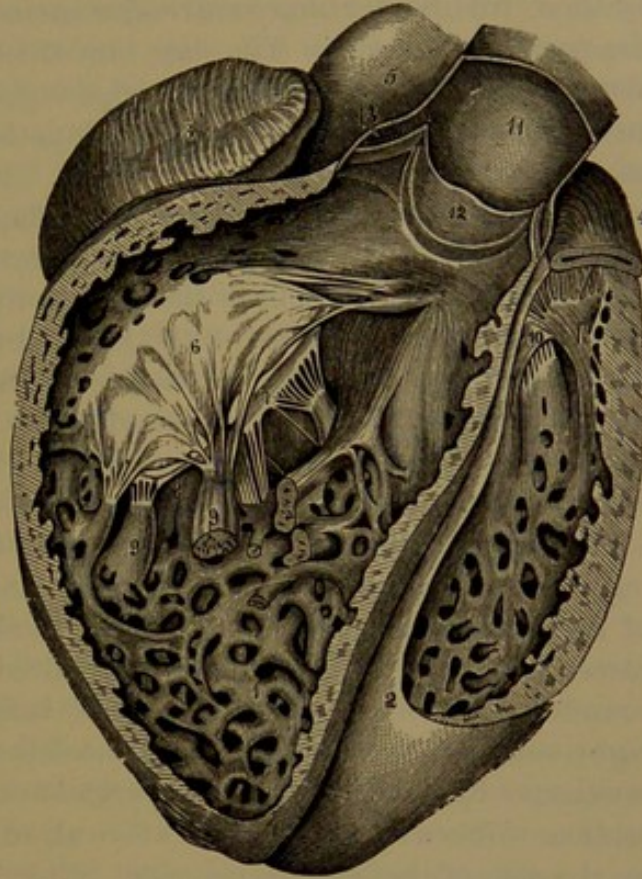
<sup>4</sup> Septum ventriculorum.



left in the **arterial cone**,<sup>1</sup> from which springs the pulmonary artery, continued in the same direction. The ventricular septum forms the inner wall, and bulges into the cavity with a convex surface, to which the outer wall presents a concave surface, so that a cross-section of the cavity is crescentic in shape. The outer wall is about the fourth of an inch in thickness, but is not uniform, being thickest at the base and becoming thinner towards the apex. The surface of the cavity, for the most part, is broken up by a multitude of **carneous columns**,<sup>2</sup> which are of various sizes and intersect one another in all directions; many partially projecting in their length from the wall, others attached at the extremities and free at the middle, while a few project from their base into the ventricle as the **papillary muscles**.<sup>3</sup> These are directed upward and end in a number of thread-like **tendinous cords**,<sup>4</sup> which diverge to be inserted into the tricuspid valve. Two of the muscles conspicuous for their size spring from the fore and back part of the ventricle, and are called from their position the **anterior** and **posterior papillary muscles**. The others, two or three, are small, and proceed from the septum. The inner surface of the arterial cone is devoid of the fleshy columns and is smooth, so as to facilitate the flow of blood in its course to the pulmonary artery.

At the base of the ventricle is the **right auriculo-ventricular orifice**, communicating with the corresponding auricle and bordered

FIG. 256.



VIEW OF THE HEART, WITH THE ANTERIOR PORTIONS OF THE VENTRICLES REMOVED. 1, interior of the right ventricle, exhibiting its carneous columns; 2, left ventricle; 3, right auricle; 4, left auricle; 5, aorta; 6, 7, 8, divisions of the tricuspid valve; 9, papillary muscles attached by tendinous cords to the tricuspid valve; 10, mitral valve; 11, pulmonary artery laid open; 12, one of the semilunar valves; the other two are seen in section on each side of the former; 13, sinus or dilatation of the artery behind one of the semilunar valves.

<sup>1</sup> Conus arteriosus; infundibulum.

<sup>2</sup> Columnæ carneæ; trabeculæ; fasciculi teretes; lacerti or lacertuli cordis.

<sup>3</sup> Musculi papillares.

<sup>4</sup> Chordæ tendineæ.



by a fibrous ring, which gives attachment to the **tricuspid valve**<sup>1</sup> guarding the aperture. The valve is a thin, fibrous membrane invested by the endocardium, and incompletely divided into three unequal triangular flaps, from which it is named. As commonly seen, the flaps descend from around the orifice into the ventricle, and are attached by their free border and ventricular surface to the tendinous cords of the papillary muscles. The flaps are thickest centrally, and thinnest along the free border, where the edge is festooned between the attachment of the tendinous cords. The flaps hold the relative position of posterior, and of right and left anterior. The tendinous cords attached to the adjacent margins of the anterior flaps proceed from the anterior papillary muscle; those from the adjacent margins of the right and posterior flaps proceed from the posterior papillary muscle; and those from the adjacent margins of the left and posterior flaps proceed from the smaller papillary muscles or directly from the surface of the ventricular septum. In the attachment of the cords their component fibro-connective-tissue bundles diverge and interlace with one another in the fibrous layer of the valve.

The **left ventricle**<sup>2</sup> occupies the left border of the heart, appearing to a small extent in the front view, and forming a greater portion of its posterior surface. It is conical in shape, and is longer and narrower than the right ventricle, beyond which it extends to form the rounded **apex** or **point** of the heart. It is embraced inwardly by the right ventricle, and its base joins the left auricle, with which it communicates by the corresponding auriculo-ventricular orifice. The cross-section of its cavity is fore and aft oval, so that the ventricular septum on the side of the latter is concave.

The left ventricle is constructed on nearly the same plan as the right one, but all its parts display a greater strength. The wall is more than twice the thickness, being about seven lines; but is thickest where it is broadest, about a fourth of its length from the base, towards which it becomes thinner, and still more towards the apex, where it is thinnest. In cross-section it forms a continuous ring, with the ventricular septum of nearly uniform thickness; while that of the right ventricle appears as a thinner half ring continuous with the former by its extremities. The interior surface of the cavity is furnished with **carneous columns** like those of the right ventricle, but in greater number, generally smaller and more reticulated, especially near the bottom of the ventricle and on its posterior wall. On the upper part of the anterior wall and the septum they disappear, and the surface approaching the aortic orifice is smooth. From among the fleshy columns project two groups, more or less conjoined, and forming the **papillary muscles**, of more robust proportion than those of the right

<sup>1</sup> Valvula tricuspidalis; valvulæ tricuspidēs.

<sup>2</sup> Ventriculus sinister, aorticus, posterior, or secundus; cor aorticum or arteriosum.



ventricle. The anterior papillary muscle springs from the left wall of the ventricle, and the posterior muscle from the back wall on the right. They terminate in **tendinous cords**, which diverge to be inserted into the mitral valve.

The **left auriculo-ventricular orifice** is bordered by a fibrous ring, which affords attachment to the **bicuspid**<sup>1</sup> or **mitral valve**.<sup>2</sup> This is constructed like the tricuspid valve, but is thicker and stronger, and is divided into two unequal, broad, half-oval flaps, with a small offset at their angles of conjunction. The flaps, as usually seen, descend into the ventricle, and receive at their free border and under surface the attachment of the tendinous cords of the papillary muscles and adjacent portion of the wall of the ventricle. The flaps are situated obliquely below the orifice, the larger in front and to the right, the other behind and to the left. Their tendinous cords, fewer and stronger than those of the tricuspid valve, have a similar arrangement, those attached to the adjacent borders of the flaps to the right proceeding from the posterior papillary muscle and adjacent part of the posterior wall of the ventricle; the others in like manner on the left proceeding from the anterior papillary muscle and adjacent posterior wall of the ventricle.

The aortic orifice lies close to the auriculo-ventricular orifice, in front and to the right, and is separated from it only by the basis of attachment of the anterior flap of the mitral valve.

The pulmonary artery and the aorta, at their origin, are connected with the ventricles by fibrous rings, contiguous to those which encircle the auriculo-ventricular orifices. The two vessels are alike at their commencement, are both provided with the same kind of valves, and differ from each other only in the stronger construction of the aorta and its accessories. In each artery the valve consists of three semi-circular, crescentic flaps, from which it receives the name of the **semilunar valve**.<sup>3</sup> The flaps are arranged in a circle, immediately above the entrance of the artery, attached to this by their convex border, whence they project upward into the vessel, and terminate in a free, loose, concave edge. Opposite each flap the artery is dilated, and thus forms with it a pouch,<sup>4</sup> the mouth of which is directed upward into the vessel. The three pouches outwardly are indicated by a corresponding circle of convex eminences at the commencement of the artery, more conspicuous in the aorta from their being larger. When the pouches are distended by the reflux of blood in the arteries, the flaps of the valve assume a trilateral form, and the angular, free, projecting borders are brought into contact and completely close the orifice of the vessels.

<sup>1</sup> Valvula bicuspidalis; valvulæ bicuspidatæ.

<sup>2</sup> V. mitralis; valvulæ mitrales or episcopales.

<sup>3</sup> V. semilunaris; valvulæ semilunares or sigmoideæ.

<sup>4</sup> Sinus of Valsalva; Valsalval sinus.



The semilunar valves are composed of laminae of fibro-connective tissue invested by the endocardium and continuous with the adjacent endangium. The segments are strongest along their attached border, and the free marginal portion of each is formed by two thinner crescents,<sup>1</sup> which join at the middle of the edge in a little fibrous nodule.<sup>2</sup>

The heart is of a deep reddish-brown color, due to its fleshy structure. It is invested with a delicate, transparent membrane, the **epi-cardium**, beneath which, along the grooves of the heart, accompanying the vessels, are yellowish-white streaks, due to adipose tissue, which often accumulates and spreads more or less over the adjacent surfaces.

The heart is variable in size and weight, and in a measure is related with the same conditions of the person. In the adult it is commonly about five inches long, three and a half inches where broadest, and two and a half inches where thickest. Its ordinary weight is about nine or ten ounces in the male, and an ounce or two less in the female. It increases with the advance of life, and proportionately to a greater degree before thirty; but after fifty years it commonly undergoes a slight decrease.

The capacity of the cavities is about three ounces. That of the auricles is commonly regarded as smaller than that of the ventricles, and that of the left cavities as less than that of the right ones. It is probable that during life there is but little difference in the capacity of the four cavities. Usually after death the left ventricle is found most contracted, and nearly empty, while the right ventricle is of greater capacity and filled with blood.

**Structure of the heart.** The chief substance of the heart is the muscular tissue, which is more compact than that of the muscles of locomotion, the fascicles being more closely associated, and the interstices occupied with a comparatively small proportion of areolar connective tissue. With the muscular tissue is the usual accompaniment of blood and lymphatic vessels and nerves. There is also a variable amount of adipose tissue, mainly collected along the base of the ventricles and the grooves of the heart. The auriculo-ventricular orifices and those of the aorta and pulmonary artery are bordered by fibro-connective tissue rings, which afford a base of attachment to the valves, and serve a similar purpose to many of the fleshy fibres of the walls of the heart. Fibro-cartilaginous tissue in the angle between the aortic orifice in front and the auriculo-ventricular orifices behind gives additional firmness to the structure. In this position in the larger ruminating animals, as the ox and deer, a bone partly takes the place of the fibro-cartilage.

The muscular portion of the walls of the auricles is composed of a superficial layer common to both, and a deeper layer for each. The fascicles of the superficial layer generally run transversely across the

<sup>1</sup> Lunulae.

<sup>2</sup> Corpusculus or nodulus Arantii or Morgagni.



atria, and are more numerous in front, while some pass into the auricular septum. Of the deeper layer for each auricle, some of the fascicles pass over the latter from the fibrous ring of the auriculo-ventricular orifice, and others encircle the auricular appendix, within which there are also some longitudinal fibres. Annular fibres also surround the entrance of the different veins, and extend some distance upon them, especially the superior cava and the pulmonary veins. Others likewise surround the oval fossa of the auricular septum.

The muscular portion of the walls of the ventricles is composed of a number of layers intimately associated, and only more or less separable after the heart is hardened by boiling, or by other means. The fascicles composing the layers are also closely connected, and have a most intricate arrangement, in general proceeding from the fibrous rings encircling the orifices at the base of the ventricles, and thence descending obliquely in a whorl to the apex of the heart. Here they become closely twisted upon one another, producing the **vortex**, in which they enter the ventricles, and ascend on their interior to the rings from which they started, and contribute to form the carneous columns and papillary muscles. In front of the heart the fascicles of the superficial fleshy layer descend from right to left across the ventricles; many from the right ventricle turning in at the interventricular groove, where they intersect others coming out from the ventricular septum, while those towards the base and apex proceed uninterruptedly over the groove. Behind the heart the fascicles descend from left to right, and pass uninterruptedly across the interventricular groove. At the apex of the heart the fascicles ascend the vortex and enter the left ventricle, whence they proceed upward in its inner surface to the base, and mainly form the papillary muscles. The fascicles of the deeper, fleshy layers of the ventricles pursue the same general course as those of the superficial layer, but in the outer portion of the former they are successively less inclined in their descent. From the vortex many of the fascicles ascend in the ventricular septum to the fibro-cartilage and fibrous rings at the base of the ventricles, while others proceed forward through the septum, emerge at the fore part of the interventricular groove, and become continuous with those in front of the left ventricle; and a third set pass upward and backward, and diverge in the posterior walls of the ventricles, those to the right ascending to the orifice at the base of the right ventricle, while those to the left encircle the cavity of the left ventricle nearly horizontally. Additional fascicles cross the ventricular septum fore and aft, and encircle both ventricles. The fascicles of the deeper layers of the ventricles are usually regarded as not reaching the fibrous rings at the base of the latter, but as commencing and terminating below them. The centre of the vortex at the apex of the heart forms a narrow passage communicating with the cavity of the left ventricle, but closed by the epicardium and the endocardium.



The muscular tissue of the heart consists of fibres transversely striped like those of the voluntary muscles, but otherwise quite different. They are smaller, and are composed of rows of short columnar cells attached end to end, and have lateral offsets which join those of contiguous cells, uniting the whole in a sponge-like intertexture. The fibres are tolerably uniform, apparently devoid of a sarcolemma, and with the transverse stripes less distinctly marked than in the voluntary muscles. They are also longitudinally striated, and may be resolved into fibrillæ. The muscle-cells are provided usually with a single central oval nucleus.

The **epicardium** is a serous membrane continuous with the inner layer of the pericardium. It consists of an external layer of irregular, polygonal pavement cells, and a serosa with a subserous layer of areolar connective tissue, by which it adheres to the muscular structure of the heart and is continuous with the interstitial connective tissue. In this layer are distributed the vessels and nerves before they penetrate the muscular structure, and these are usually associated with more or less fat, which is chiefly collected along the grooves of the heart, but often extends more or less over the surface of the latter.

The **endocardium**, similar to the former membrane, lines the cavities of the heart, invests its valves and other parts, and is continuous with the endangium of the blood-vessels. It is thicker in the auricles than in the ventricles, and is thickest in those of the left side; and is thinner on the pectinate muscles and carneous columns than elsewhere. It consists of a superficial layer of pavement endothelium, a serosa, and a subjacent layer of connective tissue, by which it is attached to the muscular structure. The connective tissue is associated with elastic tissue, which partially assumes the condition of fenestrated membrane, and is also mingled with some unstriped muscular fibres. It becomes more or less pervaded with adipose tissue in fat persons.

The valves and their tendinous cords of the heart consist of a basis of fibro-connective tissue invested with the endocardium. They are non-vascular.

#### VESSELS AND NERVES OF THE HEART.

The chief blood-vessels of the heart are the coronary arteries and veins, mainly running along the grooves of its surface. The branches ramify beneath the epicardium, and thence penetrate the muscular substance, in which they terminate in numerous fine capillaries, which have the same arrangement as in the voluntary muscles. The lymphatics of the heart are numerous, and the larger ones mostly accompany the coronary vessels along the grooves. They generally commence in lymphatic spaces or clefts of the interstitial fibro-connective tissue of the muscular structure.

The nerves of the heart are also numerous, but appear of small size in proportion to that of the organ when compared with those of voluntary muscles. They come from the cardiac plexuses formed by



the sympathetic and vagus nerves at the base of the heart, and mainly pursue the course of the coronary vessels. The nerves to the auricles end in fine plexuses of non-medullated fibres mingled with little groups of nerve-cells, situated for the most part beneath the epicardium, and from which the filaments penetrate the muscular structure. The nerves of the ventricles proceed from the coronary plexuses, which extend along the corresponding vessels from the cardiac plexuses. They descend for the most part beneath the epicardium, where they are associated with minute groups of nerve-cells, and are thence distributed to the muscular structure.

#### RELATIVE POSITION OF IMPORTANT PARTS OF THE HEART TO THE ANTERIOR WALL OF THE CHEST.

About two-thirds of the heart lie to the left of the median line of the sternum, with the remaining third to the right, extending from the second intercostal spaces to the anterior extremity of the sixth intercostal space on the left side. The right auricle lies behind the inner extremities of the third, fourth, and fifth costal cartilages on the right side. The right ventricle extends from the third to the sixth costal cartilage on the left side.

The apex of the heart is opposite the fifth intercostal space, about three and a half inches to the left of the median line.

The auriculo-ventricular groove is in an oblique line from the inner end of the third costal cartilage on the left to the inner end of the sixth costal cartilage on the right. The auriculo-ventricular orifices, with the mitral valve above and the tricuspid valve below, lie a little to the left of that line.

The aortic orifice and that of the pulmonary artery lie behind the inner end of the third costal cartilage, third intercostal space, and contiguous portion of the sternum on the left side, the former a little lower and a little to the right of the latter.

#### THE AORTA.

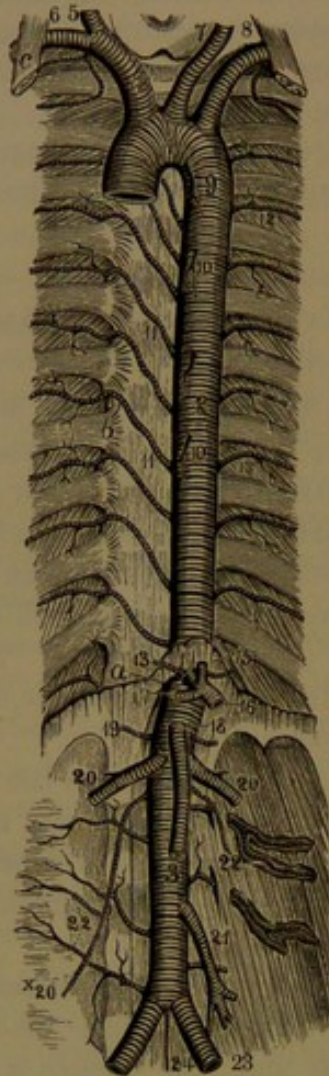
The **aorta**<sup>1</sup> is the principal trunk of the arteries distributed to all the organs of the body, and is contained within the thorax and abdomen. It is a large cylindrical tube, narrowing somewhat in its course, about an inch in diameter in the thorax or larger at the commencement, and considerably less towards its termination in the abdomen. It springs, near the centre of the heart, from the left ventricle, thence ascends and obliquely arches from the right to the left side of the body, where it descends on the vertebral column, usually to the front of the fourth lumbar vertebra, on which it forks into the common iliac arteries. Its commencement is variably somewhat expanded in a bulb-like man-

<sup>1</sup> Arteria maxima; hæmal axis.



ner,<sup>1</sup> and is encircled by three lesser expansions, the **valvular sinuses**,<sup>2</sup> which are due to dilatation of the vessel opposite the semilunar valves,

FIG. 257.



THE AORTA. 1, arch of the aorta; 2, thoracic aorta; 3, abdominal aorta; 4, innominate artery; 5, right common carotid; 6, right subclavian; 7, left common carotid; 8, left subclavian; 9, bronchial artery, a small branch of the aorta; 10, oesophageal arteries; 11, intercostal arteries of the right side; 12, of the left side; 13, phrenic arteries; 14, coeliac axis; 15, gastric artery; 16, splenic artery; 17, hepatic artery; 18, superior mesenteric artery; 19, suprarenal arteries; 20, renal arteries; x20, spermatic artery; 21, inferior mesenteric artery; 22, lumbar arteries; 23, common iliac arteries; 24, middle sacral artery. a, aortic orifice of the diaphragm; b, articulation of the head of the ribs; c, anterior scalene muscle.

which guard the orifice of the artery. The first portion of the aorta, from its course, is named the **arch**, and the remainder the **descending aorta**, which follows the flexures of the spine, and is further divided into the **thoracic** and **abdominal aorta**, from the cavities through which it passes.

The aorta varies in the relative height to which its arch rises; usually ascending to within an inch of the upper border of the sternum, it may reach a level with it, or it may recede to a level with the fifth thoracic vertebra. Its termination may also vary to the extent of a lumbar vertebra, and from the usual position may extend to the fifth or may only reach the third vertebra.

Rarely, cases occur of transposition of the aorta, the pulmonary artery, and the heart, either with or without a corresponding change of position of other viscera. A specimen in the museum of the University of Pennsylvania exhibits a complete transposition from left to right of all the thoracic and abdominal viscera, together with the blood-vessels.

Variations in the arch of the aorta are related with the course of development of the fourth and fifth branchial arches of the embryo. The normal aortic arch of man and his class is to the left, and is dependent on the persistence and growth of the fourth left branchial artery of the embryo. In birds it

is derived from the right fourth branchial artery; and in reptiles both are retained, and thus produce a double arch to the aorta.

<sup>1</sup> Bulbus aortæ.

<sup>2</sup> Sinuses of Valsalva or of the aortic valves.



## THE ARCH OF THE AORTA.

The **arch of the aorta**,<sup>1</sup> commencing at the upper part of the left ventricle of the heart, ascends with a slight inclination to the right, and curves to the left obliquely backward over the right pulmonary artery and left bronchus to the left of the third or fourth thoracic vertebra, whence the vessel descends as the thoracic aorta.

The **ascending portion**<sup>2</sup> of the arch, little over two inches long, commonly exhibits to the right a variable bulge,<sup>3</sup> which is disposed to increase with the advance of age. It is in great part enclosed in the pericardium, but is free above, and in this position is covered by the edge of the right lung with the pleura. At its commencement in front it is covered by the right auricular appendix and the origin of the pulmonary artery.

The **transverse portion** of the arch, an inch and a half or more long, crosses fore and aft from right to left, behind the upper part of the sternum, in front of the trachea, and above the bronchi. In front of it above are the innominate veins, and below it is the bifurcation of the pulmonary artery. From its convex upper part spring, in near succession, three great vessels, the innominate, left common carotid, and left subclavian arteries.

The **descending portion** of the arch, less than two inches long, is applied to the left side of the centrum of the fourth thoracic vertebra, below which it becomes the thoracic aorta. To its left and in front is the root of the left lung, and to its right are the œsophagus and thoracic duct.

## BRANCHES OF THE AORTA.

These consist of the coronary arteries, which supply the heart, and the innominate, left common carotid, and left subclavian arteries, which supply the head and neck, the upper limbs, and part of the walls of the thorax.

The **coronary arteries**<sup>4</sup> are two small vessels which arise from the commencement of the aortic arch, and are distributed to the walls of the heart.

The **right coronary**<sup>5</sup> **artery** arises from the aortic arch above the anterior valvular sinus, passes forward between the right auricular appendix and the pulmonary artery, and runs outward in the right auriculo-ventricular groove to the back of the heart, where it gives a branch to the left auriculo-ventricular groove, and then descends along the interventricular groove to the apex of the heart. In its course along the grooves of the heart it furnishes branches to the walls of the

<sup>1</sup> Arcus aortæ.

<sup>2</sup> Aorta adscendens.

<sup>3</sup> Sinus maximus or quartus; greater sinus of the aorta.

<sup>4</sup> Arteriæ coronariæ cordis; a. cardiacæ.

<sup>5</sup> Arteria coronaria dextra, anterior or inferior.



contiguous cavities, and also supplies small branches to the aorta and pulmonary artery.

The **left coronary artery**,<sup>1</sup> usually the larger, arises from the aorta above the left posterior valvular sinus, passes forward between the pulmonary artery and left auricular appendix, and divides into two branches, of which the larger<sup>2</sup> descends along the interventricular groove in front of the heart to its apex, while the other branch<sup>3</sup> runs outward in the left auriculo-ventricular groove to the back of the heart. In its course, like the former, it supplies the contiguous cavities of the heart, and also gives small branches to the aorta and pulmonary artery. The two coronary arteries together form fine anastomoses at the surface of the heart.

The remaining branches of the aortic arch spring from the top of the transverse portion in close succession. They consist of three large vessels, the innominate, left common carotid, and left subclavian arteries, forming a row inclining from right to left and backward in the direction of the arch, having immediately behind them the trachea, and in front of them the innominate veins. In their ascent the innominate and left common carotid arteries diverge at the sides of the trachea, while the left subclavian artery is placed vertically to the left of the latter. They arise behind the sternum, on a level with the second costal cartilages, about an inch below the upper border of the former, from which the vessels are separated by the atrophied thymus gland. In youth and advanced age the relative position is lower, usually little more than half the distance indicated from the upper border of the sternum.

#### THE INNOMINATE ARTERY.

The **innominate artery**,<sup>4</sup> the first and largest of the three great branches from the top of the aortic arch, ranges from one to two inches, and ascends obliquely to the position behind the right sterno-clavicular articulation, where it divides into the right subclavian and right common carotid arteries. In front of it is the right innominate vein joined by the left one, to its left is the trachea, and to its right below and behind is the apex of the right lung with the pleura. In its course ordinarily it gives off no branches.

#### THE COMMON CAROTID ARTERIES.

The **left common carotid artery**,<sup>5</sup> immediately succeeding the innominate artery, diverges from this to the left of the trachea, and ascends the neck to the upper border of the larynx, where it divides into the internal and external carotid arteries.

<sup>1</sup> A. coronaria sinistra, posterior or superior.

<sup>2</sup> Ramus anterior or descendens.

<sup>3</sup> R. posterior or circumflexus.

<sup>4</sup> A. innominata, anonyma, or brachio-cephalica.

<sup>5</sup> A. carotis communis sinistra or primitiva.

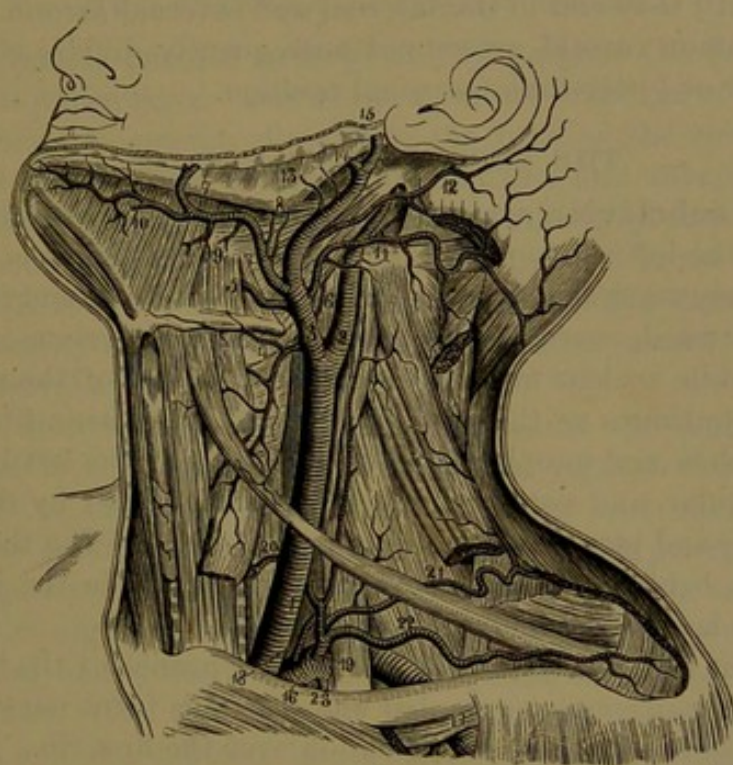


The **right common carotid artery**,<sup>1</sup> the inner branch of the innominate artery, ascends the neck nearly vertically to the same point as the former, and divides in like manner.

As the left common carotid artery springs directly from the aorta, it is longer than the right; and as it comes off later in the course of the latter, it is somewhat more deeply removed from the front of the chest.

Ascending the neck, the common carotid arteries diverge from the sides of the trachea to the sides of the larynx, and, after the obliquely

FIG. 258.



LEFT COMMON CAROTID DIVIDING INTO THE EXTERNAL AND INTERNAL CAROTID ARTERIES. 1, common carotid artery; 2, internal carotid; 3, external carotid; 4, superior thyroid; 5, lingual; 6, pharyngeal artery; 7, facial; 8, inferior palatine and tonsillar arteries; 9, submaxillary; 10, submental; 11, occipital; 12, posterior auricular; 13, parotid branches; 14, internal maxillary; 15, temporal artery; 16, subclavian artery; 17, axillary; 18, vertebral artery; 19, thyroid axis; 20, inferior thyroid giving off the ascending cervical; 21, transverse cervical; 22, suprascapular; 23, internal mammary artery.

outward course of the first portion of the left one, they ascend nearly vertically and parallel with each other, though from the projection forward of the larynx they appear to incline backward. In the neck the common carotid artery rests on the prevertebral muscles, enclosed in a sheath of the cervical fascia, in company with the internal jugular vein and vagus nerve, the former to the outer side of the artery, and the latter between the two vessels behind. At the lower part of the neck the artery and its companions are covered by the sterno-mastoid,

<sup>1</sup> A. c. c. dextra or primitiva.



sterno-hyoid, and sterno-thyroid muscles, besides the fascia, platysma, and skin; and they are crossed by the omo-hyoid muscle. Above this the artery is covered by the skin, platysma, fascia, and edge of the sterno-mastoid muscle. To its inner side are the trachea and œsophagus, the larynx, thyroid gland, and pharynx.

The sympathetic nerve descends behind the sheath of the common carotid artery and its companions, while the recurrent laryngeal nerve ascends inwardly behind the lower part of the sheath. The cervical branch of the hypoglossal nerve descends in front of the sheath. The common carotids are of uniform diameter, except at their termination, where they are somewhat expanded, and they commonly give off no branches until they end in the internal and external carotid arteries.

The common carotid artery not unfrequently divides either somewhat higher or lower than the usual position.

#### THE SUBCLAVIAN ARTERIES.

The **left subclavian artery**<sup>1</sup> arises from the aortic arch immediately succeeding the left common carotid artery, than which it is larger. It ascends nearly vertically from the thorax into the neck, and turns rather abruptly outward, over the first rib between the insertion of the anterior and middle scalene muscles to the outer border of the rib, whence the vessel continues as the axillary artery. In its ascent to the rib it has the trachea and œsophagus to the right, with the left innominate, internal jugular, and vertebral veins in front, covered by the apex of the left lung and pleura extending to the outer side. The thoracic duct arches from behind forward above it, to terminate in the junction of the left subclavian and internal jugular veins.

The **right subclavian artery**,<sup>2</sup> the outer branch of the innominate, pursues the same course as the left one after this turns outwardly from behind the sterno-clavicular articulation over the first rib. In front of it are the right innominate, internal jugular, and vertebral veins, and below it is in contact with the apex of the right lung and pleura.

The vagus and phrenic nerves descend in front of the first portion of the course of the subclavian artery, and the brachial plexus accompanies it over the rib, mostly above the artery, but the lower cord, formed by the last cervical and the first thoracic nerve, is behind and in close contact with it.

The branches of the subclavian artery arise in a group as it is about to pass between the scalene muscles, and usually none are given off near the commencement of the artery, nor after it emerges from the muscles over the outer part of the rib.

**Variations in the branches from the aortic arch.** These are numerous, the most striking of which affect the great vessels from the top of the arch. They may arise at variable distances, all separately

<sup>1</sup> A. subclavia sinistra.

<sup>2</sup> A. subclavia dextra.



or variably united, or they may be multiplied. Not unfrequently the left common carotid arises together with the innominate artery, the normal state in the gibbon and cat, less commonly there are two innominate arteries, as in the dolphin, and more rarely the subclavians are separate and the carotids united, or all may arise from a single trunk, as in the ox. One of the most common variations in the disposition of these vessels is that in which the right subclavian artery arises after the others, in which case it takes its course from the left side behind the trachea and œsophagus to its ordinary position over the rib on the right side.

#### THE INTERNAL CAROTID ARTERY.

The **internal carotid artery**<sup>1</sup> chiefly supplies the brain and the eye with its appendages. One of the terminal branches of the common carotid artery, it ascends directly to the base of the skull, where it enters the carotid canal of the temporal bone and thence the cavity of the cranium. Here it passes along the carotid groove on the side of the sphenoidal body, and turns abruptly upward in the notch at the inner side of the anterior clinoid process, pierces the dura, and at the inner extremity of the sylvian fissure terminates in the anterior and middle cerebral arteries.

In the neck the internal carotid lies behind the external carotid artery, and is accompanied by the internal jugular vein, which lies behind and to its outer side, enclosed together with the vagus nerve in the same sheath. It rests behind on the greater pre-rectus muscle, with the pharynx and tonsil to its inner side. It is crossed externally by the digastric, stylo-hyoid, and stylo-pharyngeal muscles and the occipital and posterior auricular arteries, and is covered by the parotid gland. The first cervical ganglion and the vagus nerve are behind it, and the superior laryngeal branch of the latter passes internally to it. The hypoglossal and glosso-pharyngeal nerves and the pharyngeal branch of the vagus pass forward externally to it. Near its entrance into the carotid canal the glosso-pharyngeal, vagus, accessory, and hypoglossal nerves pass outwardly between it and the internal jugular vein.

In the carotid canal the artery is accompanied by the sympathetic nerve, and is separated from the lining periosteum by a venous plexus, which communicates with the cavernous sinus above, and by one or two veins joins the internal jugular vein below the entrance of the canal. Within the cranium it lies along the floor of the cavernous sinus, accompanied by the sympathetic nerve and having the abducent nerve to its outer side, all covered by the lining membrane of the sinus.

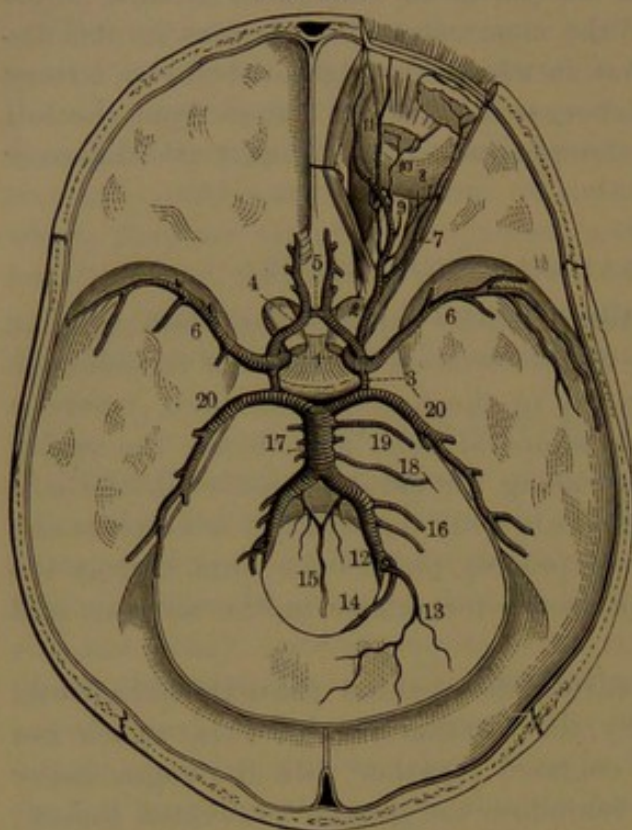
The cervical portion of the internal carotid artery gives off no branches. Usually straight, it is sometimes more or less tortuous. In

<sup>1</sup> A. carotis interna; a. carotis cerebialis.



the carotid canal the artery gives off a little **tympanic branch**<sup>1</sup> to the tympanum. In the cavernous sinus it gives off little branches to the dura, the pituitary body, and the trifacial-ganglion.

FIG. 259.



ARTERIES OF THE INTERIOR OF THE CRANIUM. 1, internal carotid arteries; 2, ophthalmic artery; 3, posterior communicating arteries; 4, anterior cerebral arteries; 5, anterior communicating artery; 6, middle cerebral arteries; 7, lachrymal; 8, short ciliary arteries piercing the back part of the eyeball; 9, central retinal artery piercing the optic nerve to reach the interior of the eyeball; 10, muscular artery; 11, frontal and nasal artery; 12, vertebral arteries; 13, posterior meningeal artery; 14, posterior spinal artery; 15, anterior spinal arteries conjoining in a single one; 16, inferior cerebellar arteries; 17, basilar artery formed by the union of the vertebrals; 18, internal auditory; 19, superior cerebellar; 20, posterior cerebral arteries.

hippocampal fissure of the cerebrum, to be distributed to the choroid plexus.

The **anterior cerebral artery**,<sup>4</sup> one of the terminal branches of the internal carotid, runs forward and inward to the great longitudinal fissure, within which it proceeds on the inner surface of the cerebral hemisphere forward and upward around the fore part of the callosum, and backward. In the longitudinal fissure it lies close to its fellow of

After perforating the dura at the notch of the anterior clinoid process, the internal carotid artery gives off in advance the ophthalmic artery, and ascends to the inner extremity of the sylvian fissure of the brain. Here it is joined by the posterior communicating artery, gives off the choroid artery, and then terminates in the anterior and middle cerebral arteries.

The **posterior communicating artery**<sup>2</sup> is a short, slender vessel, directed backward from the internal carotid to join the posterior cerebral artery, derived from the basilar, which is formed by the confluence of the vertebral arteries.

The **choroid artery**,<sup>3</sup> a small branch given off by the internal carotid externally to the posterior communicating artery, ascends outwardly, and enters the descending horn of the lateral ventricle through the

<sup>1</sup> A. carotico-tympanica.

<sup>3</sup> A. choroidea anterior.

<sup>2</sup> A. communicans posterior.

<sup>4</sup> A. cerebri anterior; a. corporis callosi.



the opposite side, and both as they enter the fissure are joined by a vessel, a line or two long, the **anterior communicating artery**.<sup>1</sup> The branches of the anterior cerebral artery are mainly distributed to the under part of the frontal lobe and the inner surface of the cerebral hemisphere.

The **middle cerebral artery**,<sup>2</sup> the remaining and larger terminal branch of the internal carotid, ascends outwardly in the sylvian fissure, distributing its branches to the central lobe and outer surface of the cerebral hemisphere. At its commencement it gives off half a dozen or more fine vessels, which ascend in the anterior perforated space of the brain to the striatum.

**Circle of Willis.**<sup>3</sup> In the union of the anterior cerebral arteries through the anterior communicating artery, and the union of the middle cerebral with the posterior cerebral arteries through the posterior communicating arteries, a continuous vascular circle is produced, by which the four great vessels that supply the brain, the internal carotid and vertebral arteries, are brought into free communication. To this remarkable anastomosis is given the name of the **circle of Willis**. It is of hexagonal outline, and includes within its area the optic commissure, the infundibulum and cinereous tuber, the mammillary eminences, and the posterior perforated space.

#### THE OPHTHALMIC ARTERY.

The **ophthalmic artery**<sup>4</sup> springs from the internal carotid internally to the position of the anterior clinoid process, and is directed forward through the optic foramen in company with the optic nerve into the orbit. Entering this to the outer side and below the nerve, it proceeds forward and commonly over the latter to the inner wall of the orbit, along which it runs below the trochlearis muscle to the pulley, and terminates in the frontal and nasal branches. In its course it gives off a number of branches, more or less variable, as follows:

The **lachrymal artery**<sup>5</sup> arises to the outer side of the optic nerve, and runs along the external rectus muscle to the lachrymal gland, to which it is mainly distributed. It gives branches to the eyelids and conjunctiva and contiguous muscles, and others which pass through foramina of the malar bone to the cheek and temple.

The **central retinal artery**,<sup>6</sup> a delicate vessel, enters the outer side of the optic nerve a short distance from the eyeball, and proceeds in the axis of the nerve to the retina, to which it is distributed.

The **supraorbital artery**<sup>7</sup> springs from the ophthalmic as it passes over the optic nerve, and proceeds along the roof of the orbit

<sup>1</sup> A. communicans anterior.

<sup>2</sup> A. cerebri media or transversa; a. fossæ Sylvii.

<sup>3</sup> Circulus arteriosus Willisii.

<sup>5</sup> A. lachrymalis.

<sup>6</sup> A. centralis retinæ.

<sup>4</sup> A. ophthalmica.

<sup>7</sup> A. supraorbitalis.



to the supraorbital foramen, through which it passes, and thence ascends to the forehead. It gives branches to the upper eyelid, and anastomoses with the frontal arteries.

The **ciliary arteries**, of which there are three sets. The **short ciliary arteries**,<sup>1</sup> commonly two from the ophthalmic artery, or sometimes one from the lachrymal branch, are directed forward, and divide into ten or more fine vessels, which pierce the sclerotica in a circle around the optic nerve, and thence proceed to be distributed to the choroidea and ciliary processes.

The **long ciliary arteries**,<sup>2</sup> also two, but larger than the former, come from the ophthalmic artery or one of its larger branches, proceed along the optic nerve, and pierce the back of the sclerotica on each side. Entering the eyeball, they continue forward between the sclerotica and choroidea to the ciliary muscle, to which and the iris they are distributed.

The **anterior ciliary arteries**,<sup>3</sup> half a dozen or more in number, are little vessels arising from the contiguous muscular and lachrymal arteries. They form together a vascular circle beneath the conjunctiva around the cornea, and pierce the sclerotica to communicate with the long and short ciliary arteries.

The **muscular arteries**.<sup>4</sup> Commonly two larger ones, the **superior**<sup>5</sup> and the **inferior**,<sup>6</sup> from the ophthalmic artery or some of its branches, the former supplying the upper and inner muscles, the latter the lower and outer muscles. They furnish most of the anterior ciliary arteries, and often other branches.

The **ethmoidal arteries**,<sup>7</sup> of which there are two. The **posterior**<sup>8</sup> enters the corresponding canal, and supplies the posterior ethmoidal sinuses and upper part of the nasal fossa. The **anterior**,<sup>9</sup> larger than the former, passes through the corresponding canal into the cranial cavity, and thence into the nasal cavity. It gives a **meningeal branch** to the dura of the anterior cranial fossa, and supplies the mucous membrane at the fore part of the nasal fossa, and of the frontal sinus and anterior ethmoidal sinuses.

The **palpebral arteries**,<sup>10</sup> two, or one dividing into two, coming from the fore part of the ophthalmic, and directed outward to the eyelids, near the edges of which they form circles by anastomosing with palpebral branches of the lachrymal artery. They also supply branches to the lachrymal sac and conjunctiva.

The **nasal artery**,<sup>11</sup> one of the terminal branches of the ophthalmic, passes from the orbit above the internal palpebral ligament, and is

<sup>1</sup> A. ciliares posticæ breves.

<sup>2</sup> A. c. anteriores.

<sup>3</sup> Ramus muscularis superior.

<sup>4</sup> A. ethmoidales.

<sup>5</sup> A. ethmoidalis anterior.

<sup>6</sup> A. nasalis; a. dorsalis nasi.

<sup>7</sup> A. c. p. longæ.

<sup>8</sup> A. musculares.

<sup>9</sup> R. m. inferior.

<sup>10</sup> A. ethmoidalis posterior.

<sup>11</sup> A. palpebralis superior et inferior.



distributed to the nose, communicating with the nasal and angular branches of the facial artery.

The **frontal artery**,<sup>1</sup> the remaining terminal branch of the ophthalmic, passes from the inner upper part of the orbit to the forehead, supplying the contiguous structures and anastomosing with the supra-orbital artery.

#### EXTERNAL CAROTID ARTERY.

The **external carotid artery**,<sup>2</sup> nearly as large as the internal carotid, is distributed to the face, except the orbit, and to the wall of the cranium. It ascends from the common carotid, opposite the upper border of the larynx, to the neck of the mandible, where it terminates in the temporal and internal maxillary arteries. At first situated in advance and a little inwardly of the internal carotid, it is then directed slightly outward, so as to become more superficial than that vessel, and ascends in the interval of the ramus of the jaw and the mastoid process, enclosed in the deeper part of the parotid gland. Below, it rests on the side of the pharynx, covered by the fascia, platysma, and skin, and at a higher point by the stylo-hyoid and digastric muscles, and crossed by the hypoglossal nerve. It ordinarily has no companion vein, but the external jugular vein lies superficial to its upper part, and it is crossed below by the facial and lingual veins. In the parotid gland it is crossed by the facial nerve.

The branches of the external carotid artery are as follows: three directed forward, the superior thyroid, lingual, and facial arteries; from the inner side, the pharyngeal artery; two from behind, the occipital and posterior auricular arteries; and the terminal ones, the temporal and internal maxillary arteries. Besides these, in its course it gives small branches to the parotid gland, and twigs to the masseter muscle.

The **superior thyroid artery**<sup>3</sup> arises near the commencement of the external carotid, just below the hyoid bone, and curves forward and downward to the upper part of the thyroid gland, to which it is mainly distributed. It gives **muscular branches** to the omo-hyoid, thyro-hyoid, and sterno-thyroid muscles, under which it lies, and another which descends in front of the carotid sheath to the sternomastoid muscle, the platysma, and the contiguous skin. It also supplies the inferior constrictor of the pharynx, and gives off a small **hyoid branch**, which runs forward below the hyoid bone. A **laryngeal branch** pierces the thyro-hyoid membrane to supply the interior muscles, lining membrane, and other structures of the larynx. Sometimes it enters the latter, on one or both sides, through a foramen of the thyroid cartilage. A little **crico-thyroid branch** runs in front of

<sup>1</sup> A. frontalis.

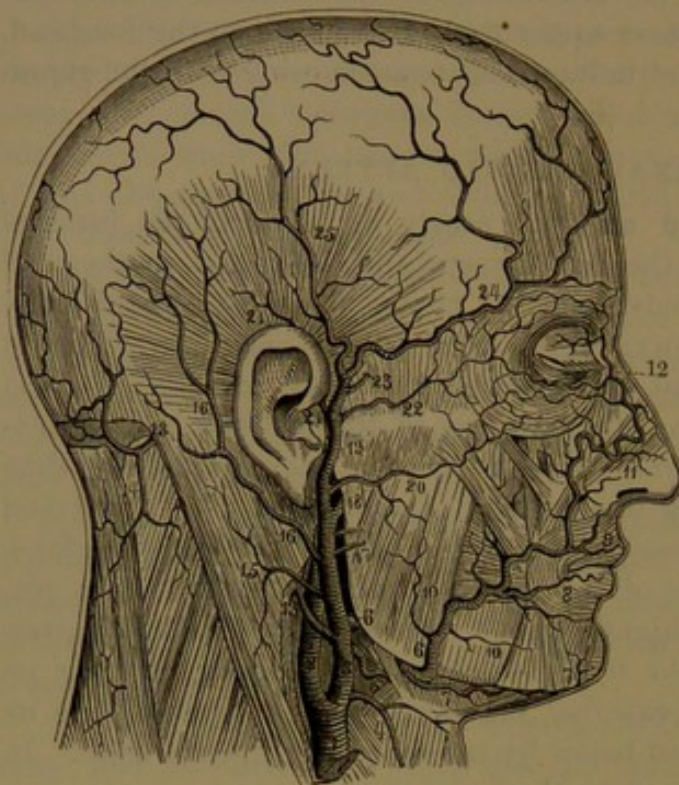
<sup>2</sup> A. carotis externa or facialis.

<sup>3</sup> A. thyroidea superior.



the crico-aryo-thyroid membrane, and communicates with that of the opposite side of the larynx.

FIG. 260.



THE EXTERNAL CAROTID ARTERY AND ITS BRANCHES. 1, right common carotid; 2, internal carotid; 3, external carotid; 4, superior thyroid; 5, lingual; 6, facial; 7, submental; 8, inferior labial; 9, superior labial; 10, muscular branches; 11, lateral nasal artery; 12, angular artery; 13, occipital artery; 14, descending cervical; 15, muscular branch; 16, posterior auricular artery; 17, parotid branches; 18, internal maxillary; 19, temporal; 20, transverse facial; 21, anterior auricular; 22, supraorbital; 23, middle temporal; 24, anterior temporal; 25, posterior temporal artery.

The superior thyroid artery sometimes arises directly from the common carotid, and occasionally it arises together with the succeeding branch.

The **lingual artery**<sup>1</sup> arises from the external carotid above the preceding, usually opposite the hyoid bone. Pursuing a flexuose course forward and upward immediately above the greater cornu of the latter, resting inwardly on the middle constrictor of the pharynx under the digastric and stylohyoid muscles, it continues forward beneath the tongue, covered by the hyoglossal muscle. At its commencement it is crossed externally by the hypoglossal nerve,

which afterwards lies above it as the nerve passes forward to the outer side of the hyoglossal muscle. From it are derived the following-named branches:

The **hyoid branch** is a small vessel, which runs forward along the upper border of the hyoid bone, supplies the contiguous muscles and skin, and anastomoses with that of the opposite side. The **dorsal branch**,<sup>2</sup> a little longer than the former and often double, ascends from above the hyoid cornu, under the hyoglossal muscle, to the root of the tongue, to which it is distributed. It extends to the mucous membrane of the dorsum of the tongue, beneath which it anastomoses with its fellow of the opposite side. The **sublingual branch** advances between the mylo-hyoid muscle and the mucous membrane of the floor of the mouth to the inner side of the submaxillary duct and sublingual gland, which it mainly supplies, together with the contiguous muscles and

<sup>1</sup> A. lingualis.

<sup>2</sup> A. dorsalis linguae.



mucous membrane. The **ranine artery**<sup>1</sup> proceeds forward as a continuation of the trunk in a more tortuous manner between the genio-glossal and infralingual muscles to the tip of the tongue, where it anastomoses in a loop with that of the opposite side. Beneath the tip of the tongue at the side of the frænum it is comparatively superficial. In its course it gives many branches to the tongue.

The lingual artery not unfrequently arises in common with the facial, less frequently with the superior thyroid, and rarely all arise together. The hyoid branch is often absent and compensated by a larger hyoid branch of the superior thyroid artery. The sublingual branch sometimes comes from the facial artery.

The **facial artery**<sup>2</sup> arises a little above the lingual artery, and pursues a flexuose course upward and forward, resting on the mylohyoid muscle beneath the digastric and stylo-hyoid muscles towards the angle of the jaw, then runs in a groove of the submaxillary gland along the base of the jaw, and turns outward over this, in advance of the insertion of the masseter muscle, to the side of the face. In a more tortuous condition, which increases with age, it ascends obliquely to near the oral angle, the side of the nose, and to the inner corner of the eye, where it anastomoses with the nasal branch of the ophthalmic artery. At the side of the face it rests on the buccinator and supralabial elevator, and near its termination is involved in the naso-labial elevator; and is covered below by the fascia and platysma and the zygomatic muscles. At the base of the jaw, where it is covered by the platysma and skin, from the resistance of the subjacent bone, during life its pulsations may readily be felt. The facial vein on the side of the face is situated some distance outwardly from the artery, but is close to this vessel at the base of the jaw; and in the neck is more superficial and separated from the artery by the submaxillary gland.

The branches of the facial artery, besides small muscular and cutaneous twigs, are as follows: in the neck, the inferior palatine, tonsillar, submaxillary, and submental arteries; and in the face, the inferior and superior labial, nasal, and angular arteries.

The **inferior palatine artery**<sup>3</sup> arises near the commencement of the facial, and ascends at the side of the pharynx between the stylo-pharyngeal and stylo-glossal muscles, and then between the former and the internal pterygoid muscle, to all of which it gives branches, and also supplies the soft palate, the tonsil, and opening of the eustachian tube; and it anastomoses with that of the opposite side. The branches to the palate are not unfrequently substituted by others from

<sup>1</sup> A. ranina; a. profunda linguæ.

<sup>2</sup> A. facialis; a. maxillaris externa; a. labialis or angularis.

<sup>3</sup> Ascending palatine artery; a. palatina inferior or adscendens; a. pharyngo-palatina.



the pharyngeal artery, when the inferior palatine is proportionately reduced.

The **tonsillar artery**,<sup>1</sup> sometimes a branch of the former, comes from the facial near the angle of the jaw, and ascends in the root of the tongue, to which and the pharynx it gives branches, but mainly to the tonsil.

The **submaxillary branches**,<sup>2</sup> a variable number of short twigs, come from the artery in its course through the submaxillary gland, which it supplies.

The **submental artery**,<sup>3</sup> larger than any of the preceding branches, arises from the facial, at the base of the jaw, and runs forward below the mylo-hyoid muscle to the chin, where it turns over the base of the jaw near the symphysis. It distributes branches to the mylo-hyoid and genio-hyoid muscles and the contiguous skin, and to the muscles and skin of the chin and lower lip, forming anastomoses with the sublingual, mental, and inferior labial arteries.

The **inferior labial artery**<sup>4</sup> arises from the facial, variably between the base of the jaw and the oral angle, and passes beneath the depressor of the latter to the lower lip, along the border of which it runs in a tortuous manner between the oral sphincter and mucous membrane of the mouth, and inosculates with that of the opposite side. It distributes branches to the chin and lower lip, and anastomoses with the mental and submental arteries. Frequently a larger branch,<sup>5</sup> sometimes arising separately from the facial, passes beneath the oral angle depressor along the attachment of the lower lip.

The **superior labial artery**<sup>6</sup> arises near the oral angle, and, like the inferior one, pursues a tortuous course in the upper lip and inosculates with its fellow. Besides supplying the upper lip, it gives off a branch which runs along the nasal column to the tip of the nose.

Through the inosculation of the inferior and superior labial arteries of the two sides a complete arterial circle is formed around the mouth, which in the usual condition is very tortuous, but is extended in the opening of the mouth.

The **nasal artery**,<sup>7</sup> a terminal branch of the facial, often replaced by several branches,<sup>8</sup> turns inward to be distributed to the side and back of the nose, and anastomoses with the nasal branch of the ophthalmic artery.

The second terminal branch, or the terminal portion of the facial artery much reduced, is named the **angular artery**,<sup>9</sup> and inosculates

<sup>1</sup> A. tonsillaris.

<sup>2</sup> Rami submaxillares; glandular branches.

<sup>3</sup> A. submental.

<sup>4</sup> Inf. coronary artery; a. labialis inf.; a. coronaria inf.

<sup>5</sup> Inferior labial artery.

<sup>6</sup> Superior coronary artery; a. labialis sup.; a. coronaria sup.

<sup>7</sup> Lateral nasal artery; a. nasalis lateralis or externa.

<sup>8</sup> Rami pinnales and dorsales.

<sup>9</sup> A. angularis.



at the inner side of the orbit with the nasal branch of the ophthalmic artery.

The **pharyngeal artery**<sup>1</sup> is a long, slender branch, which arises from the inner side of the external carotid, usually near the lingual artery, and ascends between the two carotids and the pharynx to the base of the skull. It distributes small branches to the prevertebral muscles, to the constrictors of the pharynx, to the elevator and tensor muscles of the palate, to the tonsil, and to the eustachian tube. From it a small **meningeal branch**<sup>2</sup> ascends through the jugular foramen to the dura, and in its course gives twigs to the nerves which pass through the former, and others to the superior cervical ganglion of the sympathetic nerve.

The pharyngeal artery is very variable in its origin. It sometimes springs from the bifurcation of the common carotid artery or from the internal carotid, from the facial directly or in union with the palatine artery, or it may be derived from the occipital artery.

The **occipital artery**<sup>3</sup> springs from behind the external carotid, usually opposite the facial, and ascends beneath the posterior belly of the digastric and stylo-hyoid muscles, thence passes backward through the occipital groove of the mastoid process, resting on the complexus and supraoblique muscles, and, covered by those attached to the mastoid process, emerges at the back of the neck between the insertion of the sterno-mastoid and trapezius, and ascends to be distributed over the occipital region of the cranium. In the early part of its course it crosses over the internal carotid artery and internal jugular vein, and the vagus and accessory nerves; and is crossed from behind outwardly by the hypoglossal nerve. Near its commencement it gives off a **muscular branch**,<sup>4</sup> which descends with the accessory nerve to the sterno-mastoid muscle, in which it is distributed. It also supplies branches to the digastric, stylo-hyoid, complexus, trachelo-mastoid, and splenius muscles. Commonly a large but variable **descending branch**<sup>5</sup> divides into two, the **superficial** and **deep cervical arteries**,<sup>6</sup> of which the former is distributed between the splenius and the trapezius, and gives twigs through the latter to the skin, while the deep one enters the space between the oblique and recti muscles, supplies these and others contiguous, and anastomoses with branches of the vertebral and ascending cervical arteries. A little **meningeal branch**<sup>7</sup> enters the mastoid foramen to the neighboring dura. The **occipital branches**<sup>8</sup> pursue a tortuous course over the occipital region of the cranium between the

<sup>1</sup> Ascending pharyngeal artery; a. pharyngea adscendens or inferior.

<sup>2</sup> A. meningea posterior.

<sup>3</sup> A. occipitalis.

<sup>4</sup> Sterno-mastoid branch.

<sup>5</sup> Cervical branch; ramus cervicalis princeps, or a. princeps cervicis.

<sup>6</sup> Ramus cervicalis superficialis superior and r. c. profundus sup.

<sup>7</sup> Mastoid branch.

<sup>8</sup> Superficial or cranial branches; rami occipitales.



skin of the scalp and the occipital muscle with its aponeurosis, and freely anastomose with one another and with the posterior auricular and temporal arteries. Rarely the occipital artery arises from the internal carotid.

The **posterior auricular artery**,<sup>1</sup> smaller than the occipital, arises above it from the external carotid artery after this vessel has entered the parotid gland, and ascends to the outer side of the styloid process above the digastric muscle to the interval between the mastoid process and the auricle, where it divides into the auricular and mastoid branches. In its course it is crossed by the facial nerve. It gives small branches to the parotid gland, and to the digastric and styloid muscles. The **stylo-mastoid artery**,<sup>2</sup> a long, slender branch, enters the corresponding foramen, and traverses the facial canal in company with the facial nerve. It gives branches to the mastoid cells, the stapedial muscle, and the tympanum. A branch to the latter anastomoses with one from the tympanic branch of the internal maxillary artery, forming a circle around the tympanic membrane. The stylo-mastoid artery terminates by anastomosis with the petrosal branch of the great meningeal artery. It is frequently a branch of the occipital artery. The **auricular branch**<sup>3</sup> ascends beneath the postauricular muscle, which is supplied by it, and is distributed over the back of the auricle beneath the skin. The **mastoid branch**<sup>4</sup> is directed backward, and is distributed over the insertion of the sterno-mastoid muscle into the mastoid process, anastomosing with branches of the occipital artery.

The posterior auricular is frequently a branch of the occipital artery. It may be smaller or larger than usual, in the former case being compensated through branches of the occipital artery, in the other case partially taking the place of the latter.

The **temporal artery**,<sup>5</sup> the more superficial and smaller terminal branch of the external carotid, starting from the neck of the mandible, ascends the temple in a flexuose manner for about an inch, more or less, and divides into the anterior and posterior temporal branches. At first enveloped in the parotid gland, it emerges from this between the auditory meatus and the articulation of the jaw, and then, passing over the root of the zygoma, rests on the deep temporal fascia covered by the skin. In its course it gives off the following branches:

The **transverse facial artery**,<sup>6</sup> a variable branch and sometimes absent, runs forward beneath the parotid gland, resting on the masseter muscle, between the zygoma and the parotid duct, to the cheek. It is distributed to the parts mentioned and to the contiguous skin, and anastomoses with branches of the facial, buccal, and infraorbital ar-

<sup>1</sup> A. auricularis post.

<sup>2</sup> A. stylo-mastoidea

<sup>3</sup> Ramus auricularis.

<sup>4</sup> R. occipitalis, mastoideus, or posterior.

<sup>5</sup> A. temporalis; superficial temporal artery.

<sup>6</sup> A. transversa faciei.



teries. Occasionally it is unusually large, and may substitute the upper portion of the facial artery.

The **anterior auricular branches**,<sup>1</sup> two or three small vessels, come from the adjacent part of the temporal artery and are distributed to the fore part of the auricle, the auditory meatus, and the pre- and supra-auricular muscles. They anastomose with branches of the posterior auricular artery.

The **middle temporal branch**<sup>2</sup> arises above the zygoma, pierces the temporal fascia, and ascends beneath the temporal muscle, to which it is distributed, anastomosing with the deep temporal branches of the internal maxillary artery. It usually impresses the temporal squama with a slight groove.

The **orbital branch**,<sup>3</sup> small and inconstant, runs forward above the zygoma to the eyelids, to which it is distributed, anastomosing with the lachrymal and anterior temporal arteries.

The **anterior temporal branch**<sup>4</sup> diverges from the bifurcation of the temporal artery forward and upward to the fore border of the temporal fossa, where it curves backward and upward. It gives off numerous branches to the forehead and temple, which anastomose with one another, and with the frontal, orbital, and posterior temporal arteries.

The **posterior temporal branch**<sup>5</sup> ascends and is distributed on the side of the cranium to the vertex, where it anastomoses with branches of the opposite side, in front with the anterior temporal, and behind with the occipital and posterior auricular arteries.

The temporal branches supply the scalp. Sometimes one and sometimes the other is the larger.

The **internal maxillary artery**,<sup>6</sup> the larger of the terminal branches of the external carotid, is concealed at its commencement by the parotid gland. It turns horizontally inward behind the neck of the mandible, from the inner side of which it pursues a winding course through the zygomatic fossa to the upper part of the spheno-maxillary fossa, where it ends in the nasal branch. In its course it first passes forward between the pterygoid muscles, then abruptly ascends and turns forward between the internal pterygoid and the temporal muscle, and in advance of this ascends to its termination. The branches of the internal maxillary artery are numerous, and, though mostly small, are important.

The **deep auricular branch**,<sup>7</sup> a small vessel from the commence-

<sup>1</sup> A. auriculares anteriores; a. auric. ant. inferior and a. auric. ant. superior.

<sup>2</sup> A. temporalis media.

<sup>3</sup> A. orbitalis or supraorbitalis; a. supraorbitalis externa; a. zygomatico-orbitalis.

<sup>4</sup> A. temporalis superficialis anterior or frontalis.

<sup>5</sup> A. temp. superf. post. or occipitalis.

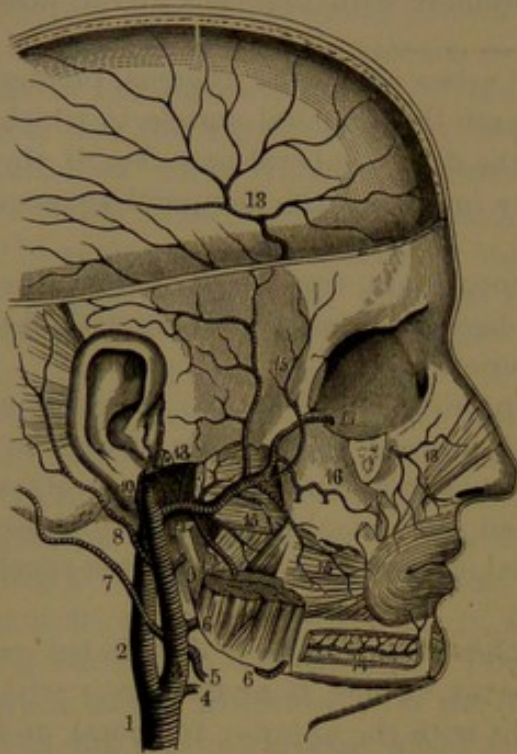
<sup>6</sup> A. maxillaris interna; deep facial artery.

<sup>7</sup> A. auricularis profunda.



ment of the artery, ascends and is distributed to the auditory meatus, extending to the bottom and supplying the tympanic membrane and anastomosing with the tympanic branch of the stylo-mastoid artery.

FIG. 261.



INTERNAL MAXILLARY ARTERY. 1, right common carotid; 2, internal carotid; 3, external carotid; 4, superior thyroid; 5, lingual; 6, facial; 7, occipital; 8, posterior auricular; 9, parotid branch; 10, temporal artery; 11, internal maxillary; 12, tympanic; 13, great meningeal artery; 14, inferior dental artery; 15, muscular branches; 16, superior maxillary artery giving off the posterior dental arteries; 17, 18, infra-orbital artery.

after giving twigs to the trifacial semilunar ganglion is distributed to the dura in the vicinity of the cavernous sinus. Within the cranium the great meningeal artery gives off a little **petrosal branch**,<sup>4</sup> which enters the hiatus of the facial canal and anastomoses with the termination of the stylo-mastoid artery. It further gives fine twigs through the petro-squamous fissure to the tympanum and mastoid sinuses. In its course it gives some little branches of communication through foramina of the great sphenoidal wing to the deep temporal arteries.

The **inferior dental artery**<sup>5</sup> arises about opposite the former, and descends to the dental canal of the mandible, which it traverses in

The **tympanic branch**,<sup>1</sup> frequently arising in common with the former, ascends through the glenoid foramen into the tympanum, in which it is distributed. It sometimes arises from the great meningeal, the inferior dental, or the temporal artery.

The **great meningeal artery**,<sup>2</sup> the largest branch of the maxillary, ascends under the external pterygoid muscle, embraced by the two roots of the auriculo-temporal nerve, and enters the cranium through the sphenoidal spinous foramen. Within the cranium it ascends in the dura and divides into two principal branches, which are distributed in the course of the arborescent channels so conspicuous on the interior of the cranial vault. Before entering the cranium it usually gives off the **small meningeal artery**,<sup>3</sup> sometimes directly derived from the internal maxillary, which enters the cranium through the sphenoidal oval foramen, and

<sup>1</sup> A. tympanica; a. cavi tympani.

<sup>2</sup> A. meningeal magna or media; a. speno-spinosa; middle menin. art.

<sup>3</sup> A. meningeal parva.

<sup>4</sup> Ramus petrosus.

<sup>5</sup> A. dentalis, maxillaris, or alveolaris inferior.



company with the corresponding vein and nerve. Before entering the canal it gives off a **mylo-hyoid branch**,<sup>1</sup> which runs along the inner side of the mandible beneath the mylo-hyoid muscle, to which it is distributed. In its course through the canal it gives off many fine branches, which in part supply the marrow of the bone and the lower gum, and in part ascend through the apertures at the ends of the fangs of the teeth to supply the dental pulps. At the fore part of the canal the artery divides into two terminal branches, of which one supplies the incisor teeth and the other emerges at the mental foramen to be distributed to the chin, where it anastomoses with the inferior labial and submental arteries.

The **muscular branches** usually arise from the middle portion of the artery, and are distributed to the muscles of mastication, including the buccinator. They consist of the **posterior** and **anterior deep temporals**,<sup>2</sup> which ascend beneath the temporal muscle supplying this and anastomosing with the middle temporal artery; the **pterygoids**,<sup>3</sup> short and variable in number, size, and origin, distributed to the pterygoid muscles; the **masseteric**,<sup>4</sup> which passes over the notch of the ramus of the mandible beneath the masseter, which it supplies; and the **buccal branch**,<sup>5</sup> which passes downward and forward to the buccinator and the contiguous mucous membrane, and anastomoses with branches of the facial artery.

The **posterior dental artery**<sup>6</sup> arises from the internal maxillary separately or in common with the succeeding branch, near the back of the maxilla, on which it descends, giving small branches to the gum, and others which traverse the posterior dental canals to supply the molar teeth and maxillary antrum.

The **infraorbital artery**<sup>7</sup> runs through the corresponding canal in company with the superior maxillary nerve, and emerges on the face to end in branches to the muscles of the upper lip and lower eyelid, where they anastomose with branches of the facial, transverse facial, buccal, and ophthalmic arteries. In its course it gives a branch through the sphenomaxillary foramen to the orbit, where it anastomoses with the ophthalmic artery, and is distributed to the inferior muscles and lachrymal gland. In the infraorbital canal it gives off the **anterior dental artery**, which descends through the corresponding canal and its divisions to supply the front teeth and the maxillary antrum.

The **superior palatine artery**<sup>8</sup> descends through the posterior palatine canal in company with the large palatine nerve to the hard palate, to which it is distributed, including the mucous membrane with

<sup>1</sup> A. mylo-hyoidea.

<sup>2</sup> A. temporales profundæ.

<sup>3</sup> A. pterygoideæ.

<sup>4</sup> A. masseterica.

<sup>5</sup> A. buccinatoria or buccalis.

<sup>6</sup> A. dentalis sup.; a. maxillaris or alveolaris sup.; a. supramaxillaris.

<sup>7</sup> A. infraorbitalis.

<sup>8</sup> Descending palatine artery; a. palatina superior or descendens; a. pterygo-palatina.



the gum and the palatine glands. In its course it gives branches through the smaller palatine canals to the soft palate and tonsil, where they anastomose with branches of the inferior palatine artery.

The **vidian artery**,<sup>1</sup> a small vessel, traverses the corresponding canal, in company with the nerve, to the top of the pharynx and the eustachian tube.

The **pterygo-palatine artery**,<sup>2</sup> another little vessel, passes through the corresponding canal to the upper back part of the nasal fossa, the top of the pharynx, and the sphenoidal sinus.

The **nasal artery**,<sup>3</sup> the termination of the internal maxillary, passes through the spheno-palatine foramen into the nasal fossa, and divides into two branches. Of these the **external**<sup>4</sup> is distributed to the outer wall of the nasal fossa, including the turbinals and the ethmoidal and maxillary sinuses. The **internal branch**<sup>5</sup> crosses to the nasal septum, on which it descends obliquely forward supplying it with branches, and ends by passing through the naso-palatine canal to anastomose with the superior palatine artery.

#### THE SUBCLAVIAN ARTERY.

The **subclavian artery**<sup>6</sup> is mainly destined to supply the upper limb, but also supplies part of the brain and spinal cord, and part of the neck and wall of the thorax. Its origin, course, and mode of termination are described on page 482. Its branches are many, and commonly come off in a group immediately before the artery passes between the scaleni muscles, and usually none are given off at or near its commencement, or after it emerges from between the muscles over the first rib.

Four or five principal branches emanate from the subclavian artery: the vertebral artery, the thyroid axis, and the internal mammary, superior intercostal, and deep cervical arteries.

The **vertebral artery**,<sup>7</sup> the largest and most important branch of the subclavian, comes off from the upper back part of this vessel, and passes a little backward and outward to enter the foramen of the costo-transverse process of the sixth cervical vertebra. Thence ascending through the corresponding foramina above, in that of the axis it turns outward, and then upward through that of the atlas, winds backward and inward in the groove behind the prearticular process of the latter, and once more ascends, perforates the dura, and enters the cranium through the occipital foramen. Finally it proceeds forward

<sup>1</sup> A. Vidiania or pterygoidea.

<sup>2</sup> A. pterygo-palatina; a. pharyngea suprema or descendens.

<sup>3</sup> A. nasalis posterior; spheno-palatine artery; a. spheno-palatina.

<sup>4</sup> A. nasalis posterior externa or lateralis.

<sup>5</sup> A. septi narium posterior.

<sup>6</sup> A. subclavia; a. brachio-cephalica.

<sup>7</sup> A. vertebralis.



and upward, turning from the side to the front of the medulla oblongata, and converges to join its fellow at the lower border of the pons, to form the basilar artery. In front of its commencement is the internal jugular vein, and also the vertebral vein, which accompanies it through the costo-transverse processes of the vertebræ and encloses it in a plexus. On the left side the thoracic duct arches in front of it from within outwardly. The cervical nerves, as they issue from the intervertebral foramina, pass behind the artery, but the first one passes beneath it in the groove of the atlas.

Occasionally the vertebral artery, especially that of the left side, arises directly from the aorta. Sometimes one artery is considerably larger than the other, usually the left. Within the cranium, where the arteries converge, they are sometimes curved towards the same side.

The vertebral artery, in its course through the neck, gives off several small **muscular** and **spinal branches**, the former distributed to the contiguous muscles and anastomosing with the ascending and deep cervical and occipital arteries, and the latter passing through the intervertebral foramina, to be distributed to the spinal canal and its contents. Within the cranium, besides small branches to the medulla oblongata, it gives off the posterior meningeal, posterior and anterior spinal, and posterior inferior cerebellar arteries.

The **posterior meningeal artery**,<sup>1</sup> a small branch, is given from the vertebral as this pierces the dura, and is distributed to this membrane in the cerebellar fossa.

The **posterior spinal artery**,<sup>2</sup> a small, flexuose vessel, descends on the medulla oblongata, in the pia, to the back of the spinal cord, along which it continues to the lower end, inosculating in its course with the lateral spinal arteries, which ascend on the roots of the spinal nerves to the cord.

The **anterior spinal artery**,<sup>3</sup> larger than the former, is given from the vertebral near its termination, descends, converging in front of the medulla oblongata, and near the occipital foramen unites with its fellow in a common trunk. This descends in a tortuous manner in front and along the middle of the spinal cord and its terminal filum to the end of the spinal canal, in its course inosculating with the lateral spinal arteries.

The posterior and anterior spinal arteries pursue their course, inosculate with the lateral spinal arteries, and together form a plexus in the pia of the cord before they are distributed directly to the cord itself.

The **posterior inferior cerebellar artery**,<sup>4</sup> the largest branch of the vertebral, but sometimes arising from the basilar artery, turns outward and backward at the side of the medulla oblongata and the fourth

<sup>1</sup> A. meningeal post.

<sup>3</sup> A. spinalis ant.

<sup>2</sup> A. spinalis post.

<sup>4</sup> A. cerebelli inf. post. or magna.



ventricle to the valley of the cerebellum, in which it divides into two branches. Of these, the **internal branch** is mainly distributed to the vermis, anastomosing with its fellow, while the **external branch** is distributed to the inferior part of the hemisphere of the cerebellum. Before division the artery supplies branches to the choroid plexuses of the fourth ventricle.

The **basilar artery**,<sup>1</sup> a single vessel formed by the confluence at an acute angle of the vertebral arteries, lies along the median groove be-

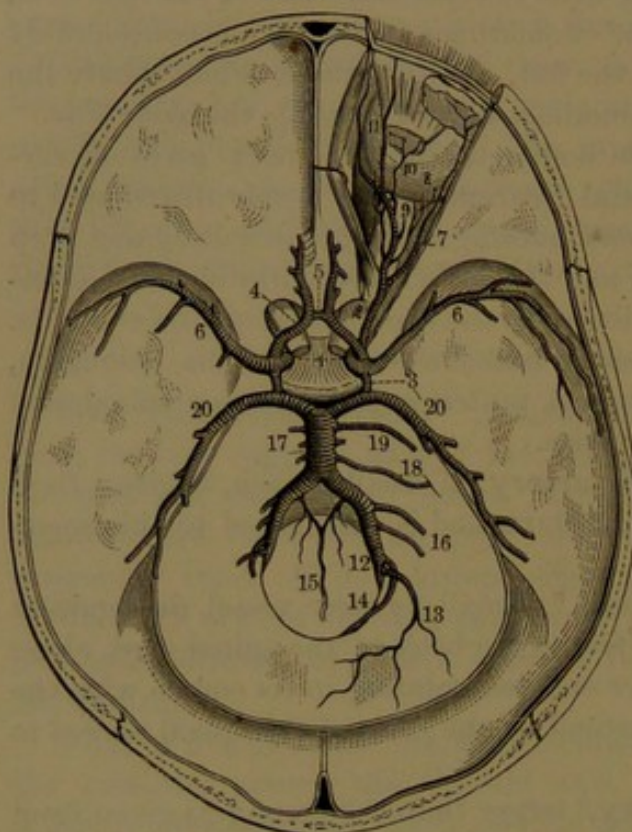
neath the pons, sometimes curved more or less to one side, and divides at the anterior border of the latter into the posterior cerebral arteries. Besides a number of small branches on each side distributed to the pons, it gives off the auditory and the anterior inferior and superior cerebellar arteries.

The **auditory artery**,<sup>2</sup> a small but important vessel, is derived from the basilar or from the anterior inferior cerebellar artery, and accompanies the auditory nerve through the auditory meatus to the labyrinth of the ear, to which it is distributed.

The **anterior inferior cerebellar artery**,<sup>3</sup> varying proportionately in size with its fellow and with the posterior inferior cerebellar artery, arises from the basilar back of the middle, and passes outward and backward to the fore part of the inferior surface of the cerebellum, to which

it is distributed, anastomosing with the posterior inferior cerebellar arteries.

FIG. 262.



ARTERIES OF THE INTERIOR OF THE CRANIUM. 1, internal carotid arteries; 2, ophthalmic artery; 3, posterior communicating arteries; 4, anterior cerebral arteries; 5, anterior communicating artery; 6, middle cerebral arteries; 7, lachrymal; 8, short ciliary arteries piercing the back part of the eyeball; 9, central retinal artery piercing the optic nerve to reach the interior of the eyeball; 10, muscular artery; 11, frontal and nasal artery; 12, vertebral arteries; 13, posterior meningeal artery; 14, posterior spinal artery; 15, anterior spinal arteries conjoining in a single one; 16, inferior cerebellar arteries; 17, basilar artery formed by the union of the vertebrals; 18, internal auditory artery; 19, superior cerebellar artery; 20, posterior cerebral arteries.

<sup>1</sup> A. basilaris; a. meso-cephalica.

<sup>2</sup> Internal auditory artery; a. auditoria interna.

<sup>3</sup> A. cerebelli inf. ant.



The **superior cerebellar artery**<sup>1</sup> arises near the termination of the basilar, and turns outward and backward in the groove between the pons and the cerebral crus to the upper surface of the cerebellum, over which it is distributed.

The **posterior cerebral artery**,<sup>2</sup> formed on each side by the division of the basilar artery, curves outward and backward around the cerebral crus, parallel with the superior cerebellar artery, and proceeds on the under part behind of the cerebral hemisphere to the temporo-sphenoidal and occipital lobes, to which it is mainly distributed. At its commencement it gives off some small branches to the posterior perforated space. As it turns backward it is joined in front by the **posterior communicating artery**, by which it is connected with the internal carotid artery. In its subsequent course, passing near the posterior border of the callosum, it gives one or two small branches, the **posterior choroid arteries**, to the choroid plexus of the lateral ventricle.

The **thyroid axis**<sup>3</sup> is a short, variable trunk, about the fourth of an inch long, arising from the subclavian artery at the inner border of the anterior scalenus muscle, and dividing into branches,—the inferior thyroid, suprascapular, and transverse cervical arteries, or in place of the latter the superficial cervical artery, usually one of its branches. It may arise together with any other branch of the subclavian artery, or any of its branches may arise separately from the latter.

The **inferior thyroid artery**<sup>4</sup> ascends from the thyroid axis in front of the vertebral artery, and turns inwardly behind the sheath of the great cervical vessels and the sympathetic nerve to the thyroid gland, in which it is distributed, anastomosing with the superior thyroid artery and those of the opposite side. As it turns inward behind the sheath of the cervical vessels it gives off the **ascending cervical branch**,<sup>5</sup> passing up along the origin of the anterior scalenus and greater pre-rectus muscles, supplying them with branches, and giving off several **spinal branches**, which enter the adjacent intervertebral foramina. Other branches from the inferior thyroid supply the anterior scalenus and infrahyoid muscles, the contiguous portions of the pharynx and œsophagus, and the larynx and trachea.

The **suprascapular artery**<sup>6</sup> springs from the thyroid axis, and runs outwardly and deeply in the supraclavicular fossa, behind the clavicle, to the upper border of the scapula, over which it descends into the supraspinous fossa, and thence back of the neck of the scapula into

<sup>1</sup> A. cerebelli sup.

<sup>2</sup> A. cerebri post. or profunda.

<sup>3</sup> Arteria thyreo-cervicalis.

<sup>4</sup> A. thyroidea inf.

<sup>5</sup> A. cervicalis adscendens; a. dorsalis suprema.

<sup>6</sup> A. suprascapularis; a. scapularis superior; a. transversa scapulæ; transverse scapular or transverse humeral artery.



the infraspinous fossa, where it terminates by anastomosing with the dorsal and posterior scapular arteries. In its course it crosses the scaleni muscles and brachial plexus of nerves, or sometimes passes through the latter, and gives branches to the sterno-mastoid, subclavian, and other contiguous muscles. Approaching the scapula it is joined by the suprascapular nerve, which passes through the coracoid foramen, while the artery usually passes over it. It also gives off a **supra-acromial branch**, which perforates the insertion of the trapezius muscle, and is distributed on the surface of the acromion, anastomosing with the acromial thoracic artery. In the supraspinous fossa it distributes branches beneath the supraspinatus muscle, and supplies the latter, the scapula, and the shoulder-joint.

The suprascapular artery sometimes arises separately from the subclavian in any lower position, and sometimes from the axillary artery or from its subscapular branch. It is sometimes very small, when it may be compensated by a branch of the posterior scapular artery.

The **transverse cervical artery**<sup>1</sup> springs from the thyroid axis, and proceeds in a tortuous course outward beneath the sterno-mastoid muscle in the supraclavicular fossa, a short distance above the clavicle and the preceding vessel. Crossing over the scaleni muscles and the brachial plexus of nerves, behind the sterno-mastoid muscle, to the edge of the trapezius, it divides into two branches, the superficial cervical and posterior scapular arteries. Sometimes it is very small, and is compensated by a considerable branch arising from the lower part of the subclavian artery and passing outward to near the edge of the trapezius, where it divides into two branches. Of these, one corresponds with the greater portion of the superficial cervical artery, and the other is the posterior scapular artery.

The **superficial cervical artery**<sup>2</sup> ascends beneath the trapezius, and distributes branches to this, the scapular elevator, and splenius muscles, and to the skin, platysma, and contiguous lymphatic glands of the neck.

The **posterior scapular artery**,<sup>3</sup> larger than the preceding, passes backward within the position of the scapular elevator to the upper angle of the scapula, and then descends within the position of the rhomboid muscles to the lower angle of the bone. It anastomoses with the branches of the supra- and subscapular arteries, and supplies branches to the trapezius, supraspinatus, scapular elevator, rhomboid, serrati, and latissimus muscles. It sometimes arises from the subclavian directly, or from the axillary artery, in which case usually the transverse cervical artery is small, and continues as the superficial cervical artery.

<sup>1</sup> A. transversa colli; a. cervico-scapularis.

<sup>2</sup> A. superficialis cervicis.

<sup>3</sup> A. scapularis post.; a. dorsalis scapulæ or descendens.



The **mammary artery**<sup>1</sup> springs from the subclavian below the thyroid axis, inclines forward and inward, and descends behind the costal cartilages, about half an inch from the lateral border of the sternum, to the sixth intercostal space, where it terminates in the musculo-phrenic and superior epigastric artery. At first crossing the innominate vein, with the phrenic nerve descending to its inner side, it lies on the pleura, and subsequently in its descent is placed between the costal cartilages and the internal intercostal muscles in front and the sternal triangular muscle behind. Its numerous branches are as follows:

The **mediastinal arteries**.<sup>2</sup> Small branches to the thymus, lymphatic glands, and pericardium, in the anterior mediastinum.

The **phrenic artery**,<sup>3</sup> a slender vessel accompanying the phrenic nerve to the diaphragm. In its descent it gives twigs to the pericardium and pleura.

The **sternal branches** to the sternum and sternal triangular muscle.

The **perforating arteries**, which pierce the intercostal muscles near the sternum, to be distributed to the contiguous portion of the greater pectoral muscle, the mammary gland, and the skin. In the female, during lactation, those which go to the mammary gland become much enlarged.

The **anterior intercostal arteries**,<sup>4</sup> a pair, or one dividing into a pair, for each of the upper six intercostal spaces, in which they run outwardly along the costal cartilages. First passing between the pleura and the internal intercostal muscle, and then between the latter and the external intercostal muscle, they anastomose with the aortic intercostal arteries. They supply the contiguous portions of the intercostal and pectoral muscles and the skin.

The **musculo-phrenic artery**,<sup>5</sup> the outer terminal branch of the mammary, runs downward and outward behind the asternal costal cartilages to the last intercostal space along the attachment of the diaphragm. It gives branches backward to the latter, and furnishes the **anterior intercostal arteries** to the lower intercostal spaces, in which they are distributed in the manner of the upper ones.

The **superior epigastric artery**,<sup>6</sup> the remaining terminal branch of the mammary, descends between the sternal and costal portions of the diaphragm into the sheath of the abdominal rectus muscle. Continuing downward behind the latter, it enters the muscle, to which it is mainly distributed, and anastomoses freely with the epigastric artery from the external iliac. It supplies branches to the broad abdominal muscles and their tendons, to the integument, and to the diaphragm.

<sup>1</sup> Internal mammary artery; a. mammaria or thoracica interna.

<sup>2</sup> A. mediastinales anteriores, thymicæ, etc.

<sup>3</sup> Superior phrenic artery; a. phrenica sup.; a. pericardiaco-phrenica; comes nervi phrenici.

<sup>4</sup> A. intercostales ant.

<sup>5</sup> A. musculo-phrenica.

<sup>6</sup> A. epigastrica sup.



The **superior intercostal artery**<sup>1</sup> springs from the back of the subclavian artery, curves upward, backward, and outward, and descends in front of the neck of the first rib. After giving off a branch to the first intercostal space it descends in front of the second rib, to be distributed in the second intercostal space. The branches to the intercostal spaces correspond with the aortic intercostal arteries, and have the same manner of distribution. The branch to the second space is frequently joined by a branch from the first of the latter, and is sometimes replaced by it.

The **deep cervical artery**<sup>2</sup> arises from the subclavian, close to the former, or frequently in common with it,<sup>3</sup> passes backward over the neck of the first rib, and ascends the back of the neck between the complexus and semispinalis muscles. It is distributed to the latter and other contiguous muscles, gives off a **spinal branch** or two, and anastomoses with branches of the vertebral and occipital arteries.

**Surgical relation of the subclavian artery.** In this relation the vessel is described in three portions: the *first*, extending from the origin of the artery to the inner border of the anterior scalenus muscle; the *second*, that portion placed behind the latter; and the *third*, that extending from the outer border of the muscle to the outer border of the first rib. The branches of the artery come off, for the most part, from the first portion, close to the anterior scalenus muscle, and partly behind the latter from the second portion. The first portion of the left subclavian artery arising from the aorta is much longer than that of the right artery arising from the innominate, but from the point where the left artery turns outward the two vessels are alike in all respects. The first portion of the artery, from its comparative depth and other circumstances, is difficult of access. The third portion, comparatively superficial and usually free from branches, is most favorably situated for the application of a ligature. After this operation the circulation of the upper limb is restored through anastomosis of the suprascapular, posterior scapular, and subscapular arteries, and also through the intercostals and thoracic branches of the axillary artery.

#### THE AXILLARY ARTERY.

The **axillary artery**<sup>4</sup> is the continuation of the subclavian through the axilla, after passing which the vessel becomes the brachial artery. Emerging from beneath the middle of the clavicle, from which it is separated by the subclavian muscle, it lies along the inner side of the shoulder-joint and upper extremity of the humerus, extending from the outer border of the first rib to the outer border of the axilla. Its direction varies with a change in the position of the upper limb, curving outward and downward in the usual pendent condition of the latter,

<sup>1</sup> A. intercostalis suprema.

<sup>3</sup> A. costo-cervicalis.

<sup>2</sup> A. cervicalis profunda.

<sup>4</sup> A. axillaris.



and passing directly outward when the limb is horizontally extended. In succession it rests on the first intercostal space and great serratus muscle, then the subscapular muscle, and finally the tendons of the latissimus and greater teres muscles. It is at first covered by the subclavian and then by the pectoral muscles. The axillary vein lies to its inner side. The brachial plexus of nerves is first situated above and partly behind it, at the middle surrounds it, and diverges below.

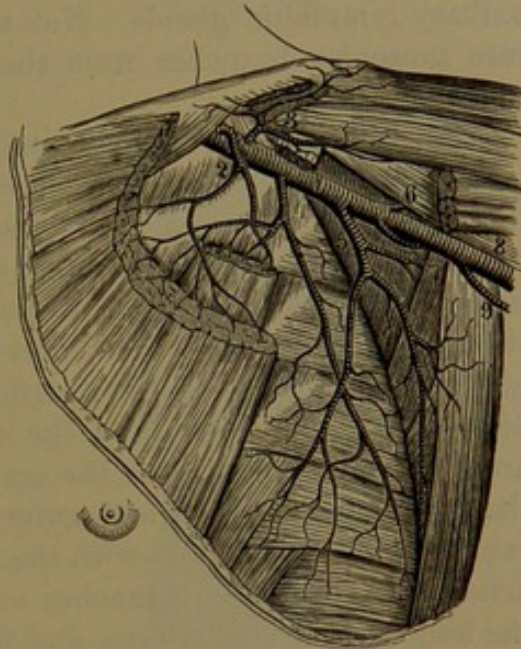
The branches of the axillary artery, very variable in number, origin, and size, commonly consist of three thoracic arteries,<sup>1</sup> the subscapular artery, and two circumflex arteries.

The **superior thoracic artery**,<sup>2</sup> usually a small branch, comes from near the commencement of the axillary and descends forward between the pectoral muscles, to which it is distributed, giving also branches to the contiguous portion of the great serratus muscle, the mammary gland, and the skin.

The **acromial thoracic artery**,<sup>3</sup> succeeding the former, is directed outwardly between the pectoral muscles, to which, the subclavian muscle, and the contiguous portions of the great serratus and deltoid muscles, it is distributed. A slender branch descends in the groove, occupied by the cephalic vein, between the deltoid and pectoral muscles, to which and the adjacent skin it is distributed. The **acromial branch** ascends outwardly beneath the origin of the deltoid muscle, supplying the shoulder-joint and perforating the former to ramify over the surface of the acromion and anastomose with the acromial branch of the suprascapular artery.

The **inferior thoracic artery**<sup>4</sup> descends at the side of the chest along the lower border of the small pectoral muscle and on the great serratus muscle, to which and the greater pectoral muscle it is distributed. It anastomoses with branches of the contiguous intercostal arteries and of the subscapular artery.

FIG. 263.



VIEW OF THE AXILLARY ARTERY; portions of the pectoral and deltoid muscles removed. 1, axillary artery; 2, superior thoracic; 3, acromial thoracic; 4, inferior thoracic; 5, subscapular; 6, anterior circumflex; 7, posterior circumflex; 8, brachial artery; 9, superior profunda artery.

<sup>1</sup> A. thoracicae externae.

<sup>2</sup> A. thoracica suprema, prima, or minor.

<sup>3</sup> A. thoracica acromialis or humeraria.

<sup>4</sup> Long thoracic artery; a. thoracica inferior, longa, or major; a. mammaria externa.



The inferior thoracic artery sometimes comes off in common with the acromial thoracic. Sometimes it is very small or is absent, when it may be substituted by a branch of the subscapular artery.

A branch<sup>1</sup> or several smaller ones from the axillary artery, or from one or several of the above-named thoracic arteries, supply the axillary lymphatic glands. Not unfrequently, also, one or two separate muscular branches from the axillary artery go to the pectoral muscles.

The **subscapular artery**,<sup>2</sup> the largest branch of the axillary, arises near the lower border of the subscapular muscle, on which it descends in a flexuose manner and divides into two branches. Of these the smaller or **descending branch**,<sup>3</sup> continuing in the course of the trunk towards the lower angle of the scapula, proceeds downward between the great serratus and latissimus muscles, to which and the subscapular and teres muscles it is distributed. The larger **dorsal branch**,<sup>4</sup> derived about an inch from the origin of the trunk, turns backward around the outer border of the scapula, between the greater teres and the subscapular muscle, and enters the infraspinous fossa, in which it ramifies and anastomoses with the suprascapular and posterior scapular arteries. It furnishes branches to the subscapular and teres muscles, the long head of the triceps, and the infraspinatus muscles.

The **anterior circumflex artery**,<sup>5</sup> a small branch, arises just below the former, and passes forward between the common head of the biceps and coraco-brachialis muscles and the humerus to the bicipital groove, where it divides into a branch ascending the latter to the shoulder-joint, and another continuing outward to anastomose with the succeeding artery.

The **posterior circumflex artery**,<sup>6</sup> second in size to the subscapular artery, arises below this and passes backward between the teres muscles. Winding around the humerus, between this and the triceps muscle, it breaks up into branches distributed to the deltoid muscle. It also gives branches to the triceps muscle and the skin, and anastomoses with the anterior circumflex, acromial thoracic, and superior profunda arteries.

#### THE BRACHIAL ARTERY.

The **brachial artery**,<sup>7</sup> the continuation of the axillary, extends along the inner part of the arm from the outer border of the axilla to the bend of the elbow, where it terminates by dividing into the radial and ulnar arteries. In the usual position of the upper limb,

<sup>1</sup> Axillary or alar thoracic artery; a. thoracica axillaris or alaris.

<sup>2</sup> A. subscapularis or infrascapularis; a. scapularis inferior or communis.

<sup>3</sup> Ramus descendens, thoracica longa, or thoracica dorsalis.

<sup>4</sup> A. dorsalis scapulæ; a. circumflexa scapulæ.

<sup>5</sup> A. circumflexa anterior.

<sup>6</sup> A. c. posterior.

<sup>7</sup> A. brachialis; a. humeraria.



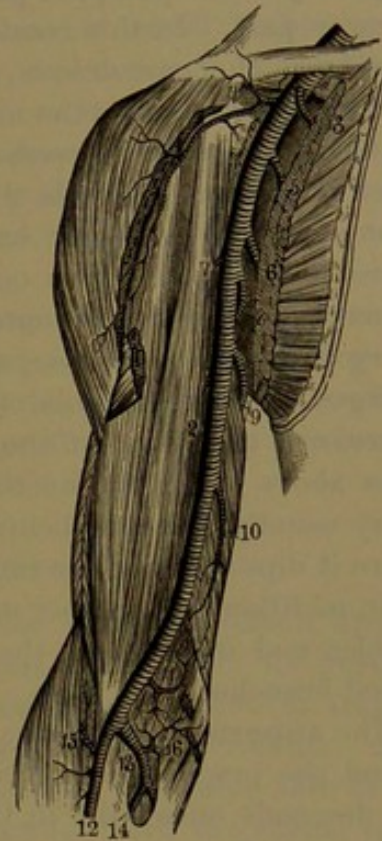
in the descent of the vessel it gradually inclines from the inner side forward to the central depression in front of the elbow. In its course it lies in the groove along the inner border of the coraco-brachialis and biceps muscles, resting above on the triceps and below on the brachialis muscle, and covered by the fasciæ and skin. Approaching its termination, it sinks in the interval between the terete pronator and long supinator muscles, covered by the offset of the biceps tendon to the fascia of the forearm.

The two brachial veins and the median nerve accompany the brachial artery, included in the same sheath. The veins lie at the inner and outer sides of the artery, united here and there by branches crossing the latter. The nerve at first lies to the outer side of the artery, in its descent gradually crosses the vessel, and then lies to the inner side. The basilic vein lies along the inner side of the artery, separated from it below by the deep fascia. The musculo-spiral nerve is behind the artery for a short distance above. The ulnar nerve lies at the inner side to near the middle of the arm, when it gradually diverges to the internal condyle; and the internal cutaneous nerve runs in front and at the inner side to near the same position, when it pierces the fascia to become subcutaneous. The median basilic vein crosses the artery at the bend of the elbow, separated by the offset from the biceps tendon to the fascia of the forearm.

In the extended position of the upper limb horizontally outward from the body, a line from the middle of the clavicle to the depression in front of the elbow indicates the continued course of the axillary and brachial artery.

**Variations of the brachial artery.** Rarely it divides in its course, and the two vessels again reunite approaching the elbow. Occasionally, a long slender vessel arises from the brachial or from the axillary, and descends superficially to join one of the arteries of the

FIG. 264.



VIEW OF THE AXILLARY AND BRACHIAL ARTERY; portions of the pectoral and deltoid muscles removed. 1, axillary artery; 2, brachial artery; 3, superior thoracic artery; 4, acromial thoracic; 5, inferior thoracic; 6, subscapular; 7, anterior circumflex; 8, posterior circumflex; 9, superior profunda, the first branch of the brachial artery; 10, inferior profunda; 11, anastomotica; 12, radial; 13, ulnar; 14, interosseous; 15, radial recurrent; 16, ulnar recurrent artery.



forearm, usually the radial artery. Besides the variations in the origin of the branches arising in the course of the brachial artery above indicated, variations in the origin of the terminal branches are of frequent occurrence. The radial or ulnar artery, or the interosseous artery normally a branch of the latter, may arise at any position of the brachial or may come from the axillary artery. Either arises more frequently from the upper part of the brachial than from the middle or lower part. In this condition there appear to be a pair of brachial arteries, as the two vessels commonly lie close together, and usually the additional vessel is the more superficial. The radial artery is most frequently the abnormal vessel, and the interosseous artery most rarely. When the radial artery is the abnormal one, it usually runs along the inner side of the larger brachial artery to the front of the elbow, where it crosses over or occasionally under the latter vessel to its ordinary position at the outer part of the forearm. When the ulnar artery is the abnormal one, as it descends the arm at the lower part it diverges from the brachial towards the inner part of the elbow, and passes over the origin of the flexors of the forearm, beneath but sometimes above the fascia, to the inner side. The abnormal interosseous artery usually descends behind the brachial to the bend of the elbow, where it dips between the muscles to pursue its usual course.

In addition to a number of variable small branches to the contiguous muscles and integument, the brachial artery gives off the following-named branches:

The **superior profunda artery**,<sup>1</sup> the largest branch, springs from behind the brachial artery below the border of the latissimus muscle, and descends outwardly in the groove at the back of the humerus in company with the musculo-spiral nerve, covered by the triceps muscle. It distributes branches to the heads of the latter, and at the outer part of the humerus, below the insertion of the deltoid muscle, divides into two terminal branches. Of these the smaller continues in company with the musculo-spiral nerve, and descends in the interval of the brachialis and long supinator muscles, to which it gives branches, and anastomoses with the radial recurrent artery. The other and deeper branch descends behind the external intermuscular septum and epicondyle of the humerus, and anastomoses with the posterior interosseous recurrent artery, and across the back of the bone with the inferior profunda and anastomotica.

The **inferior profunda artery**,<sup>2</sup> a very variable and usually much smaller branch than the preceding, arises from near the middle of the brachial artery, and descends in company with the ulnar nerve behind the intermuscular septum on the triceps muscle to the inner epicondyle.

<sup>1</sup> A. profunda superior; a. p. humeri; a. brachialis profunda; a. collateralis magna or externa.

<sup>2</sup> A. p. inferior; a. collateralis ulnaris superior or prima.



It gives branches to the triceps muscle, and anastomoses with the anastomotica artery in front and with the superior profunda and posterior interosseous recurrent arteries across the back of the humerus.

The **medullary nutritious artery**,<sup>1</sup> a small vessel, comes from the brachial, or from one of its muscular branches or the inferior profunda, and traverses the medullary nutritious canal of the humerus to the interior marrow.

The **anastomotica artery**,<sup>2</sup> a constant but small branch, arises from the lower part of the brachial artery, and descends on the brachialis muscle to the internal epicondyle, where it anastomoses in front with the inferior profunda and anterior ulnar recurrent arteries, and behind with the superior profunda and posterior interosseous recurrent arteries. It gives branches to the brachialis and terete pronator muscles and to the elbow-joint.

The superior profunda artery sometimes arises directly from the axillary, and sometimes it is derived from a common trunk, together with the subscapular and circumflex arteries. The inferior profunda not unfrequently arises from the superior profunda; and in like manner the anastomotica frequently springs from the former.

#### RADIAL ARTERY.

The **radial artery**,<sup>3</sup> somewhat smaller than the ulnar, appears more like the continuation of the brachial artery, from its pursuing the same direction, in a line from the central depression in front of the elbow to the front of the styloid process of the radius. More superficial than the ulnar artery, it occupies the outer side of the front of the forearm, in a straight line parallel with the radius to the wrist, where it turns back around the outer part of the carpus, and descends to the upper angle of the first interosseous space. Here it penetrates to the palm of the hand, and curves inward to join the deep communicating branch of the ulnar artery, and thus form the **deep palmar arch**.<sup>4</sup> In its course in front of the forearm, with its pair of companion veins, it rests in succession on the short supinator, the insertion of the terete pronator, the radial origin of the superficial digital flexor, the long pollical flexor, the quadrate pronator, and the lower extremity of the radius. To its outer side is the long supinator, the inner edge of which covers it above, while it is covered below by the fasciæ and skin only. To its inner side are the terete pronator and long palmar muscles. Along the middle of its course outwardly it is accompanied by the radial nerve. Below the styloid process of the radius the artery passes backward around the carpus, beneath the extensor tendons of the thumb, and, reaching the first interosseous

<sup>1</sup> A. nutritia humeri.

<sup>2</sup> A. anastomotica; a. collateralis interna; a. c. ulnaris inferior or secunda.

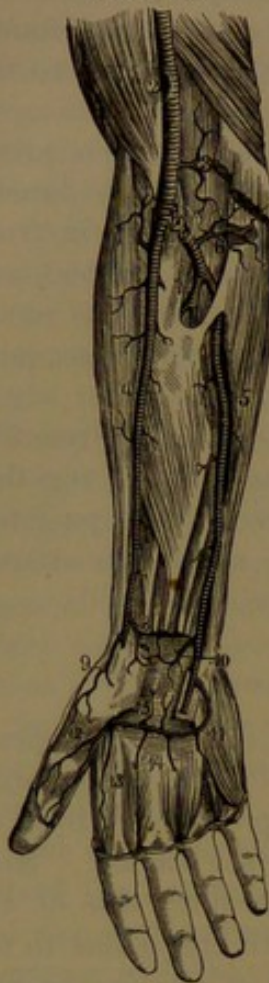
<sup>3</sup> A. radialis.

<sup>4</sup> Arcus palmaris profundus; a. volaris prof.



space, penetrates between the heads of the interosseous muscle to the palm of the hand. The deep palmar arch rests on the metacarpal bones and interosseous muscles, beneath the flexor tendons of the fingers; it is situated nearer the carpus than the superficial arch, and is also of more uniform diameter.

FIG. 265.



ARTERIES OF THE FOREARM.  
2, brachial artery; 3, anastomotic artery; 4, radial artery; 5, ulnar artery; 6, ulnar recurrent; 7, interosseous; 8, anterior carpal; 9, volar artery; 10, anterior carpal branch of the ulnar; 11, superficial palmar arch; 12, digital artery of the thumb; 13, radial digital artery of the index finger; 14, digital arteries; 15, recurrent branches.

The branches of the radial artery and its continuation the deep palmar arch, in addition to small and variable **muscular** and **cutaneous branches** to the contiguous muscles and skin, are as described below.

The **radial recurrent artery**,<sup>1</sup> of variable size, arises near the origin of the radial artery, and is directed outward and upward between the long supinator and brachialis muscles, to which it gives branches, and anastomoses with the superior profunda artery. It also gives branches outward and downward to the long supinator and radio-carpal extensors, and beneath them anastomoses with the interosseous recurrent artery.

The radial recurrent artery is sometimes much enlarged, and not unfrequently is represented by several branches. It is sometimes derived from the brachial, especially when the radial artery rises high up from the latter, or less commonly it comes from the ulnar, or rarely from the interosseous artery.

The **anterior carpal artery**,<sup>2</sup> a little branch from the radial below the quadratus pronator, proceeds inward beneath the flexor tendons to the front of the carpus, where it anastomoses with a similar branch of the ulnar artery to form the **anterior carpal arch**.<sup>3</sup> The arch also anastomoses with the communicating branch of the anterior interosseous artery of the forearm and with the recurrent branches of the deep palmar arch,

and forms a fine net-work of vessels supplying the contiguous articulations.

The **volar artery**,<sup>4</sup> usually a small branch, arises from the radial

<sup>1</sup> A. radialis recurrens.

<sup>2</sup> A. carpea anterior; a. radio-carpalis ant.; a. carpea volaris; a. transversa carpi anterior.

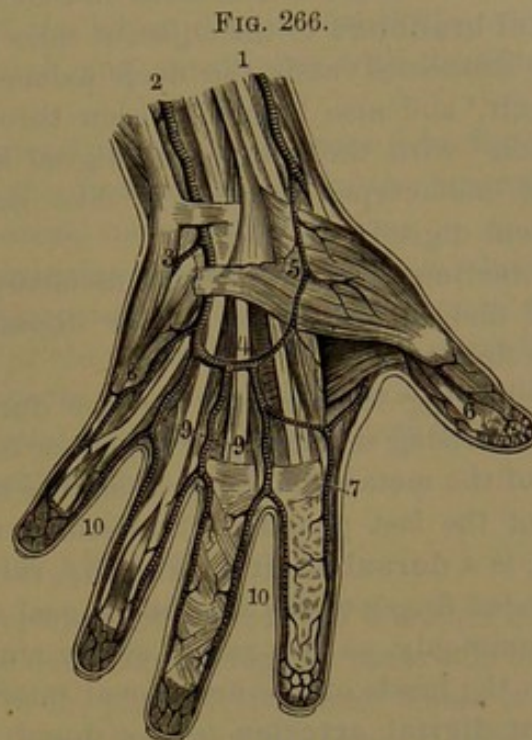
<sup>3</sup> Rete carpeum anterius or volare.

<sup>4</sup> Ramus volaris; superficial volar artery; a. superficialis volæ; a. radio-palmaris.



near where this turns to the back of the wrist, and descends subcutaneously to the ball of the thumb, to the muscles and skin of which it distributes branches, and in the palm of the hand anastomoses with the termination of the ulnar artery to form the **superficial palmar arch**.<sup>1</sup>

The volar artery may be distributed to the ball of the thumb alone, and take no part in the superficial palmar arch. Sometimes it rises much higher, and may be much enlarged, so as to appear like one of the terminal divisions of the radial artery, in which case it usually supplies the digital arteries to the thumb and contiguous side of the index finger, and does not contribute to form the superficial palmar arch.



ARTERIES OF THE HAND; PALMAR SURFACE. 1, radial artery; 2, ulnar; 3, communicating branch with the deep palmar arch; 4, superficial palmar arch; 5, volar artery; 6, digital arteries of the thumb; 7, radial digital artery of the index finger; 8, digital artery to the little finger; 9, common digital arteries; 10, digitals to the fingers.

The **posterior carpal artery**,<sup>2</sup> a small branch, arises from the radial, beneath the extensor tendons of the thumb, and proceeds to the carpus, where it anastomoses with the corresponding branch of the ulnar artery to form the **posterior carpal arch**. This also anastomoses above with the termination of the anterior interosseous artery of the forearm, supplies the contiguous articulations, and gives off below two **dorsal metacarpal arteries**,<sup>3</sup> the second and third of the series of these vessels. Joined each at their commencement by a short **communicating branch**<sup>4</sup> from the deep palmar arch, they descend on the inner two dorsal interosseous muscles to the cleft of the fingers, where they divide each into a pair of **dorsal digital branches**. These run along the adjoining sides of the middle, ring, and little fingers, to the first phalangeal articulation, and anastomose with branches of the adjacent palmar digital arteries.

<sup>1</sup> Arcus palmaris superficialis.

<sup>2</sup> A. carpea posterior or dorsalis; a. transversa carpi dorsalis; posterior radio-carpal artery.

<sup>3</sup> A. metacarpæ dorsales; a. interossee dorsales; second and third dorsal interosseous arteries.

<sup>4</sup> Ramus interossea perforans; perforating artery.



Succeeding the posterior carpal artery, but often arising in common with it, is the **first dorsal metacarpal artery**,<sup>1</sup> which proceeds on the second dorsal interosseous muscle, and ends in a pair of **dorsal digital branches** to the adjacent sides of the middle and index finger. It is connected with the deep palmar arch by a **communicating branch**,<sup>2</sup> and also before division through another **communicating branch**<sup>3</sup> with the contiguous digital artery. Occasionally the other dorsal metacarpal arteries in like manner communicate with the adjacent digitals.

Sometimes the first dorsal metacarpal artery is much larger than usual, and furnishes the palmar digital branches of the middle and index fingers.

Following these vessels are the **dorsal digital branches**<sup>4</sup> of the thumb, arising separately or together from the radial artery, near the base of the metacarpal bone, along the back of which they run on each side of the last phalanx. Succeeding these, or arising together with them, is a **dorsal digital branch**,<sup>5</sup> running along the radial side of the index finger to the first phalangeal articulation.

Commonly, as the radial artery enters the palm of the hand, between the heads of the first dorsal interosseous muscle, it gives off the palmar **digital arteries** to the thumb and adjacent side of the index finger.

The **digital artery**<sup>6</sup> of the thumb descends in front of the first dorsal interosseous muscle, between the metacarpal bone of the thumb and the muscles covering it, to the interval of the short pollical flexor, and divides under the tendon of the long pollical flexor into two branches, which run along the sides of the thumb.

The **digital artery**<sup>7</sup> of the index finger arises from the radial, close to the former, or in common with it, proceeds between the first dorsal interosseous and pollical adductor muscles, and continues along the radial side of the index finger. Frequently it arises in common with the inner branch of the digital artery of the thumb.

Occasionally the digital artery of the thumb arises from the radial before it enters the palm of the hand, in which case it descends behind the first dorsal interosseous muscle to the interval of the thumb and index finger, where it may end in the two branches to the thumb, or, in addition, give off the contiguous digital artery of the index finger.

Sometimes the radial artery appears to divide at the back of the wrist into two branches, of which the outer passes in the usual manner between the heads of the first dorsal interosseous muscle to the palm

<sup>1</sup> First dorsal interosseous artery.

<sup>2</sup> First perforating artery.

<sup>3</sup> Inferior perforating artery.

<sup>4</sup> Dorsal arteries of the thumb; a. dorsales pollicis.

<sup>5</sup> Dorsal artery of the index finger; a. dorsalis indicis.

<sup>6</sup> Principal or large artery; a. pollicis princeps or magna.

<sup>7</sup> Radial branch; a. radialis indicis; a. volaris indicis radialis.



of the hand, and terminates in the digitals of the thumb and contiguous side of the index finger, while the other branch pursues the usual course of the first perforating artery, and continues as the deep palmar arch.

The **recurrent branches** of the latter, four or five little arteries, ascend from the deep palmar arch, and anastomose with the anterior carpal arch.

The **communicating arteries**,<sup>1</sup> usually three, pass from the deep palmar arch backward through the upper extremity of the inner three interosseous spaces, to join the dorsal metacarpal arteries.

The **palmar metacarpal arteries**,<sup>2</sup> usually three, from the deep palmar arch, descend on the interosseous muscles of the inner three spaces, which they supply, and at the clefts of the fingers anastomose with the digital arteries. Sometimes they are unusually enlarged, and in a measure substitute the digital arteries of the superficial palmar arch, which are then proportionately small.

#### ULNAR ARTERY.

The **ulnar artery**,<sup>3</sup> the larger of the two terminal branches of the brachial artery, runs inward and downward along the inner side of the front of the forearm and wrist to the palm of the hand, where it ends in the superficial palmar arch. From its commencement it passes inward and downward, resting on the insertion of the brachialis muscle, under cover of the muscles arising from the inner epicondyle of the humerus, and then descends the forearm, resting on the deep digital flexor, with the ulno-carpal flexor to the inner side, and the superficial digital flexor covering it. Near the wrist it rests on the quadratus pronator, with the tendons of the digital flexors to the radial side, and the tendon of the ulno-carpal flexor to the inner side, covered by the fascia and skin. At the wrist it passes over the anterior annular ligament, guarded inwardly by the pisiform bone, and covered by the superficial palmar muscle. Entering the palm of the hand, it arches outwardly, and anastomoses with the volar branch of the radial artery to form the **superficial palmar arch**, which rests on the flexor tendons, just below the annular ligament, covered by the palmar fascia. The ulnar artery is accompanied by a pair of veins, and in the lower two-thirds of its course by the ulnar nerve, which at the wrist intervenes between the vessels and the pisiform bone. Near its commencement the artery is crossed by the median nerve, separated from it by a slip of the terete pronator muscle.

The branches of the ulnar artery including the superficial palmar arch, besides a variable number of small **muscular** branches to the

<sup>1</sup> Perforating arteries; a. perforantes; r. interosseæ perforantes; superior perforating branches.

<sup>2</sup> A. metacarpeæ or interosseæ volares; palmar interosseous arteries.

<sup>3</sup> A. ulnaris or cubitalis.



contiguous muscles, give off the ulnar recurrent, interosseous, posterior and anterior carpal, deep communicating, and digital arteries.

The **ulnar recurrent artery**,<sup>1</sup> a considerable branch from near the commencement of the ulnar artery, turns inward beneath the muscles arising from the inner epicondyle of the humerus, and divides into two branches. Of these, the **anterior branch**<sup>2</sup> ascends on the brachialis muscle, and anastomoses with the anastomotica artery. The **posterior branch**<sup>3</sup> turns backward, and ascends in company with the ulnar nerve between the olecranon and inner epicondyle, and the two heads of the ulno-carpal flexor, and anastomoses with the inferior profunda, anastomotica, and interosseous recurrent arteries. The branches are distributed to the muscles arising from the internal epicondyle, the brachialis, ulno-carpal flexor, insertion of the triceps, the articulation of the elbow, and the contiguous skin. Frequently the two principal branches arise separately from the ulnar artery, and occasionally one or both together arise from the brachial artery, or from the succeeding branch.

The **interosseous artery**,<sup>4</sup> the largest branch, arises from the ulnar artery, below the bicipital tuberosity of the radius, and after a short course backward divides into two nearly equal branches. Of these, the **anterior interosseous artery**<sup>5</sup> descends in front of the interosseous membrane, between the deep digital and long pollical flexors, to the quadrate pronator, above which it perforates the membrane, and descends behind this to the back of the carpus, where it anastomoses with the posterior carpal arteries. Near its commencement it gives off the **median artery**, usually a long, slender branch, accompanying the median nerve. In its course it gives **muscular branches** to the contiguous muscles and the **medullary nutritious arteries**, which enter the corresponding canals of the radius and ulna. As it is about to perforate the interosseous membrane it gives off the **communicating branch**, which descends beneath the quadrate pronator to the front of the carpus, where it anastomoses with the anterior carpal arteries.

The **posterior interosseous artery**<sup>6</sup> passes backward through the aperture above the interosseous membrane, and, appearing behind and between the short supinator and first pollical extensor, descends the back of the forearm, between the superficial digital and the pollical and indicial extensors, to the back of the carpus, where it anastomoses with the anterior interosseous and posterior carpal arteries. Besides muscular **branches** to the contiguous muscles in its course, near its origin it gives off the **interosseous recurrent branch**,<sup>7</sup> which ascends beneath the anconeus, between the olecranon and outer epicon-

<sup>1</sup> A. ulnaris recurrens.

<sup>2</sup> Anterior ulnar recurrent artery.

<sup>3</sup> Posterior ulnar recurrent artery.

<sup>4</sup> A. interossea.

<sup>5</sup> A. interossea anterior or interna.

<sup>6</sup> A. interossea posterior, externa, or perforans suprema.

<sup>7</sup> Posterior interosseous recurrent artery; a. interossea recurrens.

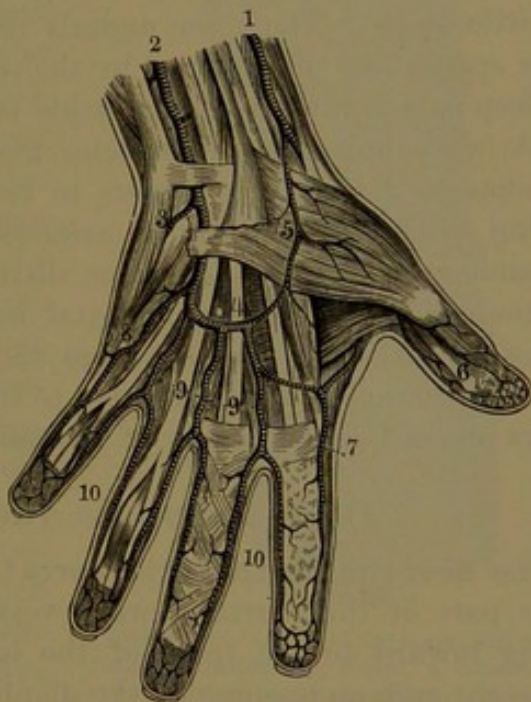


dyle, where it anastomoses with the superior profunda and the ulnar and radial recurrent arteries.

Sometimes the interosseous artery is a branch of the brachial, and rarely of the radial. When the ulnar artery arises above its usual position from the brachial, this then divides into the radial and interosseous arteries. The anterior and posterior interosseous arteries may arise separately from the ulnar artery. Occasionally the anterior interosseous artery is of larger size, and through its enlarged median or anterior communicating branch may join the superficial arch, and in a measure substitute the ulnar or radial artery in the supply of the hand. Sometimes in this enlarged condition it gives off a transverse branch, which joins the radial, or more rarely the ulnar artery.

The **posterior carpal artery**,<sup>1</sup> variable in size and exact position, arises from the ulnar artery above the wrist, and winds around the ulna under the tendon of the ulno-carpal flexor, and proceeds beneath the extensor tendons to the back of the carpus, where it anastomoses with the posterior carpal branch of the radial artery to form the posterior carpal arch. From the same artery, or sometimes directly from the ulnar, a small **dorsal digital branch**<sup>2</sup> runs along the inner border behind of the metacarpal bone and first phalanx of the little finger. The **posterior carpal arch** anastomoses with terminal branches of the anterior interosseous artery, and gives off below two **dorsal metacarpal arteries**,<sup>3</sup> which

FIG. 267.



ARTERIES OF THE HAND; PALMAR SURFACE. 1, radial artery; 2, ulnar; 3, communicating branch with the deep palmar arch; 4, superficial palmar arch; 5, volar artery; 6, digital arteries of the thumb; 7, radial digital artery of the index finger; 8, digital artery to the little finger; 9, common digital arteries; 10, digitals to the fingers.

are joined by two short **communicating branches**,<sup>4</sup> proceeding from the deep palmar arch. The dorsal metacarpal arteries then descend on the inner two dorsal interosseous muscles to the clefts of the corresponding fingers, and divide each into a pair of **dorsal digital**

<sup>1</sup> A. carpea dorsalis; a. dorsalis; post. ulno-carpal artery.

<sup>2</sup> Metacarpal branch; a. digitalis dorsalis.

<sup>3</sup> Second and third dorsal interosseous arteries.

<sup>4</sup> Perforating arteries.



**branches**, which run along the contiguous borders of the first phalanges to the first phalangeal articulation, where they anastomose with branches of the palmar digital arteries.

Near the pisiform bone a little branch, or two, the **anterior carpal artery**,<sup>1</sup> proceeds from the ulnar artery beneath the flexor tendons to the front of the carpus, and anastomoses with a similar branch of the radial artery.

The deep **communicating artery**<sup>2</sup> comes from the ulnar artery below the pisiform bone, and dips between the abductor and short flexor of the little finger into the palm of the hand, where it joins the termination of the radial artery to form the deep palmar arch. It distributes branches to the muscles of the little finger.

The **digital arteries**,<sup>3</sup> usually four from the superficial palmar arch, diverge in the intervals of the flexor tendons, resting on the lumbrical muscles and digital nerves. The innermost digital artery proceeds to the inner side of the palm, and continues to the end of the little finger. The other digitals reaching the ends of the interosseous spaces are there joined by the palmar metacarpal arteries from the deep palmar arch, and then divide each into two **digital branches**, which, with their companion veins and the digital nerves, run along the adjacent sides of the fingers to their tips. In all the fingers, including the thumb, the digital arteries pursue the same course, have the same relations, and the same distribution. In their course they anastomose with the dorsal digital branches, and about the middle of the last phalanx they converge and unite in an arch from which numerous branches are distributed to the tip of the finger, while many others proceed to the matrix of the nail.

#### THE DESCENDING THORACIC AORTA.

The **descending thoracic aorta**<sup>4</sup> extends from the arch at the lower part of the fourth thoracic vertebra on the left, gradually inclining inward to the front of the last thoracic vertebra, where it passes through an opening of the diaphragm, subsequently to continue as the abdominal aorta. It lies in the posterior mediastinum, covered in front by the pericardium and the pleura of the root of the left lung. To its right above is the œsophagus, which gradually obtains a position in front below, and then to the left at its termination. The thoracic duct and azygos vein are also situated to the right. In its course it gives off numerous but small branches, so that its diameter is nearly uniform.

<sup>1</sup> Anterior ulno-carpal artery.

<sup>2</sup> Deep branch of the ulnar artery; ramus communicans profundus.

<sup>3</sup> A. digitales communes or volares.

<sup>4</sup> A. thoracica descendens; a. thoracica.



## BRANCHES OF THE DESCENDING THORACIC AORTA.

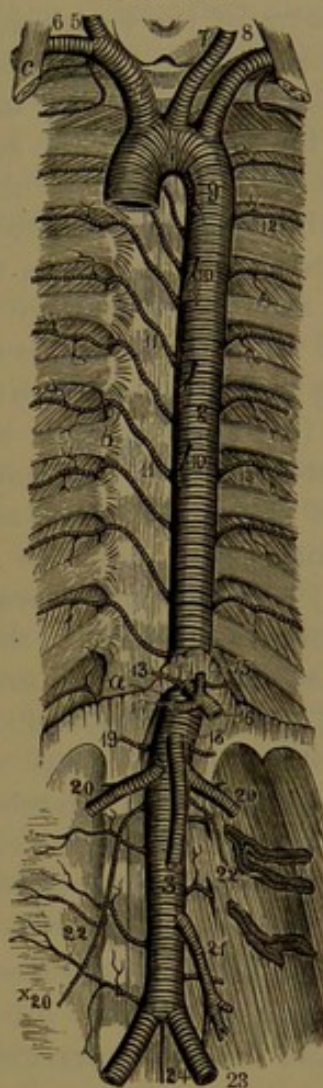
These consist of small vessels, the bronchial, œsophageal, and mediastinal arteries; and larger ones to the walls of the thorax, the intercostal arteries.

The **bronchial arteries**,<sup>1</sup> very variable in number and mode of origin, commonly consist of one for each side, though frequently there are three, of which usually one is to the right and the others are to the left; and they may arise separately or together. The **right bronchial artery** arises from the aorta or from the first aortic intercostal artery, and proceeds along the back of the right bronchus to the root of the lung. The **left bronchial artery** also arises from the aorta directly or in common with the right, and proceeds in the same manner to the left lung. When there is a second left bronchial artery it usually arises lower and separately from the aorta. Entering the lungs, the bronchial arteries ramify in company with the bronchial tubes, to the tissues of which they are chiefly distributed. Before entering the lungs they give branches to the bronchial lymphatic glands, the œsophagus, the pericardium, and the pleura.

The **œsophageal arteries**,<sup>2</sup> also variable, commonly consist of three or four little branches, which arise from the fore part of the aorta and proceed to be distributed to the œsophagus.

The **mediastinal arteries**<sup>3</sup> are the smallest branches from the aorta, to the lymphatic glands, peri-

FIG. 268.



THE AORTA. 1, arch of the aorta; 2, thoracic aorta; 3, abdominal aorta; 4, innominate artery; 5, right common carotid; 6, right subclavian; 7, left common carotid; 8, left subclavian; 9, bronchial artery, a small branch of the aorta; 10, œsophageal arteries; 11, intercostal arteries of the right side; 12, of the left side; 13, phrenic arteries; 14, coeliac axis; 15, gastric artery; 16, splenic artery; 17, hepatic artery; 18, superior mesenteric artery; 19, suprarenal arteries; 20, renal arteries; x20, spermatic artery; 21, inferior mesenteric artery; 22, lumbar arteries; 23, common iliac arteries; 24, middle sacral artery. a, aortic orifice of the diaphragm; b, articulation of the head of the ribs; c, anterior scalene muscle.

<sup>1</sup> A. bronchiales or bronchicæ.

<sup>2</sup> A. œsophageæ.

<sup>3</sup> A. mediastinales posteriores, a. pericardiaci, and a. phrenicæ superiores.



cardium, and pleura, the wall of the aorta itself, and the crura of the diaphragm.

The **intercostal arteries**,<sup>1</sup> of which there are nine pairs, arise from the back of the aorta directed a little upward and outward on the centra of the vertebræ, and then run outward in the lower nine intercostal spaces, the upper two of these being supplied in the same manner by the superior intercostal branch of the subclavian artery. From the position of the aorta on the left of the spine the right intercostals are longer than the left, and cross in front of the vertebræ behind the œsophagus, thoracic duct, and azygos vein. On both sides the intercostal arteries in their course are crossed by the sympathetic nerve, and are covered by the pleura. In the intercostal spaces they ascend obliquely to the lower border of the rib above near the angle, resting on the external intercostal muscle covered by the pleura, and divide into two branches, which continue forward between the external and internal intercostal muscles. The **superior branch**, a continuation of the main trunk, runs along the subcostal groove, while the **inferior branch** descends and runs along the upper border of the rib below; both branches terminating by anastomosis with the anterior intercostal branches of the mammary and musculo-phrenic arteries. Each aortic intercostal artery, besides the companion vein, is accompanied by the corresponding nerve, which is placed below the artery, while the vein is above it.

The first aortic intercostal artery anastomoses with the superior intercostal of the subclavian artery, and the lower two intercostal arteries run into the abdominal wall and anastomose with the epigastric artery.

The intercostal arteries in their course distribute branches to the intercostal muscles and others contiguous to them, to the pleura, to the skin, and the mammary gland, and anastomose with thoracic branches of the axillary artery. From each intercostal artery, before turning outward in the intercostal space, a **dorsal branch**<sup>2</sup> runs backward between the transverse processes of the vertebræ to the muscles of the back, and divides into two branches. Of these the **internal branch** passes towards the spinous processes between the multifidus and semispinalis, to which and other contiguous muscles and the skin it is distributed. The **external branch** passes between the longissimus and ilio-costalis, to which and other muscles and the skin it is likewise distributed.

From the dorsal branch of the intercostal arteries emanates a **spinal branch**,<sup>3</sup> which enters the adjacent intervertebral foramen to be distributed to the spinal canal and cord.

Besides the **anterior** and **posterior spinal branches** given off

<sup>1</sup> A. intercostales aorticæ or inferiores.

<sup>2</sup> Ramus dorsalis or posterior.

<sup>3</sup> R. spinalis or vertebralis.



within the cranium by the vertebral arteries, the spinal cord and its membranes, together with the spinal canal, are supplied with **spinal branches**, along the vertebral column, derived from the neighboring arteries of the different regions; in the neck from the vertebral and the ascending and deep cervical arteries, in the thorax from the dorsal branches of the intercostal arteries, in the loin from the dorsal branches of the lumbar and ilio-lumbar arteries, and in the pelvis from the lateral sacral arteries. These spinal branches have the same mode of distribution, and generally each consists of a short stem, which divides into two or three branches, the entovertebral, meningeal, and lateral spinal.

The **entovertebral branch**<sup>1</sup> is distributed to the parietes of the spinal canal, the vertebræ, and ligaments, and anastomoses with the corresponding branches above, below, and laterally, forming together, around the canal, a plexus of fine vessels.

The **meningeal branch**,<sup>2</sup> the smallest and usually arising with the former, is distributed to the dural sheath of the cord and the surrounding areolar and adipose tissue.

The **lateral spinal branch**,<sup>3</sup> arising separately or with one of the preceding branches, enters the dural sheath of the cord on the roots of the spinal nerves, and ascends with them to the pia of the spinal cord, in which it is distributed. Like the roots of the spinal nerves, the lateral spinal arteries become successively longer, and on the cauda equina they appear as slender, thread-like vessels ascending vertically on the nerves of the latter. In the pia of the cord they inosculate, in front and behind the latter, with the anterior and posterior spinal branches of the vertebral arteries, and incessantly reinforce them in their course.

#### THE ABDOMINAL AORTA.

The **abdominal aorta**<sup>4</sup> is situated in the abdomen on the centre of the lumbar vertebræ to the left of the median line, extending from the thoracic aorta at the opening of the diaphragm in front of the last thoracic vertebra to the middle or lower part of the fourth lumbar vertebra, where it forks into the common iliac arteries. It is covered in front by the pancreas, duodenum, and root of the mesentery, and to its right is the inferior cava, with the right crus of the diaphragm intervening above. It gives off many branches, of which the largest arise near together at the commencement, after which the vessel exhibits a marked reduction in diameter.

<sup>1</sup> Ramus vertebralis.

<sup>3</sup> R. spinalis lateralis.

<sup>2</sup> R. meningeus.

<sup>4</sup> A. abdominalis.



## BRANCHES OF THE ABDOMINAL AORTA.

Of the branches of the abdominal aorta three are single vessels arising from its fore part, the cœliac, and the superior and inferior mesenteric arteries, distributed to the stomach, intestines, liver, pancreas, and spleen; others in pairs are the suprarenal, renal, and spermatic or ovarian arteries, to the suprarenal bodies, kidneys, and testicles or ovaries, and the phrenic and lumbar arteries, to the diaphragm and lateral walls of the abdomen. A single terminal branch, the **middle sacral artery**,<sup>1</sup> is a small vessel which springs from behind the aorta immediately above the bifurcation into the common iliac arteries. It descends in front of the last lumbar vertebra, and along the middle of the sacrum and coccyx to the end. In its course it gives off small lateral branches, which anastomose with the lateral sacral arteries and others which proceed to the rectum, where they anastomose with the hemorrhoidal arteries.

The middle sacral artery is actually the continuation of the aorta, and in all vertebrate animals is proportioned in volume to the degree of development of the tail. In fishes, snakes, and cetaceans the aorta gradually tapers to the end of the tail, with no appearance of division into iliac arteries. In animals with hind limbs the iliacs are developed proportionately to their size, and if the limbs are large and the tail small or rudimental, as in man and the higher apes, the iliacs appear as the bifurcation of the aorta, with the rudimental remainder as a middle sacral artery.

The **cœliac artery**, or **axis**,<sup>2</sup> is a short trunk, commonly not over half an inch long, arising from the front of the aorta opposite the last thoracic vertebra, directed forward and dividing into three divergent branches, the gastric, hepatic, and splenic arteries. It is immediately above the pancreas, and has the semilunar ganglion of the sympathetic nerve on each side. It is sometimes longer than usual, in which case commonly one of the branches has a separate origin.

The **gastric artery**,<sup>3</sup> ordinarily the smallest branch of the cœliac axis, ascends to the left to reach the right of the cardiac orifice of the stomach, whence it turns to the right along the small curvature, in the small omentum, and inosculates with the pyloric branch of the hepatic artery. It gives off **œsophageal branches**,<sup>4</sup> which are distributed to the œsophagus, and anastomose with those from the aorta; and in its further course is distributed in branches to the fundus, anterior and posterior surfaces of the stomach, where they anastomose with those from the arterial arch along the greater curvature. The gastric artery

<sup>1</sup> A. sacralis; a. sacra media or anterior.

<sup>2</sup> A. cœliaca; a. opisto-gastrica; tripod of Haller; tripus Halleri.

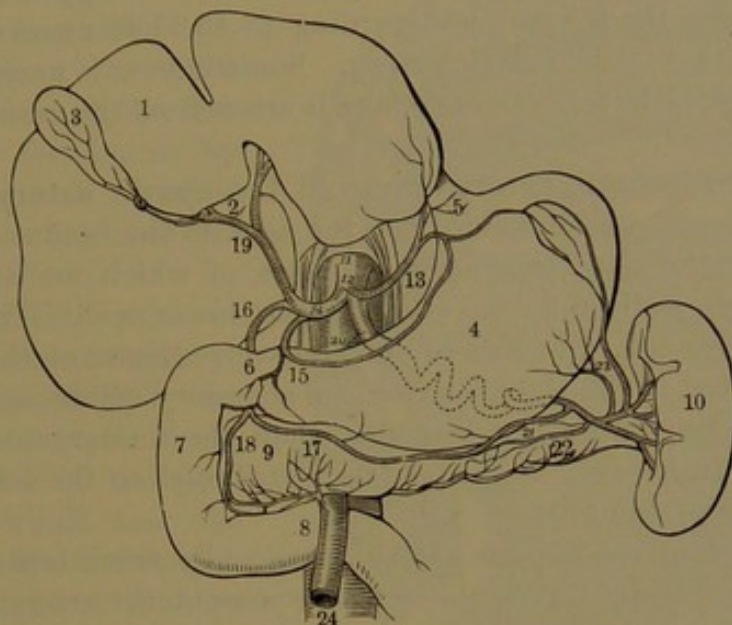
<sup>3</sup> Coronary artery; a. gastrica or coronaria, a. g. major, superior, or sinistra superior; a. coronaria ventriculi.

<sup>4</sup> Rami œsophagei inferiores.



sometimes arises directly from the aorta. Occasionally it gives a branch to the left lobe of the liver, which is sometimes large enough to replace the usual branch from the hepatic artery.

FIG. 269.



DISTRIBUTION OF THE CELIAC ARTERY. 1, liver turned upward, and showing its lower surface; 2, transverse fissure; 3, gall-bladder; 4, stomach; 5, œsophagus; 6, 7, 8, duodenum; 9, pancreas; 10, spleen; 11, aorta; 12, celiac artery; 13, gastric artery; 14, hepatic artery; 15, pyloric artery; 16, gastro-duodenal artery; 17, right gastro-epiploic artery; 18, pancreatico-duodenal artery; 19, hepatic artery dividing into the right and left branches for the liver; 20, splenic artery; its course indicated behind the stomach by dotted lines; 21, left gastro-epiploic artery; 22, pancreatic branch; 23, gastric branches; 24, superior mesenteric artery, emerging from between the pancreas and the duodenum.

The **hepatic artery**<sup>1</sup> in the infant is the largest branch of the celiac axis, but is the second in size at maturity. Directed transversely to the right, it passes over the pancreas to the pylorus, and divides into the gastro-duodenal and hepatic branches, nearly equal in size. The **gastro-duodenal branch**<sup>2</sup> descends behind the pylorus between the duodenum and head of the pancreas, gives off the **superior pancreatico-duodenal artery**,<sup>3</sup> and then continues as the right gastro-epiploic artery. The former is a small branch which descends between the head of the pancreas and the duodenum, supplying them both, and anastomosing with the inferior pancreatico-duodenal branch of the superior mesenteric artery. The **right gastro-epiploic artery**<sup>4</sup> runs from right to left in the great omentum along the greater curvature of the stomach, and joins the left gastro-epiploic artery, with which it forms a continuous arch. It distributes branches to the anterior and posterior walls of the stomach, where they anastomose with the branches of the gastric artery, and also sends long, slender branches

<sup>1</sup> A. hepatica.      <sup>2</sup> Ramus gastro-duodenalis.      <sup>3</sup> A. pancreatico-duodenalis.

<sup>4</sup> A. gastro-epiploica dextra; a. coronaria ventriculi; a. gastrica dextra inferior.



downward to the omentum. The **hepatic branch**<sup>1</sup> of the hepatic artery is directed forward in the small omentum, in which it ascends in front of the foramen of Winslow, and divides into the right and left hepatic branches. In its course it lies in front of the portal vein, with the common bile-duct to its right. It gives off a small **pyloric branch**,<sup>2</sup> which supplies the pylorus, and turning to the left anastomoses with the termination of the gastric artery. Sometimes it is unusually large, and replaces the latter. Occasionally it arises from the gastro-duodenal artery.

The **right hepatic artery**<sup>3</sup> gives off the **cystic artery**,<sup>4</sup> which is directed forward, and extends from the neck to the fundus of the gall-bladder, dividing into two main branches, of which one is distributed in the upper wall, and the other in the lower wall. The terminal branches enter the right side of the transverse fissure of the liver, and are distributed to the right lobe and its accessory quadrate lobe.

The **left hepatic artery**,<sup>5</sup> smaller than the former, enters the left side of the transverse fissure, and is distributed to the left lobe and caudate lobe of the liver.

The trunk of the hepatic artery occasionally arises separately from the aorta, or together with the superior mesenteric artery. The two chief terminal branches may arise from the cœliac axis or from the aorta, or, more frequently, the right one comes from the former and the left one from the latter.

The **splenic artery**,<sup>6</sup> at maturity the largest branch of the cœliac axis, proceeds transversely, in a more or less tortuous course, to the left and backward, along the upper border of the pancreas to the hilus of the spleen. In its course it gives off from three to six **pancreatic branches**,<sup>7</sup> which are distributed to the pancreas. On the left it gives off the **left gastro-epiploic artery**,<sup>8</sup> which proceeds in the great omentum to the right, along the great curvature of the stomach, to join the right gastro-epiploic branch, in like manner with which it is distributed.

The terminal or **splenic branches**<sup>9</sup> of the splenic artery, four or five, and subdividing into more, diverge and enter the hilus of the spleen, to which they are distributed.

The **short gastric branches**,<sup>10</sup> usually four or five, come from the splenic artery and its terminal branches, and proceed to the fundus of the stomach, to which they are distributed, anastomosing with the gastric and left gastro-epiploic arteries.

<sup>1</sup> Ramus hepaticus.

<sup>3</sup> A. hepatica dextra.

<sup>5</sup> A. hepatica sinistra.

<sup>7</sup> A. pancreatici.

<sup>8</sup> A. gastro-epiploica sinistra; a. coronaria ventriculi; a. gastrica sinistra inferior.

<sup>9</sup> Rami splenici or lienales.

<sup>2</sup> R. pyloricus.

<sup>4</sup> A. cystica.

<sup>6</sup> A. splenica; a. lienalis.

<sup>10</sup> A. gastricae breves; vasa brevia.



The **superior mesenteric artery** is smaller than the cœliac axis, just beneath which it arises from the aorta, and curves forward and downward behind the pancreas and over the duodenum to the root of the mesentery, in which it descends with a curvature towards the right iliac fossa, and terminates by joining its own ileo-colic branch. Its branches are as follows:

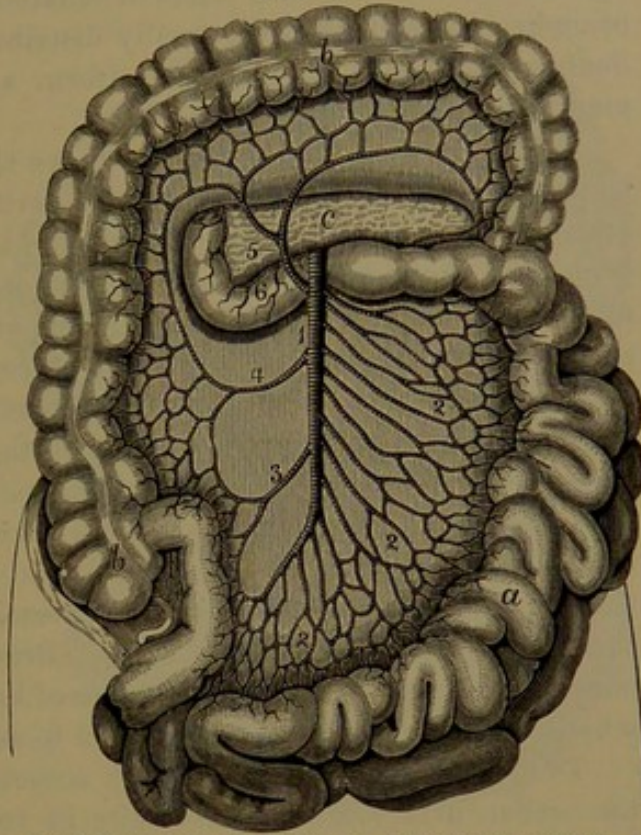
The **inferior pancreatico-duodenal artery**, a small branch from the superior mesenteric at the lower border of the pancreas, to which and the duodenum it is distributed, anastomosing with the superior branch, derived from the gastro-duodenal artery.

The **intestinal branches**, commonly a dozen or more, spring in close succession from the left or convex side of the superior mesenteric, and proceed downward and forward in the mesentery, to supply the jejunum and ileum. They run parallel with one another, and after some distance divide each into two branches, of which the contiguous ones unite in loops. From the first series of these loops a greater number of branches proceed, divide, and unite to form a second series of smaller and more numerous loops. In the same manner is formed a third series of the smallest and most numerous loops, and from these proceed a multitude of nearly uniform branches to the intestine, to the right and left of which they are distributed, freely anastomosing with one another. In the mesentery numerous fine branches are distributed to the lymphatic glands and other contiguous structures.

From the right side of the superior mesenteric artery there usually proceed two or three branches, named successively from below upward the ileo-colic, right colic, and middle colic arteries.

The **ileo-colic artery** arises from near the middle of the superior mesenteric, descends obliquely beneath the peritoneum towards the cæcum, and divides into two widely-diverging branches. Of these the lower one joins the termination of the superior mesenteric, forming

FIG. 270.



DISTRIBUTION OF THE SUPERIOR MESENTERIC ARTERY. 1, superior mesenteric artery; 2, intestinal branches; 3, ileo-colic artery; 4, right colic; 5, middle colic artery; 6, inferior pancreatico-duodenal artery. *a*, small intestine turned to the left; *b*, large intestine; *c*, pancreas.



with it a large loop, while the other ascends and inosculates with the middle colic artery, forming another loop. From the loops proceed many branches, the longer of which, by division and union of the contiguous branches, form a series of smaller, irregular loops, from which branches proceed, all being finally distributed to the termination of the ileum, the cæcum with its vermiform appendix, and the commencement of the ascending colon.

The **right colic artery** arises above the former, or in common with it, proceeds to the right beneath the peritoneum, and divides into two widely-divergent branches, of which the lower one joins the contiguous branch of the ileo-colic artery, and the other one ascends and joins the middle colic artery, forming with it one of the largest loops. The terminal branches form here and there a few secondary loops in the usual manner, and are distributed to the ascending colon.

The **middle colic artery** arises on the right of the upper part of the superior mesenteric, runs forward and downward in the transverse mesocolon, and divides in two widely-diverging branches, of which the right one inosculates with the right colic artery, and the left one joins the left colic branch of the inferior mesenteric artery, forming with it the largest of the mesenteric loops. Branches from the two principal ones produce a second and third series of loops in the usual manner, from which the terminal branches proceed to supply the transverse colon.

The superior mesenteric artery sometimes arises in common with the celiac artery, and occasionally in two separate trunks from the aorta. The number and arrangement of its branches are variable, and sometimes it furnishes branches to other organs. It sometimes gives off the right hepatic artery to the liver. Occasionally, with unusual enlargement of the inferior pancreatico-duodenal branch, it gives off the right gastro-epiploic artery. The ileo-colic artery is not always distinct from the termination of the main artery, nor the right colic from the former; and sometimes there are two middle colic arteries.

The **inferior mesenteric artery**,<sup>1</sup> much smaller than the preceding, arises an inch or two below it, from the front of the aorta, and descends in advance of this, inclining to the left, gives off the left colic and sigmoid arteries, and continues downward as the superior hemorrhoidal artery.

The **left colic artery**<sup>2</sup> is directed to the left side behind the peritoneum, in front of the kidney, and divides into two branches, of which the upper one inosculates with the left branch of the middle colic of the superior mesenteric artery, while the other one descends to join the sigmoid artery. It forms a series of large and small loops, as in the other colic arteries, from which proceed branches to be distributed to the descending colon.

<sup>1</sup> A. mesenterica inf.

<sup>2</sup> A. colica sinistra superior.



The **sigmoid artery**<sup>1</sup> enters the mesocolon in the left iliac fossa, and divides into two or three or more branches, of which the upper and lower inosculate with the left colic and superior hemorrhoidal arteries, and in the usual manner form one or two series of loops, from which the terminal branches proceed, to be distributed to the sigmoid flexure of the colon. Several separate branches may substitute the single sigmoid artery.

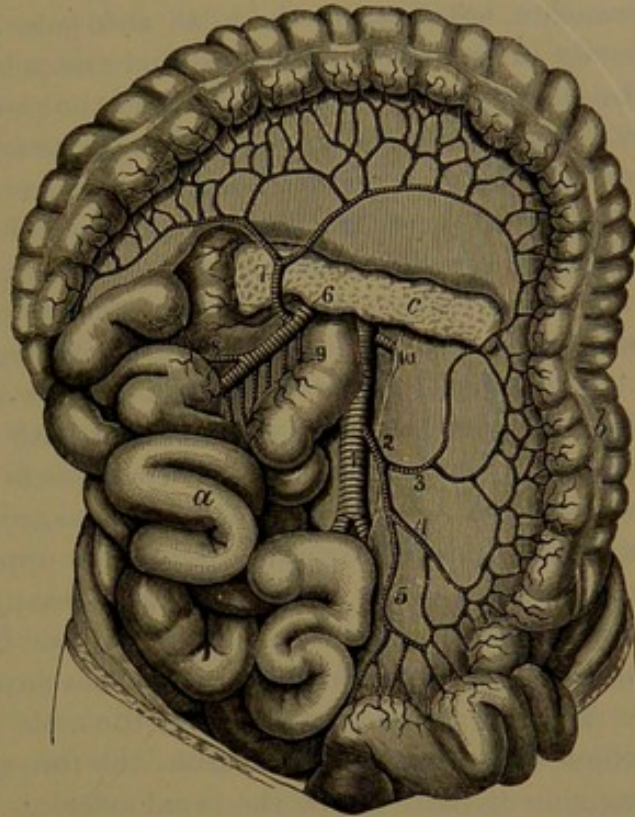
The **superior hemorrhoidal artery**,<sup>2</sup> the continuation of the inferior mesenteric, descends to the pelvis, in its course crossing the left common iliac vessels and entering the mesorectum, and divides into two branches, which are distributed to the sides of the rectum, extending to the lower part, where they anastomose with the middle and inferior hemorrhoidal arteries, derived from the internal iliac artery.

The inferior mesenteric artery may be absent, and its place supplied by branches from the superior mesenteric artery. Sometimes it gives off the middle colic artery.

The **suprarenal arteries**<sup>3</sup> are little vessels which arise from the aorta, one on each side of the superior mesenteric artery. They pass outwardly over the crura of the diaphragm to the suprarenal bodies, to which they are distributed, anastomosing with other branches from the phrenic and renal arteries. They are sometimes very small, and substituted by the latter branches.

The **renal arteries**,<sup>4</sup> large vessels, whether compared with the preceding or in proportion with the organs they supply, come from

FIG. 271.



DISTRIBUTION OF THE INFERIOR MESENTERIC ARTERY. 1, aorta; 2, inferior mesenteric artery; 3, left colic artery; 4, sigmoid artery; 5, superior hemorrhoidal artery; 6, superior mesenteric artery; 7, middle colic artery anastomosing with the left and right (8) colic arteries; 9, branches to the small intestine; 10, left renal artery. *a*, small intestine turned to the right side; *b*, large intestine; *c*, pancreas.

<sup>1</sup> *A. sigmoidea*; *a. col. sin. inferior*.

<sup>2</sup> *A. hæmorrhoidalis superior* or *interna*.

<sup>3</sup> *A. suprarenales mediæ* or *aorticæ*; *a. capsulares*; *a. atrabiliaræ*.

<sup>4</sup> *A. renales*; *emulgent arteries*; *a. emulgentes*.



the sides of the aorta, a short distance below the superior mesenteric artery, the right one usually being situated a little lower than the left one. They proceed outward, with a curve backward on the sides of the spine, and divide each usually into two, and then four or five branches, which enter the hilus and pass into the sinus of the kidney, partly in front and partly behind the pelvis, subdivide, and penetrate the substance of the organ. From the position of the aorta on the left of the spine the right artery is longer, and proceeds across the spine behind the inferior cava. Both arteries have the accompanying vein in front, with the renal pelvis and ureter behind. Before entering the kidney the renal artery gives off one or two little branches to the suprarenal body, and others yet smaller to the pelvis and ureter, the contiguous lymphatic glands, and investing tissues.

The renal arteries exhibit many variations, especially in number, there frequently being two on one or both sides, and occasionally three or four. When there are two the vessels commonly pursue the usual course together, but when there are more the additional vessel is apt to arise higher or lower and enter the upper or lower extremity of the kidney. An upper additional branch may arise from the aorta or from the superior mesenteric artery; a lower branch from any part of the aorta below the usual position or from any of its branches.

The **spermatic arteries**,<sup>1</sup> of the male, are two long, slender vessels, which arise near together from the fore part of the aorta a short but variable distance below the renal arteries. They descend obliquely, the right one across the inferior cava, each resting on the psoas muscle, and crossing the ureter and the external iliac vessels, covered by the peritoneum, to the internal abdominal ring. Here it joins the vas deferens, and as a constituent of the spermatic cord traverses the inguinal canal, from which it issues and descends to the scrotum, where, after giving a branch to the epididymis, it enters the back of the testicle, to which it is distributed. In its course it gives a delicate branch to the ureter, and in the spermatic cord anastomoses with the cremasteric and deferential arteries.

The spermatic artery sometimes arises from the renal artery, especially on the left side. Sometimes it arises in common with the suprarenal artery, and occasionally the right and left arteries arise together.

In the female the **ovarian arteries** correspond with the former, and have the same mode of origin and course to the entrance of the pelvis, whence they proceed in a tortuous manner in the broad ligaments of the uterus to the attached border of the ovaries, to which they are mainly distributed, a considerable branch running inward towards the uterus to anastomose with the uterine artery. Small branches also supply the oviduct, the broad and round ligaments. In pregnancy the ovarian arteries become much enlarged.

---

<sup>1</sup> A. spermaticæ internæ.



The **phrenic arteries**<sup>1</sup> are two small vessels, which usually arise together at the upper border of the aortic orifice of the diaphragm from the fore part of the aorta or the root of the cœliac axis. They diverge and ascend beneath the peritoneum on the crura and under surface of the diaphragm, to which they are distributed. Before reaching the central tendon each gives off an external branch, which is directed outwardly towards the side of the thorax, and anastomoses with the aortic intercostal arteries. The internal branch is directed towards the fore part of the chest, and anastomoses with that of the opposite side. The phrenic arteries give small branches to the suprarenal bodies; and the left one gives small branches to the œsophagus, which anastomose with the other contiguous œsophageal arteries.

The **lumbar arteries**,<sup>2</sup> of which there are usually five pairs, correspond with the intercostal arteries. They arise from the back of the aorta and run outwardly on the spine, the first pair across the last thoracic vertebra, the others on the upper four lumbar vertebræ. The right ones pass beneath the inferior cava, and the upper ones on both sides beneath the origin of the crura of the diaphragm. Turning backward on each side beneath the psoas muscle opposite the interval of the transverse processes, they divide into an abdominal and a dorsal branch. The **abdominal branch** runs outward, mostly behind the quadratus lumbar muscle, and then divides into branches which run forward between the abdominal muscles, to which and to the contiguous skin they are distributed, anastomosing with one another, and with the epigastries in front, the intercostals above, and the ilio-lumbar and circumflex arteries below. They also furnish branches to the diaphragm, the psoas and quadratus muscles. The first branch runs along the lower border of the last rib in company with the last thoracic nerve; the fifth branch runs along the crest of the ilium and gives branches to the iliac and gluteal muscles. The **dorsal branch** passes backward between the transverse processes to be distributed to the muscles and skin of the back in the same manner as the corresponding branch of the intercostal arteries. It likewise gives off a **spinal branch**, which enters the adjacent intervertebral foramen, to be distributed as already described. See page 516.

#### THE COMMON ILIAC ARTERIES.

The **common iliac arteries**<sup>3</sup> are forks of the abdominal aorta, which descend obliquely at the sides of the last lumbar vertebra towards the sacro-iliac articulation, above which each divides into the internal and external iliac arteries. The right one, slightly the longer, crosses over the termination of the inferior cava, upon which it rests in contact below with the inner border of the psoas muscle. The left

<sup>1</sup> A. phrenicæ; a. p. inferiores or magnæ; a. diaphragmaticæ.

<sup>2</sup> A. lumbales or lumbares.

<sup>3</sup> Primitive iliac arteries; a. iliaca communis or primitiva.



one rests on the bodies of the fourth and fifth lumbar vertebræ to the inner side of the corresponding psoas muscle. Both are covered by the peritoneum, behind the small intestine, and are crossed by the descending branches of the sympathetic from the aortic to the hypogastric plexus, and near their termination by the ureters. The accompanying veins lie partly behind and to their inner side. They usually give off no branches of importance, other than little vessels to the contiguous lymphatic glands, the psoas muscle, and the ureter. Commonly about three inches in length, they frequently range to one-half the extent, and when longer are more or less curved or tortuous. The point at which they divide often varies from about the middle of the last lumbar vertebra to the upper border of the sacrum.

#### THE INTERNAL ILIAC ARTERY.

The **internal iliac artery**<sup>1</sup> descends from the bifurcation of the common iliac artery in front of the sacro-iliac articulation to near the upper border of the great sciatic foramen, where it commonly divides into two principal branches, though frequently more, or gives them off in succession. Besides being much shorter, it is smaller in the adult, but is larger in the fœtus, when it is continuous with the umbilical artery. It rests against the sacrum and the sacro-lumbar nerve, with its companion vein behind and to the inner side covered by the peritoneum, beneath which it is crossed by the ureter.

The position at which the internal iliac artery divides is often variable, and occurs at any point between the upper border of the sacrum and the great sciatic foramen. Sometimes the greater part or all of its branches are given off before the ultimate division. Though very variable in their origin, the branches are quite constant and regular in their distribution.

Continuous with the trunk of the internal iliac artery or with its usual anterior division is a fibrous cord, the obliterated umbilical artery of the fœtus, which proceeds to the side and summit of the bladder, and thence to the umbilicus. At maturity the commencement of the cord for an inch or two encloses a narrow channel and constitutes the **superior vesical artery**,<sup>2</sup> which gives off two or three branches to be distributed to the sides and summit of the bladder, anastomosing with those of the opposite side and of the inferior vesical artery.

Besides the foregoing branch, the anterior division of the internal iliac artery usually gives off the inferior vesical, obturator, internal pudic, and ischiatic branches; and the posterior division the ilio-lumbar and lateral sacral branches, and continues as the gluteal artery.

The **inferior vesical artery**<sup>3</sup> commonly springs from below the superior and descends to the base of the bladder, to which and to

<sup>1</sup> Hypogastric artery; a. iliaca interna; a. hypogastrica.

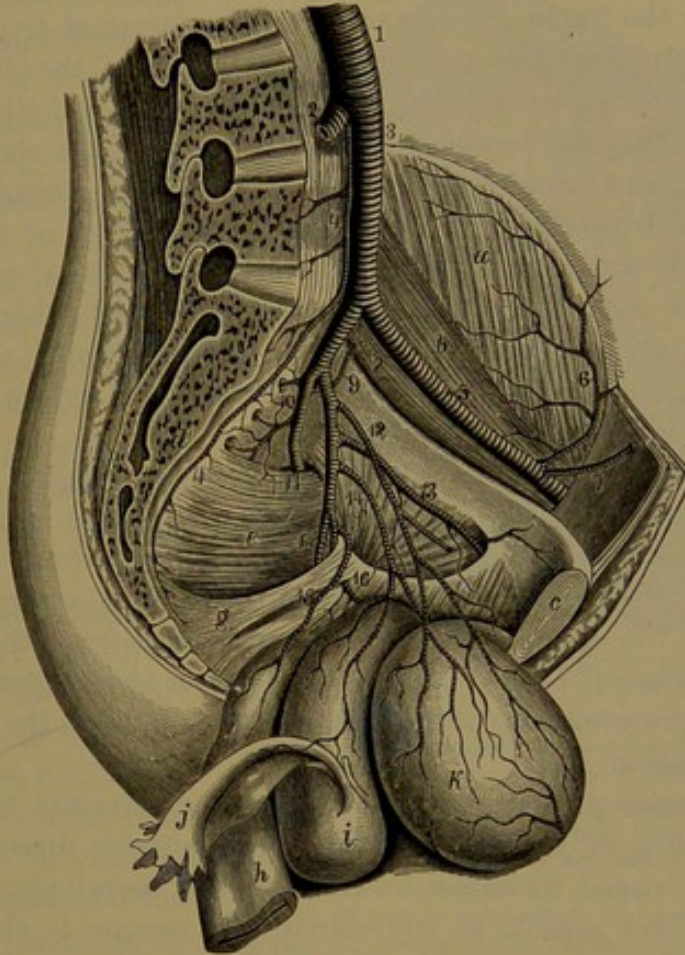
<sup>2</sup> A. vesicalis sup.; a. umbilicalis.

<sup>3</sup> A. vesicalis inf.



the prostate and seminal vesicle it is distributed, anastomosing with that of the opposite side. From this or the superior vesical artery is given off the **deferential artery**,<sup>1</sup> a slender vessel which accompanies the vas deferens, giving a branch to the commencement and running upward to the inguinal canal and sometimes to the epididymis. The

FIG. 272.



VIEW OF THE LEFT SIDE OF THE PELVIS, THE BLADDER, UTERUS, VAGINA, AND RECTUM, turned downward so as to exhibit the distribution of the internal iliac artery. 1, aorta; 2, right common iliac artery; 3, left common iliac; 4, middle sacral; 5, external iliac; 6, circumflex iliac; 7, epigastric; 8, internal iliac; 9, ilio-lumbar; 10, lateral sacral arteries; 11, gluteal artery passing from the pelvis, above the pyriform muscle, at the upper part of the great sciatic foramen; 12, superior vesical artery; the branch cut off is extended into the remains of the umbilical artery; 13, obturator artery; 14, inferior vesical artery giving off the uterine artery to the vagina and uterus; 15, middle hemorrhoidal artery; 16, internal pudic artery, seen emerging from and again entering the pelvis; 17, ischiatic artery. *a*, iliac muscle; *b*, psoas muscle; *c*, pubic symphysis; *d*, sacrum; *e*, pyriform muscle; *f*, internal obturator muscle; *g*, sacro-sciatic ligaments; *h*, rectum; *i*, uterus and vagina; *j*, fallopian tube; *k*, bladder.

inferior vesical artery is sometimes double, or it may arise from the internal pudic, the ischiatic, or the obturator artery.

The **obturator artery**,<sup>2</sup> usually from the anterior division of the internal iliac, frequently springs from the posterior division or the trunk, and runs forward below the brim of the pelvis to the aperture

<sup>1</sup> A. deferentialis.

<sup>2</sup> A. obturatoria.



at the upper part of the obturator membrane, through which it passes, and divides into two branches. In its course it rests on the pelvic fascia, accompanied by the obturator vein and nerve, and covered by the peritoneum. Besides small branches to the internal obturator and anal elevator muscles, the contiguous lymphatics and inner surface of the pubis, it gives off a larger **iliac branch**, which ascends to the iliac fossa, where it is distributed to the psoas and iliac muscles, and anastomoses with the ilio-lumbar artery. Of the terminal divisions the **internal branch**<sup>1</sup> descends along the inner border of the obturator foramen, and anastomoses with the external branch; is distributed to the obturator muscles, the heads of the adductors, and the contiguous skin of the thigh, and anastomoses with the internal circumflex artery. The **external branch**<sup>2</sup> descends at the outer border of the obturator foramen, and is distributed to the obturator and femoral quadrate muscles, the heads of the flexors arising from the ischial tuberosity, and to the hip-joint, a branch entering the cotyloid foramen to supply the interior; and it anastomoses with the ischiatic and external circumflex arteries.

The obturator artery is very variable in its origin. Besides the sources mentioned, it may arise in common with the superior vesical, the internal pudic, the ischiatic, or the ilio-lumbar artery. Frequently it arises from the termination of the external iliac artery, usually in common with the epigastric artery, or sometimes from the commencement of the femoral artery. In the latter cases the obturator descends to the inner or outer side of the femoral ring behind the pubis to the obturator foramen.

The **internal pudic artery**,<sup>3</sup> the smaller terminal branch of the anterior division of the internal iliac, or otherwise directly from the trunk of this vessel, descends in front of the sacral plexus of nerves and the pyriform muscle at the side of the rectum to the lower part of the great sciatic foramen, through which it passes out of the pelvis. Thence it curves behind the ischial spine and re-enters the pelvis, in company with the internal pudic nerve, through the small sciatic foramen, and proceeds forward above the ischial tuberosity and upward along the inner side of the pubic arch to the union of the crura of the cavernous bodies of the penis, where it divides into two terminal branches.

Before leaving the pelvis the internal pudic artery usually gives off the **middle hemorrhoidal artery**,<sup>4</sup> which often, however, proceeds directly from the anterior division of the internal iliac. It descends to the side of the rectum, to the lower part of which it is mainly distributed, anastomosing with the superior and inferior hemorrhoidal

<sup>1</sup> Ramus internus or anterior.

<sup>2</sup> R. externus or posterior.

<sup>3</sup> A. pudenda; a. p. interna, communis, or circumflexa; a. hæmorrhoidæ externa.

<sup>4</sup> A. hæmorrhoidalis media.



and inferior vesical arteries. It gives branches to the prostate and seminal vesicle, or in the female to the vagina. It sometimes arises, in common with the superior vesical artery, from the ischiatic or lateral sacral artery, and at times it is absent.

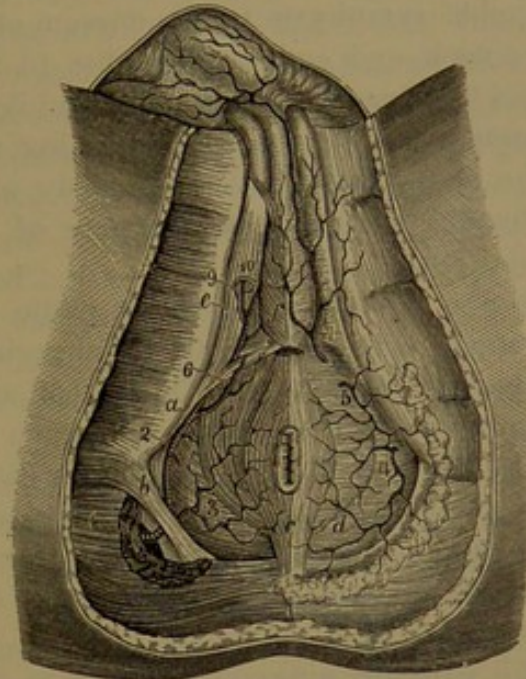
The **inferior hemorrhoidal artery**,<sup>1</sup> often replaced by two or three branches, comes from the internal pudic in the ischio-rectal fossa, and descends inwardly through the areolar tissue and fat of the latter to the end of the rectum, to which it is distributed, including the sphincter and anal elevator muscles, and anastomosing with the other hemorrhoidal and the superficial perineal arteries.

The **superficial perineal artery**<sup>2</sup> arises from the pudic at the fore part of the ischio-rectal fossa, descends from behind the transverse perineal muscle, and runs forward beneath the superficial fascia of the perineum to the scrotum, or in the female to the labium. It is distributed to the muscles and other structures and skin of the perineum. A branch, the **transverse perineal artery**,<sup>3</sup> important in its surgical relations, runs inward to the perineal centre, and anastomoses with that of the opposite side.

The **bulbar artery**<sup>4</sup> arises from the pudic between the layers of the triangular ligament, passes inward, and penetrates the side of the bulb of the spongy body of the penis, to which it is distributed, extending to the glans. In the female it enters the semi-bulb of the spongy body of the clitoris, and is distributed as in the preceding.

The **cavernous artery**,<sup>5</sup> one of the terminal branches of the in-

FIG. 273.



VIEW OF THE PERINEUM, EXHIBITING THE DISTRIBUTION OF THE INTERNAL PUDIC ARTERY. 1, the internal pudic issuing from the pelvis at the lower part of the great sciatic foramen; 2, the same vessel after it has returned into the pelvis through the small sciatic foramen; 3, inferior hemorrhoidal artery; 4, 5, superficial perineal branches to the perineum; 6, transverse perineal; 7, perineal branch to the scrotum and skin of the penis; 8, bulbar artery; 9, cavernous artery; 10, dorsal artery of the penis. a, tuberosity of the ischium; b, greater sacro-sciatic ligament; c, sphincter of the anus; d, perineal fascia, which is removed on the opposite side so as to expose the anal elevator muscle; e, ischio-cavernous muscle; f, bulbo-urethral muscle.

<sup>1</sup> A. h. inf. or externa.<sup>2</sup> A. perinea.<sup>3</sup> A. transversa perinei.<sup>4</sup> A. bulbo-urethralis; artery of the bulb.<sup>5</sup> Artery of the corpus cavernosum; a. cavernosa; a. profunda penis or clitoridis.



ternal pudic, penetrates the inner side of the crus of the cavernous body of the penis, and proceeds forward to the anterior extremity, and is distributed to the erectile tissue. In the female it in the same manner supplies the cavernous body of the clitoris.

The **dorsal artery of the penis**,<sup>1</sup> the smaller terminal branch of the internal pudic, ascends between the crus of the cavernous body and pubic symphysis to the dorsum of the penis, along which it runs to the neck, and ends in branches to the glans and prepuce. It perforates the suspensory ligament, and lies at the side of the dorsal vein, in company with the corresponding nerve. It distributes branches to the wall of the cavernous body and the skin of the penis. In the female, as the **dorsal artery of the clitoris**, it has a similar distribution.

In the female the internal pudic artery is considerably smaller than in the male. The superficial perineal artery is larger, and is distributed to the labium. The bulbar and cavernous arteries and the dorsal artery of the clitoris are much smaller than the corresponding ones of the male, but have a similar distribution.

The **vesico-vaginal artery**<sup>2</sup> substitutes the inferior vesical artery of the male. Arising as in the latter, it descends to the side of the vagina, to the wall of which and the lower part of the bladder it is distributed.

The **uterine artery**<sup>3</sup> arises from the anterior division of the internal iliac, separately or in common with the preceding, passes in the broad ligament towards the neck of the uterus, and then ascends in a tortuous manner on the side of that organ, to which it is distributed. Anastomosing with the ovarian artery it forms a continuous arch, from which branches are distributed to the oviduct. During pregnancy the uterine artery and its branches become greatly enlarged and very tortuous.

The internal pudic artery sometimes arises higher and sometimes lower than usual, and not unfrequently it divides into two branches, of which one pursues the usual course and gives off the hemorrhoidal, superficial perineal, and bulbar arteries, while the other descends in the pelvis beneath the bladder to the arch of the pubis, and ends in the cavernous and dorsal arteries of the penis, sometimes including the bulbar artery.

The **ischiatric artery**,<sup>4</sup> the larger terminal branch of the anterior division of the internal iliac, and appearing as its continuation, descends in front of the sacral plexus of nerves and the pyriform muscle to the lower part of the great sciatic foramen, through which it leaves the pelvis in company with the internal pudic artery and the sciatic nerves. It thence continues to descend beneath the great gluteal mus-

<sup>1</sup> A. dorsalis penis or clitoridis.

<sup>2</sup> A. vesico-vaginalis.

<sup>3</sup> A. uterina.

<sup>4</sup> Sciatic artery; a. ischiadica; a. glutæa inferior.



ele, resting on the internal obturator and geminus muscles, and terminates in a **descending branch**, which accompanies the small sciatic nerve down the back of the thigh, to the fasciæ and skin of which it is distributed, anastomosing with branches of the femoral perforating arteries. Beneath the great gluteal it gives off branches to that muscle, in which they anastomose with the gluteal artery, others to the small rotator muscles and those arising from the ischial tuberosity, anastomosing with the obturator and internal circumflex arteries. Several **cutaneous branches** proceed to the skin of the buttock. A **coccygeal branch**,<sup>1</sup> which penetrates the great sacro-sciatic ligament, is distributed to the great gluteal muscle and the adjacent connective tissue and fat over the sacrum and coccyx and in the perineum. An **anastomotic branch**, directed to the trochanteric fossa, supplies the rotator muscles and hip-joint, and anastomoses with the gluteal and internal circumflex arteries. A **sciatic branch**,<sup>2</sup> long and slender, penetrates among the fascicles of the great sciatic nerve, and descends with it to about the middle of the thigh.

The ischiatic artery sometimes arises much higher than usual, and sometimes much lower, even to the point at which it leaves the pelvis.

The **ilio-lumbar artery**,<sup>3</sup> usually derived from the posterior division of the internal iliac, or from the trunk before division, ascends outward behind the obturator nerve and between the base of the sacrum and the psoas muscle, and divides into two branches. Of these the **lumbar branch**<sup>4</sup> ascends beneath the psoas to the quadratus lumbar muscle, to both of which it is distributed, anastomosing with the last lumbar artery. It gives off a **spinal branch**, which passes through the adjacent intervertebral foramen to the spinal canal. The **iliac branch**<sup>5</sup> is directed outward in the iliac fossa, and is distributed below and above the iliac muscle, and anastomoses with the last lumbar, obturator, and circumflex iliac arteries. The ilio-lumbar artery sometimes arises from the external iliac or from the common iliac artery, and sometimes its branches arise separately.

The **lateral sacral arteries**,<sup>6</sup> usually two, sometimes arising together as one from the posterior division of the internal iliac or the trunk of this vessel, descends at the side of the sacrum internally to the anterior sacral foramina. They distribute small branches to the pyriform, coccygeal, and anal elevator muscles, anastomosing with the ilio-lumbar, lateral sacral, and hemorrhoidal arteries. The terminal branches enter the anterior sacral foramina, and give **spinal branches** to the sacral canal and its contents, and **dorsal branches**<sup>7</sup> through the posterior sacral foramina to the muscles and skin on the back of

<sup>1</sup> A. coccygea.

<sup>3</sup> A. ilio-lumbaris or lombalis; a. iliaca parva.

<sup>4</sup> Ramus lumbaris or adscendens.

<sup>6</sup> A. sacrales laterales.

<sup>2</sup> Comes nervi ischiadici.

<sup>5</sup> R. iliacus or transversalis.

<sup>7</sup> R. dorsales or posteriores.



the sacrum, anastomosing with the gluteal and ischiatic arteries. The lateral sacral arteries sometimes arise in three or four separate branches. The upper one sometimes arises in common with the ilio-lumbar artery, or it may arise from the external iliac or the common iliac artery.

The **gluteal artery**,<sup>1</sup> the largest branch of the internal iliac, ordinarily appears as a continuation of its posterior division or of the trunk itself. It turns backward between the lumbo-sacral and first sacral nerves, and passes from the pelvis at the upper border of the great sciatic foramen, and under cover of the great gluteal muscle divides into a superficial and a deep branch. Before leaving the pelvis it supplies several small variable branches to the pyriform, internal obturator, and anal elevator muscles, and a nutritious branch to the ilium. The **superficial branch** runs backward between the great and middle gluteal muscles, distributed to these, the pyriform muscle, and contiguous skin, and anastomoses with branches of the ilio-lumbar and dorsal branches of the lateral sacral arteries. The **deep branch**, directed forward between the middle and small gluteal muscles, usually divides into an upper and a lower branch, distributed to these, the pyriform muscle, and the hip-joint, giving nutritious branches to the ilium, and anastomosing behind with the ischiatic artery and in front with the external circumflex and epigastric arteries.

When the internal iliac artery does not divide as usual, the gluteal appears as a continuation of the trunk, or it may arise higher up from the latter.

#### THE EXTERNAL ILIAC ARTERY.

The **external iliac artery**,<sup>2</sup> the anterior terminal branch of the common iliac, continues in the line of the latter within the abdomen, and runs above the brim of the pelvis to the middle of the groin, where it passes through the femoral arch into the thigh, and subsequently continues under the name of the femoral artery. A line on the outside of the abdomen, from the left side of the umbilicus to the middle of the groin, indicates the course of the common iliac and external iliac arteries on either side. The external iliac artery rests against the inner side of the psoas, but approaching the femoral arch lies in front of that muscle. It is enclosed in a sheath, with the accompanying vein tightly adherent to the iliac fascia investing the psoas muscle, and is covered by the peritoneum and a number of lymphatic glands. The external iliac vein at first is behind and then to the inner side of the artery, and at the femoral arch is on the same plane. It is larger and longer than the internal iliac, usually about three and a half to four inches, and is of uniform diameter. Except small twigs to the psoas and contiguous lymphatics, it gives off no branches until near its termination.

<sup>1</sup> A. glutæa; a. g. superior; a. iliaca posterior.

<sup>2</sup> A. iliaca externa or anterior; a. cruralis or c. iliaca.



The **epigastric artery**<sup>1</sup> arises near the termination of the external iliac from its inner fore part, and ascends inwardly involved in the transversalis fascia of the abdomen, covered by the peritoneum, to the sheath of the abdominal rectus muscle. Entering the sheath it continues upward behind the rectus, which it penetrates, and is mainly distributed to that muscle, giving twigs through the fore part of the sheath to the adjacent fascia and skin, and anastomosing with the epigastric branch of the internal mammary artery. It is accompanied by a pair of veins, and near its commencement crosses the course of the inguinal canal, through which it gives a small **spermatic branch**<sup>2</sup> to the cremaster muscle and tunics of the spermatic cord, anastomosing with the spermatic artery. It also gives off a small **pubic branch** to the back of the pubis, anastomosing with that of the obturator artery. Lateral branches are also given to the broad muscles of the abdomen, anastomosing with the circumflex iliac, lumbar, and lower intercostal arteries.

The epigastric artery sometimes arises higher or lower than the usual position, and not unfrequently it arises together with the obturator artery from the external iliac.

The **circumflex iliac artery**<sup>3</sup> arises from the external iliac near the preceding, and runs upward and outward behind Poupart's ligament, in the conjunction of the transversalis and iliac fasciæ, to the iliac crest, along which it runs backward and anastomoses with the iliac branch of the ilio-lumbar artery. It gives branches to the psoas and iliac muscles, the origin of the sartorius and fascial tensor, and the transversalis and internal oblique muscles, and anastomoses with the epigastric and lumbar arteries.

#### THE FEMORAL ARTERY.

The **femoral artery**,<sup>4</sup> the continuation of the external iliac, runs along the upper two-thirds of the inner fore part of the thigh, and then passes through an opening of the tendon of the great adductor to the back of the thigh, where it receives the name of the popliteal artery. Commencing beneath the femoral arch at the middle of the groin, its course is indicated by a line drawn from the latter position to the inside of the knee. It extends along the middle of a wide depressed space, named **Scarpa's triangle**, of which the base is formed by Poupart's ligament, the inner lateral boundary by the adductors, and the outer by the extensors in front of the thigh. At first it rests on the psoas muscle, which separates it from the ilio-pubic eminence and the hip-joint, next upon the pectineus and short adductor, and then the long adductor, after which it passes through the opening of the

<sup>1</sup> A. epigastrica; a. e. inferior or inf. interna.

<sup>2</sup> A. spermatica externa; a. cremasterica.

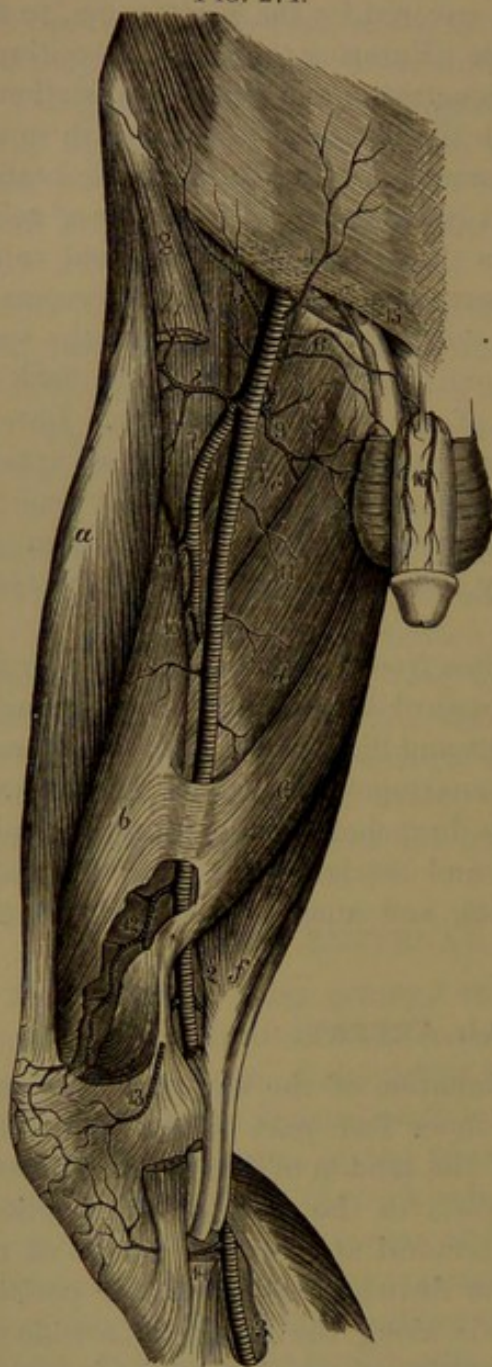
<sup>3</sup> A. circumflexa iliaca; a. epigastrica externa; a. abdominalis.

<sup>4</sup> A. femoralis; crural artery; a. cruralis.



great adductor. It is enclosed in a sheath accompanied by the femoral

FIG. 274.



ARTERIES OF THE FRONT OF THE THIGH. 1, femoral artery; 2, popliteal artery; 3, posterior tibial artery; 4, superficial epigastric artery; 5, superficial circumflex iliac; 6, external pudic; 7, femoral profunda; 8, 9, external and internal circumflex arteries; 10, perforating arteries; 11, muscular branches; 12, anastomotic artery; 13, 14, internal articular arteries; 15, small branch from the epigastric; 16, dorsal arteries of the penis. *a*, rectus muscle; *b*, internal vastus; *c, d, e*, adductor muscles; *f*, semi-tendinosus muscle; *g*, sartorius muscle.

the femoral artery in its course gives off a half-dozen or more variable muscular branches, to the sartorius, gracilis, adductors, and extensors.

vein, which is at first situated along its inner side, but gradually inclines backward, and is placed behind the artery as it passes through the opening of the adductor tendon. Above, it is covered by the fasciæ and skin, and subsequently in addition by the sartorius and an aponeurotic offset from the inner side of the long and great adductor tendons to that of the internal vastus muscle. At the commencement, the artery is most advanced in position, situated in front of the border of the pelvis and the inner part of the head of the femur, in its descent gradually acquires a more posterior position, and at the lower part of the thigh lies close to the shaft of the femur, separated from it by the internal vastus. At the groin the crural nerve lies a little way to the outer side of the artery, and about the middle of the thigh it is accompanied by the long saphenous nerve until the vessel passes through the opening of the adductor tendon. Usually, about an inch and a half below its commencement the femoral artery gives off a branch, the profunda, nearly as large as the main trunk, which is subsequently considerably reduced in size. Other branches of the femoral artery are mostly small.

In addition to several little branches to the lymphatic glands and skin of the groin,



The **superficial epigastric artery**,<sup>1</sup> usually a small and constant branch, comes from the femoral just below the groin, pierces the femoral fascia, and ascends in the superficial abdominal fascia towards the umbilicus. It is distributed to the fascia and skin, and anastomoses with branches of the deep epigastric artery.

The **superficial circumflex iliac artery**,<sup>2</sup> another small branch, often arising together with the former, ascends outwardly in the superficial fascia of the groin to the iliac crest. It supplies branches to the contiguous glands and skin, and gives others through the deep fascia to the iliac and sartorius and other contiguous muscles, and anastomoses with the corresponding deep artery.

The **external pudic arteries**,<sup>3</sup> usually a couple of branches, come from the front and inner part of the femoral, within an inch or two below the groin. The superior, more superficial branch passes inward through the cribriform fascia of the saphenous opening, to be distributed in front of the pubis. The inferior, deeper branch, often divided into two, is directed inwardly on the pectineus and small adductor muscles, and pierces the femoral fascia to be distributed to the skin of the scrotum, or in the female to the labium. The external pudic arteries anastomose with one another and with the superficial epigastric and external spermatic arteries.

The **femoral profunda artery**<sup>4</sup> arises from the outer back part of the femoral, usually about an inch and a half below the groin, is directed backward and a little outward, and descends behind the femoral artery close to the inner side of the femur. In its course it first rests on the iliac, then the pectineus and small adductor muscles, and finally the great adductor, continuing on this beneath the long adductor. It sometimes arises higher or lower than the usual point; sometimes from the inner side of the parent trunk, or occasionally directly from the back part. It is the chief nutrient vessel of the thigh, and breaks up into the circumflex and perforating arteries, besides giving off smaller and less regular branches to the internal vastus and adductor muscles.

The **internal circumflex artery**<sup>5</sup> arises from the inner side of the profunda near its commencement, and passes backward between the psoas and pectineus muscles over the short adductor towards the small trochanter, and divides into an ascending and a transverse branch. It supplies the external obturator and adductor muscles, and anastomoses with the obturator artery. It also furnishes an **articular branch**<sup>6</sup> to the hip-joint, which enters through the cotyloid foramen, and varies proportionately with the corresponding branch of the latter.

<sup>1</sup> A. epigastrica superficialis; a. abdominalis subcutanea; a. ad cutis abdominis.

<sup>2</sup> A. circumflexa superficialis or externa; ramus iliacus of the a. epig. superf.

<sup>3</sup> A. pudendæ externæ.

<sup>4</sup> Deep femoral artery; a. profunda; a. p. femoris; a. femoralis profunda.

<sup>5</sup> A. circumflexa femoris interna.

<sup>6</sup> R. articularis; a. acetabuli.



The **ascending branch**<sup>1</sup> proceeds to the trochanteric fossa, supplies the small rotator muscles, and anastomoses with branches of the gluteal, ischiatic, and first perforating arteries. The **transverse branch**, larger than the former, passes back between the femoral quadrate and great adductor muscles, and is distributed to the heads of the flexors, anastomosing with the sciatic and first perforating arteries.

The internal circumflex artery frequently arises directly from the femoral, and occasionally from the external iliac, separately or in common with the epigastric or circumflex iliac artery.

The **external circumflex artery**,<sup>2</sup> larger than the preceding, sometimes arises together with it, but usually separately, and opposite, or a little lower from the profunda artery. Directed outward between the sartorius and femoral rectus, and between the divisions of the crural nerve, after giving branches to the contiguous muscles it commonly terminates in a pair of widely-divergent branches. Of these, the **ascending branch**<sup>3</sup> is distributed to the upper part of the sartorius, rectus, and external vastus, and the fore part of the middle and small gluteal muscles, gives a branch<sup>4</sup> to the hip-joint, and anastomoses with branches of the gluteal and circumflex iliac arteries. The **descending branch**,<sup>5</sup> larger than the former, supplies the extensors and the fasciæ and skin at the outer part of the thigh, the terminal branch descending at the outer border of the rectus to the knee.

The external circumflex artery sometimes arises from the femoral above the profunda, and sometimes its ascending branch arises from either of the former, independent of the descending branch.

The **perforating arteries**,<sup>6</sup> variable in number and arrangement, usually three or four, including the terminal branch of the profunda, come off in succession, and pass backward close to the femur through apertures in the tendinous insertion of the short and great adductors to the back of the thigh. Here they are chiefly distributed to the femoral flexors, the fasciæ, and skin; give twigs to the sciatic nerve, and anastomose with branches of the ischiatic, gluteal, circumflex, and popliteal nerves. Terminal branches directed outwardly pierce the attachments of the external gluteal muscle, short head of the biceps, and external intermuscular septum, and end in the external vastus and crureus, in which they anastomose with branches of the external circumflex artery. The **first perforating artery**, commonly the largest, passing through the short and great adductors, furnishes branches to these, and then mainly supplies the flexors. An ascending branch beneath the insertion of the external gluteal muscle to the back of the neck of the femur supplies the former and the femoral quadrate muscle, and anastomoses with the gluteal, ischiatic, and cir-

<sup>1</sup> R. adscendens; r. trochantericus.

<sup>2</sup> A. adscendens or circumflexa.

<sup>3</sup> R. descendens.

<sup>4</sup> A. circ. fem. externa.

<sup>5</sup> R. trochantericus anterior.

<sup>6</sup> A. perforantes.



cumflex arteries. The **second perforating artery**, passing through the great adductor, is mainly distributed to this, the external vastus, and crureus. The **third perforating artery**, the terminal branch of the profunda, pierces the great adductor a short distance above the aperture for the femoral artery, and is mainly distributed to that muscle, the short head of the biceps, and the semimembranosus.

The **medullary nutritious artery** of the femur, when single, usually comes from the first or second perforating artery, and when a second exists, this comes from the third perforating artery.

The **anastomotic artery**,<sup>1</sup> a slender vessel, arises from the femoral as this is about to pass through the aperture of the great adductor, and quickly divides into a superficial and a deep branch, which frequently also come directly from the femoral artery. The **superficial branch**<sup>2</sup> accompanies the long, saphenous nerve to the knee, and is distributed to the sartorius and gracilis and the skin of the region, and anastomoses with the lower internal articular branch of the popliteal artery. The **deep branch**<sup>3</sup> penetrates the internal vastus muscle, descends to the inner condyle of the femur, and anastomoses with the internal articular arteries. It supplies the lower part of the internal vastus and crureus, and sends branches across the knee to anastomose with the upper external articular branch of the popliteal artery.

#### POPLITEAL ARTERY.

The **popliteal artery**,<sup>4</sup> continuous with the femoral, occupies the bottom of the depressed space at the back of the knee, extending from the perforation of the great adductor at the lower third of the inner side of the thigh to the perforation of the interosseous membrane at the upper part of the leg, where it divides into the anterior and posterior tibial arteries. In the early part of its course the artery inclines from the front on the inner side of the femur downward and outward to the back part, where it descends vertically behind the middle of the knee-joint to its termination. It first rests on the inner side of the femur, and then behind this on a layer of areolar and adipose tissue, subsequently on the capsular ligament of the knee-joint, and finally on the popliteal muscle. Its upper end is covered by the semimembranosus; its lower end by the heads of the gastrocnemius and soleus muscles. In the intermediate position, in company with the popliteal vein and nerve, it is enveloped in areolar and adipose tissue, invested superficially by the fasciæ and skin of the popliteal space. The companion vein lies more superficially in close contact with the artery, at first behind and a little to the outer side, gradually inclining below to the inner side. The internal popliteal nerve, more superficial behind

<sup>1</sup> A. anastomotica magna.

<sup>2</sup> A. articularis genu superficialis; a. a. g. superior interna superficialis or prima.

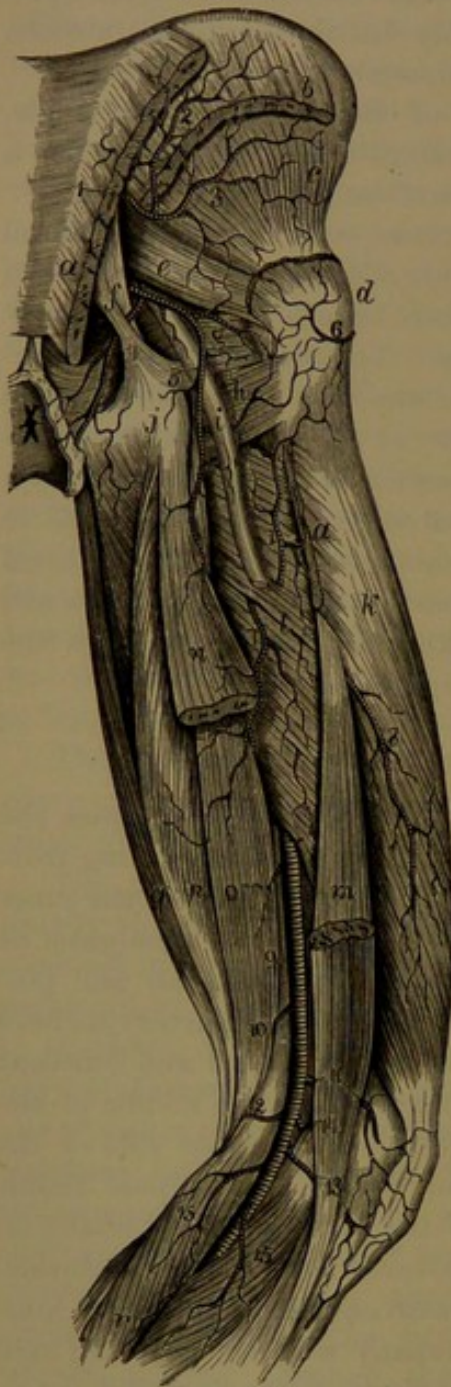<sup>3</sup> Ramus musculo-articularis.

<sup>4</sup> A. poplitea.



than the corresponding vessels, lies first to the outer side, gradually gaining the inner side below.

FIG. 275.



ARTERIES OF THE BACK OF THE THIGH. 1, gluteal artery; 2, 3, its superficial and deep branch; 4, internal pudic artery; 5, ischiatic artery; 6, branch of the external circumflex; 7, 8, terminal branches of the perforating arteries; 9, popliteal artery; 10, 11, superior internal and external articular arteries; 12, 13, inferior internal and external articular arteries; 14, middle articular artery; 15, gastrocnemial branches. *a*, origin and insertion of the great gluteal muscle; *b*, origin of the middle gluteal muscle; *c*, small gluteal muscle; *d*, great trochanter; *e*, pyriform muscle; *f*, sacro-sciatic ligaments; *g*, internal obturator muscle; *h*, femoral quadrate muscle; *i*, sciatic nerve; *j*, tuberosity of the ischium; *k*, external vastus muscle; *l*, great adductor; *m*, short head of the femoral biceps; *n*, long head; *o*, *p*, semimembranosus and semitendinosus muscles; *q*, gracilis; *r*, gastrocnemius.

The branches given off in the course of the popliteal artery are small, and consist of muscular and articular.

Of the **muscular arteries**, three or four<sup>1</sup> are distributed in the thigh to the lower part of the flexors, great adductor, internal vastus, and crureus, and also give branches to the popliteal nerves, the fasciæ, and skin of the popliteal space. Others, the **gastrocnemial arteries**,<sup>2</sup> usually two, though sometimes arising together, spring from the back of the popliteal just above the knee-joint, and descend, one on each side, to the heads of the gastrocnemius, which they enter and supply, besides giving branches to the plantaris and soleus. A **superficial branch**<sup>3</sup> from each, or from the popliteal directly, descends on the surface of

the gastrocnemius to be distributed to the skin of the calf.

Of the **articular arteries**<sup>4</sup> there are commonly five, named from their relative position. Four are in pairs, one on each side, passing above and below, around the knee-joint, the fifth one proceeding directly forward to the centre of the joint behind.

<sup>1</sup> Superior muscular arteries.

<sup>3</sup> *A. suralis superficialis*.

<sup>2</sup> *A. surales*; *a. gemellæ*.

<sup>4</sup> *A. articulares genu*.



The **superior internal articular artery**<sup>1</sup> passes from the popliteal inward above the internal condyle of the femur beneath the attachment of the contiguous muscles, and is distributed on the condyle and among the adjacent tendons at the inner side of the knee to the patella. It anastomoses with the anastomotica and other articular arteries. It varies in size proportionately with the anastomotica.

The **superior external articular artery**,<sup>2</sup> larger than the former, passes outward above the external condyle of the femur beneath the contiguous muscular attachments, and is distributed on the condyle and among the adjacent tendons extending on the outer side of the knee-joint. It anastomoses with the descending branch of the external circumflex artery, the deep branch of the anastomotica, and the articular arteries.

The **inferior internal articular artery**<sup>3</sup> passes downward and inward along the upper border of the popliteal muscle, and then forward below the inner tuberosity of the tibia beneath the internal lateral ligament, to be distributed at the inner side of the knee-joint. It gives branches to the popliteal muscle, and anastomoses with the anastomotica and other articular arteries.

The **inferior external articular artery**,<sup>4</sup> smaller than the former, passes outward along the border of the external semilunar cartilage, above the head of the fibula, beneath the external lateral ligament to the outer side of the knee-joint, where it anastomoses with the recurrent tibial and other articular arteries.

The **middle articular artery**<sup>5</sup> is a small branch, which proceeds from the popliteal artery directly forward, and perforates the centre of the capsular ligament to be distributed to the crucial ligaments and other structures within the joint.

All the articular arteries, together with the anastomotica and recurrent tibial arteries, anastomose freely, forming a superficial wide-meshed net-work between the fascia and skin, and a deeper, closer one of larger vessels on the bones and the ligaments enclosing the knee-joint.

Deviations of the popliteal artery from the usual condition are unfrequent. Rarely, it divides at a higher point into its terminal branches.

#### ANTERIOR TIBIAL ARTERY.

The **anterior tibial artery**,<sup>6</sup> the smaller terminal branch of the popliteal, occupies the outer fore part of the leg, extending to the back of the foot, on which the vessel is continued forward as the dorsal

<sup>1</sup> A. articularis genu superior interna or interna secunda or profunda.

<sup>2</sup> A. articularis genu superior externa.

<sup>3</sup> A. articularis genu inferior interna.

<sup>4</sup> A. articularis genu inferior externa.

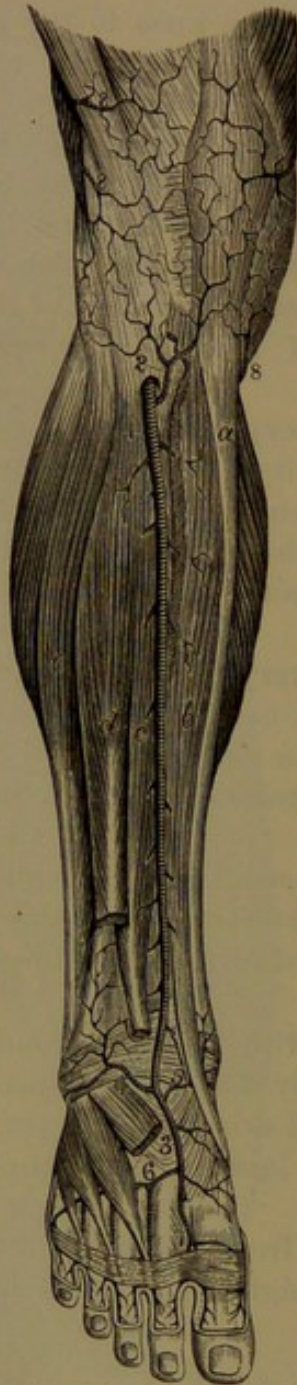<sup>5</sup> A. articularis genu media; a. azygos inferior.

<sup>6</sup> A. tibialis antica.



pedal artery. Passing from the lower end of the popliteal space, through

FIG. 276.



ARTERIES OF THE FRONT OF THE LEG. 1, anterior tibial artery; 2, recurrent tibial; 3, dorsal pedal; 4, 5, external and internal malleolar arteries; 6, metatarsal artery; 7, dorsal artery of the great toe; 8, terminal branches of the articular arteries. *a*, tibia; *b*, anterior tibialis muscle; *c*, hallucal extensor; *d*, long digital extensor: the short extensor occupies the back of the foot; *e*, peroneal muscles: on each side of the leg the bellies of the gastrocnemius are visible.

the opening of the interosseous membrane, close to the neck of the fibula, it descends in front of that membrane, and gradually inclines inward and forward, and continues downward on the lower part of the tibia to the middle of the bend in front of the ankle. In company with a pair of veins and the corresponding nerve it is closely adherent to the contiguous structures. In the upper two-thirds of its course it is deeply placed between the anterior tibialis muscle on the inner side and the long digital and hallucal extensors on the outer side. In the lower third, inclining forward, it becomes more superficial, and is crossed from the outer to the inner side by the tendon of the hallucal extensor, and above the ankle is covered by the upper band of the anterior annular ligament. A line drawn from a point midway between the head of the fibula and the outer tuberosity of the tibia to the middle of the ankle-joint in front indicates the direction of the artery. The following branches are derived from the anterior tibial artery:

The posterior recurrent branch,<sup>1</sup> a small ves-

<sup>1</sup> A. t. recurrens post.



sel, ascends beneath the popliteal muscle to the knee-joint, to both of which it is distributed.

The **anterior recurrent artery**,<sup>1</sup> larger than the former, comes from the tibial after passing the interosseous aperture, ascends through the upper extremity of the anterior tibialis muscle, and ramifies over the outer tuberosity of the tibia, anastomosing with the contiguous articular arteries.

Numerous small **muscular branches** arise in the course of the anterior tibial artery, and supply the contiguous muscles.

The **malleolar arteries** are variable in their origin and number; usually an external and an internal, they arise near the ankle, the former being commonly the higher. Not unfrequently two branches or more substitute either or both, especially the internal smaller one. The **external malleolar artery**<sup>2</sup> descends obliquely outward beneath the extensor tendons to be distributed over the external malleolus, where it supplies the contiguous articulations and anastomoses with the anterior peroneal and tarsal arteries. The **internal malleolar artery**<sup>3</sup> passes inward beneath the tendon of the anterior tibialis, and is distributed over the internal malleolus, supplying the contiguous parts and anastomosing with the internal tarsal arteries and branches of the posterior tibial artery.

#### DORSAL PEDAL ARTERY.

The **dorsal pedal artery**,<sup>4</sup> the continuation of the anterior tibial, runs forward on the back of the foot from the middle of the front of the ankle-joint to the first metatarsal interval, where it descends between the heads of the interosseous muscle to the sole, in which it joins the external plantar artery to complete the plantar arch. It rests on the tarsus between the tendons of the hallucal and long digital extensors, covered by the lower band of the anterior annular ligament. It is accompanied by a pair of veins and the anterior tibial nerve, and gives off the following branches:

The **internal tarsal arteries**,<sup>5</sup> two or three small and variable branches, descending on the inner side of the tarsus, to the articulations of which they are distributed, anastomosing with the internal malleolar and branches of the posterior tibial arteries.

The **external tarsal artery**,<sup>6</sup> usually arising near the head of the astragalus, passes outwardly beneath the short digital extensor, to which and the contiguous articulations it is distributed, and anastomoses with the external malleolar, peroneal, external plantar, and metatarsal arteries.

The **metatarsal artery**<sup>7</sup> arises near the bases of the metatarsal

<sup>1</sup> A. t. recurrens ant.

<sup>2</sup> A. malleolaris externa.

<sup>3</sup> A. mal.interna.

<sup>4</sup> Dorsal artery of the foot.

<sup>5</sup> Rami tarsei interni.

<sup>6</sup> Tarsal artery; a. tarsea externa; a. t. ext. posterior.

<sup>7</sup> A. metatarsa; a. tarsea externa anterior.



bones, runs outwardly beneath the short digital extensor, to which and the contiguous articulations it is distributed, and anastomoses with the external plantar and tarsal arteries. With the latter it forms an arch,<sup>1</sup> from which proceed three **interosseous arteries**<sup>2</sup> to the outer three metatarsal spaces, resting on the corresponding interosseous muscles and supplying them with twigs. At the fore part of the metatarsal intervals each interosseous artery bifurcates into a pair of **dorsal digital branches**, which proceed along the adjacent sides of the corresponding toes. At the back of the metatarsal intervals each interosseous artery is connected with the plantar arch by a **communicating branch**;<sup>3</sup> and likewise less constantly at its bifurcation in front it is united by an anterior **communicating branch**<sup>4</sup> with the contiguous plantar digital artery. From the outermost of the interosseous arteries a **dorsal digital branch** proceeds along the inner border of the little toe.

The first **interosseous artery**,<sup>5</sup> larger than the others, proceeds from the fore part of the dorsal pedal artery on the interosseous muscle of the first metatarsal interval, and, after giving a **dorsal digital branch** to the outer side of the great toe, bifurcates into **dorsal digital branches** for the adjacent sides of the latter and the second toe; and at the bifurcation, by a **communicating branch** joins the contiguous plantar digital artery.

The external tarsal and metatarsal arteries are not unfrequently represented by three or four branches, and sometimes they are replaced by branches from an enlarged anterior peroneal artery.

#### POSTERIOR TIBIAL ARTERY.

The **posterior tibial artery**,<sup>6</sup> the larger terminal branch of the popliteal and appearing as its continuation, descends the leg behind the tibia between the muscles of the calf and the deep muscles, enclosed with the latter by the deeper layer of the deep fascia. It extends from the lower border of the popliteal muscle to that of the internal annular ligament, which encloses it behind the internal malleolus, where it divides into the internal and external plantar arteries. In its course it rests successively on the posterior tibialis and the long digital flexor, and at its termination directly on the tibia and the ankle-joint. Above, it is covered by the bellies of the gastrocnemius and soleus, and below these by two layers of the deep fascia, the superficial fascia, and skin. It is accompanied as usual by two veins, and with

<sup>1</sup> Arcus tarseus; a. dorsalis pedis.

<sup>2</sup> Dorsal interosseous arteries; a. interossee dorsales.

<sup>3</sup> Posterior perforating artery; ramus perforans post.

<sup>4</sup> Anterior perforating artery; ramus perforans ant.

<sup>5</sup> A. metatarsæ or interossea dorsalis prima; first dorsal interosseous artery.

<sup>6</sup> A. tibialis postica.



the posterior tibial nerve at the start on its outer side, and afterwards running along its inner side. At the ankle it lies about midway between the prominences of the heel and the inner malleolus, and in this position ends in its terminal branches.

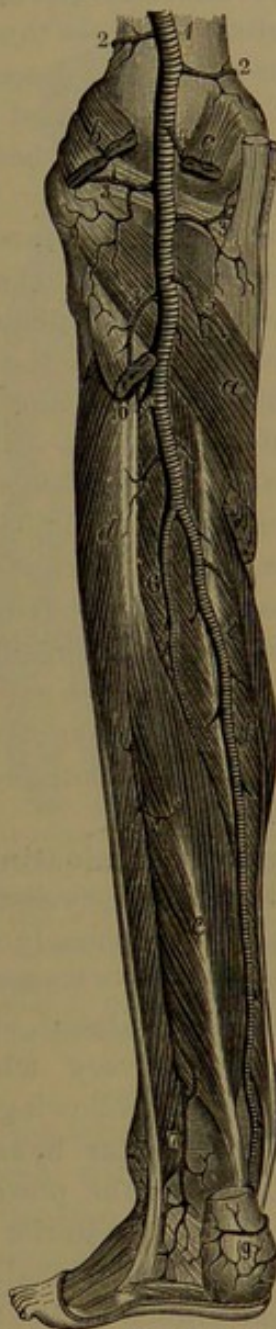In its course the posterior tibial artery gives off the medullary artery of the tibia, muscular branches, the peroneal artery, and the communicating and malleolar branches.

The **medullary nutritious artery**,<sup>1</sup> the largest of its kind, arises near the commencement of the posterior tibial, and descends on the surface of the tibia to the medullary nutritious canal. It usually gives some muscular branches to the contiguous muscles.

The **muscular branches** are numerous, several of the largest being distributed to the soleus, while the others supply the posterior tibialis and flexor muscles, and give cutaneous branches to the adjacent fasciæ and skin.

The **peroneal artery**,<sup>2</sup> the largest branch of the posterior tibial, springs from the outer side of this vessel an inch or two below its commencement. It descends deeply close along the inner side of the fibula to the lower end of the interosseous space, where it divides into the anterior and posterior peroneal arteries. Accompanied by the usual pair of veins, it rests on the posterior tibialis muscle, covered above by the soleus and below by the long hallucal flexor. In its course it gives many small **muscular branches** to the soleus, posterior tibialis, long hallucal flexor, and the peroneal muscles, with **cutaneous branches** to the skin and a **medullary nutritious branch** to the fibula. The lower part of the artery

FIG. 277.



ARTERIES OF THE BACK OF THE LEG. 1, popliteal artery; 2, 2, superior internal and external articular arteries; 3, 3, inferior internal and external articular arteries; 4, middle articular artery; 5, gastrocnemial arteries; 6, peroneal artery; 7, posterior peroneal branch; 8, posterior tibial artery; 9, calcaneal branches. *a*, popliteal muscle; *b*, *c*, origin of the gastrocnemius; *d*, peroneal muscles; *e*, long hallucal flexor; *f*, long digital flexor; that between the two latter is the posterior tibialis muscle.

<sup>1</sup> A. nutritia tibiæ.

<sup>2</sup> A. peronæa; *a*. fibularis.



is commonly joined by a **communicating branch**,<sup>1</sup> which crosses the tibia from the adjacent part of the posterior tibial artery.

The **anterior peroneal artery**,<sup>2</sup> one of the terminal divisions of the peroneal, passes through an aperture at the lower end of the interosseous space, and descends in front of the articulation of the tibia and fibula, to be distributed over the external malleolus and the outer part of the ankle-joint, where it anastomoses with the external malleolar branch of the anterior tibial, and with branches of the posterior peroneal and external tarsal arteries. It supplies the third peroneal muscle, the contiguous articulations, the fascia, and skin.

The **posterior peroneal artery**,<sup>3</sup> the remaining terminal division and continuation of the peroneal, descends behind the articulation of the tibia and fibula and the external malleolus, and is distributed over the outer side of the calcaneum. It supplies the contiguous articulations, and anastomoses with the external malleolar, tarsal, and calcanean arteries.

The peroneal artery sometimes arises either higher or lower than the usual position. It occasionally comes from the end of the popliteal or from the anterior tibial artery. Rarely it is absent. The anterior peroneal artery is sometimes enlarged to compensate for deficiency in the terminal portion of the anterior tibial artery; and sometimes it is very small or absent, and is replaced by an enlarged external malleolar artery.

The **communicating branch**<sup>4</sup> of the posterior tibial artery, usually a considerable vessel, springs from behind the internal malleolus, and passes transversely across the tibia, to join the termination of the peroneal artery. Sometimes it is represented by a smaller pair; and sometimes it is absent, and then may be represented by a branch from the peroneal artery, which proceeds to the internal malleolus, and substitutes the following.

The **malleolar branch**,<sup>5</sup> small and often double, from near the termination of the posterior tibial artery, passes inward beneath the tendons of the posterior tibialis and long digital flexor, to be distributed on the internal malleolus, where it anastomoses with the internal malleolar branch of the anterior tibial artery.

#### PLANTAR ARTERIES.

The **plantar arteries**, the terminal branches of the posterior tibial, proceed from this vessel at the lower border of the internal annular ligament, covered by the origin of the hallucal abductor. The **internal plantar artery**,<sup>6</sup> the smaller branch, runs forward along the

<sup>1</sup> Ramus anastomoticus transversus.

<sup>2</sup> A. peronæa antica or perforans.

<sup>3</sup> A. p. post.; rami calcanei externi.

<sup>4</sup> Ramus anastomoticus transversus or superior.

<sup>5</sup> A. malleolaris interna posterior.

<sup>6</sup> A. plantaris interna.



inner side of the sole of the foot between the hallucal abductor and short flexor to the fore part of the first metatarsal interval, where it usually ends by joining the internal branch of the first plantar digital artery. In its course it gives off numerous branches, of which the deeper ones are distributed to the articulations of the inner side of the foot, anastomosing with branches of the external plantar artery; and the superficial branches supply the muscles, fascia, and skin on the inner side of the foot, anastomosing with branches of the dorsal pedal artery.

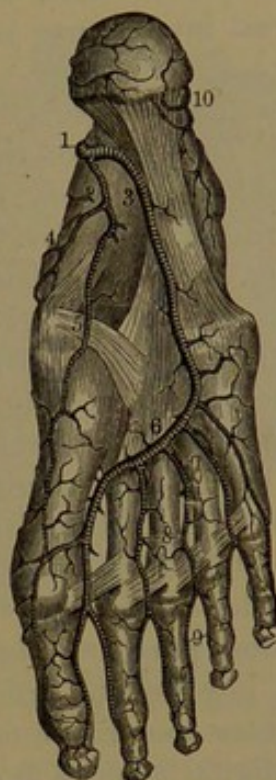The **external plantar artery**,<sup>1</sup> appearing as the continuation of the posterior tibial, runs through the arch of the calcaneum, outward and forward into the sole of the foot, passing along the outer part to the base of the last metatarsal bone, where it turns obliquely inward to the first metatarsal interval and joins the dorsal pedal artery, to form the **plantar arch**.<sup>2</sup> At first the artery, with its accompanying veins and nerve, is placed between the calcaneum and hallucal abductor, afterwards between the

accessory and short digital flexors, and then in the interval of the latter and the minimal abductor. The plantar arch, with its convexity directed forward, rests on the interosseous muscles, covered by the digital flexors and lumbrical muscles. In its course the external plantar artery gives off numerous branches, as follows:

Two or three **calcanean branches**,<sup>3</sup> often partly derived from the termination of the posterior tibial. They pierce the origin of the hallucal abductor, which they supply, and are distributed over the heel, anastomosing with corresponding branches of the posterior peroneal artery.

Many **muscular branches** supply the contiguous muscles in the outer part of the sole of the foot, and other branches are devoted to the adjacent articulations and skin, and anastomose with the internal tarsal and metatarsal arteries.

FIG. 278.



ARTERIES OF THE SOLE OF THE FOOT. 1, posterior tibial artery dividing into, 2, the internal, and, 3, external, plantar arteries; 4, branch to the inner side of the foot; 5, branch to the great toe; 6, plantar arch; 7, perforating arteries; 8, common digitals; 9, digitals to the contiguous sides of the toes; 10, calcanean branches of the peroneal and posterior tibial arteries.

<sup>1</sup> A. plantaris externa.<sup>2</sup> Arcus plantaris.<sup>3</sup> Rami calcanei interni.



From the plantar arch small branches proceed backward to supply the contiguous articulations, and anastomose with branches of the internal plantar artery. Three posterior **communicating branches**<sup>1</sup> proceed from the arch through the back ends of the corresponding metatarsal intervals to join the interosseous arteries on the back of the foot.

From the fore part of the plantar arch, proceed five **digital arteries**.<sup>2</sup> The first<sup>3</sup> of these, usually regarded as the last branch of the dorsal pedal artery, runs forward in the first metatarsal interval to its fore part, and divides into a pair of **digital branches**,<sup>4</sup> which run along the adjacent borders of the great and adjoining toes to the tips. In its course it gives off a **digital branch**, which crosses the first metatarsal bone and runs along the inner border of the great toe. The succeeding three **digital arteries**<sup>5</sup> proceed forward in the corresponding metatarsal intervals, and divide like the former, each into a pair of **digital branches**, which run along the adjacent borders of the toes. The fifth **digital artery**<sup>6</sup> proceeds from the outer part of the arch obliquely across the last metatarsal bone, and runs along the outer border of the little toe. At their bifurcation the digital arteries, for the most part, are joined by a **communicating branch**<sup>7</sup> from the adjacent interosseous arteries of the back of the foot; often failing in the outer one or two metatarsal intervals. The distribution of the plantar digital arteries in all respects accords with that of the palmar digitals.

The arteries of the foot deviate from the ordinary condition much less frequently than those of the hand. The internal plantar is sometimes larger, and may play a more important part in the formation of the plantar arch; and sometimes it continues forward as the first plantar digital artery. Sometimes it is small, and ends in the short hallucal flexor. The external plantar is observed to vary proportionately with the dorsal pedal artery, so that one or the other may contribute more or less to the plantar arch. The posterior communicating arteries, usually small, may be larger and form the interosseous arteries, in which case the metatarsal branch of the dorsal pedal artery is smaller than normally.

#### VEINS OF THE HEART.

The principal veins of the heart, for the most part, accompany the arteries along the grooves and unite in a trunk, the terminal portion of

<sup>1</sup> Posterior perforating branches; rami perforantes posteriores.

<sup>2</sup> A. interosseæ plantares.

<sup>3</sup> Plantar digital branch of the dorsal artery of the foot.

<sup>4</sup> Collateral digital arteries; a. digitales plantares.

<sup>5</sup> A. interosseæ plantares.

<sup>6</sup> A. plantaris externa digiti minimi.

<sup>7</sup> Anterior perforating artery; a. perforans ant.



which, for about an inch, is slightly dilated, and is named the coronary sinus. They are the great and small, the middle, and the posterior coronary veins. In addition to these are the anterior cardiac veins and some still smaller ones, which open separately into the right auricle.

The **great coronary vein**<sup>1</sup> commences at the apex of the heart, ascends along the anterior interventricular groove in company with the anterior branch of the left coronary artery, and turns to the left along the left auriculo-ventricular groove backward to end in the commencement of the coronary sinus. As it ascends in its course it receives branches from the front of the ventricles and the interventricular septum, and as it turns to the left backward it receives descending branches from the left auricle and ascending branches from the left ventricle. At its termination its orifice is protected by a valve, usually consisting of a pair of folds.

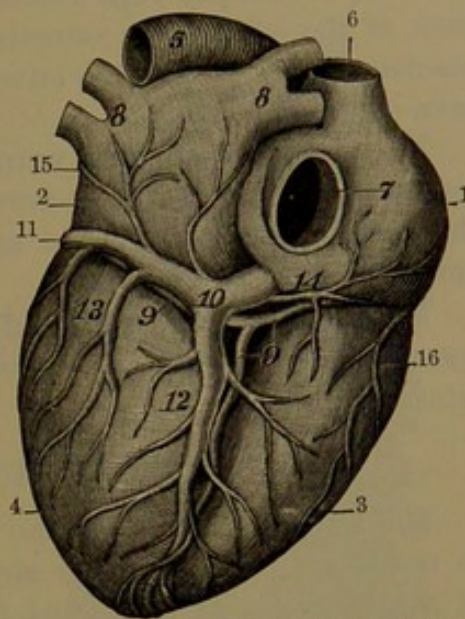
The **small coronary vein**<sup>2</sup> runs backward along the right auriculo-ventricular groove, receiving branches from the back of the right auricle and ventricle, and ends in the coronary sinus near its termination.

The **middle coronary vein**<sup>3</sup> commences at the apex of the heart, and ascends along the posterior interventricular groove, receiving branches from the back of both ventricles and the interventricular septum, and terminates in the coronary sinus near its termination and behind the former vein.

The **posterior coronary veins** are several small branches, of which one is sometimes considerably the largest, ascending from the back of the left ventricle to end in the coronary sinus.

The **coronary sinus**,<sup>4</sup> about an inch long, occupies the back part of the left auriculo-ventricular groove, continued from the great cardiac vein to the inner lower back corner of the right auricle, into which it opens between the auriculo-ventricular orifice and the aperture of the inferior cava. The sinus is enclosed by muscular fibres extending from the wall of the right auricle. Its orifice communicating with the latter

FIG. 279.



POSTERIOR VIEW OF THE VEINS OF THE HEART. 1, 2, right and left auricles; 3, 4, right and left ventricles; 5, aorta; 6, 7, superior and inferior cavæ; 8, pulmonary veins; 9, right coronary artery; 10, coronary sinus; 11, great coronary vein; 12, middle coronary vein; 13, posterior coronary veins; 14, small coronary vein; 15, oblique vein; 16, anterior coronary vein.

<sup>1</sup> Great cardiac vein; v. cardiaca, coronaria, or cordis magna.

<sup>2</sup> Small or right cardiac vein.

<sup>3</sup> V. cordis media; posterior cardiac vein.

<sup>4</sup> Valve of Thebesius.



is protected by the **coronary valve**, a semilunar fold of the endocardium. All the chief veins, at their communication with the coronary sinus, are protected by valves more or less complete.

A small **oblique vein** descending obliquely from left to right at the back of the left auricle, sometimes obliterated, and connected with the coronary sinus, is with the latter the representative of the left superior cava of the embryo.

The **anterior cardiac veins**<sup>1</sup> are several small vessels, which ascend on the front and right border of the right ventricle and open into the right auricle above the auriculo-ventricular groove. They are devoid of valves.

Many of the **smallest cardiac veins**,<sup>2</sup> from the walls of the heart, open into its cavities, but especially into the right auricle about the interauricular septum.

#### THE SUPERIOR CAVA.

The **superior cava**<sup>3</sup> is the principal vein which returns the blood to the heart from the head and neck, the upper limbs, and the walls of the thorax. It is a short trunk, about three inches long, and is of less diameter than the aorta, to the right of which it lies. It is formed by the conjunction of the two innominate veins, behind the right costo-sternal articulation, descends vertically with a slight curve to the right, and terminates in the upper back part of the right auricle of the heart. It is unprovided with valves. About the middle of its course it is joined by the azygos vein, and immediately below enters the pericardium.

#### THE INNOMINATE VEINS.

The **innominate vein**,<sup>4</sup> on each side of the body behind the inner end of the clavicle, is formed by the union of the internal jugular and subclavian veins, and terminates on the right side, behind the first costo-sternal articulation, by joining its fellow to form the superior cava. The **right innominate vein**, about an inch long, descends to the right of the corresponding artery; the **left innominate vein**, nearly three times as long, passes from right to left with a slight downward inclination to join its fellow. Crossing in front of the three large arteries springing from the arch of the aorta, behind the upper border of the sternum, the left vein, from its course, has also been called the **transverse vein**.

The innominate veins are destitute of valves. Each is joined by the corresponding vertebral, inferior thyroid, and mammary veins.

<sup>1</sup> Venæ Galeni.

<sup>2</sup> Venæ Thebesii; v. cordis minimæ.

<sup>3</sup> Vena cava superior, descendens, or thoracica.

<sup>4</sup> Vena innominata or anonyma; brachio-cephalic vein; v. brachio-cephalica; v. jugularis communis.



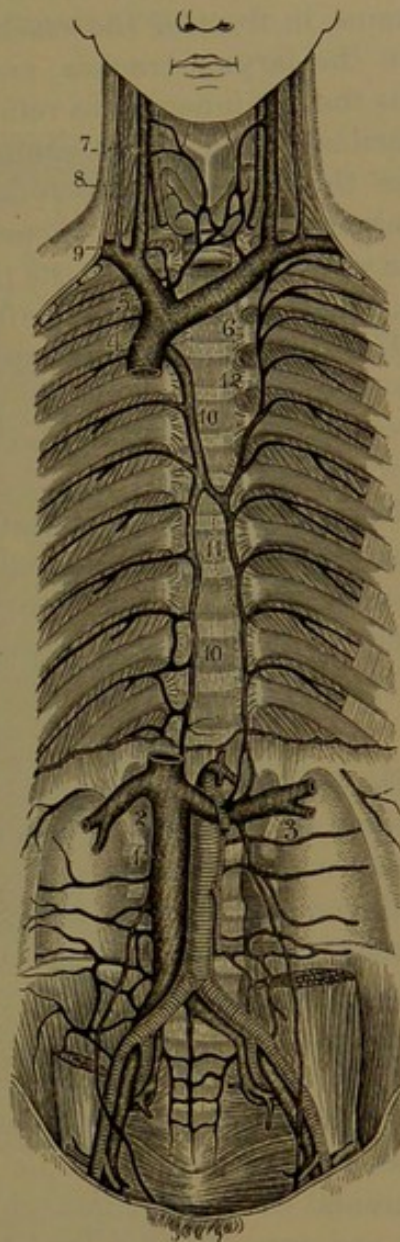
The **vertebral vein**,<sup>1</sup> with a plexiform arrangement, pursues the course of the vertebral artery through the foramina in the costo-transverse processes of the cervical vertebræ, but does not accompany it within the cranium. It commences in branches which proceed from the pericranium and the muscles contiguous to the occipital foramen, and in its course receives branches from the spinal canal through the intervertebral foramina, and communicates with the neighboring superficial vertebral veins. Emerging from the sixth cervical vertebra it passes forward over the subclavian artery, and ends in the commencement of the innominate vein. Near its termination it receives the anterior vertebral, deep cervical, and superior intercostal veins. Occasionally it continues its course by entering the costo-transverse process of the last cervical vertebra.

The **anterior vertebral vein**<sup>2</sup> commences in a plexus in front of the cervical vertebræ, descends in company of the ascending cervical artery, receiving branches from the contiguous muscles, and joins the vertebral vein near its termination.

The **deep cervical vein**<sup>3</sup> descends at the back of the neck, between the complexus and semispinalis muscles, receiving in its course the occipital vein, and branches from the dorsi-spinal plexus and contiguous muscles. Turning forward beneath the costo-transverse process of the last cervical vertebra, it ends in the termination of the vertebral vein.

The **inferior thyroid vein**,<sup>4</sup> of large proportionate size, proceeds

FIG. 280.



VEINS OF THE THORAX AND ABDOMEN. 1, inferior cava; 2, right, 3, left, renal veins; 4, superior cava; 5, right, 6, left, innominate veins; 7, internal, 8, external, jugular veins; 9, subclavian vein; 10, azygos vein; 11, inferior, 12, superior, hemi-azygos veins.

<sup>1</sup> V. vertebralis.

<sup>2</sup> V. vertebralis ant.

<sup>3</sup> V. cervicalis profunda; v. vertebralis externa or superficialis.

<sup>4</sup> V. thyroidea inf. or ima.



from the lateral lobe of the thyroid body, in which its many branches freely anastomose with the middle and superior thyroid veins. It anastomoses with its fellow, forming a plexus below the thyroid isthmus, in front of the trachea. In its descent it receives branches from the larynx, trachea, and œsophagus. The left inferior thyroid joins the left innominate vein; and the right inferior thyroid, the right innominate vein, or its conjunction with the left innominate. Sometimes the inferior thyroids unite in a common trunk,<sup>1</sup> which usually terminates in the left innominate vein; and occasionally an intermediate vein descends from the thyroid isthmus, or a venous plexus below this, to end in the left innominate vein.

The **internal mammary vein**,<sup>2</sup> a short trunk joining the innominate vein, is formed by the union of the pair of companions of the corresponding artery, derived from similar branches in the walls of the thorax and abdomen.

The **superior intercostal vein**,<sup>3</sup> subsequently to be again noticed, opens into the innominate vein.

Small veins from the thymus gland, the pericardium, and other structures of the mediastinum join the innominate vein.

#### VEINS OF THE HEAD AND NECK.

The principal venous trunks of the head and neck are the jugulars, of which there are two on each side, a larger and deeper, the internal jugular vein, and an external jugular vein. Besides these are the vertebral and inferior thyroid veins, already described. All the veins of the head, and those of the neck, are without valves, except the internal and external jugulars.

#### THE INTERNAL JUGULAR VEIN.

The **internal jugular vein**,<sup>4</sup> much the larger of the principal trunks, and usually about the size of a finger, receives the blood of the cranial cavity and the orbit, and portions of that of the face and neck, and terminates in the innominate vein. It commences with the termination of the lateral sinus of the dura in the jugular foramen of the skull, where it forms a variable dilatation, the **jugular gulf**.<sup>5</sup> From the foramen the vein descends the neck at the outer side of the internal carotid and then the common carotid artery, enclosed in the same sheath, and behind the inner end of the clavicle joins the subclavian vein to form with it the innominate vein. Its termination is guarded by a pair of valves.

<sup>1</sup> V. thyroidea ima impar.

<sup>2</sup> V. mammaria interna.

<sup>3</sup> V. intercostalis sup.

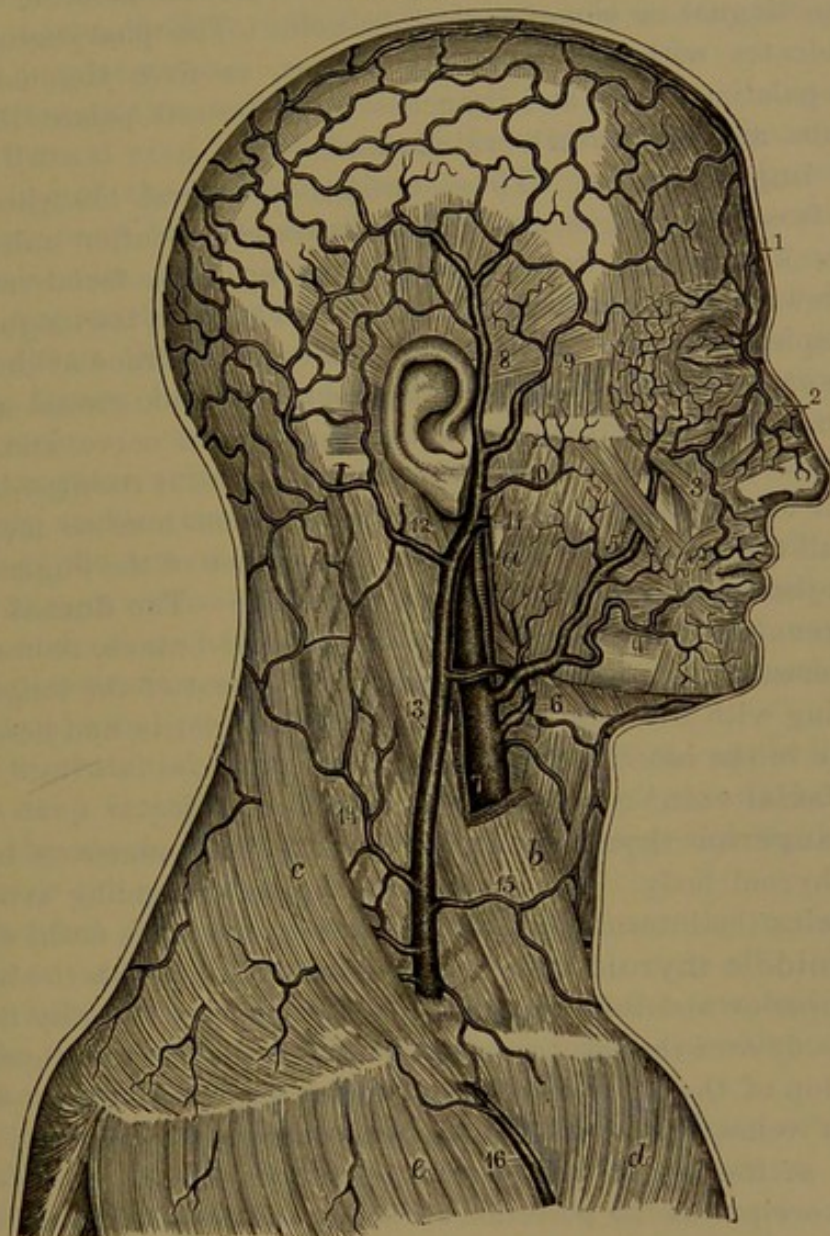
<sup>4</sup> V. jugularis interna, magna, or cerebralis; v. cephalica interna and communis; v. cerebralis.

<sup>5</sup> Bulb or sinus of the jugular vein; bulbus venæ jugularis.



The internal jugular vein is very variable in size in different persons and on the two sides of the neck, the right one usually being the longer, but it maintains a reciprocal proportion with its fellow, and also in a measure with the external jugular vein.

FIG. 281.



VEINS OF THE HEAD AND NECK. 1, frontal vein; 2, nasal vein; 3, 4, labial veins; 5, facial vein; 6, lingual vein; 7, internal jugular vein; 8, 9, posterior and anterior temporal veins; 10, transverse facial vein; 11, internal maxillary vein; 12, posterior auricular vein; 13, external jugular vein; 14, posterior, 15, anterior, jugular veins. *a*, external carotid artery; *b*, sterno-mastoid muscle; *c*, trapezius; *d*, pectoral muscle; *e*, deltoid muscle.

In its course the internal jugular vein receives the following tributaries:

The **inferior petrosal sinus**,<sup>1</sup> which issues from the cranium at

<sup>1</sup> S. petrosus inf.



the inner division of the jugular foramen, and thence opens into the internal jugular vein.

The **pharyngeal vein**<sup>1</sup> descends from the **pharyngeal plexus**, a net-work of veins in the walls of the pharynx, and joins the internal jugular vein near the hyoid bone. Several branches may substitute it, partly joining the latter and partly the facial vein, alone or together with the lingual or superior thyroid vein. The pharyngeal plexus communicates with the maxillary plexus, receives the vidian and pterygo-palatine veins, and branches from the soft palate, the eustachian tube, and the prevertebral muscles.

The **lingual veins**. These consist of several branches which emerge from the tongue, and either separately or after uniting in a short trunk terminate in the internal jugular or the facial vein. The longest branch, the **ranine vein**,<sup>2</sup> commences beneath the tongue, where it is conspicuously seen through the mucous membrane at the side of the frænum. It runs backward between the genio-glossal and hyoglossal muscles, in company with the hypoglossal nerve, and ends in the internal jugular or facial vein. In its course it receives branches from the tongue, sublingual gland, and adjacent mucous membrane. Two small **companion veins**<sup>3</sup> pursue the course of the lingual artery, and join the ranine or either of the other veins. The **dorsal lingual vein**,<sup>4</sup> accompanying the corresponding arterial branch, issues from a plexus beneath the mucous membrane at the root of the tongue, communicating with the veins of the tonsil and epiglottis, and descends to terminate in the internal jugular vein.

The **facial vein**<sup>5</sup> is subsequently described.

The **superior thyroid vein**<sup>6</sup> is derived from numerous branches of the thyroid body. It accompanies the corresponding artery, and usually joins the internal jugular vein or sometimes the facial vein.

The **middle thyroid vein**,<sup>7</sup> freely anastomosing with the branches of the superior and inferior thyroid veins, passes outwardly from the thyroid body over the carotid artery, and joins the internal jugular vein.

The top of the head is covered with a subcutaneous net-work or plexus of veins, from which branches converge and descend on the forehead as the frontal vein, on the temple as the temporal vein, and from the occiput as the posterior auricular and occipital veins.

The chief superficial vein of the face is the facial vein; the chief deep ones are the internal maxillary and ophthalmic veins. The first commonly terminates in the internal jugular vein, the second by joining the temporal vein, and the last by passing backward from the orbit and opening into the cavernous sinus.

The **facial vein**<sup>8</sup> pursues nearly the course of the facial artery,

<sup>1</sup> V. pharyngea.

<sup>2</sup> V. ranina.

<sup>3</sup> V. linguales.

<sup>4</sup> V. dorsalis linguæ.

<sup>5</sup> V. facialis.

<sup>6</sup> V. thyroidea sup.

<sup>7</sup> V. thyroidea media.

<sup>8</sup> V. facialis; v. f. anterior or interna.



but is less tortuous and placed more back. Commencing at the inner border of the orbit as the angular vein, it descends obliquely to the base of the mandible in advance of the masseter muscle. Below the jaw, covered by the platysma muscle and cervical fascia, it is commonly joined by the anterior fork of the external jugular vein, and near the hyoid bone terminates in the internal jugular vein. Occasionally it turns backward on the sterno-mastoid muscle, and joins the external jugular vein.

Its tributaries are as follows :

The **frontal vein**.<sup>1</sup> This descends from the cranial plexus near the median line of the forehead, parallel with and joining its fellow by one or two cross branches, and at the root of the nose terminates in the angular vein.

The **supraorbital vein**.<sup>2</sup> Smaller than the former, it receives its branches from the brow and upper eyelid, and is directed inward to join the former in the angular vein. It anastomoses with the ophthalmic vein.

The **angular vein**<sup>3</sup> is the commencement of the facial vein, and is commonly visible through the skin near the inner angle of the eye at the side of the root of the nose. Formed by the union of the two preceding veins, it receives small branches from the eyelids, the **palpebral veins**,<sup>4</sup> and others ascending from the nose, the **nasal veins**.<sup>5</sup> It freely communicates with the ophthalmic vein. In its further course as the facial vein it receives the following :

The **supralabial vein**,<sup>6</sup> arising in a plexus of the upper lip.

The **deep facial vein**,<sup>7</sup> from the maxillary plexus within the position of the ramus of the jaw, and communicating with the facial vein from below the malar bone.

**Branches** from the parotid gland and from the masseter and buccinator muscles.

The **submental vein**,<sup>8</sup> below the base of the jaw, and receiving branches from a plexus of the lower lip and from the chin.

**Branches** from the submaxillary gland.

The **inferior palatine vein**,<sup>9</sup> derived from a plexus of the tonsil and soft palate, and descending at the side of the pharynx.

The **external jugular vein**<sup>10</sup> is variable in size and manner of origin: it is commonly a very small vessel compared with the internal jugular vein, and is mostly formed by the conjunction of the

<sup>1</sup> V. frontalis ; v. preparata.

<sup>2</sup> V. supraorbitalis.

<sup>3</sup> V. angularis.

<sup>4</sup> V. palpebrales.

<sup>5</sup> V. nasales dorsales et laterales, pinnales, or alares.

<sup>6</sup> V. supralabialis.

<sup>7</sup> V. facialis profunda, maxillaris interna anterior, ramus anastomoticus profundus.

<sup>8</sup> V. submental.

<sup>9</sup> V. palatina ; inferior palatine vein.

<sup>10</sup> V. jugularis externa or externa posterior ; v. cutanea colli posterior ; v. trachelo-subcutanea.



temporal and maxillary veins. Commencing behind the neck of the mandible, it descends nearly vertically at the side of the neck, behind the angle of the jaw, and across the sterno-mastoid muscle to the supraclavicular fossa, about the middle of the position of the clavicle.<sup>1</sup> It is covered by the platysma muscle, and perforates the cervical fascia of the supraclavicular fossa to terminate in the subclavian vein, or sometimes in the end of the internal jugular vein. In the vicinity of the angle of the jaw it commonly gives off a considerable branch, which descends obliquely forward to join the termination of the facial vein or the contiguous portion of the internal jugular vein. In its course it commonly receives the posterior auricular vein, the anterior and posterior jugular veins, and the transverse cervical and suprascapular veins. Sometimes it also receives the facial vein, in whole or part, and sometimes it does not receive the posterior auricular vein. Rarely it does not commence in the temporal and internal maxillary veins together, and then appears to commence in the latter alone, or in conjunction with a branch of the occipital vein. It has an imperfect valve at its termination, and another more complete a short distance above.

The **temporal vein**<sup>2</sup> arises in the cranial plexus of veins by two main branches, the **anterior** and **posterior temporal veins**,<sup>3</sup> corresponding with but not closely accompanying the arteries of the same name, and lying more superficially. Descending the temple the two branches unite in front of the ear, whence the temporal vein passes over the zygoma and beneath the parotid gland to the neck of the mandible, where it joins the internal maxillary vein to form the external jugular. Other tributaries of the temporal vein are as follows:

The **middle temporal vein**,<sup>4</sup> derived from a plexus in the temporal fossa communicating with the deep temporal veins and with the pterygoid plexus of veins. It pierces the temporal fascia, and receives an **orbital branch** proceeding from the palpebral veins.

The **anterior auricular veins**, small branches from a fine plexus of the pinna.

**Branches**<sup>5</sup> from an **articular plexus** surrounding the articulation of the mandible.

**Branches** from the parotid gland.

One or two **transverse facial veins** from the cheek.

The **internal maxillary vein**<sup>6</sup> is a short trunk, sometimes double,

<sup>1</sup> Many authorities name the trunk formed by the union of the temporal and internal maxillary veins the temporo-maxillary vein, which is then described as descending to the vicinity of the angle of the jaw and dividing into two branches, of which one joins the facial vein, and the other joins with the posterior auricular vein to form the external jugular vein.

<sup>2</sup> V. temporalis.

<sup>3</sup> V. t. superficialis ant. et post.

<sup>4</sup> V. t. media.

<sup>5</sup> V. articulares.

<sup>6</sup> V. maxillaris interna or interna posterior; deep branch of the posterior facial vein.



proceeding in company with the internal maxillary artery, behind the neck of the mandible, from the pterygoid plexus, to join the temporal vein in the formation of the external jugular vein. Occasionally a division of it descends within the ramus of the jaw and joins the internal jugular vein. The **pterygoid plexus**<sup>1</sup> is a close net-work of veins accompanying the internal maxillary artery between the pterygoid muscles. It communicates with the temporal, pharyngeal, and alveolar venous plexuses, and receives the following tributaries:

Two or three **deep temporal veins** issuing from the temporal muscle and plexus of veins on its surface.

**Pterygoid, masseter, and buccinator** branches, issuing from the corresponding muscles.

An **alveolar branch** from the alveolar plexus, on the surface of the maxilla.

An **inferior dental vein** from the dental canal of the mandible.

A pair of **great meningeal veins**,<sup>2</sup> companions of the corresponding artery, descending through the spinous or oval foramen.

The **superior palatine, infraorbital, and nasal veins**, accompanying the corresponding arteries.

The **posterior auricular vein**,<sup>3</sup> much larger than the corresponding artery, issues from the cranial venous plexus back of the ear, descends on the mastoid process and contiguous portion of the sternomastoid muscle, and commonly joins the external jugular vein, but sometimes turns inwardly and ends in the internal jugular vein. It receives the **stylo-mastoid vein**.

The **occipital vein**<sup>4</sup> issues from the occipital portion of the cranial venous plexus, and mainly pursues the course of the corresponding artery between the muscles at the back of the neck, descending to terminate in the deep cervical vein or the internal jugular vein. An outer branch communicates with the mastoid vein and the lateral sinus. Superficially, it may communicate with the posterior auricular vein or with the external jugular vein.

The **anterior jugular vein**<sup>5</sup> springs from superficial branches in the submaxillary region, and descends in front of the neck to near the inner end of the clavicle, where it pierces the fascia and proceeds outwardly within the insertion of the sternomastoid muscle to join the termination of the external jugular vein. In descending the neck it commonly communicates with its fellow by cross-branches, and sometimes joins it part way in a single median vessel.

The **posterior jugular vein**,<sup>6</sup> at the back of the neck, issues from branches of the integument in the suboccipital region, and descends to

<sup>1</sup> P. pterygoideus.

<sup>2</sup> Venæ meningeæ mediæ.

<sup>3</sup> V. auricularis posterior.

<sup>4</sup> V. occipitalis.

<sup>5</sup> V. jugularis anterior or externus anterior; v. mediani colli; v. cutanea colli.

<sup>6</sup> V. jugularis posterior.



join the external jugular vein about the middle of the course of the latter.

The **transverse cervical**<sup>1</sup> and **suprascapular veins**<sup>2</sup> accompany the corresponding arteries, and run forward in the supraclavicular fossa to join the external jugular vein, but not unfrequently end in the subclavian vein.

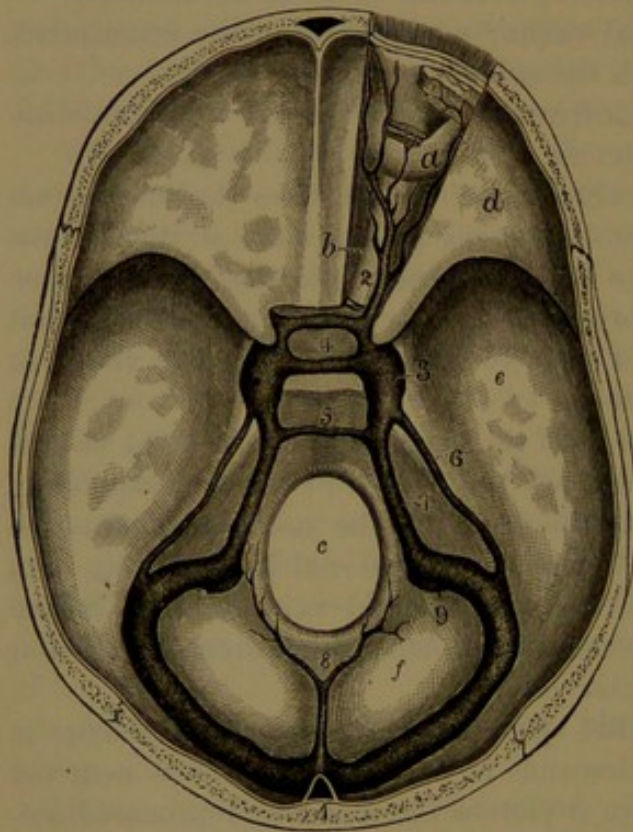
#### VEINS OF THE CRANIUM.

The veins of the cranial cavity consist of the sinuses of the dura mater and the veins of the brain, the sinuses being intermediate channels of the circulation between the latter and the internal jugular veins.

#### SINUSES OF THE DURA.<sup>3</sup>

These are venous channels of the dura, or dura mater, which in

FIG. 282.



SINUSES AT THE BASE OF THE CRANIUM, with the right orbit exposed. *a*, eyeball; *b*, optic nerve; *c*, occipital foramen; *d, e, f*, anterior, middle, and posterior cranial fossae. 1, confluence of the sinuses from which the lateral sinus on each side passes off to terminate at the jugular foramen; 2, ophthalmic vein; 3, cavernous sinus; 4, circular sinus surrounding the sella; 5, anterior occipital sinus; 6, 7, superior and inferior petrosal sinuses; 8, posterior occipital sinus; 9, commencement of the internal jugular vein.

their course are joined by the veins of the brain and the ophthalmic vein from the orbit, and terminate at the jugular foramen in the internal jugular vein. The sinuses are formed between the layers of the dura, and are lined by a delicate membrane like that of veins generally. They possess no muscular coat, are free from valves, and do not accompany corresponding arteries.

The **lateral sinuses**<sup>4</sup> are the main channels to which the other sinuses converge. They commence at the internal occipital protuberance, turn outward in the lateral groove of the occipital bone, in the attachment of the tentorium, to the posterior inferior angle of the parietal bone, curve downward in the groove of the mastoid portion of the temporal bone, and forward over the occip-

<sup>1</sup> *V. transversa colli.*

<sup>2</sup> *V. transversa scapulæ.*

<sup>3</sup> Sinus duræ matris; fistulæ, tubuli, or sanguiductus duræ matris.

<sup>4</sup> *S. laterales or transversi.*

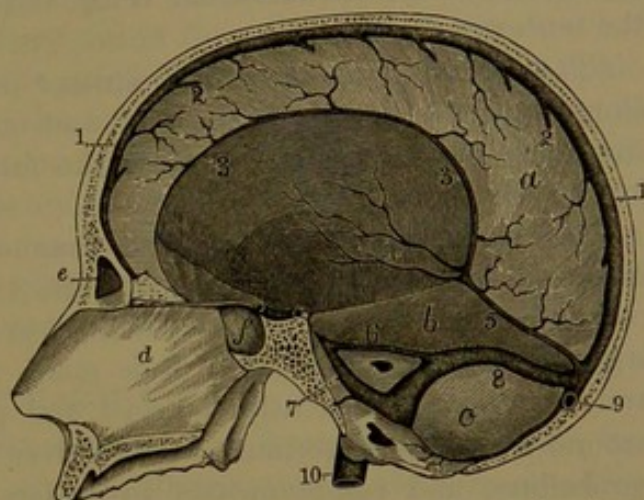


ital jugular process, and terminate at the jugular foramen in the gulf of the internal jugular vein. They commonly differ more or less in size, usually the right one being the larger. Occasionally one sinus exhibits a great reduction in size when the other is proportionately enlarged.<sup>1</sup>

In its course the lateral sinus is joined by the superior petrosal sinus, and receives veins from the back of the cerebrum and from the cerebellum. It also receives the occipital diploic vein, and communicates with veins of the scalp by emissary veins through the mastoid and posterior condylar foramina.

The **longitudinal sinus**,<sup>2</sup> a single median channel, commences at the anterior extremity of the falx, and extends back along its attached border, occupying the median groove of the cranial vault and gradually enlarging in its course. It is trilateral, and has the lower angle of its passage bridged here and there by fibrous bands.<sup>3</sup> It usually communicates with the veins of the scalp by emissary veins through the parietal foramina, and in its course receives the superior cerebral veins of the brain. Descending on the occipital bone, the sinus usually deviates a little from the median line

FIG. 283.



VERTICAL SECTION OF THE SKULL, exhibiting the sinuses of the dura. 1, superior longitudinal sinus; 2, termination of the superior cerebral veins; 3, inferior longitudinal sinus; 4, internal cerebral veins; 5, straight sinus; 6, 7, superior and inferior petrosal sinuses of the right side; 8, right lateral sinus; 9, commencement of the left lateral sinus; 10, internal jugular vein. a, cerebral falx; b, tentorium; c, cerebellar fossa; d, partition of the nose; e, frontal sinus; f, sphenoidal sinus.

to one side of the occipital protuberance, mostly the right, where it becomes somewhat dilated, and then abruptly turns into the corresponding lateral sinus. The dilatation, named the **torcular**,<sup>4</sup> or **confluence of the sinuses**,<sup>5</sup> is variable, and occupies a usually well-marked depression of the occipital bone. From it a branch of variable size passes over the occipital protuberance to the straight sinus, as this curves to the opposite lateral sinus. Sometimes the longitudinal sinus approaching its termination retains the median position, and the

<sup>1</sup> In a specimen in the University museum, one lateral sinus is reduced to the condition of a small vein, which empties itself at the mastoid foramen, while the venous portion of the jugular foramen of that side is almost closed, and on the opposite side the lateral sinus and jugular foramen are very large.

<sup>2</sup> Superior longitudinal sinus; s. longitudinalis sup.; s. triangularis; s. falci-formis.

<sup>4</sup> T. Herophili; wine-press of Herophilus.

<sup>3</sup> Chordæ Willisii.

<sup>5</sup> Confluens sinuum.



straight sinus opens into it directly in front, at the torcular, from the sides of which issue the lateral sinuses. Sometimes, also, the branch from the torcular to the straight sinus is as large as that to the opposite lateral sinus, in which case the lateral sinuses may be nearly or quite equal in size.

The **straight sinus**<sup>1</sup> inclines backward along the union of the falx and tentorium to the occipital protuberance, where it is commonly continued into the lateral sinus opposite that into which the longitudinal sinus is prolonged, and is connected by a smaller diverging channel with the torcular. It receives at its commencement in front the inferior longitudinal sinus and the vein of Galen, and along its course some of the superior cerebellar veins, and several small branches from the tentorium.

The **inferior longitudinal sinus**<sup>2</sup> is a narrow channel running along the lower border of the falx, and ending behind in the straight sinus. It receives branches from the falx, and occasionally from the inner surfaces of the cerebrum.

The **occipital sinus**,<sup>3</sup> a small channel, sometimes double, ascends in the cerebellar falx and opens into the torcular. It forks below, and continues around the occipital foramen to join the termination of the lateral sinuses. Occasionally it is much reduced, or is even absent; and sometimes it is greatly enlarged, and produces a conspicuous ring around the occipital foramen. It receives several small veins from the cerebellum, and communicates by others with the posterior spinal veins.

The **cavernous sinus**<sup>4</sup> is situated at the side of the sphenoidal body, and is a venous plexus extending from the inner extremity of the sphenoidal foramen to the apex of the temporal pyramid. The two sinuses communicate with each other by a pair of **transverse sinuses** crossing through the sella, thus forming together a **circular sinus**<sup>5</sup> around the pituitary body. Either of the transverse sinuses may be absent, and occasionally there is a third. The cavernous sinus in front receives the ophthalmic vein through the sphenoidal foramen, and behind it communicates with the petrosal sinuses. It also receives several small veins from the cerebrum.

The venous plexus of the cavernous sinus is continued along the carotid canal, around the internal carotid artery, and ends below in one or two branches, which join the internal jugular vein.

Lying along the floor of the cavernous sinus inwardly, covered by the lining membrane, is the internal carotid artery, with the cavernous plexus of the sympathetic nerve and the abducent nerve, and passing

<sup>1</sup> S. rectus, quartus, obliquus, perpendicularis, or tentorii medius.

<sup>2</sup> S. longitudinalis inf., or minor; s. falciformis.

<sup>3</sup> S. occipitalis posterior.

<sup>4</sup> S. cavernosus; receptaculum cavernosum.

<sup>5</sup> S. circularis Ridleyi; s. coronarius or ellipticus.



through the outer wall of the sinus are the oculo-motor, pathetic, and ophthalmic nerves.

The **superior petrosal sinus**<sup>1</sup> is a narrow channel running from the cavernous sinus along the upper border of the temporal pyramid, within the attachment of the tentorium, to the lateral sinus as it curves downward into the groove of the mastoid portion of the temporal bone. It receives small veins from the cerebrum and cerebellum, and others from the tympanum through the petro-squamous fissure.

The **inferior petrosal sinus**,<sup>2</sup> much shorter than the former, runs from the cavernous sinus along the course of the petro-occipital suture to the inner compartment of the jugular foramen, through which it descends to end in the jugular vein. It receives some small veins from the cerebellum and the **auditory veins** from the internal ear.

The **sphenoidal sinus**<sup>3</sup> is a small channel beneath the small sphenoidal wing, terminating in the cavernous sinus. It receives small veins of the dura, and communicates with the anterior temporal diploic veins and the great meningeal veins.

The **basilar sinus**<sup>4</sup> is a transverse venous plexus of the dura on the basilar process of the occipital bone, communicating laterally with the inferior petrosal sinuses, and below with the anterior spinal veins.

#### OPHTHALMIC VEIN.

The **ophthalmic vein**<sup>5</sup> returns the blood from the parts within the orbit, and in general accords with the distribution of the corresponding artery. It commences at the inner angle of the eye, where it freely communicates with the angular vein; thence passes backward in company with the ophthalmic artery, above the optic nerve to its outer side, and proceeds through the inner end of the sphenoidal foramen to terminate in the cavernous sinus. Its branches, which mainly correspond with those of the artery, are the **ethmoidal**,<sup>6</sup> **muscular**, **anterior** and **long ciliary**, **central retinal**, and **lachrymal veins**. The **short ciliary veins**,<sup>7</sup> usually four, issue at equidistant points from the sides of the eyeball, and join the ophthalmic or contiguous muscular veins. The lower ciliary and muscular veins commonly unite in a considerable branch,<sup>8</sup> which communicates by an anastomotic branch through the sphenomaxillary foramen with the deep facial vein, and joins the trunk<sup>9</sup> of the ophthalmic vein or ends directly in the cavernous sinus.

<sup>1</sup> S. petrosus sup.; s. tentorii lateralis.

<sup>2</sup> S. petrosus inf.

<sup>3</sup> Spheno-parietal sinus; s. spheno-parietalis; s. alæ parvæ.

<sup>4</sup> S. basilaris; s. transversus; s. occipitalis ant.; plexus basilaris.

<sup>5</sup> V. ophthalmica; superior ophthalmic vein.

<sup>6</sup> V. ethmoidalis ant. et post.

<sup>7</sup> Posterior ciliary veins.

<sup>8</sup> Inferior ophthalmic vein; v. ophthalmica inferior, externa, or facialis.

<sup>9</sup> Sinus ophthalmicus.



## VEINS OF THE BRAIN.

The more conspicuous veins of the brain occupy the pia, which closely invests the surface of the organ and penetrates its many fissures, and generally only the finest hair-like veins pervade and issue from the substance of the brain to join those of the pia. They do not accompany the arteries, but are closely associated with them in the pia, and freely anastomose with one another, everywhere forming a continuous net-work or plexus, from which the larger veins emerge and terminate in the nearest sinus of the dura.

The **superior cerebral veins**,<sup>1</sup> six to ten or more on each side of the cerebrum, ascend from the outer surface of the hemispheres inwardly, mostly along the fissures between the convolutions, to the longitudinal fissure, where they are joined by branches from the mesial surface of the hemispheres, and then terminate in the longitudinal sinus. With the exception of the most anterior smaller ones they run obliquely forward, and open into the sinus in a direction opposite to that of the current of the blood in the latter.

The **inferior cerebral veins**<sup>2</sup> run from the outer and lower surfaces of the cerebral hemispheres to the cavernous, superior petrosal, and lateral sinuses.

A large branch, the **middle cerebral vein**,<sup>3</sup> derived from the lower surface of the frontal and temporo-sphenoidal lobes, passes from the sylvian fissure and terminates in the cavernous sinus. Another branch, the **anastomotic vein**,<sup>4</sup> derived from the outer surface of the parietal lobe, where it communicates with the superior cerebral veins, runs along the posterior fork of the sylvian fissure, perforates the dura near the apex of the small sphenoidal wing, and then passes back through the middle cranial fossa to the superior petrosal sinus; in its course communicating with the great meningeal veins.

The veins in the central part of the cerebrum collect finally in a short trunk, the **vein of Galen**,<sup>5</sup> which is formed by the union of two chief branches, the **internal cerebral veins**, and terminates immediately behind in the commencement of the straight sinus. It also receives small branches from the contiguous part of the callosum, from the posterior cornu of the lateral ventricle and the quadrigeminal and pineal bodies. In addition it receives the **basilar vein**,<sup>6</sup> which ascends from the base of the cerebrum, where it derives tributaries from the anterior perforated space, the cinereous tuber, the mammillary eminences, and the cerebral crus.

The **internal cerebral veins**<sup>7</sup> commence at the foramen of Monro,

<sup>1</sup> Venæ cerebri superiores.

<sup>2</sup> Vena fossæ Sylvii.

<sup>3</sup> V. magna Galeni.

<sup>4</sup> V. cerebri internæ or magnæ; venæ Galeni; v. choroideæ mediæ.

<sup>5</sup> V. cerebri inferiores.

<sup>6</sup> Great anastomotic vein.

<sup>7</sup> V. basilaris; v. adscendens.



each by the conjunction of the striatum and choroid veins, run backward near together along the middle of the choroid tela, and unite to form the vein of Galen. In their course they receive branches from the thalami and choroid plexuses beneath of the third ventricle.

The **striatum vein**<sup>1</sup> runs forward in the groove between the striatum and the thalamus, receiving branches from both, and from the ventricular septum, the callosum, and the fornix, and unites with the choroid vein.

The **choroid vein**<sup>2</sup> starts from the bottom of the descending cornu of the lateral ventricle, where it communicates with veins in the sylvian fissure, and ascends along the course of the choroid plexus to the foramen of Monro, where it joins the striatum vein to form the internal cerebral vein. It receives branches from the choroid plexus and the hippocampus.

The veins of the cerebellum are disposed in two series. The **superior cerebellar veins**<sup>3</sup> are partly directed inward and upward to the straight sinus and the vein of Galen, and partly outward to the superior petrosal and lateral sinuses. The **inferior cerebellar veins**,<sup>4</sup> and veins of the pons and oblongata, join the inferior petrosal, lateral, and occipital sinuses.

#### THE DIPLOIC VEINS.

The **diploic veins**<sup>5</sup> form an irregular net-work or plexus in the diploe of the cranial vault, and may be exposed by removal of the external table of the bones. They enlarge and become more conspicuous in the advance of life, and in old age communicate more or less across the sutures. Lodged in canals of the diploe, they have a delicate membranous wall, corresponding with the internal tunic of veins, and are devoid of a muscular tunic. They are, for the most part, directed downward, and communicate with the superficial veins, and with the sinuses and veins of the dura. Four principal veins are commonly evident on each side of the cranium, and are named from their position.

The **frontal diploic vein**<sup>6</sup> arises from the plexus of the frontal diploe, and commonly issues at the supraorbital foramen to join the supraorbital vein. This outlet being sometimes absent, the frontal diploic vein may terminate in the succeeding vein.

The **anterior temporal diploic vein**<sup>7</sup> arises in the frontal diploe, and often also in the contiguous parietal diploe, passes through a foramen of the great sphenoidal wing, and thence proceeds in the dura to end in the cavernous sinus. It also communicates externally

<sup>1</sup> Vena corporis striati; v. reflexa; v. velata.

<sup>2</sup> V. choroidea; v. c. lateralis.

<sup>4</sup> V. cerebelli inferiores.

<sup>6</sup> Vena diploica frontalis.

<sup>3</sup> Venæ cerebelli superiores.

<sup>5</sup> V. diploicae or diploeticæ.

<sup>7</sup> V. d. temporalis anterior.



with the deep temporal veins, and internally with the great meningeal veins.

The **posterior temporal diploic vein**<sup>1</sup> arises in the plexus of the parietal diploe, and emerges through a foramen at the lower posterior angle of the parietal bone, or through the mastoid foramen, to open in the lateral sinus.

The **occipital diploic vein**<sup>2</sup> descends from the plexus of the occipital diploe, and opens into the occipital vein, the torcular, or the lateral sinus.

#### THE EMISSARY VEINS.

The **emissary veins**<sup>3</sup> are those which pass through foramina of the cranium and communicate between the sinuses of the dura and the superficial veins. They are inconstant, and vary much in size.

The **mastoid vein**,<sup>4</sup> the most constant and the largest of the emissaries, communicates through the mastoid foramen, between the lateral sinus and a branch of the occipital, or of the posterior auricular vein.

The **parietal vein**,<sup>5</sup> usually small and often absent, communicates through the parietal foramen, between the longitudinal sinus and the contiguous veins of the scalp.

The **condylar vein**,<sup>6</sup> also inconstant and variable in size, communicates through the posterior condylar foramen, between the lateral sinus and the dorsi-spinal plexus of veins of the cervical vertebræ.

#### VEINS OF THE UPPER LIMBS.

The deep veins of the upper limb retrace the course of the arteries, closely accompanying them in their distribution, all, except the principal trunk, the subclavian and its continuation the axillary artery, having two companion veins, which lie on each side of the arteries and communicate here and there by branches crossing the latter. In their course the deep veins frequently communicate with the superficial veins by branches which ascend from the former through the deep fascia.

The **subclavian vein**<sup>7</sup> is the continuation of the axillary vein over the first rib, and is separated from the subclavian artery by the insertion of the anterior scalenus muscle. It receives the external jugular vein in front of the latter, and terminates at the inner border of the muscle by joining the internal jugular in the formation of the innominate vein.

The **axillary vein**<sup>8</sup> extends along the inner side of the axillary artery to the outer border of the first rib, whence it continues as

<sup>1</sup> Vena diploica t. posterior.

<sup>3</sup> Venæ emissariæ Santorini.

<sup>5</sup> V. e. parietalia.

<sup>7</sup> V. subclavia.

<sup>2</sup> V. d. occipitalis.

<sup>4</sup> Vena emissaria mastoidea.

<sup>6</sup> V. e. condyloidea.

<sup>8</sup> V. axillaris.

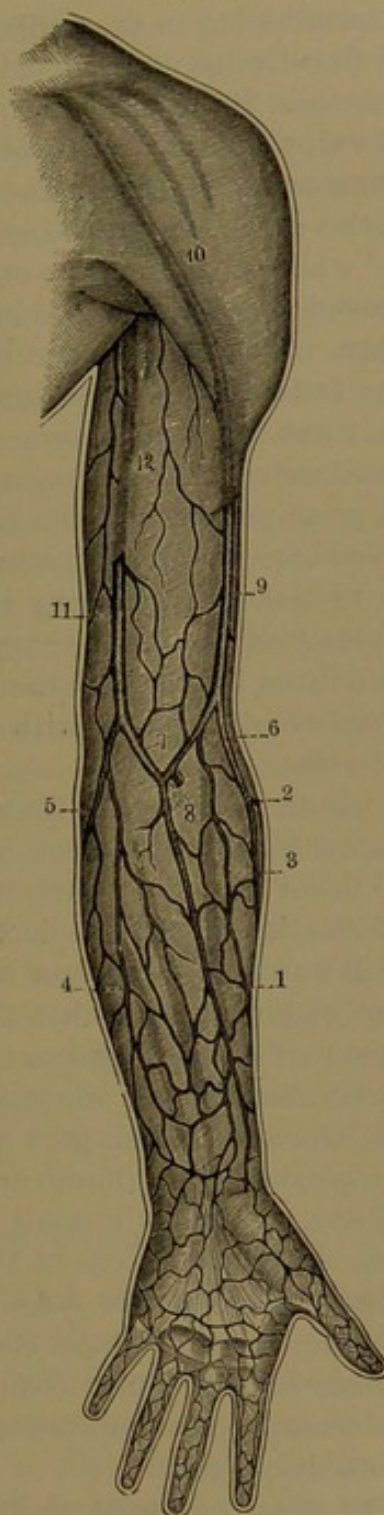


the subclavian vein. It commences at the outer border of the axilla by the union of the brachial veins, and the inner of these with the basilic vein. In its course it receives the **circumflex, subscapular, and thoracic veins** accompanying the corresponding arteries, and near its termination the cephalic vein.

The **brachial veins**,<sup>1</sup> companions to the brachial artery, lie closely applied to the outer and inner side, communicating by short branches crossing the artery. The inner vein, commonly the larger, is usually joined at some part of its course above the middle of the arm by the basilic vein, and the vessel is thus continued into the axillary vein, joined at the axilla by the outer brachial vein. In other instances the brachial veins continue to the axilla, unite, and then join with the basilic vein, or they successively unite with the latter to form the axillary vein.

The subcutaneous veins of the upper limb form a network or plexus in the superficial fascia and adipose tissue between the skin and the deep fascia. Commencing in plexuses of the fingers, those of the hand, forearm, and arm successively enlarge and communicate with the plexus of the shoulder and thorax. As constituents of the plexuses, larger and continuous veins,

FIG. 284.



SUPERFICIAL VEINS OF THE UPPER LIMB. 1, median vein; 2, 3, radial cutaneous veins; 4, 5, ulnar cutaneous veins; 6, median cephalic vein; 7, median basilic vein; 8, anastomosis with the deep veins; 9, cephalic vein; 10, its further course seen through the brachial fascia; 11, 12, basilic vein.

<sup>1</sup> Venæ brachiales.



more or less variable, form the chief branches, which ordinarily unite in the two superficial trunks of the arm, the cephalic and basilic veins, finally terminating in the axillary vein.

The dorsal veins of the hand are, for the most part, larger than the palmar veins. From the dorsal plexuses of the digits ascend at the sides **digital veins**,<sup>1</sup> of which the collateral ones unite between the knuckles in **interosseous veins**.<sup>2</sup> The dorsal veins of the thumb, contiguous side of the index finger, and outer part of the hand unite in a large branch,<sup>3</sup> while those from the other fingers and back of the hand unite in a second large branch,<sup>4</sup> which ascends to join the former at the outer part of the forearm, and produces with it the radial vein. Veins from the little finger and the inner part of the dorsal plexus of the hand unite to form the commencement of the ulnar vein ascending behind the inner border of the forearm.

The principal veins of the forearm issuing from its plexus and that of the hand are the radial, ulnar, and median veins.

The **radial vein**,<sup>5</sup> arising in the manner above indicated in the dorsal plexus of the hand, ascends outwardly on the back of the forearm, and turns forward to the outer groove in front at the bend of the elbow, where it unites with the median cephalic vein to form the cephalic vein.

The **ulnar vein**<sup>6</sup> arises from the inner part of the plexus of the hand, ascends along the back inner border of the forearm, and turns forward below the inner condyle to unite with the median basilic vein in the formation of the basilic vein. Besides smaller branches in its course, it commonly receives a large one near its termination, the **anterior ulnar vein**, which arises from the palmar plexus, at the inner fore part of the forearm.

The **median vein**,<sup>7</sup> very variable, sometimes arises in several branches from the outer part of the palmar plexus, and sometimes from the plexus of the thumb and the outer part of the dorsal plexus of the hand. Commonly small, it may be large and form the chief vein from the dorsal plexus of the hand, in which case the radial vein is proportionately reduced. Ascending in front of the forearm to the depression in the bend of the elbow, it forks into the median cephalic and median basilic veins. Near its bifurcation it receives the **deep median vein**, a communicating branch ascending from one of the contiguous deep veins.

The **median cephalic vein**<sup>8</sup> ascends outwardly in the groove of the biceps and long supinator muscles, and joins the radial vein to

<sup>1</sup> Venæ digitales.

<sup>3</sup> Vena cephalica pollicis.

<sup>5</sup> V. radialis; v. r. cutanea or cephalica.

<sup>6</sup> V. ulnaris; v. u. cutanea; v. basilica; posterior ulnar vein.

<sup>7</sup> V. mediana.

<sup>2</sup> V. interossee superficiales; v. metacarpeæ.

<sup>4</sup> V. salvatella.

<sup>8</sup> V. m. cephalica.



form the commencement of the cephalic vein. The musculo-cutaneous nerve, in its course, passes beneath it.

The **median basilic vein**,<sup>1</sup> usually larger than the former, ascends inwardly over the position of the brachial artery, from which it is separated by an offset of the biceps tendon to the fascia, and joins the ulnar vein to form the commencement of the basilic vein. In its course it may receive the anterior ulnar vein and other branches from the plexus of the forearm. Branches of the internal cutaneous nerve cross above and beneath the vein.

The median vein is liable to much variation in its termination. The median cephalic vein may be very small or absent, and the median basilic vein proportionately large. In such instances the radial vein may fork, and one branch continue as the cephalic vein, while the other branch may join the median vein, and together with the median basilic vein form an oblique trunk, which crosses the forearm from without inward, and receives in its course branches from the plexus below.

The **cephalic vein**<sup>2</sup> ascends along the arm in the groove at the outer border of the biceps muscle, thence between the pectoral and deltoid muscles to the clavicle, below which it dips to join the axillary vein. In its course it receives branches from the subcutaneous plexus of the arm, shoulder, and breast. It is sometimes much reduced, and may be absent. Occasionally it passes over the clavicle and joins the external jugular vein, or it may be united with this by a communicating branch.

The **basilic vein**,<sup>3</sup> much larger than the former or either of the brachial veins, ascends the arm along the inner border of the biceps muscle, and inwardly to the position of the brachial vessels. Perforating the fascia near the middle of the arm, it joins the inner of the brachial veins, or continues upward into the axillary vein. Its lower part receives branches communicating with the cephalic vein.

#### THE INFERIOR CAVA.

The **inferior cava**<sup>4</sup> is the main trunk which returns the blood to the heart from the lower limbs and abdomen. It commences in the latter cavity, by the union of the iliac veins in front of the last lumbar vertebra, ascends to the right of the aorta, and passes through an opening in the central tendon of the diaphragm into the thorax, where it enters the pericardium, and terminates in the lower part of the right auricle of the heart. In its course it is covered by the mesentery, the duodenum, and the pancreas, and is then lodged in a deep groove of the liver; and rests behind upon the lumbar vertebrae and the right crus of the diaphragm. It is a larger trunk than

<sup>1</sup> Vena mediana basilica.

<sup>2</sup> V. cephalica.

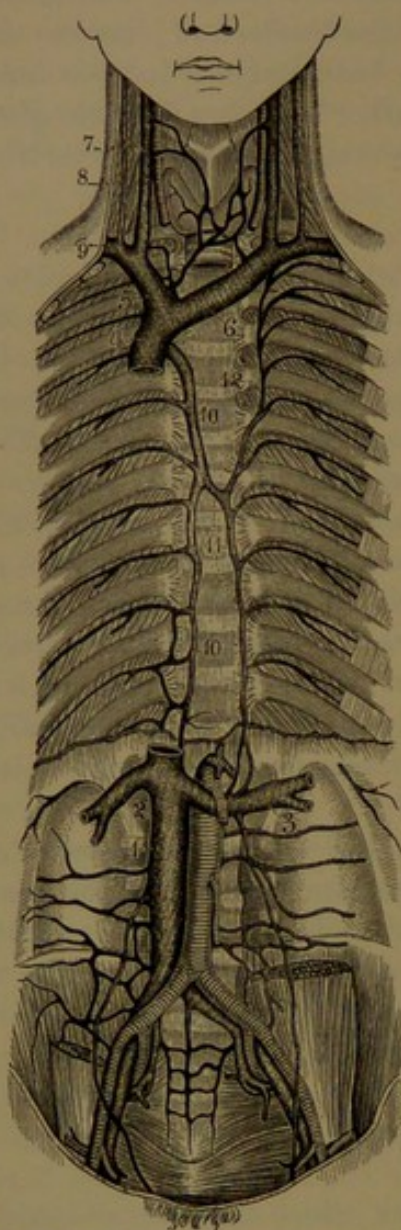
<sup>3</sup> V. basilica.

<sup>4</sup> V. cava inferior or adscendens.



the superior cava or the aorta, and contains no valves. Besides the common iliac veins it receives the following:

FIG. 285.



VEINS OF THE THORAX AND ABDOMEN. 1, inferior cava; 2, right, 3, left, renal veins; 4, superior cava; 5, right, 6, left, innominate veins; 7, internal, 8, external, jugular veins; 9, subclavian vein; 10, azygos vein; 11, inferior, 12, superior hemi-azygos veins.

The **lumbar veins**,<sup>1</sup> accompanying the corresponding arteries. They arise in an **anterior branch** from the wall of the abdomen, where it anastomoses with the epigastric and other contiguous veins, and a **posterior branch**, larger than the former, derived from the intraspinal and dorsi-spinal plexuses and from the muscles of the back. Passing forward on the lumbar centra, behind the psoas muscle, and on the left behind the aorta, they terminate in the back part of the inferior cava. In front of the transverse process they are united by longitudinal branches, together forming, on each side, the **ascending lumbar vein**,<sup>2</sup> which anastomoses variably with the lateral sacral, ilio-lumbar, and common iliac veins, and terminates in the azygos vein on the right and the inferior hemi-azygos on the left side.

#### AZYGOS AND HEMI-AZYGOS VEINS.

The azygos and hemi-azygos veins ascend along the back of the thoracic cavity, and arise from the veins which accompany most of the intercostal and partly the lumbar arteries.

The **azygos vein**<sup>3</sup> commences in the abdomen in the right ascend-

ing lumbar vein, whence it ascends on the right side of the lumbar centra, enters the thorax through the right crus of the diaphragm or the aortic orifice, and continues upward on the thoracic centra to the fourth one, where it arches forward over the root of the right lung,

<sup>1</sup> Venæ lumbares.

<sup>2</sup> Vena lumbaris adscendens.

<sup>3</sup> Right or large azygos vein; v. azygos major or dextra; v. sine pari.



and ends in the superior cava as this vessel enters the pericardium. In its course it is situated close to the right of the thoracic duct and the aorta, crosses over the right intercostal arteries, and lies behind the pleura. Besides the ascending lumbar vein, it commonly receives the right intercostal veins, except the upper one or two, the hemi-azygos veins separately or in common, the right bronchial vein, and small branches from the œsophagus, pericardium, and other structures contiguous. There is ordinarily a valve in the arch of the azygos vein.

The hemi-azygos veins commonly appear as two trunks, which relate with the left intercostal veins as the azygos does with the right ones, and they open separately or in conjunction with each other into the azygos vein. They usually receive the lower nine or ten left intercostal veins variably divided between them, but sometimes one to three of the intermediate intercostals open alone or in conjunction directly into the azygos vein.

The **superior hemi-azygos vein**,<sup>1</sup> formed by the union of the upper four to six intercostal veins, excepting the first one or two with which it anastomoses, descends on the left side of the vertebræ to near the middle of the thorax, where it crosses behind the aorta and thoracic duct, and ends in the azygos vein, or it unites below with the inferior hemi-azygos vein. It receives the left bronchial vein, some of the larger œsophageal veins, and other small ones from the mediastinum.

The **inferior hemi-azygos vein**,<sup>2</sup> commences on the left side in the manner of the azygos, ascends through the left crus of the diaphragm, and on the left side of the thoracic vertebræ to the ninth, eighth, or seventh, and crosses behind the aorta and thoracic duct to join the azygos vein. It usually receives the lower three or four left intercostal veins, some of the larger œsophageal veins, and other small ones from the mediastinum.

The **intercostal veins**<sup>3</sup> accompany the corresponding arteries in the intercostal spaces lying above the latter. They are single vessels, and are joined by **dorsal branches** derived from the veins of the back of the thorax, from the dorsi-spinal plexus, and those of the spinal canal through the intervertebral foramina. Those of the lower ten or nine intercostal spaces usually terminate in the azygos and inferior hemi-azygos veins, as already described. The first one, alone or conjoined with the second, forms the **superior intercostal vein**,<sup>4</sup> which usually terminates in the corresponding innominate vein, or may join the vertebral vein. Sometimes by an enlargement the left superior intercostal vein substitutes the superior hemi-azygos vein, and occasionally all the left intercostal veins unite in a common trunk opening into the left

<sup>1</sup> Left upper azygos vein; v. hemi-azygos superior or accessoria.

<sup>2</sup> Left lower or small azygos vein; v. hemi-azygos; v. hemi-azyga; v. azygos sinistra or parva.

<sup>3</sup> Venæ intercostales.

<sup>4</sup> Vena intercostalis superior.



innominate vein. Rarely, the azygos vein receives directly the intercostal veins of both sides.

Commonly the upper intercostal veins have valves at their communication with the azygos and hemi-azygos veins.

The **bronchial veins** are small vessels accompanying the corresponding arteries and emerging from the roots of the lungs, where they receive branches from the lower part of the trachea. The right bronchial vein opens into the azygos vein near its termination, and the left one ends in the superior hemi-azygos vein.

Besides the usual manner of commencement of the azygos and inferior hemi-azygos veins, they often communicate with other veins of the region, with the inferior cava, or with the renal, suprarenal, spermatic, or phrenic veins.

#### VEINS OF THE SPINE.

These form plexuses which extend the length of the vertebral column, and freely communicate with one another. They consist of the dorsi-spinal plexus, the intraspinal plexus, the central veins, and the veins of the spinal cord.

The **dorsi-spinal plexus**<sup>1</sup> is a net-work of veins investing the arches of the vertebræ and receiving branches from the contiguous muscles and skin of the back. The largest branches pass inward between the spinous processes, after proceeding from a median vein passing over the ends of the latter. It communicates by branches perforating the yellow ligaments with the posterior veins of the intraspinal plexus. From it pass off branches between the transverse processes, which terminate in the dorsal branches of the intercostal and lumbar veins, or in the neck in the vertebral vein.

The **intraspinal plexus**<sup>2</sup> is an irregular net-work of veins investing the spinal canal and discharging itself through branches which emerge at the intervertebral foramina into the dorsal branches of the intercostal and lumbar veins, and into the vertebral and lateral sacral veins. It is composed of a pair of plexiform **anterior longitudinal veins**, situated at the sides of the centra in front of the canal, and a smaller pair of **posterior longitudinal veins** at the sides of the arches behind the canal, all freely communicating with one another by cross branches. The anterior longitudinal veins are more expanded at the centra and narrowed at the intervertebral disks, and are joined by **transverse veins**, which receive the central veins and emerge from between the centra and the posterior vertebral ligament.

The **central veins**<sup>3</sup> occupy the interior canals of the centra, anastomosing with veins in front of the vertebræ, and communicating be-

<sup>1</sup> Dorsal spinal veins.

<sup>2</sup> Anterior and posterior internal plexus of the spinal canal.

<sup>3</sup> Veins of the bodies of the vertebræ.



hind through the single or double foramen with the transverse veins of the intraspinal plexus.

The **veins of the spinal cord** are small and tortuous, and form a plexus with elongated meshes in the pia. They are larger below, and one exceeding the others ascends along the anterior median fissure behind the anterior spinal artery. They open into the intraspinal plexus by branches which follow the nerves to the intervertebral foramina, and above they communicate by several small branches with the inferior cerebellar veins or open into the inferior petrosal sinus.

#### BRANCHES OF THE INFERIOR CAVA.

The **spermatic veins**.<sup>1</sup> The veins issuing from the testicle and epididymis form the **spermatic plexus**,<sup>2</sup> which is composed of tortuous vessels ascending in the spermatic cord and passing through the inguinal canal. From the plexus two or three veins continue and unite in a single trunk, the **spermatic vein**, which ascends in company with the spermatic artery in front of the psoas muscle under the peritoneum, and terminates on the right in the inferior cava and on the left in the renal vein. Occasionally it divides near its termination, when one branch may end in the inferior cava and the other in the renal vein.

Incomplete valves are found in the spermatic plexus, and generally there is a valve at the termination of each spermatic vein. Sometimes the valve is absent in the left vein, and it is then usually substituted by one in the renal vein.

The **ovarian veins**<sup>3</sup> have the same general course as the corresponding arteries, and they are derived from the ovarian plexus enclosed in the broad ligament.

The **renal veins** consist of a short, thick trunk on each side, formed by branches emerging from the sinus of the kidney, and passing inward and forward in front of the corresponding arteries to join the inferior cava. The left renal vein, longer and usually a little higher than the right, passes in front of the aorta. Occasionally the veins are multiplied, though not so frequently as the arteries. They receive small branches from the suprarenal bodies, and the left one is also joined by the left spermatic or ovarian vein. Occasionally they contain valves.

The **suprarenal veins**,<sup>4</sup> large in relation to the size of the suprarenal body, terminate the one on the right in the inferior cava, the other in the left renal vein.

The **hepatic veins**<sup>5</sup> are two or three large trunks, which return the blood from the liver, converging to the posterior notch, where they emerge, and open immediately in an oblique direction upward into the

<sup>1</sup> Venæ spermaticæ.

<sup>3</sup> V. renales or emulgentes.

<sup>5</sup> V. hepaticæ.

<sup>2</sup> P. spermaticus or pampiniformis.

<sup>4</sup> V. suprarenales, capsulares, or atrabiliaræ.



inferior cava. Besides the chief trunks there are some small branches from the liver, directly opening into the inferior cava. The hepatic veins are destitute of valves.

The **phrenic veins**<sup>1</sup> consist of a pair of companions to each corresponding artery, terminating in the inferior cava, though those of the left side frequently end together with the corresponding suprarenal vein.

#### VEINS OF THE PELVIS AND LOWER LIMBS.

The **common iliac vein**,<sup>2</sup> on each side, is formed by the union of the external and internal iliac veins. Ascending from near the sacro-iliac articulation to near that of the fourth and fifth lumbar vertebræ to the right of the median line, it joins its fellow at an acute angle to form the commencement of the inferior cava. The right vein is less inclined and shorter than the left, and ascends behind the right iliac artery, and then to its outer side, while the left vein is placed at the inner side of the left iliac artery, and then ascends behind the right artery. Usually the common iliac veins are destitute of valves. They receive the following tributaries:

The **ilio-lumbar vein**<sup>3</sup> arises in branches from the back of the abdominal wall, the dorsal muscles, and the spinal plexuses, and issues from behind the psoas muscle to end in the lower part of the iliac vein. It communicates with the lumbar and lateral sacral veins.

The **middle sacral vein**<sup>4</sup> is formed by the union of a pair of companion veins of the middle sacral artery, and terminates in the left iliac vein or the conjunction of both iliac veins. The two branches anastomose with the lateral sacral veins, and communicate with the veins of the rectum.

The veins of the lower limb, like those of the upper limb, consist of a deep set accompanying the arteries and a superficial set forming a subcutaneous plexus. All are provided with valves, more numerous than in those of the upper limb, and also in greater number in the deep veins.

The deep veins of the lower limb closely follow the course of the arteries, and for the most part form a pair of companions for each of the latter, as in the upper limb. The companion veins of the chief arteries of the leg, the **anterior** and **posterior tibial veins**, unite near the lower border of the popliteal muscle to form the **popliteal vein**.<sup>5</sup> This is placed behind the popliteal artery, ascending gradually from the inner to the outer side, and passes with the artery through the aperture in the great adductor muscle to become continuous with the femoral vein. In its course it receives the **articular** and **muscular veins**, accompanying the corresponding arteries, and is joined also by the external saphenous vein.

<sup>1</sup> V. phrenicæ; p. inferiores or diaphragmaticæ.

<sup>3</sup> V. ilio-lumbalis.

<sup>4</sup> V. sacralis media.

<sup>2</sup> Vena iliaca communis.

<sup>5</sup> V. poplitea.



The **femoral vein**<sup>1</sup> accompanies the femoral artery; placed first behind and somewhat to the outer side, it gradually inclines to the inner side and at the groin passes under Poupart's ligament, where it becomes the external iliac vein. It receives branches which accompany those of the femoral artery, the **femoral profunda vein**, formed by the companions of the profunda artery, and near its termination by the internal saphenous vein. It contains several valves, of which one is situated at the entrance of the profunda vein.

The **external iliac vein**,<sup>2</sup> the continuation of the femoral vein, ascends from the groin at the inner side of the external iliac artery, gradually inclining behind this vessel to join the internal iliac in the formation of the common iliac vein. It is usually provided with a valve. Near its commencement it receives the **circumflex iliac** and **epigastric veins**, accompanying the corresponding arteries, and a **pubic vein**, which ascends from the obturator vein, and sometimes forms the chief termination of the latter.

The subcutaneous venous plexus of the toes and foot commonly gives rise to the production of a more or less regular transverse arch<sup>3</sup> on the dorsum, from which the emerging branches unite in two superficial trunks, the external and internal saphenous veins.

The **external or short saphenous vein**<sup>4</sup> springs from the outer side of the **dorsal plexus of the foot**, ascends the leg behind the outer ankle and Achilles tendon and over the interval of the two heads of the gastrocnemius muscle to the popliteal space, where it perforates the deep fascia, and ends in the popliteal vein. In its course it receives branches from the outer part of the leg, and from the back of the thigh. At the ankle it communicates with the contiguous deep veins, and near its termination by a branch with the internal saphenous vein, which occasionally becomes the chief termination of the latter. It is accompanied in its course by the external saphenous nerve.

The **internal or long saphenous vein**<sup>5</sup> rises in the inner part of the dorsal plexus and arch of the foot, ascends the leg in front of the inner ankle and behind the inner border of the tibia, up the thigh, over the inner condyle of the femur and the course of the sartorius muscle to the groin, where it enters the saphenous opening of the femoral fascia, and terminates in the femoral vein. In its course it receives numerous branches from the subcutaneous plexus of the leg and thigh, among which there is usually a large anterior branch ascending from the fore part of the thigh, and frequently a posterior branch from the back of the same. At the saphenous opening it receives the **superficial epigastric** and **circumflex iliac** and the

<sup>1</sup> Vena femoralis or cruralis.

<sup>2</sup> V. iliaca externa.

<sup>3</sup> Arcus dorsalis superficialis.

<sup>4</sup> Small saphenous vein; v. saphena breva, parva, or externa.

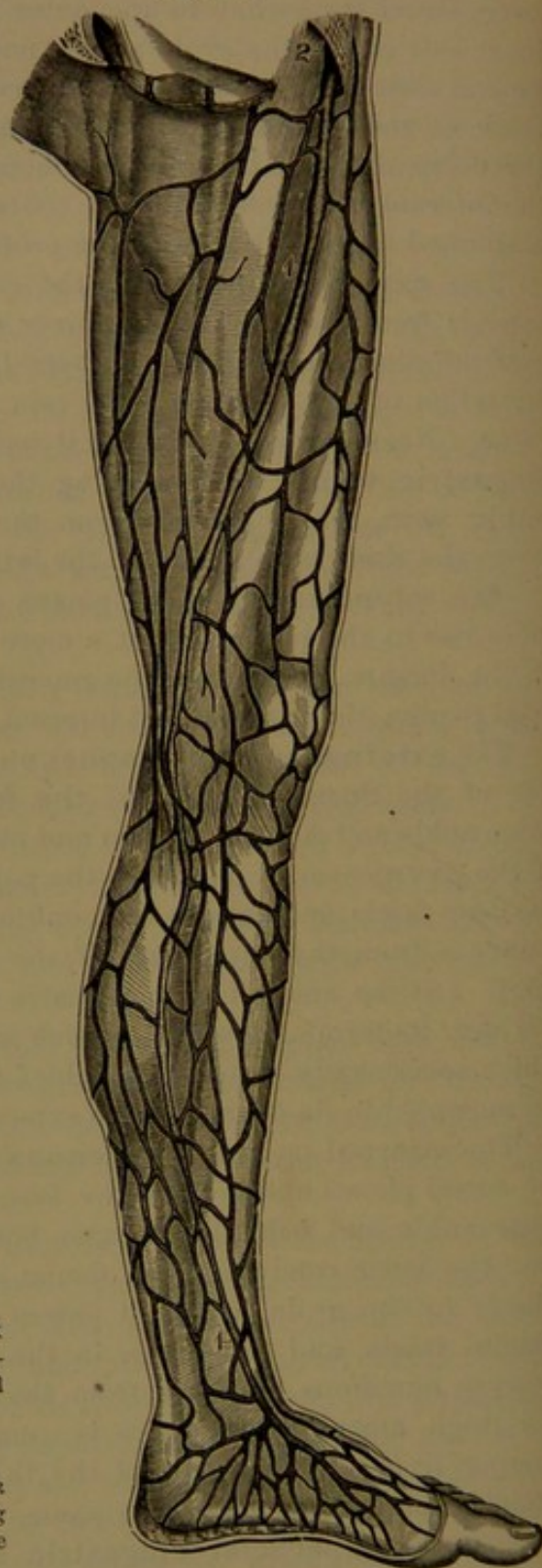
<sup>5</sup> Great saphenous vein; v. saphena longa, magna, or interna.



FIG. 286.

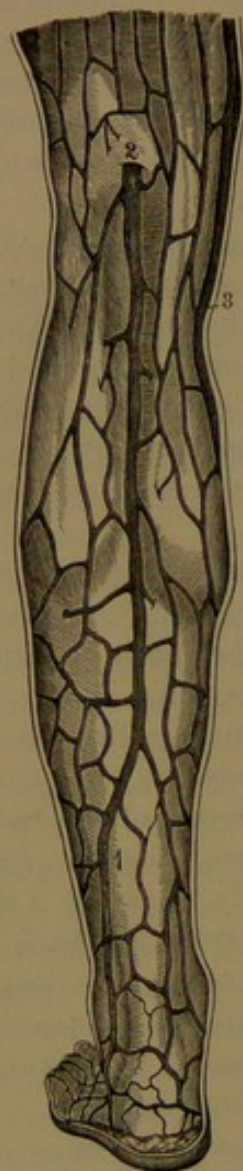

FIG. 287.



*Fig. 286. SUPERFICIAL VEINS OF THE BACK OF THE LEG. 1, short saphenous vein; 2, position at which it terminates in the popliteal vein; 3, long saphenous vein.*

*Fig. 287. SUPERFICIAL VEINS OF THE INNER PART OF THE LOWER EXTREMITY. 1, long saphenous vein; 2, its termination at the saphenous opening into the femoral vein.*

**external pudic veins,**<sup>1</sup> accompanying the corresponding arteries. Below the knee it is accompanied by the internal saphenous nerve.

<sup>1</sup> Venæ pudendæ externæ.



The **internal iliac vein**<sup>1</sup> is formed by branches which, for the most part, accord with those of the internal iliac artery. It lies behind and somewhat to the inner side of the latter, ascending from near the great sciatic foramen to join the external iliac in the formation of the common iliac vein. The veins of the pelvic viscera contributing to form the internal iliac vein are remarkable for their size and frequent union into conspicuous plexuses, which are named from their position.

The **gluteal, sciatic, and obturator veins**, commonly single, accompany closely the corresponding arteries.

The **lateral sacral veins**, two, three, or more, anastomose freely with the middle sacral veins, and form a plexus in front of the sacrum. They receive branches from the intraspinal plexus through the anterior sacral foramina.

The **pudic vein**<sup>2</sup> is formed by tributaries mostly corresponding with the branches of the pudic artery, and also receives a communicating branch from the dorsal vein of the penis.

The **dorsal vein of the penis**,<sup>3</sup> a proportionately large vessel furnished with valves, is common to the dorsal arteries of the two sides of the organ between which it lies. It arises in numerous tributaries issuing from the glans and prepuce around the neck of the penis, where they unite in two branches, which converge behind and run backward close together in the dorsal groove of the penis. Often of unequal size, after a short or variably longer distance they unite in a single median trunk, which continues to the root of the penis, where it perforates the triangular ligament and then forks to open on each side in the pudendal plexus. In its course the dorsal vein receives branches from the cavernous bodies along the dorsal groove of the penis, others which issue between the spongy and cavernous bodies and run around the sides of these to the trunk of the vein, and superficial branches from the skin of the penis. At the root of the latter a communicating branch on each side joins the pudic vein.

The **dorsal vein of the clitoris**,<sup>4</sup> of the female, accords with the former.

The **pudendal plexus**<sup>5</sup> is a close net of large veins occupying the upper part of the pubic arch between the layers of the triangular ligament, and mainly derived from the dorsal vein of the penis or of the clitoris. In the male it closely embraces the upper part of the membranous portion of the urethra, and communicates above and behind, extending laterally, with the prostatic and vesical plexuses and with the pudic veins. In the female it embraces the fore part of the urethra, and communicates with the vaginal and vesical plexuses and the pudic veins.

<sup>1</sup> Vena iliaca interna; hypogastric vein; v. hypogastrica.

<sup>2</sup> V. pudenda interna; v. pudica.

<sup>3</sup> V. dorsalis penis; v. profunda penis.

<sup>4</sup> V. dorsalis clitoridis.

<sup>5</sup> P. pudendalis; p. pudendo-vesicalis; p. prostaticus; p. prostatico-vesicalis; p. pudicus impar; p. Santorini; labyrinthus venosus Santorini.



The **prostatic plexus** mainly occupies the sides of the prostate, and is continuous below and in front with the pudendal plexus, and above and behind with the vesical plexus and the pudic veins.

The **vesical plexus** occupies the wall of the bladder exterior to its muscular coat, with the veins mainly descending from the summit to the base of the bladder, where the plexus is closest and most conspicuous, and the large veins proceed from the fore part of the neck backward and upward around the sides of the base, including the seminal vesicles. At the neck of the bladder the plexus freely communicates with the pudendal, prostatic, or vaginal, and hemorrhoidal plexuses, and the efferent branches proceeding from the sides of the base join the internal iliac veins.

The **vaginal plexus** of the female, occupying the walls of the vagina, is best produced and closest around the entrance of the canal, where it communicates with the pudendal, vesical, and hemorrhoidal plexuses.

The **uterine plexus**, in the walls of the uterus, extends into the broad ligaments, where it communicates with the ovarian plexus, and is mainly discharged by the ovarian veins.

The **hemorrhoidal plexus** is formed by numerous freely anastomosing veins in the walls of the rectum, commencing beneath the mucous membrane. Its efferent branches form the inferior, middle, and superior hemorrhoidal veins, which accompany the corresponding arteries. As the superior hemorrhoidal vein joins the portal system, the hemorrhoidal plexus freely communicates between the latter and the internal iliac vein.

#### PORTAL SYSTEM OF VEINS.

The **portal vein**<sup>1</sup> is peculiar in the fact that it forms an intermediate trunk derived from branches in the usual way, arising from the abdominal alimentary canal, the pancreas, and the spleen, and is distributed in branches like an artery throughout the liver, whence the blood is conveyed to the inferior cava by the hepatic veins. All the veins of the system are single, or never occur in pairs accompanying arteries, and they are for the most part unprovided with valves.<sup>2</sup> The trunk of the portal vein is about three inches long and over half an inch in diameter. It commences behind the head of the pancreas by the union of the splenic and superior mesenteric veins, and ascends behind the duodenum in front of the inferior cava to the transverse fissure of the liver. It is enclosed in the small omentum, with the

<sup>1</sup> Vena portæ or portarum.

<sup>2</sup> Valves have been recently reported to exist in infancy in the gastric and intestinal branches of the portal system, but are said to become inefficient or obliterated approaching maturity. (HOCHSTETTER, *Archiv f. Anat. u. Phys.*, 1887, p. 137; BRYANT, *Boston Med. and Surg. Jour.*, 1888, p. 400.)



hepatic artery and bile-duct in front, accompanied by lymphatics and nerves invested with a connective-tissue sheath.<sup>1</sup> At the transverse fissure the vein is somewhat enlarged, as the **portal sinus**,<sup>2</sup> and divides in widely-divergent branches. The **right branch**, much the larger, enters the right portion of the transverse fissure and immediately penetrates the liver, in which it ramifies in a dichotomous manner. Usually it receives the **cystic vein**,<sup>3</sup> which accompanies the corresponding artery of the gall-bladder, but sometimes ends in the trunk of the portal vein. The **left branch**, longer and smaller than the right one, divides into several branches, which enter the left part of the transverse fissure and penetrate the liver, to be distributed like the former.

FIG. 288.

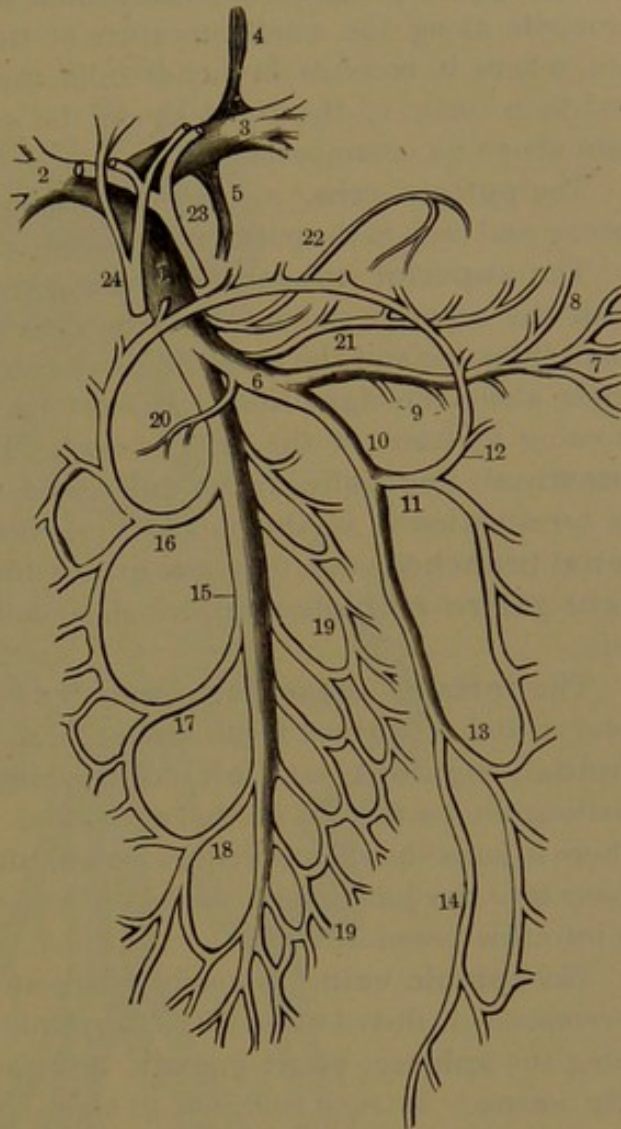


DIAGRAM OF THE PORTAL SYSTEM OF VEINS. 1, trunk of the portal vein; 2, 3, right and left branches to the liver; 4, round ligament, the remains of the umbilical vein; 5, remains of the ductus venosus; 6, splenic vein; 7, branches from the spleen; 8, left gastro-epiploic vein; 9, pancreatic branches; 10, inferior mesenteric vein; 11, left colic vein; 12, branch joining the middle colic vein; 13, sigmoid vein; 14, superior hemorrhoidal vein; 15, superior mesenteric vein; 16, 17, 18, middle and right colic and ileo-colic branches; 19, branches from small intestine; 20, pancreatico-duodenal vein; 21, right gastro-epiploic vein; 22, gastric vein; 23, hepatic artery dividing into right and left branches; 24, common bile-duct formed by union of the hepatic and cystic ducts.

At the fore part of the longitudinal fissure the portal vein is continuous with a fibrous cord, the **round ligament** of the liver, which is the remains of the obliterated umbilical vein of the fœtus. A similar cord, connected with the vessel behind and passing through the back part of the longitudinal fissure to the inferior cava, is in like manner the remains of the ductus venosus of the fœtus.

<sup>1</sup> Capsule of Glisson.<sup>2</sup> Sinus venæ portarum.<sup>3</sup> Vena cystica.



The principal tributaries of the portal vein are the superior mesenteric and splenic veins, besides which it separately receives the gastric and pyloric veins from the small curvature of the stomach.

The **gastric vein**,<sup>1</sup> the companion of the corresponding artery, proceeds along the small curvature of the stomach to the cardiac orifice, where it receives branches from the œsophagus and diaphragm, and then turns to the right above the cœliac axis to join the portal vein above its commencement.

The **pyloric vein**,<sup>2</sup> a small branch, accompanies the corresponding artery, and ends in the portal vein below the former, or sometimes joins it.

The **superior mesenteric vein**<sup>3</sup> corresponds in its distribution with the superior mesenteric artery, and returns the blood from the small intestine and the ascending and transverse colon. The trunk ascends along the right side of the artery, with the intestinal branches crossing in front of the latter vessel. The chief tributaries are the **intestinal, ileo-colic, right colic, and middle colic veins**. Near its termination it is also joined by several small **pancreatico-duodenal branches**, and, from the great curvature of the stomach, by the **right gastro-epiploic vein**, which sometimes also joins the right colic vein.

The **inferior mesenteric vein**<sup>4</sup> accompanies the corresponding artery, and is derived from similar branches, the **superior hemorrhoidal, sigmoid, and left colic veins**. It ascends beneath the peritoneum to the left of the aorta, and passes behind the pancreas, where it joins the splenic vein at a right angle, or, inclining to the right, opens into the junction of the latter with the superior mesenteric vein or into this vessel directly.

The **splenic vein**,<sup>5</sup> the second largest tributary of the portal vein, corresponds in distribution with the splenic artery, its principal branches being the **splenic, short gastric, left gastro-epiploic, and pancreatic veins**. It runs from left to right along the upper border of the pancreas, below and behind the splenic artery, pursuing a straight course instead of the tortuous course of the latter.

#### THE VASCULAR SYSTEM OF THE FŒTUS.

In the child before birth, in accordance with its peculiar circumstances, the vascular system exhibits important differences from its subsequent condition. In the early part of foetal life the heart is vertical in position; its auricles are proportionately larger, the right being the more capacious; and the ventricles are nearly of equal thickness. These conditions gradually change; but at the time of birth the heart is proportionately larger and more vertical than later.

<sup>1</sup> Coronary vein; vena gastrica; v. g. superior; v. coronaria.

<sup>2</sup> V. pylorica.

<sup>4</sup> V. mesenterica inferior or minor.

<sup>3</sup> V. mesenterica superior or magna.

<sup>5</sup> V. splenica; v. lienalis.



The auricles communicate by a large aperture, the **oval foramen**,<sup>1</sup> situated at the lower back part of the auricular septum, and protected by a valve, which is next the left auricle, and extends from behind upward. The arrangement permits the flow of blood from the right into the left

FIG. 289.

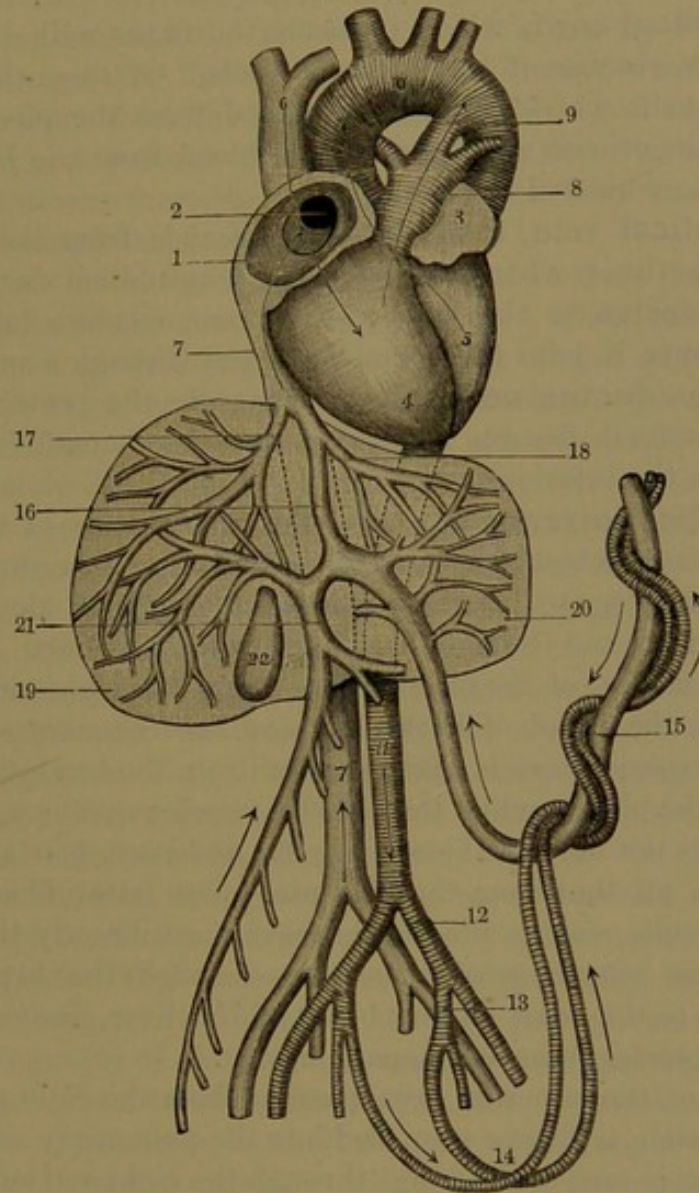


DIAGRAM OF THE FŒTAL CIRCULATION. The arrows indicate the course of the flow of blood. 1, right auricle laid open; 2, oval foramen, with its valve, opening into the left auricle, 3; 4, 5, right and left ventricles; 6, superior cava; 7, inferior cava; 8, pulmonary artery dividing into the right and the left branch, and giving off the ductus arteriosus, 9; 10, arch of the aorta; 11, abdominal aorta; 12, common iliac artery; 13, internal iliac or hypogastric artery; 14, umbilical arteries; 15, umbilical vein; 16, ductus venosus; 17, 18, right and left hepatic veins; 19, 20, right and left lobes of the liver; 21, portal vein; 22, gall-bladder.

auricle, but not in the opposite direction. At the bottom of the right auricle is the eustachian valve, which extends from the anterior border of the inferior cava to the oval foramen, and serves to direct the flow of blood from the former through the latter into the left auricle.

<sup>1</sup> F. ovale; f. Botale.



From the pulmonary artery, at its fork, proceeds a vessel, named the **ductus arteriosus**, which is larger than the right and left branches of the former, and opens into the aorta after this gives off the left subclavian artery. It is about half an inch long, and as thick as a goose-quill, and serves to conduct the main portion of the blood of the right ventricle into the descending aorta.

The **umbilical cord**, which connects the fœtus with the placenta of the mother, consists of three large vessels. Of these the largest is the umbilical vein, which conveys the blood from the placenta to the fœtus, while the others, which return the blood from the latter to the former, are the umbilical arteries.

The **umbilical vein**, from the cord, ascends from the umbilicus, or navel, to the liver, where it enters the longitudinal fissure. After giving off branches to the left, quadrate and caudate lobes, at the transverse fissure it joins the portal vein, and through a smaller division, named the **ductus venosus**, continues in the posterior portion of the longitudinal fissure, and joins the left hepatic vein at its termination in the inferior cava.

The **umbilical arteries** appear as the continuation of the internal iliac arteries, from which they ascend at the sides to the summit of the bladder, and converge to the navel, whence they proceed along the cord, coiled together around the umbilical vein, to the placenta.

In the circulation of the blood of the fœtus, the right auricle of the heart receives the blood of both cavæ and the coronary sinus. The blood of the superior cava is that returned from the head, upper limbs, and walls of the chest; while that of the inferior cava, a considerably larger vessel, is not only the blood from the abdomen, pelvis, and lower limbs, but also all that from the placenta. The latter blood, through the umbilical vein, reaches the inferior cava most directly through the ductus venosus, but in greater measure through the hepatic veins, which convey to the cava all the blood of the liver, derived from the umbilical and portal veins and hepatic artery.

The blood of the superior cava, passing from the right auricle into the right ventricle, is thence propelled into the pulmonary artery. The smaller portion is sent to the lungs through the right and left branches, but, as these remain contracted until after birth, the larger portion passes through the ductus arteriosus to the descending aorta, by which it is distributed to the lower division of the body, and in part is sent to the placenta.

Of the blood which enters the right auricle from the inferior cava but a small portion is mingled with that of the superior cava to pass into the right ventricle, while the much larger portion, directed by the eustachian valve through the oval foramen, passes into the left auricle. Here, mingled with a smaller quantity of blood from the pulmonary veins, it is forced into the left ventricle, whence it is propelled into the arch of the aorta, and is almost entirely distributed to the head, upper



limbs, and walls of the chest. To the fact that these parts of the body receive a purer supply of the placental blood than the lower parts is probably due their comparatively more advanced development at the time of birth.

The placental circulation is at once stopped at birth by the closure of the umbilical vessels at the navel. With the first act of inspiration the lungs expand, and the pulmonary vessels rapidly dilate and give passage to a greater flow of blood. The ductus arteriosus and the umbilical arteries from the internal iliaes to the navel rapidly contract and cease to give passage to the blood. The flow also ceases through the oval foramen, through the umbilical vein from the navel to the liver, and through the ductus venosus.

The ductus arteriosus is completely closed in from four to ten days, and is ultimately converted into a fibrous cord, which extends from the commencement of the left pulmonary artery to the under part of the arch of the aorta after this gives off the left subclavian artery.

The umbilical arteries become much shrunken and for the most part completely closed in three or four days, and are ultimately converted into fibrous cords, which form the basis of the superior and lateral false ligaments of the bladder. From the internal iliac arteries to the side of the bladder they remain partially pervious, and continuous on the latter with the superior vesical artery.

The umbilical vein and ductus venosus become closed in about a week, and are finally converted into fibrous cords, of which one forms the round ligament of the liver, and the other occupies the back part of the longitudinal fissure of the latter and connects the left branch of the portal vein with the inferior cava.

The oval foramen, though ceasing at once to permit the passage of blood after birth, does not become actually closed until a considerable time afterwards. The closure takes place gradually, in the course of ten days or more, by the union of the fore part of the valve with the contiguous annulus of the foramen, but not unfrequently the latter, at its upper part, remains as a permanent cleft communicating between the auricles. Sometimes in the first year of infancy a wider aperture continues, and permits the flow of blood from the right into the left auricle, giving rise to the condition known as the blue disease, or *morbus cæruleus*.

#### THE LYMPHATIC SYSTEM.

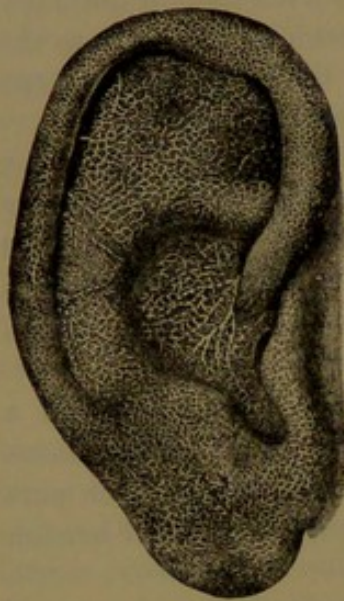
The **lymphatic system**, also called from its habitual function the **absorbent system**, consists of numerous tubular and branching **lymphatic vessels** and certain nodular bodies, the **lymphatic glands**, which are situated in the course of the chief vessels. The lymphatics are generally associated with the blood-vessels, and the larger ones pursue nearly the same course, and often accompany them. The principal lymphatic vessels are more numerous than the corresponding blood-vessels,



but are much smaller, and are of greater delicacy and transparency, from which circumstances, together with the fact that they convey a colorless liquid, they are inconspicuous, and in ordinary dissections usually escape notice. The liquid conveyed by the lymphatics is **lymph**, which is derived through absorption from the various tissues and organs of the body, besides which it receives constant accessions from the dissolved nutritive matter of the food absorbed from the stomach and intestines.

In the different parts of the body the lymphatics generally consist of a deep and a superficial set, the former commencing everywhere in the interstices of the tissues and organs, and thence pursuing the course

FIG. 290.



NET-WORK OF LYMPHATIC VESSELS IN THE SKIN OF THE EAR.

of the blood-vessels, while the latter commence in intricate plexuses on the surface of organs, freely communicate with the deep set, and unite in trunks which pursue the course of the superficial venous trunks.

The larger lymphatic vessels mostly run in nearly direct lines with a straight or slightly flexuose course, but sometimes more irregularly; and usually they are pretty uniform in their diameter when undivided. They are especially remarkable in the possession of numerous valves, which are uniformly disposed in pairs at short distances apart,—about the fourth to the third of an inch in the largest vessels and a line or less in smaller ones. The valves have the same form and arrangement, together with corresponding saccular expansions of the vessels, as in the veins, and their frequent succession

in the distended condition of the lymphatics gives these vessels a jointed or beaded appearance.

In proportion to their size the lymphatic vessels have thin walls, and these, as in the case of the blood-vessels, consist of three tunics. The **external tunic**, or **adventitia**, is a delicate fibro-connective-tissue

FIG. 291.



A LYMPHATIC VESSEL, laid open and exhibiting the arrangement of its valves: magnified.

layer associated with longitudinal elastic fibres and unstripped muscle-fibres. The **media** is composed of transverse muscle-fibres with some elastic fibres; and the **intima** is composed of longitudinal, reticular



elastic fibres lined by an endothelium of elongate lozenge-shaped cells with sinuous outlines. The valves are semilunar folds of the intima.

The lymphatic vessels commence in intricate plexuses, which occupy the interstices of most tissues and organs of the body, where they are commonly associated with the capillary blood-vessels. The lymphatics immediately proceeding from the plexuses, generally more regularly tubular than those which precede them and provided

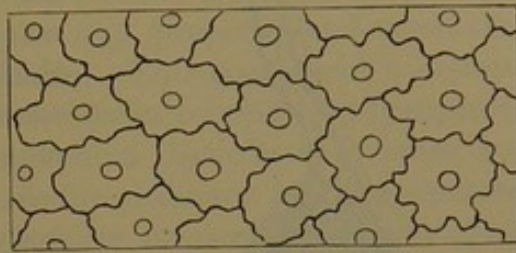
with valves, are regarded as the commencement of the **lymphatic trunks**, while the others are distinguished as the **lymphatic capillaries**. These are as numerous as the capillary blood-vessels with which they are commonly interwoven, but are of less uniform calibre, very variable, and often greatly exceed the blood-capillaries, and frequently, also, the lymphatic trunks they join. They are often irregularly expanded, and are devoid of valves. In the intestinal villi they mostly appear as single club-like vessels, which join the reticular plexus at their base. The walls of the lymphatic capillaries and of the commencing trunks, like those of the capillary blood-vessels, are composed of a single layer of elongate lozenge-shaped endothelial cells, of which those of the capillaries are generally proportionately shorter and more sinuous at the borders than in the trunks.

The lymphatic capillaries commonly communicate with or commence in clefts, or **lymph-spaces**, which occupy the intervals of the connective-tissue bundles of most other tissues of the body. The lymph-spaces conform to the intervals of the surrounding elements of structure of the tissues, and are lined with endothelial cells continuous with those of the more distinct lymphatic capillaries. The latter, also, commence in spaces which include the connective-tissue corpuscles and the similar corpuscles of the bones and of the cornea of the eye, all of which freely communicate with one another by minute canaliculi. In like manner, lymphatics commence in spaces enclosing the nerve-cells of the brain and spinal marrow. In some positions, as in the latter organs and the vascular canals of bones, lymphatic capillaries ensheathe the capillary blood-vessels, constituting the **peri-vascular lymphatics**, which are lined by endothelial cells.

The lymphatics of the peritoneum of the diaphragm and of the intercostal pleura communicate with the cavities of these membranes by minute apertures or **stomata**, which are enclosed by a circle of small polyhedral, granular cells pertaining to the endothelium.

**Lymphatic glands.** These are solid, mostly flattened, oval or spheroidal bodies situated in the course of the chief lymphatic vessels, usually of a reddish-gray color, and ranging in size from a hemp-seed

FIG. 292.

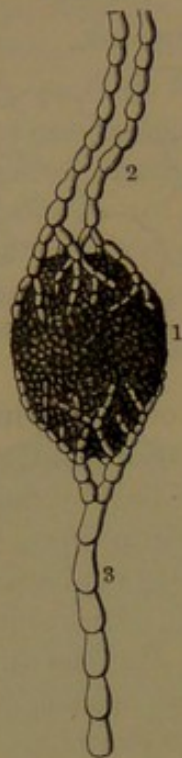


ENDOTHELIUM OF A COMMENCING LYMPHATIC VESSEL. 250 diameters.



to an almond or larger. They are most numerous along the course of

FIG. 293.



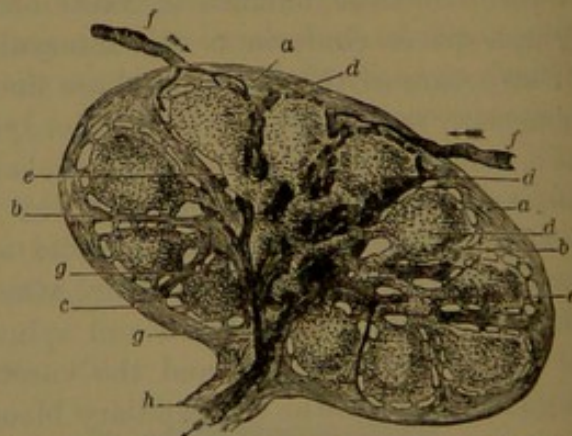
LYMPHATIC GLAND AND VESSELS. 1, lymphatic gland; 2, afferent vessels; 3, efferent vessel.

the great blood-vessels of the neck, thorax, abdomen, and pelvis, and especially in the mesentery and mesocolon. There are also many in the armpit and groin, and a few at the back part of the head, in the popliteal space, and in the bend of the elbow. Commonly several of the chief lymphatic vessels, proceeding from the periphery of the body, on reaching the vicinity of a lymphatic gland break up into many branches, the **afferent vessels**,<sup>1</sup> which enter and are distributed through the gland, whence another series, the **efferent vessels**,<sup>2</sup> emerge and unite in a similar manner to form a smaller number of trunks than those approaching the gland. In the position at which the efferent glands make their exit, the gland usually exhibits a depression, the **hilus**, at which, also, the principal blood-vessels and nerves enter to supply the body.

an inner, darker, medullary portion, which latter approaches the surface at the hilus. They are invested with a capsule of fibro-connective tissue, which extends into the hilus upon the blood-vessels. From the capsule laminae and bands of the same tissue extend through the interior of the gland, forming a trabecular framework,<sup>3</sup> which supports the proper gland-substance. In the largest glands the cortical substance is from half a line to a line in thickness. In the more superficial subcutaneous glands it is proportionately less than in those occupying the great cavities of the body, being apparently substituted by more connective tissue.

The lymphatic glands consist of an outer, lighter-colored, cortical portion and

FIG. 294.



A SMALL LYMPHATIC GLAND, in section. *a*, the fibro-connective-tissue capsule; *b*, partitions of the same; *d*, nodules or follicles of lymphoid tissue of the cortex; *e*, bars of the same tissue of the medulla; *f*, afferent vessels opening into lymph-spaces; *c*, *g*, efferent vessels converging to a single vessel, *h*, passing out at the hilus of the gland: magnified.

<sup>1</sup> Vasa afferentia.<sup>2</sup> V. efferentia.<sup>3</sup> Trabeculae.



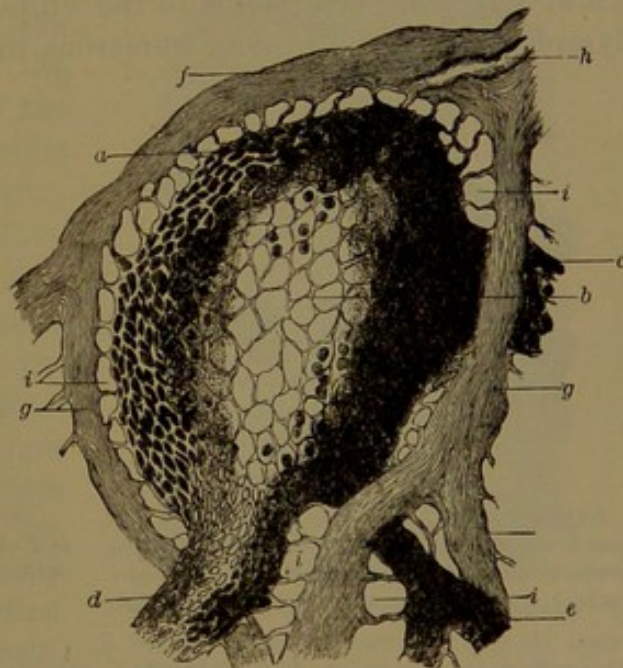
In the cortical portion of the lymphatic glands the trabecular framework forms spheroidal receptacles, or **follicles**,<sup>1</sup> and in the medullary portion cylindrical **passages**, which communicate with the former and in all directions with one another. The follicles and interior passages are continuously filled throughout by the proper gland-substance,<sup>2</sup> which is **lymphoid** or **adenoid tissue**. This consists of a delicate reticular connective tissue with its interspaces occupied by **lymphoid corpuscles**. The interior of the lymphoid tissue is more dense, and the lymphoid corpuscles differ from the ordinary lymph-corpuscles in having a larger nucleus and a smaller proportion of enveloping protoplasm. The peripheral portion of the lymphoid tissue, in a narrow space of pretty uniform width, is of looser texture than the interior, and the included corpuscles are more like ordinary lymph-corpuscles. This peripheral space of the glandular substance is in free communication with the afferent and efferent lymphatic vessels, is traversed by the lymph passing from one to the other, and is named the **lymph-path**.<sup>3</sup> The afferent vessels after entering the gland continue to branch, and finally end in the cortical lymph-paths, with the endothelium of the vessels continued as a lining of the latter. The efferent vessels in like manner commence in the lymph-paths of the medullary portion of the gland, and thence emerge at the hilus.

From the latter and other positions the blood-vessels traverse the trabecular framework and communicate with capillary nets of the lymphoid tissue. The nerves which accompany the blood-vessels are mainly derived from the sympathetic system.

As part of the lymphatic system, accumulations of lymphoid or adenoid tissue, in variable nodular masses

or in a more diffused condition, exist in many organs. The essential structure of the tonsils consists of nodular masses of lymphoid tissue

FIG. 295.



A FOLLICLE FROM THE CORTEX OF A LYMPHATIC GLAND, in longitudinal section. *a*, nodular mass of lymphoid tissue; *b*, sustaining reticular connective tissue, with most of the lymph-corpuscles washed out; *c, d, e*, bars of lymphoid tissue of the medulla; *f*, portion of the investing fibro-connective-tissue capsule; *g*, partitions of the same; *h*, afferent vessel opening into the lymph-spaces, *i*: magnified.

<sup>1</sup> Alveoli.<sup>2</sup> Glandular pulp.<sup>3</sup> Lymph-sinus.



embedded in the submucosa of follicles of the mucous membrane. Nodular masses also constitute many of the glands of the root of the tongue, the upper part of the pharynx, the soft palate, and the uvula. Similar nodules form the solitary glands of the small and large intestine, in addition to which diffused lymphoid tissue enters into the constitution of the mucous membrane, including that of the villi. Nodules or more diffused masses also occur in the mucous membrane of the œsophagus and pyloric extremity of the stomach, in that of the larynx and air-passages, and in the conjunctiva. Nodules and tracts in the course of the blood-vessels are also found in serous membranes, as in the mediastinal pleura and the omentum. Further, cord-like masses often with nodular enlargements<sup>1</sup> sheathe many of the arteries distributed in the spleen.

### LYMPH.

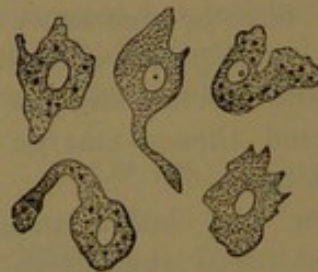
The **lymph**,<sup>2</sup> contained in the lymphatic vessels generally throughout the body, is a transparent, pale amber-colored liquid. Examined with the microscope, it is observed to consist of a clear liquid, the **lymph-plasma**,<sup>3</sup> which is like that of the blood, and **lymph-corpuscles**,<sup>4</sup> which are identical with the white corpuscles of the latter. The lymph-corpuscles are more numerous in the lymphatic vessels after

FIG. 296.



LYMPH-CORPUSCLES, highly magnified. 1, corpuscle at rest; 2-10, in movement, exhibiting projections of the protoplasm called pseudopods; b, one which has assumed a stellate shape.

FIG. 297.



LYMPH-CORPUSCLES, more highly magnified, and observed at the temperature of the body, exhibiting the changes of shape in movement.

they have emerged from the lymphatic glands than in those which enter them, indicating these bodies to be an important source of the corpuscles. These probably have their source in many other positions, especially in the solitary and agminated glands, the lymphoid follicular glands, and the more generally diffused lymphoid tissue of the mucous membrane of the alimentary canal, also in the spleen and in the marrow of the bones, and through proliferation of connective-tissue corpuscles in the fibro-connective tissue generally.

<sup>1</sup> Corpuscles of Malpighi.

<sup>3</sup> Coagulable lymph.

<sup>2</sup> Lympha; white blood.

<sup>4</sup> Lymph-globules; white corpuscles.



**Chyle**<sup>1</sup> is lymph, mingled with some of the absorbed products of digestion, contained in the lymphatic vessels of the stomach and intestines. The visible products mainly consist of fine molecules and minute globules of fat, which give to the chyle a milky aspect, whence the name of **lacteals**<sup>2</sup> applied to the lymphatics containing it.

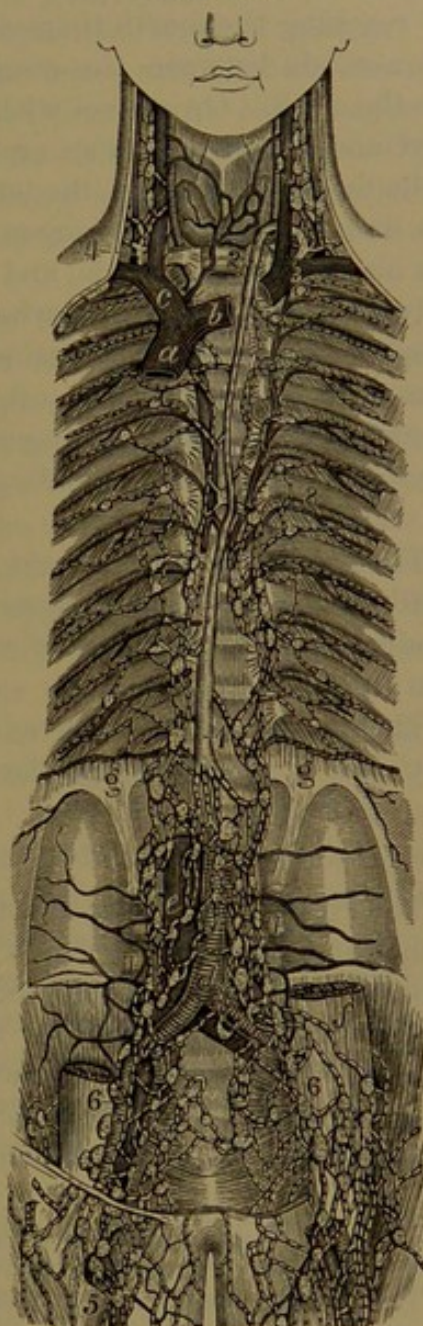
#### THE CHIEF TRUNKS OF THE LYMPHATICS.

The lymphatics terminate in two principal trunks, which are distinguished as the thoracic duct and the right lymphatic duct, the former being very much the longer and larger, and receiving all the lymphatics of the left side of the body, together with those of the lower half of the right side, while the remainder join the smaller duct.

#### THE THORACIC DUCT.

The **thoracic duct**<sup>3</sup> ascends from the abdomen through the thorax, lying in front of the spine, between the aorta and azygos vein. It is from fifteen to eighteen inches long, and more or less flexuose in its course. It usually commences in front of the first lumbar vertebra, behind the aorta, and thence passes between this and the right crus of the diaphragm through the aortic orifice. The commencement commonly presents a variable expansion, an inch or more in length, named the **receptacle of the chyle**,<sup>4</sup> which is inconstant, and often obscurely

FIG. 298.



VIEW OF THE GREAT LYMPHATIC TRUNKS. 1, 2, thoracic duct; 3, its termination at the angle of conjunction of the left internal jugular and subclavian veins; 4, the right lymphatic duct; 5, lymphatics of the thigh; 6, iliac lymphatics; 7, lumbar lymphatics; 8, intercostal lymphatics. a, superior vena; b, left innominate vein; c, right innominate vein; d, aorta; e, inferior vena; f, psoas muscle; g, origin of the diaphragm.

<sup>1</sup> Chylus; succus entericus.

<sup>2</sup> Vasa lactea or chyliifera; chyliiferous vessels.

<sup>3</sup> Ductus thoracicus or chyliiferus; truncus lymphaticus sinister.

<sup>4</sup> Receptaculum chyli; r. Pecqueti; cisterna chyli; saccus lacteus.



defined. In the upper part of its course the duct inclines to the left, and reaching the fourth thoracic vertebra passes behind the aortic arch, and ascends between the œsophagus and the left subclavian artery into the neck. On a level with the last cervical vertebra it turns outward and downward, in an arch over the apex of the pleura, and ends in the angle of union of the left internal jugular and subclavian veins. The duct is usually narrowest about the middle of its course, where it is about two lines wide, and enlarges towards the extremities, especially the commencement, where it is about three lines wide. It is subject to considerable variation, and frequently is more or less divided in its course, once, twice, or oftener, and sometimes for a short distance may have a plexiform arrangement. Rarely it is double throughout; and it has been observed ending in the azygos, or some other neighboring vein.

The valves of the thoracic duct are fewer than in its tributaries, usually being an inch or more apart, but are nearer approaching its termination, where a pair of valves prevents the reflux of the blood from the veins.

The thoracic duct receives the lymphatics of the left half of the body, and those of the right lower limb and right side of the abdomen.

#### THE RIGHT LYMPHATIC DUCT.

The **right lymphatic duct**<sup>1</sup> is commonly from a quarter to half an inch in length, and about a line in width, and ends in the angle of union of the internal jugular and subclavian veins of the right side. It receives the lymphatics of the right side of the upper half of the body extending to the upper surface of the liver. The duct is formed by the conjunction usually of two or three principal vessels, which sometimes end separately in the contiguous veins.

#### LYMPHATICS OF THE LOWER LIMBS.

The **deep-seated lymphatics of the lower limb** pursue the course of the corresponding blood-vessels. Those accompanying the blood-vessels of the foot and leg enter the popliteal glands, while the trunks from the latter and other deep lymphatics of the thigh pursue the course of the femoral blood-vessels and enter the deep inguinal glands. Deep lymphatics from the gluteal region and the femoral adductors accompany the gluteal, sciatic, and obturator blood-vessels into the pelvis to the internal iliac glands.

The **superficial lymphatics** form two series, of which the inner and more numerous arise from the inner side of the back and sole of the foot, commencing in the toes; thence proceed in front and behind the inner ankle, and ascend on the inner side of the leg and knee to

<sup>1</sup> Truncus lymphaticus dexter or minor.



the thigh, whence they continue in the general direction of the long saphenous vein and enter the lower superficial inguinal glands. The outer series arise, like the former, on the outer side of the foot, ascend on the outer side of the leg in the direction of the short saphenous vein, and partly enter the popliteal glands, while others ascend obliquely across the popliteal space and join the inner series. From the back of the thigh the superficial lymphatics pass around on both sides to enter the superficial inguinal glands.

The **popliteal glands**,<sup>1</sup> commonly four or five little ones, are embedded in the connective tissue and fat surrounding the popliteal blood-vessels. They receive the deep lymphatics of the leg and a few superficial ones accompanying the short saphenous vein. Their efferent vessels usually give rise to four trunks, which follow the course of the popliteal and femoral blood-vessels to the deep inguinal glands.

The **deep inguinal glands**,<sup>2</sup> commonly three or four, surround the femoral blood-vessels; one of them occupying the femoral ring. They receive the deep lymphatics of the lower limb and some of those of the superficial inguinal glands. Their efferent vessels ascend with most of those of the latter through the femoral ring and along the femoral blood-vessels to join the external iliac lymphatics.

The **superficial inguinal glands**<sup>3</sup> vary from eight to a dozen or more, and from the size of a small pea to that of an almond-kernel. The largest occupy the inner or lower part of the groin, extending a couple of inches around the long saphenous vein, and the others extend outward along the groin. They receive the superficial lymphatics of the abdomen, the buttock, the perineum, and the genital organs, and most of those of the lower limb. The efferent vessels pierce the subjacent fascia, and mainly enter the saphenous opening partly to join the deep inguinal glands, and partly ascend to join the external iliac lymphatics.

The **superficial lymphatics of the abdomen** mostly converge in the general direction of the superficial epigastric and circumflex iliac blood-vessels, and end in the superficial inguinal glands.

The **superficial lymphatics of the penis** commence in copious plexuses of the prepuce and skin of the glans, whence they proceed around the cervix to the dorsum, and there converge in a pair of lateral trunks or a single large median trunk. The former run backward on each side of the dorsal blood-vessels, and at the root of the penis turn outwardly to end in the lower superficial inguinal glands. In the case of a single trunk this divides at the root of the penis, and the branches proceed as in the former. The **urethral lymphatics**, remarkable for their size, form a reticular plexus the whole length of the urethra. They communicate with the superficial plexus of the glans, and at the frænum form two trunks, which join the others at the cervix. The

<sup>1</sup> Glandulæ popliteæ profundæ.

<sup>2</sup> G. inguinales prof.

<sup>3</sup> G. ing. sup.



**deep lymphatics of the penis** pursue the course of the pudic blood-vessels, and end in the internal iliac glands.

The **lymphatics of the scrotum** are abundant, and form from ten to twelve trunks, which pursue the course of the external pudic blood-vessels to the superficial inguinal glands.

The **lymphatics of the external genital organs** of the female accord with those of the male, are proportioned in development with the parts, and pursue a similar course.

#### LYMPHATICS OF THE PELVIS AND ABDOMEN.

The **external iliac lymphatics**, continued from the femoral lymphatics, ascend along the external iliac blood-vessels, and are commonly associated with three or four glands surrounding the latter just above the femoral ring. They are joined by the lymphatics of the abdominal wall, converging in the direction of the epigastric and circumflex iliac blood-vessels. Two or three trunks ordinarily proceed from the external iliac glands to join the internal iliac and lumbar lymphatics.

The **internal iliac lymphatics** pursue the general course of the corresponding blood-vessels, and are associated with many glands, at the side of the pelvis in the interval of the external iliac and internal iliac blood-vessels. They receive the **obturator, gluteal, ischiatic,** and **pudic lymphatics**, pursuing the course of the corresponding blood-vessels, and also the lymphatics from the pelvic viscera.

The **sacral lymphatics**, associated with glands, occupy the hollow of the sacrum, receive lymphatics from the contiguous walls and pelvic viscera, and communicate with the internal iliac and lumbar lymphatics.

The **lymphatics of the rectum** are numerous and of considerable size, and at the anus communicate with the cutaneous lymphatics. The trunks partially join the sacral lymphatics, and partially ascend to the glands of the mesorectum.

Though lymphatics have been abundantly attributed to the urinary bladder, it would appear from the researches of Sappey that this organ is remarkable for their absence. A few trunks at the base of the bladder emanate from numerous lymphatics of the prostate and seminal vesicles, and proceed to join the internal iliac and inguinal lymphatics.

The **lymphatics of the vagina** partly join the inguinal lymphatics and partly the internal iliac lymphatics.

The **lymphatics of the uterus** are small in the ordinary condition of the organ, but in gestation are observed to be exceedingly numerous and enlarged to an extraordinary degree. Issuing from the sides of the uterus in the broad ligament, they partially pursue the course of the uterine blood-vessels, and, in company with the vaginal lymphatics, join the internal iliac vessels, while others are joined by the lymphatics of the ovary and oviduct, and proceed with the ovarian blood-vessels to join the lumbar lymphatics.

The **lumbar lymphatics** of the two sides of the body freely com-



municate, and lie in front and behind the psoas muscles, and the great abdominal blood-vessels between these, extending from the common iliac blood-vessels to the first lumbar vertebra, where they communicate with the celiac glands. They are associated with many glands, large and small, twenty to thirty or more, the largest lying in front of the aorta and the smallest behind the psoas muscles, in the intervals of the lumbar transverse processes.

The **lumbar glands**<sup>1</sup> receive several trunks from the external iliac lymphatics, and others from the internal iliac and sacral lymphatics. They also receive lymphatics from the rectum and sigmoid flexure of the colon, from the uterus with those of the ovary and oviduct, those of the testicle, kidney, and suprarenal body, and those from the vertebral portion of the diaphragm and the deep ones of the posterior abdominal wall. The efferent vessels mostly unite on each side in a short **lumbar lymphatic trunk**,<sup>2</sup> which joins its fellow and with several smaller vessels forms the commencement of the thoracic duct.

The **renal lymphatics** consist of a deep set pursuing the course of the blood-vessels, and a superficial set of small vessels which form a plexus in the capsule of the kidney. The two sets unite in the hilus, where they are also joined by lymphatics from the ureter and the suprarenal body, and thence proceed to end in the upper lumbar glands.

The **spermatic lymphatics** commence in the testicle, where they are remarkable for their comparative abundance. A half-dozen or more trunks, also remarkable for their great proportionate size, ascend in the spermatic cord, and, after passing through the inguinal canal, accompany the spermatic blood-vessels, and terminate in the upper lumbar glands.

The **deep lymphatics of the posterior wall of the abdomen** follow the direction of the lumbar and ilio-lumbar blood-vessels, are joined by the lymphatics from the dorsal muscles and the spinal canal, and end in the lumbar glands behind the psoas muscles.

The lymphatics of the alimentary canal, as usual in the viscera, originate in a deep series forming an abundant plexus in the mucous membrane, and a superficial series from the serous and muscular coats. They absorb and convey the dissolved nutritive matter, the result of digestion of the food, as well as the ordinary lymph. The nutritive liquid derived from the small intestine, commonly emulsified with fat and distinguished under the name of **chyle**, gives to the lymphatics of this portion of the canal a milk-white appearance, whence they are called the lacteals.

The **lacteals** on leaving the small intestine pass through the mesentery, converging to its root, and traverse in their course the numerous **mesenteric glands**. These range from a hundred to double the number, and from the size of a hemp-seed to that of an almond-kernel,

<sup>1</sup> Glandulæ lumbales.

<sup>2</sup> Truncus lymphaticus lumbalis.



in the healthy condition, but often appear much larger from disease. They have a general arrangement in three imperfect rows, of which those of the first row, nearest the intestine, are most numerous and smallest, and those of the last row are fewest, largest, and crowded around the trunk of the mesenteric blood-vessels. The outer rows occupy loops of the latter, and they are usually removed an inch or more from the intestine. The efferent vessels commonly unite in a single **intestinal lymphatic trunk**, or in two or three smaller ones, opening into the commencement of the thoracic duct.

The **colic lymphatics** on leaving the colon traverse thirty or more **colic glands** lying along the course of attachment of the intestine and within the layers of the mesocolon. Those of the sigmoid flexure, together with part of those of the rectum, terminate in the lumbar glands, while those of the rest of the colon converge to unite with the mesenteric lymphatics to form the **intestinal lymphatic trunk**.

The **gastric lymphatics** pass from the walls of the stomach to its curvatures, where they run in company with the blood-vessels, traversing in their course a number of little **gastric glands**. Those of the small curvature proceed to the cardia and descend behind the pancreas to join the celiac glands. Those from the great curvature on the right proceed to the pylorus, and also join the latter; while those on the left proceed to join the splenic lymphatics.

The **splenic lymphatics** arise in a deep series, and pursue the course of the blood-vessels of the spleen and emerge at the hilus, where they are joined by a superficial series, and form a plexus beneath the peritoneal investment of the organ. The trunks continue in the course of the splenic blood-vessels, where they traverse eight or ten **splenic glands**, which also receive the **pancreatic lymphatics**, and they finally end in the celiac glands.

The **hepatic lymphatics** also consist of a deep and superficial series, both exceedingly abundant, but the former much the larger. The **deep lymphatics** form two sets, of which one pursue the reverse course of the portal blood-vessels and emerge at the transverse fissure, where they enter a lymphatic gland resting on the neck of the gall-bladder, whence the efferent vessels descend in the small omentum to the celiac glands. The other set of deep lymphatics, more numerous and larger than the former, follow the hepatic veins and converge to half a dozen trunks, which accompany the inferior cava through the diaphragm to a group of small glands surrounding the termination of the latter vessel. The efferent vessels from these **superior phrenic glands** descend behind the crura of the diaphragm, and end in the commencement of the thoracic duct. Of the **superficial lymphatics**, many of those beneath the liver join the deep lymphatics issuing from the transverse fissure, while others run backward to the celiac glands, and others of the left lobe join the gastric lymphatics from the small curvature. The lymphatics of the gall-bladder usually converge to



two or three trunks, which descend to the cœliac glands. Most of the lymphatics from the upper surface of the liver proceed to the suspensory ligament, and thence pass in front, through the diaphragm, behind the ensiform process, to the anterior mediastinal lymphatics. Others are directed backward to the lateral ligaments and descend to the cœliac glands, while an intermediate series converge and ascend to the superior phrenic glands.

The **cœliac glands**, sixteen to twenty, and of considerable size, surround the cœliac axis and aorta, extending to the superior mesenteric blood-vessels. They communicate with the lumbar glands, and receive the lymphatics of the stomach, the spleen and pancreas, the greater part of those of the liver, and those of the gall-bladder. Their efferent vessels commonly unite with the mesenteric lymphatics to form the **intestinal lymphatic trunk**, ending in the commencement of the thoracic duct.

#### LYMPHATICS OF THE THORAX.

The **cardiac lymphatics** proceed from a deep and superficial set in the walls of the heart, and thence mainly pursue the course of the coronary blood-vessels. Those accompanying the left coronary vessels end in a single trunk, which ascends behind the pulmonary artery, and then forward between this and the aorta to the front of the arch, above which it joins one of the cardiac glands. Those accompanying the right coronary vessels likewise end in a single trunk, which joins the left trunk between the commencement of the aorta and pulmonary artery, or proceeds to join one of the cardiac glands behind the aortic arch.

The **cardiac glands**,<sup>1</sup> eight to ten, occupy the superior mediastinum around the aortic arch and innominate veins, extending in front of the trachea below and communicating with the bronchial glands. They receive the cardiac lymphatics, most of those of the pericardium, and those of the thymus gland. Their efferent vessels form two or three trunks, which proceed left and right on the trachea to join the thoracic and right lymphatic ducts.

The **pulmonary lymphatics** consist of a deep series pursuing the course of the bronchial tubes and accompanying blood-vessels, and a superficial series forming an abundant reticular plexus beneath the pleura. Both series converge to the root of the lung, where they enter the bronchial glands.

The **bronchial glands** are numerous, twenty to thirty, large and small, and occupy the interval of the bifurcation of the trachea; thence extending on the bronchi and their primary divisions into the hilus of the lungs. They receive the pulmonary lymphatics, and their efferent vessels form several considerable trunks, which ascend on the trachea to join the thoracic and right lymphatic ducts. The bronchial glands

---

<sup>1</sup> Superior mediastinal glands.



are remarkable for their liability to alteration, both ordinarily and pathologically. In infancy they are pink in hue; later they become grayish and more or less mottled; and in advanced age they assume a variable dark slate hue to an intense black color.

The **œsophageal lymphatics** form a plexus between the mucous and muscular coats of the œsophagus, and pierce the latter to join the posterior mediastinal glands.

The **posterior mediastinal lymphatics**, with from eight to a dozen glands, are situated along the œsophagus, from which they receive many tributaries, and others from the back of the diaphragm and pericardium. Their efferent vessels above partly join the bronchial glands and partly end in the thoracic duct.

The **intercostal lymphatics** pursue the course of the corresponding blood-vessels, and usually form two trunks, which run backward and commonly enter a couple of glands situated between the heads of the ribs beneath the pleura. The efferent vessels either open into the thoracic duct with a few of the upper right ones into the right lymphatic duct, or, in whole or part, they form a pair of lateral trunks, which descend on the sides of the spine and join the lower extremity of the thoracic duct.

The **sternal lymphatics** ascend along the course of the internal mammary blood-vessels, and commonly form two or three trunks associated with half a dozen or more little glands. They receive lymphatics from the upper part of the front wall of the abdomen, the fore part of the diaphragm, and the front wall of the thorax, including the inner part of the mammæ. Some of their efferent vessels below join the anterior mediastinal lymphatics, and those above terminate in the thoracic and right lymphatic ducts.

The **anterior mediastinal lymphatics**, with usually three or four small glands, are situated in the corresponding space in front of the pericardium. They receive lymphatics from the mesial portion of the upper surface of the liver, others from the fore part of the diaphragm, and some from the lower sternal lymphatics. Their efferent vessels ascend to join the thoracic and right lymphatic ducts.

The **lymphatics of the diaphragm**, forming a plexus of small vessels in the tendinous centre and of conspicuously large ones in the muscular portion, mainly converge to four trunks, of which a pair proceed to join the sternal lymphatics, and the others descend to join one of the celiac glands.

#### LYMPHATICS OF THE UPPER LIMBS.

The **deep lymphatics of the upper limb**, together with some of those from the exterior of the walls of the chest, accompany the corresponding deep blood-vessels and converge to the axillary glands. Commonly each artery is accompanied by a pair of lymphatic trunks, as in the case of the veins. Several little glands not unfrequently exist in the



course of the radial and ulnar lymphatic trunks, and more constantly three or four in the course of the brachial lymphatic trunks.

The **superficial lymphatics** commence in the hand, in an extremely rich and close plexus of the palmar surface, and are joined by others from the dorsal surface. The trunks proceeding from the hand form three series, following the principal superficial veins of the forearm, and thence ascending on the front and inner surface of the arm to the axillary glands. They are joined by others from the back of the arm; and two or three trunks, joined by others from over the shoulder, follow the cephalic vein and enter the infraclavicular fossa to join the axillary glands. Several of the lymphatics from the inner side of the forearm after passing the elbow enter one, two, or three glands situated a short distance above the internal condyle.

The **lymphatics of the mamma** are large and extremely numerous. The trunks converge from between and around the lobes to the areola, where they unite in a **subareolar plexus**, which is also joined by the finer lymphatics of the skin of the areola and nipple. From the subareolar plexus the large vessels are directed outwardly, and converge commonly into two or three trunks, which proceed to enter the more anterior of the axillary glands.

The **superficial lymphatics of the side and front of the chest**, including those of the upper part of the abdomen, derived from the skin, subjacent fascia, and superficial muscles, converge and ascend outwardly to the axillary glands. In the loins they communicate with the lymphatics, which converge to the inguinal glands.

The **superficial lymphatics** of the back of the trunk, over the position of the trapezius, deltoid, and latissimus muscles, communicate with the former, and likewise converge to the axillary glands.

The **axillary glands**, ten to a dozen, are very unequal, large and small, and are mostly collected around the axillary blood-vessels. A few lie forward on the great serratus at the lower border of the pectoral muscles, and receive the lymphatics from the front of the chest and the mamma; others are situated at the back of the axilla on the subscapular blood-vessels, and especially receive the lymphatics of the back; and one or two small ones occupy the infraclavicular fossa, communicate with the inferior cervical glands, and receive the lymphatics accompanying the cephalic vein. The glands on the axillary blood-vessels especially receive the brachial lymphatics.

The efferent vessels of the axillary glands ascend with the subclavian vein, and sometimes unite in a single **subclavian lymphatic trunk**, or two or three trunks of unequal calibre. On the left side the trunk opens into the thoracic duct near its termination, and on the right side into the right lymphatic duct, or on either or both sides it may end directly in the corresponding subclavian vein. When there are several trunks, one may end in the duct of the corresponding side, and the other in the contiguous subclavian vein.

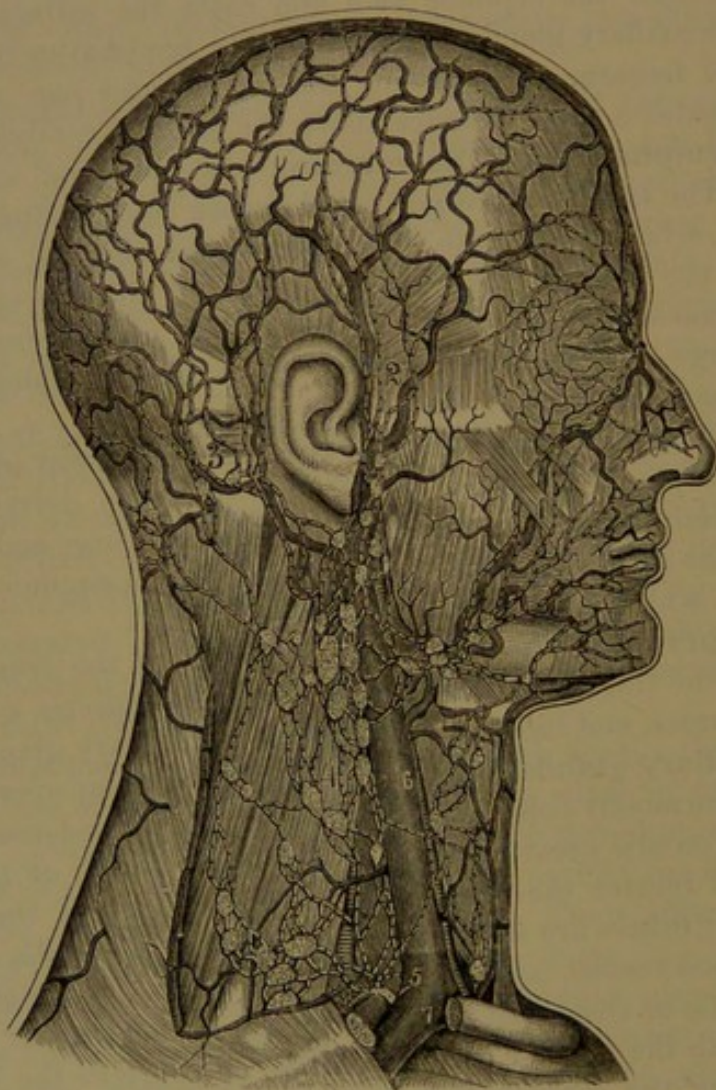


## LYMPHATICS OF THE HEAD AND NECK.

The lymphatics of the upper part of the head, proceeding from the scalp and subjacent structures, form three series, the frontal, parietal, and occipital lymphatics.

The **frontal lymphatics**, from the forehead and eyebrow, converge in ten or more trunks to the front of the ear, where they enter

FIG. 299.



LYMPHATICS OF THE HEAD AND NECK. 1, facial lymphatics; 2, temporal lymphatics; 3, posterior auricular and occipital lymphatics; 4, cervical lymphatics; 5, the right lymphatic duct; 6, internal jugular vein; 7, subclavian vein.

the parotid lymphatic glands. The **parietal lymphatics** communicate with the former and the occipital lymphatics, and converge in six or more trunks, which descend behind the ear to the mastoid glands.

The **occipital lymphatics** partly converge to a trunk which descends behind the sterno-mastoid muscle, and then beneath it to the deep cervical glands, and partly join one or two occipital glands, resting



on the complexus in advance of the occipital attachment of the trapezius muscle. The efferent vessels of the occipital glands enter the superficial cervical glands.

The **parotid lymphatic glands**, four or five small ones, lie under the parotid fascia, and in part are embedded in the parotid gland. The largest one is placed immediately in front of the tragus, and receives the frontal lymphatics accompanying the temporal blood-vessels and the lymphatics of the fore part of the pinna. The others receive the lymphatics of the eyebrow and outer part of the eyelids, of the parotid gland and the cheek. The efferent vessels enter the superficial cervical and submaxillary lymphatic glands.

The **mastoid glands**, four or five, lie partly on and partly under the insertion of the sterno-mastoid muscle. They receive the parietal lymphatics and those from the back of the pinna, and their efferent vessels join the cervical glands.

The **lymphatics of the external ear**, or pinna, form a rich, close plexus in the integument, from which the trunks joined by deeper ones converge towards the meatus, whence those in front proceed to the parotid glands, and those behind to the mastoid glands.

The **facial lymphatics** are derived from the region of the face occupied by the corresponding blood-vessels, and mainly descend in their course to enter the submaxillary glands. The **deep facial lymphatics**, from the orbit, nasal fossa, roof of the mouth, and inside of the cheek, join the internal maxillary lymphatics. These pursue the course of the corresponding blood-vessels, and further receive lymphatics from the temporal and zygomatic fossæ and upper part of the pharynx. They are associated with several glands lying on the blood-vessels and on the back part of the buccinator muscle and pharynx. Their efferent vessels enter the deep cervical glands.

The **lymphatics of the cranial cavity** mainly originate in the perivascular lymphatics of the brain and pia mater, whence the trunks proceed and accompany the internal carotid and vertebral arteries and the internal jugular vein to enter the deep cervical glands.

The **lymphatics of the eyeball** are, for the most part, perivascular, and accompany the blood-vessels to join those of the orbit.

The **lymphatics of the middle ear** accompany the corresponding blood-vessels to the internal maxillary and deep cervical lymphatics. The relation of the internal ear to the lymphatic system is not satisfactorily determined.

The **lymphatics of the nasal cavity** form a rich plexus in the mucous membrane, from which the trunks pass backward and enter the deep cervical glands.

The **lymphatics of the tongue** form a close plexus in the mucous membrane, especially in that of the dorsum, while a deep set proceed from the muscles. The trunks mainly pursue the course of the lingual blood-vessels, in which they are associated with two or three little



glands, and terminate partly in the submaxillary and partly in the deep cervical glands.

The **submaxillary lymphatic glands**, eight to ten or more, lie below and within the base of the mandible, and receive the superficial lymphatics of the face, those of the floor of the mouth and of the sublingual and submaxillary salivary glands, and most of those from the parotid lymphatic glands. Their efferent vessels enter both the superficial and the deep cervical glands.

The **superficial cervical lymphatics**, associated with from four to six glands, follow the course of the external jugular vein, and enter the deep cervical glands at the bottom of the neck. They receive the efferent vessels of the occipital and mastoid glands and part of those of the parotid and submaxillary glands, and the superficial lymphatics of the neck.

The **deep cervical lymphatics**, with twenty to thirty glands, large and small, form a chain along the great blood-vessels from the base of the cranium to the bottom of the neck. They are mostly collected about the internal jugular vein, and communicate above with the mastoid, parotid, and submaxillary lymphatic glands, and below with the cardiac and axillary glands. They receive the lymphatics of the cranial cavity, those of the deeper parts of the neck, and those of the nasal cavity, the tongue, lower part of the pharynx and the larynx, and the efferent vessels of the internal maxillary and most of those of the submaxillary glands. Their efferent vessels commonly terminate in the **jugular lymphatic trunk**, which ends in the thoracic duct of one side and the right lymphatic duct of the other side, or it may terminate in either of the contiguous veins.



## CHAPTER X.

### THE RESPIRATORY APPARATUS AND LARYNX.

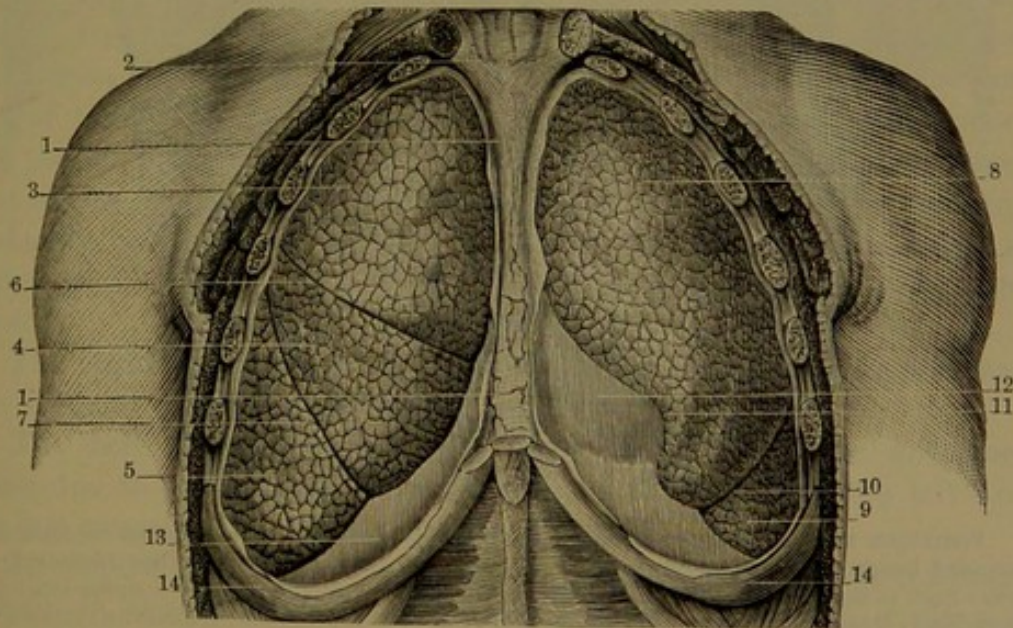
#### THE RESPIRATORY APPARATUS.

THE organs of respiration comprise the lungs, with the windpipe and the larynx, together with the chest and the appropriate muscles. The latter are chiefly the diaphragm, and the scaleni, serrati, pectoral, and intercostal muscles, assisted by those of the abdominal wall.

#### THE LUNGS.

The **lungs**<sup>1</sup> are two large spongy organs permeable by air, and are contained within the chest, with the heart enclosed in the pericar-

FIG. 300.



ANTERIOR VIEW OF THE LUNGS. The chest and pleural cavities laid open. 1, anterior mediastinum; 2, superior mediastinum; 3, 4, 5, superior, middle, and inferior lobes of the right lung; 6, 7, interlobular fissures; 8, 9, superior and inferior lobes of the left lung; 10, interlobular fissure; 11, notch of the left lung; 12, pericardium enclosing the heart; 13, diaphragm; 14, seventh rib.

dium lying between them. Each occupies a distinct cavity, lined by a serous membrane, the pleura, which is thence reflected on and invests the lung. Each is suspended or attached near the middle of its inner surface by the **root**, which consists of a branch of the trachea, named

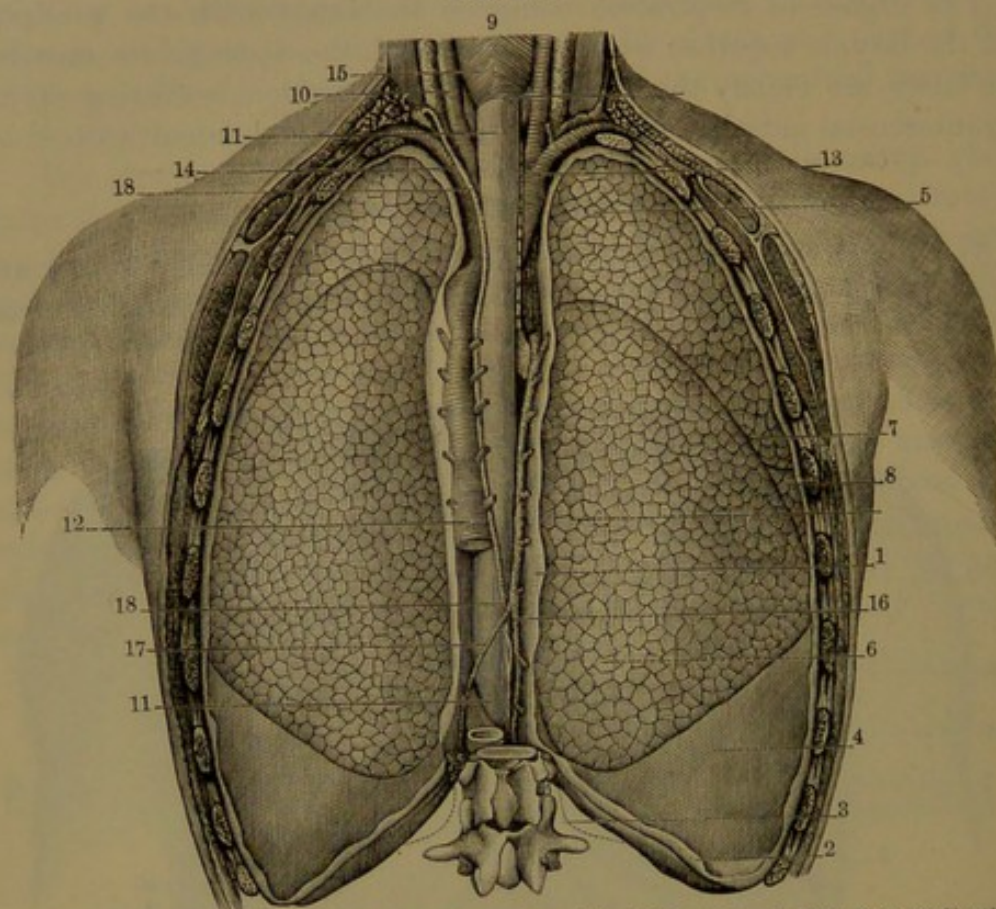
<sup>1</sup> Pulmones; pneumones; lights.



the **bronchus**, and the pulmonary blood-vessels connected with the heart. Elsewhere the lungs are free and smooth, and closely conform to the cavities containing them, with the surface of which they are perpetually maintained in all the movements of respiration; the opposed surfaces of the pleura being lubricated with serum, which alleviates friction.

Each lung is pyramidal, with the base concave, and closely conforming to and resting on the diaphragm. The outer, most extensive, lateral surface is evenly convex, and the inner surface, next the heart,

FIG. 301.



POSTERIOR VIEW OF THE LUNGS; the pleural cavities laid open. 1, posterior mediastinum, bounded laterally by the pleuræ; 2, lower border of the costal pleura; 3, outline indicating the lower limit of the pleural cavity; 4, phrenic pleura covering the diaphragm; 5, upper lobe of the right lung; 6, lower lobe; 7, fissure separating the lobes; 8, middle lobe; 9, pharynx; 10, its lower limit; 11, œsophagus; 12, thoracic aorta, giving off intercostal arteries; 13, innominate artery, dividing into the right common carotid and subclavian arteries; 14, left subclavian artery; 15, left common carotid artery and the accompanying internal jugular vein; 16, azygos vein; 17, hemi-azygos vein; 18, thoracic duct.

is concave, and for the most part in contact with the pericardium. The apex is rounded, and extends into the neck above the position of the first rib, which impresses it; as usually does also the subclavian artery at its summit. The posterior border, the longest portion of the lung, is thick and convex, and occupies the dorsal recess of the chest at the side of the spine. The anterior border is thin and acute, overlaps the



front of the heart within the pericardium, and in full inspiration approaches that of the opposite side, behind the middle of the sternum, where the lungs are separated only by the two pleuræ of the anterior mediastinum. The border of the base is likewise thin and acute, and outwardly descends between the diaphragm and its attachment to the ribs.

The **root of the lung**<sup>1</sup> is situated somewhat above the middle of the inner surface nearer the posterior border, and is composed of the corresponding bronchus, the pulmonary artery, two pulmonary veins, the bronchial vessels, lymphatics with glands, and the nerves, all enveloped in areolar tissue and a reflection of the **pleura**. Where the bronchus, vessels, etc., enter the lung and emerge from it there is an elongated elliptical recess, the **hilus**,<sup>2</sup> which is about three inches long and half an inch wide, and has a slightly prominent border in front and behind. Back of the hilus the surface of the lung is depressed longitudinally to conform to the convex side of the spine.

Each lung is divided by a long and deep oblique fissure,<sup>3</sup> which is seen on the outer surface, commencing behind, two or three inches below the apex, and descending to the base in front. The fissure inwardly approaches the root and divides the lung into two lobes,<sup>4</sup> of which the lower is the larger, but it does not completely separate them. In the right lung a second fissure<sup>5</sup> proceeds horizontally forward from the former, and divides off above a smaller, triangular portion of the lower lobe, thus giving three lobes to this lung. Occasionally the left lung exhibits a trace of a similar division, and sometimes that of the right lung is less well produced than usual. The left lung is deeply notched<sup>6</sup> at its fore part below, between the two lobes, in which position the apex of the heart approaches the front wall of the chest.

The **right lung**<sup>7</sup> is shorter, broader, more bulky, and heavier than the left, and the extent of its base is considerably greater.

The **left lung**<sup>8</sup> is longer, narrower, and deeper, the difference being due to the greater encroachment of the heart on the left and the less ascent of the diaphragm on that side.

In respiration the upper extremity and posterior border of the lungs remain in close contiguity with their pleural sac; but in expiration the anterior margin retires from the corresponding border of the sac, and only occupies it in full inspiration. The outer basal margin likewise retires in expiration, and probably at no time does it descend to the entire depth of the pleural cavity.

The apex of the lung, with the parietal pleura, ascends through the

<sup>1</sup> Radix or pedunculus pulmonis.

<sup>2</sup> Porta pulmonis.

<sup>3</sup> Incisura interlobularis.

<sup>4</sup> Lobus superior or anterior and inferior or posterior.

<sup>5</sup> Incisura interlobularis inferioris.

<sup>6</sup> Incisura cardiaca.

<sup>7</sup> Lobus dexter.

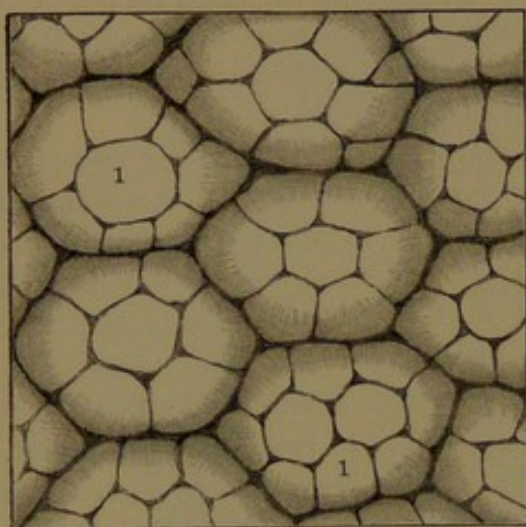
<sup>8</sup> L. sinister.



upper aperture of the chest, an inch or more into the neck, though sometimes not so high, or even above the level of the first rib. From the apex, the anterior margin of the lung curves inward behind the sterno-clavicular articulation, and thence nearly to the median line of the mesosternum, whence it descends, in the right lung to the sixth costal cartilage, or lower, and in the left lung to the fourth, and recedes in a curve downward, outward, and backward to the tenth thoracic vertebra. The inferior margin of the lungs descends to a considerable extent in inspiration, and in a corresponding degree ascends in expiration.

The surface of the lungs in the usual distended condition is perfectly smooth, and is everywhere marked by polygonal areas, com-

FIG. 302.



PORTION OF THE EXTERIOR SURFACE OF THE INFLATED LUNG; magnified and exhibiting the hexagonal outlines of the bases of the primary lobules or infundibula, with the air-cells, 1.

monly four- to six-sided, and variably approaching about half an inch in width. These areas are similarly but less distinctly marked with smaller ones, about a line, more or less, in diameter. The marks are the outlines of subdivisions or lobules of which the lung-substance is composed, the whole being united by connective tissue and invested by the pleura. In infancy the lungs are of a pale-pink or rose color, but as life advances they become more or less violaceous and gray, and marked by spots and streaks of dull bluish-black or slate color, all of which ap-

pear darker in the collapsed condition of the organ.

The slate-colored marks commonly increase with age, and appear in considerable measure to be promoted by certain pursuits, as those of the smith, the miner, and the collier. The coloring-matter is disposed to accumulate between the lobules, thus rendering their outlines more distinct, and not unfrequently it is observed in greater degree along the position of the ribs, giving the lungs a banded appearance.

The lung-substance is of a loose or spongy texture, and even in the collapsed condition readily floats on water; its specific gravity ranging from 0.345 to 0.746, and when fully distended being only 0.126. Completely deprived of air, or in the fœtus before breathing, it has a specific gravity of 1.056, and sinks in water. When pressed between the fingers the lungs crepitate, from the escape of air from the tissue; and when torn they exude a reddish frothy liquid, consisting of mucus tinged with blood and mingled with air-bubbles.

The lungs are highly elastic, so that they collapse to about a third of their bulk when exposed by opening the chest. They range from



two to three pounds avoirdupois, and commonly are rather above the average of these weights. In the female they weigh about a fourth less.

The lungs are provided each with a serous membrane, the **pleura**, which forms a closed sac, and consists of a **parietal portion** lining the cavity containing the lung, and a **visceral portion** reflected from the cavity over the root and investing the lung, whence it is called the **pulmonary pleura**.<sup>2</sup> Where the visceral portion lines the ribs and costal cartilages it is named the **costal pleura**,<sup>3</sup> that covering the diaphragm is the **phrenic pleura**, and inwardly the two pleuræ together form the **mediastinum** and envelop the pericardium. From the root of the lung a narrow fold of the pleura, the **pulmonary ligament**,<sup>4</sup> descends to the base of the lung, connecting the posterior border of its inner surface to the contiguous border of the spine.

The apex of the pleura, with that of the lung, rises into the root of the neck an inch or two above the fore end of the first rib, and a short distance above the clavicle under the attachment of the scaleni muscles. In front, the pleuræ come nearly or quite into contact behind the mesosternum, but at the lower end of the latter, while the right pleura remains at or near the median line, the left pleura retires to a variable distance from it. Behind, the pleuræ descend as low as the head of the last rib; in the line of the axilla the right pleura reaches the lower margin of the ninth rib, and the left pleura the lower margin of the tenth rib. In front, the former reaches the junction of the seventh rib with its cartilage, and the left one a little lower.

The pleura resembles other serous membranes in structure, and has the same object, to facilitate the movement of the lungs on the surface of the cavities containing them. The costal pleura is the thickest, and is strengthened by a considerable connective-tissue layer, by which it adheres to the subjacent parts, and more firmly to the ribs than to the intercostal muscles. The phrenic pleura is thinner and more tightly adherent than the former. That of the mediastinum and that covering the pericardium is also thin, and is the most disposed to the accumulation of fat in its subserous connective tissue. The pulmonary pleura is the most delicate, is colorless and transparent, and is always clear of subjacent fat. Though easily detached from the lung, it closely adheres to the surface by a thin, firm layer of connective tissue, with considerable elastic tissue, continuous with the intervening areolar tissue of the lobules. This subserous layer contains a uniform net of capillary blood-vessels supplied by the bronchial arteries. It further contains an abundant plexus of lymphatics, which communicate by stomata with the pleural cavity and with the lymphatics in the interior of the lung.

<sup>1</sup> Pleurum; membrana pleuritica.

<sup>2</sup> Pleura pulmonalis; membrana or velamentum pulmonis.

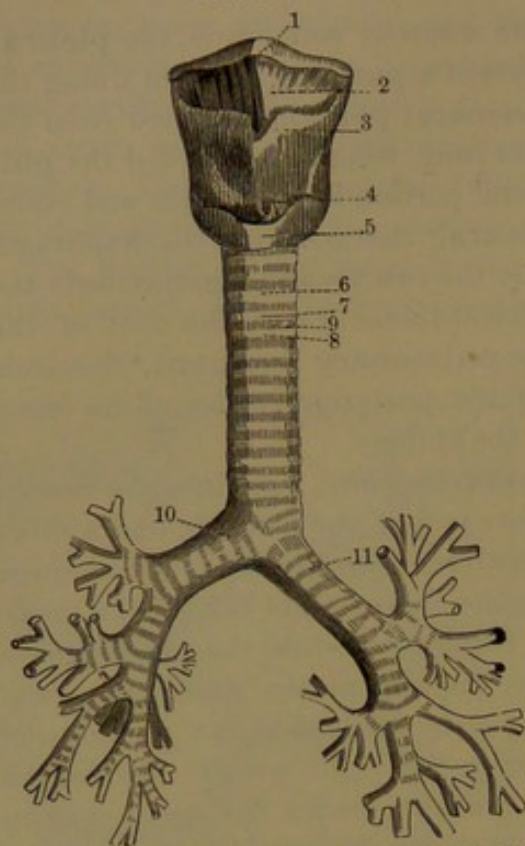
<sup>3</sup> P. costalis.

<sup>4</sup> Ligamentum pulmonis.



The **trachea**, or **windpipe**,<sup>1</sup> is the common air-passage of both

FIG. 303.



FRONT VIEW OF THE LARYNX, TRACHEA, AND BRONCHI. 1, hyoid bone; 2, thyro-hyoid membrane; 3, thyroid cartilage; 4, lower part of the vocal membrane; 5, cricoid cartilage; 6, trachea; 7, 8, cartilaginous rings; 9, intervening fibro-elastic membrane connecting the rings; 10, 11, right and left bronchi dividing into the bronchial tubes.

lungs, commences at the larynx on a level with the lower border of the fifth cervical vertebra, and descends through the fore part of the neck into the chest, where it forks into two branches, the **bronchi**, or **bronchial tubes**,<sup>2</sup> opposite the upper border of the fifth thoracic vertebra. It is a cylindrical tube, about four inches long and from three-fourths to one inch in diameter, but of slightly less width fore and aft; and is proportionately smaller in the female. It is retained permanently open by a series of cartilaginous rings, which are, however, incomplete behind, where the trachea is solely membranous, and is there somewhat flattened. The lower end slightly expanded laterally divides at an obtuse angle into the right and left bronchi, which have the same form and construction as the trachea. The **right bronchus**<sup>3</sup> is the shorter and wider, about an inch long, and is directed obliquely outward and downward to the root of the

corresponding lung, which it enters opposite the fifth thoracic vertebra. The **left bronchus**,<sup>4</sup> twice the length of the former, but narrower, is directed more obliquely to the root of the left lung, which it enters opposite the sixth vertebra.

In the neck the common carotid artery lies on each side of the trachea, and its upper extremity is embraced by the thyroid gland. It is covered in front by the sterno-thyroid and -hyoid muscles, with a narrow interval occupied by the deep cervical fascia. At the bottom of the neck it is received in the angle of divergence of the innominate and left common carotid arteries, and above these the inferior thyroid veins lie upon it. In the thorax the trachea is situated behind the presternum covered by the origin of the sterno-hyoid and -thyroid

<sup>1</sup> Aspera arteria; bronchus; canna; syrinx; weasand; throttle; fistula pulmonalis.

<sup>2</sup> Bronchia; bronchiæ; cannulæ pulmonum.

<sup>3</sup> Bronchus dexter.

<sup>4</sup> B. sinister.



muscles. Lower, it is covered in front by the left innominate vein, then by the diverging innominate and left carotid arteries, and finally by the arch of the aorta. Placed between the pleuræ in the superior mediastinum, to its right is the corresponding vagus nerve, and to its left are the corresponding common carotid artery, the vagus, and the inferior laryngeal nerve.

The root of the right lung extends behind the superior cava and ascending portion of the aortic arch, and has the azygos vein arching from behind forward above and over it to join the cava. The root of the left lung extends beneath the aortic arch in front of the descending aorta. The phrenic nerve descends in front of the root of each lung, and the vagus nerve behind it.

The bronchi diverge from the trachea back of the pulmonary vessels, and enter the hilus between the artery above and the veins below and in front. They divide at the entrance of the hilus each into two principal branches for the upper and lower lobes of the lung, and the lower branch of the right bronchus gives a division to the third lobe.

The right bronchus proceeds from above downward and outward behind the right pulmonary artery to the hilus of the lung, and the left bronchus passes in the same manner beneath the left pulmonary artery to the corresponding lung. Within the lungs the bronchi, or bronchial tubes, ramify throughout the organs, branching at acute angles and diverging in all directions, the terminal branches being distinguished as the **bronchioles**. The pulmonary blood-vessels accompany the bronchi and ramify in the same manner, the arteries running behind and the veins in front of them. The bronchial arteries and veins, the lymphatics, and the nerves likewise pursue the same course.

The trachea and its chief divisions, the bronchi, are composed of incomplete **cartilaginous rings**<sup>1</sup> joined by intervening ligaments, united by a posterior membranous layer and lined by mucous membrane. The rings form about two-thirds of a circle, with the inner surface convex from above downward, the outer surface flat, and the ends rounded. In the trachea there are usually from sixteen to twenty, each about two lines deep and half a line thick; in the bronchi they are proportionately smaller, from six to eight in the right bronchus and from nine to twelve in the left. They are generally parallel with one another across the trachea, and are most uniform along the middle of the latter, but are variable especially at the extremities. Often several fork, usually on alternate sides, so as to preserve the conformity of the series, and sometimes those adjacent unite at the ends. The last tracheal ring is especially variable, and usually is prolonged in front in a downward angle so as to conform to the first pair of rings of the bronchi. The rings of the latter are even more variable than those of the trachea, and are often more or less irregularly conjoined.

---

<sup>1</sup> Annuli cartilaginei.



The tracheal and bronchial cartilages are non-vascular, and are invested with a dense and closely-adherent perichondrium, which is continuous with the intervening ligaments. The latter are strong, thin bands of fibro-connective with considerable elastic tissue. A membranous layer of the same character but of looser texture is extended across the interval of the cartilages at the back of the trachea and bronchi. Within the position of this layer is a pale-reddish layer of unstriped muscular fibres, which pass transversely between the rings and are attached to their ends, and for a short distance to their inner surface. The ligament connecting the trachea with the larynx is stronger than the rest.

The lining mucous membrane of the trachea is mostly even and of a pale pink hue, though it readily assumes a crimson or purple color from inflammation and congestion. Along the membranous back part of the passage it is finely wrinkled longitudinally, especially approaching the bronchi, the wrinkles being mainly due to subjacent longitudinal bundles of elastic tissue. The membrane exhibits in many positions a finely-punctate appearance, especially in the intervals of the tracheal rings and between the posterior wrinkles, due to the orifices of the ducts of the numerous subjacent mucous glands of the trachea. The epithelium of the mucous membrane consists of a layer of comparatively long columnar, ciliated cells, which taper and are more or less irregular at their deeper extremity, where they are intercalated with a stratum of short, immature cells conforming to the intervals they occupy. The mucosa of the tracheal mucous membrane consists of a well-marked basement membrane with a layer of fibro-connective tissue containing capillary blood-vessels and lymphatics, and associated with some lymphoid tissue.

Following the fibro-connective-tissue layer there is a considerable layer of elastic tissue collected in longitudinal reticular bundles. The submucous layer of the trachea, composed of areolar with elastic tissue, contains the larger blood-vessels, lymphatics, and nerves of the mucous membrane, together with numerous small racemose glands whose ducts open into the trachea. The tracheal glands are largest and most numerous in the posterior membranous layer of the trachea, where many of them extend from the submucous layer between the muscular fibres into the exterior fibro-connective-tissue layer. They are also especially numerous between the tracheal rings, but are there smaller.

The bronchi as forks of the trachea are identical in structure.

The arteries of the trachea and bronchi are derived from the inferior thyroid and bronchial arteries, and for the most part terminate in the submucous coat in a plexus, which is connected with the ample capillary nets of the mucosa of the mucous membrane and of the tracheal and bronchial glands. The veins end in the thyroid and bronchial veins. Rich plexuses of lymphatics occupy the mucosa and submu-



cous layer of the lining membrane of the trachea and bronchi, and the chief vessels join the cervical and bronchial lymphatic glands. The nerves are derived from the trunk of the vagus, from its inferior laryngeal branch, and from the sympathetic nerve.

**Structure of the lungs.** The substance of the lungs is composed of small polyhedral subdivisions, the **primary lobules**, which are closely associated into larger lobules from about a fourth of a line to a line in diameter, and these again into still larger ones variably approximating half an inch, and aggregated in the formation of the lobes of the lungs. The lobules of the lungs are connected together by the bronchi and blood-vessels, as the foliage of a tree is attached to its boughs, but are closely aggregated and conjoined by interstitial areolar tissue. The primary lobules are somewhat pyramidal, whence they are also called **infundibula**, and are composed of rounded saccules, the **air-cells**. These do not directly communicate with one another, but are closely grouped around a central air-passage, into which they open. The air-passage narrows and proceeds from the apex of the infundibulum as a **bronchiole**, which joins others in the formation of the larger bronchial tubes or bronchi. At the surface

FIG. 304.

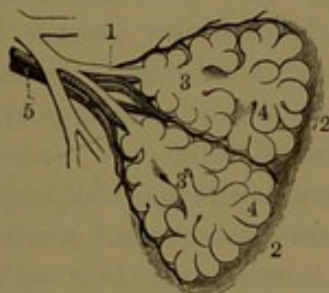


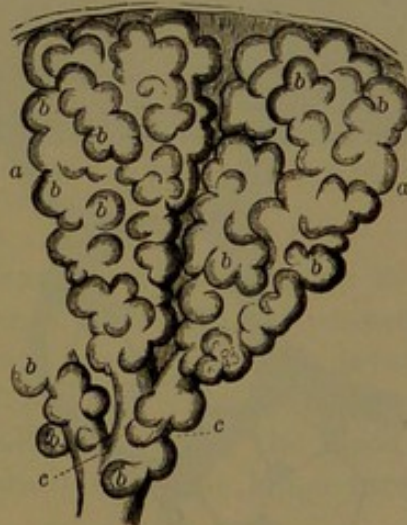DIAGRAM OF TWO PRIMARY LOBULES OF THE LUNGS, magnified. 1, bronchiole; 2, a pair of primary lobules connected by fibro-connective tissue; 3, intercellular air-passages; 4, air-cells; 5, branches of the pulmonary artery and vein.

of the lungs the bases of the contiguous primary lobules appear in polygonal areas, which include from four or five to double the number of air-cells. Both the for-

mer and the latter are larger at the periphery than in the interior of the lungs. The air-cells generally range from about  $\frac{1}{150}$  of an inch to double the size. In the infant they are about  $\frac{1}{200}$  of an inch, and they increase in size with the advance of age. They are smaller in the female than in the male.

The bronchi, traced from the main trunks after ramifying throughout the lungs, by their terminal branches or bronchioles end in the primary lobules. They are permanently open cylindrical tubes, and in general are composed of an outer fibro-connective-tissue coat, with an

FIG. 305.



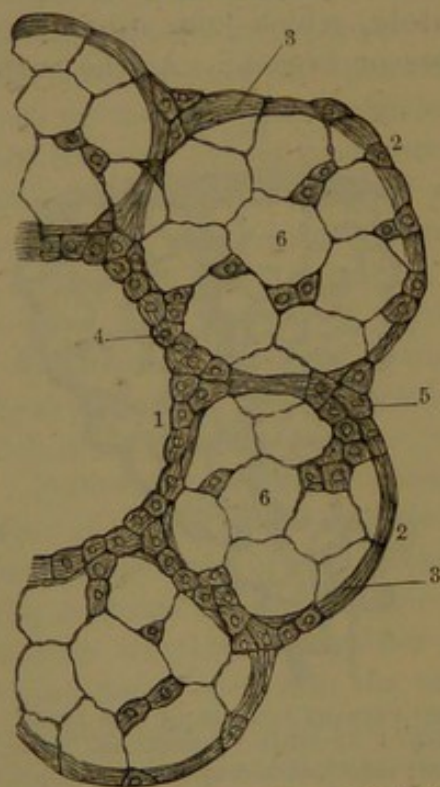
TWO PRIMARY LOBULES OF THE LUNGS. a, lobules; b, air-cells; c, bronchioles. From an infant: magnified 25 diameters.



inner layer of circular, unstripped muscular fibres and a lining mucous membrane. The latter is like that of the chief bronchi, but is more uniformly longitudinally striate or narrowly wrinkled, and possesses the same kind of columnar, ciliated epithelium throughout. The mucosa also contains considerable elastic tissue collected in longitudinal bundles. In the larger bronchi the wall is furnished with plates of cartilage, mostly irregular both in shape and in their disposition around the tubes. At the division of the tubes, plates of crescentic form are placed below the entrance of branches, with the concave border embracing the orifice so as to retain it open. The cartilaginous plates gradually diminish in number and size as the bronchi decrease, and they finally disappear. The bronchi are also furnished with small racemose mucous glands, which are more numerous in the larger tubes and cease in the smaller ones.

The smallest bronchi, or bronchioles, merge into the central air-

FIG. 306.



SECTION OF THE TISSUE OF THE LUNG, highly magnified. 1, an intercellular air-passage; 2, air-cells; 3, fibro-connective with elastic tissue, surrounding them, in which lie the capillary blood-vessels; 4, 5, small granular nucleated cells; 6, large pavement epithelial cells lining the air-cells.

passages of the primary lobules of the lung. The fibro-connective-tissue coat of the bronchioles with elastic tissue extends between the lobules and surrounds the air-cells. The ciliated columnar epithelium of the bronchioles merges in the air-passages of the lobules into the condition of short, polygonal, non-ciliated cells.

The air-cells open by large orifices into the central air-passage of the lobules, but their walls and bottom are entire. They are composed of a delicate membrana propria of fibro-connective with elastic tissue enclosing a close net of capillary blood-vessels, the meshes of which are scarcely wider than the vessels. A single net is included between the air-cells laterally, and is continued around their fundus, where it is distinct from that of the air-cells of the contiguous lobules. At the mouths of the air-cells the capillary nets are defined by circular vessels twining along their

border. The air-cells are lined, for the most part, with a single layer of irregular, clear, pavement, non-nucleated cells. Scattered among the latter, here and there, are small, granular, polygonal, nucleated cells, single or two or three together, and forming rows at the mouths of the



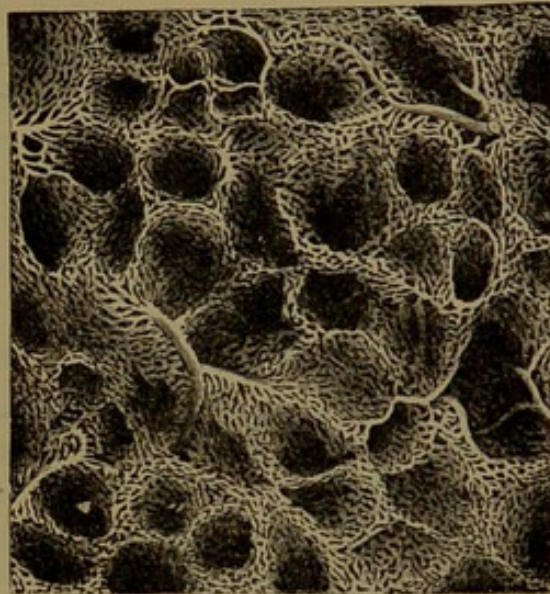
air-cells, where they are continuous with the similar epithelium of the air-passage.

The nets of capillary blood-vessels of the air-cells of the lungs receive the terminal branches of the pulmonary artery, which accompanies the bronchus in its distribution; the arterial branches generally running above and behind the bronchial tubes, and finally entering between the primary lobules. The veins from the capillary nets emerge from between the lobules and pursue the same course as the arteries, generally in front and below the bronchial tubes. The veins from the peripheral lobules also in part unite in a superficial plexus, from which the main vessels converge and join the deep veins as they emerge at the hilus of the lungs.

The bronchial blood-vessels, very small in comparison with the special pulmonary blood-vessels, are devoted to the nutrition of the component parts of the lungs. Accompanying the bronchi, they are distributed to their walls, to those of the pulmonary vessels, the bronchial lymphatic glands, the interlobular connective tissue, and to the pulmonary pleura. Capillary plexuses of blood-vessels of the bronchi, of their mucous membrane, glands, muscular and connective tissue and elastic coat, and the subserous connective-tissue layer of the pleura, are supplied by the bronchial arteries. The corresponding veins accompanying the arteries are smaller, as part of the blood distributed by the bronchial veins is returned from the lungs through the pulmonary veins.

The lymphatics of the lungs are numerous, commencing in the walls of the air-cells and bronchioles, and forming intricate plexuses in the intervals of the primary lobules. A rich plexus also exists in the bronchial mucous membrane, and a superficial one in the subserous connective tissue of the pulmonary pleura. From all the plexuses, the principal lymphatic vessels follow the course of the bronchi and blood-vessels, and emerge at the hilus of the lungs, where they are joined by other branches emerging from the surface of the lungs, derived from the superficial plexus. The latter communicates by stomata of the pulmonary pleura with the pleural cavity. The deep lymphatic plexuses are also said to communicate with the air-cells; and these frequently contain free lymphoid corpuscles, which under favorable

FIG. 307.



CAPILLARY NETS OF THE AIR-CELLS OF THE LUNG: magnified 60 diameters.



circumstances exhibit amœboid movements. The lymphatic vessels emerging from the lungs enter the bronchial lymphatic glands.

The nerves of the lungs are derived from the pulmonary plexus, which is mainly formed by branches of the vagus nerve, with others from the sympathetic nerve. Fine nerves from the plexus accompany the bronchi in their distribution, and are associated in their course with minute ganglia, consisting of single nerve-cells or little groups of cells. The nerves contain both medullated and non-medullated fibres, the former probably pertaining to the vagus, and the latter to the sympathetic nerve.

The black coloring-matter of the lungs appears as minute granules, and especially occurs as a deposit in the interstitial areolar tissue of the lobules and air-cells, more abundantly at and near the surface than in the interior of the lungs. It also occurs, often in considerable quantity, in the bronchial lymphatic glands, in which it appears to accumulate from the lungs. It is also occasionally observed in the free mucous corpuscles expectorated with the mucus of the lungs.

#### THE LARYNX.

The **larynx** forms the commencement of the respiratory passage, and serves to prevent the entrance of foreign bodies, while it also acts as the especial organ of the voice. It is placed in front of the neck, producing in the male the prominence known as "Adam's apple,"<sup>1</sup> but this in the female, and likewise in the boy before puberty, from less development, is inconspicuous. It is situated in advance of the pharynx, with which it communicates by its upper orifice, and opens below into the trachea, or windpipe. Attached above to the hyoid bone, it is subcutaneous in the median line, and at the sides is covered by the infra-hyoid muscles, the inferior constrictor of the pharynx, and the thyroid body. It is a three-sided receptacle, narrowing below in a short cylinder, and is composed of a framework of cartilages which are connected with one another, the hyoid bone and the trachea by ligaments, is provided with muscles, and is lined by mucous membrane continuous with that of the pharynx and trachea.

For the relative position of the larynx, see Fig. 194, page 376.

#### THE CARTILAGES OF THE LARYNX.

The larynx is composed of five principal cartilages, the thyroid, cricoid, epiglottic, and two arytenoid cartilages. Small ones in pairs are the corniculate and cuneiform cartilages, the latter often being absent.

The **thyroid cartilage**,<sup>2</sup> the largest, occupies the front and sides of the larynx, and embraces nearly all the rest of the organ, besides

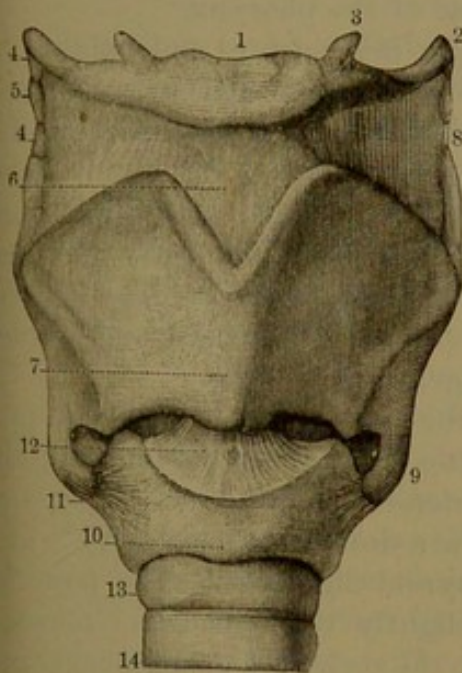
<sup>1</sup> Pomum Adami; protuberantia or prominentia laryngea; nodus gutturis.

<sup>2</sup> Cartilago thyreoidea or scutiformis.



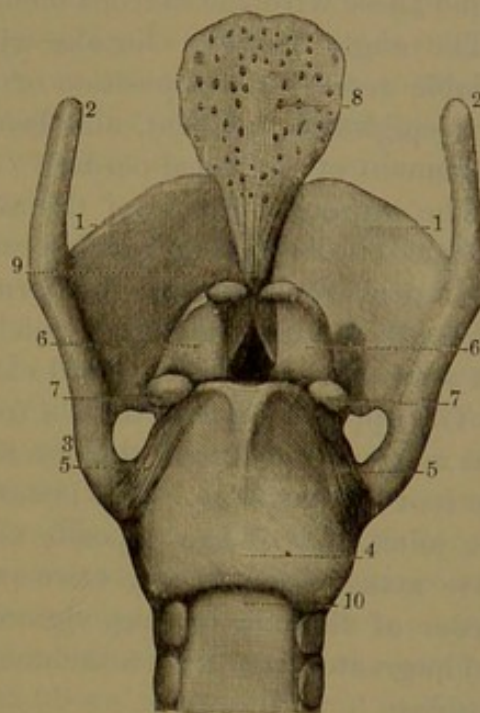
contributing to form the lateral walls of the pharynx. It consists of a pair of broad quadrate plates, or *alæ*, united in an angle in front, and diverging behind, and in a less degree above, into the cavity of the pharynx. The *alæ* are widest fore and aft, have nearly plane, slanting surfaces and sinuous free borders, which are prolonged behind in the horns. The angle formed by the union of the *alæ* is rounded below, and is produced prominently forward above in a *beak*, which is deeply

FIG. 308.



FRONT VIEW OF THE LARYNX. 1, hyoid bone; 2, greater cornu; 3, small cornu; 4, lateral thyro-hyoid ligament; 5, nodular cartilage; 6, middle thyro-hyoid ligament; 7, thyroid cartilage; 8, superior horn; 9, inferior horn; 10, cricoid cartilage; 11, crico-thyroid ligament; 12, crico-arythyroid ligament; 13, 14, first and second rings of the trachea.

FIG. 309.



BACK VIEW OF THE LARYNX. 1, thyroid cartilage; 2, superior horn; 3, inferior horn; 4, cricoid cartilage; 5, crico-thyroid ligament; 6, arytenoid cartilage; 7, prominent external angle of the base into which the crico-arythyroid muscles are inserted; 8, epiglottic cartilage; 9, thyro-epiglottic ligament; 10, posterior membrane of the trachea.

notched from the upper border of the cartilage. The beak is more or less conspicuously prominent in the male after puberty, but does not become so in the female.

The outer surface of each *alæ* at the posterior third is divided by a slight ridge, the *oblique line*,<sup>1</sup> which descends from the upper to near the lower border and then proceeds more abruptly forward. The ridge is variably more prominent at the upper extremity, and below where it turns forward. In front it gives origin to the thyro-hyoid muscle, and behind to the inferior constrictor of the pharynx and the sterno-thyroid muscle. Sometimes the ridge is scarcely produced, or is absent, when

<sup>1</sup> *Linea obliqua*; *limbus angulosus*.



it is substituted by a tendinous line. Not unfrequently the ala is perforated, on one or both sides, near the upper eminence of the ridge, by a foramen of variable size, which gives passage to a branch of the superior thyroid artery.

The inner surface of the ala, more uniformly even than the outer one, is slightly concave, and is somewhat everted near the lower border to accommodate the insertion of the crico-thyroid muscle. Above this position the surface is in contact with the muscles intervening between it and the crico-ary-thyroid ligament, the ventricle of the larynx, and behind these with the mucous membrane of the pharynx.

The angle between the alæ within is more acute, and exhibits a variable recess in the position of the beak for the attachment of the thyro-epiglottic ligament, and below this a slight prominence for the attachment of the vocal cords.

The **superior horn**<sup>1</sup> of the ala curves backward and inward from the back border, and is cylindrical and rounded at the end; the **inferior horn**,<sup>2</sup> shorter than the former, curves forward, inclines inward, and ends in a circular facet, which is directed downward and inward and articulates with the cricoid cartilage.

The upper border of the ala from the end of the superior horn pursues a sigmoid course to the notch of the beak, which extends half the depth of the cartilage. The lower border, shorter and less deeply sinuous, joins that of the opposite side in a downward convexity, which gives attachment to the crico-ary-thyroid ligament. The posterior border of the ala is long, sigmoid, slightly thickened, and rounded, and in greater part gives attachment to the stylo- and palato-pharyngeal muscles.

The **cricoid cartilage**,<sup>3</sup> second in size and thickest of the cartilages, occupies the lower part of the larynx, and joins the trachea. It is below the thyroid cartilage, is included between the inferior horns of the latter, and rises behind into the space embraced by the alæ. It resembles a seal ring in shape, is narrowest in front, and widens to the back part, where it is three or four times the depth of the fore part. Its passage is circular below, conforming to that of the trachea, but is somewhat laterally narrowed above, so that the upper aperture is oval, and it is lined by the laryngeal mucous membrane. The lower border is horizontal and sinuous, convex downward in front, and emarginate behind, and joins the trachea by a ligament. The upper border ascends obliquely from the front to the back part, where it is transversely horizontal, and forms a pair of articular facets, separated by a slight median notch. The facets for articulation with the arytenoid cartilages are convex and elliptical, with the longer diameter nearly

<sup>1</sup> Cornu superius, longus, or majus.

<sup>2</sup> C. inferius, brevis, or minus.

<sup>3</sup> Cartilago cricoidea or annularis.



twice that fore and aft, and directed outward and slightly downward and forward. Below and in advance of each facet the border exhibits a triangular surface, which gives origin to the lateral crico-arytenoid muscle. The outer surface of the cartilage on each side in front is convex, and gives origin to the crico-thyroid muscle. Behind this it presents a variable low **tubercle**<sup>1</sup> with wide base and truncated summit, which forms a circular facet for articulation with the inferior horn of the thyroid cartilage. The facet,<sup>2</sup> nearly flat or feebly depressed, looks outward, with a slight inclination upward and backward. Its base behind affords partial origin to the inferior constrictor of the pharynx. The posterior, broad surface of the cartilage is divided by a low median ridge<sup>3</sup> expanding at the ends, and gives attachment above to the commencement of the longitudinal muscular layer of the œsophagus. The surface on each side of the ridge is variably depressed, and is occupied by the posterior crico-arytenoid muscle.

The **arytenoid cartilages**<sup>4</sup> are placed at the back of the larynx, on the upper border of the cricoid cartilage, separated from each other by a rectangular interval, which may be widened or narrowed by movement of the two cartilages. Each is a trilateral pyramid curved backward, with the inner surface vertical, and the outer border, separating the front and back surfaces, oblique and sigmoid. The inner surface is narrowest and flat, abruptly tapers above, and is covered by the laryngeal mucous membrane. The back surface looks into the pharynx, is concave from above downward, and straight transversely, and with that of the other cartilage forms a recess, which is occupied by the arytenoid muscle. The front surface looks into the cavity of the larynx, is in general convex from above downward, and is directed slightly outward. Below the apex of the cartilage it presents a low tubercle,<sup>5</sup> and beneath this is divided into two fossæ, of which the lower one<sup>6</sup> gives attachment to the thyro-arytenoid and lateral crico-arytenoid muscles, and the upper, smaller one<sup>7</sup> forms the posterior extremity of the laryngeal ventricle. The base of the cartilage has its inner anterior angle prolonged and tapering forward, as the **vocal process**,<sup>8</sup> which gives attachment to the back end of the vocal cord. The inner posterior angle is truncated and rounded, and gives attachment to the crico-arytenoid ligament. The external angle<sup>9</sup> is prominent, thick and rounded, and receives the insertion of the crico-arytenoid muscles. Beneath this angle is a circular facet, for articulation with the cricoid cartilage, concave from within outward and backward, and straight in the opposite direction. The apex of the arytenoid cartilage curves

<sup>1</sup> Eminentia lateralis.      <sup>2</sup> Superficies articularis.      <sup>3</sup> Linea eminens or media.

<sup>4</sup> C. arytenoideæ, pyramidales, triquetrae, or gutturales.

<sup>5</sup> Spina superior; colliculus.

<sup>6</sup> Fossa inferior or obliqua.

<sup>7</sup> F. superior or triangularis.

<sup>8</sup> Processus vocalis or glottidis; mucro baseos.

<sup>9</sup> P. muscularis; tuberculum baseos.



backward, and has appended inwardly the **corniculate cartilage**.<sup>1</sup> This is a little, conical nodule of fibro-cartilage, which is movably connected with the former by an elastic ligament, and is directed backward and inward, and may come in contact with its fellow. It is enveloped in the mucous membrane and produces the rounded eminence of the ary-epiglottic fold on each side of the lower extremity of the laryngeal aperture. It is sometimes a continuous structure with the apex of the arytenoid cartilage.

The **epiglottic cartilage**<sup>2</sup> forms the basis of the epiglottis, a trap-door-like arrangement in front of the entrance of the larynx, and projecting upward and backward behind the root of the tongue. It is a cordate or oval leaf-like plate of elastic fibro-cartilage prolonged below in a stem or pedicle, by which it is attached within the beak of the thyroid cartilage. The upper or anterior surface is in general convex, and the lower or posterior surface concave, but becomes convex along the middle part below extending on the pedicle.<sup>3</sup> The edges are thin, and the surfaces are more or less irregularly pitted with recesses for the lodgement of glands. It is enveloped beneath and for the upper half above by the mucous membrane.

The **cuneiform cartilages**<sup>4</sup> are variable in development, and frequently are absent. They occur, one on each side, in association with a little group of glands, which produce an eminence of the ary-epiglottic fold just in advance of that formed by the corniculate cartilage. They are fusiform or conical, straight or bent, and from one to three lines long. When absent, the eminence of the ary-epiglottic fold is produced alone by the accumulation of glands, which ordinarily occupy the same position.

The chief cartilages of the larynx, except that of the epiglottis, are composed of pure or hyaline cartilage. They are prone to ossification towards the middle of life, and the process continues with the advance of age. It occurs later in the female and is usually less complete. It commences in the thyroid cartilage with the horns and posterior border, thence extends along the inferior border, and subsequently spreads upward and forward. Following in the cricoid cartilage, it proceeds from the sides forward and backward, and occurring last in the arytenoids, they ossify from below upward.

#### LIGAMENTS AND ARTICULATIONS OF THE LARYNX.

The larynx is connected with the hyoid bone by the middle and lateral thyro-hyoid ligaments. The cricoid cartilage is connected with the thyroid and both arytenoid cartilages by the crico-ary-thyroid ligament.

<sup>1</sup> Cartilago corniculata, teres, or Santorini; corniculum, corpusculum, or capitulum arytenoideum.

<sup>2</sup> C. epiglottica; lingula.

<sup>3</sup> Petiolus; radix.

<sup>4</sup> C. cuneiformes or cruciformes; cartilages of Wrisberg; corpuscula Wrisbergii; fibro-cartilage of the arytenoid gland.



It also forms two pairs of movable synovial joints, the crico-thyroid and the crico-arytenoid articulations. The epiglottic cartilage is connected with the thyroid cartilage by the thyro-epiglottic ligament, and with the hyoid bone by the hyo-epiglottic ligament. It is further connected with the thyroid and arytenoid cartilages by the thyro-ary-epiglottic fascia.

The **middle thyro-hyoid ligament**<sup>1</sup> is a broad, fibro-elastic membrane extended between the upper border internally of the hyoid bone and the upper border of the thyroid cartilage; an arrangement which permits the larynx to be raised within the position of the hyoid bone. The median portion of the ligament is strongest, and commonly is bounded in front by a subcutaneous synovial bursa,<sup>2</sup> which commences behind the body of the hyoid bone and reaches variably downward towards the beak of the thyroid cartilage. The sides of the ligament are thin and of looser texture, are perforated by the superior laryngeal blood-vessels and nerve, are covered by the thyro-hyoid and inferior constrictor muscles, and internally are invested with the mucous membrane of the pharynx.

The **lateral thyro-hyoid ligaments**<sup>3</sup> are fibro-elastic rounded cords, of variable length and thickness, connecting the superior horns of the thyroid cartilage with the ends of the hyoid bone. Each commonly contains a spheroidal nodule<sup>4</sup> of cartilage, thicker than the ligament and prone to ossification.

The **crico-ary-thyroid ligament**,<sup>5</sup> or **vocal membrane**, is a strong, yellowish membrane, which is attached to the upper border of the cricoid cartilage from in front along the inner lateral margin to the crico-arytenoid articulation, and is attached above in front to the lower border and lower half of the entering angle of the thyroid cartilage, and behind to the vocal process of the arytenoid cartilage. It is composed of elastic and fibro-connective tissue, is lined by the laryngeal mucous membrane, and is closely connected externally with the lateral crico-arytenoid and thyro-arytenoid muscles, which separate it from the inner side of the thyroid cartilage. It is thickest and densest in front, where it occupies an interval between the thyroid and cricoid cartilages bounded laterally by the crico-thyroid muscles. In this position it presents several small but conspicuous foramina for blood-vessels, is partly subcutaneous and partly covered by the sterno-hyoid muscles. At the sides the ligament is thinner and extends from the cricoid cartilage within the position of the thyroid ala, and terminates above in a defined border enclosed by the mucous membrane, forming the **inferior**

<sup>1</sup> Ligamentum hyo-thyroideum medium; membrana hyo-thyroidea or obturatoria laryngis.

<sup>2</sup> Bursa mucosa hyoidea.

<sup>3</sup> L. hyo-thyroideum laterale.

<sup>4</sup> Cartilago triticea; corpusculum triticeum.

<sup>5</sup> Crico-thyroid membrane, including the inferior thyro-arytenoid ligament or vocal cord; ligamentum crico-thyroideum medium; l. conicum, conoideum, or pyramidale; l. crico-thyreo-arytænoidea.



**thyro-arytenoid fold, or vocal cord.**<sup>1</sup> This appears as a band extending from within the thyroid angle backward and slightly divergent from its fellow to the vocal process of the arytenoid cartilage.

The **crico-thyroid articulation**, on each side of the larynx, is formed by the lateral articular eminence of the cricoid cartilage and the end of the inferior thyroid horn. It is a synovial joint enclosed by a strong capsular ligament.<sup>2</sup> The opposed articular facets, nearly flat and circular, permit a slight rotary and gliding motion of the thyroid on the cricoid cartilage. The capsular ligament is reinforced by bands, of which the stronger<sup>3</sup> proceeds from within the thyroid horn upward and inward to the posterior contiguous portion of the cricoid cartilage, and another<sup>4</sup> proceeds from the end of the horn forward to the side of the latter.

The **crico-arytenoid articulation**, formed between the base of the arytenoid cartilage and the upper border of the cricoid cartilage, is a freely movable synovial joint enclosed by a capsular ligament.<sup>5</sup> The cricoid articular facet is twice the width of the opposed facet of the arytenoid cartilage, from side to side, but is of the same width in the opposite or fore and aft direction. The capsular ligament is thin at its outer part, where it is supported by the tendinous insertion of the crico-arytenoid muscles, and it is reinforced on its inner side by a strong, fan-shaped band, the **crico-arytenoid ligament.**<sup>6</sup> This starts from the highest point behind, of the cricoid cartilage, and passes upward and outward to be attached to the truncated inner posterior angle of the base of the arytenoid cartilage.

In the articulation just described the cricoid cartilage is immovable, while the arytenoids move freely on it, and from their connection with the vocal cords are the chief agents of change in their lax or tense state. At rest, the arytenoids are supported on the outer part of the articular facets of the cricoid cartilage, and thence may be moved to the inner part and may be inclined in any direction, and also permit a limited degree of rotation.

The **thyro-epiglottic ligament**<sup>7</sup> is a fibro-elastic band, which springs from the pedicle of the epiglottic cartilage, and is attached to a recess within the thyroid angle below the notch of the beak. It is continuous with the adjacent ligamentous structures and is invested with the laryngeal mucous membrane, in which it produces a vertical prominence at the fore part of the cavity of the larynx.

The **hyo-epiglottic ligament**<sup>8</sup> is an elastic membrane, which is

<sup>1</sup> Inferior or true vocal cord; chorda vocalis; inferior thyro-arytenoid ligament; l. thyreo-arytænoideum inferius.

<sup>2</sup> Ligamentum crico-thyroideum laterale; l. capsulare inferius.

<sup>3</sup> L. cerato-cricoidæum posticum or superius.

<sup>4</sup> L. c. c. anticum or inferius.

<sup>5</sup> L. crico-arytænoideum; l. capsulare superius.

<sup>7</sup> L. thyreo-epiglotticum.

<sup>6</sup> L. triquetrum.

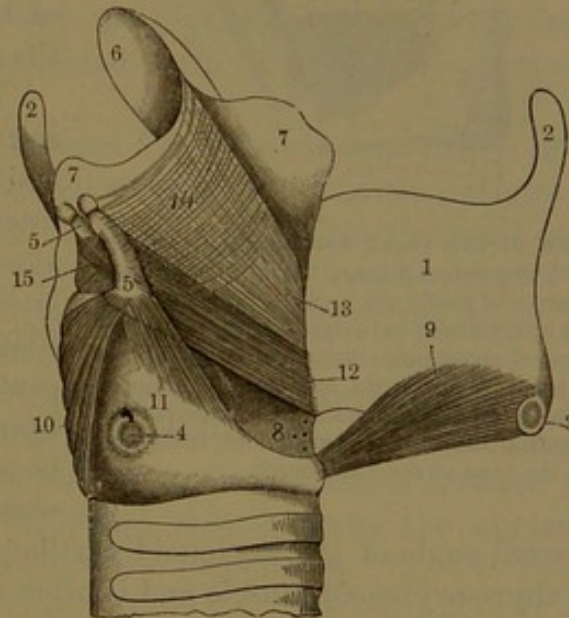
<sup>8</sup> L. hyo-glotticum.



attached to the upper internal border of the hyoid bone and is thence reflected to the anterior surface of the epiglottic cartilage. It is thickest at the middle, and thins away laterally where it blends with the middle thyro-hyoid ligament, with which it is also connected above, and with the thyro-epiglottic ligament below. In an intermediate position the conjunction of the three ligaments is occupied by a considerable accumulation of areolar tissue and fat, bounded in front by the middle thyro-hyoid ligament, behind and above by the hyo-epiglottic ligament, and below by the thyro-epiglottic ligament.

The **laryngeal fascia**<sup>1</sup> is a layer of fibro-connective with elastic tissue, which extends from the vocal membrane between the thyroid and arytenoid cartilages upward to the lateral border of the epiglottic cartilage, where it is continuous with the thyro- and hyo-epiglottic ligaments. It is slightly thickened along the upper edge of the entrance of the ventricle of the larynx, where it forms the basis of the **superior thyro-arytenoid fold**, or so-called false vocal cord,<sup>2</sup> and its upper margin is the basis of the ary-epiglottic fold at the entrance of the larynx. It invests the thyro-arytenoid muscle, is in contact internally with the lining mucous membrane of the larynx and externally with the inner surface of the thyroid ala.

FIG. 310.



**MUSCLES OF THE LARYNX.** 1, right ala of the thyroid cartilage, turned forward; 2, superior horns; 3, inferior horn marked by the crico-thyroid articulation; 4, the other portion of the latter on the side of the cricoid cartilage; 5, arytenoid cartilage, surmounted by the corniculate cartilage; 6, epiglottis; 7, the two laminae of the ary-epiglottic fold separated so as to expose the muscles; 8, lower part of the vocal membrane; 9, crico-thyroid muscle; 10, posterior crico-arytenoid muscle; 11, lateral crico-arytenoid; 12, thyro-arytenoid; 13, thyro-epiglottic muscular fibres; 14, ary-epiglottic muscular fibres; 15, arytenoid muscle.

#### MUSCLES OF THE LARYNX.

Besides the muscles connected with the larynx already described, there are a number of others, more especially concerned in producing changes in the vocal cords, by which they modify the

sound of the voice. These consist of the crico-thyroid, the lateral and posterior crico-arytenoid, and the thyro-arytenoid muscles, in pairs, and the arytenoid muscle, which is single.

<sup>1</sup> F. thyreo-arytæno-epiglottica.

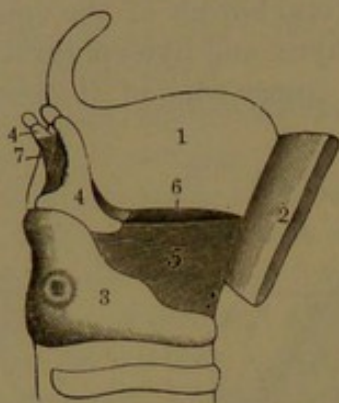
<sup>2</sup> Ligamentum thyreo-arytænoideum superior.



The **crico-thyroid muscle**<sup>1</sup> is situated externally at the side of the larynx, and is short, thick, and fan-shaped. It arises tendinous and fleshy near the middle in front and from the side of the cricoid cartilage, and ascends outward and backward to be inserted into the inferior border and horn and adjacent inner surface of the ala of the thyroid cartilage. An offset from the muscle commonly joins the inferior constrictor of the pharynx.

The **posterior crico-arytenoid muscle**<sup>2</sup> is situated at the back of the larynx, covered by the fore part of the commencement of the œsophagus. It lies behind the cricoid cartilage and occupies its lateral depressed surface, from which it arises at the inner and lower portion, and thence converges and ascends outwardly to be inserted into the external angle of the base of the arytenoid cartilage.

FIG. 311.



VIEW OF THE VOCAL MEMBRANE. 1, left ala of the thyroid cartilage; 2, right ala turned forward and partly cut away; 3, cricoid cartilage; 4, arytenoid cartilages; 5, right half of the vocal membrane; 6, upper border of the left half; 7, arytenoid muscle. The upper borders of the vocal membrane, extended between the thyroid and arytenoid cartilages, form the basis of the vocal cords.

The **lateral crico-arytenoid muscle**,<sup>3</sup> smaller than the former, is situated at the side of the larynx, internal to the thyroid ala. It lies along the outer part of the upper lateral border of the cricoid cartilage, from which and the adjacent portion of the vocal membrane it arises, thence passes backward and upward and is inserted into the lower fossa and

external angle of the arytenoid cartilage. It is in contact above with the thyro-arytenoid muscle and is often more or less united with it.

The **thyro-arytenoid muscle**<sup>4</sup> is situated above the former, internal to the thyroid ala, with which it lies in contact. It exhibits much variability in the development and arrangement of its fascicles. It arises from the side of the entering angle of the thyroid cartilage extending along the thyro-epiglottic ligament, and thence passes backward to be inserted into the vocal process and outer portion of the front surface of the arytenoid cartilage. Its upper thinner part,<sup>5</sup> usually not well defined, passes backward and upward in the thyro-ary-epiglottic fascia,

<sup>1</sup> M. crico-thyreoideus; m. c.-t. rectus et obliquus.

<sup>2</sup> M. crico-arytænoideus posticus.

<sup>3</sup> M. crico-arytænoideus lateralis or anterior.

<sup>4</sup> M. thyreo-arytænoideus; m. t.-a. externus et internus.

<sup>5</sup> M. thyreo-epiglotticus; m. thyreo-epiglottidæus major; m. thyreo-ary-epiglotticus; stratum thyreo-membranosum.



and thins away approaching the ary-epiglottic fold at the entrance of the larynx. Commonly a variable band<sup>1</sup> crosses the general plane of the muscle externally from the upper border of the thyroid ala to the external angle of the arytenoid cartilage. Internally the muscle is in contact with the vocal membrane, the laryngeal ventricle, and the thyro-ary-epiglottic fascia.

The **arytenoid muscle**<sup>2</sup> is a quadrate, fleshy layer occupying the recess behind the arytenoid cartilages and extending between them. It mainly consists of transverse fascicles attached to the outer portion of the posterior surfaces and external borders of the cartilages, some of the fascicles turning outward and forward to reinforce the thyro-arytenoid muscles. Oblique fascicles,<sup>3</sup> behind and intimately connected with the former, arise from the external angles of the arytenoid cartilages and cross one another to the summits of the latter, to which they are partially attached, partially reinforce the thyro-arytenoid muscles, and partially<sup>4</sup> ascend in the ary-epiglottic fold. In front, the muscle is in contact with the arytenoid cartilages and laryngeal mucous membrane, and behind with the pharyngeal mucous membrane.

The lateral crico-arytenoid muscles draw the external angles of the arytenoid cartilages forward and downward, which action rotates the vocal processes inward and approximates and relaxes the vocal cords. The posterior crico-arytenoid muscles draw the external angles of the same cartilages backward and inward, which rotates the vocal processes outward and separates and renders more tense the vocal cords. When both sets of the muscles act together the arytenoid cartilages are drawn outward and the vocal cords widely separated. The thyro-arytenoid muscles mainly draw the arytenoid cartilages forward and relax the vocal cords. The arytenoid muscle draws the arytenoid cartilages together and approximates the vocal cords.

#### INTERIOR OF THE LARYNX.

The **aperture of the larynx**<sup>5</sup> occupies an inclined plane beneath the root of the tongue, and looks upward and backward into the cavity of the pharynx. It is angular ovate, and more than twice the length of the breadth. Its upper, rounded extremity is formed by the projecting part of the epiglottis, its lower, narrow end by a notch between the summits of the arytenoid cartilages, and its sides by the **ary-epiglottic folds**,<sup>6</sup> extended between the summits of the arytenoid

<sup>1</sup> M. thyreo-arytænoideus superior or minor.

<sup>2</sup> M. arytænoideus; m. a. transversus; m. ary-arytænoideus.

<sup>3</sup> M. arytænoideus obliquus; m. thyreo-ary-epiglotticus.

<sup>4</sup> M. aryteno-epiglotticus, ary-epiglottidæus, or thyreo-ary-epiglotticus; stratum ary-membranosum obliquum.

<sup>5</sup> Aditus laryngis or a. ad glottidem.

<sup>6</sup> Aryteno-epiglottic folds; plicæ aryteno-epiglottidæ.



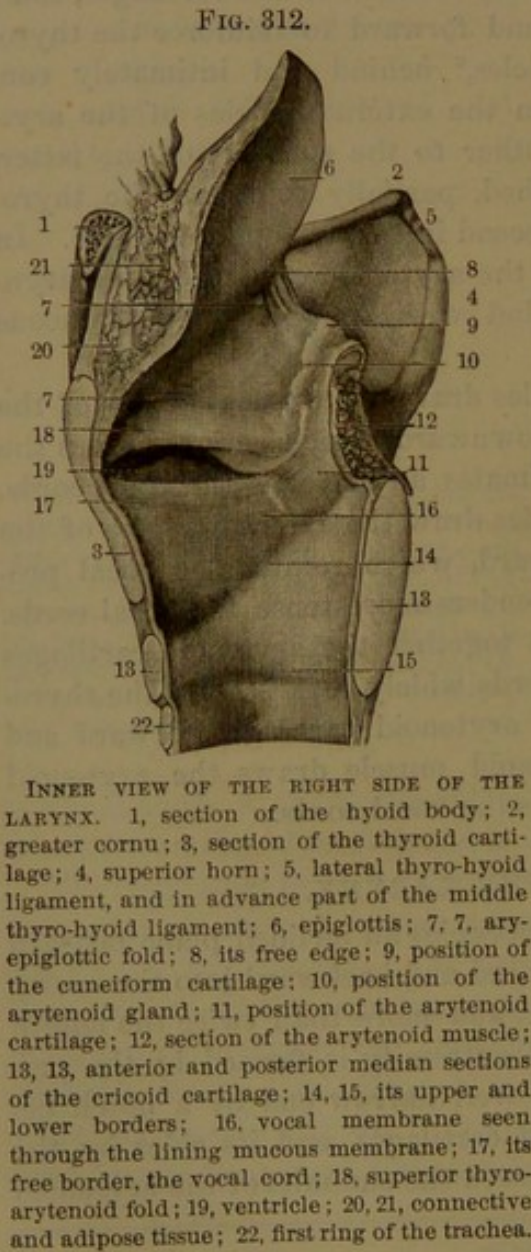
cartilages and the lateral borders of the epiglottis. A pair of rounded eminences on each side of the lower extremity of the aperture indicate the position of the summits of the arytenoid and corniculate cartilages, and of the cuneiform cartilages with the arytenoid glands.

From the aperture of the larynx, the cavity<sup>1</sup> descends and contracts laterally to the glottis, which is the narrowest portion of the passage, whence it again expands to a cylindrical form within the cricoid cartilage, thence continued into the trachea.

The **glottis**<sup>2</sup> is the space between the vocal cords and thence ex-

tended backward between the arytenoid cartilages.<sup>3</sup> When closed it appears as a fore and aft fissure, nearly an inch long in the male, and about a third less in the female. When moderately open, as in ordinary breathing, it resembles the opening of the half-closed eyelids, being acute in the thyroid angle, whence it gradually widens to the arytenoid vocal processes and is again slightly narrowed to its posterior obtuse extremity. When widely open, it assumes a more lozenge shape, and is widest opposite the ends of the arytenoid vocal processes, where it may be nearly half an inch.

The cavity of the larynx above the glottis is oval in horizontal section, with the longer diameter fore and aft. Its fore part presents a convex projection, the **epiglottic cushion**, corresponding with the lower median portion of the epiglottis. The sides are nearly vertical planes, slightly divergent from the cushion to the arytenoid cartilages and slightly approaching in their descent to the **ventricles of the larynx**.<sup>4</sup> These are half-elliptical, horizontal recesses, im-



mediately above the glottis, opening into the larynx opposite each other by a slightly constricted orifice, which is close to its fellow in the thyroid

<sup>1</sup> Cavitas laryngis.

<sup>2</sup> Rima glottidis or vocalis.

<sup>3</sup> Lumen glottidis.

<sup>4</sup> Ventriculi laryngis or Morgagni; alveoli; sinuses.



angle and diverges to the front surface of the arytenoid cartilages. The inferior border of the orifice is straight and is formed by the **inferior thyro-arytenoid fold**,<sup>1</sup> or **vocal cord**; and its upper, arched border is the **superior thyro-arytenoid fold**.<sup>2</sup> At their fore part the ventricles are prolonged as the **laryngeal pouch**,<sup>3</sup> which extends upward in the laryngeal fascia within the position of the thyroid ala and is covered externally by the thyro-arytenoid muscle.<sup>4</sup> It is half oval, laterally compressed, about half an inch in height, and about half the width of the ventricle into which it opens.

From the aperture of the larynx the pharyngeal mucous membrane extends to the hyoid bone and the inside of the thyro-hyoid ligaments and thyroid cartilage, and thence to the sides of the pharynx behind, and it extends downward back of the arytenoid cartilages and the cricoid cartilage to the œsophagus. Covering the upper part of the epiglottis, the mucous membrane extends thence to the root of the tongue and forms the three glosso-epiglottic fræna, previously indicated.

The pharyngeal mucous membrane is bright red and furnished with squamous epithelium. The laryngeal mucous membrane lines the cavity throughout, including the ventricles and laryngeal pouches. It is pale pink and thin, and adheres intimately to the subjacent parts, especially to the lower surface of the epiglottis, and yet more closely to the vocal cords. For the most part, like the tracheal mucous membrane, it is provided with a ciliated columnar epithelium, which extends upward in front to about the middle of the epiglottis, and at the sides a short distance above the orifice of the ventricles. Above these points, and on the vocal cords, the epithelium is squamous, like that of the pharynx.

The laryngeal mucous membrane is provided with numerous small, racemose mucous glands, like those of the trachea, the ducts of which open upon the surface everywhere except on the vocal cords and their immediate vicinity. They are especially numerous in the mucous membrane of the epiglottis, where they are distinguished as the **epiglottic glands**,<sup>5</sup> and deeply impress the epiglottic cartilage. An accumulation, as the **arytenoid glands**,<sup>6</sup> forms a variably distinct prominence of the ary-epiglottic fold adjacent to the arytenoid cartilage. Many glands<sup>7</sup> are also embedded in the laryngeal fascia and open into the laryngeal pouches.

The **arteries** of the larynx are derived from the superior and inferior thyroids, and the **veins** join the superior, middle, and inferior thyroids. The **lymphatics** in their origin are like those of the trachea, and they join the neighboring cervical glands. The **nerves** are supplied from the superior and inferior laryngeal branches of the vagus,

<sup>1</sup> Plica thyreo-arytænoidea inferior.

<sup>2</sup> P. th.-aryt. sup.; superior vocal cord.

<sup>4</sup> Compressor sacculi laryngis; m. aryteno-epiglottideus inferior.

<sup>5</sup> Glandulæ epiglotticæ.

<sup>6</sup> G. arytenoideæ.

<sup>3</sup> Sacculus laryngis.

<sup>7</sup> G. ventriculorum.



joined by branches from the sympathetic system. The superior laryngeal nerve supplies the laryngeal mucous membrane, the crico-thyroid muscle, and partially the arytenoid muscle. The inferior laryngeal nerve supplies all the other muscles, and partially the latter, but not the former. The mucous membrane is very sensitive at the upper portion of the larynx, and where covered with squamous epithelium contains bodies like the taste-buds of the tongue. End-bulbs are also attributed to the mucous membrane on the under surface of the epiglottis. The superior and inferior laryngeal nerves communicate behind the larynx under the pharyngeal mucous membrane, and at the side of the larynx under the thyroid ala. Numerous ganglion cells are attached to the branches, both those which enter the muscles and those which pass beneath the mucous membrane.



## CHAPTER XI.

### THE URINARY ORGANS.

THE urinary organs consist of the two kidneys, with their excretory ducts, named the ureters, the urinary bladder, and the urethra.

#### THE KIDNEYS.

The **kidneys**<sup>1</sup> are the glandular organs which excrete the urine, and are situated in the loins, one on each side of the spine, resting behind on contiguous portions of the diaphragm, psoas, and lumbar quadrate muscles. They extend from in front of the last thoracic vertebra to near the iliac crest, opposite the former and the two or three upper lumbar vertebræ. The right kidney is a little lower than the left, apparently to accommodate the liver, which is impressed by its upper part. The kidneys are placed behind the peritoneum, which covers their upper fore part; and they are maintained in position by their blood-vessels and a quantity of connective tissue, which attaches them to the adjacent parts.

The kidneys are indian-red in color, and are elliptical, fore and aft flattened, and notched on the inner side, the shape being so marked that similar-formed bodies are said to be kidney-shaped or reniform. The front surface is the more convex, and the upper extremity is the larger, and is placed rather more outward than the lower end, which is nearer that of the opposite kidney. The left kidney is commonly somewhat narrower and larger than the right. Their length is about four inches, their greatest width two and a half inches, and their thickness one and a quarter inches. The weight of each is between four and five ounces, and is less in the female.

The **notch**, or **hilus**,<sup>2</sup> of the kidney communicates with an interior recess, the **sinus**, both of which accommodate the chief vessels and excretory duct of the organ.

The surface of the kidney is smooth, but not always perfectly even, and not unfrequently is more or less marked with linear furrows, which remain from the foetal condition of the organ when it is divided into lobes. The substance of the kidney is firm, but is not tenacious, and is readily broken.

---

<sup>1</sup> Renes. Singular: ren; nephros.

<sup>2</sup> Porta renis.



The kidney is provided with a thin, firm membranous capsule,<sup>1</sup> which is closely adherent but readily detached. It extends from the hilus into the sinus, where it is continuous with the sheath and external coat of the blood-vessels and duct. It is composed of fibro-connective tissue in interlacing bundles, mingled with elastic fibres and with an inner incomplete stratum of unstriped muscular fibres. Its outer surface is continuous with the looser investing areolar tissue,<sup>2</sup> and therefore does not present the usual smooth shining appearance of the peritoneal covering of most other of the abdominal viscera.

The upper extremity of the kidney, thick and convex, supports the suprarenal body. The right kidney in front is in contact above with the under surface of the liver, and below with the duodenum and transverse colon, which in this position are destitute of peritoneum behind. The left is in contact with the stomach and below this with the pancreas.

The kidneys are liable to variation. They are sometimes longer and narrower than usual, at other times shorter and more oval, and occasionally one is small and the other proportionately larger. Occasionally they are situated in a lower position, and even in the pelvic cavity. Rarely the two are united by their lower extremities across the spine and great vessels, so as to present together a horseshoe shape.

A median longitudinal section through the kidney from within out-

ward exposes the sinus, which extends into the interior about half its depth, and is enclosed by the solid substance of the organ, except at the hilus. This is deepest in front, and is bordered by a thick, rounded anterior and posterior lip. Within the sinus the blood-vessels penetrate its sides and bottom, and from among the vessels the excretory duct has its origin in branches which unite to form the **renal pelvis**.<sup>3</sup> This is a flattened funnel-shaped receptacle situated behind the blood-vessels, whence it descends from the hilus to become the ureter. The branches of the renal artery enter the hilus in advance of the pelvis, and the branches of the renal vein emerge in front of the

former. The intervals of the vessels and pelvis are occupied by areo-

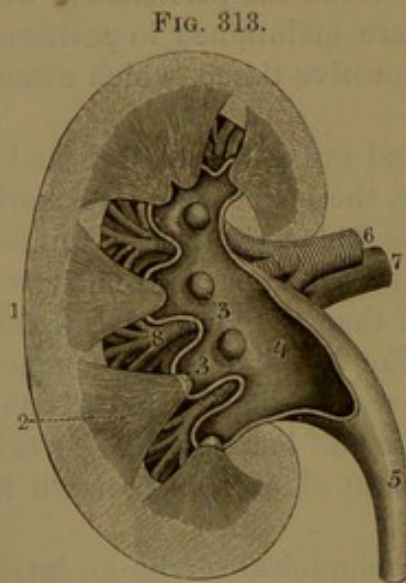


FIG. 313.

LONGITUDINAL SECTION OF A KIDNEY. 1, cortical substance; 2, renal pyramid; 3, renal papillæ; 4, pelvis; 5, ureter; 6, renal artery; 7, renal vein; 8, branches of the latter vessels in the sinus of the kidney.

<sup>1</sup> Tunica propria; capsula fibrosa.

<sup>2</sup> Tunica or capsula adiposa.

<sup>3</sup> P. renalis; sinus, venter, or alvus renum.



lar tissue and fat, together with the lymphatics and nerves of the kidney.

The substance of the kidney as seen in the section consists of two portions, of which the inner is distinguished as the medulla and the outer as the cortex.

The **medulla**<sup>1</sup> is collected in conical masses, the **renal pyramids**,<sup>2</sup> which are embedded the greater part of their depth in the cortex, and have only their summits free and projecting into the sinus as the **renal papillæ**.<sup>3</sup> The **cortex**<sup>4</sup> forms the superficial part of the kidney, generally reaching several lines in depth, but also extends between the pyramids to the sinus, where it is defined by low convex prominences<sup>5</sup> in the intervals of the papillæ. It is of uniform light brownish red, of granular aspect, and is especially friable in the direction vertical to the surface of the kidney. The medulla mostly is lighter colored, but is darker and usually purplish at the base of the pyramids, and is distinctly striated longitudinally, radiating from the summits. The renal pyramids vary in size and in number, there commonly being from seven to nine, sometimes more, sometimes less, and they are single or isolated, or partly more or less connate in groups of two or three. They are disposed irregularly in three rows, outward, in front, and behind, with their free summits, the renal papillæ, convergent in the sinus of the kidney.

The renal pelvis commences by two or three divisions, each formed by several short, cup-like branches, the **calyces**.<sup>6</sup> Each calyx receives in its expanded mouth a renal papilla, around the base of which the calyx is attached. On pressing the kidney, urine may be observed to appear at the summits of the renal papillæ and thence trickle into the calyces. The summits of the papillæ exhibit a number of minute orifices, usually one to two dozen, which are the terminations of the excretory ducts, named the **uriniferous tubules**.<sup>7</sup> Traced backward in the pyramids, the tubules are observed repeatedly to fork at very acute angles, and lie side by side slightly diverging.<sup>8</sup> In the base of the pyramids they are collected into narrow bundles, the **medullary rays**,<sup>9</sup> which pass into the cortex, the central tubules continuing farthest and approaching nearest the exterior surface of the kidney. In the pyramids the medullary rays are separated by pencil-like bundles of blood-vessels, while in the cortex the corresponding

<sup>1</sup> Substantia medullaris, cineritia, tubulosa, fibrosa, or interna.

<sup>2</sup> Pyramides Malpighianæ; coni tubulosi; lobi medullares; pyramids of Malpighi.

<sup>3</sup> P. renales.

<sup>4</sup> Substantia corticalis, glandulosa, rubicunda, or externa.

<sup>5</sup> Columnæ Bertini; septula renum.

<sup>6</sup> Infundibula.

<sup>7</sup> Tubuli uriniferi.

<sup>8</sup> Ductus recti, medullares, or renales; tubuli Bellini.

<sup>9</sup> Pyramides Ferreinii; lobuli renales; fasciculi tubulosi.



intervals are occupied by tortuous uriniferous tubules and blood-vessels, named together from the intricacy of their arrangement the

FIG. 314.

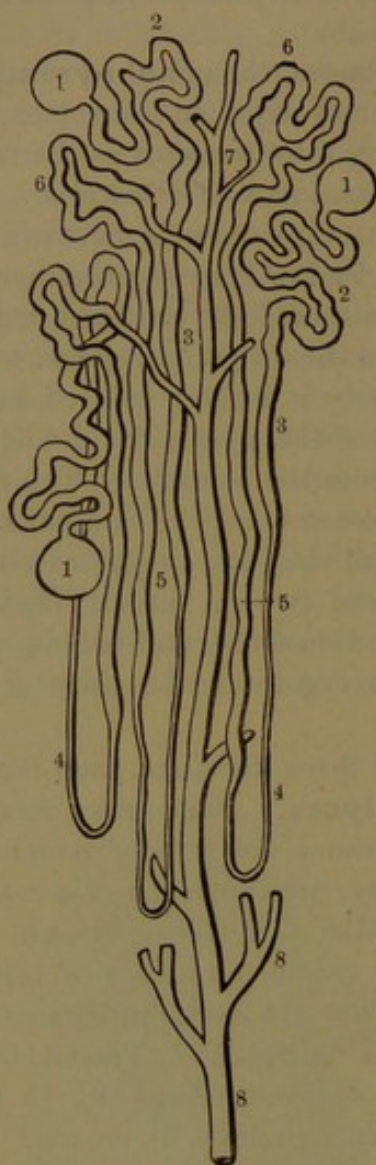


DIAGRAM OF URINIFEROUS TUBULES. 1, commencing capsule; 2, tortuous tubule of the cortex; 3, straight tubule of a medullary ray; 4, first loop in the pyramid; 5, enlarging return portion of the tubule; 6, second and tortuous loop of the cortex; 7, narrowed portion joining a collecting tubule, 8, descending to end at the summit of a renal papilla: magnified.

**cortical labyrinth.** In this the uriniferous tubules have their origin, each commencing in a spherical **capsule**,<sup>1</sup> which encloses a similar-shaped mass of capillary blood-vessels, named the **renal glomerulus**,<sup>2</sup> separated, however, from the cavity of the capsule by the epithelial lining, which is reflected from the latter. Starting from the capsule with a narrowed neck, the uriniferous tubule widens and pursues a tortuous course<sup>3</sup> in the cortical labyrinth, then enters a medullary ray, and proceeds in a flexuose manner<sup>4</sup> into the corresponding pyramid. Here becoming much narrowed, the tubule continues a greater or less distance, and turns back producing a long loop,<sup>5</sup> of which the return portion is flexuose and widens, and again enters the cortical labyrinth, where it forms a second and tortuous loop.<sup>6</sup> This widens irregularly,<sup>7</sup> finally narrows,<sup>8</sup> and once more enters the medullary ray, where with others it successively joins the **collecting tubules**.<sup>9</sup> These pursue a straight course through the pyramid, and unite with others in the formation of the principal uriniferous tubules, which end at the summit of the renal papilla.

The uriniferous tubules are composed of a basement membrane supported by connective tissue and lined by a single layer of epithelial cells, which, except in the capsule, are mostly proportioned in length

<sup>1</sup> Capsule of Bowman.

<sup>3</sup> *Laquei tubulorum corticalium*; first convoluted tubule.

<sup>4</sup> Spiral tubule of Schachowa.

<sup>6</sup> Second convoluted tubule.

<sup>8</sup> Junctional tubule.

<sup>2</sup> *Glomeruli renum*.

<sup>5</sup> Looped tubule of Henle.

<sup>7</sup> Irregular tubule.

<sup>9</sup> Excretory tubes.



with the diameter of the tubules. The capsule is lined by a layer of flat, nucleated cells, and the layer is reflected upon and invests the enclosed glomerule. In the first convoluted portion of the tubule the cells form short, stout, granular columns with a large nucleus, and for the greater part of their length towards the base have the appearance of bundles of vertical rods. In the narrow portion of the looped tubule the cells are flattened, being shorter than wide, are clear, and have a large nucleus. In the wider, tortuous, ascending portion of the loop the cells assume the appearance of those of the first convoluted portion, but are smaller. In the irregular portion of the second convolution they are proportionately longer and shorter with the variation of the tubule, and are remarkable for their well-marked rod-like structure. In the even portion of the convolution following, the cells are identical with those of the first convoluted portion of the tubule. As the tubule narrows and returns to the ray the cells become short, flattened, and clear. The descending terminal branches and trunks of the tubules have a distinct lumen, and are lined with clear cells, at first of about equal length and breadth, but gradually becoming longer and decidedly columnar as they approach their termination.

The kidneys are exceedingly vascular, and receive blood from the renal arteries, which are very large in proportion to the size of the organs they supply. Each artery divides into four or five branches, which pass from the hilus into the sinus, where they subdivide and penetrate the walls in the intervals of the calyces. Proceeding through the cortical substance between the pyramids, they continue to branch, and finally reach the base of the latter, where they form numerous arches.<sup>1</sup> From the convexity of these, they give off branches<sup>2</sup> which pass directly outward in the cortical labyrinth, between the medullary

FIG. 315.

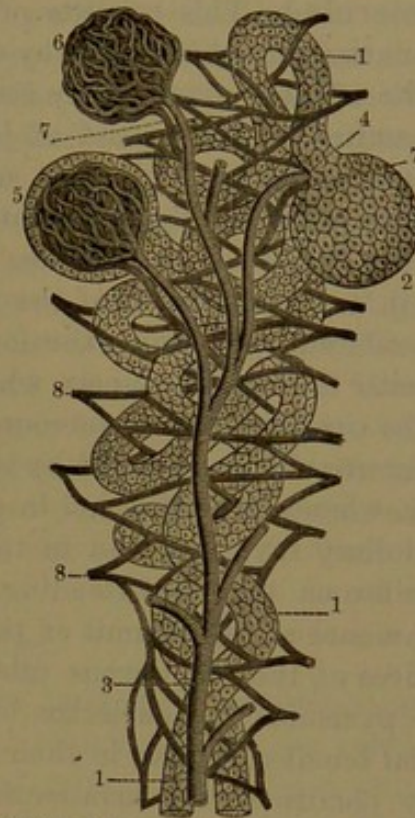


DIAGRAM OF THE STRUCTURE OF THE KIDNEYS. 1, two uriniferous tubules lined with epithelium; 2, capsule enclosing a renal glomerule; 3, branch of the renal artery ending in afferent vessels which enter the glomerules as seen at 4, 5; 6, glomerule freed from its investment; 7, efferent veins; 8, plexus formed by the latter veins among the uriniferous tubules, from which plexus originate the branches of the renal vein: highly magnified.

<sup>1</sup> Arcus or fornices arteriosi.

<sup>2</sup> Arteriolæ radiatæ; interlobular arteries.



rays, to end near the surface of the kidney. In their course they give off short, lateral, mostly curved branches, the **afferent arteries**,<sup>1</sup> which proceed to the capsules of the uriniferous tubules. Each capsule receives an afferent artery, which ends in a spherical body, named the **renal glomerule**.<sup>2</sup> This consists of branching tufts of looped convoluted capillaries, united in a mass by connective tissue. Close to the entrance of the afferent artery there issues from the glomerule a smaller **efferent vein**,<sup>3</sup> which, instead of joining others to form trunks as usual, ends in a capillary **plexus**<sup>4</sup> surrounding the neighboring uriniferous tubules. Among the convoluted tubules of the cortical labyrinth the meshes of the capillary plexus are of uniform diameters, but are elongated in the direction of the straight tubules of the medullary rays. The efferent veins from the lowest series of glomerules break up into pencils<sup>5</sup> of straight vessels, which descend between the medullary rays to the capillary plexus surrounding the tubules of the pyramids. The latter are chiefly supplied by branches from the arterial arches at their base, whence they descend in pencil-like bundles,<sup>6</sup> alternating with the medullary rays, and end in the capillary plexus which surrounds the uriniferous tubules extending to those of the renal papillæ. Veins commence at the summit of the papillæ in a net-work surrounding the orifices of the uriniferous tubules, and thence proceed to the base of the pyramids in pencil-like bundles,<sup>7</sup> which are mingled with the arterial bundles, receive in their course lateral tributaries from the capillary plexus of the uriniferous tubules, and finally unite in arching trunks,<sup>8</sup> accompanying the corresponding arteries. The venous trunks then pursue the course of the arteries through the cortical substance between the pyramids, and emerge into the sinus of the kidney. The principal veins<sup>9</sup> of the cortex accompany the arteries of the labyrinth, receive in their course branches from the capillary plexus of the neighboring tubules, together with branches ascending from the pyramids, and join the convexity of the venous arches at their base. Other veins commence at the surface of the kidney, beneath the capsule, and converge in a stellate manner<sup>10</sup> to branches which descend through the cortex to join the venous arches. The stellate veins at their commencement communicate freely with the veins of the cortical labyrinth. The veins within the sinus of the kidney converge and pass from the hilus and unite in a trunk, the **renal vein**, which proceeds in front of the renal artery and ends in the inferior cava.

Though the uriniferous tubules and renal vessels are closely and

<sup>1</sup> Vasa afferentia.

<sup>2</sup> Glomeruli renum; corpuscula, glomeruli, or acini Malpighiani; corpuscles of Malpighi.

<sup>3</sup> Vas efferens.

<sup>5</sup> Vasa recta spuria.

<sup>7</sup> Venæ rectæ.

<sup>9</sup> Interlobular veins.

<sup>4</sup> Vasa urinifera.

<sup>6</sup> Arteriæ rectæ.

<sup>8</sup> Arcus venosi.

<sup>10</sup> Venæ stellulæ Verheyenii.



compactly arranged together, they are separated from one another by a small proportion of connective tissue, which is most abundant around the larger vessels and the tubules of the pyramids.

The lymphatics of the kidney are numerous, and consist of a superficial plexus in the capsule communicating with the deep series. This is composed of a net-work of lymphatic spaces occupying the connective tissue surrounding the uriniferous tubules, especially abundant in the cortex, and communicating with lymphatic vessels which accompany the blood-vessels to emerge in the sinus.

The nerves of the kidney are derived from the renal plexus of the sympathetic nerve, and accompany the arteries.

The pyramids of the mature kidney, together with the contiguous portion of the cortex of each, correspond with the separation of the organ into lobes in the fœtus. Later the lobes coalesce and the kidney becomes a continuous mass; but not unfrequently some of the original lines of separation may be observed on the surface in the adult. In many animals of our class the lobar construction is permanently retained, as exemplified in the kidney of the ox.

#### THE URETERS.

The excretory duct of the kidney, as previously mentioned, commences in cup-like tubes, the **calyces**,<sup>1</sup> which enclose the renal papillæ and receive from them the excreted urine. The calyces unite in two or three common tubes,<sup>2</sup> which conjoin to form the **renal pelvis**.<sup>3</sup> This is fore and aft flattened funnel-shaped, and turns inward and downward from the sinus of the kidney, and narrows at the lower part of the hilus into the **ureter**,<sup>4</sup> a compressed cylindrical tube about the diameter of a goose-quill. The ureter is from a foot to fifteen inches long, and descends to the bladder, to which it conveys the urine. In its course it rests on the psoas fascia covered by the peritoneum, then passes over the iliac blood-vessels into the pelvis, and proceeds to the side of the bladder near the base on which it runs forward. The right ureter is close to the inferior cava, and descends behind the ileum; and the left ureter descends behind the sigmoid flexure of the colon. The ureters are crossed by the spermatic blood-vessels in front of the psoas muscle, and in the pelvis they cross to the inner side of the deferent canal, which descends between the ureter and the bladder. In the female the ureter descends in the broad ligament at the side of the neck of the uterus and upper part of the vagina before reaching the bladder. The lower extremity of the ureter narrows and descends obliquely through the wall of the bladder for half an inch or more, and opens into the cavity about an inch and a quarter from its fellow and

<sup>1</sup> Calyces minores.

<sup>3</sup> Pelvis renum.

<sup>2</sup> Calyces majores.

<sup>4</sup> Ductus urinæ; vas urinarium.

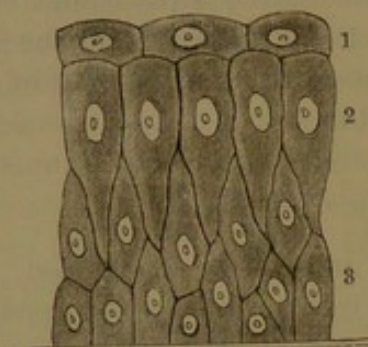


about the same distance from the orifice of the urethra. The openings of the ureters into the bladder are narrow, elliptical, and oblique, well adapted to permit the ready entrance of the urine into the bladder while they prevent its reflux.

The walls of the ureter, including the pelvis and calyces, are membranous, thin, and moderately strong and somewhat extensible. They consist of three tunics, of which the outer one is thin, and is composed of an intertexture of fibro-connective tissue with elastic fibres. The middle coat is thickest, and is composed of unstriated muscular tissue in three strata, of which the inner and outer consist of longitudinal fibres, and the middle one of transverse fibres.

The lining mucous membrane is grayish and smooth, or may be slightly wrinkled longitudinally. It is composed of a mucosa of connective tissue pervaded with a

FIG. 316.



EPITHELIUM OF THE URETER, highly magnified. 1, superficial layer of flattened polyhedral cells; 2, columnar cells; 3, deep layers of irregular polyhedral cells.

dense net-work of capillary blood-vessels and a peculiar stratified epithelium. The superficial stratum of the latter consists of variable-sized, thick, polyhedral cells, from one to several times the breadth of those of the succeeding layer, by which their under surface is impressed. They are provided with granular contents, and have one or several spherical or oval nuclei. In the second stratum the cells are vertically clavate, with

their lower part tapering away among the cells of the succeeding strata. These consist of fusiform and obovate cells occupying the intervals of the second stratum and also forming several strata beneath. The contents of the deeper cells are of the same character as those of the superficial stratum.

The ureters appear to be destitute of mucous glands. The blood-vessels are branches of the renal, spermatic, internal iliac, and inferior vesical arteries and veins. The nerves are derived from the inferior mesenteric, spermatic, and hypogastric plexuses of the sympathetic. They form plexuses with a few ganglion cells in the outer coats of the ureter.

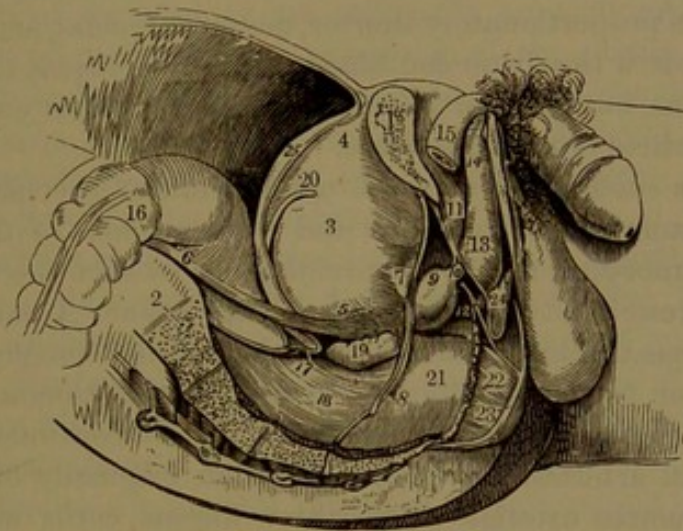
The ureters are liable to considerable variation. Not unfrequently from the passage of calculi they become more or less dilated, sometimes to an enormous extent. Occasionally the calyces unite in several narrow tubes which do not conjoin in a renal pelvis, and coalesce lower down in the ureter. Rarely the division continues so as to produce a double ureter.



## THE URINARY BLADDER.

The **urinary bladder**<sup>1</sup> is a musculo-membranous reservoir for the urine, situated within the pelvis behind the pubes, in advance and above the rectum in the male, and in advance of the uterus and above the vagina in the female. Its capacity varies under many circumstances, such as age, sex, habit, disease, etc. Its ordinary capacity in the adult male is about a pint, more or less, but is capable of considerable increase. It is larger in individuals who by necessity are obliged to retain the urine during long periods, and is smaller when the organ

FIG. 317.



SIDE VIEW OF THE MALE PELVIS AND ITS CONTENTS. 1, the right pubis sawed through; 2, sacrum; 3, bladder; 4, its summit; 5, its base; 6, right ureter; 7, fore part of the bladder; 8, attachment of the pelvic fascia; 9, prostate; 10, membranous portion of the urethra; 11, triangular ligament; 12, suburethral gland between the two layers of the latter; 13, 14, spongy body; 15, right cavernous body; 16, sigmoid flexure of colon; 17, recto-vesical fold of peritoneum; 18, rectum, with its muscular coat seen; 19, right seminal vesicle; 20, spermatic duct; 21, pelvic fascia descending to the rectum; 22, anal elevator muscle; 23, anal sphincter; 24, union of the superficial perineal fascia with the triangular ligament or deep fascia; 25, peritoneum passing from the summit of the bladder to the anterior abdominal wall.

is irritated by the presence of a calculus or by other conditions which lead to a frequent discharge of the contents.

When empty the bladder is smallest and its walls are thickest, and in this condition it lies deeply in the pelvic cavity, where it appears as a fore and aft flattened conical body, with the base downward and the apex directed forward and resting against the pubic symphysis. As the bladder begins to fill it becomes more regularly conical, and when moderately distended assumes a spheroidal shape and still occupies the pelvic cavity. When completely distended it nearly fills the latter, and rises partially above the pubic symphysis into the hypogastrium, assuming an ovoid or oval form, of which the upper part is called the **summit**<sup>2</sup> and

<sup>1</sup> Vesica urinaria.<sup>2</sup> Superior fundus.



the lower part the **base**.<sup>1</sup> In this condition the bladder often appears slightly compressed fore and aft or broader from side to side, usually with the base somewhat larger. The summit is placed below and in advance of the highest level of the bladder, and is retained in contact with the linea alba by means of a narrow fibrous cord. In the distended bladder the long axis is oblique, and nearly corresponds with that of the superior strait of the pelvis. The base of the bladder converges downward and forward in front in a funnel-like portion, called the **neck**,<sup>2</sup> which terminates in the urethra. In the male it is connected with the prostate, and in the female with the anterior wall of the vagina.

The bladder is commonly smaller in the female, and is also more variable in shape and size than in the male. Occasionally it is larger, and usually it is proportionately shorter, more spheroidal, and sometimes broader. At birth the distended bladder chiefly occupies the abdomen above the pubes, but as growth proceeds and the pelvis enlarges, it in greater part retires within the latter.

The fibrous cord which attaches the summit of the bladder to the linea alba extends to the umbilicus, and is the remains of the urachus, which in the embryo is a tube communicating between the bladder and the allantoic vesicle situated outside the abdomen. A pair of fibrous cords also proceed from the sides of the bladder and converge to ascend with the former to the umbilicus. These are the remains of the obliterated hypogastric arteries of the foetus, and are continuous with the superior vesical arteries, the trunks of which originally formed those of the hypogastric arteries. The three fibrous cords maintain the median position of the bladder, and thus serve as suspensory ligaments. They are enclosed by slight folds of the adjacent peritoneum, commonly called false ligaments of the bladder.

From the summit of the bladder backward to the base the surface is free, but invested by the peritoneum. In the male it comes into contact with the rectum, in the female with the uterus, and in both sexes with the small intestine. From the summit of the bladder the peritoneum is reflected upward to the front wall of the abdomen and on each side to the pelvis. In the male the peritoneum is reflected from the bladder to the rectum, producing the recto-vesical pouch, which descends to the base and is bounded laterally by the recto-vesical folds of the peritoneum passing between the sides of the rectum and bladder. In the female, in the same manner, the peritoneum is reflected from the bladder to the uterus, producing the vesico-uterine pouch, of less depth than the former, and laterally bounded by the vesico-uterine folds of the peritoneum. In front and below, the bladder is destitute of peritoneum, and is attached to the adjacent part of the pelvis, behind the pubes, by loose areolar tissue.

<sup>1</sup> Inferior fundus; bas-fond.

<sup>2</sup> Cervix.



The base of the bladder, which is commonly its widest portion, in the male rests on the rectum, where this curves forward, and is firmly attached thereto by connective tissue over a triangular space bounded laterally by the deferent canals and seminal vesicles extending in front to the prostate. In the female it rests in front of the neck of the uterus firmly attached to the upper part of the vagina.

The recto-vesical fascia, a connective-tissue layer, which invests the rectum and bladder at the base on each side, is continuous with the pelvic fascia, the lines of junction being distinguished as the **lateral ligaments of the bladder**. Stronger bands of the same fascia, extending from the neck of the bladder, one on each side of the prostate, to the pubic symphysis, form the **anterior ligaments of the bladder**.

The walls of the bladder are ordinarily proportioned in thickness to the degree of contraction or expansion of the organ, ranging from about half an inch in the collapsed state to about a line in the fully distended condition. Exclusive of the peritoneal covering above and behind, the bladder is composed of two principal layers, the muscular coat and the lining mucous membrane.

The muscular coat of the bladder is thickest, and is externally invested with a thin, extensible, fibro-connective-tissue layer forming part of the recto-vesical fascia. It is composed of unstriped fibres, which are collected in flattened, cylindrical fascicles of variable size, anastomosing with one another and disposed in two principal strata. The external stratum<sup>1</sup> is best produced in front and behind the bladder, and has its fascicles in general pursuing a longitudinal course. From the neck and base of the bladder they ascend in front and behind, and pass around the top, many of them converging to the summit. Others from the sides of the base and around the termination of the ureters ascend and curve both fore and aft, and intersect one another. In the male, at the neck of the bladder, the fascicles spring from the anterior ligaments and the fore part and base of the prostate; and in the female, instead of the latter, from the vagina. The internal muscular stratum<sup>2</sup> has its fascicles in general pursuing a transverse course united in a reticular manner, while many, especially at the sides, curve into and join those of the external stratum. Other fascicles, in variable proportion in different cases, turn in at the base of the bladder and ascend on the inner surface of the internal stratum, and thus form an imperfect third stratum. At the neck of the bladder the internal stratum is thicker, and thence extends upon the urethra, where it forms the circular **vesical sphincter**.<sup>3</sup> The muscular strata and their individual fascicles vary in thickness and compactness with the degree of contraction of the bladder, and the intervals of their fascicles enlarge or diminish accordingly.

<sup>1</sup> Musculus detractor urinæ.

<sup>2</sup> Circular fibres.

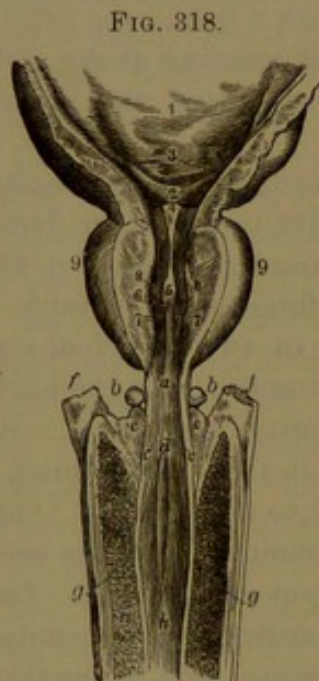
<sup>3</sup> Sphincter vesicæ.



The lining **mucous membrane** of the bladder is soft, smooth, shining, and commonly of a grayish color, but later in life becomes of a pinkish color. It is united with a fibro-connective-tissue layer, the **submucous coat**, with which it forms a continuous elastic membrane, much thinner than, and loosely attached to, the muscular coat. In the contraction of the bladder it becomes thicker, but also becomes wrinkled in the collapsed condition of the organ. From its close adherence to the muscular coat it appears more or less reticular, and this condition becomes especially conspicuous in hypertrophy of the latter.

The mucous membrane is destitute of mucous glands. The mucosa is provided with a dense net of capillary blood-vessels, but is devoid of a muscularis. The epithelium is like that of the ureters.

The surface of the bladder between the orifices of the ureters and the urethra is slightly prominent and convex, and is named the **vesical triangle**.<sup>1</sup> This is concave at the sides



PART OF THE BLADDER AND PENIS, WITH THE URETHRA LAID OPEN FROM ABOVE. 1, internal surface of the bladder; 2, vesical triangle; 3, position of the orifice of the ureter on each side; 4, vesical uvula; 5, urethral crest; 6, position of the utricle; 7, 8, prostatic sinus; 9, prostate. *a*, membranous portion of the urethra; *b*, sub-urethral gland; *c*, position at which the ducts of the latter open; *d*, spongy portion of the urethra within the bulb, *e*; *f*, crura of the cavernous bodies; *g*, erectile tissue; *h*, continuation of the urethra.

and base, and its rounded apex projecting upward into the mouth of the urethra is called the **vesical uvula**.<sup>2</sup> The triangle is produced by a corresponding **muscle**,<sup>3</sup> subjacent to and united with the mucous membrane, and attached beneath to the internal stratum of the muscular coat of the bladder. It is a compact layer of un-striped muscular fibres, not fasciculate like the latter, and in its relation with the mucous membrane substitutes the submucous coat. It is continuous with the muscular walls of the ureters, and thence extends to the mouth of the urethra.

The triangular muscle probably regulates the orifices of the ureters, and closes them during the discharge of the urine from the bladder.

The bladder is supplied on each side by the superior and inferior vesical arteries, branches of the internal iliaes, the former proceeding from the remaining pervious portion of the hypogastric artery. In the female the uterine arteries also give branches

to the bladder. The veins of the bladder collect in large plexuses

<sup>1</sup> Trigonum vesicæ; t. Lieutaudi; corpus trigonum.

<sup>3</sup> Muscle of the vesical triangle; muscles of the ureters.

<sup>2</sup> Uvula vesicæ.



upon the base and around the neck, and finally join the internal iliac veins.

Lymphatics, according to Sappey, are absent in the mucous membrane of the bladder. The nerves are partly derived from the hypogastric plexus of the sympathetic, and partly from the sacral plexuses of the spinal nerves. They form gangliated plexuses, accompanying the blood-vessels, and are thence distributed in the muscular coat and mucous membrane.



## CHAPTER XII.

### THE MALE REPRODUCTIVE APPARATUS.

THE reproductive apparatus of the male<sup>1</sup> consists of the testicles with their appendages and the penis with certain accessories. The urethra of the male is the outlet from the bladder for the discharge of the urine, and also serves as the passage for the emission of the spermatic liquid. Extending from the bladder, its first portion, included within the pelvis, is surrounded by the prostate and here receives the ejaculatory ducts; its second shortest portion passes through the triangular ligament of the pubic arch, and its third or longest portion traverses the spongy body of the penis and terminates at the summit of the head or glans.

#### THE PENIS.

The penis,<sup>2</sup> of variable size, is appended to the front of the pelvis, and is formed by a group of three columns, named the cavernous and spongy bodies, sheathed by the skin. Its attached portion is the **root**, its free extremity the **glans**, and the intermediate portion the **body**. In the ordinary condition the root ascends from the pubic arch to the front of the symphysis, and thence the body hangs downward; its fore part is called the **dorsum**, or back, because this is directed backward in the erect condition of the organ. The cavernous bodies lie parallel with each other along the dorsum, and the spongy body is placed between them along the opposite surface, which is directed forward during erection. The three bodies are fibrous cylinders occupied by erectile tissue, which freely communicates with the blood-vessels, and under excitement becomes distended with blood and thus produces erection of the penis. The cavernous bodies have alone the construction indicated, but the spongy body in addition is traversed by the urethra.

Viewed in the erect condition, the **body** of the penis appears as a rounded, three-sided prismatic column, somewhat narrowed towards the extremities. The wider, more flattened side directed backward and upward is the dorsum, and the lateral, lower sides are convex. The **glans**,<sup>3</sup> or head of the penis, is conical, with rounded summit and expanded base, broader than the adjacent body, and slanting from be-

<sup>1</sup> Organa sexualia masculina or virilia.

<sup>2</sup> Membrum virile; virga; priapus; yard.

<sup>3</sup> Caput; cuspis; balanus.



fore backward and downward. It is hollowed beneath, and caps the conical end of the united cavernous bodies. The border of the base, named the **corona**,<sup>1</sup> is rounded and projecting and extends forward in a notch to the summit of the glans, where the urethra terminates in a narrow, fore and aft, elliptical orifice. Below the glans the narrowed part of the penis is the **neck**.<sup>2</sup>

The skin of the penis continued from that of the pubes and scrotum envelops the organ, and at the extremity forms a collar-like doubling, the **prepuce** or **foreskin**,<sup>3</sup> which encloses the glans. It is thin and extensile, and is movably attached by a loose membranous layer, the fascia of the penis. Approaching the prepuce, the skin becomes thinner and more translucent, and permits its blood-vessels to be seen. It is furnished with hairs, which are absent on the prepuce, become numerous at the root of the penis, and project from conspicuously whitish prominent groups of sebaceous glands. Underneath, it is divided by a median, slightly elevated line, the **raphé**, which continues on the scrotum and thence on the perineum. The prepuce is a loose and movable doubling of the skin, the internal layer of which is thinner, redder, and more translucent, assuming the condition of a mucous membrane. Reflected upon the neck, it becomes more closely attached, and is here provided with numerous small sebaceous glands, the **preputial glands**,<sup>4</sup> the secretion of which moistens the part. The inspissated secretion mingled with the shed epithelium forms the **smegma**,<sup>5</sup> which quickly decomposes and emits a peculiar odor. On the glans the skin becomes firmly attached to the subjacent structure, and at the urethral orifice is continuous with the mucous membrane. In this position it is bright red, devoid of glands, and is furnished with numerous vascular and highly sensitive papillæ. From the fore part of the urethral orifice and the notch of the glans a median fold, the **frænum**,<sup>6</sup> is continuous with the prepuce.

The **fascia of the penis**<sup>7</sup> is a fibro-connective-tissue layer, with elastic and unstriped muscle-fibres, enveloping the penis and continuous with the superficial fascia of the abdomen and the dartos of the scrotum. It resembles the latter membrane, like it being completely destitute of fat, but is paler and less muscular. Loosely connecting the skin with the penis, it permits free movement between them, except on the glans, where it merges into the union of the skin with the albuginea. At the root of the penis dense bundles of connective and elastic tissue descend from the pubic symphysis to the dorsum, and spread on the sides of the penis, constituting its **suspensory ligament**.<sup>8</sup> Many of the bundles spring from the aponeurosis of the abdominal muscles,

<sup>1</sup> Corona glandis.

<sup>2</sup> Cervix ; collum.

<sup>3</sup> Præputium.

<sup>4</sup> Glandulæ odoriferæ Tysoni, or Litrii ; cryptæ præputiales.

<sup>5</sup> S. præputii.

<sup>6</sup> Frænulum glandis.

<sup>7</sup> Fascia penis.

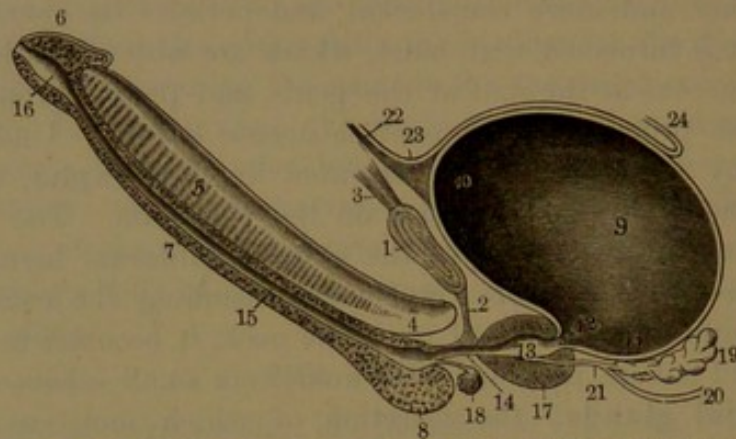
<sup>8</sup> Ligamentum suspensorium penis.



especially the linea alba, and converge to the pubic symphysis, thence descending to the penis.

The **cavernous bodies**.<sup>1</sup> These form the principal part of the body of the penis, and mainly determine its shape and rigidity in the erect state of the organ. They are cylindrical columns, which are flattened and closely united in the median line for three-fourths their length, but separate at the root in a pair of tapering **crura**.<sup>2</sup> These proceed from the everted borders of the pubic arch, to which they are firmly attached by tendinous fibres. Intermediately the crura are more or less

FIG. 319.



VERTICAL SECTION OF THE PENIS AND BLADDER. 1, pubic symphysis; 2, triangular ligament; 3, linea alba; 4, crus of the right cavernous body; 5, pectiniform septum; 6, glans; 7, spongy body; 8, its bulb; 9, bladder; 10, its summit; 11, its base; 12, its neck; 13, prostatic portion of the urethra; 14, membranous portion; 15, spongy portion; 16, navicular fossa; 17, prostate; 18, suburethral gland; 19, right seminal vesicle; 20, deferent canal; 21, ejaculatory duct; 22, suspensory ligament; 23, peritoneum; 24, its recto-vesical fold.

bulging, and they are embraced by the ischio-cavernous muscles. The upper extremity of the cavernous bodies together end in a blunt conical point, which is received in a pit in the base of the glans and is firmly united with it by fibro-connective tissue. The dorsal surface of the cavernous bodies is impressed with a median groove, which is occupied by the dorsal vein of the penis, and the opposite surface forms a more capacious groove for the accommodation of the spongy body.

The cavernous bodies possess a strong exterior envelope, the **albuginea**,<sup>3</sup> from half a line to a line thick, enclosing erectile tissue. The albuginea consists mainly of two closely-connected strata of fibro-connective tissue collected into glistening tendinous bands, which are longitudinal in the outer and transverse in the inner stratum. The bands conjoin in a reticular manner, and the narrow intervals permit the passage of blood-vessels. With the albuginea there is associated some elastic and unstriped muscular tissue. Where the cavernous bodies unite they are separated by a partition, named from its comb-

<sup>1</sup> Corpora cavernosa, spongiosa, lateralia, fibro-spongiosa, or tendinea.

<sup>2</sup> Radices, thalami, or capita corporum cavernosum.

<sup>3</sup> Tunica albuginea.

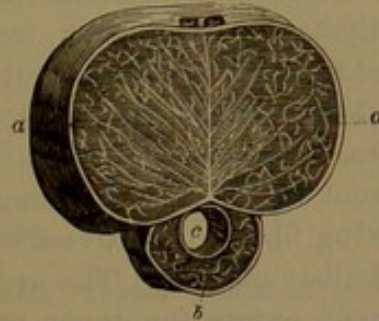


like appearance the **pectiniform septum**.<sup>1</sup> It is composed of fibrous bands proceeding from the inner stratum of the albuginea directed fore and aft. It is thicker and complete towards the root of the penis, but is rendered incomplete in advance from numerous fissures widening towards the dorsal border. Through the fissures the erectile tissue of both cavernous bodies is continuous. From the pectiniform septum numerous bands radiate to the interior surface of the albuginea.

The erectile tissue of the cavernous bodies consists of a sponge-like matrix of narrow cords, thin bands, and laminae, called **trabeculae**. These are strongest at the circumference of the erectile tissue and within the crura, and are weakest centrally and at the dorsal part of the cavernous bodies. They spring from the inner surface of the albuginea and the pectiniform septum, and in all directions intersect one another. The interspaces of the trabeculae, or **caverns**, form together a plexus of venous channels, which are largest centrally, and finally merge in the efferent veins of the cavernous bodies. They are lined by endothelial cells continuous with the endothelium of the veins. The arteries of the cavernous bodies end in capillary nets, the vessels of which are enclosed by the trabeculae of the erectile tissue and finally for the most part open into the caverns of the latter, while others directly terminate in the efferent veins. Some of the terminal arterial branches form dilated curls or loops, the **helicine arteries**, which end abruptly in capillaries terminating in the caverns of the erectile tissue. The helicine arteries are most abundant in the root of the penis, both in the cavernous and spongy bodies.

The chief arteries which supply the cavernous bodies are the cavernous branches of the pudic arteries, while others proceed from the dorsal arteries. The cavernous artery penetrates the inner side of the corresponding crus of the cavernous body and proceeds through the erectile tissue to its extremity, giving off in its course numerous branches, which are sheathed in the trabeculae. Branches of the dorsal artery penetrate the albuginea, especially near the glans, and are in like manner distributed to the erectile tissue. The chief veins pass from the cavernous bodies in the course of the cavernous arteries, while others pass through the albuginea in the course of the dorsal vein and open directly into it, and still others pass out between the cavernous

FIG. 320.



TRANSVERSE SECTION OF THE PENIS. *a*, cavernous bodies: the vertical line in the middle is the pectiniform septum; those diverging from it are trabeculae; the intervening spaces are occupied by erectile tissue; *b*, spongy body; *c*, urethra.

<sup>1</sup> Septum pectiniforme.



and spongy bodies and turn round the former also to end in the dorsal vein.

The **spongy body**.<sup>1</sup> This commences in an enlarged portion, the **bulb**, placed in front of the triangular ligament of the pubis between the crura of the cavernous bodies. Thence it extends in a cylindrical slightly tapering **column**, lodged in the groove in advance of the conjoined cavernous bodies, to their extremity, where it expands to form the **glans** which caps them. The **bulb**<sup>2</sup> is pyriform, of variable size, and has its base slightly divided below by a median groove. It is adherent behind to the triangular ligament, from which it receives an investing fibro-connective-tissue layer, and it is embraced by the urethro-bulbar muscles. The urethra, after passing through the triangular ligament, enters the upper part of the bulb and thence traverses the axis of the spongy body to the summit of the glans.

The spongy body has essentially the structure of the cavernous bodies, but is of much less strength and does not acquire the same degree of firmness or rigidity during erection. The albuginea is thin, does not present the fasciculate, tendinous appearance of that of the cavernous bodies, and is mostly composed of transverse fibro-connective-tissue bundles with considerable elastic tissue. In the bulb it forms a partial septum extending from the median groove of its base, and on the glans it merges into the derm of the skin. The erectile tissue occupying the interval of the albuginea and urethra is of more delicate texture than that of the cavernous bodies, having its trabeculæ finer and its venous channels smaller, more uniform, and in general longitudinally disposed. The urethra is immediately surrounded with a plexus of smaller veins associated with longitudinal bundles of unstriped muscular fibres. In the superficial part of the glans the veins pursue a more tortuous course.

The arteries which supply the spongy body are the urethro-bulbar and dorsal arteries. Of the former, on each side, the principal branch enters the base of the bulb, while a smaller one enters its upper fore part, and both proceed in the erectile tissue to the glans, which is chiefly supplied by the terminal branches of the dorsal arteries. The veins return the blood from the spongy body partly in the course of the urethro-bulbar arteries, while others issue at the base of the glans and adjoining portion of the column and converge to form the commencement of the dorsal vein of the penis.

The skin of the penis is supplied by branches of the dorsal and external pudic arteries, and the veins join the dorsal vein and the external pudic veins.

The lymphatics of the penis form a close plexus in the skin of the glans and prepuce and in the mucous membrane of the urethra, and the principal trunks accompany the dorsal vein and enter the inguinal

<sup>1</sup> Corpus spongiosum or cavernosum urethræ.

<sup>2</sup> Bulbus urethræ.



glands. Others from the cavernous and spongy bodies pursue the course of the corresponding blood-vessels and join the internal iliac lymphatics.

The nerves of the penis are chiefly derived from the dorsal and superficial perineal branches of the pudic nerve, and are distributed to the skin, including that of the glans. Many of them terminate in pacinian corpuscles and end-bulbs. Other nerves from the hypogastric plexus of the sympathetic accompany the blood-vessels to the cavernous and spongy bodies.

#### THE PROSTATE.

The **prostate**<sup>1</sup> of the male, an enigmatic organ which is probably homologous with the uterus and vagina of the female, is situated within the pelvis, below and in advance of the bladder, surrounding the commencement of the urethra. It has nearly the shape and size of a large chestnut, but is variable, and commonly enlarges later in life. It is usually about an inch and a quarter from apex to base, a little wider transversely, and rather less in thickness. It is placed obliquely with the apex directed downward and forward to the triangular ligament of the pubes and the base directed upward to the bladder. Its front surface is smallest, laterally rounded, and looks forward and upward to the pubic symphysis; its back surface is largest, flat or variably concave transversely, is directed downward and backward, and is attached to the rectum. The base of the prostate is closely united with the neck of the bladder, behind which it strongly projects, while the urethra descends obliquely through the prostate in advance of the middle. The sides of the base are variably convex and prominent, and form its **lateral lobes**,<sup>2</sup> between which the prostate is excavated in a fore and aft compressed conical pit, receiving the conjoined ends of the deferent canals and seminal vesicles. In front of these the lateral lobes are commonly united by a variably prominent rounded isthmus, named the **middle lobe**<sup>3</sup> of the prostate, attached to the neck of the bladder, but sometimes absent. In the enlargement to which the prostate is liable in the advance of life, the lobes become more conspicuous, and not uncommonly undue increase in the middle lobe produces a corresponding projection within the bladder, obstructing the orifice of the urethra.

The prostate is invested with a compact fibro-connective-tissue layer, which is continuous with the recto-vesical fascia and the posterior layer of the triangular ligament of the pubes. Its back part is provided with a compact layer of unstriated muscular tissue in transverse fascicles, which also extend across the base of the prostate behind the seminal vesicles and deferent canals, closely connecting the whole together.

<sup>1</sup> Prostate gland; prostata; parastata adenoides.

<sup>2</sup> Lobi laterales.

<sup>3</sup> Lobus medius; isthmus prostatæ.



The substance of the prostate is reddish gray, firm and tenacious, and is chiefly composed of a matrix of unstriped muscle-fibres including numerous small racemose glands.

According to Sappey, the basal third of the prostate is mainly formed by a compact muscular bundle encircling the commencement of the urethra as the **vesical sphincter**. It is continuous above with the internal stratum of the muscular coat of the bladder and below with the circular fibres of the urethra. From its outer part spring many of the fibres of the external stratum of the muscular coat of the bladder. The posterior surface of the prostate is formed by a layer of transverse muscular fibres. Elsewhere the muscular fibres proceed in different directions and intersect one another in the intervals of the glands.

The **prostatic glands** are numerous and of variable size. Their ducts converge to the urethra, and for the most part open into the prostatic sinuses, into which they emit an opalescent viscid secretion.<sup>1</sup> They have the usual construction of racemose glands, the branching ducts commencing in alveoli of variable length. The alveoli are of two kinds,—those in which the epithelium consists of a single stratum of long, narrow columnar cells, and those in which there is a stratum of short columnar cells succeeded by a second of small polyhedral cells. The ducts also are lined by a stratum of columnar cells succeeded by another of small polyhedral cells.

The prostate is supplied by branches of the vesical, hemorrhoidal, and pudic arteries. The veins, enclosed in the investing capsule, form a plexus especially produced at the sides, communicating below with the pudendal plexus, and above and behind with the vesical plexus, and discharging into the internal iliac veins. The nerves are derived from the hypogastric plexus of the sympathetic and in their distribution are associated with ganglionic cells. Pacinian corpuscles also occur on some of the nerves.

#### THE URETHRA.

The **urethra** extends from the bladder to the end of the penis, and varies in length mainly in accordance with it. When distended it is cylindrical, but variable in diameter in different positions. In the collapsed state in section it is narrowly transverse elliptical and the lining membrane is finely folded longitudinally.

The lining mucous membrane is sustained by a fibro-connective submucosa, succeeded by a stratum of erectile tissue with longitudinal bundles of unstriped muscular fibres, and with the venous channels disposed longitudinally and tortuously, the whole being enclosed by a stratum of circular muscular bundles.

The urethra consists of the prostatic, membranous, and spongy portions.

---

<sup>1</sup> Liquor prostaticus.

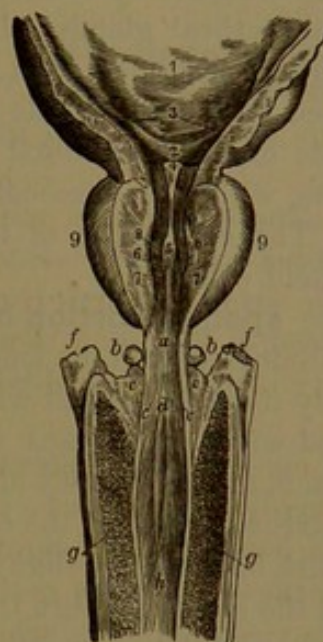


The **prostatic portion of the urethra** descends obliquely forward and passes through the fore part of the prostate, with which it corresponds in length. It is the widest and most dilatable portion of the canal, but is most resistant at its commencement. When distended it is elliptical, widest at the middle and narrowest at the termination. Along the bottom there extends a median fold, the **urethral crest**,<sup>1</sup> which is most elevated, thickest and rounded at the middle, and tapers away towards the extremities. On each side of the crest the bottom of the urethra is more depressed, and forms the **prostatic sinus**, into which open the ducts of the prostatic glands. At the fore part of the more prominent portion of the crest is a fore and aft elliptical aperture, the mouth of the **utricle**.<sup>2</sup> This is a little clavate pouch, from one-fourth to half an inch in length, directed from its mouth upward and backward behind the middle lobe of the prostate. It is lined by the mucous membrane, containing minute glands, and is enclosed in a stratum of erectile tissue. On each side of the mouth of the utricle, the aperture of the ejaculatory duct opens into the urethra.

The lining mucous membrane of the prostatic portion of the urethra at its commencement has the same kind of epithelium as that of the bladder, but lower it is provided with a stratified pavement epithelium. This is succeeded by a layer of erectile tissue forming a longitudinal venous plexus, and then by a muscular layer continuous with the muscular coat of the bladder. The urethral crest is a fold of the mucous membrane.

The **membranous portion of the urethra**<sup>3</sup> is the shortest, narrowest, and least dilatable, and passes from the apex of the prostate to the upper part of the bulb of the spongy body. It is a cylindrical

FIG. 321.



PART OF THE BLADDER AND PENIS, WITH THE URETHRA LAID OPEN FROM ABOVE. 1, internal surface of the bladder; 2, vesical triangle; 3, position of the orifice of the ureter on each side; 4, vesical uvula; 5, urethral crest; 6, position of the utricle; 7, 8, prostatic sinus; 9, prostate. a, membranous portion of the urethra; b, sub-urethral gland; c, position at which the ducts of the latter open; d, spongy portion of the urethra within the bulb; e, f, crura of the cavernous bodies; g, erectile tissue; h, continuation of the urethra.

<sup>1</sup> Crista urethralis; caput gallinaginis; veru montanum; colliculus or caruncula seminalis.

<sup>2</sup> U. prostaticus; vesica prostatica; vesicula spermatica spuria; sinus pocularis; prostatic sinus.

<sup>3</sup> Pars membranacea or muscularis, or isthmus urethræ.



tube, little more than half an inch long and scarcely that width, issuing from the pelvis through the triangular ligament, about an inch below the pubic symphysis. Between the layers of the triangular ligament it is enclosed above by the pudendal plexus of veins, and below is in relation with the interval between the bulb of the spongy body and rectum, occupied by connective tissue and fat, in which are embedded the suburethral glands. Its walls are formed of the lining mucous membrane, sustained by a submucous layer of fibro-connective tissue, enclosed by erectile tissue and a muscular layer. The erectile tissue consists of a longitudinal venous plexus with longitudinal muscular bundles, while the succeeding muscular layer consists of circular bundles. The epithelium of the mucous membrane consists of stratified pavement cells.

The **spongy portion of the urethra**<sup>1</sup> traverses the spongy body, and accords with it in length and direction. It is cylindrical, but is slightly more expanded within the bulb, and is again considerably expanded within the glans, where it forms the **navicular fossa**.<sup>2</sup> This contracts at the summit of the glans in the **mouth of the urethra**,<sup>3</sup> the narrowest part of the canal, forming a fore and aft narrow elliptical aperture bounded by slightly prominent lateral lips.

In the closed urethra the lining membrane is thrown into numerous fine longitudinal folds, which disappear on distention of the canal. It consists of the mucous membrane sustained by a submucous layer of fibro-connective tissue mingled with considerable elastic tissue. This is succeeded by a layer of erectile tissue and a circular muscular layer, as in the membranous portion. The epithelium for the most part superficially is columnar, but in the bulb passing into the former and in the navicular fossa it is of the stratified kind.

The mucous membrane of the spongy portion of the urethra is provided with many minute racemose mucous glands,<sup>4</sup> whose ducts are directed forward to open in the canal. Besides these, numerous little pockets or lacunæ open in the same direction on the surface of the mucous membrane, their mouths being sufficiently large to admit a bristle. A larger, conspicuous recess of the same character on the upper surface of the navicular fossa is named the **great lacuna**.<sup>5</sup>

The **suburethral glands**.<sup>6</sup> These are two whitish, rounded bodies, situated below the membranous portion of the urethra, close to the bulb of the spongy body. They are enclosed by the urethral compressor muscle, between the layers of the triangular ligament, and are closely adherent to the adjacent structures. They are of variable size, commonly about that of a pea, are of firm consistence, and lobulated. Sometimes they are feebly produced, and occasionally there is but a

<sup>1</sup> Pars spongiosa, or cavernosa urethræ.

<sup>2</sup> F. navicularis, or of Morgagni.

<sup>4</sup> Glands of Littré, or of Morgagni.

<sup>6</sup> Glands of Mery; Cowper's glands; bulbo-urethral glands.

<sup>3</sup> Meatus urinarius.

<sup>5</sup> Lacuna magna.



single gland. They are racemose mucous glands, and their ducts, after entering the spongy body, proceed near together through the erectile tissue, and then beneath the mucous membrane of the urethra to open into it, an inch to an inch and a half from their commencement.

#### THE TESTICLES.

The **testicles**<sup>1</sup> are two glandular organs which secrete the characteristic male element, the **sperm**, or **semen**. They are each suspended from the pubic region by the spermatic cord within a pouch of the skin, the scrotum.

The **scrotum** hangs from the pubes at the root of the penis, and is variable in extent and in other respects, under different conditions. Thus, it is shorter, rounder, more contracted and wrinkled in the young and vigorous, especially under the impression of cold, and it becomes more pendulous and lower in the aged and feeble and under the influence of warmth.

The skin of the scrotum is thin and extensible, darker than elsewhere, and is free from subcutaneous fat. It has a rather thick epidermis, and is provided with long, scattered, crisp, and flattened hairs, which project from conspicuous, oblong, whitish groups of sebaceous glands. It is divided by a median line or slight ridge, the **raphé**, continuous with that of the penis and perineum. In the contracted condition the skin becomes proportionately thicker, and is thrown into numerous more or less corrugated folds generally proceeding outwardly from the raphé.

Within the scrotum the testicle and spermatic cord have several additional envelopes, named the dartos and the spermatic fascia.

The **dartos** is a loose extensible membrane continuous with the superficial fascia of the abdomen, from which it differs in structure and in the fact that it is completely destitute of fat. It is of a pale-reddish color, and is composed of fibro-connective with elastic tissue and a large proportion of unstriped muscular tissue, the fibres of which generally pursue a longitudinal course. It outwardly blends with the skin of the scrotum and inwardly is connected with the spermatic fascia. It is thickest at the fore part of the scrotum, and it forms a median partition extending from the root of the penis to the perineum, separating the testicles. The muscular fibres of the septum mainly proceed fore and aft. To the dartos is due the remarkable contractility of the scrotum.

The **spermatic fascia**<sup>2</sup> is a thin, fibro-connective-tissue layer succeeding the dartos and enveloping the spermatic cord and testicle, and enclosing between its laminae the cremaster muscle. Along the cord it is of looser texture, forms partitions between its constituents, and usually contains considerable fat in the fore part of the cord associ-

<sup>1</sup> Testes; didymi; orchides.

<sup>2</sup> Tunica vaginalis communis.



ated with the spermatic veins. Its outer lamina<sup>1</sup> above is connected with the margin of the external abdominal ring, and its inner lamina<sup>2</sup> extends upon the cord within the inguinal canal, and at the internal abdominal ring becomes continuous with the transversalis fascia. Approaching the testicle, the spermatic fascia becomes more compact and distinctly membranous, and thus spreads over the vaginal tunic, with which and the back of the testicle it is closely united.

The **cremaster muscle**<sup>3</sup> forms a thin stratum of fascicles of striped muscular fibres enclosed in the spermatic fascia and descends from the inguinal canal to the testicle. It arises by an inner portion from the spine and crest of the pubis, and by an outer usually better developed portion from Poupart's ligament below the inferior attachment of the internal oblique and transversalis muscles. Descending on opposite sides of the cord, the fascicles mostly curve forward and form a series of loops successively longer and more separated, with the lower ones spreading in the spermatic fascia and embracing the sides and front of the upper half or three-fourths of the vaginal tunic. Some of the fascicles diverge and end in the spermatic fascia without joining in loops. The inner portion of the cremaster muscle is often feebly produced or even absent, but rarely it is even stronger than the outer portion.

The testicles are suspended obliquely, each from the spermatic cord, which is attached along their back part, where the vessels and nerves are transmitted; and the left one commonly hangs a little lower than the right. They are oval bodies slightly compressed laterally, and have their upper extremity divergent and directed forward and outward, with their lower extremity and posterior border directed in the opposite direction and nearer each other. The fore part and sides are smooth and free, but to the back part the epididymis and spermatic cord are attached.

The **epididymis**<sup>4</sup> is an elongated, curved, leech-shaped appendage lying along the back of the testicle, largest above and narrowing below. Its upper posterior surface is convex and free, and directed outwardly, while its under surface, resting on the testicle, is concave and separated from it outwardly by a fissure which is lined by an inflection of the vaginal tunic. Its inner border is attached both to the testicle and the spermatic cord. Its upper end, or **head**,<sup>5</sup> is thick and rounded, and projects forward on the testicle to which it is attached. The lower, narrower end, or **tail**,<sup>6</sup> is attached by fibrous tissue to the testicle, and thence turns upward internally as the commencement of the deferent canal.

The testicles, though variable, are commonly one and a half inches

<sup>1</sup> Intercolumnar fascia; spermatic fascia.

<sup>2</sup> Infundibuliform fascia; tunica vaginalis propria.

<sup>3</sup> Tunica carnea; t. erythroides.

<sup>4</sup> Parastata or p. cirroides; glandula supergeminalis.

<sup>5</sup> Caput epididymis; globus major.

<sup>6</sup> Cauda epididymis; globus minor.

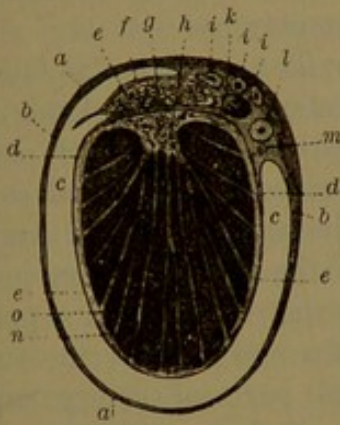


or more long, one to one and a quarter inches fore and aft, and from three-quarters to one inch transversely. The weight of each is from three-quarters to one ounce; and one is not unfrequently a little larger than the other.

The testicle and epididymis are provided with an outer tunic, named the albuginea, which is closely invested with a serous membrane, the vaginal tunic. The testicle is smooth and white, while the epididymis is less white from the greater thinness of its albuginea.

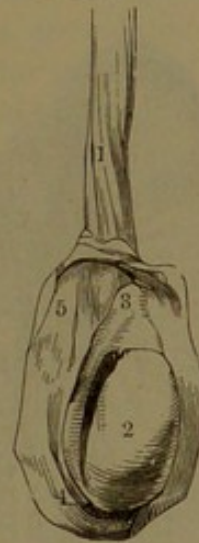The **albuginea**<sup>1</sup> of the testicle is a thick, dense, inextensible membrane enclosing the glandular substance of the organ. It is composed of bundles of fibrous tissue interlacing in all directions, and is but slightly vascular. Its outer surface is closely invested by the

FIG. 322.



TRANSVERSE SECTION OF THE TESTICLE. *a*, spermatic fascia; *b*, reflected portion of the vaginal tunic; *c*, cavity of the latter; *d*, investing portion of the same membrane; *e*, albuginea; *f*, vaginal tunic and albuginea of the epididymis; *g*, its interior tubular structure; *h*, mediastinum; *i*, branches of the spermatic artery; *k*, spermatic vein; *l*, deferent canal; *m*, deferent artery; *n*, lobules of the testicle; *o*, septula between them.

FIG. 323.



TESTICLE, WITH THE VAGINAL TUNIC LAID OPEN. 1, lower part of the spermatic cord; 2, body of the testicle; 3, head, and 4, tail, of the epididymis; 5, reflected portion of the vaginal tunic.

vaginal tunic except along the back part of the testicle, where it is connected with the epididymis and spermatic fascia, and is perforated for the ducts, vessels, and nerves of the organ. At the back part of the interior of the testicle, the albuginea forms a prismatic, longitudinal projection, the **mediastinum**,<sup>2</sup> from which diverge numerous fibrous bands, or **septula**, which extend between the lobes of glandular substance to the inner surface of the albuginea.

The albuginea of the epididymis is much thinner than that of the testicle, and on the inner side is connected with the spermatic fascia of the cord.

The **vaginal tunic**<sup>3</sup> is a serous membrane, forming a closed sac, of which the visceral portion closely invests the testicle and epididymis,

<sup>1</sup> Tunica albuginea, fibrosa, anonyma, or propria; dura mater testis.

<sup>2</sup> Corpus Highmori.

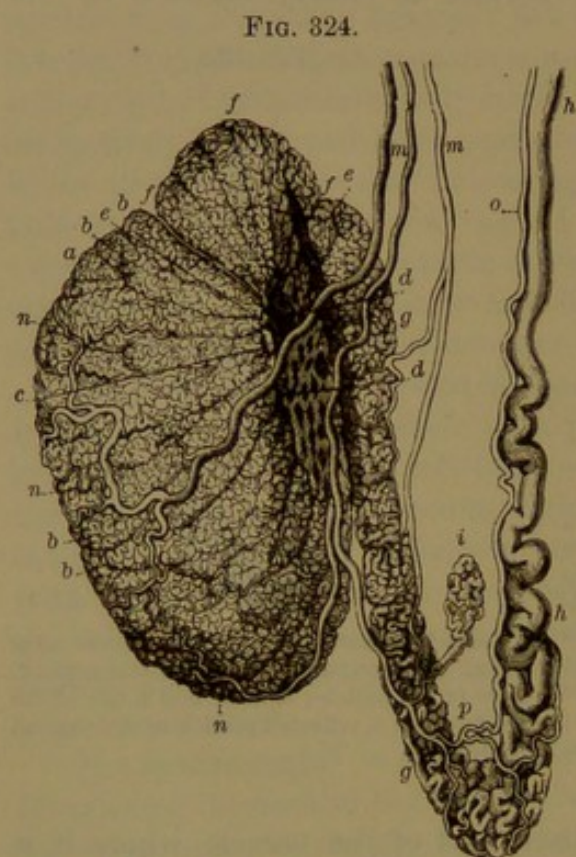
<sup>3</sup> Tunica vaginalis propria.



while the parietal portion is reflected from their inner posterior border and forms for them a second envelope. It covers the albuginea evenly except along the back of the testicle and inner border of the epididymis, where these are connected together and with the spermatic cord. Outwardly it dips into and lines the intervening fissure of the testicle and epididymis. It is intimately united to the albuginea of the testicle, but is less closely joined to that of the epididymis. The parietal portion of the vaginal tunic is stronger, and is closely connected with the spermatic fascia, which encloses it. When inflated the cavity of the vaginal tunic is double the volume of the testicle; but in the usual condition the opposed surfaces lie in contact, bathed with

the serous secretion of the membrane. The epithelium is like that of other serous membranes.

The arteries of the scrotum and of other envelopes of the testicle and spermatic cord are derived from several sources. The external pudic branches of the femoral artery proceed to the scrotum and supply the skin and dartos; the superficial perineal artery supplies the back part of the scrotum; and a branch of the epigastric artery supplies the cremaster muscle and spermatic fascia. The veins accompany the arteries. Of the nerves, the ilio-inguinal, a branch of the lumbar plexus, emerges at the external abdominal ring and is distributed to the scrotum; while the superficial perineal branches of the pudic nerve supply its back part. The spermatic branch of the genito-crural nerve joins the sper-



TESTICLE, DEPRIVED OF ITS TUNICS. *a*, body of the testicle; *b*, lobules; *c*, position at which they end in the straight tubules; *d*, spermatic rete; *e*, efferent vessels; *f*, spermatic cones; *g*, epididymis; *h*, commencement of deferent canal; *i*, vas aberrans; *m*, *n*, branches of the spermatic artery; *o*, deferent artery; *p*, anastomosis between the two vessels.

matic cord at the internal abdominal ring, and thence is distributed to the cremaster muscle.

The glandular substance of the testicle<sup>1</sup> forms a yellow-brown inelastic mass of dough-like consistence. It is composed of numerous elongated pyramidal lobes<sup>2</sup> of different sizes and rounded on the ex-

<sup>1</sup> Pulpa or parenchyma testiculi.

<sup>2</sup> Lobi testis.



terior, the longest ones in the middle and the shortest laterally. The number varies with the size of the testicle, and is estimated from several hundred to more than double that number. They are closely aggregated, enclosed by the albuginea with their bases next the surface of the membrane and their apices converging to the mediastinum. They are separated by the septula diverging from the latter and by their delicate connective-tissue sheaths with the blood-vessels.

According to the size of the glandular lobes, each is composed of from one to half a dozen **seminiferous tubules**,<sup>1</sup> which when unravelled appear as very long, flexuose, cylindrical threads of uniform diameter and commonly from the  $\frac{1}{120}$  to the  $\frac{1}{80}$  of an inch. The tubules average about two feet in length, but are closely convoluted and occasionally anastomose through communicating branches, or they conjoin in loops. In each lobe the tubules finally join one another at acute angles, and the common tubule becomes less convoluted and tapers into a short, narrower, **straight tubule**. The tubules of contiguous lobes also occasionally anastomose through communicating branches.

The straight tubules<sup>2</sup> enter the mediastinum, and there communicate with a longitudinal series of larger and closely-anastomosing channels, which form the **spermatic rete**.<sup>3</sup> From the upper part of this, there commonly proceed from nine to a dozen or more **efferent tubules**,<sup>4</sup> which pierce the albuginea and enter the head of the epididymis. At first straight, each tubule becomes closely coiled into a **spermatic cone**,<sup>5</sup> about the third of an inch in length, the series of cones occupying the head of the epididymis. Unravelled, the tubule of each cone is from six to ten inches long, about one-fortieth of an inch at the commencement and narrowed to one-sixtieth at the termination. The tubules at the base of the cones, generally at intervals of several inches in the uncoiled state, successively unite in the single canal of the epididymis. This is also exceedingly tortuous, forming a multitude of coils in lobar masses extending to the tail. Here it turns upward, enlarges, and still much convoluted ascends in the spermatic cord as the **deferent canal**, which approaching the top of the testicle becomes straight, and in this position is a line or more in diameter. Uncoiled, the canal of the epididymis is observed to be about twenty feet in length, about one-sixtieth of an inch at its commencement and gradually increasing to the tail.

The seminiferous tubules are provided with a thick epithelium, and have their wall outwardly defined by a hyaline, elastic basement membrane. The epithelium consists of a number of strata of **seminal cells**, which exhibit variable phases in the production of the sperm. The stratum next the basement membrane consists mostly of uniform,

<sup>1</sup> Tubuli or canaliculi seminiferi or seminales; vascula serpentina.

<sup>2</sup> Tubuli or ductuli seminiferi recti.

<sup>3</sup> Rete vasculosum testis Halleri.

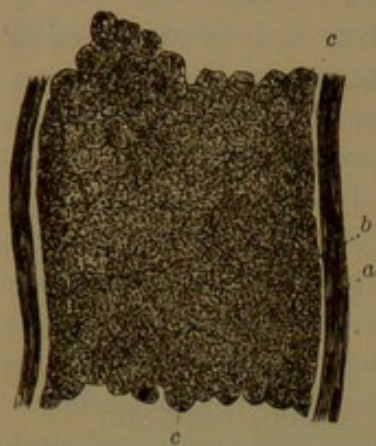
<sup>4</sup> Vasa efferentia; v. Graafiana.

<sup>5</sup> Conus vasculosus; corpus pyramidalis.



polygonal, transparent nucleated cells with little difference in their diameters. Within is a stratum, or several strata, of larger, rounded and less regular transparent cells, which together with their nuclei show evidences of proliferation. Inwardly succeed a variable number of strata of more or less ill-defined cells, forming a granular layer with small,

FIG. 325.



PORTION OF A SEMINIFEROUS TUBULE, highly magnified. *a*, fibrous coat; *b*, basement membrane; *c*, seminal cells.

scattered, indistinct nuclei. Embedded in the epithelium, **spermatozoa** are observed in different stages of development; in an early condition appearing as groups of narrow clavate cells standing vertically with the thick end upward; later as bunches of long filaments partially embedded at variable depths in the epithelium and partially projecting into the lumen of the seminiferous tubule; and finally as the complete spermatozoa with the heads embedded in the surface of the epithelium and the tails extending along the passage of the tubule. In those tubules in which the semen has been recently discharged the superficial granular layer is in a great measure absent, and its

position occupied by several layers of more distinct proliferating cells.

The straight tubules differ from the seminal tubules in structure, in that the epithelium consists of a single layer of short columnar cells. The channels of the spermatic rete, wider than the former, are provided with a similar epithelium.

The interior surface of the albuginea, the mediastinum, and the septula of the testicle are closely invested with a delicate **vascular tunic**<sup>1</sup> composed of fibro-connective tissue, in which the spermatic blood-vessels ramify. Laminae and bands of the same enclose the glandular lobes and seminiferous tubules, and the vessels communicate with close capillary nets of the latter. The cleft-like interstices of the vascular tunic are lymph-spaces lined by endothelial cells.

The efferent tubules forming the cones and the canal of the epididymis have a thin wall with a proportionately large lumen. Next the basement membrane outwardly, they are composed chiefly of circular, unstriped muscular fibres, and are provided with a close net of capillary blood-vessels. The epithelium consists of narrow, prismatic, columnar cells, shortest in the cones, and provided with long cilia, except in the lower part of the epididymis. The cilia produce an outward current.

Succeeding the albuginea, the epididymis is invested with connective tissue, which surrounds the tubes, sustains their convolutions, and supports the branches of the spermatic artery and veins.

<sup>1</sup> Tunica vasculosa testis; pia mater testis.



The **deferent canal**,<sup>1</sup> or excretory duct of the testicle, is the continuation of the convoluted canal of the epididymis, from the inner side of the tail of which it ascends at the back of the testicle as part of the spermatic cord. It is separated from the epididymis and testicle by the spermatic blood-vessels passing in and out of the organ, and thence ascends to the external abdominal ring behind the vessels, where it may be readily distinguished by its wiry feel. Passing through the inguinal canal at the internal abdominal ring, it leaves the spermatic blood-vessels and curves downward and backward into the pelvis. It proceeds beneath the peritoneum to the side and then behind the bladder, converging to the base of the prostate close to that of the opposite side. From the internal abdominal ring it turns outwardly around the epigastric blood-vessels and crosses the external iliac vessels to the inner side, then passes over the cord of the obliterated hypogastric artery and crosses the ureter to its inner side. After leaving the peritoneum it adheres to the bladder and less closely to the contiguous portion of the rectum, and then passes along the inner border of the seminal vesicle, the duct of which it joins to form the ejaculatory duct.

The deferent canal is usually about eighteen inches long, but with its commencement uncoiled is about two feet. In the greater portion of its course it is nearly uniformly cylindrical, and from a line to a line and a half in diameter, proportioned to the size of the testicle. Approaching its termination for about three inches it becomes enlarged and flexuose, as the **ampulla**, which tapers below and joins the duct of the seminal vesicle to end in the ejaculatory duct. The ampulla varies considerably in different individuals, in some being small and in others two or three times larger, more or less tortuous, and occasionally provided with a few short caecal pouches. It is fore and aft compressed, attached to the bladder, and lies close to that of the opposite side and to the seminal vesicle.

The deferent canal is remarkable for its thick, dense wall and the narrowness of its passage, which is about a fifth of the whole diameter and barely admits an ordinary bristle. In the ampulla the wall is thinner and the passage considerably more capacious.

The wall of the deferent canal is chiefly composed of yellowish, unstriped muscular tissue lined by mucous membrane and invested with a fibro-connective-tissue layer, which externally merges into the spermatic fascia. The muscular tunic consists of a thicker inner stratum of circular fascicles and an outer stratum of longitudinal fascicles. The mucous membrane, slightly wrinkled longitudinally, or smooth when distended, consists of a propria of connective tissue with elastic fibres, mostly circular inwardly and longitudinal outwardly, and an epithelium of columnar cells devoid of cilia. In the ampulla the mucous membrane is reticularly folded and encloses numerous angular pits,

---

<sup>1</sup> Ductus or vas deferens; ductus spermaticus.



and in miniature resembles the condition of the mucous membrane of the gall-bladder, or of the honey-comb stomach of ruminating animals. Embedded in the mucous membrane are numerous flask-like tubular glands, like those of the intestines, but in many cases compounded by the union of several in a common outlet or duct.

The spermatic cord consists of the deferent canal, the spermatic artery, veins, lymphatics, and nerves, and the cremaster muscle enclosed in the spermatic fascia. As the complete cord, it extends through the inguinal canal to the back of the testicle.

The deferent canal ascends from the inner part of the tail of the epididymis, along the back of the spermatic cord, to the external abdominal ring and thence passes along the inguinal canal to the internal abdominal ring, where it leaves all other constituents of the cord and enters the pelvis as above described.

The **spermatic artery**, a long, narrow vessel, springs from the aorta below the renal artery, descends along the psoas muscle, crosses the ureter and external iliac blood-vessels, and enters the internal abdominal ring, where it joins the spermatic cord and descends in advance of the deferent canal to the testicle. Approaching the latter it gives off a smaller branch to the epididymis, while the larger one divides into others which penetrate the albuginea along the back of the testicle and enter the mediastinum, whence they are distributed in the vascular tunic, partly on the inner surface of the albuginea and partly along the septula between the lobes of the testicle.

A long thread-like vessel, the **deferent artery**, comes from one of the vesical arteries and runs upon the deferent canal its entire length, supplying it in its course and terminating by anastomosing with the branch of the spermatic artery distributed to the epididymis.

The **spermatic veins**, passing from the vascular tunic of the testicle, emerge from the albuginea in a number of branches along the back of the testicle, where they are joined by others from the epididymis. The veins ascend in company with the spermatic artery in the fore part of the cord and anastomose with one another, forming a plexus. From this two or three veins enter the abdomen and unite in a single trunk, which follows the course of the spermatic artery; that of the right side terminating in the inferior cava and that of the left side in the corresponding renal vein.

The **lymphatics** of the testicle are numerous and chiefly commence in the lymph-spaces in the intervals of the seminiferous tubules. From finer plexuses in the vascular tunic and epididymis a half-dozen large trunks pursue the course of the spermatic veins and terminate in the lumbar lymphatic glands.

The **nerves** of the testicle are mainly those of the spermatic plexus of the sympathetic accompanying the spermatic artery. Other nerves from the hypogastric plexus accompany the deferent artery.

The spermatic fascia and the included cremaster muscle have already



been described. Accompanying the vessels of the spermatic cord are isolated longitudinal fascicles of unstriated muscle-fibres, distinguished by the name of the **internal cremaster muscle**.

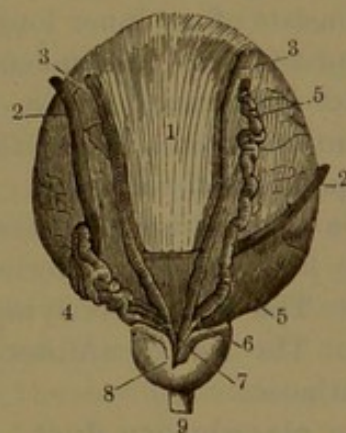
**Enigmatic appendages of the testicle.** Among the blood-vessels of the spermatic cord, between the head of the epididymis and the deferent canal, there commonly lie two or three small, irregular, rounded bodies, which consist each of a convoluted tube with expanded cæcal ends. They have been named the **par-epididymis**,<sup>1</sup> and are regarded as vestiges of the Wolffian body of the embryo.

On the head of the epididymis there is commonly a little spheroidal pediculate appendage,<sup>2</sup> which is regarded as the remains of the duct of Müller of the embryo. One or more similar clavate appendages occur on the top of the testicle near or under the head of the epididymis. These sometimes communicate with the interior of the testicle and contain seminal elements.

In the epididymis there commonly occurs a long narrow tube, the **vas aberrans**,<sup>3</sup> which is coiled into an elongated lobe lying usually along the lower part of the epididymis. The tube is mostly closed at the upper extremity, and opens below into the canal of the epididymis or the commencement of the deferent canal. Rarely similar vessels are found in other parts of the epididymis.

The **seminal vesicles**<sup>4</sup> are two bodies, which serve as reservoirs for the semen, situated nearly vertically on the base of the bladder, converging downward and forward and firmly attached to the base of the prostate. They are very variable in size and shape in different individuals and often on the two sides. They are commonly fore and aft compressed elliptical, from an inch to two inches long, a half to two-thirds of an inch where widest, and a third of an inch or more where thickest. They have an uneven, tuberculate surface, flattened in front, where they are closely attached to the bladder by connective tissue, and are more convex behind, where they are less closely attached by the same means to the rectum. The upper ex-

FIG. 326.



POSTERIOR VIEW OF THE FUNDUS OF THE BLADDER. 1, peritoneum extending as far down as the transverse line; 2, ureters; 3, deferent canals; 4, seminal vesicle of the left side; 5, right seminal vesicle dissected so as to show its tubular character; 6, duct of the seminal vesicle, joining the deferent canal to form, 7, the ejaculatory duct; 8, prostate; 9, membranous portion of the urethra.

<sup>1</sup> Corpus innominatum; organ of Giraldez.

<sup>2</sup> Hydatid of Morgagni; hydatid tunica vaginalis.

<sup>3</sup> V. a. Halleri.

<sup>4</sup> Vesiculæ seminales.



tremity is rounded and most remote from that of the other side, and the lower narrowed extremity joins the deferent canal internally and enters the median pit in the base of the prostate. The outer border is convex, free above and contiguous to the termination of the ureter, and firmly connected below with the lateral lobe of the prostate. The inner border below is closely adherent to the deferent ampulla, is sometimes grooved and overlaps the latter behind, or in this position joins the opposite vesicle and thus encloses the deferent canals, with the bladder in front.

The narrowed terminations of the seminal vesicles and intervening deferent canals are closely united side by side and enter a compressed conical pit at the base of the prostate between the lateral lobes and behind the middle lobe. They are here firmly connected by connective tissue and transverse fascicles of unstriated muscular tissue.

Each seminal vesicle consists of an irregular, tortuous tube about the width of a small goose-quill, wound upon itself and provided with a few short or longer caecal branches. The tube tapers below in a short, straight duct, which joins the deferent canal to form the ejaculatory duct. It is enveloped in connective tissue continuous with the recto-vesical fascia and containing the principal blood-vessels, lymphatics, and nerves of the organ. In structure the tube resembles the ampulla of the deferent canal. The muscular coat is thinner and consists of an inner longitudinal and an outer circular stratum of unstriated fibres. The mucous membrane presents a minutely honey-combed appearance, and is furnished with tubular glands, as in the deferent ampulla. The epithelium is columnar, with a substratum of small polyhedral cells.

The seminal vesicles receive branches from the inferior vesical and middle hemorrhoidal arteries and are accompanied by corresponding veins. The numerous lymphatics end in glands at the side of the pelvis. The nerves are derived from the hypogastric plexus of the sympathetic.

The **ejaculatory duct**,<sup>1</sup> formed on each side by the union of the corresponding duct of the seminal vesicle and deferent canal, is a tapering tube about three-fourths of an inch long. From the pit in the base of the prostate it proceeds in a deep groove between the lateral and the middle lobe, converging downward and forward to end in a minute elliptical orifice, in the prostatic portion of the urethra, at the side of the mouth of the utriculus. The passage of the duct at its commencement is about one-twenty-fifth of an inch, and gradually decreases to the termination, where it is about one-half that size.

The wall of the ejaculatory duct is thin and consists of a muscular coat with a mucous membrane like that of the deferent canal and seminal vesicle, but becoming smooth approaching its termination. The

---

<sup>1</sup> D. ejaculatorius.



muscular coat consists of an inner longitudinal stratum and an outer circular stratum of fibres, with elastic tissue, and a venous plexus continuous with that of the urethra.

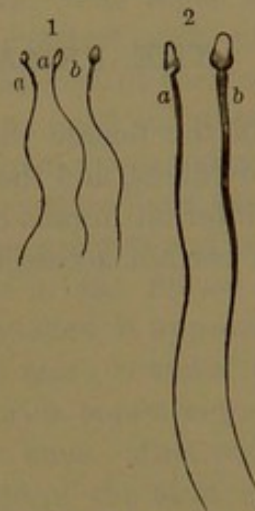
The **semen**, or **sperm**.<sup>1</sup> This is a glairy, whitish liquid secreted by the testicles, mingled with the mucoid secretion of the deferent ampullæ and seminal vesicles. It contains a multitude of exceedingly minute filamentary bodies, about  $\frac{1}{5000}$  of an inch long, the **spermatozoa**,<sup>2</sup> which constitute the essential element of the male in reproduction. Each **spermatozoon** consists of a compressed ovoid extremity, the head, about  $\frac{1}{5000}$  of an inch long, succeeded by a slightly thickened neck about as long as the former and then a long, tapering tail. The narrow end of the head is free, the flattened sides are slightly depressed centrally, giving the appearance of a nucleus, and the tail becomes more abruptly narrowed towards the extremity.

The spermatozoa are endowed to a wonderful degree with the power of motion, which persists after discharge of the semen, under favorable circumstances, for several days. The movement, which is of the nature of ciliary motion, consists in rapid undulation of the tail, by which the spermatozoa progress, head forward, in any direction.

Another less important element of the semen, in small comparative number, consists of minute highly refracting globules, the **seminal granules**.

The fully-formed semen is first found in the straight seminiferous tubules, thence in the spermatic rete, the epididymis, and the deferent canal. In the ampullæ of the latter and the seminal vesicles it accumulates prior to discharge.

FIG. 327.



SPERMATOOA. 1, magnified 350 diameters; 2, magnified 800 diameters; a, viewed on the narrower side; b, on the broader side.

<sup>1</sup> Semen virile.

<sup>2</sup> Animalcula or filamenta spermatica; spermatozooids.

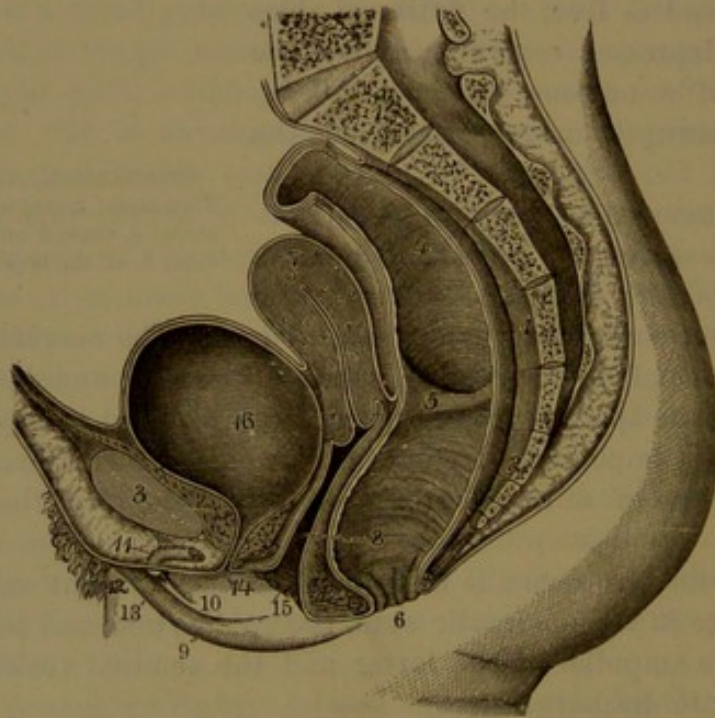


## CHAPTER XIII.

### THE FEMALE REPRODUCTIVE APPARATUS.

In the female the reproductive apparatus consists of the ovaries, the oviducts, and the uterus with its appendages, included together as the internal organs of generation; and the vagina, clitoris, and vulva, with certain accessories, as the external organs. The urethra of the

FIG. 328



SECTION OF FEMALE PELVIS, FROM BEFORE BACKWARD. 1, sacrum; 2, coccyx; 3, pubic symphysis; 4, rectum; 5, one of its valvular folds; 6, anus; 7, uterus; 8, vagina; 9, right labium; 10, right nymphæ; 11, clitoris, attached by the suspensory ligament to the front of the pubic symphysis; 12, glans; 13, prepuce; 14, urethra; 15, entrance of the vagina; 16, bladder.

female, comparatively very short, serves alone as the outlet of the urinary bladder and terminates in the vulva. The mammary glands are accessories to the reproductive apparatus.

#### THE VULVA.

The **vulva**<sup>1</sup> occupies the exterior of the pelvis at the entrance of the genital organs. It appears as a triangular prominence with the

<sup>1</sup> Pudendum; cunnus.



base upward and extends from the front of the pubic symphysis downward and backward between the thighs to the perineum. From the thighs it is sharply defined by a pair of narrow grooves descending from the groins and converging to the perineum. Its upper part, resting on the pubic symphysis, is named the **mons veneris**, and from this descend a pair of rounded columns, the **labia**, separated by a median cleft, the **fissure**<sup>1</sup> or orifice of the vulva. The mons is a cushion-like eminence of the skin abundantly furnished with crisp hairs. The **labia**<sup>2</sup> are rounded folds of the skin, thickest at their junction with the mons and gradually narrowing to their conjunction in the perineum. They are convex outwardly and furnished with hairs like those of the mons, but fewer and more scattered and diminishing behind. In the fissure of the vulva the sides are flat and come into contact with each other, and the extremities of the fissure are called the **commissures**. When the fissure is expanded, it appears as an elliptical orifice, with the anterior commissure more rounded and situated immediately below the mons. The posterior commissure, at the perineum, is about an inch in advance of the anus. Just within it, the labia are united by a narrow crescentic fold of the skin, commonly known by the French name of the "fourchette."<sup>3</sup> Between this and the entrance of the vagina above is a depression called the **navicular fossa**.<sup>4</sup>

The prominence of the mons is due to an accumulation of areolar and adipose tissue. The labia are likewise rendered prominent and firm by an accumulation of the same materials; but after repeated childbirth and in the aged and emaciated they become more or less relaxed and flaccid. The mons and labia further contain beneath the skin a variable yellowish layer of elastic tissue with unstripped muscular fibres, which corresponds with the dartos of the male scrotum. The skin of the mons and labia is abundantly furnished with large sebaceous and sweat glands. On the inner surface of the labia it partakes of the character of mucous membrane; is thin, smooth, red, and moist.

#### THE CLITORIS.

The **clitoris**<sup>5</sup> is a reduced representative of the penis, with which it essentially accords in construction, but differs in having its spongy body divided and not enclosing the urethra.

The **body** of the clitoris appears in the recess at the upper part of the fissure of the vulva as a median rounded ridge, which is directed downward from the anterior commissure and ends in a rounded papilla,

<sup>1</sup> Rima or fissura pudendi.

<sup>2</sup> L. pudendi; l. majora; l. externa.

<sup>3</sup> Navicula, frenulum.

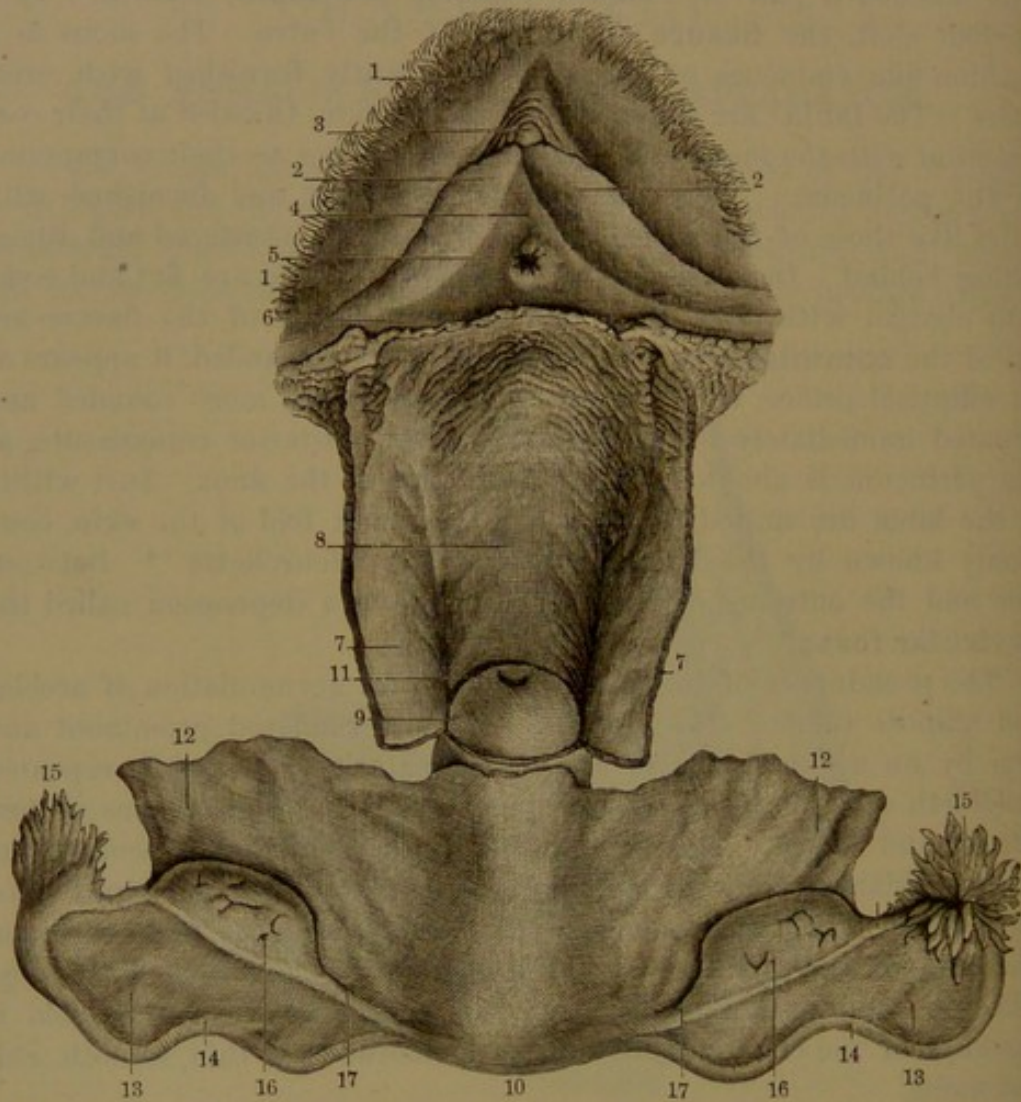
<sup>4</sup> F. navicularis, scaphula. The English anatomists have it below the fourchette; the French and German above.

<sup>5</sup> Membrum muliebre.



the **glans**.<sup>1</sup> It is covered by the mucous membrane, which is extended between the labia and forms the prepuce of the clitoris and the nymphæ below. The body is an inch and a half in length, is cylindrical, and is composed of a pair of cavernous bodies<sup>2</sup> like those of the

FIG. 329.



FEMALE ORGANS OF GENERATION; the vulva laid open and viewed in front; the internal organs turned down and viewed on their posterior surface, with the vagina laid open. 1, labium; 2, nymphæ; 3, glans of the clitoris surrounded by the prepuce; 4, vestibule; 5, urinary meatus; 6, hymen; 7, posterior wall of the vagina; 8, anterior wall; 9, extremity of the uterus; 10, fundus of the uterus; 11, mouth of the uterus; 12, broad ligament; 13, portion extending to the oviduct, 14; 15, fimbriated extremity; 16, ovary; 17, ovarian ligament.

penis. From its upper part, at the superior commissure of the vulva, the **crura**, about as long as the body, diverge and descend to be connected with the pubic arch in the same manner as those of the penis. The clitoris thus appears like a tripod, to the summit of which the **suspensory ligament**<sup>3</sup> proceeds from the pubic symphysis. The

<sup>1</sup> Glans clitoridis.

<sup>2</sup> Corpora cavernosa clitoridis.

<sup>3</sup> Lig. suspensorium clitoridis.



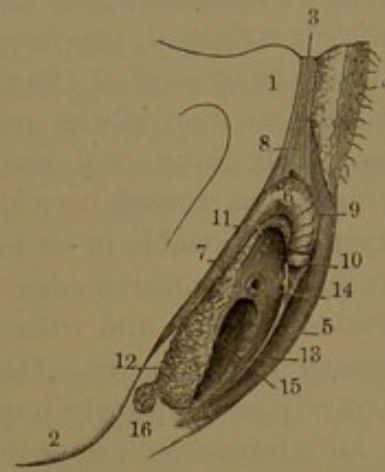
composition of the cavernous bodies, and their muscles, vessels, and nerves, are the same as in the penis.

The **glans** of the clitoris consists of a little mass of erectile tissue at the lower extremity of the organ, invested by a reflection of the mucous membrane, which is continuous with that of the prepuce.

The **spongy body**<sup>1</sup> of the clitoris chiefly consists of a pair of flattened elliptical masses, the **semi-bulbs**,<sup>2</sup> which are over an inch long and less than half as wide and are composed of erectile tissue enclosed in a fibrous membrane. They appear to be suspended from behind the body of the clitoris, from which they extend beneath the vestibule downward at the sides of the entrance of the vagina behind the nymphæ. They are widest and are rounded below and are narrowest at the upper extremity, where they are continuous with a plexus of vessels<sup>3</sup> which join those of the glans. The vessels and nerves of the spongy body likewise correspond with those of the same part of the penis.

**Nymphæ.**<sup>4</sup> These are a pair of conspicuous falcate folds of the mucous membrane within the fissure of the vulva. Starting from the lower end of the clitoris, they diverge, extend backward, and narrow away at the sides of the entrance of the vagina. Externally they lie in contact with the inner surface of the labia and are continuous with them; internally they are continuous with the vestibule and vagina. At their upper extremity they fork and together encircle the glans to form the **prepuce**,<sup>5</sup> which is free from the glans in front but joins it behind. Commonly the nymphæ are concealed within the vulva, but sometimes they are larger than usual and project more or less from the fissure. In such cases the exposed part assumes the appearance of the skin. In some of the African tribes, as the Hottentots, the nymphæ are reputed to be greatly enlarged and to project from the vulva to the extent of from three to six inches. It is also stated that the operation of circumcision in the women of Abyssinia refers to the removal of enlarged nymphæ.

FIG. 330.



EXTERNAL ORGANS OF GENERATION. 1, right pubis; 2, tuberosity of the ischium; 3, symphysis of the pubes; 4, left half of the mons veneris; 5, left labium; 6, clitoris; 7, crus of the right cavernous body; 8, suspensory ligament; 9, dorsal vein; 10, glans; 11, pedicle of the right half of the spongy body; 12, right semi-bulb; 13, left nymphæ, terminating above in the prepuce; 14, urethral orifice at the base of the vestibule; 15, vagina; 16, right sub-urethral gland.

<sup>1</sup> Corpus cavernosum uretræ.<sup>2</sup> Bulbi vestibuli.<sup>3</sup> Pars intermedia.<sup>4</sup> Labia minora; l. interna.<sup>5</sup> Præputium clitoridis.



**Vestibule.**<sup>1</sup> Below the clitoris and in advance of the orifice of the vagina the interval of the nymphæ forms a triangular recess of the mucous membrane, named the vestibule. At the middle of its base immediately in front of the orifice of the vagina is the orifice of the urethra,<sup>2</sup> a round aperture usually marked by a rounded and variably prominent, wrinkled, papillary eminence.

At the back part of the fissure of the vulva, extending to within about half an inch of the posterior commissure, is the orifice of the vagina. This is an oval aperture, which in the virgin is commonly more or less narrowed by a thin fold of the mucous membrane, called the **hymen**,<sup>3</sup> variable in its form and development. It is usually crescentic, with the concave edge directed forward, but sometimes annular, of variable breadth, and with an irregular, rounded opening commonly in advance of the centre. Occasionally it is pierced with several apertures, rarely is completely imperforate, and sometimes is almost obsolete. In intercourse it is ordinarily ruptured, and after parturition its remains appear as papillary eminences, which are called the **myrtiform caruncles**.<sup>4</sup>

The lining mucous membrane of the vulva is red, smooth, and provided with a squamous epithelium, beneath which it is furnished with minute papillæ, which are most numerous and largest on the inner surface of the nymphæ. It is also supplied with sebaceous glands, which are most numerous on the inner surface of the nymphæ.

**Suburethral glands.**<sup>5</sup> These are two variable, flattened oval or rounded bodies, commonly about half an inch in their largest diameter; of a reddish-yellow color, and situated near the entrance of the vagina, behind the lower extremity of the semi-bulbs of the spongy body. They are lobulated, racemose glands, and their duct, about half an inch long, is directed forward and opens near the orifice of the vagina, on the inner surface of the nymphæ.

**Vessels and nerves.** The vulva is supplied by the external pudic and perineal arteries, and the deeper parts, as in the male, by corresponding branches of the internal pudic arteries. The veins also have the same general arrangement. The dorsal vein of the clitoris receives branches from the glans, the cavernous bodies, and the semi-bulbs of the spongy body. Veins of the latter also pass back to the vaginal plexus. The lymphatics follow the course of the blood-vessels. The nerves are derived from the genito-crural, inferior pudendal, and pudics, while branches of the sympathetic accompany the arteries.

**The urethra.** A comparatively short canal in the female, about an inch and a half long and a fourth of an inch wide, descends from the bladder in the anterior wall of the vagina. Curving slightly forward,

<sup>1</sup> Vestibulum pudendi.

<sup>2</sup> Orificium uretræ; meatus urinaris.

<sup>3</sup> Valvula vaginæ; maidenhead.

<sup>4</sup> Carunculæ myrtiformes.

<sup>5</sup> Vulvo-vaginal glands; glands of Cowper, of Bartholin, of Duverney, etc.



it ends near the base of the vestibule in the fissure of the vulva, its terminal orifice<sup>1</sup> being usually marked by a papillary elevation of the mucous membrane.

The lining mucous membrane is longitudinally folded, is furnished with many mucous glands, and is provided with a stratified squamous epithelium. It is sustained by a fibro-connective-tissue layer with elastic fibres, outside of which is a vascular plexus consisting mostly of veins. As the urethra passes through the triangular ligament between the layers it is ensheathed by the urethral compressor muscle.

The vessels and nerves of the urethra are derived from the same sources as those of the vagina.

### THE VAGINA.

The **vagina** is a musculo-membranous passage within the pelvis, communicating from the vulva below to the uterus above. It is directed obliquely backward and upward between the bladder in front and the rectum behind, and together with these is enclosed at the sides by the anal elevator muscles. Slightly curved in its course, its axis corresponds with that of the pelvic cavity and its outlet. Ordinarily the cavity of the vagina does not exist as such, and the inner surfaces for the most part lie fore and aft in contact with each other. When expanded it is club-shaped, being narrowest at the lower end, and gradually expanded above to the summit, where it is rounded and receives the extremity of the uterus. In the virgin, from the orifice of the hymen it expands in a hemi-oval, widest fore and aft, but at the middle is widest transversely. Its upper extremity embraces the neck of the uterus, with which it is continuous, and it is attached at a higher point behind than in front. From the direction and curve of the vagina and its higher attachment to the uterus at the back part, it is an inch or more longer behind than in front. Commonly it is about four inches in length at the fore part and from five to five and a half inches at the back.

The wall of the vagina is not of uniform thickness, and is thinnest above, where it is about a line, and is thickest at the lower extremity and especially in front, where it is intimately connected with the neck of the bladder and encloses the urethra. Behind, it is loosely attached by connective tissue with the rectum, but for an inch or more at the upper part is separated from the latter by a peritoneal fold, the recto-vaginal pouch.<sup>2</sup>

The vagina is lined with mucous membrane continuous below with that of the vulva, and above with that of the uterus. It is red or reddish gray, and in the virgin state is more or less rugose below, but nearly or quite smooth above. At the lower extremity, both in front and behind, it presents a variably prominent median ridge, named the

<sup>1</sup> Meatus urinarius.

<sup>2</sup> Pouch of Douglas.



**column of the vagina.**<sup>1</sup> This is thick and rounded near the hymen, or the remains of it at the orifice of the vagina, and tapers away towards the middle of the latter.

Of the two columns the anterior is usually the more marked and constant. From both numerous folds<sup>2</sup> more or less broken, or rows of oblong papillæ, proceed transversely and upward towards the sides of the vagina, gradually diminishing and at the upper part completely subsiding. These folds or papillæ possess a certain amount of firmness unusual in similar processes of the mucous membranes. From the distention of the vagina attending parturition the folds are permanently obliterated; and this also is the case, for the most part, with the columns of the vagina, the lower thickened ends of which alone persist.

The mucous membrane of the vagina has a stratified squamous epithelium, beneath which it is furnished with minute papillæ. According to both Henle and Sappey, it is not provided with mucous glands, though others assert the contrary.<sup>3</sup>

Externally the vagina is furnished with a thin but moderately firm fibrous tunic composed of an intertexture of connective-tissue bundles with mingled elastic fibres.

The intermediate tunic of the vagina, forming two-thirds the thickness of its wall, is muscular, and consists of an outer layer of longitudinal bundles of unstriated fibres and an inner layer of circular bundles, with oblique bundles connecting the layers.<sup>4</sup> The longitudinal bundles are especially abundant in the anterior wall of the vagina, where it is connected with the bladder.

The mucosa of the mucous membrane also contains intermingled unstriated muscular fibres.

The lower extremity of the vagina is likewise enclosed by the sphincter muscle. (See page 678.)

A close venous plexus occupies the external fibrous tunic next the muscular tunic, whence fibres proceed through the meshes of the plexus.

**Vessels and nerves.** The vagina is highly vascular, and its arteries are chiefly supplied by the vaginal branch of the internal iliac artery. The veins derived from the vaginal plexus take a corresponding course. The lymphatics likewise join those accompanying the internal iliac blood-vessels. The numerous nerves mostly proceed from the hypogastric plexus, but others are derived from the fourth sacral and the pudic nerves.

<sup>1</sup> Columna vaginalis; c. carneo-papillosa.

<sup>2</sup> Rugæ; columna rugarum; c. plicarum.

<sup>3</sup> Quain's Anatomy states that it is provided with numerous mucous glands, especially in its upper, smoother portion and round the neck of the uterus.

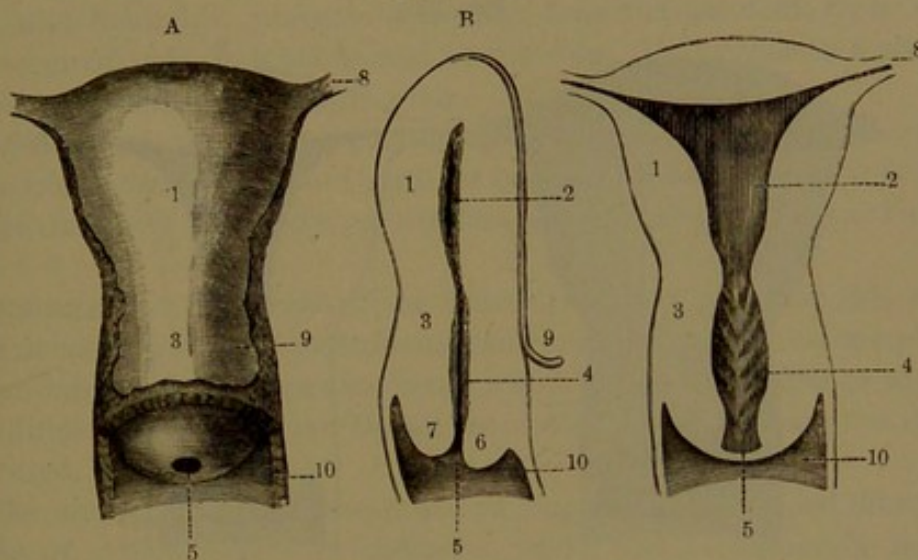
<sup>4</sup> Henle says the two layers hold the reverse position.



## THE UTERUS.

The **uterus**,<sup>1</sup> or **womb**, is the receptacle in which the embryo, or offspring, undergoes development from the egg. In its ordinary condition at maturity it appears as a flattened pear-shaped body, and it has an interior narrow cleft-like cavity enclosed by thick, compact walls. It is situated within the pelvis between the bladder and the rectum, and below joins the vagina, into which its cavity opens. From the vagina, the uterus with its long axis is directed obliquely forward and upward in the axis of the inlet of the pelvis, from which it variably inclines according as it may be affected by the more or less distended condition of the bladder. The larger portion, or **body**,<sup>2</sup> of the uterus is upward

FIG. 331.



VIRGIN UTERUS AT MATURITY; two-thirds size. A, anterior view; B, fore and aft median section, looking at the left half; C, vertical section from side to side. 1, body of the uterus; 2, cavity of the body; 3, neck; 4, cavity of the neck; 5, mouth of the uterus; 6, anterior lip; 7, posterior lip; 8, oviduct; 9, peritoneum; 10, vagina laid open.

and projects free into the pelvic cavity, lying in contact with the bladder in front, the rectum behind, and the small intestine above; while the narrow portion, or **neck**,<sup>3</sup> is downward and is embraced by the vagina, into which its end projects. The uterus is enclosed and in a measure retained in its median position by a broad fold of the peritoneum, which extends from its sides to those of the pelvis as the **broad ligaments**. The peritoneum closely and smoothly invests the body above, in front and behind, and from its lower part is reflected to the bladder; but at the back part descends to the vagina and is thence reflected to the rectum.

The size of the uterus in the usual condition at maturity is about three inches long, two inches where widest from side to side, and

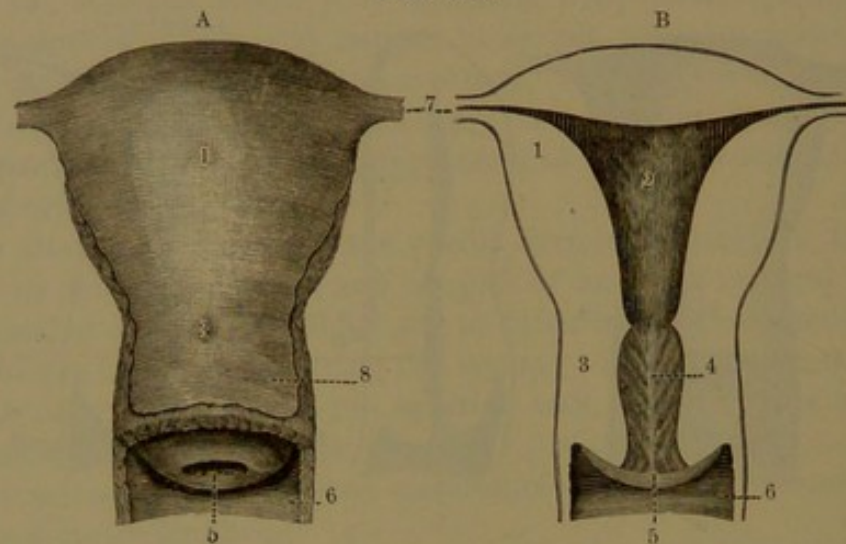
<sup>1</sup> Matrix, hystera, metra.<sup>2</sup> Corpus.<sup>3</sup> Cervix; collum.



nearly an inch thick fore and aft. In the uterus which has been par-turient the body is larger and the neck about a third of the length of the whole; in the virgin the body is proportionately narrower and the neck longer, or two-fifths of the whole. In infancy the uterus is less pyriform and more cylindroid, and the neck is larger and longer than the body.

From the upper part of the sides of the uterus the oviducts, or fal-lopian tubes, proceed outwardly enclosed within the upper border of the broad ligaments, and near the same points the round and ovarian ligaments are attached. The convex portion of the body projecting above the oviducts is the **fundus**,<sup>1</sup> and from this the convex sides grad-ually narrow to the neck. The anterior surface of the body is slightly convex and the posterior is considerably more so. The neck is flattened

FIG. 332.



UTERUS WHICH HAS GIVEN CHILDBIRTH; two-thirds size. A, anterior view of the uterus; B, vertical section from side to side. 1, body of the uterus; 2, cavity of the body; 3, neck; 4, cavity of the neck; 5, mouth of the uterus; 6, vagina laid open; 7, oviducts; 8, peritoneum.

cylindroid, or in the virgin somewhat widened at the middle so as to appear more oval. The lower rounded extremity projects into the vagina, where it presents a central funnel-like depression with a round or transverse oval aperture, which is the **mouth** of the uterus.<sup>2</sup> This is enclosed by a thick convex border forming the **lips**, of which the anterior descends lower in the vagina, though the posterior appears the longer from the higher attachment of the latter behind. From the obliquity of the uterus and the different depths to which the lips descend, both come into contact with the posterior wall of the vagina, and the mouth is directed backward and downward. The mucous membrane of the vagina is smoothly extended over the lips to the mouth of the uterus. After childbirth the mouth of the uterus is larger, transversely elliptical, and often appears roughened.

<sup>1</sup> Basis uteri.

<sup>2</sup> Os uteri externum; os tincæ; orificium vaginale.



In the body of the uterus the cavity extends from side to side as a broad triangular cleft, and in a vertical fore and aft section of the organ appears as a linear, nearly straight slit. The base of the triangular cavity at the fundus and the sides are convex inward, while the flat surfaces in front and behind come into contact. The upper angles are prolonged into narrow canals continued into the oviducts, and the lower angle descends into the cavity of the neck, the communication being slightly narrowed, and distinguished as the **internal orifice**<sup>1</sup> of the uterus.

The **cavity of the neck**<sup>2</sup> in the virgin uterus is elliptical, and widest from side to side. In the uterus which has been parturient it widens downward to the transversely elliptical mouth.

The inner surface of the cavity of the body is dull reddish, ordinarily smooth and finely punctate. In the cavity of the neck, both in front and behind, it presents a median longitudinal fold, from which a number of oblique folds ascend at the sides, giving rise to a tree-like appearance, named the **arbor vitæ**.

After death the uterus commonly appears more or less hard and rigid, which does not accord with its condition in life, when it is softer and flexible, and the body readily bends backward or forward on the neck.

**Structure.** The walls of the uterus consist of an outer thin serous layer derived from the peritoneum, an inner lining mucous membrane, and an intermediate muscular layer, which forms four-fifths or more of their thickness. The three layers are closely united, and are not readily separated.

The muscular layer is composed of bundles of unstriated fibres, the course of which differs in different parts, and is obscurely defined. According to Henle, it consists of three strata. On the body a thin superficial stratum consists chiefly of longitudinal fibres, in the deeper part mingled with oblique fibres. The succeeding strata are thick, and mainly consist of circular bundles of fibres with numerous small longitudinal and oblique bundles. Usually the deeper strata on the body consist of circular bundles in the vicinity of the oviducts and thence approach from opposite sides to the middle of the uterus. In the neck the three strata consist of an outer and an inner longitudinal and an intermediate circular stratum. All the strata are intimately associated through an intertexture of bundles of fibres. From the outer stratum bundles pass into the contiguous parts, the oviducts, the round ligaments, and the wall of the vagina.

The mucous membrane of the cavity of the body and upper part of the neck of the uterus is furnished with an epithelium consisting of a single layer of ciliated columnar cells. In the vaginal extremity of the neck extending to the middle it has the same kind of epithelium as

<sup>1</sup> Os uteri internum; ostium or isthmus uteri.

<sup>2</sup> Canalis cervicis.



that of the vagina. The mucous membrane is provided with numerous glands, the **uterine glands**. These are simple cylindrical tubes, which descend in the thickness of the membrane in a somewhat tortuous or convoluted course and terminate in a single or forked caecal dilatation. They are lined with a layer of epithelium like that of the uterine cavity. The glands are embedded in the connective tissue of the mucosa, which also serves as a matrix for the blood-vessels. During menstruation and pregnancy the uterine mucous membrane becomes much thickened, and the glands much elongated and enlarged. The mucous membrane of the neck is likewise provided with tubular glands which accord in structure with those of the body of the uterus. Not unfrequently in the aged some of these glands are observed to be transformed into little cysts, which are of no interest other than that they formerly were regarded as eggs<sup>1</sup> which had dropped from the body of the uterus.

During pregnancy the glands of the neck secrete a tenacious yellow mucus, which serves to plug up the mouth of the uterus.

The **broad ligaments**.<sup>2</sup> These extend from the sides of the uterus as a double layer of the peritoneum to the sides of the pelvis, dividing the cavity of the latter into two portions, of which the anterior contains the bladder and the posterior the rectum. Approaching the bottom of the pelvis, they are continued into the vesico-uterine and recto-uterine folds. The two peritoneal layers of the broad ligaments are united by connective tissue containing unstripped muscular fibres prolonged from the walls of the uterus and mostly pursuing a transverse direction. This intermediate stratum is pervaded by the vessels and nerves of the uterus, vagina, and ovaries.

Along the upper folded border of the broad ligament runs the oviduct, and near it, starting from the uterus a little lower in front, is the round ligament. Projecting from it behind is the ovary, which is further connected with the uterus by the ovarian ligament immediately behind and below the connection of the oviduct.

The **round ligaments**<sup>3</sup> are flat, fibro-muscular cords, which traverse the broad ligaments, occupying a slight superficial fold in the anterior layer. Each starts from the fundus of the uterus in front of the oviduct and proceeds outward and forward to the inguinal canal, through which it continues of diminished size to finally end in the tissues of the mons veneris. They are five or six inches long, and are composed of connective with elastic tissue, and unstripped muscular fibres proceeding from the wall of the uterus and joined in their course by some striped fibres.

**Vessels and nerves.** The uterus is supplied by the **ovarian** and **uterine arteries**, which reach the organ through the broad ligaments

<sup>1</sup> Ovula Nabothi; glandulae Nabothi.

<sup>2</sup> Ligamenta lata; alae vespertilionis.

<sup>3</sup> Ligamenta rotunda.



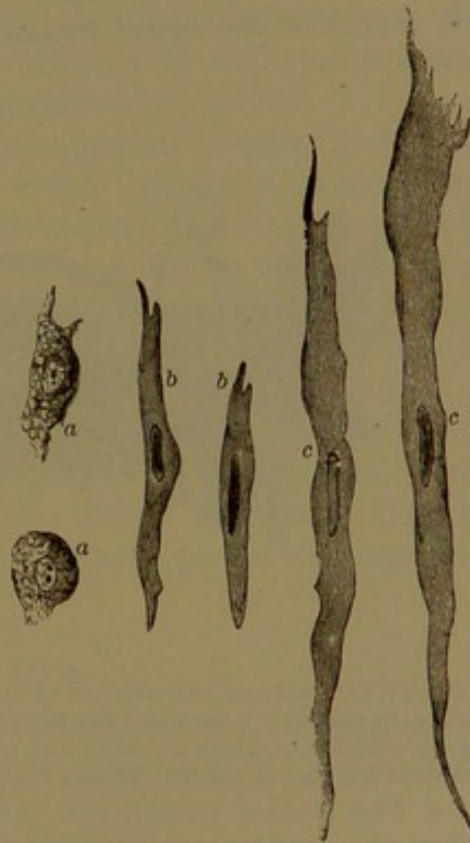
and enter its sides in numerous branches. Pursuing a remarkably tortuous course and frequently anastomosing, they are distributed throughout the thick muscular layer and the mucous membrane, and in the latter terminate in a superficial net-work of large capillaries. The **veins** correspond with the arteries, but are much larger. As they emerge from the muscular wall they form an intricate superficial plexus, from which the chief veins pursue the course of the principal arteries. The **lymphatics** commence as clefts and vessels in both the mucous membrane and muscular layer, and communicate with a superficial plexus from which the chief vessels accompany the corresponding blood-vessels. The **nerves** are derived from the hypogastric and ovarian plexuses, and consist of both medullated and non-medullated fibres.

**Periodic changes in the uterus.** The function of menstruation is accompanied by changes in the condition of the uterus. From turbulence of the vessels the organ becomes somewhat enlarged. At the same time the mucous membrane of the cavity of the body is thickened, softens, undergoes disintegration, and is shed; its products, together with blood from the ruptured capillaries, forming the menstrual discharge. The process commences at the inner orifice of the uterus and thence proceeds to the fundus, and in the subsequent repair the same course is pursued. The destruction of the mucous membrane extends deeply, and its reproduction takes place from the deeper epithelial cell-elements.

In pregnancy still more remarkable changes occur in the uterus. Gradually enlarging, it becomes egg-shaped, and finally over a foot in length, eight or nine inches in breadth, and from one and a half to two or three pounds in weight. Rising from the pelvis into the abdomen, the small intestine is displaced backward and the

abdominal parietes are greatly distended. The wall of the uterus loses its compact texture and becomes loose, spongy, more extensible, and darker. The blood-vessels greatly increase in size, especially the veins, and the arteries are exceedingly tortuous. The lymphatics and nerves

FIG. 333.



MUSCLE-FIBRE CELLS OF THE UTERUS, in the fifth month of pregnancy. *a*, preformative muscle-cells; *b*, young muscle-fibres; *c*, more developed muscle-fibres. Magnified 350 diameters.

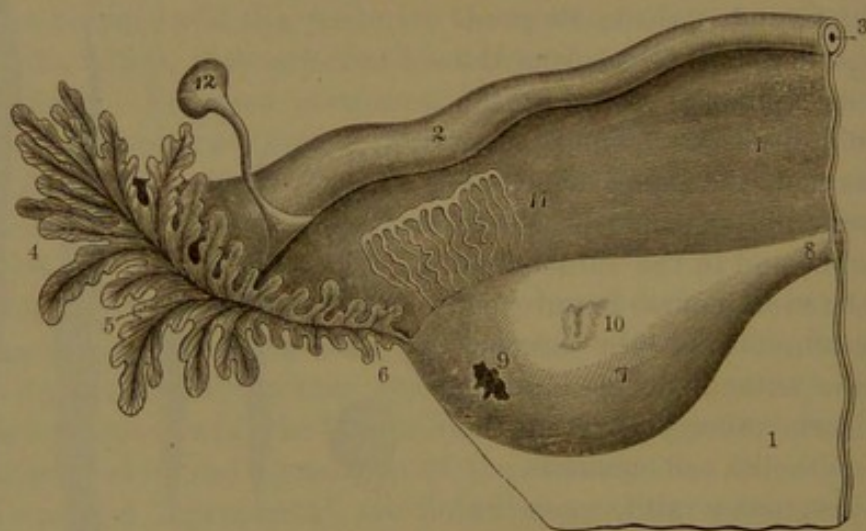


also increase. In the muscular structure the bundles are rendered more evident, and the fibres enlarge to seven times their former length and from three to five times the breadth, while new fibres are added. The round ligaments likewise are greatly enlarged and their muscular structure made more distinct. The broad ligaments expand with the enlarging uterus and also become more extended. The mucous membrane of the cavity of the body of the uterus undergoes transformation, gives rise to the production of the decidua and contributes to the formation of the placenta, both essential to the development of the new being. After parturition the uterus rapidly subsides, and with its appendages gradually approximates the original condition, though the uterus subsequently remains several times larger than it was before impregnation. The enlarged muscular bundles degenerate and are absorbed, to be replaced by new ones.

#### THE OVIDUCTS.

The **oviducts**, or **fallopian tubes**,<sup>1</sup> are enclosed within the upper free border of the broad ligaments, and serve as a communication be-

FIG. 334.



Ovary, parovarium, and oviduct of the left side. 1, broad ligament; 2, oviduct; 3, its canal; 4, its pavilion; 5, mouth of the latter; 6, process attached to the ovary; 7, 8, ovarian ligament; 9, orifice from which an ovum had recently escaped; 10, a cicatrix; 11, parovarium; 12, remains of the duct of Müller. From a virgin about eighteen years of age.

tween the ovaries and uterus. Commencing at the upper angles of the latter they proceed outward, are flexuose in their course, and then curve downward, backward, and inward towards the ovary. To the outer side they terminate in a widely-expanded and open trumpet-like mouth, named the **pavilion**,<sup>2</sup> or, from its deeply-fringed border, the **fimbriated extremity**.<sup>3</sup> The oviducts range from three to five inches

<sup>1</sup> Tubæ; t. uterinæ; t. Fallopianæ; cornua uteri.

<sup>2</sup> Of the French anatomists. Infundibulum; trumpet.

<sup>3</sup> Morsus diaboli.



in length, and are about a tenth of an inch thick at their commencement, from which they gradually increase to about the fourth of an inch or more, when they become again slightly narrowed, and then abruptly expand in the pavilion. Their capacity is variable, and usually at the commencement<sup>1</sup> in the uterus they barely admit an ordinary bristle; but gradually enlarge to the pavilion, where they contract to a round aperture, from one to three lines in diameter, communicating with the abdominal cavity, and hence named the **abdominal orifice**.<sup>2</sup> The pavilion hangs movably free from the broad ligament, directed downward and backward, with its mouth inward towards the ovary. Its breadth is very variable, but commonly about three-fourths of an inch or more, and by a narrow prolongation is extended and connected with the outer extremity of the ovary.

The lining mucous membrane of the oviducts is finely folded, and that to such a degree that the folds fill up their cavity. From the abdominal orifice the folds multiply, enlarge, and radiate within the pavilion, whence they are extended in numerous irregular laminar processes<sup>3</sup> of different lengths to form the fimbriated border. The mucous membrane is rose-colored, is provided with a ciliated columnar epithelium like that of the uterus, but contains no glands.

The exterior of the pavilion with its fimbriated border is invested with the peritoneal extension of the broad ligament, is white, and is furnished with the usual pavement endothelium of serous membranes.

The oviducts are provided with a muscular coat, to which the lining mucous membrane is closely adherent. The muscular coat, of unstriped fibres, is composed of an outer longitudinal layer extending from that of the wall of the uterus and an inner layer of circular bundles.

The ovarian artery in its course along the oviduct supplies it with numerous branches. The emerging venous branches join the ovarian vein. The lymphatics join those of the uterus and ovary. The numerous nerves are derived from the sympathetic plexus accompanying the ovarian blood-vessels.

#### THE OVARIES.

The **ovaries**<sup>4</sup> are the organs from which the ova, or eggs, are derived, and are two flattened oval bodies suspended one on each side from behind the broad ligaments. They are placed behind and below the oviducts next to the rectum, and have their long diameter directed obliquely between the fundus of the uterus and the pavilion of the oviduct. They are attached to the broad ligament along their anterior border, which is narrow and nearly straight, and forms their **hilus**, or position along which the vessels and nerves enter the organ. Elsewhere they are free, and their posterior border, which is thick and con-

<sup>1</sup> Ostium uterinum.

<sup>2</sup> O. abdominale.

<sup>3</sup> Fimbriæ, laciniae.

<sup>4</sup> Sing., ovarium; pl., ovaria; testes muliebres.



vex, is directed upward. Of the broad convex surfaces, one is directed upward and forward and the other downward and backward. The inner, narrower extremity is connected with the uterus by the ovarian ligament, and its outer, more rounded extremity is connected with a prolongation of the pavilion of the oviduct.

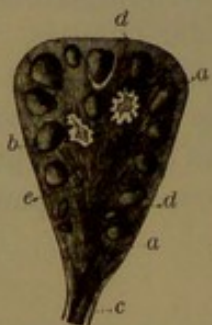The ovaries are variable in size in different individuals. Commonly they are about an inch and a half long, three-fourths of an inch between the anterior and posterior borders, and half an inch thick. The weight is proportioned to the size, and ordinarily each ovary ranges from sixty grains to twice that much.

The ovaries, prior to the commencement of menstruation, are even, white, and shining. After puberty, from the periodic escape of ova and the subsequent reparation and formation of cicatrices, they gradually become more or less uneven. After middle age they often appear irregularly furrowed and tuberculate, and yellowish or brownish in color.

The **ovarian ligament** is a cord which attaches the inner, narrower end of the ovary with the fundus of the uterus immediately below and behind the oviduct. It is about an inch and a half long, often more or less, is composed of bundles of connective tissue and unstriated muscular fibres, and is enclosed in a superficial fold of the posterior layer of the broad ligament.

**Structure.** The ovary is composed of an interior reddish spongy **stroma** with an outer more compact, paler layer, in which the ovisacs

FIG. 335.



TRANSVERSE SECTION OF AN OVARY, in the fifth month of pregnancy. *a, b*, ovisacs; *c*, ovarian ligament; *e*, stroma. In the interior, two old corpora lutea are visible.

containing the ova are embedded, whence it is named the **ovigenous layer**. It is defined by a thin, dense, white, connective-tissue layer, the **albuginea**,<sup>1</sup> invested externally with a simple columnar epithelium, which at the hilus is continuous with the pavement epithelium of the broad ligament. The interior stroma extends from the hilus, where it transmits the vessels and nerves of the ovary. It is composed of an intertexture of connective-tissue bundles with blood-vessels, which in general have a radial disposition, and outwardly become associated with bundles of spindle-shaped, nucleated cells.

The numerous vessels are accompanied by considerable bundles of unstriated muscle-fibres continuous with those of the ovarian and broad ligaments. The arteries are remarkable for their serpentine and often spiral course. The **ovigenous layer**, though not distinct from the interior stroma, appears more or less defined, and is chiefly composed of an intertexture of the spindle-shaped cells

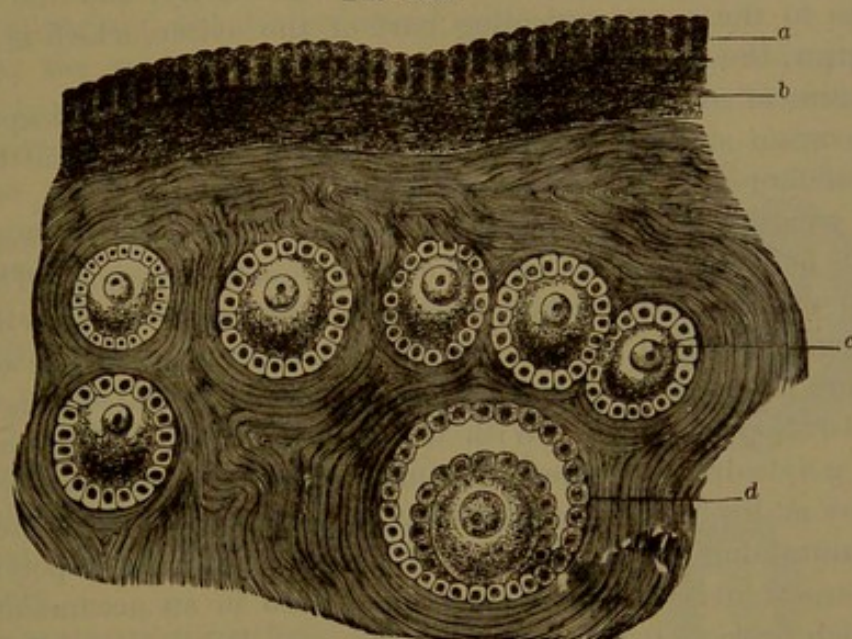
<sup>1</sup> Tunica albuginea. Sappey denies its existence altogether.



surrounding the ovisacs. The albuginea, continuous with the former, is mainly composed of fibro-connective tissue in several strata, and contains no ovisacs.

In the infant at birth the ovigenous layer is densely crowded with ovisacs of uniform size and estimated at many thousands; but subsequently they become more diffused, through the greater development of the stroma. At puberty the ovisacs, for the most part, retain their original condition, spherical shape, and uniform size, from 0.03 to 0.04 millimetre in diameter, and they form an almost continuous layer beneath the albuginea from one to three deep. In the ovary of a maiden of eighteen years, Henle estimated there were about thirty-six thou-

FIG. 336.



SECTION OF AN OVARY OF THE RABBIT. *a*, columnar epithelium of the free surface; *b*, external fibrous layer; *c*, young ovisacs embedded in the stroma, and each containing an ovum enveloped in a layer of epithelial cells; *d*, a more advanced ovisac, lined with an epithelial layer and containing an ovum invested with another layer, the space between filled with liquid.

sand of them. Embedded more deeply in the ovary are less numerous ovisacs, which present every gradation of size from the former to that of a large pea. The largest ovisacs, always few, are commonly deepest, although one or more may extend through the ovigenous layer from the surface of the ovary into the stroma beneath in a degree proportioned to its size, which in the ripe condition may be half an inch or more in diameter.

The larger ovisacs possess a more distinct and vascular envelope,<sup>1</sup> separable into two layers,<sup>2</sup> which are composed of the elements of the stroma concentrically arranged.

After puberty, among the multitude of ovisacs, some of them period-

<sup>1</sup> Theca folliculi.

<sup>2</sup> Tunica propria and fibrosa of Henle.



ically undergo more rapid development with increase of size, and every month one, or rarely several, at the surface of the ovary bursts and discharges its contents from the organ, the process being accompanied by the usual phenomena of menstruation.

The facts observed in the condition of the ovary appear to demonstrate that as the ovisacs grow they retire from the more crowded portion of the ovigenous layer to the deeper portion of the stroma, where they secure more room and nutriment for development. From time to time the most advanced ovisac reverses its course to the surface of the ovary, where it becomes prominent, and finally bursts and discharges its contents, including the ovum, which is received by the pavilion of the oviduct. Previous to the bursting of the ovisac its capsule exhibits the highest degree of vascularity, and the vessels converge to the most projecting part of the ovisac, which is named the **stigma**, the point at which the ovisac finally bursts.

Remains of ovisacs in various stages of atrophy in the deeper part of the ovarian stroma indicate that many, after development to some extent, undergo a retrograde course and disappear.

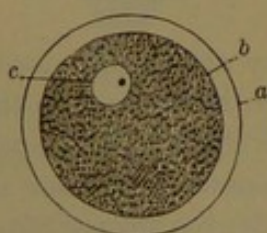
The **ovisacs**<sup>1</sup> are generally spherical, though some of the larger ones may be oblong, or the largest even irregular in shape. They are provided with a transparent homogeneous membrane,<sup>2</sup> which is thickest in the larger ones, and here and there presents a nucleus. The smallest ovisacs are lined with an epithelial layer<sup>3</sup> of flat, nucleated cells, which closely envelop an ovum. With the growth of the ovisac the cells become polyhedral and then columnar. With a further growth the cell-layers multiply to two, three, four, or more, the cells of the outer layer maintaining the columnar form, while the others are polyhedral. In the largest ovisacs the ovum is embedded in an accumulation of cells which projects from one side of the epithelial lining of the ovisac into a central cavity filled with serous liquid. The accumulation is

named the **proligerous disk**,<sup>4</sup> and its cells, like the rest, consist of a columnar layer next the ovum with succeeding polyhedral cells. All transitional stages are to be observed between the primitive ovisacs and the ripe ones as described.

The **ovum**, or **egg**,<sup>5</sup> is essentially a nucleated cell, of globular shape, and varying in size with that of the ovisac which contains it. In the smallest ovisacs it is in immediate contact with the flat epithelial cells, but in the next

stage, when the latter are polyhedral, it becomes defined by a clear

FIG. 337.



HUMAN OVUM, highly magnified. a, vitelline membrane; b, yolk; c, germinal vesicle containing the germinal spot.

<sup>1</sup> Vesiculæ Graafiana; Graafian follicles.

<sup>2</sup> Membrana propria.

<sup>3</sup> Stratum granulosum or proligerum; membrana granulosa or cumuli; ependyma folliculi; couche celluleuse.

<sup>4</sup> Discus proligerus; cumulus proligerus; zona granulosa.

<sup>5</sup> Ovulum.

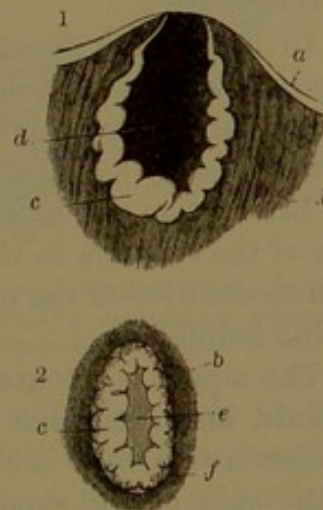


membrane, which increases in thickness with the subsequent growth of the ovum. The ripe ovum, ready to be discharged from the ovisac, is a minute spherical body, about the  $\frac{1}{120}$  of an inch in diameter, and exemplifies a complete cell. It has a thick, transparent envelope, named the **chorion**,<sup>1</sup> which under high magnifying power exhibits passing through its thickness fine striæ, regarded as pores, as is more evidently the case in the eggs of fishes and some other animals. The contents of the ovum, called the **yelk**, or **vitellus**, is a transparent viscid protoplasm with diffused oil-like granules of various sizes, named the **vitelline corpuscles**. To one side the yelk contains a clear spherical nucleus, the **germinal vesicle**,<sup>2</sup> which consists of a reticular mass of nucleoplasm with a delicate, vesicular, investing membrane. Within the vesicle there is commonly a highly-refractive nucleolus, the **germinal spot**,<sup>3</sup> and sometimes several are present.

After the escape of the contents of the ovisac its cavity is filled with a blood-clot. The wall subsequently becomes thickened, folded, and contracted on the clot, which finally in great measure loses its color, and the two together assume the appearance of a corrugated, yellow mass, called the **corpus luteum**. This subsequently atrophies, and is resolved into the tissue of the ovarian stroma. The **corpus luteum of pregnancy**<sup>4</sup> undergoes a greater degree of hypertrophy up to about the middle of the term, after which it begins to diminish, but does not disappear until near the end of pregnancy.

The ovaries are supplied by the ovarian artery, which runs through the broad ligament, below the attachment of the ovary, towards the uterus, where it anastomoses with the uterine artery. Numerous branches enter the hilus and are thence distributed through the organ. The veins are also numerous and large, and form a terminal plexus, from which the chief veins accompany the ovarian artery. The lymphatics, likewise numerous and large, emerging from the hilus, proceed to the lumbar glands. The nerves are derived from the ovarian plexus of the sympathetic accompanying the ovarian vessels.

FIG. 338.



TWO CORPORA LUTEA; in section, natural size. 1, eight days after conception; 2, at the fifth month of pregnancy. *a*, fibrous tunic of the ovary; *b*, stroma; *c*, thickened and plicated membrane of the ovisac; *d*, blood-clot; *e*, the same, later, without its red color; *f*, fibrous stroma bounding the corpus luteum.

<sup>1</sup> Membrana vitellina; oolemma pellucidum; zona pellucida, a common and much misleading name, applying only to an optical section of the membrane.

<sup>2</sup> Vesicula germinativa or prolifera; Purkinjean vesicle.

<sup>3</sup> Macula germinativa.

<sup>4</sup> True corpus luteum.



The **parovarium**.<sup>1</sup> This is a rudimentary organ placed between the layers of the broad ligament, in the interval outwardly between the ovary and oviduct. It appears as a series of irregular whitish tubes, somewhat divergent from the position of the ovary to a main tube lying near to and parallel with the oviduct. It is the remains of the primordial kidney or wolffian body of the embryo. The outermost tube sometimes appears as a little cyst suspended by a narrow cord from the broad ligament. A similar cyst, not unfrequently suspended from the pavilion of the oviduct, is the remains of the **duct of Müller**, another organ of embryonic life.

#### THE MAMMÆ.

The **mammæ**, or **mammary glands**,<sup>2</sup> are the milk-secreting organs of the female, and exist only in a rudimentary condition in the male. Their presence is characteristic of the highest class of animals, whence these are named mammals,<sup>3</sup> in most of which they are attached to the abdomen; but in man and his order, the primates, they occupy the front of the chest.

In the human female, when fully produced, the mammary glands, together with the enveloping skin and the fascia associated with more or less fat, form a pair of hemispherical prominences, the **breasts**, surmounted by a conical eminence, the **nipple**, or **teat**.<sup>4</sup>

The breasts extend from the third to the seventh rib and from the side of the sternum to the axilla, and are variably prominent according to the condition of the mammary gland and the general nutritive state of the individual.

The nipple is situated on a line with the fourth rib, and is directed forward and somewhat outward and upward. It is of a roseate or reddish-brown color and is surrounded at its base by a zone or areola of the skin of the same color. Both enlarge and become darker in pregnancy, and the change to some extent is permanent. The color increases with the advance of the pregnant condition, grows darker, but again diminishes after the mammary gland ceases its secretory function. The skin of the nipple is wrinkled and furnished with sensitive papillæ. It is highly vascular and contains much muscular tissue; hence under excitement it becomes larger and more rigid. On its rounded summit are the mouths of the milk-ducts, of which there are from fifteen to twenty, each opening into a little pit.

The skin of the areola is thin and exhibits a number of scattered, whitish, pimple-like eminences,<sup>5</sup> which are due to groups of sebaceous glands, which open by three or four ducts on the surface. The glands

<sup>1</sup> Parovarium; paroöphoron; corpus pampiniforme or conicum; organ of Rosenmüller.

<sup>2</sup> Masthos; mastus; ruma; uber.

<sup>4</sup> Mammilla; papilla; mastus; uber.

<sup>3</sup> Mammalia.

<sup>5</sup> Tubercles.



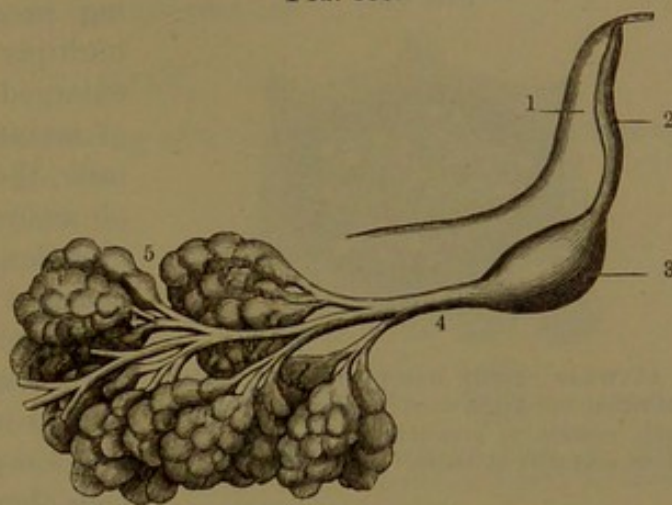
enlarge during suckling, and they secrete an oily matter, which appears to protect the part from excoriation.

The **mammary gland**<sup>1</sup> is a segment of a sphere, and is nearly circular, with its front surface convex and prolonged at the nipple, and its posterior surface nearly flat or slightly concave, and attached by connective tissue to the deep fascia investing the greater pectoral muscle. From the weight of the breasts during the full development of the mammae, when unsupported, the connective tissue of attachment becomes elongated and the breasts proportionately pendent.

The mammary gland is of firm consistence and of a pinkish-white color. It is a racemose

gland, and is composed of from fifteen to twenty lobes, which are closely conjoined by fibro-connective tissue which also invests the gland and is continuous with the superficial fascia of the chest. The lobes, which may be regarded as so many separate glands, are pyramidal, with the bases at the circumference of the mamma and the apices convergent to the nipple. From each

FIG. 339.



MILK-DUCT AND LOBULES OF THE MAMMARY GLAND, enlarged.  
1, nipple; 2, terminal milk-duct; 3, ampulla; 4, principal duct from a lobe; 5, lobules composed of alveoli.

lobe proceeds a **lactiferous** or **milk duct**,<sup>2</sup> which expands at the areola, and during lactation becomes enlarged into a fusiform receptacle, the **lactiferous ampulla**,<sup>3</sup> from a sixth to a fourth of an inch wide. From the ampullæ, which serve as little temporary reservoirs of milk, the milk-ducts, again reduced in size, ascend in a group through the nipple to its summit, where they terminate in contracted and separate orifices. Besides the milk-ducts, of which the central ones of the group are larger, the nipple contains numerous blood-vessels, with bundles of unstriped muscle-fibres and areolar tissue free from fat. The muscle-fibres form concentric circles at the base of the nipple, whence others radiate to its summit.

In the usual healthful condition between the mammary gland and the skin, the investing areolar tissue of the former is occupied by a variable accumulation of fat, often in considerable quantity and proportionately contributing to the prominence of the breasts. The fat is intersected by irregular partitions of fibro-connective tissue and par-

<sup>1</sup> Glandula lactifera.

<sup>2</sup> Galactophorous duct.

<sup>3</sup> Galactophorous ampulla or sinus; sinus lactei.

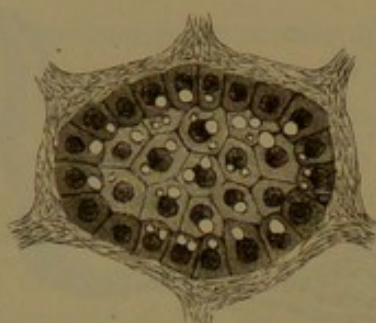


tially extends among the lobes of the mammary gland. In thin persons the fat is in great measure absent and its place is occupied by an abundant layer of areolar tissue.

The lobes of the mammary gland have the usual construction of racemose glands, and are composed of polyhedral lobules subdivided into smaller ones, all united by branching ducts with blood-vessels and conjoined by fibro-connective tissue. The smallest lobules consist of clusters of rounded polyhedral follicles or alveoli, which communicate with the smallest milk-ducts.

The alveoli of the mammary gland during the resting condition are filled with polyhedral cells. During pregnancy the cells rapidly multiply and the alveoli become enlarged. At the commencement of lactation, or the production of milk, the central cells of the alveoli are resolved into masses of oil-globules, which are discharged in the first milk and are known as the colostrum-corpuscles. The peripheral cells of the alveoli distended with their contents appear as a simple epithelium of flattened cells, but in the active secretion

FIG. 340.



ALVEOLUS OF THE MAMMARY GLAND, during lactation, lined with short columnar polyhedral cells, containing granular protoplasm, a nucleus, and milk-globules. Highly magnified.

of milk these assume a short columnar polyhedral form. They contain a granular protoplasm with a large round nucleus and oil-globules, which are discharged as milk-globules. The alveoli are defined by a membrana propria supported by fibro-connective tissue, with close nets of capillary blood-vessels.

The walls of the lactiferous ducts are composed of fibro-connective tissue with longitudinal and circular elastic fibres, and are lined by a columnar epithelium, which near their termination merges into stratified epithelium, continuous at the mouths of the ducts with the epidermis of the skin of the nipple.

The mammary gland makes its appearance in the fourth month of embryonic life, but its later growth is slow. There is no difference in the organ in the male and female infant for some years. The further development of the gland takes place in the female at puberty, but it is not until pregnancy that it proceeds to completion. Even in the male, at puberty, the gland undergoes some development, but this soon ceases and it becomes completely atrophied. Cases are reported in which it has so far advanced in its development in the male as to secrete milk.

With the decline of reproductive power in the female the mammary gland gradually atrophies, the alveoli with their epithelium and the smaller ducts disappear, and finally nothing remains but the larger ducts with areolar tissue and fat.



The arteries which supply the mammary gland are derived from the thoracic branches of the axillary, the intercostals, and the mammary. Those which directly go to the gland become considerably enlarged during lactation. The veins correspond with the arteries. Around the base of the nipple they form an anastomotic circle. The lymphatics commence in the fibro-connective tissue surrounding the alveoli, and the larger vessels pursue the general course of the ducts and blood-vessels. The chief lymphatics, for the most part, run along the outer border of the greater pectoral muscle to the axillary glands; others pass through the fore part of the intercostal spaces and enter the anterior mediastinal glands. The nerves are supplied from the anterior and lateral cutaneous branches of the intercostals.

#### MILK.

Milk<sup>1</sup> is an emulsion consisting of a clear liquid in which innumerable minute fat-globules are suspended. The latter are called the **milk-globules**, and measure from the  $\frac{1}{12000}$  to the  $\frac{1}{5000}$  of an inch. They seem to be coated with an albuminous substance, which prevents them from running together into larger drops. Chemically, human milk, according to Simon, has the following composition:

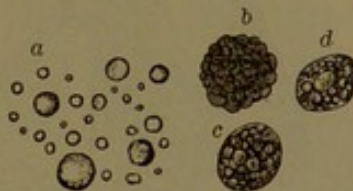Water, 880.6; casein, 37; milk-sugar, 45.4; fatty matters, 34; extractives and salts, 3: = 1000. Among the salts phosphatic earths predominate.

#### THE PERINEUM.

The perineum is that portion of the body which is included by the outlet of the pelvis; bounded in front by the pubic arch, behind by the coccyx and great sacro-sciatic ligaments, and at the sides by the ischial tuberosities. The space within this boundary is separated from the pelvic cavity by the anal elevator muscles and recto-vesical fasciæ descending from the sides of the cavity to the bladder and anus. It is occupied by the termination of the rectum, the urethra, and the root of the penis, together with their muscles, fasciæ, vessels, and nerves. In a more restricted sense the name of perineum<sup>2</sup> is applied to the space in advance of the anus; in the female occupied by the termination of the vagina, the vulva, and the clitoris.

The skin of the perineal region is comparatively thin and dark-colored, especially approaching the anus, where it is corrugated and continuous with the mucous membrane of the rectum. Its fore part is continuous with that of the penis and scrotum, and in the median line

FIG. 341.



CORPUSCLES OBSERVED IN MILK. *a*, milk-globules; *b*, *c*, *d*, colostrum-corpuscles in various stages. Highly magnified.

<sup>1</sup> Lac.

<sup>2</sup> True perineum.

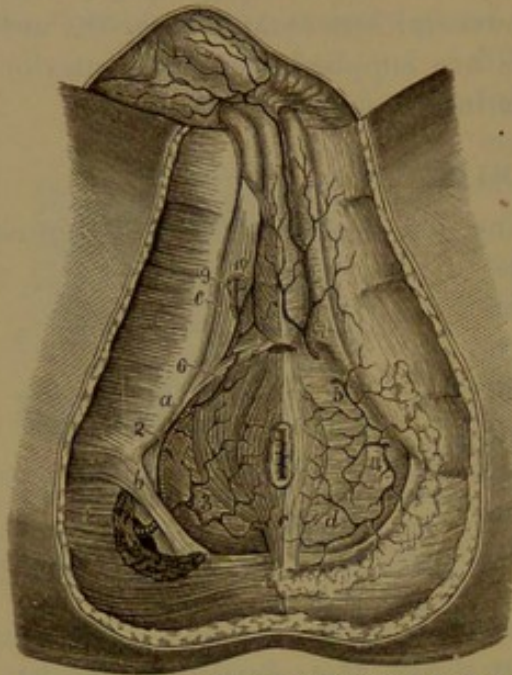


presents a slight ridge, the **raphé**, which extends from the anus to the prepuce. In the female its fore part is continuous with that of the labia and mucous membrane of the vulva, and the raphé extends from the anus to the posterior commissure of the latter.

#### MUSCLES AND FASCIÆ OF THE PERINEUM.

The **superficial fascia**<sup>1</sup> of the perineum, as elsewhere, consists of

FIG. 342.



VIEW OF THE PERINEUM; the superficial fascia removed from the left side of the figure. *a*, transverse perineal muscle proceeding from the tuberosity of the ischium to the perineal centre; *b*, greater sacro-sciatic ligament; *c*, anal sphincter; *d*, anal elevator; *e*, ischio-cavernous muscle; *f*, bulbo-urethral muscle enclosing the bulb of the spongy body. 1, 2, pudic artery; 3, inferior hemorrhoidal artery; 4, 5, 6, 7, superficial perineal branches; 8, bulbo-urethral artery; 9, cavernous artery; 10, dorsal artery of the penis.

two layers. The subcutaneous layer, accompanied by the usual adipose tissue, is continuous with that of the surrounding parts, the inner side of the thighs and the buttocks. Thin immediately around the anus, between this and the ischial tuberosity it forms a large accumulation occupying the ischio-rectal fossa, the deep interval extending upward between the rectum and the ischium. The disappearance of the fat in this position in emaciation produces more or less depression of the perineum around the anus. The deeper membranous layer of the superficial fascia occupies the fore part of the perineum, and closely invests the root

of the penis with its muscles. It is tightly attached to the sides of the pubic arch beneath the crura of the penis, and joins the deep perineal fascia behind the transverse perineal muscles. In front it is continuous with the investing fascia of the penis and with the dartos membrane of the scrotum. Behind the transverse perineal muscles it is continuous with the fasciæ lining the ischio-rectal fossæ.

The **deep perineal fascia**<sup>2</sup> is a strong membranous layer extended across the pubic arch behind the root of the penis, attached above to the pubic symphysis, continuous with the subpubic ligament and connected below with the obturator fascia behind and the deeper layer

<sup>1</sup> Fascia of Colles.

<sup>2</sup> Anterior or inferior layer of the deep perineal fascia.



of the superficial fascia in front. In contact with it in front are the crura of the cavernous body and the bulb of the spongy body. With the corresponding layer<sup>1</sup> within of the obturator fascia, the deep perineal fascia forms the **triangular ligament of the urethra**,<sup>2</sup> which gives passage to the isthmus of the urethra in the median line, about an inch below the pubic symphysis. At the latter the ligament is strengthened by a transverse fibrous band,<sup>3</sup> beneath which it is perforated for the passage of the dorsal vein of the penis. Between the two layers of the triangular ligament are the urethral compressor muscles closely connected with it, a venous plexus, the pudic vessels and nerve on each side, and the suburethral glands. In the female the triangular ligament is partially divided to accommodate the vagina.

The **anal sphincter**<sup>4</sup> is a subcutaneous, elliptical muscle surrounding the anus, and consists of a fleshy layer on each side of the aperture, convergent and united with its fellow behind, and attached tendinously to the end of the coccyx, and in the same manner convergent in front to the perineal centre, where it terminates by joining the urethro-bulbar muscle and the adjacent skin. Internally it is in contact with the internal sphincter and is separated from the anal elevator by loose connective tissue.

The **anal elevator**<sup>5</sup> is a broad, thin muscle, which descends from the side of the pelvic cavity, curving inward to the middle of the perineum. It arises in front from the posterior surface of the body and descending ramus of the pubis, behind from the spine of the ischium, and between these two points from the curved line of division of the pelvic fascia into the obturator and recto-vesical fasciæ. The anterior, longer fascicles descend to the side of the prostate and unite beneath it with those of the opposite muscle, blending with the anal sphincter at the perineal centre. The middle fascicles, forming the thicker portion of the muscle, descend to the side of the rectum between the sphincter and internal sphincter and become more or less blended with them. The posterior fascicles descend to be inserted into the end of the coccyx and into a median fibrous raphé extending from it to the anus. In the female the anterior portion of the muscle descends to the side of the vagina. Sometimes this portion is separated from the rest and has been described as a distinct muscle.<sup>6</sup>

The inner surface of the anal elevator is invested by the recto-vesical fascia, which separates it from the peritoneum. Its outer surface forms the inner boundary of the ischio-rectal fossa and is invested by the thin **anal fascia** continuous at the origin of the muscle with

<sup>1</sup> Posterior or superior layer of the deep perineal fascia.

<sup>2</sup> T. l. of the pubis; subpubic fascia; deep perineal fascia.

<sup>3</sup> Transverse ligament of the pelvis.

<sup>4</sup> M. sphincter ani; m. s. a. externus.

<sup>5</sup> M. levator ani.

<sup>6</sup> M. levator prostatae; m. adductor or compressor prostatae.



the obturator fascia. Its posterior border is continuous with the coccygeus muscle, and its anterior border is separated from that of the opposite muscle by a triangular space traversed by the urethra, in the female giving passage to the vagina.

The **coccygeal muscle**<sup>1</sup> is situated behind, in the same plane as the preceding. It is a triangular layer, partly fleshy and tendinous, which arises by its apex from the spine of the ischium and passes backward and inward to be inserted into the side of the coccyx and last segment of the sacrum. The rectum rests against its inner surface, and its outer surface is in contact with the small sacro-sciatic ligament.

The **ischio-cavernous muscle**<sup>2</sup> is a fleshy band embracing the unattached portion of the crus of the cavernous body of the penis. It arises tendinous and partially fleshy from the inner part of the tuberosity and ramus of the ischium and proceeds forward to terminate in an aponeurosis which is inserted into the under surface and sides of the fore part of the crus of the penis.

The **urethro-bulbar muscle**,<sup>3</sup> together with its fellow, forms a fleshy layer embracing the bulb of the spongy body of the penis. It arises from the perineal centre, connected with the anal sphincter and transverse perineal muscles, and from a narrow, median fibrous raphe which unites it with its fellow and extends forward beneath the urethral bulb. From this origin the fleshy fibres proceed outward and forward around the bulb and terminate in an aponeurosis, partly united with that of the opposite side above the bulb, partly inserted in advance into the outer side of the cavernous body, and partly united with its fellow in a slip which passes over the latter and includes the dorsal vessels of the penis.

In the female the ischio-cavernous muscle<sup>4</sup> holds the same relation to the clitoris that it does to the penis in the male, the size being in accordance and the attachments the same. The urethro-bulbar muscles become the vaginal sphincter, the two sides of which correspond with the two muscles in the male.

The **vaginal sphincter**<sup>5</sup> appears as an elliptical muscle, which embraces the orifice of the vagina and the vestibule and includes the semi-bulbs of the spongy body. It converges behind to the perineal centre, where it unites with the anal sphincter and transverse perineal muscles. It also converges in front and is inserted into the cavernous body of the clitoris, around which it gives a loop enclosing the dorsal vessels, as in the corresponding muscles of the male.

The **transverse perineal muscle**,<sup>6</sup> a narrow fleshy slip, arises tendinous from the inner side of the ischial tuberosity and proceeds

<sup>1</sup> M. coccygeus.

<sup>2</sup> M. ischio-cavernosus; m. erector penis.

<sup>3</sup> M. bulbo-cavernosus; m. accelerator or ejaculator urinæ or seminis.

<sup>4</sup> M. erector clitoridis.

<sup>5</sup> M. sphincter or constrictor vaginæ.

<sup>6</sup> M. transversus perinei.



obliquely inward and forward to terminate in the perineal centre, where it is united with its fellow and other contiguous muscles. It is variable, and is sometimes very small, or may be absent. It is not unfrequently accompanied by a smaller slip<sup>1</sup> in front or behind. It may be inserted partially or wholly into the urethro-bulbar or the anal sphincter muscle.

The **urethral compressor**<sup>2</sup> is a thin muscle situated between the layers of the triangular ligament and embracing the isthmus of the urethra. Composed of variable fascicles, mostly transverse, it arises by an aponeurosis from the descending ramus of the pubis and proceeds inwardly to join its fellow in the median line above and below the urethra, partially by an interchange of fibres and partially by a fibrous raphé. Included by the compressors, the urethral isthmus is surrounded with circular muscular fibres which are continuous with the former.

The anal sphincter is supplied by branches from the fourth sacral and the inferior hemorrhoidal branch of the pudic nerve. The anal elevator is supplied by the fourth sacral and the perineal branch of the pudic nerve, and the coccygeus muscle by the former. The ischio-cavernous, urethro-bulbar, and transverse perineal muscles are supplied by the perineal nerve, and the urethral compressor by the dorsal nerve of the penis.

The action of the anal sphincter and anal elevator is indicated by the names. The ischio-cavernous muscle, by compression of the organ, may aid in maintaining the erection of the penis, but ordinarily would appear rather to draw it downward. The urethro-bulbar muscle, by compressing the bulb, will forcibly eject liquids from the urethra.

---

<sup>1</sup> M. transversus perinei alter.

<sup>2</sup> M. compressor or constrictor urethræ; m. constrictor urethræ membranacea; m. constrictor isthmi urethræ.



## CHAPTER XIV.

### GLAND-LIKE ORGANS WHOSE FUNCTION IS OBSCURE OR UNKNOWN.

CERTAIN organs having the general appearance of glands, and distinguished as ductless glands, the functions of which are obscure or unknown, are the spleen, the thymus, the thyroid body, the suprarenal body, and the carotid and coccygeal glands.

#### THE SPLEEN.

The **spleen**<sup>1</sup> is a massive organ of a dark-purple color, situated within the abdomen, in the back part of the left hypochondrium, lying against the fundus of the stomach to the right, and in contact behind with the diaphragm, opposite the three or four lower ribs. It is variable in shape, and commonly is demi-ovoid with the broader extremity upward, the long diameter directed obliquely downward and outward. The external surface is convex, conforms closely to the diaphragm, and is directed to the left, backward and upward. The internal surface is divided longitudinally near the middle by a ridge usually impressed by a shallow furrow, the **hilus**,<sup>2</sup> along which the vessels pass in and out of the spleen. The narrower back part of the surface lies against the outer border of the left kidney, and the more concave anterior part is applied to the fundus of the stomach. The borders of the spleen are for the most part obtuse, and the anterior narrower border, usually below, presents one or more shallow notches or clefts. The lower narrow end of the spleen rests on the **costo-colic ligament**,<sup>3</sup> a fold of peritoneum attaching the splenic flexure of the colon to the diaphragm. Sometimes the spleen presents no ridge on its inner surface, and occasionally the furrow-like hilus is absent.

Besides through its vessels, the spleen is especially sustained in position by folds of the peritoneum. Of these, the **suspensory ligament**<sup>4</sup> extends from the upper part of the hilus to the contiguous diaphragm and the **gastro-splenic omentum** extends from the sides of the hilus to the fundus of the stomach.

The spleen is very variable in size, but ordinarily is about five inches long, an inch or two less in width, and from an inch to an inch

---

<sup>1</sup> Lien ; splen ; hepar sinistrum.

<sup>3</sup> Phrenico-colic ligament.

<sup>2</sup> Porta lienis.

<sup>4</sup> Phrenico-splenic ligament.



and a half in thickness, and weighs six or seven ounces. In advanced age it is considerably diminished; in some fevers, like intermittent, it becomes very much enlarged, even to several pounds.

Occasionally there is a small **accessory spleen**<sup>1</sup> and sometimes several together, attached to the gastro-splenic omentum, near the lower part of the spleen. It is commonly spheroidal, and ranges from the size of a pea to that of a walnut.

**Structure of the spleen.** The spleen is a highly vascular organ, proportioned to its size more so than any other organ of the body. It is comparatively soft, and is easily broken, and the ruptured surface presents a pulpy black or dark brownish-red appearance, resembling coagulated blood. It consists of an elastic, sponge-like matrix of fibro-connective and elastic tissue, which sheathes and supports the blood-vessels and encloses in its areolæ a soft substance, the splenic pulp, the whole enveloped in a membranous capsule.

FIG. 343.

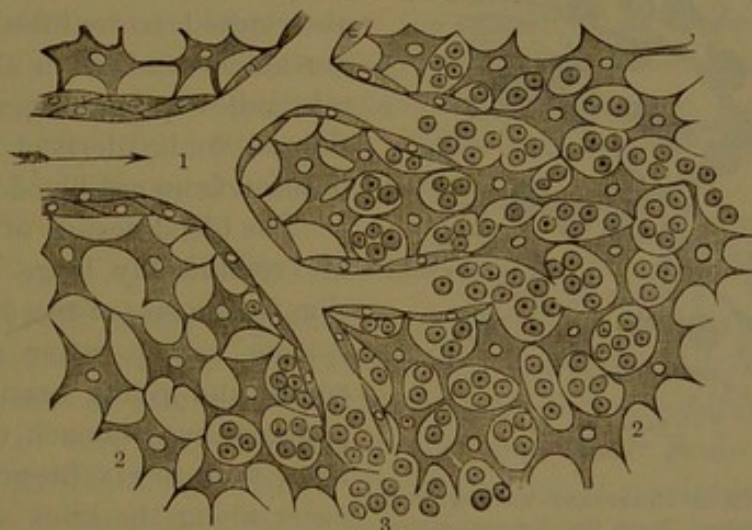


DIAGRAM OF THE TERMINATION OF A CAPILLARY VESSEL IN THE SPLENIC PULP. 1, capillary; 2, supporting cells of the pulp; 3, lymph-corpuscles. Highly magnified.

The **capsule** of the spleen is whitish, smooth, shining, and elastic, and is composed of a proper tunic invested by a serous layer derived from the peritoneum.

The **external serous layer** is thin and transparent, intimately connected with the subjacent tunic, and invests the spleen throughout except at the hilus.

The **proper tunic**<sup>2</sup> is much thicker and stronger than the former, and is composed of a dense intertexture of fibro-connective and elastic tissue. At the hilus, extensions of the tunic, from their supporting character distinguished as **trabeculæ**,<sup>3</sup> accompany and sheathe the blood-vessels in their distribution through the structure of the spleen.

<sup>1</sup> Splenculus; lienculus.

<sup>2</sup> Tunica propria.

<sup>3</sup> From the Latin *trabs*, a bean.



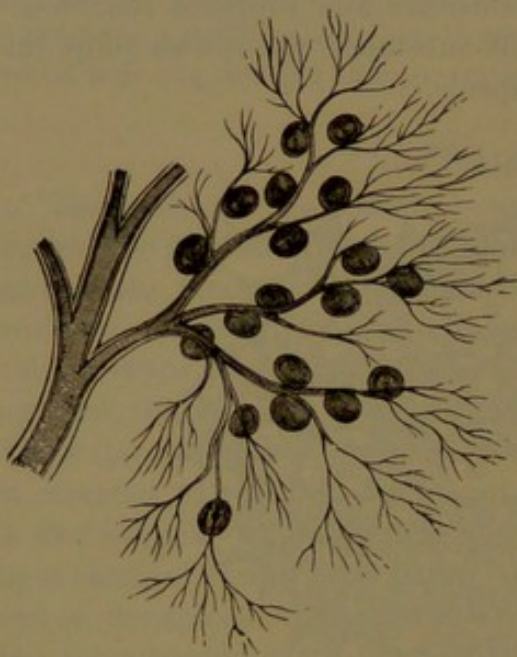
Numerous other trabeculae proceed from the interior of the tunic and from the blood-vessels to contribute to form the sustaining matrix of the spleen.

The areolae of the splenic matrix are occupied by a delicate interlacement of stellate connective-tissue corpuscles, distinguished as the **supporting cells**<sup>1</sup> of the splenic pulp. These cells conjoin through their radial fibres, and their interstices communicate with the splenic capillaries and are filled with blood.

The blood of the splenic pulp differs from the blood generally in containing a greater proportion of white corpuscles. Among the con-

stituents of the pulp are other corpuscles resembling the latter, but larger. These exhibit amœboid movement and often contain some red blood-corpuscles, together with yellowish pigment-granules. The supporting cells of the pulp are also stated to exhibit amœboid movement and often also to contain yellow pigment-granules, considered to be derived by decomposition from red blood-corpuscles.

The blood-vessels of the spleen are remarkably large in proportion to the size of the organ. The splenic artery, after a tortuous course and giving branches to the pancreas and stomach, divides into from four to six branches, which enter along the hilus and are distributed through the structure of the spleen supported by its tra-



SMALL BRANCH OF THE SPLENIC ARTERY, with lymphoid nodules. From the dog: magnified 10 diameters.

beculae. The main branches run outwardly and supply corresponding regions of the spleen without anastomosing with those of contiguous regions. The arteries after extensive ramification, sheathed by the trabeculae, leave these and break up into little tufts of fine, straight arterioles, the external coat of which, from its ordinary composition of connective tissue, gradually assumes the condition of adenoid or lymphoid tissue. The arterioles, supported by small trabeculae, terminate in capillaries, which traverse the splenic pulp and finally merge and end in the interstices of its supporting cells.

The lymphoid tissue of the splenic arterioles resembles that of the lymphatic glands, and consists of delicate interlacing fibrils enclosing in their meshes lymphoid corpuscles and supplied by small branches from

<sup>1</sup> Sustentacular cells.



the arterioles ending in capillary plexuses. In many positions the investing lymphoid tissue of the arterioles forms nodules<sup>1</sup> surrounding the vessel or placed on one side of it and supplied by branches from the latter as elsewhere in the tissue. The lymphoid nodules resemble the solitary glands of the intestine and appear as whitish dots in the dark pulp of the fresh spleen, measuring a millimetre or less.

The veins of the spleen commence in the splenic pulp in the same manner as the arteries terminate. Pursuing a different course from the latter, they also sooner pass to the trabeculæ, on and within which, unlike the arteries, they frequently anastomose. Emerging from the hilus of the spleen in from four to six branches, they unite in the splenic vein, the largest tributary of the portal vein.

The lymphatics of the spleen consist of two sets. Of these the **perivascular lymphatics** commence in the lymphoid sheath of the splenic arterioles, whence the vessels pursue the course of the arteries and veins from the spleen. The **trabecular lymphatics** commence in the splenic trabeculæ, where they communicate with the former, and they join a superficial plexus of the splenic capsule, whence vessels converge to the hilus to join the deep lymphatics, which then enter the lymphatic glands of the gastro-splenic omentum. The nerves of the spleen are derived from the splenic plexus of the solar plexus, accompanying the splenic artery and its branches.

#### THE THYROID BODY.

The **thyroid body**, or **gland**,<sup>2</sup> is a brownish-red organ of unknown function situated in the neck, embracing the front and sides of the commencement of the trachea, extending on the sides of the larynx. It consists of two **lateral lobes**, united near their lower ends by a transverse portion or **isthmus**. In its position it produces a rounded prominence, is covered by the infra-hyoid muscles, and comes into contact with the sheath of the principal blood-vessels of the neck. Each lobe is ovoid with the narrower end upward and extends from the fifth or sixth ring of the trachea to the side of the thyroid cartilage. The external surface is convex; the internal surface is concave and closely adheres to the trachea and larynx. The isthmus, variable in size, shape, and position, usually crosses the third and fourth rings of the trachea.

Not unfrequently a **pyramidal process**<sup>3</sup> of variable length extends upward from the thyroid isthmus or from the adjacent part of either lobe, more commonly the left one, and is attached by a band of loose connective tissue to the body of the hyoid bone. Occasionally a muscular slip<sup>4</sup> is substituted for the latter band, or independently

<sup>1</sup> Malpighian corpuscles; splenic corpuscles.

<sup>2</sup> Corpus thyroideum; glandula thyroidea.

<sup>3</sup> Processus pyramidalis.

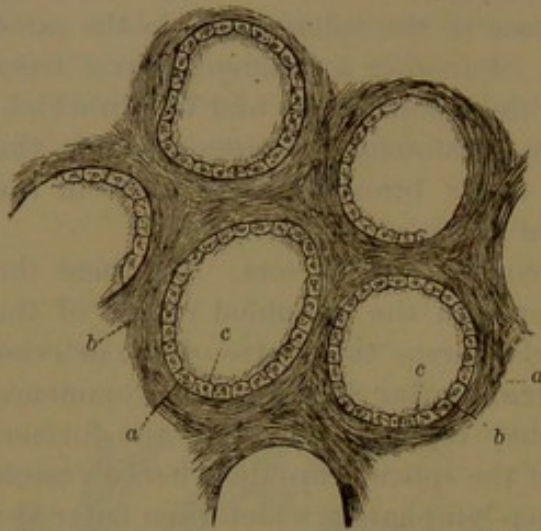
<sup>4</sup> Levator glandulæ thyroideæ.



extends in the same manner from the thyroid isthmus to the hyoid bone.

The thyroid body is solid and moderately firm, and is provided with a thin connective-tissue capsule, from which processes extend into the

FIG. 345.



PORTION OF THE THYROID BODY IN SECTION, highly magnified. a, fibrous stroma; b, vesicles; c, the epithelium and colloid contents.

substance of the body and divide it incompletely into small, irregular portions or lobules.

The organ is highly vascular, and, besides its numerous vessels, consists of rounded polyhedral, closed **vesicles**<sup>1</sup> of different sizes embedded in a connective-tissue matrix and collected into irregular groups or lobules. The vesicles range from about  $\frac{1}{30}$  to a millimetre; are defined by a basement membrane<sup>2</sup> of flat endothelial cells lined by an epithelial layer of short columnar polyhedral cells, and contain a yellow glairy liquid or colloid substance.

The arteries of the thyroid body are the superior and inferior thyroid. They are remarkable for their large relative size and frequent anastomoses, and they end in capillary nets around the thyroid vesicles. The veins are numerous and large and form a superficial plexus, from which proceed the superior, middle, and inferior thyroid veins.

The lymphatics of the thyroid are also numerous and large. They originate in the connective-tissue matrix of the thyroid vesicles and form large anastomosing trunks following the course of the blood-vessels, joined by others from a superficial plexus.

The nerves are derived from the middle and inferior cervical ganglia of the sympathetic and accompany the blood-vessels.

The thyroid body ordinarily weighs from one to two ounces, and is larger in the female than in the male. In the former frequently it exhibits a periodical increase about the time of menstruation. It is proportionately larger at birth, and often in the advance of age its vesicles become enlarged by an accumulation of the colloid substance, accompanied by a decrease of the connective-tissue matrix. It is also liable to hypertrophy, constituting the affection known as goitre, in which there is an excessive accumulation of colloid substance in the vesicles.

<sup>1</sup> Alveoli.

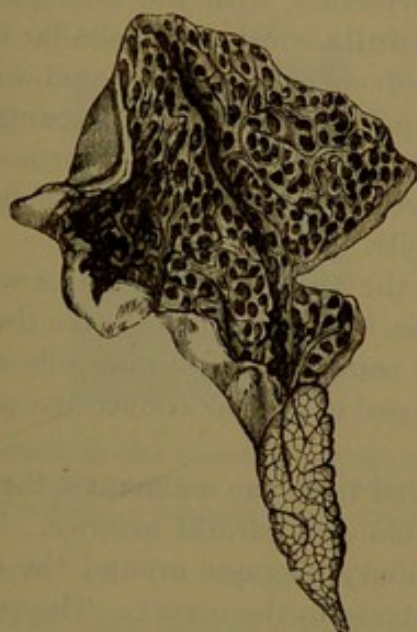
<sup>2</sup> Membrana propria.



## THE THYMUS.

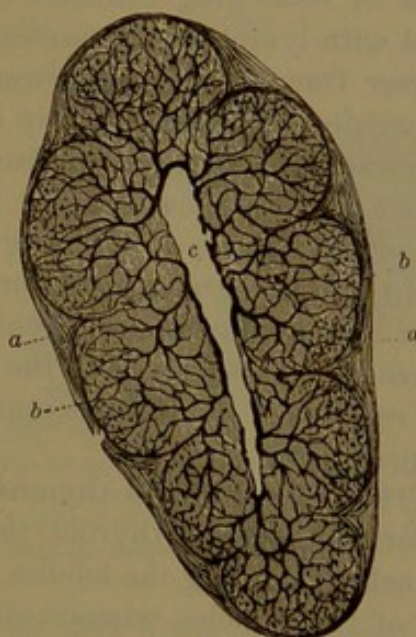
The **thymus**, or **thymus gland**,<sup>1</sup> is a temporary organ of unknown function, situated in the superior mediastinum, extending into the neck. It lies immediately behind the upper part of the sternum, in front of the pericardium, between the pleuræ, reaching down as far as the fourth costal cartilage and extending upward in front of the great blood-vessels of the heart and the trachea to the thyroid gland. It is a soft, pinkish-gray, lobulated body, resembling in appearance a racemose gland, and is very variable in shape and size. At birth it is ordinarily about two inches long, an inch to an inch and a quarter

FIG. 346.



ONE LOBE OF THE THYMUS BODY LAID OPEN, AND EXHIBITING THE LOBULES AND ACINI. The lower extremity of the figure exhibits the outlines of the lobules.

FIG. 347.



SECTION OF A LOBULE OF THE THYMUS BODY, magnified. *a*, fibrous investment of the lobule; *b*, acini penetrated by blood-vessels; *c*, cleft resulting from the laceration of the medulla.

wide below, three or four lines thick, and ranges in weight from one to two drachms or more. It consists of a pair of **lateral lobes**, mostly of unequal size and usually of elongated, pyramidal shape, with the broader part downward, and lying in contact with each other in the median line. Sometimes the two lobes are fused together.

From birth the thymus continues to grow for a couple of years, after which it gradually atrophies and commonly is much reduced at puberty, though sometimes it remains, partially diminished, to maturity, and commonly traces can be detected much later, even to old age.

Each lobe of the thymus consists of numerous polyhedral lobules

<sup>1</sup> Glandula thymus; corpus thymianum; c. incomprehensibile; sweetbread of the butchers.



united by delicate connective tissue, which also forms a thin capsule to the organ. The lobules when unravelled by dissection are found to be joined by an axial cord, which has commonly been regarded as tubular,<sup>1</sup> but appears to be solid and composed of connective tissue. The lobules are aggregations of **acini**,<sup>2</sup> from one-half to two millimetres in diameter, and while they are distinct at the periphery of the lobule they are confluent towards the centre, as represented in the figure on the preceding page. The acini and lobules have been described as having an interior cavity freely communicating and filled with liquid,<sup>3</sup> but from recent researches they would appear to be solid and to consist of a thick peripheral cortex with an interior softer medulla. The **cortex** resembles adenoid or lymphoid tissue, and like it consists of a delicate framework of branching connective-tissue corpuscles, with the interspaces filled with lymphoid corpuscles. The **medulla** consists of a similar but coarser framework with fewer lymphoid corpuscles associated with others, distinguished by their striated appearance as the **concentric corpuscles**. These range from the size of a colorless blood-corpuscle to two or three times the size, and consist of an envelope of epithelioid cells enclosing one or several granular cells.

In the retrograde metamorphosis of the thymus, the follicles with their lymphoid contents atrophy and the interstitial connective tissue increases. Plasma-cells in the latter are transformed into fat-cells, and the remains of the thymus appear composed of areolar connective with adipose tissue.

The arteries of the thymus are derived from the mammary, the inferior and superior thyroid, the subclavian and carotid arteries. The branches reaching the lobules form capillary plexuses around the cortex of the follicles, whence others penetrate to the cortex. The veins terminate in the left innominate vein. The lymphatics arise around the follicles and form interlobular plexuses, whence the trunks follow the course of the blood-vessels. The nerves are small and chiefly derived from the sympathetic.

#### THE SUPRARENAL BODIES.

The **suprarenal body**<sup>4</sup> is a flat, triangular, brownish-yellow organ placed on the upper extremity of the kidney in each side of the abdomen. The upper thinnest part has a transversely convex border variably elevated towards the middle and directed upward and inward. The lower thickest part is transversely concave, commonly deeply grooved, and is applied to the inner fore part of the top of the kidney, to which it is attached by loose connective tissue. The posterior sur-

<sup>1</sup> Central canal; reservoir of the thymus.

<sup>2</sup> Follicles; granules; nodules.

<sup>3</sup> Thymic juice; succus thymicus.

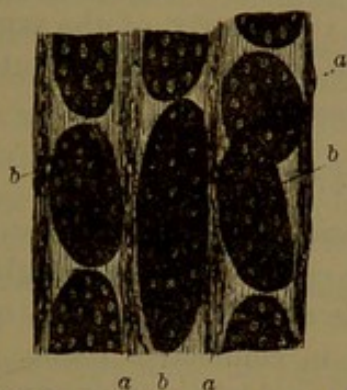
<sup>4</sup> Suprarenal capsule or gland; glandula or capsula suprarenale; capsula atrabiliaria; ren succenturiatus.



face rests against the diaphragm, and the anterior surface presents a transverse furrow, the **hilus**. The right suprarenal body in front is in contact with the under surface of the liver, and the left one with the spleen and pancreas. The right body is usually smaller and more triangular than the left, which is more crescentic. Each weighs about two drachms, and they commonly measure about two inches high and nearly the same width, and a fourth of an inch or less thick.

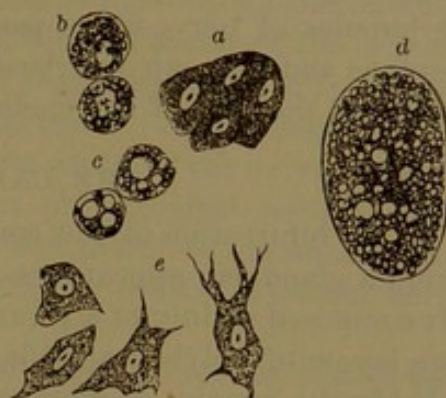
The suprarenal body is invested with loose areolar tissue, by which it adheres to the contiguous parts, and often contains more or less fat. It is provided with a thin fibro-connective-tissue capsule, which is continuous with the matrix or stroma of the organ and consists of two portions distinguished as cortical and medullary.

FIG. 348.



SECTION OF THE CORTEX OF A SUPRARENAL BODY, highly magnified. *a*, stroma of fibro-connective tissue; *b*, columnar groups of cells.

FIG. 349.



CELLS FROM THE SUPRARENAL BODY, highly magnified. *a*, nucleated cells from the cortex; *b*, *c*, *d*, cells from the same containing fat; *e*, cells from the medulla.

The **cortical portion** forms the greater part of the thickness of the body, is of a deep yellow color, of firm consistence, and has a distinctly striated appearance directed through the thickness. It consists chiefly of columnar groups of polyhedral cells with granular contents, often mingled with yellow oil-globules, and with a clear, spherical nucleus. At the outer boundary of the cortex is a zone<sup>1</sup> of small groups of cells, and at the inner boundary another zone<sup>2</sup> of still smaller groups, but these do not appear to be different in character from the intermediate thicker zone<sup>3</sup> of columnar groups. The cell-groups occupy corresponding areolæ of the connective-tissue matrix, but intercommunicate with one another.

The **medullary portion** is dark chocolate-brown and soft, so as to be readily torn, from which accident the suprarenal bodies have often been described as having a central cavity. It is composed of a more diffused intertexture of connective tissue, with the areolæ occupied by groups of cells of irregular shape, clearer than those of the cortex, free from yellow oil, and having a different chemical reaction.

<sup>1</sup> Zona reticularis.<sup>2</sup> Z. glomerulosa.<sup>3</sup> Z. fasciculata.



The suprarenal bodies are supplied by arteries directly from the aorta and from the phrenic and renal arteries. These end in large venous capillaries of the cortex, extending thence into the medulla. The capillaries traverse the fibrous matrix and are associated with unstriated muscle-fibres arranged parallel with the vessels. The veins converge from the centre of the body and emerge at the hilus, usually uniting in a single trunk, which joins the inferior cava on the right and the corresponding renal vein on the left.

Lymphatics commence in clefts of the connective-tissue matrix of the suprarenal body, and also, according to Klein, among the cells of the cell-groups. The vessels pursue the course of the blood-vessels from the organs and are joined by others from a superficial plexus.

The nerves are remarkably numerous, and are derived partly from the solar plexus and partly from the renal plexus of the sympathetic. The bundles of nerve-fibres pass through the matrix of the cortical substance and form an interlacement in the medulla. Some authorities regard the cells of the medulla as nerve-cells.

#### THE CAROTID GLAND.

At the bifurcation of the common carotid artery is a minute body having a glandular appearance and hence called the **carotid gland**.<sup>1</sup> It is composed mainly of a plexus of minute arteries invested by one or more layers of polyhedral cells enveloped in connective tissue. It is probably the remains of some part of the branchial vascular apparatus of the embryo.

#### THE COCCYGEAL GLAND.

The **coccygeal gland**<sup>2</sup> is a body about the size of a small pea, situated near the end of the coccyx, at the tendinous insertion of the anal elevator muscles. It is composed of a tuft of small vessels derived from the middle sacral artery, freely anastomosing and invested with polyhedral cells and embedded in a matrix of fibro-connective tissue, which also forms a capsule for it. It is furnished with nerves from the sympathetic system.

<sup>1</sup> Glandula carotica; ganglion intercaroticum.

<sup>2</sup> Gland of Luschka.



## CHAPTER XV.

### THE NERVOUS SYSTEM.

**THE nervous system** consists of the brain and spinal cord with their nerves and ganglia, and of the sympathetic nerves, likewise with their nerves and ganglia.

The brain is the remarkably large mass of nervous substance which, together with its enveloping membranes, fills the cavity of the cranium, and the spinal cord is a prolongation of that mass enclosed in a sheath of the same membranes within the spinal canal. The two together constitute the **cerebro-spinal axis**, the great centre of the nervous system, but regarded as consisting of numerous physiological centres, which are more or less fused with one another and therefore not anatomically distinct. They are bilaterally symmetrical, or consist of similar halves united in the median line.

The sympathetic nerves consist of two systems or sets, one on each side of the body and communicating with the nerves of the cerebro-spinal system.

The ganglia in the more restricted meaning are small nodular bodies or nerve-centres, situated in various positions in the course of the nerves. In a general sense the name of ganglion is synonymous with a nerve-centre, and this is regarded to be the point or focus to which impressions are communicated and from which impulses are derived.

The nerves in general are cords distributed throughout the body and connecting the nerve-centres with all other organs, which in their relative position to these centres are distinguished as peripheral organs. They also often connect the nerve-centres with one another, when they are distinguished as commissures. They are the avenues through which impressions and impulses are conveyed to and from the nerve-centres.

The nervous system is comparable to a telegraphic system; the cerebro-spinal axis accords with the chief station, the nerves accord with the wires, and the ganglia with lesser stations.

The larger and more conspicuous nerves are those which proceed from the cerebro-spinal axis, thence called the **cerebro-spinal nerves**. They are generally more or less distinctly marked in contrast with surrounding structures by their whiter color. They usually run in the most direct manner for variably long and often the longest distances,



and are with few exceptions distributed to the skin, the special sense organs, and all the more distinct muscles, especially those which may or do act intentionally. One pair only, the vagus nerves, are distributed to the internal viscera.

Each lateral set or system of the cerebro-spinal nerves in its distribution is confined to the corresponding side of the body, with perhaps the exception of the vagus nerve, though in many instances the nerve-fibres forming the nerves in part are derived from opposite sides of the centres in which they originate.

The nerves of the sympathetic system are in general very much smaller than those of the cerebro-spinal system, much less conspicuous, mostly of a gray color, and not so readily distinguished among the surrounding structures. They are provided with many ganglia, and are distributed to the internal viscera and especially to the vascular system. The two sympathetic nerves freely communicate with each other, and each also freely communicates with the corresponding lateral cerebro-spinal system. Where the sympathetic nerves communicate with those of the cerebro-spinal system there is a mutual interchange of fibres, and the former usually exhibit variable proportions of the fibres of both systems mingled.

The material of the nervous system, commonly called **nerve-matter**, is composed of a number of distinct anatomical elements, of which the nerve-cells and nerve-fibres are the special or essential elements, while the others consist of the connecting or supporting elements and the nutrient vessels.

In the cerebro-spinal axis the mass of nerve-matter is of two kinds, distinguished by their color as the white and the gray.

The **white matter**,<sup>1</sup> milk-white and of soft consistence, is mainly composed of nerve-fibres supported in a soft matrix, the neuroglia. In the fresh state it appears pulpy and homogeneous, but when hardened in alcohol or by other means it readily tears into fibres.

The **gray matter**<sup>2</sup> is mostly pale reddish-brown, but darker or lighter in some positions, and is also of soft, pulpy consistence when fresh. It consists of an abundant matrix of neuroglia with nerve-fibres and embedded nerve-cells. When hardened in alcohol it breaks up into granular matter.

The **nerves** in general are composed of bundles of nerve-fibres, enveloped in sheaths of fibro-connective tissue. Those of the cerebro-spinal system are opaque white or pinkish white, flexible and tenacious; those of the sympathetic system are usually gray and less tenacious.

The **ganglia** are composed of a matrix of fibro-connective tissue with embedded groups of nerve-cells and traversed by bundles of nerve-fibres.

---

<sup>1</sup> Medullary matter; fibrous substance.

<sup>2</sup> Cineritious substance; vesicular substance; cortical matter.



## THE NERVE-FIBRES.

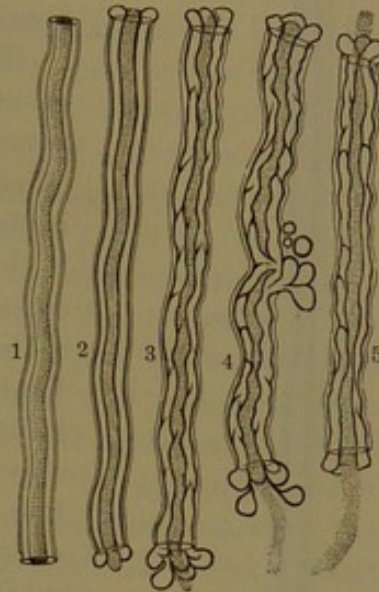
The **nerve-fibres**,<sup>1</sup> one of the essential elements of structure of the nervous system, are distinguished as of two kinds, the white or medullated and the gray or non-medullated fibres, the difference being due to the presence or absence of a medullary sheath.

The **medullated nerve-fibres**<sup>2</sup> form the chief component of the white matter of the brain and spinal cord, and it is to them that the white color is due. They also form the chief nervous element of structure of the cerebro-spinal nerves, to which they also give the white color. They further contribute to the structure of the gray substance of the brain and spinal cord, also to the ganglia and the sympathetic nerves.

They are cylindrical threads, straight or slightly flexuose, elastic, even and except near their extremities uninterruptedly continuous and of pretty uniform diameter. In the nerves they are collected in distinct bundles, which often divide and conjoin in other bundles. The branching of nerves is due to the separation and distribution of smaller bundles of nerve-fibres. In the same bundle the fibres generally approximate uniformity, but others present considerable difference in size, which varies greatly in different parts of the nervous system. The fibres are mostly smallest in the cerebro-spinal axis, especially in the gray matter. In the white matter they are closely aggregated and vary considerably in size. They range from about  $\frac{1}{1000}$  to  $\frac{1}{125}$  of a line in thickness. Though normally even, they are very prone to change, and thus after death become more or less varicose, especially in those of the white matter of the cerebro-spinal axis, where they assume a beaded appearance.

In the fresh, unaltered state, under a microscope of moderate power, the medullated nerve-fibres are colorless and translucent, and bordered at the sides by a distinct double outline, so that they appear

FIG. 350.



STRUCTURE OF NERVE-FIBRES, partly ideal. 1, a nerve-fibre represented in the fresh condition, exhibiting in succession its membranous sheath, medullary sheath, and axis-fibre; 2, 3, 4, 5, exhibit the same constituents; the medullary sheath indicated, as it appears shortly after death, by heavy outlines; the axis-fibre represented as dotted. In 4, 5, the axis-fibre is seen projecting from the cut ends of the nerve-fibres. In 4, the medullary sheath is seen exuding in drops through a rupture of the membranous sheath. Highly magnified.

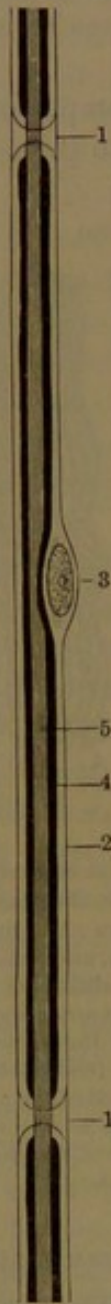<sup>1</sup> Ganglionic nerves.

<sup>2</sup> Dark or double-bordered nerve-fibres.



to be tubular. In those of the nerves the application of water produces a division of the double border, so that the fibres exhibit three portions, which are distinguished as the axis-fibre enclosed by the medullary sheath and the outer membranous sheath. The further action of water renders the distinction of the cylinder axis from the medullary sheath less evident. In the medullated fibres of the brain and spinal cord the membranous sheath is absent, and hence their greater softness and delicacy.

FIG. 351.



A MEDULLATED NERVE-FIBRE, treated with osmic acid, and highly magnified. 1, nodes; 2, membranous sheath of the internode; 3, its nucleus; 4, medullary sheath (the thick black line); 5, the axis-fibre.

The **axis-fibre**<sup>1</sup> is the essential<sup>2</sup> portion of every nerve-fibre, both medullated and non-medullated, and is always the means of connection with the nerve-cells. In the medullated fibres, as expressed by the name, it forms the axis or central portion and is closely embraced by the medullary sheath, which seems to serve as an insulator to it. Under a high power of the microscope it exhibits a longitudinally striated and granular appearance. It is composed of exceedingly fine filaments, the **nerve-fibrils**,<sup>2</sup> which are collected together in a bundle united by a minutely granular cement and enclosed in a delicate homogeneous membranous sheath. Each fibril appears to be composed of a single row of granules, which in uniformity of size and regularity of arrangement resemble the sarcous elements of primitive muscular fibrils, though not so distinctly evident.

The **medullary sheath**<sup>3</sup> which encloses the axis-fibre is less consistent and is clearer. In fresh nerve-fibres it is semi-liquid and resembles in appearance thick oil.<sup>4</sup> When in manipulation the fibres are torn, the substance oozes out and collects in irregular drops, like oil-globules. To it the white color and lustre of the nerves and of the medullary substance of the centres are mainly due.

The thickness of the medullary sheath is variable, and the difference in size of nerve-fibres depends more on it than on the axis-fibre. In medullated fibres

<sup>1</sup> Cylinder axis.

<sup>3</sup> White substance of Schwann.

<sup>2</sup> Primitive fibrillæ; granular fibrils.

<sup>4</sup> Myelin.



of the sympathetic nerves it is often so thin that they can only be distinguished from the associated non-medullated fibres by their distinctly darker outline. The substance of the medullary sheath has commonly been regarded as a homogeneous, semi-liquid, fat-like material, but the able investigator Schmidt describes it as consisting of a more consistent fibrillar material, with a granular semi-liquid which predominates next the axis-fibre.

The **membranous sheath**, or **neurilemma**,<sup>1</sup> is a delicate, elastic, structureless layer, which closely invests the medullary sheath in the peripheral nerve-fibres, but is absent in the central fibres or those of the brain and spinal cord. A closer examination of the nerves has shown that the medullated nerve-fibres in their course are constricted at nearly regular intervals, the constrictions being distinguished as **nodes**,<sup>2</sup> while the intermediate portions of the fibres are called **internodes**.<sup>3</sup> The axis-fibre is continued uninterruptedly and evenly through the nodes, but the medullary sheath is interrupted by the constrictions, which are filled in, outside the membranous sheath, with a clear cementing substance. The arrangement thus described is rendered more evident through the action of osmic acid, which stains the medullary sheath black while the membranous sheath and nodes remain nearly colorless and clear. Silver nitrate stains the nodes and adjacent portion of the axis-fibre, so as to give rise to the appearance of a black cross in these positions. Perosmic acid causes the medullary sheath to break up into imbricating cylindrical segments of variable length, but it is doubtful whether this condition is related with a pre-existing structure of the sheath. About the middle of the internodes an oval nucleus lies within the membranous sheath, in a recess of the contents, and causes a slight bulging of the sheath to which it belongs. The distinction of nodes and internodes is not evident in the central medullated nerve-fibres.

At the origin of the medullated nerve-fibres in the centres generally the axis-fibre extends beyond the medullary sheath and is continuous with the prolongation of a nerve-cell. To their destination they remain undivided, but reaching the peripheral tissues in which they are distributed they commonly undergo division at the nodes, and after branching several times the medullary sheath ceases, but the axis-fibre is continued. This, too, usually branches and finally breaks up into its constituent nerve-fibrils, which are distributed directly to or among the structural elements of the tissues.

The **non-medullated nerve-fibres**<sup>4</sup> predominate in the nerves generally of the sympathetic system, in which they are mingled with

<sup>1</sup> Membranous sheath; tubular membrane; primitive sheath; sheath of Schwann.

<sup>2</sup> Nodes of Ranvier.

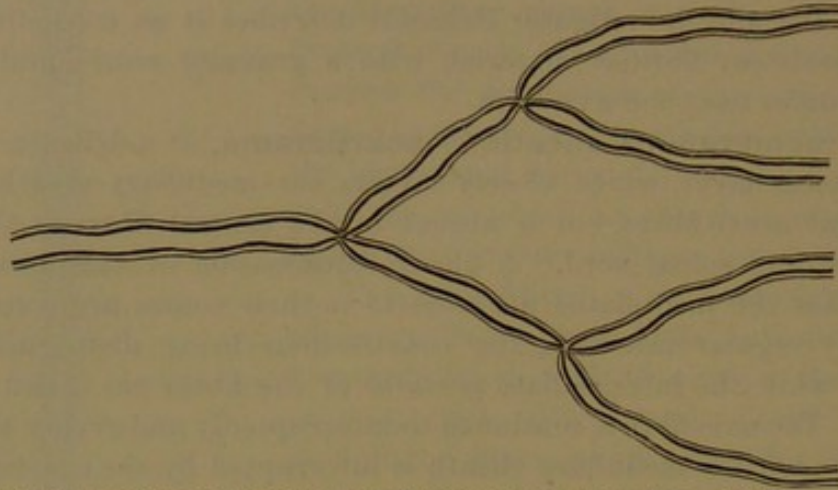
<sup>3</sup> Internodes of Ranvier; interannular segments.

<sup>4</sup> Pale, gray, or gelatinous fibres; fibres of Remak.



variable proportions of medullated fibres. The usually gray aspect and less distinct appearance of the sympathetic nerves are mainly due to

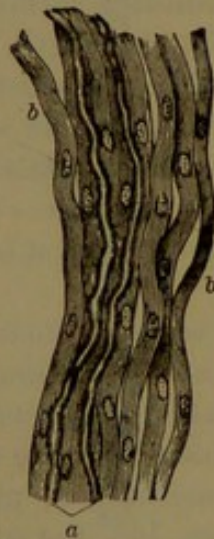FIG. 352.



MODE OF BRANCHING OF A MEDULLATED NERVE-FIBRE, at the nodes. Highly magnified.

the comparative fewness, or it may be the absence, of the medullated fibres, and the whiteness of some of them is owing to the preponderance of the latter. Generally the non-medullated fibres are smaller,

FIG. 353.



PORTION OF A SYMPATHETIC NERVE. *a*, two medullated nerve-fibres with a number of non-medullated fibres, *b*. Highly magnified.

but otherwise accord with them in structure, except that they possess no medullary sheath. In nerves they are furnished with a delicate membranous sheath, which is intimately connected with the axis-fibre and is nucleated. Unlike the medullated nerve-fibres, the non-medullated fibres in their course divide and anastomose and ultimately are distributed in the same manner. The medullated nerve-fibres commence and terminate as non-medullated nerve-fibres.

The nerve-fibres generally are regarded as being functionally of two kinds,—those which convey impressions of stimuli from peripheral and sensory organs to the nerve-centres and those which communicate motor impulses in the opposite direction to muscular and secretory structures and the like. The former are called **afferent, centripetal, or sensory fibres**;

the latter, **efferent, centrifugal, or motor fibres**. These are not clearly distinct anatomically, though there often seems to be some difference in the size of the two kinds of fibres. Most of the nerves of the brain are observed to be distinct, as sensory or motor, and as such the spinal nerves are completely separated at their roots. The destination of the nerve ordinarily rather than its structure serves to determine its

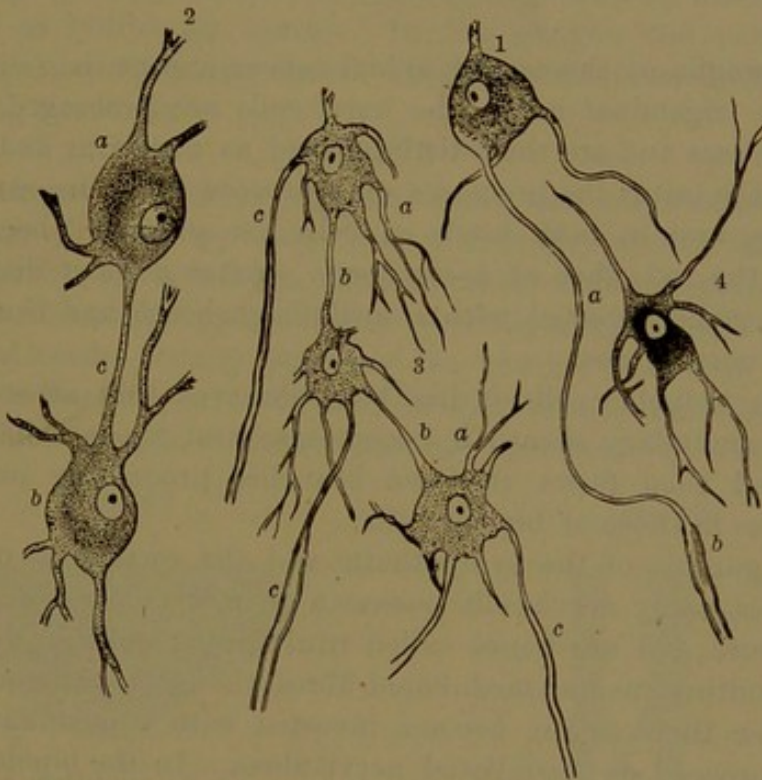


physiological character. Thus, a nerve to a muscle is almost completely a motor nerve, while one to the skin is mainly sensory. The optic nerve to the retina of the eye is purely sensory. In the nerves of the sympathetic system the same physiological difference exists, but is much more obscure anatomically.

#### NERVE-CELLS.

The **nerve- or ganglion-cells**, another and the more essential element of the nervous system as the immediate centres of nerve-power, are, for the most part, embedded in the gray matter of the cerebro-spinal axis and in the ganglia. They also occur in the course of some

FIG. 354.



NERVE-CELLS FROM THE BRAIN: highly magnified. 1, cell with one of its processes continuous as the axis-fibre *a* of the medullated fibre *b*; 2, two cells, *a*, *b*, united by a commissural fibre *c*; 3, three cells *a* united by commissural fibres *b*, and joined by axis-fibres with medullated fibres *c*; 4, nerve-cell with an accumulation of dark pigment.

of the sympathetic nerves, while in a modified form they enter into the composition of several of the special sense organs. They exhibit considerable variety in shape and size, and in these respects are to some degree characteristic of different parts in which they occur. They are spheroidal, ovoidal, pyriform, fusiform, pyramidal, and irregularly multangular, and are provided with one, two, or more tapering processes or appendages, which are simple or branched. In the cerebral convolutions they are pyramidal and of moderate and variable sizes at different depths; in the cerebellar folds there is a deep stratum



of large ovoid cells with conspicuous branching processes. In the anterior cornua of the spinal cord they are large, multangular, and provided with many radiating processes, and in the posterior cornua there are similar but smaller and narrower cells. In the spinal ganglia they are spheroidal or pyriform, with one or two processes directed from the same or opposite poles; in the sympathetic ganglia they are smaller, irregularly angular, and with more processes. In the course of nerves they are fusiform and prolonged into the nerve-fibres. In some parts of the brain, as in the gray matter of the cerebellar folds beneath the stratum of large nerve-cells, there are numerous small spheroidal and angular cells about the size of colorless blood-corpuscles or much less. They appear to be miniature forms of the larger cells, which they resemble in composition, and their processes generally seem to join one another and the finer ones of the contiguous larger nerve-cells.

In the ganglia of the cerebro-spinal nerves, except the four smaller ones of the trigeminal nerve, the nerve-cells are prolonged into one or two processes and are thus distinguished as **unipolar** and **bipolar cells**. In the latter the processes may proceed from the same or opposite poles, and in both kinds of cells the processes become continuous as the axis-fibre of nerve-fibres. After a short distance the processes become invested with a medullary sheath and thus become medullated nerve-fibres.

In some unipolar cells it has been observed that after the fibre acquires a medullary sheath it becomes several times coiled around the cell and then forks, the two branches proceeding in opposite directions, as in those of bipolar cells.

In the ganglia of the sympathetic and the small ones of the tri-facial nerves, many nerve-cells possess a greater number of processes, three or more, and are hence called **multipolar cells**. Most of the processes continue as non-medullated fibres, though usually one or two, shortly after their origin, become invested with a medullary sheath and then proceed as medullated nerve-fibres. In the bipolar cells of the sympathetic nerves one process may continue as a non-medullated fibre, while the other becomes a medullated fibre. Some nerve-cells, apparently devoid of processes and hence called **apolar**, have been regarded as partially-developed forms.

The nerve-cells of the cerebro-spinal axis are multipolar and generally characterized by many tapering, radiating, and mostly branching processes. In the large nerve-cells of the anterior cornua of the spinal cord, from among the processes commonly a single one is prolonged in a cylindrical filament, which soon becomes furnished with a medullary sheath and thus constitutes the beginning of a medullated nerve-fibre. All the other processes taper and branch into the finest filaments, which are diffused in the surrounding neuroglia. The nerve-cells generally of the cerebro-spinal axis are considered to have a



similar arrangement and relation with medullated nerve-fibres as that described, except in the case of the numerous small cells.

The processes of all nerve-cells are fibrillar, and the fibrils are minutely granular, or they are identical in structure with the axis-fibre of nerve-fibres, with which commonly one or more become directly continuous. The body of the nerve-cell consists of a granular fibrillated protoplasm, containing a comparatively clear, distinct, and highly-refracting nucleus.

The cells exhibit a faintly yellowish or brownish tint, due to diffused colored pigment, which is often accumulated in a mass among the contents.

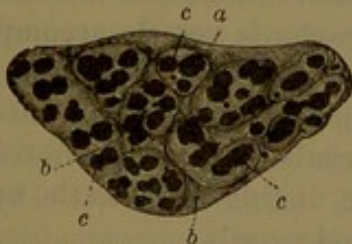
In the cerebro-spinal axis the nerve-cells, like the nerve-fibres, have no membranous sheath. In prepared sections they are observed to occupy clearer areas than the surrounding matrix, which areas are regarded as lymphatic spaces. In the ganglia the nerve-cells are enclosed in a membranous sheath which is continuous with that of the connecting nerve-fibres.

#### THE NERVES.

The **nerves** are cords which connect the nerve-centres with all other parts of the body, to and from which they convey impressions.

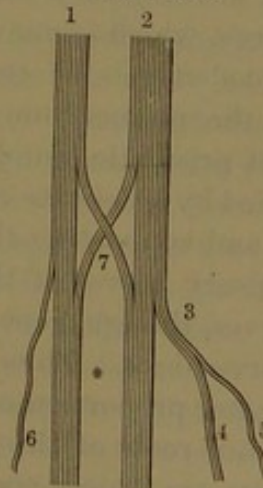
The cerebro-spinal nerves, conspicuous for their comparatively large size and white color, appear mostly as straight cylindrical or flattened cylindrical cords, usually pursuing the general course of the blood-vessels, but running more directly to their destination. They possess considerable strength, moderate elasticity and tenacity, which qualities

FIG. 355.



TRANSVERSE SECTION OF THE SMALL SCIATIC NERVE OF A CALF, magnified fifteen diameters. *a*, common sheath, or epineurium; *b*, perineurium; *c*, funicles, or bundles of nerve-fibres.

FIG. 356.



MODE OF ANASTOMOSIS AND BRANCHING OF NERVES. 1, 2, two fasciculi of nerve-fibres; 3, a branch of three fibres; 4, a branch of two fibres; 5, 6, branches of single fibres; 7, anastomosis between two nerves.

are mainly due to their abundant connective-tissue envelopes. Their essential structural element consists chiefly of medullated nerve-fibres, which pursue an uninterrupted course from their origin to their termination, where they alone divide. Their connection with the cerebro-spinal axis is regarded as their origin, and their commencement at the surface or in the interior of the centre is distinguished as the **root** of the nerve.



In their distribution the nerves divide and subdivide mostly at very acute angles, and the branching consists in the separation of bundles of the nerve-fibres, the branches being proportioned in size to the number of the fibres which form them. Often in their course branches of contiguous nerves unite and again divide, forming an intertexture or plexus, even with the largest nerves, as exemplified by the brachial plexus. In all such cases the branching and anastomosis of nerves are essentially a division and interchange of bundles of nerve-fibres, not a division and anastomosis of the fibres individually.

The smaller nerves, except such as consist of a single nerve-fibre, are cylindrical bundles of fibres, or **funicles**, enclosed in a membranous sheath, the **perineurium**,<sup>1</sup> and larger nerves consist of several prismatic funicles collected in a cylindrical cord and enclosed by a common perineurium. A number of such cords united by and enclosed in a common connective-tissue sheath, or **epineurium**,<sup>2</sup> form the largest nerves.

The funicles of the same nerve may frequently divide and anastomose, but in all cases it is the interchange of larger or smaller bundles of fibres.

The **perineurium** in the smallest nerves consists of a single membranous lamina,<sup>3</sup> composed mainly of transverse fibres of connective tissue with elastic tissue, invested on both surfaces with a delicate endothelium.

In the larger nerves the perineurium consists of several concentric laminae, attached by fibres of connective tissue, having the opposed surfaces invested with an endothelium, the cell-plates of which become evident by silver-nitrate staining. The intervals of the laminae are lymph-spaces, which communicate with lymphatic vessels accompanying the blood-vessels of the nerves. Partitions from the innermost lamina of the perineurium divide the funicle of nerve-fibres into different-sized prismatic bundles. The intervals of the nerve-fibres are also occupied by a delicate connective tissue, distinguished as the **endoneurium** and supporting the capillary blood-vessels.

The sensory nerves of the cerebro-spinal system are larger than its motor nerves, though generally they possess a greater proportion of smaller nerve-fibres. Thus the larger sensory roots of the spinal nerves have a greater proportion of small nerve-fibres than the corresponding smaller motor roots of the same nerves. The nerves also to the voluntary muscles are mainly composed of comparatively large nerve-fibres, while those to the skin contain many more small ones.

The nerves of the sympathetic system are generally very much smaller and shorter than those of the cerebro-spinal system, are mostly gray or dull reddish, comparatively inconspicuous, and more closely

<sup>1</sup> Neurilemma.

<sup>2</sup> Common or cellular sheath; vagina cellulosa.

<sup>3</sup> Sheath of Henle.



attached to contiguous parts, from which they are often obscurely defined. They usually proceed to the nearest blood-vessels, by frequent division and anastomosis form intricate plexuses around them, and accompany them in their distribution. They are chiefly composed of non-medullated fibres, while those which appear whiter than usual contain a greater proportion of medullated fibres.

Few nerves of either system are composed exclusively of one kind of fibres. Those which go to the skin contain a larger proportion of non-medullated fibres than those which go to the voluntary muscles. The vagus nerve among those of the cerebro-spinal system contains a more than usual proportion of non-medullated nerve-fibres.

The connection of the cerebro-spinal nerves with the brain and spinal cord is commonly regarded as their origin or commencement, and their communication with peripheral organs as their termination.

The parts by which nerves commence in the cerebro-spinal axis are called their roots, and most nerves, as all those of the spinal cord and the trifacial nerve of the brain, commence by two roots differing in quality or function, while others arise in a single root. The position at which the nerve-roots start from the surface of the brain and spinal cord is distinguished as their **superficial** or **apparent origin**. The source from which they spring in the interior is their **deep** or **true origin**. This consists of gray matter with embedded nerve-cells, sometimes in more or less distinct accumulations, called the **nuclei** of origin of the nerve-roots. Many of the individual fibres of the roots are traceable to their connection with nerve-cells of the nuclei, whence it is inferred that all nerves have the same mode of origin.

In a general way the term "root" is also applied to the constituent fibres, or bundles of fibres, more or less distinct or collected in larger bundles, composing the special nerve-roots. Thus each root of the spinal nerves comes from the cord in a longitudinal series of smaller, isolated roots or rootlets. The accessory nerve starts from both the cord and oblongata by a similar series of widely-separated rootlets. The trifacial nerve, as it springs from the brain, has its large root composed of a bundle of numerous loosely-attached rootlets, while the small root corresponds with but one or two of the latter.

On reaching the peripheral organs and tissues in which the cerebro-spinal nerves terminate, after repeated branching, which consists in the separation of smaller and smaller bundles of nerve-fibres, these then continue singly. Now for the first time branching, they then lose their medullary sheath, when the axis-fibre alone proceeds, and still branching finally ends among the structural elements of the organs and tissues in various ways according to their character. Thus in some of the epithelial tissues, as the epidermis and conjunctiva, they are resolved into their ultimate nerve-fibrils, which are distributed in the cell-structure. Other modes of termination of the nerves are



described with the different structures of the body, while many remain obscure or undetermined.

The non-medullated nerve-fibres of the sympathetic system have a similar origin in the ganglia and a similar mode of termination in peripheral organs like that which has been more definitely recognized in the cerebro-spinal nerves.

The arteries of nerves are derived from the neighboring trunks in their course. Entering the common connective-tissue sheath or epineurium and running parallel with the bundles of nerve-fibres, the branches enter the perineurium of these and end in fine capillaries, which have an arrangement related to the nerve-fibres like that observed in the muscles. The lymphatics commence in clefts of the connective tissue in the intervals of the nerve-fibres communicating with the perineurial interspaces, which open into lymphatic vessels accompanying the blood-vessels.

#### THE GANGLIA.

While the cerebro-spinal axis may be regarded as an aggregate of many nerve-centres more or less fused together, the ganglia are small isolated centres situated in the course of the nerves. They generally appear on the nerves as knots or swellings of varied size and shape, of a reddish-gray color. The larger and more conspicuous are found on the sensory roots of the spinal nerves and that of the trifacial nerve. In the sympathetic system they form a connected series or chain, the gangliated cord on each side of the spine, and they also occur especially in the solar plexus. Numerous microscopic ones likewise occur in the terminal plexuses of the sympathetic and vagus nerves.

When a ganglion is situated in the course of a nerve it is commonly connected by its opposite poles, which may be its only connection, as in the ganglia on the roots of the spinal nerves, but in other cases they may have additional connections and also give off branches of distribution, as in the sympathetic ganglia.

The ganglia are generally provided with a thin but strong and closely-adherent capsule or sheath, which is continuous with the epineurium of its connecting nerves. They are composed of masses of nerve-cells embedded in a fibro-connective-tissue matrix, traversed by bundles of nerve-fibres which are continuous with those of the nerves joining the ganglia. The bundles of nerve-fibres within the ganglion separate and run among the nerve-cells, most of them becoming connected with the latter, a few only continuing without interruption through the ganglion. In the ganglia of the spinal nerves the nerve-cells generally are bipolar and connected with a pair of nerve-fibres running in opposite directions in the nerve on which the ganglion is situated. In the sympathetic ganglia the nerve-cells, unipolar, bipolar, and multipolar, join nerve-fibres of the nerve-trunks and branches of the ganglia.



The nerve-fibres connected with the nerve-cells of the sympathetic ganglia for the most part continue as non-medullated fibres, but among them one or several may assume the condition of medullated fibres.

Each ganglionic nerve-cell is enclosed in a delicate, structureless membranous sheath, with scattered nuclei, and continuous with the

FIG. 357.

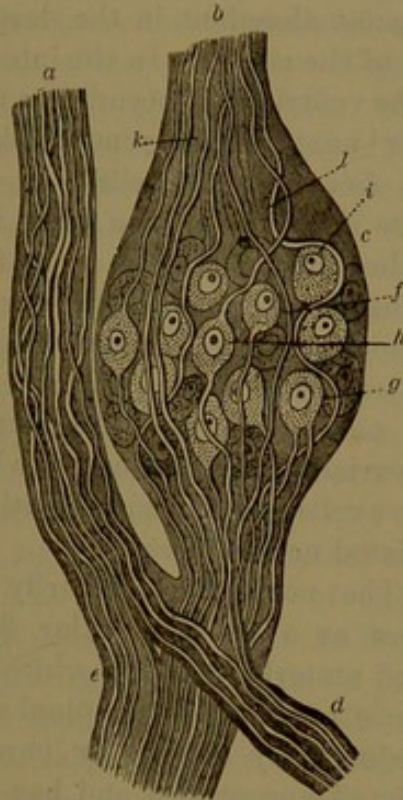


DIAGRAM OF A SPINAL GANGLION AND ITS CONNECTIONS. *a*, anterior, motor root of a spinal nerve; *b*, posterior, sensory root; *c*, ganglion; *d*, posterior division of the trunk of the nerve; *e*, anterior division; *f*, unipolar ganglion or nerve-cell; *g*, bipolar cell with both nerve-fibres directed outward; *h*, bipolar cell with nerve-fibres proceeding in opposite directions; *i*, apolar nerve-cell; *j, k, l*, nerve-fibres passing through the ganglion without connection with the nerve-cells. Highly magnified.

FIG. 358.

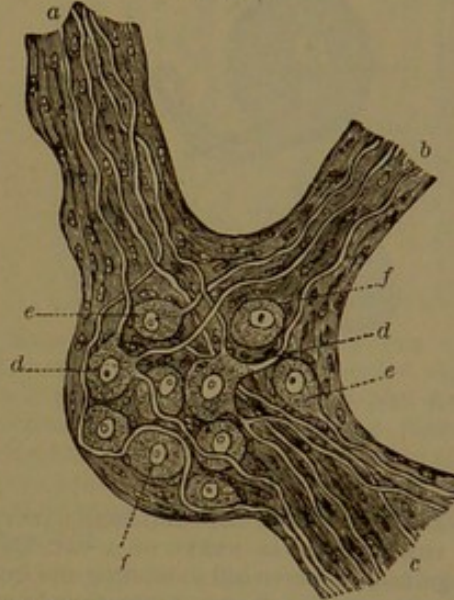


DIAGRAM OF A GANGLION OF THE SYMPATHETIC NERVE. The narrow white are medullated nerve-fibres; the dark shaded with nuclei, non-medullated fibres. *a, b, c*, nerve-trunks; *d*, multipolar nerve-cells; *e*, unipolar cells; *f*, apolar cells. Highly magnified.

neurilemma or membranous sheath of the nerve-fibre connected with the cell. After death the nerve-cell shrinks from its sheath, leaving a considerable clear space, filled with liquid and corresponding with a lymph-space.

**Supporting material of the special nerve-elements of the**

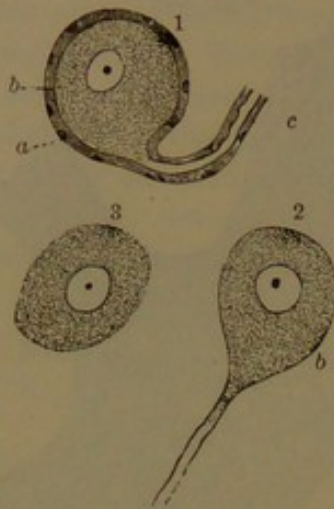
**cerebro-spinal axis.** The special nerve-elements of the brain and spinal cord, the nerve-cells and nerve-fibres, together with their nutrient vessels, are supported by a soft matrix or cementing substance named **neuroglia**.<sup>1</sup> This is commonly regarded as a kind of connective tissue, and in some positions appears gradually to merge into the more ordinary fibrous form. In the spinal cord it occurs in a considerable but variably thick layer next the investing pia, where it is comparatively free from the characteristic nerve-elements. In thinner strata it extends along the septal processes of the pia and

<sup>1</sup> Reticulum of Kölliker.



thence among the nerve-fibres of the white matter. From the latter it continues into the gray matter, where it forms the matrix of the embedded nerve-cells and associated nerve-fibres. In the brain it forms a large proportion of the cortical gray substance of the cere-

FIG. 359.



NERVE-CELLS FROM THE SEMILUNAR GANGLION OF THE TRIGEMINAL NERVE OF A CAT, highly magnified. 1, nerve-cell exhibiting the origin of a nerve-fibre: *a*, sheath of the cell and nerve-fibre with nuclei; *b*, the nerve-cell within; *c*, the nerve-fibre within its sheath; 2, cell with the origin of a nerve-fibre deprived of its sheath; 3, nerve-cell without sheath or nerve-fibre.

acid, it exhibits a finely-reticular fibrillated appearance and has mingled with it as an integral element minute flattened cells which resemble ordinary connective-tissue corpuscles. In the gray substance it generally appears more densely fibrillar, in a great measure due to the intermingled fibrils from the branching processes of the nerve-cells.

In the ganglia and nerves the neuroglia of the cerebro-spinal axis is represented by delicate fibro-connective tissue connecting the nerve-fibres and the nerve-cells.

The nutrient blood-vessels of the nervous system in their relation with the special nerve-elements traverse the neuroglia and are confined to it.

**The white matter of the cerebro-spinal axis.** This is of comparatively simple constitution, on the natural surfaces has more or less a striated appearance, and on the freshly-cut surface, to the naked eye, appears homogeneous. It is mainly composed of medullated nerve-fibres devoid of a membranous sheath, embedded in neuroglia traversed by the nutrient vessels. Examined under ordinary circumstances with

brum and cerebellum, superficially next the pia comparatively free of the special nerve-elements, which are most abundant in the deepest part of the cortex. In the interior of the ventricles it occurs as a thin layer<sup>1</sup> next the lining endothelium, also free of nerve-cells. In the white substance of the brain it is of the same character as in that of the spinal cord. In the various accumulations or nuclei of gray matter in the interior of the brain the neuroglia forms the matrix, in variable proportions, in which nerve-cells are embedded with associated nerve-fibres.


The neuroglia ordinarily appears as a finely-granular fibrillated material. In the white substance of the cerebro-spinal axis, hardened by alcohol or chromic

<sup>1</sup> Ependyma, Quain's Anatomy. Henle applies the name to the lining endothelium of the ventricles.



the microscope, the nerve-fibres appear as beaded filaments, with double outlines and of various sizes. They are soft and with little manipulation assume a multitude of irregular forms, as represented in the adjoining figure. Careful investigation proves them to have the same form and constitution as the more tenacious medullated nerve-fibres of the nerves, but to possess no membranous sheath, whence their comparative softness. They run in different but definite directions in different portions of the spinal cord and brain, often in flattened bundles. From the white they enter the gray matter and become connected with the nerve-cells of the latter, and on the other hand also become continuous with the roots of the nerves originating in the cerebro-spinal axis.

FIG. 360.



MEDULLATED NERVE-FIBRES OF THE WHITE MATTER OF THE CEREBRUM. 1, beaded appearance presented by the fibres, which are of various sizes; 2, various irregular forms assumed by the fibres as they ordinarily appear when examined mingled with a little water; 3, ideal representation of the unchanged fibres. Magnified.

The **gray matter of the cerebro-spinal axis**. Of more complex constitution than the former, this consists of an abundant matrix of neuroglia, with variable proportions of embedded nerve-cells large and small, other small cells of uncertain character, nerve-fibres both medullated and non-medullated, and nutrient vessels. It is commonly of a rust color and is variably translucent and pulpy. Varieties of the gray matter are distinguished as the **spongiosa**<sup>1</sup> and **gelatinosa**,<sup>2</sup> accordingly as they appear spongy or gelatinous, due to differences in the proportions and arrangement of the mingled nerve-elements. The matter appears to be more spongy with an increase of the nerve-fibres and more gelatinous with their decrease. As the nerve-cells vary in their depth of color in different positions they accordingly affect the color of the gray matter of which they form part.

#### THE CEREBRO-SPINAL AXIS.

The **cerebro-spinal axis** consists of the brain and spinal cord. In describing these it is usual to commence with an account of the latter, as taking precedence of the former in development.

#### THE SPINAL CORD.

The **spinal cord**, or **spinal marrow**,<sup>3</sup> together with its membranous envelopes, is contained within the vertebral canal. It is con-

<sup>1</sup> Substantia spongiosa.

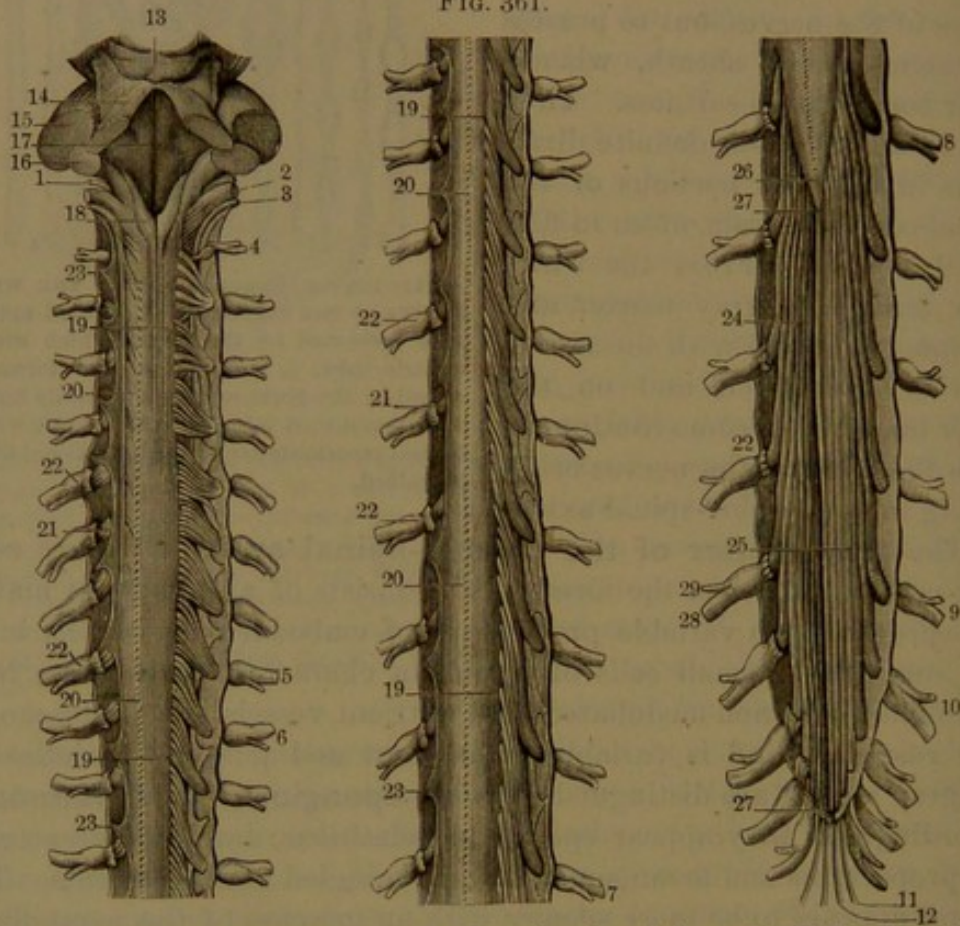
<sup>2</sup> S. gelatinosa.

<sup>3</sup> Chorda spinalis or dorsalis; medulla spinalis; funiculus spinalis.



tinuous with the oblongata of the brain on a level with the articulation of the skull and vertebral column, and extends to the lower part of the first lumbar vertebra. Stripped of its membranes, it appears as a cylindrical, milk-white cord, about eighteen inches long, tapering at the lower extremity to a conical point. It is slightly compressed fore and aft, and is most nearly circular in transverse section in the thoracic region. It is not of uniform diameter, but is swollen towards

FIG. 361.



THE SPINAL CORD WITH THE OBLONGATA. Posterior view of the cord with the dural sheath laid open; in three sections. 1, glosso-pharyngeal nerve; 2, vagus nerve; 3, accessory nerve; 4 to 5, the eight cervical nerves; 6 to 7, twelve thoracic nerves; 8 to 9, five lumbar nerves; 10 to 11, five sacral nerves; 12, coccygeal nerve; 13, quadrigeminal body; 14, superior peduncle of the cerebellum; 15, middle peduncle of the cerebellum; 16, inferior peduncle of the cerebellum; 17, floor of the fourth ventricle; 18, posterior pyramid; 19, posterior roots of the spinal nerves of the right side; 20, line of attachment of the roots of the spinal nerves on the left side; 21, anterior roots of the spinal nerves; 22, ganglion of the posterior root; 23, denticulate ligament; 24, anterior roots of the cauda equina; 25, posterior roots of the cauda equina; 26, conical end of the cord; 27, terminal filum; 28, anterior division of a spinal nerve; 29, posterior division.

the extremities, where it forms the cervical and lumbar enlargements, of which the former is both the longer and larger.

The cord is of soft consistence, and ordinarily weighs from an ounce and a half to an ounce and three-quarters.

The **cervical enlargement**<sup>1</sup> is widest opposite the fifth cervical vertebra, where it is a little over half an inch from side to side, slightly

<sup>1</sup> Intumescencia cervicalis.



narrowing above and also below to about the second thoracic vertebra. The **lumbar enlargement**<sup>1</sup> begins at the tenth thoracic vertebra, is largest opposite the twelfth, and then tapers away in a cone<sup>2</sup> to the end of the cord. It is less compressed than the cervical enlargement and is about half an inch or slightly less transversely.

The intermediate thoracic portion of the cord, more uniformly cylindrical, is about five lines from side to side and slightly less fore and aft.

In front and behind, the cord is divided by fissures which nearly reach its centre.

The **anterior median fissure**,<sup>3</sup> the wider but shallower, in the greater part of its extent penetrates about a third of the thickness of the cord and receives a fold of the investing pia. The **posterior median fissure**,<sup>4</sup> a narrow slit, penetrates about half the thickness of the cord and receives a thin partition of the pia.

Connected with the cord on each side in front and behind are the numerous rootlets of the spinal nerves arranged in a close longitudinal series and extending the entire length of the cord. The line of the posterior series of rootlets is marked by a slight furrow, which is distinguished as the **posterior lateral fissure**<sup>5</sup> of the cord. The line of the anterior series, though not indicated by a furrow nor so exactly straight in its course, is conveniently called the **anterior lateral fissure**. These so-called fissures, though not actually such, indicate the lines of emergence of the roots of the nerves from the substance of the cord and serve to divide the exterior white portion of the latter into the **anterior**,<sup>6</sup> **lateral**,<sup>7</sup> and **posterior**<sup>8</sup> columns.

The posterior column in the cervical enlargement is further divided by a fissure<sup>9</sup> into two portions, distinguished as the **posterior median** and **posterior lateral columns**, of which the former, in the thoracic region, gradually diminishes, while the fissure separating it from the other column inclines inwardly and ends in the posterior median fissure. At the bottom of the anterior median fissure the anterior columns are conjoined by a thin layer of white matter, the **anterior or white commissure**.<sup>10</sup>

The cord is solid, except that it is traversed by a fine central canal and is composed of white matter enclosing gray matter in the interior. The gray matter is in greater quantity within the cervical and lumbar enlargements, especially in the latter, in which the white

<sup>1</sup> Intumescencia lumbaris.

<sup>2</sup> Conus terminalis or medullaris.

<sup>3</sup> Ant. longitudinal fissure; fissura longitudinalis ant.

<sup>4</sup> Post. long. fis.; fis. long. post.

<sup>5</sup> Sulcus lateralis posticus; posterior lateral groove.

<sup>6</sup> Funiculus anterior.

<sup>7</sup> F. lateralis; fasciculus cerebialis.

<sup>8</sup> F. posterior; fasciculus cerebelli.

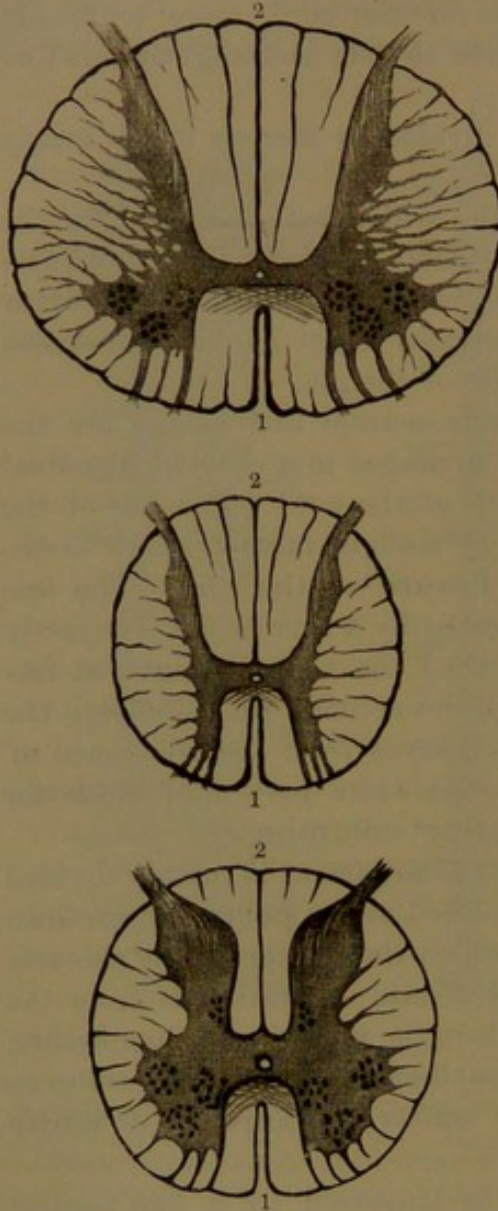
<sup>9</sup> Sulcus intermedius posticus; s. lateralis postremus.

<sup>10</sup> Commissura ant. or alba.



matter is proportionately smaller than elsewhere in the cord. In horizontal sections of the cord it appears of an irregular H-like form surrounded by the white matter, and more or less modified from that form

FIG. 362.



TRANSVERSE SECTIONS OF THE SPINAL CORD; in succession opposite the cervical enlargement, the thoracic portion, and the lumbar enlargement. 1, anterior median fissure; 2, posterior median fissure. Magnified about two and a half diameters. For details, see Fig. 363.

The **anterior cornu**,<sup>3</sup> or **gray column**, is in general shorter but larger and thicker than the posterior cornu, and is variably more or less angular or rounded in different positions. It is largest in the

it extends the entire length of the cord. It consists of a pair of bands, one on each side, bent outwardly and united by a narrower and thinner straight band. The latter reaches the bottom of the posterior median fissure, is named the **posterior or gray commissure**,<sup>1</sup> and is in contact in front with the anterior or white commissure. In its axis is the **central canal**<sup>2</sup> of the cord, continuous above through the oblongata with the fourth ventricle of the brain and at the lower end opening into the posterior median fissure.

Through the greater part of the length of the cord the gray commissure joins the lateral gray bands about their anterior third, but near the lower end it joins them about the middle. The lateral gray bands in horizontal section appear curved, club-shaped, or irregularly crescentic, whence they are commonly called the **crescents**. They extend fore and aft more than half the thickness of the cord, have their concave border directed outward and their more convex borders towards each other. The **cornua** or **horns** of the crescents, called from their relative position anterior and posterior, are extended through the cord in continuous bands forming so many gray columns.

<sup>1</sup> Commissura post., grisea, or cinerea; nucleus cinereus; centrum cinereum.

<sup>2</sup> Canalis centralis.

<sup>3</sup> Crus anterior.

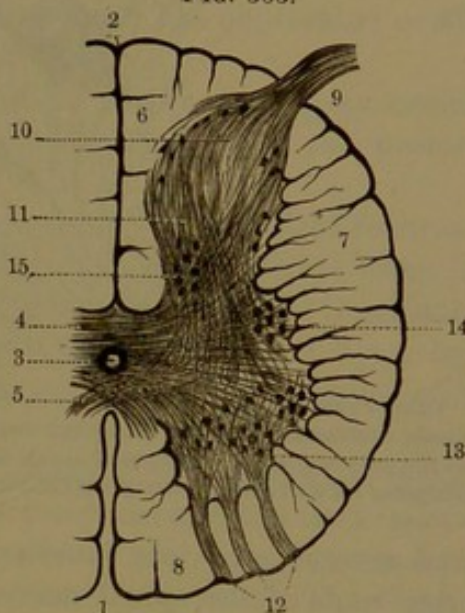


cervical and lumbar enlargements and smallest in the intervening thoracic region. The **posterior cornu**,<sup>1</sup> or **gray column**, in general is longer and narrow compared with the former and becomes considerably thicker in the lumbar enlargement. From its conjunction with the anterior cornu and gray commissure, passing backward it slightly narrows as the neck,<sup>2</sup> then slightly enlarges as the head,<sup>3</sup> and finally tapers to a point, whence bundles of nerve-fibres pass to the posterior lateral fissure and emerge from the cord as the posterior roots of the spinal nerves.

In the upper part of the thoracic region, at the union of the cornua with their commissure, outwardly there is an angular projection of the gray matter, named the **middle cornu**, which continued in the length of the cord is the **inter-medio-lateral tract**. It merges above in the gradually-expanding anterior cornu of the cervical enlargement and gradually diminishes and ceases below. In the recess behind it, thin offsets of gray matter extend into the contiguous white matter and intersect one another, giving to horizontal sections of the cord in this position a reticular appearance.<sup>4</sup> Similar offsets extend from the principal body of gray matter elsewhere, especially from the anterior cornua.

The gray matter of the spinal cord consists of variable proportions of neuroglia matrix with embedded nerve-cells and traversed by nerve-fibres and blood-vessels. For the most part it is pervaded by nerve-fibres, chiefly medullated and in bundles, running in different directions and producing an appearance in the gray matter distinguished as the **spongiosa**.<sup>5</sup> The posterior cornua are capped with neuroglia with comparatively few nerve-fibres, distinguished as the **gelatinosa**.<sup>6</sup> The nerve-cells generally are collected in more or less circumscribed posi-

FIG. 363.



TRANSVERSE SECTION OF THE LUMBAR ENLARGEMENT OF THE SPINAL CORD. 1, anterior median fissure; 2, posterior median fissure; 3, central canal; 4, posterior commissure; 5, anterior commissure; 6, posterior column; 7, lateral column; 8, anterior column; 9, posterior root of a spinal nerve; 10, head of the posterior cornu; 11, neck of the posterior cornu; 12, anterior roots of a spinal nerve; 13, anterior cornu with groups of nerve-cells of the anterior ganglionic tract; 14, nerve-cells of the middle ganglionic tract; 15, nerve-cells of the posterior ganglionic tract. The fine lines indicate the course of the nerve-fibres.

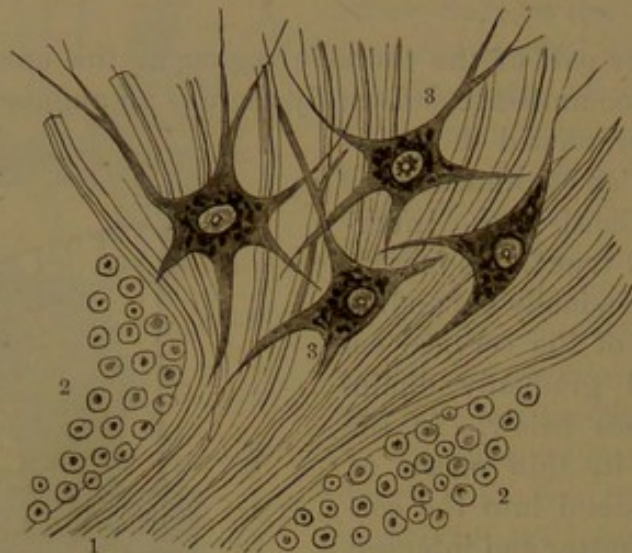
<sup>1</sup> Crus posticus.<sup>4</sup> Processus reticularis.<sup>6</sup> Substantia gelatinosa.<sup>2</sup> Cervix.<sup>5</sup> Substantia spongiosa.<sup>3</sup> Caput.



tions; in horizontal sections of the cord appearing in groups and corresponding with columnar tracts in the length of the cord.

The **anterior ganglionic tract**<sup>1</sup> occupies the anterior cornua and extends the entire length of the cord. It consists of large nerve-cells lying among numerous medullated nerve-fibres, of which many are connected with the nerve-cells by their axis-fibre and on the other

FIG. 364.



TRANSVERSE SECTION OF A PORTION OF THE SPINAL CORD AT THE ENTRANCE OF THE ANTERIOR ROOT OF A NERVE. 1, bundle of medullated fibres of the nerve-root passing through the white into the gray matter; 2, sections of longitudinal medullated fibres of the white matter; 3, large multipolar cells in the anterior ganglionic tract. Highly magnified.

hand are collected into bundles, which pass from the cord as the anterior roots of the spinal nerves. In some positions the cells of this tract are separated into several smaller tracts or groups: thus one is situated nearer the lateral column of the cord, a second nearer the anterior column, and a third more deeply seated in the lumbar enlargement. Some of the nerve-cells nearest the anterior commissure are connected with its nerve-fibres passing to the opposite side, where they appear to be continuous with those of the anterior roots of the spinal nerves.

The **posterior ganglionic tract**<sup>2</sup> of nerve-cells occupies the inner portion of the posterior cornua near the gray commissure. It is largest in the lower part of the thoracic region, in which position the anterior ganglionic tract is smallest. Its cells are of moderate size, and are connected with medullated nerve-fibres, which mostly proceed to the lateral columns of the cord.

The **middle ganglionic tract**<sup>3</sup> occupies the middle lateral gray cornu of the thoracic region of the cord, and at its upper part merges

<sup>1</sup> Motor ganglionic column; anterior vesicular column.

<sup>2</sup> Column of Clarke; posterior vesicular column.

<sup>3</sup> Column of the intermedio-lateral tract.



into the anterior ganglionic tract, than which it consists of smaller nerve-cells. In the upper part of the cervical region a distinct tract of nerve-cells, in a similar position, is traversed by the nerve-fibres of origin of the accessory nerve.

Besides the above tracts of nerve-cells other nerve-cells of smaller size and mostly spindle-shaped are scattered in the posterior cornua, extending into the gelatinosa.

The gray commissure consists mainly of a matrix of neuroglia traversed by nerve-fibres, mostly medullated, crossing transversely and somewhat obliquely between the gray columns of the two sides of the cord. The central canal, situated in the gray commissure, is enclosed by a layer<sup>1</sup> of the gelatinosa, or neuroglia comparatively free from nerve-fibres. In infancy the canal is clothed with a ciliated columnar epithelium, but after adult age becomes more or less obliterated or filled with small polyhedral cells.

Near the point of the terminal cone of the cord the gray commissure ceases and the central canal communicates with the posterior median fissure by a cleft.

From the partitions of the pia, occupying the principal fissures of the cord, offsets extend into the white columns and divide them into smaller portions. The white matter is chiefly composed of longitudinal bundles of medullated nerve-fibres, the whole enveloped by a layer of neuroglia, which also extends between and fills the intervals of the fibres. These are of variable size, and in many positions the larger and smaller are intermingled, but in others there is a greater proportion of one or the other. The largest fibres occupy the back part of the lateral columns; the smallest, that part of the same columns which lies in the recess of the anterior and posterior cornua. The fibres of the posterior median column are also among the smallest.

The anterior or white commissure connects the anterior columns of the cord at the bottom of the anterior median fissure in front of the gray commissure, than which it is thicker in the cervical and lumbar enlargements but considerably thinner elsewhere. It is composed of medullated fibres, which obliquely cross one another from side to side and partly become continuous with the longitudinal fibres of the anterior columns and partly pass into the anterior gray columns, where some of them join the anterior roots of the spinal nerves.

The nerve-fibres of the roots of the spinal nerves pass through or between the white columns of the cord nearly at right angles to the fibres of the latter. They proceed outwardly in the trend of the cornua with a slight downward inclination. Those of the anterior roots mainly spring from the fore part of the anterior cornua and thence proceed in several bundles on the same horizontal plane through the antero-lateral column to their point of emergence from the cord.

---

<sup>1</sup> Substantia gelatinosa centralis.



Those of the posterior roots are derived partly from the posterior cornua and partly from the posterior white columns and thence proceed in a single, stouter bundle on the same horizontal plane between the posterior and lateral white columns.

Many laborious investigations have been made to determine the course and connections of the nerve-fibres in the brain and spinal cord.

Though much has been ascertained through dissection and the use of the microscope, much yet remains to be discovered. Experiment and observation in development and disease have aided in tracing the course and connections of different bundles or tracts of nerve-fibres.

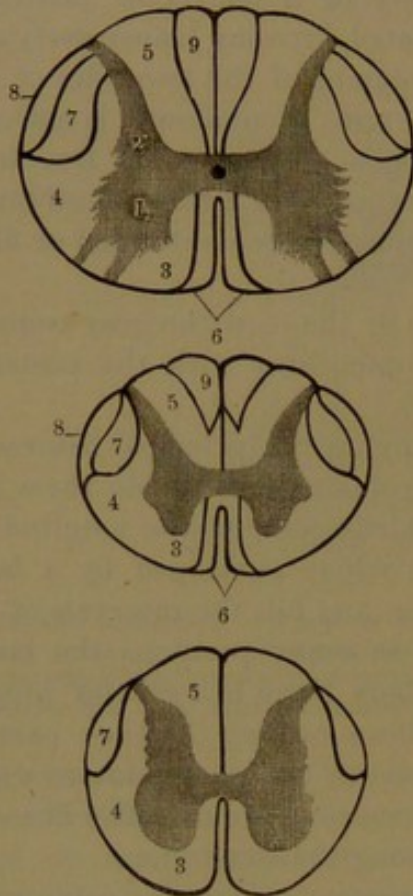
A division of the lateral column of the cord is named from its position and course the **lateral or crossed pyramidal tract**.<sup>1</sup> Largest above, it gradually narrows downward. In the cervical enlargement it is enclosed in the back part of the column, below comes more into contact with the posterior cornu and near the lower end of the cord reaches the outer surface. Its upper extremity enters the oblongata and splits into several bundles, which obliquely cross and intersect those of the opposite side, and thus form the decussation of the pyramids.

A smaller division of the lateral column situated at its outer side is the **cerebellar tract**.<sup>2</sup> Its upper extremity enters the oblongata behind the olive and contributes to form the restiform body, while below it tapers and ceases near

the middle of the lumbar enlargement. The portion of the lateral column in the recess of the gray matter is the **mixed lateral tract**, and the remainder the **anterior radicular tract**, which in the oblongata ascends behind the olive in the outer portion of the reticular formation.

A narrow division of the anterior column of the cord, the **anterior**

FIG. 365.



DIAGRAMS OF SECTIONS OF THE SPINAL CORD, exhibiting the relative position of the tracts in the white matter, in succession in the cervical enlargement, the thoracic portion, and the lumbar enlargement. 1, anterior cornu; 2, posterior cornu; 3, principal tract of the anterior column; 4, mixed lateral and anterior radicular tracts; 5, cuneate tract of the posterior column; 6, anterior or direct pyramidal tract; 7, lateral or crossed pyramidal tract; 8, cerebellar tract; 9, posterior median column.

<sup>1</sup> Fasciculus of Türek.

<sup>2</sup> Direct cerebellar tract; direct lateral tract.



or **direct pyramidal tract**,<sup>1</sup> occupies the side of the anterior median fissure descending to about the middle of the thoracic portion of the cord. Its upper part enters the pyramid of the oblongata on the same side and then ascends in company with the lateral pyramidal tract. The remainder of the column, for the most part as its **principal tract**,<sup>2</sup> enters the oblongata and ascends behind the pyramid in the inner portion of the reticular formation. This tract is proportioned in size with the anterior cornu and corresponding roots of the spinal nerves. By part of its fibres it is connected with the anterior cornu of the same side and by others through the anterior commissure with that of the opposite side.

The **posterior median column**<sup>3</sup> of the cord is continuous above with the gracile funicle of the oblongata. Its upper part extends to the gray commissure, but recedes below and ceases about the middle of the thoracic region.

The **posterior lateral column**<sup>4</sup> of the cord below occupies all the space between the posterior cornu and posterior median fissure, but above has the former column interposed between it and the latter. It increases as it ascends, and is thickest in the lumbar and cervical enlargements. It appears to be mainly in continuation with the posterior spinal nerve-roots, which ascend in it some distance before entering the posterior cornu. Its upper extremity is continuous with the cuneate funicles of the oblongata.

#### ORIGIN OF THE SPINAL NERVES.

Thirty-one pairs of nerves are connected with the spinal cord, in which they are ordinarily said to have their origin. Each nerve arises by two **roots** from the side of the cord, one in front and the other behind. Each root consists of a longitudinal series of filaments or **rootlets**, which spring from the cord in such near succession as to form a continued and close series extending the whole length of the cord. The **anterior roots** spring from a linear area along the side of the cord in front, while the **posterior roots** emerge from the postero-lateral fissure.

In transverse sections of the cord, the anterior roots of the nerves are observed to pass through the white substance and enter the gray cornu in several bundles of fibres, which have an upward inclination, as indicated by the oblique cut they present in exact horizontal sections of the cord. On reaching the gray matter the fibres diverge, some proceeding towards the anterior commissure, others to the posterior commissure, and others outward to the anterior part of the lateral column of the cord. Of those directed inward some are con-

<sup>1</sup> Uncrossed portion of the pyramidal tract.

<sup>2</sup> Fundamental fasciculus; tract of Flechsig.

<sup>3</sup> Tract of Goll.

<sup>4</sup> Cuneate fasciculus; column of Burdach.



ned with the inner group of nerve-cells of the anterior cornu and others appear to go through the anterior commissure to the other side of the cord, probably to be connected with the corresponding cells of the anterior cornu. The middle fibres are partly connected with the lateral group of cells of the anterior cornu and partly run to the posterior cornu, without joining those cells. The fibres directed outward are partly connected with the lateral group of cells and partly enter and turn upward in the lateral white column.

The posterior roots of the nerves as they enter the cord separate into two bundles, which, as in those of the anterior roots, are directed obliquely upward. The outer and smaller bundle enters the posterior cornu, partly curving round and partly passing through the gelatinosa. In this the fibres become longitudinal, turning both upward and downward, while others pass horizontally and more deeply into the gray matter. The inner and principal bundle enters the posterior white column, in which it turns up and runs longitudinally, gradually inclines inward, and enters the base of the posterior cornu. Here the fibres traverse the gray matter, passing obliquely towards the anterior cornu and cutting off a distinct area of gray matter, which in the thoracic portion of the cord contains the cells of the posterior ganglionic tract.<sup>1</sup> Some of the fibres enter that area, others pass towards the lateral group of cells of the anterior cornu, and others curve towards the anterior commissure.

The trunks of the spinal nerves emerge from the spinal canal through the intervertebral foramina, commencing with those between the occiput and atlas and terminating with those between the first and second coccygeal vertebrae. In consequence of the comparative shortness of the spinal cord and the length of its canal, the roots of the nerves to reach their trunks successively increase in length, so that while the uppermost are short and directed outward to the intervertebral foramina the others gradually incline more and more downward and the lower ones are collected in a perpendicular bunch, below the spinal cord, called, from its resemblance to a horse's tail, the **cauda equina**.

The filaments or rootlets of each nerve-root converge into two bundles, and those in each pair of roots also converge together. Those of the posterior root end in a **ganglion**, from which the root proceeds in a single bundle and is immediately joined by the bundle of the anterior root to form the trunk of the spinal nerve.

The posterior roots of the spinal nerves, except in the first pair, are conspicuously larger than the anterior roots, and this is likewise the case with their constituent filaments or rootlets. Both roots are proportioned in size to the nerve-trunks they form, and the latter are proportioned to the size of the parts they supply; hence those destined

---

<sup>1</sup> Clarke's column.



to the limbs are the largest of the spinal nerves. The ganglia are also proportioned in size to the nerve-trunks. They are generally situated in the intervertebral foramina, immediately outside the dural sheath, as this is perforated by the nerve-roots. Those of the upper two pairs of nerves are situated opposite their respective foramina, those of the sacral nerves are contained within the sacral canal, while the last one is within the dural sheath.

The roots of the spinal nerves and the spinal cord are enclosed together in the dural sheath, from which the roots of the nerves escape by separate apertures opposite the intervertebral foramina, but are afterwards enclosed together in a tube of the dura, continuous with the periosteum of the latter. On the rootlets of the nerve-roots the pia of the cord becomes continuous with their connective-tissue sheath, and the roots occupy the subarachnoid space, lying in contact with the cord above and with one another in the cauda equina below and enclosed in funnel-like sheaths of the arachnoid extending to the apertures of the dura, through which they emerge.

#### THE BRAIN.

The **brain**<sup>1</sup> is the large mass of nerve-substance which, together with its investing membranes and blood-vessels, completely fills the cavity of the cranium. The spinal cord is a prolongation of the same structures occupying the vertebral canal.

The general shape of the brain accords with that of the cranium, and it closely conforms to the cavity, apparently as if moulded in it. Commonly it is ovoid, with the narrower end occupying the forehead and the broader end the occiput, but it varies to an oval and a more or less spheroid form. Usually longest fore and aft, it is also commonly of greater transverse breadth than depth, but it varies in its relative proportions.

The size of the brain in the normal state independent of age varies greatly in different individuals, as well as in different races and sexes. To some extent it is related to the size of the body, being usually larger in tall than in short persons. All other conditions being equal,

FIG. 366.

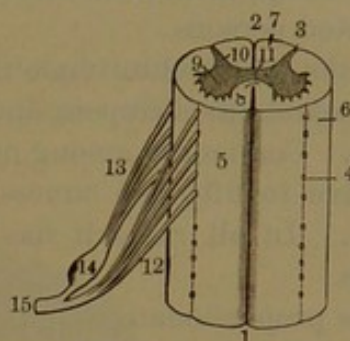


DIAGRAM OF ORIGIN OF A SPINAL NERVE. 1, anterior median fissure; 2, posterior median fissure; 3, postero-lateral fissure; 4, antero-lateral fissure; 5, anterior column; 6, lateral column; 7, posterior column; 8, anterior commissure; 9, anterior horn of the gray substance; 10, posterior horn; 11, gray commissure; 12, anterior root of a spinal nerve springing by a number of rootlets from the antero-lateral fissure; 13, posterior root from postero-lateral fissure; 14, ganglion on the posterior root; 15, spinal nerve formed by the union of the two roots.

<sup>1</sup> Encephalon; cerebrum.



it is observed also to hold a relation in size to the degree of mental development: hence the more civilized races and the more cultivated and intelligent people are distinguished by a larger and heavier brain, while the opposite condition exists in the barbarous races and the least cultivated persons.

In the adult white male the brain ordinarily averages upwards of three pounds avoirdupois, and is about a third of a pound less in the female. Commonly among our own people, in the male it ranges from forty-five to fifty-five ounces, in the female from forty to forty-seven ounces. In all races it has been found to range from two to four pounds.

The proportionate weight of the brain to that of the body is very variable, especially on account of the great variability of the latter. Considering this to be one hundred and fifty pounds, that of the brain would be about one to fifty. In early life it is much greater, at birth being in the proportion of one to six, after which it gradually decreases from the greater rapidity of growth of the rest of the body.

The brain of the new-born child averages for the male about eleven and a half ounces, for the female ten ounces. It grows most rapidly up to about the seventh year, then more slowly to fifteen or twenty, and subsequently still slower to thirty-five or forty, when ordinarily it has attained its full growth. It then remains stationary until fifty or later, and from sixty begins to decrease, estimated at the rate of an ounce in ten years to the end of life.

The human brain compared with that of other animals is actually larger than in any except the elephants and great whales; but proportionately to the size of the body is much larger than in these. It is twice the weight of the brain of the horse or ox. In several elephants it ranged from eight to ten pounds, and in a whalebone whale of seventy-five feet, which weighed more than a regiment of men, it was only four pounds.<sup>1</sup>

The brain of the great French naturalist Cuvier weighed upwards of four pounds; that of idiots averages about one and a half pounds. The brain of a gorilla, one of man's nearest allies, weighed fifteen ounces.

In the infant at birth the brain is of a soft, pulpy consistence, but gradually assumes more firmness; in the adult it is about that of freshly-made cheese. Its specific gravity, but little more than that of water, is about 1036.

The brain is a symmetrical organ composed of similar halves, in the median line partly separated by the great longitudinal fissure and

---

<sup>1</sup> It is reported that in some small animals the brain is even proportionately larger than in man, as the common mouse, but this I have found not to be the case. In a mature male which weighed three hundred and fifty-six grains the brain was six and a half grains, in the proportion of about one to fifty-five.

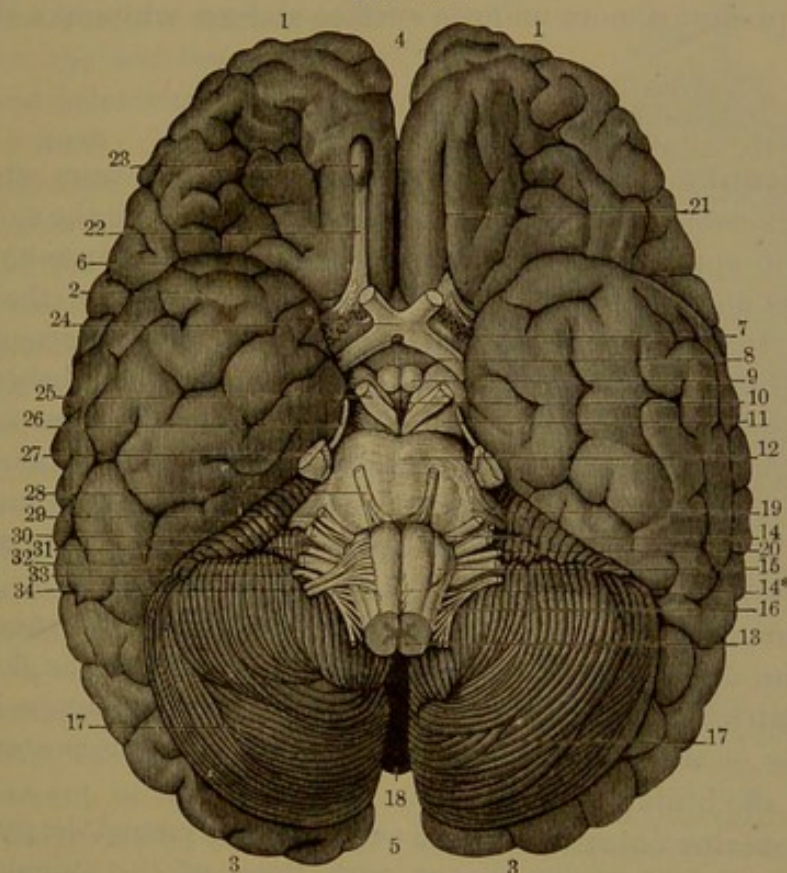


partly conjoined. The upper part is hemiovoid and conforms to the vault of the cranium, while the lower part, or **base**, conforms to the three pairs of cranial fossæ.

The brain consists of four conspicuous divisions, the cerebrum, cerebellum, pons, and medulla oblongata.

The **cerebrum** comprises about seven-eighths of the whole brain and extends its entire length and breadth above, while the other parts

FIG. 367.



**BASE OF THE BRAIN.** 1, frontal lobes of the cerebrum; 2, temporal lobes; 3, occipital lobes; 4, 5, anterior and posterior extremities of the great longitudinal fissure; 6, sylvian fissure; 7, anterior perforated space; 8, infundibulum; 9, mammillary eminences; 10, posterior perforated space; 11, crura of the cerebrum; 12, pons; 13, oblongata; 14, pyramid; 14\*, decussation of the pyramids; 15, olive; 16, restiform body; 17, hemispheres of the cerebellum; 18, vermis at the bottom of the valley separating the latter; 19, middle peduncle of the cerebellum; 20, floccule; 21, fissure which accommodates the olfactory lobe; 22; 23, bulb of the olfactory lobe; 24, optic commissure; 25, oculo-motor nerve; 26, trochlear nerve; 27, trifacial nerve; 28, abducent nerve; 29, facial nerve; 30, auditory nerve; 31, glosso-pharyngeal nerve; 32, vagus nerve; 33, accessory nerve; 34, hypoglossal nerve.

lie beneath its back portion. It occupies the vault of the cranium together with the anterior and middle fossæ of its base. The **cerebellum** in size is related to the former as about one to eight and a half, and occupies the posterior fossæ of the base of the cranium beneath the cerebrum. The **pons**, third in size of the divisions of the brain, occupies a position just back of the centre beneath the cerebrum and in advance of the cerebellum, resting on the upper part of the spheno-



basilar groove. The **oblongata**, the smallest division of the brain, lies on the lower part in advance of the cerebellum, connected with the pons above and continuous with the spinal cord below.

The cerebrum on its exterior surface is everywhere of a reddish-gray color. It resembles a mass of small intestines or of worms, due to its being covered with tortuous ridges, the **convolutions**, or **gyri**, which are separated by corresponding fissures. The cerebellum presents the same color, but is divided by horizontal fissures into thinner parallel layers, so as to exhibit a laminar appearance. The pons and oblongata present a more uniform surface and are white like the spinal cord.

#### THE MEDULLA OBLONGATA.

The **medulla oblongata**<sup>1</sup> above joins the pons, from which it is defined by a constriction. It is continuous below with the spinal cord, of which it appears to be the upper expanded extremity, but is regarded as distinct, on a level with the lower border of the occipital foramen. It occupies a position between the basilar groove of the occipital bone in front and the valley of the cerebellum behind. It is pyriform, for the most part white, about an inch long, three-fourths of an inch at its widest part above and little more than half an inch thick. It is partially divided fore and aft by median fissures continuous with those of the spinal cord. The **anterior median fissure** is interrupted below by the decussation of the pyramids and ends above in a little triangular pit<sup>2</sup> next the pons. The **posterior median fissure** at the upper half of the oblongata expands into the floor of the fourth ventricle of the brain. Each half of the oblongata is formed by a group of three columns, from which originate the posterior seven nerves of the brain.

The **anterior columns**<sup>3</sup> of the oblongata are named the **pyramids**,<sup>4</sup> are apparently continuous below with those of the spinal cord, but are so only to a small extent and are mainly continuous with its lateral columns. The pyramids are trilateral prismatic bodies placed at the sides of the anterior median fissure and appear superficially as pyriform eminences most prominent at the upper extremity, where they are rounded and separated by a narrow constriction from the pons. They are almost wholly composed of white matter consisting of longitudinal nerve-fibres, which subsequently ascend in divergent bundles through the pons. At their lower extremity they also divide into bundles, which, for the most part, cross one another at the anterior median

<sup>1</sup> Bulbus rachidicus; metencephalon. French, Moëlle allongé; German, verlängerte Mark.

<sup>2</sup> Foramen cæcum.

<sup>3</sup> Funiculi pyramidales.

<sup>4</sup> Pyramis; p. anterior; corpus pyramidale; prepyramid; ventripyramid; pyramidal body.

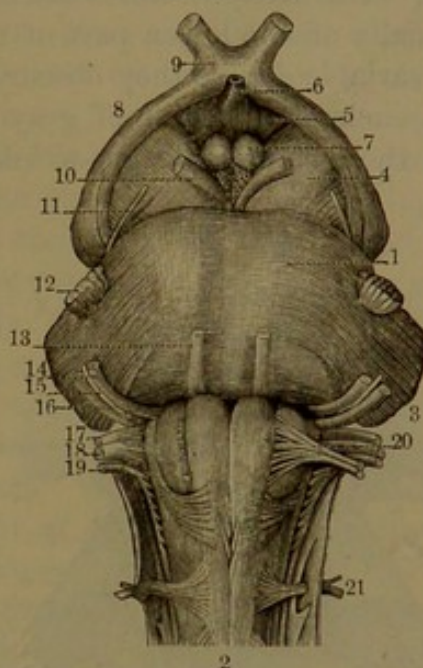


fissure and thus produce the **decussation of the pyramids**.<sup>1</sup> In this the bundles descend from the pyramids, cross one another backward and inward, and thence continue on opposite sides backward and outward to the lateral columns of the cord, in which they descend as the lateral pyramidal tract. As the bundles proceed from the decussation to the latter they pass through the gray matter continued from the cord and sever the cornua from the rest of that substance.

The extent of the decussation of the pyramids, which is visible in different cases, is variable, for sometimes the bundles pursue a deeper and sometimes a more superficial course. In some cases, also, a larger portion of the fibres descends directly in the anterior columns of the cord and a proportionately smaller quantity through the decussation in the lateral columns. Occasionally nearly or quite all of the fibres of the pyramids enter into the decussation, in which instances it becomes most obvious.

The **lateral columns**<sup>2</sup> of the oblongata seem to be a continuation of those of the spinal cord, and are so to a small extent, but are mainly continuous with the anterior columns of the cord, which, in their ascent in the oblongata, are shifted outwardly, through the decussation of the pyramids with the lateral columns of the cord. Directed upward and outward externally and behind the pyramids, they are composed of bundles of fibres, which for the most part ascend to the pons, while a small portion in continuation of the cerebellar tract from the lateral column of the cord turns backward in the restiform body. From the upper part of the lateral column projects the **olive**,<sup>3</sup> which appears as a conspicuous, longitudinal, oval eminence. It extends about half the length of the oblongata, and its upper extremity is separated from the pons by a deep recess. Along its anterior border, between it and the pyramid, emerge the roots of the hypoglossal nerve, and at its pos-

FIG. 368.



FORE PART OF THE PONS AND OBLONGATA. 1, pons; 2, oblongata; 3, middle peduncle of the cerebellum; 4, crus of the cerebrum; 5, cinereous tuber; 6, infundibulum; 7, mammillary eminences, and behind them the posterior perforated space; 8, optic tract; 9, optic commissure; 10, oculo-motor nerve; 11, trochlear nerve; 12, trifacial nerve, the small or motor root internal; 13, abducent nerve; 14, facial nerve; 15, intermediate portion; 16, auditory nerve; 17, glosso-pharyngeal nerve; 18, vagus nerve; 19, accessory nerve; 20, hypoglossal nerve; 21, first spinal or suboccipital nerve.

<sup>1</sup> Decussatio pyramidum.

<sup>2</sup> Funiculi olivares.

<sup>3</sup> Oliva; olivary body; corpus olivare; c. semiovale.



terior border is a groove occupied by ascending fibres of the lateral column, behind which emerge the roots of the glosso-pharyngeal, vagus, and accessory nerves. The olive is embraced by the ascending fibres of the lateral column, which diverge in front and behind it as they proceed to the pons and restiform body. Superficially it is formed by a layer of transversely curving or **arciform fibres**,<sup>1</sup> which proceed from the anterior median fissure and from the outer side of the pyramid, and thence turn backward and upward behind the olive to the restiform body. The arciform fibres often form more or less well-marked loops, especially on the lower part of the olive and frequently below it, and to a variable degree they obscure the subjacent ascending fibres. The olive encloses a lamina of gray matter, the **olivary nucleus**,<sup>2</sup> which is in the form of a deeply-wrinkled ovoid pouch, with the mouth directed inward. The interior of the

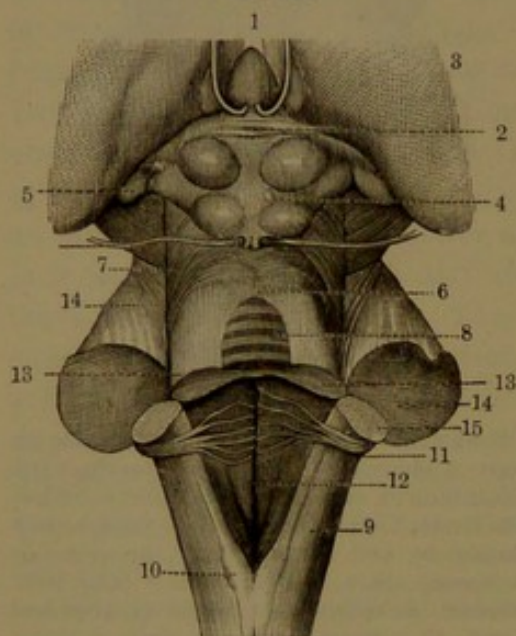
pouch is filled with white matter, which consists of fibres passing from the pouch through its mouth and becoming continuous with ascending fibres behind the pyramid.<sup>3</sup> Bundles of the fibres also penetrate the pouch and form part of the external arciform fibres of the olive. Sections of the nucleus have a toothed appearance, whence the older name of the **corpus dentatum**.

The **posterior columns** of the oblongata, like the others, appear to be a continuation of those of the spinal cord, and in this case are so in great measure. They ascend behind the lateral columns and are divided into three lesser columns or funicles, which gradually enlarge in their ascent and then taper away to the side of the restiform body.

The **gracile funicle**<sup>4</sup> lies next the posterior median fissure and

is continuous below with the posterior median column of the cord. Above, as the **posterior pyramid**<sup>5</sup> or **clava**, it appears as an emi-

FIG. 369.



VIEW BACK OF THE PONS AND OBLONGATA; the cerebellum removed. 1, pineal body turned forward, showing the posterior commissure, 2; 3, thalamus; 4, quadrigeminal body; 5, internal geniculate body; 6, anterior velum; 7, fillet; 8, lingule; 9, oblongata; 10, posterior pyramid; 11, restiform body; 12, floor of fourth ventricle; 13, superior peduncle of the cerebellum cut through; 14, middle peduncle of the cerebellum cut through; 15, inferior peduncle of the cerebellum cut through.

<sup>1</sup> Arcuate fibres.

<sup>2</sup> Nucleus olivaris; n. dentatus; corpus fimbriatum, ciliare, or rhomboidæum.

<sup>3</sup> Pedunculus olivæ.

<sup>4</sup> Funiculus gracilis.

<sup>5</sup> Pyramis posticus.



nence<sup>1</sup> just below the inferior angle of the fourth ventricle, and thence diverges and tapers away at the side of it in the restiform body. It contains a tract of gray matter, the **gracile nucleus**,<sup>2</sup> which enlarges upward and is thickest in the eminence of the clava.

To the outer side of the gracile funicle are the **internal** and **external cuneate funicles**,<sup>3</sup> continuous below with the lateral posterior column of the cord and above with the restiform body. Between them emerge the roots of the glosso-pharyngeal, vagus, and accessory nerves. The internal funicle is slightly swollen<sup>4</sup> near the eminence of the clava, and it contains a tract of gray matter, the **internal cuneate nucleus**.<sup>5</sup> The external funicle also contains a tract of gray matter, the **external cuneate nucleus**,<sup>6</sup> which enlarges above and produces at the surface a slight grayish prominence, the **external cuneate eminence**.<sup>7</sup>

The bundles of white fibres of the three funicles composing the posterior column of the oblongata are continued below as those of the posterior column of the cord and above partly end in their gray nuclei and partly ascend in the restiform body.

The **restiform body**<sup>8</sup> appears as a continuation of the posterior column of the oblongata upward and outward at the side of the fourth ventricle and reflected backward to the corresponding hemisphere of the cerebellum as its inferior peduncle. It appears to be formed mainly by the convergence and ascent of the arciform fibres of the oblongata, joined by others from its lateral column and from the cerebellar tract of the spinal cord. The fibres of the cerebellar tract in their ascent pass superficially behind the olive and obliquely cross the cuneate funicles and the line of emergence of the adjacent nerves into the restiform body.

#### FOURTH VENTRICLE OF THE BRAIN.

The **fourth ventricle of the brain**,<sup>9</sup> which may now be conveniently examined, is situated at the back of the oblongata and pons in front of the central portion of the cerebellum. Its fore part, distinguished as the **floor**, is a lozenge-shaped recess; its back part, or **roof**, is formed above by the anterior velum and below by the posterior velum and choroid tela. The superior angle of the ventricle communicates through the ventricular aqueduct with the third ventricle, and the inferior angle, or **calamus scriptorius**, with the central canal of the oblongata and spinal cord.

<sup>1</sup> Eminentia gracilis.

<sup>2</sup> N. gracilis.

<sup>3</sup> Funiculus cuneatus internus or medius and externus, lateralis, or Rolandi; corpus restiforme; pyramis lateralis.

<sup>4</sup> Eminentia cuneatus.

<sup>5</sup> N. cuneatus.

<sup>6</sup> N. cuneatus externus; n. of Rolando.

<sup>7</sup> Tubercle of Rolando; tuberculum cinereum.

<sup>8</sup> Corpus restiforme; pyramis lateralis; funiculus restiformis.

<sup>9</sup> Ventriculus quartus; v. Arantii.



The floor of the fourth ventricle<sup>1</sup> slopes gently downward and backward. Its inferior triangle<sup>2</sup> is formed by the oblongata, and is produced by the divergence of the clavæ and restiform bodies. The

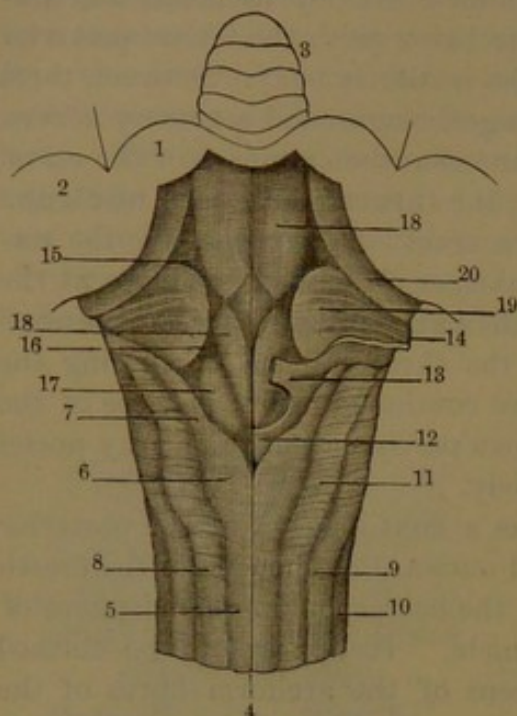
superior triangle<sup>3</sup> is formed by the pons and is produced by the divergence from above of the superior peduncles of the cerebellum. The lateral triangles are produced by the convergence of the superior and inferior peduncles of the cerebellum outward and backward behind the position of the middle peduncles. Each is prolonged into a lateral recess or finger-like pouch, the **cornucopia**, which curves outward around the restiform body to the floccule of the cerebellum.

The upper part of the roof of the fourth ventricle is formed by the **anterior velum**,<sup>4</sup> a lamina of white matter which descends in a slope from the quadrigeminal body to the stem of the vermis and laterally connects the superior peduncles of the cerebellum. The lower part of the roof immediately succeeding the anterior velum is formed by the fore part of the nodule of the vermis and on each side of this by the **posterior velum**,<sup>5</sup> whence the **choroid tela**,<sup>6</sup> an extension of the pia, de-

scends to the inferior angle of the ventricle and closes the lower back part of this cavity.

The floor of the fourth ventricle is chiefly composed of gray matter which is continuous with that in the interior of the oblongata and is divided by a median furrow. On each side of this is a slightly prominent column, the **terete funicle**,<sup>7</sup> which commences in the inferior

FIG. 370.



POSTERIOR PART OF OBLONGATA AND FLOOR OF FOURTH VENTRICLE: magnified one and a half times. 1, superior peduncle of the cerebellum, cut surface; 2, cut surface of the middle and inferior peduncles; 3, lingule lying on the anterior velum; 4, posterior median fissure; 5, gracile funicle; 6, clava tapering away at 7; 8, internal cuneate funicle; 9, external cuneate funicle; 10, lateral funicle; 11, cuneate eminence; 12, obex; 13, ponticulus; 14, inferior velum; 15, superior fovea; 16, cinereous eminence; 17, terete funicle; 18, auditory eminence crossed by the auditory striae; 19, root of auditory nerve; 20, root of auditory nerve.

<sup>1</sup> Fossa or sinus rhomboidalis.

<sup>2</sup> Medullary portion of the fourth ventricle.

<sup>3</sup> Pontal portion.

<sup>4</sup> V. medullare anterior or superior; valve of the brain; valve of Vieussens; valvula cerebri or cerebelli.

<sup>5</sup> V. med. post.

<sup>6</sup> T. choroidea inferior; t. ventriculi quarti or cerebelli.

<sup>7</sup> Funiculus or corpus teres; pyramides posteriores.



angle in a somewhat lighter point, gradually widens to about the middle of the ventricle, where it is slightly but variably thickened as the **terete eminence**,<sup>1</sup> and thence ascends more uniformly to the superior angle of the ventricle.

External to the lower end of the terete funicle is an angular depression, the **inferior fovea**,<sup>2</sup> which includes a slight elevation, the **cinereous eminence**.<sup>3</sup> This is darker than the adjacent surface, but is continuous with the gray matter of the terete funicle and also that within the oblongata. Above the middle of the floor, external to the terete eminence, is another slight angular depression, the **superior fovea**.<sup>4</sup> The more prominent portion of the floor to the outer side between the latter and the inferior fovea is the **auditory eminence**.<sup>5</sup> This is crossed transversely by several variable white lines, the **auditory striæ**,<sup>6</sup> which spring from the floor near the median furrow and thence proceed outward round the restiform body to the auditory nerve. Among them there is commonly to be seen a variably prominent gray stria.<sup>7</sup>

In the superior triangle of the ventricle along the lateral border is a variable slate-blue streak, named the **locus cæruleus**. It extends from the superior fovea to the ventricular aqueduct, and is due to a subjacent tract of gray matter containing large and unusually dark pigmented cells. It is commonly better marked after adult age.

At an early period of the development of the brain the fourth ventricle, in the position of the choroid tela, is closed by a thin white lamina which subsequently is rendered incomplete. Remains of this plate, somewhat variable, are distinguished as the inferior velum, obex, and ponticulus.

The **inferior velum**<sup>8</sup> is a thin band extending from the restiform body, below the auditory striæ, outwardly to the floccule, where it is continuous with the posterior velum, forming together an oval pouch, the **cornucopia**, which is open below. The inferior velum lies in front against the roots of the glosso-pharyngeal and vagus nerves and is often closely adherent to them.

The **obex**<sup>9</sup> is a little triangular furcate plate inserted in the inferior angle of the fourth ventricle, between the clavæ.

The **ponticulus**<sup>10</sup> consists of a pair of little bands, above the obex, springing from the respective restiform bodies and approaching but not usually joining each other, thus forming an imperfect bridge.

Immediately above the obex the choroid tela exhibits a slit-like

<sup>1</sup> Eminentia teres; colliculus rotundus.

<sup>3</sup> Eminentia cinerea cuneiformis; ala cinerea.

<sup>5</sup> Eminentia acustica.

<sup>6</sup> S. medullares; tæniæ acusticæ.

<sup>8</sup> V. medullare inferius; upper part of the tænia plexus choroidei.

<sup>9</sup> Obex sinus rhomboidalis.

<sup>10</sup> Alæ pontis; ligulæ; lower part of the tænia plexus choroidei.

<sup>2</sup> F. posterior.

<sup>4</sup> F. anterior.

<sup>7</sup> Tæniola cinerea.



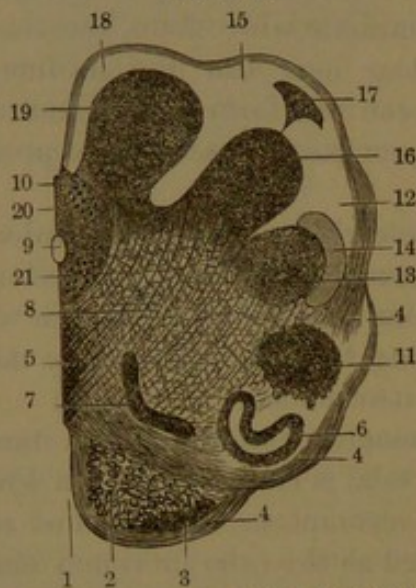opening, the **foramen of Magendie**,<sup>1</sup> through which the fourth ventricle communicates with the adjacent subarachnoid space.

Projecting into the fourth ventricle along the middle of the choroid tela are two narrow vascular appendages, the **median choroid plexuses**.<sup>2</sup> From the extension of the tela along the posterior velum, on each side, the **lateral choroid plexus**<sup>3</sup> projects from the cornucopia.

#### INTERIOR OF THE OBLONGATA.

The interior arrangement of the structure of the oblongata is most readily studied by the examination of successive horizontal sections from below upward.

FIG. 371.



HORIZONTAL SECTION OF THE OBLONGATA AT THE UPPER PART OF THE DECUSSATION OF THE PYRAMIDS, right half: four diameters. 1, anterior median fissure; 2, pyramid; 3, arciform nucleus; 4, arciform fibres; 5, decussation of the pyramids; 6, olivary nucleus; 7, accessory nucleus; 8, reticular formation; 9, central canal; 10, gray matter enclosing central canal; 11, lateral nucleus; 12, external cuneate funicle; 13, nucleus of gelatinosa of the external cuneate funicle; 14, ascending root of trifacial nerve; 15, internal cuneate funicle; 16, nucleus of internal cuneate funicle; 17, accessory nucleus of the internal cuneate funicle; 18, gracile funicle; 19, gracile nucleus; 20, nucleus of accessory nerve; 21, nucleus of hypoglossal nerve.

sides of the oblongata, through the gray matter severing the cornua from the more central portion.

In tracing the bundles of fibres from the pyramidal tract of the lateral column of the spinal cord they are observed to cross through the decussation of the pyramids and ascend in the fore part of that

The gray matter of the spinal cord is continued in the oblongata, but is much altered in its arrangement, besides which it is augmented by additional tracts or nuclei.

The decussation and production of the pyramids and the introduction of the olives into the oblongata cause the recession of the ascending gray matter of the cord and other displacements of its parts. At the limit of the cord the posterior cornua are reflected more outward and are more narrowed at their neck and rounded at their head. The anterior commissure is thicker and is continuous above with the decussation of the pyramids.

In sections through the decussation the bundles of fibres are seen to pass from the pyramids backward and inward, cross one another through the anterior median fissure, and thence pass backward and outward, on the opposite

<sup>1</sup> F. Magendii; f. ventriculi quarti.

<sup>2</sup> P. choroidei superior or medialis.

<sup>3</sup> P. chor. inferior or lateralis.



of the opposite side. Those from the pyramidal tract of the anterior column of the cord are reflected outwardly and ascend in the pyramid of the same side, at first external to the decussation and then behind the others.

The central gray matter of the oblongata, after the separation of the cornua, in section appears triangular with the apex directed forward and enclosing the central canal continued from the cord. In its ascent it gradually recedes to the posterior surface of the oblongata, divides behind and spreads laterally until the central canal is laid open, when it is extended on the floor of the fourth ventricle.

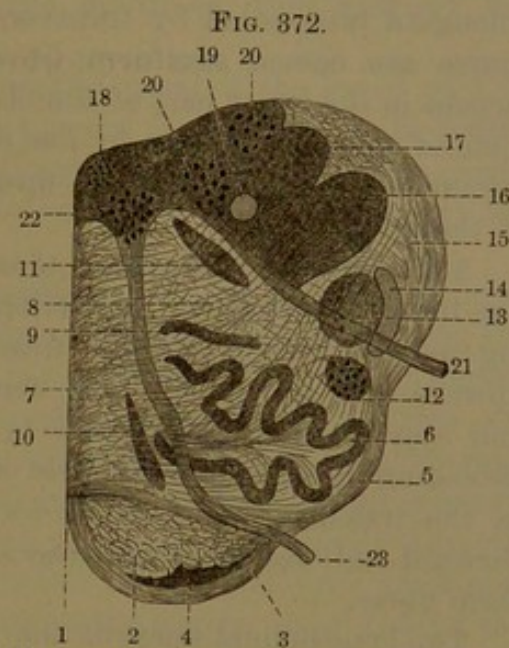
The anterior cornu of the cord ascends in the oblongata, behind the olive, as the **lateral nucleus**, which gradually decreases. The posterior cornu, enlarged and rounded, ascends behind the anterior, within the external cuneate funicle, as its nucleus. This in its course approaches the surface, produces the slight grayish external cuneate eminence,<sup>1</sup> and continues upward into the pons. A conspicuous bundle of fibres embracing it externally forms the ascending root of the trifacial nerve.

A columnar tract of gray matter in the gracile funicle is the **gracile nucleus**. It commences in the oblongata below, gradually enlarges in its ascent, and at its upper extremity produces the eminence of the clava.

A similar tract in the internal cuneate funicle is the **cuneate nucleus**, which springs from the central gray matter of the cord and becomes continuous with the former nucleus.

A section of the olive at either extremity exhibits the **olivary nucleus** as a bent elliptical ring and at the middle as a deeply-folded loop.

Behind the olive is the **accessory olivary nucleus**, which is a vertically ovoid gray plate. A similar smaller plate in the outer side of the pyramid is also indicated as an **accessory olivary nucleus**.



HORIZONTAL SECTION OF THE OBLONGATA, about the middle of the olive, right half; four diameters. 1, anterior median fissure; 2, pyramid, interior ascending bundles; 3, arciform fibres; 4, arciform nucleus; 5, arciform fibres of the olive; 6, olivary nucleus; 7, raphé; 8, reticular formation; 9, 10, accessory olivary nuclei; 11, nucleus ambiguus; 12, lateral nucleus; 13, nucleus of gelatinosa; 14, ascending root of the trifacial nerve; 15, restiform body; 16, cuneate nucleus; 17, gracile nucleus; 18, terete funicle; 19, longitudinal bundle of nerve-fibres; 20, 20, two portions of the vagus nucleus; 21, root of vagus nerve; 22, hypoglossal nucleus; 23, root of hypoglossal nerve.

<sup>1</sup> Tubercle of Rolando.



A thin tract of gray matter in the superficial fore part of the pyramid is the **arciform nucleus**,<sup>1</sup> which gives origin to the contiguous arciform fibres.

The space between the pyramids and olives in front and the principal tracts of gray matter of the oblongata behind is occupied by the **reticular formation**,<sup>2</sup> named from its appearance. It is chiefly composed of longitudinal fibres ascending from the lateral columns of the oblongata intersected by transverse fibres, which from their curving course are named **arciform fibres**. The reticular formation commences in the lower part of the oblongata through the breaking up of some of the gray matter by the decussating bundles of fibres of the pyramids; thence it increases upward and is continued into the back of the pons.

A decussation of the fibres of the reticular formation in the median line forms the **raphé**. It is mingled with some gray matter containing nerve-cells and extends from the decussation of the pyramids upward into the pons. The nerve-fibres pursue different directions and appear mainly to pertain to the arciform series. Longitudinal ascending fibres from either side cross one another and turn outwardly in the reticular formation as deep arciform fibres, while others pass forward and emerge at the anterior median fissure as superficial arciform fibres.

The longitudinal fibres of the reticular formation are reinforced in their ascent by many of the arciform fibres, which proceed from the decussation of the pyramids and raphé and from the gracile, cuneate, and olivary nuclei.

The outer area of the reticular formation contains gray matter with many large nerve-cells, while the inner area is devoid of them.

The **arciform fibres** are in general distinguished as a deep and a superficial series. The **deep arciform fibres** mainly proceed from the decussation of the pyramids and the raphé and curve outward and backward, partly running to the gracile and cuneate nuclei and partly to and through the olivary nucleus, thence into the restiform body. Of the **superficial arciform fibres** proceeding from the same source, a portion passes forward at the anterior median fissure, turns outward on the pyramid and olive, thence ascends in the restiform body, while another portion passes out laterally behind the pyramid and joins the former portion. The superficial arciform fibres are also reinforced by others proceeding directly from the outer part of the pyramids, in addition to some deep ones issuing from the olivary nucleus.

The extension of the posterior cornu of the cord into the oblongata, where it forms the external cuneate nucleus, is an accumulation of gelatinosa with nerve-cells, from which arise the fibres of the ascending root of the trifacial nerve embracing the outer side of the nucleus.

<sup>1</sup> Nucleus of the pyramid.

<sup>2</sup> *Formatio reticularis.*



The extension of the anterior cornu as the lateral nucleus of the oblongata appears to become diffused as the gray matter of the lateral area of the reticular formation, in which there are many large nerve-cells.

The olivary nucleus is a lamina of gelatinosa with numerous medium-sized multipolar nerve-cells and nerve-fibres, which pass through the nucleus and continue as arciform fibres.

The gracile nucleus contains large multipolar cells sparsely distributed.

The gray matter enclosing the central canal of the lower part of the oblongata and thence extending upward in the floor of the fourth ventricle is chiefly composed of gelatinosa. Embedded in it are groups of nerve-cells, which are the nuclei or centres of origin of some of the important nerves of the brain.

The **hypoglossal nucleus** consists of a columnar tract of large multipolar nerve-cells, which give origin to the nerve-fibres forming the rootlets of the hypoglossal nerve. It is embedded in the gray matter of the terete funicle in the inferior triangle of the fourth ventricle, extending downward into that enclosing the central canal of the oblongata.

The **nucleus of the glosso-pharyngeal, vagus, and accessory nerves** is a continuous columnar tract of smaller nerve-cells than the preceding, embedded in the gray matter of the cinereous eminence, extending downward into that enclosing the central canal behind the former tract.

Two auditory nuclei are distinguished on each side in the floor of the fourth ventricle. The **internal or principal auditory nucleus** corresponds in position with the auditory eminence crossed by the auditory striæ. It is a columnar tract of small multipolar cells embedded in the eminence, and is widest at the striæ, whence it narrows towards the extremities. The **external auditory nucleus**<sup>1</sup> is a tract of large nerve-cells situated to the outer side of the former, is largest at the upper extremity in the superior fovea, and tapers below to the position of the auditory striæ. It is traversed by longitudinal bundles of nerve-fibres, which pass to or from the cerebellum. From these bundles, as well as from the nucleus, the superior root of the auditory nerve appears to have its origin, proceeds forward and outward, and emerges from among the ascending fibres of the restiform body to join the inferior root in front of that body.

The auditory striæ proceed from behind the principal auditory nucleus and pass outward around the restiform body to its fore part as the **posterior division** of the inferior root of the auditory nerve. The **anterior division** of the inferior root proceeds from the deep part of the nucleus outward to the inner side of the restiform body and there joins the posterior division.

---

<sup>1</sup> Superior aud. nucleus; nucleus of Deiters or of Laura.



Some gray matter situated between the superior root of the auditory nerve and the restiform body, thence extending into the angular interval of the two divisions of the anterior root, contains the **accessory auditory nucleus**. This is a group of small multipolar nerve-cells, which are peculiar among those of the brain in that they are provided with a nucleated sheath like the nerve-cells of ganglia.

### THE PONS.

The **pons**<sup>1</sup> appears superficially as a conspicuous white eminence situated at the base of the brain behind its centre. It is placed above the oblongata with which it is connected below, in front of the cerebellum with which it is connected behind, and beneath the cerebrum with which it is connected above. It is quadrate, with the prominent fore part convex and with a median furrow<sup>2</sup> which accommodates the basilar artery. It rests in front against the spheno-basilar groove of the cranium. Laterally it is contracted and prolonged backward and outward into the middle peduncles<sup>3</sup> of the cerebellum. Its back part is narrower than the fore part, forms the upper triangle of the floor of the fourth ventricle extending to the ventricular aqueduct, and is flanked above and below by the superior and inferior peduncles of the cerebellum. The upper part of the pons is transversely arched, but depressed at the middle. Laterally it is extended obliquely outward and backward as the fore part of the middle peduncles of the cerebellum, and from its sides ascend the **crura of the cerebrum**. The lower part is more nearly straight, and laterally bends outward as the back part of the middle peduncles of the cerebellum. The front of the pons is strongly striate transversely, indicating the course of the fibres which compose its more superficial portion. It also exhibits many little perforations due to blood-vessels from the investing pia.

As in the case of the oblongata, the interior structure of the pons is best studied by the examination of horizontal sections in succession from below upward. In these it is observed that the pons for more than half its thickness from the front is mainly composed of transverse bundles of nerve-fibres crossed in their course by longitudinal bundles ascending from the pyramids. To the latter bundles is due the greater prominence on each side of the front of the pons. The pyramidal bundles enter the pons in columns which separate the superficial<sup>4</sup> from the deeper portion<sup>5</sup> of the transverse bundles.

<sup>1</sup> Pons Varolii or cerebelli; commissura cerebelli; nodus encephali; eminentia or protuberantia annularis; tuber annulare.

<sup>2</sup> Sulcus basilaris.

<sup>3</sup> Crura cerebelli ad pontem; c. media or lateralia; brachia pontis; c. cerebri; cerebral peduncles.

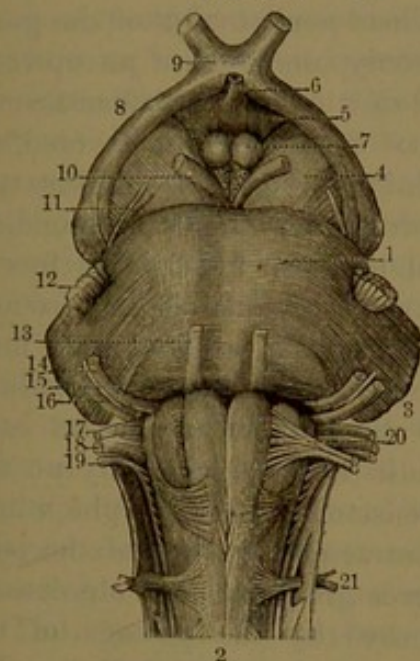
<sup>4</sup> Fasciculus pontis anterior or inferior.

<sup>5</sup> F. p. posterior or superior; trapezium.



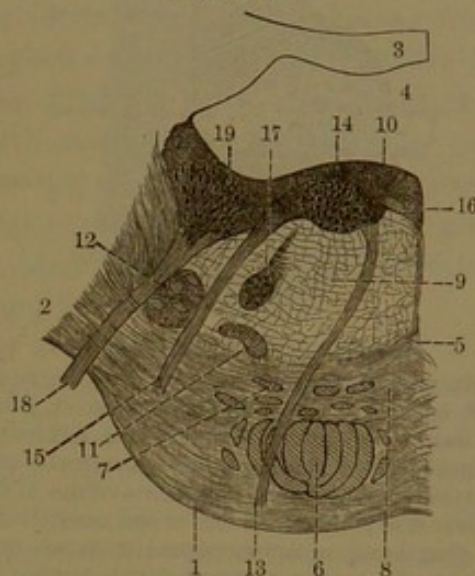
In their further ascent the columns break up into smaller bundles, which spread in layers separated by corresponding divisions of the transverse bundles of the pons. The ascending bundles multiply and become smaller, but collectively larger, due to an accession of fibres in passing through the pons. In the upper part of this the pyramidal bundles collect together and emerge to ascend in the cerebral crura. The transverse bundles of the pons, after passing the crura outwardly,

FIG. 373.



FORE PART OF THE PONS AND OBLONGATA. 1, pons; 2, oblongata; 3, middle peduncle of the cerebellum; 4, crus of the cerebrum; 5, cinereous tuber; 6, infundibulum; 7, mammillary eminences, and behind them the posterior perforated space; 8, optic tract; 9, optic commissure; 10, oculo-motor nerve; 11, trochlear nerve; 12, trifacial nerve, the small or motor root internal; 13, abducent nerve; 14, facial nerve; 15, intermediate portion; 16, auditory nerve; 17, glosso-pharyngeal nerve; 18, vagus nerve; 19, accessory nerve; 20, hypoglossal nerve; 21, first spinal or suboccipital nerve.

FIG. 374.



SECTION ACROSS THE PONS, left half, near the middle of the fourth ventricle: magnified two diameters. 1, transverse bundles of fibres passing to the middle peduncle of the cerebellum; 2, 3, anterior velum; 4, fourth ventricle; 5, raphé; 6, bundles of fibres ascending from the pyramid; 7, others separated from the former; 8, deep transverse bundles forming the trapezium; 9, reticular formation; 10, terete funicle; 11, superior olivary nucleus; 12, ascending root of the trifacial nerve; 13, abducent nerve; 14, its nucleus; 15, facial nerve; 16, intermediate portion of the facial nerve; 17, nucleus and commencement of the facial nerve; 18, upper root of the auditory nerve; 19, part of its outer or upper nucleus.

collect together to form the middle peduncles of the cerebellum. The intermediate transverse bundles are most direct in their course, and on each side turn outward and backward in the peduncles. The lower bundles curve forward at the sides, then likewise turn outward and backward in them; the upper bundles laterally curve backward superficially over the others and then continue in the same course.

The intervals in the bundles of fibres of the ventral portion of the pons include some gray matter<sup>1</sup> containing many small nerve-cells from

<sup>1</sup> Nucleus pontis.



which nerve-fibres proceed both in a longitudinal and a transverse direction. At the upper part of the pons a narrow bundle of fibres<sup>1</sup>

emerges from the recess between the cerebral crura and runs outwardly around each crus to the groove between the superior and middle cerebellar peduncles and accompanies them into the cerebellum.

The dorsal portion of the pons is mainly composed of an upward extension of the reticular formation of the oblongata, covered behind by a layer of gray matter which forms the corresponding portion of the floor of the fourth ventricle. It is flanked above and below by the superior and inferior peduncles of the cerebellum. The reticular formation on each side is also conjoined by an upward extension of the raphé, which in the ventral portion of the pons is in a great measure obsolete or obscured by the passage of the transverse bundles of fibres. Besides the more generally diffused gray matter of the reticular forma-

tion, at the fore part of its lateral area it encloses a small, folded gray lamina, distinguished as the **superior olivary nucleus**.<sup>2</sup> The stratum of gray matter at the back of the pons, in the floor of the fourth ventricle, has been described in the account of that cavity.

#### THE CEREBELLUM.

The **cerebellum**<sup>3</sup> is the lower posterior division of the brain and occupies the posterior cranial fossæ beneath the cerebrum, from which it is separated by the tentorium. It is connected at its fore part above to the other divisions of the brain by means of its peduncles, which communicate with them through the great oval foramen of the dura. Its widest part is commonly three and a half to four inches transversely, about two to two and a half inches fore and aft, and about two inches in depth. It consists of a pair of solid, half-spheroidal

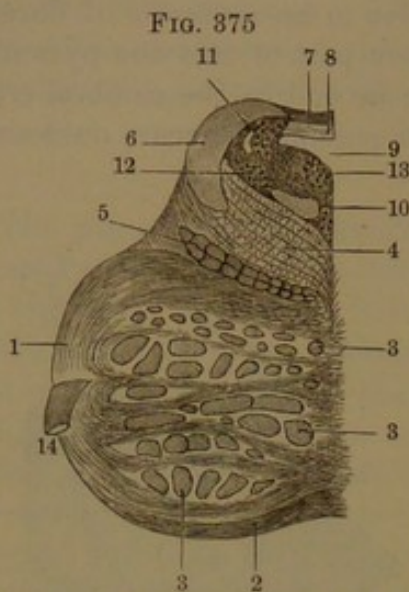


FIG. 375  
SECTION ACROSS THE UPPER PART OF THE PONS; left half: one and a half diameters. 1, pons; 2, transverse bundle of fibres; 3, 3, 3, ascending bundles of the pyramids; 4, reticular formation; 5, longitudinal bundles of fibres of the fillet; 6, superior peduncle of the cerebellum; 7, lingule; 8, anterior velum; 9, fourth ventricle; 10, posterior longitudinal bundle of fibres; 11, descending root of the trifacial nerve with its nucleus; 12, substantia ferruginea; 13, nucleus continued upward in the floor of the ventricular aqueduct; 14, trifacial nerve.

<sup>1</sup> Tænia pontis.

<sup>2</sup> N. olivarius superior.

<sup>3</sup> Parencephalis; cerebrum parvum or posterior; little or after brain.



masses, the **hemispheres**, joined by a median portion, the **vermis**.<sup>1</sup> The fore part above is deeply notched at the middle for the accommodation of the cerebellar peduncles, likewise below for the reception of the oblongata. Above, the hemispheres are continuous in a median rounded ridge,<sup>2</sup> formed by the upper part of the vermis, but they are separated at the posterior border by a wide notch,<sup>3</sup> which receives the cerebellar falx. The anterior border is nearly straight, and is directed obliquely outward and backward from the peduncles, which enter its inner extremity. The posterior rounded border curves from the median notch outward and forward to the anterior border. The upper surface slants from the vermis outward and backward, is slightly concave in the same direction, and slightly convex from the front backward and inward. Below the upper surface, the hemispheres, as implied by the name, are nearly hemispherical and are separated by a deep interval, the **valley**,<sup>4</sup> which extends from the posterior notch downward and forward. Into the valley projects the inferior portion of the vermis,<sup>5</sup> which here appears as a worm-like ridge, whence its name.

The cerebellum is characterized by its laminated appearance, the surface being everywhere divided into plates separated by narrow fissures which receive folds of the pia. The plates are in general of uniform thickness, nearly parallel and for the most part disposed horizontally. The fissures are of variable length and depth and often run into one another. The laminar appearance of the cerebellum is accompanied by a corresponding arrangement of its structure.

The interior white matter extends from the cerebellar peduncles within each hemisphere as a conical **trunk**, which is continuous with its fellow through the **stem** of the vermis. Both the trunk and the stem divide into divergent plates, and these again divide two or three times in the same manner. The terminal plates are short, thin, and uniform, and have folded around them a comparatively thick layer of gray matter, which is everywhere continuous as the **cortex** of the cerebellum. In consequence of the arrangement thus described, sections of the cerebellum crossing the laminae exhibit a remarkable arborescent appearance, distinguished as the **arbor vitæ**. In the vermis the appearance is the more striking from the more graceful proportions of the stem and its branches than in the hemispheres.

The deepest fissures of the cerebellum are usually the most obvious on the surface, and serve to distinguish the principal divisions or **lobes**, which consist of groups of laminae. One of the most conspicuous is the **great horizontal fissure**,<sup>6</sup> which divides each hemisphere near

<sup>1</sup> Worm; lobus medius cerebelli.

<sup>2</sup> Vermis superior; sup. vermiform process.

<sup>3</sup> Incisura marginalis posterior.

<sup>4</sup> Vallis; vallecule; scissura longitudinalis.

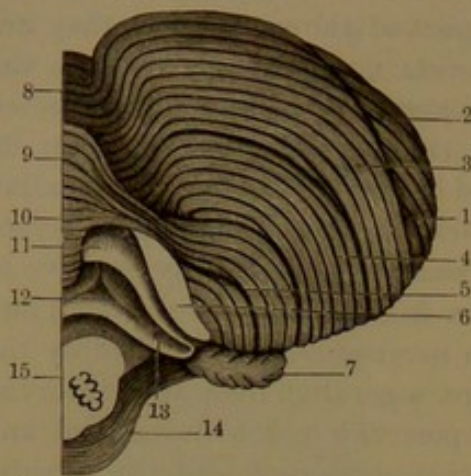
<sup>5</sup> Vermis inferior; inf. vermiform process.

<sup>6</sup> Sulcus magnus horizontalis.



its middle. Starting in front to the outer side of the middle peduncle, it passes outward and backward, turns under the posterior border of the hemisphere and then upward and inward over the border to the bottom of the notch between the hemispheres.

FIG. 376.



RIGHT HEMISPHERE OF THE CEREBELLUM, seen from beneath: two-thirds size. 1, great horizontal fissure; 2, 3, posterior superior and inferior lobes; 4, gracile lobe; 5, inferior or bi-ventral lobe; 6, cut surface from removal of the tonsilla; 7, floccule; 8-10, vermis; 8, tuber; 9, pyramid; 10, uvula; 11, posterior velum; 12, inferior velum; 13, cornucopia; 14, pons; 15, cut surface of oblongata.

The lobes of the cerebellum are commonly distinguished as follows:

The **superior lobe**<sup>1</sup> includes all the visible upper part of the hemisphere, except the posterior primary division and the lower secondary portion of the posterior primary division of the vermis. The laminae and intervening fissures, seen on the surface of these lobes, pass obliquely from in front on each side inward and backward to the vermis, on which they become abruptly bent from their previous course and more or less interrupted. A more distinct por-

tion of these lobes behind has been named the **crescentic lobe**.<sup>2</sup>

The first division of the superior lobe corresponding with the anterior primary division of the vermis is the **central lobe**.<sup>3</sup> It is concealed by the greater portion of the superior lobes behind and rests in front against the anterior velum and superior peduncles of the cerebellum. From its lower part extends upward and forward on the velum the **lingule**,<sup>4</sup> which is a tongue-like process of gray matter consisting of four or five transverse bars, which correspond with other laminae of the cortex of the cerebellum.

The **posterior lobe**<sup>5</sup> forms the thick rounded border of the hemisphere back of the superior lobe, from which it is separated by a deep fissure which curves from the outer border of the hemisphere backward and inward to the bottom of the posterior median notch. It includes the greater part of the hemisphere beneath, where it is separated from the inferior lobe by a shorter fissure pursuing a similar course from the outer part of the hemisphere to the lower part of the valley. It is composed of the three posterior inferior primary divisions of the hemisphere and is divided by the great horizontal fissure. The portion above the fissure, the **posterior superior lobe**,<sup>6</sup>

<sup>1</sup> Quadrate lobe; lobus quadratus or quadrangularis; antero-superior lobe.

<sup>2</sup> Posterior crescentic lobe.

<sup>3</sup> Lobus centralis.

<sup>4</sup> Lingula.

<sup>5</sup> Lobus semilunaris.

<sup>6</sup> L. semilunaris superior.



is thick and crescentic, and commonly joins its fellow through the vermis by a single plate.<sup>1</sup> The **posterior inferior lobe**<sup>2</sup> forms the greater part of the inferior surface of the hemisphere. It presents several more conspicuous fissures besides the lesser ones, and its lowest division has been regarded as distinct under the name of the **gracile lobe**.<sup>3</sup> In advance of the latter and outwardly embraced by it is the **inferior lobe**,<sup>4</sup> which appears prominently at the fore part of the hemisphere to the outer side of the oblongata. It is composed of the lower largest primary division of the hemisphere divided into two secondary ones, whence the name of **biventral lobe**.

The **tonsilla**<sup>5</sup> is an oval lobe situated at the inner side of the hemisphere, occupying a recess of the inferior lobe and projecting into the valley behind the lower part of the oblongata. It is attached by a stem which springs from the inner part beneath, of the central white trunk of the hemisphere.

The **floccule**<sup>6</sup> is a little elliptical lobe, which occupies the outer part of the angular space in front of the middle peduncle of the cerebellum, between the superior and inferior lobes. Its stem springs from the inner side below, of the middle peduncle. It is sometimes accompanied by a smaller **accessory floccule**,<sup>7</sup> which is partially concealed by the larger one.

The inferior more distinct portion of the vermis is also divided into lobes. Of these, the **tuber**<sup>8</sup> is an eminence composed of four or five plates which belong to the lower branch of the posterior primary division of the vermis and connect the posterior lobes of the cerebellum across the upper part of the valley.

Immediately below the tuber a more conspicuous portion of the vermis is distinguished as the **pyramid**,<sup>9</sup> which occupies a recess between the posterior lobes of the cerebellum. Its apex is directed backward, while the base, more in advance, unites the inferior lobes of the cerebellum.

In front of the pyramid is the **uvula**,<sup>10</sup> a lobe formed of a series of transverse plates successively decreasing and producing together a keel-like ridge, which projects forward into the valley between the tonsillæ and behind the fourth ventricle. Its widest part behind is extended on each side in a ridge<sup>11</sup> which joins the corresponding tonsilla.

<sup>1</sup> Folium or lamina cacuminis; commissura tenuis; c. lorum semilunarium.

<sup>2</sup> Lobus semilunaris inferior.

<sup>3</sup> Lobus gracilis; l. inferior medius.

<sup>4</sup> Lobus inferior anterior; l. cuneiformis.

<sup>5</sup> Amygdala; lobus inferior internus; l. med. oblongatæ.

<sup>6</sup> Flocculus; lobus nervi pneumogastrici.

<sup>7</sup> F. secundarius.

<sup>8</sup> T. valvulæ; vermis posterior.

<sup>9</sup> Pyramidal lobe; pyramis; lobus inferior anterior.

<sup>10</sup> Lobus intertonsillaris.

<sup>11</sup> Ala uvulæ; commissura transversa sulcata; furrowed band.



Surmounting the uvula is a smaller lobe, the **nodule**,<sup>1</sup> which is formed by the first primary lower branch of the vermis, projecting behind the fourth ventricle.

In front of the nodule on each side is a thin white crescentic lamina, the **posterior velum**,<sup>2</sup> which forms part of the lower slope of the roof of the fourth ventricle. It springs from the central stem of the vermis, extending outward to the floccule, and arches forward and downward over the corresponding tonsilla and terminates in a sharp concave edge. It extends along the posterior border of the lateral recess of the fourth ventricle, and near the floccule joins the inferior velum of the oblongata, to form with it an open pouch, the **cornucopia**.

The **peduncles of the cerebellum** consist of three pairs of stout bundles of nerve-fibres, which connect it with the other chief divisions of the brain, and are distinguished from their relative position as superior, middle, and inferior.

The **middle peduncle**,<sup>3</sup> much larger than the others, is a cylindrical process which passes from each side of the pons obliquely outward and backward and enters the inner fore part of the corresponding hemisphere of the cerebellum. It is formed by the convergence of the transverse bundles of fibres of the ventral portion of the pons.

The **superior peduncle**<sup>4</sup> is a flattened, cylindrical process which passes from behind and beneath the quadrigeminal body on each side, descends obliquely outward and backward, and enters the hemisphere of the cerebellum behind and beneath the middle and inferior peduncles.

The **inferior peduncle**,<sup>5</sup> about the size of the former, but more cylindrical, is the continuation of the restiform body on each side of the oblongata. Ascending obliquely outward it turns abruptly backward and enters the hemisphere of the cerebellum between the superior and middle peduncles.

The superior peduncles descend at the sides of the upper triangle of the fourth ventricle, connected together by the anterior velum, while the inferior peduncles ascend at the sides of the lower triangle of the ventricle. By the convergence of the three peduncles on each side the lateral angle of the ventricle is produced. In its descent the superior peduncle crosses and enters the cerebellum beneath the inferior peduncle, which enters between the superior and middle peduncles.

The **anterior velum**,<sup>6</sup> connecting the superior peduncles, is a white lamina which forms the upper part of the roof of the fourth ventricle and descends obliquely from the quadrigeminal body to the stem of the vermis of the cerebellum. Its upper surface, slightly depressed, is for the most part covered by the **lingule**,<sup>7</sup> a process of the

<sup>1</sup> Nodulus.

<sup>2</sup> V. medullare posticum; v. Tarini; v. semilunaris.

<sup>3</sup> Crus ad pontem.

<sup>4</sup> Crus ad cerebrum.

<sup>5</sup> Crus ad medullam.

<sup>6</sup> V. medullare anterius or superius.

<sup>7</sup> Lingula.



cerebellar cortex. Extended from the velum to the median groove of the quadrigeminal body is a little white band, the **frenule**, on each side of which the trochlear nerve issues.

To the outer side of the superior peduncles above, is a prominent white band, the **fillet**,<sup>1</sup> which emerges from the groove between the middle and superior peduncles and ascends obliquely forward and inward to the quadrigeminal body.

The three peduncles of the cerebellum on entering the corresponding hemisphere unite in a large compressed conical trunk, which subsequently divides into plates, and the division is several times repeated, until finally the thin terminal plates reach the cortex. The trunk and plates consist of bundles of fibres, which emanate from the peduncles and radiate in all directions to reach the interior surface of the folded gray cortex of the cerebellum. The stem of the vermis is continuous with the anterior velum and with the superior peduncles, and in a similar manner to the trunk of the hemisphere extends to the cortex.

Embedded in the central white trunk of each hemisphere of the cerebellum is a wrinkled gray lamina, named from its appearance in section the **dentate nucleus**.<sup>2</sup> It is in the form of an oval pouch and has the mouth directed inward, forward, and downward. It is filled with white matter<sup>3</sup> consisting of fibres mainly continuous with those of the superior peduncle and anterior velum. In structure the dentate resembles the olivary nucleus of the oblongata.

Between the dentate nucleus and the median line of the vermis in each hemisphere there are several smaller and less conspicuous accumulations of gray matter, which are not completely isolated, but are continuous with the dentate nuclei and with one another. The largest, the **fastigiate nucleus**,<sup>4</sup> is an oval plate in the fore part of the vermis separated from its fellow by a narrow strip of white matter. The second in size, the **emboliform nucleus**,<sup>5</sup> is a fore and aft clavate streak close to the mouth of the dentate nucleus. The remaining one, the **globose nucleus**,<sup>6</sup> is a rounded streak lying intermediate to and a little lower than the others.

The emboliform nucleus in structure resembles the dentate nucleus, but the others have larger nerve-cells.

The **cortex**<sup>7</sup> of the cerebellum consists of two nearly equally thick strata of gray matter separated by a thin stratum less gray or nearly white.

The cortex of the cerebellum forms a pretty uniform layer, but is thicker at the free borders and sides of the folds than at the bottom.

<sup>1</sup> Lemniscus; laqueus; band of Reil.

<sup>2</sup> N. dentatus; corpus dentatum, fimbriatum, lenticulatum, or ciliare; ganglion cerebelli.

<sup>3</sup> Medulla centralis or ciliaris.

<sup>4</sup> N. fastigii.

<sup>5</sup> N. emboliformis.

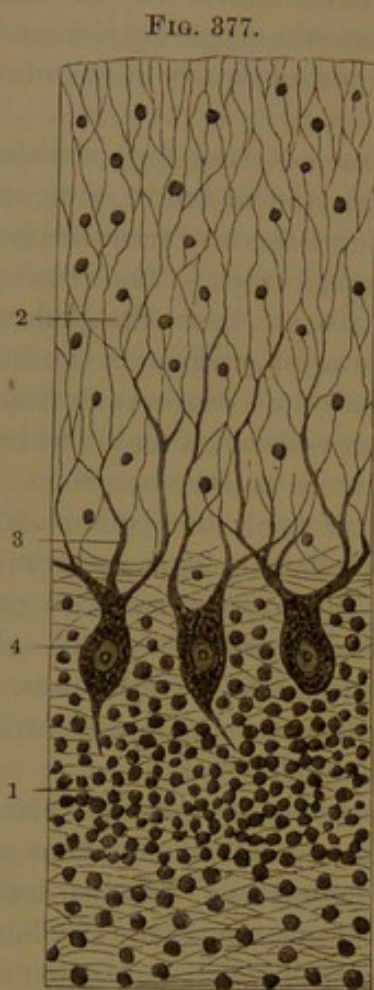
<sup>6</sup> N. globosus.

<sup>7</sup> Cortical gray substance.



It consists of two principal layers, of which the external is the thicker.

The **internal cortical layer**,<sup>1</sup> of a yellowish or rust-brown hue, is composed of a matrix of neuroglia, with numerous fine capillary vessels, densely crowded with small rounded nerve-cells and pervaded by fine medullated nerve-fibres. The nerve-cells are mostly bipolar and by means of their nerve-fibres are continuous with those of the terminal plates of the white matter enclosed by the cortex.



VERTICAL SECTION OF THE CORTEX OF THE CEREBELLUM: highly magnified. 1, internal cortical layer, crowded with small nerve-cells (only a few represented); 2, external cortical layer of neuroglia and branching processes 3, of the large nerve-cells 4.

Partially embedded in the outer surface of the internal cortical layer is a single stratum of **large nerve-cells**,<sup>2</sup> many of which range from  $\frac{1}{1000}$  to  $\frac{1}{800}$  of an inch in diameter. They are mostly flask-shaped and are generally arranged vertically with their neck-like processes directed towards the free surface of the cortex and forking into two widely-diverging branches which ramify through the external cortical layer. From their base a single smaller process becomes the axis-fibre of a medullated nerve-fibre. The large nerve-cells partially lie in a very thin whitish stratum of nerve-fibres between the two principal layers of the cortex.

The **external cortical layer**, of a clearer gray hue than the former, consists of an abundant matrix of neuroglia pervaded by the branching fibres of the large nerve-cells beneath, with a few scattered and small rounded nerve-cells and numerous capillary vessels.

#### THE CEREBRUM.

The **cerebrum**,<sup>3</sup> the largest principal division of the brain, is horizontally ovoid or oval, with the length fore and aft and the greater breadth opposite the parietal eminences. It is deeply divided in the

<sup>1</sup> Granular layer.

<sup>2</sup> Cells or corpuscles of Purkinje.

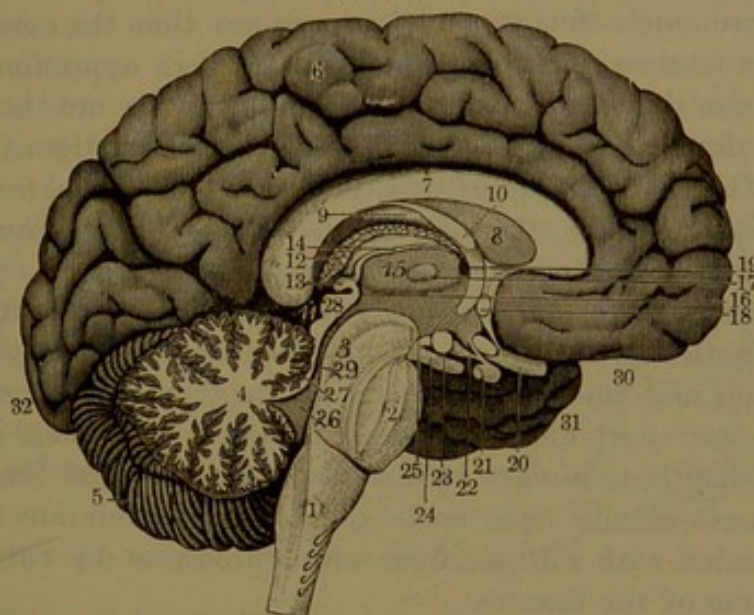
<sup>3</sup> Fore-brain; great brain; pro-encephalon.



median line by the **great longitudinal fissure**<sup>1</sup> into two hemispheres.

Each **cerebral hemisphere**<sup>2</sup> presents an outer convex surface next the cranial vault, an inner, vertical flat surface which forms the side of the longitudinal fissure, and an under surface. This is divided at the fore part by a deep cleft, the **sylvian fissure**, into two prominent lobes, which closely conform to the anterior and middle cranial fossæ, while the back part is concave and rests on the **tentorium**, a partition of the dura, which separates it from the cerebellum.

FIG. 378.



SECTION OF THE BRAIN ALONG THE GREAT LONGITUDINAL FISSURE. 1, oblongata; 2, pons; 3, crus of the cerebrum; 4, arborescent appearance in section of the vermis of the cerebellum; 5, left hemisphere of the cerebellum; 6, inner surface of the left hemisphere of the cerebrum; 7, callosum; 8, ventricular septum; 9, fornix; 10, anterior crus of the fornix descending to join the corresponding mammillary eminence; 11, fissure through which the choroid tela, 12, is introduced into the third ventricle; 13, pineal body; 14, its peduncle; 15, rests on the thalamus within the third ventricle; 16, posterior commissure of the latter; 17, middle commissure; 18, anterior commissure; 19, foramen of communication between the third and lateral ventricles; 20, optic nerve; 21, pituitary body; 22, infundibulum; 23, mammillary eminence; 24, oculo-motor nerve; 25, posterior perforated space; 26, fourth ventricle; 27, anterior velum; 28, quadrigeminal body; 29, ventricular aqueduct; 30, 31, 32, frontal, temporal, and occipital lobes of the cerebrum.

By gently pressing apart the cerebral hemispheres they are observed to be conjoined centrally along the middle of the longitudinal fissure by a bridge of white nerve-substance, the **callosum**, **corpus callosum**, or **great cerebral commissure**. In advance and behind the latter the fissure extends to the bottom of the cerebrum and receives a partition of the dura, the **cerebral falx**, which reaches the callosum behind, but not within a short distance in front.

The cerebral hemispheres are each composed of a central mass of

<sup>1</sup> Fissura longitudinalis; scissura cerebri longitudinalis.

<sup>2</sup> Hemisphæria cerebri.



**white matter**<sup>1</sup> enveloped by a thick and nearly uniform layer of gray matter, the **cortex**.<sup>2</sup> The white matter consists of a dense aggregation of nerve-fibres, which mainly proceed from the cerebral crura and callosum and thence diverge in every direction to the cortex. Approaching the latter, the central mass of white matter breaks up into short, thick plates, which pursue a tortuous course, intersect one another, and are enclosed by corresponding thick folds of the cortex. The arrangement is essentially the same as that in the cerebellum, in which the peripheral divisions lie parallel with one another instead of being tortuous.

The **convolutions**,<sup>3</sup> or tortuous divisions of the surface of the cerebrum, are much thicker and less uniform than the corresponding divisions or laminae of the cerebellum. Though approximating uniformity in size they vary considerably and generally are thicker about the middle than at the anterior and posterior extremities of the hemispheres. They are mostly of greater height than thickness and are slightly thicker at the top than at the bottom. They are even and smooth, flat at the sides, slightly flattened along the top, and rounded at the opening of the fissures separating them. The **fissures**<sup>4</sup> are of variable length and depth, accord in direction with the convolutions, often branch and run into one another, or they are interrupted and sometimes are short and isolated. Commonly from half an inch to an inch in depth, they vary in this respect in different brains and in different parts of the same brain. The convolutions are closely and evenly invested with the pia, from which processes dip between them to the bottom of the fissures.

The cerebral convolutions are to a variable degree unlike on the two sides of the brain. In different individuals they vary considerably in number, size, and direction. The principal ones recognized as most constant in position, though more or less modified by division or union and deviation of course, are regarded as of primary importance, while the others are viewed as offsets and of secondary importance. Of the fissures, equally variable in their course, the more constant serve to define the principal convolutions, and also groups of these distinguished as the lobes of the cerebrum.

The chief divisions\* of the cerebral hemispheres, with their principal convolutions and fissures, may now be conveniently examined. The former are distinguished as the frontal, parietal, occipital, temporal, and central lobes, and are to some extent defined by the sylvian, central, and parieto-occipital fissures.<sup>5</sup> The first three lobes lie in contact with the corresponding bones, but do not accord with their limits; the fourth occupies the middle cranial fossa, and the fifth is enclosed by the others.

<sup>1</sup> S. medullaris or alba.

<sup>2</sup> Substantia cinerea.

<sup>3</sup> Gyri.

<sup>4</sup> Sulci; furrows.

<sup>5</sup> Interlobar sulci.

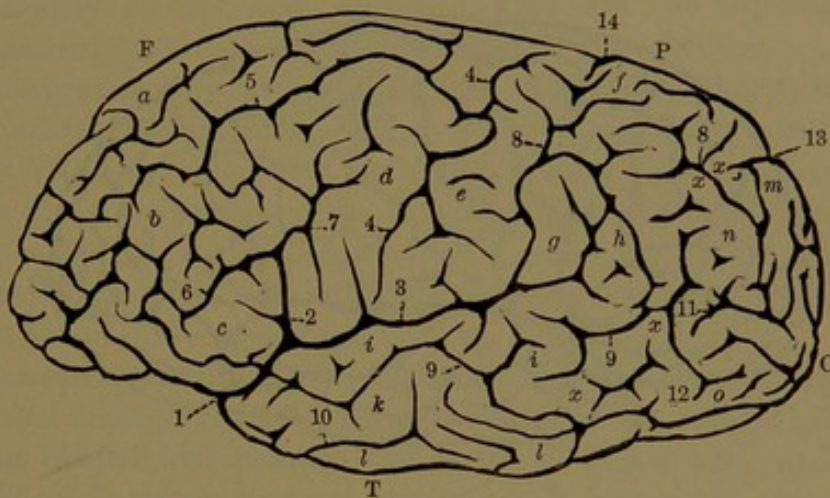


The **sylvian fissure**<sup>1</sup> is the most conspicuous of those of the cerebrum. It commences at the base of the latter, in the depression<sup>2</sup> forming the anterior perforated space, thence curves outwardly to the lateral surface of the hemisphere and divides into a short anterior and a long posterior branch. The inner lower portion of the fissure separates the frontal and temporal lobes and is occupied by the small wing of the sphenoid bone.

The **anterior branch**<sup>3</sup> ascends a short distance into the frontal lobe and terminates abruptly or opens into a contiguous fissure.

The **posterior branch**<sup>4</sup> runs backward and a little upward at about the middle third of the hemisphere and separates the parietal

FIG. 379.



LEFT HEMISPHERE OF THE CEREBRUM OF A WHITE MAN, outer view: one-fourth size. F, frontal lobe; P, parietal lobe; O, occipital lobe; T, temporal lobe; 1, sylvian fissure; 2, anterior branch; 3, posterior branch; 4, central fissure; 5, 6, 7, superior, inferior, and posterior frontal fissures; 8, interparietal fissure; 9, 10, superior and inferior temporal fissures; 11, 12, superior and inferior occipital fissures; 13, occipito-parietal fissure; 14, calloso-marginal fissure; a, b, c, superior, middle, and inferior frontal convolutions; d, e, anterior and posterior central convolutions; f, g, superior and inferior parietal convolutions; h, angular convolution; i, k, l, superior, middle, and inferior temporal convolutions; m, n, o, superior, middle, and inferior occipital convolutions; x, x, x, x, annectant convolutions.

and temporal lobes. Usually it turns up behind and ends abruptly in the parietal lobe, or occasionally into one of the contiguous fissures.

The group of convolutions included in the angle between the two branches of the sylvian fissure overlaps and conceals from view the central lobe. From its lid-like character it is called the **operculum**.<sup>5</sup>

The fore part of the sylvian fissure outwardly nearly ascends in position with the summit of the great sphenoidal wing. Its anterior branch ascends near the lower extremity of the fronto-parietal suture, and the posterior branch, after passing back over the fore part of the

<sup>1</sup> Fissura Sylvii; f. inferior, anterior, or transversa.

<sup>2</sup> Vallecule Sylvii.

<sup>4</sup> F. lateralis posticus.

<sup>3</sup> F. lateralis anticus or adscendens.

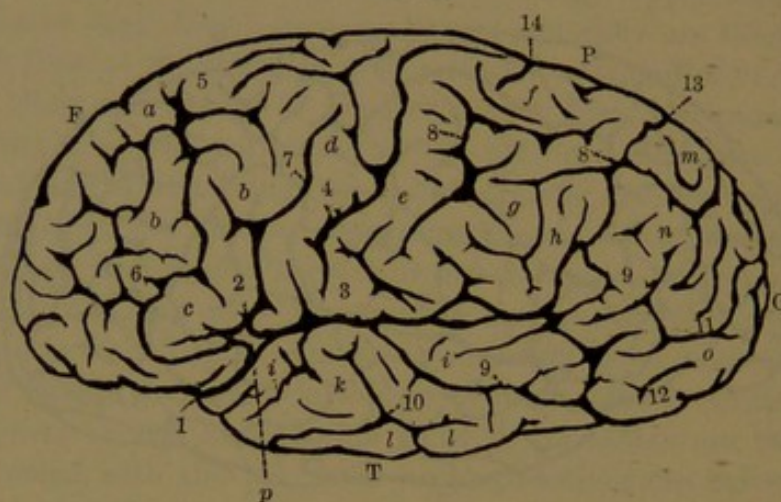
<sup>5</sup> O. lobi superioris.



temporo-parietal suture, ascends obliquely towards the centre of the parietal bone.

The **central fissure**,<sup>1</sup> or **fissure of Rolando**, though not specially conspicuous, is one of the most constant in its position and course. It runs obliquely across the lateral surface of the hemisphere near its middle. It usually commences just behind the vertex, or top of the hemisphere, close to the great longitudinal fissure, and descends obliquely forward to and near the sylvian fissure, into which it occasionally opens. It defines the frontal from the parietal lobe, and runs nearly parallel with the coronal suture, but is situated a considerable distance behind it.

FIG. 380.



LEFT HEMISPHERE OF THE CEREBRUM OF A NEGRO MALE, outer view: one-fourth size. References as in the preceding figure. 3, the posterior branch of the sylvian fissure, continuous through intermediate fissures with the parieto-occipital fissure 13, and with another separating the temporal and occipital lobes. *p*, points to the position where the sylvian fissure forks, in which the central lobe is visible externally.

The central fissure is remarkably constant and uniform in man and the higher apes, but is not present in mammals generally. It seems to be the result of an early communication in its position between the longitudinal sinus and the middle cerebral vein, which is well marked to about the middle of foetal life, but is subsequently obliterated.

The **parieto-occipital fissure**<sup>2</sup> in its usually greater extent is seen on the median surface of the cerebral hemisphere, where it descends from the upper margin, some distance behind the callosum, to the calcarine fissure, which runs from beneath the latter to near the posterior extremity of the hemisphere. Its external portion,<sup>3</sup> usually short, turns

<sup>1</sup> *F. centralis*; *f. transversa anterior*; *sulcus parietalis anterior*; *scissura perpendicularis*.

<sup>2</sup> *F. parieto-occipitalis internus*; *f. occipitalis perpendicularis* or *posticus*; *sinus parieto-occipitalis*; *s. opertus minor*.

<sup>3</sup> External parieto-occipital fissure.



outward and ends abruptly or terminates in a contiguous fissure. It partially defines the parietal and occipital lobes. Occasionally through one or more of the intermediate fissures it is continuous with the sylvian fissure and completely separates the parietal and occipital lobes, as in the negro brain represented in Fig. 380.

The **frontal lobe**<sup>1</sup> of the cerebral hemisphere is that portion in advance of the central fissure laterally and the sylvian fissure beneath. It is not defined on the inner surface of the hemisphere behind, but is separated from the fornicate convolution at its lower part by the calloso-marginal fissure. It displays four principal convolutions,<sup>2</sup> variably modified in different brains by division into secondary convolutions and by difference in their connections. All are seen on the outer or frontal surface of the lobe, and they extend on the lower or orbital surface and partially on the inner surface. They are the superior, middle, and inferior frontal and the anterior central convolutions.

The **anterior central convolution**<sup>3</sup> descends obliquely in advance of the central fissure, around the ends of which it is commonly continuous with the posterior central convolution. Its upper extremity<sup>4</sup> reaches the inner surface of the frontal lobe bordering the longitudinal fissure, where it is continuous with the superior frontal convolution. Its lower extremity, at the sylvian fissure, is usually continuous with the inferior frontal convolution.

The **superior frontal convolution**<sup>5</sup> borders the great longitudinal fissure and is displayed on all three surfaces of the frontal lobe. Commencing behind and beneath the latter in union with the fornicate convolution, it winds forward, upward, and backward around it and joins the upper extremity of the anterior central convolution. It is variably subdivided on both the inner and outer surfaces, and on the orbital surface forms the inner convolution,<sup>6</sup> which is divided fore and aft by the **olfactory fissure**<sup>7</sup> for the accommodation of the olfactory lobe.<sup>8</sup>

The **middle frontal convolution**,<sup>9</sup> variously subdivided and connected with the adjacent convolutions, occupies the outer surface of the frontal lobe in an intermediate position to the others and is also continued beneath as the intermediate convolution<sup>10</sup> of the orbital surface.

The **inferior frontal convolution**,<sup>11</sup> below the preceding outwardly,

<sup>1</sup> Lobus frontalis.

<sup>2</sup> Gyri frontales.

<sup>3</sup> Ascending or transverse frontal convolution; gyrus centralis anticus; tractus parietalis anticus; premier pli ascendant; circonvolution transverse pariétale antérieure.

<sup>4</sup> Lobus paracentralis.

<sup>5</sup> Gyrus frontalis superior; first frontal convolution.

<sup>6</sup> Internal orbital convolution.

<sup>7</sup> Sulcus olfactorius; s. rectus.

<sup>8</sup> Olfactory nerve.

<sup>9</sup> Gyrus frontalis medius; second frontal convolution.

<sup>10</sup> Anterior orbital convolution.

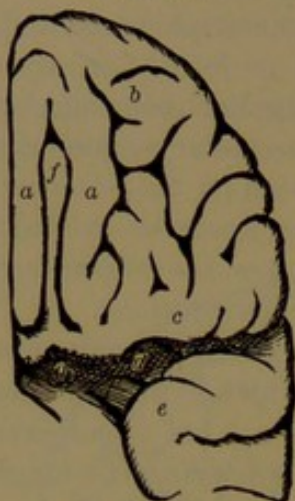
<sup>11</sup> Gyrus frontalis inferior; third frontal convolution.



borders the sylvian fissure, arching over its anterior branch to join the lower extremity of the anterior central convolution. A continuation<sup>1</sup> inwardly forms the back part of the orbital surface bordering the sylvian fissure.

On the frontal surface of the frontal lobe the anterior central con-

FIG. 381.



UNDER SURFACE OF THE FRONTAL LOBE OF THE LEFT CEREBRAL HEMISPHERE: one-fourth size. *a, a*, superior frontal convolution; *b*, middle frontal convolution; *c*, inferior frontal convolution; *d*, sylvian fissure; *g*, anterior perforated space; *e*, temporal lobe; *f*, olfactory lobe.

volution is separated by the **posterior frontal fissure** from the frontal convolutions, and these are separated by the **superior** and **inferior frontal fissures**. The fissures are very variable and more or less interrupted or bridged by connecting convolutions. On the orbital surface the convolutions are separated by a variably-irregular **triradiate fissure**.<sup>2</sup>

The **parietal lobe**<sup>3</sup> occupies the outer surface of the cerebral hemisphere behind the middle. It is defined in front by the central fissure, below in part by the sylvian fissure, and usually in a less degree behind by the parieto-occipital fissure. Commonly behind and below it is continuous with

both the occipital and temporal lobes. Rarely, as seen in Fig. 380, by an extension of the parieto-occipital fissure and its continuity through intermediate fissures with the sylvian fissure, the parietal lobe becomes completely separated from the occipital and temporal lobes.

Three principal convolutions occupy the outer surface of the parietal lobe, and two of them extend to the inner surface of the hemisphere as the quadrate lobule. They are the posterior central and the superior and inferior parietal convolutions.

The **posterior central convolution**<sup>4</sup> borders the central fissure behind and parallel with the anterior central convolution, with which it is ordinarily continuous at both extremities around the ends of the central fissure.

The superior and inferior parietal convolutions, behind the former, are separated by the variable fore and aft **interparietal fissure**,<sup>5</sup> which is sometimes interrupted and sometimes is continuous with the

<sup>1</sup> Posterior orbital convolution.

<sup>2</sup> Sulcus triradiatus; s. orbitalis.

<sup>3</sup> Lobus parietalis; l. temporalis.

<sup>4</sup> Ascending parietal convolution; gyrus centralis posticus; tractus parietalis medius; deuxième pli ascendant; circonvolution transverse médio-pariétale.

<sup>5</sup> Intraparietal sulcus.

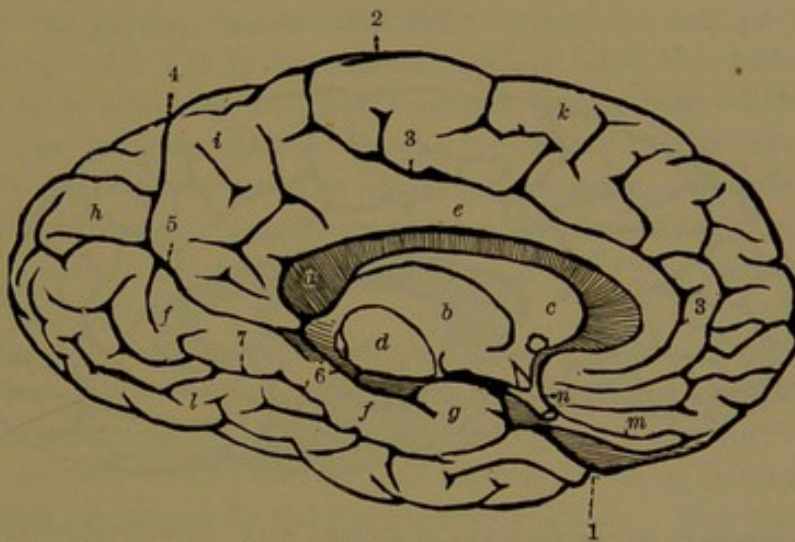


parieto-occipital fissure, or more rarely with the sylvian fissure and occasionally with both.

The **superior parietal convolution**,<sup>1</sup> variously subdivided, occupies the upper part of the parietal lobe, and is commonly continuous in front with the posterior central convolution. Behind it is the parieto-occipital fissure, below the end of which it usually joins the occipital lobe by a narrow bridge, distinguished as the **first annectant convolution**.

The **inferior parietal convolution**,<sup>2</sup> below the former and often united with it across the interparietal fissure, is tortuous and variably subdivided and connected. Commonly it exhibits two chief portions, distinguished as the superior marginal and angular convolutions.

FIG. 382.



RIGHT HEMISPHERE OF THE CEREBRUM OF A WHITE MAN, inner view: one-fourth size. 1, sylvian fissure; 2, upper end of the central fissure; 3, calloso-marginal fissure; 4, parieto-occipital fissure; 5, calcarine fissure; 6, hippocampal fissure; 7, collateral fissure. a, callosum; b, thalamus; c, striatum; d, section of crus; e, fornicate convolution; f, hippocampal convolution; g, hippocampal hook; h, cuneate lobule; i, quadrate lobule; k, superior frontal convolution; l, temporo-occipital convolution; m, olfactory lobe; n, optic nerve.

The **superior marginal convolution** is usually continuous with the lower extremity of the posterior central convolution and thence arches over the posterior extremity of the sylvian fissure, behind which it joins the superior temporal convolution of the temporal lobe.

The **angular convolution**, behind the former, in like manner usually arches over the turned-up extremity of the superior temporal fissure, running below and nearly parallel with the sylvian fissure, and commonly joins the middle temporal convolution and the occipital lobe. With the latter it is commonly connected through the middle occipital convolution by two branches, distinguished as the **second and third annectant convolutions**.

<sup>1</sup> Sup. par. lobule; gyrus parietalis superior.

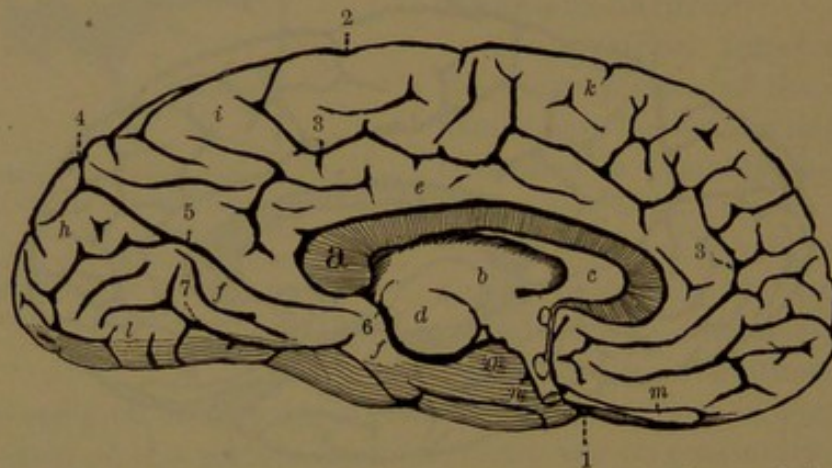
<sup>2</sup> Inf. par. lobule; gyrus parietalis inferior.



On the median surface of the cerebral hemisphere the upper extremity of the posterior central convolution, together with the contiguous portion of the superior parietal convolution, forms the **quadrate lobule**,<sup>1</sup> which is variously subdivided and is defined before and behind by the central and parieto-occipital fissures and is continuous inwardly below with the fornicate convolution.

The **occipital lobe**<sup>2</sup> of the cerebral hemisphere is the pyramidal portion behind the parieto-occipital fissure, and is commonly continuous by its convolutions with those of the parietal and temporal lobes. It occupies the upper fossa of the occipital bone and rests on the tentorium. Its outer surface exhibits three principal convolutions, as usual variously subdivided, and distinguished from their relative position as the superior, middle, and inferior occipital convolutions. These

FIG. 383.



RIGHT HEMISPHERE OF THE CEREBRUM OF A NEGRO MALE. From the same brain as Fig. 380. References as in Fig. 382.

are separated by the equally variable **superior** and **middle occipital fissures**, of which the former is often continuous with the parieto-occipital fissure.

The **superior occipital convolution**<sup>3</sup> commonly joins the superior parietal convolution below the parieto-occipital fissure by means of the first annectant convolution.

The **middle occipital convolution**<sup>4</sup> ordinarily joins the inferior parietal convolution by two branches, the second and third annectant convolutions.

The **inferior occipital convolution**<sup>5</sup> usually joins both the middle and the inferior temporal convolution by a **fourth annectant convolution**.

On the inner surface of the cerebral hemisphere the superior oc-

<sup>1</sup> Lobulus quadrilateralis; l. parietalis; præcuneus; lobule du deuxième pli ascendant.

<sup>2</sup> Lobus occipitalis.

<sup>4</sup> G. occipitalis medius.

<sup>3</sup> Gyrus occipitalis superior.

<sup>5</sup> G. occipitalis inferior.



occipital convolution occupies a triangular area, in which it forms the **cuneate lobule**,<sup>1</sup> variably subdivided, defined in front by the parieto-occipital fissure, behind and below by the calcarine fissure.

The under or tentorial surface of the occipital lobe is formed by two principal convolutions, which extend fore and aft from the temporal lobe separated by the collateral fissure and variously subdivided. The innermost convolution is a prolongation<sup>2</sup> of the hippocampal convolution from the inner side of the temporal lobe and is separated from the cuneate lobule by the calcarine fissure. The outermost lower convolution is the occipital portion of the **occipito-temporal convolution**,<sup>3</sup> which usually runs the length of both the temporal and occipital lobes, and is separated from the inferior occipital convolution by the **inferior occipital fissure**.

The **temporal lobe**<sup>4</sup> occupies the middle cranial fossa and is separated by the sylvian fissure from the frontal lobe and partially from the parietal lobe. It is continuous behind with the latter and the occipital lobe, while its anterior rounded apex is free. Five principal convolutions, variable as usual, occupy its surface. Three are displayed outwardly, distinguished as the **superior, middle, and inferior temporal convolutions**,<sup>5</sup> usually pursuing a fore and aft course, separated from one another and from the remaining pair of convolutions by corresponding fissures.

The superior and middle temporal convolutions commonly turn up behind the sylvian fissure and join the inferior parietal convolution. The **superior temporal fissure**,<sup>6</sup> separating them, usually runs parallel with the sylvian fissure and in like manner turns up behind, where it is ordinarily embraced by the angular convolution. The inferior temporal convolution and sometimes the middle one join the occipital lobe by an annectant convolution.

Rarely the temporal convolutions are separated from the parietal and occipital lobes by fissures continuous with the sylvian fissure, when the temporal lobe appears outwardly distinct from the others, as in the case of the negro brain represented in Fig. 380. The remaining convolutions of the temporal lobe occupy its lower surface and are thence commonly continued backward on the under surface of the occipital lobe. The outer convolution succeeds the temporal convolutions and is the fore part of the **occipito-temporal convolution**,<sup>7</sup> which variably subdivided extends the length of both the temporal and occipital lobes.

Separated from the occipito-temporal convolution by the collateral

<sup>1</sup> Cuneus; lobulus occipitalis; l. interparietalis superius; l. falciformis posticus or minor.

<sup>2</sup> Lobulus lingualis.

<sup>3</sup> Gyrus occipito-temporalis inferius.

<sup>4</sup> Lobus temporo-sphenoidalis, temporalis, or sphenoidalis.

<sup>5</sup> Gyri temporo-sphenoidales; transverse temporal gyri.

<sup>6</sup> Sulcus temporo-sphenoidalis superius; s. temporalis parallelus.

<sup>7</sup> Gyrus occipito-temporalis inferius; lobulus fusiformis.



fissure inwardly is the **hippocampal convolution**.<sup>1</sup> This commences near the apex of the temporal lobe, winds backward round the outer side of the cerebral crus, and, after giving a division<sup>2</sup> behind the callosum to the fornicate convolution, is continued beneath the occipital lobe below the calcarine fissure. It forms the floor of the descending horn of the lateral ventricle, and its lower extremity is bent upward and backward on itself in the **hippocampal hook**,<sup>3</sup> which embraces the lower end of the horn.

The hippocampal convolution is separated from the cerebral crus by the **hippocampal fissure**,<sup>4</sup> which dips into the hippocampus and extends from within the fornicate convolution behind the callosum downward to the hippocampal hook. From the bottom of the fissure projects inwardly the **dentate band**,<sup>5</sup> an indented gray ridge or narrow convolution, which descends along the upper border of the hippocampal convolution.

Above the position of the dentate band the pia is connected with the choroid plexus occupying the descending horn of the lateral ventricle.

The hippocampal convolution is peculiar in the fact that it is invested inwardly with a thin reticular layer of white nerve-matter.<sup>6</sup>

The **collateral fissure**,<sup>7</sup> named from its penetrating at bottom the collateral eminence of the descending horn of the lateral ventricle, pursues a fore and aft course, variably divided and separating the hippocampal and occipito-temporal convolutions.

The **calcarine fissure**,<sup>8</sup> named from its penetrating at bottom into the calcar of the posterior horn of the lateral ventricle, commences by dividing the hippocampal convolution beneath the back part of the callosum, whence it extends backward to the posterior extremity of the hemisphere. About midway it is joined by the parieto-occipital fissure, and it separates the occipital portion of the hippocampal convolution from the fornicate convolution and the cuneate lobule.

The **central lobe**,<sup>9</sup> or **island of Reil**, lies within the cerebral hemisphere, concealed by the operculum. It is a triangular eminence composed of five or six convolutions<sup>10</sup> which start from the inner extremity of the sylvian fissure, at the anterior perforated space, and thence diverge upward, enlarge in their ascent, and become continuous with those of the operculum. In front it is defined from the frontal lobe by

<sup>1</sup> G. hippocampus or uncinatus; g. occipito-temporalis superius or medialis; subiculum cornu ammonis; pli temporal supérieur interne.

<sup>2</sup> Isthmus.

<sup>3</sup> Processus unciformis; uncus.

<sup>4</sup> Dentate fissure.

<sup>5</sup> Fascia dentata.

<sup>6</sup> Substantia alba reticularis.

<sup>7</sup> Sulcus occipito-temporalis.

<sup>8</sup> Fissura calcarina; f. hippocampi; f. occipitalis horizontalis or posticus.

<sup>9</sup> Lobus centralis, caudicus, opertus, or medius; insula; i. Reilii; lobulus corporis striati; l. fissuræ Sylvii.

<sup>10</sup> Gyri operti, unciformes, or breves.



a fissure proceeding outwardly into the anterior branch of the sylvian fissure, and behind from the temporal lobe by another running into the posterior branch of the sylvian fissure. It projects below and to the outer side of the position of the striatum and thalamus. It is earlier produced in the embryo than the other lobes of the hemisphere which enclose it. Occasionally, especially in the negro brain, a small portion of this lobe is visible immediately below the point of division of the sylvian fissure, as seen in Fig. 380.

An additional portion of the cerebral hemisphere, distinct from the lobes above described, is the **fornicate convolution**,<sup>1</sup> situated centrally on the median surface. It commences narrowly beneath the fore part of the callosum where it joins the superior frontal convolution, thence arches round and over the former, widening and variously subdivided, and continuous behind into the quadrate lobule. From the superior frontal convolution, continuous with the upper extremity of the anterior central convolution, it is separated by the **calloso-marginal fissure**, which pursues nearly the same course and ascends behind, in front of the quadrate lobule, to end at the vertex a short distance back of the central fissure. From the callosum, closely embraced by it, it is separated by the **callosal fissure**, at the bottom of which outwardly the gray cortex of the convolution abruptly ceases.

The superior and inferior frontal convolutions beneath the frontal lobe behind conjoin in a low pyramidal eminence, the **olfactory tuber**,<sup>2</sup> from which the olfactory lobe is extended forward beneath the olfactory fissure. Externally the tuber is continuous with the lower end of the central lobe of the cerebral hemisphere and inwardly with the commencement of the superior frontal and fornicate convolutions. The gray cortex of the tuber is continuous above with the bottom of the lenticular nucleus and claustrum in the interior of the hemisphere.

Behind the olfactory tuber is a slightly depressed area, the **anterior perforated space**,<sup>3</sup> which extends outwardly to the commencement of the sylvian fissure and is limited behind by the optic tract. It is pierced with many small foramina for the passage of blood-vessels, which mainly ascend to the striatum. It is chiefly composed of gray matter<sup>4</sup> continuous above with the nuclei of the striatum, but is crossed superficially by a band of white matter continued from the peduncle of the callosum and proceeding from the longitudinal fissure outward to the sylvian fissure.

The **olfactory lobe**,<sup>5</sup> which has been usually described as the olfactory nerve, is in man a feebly-developed part of the brain in com-

<sup>1</sup> Gyrus fornicatus; g. supracallosus; fornix periphericus; circumvolutio cristata; circonvolution de l'ourlet; grande circonvolution du corps calleux.

<sup>2</sup> Tuber olfactorius.

<sup>3</sup> Locus perforatus anticus.

<sup>4</sup> Substantia perforata anterior; s. cribrosa lateralis; lamina cribrosa.

<sup>5</sup> Lobus olfactorius; rhinencephalon.



parison with its ordinary condition in most vertebrates. It is a long club-shaped body lying along the olfactory fissure beneath the superior frontal convolution on the orbital surface of the frontal lobe of the cerebrum. The narrow portion, or **olfactory tract**,<sup>1</sup> is three-sided, with two sides slanting laterally, adapted to the olfactory fissure, and the remaining side directed downward. The posterior extremity is expanded and continuous with the olfactory tuber. The anterior extremity swells into an oval mass, the **olfactory bulb**,<sup>2</sup> which lies in the ethmoidal gutter and from beneath gives off the olfactory nerves.

The lower part of the olfactory tract is white and composed of longitudinal bundles of medullated nerve-fibres, which diverge at the posterior extremity in two portions, entering the olfactory tuber as the **external**<sup>3</sup> and the **internal root**.<sup>4</sup> The upper border of the tract appears gray, and its connection with the olfactory tuber is the **middle root**.<sup>5</sup> The olfactory bulb is softer than the tract, is gray below and white above.

The olfactory tract below and at the sides is mainly composed of longitudinal bundles of medullated nerve-fibres enclosing neuroglia, which extends to the upper border of the tract. The olfactory bulb is, for the most part, composed of gray matter, except above, where it appears white. The upper portion, nearly a third of the thickness of the bulb, is chiefly composed of bundles of medullated fibres proceeding from those of the tract and arranged in the form of a flattened pouch, which is filled with neuroglia containing small nerve-cells sparsely scattered. The intermediate portion of the bulb, more than a third of its thickness, is composed chiefly of neuroglia with numerous nerve-cells more or less scattered and in groups. In the upper stratum<sup>6</sup> of this portion the cells are more numerous and more grouped and resemble those in the deeper layer of the cortex of the cerebellum. In the lower stratum<sup>7</sup> the cells are generally pyramidal, the largest ones above and resembling those of the cortex of the cerebrum. The lower portion<sup>8</sup> of the bulb is mainly composed of a dense plexus of bundles of non-medullated nerve-fibres, descending from above and arranged horizontally below. Embedded among the descending bundles of fibres are many rounded groups of nerve-cells, the **olfactory glomeruli**, which give origin to nerve-fibres.

The olfactory nerves proper appear as bundles of non-medullated fibres, which emerge from the plexus forming the lower portion of the olfactory bulb.

<sup>1</sup> Tractus olfactorius; crus olfactorium; c. rhinencephalicum.

<sup>2</sup> Bulbus olfactorius; b. cinereus.

<sup>3</sup> Radix externus or longus.

<sup>4</sup> R. internus or brevis.

<sup>5</sup> Upper or gray root; trigonum olfactorium; pyramis grisea.

<sup>6</sup> Granule layer.

<sup>7</sup> Intermediate or nerve-cell layer.

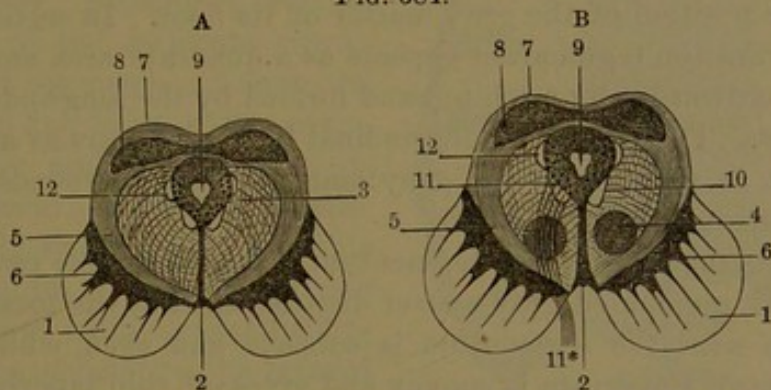
<sup>8</sup> Layer of olfactory nerve-fibres.



## THE CEREBRAL CRURA.

The **crura of the cerebrum**<sup>1</sup> emerge from the upper part of the pons, thence ascend obliquely forward and outward and enter the hemispheres beneath and internally about their centre. They are robust, cylindrical white columns, longitudinally striated and expanded in their ascent. Behind them is the quadrigeminal body, from which outwardly, as they enter the hemispheres, they are embraced by the geniculate bodies and optic tracts. From their divergence, in front they leave a space, the **intercrural recess**,<sup>2</sup> which is lozenge-shaped in outline and defined in front by the convergence of the optic tracts and chiasm. The recess deepens behind into an angular pit,<sup>3</sup> from the sides of which, at about half its depth, emerge the oculo-motor nerves. From the position of the nerves the bottom of the pit is distinguished as the **posterior perforated space**,<sup>4</sup> which is composed of gray matter traversed

FIG. 384.



SECTIONS ACROSS THE CEREBRAL CRURA AND QUADRIGEMINAL BODY: size of nature. A, section through the lower pair of tubercles of the quadrigeminal body; B, through the upper pair. 1, crusta; 2, posterior perforated space and raphé; 3, reticular formation of the tegmentum; 4, tegmental nucleus; 5, fillet; 6, locus niger; 7, quadrigeminal body; 8, nucleus of the quadrigeminal body; 9, ventricular aqueduct surrounded by gray matter; 10, posterior longitudinal bundle of nerve-fibres; 11, nucleus of the oculo-motor nerve 11\*; 12, nucleus and descending root of the trifacial nerve.

by many foramina for blood-vessels. Behind and outward the crura are defined from the quadrigeminal body and fillet by a groove, which together with the line of emergence of the oculo-motor nerve indicates the position of division of the crura into two portions, distinguished as the crusta and the tegmentum.

The **crusta**<sup>5</sup> forms the anterior portion of the crus, including about half its thickness, and is composed of bundles of fibres mainly proceeding from the pyramidal bundles of the pons and ascending to the corresponding cerebral hemisphere. Superficially the inner fibres of

<sup>1</sup> C. cerebri; cerebral peduncles; pedunculi cerebri.

<sup>2</sup> Interpeduncular space.

<sup>3</sup> Foramen cæcum anterius.

<sup>4</sup> Locus perforatus posterius; pons Tarini; substantia or lamina posterior perforata; l. cribrosa.

<sup>5</sup> Basis; pes; proper cerebral peduncle.



the crura are observed to diverge with an outward twist and ascend to the under and outer part of the thalami. In horizontal sections of the crura, the crusta is seen as a crescentic area, separated by an interval corresponding with the intercrural recess.

The **tegmentum** forms the back part of each cerebral crus, having the crusta in front and outwardly and the quadrigeminal body and ventricular aqueduct behind. It is the continuation upward of the reticular formation of the pons, associated with a considerable quantity of gray matter which between the crura forms the posterior perforated space. Its longitudinal bundles of fibres partly appear as those which directly ascend from the anterior columns of the spinal cord through the reticular formation of the oblongata and pons. Others are derived from the superior peduncles of the cerebellum, intersect one another through the raphé, and thence ascend to the thalami of opposite sides. A more defined band, the **posterior longitudinal bundle**, ascends along the course of the ventricular aqueduct just outside the position of the gray matter of its floor. In sections of the cerebral crura the tegmentum appears as a quadrate area embraced in front and outwardly by a white band formed by the longitudinal fibres of the fillet. The posterior longitudinal bundle appears as a pyriform white islet at the side of the gray matter which surrounds the ventricular aqueduct.

Between the crusta and tegmentum is a considerable patch of unusually dark pigmented gray matter distinguished as the **locus niger**.<sup>1</sup> Its surface next the tegmentum is concave and even, while that directed towards the crusta is convex and gives off thin tapering laminae which penetrate among the fibrous bundles of the crusta. In cross-sections of the crura it appears like a crescentic comb with the teeth directed from the convex border.

In the upper part of the cerebral crura, embedded among the ascending fibres of the tegmentum, is an oval accumulation of pale reddish-gray matter, named the **tegmental nucleus**.<sup>2</sup>

The space between the cerebral crura, or the intercrural recess, defined in front by the optic tracts and commissure, is occupied by a lozenge-shaped gray eminence, the **cinereous tuber**.<sup>3</sup> Continuous behind with the posterior perforated space, it forms the lower part of the third ventricle, from which it is prolonged in the **infundibulum**. This is a hollow conical process descending from the third ventricle behind the optic commissure and ending by joining the pituitary body.

Embedded in the outer part of the cinereous tuber is a small group of nerve-cells,<sup>4</sup> which give origin to some of the fibres of the contiguous optic tract.

From the cinereous tuber beneath and behind the infundibulum,

<sup>1</sup> Substantia nigra; stratum nigrum.

<sup>3</sup> T. cinereum; basis infundibuli.

<sup>2</sup> N. tegmenti; the red nucleus.

<sup>4</sup> Basal optic ganglion.

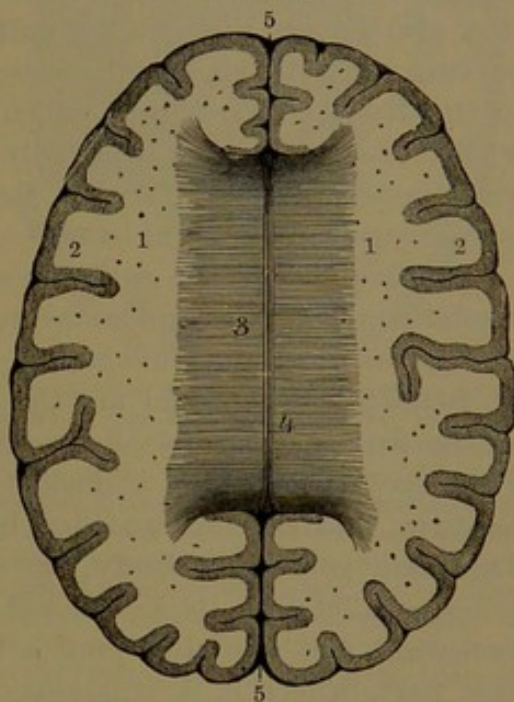


project the **mammillary eminences**,<sup>1</sup> a pair of white spherical bodies lying side by side. Each is formed by the conjunction of two roots or bundles of nerve-fibres, which descend through the cinereous tuber and converge in a twisted fold enclosing a gray nucleus. The **anterior root**<sup>2</sup> corresponds with the anterior pillar of the fornix, while the **posterior root**<sup>3</sup> is derived from the anterior nucleus of the thalamus.

The **interior of the cerebrum**. On separating the hemispheres towards the bottom of the great longitudinal fissure the **callosum**<sup>4</sup> is seen extending along the middle for nearly half its length and passing laterally beneath the calloso-marginal fissure into the hemispheres. By removing the upper part of these on a line with the fissure, the callosum is observed to be a wide bridge connecting the white mass of matter<sup>5</sup> of the interior of the hemispheres. Arching over it on each side is the fornicate convolution. It approaches nearer the front than the back of the brain, is strongly arched fore and aft and is concave from side to side, or is nearly straight at the middle and curved up at the sides. It is a thick plate of white matter roofing over a pair of cavities, the **lateral ventricles**<sup>6</sup> of the brain; it is thinner along the middle and thickest at the posterior border, where it is also widest. It is transversely striated above and below, and is composed of flattened bundles of medullated nerve-fibres closely aggregated and passing into the white matter of the cerebral hemispheres extending in every direction to the enveloping cortex.

The posterior thickened rounded border of the callosum, named the **splenium**, is situated at the bottom of the interval between the cerebrum and the cerebellum just above the transverse cerebral fissure,

FIG. 385.



TRANSVERSE SECTION OF THE HEMISPHERES OF THE CEREBRUM ON A LEVEL WITH THE CALLOSUM. 1, white substance of the hemispheres, dotted with divided blood-vessels; 2, gray cortex of the convolutions; 3, callosum, with the direction of its fibres indicated by transverse striæ; 4, longitudinal median striæ; 5, anterior and posterior portions of the great longitudinal fissure.

<sup>1</sup> Eminentia or corpora mammillaria, albicantia, candicantia, or papillaria; bulbs of the fornix.

<sup>2</sup> Radix adscendens fornicis.

<sup>3</sup> R. descendens fornicis.

<sup>4</sup> Corpus callosum; trabs cerebri or medullaris; commissura cerebri magna.

<sup>5</sup> Centrum ovale or semiovale Vieussenii; c. medullare; c. ovale minus and majus; tegmentum ventriculorum.

<sup>6</sup> Ventriculi laterales or tricornes.



which communicates between that interval and the third ventricle of the brain.

In front the callosum folds from above downward and backward in the **knee**,<sup>1</sup> and the under part of this tapers into the **rostrum**,<sup>2</sup> which curves downward to the bottom of the cerebrum. At the sides the rostrum is connected with the frontal lobes and below with the cinereous lamina, by which it is attached to the optic commissure.

Crossing the middle of the callosum above, fore and aft, are the **median longitudinal striæ**,<sup>3</sup> two white lines separated by a furrow<sup>4</sup> and consisting of slender bundles of nerve-fibres. At the back of the callosum they diverge and enter the occipital lobes. On the knee they also diverge and join the **callosal peduncles**.<sup>5</sup> These appear as narrow white bands, which descend at the sides of the rostrum close to the frontal lobes, from which they also receive fibres and then widely diverge and run outwardly across the anterior perforated space contiguous to the optic tract. Below the rostrum they are joined by a transverse commissural band.<sup>6</sup>

At the sides of the callosum are the **lateral longitudinal striæ**,<sup>7</sup> similar to the former and connected with the longitudinal fibres of the contiguous fornicate convolution.

Beneath the callosum are the **right and left lateral ventricles**,<sup>8</sup> or the first and second of the five like-named cavities of the brain. They are separated by a median vertical partition, the **ventricular septum**, and each is extended by prolongations, named the **horns**.<sup>9</sup> The main portion, or **body**,<sup>10</sup> of each ventricle is a fore and aft cleft, lying parallel with its fellow and arching from in front upward and backward and then diverging a little outward. It is deepest at the fore part, where it is trilateral, and it gradually becomes shallower behind. Its roof is formed by the callosum; its inner wall by the ventricular septum which merges behind into the fornix. Its outer wall gradually passes behind into the floor and is formed in succession by the striatum, the semicircular band, the thalamus, the choroid plexus, and the lateral band of the fornix.

The fore part of the lateral ventricle extends a little way into the frontal lobe as the **anterior horn**,<sup>11</sup> into which projects the thick anterior extremity of the striatum, and is enclosed within the anterior folded portion of the callosum. Its posterior extremity is continuous with the longer and more conspicuous prolongations, the posterior and middle horns.

<sup>1</sup> Genu corporis callosi.

<sup>2</sup> R. corporis callosi.

<sup>3</sup> S. longitudinales mediales or internæ; nerves of Lancisi.

<sup>4</sup> Raphé.

<sup>5</sup> Pedunculi corporis callosi.

<sup>6</sup> Commissura baseos alba.

<sup>7</sup> S. longitudinales laterales or externæ; ligamenta tecta or obtecta.

<sup>8</sup> Ventriculi laterales, tricornes, anteriores, or magni; procœliæ.

<sup>9</sup> Cornua.

<sup>10</sup> Corpus ventriculi; aula.

<sup>11</sup> Cornu anterius; præcornu.



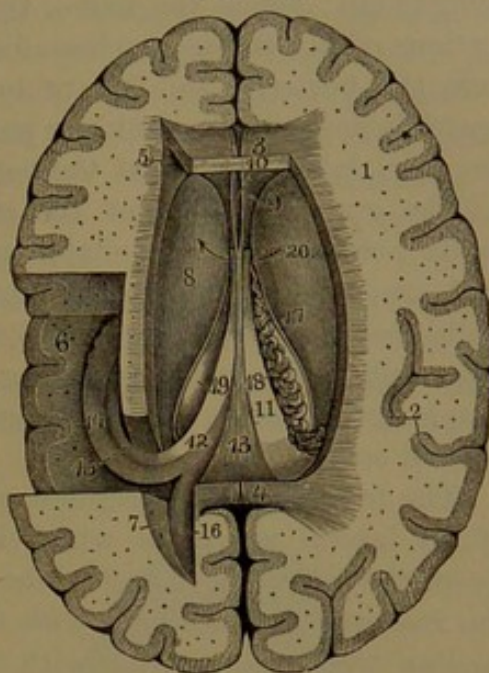
Near the middle of the body of each ventricle, at its lowest point, is a rounded aperture, the **foramen of Monro**, by which the lateral ventricles communicate with the third ventricle.

The **ventricular septum**,<sup>1</sup> the median partition of the lateral ventricles, is deepest in front, where it is included in the knee of the callosum, and it tapers away behind between the latter and the fornix. It is also thickest in front, thins away and becomes pellucid behind. Its outer surfaces are concave, due to the gradual thickening of the septum approaching the contiguous surfaces of the ventricle. It encloses a cleft, the **fifth ventricle**,<sup>2</sup> widest forward and above and extending the greater part of the depth of the septum, but everywhere closed. Each side of the ventricle composing the septum consists of an external lamina of white matter continuous with that of the callosum and interior of the hemisphere, and a thinner internal lamina of gray matter, which is isolated from the gray matter of the cerebrum.

In the development of the brain the fifth ventricle at first appears as a part of the great longitudinal fissure and is subsequently closed from it in the production of the callosum.

The **striatum**, or **corpus striatum**,<sup>3</sup> appears in the body of the lateral ventricle as a smooth, convex gray eminence projecting from its outer wall into the anterior horn and tapering behind outside and above the thalamus, where it disappears from view. Its fore part is directed towards its fellow and is separated from it by the deeper portion of the ventricular septum. It is chiefly a pyriform mass of gray matter embedded in the white matter of the cerebral hemisphere with

FIG. 386.



TRANSVERSE SECTION OF THE CEREBRAL HEMI-SPHERES, THE CALLOSUM REMOVED, AND THE LATERAL VENTRICLES EXPOSED. 1, white substance of the interior of the cerebral hemispheres; 2, gray cortex of the convolutions; 3, 4, anterior and posterior extremities of the callosum; 5, anterior horn of the left lateral ventricle; 6, middle or descending horn; 7, posterior horn; 8, striatum; 9, ventricular septum; 10, fifth ventricle; 11, fornix; 12, posterior crus of the fornix; 13, attachment of the fornix to the under part of the callosum; 14, hippocampus; 15, fimbria; 16, calcar; 17, semicircular band; 18, choroid plexus; 19, edge of the thalamus; 20, arrow through the foramen of Monro.

<sup>1</sup> S. ventriculorum, lucidum or pellucidum, medium, or medullare triangulare.

<sup>2</sup> Ventriculus quintus, septi lucidi, or Sylvii; incisura, camera, or sinus septi lucidi; pseudocœlia.

<sup>3</sup> Eminentia striata or pyriformis; ganglion magnum superior cerebri.



its free surface projecting into the lateral ventricle. The greater part inwardly is of uniform structure, but its outer lower part is streaked, due to the entrance of laminae from the contiguous white matter of the hemisphere; hence the name, though the appearance is seen only in sections of it. It has also been distinguished as the **caudate nucleus**,<sup>1</sup> from the posterior tail-like prolongation,<sup>2</sup> which from the back of the ventricle descends in the inner part of the roof of the middle horn to the amygdaloid nucleus at the bottom of the cerebral hemisphere.

The gray substance of the striatum consists of a matrix of neuroglia pervaded by medullated nerve-fibres ascending from the cerebral crus and others communicating with the cerebral cortex, with embedded multipolar nerve-cells, moderately large and small, and with other spheroidal cells containing several nuclei. The ventricular surface is covered with a layer of neuroglia invested with an ependyma of ciliated cells.

The **fornix**<sup>3</sup> is a triangular white plate situated at the back part of the lateral ventricles, which it separates from the third ventricle. From the splenium it arches forward beneath the callosum nearly to the rostrum, is continuous with the former behind, is connected by a median triangular portion with the callosum above, and is connected in front with the posterior inferior border of the ventricular septum. The sides of the fornix are free and appear as a pair of flat cylindrical bands projecting from beneath the callosum into the lateral ventricles and resting on the thalami. In front they conjoin and curve forward and downward in advance of the thalami and become the **anterior pillars of the fornix**,<sup>4</sup> which descend as cylindrical cords, at first close together and then slightly diverging, and, after penetrating the cinereous tuber on each side, end in the mammillary eminences at the base of the brain. From the posterior angles of the fornix, the lateral bands, as the **posterior pillars**,<sup>5</sup> enter the middle horns of the ventricles and thence descend as the fimbriae. The under part of the fornix exhibits a median triangular depression enclosed by the lateral bands and the splenium, marked by longitudinal, oblique, and transverse striae and distinguished as the **lyre**.<sup>6</sup>

The **lateral bands** of the fornix, extended as the anterior and posterior pillars, are antero-posterior commissures composed of longitudinal bundles of nerve-fibres.

The **semicircular band**<sup>7</sup> is a narrow, semi-transparent whitish streak lying along the groove between the striatum and the thala-

<sup>1</sup> Interventricular portion of the corpus striatum.

<sup>2</sup> Cauda; surcingle.

<sup>3</sup> F. tricuspidalis; trigonum cerebris; corpus cameratum.

<sup>4</sup> Crura or columnae fornicis anteriora.

<sup>5</sup> Crura or columnae fornicis posteriora.

<sup>6</sup> Lyra; psalterium; corpus psaloides.

<sup>7</sup> Stria terminalis or cornea; tænia semicircularis or striata.



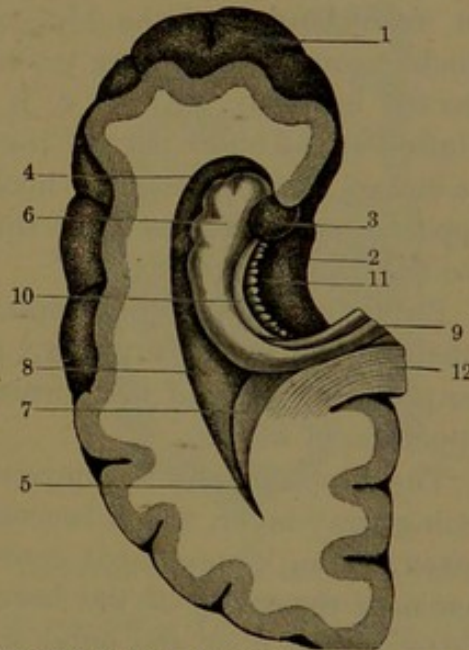
mus, having beneath it a vein which receives its branches from those bodies and ends in the internal cerebral vein. The band is a thin lamina of nerve-fibres ascending between the striatum and thalamus from the cerebral crus. Its fore part is continuous with the anterior pillar of the fornix, and its back part is prolonged and descends in the roof of the middle horn of the ventricle to the amygdaloid nucleus.

Between the semicircular band and the edge of the fornix, against which lies the choroid plexus, a narrow strip of the thalamus is visible, but as it mainly enters into the construction of the third ventricle it will be described with that cavity.

The **posterior horn**<sup>1</sup> of the lateral ventricle is a conical prolongation from the body curving outward, backward, and inward into the occipital lobe. From its bottom inwardly projects a claw-shaped white eminence, the **calcar**,<sup>2</sup> which is continuous with the hippocampus of the middle horn of the ventricle and is produced by the inward fold of the contiguous convolutions of the bottom of the calcarine fissure. A less conspicuous prominence<sup>3</sup> above the calcar inwardly is produced by the bundles of fibres which curve from the splenium backward and outward into the occipital lobe. The roof of the horn is formed by the fibres of the callosum arching above the cavity into the occipital lobe.

The **middle, inferior, or descending horn**<sup>4</sup> of the lateral ventricle, much longer than the others, joins the posterior horn. It curves outward around the back of the thalamus and beneath it descends forward and inward to end within the anterior thickened extremity of the hippocampal convolution. Internally it opens along the hippocampal fissure, but is closed by the lining ependyma and contiguous pia. It is curved clavate, widening towards the bottom. Its roof is formed in part by the thalamus and partly by the radiating

FIG. 387.



SECTION OF THE LEFT CEREBRAL HEMISPHERE, exposing the middle and posterior horns of the lateral ventricle. 1, frontal lobe; 2, hippocampal convolution; 3, hippocampal hook; 4, lower end of the middle horn of the lateral ventricle; 5, posterior horn; 6, hippocampus; 7, calcar; 8, collateral eminence; 9, posterior crus of the fornix; 10, fimbria; 11, dentate band; 12, posterior extremity of the callosum.

<sup>1</sup> Cornu occipitale or ancyroide; cavitas digitata; postcornu; posterior cornu.

<sup>2</sup> C. avis; hippocampus minor; ergot; eminentia unciformis or digitata.

<sup>3</sup> Bulbus cornu posterioris.

<sup>4</sup> Cornu medium, inferius, descendens, magnum, laterale, or sphenoidale; ventriculus or sinus inferior hippocampi or cornu Ammonis; medicornu.



bundles of fibres of the callosum; its floor<sup>1</sup> by bundles curving from the splenium outward, downward, and forward, together with others extending from the occipital lobe to the end of the middle horn in the temporal lobe.

Projecting from the inner side of the horn, lying along its bottom is a conspicuous rounded ridge, the **hippocampus**,<sup>2</sup> which is continuous above with the posterior lateral angle of the fornix and gradually enlarges in its descent to the lower extremity. This outwardly exhibits three or four slight indentations, giving it the appearance of a paw, whence the name of **pes hippocampi**, conveniently substituted by that of hippocampus.

The hippocampus is formed by the out and in folding of the upper border of the hippocampal convolution, the hook of which encloses its lower end. The cavity of the horn curves from the hippocampal fissure outwardly above the hippocampus, then downward and inward beneath it into the middle of the hippocampal convolution. Beneath the inner border of the hippocampus projects the **dentate band**,<sup>3</sup> which is composed of gray matter and is dentated at the free border directed inwardly. Above, it is connected with the hippocampal convolution at the outer part of the splenium, and ends below by joining the end of the hippocampal hook. It is separated beneath from the hippocampal convolution by the **dentate fissure** opening inwardly into the hippocampal fissure.

Extending along the hippocampus, reflected outwardly from its inner border, is the **fimbria**,<sup>4</sup> a white band continuous above with the posterior pillar of the fornix and ending below in the end of the hippocampal hook.

The hippocampus is composed of two white layers with an intervening gray layer, which becomes superficial as the lower part of the cortex of the hippocampal convolution. The revolute white layer, or that next the cavity of the horn, is continuous with the interior white matter of the floor and outer wall, and along the inner border of the hippocampus is reflected outwardly as the fimbria. The involute white layer extends from the dentate fissure inwardly upon the hippocampal convolution and at the bottom of the fissure embraces the dentate band. This is a flattened cylindrical tract of gray matter continuous with that of the hippocampus beneath the upper part of the revolute white layer.

The gray layer of the hippocampus in composition resembles the cerebral cortex and consists of neuroglia with numerous large pyramidal nerve-cells mostly embedded next the revolute white layer, while

<sup>1</sup> Tapetum.

<sup>2</sup> H. major; cornu Ammonis or arietis; bombyx; vermis; appendix bombycinus.

<sup>3</sup> Fascia or fasciola dentata, denticulata, or cinerea; margo denticulatus Tarini.

<sup>4</sup> Corpus fimbriatum; limbus fimbriatus; tænia hippocampi.



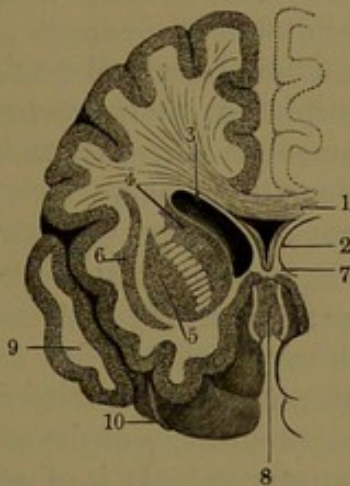
numerous smaller cells form a stratum contiguous to the involute white layer.

The axial portion of the dentate band consists of neuroglia with numerous nerve-cells like those of the hippocampal gray layer, with which it is continuous. Below and inwardly it has a stratum of minute cells. The whole is enclosed in a cortical layer of vascular neuroglia also containing many minute cells.

From the conjunction of the middle with the posterior cornu a smooth convex white ridge, the **collateral eminence**,<sup>1</sup> extends along the outer part of the inferior horn opposite the hippocampus. It is produced by the fold of the contiguous convolutions at the bottom of the collateral fissure.

Outside of the position of the lateral ventricle, embedded in the white matter of the central lobe of the cerebral hemisphere, is a mass

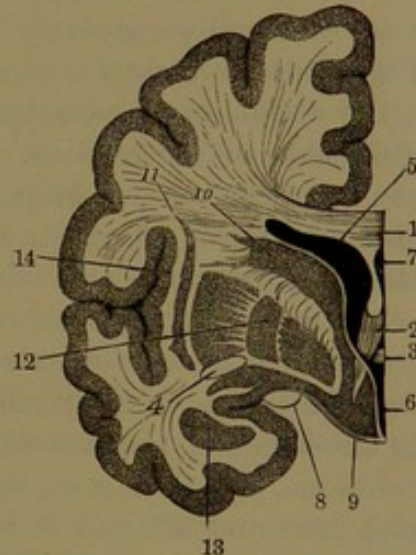
FIG. 388.



TRANSVERSE VERTICAL SECTION OF THE RIGHT HEMISPHERE OF THE CEREBRUM: the back part viewed from behind. 1, callosum; 2, ventricular septum with the fifth ventricle; 3, lateral ventricle; 4, striatum; 5, lenticular nucleus; 6, claustrum; 7, commissure of the floor of the third ventricle; 8, cinereous lamina closing the fore part of the latter; 9, temporal lobe; 10, olfactory nerve.

of gray matter, named from its general shape the **lenticular nucleus**.<sup>2</sup> It occupies an angular interval outwardly from the striatum and thalamus, from both of which it is separated by a considerable white layer, distinguished as the **internal capsule**<sup>3</sup> and consisting of ascending bundles of nerve-fibres

FIG. 389.



TRANSVERSE VERTICAL SECTION OF THE LEFT HEMISPHERE OF THE CEREBRUM: the back portion viewed from in front. 1, callosum; 2, anterior crus of the fornix; 3, anterior commissure of the third ventricle; 4, extension of the same into the hemisphere; 5, lateral ventricle; 6, bottom of the third ventricle; 7, fifth ventricle; 8, optic tract; 9, cinereous tuber; 10, striatum; 11, claustrum; 12, three zones of the lenticular nucleus; 13, amygdaloid nucleus; 14, central lobe of the cerebrum.

<sup>1</sup> Eminentia collateralis; pes accessorius.

<sup>2</sup> N. lentiformis; corpus striatum externum; extra-ventricular portion of the corpus striatum. It is common to include the lenticular nucleus with the corpus striatum, while the latter, as above described, is called the caudate nucleus.

<sup>3</sup> Capsula interna; triangulum medullare.



diverging from the cerebral crus. In sections of the fore part of the striatum it is observed to be continuous beneath with the lenticular nucleus, and both are also connected by many tapering gray striæ<sup>1</sup> which cross the internal capsule. Similar striæ from the inner side of the lenticular nucleus curve through the capsule towards the thalamus and downward among the ascending bundles of nerve-fibres. The outer surface of the lenticular nucleus gives off no processes and is evenly convex. In a frontal section of the brain, about the middle of the lenticular nucleus, it is observed to differ from the shape expressed by the name and to exhibit a wedge-like outline with the apex directed inward and downward to the cinereous tuber. The gray area further appears divided by two perpendicular curved white lines into three nearly equally wide bands, of which the external is the largest, darkest in color, and inwardly marked with radiant white striæ. The other bands are paler and in this respect resemble the tegmental nucleus. As the divisions from within outwardly extend fore and aft, in sections they are observed successively to decrease in number.

The lenticular nucleus is traversed by bundles of nerve-fibres derived from the crista of the cerebral crus, conspicuous as they enter the outer division of the nucleus. The intermediate lines separating its divisions indicate the position at which bundles of nerve-fibres enter the different parts. Bundles of nerve-fibres also connect the striatum and lenticular nucleus, and others radiating from the latter diverge in the white matter of the cerebral hemisphere. The gray matter of the lenticular nucleus contains many yellowish nerve-cells.

Outside the position of the lenticular nucleus, embedded in the white substance of the central lobe of the cerebrum near its external convolutions, is a thin, gray layer, the **claustrum**.<sup>2</sup> It is of greatest breadth fore and aft and is higher than the lenticular nucleus, with which it is continuous at its fore part beneath within the olfactory tuber and the anterior perforated space. Its inner surface is concave and even and is directed towards the lenticular nucleus, but the outer surface is convex and somewhat uneven.

The nerve-cells of the claustrum are mostly small and fusiform and generally arranged parallel with the surfaces like those in the deep part of the cerebral cortex.

The white layer separating the claustrum from the lenticular nucleus is the **external capsule**.<sup>3</sup> It consists of bundles of nerve-fibres derived from the cerebral crus and from the anterior commissure of the third ventricle.

Beneath the fore part of the lenticular nucleus, situated within the anterior extremity of the hippocampal convolution, is an irregular

<sup>1</sup> Striæ griseæ communicantes.

<sup>2</sup> Stratum cinereum; nucleus tæniæformis.

<sup>3</sup> Capsula externa; c. medullaris nuclei lentiformis.



rounded gray mass, the **amygdaloid nucleus**.<sup>1</sup> It is connected with the contiguous cortex of the convolution and is similar in structure to the lenticular nucleus.

The **foramen of Monro**<sup>2</sup> is a short Y-shaped canal situated between the anterior pillars of the fornix and the thalami, of which the upper branches communicate with the lateral ventricles and the lower one with the fore part of the third ventricle. Through it the veins of the striata and choroid plexuses reach the internal cerebral veins.

The **third ventricle**<sup>3</sup> of the brain is a median cleft of the cerebrum, situated between the thalami laterally, roofed over by the fornix and extending downward into the infundibulum at the base of the brain. It is widest above and behind, narrows below to a vertical fissure,<sup>4</sup> and is deepest in front. The bottom is formed in succession from before backward by the chiasmal recess, the infundibulum, the cinereous tuber, the posterior perforated space, and the groove of divergence of the tegmenta of the cerebral crura. Beneath the splenium it communicates by the **transverse cerebral fissure**<sup>5</sup> with the interval of the cerebrum and cerebellum, in which position the **choroid tela**,<sup>6</sup> a process of the pia, enters and the internal cerebral veins escape from it. At the lower back part it communicates by the ventricular aqueduct with the fourth ventricle. Its fore part extends forward between the descending and diverging anterior pillars of the fornix and is closed in front from the great longitudinal fissure by the **cinereous lamina**,<sup>7</sup> situated immediately in advance of the chiasmal recess.

The third ventricle is crossed by three commissures, named from their relative position anterior, middle, and posterior. The bottom is lined with gray matter which forms a commissural union between the cerebral hemispheres.

The **thalamus**<sup>8</sup> appears as a large oval eminence which projects from the corresponding hemisphere inwardly into the third ventricle and along its upper part into the lateral ventricle, where it is separated from the striatum by a groove, which ascends from the bottom of the fore part of the ventricle and winds backward and outward to the middle horn. The upper part, visible in the lateral ventricle, is defined from that of the third ventricle by a shallow groove, which accommodates the lateral band of the fornix, to the outer edge of which lies the choroid plexus of the lateral ventricle. The anterior somewhat prominent extremity of the thalamus is its **tubercle**,<sup>9</sup> and

<sup>1</sup> Amygdala; nucleus amygdalæ.

<sup>2</sup> F. Monroi or commune antierius; porta; vulva.

<sup>3</sup> Ventriculus tertius or medius cerebri; diacœlia.

<sup>4</sup> Sulcus Monroi.

<sup>5</sup> Fissura cerebri transversa anterior; rima transversa cerebri.

<sup>6</sup> Tela choroidea; velum interpositum.

<sup>7</sup> L. terminalis; l. cinerea.

<sup>8</sup> T. opticus or nervus optici; ganglion cerebri medium, posticum, or magnum inferius; eminentia magna cerebri.

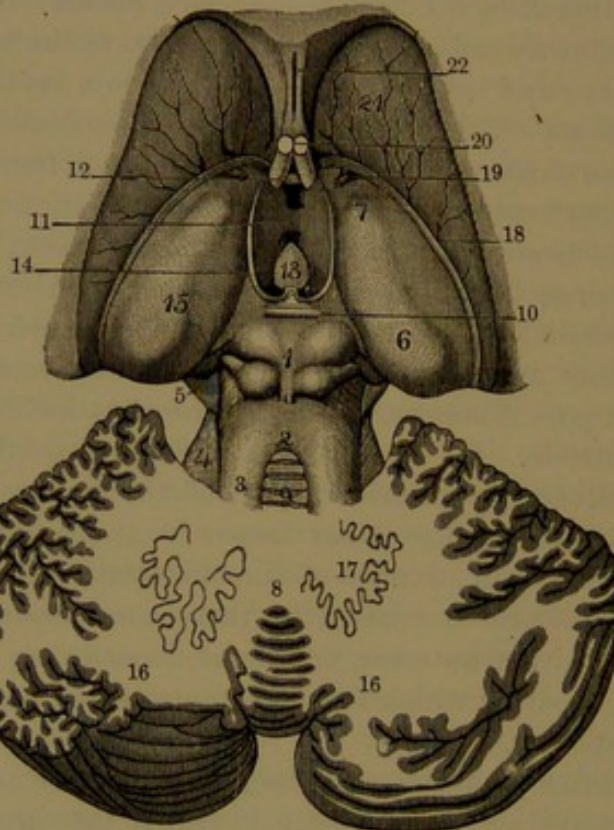
<sup>9</sup> Tuberculum antierius or ant. superius; corpus album subrotundum.



this likewise lies to the outer side of the apex of the fornix within the lateral ventricle. The posterior extremity of the thalamus forms a wide, transverse bolster-like process, the **pulvinar**,<sup>1</sup> which is placed to the outer side of the quadrigeminal body and overhangs the entrance of the middle horn of the lateral ventricle.

Within the third ventricle the nearly vertical surface of the thalamus is divided by a prominent white line, the **pineal stria**,<sup>2</sup> which

FIG. 390.



STRIATA, THALAMI, QUADRIGEMINAL BODY, AND CEREBELLUM. 1, quadrigeminal body; 2, anterior velum; 3, superior peduncle of the cerebellum; 4, upper portion of the middle peduncle; 5, upper portion of the crus of the cerebrum; 6, pulvinar of the thalamus; 7, its tubercle; 8, vermis of the cerebellum; 9, lingule; 10, posterior commissure of the third ventricle; 11, middle commissure; 12, anterior commissure; 13, pineal body turned forward; 14, its peduncle; 15, thalamus; 16, hemispheres of the cerebellum; 17, dentate nucleus; 18, semicircular band; 19, vein of the striatum; 20, anterior crura of the fornix; 21, striatum; 22, ventricular septum.

proceeds from the peduncle of the pineal body forward to the inner side of the tubercle. From the latter a slightly prominent band, produced by the anterior pillar of the fornix, descends in a curve, convex forward, to the bottom of the ventricle and passes through the cinereous tuber to end in the corresponding mammillary eminence. Near their middle, crossing the narrowest part of the third ventricle, the thalami

<sup>1</sup> Tuberculum posterius.

<sup>2</sup> S. pinealis or medullaris thalami; tænia fornicis or thalami.



are conjoined by a thin oval disk of gray matter, the **middle commissure**.<sup>1</sup>

The **anterior commissure**<sup>2</sup> of the third ventricle is a rounded cord crossing the fore part immediately in advance of the anterior pillars of the fornix and behind the cinereous lamina of the ventricle. It is a cylindrical bundle of white nerve-fibres which enters the striatum on each side and extends below the lenticular nucleus, thence curving outward and backward, somewhat twisted and spreading in the central lobe. It is further traceable into the temporal lobe above the middle horn of the lateral ventricle to the amygdaloid nucleus.

The **posterior commissure**<sup>3</sup> is situated at the back of the third ventricle, immediately above the entrance of the ventricular aqueduct. It is a white plate doubled on itself, with the closed part of the fold directed forward and the open part backward and transversely wrinkled. It is extended between the thalami laterally, while its upper part joins the pineal body and its lower part behind the quadrigeminal body. It is composed of transverse bundles of nerve-fibres which pass between the thalami and partly through them into the white matter of the cerebral hemispheres.

Beneath the pulvinar of the thalamus are two elliptical white eminences, the **geniculate bodies**.<sup>4</sup> Of these the **internal**<sup>5</sup> is the more prominent and better defined, and is situated transversely between the pulvinar, the quadrigeminal body, and the cerebral crus. The **external**,<sup>6</sup> somewhat larger, is situated fore and aft to the outer side of the former, at the outer fore part of the pulvinar. From the geniculate bodies proceed a pair of bands uniting in the **optic tract**,<sup>7</sup> which also receives less conspicuous bundles of nerve-fibres from the anterior tubercles of the quadrigeminal body and from the pulvinar.

The **optic tract** appears as a flattened cord proceeding in two conspicuous bands from the geniculate bodies, winding from the outer side of the cerebral crus, as this is about to enter the cerebral hemisphere, downward, forward, and inward. Gradually becoming more defined as a flattened cylindrical cord it proceeds downward and inward in front of the cinereous tuber at the base of the brain and joins its fellow to form the **optic commissure**. The optic tract in its descent

<sup>1</sup> Commissura media or mollis; soft commissure; medicommissura.

<sup>2</sup> Commissura anterior cerebri; præcommissura.

<sup>3</sup> Commissura posterior cerebri, parva posterior, or posterior ventriculi tertii; trigonum molle, fluctuans, or pensile; postcommissura.

<sup>4</sup> Corpora geniculata.

<sup>5</sup> Corpus geniculatum internum or mediale; tuberculum posticum medium; postgeniculatum.

<sup>6</sup> C. g. externum or laterale; tub. post. inferius or laterale; optical nucleus; prægeniculatum.

<sup>7</sup> Tractus opticus.



is closely connected with the cerebral crus and cinereous tuber, from both of which it derives nerve-fibres.

The **optic commissure**, or **chiasm**,<sup>1</sup> is formed by the conjunction of the optic tracts in front of the cinereous tuber, and from it proceed the optic nerves. In the commissure most of the nerve-fibres of one tract diagonally cross those of the other tract and enter the optic nerve of the opposite side, a few fibres passing into the nerve of the same side. A small arching bundle of fibres at the back of the commissure passes from one tract to the other. A similar bundle has been stated to pass between the two optic nerves.

The thalamus chiefly consists of an accumulation of gray matter, covered on its ventricular surface with a thin layer of white matter,<sup>2</sup> and is embedded outwardly and beneath in the white matter of the

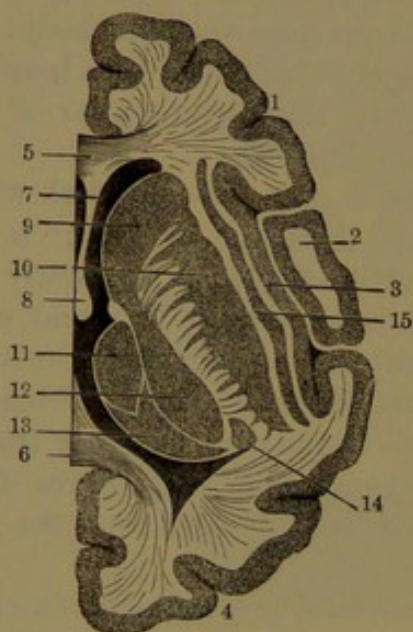
cerebral hemisphere. The white matter externally forms the inner capsule, consisting of bundles of nerve-fibres ascending and diverging from the crista of the cerebral crus. Beneath is the extension of the tegmentum of the crus, chiefly composed of nerve-fibres ascending into the inner capsule and the outer part of the thalamus. Between the **subthalamie tegmentum** and the crista, as this ascends outwardly to the inner capsule and externally to the locus niger, is some gray matter, the **subthalamie nucleus**.<sup>3</sup>

The gray matter of the thalamus is partially separated by thin white laminae into three portions or nuclei. Of these the **anterior nucleus** occupies the tubercle of the thalamus, and behind it is the **internal nucleus**, joined to that of the opposite side by the middle commissure of the

third ventricle. The **external nucleus**, larger than the others, is situated to their outer side and is separated from them by a sigmoid lamina slanting from without downward and inward. It also extends beneath them and into the pulvinar. The geniculate bodies also contain gray nuclei continuous with the external nucleus of the thalamus.

Numerous nerve-cells are scattered through the gray matter of the

FIG. 391.



HORIZONTAL SECTION THROUGH THE RIGHT HEMISPHERE OF THE CEREBRUM. 1, frontal lobe; 2, parietal lobe; 3, central lobe; 4, occipital lobe; 5, 6, fore and back parts of the callosum; 7, ventricular septum; 8, anterior pillar of the fornix; 9, striatum; 10, lenticular nucleus; 11, 12, 13, three nuclei of the thalamus; 14, nucleus of the external geniculate body; 15, claustrum.

<sup>1</sup> Chiasma opticum.

<sup>2</sup> Stratum zonale.

<sup>3</sup> Corpus subthalamieum.



thalamus, and they are largest in the anterior nucleus. The darker gray nucleus of the external geniculate body also contains many yellow pigmented, mostly fusiform nerve-cells. The external nucleus of the thalamus at its outer part is streaked with white, due to bundles of nerve-fibres passing thence into the contiguous inner capsule. The subthalamic nucleus is a lenticular layer of gray matter with many pigmented nerve-cells.

From the outer part of the thalamus and the striatum, bundles of nerve-fibres radiate in all directions to the cerebral cortex.

The bottom or floor of the third ventricle extends as a groove, curving from the entrance of the ventricular aqueduct forward and downward to the position of the optic commissure, in front and above which the ventricle is closed from the fore part of the great longitudinal fissure by the cinereous lamina. The floor is formed of gray matter ascending a short distance on the sides and connecting the cerebral hemispheres, whence it has been named the **gray commissure of the floor**. Below the position of the thalami the basis of the floor is formed by the tegmenta of the cerebral crura as they diverge and proceed upward and outward beneath the thalami. In advance of the tegmenta the gray matter of the floor increases and reaches the base of the brain between the cerebral crura, where it forms the posterior perforated space, the cinereous tuber, and the infundibulum.

The third ventricle is prolonged in the infundibulum in a conical pit to its termination.

In advance of the infundibulum is another conical pit, the **chiasmal recess**,<sup>1</sup> which is bounded behind by the optic chiasm and in front by the cinereous lamina.

The **cinereous lamina**<sup>2</sup> of the third ventricle is a thin gray band which descends from the rostrum of the callosum to the front of the anterior commissure, thence to the anterior upper border of the optic chiasm, connected on each side with the corresponding anterior perforated space. In front of it at the sides descend the callosal peduncles, between which the lamina is visible at the bottom of the great longitudinal fissure.

The **quadrigeminal body**<sup>3</sup> is a quadrate plate divided on its upper surface by a crucial groove into four rounded white **tubercles**. It is situated in the interval of the cerebrum and cerebellum beneath the splenium. It is connected in front with the thalami, from which it inclines downward and backward to the superior cerebellar peduncles and anterior velum and on each side joins the tegmentum of the cerebral crus. With its tubercles directed upward and backward, beneath it in the median line, is the ventricular aqueduct. The anterior pair

<sup>1</sup> Recessus chiasmatis.

<sup>2</sup> L. cinerea terminalis; terma.

<sup>3</sup> Corpora, tubercula, eminentia, or lamina quadrigemina, or bigemina; protuberantiae or prominentiae orbitales or encephali; optic lobes.



of tubercles<sup>1</sup> is the larger, but the posterior pair<sup>2</sup> is slightly more prominent. Laterally they are prolonged obliquely forward and outward in slightly less prominent **arms**.<sup>3</sup> The median groove as it widens in front supports the pineal body, and from its back part a little ridge, the **frenule**,<sup>4</sup> extends to the anterior velum. The tubercles are composed superficially of a layer of white matter<sup>5</sup> mainly consisting of transverse fibres which pass into the arms. The layer is thicker on the anterior tubercles and in front is connected with the posterior commissure of the third ventricle. Beneath it is a gray layer,<sup>6</sup> which is thickest where the tubercles are most prominent and contains numerous small nerve-cells. A third layer,<sup>7</sup> also of gray matter with small nerve-cells, is traversed by longitudinal fibres, which diverge laterally and pass into the arms and optic tract. A fourth layer<sup>8</sup> consists of fibres from the fillet, passing between the former layer and the wall of the aqueduct to the opposite side and thence to the layer above. The posterior tubercles next their thinner white layer are mainly composed of gray matter with many small and a few large nerve-cells. It is separated from the wall of the aqueduct by a thin layer of fibres from the fillet.

The **ventricular aqueduct**,<sup>9</sup> a canal communicating between the third and fourth ventricles, is enclosed between the tegmenta of the cerebral crura beneath the median line of the quadrigeminal body. It is a narrow passage, little more than half an inch long, and is enclosed in a thick wall of gray matter lined with an ependyma of ciliated columnar cells. The gray matter contains many scattered nerve-cells of varied form and size, besides which it includes several important accumulations as nuclei of several of the cerebral nerves.

The **pineal body**<sup>10</sup> is a little ovoid, conical, reddish organ situated in the posterior part of the third ventricle, immediately above the posterior commissure, to which it is attached by its base, and thence rests obliquely backward and downward between the anterior pair of tubercles of the quadrigeminal body. From its base on each side a narrow white band, the **peduncle**,<sup>11</sup> curves outward and forward and is continued as the pineal stria of the thalamus. The peduncle extends outwardly to the thalamus in a narrow triangular shelf<sup>12</sup> directed back-

<sup>1</sup> Corpora, eminentiæ, or prominentiæ anteriores, superiores, majores, or nati-formes; nates; præoptici; anterior lobes of the mesencephalon.

<sup>2</sup> C., e., or p. posteriores, inferiores, minores, or testiformes; testes; postoptici; posterior lobes of the mesencephalon.

<sup>3</sup> Brachia conjunctiva.

<sup>4</sup> Frenulum; f. veli medullare antici.

<sup>5</sup> Stratum zonale.

<sup>6</sup> S. cinereum.

<sup>7</sup> S. opticum.

<sup>8</sup> S. lemnisci.

<sup>9</sup> Aquæductus Sylvii; iter e tertio ad quartum ventriculum; ventriculus opticus or mesencephali; mesocœlia; mesial part of mesocœle; vulva; fistula sacra.

<sup>10</sup> Pineal gland; glandula pinealis; conarium; pinus; epiphysis cerebri.

<sup>11</sup> Pedunculus or habenula conarii or pinealis.

<sup>12</sup> Trigonum habenulæ.



ward in a groove beneath the pulvinar. The peduncles conjoin, and between their conjunction and the posterior commissure is a little conical recess<sup>1</sup> opening forward into the third ventricle.

The pineal body is smooth, or sometimes more or less uneven. It consists of a matrix of soft connective tissue with follicles filled with cells, which are generally regarded as being of the character of epithelial cells, though they are also looked upon as nerve-cells. It also commonly contains more or less sand-like grains,<sup>2</sup> of variable size and resembling bone-earth in composition, with a small proportion of organic matter.

The **pituitary body**<sup>3</sup> is enclosed in the sella of the sphenoid bone attached by a narrow **stem**<sup>4</sup> to the infundibulum of the brain. It is solid, of a pale-reddish color, is surrounded by vascular connective tissue continuous with the pia, and is enclosed in a sac of the dura, perforated for the connection of its stem with the infundibulum. It consists of an anterior, larger, transverse reniform lobe, with a smaller rounded lobe closely connected with the recess of the other behind. It is very enigmatic in character, very unlike the rest of the brain in structure, though a constant accessory to it in vertebrate animals. The anterior lobe, of darker color, is composed of a matrix of connective tissue with convoluted follicles of the same material filled with nucleated cells of varied size resembling those of glandular epithelium. The posterior lobe contains in its connective-tissue matrix numerous spindle-shaped and branching cells, together with a few larger pigmented cells.

The anterior lobe of the pituitary body is developed as a tubular prolongation from the ectoderm of the buccal cavity of the embryo. The posterior lobe is a development extending from the third ventricle of the brain, subsequently becoming solidified. In fishes it remains hollow in conjunction with the infundibulum.

The **gray cortex**<sup>5</sup> of the cerebral hemispheres, in each, is continuous throughout, and is a much-folded pouch with the mouth directed centrally inward and downward. The pouch is filled with **white matter**<sup>6</sup> which is continuous through the mouth with that of the opposite hemisphere and of the isthmus connecting the cerebrum with the other chief divisions of the brain. The white matter consists of a dense aggregation of flattened bundles of medullated nerve-fibres, which for the most part extend from the isthmus and callosum and spread in every direction within each hemisphere to the cortex. Embedded in the white matter are accumulations of nuclei of gray matter, from which emanate additional bundles of fibres to reinforce the former. Separations in the direction of the main trunks of white matter proceeding from the callosum and isthmus form the lateral and third

<sup>1</sup> Ventriculus conarii.

<sup>2</sup> Acervulus cerebri; brain-sand.

<sup>3</sup> P. gland; glandula pituitaria; hypophysis cerebri.

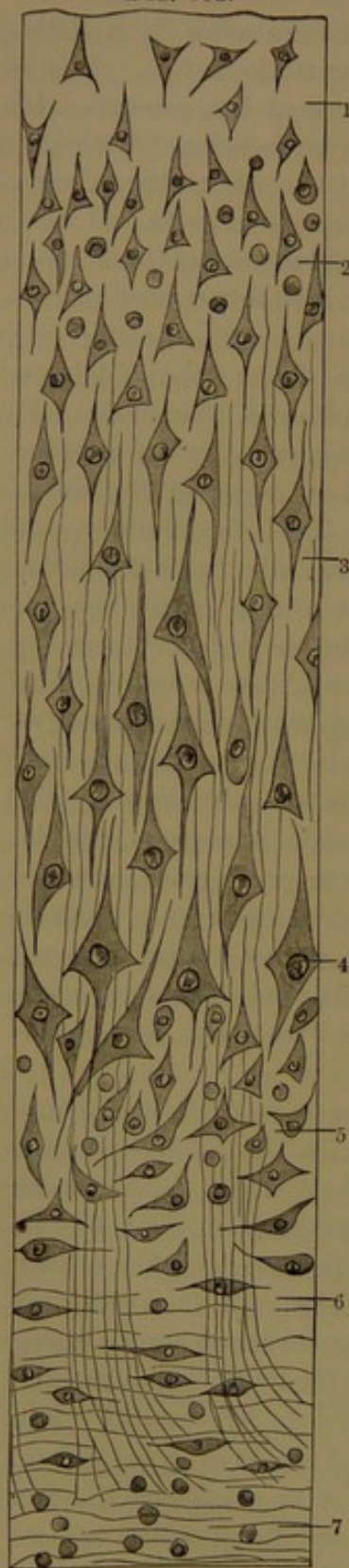<sup>4</sup> Pedunculus hypophyseos.

<sup>5</sup> Substantia cinerea.

<sup>6</sup> Substantia medullaria.



FIG. 392.



ventricles of the cerebrum. The white matter of the cerebral convolutions consists of bundles which enter them along their middle, perpendicular to their summit, and then spread out in curves to the cortex. According to Henle, the extension of fine bundles of fibres from the white matter of the convolutions into the cortex for about half its thickness divides it into an outer pure gray layer and an inner more whitish layer. At the bottom of contiguous convolutions, bundles of fibres curve from one to the other around the cortex at the bottom of the intervening fissure.

Vertical sections across the cerebral cortex exhibit to the naked eye the appearance of several strata slightly differing in color and translucency. Though not uniform, throughout its greater extent a half-dozen layers are distinguishable, as follows: 1, a thin external layer of whitish neuroglia, variable in thickness in different positions, and especially well marked on the inner surface

FIG. 392.—VERTICAL SECTION THROUGH THE DEEPER PORTION OF THE CEREBRAL CORTEX; highly magnified. 1, 2, small pyramidal nerve-cells below the neuroglia layer containing few or no cells; 3, 4, intermediate layer of large pyramidal cells; 5, 6, deep layer of small cells, and groups of ascending fibres; 6, 7, white matter with fusiform nerve-cells.

of the lower part of the hippocampal convolution; 2, a layer of reddish-gray matter; 3, a white layer,<sup>1</sup> which is especially well marked on the convolutions of the occipital lobe bounding the calcarine fissure; 4, a second and lighter gray layer; 5, a second thin white layer;<sup>2</sup> 6, a yellowish-gray layer.

The cerebral cortex is composed of an abundant neuroglia matrix, with variable proportions of nerve-cells and nerve-fibres in its different strata. The nerve-cells are of various sizes and shapes and in a measure are disposed in strata and columns not sharply defined. The largest and longest cells, regarded as characteristic, are

<sup>1</sup> Line of Vicq d'Azyr; outer line of Baillarger.

<sup>2</sup> Inner line of Baillarger.



mostly pyramidal, with the apex directed to the surface of the convolution and prolonged into a branching process. From the angles of the base fine processes proceed in the opposite direction, mostly branch and anastomose and form a net-work in the surrounding neuroglia. From each cell an undivided branch may be traced into a medullated nerve-fibre as its axis-fibre. The cells appear to be contained in clearer areas, which are regarded as lymphatic spaces. With the more characteristic nerve-cells are mingled others, which are smaller and angular and provided with branches radiating in various directions. In the deeper stratum of the cortex there are also small spindle-shaped cells with processes proceeding in opposite directions. Mingled with the others there occur many small cells, which resemble ordinary colorless blood-corpuscles.

The external neuroglia layer of the cortex contains only a few small branching cells and next the pia a few medullated nerve-fibres. In the next layer the pyramidal nerve-cells are more abundant and crowded than elsewhere and generally smaller. In the succeeding layers they are more widely separated, generally larger and with the deeper ones largest. In the deepest layers they are fewest and mingled with numerous smaller and less characteristic forms. From the white matter beneath the cortex, bundles of fibres ascend through its deeper layers, separating the cells into columns, and become more diffused in the upper layers.

The interior white matter, or **medullary centre**, of the cerebral hemispheres, which in the fresh condition appears homogeneous, is composed of flattened bundles of medullated nerve-fibres densely aggregated and united together by neuroglia. When a brain is hardened in alcohol, on tearing it apart the general course of the bundles of nerve-fibres becomes quite obvious. In each hemisphere they for the most part radiate from the cerebral crus, thalamus, striatum, and callosum to the cerebral cortex. The fibres are referable to three systems, distinguished according to the general direction they pursue, as the ascending, transverse, and longitudinal.

The **ascending fibres** of each hemisphere partly proceed from the crusta and partly from the tegmentum of the corresponding cerebral crus. Those from the crusta chiefly enter the inner capsule, separating the thalamus and striatum from the lenticular nucleus, in their course give fibres to these and receive others from them and thence diverge in all directions to the cerebral cortex, producing an arrangement which is called the **corona radiata**. While many of the fibres of the crusta appear directly to pass through the inner capsule into the medullary centre continuing to the cortex, only a portion of them have been definitely traced throughout their entire course. Thus the **pyramidal tract** from the oblongata has been followed through the crusta and inner capsule to the ascending frontal and parietal convolutions and contiguous parts of the cerebral hemisphere. The fact is of interest



from the circumstance that experiment indicates the gray matter of these convolutions to be concerned in the movements of the principal groups of muscles of the body. Another portion of the crusta outwardly, as the **direct sensory tract**, has been traced into the white matter of the occipital lobe of the hemisphere. A small portion of the crusta inwardly does not enter the inner capsule, but its fibres collected in a bundle<sup>1</sup> pass outward beneath the thalamus and enter the lenticular nucleus.

The fibres proceeding from the tegmentum of the cerebral crus derived from the reticular formation of the oblongata, reinforced by others from the superior peduncle of the cerebellum and probably also from the middle peduncle, the quadrigeminal body, and the gray nuclei in their course, mostly appear to terminate in the subthalamie region and in the thalamus. Further, numerous fibres emerge from the outer side of the thalamus and join those of the corona radiata in their distribution, but particularly proceed to the temporal and occipital lobes; which experiments appear to indicate as being concerned with the functions of the special sense-organs. Some of the fibres from the back of the thalamus enter the optic tract, and others from the lower part in front form a bundle,<sup>2</sup> which curves below around the lenticular nucleus and enters the white matter of the cerebral hemisphere.

The **transverse fibres**<sup>3</sup> of the cerebrum are chiefly those of the callosum, which radiate in all directions within the hemispheres, where they intersect the fibres of the corona radiata. The fibres proceeding into the parietal lobe and the back part of the frontal lobe are nearly transverse in their course, but those from the callosal knee curve round into the anterior part of the frontal lobe. From the splenium they mostly arch round the posterior and middle horns of the lateral ventricle into the temporal and lower part of the occipital lobe; while others from beneath proceed in a curve<sup>4</sup> into the back and upper parts of the occipital lobe.

To the transverse fibres of the cerebrum also belong those of the anterior commissure of the third ventricle.

To the **longitudinal fibres**<sup>5</sup> of the cerebral hemispheres belong the following:

1. The **fornicate fascicle**.<sup>6</sup> This forms the white matter of the fornicate convolution, in which the fibres pursue a longitudinal course and give offsets upward and backward into its secondary convolutions. In front the fibres turn down in the convolution to the anterior perforated space; behind they turn round the splenium and descend to the end of the temporal lobe.

<sup>1</sup> Ansa lenticularis.

<sup>2</sup> Inferior peduncle of the thalamus.

<sup>3</sup> Commissural fibres of the corpus callosum.

<sup>4</sup> Forceps major.

<sup>5</sup> Collateral or association fibres.

<sup>6</sup> Fillet of the corpus callosum.



2. The **uncinate fascicle**.<sup>1</sup> A bundle which crosses the bottom of the sylvian fissure and connects the frontal and temporal lobes.

3. The **inferior longitudinal fascicle**. A bundle which lies close to the outer wall of the posterior and middle horns of the lateral ventricle and connects the occipital and temporal lobes.

4. The **gyral fascicles**.<sup>2</sup> These are fibres which connect the adjacent convolutions arching across the bottom of the intervening fissure and situated close to the cortex. Deeper and longer fibres also connect convolutions more widely separated.

5. Other longitudinal fibres of the cerebrum are the longitudinal striæ of the callosum, the semicircular band of the lateral ventricles, and the lateral bands of the fornix, with its anterior pillars and its posterior pillars prolonged as the fimbriæ.

#### BRAIN OF THE EMBRYO.

In the development of the cerebro-spinal axis, it early makes its appearance in the embryo as a simple tube, which is expanded at the anterior or cephalic extremity. The expanded portion becomes constricted into two and then three successive portions, distinguished as the **cerebral vesicles**,<sup>3</sup> which represent the future brain or encephalon, while the remaining portion of the tube represents the spinal cord. The continuous cavity of the cerebral vesicles and spinal portion of the tube subsequently become the ventricles of the brain and the central canal of the spinal cord. The cerebral vesicles by further development form five fundamental divisions, which correspond with as many parts of the mature brain. The **first**, or **anterior cerebral vesicle**,<sup>4</sup> forms two divisions, of which the anterior, named the **prosencephalon**,<sup>5</sup> consists of the cerebral hemispheres together with the callosum, striata, fornix, and lateral ventricles. The posterior division, named the **thalamencephalon**,<sup>6</sup> consists of the thalami, the third ventricle, the pituitary and pineal bodies. The **second**, or **middle cerebral vesicle**,<sup>7</sup> forms the **mesencephalon**,<sup>8</sup> which consists of the quadrigeminal body, the cerebral crura, and the ventricular aqueduct. The **third**, or **posterior cerebral vesicle**,<sup>9</sup> forms two divisions, of which one, the **epencephalon**,<sup>10</sup> consists of the cerebellum and pons, with the upper portion of the fourth ventricle; while the other division, the **metencephalon**,<sup>11</sup> consists of the oblongata<sup>12</sup> and the lower portion of the fourth ventricle.

<sup>1</sup> Arcuate fasciculus.

<sup>3</sup> Primary vesicles.

<sup>5</sup> Fore-brain.

<sup>7</sup> Middle primary vesicle.

<sup>9</sup> Posterior primary vesicle.

<sup>11</sup> After-brain.

<sup>2</sup> Association fibres.

<sup>4</sup> Anterior primary vesicle.

<sup>6</sup> Inter-brain; di-encephalon.

<sup>8</sup> Mid-brain.

<sup>10</sup> Hind-brain.

<sup>12</sup> Myelencephalon.



## CHOROID TELÆ AND PLEXUSES.

The **choroid tela**<sup>1</sup> of the **third ventricle** is a process of the pia extending into that cavity through the transverse cerebral fissure, beneath the callosum and above the quadrigeminal body. It occupies the roof of the ventricle adherent to the under surface of the fornix and below to the quadrigeminal and pineal bodies and to the thalami above the position of the pineal striæ. It thins away to the foramen of Monro and at the sides, where it is connected with the choroid plexuses of the lateral ventricles.

Beneath the tela are the **choroid plexuses**<sup>2</sup> of the **third ventricle**, narrow, vascular, villous appendages, similar to those of the lateral ventricles. They extend from the foramen of Monro along the tela, one on each side of the median line, to its back part. Running near the plexuses from the same point are the two internal cerebral veins, derived from branches of the lateral and third ventricles and from their choroid plexuses and terminating at the transverse cerebral fissure in the vein of Galen, which opens into the straight sinus of the dura.

The **choroid plexuses**<sup>3</sup> of the lateral ventricles are two highly-vascular, curly-looking, dark-red appendages of the choroid tela of the third ventricle, though contained within the lateral ventricles. Each lies along the outer edge of the fornix and then on the hippocampus and fimbria. They commence in a pointed manner at the foramen of Monro, through which they conjoin, thence pass backward in the lateral ventricles, gradually enlarging, and descend in the middle horns to near their lower extremity, where they taper away. At the entrance of the middle horn they are often thickened, apparently the result of disease. Along the fornix they are continuous with the choroid tela beneath the edge of that body, and in the middle horn of the ventricle are connected with the pia of the hippocampal fissure. They are more or less lobulated, and the lobules are composed of bunches of rounded villous processes. They contain numerous blood-vessels, which form looped capillaries within the villi. The arteries are furnished by the anterior choroid artery on each side, entering the lower part of the plexus through the hippocampal fissure, and behind by the posterior choroid artery entering the transverse cerebral fissure. The veins partly run forward in the plexus and join the vein of the striatum to end in the internal cerebral vein, and partly inward through the choroid tela to end in the same vein.

The **choroid tela of the fourth ventricle**<sup>4</sup> is an extension of the pia closing the lower back part of that cavity. Above, it is attached

<sup>1</sup> T. choroidea; t. c. superior or cerebri; velum interpositum; v. triangulare.

<sup>2</sup> P. choroidei ventriculi tertii; p. choroideus tertius.

<sup>3</sup> P. choroideus.

<sup>4</sup> T. choroidea ventriculi quarti or inferior.



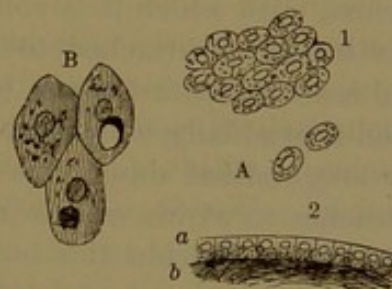
to the nodule of the vermis extending laterally to the posterior and then the inferior velum. In its descent it is attached to the restiform bodies and clavæ, extending to the obex at the inferior angle of the ventricle. Immediately above the obex it presents an opening, the **foramen of Magendie**,<sup>1</sup> through which the fourth ventricle communicates with the adjacent subarachnoid space. Two other openings exist in the tela, one on each side, communicating between the cornucopie and the subarachnoid space.

From the under surface of the tela project into the ventricle the **median choroid plexuses**.<sup>2</sup> These are two long, narrow, vascular, villous appendages, which lie side by side along the tela and extend through its opening on the under part of the vermis. **Lateral choroid plexuses**<sup>3</sup> also occupy the fourth ventricle, one on each side, extending from the lateral recess along the cornucopia to the floccule and projecting from the adjacent aperture.

#### EPENDYMA.

The ventricles of the brain, except that of the ventricular septum, and the central spinal canal are lined throughout with an endothelial membrane, the **ependyma**.<sup>4</sup> On the nerve-structures it is closely adherent to a variably-thick stratum of neuroglia,<sup>5</sup> and is thence reflected on and closely invests the choroid telæ and plexuses where these exist. It closes the lateral ventricles at the sides from the third ventricle, so that they only communicate through the foramen of Monro, and it also shuts off the inferior horns of the lateral ventricles at the hippocampal fissure. The endothelium chiefly consists of short columnar, ciliated cells, though the cilia mostly disappear by adult age, except in the ventricular aqueduct. On the choroid plexuses the endothelium consists of larger pavement cells, and in the adult, besides the nucleus, each commonly contains a yellowish or reddish corpuscle.

FIG. 393.



EPENDYMA OF THE VENTRICLES: 350 diameters. A, from the striatum of the lateral ventricle. 1, viewed on the free surface; 2, through the thickness; a, endothelial cells; b, neuroglia. B, endothelial cells, free surface, from the middle commissure of the third ventricle.

#### MEMBRANES OF THE CEREBRO-SPINAL AXIS.

The cerebro-spinal axis is provided with three membranous envelopes, the dura, the pia, and the arachnoid.

<sup>1</sup> F. Magendii.

<sup>2</sup> Plexus choroideus medialis or superior.

<sup>3</sup> P. choroideus lateralis, inferior, or nervi vagi.

<sup>4</sup> Henle's Anatomy, 1871.

<sup>5</sup> Ependyma. Quain's Anatomy, 1882.



MEMBRANES OF THE BRAIN.<sup>1</sup>

The **dura**, or **dura mater**,<sup>2</sup> is a thick, dense, white, inelastic fibrous membrane which lines the interior of the cranium and gives off several partitions which separate the chief divisions of the brain. Its exterior portion next the cranium is the periosteum of the adjacent bones, to which it closely adheres in the usual manner by small blood-vessels and fibrous processes passing between them. The adhesion is not so firm as on the exterior of the bones of the skeleton, as exemplified in the ready detachment of the dura in ordinary post-mortem examinations of the brain. It adheres more intimately along the sutures and at the base of the cranium, which is perforated by numerous foramina, through which the dura is prolonged and becomes continuous with the pericranial periosteum. It also becomes continuous with the fibrous sheaths of the nerves and blood-vessels which pass out and in the cranium.

The processes of the dura which form membranous partitions to the brain are the cerebral falx, the tentorium, and the cerebellar falx.

The **cerebral falx**<sup>3</sup> is a large sickle-shaped process of the dura which extends as a median partition in the great longitudinal fissure between the hemispheres of the cerebrum. Narrow in front where it is attached to the ethmoidal crest, it gradually widens backward to the tentorium, with which it is continuous in the median line. Its upper convex border is attached to the cranium from the fore part of the frontal crest backward to the internal occipital protuberance, in which position it gradually widens in the same direction and contains the superior longitudinal sinus. Its lower concave border is free and sharp and reaches to within a little distance of the callosum, nearer behind than in front. Within this border the inferior longitudinal sinus runs backward.

The **tentorium**<sup>4</sup> is a broad membrane stretched over the cerebellar fossæ, slanting down from the attachment of the cerebral falx to its circumference and separating the occipital lobes of the cerebrum, which rest upon it, from the hemispheres of the cerebellum beneath. It is attached along its convex border on each side from the internal occipital protuberance to the horizontal limb of the occipital cross and thence along the upper margin of the temporal pyramid to the apex, where it divides into two short folds, of which one extends inward to the posterior clinoid process and the other forward to the anterior clinoid process. Its anterior free border encircles a large oval aperture, through which the cerebral crura ascend from the pons to the cerebral hemispheres. Within its posterior border on each side runs the lateral sinus; within its attachment to the temporal pyramid

<sup>1</sup> Meninges.<sup>2</sup> Dura meninx.<sup>3</sup> F. cerebri or major; processus falciformis; mediastinum cerebri.<sup>4</sup> T. cerebelli; septum encephali.



runs the superior petrosal sinus, and along its attachment to the tentorium runs the straight sinus.

The **cerebellar falx**<sup>1</sup> is a small triangular process of the dura attached behind to the occipital bone, descending to the occipital foramen and projecting forward into the notch separating the hemispheres of the cerebellum. Its lower extremity diverges in two smaller processes which subside at the sides of the occipital foramen. It contains the posterior occipital sinus or sinuses.

The dura is separable into two layers, which are composed of bands and laminae of fibro-connective tissue, with some elastic tissue, obliquely intersecting one another in the two layers. By the separation of the two layers the venous sinuses of the dura are formed, lined by the common internal tunic of the veins. The interior surface of the dura, smooth and shining, is invested with a pavement endothelium of clear, nucleated cells.

The blood-vessels of the dura are numerous, the arteries being branches of the meningeals and mainly destined to supply the adjacent bones. The corresponding veins communicate with the diploic veins and the sinuses, but mostly accompany the meningeal arteries, of which notably the great meningeal artery has two companion veins. The nerves of the dura are small and are derived from the trifacial, hypoglossal, and sympathetic nerves.

The **pia**, or **pia mater**, is a highly-vascular membrane, mainly consisting of an intricate plexus of blood-vessels formed by the chief arteries and veins of the brain and finally giving off a multitude of the finest vessels, which alone directly enter the brain-substance. It is associated with an intertexture of delicate connective tissue with elastic fibres, and the same tissue forms tubular sheaths to the vessels. The sheaths accompany the finer vessels into the brain and serve as lymphatic channels.

The pia closely invests the cortical substance of the cerebral convolutions, penetrating all the intervening fissures, in which it forms a double layer. In the same manner it closely invests the cerebellum, but on this the membrane is finer and it only forms a double fold in the principal fissures. As the choroid tela it extends through the transverse cerebral fissure into the third ventricle, connected with the choroid plexuses of that and the lateral ventricles. It also forms the choroid tela of the floor of the fourth ventricle, likewise connected with its choroid plexuses. Investing the cerebral crura, the pons, and the oblongata, it is less vascular and is of a more fibrous and dense character. From the inner surface its finest vessels everywhere perpendicularly penetrate the substance of the brain, and at the base groups of long vessels from the pia produce the anterior and posterior perforated spaces.

---

<sup>1</sup> F. cerebelli or minor.



Nerves to the pia, destined to its numerous vessels, are probably derived from the sympathetic and from all of those of the brain, except the nerves of special sense and the hypoglossal.

The **arachnoid**<sup>1</sup> is a delicate and mostly transparent membrane, which is attached to the pia by loose areolar tissue or by thin bands and laminae, leaving between the membranes an interval, the **subarachnoid space**, filled with a clear liquid, the **cerebro-spinal fluid**. It is free from the dura, from which it is separated by the **subdural space**, occupied also by a small portion of liquid. On the surface of the hemispheres of the cerebrum and cerebellum it passes over the convolutions and ridges without dipping into the fissures between them. At the base of the brain it is thicker and towards the centre is less transparent and whitish.

The subarachnoid space for the most part over the surface of the hemispheres of the cerebrum and cerebellum is a narrow interval, but at the base of the brain in several positions forms considerable interspaces. One<sup>2</sup> of these extends from the fore part of the oblongata over the front of the pons and intercrural recess to the optic commissure and laterally between the temporal lobes, and another<sup>3</sup> between the lower part of the hemispheres of the cerebellum and the back of the oblongata. With the latter space the ventricles of the brain communicate through the openings of the choroid tela of the fourth ventricle.

The arachnoid is composed of an intertexture of bands of fibro-connective tissue laminated; the subarachnoid tissue of more delicate bundles of the same material. The free surface of the membrane is covered with a pavement endothelium; the subarachnoid space is likewise lined throughout in the same manner. The blood-vessels are comparatively few, and its nerves are derived from the fifth, seventh, and eleventh.

The **cerebro-spinal fluid**, filling the ventricles and subarachnoid space of the brain, is a limpid liquid with a salty taste and a slightly alkaline reaction. It consists of 98.5 per cent. of water and 1.5 per cent. of animal and saline matters.

**Pacchionian bodies.** Commonly there are found attached to the outer surface of the dura along the superior longitudinal sinus, whitish, granular bodies, often in clusters, and when large received into pits on the inner surface of the cranial vault. They are also found in the same position on the inner surface of the dura and likewise projecting from the latter into the longitudinal sinus and further, on the pia at the margins of the cerebral hemispheres. Less frequently these bodies are found in other positions of the brain. They are known as the **glands or bodies of Pacchioni**.<sup>4</sup> They are enlarged villi of the

<sup>1</sup> Tunica arachnoidea.

<sup>2</sup> Anterior subarachnoid space.

<sup>3</sup> Posterior subarachnoid space.

<sup>4</sup> Glandulae Pacchioni; cerebral granulations.



arachnoid normally existing in the same position. In their growth they perforate the dura and by further enlargement cause absorption of the contiguous portion of the skull. They do not exist in early infancy, but usually appear after seven years and are disposed to increase with the advance of age. Occasionally they are absent.

#### MEMBRANES OF THE SPINAL CORD.

The **dura**<sup>1</sup> of the spinal cord is continuous with that of the brain, but, unlike it, consists of a single layer which is independent of the periosteum. It is tightly attached around the occipital foramen and thence envelops the cord and roots of the spinal nerves in a capacious sheath, which is separated from the walls of the spinal canal by loose areolar tissue with fat and the spinal plexus of veins. It is widest in the cervical and lumbar regions, narrower in the thoracic region, and tapers away in the sacral canal, ending in a slender solid string which is attached to the back of the coccyx. In the sheath near the intervertebral and sacral foramina is a pair of apertures close together for the passage of the corresponding roots of a spinal nerve, which are then together enclosed in a tubular prolongation of the dura, fixed to the intervertebral or sacral foramen, and becoming continuous with the nerve-sheath.

Unlike that of the brain, the spinal dura is moderately elastic. It is thicker behind than in front, and is composed of bands of fibro-connective tissue, with elastic fibres, for the most part, arranged longitudinally. The interior smooth surface is lined by a simple pavement endothelium, and such is likewise the case with the outer surface. The spinal dura is supplied by the meningeal branches of the spinal arteries. Its veins terminate in the plexus of spinal veins. Nerves have been traced into it.

The **pia**<sup>2</sup> of the spinal cord is a thicker, denser, and less vascular membrane than that of the brain, with which it is continuous and corresponds in general anatomical and physiological character. It is closely adherent to the subjacent nerve-substance of the cord and gives a fold into the anterior median fissure and a delicate partition into the posterior median fissure. It gives a sheath to each of the threads or rootlets of the spinal nerve-roots, subsequently continuous with the connective-tissue sheath of the nerves. From the lower end of the cord it is continued as a long slender thread, the **terminal filum**,<sup>3</sup> which descends in the centre of the bunch of nerves forming the cauda equina to the end of the dural sheath, which it joins.

In front the pia is thickened by a glistening, white, longitudinal, fibrous band, the **splendid line**.<sup>4</sup>

<sup>1</sup> Dura mater.

<sup>2</sup> Pia mater.

<sup>3</sup> Filum terminale; nervus impar.

<sup>4</sup> Linea splendens Halleri.



From each side of the pial sheath extends the **denticulate ligament**,<sup>1</sup> a narrow, translucent, fibrous band directed outward in the subarachnoid space and forming a partial partition between the anterior and posterior roots of the spinal nerves. Its inner border is continuous with the pial sheath of the cord; its outer border is divided by wide festooned notches into angular points, which are fixed at their end to the inside of the dural sheath. There are about twenty of the points, of which the first is fixed to the dura opposite the occipital foramen between the hypoglossal nerve and the vertebral artery; the others alternate in position with the roots of the spinal nerves. At the lower end of the cord the ligament is continuous with the terminal filum, which may be regarded as its last point.

The pia is composed of fibro-connective-tissue bundles with elastic fibres, mostly arranged longitudinally, includes an intricate plexus of blood-vessels formed by the numerous spinal arteries and veins, and finally gives off from its interior surface multitudes of fine vessels which penetrate the substance of the cord. The denticulate ligament is also composed of connective tissue with elastic fibres. The exterior surface of the pia and of the denticulate ligaments, corresponding with the subarachnoid space, is invested with a simple pavement endothelium, and such likewise is the case with the surface next the cord. The spinal pia is supplied with nerves from the sympathetic pursuing the course of the blood-vessels.

The spinal **arachnoid**<sup>2</sup> is a delicate, translucent, whitish membrane continuous with that of the brain and holding the same relative position with the cord. It is loosely attached to the pia and cauda equina, with a large intervening subarachnoid space filled with the cerebro-spinal fluid,<sup>3</sup> and is in contact by its free surface with the inner surface of the dural sheath; the subdural space being occupied by a small quantity of liquid. The arachnoid is connected with the pia by threads and slender bands of fibro-connective tissue and at the back of the cord by a thin median partition, most complete in the cervical region but imperfect and cribriform below. Through the subarachnoid space laterally extend the roots of the spinal nerves and the points of the denticulate ligament enclosed in funnel-like prolongations of the arachnoid.

The arachnoid is composed of fibro-connective tissue mostly arranged longitudinally, and is covered on the free surface by a pavement endothelium, which likewise lines the subarachnoid space throughout.

The spinal subarachnoid space is continuous with that of the brain and its ventricles through the openings of the choroid tela of the fourth ventricle.

The spinal cord within its capacious dural sheath maintains its central position, bathed in the cerebro-spinal fluid of the subarachnoid

<sup>1</sup> Ligamentum denticulatum; l. serratum.

<sup>2</sup> Tunica arachnoidea.

<sup>3</sup> Cephalo-rachidian fluid.



space, through its connection with the brain above, through the roots of the spinal nerves and denticulate ligaments laterally with the dural sheath, and below through the terminal filum with the sheath.

#### BLOOD-VESSELS OF THE CEREBRO-SPINAL AXIS.

The brain and spinal cord are highly vascular, though no conspicuously large blood-vessels enter them to be distributed to their structure. Their many large arteries derived from the internal carotids and vertebrals first ramify throughout the pia, forming a wide-spread plexus, from which a multitude of arterioles directly penetrate and are distributed to the nervous substance.

In the spinal cord, numerous arterioles form the anterior spinal artery in the pia of the anterior median fissure, enter the anterior commissure and divide each into a right and left branch, which anastomose with the corresponding ones above and below and proceed to the base of the anterior gray cornua in which they are distributed. Other fine arterioles in the posterior median fissure penetrate the gray commissure, and give branches to the posterior white columns and to the posterior ganglionic tracts.<sup>1</sup> Arterioles also enter with the spinal nerve-roots and follow them to the corresponding gray cornua in which they are distributed. A number also radially penetrate the white columns to which some are distributed, while others continue to the central gray matter, where they anastomose with those entering the cornua. The veins pursue the course of the arterioles, and among them is a longitudinal vein, on each side of the central canal, accompanying the corresponding anastomotic arteries.

At the base of the brain, from the cerebral arteries spring half a dozen groups of arterioles, which ascend to supply the central ganglia or accumulations of gray matter in the cerebral hemispheres and are named from their relative position.

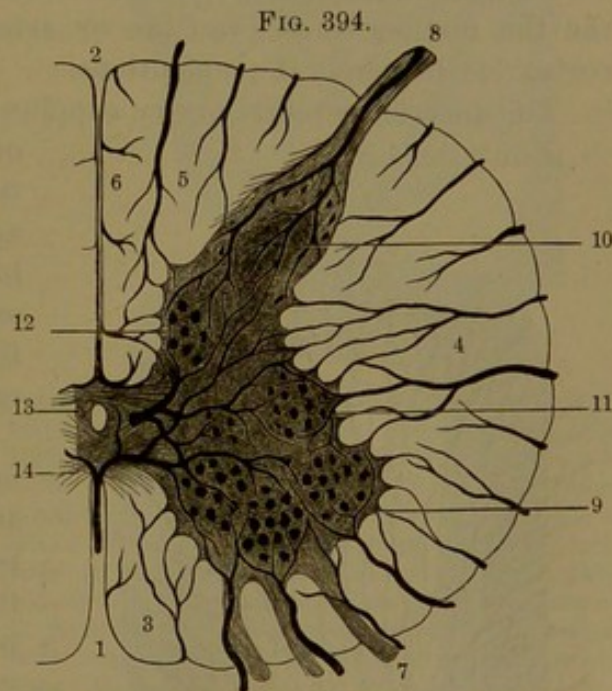


FIG. 394.  
HORIZONTAL SECTION OF THE SPINAL CORD, SHOWING THE GENERAL MODE OF DISTRIBUTION OF THE ARTERIES: magnified. 1, anterior median fissure; 2, posterior median fissure; 3, anterior column; 4, lateral column; 5, posterior lateral column; 6, posterior median column; 7, anterior rootlets of a spinal nerve; 8, posterior rootlet; 9, anterior gray column or cornu; 10, posterior cornu; 11, intermedio-lateral tract; 12, posterior ganglionic tract; 13, gray commissure; 14, anterior commissure.

<sup>1</sup> Clarke's column.



The **antero-median group** spring from the lower part of the anterior cerebral arteries and their communicating artery and penetrate the contiguous part of the cerebrum to supply the fore part of the striatum.

The **antero-lateral group**, on each side, spring from the middle cerebral artery and thence ascend through the anterior perforated space to supply the striatum and fore part of the thalamus. A branch, named the **lenticulo-striate artery**,<sup>1</sup> to the outer part of the lenticular nucleus and striatum, is said to be a frequent source of hemorrhage of the brain.

The **postero-median group** spring from the commencement of the posterior cerebral arteries and ascend in the posterior perforated space to supply the walls of the third ventricle.

The **postero-lateral group**, on each side, come from the posterior cerebral artery after turning round the cerebral crus, which it partly supplies, together with the back of the thalamus and the geniculate and quadrigeminal bodies.

In the further course and distribution of the cerebral arteries in the pia, the terminal branches or arterioles penetrate the subjacent cortex of the cerebral convolutions.

The anterior cerebral artery supplies the superior and the fore part of the middle frontal convolutions, the upper part of the anterior central convolution, the lower part of the frontal lobe outside the olfactory fissure, the fornicate convolution, the quadrate lobule, and the callosum.

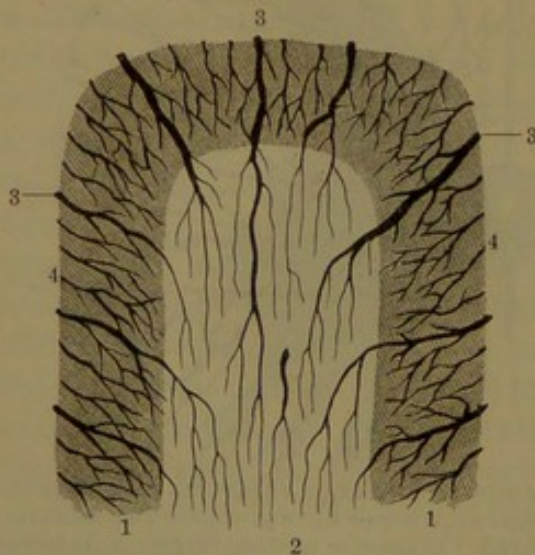
The middle cerebral artery, most extensive of the three, supplies the inferior and the posterior part of the middle frontal convolutions, the lower part of the anterior central convolution, those of the central and parietal lobes, and the superior and upper lateral part of the temporal lobe.

The posterior cerebral artery supplies the lower part of the temporal lobe, including the hippocampal convolution, the cune-

ate lobule, and the convolutions of the occipital lobe.

In the final distribution of the cerebral arteries from the pia a pro-

FIG. 395.



SECTION ACROSS A CEREBRAL CONVOLUTION, EXHIBITING THE ARTERIAL ARRANGEMENT. 1, the gray cortex; 2, interior white matter; 3, medullary arteries penetrating the cortex to the white matter; 4, cortical arteries distributed to the cortex.

<sup>1</sup> Artery of cerebral hemorrhage.



fusion of distinct thread-like arterioles leave the under surface of the membrane and penetrate the surface of the subjacent convolutions. Those at the summit enter perpendicularly, at the sides in the intervening fissures obliquely, and at the bottom less so. Of the entering vessels the more numerous, finer, and shorter **cortical branches** are distributed in the gray cortex; while the fewer, larger, and longer **medullary branches** pass into the white substance, in which they continue some distance and end in a delicate capillary plexus. The two systems of vessels, those entering from the convolutions and those from the base of the brain to the central ganglia, have little or no communication through anastomosis.

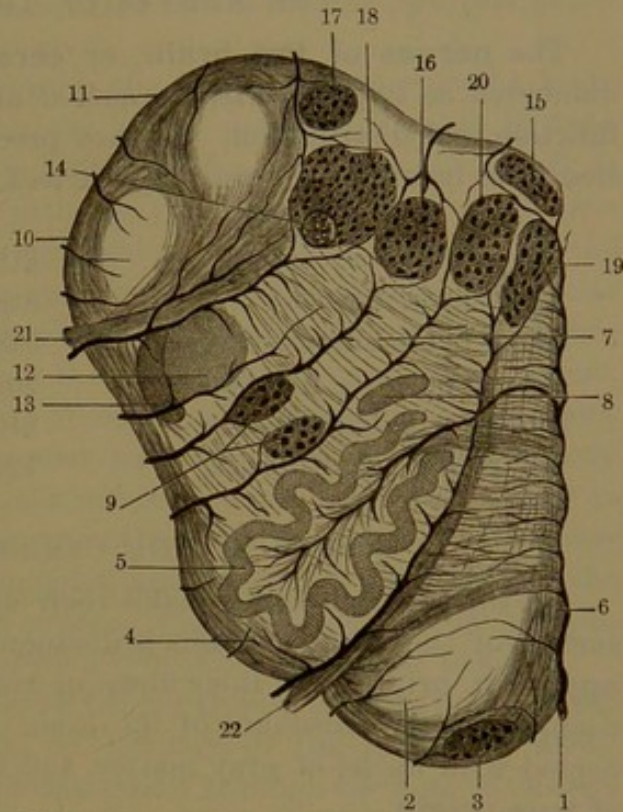
The central white matter of the cerebral hemispheres is much less vascular than the cortical gray substance, and of this the intermediate layer is most abundantly supplied with capillaries.

The cerebellar arteries in their ramification and formation of a wide-expanded plexus in the pia investing the cerebellum and in their final distribution to it conform to the cerebral arteries.

The oblongata and pons are supplied by the anterior spinal, vertebrals, basilar, and posterior cerebral arteries. In their final distribution from the pia many of the chief arterioles enter and follow the course of the nerve-roots. In the oblongata others enter the anterior median fissure and between its different columns, supplying them with branches and converging to the gray matter in the floor of the fourth ventricle.

While the chief arteries of the brain are distributed from its base upward in the pia, the chief veins in general pursue a reverse course; the larger cerebral veins ascending and ending in the superior longitudinal sinus, while the internal cerebral veins from the lateral and

FIG. 396.



HORIZONTAL SECTION OF THE OBLONGATA, SHOWING THE DISTRIBUTION OF THE ARTERIES. 1, artery entering the median fissure and raphé; 2, pyramid; 3, arciform nucleus; 4, olive; 5, olivary nucleus; 6, arciform fibres; 7, reticular formation; 8, accessory olivary nucleus; 9, lateral nuclei; 10, 11, arciform fibres of the restiform body; 12, gelatinosa nucleus; 13, ascending root of the trifacial nerve; 14, longitudinal bundle of nerve-fibres; 15, facial nucleus in the terete funicle; 16, external facial nucleus; 17, inferior portion of the auditory nucleus; 18, vagus nucleus; 19, 20, hypoglossal nuclei; 21, vagus nerve; 22, hypoglossal nerve. The black branching lines represent the chief arteries.



third ventricles run backward and unite in the vein of Galen, which ends in the straight sinus.

The lymphatics of the brain and spinal cord appear to originate in perivascular spaces of the blood-vessels in the nerve-substance, and these communicate with lymphatic spaces of the pia and with the subarachnoid space.

#### THE NERVES OF THE BRAIN.

The **nerves of the brain**, or **cerebral nerves**, are commonly numbered as twelve pairs, are named numerically and also from their function and distribution. As they proceed from the brain, in succession from before backward they are as follows:

1st, or olfactory nerves,	7th, or facial nerves,
2d, or optic nerves,	8th, or auditory nerves,
3d, or oculo-motor nerves,	9th, or glosso-pharyngeal nerves,
4th, or pathetic nerves,	10th, or vagus nerves,
5th, or trifacial nerves,	11th, or accessory nerves,
6th, or abducent nerves,	12th, or hypoglossal nerves.

#### ORIGIN OF THE CEREBRAL NERVES.

All the cerebral nerves make their appearance at some part of the surface of the brain, and this is distinguished as their **superficial** or **apparent origin**, but their fibres or roots may be traced more or less deeply into the substance of the brain, where they appear to be connected with nuclei of gray matter, and this is regarded as their **deep** or **true origin**.

The **first**, or **olfactory nerve**,<sup>1</sup> as commonly named, is not a nerve in the sense of the rest of the series, but is really one of the divisions of the brain, the **olfactory lobe**, as described on page 745.

The olfactory lobes of man are relatively very small compared with their condition in other animals of his class, and in fishes especially they appear as conspicuous divisions of the brain.

The **second**, or **optic nerve**,<sup>2</sup> one of the largest of those of the brain in its origin from the optic tract, has been described on page 760.

The **third**, or **oculo-motor nerve**,<sup>3</sup> much smaller than the preceding, is of considerable size. It springs from a nucleus of large pigmented cells embedded in the gray matter at the side of the floor of the ventricular aqueduct, beneath the quadrigeminal body, whence it proceeds through the tegmentum and locus niger and emerges from the inner side of the cerebral crus, between the tegmentum and crusta, in from nine to twelve filaments or slender bundles, which speedily

<sup>1</sup> N. olfactorius; tractus olfactorius.

<sup>2</sup> N. opticus.

<sup>3</sup> N. oculo-motorius; n. oculo-muscularis communis.



unite in a rounded cord. Not unfrequently one of the filaments is separated from the rest and issues from the crus in advance.

The **fourth**, or **trochlear nerve**,<sup>1</sup> the smallest of those of the brain, springs from a nucleus of large nerve-cells situated immediately below that of the third nerve in the gray matter of the floor of the ventricular aqueduct. Thence it turns upward and inward above the aqueduct and enters the anterior velum, in which it partially decussates with its fellow and emerges on the opposite side near the median line, just below the quadrigeminal body.

The **fifth**, or **trifacial nerve**,<sup>2</sup> is the largest of those of the brain and in several points resembles the spinal nerves. It arises by **two roots**, of which the smaller is motor in function and the larger is sensory. Each root also originates in two chief portions which proceed from different nuclei, distinguished as motor and sensory. In the small, motor root, one portion comes from a nucleus of large multipolar cells situated just below the lateral angle of the fourth ventricle, thence proceeds forward and outward in the pons, joined by the other portion, which descends from a nucleus of large cells embedded in the gray matter at the side of the ventricular aqueduct. In the large, sensory root, one portion comes from a nucleus of small nerve-cells lying to the outer side of the lower motor nucleus and is joined by the other portion, which ascends from the gelatinosa prolonged upward from the cuneate eminence.<sup>3</sup> The roots proceed together through the pons to emerge from the side, separated by a few of its transverse fibres.<sup>4</sup>

The **sixth**, or **abducent nerve**,<sup>5</sup> arises from a nucleus in the terete funicle of the fourth ventricle, in advance of the medullary striæ, whence it proceeds outward and downward through the pons to emerge between its lower border and the top of the pyramid of the oblongata.

The **seventh**, or **facial nerve**,<sup>6</sup> has its origin in the **facial nucleus** of the reticular formation at the back of the pons. The upper end of the nucleus is close to the motor nucleus of the fifth nerve and its lower end near an accumulation of gray matter of the oblongata named the **ambiguous nucleus**.<sup>7</sup> The fibres of the nerve-root pass backward from the nucleus and collect into a compact bundle, which turns up in the terete funicle, then outward and forward around the nucleus of the sixth nerve and passes through the pons to emerge from the oblongata in the interval of the olive and restiform body. Close to the emerging nerve on the outer side is the auditory nerve, and between them lies a filament, the **intermediate portion**,<sup>8</sup> which is commonly connected with both nerves.

<sup>1</sup> N. patheticus or trochlearis; n. oculo-muscularis superior.

<sup>2</sup> N. quintus, trifacialis, or trigeminus.

<sup>3</sup> Tubercle of Rolando.

<sup>4</sup> Lingula Wrisbergii.

<sup>5</sup> N. abducens.

<sup>6</sup> N. facialis; n. communicans faciei; portio dura of the seventh nerve of Willis.

<sup>7</sup> N. ambiguus.

<sup>8</sup> Pars intermedia.



The **eighth, or auditory nerve**,<sup>1</sup> arises by two principal roots from the auditory nuclei of the floor of the fourth ventricle. (See page 725.) The **superior root** springs from the external auditory nucleus, including fibres from within it traceable to the cerebellum. The **inferior root** arises from the internal auditory nucleus and is reinforced by the auditory striæ of the fourth ventricle. Both roots from their origin proceed outward and unite in a common trunk, which turns around the restiform body at the lower border of the pons, to the outer side of the facial nerve.

The **ninth, or glosso-pharyngeal nerve**,<sup>2</sup> arises from the glosso-pharyngeal nucleus, which occupies the cinereous eminence in the floor of the fourth ventricle. The fibres of the nerve pass outward and forward through the oblongata and emerge in a series of five or six rootlets, in the furrow between the olive and restiform body immediately below the auditory nerve.

The **tenth, vagus, or pneumogastric nerve**,<sup>3</sup> arises from the vagal nucleus, which is continuous above with that of the glosso-pharyngeal nerve and is extended below as the accessory nucleus. The fibres of the nerve proceed through the oblongata in the same direction as those of the ninth nerve and emerge below in from ten to fifteen rootlets, from the same furrow.

The **eleventh, or accessory nerve**,<sup>4</sup> has its origin in part from the oblongata in the downward extension of the vagal nucleus, but in greater part from the cervical portion of the spinal cord in the intermedio-lateral tract and in the adjacent part below of the anterior cornu, and above in the reticular formation and base of the posterior cornu. The smaller portion emerges from the oblongata in a series of four or five rootlets immediately below and in the same line as the vagus nerve; while the larger spinal portion emerges through the lateral column of the spinal cord in five or six rootlets, which successively unite in a trunk ascending from the spinal canal through the occipital foramen, where the two portions conjoin in a common trunk.

The **twelfth, or hypoglossal nerve**,<sup>5</sup> arises from the hypoglossal nucleus, a column of large, multipolar nerve-cells, which extends from within the lower part of the terete funicle of the fourth ventricle downward at the side of the central canal in the lower part of the oblongata. From the nucleus spring numerous nerve-fibres, which pass outward and forward in the oblongata and emerge in from ten to fifteen rootlets, from the furrow between the pyramid and olive.

<sup>1</sup> N. auditorius or acusticus; acoustic nerve; portio mollis of the seventh nerve of Willis.

<sup>2</sup> N. glosso-pharyngeus; part of the eighth nerve of Willis.

<sup>3</sup> N. vagus; n. pneumogastricus; part of the eighth nerve of Willis.

<sup>4</sup> N. accessorius; spinal accessory nerve; part of the eighth nerve of Willis.

<sup>5</sup> N. hypoglossus; ninth nerve of Willis.



## DISTRIBUTION OF THE NERVES OF THE BRAIN.

## I. OLFACTORY NERVES.

The **first**, or **olfactory nerve**, is described with the nose.

## II. OPTIC NERVES.

The **second**, or **optic nerve**, is described with the eye.

## III. OCULO-MOTOR NERVES.

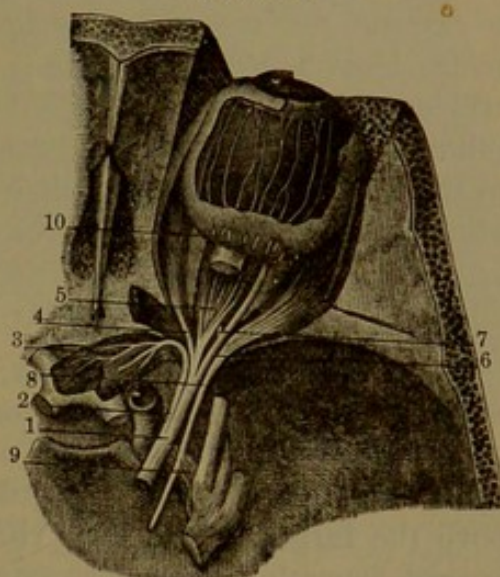
The **third**, or **oculo-motor nerve**,<sup>1</sup> of medium size among those of the brain, makes its appearance at the base in the intercavernous recess, where it emerges from the side of the cerebral crus in slender bundles of fibres, which unite in a firm, rounded trunk. Proceeding forward between the posterior cerebral and superior cerebellar arteries to the outer side of the posterior clinoid process, it passes through an aperture of the dura and runs through the outer wall of the cavernous sinus to the sphenoidal foramen. Here it divides into two branches, which enter the orbit between the heads of the external rectus muscle and are separated by the nasal branch of the ophthalmic nerve.

The **superior branch**, smaller, runs inward above the optic nerve to the superior rectus and palpebral elevator muscles.

The **inferior branch** divides into three, which run to the inferior and internal recti and inferior oblique muscles. The branch to the last muscle gives off a short, thick one to the ophthalmic ganglion, forming its inferior or short root.

The branches to the recti and palpebral elevator muscles enter in diverging twigs on the surface directed towards the eyeball, while that to the inferior oblique muscle enters its back border. The name indicates the function of the oculo-motor nerve.

FIG. 397.



OCULO-MOTOR AND ABDUCENT NERVE, the upper part of the right orbit removed. 1, oculo-motor nerve; 2, 3, branch to the superior rectus and palpebral elevator muscles; 4, 5, branches to the internal and inferior recti muscles; 6, branch to the inferior oblique muscle; 7, branch from the latter to the ophthalmic ganglion; 8, abducent nerve to the external rectus muscle; 9, communicating filaments between the abducent nerve and the carotid plexus of the sympathetic. To their outer side is the trifacial nerve. 10, ciliary nerves perforating the sclerotic and passing forward between it and the choroidea to the ciliary muscle and iris.

<sup>1</sup> N. oculo-motorius; common motor nerve of the eyeball.



## IV. TROCHLEAR NERVES.

The **fourth**, or **trochlear nerve**,<sup>1</sup> the smallest of those of the brain, pursues the longest course within the cavity of the cranium. From its superficial origin in the anterior velum, immediately behind the quadrigeminal body, it turns outward across the superior cerebellar peduncle, thence forward round the outer side of the cerebral crus. Lying between and parallel to the posterior cerebral and superior cerebellar arteries, it passes through an aperture of the dura, just below the free edge of the tentorium a little behind the posterior clinoid process, and runs through the outer wall of the cavernous sinus to the inner extremity of the sphenoidal foramen. Entering the orbit above the external rectus, it proceeds inward over the palpebral elevator to the trochlear muscle, which it enters at the outer part of its upper surface. In its course through the cavernous sinus it lies on the ophthalmic nerve, crosses the oculo-motor nerve from the outer side below upward, and is connected by filaments with the ophthalmic and sympathetic nerves. The trochlear is a purely motor nerve.

## V. TRIFACIAL NERVES.

The **fifth**, or **trifacial nerve**,<sup>2</sup> the largest of those of the brain, resembles the spinal nerves in that it has a sensory and a motor root and the former is provided with a ganglion. Of the two roots which appear at the side of the pons, the **small**, or **motor root**,<sup>3</sup> emerges above the **large**, or **sensory root**,<sup>4</sup> and both together are directed forward beneath the anterior extremity of the tentorium, where they pass through an elliptical aperture of the dura above the apex of the temporal pyramid. Here the larger root expands, its bundles of fibres assume a plexiform arrangement,<sup>5</sup> and in this condition ends in the semilunar or trifacial ganglion. The small root inclines forward on the inner side of the large root, then passes beneath it and the ganglion, but without forming any connection with it.

The **semilunar ganglion**<sup>6</sup> is a flattened, oval, somewhat crescentic body lying in the depression in front of the apex of the temporal pyramid attached to the subjacent periosteum, but more intimately adherent to the dura which covers it. Its surface is striate, and on the inner side it is joined by filaments of the contiguous carotid plexus of the sympathetic nerve. Its upper concave border receives the large root of the trifacial nerve and its forward convex border gives off three nerves. Of these the inner uppermost and smallest, the ophthalmic

<sup>1</sup> N. trochlearis; n. patheticus, quartus, or oculo-muscularis superior.

<sup>2</sup> N. trifacialis; n. trigeminus, trimellus, quintus, or mixtus.

<sup>3</sup> Radix minor, superior, or anterior.

<sup>4</sup> R. major, inferior, posterior, or longior.

<sup>5</sup> Plexus triangularis.

<sup>6</sup> G. semilunare; g. Gasseri; Gasserian ganglion.



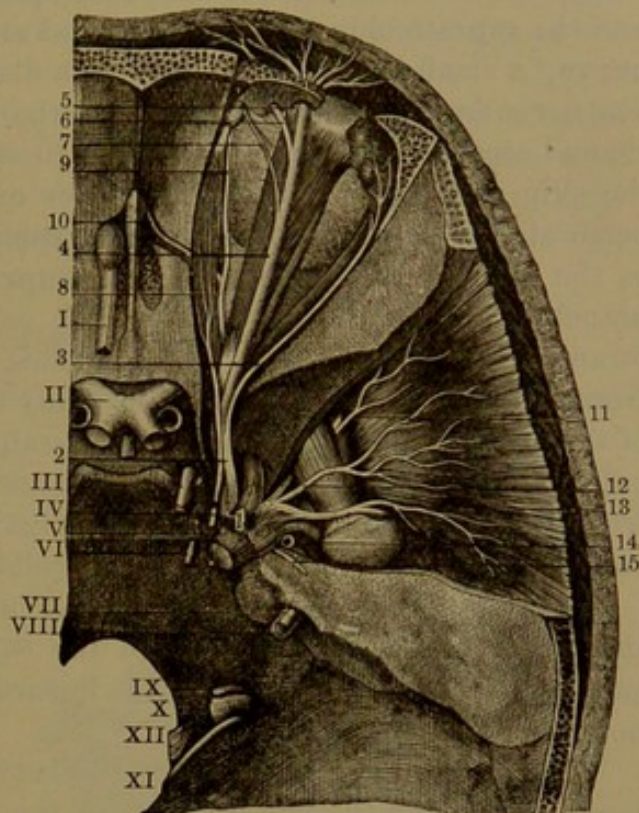
nerve, proceeds forward through the sphenoidal foramen into the orbit; the second, intermediate in position and size, the superior maxillary nerve, proceeds forward from the cranial cavity through the rotund foramen. The third, outermost and largest, descends through the oval foramen in company with the small root and then unites with it to form the inferior maxillary nerve. Thus the first two nerves proceeding from the ganglion are purely sensory nerves, while the third, derived from the ganglion, has associated with it the motor root of the trifacial and is therefore a sensory motor nerve.

#### OPHTHALMIC NERVE.

The **ophthalmic nerve**,<sup>1</sup> the first and smallest branch from the semilunar ganglion of the fifth, is flattened and about an inch long. It runs forward in the outer wall of the cavernous sinus, in company with and below the third and fourth nerves, to the sphenoidal foramen, where it divides into three branches, the lachrymal, frontal, and nasal nerves. At its commencement it gives off a small recurrent branch<sup>2</sup> to the tentorium, and in its further course is connected by filaments with the cavernous plexus of the sympathetic and with the third, fourth, and sixth nerves.

The **lachrymal nerve**<sup>3</sup> runs along the outer part of the orbit above the external rectus muscle to the lachrymal gland and upper eyelid, to which it is distributed. In its course it gives off a branch<sup>4</sup> which

FIG. 398.



TRIFACIAL NERVE, the upper part of the orbit and temporal fossa removed. 1, semilunar ganglion; 2, ophthalmic nerve; 3, lachrymal nerve; 4, frontal nerve; 5, 6, its supraorbital branches; 7, supratrochlear branch; 8, nasal nerve; 9, its infratrochlear branch; 10, course of the nasal nerve from the orbit into the cranium and nose; 11, 12, 13, deep temporal branches of the inferior maxillary nerve; 14, commencement of the auriculo-temporal nerve; 15, superficial petrosal nerve; I, olfactory nerve; II, optic nerves; III, oculo-motor nerve; IV, trochlear nerve to the trochlear muscle of the eye; V, trifacial nerve; its small root visible beneath the cut end of the large root, which ends in the semilunar ganglion giving off three divisions; VI, abducent nerve; VII, facial, included in a groove of the auditory nerve; VIII, both entering the auditory meatus; IX, glossopharyngeal; X, vagus, and XI, accessory nerves emerging at the jugular foramen; XII, hypoglossal nerve.

<sup>1</sup> N. ophthalmicus; n. orbitalis.

<sup>3</sup> N. lachrymalis; n. lachrymo-palpebralis.

<sup>2</sup> N. recurrens; n. tentorii.

<sup>4</sup> Ramus temporo-malaris.



joins the temporo-malar branch of the superior maxillary nerve, and its terminal filaments anastomose with the facial nerve.

The **frontal nerve**,<sup>1</sup> the largest division of the ophthalmic, runs along the roof of the orbit above the palpebral elevator and divides into the supratrochlear and supraorbital nerves. The **supratrochlear nerve**,<sup>2</sup> a small branch, after sending a filament to join the infratrochlear nerve leaves the orbit external to the pulley of the trochlear muscle and ascends to the forehead close to the bone. It gives twigs to the skin and conjunctiva of the upper eyelid; its terminal branches perforate the palpebral orbicular and frontal muscles to be distributed to the skin of the forehead. The **supraorbital nerve**,<sup>3</sup> the main branch of the frontal, passes from the orbit through the supraorbital foramen and divides into two branches, which ascend beneath the frontal muscle to be distributed in many slender filaments to the skin of the forehead and upper part of the scalp. The outer larger branch<sup>4</sup> extends far back over the scalp, the inner one<sup>5</sup> but little beyond the frontal bone. The nerve also gives twigs to the pericranium and as it emerges from the orbit to the upper eyelid.

The supraorbital nerve often divides before leaving the orbit, when the larger branch passes through the supraorbital foramen and the smaller one passes from the orbit inwardly and sometimes through a notch or foramen.

The **nasal nerve**<sup>6</sup> enters the orbit between the two heads of the external rectus and the two branches of the third nerve, proceeds inward beneath the upper muscles and over the optic nerve to the anterior ethmoidal foramen. Through this it reaches the cranial cavity, runs forward in a groove of the ethmoidal cribriform plate and through a foramen at its fore part descends to the nasal cavity, where it divides into two branches. Of these the **internal branch**<sup>7</sup> is distributed to the mucous membrane at the fore part of the nasal partition, while the **external branch**<sup>8</sup> descends in a groove behind the nasal bone, supplies the mucous membrane at the fore part of the outer wall of the nose, then leaves the cavity between the nasal bone and nasal cartilage and is distributed to the skin of the tip and wing of the nose.

In its course the nasal nerve gives off the following: a **branch to the ophthalmic ganglion**, constituting its **long root**, a slender filament which runs forward on the outer side of the optic nerve and enters the ganglion at its upper back angle. The **long ciliary nerves**,<sup>9</sup> usually two, sometimes three slender filaments, which proceed to the eyeball and pierce the back of the sclerotica and run forward between it and the choroidea to supply the ciliary muscle and iris. The **infra-**

<sup>1</sup> N. frontalis; n. supraorbitalis.

<sup>2</sup> N. supratrochlearis.

<sup>3</sup> N. supraorbitalis.

<sup>4</sup> External frontal nerve.

<sup>5</sup> Internal frontal nerve.

<sup>6</sup> N. nasalis; n. oculo-nasalis; internal nasal nerve; n. nasalis internus.

<sup>7</sup> N. anterior septi.

<sup>8</sup> N. nasalis externus or anterior.

<sup>9</sup> N. ciliares longi.



**trochlear nerve**<sup>1</sup> is given from the nasal as it is about to enter the anterior ethmoidal foramen. It proceeds beneath the pulley of the trochlear muscle, is joined by a filament from the supratrochlear nerve, then leaves the orbit at the inner corner of the eye and is distributed to the lachrymal sac and caruncle, the conjunctiva, and the skin of the eyelids and root of the nose.

The ophthalmic nerve is altogether sensory in function and supplies the eyeball, the lachrymal gland, the mucous membrane of the nose and eyelids, the skin of the nose, upper eyelid, forehead, and scalp. It communicates with the sympathetic, the third, fourth, sixth, and seventh nerves.

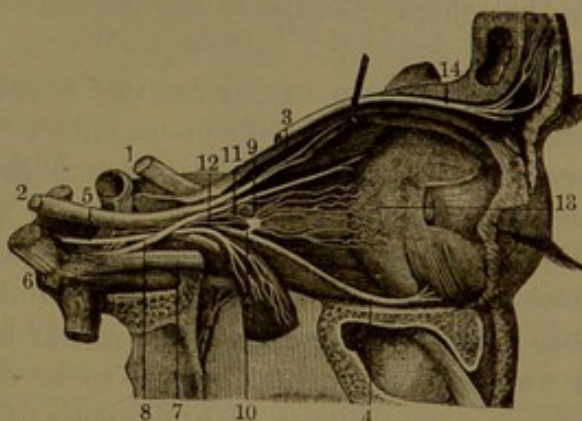
#### OPHTHALMIC GANGLION.

Connected with the main divisions of the trifacial nerve are several ganglia, which, though regarded as more directly pertaining to the sympathetic system, are conveniently described with the trifacial.

Within the orbit is the **ophthalmic ganglion**,<sup>2</sup> placed between the optic nerve and external rectus muscle, embedded in areolar tissue and fat and usually lying in contact with the ophthalmic artery. It is a little, reddish, quadrangular body, joined behind by branches from the oculo-motor, ophthalmic, and sympathetic nerves, and giving off in front the short ciliary nerves. Its communication with the oculo-motor nerve is its **short, or motor root**, a short, thick branch from the inferior division of that nerve joining the ganglion at its lower back angle. The communication with the ophthalmic nerve is its **long, or sensory root**, a slender filament from the nasal branch, joining the upper back angle of the ganglion. The **median, or sympathetic root**, is another slender filament from the cavernous plexus of the sympathetic, often joining the long root.

The **short ciliary nerves**,<sup>3</sup> from six to nine, come from the front

FIG. 399.



OPHTHALMIC GANGLION—THE OUTER PART OF THE RIGHT ORBIT REMOVED. 1, optic nerve; 2, oculo-motor nerve; 3, branch to the superior rectus and palpebral elevator muscles; 4, branch to the inferior oblique muscle; 5, abducent nerve to the external rectus muscle; 6, trifacial nerve, its ganglion and three principal branches; 7, ophthalmic nerve; 8, nasal nerve; 9, ophthalmic ganglion; 10, its communicating branch with the oculo-motor nerve; 11, communicating branch with the ophthalmic nerve; 12, communicating branch with the cavernous plexus of the sympathetic; 13, the ciliary nerves; 14, supraorbital nerve.

<sup>1</sup> N. infratrochlearis; n. nasalis externus.

<sup>2</sup> G. ophthalmicum, lenticulare, or ciliare.

<sup>3</sup> N. ciliares breves.



of the ganglion, usually in two groups from the upper and lower angles, thence proceed along the optic nerve above and below and divide into from a dozen to twenty slender filaments. The lower larger bundle is joined by the long ciliary nerves from the nasal branch of the ophthalmic, and all enter the back of the eyeball by apertures of the sclerotica around the entrance of the optic nerve, whence they run forward between the sclerotica and choroidea to be distributed to the ciliary muscle, iris, and cornea.

#### SUPERIOR MAXILLARY NERVE.

The **superior maxillary nerve**,<sup>1</sup> the second branch of the semilunar ganglion of the fifth, intermediate in size and position to the others, runs forward and leaves the cranial cavity through the sphenoidal rotund foramen, thence crosses the upper part of the sphenomaxillary fossa, enters the infraorbital canal,<sup>2</sup> and continues to the face. In the sphenomaxillary fossa it gives off the temporo-malar and sphenopalatine nerves.

The **temporo-malar nerve**,<sup>3</sup> a small cutaneous branch, enters the orbit through the sphenomaxillary foramen and divides into two branches. Of these the **temporal branch**,<sup>4</sup> after receiving one from the lachrymal nerve, passes through a foramen of the malar bone to the temporal fossa, where it ascends beneath the temporal muscle, perforates it and the temporal fascia, and is distributed to the skin at the fore part of the temple. The **malar branch**<sup>5</sup> likewise passes through a foramen of the malar bone to be distributed to the cheek. Both branches anastomose with filaments of the facial nerve.

The **spheno-palatine nerves** are two short branches descending to the sphenopalatine ganglion, which is situated below the trunk of the superior maxillary nerve in the sphenomaxillary fossa.

In the further part of its course the superior maxillary nerve gives off the **dental nerves**,<sup>6</sup> which supply the upper teeth, the gum, and the maxillary antrum.

The **posterior dental nerve**<sup>7</sup> comes from the superior maxillary as it is about to enter the infraorbital canal, and immediately divides into two branches, which frequently also come off separately from the trunk. Descending on the maxilla in company with the corresponding artery, one branch is distributed to the mucous membrane of the cheek and gum and the other branch enters the posterior dental canal and its divisions to supply the back teeth and maxillary antrum.

<sup>1</sup> N. maxillaris superior.

<sup>2</sup> Infraorbital nerve, passing through the canal.

<sup>3</sup> N. temporo-malaris; n. orbitalis; n. subcutaneus malar.

<sup>4</sup> Ramus temporalis.

<sup>5</sup> R. malaris or facialis.

<sup>6</sup> Nervi dentales; n. alveolo-dentales.

<sup>7</sup> Post. superior dental nerve; n. alveolaris sup. posticus.

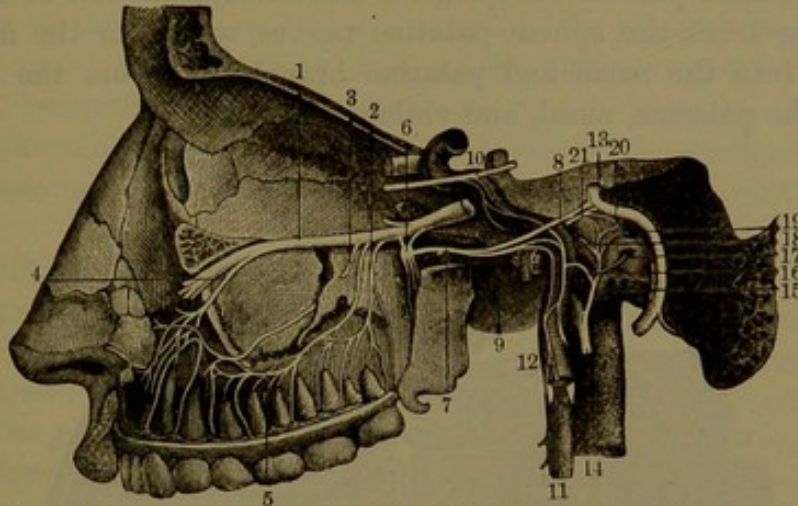


The **anterior dental nerve**<sup>1</sup> comes from the superior maxillary at the fore part of the infraorbital canal and descends in the corresponding dental canal of the maxilla to supply the front teeth and contiguous part of the antrum.

Sometimes there is a **middle dental nerve**, variable in its origin between the others and supplying the intermediate teeth.

The dental arteries anastomose<sup>2</sup> and together form the **superior**

FIG. 400.



**SUPERIOR MAXILLARY NERVE**—THE EXTERNAL WALL OF THE LEFT ORBIT AND OF THE MAXILLA REMOVED. 1, superior maxillary nerve in its course through the infraorbital canal; 2, posterior dental nerves; 3, middle dental nerve; 4, anterior dental nerve; 5, superior dental plexus; 6, spheno-palatine ganglion; the branch from the superior maxillary nerve above is the commencement of the temporo-malar nerve; 7, vidian nerve; 8, superficial petrosal nerve joining the facial nerve; 9, deep petrosal nerve joining the carotid plexus of the sympathetic; 10, abducent nerve and its communicating branches with the latter plexus; 11, superior cervical ganglion; 12, ascending branches to the carotid plexus; 13, facial nerve; 14, glosso-pharyngeal nerve; 15, the tympanic nerve; 16, branch to the carotid plexus; 17, 18, 19, branches to the round and oval windows and eustachian tube; 20, communicating branch of the small petrosal nerve, 21.

**dental plexus**, which occupies corresponding canals of the alveolar border and gives off branches to the teeth and gum.

The superior maxillary nerve finally emerges at the infraorbital foramen and breaks up into a group of palpebral, nasal, and labial branches.

The **palpebral branches**, commonly an inner and an outer, ascend to supply the skin and conjunctiva of the lower eyelid.

The **nasal branches**, two or three, are directed inward between the fibres of the naso-labial elevator to the skin of the nose.

The **labial branches**, the largest and three or four in number, descend between the supralabial and oral angle elevators and supply the skin and mucous membrane of the upper lip and contiguous part of the cheek.

<sup>1</sup> Ant. sup. dental nerve; n. alveolaris sup. anterior.

<sup>2</sup> Forming the ansa supramaxillaris.

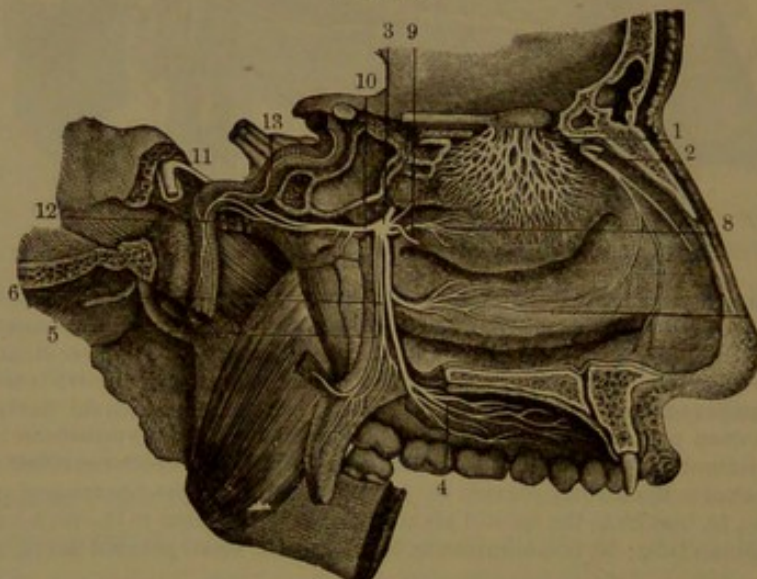


The terminal branches of the superior maxillary nerve are connected with branches of the facial nerve and together form the **infraorbital plexus**.

#### SPHENO-PALATINE GANGLION.

The **spheno-palatine ganglion**<sup>1</sup> is a reddish-gray, ovoid body, about a fifth of an inch in diameter, situated in the spheno-maxillary fossa just below the superior maxillary nerve, with which it is connected by the two spheno-palatine nerves. Its nerve-cells mainly occupy the back part of the ganglion and involve but few of the fibres descending from the spheno-palatine nerves, which for the most part continue into the nasal and palatine branches. From the ganglion proceed the palatine, nasal, and vidian nerves.

FIG. 401.



VIEW OF THE SPHENO-PALATINE GANGLION, THE OUTER WALL OF THE LEFT NASAL CAVITY, AND THE OLFACTORY NERVE. 1, external olfactory nerves; 2, nasal branch of the ophthalmic nerve; 3, sphenopalatine ganglion; 4, 5, 6, palatine nerves; 7, inferior nasal nerve; 8, superior nasal nerves; 9, naso-palatine nerve; 10, vidian nerve; 11, facial nerve; 12, deep petrosal nerve joining the carotid plexus, 13; the other branch of the vidian is the superficial petrosal nerve, which joins the facial.

The **palatine nerves**,<sup>2</sup> of which there are three, descend through the posterior palatine canal and its divisions to the palate.

The **large, or anterior palatine nerve**,<sup>3</sup> is directed forward from the canal in a groove of the hard palate, the mucous membrane and glands of which it supplies. In its course through the canal it gives off the **inferior nasal nerves**,<sup>4</sup> two branches which pass through small foramina in the outer wall of the nasal cavity to supply the mucous membrane on the middle and lower turbinals and in the middle meatus.

<sup>1</sup> G. sphenopalatinum; Meckel's ganglion; g. nasale.

<sup>2</sup> N. palatini descendentes.

<sup>3</sup> N. palatinus major or anticus.

<sup>4</sup> N. nasales posteriores inferiores.



The **small palatine nerves**<sup>1</sup> pass through the canals of the pyramidal process of the palate bone and supply the soft palate, uvula, and tonsil, including the palatal elevator and uvular muscles.

The **superior nasal nerves** are two or three small ones which proceed from the inner side of the ganglion through the sphenopalatine foramen into the nasal cavity, where they are distributed to the mucous membrane of the back part of the roof, of the superior and middle turbinals, and of the adjacent part of the nasal partition.

The **naso-palatine nerve**,<sup>2</sup> a long slender branch, comes from the inner side of the ganglion and accompanies the superior nasal nerves into the nasal cavity, where it descends obliquely forward on the partition, beneath the mucous membrane, to the naso-palatine canal. Passing through this and the incisive foramen, it terminates in the mucous membrane of the hard palate behind the position of the incisor teeth.

The **vidian nerve**,<sup>3</sup> from the sphenopalatine ganglion runs backward through the vidian canal and divides into the deep and superficial petrosal nerves. The vidian gives some small **nasal branches** to the contiguous mucous membrane and a **small pharyngeal branch**, through the pterygo-palatine canal, to the roof of the pharynx.

The **deep petrosal nerve**,<sup>4</sup> of a reddish color and comparatively soft texture, is directed backward and joins the carotid plexus of the sympathetic nerve.

The **superficial petrosal nerve**<sup>5</sup> perforates the fibro-cartilage occupying the middle lacerate foramen, enters the cranium to the outer side of the carotid artery and beneath the semilunar ganglion, is thence directed outward and backward in a groove of the temporal pyramid, and enters the hiatus<sup>6</sup> of the facial canal<sup>7</sup> to join the geniculate ganglion of the facial nerve.

The sphenopalatine nerves may be regarded as the sensory roots of the sphenopalatine ganglion, the superficial petrosal as its motor root, and the deep petrosal as its sympathetic root.

The superior maxillary nerve is sensory in function. It supplies the skin of the upper lip, side of the nose, cheek and lower eyelid, the mucous membrane of the back part of the nasal cavity, posterior ethmoidal sinuses and maxillary antrum, the upper teeth, the hard and soft palate, the uvula, and the tonsil.

<sup>1</sup> N. palatinus minus or posticus and n. p. minimus or externus.

<sup>2</sup> N. naso-palatinus; n. septi narium; n. sphenopalatinus internus; nerve of Scarpa; nerve of Cotunnus.

<sup>3</sup> N. Vidianus; n. pterygoideus; n. anastomoticus; n. quinti recurrens.

<sup>4</sup> N. petrosus profundus major; greater deep petrosal nerve.

<sup>5</sup> N. petrosus superficialis major; greater superficial petrosal nerve.

<sup>6</sup> H. Fallopii.

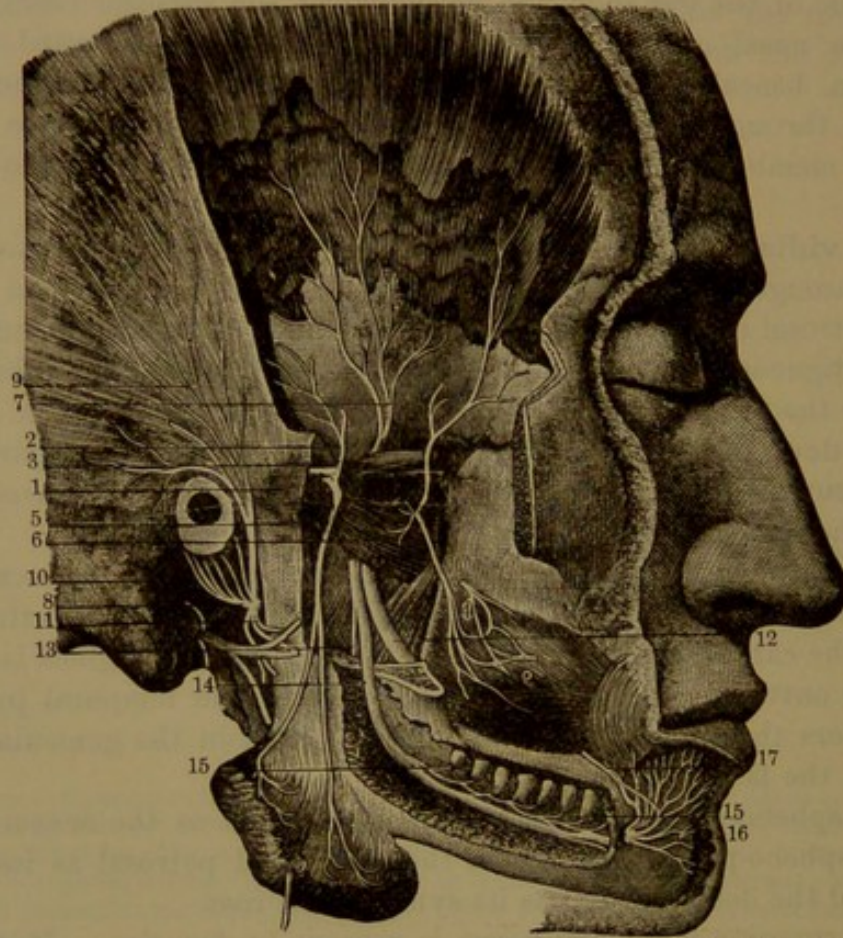
<sup>7</sup> Canalis Fallopii.



## INFERIOR MAXILLARY NERVE.

The inferior maxillary nerve,<sup>1</sup> the third and largest branch of the trifacial, is formed by the union of the small motor root with the largest branch from the semilunar ganglion. The two parts of the nerve descend together from the cranium through the sphenoidal oval foramen and immediately at their exit unite in a short, flat, plexiform

FIG. 402.



DISTRIBUTION OF THE INFERIOR MAXILLARY NERVE. 1, muscular branch to the masseter muscle; 2, 3, 7, branches to the temporal muscle; 5, branch to the buccinator, anastomosing with one from the facial at 4; 6, external pterygoid muscle; 8, auriculo-temporal nerve; 9, superficial temporal branch; 10, branches to the ear; 11, its anastomosis with the facial; 12, lingual nerve; 13, branch to the mylo-hyoid muscle from the inferior dental nerve, 14; 15, branches to the teeth; 16, mental nerve to the lower lip and chin; 17, anastomosis with the facial nerve.

trunk, which lies between the pterygoid muscles. The trunk separates into a small and a large division, each of which at once breaks up into two groups of branches. The small division receives most of the fibres of the small root of the nerve and is mainly distributed to the muscles of mastication, while the large division is chiefly sensory.

The trunk of the inferior maxillary nerve gives off a little recur-

<sup>1</sup> N. maxillaris inferior; n. inframaxillaris.



rent branch,<sup>1</sup> which passes through the adjacent spinous foramen to the great meningeal artery. It also commonly gives off the **internal pterygoid nerve**, which descends and enters the inner surface of the corresponding muscle.

The small division of the inferior maxillary nerve divides into deep temporal, masseteric, external pterygoid, and buccal branches.

The **deep temporal nerves**, usually an anterior and a posterior, ascend beneath the temporal muscle, to which they are distributed, entering its inner surface. The anterior not unfrequently arises together with the buccal and the posterior with the masseteric nerve; sometimes there is a third or middle temporal branch.

The **masseteric nerve** is directed outward, behind the temporal and over the external pterygoid muscle, through the mandibular notch to the back part of the inner surface of the masseter muscle, to which it is distributed. It also gives a filament to the articulation of the jaw.

The **external pterygoid nerve** enters the inner surface of the corresponding muscle.

The **buccal nerve**, usually arising together with the external pterygoid and the anterior deep temporal nerve, runs forward between the heads of the external pterygoid muscle and descends to the outside of the buccinator, on which it forms a plexus with branches of the facial nerve, and is finally distributed to the skin and mucous membrane of the cheek. The destination of the nerve indicates its sensory character.

The **internal pterygoid nerve**, as before mentioned, is commonly a branch of the main trunk of the trifacial. At its commencement it is closely connected with the otic ganglion.

The large division of the inferior maxillary nerve gives off the auriculo-temporal, inferior dental, and lingual nerves.

The **auriculo-temporal nerve**,<sup>2</sup> the smallest of the three just indicated, commonly arises by two branches, which pass backward, unite, and enclose the great meningeal artery. Thence it turns outward and backward around the articulation of the jaw and upwards in company with and behind the temporal artery to the temple. The branches of origin are connected by filaments with the otic ganglion, and as the nerve turns up to the temple it sends forward around the temporal artery one or two considerable branches, which join the temporo-facial division of the facial nerve. In its course the nerve gives branches to the articulation of the jaw, the auditory meatus and pinna, and the parotid gland. The ascending portion, or **superficial temporal nerve**,<sup>3</sup> is distributed to the skin of the temporal region, its anterior filaments communicating with the temporal branches of the facial nerve.

<sup>1</sup> N. recurrens.

<sup>2</sup> N. auriculo-temporalis.

<sup>3</sup> N. temporalis superficialis or cutaneus.



The **inferior dental nerve**,<sup>1</sup> the largest of the branches of the fifth, descends between the pterygoid muscles behind and to the outer side of the lingual nerve and passes between the stylo-maxillary ligament and ramus of the mandible to the inferior dental canal. In company with the dental artery it runs through the canal, supplies branches to the teeth, and near the mental foramen divides into the **incisor branch** for the corresponding teeth and the **mental branch**, which emerges at the mental foramen. The **dental branches** together form a plexus like that of the upper jaw. Before entering the dental canal the inferior dental nerve gives off the **mylo-hyoid branch**,<sup>2</sup> which descends on the inner side of the mandible beneath the mylo-hyoid muscle, to which and the anterior belly of the digastric muscle it is distributed. The fibres of this branch are traceable within the sheath of the inferior dental nerve to the motor division of the inferior maxillary.

The **mental branch**,<sup>3</sup> proceeding from the inferior dental nerve through the mental foramen, breaks up into branches beneath the oral angle depressor, distributed to the skin and mucous membrane of the lower lip and chin and communicating with the adjacent branches of the facial nerve.

The **lingual, or gustatory nerve**,<sup>4</sup> descends between the pterygoid muscles in advance of the dental nerve, curves forward between the internal pterygoid muscle and the ramus of the mandible and to the outer side of the superior pharyngeal constrictor. Passing between the stylo-glossal muscle and the submaxillary gland, it proceeds below across the duct of the gland and along the side of the tongue to its tip immediately beneath the mucous membrane.

Near its commencement the lingual nerve is commonly joined by a branch from the inferior dental. It also receives at an acute angle the **tympanic branch**<sup>5</sup> of the facial nerve, which descends from the tympanum through the glenoid foramen behind the articulation of the jaw.

Contiguous to the submaxillary gland the lingual nerve gives off several small branches to the submaxillary ganglion and subsequently several filaments which anastomose with others of the hypoglossal nerve. At the side of the tongue it gives branches to the mucous membrane and to the sublingual gland and gum. The terminal branches ascend through the muscular structure of the tongue and are distributed in the mucous membrane of the anterior two-thirds, mainly in the conical and fungiform papillæ.

<sup>1</sup> N. alveolaris inf. ; n. mandibularis.

<sup>3</sup> N. mentalis.

<sup>4</sup> N. lingualis ; n. gustatorius.

<sup>2</sup> N. mylo-hyoideus.

<sup>5</sup> Chorda tympani.

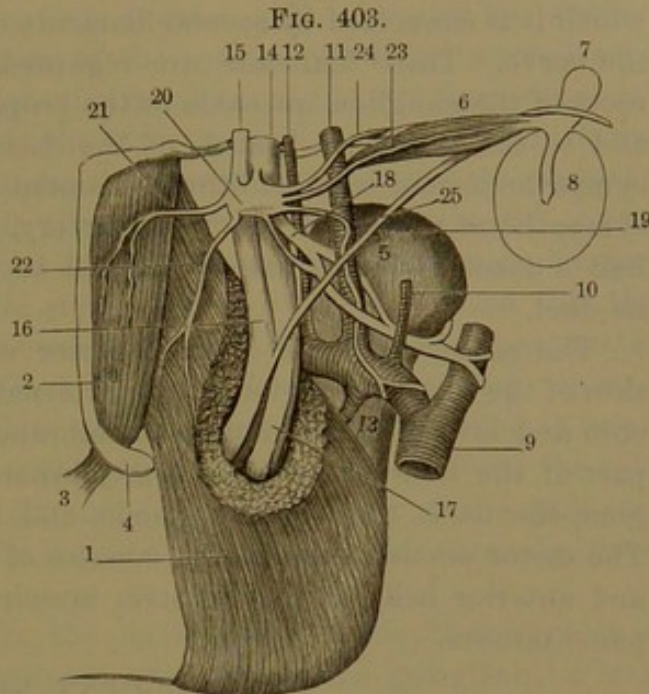


## OTIC GANGLION.

The **otic ganglion**<sup>1</sup> is an oval, reddish-gray body, about the sixth of an inch in its longer, fore and aft diameter. It is situated on the inner side of the trunk of the inferior maxillary nerve, from which it receives a little bundle of fibres, regarded as the **sensory root**<sup>2</sup> of the ganglion. It commonly encloses the internal pterygoid nerve and likewise includes the branch to the palatal tensor, from both of which it derives filaments apparently representing the **motor root** of the ganglion. The **sympathetic root**<sup>3</sup> is a filament ascending from the contiguous sympathetic plexus of the great meningeal artery.

The nerves of the otic ganglion, besides its several roots, consist of communicating filaments with the two branches of origin of the auriculo-temporal nerve, two muscular branches, and the small petrosal nerve. Of the muscular branches one runs forward and downward to the palatal tensor and the other backward and upward to the tympanic tensor.

The **small petrosal nerve**<sup>4</sup> ascends through a fine canal of the sphenoidal angular process, close to the spinous foramen, into the cranial cavity, whence it runs through another fine canal of the tympanic tegmen into the facial canal. Here it communicates by a filament<sup>5</sup> with the facial nerve a little beyond the geniculate ganglion and then descends into the tympanum to join the tympanic branch<sup>6</sup> of the glossopharyngeal nerve.



THE OTIC GANGLION AND ITS CONNECTIONS: view from within. 1, internal pterygoid muscle; 2, palatal tensor muscle; 3, its tendon passing round the hook, 4, of the internal pterygoid process; 5, condyle of the jaw; 6, tympanic tensor muscle; 7, malleus; 8, tympanic membrane; 9, external carotid artery dividing into the temporal and internal maxillary arteries; 10, tympanic branch; 11, great meningeal artery; 12, small meningeal artery; 13, inferior dental artery; 14, third division of the semilunar ganglion of the trifacial nerve; 15, motor root of the latter; 16, lingual nerve; 17, inferior dental nerve; 18, auriculo-temporal nerve; 19, tympanic branch of the facial nerve joining the lingual nerve; 20, otic ganglion; 21, nerve to palatal tensor; 22, nerve to internal pterygoid muscle; 23, branch to tympanic tensor; 24, small petrosal nerve; 25, communicating branch with the sympathetic nerve.

<sup>1</sup> G. oticum; g. Arnoldi; g. auriculare.

<sup>2</sup> Radix brevis.

<sup>3</sup> R. sympathica or trophica.

<sup>4</sup> N. petrosus superficialis minor.

<sup>5</sup> Ramus communicans cum plexu tympanico.

<sup>6</sup> N. Jacobsonii.



## SUBMAXILLARY GANGLION.

The **submaxillary ganglion**<sup>1</sup> is a little fusiform body lying on the submaxillary salivary gland below the trunk of the lingual nerve, with which it is connected by several filaments converging fore and aft from the nerve. These filaments are regarded as the sensory and motor roots of the ganglion traceable to the proper fibres of the lingual nerve and to the tympanic branch of the facial associated with it. The sympathetic root is an additional filament derived from the contiguous sympathetic plexus of the facial artery. From the ganglion about half a dozen filaments are distributed to the submaxillary gland and its duct.

The sensory portion of the inferior maxillary nerve supplies the skin of the temporal region, of the external ear, of the cheek, and of the chin and lower lip, the mucous membrane and papillæ of the greater part of the tongue, the mucous membrane of the cheek, lower lip and gum, the teeth, the salivary glands, and the articulation of the jaw. The motor portion supplies the muscles of mastication, the mylo-hyoid and anterior belly of the digastric muscles, and the palatal and tympanic tensors.

## VI. ABDUCENT NERVES.

The **sixth, or abducent nerve**,<sup>2</sup> appears as a band of filaments springing from the groove between the pons and the upper extremity of the pyramid of the oblongata. Advancing beneath the pons, it speedily becomes a rounded cord and proceeds to an aperture of the dura below and to the outer side of the clivus of the sphenoid bone. Thence it runs through the floor of the cavernous sinus, at the outer side of the internal carotid artery, to the sphenoidal foramen, and enters the orbit between the heads of the external rectus muscle, to which the nerve is distributed, entering its inner surface. The nerve passes through the sphenoidal foramen below the ophthalmic vein and below all the other nerves accompanying it. In its course through the cavernous sinus it is connected by filaments with the contiguous plexus of the sympathetic, and on entering the orbit it receives a filament from the ophthalmic nerve.

The destination of the abducent indicates its character as a motor nerve.

## VII. FACIAL NERVES.

The **seventh, or facial nerve**,<sup>3</sup> makes its appearance in the depression between the olive and restiform body of the oblongata immediately below the pons. Close to its outer side lies the auditory

<sup>1</sup> G. submaxillare Merkelii; g. linguale.

<sup>2</sup> N. abducens; n. oculo-motorius externus.

<sup>3</sup> N. facialis; n. communicans faciei; portio dura of the seventh nerve.



nerve, and between them is a filament, the **intermediate portion**,<sup>1</sup> connected with both nerves, which pass together forward and outward to the internal auditory meatus. In this they proceed to the bottom, the facial nerve lying in a groove in the upper fore part of the auditory nerve, with the intermediate portion still retaining its position between them. At the bottom of the meatus the facial nerve leaves the auditory nerve and enters the facial canal, the winding course of which it follows to the exit, the stylo-mastoid foramen. The facial nerve at first runs a short distance forward and outward to near the hiatus of the canal, when it abruptly turns backward in the supra-promontory of the tympanum and then curves downward in its posterior wall to emerge at the stylo-mastoid foramen. From this the nerve runs downward and forward in the parotid gland and separates in the temporo-facial and cervico-facial divisions. These split up into eight or ten principal branches, subdividing and anastomosing in loops and forming together the **parotid plexus**,<sup>2</sup> which spreads over the side of the face and temple and extends to the upper part of the neck and freely communicates with the terminal branches of the three divisions of the trifacial nerve.

In the facial canal where the facial nerve bends backward in a **knee**,<sup>3</sup> it presents an enlargement, the **geniculate ganglion**,<sup>4</sup> which is reddish gray and contains an accumulation of nerve-cells.

With the geniculate ganglion are connected the following nerves: a filament from the auditory nerve at the bottom of the internal auditory meatus, the superficial petrosal nerve<sup>5</sup> through the hiatus of the facial canal, and a filament<sup>6</sup> connected with the sympathetic on the great meningeal artery. Just beyond the ganglion the facial nerve is joined by a filament,<sup>7</sup> opposite to its course, from the small petrosal nerve.<sup>8</sup>

The facial nerve in its descent in the back part of the facial canal gives off a small branch to the stapedial muscle, a tympanic branch, and a filament<sup>9</sup> communicating with the auricular branch of the vagus nerve.

The **tympanic branch**,<sup>10</sup> from the facial nerve, ascends forward through a canal and enters the back part of the tympanum close to the border of the tympanic membrane, arches across its upper part, to the inner side of the handle of the malleus, covered by the lining

<sup>1</sup> Pars or portio media Wrisbergii; nervus medius.

<sup>2</sup> Plexus parotideus; plexus or pes anserinus.

<sup>3</sup> Genu n. facialis.

<sup>4</sup> G. geniculatum; intumescencia gangliiformis.

<sup>5</sup> N. petrosus superficialis major.

<sup>6</sup> N. petrosus superficialis minimus or externus.

<sup>7</sup> Ramus communicans cum plexu tympanico.

<sup>8</sup> N. petrosus superficialis minor.

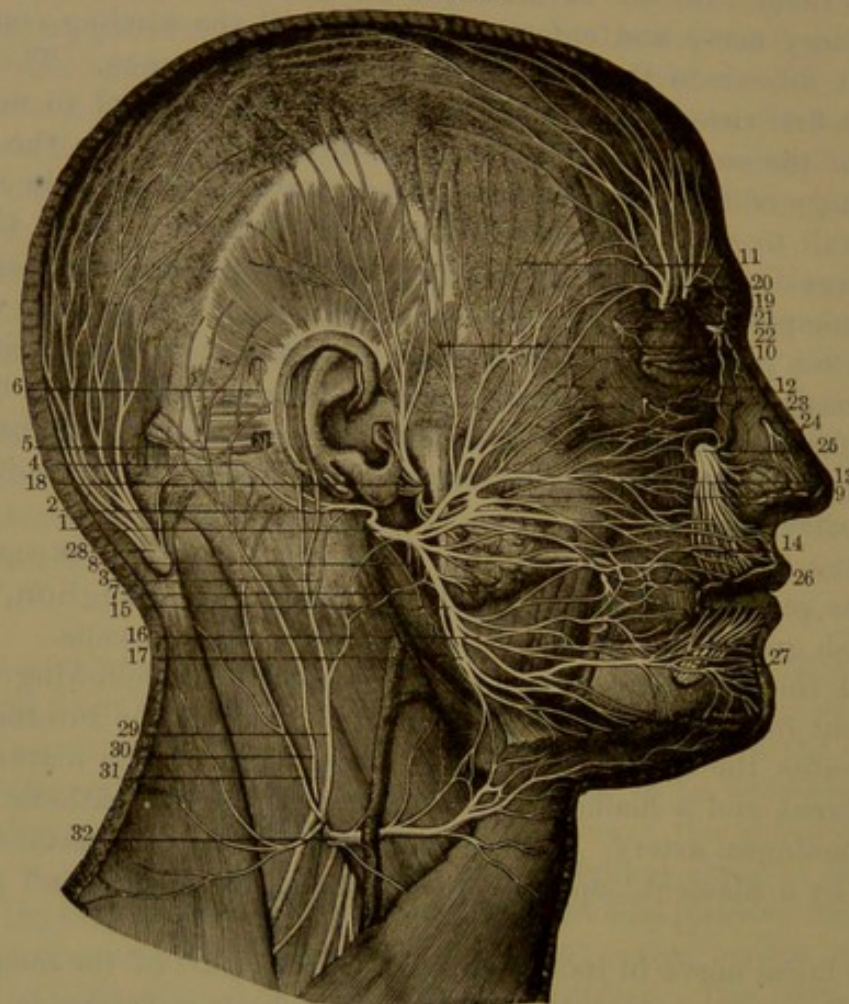
<sup>9</sup> N. communicans cum ramo auriculari nervi vagi.

<sup>10</sup> Chorda tympani; n. tympano-lingualis.



membrane of the tympanum, and leaves the cavity through the glenoid foramen. It then descends obliquely forward to the inner side of the stylo-maxillary ligament and at an acute angle joins the lingual nerve. Within the sheath of the latter its fibres are traceable, partly continu-

FIG. 404



**THE FACIAL NERVE.** 1, trunk of the nerve after emerging at the stylo-mastoid foramen; 2, its posterior auricular branch; 3, anastomosis of the latter with the great auricular nerve of the cervical plexus; 4, 5, 6, branches to the contiguous muscles; 7, 8, branches of the facial to the digastric and stylo-hyoid muscles; 9, temporo-facial division of the nerve; 10, branch to the temple, anastomosing with the auriculo-temporal nerve; 11, temporal branches; 12, 13, infraorbital branches; 14, 15, cervico-facial division of the facial nerve; 14, buccal branches; 16, mandibular branches; 17, cervical branches; 18, auriculo-temporal nerve; 19, 20, supraorbital nerves; 21, terminal branch of the lachrymal nerve; 22, infratrochlear nerve; 23, branch of the temporo-malar nerve; 24, external branch of the nasal nerve; 25, infraorbital nerves; 26, anastomosis between the buccal branch of the inferior maxillary nerve and the buccal branches of the facial nerve; 27, mental branches of the inferior dental nerve; 28, great occipital nerve; 29, 31, branches of the great auricular nerve; 30, small occipital nerve; 32, superficial cervical nerve, anastomosing with the facial nerve.

ous with those of the lingual nerve and partly leaving it to form the motor root of the submaxillary ganglion.

After its exit from the cranium, the facial nerve gives off the **posterior auricular nerve**,<sup>1</sup> which turns upward between the ear and

<sup>1</sup> N. auricularis posterior profundus.



the mastoid process and after anastomosing with the great auricular and small occipital nerves of the cervical plexus is distributed to the postauricular and occipital muscles, and to the transversalis muscle on the back of the pinna.

Closely succeeding the posterior auricular nerve is a branch<sup>1</sup> which supplies the stylo-hyoid and the posterior belly of the digastric muscle and is connected by a filament<sup>2</sup> with the glosso-pharyngeal nerve.

The facial nerve then communicates by **anastomotic branches**,<sup>3</sup> usually two, with the auriculo-temporal branch of the fifth nerve.

The **temporo-facial division** of the facial nerve, the larger of the two, is directed forward through the upper part of the parotid gland, across the external carotid artery and temporo-maxillary vein, and is distributed in temporo-frontal, infraorbital, and buccal branches over the side of the face, extending from the fore part of the temple to the cheek on a line with the angle of the mouth.

The **temporo-frontal branches**,<sup>4</sup> of which there are two or three, ascend over the zygoma and are distributed to the supra- and pre-auricular muscles, to those of the outer surface of the pinna, and to the frontal, superciliary, and palpebral orbicular muscles. They anastomose with the auriculo-temporal nerve, the temporal branch of the superior maxillary nerve, and the lachrymal and supraorbital branches of the ophthalmic nerve.

The **infraorbital branches**,<sup>5</sup> of which there are three or four, are directed forward over the malar bone, supply the palpebral orbicular muscle, the zygomatic and other muscles of the upper lip and those of the nose, and anastomose with the lachrymal branch of the ophthalmic nerve and the malar and infraorbital branches of the superior maxillary nerve.

The **buccal branches**,<sup>6</sup> of which there are two or three, are directed forward towards the angle of the mouth, supply the buccinator muscle, those of the upper lip and nose and the oral sphincter, and anastomose with the buccal branch of the inferior maxillary, the infraorbital branches of the superior maxillary and those of the next division of the facial nerve.

The **cervico-facial division** of the facial nerve descends obliquely through the parotid gland towards the angle of the lower jaw and divides into mandibular and cervical branches.

The **mandibular branch**<sup>7</sup> runs over the masseter muscle, divides into two, and is distributed to the muscles of the lower lip, anastomosing with the buccal branch of the inferior maxillary as well as those of

<sup>1</sup> N. styloideus; n. stylo-hyoideus and digastricus.

<sup>2</sup> N. communicans glosso-pharyngei.

<sup>3</sup> Rami anastomotici.

<sup>4</sup> Rami temporo-frontales; r. temporales.

<sup>5</sup> R. zygomatici; malar and infraorbital branches.

<sup>6</sup> R. buccales.

<sup>7</sup> R. subcutaneus mandibulæ; r. s. maxillæ inferioris; supramaxillary branches.



the temporo-facial division of the facial and with the branches of the mental nerve.

The **cervical branch**<sup>1</sup> descends below the mandible, anastomoses with the superficial cervical nerve, and is distributed to the platysma muscle.

The facial is the principal motor nerve of the head, supplying all the superficial and some of the deep muscles. Besides those of the scalp, temple, auricle, eyelids (except the palpebral elevator), nose, and mouth, it likewise supplies the stapedial muscle, the stylo-hyoid, the posterior belly of the digastric, and the platysma muscle. It anastomoses with the three divisions of the trifacial nerve, is connected with all their ganglia, and also communicates with the auditory, glosso-pharyngeal, vagus, sympathetic, and spinal nerves.

#### VIII. AUDITORY NERVES.

The **eighth, or auditory nerve**, is described with the ear.

#### IX. GLOSSO-PHARYNGEAL NERVES.

The **ninth, or glosso-pharyngeal nerve**,<sup>2</sup> makes its appearance at the side of the oblongata in the groove between the olive and restiform body, immediately below the facial and auditory nerves. Its five or six rootlets unite in a pair of bundles which pass outward to the jugular foramen, descend through its middle passage, and conjoin in a single trunk. On this is an enlargement, the **petrous ganglion**, from which the nerve passes between the internal carotid artery and jugular vein outwardly and then across the former beneath the styloid process and its muscles. It then curves forward from behind the stylo-pharyngeal and beneath the hyo-glossal muscle to be distributed to the root of the tongue.

In the jugular foramen the glosso-pharyngeal nerve is accompanied by the vagus and accessory nerves, but occupies a separate tube of the dura. It lies in front of its companions, and in this position its posterior bundle commonly exhibits a little enlargement, the **jugular ganglion**.<sup>3</sup>

The **petrous ganglion**,<sup>4</sup> situated on the nerve at the exit of the jugular foramen, is an elliptical body, two or three lines long, occupying a recess in the jugular groove of the petrosal. It is connected by a filament with the first cervical ganglion of the sympathetic and by a second filament with the auricular branch of the vagus nerve. It gives off an important branch, the tympanic nerve.

The **tympanic nerve**<sup>5</sup> passes up a canal of the temporal bone, in

<sup>1</sup> R. subcutaneus colli superior; inframaxillary branch.

<sup>2</sup> N. glosso-pharyngeus; first division of the eighth nerve of Willis.

<sup>3</sup> G. jugulare; g. Ehrenritteri.

<sup>4</sup> G. petrosum; g. Anderschii.

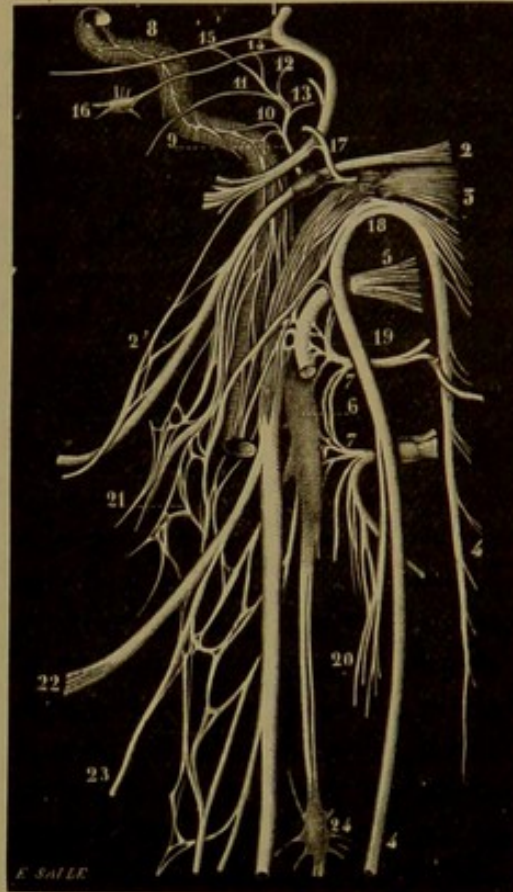
<sup>5</sup> N. tympanicus; Jacobson's nerve; n. Jacobsonii or Anderschii.



the partition between the jugular foramen and carotid canal, into the tympanum, ascends in a groove on the promontory and leaves the cavity through a canal behind the receptacle of the tympanic tensor, opening on the upper surface of the inner end of the tympanic tegmen, where the nerve is continued as the **small petrosal nerve** to the otic ganglion. In its course it is connected with the cavernous plexus of the sympathetic by a couple of filaments<sup>1</sup> through foramina in the wall of the carotid canal, and by another filament<sup>2</sup> running through a minute canal in the receptacle of the tympanic tensor. In the canal by which it leaves the tympanum it gives a small **communicating branch**<sup>3</sup> to the facial nerve just beyond the geniculate ganglion in a direction opposite to the course of that nerve. On the promontory the tympanic nerve gives branches to the lining membrane of the cavity, especially one<sup>4</sup> to the commencement of the eustachian tube and others to the oval and round windows of the labyrinth.

In the neck the glosso-pharyngeal nerve communicates by a couple of filaments with the trunk of the vagus nerve and with the branch of the facial nerve to the stylo-hyoid and digastric muscles.

FIG. 405.



THE LAST FOUR CEREBRAL NERVES, THE FACIAL NERVE, THE SYMPATHETIC, AND THE UPPER TWO CERVICAL NERVES. 1, facial nerve; 2, glosso-pharyngeal; 2', anastomosis between a branch of the facial and the glosso-pharyngeal; 3, vagus; 4, accessory; 5, hypoglossal; 6, first cervical ganglion of the sympathetic; 7, first and second cervical nerves; 8, cavernous plexus of the sympathetic on the internal carotid artery; 9, tympanic nerve from the petrous ganglion of the glosso-pharyngeal; 10, its connection with the carotid plexus; 11, branch to the eustachian tube; 12, 13, branches to the oval and round windows of the ear; 14, 15, branches joining the small and superficial petrosal nerves; 16, otic ganglion; 17, auricular branch from the jugular ganglion, connected by filaments with the petrous ganglion and the facial nerve; 18, anastomosis of the accessory with the vagus; 19, anastomosis of the first cervical nerve with the hypoglossal; 20, anastomosis of the second cervical nerve with a branch of the accessory; 21, pharyngeal plexus; 22, superior laryngeal nerve; 23, its external branch; 24, second cervical ganglion of the sympathetic.

<sup>1</sup> Nervi carotico-tympanici.<sup>2</sup> N. petrosus profundus minor.<sup>3</sup> Ramus communicans.<sup>4</sup> N. tubæ.



It also gives off several **pharyngeal branches** to the side of the pharynx, of which the largest joins the pharyngeal branch of the vagus to form the pharyngeal plexus, supplying the superior and middle constrictors and contiguous mucous membrane of the pharynx.

It subsequently sends a **muscular branch**<sup>1</sup> to the stylo-pharyngeal muscle.

Finally reaching the root of the tongue beneath the tonsil, the glosso-pharyngeal nerve gives to the latter the **tonsillitic nerves**,<sup>2</sup> which supply the tonsil and the mucous membrane of the side of the fauces.

The remainder of the nerve, the **lingual branch**,<sup>3</sup> passing beneath the hyo-glossal muscle, is distributed to the mucous membrane of the posterior third of the root of the tongue, including the circumvallate papillæ and extending to the epiglottis.

#### X. VAGUS NERVES.

The **tenth, vagus, or pneumo-gastric nerve**,<sup>4</sup> the longest and most widely distributed of the nerves of the brain, at the side of the oblongata immediately succeeds the glosso-pharyngeal nerve, than which it is much larger. Springing in the same line below it, from the groove between the olive and restiform body, in a close series of from ten to fifteen rootlets, these unite in a band which becomes the rounded trunk of the nerve. This descends through the middle passage of the jugular foramen in company with the glosso-pharyngeal and accessory nerves, separated from the former and enclosed in the same tube of the dura with the latter.

In the foramen the vagus presents a fusiform enlargement, the **jugular ganglion**,<sup>5</sup> about the sixth of an inch long. Immediately below the foramen is a second enlargement, the **gangliform plexus**,<sup>6</sup> flattened cylindrical, about two-thirds of an inch long, composed of a loose intertexture of the bundles of nerve-fibres of the trunk of the vagus.

The vagus from the gangliform plexus descends the neck between the jugular vein and internal carotid artery, then between the vein and the common carotid artery, in the interval behind and all together enclosed in the same sheath of the cervical fascia. From the neck the vagus passes into the thorax, differently on the two sides.

The **right vagus** crosses over the commencement of the right sub-clavian artery behind the innominate vein and descends on the side of the trachea to the back of the root of the right lung, where it expands in the posterior pulmonary plexus. Thence the nerve emerges in two

<sup>1</sup> N. stylo-pharyngeus.

<sup>2</sup> N. tonsillares.

<sup>3</sup> R. lingualis.

<sup>4</sup> N. vagus or pneumo-gastricus; second division of the eighth nerve of Willis.

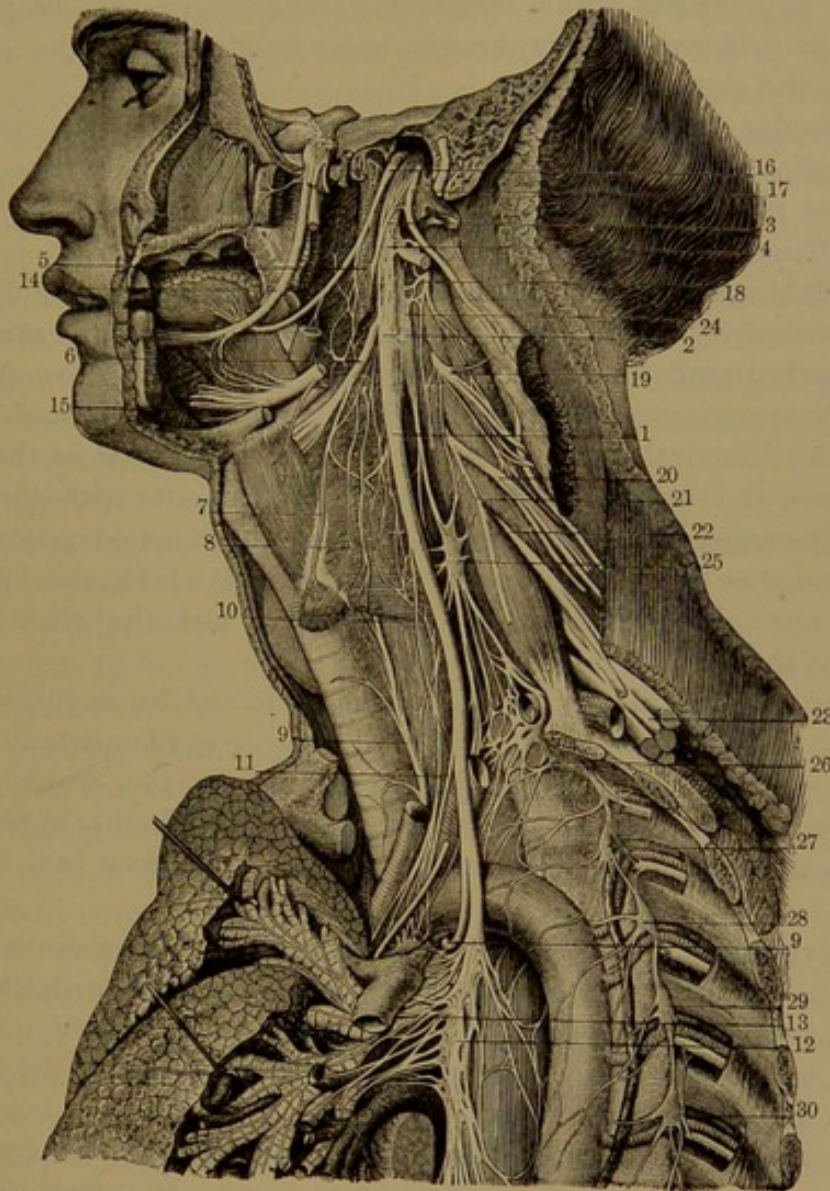
<sup>5</sup> G. jugulare; g. superius.

<sup>6</sup> P. gangliformis; p. nodosus; ganglion trunci nervi vagi.



portions which apply themselves to the œsophagus and by their division and union with similar branches of the left vagus form the œsophageal plexus. At the lower part of the œsophagus the branches for the most

FIG. 406.



THE VAGUS NERVE. 1, trunk of the vagus; 2, gangliiform plexus; 3, its anastomosis with the accessory nerve; 4, anastomosis with the hypoglossal; 5, pharyngeal nerve; 6, superior laryngeal nerve; 7, its external branch; 8, pharyngeal plexus; 9, inferior laryngeal nerve; 10, superior cardiac nerve; 11, middle cardiac nerve; 12, commencement of the œsophageal plexus; 13, posterior pulmonary plexus; 14, lingual nerve; 15, lower part of the hypoglossal nerve; 16, glosso-pharyngeal nerve; 17, accessory nerve; 18, 19, 20, second, third, and fourth cervical nerves; 21, commencement of the phrenic nerve; 22, 23, the lower four cervical nerves which with the first thoracic nerve form the brachial plexus; 24, 25, first and second cervical ganglia of the sympathetic; 26, third cervical united with the first thoracic ganglion; 27-30, second to fifth thoracic ganglia.

part collect again in a principal trunk which descends behind the œsophagus, through the œsophageal orifice of the diaphragm, to be distributed on the posterior surface of the stomach.

The **left vagus** enters the thorax between the left common carotid



and subclavian arteries and behind the innominate vein, crosses over the arch of the aorta, and runs behind the root of the left lung, where it forms the corresponding posterior pulmonary plexus. Thence the nerve passes to the œsophagus, where it contributes to form the œsophageal plexus, from which the branches for the most part again collect in a principal trunk descending in front of the œsophagus, through the orifice of the diaphragm, to be distributed on the anterior surface of the stomach.

The jugular ganglion is connected by filaments with the first cervical ganglion of the sympathetic, the petrous ganglion of the glosso-pharyngeal nerve, and the contiguous trunk of the accessory nerve. It gives off meningeal and auricular branches.

The **meningeal branch**<sup>1</sup> runs backward from the jugular foramen and is distributed to the dura of the cerebellar fossa of the cranium.

The **auricular branch**<sup>2</sup> receives a filament from the glosso-pharyngeal nerve, runs outward from the jugular foramen through a fine canal of the temporal pyramid, and crosses the lower part of the facial canal, where it is connected by a couple of filaments with the facial nerve. Emerging from the fissure between the mastoid process and auditory meatus it divides into two branches, of which one joins the posterior auricular branch of the facial nerve and the other is distributed to the skin of the ear.

The gangliform plexus of the vagus is joined by a considerable portion of the accessory nerve, which also receives filaments in return from it. In addition the gangliform plexus, or the trunk of the nerve above or below, is connected by filaments with the hypoglossal and sympathetic nerves, sometimes also with the upper two cervical nerves.

The division of the accessory nerve joining the gangliform plexus gives to the vagus its motor fibres, most of which pass in front of the plexus and are continued into the pharyngeal and superior laryngeal branches, while a few descend in the main trunk and enter the inferior laryngeal and cardiac branches.

The branches of the vagus nerve, succeeding those above described, are the pharyngeal, superior and inferior laryngeal nerves, and the cardiac, pulmonary, œsophageal, and gastric branches.

The **pharyngeal nerve**,<sup>3</sup> or several branches in its place, proceeds from the upper part of the gangliform plexus inward over the internal carotid artery to the middle constrictor of the pharynx, on which it divides into branches. These, together with the pharyngeal branches of the glosso-pharyngeal nerve and a filament or two from the first cervical ganglion of the sympathetic, form the **pharyngeal plexus**, which supplies the constrictors and mucous membrane of the pharynx.

<sup>1</sup> Ramus meningeus; r. recurrens.

<sup>2</sup> R. auricularis Arnoldi; nervus fossæ jugularis.

<sup>3</sup> N. pharyngeus.



A filament<sup>1</sup> from the plexus joins the hypoglossal nerve as it crosses the external carotid artery below the occipital artery.

The **superior laryngeal nerve**,<sup>2</sup> a larger branch than the pharyngeal, proceeds from the lower part of the gangliform plexus of the vagus downward and forward to the inner side of the internal carotid artery and to the upper part of the larynx. It is joined by filaments from the pharyngeal plexus and first cervical ganglion of the sympathetic and divides into the external and internal laryngeal branches.

The **external laryngeal branch**<sup>3</sup> runs beneath the depressor muscles of the hyoid bone and is distributed to the crico-thyroid muscle and the inferior constrictor of the pharynx. It commonly gives off a **cardiac branch**, which is joined by the superior cardiac nerve from the first cervical ganglion and descends on the common carotid artery into the thorax, where it contributes to form the cardiac plexus. From the influence of this branch on the heart it has been called the inhibitory or depressor nerve. It is sometimes reinforced by a filament from the internal laryngeal branch.

The **internal laryngeal branch**,<sup>4</sup> considerably larger than the external, runs to the interval between the hyoid bone and thyroid cartilage and divides into branches which perforate the thyro-hyoid membrane to be distributed to the mucous membrane of the larynx, from the epiglottis to the glottis. A descending branch along the inner side of the thyroid cartilage joins one from the inferior laryngeal nerve.

The **cardiac branches**<sup>5</sup> of the vagus are variable in number and size, even on the two sides, and are generally in greater number on the right. Commonly several long slender filaments proceed from the cervical portion of the trunk, descend in front and behind the common carotid artery, partly join the cardiac nerves of the sympathetic and partly end in the cardiac plexus. At the bottom of the neck a larger filament on the right runs along the innominate artery to the deep cardiac plexus, and on the left crosses the aorta to the superficial cardiac plexus. In the thorax several cardiac branches proceed from the right vagus at the side of the trachea to the deep cardiac plexus. The corresponding branches of the left vagus proceed from the inferior laryngeal nerve.

The **inferior, or recurrent laryngeal nerve**,<sup>6</sup> larger than the superior, on the right side comes from the vagus at the bottom of the neck, thence turns backward around and below the subclavian artery. That of the left side comes from the vagus in the chest and turns backward around and below the transverse portion of the aortic arch. Each nerve ascends in the neck behind the common carotid and inferior thyroid arteries, continues up in the groove between the

<sup>1</sup> Ramus pharyngeus vagi.

<sup>2</sup> N. laryngeus superior.

<sup>3</sup> R. laryngeus externus.

<sup>4</sup> R. laryngeus internus.

<sup>5</sup> Rami cardiaci; nervi molles.

<sup>6</sup> N. laryngeus inferior or recurrens.



trachea and œsophagus to the larynx, which it enters between the cricoid cartilage and inferior constrictor of the pharynx and ends in branches which supply all the muscles of the larynx except the cricothyroid. It also supplies the mucous membrane of the larynx below the glottis and gives a branch of communication with the superior laryngeal nerve.

Where the recurrent nerve turns up it gives branches to the cardiac plexus and is connected by filaments with the inferior cervical ganglion of the sympathetic. In its further ascent it gives branches to the trachea and œsophagus and finally to the inferior constrictor of the pharynx.

The **pulmonary branches** of the vagus proceed from the trunk of the nerve, in the thorax at the side of the trachea, in two divisions, one to the fore and the other to the back part of the root of the lung. The **anterior pulmonary branches**<sup>1</sup> consist of two or three filaments, which join with others from the sympathetic and proceed in front of the bronchus, where they form the **anterior pulmonary plexus**,<sup>2</sup> whence branches are distributed through the lung. Behind the root of the lung the trunk of the vagus becomes flattened and gives off several **posterior pulmonary branches**,<sup>3</sup> much larger than the anterior. They conjoin with filaments from the second to the fourth thoracic ganglia of the sympathetic to form the **posterior pulmonary plexus**<sup>4</sup> at the back of the bronchus, whence branches are distributed throughout the lung.

The pulmonary plexuses of both vagi intercommunicate across the lower extremity of the trachea in a loose plexus, whence branches of each nerve proceed to the opposite lung.

From the position of the pulmonary plexus the vagus descends on the œsophagus, divides and subdivides, and with that of the opposite side forms the **œsophageal plexus**,<sup>5</sup> from which the branches supply the œsophagus. Other œsophageal branches which come from the vagus above the pulmonary branches supply the contiguous portion of the œsophagus.

The terminal, or **gastric branches**,<sup>6</sup> of the vagus are mainly distributed to the stomach. The left vagus runs in front of the lower part of the œsophagus and at the cardiac orifice of the stomach breaks up into numerous branches, which form the **anterior gastric plexus**<sup>7</sup> in the anterior wall of the organ and partly run along its lesser curvature, where they communicate with branches of the right vagus and sympathetic, some of the filaments being continued in the small omentum to the hepatic plexus. The right vagus proceeding from behind the œsophagus is mainly distributed in the **posterior gastric plexus**<sup>8</sup>

<sup>1</sup> Nervi bronchiales anteriores.

<sup>2</sup> N. bronchiales posteriores.

<sup>6</sup> Rami gastrici.

<sup>4</sup> P. pulmonalis post.

<sup>7</sup> P. gastricus anterior.

<sup>2</sup> P. pulmonalis ant.

<sup>5</sup> P. œsophageus.

<sup>8</sup> P. gastricus posterior.



to the posterior wall of the stomach, but many of its branches run to the celiac, mesenteric, splenic, and renal plexuses of the sympathetic.

The vagus nerves are sensory-motor. They supply the pharynx, œsophagus, and stomach, the larynx, trachea, and lungs, and through their connection with the sympathetic nerves the heart and great blood-vessels, the liver, pancreas, spleen, and to a less extent the kidneys and small intestine. They also give branches to the dura and the external ear.

#### XI. ACCESSORY NERVE.

The **eleventh**, or **accessory nerve**,<sup>1</sup> consists of a portion arising from the oblongata accessory to the vagus nerve, and a larger spinal portion from the spinal cord destined to supply the sterno-mastoid and trapezius muscles. The **accessory portion**<sup>2</sup> is directed outward in company with and below the vagus nerve. The spinal portion ascends from the dural sheath of the spinal cord between the denticulate ligament and the posterior roots of the cervical nerves, enters the cranium through the occipital foramen, where it joins the small portion of the nerve, and they proceed together to the jugular foramen. Through this they descend in company with the vagus nerve contained in the same dural tube, which separates them from the glosso-pharyngeal nerve. The two portions of the eleventh nerve quickly separate, and the small or accessory portion, after communicating by one or several short filaments with the jugular ganglion of the vagus, joins the gangliform plexus, whence most of the fibres pass into the pharyngeal and superior laryngeal nerves and the rest into the trunk of the vagus below.

The larger, or **spinal portion**,<sup>3</sup> of the accessory nerve runs to the outer side of the internal jugular vein backward and downward and perforates the sterno-mastoid muscle, which it supplies with branches. Joined by a branch of the cervical plexus to the same muscle, the nerve then descends across the triangular space behind, passes beneath the trapezius muscle, where it communicates with branches of the third and fourth cervical nerves, and is distributed to the trapezius.

#### XII. HYPOGLOSSAL NERVE.

The **twelfth**, or **hypoglossal nerve**,<sup>4</sup> in its origin from the oblongata emerges from the groove between the pyramid and olive in a series of rootlets, which converge into a pair of bundles. These pass through separate apertures of the dura opposite the condylar foramen and unite in a single trunk in their course through it. As the nerve

<sup>1</sup> N. accessorius; n. recurrens; spinal accessory nerve; third portion of the eighth nerve of Willis.

<sup>2</sup> Ramus internus; r. anastomoticus.

<sup>3</sup> R. externus; r. muscularis.

<sup>4</sup> N. hypoglossus; n. motorius lingue; n. loquens; ninth nerve of Willis.



leaves the foramen it is situated to the inner side of those passing through the jugular foramen and turns outwardly between the accessory and vagus nerves. It then passes between the internal jugular vein and internal carotid artery, winding forward to the outer side of the artery and sweeping in a curve with the convexity downward to the under part of the tongue. In its course it crosses the outside of the external carotid artery at the origin of the occipital artery, thence crosses the facial artery beneath the digastric tendon and ascends on the outer side of the hyo-glossal and through the genio-glossal muscle to the tip of the tongue. The terminal branches are distributed to the genio-, hyo-, and stylo-glossal, genio-hyoid and other muscles of the tongue. A separate branch from the hypoglossal nerve as it approaches the hyoid bone is given to the thyro-hyoid muscle.

Below the condylar foramen the hypoglossal nerve is connected by a filament with the first cervical ganglion of the sympathetic, by one or several filaments with the loop of the first and second cervical nerves and with the gangliform plexus of the vagus nerve. It also receives a filament<sup>1</sup> from the pharyngeal plexus as it passes below the occipital artery. In the submaxillary region filaments join others of the lingual nerve in one or two loops on the fore part of the hyo-glossal muscle.

As the hypoglossal nerve crosses the external carotid artery it gives off a **descending cervical branch**.<sup>2</sup> This runs down the neck on the sheath of the common carotid artery and communicates with a couple of filaments<sup>3</sup> descending from the second and third cervical nerves, which interlace and together form a loop,<sup>4</sup> whence branches are distributed to the omo- and sterno-hyoid and the sterno-thyroid muscles. Commonly, also, a filament from the loop runs down on the common carotid artery to the cardiac plexus of the sympathetic nerve.

The hypoglossal nerve, motor in function, supplies the muscles of the tongue, including the genio-hyoid and thyro-hyoid, and reinforces branches of the second and third cervical nerves in supplying the infra-hyoid muscles. It anastomoses with the vagus, lingual, upper three cervical, and sympathetic nerves.

#### DISTRIBUTION OF THE SPINAL NERVES.

The **spinal nerves** are divided, according to the region in which they issue from the spinal canal, into eight pairs of **cervical**, twelve **thoracic**, five **lumbar**, five **sacral**, and one of **coccygeal nerves**. The first pair of cervical nerves emerge from the intervertebral foramina between the occiput and atlas, and the eighth pair between the last cervical and first thoracic vertebræ; the others emerge in succession

<sup>1</sup> Lingual branch of the vagus; ramus pharyngeus vagi.

<sup>2</sup> Ramus cervicalis descendens; r. descendens noni.

<sup>3</sup> Ansa hypoglossi.

<sup>4</sup> Rami communicantes noni.



from the intervertebral foramina corresponding in number and position; the coccygeal nerve emerges from the end of the sacral canal and the intervertebral foramen between the first and second coccygeal vertebrae.

The short **trunk** of each spinal nerve at once divides into two branches, distinguished as the **posterior** and **anterior spinal nerves**, the former distributed to the back of the body, the latter to the front of the body and to the limbs.

The spinal nerves, which are sensory-motor, supply the muscles and skin of the trunk of the body and limbs. The anterior roots are purely sensory, the posterior roots purely motor, and by their union the short trunk becomes of mixed quality, which is continued in its branches.

#### POSTERIOR SPINAL NERVES.

The **posterior spinal nerves** are generally much smaller than the anterior. They spring from the trunk, immediately after the conjunction of the roots succeeding the ganglion on the posterior root, generally in the intervertebral foramen, frequently by separate bundles from the two roots. Each nerve turns backward between the transverse processes of the vertebrae and generally divides into an external and an internal branch, which are distributed to the muscles and skin behind the body. Those which do not divide are the first posterior cervical, fifth and sixth posterior sacral, and coccygeal nerves.

The **first cervical nerve**, emerging between the occiput and atlas, is distinguished as the **suboccipital nerve**. Its **posterior branch**, slightly larger than the anterior, emerges over the arch of the atlas, between it and the vertebral artery, and runs into the interval between the recti and oblique muscles, to which and the complexus it is distributed.

Of the succeeding **posterior cervical nerves**, the **external branches** are distributed to the cervical ascending and transversalis and splenius muscles. Of the **internal branches**, that from the second cervical nerve, from its size and destination, is named the **great occipital nerve**. It passes over the inferior oblique muscle, perforates the complexus and trapezius, giving branches to the former, ascends in company with the occipital artery to the scalp, to which it is distributed, and anastomoses with the small occipital nerve. The internal branches from the third to the fifth cervical nerve pass over the semispinalis muscle beneath the complexus, supply them and the multifidus muscle, then near the spinous processes of the vertebrae turn outward to supply the skin of the neck over the trapezius. The internal branches from the lower three cervical nerves run beneath the semispinalis and are distributed to it and the contiguous muscles.

Of the **posterior thoracic nerves**, the **external branches** increase in size from above downward and pass through or beneath the longissimus muscle to the interval between it and the ilio-costalis and



accessory muscles, which they supply. The lower five or six give cutaneous branches outward to the skin in a line with the angle of the ribs. Of the **internal branches**, the upper six or seven appear between the multifidus and semispinalis muscles, supply them and others contiguous, then turn outward from the vicinity of the spinous process of the vertebræ to be distributed to the skin. The internal branches of the lower nerves are for the most part distributed to the multifidus muscle.

Of the **posterior lumbar nerves**, the **external branches** supply the contiguous part of the dorsal extensor and intertransverse muscles. Cutaneous branches from the upper three pierce the ilio-costalis and aponeurosis of the longissimus and descend outward and forward over the iliac crest to the skin of the gluteal region. An anastomotic branch from the last nerve descends to join the corresponding branch of the first sacral nerve. The **internal branches** turn round the contiguous articular processes of the vertebræ to be distributed to the multifidus muscle.

The **posterior sacral nerves** emerge from the posterior sacral foramina and the corresponding one below. The first three as usual divide into external and internal branches, while the others remain undivided.

The **internal branches** of the first three posterior sacral nerves terminate in the contiguous portion of the multifidus muscle. The **external branches** anastomose with one another, with the last lumbar nerve, and with the fourth sacral nerve, which in like manner anastomoses with the fifth sacral, and this with the **posterior coccygeal nerve**. Thus on the back of the sacrum and coccyx is formed a series of loops, the **posterior sacro-coccygeal plexus**.

The coccygeal nerve divides in the sacral canal and its **posterior branch** emerges from the end of the canal and through the foramen between the first two coccygeal vertebræ to join the plexus just named.

From the upper part of the posterior sacro-coccygeal plexus two or three cutaneous branches, of the corresponding sacral nerves, penetrate the origin of the great gluteal muscle in a line from the posterior superior iliac spine to the end of the coccyx and turn outwardly to be distributed to the skin over that muscle. From the lower part of the plexus cutaneous branches are distributed on the back of the coccyx.

#### ANTERIOR SPINAL NERVES.

The **anterior spinal nerves** are distributed to the trunk of the body in advance of the vertebral column and to the limbs, supplying the muscles and skin of those parts. Each as it passes outward and forward from the intervertebral foramen communicates by filaments with the adjacent ganglion of the sympathetic nerve.

The anterior cervical, lumbar, and sacral nerves branch and anasto-



mose and form plexuses, but the thoracic nerves for the most part remain independent.

The upper four anterior cervical nerves make their appearance at the side of the neck between the greater pre-rectus and anterior scalenus muscles, and by division and anastomosis form the cervical plexus. Each nerve at its commencement is connected by a filament with the first cervical ganglion of the sympathetic or with the trunk of this nerve below. The first anterior cervical nerve is the smallest of the series, the second and third successively increase in size, and the fourth is about as large as the third.

#### THE CERVICAL PLEXUS.

The **cervical plexus**,<sup>1</sup> formed by the upper four anterior cervical nerves, is situated opposite the corresponding vertebræ and rests on the middle scalenus and scapular elevator muscles covered by the sternomastoid muscle. In the construction of the plexus the first cervical nerve turns downward, the others each divide into an ascending and a descending branch, and the contiguous branches and first nerve of the series conjoin in a series of loops.

The **first anterior cervical nerve** runs forward to the outer side of the prearticular process of the atlas beneath the vertebral artery and turns down in front of the costo-transverse process to join the second cervical. In its course it supplies the lateral rectus and pre-recti muscles, and is connected by filaments with the vagus, hypoglossal, and sympathetic nerves.

The **second anterior cervical nerve** passes forward between the costo-transverse processes of the atlas and axis to the outer side of the vertebral artery and divides into an ascending branch to the first cervical and a descending branch to the third cervical nerve.

The nerves of the cervical plexus consist of a deep set principally distributed to the muscles and a superficial set which perforate the cervical fasciæ and are distributed to the skin.

**Deep branches of the cervical plexus.** Besides the **communicating branches**<sup>2</sup> between the loop of the first and second cervical nerves and the vagus, hypoglossal, and sympathetic nerves, the fourth cervical is connected by a branch with the fifth cervical nerve. Branches also descend from the second and third cervical nerves to anastomose with the descending cervical branch of the hypoglossal nerve distributed to the depressor muscles of the hyoid bone.

**Muscular branches** from the cervical nerves close to the vertebræ supply the prevertebral muscles. Others go to the scapular elevator and middle scalenus muscles. Branches from the second and third cervicals communicate with the accessory nerve and are distributed to the sternomastoid and trapezius muscles.

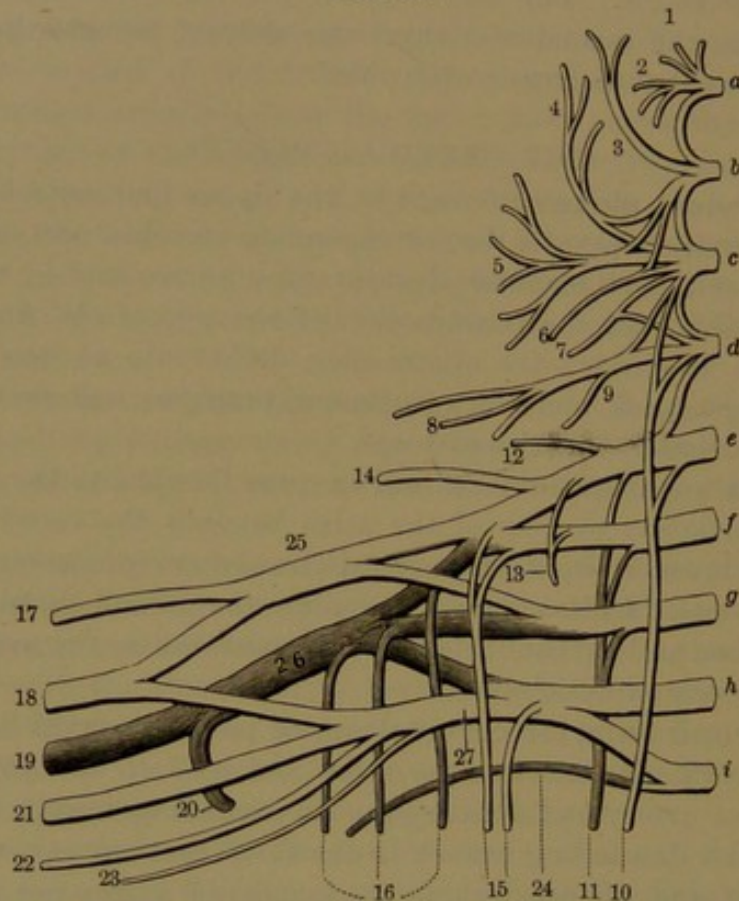
<sup>1</sup> P. cervicalis.

<sup>2</sup> Rami communicantes noni.



The **phrenic nerve**<sup>1</sup> springs from the third and fourth cervical nerves and commonly also receives a contribution from the fifth. Descending the neck on the anterior scalenus muscle, it enters the thorax between the subclavian artery and vein and crosses the mammary artery near its commencement. Continuing downward in front of the root of the lung, enclosed between the pericardium and medias-

FIG. 407.



CERVICAL AND BRACHIAL PLEXUSES OF NERVES. *a-h*, cervical nerves; *i*, first thoracic nerve; *a-d*, cervical plexus; *e-i*, brachial plexus. 1, branch to pre-recti muscles; 2, anastomotic branch, with vagus, hypoglossal, and sympathetic nerves; 3, small occipital nerve; 4, great auricular nerve; 5, superficial cervical nerve; 6, anastomotic branch with the accessory nerve; 7, anastomotic branch with the descending cervical branch of the hypoglossal nerve; 8, supraclavicular nerves; 9, branch to scaleni muscles; 10, phrenic nerve; 11, posterior thoracic nerve; 12, branch to rhomboid muscles; 13, branch to subclavius; 14, suprascapular nerve; 15, anterior thoracic nerves; 16, three subscapular nerves; 17, musculo-cutaneous nerve; 18, median nerve; 19, musculo-spiral nerve; 20, circumflex nerve; 21, ulnar nerve; 22, internal cutaneous nerve; 23, small cutaneous nerve; 24, first intercostal nerve; 25, upper cord of the brachial plexus; 26, posterior cord; 27, lower cord.

tinal pleura, it approaches the diaphragm and divides into branches, which perforate the muscle to be divergently distributed on its lower surface. The **right nerve** is more deeply placed than the left, is more vertical, and enters the chest along the outer side of the right innominate vein and superior cava. The **left nerve** is somewhat longer, and on entering the chest crosses in front of the arch of the aorta to the side

<sup>1</sup> N. phrenicus; internal respiratory nerve of Bell.



of the pericardium. In its course near the chest it is joined by a filament from the sympathetic and usually by another from the branch of the fifth and sixth cervical nerves to the subclavian muscle. It also gives filaments to the pericardium and pleura.

**Superficial branches of the cervical plexus.** These consist of the superficial cervical, great auricular, small occipital, and supra-scapular nerves.

The **superficial cervical nerve**,<sup>1</sup> derived from the second and third cervicals, turns from behind forward across the outer side of the sterno-mastoid muscle, about its middle, beneath the external jugular vein, to the anterior border of the muscle. Here it perforates the cervical fascia and divides into diverging branches, commonly two principal ones,<sup>2</sup> which penetrate the platysma and are distributed to the skin of the fore part of the neck extending from the face to the breast. The upper larger branch anastomoses with the cervico-facial division of the facial nerve.

The **great auricular nerve**,<sup>3</sup> from the same source as the preceding, winds from behind and ascends obliquely upward across the sterno-mastoid muscle to the back of the ear, to which it is distributed, giving branches to the skin over the mastoid process and to the face over the parotid gland.<sup>4</sup> It anastomoses with the posterior auricular branch of the facial and with some of its filaments to the face.

The **small occipital nerve**,<sup>5</sup> from the third cervical, ascends along the posterior border of the sterno-mastoid muscle to the scalp in the position between the great auricular and occipital nerves, with both of which its contiguous filaments anastomose and also with the posterior auricular branch of the facial nerve.

The **least occipital nerve**,<sup>6</sup> derived from the plexus in common with one of the former nerves, gives a branch to the skin at the back of the neck and then ascends between the great auricular and small occipital nerves to the skin over the mastoid process.

The **supraclavicular nerves**,<sup>7</sup> usually three or four branches<sup>8</sup> from the third and fourth cervicals, descend in the interval of the sterno-mastoid and trapezius muscles and diverge over the clavicle and acromion to be distributed to the skin of the upper part of the breast, extending as far as the position of the fourth rib and over the shoulder.

The cervical plexus supplies cutaneous branches to the side of the head behind the ear, to part of the auricle, face, the neck, and to the upper part of the breast and shoulder. It furnishes muscular branches to the pre-recti, the scapular elevator, the middle scalenus, the infra-

<sup>1</sup> N. superficialis or subcutaneus colli.

<sup>2</sup> Upper or ascending and lower or descending branches; n. subcutaneus colli medius and inferior.

<sup>3</sup> N. auricularis magnus.

<sup>4</sup> Ramus facialis, auricularis, and mastoideus.

<sup>5</sup> N. occipitalis minor.

<sup>6</sup> N. occipitalis minimus.

<sup>7</sup> N. supraclaviculares.

<sup>8</sup> Internal, middle, and external; sternal, clavicular, and acromial.



hyoid, the sterno-mastoid muscles, the trapezius, and the diaphragm. It anastomoses with the facial, vagus, accessory, hypoglossal, and sympathetic nerves.

#### THE BRACHIAL PLEXUS.

The **brachial plexus**<sup>1</sup> is formed by the lower four anterior cervical and greater part of the first anterior thoracic nerves, which are remarkable for their large size, all being nearly equal and much larger than the preceding nerves. It extends from the lower part of the side of the neck beneath the clavicle into the axilla and is accompanied by the great blood-vessels of the upper limb. It is broad and plexiform at its commencement, narrows opposite the clavicle, forms an intricate interlacement in the axilla, and finally separates into many long branches distributed to the upper limb.

The arrangement of the brachial plexus is very variable. Commonly the fifth and sixth cervical nerves converge and unite in a short trunk; the first thoracic nerve ascends over the neck of the first rib and joins the eighth cervical nerve to form a second trunk, while the seventh cervical nerve continues as a middle trunk. Each trunk divides into an anterior and a posterior branch, and the posterior branches converge behind the axillary blood-vessels into the posterior cord of the plexus; the anterior branches of the upper and middle trunks converge and unite in the outer cord of the plexus; the anterior branch of the lower trunk continues as the inner cord of the plexus. The posterior cord of the plexus divides into the circumflex and musculo-spiral nerves. The outer and inner cords divide, their contiguous branches converge above and below the axillary vessels and in front of them conjoin in the median nerve, while the remaining branch of the outer or upper cord is continued as the musculo-cutaneous nerve, and that of the inner or lower cord as the ulnar and internal cutaneous nerves.

Sometimes the fifth, sixth, and seventh cervical nerves successively conjoin in the upper trunk, while the other nerves unite as usual in the lower trunk. Branches from the two trunks conjoin to form the posterior cord of the plexus, while the remainder of the trunks form the upper and lower cords. In some instances before the union of the upper two nerves of the plexus each gives off a branch which joins the other and that of the lower trunk to form the posterior cord.

Besides the common variations in the disposition of the chief nerves of the brachial plexus, others, in the mode of origin of its different branches, are frequent.

The brachial plexus in the neck is situated between the anterior and middle scalenus muscles and extends outward and downward under the clavicle and subclavian muscle, with the subclavian artery

---

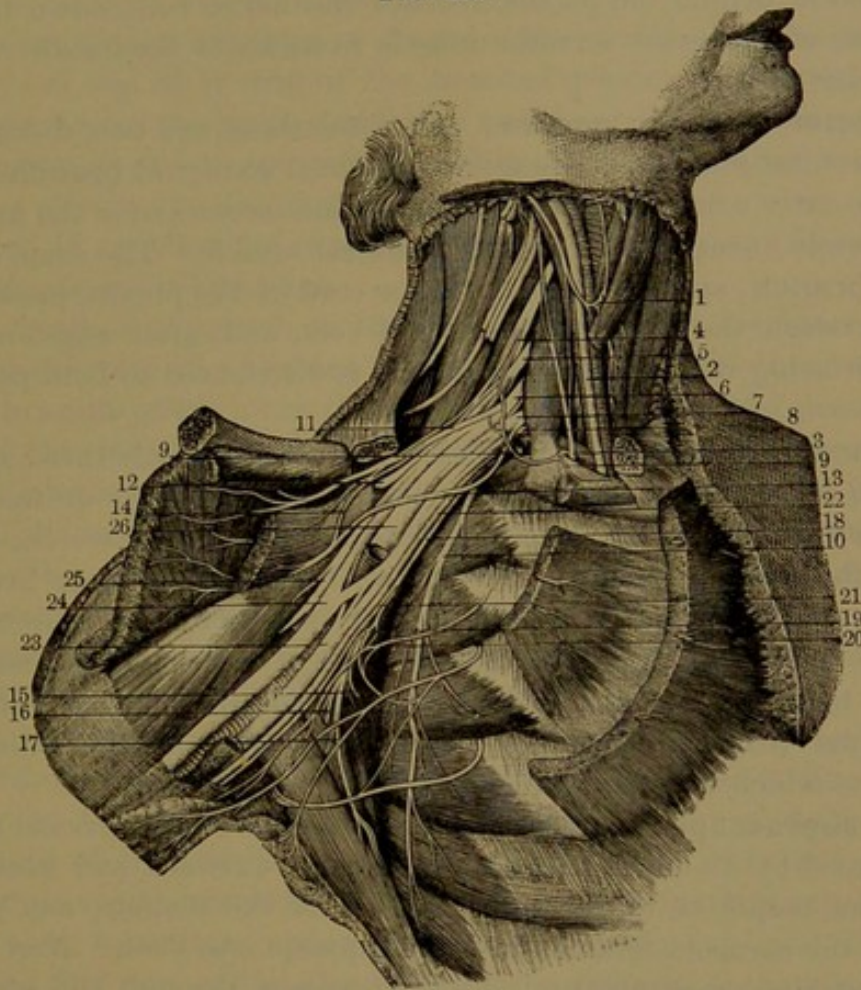
<sup>1</sup> P. brachialis; p. axillaris.



in advance of its lower part as they pass together over the first rib. In the axilla it rests on the upper head of the great serratus and the subscapular muscles, to the outer side of the axillary vessels. It then surrounds the vessels, one cord to the outer side, one to the inner side, and the other behind.

At their commencement the nerves of the brachial plexus are con-

FIG. 408.



**THE BRACHIAL PLEXUS.** 1, anastomosis between the descending cervical branch of the hypoglossal and a branch of the cervical plexus; 2, vagus nerve; 3, phrenic nerve; 4-8, the lower four cervical and the first thoracic nerves, forming the brachial plexus; 9, branch to the subclavian muscle giving a filament to the phrenic nerve; 10, posterior thoracic nerve; 11, 13, anterior thoracic nerves; 14, anastomosis between the latter; 12, suprascapular nerve; 15-17, subscapular nerves; 18, small cutaneous nerve; 19, anastomosis of a branch of the latter with the intercostohumeral nerve, 20; 21, continuation of the small cutaneous nerve in company with the internal cutaneous, 22; 23, ulnar nerve; 24, median; 25, musculo-cutaneous; 26, musculo-spiral nerve.

nected with the first and second cervical ganglia of the sympathetic. The fifth nerve receives a communicating branch from the fourth cervical and gives a filament to the phrenic nerve as it lies on the anterior scalenus muscle.

The branches of the brachial plexus are the following: muscular, thoracic, subscapular, circumflex, musculo-cutaneous, cutaneous, median, ulnar, and musculo-spiral nerves.

**Muscular branches.** Of these several small ones go to the long



cervical and scalmi muscles. Another from the fifth nerve passes backward through the middle scalenus to the rhomboid muscles, to which it is distributed. A small one also goes to the subclavian muscle, frequently connected by a filament with the phrenic nerve.

The **posterior thoracic nerve**<sup>1</sup> springs from near the commencement of the upper two or three cervical nerves of the brachial plexus, by as many roots, which descend and conjoin within the middle scalenus muscle, behind the plexus, whence the nerve runs down on the outer side of the great serratus muscle to its lower border distributed in branches to it.

**Anterior thoracic nerves.**<sup>2</sup> Of these there are two, distributed to the pectoral muscles. The more superficial **external branch** comes from the outer cord of the brachial plexus and crosses over the axillary blood-vessels to supply the greater pectoral muscle. The deep, or **internal branch**, springs from the inner cord of the plexus, passes forward between the axillary artery and vein, and, after anastomosing and interlacing with the former branch, is distributed to both pectoral muscles.

**Subscapular nerves.**<sup>3</sup> Of these there are commonly three, springing from the corresponding upper nerves of the plexus or from the posterior cord formed by them. The **upper branch** enters the upper part of the subscapular muscle, which it supplies; the **lower branch**, larger than the former, enters the axillary border of the same muscle and ends in the greater teres muscle, both of which it supplies; the **middle branch**, largest and longest, descends in company with the subscapular artery and enters the inner surface of the latissimus muscle, to which it is distributed.

The **suprascapular nerve**<sup>4</sup> springs from the fifth cervical or the cord formed by its union with the sixth, runs outward and backward under the trapezius to the upper border of the scapula, and passes through the coracoid foramen into the supraspinous fossa. Here, after supplying the supraspinatus muscle, it passes through the scapular notch to be distributed to the infraspinatus muscle, in its course giving filaments to the shoulder-joint.

The **circumflex nerve**,<sup>5</sup> a terminal branch of the posterior cord of the brachial plexus, from behind the axillary blood-vessels, winds backward around the inner side of the humerus below its head in company with the posterior circumflex artery, in the interval between the teres muscles and the long head of the triceps, and divides into two branches. Of these the **upper branch** winds outward around the humerus beneath the deltoid, nearly to the anterior border of the

<sup>1</sup> N. thoracicus posterior or longus; external respiratory nerve of Bell.

<sup>2</sup> Nervi thoracici anteriores.

<sup>3</sup> N. subscapulares.

<sup>4</sup> N. suprascapularis; n. scapularis.

<sup>5</sup> N. circumflexus; n. axillaris; n. scapulo-humeralis.



muscle, to which it is distributed, one or two of its filaments penetrating between the fleshy fascicles and supplying the skin over the lower part of the muscle. The **lower branch** gives filaments to the back part of the deltoid and supplies the small teres muscle, and finally penetrating the deep fascia is distributed to the skin over the lower part of the deltoid and adjacent part of the triceps muscle. An **articular filament** from the nerve before its division supplies the capsular ligament of the shoulder-joint.

The **musculo-cutaneous nerve**,<sup>1</sup> the smaller of the terminal branches of the outer cord of the brachial plexus, is directed downward, perforates the coraco-brachialis muscle and passes obliquely outward between the biceps and brachialis muscles to near the elbow, where it pierces the deep brachial fascia and becomes cutaneous. In its course it supplies the muscles just named and gives filaments to the humerus and elbow-joint.

The cutaneous portion of the nerve passes along the outer side of the cephalic vein and divides into two branches. Of these the **anterior branch** passes over the median cephalic vein and descends in front of the radial side of the forearm to the ball of the thumb, distributing branches to the skin in its course. Near the wrist it lies in front of the radial vessels and is connected with a branch of the radial nerve. The **posterior branch** is directed outward to the back of the forearm, on which it descends to the wrist, supplying the skin in its course and communicating by filaments with the radial and lower cutaneous branch of the musculo-spiral nerve.

The **internal cutaneous nerve**,<sup>2</sup> smaller than the preceding, is derived from the inner cord of the brachial plexus and is situated internally to the axillary vessels. Piercing the brachial fascia about the middle of the arm, it descends along the basilic vein and divides into two principal branches. Of these the **anterior branch** usually passes over, sometimes under, the median basilic vein and descends along the fore part of the ulnar side of the forearm to the wrist, supplying the skin in its course and communicating with cutaneous branches of the ulnar nerve. The **posterior branch** passes down on the inner side of the basilic vein, thence behind the inner epicondyle and along the back part of the ulnar side of the forearm to the wrist, supplying the contiguous skin and communicating with the dorsal branch of the ulnar nerve. In the arm some filaments from the internal cutaneous nerve supply the skin over the biceps muscle.

The **small cutaneous nerve**<sup>3</sup> usually comes from the inner cord

<sup>1</sup> N. musculo-cutaneus; n. cutaneus externus or brachii externus; n. perforans Casserii.

<sup>2</sup> N. cutaneus internus; n. c. brachii medius.

<sup>3</sup> Small internal cutaneous nerve; n. cutaneus minor or internus minor; n. cut. brachii internus.



of the brachial plexus or arises together with the former nerve. In the axilla it lies close to the axillary vein and descends along the inner side of the brachial vessels to near the middle of the arm, where it pierces the fascia and descends to the interval between the olecranon

FIG. 409.

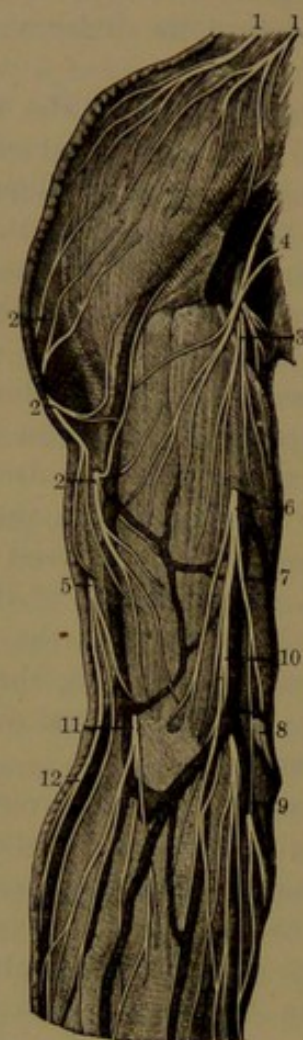
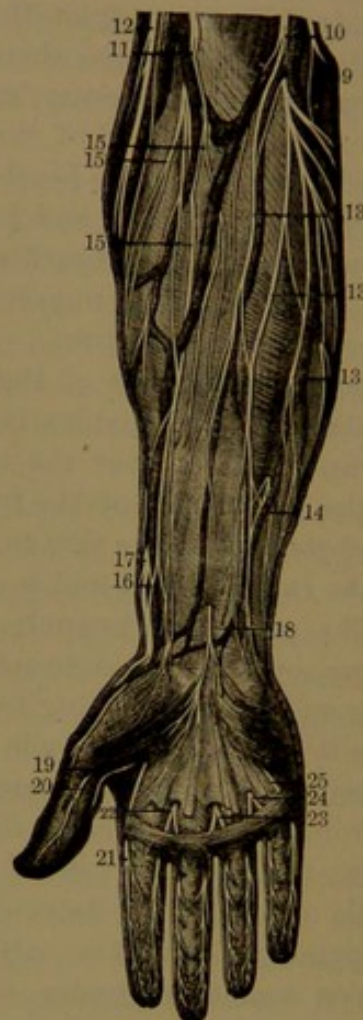
FIG. 410.



CUTANEOUS NERVES OF THE UPPER EXTREMITY. 1, supraclavicular nerves of the cervical plexus; 2, cutaneous branches of the circumflex nerve; 3, branch of the internal cutaneous nerve; 4, small cutaneous nerve, and its anastomosis with the intercosto-humeral; 5, cutaneous branch of the musculo-spiral nerve; 6, internal cutaneous nerve piercing the brachial fascia; 7, posterior branch anastomosing with 8, the ulnar nerve and 9, the anterior branch; 10, the internal cutaneous dividing into branches, some passing over and others under the median basilic vein; 11, musculo-cutaneous nerve; 12, cutaneous branch of the musculo-spiral nerve; 13, branches of the internal cutaneous to the front of the forearm; 14, anastomosis of one of the latter branches with one from the ulnar nerve; 15, terminal branches of the musculo-cutaneous nerve; 16, 17, anastomosis between the latter and the radial nerve; 18, superficial palmar branch of the median nerve; 19-25, digital nerves.

and internal epicondyle. It anastomoses with the intercosto-humeral nerve and supplies the contiguous skin.

The **ulnar nerve**,<sup>1</sup> the larger branch of the inner cord and one of the largest nerves of the brachial plexus, passes along the inner side

<sup>1</sup> N. ulnaris; n. cubitalis.



of the axillary and brachial vessels to near the middle of the arm, where it gradually diverges behind the internal intermuscular septum on the triceps muscle to the interval between the olecranon and inner epicondyle. From the elbow, it passes between the heads of the ulno-carpal flexor, beneath which it descends the forearm, resting on the deep digital flexor and covered at the lower part by the fasciæ and skin. From the wrist, it crosses the anterior annular ligament close to the pisiform bone, below which it divides into a superficial and a deep palmar branch. From the upper third of its course in the forearm it is accompanied by the ulnar blood-vessels, which lie to its outer side.

In the arm the ulnar nerve gives off no branches. At the elbow it gives a couple of small **articular branches** to the elbow-joint, and below it supplies **muscular branches** to the ulno-carpal and deep digital flexors.

A small **cutaneous branch** comes from the ulnar nerve about the middle of the forearm, sometimes communicating by a filament with the internal cutaneous nerve, and accompanies the ulnar artery to the hand, where it is distributed to the skin.

The **dorsal cutaneous branch**,<sup>1</sup> larger than the former, comes from the ulnar nerve a couple of inches above the wrist. Turning backward beneath the tendon of the ulno-carpal flexor it descends on the ulnar side of the back of the wrist and hand, to which it is distributed. It gives a **dorsal digital branch** to the inner side of the little finger, other branches dividing into the collateral **dorsal digitals**<sup>2</sup> of the adjoining sides of the little, ring, and middle fingers, and a **communicating branch** or two to the radial nerve, which in like manner supplies the other fingers.

The **superficial palmar branch**,<sup>3</sup> one of the terminal divisions of the ulnar, gives filaments to the short palmar muscle and adjacent part of the skin and divides into two digital branches. One of these runs along the inner side of the little finger, to which it is distributed; the other is connected in the palm of the hand with a digital branch of the median nerve, and afterwards divides into collateral digital branches which supply the adjoining sides of the little and ring fingers.

The **deep palmar branch**<sup>4</sup> of the ulnar nerve accompanies the ulnar artery between the abductor and short flexor of the little finger and subsequently the deep palmar arch beneath the flexor tendons in the palm of the hand. It supplies the short muscles of the little finger, the interosseous and two inner lumbrical muscles, and ends in the adductor and inner head of the short flexor muscles of the thumb. Filaments also ascend to the articulations of the wrist and others to the metacarpo-phalangeal articulations.

<sup>1</sup> N. dorsalis ulnaris.

<sup>3</sup> N. palmaris superficialis.

<sup>2</sup> Nervi digitorum dorsales.

<sup>4</sup> N. palmaris profundus.



The **median nerve**,<sup>1</sup> larger than the ulnar, springs from the outer and inner cords of the brachial plexus by two roots which unite at an acute angle in front, or on the outer side of the axillary blood-

FIG. 411.

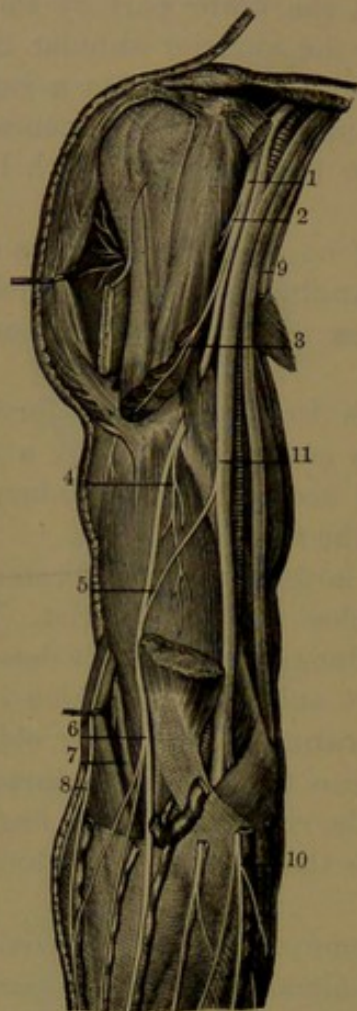
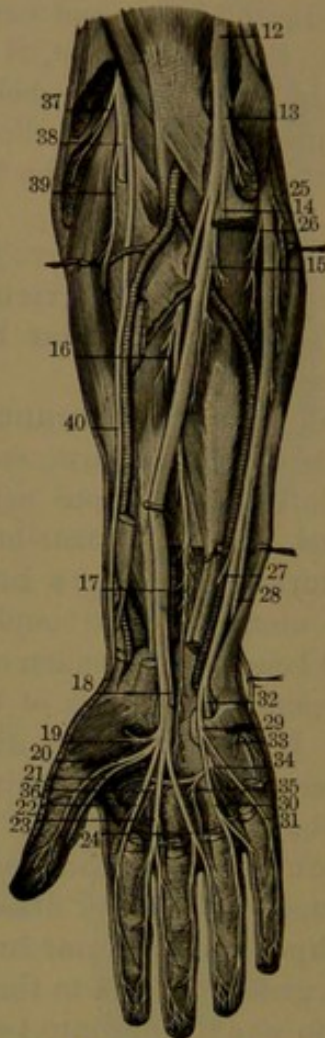


FIG. 412.



MUSCULO-CUTANEOUS, MEDIAN, ULNAR, AND MUSCULO-SPIRAL NERVES. 1, musculospiral nerve; 2, 3, 4, muscular branches; 5, anastomotic filament from the median; 6, division of the musculospiral nerve into branches to the forearm; 7, musculospiral nerve; 8, cutaneous branch; 9, internal cutaneous nerve; 10, its branches to the forearm; 11, median and ulnar nerves; 12, median nerve; 13-16, muscular branches; 17, anterior interosseous nerve; 18, superficial palmar branch; 19, branch to the muscles of the ball of the thumb; 20-24, digital nerves of the thumb, index, middle, and one side of the ring finger; 25, ulnar nerve; 26, muscular branches; 27, 28, cutaneous and dorsal cutaneous branches; 29, 30, 31, digitals to the little and ring fingers; 32, deep palmar branch; 33-36, muscular branches; 37, musculospiral nerve; 38, posterior interosseous nerve; 39, a muscular branch; 40, radial nerve.

vessels. The nerve descends in company with the brachial vessels, gradually passing inward over them, and near the elbow lies at their inner side. Passing over the bend of the elbow in front, it runs beneath the terete pronator, separated by the deeper portion of the muscle from the ulnar vessels, and continues down the forearm be-

<sup>1</sup> N. medianus.



tween the superficial and deep digital flexors to near the wrist, where it lies between the tendons of the radio-carpal and superficial digital flexors, covered by the fascia. It then enters the palm of the hand under the annular ligament, resting on the flexor tendons, where it becomes somewhat expanded and divides into two portions, of which one supplies the thumb and part of the index finger, and the other supplies the remaining part of the index, the middle, and part of the ring finger.

The median nerve gives off no branches in the arm. It gives an **articular filament** to the front of the elbow-joint.

**Muscular branches** arise separately or together near the elbow and proceed to supply the terete pronator, the radio-carpal and superficial digital flexors, and the long palmar muscle.

The **anterior interosseous nerve**<sup>1</sup> arises from the median below the elbow and accompanies the corresponding vessels in front of the interosseous membrane to the quadrate pronator, in the deep surface of which it terminates. It supplies the long pollical and outer half of the deep digital flexors, between which it lies. It also gives filaments to the interosseous membrane, bones of the forearm and the wrist-joint.

A **cutaneous branch**<sup>2</sup> near the middle of the forearm pierces the fascia and descends in the direction of the tendon of the long palmar muscle to the skin of the palm of the hand.

In the hand the median nerve gives off a short **muscular branch**, which is distributed to the abductor, opponens, and outer head of the short flexor muscles of the thumb, and then divides into three **common digital nerves**.<sup>3</sup> Of these the first divides into three collateral **digital nerves**, of which one runs along the outer side of the thumb to the end, while the others in the same manner run along the adjacent sides of the thumb and the index finger; the others each divide in a pair of collateral **digital nerves**, which, like the former, run along the adjacent sides of the index, ring, and middle fingers. The branch of the first common digital to the index finger and the second give branches to the first and second lumbrical muscles. The outer branch of the first common digital communicates with the radial nerve, and the third common digital is connected by a branch with the contiguous digital of the ulnar nerve.

The collateral or terminal digitals of both the ulnar and median nerves are distributed to the digits in the same manner. In their course they send branches forward and backward to the skin, those passing behind anastomosing with the dorsal digital nerves. At the ends of the fingers each digital nerve divides into two branches, of which one supplies the soft tip of the finger, while the other is distributed beneath the nail.

<sup>1</sup> N. int. anterior, internus, or profundus.

<sup>2</sup> N. cutaneus antibrachii palmaris.

<sup>3</sup> N. digitorum volares.



The **musculo-spiral nerve**,<sup>1</sup> the largest branch of the brachial plexus, springs from its upper cord in conjunction with the circumflex nerve. From behind the position of the axillary blood-vessels it turns backward and outward and descends in the musculo-spiral groove of the humerus, between it and the triceps muscle, accompanied by the superior profunda artery. Piercing the external intermuscular septum it descends between the long supinator and the brachialis muscle to near the outer condyle of the humerus, where it divides into the posterior interosseous and radial nerves.

In its course through the arm the musculo-spiral nerve gives numerous **muscular branches** to the triceps and a long one which descends to the anconeus. It also gives others to the long supinator and the longer radio-carpal extensor.

It also gives off several **cutaneous branches**, of which the **internal** descends from the axilla along the inner and back part of the arm to the olecranon, supplying filaments to the contiguous skin. Of two which are external and perforate the external intermuscular septum, an **upper branch** accompanies the cephalic vein to the elbow, distributed to the skin on the lower outer part of the arm, while a **lower branch** runs along the outer side of the arm and the back of the radial side of the forearm to the wrist, supplying the skin in its course and connected near the wrist with a branch of the external cutaneous nerve.

The **posterior interosseous nerve**,<sup>2</sup> the larger of the terminal branches of the musculo-spiral, turns backward and penetrates the short supinator, descends between the superficial and deep portion of the extensors to about the middle of the forearm, where it runs under the second pollical extensor to the lower part of the interosseous membrane. Passing to the back of the carpus, it expands in a small gangliform enlargement which distributes filaments to the contiguous articulations. In its course it supplies the short supinator and all the extensors of the forearm, except the longer radio-carpal extensor, which is furnished by a branch from the trunk of the musculo-spiral nerve.

The **radial nerve**<sup>3</sup> passes down the forearm beneath the long supinator and lies a short distance to the outer side of the radial blood-vessels. Near the lower end of the radius it turns backward under the tendon of the long supinator and divides into two branches, which are distributed to the skin on the back of the radial side of the hand. The **external branch**, joined by a branch from the musculo-cutaneous nerve, runs along the radial side of the thumb as its **dorsal digital nerve**, giving filaments to the ball of the thumb. The **internal branch**, larger than the external, communicates with the musculo-

<sup>1</sup> N. musculo-spiralis; n. radialis.

<sup>2</sup> N. interosseus posterior or externus.

<sup>3</sup> N. radialis; n. spiralis.



cutaneous nerve, divides into two common **dorsal digital nerves**, and by a communicating branch joins the contiguous digital of the dorsal cutaneous branch of the ulnar nerve. The common digital nerves fork into collateral **digitals** supplying the adjacent sides of the thumb, index and middle fingers.

The radial nerve and the dorsal cutaneous branch of the ulnar nerve are variable and proportioned to each other; sometimes each supplies digital branches to the digits equally, and at other times the radial supplies all except the little finger and one side of the ring finger, which are supplied by the ulnar.

#### ANTERIOR THORACIC NERVES.

The twelve **anterior thoracic nerves**<sup>1</sup> are almost entirely distributed to the walls of the thorax and abdomen, the exceptions being the great part of the first one, which forms one of the trunks of the brachial plexus, and the second and twelfth, which give branches respectively to the arm and the hip. Near their commencement each communicates by a pair of filaments with the adjacent ganglion of the sympathetic nerve.

The small part of the first thoracic nerve and the succeeding ten nerves run outward and forward in the intercostal spaces and are thence called **intercostal nerves**.<sup>2</sup> The first six, mainly confined to the wall of the thorax, are distinguished as the **upper** or **pectoral intercostal nerves**, and the succeeding five, partly distributed to the wall of the abdomen, as the **lower** or **abdominal intercostal nerves**, while the twelfth nerve runs below the last rib in the abdominal wall.

The **upper intercostal nerves** run outward and forward in the intercostal spaces below and in company with the corresponding vessels; at first situated next the pleura on the external intercostal muscle and then between it and the internal muscle to about the middle of the rib, where they each give off a lateral cutaneous nerve of the thorax. Reduced in size, they proceed forward through the internal intercostal muscle and then between it and the pleura towards the sternum, crossing the sternal triangular muscle and mammary vessels. Finally they perforate the internal intercostal and greater pectoral muscles and then continue as the anterior cutaneous nerves of the thorax. In their course they supply the intercostal, costal elevators, great serratus, and sternal triangular muscles.

The **lateral cutaneous nerves of the thorax**<sup>3</sup> pierce the external intercostal and great serratus muscles near the axillary border and divide into anterior and posterior branches which are distributed to the skin. The first intercostal commonly gives off no lateral cutaneous

<sup>1</sup> Nervi thoracici; dorsal nerves.

<sup>2</sup> N. intercostales.

<sup>3</sup> N. cutanei pectoris laterales.



nerve, and that from the second intercostal, under the name of the intercosto-humeral nerve, goes to the arm.

The **anterior branches** of the lateral cutaneous nerves run forward over the outer border of the greater pectoral muscle to be distributed to the skin of the breast and the mammary gland, a few filaments from the lower nerves supplying the upper digitations of the external oblique muscle of the abdomen. The **posterior branches** run backward to be distributed to the skin over the scapula and the latissimus muscle; that from the third nerve ramifying in the axilla and giving filaments to the arm.

The **intercosto-humeral nerve**,<sup>1</sup> the lateral cutaneous branch of the second intercostal, corresponding with the posterior branch of the succeeding lateral cutaneous nerves, runs across the axilla to the arm to be distributed to the skin on the inner and back surface nearly to its middle. In its course in the axilla it communicates by a branch with the small cutaneous nerve and subsequently with the internal cutaneous branch of the musculo-spiral nerve. It varies in size and extent of distribution proportionately with the small cutaneous nerve and other cutaneous branches of the arm.

The **anterior cutaneous nerves of the thorax**,<sup>2</sup> the terminal branches of the upper intercostal nerves, turn outward to be distributed to the skin over the greater pectoral muscle and mamma.

The **lower intercostal nerves** in their course between the ribs accord with the upper ones, and like them give off lateral cutaneous nerves. From the fore part of the intercostal spaces they continue forward across the costal cartilages inwardly and between the internal oblique and transversalis muscles of the abdomen to the edge of the rectus muscle. Piercing the sheath of the rectus they pass through it and end as the anterior cutaneous nerves of the abdomen. They supply the corresponding intercostal muscles, the *infraserratus*, and the abdominal muscles through which they pass.

The **lateral cutaneous nerves of the abdomen**<sup>3</sup> pass through the external intercostal and oblique muscles in a line with those above, and like them divide into anterior and posterior branches.

The **anterior branches**, the larger, run inward in the superficial fascia of the abdomen nearly to the rectus muscle, supplying the contiguous skin. The **posterior branches** run backward to the skin over the latissimus muscle.

The **anterior cutaneous nerves of the abdomen**,<sup>4</sup> small and variable in number and position, usually two or three twigs for each nerve, perforate the sheath of the rectus near its outer edge and near the *linea alba* to be distributed to the contiguous skin.

<sup>1</sup> N. intercosto-humeralis; n. cutaneus brachii internus.

<sup>2</sup> N. cutanei pectoris anteriores.

<sup>3</sup> N. cut. pectoris laterales.

<sup>4</sup> N. cutanei abdominis anteriores.



The **last thoracic nerve** runs along the lower border of the last rib and in company with the first lumbar artery crosses the inner surface of the quadratus lumborum muscle, then passes between the internal oblique and transversalis muscles of the abdomen and pursues a similar course to the lower intercostal nerves. From near its commencement a small **communicating branch** descends to the first lumbar nerve. Its branches are the same as those of the lower intercostal nerves; the anterior cutaneous twigs being distributed to the skin about midway between the umbilicus and the pubis.

The **lateral cutaneous branch** of the last thoracic nerve, passing through both oblique muscles of the abdomen, descends over the iliac crest to be distributed to the skin at the fore part of the gluteal region, extending to the position of the great trochanter.

#### ANTERIOR LUMBAR, SACRAL, AND COCCYGEAL NERVES.

The anterior lumbar, sacral, and coccygeal nerves unite in a continuous plexus which is conveniently divided into the lumbar, sacral, and coccygeal plexuses. All are connected near their commencement by filaments with the adjacent ganglia of the sympathetic nerve.

#### LUMBAR PLEXUS.

The five **lumbar nerves**<sup>1</sup> successively increase in size, and the upper three with part of the fourth form the **lumbar plexus**,<sup>2</sup> which is joined by a descending branch from the twelfth thoracic nerve. The plexus occupies the interior of the psoas muscle and is arranged as follows: The first nerve gives off two branches, the ilio-hypogastric and ilio-inguinal nerves and a communicating branch with the second nerve, and this gives off part of the genito-crural and external cutaneous nerves and a communicating branch with the third nerve. The latter unites with the greater portion of the upper division of the fourth nerve to form the largest branch of the plexus, the anterior crural nerve, while branches from the second, third, and fourth nerves unite to form the obturator nerve.

The **ilio-hypogastric nerve**<sup>3</sup> from the first lumbar emerges from the upper outer part of the psoas muscle, runs obliquely across the quadratus lumborum muscle to the iliac crest, perforates the transversalis muscle and between it and the internal oblique muscle divides into the iliac and hypogastric branches.

The **iliac branch** pierces both oblique muscles and descends over the iliac crest to be distributed to the skin of the gluteal region behind the position supplied by the lateral cutaneous branch of the last thoracic nerve. The **hypogastric branch** continues between the trans-

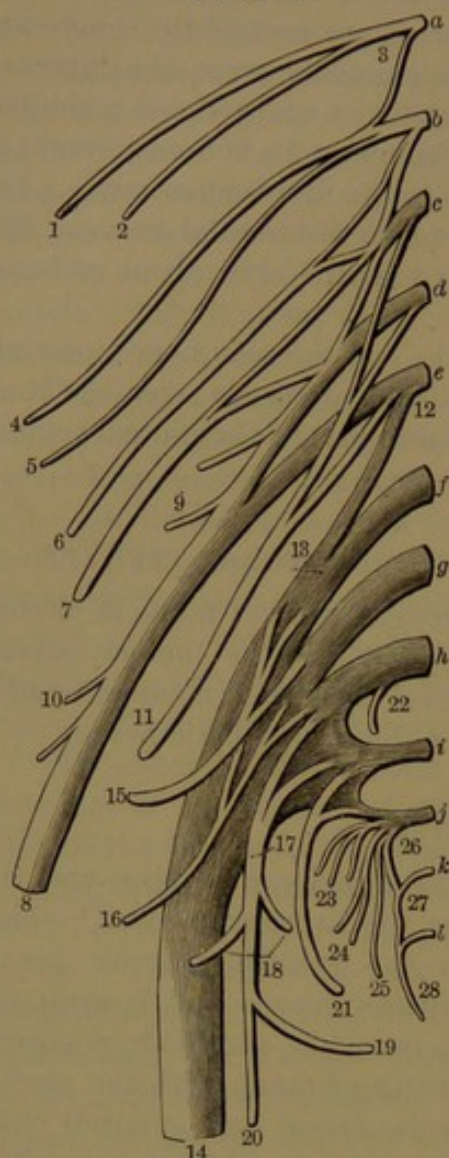
<sup>1</sup> Nervi lumbales or lumbares.

<sup>2</sup> P. lumbalis.

<sup>3</sup> N. ilio-hypogastricus.



FIG. 413.



LUMBAR, SACRAL, AND COCCYGEAL PLEXUSES. *a*, last thoracic nerve; *b-f*, lumbar nerves; *g-k*, sacral nerves; *l*, coccygeal nerve; 3, *b-c*, lumbar plexus; 12, *f-j*, sacral plexus; 26, *k, l*, coccygeal plexus. 1, anterior branch of the last thoracic nerve; 2, lateral cutaneous branch; 3, thoracico-lumbar nerve; 4, ilio-hypogastric nerve; 5, ilio-inguinal nerve; 6, genito-crural nerve; 7, external cutaneous nerve; 8, crural nerve; 9, psoas branches; 10, iliac branches; 11, obturator nerve; 12, connecting branch from the fourth lumbar nerve with the sacral plexus; 13, lumbo-sacral cord; 14, great sciatic nerve; 15, superior gluteal nerve; 16, inferior gluteal nerve; 17, small sciatic nerve; 18, gluteal branches; 19, pudendal nerve; 20, femoral cutaneous nerve; 21, pudic nerve; 22, branch to pyriform muscle; 23, visceral branches; 24, muscular branches; 25, perforating cutaneous branch; 26, descending branch to the fifth sacral nerve; 27, descending branch to the coccygeal nerve; 28, coccygeal branch.

versalis and internal oblique muscles, to both of which it gives filaments and anastomoses with the ilio-inguinal nerve, then perforates the external oblique aponeurosis just above the external abdominal ring and is distributed to the skin above the pubis.

The **ilio-inguinal nerve**<sup>1</sup> crosses the quadrate lumbar muscle below the preceding nerve and at the iliac crest perforates the transversalis muscle in advance of the ilio-hypogastric nerve, with which it anastomoses. Piercing the internal oblique muscle, it descends through the inguinal canal, emerges at the external abdominal ring and is distributed to the skin of the inner part of the groin, of the penis and scrotum, or in the female to that of the labium.

The ilio-hypogastric and ilio-inguinal nerves are variable in size proportioned to one another and their extent of distribution.

The **genito-crural nerve**,<sup>2</sup> derived from the second lumbar and the connecting cord between that and the first nerve, passes through and descends in front of the psoas muscle towards the groin and divides into the genital and the crural branch.

The **genital branch**<sup>3</sup> lies near the external iliac artery, to which it gives a filament, and descends in the inguinal canal to the cremaster muscle, which it supplies. The **crural branch**<sup>4</sup> passes under the femoral arch and pierces the fascia lata to be distributed to the skin below the groin; some of its fila-

<sup>1</sup> N. ilio-inguinalis.

<sup>3</sup> N. spermaticus or pudendus externus.

<sup>2</sup> N. genito-cruralis.

<sup>4</sup> N. lumbo-inguinalis.



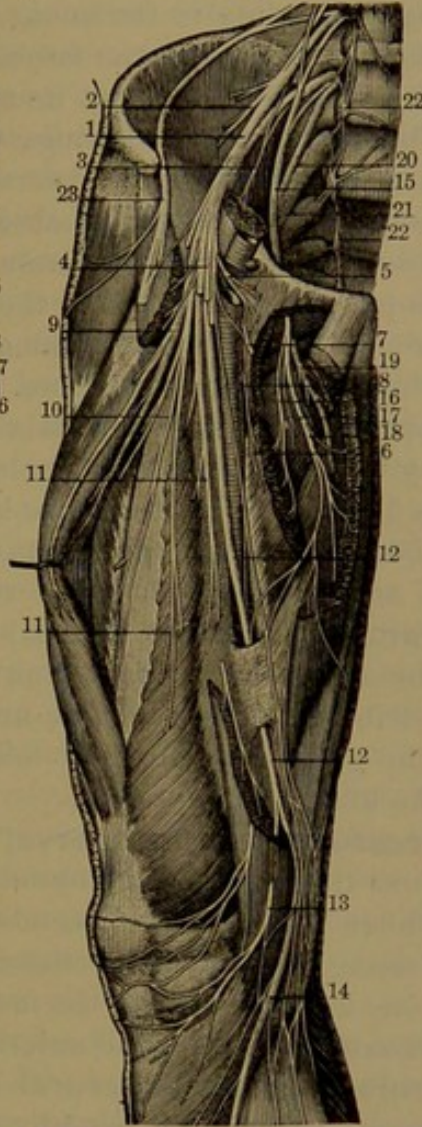
ments passing to the femoral artery as it passes beneath Poupart's ligament.

The **external cutaneous nerve**,<sup>1</sup> derived from the second and

FIG. 414.

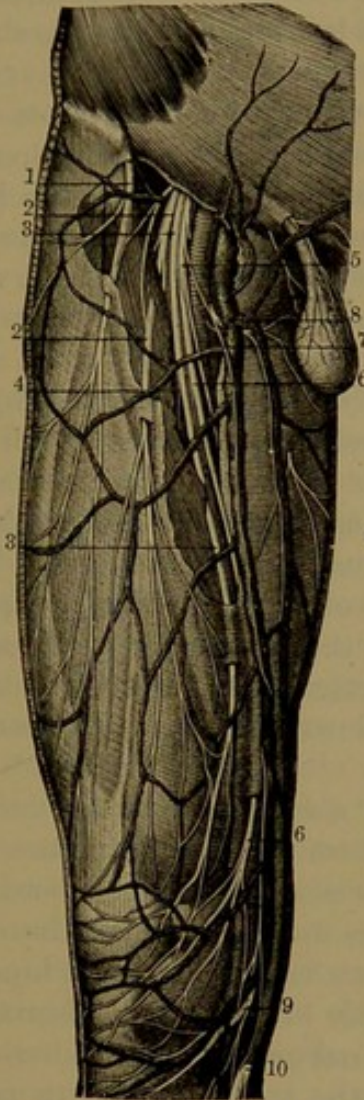

FIG. 415.



*Fig. 414.*—CUTANEOUS NERVES OF THE FRONT OF THE THIGH. 1, external cutaneous nerve; 2, middle cutaneous nerve; 3, 4, 5, 6, 7, internal cutaneous nerve and its branches; 8, cutaneous filaments to the inner part of the thigh; 9, 10, branches of the long saphenous nerve.

*Fig. 415.*—LUMBAR PLEXUS AND ITS BRANCHES. 1, crural nerve; 2, 3, branches to the iliac and psoas muscles; 4, commencement of the cutaneous nerves; 5, 6, muscular filaments to the pectineal and adductor muscles; 7, origin of the cutaneous filaments seen in the preceding figure on the inner part of the thigh; 8, cutaneous filament descending to the inner part of the knee; 9, 10, 11, muscular branches of the crural to the quadriceps extensor; 12, long saphenous nerve; 13, branch to the knee; 14, branch descending the leg in company with the saphenous vein; 15, obturator nerve; 16, 17, 18, 19, branches to the adductor and gracilis muscles; 20, branch of the fourth lumbar nerve, with the fifth lumbar nerve descending to join the first sacral nerve, 21; 22, lumbar and sacral ganglia of the sympathetic; 23, external cutaneous nerve.

third lumbar nerves, passes from the outer border of the psoas and across the iliac muscle, parallel with and below the ilio-inguinal nerve,

<sup>1</sup> N. cutaneus anterior externus.



then descends under the femoral arch and appears on the thigh below the anterior superior iliac spine, where it divides into anterior and posterior branches.

The **anterior branch** passes obliquely through the fascia lata below the groin and is distributed to the skin on the outer fore part of the thigh extending to the knee. The **posterior branch**, smaller than the former, perforates the fascia lata and supplies the skin on the outer part of the thigh to about its middle.

The **obturator nerve**<sup>1</sup> springs usually by three roots from the second, third, and fourth lumbar nerves near their commencement, but sometimes the uppermost root is absent. Passing from the inner side of the psoas muscle near the entrance of the pelvis, it runs along its side in company with and above the obturator vessels and with them passes through the obturator foramen into the thigh, where it divides into anterior and posterior branches.

The **anterior branch** descends in front of the short adductor, covered by the pectineus and long adductor muscles, to all of which it supplies filaments. In its course it gives a filament to the hip-joint, a terminal one to the femoral artery, and anastomoses with the internal cutaneous and a branch of the internal saphenous nerve. The **posterior branch** pierces the external obturator, which it supplies, and passes behind the short adductor on the great adductor, in which it is mainly distributed. It gives off an **articular filament** which descends through the great adductor and follows the popliteal vessels to the back of the knee-joint.

An **accessory obturator nerve**,<sup>2</sup> a small branch, not unfrequently springs from the trunk of the obturator nerve or from the third and fourth lumbar nerves, and descends along the inner border of the psoas. Passing beneath the pectineus muscle, it divides into branches, of which one is distributed to the muscle, another to the hip-joint, and a third communicates with the anterior branch of the obturator nerve.

The **crural, or anterior crural nerve**,<sup>3</sup> the largest branch of the lumbar plexus, is mainly formed by the third and fourth nerves, but also receives a reinforcement from the second. Descending through the psoas muscle, it emerges at its outer border and passes down between it and the iliac muscle and under the femoral arch into the thigh, where it becomes somewhat expanded and divides into an anterior and a posterior portion. In the thigh it is separated from the femoral blood-vessels by the psoas muscle, covered by the iliac portion of the fascia lata.

Within the pelvis the crural nerve gives small branches to the iliac muscle and a filament which descends on the femoral artery.

The anterior or superficial division of the crural nerve gives off the middle and internal cutaneous nerves.

<sup>1</sup> N. obturatorius.

<sup>2</sup> N. obt. accessorius.

<sup>3</sup> N. cruralis; n. femoralis.



The **middle cutaneous nerve**<sup>1</sup> pierces the fascia lata several inches below the groin and is distributed in numerous filaments to the skin along the fore part of the thigh to the knee, where it communicates with others of the long saphenous nerve. Its outer filaments also communicate with the crural branch of the genito-crural nerve, and its inner ones with the internal cutaneous nerve. This or the following nerve supplies the sartorius muscle.

The **internal cutaneous nerve**<sup>2</sup> turns inward across the sheath of the femoral blood-vessels and divides into internal and anterior branches. The **internal branch** descends along the inner border of the sartorius muscle to the knee, where it pierces the fascia lata, communicates with the long saphenous nerve, gives cutaneous branches to the knee, and then runs down on the inner side of the leg distributed to the contiguous skin. In the thigh it gives off filaments on the inner side along the course of the long saphenous vein. The **anterior branch** perforates the fascia lata at the lower third of the thigh, is distributed to the skin along the front and inner side to the knee, and communicates with the long saphenous nerve.

The **posterior or deep division** of the crural nerve is expended principally in muscular branches to the extensors of the thigh. It gives off a considerable cutaneous branch, the long saphenous nerve.

The **muscular branches** supply all the muscles of the front of the thigh except the fascial tensor, which is supplied by the superior gluteal nerve and the sartorius, which is supplied by branches coming off with the internal or middle cutaneous nerve. A branch or two pass behind the femoral vessels to the pectineus muscle; that to the femoral rectus enters the posterior surface; the branches to the crureus and internal vastus enter about their middle in front; that of the external vastus accompanies the descending branch of the external circumflex artery to the lower part of the muscle.

Of **articular branches**, a slender filament from the branch to the external vastus muscle descends to the knee-joint and another from the branch to the internal vastus accompanies the deep branch of the anastomotic artery to the inner side of the joint.

The **long, or internal saphenous nerve**,<sup>3</sup> the largest branch of the anterior crural, accompanies the femoral blood-vessels, at first lying to their outer side, gradually crossing to their front and descending with them in the canal of the great adductor tendon. Leaving the vessels, by piercing the canal, it continues down beneath the sartorius to the inner side of the knee. Here giving off the patellar branch, it pierces the fascia at the lower border of the sartorius and accompanies the long saphenous vein down the inner side of the leg and divides into two branches. Of these one runs along the tibia to the inner ankle

<sup>1</sup> N. cutaneus medius; n. perforans.

<sup>2</sup> N. cut. internus; n. saphenus minor.

<sup>3</sup> N. saphenus major.



and the other passes in front of it and runs along the inner side of the foot to the great toe.

In its course the long saphenous nerve, about the middle of the thigh, gives off a communicating branch, which interlaces with filaments of the obturator and internal cutaneous nerves beneath the sartorius muscle. The **patellar branch** pierces the sartorius and fascia lata and is distributed to the skin over the front of the knee, where with filaments of the cutaneous nerves it forms a reticular plexus.<sup>1</sup>

To the skin of the leg and inner part of the foot the long saphenous nerve distributes many branches, communicating with those of the internal cutaneous and musculo-cutaneous nerves.

#### SACRAL PLEXUS.

Of the five anterior sacral nerves the upper four issue from the anterior sacral foramina, the last one from the intervertebral foramen between the sacrum and coccyx. The first two sacral nerves are large and of nearly equal size, the others are small and successively decrease, the last being a short thread.

A division of the fourth lumbar nerve descends obliquely and joins the fifth to form the lumbo-sacral cord, which together with the upper three and part of the fourth sacral nerves forms the **sacral plexus**.<sup>2</sup> This does not present the usual appearance of plexuses, for the principal nerves converge and for the most part conjoin in a single large band, which is continued as the great sciatic nerve, while a small, more plexiform portion, derived partly from the third and partly from the fourth nerve, is continued into the pudic nerve. The upper nerves in their convergence to the plexus descend obliquely, while the lower ones become more horizontal, thus all becoming successively shorter.

The plexus is vertically flat and triangular and rests in front of the pyriform muscle, separated from the sciatic and pudic branches of the internal iliac vessels and from the pelvic viscera by the pelvic fascia. It converges and passes from the pelvis through the great sciatic foramen below the pyriform muscle and ends in the great sciatic and pudic nerves. In addition it gives origin to some small muscular branches, the superior and inferior gluteal, small sciatic, and perforating cutaneous nerves.

The small **muscular branches** are two from the upper nerves of the plexus to the pyriform muscle; a third which passes below the latter around the ischial spine in company with the pudic vessels and passes through the small sciatic foramen to the internal obturator muscle, in its course supplying the upper division of the geminus muscle; a fourth which passes from the plexus under the geminus

---

<sup>1</sup> Patellar plexus.

<sup>2</sup> P. ischiadicus.



muscle to the femoral quadrate muscle, giving the lower division of the geminus a filament, as well as one to the hip-joint.

The **superior gluteal nerve**<sup>1</sup> springs from the lumbo-sacral cord and first sacral nerve, leaves the pelvis in company with the gluteal vessels through the great sciatic foramen above the pyriform muscle, and divides into an **upper** and a **lower branch**, which proceed forward between the middle and small gluteal muscles and supply them and the fascial tensor.

The **inferior gluteal nerve**,<sup>2</sup> from the back of the plexus, springs from the lumbo-sacral cord and the first and second sacral nerves, turns backward below the pyriform muscle, and enters the lower part of the great gluteal muscle in diverging branches.

The **small sciatic nerve**,<sup>3</sup> receiving a branch from the former, also derives its roots from the second and third sacral nerves. Emerging from below the pyriform muscle, it descends beneath the great gluteal muscle, behind the great sciatic nerve, and continues down the back of the thigh, covered by the fascia lata, to below the knee. Here perforating the fascia, it follows the short saphenous vein below the middle of the leg and is connected with filaments of the short saphenous nerve.

The small sciatic is a cutaneous nerve and supplies the lower part of the buttock, perineum, back of the thigh, and upper back part of the leg. In the thigh it gives off the gluteal and femoral cutaneous branches and the inferior pudendal nerve.

The **gluteal cutaneous branches**,<sup>4</sup> of which there are several, turn up round the lower border of the great gluteal muscle to be distributed to the skin of the lower and outer part of the buttock. The **inferior pudendal nerve**<sup>5</sup> turns inward below the ischial tuberosity, gives branches to the skin of the upper and inner part of the thigh and its terminal ones to the outer surface of the scrotum; in the female to the labium. The **femoral cutaneous branches** are numerous and are distributed to the skin of the back of the thigh, the greater number to the inner side.

The **perforating cutaneous nerve**, a small branch derived from the fourth sacral nerve, passes backward through the great sacro-sciatic ligament and turns up round the lower border of the great gluteal muscle to the skin.

The **pudic nerve**,<sup>6</sup> the smaller terminal division of the sacral plexus, is derived from the third and fourth sacral nerves, with occa-

<sup>1</sup> N. glutæus superior.

<sup>2</sup> N. glutæus inferior; n. ischiadicus minor; inf. gluteal branch of the small sciatic nerve.

<sup>3</sup> N. ischiadicus minor; n. cutaneus posterior or post. medius, magnus, or communis; n. cut. n. glutei inf.

<sup>4</sup> N. subcutanei glutei inf.

<sup>5</sup> N. pudendus longus inferior.

<sup>6</sup> N. pudendalis communis; plexus pudendalis; p. pudendo-hæmorrhoidalis.



sional reinforcements from those above. Issuing from the pelvis below the pyriform muscle, in company with the pudic vessels at their inner side, it turns round behind the ischial spine and through the small sciatic foramen re-enters the pelvis. Here it runs forward and upward along the outer side of the ischio-rectal fossa enclosed in the obturator fascia and ends in the perineal nerve and dorsal nerve of the penis.

Near its commencement the pudic gives off the **hemorrhoidal nerve**,<sup>1</sup> which after anastomosis with filaments of the hemorrhoidal plexus of the sympathetic is distributed to the anal elevator and sphincters, the neck of the bladder and skin of the anus; in the female to the lower part of the vagina.

The **perineal nerve**,<sup>2</sup> the larger terminal branch of the pudic, runs forward along the outer side of the ischio-rectal fossa below the pudic vessels and divides into superficial and deep branches. The **superficial perineal branch**<sup>3</sup> is distributed to the skin of the perineum; the **deep perineal branch**<sup>4</sup> to the muscles of the perineum and to the skin of the back of the scrotum;<sup>5</sup> in the female to the labium, the nymphæ, and the vestibule.<sup>6</sup>

The **dorsal nerve of the penis**<sup>7</sup> accompanies the pudic artery along the ramus of the ischium, passes through the deep perineal fascia, then in company with the corresponding artery runs along the dorsum of the penis to the glans, to which its terminal branches<sup>8</sup> are distributed. In its course it gives filaments to the ischio-cavernous and urethro-bulbar muscles, others to the cavernous body anastomosing with filaments of the sympathetic, and numerous filaments to the skin of the penis and prepuce. In the female the corresponding **dorsal nerve of the clitoris** has a similar distribution and ends in branches to the glans, the prepuce, and the nymphæ.

The **great sciatic nerve**,<sup>9</sup> remarkable as the largest nerve of the body, the continuation in great part of the sacral plexus, appears as a flattened cylindrical cord, about two-thirds of an inch broad. It issues from the pelvis through the great sciatic foramen below the pyriform muscle and descends vertically behind the thigh, commonly below the middle, where it forks acutely into the popliteal and peroneal nerves. In its descent it first rests on the small rotator muscles between the ischial tuberosity and great trochanter, in company with the small sciatic nerve and artery, covered by the great gluteal muscle, afterwards on the great adductor covered by the long head of the femoral

<sup>1</sup> Inferior hemorrhoidal nerve; *nervus hæmorrhoidalis externus* or *medius* and *inferior*.

<sup>2</sup> *N. perinealis* or *perineus*; *n. pudendus inf.* or *int.*

<sup>3</sup> *Sup. perin. nerves*, external or posterior and internal or anterior.

<sup>4</sup> *N. profundus*; *n. musculo- or bulbo-urethralis*.

<sup>5</sup> *Nervi scrotales posteriores*.

<sup>6</sup> *N. labiales posteriores*.

<sup>7</sup> *N. penis dorsalis*.

<sup>8</sup> *Rami glandis*.

<sup>9</sup> *N. ischiadicus magnus* or *major*.



biceps muscle. The position of division is variable and may occur at any point from near the plexus to the upper part of the popliteal space.

Before division the great sciatic nerve gives **articular filaments**

FIG. 416.

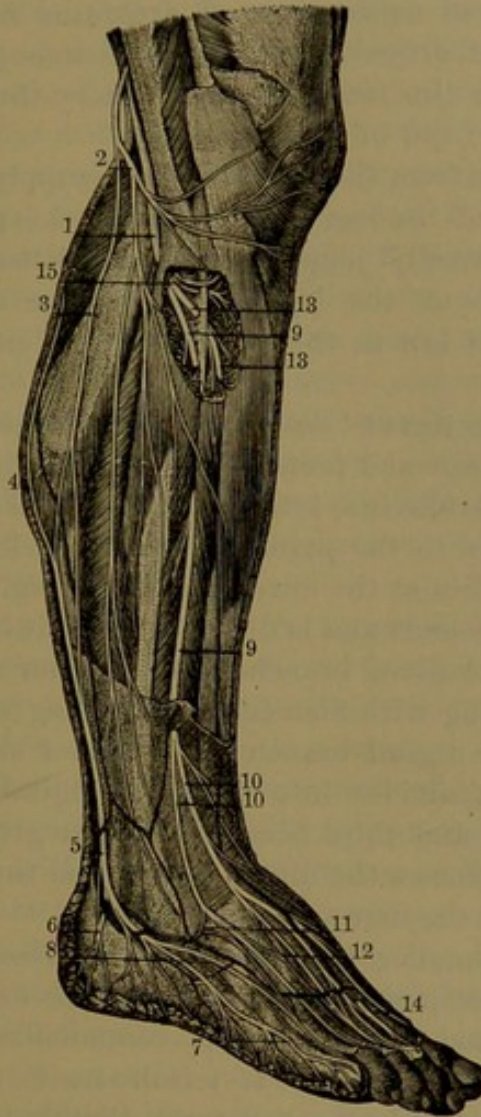
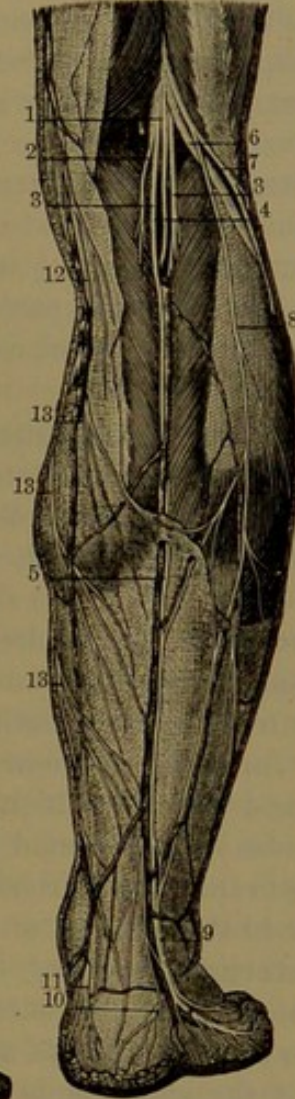


FIG. 417.



*Fig. 416.*—PERONEAL NERVE AND ITS BRANCHES. 1, peroneal nerve; 2, cutaneous branch to the outer part of the leg; 3, peroneal communicating branch anastomosing with the short saphenous nerve 4, 5; 6, 7, 8, terminal branches of the latter to the outer part of the foot; 9, musculo-cutaneous nerve; 10, 11, 12, terminal branches to the back of the foot; 13, anterior tibial nerve; 14, terminal branch of the latter anastomosing with branches of the musculo-cutaneous nerve; 15, muscular branches.

*Fig. 417.*—POPLITEAL NERVE. 1, popliteal nerve; 2, 3, 4, muscular branches; 5, short saphenous nerve; 6, peroneal nerve; 7, cutaneous branch; 8, peroneal communicating branch joining the short saphenous nerve; 9, common trunk of the peroneal communicating and saphenous nerves to the outer part of the foot; 10, branch to the heel; 11, cutaneous branch from the posterior tibial nerve; 12, 13, branches of the long saphenous nerve.

to the hip-joint and in the thigh **muscular branches** to the biceps, semi-tendinosus, semi-membranosus, and great adductor muscles.

The **peroneal nerve**,<sup>1</sup> the smaller division of the great sciatic,

<sup>1</sup> N. peroneus; external popliteal nerve; n. popliteus externus; n. fibularis.



descends obliquely along the outer side of the popliteal space close to the biceps muscle, then between it and the gastrocnemius. Below the head of the fibula, it turns forward round the bone beneath the long peroneal muscle and divides into the anterior tibial and musculo-cutaneous nerves.

Before division the peroneal nerve gives off **articular filaments** which accompany the external articular arteries to the knee-joint, and a **recurrent branch**<sup>1</sup> follows the recurrent tibial artery through the anterior tibialis muscle to the front of the joint.

Two **cutaneous branches** from the peroneal nerve supply the skin on the outer and back part of the leg. One of them, the **peroneal communicating branch**,<sup>2</sup> usually joins the short saphenous nerve below the middle back part of the leg, but sometimes continues separate and is distributed as low as the heel and outer side of the foot.

The **musculo-cutaneous nerve**<sup>3</sup> descends between the peroneal muscles and long digital extensor and perforates the fascia at the lower fore part of the leg, where it divides into internal and external branches. In its course it gives branches to the peroneal muscles and filaments which are distributed to the skin at the lower part of the leg.

The **internal branch**<sup>4</sup> descends and is distributed to the inner part of the dorsum of the foot and gives branches to the inner ankle and side of the foot, communicating with filaments of the long saphenous nerve. It furnishes a dorsal digital branch to the inner side of the great toe and another which divides into collateral digitals for the adjoining sides of the second and third toes. It further gives a communicating branch which reinforces the digital nerve from the anterior tibial nerve in the interval of the first and second toes.

The **external branch**,<sup>5</sup> smaller than the internal, descends and supplies the skin on the outer part of the dorsum of the foot, giving branches to the outer ankle and side of the foot, communicating with filaments of the short saphenous nerve. It terminates in a pair of dorsal digital branches which supply the collateral digitals to the adjoining sides of the outer three toes.

The two terminal divisions of the musculo-cutaneous nerve are variable and proportioned to each other and in a measure to those with which they communicate. They commonly supply dorsal digital nerves to the toes, except the outer side of the last toe, which is supplied by a corresponding branch from the short saphenous nerve, and the

<sup>1</sup> Recurrent articular nerve.

<sup>2</sup> N. communicans peronei or fibularis; n. cutaneus cruris posterior; n. saphenus peroneus.

<sup>3</sup> N. cutaneus peroneus; n. peroneus superficialis.

<sup>4</sup> N. dorsi pedis cutaneus anterior or internus.

<sup>5</sup> N. dorsi pedis cutaneus medius; n. peroneus externus.



contiguous sides of the great and second toes which are supplied by the anterior tibial nerve.

The **anterior tibial nerve**,<sup>1</sup> starting between the fibula and long peroneal muscle, descends obliquely forward beneath the long digital extensor to the front of the interosseous membrane, where joining the anterior tibial vessels it accompanies them to the ankle and divides into internal and external branches. The nerve joins the vessels at the upper fourth of the leg and descends in front of them to the ankle, where it lies at their inner side.

In its course the anterior tibial nerve supplies the anterior tibialis, long digital and hallucal flexors, and third peroneal muscle. It also gives off **articular filaments** to the ankle-joint.

The **internal branch**<sup>2</sup> follows the anterior tibial and dorsal pedal vessels to the first interosseous space, where it is joined by a branch from the musculo-cutaneous nerve and ends in digital branches to the adjoining sides of the great and second toes. It gives filaments to the contiguous metatarso-phalangeal articulations and interosseous muscles. The **external branch**<sup>3</sup> turns outward across the tarsus beneath the short digital extensor and is distributed to it and to the articulations of the tarsus.

The **popliteal nerve**,<sup>4</sup> the larger division of the great sciatic, pursues the course of the trunk and descends through the popliteal space, in company with the popliteal vessels, to the lower border of the popliteal muscle, after which it continues as the posterior tibial nerve. At first the nerve is a short distance behind and outward from the popliteal vessels, but gradually approaches them, behind the knee lies in contact with the vein, and crosses to the inner side of the vessels.

From the upper part of the popliteal nerve two or three **articular filaments** descend and accompany the internal and middle articular arteries to the knee-joint. **Muscular branches** also descend from it in the popliteal space, a pair separately or together, to the heads of the gastrocnemius, a small one to the plantaris, a considerable branch to the soleus, and one lower down for the popliteal muscle.

A cutaneous branch of the popliteal, the **short saphenous nerve**,<sup>5</sup> descends at the back of the calf in the furrow between the heads of the gastrocnemius to near the middle of the leg, where it perforates the fascia and shortly after is usually joined by the **peroneal communicating branch**. It then descends in company with the short saphenous vein and runs forward behind the external ankle to end in the skin on the outer side of the foot, communicating with the mus-

<sup>1</sup> N. tibialis anticus; n. peroneus profundus.

<sup>2</sup> Ramus internus profundus dorsi pedis.

<sup>3</sup> R. ext. prof. dorsi pedis.

<sup>4</sup> N. popliteus; internal popliteal nerve; n. tibialis or t. posticus.

<sup>5</sup> N. saphenus externus or inferior; n. communicans tibialis or suræ; n. cutaneus brevis cruris et pedis.



culo-cutaneous nerve, and furnishing the **dorsal digital branch** to the outer side of the little toe.

The **posterior tibial nerve**,<sup>1</sup> the continuation of the popliteal, descends the leg in company with and behind the corresponding blood-vessels, lying at first for a short distance to their inner side, but crossing them and the greater part of their course lying on the outer side. With the accompanying vessels it lies on the deep muscles, covered above by those of the calf and below by the fasciæ and skin. Reaching the interval between the inner ankle and the heel, to the outer side of the vessels, it divides into two terminal branches, the internal and external plantar nerves.

In the upper part of its course the posterior tibial nerve gives **muscular branches** to the posterior tibialis, the long digital and hallucal flexors, and the soleus.

A **cutaneous branch**<sup>2</sup> from the lower part of the nerve pierces the internal annular ligament of the ankle and is distributed to the skin of the heel and inner back part of the sole of the foot. One or two **articular filaments** in the vicinity supply the ankle-joint.

The **external plantar nerve**,<sup>3</sup> the smaller terminal branch of the posterior tibial, runs obliquely across the sole of the foot in company with the corresponding vessels, between the short digital and accessory flexors, to the interval between the former and the minimal abductor, where it divides into superficial and deep branches. It gives **muscular branches** to the accessory flexor and minimal abductor muscles. The **superficial branch** divides into two **digitals**, of which one gives twigs to the minimal flexor and runs along the outer side of the little toe; while the other, after giving a **communicating branch** to the internal plantar, ends in collateral **digital nerves** to the contiguous sides of the fourth and fifth toes. The **deep branch** accompanies the external plantar vessels above the flexor tendons and is distributed to the interosseous, the outer two lumbrical, and the hallucal adductor and transverse muscles.

The **internal plantar nerve**,<sup>4</sup> larger, appearing as the continuation of the posterior tibial, runs forward in the sole of the foot in company with the corresponding vessels. It passes above the hallucal abductor, then between it and the short digital flexor, gives off the internal **digital nerve** of the great toe and divides into three **common digital branches**.<sup>5</sup> These pass from under cover of the plantar fascia and near the cleft of the toes divide into the collateral digital nerves of the adjacent sides of the inner four toes. Before dividing, the internal plantar nerve gives **muscular branches** to the hallucal abductor

<sup>1</sup> N. tibialis posticus.

<sup>2</sup> N. cutaneus calcis; n. cut. internus; n. cut. plantaris proprius.

<sup>3</sup> N. plantaris externus or lateralis.

<sup>4</sup> N. plantaris internus or medialis.

<sup>5</sup> Nervi digitales communes.



and short digital flexor and several **cutaneous branches** to the skin of the sole of the foot. The first digital nerve gives twigs to the short hallucal flexor; the second and third digitals, twigs to the contiguous pair of lumbrical muscles. The fourth digital receives a **communicating branch** from the external plantar nerve.

The distribution of the plantar nerves is similar to that of the median and ulnar nerves in the palm of the hand.

#### COCCYGEAL PLEXUS.

The **coccygeal plexus**<sup>1</sup> is formed by the fifth anterior sacral nerve, with a division of the fourth sacral and the anterior coccygeal nerve.

The fifth sacral nerve, the smallest of the series, emerges through the intervertebral foramen below the sacrum and perforates the coccygeus muscle, in front of which it is joined by the descending branch of the fourth nerve and receives from below the anterior coccygeal nerve. This, the smallest of the anterior spinal nerves, descends from the end of the spinal canal, turns forward through the last intervertebral foramen, between the first two coccygeal vertebræ and the sacro-sciatic ligaments, and joins the coccygeal plexus, the filaments<sup>2</sup> of which are distributed to the coccygeus muscle and skin about the end of the coccyx.

#### SYMPATHETIC NERVES.

The nerves of the sympathetic system supply the internal viscera and the walls of the blood-vessels and lymphatics, though some of the organs, as the heart, the lungs, the upper part and lower extremity of the alimentary canal, also receive nerves from the cerebro-spinal system.

Each **sympathetic nerve**<sup>3</sup> consists of a main gangliated cord, with three great prevertebral plexuses associated with ganglia, and numerous small plexuses distributed with the blood-vessels.

The **gangliated cord** of the sympathetic nerve consists of a series of ganglia in the course of a cord placed at the side of the vertebral column, extending from the base of the cranium to the coccyx. The upper extremity of the cord is continued by a plexus through the carotid canal into the cranial cavity, the lower extremity joins that of the opposite side in a loop<sup>4</sup> or in a median ganglion<sup>5</sup> in front of the coccyx. The cord is conveniently divided according to the regions it occupies into the cervical, thoracic, lumbar, and sacral portions, and on them the ganglia nearly agree in number with the vertebræ of the regions, except the cervical portion, on which there are only three ganglia.

<sup>1</sup> P. coccygeus.

<sup>2</sup> Nervi ano-coccygei.

<sup>3</sup> N. sympatheticus; n. symp. magnus; n. intercostalis magnus; n. trisplanchnicus; n. gangliosus.

<sup>4</sup> Ansa sacralis; arcus nervosus sacralis.

<sup>5</sup> G. impar; g. Walteri.



The **ganglia** are joined with the commencement of the nearest anterior spinal nerves by **communicating branches**, each of which consists of a white and a gray portion, the former consisting of fibres derived from the spinal nerves, the latter being a contribution to them. The intervening portions of the main cord connecting the ganglia are likewise composed of white and gray portions, of which the former is continuous with the fibres of the spinal nerves communicating with the ganglia.

The **great prevertebral plexuses** consist of three single median interlacements of nerves associated with ganglia, common to the two sympathetic nerves, situated in front of the spine in succession in the cavity of the thorax, abdomen, and pelvis, named the cardiac, solar, and hypogastric plexuses. These also receive branches from the neighboring cerebro-spinal nerves, while from them proceed divisions or small plexuses following the course of the blood-vessels.

#### CERVICAL PORTION OF THE SYMPATHETIC NERVE.<sup>1</sup>

In the neck the gangliated cord is placed on the prevertebral muscles behind the great cervical vessels enclosed in their sheath, and has upon it three ganglia distinguished by number or relative position.

##### FIRST CERVICAL GANGLION.

The **first**, or **superior cervical ganglion**,<sup>2</sup> the largest of the cord, is a variable reddish-gray body, usually fusiform, about an inch in length, resting on the greater prerectus muscle, behind the internal carotid artery, the vagus and hypoglossal nerves. Its upper tapering end is the upper extremity of the gangliated cord and in company with the internal carotid artery enters the carotid canal, where it forms the carotid plexus; its lower end is continuous with the cord descending the neck.

Outwardly the ganglion is joined by **communicating branches**<sup>3</sup> with the upper three or four cervical nerves. It is also connected by others with the jugular ganglion and gangliform plexus of the vagus, with the jugular and petrous ganglia of the glosso-pharyngeal and with the hypoglossal nerve.

The branches from the ganglion are the vascular and pharyngeal and the superior cardiac nerve.

The **vascular branches**,<sup>4</sup> a variable number of delicate filaments, twine round the external carotid artery, on which they form the **external carotid plexus**,<sup>5</sup> whence divisions proceed along the branches of the vessel. From the plexus on the facial artery is given the fila-

<sup>1</sup> Pars cervicalis nervi sympathetici.

<sup>2</sup> G. cervicale superior or magnum; g. fusiforme; g. olivare.

<sup>3</sup> Rami communicantes; r. externi.

<sup>4</sup> Nervi molles.

<sup>5</sup> P. caroticus externus.

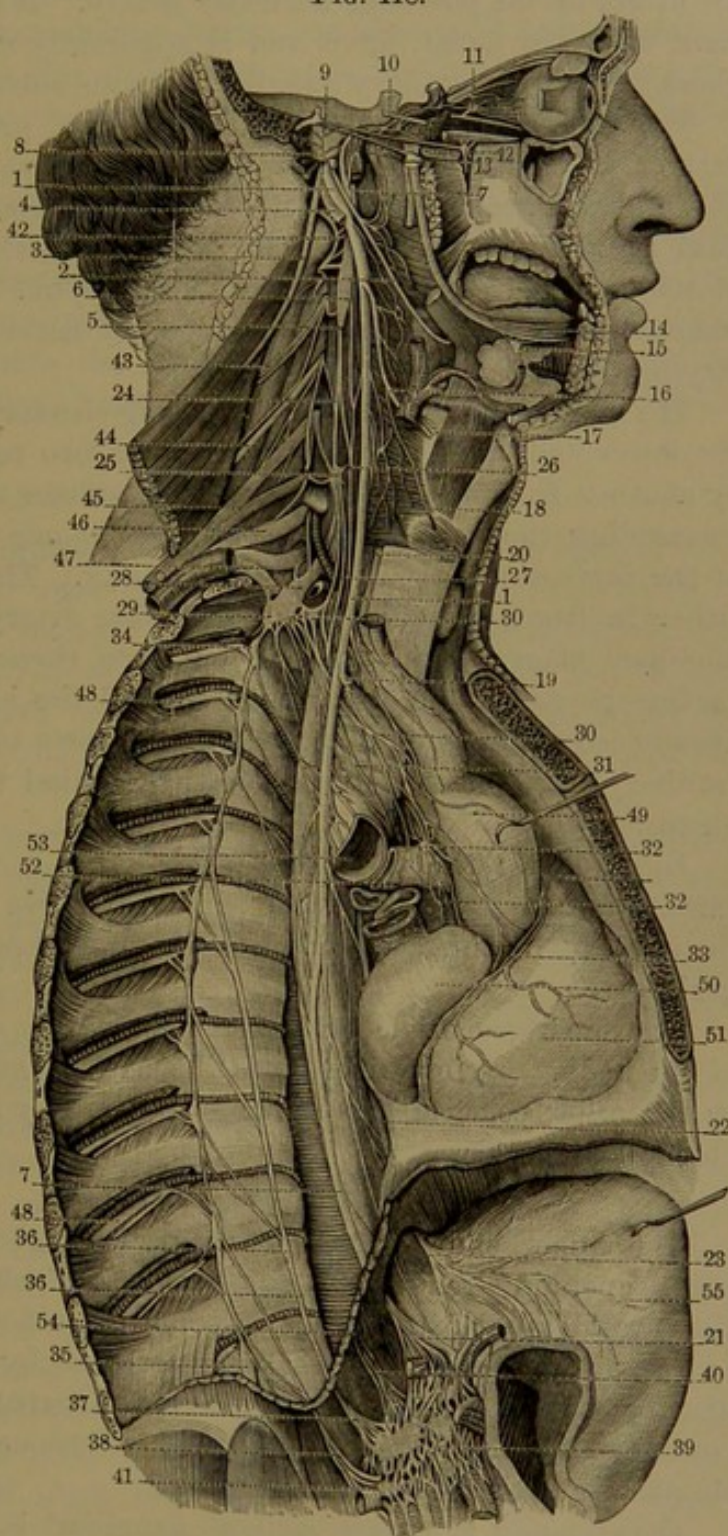


ment to the submaxillary gland, and from that on the great meningeal artery a filament to the otic ganglion and another<sup>1</sup> to the facial nerve.

FIG. 418.

FIG. 418.—THE SYMPATHETIC, VAGUS, AND OTHER ASSOCIATED NERVES.

1, vagus nerve; 2, glosso-pharyngeal nerve; 3, accessory nerve; 4, hypoglossal nerve; 5, gangliated cord of the sympathetic nerve; 6, first cervical ganglion; 7, upper end of the cord dividing and forming the carotid plexus; 8, tympanic branch of the glosso-pharyngeal nerve on the promontory of the tympanum; 9, geniculate ganglion of the facial nerve joined by the superficial petrosal nerve; 10, abducent nerve joined by filaments of the cavernous plexus; 11, ophthalmic ganglion; 12, sphenopalatine ganglion; 13, otic ganglion; 14, lingual nerve; 15, submaxillary ganglion; 16, superior laryngeal nerve; 17, internal laryngeal nerve; 18, external laryngeal nerve; 19, 20, inferior laryngeal nerve; 21, termination of the right vagus nerve back of the stomach; 22, 23, left vagus nerve; 24, cord of the sympathetic nerve descending from the first to the second cervical ganglion, 25; 26, superior cardiac nerve; 27, middle cardiac nerve; 28, 29, third cervical and first thoracic ganglia fused together; 30, inferior cardiac nerve; 31, cardiac branches from the vagus and first thoracic ganglion to the cardiac plexus, 32; 33, coronary plexus; 34, 35, thoracic ganglia from the second to the last; 36, great splanchnic nerve; 37, its termination in the semi-lunar ganglion; 38, small splanchnic nerve; 39, solar plexus; 40, phrenic plexus; 41, renal ganglion; 42, loop



formed between the first and second cervical nerves; 43, third anterior cervical nerve; 44, fourth anterior cervical nerve; 45-47, four lower cervical and first thoracic nerves forming the brachial plexus; 48, anterior thoracic or intercostal nerves; 49, aorta drawn forward; 50, right auricle; 51, right ventricle; 52, right pulmonary artery; 53, right bronchus; 54, cut edge of the diaphragm; 55, stomach dragged aside to exhibit the solar plexus.

<sup>1</sup> N. petrosus superficialis.



In the course of the vascular branches are some microscopic but inconstant ganglia. Besides these there is commonly one, the **temporal ganglion**,<sup>1</sup> about a line long, situated on the external carotid at the origin of the posterior auricular artery. It is connected by a filament with the facial nerve, and is apparently related to the parotid gland as the submaxillary ganglion is to the submaxillary gland.

The **pharyngeal branches**,<sup>2</sup> two to four, proceed from the inner part of the ganglion and join with the pharyngeal branches of the glosso-pharyngeal and vagus nerves in the formation of the **pharyngeal plexus**.<sup>3</sup> This lies on the middle constrictor and supplies the muscles and mucous membrane of the pharynx. One of the branches communicates with the superior laryngeal nerve and with its external laryngeal branch.

The **superior cardiac nerve**,<sup>4</sup> a long slender branch, springs from the lower end of the ganglion by one or two roots, sometimes joined by another from the cord below, or sometimes arising from it alone. Descending the neck on the long cervical muscle behind the sheath of the cervical vessels, it enters the thorax. The **right nerve** passes either in front or behind the subclavian artery, runs along the innominate artery to the back of the aorta, thence to end in the deep cardiac plexus. The **left nerve** follows the left carotid artery and usually crosses in front of the arch of the aorta to end in the superficial cardiac plexus, but sometimes descends behind the aorta to the deep plexus.

In its course the superior cardiac nerve is usually joined by the cardiac branch of the superior laryngeal nerve of the vagus, and in the chest by one or more of the cardiac branches of the inferior laryngeal nerve.

The superior cardiac nerve is very variable, even on the two sides of the body. It sometimes joins the cardiac nerve derived from one or the other cervical ganglia, and occasionally has been found to be absent on one side.

#### CAROTID PLEXUS.

The upper end of the first cervical ganglion of the sympathetic nerve tapers in a reddish-gray, flattened cord,<sup>5</sup> which ascends and enters the carotid canal beneath the internal carotid artery and divides into two branches. These in their further course by repeated division and anastomosis form, around the artery, the **carotid plexus**,<sup>6</sup> which is continuous on the vessel through the cavernous sinus, where it is distinguished as the **cavernous plexus**.<sup>7</sup>

Occasionally a minute stellate ganglion<sup>8</sup> is found on the carotid

<sup>1</sup> G. temporale.

<sup>2</sup> P. pharyngeus.

<sup>3</sup> Nervus caroticus.

<sup>4</sup> P. cavernosus.

<sup>2</sup> Rami pharyngei ; r. pharyngeolaryngei.

<sup>4</sup> N. cardiacus superior, superficialis, or longus.

<sup>6</sup> P. caroticus internus.

<sup>8</sup> G. caroticum or cavernosum.



plexus to the outer side of the carotid artery, but more frequently is substituted by a little narrow-meshed plexus.

The carotid plexus is connected by the **deep petrosal nerve**,<sup>1</sup> a branch of the vidian nerve, with the sphenopalatine ganglion. (See page 789.) Of two other communicating branches, one<sup>2</sup> passes through a minute foramen and the other<sup>3</sup> through a fine canal into the tympanum, where they join the tympanic branch<sup>4</sup> of the glosso-pharyngeal nerve.

From the cavernous plexus filaments proceed to the semilunar ganglion of the trifacial nerve, to the ophthalmic branch, and to the oculomotor nerve. Two filaments also are given by the plexus to the abducent nerve as it crosses the internal carotid artery in the cavernous sinus. From it proceeds the **sympathetic root** of the ophthalmic ganglion, either directly or joined by the nasal branch of the ophthalmic nerve.

## SECOND AND THIRD CERVICAL GANGLIA.

The **second, or middle cervical ganglion**,<sup>5</sup> of the sympathetic nerve is much smaller than either of the others and is situated at the inner side of the inferior thyroid artery opposite the sixth cervical vertebra. It is connected by communicating branches usually with the fifth and sixth cervical nerves, and gives filaments to the inferior thyroid artery, on which they form a plexus continued to the thyroid gland.

From the second cervical ganglion springs the **middle cardiac nerve**,<sup>6</sup> which on the right side runs either in front or behind the subclavian artery and on the trachea, where it is joined by filaments from the recurrent laryngeal nerve, and finally ends in the deep cardiac plexus; on the left side it runs between the left carotid and subclavian and likewise ends in the deep cardiac plexus.

Sometimes the second ganglion is absent, in which case the middle cardiac nerve comes from the sympathetic trunk.

The **third, or inferior cervical ganglion**,<sup>7</sup> is large, irregularly angular, and flattened, and is frequently united with the first thoracic ganglion. It lies in the recess between the front of the costo-transverse process of the last cervical vertebra and the neck of the first rib behind the vertebral artery. It is connected by **communicating branches** with the lower two cervical and first thoracic nerves, and by another with the first thoracic ganglion, forming a loop<sup>8</sup> around the subclavian artery. It gives **vascular filaments** to the artery and its branches; some of these filaments with others from the second

<sup>1</sup> N. petrosus profundus major.

<sup>2</sup> N. carotico-tympanicus inferior.

<sup>3</sup> N. car.-tym. superior; n. petrosus profundus minor.

<sup>4</sup> N. Jacobsonii.

<sup>5</sup> G. cervicale medius.

<sup>6</sup> N. cardiacus medius, magnus, or profundus.

<sup>7</sup> G. cervicale inferius.

<sup>8</sup> Ansa Vieussensii.



thoracic ganglion on the vertebral artery form the **vertebral plexus**,<sup>1</sup> which is reinforced in its course by filaments from the lower four to six cervical nerves.

From the third cervical ganglion is derived the **inferior cardiac nerve**,<sup>2</sup> which runs inward behind the subclavian artery and in front of the trachea to end in the deep cardiac plexus. It is often joined by the middle cardiac nerve, especially on the left side, when the common trunk<sup>3</sup> pursues the usual course to the deep cardiac plexus. Sometimes it has its origin from the first thoracic ganglion.

#### CARDIAC PLEXUS.

The **cardiac plexus**,<sup>4</sup> contained within the chest, is formed by the convergence, division, and anastomosis of the three cardiac nerves from the cervical ganglia of both sympathetics, together with the cardiac branches from the first thoracic ganglia and from both vagus nerves. It extends from the top of the aortic arch to the base of the heart and embraces the ascending portion of the aorta and the trunk of the pulmonary artery. The smaller portion is distinguished as the **superficial cardiac plexus**,<sup>5</sup> situated between the arch of the aorta and the front of the right pulmonary artery. The larger and more intricate portion is the **deep cardiac plexus**,<sup>6</sup> situated behind the arch of the aorta next the bifurcation of the trachea and above that of the pulmonary artery.

The superficial cardiac plexus receives the superior cardiac nerve of the left sympathetic and the lower cervical cardiac branch of the left vagus nerve; while the deep plexus receives all the other cardiac nerves of both sympathetics and the cardiac branches of both vagus nerves.

In the superficial cardiac plexus above the bifurcation of the pulmonary artery there is usually a **cardiac ganglion**,<sup>7</sup> occasionally a smaller pair, but sometimes none. The plexus gives filaments along the pulmonary artery to the anterior pulmonary plexus of the left side, but mainly ends in the right coronary plexus.

The deep cardiac plexus gives filaments directly to the auricles, a few to the superficial cardiac plexus, and others to both anterior pulmonary plexuses, while the greater number end in the left coronary plexus.

The cardiac plexus gives filaments to all the great vessels springing from the base of the heart and to the pericardium. Its extension

<sup>1</sup> P. vertebralis; p. vertebro-basilaris.

<sup>2</sup> N. cardiacus inferior, parvus, or tertius.

<sup>3</sup> N. cardiacus crassus.

<sup>4</sup> P. cardiacus.

<sup>5</sup> P. card. superficialis; p. aorticus anterior.

<sup>6</sup> P. card. profundus or magnus.

<sup>7</sup> G. cardiacum magnum; g. card. Wrisbergii.



reinforced by filaments from the upper thoracic ganglia of both sympathetics forms the aortic plexus accompanying the aorta through the thorax. Other filaments from the plexus are directly distributed to the walls of the heart independent of the course of the coronary blood-vessels. The œsophageal and pulmonary plexuses derived from the vagus nerves receive few filaments from the cardiac and aortic plexuses and the thoracic ganglia.

The **right coronary plexus**,<sup>1</sup> derived from the superficial cardiac plexus and the right side of the deep cardiac plexus, accompanies the right coronary artery in its distribution to the heart.

The **left coronary plexus**,<sup>2</sup> larger than the right and derived from the left of the deep cardiac plexus, accompanies the left coronary artery and its branches in their distribution to the heart.

The nerves of the cardiac plexus and its divisions, the coronary plexuses distributed to the muscular walls of the heart, contain numerous microscopic ganglia in their course. These minute ganglia, readily observed without preparation in the transparent wall of the auricles of the heart in frogs and salamanders, are regarded as motor centres, and seem to explain why this organ may continue to pulsate after it has been removed from the animal.

#### THORACIC PORTION OF THE SYMPATHETIC NERVE.<sup>3</sup>

In the thorax the gangliated cord lies in front of the heads of the ribs, crossing the intercostal blood-vessels and covered by the pleura through which it is visible. It is provided commonly with twelve ganglia, each lying on the head of the corresponding rib, but occasionally a contiguous pair of ganglia coalesce, when the number is accordingly reduced. The first ganglion is the largest and is often more or less blended with the last cervical ganglion; the others are small and usually oval, though variable in shape. Each ganglion is connected usually by a pair of **communicating branches** with the commencement of the nearest spinal nerve.

Besides a **cardiac branch** from the first thoracic ganglion to join the inferior cardiac nerve of the last cervical ganglion or directly to the deep cardiac plexus, branches from the upper five or six thoracic ganglia proceed to reinforce the contiguous plexuses, mainly the aortic plexus, but also the œsophageal and pulmonary plexuses.

The branches of the lower thoracic ganglia commonly unite in the formation of the great and small splanchnic nerves, which descend into the abdomen and terminate in the solar plexus. The **splanchnic nerves**<sup>4</sup> are white, due to the predominance of medullated fibres which

<sup>1</sup> P. coronarius dexter or anterior.

<sup>2</sup> P. coronarius sinister or posterior.

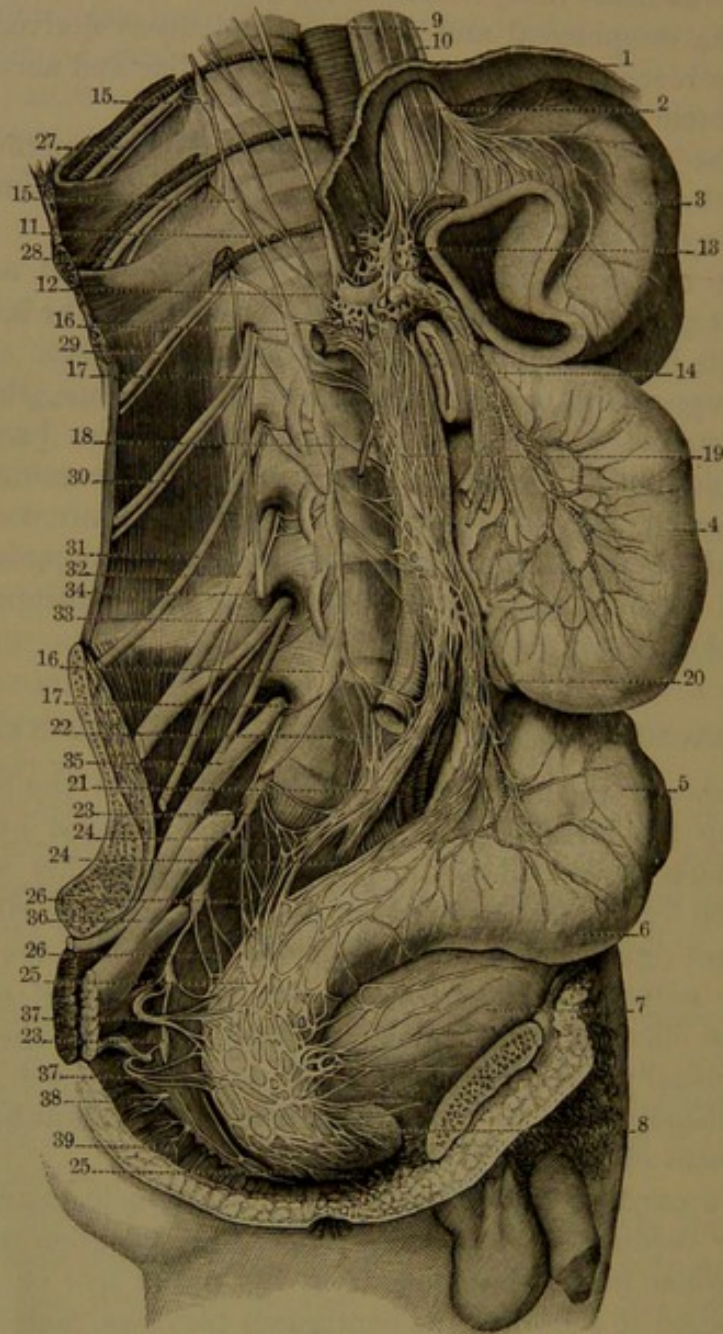
<sup>3</sup> Pars thoracica nervi sympathici.

<sup>4</sup> N. splanchnici.



are derived through the communicating branches of the sympathetic from the spinal nerves.

FIG. 419.



THE SYMPATHETIC NERVE; lumbar and sacral portions. 1, diaphragm; 2, cardia; 3, stomach; 4, small intestine; 5, sigmoid flexure of the colon; 6, rectum; 7, bladder; 8, prostate; 9, left vagus nerve; 10, right vagus nerve; 11, great splanchnic nerve terminating in the semilunar ganglion, 12; small splanchnic nerve ending in the solar plexus; 13, 14, superior mesenteric plexus; 15, 15, lower two thoracic ganglia; 16, 16, four lumbar ganglia in succession; 17, 17, communicating branches with the adjacent lumbar nerves; 18, branches to the aortic plexus, 19; 20, inferior mesenteric plexus; 21, hypogastric plexus; 22, branches to hypogastric plexus from the lower lumbar ganglion; 23, 23, series of four sacral ganglia; 24, 24, pelvic plexuses; 25, 25, hemorrhoidal plexus; 26, 26, branches to hemorrhoidal plexus from the sacral ganglia; 27, 28, 29, lower three thoracic nerves; 30, first lumbar nerve dividing into the ilio-hypogastric and ilio-inguinal branches; 31-33, second, third, and fourth nerves forming the lumbar plexus; 34, genito-crural nerve; 35, lumbo-sacral cord descending to the sacral plexus. 36; 37, 37, branches from the third and fourth sacral nerves to the hemorrhoidal plexus; 38, fifth sacral nerve; 39, coccygeal nerve.



The **great splanchnic nerve**<sup>1</sup> springs by roots usually from the sixth to the ninth thoracic ganglion and often from one or two above. The roots successively unite on the sides of the vertebral centra, and the trunk formed by their union passes through the crus of the diaphragm or rarely through the aortic orifice and ends in the semilunar ganglion of the solar plexus.

The **small splanchnic nerve**<sup>2</sup> springs from the tenth and eleventh thoracic ganglia and descends in company with the great splanchnic, or through a separate opening in the crus of the diaphragm, to end in the celiac plexus, in its course usually giving off a considerable branch, the **superior renal nerve**,<sup>3</sup> to the renal plexus. The latter branch sometimes comes from the trunk of the gangliated cord or from the last thoracic ganglion and is distinguished as the **smallest splanchnic nerve**.<sup>4</sup>

Rarely a fourth splanchnic nerve<sup>5</sup> has been observed arising from the upper thoracic ganglia and cardiac plexus and descending to the œsophageal plexus of the vagus, to the great splanchnic nerve, or the semilunar ganglion.

The **thoracic aortic plexus**,<sup>6</sup> the continuation of the cardiac plexus, entwines the descending thoracic aorta reinforced by filaments from the upper thoracic ganglia. It is a net-work of delicate threads and is continuous below with the solar plexus.

#### SOLAR PLEXUS.

The **solar plexus**,<sup>7</sup> the largest and most intricate of the plexuses common to both sympathetic nerves, is situated in the upper part of the abdomen, behind the stomach on the front of the aorta, around the commencement of the celiac axis and superior mesenteric artery. It consists of a net-work of nerves, associated with ganglia, and receives the splanchnic nerves of both sides, together with filaments from the thoracic aortic plexus and from the right vagus nerves.

Among the ganglia of the solar plexus, variable in number, shape, and size, are usually two conspicuous ones, the **semilunar ganglia**.<sup>8</sup> These are likewise variable, commonly irregular lunate or reniform, sometimes horse-shoe-shaped or even annular, and occasionally they are more or less fused into one. They are situated one on each side of the celiac artery with the extremities turned up, and usually receive by their outer extremity the great splanchnic nerve.

From the solar plexus proceed divisions or secondary plexuses on

<sup>1</sup> N. splanchnicus major.

<sup>2</sup> N. splanchn. minor.

<sup>3</sup> N. renalis sup. or posterior.

<sup>4</sup> N. splanchnicus imus, inferior, or tertius.

<sup>5</sup> N. splanchn. supremus.

<sup>6</sup> P. aorticus thoracicus.

<sup>7</sup> P. solaris; epigastric or celiac plexus; p. celiacus or epigastricus.

<sup>8</sup> G. semilunare, splanchnicum, celiacum, abdominale, or solare.



all the adjacent arteries, twining and interlacing around and accompanying them in their ramifications and distribution to the viscera.

The plexuses derived from the solar plexus are as follows:

The **cœliac plexus**.<sup>1</sup> Derived from the fore part of the solar plexus, it surrounds the cœliac artery, receives a few filaments from the right vagus, and divides into the **gastric**,<sup>2</sup> **hepatic**,<sup>3</sup> and **splenic**<sup>4</sup> plexuses, which accompany the corresponding arteries and are distributed with them.

The **superior mesenteric plexus**. This forms a copious intertexture of white filaments proceeding from the solar plexus and reinforced by filaments from the abdominal aortic plexus, accompanying the superior mesenteric artery in its distribution. At its commencement, to the right of the base of the superior mesenteric artery, it is usually furnished with a **superior mesenteric ganglion**.

The **phrenic plexus**.<sup>5</sup> This proceeds from the upper part of the plexus and accompanies the phrenic arteries to the diaphragm. It gives filaments on each side to the suprarenal body, and on its right it commonly contains the small **phrenic ganglion**,<sup>6</sup> which gives filaments to the contiguous suprarenal body, the inferior cava, and the hepatic plexus.

The **suprarenal plexus**. On each side this accompanies the corresponding artery to the suprarenal body.

The **renal plexus**.<sup>7</sup> This is continued on each side from the solar plexus, and receives the renal branch of the small splanchnic nerve, at the termination of which on the right side there is usually a **renal ganglion**.<sup>8</sup> The renal plexus is reinforced by filaments from the superior mesenteric and aortic plexuses and accompanies the renal artery in its distribution.

The **spermatic plexus**.<sup>9</sup> This proceeds from the superior mesenteric and renal plexuses and accompanies the spermatic artery to the testicle, or in the female the ovarian artery to the ovary and uterus. In its course it is reinforced by filaments from the aortic and hypogastric plexuses.

#### LUMBAR PORTION OF THE SYMPATHETIC NERVE.<sup>10</sup>

The lumbar portion of the gangliated cord, in the abdomen, lies on the side of the vertebral centra along the inner border of the psoas muscle, that of the right cord behind the inferior cava, that of the left cord behind the aorta. The **lumbar ganglia**,<sup>11</sup> of which there are commonly four, are small and oval, but occasionally they are fewer

<sup>1</sup> P. cœliacus.

<sup>3</sup> P. hepaticus.

<sup>5</sup> P. diaphragmaticus.

<sup>7</sup> P. renalis.

<sup>10</sup> Pars lumbalis nervi sympathici.

<sup>2</sup> P. coronarius ventriculi.

<sup>4</sup> P. lienalis.

<sup>6</sup> G. diaphragmaticum.

<sup>9</sup> P. spermaticus.

<sup>11</sup> G. lumbalia.

<sup>8</sup> G. renali-aorticum.



and proportionately larger. Each is connected with the commencement of the nearest spinal nerve, somewhat variably with one or the other, usually by two **communicating branches**. These accompany the lumbar arteries across the vertebræ, and are longer than elsewhere in consequence of the greater distance of the gangliated cord from the intervertebral foramina.

The branches from the lumbar ganglia are variable, and partly proceed to the abdominal aortic plexus, while others descend to the hypogastric plexus.

The **abdominal aortic plexus**<sup>1</sup> is continued from the solar and renal plexuses and descends on the abdominal aorta to its fork, where it runs into the hypogastric plexus included between the iliac arteries. It commonly exhibits on each side of the aorta a variably distinct and thicker string, which receives the obliquely descending branches of the lumbar ganglia and is united with its fellow in front of the aorta by a wide-meshed net of fibres.

From the aortic plexus proceeds the **inferior mesenteric plexus**,<sup>2</sup> at its commencement including the **inferior mesenteric ganglion**,<sup>3</sup> and accompanying the corresponding artery in its distribution to the intestines.

#### SACRAL PORTION OF THE SYMPATHETIC NERVE.<sup>4</sup>

The gangliated cord in the pelvis, much diminished in size, descends in front of the sacrum convergent along the inner side of the sacral foramina. The lower end usually unites with that of the opposite side in a loop, on which sometimes there is a little, median **coccygeal ganglion**,<sup>5</sup> situated in front of the coccyx.

The **sacral ganglia**<sup>6</sup> are usually four, often only three, and are small fusiform bodies. Each is variably connected, usually by two **communicating branches**, with the contiguous sacral nerve. The branches distributed by the sacral ganglia are small and proceed to the hypogastric and coccygeal plexuses.

#### HYPOGASTRIC PLEXUS.

The **hypogastric plexus**,<sup>7</sup> an intricate net-work of nerve-threads, without distinct associated ganglia, enveloped in a copious layer of areolar tissue, lies in front of the last lumbar vertebra in the interval of the common iliac arteries, covered by the peritoneum. It is continued from the abdominal aortic plexus reinforced by branches from the

<sup>1</sup> P. aorticus abdominalis; p. intermesentericus.

<sup>2</sup> P. mesentericus inferior.

<sup>3</sup> G. mesent. inferior.

<sup>4</sup> Pars sacralis nervi sympathici.

<sup>5</sup> G. coccygeum impar; g. Waltheri.

<sup>6</sup> G. sacralia.

<sup>7</sup> P. hypogastricus.



lumbar ganglia, and below divides into two portions, the inferior hypogastric plexuses.

The **inferior hypogastric**, or **pelvic plexus**,<sup>1</sup> reinforced by the branches of the sacral ganglia and additional filaments from the lower two or three sacral nerves, extends forward at the side of the rectum, and also the vagina in the female. Associated with the plexus are many minute ganglia, and from it proceed the following secondary plexuses:

The **hemorrhoidal plexus**,<sup>2</sup> consisting of fine filaments, partly from the pelvic plexus and partly from the vesical plexus, proceeding upward and forward to the rectum, in which they communicate with filaments of the inferior mesenteric plexus.

The **vesical plexus**,<sup>3</sup> formed by many filaments derived from the pelvic plexus and distributed to the lower part and side of the bladder, the prostate, and the seminal vesicle. In the female its filaments are distributed to the vagina as well as to the bladder, whence its name of the **vesico-vaginal plexus**.<sup>4</sup>

The **cavernous plexus**,<sup>5</sup> continued from the vesical plexus. It follows the pudic artery and its branches to the root of the penis, where filaments<sup>6</sup> penetrate the cavernous body to be distributed to the erectile tissue, while a larger filament<sup>7</sup> runs along the dorsum of the penis anastomosing with the dorsal branch of the pudic nerve and distributed to the cavernous body. Filaments also supply the spongy body and other parts of the penis.

The **uterine plexus**,<sup>8</sup> derived from the pelvic plexus, passing through the broad ligament in company with the uterine artery and its branches, to be distributed to the uterus. On its filaments in the walls of the uterus are numerous microscopic ganglia.

<sup>1</sup> P. hypog. inferior or lateralis.

<sup>3</sup> P. vesicalis.

<sup>5</sup> P. cavernosus.

<sup>7</sup> Large cavernous nerve.

<sup>2</sup> P. hæmorrhoidalis.

<sup>4</sup> P. vesico-vaginalis.

<sup>6</sup> Small cavernous nerves.

<sup>8</sup> P. uterinus.



## CHAPTER XVI.

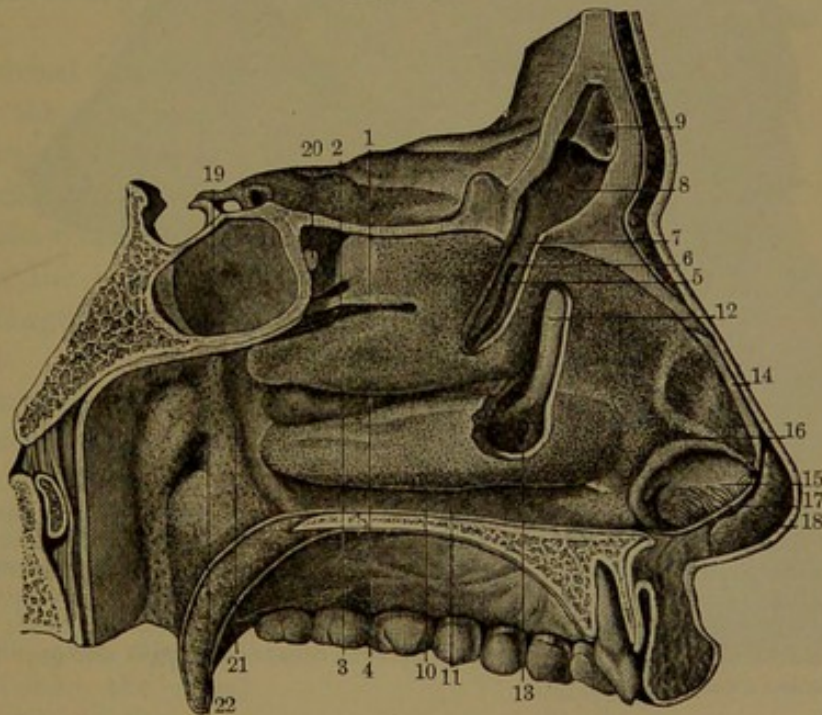
### ORGANS OF SPECIAL SENSE.

The **organs of special sense** comprise the nose, the eyes, the ears, the tongue, and the skin.

#### THE NOSE.

The **nose**<sup>1</sup> includes the prominent feature of the face, together with the nasal cavities. Besides being the special organ of the sense of smell, it serves as the chief avenue of respiration.

FIG. 420.



OUTER WALL OF THE LEFT NASAL CAVITY. 1, superior turbinal; 2, superior meatus; 3, middle turbinal; 4, middle meatus; 5, portion of the turbinals of the ethmoid bone, removed to exhibit the orifice of communication, 6, with the anterior ethmoidal sinuses; 7, communication with the frontal sinus; 8, left frontal sinus; 9, portion of the unsymmetrical partition which separates the frontal sinuses; 10, inferior turbinal; 11, inferior meatus; 12, nasal duct exposed by removing a portion of the bones; 13, its termination; 14, edge of the upper lateral cartilage; 15, 16, outer portion of the left lower lateral cartilage; 17, cut edge of the septal cartilage; 18, inner portion of the left lower lateral cartilage; 19, sphenoidal sinus; 20, its orifice; 21, pharynx; 22, orifice of the eustachian tube.

The **nasal cavities**<sup>2</sup> are two capacious air-chambers occupying the middle part of the skull between the orbits, communicating with

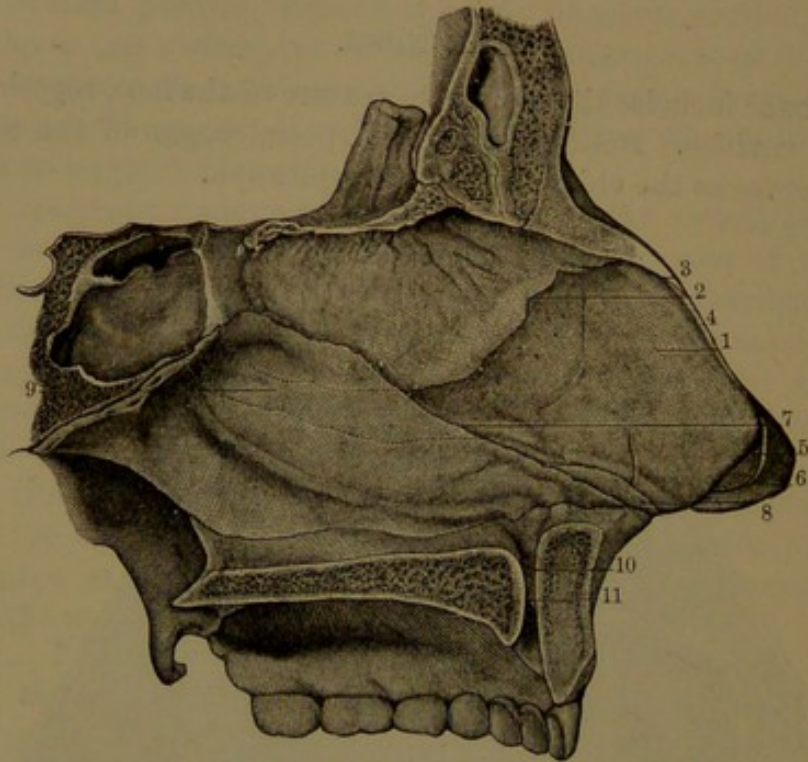
<sup>1</sup> Nasus; organon olfactorium.

<sup>2</sup> Cavi or caverna narium; fossæ nasales.



the exterior in front through the nostrils or anterior nares, and behind with the pharynx through the posterior nares. They are completely separated by the nasal partition, which forms the inner wall of each cavity. Their outer wall presents the three prominent turbinals, separated from one another and the floor by the three meatuses. Their roof separates them from the cranial cavity and their floor from that of the mouth. With each nasal cavity communicate the corresponding frontal, ethmoidal, sphenoidal, and maxillary sinuses, and into the inferior meatus of each opens the nasal duct from the lachrymal sac. The

FIG. 421.



PARTITION OF THE NOSE. 1, cartilage of the partition; 2, its junction with the nasal plate of the ethmoid bone; 3, its junction with the nasal bones; 4, margin of continuation with the lateral triangular cartilage; 5, fibrous membrane connecting the cartilage of the partition with the oval cartilage; 6, inner portion of the left oval cartilage; 7, anterior border of the vomer; 8, accessory cartilage; 9, prolongation of the cartilage of the partition, in a groove between the vomer and nasal plate of the ethmoid bone; 10, naso-palatine canal of the right side opening into the anterior palatine foramen, 11.

construction of the nasal cavities as formed by the surrounding bones is described in the account of the skull. (See page 146.)

The nasal cavities are completed in front by the nasal cartilages, and they are lined throughout by mucous membrane.

The **olfactory region**,<sup>1</sup> or that which is especially the seat of the sense of smell, accords with the nasal surface of the ethmoid bone, comprising the nasal plate of the inner wall and the opposed surface of the turbinals of the outer wall. From the conformation of the nasal

<sup>1</sup> Regio olfactoria.



cavities the currents of air ascending through the nostrils pass in a curve upward, backward, and downward, traversing the olfactory regions into the pharynx.

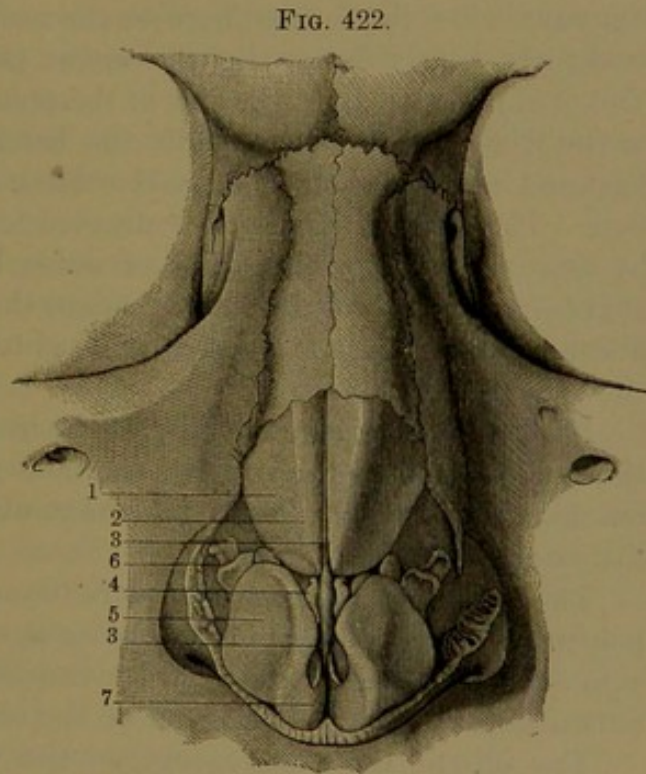
The **nose**<sup>1</sup> is formed by its bony bridge and the nasal cartilages covered by the skin and nasal muscles. The **sides** conjoin in the median ridge or **back**,<sup>2</sup> which slopes from beneath the forehead to the **point**. Below they bulge outward in the **wings of the nose**.<sup>3</sup> Beneath are the **nostrils**, or **anterior nares**,<sup>4</sup> communicating above with the nasal fossæ and separated by the **column of the nose**,<sup>5</sup> which is formed by the lower part of the nasal partition enclosed by the skin.

The nostrils are horizontal, fore and aft elliptical apertures, situated below the level of the entrance of the nasal aperture of the skull. The column is fixed behind to the nasal spine.

Within the border of the nostrils the skin is continuous with the nasal mucous membrane and is here furnished with a number of short stiff hairs.

The nasal cartilages complete the fore part of the partition and serve to support the lower fore part of the nose. They consist of the septal and lateral triangular and oval cartilages.

The **septal cartilage**<sup>6</sup> is a quadrilateral plate placed at the fore part of the nasal partition, which it completes in front. Its posterior borders are received in the angular notch between the nasal ethmoid plate and the vomer. Its upper anterior border is fixed to the conjunction of the nasal bones; below them it is continuous laterally with the triangular cartilages.



CARTILAGES OF THE NOSE. 1, upper lateral cartilage; 2, its anterior border; 3, anterior margin of the septal cartilage appearing between the lateral cartilages; 4, small accessory cartilage; 5, lower lateral cartilage, back of which is the wing of the nose; 6, accessory cartilages; 7, point of the nose where the lower lateral cartilages are bent inwardly along the column.

Its lower anterior and shortest border

<sup>1</sup> Nasus; rhin; promontorium faciei; snout.

<sup>3</sup> Alæ nasi; pinnae.

<sup>5</sup> Columna nasi.

<sup>2</sup> Dorsum.

<sup>4</sup> Aperturæ nasi externæ.

<sup>6</sup> Septum cartilagineum.



contributes to form the column of the nose, extending from the nasal spine to the point of the nose.

In early life a prolongation of the septal cartilage occupies a narrow channel along the sutural conjunction of the ethmoid nasal plate and vomer to the sphenoidal rostrum.

The septal cartilage is the thickest of those of the nose and is thinnest at the middle. It often exhibits a want of symmetry and with the bones of the nasal partition may be more or less bent to one or the other side.

The **upper lateral, or triangular cartilage**,<sup>1</sup> is a thin plate continuous with the anterior border of the septal cartilage, reflected from it outwardly on each side and attached by connective tissue with the lower margin of the nasal bone and the nasal notch of the maxilla. Its lower border is connected by fibrous membrane with the corresponding oval cartilage.

The **lower lateral, or oval cartilage**,<sup>2</sup> situated on each side of the nose below the former, borders the nostril. It consists of an outer oval plate, nearly flat or slightly convex externally, and an inner band. The oval plate occupies the side of the point of the nose attached above to the triangular cartilage, while the band bends inward from its fore part and extends along the nasal column attached to the septal cartilage. The oval cartilages are connected together at the tip of the nose by loose fibrous tissue, the line of union being usually indicated by a slight groove of the skin. In the negro the oval cartilages make a less abrupt bend, so that the nose is more obtusely rounded and devoid of the groove.

From the posterior extremity of the oval cartilage a band of fibrous tissue extends over the wing of the nose to be attached to the nasal notch of the maxilla. The band commonly contains from one to three little **accessory cartilages**.<sup>3</sup>

The **wing of the nose**<sup>4</sup> borders the nostril outwardly behind the point and below the position of the oval cartilage. It is a fold of the skin enclosing a thick layer of fibro-connective with adipose tissue and muscular bundles which are part of the contiguous nasal muscles.

The skin of the nose, except on the wings, is, together with the subjacent nasal muscles, loosely and movably attached to the parts beneath. It is remarkable for the number and size of its sebaceous glands.

The **muscles of the nose**. See page 250.

The nasal cavities, completely separated from each other by the nasal partition and communicating behind with the pharynx, are throughout lined by mucous membrane continuous with that of the latter cavity.

<sup>1</sup> Cartilago triangularis or lateralis superior.

<sup>2</sup> Cartilago ovalis; c. lateralis inferior; c. alæ nasi; c. pinnalis.

<sup>3</sup> Cartilagine sesamoideæ; c. accessorii.

<sup>4</sup> Ala nasi.



The **nasal mucous membrane**,<sup>1</sup> highly vascular, bright red and sensitive, is closely connected with the subjacent periosteum and perichondrium. It varies in thickness in different positions and contributes to diminish the passages of the nose. It is thickest on the turbinals, especially the inferior one, and is prolonged on their free border so as to make them appear considerably larger than the corresponding turbinals in the macerated skull. It is also thick on the nasal partition and is thinner along the floor and meatuses. It lines the sinuses communicating with the nose, and in them is thinnest and least vascular. It reduces the orifices of communication to round apertures. Of these there is usually one which is common to the frontal and anterior ethmoidal sinuses of each side opening into the fore part of the middle meatus. Another aperture behind the former opens from the maxillary antrum into the latter. A third opens from the posterior ethmoidal sinuses into the superior meatus, and a fourth from the corresponding sphenoidal sinus opens into the upper back part of the nasal cavity.

The nasal mucous membrane closes the foramina of the ethmoidal cribriform plate, likewise the speno-palatine, pterygo-palatine, pterygoid, and naso-palatine foramina.

Opening into the fore part of the inferior nasal meatus is the nasal duct from the lachrymal sac, the orifice guarded by one or two slight folds of the mucous membrane.

The nasal mucous membrane, except in the olfactory region and on the nasal cartilages, is provided with a ciliated columnar epithelium. On the cartilages the epithelium is squamous and stratified and is continuous with the epidermis of the skin at the nostrils.

In the olfactory region<sup>2</sup> the mucous membrane is thick, soft, pulpy, and most vascular. It exhibits a yellowish-red hue and is furnished with a non-ciliated columnar epithelium, with peculiar elements, the **olfactory cells**. The columnar cells are prolonged beneath into branching processes which contribute to sustain several strata of the olfactory cells. These are upright, spindle-shaped, and have an oval nucleus enveloped in a small mass of granular protoplasm. The upper extremity of the cells extends as a rod-like prolongation between the sustaining cells to the free surface of the mucous membrane.

In birds, reptiles, and amphibians the rod-like prolongation of the olfactory cells is furnished with long hair-like processes, but in man and his class they are absent.

From the lower end of the olfactory cells descends a filament, which sometimes presents a varicose appearance. It is supposed to be connected with a terminal fibril of the olfactory nerves, but the continuity has not been satisfactorily determined.

---

<sup>1</sup> Schneiderian membrane; pituitary membrane; membrana pituitaria; m. Schneideriana.

<sup>2</sup> Regio olfactoria.



Mingled with the columnar and olfactory cells are transitional forms between the two. All are regarded as being probably connected with olfactory nerve-fibrils.

The nasal mucous membrane is abundantly supplied with glands, which are most numerous about the middle and back parts of the

nasal cavities, and are largest on the back of the partition. In the olfactory region the glands are mostly tubular and simple, and somewhat enlarged and convoluted in their deeper part.<sup>1</sup> Elsewhere the nasal glands are racemose.<sup>2</sup>

The **olfactory nerves**, from the corresponding olfactory lobe, pass through the numerous foramina of the ethmoidal cribriform plate in an inner and an outer series, and these descend in canals, partly bony and partly membranous, in the inner and outer walls of the nasal cavity. Diverging fore and aft they enter the mucous membrane of the olfactory region, the outer series being the larger. In their distribution they branch into flattened tufts, which anastomose in close plexuses with narrow, elongated meshes. The fibres of the olfactory nerves are

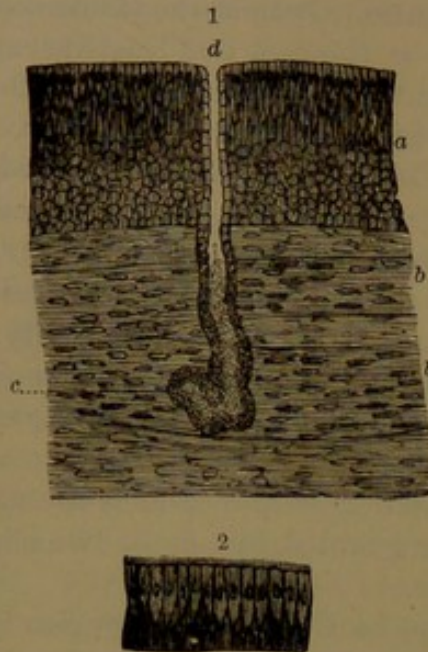
non-medullated and consist of axis-fibres with a nucleated neurilemma, in which the nuclei are fewer than in the similar fibres of the sympathetic system.

The nasal mucous membrane is further supplied with sensory nerves by the trifacial, as already described.

The arteries of the nasal cavity are the sphenopalatine and descending palatine branches of the internal maxillary, the posterior and anterior ethmoidal branches of the ophthalmic, and branches from the superior labial of the facial artery.

The veins of the nasal cavity form a close plexus in the mucous membrane, best produced on the inferior turbinal and lower back part of the partition. The trunks return in the course of the arteries, the sphenopalatine vein entering the pterygoid plexus, the ethmoidal veins ending in the ophthalmic vein. Other and smaller veins join the superior labial and facial veins.

FIG. 423.



VERTICAL SECTIONS FROM THE NASAL MUCOUS MEMBRANE; magnified 150 diameters. 1, from the olfactory region; a, non-ciliated columnar epithelium; b, olfactory nerve-fibres; c, nasal tubular gland; d, its outlet. 2, ciliated epithelium in other positions of the mucous membrane.

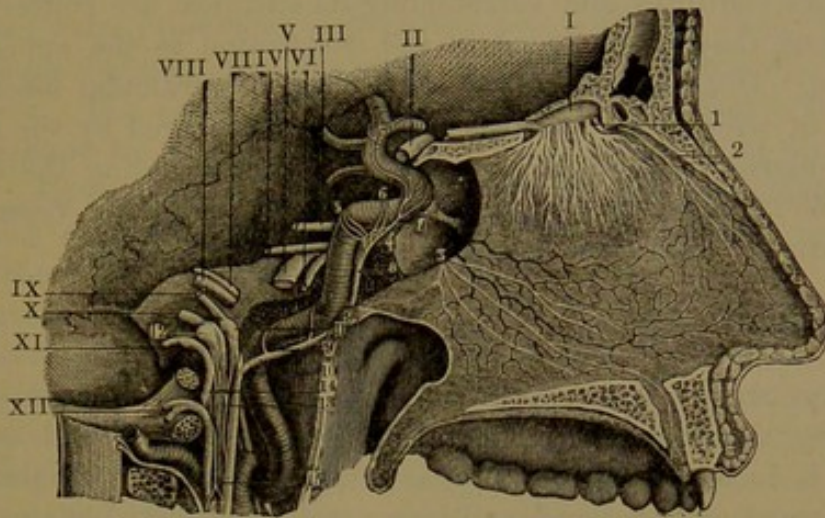
<sup>1</sup> Glands of Bowman.

<sup>2</sup> Glandulæ muciparæ aggregatæ.



The lymphatics of the nose are numerous and large. They form a close plexus of vessels in the mucous membrane, communicating with

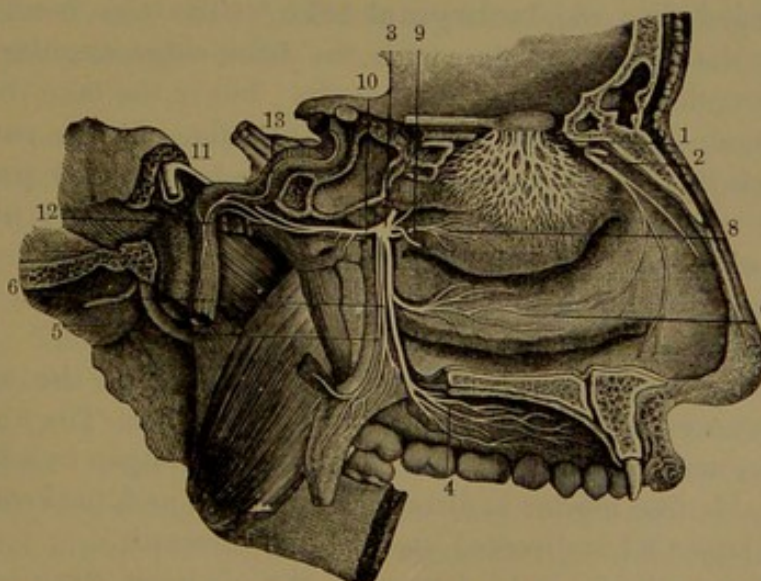
FIG. 424.



NERVES OF THE PARTITION OF THE NOSE. I, olfactory bulb; 1, its nerves descending to the nasal mucous membrane; 2, internal nasal branch of the nasal nerve of the ophthalmic; 3, nasal branches from the sphenopalatine ganglion. II, optic nerve; III, oculo-motor; IV, trochlear; V, trifacial; VI, abducent; VII, facial; VIII, auditory; IX, glosso-pharyngeal; X, vagus; XI, accessory; XII, hypoglossal. 4, cavernous plexus of the sympathetic; 5, filaments of communication with the semilunar ganglion of the trifacial; 6, filaments of communication with the oculo-motor nerve; 7, branches of the sympathetic following the internal carotid artery; 8, branch connected with the superior cervical ganglion; 9, 10, filaments forming a plexus upon the internal carotid artery; 11, petrous ganglion of the glosso-pharyngeal; 12, jugular ganglion of the vagus nerve; 13, 14, 15, anastomotic filaments between the sympathetic, the glosso-pharyngeal, vagus, accessory, and hypoglossal nerves.

lymphatic spaces around the olfactory nerves and among the nasal glands.

FIG. 425.



NERVES OF THE OUTER WALL OF THE LEFT NASAL CAVITY. 1, olfactory nerves; 2, nasal branch of the ophthalmic nerve; 3, sphenopalatine ganglion; 4, 5, 6, palatine nerves; 7, branch to the nose; 8, nasal nerve to the outer wall of the nose; 9, nasal nerve to the inner wall; 10, vidian nerve; 11, facial nerve; 12, deep petrosal nerve joining the carotid plexus; 13, the other branch of the vidian is the superficial petrosal nerve, which joins the facial.



## THE EYES AND THEIR APPENDAGES.

The **eye**, or **eyeball**, is the special organ of sight, but as all the parts within the orbit and surrounding its entrance are concerned in its functions, they are included in the description as the appendages of the eye. The contents of the orbit form a pyramidal mass, from the front of which the eyeball projects and is covered by the eyelids protected above by the eyebrow. The mass surrounding the eyeball consists of its muscles, the lachrymal gland, and their vessels and nerves, with the intervals filled with areolar tissue and fat.

## THE EYEBROW AND EYELIDS.

The **eyebrow**<sup>1</sup> is the arch of skin and hairs, supported on the superciliary ridge and supraorbital margin of the frontal bone, to which it is loosely and movably attached. The hairs project from within upward and outward and in general are directed in the course of the brow. The skin is thick and dense, resembling that of the scalp, and is closely adherent to the subjacent muscles, which produce the movements of the brow and consist of the frontal, palpebral, orbicular, and superciliary muscles. Besides the hair-follicles embedded in the subcutaneous connective tissue and fat, it contains numerous sebaceous and sweat glands.

The **eyelids**<sup>2</sup> are horizontal, movable covers across the front of the eyeball, fringed at their borders by the **cilia**, or eyelashes. They are separated by the **palpebral fissure**,<sup>3</sup> the extremities of which are **angles of the eye**.<sup>4</sup> When the lids are open the fissure becomes more or less widely elliptical, with the outer angle acute and the inner angle prolonged into the **lachrymal lake**.<sup>5</sup> The free borders of the lids are for the most part flat, with the back edge angular and the front edge rounded and fringed by the cilia; but in the lake the borders are less pronounced, rounded, and devoid of cilia. At the entrance of the lake each lid forms a slight eminence, the **lachrymal papilla**, on the summit of which is a minute orifice, the **lachrymal punctum**. This is the commencement of the lachrymal canal, by which the tears are conveyed to the lachrymal sac. The lake is occupied by a convex red body, the lachrymal caruncle.

The eyelids are opened chiefly by the raising of the upper one through the action of the palpebral elevator muscle. The upper lid is much larger, more prominently convex, and when open overhangs the lower one. Its free border is directed downward and backward, while that of the lower lid is directed upward and forward.

The upper eyelid is continuous with the eyebrow, from which it is

<sup>1</sup> Supercilium.<sup>2</sup> Palpebræ.<sup>3</sup> Fissura palpebrarum.<sup>4</sup> Canthus oculi internus et externus; corners.<sup>5</sup> Lacus lachrymalis.



defined by a deep arching furrow,<sup>1</sup> which corresponds with the reflection of the conjunctiva from the eyelid to the eyeball. Above, the furrow is bounded by a fold, prominent and convex outwardly and overhanging the eyelid. In the advance of age the fold commonly becomes more prominent, due to the accumulation of fat in the areolar tissue between the palpebral elevator tendon and the palpebral ligament. The lower lid is continuous with the cheek, from which it is defined by a slight depression<sup>2</sup> of the surface in front of the orbit. Laterally the lids unite in the **palpebral commissures**,<sup>3</sup> of which the inner forms a concave hollow at the side of the nose, while the outer is slightly depressed.

**Structure of the eyelids.** The eyelids are composed of four successive layers, the skin, the palpebral orbicular muscle, the palpebral scutes with their ligaments, and the conjunctiva.

The skin of the eyelids has the same structure as elsewhere, but is very thin and is darker than in most other positions. It is furnished with papillæ, fine hairs and proportionately small sebaceous and sweat glands. It adheres closely to the subjacent muscle by thin connective tissue destitute of fat. In the inner commissure it exhibits a conspicuous whitish spot, due to the internal palpebral ligament shining through. The skin is thrown into wrinkles by the action of the subjacent muscle.

The **cilia**, or **eyelashes**,<sup>4</sup> are short, stiff hairs arranged in rows along the front rounded edge of the margins of the eyelids. The upper cilia are more numerous and longer than the lower and curve upward, while those below curve in the opposite direction. The roots of the cilia with their follicles are inserted into the subcutaneous connective tissue among the muscular bundles at the border of the palpebral orbicular muscle. They are accompanied by numerous sebaceous glands, together with others resembling in structure the sweat-glands.

The second layer of the eyelids is formed by the concentric fibres of the palpebral orbicular muscle closely attached to the skin externally and more loosely to the subjacent layer.

The **palpebral scutes**<sup>5</sup> of the third layer serve to give shape and firmness to the lids, and are dense plates of felted connective-tissue bundles. The upper scute is the larger and thicker, is half oval, and at its middle more than twice the height of the lower one, which is a narrow band of nearly uniform depth. Their free border is straight and thickest; their attached border is connected with a thin fibrous membrane extending from the periosteum of the orbital margin. The upper and lower portions of the membrane are distinguished as the

<sup>1</sup> Superior orbito-palpebral furrow.

<sup>2</sup> Inferior orbito-palpebral furrow.

<sup>3</sup> Commissura palpebrarum.

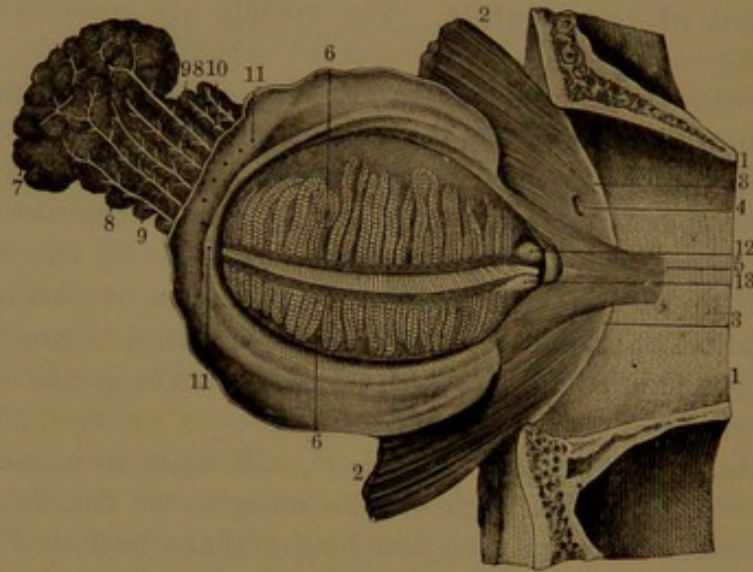
<sup>4</sup> Cils; blepharides.

<sup>5</sup> Palpebral cartilages or plates; tarsi; tarsal cartilages.



superior and inferior palpebral ligaments,<sup>1</sup> and their slightly thicker conjunction outwardly is the **external palpebral ligament**,<sup>2</sup> which connects the scutes with the adjacent border of the malar bone. The **internal palpebral ligament**<sup>3</sup> is a well-marked, strong, fibrous band, which connects the inner ends of the scutes with the nasal process of the maxilla in front of the lachrymal fossa. The superior palpebral ligament is joined behind by the expanded tendon of the palpebral elevator muscle as it descends to be inserted into the border of the upper palpebral scute. The superior and inferior palpebral ligaments

FIG. 426.



THE LEFT EYELID AND LACHRYMAL GLAND, TURNED FORWARD AND INWARD SO AS TO SHOW THEIR INNER SURFACE. 1, upper and lower part of the orbit; 2, portion of the palpebral orbicular muscle; 3, attachment of this muscle to the inner margin of the orbit; 4, perforation for the passage of the nasal branch of the ophthalmic artery; 5, palpebral tensor muscle; 6, palpebral glands; 7, orbital and 8, palpebral portions of the lachrymal gland; 9, 10, ducts; 11, orifices opening on the inner surface of the upper eyelid; 12, 13, lachrymal puncta on the lachrymal papillae.

are associated with some unstriped muscle-fibres, most numerous in the upper lid.<sup>4</sup>

Embedded in the back part of the scutes are the **palpebral glands**,<sup>5</sup> distinctly seen through the lining conjunctiva. They appear as yellow, granular-looking bodies, arranged vertically in a row, extending nearly the depth of the scutes. There are thirty or more in the upper lid and about twenty in the lower one, and their ducts open in a regular series along the posterior edge of the margin of the lids. In structure they resemble the sebaceous glands, and each is composed of a central straight duct extending the length of the gland, surrounded

<sup>1</sup> Superior and inferior tarsal ligaments.

<sup>2</sup> External tarsal ligament; ligamentum angulare externum.

<sup>3</sup> Internal tarsal ligament; l. angulare internum; tendo palpebrarum.

<sup>4</sup> Musculus orbito-palpebralis.

<sup>5</sup> Glandulæ palpebrarum or Meibomianæ; Meibomian glands; folliculi ciliares.



by numerous alveoli,<sup>1</sup> which are variably long, simple, or branched and flask-shaped. The glands secrete an oleaginous liquid,<sup>2</sup> which lubricates the edges of the lids and serves to prevent the overflow of the tears. It is often observed, especially after sleep, accumulated as a yellowish-white matter in the lachrymal lake. In the dried condition it is also sometimes seen adherent to the eyelashes as a yellow solid.

#### CONJUNCTIVA.

The **conjunctiva**<sup>3</sup> is a delicate transparent mucous membrane, which lines the eyelids and is thence reflected over the front of the eyeball. Between the lids as defined by the scutes, and the cornea, it forms, above and below, a freely movable fold, the **fornix**, which is of much greater depth in the upper than in the lower lid. In its different positions the conjunctiva is distinguished as the palpebral, sclerotic, and corneal portions, each presenting important differences.

The **palpebral portion** of the conjunctiva<sup>4</sup> is thicker, more vascular and sensitive than elsewhere, and is closely and tightly adherent to the posterior surface of the palpebral scutes. It is bright red in color, due to its numerous vessels, and exhibits the palpebral glands beneath. At the edge of the lids it is continuous with the skin, and at the lachrymal puncta with the lining membrane of the lachrymal canals. Though for the most part smooth, near the fornix under a lens it exhibits minute transverse folds.

The **sclerotic portion** of the conjunctiva<sup>5</sup> forms the fornix, and is loosely attached to the subjacent parts by areolar tissue. In the upper lid, from the corresponding scute, it extends on the palpebral elevator tendon, thence descends on the sclerotica to the cornea. In the lower lid it is reflected from the scute on the inferior palpebral ligament and sclerotica to the cornea. Thin and transparent, the sclerotica is seen through it, and is commonly named with the latter the "white of the eye." At the entrance of the lachrymal lake, adjoining the caruncle, it exhibits a red, variable fold, the **semilunar plica**,<sup>6</sup> which is a rudiment of the nictitating membrane or third eyelid of many of the lower vertebrates. Frequently the sclerotic portion of the conjunctiva exhibits vessels proceeding from the angles of the eye and radiating towards the cornea. In the advance of age it sometimes shows here and there little yellowish eminences, which are due to accumulations of fat in the subjacent connective tissue. About the commencement of the fornix, embedded in the scutes there is a narrow zone of little racemose glands, the ducts of which open on the surface of the conjunctiva near the line of reflection of the membrane.

<sup>1</sup> Acini.

<sup>3</sup> Membrana conjunctiva.

<sup>5</sup> C. scleroticæ, bulbi, or adnata oculi.

<sup>6</sup> P. semilunaris; palpebra tertia.

<sup>2</sup> Sebum palpebrale; lema.

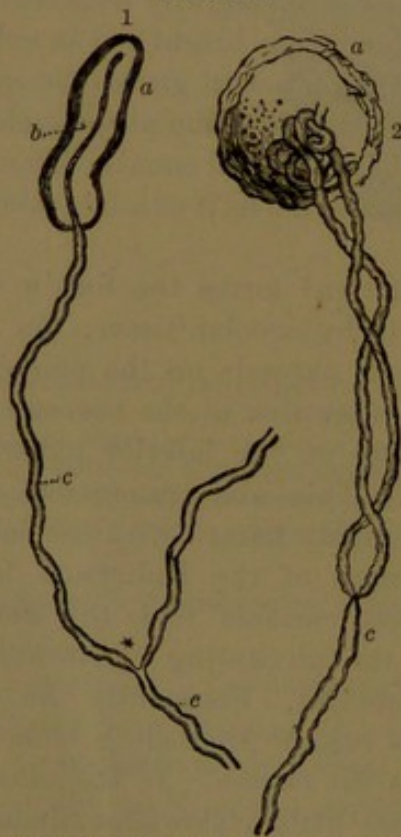
<sup>4</sup> C. palpebrarum.



The **corneal portion** of the conjunctiva,<sup>1</sup> thinner than the rest and devoid of blood-vessels, merges in the cornea, with which it is closely united and forms its anterior layer.

The epithelium of the conjunctiva varies in different portions, and for the most part is thin and stratified. It is thickest on the margin of the lids and on the sclerotic portion, where it consists of superficial strata of pavement cells succeeded by others gradually becoming thicker and finally resting on a single stratum of columnar cells. Thinnest on the palpebral conjunctiva, it here consists of several strata of flattened polygonal cells resting on short columnar cells. On the folded portion of the membrane extending to the fornix it consists of a few strata of polygonal cells with a single superficial stratum of short thick columnar cells. On the cornea it consists of several superficial strata of flattened cells, succeeded by others more uniformly polyhedral, resting on a stratum of columnar cells.

FIG. 427.



NERVE END-BULBS, FROM THE CONJUNCTIVA. 1, from a calf; 2, from man. *a*, end-bulb; *b*, axis-fibre of the medullated nerve-fibre *c*; \*, division of a nerve-fibre at a node. Highly magnified.

The **lachrymal caruncle**,<sup>2</sup> the reddish eminence occupying the lachrymal lake, is a process of the conjunctiva enclosing a group of sebaceous glands and furnished with a few minute scattered hairs.

A few conspicuous vessels are commonly to be observed in the sclerotic portion of the conjunctiva, proceeding from the angles of the eye and radiating towards the cornea; but in inflammation many more become visible. At the border of the cornea the vessels form a plexus of capillary loops. The conjunctival arteries are derived from the palpebral and lachrymal branches of the ophthalmic artery. The vessels of the sclerotica when congested also become visible through the conjunctiva. They are finer and less tortuous than the vessels of the conjunctiva, and are derived from the anterior ciliary branches of the ophthalmic artery. On pressure of the eye-

lids the sclerotic vessels remain stationary, while those of the conjunctiva move with the shifting of the membrane.

The conjunctiva contains some lymphoid tissue, and it is provided

<sup>1</sup> C. corneæ.

<sup>2</sup> Caruncula lachrymalis.



with an abundant plexus of lymphatics, which are much reduced in size at the margin of the cornea, where they communicate with its branching cell-spaces. Many of the nerves of the conjunctiva derived from the branches of the ophthalmic nerve terminate in **end-bulbs**. These are minute spherical bodies connected with one or two terminal nerve-fibres. The end-bulb consists of a connective-tissue capsule enclosing a little mass of polyhedral cells in which the axis-fibres of the nerves terminate. The nerve-fibres approaching the bulb are often twisted on each other before the axis-fibres enter it.

**The muscles of the eyebrow and eyelids.** See page 248.

#### THE LACHRYMAL APPARATUS.

The **lachrymal apparatus** concerned in the production and conveyance of the tears consists chiefly of the lachrymal gland, canals, and sac, and the nasal duct.

The **lachrymal gland**,<sup>1</sup> which secretes the tears, consists of an orbital and a palpebral portion, the former occupying the recess of the orbit within the position of the external angular process of the frontal bone, the latter extending to the border of the upper eyelid. The orbital portion<sup>2</sup> is flattened oval and curved, with the upper convex surface attached to the adjacent periosteum by connective tissue; the lower surface, next the eyeball, resting on the palpebral elevator, superior and external rectus muscles. The palpebral portion<sup>3</sup> is smaller, thinner, and irregularly quadrate, and is in contact beneath with the conjunctival fornix. The orbital portion of

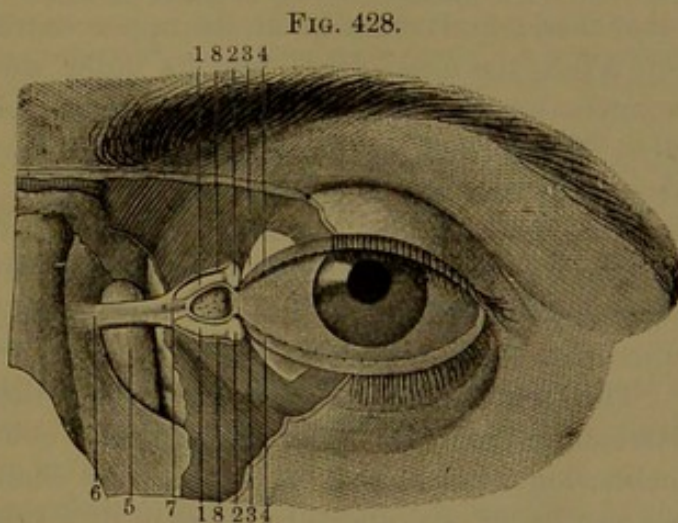


FIG. 428.  
THE LEFT EYE, WITH A PORTION OF THE EYELIDS REMOVED, TO EXHIBIT THE LACHRYMAL CANALS AND SAC. 1, lachrymal canals; 2, commencement of these on the lachrymal papillæ; 3, palpebral scutes; 4, edges of the eyelids; 5, lachrymal sac; 6, internal palpebral ligament; 7, its point of division in front of the lachrymal canals; 8, branches of the ligament giving attachment to the fibres of the palpebral orbicular muscle.

The orbital portion of the gland is about three-fourths of an inch fore and aft, five lines wide, and two lines thick; the palpebral portion four lines long, nearly as wide, and a line thick. The lachrymal gland is a compound, lobulated, racemose gland, of a pale red color, and resembles in structure the salivary glands. Its ducts, a dozen or fifteen, proceed forward

<sup>1</sup> Glandula lachrymalis.

<sup>2</sup> G. l. superior or innominati Galeni.

<sup>3</sup> G. l. inferior Rosenmulleri or congregata Monroi.



and downward and open in a row along the upper outer part of the conjunctival fornix.

The **tears**<sup>1</sup> bathe the conjunctiva throughout, and are especially important in maintaining the bright moist appearance of the cornea. The excess of tears flowing into the lachrymal lake is absorbed by the **lachrymal puncta**,<sup>2</sup> the minute apertures at the summits of the lachrymal papillæ. From the puncta the **lachrymal canals**<sup>3</sup> proceed to the lachrymal sac, into which they open separately or in union. The lower canal descends a short distance, bends abruptly inward and upward and proceeds to the sac; the upper canal, slightly longer and narrower, ascends and bends inward and downward in its course to the sac. From their commencement the canals expand to the bend, and then become narrowed to their termination. They are enclosed by the palpebral and tensor muscles, offsets of which encircle the vertical portion of the canals as sphincters. They are lined by mucous membrane, with a thick, stratified, squamous epithelium.

The **lachrymal sac**<sup>4</sup> occupies the lachrymal fossa at the inner fore part of the orbit, and is continuous downward in the corresponding osseous canal as the nasal duct. The lachrymal sac is a cylindrical tube closed and rounded at its upper extremity, slightly narrowing below into the nasal duct. On its outer side in front it receives the lachrymal canals, behind the position of the internal palpebral ligament and in front of the palpebral tensor muscle. The **nasal duct**,<sup>5</sup> about half an inch long, descends from the lachrymal sac and opens into the fore part of the inferior meatus of the nose. The sac and duct are composed of fibrous membrane united with the subjacent periosteum and lined by mucous membrane, with a columnar ciliated epithelium like that of the nose.

The lachrymal sac and nasal duct together form a continuous tube, descending from the inner angle of the eye to the nose, with a slight inclination inward and backward. Its communication with the nose is a vertically oval aperture guarded by a semilunar fold of the mucous membrane.

#### MUSCLES OF THE EYEBALL.

The muscles of the eyeball consist of four recti, the trochlear and inferior oblique muscles.

The four **recti muscles**<sup>6</sup> arise tendinously at the bottom of the orbit from the sphenoid bone around the optic foramen and entrance of the optic nerve and ophthalmic artery. Thence passing forward and

<sup>1</sup> Lachrymæ.

<sup>2</sup> Puncta lachrymalia.

<sup>3</sup> Canaliculi lachrymales; cornua limacum; spiraculi.

<sup>4</sup> Saccus or utriculus lachrymalis; infundibulum.

<sup>5</sup> Ductus naso-lachrymalis or nasalis; canalis lachrymalis membranaceus; lachrymo-nasal duct; nasal canal.

<sup>6</sup> M. recti oculi; straight muscles of the eye.



diverging equidistant from one another, above, below, and at the sides of the eyeball, they are inserted by thin tendons into the fore part of the sclerotica, about the fourth of an inch behind the cornea.

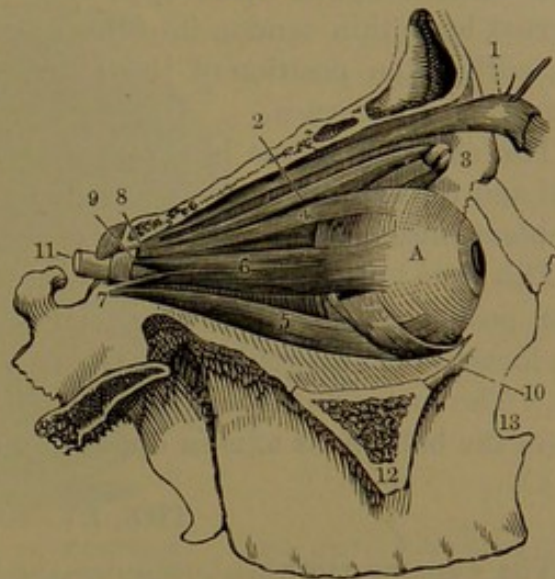
The **superior rectus** arises above the optic foramen immediately beneath the origin of the palpebral elevator muscle. The **internal** and **inferior recti** arise by a common tendon to the inner side and below the optic foramen. The **external rectus** arises by two heads, one in common with that of the superior rectus and the other partly with that of the inferior rectus and partly from a process at the outer border of the sphenoidal foramen.

The external and inferior recti are longer than the others, the internal rectus is broadest, and the superior is narrowest. At their insertion the internal rectus approaches nearest the cornea and the superior rectus is the farthest from it.

Between the two heads of the external rectus the angular interval gives passage to the third, the nasal branch of the fifth and sixth nerves, and the ophthalmic vein.

The **trochlear**, or **superior oblique muscle**,<sup>1</sup> is situated at the inner upper part of the orbit along the roof, internal to the palpebral elevator muscle. It is a slender muscle, which arises tendinously a short distance in advance and to the inner side of the optic foramen. Proceeding forward it ends in a cylindrical tendon, which passes through a fibro-cartilaginous ring, the **trochlea**, or pulley, occupying a little fossa just within the supraorbital margin of the frontal bone. From the trochlea the tendon is directed downward, backward, and outward, and passing beneath the superior rectus is inserted into the sclerotica a little way to the outer border of the latter muscle and about midway between the cornea and entrance of the optic nerve into the eye. The tendon as it passes through the trochlea is invested with a synovial sheath.

FIG. 429.



MUSCLES OF THE EYE. 1, the palpebral elevator; 2, the trochlear muscle; 3, the pulley through which the tendon of insertion plays; 4, superior rectus muscle; 5, inferior rectus muscle; 6, external rectus muscle; 7, 8, its two points of origin; 9, interval through which pass the oculo-motor and abducent nerves; 10, inferior oblique muscle; 11, optic nerve; 12, cut surface of the malar process of the superior maxillary bone; 13, the nasal notch. A, the eyeball.

<sup>1</sup> M. trochlearis; m. obliquus superior.



The **inferior oblique muscle**,<sup>1</sup> situated at the bottom of the orbit, arises from a slight depression of the orbital plate of the maxilla near the entrance of the nasal duct and the orbital margin. Directed outward, backward, and upward, passing beneath the inferior rectus, it is inserted by a thin tendon into the sclerotica at the outer part of the eye, within the position of the external rectus and nearer the optic nerve than the cornea.

The external rectus is supplied by the abducent nerve, the other recti and the inferior oblique muscle by the oculo-motor nerve, and the trochlear muscle by the trochlear nerve.

The recti muscles move the eye in the four directions according to their position. Together they tend to retract the eye, which action in a measure is antagonized by the trochlear and inferior oblique muscles. The latter antagonize each other in any disposition of either to rotate the ball on its axis in opposite directions.

#### THE EYEBALL.

The **eye**, or **eyeball**,<sup>2</sup> occupies the fore part of the orbit, partially embedded in a mass formed by its muscles, vessels, and nerves, together with a quantity of connective tissue and fat, from which its fore part projects and is covered by the eyelids, while its back part receives the optic nerve. Both eyes have their visual axis directed forward and parallel, while the optic nerves are widely divergent at their entrance into the orbit, but bend so as to join the balls to the inner side of their axes.

The eyeball is nearly spherical, but is composed of parts of two different-sized spheres, of which the posterior and larger, formed by the sclerotica, constitutes five-sixths of the ball, while the smaller projects from the front of the former as the transparent cornea, commonly called the "sight of the eye."

The eyeball is about an inch in diameter, slightly varying in different directions and usually greatest fore and aft.

The posterior part of the ball, formed by the sclerotica, is invested with a thin, loose, and viscid fibrous capsule, the **vaginal tunic**,<sup>3</sup> which is attached to the eye by delicate connective tissue and permits free movement of the ball on the adjacent parts. The tunic is perforated by the tendons of insertion of the muscles of the ball and is intimately connected with the sclerotica behind where it is perforated by the ciliary vessels and nerves.

The attachment of the eyeball to the vaginal tunic is so slight that in a surgical operation it is readily removed with little injury to the adjacent parts.

The eyeball is composed of three concentric coats enclosing as many

<sup>1</sup> M. obliquus inferior.

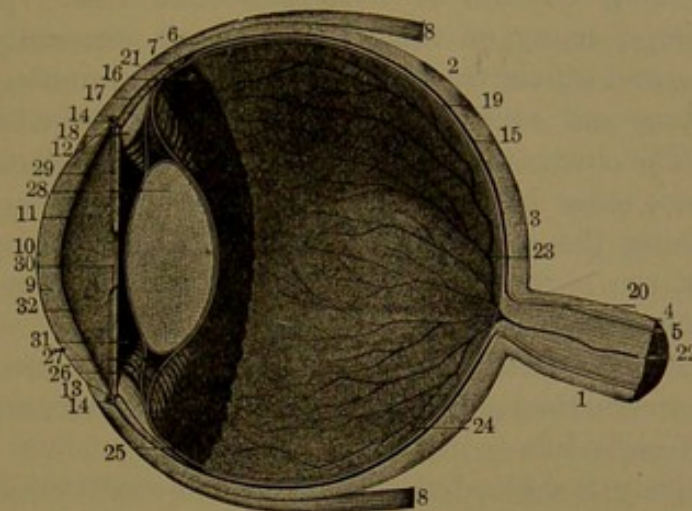
<sup>2</sup> Globe or apple of the eye.

<sup>3</sup> Capsule of Tenon; tunica vaginalis; membrana albuginea.



different transparent media. The coats successively from without inward are, 1, the sclerotica and cornea; 2, the choroidea and iris; 3, the

FIG. 430.



VERTICAL SECTION ANTERO-POSTERIORLY OF THE EYEBALL. 1, optic nerve; 2, sclerotica; 3, its posterior thicker portion; 4, sheath of the optic nerve continuous with the sclerotica; 5, the nerve within the sheath; 6, insertion of the recti muscles into the sclerotica; 7, 8, superior and inferior recti muscles; 9, cornea; 10, its conjunctival surface; 11, entocornea; 12, 13, bevelled edge of the cornea fitting into the sclerotica; 14, circular sinus of the iris; 15, choroidea; 16, the anterior portion, constituting the ciliary body; 17, the ciliary muscle; 18, the ciliary processes; 19, retina; 20, its origin; 21, the ora; 22, central retinal artery; 23, vitreous humor; 24, 25, 26, hyaloid tunic; 27, suspensory ligament of the crystalline lens; 28, 29, iris; 30, pupil; 31, posterior chamber, and 32, anterior chamber occupied by the aqueous humor.

retina. The humors from without inward are the aqueous, crystalline, and vitreous humors.

#### THE SCLEROTICA.

The sclerotica and cornea form the external coat of the eyeball and serve to give and preserve the shape of the organ and protect its more delicate interior structure.

The **sclerotica**<sup>1</sup> is an opaque white, dense, inelastic, fibrous membrane occupying the greater extent of the eyeball, with the transparent cornea projecting from its front and the optic nerve penetrating its back part. It is thickest behind, and gradually becomes thinner to within a short distance of the cornea, when it again thickens to the anterior border. Its outer surface, for the most part smooth, has inserted into its fore part the tendons of the muscles of the ball. The inner surface is brown, due to pigmented connective tissue by which it is attached to the choroidea. The optic nerve perforates the sclerotica about an eighth of an inch to the inner side of the axis of the ball and slightly below the centre. The passage<sup>2</sup> is funnel-like, smaller in front, and the sheath of the nerve is continuous with its sides. When the passage is cut across it exhibits a sieve-like plate, the

<sup>1</sup> Sclera; albuginea; alba; cornea opaca.

<sup>2</sup> Foramen opticum scleroticæ.



**cribrose lamina**,<sup>1</sup> through the perforations of which the bundles of nerve-fibres enter the eye.

**Structure of the sclerotica.** The sclerotica is composed of closely-intersecting bundles of fibro-connective tissue, pursuing different directions; many of them fore and aft, especially at the external surface, and others transversely. With the bundles are mingled fine elastic fibres and connective-tissue corpuscles, of which some are pigmented. The internal surface contains many stellate pigmented cells, which also enter into the composition of the delicate connective tissue<sup>2</sup> attaching the sclerotica to the choroidea. Both surfaces of the sclerotica are covered by an endothelium, lining corresponding lymphatic spaces.

In infancy the sclerotica presents a more or less bluish tint, due to the dark inner structure shining through the thinner and more translucent coat of early life.

Comparatively few blood-vessels are distributed in the dense structure of the sclerotica. The capillaries form wide-meshed nets and are most numerous around the cornea.

#### THE CORNEA.

The **cornea**<sup>3</sup> is the transparent part of the external coat of the ball in front of the eye, into the interior of which it admits the light. The segment of a smaller sphere, it projects beyond the curving surface of the sclerotica and forms about a sixth of the circumference of the ball. It is circular or nearly so, and is of greater extent behind than in front, due to the border being bevelled forward. In this position it is overlapped by the contiguous border of the sclerotica, so as to resemble the insertion of a watch-crystal in its frame. It differs but little in thickness from the sclerotica, is greatest at the border and becomes slightly thinner to the centre. It is more convex in youth than later and gradually decreases in this respect in the latter part of life. Sometimes also it is more or less unduly convex for convenient vision, one of the conditions of near-sightedness.

**Structure of the cornea.** The cornea consists of three distinct layers, which may be distinguished as the ectocornea, the mesocornea, and the entocornea.

The **ectocornea**, already noticed as the corneal conjunctiva, is thin and dense and is composed of an epithelium and a basement membrane. The epithelium (see Fig. 175, page 349) is stratified. The deepest cell-stratum consists of columnar cells, those following are polyhedral and become successively larger and relatively broader, and the superficial strata consist of flattened cells or scales. The deeper cells are corrugated, and the ridges of adjacent cells conjoin so as to

<sup>1</sup> L. cribrosa.

<sup>2</sup> Lamina fusca.

<sup>3</sup> C. pellucida.



leave between them narrow intercellular channels occupied by liquid. The basement membrane is a considerable homogeneous layer intimately connected with the mesocornea and defining it from the epithelium.

The **mesocornea**, or proper substance of the cornea, is its thickest portion, and is continuous in structure with the sclerotica, but is composed of a modified connective tissue, in which the elements are so nearly alike in refractive character that in the fresh condition it appears homogeneous. It is composed of numerous laminae of connective-tissue bundles embedded in homogeneous cementing substance. Generally the bundles pursue a nearly straight course in each lamina, but cross one another at right angles in the alternate laminae. The adjacent laminae are joined by intersecting bundles, and the intervals of the laminae are occupied with a greater proportion of the cementing substance, in which are embedded the **corneal corpuscles**. These are irregularly stellate, protoplasmic cells, which are flat and broad parallel with the surface of the cornea and narrow, spindle-shaped in the cross-section. The rays of contiguous corpuscles conjoin, not only between but also through the laminae, so as to form an extensive net-work throughout the cornea. The corpuscles have an oval nucleus, around which the protoplasm appears granular, but becomes clear towards the periphery of the cells. The corpuscles occupy corresponding cell-spaces of the cementing ground substance of the cornea and are readily brought into view by staining this with silver nitrate. By means of their rays the cell-spaces communicate with one another, thus forming an anastomosing system of canals throughout the cornea. The corpuscles do not entirely fill the cell-spaces, but leave sufficient way for the passage of lymph with lymph-corpuscles. The corneal corpuscles are endowed with slight contractility, which is exhibited under various stimuli, as mechanical irritation, heat, electricity, and inflammation.

The **entocornea**<sup>1</sup> adheres to the mesocornea, from which it may readily be detached, and is in contact behind with the aqueous humor. It is composed of a thin, compact, highly-elastic, and apparently homogeneous layer lined with an endothelium like that of the serous membranes. At the border of the cornea it is reflected over the processes of the pectinate ligament and becomes continuous with the ectiris.

At the junction of the cornea and sclerotica, but rather within the boundary of the latter, is a venous channel, the **circular sinus**, which communicates with the anterior ciliary veins.

At birth the cornea is of more uniform thickness and less transparent than subsequently. In advanced age it also becomes less

<sup>1</sup> Membrana humoris aquei; m. Demoursiana, Descemetiani, or Duddeliana; capsula aquea cartilaginosa or praeaquea; membrane of Descemet, or of Demours, or of the aqueous humor; posterior elastic lamina.



transparent, especially at the circumference, where commonly a white ring, the **arcus senilis**, makes its appearance, due to fatty deposit.

**Vessels and nerves of the cornea.** In the normal condition of the cornea it is unprovided with vessels, but is abundantly supplied with nerves derived from the ciliary nerves. The capillary blood-vessels of the sclerotica and conjunctiva end in a circle of loops at the border of the cornea. Lymphatics appear to be substituted by the free communication of the cell-spaces occupied by the corneal corpuscles. The nerves enter the cornea from the sclerotica as medullated fibres, which divide into transparent non-medullated branches. Of these the deeper series is distributed in bundles and finally in individual fibrils between the laminae of the mesocornea, where they freely anastomose and come into intimate relation with the corneal corpuscles. The superficial series proceeds to the ectocornea and after piercing the basement membrane splits up into numerous fibrils, which form together a **subepithelial plexus**. From this the ultimate fibrils are distributed among the epithelial cells, freely anastomosing to form an **intra-epithelial plexus**. The ultimate fibrils of the corneal nerves are minutely beaded or varicose. The abundance of nerves accords with the sensitiveness of the cornea.

#### THE CHOROIDEA.

The **choroidea**<sup>1</sup> is a thin, chocolate-brown, highly-vascular membrane, adhering to the inside of the sclerotica, and like it is perforated by the optic nerve. In front it is continuous with the iris by the ciliary body, and exterior to this is connected with the junction of the sclerotica and cornea by the ciliary muscle. Externally it is attached to the sclerotica, as previously described. Internally it is smooth and adheres to the pigmental layer of the retina, which in ordinary preparations of the choroidea is detached with it and until recently was regarded as an integral part of this membrane.

**Structure of the choroidea.** The choroidea may be regarded as consisting of three principal layers, the ecto-, meso-, and entochoroidea.

The **ectochoroidea**<sup>2</sup> is composed of laminated fibro-connective tissue, fine elastic fibres, and flat, branching, pigmented and colorless cells embedded in a homogeneous ground substance. Between the laminae are lymph-spaces lined by endothelial cells.

The **mesochoroidea**<sup>3</sup> resembles the former, with which it is continuous, but contains numerous blood-vessels, both arteries and veins. The arteries are derived from the short ciliaries which pierce the sclerotica around the optic nerve and enter the choroidea. Proceeding forward they expand in the membrane in numerous inosculating branches,

<sup>1</sup> Tunica choroidea, vasculosa, uvea, or ragoides; choroid coat.

<sup>2</sup> T. suprachoroidea, cellulosa, arachnoidea, or villosoglandulosa.

<sup>3</sup> T. vasculosa or choroidea propria.



the longest of which reach the ciliary muscle and there anastomose with the long and anterior ciliary arteries. The veins are situated

FIG. 431.

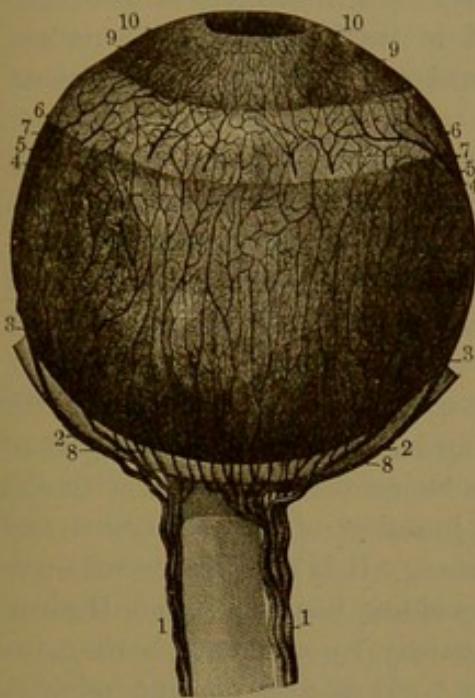
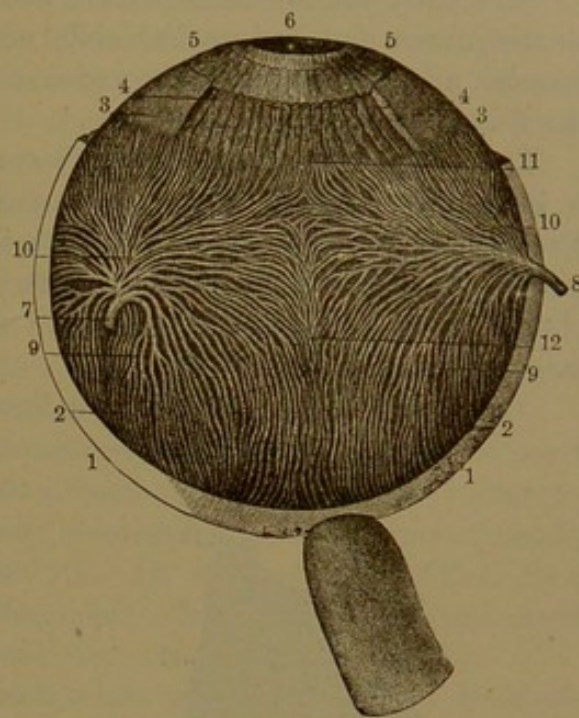


FIG. 432.

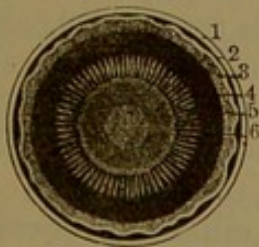


*Fig. 431.*—THE CHOROIDEA AND IRIS. 1, ciliary arteries situated at the sides of the optic nerve; 2, the long ciliary arteries; 3, the same after having pierced the sclerotica; 4, 5, the main divisions of the same vessels; 6, the ciliary muscle; 7, the anterior ciliary arteries; 8, the short ciliary arteries to the choroidea; 9, the iris supplied by the long and anterior ciliary arteries; 10, the pupil.

*Fig. 432.*—VEINS OF THE CHOROIDEA AND IRIS. 1, sclerotica; 2, choroidea; 3, ciliary muscle, of which a portion has been removed to exhibit the ciliary processes; 4, 5, the iris; 6, pupil; 7, 8, trunks of the choroid veins; 9, 10, vorticosse vessels; 11, their conjunction with the veins of the ciliary processes; 12, anastomosis between the groups of vorticosse vessels.

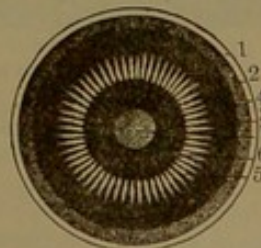
exterior to the arteries, than which they are considerably larger. They are remarkable for their whorled arrangement, from which they have

FIG. 433



VIEW FROM BEHIND OF THE ANTERIOR HALF OF THE EYEBALL. 1, sclerotica; 2, choroidea; 3, retina; 4, the ora; 5, ciliary processes; 6, the crystalline lens behind the iris and pupil.

FIG. 434.



THE SAME VIEW, WITH THE CRYSTALLINE LENS AND RETINA REMOVED. 1, sclerotica; 2, choroidea; 3, ciliary body; 4, the ora; 5, ciliary processes; 6, iris; 7, cornea seen through the pupil.

received the name of the **vorticose veins**.<sup>1</sup> From the four quarters of the choroidea the branches pursue a nearly parallel curved course

<sup>1</sup> Vasa vorticosa.



and converge to four central trunks, which pierce the sides of the sclerotica, at equidistant points, to end in the ophthalmic vein. Sometimes a pair of these trunks unite before passing from the sclerotica.

Internally the mesochoroidea is defined by a thin layer of reticular elastic fibres and endothelial cells and is traversed by the smallest arteries and veins of the choroidea connected with the capillaries of the following layer.

The **entochoroidea**<sup>1</sup> is chiefly composed of capillary vessels and is internally defined by a thin, apparently homogeneous membrane. The capillaries form a close net, with intervals narrower than the vessels which compose it. The net receives the arteries of the mesochoroidea, and its veins converge in vortices which terminate in the larger vorticoso veins of the latter.

The **ciliary body**.<sup>2</sup> This is a light-colored zone about the fourth of an inch wide at the fore part of the choroidea, connected with the conjunction of the sclerotica and cornea. It is continuous with the choroidea, but is defined from it inwardly by a serrate border, the **ora**.<sup>3</sup> It is also continuous with the iris. Outwardly it is formed by the ciliary muscle and at its anterior third inwardly is produced into the ciliary processes.

The posterior portion<sup>4</sup> of the ciliary body appears as a continuation of the choroidea, has about the same thickness and nearly the same constitution, but is finely and uniformly striate longitudinally and is outwardly lighter in color. Its vessels from the choroidea run in the same direction as the striation, but it is devoid of the capillary layer of the choroidea, which ceases at the ora.

The **ciliary processes**,<sup>5</sup> of which there are about six dozen, form a circle of half-elliptical ridges projecting inward, side by side, from the fore part of the ciliary body. They consist of a larger

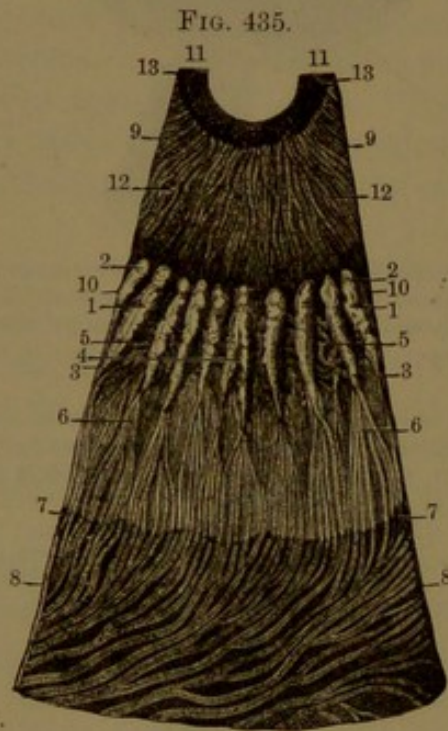


FIG. 435.  
SEGMENT OF THE CHOROIDEA AND IRIS, SEEN ON ITS INNER SURFACE, magnified four diameters. 1, ciliary processes; 2, their free extremities behind the iris; 3, 4, commencement of the processes; 5, intervals of the processes; 6, veins of the ciliary processes; 7, posterior margin of the ciliary body; 8, choroidea with its veins; 9, iris; 10, its outer border; 11, the pupillary border; 12, radiating fibres of the iris; 13, circular fibres.

<sup>1</sup> Membrana chorio-capillaris; m. Ruyschiana or Hovii.

<sup>2</sup> Corpus ciliare; corona ciliaris.

<sup>3</sup> Ora serrata.

<sup>4</sup> Orbiculus ciliaris.

<sup>5</sup> Processus ciliaris; ligamenta ciliaria; plicæ corporis ciliaris.



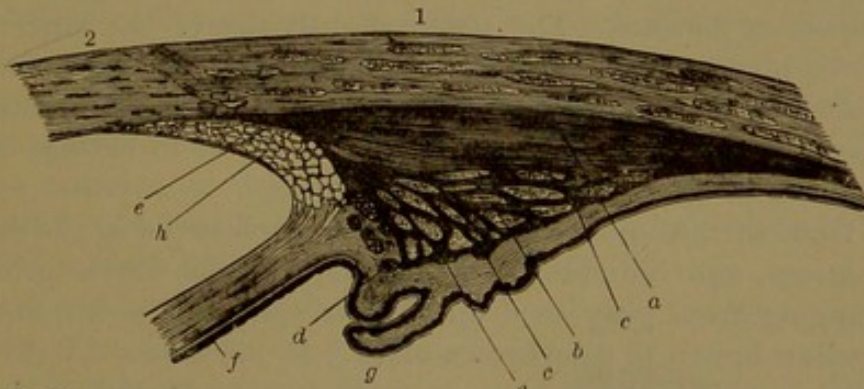
series, about one-eighth of an inch long, alternating irregularly with a smaller series. They are deepest and thickest at their fore part and gradually taper away behind. Their anterior extremities are rounded, free, and suspended in the aqueous humor, in a circle behind the outer border of the iris. Their posterior extremities, about two-thirds of their length, are received in corresponding grooves of the vitreous humor, to which they give the appearance of a striated band, the **ciliary zone**,<sup>1</sup> which surrounds the crystalline lens.

The ciliary processes are each composed of a tortuous plexus of capillary vessels, supplied by branches from the short ciliary arteries and others from the choroidea. The veins run backward to join the vorticose veins of the choroidea. The largest artery runs along the free border of each process; in like manner the longest vein runs along its attached border.

Internally the ciliary body is defined by a thin homogeneous membrane<sup>2</sup> and is covered by a brown-black pigmented layer,<sup>3</sup> consisting of several strata of polyhedral cells, continuous with the corresponding pigmented layers of the retina and iris. On the free ends of the ciliary processes the cells are devoid of pigment; they therefore appear uncolored, or red only from their vascularity.

The **ciliary muscle**<sup>4</sup> is a thick white ring of the exterior of the

FIG. 436.



SECTION THROUGH THE CILIARY REGION OF THE EYE. 1, sclerotica; 2, cornea. a, radiating fibres of the ciliary muscle; b, c, deeper radiating bundles enclosing annular bundles; d, annular bundles at the border of the iris; e, tendinous origin of the ciliary muscle at the conjunction of the sclerotica and cornea; f, iris; g, ciliary process; h, pectinate ligament.

ciliary body, at its conjunction with the sclerotica and cornea and with the iris. Its outer portion consists of short, radiant bundles of muscular fibres, which arise tendinously from the sclerotica at its conjunction with the cornea and are directed backward and inward to terminate in the ciliary body. The inner portion<sup>5</sup> of the muscle consists of bundles of fibres, which pursue a circular course, within the position of the

<sup>1</sup> Zonula ciliaris.

<sup>2</sup> Lamina vitrea.

<sup>3</sup> Uvea.

<sup>4</sup> Musculus ciliaris; ligamentum ciliare, iridis, or sclerotico-choroidale.

<sup>5</sup> Circular ciliary muscle.



outer portion, at the conjunction of the ciliary body and iris. It is composed of unstriped muscle-fibres. In birds it is composed of striped fibres.

The ciliary muscle is more than usually developed in hypermetropia, but is less produced in myopia.

#### THE IRIS.

The **iris**,<sup>1</sup> seen during life through the transparent cornea, is a colored membranous disk, with a central black spot, which is a circular hole, the **pupil**.<sup>2</sup> It is placed vertically in advance of the choroidea and ciliary body, with which it is a continuous structure. It is also connected with the adjacent border of the sclerotica and cornea by the ciliary muscle and pectinate ligament. Situated in the interval between the cornea and lens, it divides the space occupied by the aqueous humor into two compartments, the **anterior** and **posterior chambers**, which communicate through the pupil.

Like the diaphragm of optical instruments, the iris serves to moderate and otherwise regulate the light admitted into the eye. Exceedingly sensitive to light, under its influence the iris is excited to movement: thus, with an increase of light it expands and the pupil diminishes; with a decrease it contracts and the pupil proportionately enlarges.

The iris is about half an inch in breadth and is nearly flat or very slightly convex forward. The pupil, slightly nearer the inner border of the iris, moderately dilated is from one-eighth to one-sixth of an inch wide, but may expand to one-third of an inch and contract to one-sixteenth of an inch. The iris is less sensitive in old age and the pupil appears habitually smaller than in youth.

The front surface of the iris, as ordinarily observed in the different races, nations, and individuals of the same people, varies greatly in color, ranging from gray to deep blue or yellowish green, and from bright yellow-brown to deep brown-black. In fair-skinned, light-haired people it is usually gray or blue; in dark-skinned, black-haired people, more or less brown. In the negro the dark-brown hue is so deep that at a little distance the pupil is scarcely distinguishable from the surrounding iris. The iris also often appears variably spotted with brown.

The front of the iris exhibits an outer zone<sup>3</sup> and a smaller one<sup>4</sup> immediately surrounding the pupil. The outer zone is commonly darkest at the corneal border, especially in light eyes, while the inner border is slightly prominent and fringed. It is radially striated, the striæ being wavy in the contracted state of the iris and straight in its

<sup>1</sup> Tunica cœrulea.

<sup>2</sup> Pupilla; pupula.

<sup>3</sup> Annulus major iridis; a. externus or ciliaris.

<sup>4</sup> A. minor iridis; a. internus or pupillaris.



most expanded condition. The inner zone, about a third the width of the outer, is usually darker, often differently colored, and more evenly and finely striated.

The posterior surface of the iris is radially striated and of a deep brown-black color.

Of less thickness than the ciliary body, with which it is continuous, the iris gradually increases to about the position of the small zone, and then diminishes to the pupil.

**Structure of the iris.** The iris, like the choroidea, may be regarded as consisting of three layers, distinguished as the ectiris, mesiris, and entiris.

The **ectiris**<sup>1</sup> is continuous with the entocornea and is an extension of that membrane. The cells of its endothelium are smaller and less clear than those of the cornea, and in dark-colored eyes contain some brown pigment-granules.

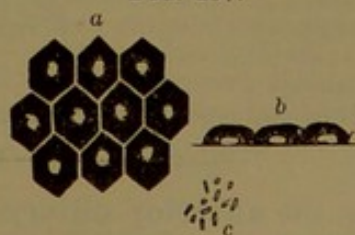
The **mesiris**,<sup>2</sup> the principal layer, is directly continuous with the ciliary body. It consists of a matrix of fibro-connective tissue with the muscles, blood-vessels, and nerves of the iris. The connective-tissue bundles generally have a radial disposition, and mingled with them are numerous flat, branching corpuscles, which in dark eyes contain variable proportions of brown pigment-granules.

The muscles which occupy the inner or deeper part of the mesiris are the dilator and sphincter of the iris, and are composed of unstriated fibres. The **dilator**<sup>3</sup> is a thin stratum of fibres which radiate from the pupil to the ciliary border of the iris, where they are associated with some circular fibres. The **sphincter**<sup>4</sup> is a narrow zone of circular fibres around the pupil.

The **entiris**, or **uvea**,<sup>5</sup> consists of several strata of polyhedral pigmented cells, which all together appear intensely black. They are filled with dark-brown pigment-granules and contain a spheroidal nucleus. The cells lie on a thin, homogeneous basement membrane.

In blue eyes, the cells of the entiris alone contain pigment-granules, there being no pigment in the other layers. In albinos the pigment is altogether absent in the iris. The blue color of the iris seems due to the uvea seen through the white connective tissue of the mesiris; the gray color, to the greater proportion and compactness of the same tissue.

FIG. 437.



PIGMENT-CELLS OF THE UVEA: highly magnified. *a*, viewed on the broad surface; *b*, viewed on the side; *c*, pigment-granules.

<sup>1</sup> Membrane of Descemet or of Zinn; lamella iridis anterior.

<sup>2</sup> Fibrous layer of K  lliker.

<sup>4</sup> S. iridis.

<sup>3</sup> M. dilatator pupill  .

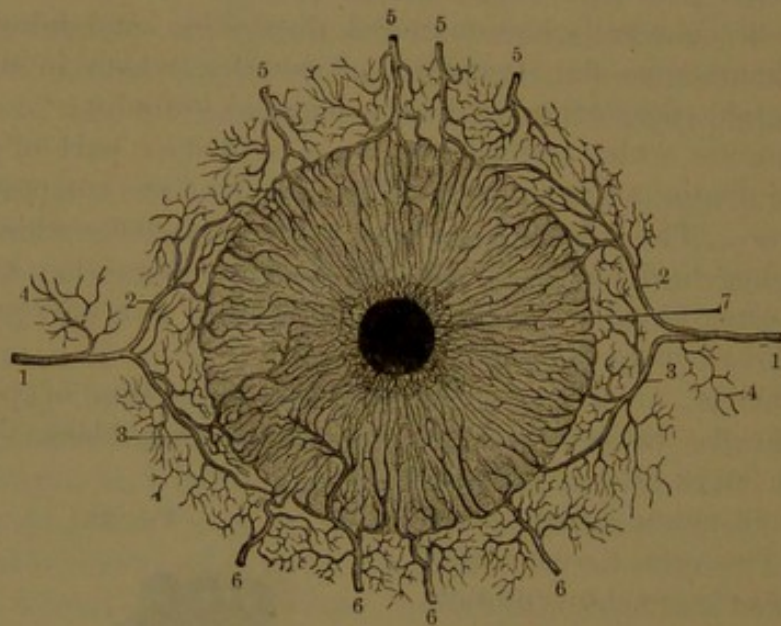
<sup>5</sup> Pigmentary layer.



The **pectinate ligament**<sup>1</sup> appears around the adjacent borders of the iris and cornea as minute bands extended between them. It consists of bands and laminae of elastic tissue forming a bond of union between the contiguous borders of the cornea, sclerotica, iris, and ciliary body. It is continuous with the connective-tissue bundles of the sclerotica around the circular sinus, with the tendinous origin of the ciliary muscle, and with the stroma of the iris. Next the cornea some of its fibres pursue a circular course.<sup>2</sup> It is closely invested by the entocornea which dips into its recesses and thence becomes continuous with the ectiris.

**Vessels of the ciliary muscle and iris.** Two branches of the ophthalmic artery, the **long ciliary arteries**, enter the eyeball, by piercing the sclerotica, on each side of the entrance of the optic nerve. Proceeding forward between the sclerotica and choroidea, on each side of the eye, near the ciliary muscle they divide into two branches, which diverge above and below and enter the muscle. Half a dozen smaller

FIG. 438.



ARTERIES OF THE IRIS. 1, long ciliary arteries; 2, 3, their principal divisions; 4, small branches to the ciliary muscle; 5, 6, anterior ciliary arteries; 7, the pupil.

vessels, the **anterior ciliary arteries**, derived from the muscular and lachrymal branches of the ophthalmic artery, after giving off minute branches to the conjunctiva, pierce the sclerotica near the cornea and anastomose with the branches of the long ciliary arteries, forming with them the **arterial circle of the iris**. This occupies the anterior border of the ciliary muscle and gives off numerous branches to the iris, freely inosculating and converging to the pupil, where they terminate in a circular plexus of minute vessels. From the ciliary arteries

<sup>1</sup> Ligamentum pectinatum iridis; processus peripherici.

<sup>2</sup> Limiting ring of Schwalbe.



and the circle formed by their union small branches are distributed to the ciliary muscle and processes. From the capillary nets of the mesiris the veins run to the venous plexuses of the ciliary processes and finally to the vorticosae veins of the choroidea. Other veins from the iris and ciliary muscles accompany the anterior ciliary arteries, in their course communicating with the circular sinus, at the conjunction of the cornea and sclerotica.

The lymphatics of the iris consist of lymph-spaces around the blood-vessels, chiefly the arteries, and among the connective-tissue bundles of the stroma. They communicate with the recesses of the pectinate ligament around the iris.

#### Nerves of the choroidea and iris.

Fifteen or more **ciliary** nerves, derived from the ophthalmic ganglion and nasal branch of the ophthalmic nerve, pierce the sclerotica around the entrance of the optic nerve. They proceed forward in shallow grooves of the sclerotica lying in contact with the choroidea, to which they give branches, then after dividing they enter the ciliary muscle. Within this they continue to branch, and together form the **ciliary plexus**, encircling the iris. From the plexus proceed the nerves of the cornea, of the ciliary muscle, and of the iris.

The nerves of the cornea pierce the contiguous portion of the sclerotica and proceed to the cornea.

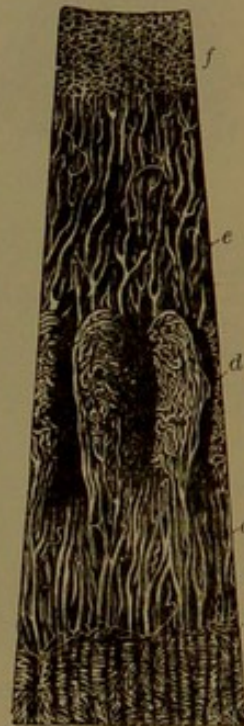The nerves of the ciliary muscle end in a gangliated plexus of nerve-axis fibres.

The nerves of the iris enter it and divide into branches which anastomose and form together an irregularly-looped plexus in the ciliary border. From this plexus proceed many branches, which in a similar manner form a succession of several plexuses, the last and smallest surrounding the pupil. Branches from the larger plexuses of the iris end in plexuses of nerve-axis fibres of the dilator and sphincter muscles and of the front superficial part of the iris.

#### THE RETINA.

The **retina**<sup>1</sup> is the interior, delicate, soft membrane of the eye, in which the optic nerve terminates, and is the immediate seat of visual

FIG. 439.



VESSELS OF THE CILIARY BODY AND IRIS: magnified ten diameters. From a child: viewed from within. *a*, capillary plexus of the anterior part of the choroidea; *b*, the ora; *c*, arteries of the ciliary body passing into the ciliary processes *d*, and partly into the iris at *e*; *f*, capillary plexus around the pupil.

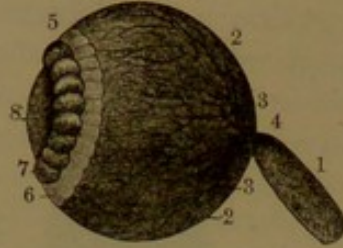
<sup>1</sup> Tunica nervea oculi.



impressions. It is intimately connected with the inner surface of the choroidea, gradually thinning away to the ora, where it for the most part abruptly terminates, but is continued through one of its constituent laminae, distinguished as the **preretina**.

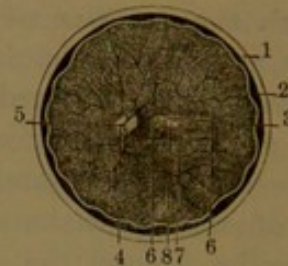The retina is thickest at the entrance of the optic nerve into the eye, where it is about one-fiftieth of an inch, thence it is gradually reduced to the ora, where it is about one-fourth that measurement. The internal surface is smooth, and lies in contact with the vitreous body.

FIG. 440.



EYEBALL, WITH THE SCLEROTICA, CORNEA, CHOROIDEA, AND IRIS REMOVED. 1, optic nerve; 2, 3, retina; 4, central retinal artery distributed to the retina; 5, 6, ciliary zone; 7, space at the circumference of the crystalline lens 8, artificially inflated and assuming the form of a beaded canal.

FIG. 441.



RETINA, SEEN ON ITS POSTERIOR INNER SURFACE. 1, sclerótica; 2, choroidea; 3, retina; 4, the optic papilla; 5, central retinal artery; 6, a slight fold of the retina; 7, the yellow spot; 8, its central fovea.

The exterior layer of the retina, or the **ectoretina**, is deep brown-black. It was formerly regarded as part of the choroidea. The interior layer, composing the chief thickness of the membrane, during life is clear, transparent, and of a pale-pink tint, but shortly after death, when not exposed to light, it assumes a purplish-red hue. It quickly undergoes change and under the influence of light loses its transparency and becomes white, ordinarily presenting the appearance of ground glass.

In the fresh condition, at the bottom of the eye, directly in the axis of vision, the inner transparent layer of the retina exhibits a circular or transverse oval **yellow spot**,<sup>1</sup> with a conical pit or **central fovea**.<sup>2</sup> The spot is about a line in diameter, and the portion of the retina which forms it increases in thickness to the border of the central fovea, when it rapidly thins away to the bottom. Here it is so much reduced that the dark ectoretina is visible through and appears like an aperture.<sup>3</sup>

About one-tenth of an inch to the inner side of the yellow spot, a circular white one<sup>4</sup> indicates the position of entrance of the optic nerve into the eye. The retina is here thickest and forms a little elevation, the **optic papilla**,<sup>5</sup> from the centre of which the retinal blood-

<sup>1</sup> Macula flava or lutea; limbus luteus.

<sup>3</sup> Foramen centrale.

<sup>5</sup> Papilla optica; colliculus opticus.

<sup>2</sup> Fovea centralis.

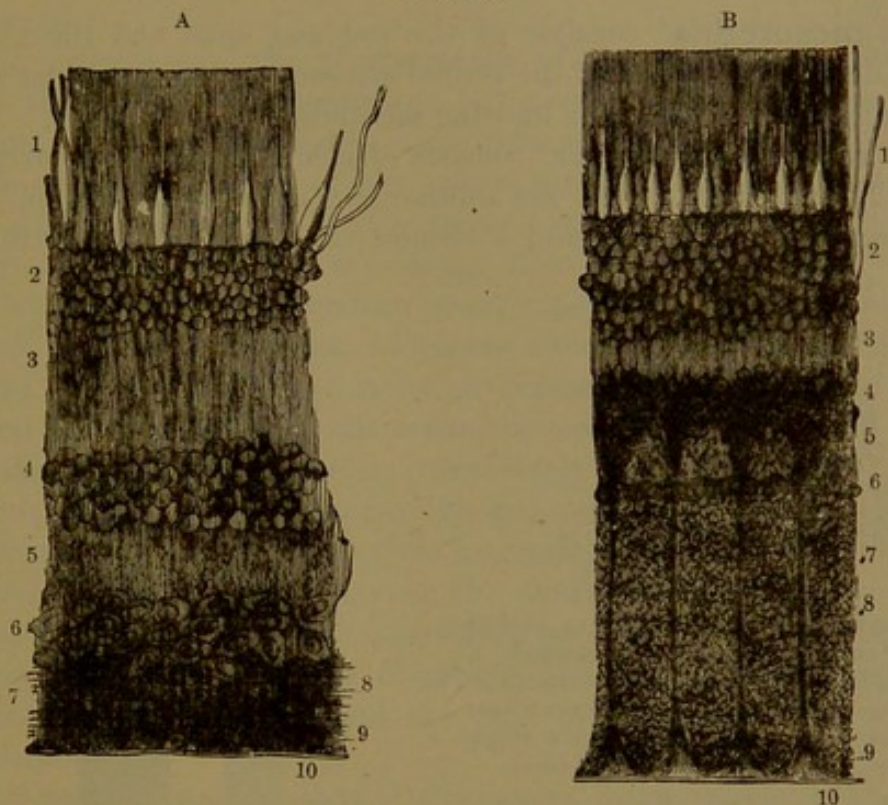
<sup>4</sup> Porus opticus.



vessels diverge above and below. After death, as a result of evaporation, commonly a transverse fold<sup>1</sup> makes its appearance in the retina directed outward from the optic papilla.

**Structure of the retina.** The retina is exceedingly complex, and has its chief elements arranged in strata, which may be regarded as pertaining to three divisions of the membrane, distinguished as the

FIG. 442.



VERTICAL SECTIONS OF THE RETINA: highly magnified. A, section about the middle of the retina; B, section near the entrance of the optic nerve. 1, rod and cone layer of the mesoretina; 2, nuclear layer of the mesoretina; 3-10, entoretina; 3, outer granular layer; 4, nuclear layer; 5, inner granular layer; 6, ganglionic layer; 7, layer of nerve-fibres; 8, sustentacular fibres; 9, thin expanded base; 10, inner limiting membrane.

ectoretina, mesoretina, and entoretina. A further extension of one of the strata is the preretina.

The **ectoretina**,<sup>2</sup> or pigmentary layer of the retina, until recently was regarded as a constituent layer of the choroidea. In ordinary preparations of the eye it readily separates from the mesoretina and remains closely adherent to the choroidea. On the other hand, in vertical sections through the tunics of the eye prepared for the microscope the pigmentary layer is observed to hold a more intimate relation with the other layers of the retina than with the choroidea. It is composed of a stratum of thick, hexagonal pigment-cells united by a colorless cement. The outer ends of the cells are nearly flat and

<sup>1</sup> Plica centralis; p. transversa retinae.

<sup>2</sup> Pigment-layer of the choroidea; stratum pigmenti; uvea.

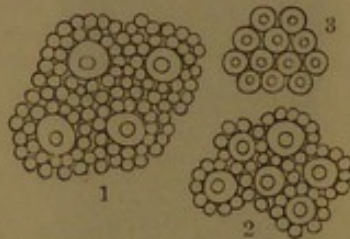


adhere to the inner surface of the choroidea; while the inner part of the cells is broken up into a brush of tapering filaments which dip into the intervals of the rods of the mesoretina. The superficial portion of the cell contents, or that next the choroidea, is clear, finely granular, and contains a central nucleus, while the deeper portion consists largely of dark-brown pigment-granules which extend into the tapering filaments and give to the ectoretina its characteristic deep brown-black color.

The **mesoretina**<sup>1</sup> consists of the rod and cone and the nuclear layers, defined by offsets of the retinal stroma forming a lamina which is distinguished as the outer limiting membrane.

The **rod and cone layer**<sup>2</sup> consists of elements which are arranged vertically and parallel with one another in a continuous stratum. The rods greatly predominate, and surround the cones, which are isolated

FIG. 443.

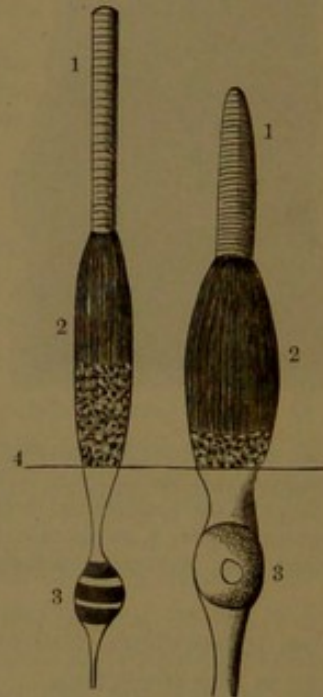


ROD AND CONE LAYER OF THE RETINA, viewed from the outer surface: highly magnified. 1, at the middle of the retina, four cones surrounded by numerous rods; 2, from the border of the yellow spot, each cone with a single circle of rods; 3, cones of the central fovea.

and scattered among the rods, except within the yellow spot, where they alone exist. From the vicinity of the yellow spot, where they are most numerous, they gradually diminish in number approaching the ora.

The **rods** are club-shaped; the **cones** are shorter, broader, and in shape resemble ninepins. Both are divided into an inner thicker segment or body and an outer segment or process, besides which they have attenuated extensions which run inward through the nuclear layer. The body is elliptical, homogeneous, or faintly granular and longitudinally striated. In the cones it is shorter and thicker than in the rods.

FIG. 444.



ROD AND CONE FROM THE RETINA: highly magnified. 1, outer segment, or process; 2, inner segment, or body; 3, nucleus; 4, line of the outer limiting membrane.

<sup>1</sup> Mosaic layer of Henle.

<sup>2</sup> Stratum bacillosum; s. cylindrorum; tunica Jacobi; membrana Jacobiana.



The process of the rods is about as long as the body, cylindrical, with a rounded end, and striated longitudinally and transversely. The process of the cones is shorter than the body, much shorter than that of the rods, tapers to a blunt point, and is striated transversely.

The body of the cones and rods is optically singly refractive, while the process is doubly refractive and exhibits a disposition to break up into transverse disks, especially in the rods. The purple-red color observed in the retina after death appears to have its seat in the processes of the rods.

The processes of the pigment-cells of the ectoretina extend between the rods of the mesoretina, but elsewhere the intervals of the rods and cones are occupied by a colorless semi-liquid material.

The inner extremity of the cones contracts, passes through the outer limiting membrane, and encloses a clear oval nucleus, from the opposite pole of which a cylindrical fibre proceeds through the nuclear layer to join the entoretina by an expansion. In like manner the rods contract into fine fibres, which are minutely varicose and likewise proceed to join the entoretina by an expanded end. In their course the rod-fibres, at variable distances, enclose a nucleus, which differs from that of the cones in being transversely banded.

The nuclei of the rods and cones, proportioned in number to them, are arranged in strata forming the **nuclear layer**<sup>1</sup> of the mesoretina; the nuclei of the cones occupying the outer stratum. Where the expanded ends of the rod- and cone-fibres join the entoretina they send into its outer granular layer diverging filaments, which are supposed to join similar filaments from the cells of the nuclear layer of the entoretina.

The **entoretina**<sup>2</sup> consists of five layers, distinguished as the outer granular, nuclear, inner granular, ganglionic, and nerve-fibre layers, defined by the inner limiting membrane.

The **outer granular layer**<sup>3</sup> of the entoretina is comparatively thin, and consists of a homogeneous, finely-granular matrix, with a dense interlacement of fine varicose filaments and of flattened branching corpuscles with a clear nucleus. It receives the filaments of the rod- and cone-fibres of the nuclear layer of the mesoretina and those of the cell-fibres of the succeeding layer.

The **nuclear layer**<sup>4</sup> of the entoretina, of less thickness than that of the mesoretina, consists of fewer strata of generally larger nuclei, which are vertically oval and contained in bipolar spindle-shaped cells prolonged into fibres. The outer fibres are thicker and enter the outer granular layer, where they branch into filaments mingled with those of

<sup>1</sup> Outer nuclear layer; *körner and ausser faser Schichte* of Henle.

<sup>2</sup> Nervous layer of Henle; *lamina vasculosa retinae*.

<sup>3</sup> Outer molecular or intergranular layer.

<sup>4</sup> Inner nuclear layer; outer ganglionic layer of Henle.



the latter. The inner fibres are varicose and enter the inner granular layer, through which they run without dividing. Nuclei of more elongated form, mingled with the others, pertain to the fibres of the retinal stroma. The nuclear layer is defined inwardly by a stratum of flat nucleated cells.

The **inner granular layer**<sup>1</sup> of the entoretina, very much thicker than the outer granular layer, has a similar structure. It receives the inner fibres of the bipolar cells of the adjacent nuclear layer and the branching processes of the nerve-cells beneath.

The **ganglionic layer**<sup>2</sup> of the entoretina mainly consists of large nerve-cells, mostly spheroidal or pyriform, of beautiful clear aspect, containing a central, spherical nucleus. Each cell is connected beneath with a nerve-fibre proceeding from the adjoining layer, and the outer part gives off one or more processes, which extend into the inner granular layer and branch into fibres, which are lost among the interlacing filaments of the layer. Over the greater part of the retina the nerve-cells form a single stratum, which becomes less continuous near the ora. In the vicinity of the yellow spot the nerve-cells increase to several strata and within it augment to half a dozen strata.

The **nerve-fibre layer**<sup>3</sup> of the entoretina, the innermost of the retinal layers, is thickest at the optic papilla, thence gradually thins away to the ora. It is composed of bundles of nerve axis-fibres, which enter the retina from the optic papilla and spread out on the inner surface of the membrane. The bundles of fibres in their divergence interchange so as to form a continuous net with narrow meshes. In the yellow spot the layer is interrupted by the many strata of nerve-cells. The intervals of the nerve-bundles enclose lymph-spaces lined with endothelial cells.

The **stroma**,<sup>4</sup> which pervades the greater part of the retina and connects and supports its more essential elements of structure, is a peculiar kind of connective tissue, arranged in columns, called the **sustentacular fibres**.<sup>5</sup> These commence internally in a pyramidal expansion, narrowing outwardly in a column, which proceeds through the layers of the ento- and mesoretina, conforming to the intervals of the nerve-elements and giving off laminar and filamentous processes which unite and enclose the nerve-elements. In passing through the nuclear layer of the entoretina, each fibre encloses an oval nucleus and another occupies the pyramidal expansion at its commencement. The broad bases of the pyramidal expansions unite by their adjoining edges and thus form a thin lamina, which defines the retina within and is hence called its **inner limiting membrane**.<sup>6</sup> Viewed on

<sup>1</sup> Inner molecular or granular layer.

<sup>2</sup> Inner ganglionic layer of Henle.

<sup>3</sup> Layer of nerve-fibres; inner nerve-fibre layer of Henle.

<sup>4</sup> Sustentacular tissue.

<sup>5</sup> Müllerian fibres; radial fibres.

<sup>6</sup> Membrana limitans interna.



the surface, from the polygonal outlines of the bases of the sustentacular fibres, the membrane resembles in appearance an endothelium. At the outer part of the nuclear layer of the mesoretina lateral offsets from the sustentacular fibres unite in a thin **outer limiting membrane**,<sup>1</sup> which separates the two layers of the mesoretina and sends processes outward between the rods and cones. The substance of the sustentacular fibres is longitudinally striated, but, unlike ordinary connective tissue, is not dissolved by boiling in water.

The **yellow spot**<sup>2</sup> of the retina owes its color to pigment diffused among its structural elements, and, as the pigment is readily soluble in water, the yellow color quickly disappears after death. From its periphery the spot thickens inwardly to the border of the **central fovea**<sup>3</sup> and then rapidly thins away to its bottom.

In the position of the yellow spot the ectoretina continues unchanged.

The mesoretina thickens to the border of the fovea and thins away towards the bottom. Beyond the periphery of the yellow spot the rods disappear, and the remainder of the stratum consists entirely of cones, which become narrower and considerably longer approaching the bottom of the central fovea. The nuclear layer thickens to the fovea and thins away to its bottom. The nuclei are collected in a dense outer

FIG. 445.

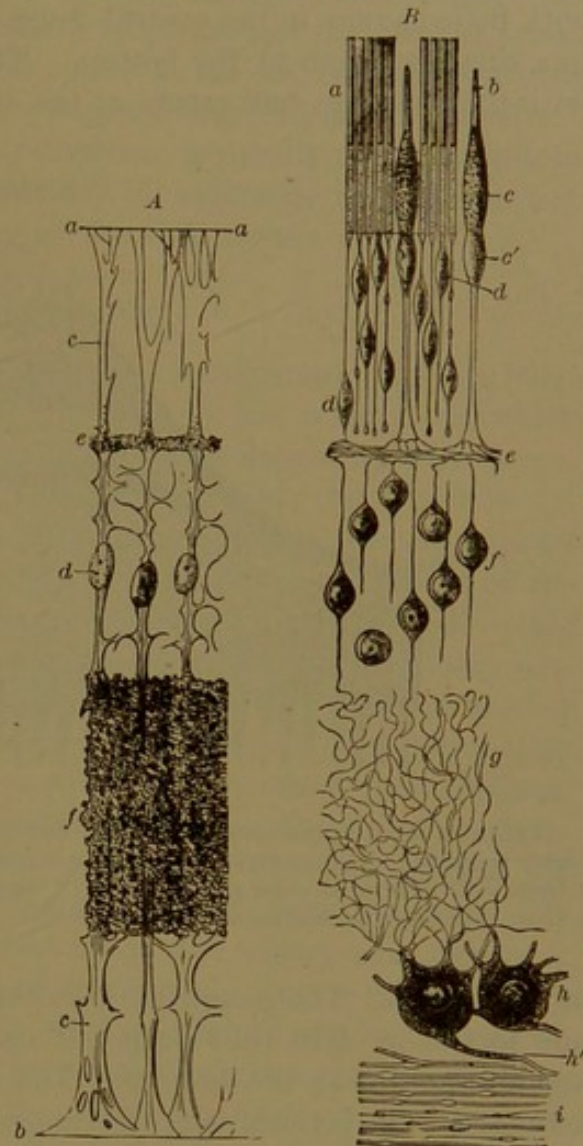


DIAGRAM OF THE ARRANGEMENT OF THE STRUCTURAL ELEMENTS OF THE RETINA. A, the retinal stroma or sustaining element: a, outer limiting membrane; b, inner limiting membrane; c, c, sustentacular fibres; d, nuclei of sustentacular fibres; e, outer granular layer; f, inner granular layer. B, the nerve-elements: a, rods; b, cone; c, its expanded base; c', nucleus of the cone-fibre; d, nucleus of the rod-fibre; e, division of the cone-fibre in the outer granular layer; f, nuclei of the inner nuclear layer; g, maze of fibrils of the inner granular layer; h, nerve-cells; h', optic nerve-fibre joining a cell; i, layer of nerve-fibres.

<sup>1</sup> M. limitans externa.

<sup>2</sup> Macula flava or lutea.

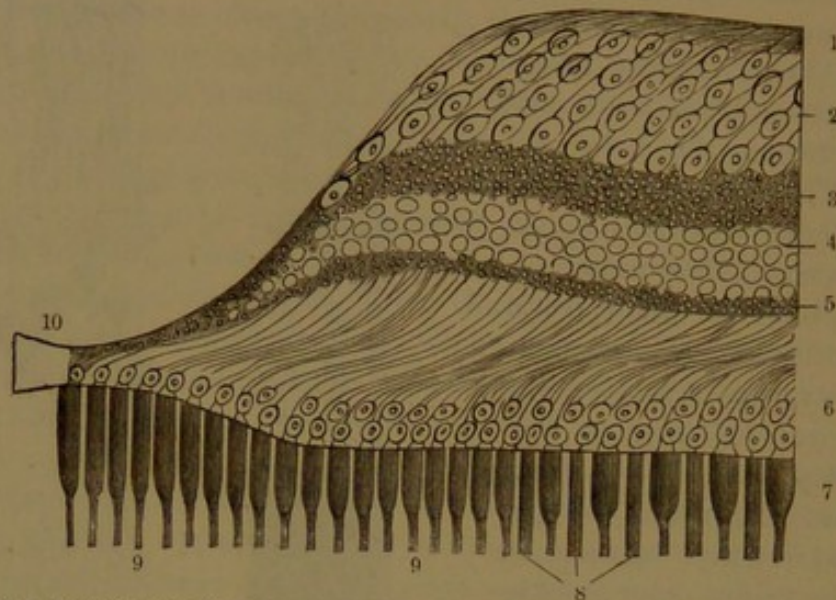
<sup>3</sup> Fovea centralis.



stratum; the nuclear fibres form a much thicker inner stratum, with the long fibres sweeping in curves from the nuclei to the entoretina.

In the entoretina of the yellow spot the granular layers continue with little change to the central fovea, when they converge and unite in a single stratum at the bottom. The nuclear layer also continues with little change, but tapers at the side of the fovea and disappears

FIG. 446.



VERTICAL SECTION THROUGH ONE SIDE OF THE YELLOW SPOT AND CENTRAL FOVEA: diagram highly magnified. 1, inner layer of nerve-fibres; 2, layer of nerve-cells; 3, inner granular layer; 4, inner nuclear layer; 5, outer granular layer; 6, outer nuclear layer; 7, layer of rods and cones; 8, rods; 9, cones; 10, bottom of the central fovea.

at the bottom. The ganglionic layer especially enlarges, becomes from one to six or eight cells deep, but narrows at the sides of the fovea and disappears at the bottom. The cells are bipolar and obliquely arranged. The layer of nerve-fibres gradually thins away to the border of the fovea, the fibres turning inward to join the adjacent nerve-cells.

Excepting the pigmentary layer, the retina thins away as it proceeds forward, and finally ceases at the ora, except a delicate layer, which is continued on the ciliary body and is distinguished as the *preretina*.<sup>1</sup> This consists of a single stratum of clear, columnar, nucleated cells, which appear to correspond with the fibres of the retinal stroma.

**Vessels of the retina.** The retina is supplied by the **central artery**, a branch of the ophthalmic artery, which pierces the optic nerve about the fourth of an inch behind the eyeball and enters it in the axis of the nerve. Accompanied by the corresponding vein, it enters the retina in the centre of the optic papilla and divides usually into two branches, which diverge, the one above, the other below.

<sup>1</sup> Pars ciliaris retinæ; corpus ciliare retinæ; margo flocculosus retinæ.



Advancing, they ramify in the inner part of the nerve-layer and end in capillary nets, which pervade the different layers of the entoretina, but do not enter the mesoretina or ectoretina. Minute branches enter the yellow spot and terminate in capillary loops around the central fovea. The veins pursue the same general course as the arteries, and resemble capillaries in structure, their wall composed only of endothelial cells.

The lymphatics of the retina commence generally as lymph-spaces invaginating the blood-vessels, especially the capillaries and veins; they communicate with the lymphatics of the optic nerve.

#### THE VITREUM.

The **vitreum**, or **vitreous body**,<sup>1</sup> is the transparent, colorless, jelly-like mass which occupies the space included by the retina, with which it is in close contact. In its front is a concave depression<sup>2</sup> accommodating the lens. Around this it is impressed by the ciliary body, producing the **ciliary zone**,<sup>3</sup> which in the detached vitreum appears conspicuously marked by radial grooves and adherent portions of the black uvea. The axis of the vitreum is traversed by a narrow canal,<sup>4</sup> which in foetal life accommodates a branch of the retinal artery destined to the capsule of the lens. The mature vitreum contains neither vessels nor nerves. It consists chiefly of a clear, slightly viscid, albuminoid liquid<sup>5</sup> occupying the interstices of a delicate, homogeneous, membranous structure, the **hyaloidea**,<sup>6</sup> which is disposed in concentric laminae, especially towards the periphery. On the surface the hyaloidea is continuous and separates the vitreum from the retina. It is strongest in advance, and is thickest in the ciliary zone, where it forms the **suspensory ligament of the lens**.<sup>7</sup> This is reinforced by fine elastic fibres extending radially between the ora and the margin of the lens. Approaching the lens the ligament divides into two laminae, attached in front and behind to the contiguous parts of the capsule. The space<sup>8</sup> between the laminae, when inflated artificially, appears as a beaded canal encircling the lens, the constrictions being due to the alternating narrower intervals of attachment of the fibres of the ligament. The vitreum contains many scattered corpuscles, especially beneath the hyaloidea at the surface. They are endowed with amœboid power of movement and appear to be colorless blood-corpuscles.

<sup>1</sup> Corpus vitreum; c. hyaloideum; vitreous humor.

<sup>2</sup> Fossa hyaloidea, patellaris, or lenticularis.

<sup>3</sup> Zonula ciliaris or Zinni; orbiculus capsulo-ciliaris; lamina ciliaris.

<sup>4</sup> Canalis hyaloideus; area Martegiani; canal of Stilling.

<sup>5</sup> Vitreous humor; vitrina ocularis.

<sup>6</sup> Tunica hyaloidea or arachnoidea; hyaloidea interna; pars cellularis.


<sup>7</sup> Ligamentum suspensorium lentis.

<sup>8</sup> Canal of Petit; circulus Petiti; camera tertia aquosa.



## THE LENS.

The **lens**, or **crystalline lens**,<sup>1</sup> is a transparent, colorless body, the shape of which is indicated by the name. Doubly convex, with rounded border, its posterior surface occupies the concave depression in front of the vitreum, while its anterior surface comes into contact with the back of the iris and is bathed in the aqueous humor. It is about one-third of an inch broad, and about one-sixth of an inch fore



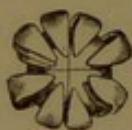THE CRYSTALLINE LENS. 1, lens of a foetus of seven months; 2, lens of a foetus of nine months; 3, lens of a child of ten years; 4, lens of an adult viewed in profile; 5, the same seen on its anterior surface.

and aft; the posterior surface is more convex than the anterior.

The lens consists of a membranous capsule enclosing a semi-solid albuminoid mass. The **capsule**<sup>2</sup> is elastic and homogeneous, with the anterior half much thicker than the posterior half, which is continuous with the hyaloidea of the vitreous body. In the mature state it is entirely devoid of vessels and nerves. Its fore part is lined with an epithelium consisting of a single stratum of hexagonal cells, with transparent granular contents and a clear spheroidal nucleus. The back part of the capsule is in contact with the lens-substance; commonly after death it is found to be separated from it by some infiltrated liquid.<sup>3</sup>

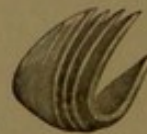The **lens-substance**<sup>4</sup> is soft on the exterior and gradually increases in consistence to the centre, where it is comparatively hard. It is not a continuous homogeneous structure, but consists of segments

FIG. 448.



CRYSTALLINE LENS, BREAKING UP INTO SEGMENTS.

FIG. 449.



SEGMENT OF THE CRYSTALLINE LENS, exhibiting the concentric arrangement of the laminae.

composed of concentric laminae. In the foetus three rays<sup>5</sup> appear on each surface of the lens, directed from the poles to the circumference, alternating in the position of the rays. Thus, in front one ray is directed downward and the others laterally upward, while behind one is directed upward and the others laterally downward. In the adult

<sup>1</sup> Lens crystallina; corpus crystallinum.

<sup>2</sup> Capsula lentis; tunica crystalloidea or arachnoidea.

<sup>3</sup> Liquor Morgagni.

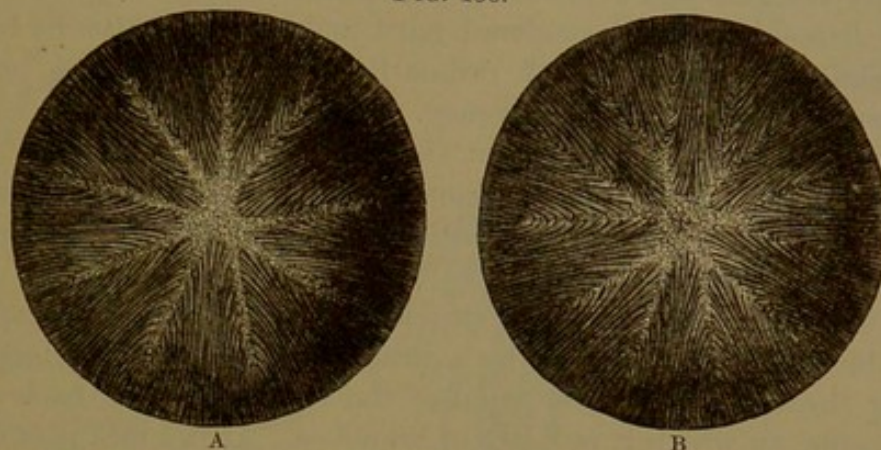
<sup>4</sup> Humor crystallinus.

<sup>5</sup> Septa radiata; s. lateralia.



several additional rays<sup>1</sup> diverge from the former and divide the lens into a proportionate number of segments. The *laminæ* are single strata of six-sided bands, the *lens-fibres*,<sup>2</sup> with the width in the same plane, and mutually co-adapted by minutely serrated borders. The ser-

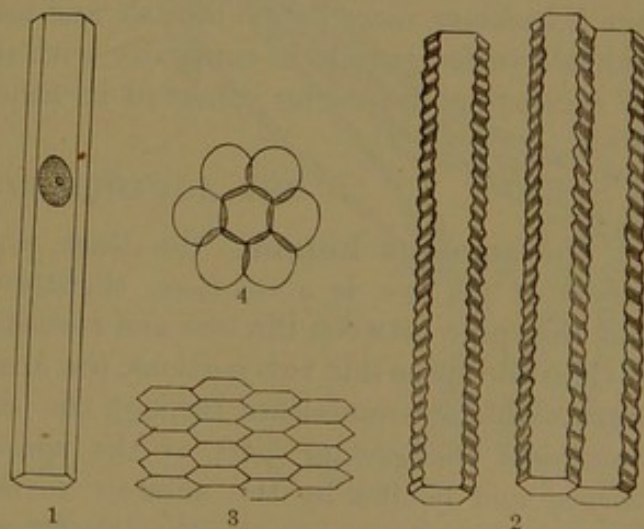
FIG. 450.



CRYSTALLINE LENS OF THE ADULT, EXHIBITING THE ARRANGEMENT OF THE FIBRES: magnified. A, viewed in front; B, viewed behind.

rations are due to transverse ridges, which are more strongly marked on the lateral narrow sides of the fibres than on the broad sides. The fibres follow the curvature of the *laminæ* from one surface of the lens to the other, pursuing a sigmoid course; those starting from the rays near the pole on one surface proceeding to the rays near the margin of the lens on the opposite surface, and the intervening fibres proceeding to corresponding points between the former. The ends of the lens-fibres of contiguous segments of the lens come into contact in the rays and are there joined by a homogeneous cement. The lens-fibres of the peripheral *laminæ* are broader, thicker, and softer than those of the interior *laminæ*, and possess a distinct, clear, oval nucleus, which is indistinct or absent in the latter. The nuclei are nearer the anterior extremity

FIG. 451.



FIBRES OF THE CRYSTALLINE LENS: highly magnified. 1, nucleated fibre from the peripheral layer of the lens; 2, deeper fibres most strongly serrated at the lateral borders; 3, transverse section of the fibres, exhibiting their compressed hexagonal columnar form; 4, outline of the epithelial cells of the fore part of the lens.

<sup>1</sup> S. l. accessoria.

<sup>2</sup> Fibrillæ lentis.



of the fibres and together occupy a zone<sup>1</sup> in front of the lens near its margin. The superficial lens-fibres have their posterior ends slightly enlarged and come into contact with the lens-capsule, while the anterior ends touch the contiguous epithelium. At the margin of the lens the cells of the epithelium merge into the adjacent lens-fibres, which gradually elongate and curve from before backward.

The lens-substance is rendered hard and opaque-white by boiling water and other agents which ordinarily coagulate albumen, but the lens-capsule retains its transparency. In strong alcohol the lens becomes hard and opaque-white on the exterior, but retains its transparency on the interior and becomes still harder and amber-colored. In the hardened condition the lens-substance is readily broken into its constituent laminae and fibres.

In the fœtus the capsule of the lens is provided with a capillary net of blood-vessels,<sup>2</sup> supplied by a branch of the retinal artery, proceeding through the central canal of the vitreum to the back of the lens-capsule, on which it radiates in branches. At the fore part of the capsule the capillary net communicates with the vessels of the iris at the margin of the pupil, which is then closed by a pupillary membrane.

The lens varies in size, proportions, and other respects, with age, myopia, presbyopia, and other conditions. In the fœtus it is nearly spherical, of a pinkish hue, and less transparent than subsequently. At maturity it is distinctly less convex in front than behind; in old age it becomes more flat, yellowish, and less transparent. The lens of animals varies greatly in convexity with the character of the medium in which they live, being spherical in fishes, and of least sphericity in birds.

#### THE AQUEOUS HUMOR.

The **aqueous humor**,<sup>3</sup> the least consistent of the transparent media of the eye, is a colorless, slightly-viscid, serous liquid, which fills the space between the lens and cornea, and includes the iris. This divides the space into two portions, the **anterior** and **posterior chambers**,<sup>4</sup> which communicate through the pupil. The anterior chamber comprises the greater part of the space bounded in front by the cornea and behind by the anterior surface of the iris bordered by the pectinate ligament. As the iris in great part lies close to if not in actual contact with the lens, the posterior chamber is a mere fissure widened at the border, where it receives the ends of the ciliary processes, which dip into the humor.

The aqueous humor probably has its source in the vascular plexuses of the iris and ciliary processes.

<sup>1</sup> Nuclear zone of Mayer.

<sup>3</sup> H. aqueus.

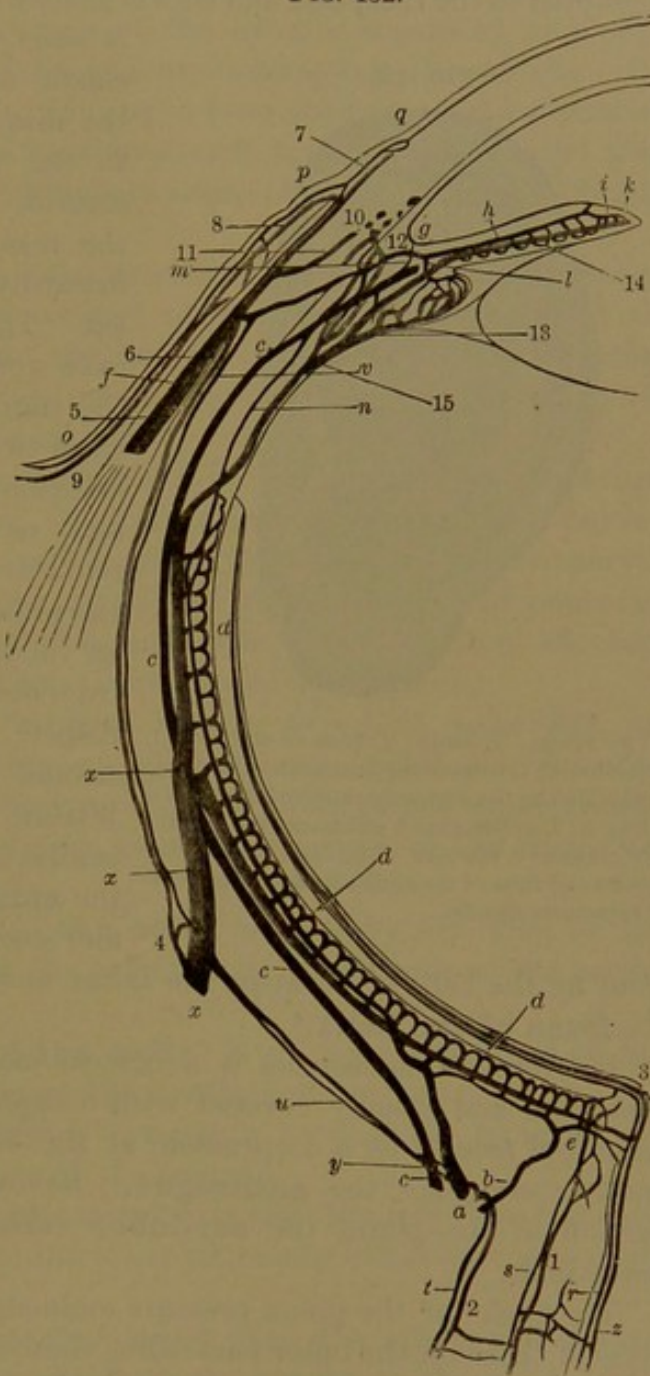
<sup>2</sup> Vasa capsularia lentis.

<sup>4</sup> Camera oculi anterior et posterior.



FIG. 452.—DIAGRAM OF THE BLOOD-VESSELS OF THE EYE. *a*, large anterior, and *b*, small posterior branches of a short ciliary artery perforating the sclerotica; *c*, a long ciliary artery; *d*, choroid capillary plexus; *e*, branches of the short ciliary artery to the optic nerve; *f*, anterior ciliary artery; *g*, arterial circle of the iris formed mainly by the long ciliary arteries; *h*, artery from the circle to the iris; *i*, arterial circle of the pupil; *k*, capillary zone of the sphincter of the pupil; *l*, artery to the ciliary process; *m*, artery to the ciliary muscle; *n*, branch from a short ciliary artery to the circle of the iris; *o*, conjunctival artery; *p*, branch to the arterial zone, *q*, at the border of the cornea; *r*, central artery of the retina; *s*, branch to the inner sheath of the optic nerve; *t*, branch to the outer sheath; *u*, branch from a short ciliary artery to the sclerotica; *v*, branch to the same from an anterior ciliary artery; *x*, a choroid vein from a vortex of the choroidea; *y*, posterior ciliary vein; *z*, central vein of the retina. 1, vein of the inner sheath of the optic nerve; 2, vein of the outer sheath; 3, vein and artery of the retina; 4, sclerotic vein joining the choroid vein; 5, anterior ciliary vein; 6, junction of sclerotic vein with the latter; 7, vein from the capillary zone at the border of the sclerotica and cornea; 8, anterior conjunctival vein; 9, posterior conjunctival vein; 10, venous circular ciliary plexus (canal of Schlemm); 11, connection of the latter with an anterior ciliary vein; 12, vein from the ciliary muscle ending in the circular ciliary plexus; 13, vein of a ciliary process; 14, vein of the iris; 15, vein of a ciliary process and muscle joining the vorticos veins of the choroidea.

FIG. 452.



## THE EARS.

The ear,<sup>1</sup> or organ of hearing,<sup>2</sup> is divisible into the external, the middle, and the internal ear.

### THE EXTERNAL EAR.

This includes the pinna, the portion of the ear which projects from the side of the head, and the auditory meatus, which leads to the middle ear and is closed at bottom by the tympanic membrane.

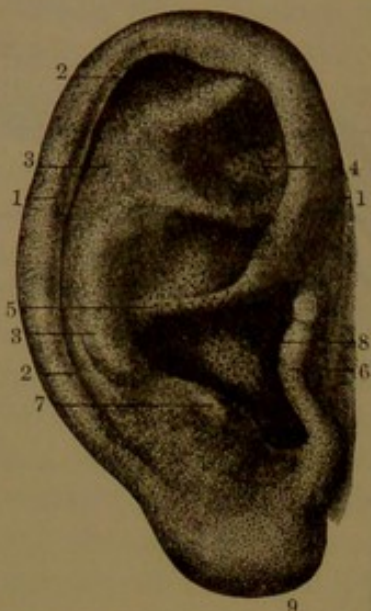<sup>1</sup> Auris.

<sup>2</sup> Organon auditus.



The **pinna**, or **auricle**,<sup>1</sup> the only outer or visible portion of the ear, is adapted to the reception and convergence of sounds to the meatus. It

FIG. 453.



THE PINNA. 1, helix; 2, fossa of the helix; 3, antihelix; 4, fossa of the antihelix; 5, concha subdivided by the commencement of the helix; 6, tragus; 7, antitragus; 8, entrance of the auditory meatus; 9, the lobe. The large dots in the concha and fossa of the antihelix are the orifices of sebaceous glands.

is chiefly composed of a plate of elastic fibro-cartilage invested by the skin, and is movably appended to the entrance of the osseous meatus. Mainly projecting behind the meatus, the surface directed inwardly is called the back of the ear. The largest and deepest concave recess of its outer surface, the **concha**, directly communicates with the meatus, the entrance of which is vertically oval and narrows inwardly. About two-thirds of the circumference of the pinna is formed by the **helix**,<sup>2</sup> an incurved ridge which springs from near the centre of the concha, thence passes up in front and around backward and downward. Within the position of the helix, behind the concha is another ridge, the **antihelix**, which forks above and encloses a fossa<sup>3</sup> bounded in

front by the helix. Between the latter and the antihelix is a groove, the **fossa of the helix**.<sup>4</sup>

In front of the concha is a conical eminence, the **tragus**,<sup>5</sup> bent backward and usually covered with conspicuous hairs. Behind this, separated from it by a deep notch, at the outer part of the concha is another eminence, the **antitragus**. Below it is the soft, pendulous portion of the pinna, the **ear-lobe**,<sup>6</sup> variably produced in different individuals.

The back<sup>7</sup> of the pinna presents eminences and depressions the reverse of those on the outer part: thus there are three successive prominences which accord with the fossæ of the helix, antihelix, and concha.

The **cartilage of the pinna**,<sup>8</sup> of nearly uniform thickness, and invested with perichondrium, conforms to the outward appearance of the pinna, of which it forms the basis, but does not enter into the composition of the ear-lobe, which is a pouch of skin filled with areolar tissue and fat.

<sup>1</sup> Auricula; pavilion.

<sup>2</sup> Fossa triangularis, innominata, or ovalis.

<sup>4</sup> F. scaphoidea or navicularis; scapha.

<sup>6</sup> Lobulus.

<sup>7</sup> Dorsum auriculæ.

<sup>2</sup> Capreolus.

<sup>5</sup> Hircus.

<sup>8</sup> Cartilago auris.



From the fore part of the helix a conical process<sup>1</sup> of the cartilage projects forward and gives attachment to the preauricular muscle. The lower end of the cartilage of the helix is separated by a deep cleft from that of the antihelix and tapers away into the ear-lobe. The portion of the cartilage contributing to form the meatus and producing the tragus is also separated by a deep cleft inwardly and behind from that of the concha. The contiguous edges of the clefts are united by connective tissue.

The skin of the pinna adheres closely to the subjacent perichondrium, loosely behind the ear and on the helix, but tightly on the outer part, especially within the fossæ. It has the common structure, but the sebaceous glands are more abundant than usual within the concha and the fossa of the antihelix.

Of the ligaments of the pinna, there are two which serve to connect it with the side of the head. The **anterior auricular ligament** is a strong fibrous band which extends from the process at the fore part of the cartilage of the helix to the root of the zygoma. The **posterior auricular ligament** is a fibrous band which extends from the back of the concha to the outer surface of the mastoid process.

Besides the auricular muscles already described, page 248, the pinna is provided with others, of which four are situated on the outer part and another at the back of the ear. Two of the outer muscles occupy the fore part of the helix, two the outer part of the tragus and antitragus.

The **smaller muscle of the helix**<sup>2</sup> is a fleshy slip lying on and attached to the cartilage of the helix where it springs from the bottom of the concha.

The **larger muscle of the helix**<sup>3</sup> is a longer slip lying on and attached to the front border of the cartilage of the helix.

The **muscle of the tragus**<sup>4</sup> is a nearly vertical slip lying on and attached to the outer surface of the tragus.

The **muscle of the antitragus**<sup>5</sup> extends obliquely from the outer surface of the antitragus to the lower extremity of the cartilage of the helix.

The **transversalis muscle**,<sup>6</sup> larger than the others and situated on the back of the ear, extends from the concha to the ridge of the helix across the intervening groove.

The muscles of the pinna are composed of striped fibres, but their office is obscure. They are probably rudiments of more important ancestral organs.

The **auditory meatus**<sup>7</sup> extends from the concha to the tympanum,

<sup>1</sup> Spina helicis; processus acutus helicis.

<sup>2</sup> Musculus helicis minor.

<sup>4</sup> M. tragicus.

<sup>6</sup> M. transversalis auriculæ.

<sup>3</sup> M. helicis major.

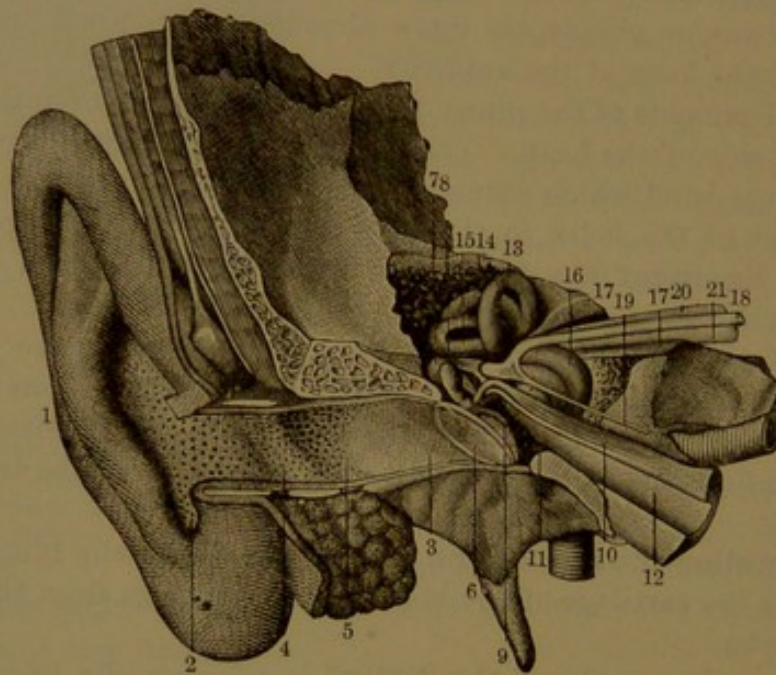
<sup>5</sup> M. antitragicus.

<sup>7</sup> M. auditorius externus.



to which it conveys sounds from the exterior. With an inclination from without inward and forward, conforming to that of the petrosal, it curves upward and then downward and pursues a somewhat sinuous course. From an inch to an inch and a quarter long, it is narrowest about the middle, is oval in cross-section, widest vertically at the outer part and widest fore and aft at the inner extremity. The bottom is closed by the tympanic membrane, which is obliquely inclined from above downward and inward, at an angle of about fifty degrees to the axis of the meatus and at about one-half that angle to the inner

FIG. 454.



GENERAL VIEW OF THE EAR, RIGHT SIDE, LAID OPEN FROM THE FRONT. 1, pinna; 2, concha; 3, auditory meatus; 5, ceruminous glands; 6, tympanic membrane; 7, incus; 8, malleus; 9, its handle inserted into the tympanic membrane; 10, tympanic tensor muscle; 11, cavity of the tympanum; 12, eustachian tube; 13, 14, 15, the three semicircular canals; 16, cochlea; 17, the internal auditory meatus; 18, facial nerve; 19, superficial petrosal nerve to the geniculate ganglion; 20, 21, auditory nerve.

extremity of the floor. The meatus consists of an outer portion extending from the pinna and an inner osseous portion, both lined by a prolongation of the skin.

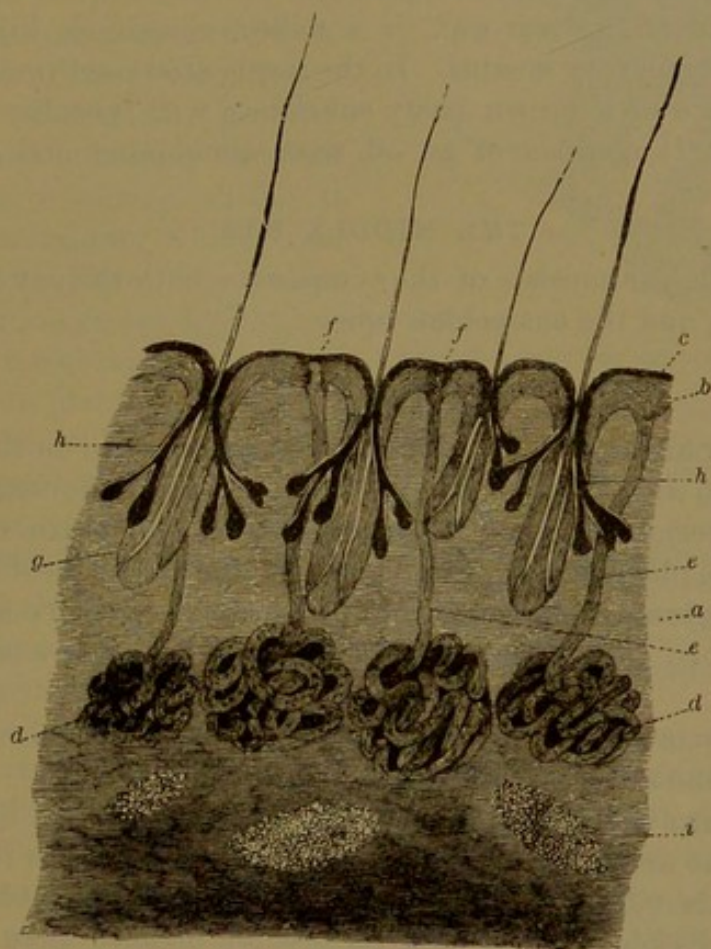
The **cartilage of the meatus** is a wide curved plate occupying the outer fore part of the passage and continuous by a strip with the rest of the pinna. In front, the plate is quadrate in outline; its outer border forms the prominence of the tragus. Beneath, it forms a triangle with the apex directed inward and occupies the space between the mastoid and postglenoid processes. Its inner border is attached by connective tissue to the auditory process. The wide interval of the plate behind the meatus is completed by a layer of connective tissue, which is attached to the upper and back border of the osseous meatus and outwardly to the border of the cartilage of the concha. The plate



has two or three elliptical fissures<sup>1</sup> which are closed by connective tissue.

The **osseous portion of the meatus**, a little longer and narrower than the outer portion, is formed above by the auditory plate of the squamosal and below by the tympanic plate. The auditory plate extends inwardly to the tympanum, where it terminates in an acute

FIG. 455.



SECTION THROUGH THE SKIN OF THE AUDITORY MEATUS: magnified twenty diameters. *a*, dermis; *b*, *c*, rete and cuticle of the epidermis; *d*, ceruminous glands; *e*, their ducts; *f*, outlet of ducts; *g*, hair-follicles; *h*, sebaceous glands; *i*, masses of fat.

margin. The tympanic plate is involute, so as to form the floor and sides of the meatus, at the inner end of which it is grooved for the insertion of the tympanic membrane.

The skin of the meatus is continuous with that of the pinna, and in the outer portion of the passage, in most respects, is like it. In the inner portion of the meatus it is very thin, tightly adheres to the subjacent periosteum, and is extended over the tympanic membrane, of which it forms the external layer. In the outer portion of the meatus it closely adheres to the subjacent structures and is furnished with

<sup>1</sup> Incisura Santorini.



numerous hairs and sebaceous glands, which diminish at the commencement and altogether disappear in the inner portion of the passage. In the subcutaneous tissue of the outer portion of the meatus are numerous brownish-yellow, spheroidal bodies, the **ceruminous glands**,<sup>1</sup> which secrete the cerumen, or ear-wax. They resemble in structure the sweat-glands, but are larger. Their ducts open on the surface, in the interval of the hairs, and are quite obvious after the detachment of the cuticle. The glands are absent in the osseous portion of the meatus except along the roof.

The **cerumen**, or ear-wax, is a milky, oleaginous liquid, which lubricates the auditory meatus. In the inspissated condition it assumes the appearance of a brown pasty substance, with peculiar smell and bitter taste. It consists of an oil, with albuminoid and a little extractive matter.

#### THE MIDDLE EAR.

The middle ear consists of the tympanum, with the ear ossicles, the mastoid cells, and the eustachian tube.

#### THE TYMPANUM.

The **tympanum**,<sup>2</sup> or **ear-drum**, is an air-chamber in the temporal bone between the auditory meatus and the labyrinth, communicating with the exterior air indirectly through the eustachian tube, which opens into the pharynx. Within the tympanum is a series of little bones, the **ear ossicles**, which are movably articulated with one another and extend between the tympanic membrane and the oval window of the labyrinth.

The tympanum may be conveniently divided into three portions, the atrium, the attic, and the antrum.

The **atrium** of the tympanum is the portion visible in the prepared temporal bone at the bottom of the auditory meatus. In the ordinary condition it is closed outwardly by the tympanic membrane. It is a biconcave discoidal cavity of little greater breadth than that membrane, is about a line in depth centrally from without inwardly, increasing to about two lines towards the borders. Its inner wall is formed by the labyrinth; above, it is continuous with the attic and at the fore part is prolonged into the eustachian tube.

In the prepared temporal bone the attic exhibits the following important parts. Outwardly is the **tympanic orifice**, an obliquely oval ring, into which the tympanic membrane is inserted, closing the auditory meatus from the tympanum. The lower part and sides of the orifice are formed by the tympanic margin of the tympanic plate, which is grooved for the reception of the tympanic membrane and ends above in a pair of slightly projecting points.<sup>3</sup> The interval

<sup>1</sup> Glandulæ ceruminosæ.

<sup>2</sup> Cavitas tympani; c. antrorsa auris.

<sup>3</sup> Spina tympanica major and minor.



of these points, the **tympanic notch**,<sup>1</sup> is completed by the sharp tympanic margin of the auditory plate of the squamosal.

On the inner wall of the atrium, opposite the tympanic orifice, is the **promontory**,<sup>2</sup> a conspicuous convex eminence, produced by the outward projection of the cochlea. Its surface is marked by a branching groove, which ascends from a fine canal in the floor of the atrium and accommodates the tympanic branch of the glosso-pharyngeal nerve. Behind the promontory is a niche looking outward and backward, having within it the **round window**,<sup>3</sup> which communicates with the cochlea, in the recent condition closed by the entotympanic membrane.

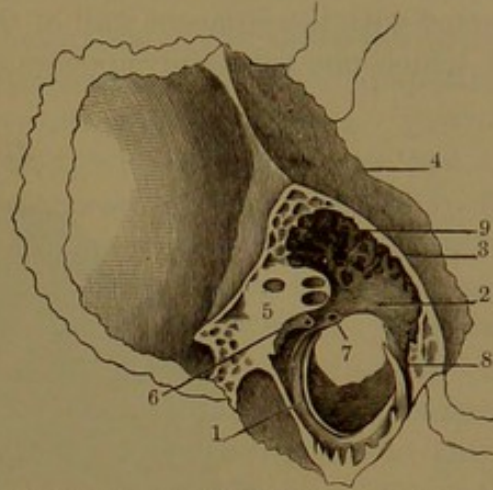
Above the promontory is a recess, in which is the **oval window**,<sup>4</sup> a larger aperture than the former, communicating with the vestibule. The window looks outward and is half oval with the convex border upward. In the complete condition of the ear it is closed by the base of the stapes.

In advance of the promontory is the **tympanic tensor receptacle**,<sup>5</sup> a cylindrical tube, about half an inch long, which extends from in front of the oval window obliquely downward and inward above the eustachian tube. Its upper, posterior end<sup>6</sup> is narrowed, curves outwardly, and projects into the atrium, into which it opens. Its lower, anterior end opens beneath the end of the tympanic tegmen, above the lower orifice of the osseous portion of the eustachian tube. Commonly, in the prepared bone, the receptacle is incomplete along its outer part, when it appears as an open scroll-like shelf,<sup>7</sup> which in the recent state is completed by fibrous membrane.

The receptacle encloses the tympanic tensor muscle.

The **posterior wall** of the atrium is uneven. It encloses the

FIG. 456.



SECTION ACROSS THE PYRAMID OF THE LEFT TEMPORAL BONE, giving a view of the outer boundary of the tympanic cavity. 1, tympanic orifice of the atrium, with groove for the tympanic membrane; 2, tympanic scute forming the outer wall of the attic; 3, tympanic tegmen; 4, petro-squamosal fissure; 5, supra-promontory, with orifices above, of the inferior semicircular canal and below of the facial canal; 6, pyramid; 7, orifice of entrance of the tympanic branch of the facial nerve; 8, glenoid canal, the exit of the same branch; 9, antrum and mastoid cells.

<sup>1</sup> Notch of Rivini.

<sup>2</sup> Promontorium; tuber cochleæ.

<sup>3</sup> Fenestra rotunda, cochleæ, or triquetra; foramen rotundum or posterius; porta labyrinthi.

<sup>4</sup> Fenestra ovalis, semi-ovalis, or vestibuli; foramen ovale.

<sup>5</sup> Canalis tensoris tympani.

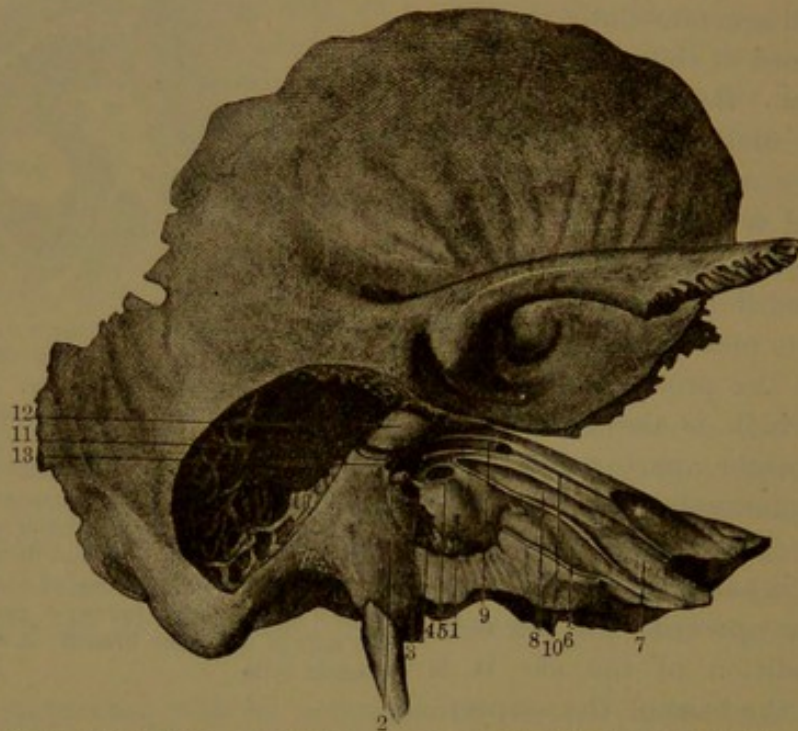
<sup>6</sup> Rostrum cochleare.

<sup>7</sup> Semi-canal tensoris tympani; sulcus muscularis tympani; processus cochleariformis.



descending portion of the facial canal and the **stapedial receptacle**, which is situated in advance of the canal and is about a third of an inch long. Its upper end is narrowed, curves forward, and projects into the atrium as a little conical process, the **pyramid**,<sup>1</sup> from the end of which the receptacle opens into the atrium. The pyramid is connected with the adjacent wall of the atrium by several diverging ridges, of which one commonly appears as a little bar extending to the prom-

FIG. 457.



CAVITY OF THE TYMPANUM; exposed by removing part of the bone, right side. The atrium opposite the auditory meatus, 1, promontory; 2, pyramid; 3, bar connecting it with the promontory; 4, round window; 5, oval window; 6, eustachian tube; 7, surface of attachment of the cartilage of the tube; 8, receptacle of the tympanic tensor muscle; 9, facial canal, laid open; 10, canal for the superficial petrosal nerve; 11, antrum and mastoid cells; 12, supra-promontory on the inner wall of the attic; 13, entrance of the tympanic branch of the facial nerve.

ontory. Around its base are several fossæ. The stapedial receptacle communicates with the facial canal by an aperture for the passage of the vessels and nerve of the stapedial muscle, and often by a larger opening which is closed by fibrous membrane.

Close to the tympanic orifice, in the posterior wall of the atrium, a fine canal,<sup>2</sup> ascending from the lower part of the facial canal, opens into the atrium and transmits the tympanic branch of the facial nerve.

The **anterior part** of the atrium above is prolonged obliquely downward, forward, and inward as the upper division or osseous portion of the eustachian tube. Above the communication of the tube, just within the anterior margin of the tympanic orifice, is the **glenoid**

<sup>1</sup> Pyramis; eminentia pyramidalis or papillaris.

<sup>2</sup> Canalis chordæ.



**canal,**<sup>1</sup> a short passage which descends through the glenoid fissure. It receives the long process of the malleus and gives exit to the tympanic branch of the facial nerve.

The **floor** of the atrium is a wide semicircular groove, extending between the posterior wall and fore part of the atrium, uneven and cellular.

The **attic**<sup>2</sup> of the tympanum is a pyramidal cavity above the atrium, with which it communicates by a horizontal, fore and aft oval aperture. It opens upward, backward, and outward into the antrum. In front it is bounded by the tympanic tegmen, which forms for it and the antrum a continuous sloping roof. Outwardly it is bounded by the **tympanic scute**, a broad crescentic plate ascending from the auditory plate of the squamosal, separating the attic from the outer mastoid cells. The lower concave edge of the scute corresponds with the tympanic margin of the auditory plate and forms the tympanic notch at the top of the tympanic orifice. Inwardly the attic is bounded by the **suprapromontory**,<sup>3</sup> which overhangs the promontory of the atrium and is a conspicuous convex eminence produced by the course of the facial canal over the oval window and the inferior semicircular canal above.

The **antrum**,<sup>4</sup> the highest portion of the tympanum, is a variable-sized, pouch-like cavity prolonged from the attic upward, backward, and outward in the commencement of the mastoid cells, by which it is surrounded. It is more or less irregularly extended downward among the cells of the mastoid process. Frequently a smaller passage is directed outward and upward among the cells of the squamosal over the position of the auditory meatus.

While the atrium varies little in size in different individuals, the attic and antrum vary greatly in capacity, ranging from one to six times.

The **mastoid cells**<sup>5</sup> mainly occupy the interior of the mastoid portion of the temporal bone, especially the mastoid process, but also extend into the contiguous portion of the squamosal above the auditory meatus and on the under side of the tympanic tegmen. In the prepared bone they resemble the ordinary spongy substance, but are of relatively greater capacity and are differentiated, from that substance in other parts of the temporal bone, as air-cavities, communicating with one another and with the antrum. With the advance of age the number of cells appears to diminish through coalescence, and thus they acquire increased capacity. Ordinarily the largest cells occupy the mastoid process. In old age some of them occasionally even exceed in size the antrum into which they open.

<sup>1</sup> Canal of Huguier.

<sup>2</sup> Recessus epitympanicus.

<sup>3</sup> Suprapromontorium; canal petro-mastoidien, of Sappey.

<sup>4</sup> Antrum mastoideum; aditus ad cellulus.

<sup>5</sup> Cellulæ mastoideæ; mastoid sinuses.



## THE TYMPANIC MEMBRANE.

The **tympanic membrane**<sup>1</sup> closes the cavity of the tympanum at the bottom of the auditory meatus. It is variably oval to nearly circular and is about five lines in diameter. It is inserted obliquely, at an angle of about fifty degrees, into the tympanic orifice of the meatus, into which its external face is directed with a downward inclination. Externally it is centrally depressed in a shallow funnel-like manner, and is conformably prominent internally.

The handle of the malleus is inserted into the tympanic membrane, descending between its middle and internal layers to the centre. The short process of the malleus directed outward produces a corresponding prominence of the membrane, a little below its upper border.

The tympanic membrane is thin, translucent grayish, and composed of three layers, of which the middle layer especially pertains to it, while the external layer<sup>2</sup> is an extension of the skin of the auditory meatus, and the internal layer<sup>3</sup> a continuation of the lining mucous membrane of the tympanum.

The **middle layer**<sup>4</sup> of the tympanic membrane is for the most part composed of two strata of fibro-connective-tissue bundles. In the outer, thicker stratum the bundles radiate from the insertion of the handle of the malleus to the circumference of the membrane. The inner stratum consists of circular fibres which are most abundant at the circumference, where they form an annular ligament,<sup>5</sup> occupying the groove in the tympanic margin of the tympanic plate and continuous with the adjacent periosteum. In the tympanic notch, a triangular segment of the middle layer of the tympanic membrane, between the short process of the malleus and the tympanic margin of the auditory plate, is formed by a looser texture of connective tissue.<sup>6</sup>

The **entotympanic membrane**<sup>7</sup> closes the round window of the labyrinth and separates the tympanic passage of the cochlea from the cavity of the tympanum. Like the tympanic membrane, it is composed of a middle fibro-connective-tissue layer in conjunction with the lining membranes of the adjacent cavities.

## THE EUSTACHIAN TUBE.

The **eustachian tube**<sup>8</sup> is a passage through which the tympanum communicates with the pharynx. It commences in the tympanum im-

<sup>1</sup> Membrana tympani; septum membranaceum auris; ear-drum.

<sup>2</sup> Stratum cutaneum or externum; cuticula membranæ tympani; dermoid layer.

<sup>3</sup> Stratum tympanicum or internum; lamina mucosa.

<sup>4</sup> Lamina fibrosa or propria.

<sup>5</sup> Annulus cartilagineus.

<sup>6</sup> Membrana flaccida; Rivinian segment.

<sup>7</sup> Secondary membrane of the tympanum; membrana tympani secundaria.

<sup>8</sup> Tuba Eustachii or acustica; salpinx; canalis gutturalis or palatinus tympani; ear-trumpet.



mediately in advance of the tympanic membrane and descends obliquely forward, inward, and downward to open at the side of the pharynx, about half an inch behind the lower turbinal of the nose. It is trumpet-shaped, about an inch and a quarter or more in length, and is widest at the inner extremity. It consists of an upper or outer osseous portion and a lower or inner cartilaginous and partly fibrous portion, and is lined throughout by mucous membrane continuous with that of the tympanum and pharynx.

The osseous portion, about one-third of the tube, more open than the rest, is trilateral cylindroid, widest at the commencement, narrowing rapidly at first, then more gradually to the inner end at the notch between the pyramid and squamosal of the temporal bone.

The inner portion of the tube is laterally compressed conical and gradually widens from the osseous portion to the **pharyngeal orifice**, which is obliquely oval. In cross-section its passage appears as a vertical and narrow elliptical fissure, widened at the upper extremity<sup>1</sup> and expanding at the pharyngeal orifice. The cartilage is a thick, elongated, triangular plate, bent scroll-like, situated along the upper and inner part of the tube. Its anterior thinner border is bent outward and backward on itself; the posterior border at the lower extremity is in a less degree bent outward and forward. The interval of the two borders of the cartilage, below and outward, is occupied by a connective-tissue layer, which completes the tube in this position. The border of the cartilage at the pharyngeal orifice is thick and obtusely rounded and forms a prominent arch above the opening. The cartilage is attached above to the dense connective tissue occupying the groove between the temporal pyramid and the sphenoidal angular process; at its inner extremity it is attached to the inner side of the root of the internal pterygoid process. In contact with it outward and behind and partially giving origin to it is the palatal elevator muscle, and in advance of this is the palatal tensor, an offset of which is connected with the anterior border of the cartilage.

#### THE EAR OSSICLES.

Three little bones, the **ear ossicles**,<sup>2</sup> are contained within the tympanum, articulated in a chain between the tympanic membrane and the oval window of the labyrinth, so as to transmit the vibrations of sound from the membrane to the labyrinth. In the order of their succession from without inward they are the malleus, incus, and stapes.

The **malleus**,<sup>3</sup> the anterior and largest of the ossicles, is a bent club-shaped bone, placed vertically with the head uppermost and with a process, as long or longer than the handle, directed at a right angle

<sup>1</sup> Safety-tube of Rüdinger.

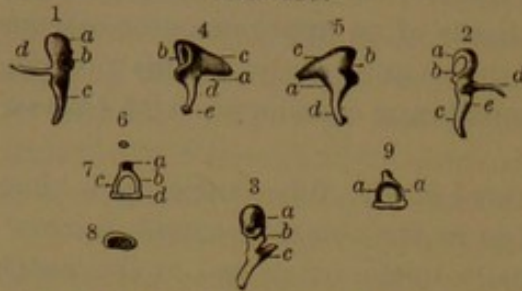
<sup>2</sup> Ossicula auditus or aurium.

<sup>3</sup> Hammer; mallet.



forward from the middle. The **head**,<sup>1</sup> nearly half the length of the bone, is irregularly ovoid, thickest and rounded at the upper extremity.

FIG. 458.



EAR OSSICLES. 1. Malleus seen on its inner surface. *a*, head; *b*, articular surface for the incus; *c*, handle; *d*, the long process. 2. Malleus seen on its outer surface. *a*, head; *b*, articular surface; *c*, handle; *d*, long process; *e*, short process. 3. Malleus seen from behind. *a*, head and articular facet; *b*, short process; *c*, long process. 4. Incus seen on its inner surface. *a*, body; *b*, articular facet for the malleus; *c*, superior process; *d*, inferior process; *e*, lenticular process. 5. Incus seen on its outer surface. *a*, body; *b*, articular facet; *c*, *d*, superior and inferior processes. 6. Lenticular process, at birth a distinct bone. 7. Stapes. *a*, head; *b*, *c*, crura; *d*, base. 8. Base of the stapes, which is applied to the oval window. 9. Stapes cut so as to exhibit the groove on the inner side of its crura, *a*.

Crossing it obliquely behind from above downward and inward is an elliptical, slightly prominent articular plate, bent and slightly narrowed at the middle, convex in the long and concave in the short diameter. In the fresh state the plate is covered by cartilage and articulates with the incus.

Below the head is the short **neck**,<sup>2</sup> compressed from without inward, and giving off from its fore part the **long process**.<sup>3</sup> This is a slender spicule, which extends forward with an outward curve and is received within the glenoid canal. It is flattened, often expanded towards the end, where it tapers to a point. Well produced at birth, commonly with the advance of life it undergoes retrograde metamorphosis and becomes

fibrous and continuous with the anterior ligament of the malleus. It is the upper remaining extremity of the cartilage of Meckel.

The **handle**<sup>4</sup> of the malleus makes a sigmoid twist with the neck and in its descent is bent inward. It is flattened triangular, viewed in front or behind, is rounded and tapering below, and terminates in a rounded end. Its base projects outward in a little cone, the **short process**<sup>5</sup> of the malleus, which produces a corresponding prominence of the tympanic membrane.

The **incus**,<sup>6</sup> broader but shorter than the malleus, is situated behind and internal to it. It is a flattened quadrate bone extending behind in two tapering and somewhat divergent processes, and with its broad surfaces directed outward and inward. It is thickest in front, where it presents an articular plate conformable to that of the malleus; obliquely elliptical, narrowed at the middle, concave in the long and convex in the short diameter. The **superior process**,<sup>7</sup> directed backward and downward from the body, is flattened triangular viewed from with-

<sup>1</sup> Capitulum.<sup>2</sup> Cervix; collum.<sup>3</sup> Processus longus, gracilis, tenuis, anterior, or tertius.<sup>4</sup> Manubrium; processus inferior or primus; pedunculus; cauda.<sup>5</sup> Processus brevis, externus, conoideus, or secundus; tuberculum mallei.<sup>6</sup> Anvil. <sup>7</sup> Short process; processus brevis, superior, posterior, or transversus.



out or within. The **inferior process**,<sup>1</sup> slightly longer than the superior, diverges from it, descending into the atrium. It is more abruptly tapering into an elongated cone, slightly bent inward at the point, to which is attached the **lenticular process**.<sup>2</sup> This is a minute button-like disk connected by a narrow pedicle with the incus, tipped with cartilage in the recent state and articulating with the stapes. In infancy the process is a separate ossicle,<sup>3</sup> but it quickly ankyloses with the incus.

The **stapes**,<sup>4</sup> the smallest and innermost of the ossicles, resembles in shape a stirrup. The **head**<sup>5</sup> is a short, flattened cylindrical process ending in a transverse oval discoid surface which articulates with the lenticular process of the incus. From the head extend the arching **crura** to join the base of the bone. They are inwardly grooved, and with the base include an arch-like aperture, which is closed in the fresh condition by a drum-like membrane<sup>6</sup> invested with the mucous membrane enveloping the bone. The **anterior crus**<sup>7</sup> is slightly shorter and less curved than the **posterior crus**.<sup>8</sup> The **base**<sup>9</sup> of the stapes is a half-oval or slightly-reniform plate which conforms to the oval window it occupies.

#### ARTICULATION AND CONNECTION OF THE EAR OSSICLES.

The ear ossicles are movably articulated with one another by synovial-lined joints, and are connected with the adjacent parts of the tympanum by ligaments and folds of the lining mucous membrane.

The head of the malleus and the greater part of the incus occupy the outer side of the attic, the former in front and articulated behind with the latter. The handle of the malleus and the inferior process of the incus descend into the atrium nearly parallel with each other, the former a little in advance and external to the latter. The stapes is situated in the atrium at its inner part just above and behind the centre, directed from the end of the inferior process of the incus horizontally inward to the oval window, which it closes.

The handle of the malleus is inserted into the tympanic membrane, descending between the internal and middle layers to about the centre; its short process is directed outwardly and produces a slight projection of the membrane a little below the upper border.

The base of the stapes, on its inner or vestibular surface, is invested with cartilage, as is likewise the case with the border of the oval

<sup>1</sup> Long process; p. longum, inferior, or anterior.

<sup>2</sup> Processus lenticularis; lenticulus; epiphysis incudis.

<sup>3</sup> Os lenticulare, orbiculare, or subrotundum; ossiculum ovale, semilunare, orbiculare, or Sylvii.

<sup>4</sup> Stapha; deltoidea; stirrup.

<sup>5</sup> Capitulum.

<sup>6</sup> Membrana obturatoria stapedis; ligamentum obturatorium stapedis.

<sup>7</sup> Crus anterior or rectilineum.

<sup>8</sup> C. posterius or curvilineum.

<sup>9</sup> Basis.



window of the vestibule, into which the base of the stapes is fitted and united by a fibro-elastic **annular ligament**.

The articulation between the head of the malleus and the body of the incus is hinge-like. The opposed surfaces are covered with cartilage, and the joint is enclosed by a capsular ligament lined with synovial membrane.

The articulation between the head of the stapes and the lenticular process of the incus is provided with a capsular ligament usually lined by a synovial membrane, though sometimes the cavity is absent.

The malleus is attached to the adjacent parts of the tympanic wall by three ligaments. The **anterior ligament**<sup>1</sup> is a comparatively strong fasciculus extending from the root of the long process of the malleus and attaching it to the fore part of the tympanum and the sides of the glenoid canal. The anterior ligament has been regarded as a muscle.<sup>2</sup> The **external ligament**<sup>3</sup> is a thin band extending from the short process to the contiguous portion of the tympanic scute. The **suspensory ligament**<sup>4</sup> is a slender cord attaching the head of the malleus to the roof of the attic.

The **ligaments of the incus**<sup>5</sup> usually consist of a pair of little fibrous bundles which diverge from the end of the posterior process to the adjacent back part of the attic just below the entrance of the antrum.<sup>6</sup>

#### MUSCLES OF THE TYMPANUM.

The **tympanic tensor**<sup>7</sup> is a fusiform muscle which occupies the corresponding receptacle, arising from its lower part, from the contiguous portion of the cartilage of the eustachian tube and the sphenoid bone. It terminates in a rounded tendon which curves outward from the upper projecting end of the receptacle and is inserted to the inner side of the root of the handle of the malleus opposite its short process.

The **stapedial muscle**,<sup>8</sup> like the former, lodged within its osseous receptacle, arises from its bottom part. It ends in a rounded tendon which turns forward, issues from the pyramid, and is inserted into the back part of the head of the stapes.

Both muscles within their osseous receptacles are invested with a fibrous sheath, within which they freely move.

The tympanic tensor draws the malleus inward, and thus renders

<sup>1</sup> Ligamentum mallei anterius.

<sup>2</sup> Musculus laxator tympani major.

<sup>3</sup> Lig. mallei externus.

<sup>4</sup> L. m. superius; l. suspensorium mallei.

<sup>5</sup> Lig. incudis posterius; ligamenta processus brevis incudis.

<sup>6</sup> Henle describes this connection as a synovial-lined articulation and represents it with a single fibrous ligament, Fig. 570, p. 743. Quain's Anatomy represents the ligament as consisting of three divergent bundles, Fig. 381, p. 442, 9th ed., 1882.

<sup>7</sup> Musculus tensor tympani; m. mallei internus; rotator mallei.

<sup>8</sup> M. stapedius; m. pyramido-stapedius; m. auris membranarum laxator.



the tympanic membrane more tense. From the connection of the malleus with the other ossicles pressure would be communicated to the oval window. The stapedial muscle from the direction of its action would in a measure antagonize the former muscle.

#### THE LINING MUCOUS MEMBRANE OF THE TYMPANUM.

The tympanum is lined throughout by a thin, pale-red mucous membrane, which also invests the ear ossicles and is continuous with that of the eustachian tube and mastoid cells. In several positions it forms more or less conspicuous folds.

The **suspensory fold** proceeds from the suspensory ligament of the malleus forward between its head and the tympanic tegmen and is continuous with the falcate and circular folds.

The **falcate fold** extends from the suspensory backward between the malleus and incus inwardly and the lower border of the tympanic scute outwardly. It forms a nearly horizontal septum and cuts off the communication between the attic and atrium in the interval of the ossicles and the tympanic scute; but is sometimes perforated.

The **circular fold** is stretched between the head of the malleus, its long process, the receptacle and tendon of the tympanic tensor. It also closes the fore part of the attic from the atrium, but is sometimes perforated, when it appears as an annular fold.

In the complete state of the tympanum the attic communicates with the atrium by a horizontal fore and aft reniform aperture, about two and a half lines long and scarcely a line wide, between the ossicles and the suprapromontory.

The **stapedial fold** encloses the stapes stretched across its aperture, but is occasionally perforated. It is sometimes extended from the stapes to the pyramid, and sometimes an offset ascends from it between the inferior process of the incus and the inner wall of the atrium.

The **cordal fold** encloses the tympanic branch of the facial nerve, attaching it to the tympanic scute as it passes across the tympanum between the incus and malleus. It gives offsets to the inferior process of the incus and to the handle of the malleus, and sometimes to the pyramid.

Other folds, variable and inconstant, proceed between adjacent parts of the tympanum, usually enclosing blood-vessels.

The mucous membrane adheres closely to the subjacent periosteum, and in positions in which the osseous surface is uneven it reduces the irregularities. On the tympanic membranes, on the promontory, on the ossicles, and in the attic and antrum, it is provided with an epithelium consisting of a single layer of polygonal pavement-cells. In other positions it is covered with a columnar ciliated epithelium.

The mastoid cells are lined by a thin, pale-red mucous membrane provided with a simple, polygonal pavement epithelium.

In the osseous portion of the eustachian tube the mucous membrane



is like that of the tympanum. In the inner cartilaginous and membranous portion it is thicker, and like that of the pharynx has numerous mucous glands. Throughout, it is furnished with ciliated columnar epithelium.

#### VESSELS AND NERVES OF THE TYMPANUM.

The lining membrane and other parts of the tympanum are supplied with arteries from a number of sources. The tympanic branch of the internal maxillary artery enters the tympanum through the glenoid canal. The tympanic branch of the stylo-mastoid artery enters the cavity in company with the tympanic branch of the facial nerve, accompanies it to the malleus, and descends upon the handle, whence it is distributed in radiating twigs to the tympanic membrane. By anastomosis with the former branch it produces an arterial circle around the border of the membrane. A branch from the internal carotid artery enters the tympanum from the carotid canal; several small ones in the cranium from the great meningeal artery enter through the petro-squamosal suture and the hiatus of the facial canal, and a branch from the ascending pharyngeal artery enters through the eustachian tube.

The mastoid cells are supplied with branches from the stylo-mastoid, posterior auricular, and occipital arteries.

The eustachian tube is supplied by the vidian, pterygo-palatine, ascending pharyngeal, and descending palatine arteries.

The veins of the tympanum, for the most part, pursue the course of the corresponding arteries. Some terminate in the temporo-maxillary and posterior auricular veins, others communicate with the internal jugular, and others pass through the petro-squamosal suture to the great meningeal veins.

The veins of the mastoid cells join the posterior auricular vein; those of the eustachian tube the accompanying veins of the arteries.

The nerves of the tympanum are mainly those of the tympanic plexus derived from the tympanic branch of the glosso-pharyngeal nerve, joined by a branch from the carotid plexus of the sympathetic, a filament from the great superficial petrosal nerve, and the small superficial petrosal nerve.

The tympanic tensor muscle is supplied by a branch from the otic ganglion; the stapedial muscle by a branch from the facial nerve.

The tympanic branch of the facial nerve traverses the tympanum, but does not supply it.

Lymphatics are numerous in the mucous membrane of the tympanum and its accessory parts. They commence in the usual manner, and the chief vessels accompany the temporo-maxillary and posterior auricular blood-vessels.



## THE INTERNAL EAR.

The internal ear includes the labyrinth, with the internal auditory meatus and the auditory nerve.

The **internal auditory meatus**,<sup>1</sup> situated within the cranial cavity, is a short, wide, cylindrical passage, directed outward from near the centre of the temporal pyramid. Its bottom is formed by a perforated plate, the **cribriform lamina**. It is occupied by the auditory and facial nerves and the auditory vessels.

The **cribriform lamina**<sup>2</sup> separates the labyrinth from the internal auditory meatus, in which it is concave and divided by a transverse ridge or **crest**<sup>3</sup> into two fossæ. In the upper fossa inwardly is an oval or reniform foramen, the entrance of the **facial canal**,<sup>4</sup> for the transmission of the facial nerve. To the outer side of the entrance of the canal is a circular recess with a group of minute foramina, which communicate with the vestibule of the labyrinth as its **superior cribriform spot**.<sup>5</sup> Several variable smaller groups of foramina occupy the outer part of the crest dividing the cribriform lamina and also communicate with the superior cribriform spot.

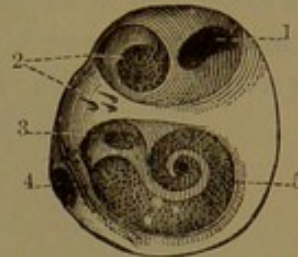
The lower, larger fossa of the cribriform lamina is mainly impressed with a **spiral tract**,<sup>6</sup> which is situated at the base of the **modiolus**, or axis of the cochlea. The tract is pierced with a multitude of minute foramina collected into little groups arranged in two rows. The foramina transmit the filaments of the cochlear division of the auditory nerve.

Above the outer extremity of the spiral tract is a slight recess with a group of minute foramina, which communicate with the **middle cribriform spot**<sup>7</sup> of the vestibule.

In the outer wall of the meatus near the bottom is a deep narrow pit, at the bottom of which is another group of minute foramina, which communicate with the **inferior cribriform spot**<sup>8</sup> of the ampulla of the posterior semicircular canal of the labyrinth.

The groups of foramina communicating with the cribriform spots transmit the filaments of the three branches of the vestibular division of the auditory nerve.

FIG. 459.



CRIBRIFORM PLATE OF THE LEFT INTERNAL AUDITORY MEATUS: magnified three times. 1, entrance of the facial canal; 2, superior cribriform spot; 3, middle cribriform spot; 4, canal leading to the inferior cribriform spot; 5, spiral tract.

<sup>1</sup> M. auditorius internus.

<sup>3</sup> Crista transversa.

<sup>5</sup> Macula cribrosa sup.

<sup>7</sup> Macula cribrosa media.

<sup>2</sup> L. cribrosa.

<sup>4</sup> Fallopian canal; canalis Fallopii.

<sup>6</sup> Tractus spiralis foraminulosus.

<sup>8</sup> M. cribrosa inf.



The auditory and facial nerves together enter the internal auditory meatus and proceed to the bottom, the facial lying in a groove at the outer part of the auditory nerve and with the auditory artery between them. The two nerves are connected by one or two small intervening filaments. Reaching the bottom of the meatus the facial nerve leaves the auditory nerve and pursues its further course through the facial canal, as described in another place. See page 794.

The **auditory nerve**<sup>1</sup> in the meatus divides into the vestibular and cochlear nerves, of which the former is the more external and posterior.

FIG. 460.

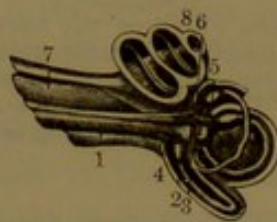
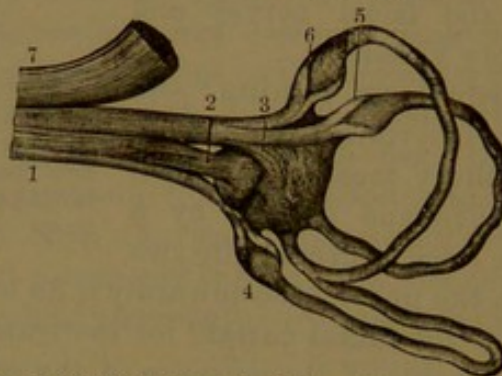


FIG. 461.



*Fig. 460.*—INTERNAL EAR LAID OPEN. 1, vestibular branch of the auditory nerve; 2, branch to the saccule; 3, branch to the utricle; 4, 5, 6, branches to the ampullæ of the membranous semicircular canals; 7, cochlear branch of the auditory nerve; 8, cochlea.

*Fig. 461.*—NERVES OF THE VESTIBULE AND SEMICIRCULAR CANALS, magnified three diameters. 1, vestibular branch of the auditory nerve; 2, branch to the saccule; 3, branch to the utricle; 4, 5, 6, branches to the ampullæ of the semicircular canals; 7, cochlear nerve.

The **vestibular nerve**,<sup>2</sup> after a slight enlargement,<sup>3</sup> divides into three branches. Of these the **superior branch** splits up into filaments, which pass through the foramina of the superior cribriform spot of the vestibule and form three bundles, of which one enters and terminates in the acoustic spot of the utricle, while the others proceed to terminate in the acoustic crests of the ampullæ of the superior and inferior semicircular canals. The **middle branch** splits up into filaments, which pass through the foramina of the middle cribriform spot of the vestibule and terminate in the acoustic spot of the saccule. The **inferior branch** enters the deep pit in the back wall of the meatus, passes through the inferior cribriform spot of the ampulla of the posterior semicircular canal, and terminates in its acoustic crest.

In the acoustic spots and crests the nerve-fibres of the terminal branches of the vestibular nerve appear to lose their medullary sheath, while the ultimate fibrils of the axis-fibres terminate by joining the auditory cells.

The **cochlear nerve**<sup>4</sup> breaks up into numerous bundles of nerve-

<sup>1</sup> Nervus auditorius; n. acusticus.

<sup>3</sup> Intumescencia gangliiformis.

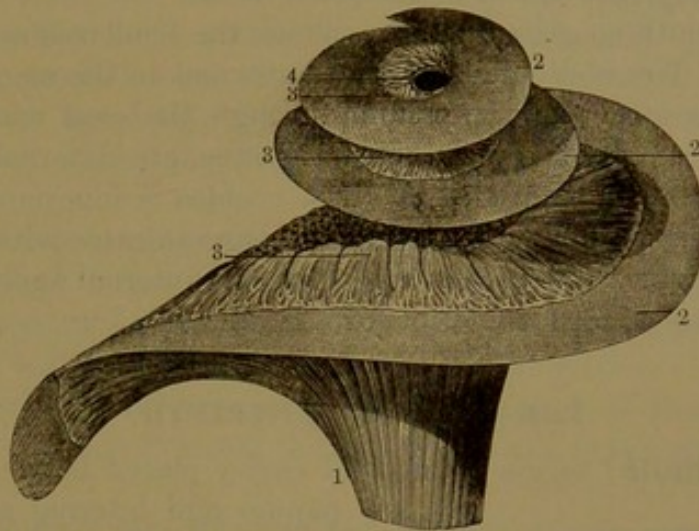
<sup>2</sup> N. vestibuli or vestibularis.

<sup>4</sup> N. cochlearis or cochleæ.



fibres, which enter the foramina of the spiral tract in the base of the modiolus. Proceeding through canals of the modiolus, the largest bundles centrally, the branches are successively reflected to the **spiral ganglion**,<sup>1</sup> which occupies the corresponding canal of the modiolus.

FIG. 462.



DISTRIBUTION OF THE COCHLEAR NERVE. 1, trunk of the cochlear nerve; 2, basilar membrane; 3, terminal filaments of the cochlear nerve emerging from the osseous spiral lamina to enter the cochlear duct; 4, orifice of communication of the tympanic and vestibular passages.

The ganglion consists of an intricate intertexture of the cochlear nerves with numerous bipolar nerve-cells. From it the nerve-fibres proceed through the canals of the spiral lamina, in which they conjoin in an intricate plexus, and finally emerge through a row of foramina of the basilar membrane along the tympanic lip of the spiral lamina. Here, losing their medullary sheath, the nerve axial fibres enter the acoustic organ, but their exact mode of termination has not been positively determined. According to Waldeyer, many of them appear to terminate by joining the auditory cells.

#### THE LABYRINTH.

The **labyrinth** is an exceedingly intricate portion of the ear, embedded in the dense osseous structure of the temporal pyramid, situated internally to the tympanum, with which it communicates. To it alone the auditory nerve is distributed, reaching it through the internal auditory meatus. It is an osseous receptacle with conformable membranous and other contents, and in description is usually considered in two parts, as the osseous and membranous labyrinth. Between the two is an interval occupied by a serous liquid, the perilymph, and the membranous labyrinth is filled with a similar liquid, the endolymph.

At the period of birth the labyrinth already appears, like the ear ossicles, of mature size, embedded in the temporal bone, with its position and shape partially defined and visible on the exterior of the pyr-

<sup>1</sup> Ganglion spirale; g. Cortii; habenula ganglionaris.



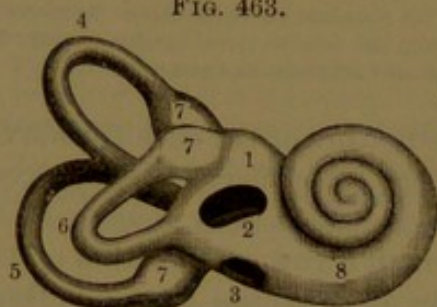
amid. In this condition it has a complete and dense osseous wall fused with the surrounding more spongy bone, from which it can readily be excavated with the knife. In the subsequent growth of the pyramid the labyrinth becomes more completely embedded and concealed from view, while the surrounding osseous substance becomes as dense as the wall of the labyrinth and is undefined from it.

The labyrinth consists of the vestibule, the semicircular canals, and the cochlea. The vestibule is intermediate, and in the macerated bone communicates with the tympanum through the oval window. The semicircular canals, of which there are three, are external to the vestibule and communicate with it. The cochlea is innermost, produces the promontory of the tympanum, and communicates with it through the round window. Its base is applied to the internal auditory meatus and contributes to form the cribriform lamina.

### THE OSSEOUS LABYRINTH.<sup>1</sup>

The **vestibule**<sup>2</sup> forms an ovoidal cavity placed between the tym-

FIG. 463.



THE RIGHT LABYRINTH; viewed outwardly in front: magnified two and a half times. 1, vestibule; 2, oval window; 3, round window; 4, superior semicircular canal; 5, posterior semicircular canal; 6, inferior semicircular canal; 7, ampullæ; 8, cochlea.

panum and internal auditory meatus, with the semicircular canals directed outward and backward and the cochlea inward and forward. In its outer wall is the **oval window**,<sup>3</sup> communicating with the tympanum, but closed by the base of the stapes.

At the inner fore part of the cavity of the vestibule are two concave recesses, of which the lower is the **hemispherical fossa**<sup>4</sup> and the upper the **hemi-elliptical fossa**.<sup>5</sup> They are separated by

a ridge, the **vestibular crest**,<sup>6</sup> which ascends from below and behind the hemispherical fossa, curves forward and outward between the two fossæ, and near the upper fore part of the oval window ends in a little **pyramidal eminence**.<sup>7</sup> Behind the two fossæ is a shallow furrow, the **sulciform fossa**,<sup>8</sup> into which opens a fine canal, the **vestibular aqueduct**.<sup>9</sup>

At the back of the vestibule are five circular holes which communi-

<sup>1</sup> Labyrinthus osseus or durus.

<sup>2</sup> Vestibulum.

<sup>3</sup> Fenestra ovalis; foramen ovale.

<sup>4</sup> Fossa hemisphærica, sphærica, orbicularis, rotunda, or subrotunda.

<sup>5</sup> Fossa hemi-elliptica, semi-ovalis, or ovalis.

<sup>6</sup> Crista vestibularis.

<sup>7</sup> Eminentia pyramidalis; pyramis vestibuli.

<sup>8</sup> Sinus sulciformis; sulcus ad aquæductum vestibuli; recessus labyrinthi.

<sup>9</sup> Aquæductus vestibuli.



cate with the semicircular canals. At its lower part, below the oval window, is a large elliptical pit, the **cochlear recess**,<sup>1</sup> which forms part of the cochlea, and in the macerated bone freely communicates with it and with the tympanum through the round window.

The **semicircular canals** are three horseshoe-like tubes, situated outwardly, behind and above the position of the vestibule, into which they open by five holes. They are of unequal length, cylindrical and slightly compressed laterally; each at one end is enlarged in a pyriform expansion, the **ampulla**.<sup>2</sup> The three canals are related in position with one another like three contiguous sides of a cube, inward, below, and behind.

The **superior semicircular canal**<sup>3</sup> is nearly vertical, directed fore and aft, internal to the others, and ascends highest.

The **posterior semicircular canal**<sup>4</sup> is the longest, and is directed from within outward and backward, behind the others.

The **inferior semicircular canal**<sup>5</sup> is shortest, is directed horizontally outward, and is external to the superior and in advance of the posterior canal.

The ampullæ of the superior and inferior canals occupy their fore ends, are contiguous, and open near together into the vestibule above the oval window. The ampulla of the posterior canal occupies its lower end and opens into the lower back part of the vestibule. The back end of the superior canal and the upper end of the posterior canal unite in a common canal which opens into the upper back part of the vestibule, while the back end of the inferior canal opens into it at its middle back part.

In the temporal bone at birth the internal semicircular canal produces an arching ridge across the middle of the upper border of the pyramid, usually with a deep recess beneath as large as the adjacent internal auditory meatus. In the mature bone the canal produces a conspicuous prominence at the upper fore part of the pyramid, with a remaining trace of the recess beneath. The summit of the posterior semicircular canal produces a less-marked ridge on the posterior surface of the pyramid, which also is visible at maturity. The inferior semicircular canal, with the facial canal, forms the suprapromontory of the tympanic attic.

Communicating with the vestibule and the ampulla of the posterior semicircular canal are three groups of minute foramina which transmit the filaments of the three branches of the vestibular division of the auditory nerve from the internal auditory meatus. The groups are circular, have a chalky appearance, and are distinguished as the **cribriform spots**.<sup>6</sup>

<sup>1</sup> Recessus cochlearis.

<sup>3</sup> Frontal.

<sup>5</sup> Horizontal, external, or middle.

<sup>2</sup> Sinus or recessus ampullaceus.

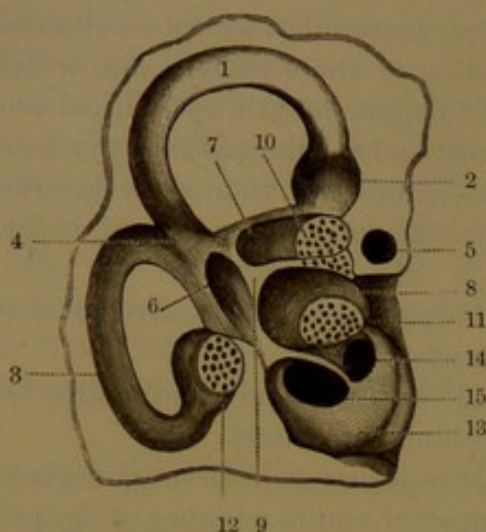
<sup>4</sup> Sagittal, internal, or inferior.

<sup>6</sup> Maculæ cribrosæ.



The **superior cribriform spot**, the largest, occupies the pyramidal eminence of the vestibular crest and the contiguous outer extremity of the hemi-elliptical fossa. The

FIG. 464.



INTERIOR OF THE VESTIBULE, SUPERIOR AND POSTERIOR SEMICIRCULAR CANALS; right side, looking from behind: magnified three diameters. 1, superior semicircular canal; 2, its ampulla; 3, posterior semicircular canal; 4, union of the two canals; 5, section of the facial canal; 6, sulciform fossa; 7, hemi-elliptical fossa; 8, hemispherical fossa; 9, vestibular crest; 10, superior, 11, middle, and 12, inferior cribriform spots; 13, promontory; 14, vestibular passage; 15, round window, communicating with the tympanic passage.

**middle cribriform spot** occupies the bottom of the hemispherical fossa. The **inferior cribriform spot** occupies the ampulla of the posterior semicircular canal.

The **cochlea**,<sup>1</sup> named from its resemblance to a snail-shell, forms the innermost of the three portions of the labyrinth. Situated to the inner side and in advance of the position of the vestibule, it communicates with its lower fore part. It is a cone wider than long, and is directed fore and aft, with its base applied to the internal auditory meatus and its apex contiguous to the bend of the carotid canal, close to the eustachian tube. It is completely concealed within the temporal pyramid, except that its commencement produces the promontory of the tympanum.

Inwardly its compact osseous wall is separated from the axis of the pyramid by spongy substance with marrow.

The cochlea is a cylindrical tube, the **cochlear canal**,<sup>2</sup> compressed fore and aft and somewhat tapering, wound spirally round a central axis, the modiolus. The canal makes about two and a half turns concentrically, the turns successively projecting forward and ending in a rounded summit, the **cupola**.<sup>3</sup> From its commencement in the promontory below the oval window, in each ear, it turns downward and inward, then upward and outward, and so on to the cupola.

The **modiolus**<sup>4</sup> is a spirally-grooved, conical column, in the first turn of the cochlea about as thick as it is long, but rapidly decreasing in the successive turns of the canal. Its bottom forms part of the cribriform lamina of the internal auditory meatus and is impressed by the spiral tract, the numerous foramina of which communicate with canals of the modiolus for the transmission of the cochlear nerves and blood-vessels.

From the modiolus, along the middle of the cochlear canal, projects

<sup>1</sup> Cavitas cochleata.

<sup>3</sup> Cupula.

<sup>2</sup> Canalis cochlearis; c. spiralis cochleæ.

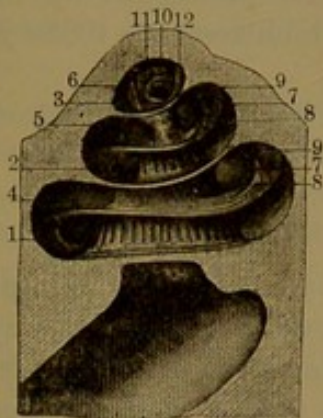
<sup>4</sup> Columella; pyramis.



a thin osseous shelf, the **spiral lamina**,<sup>1</sup> which extends about half-way across the canal. Widest at its commencement, it gradually narrows in its course and in the cupola ends in a little **hook**,<sup>2</sup> which projects from the summit of the modiolus.

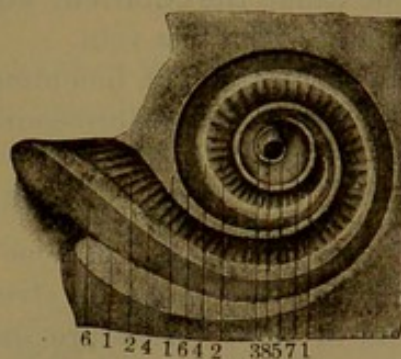
The spiral lamina divides the cochlear canal into two passages, which in the entire condition of the labyrinth are completely separated by the membranous cochlea. One of the passages, opening directly into the vestibule, is distinguished as the **vestibular passage**,<sup>3</sup> and the other,

FIG. 465.



THE COCHLEA, LAID OPEN, ITS SUMMIT TURNED UPWARD: magnified three diameters. 1, 2, 3, the tympanic passage; 4, 5, 6, the vestibular passage; 7, 8, osseous spiral lamina; 9, membranous spiral lamina; 10, orifice of communication of the two passages at the summit of the cochlea; 11, 12, termination of the osseous and membranous spiral laminae.

FIG. 466.



THE COCHLEA, LAID OPEN, AND VIEWED FROM ITS SUMMIT: magnified three diameters. 1, cut edges of the osseous wall of the cochlea; 2, osseous spiral lamina, seen within the vestibular passage; 3, end of the lamina; 4, 5, its outer border; 6, basilar membrane; 7, its end; 8, foramen of communication with the tympanic passage.

communicating with the round window of the tympanum, is the **tympanic passage**.<sup>4</sup> The two passages communicate by a common orifice<sup>5</sup> within the cupola.

The numerous canals proceeding through the modiolus for the passage of the cochlear nerves and vessels are successively reflected outward towards the spiral lamina and communicate with a **spiral canal**,<sup>6</sup> which traverses the modiolus along the course of the spiral lamina and is occupied by the spiral ganglion of the cochlear nerve and by a spiral vein. Among the longitudinal canals of the modiolus a larger **central canal**<sup>7</sup> transmits the **central artery**.

The spiral lamina consists of two layers with an intervening more spongy layer traversed by numerous anastomosing canals, which communicate with the spiral canal of the modiolus and with a series of apertures along the free border of the lamina.

<sup>1</sup> L. spiralis ossea; zonula ossea; septum osseum cochleæ.

<sup>2</sup> Hamulus; rostrum.

<sup>4</sup> Scala tympani.

<sup>6</sup> Canalis spiralis modioli.

<sup>3</sup> Scala vestibuli.

<sup>5</sup> Helicotrema.

<sup>7</sup> Canalis centralis modioli.



The surfaces of the modiolus and spiral lamina are more or less porous in different positions, for the transmission of blood-vessels to the interior membranous structures. In the vestibular passage, at the conjunction of the spiral lamina and modiolus, is a row of comparatively large foramina, which extend in grooves on the latter and give to it a somewhat fluted appearance. Elsewhere the surface of the cochlear canal is less porous. Opposite the spiral lamina it exhibits a slight linear ridge,<sup>1</sup> which indicates the course of attachment of the spiral ligament.

Near the commencement of the tympanic passage is the opening of a fine canal, the **cochlear aqueduct**,<sup>2</sup> which descends to the jugular fossa and transmits a vein.

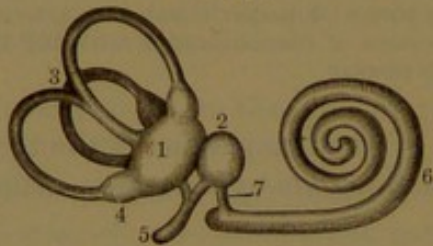
The cochlear canal, including the spiral lamina, is lined throughout with a periosteum of fibro-connective tissue with elastic tissue.

#### THE MEMBRANOUS LABYRINTH.

The interior of the osseous labyrinth is lined with a thin **periosteum**,<sup>3</sup> which resembles in structure the ectochoroidea of the eye. It consists of an intertexture of fibro-elastic tissue with cell-elements, including scattered stellate pigment-cells, and is well supplied with blood-vessels.

The **membranous labyrinth**<sup>4</sup> consists of corresponding parts, which nearly accord in form with those of the osseous labyrinth.

FIG. 467.



THE MEMBRANOUS LABYRINTH: magnified two and a half times. 1, utricle; 2, saccule; 3, semicircular canals; 4, ampullæ of semicircular canals; 5, vestibular aqueduct; 6, cochlear duct; 7, canal connecting the latter with the saccule.

Narrow membranous semicircular canals are contained within the osseous canals attached along their convex border; the membranous vestibule occupies the osseous cavity attached at the points of entrance of the nerves; the membranous cochlea as the cochlear duct is fixed to the spiral lamina and the opposite wall of the cochlear canal. The intervals of the

membranous and osseous labyrinths are filled with the perilymph, and the interior of the membranous labyrinth with the endolymph.

The **membranous vestibule**<sup>5</sup> occupies about two-thirds of the cavity of the osseous vestibule, and consists of two pouches separated by a constriction but not directly communicating.

The smaller pouch, or **saccule**,<sup>6</sup> occupies the lower fore part of the

<sup>1</sup> Lamina spiralis externa or secundaria.

<sup>3</sup> External membranous labyrinth.

<sup>5</sup> Vestibulum membranousum.

<sup>6</sup> Sacculus rotundus, sphaericus, or proprius; small vestibular vesicle.

<sup>2</sup> Aquæductus cochleæ.

<sup>4</sup> Labyrinthus membranosus.



osseous vestibule, including the hemispherical fossa. It is fore and aft compressed flask-shaped, with the neck narrowing to a short canal,<sup>1</sup> which opens into the cochlear duct.

The larger pouch, or **utricle**,<sup>2</sup> occupies the upper and back part of the osseous vestibule, including the hemi-elliptical fossa, and at its outer, upper, and back part is joined by the three membranous semicircular canals.

The saccule is attached to the wall of the osseous vestibule at the bottom of the hemispherical fossa, and the saccule to the outer part of the vestibular wall and hemi-elliptical fossa. Elsewhere the pouches are separated from the wall, especially outwardly and next the oval window.

Though not directly opening into each other, the saccule and utricle communicate through a narrow Y-shaped canal, the **vestibular aqueduct**,<sup>3</sup> the common branch of which occupies the corresponding osseous aqueduct, in which it ends in a blind pouch.

The **membranous semicircular canals**<sup>4</sup> nearly conform to the osseous canals which contain them. They are compressed cylindrical, and about one-third of the diameter of the osseous canals, along the outer side of which they lie attached to the periosteum. The ampullæ are proportionately so much larger that they nearly fill the corresponding osseous ampullæ. The three canals communicate with the utricle of the vestibule by five openings.

FIG. 468.

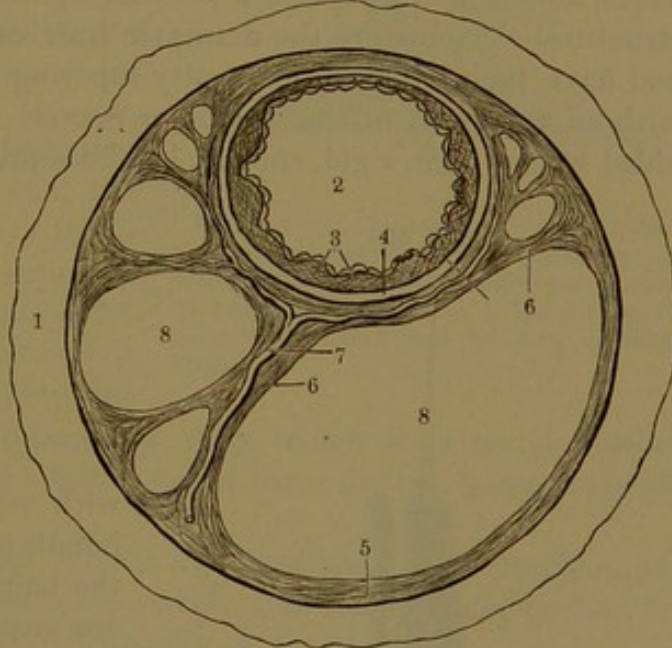


DIAGRAM OF A CROSS-SECTION OF A SEMICIRCULAR CANAL, magnified. 1, osseous canal; 2, section of the membranous canal; 3, papillary layer with endothelium; 4, membrana propria; 5, periosteum of the osseous canal; 6, band of the same; 7, blood-vessel; 8, 8, spaces occupied by the perilymph.

**Structure of the membranous vestibule and semicircular canals.** The walls of the saccule, the utricle, and the semicircular canals are delicate and transparent. They are not of uniform thickness, and are composed of three principal layers.

<sup>1</sup> Canalis reuniens.

<sup>2</sup> Utriculus; sacculus communis, hemi-ellipticus, oblongus, or semi-ovalis; alveus utriculosus; sinus medianus.

<sup>3</sup> Aquæductus vestibuli.

<sup>4</sup> Canales semicirculares membranacei; tubuli or ductus semicirculares.



The **external layer** is like the adjacent periosteum, with which it is continuous. Where the parts are not immediately in contact with the periosteum, they are connected with the opposite osseous walls by delicate cords of the same structure, which also serve to support accompanying blood-vessels. The **middle layer**, or **membrana propria**, is a denser and apparently homogeneous stratum of variable thickness and is thinnest at the attachment of the parts to the subjacent osseous wall. Within the semicircular canals it is variably produced into broad conical papillæ, which are absent where the wall is thinnest, next the attachment of the membranous to the osseous canal. The papillæ are undeveloped at birth, and sometimes are not evident even at maturity. The **internal layer** is a pavement endothelium.

Where the utricle and saccule adhere to the wall of the osseous vestibule, over the position of the corresponding cribriform spot, the membrane exhibits a circular thickening, distinguished as the **acoustic spot**.<sup>1</sup> It receives the terminal fibrils of the branches of the vestibular nerve, and is invested with a peculiar epithelium, of which the chief structural elements are the **acoustic hair-cells**. These are columnar and have their attached extremity tapering and apparently connected with an axial fibre of the vestibular nerve. The free extremity is provided with a long, rigid, conical, hair-like process, which when treated

FIG. 469.

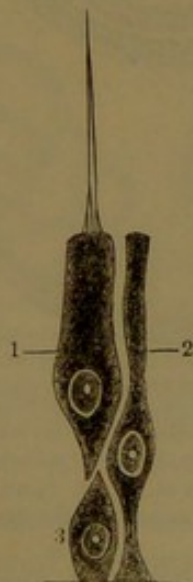


DIAGRAM OF ACOUSTIC EPITHELIUM: highly magnified. 1, acoustic hair-cell; 2, supporting cell; 3, immature cell.

FIG. 470.



OTOLITES, highly magnified.

with reagents breaks up into a bundle of cilia-like filaments. With the hair-cells are mingled numerous **supporting cells** of narrower form, devoid of the hair-like process and not connected with a nerve-fibril.

The acoustic hairs are not directly bathed in the surrounding endolymph, but seem enveloped in a more viscid mass, which is especially remarkable from its being mingled with a multitude of minute crystals, the **otoliths**.<sup>2</sup> These are of various sizes, composed of calcium carbonate, and generally in the form of six-sided prisms with short pyramidal terminations.

<sup>1</sup> Macula acustica.

<sup>2</sup> Otoconia; otolithes; ear-sand.



Similar bodies are found in the vestibule of the ear of all vertebrate animals.

In the membranous ampullæ of the semicircular canals a more conspicuous thickening forms the **acoustic crest**.<sup>1</sup> This appears as a transverse reniform ridge projecting from the inner side of the corresponding ampulla. Like the acoustic spot, it receives the terminal fibrils of branches of the vestibular nerve and has the same kind of peculiar epithelium. The auditory hairs are enveloped in a dome-like mass, or **cupola**,<sup>2</sup> of viscid, semi-liquid matter distinct from the surrounding endolymph.

The **membranous cochlea**,<sup>3</sup> or **cochlear duct**,<sup>4</sup> is a trilateral, prismatic tube, which commences in a rounded pouch within the promontory of the tympanum, below the oval window of the vestibule, thence winds along the middle of the cochlear canal and ends in a closed extremity in the cupola. It occupies a position in advance of the spiral lamina, between it and the opposite wall of the cochlear canal, separating the vestibular and tympanic passages, than which it is much smaller. The cochlear duct with the latter forms three distinct passages in the cochlea.

In a cross-section of the cochlea the vestibular and tympanic passages in general appear transverse oval; that of the cochlear duct triangular and less than half the capacity of the others.

The vestibular passage commences above the tympanic passage, but subsequently runs outward and in advance of it and the cochlear duct to the cupola. The tympanic passage is at first considerably larger than the vestibular passage, but after the first turn the difference disappears; approaching the third turn the vestibular becomes the larger. The cochlear duct, though slightly decreasing, is more uniform in size throughout its course.

The cochlear duct, a little in advance of its commencement, is joined by the short descending neck or canal<sup>5</sup> of the saccule of the mem-

FIG. 471.

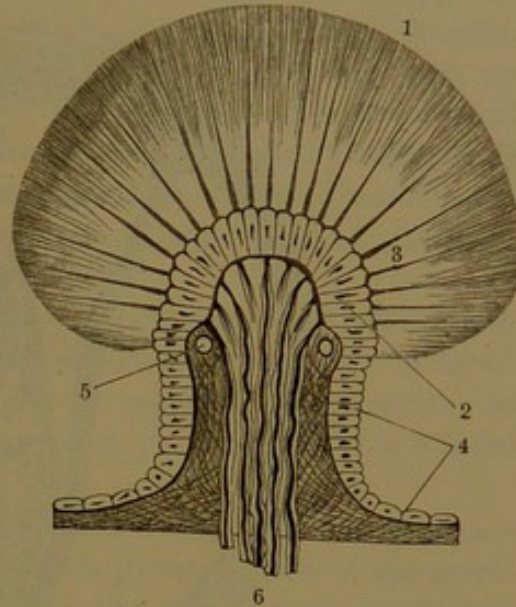


DIAGRAM OF A CROSS-SECTION OF THE ACOUSTIC CREST OF AN AMPULLA: highly magnified. 1, acoustic cupola; 2, acoustic hair-cells; 3, acoustic hairs; 4, epithelium; 5, blood-vessel; 6, medullated nerve-fibres of the vestibular nerve.

<sup>1</sup> Crista acustica; septum nerveum or transversum; papilla semilunaris.

<sup>2</sup> Cupula acustica.

<sup>3</sup> Canalis membranaceus cochleæ; canalis cochleæ.

<sup>4</sup> Ductus cochlearis; scala media.

<sup>5</sup> Canalis reuniens.



branous vestibule, but elsewhere is closed throughout. Its exterior surface is bathed with the perilymph of the vestibular and tympanic passages; its interior is filled with endolymph.

The **outer wall** of the cochlear duct, or that opposite the spiral lamina, is formed by the contiguous periosteum of the cochlear canal,

FIG. 472.

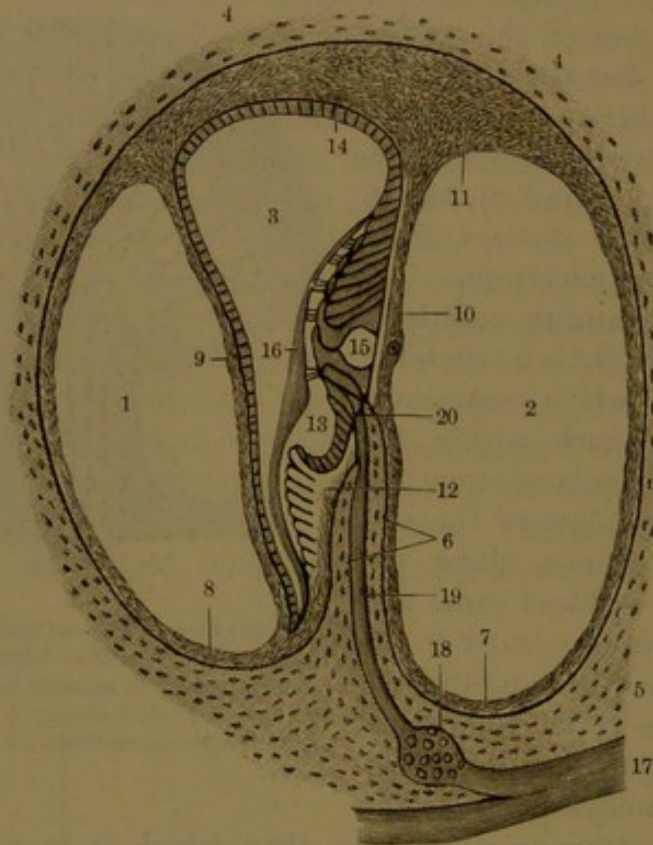


DIAGRAM OF A CROSS-SECTION OF ONE OF THE TURNS OF THE COCHLEA: much magnified. 1, vestibular passage; 2, tympanic passage; 3, cochlear duct; 4, osseous wall of the cochlea; 5, modiolus; 6, two layers of the osseous spiral lamina; 7, 8, periosteum; 9, vestibular membrane; 10, basilar membrane; 11, spiral ligament; 12, spiral crest; 13, spiral groove; 14, lining epithelium of the cochlear duct; 15, acoustic organ, the number placed within the spiral tunnel; 16, tectorial membrane; 17, cochlear nerve; 18, spiral ganglion; 19, nerve passing through the spiral lamina; 20, emergence of the nerve into the cochlear duct.

thicker than elsewhere, and lined by a simple epithelium of short columnar cells, defined from the periosteum by a thin, clear basement membrane.

The **anterior wall** of the cochlear duct, or the **vestibular membrane**,<sup>1</sup> is a thin partition which separates the passage of the duct from the vestibular passage. It is extended obliquely from the outer fore part of the spiral lamina to the outer fore part of the cochlear canal. It consists of a delicate connective-tissue layer continuous with the periosteum of the canal, lined in the cochlear duct with a simple pavement epithelium, and in the tympanic passage with an endothelium of larger cells.

<sup>1</sup> Membrana vestibularis; membrane of Reisner.



The **posterior wall** of the cochlear duct, the **basilar membrane**,<sup>1</sup> is continued in the same plane from the spiral lamina to the spiral ligament and separates the passage of the duct from the tympanic passage. It is narrowest in the commencement of the cochlea and widens with the decrease of the spiral lamina in its course to the cupola. The membrane consists of a somewhat rigid, clear, homogeneous layer, with a stratum of transverse fibres next the passage of the cochlear duct, and a thin stratum of connective tissue with spindle-shaped cells next the tympanic passage. In the cochlear duct an inner zone<sup>2</sup> of the membrane supports the acoustic organ, continuous with the epithelial covering of the outer zone.<sup>3</sup> Externally the basilar membrane is continuous with the spiral ligament. Blood-vessels penetrate the inner portion of the connective-tissue stratum, and along the middle of the membrane runs a **spiral vein**.<sup>4</sup>

The **spiral ligament**<sup>5</sup> is a prismatic thickening of the periosteum and outer wall of the cochlear duct, composed of fibro-connective tissue with numerous stellate corpuscles and well supplied with vessels. In advance of it is a less prominent ridge,<sup>6</sup> and parallel with this a more vascular belt<sup>7</sup> of the wall of the duct.

The free border of the osseous spiral lamina forms the inner corner of the cochlear duct. The periosteum of the front surface of the spiral lamina ends in a prominent convex ridge, the **spiral crest**,<sup>8</sup> which is outwardly excavated in a wide **spiral groove**.<sup>9</sup> The front or top of the crest is broken up into irregular rows of tubercles,<sup>10</sup> with flat summits and separated by deep furrows which widen at the bottom. The last tubercles are largest and longest and form a uniform row, distinguished as the **auditory teeth**. They have wide, flat summits, which overhang the spiral groove and define it by a sharp border, called its **vestibular lip**.<sup>11</sup> The thickened ends of the tubercles resemble cartilage and are homogeneous in structure. Their flat summits are naked, smooth, and shining, but the intervals of the tubercles are occupied by cells of the epithelium of the cochlear duct.

The **tympanic lip**<sup>12</sup> of the spiral duct is formed by the periosteum from behind the osseous spiral lamina extended beyond it into the basilar membrane. Along the lip a row of foramina<sup>13</sup> open from the canals

<sup>1</sup> Membrana basilaris; zona membranacea.

<sup>2</sup> Zona interna or lævis; habenula tecta or arcuata.

<sup>3</sup> Zona externa or pectinata; portio or habenula pectinata. <sup>4</sup> Vas spirale.

<sup>5</sup> Ligamentum spirale membranæ basilaris; cochlear ligament and muscle.

<sup>6</sup> Vas prominens.

<sup>7</sup> Stria vascularis,

<sup>8</sup> Crista spiralis; limbus laminæ spiralis; zona cartilaginea, choriacea, mediana, or nervea.

<sup>9</sup> Sulcus spiralis; s. s. internus; s. semicanalis spiralis.

<sup>10</sup> Lamina or zona denticulata; crista or habenula sulcata.

<sup>11</sup> Labium vestibulare; crista spiralis acustica.

<sup>12</sup> Labium tympanicum.

<sup>13</sup> Habenula perforata.



of the spiral lamina into the cochlear duct and transmit the terminal branches of the cochlear nerve to the acoustic organ.

The spiral groove is lined with a short columnar epithelium, continuous inwardly with that occupying the intervals of the auditory teeth and outwardly with the acoustic organ.

The **acoustic organ of the cochlea**, or **organ of Corti**,<sup>1</sup> is attached to the **inner zone** of the basilar membrane within the cochlear duct, and consists in a peculiar modification of its lining epithelium. It produces a convex **spiral ridge**<sup>2</sup> external to the position and course of the spiral groove, continuous with its epithelium and that investing the **outer zone** of the basilar membrane. Its chief structural elements are distinguished as the acoustic rods and hair-cells.

The **acoustic rods**<sup>3</sup> are long narrow columnar cells with expanded extremities, arranged in an inner and an outer row. They are comparatively rigid, bent in a sigmoid manner, and are attached by a broad conical base to the inner zone of the basilar membrane. The inner rods rest on it immediately external to the foramina of the cochlear nerves, while the outer rods rest on the membrane some distance from the others externally. From their base the two rows of rods incline towards each other and interlock by their opposite extremity or head. They thus enclose a **spiral canal**<sup>4</sup> in the course of the cochlear duct, filled with endolymph. The inner rods are more numerous and more closely applied together than the outer rods, which are longer and come near together laterally only at the extremities. The head of the inner rods is externally excavated, and embraces that of the outer rods, from which a paddle-like process, or **phalanx**, is directed outward.

The acoustic rods are longitudinally striated and within the head contain a nucleus. In the angle at their base, on each side of the spiral canal, lies a wedge-shaped cell with granular contents and a nucleus.

Adjoining the inner acoustic rods internally is a row of **acoustic hair-cells**; externally to the outer rods are four successive rows, in which the hair-cells alternate in position. The acoustic hair-cells are long columns in general fixed by an abrupt tapering process to the basilar membrane. They conform to the inclination of the acoustic rods and end in a rounded extremity which is furnished with a curved row of short, stiff, hair-like filaments.

The acoustic hair-cells have a granular protoplasm with a central nucleus. They are regarded as being directly connected with the ultimate axial fibrils of the cochlear nerves.

The intervals of the rods and hair-cells extending to the basilar membrane are occupied by long, narrow, columnar **supporting cells**,<sup>5</sup> which conform to the spaces and are for the most part fusiform.

<sup>1</sup> Terminal acoustic apparatus.

<sup>2</sup> Papilla spiralis.

<sup>3</sup> Rods, pillars, or fibres of Corti; bacilli acustici.

<sup>4</sup> Arch of Corti.

<sup>5</sup> Prop-cells; cells of Deiters.



The sloping sides of the acoustic ridge are formed of columnar cells successively decreasing in length, finally merging into the lining epithelium of the spiral groove and of the outer part of the basilar membrane.

Covering the area of the outer hair-cells is a **reticular membrane**,<sup>1</sup> which is composed of elongate, fiddle-shaped plates, or **phalanges**. These are connected with one another and with those of the outer rods, and leave between them apertures, through which protrude the ends of the acoustic hair-cells with their hairs. The ends of the inner hair-cells are also enclosed by a cuticular ring connected with a slight projection from the head of the inner rods, which appears to accord with the reticular membrane of the outer hair-cells.

Covering the acoustic organ is the **tectorial membrane**,<sup>2</sup> which springs from the spiral crest, is thence extended over the spiral groove and rests on the spiral ridge in contact with the acoustic rods and hair-cells. At its commencement it is thin, but thickens into a cushion, which partially fills the spiral groove and then thins away as it lies on the spiral ridge over the area of the acoustic rods and hair-cells. It is finely striated, appears filamentous in structure, and seems to be a cuticular production from the adjacent epithelium. In relation to the acoustic hair-cells, it holds the same position as the otolites and cupolas do to the hair-cells of the acoustic spots and crests of the vestibule and semicircular canals.

The labyrinth is supplied by the auditory artery, a branch of the basilar artery. It accompanies the auditory and facial nerves, and in the auditory meatus divides into vestibular and cochlear branches, which accompany the corresponding nerves. The veins generally pursue the same course, to end in the auditory vein, which emerges from the internal auditory meatus and joins the inferior petrosal vein. Small veins from the cochlea and vestibule also pass through the corresponding aqueducts, to end in the internal jugular vein and inferior petrosal sinus.

#### THE SKIN.

The **skin**, or **integument**,<sup>3</sup> forms a complete covering to the body, and serves as a protection as well as other important functions. It is highly sensitive, and constitutes the special sense organ of touch. While it prevents undue evaporation, it is the seat of the perspiratory function. The hairs and nails are appendages of the skin, and embedded in it besides the perspiratory glands are numerous sebaceous glands.

The skin is not of uniform thickness, but varies considerably on different parts of the body. Generally it is thickest on those parts which are least protected, as on the back of the trunk, on the upper

<sup>1</sup> Membrana or lamina reticularis.

<sup>2</sup> Membrana or lamina tectoria; membrane of Corti.

<sup>3</sup> Integumentum; cutis.



and back parts of the skull, and on the outer back part of the limbs; also on those parts habitually exposed to friction, as on the palms of the hands and soles of the feet. It is thinnest on the eyelids and lips, on the prepuce, at the entrance of the vulva, and at the margin of the anus.

The skin is flexible, very tenacious, moderately extensible, and elastic. Smooth in infancy, it subsequently becomes more or less furrowed and wrinkled, especially at points of habitual flexion and extension and at other more movable parts. From emaciation, especially in the advance of age, it becomes more wrinkled, but under active nutrition and in obesity it remains comparatively smooth.

The skin beneath is connected with the superficial fascia, in most positions more or less loosely and movably, but in others very closely,

as in the scalp, the palms, and the soles. The connection is between the deeper looser structure of the skin and the superficial layer of the superficial fascia, the two more or less merging and forming the usual seat of the accumulation of subcutaneous fat.

Where the skin is thinnest it is about one-twenty-fifth of an inch; where thickest it reaches one-eighth of an inch or more. It consists of two chief layers, the dermis and the epidermis.

The **dermis**<sup>1</sup> forms the deeper layer of the skin, and it is for the most part proportioned in thickness to the skin. It is chiefly composed of a close intertexture of bundles of fibro-connective tissue, interwoven in different directions and mingled with more or less elastic tissue varying in different parts. Its structure is more compact next the outer surface, while its deeper part is looser and of more open texture. Beneath it gradually blends with the super-

ficial fascia, and its meshes are filled with adipose tissue often enclosing sweat-glands, and in some parts the roots of the hairs.

Unstriped muscular tissue also enters into the structure of the dermis. Mostly it occurs in little bundles of fibres connected with the

FIG. 473.

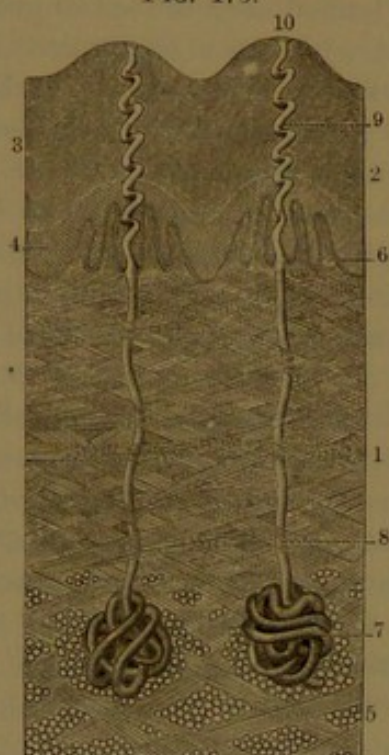


DIAGRAM OF A VERTICAL SECTION OF THE SKIN OF THE FOREFINGER ACROSS TWO OF THE RIDGES OF THE SURFACE: highly magnified. 1, dermis composed of an intertexture of bundles of fibro-connective tissue; 2, epidermis; 3, its cuticle; 4, its rete; 5, subcutaneous connective and adipose tissue; 6, tactile papillæ; 7, sweat-glands; 8, duct; 9, spiral passage from duct through the epidermis; 10, termination of the passage on the summit of the ridge.

<sup>1</sup> Derm; derma; cutis vera; corium; true skin.



hair-follicles embedded in the dermis. In other parts it is an abundant constituent of the skin, as in that of the scrotum, the perineum, the penis, and the nipple.

The various markings seen on the surface of the skin, the minute pits, the reticular lines and furrows, extend into the superficial portion of the dermis.

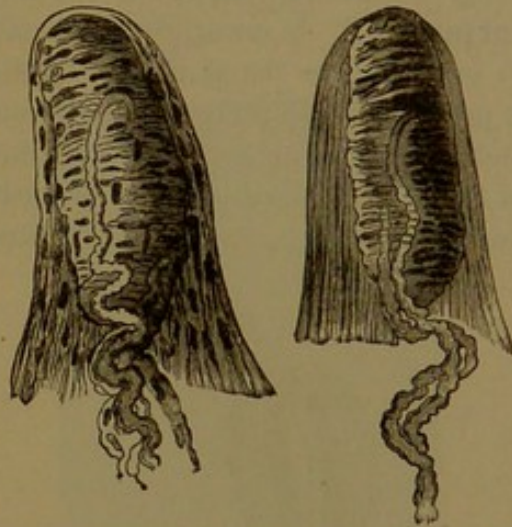
The dermis is furnished with little eminences, the **tactile papillæ**, or **papillæ of touch**,<sup>1</sup> which are most abundant and largest where the sense of touch is most acute, as on the palms and soles, and especially on the digits. They are conical processes of the dermis, with a rounded summit. The larger ones are commonly divided into two or three, thus forming compound papillæ.

On the palms and soles the tactile papillæ are arranged closely in double rows, which form the conspicuous linear ridges observed in these positions running parallel with one another in curving lines and separated by narrow furrows. In other parts of the skin the papillæ are fewer, smaller, and irregularly scattered, and in some parts almost disappear or seem to be substituted by the slightest ridges.

The larger tactile papillæ range from  $\frac{1}{200}$  to  $\frac{1}{100}$  of an inch in height; on the face they are much reduced and range from  $\frac{1}{800}$  to  $\frac{1}{500}$  of an inch.

The dermis is highly vascular and also well supplied with nerves. The arteries, which enter beneath from the superficial fascia and freely ramify and anastomose throughout the dermal structure, supply in their course the numerous perspiratory and sebaceous glands and the hair-follicles. They end in a rich capillary net at the surface, whence loops extend into most of the tactile papillæ. Veins closely accompany the arteries, to end in the subcutaneous venous plexuses. Lymphatics are exceedingly abundant, commencing in lymph-spaces in the interstices of the connective-tissue structure of the dermis. They form a capillary plexus at the external surface beneath that of the blood-vessels, and the capillary lymphatics are larger than those of the blood-vessels. A coarser plexus in the deeper part of the dermis communicates with the superficial plexus and with lymphatic trunks, which mostly pursue the course of the subcutaneous blood-vessels.

FIG. 474



TWO TACTILE PAPILLÆ: highly magnified; from the skin of the finger. The tactile corpuscle seen in the interior, and medullated nerve-fibres connected with them.

<sup>1</sup> Papillæ tactus.



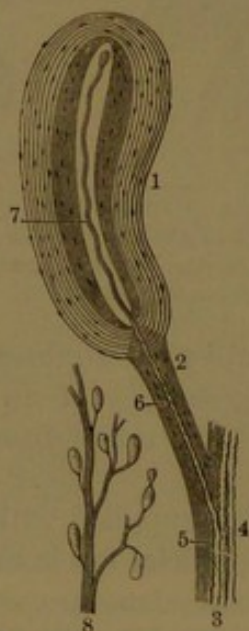
The nerves of the dermis are numerous, and are everywhere conspicuous in the subcutaneous fascia as the cutaneous branches of the cerebro-spinal nerves. They ascend obliquely into the dermis and form a plexus which becomes closer and finer approaching the external surface. From the plexus medullated nerve-fibres enter the tactile papillæ; from many the axial fibres proceed to be distributed in the epidermis. The cutaneous nerves also supply the hair-follicles and their muscles, and the sweat and sebaceous glands.

In the skin of the hands and feet, especially in the palm and sole, many of the tactile papillæ contain a peculiar body, named the **tactile corpuscle**.<sup>1</sup> It occupies the greater part of the papillæ and appears to exclude the usual looped capillary vessel. It is elliptical in shape, is provided with a connective-tissue capsule with incomplete partitions, and is continuous with the surrounding tissue of the papilla and that of the nerve-sheath connected with it. Usually one or two medullated nerve-fibres enter a corpuscle, directly or after winding several times

around it. Within the corpuscle the nerve-fibres lose their medullary sheath, the axis-fibres branch, and the divisions, often more or less varicose, become convoluted and terminate in a bulbous enlargement at the surface of the enclosing capsule.

**Pacinian corpuscles.** Along the course of the cutaneous nerves of the hand and foot attached to the branches are many little, oval, pearly-white, glistening bodies embedded in the areolar tissue and fat, named the **pacinian corpuscles**.<sup>2</sup> A few are found on other cutaneous nerves, as in those of the neck and arm. They also occur on the branches of the pudic nerves in the penis and clitoris, also on the intercostal nerves, on those of the mammæ, and elsewhere. They have been likewise found on the nerves of the solar plexus of the sympathetic nerve.

FIG. 475.



PACINIAN CORPUSCLES, from the digital nerve of the finger of a new-born child. 1, much magnified corpuscle, which was reniform; 2, the pedicle; 3, portion of the digital nerve; 4, several nerve-fibres; 5, the fibrous sheath; 6, medullated nerve-fibre to the corpuscle; 7, axis-fibre of the nerve-fibre; 8, portion of a digital nerve with pacinian corpuscles attached, of the natural size.

In the mesentery of the cat they are remarkable for their distinctness.

On the digital nerves they are commonly from half a line to a line in length or more, and are readily distinguishable from the

<sup>1</sup> Corpusculum tactus.

<sup>2</sup> Corpuscles of Vater.



surrounding yellowish fat and connective tissue.

Each corpuscle is attached by a short stalk or pedicle of connective tissue, traversed by a single medullated nerve-fibre, with a small accompanying artery and vein.

The corpuscle is composed of numerous concentric tunics, which in the larger ones are from thirty to double the number. The central capsule, which is long and narrow, is filled with a clear core traversed by a nerve-fibre. The tunics are continuous with the neurilemma of the nerve-fibre of the pedicle, and are composed of fibro-connective with elastic tissue, invested on their surfaces with an endothelium. The nerve-fibre of the pedicle passes directly through to the inner capsule, where it loses its medullary sheath, thence runs through the central core to the opposite extremity and ends in a little knob, or sometimes divides into two or three short branches, which end in the same manner.

No satisfactory function has been ascertained for the pacinian corpuscles.

The **epidermis**,<sup>1</sup> forming the free or exterior surface of the skin, is in general much thinner than the subjacent dermis, and is of more uniform thickness, though for the most part proportioned to it. It is thickest in the palm of the hand and sole of the foot, where the skin is habitually subjected to pressure and friction, and, though the condition is in a measure independent of these circumstances, they nevertheless greatly promote it, as exemplified by the

FIG. 476.

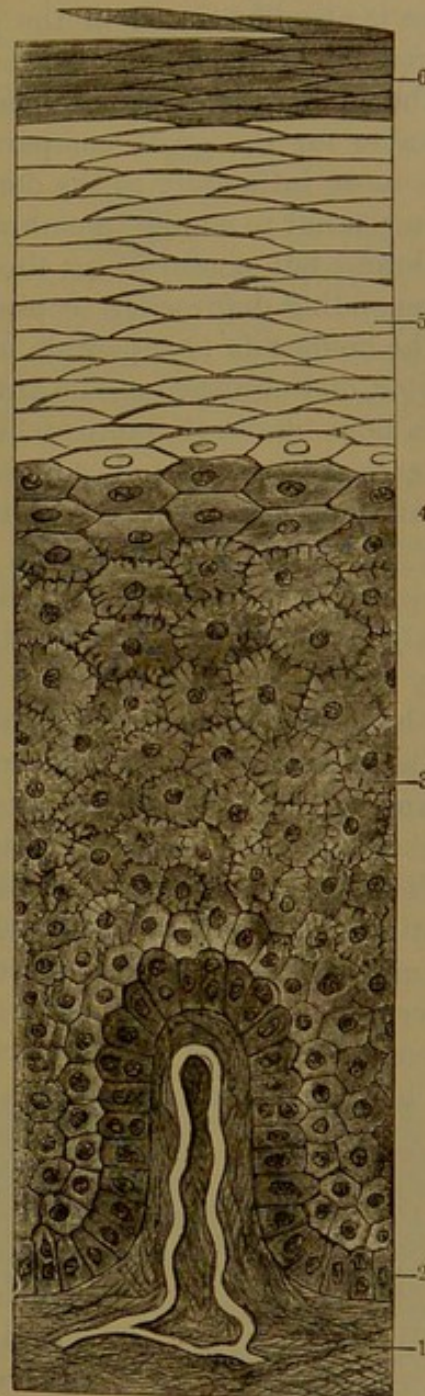


DIAGRAM OF THE EPIDERMIS WITH A TACTILE PAPILLA, in perpendicular section: highly magnified. 1, dermis with a tactile papilla containing a looped capillary vessel; 2-6, epidermis; 2, deep stratum of columnar cells of the epidermal rete; 3, strata of polyhedral corrugated cells of the epidermal rete; 4, the lucid layer; 5, cell-strata of the cuticle; 6, superficial dry scales of the cuticle.

<sup>1</sup> Epiderma; cuticula.



hard hands of the laborer. Its increase in thickness from the same causes is also illustrated in the production of corns, which consist of thickenings of the epidermis.

The epidermis is a stratified, cellular, or epithelial structure, remarkable for the great comparative number of its cell-strata. It adheres most intimately to the dermis, though this is not defined in the manner usual to similar membranous structures by an even basement membrane, but conforms to the adjacent cells, which seem to fit into corresponding depressions or pits of the surface.

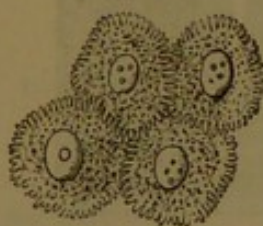
The epidermis is separable into two principal layers, of which the exterior, distinguished as the **cuticle**,<sup>1</sup> is the thicker, drier, and harder, and is horn-like in character where it is thickest. The deeper layer, or **epidermal rete**,<sup>2</sup> is soft, adheres to the dermis beneath, and merges into the cuticle above. From its soft condition and reticular appearance, due to its being impressed by the papillary surface of the dermis, it acquired the name of the rete mucosum. Ordinarily after death it quickly softens from decomposition and thus permits the cuticle to be easily detached. Through burns and blisters it is readily broken up and the cuticle is separated by the effusion of liquid from the dermis.

The cell-strata of the epidermis are proportioned in number to its thickness; the cells composing them vary greatly in shape, size, and physical and chemical constitution.

The superficial strata of the cuticle are incessantly shed, constituting scurf and dandruff, while the deep strata of the epidermal rete are as incessantly produced and the successive cell-strata of the epidermis are constantly undergoing transformation; the deeper into the condition of the more superficial.

The **epidermal rete**,<sup>3</sup> the soft, deep layer of the epidermis, is thinner and more uniform than the cuticle.

FIG. 477.



CORRUGATED OR FURROWED  
CELLS FROM THE EPIDERMAL  
RETE: highly magnified.

It consists of many cell-strata, of which the deepest, or that adherent to the dermis, is composed of columnar cells, while the others consist of polyhedral cells, in the deeper layers of nearly uniform diameter, but successively becoming larger, and in the higher layers proportionately of greater horizontal breadth. The cells<sup>4</sup> are corrugated or ridged; the ridges of contiguous cells conjoining so as to leave intercellular channels permeable to nutritive liquid from the dermis.

Where the epidermal rete is about to merge into the cuticle, several strata, in which the cells are flatter or of greater breadth and less

<sup>1</sup> Cuticula.

<sup>2</sup> Stratum or rete Malpighi; corpus reticulare, cribrosum, or mucosum.

<sup>3</sup> Rete mucosum; r. Malpighi.

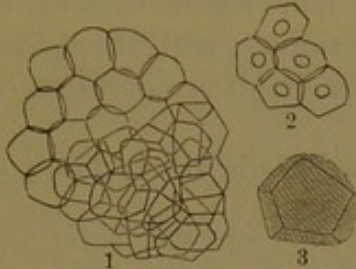
<sup>4</sup> Spinous, furrowed, or ridged cells.



depth and less distinctly outlined, form a layer which has been distinguished as the **lucid stratum**.<sup>1</sup>

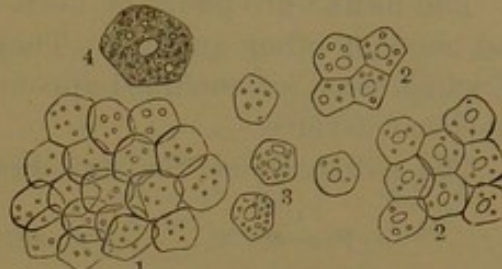
The **cuticle**<sup>2</sup> consists of many strata of polyhedral cells larger than those of the epidermal rete, mainly in the breadth, as in the lucid

FIG. 478.



SCURF FROM THE LEG: magnified. 1, a fragment of scurf, consisting of dried, flattened, non-nucleated cells or scales; 2, a few cells with a nucleus; 3, a cell more highly magnified, to exhibit its polyhedral form.

FIG. 479.



FRAGMENT OF DANDRUFF FROM THE HEAD: magnified. 1, portion of dandruff, consisting of non-nucleated cells; 2, several fragments, consisting of nucleated cells; 3, isolated cells, some with and others without nuclei; 4, a cell more highly magnified, from the deep part of the cuticle.

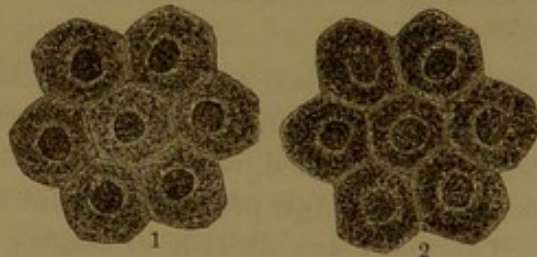
stratum regarded as pertaining to the rete. The cells are also more translucent and homogeneous and generally without a nucleus or with only indistinct traces. At the exterior surface the cell-strata form a comparatively dry layer of flat, homogeneous scales. The more superficial cell-strata are readily detached in fragments or flakes by friction, and these are constantly removed in ablution.

The soft cells of the epidermal rete are readily dissolved by certain reagents, as acetic acid, which has no effect on the cells of the cuticle. The dry scales of this layer, when acted on by a solution of potash, swell up and assume the appearance of vesicular cells.

The cells of the epidermis contain some coloring matter. In the negro and other dark-skinned races the pigment, as minute black granules, is in great measure contained in the cells of the epidermal rete. It disappears in the transformation of the cells into those of the cuticle; hence the thick cuticle of the hand of the blackest man differs but little in color from that of the white man.

The epidermis, like all other epithelial structures, is entirely devoid of blood-vessels and lymphatics. The cuticle is utterly insensible, though nerves, as fine varicose nerve-fibrils, have been traced proceeding from the dermis and ramifying among the cells of the epidermal rete.

FIG. 480.



CELLS FROM THE EPIDERMAL RETE. 1, from the face of a white man; 2, from a negro: highly magnified.

<sup>1</sup> Stratum lucidum.

<sup>2</sup> Cuticula; stratum corneum.

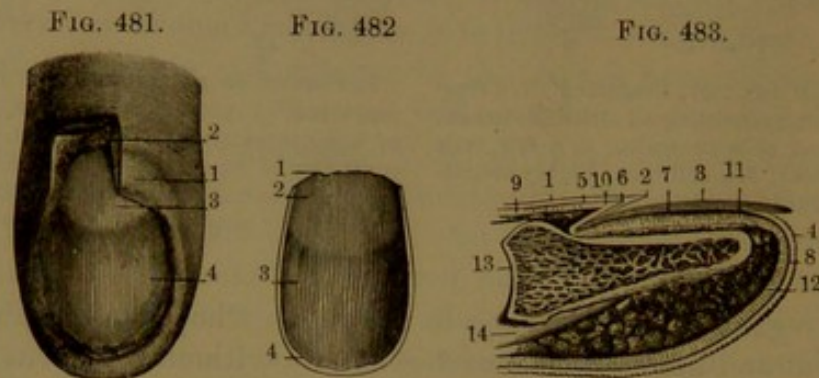


Certain cells, distinguished as **tactile cells**,<sup>1</sup> have been indicated as occurring in the epidermal rete and the superficial layer of the dermis. They are described as pyriform cells, which terminate nerve-fibrils.

#### THE NAILS.

The **nails**<sup>2</sup> are plates of horn, and are homologous with the claws and hoofs of other animals. They are continuous with the epidermis, of which they are modified appendages, and like it are products of the subjacent dermis.

The nail rests on the **nail-bed**<sup>3</sup> of the dermis, the middle portion



*Fig. 481.*—BED OF THE NAIL. 1, fold of the skin which covers the root of the nail; 2, the fold partially turned up to show the depth of the groove beneath; 3, 4, posterior and anterior portions of the nail-bed, the former the less vascular, and giving rise to the appearance called the lunula. The longitudinal lines indicate the ridges bordered with papillæ.

*Fig. 482.*—UNDER SURFACE OF THE NAIL. 1, root; 2, part corresponding with the lunula; 3, grooved surface adapted to the ridges of the nail-bed; 4, free border.

*Fig. 483.*—VERTICAL SECTION OF THE END OF A FINGER.—1, epidermis on the back of the finger; 2, point at which it is reflected to become continuous with the nail; 3, the nail; 4, epidermis at the end of the finger; 5, 6, 7, 8, epidermal rete; 9, 10, 11, 12, dermis; 13, last phalanx; 14, flexor tendon.

being distinguished as its **body**. The back portion, or **root**, a fourth or more of the length of the whole nail, occupies a deep crescentic cleft of the nail-bed, while the lateral margins occupy shallower grooves and the **free edge** projects beyond the end of the digit.

The nails are whitish or nearly colorless, and translucent, and on the bed appear pink from its vascularity. Next the root there often appears the segment of a circle, the **lunule**, of whiter hue, due to less vascularity in the corresponding portion of the bed. Not unfrequently irregular white spots occur in the nails.

The nails are longitudinally striate, and their under surface is finely and deeply furrowed in accordance with the striæ. The body of the nail is of uniform thickness, but the root is thinner and tapers to a sharp edge.

Beneath the free edge and at the lateral borders the nail is continuous with the epidermis, and is also continuous with it in advance of the root above, where it forms a narrow band adherent to the nail.

<sup>1</sup> Cells of Merkel.

<sup>2</sup> Ungues.

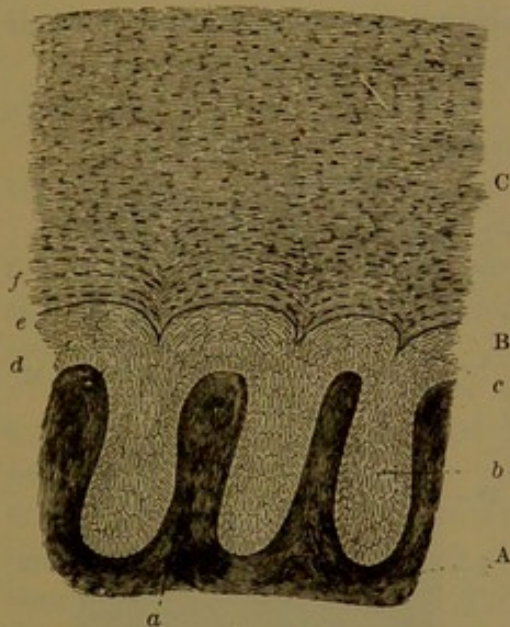
<sup>3</sup> Matrix.



In the nail-bed the dermis presents numerous fine longitudinal ridges divided at their summits into rows of vascular papillæ and received in furrows of the nail.

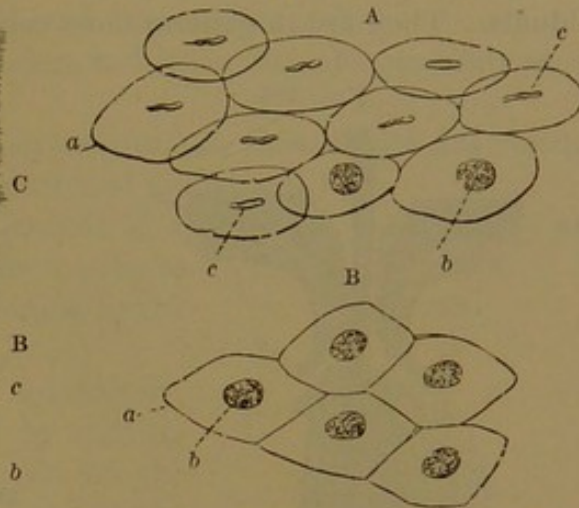
The nails are composed of numerous strata of cells, of which the

FIG. 484.



TRANSVERSE SECTION THROUGH THE NAIL AND ITS BED: magnified 250 diameters. A, dermis; B, deep layer of the nail; C, horny layer. a, ridges of the bed; b, deep cell-strata; c, ridges of the under surface of the nail; d, deep stratum of columnar cells; e, upper strata of polyhedral cells; f, cell-strata of the horny layer.

FIG. 485.



CELLS OF THE NAIL, after boiling in solution of soda. A, cells viewed laterally; B, from the upper surface. a, cell-membrane; b, nuclei seen on the broad surface; c, nuclei seen on the side.

deeper correspond with the epidermal rete, are continuous with it, and accord with it in structure. The thicker, hard portion of the nail, corresponding with the cuticle of the epidermis, consists of many strata of broad, flattened cells intimately coherent and indistinctly defined. Treated with caustic soda, the constituent cells of the nail assume a vesicular form and exhibit a nucleus.

The nails grow like the epidermis, by an incessant production of cells in the nail-bed; the growth in length being due to the production at the bottom of the cleft enclosing the root of the nail, and the increase in thickness to the production over the general surface of the nail-bed.

#### THE HAIR.

**Hairs**<sup>1</sup> are appendages of the epidermis. They grow and project from pockets of the dermis, named the **hair-follicles**. In the smaller hairs the follicles are embedded in the thickness of the dermis, but in the larger hairs the follicles extend from the dermis beneath, into the subjacent areolar tissue and fat.

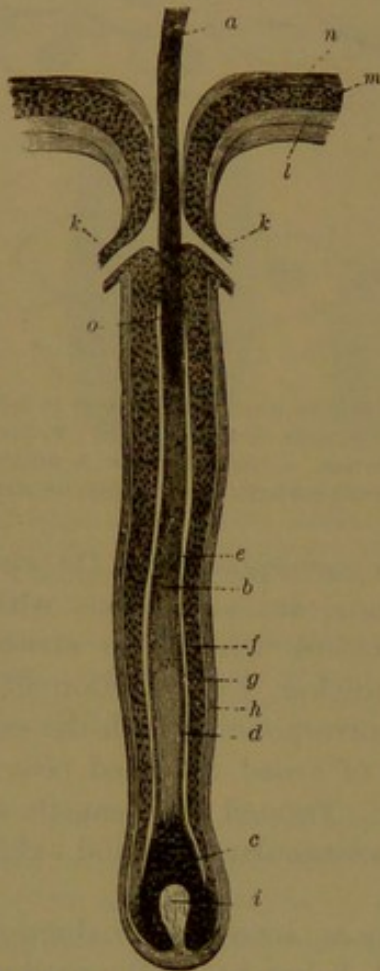
Hair is found nearly everywhere over the body except on the palms

<sup>1</sup> Pili; pile; crinis; thrinx.



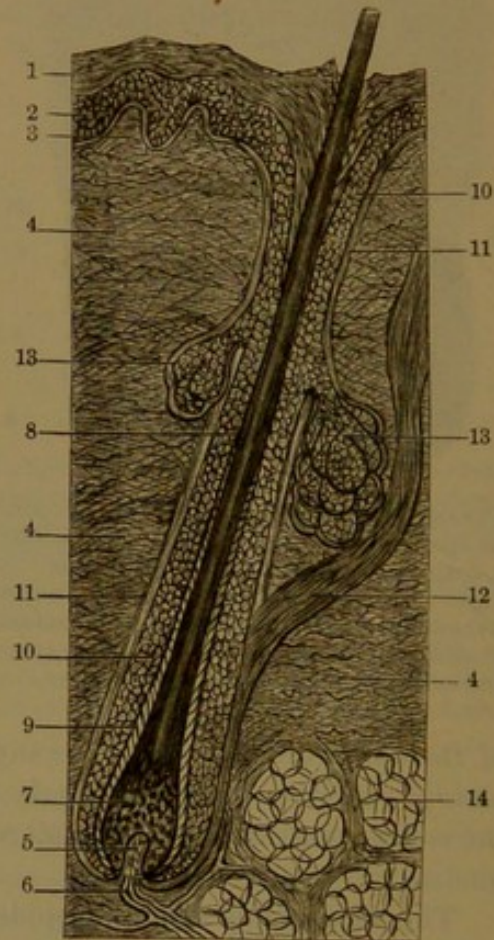
of the hands and soles of the feet, the knuckles, the back of the last joints of the digits, the lips, nipples and areolæ, the glans, prepuce, and verge of the anus. Hairs are generally implanted in the skin in a slanting manner, and only in the eyelashes do they project at right angles to it. They vary in extent of development and other characters in different parts of the body, and in different races, sexes, and individuals. They are in general most conspicuously produced as the hair

FIG. 486.



HAIR-FOLLICLE; magnified. *a*, shaft of the hair; *b*, root; *c*, bulb; *d*, cuticle of the hair; *e*, inner hair-sheath; *f*, outer hair-sheath; *g*, basement membrane defining the fibrous layer, *h*, of the follicle; *i*, hair-papilla; *k*, termination of ducts of two sebaceous glands; *l*, dermis; *m*, *n*, rete and cuticle of the epidermis.

FIG. 487.



SECTION OF THE SKIN OF THE SCALP WITH A HAIR-FOLLICLE. 1, cuticle; 2, epidermal rete; 3, tactile papilla; 4, dermis; 5, hair-papilla; 6, vessel; 7, hair-bulb; 8, hair; 9, inner root-sheath; 10, outer root-sheath; 11, wall of the hair-follicle; 12, erector muscle; 13, sebaceous follicles; 14, subcutaneous areolar tissue and fat. Highly magnified.

of the head, on the eyebrows, as the eyelashes, on the pubes, in the axillæ, and as the beard in the male. The hair of the head is longest, especially in the female, and is the finest of the larger hairs, while that of the beard is the coarsest. Elsewhere the hair is variably produced, often to the greatest extent in the male on the breast and outer part of the limbs, but in general, except in the parts mentioned, it is rudimentary compared with its condition in other animals of man's class.



The usually short and often downy hairs<sup>1</sup> spread over most parts of the body are less developed in the female than in the male, and commonly less in the negro than in the white man.

The hair of the head<sup>2</sup> in the white race is long, fine and straight or moderately curling, and variously colored. In the American Indian and Mongolian it is long, coarse, straight, and black. In the negro it is short, fine, crisp, closely curled, and commonly black.

The hairs of the beard, the pubes, and the axillæ are generally more alike, coarse, crisp, and curling.

In general straight hairs are cylindrical; in those which are curling or woolly they are more or less flattened cylindrical.

The hairs are lustrous and smooth in appearance, though they are minutely and sufficiently scabrous to possess the felting quality which is common in the hair of animals.

The long hairs usually grow indefinitely, and if not habitually reduced by cutting become worn and broken or split at the ends. Many short hairs, like those of the eyebrows and eyelashes, grow to a certain length, are tapering at the free end, and from time to time are shed, to be succeeded by others.

The main part of a hair is its **body**, **shaft**, or **stem**,<sup>3</sup> and the portion implanted in the skin is distinguished as the **root**.<sup>4</sup>

Light-colored hairs viewed with the microscope appear translucent, longitudinally finely striate, and marked on the surface by crossing wave-like lines. Dark or black hairs possess the same characters more or less obscured by the color.

The hair is mainly composed of longitudinal tapering fibres,<sup>5</sup> which are flattened, fusiform fibre-cells with a central, linear nucleus. The color of the hair is in great measure due to diffused pigment in the fibrous structure and to more defined spots and streaks of granules of pigment. In silvery-white hairs of aged people minute lacunæ in the fibrous substance contain air, which may be expelled by the application of hot oil of turpentine, when the hairs are rendered more transparent. In the whitening of hair with the advance of age the pigment matter ceases to be produced.

In many hairs, especially the coarser ones, as those of the beard,

FIG. 488.



PORTION OF A HAIR FROM THE OUTER PART OF THE THIGH: magnified. 1, shaft of the hair covered with transverse markings indicating the projecting edges of the cuticular scales; 2, fibrous substance at the end of the hair broken up into coarse fibres as the result of friction of the clothing.

<sup>1</sup> Down; lanugo.

<sup>2</sup> Capilli.

<sup>3</sup> Scapus.

<sup>4</sup> Radix pili.

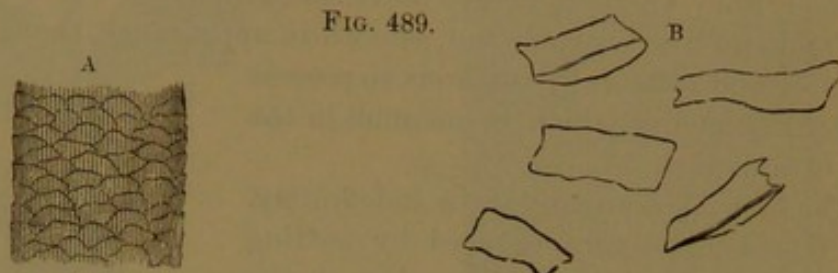
<sup>5</sup> Cortex.



the axis is occupied by a **pith** or **medulla**. This appears by transmitted light more opaque than the surrounding fibrous substance, and by reflected light is white. It is sometimes more or less interrupted, and in pointed hairs, like those of the eyebrow, ceases near the end. It is composed of rounded, polyhedral, granular cells, often with minute air-bubbles. Mostly in the hair of the scalp and the fine downy hair of the body the medulla is absent.

The hairs are covered with a delicate **cuticle**, which consists of a single stratum of imbricating scales overlapping from below, with the upper edges sufficiently projecting to render the surface uneven.

FIG. 489.



A. PORTION OF THE SHAFT OF A LIGHT HAIR: magnified. The longitudinal lines are produced by the fibrous substance; the transverse, undulating lines, by the cuticle. B. Isolated scales of the cuticle.

The **root of the hair** at its lower part gradually enlarges, is softer and lighter in color, and ends in a still softer swelling, the **hair-bulb**.<sup>1</sup> This is continuous with the bottom of the hair-follicle and encloses a papilla projecting from it. The **hair-papilla** is conical, usually a little enlarged at the extremity so as to appear fungiform. The hair-bulb is composed of polyhedral nucleated cells, which gradually merge above into the structure of the hair-shaft.

The **hair-follicle**<sup>2</sup> conforms in shape to the root of the hair, is variably deep, and mostly proportioned to the size of the hair. Near its mouth in the dermis it receives the ducts of several sebaceous glands, and above this point is funnel-shaped and formed by the epidermis.

The wall of the hair-follicle consists of an outer dermic layer and an inner epithelium continuous with that of the sebaceous glands opening into the follicle, and with the epidermis.

The dermic layer is thin and compact, outwardly composed of connective tissue, and inwardly of transverse unstriated muscle-fibres, defined from the epithelium by a clear basement membrane. At the bottom of the follicle it is continuous with the hair-papilla, which is composed of connective tissue in a hyaline matrix, and is supplied with capillary vessels and nerve-fibres.

The epithelium of the hair-follicle, from its directly enclosing the root of the hair, is named the **root-sheath**. It is thick and stratified, and is divisible into two principal layers, distinguished as the inner and the outer root-sheath.

<sup>1</sup> Bulbus or pulpa pili; capitulum; hair-button.

<sup>2</sup> Folliculus pili.



The **outer root-sheath** is continuous with the deep layer of the epidermis and accords with it in composition. Around the hair-bulb it becomes thinner and at its base is continuous with it.

The **inner root-sheath** corresponds with the cuticle of the epi-

FIG. 490.

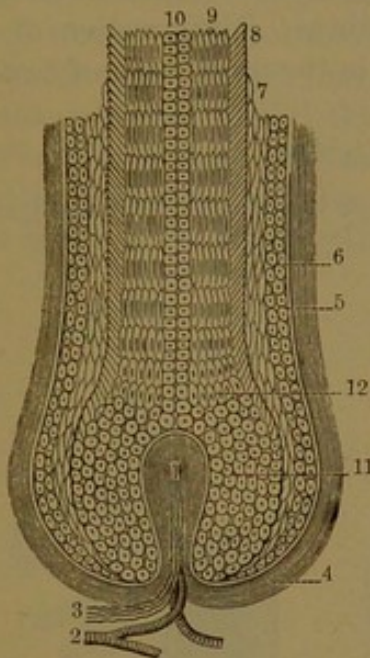


DIAGRAM OF THE STRUCTURE OF THE ROOT OF A HAIR AND ITS FOLLICLE. 1, hair-papilla; 2, capillary vessel; 3, nerve-fibres; 4, fibrous wall of the hair-follicle; 5, basement membrane; 6, outer root-sheath; 7, inner root-sheath; 8, cuticle of the hair; 9, fibrous structure; 10, medulla; 11, cellular structure of the hair-bulb; 12, transition cells. Highly magnified.

FIG. 491.

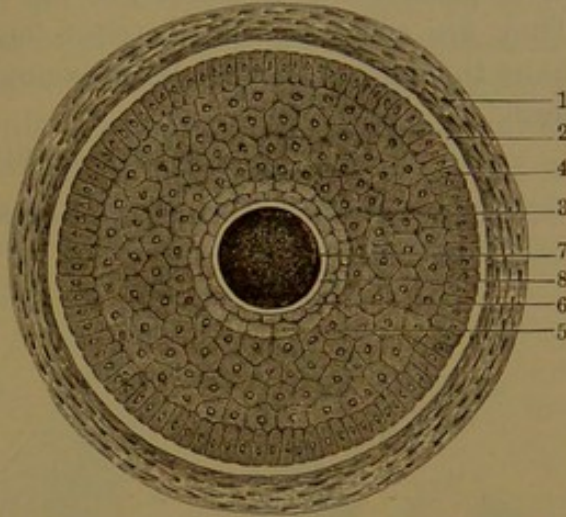


DIAGRAM OF THE STRUCTURE OF A TRANSVERSE SECTION OF A HAIR WITH ITS FOLLICLE: highly magnified. 1, fibrous and muscular layer of the follicle; 2, basement membrane; 3-6, epidermic layer of the follicle or root-sheath of the hair; 3, strata of polyhedral cells; 4, deep stratum of columnar cells; 5, 6, cuticular layer or inner root-sheath; 7, hair; 8, its cuticle.

dermis, and is composed of several cell-strata, of which the outer ones<sup>1</sup> consist of small polyhedral cells. These are succeeded by a stratum<sup>2</sup> of clear, oblong cells with frequent gaps between them, so as to appear like a perforated membrane. Internal to this is a stratum of overlapping scales, the projecting edges of which are directed downward and conform to those of the cuticular layer of the hair, the projecting edges of which are directed upward. In consequence of this relation of the inner root-sheath with the hair-root, when the hair is extracted the sheath is detached with it.

The hairs grow through the incessant reproduction of cells in the hair-bulb in contact with the hair-papilla. Successive series of cells advance and are transformed into the structural elements of the shaft of the hair, mostly into the fibre-cells, but the outer stratum into the cuticle of the hair and the central ones into the medulla, when this occurs. Most of the larger hairs grow indefinitely, while others are shed at variable periods, to be succeeded by others.

The rate of growth of the hair of the scalp is about half an inch monthly. When hairs are shed ordinarily, the papillæ are atrophied, to

<sup>1</sup> Henle's layer.

<sup>2</sup> Huxley's layer.



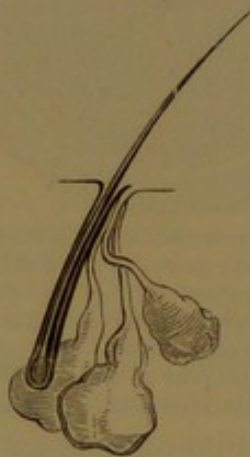be followed by the production of others. When hairs are pulled out, the new ones commonly grow from the same papillæ.

Connected with the hair-follicles, embedded in the dermis, are little **erector muscles**,<sup>1</sup> commonly one for each follicle, situated beneath the slant of the hair. They spring from the superficial part of the dermis and descend obliquely to the wall of the follicle near its bottom. They are composed of unstriped muscle-fibres. The erection of the hairs through these muscles is exemplified in the production of "goose-flesh."

#### THE SEBACEOUS GLANDS.

The **sebaceous glands**<sup>2</sup> of the skin are numerous, and are gener-

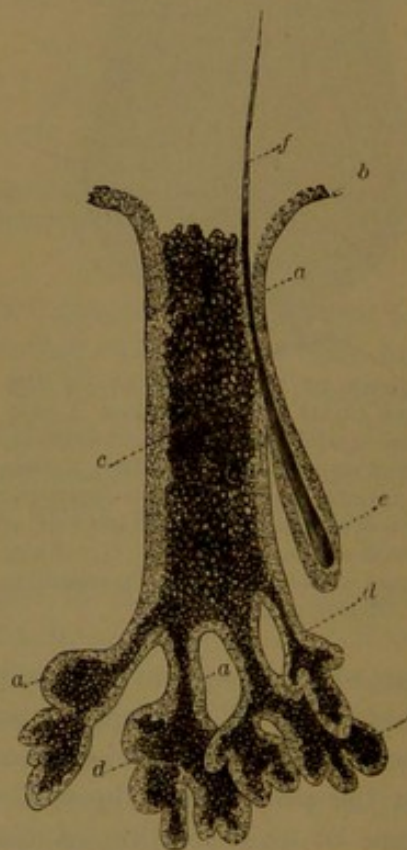
FIG. 492.



SEBACEOUS GLANDS OPENING INTO THE MOUTH OF A HAIR-FOLLICLE: much magnified.

ally associated with the hairs, into the follicles of which their ducts open. They secrete a greasy substance, the sebaceous matter, which is of service from its imbuing the hair and epidermis. The glands are embedded in the dermis at the sides of the hair-follicles, usually two or more to each follicle. Commonly proportioned in size to the hairs, in some instances the condition is reversed and the largest glands accompany the smallest hairs, as exemplified by those in the region of the nose. In the skin of the scrotum and penis they are visible in conspicuous whitish groups at the roots of the hairs. Similar groups are seen on the areolæ of the mammæ unaccompanied by hairs. On the sides of the nose the glands and their ducts are often so large in comparison with the

FIG. 493.



A LARGE SEBACEOUS GLAND FROM THE NOSE, viewed by transmitted light, and highly magnified. *a*, epithelium of the gland; *b*, the same continuous with the epidermis; *c*, the sebaceous matter; *d*, subdivisions of the gland; *e*, a hair-follicle; *f*, a hair.

<sup>1</sup> Arrectores pili.

<sup>2</sup> Glandulæ sebaceæ.



accompanying hairs that the hair-follicles appear, contrary to the usual condition, to open into them. In these and other parts of the face the ducts of the sebaceous glands frequently become more or less distended with the secretion, and adherent dirt, at the mouths of the ducts, appears as black spots. When the secretion is squeezed out, from the worm-like appearance it assumes it has been regarded as an actual worm. The sebaceous glands of the face are nevertheless remarkable from the fact that the secretion does very commonly harbor a peculiar parasitic animal, the **pimple mite**, *Demodex folliculorum*.<sup>1</sup>

The sebaceous glands are pyriform racemose glands, according to the size composed of from two or three to twenty follicles. These have a connective-tissue wall with a net of capillary blood-vessels and

FIG. 494.

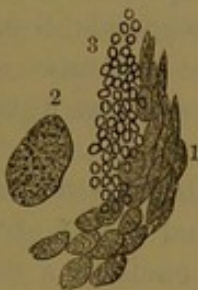

FIG. 495.

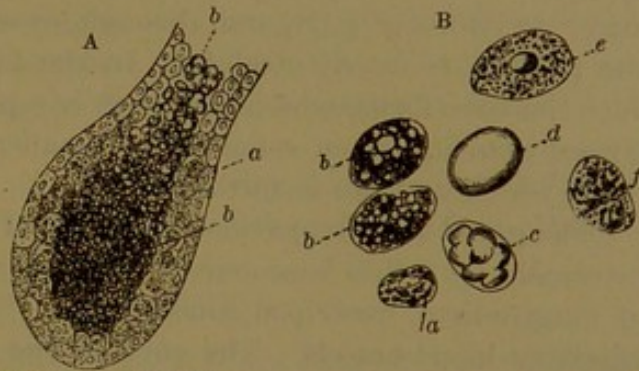


Fig. 494.—SEBACEOUS MATTER, FROM ONE OF THE SEBACEOUS GLANDS OF THE NOSE: magnified. 1, cells filled with granular matter; 2, one of the cells, more highly magnified; 3, oil-drops mingled with the cells.

Fig. 495.—STRUCTURE OF THE SEBACEOUS GLANDS. A, a simple sebaceous gland, or one of the divisions of a compound gland, highly magnified. a, epithelial cells; b, sebaceous matter. B, sebaceous cells, much more highly magnified. a, small cells from the epithelial layer; b, larger cells abounding in fat; c, cell in which the fat has accumulated in large drops; d, cell distended with fat; e, f, cells from which the fat has partially escaped.

are lined with a stratified epithelium of polyhedral cells, the contents of which are granular and mingled with numerous fat-globules. The epithelium extends into the ducts and is continuous with that of the hair-follicles. The lumen of the follicles and ducts is occupied with the cast-off epithelial cells with abundance of free fat.

#### THE SWEAT-GLANDS.

The **sweat-glands**, or **perspiratory glands**,<sup>2</sup> are mostly tiny, spheroidal, reddish bodies, existing in great numbers and situated at somewhat variable depths, embedded in the subcutaneous connective and adipose tissue of the skin. They exist nearly everywhere over the surface of the body, in variable proportions. They are most abundant in the palms and soles, where they are estimated to be several thousands to the square inch; are about half the number on the back of the hands

<sup>1</sup> *Acarus folliculorum*.

<sup>2</sup> Sudoriferous glands; glandulæ sudoriparæ; g. glomiformes.



and feet and on the forehead, a less number in front of the trunk, and the least number on the back. They are commonly about one-seventieth of an inch in diameter, but in some parts are much larger, as, for example, in the groin, and especially in the axilla.

In the palm and sole, the orifices of the sweat-ducts are visible with a pocket-lens and appear as little pits in a row along the lines of the tactile papillæ.

Ordinarily each sweat-gland consists of a fine cylindrical tube coiled up into a ball, from which the tube, somewhat reduced in diameter, proceeds as the sweat-duct. This ascends tortuously through the dermis to its surface, whence a passage continues through the epidermis and opens in a funnel-shaped orifice. Excepting where the epidermis is thin, the passage from the sweat-duct forms a tolerably close spiral, with the number of turns proportioned to the thickness of the epidermis. At its lower part, and throughout where the epidermis is thin, the passage is nearly straight. In the larger sweat-glands, from the duct the tube forks, which condition is repeated more and more in the largest glands. Even some of the smaller glands consist of a pair of tubes which unite to form the duct.

The gland-tube is provided with a wall of connective tissue defined internally by a thin basement membrane and provided with a stratum of longitudinal, unstriped muscle-fibres. The wall encloses a net of capillary blood-vessels. The coils of the tube are held together and enveloped with a looser texture of connective tissue, which supports the vessels. The epithelial lining of the tube consists of a stratum of short, stout columnar cells with granular protoplasm and a nucleus. The duct of the sweat-gland has its connective-tissue wall continuous with the dermis through which it passes, and is devoid of muscle-fibres. The epithelium of the duct consists of several strata of cells, together with a fine cuticular layer, and is continuous with the epidermis. The passage from the sweat-duct through the epidermis is formed alone by its cells, which in general conform in direction to the course of the passage.

When the epidermis, after maceration of the skin, is raised from the dermis, the extracted epithelium of the sweat-ducts appears as delicate threads proceeding from the dermis to the epidermis in the angle of separation of the two layers of the skin.

In the axilla, the sweat-glands appear beneath the skin, in a brownish patch from an inch and a half to two inches in breadth, thickest centrally and thinning out towards the circumference. They lie close together embedded in the subcutaneous connective and adipose tissue, and are irregularly rounded and polyhedral. In this position they range from one-thirty-sixth to one-twelfth of an inch, the largest being situated centrally. In the negro they are ordinarily more considerably developed, and sometimes the larger glands reach one-eighth of an inch or more in diameter.



## CHAPTER XVII.

### ANATOMY OF THE GROIN IN RELATION TO HERNIA.

ONE of the common accidents to which the body is liable is **hernia**, or protrusion of a portion of the bowels through the abdominal wall, occurring most frequently in the region of the groin. In this position the inguinal and femoral canals are especially weak points, which with undue pressure gradually or more or less abruptly yield and permit the escape of a portion of the intestines or omentum. The hernia is accompanied by a corresponding protrusion of the peritoneum, called the **hernial sac**.

The most common kind, **inguinal hernia**, occurs through the inguinal canal; while **femoral hernia** occurs through the femoral canal.

#### INGUINAL HERNIA.

The **inguinal canal** lies immediately above Poupart's ligament, and gives passage in the male to the spermatic cord and in the female to the round ligament of the uterus. It is about an inch and a half long, and extends from the internal abdominal ring at the middle of the groin to the external abdominal ring above and to the outer side of the pubic spine. It is considerably narrower in the female, who is therefore less liable to inguinal hernia.

In front the canal is formed by the aponeurosis of the external oblique muscle, and below by the same aponeurosis curving backward and forming Poupart's ligament. Behind, it is formed by the transversalis fascia, together, at the lower part, with the conjoined tendon of the internal oblique and transversalis muscles. Above, it is formed by the arching borders of these muscles.

The epigastric blood-vessels, ascending in the transversalis fascia, cross the course of the canal behind, and Poupart's ligament separates it from the femoral blood-vessels and canal.

The constituents of the spermatic cord are the spermatic duct, artery, veins, nerves, and lymphatics, united by connective tissue, often associated with more or less fat. Within the canal it is invested by the infundibuliform fascia and cremaster muscle, and, after emerging, in addition by the spermatic fascia,<sup>1</sup> the superficial fascia continuous with the dartos, and by the skin.

---

<sup>1</sup> External spermatic or intercolumnar fascia.



The round ligament in the inguinal canal has the same investment except the cremaster muscle, which is absent in the female, and after leaving the canal the ligament becomes attenuated and diffused in the tissues of the mons.

Two varieties of inguinal hernia are distinguished, the oblique and the direct.

In **oblique inguinal hernia**,<sup>1</sup> the most common form, the protruding intestine pursues the course of the spermatic cord through the inguinal canal into the scrotum. The hernia in its descent becomes successively invested with the coverings of the spermatic cord, and lies in front of the spermatic vessels. In the female, oblique inguinal hernia takes a similar course, and after emerging at the external abdominal ring it occupies the labium.

In **direct inguinal hernia**<sup>2</sup> the bowel directly protrudes through the lower end of the inguinal canal at the external abdominal ring. Behind the ring is a triangular space<sup>3</sup> covered by the conjoined tendon and defined outwardly by the epigastric blood-vessels. Through this space the hernia protrudes into the external abdominal ring, covered by the transversalis fascia, the conjoined tendon, the spermatic and superficial fasciæ, and the skin. The hernia may protrude through a slit of the conjoined tendon. Sometimes it protrudes to the outer side of the tendon into the inguinal canal and descends as in ordinary oblique inguinal hernia.

The inner surface of the anterior wall of the abdomen, on each side, exhibits a slight fold of the peritoneum in the course of the obliterated umbilical artery<sup>4</sup> from the side of the pelvis and groin to the umbilicus. The fold divides the space opposite the groin into two shallow concavities, which are called the **external** and **internal inguinal fossæ**. These correspond with the position respectively of the abdominal rings and of the two forms of inguinal hernia.

In the fœtus up to the seventh month the testicles are contained within the abdominal cavity, below the kidneys, behind the peritoneum, which invests them in front and at the sides.

In the seventh month the testicle descends through the inguinal canal, and by the end of the eighth month has usually passed into the scrotum. The vaginal tunic, as a pouch prolonged from the peritoneum, precedes the testicle in its descent. Shortly before birth the narrowed neck of the pouch generally becomes closed, and the vaginal tunic is then completely shut from the peritoneal cavity. Occasionally the neck of the pouch remains open later than usual, and may form the passage of a hernial protrusion, constituting the variety named **congenital hernia**.<sup>5</sup>

<sup>1</sup> External inguinal hernia.

<sup>2</sup> Internal or ventro-inguinal hernia.

<sup>3</sup> Triangle of Hesselbach.

<sup>4</sup> Hypogastric artery.

<sup>5</sup> Hernia tunici vaginalis.



In the female foetus a pouch<sup>1</sup> of peritoneum accompanies the round ligament a short distance at the entrance of the inguinal canal. A depression or little pocket, usually to be seen in the adult in the position of the internal abdominal ring, is the remains of the pouch. This at times becomes the commencement of a hernial sac.

## FEMORAL HERNIA.

The space between **Poupart's ligament**, or the **femoral arch**,<sup>2</sup> and the hip-bone is occupied outwardly by the ilio-psoas muscle with the crural and external cutaneous nerves; inwardly by the femoral blood-vessels and lymphatics enveloped in a common connective-tissue sheath, which is continuous above with the lining fasciæ of the abdomen. The femoral artery lies to the outer side, the vein in the middle, and the lymphatics to the inner side. The space occupied by the latter, together with a lymphatic gland, connective tissue, and fat, is distinguished as the **femoral canal**,<sup>3</sup> and is the passage of **femoral hernia**. The femoral canal is about half an inch long and of the capacity of the last joint of the little finger. Its upper extremity, the **femoral ring**,<sup>4</sup> is closed by the adjacent peritoneum and connective tissue;<sup>5</sup> its lower extremity is at the saphenous opening of the fascia lata, closed by the cribriform fascia.

To the inner side of the femoral canal extending outwardly in front are Gimbernat's ligament, the conjoined tendon, and a thickened band<sup>6</sup> of the transversalis fascia. In front of it are Poupart's ligament and its union with the upper extremity of the falciform process of the fascia lata. To its outer side is the femoral vein, separated by a partition of the common sheath. Behind it is the pubis, with the pectineus muscle covered by the pubic portion of the fascia lata.

The epigastric blood-vessels lie above to the outer side of the femoral ring, and the obturator artery, when not running in the usual course, descends into the pelvis at the outer side or rarely at the inner side of the ring.

A femoral hernia descends the femoral canal to the saphenous opening, where finding less resistance forward it takes this direction, and in a further increase turns outwardly in the groin. Its coverings, succeeding the hernial sac, are a thin connective-tissue layer<sup>7</sup> derived from that of the femoral canal and the sheath of the femoral vessels, the cribriform fascia, and the skin.

The femoral canal is commonly larger in the female; hence femoral hernia is more common in that sex than in the male.

<sup>1</sup> Canal of Nuck.<sup>2</sup> Superficial femoral or crural arch.<sup>3</sup> Crural canal.<sup>4</sup> Crural ring.<sup>5</sup> Septum crurale; crural septum.<sup>6</sup> Deep femoral or crural arch.<sup>7</sup> Fascia propria.







# INDEX.

## A.

- Abdomen, 366.  
cavity of, 366.  
muscles of, 270.  
regions of, 367.  
viscera of, 416, 621, 680, 686.
- Abdominal ring, external, 273.  
internal, 278.
- Absorbent system, 579.
- Absorbents, 579.
- Acerculus cerebri, 763.
- Acetabulum, 191.
- Acini, 360.
- Acoustic crest, 911.  
hair-cells, 910, 914.  
organ, 914.  
rods, 914.  
spots, 910.
- Acromion, 160.
- Adventitia, 454, 580.
- Afferent nerves, 694.  
vessels, 582.
- After-brain, 767.
- Agminated glands, 430.
- Air-cells, 605.
- Albuginea, 636, 645, 668.
- Alimentary canal, 376.
- Alveoli, 119, 359, 674.
- Amphiarthrosis, 50.
- Ampullæ, 673.
- Anapophysis, 61.
- Angle, of eye, 854.  
facial, 152.  
of jaw, 131.  
of mouth, 377.  
of pubis, 190.  
of ribs, 81.  
sacro-vertebral, 63, 66.  
of scapula, 158, 159.
- Ankle, 218.  
bone, 211.  
joint, 218.
- Annulus ovalis, 469.
- Antihelix, 886.
- Antitragus, 886.
- Antrum Highmorianum, 118.  
mastoid, 893.  
maxillary, 118.  
pyloric, 417.  
tympanic, 893.
- Aorta, 777.  
abdominal, 478, 517.  
arch of, 478, 479.  
branches of, 479.  
semilunar valves of, 473.  
thoracic, 478, 514.  
variations in branches of, 478.
- Aperture, nasal, 144.
- Aponeurosis, 236, 243.  
epicranial, 246.
- Apophysis, 33.
- Apparatus, alimentary, 376.  
lachrymal, 859.  
reproductive, 634, 654.  
respiratory, 597.
- Appendages of the eye, 854.
- Aqueduct, cochlear, 113, 908.  
of Sylvius, 762.  
ventricular, 762.  
vestibular, 112, 904, 909.
- Aqueous humor, 884.
- Arachnoid, 772, 774.
- Arantius, corpuscles of, 474.
- Arbor vitæ, 663, 729.
- Arch, carpal, anterior, 508.  
posterior, 509, 513.  
crural, 933.  
femoral, 933.  
of the aorta, 478, 479.  
of the colon, 435.  
palatine, anterior, 379.  
posterior, 379.  
palmar, deep, 507.  
superficial, 501, 509.  
plantar, 545.  
supraorbital, 102.  
zygomatic, 141.
- Arcus senilis, 866.
- Arm-bone, 163.
- Arterial cone, 471.
- Artery, or arteries, 453.  
adventitia of, 454.  
anastomotic, 507, 537.  
angular, of facial, 490.  
auditory, 498.  
auricular, 492, 493.  
axillary, 502.  
basilar, 498.  
brachial, 504.  
variations of, 505.  
bronchial, 515.  
buccal, 495.  
bulbar, 529.  
calcanean, 545.  
carotid, external, 487.  
internal, 483.  
left common, 480.  
right common, 481.  
carpal, anterior, 508, 514.  
posterior, 509, 513.  
cavernous, 529.  
central, of cochlea, 907.  
of retina, 485, 880.  
cerebellar, inferior, 497, 498.  
superior, 499.  
cerebral, anterior, 484.  
middle, 485.
- Artery, cerebral, posterior, 499.  
cervical, ascending, 499.  
deep, 502.  
occipital, 491.  
superficial, 500.  
transverse, 500.  
choroid, 484, 499.  
ciliary, 486, 872.  
circumflex, anterior, 504.  
external, 536.  
iliac, 533, 535.  
internal, 535.  
posterior, 504.  
coccygeal, 531.  
coeliac, 518.  
colic, left, 522.  
middle, 522.  
right, 522.  
communicating, anterior, 485.  
posterior, 484.  
coronary, left, 480.  
right, 479.  
deferential, 527, 651.  
dental, anterior, 495.  
inferior, 494.  
posterior, 495.  
digitals, 510, 514, 546.  
dorsal, 509, 513, 542.  
dorsal, of clitoris, 530.  
of intercostals, 516.  
of lateral sacral, 531.  
of lumbar, 525.  
pedal, 541.  
of penis, 530.  
emulgent, 523.  
epigastric, 533.  
superficial, 535.  
superior, 501.  
ethmoidal, 486.  
facial, 489.  
transverse, 492.  
femoral, 533.  
profunda, 535.  
frontal, 487.  
gastric, 518.  
short, 520.  
gastrocnemial, 538.  
gastro-duodenal, 519.  
gastro-epiploic, left, 520.  
right, 519.  
gluteal, deep, 532.  
superficial, 532.  
helicine, 637.  
hemorrhoidal, inferior, 529.  
middle, 528.  
superior, 523.  
hepatic, 519, 520.  
hypogastric, 526.  
iliac, 531.



- Artery, iliac, circumflex, 533.  
     common, 526.  
     external, 532.  
     internal, 526.  
 ilio-colic, 521.  
 ilio-lumbar, 531.  
 infraorbital, 495.  
 innominate, 480.  
 intercostal, 516.  
     anterior, 501.  
     superior, 502.  
 interosseous, anterior, 512.  
     metatarsal, 542.  
     posterior, 512.  
     recurrent, 512.  
 intestinal, 521.  
 intima of, 456.  
 ischiatic, 530.  
 labial, inferior, 490.  
     superior, 490.  
 lachrymal, 485.  
 lingual, 488.  
 lumbar, 525.  
 malleolar, 541, 544.  
 mammary, 501.  
 masseteric, 495.  
 maxillary, internal, 493.  
 media of, 455.  
 median, 512.  
 mediastinal, 501, 515.  
 medullary, nutritious, 507,  
     512, 537, 543.  
 meningeal, 491.  
     great, 494.  
     posterior, 497.  
     small, 494.  
 mesenteric, inferior, 522.  
     superior, 521.  
 metacarpal, dorsal, 509, 513.  
     palmar, 511.  
 metatarsal, 541.  
 musculo-phrenic, 501.  
 mylo-hyoid, 495.  
 nasal, 486, 490, 496.  
 obturator, 527.  
 occipital, 491.  
 oesophageal, 515, 518.  
 ophthalmic, 485.  
 orbital, 493.  
 ovarian, 523.  
 palatine, inferior, 489.  
     superior, 495.  
 palpebral, 486.  
 pancreatic, 520.  
 pancreatico-duodenal, 519,  
     520.  
 perforating, 501, 536.  
 peroneal, 543.  
     anterior, 544.  
     posterior, 544.  
     superficial, 529.  
     transverse, 529.  
 pharyngeal, 491.  
 phrenic, 501, 525.  
 plantar, external, 545.  
     internal, 544.  
 popliteal, 537.  
 profunda, femoral, 535.  
     inferior, 506.  
     superior, 506.  
 pterygoid, 495.  
 pterygo-palatine, 496.  
 pubic, 533.
- Artery, pudic, external, 535.  
     internal, 528.  
 radial, 507.  
 ranine, 489.  
 recurrent, radial, 508.  
     tibial, anterior, 541.  
     posterior, 540.  
     ulnar, 512.  
 renal, 523.  
 retinal, central, 485.  
 sacral, middle, 518.  
     lateral, 531.  
 scapular, posterior, 500.  
 sciatic, 531.  
 sigmoid, 523.  
 spermatic, 524, 533, 650.  
 spinal, anterior, 497.  
     posterior, 497.  
 splenic, 520.  
 sternal, 501.  
 structure of, 454, 462.  
 stylo-mastoid, 492.  
 subclavian, 496.  
     left, 482.  
     right, 482.  
     surgical relations of, 502.  
 submaxillary, 490.  
 subscapular, 504.  
 supraorbital, 485.  
 suprarenal, 523.  
 suprascapular, 499.  
 tarsal, 541.  
 temporal, 492.  
     anterior, 493.  
     deep, 495.  
     middle, 493.  
     posterior, 493.  
 thoracic, acromial, 503.  
     inferior, 503.  
     superior, 503.  
 thyroid, inferior, 499.  
     superior, 487.  
 tibial, anterior, 539.  
     posterior, 542.  
 tonsillar, 490.  
 tunics of, 454, 456.  
 tympanic, 484, 494.  
 ulnar, 511.  
 umbilical, 578.  
 uterine, 530, 664.  
 vertebral, 496.  
 vesical, inferior, 526.  
     superior, 526.  
 vesico-vaginal, 530.  
 vidian, 496.  
 volar, 508.
- Articulation, ankle-joint, 218.  
 astragalo-calcaneal, 219.  
 calcaneo-scaphoid, 220.  
 atlanto-axial, 77.  
     occipital, 77.  
 calcaneo-cuboid, 220.  
 carpo-metacarpal, 185.  
 costo-central, 85.  
     sternal, 86.  
     transverse, 82.  
 crico-arytenoid, 614.  
     thyroid, 614.  
 of the ear-ossicles, 895.  
 elbow-joint, 181.  
 of the hand, 183.  
 of the hip-joint, 200.  
 immovable, 50.
- Articulation, intercarpal, 185.  
 intercostal, 87.  
 of the jaws, 155.  
 of the knee-joint, 206.  
 of the lower jaw, 155.  
 metacarpo-phalangeal, 186.  
 movable, 51.  
 movements of, 51.  
 odonto-atlantal, 78.  
     transverse, 78.  
 of the pelvis, 195.  
 phalangeal, 186.  
 of the pubes, 196.  
 radio-carpal, 184.  
 radio-ulnar, 182.  
 sacro-iliac, 195.  
 scapulo-clavicular, 178.  
 scapulo-humeral, 180.  
 shoulder-joint, 179.  
 sternal, 87.  
 sterno-clavicular, 178.  
 of the tarsus, 219.  
 temporo-mandibular, 155.  
 temporo-maxillary, 155.  
 tibio-fibular, 210.  
 of the upper limbs, 178.
- Arthrosis, 50.  
 Astragalus, 211.  
 Atlas, 57.  
 Atrium, of the heart, 468.  
     of the tympanum, 890.  
 Attic, 893.  
 Auditory meatus, 887.  
     cartilaginous portion of,  
     888.  
     external, 887.  
     internal, 901.  
     osseous portion of, 889.  
     nerve, 902.  
 Auricle of the ear, 886.  
     of the heart, 468, 470.  
 Auricular appendix, 468, 470.  
     septum, 468, 469.  
 Auriculo-ventricular orifice,  
 468.  
 Axillary artery, 502.  
     plexus, 812.  
     vein, 562.  
 Axis, 58.  
     cerebro-spinal, 689.  
     coeliac, 518.  
     thyroid, 497.  
 Azygos vein, 566.
- B.**
- Backbone, 54.  
 Band, dentate, 754.  
     ilio-tibial, 316.  
     semicircular, 752.  
 Basement membrane, 357.  
 Basilar artery, 498.  
     groove, 91.  
     membrane, 912.  
 Basilic vein, 564.  
 Belly, 366.  
 Bicuspid teeth, 397.  
     valve, 473.  
 Bile, 452.  
     canaliculi, 448.  
     capillaries, 362, 448.  
     duct, 449.



- Bladder, gall, 451.  
urinary, 626.
- Blood, 463.  
clot, 464.  
corpuscles, 463.  
liquor, 463, 466.  
plasma, 463, 466.  
vessels, 453.
- Body, ciliary, 868.  
geniculate, 759.  
olivary, 717.  
Pachionian, 772.  
pineal, 762.  
pituitary, 763.  
pyramidal, 716.  
quadrigeminal, 761.  
restiform, 719.  
suprarenal, 686.  
thyroid, 683.
- Bone, alisphenoid, 99.  
astragalus, 211.  
atlas, 57.  
axis, 58.  
basi-hyal, 156.  
basi-occipital, 90, 93.  
basi-sphenoid, 99.  
calcaneum, 212.  
canaliculi in, 40.  
cancellated substance of, 35.  
carpal, 171.  
cerato-hyal, 157.  
clavicle, 162.  
coccyx, 65.  
collar, 162.  
compact substance of, 35.  
composition of, 34.  
cuboid, 214.  
cuneiform, 172, 214.  
development of, 44, 48.  
ectethmoid, 106, 107.  
ecto-cuneiform, 215.  
ensiform, 84.  
ento-cuneiform, 215.  
epiotic, 116.  
episternal, 85.  
ethmoid, 106.  
exoccipital, 93.  
femur, 196.  
fibula, 204.  
forms of, 33.  
frontal, 102.  
growth of, 44, 48.  
haunch, 187.  
Haversian canals in, 38.  
hip, 187.  
humerus, 164.  
hyoid, 156.  
ilium, 187.  
incisive, 121.  
inferior turbinated, 124.  
innominate, 187.  
intermaxillary, 121.  
ischium, 189.  
knee-cap, knee-pan, 200.  
lachrymal, 128.  
lacunæ of, 40, 48.  
leg, 202.  
lower jaw, 129.  
limbs, 187.  
lunar, 172.  
mandible, 129.  
magnum, 173.  
malar, 128.
- Bone, marrow of, 35, 48.  
mastoid, 110.  
maxillary, 118, 129.  
inferior, 129.  
superior, 118.  
medullary cavity of, 35.  
space of, 48.  
mesethmoid, 106.  
meso-cuneiform, 215.  
meso-sternum, 83.  
metacarpal, 174.  
metatarsal, 215.  
nasal, 126.  
nerves of, 43.  
occipital, 90.  
opisthotic, 116.  
orbito-sphenoid, 99.  
palate, 122.  
parietal, 101.  
patella, 200.  
of pelvis, 188, 190.  
perforating fibres of, 41.  
petrosal, 110, 115, 117.  
phalanges, 177, 217.  
pisiform, 172.  
prefrontal, 106, 107.  
premaxillary, 121.  
presphenoid, 99.  
presternum, 82.  
prootic, 116.  
pterygoid, 99.  
pubic, 190.  
radius, 169.  
scaphoid, 171, 213.  
scapula, 158.  
sesamoid, 178, 217.  
sphenoid, 93.  
spheno-turbinal, 96, 99, 100.  
spongy, 35, 107, 124.  
squamosal, 115, 117.  
sternum, 82, 83, 84.  
structure of, 35.  
supraoccipital, 93.  
sutural, 137.  
tarsal, 211.  
temporal, 109, 110.  
thigh, 196.  
thyro-hyal, 157.  
trapezium, 172.  
trapezoid, 173.  
turbinated, 107, 124.  
tympanal, 112, 116, 117.  
ulnar, 167.  
unciform, 173.  
unguiform, 125.  
vascular canals of, 38.  
vessels of, 43.  
vomer, 127.  
Wormian, 116.  
xiphisternum, 84.
- Bone-cartilage, 34.  
corpuscles, 40, 48.  
earth, 34.  
tissue, 34.
- Bosom, 363.
- Brachial artery, 504.  
plexus, 812.  
veins, 563.
- Brain, 713.  
arteries of, 484, 497.  
blood-vessels of, 775.  
commissures of, 749, 759.
- Brain of embryo, 767.  
membranes of, 770.  
nerves of, 778.  
ventricles of, 719, 750, 757.
- Breasts, 363, 672.
- Brim of pelvis, 193.
- Broad ligaments, 661, 664.
- Bronchial glands, 591.  
tubes, 602.
- Bronchioles, 603, 605.
- Bronchus, bronchi, 598, 602.
- Bursa mucosa, 354.  
subcutaneous, 354.  
synovial, 354.
- C.
- Cæcum, 433.
- Calamus scriptorius, 719.
- Calcaneum, 212.
- Calcar, 753.
- Calcification, 48, 233.
- Callosum, 735, 749.
- Calvaria, 134.
- Calyces of the kidney, 623, 627.
- Canal, 33.  
alimentary, 376.  
carotid, 113.  
central, of modiolus, 907.  
of spinal cord, 706.  
cochlear, 906.  
crural, 933.  
deferent, 647, 649.  
dental, 119, 131.  
digital, 307.  
facial, 112, 901.  
Fallopian, 112, 901.  
femoral, 933.  
glenoid, 113, 116.  
Haversian, 38.  
of Huguier, 113.  
Hunter's, 324.  
infraorbital, 119.  
inguinal, 277.  
lachrymal, 858.  
of Nuck, 933.  
palatine, 124.  
anterior, 120.  
posterior, 142.  
portal, 449.  
pterygoid, 98.  
pterygo-palatine, 99, 123.  
semicircular, 905, 909.  
spheno-palatine, 123.  
spiral, 907, 914.  
Vidian, 98.
- Canaliculi, bile, 448.  
bone, 40.  
lachrymal, 860.
- Canines, 396, 399.
- Capillaries, 453, 460.  
bile, 448.  
lymphatic, 581.
- Capitulum, 165.
- Capsule of cerebrum, 755, 756.  
of Glisson, 450.  
of lens, 882.
- Cardia, 416.
- Cardiac muscular tissue, 243.
- Carpus, 171.



- Cartilage or cartilages, 230.  
   accessory, of nose, 850.  
   articular, 231, 233.  
   arytenoid, 611.  
   bronchial, 603.  
   corniculate, 612.  
   costal, 80, 82.  
   cricoid, 612.  
   cuneiform, 612.  
   diarthrodial, 52.  
   of ear, 886.  
   elastic, 235.  
   ensiform, 84.  
   epiglottic, 612.  
   of eustachian tube, 895.  
   of larynx, 608.  
   lateral, of nose, 850.  
   of Meckel, 133.  
   of nose, 849.  
   oval, of nose, 850.  
   palpebral, 855.  
   permanent, 231.  
   semilunar, 207.  
   septal, 849.  
   temporary, 231.  
   thyroid, 608.  
   tracheal, 603.  
   triangular, 850.  
   tympano-mandibular, 133.  
   of Wrisberg, 612.  
 Caruncle, lachrymal, 858.  
 Cauda equina, 712.  
 Caudate lobe of the liver, 444.  
 Cava, inferior, 565.  
   superior, 548.  
 Cavernous bodies of the clitoris, 656.  
   of the penis, 636.  
 Cavity, abdominal, 366.  
   cotyloid, 191.  
   cranial, 137.  
   glenoid, 160.  
   nasal, 847.  
   oral, 377.  
   pelvic, 193.  
   thoracic, 364.  
   tympanic, 890.  
   uterine, 663.  
 Cells, acoustic hair, 910, 914.  
   air, 605.  
   apolar, 696.  
   beaker, 348.  
   bipolar, 696.  
   chalice, 348.  
   daughter, 31.  
   ganglion, 695.  
   goblet, 348, 356.  
   gustatory, 386.  
   hepatic, 448.  
   mastoid, 893.  
   migratory, 466.  
   multipolar, 696.  
   nerve, 695.  
   olfactory, 851.  
   organic, 27.  
   parietal, 422.  
   peptic, 422.  
   secreting, 349.  
   seminal, 647.  
   supporting, 682.  
   sustentacular, 682.  
   tactile, 922.  
   unipolar, 696.  
 Cell-wall, 28.  
 Cementum, 404.  
 Central canal of the spinal cord, 706.  
   fovea of the retina, 874, 879.  
 Centre, medullary, 765.  
 Centrifugal nerves, 694.  
 Centripetal nerves, 694.  
 Centrum ovale Vieussensii, 749.  
 Cerebellum, 728.  
   arteries of the, 777.  
   cortex of the, 729, 730.  
   cortical layers of the, 734.  
   hemispheres of the, 729.  
   peduncles of the, 732.  
   valley of the, 729.  
 Cerebral crura, 747.  
   nerves, 778.  
   origin of, 778.  
   vesicles, 767.  
 Cerebro-spinal axis, 689, 703.  
   blood-vessels of, 775.  
   gray matter of, 690, 703.  
   membranes of, 769.  
   white matter of, 690, 702.  
 Cerebro-spinal fluid, 772.  
 Cerebrum, 715, 734.  
   arteries of, 776.  
   convolutions of, 736.  
   crura of, 747.  
   gray matter of, 736.  
   hemispheres of, 735.  
   interior of, 749.  
   white matter of, 736.  
 Cerumen, 890.  
 Ceruminous glands, 890.  
 Chambers of the eye, 870, 884.  
 Cheeks, 377.  
 Chest, 87, 363.  
 Chiasm, optic, 760.  
 Chorda tympani, 792, 795.  
 Chorion, 671.  
 Choroid plexuses, 722, 768, 769.  
   telæ, 768, 769.  
 Choroidea, 866.  
 Chyle, 585, 589.  
   receptacle of the, 585.  
 Cilia, 348, 855.  
 Ciliary body, 868.  
   muscle, 869.  
   plexus, 873.  
   processes, 868.  
   zone, 881.  
 Cils, 348.  
 Circle, arterial, of the iris, 872.  
   of Willis, 485.  
 Claustrium, 756.  
 Clava, 718.  
 Clavicle, 162.  
 Clitoris, 655.  
 Coccyx, 65.  
 Cochlea, 906.  
   membranous, 911.  
 Cochlear duct, 911.  
 Coeliac axis, 518.  
 Collar-bone, 162.  
 Colles, fascia of, 676.  
 Colon, 432.  
 Columns, Burdach's, 711.  
   carneous, 471, 472.  
   Clark's, 708, 712, 775.  
 Columns of the oblongata, 711.  
   of the spinal cord, 705.  
 Commissure, great cerebral, 735, 794.  
   optic, 759, 760.  
 Commissures, labial, 377.  
   palpebral, 855.  
   of the spinal cord, 705, 706.  
   of the third ventricle, 759, 760.  
   of the vulva, 655.  
 Common bile-duct, 451.  
 Condyles, 33.  
   of femur, 198.  
   of humerus, 166.  
   of mandible, 132.  
   of occipital bone, 92.  
 Conjunctiva, 857.  
 Connective tissue, 223.  
 Connivent valves, 355, 426.  
 Convolutions of the cerebrum, 716, 736.  
   angular, 741.  
   annectant, 741, 742.  
   central, 739, 740.  
   fornicate, 745.  
   frontal, 739.  
   hippocampal, 744.  
   marginal, 741.  
   occipital, 742.  
   occipito-temporal, 743.  
   orbital, 739, 740.  
   parietal, 740, 741.  
   temporal, 743.  
   uncinate, 744.  
 Cord, spinal, 703.  
 Cordiform tendon, 267.  
 Cords, vocal, 614, 619.  
 Corium, 345.  
 Cornea, 864.  
 Cornua, of the lateral ventricles, 750.  
   of the spinal cord, 706.  
 Cornucopia, 720, 721, 732.  
 Corona radiata, 765.  
 Corpus callosum, 735, 749.  
   dentatum, 718.  
   Highmori, 645.  
   luteum, 671.  
   olivare, 717.  
   pyramidale, 716.  
   restiform, 719.  
   striatum, 751.  
 Corpuscles of Arantius, 474.  
   blood, 464.  
   bone, 40.  
   cartilage, 231.  
   colorless, 465.  
   colostrum, 675.  
   concentric, 686.  
   connective tissue, 224.  
   corneal, 865.  
   lymph, 584.  
   lymphoid, 583.  
   Pacinian, 918.  
   red, 464.  
   tactile, 918.  
   white, 465.  
 Cortex, cerebellar, 733.  
   cerebral, 736.  
   renal, 623.



Cortex, suprarenal, 687.  
Corti, organ of, 914.  
Cortical labyrinth of the kidney, 624.  
layers of the cerebellum, 734.  
Cranium, 89, 133.  
base of the, 134.  
fossæ of, 137.  
interior of, 137.  
Crassamentum, 464.  
Crescents of Giannuzzi, 392.  
Crest, 33.  
ethmoidal, 91.  
iliac, 187.  
occipital, 106.  
pubic, 190.  
tibial, 202.  
urethral, 641.  
vestibular, 904.  
Crista galli, 106.  
Crown of the head, 133.  
Crura of the cerebrum, 747.  
of the diaphragm, 268.  
of the fornix, 752.  
Crural arch, 272.  
canal, 933.  
ring, 933.  
Crusta, 747.  
petrosa, 404.  
Crystalline lens, 882.  
Cuneus, 743.  
Cupola, 906, 911.  
Cuticle, 920, 921.  
Cystic duct, 451.

## D.

Dartos, 271, 643.  
Daughter-cells, 31.  
Deferent canal, 647, 649.  
Deiters, nucleus of, 725.  
Demodex folliculorum, 929.  
Dental tissues, 401.  
production of, 407.  
Dentate band, 744.  
Denticulate ligament, 774.  
Dentine, 402.  
Dermis, 915.  
Diaphragm, 267.  
arcuate ligaments of, 268.  
central tendon of, 267.  
crura of, 268.  
openings of, 269.  
Diaphysis, 45.  
Diapophyses, 56.  
Diarthrosis, 51.  
Diencephalon, 767.  
Digestion, organs of, 416.  
Digits, 177, 217.  
Diploe, 35, 134.  
Diploic sinuses, 35.  
Disks, intervertebral, 71.  
Dorsum of foot, 217.  
of hand, 183.  
of tongue, 383.  
Duct, bile, 449.  
cochlear, 911.  
cystic, 451.  
ejaculatory, 652.  
glandular, 359.  
hepatic, 449.  
lactiferous, 673.

Duct, milk, 673.  
of Müller, 672.  
nasal, 860.  
pancreatic, 441.  
parotid, 390.  
right lymphatic, 586.  
of Rivinus, 389.  
spermatic, 649.  
of Steno, 389.  
thoracic, 585.  
of Wharton, 389.  
of Wirsung, 441.  
Ductus arteriosus, 578.  
communis choledochus, 449.  
venosus, 578.  
Dura of the brain, 770.  
of the spinal cord, 773.  
Dura mater, 770.

## E.

Ear, 885.  
drum, 890.  
external, 885.  
internal, 901.  
middle, 890.  
lobe, 886.  
ossicles, 895.  
articulations of, 897.  
ligaments of, 898.  
muscles of, 898.  
Ectiris, 871.  
Ectochoroidea, 860.  
Ectocornea, 864, 865.  
Ectoretina, 874, 875.  
Efferent nerves, 694.  
tubules, 647.  
vessels, 582.  
Egg, 670.  
Elements, sarcous, 241.  
structural, 27.  
Embryology, 26.  
Eminence, auditory, 721.  
cinereous, 721.  
collateral, 755.  
cuneate, 719.  
frontal, 242.  
ilio-pectineal, 190.  
ilio-pubic, 190.  
mammillary, 749.  
parietal, 101.  
terete, 721.  
Enamel, 403.  
organ, 408.  
Enarthrosis, 51.  
Encephalon, 713.  
Endangium, 456.  
Endocardium, 476.  
Endomysium, 242.  
Endoneurium, 698.  
Endothelium, 346, 352, 456.  
Entiris, 871.  
Entochoroidea, 871.  
Entocornea, 868.  
Entoretina, 877.  
Entotympanic membrane, 894.  
Epencephalon, 767.  
Ependyma, 769.  
Epicardium, 474, 476.  
Epicondyles of femur, 199.  
of humerus, 166.  
Epidermal rete, 920.

Epidermis, 346, 919.  
Epididymis, 644.  
Epigastric region, 367.  
Epigastrium, 367.  
Epiglottic cartilage, 612.  
cushion, 618.  
Epiglottis, 612.  
Epineurium, 698.  
Epiploic appendages, 436.  
Epiploon, great, 371.  
Epithelial tissue, 345.  
Epithelium, 345, 346.  
ciliated, 347.  
columnar, 346.  
cylinder, 346.  
glandular, 360.  
pavement, 346.  
polyhedral, 348.  
scaly, 346.  
simple, 346.  
squamous, 350.  
stratified, 346.  
tessellated, 346.  
transitional, 350.  
Eustachian tube, 894.  
Excretion, 358.  
Eye, 854.  
appendages of, 854.  
blood-vessels of, 885.  
Eyeball, 854, 862.  
muscles of, 860.  
Eyebrow, 854.  
Eyelashes, 854, 855.  
Eyelids, 854.  
structure of, 855.

## F.

Face, 89, 133, 144.  
Facial angle, 152.  
Fallopian tube, 666.  
Falx, cerebellar, 771.  
cerebral, 770.  
Fascia, 238.  
of abdomen, 271.  
anal, 677, 279.  
axillary, 290.  
of the back, 280.  
cervical, 257.  
of Colles, 676.  
costo-coracoid, 293.  
crural, 330.  
deep, 236.  
of the forearm, 300.  
of the leg, 330.  
of the thigh, 315.  
of the upper limb, 290.  
dorsal, of foot, 331.  
of hand, 310.  
femoral, 315.  
ilio-psoas, 317.  
infundibuliform, 271.  
laryngeal, 615.  
lata, 315.  
lumbar, 278.  
obturator, 279.  
palmar, 301.  
pelvic, 279.  
of penis, 635.  
perineal, 676.  
plantar, 331.  
prevertebral, 265.  
propria, 933.



- Fascia, recto-vesical, 279.  
   spermatic, 273, 643.  
   superficial, 236.  
     of the abdomen, 271.  
     of the back, 280.  
     of the forearm, 300.  
     of the lower limb, 315.  
     of the upper limb, 290.  
   temporal, 254.  
   transversalis, 277.  
   vertebral, 285.  
 Fascicles, fornicate, 766.  
   gyral, 767.  
   longitudinal, 767.  
   uncinate, 767.  
 Fat-cells, 230.  
   tissue, 228.  
 Fauces, 379.  
 Femoral arch, 933.  
   canal, 933.  
   ring, 933.  
 Femur, 196.  
 Fibres, arciform, 724.  
   connective-tissue, 223.  
   lens, 883.  
   muscle, 238.  
   nerve, 691.  
   osteogenic, 49.  
   perforating, 41.  
   of Remak, 693.  
   sustentacular, 878.  
 Fibrin, 464, 466.  
 Fibro-cartilages, 234.  
   circumferential, 235.  
   connecting, 234.  
   interarticular, 234.  
   intervertebral, 71.  
   investing, 235.  
 Fibro-connective tissue, 223.  
 Fibrous tissue, 223.  
 Fibula, 204.  
 Fifth ventricle, 751.  
 Fillet, 733.  
 Filum, terminal, 773.  
 Fimbria, 754.  
 Fingers, 177.  
 Fissures, calcarine, 744.  
   callosal, 745.  
   calloso-marginal, 745.  
   central, 738.  
   of the cerebellum, 729.  
   of the cerebrum, 736.  
   collateral, 744.  
   dentate, 754.  
   Glaserian, 110, 112.  
   glenoid, 110.  
   great horizontal, 729.  
     longitudinal, 735.  
   hippocampal, 744.  
   interparietal, 740.  
   of the liver, 445.  
   of the medulla oblongata, 716.  
   occipital, 742, 743.  
   palpebral, 854.  
   parieto-occipital, 738.  
   of Rolando, 738.  
   of spinal cord, 705.  
   Sylvian, 735, 737.  
   temporal, 743.  
   transverse, 757.  
   triradiate, 740.  
   of the vulva, 655.  
 Flanks, 367.  
 Flexures of the colon, 435.  
 Floccule, 731.  
 Floor of the fourth ventricle, 720.  
 Folds, ary-epiglottic, 617.  
   recto-uterine, 375.  
   recto-vesical, 375.  
   of the rectum, 438.  
   synovial, 353.  
   thyro-arytenoid, 614, 615, 619.  
   of the tympanum, 899.  
   vesico-uterine, 375.  
 Follicles, 359.  
   Graafian, 670.  
 Follicular lymphatic glands, 380.  
 Fontanels, 150.  
 Foot, 211, 217.  
 Foramen or foramina, 33.  
   Botalli, 469, 577.  
   cæcum, 104, 383.  
   condyloid, 92.  
   coracoid, 159.  
   great sciatic, 196.  
   incisive, 120, 144.  
   infraorbital, 119.  
   intervertebral, 55.  
   jugular, 140.  
   lacerate, 139.  
   lacerum, middle, 136, 139.  
   of Magendie, 722, 769.  
   magnum, 92.  
   mental, 130.  
   of Monroe, 751, 757.  
   obturator, 191.  
   occipital, 92.  
   omental, 371.  
   optic, 98.  
   oval, of the heart, 462, 469, 577.  
   oval, sphenoidal, 98.  
   pre-ethmoidal, 146.  
   quadratum, 267.  
   rotundum, 98, 142.  
   sacral, 63.  
   sciatic, great, 196.  
     small, 196.  
   sphenoidal, 98, 146.  
   spheno-maxillary, 142.  
   spheno-palatine, 142.  
   spinal, 55.  
   spinous, 98.  
   stylo-mastoid, 113.  
   supraorbital, 193.  
   of third ventricle, 757.  
   of Winslow, 371.  
 Foramina Thebesii, 469.  
 Fore-brain, 734, 767.  
 Forehead, 133.  
 Foreskin, 635.  
 Formation, reticular, 724.  
 Fornix of brain, 752.  
   of conjunctiva, 857.  
 Fossa, 33.  
   canine, 120.  
   cerebellar, 91, 140.  
   coronoid, 166.  
   digastric, 110.  
   glenoid, 110.  
   hemielliptical, 904.  
   hemispherical, 904.  
   iliac, 188.  
   incisive, 120, 131.  
   infraspinous, 159.  
   infrasternal, 364.  
   inguinal, 932.  
   intercondyloid, 199.  
   ischio-rectal, 279.  
   jugular, 113, 363.  
   lachrymal, 146.  
   mesocranial, 139.  
   nasal, 847.  
   navicular, 655.  
   olecranon, 166.  
   olfactory, 138.  
   oval, of heart, 469.  
   pituitary, 93.  
   posterianal, 139.  
   precranial, 138.  
   sigmoid, of the ulna, 168.  
   spheno-maxillary, 141.  
   subscapular, 158.  
   sulciform, 904.  
   supraclavicular, 363.  
   supraspinous, 159.  
   temporal, 141.  
   trochanteric, 198.  
   zygomatic, 141.  
 Fourth ventricle, 719.  
 Fovea, central, of retina, 874.  
 Foveæ of oblongata, 721.  
 Fræna, glosso-epiglottic, 386.  
 Frænum, 635.  
   labial, 377.  
   lingual, 379, 383.  
 Frenule, 733.  
 Fringes, synovial, 53.  
 Funicle, cuneate, 719.  
   gracile, 718.  
   of nerves, 698.  
   terete, 720.  
 G.  
 Gall, 452.  
   bladder, 451.  
 Ganglion or ganglia, 690, 700.  
   Anderschii, 798.  
   Arnoldi, 793.  
   cervical, 836, 839.  
   coccygeal, 845.  
   Ehrenritteri, 798.  
   Gasserian, 782.  
   geniculate, 795.  
   jugular, 798, 800.  
   lumbar, 844.  
   Meckel's, 794.  
   mesenteric, inferior, 845.  
     superior, 844.  
   ophthalmic, 785.  
   otic, 793.  
   petrous, 798.  
   phrenic, 844.  
   renal, 844.  
   sacral, 845.  
   semilunar, of sympathetic, 843.  
   trifacial, 782.  
   spinal, 903.  
   submaxillary, 794.  
   temporal, 838.  
   thoracic, 841.  
 Ganglion-cells, 695.



Gastric glands, 421.  
 juice, 440.  
 Gelatinosa, 707.  
 Geniculate bodies, 759.  
 Germinal spot, 671.  
 vesicle, 671.  
 Ginglymus, 51.  
 Glabella, 103.  
 Gladiolus, 83.  
 Glands, 338.  
 agminated, 430.  
 alveoli of, 359.  
 arytenoid, 619.  
 of Bartholin, 658.  
 of Brunner, 429.  
 cardiac, 422.  
 carotid, 688.  
 ceruminous, 890.  
 coccygeal, 688.  
 colic, 436.  
 of colon, 462.  
 compound, 359.  
 convoluted, 361.  
 of Cowper, 642, 658.  
 ducts of, 359.  
 duodenal, 429.  
 enteric, 428.  
 epiglottic, 619.  
 follicles of, 359.  
 follicular, 359.  
 lymphatic, 380.  
 gastric, 421.  
 of Havers, 353.  
 labial, 377.  
 lachrymal, 859.  
 of Lieberkühn, 428.  
 of Littre, 642.  
 lobes of, 360.  
 lobules of, 360.  
 of Luschka, 688.  
 lymphatic, 579, 580, 581.  
 matrix of, 359.  
 Meibomian, 856.  
 membrana propria of, 359, 360.  
 of Mery, 642.  
 of Morgagni, 642.  
 nasal, 852.  
 œsophageal, 415.  
 oxyntic, 422.  
 of Pacchioni, 772.  
 palatine, 378.  
 palpebral, 856.  
 parotid, 389.  
 peptic, 422, 423.  
 perspiratory, 929.  
 of Peyer, 430.  
 pharyngeal, 411.  
 prostatic, 640.  
 pyloric, 422.  
 racemose, 359.  
 salivary, 389.  
 sebaceous, 928.  
 secreting cells of, 360.  
 simple, 359.  
 of small intestine, 428.  
 solitary, 429, 436.  
 sublingual, 389.  
 submaxillary, 389.  
 suburethral, 642.  
 sweat, 929.  
 thymus, 685.  
 thyroid, 683.

Glands, tubular, 428, 436.  
 uterine, 664.  
 Glans of the clitoris, 656, 657.  
 of the penis, 634.  
 Globules, milk, 675.  
 Glomerules, renal, 624, 626.  
 Glottis, 618.  
 Goblet-cells, 348, 356.  
 Graafian follicles, 670.  
 Grinders, 397.  
 Groove, auriculo-ventricular, 468.  
 basilar, 140.  
 bicipital, 163.  
 inter-auricular, 468.  
 inter-ventricular, 468.  
 musculo-spiral, 164.  
 spiral, of the cochlea, 913.  
 vertebral, 167.  
 Gubernaculum dentis, 409.  
 Gullet, 414.  
 Gut, 424.  
 Gyri, 716, 736.

## H.

Hæmapophyses, 82.  
 Hæmatoblasts, 466.  
 Hæmoglobin, 467.  
 Hair, 923.  
 follicle, 926.  
 medulla of the, 926.  
 papilla, 926.  
 root of, 926.  
 Hallux, 217.  
 Hand, 171.  
 Harmonia, 50.  
 Havers, canals of, 38.  
 glands of, 53.  
 Haversian canals, 38.  
 Head, 33.  
 of the femur, 198.  
 of the fibula, 205.  
 of the humerus, 163.  
 of the radius, 170.  
 of the tibia, 203.  
 Heart, 467.  
 auricles of, 468.  
 carneous columns of, 471, 472.  
 nerves of, 476.  
 papillary muscles of, 471, 472.  
 pectinate muscles of, 470.  
 tendinous cords of, 471, 472.  
 valves of, 472, 473.  
 ventricles of, 470.  
 vessels of, 476.  
 Heel-bone, 212.  
 Helix, 886.  
 muscles of, 887.  
 Hepatic cells, 448.  
 duct, 449.  
 lobules, 446.  
 substance, 442.  
 Hernia, 931.  
 congenital, 932.  
 femoral, 933.  
 inguinal, 931.  
 direct, 932.  
 external, 932.  
 internal, 932.  
 oblique, 932.

Hernia tunicae vaginalis, 932.  
 ventro-inguinal, 932.  
 Hernial sac, 931.  
 Hesselbach, triangle of, 932.  
 Hiatus aorticus, 267.  
 Fallopii, 111.  
 Hilus of kidney, 621.  
 of lung, 599.  
 of lymphatic glands, 582.  
 of ovary, 667.  
 of spleen, 680.  
 of suprarenal capsule, 687.  
 Hind-brain, 767.  
 Hippocampus, 754.  
 Histology, 26.  
 Homo, 26.  
 Horns of the lateral ventricles, 750, 753.  
 Humerus, 164.  
 Humor, aqueous, 884.  
 crystalline, 863, 882.  
 vitreous, 863, 881.  
 Hunter's canal, 324.  
 Hyaloidea, 881.  
 Hymen, 658.  
 Hypochondriac region, 367.  
 Hypochondrium, 367.  
 Hypogastrium, 367.

## I.

Ileo-colic valve, 434.  
 Ileum, 425.  
 Ilium, 187.  
 Incisors, 395, 399.  
 Incus, 896.  
 Inferior cava, 548.  
 Infratubinal, 148.  
 Infundibula of the lungs, 605.  
 Infundibulum of brain, 748.  
 of frontal sinus, 148.  
 Inlet of the pelvis, 193.  
 Instep, 217.  
 Integument, 915.  
 Interbrain, 767.  
 Intercellular substance, 27.  
 Interlobular ducts of liver, 362.  
 veins of liver, 448.  
 Intermediate portion of auditory and facial nerves, 795.  
 Internodes of nerve-fibres, 693.  
 Intestinal juices, 440.  
 Intestine, large, 432.  
 small, 424.  
 Intima, 580.  
 Iris, 870.  
 dilator of, 871.  
 nerves of, 873.  
 sphincter of, 871.  
 structure of, 871.  
 vessels of, 872.  
 Ischium, 189.  
 Isthmus of the fauces, 379.  
 Iter dentium, 409.

## J.

Jejunum, 425.  
 Joints, 50.  
 ankle, 218.



- Joints, diarthrodial, 51.  
 elbow, 181.  
 ginglymoid, 51.  
 hip, 200.  
 knee, 206.  
 shoulder, 179.  
 wrist, 184.  
 Jugular gulf, 550.  
 vein, 550.  
 Juice, gastric, 440.  
 pancreatic, 442.
- K.**
- Karyokinesis, 30.  
 Kerkring, valve of, 426.  
 Kidneys, 621.  
 pelvis of, 622.  
 structure of, 623.  
 vessels and nerves of, 625, 626.  
 Knee-cap, 200.  
 Knee-pan, 200.
- L.**
- Labia, 655.  
 majora, 655.  
 minora, 657.  
 Labyrinth, cortical, 624.  
 ear, 903.  
 membranous, 908.  
 osseous, 904.  
 Lachrymal apparatus, 859.  
 canals, 860.  
 caruncle, 858.  
 gland, 859.  
 lake, 854.  
 papilla, 854.  
 punctum, 854, 860.  
 sac, 860.  
 Lacteals, 589.  
 Lacunæ of bone, 48.  
 Lamina, cribriform, 112, 901.  
 cribrosa, 864.  
 spiral, 907.  
 terminal, 757, 761.  
 Larynx, 597, 608.  
 articulations of, 612.  
 cartilages of, 608.  
 ligaments of, 612.  
 muscles of, 615.  
 ventricles of, 618.  
 vessels and nerves of, 619.  
 Lateral ventricles, 749, 750.  
 Laura, nucleus of, 725.  
 Lens, 882.  
 Leucocytes, 465.  
 Lieberkühn, crypts of, 436.  
 Ligaments, 52.  
 acromio-clavicular, 179.  
 of the ankle, 218.  
 annular, of the ankle, 332, 333.  
 of the wrist, 300, 301.  
 arcuate, 268.  
 articular, of the spine, 75.  
 astragalo-scaphoid, 220.  
 atlanto-axial, 76, 77.  
 atlanto-occipital, 76.  
 auricular, 887.  
 Ligaments of the bladder, 631.  
 broad, 661, 664.  
 calcaneo-cuboid, 220, 221.  
 calcaneo-scaphoid, 220.  
 capsular, 52, 75, 155, 180, 186, 201, 209, 218.  
 of the carpus, 185.  
 conoid, 179.  
 coraco-acromial, 180.  
 coraco-clavicular, 179.  
 coraco-humeral, 180.  
 coronary, 370.  
 costo-central, 85.  
 costo-clavicular, 179.  
 costo-colic, 680.  
 costo-sternal, 86, 87.  
 costo-transverse, 86.  
 costo-vertebral, 85.  
 costo-xiphoid, 87.  
 cotyloid, 200.  
 crico-arytenoid, 614.  
 crico-ary-thyroid, 613.  
 crico-thyroid, 613.  
 crucial, 207.  
 cruciform, 78.  
 denticulate, 774.  
 of the digits, 186.  
 dorsal, 221.  
 of the ear-ossicles, 898.  
 elastic, 75.  
 of the elbow, 181.  
 funicular, 52.  
 Gimbernath's, 273.  
 Hay's, 317.  
 hepatico-colic, 371.  
 hepatico-renal, 370.  
 of the hip, 200.  
 hyo-epiglottic, 614.  
 ilio-femoral, 201.  
 ilio-lumbar, 196.  
 intercarpal, 185.  
 interclavicular, 179.  
 intercostal, 87.  
 interosseous, 182.  
 interspinous, 76.  
 intertarsal, 219.  
 intertransverse, 76.  
 intervertebral, 71.  
 of the knee, 206.  
 of the larynx, 612.  
 lateral, 155, 181, 185, 208, 219, 370.  
 of the liver, 370.  
 of the lower jaw, 155, 156.  
 nuchal, 75.  
 odontoid, 78.  
 orbicular, 181.  
 ovarian, 668.  
 palmar, 185.  
 palpebral, 249, 856.  
 patellar, 207.  
 pectinate, 872.  
 of the pelvis, 195.  
 phrenico-colic, 371, 680.  
 phrenico-gastric, 371.  
 phrenico-splenic, 371.  
 of the pinna, 887.  
 plantar, 221.  
 Poupart's, 272.  
 pterygo-maxillary, 254.  
 pubic, 196.  
 pulmonary, 601.  
 radiate, 85.  
 Ligaments, rhomboid, 179.  
 of the ribs, 85, 86.  
 round, 201, 575, 664.  
 sacro-coccygeal, 73, 79.  
 sacro-iliac, 195.  
 sacro-sciatic, 196.  
 of the shoulder, 180.  
 spheno-maxillary, 156.  
 spiral, 913.  
 sterno-clavicular, 178, 179.  
 of the sternum, 87.  
 stylo-hyoid, 157.  
 stylo-maxillary, 156, 258.  
 supraspinous, 76.  
 suspensory, 370, 375, 635, 656, 680, 881.  
 of the tarsus, 219.  
 of the thorax, 85, 86.  
 thyro-epiglottic, 614.  
 thyro-hyoid, 613.  
 transverse atlantal, 78.  
 transverse metatarsal, 221.  
 trapezoid, 179.  
 triangular, 180, 273, 677.  
 uterine, 664.  
 vaginal, 307.  
 vertebral, 73, 74.  
 vesical, 280.  
 of the wrist, 185.  
 Ligamentum nuchæ, 71.  
 patellæ, 207.  
 teres, 201, 445.  
 Line, ilio-pectineal, 191.  
 intertrochanteric, 198.  
 popliteal, 203.  
 Linea alba, 276.  
 aspera, 197.  
 semilunaris, 276.  
 Lineæ transversæ, 275, 276.  
 Lingule, 94, 730, 732.  
 Lips, 662.  
 Liver, 442.  
 fissures of, 445.  
 notches of, 444.  
 structure of, 446.  
 vessels of, 448.  
 Lobe of the ear, 886.  
 Lobes of the cerebellum, 729.  
 biventral, 731.  
 central, 730.  
 crescentic, 730.  
 gracile, 731.  
 inferior, 731.  
 posterior, 730, 731.  
 superior, 730.  
 Lobes of the cerebrum, 736.  
 central, 744.  
 frontal, 739.  
 occipital, 742.  
 olfactory, 745.  
 parietal, 740.  
 temporal, 743.  
 temporo-sphenoidal, 743.  
 Lobes of the liver, 443.  
 of the lungs, 599.  
 of the prostate, 639.  
 of the thymus, 685.  
 of the thyroid, 683.  
 Lobule, cuneate, 743.  
 quadrate, 742.  
 Locus niger, 748.  
 Loins, 367.



- Longitudinal fissure, great, 735.  
of liver, 445.  
Lower jaw, 129.  
Lungs, 597.  
structure of, 605.  
vessels and nerves of, 607.  
Lymph, 584.  
Lymph-corpuscles, 584.  
path, 583.  
plasma, 584.  
spaces, 581.  
Lymphatic capillaries, 581.  
glands, 579, 581.  
axillary, 593.  
bronchial, 591.  
cardiac, 591.  
cervical, 596.  
coeliac, 591.  
colic, 590.  
femoral, 587.  
gastric, 590.  
iliac, 588.  
inguinal, 587.  
lumbar, 589.  
mastoid, 595.  
mediastinal, 592.  
mesenteric, 589.  
parotid, 595.  
phrenic, 590.  
popliteal, 587.  
splenic, 590.  
submaxillary, 596.  
system, 579.  
trunks, 581.  
intestinal, 590, 591.  
jugular, 596.  
lumbar, 589.  
subclavian, 593.  
vessels, 579.  
afferent, 582.  
efferent, 582.  
tunics of, 580.  
valves of, 580.  
Lymphatics of the abdomen, 587, 588, 589.  
back, 593.  
cardiac, 591.  
cervical, 596.  
chest, 593.  
chief trunks of the, 585.  
colic, 590.  
cranial cavity, 595.  
diaphragm, 592.  
ear, 595.  
eyeball, 595.  
facial, 595.  
femoral, 586.  
frontal, 594.  
gastric, 590.  
gluteal, 588.  
head, 594.  
hepatic, 590.  
iliac, 588.  
intercostal, 592.  
ischiatric, 588.  
limbs, lower, 586.  
limbs, upper, 592, 593.  
lumbar, 588.  
mamma, 593.  
mediastinal, 592.  
nasal cavity, 595.  
neck, 594.  
Lymphatics, obturator, 588.  
occipital, 594.  
oesophageal, 592.  
pancreatic, 590.  
parietal, 594.  
pelvis, 588.  
penis, 587.  
perivascular, 581.  
pudic, 588.  
pulmonary, 591.  
rectum, 588.  
sacral, 588.  
scrotum, 588.  
spermatic, 589.  
splenic, 590.  
subareolar plexus of, 593.  
thorax, 591.  
tongue, 595.  
urethral, 587.  
uterus, 588.  
vagina, 588.  
Lymphoid nodules, 357.  
tissue, 357.  
Lyre, 752.  
M.  
Macula lutea, 874, 879.  
Magnum of the carpus, 173.  
Malar bone, 128.  
Malleolus, external, 206.  
internal, 204.  
Malleus, 895.  
Malpighi, corpuscles of, 584, 626, 683.  
pyramids of, 623.  
Mamma, mammary gland, 672, 673.  
Mammals, 25.  
Mammillary eminences, 749.  
Mandible, 129.  
Manubrium of sternum, 82.  
Manus, 183.  
Marrow, 42.  
red, 43.  
spinal, 703.  
yellow, 43.  
Marrow-cells, 43.  
Masseter, 254.  
Mastoid cells, 893.  
Maxilla, 118.  
Meatus, 33.  
auditory, 114, 777, 887, 901.  
external, 114.  
internal, 777, 801.  
nasal, inferior, 148.  
middle, 107, 148.  
superior, 107, 148.  
Meckel, cartilage of, 133.  
Meckel's ganglion, 794.  
Media, 580.  
Mediastinum, anterior, 364.  
middle, 364.  
posterior, 364.  
superior, 365.  
testis, 645.  
Medulla, 42.  
of bones, 42.  
of brain, 702.  
of hairs, 426.  
oblongata, 716.  
renal, 623.  
spinalis, 703.  
Medullary rays of kidney, 623.  
Meibomian glands, 856.  
Meisner, plexus of, 432.  
Membrana propria, 356, 456.  
Membrane, 345.  
basement, 345, 357.  
basilar, 913.  
of brain, 770.  
fenestrated, 353.  
interosseous, 182, 211.  
limiting, 879.  
mucous, 355.  
reticular, 915.  
Schneiderian, 850.  
serous, 351.  
of spinal cord, 773.  
synovial, 353.  
tectorial, 915.  
tympanic, 894.  
vestibular, 912.  
vocal, 613.  
Meninges, 771, 773.  
Mental foramen, 130.  
protuberance, 130.  
Mesencephalon, 767.  
Mesentery, 368, 373.  
Mesiris, 871.  
Mesocæcum, 434.  
Mesochoroidea, 866.  
Mesocolon, 369, 374.  
Mesocornea, 865.  
Mesorectum, 375, 438.  
Mesoretina, 876, 877.  
layers of, 877, 878.  
Mesoturbinal, 107, 148.  
Metacarpus, 174.  
Metapophysis, 61.  
Metasternum, 84.  
Metatarsus, 215.  
Metencephalon, 767.  
Midbrain, 767.  
Milk, 675.  
teeth, 399.  
Mitral valve, 473.  
Modiolus, 906.  
Molars, 397, 399.  
Monro, foramen of, 751.  
Mons veneris, 655.  
Mother-cell, 31.  
Motorial end-plate, 246.  
Mouth, 377, 380.  
floor of, 379.  
roof of, 378.  
vestibule of, 377.  
Mucosa, 345, 356.  
Mucous membrane, 355.  
epithelium of, 355.  
of the bladder, 632.  
of the colon, 436.  
of the intestines, 428.  
of the mouth, 380.  
of the nose, 850.  
of the rectum, 439.  
of the tympanum, 899.  
of the uterus, 663.  
of the vagina, 659.  
Mucus, 358.  
Muscle or muscles, 237.  
abdominal, 271.  
external oblique, 271.  
internal oblique, 273.  
pyramidal, 275.



**Muscle or muscles:**

abdominal rectus, 275.  
transversalis, 274.  
accessory flexor, 347.  
anal elevator, 677.  
sphincter, 677.  
anconeus, 299.  
of the arm, 296.  
arytenoid, 617.  
atlantal, 264.  
auricular, 248.  
of the back, 281, 285, 293.  
belly of, 366.  
biventer, 288.  
brachial biceps, 296.  
triceps, 298.  
of the breast, 291.  
buccinator, 253.  
of the buttock, 324.  
capito-splenius, 287.  
cervical ascending, 287.  
cervico-splenius, 287.  
ciliary, 869.  
coccygeal, 678.  
extensor, 290.  
complexus, 288.  
constrictor, of pharynx,  
411, 412.  
coraco-brachial, 297.  
costal elevator, 267.  
of the cranial vault, 246.  
cremaster, 276, 644.  
inferior, 651.  
crico-arytenoid, 616.  
crico-thyroid, 616.  
crureus, 320.  
deltoid, 296.  
diaphragm, 267.  
digastric, 260.  
digital extensor, 309.  
flexor, deep, 305.  
long, 339.  
short, 341.  
superficial, 304.  
dorsal extensor, 285.  
erector, of the skin, 928.  
of the eyeball, 860.  
of the face, 248.  
fascial tensor, 318.  
femoral adductors, 323.  
biceps, 328.  
flexor, 321.  
quadrate, 327.  
rectus, 319.  
fibres of, 237.  
fibrils of, 241.  
of the foot, 341.  
of the forearm, 302, 307.  
frontal, 246.  
gastrocnemius, 337.  
geminus, 327.  
genio-glossal, 386.  
genio-hyoid, 261.  
gluteal, great, 324.  
middle, 325.  
small, 325.  
gracilis, 320.  
great serratus, 293.  
hallucal abductor, 342.  
adductor, 343.  
extensor, 334.  
flexor, long, 340.  
short, 343.

**Muscle or muscles:**

hallucal transverse, 343.  
of the hand, 312.  
of the head, 246.  
hyo-glossal, 387.  
iliac, 322.  
ilio-costalis, 286.  
ilio-psoas, 321.  
indical extensor, 311.  
infralabial depressor, 253.  
elevator, 253.  
infralingual, 387.  
infraoblique, 262.  
infraserratus, 284.  
infraspinatus, 294.  
insertion of, 239.  
intercostal, 266.  
interosseous, 314, 344.  
interspinous, 289.  
intertransverse, 289.  
involuntary, 238.  
ischio-cavernous, 678.  
of the larynx, 615.  
latissimus, 282.  
of the leg, 333.  
lingual, 388.  
long cervical, 265.  
longissimus, 285.  
lumbrical, of foot, 342.  
of hand, 312.  
masseter, 254.  
of mastication, 254.  
minimal abductor, 314, 343.  
adductor, 314.  
extensor, 311.  
flexor, 314, 344.  
multifidus, 288.  
mylo-hyoid, 260.  
nasal compressor, 250.  
depressor, 251.  
dilator, 250.  
pyramidal, 250.  
naso-labial elevator, 251.  
of the neck, 256, 264.  
of the nose, 250.  
oblique, of eye, 861, 862.  
obturator, external, 327.  
internal, 326.  
occipital, 246.  
occipito-frontal, 246.  
omo-hyoid, 262.  
oral angle depressor, 253.  
sphincter, 251.  
origin of, 239.  
palatal elevator, 382.  
tensor, 382.  
of the palate, 381.  
palato-glossal, 381.  
palato-pharyngeal, 381.  
palmar, long, 303.  
short, 312.  
palpebral elevator, 249.  
orbicular, 248.  
tensor, 249.  
papillary, 471, 472.  
pectinate, 470.  
pectineus, 322.  
pectoral, greater, 291.  
small, 292.  
penniform, 240.  
of perineum, 677.  
peroneal, anterior, 334.  
long, 335.

**Muscle or muscles:**

peroneal, short, 336.  
of the pharynx, 411.  
of the pinna, 887.  
plantaris, 338.  
platysma, 256.  
pollical abductor, 313.  
adductor, 313.  
extensor, first, 310.  
second, 311.  
third, 311.  
flexor, long, 307.  
short, 313.  
opponent, 313.  
popliteus, 338.  
postauricular, 248.  
postrectus, greater, 265.  
small, 265.  
preauricular, 248.  
prerectus, greater, 264.  
lateral, 264.  
small, 264.  
pronator, quadrate, 302.  
terete, 302.  
psoas, 322.  
small, 322.  
pterygoid, external, 255.  
internal, 255.  
pyriform, 326.  
quadrate lumbar, 279.  
pronator, 302.  
radio-carpal extensor, long-  
er, 308.  
shorter, 309.  
flexor, 304.  
rhomboid, greater, 283.  
small, 284.  
sartorius, 318.  
scalenus, anterior, 263.  
middle, 263.  
posterior, 263.  
scapular elevator, 284.  
semimembranosus, 330.  
semipenniform, 240.  
semispinalis, cervical, 288.  
thoracic, 288.  
semitendinosus, 329.  
of the shoulder, 291.  
smooth, 238.  
spinalis, 286.  
spinal rotator, 289.  
splenius, 287.  
stapedial, 898.  
sterno-costal, 266.  
sterno-hyoid, 261.  
sterno-mastoid, 258.  
sterno-thyroid, 261.  
striped, 239, 240.  
stylo-glossal, 388.  
stylo-hyoid, 260.  
stylo-pharyngeal, 413.  
subanconeus, 299.  
subclavian, 292.  
subcostal, 266.  
subscapular, 295.  
superciliary, 250.  
supinator, 307.  
supra-auricular, 248.  
supralabial elevator, 252.  
supraoblique, 265.  
supraserratus, 284.  
supraspinatus, 294.  
sural triceps, 336.



**Muscle or muscles:**

- temporal, 254.
- teres, greater, 295.
- lesser, 294.
- termination of nerves in, 245.
- of the thigh, 318, 321, 328.
- adductors, 323.
- of the thorax, 266.
- thyro-arytenoid, 616.
- thyro-hyoid, 261.
- tibialis anterior, 333.
- posterior, 340.
- of the tongue, 386.
- trachelo-mastoid, 287.
- transversalis, 287.
- of the pinna, 887.
- transverse perineal, 678.
- trapezius, 281.
- trochlear, 861.
- tympanic tensor, 898.
- of the tympanum, 898.
- ulno-carpal extensor, 309.
- flexor, 304.
- unstriated, 237, 238.
- of the upper limb, 290.
- urethral compressor, 679.
- urethro-bulbar, 678.
- vaginal sphincter, 678.
- vastus, external, 319.
- internal, 320.
- vesical sphincter, 631, 640.
- vessels and nerves of, 244.
- voluntary, 239.
- zygomatic, 252.
- lesser, 252.
- Muscular tissue, 237.**
- cardiac, 243.
- system, 237.
- Muscularis mucosa, 357.**
- Myeloplaxes, 43.**
- Myelencephalon, 767.**
- Myolemma, 241.**
- Myrtiform caruncles, 658.**

**N.**

- Nail-bed, 922.**
- Nails, 922.**
- Nares, 849.**
- posterior, 147.
- Nasal cavities, 146.**
- fossæ, 146.
- septum, 147.
- Navel, 366.**
- Neck, 363.**
- Nerve or nerves, 690.**
- abducent, 779, 794.
- accessory, 780, 805.
- afferent, 694.
- anastomotic, 797.
- articular branches of, 817, 818, 827, 831, 832.
- auditory, 780, 798, 902.
- auricular, 796, 802.
- great, 811.
- auriculo-temporal, 791.
- axis fibre of, 692.
- of brachial plexus, 813.
- buccal, 791, 797.
- cardiac, 803.
- inferior, 840.
- middle, 839.

**Nerve or nerves:**

- cardiac, superior, 838.
- cells, 675.
- centrifugal, 694.
- centripetal, 694.
- cerebral, 778.
- cerebro-spinal, 689.
- cervical, 798.
- anterior, 809, 812.
- first, 807.
- posterior, 807.
- superior, 811.
- of cervical plexus, 809.
- cervico-facial, 797, 798.
- ciliary, long, 784.
- short, 785.
- circumflex, 814.
- coccygeal, anterior, 823.
- posterior, 808.
- cochlear, 902.
- communicating, 832.
- crural, 827.
- anterior, 826.
- cutaneous, of abdomen, 822.
- external, 825.
- internal, 815, 827.
- last thoracic, 823.
- middle, 827.
- of thorax, 821.
- ulnar, 817.
- dental, anterior, 787.
- inferior, 792.
- middle, 787.
- posterior, 786.
- digitals of foot, 834.
- of hand, 817, 819, 820, 821.
- dorsal, of clitoris, 830.
- of penis, 830.
- facial, 779, 794.
- branches of, 795, 798.
- cervico-facial division, 798.
- temporo-facial division, 797.
- fibres of, 691.
- gastric, 804.
- genito-crural, 824.
- glosso-pharyngeal, 798.
- lingual branches of, 800.
- pharyngeal branches of, 800.
- tonsillitic branches of, 800.
- gluteal, 829.
- gustatory, 792.
- hemorrhoidal, 830.
- hypoglossal, 780, 805.
- descending cervical branch, 806.
- ilio-hypogastric, 823.
- ilio-inguinal, 824.
- infraorbital, 797.
- infratrochlear, 784.
- intercostal, 821.
- intercosto-humeral, 822.
- internodes of, 673.
- interosseous, 819.
- Jacobson's, 793, 798.
- labial, 787.
- lachrymal, 783.
- laryngeal, 803.
- lumbar, anterior, 823.

**Nerve or nerves:**

- lumbar, posterior, 808.
- mandibular, 797.
- masseteric, 791.
- maxillary, inferior, 790.
- superior, 786.
- median, 818.
- medullated, 691.
- membranous sheath of, 693.
- meningeal, 802.
- muscular branches of the brachial plexus, 813.
- great sciatic, 831.
- median, 819.
- musculo-spiral, 820.
- sacral plexus, 828.
- ulnar, 817.
- musculo-cutaneous, 815, 832.
- musculo-spiral, 820.
- mylo-hyoid, 792.
- nasal, 784.
- naso-palatine, 789.
- nodes of, 693.
- non-medullated, 693.
- obturator, 826.
- occipital, great, 807.
- least, 811.
- small, 811.
- oculo-motor, 778, 781.
- olfactory, 778, 781, 852.
- ophthalmic, 783.
- optic, 778, 781.
- origin of, 699.
- palatine, 788, 789.
- palmar, 817.
- palpebral, 787.
- patellar, 828.
- perforating, 829.
- perineal, 830.
- peroneal, 831, 832.
- small, 815.
- petrosal, deep, 789.
- small, 793, 799.
- superficial, 789.
- pharyngeal, 810.
- phrenic, 802.
- plantar, external, 834.
- internal, 834.
- pneumogastric, 780, 800.
- popliteal, 833.
- pterygoid, 791.
- pudendal, 829.
- pubic, 829.
- pulmonary, 804.
- radial, 820.
- recurrent, 832.
- sacral, anterior, 823.
- posterior, 808.
- saphenous, internal, 827.
- long, 827.
- short, 833.
- sciatic, great, 830.
- small, 829.
- spheno-palatine, 786.
- spinal, 806.
- anterior, 808.
- posterior, 807.
- splanchnic, 841.
- great, 842.
- small, 842.
- smallest, 842.
- suboccipital, 807.



- Nerve or nerves :  
 subscapular, 814.  
 structure of, 698.  
 supraclavicular, 811.  
 supraorbital, 784.  
 suprarenal, 842.  
 suprascapular, 814.  
 supratrochlear, 784.  
 sympathetic, 835.  
 temporal, 791.  
 temporo-facial, 797.  
 temporo-frontal, 797.  
 temporo-malar, 786.  
 thoracic anterior, 814, 821.  
   last, 823.  
   posterior, 807, 814.  
 tibial, anterior, 833.  
   posterior, 834.  
 trifacial, 779, 782.  
 trochlear, 779, 782.  
 tympanic, 795, 798.  
 ulnar, 816.  
 vagus, 800.  
 vestibular, 902.  
 vidian, 789.  
 Nervous system, 689.  
 Neurilemma, 693.  
 Neuroglia, 701.  
 Nipple, 672.  
 Nodule of cerebellum, 731.  
 Nodules, lymphoid, 357.  
 Nose, 847, 849, 850.  
   cartilages of, 849.  
   column of, 849.  
   muscles of, 250.  
   wings of, 849, 850.  
 Nostrils, 849.  
 Notch, cotyloid, 191.  
   ethmoidal, 104.  
   jugular, 92.  
   of kidney, 621.  
   of liver, 444.  
   popliteal, 203.  
   sacro-sciatic, 194.  
   scapular, 160.  
   sciatic, great, 188.  
   small, 190.  
   tympanic, 891.  
 Nuck, canal of, 933.  
 Nuclei of thalamus, 760.  
 Nucleolus, 30.  
 Nucleoplasm, 30.  
 Nucleus, 28, 29.  
   accessory, 725.  
   ambiguous, 779.  
   arciform, 724.  
   auditory, 725, 726.  
   caudate, 752.  
   cuneate, 719, 723.  
   dentate, 733.  
   emboliform, 733.  
   facial, 779.  
   fastigiate, 733.  
   globose, 733.  
   glosso-pharyngeal, 725.  
   gracile, 719, 722.  
   hypoglossal, 725.  
   lateral, 723.  
   lenticular, 755.  
   olivary, 718, 723, 728.  
   tegmental, 748.  
   vagus, 725.  
 Nymphæ, 657.
- O.  
 Obex, 721.  
 Oblongata, 716.  
   arteries of, 777.  
   columns of, 716, 717, 718.  
   interior of, 722.  
   pyramids of, 716.  
 Occipital bone, 90.  
 Occiput, 134.  
 Oesophageal glands, 415.  
 Oesophagus, 414, 415.  
 Olecranon, 167.  
 Olfactory bulb, 746.  
   glomeruli, 746.  
   lobe, 778.  
   nerve, 745, 778, 852.  
   region, 848.  
   tract, 746.  
   tuber, 745.  
 Olivary body, 717.  
 Olive, 717.  
 Omental foramen, 371.  
   sac, 371, 372.  
 Omentum, gastro-colic, 371.  
   gastro-hepatic, 371.  
   gastro-splenic, 680.  
   great, 369, 371.  
   small, 369, 371.  
 Opening, aortic, 269.  
   caval, 269.  
   oesophageal, 269.  
   saphenous, 317.  
 Operculum, 737.  
 Ophthalmic ganglion, 785.  
   nerve, 783.  
 Optic chiasm, 760.  
   commisure, 760.  
   nerve, 760, 778, 863.  
 Ora, 868.  
 Orbits, 145.  
 Organ of Corti, 914.  
 Organic cell, 27.  
 Organized bodies, 28.  
 Organs, 26.  
   of digestion, 416.  
   of reproduction, 634, 654.  
   of special sense, 847.  
 Orifice, cardiac, 416, 422.  
   pyloric, 416, 422.  
   tympanic, 890.  
 Os uteri, 662.  
 Ossein, 34.  
 Osseous tissue, 48.  
   development of, 48.  
   growth of, 48.  
 Ossicles, ear, 895.  
 Ossification, 45, 48.  
   centre of, 45.  
 Ossiterra, 34.  
 Osteoblast, 40, 48, 49.  
 Osteoclast, 43, 50.  
 Osteogenic fibres, 49.  
   tissue, 48.  
 Osteoplast, 42.  
 Otic ganglion, 737. X  
 Otolites, 910.  
 Outlet of the pelvis, 193.  
 Oval window of the ear, 891, 904.  
 Ovaries, 667.  
   structure of, 668.  
 Oviducts, 666.
- Ovigenous layer, 668.  
 Ovisac, 670.  
 Ovum, 670.
- P.  
 Pacchioni, glands of, 772.  
 Pacchionian bodies, 138, 772.  
 Pacinian corpuscles, 918.  
 Pancreas, 440.  
 Pancreatic duct, 441.  
   juice, 442.  
 Palate, 143, 378.  
   arches of, 379.  
   hard, 378.  
   muscles of, 381.  
   pillars of, 379.  
   soft, 378.  
 Palpebræ, 854.  
 Palpebral cartilages, 235.  
 Papillæ, circumvallate, 383.  
   conical, 384.  
   filiform, 385.  
   foliate, 383.  
   fungiform, 384.  
   renal, 623.  
   tactile, 916.  
   of taste, 383.  
   of touch, 916.  
 Parepididymis, 651.  
 Parovarium, 672.  
 Passage, tympanic, 907.  
   vestibular, 907.  
 Patella, 200.  
   ligament of, 207.  
 Pavilion of ear, 886.  
   of oviduct, 666.  
 Pectiniform septum, 637.  
 Peduncles, callosal, 750.  
   of the cerebellum, 732.  
 Pelvis, 192.  
   of the kidney, 622.  
 Penis, 634.  
   cavernous bodies of, 636.  
   glans, 638.  
   spongy body of, 638.  
   suspensory ligament of, 271.  
   vessels and nerves of, 638, 639.  
 Perforating bone fibres, 41.  
 Pericardium, 467.  
 Perichondrium, 231.  
 Perimysium, 242.  
 Perineum, 675.  
   fasciæ of, 676.  
   muscles of, 676.  
 Perineurium, 698.  
 Periosteum, 41.  
   osteogenic layer of, 42.  
 Peritoneum, 368.  
 Perspiratory glands, 929.  
 Pes hippocampi, 754.  
 Peyer, glands, patches, or plaques of, 430.  
 Phalanges of the cochlea, 914, 915.  
   of the fingers, 177.  
   of the toes, 217.  
 Pharyngeal glands, 411.  
 Pharynx, 410.  
   muscles of the, 411.



- Pia, 771, 773.  
 Pia mater, 771.  
 Pillars of the fauces, 379.  
   of the fornix, 752.  
 Pimple mite, 929.  
 Pinna, 886.  
   cartilage of, 886.  
   muscles of, 887.  
 Pit of the stomach, 364, 417.  
 Plane of the ischium, 194.  
 Plate, auditory, 114.  
   cribriform, 106.  
   orbital, 106, 107.  
   tympanic, 112.  
 Pleura, 601.  
 Plexuses, nervous, 698.  
   aortic, 843, 845.  
   Auerbach's, 432.  
   brachial, 812.  
   cardiac, 840.  
   carotid, 836, 838.  
   cavernous, 838, 846.  
   cervical, 809, 812.  
   ciliary, 873.  
   coccygeal, 835.  
   coeliac, 844.  
   coronary, 841.  
   crural, 826.  
   dental, 787.  
   gangliform, 800.  
   gastric, 804, 844.  
   hemorrhoidal, 846.  
   hepatic, 844.  
   hypogastric, 845, 846.  
   infraorbital, 788.  
   intraepithelial, 866.  
   lumbar, 823.  
   Meisner's, 432.  
   mesenteric, 844, 845.  
   oesophageal, 804.  
   parotid, 795.  
   pelvic, 846.  
   phrenic, 844.  
   prevertebral, 831.  
   pulmonary, 804.  
   renal, 844.  
   sacral, 828.  
   sacro-coccygeal, 808.  
   solar, 843.  
   spermatic, 844.  
   splenic, 844.  
   subepithelial, 866.  
   suprarenal, 844.  
   vertebral, 840.  
   vesical, 846.  
   vesico-vaginal, 846.  
   uterine, 846.  
 Plexuses, vascular, 458.  
   choroid, 768, 769.  
   dorsi-spinal, 568.  
   hemorrhoidal, 574.  
   intraspinal, 568.  
   pampiniform, 569.  
   prostatic, 574.  
   pterygoid, 555.  
   pudendal, 573.  
   spermatic, 569.  
   uterine, 574.  
   vaginal, 574.  
   venous, 458.  
   vesical, 574.  
 Plica semilunaris, 857.  
 Pollex, 177.  
 Pomum Adami, 363.  
 Pons, 715, 726.  
   arteries of, 777.  
   Varolii, 726.  
 Ponticulus, 721.  
 Portal canals, 449.  
   vein, 574.  
 Pouch of Douglas, 375, 659.  
   recto-uterine, 369, 375.  
   recto-vaginal, 375.  
   recto-vesical, 369, 375.  
 Præcuneus, 742.  
 Premolars, 397.  
 Prepuce, 635, 657.  
 Preretina, 874.  
 Primates, 25.  
 Process or processes, 33.  
   accessory, 61.  
   acromion, 160.  
   alveolar, 31, 119.  
   angular, 97.  
   articular, 55.  
   auditory, 113.  
   basilar, 90.  
   ciliary, 868.  
   clinoid, 94.  
   coracoid, 160.  
   coronoid, 131, 167.  
   ensiform, 84.  
   mamillary, 61.  
   mastoid, 110.  
   nasal, 120.  
   oblique, 55.  
   odontoid, 58.  
   olecranon, 167.  
   postarticular, 55.  
   prearticular, 55.  
   pterygoid, 97.  
   spinous, 55.  
   styloid, 113, 168, 171, 206.  
   transverse, 56.  
   unciform, 744.  
   vocal, 611.  
   xiphoid, 84.  
   zygomatic, 106, 109.  
 Proencephalon, 734.  
 Proligerous disk, 670.  
 Promontory of the sacrum, 63.  
   of the tympanum, 891.  
 Prosencephalon, 767.  
 Prostate, 639.  
 Protoplasm, 29.  
 Protuberance, mental, 130.  
   occipital, 91.  
 Pseudostoma, 352.  
 Pubic arch, 194.  
 Pubis, 190.  
 Pudendum, 654.  
 Pulvinar, 758.  
 Punctum ossificationis, 45.  
 Pupil, 870.  
 Purkinje, cells of, 234.  
   corpuscles of, 40.  
 Pyloric antrum, 417.  
   sphincter, 419.  
   valve, 420.  
 Pylorus, 416.  
 Pyramid of the cerebellum, 731.  
   temporal, 110.  
   of the tympanum, 892.  
 Pyramids, decussation of the, 717.  
   of Ferrein, 623.  
   of Malpighi, 623.  
   of oblongata, 716.  
   renal, 623.  
 R.  
 Radius, 169.  
 Ramus of ischium, 189.  
   of mandible, 131.  
   of pubis, 190.  
 Ranvier, nodes of, 693.  
 Raphé of oblongata, 724.  
   of penis, 635.  
   of perineum, 676.  
   of scrotum, 643.  
   of tongue, 383.  
 Receptacle of the chyle, 585.  
   stapedial, 892.  
   tympanic tensor, 891.  
 Receptaculum chyli, 585.  
 Recess, chiasmal, 761.  
   cochlear, 905.  
   intercrural, 747.  
 Rectum, 437.  
   blood-vessels of, 439.  
   coats of, 438.  
   valves of, 438.  
 Regions of the abdomen, 367.  
 Remak, fibres of, 693.  
 Restiform body, 719.  
 Rete, epidermal, 920.  
   mucosum, 920.  
 Reticular formation, 724.  
 Retina, 873.  
   central fovea of, 874.  
   structure of, 875.  
   sustentacular fibres of, 878.  
   vessels of, 880.  
 Rhinencephalon, 745.  
 Ribs, 80.  
 Ridge, 33.  
   bicipital, 165.  
   mylo-hyoid, 130.  
   superciliary, 103.  
   supracondylar, 164.  
 Ring, crural, 933.  
   external abdominal, 273.  
   femoral, 933.  
   internal abdominal, 278.  
   tympanic, 116.  
 Rivinus, duct of, 389.  
 Rods, acoustic, 914.  
   of the retina, 876.  
 Rolando, fissure of, 738.  
   funicle of, 719.  
   nucleus of, 719.  
   tubercle of, 719, 723, 779.  
 Root or roots:  
   of auditory nerve, 780.  
   of hair, 926.  
   of lung, 597.  
   of olfactory lobe, 746.  
   of ophthalmic ganglion, 785.  
   of otic ganglion, 793.  
   of spinal nerves, 711.  
   of trifacial nerve, 779, 782.  
 Root-sheath of hair, 927.  
 Rosenmüller, organ of, 672.



- Rostrum, 750.  
Round window of the ear, 891.
- S.**
- Sacculæ of labyrinth, 909.  
Sacrum, 62.  
Santorini, cartilages of, 612.  
Saphenous opening, 317.  
veins, 571.  
Sarcolemma, 238, 241.  
Sarcous disks, 242.  
elements, 241.  
Scapula, 158.  
Scarpa's triangle, 319.  
Schindylesis, 50.  
Schwann, white substance of, 692.  
Sclerotica, 863.  
Sclerobulbus cordis, 417.  
Serotum, 643.  
Seute, palpebral, 855.  
tympanic, 893.  
Sebaceous glands, 928.  
Secreting cells, 360.  
Secretion, 358.  
Sella, sphenoidal, 93.  
tursica, 93.  
Semen, 653.  
Semibulbs of clitoris, 659.  
Semicircular canals, 905, 909.  
Semilunar valves, 473.  
Seminal vesicles, 651.  
Seminiferous tubules, 647.  
Sense, organs of special, 847.  
Sensory nerves, 694.  
Septum, auricular, 468.  
intermuscular, 290, 316.  
ventricular, 470.  
Serosa, 345, 353.  
Serous membrane, 351.  
Serum, 351, 355, 464, 466.  
Shin-bone, 202.  
Sigmoid flexure of colon, 435.  
Sinews, 243.  
Sinuses, 33.  
cavernous, 558.  
circular, 558, 865.  
confluence of, 557.  
coronary, 547.  
diploic, 37, 134.  
of the dura, 556.  
ethmoidal, 107.  
frontal, 105.  
lateral, 556.  
longitudinal, 557, 558.  
occipital, 558.  
petrosal, 559.  
portal, 575.  
prostatic, 641.  
sphenoidal, 95, 559.  
straight, 558.  
tarsal, 217.  
transverse, 558.  
valvular, 478.
- Skeleton, 32.  
Skin, 915.  
Skull, 89, 133.  
base of, 133, 143.  
brachycephalic, 152.  
cavity of, 137.  
development of, 149.
- Skull, dolicho-cephalic, 152.  
eurygnathous, 152.  
growth of, 149.  
guttural region of, 144.  
inferior region of, 143.  
mechanical construction of, 153.  
occipital region, 144.  
oral region, 143.  
orthognathous, 152.  
palatine region, 143.  
prognathous, 152.  
variations of, 152.  
Small intestine, 424.  
Sole, 217.  
Space, perforated, 745, 747.  
subarachnoid, 772.  
subdural, 772.  
Sperm, 653.  
Spermatic cones, 647.  
rete, 647.  
Spermatozoa, 648, 653.  
Sphincter, anal, 677.  
of the iris, 871.  
oral, 251.  
pyloric, 419.  
vesical, 631.  
Spigelian lobe of liver, 444.  
Spinal column, 54.  
cord, 703.  
arteries of, 775.  
central canal of, 706.  
cervical enlargement of, 704.  
columns of, 705, 711.  
commissures of, 705.  
cornua of, 706.  
gray columns of, 706, 707.  
lumbar enlargement of, 705.  
marrow, 703.  
nerves, 711, 806.  
ganglia of, 712.  
origin of, 711.  
roots of, 711.  
Spine, spinal column, 54.  
of ischium, 189.  
of pubis, 190.  
of scapula, 160.  
of tibia, 203.  
Spines, iliac, 188.  
Spinous process, 33, 55.  
Spiral ganglion, 903.  
groove, 913.  
lamina, 907.  
ligament, 913.  
Spleen, 680.  
structure of, 681.  
Splendid line of Haller, 773.  
Splenic pulp, 681.  
Splenium, 749.  
Spongiosa, 707.  
Spongy body of clitoris, 657.  
of penis, 638.  
Spots, acoustic, 910.  
cribriform, 901, 908.  
Stapes, 897.  
Steno, duct of, 389.  
Sternum, 82.  
Stigma of ovary, 670.
- Stomach, 416.  
curvatures of, 416.  
glands of, 419, 420.  
Stomata, 352, 462, 581.  
Straits of the pelvis, 193.  
Striæ, auditory, 221.  
callosal, 750.  
pineal, 758.  
Striatum, 751.  
Structural elements, 27.  
Subcutaneous bursæ, 354.  
Submucous layer, 355.  
Subserous tissue, 351.  
Suburethral glands, 658.  
Superciliary ridge, 103.  
Supercilium, 854.  
Superior cava, 548.  
Suprapromontory, 893.  
Suprarenal bodies, 686.  
Supratubinals, 107, 148.  
Suspensory ligament of bladder, 375.  
of clitoris, 656.  
of lens, 881.  
of liver, 370.  
of penis, 271, 635.  
Sustentacle of calcaneum, 213.  
Sustentacular fibres of retina, 878.  
Sutures, 50, 134.  
basilar, 136.  
coronal, 135.  
dentate, 50, 134.  
fronto-parietal, 135.  
interparietal, 135.  
lambdoid, 135.  
neuro-central, 70.  
occipito-mastoid, 135.  
occipito-parietal, 135.  
petro-squamosal, 115.  
sagittal, 135.  
serrate, 50.  
squamo-parietal, 135.  
squamous, 50, 135.  
transverse facial, 136.  
palate, 136.  
Sweat-glands, 929.  
Sweetbread, 685.  
Sylvius, aqueduct of, 762.  
fissure of, 737.  
Sympathetic nerves, 835.  
cervical portion, 836.  
communicating branches, 836.  
gangliated cord, 835.  
lumbar portion, 844.  
sacral portion, 845.  
thoracic portion, 841.  
Symphysis, 50.  
of mandible, 130.  
of pubes, 190, 196.  
Synarthrosis, 50.  
Synovia, 51, 52, 355.  
Synovial bursæ, 354.  
folds, 353.  
membrane, 353.  
sheath, 354.  
System, absorbent, 579.  
arterial, 477.  
lymphatic, 579.  
nervous, 689.  
reproductive, 634, 654.



System, vascular, 453.  
venous, 546.

T.

Tactile corpuscles, 918.  
papillæ, 916.  
Tarsi, 235.  
Tarsus, 211.  
Taste-buds, 386.  
goblets, 386.  
papillæ of, 383.  
Tectorial membrane, 915.  
Teeth, 393.  
auditory, 913.  
bicuspid, 397.  
canine, 396, 399.  
deciduous, 399.  
development of, 405, 408.  
eruption of, 393, 399.  
incisor, 395, 399.  
milk, 393, 399.  
molar, 397, 399.  
permanent, 393, 394.  
premolar, 397.  
structure of, 401.  
temporary, 393, 399.  
wisdom, 397.  
Tegmentum, 748.  
subthalamie, 760.  
Tendon of Achilles, 338.  
central, of diaphragm, 267.  
conjoined, 274.  
cordiform, 267.  
Tendons, 243.  
Tentorium, 770.  
Testes, 643.  
Testicle, 643.  
structure of, 646.  
vessels and nerves of, 650.  
Thalamencephalon, 767.  
Thalamus, 757.  
Third ventricle of the brain, 757.  
Thoracic cavity, 364.  
duct, 585.  
Thorax, 87, 363.  
Thumb, 177.  
Thymus, 685.  
Thyroid axis, 497.  
body, 683.  
Tibia, 202.  
Tissue, 26.  
adenoid, 357, 583.  
adipose, 228.  
areolar, 225.  
bone, 34.  
cardiac muscular, 243.  
cartilage, 230.  
cellular, 225.  
connective, 223.  
dental, 401.  
elastic, 224, 227.  
epithelial, 345.  
erectile, 637.  
fat, 228.  
fibro-cartilage, 234.  
fibro-connective, 223.  
fibrous, 223.  
lymphoid, 357, 583.  
muscular, 237.  
nerve, 691, 695.  
osseous, 34, 48.

Tissue, osteogenic, 48.  
white fibrous, 223.  
yellow elastic, 224.  
Tongue, 383.  
muscles of, 386.  
nerves of, 388.  
papillæ of, 383.  
vessels of, 388.  
Tonsilla, 731.  
Tonsils, 381.  
Torcular, 557.  
Touch, papillæ of, 916.  
Trachea, 602.  
Tract, cerebellar, 710.  
direct sensory, 766.  
ganglionic, 708.  
intermedio-lateral, 707.  
mixed lateral, 710.  
olfactory, 746.  
optic, 759.  
principal, 711.  
pyramidal, 765.  
anterior, 710.  
crossed, 710.  
direct, 711.  
lateral, 710.  
radicular, anterior, 710.  
spiral, 901.  
Tract of Flechsig, 711.  
of Goll, 711.  
Tragus, 886.  
Triangle, Hesselbach's, 932.  
Scarpa's, 319.  
vesical, 632.  
Tricuspid valve, 472.  
Trochanters, 198.  
Trochlea of the femur, 199.  
of the humerus, 165.  
of the trochlearis muscle, 861.  
True pelvis, 193.  
Tube, eustachian, 114, 894.  
Fallopian, 666.  
Tuber of cerebellum, 731.  
cinereous, 748.  
Tubercles, 33.  
of the calcaneum, 212.  
quadrigenital, 761.  
of the thalamus, 758.  
of the tibia, 202.  
Tuberculum Loweri, 469.  
Tuberosities of the humerus, 163.  
of the tibia, 203.  
Tuberosity, 33.  
of the calcaneum, 212.  
of the ischium, 189.  
of the radius, 163.  
Tubules, efferent, 647.  
seminiferous, 647.  
straight, 647.  
uriniferous, 633.  
Tunic, vaginal, 645, 862.  
vascular, 648.  
Turbinals, nasal, 148.  
Türk, fasciculus of, 710.  
Tympanic membrane, 894.  
orifice, 890.  
tegmen, 111.  
tensor, 898.  
Tympanum, 890.  
lining membrane of, 899.  
muscles of, 898.

U.

Ulna, 167.  
Umbilical cord, 578.  
Umbilicus, 276, 366.  
Unipolar nerve-cells, 696.  
Ureters, 627.  
Urethra, female, 658.  
male, 640.  
membranous portion, 641.  
prostatic portion, 641.  
spongy portion, 642.  
Urethral crest, 641.  
Urinary bladder, 626.  
coats of, 631.  
vessels of, 632.  
organs, 621.  
Uterus, 661.  
periodic changes of, 665.  
structure of, 663.  
vessels and nerves of, 664.  
Utricle of the vestibule, 909.  
Utriculus, 641.  
Uvea, 871.  
Uvula of the bladder, 632.  
of the cerebellum, 731.  
of the palate, 378.

V.

Vagina, 659.  
Vaginal tunic, 645.  
Vagus nerve, 800, 801.  
Valsalva, sinuses of, 473, 478.  
Valves, aortic, 355.  
bicuspid, 473.  
connivent, 355, 426.  
coronary, 548.  
eustachian, 469.  
ileo-cæcal, 434.  
ileo-colic, 434.  
of lymphatics, 580.  
mitral, 473.  
pyloric, 420.  
semilunar, 473.  
tricuspid, 472.  
of veins, 458.  
of Vieussens, 720.  
Valvulæ conniventes, 355, 426.  
Thebesii, 469.  
Vas aberrans, 651.  
deferens, 649.  
Vasa vasorum, 463.  
Vaso-motor nerves, 463.  
Vault of cranium, 134.  
Veins, 454, 458.  
alveolar, 555.  
anastomotic, 560.  
angular, 553.  
auditory, 559.  
auricular, 554, 555.  
axillary, 562.  
azygos, 566.  
basilar, 559, 560.  
basilic, 564.  
median, 565.  
brachial, 563.  
bronchial, 568.  
cardiac, 547.  
central, of vertebræ, 568.  
cephalic, 564.  
median, 564.  
cerebellar, 561.



- Veins, cerebral, 560.  
   cervical, deep, 549.  
   transverse, 556.  
   choroid, 561.  
   ciliary, 559.  
   circumflex, 563.  
   colic, 576.  
   companion, 458.  
   condylar, 562.  
   coronary, 547, 548.  
   cystic, 575.  
   deep, 458.  
   dental, 555.  
   digital, 564.  
   diploic, 561, 562.  
   dorsal, of clitoris, 573.  
   of penis, 573.  
   dorsal lingual, 552.  
   emissary, 562.  
   epigastric, 571.  
   ethmoidal, 559.  
   facial, 552.  
   deep, 553.  
   transverse, 554.  
   femoral, 571.  
   frontal, 553.  
   of Galen, 560.  
   gastric, 576.  
   gastro-epiploic, 576.  
   gluteal, 573.  
   hemiazgyos, 567.  
   hemorrhoidal, 576.  
   hepatic, 569.  
   ileo-colic, 576.  
   iliac, circumflex, 571.  
   common, 570.  
   external, 571.  
   internal, 573.  
   ilio-lumbar, 570.  
   innominate, 548.  
   intercostal, 567.  
   interosseous, 564.  
   intestinal, 576.  
   jugular, anterior, 555.  
   external, 553.  
   internal, 550.  
   posterior, 555.  
   lacrimal, 559.  
   lingual, 552.  
   longitudinal, spinal, 568.  
   of lower limbs, 570.  
   lumbar, 566.  
   mammary, internal, 550.  
   masseteric, 555.  
   mastoid, 562.  
   maxillary, internal, 554.  
   median, 564.  
   mesenteric, inferior, 576.  
   superior, 576.  
   nasal, 555.  
   oblique, 548.  
   obturator, 573.  
   occipital, 555, 562.  
   ophthalmic, 559.  
   ovarian, 569.  
   palatine, inferior, 553, 555.  
   pancreatic, 576.  
   pancreatico-duodenal, 576.  
   parietal, 562.
- Veins, petrosal, 551.  
   pharyngeal, 552.  
   phrenic, 569.  
   popliteal, 570.  
   portal, 574.  
   pterygoid, 555.  
   pubic, 571.  
   pudic, 572, 573.  
   pyloric, 576.  
   radial, 564.  
   ranine, 552.  
   renal, 569.  
   retinal, central, 559.  
   sacral, lateral, 573.  
   middle, 570.  
   saphenous, external, 571.  
   internal, 571.  
   long, 571.  
   short, 571.  
   sciatic, 573.  
   sigmoid, 576.  
   spermatic, 569.  
   of the spinal cord, 569.  
   of the spine, 568.  
   spiral, 913.  
   splenic, 576.  
   striatum, 561.  
   structure of, 456, 462.  
   stylo-mastoid, 555.  
   subclavian, 562.  
   subcutaneous, 458.  
   submental, 553.  
   subscapular, 563.  
   superficial, 458.  
   supralabial, 553.  
   supraorbital, 553.  
   suprarenal, 569.  
   suprascapular, 556.  
   temporal, 554, 555.  
   thoracic, 563.  
   thyroid, inferior, 549.  
   superior, 552.  
   tibial, anterior, 570.  
   posterior, 570.  
   transverse, 548.  
   tunics of, 459, 460.  
   ulnar, 564.  
   umbilical, 578.  
   of upper limbs, 562.  
   valves of, 458, 460.  
   vertebral, 549.  
   vorticose, 867.
- Velum, anterior, 720, 732.  
   inferior, 721.  
   posterior, 720, 732.
- Vena cava ascendens, 565.  
   descendens, 548.  
   inferior, 565.  
   superior, 548.  
   innominate, 548.
- Ventricles of the brain, 719,  
   749, 750, 751.  
   of the heart, 470, 472.  
   of the larynx, 618.
- Ventricular aqueduct, 762.  
   septum of brain, 750, 751.  
   of heart, 470.
- Vermiform appendix, 433.
- Vertebrae, 54.
- Vertebrae, centrum of, 55.  
   cervical, 56.  
   coccygeal, 65.  
   dorsal, 59.  
   lumbar, 60.  
   sacral, 62.  
   structure of, 61.  
   thoracic, 59.  
   true, 54.
- Vertebral column, 54, 66.  
   articulations of, 71.  
   curves of, 66.  
   development of, 69.  
   growth of, 69.  
   movements of, 79.
- Vertebrates, 25.
- Vertex of skull, 133.
- Vesical sphincter, 631.  
   triangle, 632.  
   uvula, 632.
- Vesicles, seminal, 651.
- Vesiculæ seminales, 651.
- Vessel-arteries, 463.  
   veins, 463.
- Vessels, afferent, 582.  
   blood, 453.  
   capillary, 460.  
   efferent, 582.  
   lymphatic, 579.
- Vestibular membrane, 912.
- Vestibule of labyrinth, 904,  
   908.  
   of mouth, 377.  
   of vulva, 658.
- Villi of intestine, 427.
- Vitellus, 671.
- Vitreous body, 881.  
   humor, 881.  
   layer of the skull, 134.
- Vitreum, 881.
- Vocal cords, 614, 619.  
   membrane, 613.  
   processes, 611.
- Vulva, 654.  
   vessels and nerves of, 658.
- W.**
- Wharton, duct of, 389.
- White matter of brain, 763.  
   of cerebro-spinal axis, 702.  
   of spinal cord, 705.
- Window, oval, 891, 904.  
   round, 891.
- Windpipe, 602.
- Winslow, foramen of, 371.
- Wirsung, duct of, 441.
- Wrisberg, cartilages of, 612.
- Y.**
- Yolk, 671.
- Yellow spot of retina, 874.
- Z.**
- Zone, ciliary, 881.  
   of Zinn, 881.
- Zygapophyses, 55.
- Zygoma, 141.

























