

Horses in accident and disease : notes and sketches / by J. Roalfe Cox.

Contributors

Cox, J. Roalfe

Publication/Creation

Edinburgh : D. Douglas, 1892.

Persistent URL

<https://wellcomecollection.org/works/dg5tp4vr>

License and attribution

This work has been identified as being free of known restrictions under copyright law, including all related and neighbouring rights and is being made available under the Creative Commons, Public Domain Mark.

You can copy, modify, distribute and perform the work, even for commercial purposes, without asking permission.



Wellcome Collection
183 Euston Road
London NW1 2BE UK
T +44 (0)20 7611 8722
E library@wellcomecollection.org
<https://wellcomecollection.org>



M. xx

19/c

2/6



22101893894

Med
K51768

1. 12. 7596

This Book is the property of
THE WELLCOME PHYSIOLOGICAL
RESEARCH LABORATORIES,
BROCKWELL HALL,
HERNE HILL, LONDON, S.E.

Anyone finding and returning it to the above
address will be handsomely rewarded.

886

HORSES
IN ACCIDENT AND DISEASE

Edinburgh: Printed by George Waterston & Sons

FOR

DAVID DOUGLAS.

LONDON, SIMPKIN, MARSHALL, HAMILTON, KENT, AND CO., LIMITED.

CAMBRIDGE, MACMILLAN AND BOWES.

GLASGOW, JAMES MACLEHOSE AND SONS.

1286

H O R S E S

IN ACCIDENT AND DISEASE

NOTES AND SKETCHES

BY

J. ROALFE COX, F.R.C.V.S.



EDINBURGH: DAVID DOUGLAS

MDCCCXCH.

WELLCOME INSTITUTE LIBRARY	
Coll.	welMOmec
Call	
No.	✓

P R E F A C E.

IN introducing my Sketches of Horses in Accident and Disease, I should explain, in excuse of their appearance, that they were not drawn originally with any idea of publication, and they are now offered in response to the solicitation of several professional friends. From my earliest association with the Veterinary profession I have made notes and sketches of prominent signs of suffering in horses, and I have learnt that many of these are forcibly enough expressed in peculiar attitudes, if we only take the pains to read them. Fortunately, our patients never tell an untruth, and, with all the failings of their kind, they do not mangle; whilst their tale of disablement and pain, "though it hath no tongue, will speak with most miraculous organ."

What I have seen, so have all old practitioners, and these will recognise a true and unexaggerated presentment of familiar cases, which may not be altogether uninteresting. But utility can only serve the rising generation of Veterinary Surgeons, who have not yet come across the

PREFACE.

real article; and if to such I may happily be affording some help in their reading and their earlier practice, I shall have gained all I could hope from publicity. I have purposely abstained from any lengthened description of the disorders represented, because such is already so fully given in excellent works up to date.

J. ROALFE COX.

LONDON, *September* 1892.

SKETCHES.

CASE

- I. CHOKING.
- II. CHOKING.
- III. STOPPAGE OF THE BOWELS.
- IV. COLIC.
- V. STRANGULATED BOWEL.
- VI. STRANGULATED BOWEL.
- VII. VOMITING.
- VIII. STRANGULATED HERNIA.
- IX. RUPTURE OF STOMACH.
- X. CONGESTION OF LUNGS.
- XI. CALCULUS IN BLADDER.
- XII. DISLOCATION OF PATELLA.
- XIII. DISLOCATION OF HIP.
- XIV. LAMINITIS.
- XV. RUPTURE OF MUSCLE (*FLEXOR METATARSI*).
- XVI. DROPPED ELBOW.
- XVII. FRACTURE OF ELBOW.
- XVIII. A "SHIVERER."
- XIX. WRY NECK.
- XX. TETANUS.

SKETCHES.

CASE

XXI. MEGRIMS.

XXII. TUMOUR IN BRAIN.

XXIII. STOMACH STAGGERS.

XXIV. BROKEN BACK.

XXV. ARSENIC, POISONED BY.

XXVI. ARSENIC, OUTWARDLY APPLIED.

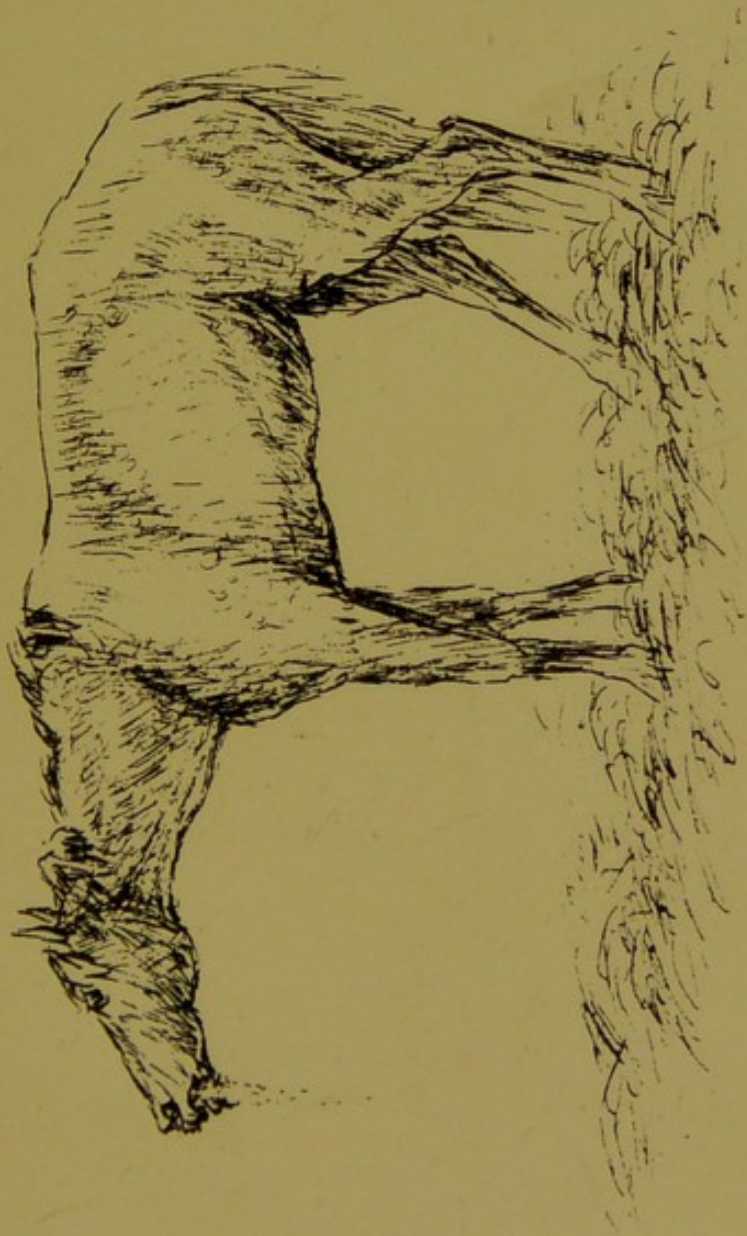XXVII. ABSCESS AT POLL—CURIOUS CASE.

XXVIII. OSTEO SARCOMA OF JAW.

CASE I.

CHOKING.

The attitude in this case is referable to forcible efforts to return the obstruction, and is rather indicative of lodgment within the lower half of the œsophagus.





CASE II.

CHOKING.

The characteristic attitude in this case is referable to forcible efforts to swallow, and is rather indicative of lodgment within the upper half of the œsophagus. In consequence of extreme compression of the throat, there is often a shrieking sound in the inspiratory act of breathing, and there is usually much slavering from the mouth.





CASE III.

STOPPAGE OF THE BOWELS.

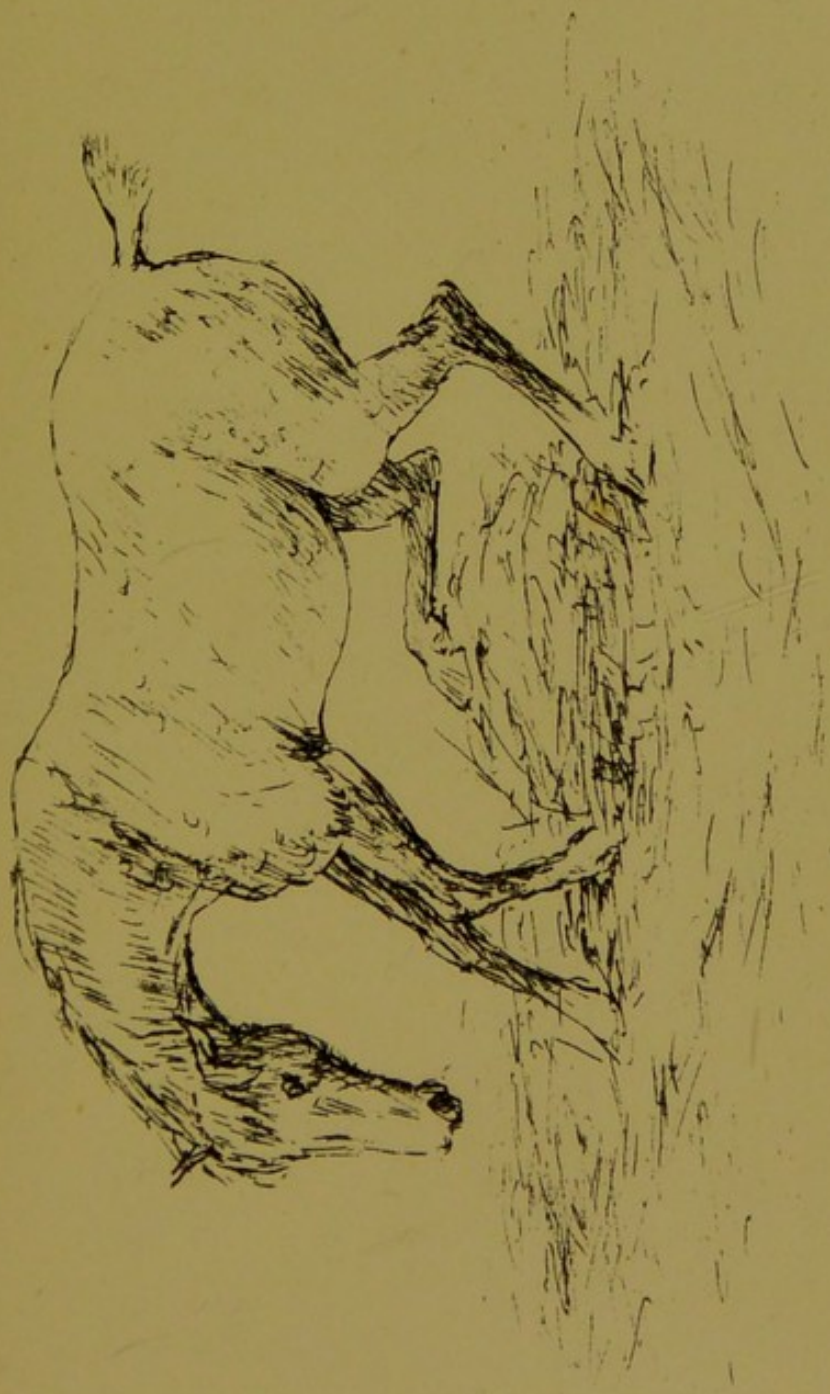The attitude in this case, indicative of weariness and dull pain, and alternating with slow wandering, and occasional backing movement, is commonly observed in protracted cases of faecal obstruction, which may even last during some days.





CASE IV.

SPASM OF THE BOWELS—COLIC.



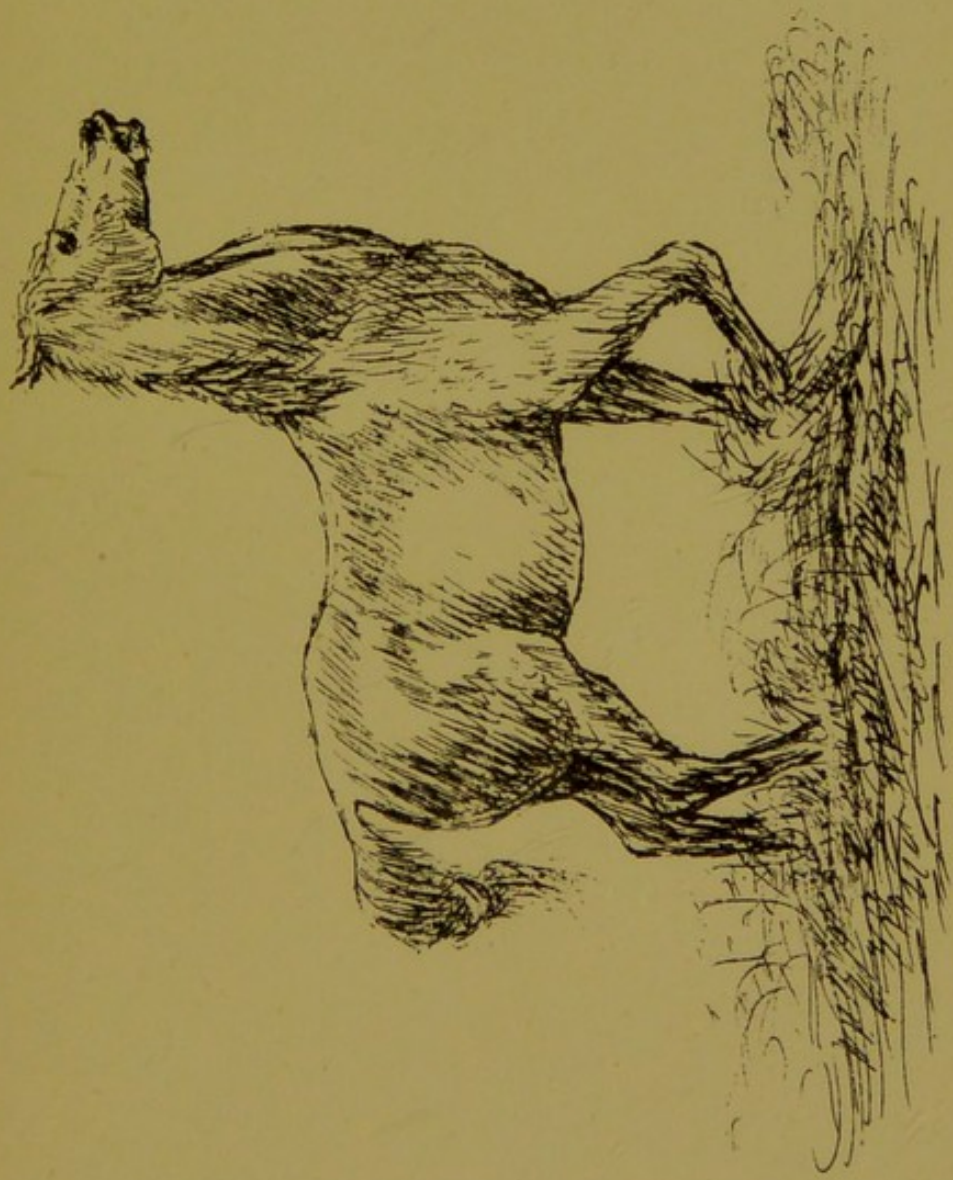


CASE V.

STRANGULATED BOWEL.

Frequent posture in a case of strangulated intestine.

Autopsy—Twist near the terminal portion of the ileum.



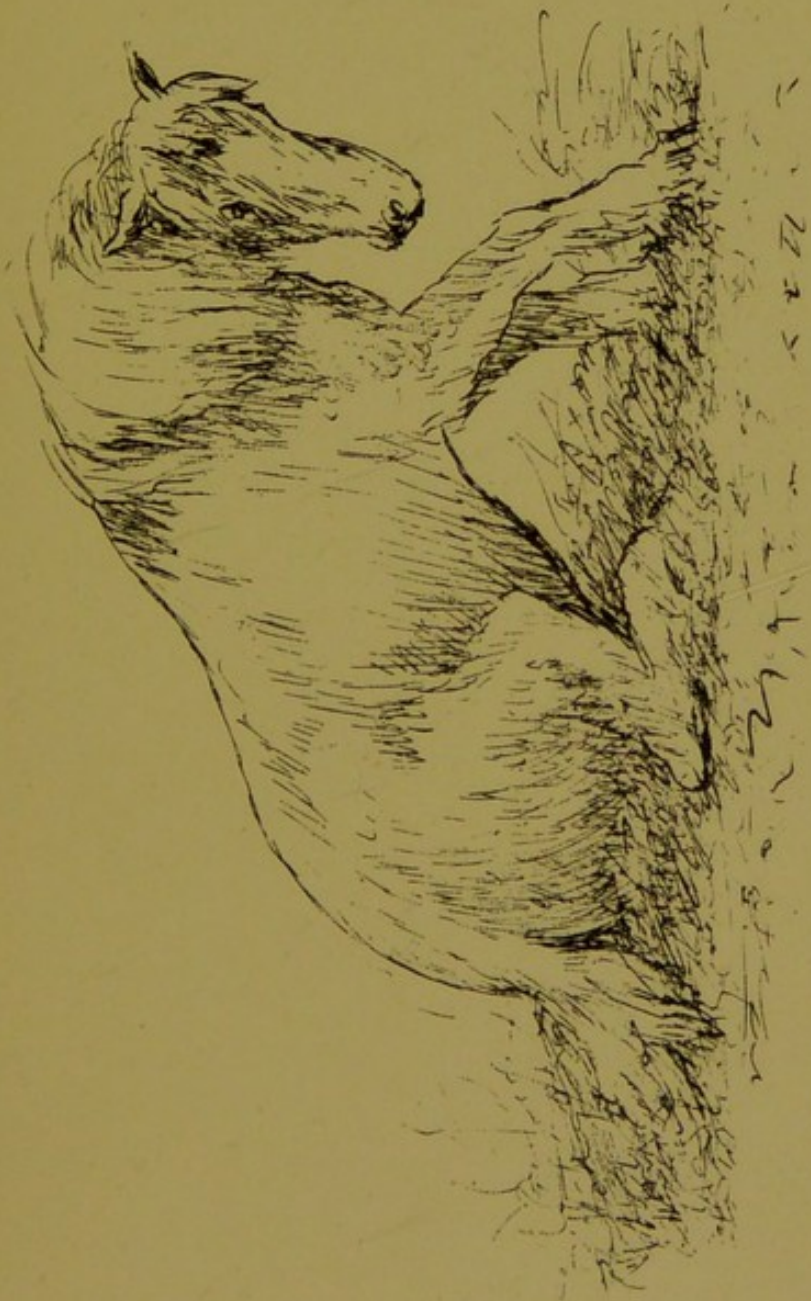

CASE VI.

STRANGULATED BOWEL.

A case of strangulated intestine.

Autopsy—Twisted intestine.



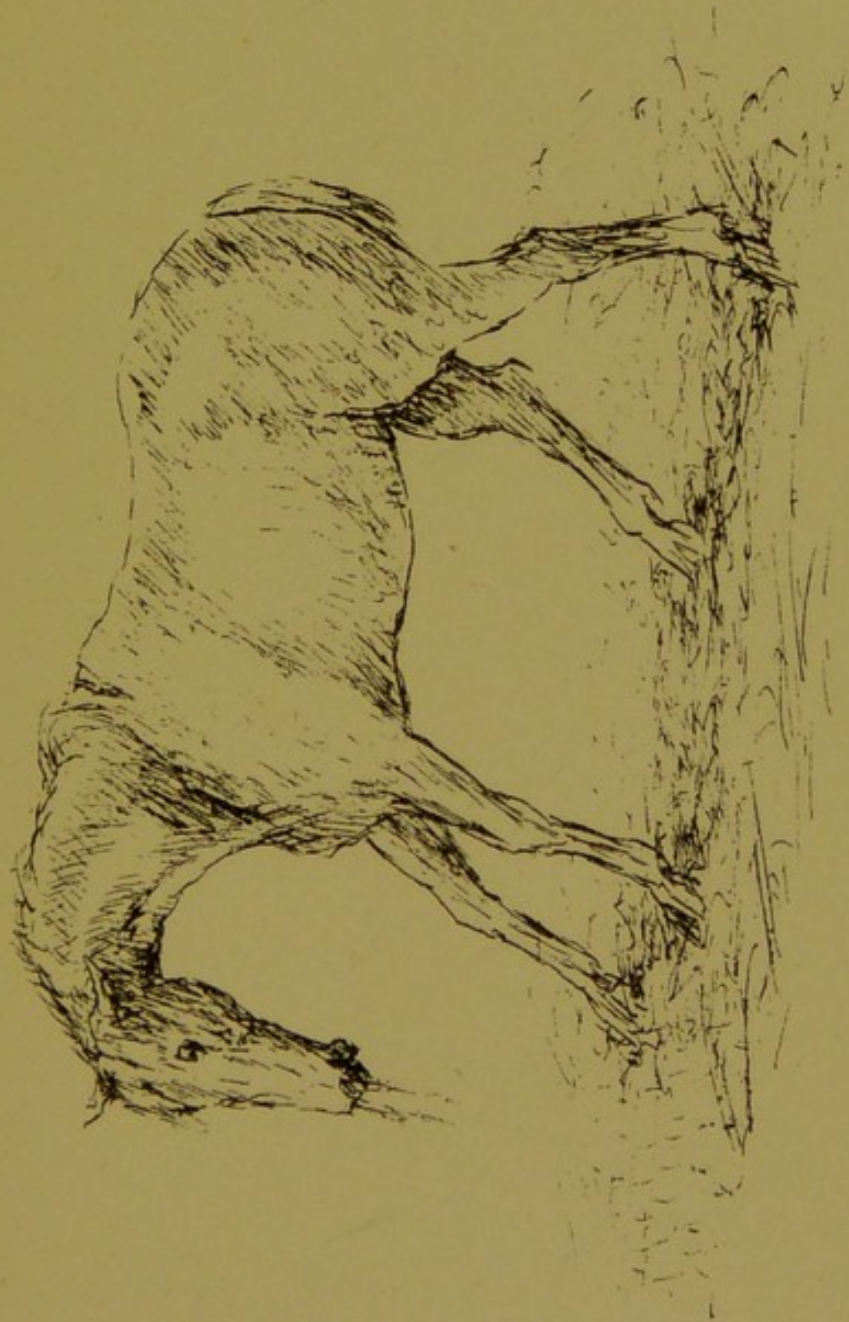

CASE VII.

VOMITING.

Vomiting in a case half an hour preceding death.

Autopsy—Strangulated, twisted intestine.

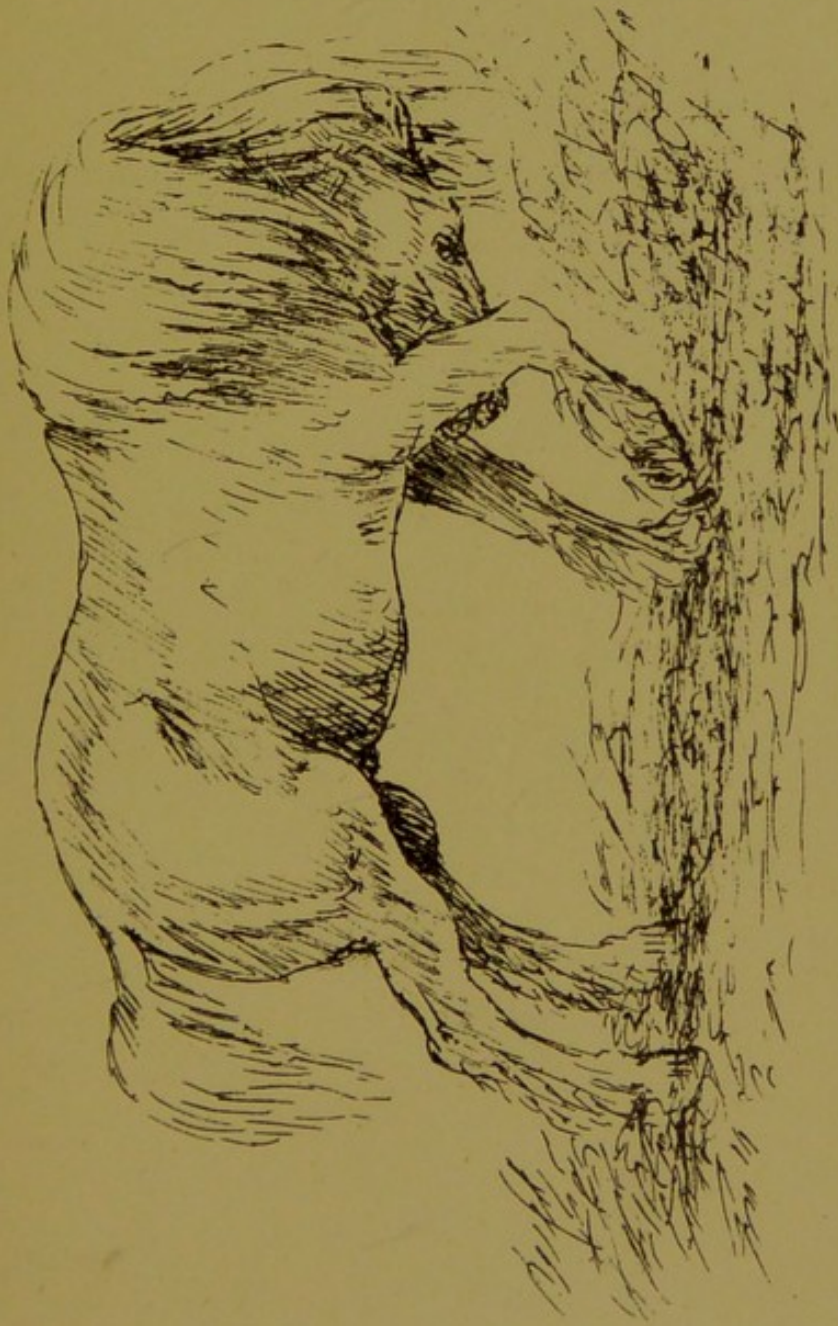




CASE VIII.

STRANGULATED SCROTAL HERNIA.

Frequent posture during several hours preceding death.



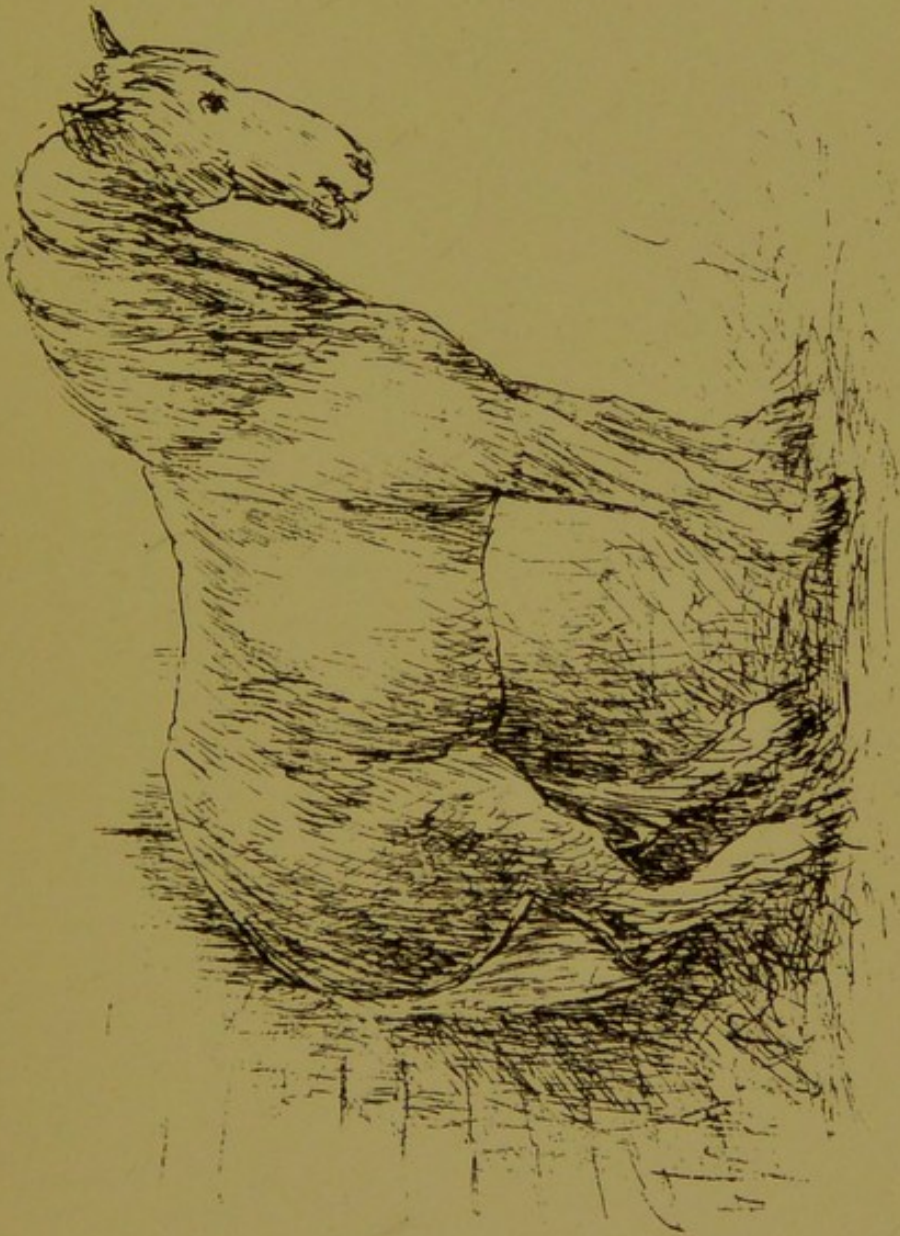


CASE IX.

RUPTURE OF THE STOMACH.

Frequent posture of a horse during several hours preceding death.

Autopsy—Rupture of the stomach.






CASE X.

CONGESTION OF THE LUNGS—OVER-EXERTION.



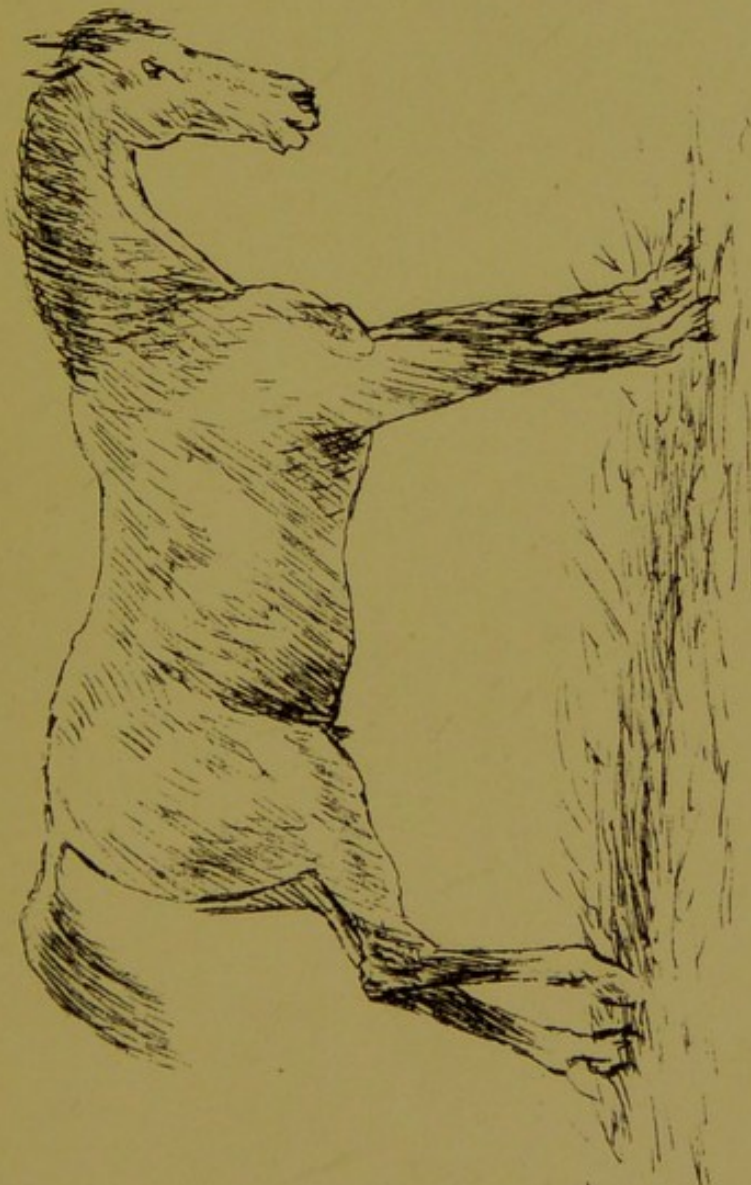



CASE XI.

CALCULUS IN THE BLADDER.

FOUR-YEAR-OLD HORSE.

An attitude frequently observed in this case. The calculus was too large to admit of removal without being previously broken for the purpose; was very hard and dense in structure. Fragments continued to be voided, or were removed from time to time, up to three weeks, at which period a newly-forming calculus was discovered in passage at the perineal opening. It was perfectly spherical, the size of a small marble. This case made good recovery.





CASE XII.

DISLOCATION OF PATELLA.



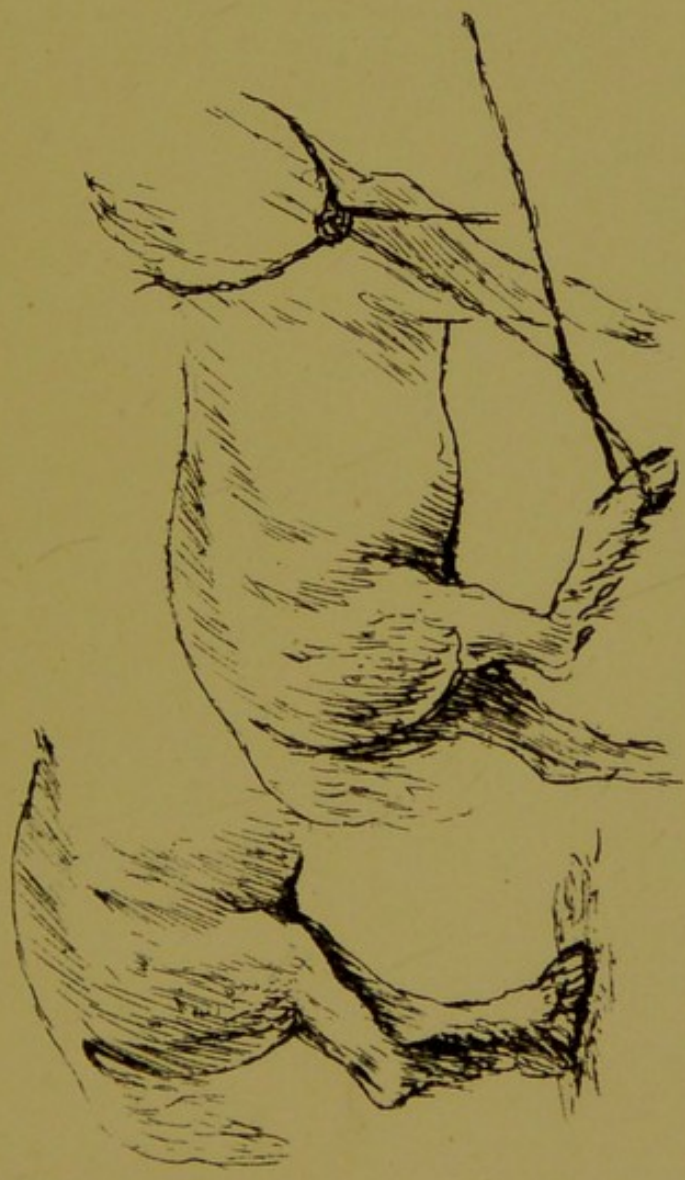


CASE XIII.

DISLOCATION OF HIP.

The posture when standing, also showing the utmost extent of forward movement which could be effected.

Autopsy—Rupture of *ligamentum teres*, and the head of femur dislodged from acetabulum.

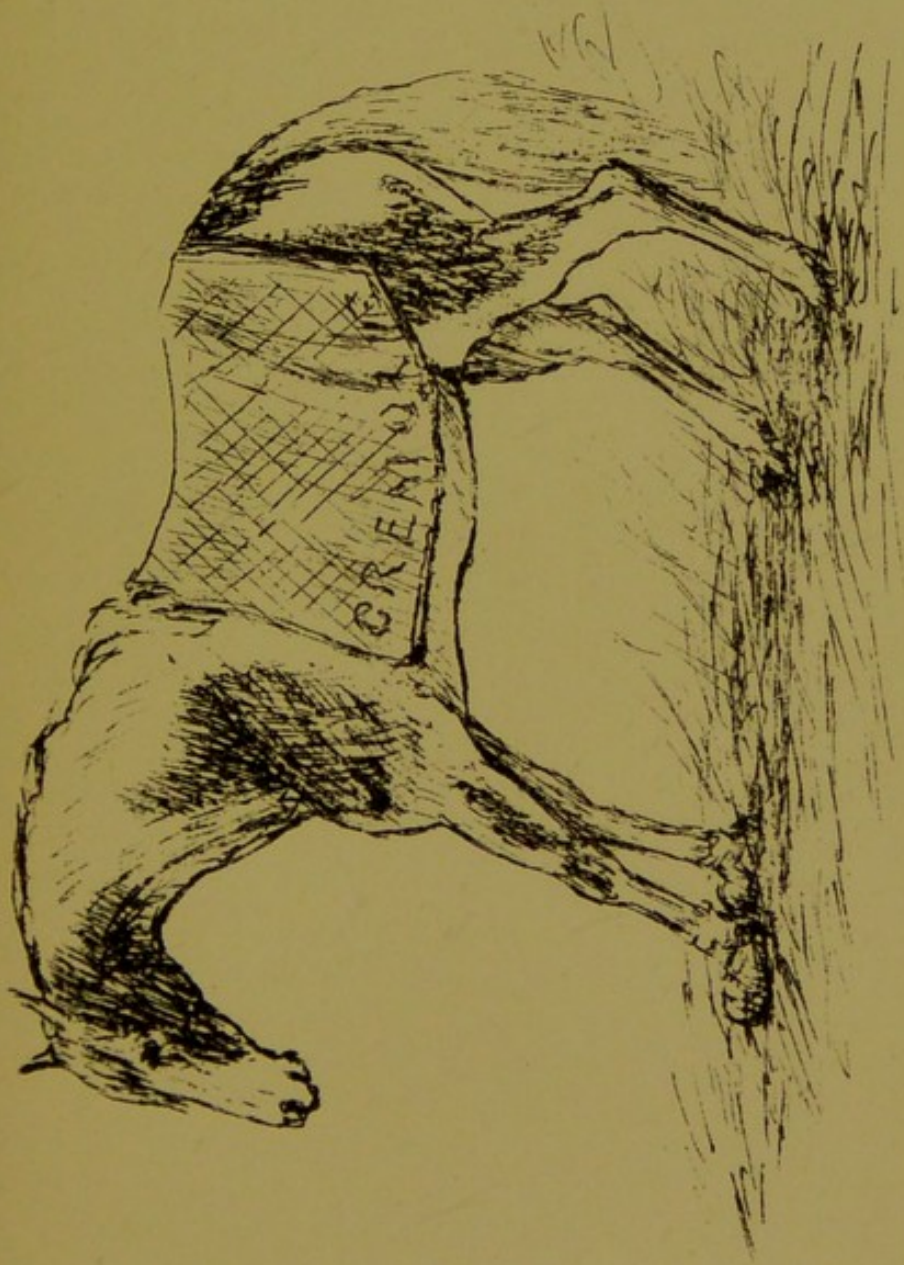




CASE XIV.

L A M I N I T I S.

Acute inflammation of fore feet.

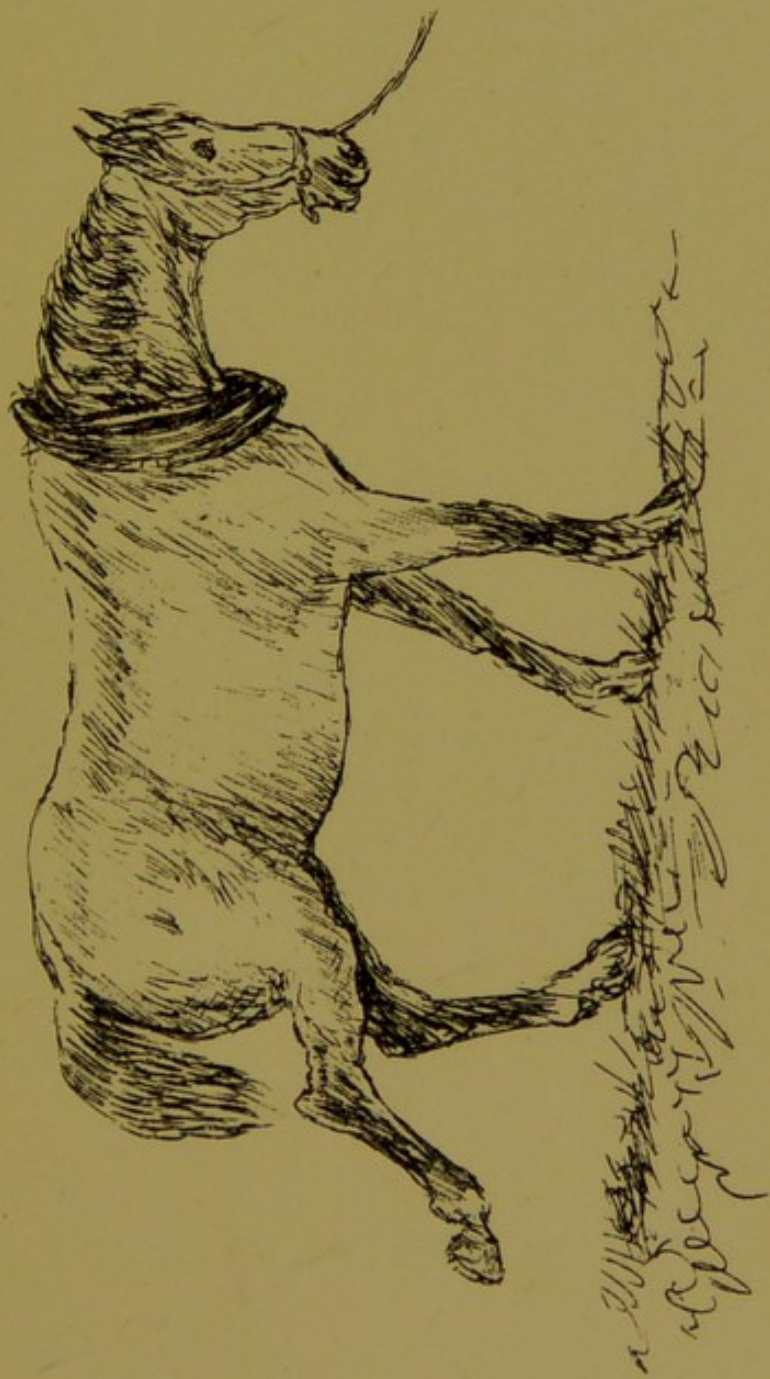





CASE XV.

RUPTURE OF THE MUSCLE AT THE FRONT OF THE
THIGH (*FLEXOR METATARSI*).

Characterised by a peculiar jerk upwards and backwards of the affected limb, on the foot being withdrawn from its support on the ground; at the same time the tendons at the back of the thigh from the point of the hock become relaxed and puckered. This case shows both conditions.



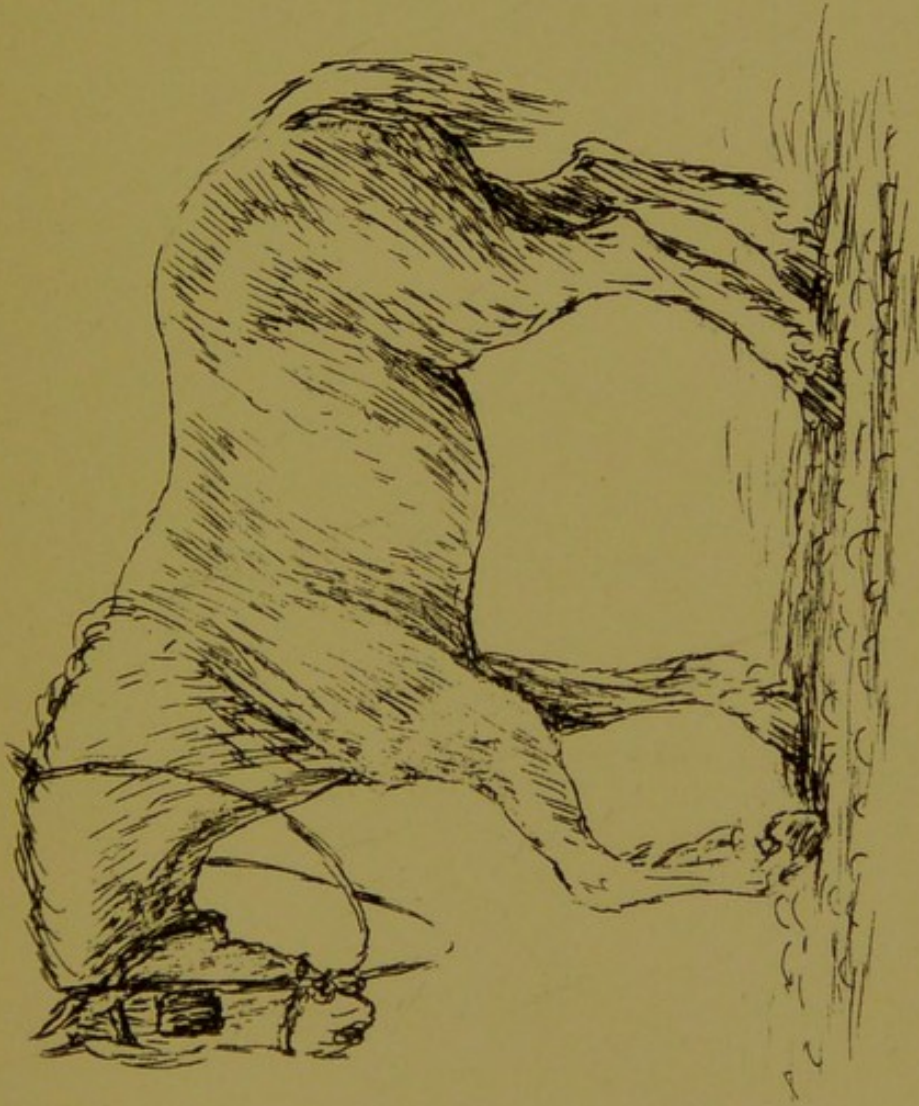


CASE XVI.

DROPPED ELBOW.

RUPTURE OF THE MUSCLES CONNECTED WITH THE PART.

This horse was at work in a heavy two-wheeled parcel-cart, had stopped for delivery, and was standing with his fore feet in the channel between the roadway and pavement. At the instant of starting he made a slip, became lame and disabled, and the full deformity was at once apparent. The limb eventually regained its position fairly well, and the horse became available for farm work. There remained much wasting of the shoulder muscles.






CASE XVII.

FRACTURE OF THE ELBOW (*ULNA*).

More or less inability to draw the limb backward.

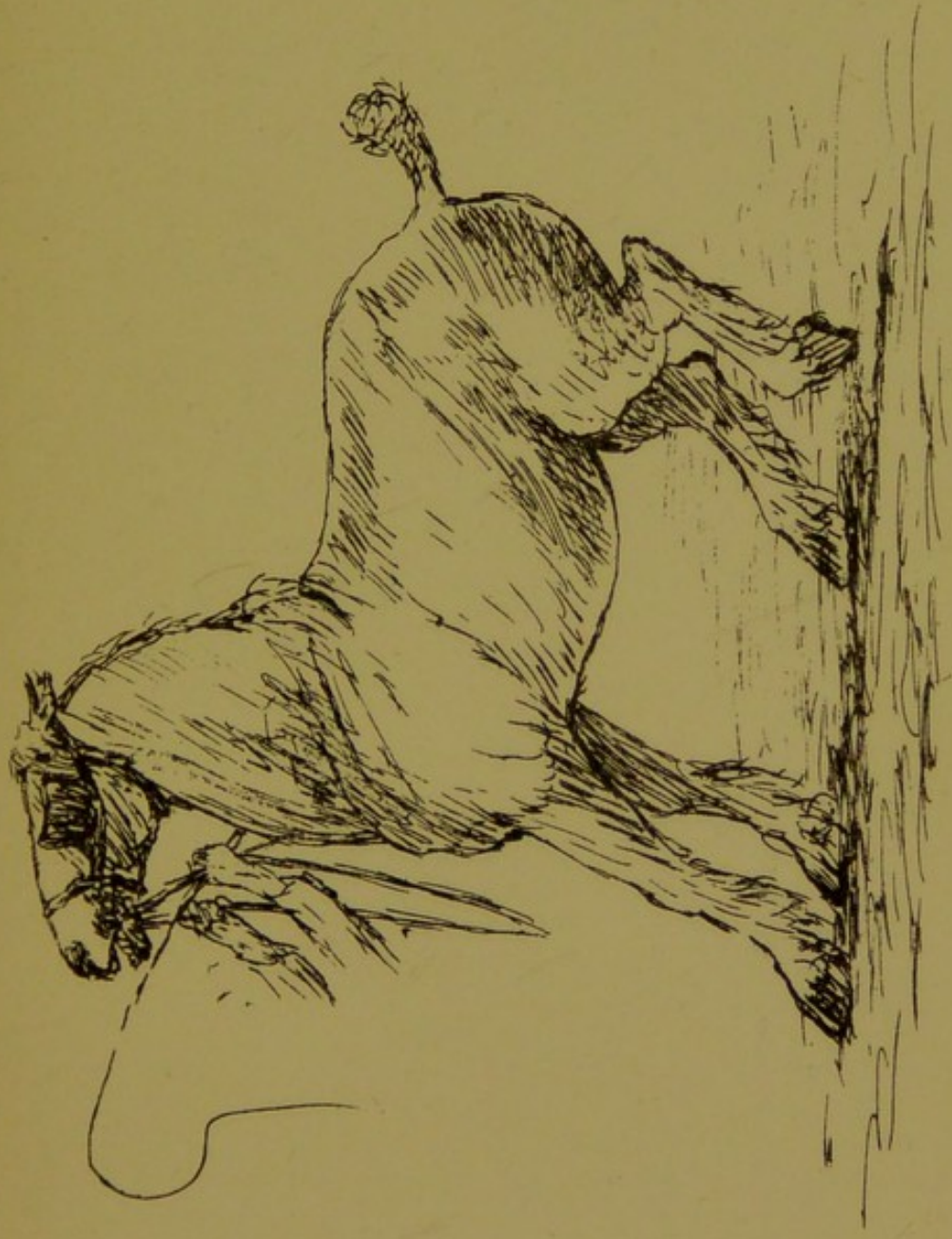




CASE XVIII.

A "SHIVERER" (SO-CALLED).

Inability to move backward, violent spasm of the hind limbs being excited by the attempt.

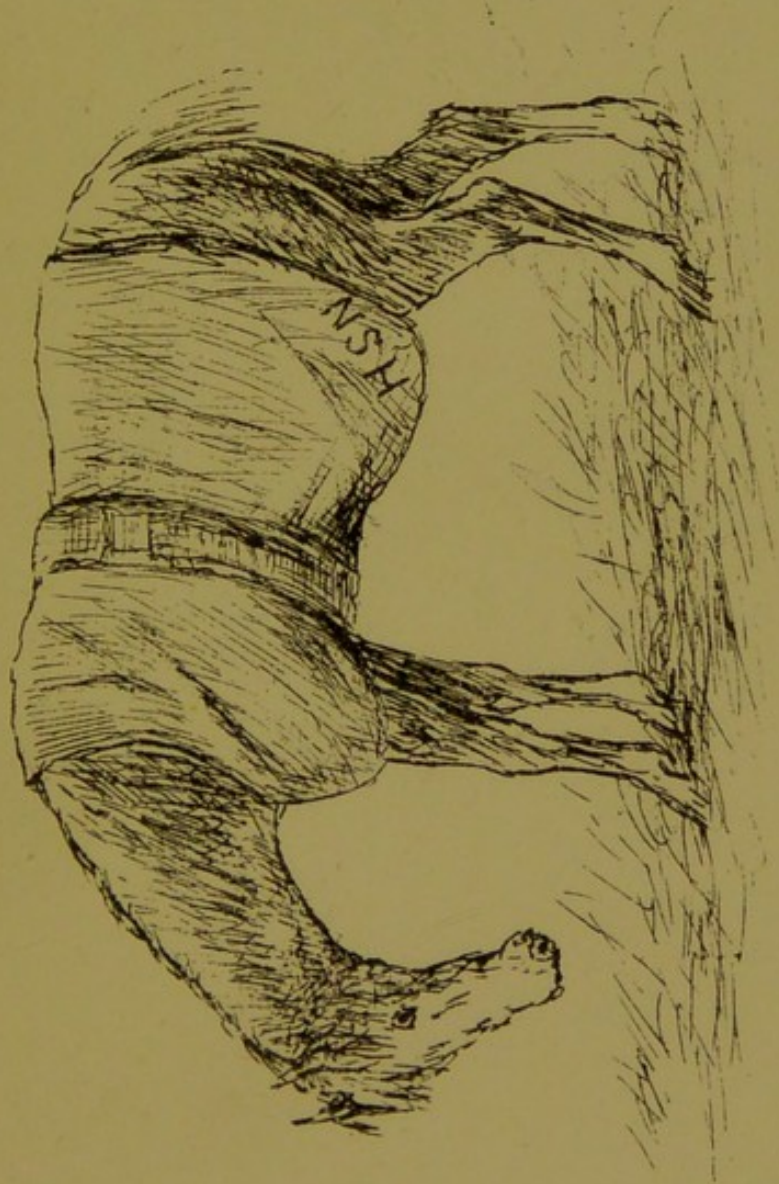




CASE XIX.

WRY NECK FROM RHEUMATIC CRAMP.

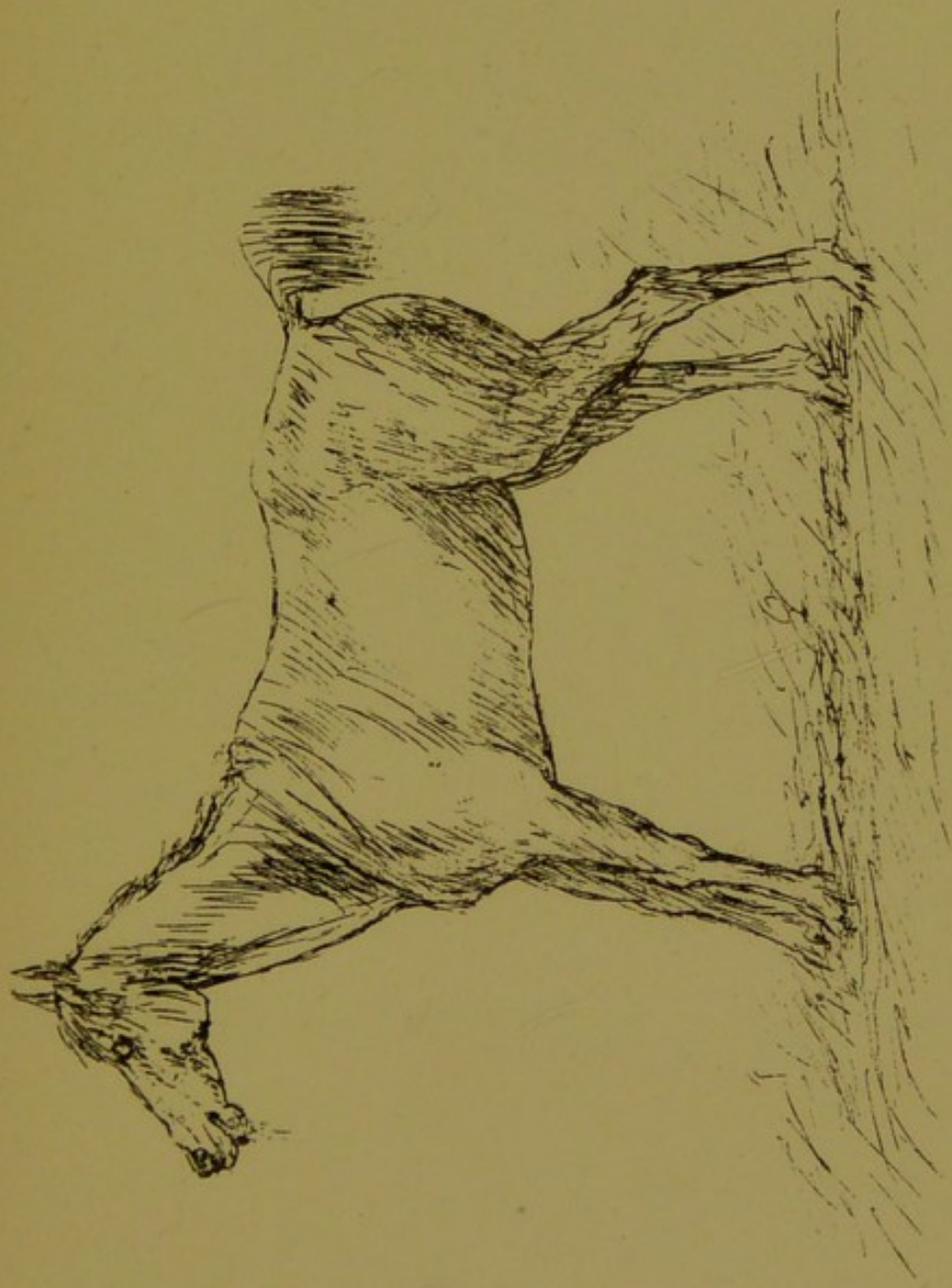This mare was attacked rather suddenly in the evening after hunting, being discovered to be unable to raise the neck. When visited she was in the attitude represented—the neck depressed and stiffened, and the head slightly turned to the near side. Was unable to alter the position, and could not bear any attempt to move the parts. She remained thus fixed for some days, and recovery was slow and gradual. At the end of three weeks no trace whatever of the ailment. The appetite good throughout, but could only partake of food and water on their being held under her at convenient angle. Reported to have had two similar attacks during the preceding hunting season, but neither so protracted or severe.






CASE XX.

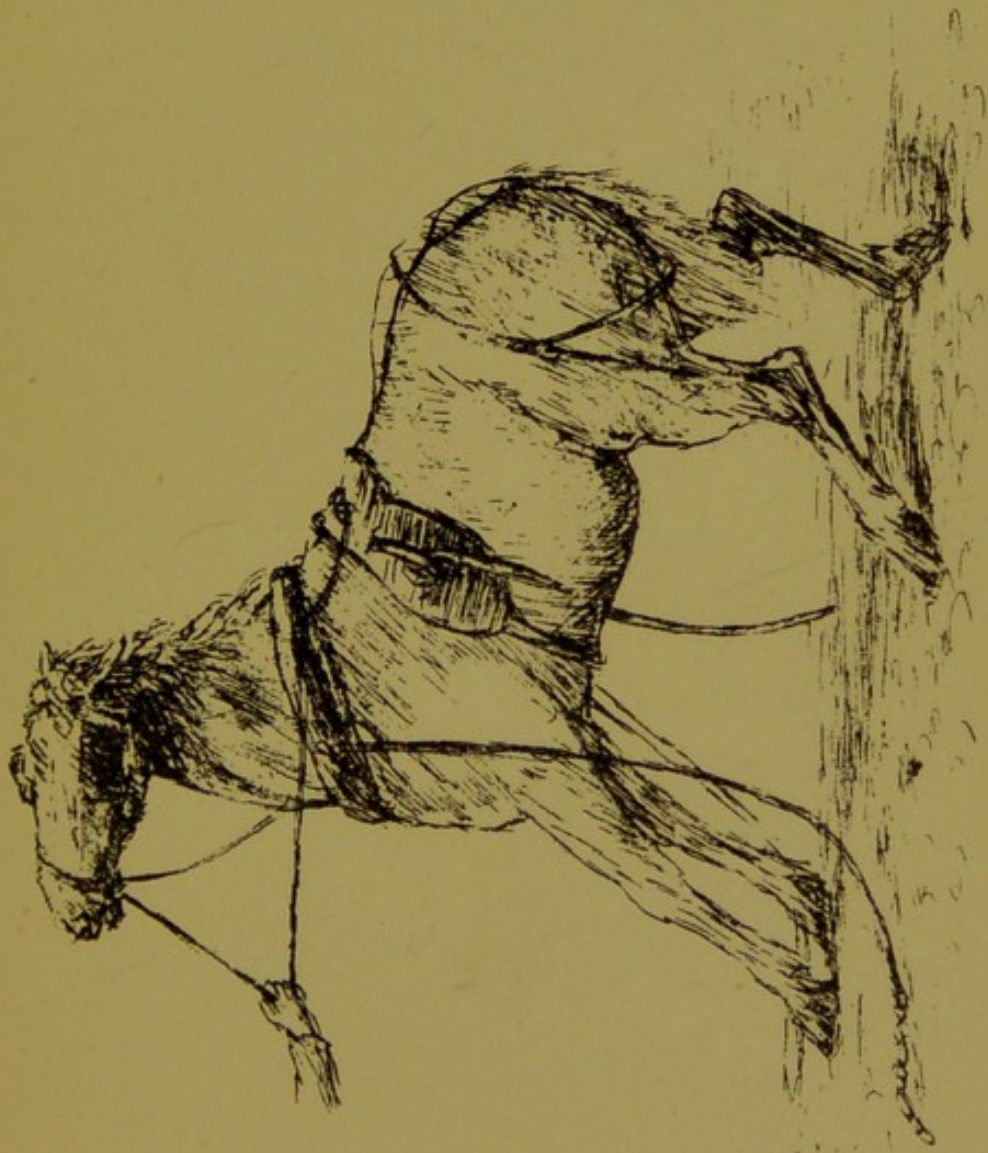
TETANUS.






CASE XXI.

MEGRIMS.



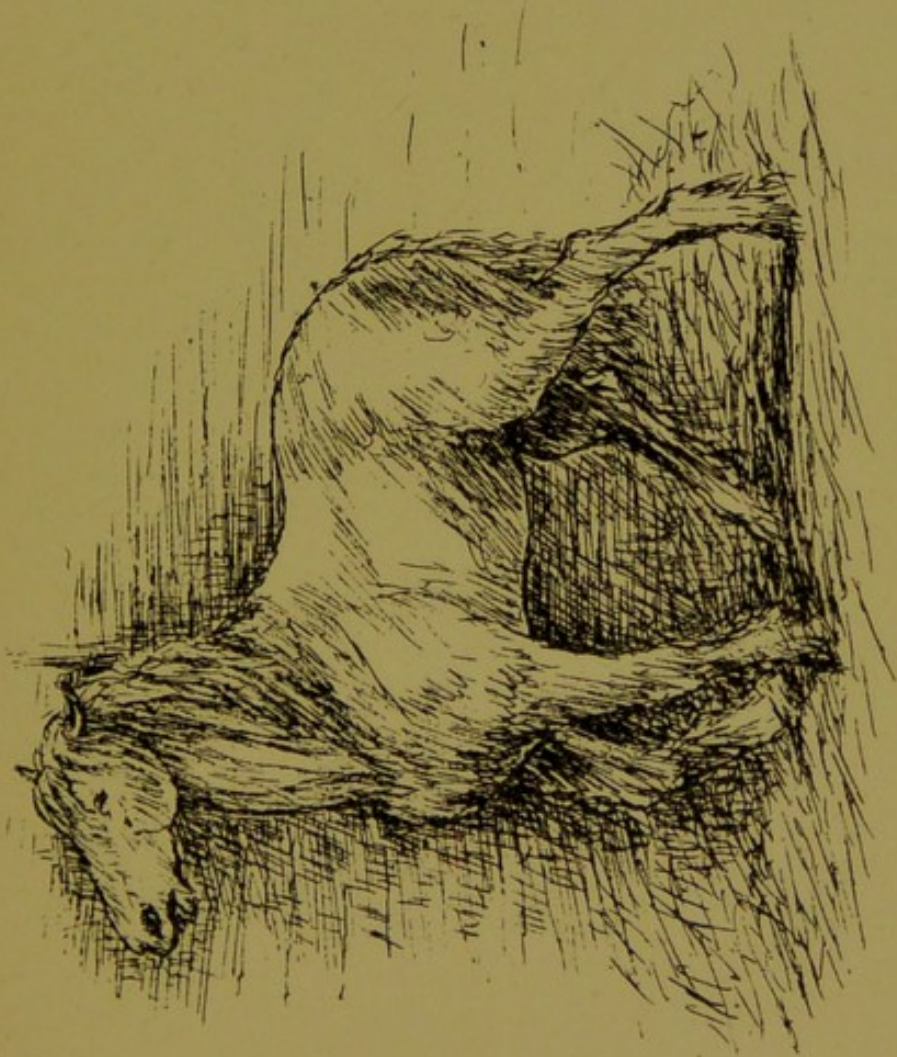


CASE XXII.

TUMOUR IN THE BRAIN.

This case was visited on the third day after the necessity arose to keep him in from work. His attitude then, and for some hours before being destroyed, was leaning in the corner of his box, with the head raised and pressed against the wall. If forced to vary this posture, he immediately staggered to point of falling; his safety in balance seemed to be in keeping the head raised, diminishing blood pressure.

Autopsy—A tumour of the usual kind and of large size in each lateral ventricle. Prior to recent urgent symptoms, it was remembered that he had been noticed to swerve unsteadily at times in work, and occasionally fell, but quickly recovered.

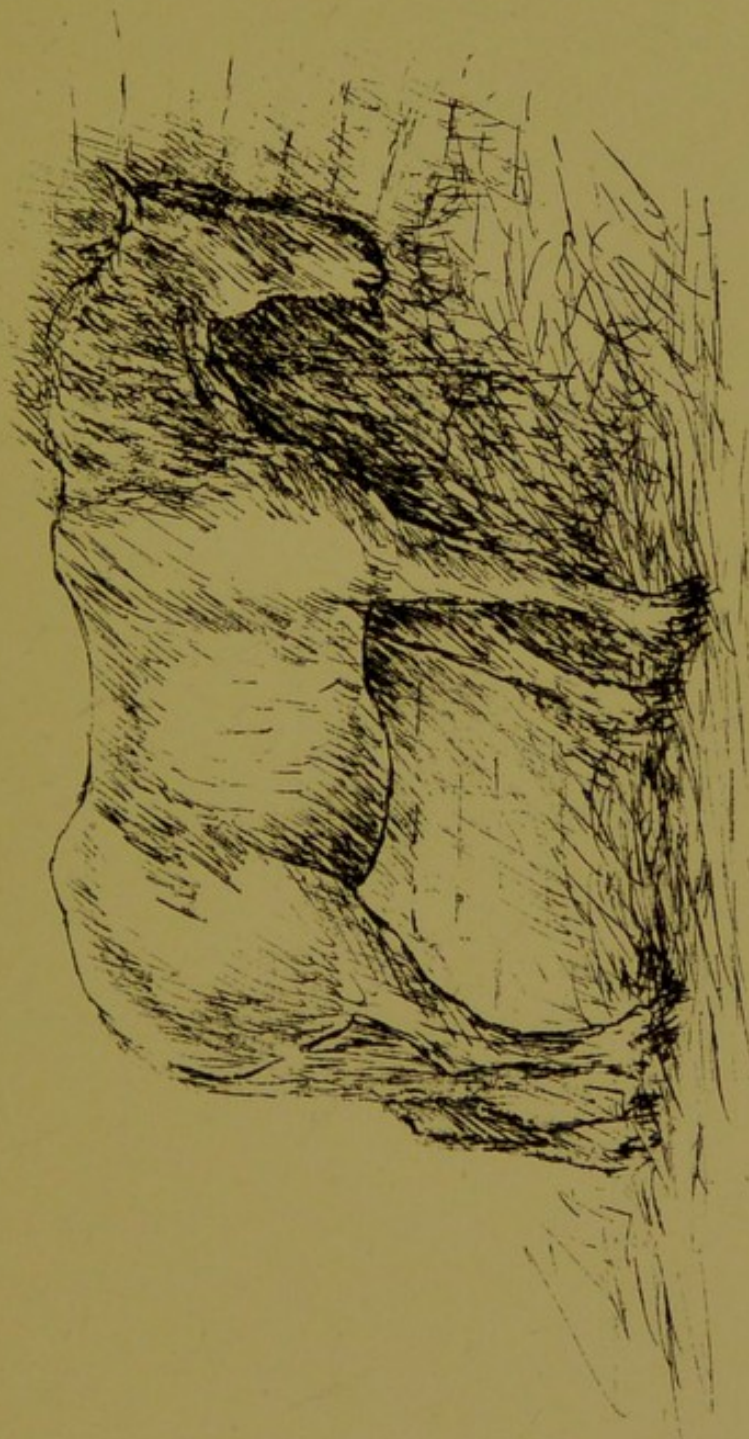




CASE XXIII.

STOMACH STAGGERS.

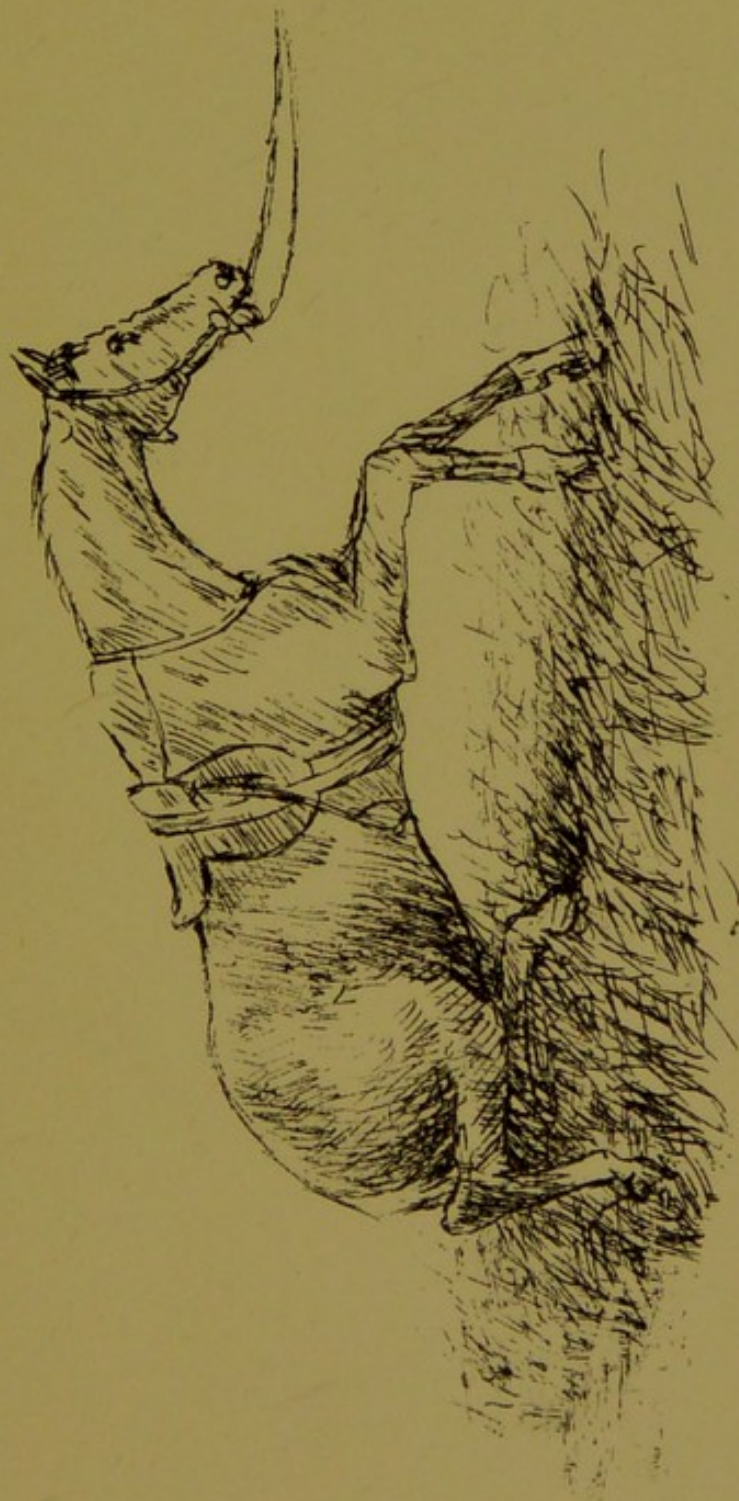A case of engorgement of the stomach, in the sleepy stage—so-called stomach staggers.






CASE XXIV.

BROKEN BACK.

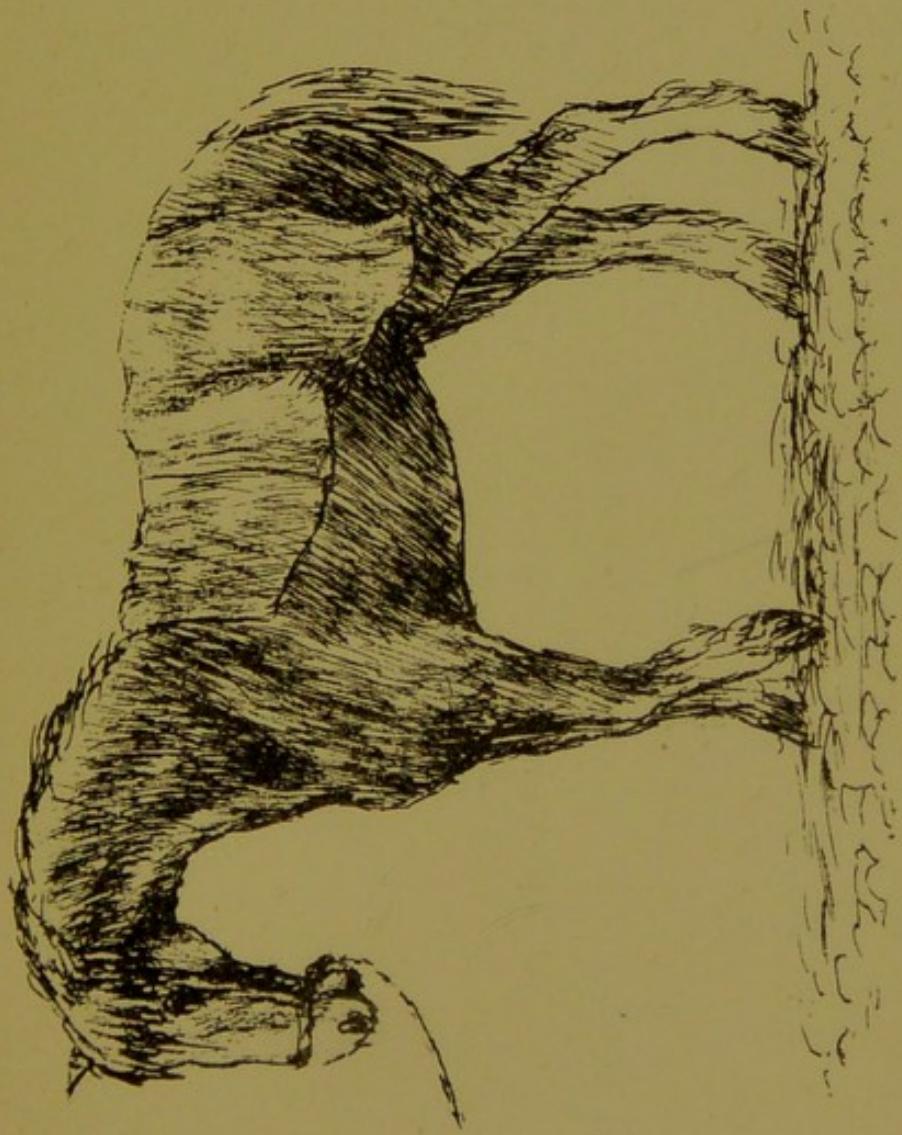




CASE XXV.

POISONED BY ARSENIC.

Showing early enfeeblement of the limbs, and little power to advance them in progression. Muscular prostration became extreme prior to death.



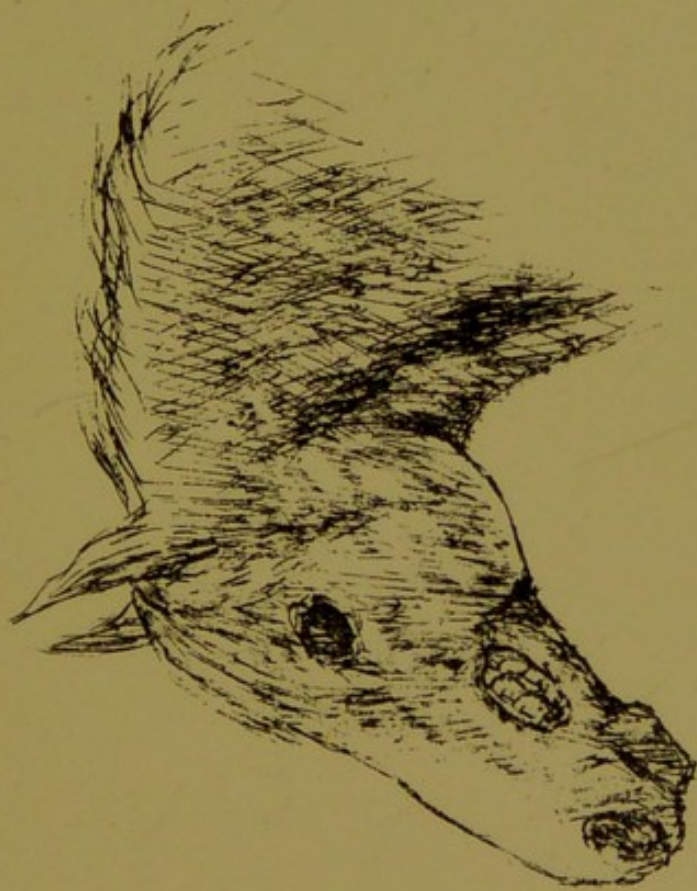


CASE XXVI.

SHOWS A PERMANENT RESULT FROM THE OUTWARD

USE OF ARSENIC.

This horse had a warty patch on the cheek. A "pretender" undertook its removal, using arsenic for the purpose. Sloughing of the parts extended much beyond the radius of the wart. Eventually a firm cicatricial margin surrounded the hole in the cheek, through which the teeth remained in view. He worked on afterwards, little inconvenienced, wearing a leather shield attached to the bridle for concealment.



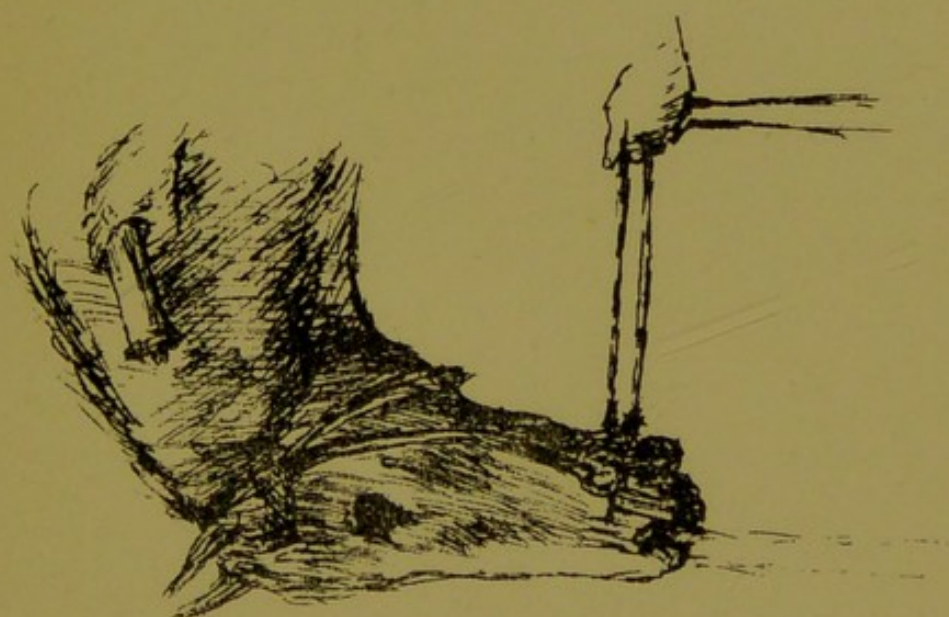



CASE XXVII.

CHRONIC DEEP ABSCESS AT THE POLL.

No enlargement or other indication at the part. The first indication was the opening of a sinus on the neck. Fluid injected into this passed in stream by the nostrils. Paralysis supervened.

Autopsy—Destruction of parts by chronic abscess, with disease of occiput and atlas. A channel had formed for passage of discharge to the pharynx.





CASE XXVIII.

DESTRUCTIVE DISEASE OF JAW (*OSTEO SARCOMA*).

This case, six years old, reported to have enlargement on the side of the jaw, like two-thirds of a cricket-ball, when purchased a year back, and explained as the result of a kick. No apparent change or inconvenience till lately, when the tumour increased rapidly. At this time the horse was feeding without apparent inconvenience. Was shortly afterwards destroyed.

Autopsy—The outer side of jaw bulged out, with a corresponding cavity beneath. The covering shell of bone extremely thin, and in places absent. Two teeth quite free, and only retained in position by wedging between others.

It is noteworthy that in these cases there is so long apparent freedom from suffering, the nerve supply being early destroyed.



