

## **Notes on dental practice / by Henry C. Quinby.**

### **Contributors**

Quinby, Henry C.

### **Publication/Creation**

London : J. & A. Churchill; Liverpool : Gilbert G. Walmsley, 1892.

### **Persistent URL**

<https://wellcomecollection.org/works/xfbzqer7>


### **License and attribution**

This work has been identified as being free of known restrictions under copyright law, including all related and neighbouring rights and is being made available under the Creative Commons, Public Domain Mark.

You can copy, modify, distribute and perform the work, even for commercial purposes, without asking permission.



Wellcome Collection  
183 Euston Road  
London NW1 2BE UK  
T +44 (0)20 7611 8722  
E [library@wellcomecollection.org](mailto:library@wellcomecollection.org)  
<https://wellcomecollection.org>








22101914791

Med  
K49266



DENTAL PRACTICE.



Digitized by the Internet Archive  
in 2016

<https://archive.org/details/b28105850>

NOTES  
ON  
DENTAL PRACTICE.

BY  
HENRY C. QUINBY, L.D.S.I.,

MEMBER OF THE ODONTOLOGICAL SOCIETIES OF LONDON AND NEW YORK;  
PRESIDENT ELECT OF THE BRITISH DENTAL ASSOCIATION.

[2ND ED.]

---

WITH ILLUSTRATIONS.

---

LONDON:  
J. & A. CHURCHILL, NEW BURLINGTON STREET.

LIVERPOOL:  
GILBERT G. WALMSLEY, 50, LORD STREET.

—  
1892.

11581711

WELLCOME INSTITUTE LIBRARY	
Coll.	weIMOmec
Call	
No.	WU



FILE COPY  
CLAUD'US & CO LIMITED.  
5 TO 12, BROAD ST., GOLDEN SQUARE, W.1.  
**CANCELLED**

## PREFACE.

---

It has not been my purpose, in this work, to attempt to wade in the deep waters of physiological and pathological research. I am content to leave the elaboration of theories, and the search after causes, in the able hands that are now, on both sides of the Atlantic, pursuing these investigations with a trained skill which cannot fail to give us much more light on the now hidden, or only suspected, sources of dental disease, and to confine myself, as strictly as a clear explanation of my meaning will permit, to the treatment of abnormal conditions of the teeth.

Dentists may well be proud of the progress that has been made in the last fifty years, not only in the facilities for teaching, but in the matter taught, in dental science. Even twenty-five years ago the men of education and social position in our profession were few in number, while the rank and file were looked upon as mere petty tradesmen—deservedly so—for they held their knowledge as a collection of trade secrets, to be jealously guarded, and


handed down from father to son as so much stock-in-trade; and they scarcely dreamed of the possibility of improving their position, and increasing their professional knowledge by the free interchange of thoughts and ideas with their fellow-practitioners. The dealer in dental instruments and materials looked upon the majority of his customers as his inferiors in every respect, and if he listened at all to any suggestions for improving his wares, it was with the indulgence and condescension of one who was quite sure he knew, better than anybody could tell him, what a dentist needed, and that what he considered proper should be accepted with thankfulness. To the general public the word dentistry meant tooth pulling, and as in the last century the barber practised blood-letting and called himself a surgeon, so, within the memory of many dentists, the chemist has considered himself a dental practitioner because he possessed a key for extracting teeth.

But a brighter prospect for dentistry began to open in the second quarter of the nineteenth century. Societies were organised and meetings held for the discussion of professional subjects. A dental hospital was established in London, and the example was soon followed in some of the other large towns, and students were admitted to see the operations. A College



of Dentistry followed naturally, and finally the Dentists' Act of 1878 was obtained from Parliament by the sheer persistency of a few of our leading men, against whom every possible form of discouragement had been hurled. But this Act gave us a position in the list of learned professions, which we may reasonably hope will continue to be, as it has been, attractive to men of education and natural mechanical ability.

There is, however, much yet to be learned; and the teachings of experience, as well as the researches of trained scientists, being valuable to the student, it becomes the duty of those who have seen much practice to make its lessons known to the profession, and thus add as much as possible to the available knowledge. This, therefore, must be my excuse for publishing these Notes.



## PREFACE TO SECOND EDITION.

---

ONE of the critics reviewing the First Edition of these Notes commenced with the remark that it was one of those books which make one wonder why it should have been published. The reason was in the hope that dental students might learn from it what was not taught at that time, viz.: that human teeth should not be treated as though they were exactly the same at all ages, and under all conditions; that the children's teeth were useful and necessary to the child's health and comfort, and not developed merely for the "'prentice hand" to practice extraction upon; that adult teeth ought not to be treated as permanent until they were mature, and the mouth in a fairly healthy condition; and that dental science meant something more than the art of filling teeth with gold. Whether it is mere coincidence, or whether the Notes have been useful in teaching these new doctrines, I cannot say, but I am glad to see that, on all these points, there has been a distinct advance in dental practice during the decade of years which has passed since these pages were prepared for the press.



I have not considered that it was necessary to make any important alterations in the text. The additional experience of ten years has not shown me that my theories are wrong or incompatible with advancing science.

The remarks about the use of certain modern appliances in operating still express my own ideas about their being absolutely necessary; but the modern teaching appears to make them necessary, which is equivalent to their being so, and the old style of operating, without these appliances, but with satisfactory results obtained in less than half the time now spent over gold fillings, will soon be one of the lost arts.

In many cases, where there is a reference to the past, it must be remembered that it is ten years since the book was written.

The few pages about anæsthetics have been omitted, and Dr. Henry Briggs, who has had much experience in the use of anæsthetics for dental operations, has been kind enough to contribute a paper on the selection and administration of these useful agents.

With these few remarks, I leave the Second Edition to the judgment of the profession.

H. C. Q.

LIVERPOOL,

*March, 1892.*

# CONTENTS.

---

## CHAPTER I.

THE TEMPORARY TEETH . . . . .	I
-------------------------------	---

## CHAPTER II.

THE PERMANENT TEETH . . . . .	26
-------------------------------	----

## CHAPTER III.

EXTRACTION AS A MEANS OF PREVENTING DECAY .	59
---	----

## CHAPTER IV.

IRREGULARITIES . . . . .	85
--------------------------	----

## CHAPTER V.

TREATMENT OF ADULT TEETH . . . . .	115
------------------------------------	-----

## CHAPTER VI.

AMALGAM . . . . .	169
-------------------	-----

## CHAPTER VII.

PIVOTING . . . . .	179
--------------------	-----


## CHAPTER VIII.

GUTTA-PERCHA FOR IMPRESSIONS . . . . .	191
--	-----

## APPENDIX.

GENERAL ANÆSTHESIA . . . . .	197
------------------------------	-----





## LIST OF ILLUSTRATIONS.

	PAGE
Partially developed bicuspid between the roots of the temporary molars . . . . .	6
Bicuspid in malpositions, which may be caused by premature extraction of the temporary molars; four illustrations . . . . .	7
The effect upon the teeth of thumb-sucking . . . . .	22
The effect upon the teeth of sucking the fingers . . . . .	23
The effect upon the teeth of sucking the tongue . . . . .	23
Gold caps for gutta-percha fillings; three illustrations . . . . .	33
Wide foramina in the imperfectly developed roots of molar and bicuspid . . . . .	38
Regulating-plate for moving a central incisor forward . . . . .	43
Regulating-plate for turning a central and moving a lateral incisor forward . . . . .	45
Retaining-plate for holding the same teeth in position until the new alveoli are formed . . . . .	46
A good mouth mirror; two illustrations . . . . .	48
Manner of holding the mirror while operating . . . . .	50
Imperfect and interrupted formation of enamel on front teeth; four illustrations . . . . .	54, 55
Approximal surfaces of teeth cut away to prevent decay . . . . .	58
Upper molar elongated so as to prevent the closing up of the gap where a lower molar has been extracted . . . . .	61
Prominent upper canines . . . . .	65
Second bicuspid extracted, and approximal surfaces of other teeth cut away to prevent decay . . . . .	66
Upper and lower teeth where the six year molars have been extracted to prevent decay . . . . .	67
Extracting instruments for six year molars; seven illustrations . . . . .	71—73
Position of twelve year molars and wisdom teeth at different periods . . . . .	76

Upper and lower teeth of a boy at sixteen years of age, the six year molars having been extracted at twelve to prevent decay . . . . .	77, 78
Effect of extracting six year molars on one side and neglecting to do so on the other . . . . .	81
Upper canine erupted in wrong position at twenty-three years of age and moved to its proper place; three illustrations . . . . .	88—90
Canine and bicuspid out of position, and plate for correcting the fault; two illustrations . . . . .	91, 92
Upper front teeth projecting and lower teeth shutting against the palate . . . . .	92
Regulating-plate to cause elongation of back teeth . . . . .	93
Treatment of projecting upper teeth with lower teeth shutting against the palate; nine illustrations . . . . .	94—100
Treatment of projecting upper teeth, with lower teeth of normal length; six illustrations . . . . .	100—104
Treatment of a narrow lower jaw, causing faulty articulation; three illustrations . . . . .	105—107
Faulty articulation and treatment, showing change of form in upper jaw; four illustrations . . . . .	108, 109
Use of jack screws in regulating; four illustrations . . . . .	110, 111
Forms of regulating plates; five illustrations . . . . .	112—114
Use of the mouth mirror in operating . . . . .	120
Various shapes of chisels and excavators; two illustrations . . . . .	123, 124
Loss of tooth substance from erosion; three illustrations . . . . .	158—160
Pivoting; five illustrations . . . . .	180, 181, 184
Pivoting to restore one cusp of a bicuspid; four illustrations . . . . .	188, 189

---


*Illustrations to Dr. Brigg's Article on General Anæsthesia.*

A two-bottle apparatus for nitrous oxide, with a lever pedal for regulating the valve . . . . .	205
---	-----

A two-bottle apparatus for nitrous oxide, with a screw pedal for regulating the valve . . . . .	205
A face-piece of Barth's design . . . . .	206
An ether inhaler of Dr. Ormsby's design . . . .	207
A chloroform inhaler of Dr. Skinner's design . .	209







# NOTES ON DENTAL PRACTICE.

---

## CHAPTER I.

### THE TEMPORARY TEETH.

ALTHOUGH the dentist may not often be called upon to watch professionally the development and eruption of the temporary teeth, or to treat the constitutional disturbances so commonly prevalent while this process is going on, he cannot fail to take an interest in the progress of first dentition, and his skill is, unfortunately, too often urgently needed to alleviate pain in these temporary organs, long before they are removed, by the natural process of absorption, to make room for their permanent successors. It cannot be too strongly impressed upon the mind of the student in dental surgery that the preservation of the milk teeth, and their retention in the mouth, in a healthy condition, if possible, are subjects worthy of his careful attention, and of the greatest importance to the proper development and arrangement of the permanent teeth. And when, as is too often the case, through neglect and inattention, or

as the result of illness, these teeth become a source of pain to the child, the scientific dentist should be able to find some method to relieve the sufferer without resorting to the only treatment which was possible when the blacksmith and the barber were the usual operators.

At about three years of age the child should have all the temporary teeth, ten in each jaw,—Mr. Tomes fixes the average age for the completion of first dentition at forty months,—and it is our duty, as professional men, to teach those who have the charge of children that the mere observation of the fact that twenty teeth have appeared, is not all that is needed. These teeth should be cared for from the first moment of their eruption. The brush must be used for the child until the little one is old enough to be trusted to use it efficiently. The teeth must be watched to see that they are not becoming carious, and in order to give the child the benefit of professional assistance as soon as possible, should any disease appear, and before it should have time to make serious progress. It is an advantage to the child to become accustomed to having the mouth examined; to be made to feel that cleanliness there is as essential as cleanliness of the skin; to establish a habit of attention to the teeth as early as possible; and to have the mind impressed with the idea that such attention is of the greatest importance to health and comfort. It cannot be supposed that a child of two or three years of age is conscious of the necessity of a daily bath and frequent washing of the hands and face, but it



submits to such attentions as a matter of obedience at first, and constant use creates the habit and maintains the practice after mere unreasoning obedience has ceased to be a controlling power; thus bridging over the period between the performance of the act in obedience to authority, and the continuance of the same from a sense of duty consequent upon the development of the reasoning powers.

The daily use of the tooth-brush in the child's mouth prevents decay, at least to a certain extent; but it does much more than this,—it creates a want, a feeling that neglecting to brush the teeth is neglect of personal cleanliness, which feeling, if it is not developed in early childhood, will not be developed at all, or, at any rate, not until it is too late for the teeth to have the advantage of care while they need it most.

If parents themselves are unable to make the needful examination of the child's mouth, the family doctor, or the dentist, should be asked to do it; though I am very decidedly of opinion that the examinations should, at least, be commenced at home, in order that no idea of fear should be associated with the performance of this duty. Children will learn much more readily to take the needful care of their teeth when the parents show a real interest in teaching them to do so; and the parents themselves will learn by experience that it is best to avoid the absurd practice of speaking and acting as though the attentions of the dentist were something to be dreaded and prepared for as if life itself were at stake.



As the child is taught by the tone of home conversation to expect something dreadful, the first work of the dentist is to correct this erroneous impression, and the task will sometimes tax his patience to the utmost limit. Possibly two or three persons will accompany the child on the first visit to the dentist, and all will eagerly unite in well-meant assurances of the harmless intentions of the good man, who only wants to cure baby's pain, mingled with expressions of pity, condolence, and entreaties for brave endurance, the only effect of which is to make the child feel instinctively that some deception is intended, and naturally to increase its terror.

The difficulty is the want of knowledge on the part of the parents as to what their children's teeth need. Most of them associate only one idea with a visit to the dentist, and it is therefore the duty of the latter to teach while he practices; to endeavour to the best of his ability to correct the false ideas of the parent as well as of the child; and to learn gentleness and patience himself, in order to make his teaching the more effective.

If the periodical examinations reveal the commencement of decay in any of the child's teeth, prompt measures must be taken to stop its progress. Sometimes this can be done by cutting away the decay with chisel and file, and sometimes by fillings. A sensible discretion on the part of the dentist will teach him what should be done, and what should be left alone. The time the teeth are to remain, and the extent and probable



progress of the decay, will have to be considered ; and, generally, the operations should be attended with as little pain to the youthful patient as the necessities of the case will permit, and such as will save the teeth as long as nature requires their presence in the mouth.

Simple fillings of some of the preparations of gutta-percha will be effective in all approximal cavities which cannot be cut away with the chisel, and amalgam will serve best in grinding surface cavities.

I have seen gold used for this purpose in temporary teeth, but the practice seems to me something worse than an absurdity. There can be no possible advantage in it. The difficulties in the way of making good gold fillings in the teeth of a child of such tender years must, indeed, render such work less effective than the more simple fillings ; and the operation itself is far too trying for a child, who is too young to see why its endurance should be so exercised ; nor should the operator ever forget the danger of teaching the child to dread a visit to his surgery.

Extraction is rarely necessary as a mere cure for pain, and should never be resorted to when this alone is the object. Probably no one would be satisfied to say that contraction results from extraction of the first teeth, and that *therefore* extraction is an unjustifiable interference with the advancement of the second teeth, for to say this and no more would be to form a very inaccurate idea of what takes place. Nevertheless, there is contraction, for absorption of the alveolus follows

the extraction of the first, as surely as it does that of the second teeth, and I have seen cases where the premature loss of the temporary molars caused so much shrinkage of the gum, that one would almost feel inclined to doubt whether the bicuspid had not also been removed. We know that in such cases the eruption of the bicuspid is often very much delayed, and there can be

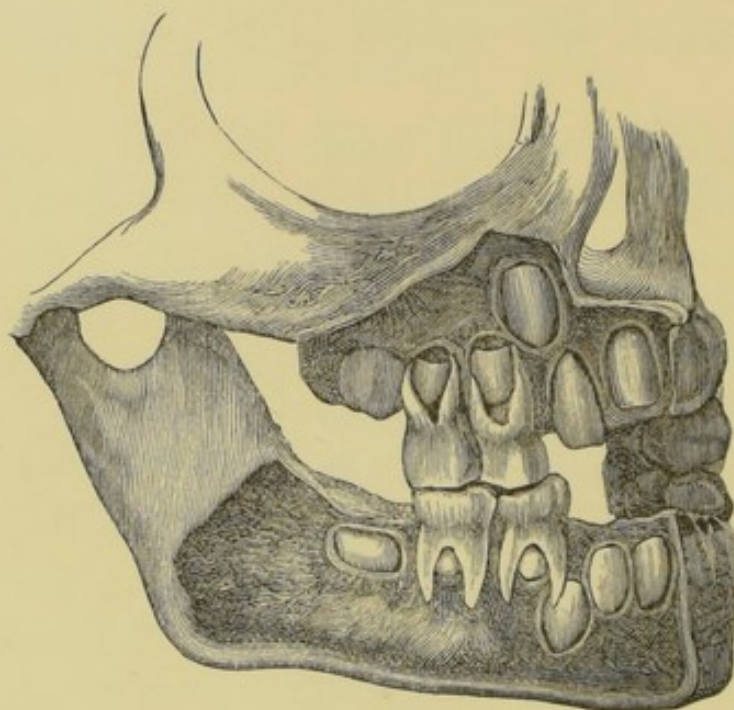
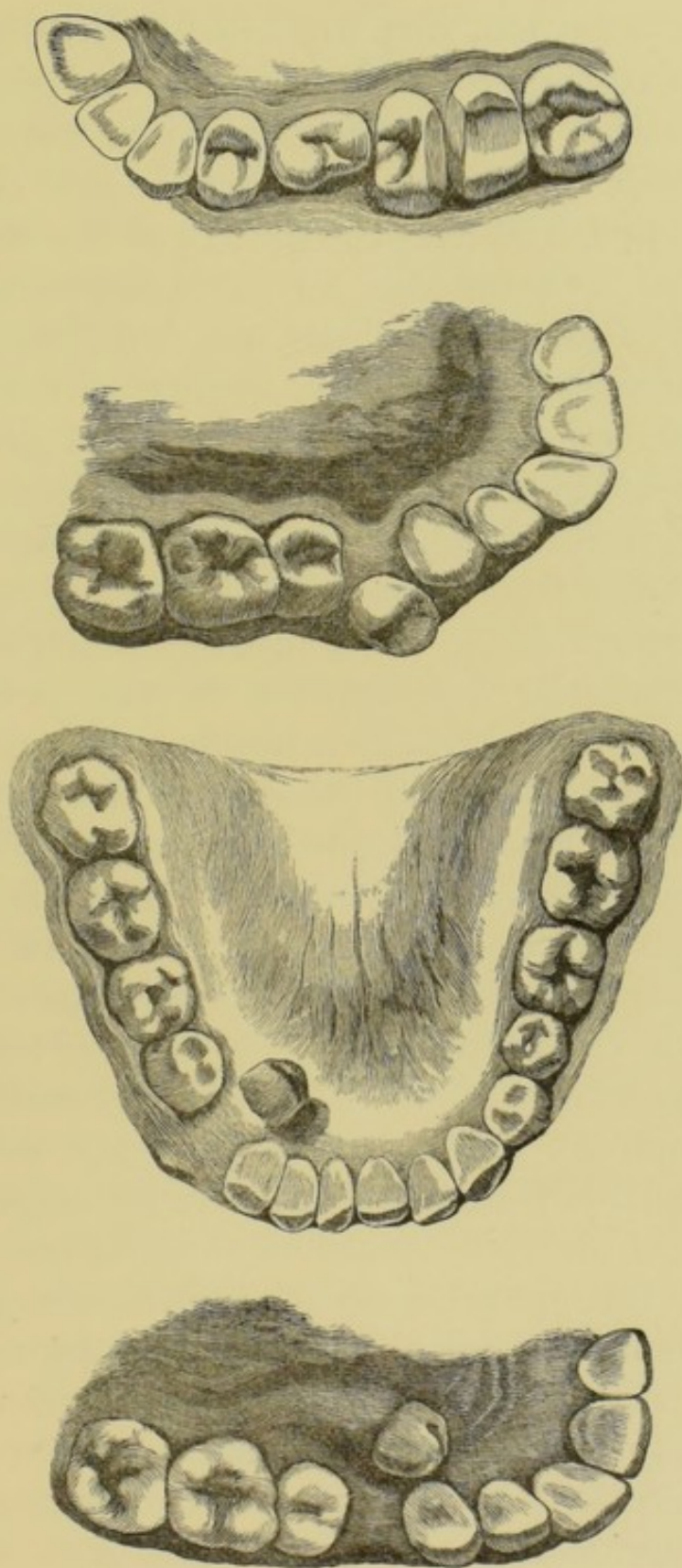


Figure 1.—Showing the partially developed bicuspid between the roots of the temporary molars.

little doubt that the partially developed crown of the bicuspid, lying, as it does, in its crypt, between the spreading roots of the temporary molar—(See Fig. 1)—may often be so displaced or turned in its position in the dental arch, by the wrenching out of the molar, as to cause its final development in some of the malpositions shown in Figs. 2, 3, 4 and 5.





Figures 2, 3, 4 and 5.—Showing the bicuspid in malpositions which may be caused by premature extraction of the temporary molars.

We know, too, that it takes but little pressure at this early age to change the position of a tooth ; that pressure will cause absorption of the alveolus on the side of the tooth opposite to that on which it is applied, and that the growth of the maxillary bones is between the second temporary molar and the tuberosity of the one, and the second temporary molar and the ramus of the other ; therefore we may infer that, as this growth is dependent upon the formation of new teeth in this locality, it would not take place if room were made for the teeth to develop in space already provided. If we extract the second temporary molar in either jaw before the development of the permanent molar is complete, there is nothing to prevent the permanent molar from occupying that space, so far as mere space is needed for the completion of its development ; the second bicuspid is still in an early stage of formation, and is a much smaller tooth than its predecessor, so that it cannot act as a barrier to the molar moving forward ; thus we may regard it as almost a certainty that, if one of the temporary molars should be extracted before the permanent ones are ready to be erupted, the growth of the jaw would be interrupted, and a part of the space reserved for the ten anterior permanent teeth would be occupied by one that should have found space by additional growth.

But there is still another, and, in some respects, a worse result from the premature extraction of the temporary molars. We have just seen that the roots of the temporary molars diverge very much to make room for the development of the bicuspids,



therefore the extraction of a tooth so formed must of necessity be a very painful operation. It is not an uncommon thing for a bicuspid to be so much smaller than the molar that it will not occupy all the space between these wide-spreading roots, and in such a case the roots of the molar may not be equally affected by the process of absorption, so that the bicuspid will be diverted from its position, and we are obliged to extract the molar before one or more of the roots will be completely absorbed; we can then judge how much more painful and difficult the extraction of such a tooth would be when its roots are in perfect development, than the extraction of a permanent molar. Yet a child of tender years is to be subjected to this operation because it is the quickest way to cure a toothache. The inevitable result must be to create, in the mind of the child, that dread of the very name of a dentist which is the greatest stumbling-block in the way of what should be our chief work—the prevention of pain by seasonable operations. It is not reasonable to suppose that a child will come willingly to us, after such an operation, to have something done to a tooth which has been painless hitherto. The dentist cannot be too careful to avoid causing this fear of his work, and although operations may be needful, it is better sometimes to win the confidence of the child, on the occasion of a first visit, by doing nothing, or only some slight operation that will not give pain, than to terrify the young patient by painful work, and thus effectually banish it from the consulting room, until dire extremity of suffering shall force a visit.



One would scarcely say that premature extraction of the temporary teeth is never necessary; but in the course of an extensive practice for nearly forty years, I have never met with a case where I considered it necessary. As I have before remarked, it is far from being an uncommon occurrence to have these small patients brought to us with aching teeth, but I believe these cases may always be treated without resort to extraction.

Toothache is a symptom, not a disease; and it may proceed from a variety of causes, which, however, rarely affect the temporary teeth; so that it will be sufficient for the present to confine our attention to the two most easily recognised causes of this pain, viz., inflammation of the pulp, and of the lining membrane of the socket. When a child is brought to us suffering from toothache, our first enquiries should be to ascertain which of these two causes is responsible for the pain. If it is due to inflammation of the pulp, the pain may not be felt at all in the tooth from which it actually proceeds, but in any of the numerous branches of the fifth nerve, or, even more remotely, through the connections of the fifth with the great sympathetic nerve. More generally, however, the source of pain may be localised to this extent, that if the pain is caused by an inflamed pulp in an upper tooth, it will be felt in some of the branches of the superior maxillary nerve; while if it proceeds from a lower tooth, the sensation is felt in some of the branches of the inferior maxillary nerve. Though this is never absolutely reliable, it is sufficiently so to be of great use in determining the source of



facial pain. If the pain is caused by inflammation of the lining membrane of the socket, there will be little, if any, difficulty in the diagnosis. The tooth is sensitive to pressure in the early stages, and this steadily increases until abscess is developed, when, of course, there cannot be any doubt as to the source of pain. Thus, if there are several decayed teeth on the painful side, a few simple questions will be of great service in helping us to decide which one is the cause of pain. We must not trust too much to the patient when we have reason to suspect an inflamed nerve, for the sufferer is more likely to point out the wrong tooth than the right one. We must rather trust our own judgment in these cases, and, when we are satisfied as to the cause of pain, the treatment is easy.

If there is inflammation and congestion of the socket, a free opening into the pulp cavity will almost invariably give instant relief. Syringing out the cavity with warm water, and, perhaps, if the tooth is not too sore, cutting away the decayed parts, so as to make the cavity self-cleansing, will be all that can be done in a case of this nature. In the majority of cases it is best to defer the cutting and shaping of the cavity until the soreness subsides, which, we may be quite sure, will quickly take place after the putrescent pulp has been removed by the syringing.

When the pain is caused by an inflamed pulp, the course of treatment is different, and we cannot always expect such speedy relief from the suffering. Having satisfied ourselves that inflammation of



the pulp is the cause of pain, we first gently remove, with a sharp excavator, the carious bone which covers the pulp, until we can see the nerve. Quite possibly we may not be able to go so far as this without causing a great deal of pain, but with a sharp instrument it can usually be done, and it is better to do it, if possible, because the patient is less likely to suffer afterwards, if the nerve is fairly uncovered and bleeding; but this should not be insisted on too strongly, as a little pain after leaving the dentist's chair is not so likely to intimidate the patient for the future, as pain that, to the child, seems needlessly inflicted by the operator.

If the nerve is wounded so as to cause a flow of blood from the congested vessels, there will be pain while the blood is flowing, but the nerve will be all the more readily acted upon by the devitalizing dressing which we are about to apply, and if it is anything more than momentary pain, a little carbolic acid on a pledget of cotton, or a bit of amadou, applied to the bleeding surface, will quickly allay the pain. The dressing for destroying the nerve should be a mixture of arsenious acid and sulphate of morphia, in equal parts, and ground in a mortar until it is a perfectly impalpable powder. Four hours' grinding for an ounce of the mixture is not too much, as the action upon the nerve being so much more certain when the mixture is finely triturated, it will well repay the extra trouble; which, however, is not much when we consider that an ounce ought to be sufficient to destroy the nerves of several thousand teeth;



quite as many, possibly, as will be presented for treatment in years of active practice. Arsenic alone is said to cause great pain, which morphia is used to prevent. The latter certainly reduces the strength of the arsenic by one-half, and as I have been satisfied with the action of the mixture in this form, I have never been tempted to try a change of proportions. The best method of using it, according to my experience, is to roll up tightly in the fingers a pledget of cotton about the size of an ordinary pin's head; moisten this with carbolic acid, but not to saturation, and then gently touching the pledget to some of the powder, a sufficient quantity will be taken up to serve the purpose; it should be placed directly on the nerve, and covered up with a larger pledget of cotton, sufficient to fill the cavity, and some stiff sandarac varnish mingled with the fibre. This will effectually prevent the escape of any of the arsenic, even if the dressing is left for a week in the tooth; but great care must be taken in all cases, and especially in approximal or buccal cavities near the gum, to avoid leaving even the most minute quantity of the powder on the gum, and to prevent its escape from the cavity after it is placed in position, as death of the part and sloughing will inevitably result from such clumsy manipulation. The use of such powerful drugs is only safe when neatness and carefulness are instinctive with the operator; but clumsiness ought never to be associated with the practice of dentistry. On grinding surfaces, where the edges are broken down so that there is very little depth of cavity, it is sometimes



better to cover the arsenical dressing with plaster of Paris, as this will adhere to the dentine better than the sandarac. The plaster should be mixed with hot water, and a few fibres of cotton may be mingled with it to give it more strength. If the dressing is quite secure in the tooth, it cannot do any harm to let it remain for a week; but if it is not very secure, owing to the form of the cavity, it may be removed in twelve or twenty-four hours. In any case, however, the tooth should be seen again in about a week or ten days, and then the pulp cavity should be thoroughly laid open, and all broken rough edges of the tooth cut away in order to facilitate cleanliness, and prevent, as much as possible, the lodgment of food, for the tooth must be left without a stopping. It cannot be treated as we should treat those of a later period, by removing the pulp and filling the roots, unless we are quite sure that there has not been any absorption of the roots to widen the apical foramina, and thus render a tight filling impossible. Mr. Tomes tells us that the roots of some of these teeth are not fully developed until the child is four and a half years of age; we may therefore be quite sure that the period of time between perfect formation and the commencement of absorption is very limited, so that, practically, we may say it does not exist for the success of this operation. It is better, therefore, to leave the tooth without a filling, but so shaped that lodgments of food may be easily removed, and the neighbouring teeth suffer no injury. What remains of the pulp will, of course, pass through



the stages of putrescence and sloughing, but if the gases have free escape into the oral cavity, there will be very slight risk of their causing what may be called secondary toothache, or inflammation of the lining membrane of the socket, which is simply a result of the poisonous action of the gases generated by decomposition of the pulp in a cavity which has no outlet except the apical foramen. We may be very sure that, if the pulp cavity is well opened, and kept open, these gases will escape harmlessly by the larger opening, rather than by the smaller one at the end of the root.

I am perfectly well aware that, to some of the members of our profession, who would probably call themselves purists if they could choose a distinctive designation for themselves, this treatment of pulps may seem dreadfully heterodox, but I should be glad to hear of one well-authenticated case where the pulp of a temporary tooth in the mouth of a child under six years of age has been capped and preserved alive, or where the nerve has been removed and the roots filled so as to prevent alveolar abscess. And if abscess does occur, what is to be done? It is absurd to talk of taking root fillings out of a tooth that is painful from this cause, when the patient is not old enough to fully appreciate the advantage of retaining a valuable tooth, knowing, as we all probably do, how extremely difficult it is to remove root fillings, under similar circumstances, from adult teeth. It is quite as much as we can do to persuade a child suffering from abscess to allow us to open the pulp



cavity and syringe it out, although we know that, in such cases, relief from pain follows so quickly that we can be quite sure of sending the little patient away happy and comfortable; but if the roots were filled, there would be very little chance of relief to the sufferer until the abscess had run its course, or the tooth had been removed. It is a choice of evils, but I maintain that less harm will be done by leaving such a tooth in the mouth, and, of course, keeping it clean, than will be done by extracting it, although it is an established fact that there is little, if any, further absorption of the roots of these teeth after the death of the pulp. When the roots are finally extracted they never show any traces of recent absorption; there is no appearance resembling the absorbent organ—nothing different from what we should see if the dead root of a permanent tooth were left in the mouth. I have never seen a case where such treatment was successfully carried out, but, supposing it to be possible for the root canals of temporary teeth to be filled satisfactorily, so far as the prevention of abscess is concerned, and the crowns preserved, it would be interesting to observe how far such treatment would prove obstructive to the progress of the permanent teeth. I do not see why it should not delay the eruption of the bicuspid for years even, always supposing the filling operation to continue to work successfully. It is a practical certainty that no absorption of the roots of a tooth so treated could take place; and the crown remaining intact, the roots could not be separated and pushed aside by



the advancing tooth, so it would seem that all progress must be blocked. On the other hand, if the temporary tooth has remained perfectly healthy, we shall almost always find the roots completely absorbed, and the absorbent organ occupying the place of what was the pulp. It may be argued that, if this is the case, it must be better to extract than to leave roots which will be obstructive in their relation to the permanent tooth. But I contend that we do not leave an obstruction in the way of the permanent tooth. After the death of the pulp and the opening of the pulp-cavity, the remainder of the crown of the tooth will rapidly disappear, and practically, even when the operation does not take place earlier than the eighth year, there will be nothing but the roots left to be displaced by the advancing tooth; and these do not prove to be an obstruction, for they are simply pushed aside, and the new tooth comes into its right position almost, if not quite, as quickly as it would have done if its predecessor had been perfectly healthy. They have also served a purpose in assisting mastication as long as anything remained of them. The worst possible thing to do is to extract them before all possible usefulness of any kind is over, and experience proves that such premature extraction causes delay, if not displacement, of the permanent teeth.

It will often happen that a child will not be taken to the dentist, although really suffering from primary toothache, because the parents are not aware of the cause of the pain. The child



does not feel the pain in a tooth, but rather in the temple, or in the ear. It is well enough all day, perhaps, and takes its food as usual, but cries with pain all night from genuine toothache, although, perhaps, there may be no disagreeable sensation in the tooth which causes the pain.

The pulp will not, however, long survive a condition of acute inflammation, and with its death the pain disappears and is forgotten. But there is left in the tooth a mass of soft tissues, which were lately nerve and blood-vessels, and these having died a natural death, will in time become putrid. It is not necessary to enter into any discussion of the nature of putrescence here, for our business is not so much with cause as with effect and treatment; and many able and practised hands are now engaged in investigations which must throw much light upon such pathological subjects as the agency of bacteria in the origin and development of alveolar abscess. But we know that the pulp of a tooth, which is so shut up in the tooth that the gases generated by decomposition have no vent except through the apical foramina, so that it would appear as though putrescence could not be the effect of external causes, may and does become putrid, and generates poisonous gases which, having no direct means of escape into the oral cavity through the only partially disintegrated dentine, that is yet sufficiently decayed to have affected and caused the death of the pulp, will find their way through the foramen by which, while the vessels were in health, the blood found access to the tooth,



and will so poison the surrounding tissues that inflammation, and perhaps abscess, will result. This is what I have called secondary toothache, and it is what the sufferer never mistakes for anything but toothache, and can always localise without any hesitation, because the pain is directly intensified by pressure on the tooth, so that, in these cases, the patient's judgment is of great use in helping the dentist to decide where his skill is needed to relieve pain.

The treatment of this form of toothache may have been sufficiently indicated in the previous pages, but it deserves special and definite mention. It is simply the free opening of the pulp cavity, the removal of all putrescent matter, for which purpose fine barbed instruments, that will reach well into the roots, will be required; syringing with warm water, to which a five per cent. proportion of carbolic acid may be added; and, when it can be done without risk to the adjacent parts, a drop of the acid of full officinal strength may be left in the tooth. But this is only possible in lower teeth, because there must not be any stopping inserted, not even of cotton, at this stage of the treatment, to prevent the free escape of gases or pus through the pulp canals. The relief from pain will be almost instantaneous;\* a certain amount of soreness

\* This well-known fact seems rather inconsistent with the theory that bacteria, originating in the mouth, are the primary cause of putrescence of the tooth pulp, and consequent local poisoning, which we treat as periostitis and alveolar abscess.



will remain, but the intensity of the suffering will be gone, as if by magic, and the soreness will disappear as surely, though more gradually; and we may with confidence make an appointment for the child to be brought back to us in three or four days, when the tooth will bear pressure without giving pain. We should then so shape what remains of the tooth, that it can be easily kept clean, and we should endeavour to impress

The question may be stated thus: If these germs have found their way to the tooth pulp through the dental tubuli, and by their life and death actions in these soft tissues have set up all the agonizing pains, which we are called upon to treat as the result of putrescence, why should the throwing wide open of the facilities for ingress and egress give instantaneous relief in so many cases? On the other hand, we appear to confirm the theory to its fullest extent when we open a tooth which contains a dead pulp, but which has never, so far as can be learned, caused any pain or discomfort whatever; and yet, with every possible care exercised in using clean instruments, and efforts to avoid the pushing of any septic matter through the apical foramen, we find an amount of local and even constitutional disturbance set up, which is startling to see and stubborn to encounter. Fortunately, such cases are few in number, while the other class of cases may be described by the word legions. But to my mind it is not yet satisfactorily proven that these germs are the primary cause either of caries, or of putrescence, but rather a result, becoming a secondary cause, and assisting and carrying on a work which had already begun before their entrance upon the scene.



upon the minds of those in charge of the child the necessity of cleanliness, if they would avoid a repetition of the suffering.

Irregularity in the position or occlusion of the temporary teeth is not of sufficient importance to justify interference, unless it is caused by the infantile habit of sucking the thumb, the fingers, the lip, or the tongue—practices which, if persevered in, as they undoubtedly are by some children, even after the temporary teeth have all disappeared, may be the cause of serious displacement of the permanent teeth, with malformation of the jaws. Some of the most troublesome irregularities we have to treat are traceable to this habit of sucking, and the dentist should, in all cases that come under his observation, see how the teeth close, and, if there is any fault in this respect, it should be pointed out to the parents, and the necessity for breaking up a habit so liable to cause disfigurement should be strongly urged.

It will be seen at once that the weight of the hand, when the thumb is constantly in the child's mouth, will have the effect of shortening the lower jaw and elongating the upper. The lower front teeth will have an inward inclination, showing a straight or even concave line from one canine to the other, while the upper teeth will project over the lower lip.

Fig. 6 is a remarkably good illustration of the effect of this habit, which, in this case, was continued until the child was twelve years of age. Two of the lower bicuspid, as will be seen, have



been extracted by some one who probably thought he had a reason for such treatment ; but I cannot

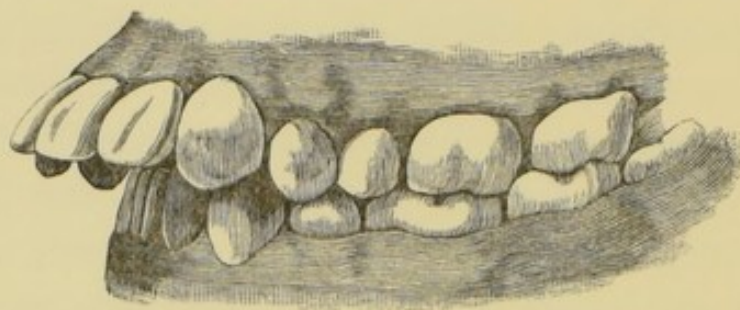


Figure 6.—Showing how thumb-sucking may affect the arrangement of the front teeth.

believe that they were so much out of place that they could not have been pressed into position, which would certainly have been better than removing them, as the effect of forcing them into their proper place must, of necessity, lengthen the lower jaw to something nearer what it should be. Like many other cases, this is one where more thought for the future of the mouth, and a little more trouble in regulating the teeth, instead of extracting those which may be out of place, would be much more creditable to us as professional men.

Sucking the fingers will have a different effect upon the development of the mouth. There is no leverage upon the upper teeth, but the weight of the hand acts directly to elongate the lower maxillary, causing what is usually described as an "under-hung jaw." Fig. 7 is an example of this.

Sucking the lower lip produces a result somewhat similar to that caused by thumb-sucking, and sucking the tongue may seriously displace the

canine and bicuspid of one side of the mouth, as the child will usually turn the tongue to one side

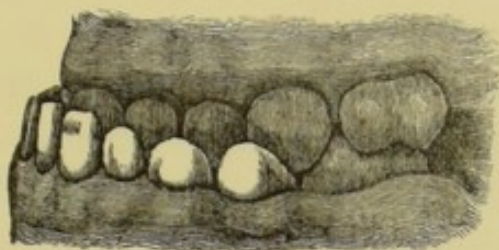


Figure 7.—Showing the effect that may be produced upon the lower jaw by sucking the fingers.

or the other, and always to the same side. Fig. 8 represents the worst case I have ever seen of the effect of sucking the tongue. The boy was eight years of age when I first saw him. His intellectual development was below the average, but he was very teachable, and seemed quite to understand the remarks I made about the condition of his mouth. The habit of sucking his tongue had

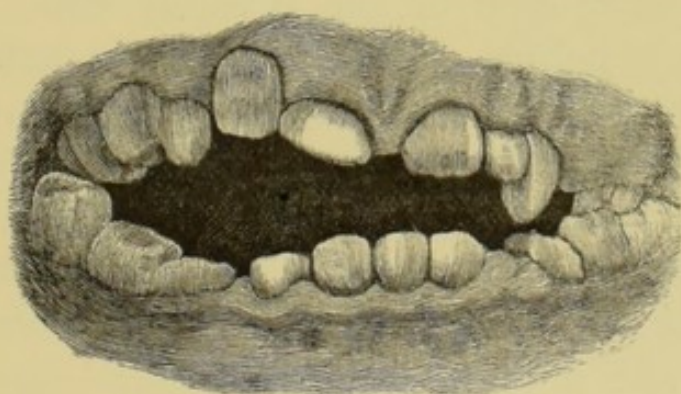


Figure 8.—Showing the effect of sucking the tongue.

been observed, but no one ever thought that any ill effects would result from it; and no one had noticed that he could not make his front teeth meet until I pointed it out to the parents. The



lower teeth on the right side were completely hidden by a mass of tartar, but there was no dribbling of saliva, and the lips met without much effort.

An attempt was made to correct the deformity by the use of a strong elastic strap on each side of the face, attached to a well-fitting chin-piece and to a sort of skull-cap, consisting of a fillet, with bands over the top of the head, from front to back and from side to side, an arrangement much better than a close cap. The apparatus was working well, and the upper and lower front teeth were nearly meeting, when a severe illness put a stop to the treatment, and, as the boy had to be sent to a milder climate when he was well enough to be moved, the treatment was necessarily abandoned.

Nurses will sometimes teach children to suck the thumb to keep them quiet. Of course it is done in ignorance of the possible effect, which they are generally very unwilling to believe in, even after the malformation has become apparent to every one, preferring to assign any other reason than the real one for the disfigurement of the child's mouth, and, perhaps, never suspecting the true cause, as the change in the form of the jaw is gradual, and it may be three or four years before it becomes so serious as I have described. It is another point on which the public need more information, although, doubtless, many a lip will curl in derision at the suggestion that any more knowledge is requisite on the subject of the management of babies. Sucking the thumb or

the fingers may be easily cured by putting the hand into a thumbless mitten, which should be sewed into the sleeve of the frock and the night-gown, so that the thumb and fingers will be inseparable and sucking impossible. Half measures will be of no use; it must be made literally impossible until the habit is forgotten. Sucking the lip or tongue is much more difficult to cure, and possibly the treatment may have to be deferred until the child is old enough to wear a plate that is made to cover the whole of the lower teeth, and keep the mouth so much open as to make sucking an impossibility.

Beyond the curing of the habit, I do not think it is well to attempt any treatment of these cases until the child is older, and has parted with all or nearly all of the temporary teeth.



## CHAPTER II.

## THE PERMANENT TEETH.

WHEN the child is about six years of age, if a boy, or five and a half, if a girl, we may begin to look for the first permanent molars; and these must be watched most carefully, for there are no other teeth in the mouth so liable to be defective. Probably the period of their formation, beginning in the first month of infancy, and extending through all the trials and illnesses of first dentition, has much to do with the defective structure of these teeth; but whether this is so or not, the fact remains that not ten per cent. of them, in the mouths of the middle and upper classes, are perfectly formed teeth. The chief defects are in the sulci, between the cusps. All the other teeth that have a grinding surface of cusps and sulci are later in development, and they certainly average better than the first molars, which is a fairly good reason for thinking that their defective nature is partly owing to the period of formation. There is often a want of perfect union in the formation of enamel in the sulci, and as every fissure that will admit the secretions to contact with the dentine will prove to be a weak spot and probable starting-point for caries, it is evident



that these weak spots should be sought for as soon as the grinding surface of the tooth has emerged from the gum, and a very little care in filling the fissures at this early period may save a great deal of pain and trouble later on.

Few parents are aware of the nature of these teeth, and it is therefore the duty of the dentist to instruct them when to look for these pioneers of the permanent denture, and of the importance also of looking after their condition. Popular information on these subjects is greatly needed, and should have a much larger space in the public papers than is conceded to it at present.\*

Every practitioner is aware of the frequency with which children suffering from pain in their six-year molars are brought to us, and of the frightfully broken down and hopeless state in which we find them on such occasions; and surely it is not charlatanism to try to increase the knowledge of those who have the care of children, in order to prevent such a condition of things. If one wrote so that it was evidently his object to direct attention to himself as the fountain of knowledge, an accusation of that nature might well be laid at his door; but there is no doubt that a sensitive shrinking from this charge is the chief cause of the want of popular literature on this subject, and of the absurd nonsense that

\* The best epitome of the causes of tooth deterioration that I have ever seen is contained in the address read by Mr. Smith Turner, on the occasion of his taking the presidential chair at the meeting of the British Dental Association in London, August, 1891, and printed in the *Journal of the Association* for September of the same year. His remarks go straight to the root of the whole matter, without any of the vague, and often improbable, theories one sometimes hears on such occasions, but are thoughtful, and full of common sense and good judgment.



we sometimes see in the public prints from lay sources.

If, however, the parents err from ignorance, they are not so much to blame; but if the dentist, who has knowledge at his command, if not in his possession, commits the, I am sorry to say, common error of extracting these teeth, merely to relieve pain, without a thought of the future of the mouth, what can be said of him? If it was important to retain the temporary molars in order to insure the proper lengthening of the jaw to make room for the permanent molars, there is still greater necessity for the preservation of the latter, inasmuch as they in their turn are necessary for the proper growth of the jaw to make room for the second permanent, or twelve-year molars. They also serve an important function in lengthening the rami, for as they are in every respect larger and longer teeth than the temporary molars, they must have more room for this additional length. Therefore the ramus must lengthen out to give the required space, and it is certain that this growth only keeps pace with the growth of the roots of the six-year molars, which are rarely complete before the ninth or tenth year. It is therefore very desirable not only to keep these teeth, but also to keep them healthy, to keep their pulps alive; and as such young teeth go very rapidly when they begin to decay, they should be examined often, every three or four months, and every cavity be filled, if possible, before it becomes a source of danger to the vitality of the tooth.



The material best suited for filling these and any other permanent teeth which may decay previous to or during the constitutional changes at puberty, is, without doubt, a preparation of gutta-percha. I am quite sure that whatever may be said of gold as a material for filling teeth after the sixteenth year—and I will say here that I believe there is no other material to be compared to it for teeth which are old enough and dense enough to stand it—it is not fit to be used in a tenth part of the teeth that one has to treat for patients who have not attained that number of years. Gutta-percha will preserve the teeth at this early age, and gold may do so, but I believe that more harm than good is generally done by using the latter too early. It is better in the grinding surface of molar teeth, such as we are now treating of, than in any other cavities at this time of life; but I say it does harm, because it subjects the patient to a needless amount of suffering in preparing the cavities and inserting the fillings, and thus keeps alive the dread of the dentist's chair, and prevents the frequent examinations that are so necessary; and again, because in using a material of this nature we convey an impression that we expect it to be a perfect safeguard against further decay. Every man of experience in our profession may judge for himself whether this impression will be justified by the result. I do not, by any means, intend to imply that all gold fillings will fail. I have some in my own mouth that have protected the teeth for more than forty years; but I was past the age of sixteen



when the first filling was made. What I do mean to say is, that a large percentage of gold fillings, made in the teeth of patients under sixteen years of age, do and will constantly fail, and will have to be renewed, and that it would be better to tell the parents plainly that the work is only meant to save the teeth from further decay until the child is old enough to have them properly filled. If the cavities are large, the gutta-percha should be protected on a grinding surface, as it is liable to be rapidly worn away. This may be done by using the porcelain caps prepared for this purpose, or by making a cap of thin gold-plate, swaged to correspond to the surface it is to replace, and a loop or stud soldered to the under side to retain it in position. A quantity of these may be prepared of different sizes and shapes, but if one is not readily found to fit the cavity, it may easily be cut and trimmed to the required form. Some gutta-percha should be pressed into the loop, or around the stud, and then, when the tooth is filled, and before the filling gets hard, the cap may be well warmed over the lamp and carefully pressed into its place. A filling of this character is a perfect protection to the tooth, and the tooth is very comfortable at once, which is not always the case when the filling is wholly metallic, for metal is a quick conductor, and in contact with the sensitive surface of a tooth it may for weeks make the patient painfully conscious of thermal changes.


I have been using these gold caps for years, and have even described them in a paper read



before the Odontological Society of New York, in 1881, as an idea of my own, and it was a surprise to me, on looking over an old report of a meeting of the Pennsylvania Association of Dental Surgeons, in March, 1877, to find a full description, with illustrations, of the same thing, by Dr. Charles Essig, of Philadelphia. I can only say that I did not intend to claim another man's ideas as my own, and as Dr. Essig carries out the idea more perfectly than I have done, I will take the liberty of copying the illustrations, with his remarks, as reported in the *Dental Cosmos*, vol. xix., p. 314.

“Professor Charles Essig presented some models of very badly decayed teeth, which, he said, he had treated according to the plan, or idea, proposed by Dr. Bing, of Paris, France. Instead, however, of using a simple plate, or disk, with loops soldered to the under surface of the plate, as proposed by Dr. Bing, he proceeded as follows:—The contour of the tooth was restored in wax, after which an impression in plaster was taken, from which a model was made, and from this a die and matrix. With these plates were swaged, covering the defective parts of the teeth to be treated or filled, and on the inner surface of these plates loops of gold, or platina wire, were soldered. Gutta-percha, or Hill's stopping, was now softened and carefully packed on these plates and through the loops, and the tooth was likewise filled with gutta-percha. The plates were now put in the mouth over the teeth they were intended to cover, and by means of a heated



instrument the gutta-percha in the tooth and on the plate was softened and united, and the edges of the plate burnished down to the remains of the tooth. When finished, the operation presented the appearance of a well-executed and laborious gold filling. Dr. Essig stated that the material, Hill's stopping, was well known as most excellent for the preservation of the teeth, cases having been brought to his attention where it had effectually done this for fifteen years, in localities not subjected to the attrition of mastication. The object of these gold caps was to overcome this liability to wear in the material. The plates were of pure gold (made from scraps of gold foil), which was milled down to number 29 of the standard gauge. Dr. Essig laid no claim to originality in this matter, according the idea entirely to Dr. Bing. The only point of difference in what he now proposed was the attempt at restoration of contour, which Dr. Bing did not resort to, so far as he was informed. For the better understanding of the two methods, Dr. Essig illustrated both plans on the blackboard. Dr. Bing's plan was to dress down the crown of the tooth; the entire cavity of decay was now filled with Hill's stopping, and a pure gold plate, to which two loops of gold or platina were soldered (thus ) , was warmed, and while warm was pressed into the gutta-percha already inserted into the tooth, after the cooling of which the edges of the gold could be neatly burnished down to the edges of the tooth. By this plan *only simple crown cavities* were attempted. Dr. Bing kept on hand, ready



made for these cases, thin plates of different sizes, and applied them in size to suit each case. Dr. Essig had acted on the suggestion, but proposed to extend the field of its usefulness in cases where proximate, buccal, or palatal walls were consumed by decay. He proposed to restore the tooth in shape as well as usefulness as follows:—cutting down the tooth wherever a comparatively firm border could be obtained, he restored the contour in wax, and, by allowing the patient to bite into it, obtained from the antagonizing tooth a complete and proper occlusion. By this plan teeth in almost any stage of decay might be made serviceable for a considerable time. The idea will be better understood by the following diagrams. (Figs. 9 and 10.) The case illustrated (*a*) was

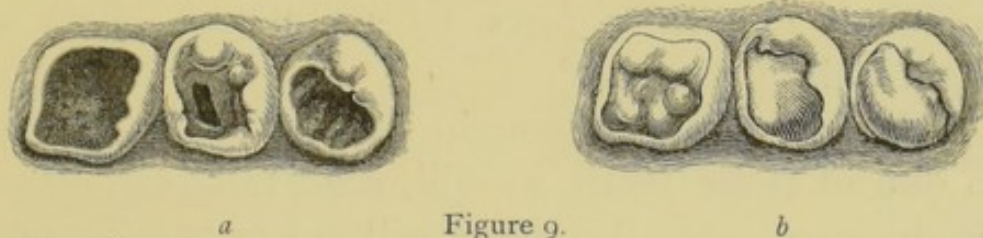


Figure 9.

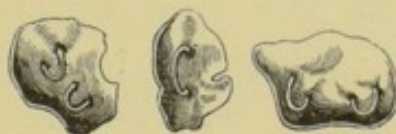

Figure 10.

now restored in wax as in (*b*); when, as stated, an impression in plaster would be taken, plaster model made, and die and counter-die obtained; a gold cap could now be swaged, and loops soldered to it, as represented in Fig. 10. The body of this gold cap is filled with softened Hill's stopping, as



well as the remains of the tooth. The cap is placed in position, and with a heated instrument the temperature is conveyed through the gold cap to the gutta-percha in both tooth and cap. The jaws may now be closed while the gutta-percha is soft, and when cooled off, the excess of Hill's stopping removed, and the edges of the gold burnished down to the tooth. To a cursory glance the whole operation presents the appearance of an artistically executed contour gold filling. These dies and plates may all be made by assistants in the laboratory, and the entire operation may not call for more than fifteen to thirty minutes of the operator's time. Dr. Essig gave the preference to Hill's stopping over oxy-chloride of zinc in these frail teeth, as he said he had found that, when large masses of the latter were used, it had sufficient expansive force to sometimes break a weak wall of enamel."

When a child is brought to us with toothache in one of these teeth, as will, unfortunately, often be the case—for all parents will not remember our teaching, or take the care which we have told them would be necessary to prevent pain—we must first ascertain whether it is primary or secondary toothache, as in the case of the temporary teeth, page 10, and then proceed to devitalize the pulp, or to open the pulp cavity and give vent to the gases or pus, as the case may require. But as this is a permanent tooth, we must try to preserve it, at least until the jaw is sufficiently grown to make room for the eruption of the twelve-year molar.



If devitalization is necessary—and we must be quite sure that it is necessary, from satisfaction of our own judgment, more than from the patient's convictions or statements—it will be best to remove the arsenical dressings within a week, and then, after cleansing the cavity, and making a sufficient opening into the pulp cavity to permit the free escape of gases, a simple dressing of cotton and stiff sandarac varnish may be placed in the tooth, to remain about a month, or until the pulp has separated, by sloughing, from its connections at the apical foramen. Then, after carefully removing all decomposing matter with fine barbed instruments, and syringing with a five per cent. solution of carbolic acid—or any other antiseptic that can be used in sufficiently weak dilution to retain its antiseptic qualities, without so much of the escharotic nature as to be unpleasant in the mouth—the roots may be filled. There are many ways of doing this,—some dentists insisting that gold is the only safe material for filling roots; some would have this used in the form of wire and screwed in; while others can only be satisfied with soft foil, malleted in; some prefer tin, some gutta-percha, others oxy-chloride, and others again prefer amalgam. Most operators enlarge the pulp canal very much in order to facilitate the process of filling, and, perhaps naturally enough, every operator thinks his own method the best, if not the only method of performing the operation; but all that is really wanted is to occupy the space, so as to exclude everything that is liable to decomposition. A



root-filling is not exposed to the action of the oral fluids, nor to attrition; therefore it cannot be necessary to expend so much labour as will be required to pack gold, or tin, into a long narrow canal. Oxy-chloride of zinc does very well indeed, but to ensure success with it, a few fibres of cotton must be used to carry the cement to the apex of the root. The same may be said of a solution of gutta-percha; but it is a question whether cotton alone, properly packed into a dry root, will not be as effective as anything else for this purpose, and, if the fibre carries with it a little sandarac varnish, I am quite sure it will make as perfect and durable a filling as can be necessary. The root may be dried with a thin twist of bibulous paper; then, as one can never be quite sure that no particle of the nerve is left, or that there is no leakage of lymph, or blood, into the end of the root before it is possible to pack a filling to occupy the space, it is best to moisten a few fibres of cotton with carbolic acid, and to pack these carefully to the apex of the root, taking up any surplus acid with another twist of paper; then a few more fibres of clean cotton, and more and more until the root is filled. I think in the case of very young patients it is best to use cotton alone, because it is desirable to be as expeditious as possible, and because, a little later, it is likely enough that it may be advisable to extract the four first molars to give more space to the rest of the teeth. If this is not found desirable, we shall want to use a filling of a more permanent nature in the crown cavity than we should insert now, and it may be just as well that



the root-filling should be removable. After treating all the roots in this way, the crown cavity may be filled with gutta-percha, with or without a gold or porcelain cap, as may seem desirable; or with amalgam; but if the latter material is used, it is best to half fill the cavity with gutta-percha and cover it with amalgam. In the majority of cases the tooth will be comfortable and useful; but it must be borne in mind that no one can be sure of permanent comfort in a dead tooth, because, with every precaution, a failure is always possible, and especially is this the case with these teeth while the jaw is still growing to make room for the twelve-year molars. It may be that the more active vascularity necessary for growth is less tolerant of the half-dead substance of dentine than is the case later, when growth has ceased; but it is certain that, from some cause, failures are more frequent in the treatment of these than of pulpless teeth in the adult mouth.

The term dead tooth is in common use, but it conveys a wrong impression; for if a tooth were absolutely dead, it could not be tolerated in the mouth; but when the pulp has been extirpated, the tooth receives the necessary sustenance through the peri-dental membrane, and is thus kept in a tolerably comfortable condition. This membrane, however, sometimes resents the increased labour which is thus thrown upon its vessels, and a slight soreness is common enough in such teeth, when, from any cause, the strength of the patient is below par, as from a cold, or over-work, mental or physical. Soreness of this



nature almost invariably follows the extirpation of the nerve within a few weeks, but is usually quite controllable by the application of a counter-irritant to the external surface of the gum. Tincture of pellitory (*Pyrethrum anacyclus*) is peculiarly valuable in these cases, used on the finger for rubbing the gum, or, in more urgent cases, on a piece of lint laid upon the gum, but it must be observed that the lint should be only moistened, not saturated.

If the toothache is caused by the presence of a putrescent pulp in the tooth, it is best to simply open the pulp cavity, syringe with warm water, and tell the patient to come again in three or four days, by which time we can probably open the tooth into the roots, remove all the putrid matter, and give the roots an antiseptic dressing. This treatment will have to be renewed several times, with thorough syringing, until the roots are quite clean and free from any fetid smell, when they may be filled. But if the pulp dies before the child is nine years old, there may be a difficulty in treating the roots, because the foramina are



Figure 11.—Showing roots of bicuspid and molar teeth not fully developed, the foramina being very large.

larger than the canals, as described in the chapter on temporary teeth; but in this case it will be owing to incomplete formation. (Fig. 11.) The age is not, however, a reliable criterion. We



must test with a probe, and if we find the canal widening towards the apex, we may as well treat it as described in the case of the temporary tooth (page 15), and try to keep the roots, at least until the twelve-year molars appear, for there will be no further development of roots after the death of the pulp, and if incomplete then, they will remain so.

As soon as the first permanent molars are fairly through the gum, we may begin to look for the lower central incisors. We often see them sooner, sometimes before any of the molars appear, but it is not in regular order. These teeth are a great source of anxiety to parents, because they are so often, apparently, out of place. I say apparently, because it really seems so to one who is not accustomed to watch the progress of second dentition; but it is only in appearance, for the teeth may be far inside the dental arch without any real cause for anxiety about them, and without any need of professional aid, other than the extracting of the two temporary centrals, if they have not already come out with a little home assistance.

It is a matter of almost daily occurrence for children to be brought to us with these teeth making their appearance more or less inside the arch, or slightly turned in a diagonal position, and probably the cutting edges serrated. The parents are anxious that we should do something at once to remedy these deformities, as they consider them; usually, however, the dentist's assurance that the teeth will move forward to their proper place as soon as the jaw has grown



sufficiently to make room for two teeth which are half as large again as the two which have occupied that position, and that the serrations are perfectly normal, and will wear away as soon as the teeth come into use, will satisfy them. But whether they are satisfied or not, nothing will justify the dentist in yielding to the desire to have something done at once, and extract four teeth to make room for two, or a central and a lateral to make room for a central. We should never extract more than the precise number we wish to make room for, and leave the rest until the appearance of more new teeth shows the necessity for further extraction. If the new central is very far inside the arch, we may find that there has been very little absorption of the root of the temporary central, but it must be removed nevertheless, and it will be enough to do this. Nothing more will be needed, although the tooth may seem much wider than the space it has to occupy. I have seen several cases where the permanent central appeared almost directly behind the temporary lateral, but it may be taken for granted that it is a central out of place, and extraction of the temporary central will almost certainly make it right. There is always an appearance of justification for the operator who thinks it right to get these teeth quickly into place by extracting more than the proper number, for a satisfactory result is quickly visible to the parent. I have often seen the four incisors occupying the position of the temporary incisors and canines, and certainly they looked very nice; and I have no doubt that the dentist who extracted the six



teeth to make room for four thought himself, and was thought by the parents, to be a clever fellow to have straightened a set of irregular teeth so quickly; but the error will be obvious two or three years later, when the permanent canines appear. The first and second bicuspid may be expected before the canine, and the distal surface of the lateral incisor and the mesial surface of the first bicuspid will be in close contact before the canine appears. The latter tooth is generally developed somewhat outside the arch, but in this case it might be a supernumerary tooth, for there is absolutely no room for it, and the cause of this is plainly and unmistakably the extraction of six teeth to make room for four. The incisors, if left to work their own way, would have been pushed forward by the pressure of the tongue, until they made room for themselves, with the temporary canines still in position; but the extractions simply stopped the growth of the jaw, because there was no longer any occasion for expansion, as the necessary space had been provided by *professional* interference.

The upper centrals are the next in order, and they, too, are a source of anxiety to the fond mother, who naturally wishes her child to have pretty and regular teeth. They are so large, or they overlap, or they are not quite straight—would it not be best to take out the little tooth which seems to make the new one stand out so at that side? How often we hear such suggestions, and how trite, to us, seems the reply that there is no cause for anxiety; that the tooth which seems so



large now will not appear so out of proportion when the face has grown more mature; that having so much more breadth than the baby teeth, they cannot stand quite in the same position the others occupied. This desire to have something done at once to hasten nature's work is a temptation which is often unconsciously held out to the young practitioner; and how many have yielded to it, not always for the mere fee, but to secure a patient, or from a want of confidence in their own judgment, a wish to oblige, or perhaps from ignorance of the right treatment. It has been a fault of teachers in our profession that they have told us too little about how and when nature should be assisted, and when left to herself in the management of the mouth, while second dentition is going on. The pupil is taught to read, and then he is at once passed on to classics and mathematics. The text-books tell him all about the origin and development of the teeth, and the minute anatomy and relation of all the surrounding tissues, and then go on to tell him how the teeth should be treated at maturity. So the young man begins a practice with the idea that he is a dentist, when he knows how many teeth should be in the mouth at a given age, and how to make a gold filling. The hiatus that is left in his training must be filled up by the teachings of his own experience, and, naturally, he makes some mistakes.

The same rule that applies to the lower teeth should be the guide in relation to extracting for the upper incisors, viz., not to extract more than



the precise number we wish to make room for. We must let nature do her own work as far as possible, giving her only such aid as is imperatively demanded. But if we find an upper incisor closing inside the lower arch—(Fig. 12)—we may

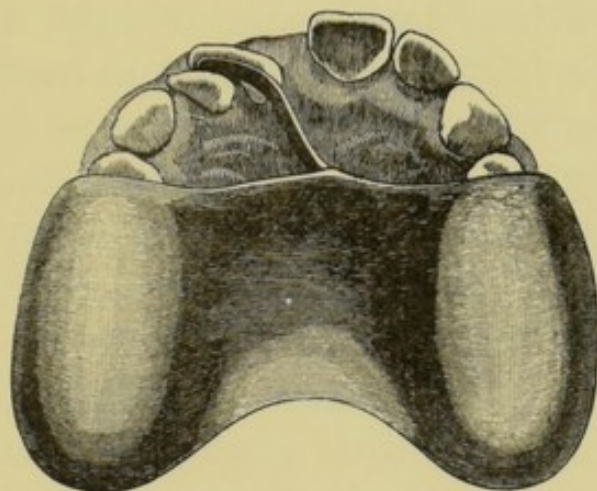


Figure 12.—Showing a central incisor which, when the mouth is closed, would be found to shut inside the lower arch, also a plate and spring for moving the tooth into its proper position.

be quite sure that here is a case which can never correct itself, and we must temporarily prevent the contact, by covering the back teeth with a plate thick enough to prevent the front ones meeting, and at the same time apply pressure to the lingual surface of the tooth to move it forward. This may be done with a vulcanite plate, having a spring of gold wire—flattened with the hammer, and not annealed—embedded in the substance of the vulcanite.

With this simple apparatus the work can be done very quickly; in some cases which I have treated, the tooth has moved an eighth of an inch in a week; but it is never advisable to undertake



these cases, unless we are sure of the hearty co-operation of parents and child, else we may be in many ways thwarted in our endeavours. There is not much pain, but the tooth becomes a little sore, and the plate is removed at once, or the child cannot eat with such a clumsy thing in the mouth, and it is laid aside at meal times; the consequence is that no progress is made, because five minutes without the plate may undo the work of twenty-four hours. It is the wisest course simply to point out the fault, and show how it can be remedied, and then, if the parents are eager to have it done, it is easy enough to do it; but if the dentist is the only person who feels any interest in these matters, very little good will result from his efforts. Good impressions are an absolute necessity, for the plates must fit accurately, and great care must be taken with the plaster casts, to prevent the cusps of the teeth, over which the plate is to fit, from being broken off. I have found some of the preparations of mixed gums for taking impressions to answer admirably for this purpose.

Sometimes both the upper centrals, or, if they have erupted, the laterals also, are found shutting inside the lower arch, forming what is called an "underhung" jaw, although overhung would be a more appropriate description. This may be treated with a similar plate, with a spring on each side, but it will take more time, as, if the pressure is too strong, the springs will throw the plate off. In some cases it may be necessary to tie the plate, or fasten it with screws through the substance of the plate, into shallow indentations in the buccal



surfaces of the temporary molars—these indentations having been made with a drill through the screw-hole in the plate. In these cases inquiry should be made whether the child has not been in the habit of sucking the fingers, and whether this habit is not still kept up while the child is asleep.

A tooth may be so misplaced in the arch that it will present the mesial or distal surface to the front, and in such a case two springs will be necessary, one from the palatine portion of the plate, pressing on the inner angle, and the other from the buccal portion of the plate, pressing on the outer angle, so as to obtain a turning force. Fig. 13 shows a good example of such an

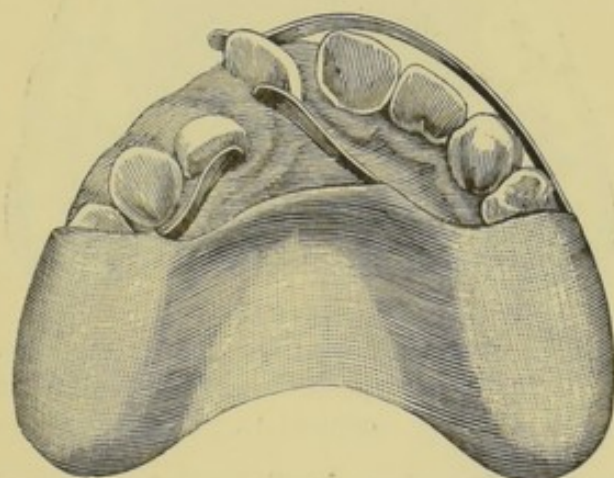


Figure 13.—Showing a central incisor which should be turned in its socket, and a lateral which should be pressed forward, also the form of plate and arrangement of springs for regulating the same.

irregularity, the right central being very much turned, and the right lateral shutting inside the lower arch. They were easily straightened with such a plate as I have described. It will be found that strong pressure, often increased by bending

the springs, and the impossibility of contact with the lower teeth, owing to the substance of vulcanite over the grinding surfaces of the molars, will soon correct such faults as these. But, unlike the other cases that have been mentioned, in which, if the teeth are once outside the lower arch, and shutting slightly past the cutting edges of the lower teeth, not merely edge to edge, they cannot easily get back to the old position, a tooth that is turned in the socket may, and probably will, go back to its old place if it is not held fast

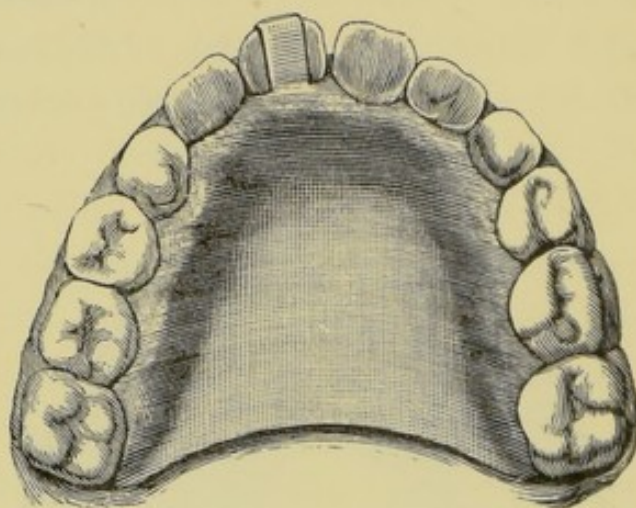


Figure 14.—Showing plate with clip over the cutting edge of the central incisor, to keep it in its new position until the alveolus closes firmly around it.

until the new alveolus is formed around it. The best way I have found to do this is to make a vulcanite plate, having a strip of gold fitted to the lingual surface of the tooth, and bent over the cutting edge, and up the labial surface sufficiently to hold the tooth firmly in its new position. (Fig. 14.) This should be worn three months, or until the tooth feels quite firm and strong in its new socket.



The lower, and then the upper laterals are now to be looked for. The latter are, more frequently than any other teeth in the mouth, liable to be misplaced, the malposition usually being that they are a little inside the arch, and if it is found on closing the jaws that either or both of them shut inside the lower arch, a plate like those previously described will soon put them right.

These are, I believe, all the cases in which the use of regulating apparatus at this early age is really necessary. The more complicated cases are better left until the permanent bicuspid and canines are well established, as we can then judge better what we must do, how to retain the apparatus in the mouth, and, if time is required for the treatment, we need not fear that we are interfering with the eruption of new teeth.

There is so much variation in the ages at which children change their teeth that no fixed period can be stated for the appearance of any of the permanent set; but in the case of well-nourished and well-cared for children, we may expect to see all the incisors, upper and lower, before the expiration of the ninth year; and in a large number of cases, of girls especially, who are generally a little more forward than boys in this respect, it will be twelve months earlier.

The first or anterior bicuspid is the next in order; but it is by no means an uncommon thing to see the second or posterior bicuspid before the first appears; indeed, it is a matter of extreme uncertainty when and in what order the bicuspid will make their appearance. In the majority of



cases, however, we shall see them all before the end of the eleventh year, and the canines a year

later. In the meantime all the new teeth must be carefully examined every three or four months for indications of approximal decay, which the practised eye will detect by the appearance of slight opacity long before the patient is aware of any defect in the tooth. The upper incisors are peculiarly liable to this, and their position in the mouth renders it a matter of extreme importance to detect and check the first symptoms of caries, so that the appearance of the mouth may not suffer. Young practitioners should accustom themselves to the constant use of the mirror in these examinations. A good mirror, kept warm by dipping it in hot water to prevent condensations from the breath upon its surface, will be of the greatest possible service

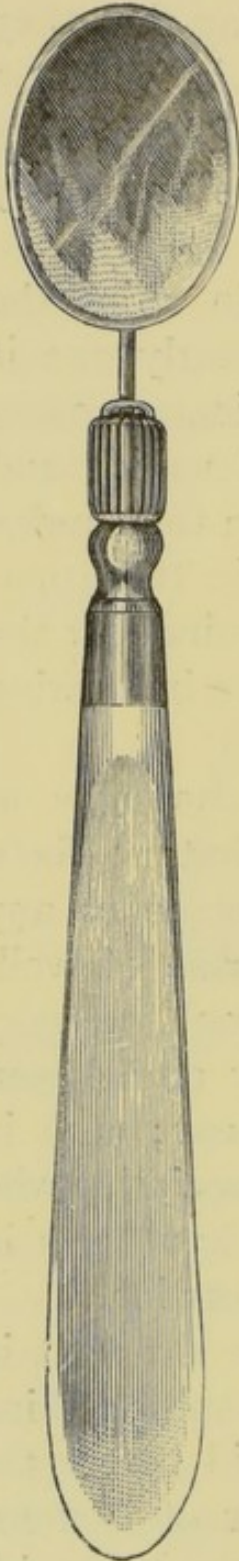


Fig. 15.—Showing form of mirror.



Fig. 16.—Side view of same.



to the operator, enabling him to detect the earliest appearance of that whitish opacity which indicates the progress of caries from the interstices. Holding the mirror so as to throw a strong light upon the lingual surface of the tooth makes this opacity distinctly visible, in many cases before sensibility in the tooth has caused a suspicion of mischief. Familiarity with the use of the mirror, and with the use of instruments from the reflected image, will be found to be a great advantage in nearly all operations on the teeth. The silvering of a good mirror can and should be done in such a manner that it cannot be affected by moisture, and the handle should be broad and thin, so that it can be held under perfect control between the fingers, leaving the finger ends free for other uses. Figs. 15 and 16 will show the form of handle which I have found most convenient for use, and the manner of holding it while operating on front teeth is shown in Fig. 17.

It is a great assistance to the dentist to be able to work with the mirror, as he can then do anything that is necessary in the preparation of cavities in approximal surfaces, and packing the fillings, without resorting to the use of wedges to press the teeth apart, and without cutting away the labial surface of the tooth, and so spoiling its appearance. All the cutting away should be from the lingual surface, and if a 000 dividing file can be passed between the teeth, it is all that is necessary to take away from the labial approximal surface for any filling, no matter how extensive the decay may be, provided, of course, that the

labial surface is not already broken down before the treatment is commenced. But, fortunately perhaps, caries in front teeth will have made most serious progress before the labial surface breaks

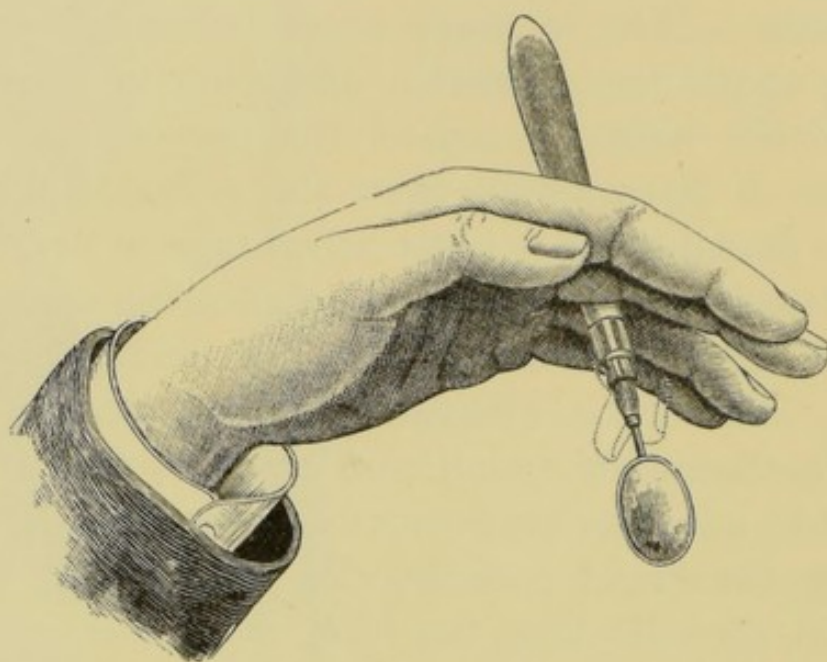


Figure 17.—Manner of holding the mirror, so as to leave the fingers free for holding the lips back, holding the napkin, etc., etc.

down, because the action of the front teeth in biting the food comes upon the lingual surface of the upper incisors, and as that breaks down, the attention of even the most careless person is called to the mischief that is going on by the sharpness of the broken edges of the cavity, and doubtless to a certain extent the decay is checked by the cleansing action of attrition, while there is very little pressure on the labial surface to cause breakage. Thus we often find extensive caries in front teeth, extending even to the pulp, while the labial surface is nearly, or quite, intact; and this teaches us a lesson in treatment, for if, in filling front teeth,



we shape the surfaces treated so as to take advantage of this self-cleansing process, we shall find that our work will stand better than if we attempt to restore the original contour of the tooth. But this is a topic that I shall refer to again, when the subject of permanent fillings is under consideration, as the teeth we are now treating of are much too young for that class of work. What we want to do is to stop the decay, if possible, before it has made serious progress, while it can be cut away with the chisel, or the engine disk; but, personally, I prefer the chisel for this work, because I can use the mirror so as to see better what I am doing, and I have never yet found a disk that I could work with as rapidly as I can with the chisel. This is a most admirable method of treating a tooth when the decay is superficial; and, if the surface is well polished after cutting away the decay, it is quite as safe, if not more so, than it can be with the best filling that can be made. Unfortunately, this treatment is limited to a comparatively small number of cases; and when the decay is too deep to be cut away without too much loss of substance, the cavity must be filled. We therefore cut away from the lingual surface all the friable, fragile edges of enamel, and remove all the softened dentine, taking care always to leave the cavity larger inside than it is at the orifice. When only the calcareous portion of the dentine is destroyed, leaving a cartilaginous substance which is tough and firmly attached, it will do no harm to leave some of the latter at the base of the cavity, although every particle must be removed



from the edges that will be exposed to the action of the oral fluids after a filling has been inserted. This substance, if protected, will often be re-calified, and become dense, healthy dentine, forming an excellent covering for the pulp; but when any of it is left in the tooth, it is good practice to wipe out the cavity with carbolic acid immediately before the filling is inserted, care being taken, of course, to dry the cavity again before filling. Whether the acid has any effect in stimulating the process of re-calcification may be a question, but it certainly acts to soothe and comfort an irritable surface of dentine, and that is quite sufficient justification for its use.

When we are satisfied with the excavation, we dry the cavity carefully with some shreds of amadou, absorbent cotton, or bibulous paper (all of which are used for this purpose, but I prefer the amadou, when it is of good quality), and then we fill with gutta-percha, which must not be overheated, but just sufficiently warmed to be compressible between the fingers. The packing should be done with fine instruments, the edges especially being packed with instruments quite as fine as would be used for gold, all being well warmed, but not hot. The corners and fissures must be carefully packed, because the use of a plastic material offers no excuse for careless work; and the surface may be smoothed with a warm burnisher; but if it cannot be made quite smooth in this way, a strip of tape may be moistened with chloroform and used as in polishing a metallic filling; the chloroform, being a solvent of the



gutta-percha, will leave a perfectly smooth surface. Such a filling will not take a quarter of the time that we should be compelled to spend in making and finishing a filling of gold, and it should be quite understood that it is not expected to be permanent. Yet, the work being done with equal care, I would much sooner trust the gutta-percha than the gold in these young mouths, and certainly the pain during the operation, and the sensibility of the tooth to thermal changes afterwards, are all in favour of the gutta-percha. If the gutta-percha fails, it will be from wearing away, and not from new decay at the cervical edge, and a new filling can be inserted in five minutes, without any new excavation; but unless there is a large surface exposed to wear, the filling will last three or four years (many of them are not touched again for ten or twelve years), and when it is desirable to renew it, a gold filling will have a much better chance than it would have had at first.

It may be said that the gold fillings would last too, if the teeth were kept clean; but we cannot make boys and girls of ten and twelve years of age as careful as they will be at eighteen or twenty, when pride in their personal appearance becomes a strong motive. We must not cease to preach cleanliness to them, for it reminds them that there is a difference between cleanliness and filthiness, but our preaching will not make all of them take as much care as they ought to take of their teeth. This being the case, I think it better to defer the gold fillings to a period nearer the time when we

shall have the assistance of personal vanity as an incentive to taking care of the work we do for them.

We shall often find teeth which are more or less imperfectly covered with enamel, sometimes from inherited malformation, and sometimes from illness occurring in early infancy, while the process of development of the permanent teeth is going on. In the former case the imperfection will have commenced with the earliest stage of development of the enamel, that is, at the cutting edge of the incisors and the points of the cusps in the molars, and it may extend over the whole crown of the tooth, or, as is more frequently the case, over a third or half of the tooth (Figs. 18 and 19), and

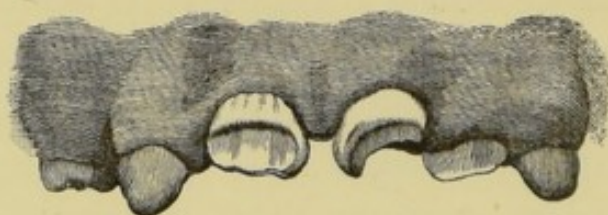

Figure 18.—Showing defective formation of enamel on two upper central incisors.

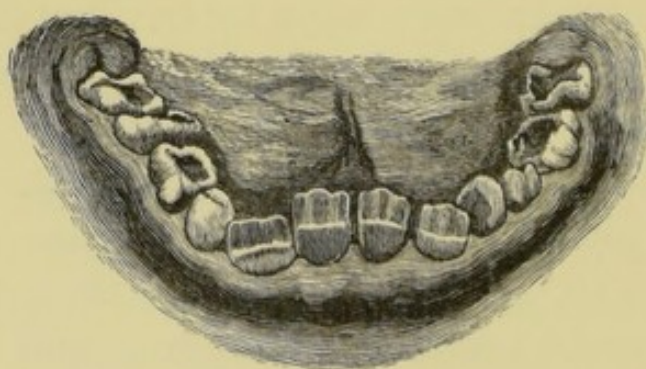


Figure 19.—Showing defective formation of enamel on lower incisors.

then the enamel may be quite perfect on the remainder of the crown. The defective portion



may be absolutely without enamel, there may be small detached patches of enamel affording no protection to the tooth, or it may be interrupted with pits and fissures, but still serviceable over a good part of the affected surface. If the defect is owing to illness in infancy, the interrupted formation may occur as a line of pits across the surface of the tooth, or a band of defective thin enamel, which may also extend across the surface of an otherwise well-formed tooth; the cutting edge, or the cusps, will be properly developed, then the band of imperfect formation appears, and then

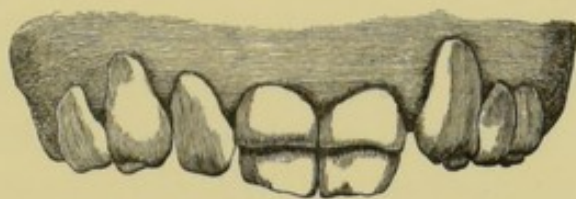


Figure 20.—Showing a band of defective enamel.

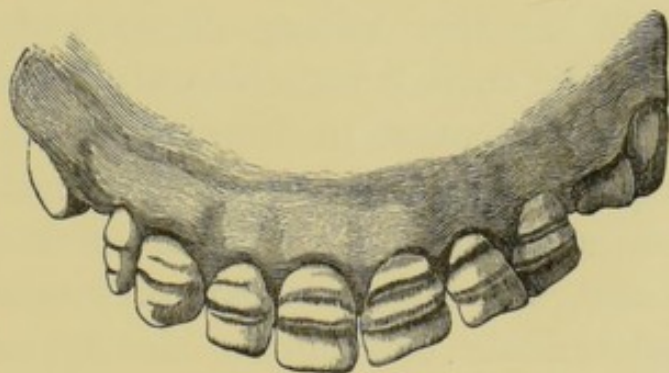


Figure 21.—Showing alternate bands of perfect and defective enamel across all the upper front teeth, including the bicuspids.

the enamel organ recovers its function, as the period of weakness passes, and the remainder of the crown will be perfectly covered with well-developed enamel. (Figs. 20 and 21.) We some-

times see two or three of these bands across the surface of the incisors, with well-formed enamel between, marking periods of alternate weakness and strength. Defects of this nature are usually confined to the incisors and first molars, though sometimes the bicuspid are affected to a less degree, which seems to indicate that the teeth of later development are not so liable to be affected by illness. It may, however, be assumed that any severe illness occurring during the first one or two years of infantile life will be likely to affect the structure of the teeth, and the administration of some of the preparations of lime, known as phosphatic food, may be very beneficial in supplying the materials for the calcification of the enamel.\*

The treatment necessary in these cases of defective enamel is to fill every pit or fissure where the dentine is exposed, and to file away as much as possible of the dentine that is quite unprotected on the cutting edges and grinding surfaces of the teeth; but the use of the file and corundum wheel must be limited to the removal of sharp points and thin edges—in short, to mere protection, until the patient is sixteen or seventeen years of age, when a great deal may be done with these instruments to improve the appearance of teeth which at first seemed almost hopelessly misshapen.

The bicuspid are quite as much predisposed to caries as the incisors, and while cavities in the

\* The syrups of hypophosphites, now so well prepared by nearly all the leading chemists, contain all the materials which must be supplied for the proper calcification of the teeth, and in a form to be readily assimilated.



sulcus between the cusps may be easily and quickly seen, much more serious mischief may be going on in the interstices. Therefore careful examination with thin delicate instruments, and with waxed silk, or the loosely-twisted linen thread used by shoemakers, is necessary to detect the earliest indications of disintegration and roughness of the enamel on the approximal surface. I believe that free excision is the best treatment for these, and for approximal decay in all teeth, when the disease is superficial, or has not penetrated so deeply that to cut it away will injure the appearance of the labial surface of the tooth. I cannot do better than to borrow from the late Dr. Arthur's valuable work\* on this method of treatment an illustration of the best way of making the V shaped spaces that will leave the surfaces self-cleansing, and, therefore, self-protecting. It will be observed that the spaces are V shaped in two directions, from the labial approximal and from the cervical approximal surfaces. (Fig. 22.)

But if the decay has penetrated to any extent into the dentine, the tooth should be filled always, I think, with gutta-percha at first, until after the constitutional changes at puberty, for the oral secretions at this period are too strongly acidulated for any other form of filling to be safe. The

\* *Treatment and Prevention of Decay of the Teeth*, by Robert Arthur, M.D., D.D.S. J. B. Lippincott & Co., Philadelphia.—A work which teaches and strongly urges the practice of a different system of treatment from that which is recommended here; but it is a book that should be read by every dental student; and if he is convinced that the teaching is sound, the student cannot do better than to follow the lead of a man who had the courage of his opinions, and consistently operated as he thought, to the lasting benefit of those who were fortunate enough to have had their teeth under his thoughtful and skilful treatment.

idea of the V shaped space should, however, be kept in mind in shaping the cavities for filling.

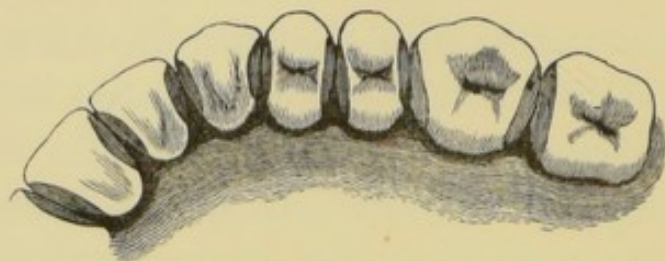


Figure 22.—Showing the method, approved by the late Dr. Arthur, of cutting away the approximal surfaces of the teeth for preventing decay.

The canines are usually more dense than the teeth on either side of them, but, nevertheless, they are often unable to resist the effect of the carious condition of a surface in contact with them, and they must be treated in the same way as their neighbours.

All the teeth anterior to the first permanent molars being now in position, and the child being twelve years old, we should find that there has been a sufficient lengthening out, or growth, of the maxillary bones beyond the first molars, to make room for the twelve-year, or second permanent molars; we may also reasonably expect to see all four of these teeth before the child is thirteen years of age.



## CHAPTER III.

## EXTRACTION AS A MEANS OF PREVENTING DECAY.

IN the preceding chapters we have noted the progress of dentition until the second permanent molars have appeared, and have endeavoured to show that extraction is an unnecessary and unjustifiable operation, except so far as may be absolutely indicated in order to permit each permanent tooth, in its turn, to come into its natural position in the dental arch. But at this period of development it is sometimes advisable to remove a tooth from each side of each jaw for the conservation of a well-arranged and comfortable set of teeth in after-life.

It now becomes the duty of the dentist to consider well whether he can hope to preserve all the teeth that are in the mouth at this age. He must take careful notice of the tendency, if any, to approximal decay; and in considering this he will do well to remember what has been his experience with other and older members of the same family. He should recall his experience with teeth that resembled these in colour, shape, and density, in the mouths of other young patients whose teeth he has watched through the natural

changes at puberty ; and he should notice whether his instructions respecting cleanliness have been and are carefully attended to. He should see how the upper and lower teeth articulate, and whether they have plenty of room, or are crowded and irregularly placed in the dental arch ; and, in short, he must exercise all the power that teaching and experience have given him to form a prognosis of the effect that the constitutional changes, now about to take place, will have upon the teeth of the individual case before him. He must not lay down hard and fast rules for practice, but study the peculiarities and probabilities of every case by itself, and in comparison with others. And if family history and local appearances indicate that the teeth will suffer seriously from the excessive acidity which is natural to the oral secretions at this period of life, there should be no hesitation in advising the immediate removal of the six-year molars, if the articulation is normal ; or the second, or first bicuspid, if abnormal articulation seems to indicate that the removal of these will more effectually relieve crowding and pressure. But in any case, the teeth which are selected for extraction should be opposites ; that is, if decay, or defective structure, or malposition, or space required, points to the extraction of a molar in one jaw, the tooth articulating with it should be the one to be extracted from the other jaw, or else the tooth which has no antagonist will elongate, and, by protruding like a wedge into the gap that is opposite, will prevent the desired separation of the other teeth, as may be seen in Fig. 23.



If there is no decided counter-indication, it is always preferable to extract molars for this purpose, because we thereby immediately protect the bicuspid and the second molars from approximal decay. We do not disturb the symmetrical arrangement of any of the anterior teeth that are seen by the ordinary observer; but, on the contrary, give them room to correct, of themselves, many ugly irregularities. We also give

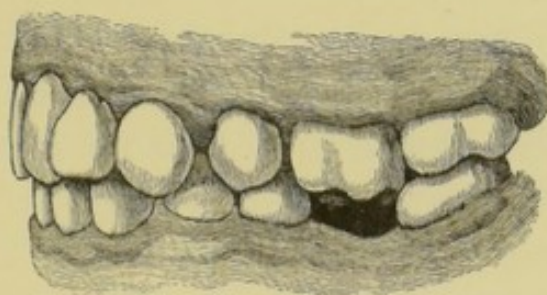


Figure 23.—Showing how a tooth will elongate, and thus prevent the closing up of gaps, when other than opposite or antagonizing teeth are extracted to relieve crowding.

space to the wisdom teeth, so that they will come earlier than they otherwise would, and are more likely to be serviceable teeth when they do come; and we shall have selected for removal the teeth that are already seriously decayed in, at least, eighty per cent. of the cases which we shall see in ordinary practice.

The bicuspid will at once begin to fall back, thus isolating themselves, and making room for the canines and incisors to gain, a little later, the amount of space which is so essential to their preservation. I have seen cases where, in one year, the gaps left by the extraction of the molars were so filled up that, in the upper arch, there was



only about the same space between the second bicuspid and second molar that there was between the bicuspids and between the first bicuspid and the canine, and the incisors were also perceptibly separated; and in the lower arch the bicuspids had fallen back so much as to be quite safe from approximal decay.

Teeth which are isolated do not suffer from approximal decay. I do not mean to say that, if decay has commenced before the separation took place, it will not go on, but it will not commence spontaneously in a tooth so situated, except in cases of severe illness, or of that peculiar condition of the oral secretions which may be seen when there is a rapid breaking up of the constitution, either prematurely, or from old age, when no part of a tooth seems exempt from what has been termed senile decay. It is therefore safe to say that, when we have succeeded in isolating all the upper teeth, and the lower bicuspids and molars, we have effectually protected them from approximal decay.

Some writers deny that there is any falling back of the bicuspids after the molars are extracted, but such writers simply do not know what they are writing about. I have watched the growing up of a good many families of young people; some of them who came to me with their first dental troubles are now men and women, with children of their own. Many families have come under my care when the elder children were well on in their teens, and the younger ones still in the nursery, so that I could compare the result



of early treatment. Many had been under the care of the best known dentists in both hemispheres; and thus I am sure that few men have had a better opportunity to judge of the results of different systems of treatment. I have extracted the molars in a good many cases, and I have never yet seen a case where, if they were extracted at the proper time, the bicuspid failed to move backwards, and so make for themselves and the front teeth more room. I have seen a few cases where extraction of the molars was not a sufficient protection, but I have never seen a case where I regretted having adopted this treatment, and I have seen many cases where, from a feeling of confidence that I could do without it, I have not recommended it, and would have given anything afterwards if I could have changed my plan of practice. One instance of this nature I can recall, the daughter of a medical man, one of my most intimate friends. At twelve years of age she was a strong healthy girl, and had teeth which seemed capable of resisting anything, and yet, before she was eighteen years old, the bicuspid and molars were decayed on both approximal surfaces; there were dead pulps in three of them; and although she was only about a month in every year absent from home, when she could not consult me, she had suffered so much pain that two of these teeth had been extracted. This was a case where the teeth were dense and hard in structure, and well covered with enamel. They were yellowish white in colour, and short and broad in form, having, in fact, all the character-



istics that we look upon as indicating the best type of teeth. The young lady was careful with them, and came often to have them examined, and when the first indications of approximal decay appeared, I filled the cavities (mere pin holes) with gold, thinking that if it was suitable for any teeth it was so for these. I know the work was well done, but the decay went on notwithstanding all this, and I am sure that it was only want of space, at the time when isolation would have absolutely prevented decay, which caused all the trouble. If I had extracted the first molars as soon as the second molars appeared, there would have been no occasion for any approximal fillings up to the present time; and when she was eighteen, the fact that four teeth had been extracted would have been perceptible only to a professional eye.

The second molars are, of course, perfectly isolated from the moment of the extractions, and approximal decay is practically impossible, but the sulci of the grinding and buccal surfaces are liable to suffer.

Prominent canines are always unsightly, but they will generally right themselves after the extraction of the molars. Unless they are much worse than those shown in Fig. 24, there is no need for mechanical assistance to straighten them. The lower canine on the right side may not come quite into its place, for the lower teeth do not change their position quite so readily as the upper ones, but it is doubtful if even that will need artificial pressure to get it into place. In this



case the molars were extracted immediately after the impressions were taken.\*

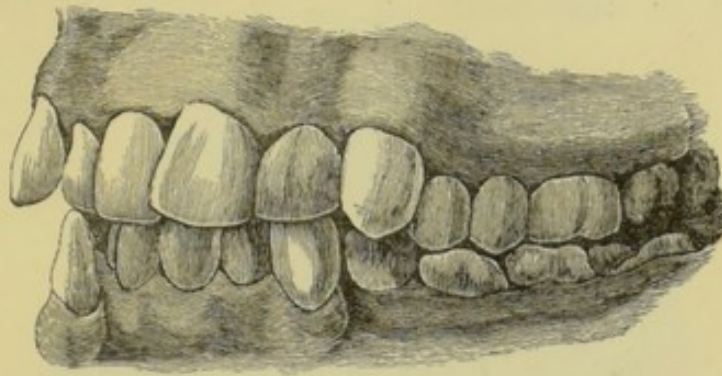


Figure 24.—Showing very prominent canines, age 13.

Dr. Arthur's method of preventing decay, by cutting away a portion of the mesial and distal surface of every tooth, may, perhaps, be as effective as extraction of the molars. I confess I have never tried it to the extent that he recommends, for I think it is better, if possible, to have twenty-eight teeth, well shaped and well covered with enamel, than to have thirty-two, with a slice taken off each side of every one of them, except the wisdom teeth, from which it will only be necessary to cut away the mesial surface. The illustrations, Figs. 25, 26 and 27, will give a good idea of the two systems of treatment. Figs. 26 and 27 are from casts taken from the mouth of a young lady of sixteen, the molars having been extracted when she was twelve years old. It will be seen that the wisdom teeth are already in position, and that they are well-developed teeth.

\* I have seen this case again, six months after the extractions, and the lower canine is now clear of the upper lateral, and will come quite into the arch.

This is by no means an exceptional case. I could in time make a collection of a large number of similar results from the extractions of the molars, but one is sufficient to show what is possible.

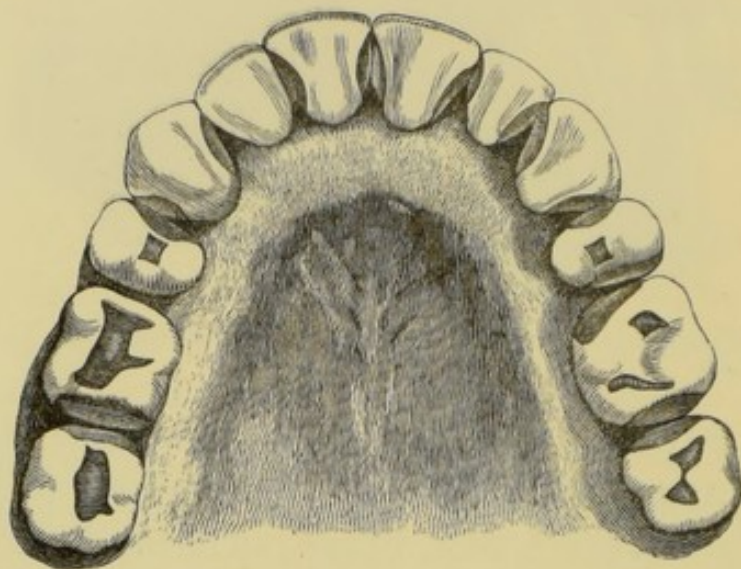


Figure 25.—Another illustration from the work of Dr. Arthur, showing only twelve teeth in the upper jaw, but giving a good idea of his method.

There is, in truth, no reason why wisdom teeth should not be quite as serviceable as any others in the mouth, although this is not usually the case with wisdom teeth, because when all the others are in the mouth, or when one has been extracted here and there without a specific plan, and the gaps remain, there is no room for the teeth that are latest in formation, and thus their development is interfered with, or their eruption is retarded. In the one case, therefore, they will be malformed or misplaced, and in the other they will be decayed before they even come into a position to be of any service, or to be treated to prevent decay. There can be no doubt that



civilisation has so fined down the human face, that the maxillary bones of Europeans and Americans

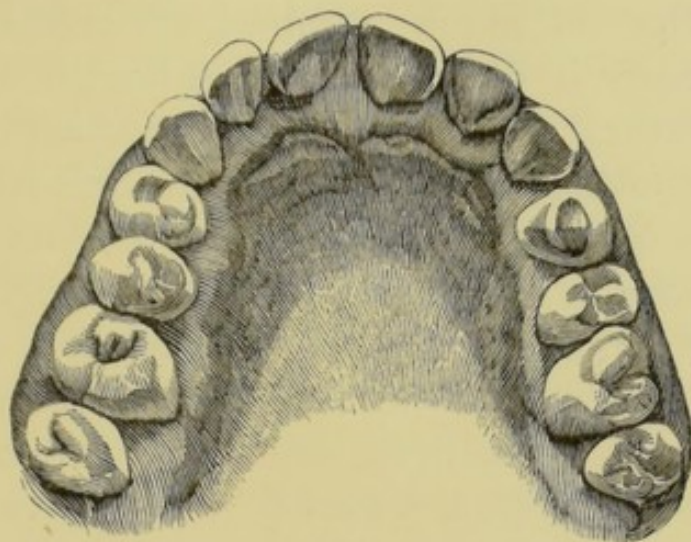


Figure 26.

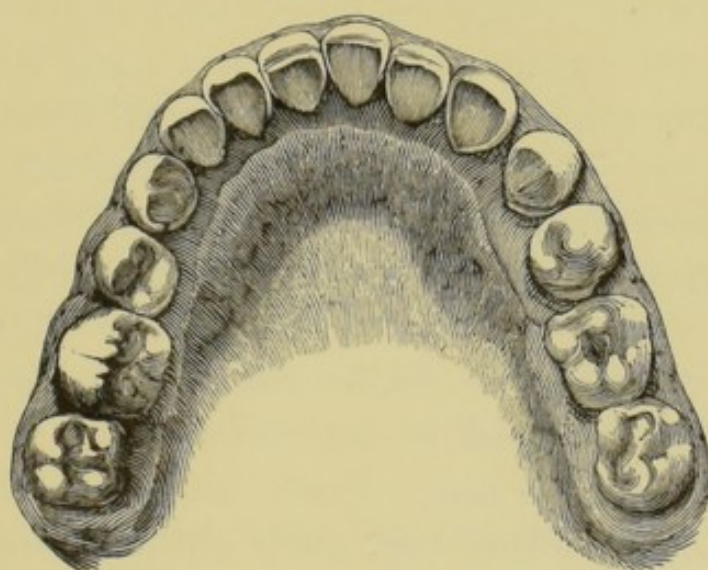


Figure 27.

Figures 26 and 27.—Showing the condition of the upper and lower teeth in the mouth of a young lady at sixteen years of age, the six year molars having been extracted about four years.

are much smaller than those of the savage races that still inhabit the earth; and, if there is anything in the theory of evolution, this is easily

accounted for. The heavy animal character which is given to the face by a large development of the maxillary bones is not a type of beauty that is much admired in civilised life, consequently it becomes fined down by the process of natural selection. Again, civilisation leads to good cookery, and this to diminished labour for the bones and muscles which are called into action in mastication; and the theory of evolution is, that the organs which are called into greater activity by new conditions of life receive increased development, while those which are of diminished importance become dwarfed and rudimentary. Thus it is easily seen that, after centuries of civilisation and good cookery, the organs of mastication are not likely to be so well developed as those of the savage, who does not hang his meat until it becomes tender, and is satisfied with rude cookery, or none at all. The maxillary bones have become smaller in these days of luxury and good living, and the wisdom teeth suffer from want of room, so that we often find them misshapen, or so much smaller than other teeth, that they might be said to be rudimentary; or else we find them coming slowly and painfully into position, protruding one cusp through the gum, and making little or no more progress for months, and often for years, because there is no room for them to advance. It is unnecessary to explain to the dental student that the soft tissues do not adhere to the enamel of a tooth, and that if one cusp has found its way through the gum, the soft tissues must form an open pouch around the



remainder of the crown of that tooth. Therefore, if this condition of things exists for any considerable period, the secretions and particles of food which find their way into the mouth of the pouch must have an injurious effect upon the tooth, and when it finally emerges from the gum, it is likely to be with a softened and chalky condition of enamel, at least, if not with its dentine also affected. Thus wisdom teeth have got a reputation for coming late, giving much pain in the process, and going early; but if they have a fair chance given them, in time to benefit by it, there is no reason why they should not be as good as any other teeth, and quite make up for the loss of the first molars, if that can be called a loss which I have attempted to show is a gain to every part of the dental arch.

The period when isolation is so essential to the preservation of the anterior teeth being past, the wisdom teeth serve another important use, for they press the second molars forward and gradually close up the spaces, until the mouth presents the appearance seen in the last illustrations, of a remarkably good and regular set of teeth.

Some of our best men tell us that extraction should never be resorted to until we have done everything in our power to preserve all the teeth. This is a well-sounding theory, but practically timid, and working harm instead of good; for when we have tried it, and have found our efforts ineffectual, as we surely shall find them, if the conditions of weakness of structure and excessive



acidity exist in conjunction, it will be too late to try back, for the period when the greatest benefit could be gained from extractions will have passed, and permanent gaps will remain in the mouth to remind us constantly of our timidity and failure.

The extraction of the molars is always a difficult and painful operation, even when they are comparatively strong and we may reasonably hope to get all the roots at once; but when they are seriously decayed and broken down, the difficulty is greatly increased, and both patient and operator must needs have plenty of nerve to contemplate the operation without the aid of anæsthesia. The certainty that there will be no suffering from the operation, except the soreness which must immediately follow, helps the patient wonderfully in making up the mind to submit to what often seems, to a child, a piece of wilful cruelty on the part of the dentist; for the child cannot be expected to see the necessity which is so apparent to the professional eye. And the same certainty helps the operator too; for, although he may have to struggle with rigidity of muscle and obscurity of view from the flow of blood, it is a help to him to know that he is not inflicting pain, and he is not discouraged if his first effort to remove an obstinate fang results in failure. Once undertaken, the work must be thorough. All fragments of roots must be removed, even though it is necessary to cut through gum and alveolus to accomplish it; indeed, if it will facilitate the extraction of a troublesome root, one should never



shrink from cutting through the alveolus, for it only takes away what would be removed afterwards by the natural process of absorption.

As I have observed, it is most important that all roots and fragments of roots should be removed, and, although there may be nothing new in my suggestions, it may not be out of place to give some general instructions for this operation. If the teeth are strong, no instrument can be better adapted for their extraction than the

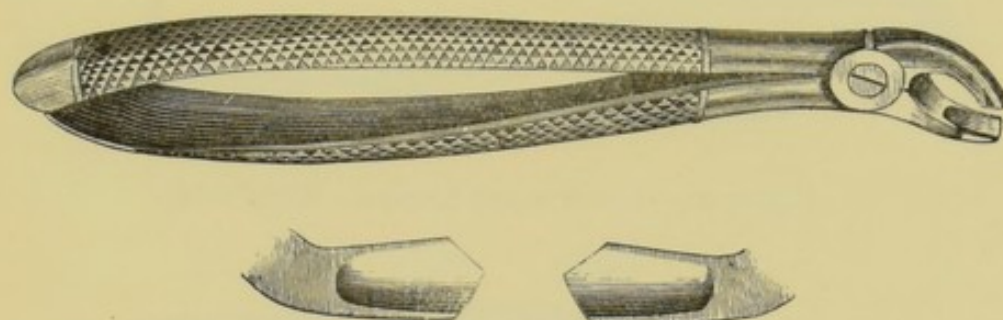


Figure 28.—Lower molar forceps.

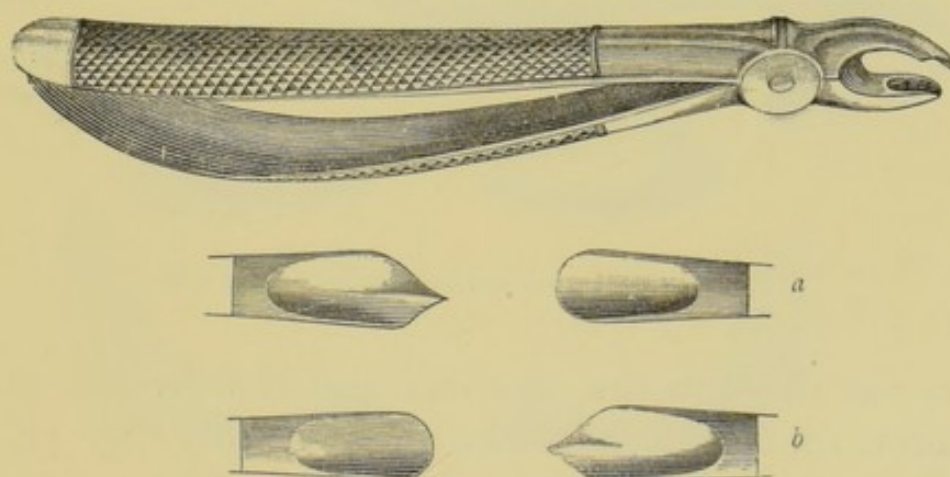


Figure 29.—Upper molar forceps. (a) Right side. (b) Left side.

ordinary forms of molar forceps of English make—Fig. 28 for lower molar of either side, and Fig. 29

for right and left upper molars. But when the teeth are much broken down, I prefer the stump forceps of American make. The strong beaks of the right-angle instruments, Fig. 30, for the right side, and Fig. 31, for the left side, lower jaw, are most useful, giving one the power, if necessary,

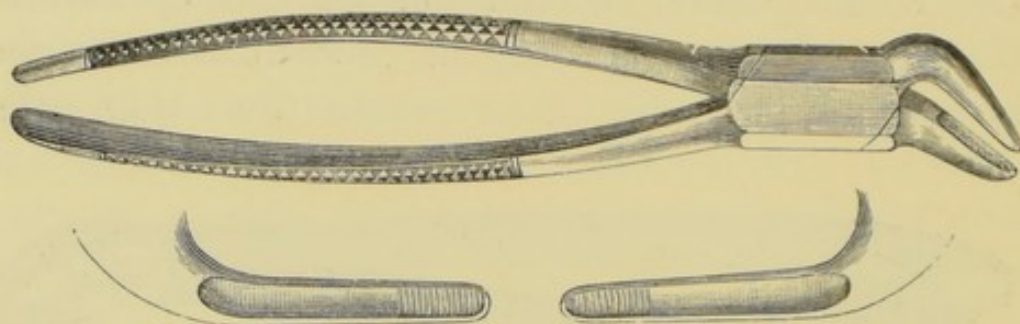


Figure 30.—Lower stump forceps. Right side.

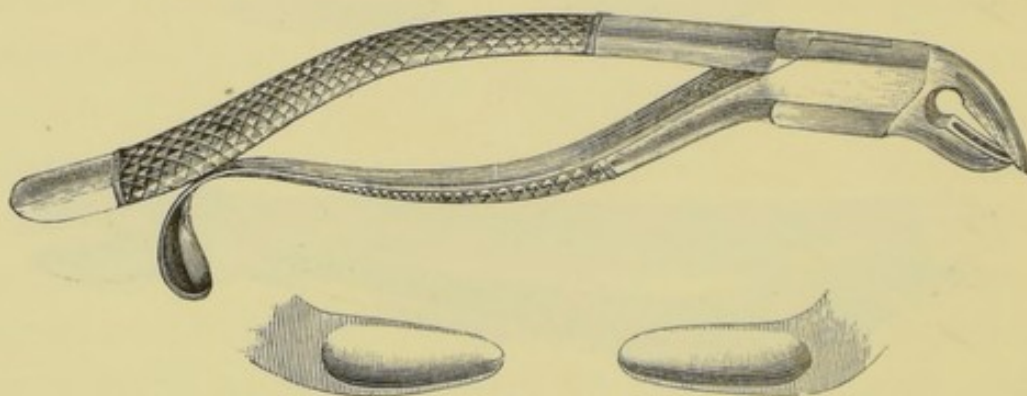


Figure 31.—Lower stump forceps. Left side.

to cut through the alveolus and remove the posterior root, and then with the elevator, Fig. 32, to push back the anterior root, so that it may be grasped by the mesial and distal surfaces with the thin flat-beaked instrument, Fig. 33, made from my own design; and the bayonet-shape, Fig. 34, for upper stumps. These instruments enable one



to remove stumps with more certainty, and actually with less laceration of surrounding tissues,

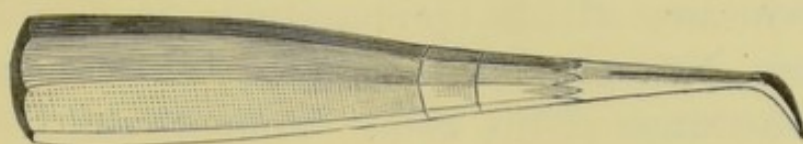


Figure 32.—Elevator.

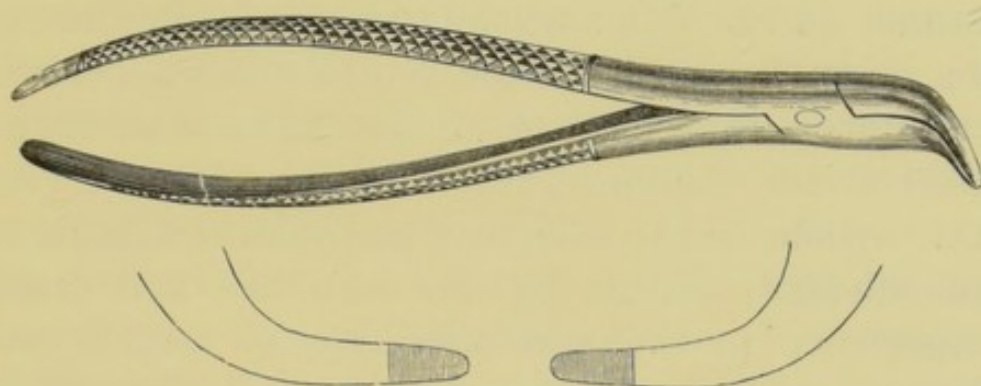


Figure 33.—Thin flat-beaked forceps, for grasping a loose root by mesial and distal surfaces.

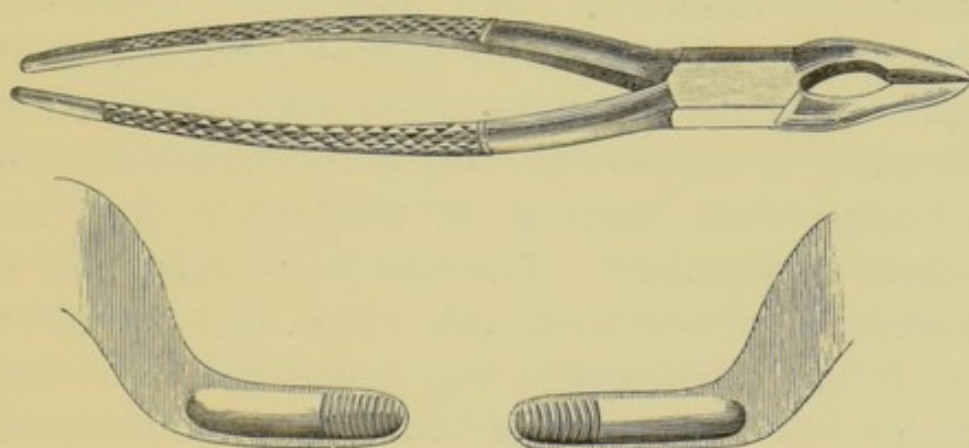


Figure 34.—Upper stump forceps.

than the ordinary stump forceps of English make, which are not strong enough in the beak for the purpose, and always bend or break in my hands.

If it is decided to make use of an anæsthetic, the assistance of a surgeon should be considered indispensable. No dentist should ever attempt to give any of the preparations used for this purpose without such assistance. A man cannot do two things at the same moment, and do both of them well, and although a dentist may understand how to administer an anæsthetic quite as well as a surgeon, and how to watch its effects, he cannot do this if his whole attention is directed to his operation, as it should be, to make success a certainty; the selection of the anæsthetic to be used would, therefore, rest with the surgeon. An able article on the selection and administration of anæsthetics, written by one who has had much experience in the administration of anæsthetics for surgical and dental operations, will be found in the appendix.

When the necessity for the extraction of the molars is admitted, there ought not to be any doubt about the best time to do it; but it appears that there is, apparently, a very considerable diversity of opinion on this point—some dentists advising their removal at the age of ten, and others at fourteen. The fact is we must not be governed by any strict rule as to age, but rather by development, which may range over the whole of the four years that lie between the advocates of early and late extraction. The object being to gain space for the teeth to be saved, we should surely choose the time when the gain is greatest, and if we extract before the second molars appear we shall stop a certain amount of growth, and



therefore lose so much space ; while, on the other hand, if we wait long after the second molars are in position, we may certainly gain a little more space from the development of the wisdom tooth, which would be making rapid progress ; but we risk more than we gain, for there is danger that decay may make serious progress on the approximal surfaces of the bicuspid while we are waiting for a small gain in growth, which, after all, is not needed, because the space gained by the extraction of the molars is usually quite enough. It appears, therefore, that the best time for extraction is immediately after the twelve-year molars are fairly in occlusion. Since the publication of the first edition, I have seen a child with all the twelve-year molars fairly in position at *nine* years of age, and, this being a case where the extraction of six-year molars was indicated, my brother extracted them at that age. The chief argument for deferring the extraction to the fourteenth year is the supposed tendency of the second molars to tip forward out of the perpendicular position, thereby diminishing their usefulness as grinding teeth. This argument, however, is based on unsubstantial grounds, for, practically, the tipping does not take place and is not likely to, because if anything is to cause tipping, it must be the development of the wisdom tooth ; and as we cannot suppose that the roots of the second molar will be quite fully formed at the time of its eruption, we should have the pressure of the wisdom tooth, which, at this time, would have no roots at all, in just the position we should wish it to be to move the



second molar bodily forward. But if we wait until the roots are fully formed, and the wisdom tooth also further advanced in development, we shall have the pressure in a position much more likely to cause tipping. Practically, however, there would be no tipping if the twelve-year molars articulated properly.

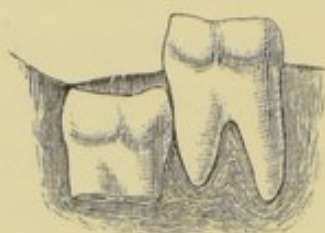

Figure 35.

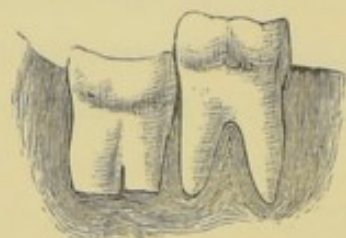


Figure 36.

Figures 35 and 36.—Showing how the pressure of a wisdom tooth may act upon the twelve-year molars at different stages of development.

It would be wrong to suppose that extraction of the molars will always prevent decay on the approximal surfaces of the anterior teeth, for in some cases it will have commenced before the time has arrived for extraction; and in other cases the wisdom teeth will have come, and all the spaces will be closed up, before the period of excessive acidity has passed. But even in these cases of failure to obtain a perfectly satisfactory result, we shall have the consolation of feeling that, without the additional space, no filling could have effectually checked the progress of decay, and we should have lost more teeth in the end. We must not relax our watchfulness, and, if decay has commenced before the extractions, we ought to discover it before it has made serious progress, and take care to stop its ravages. As I have stated before, the chisel and the engine disk are



to be relied on for removing superficial decay; but if the cavity is so deep that the appearance of the tooth will suffer from cutting it away, a filling is the best remedy. The only question is what material to use; and, although general rules are unreliable, we shall err on the right side, if we err at all, by continuing the gutta-percha fillings until the patient is quite sixteen years of age.

Figs. 37 and 38 show the present condition of the mouth of a young gentleman sixteen years of age, inheriting delicate teeth from father and mother, both of them having been, one may say, all their lives in the dentist's hands, with the result that, in the father's case, enough teeth remain to perform their various functions with

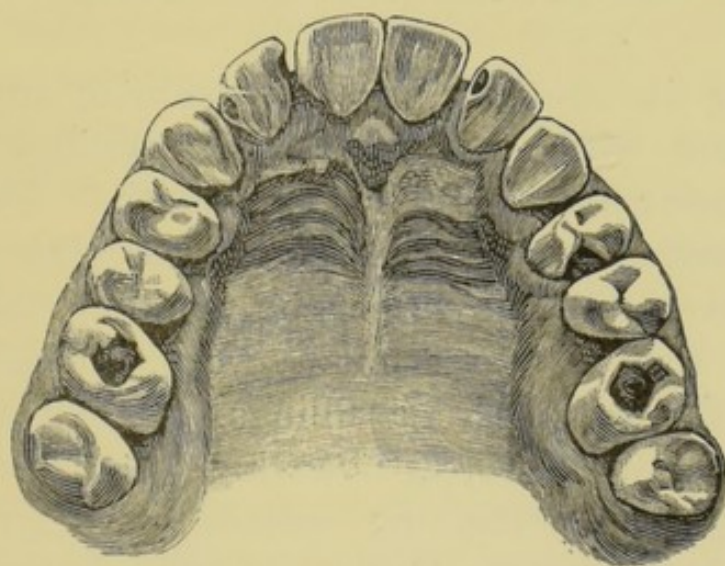


Figure 37.—Showing upper teeth of boy at sixteen years of age, the molars having been extracted at twelve.

a tolerable degree of satisfaction, though every tooth is filled in one or more places, and many of them are restorations, with but little of the original structure left. In the case of the mother,

the restorations have taken a still more prosthetic form. Educational claims, and the needed relaxations in the holiday time, have hitherto prevented

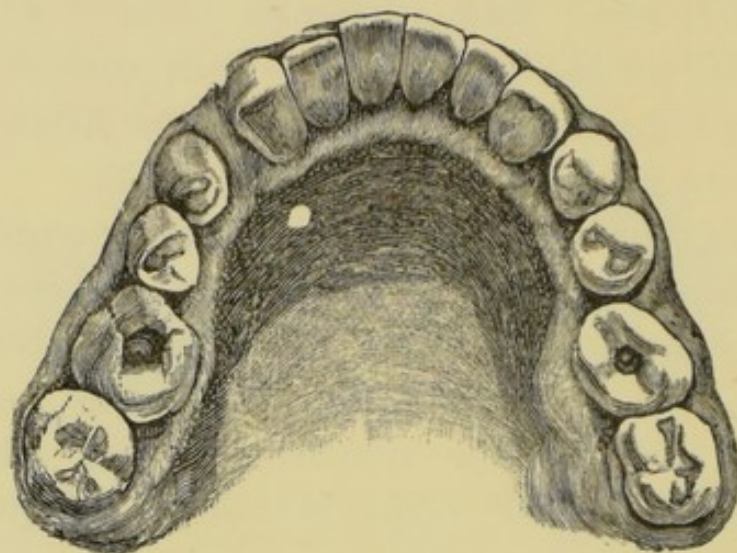


Figure 38.—Showing lower teeth of the same.

anything like an attempt to replace with any more permanent work the gutta-percha fillings which still protect the teeth in this mouth. The two upper second molars, standing in the place of the first, have gold fillings in the grinding surfaces, but all the rest are much worn, though still serviceable gutta-percha fillings. The teeth are nowhere more decayed now than they were four years ago, when the first molars were extracted; but it is easy to see that if an attempt had been made to retain all the teeth, they would have given endless trouble, with certain loss of some of them before the wisdom teeth were all erupted, and this, probably, when it would have been too late to hope for the present fairly symmetrical arrangement.



To those who would argue that extracting the molars is unjustifiable, because it is taking alarm without reasons of established certainty; that the decay might not, after all, be serious, and be perfectly under control with all the teeth in the mouth; or, if the later condition of the mouth showed that the prognosis had been correct, that it was a mere coincidence, and not to be regarded as of importance in the treatment of other cases; or, that the decay is so surely from inherent defects in the teeth, that if the secretions are acid the decay will go on all the same, whether more space is given or not, I would call attention to the cases which every practitioner must have seen, where the molars have been extracted on one side of the mouth, and left in position on the other side. Such cases are common enough. The old ideas that extraction is the only, or at least the quickest, way to relieve pain; that teeth, especially the teeth of young people, are not worth a lot of trouble and consideration; that the cheapest way is to "get it out;" or that there is no time for anything else; or any of the reasons, or want of reasons, which lead to haphazard extraction, are not yet quite extinct; and it cannot but occur in every man's practice, that he will see a mouth where upper and lower molars have been extracted at something near the right age, on one side of the mouth, and the other side has not been similarly treated. It seems to me that one has but to see such a case to be convinced of the advantage to be gained by extracting some teeth to prevent decay in all. We shall find that on the side where



space has been given at the right time, the teeth are in much better condition than they are on the other side; they may not have escaped decay, but they will not be so seriously decayed, and in all respects, except space, the conditions will be similar on both sides of the mouth. The teeth are developed in pairs, and whatever affects the structure of one is likely to affect its twin brother on the other side of the mouth. The secretions will be the same on both sides, and, therefore, if there is a tendency to decay on one side, we may look for the same thing on the other; and if we find that on the side where an upper and a lower tooth have disappeared at so nearly the same time that the filling up of the gaps by change of position of the other teeth is about equal, there is little or no decay, while on the other side, where nothing has been extracted, all the teeth are more or less seriously affected by caries, we must conclude that the additional space has been a cause of the difference in the health of the two sides of the mouth. Such a case is represented in Fig. 39, the model having been taken from the mouth of a strong healthy young man of one or two and twenty years of age, heir to a title, accustomed all his life to the comforts which wealth can give, brought up in the country, not over studious, and fond of out-door exercise and country sports. He had kept out of the dentist's hands until he got toothache at school, and, in accordance with school practice, "had it out;" that is, had an upper and a lower molar extracted on the right side, while the corresponding teeth on the left



side, not having ached, were "stuffed." After this he again kept clear of the dentists until he was past sixteen, when he came into my hands. I thought it was too late then to extract on the

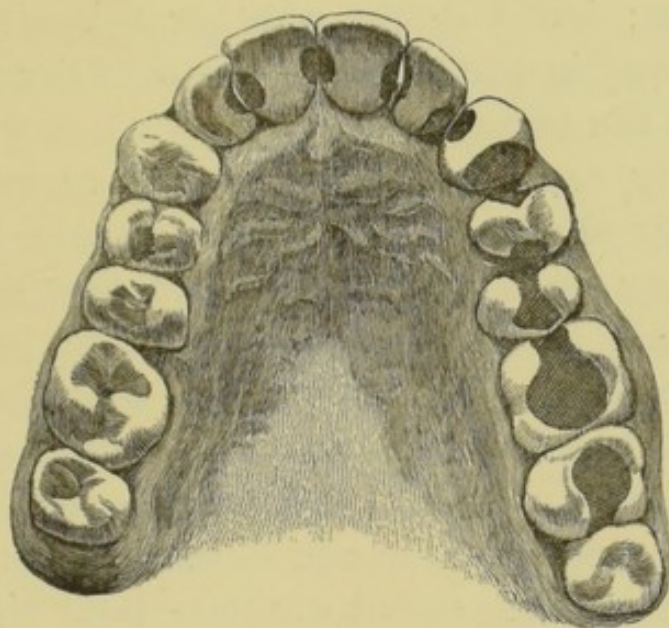


Figure 39.—Showing the effect of extracting the six year molars on one side of the mouth, and neglecting to do so on the other side.

left side, but I am convinced now that it would have been better if I had done so, even if the gaps did not quite close up, for, as will be seen, every tooth, except the wisdom tooth, on that side, together with the central and lateral incisors on the right side, have been filled on both approximal surfaces, and the molars and one of the bicuspid on the grinding surfaces. One central incisor is dead, and has been filled into the root, and the first molar has been treated in the same manner. Probably the incisors were already decayed when the two molars on the right side were extracted; but after that operation no other teeth on that



side were affected by caries, and at the present time the canine, two bicuspid, and two molars are perfectly sound. I cannot imagine a more conclusive proof of the advantage of extracting certain teeth for the preservation of the others than this; but I doubt whether this view of the subject was in the mind of the operator when he removed the two teeth.

Nearly ten years have passed away since I wrote this chapter on "Extraction as a Means of Preventing Decay," and I do not now see that I have much to add to it or anything to retract. I have read all that MM. Bogue and Davenport, of Paris, have written on this subject since the publication of the first edition of these Notes, and it is very evident, from the numerous illustrations they give of cases to substantiate their views, that they have not seen many cases in which the treatment had been carried out on the lines I have indicated as absolutely necessary in order to obtain satisfactory results. I will briefly recapitulate these essential conditions—always allowing that fixed rules are impossible in dental practice, but at the same time being fully convinced that every variation from the prescribed rules must have a more or less prejudicial effect in preventing the fullest possible advantage being derived from the operation.

It being clearly understood that the six-year molars are not to be extracted merely because they are painful, but only as a means of preventing decay, then pain must be alleviated by other methods until the proper time arrives to permit of



the operation being performed so that the greatest possible advantage may be derived from it. This is not a matter of age, but of development: the twelve-year molars must be fully erupted and in absolute occlusion, or else there is likely to be more or less tipping. The teeth to be selected are preferably the six-year molars, as giving the best results, unless there are very decided indications that other teeth must be taken, and in any case they must be occluding teeth, as there can be no appreciable advantage to the mouth as a whole if the teeth extracted are not such as meet each other fairly when the mouth is closed; of course, taking into due consideration the well-known fact that in a perfect articulation every grinding tooth will be in occlusion with two antagonists, but that there will always be one of these which, more than the other, will permit the falling apart of the remaining teeth so as to obtain clear spaces between them. Delaying the operation after the twelve-year molars are fairly in position is almost, if not quite, as disadvantageous as hastening to extract before their development is accomplished. If extraction is necessary at all, there should be no hesitation about it after we have gained all the growth we can expect at this age, for just at the period of puberty approximal decay progresses very rapidly if teeth are in a crowded condition. The four teeth must, if possible, be extracted at one sitting, the utmost concession to be allowed otherwise being the extraction of two on one side at a first sitting, and the two on the other side within a month.

If these important conditions are observed, I do not believe there will be any perceptible shortening of the bite, as MM. Bogue and Davenport predict, nor that any irregularities more important than some slight mal-occlusion will result, and this not very often; and the only possible arrest of development will be that of prominence of the teeth and lips—a kind of development which is not conducive to beauty.

In civilized life at the present time, I do not think there is an average of one person in a thousand with thirty-two sound teeth, and it is obvious to anyone that it is better to have twenty-eight, or even twenty-four, good teeth in the mouth, than to have thirty-two and be always in the hands of the dentist.



## CHAPTER IV.

## IRREGULARITIES.

AFTER the molars are extracted, the gain of additional space should be at once taken advantage of, if any considerable change is to be made in the position and articulation of the teeth; and if extractions have not been necessary, the time when irregularities can be corrected with ease is rapidly passing away. Very prominent upper teeth should be pushed back, narrow upper jaws should be widened, "underhung" jaws reduced either by forcing the lower teeth back, or pushing the upper ones forward, which is generally the easier way if it suits the face. These cases are often spoken of as family peculiarities, and therefore not to be meddled with; but it is difficult to see why a deformity which is curable should be perpetuated because it is an heirloom. It will be useless, however, for the dentist to urge the treatment if parents do not care about it. The appliances necessary for operations of this nature have to be worn constantly, day and night, at meal times and play time. They are sometimes so secured in the mouth that they cannot be taken out by the patient, but usually they can be

removed for cleansing night and morning, and this is all the indulgence that can be permitted. They are often so constructed that bands or springs of gold or platinum are conspicuously visible in the front of the mouth, and children wearing them have to make up their minds to give up parties for the time, or stand a little chaffing from their young friends, for they cannot have the plates out of their mouths for an evening's amusement. It therefore requires some degree of resolution and ability to deny one's self, on the part of the child, and such encouragement on the part of the parent as can only be given when there is an appreciative desire to assist the dentist in every possible way. The fullest co-operation on the part of parent and child must be secured, and failing this, the most skilful dentist will not accomplish anything of importance in correcting malposition of the teeth; and the most probable result will be a feeling that the one party has been unjust, and the other incompetent. On the other hand, when everybody really wishes for success in treating such cases, almost anything is possible. The dentist is not weighted with the depressing feeling that he is the only one interested in the case, and that the other parties are only obeying his instructions under protest. The child is encouraged to persevere by the quick instinct which tells when others are sympathetic or the reverse, and the parent, interested in what is shown to be possible, gains confidence as the work progresses, takes care that instructions are carried out, and that the work shall not fail from negligence.



Cleanliness should be insisted upon, and in this too the parents' aid is needed, for some of the retaining plates have to be worn for months, and if there is not scrupulous cleanliness, we may be doing harm to some of the teeth while improving others. If the plate is of such a nature that it can be taken out of the mouth, it should be removed twice a day, and those parts which are covering, or in contact with, the teeth, should be carefully cleansed with a brush. The teeth also must be kept as clean as possible, by using a soft brush, or if the teeth and gums are too sore for that, a small sponge fixed on a handle should be used, and every part that can be reached when the plate is immovable should be sponged with a weak solution of carbolic acid, or phenate of soda, or sanitas—any of which preparations can be effectively used to keep down inflammation, and assist in keeping the parts clean, and removing lodgments of food. If the gums swell, as they may do if many teeth are being moved at the same time, the pressure should not be increased for a few days, and astringents may be used with advantage.

Screws and springs, fixed in a vulcanite frame, as the case may require, will move any number of teeth to any necessary extent, even when, as the following case will show, the patient is considerably beyond the age at which these operations are usually undertaken. A young lady had never seen the left upper canine, but a peculiar thickness in the palate, immediately behind the lateral incisor, indicated that probably the tooth was there. When the young lady was three and twenty the



point became visible far inside the arch, and behind the lateral, which at this time had become very prominent. There was plenty of space for the canine in its natural position, and I determined to try to move it. Fig. 40 shows the position of the

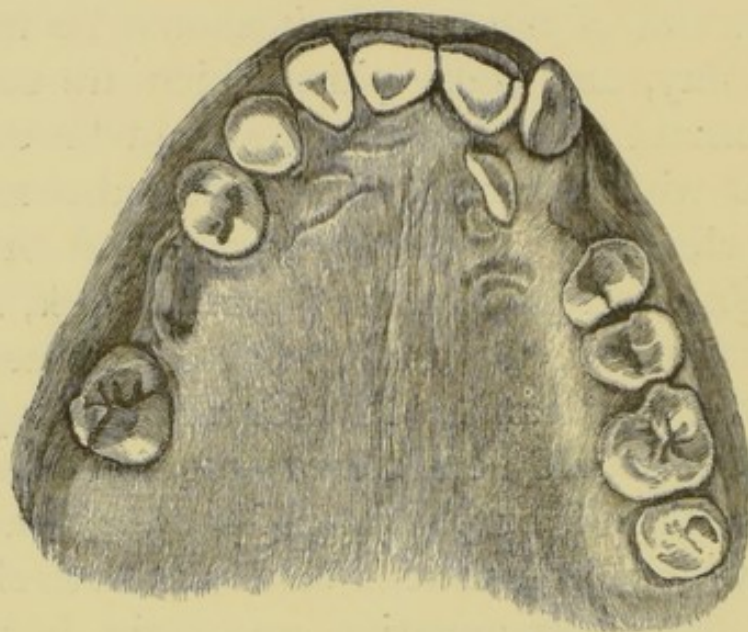


Fig. 40.—Showing a misplaced and very late erupting canine.

tooth when I commenced the operation. After several ineffectual attempts to apply the necessary amount of pressure, which was difficult because the apparatus would slip off the teeth now and then, I finally hit upon the plan shown in Fig. 41. The frame of vulcanite fitting tightly over the back teeth, so that it required considerable force to remove it, enabled the patient to masticate her food without permitting the lower front teeth to come in contact with the apparatus for moving the tooth, which consisted of a thick strong spring of gold, fixed in the buccal surface of the vulcanite, outside the second bicuspid and the molars, with



the point resting on the lateral. A triangular boss was soldered on the spring at a point immediately in front of the first bicuspid, so as to make a flat surface at a right angle to the line in which I wanted the tooth to move, and a hole was drilled

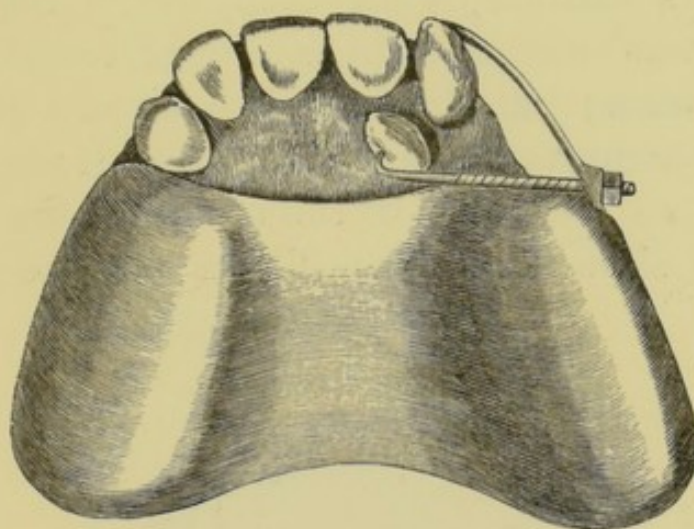


Fig. 41.—Showing apparatus for moving misplaced canine.

through this boss. A screw was then cut on a piece of strong gold wire, with a pointed hook at one end and a nut at the other. I then made with a drill a shallow indentation, in the enamel of the lingual surface of the tooth, for the point of the hook to rest in. The screw end of the hook was then passed through the hole in the boss, and the nut turned up, and a key fitting the nut given to the patient with instructions to screw it up twice in every twenty-four hours if the tooth did not get too sore, and to let me see it once a week, to remove and cleanse the plate, and to see if all was going on well. It will be seen at once that such an apparatus would move any tooth to any distance ;

the only difficulty was to make the plate itself so fast that it could not be disturbed by the turning up of the screw, or by mastication. The tooth was moved to its proper position in six weeks, without any inflammation, and the lateral also was pressed back to its place. The canine was easily kept in its position by the occlusion of the jaws—when it was once outside the lower teeth it could not get back; but the lateral required a retaining plate for some weeks, and even then it was left off too soon, as the model of the mouth at the present time will show (Fig. 42). The age of the patient,

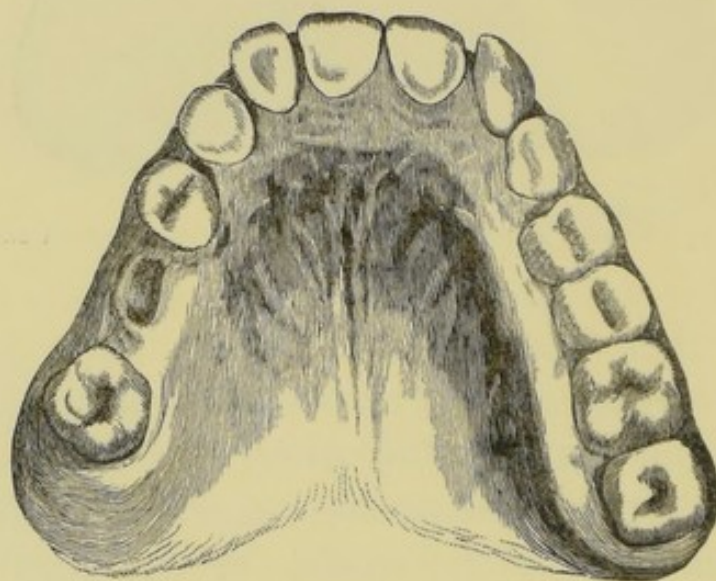


Figure 42.—Showing position of teeth from a model taken three years later.

and the distance the tooth had to be moved, made this rather a doubtful case at first, as most young ladies of that age would not care to have such a clumsy apparatus in the mouth for several months, but being convinced of the advantage to herself if it succeeded, she followed my instructions implicitly.



The result was a perfect success, for although it is three years since the operation took place, and the tooth is not even yet quite down to its full length, it is steadily advancing; and although the lateral is still a little prominent, it has not got worse in the last two years, and is not likely to change now.

Fig. 43 shows a case where a canine on the right side was very prominent, and the first bicuspid on the left side was also very prominent—

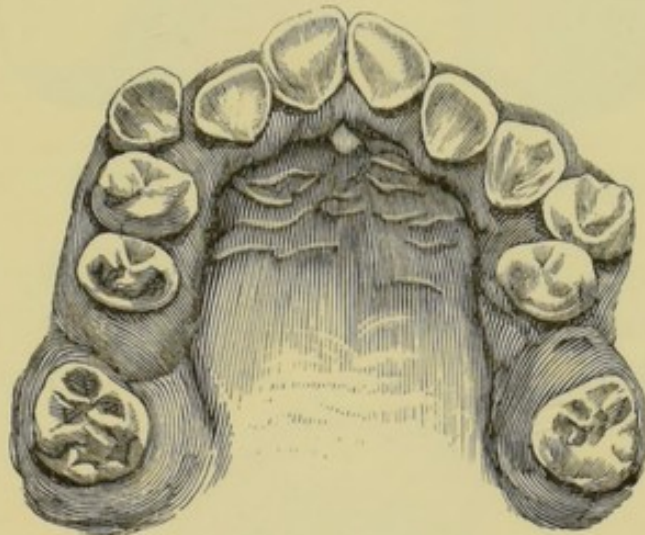


Figure 43.—Misplaced right canine and left first bicuspid.

the lingual cusp shutting outside the lower tooth. Fig. 44 shows the arrangement of springs for moving these teeth into their proper positions—the springs from the palatine surface pressing the bicuspids back into the space made by extracting the first molars, and the buccal springs pressing the prominent teeth into the desired position.

We frequently find that cases of projecting upper teeth are complicated with extreme shortness of the back teeth, which allows the lower

incisors and canines to shut quite past their proper antagonists of the upper jaw on to, and often

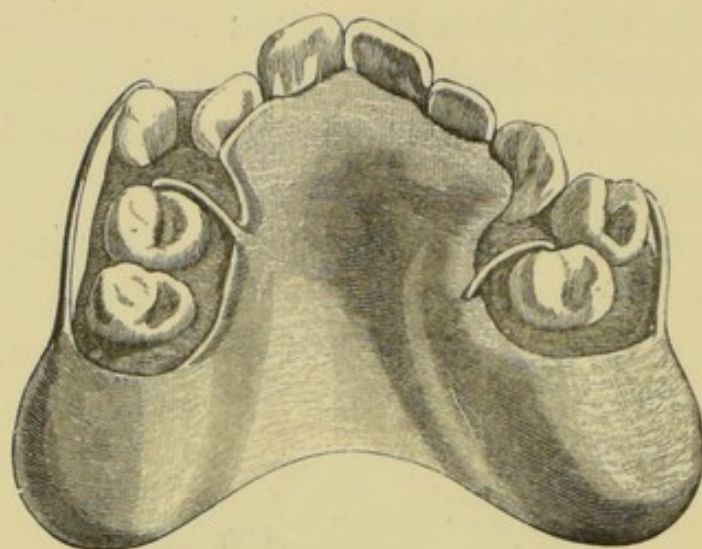


Figure 44.—Plate for regulating teeth in Figure 43.

making deep indentations into, the fleshy covering of the hard palate (Fig. 45). To move the upper teeth back in these cases, without also correcting

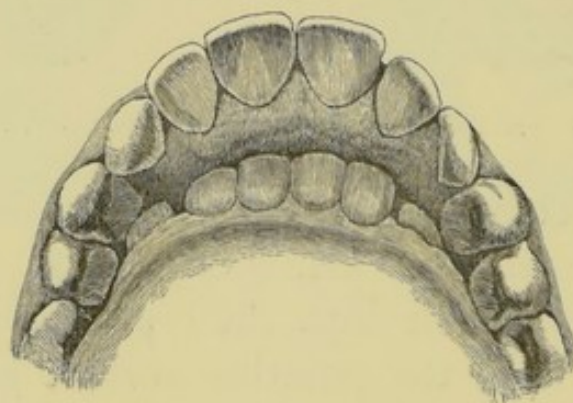


Figure 45.—Showing the upper front teeth projecting, and lower incisors and canines biting into the hard palate.

this form of occlusion, would manifestly be fruitless labour and trouble; because, when moved back, the upper front teeth would receive the bite of the



lower ones upon the incline of the lingual surface before the back teeth were in contact, and it would not take long for the powerful muscles which close the jaws to undo such a piece of work. Therefore, the first step in treating a case of this nature is to induce the molars and bicuspid to elongate sufficiently to prevent the possibility of the lower front teeth ever again touching the palate. Seeing that the back teeth would always elongate when they did not meet an antagonist of the opposite jaw, it occurred to me that, if a plate were so constructed that the whole biting force of the jaws came upon the front teeth, the back ones would increase in length to any required extent. A vulcanite plate was easily made of the required thickness at the point of contact of the lower teeth, and, fitting the palate well, it could be kept in its place by suction

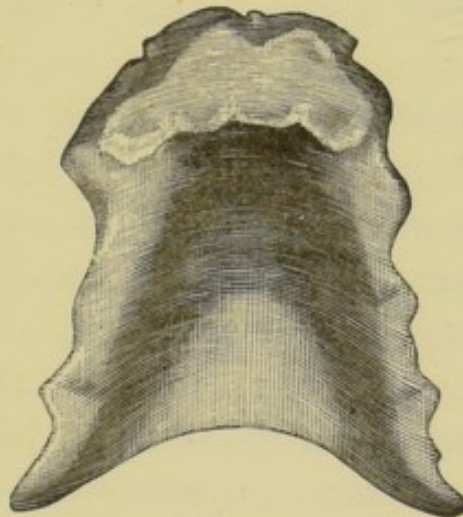


Figure 46.—Showing form of plate to take pressure off the back teeth so as to allow them to elongate.

(Fig. 46). This I have found to be perfectly successful in a number of cases that I have treated.

Three months will be about the time required to lengthen out the molars and bicuspid, so that the lower incisors would not reach nearer than a tenth or an eighth of an inch from the palate.

Fig. 47 gives a representation of a very interesting case of projecting front teeth, the

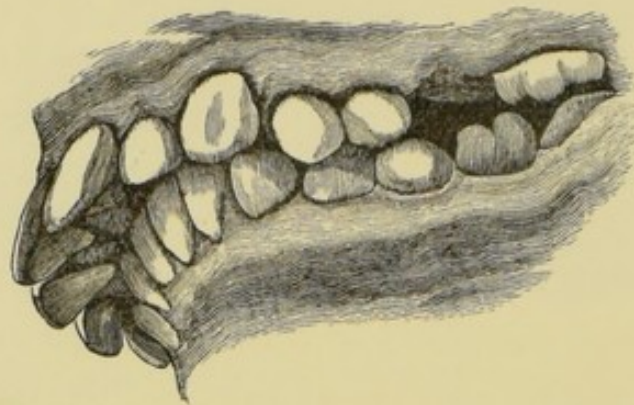


Figure 47.—Projecting upper teeth; models taken after the upper six-year molars had been extracted.

young lady being about fifteen years of age when she was first brought to me for consultation. The upper front teeth projected over, and when the mouth was closed were always lying upon the lower lip. There were wide spaces between the teeth, and the utterance of many sounds was quite indistinct—indeed it was on account of this indistinct utterance that she came to consult me. The lower front teeth made deep indentations in the mucus membrane covering the hard palate, nearly a quarter of an inch behind the central upper incisors. The age of the patient making it extremely probable that the difficulty was increasing, from the development of the wisdom teeth causing an increase of length in the upper



jaw, I determined to extract, at once, the upper six-year molars. I then made a plate such as I have just described, except that, having the spaces where the molars were extracted, I could clasp the plate to the second bicuspids, and thus leave the molars quite free (Fig. 48). It will be seen that

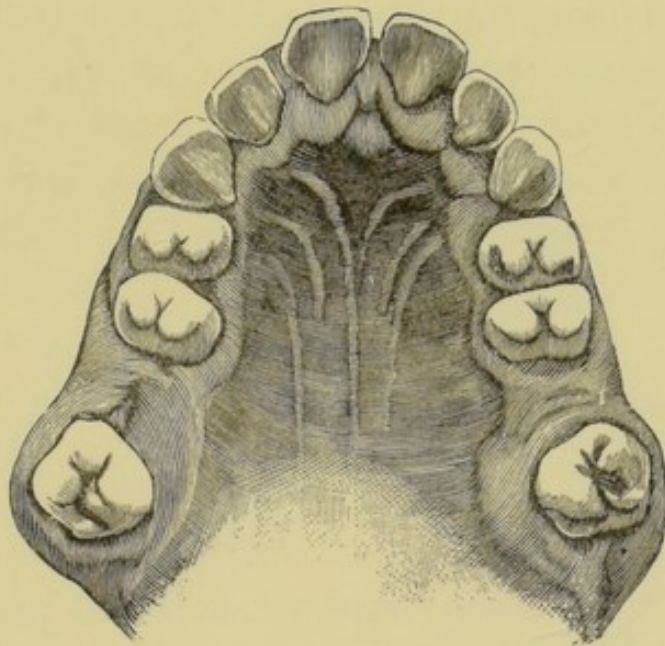


Figure 48.—Showing the position of the bicuspids three months after the extraction of the molars.

the lower molars were not extracted in this case, as it was desirable to encourage the development of the lower jaw as much as possible, and I intended to force the upper bicuspids back into the gaps left by the extraction of the upper molars. In three months all the back teeth had elongated, so that the molars and bicuspids would meet when the plate was in the mouth and the jaws closed, leaving, when the plate was taken out, a clear tenth of an inch between the ends of the lower incisors and the palate, which was in itself a great

gain, as it gave the tongue more room, and helped the power of articulation. The next step was to move the bicuspid back, which was done by making a vulcanite plate to cover the upper molars, in order to take the bite of the lower teeth on the molars and the incisors, leaving the bicuspid so that the lower teeth could not touch them. A fixed nut was placed in the substance of the vulcanite opposite the buccal surface of the molar on each side. Then a narrow strip of very thin gold, shaped like a figure eight, was made to fit tightly over the bicuspid on each side, and a piece, shaped like a letter T, was soldered to the

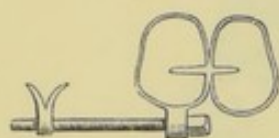

Figure 49—Showing the form of band and screw used in moving the bicuspid. The nut was fixed in the vulcanite plate.

band, so that it would slip between the two teeth and the cross lie in the sulci, to prevent the band slipping too high up under the gum. A small ring, or rather a stud with a hole in it, corresponding to the size of the screw hole in the fixed nut, was also soldered to the band opposite the buccal surface of the second bicuspid. The apparatus was then placed in position, and a long screw, with a square head, was passed through the stud into the fixed nut, and screwed up. A key fitting the head of the screw was then given to the father of the young lady, with instructions to turn the screw every day as much as she could bear, and to see that the gums and teeth were sponged twice a day with a weak solution of carbolic acid, letting me see the case once a week, to take the plate off and clean it thoroughly. This treatment soon



moved the bicuspid back. Then another plate, with the clasp fitted around the mesial surface of the first bicuspid, held them there, until the new alveoli were properly formed around them, as I thought it best to let these teeth get well established before I moved the others (Figs. 50 and 51).

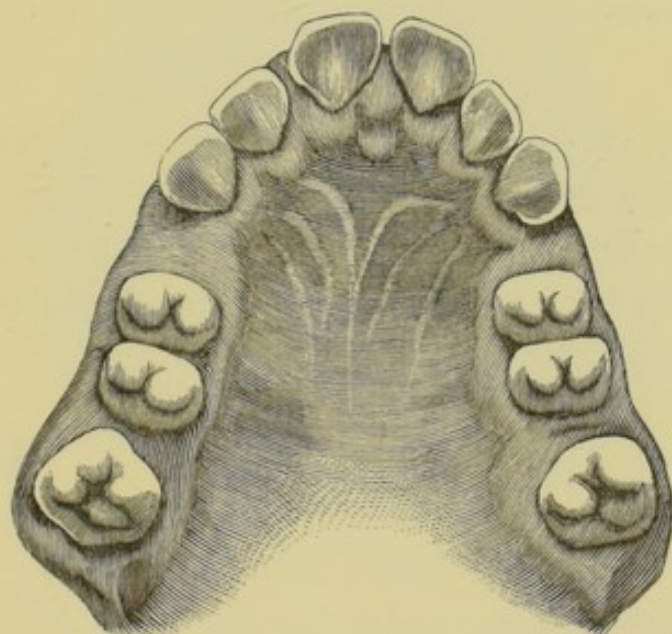


Figure 50.—Showing the position of the bicuspid after moving them.

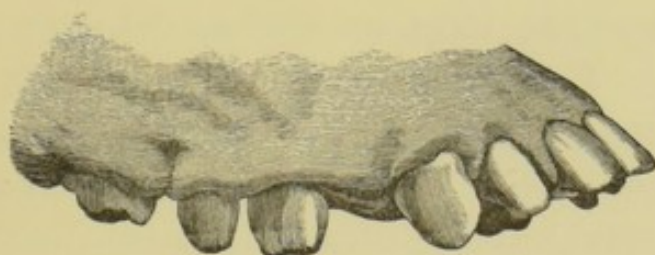


Figure 51.—Side view of the upper teeth at this stage.

The plate for moving the front teeth was fitted over the molars and bicuspid. The fixed nut was placed opposite the first bicuspid, and, of course, the plate had to be kept well back in the palate, allowing fully half an inch between its

anterior edge and the lingual necks of the front teeth. A long strip of thin gold was cut in the shape of Fig. 52, the lips being intended to be



Figure 52.—Showing the form of the strip of gold that was used for moving the front teeth.

bent over the cutting edge of the central incisors to keep the band from slipping up on to the gum, and studs were soldered to the ends for the screws to pass through. The canines being always rather difficult teeth to move, I made a separate loop for each of them, thus — Fig. 53 — having holes through the ends, which were bent so that the holes would come opposite the holes in the studs at the ends of the long strip that went round the front teeth, allowing the screw to pass through both ends of the loop, as well as through the stud (Fig. 54.) This soon forced all the teeth back to the required position. Another plate, with a plain band fixed in the vulcanite, passing around the front or labial surface of all the teeth, with hooks, as before, bent over the cutting edge of the central incisors, to keep it from slipping, kept all these teeth in position until the alveoli were properly formed and the teeth quite firm in their new position. The process of moving all these teeth to the extent necessary caused a great deal of inflammation and swelling of the gums on the



Figure 53. — Showing the form of loop used for the canines.



lingual side. Fig. 55 is from a model, taken when first the teeth were in a satisfactory position. Great care was taken to syringe the gums well, in

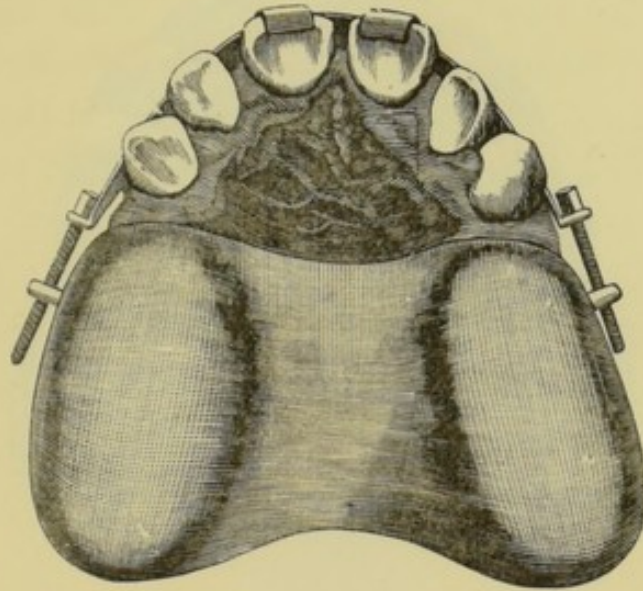


Figure 54.—Showing the regulating apparatus in position, with the loops for canines omitted.

order to remove all lodgments from around the necks of the teeth, and they were also constantly sponged with the carbolic lotion, so that the swelling soon went down without any disagreeable results. I saw the young lady about six months after she had left off the retaining plate, and the teeth were quite firm in their sockets, and there was no appearance of the old unnatural projection. This was an operation that would have been impossible without the aid of home influence and assistance, and the work, extending over a period of eighteen months, was a pretty severe trial of patience for a young girl; but she bore it extremely well, and assisted me in every way that she could.

Another case of projecting upper teeth was much more easily treated, because the back teeth

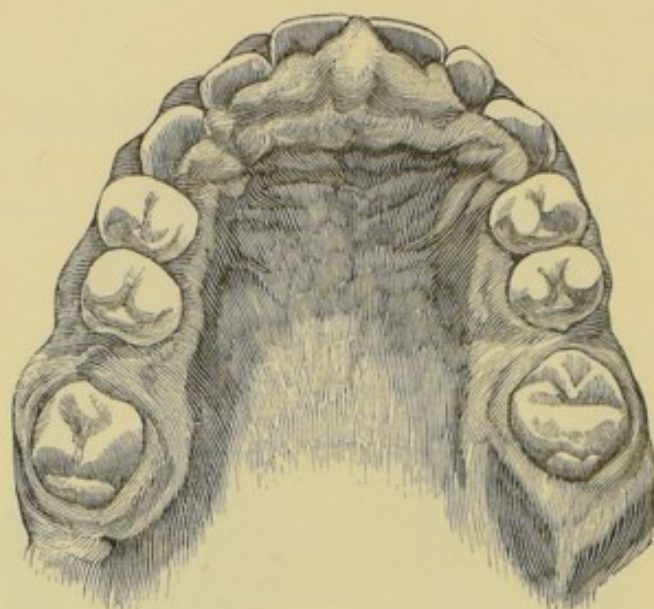


Figure 55.—Showing the condition of the gums immediately after the teeth had been moved into the desired position.

were of natural length. Fig. 56 will show the condition of this mouth when I first saw it, the

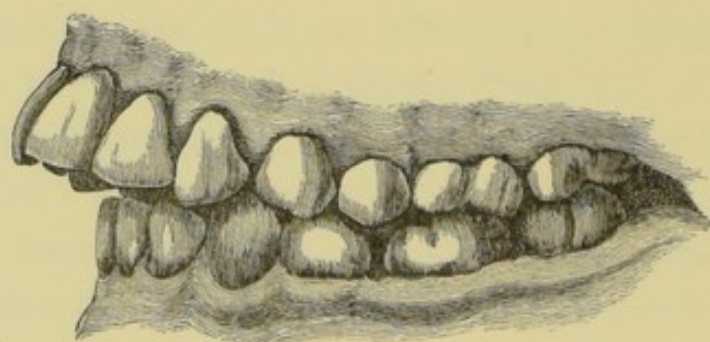


Figure 56.—Another case of projecting upper teeth.

young lady being then about thirteen years of age. Someone—I never ask who does these senseless things—had extracted two lower bicuspid; but



why this had been done it would be impossible to say, unless it was felt that something must be done to make a charge for, as any man who thought at all of what would be best for the patient would have seen that the lower jaw was already too small, and therefore that its growth should be encouraged by all possible means, and not stopped by extractions on each side. As it was, the best thing to be done was to extract the first upper bicuspid and move the canines and incisors back. I commenced with the canines, to avoid the excessive amount of inflammation that so often results

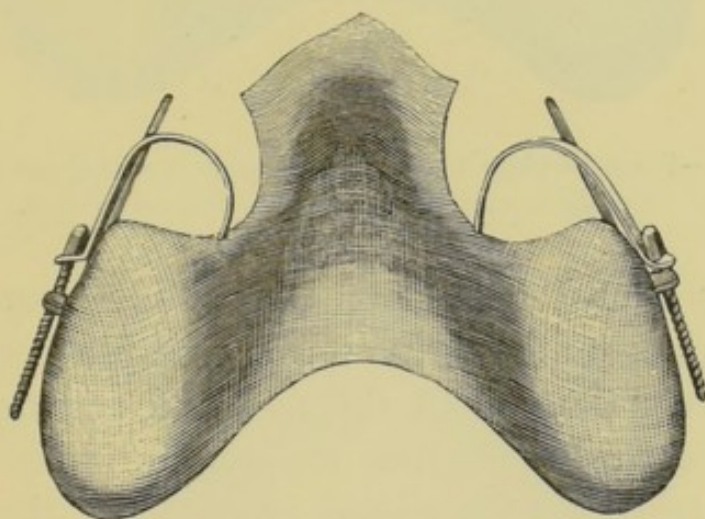


Figure 57.—Showing the form of loop used in moving the canines. The straight bar projecting from the buccal surface of the plate is intended to prevent any outward movement of the teeth.

from moving a number of teeth at the same time. A frame was made of vulcanite, covering the two molars and the second bicuspid on either side, with a fixed nut opposite the bicuspid. Then a loop of thin gold plate, like that shown in Fig. 57, was fitted to each canine, and a square-headed screw and key, as before, quickly accomplished the

removal. But they were also drawn rather out of the arch and elongated, probably from being moved so rapidly into the spaces where bicuspid had been recently extracted. To correct this I made another plate (Fig. 58), with a strong clasp

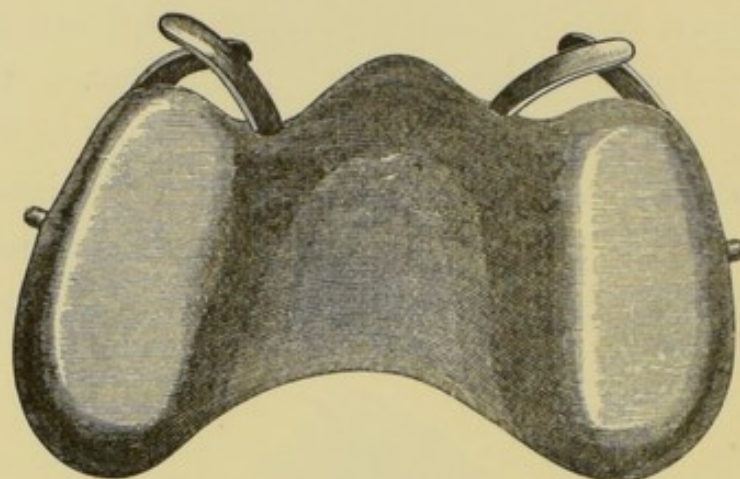


Figure 58.—Form of plate for moving canines inwards, and at the same time shortening them ; showing lingual surface.

passing round the labial and mesial surfaces of the canines, and a strip of stiff gold plate springing from the palate, with the free end resting on the points of the teeth, thus making an incline which, as the teeth were pressed inwards by the clasps, must shorten them by forcing them into the sockets. I then cut away the vulcanite from around the necks of the canines to allow them to move into their proper place in the arch, and bending the clasps so as to press on the labial surfaces of the teeth, they were very quickly in the position I wished them to be, and of the right length. This plate was worn until the canines were firmly fixed in their sockets, and then I moved the incisors back with springs of stiff gold



wire, fixed in the buccal surface of another plate shown in Fig. 59. All this was done without any

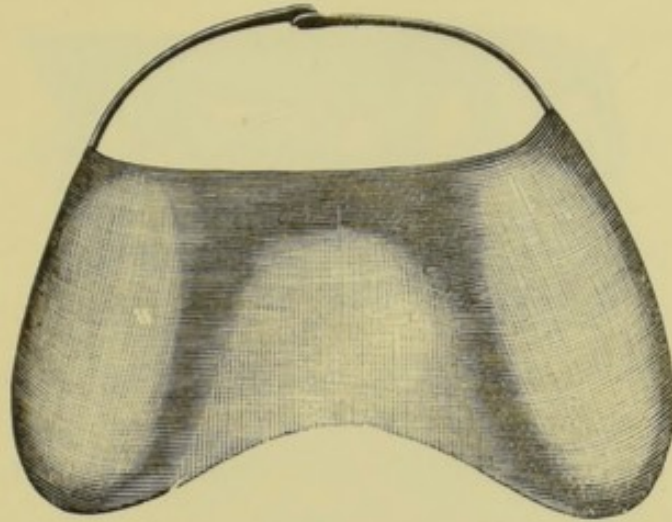


Figure 59.—Form of plate for moving all the upper incisors inward; showing lingual surface.

serious inflammation. When the teeth were as far back as I wanted them, the plate (Fig. 60)

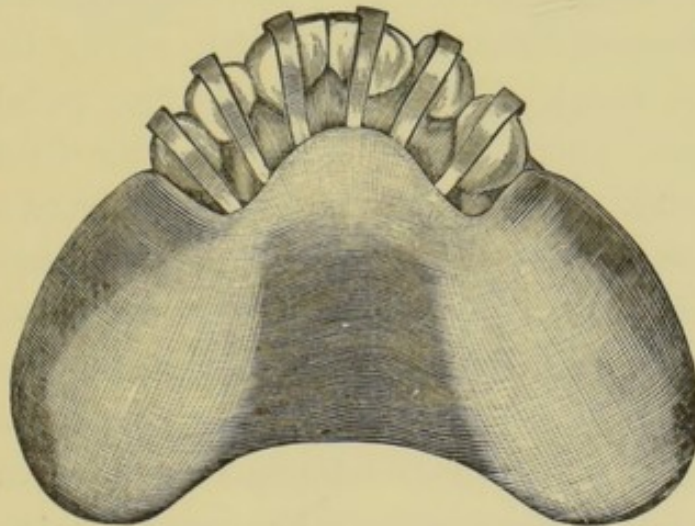


Figure 60.—Retaining plate in position.

held them all in position for six months, when the casts shown in Fig. 61 were taken.

Another member of the same family, a younger sister of ten years of age, also had projecting front

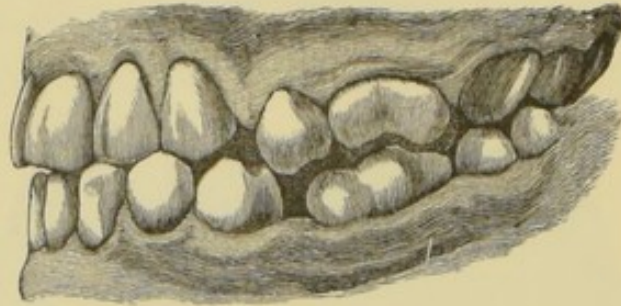


Figure 61.—Showing articulation of teeth at this stage.

teeth, with the complication shown in Fig. 45, the lower incisors shutting deeply into the palate, and the projection quite as conspicuous as in that case; but she was late in getting her second teeth, and the canines and second bicuspid were not erupted. I pressed the incisors back with springs, as in the last case, and, in making a plate to retain them in position, the same plan was adopted that I made use of in that case, strips of thick gold plate from the palate being bent over the cutting edge of the front teeth. But in this case I also made the plate of sufficient thickness, where it would receive the bite of the lower incisors, to give the back teeth a chance of elongating as much as was necessary to keep the lower front teeth from touching the palate; thus inverting the process adopted in a former case, where the lengthening of the back teeth was the first step in the treatment. But this patient was so much younger that I thought I might venture to simplify the process. The result justified my treatment, for there was no swelling of the gums



to prevent her wearing a plate of this construction after the moving of the front teeth was accomplished, whereas, in the former case, with the gums swollen, as shown in Fig. 55, this would have been impossible.

This case afterwards proved to be a disappointment, and gave me some trouble. When the lower bicuspid erupted they were so far inside the arch (Fig. 61A) that the upper bicus-

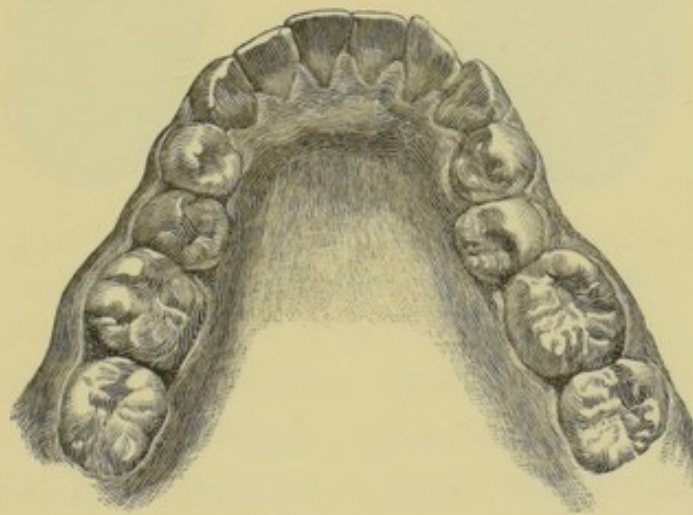


Figure 61A.—Showing form of lower jaw before treatment.

pids touched them only on the buccal surface, and were therefore being wedged apart, so that the upper jaw was becoming perceptibly wider; and the molars, being the only teeth which were fairly in articulation, were being shortened again; the lower front teeth gradually forcing their way to the old position, and, of course, pressing the uppers forward. It was evident that nothing could be done until the lower arch could be so widened as to bring the bicuspid into proper articulation, and I contrived the apparatus shown

in Fig. 61B, which proved to be effective. The plate covering the back teeth, so as to keep the

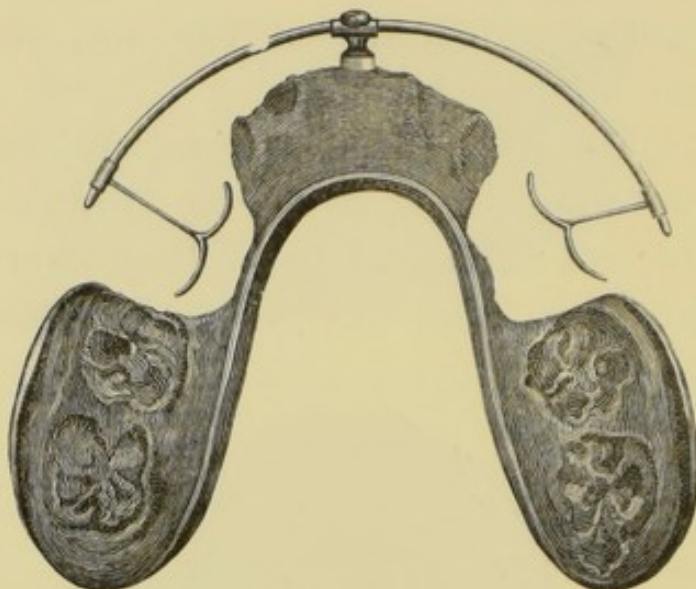


Figure 61B.—Showing the apparatus for widening the lower jaw so as to bring the bicuspid into proper articulation.

upper bicuspid from contact with the lower, supported a narrow strip of gold passing over the tops of the lower central incisors, and terminated with a half cylindrical socket, into which the half-round gold wire spring would slip readily, but be held so that it could not turn. The T-shaped hooks, made to fit the lingual surfaces of the bicuspid, were attached by strips of very thin gold to similar sockets, which would lie a little outside of and between the bicuspid on either side, to receive the ends of the spring, which would slip readily into them. These hooks, when properly fitted, were slipped between the bicuspid, and were not removed until the work was done, but the wire could easily be taken out and the plate removed for cleaning.



Figs. 61A and 61C are from casts taken before and after the operation. The increased width

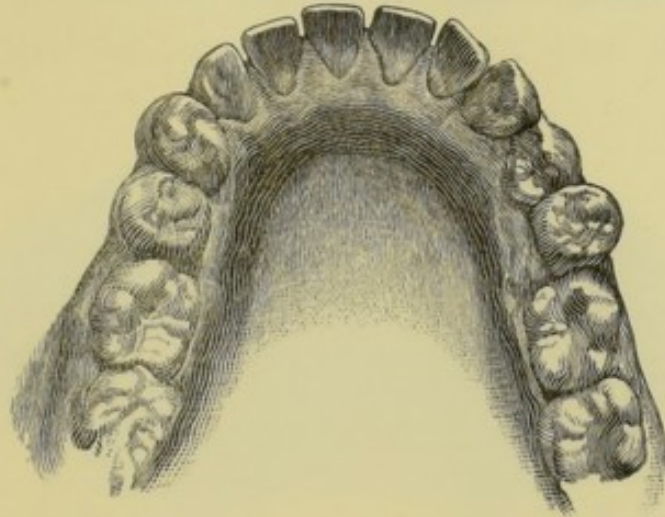


Figure 61C.—Showing form of lower jaw after treatment.

brought the bicuspid into proper articulation, and the front teeth did not require much further treatment, except that I found one of them had lost its vitality, probably from the pressure in moving it back, and had lost colour somewhat before I discovered it. I think in this case it would have been better if I had followed my own advice and left the regulation of the teeth until the bicuspid were erupted, as, although they might have come inside the arch just as much, I should not have been obliged to move the front teeth twice; nor do I think the incisor would have lost its vitality if it had been a little older.

The upper jaw may be too narrow, and from this cause alone the front teeth may be forced too far forward. A case of this nature is shown in Fig. 62. The outer instead of the inner cusp of the upper bicuspid is in the sulci of the lower teeth, thus making the upper jaw too narrow by

exactly the largest diameter of the crown of a bicuspid, or rather more than a quarter of an inch. The obvious treatment here is to press the bicuspids and canines outwards, in order to give

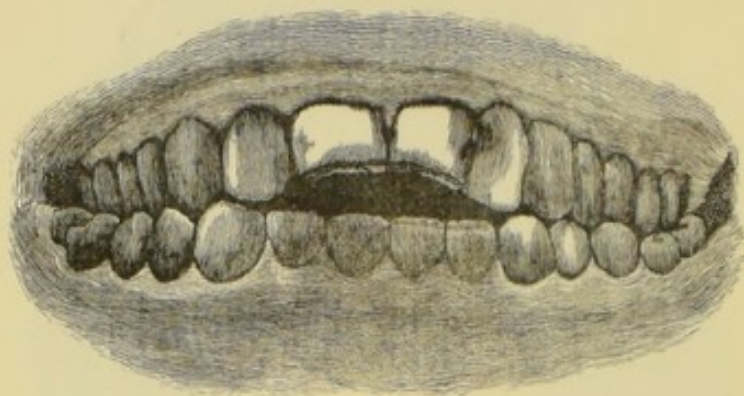


Figure 62.—Showing faulty articulation of all the teeth.

the jaw the proper width, and thereby gain room to press the incisors inwards; thus very considerably altering the form of the upper jaw, as shown

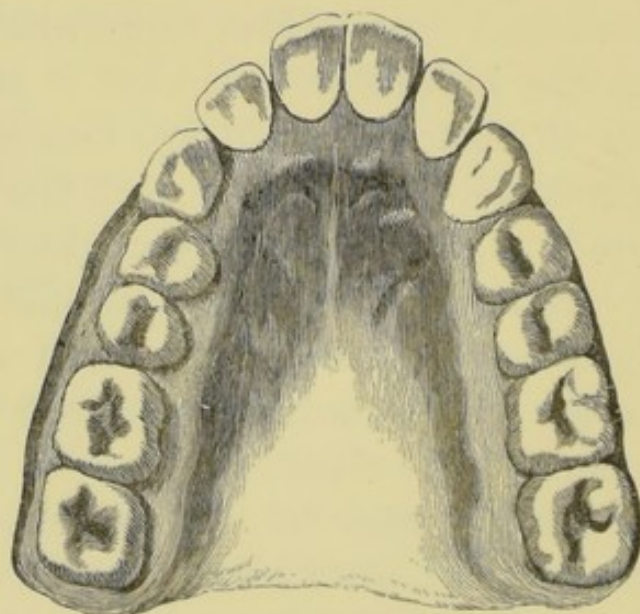


Figure 63.—Showing the form of upper jaw before treatment.

by comparison of Fig. 63 with Fig. 64. Fig. 65 shows the articulation after treatment. This was



done twenty years ago, with a vulcanite plate and wooden wedges; but a much more simple and expeditious method would be one I have adopted

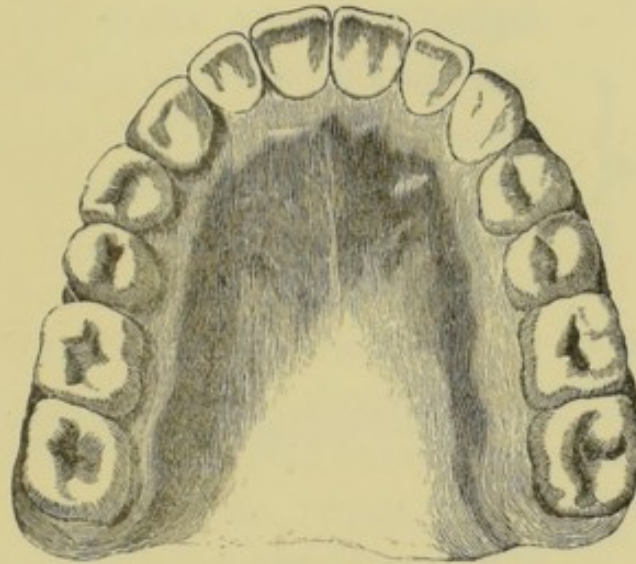


Figure 64.—Showing the form of upper jaw after treatment.

in a somewhat similar case recently under treatment. A stiff bar of gold, or platinum, is made to fit the necks of the bicuspid and canines on

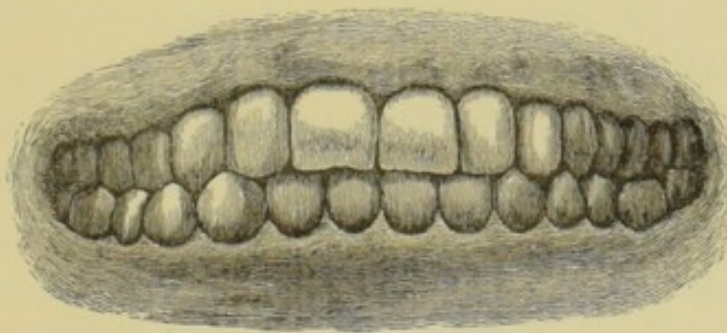


Figure 65.—Showing the articulation after treatment.

either side. One side is made with a wedge-shaped projection, or boss,—which should be notched in the middle,—opposite the first bicus-

pid, and the other with a cup-shaped projection in the corresponding position (Fig. 66). These may be tied to the teeth to prevent slipping, and then one of S. S. White's jack-screws, with one end

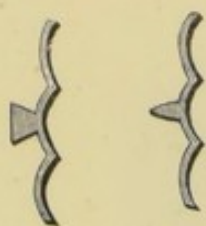


Figure 66—Showing form of braces to be used in widening the upper jaw in connection with the jack screw.

forked and the other end pointed, will do the work in a quarter of the time it took with the wedges. Then the plate, which would be necessary to keep the width that had been gained, could be utilized to press the incisors into their proper place in the arch, by using springs from the buccal surface on each side.

It might be said that no child would tolerate a jack-screw used in this way across the palatine arch; but I have not found any difficulty of this nature. On the contrary, I have used them repeatedly, and trusted the children, or their parents, to screw them up, and, as a rule, they are more apt to do too much of it than too little. In one case, a boy of fifteen used one of these screws in his own mouth so severely, in widening the jaw between the bicuspid, that he opened a space of nearly a sixteenth of an inch between the central incisors, where there was no space when the screw was put in. Apparently, he had actually opened the suture in the maxillary bone.

But another method of using screws for widening the upper jaw is quite as effective, yet by being attached to a plate fitting the palate, the apparatus is not so liable to be displaced by the tongue. The plate fits the palate and the lingual



surfaces of all the teeth, except those that are to be moved, and they are fitted with the shaped bars and bosses, shown in Fig. 66. A fixed nut is secured in the vulcanite opposite the palatine surface of the teeth to be removed, and a screw with a conical head, as in Fig. 67, will be found

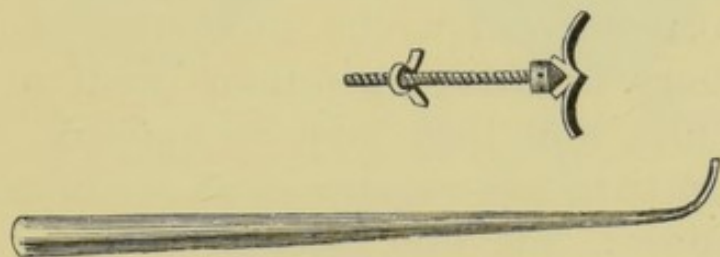


Figure 67.—Showing another form of screw to be used in widening the upper arch, with the lever for turning the screw.

effective. There must be holes through the head of the screw for turning it.

In all these cases much more time is required to allow the alveolus to close firmly around the tooth in its new position than is necessary to move the tooth; but it is essential that this time should be given and the tooth held securely until the new bone is formed. If one or two teeth are to be moved forward, and we move them far enough to make it certain that, when the jaws are closed, the lower teeth will go well inside the upper, and overlap far enough to keep them there, we need not take any further precaution. Or, in moving a bicuspid, if the cusps articulate properly, and the soreness is not such as to make the patient shrink from closing the teeth, they will be safe, but if the closing of the teeth does not make

it an impossibility for it to do so, a tooth which has been moved will certainly go back to its original position, unless we contrive some efficient means to retain it in its new position for three months at least, or until the new alveolus is properly formed.

Other cases, and the appliances used in treating them, might be described, but enough has been written to show the usefulness of screws and springs in these operations, and to give a general idea how they may be applied. Every individual case will require some modification of the treatment, and this must be wrought out by the dentist who undertakes the case, and whose inventive powers should enable him to do this, if he is ever to take any position in his profession.

I have inserted here drawings (Figs. 68 to 72) of a few forms of plates that have been used in

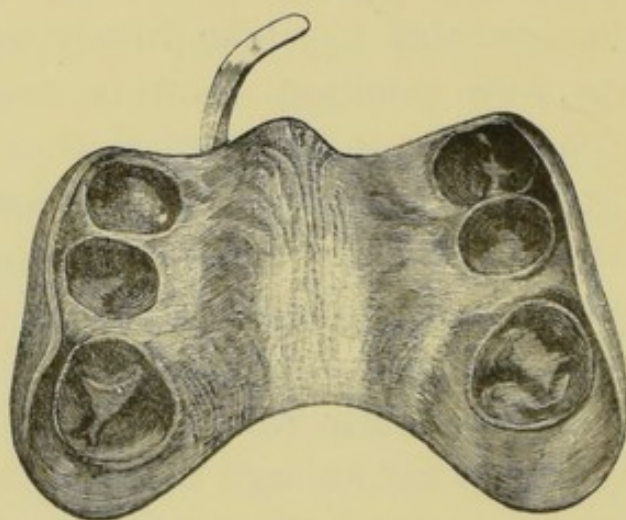


Figure 68.—Form of plate for moving a central incisor forward; showing palatine surface.

practical cases of regulating, and which may be useful as a suggestion for young practitioners.



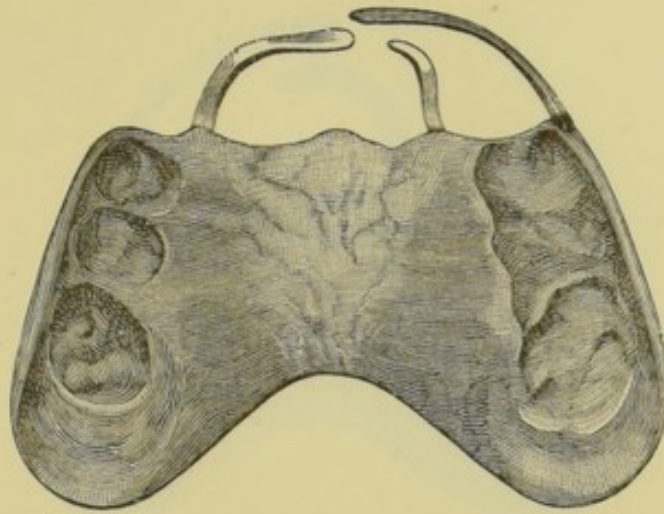


Figure 69.—Form of plate for turning right central in its socket, when it has a tendency to overlap the left central. The spring on the left side is intended to prevent any movement of the left central. Palatine surface.

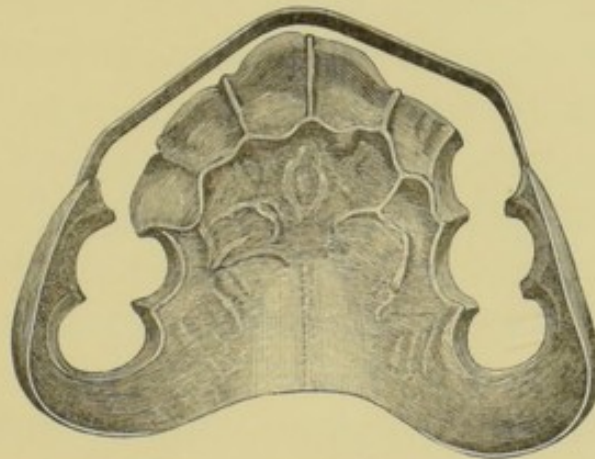


Figure 70.—A form of retaining plate; showing palatine surface.

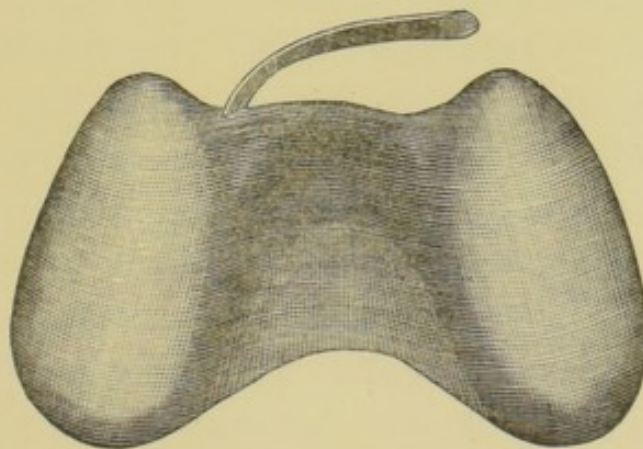


Figure 71.—Form of plate for moving a lateral incisor forward; showing lingual surface.

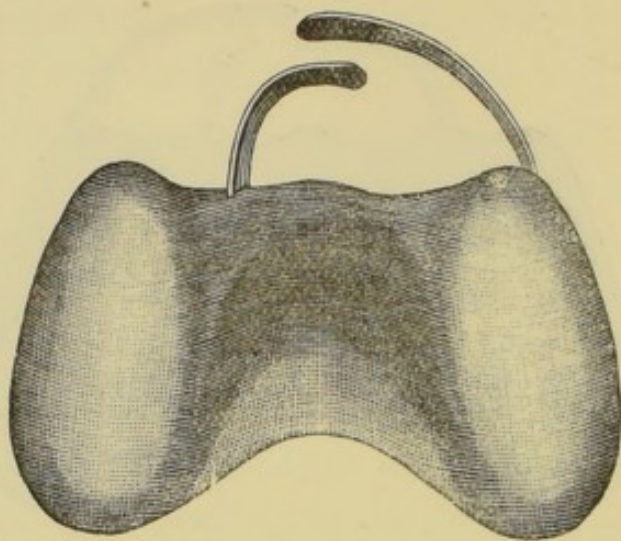


Figure 72.—Plate for regulating overlapping central incisors. Lingual surface.



## CHAPTER V.

## TREATMENT OF ADULT TEETH.

My theme so far has been the care and treatment of the teeth in childhood and youth; but there comes a time when we must begin to treat them as adult teeth, and it is an important question when this change of treatment shall commence. We cannot lay down fixed rules for our guidance in this any more than in numerous other questions that come up for consideration every day in dental practice. It is best, as I have said before, not to begin until a certain number of birthdays have passed; yet it is by no means a safe criterion for a change of practice that a patient has attained the age of sixteen. The condition of the mouth must indicate when it is time to begin what may be called permanent work. If, when the patient is sixteen, the teeth are still decaying; still very sensitive; the secretions still of the viscous ropy character indicative of acidity; or if the patient has been growing so fast as to outrun the strength; or if pride of appearance has not yet created a feeling of interest in the preservation of the teeth, we had better trust to our plastic work a little

longer, and renew it as occasion requires. But when a year has passed without a new cavity appearing in any tooth; when the gums look firm and healthy, and have lost the slippery feeling that is produced by viscid secretions; when we can remove one of the gutta-percha fillings and prepare the cavity for gold without giving any acute pain; when health and strength are keeping pace with growth; and when evidences of attention to cleanliness manifest themselves, we may begin to treat the mouth with permanent fillings, and have a reasonable hope that our work may deserve that description.

A tooth which is very sensitive, really so, is not fit to be treated with a metallic stopping of any kind. When I say really sensitive, I mean when the dentist is himself convinced of the supersensitive condition of the dentine, for we constantly have patients who cry out that we are torturing them, when the imagination has more to do with the suffering than the operator has, and in such cases we must use our own judgment. It is certain, however, that, in cases where there is truly excessive sensibility, the decay will go on in spite of the filling, if it is of metal. This is, without doubt, partly owing to the inability of the operator to make sufficiently perfect work when the patient is fidgeting under the pain he is inflicting; but I am inclined to think it is also partly due to a degree of inflammation of the dental fibrils, which is a preliminary stage of decay, and which the quick conducting nature of a metal filling, in absolute contact with them,



excites and maintains, possibly until a vitiated exudation from them becomes a destructive agent, when the dentine breaks down and is destroyed under the filling, as we know that the alveolus, and the cementum and dentine itself, are sometimes destroyed by the unhealthy exudation in alveolar abscess. In excavating a cavity in a tooth we generally find that the most sensitive parts are the extreme edges, where it is reasonable to suppose that the decay is most actively proceeding; and how often we have to lament the failure, at these points, of work that seemed to us to come very near perfection. The floor of the cavity is rarely its most sensitive point, unless the nerve is really exposed, which is a different matter, and fillings do not, as a rule, fail at this point. The change of position of two teeth that are filled on the approximal surfaces, so as to bring the edges of the fillings in contact, and the consequent lodgment of food and secretions there, when the dentist has designed them to be kept apart and to be self-cleansing, does not always satisfactorily account for these failures. A continuance of the inflammation which made that particular point so sensitive while we were operating, and a breaking down of the dentine there, would account for failures which we cannot, in justice to ourselves, admit to have been owing to unskilful work. But, if the filling is of a non-conducting nature, the inflammation is soothed and allayed, recalcification becomes possible and probable, and after a time a metal filling is tolerated, and will be an effectual preservative.



It is, therefore, not only a comfort to the patient to be saved the pain of having a gold filling inserted at once in a newly-discovered and sensitive cavity, but it is a positive advantage to have been made comfortable. It is my theory that the course of treatment I have sketched will bring the tooth to that condition of non-progressive decay and absence of inflammation in the cavities which Dr. Foster Flagg so well describes as cases which anybody can save with gold, and, however skilful we may be, it is more satisfactory to feel that we have made the conditions under which our work is done so favourable that success is easy, than to feel that we have made a difficult and troublesome operation, which may be a failure from no fault of our own.

Teeth which are decaying rapidly are always supersensitive, and it is certain that the best and safest way of reducing the sensibility in such cases is to protect the decaying surfaces with a non-conducting substance. Under ordinary circumstances, a few months of such protection will make it possible to prepare the cavity for a permanent filling, and then a metal filling may be comfortable, while, if it is inserted at once on the sensitive surface, it is anything but comfortable, and I doubt whether it will ever be so effective.

When we are satisfied that the favourable change we have been waiting for in the condition of the mouth has really taken place, we may begin to fill the front teeth with gold, and it should be the aim of every dentist to be perfect in this department of our art, which must not, however,



be regarded as the whole or the best part of dentistry. It is not my purpose to give any minute directions how to proceed to fill a tooth with gold, because written instructions, without clinical demonstrations, would never teach any one this art. Every student should have the privilege of seeing skilled operators at work, and of operating himself under the eye of a demonstrator, whose judgment and ability no one could question; but a few suggestions will not be out of place.

A good operator will keep the gold out of sight as much as possible, therefore the excavation for fillings in approximal surfaces of front teeth should always be made from the lingual surface, and in doing this the great advantage of being able to work with the mirror is obvious. Practice will make it easy for an operator to do all the work of excavating and filling approximal cavities in any of the front teeth, without looking once at the work by direct sight. Fig. 73 shows how to use the mirror while operating on front teeth. The familiar use of the mirror will also enable the operator to do all his work without resorting to the cruel, and, it seems to me, unprofessional practice of wedging the teeth apart to make room to work. It is cruel, because it adds greatly to the pain of any operation on the teeth, to have the lining membrane of the socket in a state of inflammation, from violence, at the time of operating; and it is absurd to say that the teeth can be forcibly separated, and then left to recover from the soreness, before the operation is pro-



ceeded with. When we move a tooth in a child's mouth, it is often several months before the tooth is quite firm in its socket again; and the older the patient is the longer will be the time required for the new formation of bone to support the tooth in its new position; therefore, if the operation is to be delayed until all soreness has disappeared,

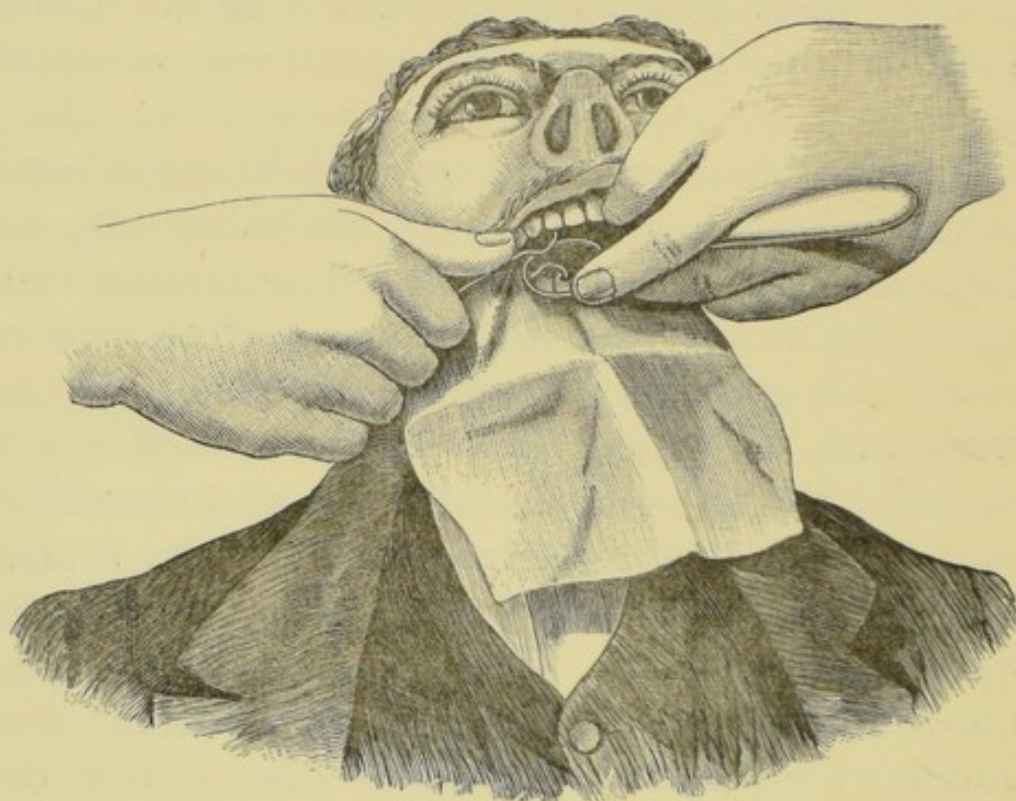


Figure 73.—Showing how the mirror is to be held while operating by reflection, the operator standing behind the right shoulder of the patient.

it would be necessary to wait two or three months at least. But it is probable that wedging does not, at once, cause absorption of the alveolus on the side to which the tooth is moved, but simply crushes it, as the alveolus is not a very dense bone, and would yield, to a certain extent, to pressure. This, however, does not make it any



easier for the patient, and does not alter the fact that the socket is widened, so that pressure on the tooth is no longer distributed over the whole of the socket, but is concentrated on the apex. If a wedge is driven into a piece of wood, nobody will deny that there is more pressure on the sides of the wedge than on its edge; but if, after the wedge has forced the fibres of the wood apart, it is removed, and a thinner one put in its place, the second one will rest on its edge; and if the socket of a tooth is widened on one side, the conditions are precisely similar. The tooth is wedge-shaped to a sufficient extent to make the bearing on the walls of the socket instead of on the end, but when the socket is enlarged the bearing must be upon the end. A tooth cannot be filled with gold without a certain amount of pressure in the direction of the apex of the root; therefore, if the conical root is not supported by the walls of the socket, this pressure must be directly upon the apical foramen, and upon the nerve and blood vessels of the tooth. Notwithstanding this, it is, as we all know, one of the favourite methods of filling teeth to wedge them apart, and then to proceed at once, or after a day or two, to pack a gold filling, condensing it with the mallet, and, of course, leaving the patient to suppose that this is the only way the work can be done. It is not surprising that nervous people dread the dentist's chair. I am sure that the vitality of many a tooth is destroyed by this process, for I have seen a number of cases where the death of the pulp could not be accounted for by any other hypothesis;



and, naturally, the great majority of the cases of suffering from this cause would go back to the operator who filled the tooth. It is not surprising that pulps die, when they are crushed and bruised as they must be by such treatment. The only wonder is that any remain alive. We know how easily a pulp is devitalized by a blow, yet we first prepare it to receive as much harm as possible, and then proceed to give it a series of hard knocks.

Well-shaped enamel chisels are indispensable, even to those who are most fond of the engine disks, for cutting away the thin, fragile enamel, and shaping the surface to be excavated. For front teeth, I think this part of the work is much more pleasantly and expeditiously done with the chisel than with the disk. They are made in great variety by all instrument makers, and they should be thin, yet strong, in the blade, and tempered as hard as steel can be made. A few desirable shapes are shown in Fig. 74.

Excavators for work with the mirror should be shaped so that the shank of the instrument will not come in the reflected line of sight from the edge of the blade. This is more important in excavators for a cavity on the left side of a tooth than for those on the right side. In the latter case, the principal part of the work is best done with an instrument bent at a very slight angle, at about a quarter to three-eighths of an inch from the edge of the blade. An extremely short blade, bent at a right angle, is also useful for the lingual edge of the cavities, but for cavities on the left



side of a front tooth the instrument should be first a long blade, bent at a right angle, for excavating the labial edge of the cavity, and then a variety of shapes, which I have called my swan-neck

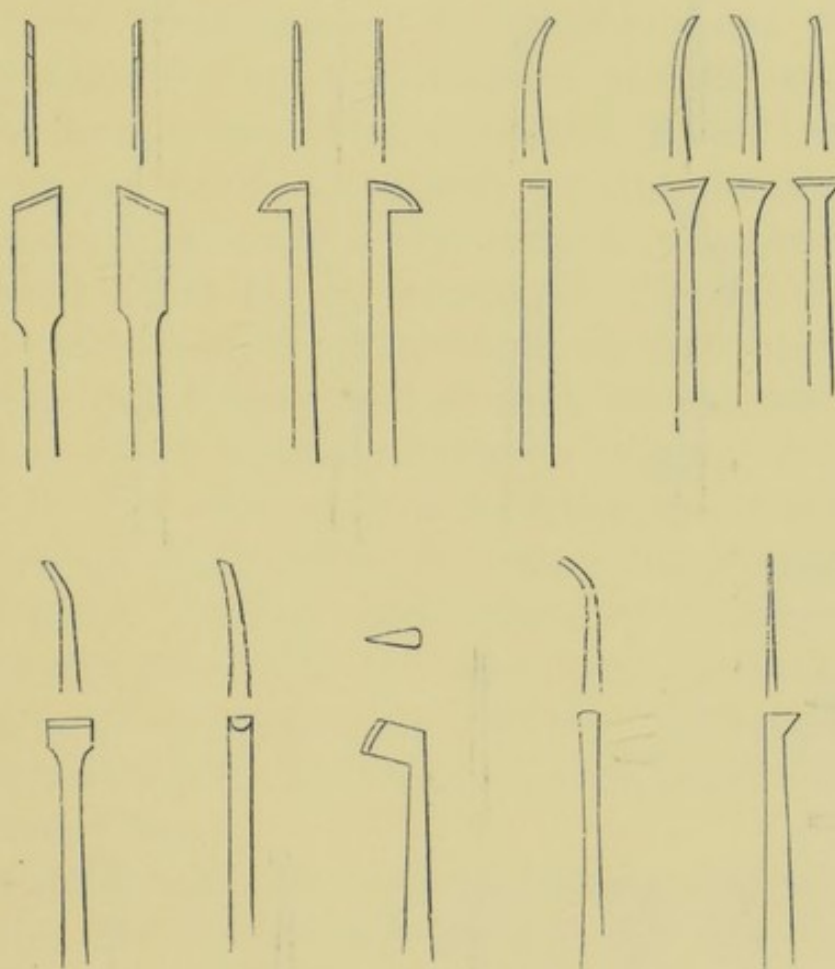


Figure 74.—A good practical set of enamel chisels.

instruments for want of a better name for them. Fig. 75 will give an idea of some of the shapes for excavators and pluggers. The same shapes are useful in packing the gold.

The importance of acquiring a habit of resting the fingers, or the thumb, firmly on some of the other teeth, or on the chin, if operating on the

lower jaw, or, if no other resting-place is available, on the fingers of the left hand (the left arm being over the patient's head, and the mirror held

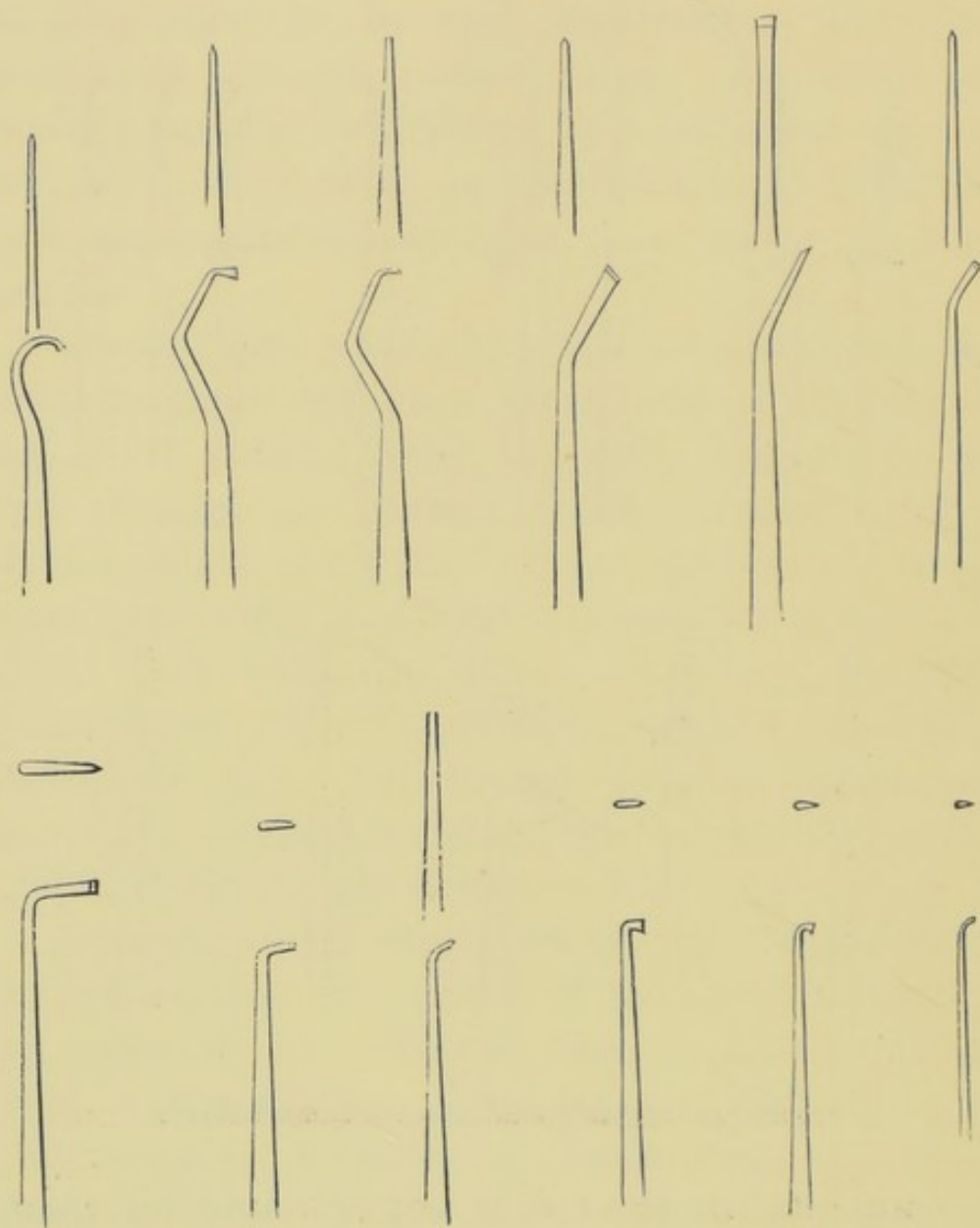


Figure 75.—A good set of excavators for use with the mirror. Nearly all these shapes are also useful as pluggers.

between the second and third fingers), so as to guard against accidents from an instrument slipping or breaking, cannot be too strongly



impressed upon the mind of the student. We often put a very considerable amount of pressure upon an instrument, and it may be one that we have tested well in all ways, but the more it is used, the more certain it is to break some time, when we least expect it; or the point of an excavator slips on a surface of smooth enamel, and a serious wound may result. When I was a student, my preceptor called me into the surgery one day to show me a scar on a lady's face from a wound made by an instrument slipping in the hands of a dentist. The lower lip had been cut through quite down to the chin, leaving an ugly cicatrix more than an inch in length. I need scarcely say that such a lesson made a deeper impression on my mind than many lectures would have done. In time, this resting of the fingers to guard against a slip becomes instinctive, and is done quite unconsciously, but it must be always in the mind until the fingers have learned to do it of themselves.

A great deal has been said about shaping the cavities for approximal fillings, but the fact is that, except in the smaller cavities, when but little skill is required to make a safe filling, the extent and position of the decay have determined the form that the cavity must take, and the dentist has only to take care not to leave too many sharp angles, nor too much overhanging enamel on the lingual surface of incisors and canines, when it may easily be broken down after the filling is completed. It would be as absurd for a dentist to attempt to shape all his cavities alike, as it



would be for an architect to plan his buildings without reference to the site on which they were to be erected.

While it is important to avoid weak edges of enamel on the lingual surface, where all the biting comes on front teeth, it is equally important to preserve as much as possible of the labial enamel, even though it may be so thin that the gold can be plainly seen through its porcelain-like transparency. Care and experience will enable the operator to pack gold against such a wall, by hand-pressure, so as to make a good safe filling without risk of breaking; and there is nothing to cause breakage in this locality after filling, unless it is an "under-hung" jaw; and although the gold may show through the enamel, it is not so conspicuous and ugly as when it is absolutely uncovered, and its glitter constantly reminding one of the quartz and gold ornaments so much worn at one time by the Californian and Australian miners. There should not be too much undercutting. The slightest possible inward inclination of the lateral walls is amply sufficient to retain the filling, and too much of it increases the difficulty and uncertainty of the packing. The form which the cavity is to take must be kept in view from the first. While we are cutting down the thin and fragile portions of the enamel, we should be noting the extent of the decay, and planning our work. The dentine decays more rapidly than the enamel, and there will always be a comparatively strong edge of enamel standing higher than the sound dentine of the same locality, and we should



preserve enough of this to make the margin of our filling safe and strong, but, at the same time, we must have free access to all parts of the cavity for our instruments. Therefore it is best, after cutting away what is obviously worthless, to put down the chisel and use the excavator, until we get a good idea of the depth of the decay and strength of the walls, and then finish shaping the edges. All that is wanted at the lingual approximal edge of the cavity is a wall that can be distinctly felt, with a good pointed excavator, to rise above the floor of the cavity, and this may be slightly, very slightly, undercut. More than this would be in the way, and in every sense a disadvantage, as at this point it is best to build up the gold quite flush with the lingual surface of the tooth, not to such an extent as to affect the V-shaped space, but enough to protect the edge of the enamel from fracture.

When the conditions are favourable, it will be found that good gold fillings in the teeth of young people of both sexes, between the ages of sixteen and twenty, will make the teeth as good as though they had never decayed at all. More than this cannot, of course, be said; for although I contend that, when a tooth needs filling, the filled surface should be left in the form that will most facilitate cleanliness, I do not mean to say that it is an improvement on nature, but only that since it has failed, and needs to be repaired, the best form that the repair can take is that which can be most easily and quickly relieved from the pressure of dangerous lodgments. Nothing can be better



than the natural form of the tooth, so long as it has its natural substance and its impermeable coating of enamel, intact, to protect it; but when this breaks down, and we have to restore, with a substance that is altogether foreign and unnatural, a part which has been cut away because it was diseased, we cannot expect a perfect welding of the restoration upon the natural structure. Therefore, we help the restoration by giving it a somewhat different shape. Knowing that the joints are the weakest portion of our defensive armour, we try to make them so that the missiles of attack will glide off without finding the weak spot. Thus it seems to me that fillings in front teeth and bicuspid are much safer when the surfaces are left in the forms shown in Figs. 22 and 25, than when the contour is fully restored.

Soft gold fillings are made by using the gold foil in twisted ropes, or in folded strips of four, six, or eight thicknesses—No. 6 being as thick as the foil can be used with advantage. The folds are slightly wider than the depth of the cavity, and they are packed by placing one end of the folded strip, or ribbon of foil, against the most available wall for commencing the work, and pressing it down, then folding down another layer and pressing it down, then another and another, pressing each a little more firmly than the fold before it, and taking care to secure the corners by wedging the gold well into them, so that the mass will not "rock," or lift at one corner when the opposite one is pressed down. Strip after strip may be packed into the cavity; or it may be



found best to use the gold in the form of cylinders, which are made by rolling strips of foil on a watchmaker's broach, but they can be bought from the dealers already prepared in all sizes and lengths. Usually it will be found that it is best to use a combination of strips and cylinders, filling the greater part of the cavity with the former, and finishing with the latter. A certain amount of condensation has, of course, been going on all the time. The corners have been secured, and the edges have been packed, but when we have packed in as many pieces as there seems room for, we go over the whole surface again, beginning in the middle of the filling with a small truncated cone-shaped instrument, and, wherever we find a soft place, we try, by pressing the gold laterally, to force the plugger down to the floor of the cavity, and thus make space for more ropes, or cylinders. Thus forcing the plugger into every soft spot, we gradually condense the mass, until the plugger will make no more impression upon it; but even now the gold should everywhere stand higher than the walls of the cavity. The burnisher may now be used over the whole surface with plenty of muscular power, and the surface filed down with a thin dividing file (a 0 0 0 file is not too thin in the case of front teeth). Then the burnisher must be used again, alternately with the file, until the surface is smooth and shaped as we wish it to be, when the polishing tape will complete the work. Very excellent fillings are made in this way, and I quite believe that in many cases it is the most trustworthy method; but we must not



be confined to one method. In general practice, one will, I think, find that lining the cavity with soft gold, packing it well against the lateral walls and floor of the cavity, filling the cavity half full, in fact, and then finishing with cohesive gold, will give better results, with less time in the manipulation, especially in front teeth which are badly decayed and have thin delicate walls. A loose twist of No. 6 foil is first packed against the cervical wall of the cavity and part of the labial wall, then, before it is wholly condensed, another piece is packed into the narrow part of the cavity towards the cutting edge, securing these two points so that there is no rocking of any portion of the gold. Another piece may then be added at the cervical and lingual corner, and secured there. Then, if the gold is sufficiently clean and dry, that is, if it has not been fingered with moist hands, the whole may be packed down together,—the loose thin ends of the twists being in this way interlaced. Only fine serrated points are to be used for a filling of this kind, and the surface is never to be smooth until the last piece of gold has been added. A small piece of cohesive gold may be added now and then, while the soft portion of the filling is being packed down and thoroughly condensed. The cohesive pieces serve to unite the loose folds of soft gold, and, being packed into the corners, are useful for anchorage to the bulk of the cohesive portion of the filling; but if sufficient care has been taken to keep the work and the material quite dry, there will be no difficulty about the parts adhering, and the filling can be built up



from the soft gold foundation, so as to make it a perfectly cohesive mass. The best soft gold can always be made sufficiently cohesive by passing it through the flame of a spirit lamp, thus thoroughly drying away the moisture it has absorbed from the atmosphere, and burning any greasy deposits it may have received in the process of manufacture, or from subsequent handling. A filling may be built up to any desired contour, if only the ultimate form of the filling is kept constantly in mind; and those parts which are most difficult to reach with the instruments are built up first, and so on, finishing with the most accessible parts. Great care must be taken to finish the gold down flush with the surface of the tooth, particularly at the cervical edge, where any projection of the gold, or overlapping, will quickly destroy the work by causing renewed decay.

Some practitioners use gold in the cohesive form from the beginning of the filling. A few retaining points are made with a drill, and are then packed with cohesive gold, which is added to, little by little, until the starting points are all connected, and then the work may proceed with a little more rapidity. Screws are sometimes used instead of retaining points, made with a drill simply, but as a drill must be used to make a screw-hole, and as one piece of gold can be united to another, by packing cohesive gold into a tube, so as to sustain a weight almost equal to what would be sustained by the same quality of gold melted and drawn into wire, it is difficult to see what advantage is derived from the screw. It may



save a little time now and then in very accessible places, but, as a rule, the difficulty of securing the screws only complicates the work without any real advantage. Indeed, to any one who has dry hands so as to be able to make up the twists, or folds of soft foil, without making the gold greasy, there can be no possible advantage in making the whole filling of cohesive gold.

The student should first learn to do these things well, and then to do them quickly. The amount of time spent in many operations on the teeth, and the appliances which become necessary, because of the time, render these operations far more formidable to the patient, and fatiguing to the operator, than is necessary or profitable. And here let us consider who is benefited by the greater part of the modern appliances used in operations on the teeth. Admitting that a man must be paid for his work, and for the time he has spent in learning to do it, the chief object in the practice of dentistry is, or should be, the good of the patient. The ideal physician is not one who makes it the chief object of his life to put money in his purse; and even looking at it from the purely selfish point of view, he would not find it for his interest to have his patients consider this to be the ruling motive of his practice. Nor would any one be willing to admit that, in our own speciality, the chief end of dental practice is the glory or profit of the dentist. What, then, is the object of the greatly increased amount of labour and time bestowed upon these operations now, compared with those of thirty years ago? The best operators



of those days saved the teeth, and made them useful. Many of their fillings are to be found in the teeth of middle-aged men and women now, yet I doubt if many of them spent four or six hours over any one filling. Someone will say that they condemned many teeth which are now saved. It may be so, but the teeth that they considered hopeless can be saved and made comfortable without spending so many hours over them, as I will show later on. But do we now, by spending so much more time and labour, save the majority of the teeth we fill any longer than they did by their much less pretentious method of practice? A case came under my observation a short time ago which will illustrate my meaning. A young man, who had been under my own and my brother's care almost from childhood, was staying in New York for a time, and while he was there an upper molar, in which my brother had been trying to save the pulp, began to give the usual indications that the pulp was in a putrescent state. The patient was well informed as to what might occur, and at once sought advice, and obtained relief by the usual treatment. When the periostitis was supposed to be cured, the tooth was filled. But it had been previously filled in several places, and it was thought expedient to remove all these fillings, and make one grand gold filling of about two-thirds the crown of the tooth. After all preparations were made, four hours were spent in packing the gold, by the malleting process, and two hours in finishing the work. This proved to be too much for the poor dead tooth,



and alveolar abscess of the most obstinate and persistent character was the result. Four months later he came back to England, and at once came to my brother for advice. Pus was oozing from around all the roots, and the probe indicated great loss of bone, which indeed was quite perceptible to the touch of the fingers. The tooth was loose and sore. Except about the neck, it was quite evident that the alveolus was entirely destroyed. Treatment was hopeless, and as the patient thought he had borne with it long enough, the tooth was extracted. I have no doubt that if this tooth had been filled with amalgam, it would have been a comfortable, useful tooth for years; only, it is possible, somebody might have made the patient believe he was being poisoned. But it was a favourable opportunity to show the dentist who had looked after this mouth what beautiful work could be done with gold, and the patient was undoubtedly pleased with the idea of having such a piece of work in his mouth. It was indeed a beautiful filling, but it was time and expense wasted, for it was an utter failure. Certainly this was not an instance where modern practice was an improvement on that of thirty years ago.

The rubber dam is very useful sometimes; but in a large proportion of the cases one has to treat, it is unnecessary, except for the convenience of the dentist, because it enables him to leave the patient, without danger to his work, and go to his lunch, or to see another case for a moment. This is a manifest injustice to the patient, who is fairly entitled to be considered, and whose time



may be as valuable as our own. There are few cavities where more than fifteen, twenty, or thirty minutes will be required for packing the gold, and there are not many mouths where a napkin, properly arranged, will not preserve absolute dryness for that length of time. If the gum has been wounded, a twist of cotton pressed up between the gum and the neck of the tooth, or a little elastic band, cut from a piece of one-eighth inch French elastic tubing, slipped over two teeth, or the cotton twist and the elastic band in conjunction, will be enough to stop any exudation of blood or lymph, and certainly these are not so formidable as the way patients are often gagged with the rubber dam. But this is not enough for some operators. The "saliva ejector" is fixed to the mouth—a sort of hydraulic pump—to take away the saliva as fast as it is secreted. A "tongue depressor" prevents any movement of that organ. And with all these fixtures in the mouth a man may go on operating for hours, if he likes, or, as a patient told me a few days ago of an occurrence which happened to himself, he was left with these fixtures in his mouth, and a filling half completed, for the "consultation hour," at the expiration of which the dentist came back refreshed, and resumed his work. It cannot be said that this is done for the good of the patient.

Again, there is the mallet, which is, without doubt, a useful instrument sometimes; but it does not follow, because a little of it is good, that a great deal must be better. It is an instrument to be used with caution, because it causes absolute



torture in some cases, and it cracks the enamel of many a delicate tooth; yet it is used persistently and constantly even in small fillings of the size of a pin's head, because it saves the strength of the dentist. This is a reason good enough in itself if it is frankly admitted, but do not let it be urged that it is entirely for the patient's benefit. No doubt it makes a harder filling than is ordinarily made by hand-pressure, but in approximal cavities it is not the hardness of the filling which saves the tooth.\* I am certain that the vitality of many a delicate incisor has been destroyed by the "tap tap" of the mallet. Every stroke is a shock, and, an assistant being required to use it, the strength of the stroke is not always under the control of the operator's will. Last, but not least, the use of the wedge is, as I have already shown, an abomination, which intensifies the torture of the poor patient from

\* Dr. M. A. Webb wrote as follows in a letter published in the *Dental Cosmos* of January, 1883—a letter which was evidently intended to correct an extreme interpretation of his teachings and practice in the use of the mallet, and which is emphatic enough in condemnation of its indiscriminate employment:—"I cannot understand why men, whose judgment seems to be so sound on everything else, should in the use of the mallet display such ignorance. They say you can pack more gold into a given cavity by the use of the electric mallet than by any other process. Just as though it was our aim to give our patients the value of their money in gold foil, regardless of the ever-existing conditions debarring us from such a course, and leading one to suppose that the greatest good to ourselves, and to those for whom we operate, depends upon the greatest power we can bring to bear in crowding and cramming the precious metal into the cavity. I believe rather that our ultimate success lies in the reverse of this—that is to crowd as little as possible, bringing very little if any pressure upon the walls of the cavity; and in order to do this to use that form of gold which requires the least force to consolidate. I think that successes are ten to one in favour of this kind of gold, manipulated by hand-pressure instead of by the mallet, no matter how light the blows may be. The mallet is a good thing in its place, but it is, in the majority of cases, out of its place in the insertion of gold fillings where cohesive gold is used in the form which I have referred to." The reference is to small loosely rolled gold cylinders.



all the other appliances, and is itself the least excusable; for the only object which can be claimed for it is, that it may enable the operator to restore a condition of things which led to caries, when the tooth was sound, and is to prevent it in the restored state, because the gold will not decay. No; but the gold filling never was made that was so perfect as the natural covering of the approximal surface of a tooth. If there are defects and fissures found by the microscope in the enamel of a tooth, are they not also to be found, by the same means, around the edges of the most perfectly made filling? I contend that a contour filling is liable to fail, because it restores the original form of the tooth, and that, being made after an unnatural inflammation has been set up in the socket by wedging, the socket being at the time widened so that the pressure comes more severely upon the end of the root, and, therefore, upon the nerve where it enters the apical foramen, the inflammation of the peridental membrane is increased to a dangerous extent; and that the shock of the repeated strokes of the mallet crushes the nerve, so as greatly to endanger the vitality of the tooth.

I cannot see that any of these appliances are for the benefit of the patient. Some of them benefit the dentist, and are at times extremely useful to him; but it is an error to think that good work cannot be done without them, and it is a greater error to use them because it has become a *sine qua non* that a man should make showy gold fillings if he wishes to stand well with his fellow-



practitioners. Any one who doubts that these operations can be done, and I do not hesitate to say well done, without wedging, and the use of the rubber dam and mallet, I would ask to look at Fig. 39, which gives a very good idea of the extent of the fillings in what may be described as a *very* wet mouth. I made all the approximal fillings in both sides of the incisors, canine and two bicuspid, by the method I have described as a combination of soft and cohesive gold. One of the laterals was so seriously decayed that a part of the labial wall was broken down, and the lip covering the tooth well, I restored the contour. All this was done without using the wedge, or rubber dam, or mallet.

The following extract from a letter to the late Dr. Robert Arthur, printed as a foot-note on page 141 of his work on the *Treatment and Prevention of Decay of the Teeth*, is a frank acknowledgment of what must occur in the practice of every man who persistently pursues this course of treatment, but not many of them are ready to admit their failures:—"I have to deplore the comparative failure of some of the most perfect and beautiful fillings, that cost me hours and days of patient painstaking labour. I particularly refer to those cases where the teeth were *wedged*\* apart, carefully and perfectly filled, without making a file scratch upon the proximate surfaces, and then allowed to drop back to their natural positions. Dr. Eleazer Parmly, of New York, paid one such of my cases the compliment of saying it presented the most

\* The italics are his own.



perfect specimens of proximate filling he had ever seen, and yet, although the patient was an attentive and appreciative one, who was fully instructed, and spared no pains in the care of her teeth, decay, after a few years, commenced around the edges of the fillings. I had to file the spaces so that the teeth were permanently separated, and refill all the cavities. This is only one very marked case in my experience. Many, very many, others have occurred in my practice, and came under my observation."

I have just had my attention recalled to a case which came into my hands two or three years ago. A lady was suffering from alveolar abscess, caused by a dead pulp in one of the upper central incisors, and she told me that she had been constantly troubled with her front teeth for several years; indeed, they were dreadfully painful when they were filled, and had been more or less troublesome ever since. She had a great deal of good work in her mouth, and the larger part of the fillings were saving the teeth. The two central incisors had fillings in the mesial surfaces, and both teeth were dead, but there was nothing in the appearance of the fillings to justify me in removing them. So I drilled into the pulp cavities from the lingual surfaces, found putrescent pulps, as I expected, removed them, or the remains of them, treated the roots with antiseptics until they were clean and healthy, and then filled them. She told me that the teeth had been wedged apart when she was about thirteen years old, and filled then with gold; that she suffered dreadfully when



it was being done, and for weeks after; that then there was a period of comfort with them, and afterwards she began to have a swollen face every time she was exposed to cold. This is a common history, such as we have all heard over and over again. Of course, it is impossible to say whether the vitality of these two teeth was destroyed by wedging, or by the mere insertion of the metallic fillings on a sensitive surface, and the consequent frequent shocks from thermal changes. But whether it was by one or the other, or by both combined, the mischief was certainly to be traced to the fillings, and as certainly it would not have occurred if the cavities had been excavated, without wedging, from the lingual surfaces, and filled with gutta-percha until the patient was a few years older. I have seen the lady again quite recently. She had not suffered again from swollen face, but one of the teeth had begun to decay around the edge of the approximal filling, and I had to refill it. This gave me an opportunity of satisfying myself about what I had before only suspected, viz., that the original cavity had not penetrated so deeply into the tooth as to affect the pulp.

The history of our professional progress in the last decade shows how men, who labour for the profession, may be misunderstood and misrepresented, as in the case of Dr. Foster Flagg, who has devoted these later years to an effort to lift our specialty out of a narrow groove, and give its practitioners the broader views which should distinguish professional men. To do this more



effectually, he refuses to treat those teeth which can be saved by gold fillings, and devotes himself solely to the saving of teeth which the gold workers would consider hopeless from their point of view. He uses only the plastic materials which those workers in precious metals affect to despise, and does more than any other man has ever done to improve the character and preparation of these materials. He sacrifices the credit which the profession gives to men who do only one kind of work well, the profit from cases which make a great show with the expenditure of mere mechanical skill, and also valuable time in analysing, testing, and preparing alloys and mixtures, the results of which he freely gives to the profession. Yet a large proportion of the members of the profession he thus tries to advance impute the basest motives of self-interest to his efforts, and apply an epithet, which is a pun upon his name, to those who try to benefit by his teachings, without following his extreme example, which he never suggested or expected that any one would do. So it may be that some who read these notes will misconstrue my meaning, and say that I am endeavouring to create a prejudice against the use of gold for filling teeth; but I emphatically deny that I have any wish or intention to say a word against the use of gold in the abstract. I do, however, mean to protest against what I consider to be a growing evil in our profession, viz., the measuring of a man's ability as a dentist by the amount of labour he bestows upon one particular kind of work, and the consequent tendency of the



teaching and practice of dentists to devote all their energies to the making of gold fillings, without sufficient consideration for the comfort or the time of their patients, and without exercising a reasonable amount of judgment as to whether the case is a suitable one for that form of treatment; thereby incurring risk of failure of the operation after the endurance and the purse of the patient have been severely taxed, with the inevitable result that confidence in our operations is destroyed, and our power to do good diminished. It amounts to this, that if a man does not treat all his cases alike, whether it be child or youth; a young, middle-aged, or elderly man or woman; whether a woman be married or single, having a child every year or two, or having none; delicate, sickly and nervous, or vigorous, healthy, and knowing nothing of nerves; if he thinks it best to use plastic fillings for some of these—no matter how much he may use gold for suitable cases—he is liable, if his work is seen by those who claim to be the *regular* practitioners, to have his practice condemned, and his claim to position in the profession disallowed.\* It is, therefore, quite time for thinking men to assert themselves, and to do all that lies in their power to assist in the dissemination of more liberal and eclectic ideas. The doctor with one medicine for every ill is a quack, and the dentist who has but one idea is no better; but, naturally enough, if a man's standing in his profession is to

\* I am glad to think that, since the publication of the first edition of these Notes, a more sensible view of these matters has been growing up.



be judged solely by his skill in one kind of work he will not think of anything else; and so long as he can persuade his patients to submit, he will take advantage of every aid which inventive talent can provide to perfect that kind of work; and he is unwilling to admit that another man can get as good results by more simple means. But, after all, it is the result that we judge ourselves by, and if a man satisfies himself, he cannot go very far wrong.

I have written to little purpose, however, if I have conveyed an impression that I think thoroughness is not essential in an operator. The aim should be to reach perfection of work; but it does not depend solely on ourselves, and we cannot attain it at once in every case. We shall have nervous and weakly children to treat, or pregnant women, whose teeth are too sensitive to bear even a breath of cold air without causing pain; or men and women recovering from severe illnesses, when their weakness is both a cause of sensitiveness, and a reason why they cannot endure thoroughness of treatment. In these cases, if we can, without attempting to remove all, or even any of the newly decalcified dentine, so shape the space between two decaying teeth that gutta-percha can be retained in contact with both surfaces, we shall have gained a step. Even an operation so slight as this may give comfort to a sufferer, as well as check the ravages of decay, while an attempt at thorough excavation would probably drive the patient out of the chair, or cause a sacrifice of valuable teeth. Protection



of carious surfaces, no more thorough than that just indicated, will in a short time make it possible to excavate more thoroughly, and so, in time, a proper filling may be possible. But it must not be supposed, because a man tries to make an operation bearable to his patient, and attain perfection of work by stages that are easy, not so much for himself as for those who seek relief at his hands, that he will be content with the result before perfection is attained. Perhaps it is too much to expect of human nature that a man will try to put himself in the place of his rival, as Charles Reade's Dr. Amboyne might suggest; but if we could, when we see a patient who has had this kind of treatment at the hands of our neighbour, try to realise the circumstances under which the operations were performed, and not say, with an expression of wonder at the incapacity of the operator, and of pity for the victim, that we cannot see why the work was not more thoroughly done, it might help us to a better position, as professional men, in the estimation of the public, and certainly it would give us more self-respect.

We may put a young man's teeth in order, and, if he is vigorous and strong, it may be quite possible that he will not need the services of a dentist again until he is past the prime of life; but a young woman, with equally good work in her mouth, has not the same chance of reaching middle age without requiring more or less of the dentist's aid; for although good work may make the teeth as safe from new decay as if they had



never decayed at all, it cannot make them better than this. The young woman gets married, and has a family of children. During pregnancy she suffers from acidity, which attacks her teeth to such an extent that she often despairs of saving any of them. Perhaps, in her despair, she relaxes her efforts to neutralise the acids and keep her teeth clean, when at such time she should redouble, and, if necessary, quadruple, her exertions. Of course, we can do but little if she will not try to help herself; but to those who do try, are we to give no help at all, because the teeth are too sensitive to bear the excavating for gold, or because, when the teeth are filled with gold to the best of our ability, the fillings fail? I do not think it would be dentistry in the highest sense, if we could not do something for her. It is possible to keep the teeth for ten, or twenty years, if necessary, with gutta-percha fillings, renewing them as often as may be needful; and then, when this temporary work is no longer requisite, we may do as much gold work as may be necessary. But to put it on the low ground of policy alone, without reference to the patient's ability to bear pain, I doubt if it is best to attempt to do the permanent work until we see the last of the babies.

The cervical edge of a filling that extends under the gum is always a weak spot, and I have very little confidence in the safety of gold in that position. I therefore generally commence a filling in that position with gutta-percha, if much of the cavity is under the gum, or with tin, if it is only slightly so. Tin never loses its compressibility,



until it is hard and dense throughout; gold, on the contrary, may become hard on the surface from packing, and perfectly soft beneath. Therefore, in packing a filling into a position that we cannot see all the time the instrument is at work, it is possible to leave a corner loosely packed; but with a few folds of tinfoil beneath the gold, this is not so likely to occur, as the tin will still be condensed, while the gold is being packed down upon it. In these positions, where the slightest deviation of the instrument from its proper direction may flood the cavity with blood, it is a help to leave the tin projecting so as to overlie the gum, and we can condense this portion of the filling more thoroughly when the gold is completely packed, and thus make a tight joint after the risk of flooding is past. I have had, in the course of my professional experience, the opportunity of examining a great many fillings in which gold and tin were used in combination—the work of a man long since dead—and there was certainly no ill result in any one instance from the contact of the two metals in the same cavity. If any failure of the fillings occurred, it was more frequently the gold that failed than the tin, because the gold had to stand the wear of mastication, and the cohesive quality of this metal had never been utilised to give a harder surface to any of the fillings. Tin makes an extremely good filling. It appears to have a better preservative effect upon the surface of dentine with which it is in contact than gold has, but it can never be hard enough to wear as gold does if properly packed. This



is, however, an objection which only applies in cavities which are actually exposed to the attrition of mastication. When tin is placed against the cervical wall in approximal cavities, and the bulk of the cavity filled with gold, all its best qualities are available without its disadvantages. But care must be taken that it is not packed in contact with the labial wall of a front tooth, as it will show discolouration, which, however, the thinnest fold of gold in that corner of the cavity will prevent. Before the tin is quite fully condensed, a twist of gold should be packed into it, and then packed down with it, so as to leave a surface of gold, and then the filling may be proceeded with exactly as in the case of soft and cohesive gold fillings previously described. When gutta-percha is used for that portion of the cavity which is under the gum, it is, of course, still soft enough to be compressed by the packing of the gold, and it makes as tight a joint as can perhaps be made; and as it is perfectly protected from attrition, it is practically indestructible. For approximal cavities in bicuspid and molars, which, as every dentist knows, are extremely liable to fail at the cervical edge, if they are to the slightest extent under the gum, the use of tin, or gutta-percha, as a foundation, makes safer work than can be made by trusting to gold alone.

A case came into my hands about three or four years ago, where the palatine cusp of an upper second bicuspid had been broken away, the fracture extending under the gum. It had been restored with gold, making a very nice-looking



operation; but the patient told me it was a very laborious one, as the operator had spent about six hours in packing and finishing the filling. A few months after I first saw the case and admired its appearance—much to the patient's satisfaction, as he thought it a very good piece of work—he called to ask me to look at his big filling, which he fancied was becoming loose. An examination showed that he was quite correct, as the whole mass of gold came away without the application of any force. The failure was due to some slight decay—very slight it was—at the point where the anchorage for the gold had been made under the gum. The question then arose, How could the mischief be remedied so as to make the tooth safe and useful? My own preference would have been to make a new cusp of porcelain, and fill in the space between that and the natural cusp with amalgam, a process which I will explain later on, but the patient was desirous that gold should be tried once more. Being satisfied that it would not be safe to make another filling like that which had failed, I determined to build down the cusp around a gold pin fixed in the root, and on a foundation of gutta-percha. I therefore proceeded to drill the root; that is, to enlarge the pulp canal, so that it would take the gold wire which is used for the English tube teeth, and this enlargement of the canal I carried as deeply as I dared go without perforation of the side of the root, feeling my way carefully by using drills that were each a trifle larger than the preceding one, and watching for



any indication of sensibility to show that I was getting too near the peridental membrane. Then, fitting my wire, I cut it to the exact length that would allow it to touch and take the bite of the lower tooth, when the mouth was closed with the wire in position. I then fitted a sort of half-hoop of eighteen carat gold to the broken edge of the root that was beneath the gum, making it wide enough to extend slightly beyond the margin of the gum. This I soldered by a connecting stud on either side to the wire. All this work was done upon a plaster model in the workroom. Finding that this gold work fitted properly when tried in the mouth, the next step was to fix the wire in the root, which was done by barbing it on four sides with a strong knife, and then pressing it up into the root with a little stiff sandarac varnish to act as a cement. I then packed the half-hoop nearly full of gutta-percha, taking care to make a tight joint where the hoop fitted the surface of the root. On this foundation I built down the gold cusp, my retaining points being the half-hoop, the wire, and the remaining natural cusp. The fixing of the wire and half-hoop, the packing of the gutta-percha, and, finally, the packing of the gold, took altogether less than an hour of my time. The gold was packed by hand-pressure. The rubber dam was not used, and a napkin sufficed to keep the work dry. The patient sat low and comfortably in the chair, not as though lying on a surgeon's operating table, and the work was wholly done by reflection from my little mirror, without stooping or dis-



comfort on my own part; and it is standing perfectly well at the present time, as I recently had an opportunity of seeing, three years after the operation was completed.

Cavities in the grinding surfaces of molars, and in the sulci between the cusps of bicuspid, are simple enough, unless, from neglect, their walls are allowed to become too weak to stand the packing of gold fillings. It is a common practice, however, to prepare all such cavities by simply driving a rose drill into them, and then inserting the filling. This is a rough and ready way of preparing for a failure, unless the drill is unnecessarily large, for such cavities are never cylindrical in shape, and a drill will either not cut out enough to make the filling safe, or it will cut away too much sound dentine. It is perhaps well enough to open a cavity of this description with a drill, but it should never be considered ready for a filling until all the fissures radiating from it are cut out, which may be done with fissure drills, or with a narrow enamel chisel. My own practice is to open all these cavities with a chisel, feeling the depth and extent of the decay, and noting the course of the fissures which are to be cut out after I have ascertained the nature of the cavity, when the fissure drills may be very useful. I find this a safer course, as one will sometimes meet with a case where, after cutting away a comparatively strong substance of enamel, the drill will plunge suddenly into a soft and sensitive dentine, to the great discomfort and alarm of the patient; and all this is better



avoided when it is possible. Not infrequently there will be two or three of these cavities in a grinding surface, and they may be connected by narrow fissures, or possibly, but more rarely, they may be separated by perfectly sound, well calcified enamel. There cannot, however, be any doubt on this point in the mind of a careful and observant operator. The fissures can be seen, if they exist to endanger the fillings, and they must be cut out as far as they can be seen to extend. It is quite unnecessary to make under-cuttings, or retaining points, in cavities of this nature. The walls may be parallel, or even in parts slightly sloping outwards, and well-packed gold fillings will never move. Cavities of this class are, I consider, the only ones where the use of the mallet is justifiable. If the walls are strong, that is, if there is a good substance of dentine, as well as of enamel, and there is no irritation in the socket, either from diseased pulp or unnatural pressure, the mallet may be very useful in attaining that degree of hardness and density which is most desirable in fillings that will be subjected to the direct wear of mastication, and which, as all operators are not equally endowed with a good physique, may not be attainable by mere wrist strength. If, however, any one of the walls is weak, if it is of enamel unsupported by dentine, the mallet should never be allowed to touch a plugger in that locality, as the suddenly-applied force will crack the enamel in every direction, and leave it liable to crumble and break down after the filling is



completed. I prefer to fill all such cavities two-thirds or three-quarters full with soft gold, and then finish with cohesive gold, as this gives greater hardness of surface than is possible with soft gold alone. If the cavities are deep and dangerously near the pulp at any point, it is a safe precaution to pack a lining of gutta-percha in that portion of the cavity (taking care that the pressure shall not be directly towards the pulp) and, when this is hard, complete with gold. The gutta-percha will save the pulp from the shock which it might be subjected to from hot or cold drinks, or food, if the gold, with its quick-conducting nature, were in close proximity to it.

In the description of the process of making and fitting gold cups and gutta-percha fillings, quoted from Dr. Essig, on page 31, that author mentions a case which had come under his observation, where a gutta-percha filling had lasted fifteen years in a position not exposed to much attrition. It is not by any means an exceptional case, but I wonder how many of our experienced operators (I use the word "experienced" because those who are not so qualified to form an opinion are usually too sanguine to put any limit to the durability of their work) would not be glad to be assured that the gold fillings they make in positions which are not exposed to much wear from mastication would last as long. It is in such situations that gutta-percha makes a safer, and certainly a more comfortable filling than can be made with gold, however well the work may be done. I do not by any means advocate the use of



gutta-percha as an unprotected permanent filling in situations where a soft material must of necessity be worn away rapidly. Gold fillings very rarely fail in the grinding surfaces of molars and bicus-pids, or in the lingual surfaces of canines and incisors, where they are always exposed to attrition in some form. It is in the nooks and corners, which are not exposed to natural friction, that we are to look for failure, and it is in these places that we shall often find gutta-percha more valuable than gold as a barrier to the ravages of decay. Constant attrition is a great safeguard to the teeth in preventing decay, and, if all their surfaces were alike exposed to it, the work of the dentist would be greatly simplified, if not rendered altogether unnecessary.

Another class of cavities are those which are found at the necks of the teeth, on the labial and buccal surfaces. Caries of this description may affect any or all of the teeth, upper and lower; but it is rarely seen in youth, while the gums retain their natural position and adhesion to the teeth in a line exactly corresponding to the cervical termination of the enamel. But when, from neglect, a formation of calculus has been allowed to accumulate at the neck of the tooth, forcing the gum back, and destroying the thin edge of alveolus which gives the gum its form; or when, on the other hand, the efforts at cleanliness have been too severe, and hard brushing, that would have been more suitable for fire-irons and fenders than for flesh and blood structures, has worn away the delicate covering of the dentine in



this locality, and the tooth is left without its natural protection, it is only too well prepared to suffer from any abnormal condition of the mucous secretion which, from a variety of constitutional causes, may become so acidulated as to overpower the neutralising effect of the saliva. This condition of the mucous secretion may arise from indigestion, from hepatic derangements, from uterine affections of every nature, or from any protracted disturbance of the mucous membrane and the sympathetic nervous system. We, have, however, more to do with the effect than with the cause. When we have a condition of this nature to deal with, we may find decay progressing so rapidly that deep cavities, with well-defined walls, are developed in a few months, or the progress may be slow, and, as the dentine is softened, the brush will wear it away, and the lesion will gradually assume an appearance as if a round file had been used to cut a groove across the necks of the teeth, and the surfaces had then been carefully polished. In the latter case there is little need for anxiety, for the causes which have operated so slowly may cease to act, and the teeth, though disfigured, be safe for years; but, if the disease is making sufficiently rapid progress to form a definite cavity, it must be checked as quickly as possible. Like all other cases of dental caries, but, perhaps, to a more marked degree in these, the rapidity with which the disease progresses has a very noticeable effect upon the sensibility; and in many such



cases it is not so much a question what is best to be used for fillings, as what is possible. When the cavities are so sensitive that it seems to be absolute cruelty to be thorough, I have always found that such slight excavation as can be done in a few seconds with a sharp excavator will enable me to put in a gutta-percha filling which will so effectually check the disease that, in a few months, it may be quite possible, if it is desirable, to fill them with gold without any unbearable pain; or if, as will often be the case, the dentine is still too sensitive to bear gold with comfort, a gutta-percha filling may be so safely made that it will last five or six years, and give more comfort, and, I think, more security too, than gold will ever give on a very sensitive surface. It is an error to suppose that any rough work is good enough for gutta-percha. A filling may certainly be made with this material in a few minutes, and yet be sufficient to check the rapid progress of decay so as to allay an intolerable sensibility of a decaying surface; but quick work does not necessarily mean rough or bad work. A few quick strokes with well-selected instruments, and a firm hand, guided by a sure knowledge of how and where to cut, may shape a cavity that will retain for months a gutta-percha stopping sufficiently impermeable for this purpose. When, however, it is possible to do so, careful excavation and careful packing with fine points is as necessary to ensure durability with this material as with gold.

When the rapid progress of decay has been stopped, and when the surface of the dentine has



regained its normal state of comparative insensibility, there can be no doubt that it is best to fill all cavities of the class under discussion, as far back at least as the second bicuspid, with gold. For molars, however, when we consider the difficulty of keeping such cavities dry long enough to pack a good gold filling, even with the rubber dam, and the difficulty of applying the rubber dam to be useful in such a locality without "dissecting away the gum"—as a dentist once coolly told me he did in such cases, without any idea that he was talking of such a dreadful thing as vivisection—I doubt whether it is not best to be content with the degree of permanency that can be got from gutta-percha, more especially if the lesion is extensive. These cavities usually extend under the margin of the gum, and, if gold is to be used, it is of the utmost importance to make sure of clean excavation there. If the operator is not confident of his ability to excavate without touching the gum with his instruments, it might be excusable to cut the gum away, and, after placing a proper clamp or clamps, apply the rubber dam; but as all this adds immensely to the formidable nature of the operation, it is better, if one can, to train the eye and hand to work without these appliances. This certainly can be done, for I have never cut away the gum to fill a cavity of this nature. I have often found the gum growing over the edge of such a cavity, perhaps filling it, so that it required to be pressed back; but these were dead teeth almost invariably, and the necessary course of dressings has always enabled



me to get the gum out of the way without cutting. If the cavity extended far under the margin of the gum, I have used gutta-percha instead of gold for the filling, whether it was a front or a back tooth, and the patient has generally been glad enough to be so mercifully treated. I can point to cases where, side by side, some such cavities are filled with gold and some with gutta-percha—the worst, of course, being treated with the latter material—and both I and the patient must live some more years before I can say which lasts the longer.

In filling these cavities, it is a very good precaution to pack against the cervical wall, leaving a good mass of gold there to be condensed after the rest of the cavity is quite full. This will serve as a breakwater, and the completion of the packing at the point where there is the greatest risk of wounding the gum, makes this risk of less importance, since the flooding with blood cannot be so serious a matter when the packing is practically finished. But there is really very little danger of even this if the packing is done with a firm, steady hand, the third and fourth fingers resting on the edges of the teeth, if the operation is on an upper tooth, and on the chin, if it is on one in the lower jaw, to prevent a slip, while the second finger guides the instrument held between the thumb and first finger. This resting of the fingers to guard against slipping soon becomes purely instinctive, though doubtless it seems to the student as if he should always have a distinct thought for every thumb and finger; but it is like a practised



performer on a musical instrument, whose fingers find the note corresponding to the melody in the mind without conscious effort.

The effect of acidity in the mucous secretion is not always confined to exposed dentine, or to cracked and abraded or imperfectly calcified enamel. You may find the whole labial surface of the incisors and canines wasting away, but so generally and uniformly that, if it were ground away with corundum wheels, and the surfaces carefully polished, the result could not be a smoother surface. One of the most remarkable features of this peculiar form of erosion is that, while the destructive process is going on, the enamel, and then the dentine, of one portion or surface of the tooth may be affected to a serious degree, and other adjoining surfaces be absolutely untouched. We may find the dentine of the labial surface of a central incisor laid bare, and the full thickness of the enamel of the mesial and distal surfaces of the same tooth, with the lingual surface, remain unaffected, the edges of enamel being as sharply defined as though the work had been done with a

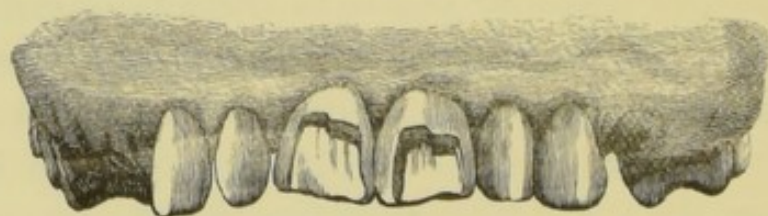

Figure 76.—Showing central incisors, with the labial surface partially destroyed by erosion.

file. It may attack the tooth in irregular patches, as shown in Fig. 76; or it may round off the



cutting edge of the incisors, gradually working its way up to the margin of the gum, until more than half the crown of the tooth is cut away, as shown in Fig. 77, a case I have watched for years. In

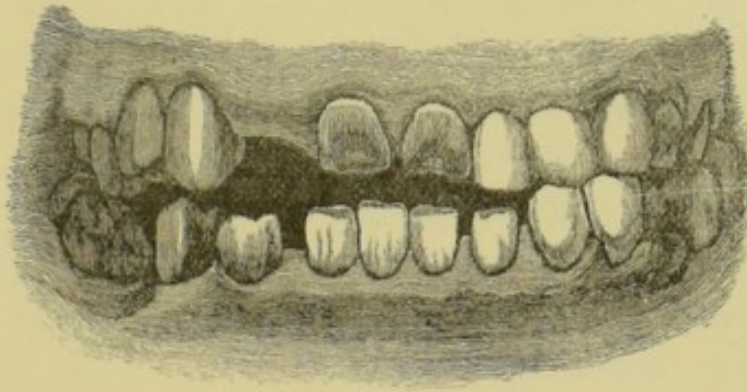


Figure 77.—Showing a peculiar case of erosion, in which the whole of the labial surface of the two central incisors has been destroyed.

this case, the sensitiveness of the teeth to thermal changes has been at times almost unbearable, but alternating with periods of perfectly normal sensibility. The articulation in this case being faulty from the first, the incisors of the upper and lower jaw never did meet, so that this has not been a case of abrasion, such as might occur in what is called an “underhung” mouth, where the lower incisors shut outside the upper, and so gradually cut away the labial surface of the teeth. Nor has it been the action of the brush, for, although the teeth have been well taken care of, the attention of the patient was early enough called to the wasting of the central incisors to prevent any harsh treatment. The enamel on the mesial and distal surfaces and on the lingual surface is of normal thickness, with sharp, clean cut edges,



and the pulp cavities, protected by the formation of secondary dentine, distinctly marked. The patient never would consent to have the crowns replaced by pivoting, and I never advised her to have the ends of the teeth restored by building them down with gold, for I would not have had it done in my own mouth. So I have recently extracted them, and Fig. 78 shows how much of the crowns had disappeared.

I have recently seen a delicate boy of nine years of age, whose incisors were apparently well covered with enamel when they first came through the gum three years ago, but now it has entirely disappeared from the labial surfaces of the lower incisors, and is very thin on the upper ones. The lingual surfaces also seem to be much affected, while the mesial and distal surfaces of all the incisors are protected by enamel of normal thickness, the different structures being clearly seen by any ordinary observer looking at the child's mouth. The six-year molars in this mouth have high cusps and deep sulci, but there are no fissures nor cavities requiring treatment. I know no way of accounting for this eccentricity of action of the oral secretions, nor has any author, so far as I know, given anything like a satisfactory explanation of it.

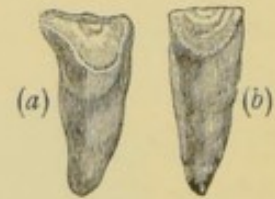

Figure 78.—Showing the two central incisors after extraction. (a)—the labial surface of the right central, with enamel destroyed to the margin of the gum. (b)—the lingual surface of the left central, showing that, except as it was destroyed from the labial surface, the enamel was unaffected; this being the case with the lingual surfaces of both teeth.



We constantly hear the statement that a patient's teeth were strong and sound until, in some illness, the doctor administered a very strong medicine, which quite ruined them. Doubtless medical men are themselves to blame for the strong hold this idea of the action of medicine has upon the public mind, for until quite recently they have failed to see that it was the illness, and not the treatment, which was doing all the mischief to these organs; and they have practically admitted their liability by advising their patients to take tonics, and all acid medicines, through a tube, so that the teeth might not be injured.

A writer in the *New York Medical Record*,—I am sorry that I cannot give the name, but I copy from an abstract of the paper, and the writer's name is not given,—says, “In any febrile condition, the fluids of the mouth are as constantly and intensely acid as any medicine that is administered by the physician; and from the high temperature at these times, the power of these acids for evil is greatly augmented. The consequence of this is a rapid decomposition of food, etc., and the elimination of other deleterious acids, all forming a mighty power, under which it is not surprising that tooth structure should melt away like dew before the sun. It is more surprising that any tooth should be left to tell the tale.”

About two years ago a young lady came to me after a severe illness, with her teeth, as she and all her friends thought, absolutely ruined. Her teeth had been regular, well shaped, and of good colour, and she had doubtless been proud



of them, and justly so. When she came to me after the illness, they were very much discoloured, indeed almost black; the surfaces were rough and uncomfortable to the touch, and they had been so sensitive that she could not bear to brush them; but in this respect there had already been a slight improvement before she came to consult me. I made a careful examination of the mouth, and found really very little deep-seated mischief, but everywhere the teeth were superficially affected by the acid bath to which they had been subjected for weeks. The surfaces were rough and friable, but I found I could easily remove all this, and by scraping, filing, and polishing, the appearance of the teeth was restored to very nearly what it had been before the illness. The frequent use of carbolic acid—a drachm of the acid to a pint of water—as a wash and gargle relieved all the sensibility, so that now it would be difficult to find a trace of the mischief which then seemed so serious. In this case all the surfaces of the teeth were affected alike; but the patient was young, and the gums everywhere covered the necks of the teeth up to the terminal edge of the enamel, or else there would probably have been serious decay at some points, and the labour necessary to put the teeth in order might have been increased to an almost indefinite extent. In many a case no worse than this, I am sure, the teeth have been pronounced hopeless by careless observers, and in the absence of a few encouraging words from an experienced practitioner, the course of events would very soon have justified the opinion; yet I do not



think that I have spent three hours altogether on this mouth since the illness three years ago, and only one tooth has been lost, and that a wisdom tooth out of position for want of room.

Another form of erosion affects only the cutting edges of the front teeth, this portion of the teeth being acted upon to such an extent that the upper and lower front teeth will not meet. In one case that came under my observation, there was more than three-sixteenths of an inch of space between the upper and lower central incisors when the back teeth were firmly closed. In this case, judging from the appearance of the six-year molars, and from the description given by the patient, I have no doubt that the ends of the teeth were of the imperfectly formed character shown in Fig. 19; but the whole of the imperfect portion of the teeth and, apparently, some of the well-developed part, had disappeared. It could not have been the result of attrition, because several years had elapsed since the lady had been able to bite anything with the front teeth, and she told me that the loss of substance had been gradual, but, as far as she knew, uninterrupted. To the ordinary observer the teeth had the appearance of being truncated as squarely as though they had been cut away with a file, but in reality the ends of all the teeth were slightly concave, showing that the dentine had been affected more rapidly than the enamel. The greatest loss of substance was from the central incisors, the least from the canines, the bicuspid being quite normal in appearance. I should have been glad to have seen more of this



case, but the lady was not in a position to afford any expensive treatment, and I simply advised her to dry the ends of the teeth every night, and touch them with strong carbolic acid. There can be no doubt that gold fillings on the ends of all these teeth would have absolutely stopped the progress of the disease, and there need not have been an attempt to restore the natural length of the tooth with gold, which would have simply made the mouth abominably conspicuous and unsightly. But if operator and patient had agreed that it was desirable to build the teeth up, or down, as the case might be, to their natural length, it would merely be necessary to keep the mouth dry a little longer to do it. A shallow cavity, very slightly undercut, should be formed in the end of each tooth, and when the anchorage of the filling is properly made, it is merely a question of keeping the cavity dry whether the filling shall be a sixteenth of an inch or an inch in thickness. But to my mind it seems quite enough to stop the progress of the disease, without attempting to make a show of gold, which would make the patient even more remarkable than "Miss Kilmansegg with her golden leg," which was probably not displayed to the admiring gaze of every person she might speak to, or greet with a smile of recognition. In all these cases of erosion the teeth affected by it are usually exquisitely sensitive to changes of temperature or to touch, even of the tooth-brush, while the disease is in active progress, and at such times the application of the strongest liquid form of carbolic acid will give relief, and



undoubtedly has the effect of checking the disease. A camel's hair brush may be used for the application. The surface on which the acid is to be used should first be dried with a towel, so that it will not flow beyond where its action is desired. This treatment, however, must not be entrusted to careless or unskilful hands. The frequent use of carbolic acid, in weak solution, as a wash for the mouth, to cleanse the mucous membrane and neutralize the acid secretions, will also be found advantageous.

If the disease has made sufficient progress to expose the nerve, as it may do, it will be a difficult matter to treat it with arsenical dressings to devitalize the pulp without using a drill, for the dressing cannot be kept in contact with the smooth surface of the tooth. Any point may be selected, where easy access to the pulp can be obtained by the use of a drill, and the dressing may be kept in position until sloughing of the nerve takes place, when it may be removed without any pain, and the pulp cavity and the drill hole may then be filled. But in these cases of erosion, the progress is generally slow enough for the nerve to protect itself from exposure, and it is wonderful to see how this is accomplished. The nerve retreats before the advancing enemy, and throws out a new formation of dentine, commonly called secondary dentine, to cover its retreat. This formation is quite translucent in appearance, and distinctly more dense in structure than ordinary dentine, although Mr. Tomes says its "tubular and inter-tubular structure is continuous with that of the



older tissue." It will sometimes fill up the whole of the coronal portion of the pulp cavity with solid substance; but it is not always so beneficial to the health of the tooth as when it thus effectually protects the pulp from exposure by the slow advance of erosion or decay; for it may be the obscure cause of a great deal of suffering when it takes the form of what are called nodules in the pulp. These pulp stones, as they are also sometimes called, are probably always connected with some of the dentinal tubes, as there is no reason to suppose that they are spontaneously and independently formed in the substance of the pulp, except that they are usually found detached. This would be accounted for by any, even the slightest, disturbance of the pulp in searching for them, as the connection with the walls of the pulp cavity may be by the smallest number of these tubes. It surely is reasonable to suppose that they have a starting point, and no foreign substance is likely to reach the pulp, through the dense structure of the tooth, to form a nucleus. But however this may be, their formation in the pulp causes in the nerve tissue great irritation, which is difficult to localize, and may therefore be referred to some totally different cause. Perhaps the teeth may not even be thought of in searching for a cause of pain, which may have its origin in these nodules. Their presence may be suspected if, during the paroxysms, percussion on the teeth of the affected side has any perceptible effect, either to intensify or to mitigate the pain, or a jet of cold



water from a dentist's syringe may be employed upon the teeth, one after another, to see if any effect is produced upon the pain. The proper treatment, when there is good reason to suspect this formation to be a source of pain, is to drill into the tooth in such a position as to give straight and direct access to the root or roots; devitalize, and then remove the nerve and fill the canals and pulp cavity.

When a number of the back teeth have been lost, so that the mastication of the food is thrown upon the anterior teeth, they will be rapidly worn down, and will then present a truncated appearance very similar to that resulting from the last-mentioned form of erosion; but as it will be from a very different cause, and one easily understood, it does not form so interesting a subject for theoretical study. The concavity at the end of the tooth will generally be more marked than when it is the result of erosion only. The dentine is worn away more rapidly than the enamel, and the enamel proves itself to be better capable of resisting the action of attrition than that of the subtle acids contained in the oral fluids. When the teeth are being worn down in this way, it is, if possible, even more necessary to protect their ends with well-condensed gold fillings than when the loss of substance is from erosion, and the occlusion of the teeth is no longer a possibility. The form the filling is to take is also a matter of much greater importance in cases of this nature, for it becomes necessary to consider how much thickness will be most useful, and how little will be possible

to save unsightliness and preserve strength and safety from breakage. These considerations are most important; for if a filling on the end of a tooth is too thin for its superficial extent, it may be broken, as I have found sometimes when I fully believed I had made a filling that had all the homogeneity of rolled metal. On the other hand, it must be borne in mind that to whatever extent we lengthen a tooth, all the rest will have to be built up to the same point, and shaped so as to give an equally good biting surface, for it is absolutely necessary to preserve uniformity of occlusion. As the teeth of both jaws are equally liable to this form of abrasion, it may be necessary to protect the end of every tooth that has an antagonist.



## CHAPTER VI.

## AMALGAM.

THERE is no other subject connected with the practice of dentistry that has been the cause of so much heated controversy as the use of amalgam for filling teeth. Other plastic materials of various kinds have been used by the skilful, as well as by the ignorant and dishonest practitioner, and when the work has failed, the failure has alike been attributed to the material, rather than to unskilful manipulation; but no other material has ever been accused of a tithe of the faults imputed to amalgam. At the time of the establishment of the earlier dental schools in America, the students were instructed that not only were the teeth in which amalgam was used absolutely ruined, but that grave constitutional effects, such as salivation, necrosis and pyæmia, might be expected to result from its presence in the mouth. Some of our best men felt themselves bound to dispute the claim to professional standing or recognition of all or any who experimented with amalgam, and lost no opportunity of coupling the epithets "charlatan" and "quack" with the names of the ostracized few who dared to think that this metallic mixture was not quite so injurious as the profession was taught to consider it. Yet, prejudiced as these



men were, they were much too conscientious to go on for ever condemning on mere hearsay evidence. Now and then they saw a tooth which had been filled with amalgam, and the patient had survived the operation and its consequences. There was no appearance of necrosis or ptyalism. Even the tooth, though rather discoloured, did not appear to have decayed any more rapidly for having the filling in it. Indeed, if it were not contrary to all preconceived ideas, they might think that the filling had saved the tooth, and, if the patient was inclined to take the risk of possibly serious consequences, they were not unwilling to leave this dangerous compound in the tooth, and see how it went on. Fortunately, some of the patients were not afraid; so the sceptics, finding that the looked-for ill results failed to appear, were inclined to try an amalgam filling themselves on some safe patient, whom they could trust to keep the secret. Thus in time, but very slowly, the prejudice wore away, the usefulness of this material came to be recognised, and now there are not many men in the profession who do not give it a place in their list of materials for fillings.

I cannot claim for myself that I was unaffected by this prejudice. On the contrary, I wrote twenty years ago as decidedly against the use of amalgam as any of my contemporaries, and, as was the case with others, it was only when I began to see that I had no real evidence of any deleterious effect from it, that I began to try it in what I then considered to be hopeless cases for anything more than mere temporary work. The



result convinced me that teeth could be saved with amalgam fillings, especially in grinding surface cavities, but I found that in approximal cavities in back teeth, where I had hoped for good results, a certain proportion of fillings failed at the cervical edge. Whether it was a larger proportion than when the fillings were of gold, I had no statistics to tell; but, though the difference could not have been great, it was probably against the amalgam, because it was used in cavities which I should have filled with tin rather than gold. I was using gutta-percha also at this time, and seeing that fillings of this material never failed at the cervical edge, but were only affected by attrition, it occurred to me to try the effect of composite fillings. The points most liable to failure from decay were first carefully packed with gutta-percha, and the remainder of the filling made up with amalgam. A filling of this nature made it essential that the patient should pay a second visit to have the whole approximal surface finished down smoothly, as it was often necessary, in order to secure perfect dryness while packing the filling, that the gutta-percha should project, and overlap and press away the gum, which, by stopping the circulation for the time, would prevent flooding of the work. This, of course, could not be cut away until the amalgam was so hard that it would not be disturbed by the instrument used for trimming the gutta-percha. The second visit made the work more satisfactory in another respect, because while amalgam can only be made smooth when it is just packed, it will take a very fine polish after



it gets hard, and, if made of good materials, will retain it. This method of filling large approximal cavities combines all the advantages of two of the most useful materials we have yet discovered for stopping teeth, and, I think, comes as near perfection as anything we are likely to find for this class of cavities in molars. It seems to me a waste of time to attempt to build up half or two-thirds of the crown of a molar tooth with gold, when it can be so effectually done in this way. Indeed, it does not matter how much of the crown of the tooth is broken down so long as enough is left to keep the roots together; it can be built up so as to make a useful tooth. In a paper read before the Odontological Society of New York, in December, 1881, I gave a full description of a method of building up these molar crowns with the help of a thin gold band to act as a matrix and give form to the crown, the band being attached to wires fixed in the roots of the tooth. I will quote this description from the report given in the *Dental Cosmos*. Screws might be used with advantage to secure the frame to the roots, and it does not matter how rough the interior of the framework may be, as the roughness will assist in retaining the filling:—

“With gutta-percha and amalgam we may often build up a useful crown upon the otherwise useless roots of a broken down molar, which it might take hours of hard labour to build up with gold. I will endeavour, as concisely as possible, to explain my method of doing this. Supposing the roots to be in a healthy condition, we will



insert short pieces of wire, loosely, in the pulp canals, with the ends projecting; then take a good impression of the root, the wires coming away with the impression; if there are fragments of the crown remaining so much the better, as they will be serviceable. When the plaster cast is made, we ought to be able to see the exact position, and judge of the direction of the canals, and into each of them we drill a small hole about a tenth of an inch deep, the holes being naturally a little divergent. We will now make a ring of thin gold plate, shaping it, if one likes to take the trouble, to the form of the tooth we are replacing, but fitting it outside any remaining fragments of the crown; then to the inside of this ring we solder two strips of gold plate, with the ends bent at such an angle and of such length that they will cover the holes in the roots; drill these at points corresponding to the holes, and insert pins in the right direction, so that when sprung into place they will hold the ring in position. It is best also to solder two or three short studs to the inside of the ring to assist in retaining the filling. We will now make such retaining points as we can in the natural root. Spring the ring into its place, with the pins in the divergent canals, adjust the articulation, and then pack gutta-percha over the whole surface of the root, half filling the ring with that preparation, and finishing with amalgam. I have made some very serviceable teeth in this way; and, as will be seen, nearly all the work is done in the laboratory, saving both patient and operator a great deal of time and trouble."



As we never have two precisely similar cases, it will be necessary to modify the treatment to suit each particular case, but adaptation is easy when once the idea is suggested.

Nearly all molar cavities are suitable for amalgam, but it is sometimes desirable and politic to make exceptions, such as small or medium-sized cavities, in first upper molars, and small cavities in the buccal sulcus, all of which may be filled with gold, if the operator feels inclined to take a little more trouble for the sake of appearance. This is a consideration which should not be lost sight of, although it ought not to be a ruling motive of practice. Cervical buccal cavities in molars will do better with gutta-percha than with anything else.

I have never yet seen an amalgam that I felt justified in using in front teeth, as at the best there is a certain amount of discolouration, which cannot be avoided. It is, I think, better to trust to gutta-percha, so long as a plastic filling is necessary, and then fill with gold, rather than try to make a composite filling, which, from the form of the cavities in front teeth, is a very difficult thing to do so as to prevent the metallic portion of the filling from showing through the labial wall of the tooth, and yet make it secure.

Here I cannot refrain from alluding to one of the difficulties which the dentist has to encounter in his practice, and that is, that all the materials for filling teeth, except gold foil, are liable to deterioration in the manufacture, as soon as a demand for them is secured. It is not very



creditable to those who prepare materials for the dentist to use in plastic fillings, that so many of the preparations fail to keep up the character in which they are first presented to the profession, after they have become sufficiently well known to create a brisk demand for them. Of course this is because the early experiments were made by some one person, who took care that everything he used should be of the best quality; the ingredients were accurately weighed, and his manipulation was as nearly as possible perfect. But when quantities are required, he must have assistance in the work, and then materials are not selected with so much care, and the exact proportions are not maintained. It ought to be possible for the dentist to trust his manufacturer as the physician does his chemist; and I hope this hint will be one step towards a better state of things.

Many preparations of alloys for amalgam have been tried, but I confess I have never had much experience with any one that took a descriptive name from any of the precious metals. If a dentist does his duty to his patient, he takes care to select, for filling teeth, the material that he thinks best suited to the case, and if asked to do so, frankly explains the nature of his selection, and the reasons for using it. There is no necessity for him to disguise the fact that he is using amalgam, by calling it a gold or a platinum alloy. Silver and tin are, and must be, the metals chiefly used in all amalgams, and, if other metals are used, it is only in very minute quantities, which cannot affect the intrinsic value of the alloy to any



appreciable extent, and are introduced to prevent shrinkage or discolouration. It is, therefore, a mere pretence, unworthy of a professional man, to call these fillings by any other than the accepted name in the profession.

The cavity must, of course, be in every sense as carefully excavated as it would be for a gold filling. There must not be any fragile walls left to break down after the filling is inserted. It is better to cut away all such walls to a point where their strength can be trusted, and then if necessary, this can be further protected by building up the filling to something near the original form of the tooth, covering the edges of enamel, and so reducing the danger of fracture to a minimum. Undercutting to any extent is always a mistake, and leaving wide overhanging edges of enamel is worse still. In the latter case the excavation may be faulty, and though it is right sometimes to leave a part of the decalcified dentine over the nerve, it can never be right to leave any at the lateral edges of the cavity when making a permanent filling. It can never be a certainty that the filling material can be packed into deep cuttings, or under wide overhanging edges; while, if it is not, a weak point is left in the work, and as the strength of a cable depends upon its weakest link, so the value of a filling, as a preservative from decay, must depend upon its weakest point.

It is important in mixing an amalgam for use, that the quantity of mercury should be as small as will suffice to make a cohesive mass of the filling. For this purpose, if for no other, it is desirable that



the bottle containing the supply of mercury should have a very small aperture to allow the mercury to be added in minute globules, and that the alloy should be finely granulated. The mixing should be done in the palm of the hand, unless the hands are moist from perspiration, when a small mortar is better. A thin ivory spatula is the only instrument necessary when the hand can be used, and I think the danger of mercurial poisoning by using the hand for this purpose is a remote contingency, worthy to be classed with the invasion of England by way of the Channel tunnel.

In packing an amalgam, small round points are by far the best, and they should be used with a gentle tapping pressure to secure the filling of every minute irregularity in the form of the cavity, and the complete union of the particles. When the cavity is full and the contour built up to the desired extent, an ordinary burnisher may be used for smoothing the surface. A bit of amadou, twisted up tightly and held in the plugging pliers, serves to remove all loose particles, and then it may be left to harden, before receiving the final polish.

Dr. C. C. Allen once paid a deserved tribute to the value of amalgam as a stopping for teeth, at a time, too, when it was not so appreciated as it is now, by saying,—“If my life and fortune depended upon the saving of a tooth without regard to its appearance, I would fill it with amalgam.”

I extract the following from a letter I have received from Dr. Foster Flagg since writing this article. Knowing of his long course of



thoroughly practical experiments in the nature and working of various combinations of metals for amalgams to be used in filling teeth, I wrote to him for further information as to the value of the precious metals in these alloys.

"Your ideas of the 'chief' positions of silver and tin, as components of alloys for amalgams for filling teeth, correspond with the conclusions I have reached in experiments. I also am 'on the record' in reference to platinum as a *valueless* metal, and one which is only useful for *its name!* I, therefore, regard its employment as fraudulent, and its acceptance as discreditable to the intelligence of the dental profession. Gold and copper and zinc I view differently. Each of these metals shows proof of its presence, by giving increased value to amalgams, as shown by appropriate *testings*. But in the so-called 'gold and platinum' alloys there is very seldom enough gold to give any appreciable increased value to the amalgam, if judged by its *working* characteristics. At least five per cent. of gold is needed, and it is not *proven* that *much more* is not beneficial—especially as regards maintenance of colour—though of this I am, as yet, sceptical. The experiments of the 'New Departure Corps' gave decided value to copper, also to zinc as a prevention to shrinkage."

The letter closes with a few sentences expressing his regret for his inability to write more upon subjects which have recently so severely taxed his strength, and his intense interest in the queries propounded.



## CHAPTER VII.

## PIVOTING.

A GREAT deal has been written in the last few years about restoring the crowns of broken-down teeth by various processes of pivoting, but some of the methods described have been such as to deter the great majority of operators from attempting them, because of the difficulties that must occur in the manipulation, and the amount of labour involved. To those who prefer to spend their time over some of these laborious processes, I have not a word to say. They will find their satisfaction in having performed a very beautiful operation, at the cost of hours of toil, with utter weariness at the finish, and the consciousness that only the professional training of a dentist will ever enable any one to appreciate the work. But to those who will be satisfied with an operation which will look as well to any ordinary observer, be as comfortable to the patient, and certainly last as long as any one of the more complicated and difficult operations, I have a few suggestions to make for improvements on the old processes, without materially increasing the labour, and without claiming originality, except in the manipulation,

and perhaps—for I do not remember that I have ever seen it suggested, except in a paper of my own—the idea of interposing a gutta-percha filling between the cervical end of the root and the artificial crown, thus preventing decay at this vital point in all pivoting operations.

We will suppose that we are operating on any one of the six upper front teeth, and that the pulp is already devitalized. We first cut away the remaining fragments of the crown, using the engine as much as possible for this purpose, and the excising forceps as little as possible, for the jar from the latter is very irritating to the peridental membrane, which, perhaps, is ripe for the development of alveolar abscess from very slight causes. A thick-edged corundum wheel, and a round or oval file, will enable the operator to shape the end of the root so as to correspond to the margin of the gum, and be just slightly hidden by it, so that, when the tooth is fixed in position, the joint will be covered by the gum (Fig. 79). With fine hooked or barbed instruments, scrape away all putrescent matter from the pulp canal, taking care that we do not push any of this poisonous substance through the apical foramen, and also taking care to keep the instrument wet with carbolic acid, washing it in the acid every time we withdraw it from the root. With a small drill that will follow the canal, open and straighten the latter, lubricating with carbolic

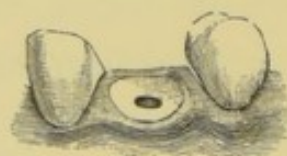

Figure 79.—Showing the root prepared for taking the impression.



acid. Use a larger and still larger drill, until the hole is large enough to admit the gold wire which is prepared for the English tube tooth, as this is of a proper size, and being already straightened, it saves trouble. The pulp canal should all the time be kept wet with carbolic acid, and the wire should slip easily in and out of the hole, but not too loosely, and the hole should be at least three-eighths of an inch in depth. The purpose of the gradually increasing size of the drill is to enable us to feel the way, and avoid perforation of the sides of the root. Flatten the end of a piece of the wire to a chisel edge, and barb the sides of the flattened portion thus (Fig. 80), cutting this so that, when the wire is in the hole, the barbed end will be a trifle shorter than the teeth on either side, to prevent the tray from pressing on the wire whilst taking the impression. We now place the wire in position thus (Fig. 81),



Figure 80.—Showing form of wire.

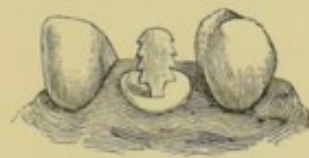

Figure 81.—Showing wire in position for taking impression.

and take an impression, which shall bring the wire away with it without altering its direction in the least; the barbing of the sides of the wire being to assist its withdrawal. The impression need not cover more than one tooth on either side of the root we are treating, and indeed is better so, as the wire is then more readily withdrawn



without altering its direction. When the model is cast, all that we want is a distinct representation of the root, with the wire in position, showing the exact direction of the hole in the root, and the form of the teeth on each side of it. Before dismissing the patient from this first sitting, we select a flat tooth of suitable form and colour, and take care that the root canal is open to and through the apical foramen. We dry the canal with a twist of bibulous paper, and apply a dressing of carbolic acid, which we cover with cotton and gum sandarac. If the tooth is broken down below the surface of the gum, and the latter growing over it, we may so pack the cotton and gum sandarac as to press the gum away, and in this case we must defer taking the impression until the end of the root is uncovered, and its surface cleaned and properly shaped. It is important that the wire should be of the right size and length, because if it is too small it tips in the hole, and thus gives a false direction, which only becomes apparent after the tooth is fitted and soldered, unless we keep the patient waiting while the laboratory work is being done, and try the tooth in before it is soldered, which may sometimes be desirable, but it is not necessary, if sufficient care is taken. If the wire is too short, or not roughened at the sides, or if it fits the hole too tightly, it will not come away with the impression. The best way is to have a drill of exactly the right size, and keep it for this purpose only, as the wire is procurable from any dental depôt in Great Britain, and is always of the same size. If more than one



tooth is to be fitted in this way, an impression must be taken for each tooth, as the pulp canals would never be so nearly parallel that two or more wires could be withdrawn in the same impression. Having made the plaster cast, we find the wire standing exactly as it was in the mouth, and with the teeth on either side indicating exactly how the new crown must be placed. Removing the wire from the cast, we now bend and shape a piece of gold plate to fit the surface of the root, and drill a hole through it to correspond exactly with the hole in the root. Then putting the wire through it and fastening with wax, we withdraw wire and plate together, and bed them in a wet mixture of plaster and sand to keep them in position until they are soldered. After this we cut off the wire from the concave side of the plate, and bevel the edges of the latter. The wire and plate should now exactly fit the hole in the root and surface of it. We may now proceed to put a backing on the tooth, and grind it to fit the anterior edge of the root. When this is satisfactorily done, we place the tooth in position on the model, fasten it with wax, and withdrawing all together, bed them in wet plaster and sand for soldering. The plate and backing of the tooth should be of eighteen or twenty carat gold, the finer the better, and the solder should be as fine as it can be to run. In selecting a tooth, colour, form and suitableness in every respect should be studied, in order to avoid the very un-art-ificial appearance that neglect of any one of these points would give the finished work; for art, in these



cases at least, is imitation of nature, and not an attempt to improve upon it. The tooth being soldered to the plate, we may smooth and polish the lingual surface, thus completing the laboratory work (Fig. 82). We are now ready to try the tooth in the mouth, and see if it is satisfactory in every respect: form, position, colour, if the bite is right, and if the tooth fits so that the joint will not show (Fig. 83). If in all

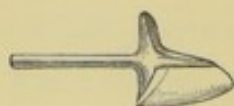

Figure 82.—Showing tooth ready for fixing.

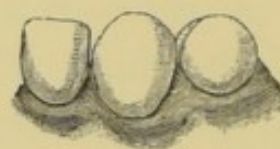


Figure 83.—Showing tooth in position.

these points the work is satisfactory, it only remains to fix the tooth in the root. We first shape a cavity in the cervical end of the root of sufficient size and depth to ensure permanence for a gutta-percha filling. The twentieth part of an inch is deep enough, and superficially it should be at least two-thirds of the surface of the end of the root. We undercut all round with an inverted cone-shaped drill attached to the engine; and with a strong thick-bladed knife we then barb the wire on four sides, so that it will require pressure to push it into the hole, and so render withdrawal difficult, if not impossible. If we have made the hole larger than was necessary, a little fine floss silk may be wound on the wire, but this must be very smoothly and evenly done. Then warming the tooth, we place a sufficient quantity of gutta-



percha around the wire, on the convex side of the plate, to fill the cavity we have shaped in the end of the root, taking care to have enough, as any surplus will be squeezed out. Now, if the root is clean and free from disease, the terminal portion of the canal, above the enlargement made with the drill, may be filled by first packing a few fibres of cotton, moistened with carbolic acid, up to the apex—being careful not to go beyond, but this can be guarded against by using a point that will not quite go through the foramen—a few more fibres with a little sandarac varnish, then more of the same, until this part of the root is filled. A little very stiff sandarac varnish is then placed in the enlarged portion of the canal; the tooth is again warmed in the flame of the lamp, this time as hot as the fingers can bear to hold it, so as to thoroughly soften the gutta-percha; and while it is in this heated condition we push it firmly up to its place, using a piece of wood, notched at the end, so as to guide the tooth while pressing it up—wood being better than metal for this purpose, because it does not chip the tooth. The surplus of gutta-percha is now smoothed away with a warm burnisher, and the work is complete. The whole time spent with the patient in the chair need not exceed half-an-hour; and I am perfectly certain that, if the work is well done, it will outlast any elaborate operation of building up a back or lingual surface of gold foil that can be made; for the gutta-percha is, I repeat, a perfect preservative from decay in positions where it is not exposed to attrition, from which the plate



protects it, while gold is never a safe protection when packed under the gum.

I had a case some years ago where a tube had been fixed in the root of a central incisor, and a gold filling packed around it down to the surface of the root, and then a tooth fitted with a wire secured into the tube, very beautiful and highly-finished work, done by a clever and celebrated man, but the filling became loose in a few months, and as the distance was too great for the lady to go back to her own dentist, she came to me in great trouble to see if I could do anything, however temporarily, for her, until she could get home to have it properly done. I could see that the filling was quite loose; indeed, it came away with the tube while I was examining it, and without the application of any force. The filling was easily removed from the tube; but the wire, to which the tooth was attached, was firmly fixed in the tube. I therefore dried the root carefully, filled it quickly with gutta-percha, and while the latter was still soft, warmed the tooth with the tube still in position, and pressed the whole firmly up to its place, holding it there until it was cool. It looked all right, and felt firm and strong, but the lady went away feeling very doubtful about my rough and ready treatment. She, however, remained abroad several years, and called on me on her return, to say that the tooth, as I had replaced it, had lasted more years than the former operation had lasted months, and she did not mean to have it disturbed.

The use of gum sandarac in solution for filling roots is, I believe, an idea that has not been



suggested to the profession, but it is worth trying. If well mingled with cotton fibre it will make a filling that will keep a cavity clean, and protect it from decay for months. I recently removed a dressing of this nature that had been two years in a tooth, owing to the sudden departure, and continued absence from home, of a patient for whom my brother had been treating a dead tooth. To my surprise, the surface of the cavity beneath the dressing was as clean and dry as it would have been with a proper filling in it. I think Dr. Foster Flagg has mentioned a case where an arsenical dressing of his remained covered up with cotton and gum sandarac for an equal length of time. The formula is—equal parts of gum sandarac and gum benzoin, dissolved in spirits of wine to the consistence of stiff varnish.

Pivoting lower teeth is rarely a necessary operation. I have never tried it in the case of lower incisors, and I doubt whether there would be sufficient thickness of root to admit a strong pivot; but the operation can be very satisfactorily done with the lower canines and bicuspid, and I have often pivoted the upper bicuspid in the way I have described for the incisors and canines. But it sometimes happens that one cusp only of an upper bicuspid breaks down, and then, if the remaining cusp is strong, I think it worth while to preserve it, and fit a new cusp of porcelain to replace that which is lost, and fill the space intervening between the natural and artificial cusps with amalgam. The process differs from those cases where a crown is replaced—or rather



the labial cusp, with a gold backing, is fixed to give the external appearance of a crown—but only in some points that would naturally suggest themselves to the operator. If the remaining cusp is strong enough to allow a reasonable hope that it will not break down when it is used for mastication, we cut away the fragments of the broken cusp down to and a little beneath the gum margin, open the root in the manner previously described—only, if it is a first bicuspid, remembering the probability of a bifurcation of the root, and a consequent increased risk of perforation of its side, and being content with an enlargement of the canal to the depth of a quarter of an inch, because the filling will assist in retaining the artificial cusp in position. If there is much overhanging surface of enamel on the remaining natural cusp, it may not be best to cut it all away, but leave all that is strong. If there is danger that the impression may drag in removing it, fill up the undercutting with some soft and easily removable preparation of gutta-percha as we should prepare a model with wax, so that it may draw properly out of the moulding sand (Fig. 84). Then, placing the wire in position, we take an impression, as in the previous case, and fit the new cusp without a plate to cover the surface of the root, soldering the wire directly to the backing of the tooth, or even to the platinum pins in the tooth, and leaving the whole as rough as possible (Fig. 85). We

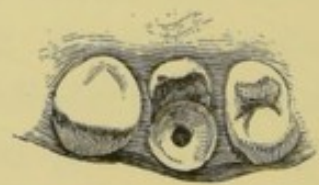


Figure 84. — Showing the root and remaining cusp ready for taking the impression.



should take care that the roughness does not anywhere quite extend to the mesial, or distal, edge of the tooth; but make it a roughness that will be grasped by, and assist in retaining, the amalgam filling. Fig. 86 represents the artificial

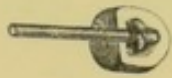


Figure 85.—Showing the artificial cusp with wire attached.

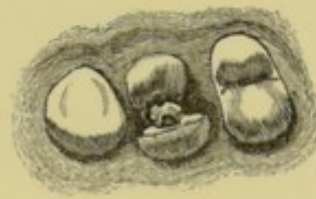


Figure 86.—Showing the cusp in position.

cusp fitted to its place. Having now cleaned and shaped the natural cusp to do its part in retaining the filling, we barb the wire, and place the gutta-percha and sandarac as before, and after the new cusp is pressed up to its place, we fill up the space between the two cusps with amalgam, taking care first that the surface of the root is well covered with the gutta-percha, and when the filling has had time to harden, smooth and polish as in the case of an ordinary amalgam filling (Fig. 87). The labial, or lingual, cusp may be fitted in this manner, and make very serviceable work. With a first bicuspid, when the pulp canal indicates bifurcation of the root, we must take care to select that which seems the thicker and stronger root, and then feel the way carefully with the drill. The patient will feel sensation before there is actual perforation of the

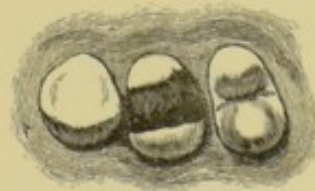


Figure 87.—Showing the operation completed.

side of the root, and the drill should be kept well lubricated, or else the heating will cause sensation so similar to that of perforation that both patient and operator may be deceived. I have had several cases where the natural cusp has broken down after a time, and the artificial one, with the filling, has remained for years; the only thing done to them being to smooth off the sharp edges of the filling where the natural cusp had broken away from it.



## CHAPTER VIII.

## GUTTA-PERCHA FOR IMPRESSIONS.

IN taking impressions for the work I have been describing in the last chapter, as well as for many other purposes where the dentist requires a good plaster cast, it is very desirable to have an accurate representation of the neighbouring teeth, as well as of the root; and to obtain this it is necessary to use some unyielding, inelastic material for the impression, like plaster of Paris, which will set firmly around the teeth, and must be broken in removing it from the mouth, and then laboriously put together again; or else a material which is sufficiently elastic in its nature to allow of its being withdrawn from around the necks of the teeth over the larger part of the crown, and then quickly contract again to the form it had assumed before it was withdrawn. Wax, and all the preparations of mixed gums that are used for taking impressions, are inelastic; and while they give a good representation of the gums, and of short teeth that are as large, or larger, at the neck than at any other part, and are especially useful in taking impressions for regulating plates, they are, as is well known, but imperfectly adapted for



impressions in which, for artistic effect, or accurate fitting, it is desirable to have a perfect representation, in plaster, of teeth which are narrow in the neck and broad in the crown.

Gutta-percha has been practically given up by the profession as a material for taking impressions, except in the form of preparations which are so largely composed of other substances that they have no claim to be called gutta-percha, and have few, or none, of its peculiar properties left. But if properly used, gutta-percha in its pure state comes nearer to being a perfect material for this purpose than anything else that has been discovered. It is elastic where elasticity is desirable, and loses this quality when it would no longer be advantageous. It gives quite as sharp an impression as plaster, and is as easily managed as wax. It has a clean resinous taste, and it is unalterable in shape after it is cooled, and as long as it can be kept cool and wet. It should be absolutely pure, and ought always to be kept in water to prevent oxidation. If it is hard and dry when first obtained it should be put in hot water, and kept for at least two hours just below the boiling point; and although boiling is one of the manufacturer's processes in cleansing and purifying gutta-percha, it should never be allowed to remain long in water that is actually boiling, as it would soon become too sticky for use. After remaining for some time in hot water, it should be thoroughly kneaded, and it may then be flattened out in small pieces—enough for an ordinary impression—and put in cold water to be kept until required for use. The method of



preparing it for taking impressions is to put it in water of about 200° Fahr., and when perfectly soft it should be slightly and quickly kneaded in the fingers, and the surface dried on a napkin, before it is put in the tray to go into the mouth. Then, after dipping the tray and its contents into cold water, to cool and moisten the surface, it may be placed in the mouth with steady, firm pressure, and allowed to remain at least two minutes before it is removed, which should be carefully done to prevent any alteration of form in withdrawing a soft bulky mass through the comparatively narrow opening of the lips. The impressions should always be very quickly cooled in water, which, if the weather is warm, should be iced.

Although this is not a work on mechanical dentistry, it may not be out of place, as I am writing of impressions with a material that is not in general use, to say that, in taking impressions of edentulous mouths, work as sharp and perfect can be done with gutta-percha as with plaster. In difficult cases a rough impression should first be taken, and such shaping given it with the fingers, after removing it from the mouth, as to allow of its being easily introduced a second time. Then let it be cooled until it is quite hard. A thin substance of quite soft gutta-percha is then placed over the whole surface, which should be first dried with a napkin, and it is again inserted in the mouth, and held for about two minutes, when it may be removed and cooled. Care is necessary to prevent alteration in shape from "sucking" of the impression. Pulling an im-



pression out of the mouth by main force is not an idea which is likely to occur to any experienced dentist, but a novice might easily be made nervous by the adhesion of a really good impression, and destroy it by pulling at it, when a lifting of the lip and cheek high enough to admit the air, and a tipping of the tray at the same instant, or instructing the patient to close the lips firmly around the handle of the tray, and by a sudden expiration to fill the mouth with air from the lungs, tipping the tray at the right moment, would release it without violence or injury.

Sometimes an impression is wanted for a partial set, when, from abnormal length of the remaining teeth, it is difficult to find a well-adapted tray; but one may be quickly extemporized by partially filling an ordinary tray, and obtaining a rough impression of the parts that are without teeth, then cooling and drying this, and placing more warm gutta-percha over all, and introducing it a second time.

For most purposes in the arts gutta-percha is largely adulterated, but it can be obtained in a pure state from the manufacturers at a cost of about nine or ten shillings a pound. The process of cleansing it, and freeing it from the impurities that are accidentally and intentionally mingled with it in collecting and preparing it for a market, is fully described in the ninth edition of the *Encyclopædia Britannica*, and some interesting statements are made about the various uses to which it is applied. I make a few extracts from this work.



"The readiness with which gutta-percha, whilst in its plastic condition, *receives an impression which it retains when cold*, early led to its employment in the decorative and fine arts, *since it reproduces the finest lines*, as in the taking of moulds from electrotypes."

I have italicized the portions of the text which refer to qualities I have mentioned as peculiarly fitting this valuable product for dental purposes. The same authority says, "Gutta-percha is resolvable into two resins—albin and fluavil. Like caoutchouc, or india-rubber, it is a hydrocarbon. Soubeiran gives its composition as carbon 87.80 and hydrogen 12.20. In commercial gutta-percha we have this hydrocarbon, or pure gutta, *plus* a soft resin, a resultant of oxidation of the hydrocarbon.

M. Payen gives the following analysis of commercial gutta-percha:—"1 Crystalbin, or albin ( $C_{20}H_{32}O_2$ ), white, and crystallising out of the alcohol as it cools, 6 to 14 per cent., 2 Fluavil ( $C_{20}H_{32}O_2$ ), yellow, falling as an amorphous powder on the cooling of the alcohol, 6 to 14 per cent. It is thus apparent that the change of pure gutta into a resin-like mass takes place naturally, if means be not taken to stop it. Many a good parcel has been thus lost to commerce, and the only remedy seems to be thorough boiling as soon after collecting as possible."

It is this tendency to degenerate into a resinous mass that so soon spoils gutta-percha for taking impressions, if it is not kept in water; for it soon becomes too sticky for either comfort in manipula-

tion or accuracy in practice; and it is no doubt this rapid failing in efficiency that has caused it to be so generally given up by the dentists as a material for this purpose. But it may be kept in water for a reasonable time without any apparent deterioration, though if it is overheated when being prepared for use, it will soon become sticky and unpleasant.

The *Encyclopædia* says further:—"At a temperature of 32° to 77° Fahr. gutta-percha has as much tenacity as thick leather, though inelastic and less flexible. In water at 110° Fahr. it becomes less hard; towards 120° Fahr. it becomes doughy, though still tough; and at from 145° to 150° it grows soft and pliable, allowing readily of being rolled and moulded. *In this state it has all the elasticity of caoutchouc*, but this it loses as it cools, gradually becoming hard and rigid again, and *retaining any form impressed on it whilst in its plastic condition.*"



## APPENDIX.

## GENERAL ANÆSTHESIA.

By H. BRIGGS, M.B., F.R.C.S. (ENG.)

IN the selection of the general anæsthetic for a dental operation, besides the complete relief of pain with the least possible risk to the patient, there are many considerations which become important by being directed against inconveniences.

Amongst the more prominent inconveniences would be the performance of a dental operation upon a patient lying in bed or on the couch because chloroform had to be given; delay of the patient and friends in the house of the dentist because there were prolonged and prostrating after-effects of chloroform or ether; the incompleteness of the extraction or extractions because nitrous oxide had been used and found insufficient for the purpose.

The greatest comfort is attained by (1) the speedy induction of the requisite anæsthesia; (2) the completion of a painless operation; (3) the rapid return of consciousness; (4) the absence of after-effects; and (5) the use of an agent which does not possess disagreeable qualities. Hence

nitrous oxide is commonly employed on the plea of comfort.

Then there is the all-important question of the relative safety, which gives nitrous oxide an immense lead amongst the general anæsthetics. On the principle of adapting the anæsthetic to the operation, nitrous oxide becomes the only anæsthetic permissible for a short dental operation, in itself free from danger. This verdict in favour of nitrous oxide is founded upon collected and combined statistics.

The advantages of nitrous oxide cannot be controverted by the universally successful etherist or chloroformist. Confidence in nitrous oxide is increased by the knowledge that its brief narcosis can be two or three times renewed by re-administration, or safely prolonged by ether, if necessary.

Occasionally with gas, or gas and ether, the operator and the anæsthetist obstruct each other; the fingers, the forceps, and the face-piece may be severally in search of the mouth, or a blood clot may be obstructing the mouth or throat. After each of the rapidly succeeding later moments of the anæsthesia the operation is expected to be over, and it is doubtful if the best work of the most adept operator has been carried out; and on more leisurely reflection it may be possible to arrive at the conclusion that chloroform would have been a more convenient and equally safe anæsthetic for the purpose.

That chloroform is a safe and certainly convenient *minor* anæsthetic has been the experience



of the writer. As a major anæsthetic, pushed to the degree of complete narcosis and total relaxation of the muscles of the jaw, chloroform becomes dangerous, and ought not to be so employed in dental operations. To induce a minor anæsthesia less chloroform is necessary, and the difficulty with chloroform really consists in estimating the dose and in adapting the dose to the individual, and the degree of narcosis required. So that a small dose of chloroform should be judged rather by the *gradual and steady rise in its effect upon the patient* than by its drop by drop deposit at long intervals upon the inhaler in the hands of a timid administrator. If the chloroform, to begin with, be *freely* supplied and *naturally* respired, the almost immediate effect is a trifling, but adequate insensibility, a quick return to consciousness, and few, if any, appreciable after-effects. Five to nine minutes are devoted to the anæsthesia and the operation. The patient often starts on the walk or drive home in fifteen to twenty minutes from the commencement of the chloroform inhalation.

Minor anæsthesia is best attained by nitrous oxide or chloroform. Ether can be used, but to most persons ether is disagreeable, and whoever, unless by the wish of the patient, commences anæsthesia with ether, either constitutes himself a poor judge of the comfort of his patient, or is in terror, without occasion, of a few more agreeable "whiffs" of chloroform. After the preliminary narcosis by gas or chloroform, patients readily breathe ether.



Ether should always be used to complete and maintain a *deep anæsthesia*. For dental purposes *profound insensibility* is seldom required; it is generally therefore an unnecessary extreme. Chloroform, pushed to the degree of total narcosis, is often, and should always be regarded as, dangerous to life, especially in the sitting posture.

Assuming that individual variations do exist in patients, the after-effects are broadly proportionate to the quantity of chloroform or ether administered. An anæsthesia, too deep or too protracted, is apt to be disagreeable to the patient and inconvenient to the dentist. Afterwards when it is found that the anæsthetic has produced results disproportionate to the character of the operation itself, and to the patient's previous understanding of what was to take place, the anæsthetic is injured in reputation without justification. If the operation be by expectation a long one, a large quantity of anæsthetic is unavoidable: the after-effects are anticipated, and therefore more patiently endured, whilst the consequent slower return of sensibility lessens the immediately subsequent tenderness and pain in the jaws.

There ought to be a fine adjustment between the work the dentist has to do, and the effect the anæsthetic will have on the patient. A short consultation between the anæsthetist and the operator is therefore desirable. Preliminary calculations with this object cannot be infallibly made, but if there be a doubt, probably a more enduring form of anæsthesia will ensure the best results.



There is an almost incredible variation in the amount of work accomplished, by different operators, during the insensibility of nitrous oxide at one sitting.

Nitrous oxide anæsthesia can be supplemented by ether. If the ether has to be continued for any length of time, uncomfortable after-effects may ensue in a degree corresponding to the total amount and duration of the etherization. The operator's access to the mouth is curtailed by the inhaler, and, unless the head is held forward and the lower jaw depressed, blood may accumulate in the throat and obstruct the air passages. Indeed, it is a question, well worth the consideration of all concerned, to determine whether the open method of giving chloroform is not more convenient, and certainly equally safe, *provided the anæsthesia induced be not too deep*. This is an application of chloroform to dental surgery not generally adopted or understood.

Chloroform will keep up a *transient minor anæsthesia*, once established, provided the open inhaler is held just above the mouth; access to the mouth is permitted, and the muscular rigidity of the lower jaw usually yields to the fingers, so that a gag is seldom required to open the mouth.

Anæsthetists are prone to use chloroform only in their most troublesome operations, and then to push it farther than is needful or convenient for dental purposes. Chloroform supplies an agreeable and almost ideal means of bringing about and keeping up a safe minor anæsthesia. It is said that there is an increased risk from shock in



operating upon persons during minor anæsthesia, that is when "incompletely" anæsthetised. An anæsthesia may be said to be complete when it answers its purpose, and in dental surgery, if all reflexes are to be abolished and a total anæsthesia brought about, chloroform should either be cast out as dangerous, or have a very restricted application.

Chloroform, as employed in obstetric practice, has an untarnished reputation; but little chloroform is necessary, and yet hemorrhage and other causes of shock are not infrequent. The condition of chloroform anæsthesia for obstetrical and dental work are not exactly on a par. Ladies often think so, and ask for chloroform. Very little chloroform goes a long way and has to be renewed from time to time in obstetrics, whereas the chloroform should be given more quickly for dental operations; in both practices the dose is relatively small.

When chloroform is freely breathed and the respirations are complete and regular, the countenance natural, the lips florid, and the pulse steady, chloroform for dental purposes should be given until the conjunctival reflex is *only partially suspended*, and until the arm, elevated as a test, drops by the side. In some instances it is a confirmatory aid to determine the absence of all ordinary sensation in the skin of the armpit. This state is best described as an exaggeration of natural sleep; it is a partial or minor anæsthesia, not adapted to the delicate cutting operation of the general surgeon, who would at once exclaim, the "patient is not under." Surgeons are there-



fore apt to produce a deeper degree of anæsthesia than a dentist desires.

The obstetrician employs chloroform to lull less severe pains. He is in the habit of spreading the administrations of chloroform over a longer period of time. He is prone to give chloroform too slowly for dental purposes, and if the adequate insensibility be ultimately attained, the system is saturated with chloroform, the return to consciousness is delayed, and the prominent after-effects complete an uncomfortable experience.

Chloroform is capable of a special and safe application to dental purposes. As generally used by surgeons and obstetricians chloroform is not seen to advantage in dentistry: what is of use in one department becomes an abuse in another.

In dentistry, ether is less popular than nitrous oxide or chloroform. The unpleasant effects are much reduced by practice in administration. As a rule, nitrous oxide or chloroform is given as a preliminary to etherization. But even when the operation is over, and hours have elapsed, ether still nauseates and irritates the patient. In the selection of an anæsthetic, the desire of the patient or the advice of a medical attendant ought not to be overlooked. Serious moral obligations devolve upon the anæsthetist. It would answer the purpose of the dentist more perfectly if all anæsthetists had special experience and could use nitrous oxide, chloroform, or ether at will, and even all three on the same patient if desirable or convenient. A training of this kind would not weaken their powers as anæsthetists. It would



make some critics more tolerant on both sides of the everlasting question of ether *v.* chloroform; and it might lead to an extension of clinical teaching in many existing and one-sided schools.

#### TABLE OF DENTAL ANÆSTHETICS.

1. NITROUS OXIDE (may be given a second or third time).
2. " " and (prolonged by) ETHER.
3. CHLOROFORM—employed as a
 

(a) transient	}	<i>minor</i> anæsthetic.
(b) continuous		

 (never to induce deep insensibility in the sitting posture).
4. ETHER—as (a) a *minor* anæsthetic—is disagreeable.  
 —for (b) *major*, deep, complete anæsthesia—should always be employed.

*Nitrous Oxide* ought to be in general use, now that it can be purchased in the liquid state in steel bottles. Two steel bottles are conveniently coupled to one tube and gas bag. The lever pedal (Fig. 88) is more easily and speedily controlled than the screw pedal (Fig. 89).

It is unnecessary to have more than one—a Barth's face-piece (Fig. 90) for child or adult.

Gas may be given to the same patient two or even three times at one sitting. Less additional gas is needed to complete the anæsthesia each time. It is important in using gas to have the lower jaw depressed, so that blood may be drained from the mouth over the chin. The prop should be secure by fitting accurately, or by being provided with a spring. Gas is often imperfectly given; it should always be *fully administered, until conjunctival reflex is abolished and there is jactitation*. The absence



of stertor from the ingress of air frequently misleads the administrator. On the other hand,

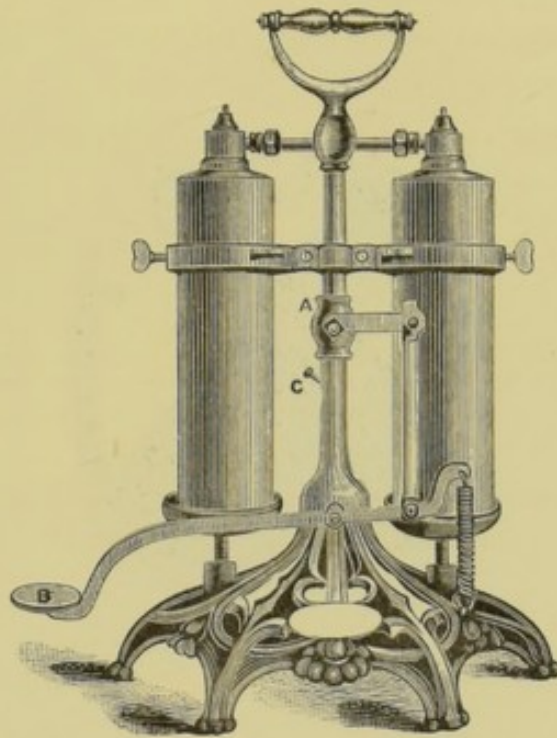


Figure 88.—This portable apparatus is the invention of Mr. Pain, a Liverpool mechanician. By means of screws, each 100 gallon bottle can be accurately adjusted to its place on the stand and securely coupled to the tube. There is a tap in the common tube at A; the tap is conveniently opened by depressing the pedal B; from the tube C rubber tubing leads to the gas bag and face-piece. The arrangement is most convenient, but the fittings might be improved, and the addition of a "silencer" would be an advantage.

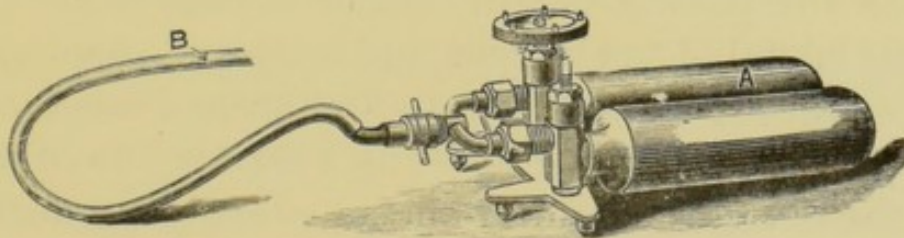


Figure 89.—Showing the ordinary method of regulating the supply of gas by a screw-tap worked by the foot.

stertor not infrequently occurs early, and induces the administrator to withdraw the face-piece before

the more important signs of complete anæsthesia are established. In second and third administrations comparatively few inhalations of gas are

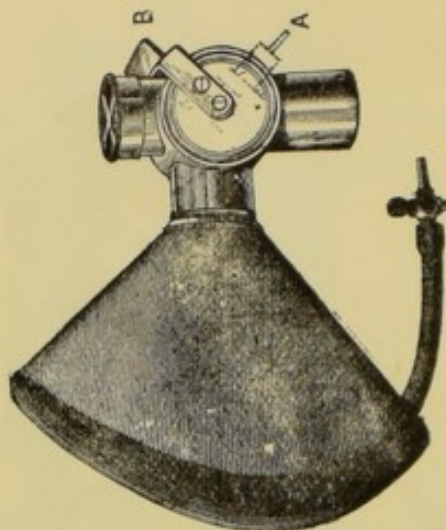


Figure 90.—This represents the medium-sized face-piece made by Messrs. Barth & Co.

necessary—stertor is then not always re-established; changes of colour ought to be accurately noted as the gas enters and leaves the blood. If there be much blood in the mouth and throat, gas should not be re-administered.

Some dentists are economical; accordingly, when the patient is fairly under nitrous oxide the same bagful of gas is given and re-given. Asphyxia is produced; poisoning with foul air and headache are the results which serve as a warning to others of the disagreeable after-effects wrongly attributed to nitrous oxide. Gas fresh from the bottle ought to be given, and gas only of good quality.

Nitrous oxide and oxygen have been used by Dr. Hewitt. The results are inconstant, and the employment of the mixed gases is not likely



to extend beyond restricted limits as Dr. Hewitt himself has suggested.

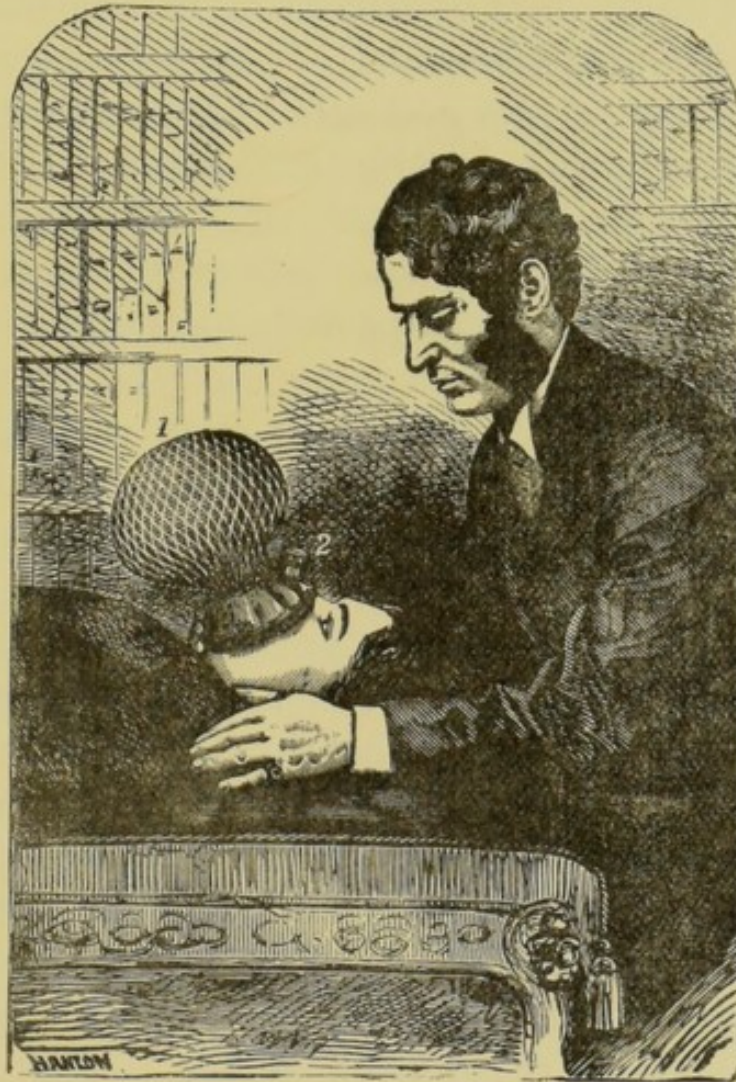


Figure 91.—The inhaler invented by Dr. Ormsby, who has kindly supplied the illustration. It is both simple and effective: by it ether is conveniently given to a patient in either the sitting or recumbent posture. In the face-piece is a valvular aperture (2) by which the admission of fresh air is regulated. Air can be more comfortably admitted between the patient's face and the pad of the face-piece of the inhaler when the inhaler is not held in close contact with the patient's face.

*Ether* can be administered by any of the various inhalers of which Ormsby's (Fig. 91) is more con-



venient than the small Clover's apparatus Dr. Cruise advocates the open stocking webbing on a wire frame, enclosed in rubber. Any one of these inhalers is all that is necessary to continue with ether after nitrous oxide. It is quite an error to suppose that a gas and ether apparatus specially constructed with numerous valves and troublesome taps is essential for the purpose. All that is needful is an ordinary inhaler allowing *air* to enter along with the ether, especially after nitrous oxide has been given. There is no need to stop the gas before stertor is established; then withdraw the face-piece, apply the ether inhaler, and let the ether be breathed, mixed with air at first, until the required insensibility is produced. When there is in prospect an incomplete operation under nitrous oxide, after one, two, or even three administrations, ether affords a welcome security against pain whilst the operation is completed. Ether has merely to be substituted for the gas at any time before consciousness returns. Blood in the mouth and throat, or any respiratory obstruction or choking should be guarded against, whilst the anæsthesia is continued to the desired degree. The patient need not "come out of the anæsthetic" before the operation is completed. Sometimes, where the ether inhaler on the face interferes with the dentist's manipulations, chloroform may be substituted for the ether, unless there be still asphyxial lividity from pushing the ether too quickly on the top of the nitrous oxide. It requires care and experience to avoid pushing ether to the exclusion of air at first.



*Ether* when given by a skilful person has few drawbacks. For general surgical and dental work it ought always to be used when chloroform is objected to. Practice in giving ether should be regularly cultivated. It would be a wise rule to insist upon the adoption of ether as the most safe anæsthetic when it is desired to have a patient deeply anæsthetised. When the administrations are continued during a long operation, *fresh air should be freely admitted* along with the ether. The same remarks, in reference to asphyxiating and poisoning with foul air, apply, in the case of ether, more rigidly than in the case of nitrous oxide, because operations under ether are more prolonged.

*Chloroform*, with care, can be given, dropped on a Skinner's inhaler (Fig. 92) or folded towel, so

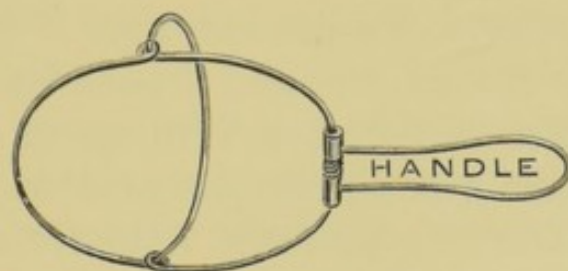


Figure 92.—Skinner's inhaler consists of a folding wire frame, on which flannel is spread and secured. Chloroform is held by the flannel in quantity sufficient to maintain anæsthesia whilst the inhaler is held a little distance above the mouth, without blistering the lips and face.

that the patient's face is gently approached with the inhaler to begin with, to avoid smarting and choking. The eyes should be closed and the patient asked to breathe the chloroform freely, with regular easy respirations, and *without extra*

*effort*. Excitement should be avoided—during loud talking, shouting, and struggling, the inhaler should be removed and less chloroform given. It is difficult to regulate the dose with *irregular* breathing; in fact chloroform then becomes *unsafe*; struggling embarrasses the respiration and circulation. Whenever the respiration does not proceed regularly and evenly, a suspension of the chloroform is indicated.

The respiration is the main index—it need not be the only one. The character of the pulse, the colour of the lips, and the aspect of the countenance may be observed with advantage, provided the respiration is understood to be the main guide.

Slow and shallow respiration may occur early; the inexperienced may be alarmed. It is merely that the patient has gone to sleep, and is not really under the influence of the chloroform. It is wise to awaken the patient, and, if in doubt, to suspend the chloroform, and if need be go on with ether. Ether ought always to be at hand, and when in doubt it is a judicious plan to give ether.

Chloroform is a powerful remedy, and in deep anæsthesia its employment is risky. In minor anæsthesia the dose is well under a full one, so close observation ought to secure safety in experienced hands. This is a contention well worthy of a careful trial and patient judgment.

The A. C. E. mixture of equal parts of alcohol, chloroform, and ether, is a favourite anæsthetising agent with those who value its diluted properties more highly than the effects, in sequence, of chloroform and ether.




Amylene, dichloride of ethylene, and bichloride of methylene, certainly differing from chloroform in name and chemical constitution, have doubtfully any remarkably dissimilar physiological influence.

During all forms of anæsthesia, the posture of the patient and the position of the lower jaw ought to be regulated so as to encourage the blood to drain from the mouth, rather than pass down the throat to obstruct breathing perhaps, or if loaded with ether or chloroform, to irritate the throat and stomach and excite vomiting. Dentists can do much to promote easy respiration by the manner in which they use and place their fingers in the mouth of the patient. Whenever a gag can be dispensed with so much the better for the patient under chloroform or ether.

The dangerous complications of anæsthesia require to be combated under a precise knowledge of their origin.

During embarrassed respiration, the entrance of air should be promoted by clearing the respiratory passages by the fingers or sponges, and by the performance of artificial respiration, if necessary.

During syncope, inversion of the patient cannot be too promptly carried out.





# INDEX.

- Anæsthesia, general (appendix), 197.  
 Advantages of, 70.  
 Surgical attendance for, 74.  
 Arsenic, preparation of, for devitalization of pulps, 12.  
 Method of using, 12.  
 Danger from, 13.  
 Carefulness in using, 13.  
 Absorption of roots, 14.  
 Absorbent organ, 14.  
 Attempt to correct deformity from tongue-sucking, 23.  
 Amadou for drying cavities, 52.  
 Approximal decay in incisors, 48.  
     "                    "      bicuspid, 57.  
     "                    "      canines, 58.  
 Attrition, loss of substance from, 167.  
 Amalgam, 169.  
     Prejudice against, 171.  
     Building up molar crowns with, 172.  
     Gold and platinum, 175.  
     Preparation of cavities for, 176.  
     Dr. C. C. Allen on, 177.  
     Dr. Foster Flagg on, 178.  
 Arthur, Dr. Robert. a method of treatment, 57, 65.  
     Letter to, on gold fillings, 138.  
 Antagonizing teeth, the extraction of, 60.  
 Adult teeth, when to begin to treat as such, 115.  
 Bicuspid, displaced by premature extraction of temporary teeth, 6.  
 Bicuspid, approximal decay in, 57.  
     Backward movement of, 61.  
     Restoring palatine cusp of, with gold, 147.  
     Restoring buccal cusp of, with porcelain, 187.  
 Building up the crown of a molar tooth, 172.  
 Bacteria in putrescent pulps, 18, 19.  
 Completion of first dentition, 2.  
 Cleanliness, 2, 3, 53.  
 Contraction from premature extraction, 5.  
 Cruelty of premature extraction, 8.  
 Cutting away decay, 51, 57, 66.  
 Carbolic acid, 19, 35, 52, 99, 164.  
 Comparative value of gold and gutta-percha for filling teeth before puberty, 53.  
 Cessation of development from death of pulp, 38.  
 Canine teeth, approximal decay in, 58.  
     Prominence of, 64.  
 Co-operation of parents and child in treating irregularities, 44, 46.  
 Case of mistaken judgment, 63.  
 Cervical cavities in buccal and labial surfaces, 153.  
 Contour fillings, 137.  
 Counter-irritant for congestion of peri-dental membrane after root filling, 38.  
 Dental subjects, popular knowledge of, 4, 27.

- Dead pulps in roots not fully developed, 38.
- Defective teaching, 42.
- Decay of temporary teeth, 4.  
Treatment by cutting away, 4, 51, 57.  
During gestation, 145.
- Defective formation of enamel, 54, 55.
- Deterioration in the manufacture of filling materials, 174.
- Effect on the minds of children of injudicious talk on dental operations, 4.
- Essig, Dr. Charles, a method of making and fitting gold caps on gutta-percha fillings, 31.
- Enamel chisels, 123.
- Excavators and pluggers, 124.
- Erosion, 158.  
Another form of, 163.
- Effect of acid secretions in illness, 161.
- Extraction of temporary teeth not necessary to cure pain, 5.  
Contraction from, 5.  
As a means of preventing decay, 59.  
Care in selecting for this purpose, 60.  
Speedy benefit from, 61.  
Anæsthesia for, 70, 74.  
Instruments for, 71, 73.  
Best time for, as a means of preventing decay, 75, 82.  
"Tipping" after, 75.  
Results of, 67, 77, 78, 81.  
Treatment of irregularities after, 85.  
Arguments against, 75, 79, 82.
- Fear of the dentist, 3, 9, 143.
- First permanent molars, 26.  
Early decay in, 26.  
Displaced by premature extraction of temporary teeth, 8.
- Filling roots, 35.
- Failure of fillings in sensitive cavities, 116.
- Facility for cleansing treated surfaces, 127.
- Family peculiarities, 85.
- Fixing artificial crowns, 184.
- Frequent examination of children's mouths, 48.
- Filling materials, 133.
- Failure of a built-up crown, 148.
- Flagg, Dr. Foster, 140.
- Gentle treatment, 5.
- Gold regarded as a permanent filling material, 127.  
Not always the best filling material, 127.  
Not advisable as a filling for temporary teeth, 5.
- Fillings in permanent teeth, 119.  
With soft gold, 128.  
With soft and cohesive gold, 130.  
With cohesive gold, 131.  
Caps for gutta-percha fillings, 31.  
And tin fillings, 147.
- Fillings, Dr. M. A. Webb on density of, 136.
- Gaining the confidence of children, 9.
- Gutta-percha for filling teeth, 5, 29, 52, 145, 155.  
For early decay in permanent molars, 29, 52.  
Safer than gold for difficult positions, 155.  
As a lining for cavities in grinding surfaces, 142.  
For cervical margins, 147.
- Durability of in cavities not exposed to attrition, 152.
- Care in preparing cavities for, and packing, 155.
- For impressions, 192.
- Guarding against slipping of the instrument while operating, 125.



- Home examinations of children's teeth, 3.  
 Attendance to cleanliness, 3.  
 Encouragement in regulating cases, 44, 99.  
 Heterodox treatment, 15.  
 Inflammation of the pulp, 11, 34.  
 Irregularities of the temporary teeth, 21.  
 Incisors, permanent lower, growing inside the arch, 39.  
 Irregularities which require early treatment, 21, 43, 45.  
 Which are best treated about the twelfth year, 85.  
 Incomplete formation of roots of pulpless teeth, 39.  
 Incisors, preservation of labial surfaces in filling, 49.  
 Jack-screws, 110.  
 Toleration of in regulating cases, 110.  
 Loss of vitality of a pulp after filling, 121.  
 Liberal and eclectic views in operating, 142.  
 Maxillary bones, growth dependant on development of molar teeth, 8.  
 Molars, first permanent, displaced by premature extraction of temporary teeth, 8.  
 Malpractice, 28.  
 Metal fillings not best for sensitive teeth, 116.  
 Mouth mirror, 48, 50, 120.  
 Mistaken judgment, 63.  
 Modern operating appliances, 134.  
 Mistaken teaching, 141.  
 Medicine, supposed effect of, on the teeth, 161.  
 Moving a late erupting and misplaced canine, 88.  
 Nurses teaching children to suck the thumb, 24.  
 Natural separation of the teeth after extraction of the molars, 61.  
 Necessity for retaining plates in some cases of regulating, 46.  
 Narrow views, 141.  
 Nature's method of protecting the pulp, 165.  
 Nodules, or pulp stones, 166.  
 Preservation of temporary teeth, 1.  
 Popular knowledge on dental subjects, 4, 27.  
 Professional discretion, 40.  
 Prevention of pain by timely operations, 4.  
 Pulpless roots not an obstruction to eruption of permanent teeth, 17.  
 Preparation of cavities for fillings, 49, 125.  
 Of materials for plastic fillings, 174.  
 Of roots for pivoting, 180.  
 Of gutta-percha for impressions, 192.  
 Preservative effect of isolation, 62.  
 Primary toothache, 10, 34.  
 Putrescent pulps, 18, 38.  
 Parental anxiety, 39.  
 Projecting upper teeth, 52.  
 Pressure of wisdom teeth, 75.  
 Permanent fillings, 118.  
 Periostitis after a prolonged operation, 133.  
 Perfection by easy stages, 144.  
 Professional jealousy, 144.  
 Pivoting, 179.  
 Partial restoration of bicuspid crowns, 188.  
 Quick observation while operating, 126.  
 Questionable appliances, 134, 137.  
 Retention of temporary teeth, 2.

- Regulating cases, good impressions for, 44.  
Retaining plates for, 46, 54, 103.  
Simple fillings in temporary teeth, 5.  
Secondary toothache, 19, 34.  
Sucking the thumb, 21.  
The fingers, 22.  
The tongue, 22.  
Screws and springs in regulating, 112.  
Swollen gums in regulating, 100.  
Shaping cavities, 125.  
Sensitive cavities, 117.  
Self-cleansing surfaces, 127.  
Temporary teeth, treatment of the roots after death of pulp, 16.  
Toothache, primary, 10, 34.  
Secondary, 19, 34.  
Causes of, 10.  
Diagnosis of, 10.  
Not always felt in the tooth which causes it, 17.  
Treatment after devitalization of the pulp, 14.  
Of early decay, 49.  
Timid, 69.  
For nodules, 166.  
For congestion of peri-dental membrane, 38.  
Of teeth after illness, 161.  
Temptation for young practitioners, 40.  
Turning a front tooth, 45.  
Teeth displaced by premature extraction of temporary teeth, 5, 8.  
Care necessary to preserve after filling, 53.  
Affected in pairs, 86.  
Elongated by backward pressure, 102.  
Time spent in operations, 133.  
Thoroughness in operating, 143.  
Tin fillings, 146.  
Tin and gold fillings, 147.  
Taking impressions, 193.  
Under-hung jaws, 44.  
Uses of the mirror, 119.  
Unsightliness of large gold fillings in conspicuous positions, 126.  
Widening upper jaw, 108.  
Lower jaw, 105.  
Wedging, effect of, 139.  
Wisdom teeth defective from overcrowding, 68.  
Weak spots in fillings, 145.  
Weak walls, 151.







1. The first part of the document discusses the importance of maintaining accurate records of all transactions and activities. It emphasizes that proper record-keeping is essential for transparency and accountability, particularly in financial matters. The text suggests that organizations should implement robust systems to track and document every aspect of their operations, from procurement to sales.

2. The second part of the document addresses the challenges associated with data management and security. It highlights the need for organizations to protect their sensitive information from unauthorized access and breaches. The text recommends the use of secure storage solutions and the implementation of strict access controls to ensure that data remains confidential and intact.

3. The third part of the document focuses on the importance of regular audits and reviews. It states that periodic assessments are necessary to identify potential weaknesses and areas for improvement. The text encourages organizations to conduct thorough audits of their financial statements, internal controls, and operational processes to ensure compliance with relevant regulations and standards.

4. The fourth part of the document discusses the role of technology in enhancing organizational efficiency and effectiveness. It mentions that the adoption of modern software and tools can significantly streamline workflows and reduce the risk of human error. The text suggests that organizations should invest in training and development to ensure that their staff is equipped with the necessary skills to utilize these technologies effectively.

5. The fifth part of the document concludes by emphasizing the importance of continuous improvement and innovation. It states that organizations should strive to stay ahead of the competition by constantly seeking new ways to optimize their processes and services. The text encourages a culture of innovation and encourages employees to contribute their ideas and suggestions for improvement.





