

Swine diseases / by A.T. Kinsley.

Contributors

Kinsley, A. T. 1877-

Publication/Creation

Chicago : American journal of veterinary medicine, 1914.

Persistent URL

<https://wellcomecollection.org/works/dpwd34ew>

License and attribution

Conditions of use: it is possible this item is protected by copyright and/or related rights. You are free to use this item in any way that is permitted by the copyright and related rights legislation that applies to your use. For other uses you need to obtain permission from the rights-holder(s).



Wellcome Collection
183 Euston Road
London NW1 2BE UK
T +44 (0)20 7611 8722
E library@wellcomecollection.org
<https://wellcomecollection.org>




M. xxiii

20/K



22101898023

Med
K52529



VETERINARY MEDICINE SERIES

No. 4

SWINE DISEASES

BY

A. T. KINSLEY, M. Sc., D. V. S.

ILLUSTRATED

Chicago

AMERICAN JOURNAL OF VETERINARY MEDICINE

1914

COPYRIGHT 1914

By

D. M. CAMPBELL

WELLCOME INSTITUTE LIBRARY	
Coll.	welM0mec
Call	
No.	✓

PREFACE

The experience of the writer in teaching, and in the manufacture and distribution of anti-hog cholera serum, no less than in practice, has forcibly impressed upon him the need of the veterinary profession for more general knowledge of the diseases of swine.

They are not few who maintain that veterinary practice in the future will be concerned largely with the food-producing animals. The automobile has already supplanted most of the fancy driving horses; the auto-truck does much that would otherwise be accomplished by horses; and predictions are rife that the gasoline tractor will soon be made practicable for work on small farms. All things considered it seems probable that the equine population of the country is destined to increase but slowly if at all. The keeping of pet animals, including dogs and cats, is being looked upon more and more as an insanitary practice, while the farm dog and the roaming cur are becoming more and more the object of antagonistic legislation. Contrasted with the foregoing, the increasing price of meat food products makes it seem desirable that veterinarians in general better equip themselves for the treatment of the ailments of food producing animals and thus qualify themselves to render greater service to the public in

a line of practice that is not likely to be affected by progress and invention.

It is the aim of this work to supply this information in a compact, readily assimilated form for both students and practitioners. Acknowledgement must be made to Dr. D. M. Campbell, editor of the *American Journal of Veterinary Medicine* for the illustrations used herein, and he wishes me to, in turn, acknowledge his indebtedness to Dr. L. Enos Day, in charge of the Branch Pathological Laboratory of the Bureau of Animal Industry of Chicago, and his assistant Dr. G. Tinsley Creech, for permission to photograph a number of specimens in the very excellent museum maintained in connection with their laboratory. And also indebtedness to the American Serum Company of Kansas City for photographs of their plant used in illustrating the manufacture of anti-hog cholera serum.

A. T. KINSLEY.

Kansas City, December 1914.

CONTENTS

SECTION I.	PAGE
THE DIGESTIVE SYSTEM.....	9
<p><i>Lips</i>; Malformations—Cheilitis—Tumors. <i>Tongue</i>; Glossitis—Tumors—Parasites. <i>Mouth</i>; Stomatitis—Scurvy—Parotiditis—Tonsillitis. <i>Pharynx</i>; Pharyngitis—Pharyngeal Paralysis—Tumors. <i>Esophagus</i>; Malformations—Stenosis—Dilatation—Perforation—Esophagitis—Tumors. <i>Stomach</i>; Malformations—Foreign Bodies—Emesis—Anemia—Hematamesis—Peptic Ulcers—Hyperemia—Gastritis—Dilatation—Tumors—Parasites. <i>Intestines</i>; Malformations—Entorrhagia—Obstruction—Dilatations—Emphysema—Enteritis—Toxic Gastritis, Gastroenteritis, Enteritis—Scours in Sucklings—Parasites—Tumors. <i>Liver</i>; Malformations—Foreign Bodies—Rupture—Icterus—Cloudy Swelling—Fatty Changes—Amyloid Changes—Glycogenic Infiltration—Cholelithiasis—Hyperemia—Hepatitis—Tumors—Parasites. <i>Pancreas</i>; <i>Peritoneum</i>; Injuries—Ascites—Peritonitis—Tumors—Parasites.</p>	
SECTION II.	
THE RESPIRATORY SYSTEM.....	75
<p><i>Nose</i>; Epistaxis—Rhinitis—Infectious Nasal Catarrh—Tumors. <i>Larynx</i>; Laryngitis—Tumors. <i>Trachea</i>; Malformations—Stenosis—Tracheitis—Tumors. <i>Bronchial Tubes</i>; Stenosis—Bronchitis—Verminous Bronchitis and Pneumonia. <i>Lungs</i>; Atelectasis—Emphysema—Edema—Hemorrhage—Pneumonia—Tumors—Parasites. <i>Pleura</i>; Hydrothorax—Hemothorax—Pneumothorax—Pleurisy—Tumors.</p>	
SECTION III.	
THE URO-GENITAL SYSTEM.....	99
<p><i>Kidneys</i>; Malformations—Hydronephrosis—Hemorrhage—Fatty Changes—Calculi—Congestion—Nephritis—Pyelonephritis—Albuminuria—Uremia—Tumors—Parasites. <i>Ureters</i>; Malformations. <i>Bladder</i>; Malformations—Hematuria—Dilatation—Calculi—Cystitis—Tumors. <i>Urethra</i>; Stricture—Urethritis. <i>Prostate-Gland</i>; <i>Cowper's Glands</i>; <i>Testicles</i>; Orchitis and Epididymitis—Tumors. <i>Sequels to Castration</i>; Hemorrhage—Infection—Botryomycosis—Actinomycosis—Parasites—Scrotal Hernia. <i>Penis</i>; <i>Ovary</i>; Malformations—Hemorrhage—Oophoritis—Cysts—Tumors. <i>Fallopian Tubes</i>; <i>Uterus</i>; Malformations—Injuries—Hemorrhage—Metritis—Tumors. <i>Vagina</i>; <i>Vulva</i>; <i>Mammary Glands</i>; Mammitis—Botryomycotic Mammitis—Actinomycotic Mammitis—Tuberculous Mammitis—Tumors.</p>	

CONTENTS—Continued

SECTION IV.

ORGANS OF LOCOMOTION..... 135

Sore Feet—Fatty Degeneration—Muscular Rheumatism—Articular Rheumatism—Rachitis—Osteomalatia—Purulent Osteomyelitis—Trichinosis—Cysticercosis (measles)—Sarcosporidiosis—Tumors.

SECTION V.

THE SKIN..... 149

Erythema—Sunburning—Freezing—Hemorrhage—Urticaria—Eczema—Dermatitis Granulosa—Necrobacillosis—Actinomycosis—Tumors—Parasites.

SECTION VI.

CIRCULATORY ORGANS..... 159

Heart; Pericarditis—Hemorrhage—Fatty Changes—Endocarditis—Tumors—Parasites. *Blood Vessels: Blood*; Anemia—Leukemia. *Spleen*; Necrosis—Hyperthrophy—Sarcomatosis.

SECTION VII.

THE NERVOUS SYSTEM..... 163

Malformations—Delirium—Viciousness—Sunstroke—Heat Stroke—Lightning Stroke—Epilepsy—Dentition—Eclampsia—Chorea—Cerebral Hyperemia—Parasites.

SECTION VIII.

INFECTIOUS DISEASES..... 169

Hog Cholera; History—Extent—Etiology—Sources of Infection—Manner of Infection—Susceptibility—Channels of Infection—Period of Incubation—Lesions—Symptoms—Diagnosis—Prognosis—Treatment—Preventative Treatment—Anti-Hog Cholera Serum—Manufacture and Use. *Swine Plague: Necrobacillosis*; Necrotic Stomatitis—Necrotic Enteritis—Necrotic Rhinitis—Necrotic Pneumonia—Necrotic Hepatitis—Necrosis of the Spleen—Vaginal, Vulvar and Preputial Necrobacillosis—Necrobacillosis of the Skin—Other Forms of Necrobacillosis. *Tuberculosis: Pyemic Arthritis; Spasms of the Diaphragm: Rabies; Foot and Mouth Disease.*

ILLUSTRATIONS

FIGURE	PAGE
1. Glossitis.....	11
2. Ascaris Suum.....	48
3. Gigantorhynchus Hirudinaceus.....	52
4. Adeno-Sarcoma of the Kidney.....	111
5. Actinomycosis.....	121
6. Scirrhus Cord due to Botryomycotic Infection.....	122
7. Infection of the Udder.....	131
8. Cysticercosis (Pork Measles).....	145
9. Pedunculated Fibroma.....	146
10. Elephantiasis.....	152
11. Mucous Membrane of the Bladder.....	177
12. Mucous Membrane of the Intestine.....	179
13. Hearts.....	181
14. Early Stages of Hog Cholera.....	183
15. Acute Hog Cholera, Advanced Stage.....	185
16. Heart Showing Hemorrhages due to Hog Cholera.....	187
17. Kidneys.....	188
18. Lymph Nodes.....	189
19. Virus Bleeding Room.....	194
20. Hyperimmunizing Room.....	196
21. Serum Centrifuging Room.....	200
22. Sterilizing Room.....	201
23. Cholera-Immune Hogs.....	203
24. Necrobacillosis.....	212
25. Fat Necrosis.....	215
26. Tuberculosis of the Tongue.....	221
27. Tuberculosis of the Skin.....	222
28. Tuberculosis of the Pleura.....	225

COLOR PLATES

PLATE I Opp. p. 182

Fig. 1. Skin Lesions of Hog Cholera.

Fig. 2. Intestinal Lesions of Hog Cholera.

PLATE II Opp. p. 198

Fig. 1. Thrombosis of the Liver.

Fig. 2. Pulmonary Lesions of Hog Cholera.

PLATE III Opp. p. 218

Fig. 1. Hepatic Lesions of Tuberculosis.

Fig. 2. Bone Lesions of Tuberculosis.

PLATE IV Opp. p. 224

Fig. 1. Splenic Lesions of Tuberculosis.

Fig. 2. Pulmonary Lesions of Tuberculosis.

SECTION I

THE DIGESTIVE SYSTEM

The Mouth and its Associated Parts

THE mouth of swine is prone to injuries and infection because they are likely to ingest foods in various states of refinement, and not infrequently they consume foreign bodies that may produce such injuries as contusions and lacerations. The comfort and health of swine are not always considered by the feeder, who may thoughtlessly give foods sufficiently hot or cold to produce damage to the buccal mucous membrane. Injuries to this membrane are predisposed to infection that may produce pathologic conditions varying from simple inflammation to suppuration or even necrosis.

LIPS

Malformations

Malformations of the lips of swine are not rare, the most frequent malformation being the condition popularly termed "hair lip" (*schistosis labii*). This condition is rarely observed in mature swine because the defect renders nursing extremely difficult and frequently impossible; such pigs, therefore, die before they have passed the nursing stage. *Schistosis labii*, when not associated with other developmental errors, is usually easily relieved by operation.

Cheilitis

The lips are also subject to injuries inflicted by rough foods or by foreign bodies in the food. Wounds, too, may be inflicted by dogs. Because of their location, lip wounds are predisposed to infection. Inflammatory processes of the lips are usually confined to the mucous surface.

Catarrhal cheilitis is of rather common occurrence, particularly in small pigs, and may be either acute or chronic. This condition is usually caused by improper food or undue exposure to very dry atmosphere. The lesions of the acute type consist of small crevices which in extreme cases may bleed freely. In the chronic type the cracks and crevices become more extensive and the surrounding tissues are infiltrated with varying quantities of newly formed fibrous tissue. Catarrhal cheilitis, either acute or chronic, is not a serious condition and is usually corrected when the cause is removed.

Suppurative cheilitis is occasionally observed. It is usually the result of infection of the subsurface labial tissues with pyogenic bacteria. The usual form of this type of cheilitis is circumscribed, and the lesions are similar to the lesions observed in the usual abscess formation. This condition is relieved by operation.

Diphtheritic cheilitis is very prevalent in some sections of the United States, particularly in young pigs. The usual causative agent is the *Bacillus necrophorus*. This microorganism produces a variety of lesions and is of so great economic importance that all of the disease processes resulting from it will be discussed under the topic, "Necrobacillosis," in Section VIII. (See p. 213.)

Vesicular cheilitis has been reported as occurring in suckling pigs. This condition is probably caused by a yeast, the *oïdium albicans*. The lesions of vesicular cheilitis are practically confined to the mucous surfaces of the lips. The mucous membrane is tumefied and scarlet red in color, and in the beginning and later small, sharply circumscribed vesicles appear and the mucosa becomes white, due to the accumulated desquamated epithelium and mucus. The vesicles rupture and the vesicular membrane may slough, leaving a denuded surface, or the vesicular membrane may collapse after the discharge of its content and appear as a small, white mass upon the mucous membrane. This condition is usually not serious, although it may cause considerable

inconvenience in sucking. It is usually relieved by the topical application of properly selected antiseptics.

Tumors

Labial tumors are not of common occurrence in swine, although fibroma, myxoma, and epithelioma have been observed.

TONGUE

The tongue is also subject to injuries of various types. Tongue injuries may be inflicted by improper food, by foreign bodies in the food, or by sharp, irregular teeth.

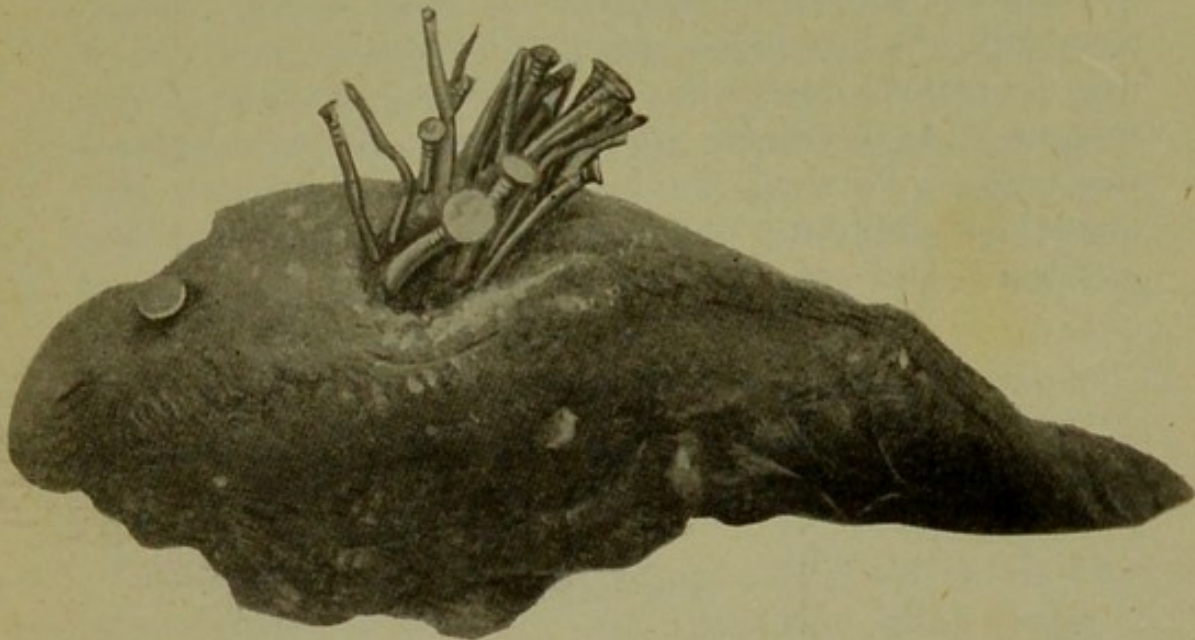

Fig. 1.— GLOSSITIS.

This tongue was taken from an apparently normal hog. It contained twenty-four polished nails lodged in one place.

Glossitis

Inflammatory disturbances of the tongue may involve the mucous membrane only or the submucous muscular portion of the tongue. The inflammations of the lingual mucous membrane are practically identical with those of the lips and will not be given further consideration. Inflammation of the lingual musculature is usually the sequel of an injury which had provided an avenue of entrance for infection. Inflammation of the substructures of the tongue may be acute or chronic, diffuse or cir-

cumscribed, nonsuppurative or suppurative. *Diffuse nonsuppurative subsurface glossitis* is usually acute and is the result of infection with streptococci or some septic microorganism. The lesions in this type of glossitis consist of a diffuse, extensive tumefaction of the tongue, which on section evidences enlargement of the blood vessels and abundant accumulations of pus, or other inflammatory products, between the muscle bundles, while the muscle tissue will have a parboiled appearance. *Acute circumscribed subsurface suppurative glossitis* partakes of the nature of an abscess. *Chronic glossitis* is most frequently diffuse and is exemplified in those cases of diffuse lingual actinomycosis. The lesions consist primarily of an excessive quantity of fibrous tissue which may contract unequally in different portions of the tongue, thus producing an irregularity of the surface of the organ. Portions of the tongue in which excessive quantities of fibrous tissues are developed become dense and hard, and cut with considerable resistance.

Tumors

Lingual tumors are relatively uncommon, but retention or obstruction cysts have been observed.

Parasites

Parasitic invasion of the tongue is not uncommon. The cystic form of the *Tænia solium*, that is, the *Cysticercus cellulosæ*, frequently occurs in the muscular portion of the tongue. The cystic form of the *Trichinella* has also been observed in lingual muscles, while psorosperms occasionally inhabit the muscle of the tongue.

MOUTH

The mucous membrane of the mouth, other than that mentioned in relation to the lips and tongue, is subject to injuries of a similar origin and nature and will not be further discussed here.

Stomatitis

Catarrhal inflammation of the buccal mucous membrane is relatively common and may be local or general, acute or chronic. *Acute catarrhal stomatitis* is usually caused by the ingestion of improper food, although it may be associated with some general infective disease or be the result of injury. The practice of catching swine by means of a rope or wire over the upper jaw is very likely to produce injury to the buccal mucous membrane. The affected mucous membrane is in the beginning tumefied and increased in redness, and later the surface becomes coated by the accumulation of desquamated epithelium and mucous. Gradually this surface coating loosens and sloughs as the inflammation diminishes in intensity. The affected animals refuse to eat, or eat sparingly, and usually select soft foods. Although they may attempt to chew hard substances, as a rule they drop them quickly to the ground. Salivation is always present, and in extreme cases an offensive odor may be detected.

The treatment consists of cleansing the affected parts with antiseptics and applying an astringent, such as myrrh. The affected animals should be given soft foods, and a good supply of clean, cool water.

Chronic catarrhal stomatitis is caused by the continuous or prolonged action of some relatively mild irritant. This condition is associated with fibrous proliferation in the submucosa which in the early stages of the disease results in tumefaction of the mucosa. Later the newly formed fibrous tissue contracts, producing an irregular surface. There is also a gradual atrophy of the mucosa and occasionally the cicatrized fibrous tissue obstructs mucous gland ducts, thereby causing small retention cysts.

Chronic catarrhal stomatitis is manifested by continuous limited salivation and champing of the jaws. The treatment depends largely upon the progress of the disease. In all cases the cause should be determined

and removed. Soft foods should be given, and mild astringent antiseptic washes may be used.

Phlegmonous stomatitis is relatively common in swine. It is usually caused by a streptococcic infection of the submucosa. The condition is usually general, the affected mucosa is intensely swollen and in the beginning is scarlet red in color, later assuming a purplish hue, and finally a dull gray color due to the accumulation of desquamated epithelium, mucous, and pus. Patches of mucous membrane may become necrotic and slough, leaving a red surface from which blood escapes freely. The tumefaction may be so intense that the mouth cavity becomes noticeably diminished, and the cheek mucous membrane may be forced between the teeth and lacerated during mastication.

The affected animals refuse to eat, and although they frequent the drinking trough, they will actually drink very little. There will be a frothy, ill-smelling discharge from the mouth. There may be a rise of from one to three degrees Fahrenheit in temperature. The treatment consists of mouth washes of antiseptics, frequently applied.

Vesicular ulcerative stomatitis is caused by the same agencies and presents lesions similar to vesicular cheilitis, and will not be further discussed.

Diphtheritic stomatitis is not uncommon, particularly in suckling pigs. The further discussion of this condition will be found under the topic, "Necrobacillosis," in Section VIII. (See p. 216)

Symptoms.—As above indicated, the symptoms of stomatitis of the various types vary only in intensity. There is more or less of salivation and drooling, champing of the jaws, and evidence of difficulty in mastication. On inspection the lesions will be evident, which are usually sufficient upon which to base a diagnosis.

Treatment.—The treatment also will vary with the type of inflammation. In all instances the cause should be removed, and in the infectious types there should be topical application of some suitable antiseptic.

Scurvy

This is a disease manifested by ulceration and hemorrhage of the gums, unthriftiness, and debility. It is of rather common occurrence in young pigs.

Etiology.—There appears to be no specific exciting cause of this condition. However, it usually occurs in pigs that are improperly fed, kept in unsanitary quarters, or those produced from continued inbreeding.

Lesions.—Scurvy is characterized by progressive ulceration of the gums. These ulcers are irregular, ragged, and bleed almost constantly. Petechial hemorrhages may be found in the skin, and in the mucous and serous membranes. The liver and kidneys may show fatty changes. The spleen and lymph nodes are enlarged.

Symptoms.—Progressive emaciation, dullness, diminished appetite, increased thirst, and a dislike to move characterize scurvy. On inspection, the gum ulcerations will be observed, and there may also be cutaneous hemorrhages visible. The disease is rather serious unless the cases are observed early.

Parotitis—Parotiditis

Parotitis is rare in swine. In *The American Veterinary Review* (Vol. 43, p. 298), Kaupp reported three fatal cases. It appears from the report that two dogs also contracted the disease. This condition is usually not serious, and when the conditions associated with it are relieved the lesions rapidly disappear.

Tonsillitis

The tonsillar tissue of swine is prone to either acute or chronic inflammation. *Acute tonsillitis* is closely associated with acute pharyngitis, and the cause is probably most frequently infectious in character. The tonsillar tissue becomes tumefied and projects above the surface, while the buccal mucous membrane is hot and red. The affected animals are indisposed and dull, and

have a tendency to extend the head and elevate the snout. There is usually a rise of temperature. Deglutition is difficult and may be associated with gagging and sometimes with vomiting. There may be spasmodic coughing.

The treatment consists, in the mild cases, in applying soothing astringents; in the more severe cases, tincture of iron chlorid may be used. Laxatives should be given to keep the bowels in an active state, and the animals should be placed in clean, well-ventilated quarters, and given liquid and easily digested foods.

Chronic tonsillitis is less common than the acute form. It is characterized by distention of the tonsillar tissue by accumulated desiccated pus or even calcareous masses in the tonsillar crypts.

PHARYNX

The pharynx, like the mouth, is subject to traumas and infection.

Pharyngitis

Catarrhal pharyngitis is the most common type of inflammation, and may be either acute or chronic. The usual cause of the disease is improper food or undue exposure, although it may be caused by infection.

The mucous membrane of the pharynx affected with acute catarrh is in the beginning dry and scarlet red, later becoming tumefied and coated with epithelium and mucous, which occasionally desquamates, leaving denuded areas.

If the causative agent persists the condition becomes chronic. The chronic condition is evidenced by fibrous proliferation in the submucosa resulting, first, in a tumefaction, and then in protrusion of the pharyngeal mucosa, which may, by contraction of the newly formed fibrous tissues, result in a corrugation of the mucous membrane, or the newly formed fibrous tissues may be so extensive that the pharyngeal mucosa becomes uni-

formly tumefied, dense and hard. In either case the epithelium of the mucous membrane becomes atrophied, leaving only a thin covering, usually of a squamous type of epithelium.

Phlegmonous pharyngitis is not infrequently associated with phlegmonous stomatitis, although it may occur independently. Streptococci are the usual cause of phlegmonous pharyngitis, and the lesions are practically identical with those of phlegmonous stomatitis.

Diphtheritic pharyngitis is not rare in swine. It is the result of the *Bacillus necrophorus*, and practically the same lesions are observed as in necrobacillosis.

Paralysis

Paralysis of the pharynx is a condition resulting from disturbances of the controlling pharyngeal nerves or of the muscles of the pharynx. This condition is usually associated with rabies, although it has been observed independent of that disease and probably resulted from the influences of some substance upon the deglutition centers of the medulla.

Tumors

Pharyngeal tumors in swine are not very common. Occasionally polypoid fibromas are observed, but they are rare. Of the malignant tumors the epitheliomas are most often met with; however, these are rare. Adenomas and carcinomas also have been observed, but infrequently.

ESOPHAGUS

Malformations

Malformations of the esophagus are rather rare. The canal may end abruptly at the lower end of the upper third, beginning lower down, and continue to the stomach, or the esophagus may form a union with the trachea. In rare instances fistulous openings have been observed in the cervical region.

Stenosis

Stenosis, or narrowing of the esophagus, is not infrequent. This condition occurs most frequently at the pharyngo-esophageal junction or at the cardiac termination, the cause being either extrinsic or intrinsic.

Etiology.—Among extrinsic causes may be pressure from enlarged thyroids, tumors, aneurysms, or abscesses. Foreign bodies, too, often produce partial obstructions of the esophagus, thus causing a temporary stenosis. The intrinsic causes are most frequently due to scars or scar tissues that have formed as a result of injuries or of diseased processes of the esophageal tissues. Hyperplasia of the esophageal muscle, also, may produce stenosis.

Lesions.—The usual anatomical changes observed in esophageal stenosis consist of cicatrized fibrous tissues. The extent of the trouble varies, but as a rule it involves only a small portion of the esophagus. The stenosis may form a regular or irregular diminished lumen.

Symptoms.—The symptoms evidenced in esophageal stenosis consist of difficult deglutition and sometimes dilatation (which see), succeeded by the formation of jabot, which may be observed in animals thin in flesh.

Treatment.—Surgical interference, which may or may not be successful, depending upon the extent of the lesions and the age of the animal involved, is the only treatment for esophageal stenosis.

Dilatation

Esophageal dilatation is less frequently met with than stenosis, particularly in swine.

Etiology.—Obstruction and stenosis of the esophagus are primary causes of esophageal dilatation, but it may be the result of traction from without.

Lesions.—Dilatation usually affects the entire circumference of the esophagus, although in some instances the dilatation may be lateral and form a true diverticulum. In the dilated portion, the esophageal walls are usually

attenuated, and, in rare instances, they may become so weak that they are easily ruptured.

Symptoms.—The usual symptoms evidenced in an animal afflicted with esophageal dilatation consist of a gradually developing tumefaction or enlargement in the cervical region while the animal is eating, due to the accumulation of the food in the dilated portion of the esophagus. The enlargement gradually subsides after eating, until no enlargement is observed.

Treatment.—The treatment of esophageal dilatation is of little avail, and is primarily confined to surgical interference.

Perforation

Esophageal perforation is not very common in swine.

Etiology.—It may be the result of erosion due to disease processes, such as actinomycosis, tuberculosis, or necrobacillosis, resulting in a complete destruction of portions of the esophageal walls and thus permitting the contents of the esophagus to infiltrate into the surrounding structures.

Perforation may also result from injury due to some foreign body that has been ingested and lodged in the esophagus. Weston reported the case, in *The American Veterinary Review* (Vol. 40, p. 658), of a hog that had swallowed a piece of sharp tin, which had perforated the thoracic portion of the esophagus. A sinus was formed in the adjacent lung, in which a small mass of food had accumulated.

Lesions.—The lesions resulting from perforation of the esophagus are quite variable and consist not only of the destruction of the esophageal walls, but also of tissue changes induced by the escape of food from the esophagus in the surrounding tissues. In some instances the primary lesions consist of an inflammatory edema, while in other instances the primary lesions are tuberculous, actinomycotic, or necrobacillary.

Symptoms.—The symptoms resulting from esophageal perforation vary according to the secondary

lesions evolved. There may or may not be tumefaction of the tissues adjacent to the perforation. In all cases, there will be more or less difficulty in deglutition, and in extreme cases there will be aphagia.

Treatment.—The treatment of esophageal perforation depends upon removing the cause and healing the injuries, combined with proper diet.

Esophagitis

Esophagitis in hogs is not very common. It may be the result of the injury from foreign bodies, exposure, or infection.

Catarrhal esophagitis is perhaps the most frequent type of inflammation and may be local or general. The usual lesions evidenced in the acute type consist of congestion, infiltration, and tumefaction of the mucous membrane, associated with desquamation of the epithelium. Ulceration may occur. The chronic type is characterized by an excessive development of fibrous tissue in the submucosa, and causes the mucous membrane to be thrown into folds. Chronic esophagitis is occasionally observed in hogs that are fed exclusively on distillery slops.

Croupous esophagitis is usually the result of an invasion of Streptococci, although this condition may be associated with hog cholera or pneumonia. The disease is characterized by the accumulation upon the mucous membrane of a yellowish or brownish coagulated exudate.

Phlegmonous esophagitis is usually observed as a sequel of perforation, or the escape of pus into the submucosa from abscesses. This condition is sometimes associated with phlegmonous pharyngitis. The accumulated pus or other inflammatory exudate is frequently so extensive that the lumen of the esophagus is entirely closed.

Tumors

Tumors of the esophagus are relatively rare. Polypoid fibromas have been observed, and more rarely myxomas

and myomas. Malignant tumors of the esophagus are quite rare, and when they do occur they are secondary.

STOMACH

Malformations

Malformations of the stomach are comparatively rare in hogs. The stomach may be abnormally small and sometimes there is a constriction in the middle line producing the so-called hour-glass stomach.

Foreign Bodies

Foreign bodies in the stomach are comparatively frequent because hogs have a marked tendency to swallow objects of various kinds. The following was found in one hog's stomach:

40 nails.	1 No. 10 shotgun shell.
15 staples.	2 buggy-top tacks.
4 screws.	5 pieces of iron.
4 nuts.	1 metal picture frame.
9 pebbles.	6 pieces of zinc.
1 snap.	8 pieces of wire.
2 bolts.	1 piece of glass.
1 brass pin.	1 piece of brass.
1 piece porcelain.	

Hair balls (trichobezoars) are occasionally observed in swine.

The damage due to foreign bodies in the stomach of swine depends upon their nature. Some sharp objects inflict wounds of various dimensions, and in some instances perforation occurs, succeeded by peritonitis.

Lesions.—The lesions will vary with the nature of the foreign objects; in some cases there is only a catarrhal condition, while in other instances there may be laceration or even perforation of the stomach walls.

Symptoms.—Evidences of gastric foreign bodies are by no means sufficiently distinct to differentiate this condition from various other gastric disorders.

Treatment.—Little is available in the form of treatment of swine that have ingested foreign bodies. Small objects may be expelled by vomiting excited by

emetics, or may be removed by gastric lavage. Objects imbedded in the gastric walls can be removed only by surgical interference, but gastric surgery in swine is not well developed at this time.

Vomition (Emesis)

Vomition is rather common in swine and is the result of stimulation of the vomition center, which is located in the medulla. This stimulation may be direct from irritation in the nerve center, but more frequently it is indirect from irritation of some portion of the gastrointestinal tract. Vomition is therefore a symptom of a variety of disease conditions. It may be caused by engorgement of the stomach, nature having provided this method of relieving an overloaded stomach. Intestinal obstruction is another frequent cause of vomition in swine, as is also irritation of the mucosa of the esophagus, intestine, and more especially the stomach. Thus hog cholera is frequently evidenced by vomition. Gastric parasites not infrequently cause sufficient irritation to produce violent vomition, particularly in small pigs, while chemical irritants acting upon the digestive mucosa may produce vomition.

Swine as a rule vomit easily. The affected animals become uneasy and restless. They extend the head and depress the nose, the esophageal muscles are relaxed, the abdominal muscles contract, and the stomach content is thus forced out. The vomited material usually consists of particles of food admixed with mucus, although it may be composed entirely of a thin, shiny mucus. The expelled material may contain intestinal as well as gastric contents.

Anemia

Anemia of the mucous membrane of the stomach occurs in swine after surgical operations in which large quantities of blood have been lost. It may also be due to obstruction of the arteries supplying the gastric walls.

A long-continued anemia of the stomach results in atrophy of its walls. An anemic stomach is pale, flabby, and bloodless.

Gastric anemia results in improper digestion, which ultimately leads to emaciation and possibly to other disturbances of the animal body.

Hemorrhage (Hematemesis)

Etiology—Hemorrhage of the stomach, or hematemesis is the result of erosion of blood vessels due to diseased processes, traumatism, and caustics. Hog cholera is the most frequent cause of gastric hemorrhages in hogs.

Petechial hemorrhage into the walls of the stomach is associated with various infective diseases.

Lesions.—Erosion or laceration of the blood vessels plus an accumulation of blood in the stomach or discharged from the stomach, are associated with gastric hemorrhage. The hydrochloric acid of the gastric juice, acting upon the blood, forms a clot, and also changes the color of the blood. As a rule the extravasation is converted into masses, which are of about the same size and color as roasted coffee beans. If the escaped blood from the stomach passes on through the intestine it will remain firmly clotted in coffee-bean masses. These masses characterize gastric hemorrhage and serve to distinguish gastric from intestinal hemorrhage.

Symptoms.—Gastric hemorrhage is evidenced by a pale mucous membrane and the escape of non-frothy, black, and more or less coagulated masses of blood from the mouth.

Peptic Ulcers

Peptic ulcers are rarely observed in swine, but when they occur are usually near the pyloric end of the stomach.

Etiology.—The cause of peptic ulcer is by some thought due to thrombotic formation; it may be due to the action of gastric juice upon anemic areas of the stomach.

Lesions.—Peptic ulcers are characteristic in their appearance. They may involve the mucous membrane only or they may extend through the submucosa and involve the muscular coat of the stomach, and even perforate the serous membrane. In size they vary from that of the cross-section of a lead pencil to the area of a silver dollar. They appear as though made by means of a punch, and if they involve more than the mucous membrane they usually have a terraced margin; their walls being clean-cut and non-inflammatory.

Symptoms.—The evidences of peptic ulcer vary, but usually there is indigestion and occasionally hemorrhages. Sometimes it results in perforation of the stomach, followed by peritonitis and death.

Hyperemia

Passive hyperemia of the stomach is the result of obstructive circulation and usually is evidenced by more or less edema of the gastric walls; in extreme cases there may be thrombotic formation and focal or even extensive necrosis.

Active hyperemia of the stomach is much more common than the passive form, and may be either physiologic or pathologic.

Pathologic gastric arterial hyperemia is caused by irritation, either from chemicals, undue exposure, or infection, and represents the primary stage of inflammation.

Gastritis

Gastritis is relatively common in hogs. It results from traumatic injuries, chemical irritants (poisons), and infection.

Catarrhal Gastritis

Catarrhal gastritis is of fairly common occurrence and usually results from mild irritation. It is evidenced by a hyperemia of the mucosa, which appears red, slightly tumefied, and covered with varying quantities of mucus.

Symptoms.—The symptoms of catarrhal gastritis vary according to the intensity of the disease, vomition after eating being one of the most common. There is usually increased thirst. In the beginning of the disease there is often constipation, followed by diarrhea with a discharge of a thin, fetid, fecal material. There is a slight rise of temperature and usually an unequal distribution of surface temperature, one part being warm while another is cold. The tail drops, and the animals have a tendency to pile up or get under their bedding. The course of the disease is usually rapid and recovery almost certain.

Treatment.—The treatment consists in determining the cause and then removing it. It is advisable to empty the stomach by use of an emetic, such as apomorphin. The affected animals should then be placed on a diet consisting of a small quantity of easily digested food. Further treatment is rarely needed.

Croupous Gastritis

Croupous gastritis is usually the result of caustics ingested with food stuff, such as lye, which is occasionally fed in large quantities for the purpose of warding off diseases of various kinds.

Lesions.—In croupous gastritis an intense tumefaction of the mucosa is present, the affected portion containing accumulation of exudate which is dirty white or brown in color, and when detached usually leaves a bleeding surface.

Symptoms.—The manifestations of croupous gastritis are similar to those of catarrhal gastritis, but are more intense. The animals evince gastric pain by uneasiness, restlessness, and frequent vomition. There is a rise of temperature of from one to two degrees Fahrenheit. The affected swine have little desire to eat, but they show a tendency to drink frequently, after which they evidence more intense pain until they vomit. The tail hangs straight, and the animals have little tendency to move.

This disease usually runs a rapid course, as a rule terminating within five to eight days.

The prognosis should be guarded.

Treatment.—The treatment consists in giving demulcent drinks after having removed the cause. The content of the bowels should be kept soft by laxatives. The affected animals should be separated from the healthy and given good quarters.

Phlegmonous Gastritis

Phlegmonous gastritis occasionally occurs in hogs and is usually the result of infection with streptococcic micro organisms.

Lesions.—The anatomical changes occurring in phlegmonous gastritis consist of an intense tumefaction of the mucosa due to accumulation of pus or other inflammatory products in the submucosa. Patches of the mucosa may become necrotic and desquamate. In other instances large sinuous tracts are formed beneath the mucosa and in these pus accumulates in large quantities. The muscular layers of the stomach frequently become infiltrated with pus; the inflammatory process may extend to and involve the serous coat.

Symptoms.—The evidences of phlegmonous gastritis are not distinct and separable from those of croupous gastritis. There is usually intense pain, indicated by the constant change in position of the animals. Vomition is usually frequent, the vomited material being small in quantity and largely mucous or mucopurulent in character, and it is not infrequently mixed with blood. There is inappetence, thirst, and a drawn-up appearance of the abdomen, with arching of the back. The temperature ranges from 104 to 107 degrees Fahrenheit. Constipation is usually quite marked in the beginning, but may be succeeded by diarrhea.

The course of this disease varies from three to seven days. The prognosis should be guarded, as the disease is usually fatal.

Treatment.—The pain should be relieved by demulcent drinks, gastric lavage, and enemas, combined with anodynes. The medication of swine, especially of mature animals, is not an easy matter.

Chronic Gastritis

Chronic gastritis is of rather frequent occurrence in hogs and may be the result of irritation by the *Arduenna strongylina*.

Lesions.—The anatomical changes in the stomach consist of a fibrous proliferation which may destroy the gland tissues or obstruct their ducts, resulting in the formation of small cysts. The mucosa is usually attenuated, due to atrophy of the mucous membrane. As a rule there is some ulceration and not infrequently the capacity of the stomach is diminished, due to the contraction of the newly formed fibrous tissues.

Symptoms.—The symptoms of chronic gastritis of swine are not distinct. There is variation of appetite. Vomition immediately after eating may or may not be present. Affected animals are unthrifty as a result of nutritive disturbances.

This is essentially a chronic disease, the courses varying from a few weeks to months. Prognosis is favorable as to the life of the animal, but unfavorable as to the relief of the condition.

Treatment.—Treatment consists in strictly limiting the diet to easily digested foods, and the maintenance of a laxative condition of the bowels.

Dilatation

Dilatation of the stomach may be acute or chronic.

Acute Gastric Dilatation

Acute dilatation is a condition resulting from a rapid distention of the stomach, a condition not very common in swine.

Etiology.—Acute dilatation is usually due to overloading the stomach. It is most frequently caused by

the ingestion of large quantities of indigestible substances, or of foods that are easily and extensively fermentable.

Lesions.—The lesions observed in acute dilatation consist of enlargement, the walls being very much attenuated. Rupture of the stomach may occur in the greater curvature.

Symptoms.—The evidences of acute dilatation are the same as those of overloading of the stomach. Restlessness, succeeded by vomiting, is the usual sign observed in the early stages of a limited dilatation. In some instances the walls of the stomach become so thin due to extreme distension, that vomition is not possible, and such cases are evidenced by gagging, salivation, and bloating, if the distension is due to foods that readily ferment. Extreme distension produces distress and expressions of pain.

Diagnosis.—Diagnosis of gastric dilatation is dependent upon history and the symptoms indicated above. Prognosis should be guarded, as the possibility of rupture must always be considered.

Treatment.—When the dilatation is not too great, the treatment should be largely confined to removal of the gastric content by emetics, and to lavage when the dilatation is extensive and likely to result in rupture.

Chronic Gastric Dilatation

Chronic gastric dilatation is not common in swine but has been observed. Accumulation of indigestible substances is the usual cause of the trouble. Occasional cases have been observed where there was a sufficient accumulation of hair in the stomach to permanently dilate it beyond the normal capacity.

Symptoms.—The usual evidences of chronic gastric dilatation consist of irregular appetite, associated with unthriftiness. The stomach is distended, and may contain various foreign bodies or indigestible substances. The gastric mucosa is usually affected with chronic catarrh.

Treatment.—This condition is not very successfully treated because of the tendency to permanent dilatation of the stomach. Dieting, especially with easily digestible, concentrated foods, is especially advised.

Tumors

Tumors of the stomach of swine are not very prevalent, or at least such cases are rarely reported.

Fibromas have been observed in only a few instances. They usually involve the serous coat and rarely become of sufficient magnitude to cause damage other than slight mechanical interference. These tumors are invariably incapsulated, and appear as a dense, fibrous mass.

Lipomas occur in the serous coat of the stomach of swine though they are not common. A few such tumors have been observed, and in one instance the tumor had become so large that it seriously interfered with the function of the organ by displacing the stomach and producing such pressure that it practically occluded the duodenum and resulted in death. Lipomas appear as more or less nodular masses, and are invariably incapsulated.

Of the malignant tumors, carcinoma and adenoma have been observed, although they too are rather infrequent and do not appear to be so injurious to the health of swine as the same kinds of tumors are to horses or even to cattle. Carcinomas may develop in the submucosa and project into the lumen of the intestine as a cauliflower-like mass, or they may develop in the mucosa, producing erosions not only of the mucous membrane, but of the other structures of the stomach wall, ultimately causing perforation and fatal peritonitis. These tumors are not incapsulated.

The symptoms evolved as a result of tumors are quite variable and not sufficiently characteristic to permit a positive antemortem diagnosis.

The treatment of gastric tumors is entirely surgical.

Parasites

Arduenna strongylina is a very common parasite in the stomach of swine. In the central United States it is probable that at least ninety per cent of swine are infested. They are a small, thread-like, white worm, varying in length from three-fourths of an inch to one and one-half inches, usually more or less coiled, although they may be found practically straight. They may be found in masses in the submucosa, free upon the mucous membrane, extending into the gastric glands, or even perforating the mucous membrane. They injure their host by direct abstraction of nutriment, by obstruction of gastric glands, by destruction of tissue, and by irritation. The usual condition resulting from infestation with these parasites is chronic gastric catarrh.

Symptoms.—Symptomatically the infestation with large numbers of the *Arduenna strongylina* is evidenced by variation of appetite, and usually by constipation, unthriftiness, and rough coat. It is doubtful if any symptoms would be sufficiently prominent upon which to base a diagnosis in cases in which the infestation is limited to a few worms.

Treatment.—Treatment of gastric parasitism is not difficult providing the parasites are free upon the surface, but successful treatment is difficult in cases where the parasites have passed through the mucous membrane into the submucosa. The usual anthelmintic treatment is most easily applied in the food or slop. Ferrous sulphate, copper sulphate, or oil of turpentine may be mixed with slops. Santonin given with food is of value, but creosote in the slop is probably most efficient.

The *Simondsia paradoxa* infests the stomach of swine, but is probably not found in the United States, although quite prevalent in some sections of Europe. The lesions, symptoms, and treatment are similar to those given for *Arduenna strongylina*.

Ascaris suum is found occasionally in the stomach, but its natural habitat is the intestine, and it will be discussed later in that relation.

INTESTINES

Malformations

Total absence of the intestine is rare and occurs practically only in acardiac monsters.

Atresia ani, that is, the failure of development of the anus, is relatively common. This condition results from the failure of invagination of the skin surface which normally extends to and fuses with the rectum. Pigs so affected, unless the defect is relieved by operation, die the first or second day after being farrowed. The defect is as a rule easily corrected by operation in which crucial incisions are made through the skin and the terminal end of the rectum, the skin and rectal triangular flaps being interdigitated and maintained by sutures.

Cloacal formation in which there is a common opening for the intestine, uterus, and vagina or ureters sometimes occurs, but this is not a serious defect, except in breeding animals.

Diverticula are not rare. They are usually the persistent remnants of the vitellin or omphalomesenteric duct. They do not as a rule interfere with the health of the animal.

Transposition, particularly of the large colon, may occur, but is not of any significance except as a pathologic condition.

Congenital hernia may occur. The outcome depends upon the extent and nature of the defect.

Hemorrhage (Enterorrhagia)

Enterorrhagia occurs rather commonly in swine.

Etiology.—Mechanical injury of the structure of the intestine by ingested foreign bodies is a common cause of hemorrhage. In extreme cases of constipation the accumulated fecal matter may become so desiccated that it readily produces abrasions of the intestinal mucosa, resulting in hemorrhage. Parasites, particularly the *Gigantorhynchus hirudinaceus*, may also produce hemorrhage. Intestinal hemorrhage is a common symptom of

hog cholera, anthrax, septicemia, cryptogamic poisoning, caustic poisoning, and severe inflammatory disturbances of the intestine.

Lesions.—The particular lesion identifying intestinal hemorrhage is the extravasated blood which may or may not be thoroughly admixed with the intestinal content. If the hemorrhage has been extensive there will be a general anemia of the entire mucosa. Lesions of the intestinal mucosa will be observed in those cases in which the hemorrhage has been induced by trauma or chemical irritants. There may be no evidence of intestinal mucous membrane lesions in the infective diseases like hog cholera, as the hemorrhages in these cases are usually the result of blood-vessel lesions rather than mucosa lesions.

Symptoms.—The first evidence of intestinal hemorrhage is the passing of the blood from the anus. If the discharged blood is thoroughly admixed with the feces and of a brownish cast it indicates that the hemorrhage has been well forward in the small intestine. If the discharged blood occurs in masses, not mixed with the fecal matter, and has the normal blood color, it indicates that the hemorrhage has been in the anterior portion of the large intestine; and if the fecal matter is streaked with blood on the outer surface only, the hemorrhage occurred in the rectum. The visible mucous membranes will be pale, pulse rapid and almost imperceptible, and there will be weakness associated with uncertain gait.

Diagnosis.—The diagnosis of enterorrhagia is usually not difficult, although it may not be an easy matter to determine the exact cause of the condition. In gastric hemorrhage the extravasated blood that passes through the bowel is granular and of a black color; the extravasate from intestinal hemorrhage is massive, occurs upon the surface of the feces, and is normal in color.

Treatment.—The treatment of intestinal hemorrhage is problematic, and the relief from this condition is dependent upon removing the cause, which is not always possible. The affected animals should be kept quiet.

Ergot may be used to advantage. Astringents combined with laudanum may produce the desired results.

Obstruction

Intestinal obstruction is a condition resulting from the occlusion of the intestine by foreign bodies, inspissated fecal material, parasites, abscesses, tumors, cicatrices, rotation of the intestine upon itself or volvulus, and invagination or intussusception. Intussusception is not as common in the hog as in some other animals because of the arrangement of the mesentery, although it may, and sometimes does, occur.

[**Lesions.**—The anatomical changes observed in intestinal obstruction vary according to the cause and duration of the condition. Thus foreign bodies, such as hair balls or nails, may be found; a tangled mass of *Ascaris suum* is sometimes the only lesion; abscess, tumor formation, or changed relation of the intestine may be the principal lesion. Aside from the obstructing agent there may be inflammatory or necrotic lesions of the mucous membrane or other portions of the intestine.

Symptoms.—The first evidence is inappetence and a tucked abdomen, followed by infrequent defecation with the passage of small quantities of mucous-covered feces. Frequent attempts at defecation without the voiding of any fecal matter may occur. Vomition is a common symptom in the later stages. In some cases there is fermentation of the intestinal content with an excessive accumulation of gas, producing tympany.

Treatment.—The relief of intestinal obstruction depends upon the cause. Obstruction from inspissated fecal matter may be overcome by the judicious use of saline laxatives or enemas. Parasitic obstruction may be overcome by the use of vermifuges given orally or in enemas. Relief from obstruction due to tumors or abscess formation may be temporarily obtained by purgatives, but permanent relief is obtained only by removing the cause. The treatment for obstruction from volvulus or intussusception is problematic and the

outcome by no means certain. Surgical operation may be resorted to in overcoming these conditions, as well as in foreign-body obstruction. If the accumulations of gas cause alarming symptoms, the trocar may be used to produce immediate relief, and further fermentation may be checked by the administration of antiferments, either through the cannula or per os. As soon as the animals have a desire to eat they should be given sparingly of easily digested liquid foods.

Dilatation

Intestinal dilatation is not of common occurrence in swine.

Etiology.—The usual cause is partial obstruction, resulting in excessive accumulations of food which produce atony and later a relaxation and dilatation of the intestinal walls. Should the dilatation be unequal, diverticular dilatation results.

Lesions.—The usual lesions observed in intestinal dilatation consist of distended intestine with an accumulation of excessive quantities of food material in it and usually an associated condition that produces the primary obstruction.

Symptoms.—Symptomatically, the dilatation is not positively differentiated antemortem from obstruction, the symptoms of both conditions being practically identical.

Treatment.—In cases of dilatation, remove that which primarily causes an obstruction and then administer tonics to facilitate the return of intestinal tonicity.

Emphysema

Single air cysts or clusters of air cysts are not of infrequent occurrence, involving and protruding the serous coat of the intestine. This condition appears to produce no inconvenience and is of no particular economic importance. It has been thought to be the result of bacteria, probably of the colon group, which have penetrated through the intestinal wall to the serous coat,

where they produce fermentation and the gas evolved is accumulated beneath the serous membrane. These air cysts vary in size from a pinhead to a pea, and there may be only a limited number of them or myriads. Occasionally they are so prevalent that the intestine will float on water.

Enteritis

Enteritis is inflammation of the intestine and may be catarrhal, croupous, diphtheritic, mycotic; simple or infective, acute or chronic.

Catarrhal enteritis may be either acute or chronic.

Acute Catarrhal Enteritis

Acute catarrhal enteritis is a common ailment of swine.

Etiology.—The usual cause of this disease is improper food. The natural habits of swine are conducive to the introduction of various microbes into their food and drink, and swine are frequently fed on materials that are partially decomposed. Their food not infrequently contains chemical substances that are sufficiently irritating to establish a catarrhal gastritis and enteritis. The ingestion of foods of extreme temperatures may excite catarrhal enteritis; not infrequently parasites occur in sufficient numbers to produce local irritation of sufficient extent to result in catarrhal enteritis; finally, acute catarrhal enteritis may be associated with a variety of infective diseases.

Lesions.—The lesions may be localized or they may be general, involving practically the entire intestinal mucosa. In the beginning the affected mucous membrane is red, tumefied, and rather dry, but later it becomes coated with mucus which is produced in excessive quantities as the disease progresses. The submucosa may be swollen, due to the accumulation of inflammatory exudate. The tumefaction of the mucosa sometimes effectually closes the ducts of the intestinal glands, thus forming retention cysts, and the villi are turgescient and

have a velvety appearance. The lymphoid tissue usually becomes swollen and contains excessive quantities of leukocytes, which may be expressed as a milky substance. There may, in the advanced stages, be areas of necrosis of the epithelium of the mucous membrane. In the submucosa, hemorrhages of varying size may occur.

Symptoms.—Acute catarrhal enteritis occurs most frequently in connection with acute catarrhal gastritis, and the symptoms of gastritis usually overshadow those of enteritis. Inappetence or variation of appetite, rise of temperature, listlessness, and arched back are common symptoms of acute gastrointestinal catarrh. The symptoms of acute intestinal catarrh are frequent defecation of small quantities of mucous-coated feces. In the beginning, there is usually constipation, but this condition is succeeded by diarrhea. The affected animals groan and roll frequently.

Treatment.—Remove the cause. Give easily digested foods when appetite returns. If constipation prevails, give some laxative, preferably oleaginous in character. Enemas of warm saline solutions sometimes give immediate relief.

Chronic Catarrhal Enteritis

Chronic intestinal catarrh is usually a sequel of acute intestinal catarrh.

Etiology.—The usual causes of chronic intestinal catarrh are the same as those causing acute intestinal catarrh, but are continued over a longer period of time and probably, in the majority of instances, are not so intense. Error of diet is the most frequent cause. Chronic heart or liver diseases that produce venous engorgement of the intestine is a common cause. Parasites, no doubt, are responsible for an occasional case of chronic intestinal catarrh.

Lesions.—The affected mucous membrane is usually of a uniform or mottled bluish, steel, slate color. The mucosa is tumefied, dense, and of a leathery consistency due to the excessive development of fibrous tissue in the

submucosa. Small retention cysts representing occluded glands may be present. The covering epithelium of the mucous membrane is attenuated and sometimes erosions, or even ulcerations, are observed.

Symptoms.—Irregular appetite, alternation of constipation and diarrhea, rough coat, emaciation, and malnutrition characterize chronic intestinal catarrh. The foregoing symptoms tend to persist, as the disease may continue for weeks.

Treatment.—A proper diet combined with good surroundings are prerequisites for the successful treatment of cases of chronic intestinal catarrh. Regulation of the bowels, with maintenance of the proper consistency of the fecal matter, is highly important. Treatment must be persistent, as success will be attained only by a long-continued course of treatment, combined with the proper diet.

Croupous and Diphtheritic Enteritis

Croupous enteritis probably occurs in swine, but is rather uncommon, while diphtheritic enteritis is fairly common.

Etiology—The most common cause of diphtheritic enteritis is the *Bacillus necrophorus*, although some caustic chemicals may produce the condition.

Lesions.—The lesions of diphtheritic enteritis usually occur in circumscribed areas or foci, although these may be disseminated over a large area of mucous membrane. In the beginning the affected portion is intensely red and tumefied, and later a coagulated exudate occurs upon the surface. This exudate is first of a dirty white or gray color, but may become brown or brownish-red and is not easily detached. After the condition has persisted for some time the affected areas have a scaly appearance due to the fact that the exudate becomes loose and later desquamates.

Symptoms.—Colicky pains, restlessness, drooping ears and tail, increased thirst, usually diminished appetite, rise of temperature, and constipation alternating with

diarrhea are manifestations of diphtheritic enteritis. The affected animals rapidly become emaciated.

Treatment.—Identify and remove the cause of the trouble. Oleaginous laxatives are indicated, and should be followed with demulcents. When the swine show an inclination to eat, give sparingly of easily digestible foods.

Toxic Gastritis, Gastro-Enteritis, Enteritis

A variety of conditions have been grouped under this heading, but this number fortunately is becoming less as more exact investigations are being concluded. It is difficult to clearly distinguish between toxic gastric, toxic gastro-intestinal, and toxic intestinal conditions, and as a matter of common observation it has been found that substances that ordinarily produce toxic gastritis have not spent their entire force in the stomach, and thus continue their action in the intestines. On the other hand, few if any substances are toxic in the intestine that are not also toxic in the stomach.

Poisoning

Sodium Chlorid (Common Salt)

Poisoning with common salt is rather common. Swine may obtain this salt in cattle yards, or it may be given them in garbage. Meat brine is a frequent source of salt poisoning and is very destructive, as, unfortunately, swine appear to relish it. Brine poisoning is not only due to the contained salt, but also to other ingredients. It has been found that from two to eight ounces of salt produce poisoning in swine, and in some instances much smaller quantities are fatal.

Lesions.—Sodium chlorid is an intense gastro-intestinal irritant, particularly when in a concentrated solution. In the beginning the mucous membrane of the stomach will be intensely congested. This is followed by hemorrhages upon the mucous membrane, and inflammatory disturbances. If absorption is retarded the stomach and bowel content will contain large quantities of blood.

The mucous membrane of the bladder will be engorged, and similar lesions may be observed in the meninges.

Symptoms.—Intense thirst, inappetence, restlessness, and vomiting are usually the first symptoms evidenced. Later there will be watery diarrhea, frequent urination, depressed heart action, muscular weakness, and paralysis. The animals may die within five or six hours after ingesting the salt, or they may not die until the second or third day; if the quantity consumed has been small, they may survive.

Treatment.—Emetics should be employed if the animals are observed immediately after consuming the salt. In cases of several hours' standing, mucilaginous drinks and rectal injections should be given. Oleaginous purgatives may be of value as eliminants. Heart stimulants should be provided to avoid cardiac depression.¹

Caustic Potash, Caustic Soda (Lye; Washing Powders)

It is a common practice to feed swine wash water, particularly water that has been used for washing dishes and in which liberal quantities of washing powder or lye have been used. Some swine breeders and feeders add varying quantities of lye to the feed to "ward off disease."

Lesions.—Caustic alkalies may produce congestion, inflammation, or necrosis, depending upon the concentration of the mixture. The lesions will be diffuse if the alkali has been in solution; they will tend to localization if the alkali has been in the powdered form. In the latter case the lesions occur where the alkali granules have been deposited upon the mucous membrane. The lesions are usually more intense in the stomach than in the intestine.

Symptoms.—Wretching, vomiting, restlessness, and muscular weakness are the usual symptoms evidenced in the beginning, followed later by diarrhea, incoördination,

¹Poisoning by herring brine produces, in addition to toxic gastroenteritis, cerebral disturbances very similar to ptomaine poisoning.

and paralysis. Death may occur within a few hours or in two or three days. Some of the affected animals may recover.

Treatment.—In the early stages emetics should be given until vomition is produced. Later acidulated water and oleaginous purgatives will be of value.

Phosphorous

In some sections of the country phosphorous compounds are used in destroying gophers, squirrels, and other similar animals, and not infrequently swine obtain a sufficient quantity of the poison to produce grave disturbances and even death.

Lesions.—The buccal, pharyngeal, gastric, and intestinal mucosa show inflammation. The liver and kidneys are enlarged, due to fatty degeneration of their parenchyma, and the heart also is usually affected by fatty changes. The content of stomach and bowel are phosphorescent when examined in the dark, and a distinct phosphorous odor emanates from the stomach and bowel when these organs are opened.

Symptoms.—Intense thirst, difficult deglutition, vomition, and colicky pains, associated with weakness and incoördination, are produced by phosphorous poisoning.

Treatment.—Emetics and the administration of turpentine in mucilaginous substances, when applied energetically, will sometimes save the patient.

Xanthium Canadense (Cocklebur)

Cocklebur poisoning prevails more or less extensively in the Missouri Valley during the early spring months. Just as the two cotyledons push through the ground is the only time in the development of the cocklebur that it is poisonous, or possibly swine eat the plant only during this stage of development. The writer assisted in an investigation of the effect of young cockleburs when eaten by swine at the Kansas Agricultural Experiment Station in 1899. Quantities of the young plants were

gathered and fed to pigs weighing from forty to sixty pounds. The symptoms, although not universally the same in all cases, clearly indicated a gastro-enteritis, which was verified by autopsy.

Lesions.—There is evidence of a marked gastro-enteritis in animals dead of cocklebur poisoning, usually involving the entire mucosa of the stomach and the small intestine and not infrequently extending to the mucous membrane of the large intestine. The involved mucous membrane may slough, leaving large areas of denuded surface.

Symptoms.—Increased thirst, colic pains, diarrhea, weakness, paralysis, and death succeed one another rather rapidly in fatal cases. In some instances the life of the affected animal is prolonged for several days, during which time there is rapid emaciation.

Treatment.—Treatment is not satisfactory. In the early stages emetics may be of value, followed by purgatives and mucilaginous drinks.

Atropa Belladonna (Deadly Nightshade)

Deadly nightshade poisoning is not of frequent occurrence, although it has been reported in sections of the country where the plant grows.

Lesions.—The lesions are not characteristic. Animals that die within a few hours will show no lesions at all, except retention of the urine or a greatly distended bladder; the blood may be somewhat darker than normal. Those that are affected for one or more days will show a gastro-intestinal inflammation.

Symptoms.—The first symptoms noticed are nausea, followed by vomiting, dryness of the mouth, more or less excitement and convulsions, increased pulse and respiration, dilated pupils, and partial blindness. The duration of this period is short and is followed by paralysis. The animals become weak, and stagger, the temperature falls, respiration is slow and weak, gradually becoming shallower, the pulse is rapid and weak, and there is a relaxation of the sphincter muscles. The affected

animals soon pass into a state of coma in which death takes place, probably due to asphyxiation and cardiac failure.

Treatment.—Treatment consists in administering the antidotes of atropin; emetics and purgatives; in stimulating the heart, and in resorting to artificial respiration. If there are periods of excitement, or convulsions, the animal should be given sedatives. A valuable aid in correctly diagnosing deadly nightshade poisoning consists in taking a few drops of urine of the dead animal and dropping it into the conjunctival sac of a normal or healthy animal. If the poisoning is due to atropin, or deadly nightshade, a dilatation of the pupil will occur.

The carcasses of animals that have died of deadly nightshade poisoning putrify very slowly.

Garbage

This is the time of conservation, and although the feeding of garbage to swine is not in keeping with present sanitary requirements, it is upheld by some as a means of utilizing products that would otherwise be wasted.

In the past rather extensive losses from garbage feeding have been reported, but since the advent of anti-hog cholera serum it has been found that many of the cases formerly reported as garbage poisoning were hog cholera, and it is certain that garbage frequently is contaminated with the virus of hog cholera.

Garbage poisoning does not signify any one definite kind of poisoning. From the various reports of investigators it is found that powdered soap, salt, brine, phosphorous, and arsenic are the most common active causes, although occasionally, no doubt, ptomaines are a factor. Because of the nature of the poisonous substance, cooking the garbage is of little value.

Lesions.—The lesions of garbage poisoning vary and are dependent upon the specific poisonous principle. In practically all cases there is evidence of gastro-enteritis, which may or may not be associated with hepatitis,

nephritis, or cystitis. In some instances, for example, those cases dying of strychnin poisoning, no lesions will be found.

Symptoms.—The symptoms, like the lesions, are variable and depend upon the nature of the poison. There is usually vomiting and diarrhea, associated with listlessness and drooped ears and tail, and as a rule there is marked evidence of colic. The affected animals may die suddenly or they may linger for several days; some of them may recover.

Treatment.—The further feeding of the polluted garbage should be prohibited. Emetics, enemas, and purgatives to effectually remove the offending material are indicated in the beginning. If the specific poison is known, the antidote should be given. In the later stages, treatment of the various symptoms as they arise is good practice.

Cryptogams (Molds, Yeast, Bacteria)

No doubt some forms of garbage poisoning are due to molds, yeast, or bacteria that are capable of producing injurious substances in the alimentary canal or have by their growth and activity produced injurious substances in or upon the foods prior to the time of their ingestion. Gastro-enteritis resulting from the action or products of the above-mentioned vegetable microorganisms is designated cryptogamic poisoning or mycotic gastro-enteritis.

This condition is not so common in swine as in some other domestic animals, notably the horse. Glover, of the Colorado Agricultural Experiment Station, has reported outbreaks of such a disease which were probably due to bacterially decomposed potatoes. Some unauthentic cases have been reported of this condition arising from the consumption of moldy alfalfa. Cases have been observed, but not frequently, of swine that had been fed upon moldy corn dying of mycotic gastro-enteritis and cerebritis.

Lesions.—There is considerable variation in the postmortem findings in swine that have died of mycotic

gastro-enteritis. This is not extraordinary, for there is a variety of molds that cause this condition. One usually finds extensive inflammation of the gastrointestinal mucosa, and in cases that have lingered for some time, ulcerations are very common. There is frequently meningeal engorgement, and in rare cases there may be cerebral softening.

Symptoms.—There is inappetence, increased thirst, rise of temperature, constipation succeeded by diarrhea, weakness, and rapid emaciation.

Treatment.—Little can be done to relieve this condition. Symptomatic treatment is of some value, and should be applied.

Cotton-Seed Meal

Fatal results frequently, but not always, attend the feeding for long periods of cotton-seed meal to swine. From experiments thus far conducted it is apparent that cotton-seed as a feed is more applicable to ruminants than to swine. The feeding for short periods has in many instances been beneficial.

Lesions.—On autopsy, excessive quantities of a serous fluid are found in the pleural and peritoneal cavities. The lung is congested, inflamed, and frequently edematous. Congestion in all internal organs may be observed.

Symptoms.—The feces are firm, although diarrhea may be present. Unthriftiness, irregular appetite or inappetence, weakness, unsteady gait, blindness, and dyspnea are common symptoms. The animals finally assume the decubital position, and may struggle or may become comatose. Death occurs in from a few hours to several days, sometimes occurring almost instantaneously with premonitory symptoms.

Treatment.—Green feed and exercise have a tendency to counteract the injurious effects of cotton-seed meal. Free access to wood ashes is a valuable but not an absolute preventive of cotton-seed poisoning. Iron compounds have also been used and proved beneficial, while the wood

ashes and iron salts are preventive but not curative agents. The treatment of affected animals has not been successful.

Scours in Sucklings

In some sections of the country scours in suckling pigs has become a menace to the swine-raising industry.

Etiology.—There is apparently no single cause that is responsible for the various cases of scours. Unfavorable surroundings, such as damp, dark, and dingy hog houses, predispose to this condition. In some instances, mammitis of the sow is a causative factor. Improper foods, such as moldy or fermented slops, probably result in elimination of injurious substances in the mother's milk that will create in the pigs digestive disturbances resulting in diarrhea. Scours may also result from infection with modified colon bacilli, *Bacillus necrophorus* and, it has been reported, certain coccidia are responsible for a type of diarrhea that is frequently fatal to suckling pigs. It is probable also that intestinal parasites may be responsible for catarrhal enteritis and an associated diarrhea. Artificial feeding is likely to produce digestive derangement and diarrhea, and exposure to extreme temperature variation must be considered as a causative factor of pig diarrhea. This condition may occur in pigs varying in age from two days to several weeks.

Lesions.—There are no constant lesions associated with scours in pigs. The intestinal content is usually quite liquid and may be putrid. Parasites may be observed. Some irritation of the intestinal mucosa may obtain, and there may be ulcerations.

Symptoms.—In pig diarrhea the evacuations are pasty, the discharges being of a grayish or slate color. Later the discharge becomes more watery and fetid, and the pig's tail and hind parts become soiled. Some pigs eat heartily, while in others the appetite gradually diminishes. The affected pigs evidence some abdominal pain. They emaciate rapidly, become weak, and soon

appear dejected and dull, having an arched back and an indisposition to move.

Treatment.—If possible, remove the cause. Give proper diet to the sow and have clean, wholesome surroundings for the pigs. Medicinal treatment of the affected pigs, particularly those depending entirely upon their mother's milk, is difficult. It is a good practice to hasten the removal of the irritating substances from the bowel, by the use of castor oil or similar purgative. If the diarrhea persists after the correction of diet and the action of castor oil, small quantities of bismuth subnitrate may be used to advantage. Intestinal antiseptics, such as salol and the sulphocarbolates of sodium, calcium, and zinc, are exceedingly beneficial where they can be administered frequently.

Parasites

The intestine of swine is a common abode for parasites. Parasitic infestation is most prevalent in young animals, but because of the mode of eating and the habits of swine it is rather the exception to find even an old hog entirely free from intestinal parasites. Their injury to the host depends upon the kind and the number of parasites. Intestinal parasites injure swine as follows:

1. Abstraction of nutrition.
2. Obstruction.
 - (a) Of the lumen of the intestine.
 - (b) Of the lumen of the hepatic duct.
3. Irritation of mucous membrane due to movement.
4. Irritation of mucous membrane due to lip attachment resulting in inflammation, necrosis, and ulceration.
5. Liberation of chemical substances that produce nervous irritation or hematology.

The following parasites infest the intestine of swine:

1. *Ascaris suum*.
2. *Esophagostoma dentatum*.
3. *Trichocephalus crenatus*.
4. *Trichinella spiralis*.
5. *Gigantorhynchus hirudinaceus*.

Ascaris Suum

Ascarids are found in practically all hogs. They are not blood suckers, but obtain their nutrition by direct absorption. The pregnant female discharges her ova in the intestine and they pass out with the feces, where they hatch and, so far as known, pass through a portion of their life cycle in decaying matter on the earth's surface and later gain entrance to the animal body with the food or drink.

Lesions.—These parasites are round, and pointed at either end; they are white or pinkish-white in color and vary from six inches to twelve inches in length. Usually they are found in the small intestine, though they may occur in the large intestine and even in the stomach. They attach themselves to the mucous membrane by means of papillæ or membranous teeth, and produce irritation to the mucous membrane as well as providing an avenue of entrance for a variety of bacteria which may produce inflammatory lesions and even necrosis and ulceration. The entire mucous membrane adjacent to the parasites is affected by a catarrhal inflammation. Similar disturbances are observed in the mucous membrane of the hepatic duct when it is infested. The worms may form a mass that completely obstructs the intestine, resulting in an engorgement of the intestine anteriorly to the obstruction. Occasionally the intestine may be perforated and the offending ascarids found protruding into the peritoneal cavity, or they may pass through the intestinal wall and some of the intestinal content, and, escaping into the peritoneal cavity, will produce a general peritonitis.

Symptoms.—Infestation with a limited number of ascarids probably does not produce any noticeable symptoms. The symptoms evidenced will vary and depend upon the manner in which the parasites are damaging their host. If the hepatic duct is obstructed, there will be digestive disturbances, associated with icterus. If the bowel is obstructed, there will be evidence of obstruction colic. Perforation of the bowel will

result in peritonitis. The presence of several of these parasites may be suspected when there is catarrhal enteritis, especially when the swine are being properly cared for and given a proper diet of wholesome food. Usually an occasional worm will be passed in the feces. Unless infestation is sufficiently extensive to produce

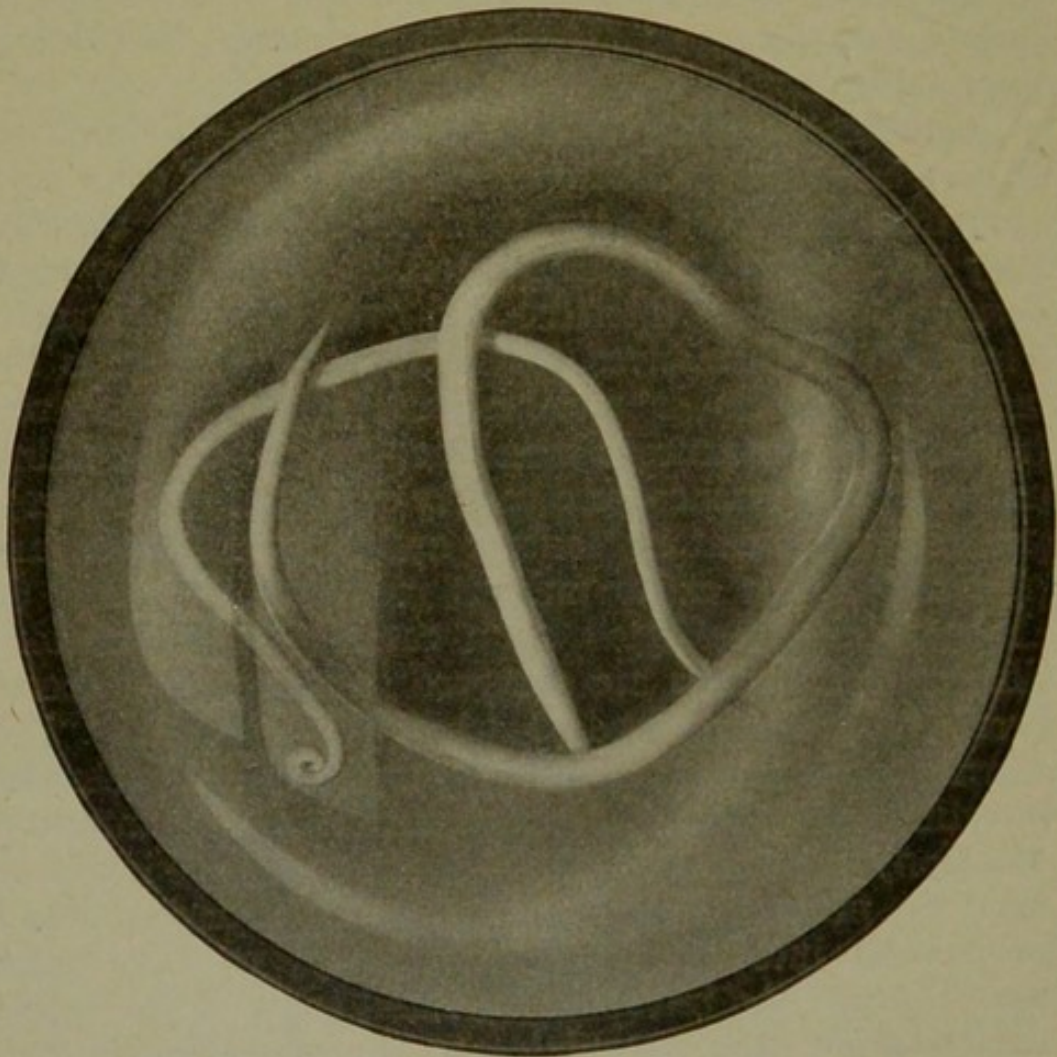


Fig. 2.—ASCARIS SUUM.

visible symptoms, a positive diagnosis may not be made until the parasites are eliminated or the ova are identified in the feces by microscopic examination. If this condition persists for some time the affected animals become unthrifty and emaciated.

Treatment.—Prevention is far more satisfactory than treatment of infested hogs. The extent of infesta-

tion can be materially diminished by keeping the quarters clean. The droppings should be gathered and limed, and the floors in the piggery should be kept clean, and limed or sprayed with some agent that is destructive to the egg and embryo of the ascarids. Common salt destroys the embryo and larvæ of practically all animal parasites, but it must be used with caution in hog premises, for it is also quite destructive to hogs.

Treatment of individual hogs by giving direct medicaments is difficult. The most effectual method of medicating swine, particularly when large numbers are to be treated, is accomplished by medicating the slops or feed. Santonin and areca nut have been used, but other less expensive and as effectual drugs may be selected, such as ferrous sulphate, copper sulphate, and creosote. When drugs are mixed with slops or feed, care must be used to have a thorough mixture, and each hog should obtain its proper portion. The medication in slop or food should be given once a day and continued for several days. The excrements laden with the worms and their ova should be properly disposed of in order that future infestation may be diminished.²

Esophagostoma Dentatum

Esophagostomiasis is a disease caused by the invasion of the *Esophagostoma dentatum* into the submucosa of the large intestine of swine, a condition not very common in America. This parasite is parasitic in its larval stage. Its life cycle has not been entirely worked out, but the ova are discharged from the animal body in the feces and hatch, if climatic conditions are favorable, into embryos. Later changes are unknown, but the larvæ are ingested with food or drink and bore into the submucosa of the large intestine, where they remain from six to seven months and produce small nodules

²The external covering of the ascarids contains a volatile chemical substance that is extremely irritating to the ocular mucous membrane, and care should be exercised that the hands be carefully cleansed after handling these worms and thus prevent the development of conjunctivitis.

in which they undergo various metamorphoses, finally becoming sexually mature. They then leave the submucosa nodules and migrate into the lumen of the intestine, where copulation occurs and the female later ovulates in the same location.

Lesions.—The principal lesion is the submucous nodules that occur in the large intestine. There may be only a few nodules, or there may be many. These nodules are inflammatory, caused by the presence of the larvæ. They are definitely circumscribed with a fibrous capsule; the content of which is inflammatory exudate that later becomes purulent, then caseous, and may ultimately calcify. The nodules first cause a slight hard, spherical elevation of the mucous membrane about the size of millet seed, but they may later become as large as a pea. In the later stages they assume a greenish-gray cast due to the accumulation in them of pus. The nodules frequently produce erosions and ulceration of the intestinal mucosa, and they may persist and appear as caseated incapsulated masses. The adult parasites may be found free in the large intestine. They are about three-fourths of an inch in length.

Symptoms.—The extent of invasion sufficient to produce visible symptoms has not been determined, but it is not uncommon to find a few nodules in the intestine of swine that were slaughtered in packing houses and were known to have been previously healthy. The usual symptoms consist of a profuse and persistent diarrhea, emaciation, weakness, and death in the intensely infested animals. The disease is essentially chronic. The course is from two to three months.

Treatment.—Because of the location of the offending larvæ, medication is of no avail. A small percentage of the animals may be saved by dieting and treating the symptoms as they arise. Prevention of further spread of the disease should be the chief consideration.

Trichocephalus Crenatus

This parasite is not of common occurrence in America. The worms are in shape similar to the old-fashioned

blacksnake whip, the head end very thin and hair-like, the posterior extremity being thicker and thread-like. They are usually coiled, and are from one to one and one-quarter inches in length. Their life cycle is similar to that of the *Esophagostoma*. Infestation is accomplished through the food or drink.

Lesions.—The *Trichocephali* are blood suckers, but they appear to do very little damage unless they occur in large numbers. When they produce anemia there is also more or less intestinal catarrh. The parasites are found firmly attached to the mucous membrane of the large intestine.

Symptoms.—The principal symptoms are diarrhea, emaciation, and weakness.

Treatment.—Practically the same as described for the *Ascaris suum*.

Trichinella Spiralis

Trichinella spiralis passes only the adult stage of its life cycle in the intestine. The larvæ are important muscle parasites. Further discussion will be found under "Muscular Parasites," on page 142.

Gigantorhynchus Hirudinaceus

This, the thorn-headed intestinal worm of swine, is quite prevalent in practically all sections of this country. It is a thick, cylindrical, white worm with an attenuated tail portion, transverse markings, and a head provided with a globular proboscis having several rows of hooks. The ova pass to the ground with the feces and are ingested by the larva of the May beetle, in which it passes a portion of its life cycle, the embryo and larval stages. Hogs consume the May-beetle larva and the inclosed *gigantorhynchus* larva is liberated and passes into and attaches to the intestine of the hog. It is thought that the ova may develop elsewhere as well as in the May-beetle larva.

Lesions.—Upon opening the abdomen of a swine infested with the *Gigantorhynchus*, shiny nodules of a

grayish color are readily visible on the serous coat of the intestine. The thorn of the worm is found to have penetrated the mucosa, and thus permits of infection which results in the production of an inflammatory zone. The parasites may become detached, the lesions produced having healed by the formation of cicatricial




Fig. 3.—GIGANTORHYNCHUS HIRUDINACEUS.

tissue, which is usually easily recognized. Not infrequently the head of the parasite bores through the entire intestinal wall and occasions general peritonitis.

Symptoms.—The usual symptoms consist of digestive disturbance the magnitude of which will depend upon the extent of infestation. The infested animal usually gives evidence of pain, as the parasite lacerates

the tissues during its attachment. There may also be muscular twitching.

Treatment.—These parasites are difficult to dislodge. Long-continued medication with creosote alternated with copper sulphate has proved effectual in many cases.

Tumors

Intestinal tumors are not prevalent and are of little economic importance.

Connective tissue tumors may develop and mechanically interfere with intestinal movement or they may obstruct the lumen of the bowel. Fibromas and myxomas have been observed, usually having their origin in the subserosa or within the serous coat of the intestine. These tumors are definitely encapsulated. It is usually not possible to make a diagnosis except by autopsy.

Of the malignant tumors, carcinoma, epithelioma, adenoma, and different varieties of sarcoma have been identified. The embryonic epithelial tumors may be primary or secondary. Primary epithelial tumors usually have their origin in or from the mucous membrane. Secondary epithelial tumors may involve any portion of the intestinal wall and are more frequently encapsulated than the primary tumors. The primary epithelial tumors, especially epitheliomas, are very prone to produce necrosis of the surface mucous membrane and thus cause ulceration.

General sarcomatosis of the entire abdominal viscera is occasionally observed. Sarcomas in swine are apparently not so malignant as in other domesticated animals, and are more frequently encapsulated. The appearance of the various malignant tumors in swine is the same or very similar to that of the same type of tumor in other animals.

Intestinal malignant tumors, generally speaking, are evidenced by unthriftiness, indigestion, emaciation, marasmus, and finally by death.

LIVER

The liver is a very important organ physiologically, and it is of such magnitude that derangement of its function and disease usually result in marked metabolic disturbance of the affected animal. The diseases of the liver of swine have not received the attention proportional with other diseases; in fact, little is known of the pathologic conditions in the liver of swine excepting those observed and recorded by men employed in the inspection of meat.

Malformations

Malformations of the liver are not of much importance. There may be too few or too many lobes. The lobes may be entirely separated. Rarely, the gall bladder is wanting.

Foreign Bodies

Several hog livers have been observed that contained quantities of sand or cinders, varying in volume from an ounce to a quart. These cases have been observed in swine killed at abattoirs, and without exception the affected animals were in prime condition.

The avenue of entrance of the sand and cinders is no doubt through the hepatic duct. Just how the foreign substances gain entrance and "back-tell" in the ducts to the gall bladder and from there into the collecting cystic ducts in the liver has not been determined. The hepatic duct orifice in the summit of the duodenal papilla probably becomes enlarged through injury, or atrophy of the surrounding mucosa, and this, in conjunction with a full stomach and intestine, would facilitate the passage of the foreign substance through the orifice and into the hepatic duct. The irritation of the foreign substance may cause relaxation of the sphincter muscles and also establish reverse peristalsis. It may be possible that the cause may be due to irregular action of the intestinal musculature. In all of the cases observed the hepatic duct was found gorged with the foreign

material, the duct in some instances being more than one inch in diameter; the cystic duct and gall bladder were found to contain varying quantities of the same material. In one case the gall bladder was so engorged with sand that it had dilated until it was fully as large as a quart measure. The foreign substance, either cinders or sand, may also be found in the ducts that convey the bile to the gall bladder. In some instances the biliary capillaries contained considerable quantities of sand. The accumulations obstructing the outflow of bile result in icterus of varying intensity. There is also a catarrhal inflammation of the adjacent intestinal mucosa and the mucous membrane of the bile tubules, gall-bladder, and hepatic duct.

Rupture

Rupture or laceration of the liver does occur, although it is not so common in swine as in most other animals because the abdominal wall of swine is comparatively thick, due to the deposition of subcutaneous fat.

Etiology.—The usual cause of hepatic rupture is mechanical interference in the form of a sudden blow, such as the kick of a mule or the penetration of the liver with some sharp object which may lacerate the hepatic tissue.

Lesions.—If the hepatic lesion has caused sudden death the peritoneal cavity will contain a large quantity of blood which may or may not be coagulated, depending upon the length of time after death that the autopsy is conducted. If the injury is an old lesion, cicatricial tissue will have sealed the wound and perhaps, by contraction, distorted the liver.

Symptoms.—The symptoms evidenced will be shock, weakness, and blanched visible mucous membranes due to loss of blood from the blood vascular system. Should the animal survive the immediate affect of the injury and the loss of blood, there may be symptoms only of impaired hepatic function, or there may be no visible symptoms.

Treatment.—Because of the nature of hepatic rupture, treatment is of no avail. In cases that will probably have a fatal termination the animal may be bled to death and the carcass thus saved for meat.

Icterus

Icterus or jaundice is a condition resulting from the deposition of bile or bile pigments in the various tissues. This condition is relatively common and is significant as a diagnostic factor.

Etiology.—Icterus may be the result of obstructed outflow of bile. It may result from excessive destruction of red blood cells, of failure of elimination of bile from the blood. Obstructed outflow of bile may be due to calculi, parasites, or foreign bodies in the bile ducts, closure of the duct by cicatrices, muscular spasms, tumors, abscess, aneurysms, fecal matter, parasitic cysts, or inflammatory disturbances of the mucous membrane of the duodenum or the various bile ducts. Excessive production of bile in the blood occurs as a result of hemolysis due to chemic substances in such diseases as hog cholera, swine plague, septicemia, pyemia, generalized anthrax, phosphorous poisoning, and also as a result of the injection of the venom of some poisonous snakes. Failure of elimination of bile occurs not only when the outlets are obstructed but also when considerable numbers of liver cells have been destroyed or their functional capacity diminished.

Lesions.—Bile staining is most evident in the conjunctiva and ocular sclera of the living animal, where it produces a lemon-yellow or greenish-yellow discoloration. If the reabsorption of bile is very extensive it may appear in the urine. In carcasses biliary pigmentation is most evident in the adipose tissue, especially the subcutaneous fat, although it is usually well marked in the subserous fat and may be detected in the lymph nodes, spleen, kidney, and muscular tissues. On microscopic examination the bile pigments may be found in

the cells or between the cells as greenish-yellow amorphous granules.

Symptoms.—The effects of icterus are variable. The tissues are discolored; there may be pruritis, cardiac depression, vomition, coma, and death. The symptoms above outlined are probably not due to the presence of the bile pigments in the tissue, but to other substances that have not been eliminated.

Treatment.—Removal of the cause is usually all that is required for complete recovery from icterus. If the cause cannot be identified, then the symptoms should be treated as they arise.

Cloudy Swelling

Cloudy swelling, or parenchymatous degeneration, is a condition in which a portion of the cell protoplasm is coagulated. This condition is very common. It is frequently the forerunner of fatty changes.

Etiology.—Coagulation of portions of the cell protoplasm may be caused by high temperature, as is evidenced in fever or overheat, or it may be caused by bacterial products and other chemical poisons.

Lesions.—The affected liver is enlarged, paler in color, and more friable than normal.

Symptoms.—The symptoms are usually associated with those of other disturbances and are therefore not specific. There is evidence of disturbed hepatic function, and often a slight icterus and tendency to constipation.

Treatment.—To ascertain and then remove the cause is of prime importance. This condition is corrected only through the efforts of the body, therefore, provide the proper diet and maintain sanitary conditions.

Fatty Changes

Fatty changes in the liver are of common occurrence in swine. The usual change is first an accumulation of fat droplets between the cells and later a fatty degeneration of the cells.

Etiology.—Fatty changes in the liver may be due to excessive nutrition, diminished exercise, hereditary influences, long-continued fever, bacterial products, and such chemical poisons as phosphorous. Fatty degeneration of hepatic tissue is sometimes observed in conditions associated with malnutrition.

Lesions.—The liver is enlarged, gray or grayish-red in color and lighter than normal in weight; when incised, droplets of fat or oil may be observed on the knife. Fatty changes are usually uniformly distributed in the entire liver; however, in exceptional cases, one lobe only may be involved.

Symptoms.—The evidence of fatty changes in the liver are not characteristic. The condition may be suspected in obese animals or those known to be affected with chronic arsenic, antimony, or phosphorous poisoning.

Treatment.—There is no treatment that is of any special value more than to correct the diet.

Amyloid Changes

Amyloid changes in the liver are rather uncommon in swine. The cause is unknown. The affected liver is larger, paler, and firmer than normal. The amyloid areas are homogenous and translucent in appearance, the amylaceous substances usually occurring in definite foci, though they may be quite diffuse. This condition may be associated with other diseases which tend to mask any specific symptoms. One case of amyloid change has been observed in a hog that clinically showed no manifestation of disease and was in prime condition at the time of slaughter. The amylaceous substance is insoluble, and the condition is therefore probably incurable.

Glycogenic Infiltration

Glycogenic infiltration is a condition in which excessive quantities of glycogen accumulate in the liver. This condition is observed occasionally in the liver of slaughtered swine.

Etiology.—Disturbed carbohydrate metabolism is inseparably associated with glycogenic infiltration, although the specific relation of disturbed carbohydrate metabolism and glycogenic infiltration is not known. Inflammatory disturbances and tumor formation appear to have some relationship with glycogenic infiltration.

Lesions.—A glycogenic infiltrated liver is pale, larger than normal, and of a putty consistency.

Symptoms.—No definite symptoms are attributed to the excessive accumulation of glycogen in the liver. The condition may be suspected when the animals are sluggish and do not exercise, as it has been demonstrated that during muscular activity glycogen is used in considerable quantities and is drawn from the storehouse, which is the liver, as it is required.

Treatment.—Regulation of diet and exercise is far more valuable than medicinal treatment.

Gall-stones (Cholelithiasis)

Gall-stones are accumulations of organic or inorganic substances in the various bile tubes or gall bladder. They are relatively common in swine.

Etiology.—The presence of a substance that will act as a nucleus is the first step in the formation of a calculus. Precipitation of some of the bile ingredients is the second step in calculus formation, and the accumulation of the precipitate upon the nucleus completes the process. Bits of mucous or any particle of foreign matter may serve as a nucleus. Precipitation may be caused by supersaturation of the bile with inorganic salts, or it may be a sequel of fermentation of bile. In addition, bacteria and other factors may be causative agents of calculus formation.

Lesions.—Cholelithiasis, or gall-stones, is found most frequently in the gall bladder. It may occur, however, in the hepatic duct or in any of the collecting bile tubes, regardless of their size. The presence of gall-stones usually causes obstruction and distention of the gall bladder or the bile tubes in which they occur.

If the obstruction has existed for some time, icterus will usually be more or less pronounced.

Upon opening the gall bladder or bile ducts containing the calculi, thick grumose bile escapes and the concretions or calculi are observed. Gall-stones may occur singly, but they are usually multiple. They are usually of a brownish-chocolate color and vary in size from mere specks to masses an inch or more in diameter. They may be round or any other shape, and when many are present they are usually faceted where they come into contact with each other. The gall-stones may be composed of organic material entirely and be quite soft or they may be incrustated with mineral matter and be quite hard. Upon sectioning them they are usually found to have been made up in layers, and it is not difficult to distinguish the nucleus. There is an inflammation of the mucous membrane of the gall bladder or affected bile tubes.

Symptoms.—Very few if any cases of cholelithiasis have been recognized clinically. If the gall-stones obstruct the outflow of bile sufficiently there will be general icterus. There are probably some digestive disturbances also.

Treatment.—The nature of this condition does not warrant treatment.

Hyperemia

Hyperemia of the liver may be physiologic or pathologic. Physiologic hepatic hyperemia occurs after eating and is of no significance economically or pathologically. Pathologic hepatic hyperemia may be either venous (passive) or arterial (active).

Passive hepatic hyperemia is caused by obstructed outflow of blood. Cardiac defects of the valves of the right side of the heart are a potent cause. Obstruction of the posterior vena cava or the hepatic vein by new growths, abscesses, and cicatricial tissue will also produce venous engorgement of the liver.

Lesions.—A careful examination will disclose the lesion producing the engorgement as well as the engorged condition of the liver. The liver will be full of blood and of a slightly darker color than normal. If the condition becomes chronic there will be fibrous proliferation.

Symptoms.—The signs of venous hepatic hyperemia vary according to the intensity of the condition and its duration. The animals become dull, and there is only a sluggish action of the bowels. If the condition progresses until there is fibrous proliferation, disturbances of nutrition become evident.

Arterial hepatic hyperemia may be the result of involvement of the hepatic artery or of the portal vein. This is a condition characterized by an increased inflow of blood into the liver. Hyperemia of the hepatic artery is not common, and when it does occur it is usually chronic. This condition is usually the result of partial occlusion of the gastric or splenic branches of the celiac axis, although it may be caused by some irritation in the terminal vessels in the hepatic interstitial tissue. No definite symptoms are evidenced, and the value of treatment is doubtful.

Portal hepatic hyperemia is usually caused by tainted foods or by infection. The liver may be increased fifty per cent in volume, and becomes gorged with blood. The symptoms are obscure. Some relief may be obtained by the free use of laxatives.

Treatment.—The removal of the cause, if that be possible, is about all that can be accomplished.

Hepatitis

Inflammation of the liver, or hepatitis, is rather common in swine. The condition may assume either an acute or chronic form. Hepatitis as a rule is secondary to other disturbances, although it may occasionally be primary. The inflammatory process may affect the liver cells and is then designated *parenchymatous hepatitis*, or it may affect the supporting framework, when it is designated *interstitial hepatitis*. With but few excep-

tions hepatitis of swine has not been made a subject of special investigation³.

Acute Parenchymatous Hepatitis

Acute parenchymatous hepatitis is a destructive inflammation involving the liver cells.

Etiology.—Chemic poisons derived from the bowel and carried to the liver by way of the portal vein is a frequent cause of this condition. Bacterial infection, entering the liver by way of the portal vein, hepatic artery, hepatic vein, umbilical vein, or hepatic duct is a common cause of hepatitis. The Distoma or liver flukes, the larval form of *Stephanurus dentatum*, and other parasites produce hepatitis.

Lesions.—The liver becomes enlarged and loses its sharp outlines; it is darker in color, gorged with blood, and is more friable than the normal liver. There may be small hemorrhagic areas.

Symptoms.—Icterus is usually the first and frequently the only evidence of the disease. The affected swine may show symptoms of pain when defecating or when moving about.

Treatment.—Laxatives may produce some relief. The proper diet should be given and the animals made comfortable.

Suppurative Hepatitis

Suppurative hepatitis as a primary condition is not very common in swine.

Etiology.—This condition is, as a rule, the result of bacterial infection, although parasites of various kinds may produce it. The infection in the liver is usually secondary and metastatic. Pyogenic Staphylococci and Streptococci are the most common infecting agents,

³An enzootic hepatitis of young pigs occurred in Russia and was investigated by Semmer. This disease has also occurred in eastern Prussia, where it has been very fatal. The cause of this condition is probably a coccus which is thought to gain entrance into the umbilicus at the time of farrowing. The affected liver is enlarged, nodular and variegated in color.

although the colon bacilli and its various derivatives have been identified in the pus from liver abscesses.

Lesions.—The liver contains suppurative centers of varying dimensions. The foci may occur throughout the entire liver and be microscopic in size, causing a uniform enlargement of the liver, or the suppurative centers may be as large as walnuts and appear as small abscesses. The liver will be engorged with blood, more friable than normal, and it may be variegated in color, due to alternating small hemorrhagic areas and suppurative foci.

Larger suppurative centers are gray in color and may or may not be circumscribed by a capsule of fibrous tissue. The content may be semifluid pus or it may be caseous or even calcified.

Symptoms.—The evidence of suppurative hepatitis consists of general depression. The animal does not move of its own volition. There is pain on palpation of the abdomen (if abdominal walls are not too thick), and icterus. Less extensive suppuration of the liver may not produce any distinct symptoms.

Treatment.—The animal should be made as comfortable as possible and the evacuation of the bowel content facilitated by the use of laxatives.

Acute Interstitial Hepatitis

Acute interstitial hepatitis is not a common condition but it does occur in swine and therefore should receive some consideration.

Etiology.—The cause of acute interstitial hepatitis probably always enters the liver by way of the hepatic artery, and is most frequently due to bacterial infection or animal parasitic invasion. The various suppurative bacteria, *Bacillus coli communis* or some of its derivatives and *Bacillus necrophorus*, may be the causative agent. Protozoan parasites and the larvæ of some vermes are responsible for some cases of acute interstitial hepatitis.

Lesions.—The liver is enlarged and appears to be affected with chronic interstitial hepatitis because the

interlobular tissue is infiltrated with leukocytes. The liver tissue is soft and friable. Microscopic study of these livers has revealed the fact that in nearly every instance the infiltration leukocytes are practically all eosinophiles.

Symptoms.—Few if any investigations of these cases have been made clinically or at least such have not been reported. The marked interlobular infiltration tends to obstruct the biliary capillaries, causing reabsorption of bile with accompanying icterus.

Treatment.—The nature of this condition permits of little if any relief by the use of drugs. Providing the proper diet and surroundings are provided, treating the symptoms as they arise is apparently all that can be advised for the relief of this condition.

Chronic Interstitial Hepatitis (Cirrhosis-Sclerosis)

Chronic interstitial hepatitis, cirrhosis or sclerosis of the liver, consists of a proliferation of fibrous tissue which damages and ultimately displaces some of the functional liver tissue. The condition is rather common, especially in swine fed upon fermented products, such as distillery waste, or garbage.

Etiology.—This condition is due to injurious chemical agents derived either from the food or from bacterial action, that is, those substances that are capable of producing a mild degree of irritation. Animal parasites, either by direct mechanical irritation or irritation by eliminated chemicals, also produce chronic interstitial hepatitis. The condition, too, may be secondary to other disease processes.

Lesions.—Chronic interstitial hepatitis is essentially a proliferation of fibrous tissue. The fibrous tissue may be produced within the liver lobule, causing an enlargement of the lobules and also of the liver. This type is designated hypertrophic sclerosis of the liver. Such a liver is enlarged, dense, increased in weight, lighter in color, and when cut gives the impression of cutting fibrous tissue. In other instances the proliferation of

fibrous tissue occurs in the interlobular tissue only. This newly formed fibrous tissue later contracts, thus diminishing the size of the affected lobules, and therefore the liver as a whole. This condition is termed atrophic sclerosis. Such a liver usually has an irregular outline (hobnail liver) and is smaller, denser, and lighter in color than a normal liver. It is possible that hypertrophic sclerosis, or the formation of new fibrous tissue throughout the entire liver lobule, follows when the irritant is introduced through the portal vein, and atrophic sclerosis occurs when the irritant is introduced through the hepatic artery.

Symptoms.—Hepatic sclerosis has an insidious onset. Probably the first evidence of the disease is digestive derangement, which later may be accompanied by icterus. The animals become unthrifty and finally weak and emaciated.

Treatment.—Remove the cause and prevent further progress of the disease. A strict diet and the maintaining of a laxative condition of the bowel may permit the affected animals to be gotten into condition for slaughter.

Tumors

Hepatic tumors are frequently observed by veterinary inspectors in abattoirs, but these tumors are rarely of sufficient magnitude to have produced visible symptoms in the animal prior to slaughter.

The various kinds of tumors that have been observed in the liver of swine are true to the type for the same tumors in other animals. The malignant tumors of the liver frequently are found to be secondary. Of the types of liver tumors the following have been identified, lipoma, myxoma, angioma, sarcoma, adenoma, epithelioma, and carcinoma.

No definite symptoms of hepatic tumors can be described; often there is no outward evidence. There may be digestive disorders, emaciation, and evidence of malnutrition.

The treatment of hepatic tumors in swine is not practicable.

Parasites

Parasitic invasion of the liver is very common in swine. The result of hepatic parasitism has not attracted the attention of the clinician, but it has caused considerable concern with the inspectors of meat and food products. In the middle section of the United States the livers of the majority of swine evidence parasitism or lesions indicating previous parasitic invasion and activity. Parasitic conditions of the liver of swine are of considerable economic importance because of the condemnation, and therefore the loss, of this organ as a food product.

Coccidiosis

Liver abscesses containing *Coccidia* have been observed. The conditions are not very common. Johne observed in swine abscesses as large as an apple that contained a *Coccidium* to which he attributed the cause.

Stephanurosis

It is rather common to observe lesions in the liver of swine caused by the *Stephanurus dentatum*. The mode of entrance of these parasites into the liver may be by way of the hepatic duct, through the portal vein, or by direct migration from the peritoneal cavity through the liver capsule. They establish inflammation accompanied by the formation of pus and later necrosis of the liver tissue. The entire lesion is surrounded by a rather dense white fibrous connective-tissue capsule. From one to three of the parasites are found in the necrotic purulent material. The content of the lesion later becomes caseous and may ultimately calcify.

No symptoms have been observed in the liver that could be attributed to the direct action of the *Stephanurus*.

Remedial treatment is not available, but preventive measures should be taken to avoid future disturbances.

The exact life cycle of the parasite is not known, but general sanitary regulations are always in order and will no doubt be of value in preventing or at least diminishing the extent of future infestations.

Ascaridiasis

An occasional ascarid migrates into the liver by way of the hepatic duct. These parasites in this location mechanically obstruct the outflow of bile and also produce sufficient local irritation to establish a catarrhal inflammation of the hepatic duct, the gall bladder, or the bile duct.

Icterus, associated with digestive derangement, will probably be the only evidence of the presence of this parasite in any portion of the liver or its excretory duct.

The location of the parasite prohibits the successful use of therapeutic agents. The possibility of invasion into any of the hepatic structures may be diminished by frequent medication of the swine with agents previously mentioned that will eliminate these parasites from the bowel. Frequent cleaning, and removal of the excrement from the pens, yards, or barns, will tend to diminish infestation.

Distomatosis

This is a condition resulting from the invasion of the liver by the *Distoma hepaticum*, *Distoma Americanum*, or *Distoma lanceolatum*. All are commonly called flukes. *Distomatosis* occurs most frequently in animals kept upon low, marshy, or swampy lands. Swine raised in the southern part of the United States are commonly infested. The exact life cycle of these parasites has been carefully worked out and may be obtained by reference to works on parasites; suffice here to say that the ova are eliminated from the liver in the bile and pass to the outside in the fecal matter. After several changes the embryos are found upon vegetation which is consumed by their hosts. They find their way up the hepatic duct and on into the bile tubes within the liver.

Lesions.—The lesions established by the different types of *Distoma* are slightly different. The *Distoma hepaticum* remains for six months in the bile tubes in the liver, where it produces obstruction of bile and inflammation of the bile tubes. The accumulated bile causes distention of the bile tube, which is usually very evident, particularly upon the posterior surface of the liver. The dilated bile tube is found to be thickened and contains thickened flocculent bile and flukes in some stage of development, depending upon the length of time after invasion that the autopsy is conducted.

The *Distoma Americanum* either remains in the bile tubes or passes out into the substance of the liver, where it produces a cyst. These cysts, which attain the size of a hen's egg, are evidenced by grayish-black elevation upon the surface of the liver. The cysts contain a chocolate-colored fluid and one or more distomes.

The *Distoma lanceolatum* produces lesions similar to those produced by the *Distoma Americanum*. The latter parasite is easily distinguished from the former by its large size and its distinctive shape.

A liver in which the *Distoma* have developed and disappeared contains cicatrices or areas of necrotic calcareous material, evidences of the parasitic invasion.

Symptoms.—It is difficult to diagnose hepatic distomiasis by the clinical symptoms. The history of the case, particularly the source of the animal affected, should be given proper consideration. The symptoms vary according to the intensity of infestation, and do not appear for from one to two months after infestation. There is more or less icterus, digestive derangement, unthriftiness, and emaciation. The disease may terminate fatally and it may be quite widespread, affecting a large percentage of swine in the Southern States, particularly during wet seasons.

Treatment.—Treatment is of no avail. Invasion may be diminished or entirely prevented by keeping swine out of pens, yards, and pastures where previous

infestation has occurred and by properly disposing of the excrements of swine that are infested.

Echinococcosis

The invasion of the liver of swine with the larvæ of the *Tænia echinococcus* is quite common. In the Old World from one per cent to seventy per cent of the swine are reported to be so infested.

The mode of entrance into the liver is by way of the portal system, the embryo passing through the intestine into capillaries that empty into radicles of the portal vein. Infestation is derived from food or drink contaminated with the feces of dogs, that harbor the *Tænia echinococcus*.

Lesions.—The liver is enlarged; the degree depending upon the number of parasitic cysts it contains. Gerard observed an infested swine liver that weighed 110 pounds. The surface of the liver may be very irregular due to the presence of the cysts near the capsule or just beneath the capsule. The cysts, which vary in size from a pear to a small hen's egg, are the primary lesions and may be polymorphous or multilocular. The polymorphous cysts are surrounded by a fibrous capsule inside of which the true cystic membrane is found and upon which daughter and granddaughter cysts and the head of the future tapeworm may be seen. The cyst contains a pale, straw-colored, limpid serum. The multilocular cyst is a mass of single cysts developing on the outside of the true cystic membrane instead of developing on the inside, as in the polymorphous cyst. The cysts necessarily displace and by pressure destroy liver tissue. Old cysts contain a cheesy or caseous substance; in some instances a purulent collection.

Symptoms.—Clinical evidence of the presence of hepatic echinococcus cysts are usually wanting. A few cases of ascites associated with hepatic echinococcosis have been recorded. There may be icterus and some digestive disturbance.

Treatment.—Because of the location and nature of the lesion, treatment for echinococcosis is ineffectual. The condition is readily prevented by treating with teniafuges all valuable dogs that are associated in any way with the swine and by destroying all worthless curs and properly disposing of their carcasses.

Cysticercosis

Hepatic cysticercosis of swine is not very common. It is found principally in young pigs, where it is the result of invasion of the liver with embryos of the *Tænia marginata* of the dog. These embryos are obtained in food that has been contaminated with dog feces. They gain entrance to the liver by way of the portal vein. Some of the embryos pass out of the liver in the hepatic vein; others bore through the organ and its capsule into the peritoneal cavity.

Lesions.—In extensive invasion the liver is enlarged. There may be evidence of perihepatitis. A small elevation may occur upon the surface and in each elevation a small opening may be observed. The liver is of a variegated color, due to alternating areas of hemorrhage and degeneration.

Symptoms.—Unthriftiness, weakness, anorexia, and increased thirst may be observed in hepatic cysticercosis. The affected animals may become rapidly emaciated; there may be evidence of peritonitis—and in exceptional cases the animals may die suddenly, but as a rule they linger for several weeks.

Treatment.—Symptomatic treatment may be resorted to, but it is doubtful if satisfactory results will be obtained. This condition may be prevented by the proper treatment or disposal of dogs as recommended under echinococcosis.

PANCREAS

Little is known concerning the diseases of the pancreas. A condition known as multiple fatty necrosis occurs in swine and is thought to be the result of obstruc-

tion to the outflow of pancreatic juice. Sarcomas involving the pancreas in swine have been observed, but they were evidently not primary in that organ.

PERITONEUM

Defects in the formation of the peritoneum are not common. Rarely cystic inclusions or exclusions may be observed.

Injuries

The peritoneum is occasionally injured in swine. The injuries may be inflicted during a surgical operation or they may be produced accidentally. The result of injury of the peritoneum varies with the location and the extent and nature of the injury; which may consist of a bruise of the peritoneum, in which case there is a local inflammatory disturbance; a puncture of the peritoneum, resulting in general peritonitis; or a laceration of the peritoneum, permitting eventration.

The results of violence from the external surface are self-evident, but the injuries may be inflicted by foreign bodies in the alimentary canal. In such cases there is more or less of digestive derangement and local or general peritonitis.

Treatment.—Medicinal treatment may be applicable when the peritoneum is intact, but in lacerations of the peritoneum surgical interference alone is of value.

Ascites

Ascites is a condition resulting from the accumulation and retention of excessive quantities of lymph or diluted lymph in the peritoneal cavity. The peritoneal cavity is in reality a large lymph space.

Ascites is very rare in swine.

Etiology.—Ascites is caused by an excessive outpouring of lymph into or a diminished absorption of lymph from the peritoneal cavity. The lymph escapes from the blood capillaries in the subserosa on to the surface of the peritoneum. The usual causes are

obstructed portal circulation, which may be due to disturbances of the liver, valvular defects of the heart, chronic nephritis, or direct pressure upon the portal vein.

Lesions.—Enlarged abdomen, due to the accumulated fluid in the peritoneal cavity. The fluid is thin, limpid, and is noncoagulable. The lesions of the primary cause may also be observed.

Symptoms.—A pendulous abdomen associated with digestive disturbances and malnutrition are the principal evidences of this disease.

Treatment.—Treatment is of little value. Temporary relief may be obtained by paracentesis abdominis.

Peritonitis

Inflammation of the peritoneum is not of as common occurrence in swine as it is in horses, and the disease is less fatal in swine than it is in most other animals.

Etiology.—Injuries, and infection following parturition, are the most common causes of porcine peritonitis. Occasionally an ascarid may perforate the bowel and establish inflammation.

Lesions.—Peritonitis may be serous, fibrinous, hemorrhagic, purulent, septic, or tubercular; local or general; acute or chronic. The lesions will vary according to the type of inflammation. There is first tumefaction, congestion, loss of gloss of surface, and exudation. The serous exudate is sticky, serum-like, and may be tinged with blood; the fibrinous exudate coagulates and causes adhesions; the hemorrhagic exudate is of a bloody appearance; and the purulent exudate is composed of pus. Septic peritonitis is associated with the accumulation of a putrid material upon the peritoneal surface. There may also be evidence of injury, or metritis, and probably some intestinal content in the peritoneal cavity. Chronic peritonitis is associated with the proliferation of fibrous tissue and usually greater or less adhesions of the visceral and parietal peritoneum.

Symptoms.—Acute peritonitis is associated with abdominal pain, the severity of which depends upon the extent and intensity of the inflammation. The pain may be manifested on palpation of the abdomen. The affected animals have a “tucked up” appearance; the appetite is diminished or perhaps wanting. There is a rise of temperature and a rapid, wiry pulse. The animals are uneasy and restless.

Animals affected with chronic peritonitis may show some digestive derangement or there may be no evidence of disease.

Treatment.—Remove the cause, and the further treatment will depend upon the cause and nature of the lesions. In all cases the bowel movement should be diminished or inhibited by the use of opiates. If the disease is the result of injury, surgical interference and the rational application of antiseptics is indicated. If the animals eat they should receive only liquid foods easy of digestion.

Tumors

Some cases of peritoneal tumors in swine have been reported. The fibroma of swine is usually benign; it may be tabular or pedunculated. Sarcoma, endothelioma, and carcinoma also have been observed, the first being the most common.

The above-mentioned tumors are pathologically identical to the same type of tumors observed elsewhere in swine or in other animals, and they produce practically the same results, with the possible exception that the malignant tumors are not so fatal as in some other animals, particularly in the human.

Parasites

The cystic form of the *Tænia echinococcus* (echinococcosis) is probably the most common parasitic invader of the peritoneum of swine. The description of these cysts will be found under the consideration of parasites of the liver.

The *Cysticercus tenuicollis* is occasionally observed involving the peritoneum of swine, although in the central United States these cysts are much more common in sheep. These cysts contain only one tapeworm embryo, differing in this particular from the cysts of the *Tænia echinococcus*. They have a double membrane, the embryo is suspended in a thin, watery fluid that fills the cyst, which may attain the size of an English walnut.

Stephanurus dentatum, both in the adult and larval stage, may be found in relation to the peritoneum. The lesions they produce in the peritoneum are the same as those produced by this parasite elsewhere in the body.

The *Ascaris suum* may bore through the intestine and be found in the peritoneal cavity. As they pass out of the intestine they carry various bacteria with them and possibly also permit the escape of some intestinal content which is always teeming with bacteria. Thus infectious, usually septic, peritonitis results.

SECTION II

THE RESPIRATORY SYSTEM

NOSE

THE habit of rooting predisposes the snout of swine to various kinds of injury regardless of the fact that this organ has been designed for such purposes. Ringing of swine produces an injury that in some instances is difficult to correct.

Epistaxis

Nose bleeding is not a disease primarily, but is usually a symptom of some other disease or abnormal condition. Epistaxis occurs rather commonly in swine.

Etiology.—True epistaxis is a result of the escape of blood from some of the blood vessels of the nasal chambers or related cavities. It is a very common symptom in hog cholera and swine plague, and has been observed in cases of anthrax. The condition is sometimes associated with ulceration of the schneiderian membrane regardless of the cause of the ulcers. In some instances, it may be due to mechanical injuries of the mucous membrane.

Lesions.—Except in epistaxis resulting from trauma, the lesions of the primary condition are more prominent than those associated with the hemorrhage.

Symptoms.—Escape of blood, usually from the nostril, is the principal evidence of epistaxis. The escaping blood may be scarlet red or dark red, depending upon whether the blood is escaping from an artery or a vein. Epistaxis can be distinguished from pulmonary hemorrhage by the fact that the discharged blood from the latter is frothy.

Treatment.—Epistaxis is usually not fatal. It is difficult to treat in swine because of the small size of the opening of the nostril. Hydrogen peroxide may be introduced by means of a syringe, and this gives immediate and sometimes permanent relief. A solution of adrenalin chlorid gives similar results.

Rhinitis

Catarrhal rhinitis is very common in swine. It may be either acute or chronic.

Etiology.—Catarrhal inflammation of the schneiderian membrane is most commonly caused by the inhalation of dust or other irritating substances. It may be caused also by sudden temperature changes. It is sometimes associated with other disease conditions, particularly swine plague and hog cholera. An infectious type of this disease has been identified and is discussed separately. (See p. 77.)

Lesions.—Acute catarrhal inflammation of the nasal mucosa is characterized by congestion and tumefaction of the mucous membrane. This membrane is at first dry, but later varying quantities of a serous fluid and mucous escape upon the surface of the mucosa and are discharged, some of the discharge accumulating upon the external surface of the nostril. The exudate may become infected and invaded by leukocytes, the discharge thus becoming mucopurulent or purulent. Chronic catarrhal inflammation may produce a hypertrophy or atrophy of the nasal mucosa. The hypertrophic change is due to the production of large quantities of fibrous tissue in the submucosa. The mucosa thus becomes thickened, dense, and leathery. The increased volume of the mucous membrane may so diminish the cavities of the nose that breathing is difficult. In other instances the mucous membrane atrophies, the nasal cavity thus becoming larger. It is not unusual to find desiccated discharges adhering to the mucosa. In either the hypertrophic or atrophic forms of chronic catarrhal rhinitis there may be ulceration of the mucous membrane. When

such ulcers occur they usually involve only the mucous membrane.

Symptoms.—Discharge from the nose of a serous, mucous, seromucous, pus, or mucopurulent material is indicative of nasal catarrh. The affected animal may sneeze and evidence some difficulty in breathing.

Treatment.—Remove the cause, and if the condition has not persisted until it is chronic there will usually be a speedy recovery. A common cause of catarrhal rhinitis is inhalation of dust, and therefore dusty pens frequently contain swine with nasal catarrh. The condition in such cases can usually be checked by sprinkling or wetting the pens. Medicinal treatment is not of great value for this condition in swine because of the difficulty of its application. Laxatives may be of some value. Those animals affected with advanced cases of the chronic form of the disease had best be put into a marketable condition, if possible, and sold for slaughter.

Infectious Nasal Catarrh

An infectious nasal catarrh of swine occurs enzoötically in Germany. It usually confines its ravages to pigs less than six months of age. A similar clinical affection occurs in some sections of the United States, but in this country the specific causative agent has not been identified.

Etiology.—In 1906, the *Bacillus pyocyaneus* was identified by Koske as the causative factor, although the infectious nature of the disease was recognized as early as 1890. The *Bacillus pyocyaneus* is found in manure heaps and mulched soils; it gains entrance to the nose while the swine are rooting and is readily transmitted from a diseased to a healthy animal by means of the nasal discharges.

Lesions.—This disease is characterized by an intense inflammation which causes a marked congestion of the mucosa and not infrequently a hemorrhagic inflammation. The lesions extend and involve the sinuses and the ethmoidal cells, and there may be involvement of the

optic and olfactory nerves, of the cerebral meninges, and of the brain itself. The usual lesions in the last-mentioned structures consist of hemorrhages beneath the sheath of the optic and olfactory nerves, congestion of the meninges, and edema of the cerebral tissue proper. Various changes may be observed in other internal organs as a result of high temperature and possibly also of metastasis of the infecting agent.

Symptoms.—High temperature and inappetence are usually the first symptoms of the disease. Sneezing, and vigorous rooting or rubbing the nose, are followed by epistaxis, edema of the snout, and difficult breathing. The affected animals may be blind in one or both eyes, and if there is meningeal involvements the pigs will evidence extreme excitement and finally die in a comatose state. The disease may result fatally in a very short time, its course in the most fatal epizoötics being from three to six days. A chronic or less fatal form has been observed in which the course of the disease varies from one week to several weeks, and some of the animals may recover.

Treatment.—In the acute form of infectious nasal catarrh treatment has not been successful. From the experience of those veterinarians where this disease prevails it seems best to recommend destruction of all affected animals. An antitoxin may be prepared and used to offset the injurious influences of the toxic substances produced and eliminated by the *Bacillus pyocyaneus*. Prophylactic sanitary measures should be instituted and rigidly enforced on premises where this disease abounds.

Tumors

Various tumors have been observed in the nasal cavity of swine or involving some related structure. Almost all of these tumors have been of the benign type and therefore interfere only mechanically. Pedunculated fibromas are not so common in swine as in some other animals.

LARYNX

Laryngitis

Inflammatory disturbances of the larynx are relatively common in swine but are not of sufficient gravity to warrant a lengthy discussion.

Etiology.—Undue exposure and inhalation of suspended or gaseous irritants are common causes of laryngitis. In swine, as in other animals, laryngitis is rarely a distinct process but is a condition associated with inflammatory disturbances of the pharynx, or trachea, and therefore the inflammatory process of the larynx is frequently an extension from an adjacent structure. Chronic laryngitis results from the same causative factors as the acute type, being merely extended over a longer period.

Lesions.—Laryngitis in swine is generally of a catarrhal type and may be either acute or chronic, although an occasional case of croupous laryngitis occurs. The lesions observed are practically identical with the usual lesions of this type of inflammation.

Symptoms.—The principal symptom of laryngitis is a cough, which is at first dry, later moist, and always painful. The cough may become convulsive. In the intense acute attacks there will be rise of temperature and probably inappetence. By palpation the laryngeal region will be found supersensitive.

Treatment.—Provide sanitary surroundings and if the patient is inclined to eat, give sparingly of easily digested slops. Medicinal treatment is so difficult to apply that frequently more harm than good is the result.

Tumors

Laryngeal tumors are rare. However, pedunculated fibromas have been observed, and epithelioma has been reported.

TRACHEA

Malformations

A case occurs occasionally in which the esophagus forms a union with the trachea. Pigs so affected usually die soon after farrowing.

Stenosis

Congenital stenosis may occur in swine, but is relatively rare. Acquired stenosis is also rare, because of the protection of the trachea from external injuries.

Tracheitis

This inflammatory disturbance is usually associated with laryngitis or bronchitis, and partakes so closely of the nature of these latter affections that further description will not be given.

Tumors

Tracheal tumors are not common in swine, though fibromas and myxomas of the benign tumors have been observed.

BRONCHIAL TUBES

The principal malformations of the bronchial tubes consists of an irregularity in the distribution of the branches of those tubes, but as a rule this produces little or no inconvenience to the animal and is therefore of scientific interest only.

Stenosis

Bronchial stenosis is relatively common in swine. The condition may affect either the large or small tubes. Bronchial stenosis is probably most frequently the result of a diseased condition of the bronchial mucosa, such as catarrhal inflammation, ulceration, tuberculosis, parasitic invasion, or mechanical injury due to some foreign body, as a needle or a nail.

Bronchitis

The principal inflammatory disturbance of the bronchial tubes is of a catarrhal nature, at least in the beginning. Catarrhal bronchitis may be either acute or chronic.

Etiology.—Undue exposure to inclement weather is one of the principal causes of bronchitis. Inhalation of dust-laden air is also an important causative factor of inflammation of the bronchial tubes. Infection is in many instances an auxiliary of other causes and the *Bacilli necrophorus* and *pyocyaneus* are many times the primary causes of bronchial catarrh. This condition may be associated with other diseases, such as swine plague or hog cholera.

Chronic bronchial catarrh results from the action of the same causative factors that produce acute catarrh, but the irritants are usually less intense and act for a longer time.

Lesions.—There is congestion of the affected mucosa, which later becomes covered with mucous or with a mucopurulent discharge. In extreme cases the discharge may be tinged with blood and become purulent. When the disease process involves the capillary bronchial tubes there is usually more or less of emphysema, due to obstruction of the tubes with exudate which prevents the escape of air from the air cells. There may be areas of atelectasis which project beyond the surface of the lung and are of a darker color than the lung.

Chronic bronchial catarrh is characterized by the presence of mucous, purulent, or even caseous material in the bronchial tubes, and by fibrous proliferation in the submucosa which may result in an attenuation of the mucosa. Dilatation or bronchiectasis is a common lesion, particularly in the dependent parts of the lung, in chronic catarrhal bronchitis. In long-standing cases there may be peribronchitis, evidenced by fibrous proliferation around the bronchial tubes, which may extend into the pulmonary tissue.

Symptoms.—The principal symptom of bronchitis is a cough which in the beginning is dry but later becomes moist. The cough may become convulsive. As the disease progresses a nasal discharge becomes evident, which is at first of the nature of mucus but later becomes mucopurulent or purulent. Râles may be detected in thin swine, or possibly in any of the bacon breeds, but the chest wall of other swine is usually so thick that it practically prohibits the recognition of pulmonary conditions. There is usually some rise of temperature in the beginning, but this may subside. The appetite may be diminished.

Treatment.—Removing the cause and providing sanitary surroundings will probably do more than medication to relieve this condition. Supply easily digested foods. If the swine can be controlled easily and placed in a piggery that can be made practically airtight, the animals may be successfully treated with medicated vapors, using such agents as oil of eucalyptus.

Verminous Bronchitis and Pneumonia

Verminous bronchitis is very common in swine in the United States; however, the infestation is only rarely of sufficient extent to produce serious damage. The lungs from a thousand swine were inspected in a Kansas City abattoir and sixty per cent of them contained pulmonary *Strongyli* in such numbers that the lesions could readily be observed by gross examination.

Etiology.—*Metastrongylus apri* is the causative parasite of porcine pulmonary strongylosis. It is a white or brownish-white thread-like worm from one inch to one and a half inches in length. The adults inhabit the middle-sized and small bronchioles, usually in the posterior superior part of the lung, although they may be found elsewhere in the lung. The ova are carried out from the lung in the discharge and may pass out directly or pass into the pharynx and be eliminated in the feces. The exact life cycle is not known, but it is probable that the ova hatch and undergo several moults before regaining the animal body. The parasites gain entrance to the

animal body in the food or water, infestation of swine being easily accomplished. Young pigs are most susceptible; however, the parasites have been identified in swine of all ages. After the parasites gain entrance to the animal body they begin to migrate, some of them ultimately reaching the bronchial tubes. The exact route of migration is still a disputed question, but they pass either by way of the pharynx through the larynx to the bronchial tubes, by way of the blood stream, or directly through the tissues.

Lesions.—The principal lesions in swine are found in the posterior lobes and in the superior part of those lobes. At first the lesions are confined to centers, or foci, which are cone-shaped and usually atelectatic, though they may protrude and be of a doughy consistency. In a later stage these foci are found to contain mucopurulent, purulent, or even caseous substances in varying quantities in addition to from one to many *Strongyli* and their ova. Similar discharges will be found in the bronchial tubes and even in the trachea, and occasionally disintegrated vermes and their ova will be found in the expectorate. There may be bronchiectasis, but this condition is not common. The visceral pleura may show evidence of chronic inflammation.

Symptoms.—The period of incubation varies from four to eight weeks. Although this condition is very prevalent, the infestation is usually limited and fatalities from this disease are exceptional. The primary symptom is a cough, which usually involves several animals at once and becomes more frequent as the disease progresses. In fatal or severe cases the cough is paroxysmal, the animals sometimes falling to the ground from exhaustion and lack of air. A sticky, adhesive discharge prevails and accumulates upon the nostrils, respiration becomes difficult, and a distinct wheezing sound can be heard. The temperature may be increased from one to three degrees Fahrenheit. Emaciation is rapid. Edema of the dependent parts occurs, and the animals become weak and finally die of exhaustion. The course of the

disease varies from one to three or four months. The diagnosis should be based upon the history of the outbreak, the number of animals involved, the character of the cough, and finally upon the detection of ova and parasites in the discharges and the presence of parasites in the lungs on autopsy.

Treatment.—This disease is difficult to treat because of the location of the parasites and the difficulty of controlling swine. The only rational method consists of the intratracheal injections of some agent that will destroy the parasites, or by the inhalation of medicated vapors. These methods are not easily adapted to the treatment of swine, particularly the intratracheal injections. Medicated vapors may be used, providing the swine can be confined in an airtight room.

Further infestation should be prevented by the proper disposal of the various excretions from the infested animals. The pens should be thoroughly cleaned and some efficient parasiticide applied. If the infestation is in pasture land, it will be necessary to change pasture, keeping all swine away from the known infested pasture for at least a year, and for two years if possible.

LUNGS

Atelectasis

This is a condition of collapse of the lung; the absence of air in the lung, and may be either congenital or acquired. The lung of the fetus is always atelectic before birth. This is one means of determining a still birth, and is often useful as evidence in legal cases. Partial congenital atelectasis may be the result of obstruction of a bronchus with meconium or mucus; it may also be the result of excessive extrathoracic pressure. Acquired atelectasis may be due to compression of the lung by inflammatory exudate (pleuritic effusions), edematous transudate, or forward displacement of the diaphragm. It may also be due to obstruction of the bronchus, the

air contained in the air cells being absorbed and permitting them to collapse.

Lesions.—The affected lung tissue collapses and does not crepitate. It is red or reddish-brown in color, feels dry, is tough, and sinks in water. If the condition is of long standing, the affected area becomes darker in color and is designated cornification. In some instances the atelectic areas become spleen-like, due to the development of fibrous tissues, and this is termed splenization.

Atelectasis diminishes the breathing capacity, which is the only symptom characterizing the condition. Small areas of the lung will not produce visible symptoms. This condition is usually associated with other disease processes, the symptoms of which mask those of atelectasis.

Atelectasis occurs in the lung of swine as a result of swine plague, hog cholera, bronchitis, pneumonia, and pleurisy, as well as of other less important diseases.

Emphysema

Pulmonary emphysema has been observed in swine but is not of common occurrence. It is due to conditions that favor the inflation of the lung with excessive quantities of air. Bronchopneumonia is occasionally associated with emphysema. The affected areas are soft, spongy, anemic, and project beyond the surface of the lung.

Edema

Pulmonary edema is not common in swine kept under ordinary conditions, but it is often found in those that are hyperimmunized for the production of anti-hog-cholera serum. Those having experience as serum producers occasionally have a swine die of pulmonary edema at the time or immediately after the intravenous injection of quantities of virulent blood.

In comparison to their size, swine have a relatively small lung. The virulent blood that is used in hyperimmunizing is defibrinated but contains both the red and

white blood cells, some of which are disintegrated. Large quantities of this defibrinated blood, containing corpuscles in various stages of disintegration as well as the virus, are introduced into an ear vein. The first capillary system it would pass through is in the lung where, no doubt, more or less obstruction of capillaries is effected and the virus, or some chemical ingredient of the blood, may cause an increased permeability of the blood vessels and facilitate the outpouring of the serum.

Lesion.—The lungs are engorged with blood. The air cells contain varying quantities of serum, the lung thus becoming soggy and edematous. No other lesion of any significance is found.

Symptoms.—The affected animal at first becomes restless and uneasy. There is increased respiration, soon followed by dyspnea, cessation of breathing, and death. In some cases all these symptoms occur within a few minutes and during the time that the virus is being introduced. If the injection is stopped instantly when the first symptom becomes evident some of the affected swine will recover, but in some of them the various symptoms occur, succeeded by death, even though the introduction of virus be stopped when the first symptom appears. An occasional case occurs where the swine will show no discomfiture at the time of the injection of the virus, but may be found in distress from a few minutes to an hour later. In such cases, death will usually result.

Treatment.—Thus far no treatment has been found that appears to be of value. It is possible that centrifuging the virus will overcome the difficulty.

Hemorrhage

Pulmonary hemorrhage is not common in swine as a primary disease. It has been reported as occurring in fattened swine that are driven to market, especially when they become very hot. It is rather common as a secondary condition in acute cases of pneumonia, swine plague, and hog cholera.

Cause.—Engorgement of the lung capillaries, due to overexertion, excessive heat, or disease, is the chief cause of hemorrhage. Weakening of the vessel walls due to malnutrition, which occurs in some infective diseases, is another cause.

Lesions.—Almost all cases of hemorrhage of the air passages posterior to the larynx are designated hemoptysis, or pulmonary hemorrhage, and it is difficult in some instances to differentiate tracheal or bronchial hemorrhage from pulmonary hemorrhage. If the hemorrhage is primary the escaped and escaping blood is practically all that will be observed. The blood that escapes from the lung or smaller bronchial tubes will contain more entangled air, that is, be more frothy than that coming from the large bronchi and the trachea. In secondary pulmonary hemorrhage the lesions of the primary disease will also be evident.

Symptoms.—If the extravasate is limited in quantity it may be absorbed and no visible symptoms become evident. Escape of frothy blood from the nose and mouth characterizes hemoptysis. In cases where there are large quantities of blood escaping there will be more or less bronchial obstruction and consequently difficult breathing, and the animal may become weak from loss of blood. The condition may terminate fatally or the affected animal, in those cases where the hemorrhage is limited, may recover.

Treatment.—Keep the affected animals cool, and where they will be least excited.

Pneumonia

Inflammation of the lung is not of common occurrence in swine as a primary condition but it is frequently associated with some other disease.

Practically all types of pneumonia based upon pathologic classification occur in swine. The following types will be described: catarrhal, croupous, purulent, and gangrenous.

Catarrhal Pneumonia

Catarrhal pneumonia is a lobular involvement characterized by occlusion of the air cells, with exudate and desquamated epithelium.

Etiology.—Catarrhal pneumonia is practically always a sequel of bronchitis and is therefore produced by the same causative factors. *Bacillus pyocyaneus* may cause catarrhal pneumonia. Catarrhal pneumonia is one of the characteristic lesions of swine plague due to the *Bacterium suisepiticus*. (Description will be found in Chapter VIII.) Bronchopneumonia is occasionally secondary to other diseases, such as hog cholera or septicemia.

Lesions.—The inflammatory process is confined to a lobule or a group of lobules. As the disease progresses, other adjacent lobules may become involved, the affected areas thus becoming confluent and larger. In the beginning the affected areas are hyperemic. The alveoli soon become filled with inflammatory exudate which is at first fluid but later coagulates and becomes dry, the diseased lobules thus becoming solid. These areas are first red in color, but early become brown, gray, then yellow or yellowish-white, and if the condition persists abscess formation may occur. Bronchitis is usually associated with bronchopneumonia and in such cases the lesions characterizing bronchitis would also be present.

Symptoms.—Catarrhal pneumonia in swine is extremely difficult to differentiate from bronchitis because of the inability to efficiently auscultate or percuss the thorax. Catarrhal pneumonia offers the same general symptoms that have been noted in bronchitis, except that pneumonic symptoms are usually more intensive than those of bronchitis. Catarrhal pneumonia has no definite course, the length or duration of the disease depending upon the cause, extent of the disease, and the resistance of the affected animal. The disease is most fatal in young swine.

Treatment.—Medicinal treatment other than inhalation of medicated vapors is of little or no value.

Proper sanitary conditions should be provided, and the affected animals should be given easily digested, wholesome food in sufficient quantities to build up the body and maintain strength. If the causative factor is an infection, isolation and proper quarantine regulations should be enforced.

Croupous Pneumonia

Croupous pneumonia is a disease involving lobes or large lung areas and is characterized by the presence of a hemorrhagic exudate in the air cells. It is not a common primary condition in swine, but is frequently associated with hog cholera.

Etiology.—Many predisposing factors enter into the causation of this disease, such as undue exposure or inhalation of irritating gases, but it is probable that the specific active cause is microbial.

Lesions.—Croupous pneumonia is characterized by the regularity of the successive changes that occur in the affected portion of the lung. The disease usually involves the dependent part of the lung and is essentially lobar, but more or less than this amount of lung may be involved. The various stages that occur in the lung are as follows: congestion, red hepatization, gray hepatization, and resolution. These stages occur in the order mentioned, and there is no distinct line of demarcation between each succeeding stage. The length of duration of each stage is subject to variation, but on the whole is quite constant. The congestive stage is of about twenty-four hours' duration. During this stage the affected portion of the lung is engorged with blood. In the beginning the air cells contain air but as the disease progresses the alveolar capillaries begin to leak or there is a hemorrhagic exudate into the alveoli. Red hepatization begins when exudation is evident, and this stage persists for from three to five days; the area affected is red, dense, heavy, and liver-like. Gray hepatization is characterized by a gray or yellow coloration of the affected lung. This stage succeeds red hepatization and is due in part to the

substitution of leukocytes for the coagulated hemorrhagic exudate that characterizes red hepatization and in part to chemical change of the hemoglobin of the extravasated red blood cells in the hemorrhagic exudate. The lung tissue affected with gray hepatization is gray in color, dense, heavy, and cuts like liver tissue. Gray hepatization persists for from three to five days, and when the alveoli are relatively free of exudate and leukocytes the lung is said to be in a stage of resolution, which includes that period of time during which the air cells are freed of all inflammatory products and return to the normal condition. This is a variable period and depends upon the resistance of the affected animals. The lung, during this stage, contains some inflammatory products in the beginning and later small quantities of mucous and debris, but in the final stages the lung is practically normal.

Symptoms.—Inappetence, high temperature, and increased respiration and heart action characterize croupous pneumonia. On the second or third day a “prune-juice” nasal discharge may be observed which later becomes mucous or mucopurulent. The affected swine are dull, listless, and will probably cough more or less when agitated.

Treatment.—Sanitary surroundings, good water to drink, and an abundance of fresh air without drafts are prerequisites in the treatment of pneumonia. Laxatives should be given to prevent constipation. Heart stimulants may be required, but should not be administered except when necessary, as indicated by a rapid, weak pulse.

Purulent Pneumonia

Purulent pneumonia is an inflammation of the lung characterized by the formation of pus. This condition is relatively common in young pigs, although it may occur in swine of any age.

Etiology.—Purulent pneumonia is of bacterial origin. The pyogenic Micrococci, *Bacillus pyocyaneus*, and

tubercle bacillus are the most frequent causative factors of this condition. These organisms may be inhaled direct but they are more frequently introduced into the lung from elsewhere as emboli. Purulent pneumonia in old swine is therefore frequently associated with pyemia, abscess formation, or purulent metritis. Several cases have been observed in the carcasses of swine that had previously been hyperimmunized intramuscularly for the production of anti-hog-cholera serum.

Lesions.—The principal lesion is suppuration, the centers of which vary in size and number but in the beginning are relatively small and in the earlier stages are not encapsulated but are surrounded by a zone of lung tissue intensely infiltrated with cells. As the condition progresses a circumscribing capsule is formed and the pus becomes thicker, and if the capsule is not destroyed the contained pus becomes caseous and may later become calcified. Should the capsule of a suppurative center become eroded the contained pus may infiltrate the adjacent lung tissue or discharge into a bronchial tube, the original suppurative center thus becoming a cavity. The pleura covering superficial suppurative centers usually shows some involvement.

Symptoms.—The evidence of purulent pneumonia varies according to the nature and extent of the lesions. The presence of a single abscess may not cause any noticeable symptoms. General embolic purulent pneumonia is characterized by intense symptoms consisting of chills, fever, difficult and hurried breathing, uneasiness, and general distress. The discharge of pus within the lung tissue is evidenced by rise of temperature and the associated cardiac and respiratory disturbances.

Treatment.—No special line of treatment is of value. The animals should be placed in good quarters and cared for properly.

Septic or Gangrenous Pneumonia

Septic pneumonia is relatively common in swine. It has occurred enzoötically in swine affected primarily

with forage poisoning associated with pharyngeal paralysis. Sometimes it is a sequel to croupous pneumonia.

Etiology.—The usual cause of septic pneumonia is the introduction of foreign substances into the lung. In cases of pharyngeal paralysis food escapes into the air tube. Drenching is another means by which foreign substances are frequently introduced into the lung. Thrombic obstruction of vessels supplying an area affected with croupous pneumonia favors the action of saprophytic bacteria, and hence putrefaction and the production of septic pneumonia. Abscesses sometimes become infected with putrefying organisms and produce septic pneumonia. The *Bacillus necrophorus* is active in the production of necrosis and putrefaction in the lung.

Lesions.—Necrotic centers are most frequently found in the dependent and anterior part of the lung. The foci vary in size from that of a pea to a baseball, and may be few or many. They appear dirty brown, red, or dirty white in color. When incised they are found to be soft, the content being semifluid in the early stages but later of a cheesy consistency. The surrounding lung tissue will be inflamed. In the beginning, an infiltration circumscribes the lesions, but in the older lesions there may be a distinct capsule. Superficial necrotic foci may be associated with pleurisy.

Symptoms.—The first symptom evidencing septic pneumonia is the foul-smelling exhaled air. This symptom does not occur in all cases, as the escape of putrid odors is dependent upon the erosion and discharge into the bronchial tubes of necrotic putrid material. Rise of temperature accompanies practically all cases of septic pneumonia. The fever may be irregular and intermittent, the thermal disturbance depending upon absorption of septic products. In those cases of croupous pneumonia in which septic pneumonia is a sequel, the general symptoms will be the same, plus the offensive breath, as those observed in a case of croupous pneumonia. A microscopic examination of the nasal discharge will reveal the presence of shreds of disintegrated lung tissue in cases of septic pneumonia,

which fact is of diagnostic value. The course of septic pneumonia is uncertain. The attack may terminate fatally in two or three days after the onset of the disease or, if the septic lesions are limited in extent, they may become encapsulated and the animal recover, the length of time required varying from a few weeks to as many months.

Treatment.—Remedial agents are of little, or no value so far as the septic process is concerned. The treatment of symptoms as they develop will be of some value. The animal should be given good care and sanitary surroundings provided.

Interstitial or Chronic Pneumonia

Interstitial pneumonia is a chronic condition characterized by proliferation of fibrous tissues. This condition is usually a sequel to chronic catarrhal bronchitis and chronic bronchopneumonia. It is observed in swine in those sections of the country where it is continuously dusty and in swine kept in quarters where slightly irritating gases prevail.

Etiology.—Constant inhalation of mild irritants, such as dust or chemical fumes.

Lesions.—Fibrous proliferation characterizes this disease. The fibrous tissue forms around the bronchioles, the process gradually extending and involving the alveoli. The bronchioles and alveoli also show evidence of catarrh. The affected lung is dense, and when cut offers more resistance than the normal lung. The degree of fibrous proliferation is quite variable in some instances; there is a limited amount, and in other cases the normal lung tissue is displaced by fibrous tissue. Encapsulated suppurative or necrotic centers may be found.

Symptoms.—A persistent cough, associated with a limited but variable nasal discharge of a mucopurulent material, characterizes chronic pneumonia. The animals are usually unthrifty and emaciated.

Treatment.—The cause should be removed and the animals properly housed and fed. Other than this, little can be done.

Tumors

Various tumors have been encountered in the lungs of swine, but principally in autopsies or at abattoirs. Lung tumors of swine are similar to the same type of tumors of other tissues. Pulmonary neoplasms produce no typical symptoms by which they may be recognized clinically.

Parasites

The principal pulmonary parasite is the *Metastrongylus Apri*, which has been described under bronchial disorders.

Echinococcosis pulmonum is a common disease of swine. This condition is caused by the larval form of *Tænia echinococcus*. The cysts of pulmonary echinococcus are the same as those occurring in the liver.

Distomiasis, or invasion of the lung with flukes or *Distoma*, occurs but is not common in swine.

Pulmonary stephanurosis has also been observed, but is rare.

Parasitic nodules, the supposed result of invasion of some unknown parasite, are occasionally noted by veterinary inspectors, but there is little significance in such invasion as the lung is not edible, according to the meat-inspection regulations in the United States.

PLEURA

Disease conditions of the pleura of swine are rarely recognized clinically, though some cases of pleuropneumonia may be determined by a clinical examination. Pathologic conditions of the pleura are occasionally observed by veterinary inspectors in the carcasses of swine that are slaughtered.

Hydrothorax

Hydrothorax is a condition resulting from the accumulation in the thoracic cavity of excessive quantities of serous fluid. It is of rather rare occurrence in swine.

Etiology.—Obstructed outflow of blood from the vena cava, with engorgement, is the principal cause of hydrothorax. Chronic disease of the cardiac valves and chronic pneumonia are the most common causes of obstruction of the outflow of venous blood from the vena cava. Tumors, abscesses, and malformed thorax may also be responsible for the causation of pneumothorax.

Lesions.—Accumulation of varying quantities of a pale yellow fluid in the thorax is the characteristic lesion, and in addition the primary lesions in the heart or lung are usually evident. The accumulated fluid will compress the lung.

Symptoms.—It is not possible in the beginning to detect any particular symptoms. Those produced by the accumulated fluid are frequently so overshadowed by the primary condition that it is not possible to clinically diagnose hydrothorax until the advanced stages. There will be difficult respiration, and if the thoracic wall is not too thick a splashing sound may be noted synchronous with the heartbeat. An exploratory puncture with a small hypodermic needle will usually result in the discharge of serous fluid.

Treatment.—Temporary relief may be obtained by withdrawing the fluid from the cavity, but permanent results cannot be expected until the primary causative factor has been removed or overcome.

Hemothorax

Hemothorax is a condition of the escape and accumulation of blood in the thoracic cavity. It is not a recognized clinical entity, particularly in relation to swine, yet it does occur, and is sometimes observed by inspectors of meat-food products.

Etiology.—This condition is observed in swine that have been transported to market, and the affected swine at the time of autopsy show evidence of having been injured, probably while in transit. The injury may be a puncture, wound, or a contusion.

Lesions.—Accumulation of blood in the thorax characterizes this condition. The blood may be coagulated, but it usually remains in the fluid state until the thorax is opened. The quantity of blood will depend upon the nature of the injury and the length of time elapsing after its infliction. If the hemorrhage is of long standing, pigmentation of the pleura may be the only evidence remaining.

Symptoms.—The majority of animals affected with hemothorax show no symptoms. There may be paleness of the visible mucous membranes, weakness of the animal, and difficult breathing due to compression of the lung, but these symptoms are evident only in those cases in which the hemorrhage is extensive.

Treatment.—Medicinal treatment is of no value.

Pneumothorax

This is characterized by the accumulation of air in the thoracic cavity, a condition extremely rare in swine. The usual cause of the condition is injury in which the lung tissue is lacerated. The injury most frequently consists of fracture of a rib occasioned by improper handling in transportation.

The principal lesion observed consists of the primary injury. The thorax is found to contain air, and the lung is compressed.

Pleurisy

Pleurisy is inflammation of the pleura and may be serous, fibrinous, hemorrhagic, or purulent; acute or chronic. It is not a common condition among swine, at least in so far as the clinical recognition of it is concerned.

Acute Pleurisy

Etiology.—Acute pleurisy is practically always the result of infection, although there are many predisposing factors that are active in diminishing resistance and thus increasing the possibility of successful infection. The

causative organisms may gain entrance to the pleura from the lungs through puncture wounds, through the blood, and through the lymph.

Lesions.—The pleura becomes hyperemic, tumefied, and dry. This stage is succeeded by an outpouring of a serous, fibrinous, or hemorrhagic exudate upon the pleural surface. Should the disease be due to the activity of pyogenic organisms the exudate will soon become purulent, and the future changes depend upon the nature of the exudate. Serous exudate may accumulate in quantities in the pleural cavity, and remain fluid although it may contain flakes of coagula. The fibrinous and hemorrhagic exudates coagulate early and produce greater or less adhesion of the visceral and parietal pleura. The hemorrhagic exudate is characterized by the presence of quantities of hemoglobin, which gives to it a red or blood color.

Chronic Pleurisy

Chronic pleurisy is characterized by the formation of varying quantities of fibrous tissue which produce permanent adhesions of the two layers of the pleura. There may also be considerable quantities of a fluid (serous) exudate in the pleural cavity, and there may be abscess formation, the pus being circumscribed by a definite capsule.

Symptoms—Difficult breathing, each effort being accompanied by a grunt, and sensitiveness of the thorax, characterize pleurisy. In the acute cases there is inappetence, high temperature, and usually constipation. Chronic cases frequently show little evidence of disturbance.

The acute type has a relatively short course, terminating in recovery, or in death within a few days. The chronic form may persist for weeks or even months.

Treatment.—Remove the cause of the trouble and establish sanitary conditions. The treatment of symptoms as they arise will be of some value. If an excessive

quantity of serous fluid accumulates in the pleural cavity it should be withdrawn.

Tumors

Pleuritic tumors are not common in swine. Fibromas have been encountered on a few occasions. Of the malignant tumors, endothelioma and sarcoma predominate, but are unusual.

SECTION III

THE URO-GENITAL SYSTEM

SWINE are prone to various disease conditions of the organs constituting the uro-genital system. This may be due to the nature of their food stuff, which is often fermented or putrid.

KIDNEYS

Kidney diseases are especially common in swine. Frequently the pathologic condition of the kidney is not of sufficient intensity to produce recognizable symptoms, but a diseased condition is easily detected by autopsy or on inspection of the carcasses of dressed hogs.

Malformations

There may be a total absence of one or the other kidney. A horseshoe-shaped kidney is also occasionally observed. Floating kidney has been reported, but from the number of recorded cases the condition is relatively rare.

Hydronephrosis

Hydronephrosis, or cystic kidney, is of frequent occurrence in swine. It is very commonly encountered by the food inspector. Tucks reported 0.67 per cent of cystic kidneys in over six thousand hogs examined, and the writer found this condition in the kidneys of twenty-nine swine in three thousand examined. The condition may affect one or both kidneys.

Etiology.—Obstructed outflow of urine is the primary cause of cyst formation in the kidney. The anatomical arrangement of the openings of the ureters into the bladder predisposes to their obstruction and therefore to the accumulation of urine in the kidney pelvis. Renal and pelvic calculi and inflammatory products occasion

obstruction of collecting tubules and favor cyst formation. Cicatrization of newly formed fibrous tissue may obstruct the outflow of urine and cause cyst formation. Complete obstruction of the ureters or kidney pelvis will not as a rule result in hydronephrosis, as this condition results in a compensatory activity on the part of the normal kidney.

Lesions.—Hydronephrosis may occur as cysts in the renal substance or the kidney may be practically replaced by a variable-sized watery bag. The cysts vary in size from a pinhead to an inch in diameter. There may be myriads of the small cysts scattered throughout the kidney but occurring primarily in the cortical portion. The larger cysts are usually not numerous and they frequently represent the fusion of small cysts. The cysts have a bluish-white color, are definitely surrounded by a distinct capsule, and the content is thin and watery. The kidney substance between the cysts is atrophied, due to pressure. In extreme cases the kidney capsule may serve as the cystic capsule, the entire mass being much enlarged and the small atrophied kidney floating within. Richter reported a case of a hydronephrotic kidney weighing over ninety pounds.

Hemorrhage

Kidney hemorrhage is relatively common in swine, not as a primary condition, but associated with some disease. The extravasated blood may escape into the uriniferous or collecting tubules, producing hematuria, or it may escape into the kidney tissue.

Etiology.—Injury of the capillaries, either glomerular or tubular, may result in hemorrhage. The vessels are most frequently damaged by chemical substances that are being eliminated in the urine or by products of bacteria produced in the kidney or elsewhere in the body.

Lesions.—Escaped blood into the uriniferous tubules may be detected by examination of the urine, which, by the way, is very infrequently done. The urine will be

discolored with hemaglobin and will contain blood casts. Renal-tissue hemorrhages may be extensive or limited, but rarely is extensive extravasation observed in the kidney. Small-tissue hemorrhages, particularly petechial hemorrhages, are of common occurrence in the kidney of swine affected with hog cholera. Such hemorrhages have been observed in the kidney of otherwise apparently healthy swine in which no other lesions of cholera could be detected, and the blood from these hogs, when injected into healthy, susceptible pigs, failed to produce evidence of hog cholera. These hemorrhages were not numerous; sometimes only a very few could be recognized by a careful examination; their exact relation has not been discovered. The petechial hemorrhage of cholera merely evidences a vascular disturbance.

Symptoms.—Hematuria indicates hemorrhage into the urine in the kidney, ureter, bladder, or urethra. Renal hematuria is characterized by bloody urine and the presence of, blood-tube casts.

Fatty Changes

The occurrence of the so-called large white kidney is a common experience, at least to those engaged in meat inspection. "Large white kidney" is a name applied to two different conditions—fatty kidney and fibrous kidney. The fatty white kidney is less common than the fibrous white kidney.

Etiology.—Some renal vascular disturbance resulting in blood disturbance in the kidney or general malnutrition appears to be the causative factor in the production of fatty kidneys.

Lesions.—The affected kidney is large and creamy white in color. The capsule is easily stripped, and the kidney substance is soft and feels greasy. Only one kidney is affected in those cases in which the kidney is exceedingly large. Both kidneys may be affected, but to a limited degree.

Symptoms.—No primary symptoms characterize this condition. It is detected only in autopsy.

Calculi

Renal calculi occur but are not common in swine. They may occur in the collecting tubules but are more likely to be found in the renal pelvis.

Etiology.—The formation of renal calculi is usually associated with an obstructed outflow of urine. Retained urine in the renal pelvis or in the collecting tubules has a tendency to undergo fermentation, with the production of an unbalanced condition of the chemical constituents resulting in precipitation. Retained urine and fermentation also favors catarrhal inflammation. The mucopurulent discharge may serve as a nucleus upon which the precipitate is deposited.

Lesions.—Retention of urine and catarrhal inflammation are usually evident. The calcular deposits may be very small and difficult to detect or they may be quite large, one having been observed that practically filled the renal pelvis. The calculi may be variable in shape, color, and consistency, depending upon their composition, and are composed of magnesium or calcium phosphates, urates, or carbonates.

Symptoms.—Cloudy urine, particularly when the last discharge contains quantities of brownish deposit, will be observed if the calculi are passing out. The animals will have colicky pains, the loins will be sensitive, and the animals will stand with arched back. If the calculi are small and remain in the kidney there may be no evident symptoms.

Treatment.—If the patient is in good condition it will be most economical to sell it for slaughter. Very little can be done toward the actual solution of the formed calculi.

Congestion

Congestion of the kidneys is common in swine fed on putrid or fermented foods. It may occur as a result of undue exposure, to cold experienced in shipping, or it may be due to injury. The condition is associated with erysipelas, hog cholera, and some forms of pneumonia.

Etiology.—Chemical poison obtained in food, by-products of infection, or destructive metabolism cause renal congestion. Exposure and injury may also produce this condition.

Symptoms.—Stiffness and a stilty gait due to hypersensitiveness of the loins usually accompany congestion. There is also frequent urination in which an excessive quantity of urine is voided.

Treatment.—Remove the cause, give good food, and provide sanitary surroundings. Alkaline diuretics may be of value, and laxatives may also be used to advantage.

Nephritis

It is not possible with the present available knowledge to classify the inflammatory disturbances of the kidney in a satisfactory manner. The principal knowledge of porcine nephritis has been obtained from investigation by veterinarians in food-inspection service. The condition is rarely recognized clinically, or at least the reports of clinical cases of nephritis in swine are very rare. Urinalysis is not practiced systematically by veterinarians, and the analysis of swine urine by practitioners is practically an unheard-of procedure. According to the findings of the veterinary inspectors, porcine nephritis is very common. In some instances nephritis appears to be the only pathologic condition existing, but it is also an accompanying pathologic factor in such diseases as hog cholera, swine plague, septicemia, and pneumonia.

Acute Parenchymatous Nephritis

This is an inflammation of the cells of the glomeruli and convoluted tubules and is characterized by a rather rapid onset, tumefaction, and frequently destruction of the affected epithelium.

Etiology.—Exposure to cold and injuries of various kinds predispose to this disease. The specific exciting causes are usually chemical substances that are being eliminated through the renal epithelium. Bacterial

products, and vegetable and mineral poisons, when present in sufficient quantities, are capable of establishing inflammation. Thus pneumonia, hog cholera, swine plague, and septic infections are usually accompanied by nephritis. Some serum producers have had losses of hyperimmune swine due to contaminated virus. In the swine that died in these cases not only the lesions evidencing general septic infection were present but also marked lesions of an acute parenchymatous nephritis. Turpentine, phenol, and the various coal-tar products are capable of producing nephritis. Corrosive sublimate, too, may be obtained in sufficient quantities to produce the disease.

Lesions.—The lesions of acute parenchymatous nephritis are practically confined to the epithelium of the glomeruli and convoluted uriniferous tubules. The affected kidney is slightly enlarged and has a parboiled appearance. The capsule is easily removed, the kidney substance is usually soft, and blood escapes freely from a cut surface. Microscopically the affected epithelium is affected with hyperemia and cloudy swelling which may become so intensive that the cells undergo necrosis. The detritus of the dead cells and coagulated exudate, accumulated in the lumina of the tubules, may be readily observed. The intertubular tissue may be infiltrated with leukocytes. If the inflammation is intense there may be hemorrhage into the kidney substance or into the glomeruli or tubules.

Symptoms.—The animals show evidence of distress. One of the first indications of the disease is arched back and stilty gait. There are frequent attempts at urination, but little urine is voided, and the animals usually have a temperature ranging from 104 to 106 degrees Fahrenheit. In the beginning of the attack they may eat, but inappetence becomes evident soon after the onset. It is possible that the foregoing symptoms are not characteristic of uncomplicated nephritis, but of cases in which nephritis was the most prominent condition. In the cases that have been observed the disease most

frequently terminated fatally in from two to four days after the onset, the few cases that recovered requiring from one to six weeks.

Treatment.—The treatment of nephritis in swine is a difficult problem. Resort should be had to the usual hygienic practices. Diaphoresis is not practical in swine, and purgation should not be resorted to as a means of elimination, for such procedure would probably aggravate the condition existing in the kidney. General treatment of symptoms as they arise is probably all that can be accomplished therapeutically until further knowledge is obtained.

Acute Interstitial Nephritis

An occasional kidney is found in which there is a leukocytic invasion and other evidence of a reaction in the interstitial or supporting tissue, the parenchymatous tissue being unaffected. But this condition is not common, and thus far has not been observed clinically in swine.

Purulent Nephritis

Purulent nephritis is inflammation of the kidney characterized by the formation of pus, a condition of frequent occurrence in swine. In the study of swine kidneys from abattoirs one-half of one per cent have been found affected.

Etiology.—Pyogenic cocci and the colon bacteria are the most common causative agents. Purulent inflammation elsewhere in the body predisposes to renal metastasis, although purulent inflammation may occur primarily in the kidney. Constipation is probably a predisposing factor of colon-bacillus invasion of the kidney.

Lesions.—Suppuration may be circumscribed, thus forming an abscess or multiple abscesses, or it may be diffuse. Metastatic purulent nephritis usually involves both kidneys, and small suppurative centers occur as gray or yellow areas which are surrounded by a hyperemic zone. The larger foci may be quite definitely circumscribed and frequently have small bands of fibrous

tissue, extending from the capsule into the purulent center. Microscopically the small centers are found in the beginning to be collections of leukocytes and later of pus. The surrounding parenchymatous tissue will be affected with cloudy swelling, as in acute parenchymatous nephritis.

Symptoms.—Practically the same symptoms are observed in purulent nephritis as in acute parenchymatous nephritis, except that in those cases in which there is absorption of quantities of pus, when there is evidence of pyemia.

Treatment.—Symptomatic treatment may be of value. The cause should be removed, and the patient given sparingly of easily digested food.

Chronic Nephritis

Chronic nephritis is a common condition in swine. It is not an important disease from the viewpoint of the practitioner, but it is of some economic importance to the packer as many kidneys are found to be affected. Chronic nephritis represents a group of pathologic conditions—at least, there is a variety of different types of lesions observed. One type of chronic nephritis has been studied and named “chronic non-indurative nephritis,” but from the general lesions in these kidneys it seems probable that the condition is confined to the parenchyma and should be called “chronic parenchymatous nephritis.”

Chronic Interstitial Nephritis

Typical chronic interstitial nephritis is characterized by the proliferation of fibrous tissue which may or may not cicatrize. This condition includes white-spotted kidneys, some large white kidneys, granular kidneys, sclerotic atrophied kidneys, and all variations of the foregoing.

Etiology.—Chronic nephritis, especially the type involving only the supporting framework, is caused primarily by relatively mild irritants acting over a long period of time. These cases have not been recognized

clinically, but by tracing the swine that show the lesions when slaughtered it is usually found that the feed of the animals has been at fault. In some cases parasites and calculi are responsible for the condition.

Lesions.—Chronic parenchymatous nephritic kidneys are enlarged. The capsule is not easily removed, and when peeled off small fragments of kidney tissue remain attached to it. The kidney is mottled, due to hemorrhages and infarction, and there is no definite line of demarcation between the medulla and cortex. Microscopically the parenchymatous cells are found enlarged and cloudy, but tube casts are rarely observed.

Chronic interstitial nephritis is characterized by fibrous proliferation. The newly formed fibrous tissue may or may not cicatrize. The gross appearance of the kidney varies according to the amount and disposition of fibrous tissue. If the condition is localized according to the distribution of small arteries the fibrous tissue will occur in foci, and spotted kidney is the result, the white spots being masses of fibrous tissue. If this fibrous tissue is uniformly deposited throughout the kidney and does not cicatrize, the kidney is enlarged, dense, and hard—one of the types of the large white kidney. Granular kidneys are the result of the proliferation, and later cicatrization, of fibrous tissue in and around the glomeruli or tubules. Granular kidneys have rough, small projections thickly studded over the surface; such kidneys are usually of a red color. The extensive proliferation and cicatrization of fibrous tissue in all the cortical substance, when associated with a thickening of the capsule, produces the small, hard, or sclerotic kidney. Microscopically excessive quantities of fibrous tissue are found, and the parenchymatous tissue is diminished, due to pressure atrophy. Sometimes there may be large areas of fibrous tissue in which no parenchymatous tissue appears or only remnants of tubules or glomeruli.

Symptoms.—Records of the clinical evidence of chronic interstitial nephritis in swine are wanting. Swine

with extensive kidney lesions are usually in fair condition when they are observed at the time of slaughter.

Treatment.—The application of therapeutic agents for the relief of chronic interstitial nephritis in swine has not been practiced. Should such a case be diagnosed, the removal of the cause and the provision of good quarters and wholesome food would probably be sufficient until the animal was in condition for slaughter.

Pyelonephritis

Pyelonephritis is an inflammation of the pelvis of the kidney, a condition that has been observed in swine but is rare.

Etiology.—Calculi and parasites are frequently predisposing factors in this disease. Primarily, the disease is the result of infection. Pyogenic bacteria may cause the condition, but more frequently it is caused by a pleomorphic organism that has been named *corynebacillus renalis*.

Lesions.—The pelvis of the kidney is dilated with a thick, brownish, purulent fluid and tissue shreds. The mucosa of the renal pelvis is thick and contains hemorrhagic spots. The kidney may contain purulent centers or it may be converted into a purulent mass.

Symptoms.—Frequent urination is a symptom of this disease, the urine voided being cloudy. Loin sensitiveness and inappetence are also observed in these cases.

Treatment.—Thus far no treatment has been found that is of any value.

Albuminuria

Albuminuria is a condition in which there is elimination of albumin in the urine.

Urinalysis is now in its infancy in veterinary medicine. Considerable time and energy have been devoted to the study of urine from some animals, particularly the horse, but little attention has been given to systematic urinalysis of swine.

Urine has been collected from the bladder of the carcasses of swine that have been slaughtered, and analyzed. It is possible that there may be some modification of the urine of slaughtered animals, but it is doubtful if the changes are of much significance.

Albuminuria has been found to exist in swine showing a high temperature, particularly cases that have been affected with cholera. The urine has also been found to contain varying quantities of albumin in which there was an acute nephritis. Pneumonic cases also evidenced albumin in the urine.

The exact cause of albuminuria is still being debated. The condition in swine, as well as in other animals, occurs in those cases where the renal epithelium is damaged either by degeneration or inflammation, although it may occur in the absence of damaged epithelium. Some veterinarians are maintaining that albuminuria is caused by acid intoxication.

At this time, with our present knowledge, albuminuria, at least in swine, must be thought of as secondary to some other conditions. Albuminuria in swine has not been studied clinically, therefore, symptoms of the condition cannot be recorded. It is an important condition because albuminous substances that should be conserved are eliminated from the body in the urine. Disturbances of nutrition follow, and the primary and associated conditions produce emaciation and marasmus. Albuminuria usually terminates fatally.

Uremia

Uremia is a condition characterized by the presence in the blood of a greater or less amount of the solid constituents of urine. This condition has not been identified clinically in swine, but the nature of the lesions observed in some kidneys by veterinary inspectors is sufficient evidence that the disease exists in swine.

Etiology.—The primary cause of uremia is obstructed outflow of urine, which may be the result of disturbance in the kidneys, ureter bladder, or urethra. Severing or

puncturing the ureters during operations, as in cesarean section, may result in uremia.

Lesions.—No particular gross tissue changes are attributed to uremia. The lesions found are those incidental to the obstruction of the outflow of urine, as calculi, tumors, and so on.

Symptoms.—Stupor, vertigo, emesis, inappetence, diarrhea, clonic muscular spasms, and convulsions are the principal symptoms of uremia. The disease, at least in the acute form, is usually fatal. Chronic uremia is associated with digestive derangements.

Treatment.—Removal of the cause is practically always successful unless the case is too far advanced. Therapeutic treatment is of no value.

Parasites

The cystic form of the *Tænia solium* of man has been observed in the kidney of swine, but is not of common occurrence in that location. The cystic forms of the tænic echinococcus also occur in this organ.

The *Stephanurus dentatum* is sometimes found in the kidney structure, although it more commonly occurs in the perirenal fat.

Tumors

The kidney of swine is affected with adenosarcoma. In the living swine the presence of these tumors is not suspected. They appear as irregular, incapsulated masses, usually involving only one kidney, and in size vary from five to fifteen pounds. Although they have not been recognized clinically, their structure and appearance evidence rapid growth. They have their origin in the kidney substance near the pelvis, and the tumor tissue produces pressure atrophy of the renal parenchyma. The outline of the tumor is irregular and frequently lobulated. On being sectioned, fibrous bands are found extending in various directions and dividing the tumor mass into lobes. The neoplastic tissue is of a white or dirty-white color, but is often mottled, due to hemor-

rhage; there may also be grayish-yellow centers of necrosis. Microscopically these tumors are composed of embryonic epithelium and connective tissue, the epithelium disposed as irregular tubules or remnants of tubules, while the connective tissue occurs around and between the epithelia tumor cells. Sometimes larger areas of embryonic

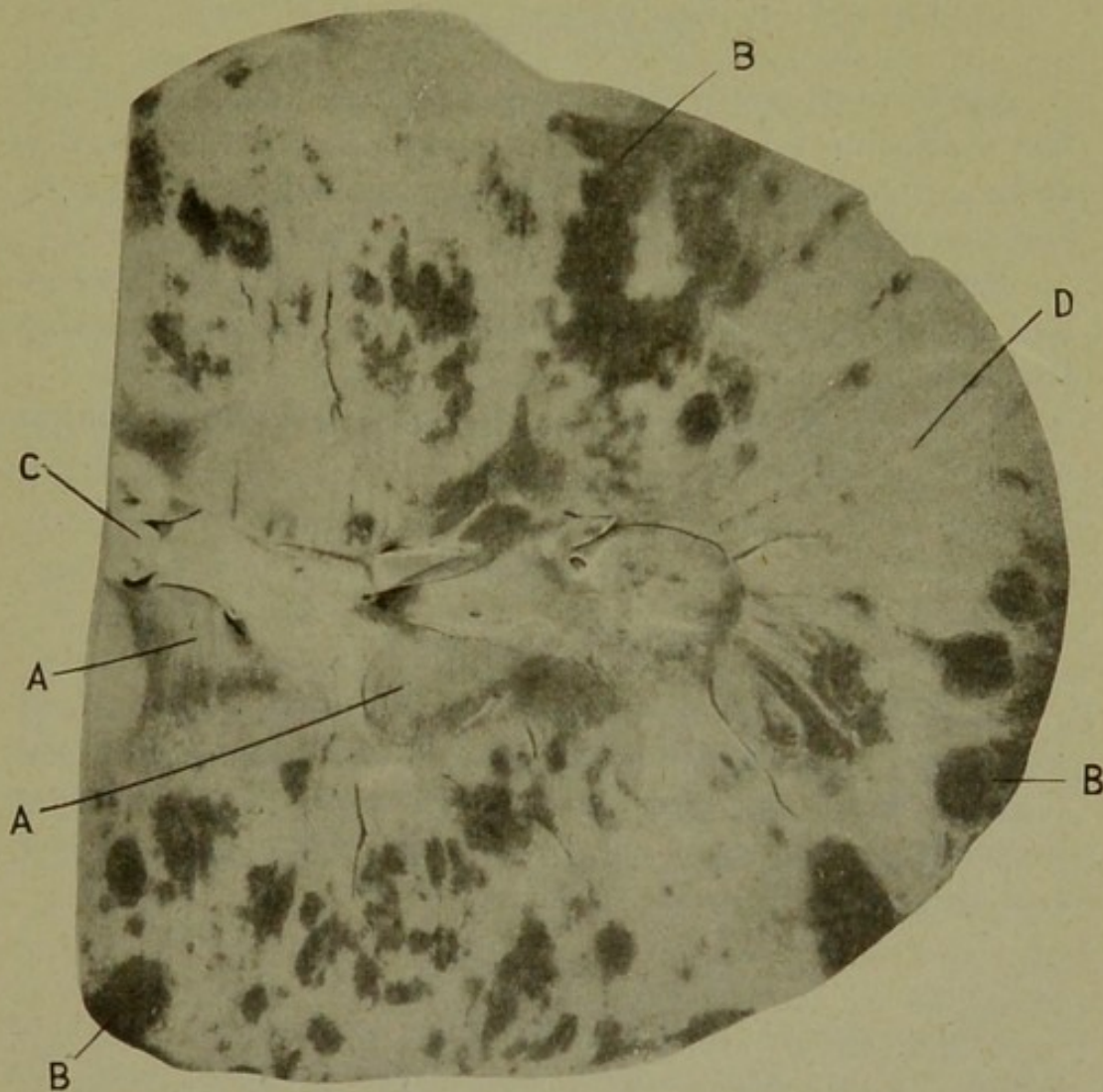


Fig. 4.—ADENO-SARCOMA OF THE KIDNEY.

A. Normal kidney tissue. B. hemorrhagic areas. C. pelvis. D. sarcomatous tissue. (This kidney was seven or eight times as large as a normal kidney.)

connective tissue cells are found independent of epithelium, and again the epithelium may occur in nests in the sarcomatous tissue.

The time for growth of these tumors has not been determined, but they are most frequently found in swine less than two years of age.

Sarcomas have also been encountered by veterinary inspectors in the kidney of swine. They are usually metastatic, although one case of a primary, large-spindle celled sarcoma has been recorded.

URETERS

Malformations

Malformations of the ureters are not uncommon, but the malformations that are observed are not of such a nature that the function of the organs is interfered with and therefore are of no practical importance.

Renal pelvic calculi may become lodged in the ureters and establish inflammatory disturbances, and also obstruct the lumen.

The ureters are subject to injuries in spaying and other abdominal operations.

BLADDER

Malformations

Malformations of the bladder are not common. A few cases of double bladder have been recorded, or the bladder may be very small, such animals urinating frequently. Vestiges of the urachus may be retained, and these may become cystic.

Hematuria

Hemorrhages into the bladder sometimes occur in swine. They are caused by injuries which may be inflicted by calculi and from diseases of the mucosa. They may also be caused by drugs, such as cantharides and turpentine, obtained accidentally in large quantities. This condition is frequently associated with such diseases as hog cholera.

Lesions.—The primary lesions observed depend upon the cause of hematuria. There may be cystic calculi, injuries of various kinds, infection, and lesions elsewhere in the body. The extravasted blood will be

accumulated in the bladder and may or may not be coagulated, and the entire bladder content will be colored red with hemaglobin liberated from the disintegrated red blood cells.

Symptoms.—Hematuria is evidenced by bloody urine in which the entire urine is uniformly red. It is distinguished from renal hemorrhage by the absence of tube casts, and from urethral hemorrhages by the fact that in urethral hemorrhage only the first urine voided is red.

Treatment.—The exact cause should be identified and removed. Urinary sedatives may also be of value.

Dilatation

Cystic dilatation is sometimes occasioned by urethral obstruction or spasms of the muscles in the neck of the bladder. The urine continues to be produced in the kidney and accumulates in the bladder until its capacity may be far in excess of the normal.

Lesions.—The characteristic lesion of dilatation consists of distention of the bladder and attenuation of its walls. In fatal cases the bladder ruptures and urine and uriniferous odor are detected when the abdomen is opened, and the rent in the bladder wall will also be evident.

Symptoms.—Distress, anuria, frequent attempts at urination, and possibly some enlargement of the abdomen characterize distended bladder. In distention succeeded by rupture the foregoing symptoms would be succeeded by stupor, vertigo, emesis, inappetence, diarrhea, clonic muscular spasms, convulsions, and death.

Treatment.—Treatment is available only during distention, and effort should be directed principally to removing the cause. If it is a urethral obstruction in the male and the obstruction is below the ischiatic arch an artificial opening may be made into the urethra where it passes over the ischiatic arch, giving temporary relief, and if the obstruction cannot then be removed the temporary opening in the urethra may be made permanent. In valuable animals obstructive calculi may be removed

from the bladder by surgical procedure and the condition thus corrected. Tumors and abscesses that affect urethral obstruction may be removed and permit of the ready outflow of urine through the urethra.

Calculi

Cystic calculi are of common occurrence in swine. There may be a single calculus or there may be myriads of them. In size they vary from mere grains of sand to masses as large as English walnuts. In shape they may be spherical, ovoid, or all kinds of irregular surfaces and outlines may be presented. Some have been observed that were practically the shape of jack straws. When several occur together they may be faceted. As a rule they are of a dirty-white color, though they may be of any color. They are usually composed of magnesium and calcium phosphates and carbonates.

Etiology.—Retention and fermentation of urine in the bladder favor calculous formation. Retention and urine fermentation also favor catarrhal inflammation, which is associated with epithelial desquamation, and this serves as a nucleus for the calculous deposits.

Lesions.—The presence of calculi is the principal thing to be sought for, and they are not difficult to identify. There is also more or less evidence of catarrhal cystitis, and there may be retention of urine.

Symptoms.—Evidence of catarrhal cystitis—that is, frequent voiding of relatively small quantities of urine—characterizes most cases of cystic calculi. The urine in these cases is frequently acrid and may produce disturbances in and around the prepuce of the male and in the perineal region of the female. Should the calculi produce obstruction to the outflow of urine there will be symptoms of cystic distention.

Treatment.—Solvents for cystic calculi are not wholly successful. If the calculi are causing such disturbance that marked symptoms are evident, operative procedure is indicated, providing the value of the animal is sufficient to justify it.

Cystitis

Inflammation of the bladder may be catarrhal or purulent. Neither type has been extensively investigated by the clinician, therefore the present knowledge concerning them has been obtained by veterinarians at abattoirs.

Catarrhal Cystitis

Catarrhal cystitis is not uncommon. In many instances the condition is associated with cystic calculi, but it may also be caused by infection. Occasionally several cases of catarrhal cystitis may occur simultaneously or successively in the same herd, and on obtaining the history it is found that the affected swine have been fed food stuff containing some urinary irritant or they have obtained quantities of turpentine or cantharides. Retention and fermentation of the urine predisposes to inflammation of the cystic mucosa because of the liberation of ammonia.

Lesions.—Catarrhal cystitis is characterized by the following sequential lesions of the mucosa: hyperemia, tumefaction, and coating of the surface with tenacious mucus, desquamated epithelia, and pus cells. Later there is desquamation of the surface epithelium, leaving a denuded granulating surface.

Symptoms.—Frequent attempts at urination in which small quantities of a turbid urine is eliminated are symptoms of catarrhal cystitis. There may be a straddling gait.

Treatment.—Remove the cause. The bladder in females may be cleansed by a weak solution of corrosive sublimate or creolin, and urinary sedatives should be administered. Internal treatment is practically all that can be given in male animals affected with cystitis.

Purulent Cystitis

Purulent cystitis is an inflammation of the urinary bladder accompanied by the formation of pus. This condition is not so common in swine as catarrhal cystitis.

Predisposing causes mentioned in catarrhal cystitis are also operative in purulent cystitis. The exciting cause is most frequently the *Bacillus coli communis*, although any of the pyogenic cocci may produce it, or even the *Bacillus pyocyaneus* being responsible for an occasional case of cystitis.

Lesions.—Hyperemia, tumefaction of the mucosa, accumulation of tenacious mucus upon the mucosa, and the production of pus in quantities characterize purulent cystitis. The surface mucosa is eroded and becomes a granulating surface.

Symptoms.—Frequent urination and the voiding of small quantities of urine admixed with pus typifies purulent cystitis.

Treatment.—Remove the cause, and cleanse the bladder of females with weak antiseptics. The males should be treated by internal medication, with urinary antiseptics and sedatives.

Tumors

Very few cases of the occurrence of tumors have been observed in the bladder of swine. Papillomata have been reported in a few cases.

URETHRA

The urethra may be imperforate, particularly in the male. Such cases are rarely observed, and those affected die soon after birth. The condition is easily remedied, providing the imperforation is near the outlet, by making a crucial incision or by puncture with a small trocar.

Injury of the urethra in males may be inflicted by contact with barbed wire or other sharp objects, and the female urethra may be injured by forceps used during parturition. These injuries are not serious, though occasionally they may result in permanent fistulas.

Stricture

Stricture of the urethra may follow injuries or inflammation. In male swine catheterization is not prac-

licable, and it is not an easy matter to locate a stricture or other obstruction in their urethræ.

Urethritis

Urethritis occurs in swine. It is most frequently a sequel of cystitis, although it may occur as a primary condition. It is probably more common in males than in females, and is evidenced by painful urination. Treatment consists in giving urinary sedatives and inducing the animals to drink large quantities of clean, wholesome water in order that the urine may be diluted.

MALE GENERATIVE ORGANS

PROSTATE GLAND

The prostate gland is located beneath the vesiculæ seminales and embraces the neck of the bladder. This gland is not well developed except in boars. It is occasionally enlarged, due to infection with tubercle bacilli, colon bacilli, or pyogenic cocci. There may be abscess formation or fibrous proliferation in the prostate. Enlarged prostates partially obstruct the urethra by pressure, thus making urination difficult.

BULBO-URETHRAL OR COWPER'S GLANDS

These are large glandular structures located on either side of the posterior portion of the pelvic urethra. They are less developed in the castrated animal, particularly if the operation be done in early life. They are also subject to infection and enlargement which produces pressure obstruction upon the urethra.

TESTICLES

Malformations of the male sexual glands are not uncommon, one or both testicles sometimes being abnormally small. Cryptorchidy is of common occurrence in swine. De Wolf inspected 4,671 male swine and found twenty-eight single and seven double cryptorchids. Nearly five per cent of the male progeny of one of Mis-

souri's most famous boars, Chief Tecumseh II, were cryptorchids. Liberty Chief and Chief I Know, two boars sired by Chief Tecumseh II, were noted breeders, and from three to five per cent of their get were cryptorchids. Chief Perfection II, sired by Chief Tecumseh II, was the sire of Chief Cherokee Perfection, that in turn sired about three per cent of cryptorchids. Cryptorchidism diminishes the value of a pig because of the greater castration risk.

Because of their location, the testicles of a boar are subject to injuries of various kinds. Some instances have been observed in which it was necessary to castrate valuable boars that had their testicles so lacerated that recovery of the function of them was not possible. Injuries may be inflicted by dogs, sharp-cutting objects, or by crushing, as a result of cattle or horses treading upon the glands.

Orchitis and Epididymitis

Inflammation of the testicle has been observed, but is not of common occurrence in swine. Orchitis and epididymitis are not easily differentiated. They are most frequently the result of mechanical injury, although they may result from infection. Tuberculous orchitis is not uncommon in swine.

Lesions.—The affected testicles or epididymi are enlarged and hyperemic. The secreting structure have a parboiled appearance. Suppurative orchitis is characterized by the formation of abscesses, or it may assume a diffuse form of suppuration in which pus infiltrates the tubular and intertubular tissue.

Microscopically, the arterioles and capillaries are gorged with blood, and there is exudation into the seminiferous tubules and intertubular spaces of leukocytes and plasma. The spermatogenic cells are cloudy and may show disintegration. The spermatozoa are more or less disintegrated and inactive.

Symptoms.—Enlarged, sensitive testicles are the chief symptoms by means of which orchitis or epididy-

mitis is identified. There may be abnormal sexual excitement.

Treatment.—Unless the animal is very valuable for breeding purposes, castration should be resorted to; otherwise, remove the cause and apply hot compresses, or alternating hot and cold compresses, upon the affected glands. Place the patient in comfortable quarters and where there will be no occasion for sexual excitement.

Tumors

Testicular tumors are not common but appear as frequently in swine as in other animals. Both dermoid and dentigerous cysts have been encountered in the testicle, and while these are not destructive to life, they damage the animal for breeding purposes. Sarcomas and endotheliomas occasionally occur in the testicle, and are usually primary. They are malignant tumors, however, and swine with enlarged testicles are usually castrated. Fortunately, the operation is commonly performed before the tumors have metastasized, and thus the lives of the swine are not sacrificed.

SEQUELS TO CASTRATION

Castration of male swine is the usual practice. The proper age that pigs should attain before being castrated depends somewhat upon climatic conditions. Castration as a rule should be done about weaning time, for if there should be any fatalities from the operation the loss will be less than later. It should not be delayed until the swine are matured, or the meat will have a strong flavor. Some have made a practice of castrating immediately after the pigs are farrowed—usually with good success, as the operation does not appear to hinder development.

Castration of swine is usually practiced by the layman and only occasionally do bad results ensue.

Hemorrhage

Rarely does a pig bleed to death as a sequel to castration, but this does occur occasionally. Old boars are prone to bleed freely unless proper precaution is taken.

Infection

The castration wounds are subject to a variety of infection because of their location and the nature and habit of swine. Various pyogenic bacteria gain entrance into the castration wound, and should the incisions be small and the wound margins closed by the inflammatory swelling an abscess may develop, the size of which will depend upon the tissue resistance. Scrotal abscesses in castration wounds are not serious if properly opened, drained, and cared for, but if the pus is allowed to accumulate it may infiltrate the surrounding tissues or, more probably, pass along the vas deferens, and ultimately enter the pelvic cavity and establish peritonitis.

The colon bacillus may also infect castration wounds and produce either suppurative or septic inflammation. In a few instances several pigs have been observed affected with septic disturbances resulting from colon infection in castration wounds. The lesions observed in septic infection consist of gaseous tumefactions containing inflammatory products. These cases usually terminate fatally, unless treatment is begun early. The treatment consists of opening the castration wounds, removing the necrotic tissue with a curette, and freely applying efficient germicidal agents.

The *Bacillus necrophorus* occasionally gains entrance to the castration wounds, but the successful infection by these germs is usually in the later stages of the healing process. The *Bacillus necrophorus* is anaërobic and probably is continuously eliminated in the feces. The lesions produced by this organism consist of a slow-going necrosis, the necrotic foci being surrounded by an inflammatory zone. A peculiar, offensive odor emanates from the lesions. The necrotic areas may later show evidence of separation from the surrounding tissue, and ultimately the lesion may become desiccated and slough, leaving a dark-colored surface upon which tissue fragments and pus may accumulate. These cases may prove fatal, but more frequently the animals linger for some time, the surrounding tissue becoming tumefied due to the

proliferation of fibrous tissue. In such cases there is a variable sized opening or unhealed surface. If the large fibrous mass is removed and incised it will be found to contain necrotic centers composed of fluid, semi-fluid, or caseous material. These centers are surrounded by fibrous tissue, the entire mass being made up of layer upon layer of fibrous lamellæ. The end of the vas deferens will be found involved in the mass, to which it usually adheres firmly, or to the external surface of the wound, by dense fibrous tissue. This condition in the




Fig. 5.—ACTINOMYCOSIS.

beginning may be identified by the tumefaction and particularly by the bad odor of the discharge. Later the large lesion is observed with the characteristic putrid discharge from the open wound.

Treatment.—In the early stages the condition may be relieved by the energetic application of disinfectants, and if necrosis is present the excision or curettment of the necrotic centers. After the dense mass of fibrous tissue has formed, only the careful removal of the entire mass by operation is successful; and in this the greatest care

must be exercised or the animal will bleed to death. The operative wound should receive the proper after-treatment.

Botryomyces

The *Botryomyces ascoformans* also infects castration wounds in swine. This condition is very common in certain localities at some seasons. It is of a chronic, insidious nature. The castration wounds may heal and be apparently normal, the first indication of the condition




Fig. 6.—SCIRRHOUS CORD DUE TO BOTRYOMYCOTIC INFECTION.

being a slight enlargement of the scrotum. The enlargement persists and gradually increases in size until it is quite large; in some instances these masses may attain the size of a football. On examination of the affected pig a rather dense mass can be outlined, apparently adhered to the substructures but not attached to the skin unless the wound has failed to heal. These masses are found to be encapsulated with dense fibrous connective tissues. On sectioning the growth, many centers are found from one-half to two inches in diameter,

These centers contain pus which may be caseous, and the various centers communicate by means of fistulous tracts.

Treatment consists of ablation of the entire mass, which is ordinarily not difficult as the lesion is subcutaneous and is definitely circumscribed.

Actinomycosis

Actinomycosis may affect the scrotum of castrated swine, but is not common.

Parasites

Infestation of the castration wounds with screw-worms (larvæ of the *Campsomyia macellaria*) are very common in the southern part of the United States. These larvæ burrow into the tissues, thus mechanically injuring them and providing an avenue of entrance for various bacteria.

Lesions.—The principal lesions consist of an active, acute inflammation with or without the production of pus. The surrounding tissues are tumefied, hyperemic, hemorrhagic, and contain the larvæ. The extensive tumefaction developing within one or two days after castration is the most evident symptom. On a close inspection, larvæ may be observed near or upon the surface, and by manipulation of the lesion larvæ may be forced out upon the surface. In cases of screw-worm infestation there is a constant sero-sanguinous discharge that by attracting the female fly favors repeated reinfestation.

Treatment.—All that can be done in cases of screw-worm infestation is to support the strength and minister to the comfort of the animal and prevent a further infestation from the deposition of more eggs or larvæ upon the wound and patiently wait for the investing larvæ to reach the stage of development when they voluntarily leave the wound to pupate in the ground. This occurs in three to five days.

The application of chloroform, naphthalene or other chemicals to the wound is worse than useless. Such

measures not only fail to effect the removal of more than a small percentage of the larvæ, but they also irritate the highly sensitive tissues and greatly aggravate the condition.

None of the ordinary fly-repellants has any deterrent effect upon the female of the screw-worm fly in the presence of fresh blood, either in recent wounds or in the discharge from screw-worm infested wounds. However, a mixture composed of turpentine one dram, phenol one dram and cottonseed oil four ounces is an effective repellent for this fly, and where there is a probability of screw-worm infestation it should be applied to fresh wounds and to infested wounds as long as the screw-worm larvæ are present and the sanguinous discharge continues. One application daily is sufficient.

Scrotal Hernia

This form of hernia occurs in the male. It consists of a protrusion of omentum or intestine through the inguinal canal and into the scrotal sac.

Scrotal hernia may be limited or extensive; in some instances the scrotum may be as large as a gallon jug. Raising the hind parts of the pig usually permits of a portion of the protruded structure passing back into the abdomen, and thus reduces the hernia.

This condition is relieved only by operation in which castration is required if it has not been done previously. The covered operation is performed, and the vaginal tunic is supported by sutures.

PENIS

Malformations of the penis are rare. One case has been observed of a double penis, the organ being double from the ischial arch. Each penis contained a normal urethra, the two uniting at the arch and continuing to the bladder as a single urethra.

Injury to the penis of barrows is rare, although incised wounds may sever this organ. The penis of boars may be injured by permitting breeding in quarters

containing machinery or other places where injuries of various kinds may be inflicted.

Preputial concretions or calculi sometimes occur in swine. They occasion difficulty in urination or even retention of urine and sometimes the urine accumulates in the sheath in considerable quantities. The accretions are easily detected by an examination and are not difficult to remove.

The lining of the prepuce may be infested with screw-worms, which will occasion considerable swelling and distress to the animal. For the treatment see page 123. Preputial inflammation due to irritation from urine and infection sometimes requires care by cleansing and antiseptics.

FEMALE REPRODUCTIVE ORGANS

OVARY

Malformations

Malformations of the ovary are much more common than is generally suspected. The most frequent anomalies consist of changed position which ordinarily does not appear to interfere with the normal functioning of the organs. There may be two ovaries on one side and one on the other, or there may be two ovaries on each side. Either ovary may be exceptionally large or small, the other being normal in size.

The ovaries may be injured, but this is rather the exception, owing to the thick body wall which serves as a protection.

Hemorrhage

Hemorrhage of the ovary may occur at the time of estrum, and is dependent upon the lacerating of a blood vessel when the graafian follicle ruptures. These hemorrhages are of no practical or economic significance.

Oöphoritis

This condition has been observed in sows, but principally at abattoirs by veterinary inspectors. It is usually

secondary to metritis or salpingitis, though it may be metastatic or even primary.

Lesions.—The affected ovary is enlarged, and, the surface being irregular, nodular projections of varying size occur. In the beginning the ovary is intensely red and cut surfaces bleed freely. The nodules represent enlarged graafian follicles, which usually contain a gelatinous substance and sometimes blood. Latent suppurative centers may occur and may or may not be definitely circumscribed by a fibrous capsule. The condition may assume a chronic form, the ovarian structure becoming dense and hard due to the proliferation of fibrous tissue.

Symptoms.—The principal evidence of ovarian inflammation is persistent sexual desire, and is manifested by excitement, frequent urination, and the search for a mate.

Treatment.—Anodynes may be used to quiet the animal temporarily, and the blood supply may be diverted by means of a saline purgative or atropine in full physiologic doses. Therapeutic agents are not at all certain in these cases, and if the patient is not especially valuable for breeding purposes, spaying is recommended.

Cysts

Ovarian cysts are quite common in sows. They probably have their origin from graafian follicles that have failed to properly mature. One or both ovaries may be affected. The cystic ovary may be uniformly enlarged or it may be lobulated, the size attained being variable. Reyer reported a case in which an ovarian cyst was found weighing seven pounds.

Lesions.—The affected ovary may contain either a single cyst or many cysts. The cyst may be ovoid, spherical, or lobulated. In those cases of multiple cysts the cysts sometimes communicate with each other or are multilocular. The cystic content may be a thin, limpid fluid, jelly-like, glue-like, bloody, or even caseous.

Symptoms.—The symptoms presented by a sow affected with cystic ovaries are variable. There may be indigestion and circulatory disturbances, but the most common symptom is persistence of the estral period, the affected animals usually failing to conceive.

Treatment.—Oöphorectomy is the only apparent relief for cystic ovaries. If only one ovary is affected, the sow may still be used for breeding purposes.

Dermoid and Dentigerous Cysts

Dermoids and dentigerous cysts occur in the ovary, but are not of common occurrence in swine.

Tumors

Endotheliomas and sarcomas have been observed in the ovary of swine, but they are rare. They partake of the same nature as do these tumors occurring elsewhere in the body.

FALLOPIAN TUBES

Malformations of the fallopian tubes are not common. Injuries to the tubes may occur during the operation of spaying or cesarean section.

An occasional case of pyosalpinx is observed in the carcasses of swine slaughtered at abattoirs. This condition is uncommon, and apparently of little clinical interest.

UTERUS

Malformations

Malformations of the uterus are not significant because the majority of swine are fattened for market and are not used for breeding purposes. An occasional anomaly is observed, such as a rudimentary uterus, double uterus, atresia of the cervix, and so on.

Injuries

Injuries to the uterus are not common except in those animals that have had difficulty in parturition and in which instruments have been used. In many instances

injuries produce no bad after effect, but occasionally they provide an avenue of entrance for infection of the peritoneum and may result in fatal peritonitis.

Hemorrhage

Uterine hemorrhage in the sow is not of the same gravity as it is in the larger animals; however, its control is more difficult in the sow than in larger animals because of the small size of the uterus.

Metritis

Metritis is not so common in the sow as it is in the larger animals, or even in the sheep and goat. This is probably because of the fact that retention of the placenta is not so common in sows as in almost all other animals. The usual cause of metritis is infection, which ordinarily is a sequel to injuries, retained placenta, or dead fetuses. The sow appears to possess considerable resistance to uterine infection, for cases of metritis are relatively rare, and as further evidence of their resistance mummified fetuses are of common occurrence in sows.

Metritis may be either purulent or septic.

Purulent Metritis

Purulent metritis is characterized by hyperemia and tumefaction of the uterine mucous membrane. Later there is desquamation of areas of the mucous membrane and accumulation of quantities of pus in the uterine cavity. Should the cervix become closed, there may be a marked distention of the uterus with the accumulated pus. The inflammation may extend into and involve the muscular coat of the uterus or even the serous membrane. In addition to the inflammatory lesions there may be lacerations and various other injuries.

Septic Metritis

Septic metritis is characterized by intensive inflammation involving in turn, as the disease progresses, the mucosa, muscularis, and serosa. The uterus usually con-

tains a bloody, putrid fetus or fetuses, as septic metritis is most frequently a sequel of retention and putrefaction of the young.

Prognosis should be guarded, as the disease is usually fatal.

Symptoms.—Prostration and a purulent or putrid discharge from the vulva are the primary signs of septic metritis. There is inappetence, fever, and hypersensitiveness of pelvic region.

Treatment.—Irrigation of the uterus and a washing away of the offending material is essential, but is attended with some difficulty in the sow owing to the small size of the genital organs. Hysterectomy has been advised but should not be practiced in those cases showing high temperature and prostration, and it is doubtful if it will prove successful in sufficient number of cases to justify its use.

Tumors

Various tumors, such as fibroma, myxoma, sarcoma, epithelioma, and carcinoma, have been observed in the uterus. The various tumors partake of the same general nature as the same type of tumor elsewhere in the body. Should an antemortem diagnosis be made, and the tumor found to be producing considerable injury, hysterectomy is indicated.

VAGINA

Cloaca formation occasionally occurs in swine. This condition results from fusion of the rectum and vagina, there being but one external opening common to the uro-genital and digestive tubes. This deformity does not interfere with health, but it practically prohibits breeding. Although it may be relieved by operation, the value of the animal usually does not warrant such procedure.

Injuries to the vagina are occasionally inflicted during parturition, but the condition is seldom recognized and rarely causes noticeable after effects.

Inflammation of the vagina usually accompanies metritis. The discharge in such cases is usually purulent and the condition is designated leukorrhœa. Vaginal douches relieve simple cases of vaginitis, but if the primary disturbance is within the uterus it must be overcome before the vaginitis will yield to treatment.

VULVA

Although the location of the vulva predisposes it to injury, such mishaps are not common.

Occasionally the *Bacillus necrophorus* infects the vulvar tissue and produces typical necrobacillosis, which may terminate fatally unless properly treated.

MAMMARY GLANDS

Although the mammary glands are modified glands of the skin, they are essential to the life of the newborn. Therefore, a discussion of the diseases liable to affect these glands belongs properly with the consideration of the reproduction organs.

The location of the mammæ of swine predisposes them to injury and infection of various kinds, and in addition the mammary gland contains a milk cistern which is also easily infected. But since swine are more resistant to infection than other domestic animals, the mammary disturbances also are less common in swine.

Mammitis

Acute inflammation of the mammary gland occurs, but is rare. The usual cause is infection, but this generally means that the gland has been injured and thus predisposed to infection.

The affected gland is tumefied, hot, and painful. On sectioning, varying quantities of milk and inflammatory exudate escape from the ducts. The blood vessels are gorged with blood, and the milk in the larger ducts and cistern contains clots.

The affected sow refuses to allow her pigs to nurse. She will change position as frequently as they attempt

it, and occasionally a sow is observed that will purposely injure the pigs if they persist in their endeavor to nurse. On examination, the gland is found enlarged, more sensitive than normally, and if any milk is forced out of the teat it will be more or less ropy.

Treatment.—Hot and cold applications alternated, when possible to apply such treatment, will be of as

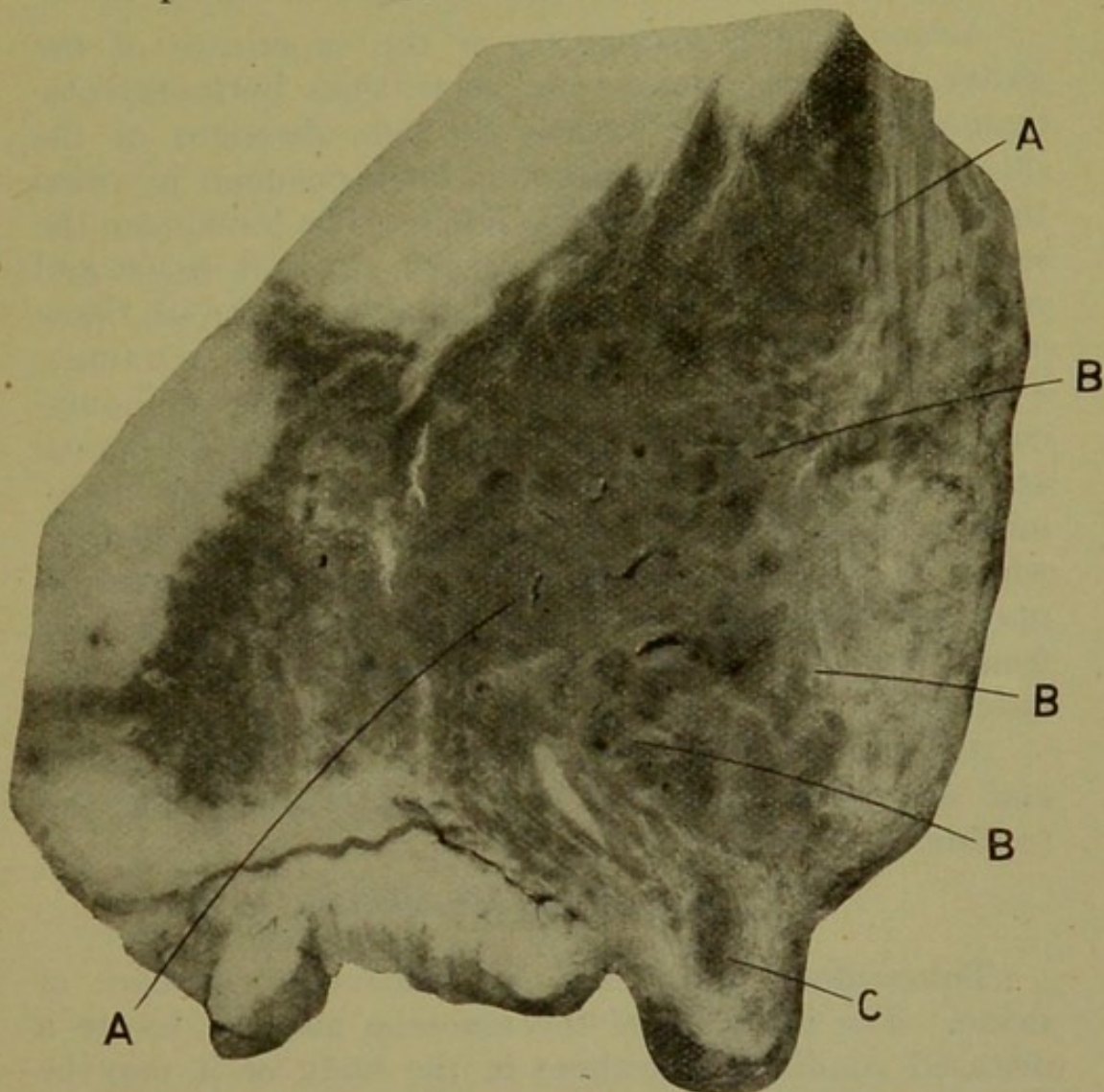


Fig. 7.—INFECTION OF MAMMARY GLAND.

A. Normal glandular tissue. B. Calcified areas. C. Galactophorous sinus.

much value as any local treatment. The administration of a purgative is also advised.

Botryomycotic Mammitis

Botryomycotic mammitis occurs in swine, but is not common. The lesions are practically the same as

those described for botryomycosis under the heading "Sequels of Castration," on page 122. Prognosis should always be guarded in those cases in which the mammary gland is removed, as a large percentage of the animals die.

Actinomycotic Mammitis

Actinomycotic mammitis, in the experience of the writer, is more common in swine than botryomycotic mammitis. Infection occurs through abrasions of the skin surface. This condition is most common in swine that are in pasture in stubble fields. The lesions are the same as lesions of actinomycosis of any soft tissue and consist of a dense surrounding capsule of fibrous tissue inclosing multilocular communicating centers containing a tenacious, granular, creamy-white pus. The actinomycotic tumefaction may become eroded and the typical actinomycotic pus discharged. Actinomycotic mammitis is characterized by the presence of the tumefaction, which may be round and have a smooth surface or it may be lobulated. These tumefactions vary in size from that of a small marble to masses larger than a baseball.

Ablation of the entire tumor is the most rational and successful manner of combating and relieving this trouble.

Tuberculous Mammitis


Tuberculous mammitis is relatively common in swine. The infection of the mammae may be due to a diseased condition elsewhere in the body or it may be introduced through wounds from the outside.

The lesions are the same as other tuberculous lesions.

Treatment.—If the infection is localized in the mammae the disease may be successfully treated by operation, but the safest and most sanitary plan is destruction of the animal and cremation of the carcass, thereby diminishing the possibility of spreading the infection.

Tumors

Mammary tumors are rare in swine, though an occasional papilloma may be observed upon the teat. Rarely do adenomas occur in the mammae of swine, although a few cases have been reported.



SECTION IV

ORGANS OF LOCOMOTION

UNDER this heading will be considered the diseases of the voluntary muscles, bones, and joints.

A great variety of malformations of the organs of locomotion have been observed in swine. Multiplicity of legs or duplication of portions of a leg are relatively common, and fusion of parts ordinarily separate is occasionally encountered. These abnormalities may be so adverse to the existence of the animal that it dies soon after birth, or the anomaly may be so slight that the animal is in no way inconvenienced and develops into maturity.

Injuries of various kinds are prone to damage and possibly destroy the usefulness of the part affected, and thus interfere with the locomotion of the animal to such an extent that it must be sacrificed. Muscle wounds usually give little trouble in swine because of their marked resistance to infection, while fractures are not so troublesome in swine as in the larger animals, and are usually repaired rapidly and frequently without intervention of the surgeon.

Sore Feet

The feet of swine that are kept on pavements or driven long distances over hard roads become sore. This condition is attracting the attention of serum producers who are required by the government regulations to keep the hyperimmune swine on concrete or other similar floors. Those producers depending upon tail bleeding are having considerable difficulty in keeping the hyperimmune swine for the required time because it is difficult to keep the pens free from filth when bedding is used.

Sore feet due to rough, hard roads and pens also occasion some trouble in swine. This condition caused more concern in former times, when swine were driven considerable distances to market, than at the present time. However, it also is a problem that confronts the serum producers.

About the only treatment is to provide ample, clean bedding or turn the swine out to pasture.

Fatty Degeneration

Fatty degeneration of muscle tissue has been observed in suckling pigs by various investigators. This disease or condition is characterized by an extensive fatty degeneration of the muscular tissue of the entire body. The cause of this degeneration is not known, although it may be a sequel of inbreeding. It affects pigs from a few days old to three or four weeks of age. The muscle has a white appearance, as if it had been cooked. Similar changes may also be noted in the lymph glands, liver, and kidneys. The affected pigs cease to nurse, lie on the ground, are weak, and may have diarrhea. The disease almost always terminates fatally, the pigs sometimes not even struggling when they die, but in other instances convulsions precede death. Thus far no medicinal treatment has proved of value, but the disease may be prevented by proper care and the frequent introduction of new breeding stock.

Muscular Rheumatism

Rheumatism may affect the muscular tissue, but more frequently it affects articulations in swine.

The cause of muscular rheumatism has not been positively identified. No doubt undue exposure predisposes the animal to this condition, but there must also be some active cause, such as infection or absorbed injurious chemical substances.

Lesions.—Muscular rheumatism primarily affects the connective tissue of the muscles. The lesion consists of a serous or hemorrhagic infiltration between the muscle

bundles and fibers, and rarely of necrosis of the intramuscular fibrous tissue. The muscle fibers are affected with parenchymatous or fatty degeneration, and the surrounding arterioles and capillaries are engorged.

Symptoms.—The principal symptom consists of expression of pain, especially evident when the animal moves. Locomotion is interfered with, and there is a shifting lameness. Some cases of so-called paralysis resulting in dragging of the hind legs are probably muscular rheumatism. If the disease is sufficiently extensive the affected animals refuse to eat. Muscular rheumatism is differentiated from trichinosis by the periodic shifting lameness of rheumatism and by the general absence of systemic disturbances. It may be necessary to distinguish it from rickets, which is not difficult, since the latter is a disease affecting the bones.

Treatment.—Provide good quarters where the animal will not experience wide variations of temperature within a short time. Laxatives and some form of salicylates or their derivatives are usually of value, but must be given judiciously to avoid impairment of digestion.

Articular Rheumatism

Articular rheumatism sometimes occurs in swine. This condition affects swine that have been unduly exposed, but probably the exciting cause is infection.

Articular rheumatism is essentially an inflammation of the periarticular structures, including the synovial membrane. The inflammation may be serous, fibrinous, or hemorrhagic, and in extreme cases it may become purulent. The exudate is accumulated in the periarticular structures and occasionally in the joint cavity. The synovia become admixed with the inflammatory exudate and appears turbid, bloody, or purulent, and may contain coagulated fibrin; the articular surfaces are rough. In cases of long standing the articulation is surrounded by varying quantities of fibrous tissue which may cicatrize and cause deformity. Various articulations are affected, but the lesions are principally confined to the carpal, tarsal, stifle, and fetlock joints.

Symptoms.—The onset of this trouble is sudden. The affected articulations become swollen and are very sensitive to palpation; the animal refuses to place weight on them or, if compelled to do so, expresses pain. If articulations of more than one leg are simultaneously affected the animal remains lying down, arising only after considerable urging. There is usually some rise of temperature and a diminished desire for food, or inappetence. The disease runs a variable course, the attacks being intermittent. An attack usually continues for about two weeks, then the animal apparently recovers, but sooner or later the attacks recur.

Treatment.—The treatment for articular rheumatism is practically the same as for muscular rheumatism. Provide good quarters, and administer laxatives and salicylates. The outcome of the disease is uncertain, and if the animals are in butcher condition they should be disposed of several days after the cessation of the symptoms of an attack.

Rickets or Rachitis

This is essentially a disease due to some disturbance of metabolism, but since the lesions are manifested principally in the bones it may be considered in this chapter.

Rickets is relatively common in swine, and is confined principally to young pigs. The disease is more prevalent in some localities than in other sections of the country, and the condition appears to prevail more extensively during some years than others.

Etiology.—The specific exciting cause of rickets is unknown. The condition is due to an insufficient deposit of lime in the bone. It may be due to an insufficient lime in the food, to intoxication which may neutralize or prevent the deposit of lime in the bone, or infection may be a causative factor.

Lesions.—The condition is not confined to any particular type or group of bones; however, the lesions are usually most pronounced in the long bones of the

legs, which are bent or curved, the animal being "bow legged." The bones are soft and so spongy that they may be cut readily with a knife. The epiphyses of the long bones are enlarged and irregularly club-shaped, while the shaft is also irregularly thickened. There is a subperiosteal, spongy layer. The yellow marrow is red in color and is of a gelatinous consistency. There may be ulceration of articular surfaces, and the flat bones of the cranium and pelvis may be thickened and rarefied. The nares and mouth may be practically obliterated by the enlarged rarefied nasal bones and hard palate; the teeth may appear deep-set on account of the tumefaction of the alveolar tissue. In advanced cases, lesions may be found elsewhere causing disturbances of the digestive or respiratory system.

Symptoms.—The first evidence of the disease is weakness, diminished or depraved appetite, and diarrhea. But lameness or stiffness of gait succeeded by bending or arching of the bones is the first positive indication of rickets. At this stage the lying posture is almost continuously assumed. When the affected animals are made to arise they complain of pain by grunting and squealing, and not infrequently they will walk on the carpal joints. There may be nervous disturbances evidenced by dizziness, somnolence, and convulsions. As the disease progresses the enlarged epiphyses become evident and appear as a swollen condition of the articulation. Similar bony enlargements may also occur elsewhere. The bulging of the long bones of the front legs exert undue pressure upon the ribs, which results in disturbed respiration, and the vertebral column is variously curved, upward, downward, or laterally.

This disease is of a chronic nature and continues for months unless death intervenes early, which is exceptional. Diagnosis is not difficult after the changes in the bones are evident, while the chronic nature of rickets is sufficient to differentiate this condition from articular rheumatism. Tuberculous osteitis is differentiated from rickets by the

limited infection and the less extensive tumefaction, and lack of density of the affected bones.

Treatment.—Treatment of rachitic swine is advised only in the early stages of the disease. Those in the advanced stages should be destroyed. The first thing to do is to place the animals in sanitary quarters, then medicinal treatment consists of administering lime in some form. Prepared chalk may be used. Bone meal is also of value, precipitated calcium phosphate is highly recommended by some, and calcium chlorate may be found serviceable. Preventive measures, as proper feeding and care, practically insure against the occurrence of this disease in swine.

Osteomalacia

This is a disease characterized by softening and fragility of bones. Osteomalacia is also a disease of disturbed metabolism which evidences itself by lesions of the bones. It is not of common occurrence in swine, and when found is due to an insufficient amount of lime in the regimen, in a form capable of assimilation.

The bones most frequently involved are those of the extremities, ribs, vertebral column, skull, and pelvis. The affected bones become enlarged and less dense, the marrow cavity of long bones is increased in size and filled with a gelatinous, usually hemorrhagic marrow, while the osseous tissue is less dense and more fragile. Fractures are very common.

The disease is usually initiated by digestive disturbances, which is succeeded by emaciation, impaired and usually difficult locomotion, fractures, and various deformities. The disease finally assumes a chronic form, evidencing periods of temporary improvement and relapses. This is essentially a disease of mature animals, and this factor is of value in differentiating osteomalacia from rickets. The prognosis is favorable in cases showing no marked enlargement of bones or deformity, and unfavorable in those cases showing deformity.

Treatment.—Provide proper food and surroundings, and administer lime salts, as outlined in the foregoing for rickets.

Purulent Osteomyelitis

Inflammation of the bone marrow occurs in swine. This condition is sporadic, and is most frequently observed in young animals.

Etiology.—Purulent osteomyelitis is caused by infection. Various pyogenic microorganisms have been identified, such as *Staphylococcus pyogenes aureus* and *albus*. *Streptococcus*, and in one instance the *Bacillus pyocyaneus*, was isolated and apparently occurred in pure culture. There is probably some predisposing cause, such as hog cholera, but all of the cases observed have shown no lesions of cholera or other than the primary disease.

Lesions.—The ribs are most frequently affected. The bone marrow becomes hyperemic and invaded with leukocytes and inflammatory products, and the internal pressure causes the bone to become enlarged and the marrow cavity to be increased in size. The marrow and the inflammatory exudate disintegrate and form pus. As pus is produced the bone becomes larger and round, although it may show some irregularities in shape. The pus in the marrow cavity may erode the bone tissue and discharge, thus producing a fistulous tract, but more frequently the pus becomes caseous and may later undergo calcification. Suppurative processes are rarely observed in other bones.

Symptoms.—There is little outward manifestation of purulent osteomyelitis other than the formation of a barrel chest (the ribs form a wider arch, the thorax appearing almost round in cross-section), and the prominent tumefied ribs. If the affected animal is in good condition the ribs are not visible. These cases are usually of long standing, and the disease is essentially chronic. Antemortem diagnosis is rarely made. Purulent osteomyelitis can be distinguished from osteomalacia by the localization of the process in the ribs.

Treatment.—Medicinal treatment is of no value.

Trichinosis

Trichinosis assumes two forms, intestinal and muscular. Both types occur in the same animal, the intestinal preceding the muscular form.

This disease is quite prevalent, particularly in North America. From two to eight per cent of American hams imported into Germany have been found infested. The disease is less prevalent in Europe, or at least the statistics so indicate.

The cause of trichinosis is the *Trichinella spiralis*. This is a small, round worm, the adult rarely exceeding one-twelfth of an inch in length. The life cycle of the parasite is as follows:

The larvæ gain entrance to the digestive tract in meat, where the surrounding capsule is dissolved by the digestive juices, and thus are liberated within twenty-four hours. They pass into the small intestine, where they become sexually mature in about three days. About five days after copulation, or within ten or twelve days after ingestion, the pregnant female and the male are found in the crypts of Lieberkühn and the female begins to deposit her young in the form of living embryos. This process is continued by the female for from six to eight weeks, during which time she produces from eight to fifteen thousand young. A few of the embryos pass out with the feces, but most of them pass through the tissue of the intestine, some of them gaining entrance to capillary lymph and blood vessels, while others wander through the tissue. Those passing into the lymphatics ultimately reach the blood stream, as do those passing directly into the blood capillaries, and finally they are distributed by the blood or by direct migration to all parts of the body. The embryos thus distributed pass into various tissues, but as a rule only those entering the muscular tissue survive and develop. The embryo matures into a larva in the muscle in a period of about two months; by this time the irritation produced has resulted in the formation of a capsule. These encapsulated larvæ will retain their vitality in swine for a period

of about eleven years, but the capsule and some of the interior of the cyst undergo calcification, the process beginning about one or one and a half years after encapsulation.

Swine become infested by eating trichinous flesh of pigs, rats, or other animals, or from eating the excretions of infested animals. All breeds of swine, regardless of age, are equally susceptible. Trichinosis is most prevalent in swine kept in small pens, especially when sanitation is not observed.

Lesions.—The adults produce an intestinal catarrh which is most evident in the proximal portion of the intestine. Soon after the embryos begin to migrate the mesenteric lymphatic glands become enlarged, and there may be pulmonary congestion and parenchymatous degeneration of the liver and kidneys. The affected muscle first becomes swollen, and appears of a gray color. About eight weeks after the embryos begin to migrate, small gray or grayish-white specks may be detected in the muscle tissue. This condition is especially evident in the diaphragm, intercostal muscles, muscles of the cervical region, and tongue. If the lesions are of long standing they will contain calcium salts, which may be detected as small, gritty masses. Microscopically, in the first year of muscular trichinosis the larvæ can be readily detected as small, coiled, thread-like worms within a capsule.

Symptoms.—Clinical trichinosis has been observed only in experiments, or at least the disease has not been recognized by the clinician. Experimentally, intestinal trichinosis becomes evident in from three to six days after infestation. The disease is manifested by the following symptoms: inappetence, vomiting, diarrhea, colic, arched back, unwillingness to move, and rapid emaciation. Evidence of muscular trichinosis appears in about two weeks, and is manifested by the following symptoms: rubbing against posts or other objects, stiffness, assumption of the lying posture the greater part of the time, dyspnea, dysphagia, and rise of tem-

perature. These symptoms, in the order mentioned, continue for four to six weeks, and the affected animal apparently recovers. Diagnosis of trichinosis may be possible clinically, but the absolute diagnosis depends upon a microscopic detection of the parasite.

Treatment.—Medicinal treatment may be of some value in eliminating the adults from the intestine, but the disease is rarely diagnosed before death. The muscular form of the disease is not relieved by treatment. Prophylactic measures, such as general sanitation and eradication of rats, should be instituted.

Cysticercosis (Measles)

Cysticercosis is a condition due to the invasion and development of the cystic form of a tapeworm. This condition prevails more or less in the swine of practically all countries. Cysticercosis in the muscular tissue of swine is due to the cystic form of the *Tænia solium*; the cystic form of this parasite being designated *Cysticercus cellulosæ*.

Etiology.—The life cycle of the *Tænia solium* is as follows. The ova of the adult, which resides in the intestinal tract of man, is eliminated in the feces. Swine eat the contaminated feces and the digestive juices dissolve the shell of the tapeworm ova and liberate a six-hooked embryo. The embryos bore through the walls of the stomach, some of them entering the blood vessels, and are thus distributed by migration and the circulation of the blood to all parts of the body. Those depositing elsewhere than in the muscular tissue do not as a rule develop. The development of the parasite is rather slow. The embryo assumes the form of a cyst and in twenty days' time is about the size of an ordinary pin-head. By this time the head of the future tapeworm is visible as a mere point. About two months after the embryo lodges in the muscle it has attained the size of a small pea, and in three months the embryo has matured, as is evidenced by the presence of sucker disks and a rostellum of hooklets on the head of the future tapeworm.

Should a human being consume uncooked swine flesh containing one of these mature bladder worms the digestive juices would dissolve the capsule and liberate the scolex, which would attach itself to the intestinal mucosa. From three to five months are required from the time of ingestion of the bladder worm by the human until ripe segments are eliminated. One ripe segment contains from ten to thirty thousand ova.

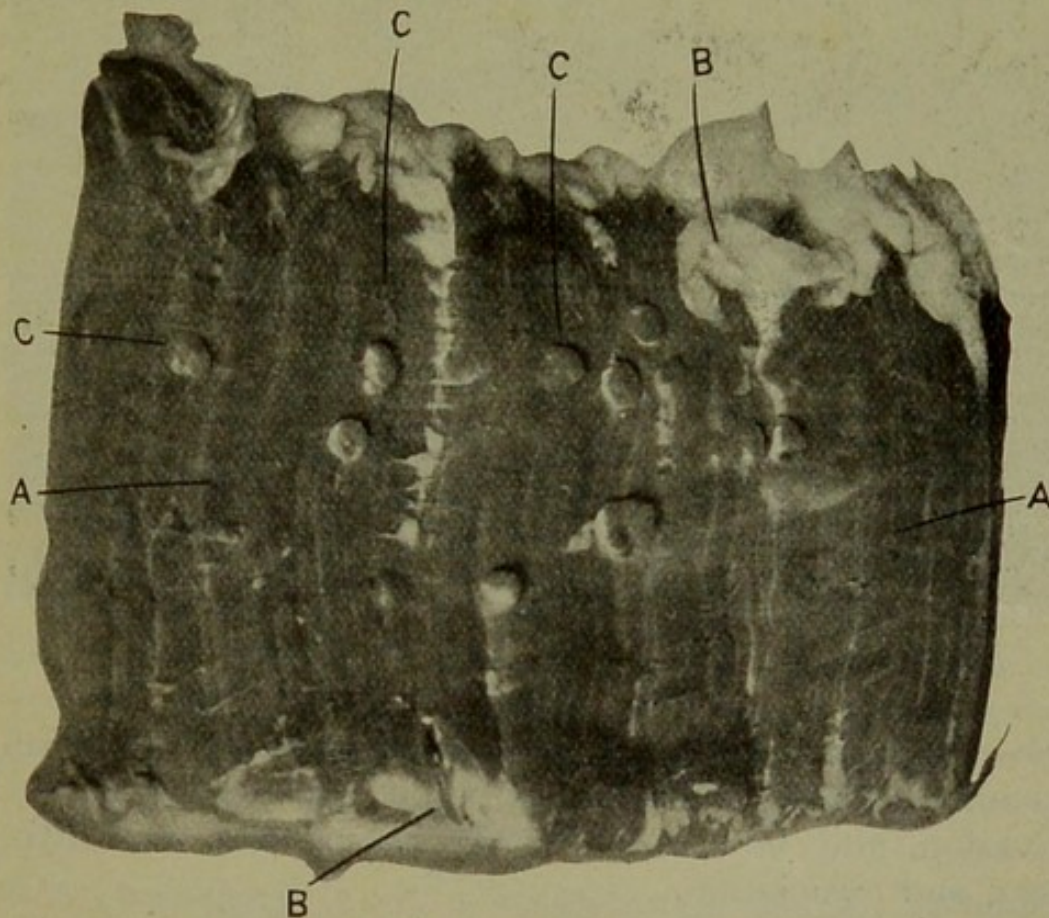


Fig. 8.—CYSTICERCOSIS (Pork Measles).
A. Muscle. B. Fat. C. *Cysticercus cellulosæ*.

Swine become infested by ingesting water or food contaminated with the ova of the *Tænia solium*. This condition occurs only in hogs that consume human excrements, and young swine are more susceptible to this condition than are the aged animals.

Lesions.—The presence of the cysts typifies *Cysticercus cellulosæ*. These cysts vary in size from visible points to small beans. They are usually oval in shape,

and the scolex can readily be recognized within as a white point or body. The cyst is surrounded by a thin capsule and contains one head and a thin, watery fluid. After the cyst has persisted for one year or longer it degenerates, the content becoming purulent, and later calcifying.

Symptoms.—Cysticercosis in swine is rarely recognized clinically. The migration into and irritation of




Fig. 9.—PEDUNCULATED FIBROMA.

the muscle may cause muscular soreness and disturbed locomotion which, depending upon the extent of the invasion, may be associated with inappetence, unthriftiness, and emaciation.

Treatment.—Prophylaxis consists of preventing contamination of swine food and water with human excrements. No curative treatment is available.

Sarcosporidiosis

Sarcosporidiosis is a disease of muscular tissue due to a parasite, the Sarcosporidia. This condition is relatively common in swine. Generally speaking, sarcosporidiosis is not considered a disease of any importance, but frequently swine are affected with a weakness of the muscles of the back that causes them to drag the hind

legs. Although no opportunity for the examination of the muscle from these cases has arisen, the writer has thought the condition is probably due to sarcosporidiosis.

Etiology.—The *Sarcocystis miescheri* is the cause of sarcosporidiosis. The exact life cycle of this parasite is unknown.


Lesions.—The cysts are usually so small that they cannot be detected without the use of a microscope. However, an unusual specimen was obtained by York at an abattoir in Chicago in which the cysts could be readily detected as grayish-white ovoid patches. Microscopically, the parasites are found within the muscle sarcolemma. They appear to destroy or displace the muscle substance, the fiber being entirely severed, the sarcolemma alone remaining intact. The sarcocysts contain many round or oval bodies, the sporozoites. The cysts undergo degeneration and calcify, but at what age these changes occur has not been determined.

Symptoms.—The disease has not been recognized clinically, but no doubt infestation would interfere with the muscle function.

Treatment.—Therapeutic treatment is not available, and in the absence of a definite knowledge of the life cycle of the parasite, preventive measures are only problematic. General sanitation should be maintained.

Tumors

An occasional tumor is encountered that has invaded the muscular or osseous tissue of swine. But, generally speaking, tumors of these structures are of little significance.



SECTION V

THE SKIN

DISEASES of the skin are probably not so common in swine as in other domestic animals. Because of the location of the skin it is subject to a variety of injuries of various kinds, but fortunately swine are not very susceptible to wound infections and therefore cutaneous lesions heal promptly and with little inconvenience to the afflicted animal.

Erythema

Erythema is a name applied to the condition resulting from congestion of the skin. It is quite common, particularly in swine having little or no pigment in the skin. It is also a common condition in some infectious diseases, such as swine plague and hog cholera.

Etiology.—Simple erythema in swine is most frequently the result of sunshine but may be due to contact with some irritant. In some instances erythema may be caused by ingested chemicals that have a special selective action on the skin or are eliminated by the skin.

Lesions.—Engorgement of the superficial vessels and redness are the only demonstrable lesions.

Symptoms.—Redness, and perhaps pruritis, are the principal symptoms.

Treatment.—Remove the cause, and the disturbance will cease to exist.

Sunburn

Swine having little pigment in the skin are injured by sunlight. In some sections it is not profitable to raise white pigs because of the irritation of the skin by the sun and the production of dermatitis.

Sunburning is a type of dermatitis characterized by erythema, tumefaction, and desquamation of the super-

ficial layers of the epidermis. In long-continued cases the skin becomes thickened, due to the formation of fibrous tissues. Swine affected with dermatitis do not thrive, and they evidence a harsh skin and bristly coat.

Treatment.—The treatment of these cases is simple, as about all that is required is to shield the animals from the direct light of the sun. Should the inflammatory process be well marked, cooling antiseptic solutions may be applied.

Freezing

Pigs farrowed in midwinter in the northern portion of the temperate zone, where not properly housed, are frequently frozen. The ears and tail are most affected because of the large surface exposure and distal location where the circulation is diminished. In some instances the tissues are destroyed by the low temperature, and slough, while in other cases the ears or tail, or both, are frosted only and an inflammatory reaction is established resulting in an engorgement and tumefaction of the part. Later the skin desquamates and the parts are tender when palpated.

Transportation of market hogs in open stock cars during very cold weather is responsible for the freezing of the surface skin. The skin sometimes evidences the lesions in strips corresponding to the openings between the boards on the car. The lesions are similar to those described in small pigs.

Treatment.—This consists of protection against further freezing and the local application of protectant dressings, as in ordinary wounds.

Hemorrhage

Cutaneous hemorrhage in which the extravasate is retained in the skin is relatively common but is practically always associated with specific infective diseases, seldom occurring as simple cutaneous hemorrhage.

Urticaria

Urticaria is a skin disease characterized by the formation of pruritic wheals. It is not common in swine and when occurring is usually found in young pigs.

Etiology.—Urticaria is of systemic origin. It is usually associated with digestive derangement, but may be caused by filth and the irritation caused by lice.

Lesions and Symptoms.—The typical lesions are red, circumscribed blotches that are hot and pruritic. Because of the pruritis the pig rubs the skin and may produce abrasions from which serum and blood may escape. The disease usually terminates in recovery on the second or third day, although in severe cases pustular formation may follow.

Treatment.—Clean the swine and the premises, and administer a saline purgative, such as Epsom salt.

Eczema

Eczema is an inflammation of the skin characterized by multiform lesions. Though this disease occurs in swine, it is not very prevalent.

Etiology.—Eczema in swine is apparently a disease of filth. Weak, anemic pigs are much more susceptible than strong and otherwise healthy animals. The specific exciting cause is not known.

Lesions and Symptoms.—Typical eczema is characterized by the following lesions, which occur in the order mentioned: erythema and papulovesicular eruption, which may or may not be succeeded by the formation of pustules. The contents of the vesicles and pustules become desiccated and accumulate, thus forming scabs. There is pruritis practically throughout the entire course of the disease. As the disease progresses the skin becomes thickened, leathery, and cracks, the crevices or rhagades extending deeply and from which more or less blood escapes.

Eczema is differentiated from parasitic dermatitis by the absence of the parasites. It is essentially a chronic

disease; there may be repeated attacks. The disease as a rule is not fatal in swine.

Treatment.—Remove all influences that predispose to the condition. Prevent injury from rubbing. Topical application of soothing agents may be used, but their




Fig. 10.—ELEPHANTIASIS.

A. Granular papillomatous, depilated areas. B. Rhagades or crevices.

value is doubtful. See that the animals obtain and digest their food properly. A good, brisk purgative occasionally will be of value.

Dermatitis Granulosa

A granular skin eruption has been identified in swine. The condition occurs in patches on the ears, back, and croup, and is probably infectious.

This condition has responded quickly to treatment with antiseptics.

Necrobacillosis, Actinomycosis

Necrobacillosis is a very common cutaneous disease in swine. Cutaneous actinomycosis and tuberculosis occur less frequently. These conditions of the skin will receive consideration under the special topics of necrobacillosis, actinomycosis, and tuberculosis, in Section VIII.

Tumors

Pigmented moles are of frequent occurrence in the skin of swine. These moles are sometimes pigmented with melanin, and when interfered with develop into malignant melanosarcomas. Many pigmented papillomas and papillo-fibromas are also encountered in the skin of swine, while multiple fibromas have been observed, they are not at all common. More rarely have primary or even secondary carcinomas and epitheliomas been recorded as cutaneous tumors in swine.

Parasites

Swine harbor many cutaneous parasites, some of which are exceedingly detrimental to the health of the animals.

Of the dipterous group one only, the *Campsomyia macellaria* (screw-worm), requires special mention. In some sections these parasites cause considerable damage and some fatalities. The larvæ only are parasitic, the adult female depositing the ova in wounds or damaged tissue. The ova hatch in from one to ten hours and immediately begin to burrow into the surrounding tissues. The fully developed larvæ are about one-half of an inch long and about one-third the diameter of a lead pencil. The damage consists not only of mechanically lacerating the tissues but also of carrying infection into the surrounding tissues. The larvæ remain in the tissue from four to six days, then drop to the ground, where they undergo the pupal metamorphosis.

The time-honored treatment consists of curetting the wound, thus removing all the larvæ possible. It may be

necessary to apply chloroform or some penetrating anti-septic to cause the larvæ in the deeper tissues to migrate to the surface, or at least to move energetically in order that they may be located and removed. The wound should be properly dressed and protected against future infestation. It is always well to observe the wound on the second day to make certain that all larvæ have been removed. However clinicians report that this line of treatment is wholly ineffective, claiming better results are obtained from the treatment for screw-worm infestation given on page 123.

Flea Infestation

Representatives of the order, Siphonaptera, constantly inhabit hog houses and pens in some sections of the country. These parasites are blood suckers and obtain their nourishment directly from the swine, but do not appear to cause any serious trouble. No doubt they produce some irritation where they pierce the skin, and swine thrive better in their absence. Fleas breed in filth, the ova being deposited in fecal matter or other filth. The larval and pupal stages also take place in filth and in the soil, the entire cycle from adult to adult requiring about one month.

Fleas may be lessened in number and ultimately eradicated from most premises by persistent cleanliness and by dipping the swine in some standard dip every ten days for a period of six weeks.

Lousiness (Phthiriasis)

Phthiriasis, or lousiness, is the most common parasitic disease of swine. The hog louse, *Hematopinus suis*, is a blood-sucking louse and one of the largest of known lice. The adult ovigerous female cements the ova on the hair behind the ears, in the flank region, and elsewhere. The ova hatch into small lice in from ten days to two weeks. These lice do damage by direct abstraction of blood and by irritation of the skin, which causes more or less of pruritis. This makes the swine restless

and, not receiving their proper rest, they probably do not do as well as they otherwise would.

It is not a difficult matter to eradicate lice, but their permanent elimination from swine entails continued vigilance. Where large numbers of swine are infested the most economical plan is to put in a dipping vat and dip the hogs every ten days for three or four dippings. In the meantime the sleeping quarters should be cleaned and dipping solution used here as a spray. If there are only a few swine to treat, hand dressing with some standard dip is the most economical method of treating them, or if the swine have a tank or place where they wallow, some dipping solution may be placed therein. The swine thus dip themselves and destroy the lice.

The rubbing post has been used with fair success as a means of holding louse infection in check. One or more posts are set in the pens and ropes wound tightly around them for a distance of two feet from the ground. These ropes should be moistened with crude petroleum from time to time. The swine will annoint themselves and destroy most of the lice by rubbing themselves against these posts.

Mange

Mange, or infestation of swine with some Acari or mange parasites, is not a rare condition in this country, where two forms of mange occur—sarcoptic mange and demodectic mange.

Sarcoptic Mange

Sarcoptic mange is enzoötic in certain sections. It is caused by infestation with the *Sarcoptes scabiei*, var. *suis*. The life cycle of this parasite is as follows:

The ovigerous female burrows into the skin, forming galleries in which she deposits her eggs, usually about fifteen in number. The ova hatch in from five to ten days into six-legged asexual larvæ which may remain in the galleries or pass out under the scabs, and in two to three days moult into nymphæ. The nymphæ have four

pairs of legs, but they have no sexual organs. In two or three days the nymphæ moult and the sexually matured males and females come forth. The sexually matured parasites mate, and in about three to five days the ovigerous female is found in the gallery in the skin, ovulating. Thus the entire life cycle does not exceed twenty-five days, and under the most favorable conditions may be accomplished in fifteen days. From each ovulation about five males and ten females are produced, and if the reproduction were to go on unhindered for three months, the total reproduction would approximate 1,500,000 parasites. The adults are mere specks, barely visible to the unaided eye.

Swine become infested from infested premises or from infested swine. Premises may remain infested for six months or even longer.

Lesions.—The lesions produced by the *Sarcoptes* are practically confined to the skin; however, secondary lesions, as emaciation, may arise. The parasite obtains tissue juice by pricking the skin with its stylet. The stylet injury produces erythema, succeeded by the formation of vesicles, which rupture, the vesicular fluid drying and forming a scab beneath which the parasites are found. Scabs are of varying thickness, and accumulate wherever the parasites are found unless the affected animal rubs them off. Galleries are formed within the skin, and this also adds to the irritation. The accumulated dry scabs break and damage the hair more or less, which falls, leaving the parts affected practically hairless. The irritation causes inflammation, and this results in fibrous proliferation and thickening of the skin. The thickened, leathery skin loses its pliability and becomes fissured or cracked. In long-continued cases the animals become emaciated.

Symptoms.—Intense pruritus, especially around the ears and eyes, and the finding of papules, vesicles, and scabs are the first evidences of scabies. Later there is depilation and thickening of the skin, with the accompanying rhagades. The disease will probably affect all the

swine that have been kept in one lot. The finding of the parasite is positive evidence upon which to base a diagnosis.

Treatment.—Sarcoptic mange may be successfully treated by the use of the lime and sulphur dip or nicotine dip, repeating every ten days for three dippings, provided that the quarters are cleaned and disinfected and the thick scabs are removed so that the dipping solution may gain access to the parasites. Some old chronic cases do not respond readily, if at all, to treatment because of the thick, wrinkled skin which protects the parasite.

Demodectic Mange

Demodectic or red mange is not so prevalent in swine in America as is sarcoptic mange. Red mange rarely occurs enzoötically.

The cause of red mange is the *Demodex folliculorum*, var. *suis*. This parasite is not visible to the unaided eye. Microscopically, it is found to be similar in shape to an oat grain and has four pairs of short legs. The life cycle of this parasite is practically the same as of the *Sarcoptes scabiei*, var. *suis*, except that the ova are deposited in a pustule in the hair follicles and sebaceous glands instead of in intradermal galleries.

Lesions.—The skin of the legs of swine is most frequently affected. The parasite gains entrance to the hair follicles, where it produces inflammation and causes depilation. The inflammatory reaction causes a redness of the skin, hence the name. In a case of long standing the skin is red, thick, wrinkled, cracked, practically hairless, and evolves a peculiar characteristic odor. The disease extends slowly upon the animal body, and it is not uncommon to find only one animal affected in spite of the fact that there are many swine in the same pen. Positive diagnosis can be made only by identifying the parasite microscopically.

Treatment.—This condition is practically incurable, at least in so far as our present knowledge is concerned. Affected animals should be sent to slaughter, as this

condition does not impair the meat for food. If for any reason the animal is to be kept upon the premises, it should be placed in rigid quarantine.

Tick Infestation

Infestation of swine with ticks, particularly the ear ticks (*Ornithodoros megnini*), has attracted the attention of some southern swine breeders. These ticks locate in the external ear and produce irritation which annoys the infested animals. They may be removed by pouring into the ear some alcohol, dilute antiseptic or bland oil.

Thread Worm Infestation

Cutaneous infestation by *Filaria* may occur in swine, but it has not been positively identified.

Ringworm Infestation

Rarely does ringworm occur in swine. The condition is caused by a *Trichophyton*.

Lesions.—The lesions are usually located on the back or the outer surface of the thighs and are seen as isolated, circumscribed, round, red spots with a raised margin which bears small vesicles. The central portion appears normal, except that it is scaly. The trouble gradually extends in all directions, the raised vesicular margin representing the outside of the lesion. When the lesion becomes very large the center, or original lesion, has apparently recovered. The disease is transmitted by actual contact.

Treatment.—Cleanse the affected parts and apply a five-percent solution of creolin, repeating the treatment on the fourth or fifth day.

SECTION VI

CIRCULATORY ORGANS

DISEASES of the circulatory organs may be of common occurrence in swine, but such disturbances are rarely recognized clinically.

HEART

Pericarditis

Pericarditis, both acute and chronic, fibrinous and purulent, occurs in relation with hog cholera, swine plague, and erysipelas, and more rarely as a primary condition. The conditions have been observed in autopsies. The acute type is characterized by hyperemia, hemorrhage, and exudation upon the serous lining of the pericardium. The serous surface of the pericardium will have lost its luster and the exudate may adhere to it in shreds. The pericardium becomes thickened in chronic pericarditis, due to the formation of fibrous tissue.

Hemorrhage

Hemorrhages of small size are frequently found in the heart muscle. These occur in infectious diseases and are the result of bacterial emboli or injury of the capillaries by chemic substances incidental to infection. They are of significance to the meat inspector and the diagnostician.

Subendocardial hemorrhages are common as a sequel of infectious diseases. They are of diagnostic value and are an indication to the meat inspector of some infective disease or septic intoxication.

Fatty Changes

Fatty changes in the heart muscle occur in practically all swine that have been fattened for market. The fat particles are found between the muscle cells at first, but

later the cells become infiltrated with fat. The heart is enlarged, is paler in color, and its density is diminished. No visible symptoms are evident, in the majority of these cases the swine being excessively fat and refusing to move about without urging. No treatment is required unless this condition arises in a breeding animal.

Endocarditis

Endocarditis has been observed by inspectors and in diagnostic autopsies, but the disease is not ordinarily recognized by the clinician. The lesions found usually consist of vegetative growths or denuded areas upon the endocardium, covering the valves. Either condition is always associated with infection, and it is not difficult to demonstrate bacteria in the lesions.

Tumors

Various tumors have been observed upon the pericardium and also in the myocardium. They are of no clinical significance, but are of interest to inspectors, as the presence of malignant tumors is considered sufficient evidence for condemnation.

Parasites

The pericardium rarely harbors the cystic form of the *Tænia echinococcus*, but *Cysticercus cellulosæ* is of common occurrence in the myocardium of swine. The lesion has the same general appearance as it does in voluntary striated muscle. *Sarcosporidiosis* is not uncommon in the heart muscle of swine.

BLOOD VESSELS

Diseases of the blood vessels of swine have received very little consideration, though a few cases of aneurism have been recorded. Thrombosis has been observed in a very few instances. Inflammatory disturbances have not been reported, or at least the available literature contains no records of such affections. Phlebitis has been observed by serum producers. This condition has occurred in the

ear veins, but has not been of sufficient importance to occasion any losses.

BLOOD

Diseases of the blood of swine have received very limited consideration up to the present time.

Anemia

Werner reported his observation of anemia in swine that had been fed watery slop food, while Braasch observed anemia in suckling pigs, but was not successful in identifying the cause. The usual lesions of anemia consist of lack of blood, paleness of the various tissues, emaciation, and a jelly-like consistency of the fat. The affected animals are depressed, weak, and gradually become emaciated. Later edematous swellings occur in the dependent parts of the body.

Leukemia

A few cases of leukemia have been observed in swine on postmortem examination. The exact cause of disease is unknown, but it is probably of an infectious origin.

Lesions.—Porcine leukemic cases thus far observed are of the lymphatic type. The lymph glands become enlarged, due to hyperplasia of the lymphoid tissue, and there are frequently necrotic centers. By scraping the cut surface of a lymph gland a milk-white fluid is obtained. The spleen contains leukemic centers and is enlarged, and the liver may be similarly affected.

Cases of leukemia have not been studied clinically. The disease is chronic in nature.

SPLEEN

The spleen is subject to hemorrhages and is engorged in hog cholera and in other septicemic diseases.

Necrosis

Necrosis of the spleen is of common occurrence in swine that have died as a result of injection of a virus containing the *Bacillus necrophorus*. These centers vary

in size from that of a dime to a fifty-cent piece, are grayish-white in color, and usually have a raised border and depressed center. There may be only one or two of these necrotic foci, or the spleen may be full of them.

Hypertrophy

Hypertrophy of the spleen is rather common. The condition occurs in leukemia, tumor formation, and in swine that are fed excessively.

Tumors

Sarcomatosis is a relatively common condition in the spleen. The majority of the cases observed were primary, but secondary splenic sarcomas do occur. The tumor is usually multiple, the foci varying in size from mere points up to masses as large as a hen's egg. The centers are white or grayish-white in color, and are rather firm. They are usually circumscribed with a thin, fibrous capsule.

SECTION VII

THE NERVOUS SYSTEM

DISEASES of the nervous system of the various domesticated animals have not been sufficiently investigated for a good description to be given of them. This is particularly true in regard to diseases of the nervous system in swine.

Malformations of the brain or spinal cord are common in swine. They are observed principally by the breeder and in small pigs, as the majority of these malformations are of such a nature that the affected animal dies soon after birth. Cranial and spinal clefts, with associated hernia of the meninges, brain, or spinal cord, are the most common deformities.

Functional disturbances of the brain, such as delirium, are sometimes observed, but this condition is not common. It is usually the result of organic disease of the brain, although it may be caused by intestinal parasites. The affected swine champ their jaws, grunt, run against the fence, posts, or similar objects, tremble, and may even bite. When the cause is removed the animals make a speedy recovery, although succeeding attacks may occur.

Viciousness is closely associated with delirium. This condition is dependent upon the nature and temperament of the animal and is manifested by a desire to attack man or other animals. Vicious swine bite, and boars use their tusks to inflict injuries, and are sometimes successful in disemboweling their victim. Viciousness is inherited or acquired, and vicious swine should never be used for breeding purposes. Viciousness is acquired by swine that are nervous. Such swine soon become irritable, then vicious, as a result of teasing or brutal treatment. One instance is recalled of a nervous sow that became vicious because the owner's son irritated and tantalized

her by catching her small pigs and, while they were squealing, carried them around the pen. The best method to pursue in cases of viciousness in swine is to prepare them for slaughter and market them as soon as possible.

Sunstroke and Heat Stroke

It may be possible to differentiate between sunstroke and heatstroke in man, and possibly also in horses, but such a distinction is scarcely warranted in swine.

Sunstroke is claimed to be due to the action upon the nerve cells of actinic rays of the sun, and heat stroke to a disturbed equilibrium of heat production and heat dissipation. The two conditions frequently occur simultaneously in the same animal.

Etiology.—These conditions are the result of direct exposure to sunshine and excessive heat. Driving swine in droves is occasionally accompanied by cases of heat stroke, and this may also be observed in carload lots in which the swine are crowded and the shipment made in extremely hot weather. The same condition arises in swine that are hauled in wagons, if proper precautions are not taken. Lack of proper shade predisposes the swine to sunstroke and to heat stroke.

Lesions.—There are no gross lesions that characterize either sunstroke or heatstroke, except a parboiled appearance of parenchymatous tissues. Microscopically, the nerve cells are found to contain coagula, and there may be cloudy swelling of all parenchymatous tissues.

Symptoms.—Uncertain gait, dullness, depression, increased respiration, and anxious expression are the principal symptoms observed in the early stages of these conditions. The temperature may be very high. Muscular tremors, falling to the ground, and convulsions are the final symptoms. The course of the disease is short. In some instances the animal succumbs within a few minutes after the onset; in other cases the animal may live for from one to three days, and in rare instances may recover.

Treatment.—Place the animal in a shady spot, give rapidly diffusible stimulants, and apply cool but not cold water over the body, and, if possible, use ice packs on the head.

Lightning Stroke

Lightning stroke sometimes occurs in swine, particularly among those in pasture. The lesions of lightning stroke are not well marked. Burning of the surface and irregular congested streaks may be observed. Tissue hemorrhage may or may not occur. The carcass of an animal dead from lightning stroke putrefies rapidly.

Swine that are struck by lightning may be instantly killed or they may be rendered unconscious or only temporarily stunned. Those that are not killed will show unsteadiness of gait, and they may even be unable to walk. The animals that are not killed instantly usually make a speedy and complete recovery. Little is required in the way of treatment. The affected animals should be made comfortable and, if necessary, stimulants should be given.

Epilepsy

Epilepsy is a nervous disorder characterized by sudden temporary loss of consciousness, with partial or general convulsions. Swine, particularly those closely confined, are frequently affected with epilepsy. This is a functional disorder, the result of a variety of causes, parasites, tumorous growths, excitement, and fear being among the common causative factors, although in many cases the cause has not been determined.

Lesions.—The disease is primarily a functional disorder, and there are no lesions that are constant and can be said to be accountable for the seizures of epilepsy.

Symptoms.—The approach of an attack is evidenced by restlessness, uneasiness, muscular tremors, rolling of the eyes, and champing of the teeth. These premonitory symptoms are succeeded by falling, and extension, and frequent jerking of the legs and head. The mouth is usually open, and from it saliva is discharged freely.

There may also be defecation, urination, and discharge of semen. The seizures are of short duration, rarely exceeding five minutes. The attacks may occur in rapid succession, or considerable time may elapse between attacks.

Treatment.—Treatment is of no practical value, except to remove the cause when known. The affected animals should be destroyed if the seizures are frequent and severe, or in mild cases the animals should be prepared for market. They should never be used for breeding, as apparently the condition is inherited.

Dentition Eclampsia

A condition called dentition eclampsia occurs in young pigs. This is very similar to epilepsy. It is caused by the irritation resulting from the eruption of teeth, and future attacks are easily obviated by lancing the gums.

Chorea

Chorea is a neurotic condition characterized by rapid contractions of muscles or groups of muscles.

Etiology.—In many instances chorea appears to be purely functional. Some have attributed it to Thrombosis; toxic substances may be a factor; in producing it and in some cases malnutrition predisposes and possibly excites the condition.

No constant tissue change has been identified with chorea.

Symptoms.—Twitching of muscles or groups of muscles more or less continuously except during sleep characterizes chorea. The disease may be outgrown in the course of one or two months, or it may become chronic.

Treatment.—Various drugs have been recommended to relieve this condition, but the best plan is to destroy pigs that have aggravated cases, and to fatten and market those having mild attacks.


Cerebral Hyperemia

Hyperemia no doubt occurs in the brain and meninges of swine, but such cases have received meager clinical investigation. A few cases of purulent cerebritis, or staggers, have been observed. Some of these cases were caused by wormeaten, moldy corn, or at least no new cases appeared after changing the feed. The cerebral tissue was affected and the lesion consisted of a liquefying necrosis, the necrotic area usually occurring in relation to the lateral ventricle and being unilateral in the cases investigated. The liquefied necrotic tissue was grayish red in color and usually represented an area about the size of an English walnut. The affected swine were generally dull in the beginning, but in one case observed the animal was excitable and delirious. Swine affected with cerebral hyperemia usually evidence an unsteady gait and may fall to the ground and show symptoms of convulsions. One case was observed that turned in a circle, jumped up from the ground, and performed other antics.

Treatment.—Treatment is of little value after the brain substance has become necrotic. In the very early stages drastic purgatives may be of value, particularly if the cause lay in the provender.

Parasites

Rarely does the *Cysticercus cellulosæ* develop in the brain of swine. The cyst does not develop as readily in the brain as in a muscle, and it is the exception to find a matured cyst in the nervous tissue. The symptoms produced will depend upon the location of the cyst in the brain.



SECTION VIII

INFECTIOUS DISEASES

HOG CHOLERA

HOG cholera is a specific septicemic disease of swine. It is contagious and infectious, and may be either acute or chronic. The disease is characterized by tissue hemorrhages and complications of the intestinal mucosa and, less frequently, by hemorrhages of the lungs.

Geographical distribution.—The first identified outbreak of hog cholera in the United States occurred in Ohio in 1833. From this original center it has spread widely and now prevails more or less continuously in every state of the Union as well as in the surrounding countries, including the island possessions of the United States. The disease was positively recognized in England in 1826, and it still prevails there. In 1896 approximately one third of the swine population of England died of cholera. The disease was introduced into Denmark in 1887, and spread into Sweden the same year. It also appeared in France in 1887. Hog cholera, or a very similar disease, appeared in Germany in 1866, Prussia, Austria, and Hungary were invaded in 1895. From all reports, it is apparent that hog cholera prevails in practically every country in which swine are maintained.

Hog cholera was first investigated systematically in America in 1885, under the directions of Salmon. The disease was thought, and apparently proved at that time, to be due to a short, rod-shaped bacteria.

De Schweinitz and Dorset further investigated the disease in 1903, and the Bureau of Animal Industry have continued their investigations up to the present time.

Extent.—Information obtained from various sources indicates that hog cholera has been prevalent in America

for the past thirty or forty years. The average annual loss in the United States for the past four decades probably exceeds \$50,000,000 annually, and in 1897 the losses due to this disease alone approximated \$100,000,000. During the years 1912-13 a severe epizootic of hog cholera extended throughout the principal hog-raising section of the United States, the loss being excessive and for the country at large amounting to over \$100,000,000 each year. In 1913 there were 61,178,000 swine in the United States, of which ten to fifteen percent died of cholera. The losses from hog cholera in 1912 in Iowa, Nebraska, Kansas, and Missouri exceeded 3,000,000 hogs valued at \$30,000,000. The losses in Iowa alone for the years 1911-14 have exceeded \$10,000,000 annually.

Hog cholera is no doubt the most surely fatal disease of swine in America, and at this time it is the most important disease economically in the United States.

Etiology.—The cause of hog cholera is attributed to a filterable virus. The relation of a filterable virus to hog cholera was first recognized by De Schweinitz and Dorset in 1904, and similar investigations by Boxmeyer of Michigan were also concluded in 1904. Other investigators have verified the findings by De Schweinitz and Dorset. The virus of hog cholera occurs in the blood and therefore in practically all the tissues of the body of an infected swine. One to two cubic centimeters of filtered blood serum from swine affected with hog cholera will produce typical symptoms of this disease when injected subcutaneously, intramuscularly, intraperitoneally, or intravenously into a healthy, susceptible pig. The symptoms become evident in from five to seven days after the inoculation.

The virus has not yet been successfully cultivated, but very recent discoveries indicate that in the near future the cultivation of it may become practicable in the production of virus for the purpose of hyperimmunization of swine for the production of anti-hog-cholera serum.

Hog-cholera virus is ultramicroscopic and passes through porcelain filters. The virus retains its virulence

in fluids at room temperature for from two to three months, but is destroyed by heating to seventy degrees Centigrade for one hour. When dried it becomes more resistant to the influence of high temperature. At the temperature of an ice box the virulence of the virus is retained for many months. It is very resistant to dilute solutions of phenol, corrosive sublimate, and chinosol. The length of time that virus may remain virulent on infected premises has not yet been determined, but it easily survives a single winter.

In addition to the filterable virus, certain bacteria, including one *Spirillum*, may be factors in the causation of hog cholera.

The *Bacillus suipestifer* is no doubt a factor in the production of secondary lesions and of some of the complications of hog cholera, and from the original investigations under the direction of Salmon and some recent experiments it seems probable that an occasional outbreak of a disease very similar symptomatically and anatomically to cholera is caused by the *Bacillus suipestifer*. In fact, the intravenous injections of the *Bacillus suipestifer* that have been recently isolated produce a septicemic disease that terminates fatally in from one to three days. It has been suggested that the disease produced by the *Bacillus suipestifer* be designated para-cholera.

The *Bacillus suipestifer* is a short, motile, rod-shaped bacteria. It forms no spores, or at least none have been demonstrated. This organism grows aërobically and anaërobically on practically all artificial media. It will withstand ordinary dessiccation for four months or even longer, but sunlight destroys it when exposed only a few minutes. This organism produces an acute or chronic inflammation, and necrosis of the intestinal mucosa and the mesenteric lymph glands. If the animals are previously starved and the acid reaction of the gastric juice neutralized before feeding the cultures of *Bacillus suipestifer*, they will contract an acute disease, with symptoms similar to those of septicemia, and usually die on the third day. Intravenous injections of the cultures pro-

duce septicemia, resulting in death in from one to three days. The infection with *suipestifer* is not transmissible from swine to swine, and swine that have recovered from the effects of infection with the *Bacillus suipestifer* are still susceptible to the filterable virus.

Bacillus suisepiticus is frequently demonstrable in the carcasses of swine that have died of hog cholera. This organism is the causative agent of swine plague, and will receive proper consideration in the discussion of that disease. Suffice to say at this place, it is frequently an associated infection with the filterable virus, the disease resulting being a mixed infection of hog cholera and swine plague.

Spirochæta suis has been investigated by King and Hoffmann. The following are the conclusions of a report on it: "Its Significance as a Pathogenic Organism," that was published in Vol. 13, No. 12, of the *Journal of Infectious Diseases*:

"*Spirochæta suis* is an organism found in the intestinal ulcers, crypts in the ceca, and external local lesions of animals suffering from hog cholera. It is a typical spirochete, simulating in many characteristics *Spirochæta pallida*, *Spirochæta gallinarum*, and other forms whose morphology and life history are becoming better understood. *Spirochæta suis* appears to be capable of breaking up into granules, and these granules may play an important part in the life cycle and physiological functions of the organism. They are present in the blood of cholera hogs, in cultures of the *Spirochæta suis*, and are capable of producing the disease in healthy hogs.

"In the blood of hogs suffering from cholera the presence of a relatively large spirochete in a few numbers has been recognized. As this organism has not been found in the blood of normal hogs it may represent *Spirochæta suis* in a transitional form. Its morphological variation from *Spirochæta suis*, as found in ulcers and local foci, may be due to the unfavorable action of blood as a medium or to its natural processes as a part of the life cycle of the species.

"*Spirochæta suis* is an obligatory anaërobic organism and usually requires several weeks' incubation for growth to take place on artificial culture medium. It may be transferred from generation to generation on artificial culture medium. Cultures containing the organism in the form of granules and spirochetes may be passed through bacteria-proof filters and the spirochetes removed, the few small granules which pass through being capable of producing hog cholera or resistance to the disease.

"*Spirochæta suis* is capable of producing typical hog cholera when injected into healthy hogs. This is true not alone of contaminated cultures made directly from the intestinal ulcers of cholera hogs; second and third generations on artificial culture media, containing the Spiro-

chæta suis, as well as the Berkefeld filtrates of the same transfers, are capable of producing hog cholera and marked reactions, which confer more or less protection against the disease. The pathogenicity of these cultures does not appear to be due to the passage of an unknown 'invisible microorganism' which is finally transmitted to healthy hogs by inoculation. Control experiments tend to show that the pathogenicity of the cultures of *Spirochæta suis* is due to the species itself in the form of spirochetes or granules.

"Finally, in those hogs which receive the disease from cultures of *Spirochæta suis*, the organism is present in the intestinal lesions or local external lesions, as demonstrated by the dark-field examination.

"From the above results, which have practically fulfilled Koch's laws, in so far as it is possible with an organism possessing the biological characteristics of spirochetes, it may logically be concluded that *Spirochæta suis* is more nearly established as the specific cause of hog cholera than any other known organism."

From the foregoing it will be noted that there is still some contention as to the cause of hog cholera. At this time the filterable virus is usually given as the cause, but future investigations may reveal faulty technic or erroneous conclusions of the experiments that have been conducted and establish a new causative factor of hog cholera.

Source of Infection.—The original source of the virus of hog cholera, like the origin of other viruses and pathogenic agents, is unknown. The following are the principal sources of virus of hog cholera: infected swine, the discharges from infected swine, the carcasses of swine dead of cholera, virus used in simultaneous immunization; food, water, vehicles of transportation, stock yards, and any other substance or objects contaminated with the discharges of infected swine, or the tissue juices or products of the carcasses of swine dead of cholera.

From the foregoing the ease of obtaining infection is readily comprehended. The virus is transmitted from an infected swine on noninfected premises to other swine, or to soil, food, water, bedding, and general surroundings, thus practically insuring infection of other swine on the same premises and other premises as well. Serious outbreaks of cholera are sometimes traceable to the introduction of a new boar, or other animal, that is infected.

If the carcass of a swine dead of cholera is permitted to remain in the hog lot, other swine will become infected

by eating of the flesh, and the soil and surroundings will be contaminated with the virus. Some men have shown their faith in the protection of swine against cholera with serum by putting the carcass of a swine dead of cholera in their pens and thus infecting their premises.

From the lack of care in the use of virus in producing a permanent immunity there is little doubt but that hundreds of farms have become infected. Food hauled in wagons or other vehicles that have been previously used in transporting cholera-infected swine may become contaminated and infect healthy, susceptible swine and thus produce hog cholera. Water, too, is frequently the source of infection. This is especially noticeable in the spread of hog cholera in sections of country in which there are many small streams. Such enzoötics usually follow the streams. The contamination of surface water is due to the discharges, and even to the carcasses of cholera-infected hogs being washed by rain water into the small streams. Many hog raisers have fenced and made pastures of the low lands and the small streams of water, thus favoring the introduction of infection into their herds.

Almost every state in the Union, and many foreign countries, permit the shipment of cholera-infected swine to market centers. By this means stock yards, stock cars, and the railroad right of way become contaminated with the discharges of cholera-infected swine, and the chances are that some of the discharges contain the virus of hog cholera in a sufficiently virulent form to produce cholera in healthy, susceptible swine. By this means cholera is, no doubt, frequently transported hundreds of miles, and new centers produced. As yet few if any states actually require the cleaning and disinfecting of cars that are known to have been used to transport cholera-infected hogs to market, and therefore the cars continue as a source of infection for some time after the cholera-infected hogs have been unloaded. By the practice of shipping cholera hogs to market, practically all public stock yards become infected and are therefore a source of

danger in the community. The cholera-infected swine are hauled or driven from the farm to the railroad station along or over the public road, which thus becomes a source of infection, the virus of which may collect on the feet of horses, on the wheels of wagons or other vehicles, and be transported to farms where infection had not before been present.

The possibility of virus carriers of hog-cholera infection must be admitted, for such carriers and distributors of infection are recognized in other infective diseases. It has been claimed by good authorities that swine immunized simultaneously do not eliminate the virus, but this claim has not been satisfactorily proved, and because of the possibility of such swine eliminating infection, they must be considered a source of infection.

Dogs, crows, buzzards, and pigeons are scavengers, and are an important factor in the dissemination of infection. Neighbors visiting back and forth and exchanging labor are prolific means of carrying infection from place to place. And careless veterinarians have in some instances apparently been responsible for the transmission of hog cholera from infected to non-infected premises.

Manner of infection.—Hog cholera may be transmitted by direct or indirect infection. Direct infection may be affected by the actual contact of a healthy, susceptible swine with one affected with cholera. Direct infection may also occur *in utero*, the pigs becoming infected before birth. This statement may be questioned by some, but the fact that pregnant sows abort when they become affected with hog cholera is common knowledge among swine breeders. It has also been observed that abortion is of frequent occurrence in pregnant sows that are simultaneously immunized. The transmission of the virus from the sow to the pig *in utero* would not seem difficult when it is remembered that this virus readily passes through porcelain filters.

Indirect infection also is of common occurrence in hog cholera. This is accomplished by the infection being introduced on food stuff, in water, in the inspired air, or

on foreign bodies, such as splinters or stubble. Indirect infection is the manner of infection that occurs when new centers are established without the introduction of a diseased animal.

Susceptibility.—Young swine are apparently most susceptible to cholera immediately after weaning. However, swine of all ages may become affected. Thus sucking pigs or old brood sows or boars may contract cholera and die of its effects.

Channels of entrance of the infection.—The virus of hog cholera most frequently gains entrance to the body of the swine by way of the digestive tube, upon contaminated food or water, or in various substances that swine are likely to chew or ingest. Infection may also be introduced through the respiratory tract, but infection by this avenue of entrance is not common. The virus may be introduced through the skin by means of barbs, awns, splinters, or similar objects, but this avenue of entrance is not common in natural infection.

In the production of a permanent immunity by the use of the virus and serum, the virus is introduced through the skin by a hypodermic syringe. Injection for the purpose of hyperimmunizing, in the production of anti-hog-cholera serum, is done intravenously in an ear vein. Infection can be successfully accomplished by intraperitoneal or intramuscular injections of the virus, but natural infection rarely occurs in this way.

Period of incubation.—The period of incubation after natural infection is variable, depending upon the virulency of the virus and the resistance of the infected swine. In most instances there will be a rise of temperature from the fifth to the seventh day, and the animals will be visibly sick by the tenth day after infection. The period of incubation in inoculation experiments varies from four to seven days.

Lesions.—The anatomical changes observed in hog cholera are quite variable because of the multiform types that it assumes, probably due to complications. The following types have been described: pure hog cholera

or septicemic form, intestinal form, pectoral form, and mixed form. The first-named is uncomplicated hog cholera; the other forms are due to complications.

Septicemic form.—In the very acute cases no gross lesions are evident except cloudy swelling of the parenchymatous organs indicating a high antemortem temperature. In the ordinary acute cases the lesions correspond to those of septicemia and consist of hemorrhages

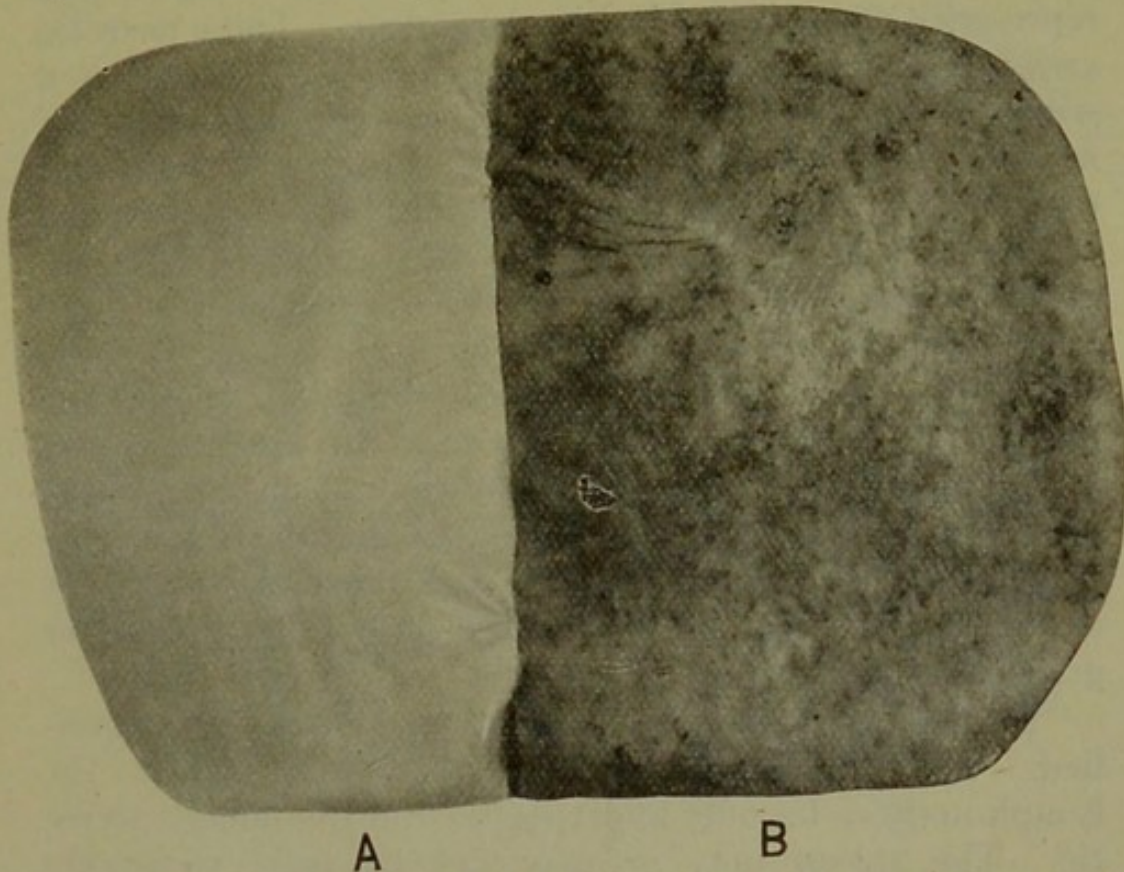


Fig. 11.—MUCOUS MEMBRANE OF THE BLADDER.
A. Normal. B. showing inflammation due to hog cholera.

in the serous membranes, in the mucous membrane of the epiglottis, trachea, lung, pharynx, and usually in the spleen and kidneys. The lymph glands are hyperemic and the lung usually contains small areas of croupous pneumonia in the cardiac lobe. The skin may be hyperemic, and there may be subcutaneous hemorrhages. The bone marrow is usually dark red or black.

Intestinal form.—This type is apparently a complication due to the simultaneous activity of the filterable virus and the *Bacillus suispestifer*, *Bacillus necrophorus*,

Bacillus coli communis, *Spirochæta suis*, or some other intestinal infection. This type of hog cholera is characterized by the general lesions of the less acute septicemic type plus intestinal lesions which are as follows. The lymphoid tissue of the mucosa of the cecum, colon, and to a less extent in the ileum, becomes tumefied and later undergoes necrosis. The necrotic tissue, remaining adherent as a dirty brown mass, has raised margins and represents the so-called hog-cholera ulcer. These necrotic areas may be mere points or they may be as large as a silver dollar or even larger. In exceptional cases the necrosis may extend through the intestinal wall and result in fatal peritonitis or intestinal adhesions. In the chronic intestinal type there is intestinal adhesions, involving especially the large intestine, although the small intestines may also evidence the same lesions. There may be a general diffuse diphtheritic inflammation of the mucosa of the intestine and stomach, the exudate covering practically the entire surface of the mucous membrane of the intestine. This organized exudate may become dry or it may become softened and mushlike, the color of the exudate changing from dirty brown to a yellow or greenish yellow.

In chronic cases the septicemic lesions become modified. The hemorrhages become pigmented areas; the lymph nodules become hyperplastic and frequently necrotic. The spleen may or may not become extensively enlarged and necrotic; the skin frequently becomes necrotic and variable sized areas slough, and the ears become tumefied and frequently necrotic, and slough. Tumefaction and necrosis may also occur in the bladder, mouth, pharynx, and in other regions.

The evidence of a previous attack of this type of hog cholera consists of granulation of the erosions of the mucous membrane of the intestine, stomach, mouth, and elsewhere, and also of granulations of the skin erosions. In other cases there may be scars and an irregular lumen of the intestine due to irregular cicatrization. The lymph nodes will contain caseous necrotic centers.

Pectoral form.—This type consists of the hemorrhagic form in varying degrees of intensity and pulmonary lesions which may or may not be associated with pleurisy. As previously stated, croupous pneumonia commonly occurs in the septicemic form, but it is more extensive in the pectoral form.

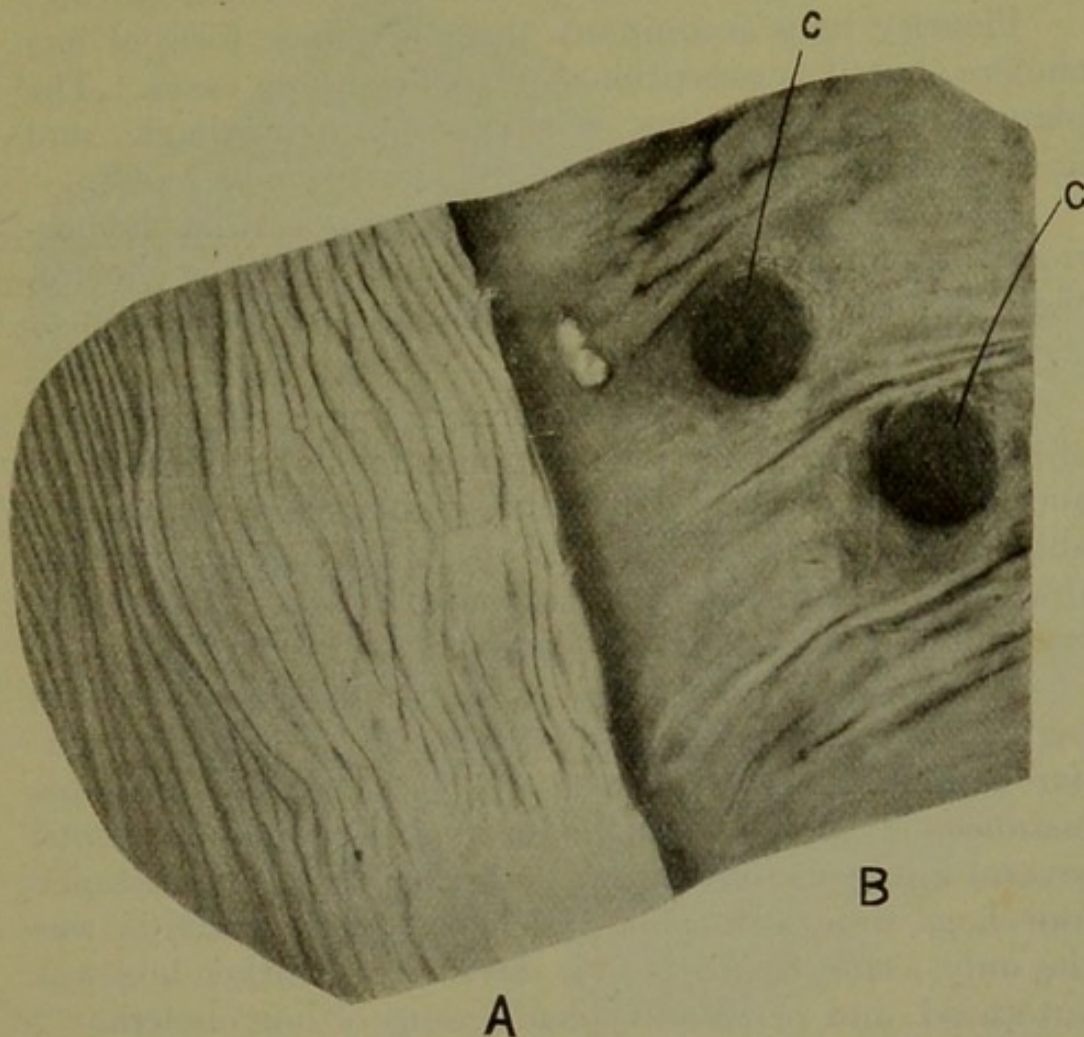


Fig. 12.—MUCOUS MEMBRANE OF THE INTESTINE.
 A. Normal. B. showing effect of chronic inflammation due to hog cholera. C. typical hog cholera ulcers.

The usual pulmonary lesion consists of croupous pneumonia involving especially the cardiac lobe of the lung. The appearance of the lung will depend upon the stage of pneumonia existing at the time of death of the animal. The affected portion may be in the congestive, red, or gray hepatization or resolution stage, and occasionally there may be abscess formation or necrosis. More

rarely will there be evidence of catarrhal pneumonia, except in those cases of the simultaneous occurrence of hog cholera and swine plague. The lesions of simple catarrhal pneumonia occur in the lower portions of the lung, and are the same when it occurs as a complication of hog cholera as in the primary affection of catarrhal pneumonia which has been previously described (p. 88).

Pleurisy may accompany the pneumonic form of hog cholera, but it is exceptional to observe such cases. The pleurisy may be serous, fibrinous, or hemorrhagic, and in exceptional cases it may become purulent or septic.

Although subepicardial and subendocardial hemorrhages are typical of the pure, uncomplicated hog cholera, these lesions are more extensive in the pectoral form of the disease.

Mixed form.—The mixed form of hog cholera consists of the septicemic form plus complications of the intestinal and pectoral forms. This form of hog cholera is probably more prevalent than any other type described, and this fact accounts for the difficulty that is frequently encountered in making a diagnosis.

All of the different forms of hog cholera described are frequently found in one herd of hogs. Occasionally peculiar combinations of lesions are observed, and in some instances it is not possible to make a diagnosis until several autopsies have been performed. In one instance four hogs were autopsied and hemorrhagic gastritis was the only lesion found. Two days later another hog was autopsied, and revealed typical lesions of hog cholera.

Symptoms.—Symptoms of hog-cholera are as variable as the lesions. For convenience in describing the symptoms will be considered in four groups corresponding to the four types mentioned in the consideration of lesions.

Septicemic form.—The most acute or so-called peracute cases are frequently found dead, having evidenced no symptoms. The ordinary acute cases evidence the following symptoms, usually in the order mentioned. The affected animals are inclined to isolate themselves and

stand with back arched and head hanging, or they may crawl under the bedding. The appetite is at first impaired, later the animals refuse all food. In the early stages vomiting may be observed. There is usually constipation in the beginning, but this is succeeded by

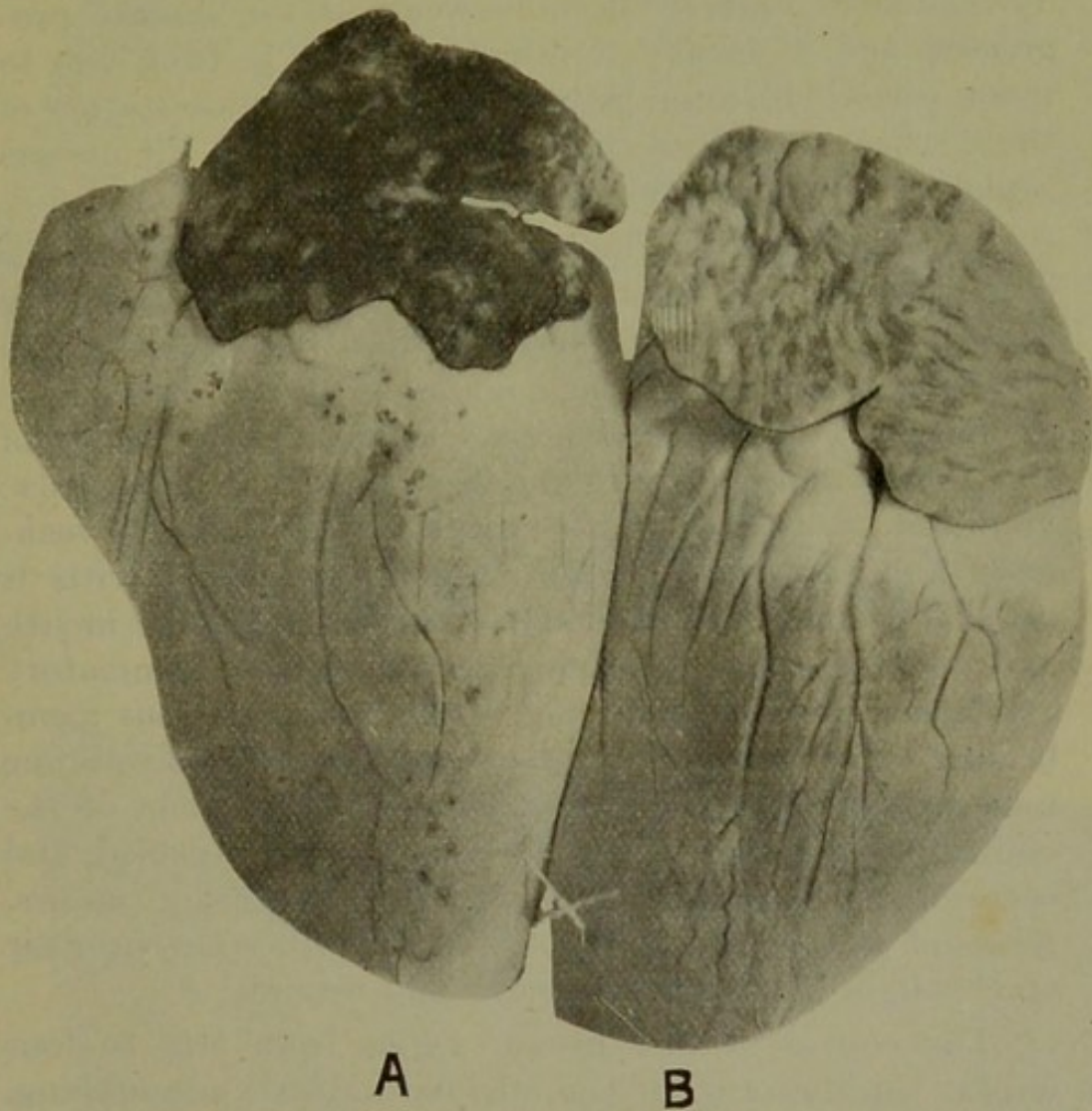


Fig. 13.—HEARTS.

A. Showing acute inflammation of the auricle and hyperemic areas in the ventricle, a common condition in hog cholera. B. normal.

diarrhea, the intestinal discharges being admixed with blood. There is usually a purulent conjunctivitis; the discharges accumulate on the eyelashes and frequently cause adhesion of the eyelids. There may be a limited mucopurulent discharge from the nose. On the second or third day erythema of the skin usually becomes evi-

dent, the discolored areas being observed on the venter surface inside the thighs, and are red or reddish purple in color. The ears become tumefied due to congestion and edema. There is a rise of temperature, the high temperature ranging from 105 to 107 degrees Fahrenheit, or even higher, persisting throughout the acute attack. The affected animals become weak as the disease progresses, and it usually terminates fatally in from two to seven days. In some instances the first manifestation of the disease consists of rheumatoid symptoms, the disease sometimes being diagnosed as rheumatism.

Intestinal form.—The intestinal form of hog cholera is manifested by symptoms similar to those described in the septicemic form but less intense. This form of the disease is less acute and runs a longer course. Symptoms of digestive derangements are the principal evidence of the disease and consist of impaired appetite, inappetence, vomition, constipation alternated with diarrhea, weakness, and rapid emaciation. Purulent conjunctivitis is usually present. A bad odor emanates from the mouth and on inspection putrefying accumulated inflammatory exudate is observed adhering to the buccal mucous membrane. The tonsils and pharyngeal mucous membrane may be hyperemic and hemorrhagic. Erythema of the ventral surface may exist, the ears become tumefied, and occasionally necrosis succeeded by sloughing occurs. Areas of skin on the back or croup may become necrotic and slough, leaving large, deep, ugly wounds.

The course of the disease varies from two to four weeks, the majority of the affected animals succumbing, but occasionally one or more recover after a long period of convalescence in which the diarrhea is gradually overcome. There is desire for food, and ultimately there is a normal appetite and the animal gradually becomes stronger and finally recovers.

Pectoral form.—The symptoms of the pectoral form of hog cholera consist of the symptoms of the septicemic form of cholera and of pneumonia. The symptoms of the septicemic type are usually evident when the pneumonia

PLATE I.

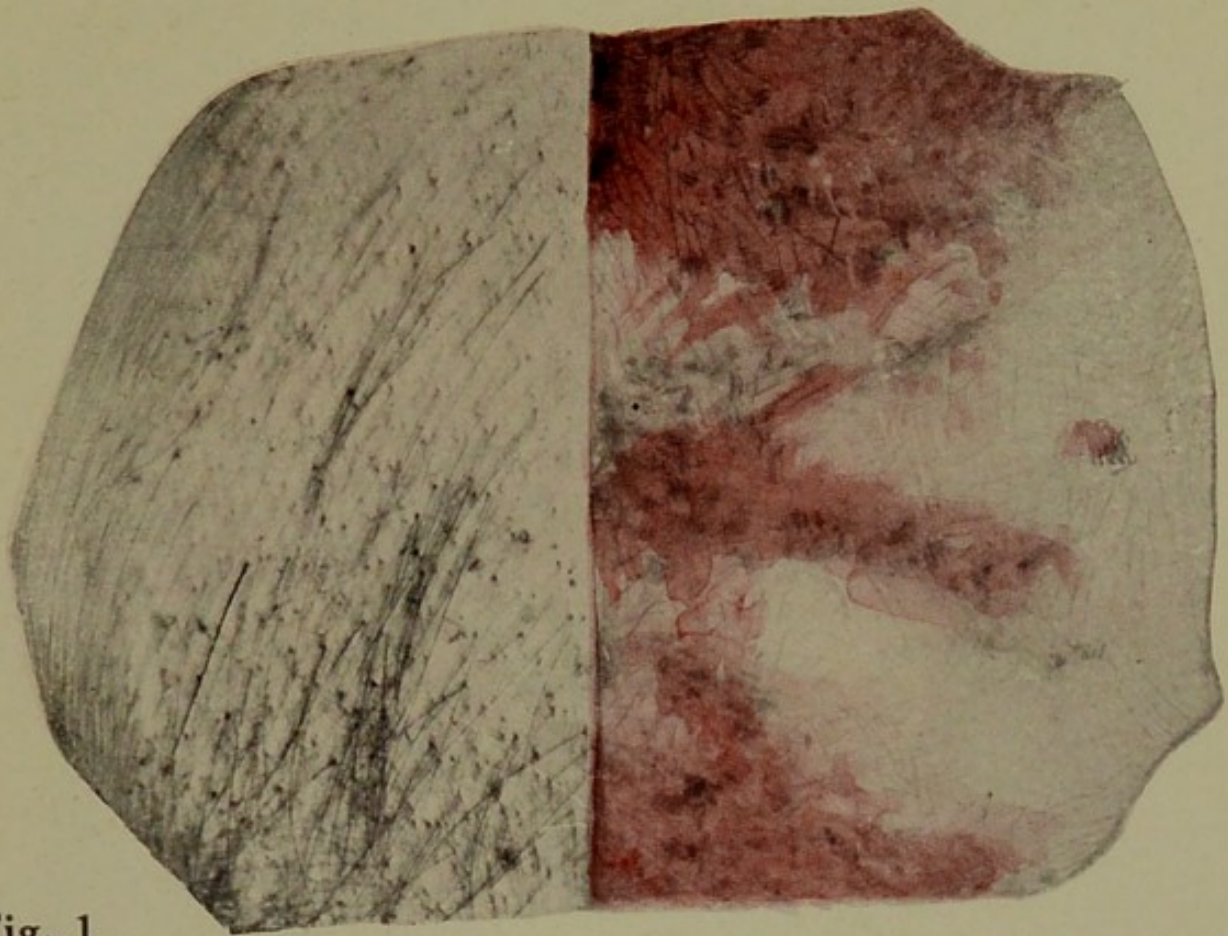



Fig. 1



Fig. 2

FIG. 1. Normal skin and skin showing red blotches characteristic of hog cholera.

FIG. 2. Serous surface of intestine, showing sharply outlined petechial hemorrhages, due to hog cholera.



begins. The affected animals show disturbance of respiration by coughing, dyspnea, and more or less nasal discharge, the intensity of the pneumonic symptoms depending upon the extent of lung involved in the pneumonic process. The physical examination of the lung is practically impossible because of the thick chest wall, and the respiratory sounds and solidity of the lung can be a matter




Fig. 14.—HOG CHOLERA, (Early Stage).

of conjecture only with the clinician. Conjunctivitis is usually prominent in the pectoral form of cholera. Erythema, tumefaction, and necrosis of the ear and other skin surfaces are not so common in the pectoral as in the intestinal form of the disease. Some digestive derangements are always present, but they are less intensive than in the intestinal form. A high temperature prevails in the pectoral form, and as a rule it will average from one to two degrees Fahrenheit higher than in the intestinal form.

The course of the pectoral form of cholera varies from one to three weeks. The disease frequently terminates fatally within one week, especially when there is extensive lung involvement. A few cases may assume a chronic form and ultimately recover.

Mixed form.—This is the usual form of cholera, and the symptoms evidenced will depend upon the complications. There will be symptoms of digestive derangements, such as inappetence, vomiting, constipation, and purgation; of pneumonia, such as cough, dyspnea, and nasal discharge; conjunctivitis and cutaneous erythema, tumefactions, and necrosis, the intensity of these various symptoms depending upon the proportionate involvement of the various groups of organs: In addition there will be more or less of the symptoms of the septicemic form of cholera, such as reluctance to move, depressed head, arched back, and high temperature. In the acute form of the mixed type of cholera the course is of brief duration, terminating fatally in from one to three days after the first symptoms become evident.

Diagnosis.—From the foregoing description of lesions and symptoms it is very evident that the diagnosis of cholera is rather difficult. There are some laymen, and an occasional veterinarian, who diagnose as hog cholera practically all diseased conditions of swine. Much has been written during the last few years concerning the diagnosis and treatment of cholera, but the bulk of this literature has come from serum producers, and some of it has apparently been written without sufficient investigation to justify the conclusions.

The symptoms evidenced may cause a clinician to suspect cholera, but the diagnosis should not be based upon symptoms alone. Lesions observed in autopsy may or may not be sufficiently characteristic for one to arrive at a positive diagnosis of cholera. The intestinal lesions—that is, the tumefied lymphoid tissue, necrosis, and ulceration that occur so commonly in the intestinal form of cholera—may occur in the intestine of swine that are not infected with the filterable virus. Necrosis and ul-

ceration have been observed as a result of infection with the *Bacillus necrophorus*, and these lesions have also been observed in swine that had been fed excessive quantities of ferrous and copper sulphate.

The study of the lesions gives assistance in the diagnosis of cholera. The pneumonic lesions are relatively common in cases of cholera excepting in the peracute




Fig. 15.—ACUTE HOG CHOLERA, (Advanced Stage).

type. The lesions in the lung consist of croupous pneumonia in some stages and involve the cardiac and frequently the cephalic lobe. This lesion cannot be considered characteristic of cholera as it is the typical lesion of croupous pneumonia, but when it occurs in conjunction with subserous and submucous hemorrhages, congestion and hemorrhages of lymph nodes, and discoloration of

bone marrow the evidence is in favor of the existence of cholera.

Swine plague is distinguished from the pectoral form of cholera by the fact that the former is characterized by catarrhal pneumonia in the early stages of the disease, and by necrotic pneumonia in the later stages, and also by the presence of fibrinous pleurisy with or without adhesions.

Petechial hemorrhages of the kidney were formerly considered pathognomonic of cholera, but these hemorrhages have been found in the kidney rather frequently when cholera was absent, or at least the blood from such cases failed to produce cholera in healthy, susceptible pigs.

Engorgement of the spleen is a common lesion in acute cholera, but this condition sometimes occurs as a result of disturbed digestion and as a result of leukemia, and is a common lesion of other septicemic diseases. Therefore enlarged spleen alone should not be considered a sufficient evidence upon which to base a diagnosis of cholera.

The congestion and hemorrhage of the lymph nodes is one of the most common and characteristic lesions of cholera, but this lesion is not always present. Hemorrhages of the subserosa and submucosa are quite constant in cholera; however, they may occur in any other septicemia. The changes of the bone marrow, although occurring to a less degree in other septic conditions, are among the most characteristic lesions of cholera, but this lesion is absent in some of the peracute cases. Petechial hemorrhages are also of common occurrence in swine erysipelas, but this disease can be differentiated from cholera by the demonstration of the organism of swine erysipelas in the blood or splenic pulp.

The principal diagnostic lesions of cholera are subserous and submucous hemorrhages, congestion and hemorrhages of the lymph nodes, and the discoloration of the bone marrow. Next, in order of frequency, is croupous pneumonia of the cardiac lobe of the lung.

In the diagnosis the history of the outbreak, and particularly the distance from known cases of cholera and whether or not any swine have recently been introduced, must always be taken into consideration. Finally, it

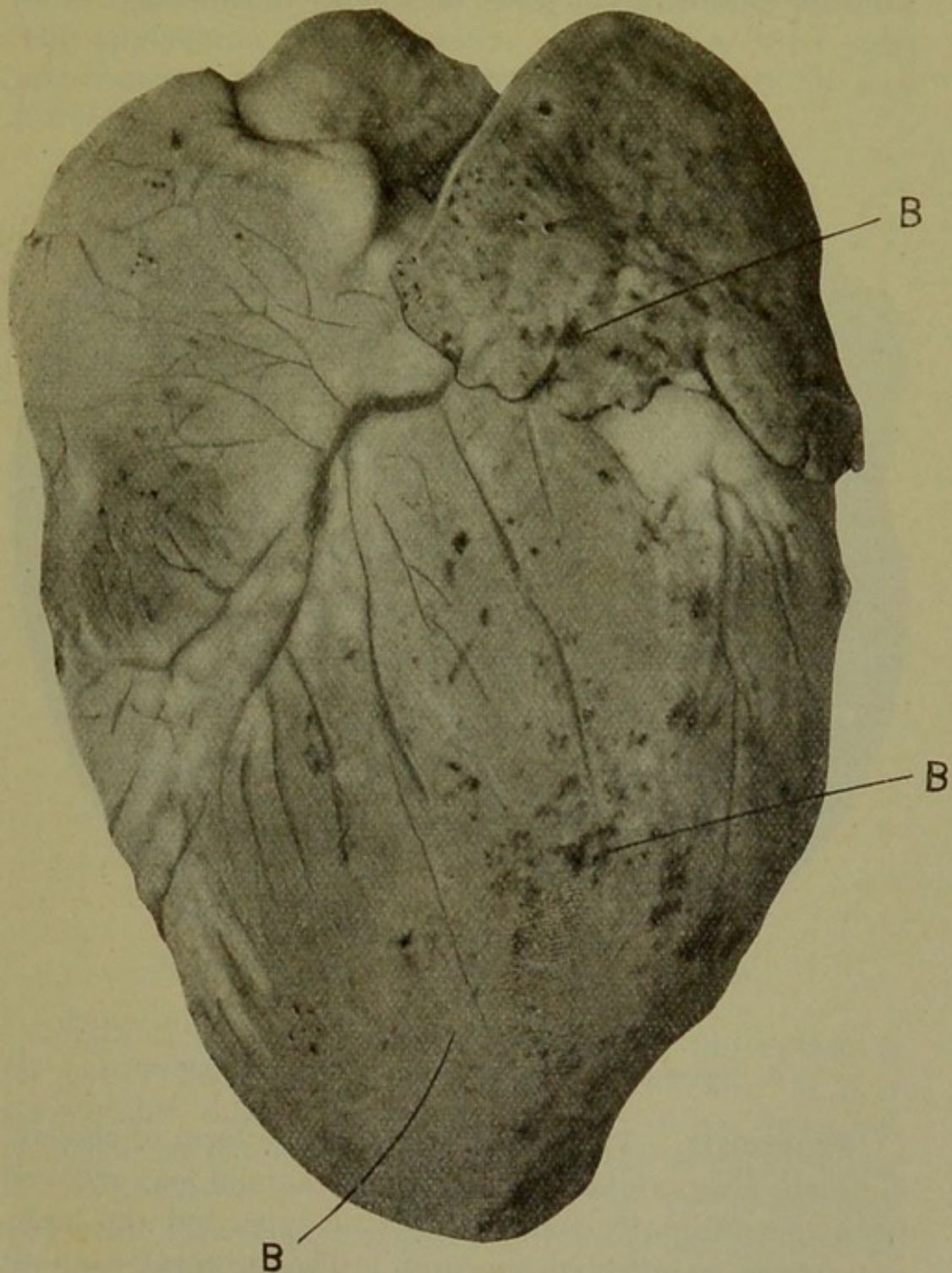


Fig. 16.—HEART SHOWING TISSUE HEMORRHAGES DUE TO HOG CHOLERA.
B. Hyperemic areas.

must be understood that the only absolute method for the diagnosis of cholera at this time is the inoculation of a known, healthy, susceptible pig with from one to five cubic centimeters of blood from the suspected animal. Thus determine the presence or absence of cholera.

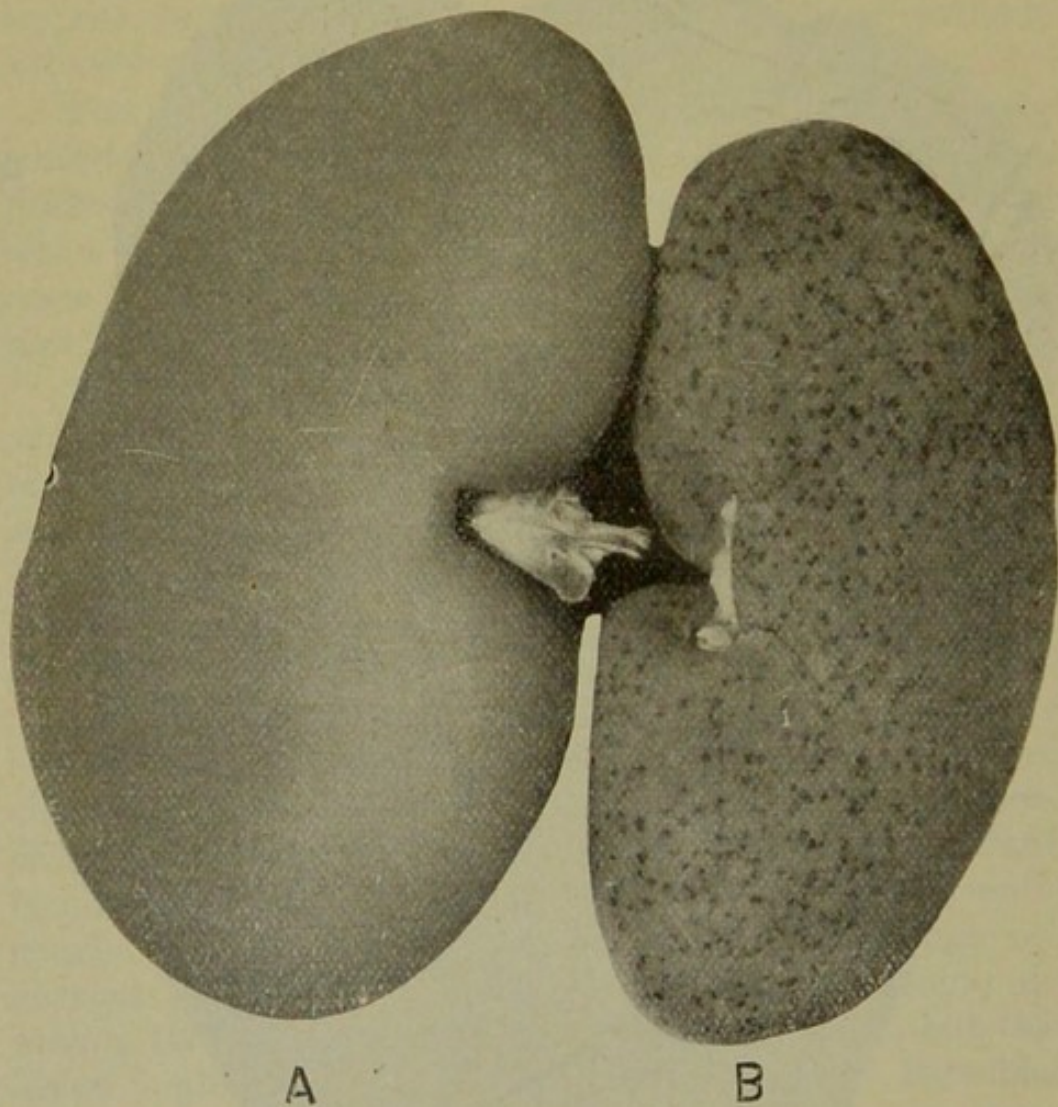


Fig. 17.—KIDNEYS.
A. Normal. B. hog cholera (turkey egg) kidney.

Prognosis.—The peracute septicemic form of cholera is nearly always fatal. An occasional animal may recover from the ordinarily acute septicemic type, but the large percentage so affected succumb. The pectoral form is usually quite fatal, in some localities fully ninety percent of the affected swine dying. The intestinal form is less

fatal and has a tendency to become chronic, the course in such cases varying from one week to two or three months.

Treatment.—It is probable that more proprietary remedies have been devised and advertised as hog-cholera cures than for any other disease of domesticated animals. The application of therapeutic agents other than anti-hog-cholera serum has not proved satisfactory in any proved outbreak of cholera.

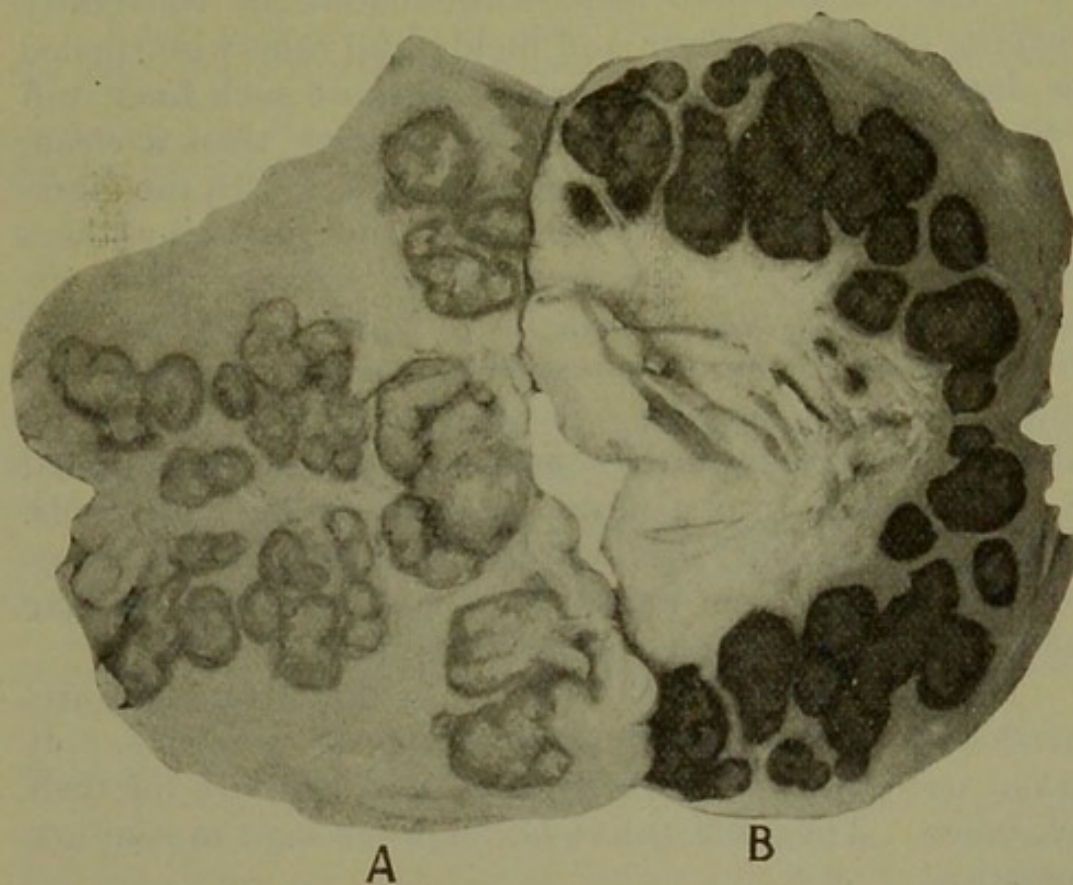


Fig. 18.—LYMPH NODES.

A. Normal. B. hyperemic due to hog cholera.

With this disease, as with any other, prevention is far better than treatment of afflicted animals. It is a preventable disease, but unfortunately it has been responsible for extensive losses of swine for so many years, in practically every country, that the swine breeders and swine raisers have apparently become accustomed to the losses and accept them as a matter of fact, and until recently with little concern as to methods of prevention. The prevention of hog cholera may be accomplished by

complying with the laws of hygiene, the enforcement of sanitary police regulations, and by immunization of swine by the use of anti-hog-cholera serum.

The laws of hygiene of other domesticated animals than swine are fairly well provided for by the stock raisers. It has been the custom, and it is still far too common at the present writing, to consider that anything is good enough for swine. Thus many men having extensive financial interests in pork production are constantly seeking fermented grain and moldy and otherwise spoiled or damaged foods for their swine because such food stuff can usually be purchased for less money than a clean, wholesome food. But such foods interfere with the digestion, thus weakening the animals and rendering them more susceptible to disease. Swine that are given the proper diet are not necessarily immune to cholera, but they are much more resistant than swine affected with digestive derangements. Swine should also receive an abundance of clean, wholesome water, and not be required to drink water from polluted streams or stagnant pools. Many cases of what would probably have been fatal cases of cholera have been nursed back to health by providing good surroundings and a diet of clean, sweet milk.

Hog pens should not be placed, as they frequently are, in locations that cannot be drained properly. It is not necessary for swine to have mud and filth for their existence. They will thrive better when kept in sanitary quarters.

Sanitary police regulations, or general sanitation in relation to control of hog cholera, have certainly not received proper consideration. If rules and regulations were instituted prohibiting the dissemination of hog cholera, the losses could be rapidly diminished. The following provisions for quarantine and shipping regulations were recommended by the committee on Uniform Methods for the Control of Hog Cholera at the meeting of the United States Live Stock Association in December, 1913:

1. The shipment or movement, interstate, of swine affected with cholera to be prohibited.

2. Exposed swine to be shipped under permit and placard.
3. The movement of cholera-infected swine over the public highways to be prohibited.
4. Provision for moving exposed swine under permit in approved manner.
5. Carcasses of animals, and particularly of swine that have died of cholera, to be burned within twenty-four hours after death, or under special permit to be disposed of otherwise.
6. The shipment by rail of swine for purposes other than immediate slaughter to be permitted only through special pens and unloading chutes, or through portable chutes directly into wagons. If unloaded in regular loading pens, to be moved under permit in approved manner.
7. Public stock yards to be under close supervision and cleaned and disinfected at intervals determined by the proper state authorities.
8. Railway cars for the transportation of swine other than such as are intended for immediate slaughter to be cleaned, washed, and disinfected before swine are loaded.
9. All cars in which diseased swine are found, or in which exposed swine were shipped for immediate slaughter, to be cleaned, washed, and disinfected within twenty-four hours after unloading, or cars to be held until the presence or absence of diseases has been determined.
10. All cars or vehicles of transportation carrying cholera-exposed swine to be placarded in a conspicuous manner, "Cholera Exposed Swine for Immediate Slaughter."
11. Owners of swine and persons in charge, including attending veterinarians, to report without delay to state authorities all outbreaks of cholera among swine.
12. Live-stock sanitary authorities to quarantine all infected herds and premises, but may permit shipment of exposed swine for immediate slaughter as above provided.
13. Infected premises to be quarantined not less than sixty days after last traces of disease have disappeared and premises have been cleaned and disinfected.
14. Infected premises to be cleaned and disinfected under supervision prescribed by live-stock sanitary authorities.
15. The live-stock sanitary authorities to be given power to provide in a practicable manner against the dangerous pollution of streams with hog-cholera virus and provide for the safe disposal of garbage liable to be infected with hog-cholera virus.
16. To prevent the spread of hog cholera by swine shown for exhibition purposes, such swine to be treated with serum and virus not less than forty days prior to the opening date of the exhibit, or with serum alone not more than fifteen days before such time.
17. Provision for controlling for thirty days, by quarantine or otherwise when deemed advisable by the proper authority, of all swine treated with serum-virus, or premises on which such swine are kept, to prevent danger of possible spread of infection from inoculated animals.

If the above or similar regulations could be instituted and enforced there is no doubt that cholera in swine would be materially diminished and could be eradicated, ultimately, by the judicious use of serum, from this or any other country. Since the advent of anti-hog-

cholera serum the enforcement of sanitary regulations has been neglected. In order to obtain and enforce efficient sanitary measures the pork producers must first be educated to the necessity of such measures.

The application of some of the simple sanitary rules have proved of great monetary value to swine raisers. As an illustration, the separation of the infected from the healthy swine by means of a clinical thermometer, and the proper after-care, have been the means of saving over fifty percent of many infected herds.

If more consideration were given to proper hygienic care and sanitary control, and less to the production, distribution, and application of serum, it is possible that hog cholera would soon become a much less serious disease economically.

Preventive Treatment.—The first use of serum for the prevention of hog cholera was made in 1897 by Preisz, who obtained it from a swine that had recovered from cholera. In 1904 De Schweinitz and Dorset demonstrated that hog cholera was caused by a filterable virus, and soon thereafter Dorset, McBryde, and Niles devised a plan of hyperimmunizing swine for the purpose of producing anti-hog-cholera serum. This serum came into general use about 1908, and is now being used extensively in the United States. It is prepared on the following general plan, different manufacturers having slightly different methods.

The production of serum is of considerable importance and a brief description of the general process follows:

Swine having a large carcass and weighing 225 to 275 pounds are selected, and if they are not known to be immune they are immunized by using twenty-five to thirty-five cubic centimeters of serum to the hundred pound hog weight, and from one to two cubic centimeter of virus. The swine used for hyperimmunes are tuberculin tested and reactors are discarded. After the swine has recovered from the immunizing process, which requires from ten to twenty days, it is then hyperimmunized. A prerequisite of the hyperimmunizing process consists in

having all instruments, bottles, and so on, sterile, and of having environments that are conducive to asepsis. The immune swine that are to be hyperimmunized should be kept in a pasture or yards that are concreted to prevent undue filthiness. The virus used may be obtained from the field, that is, from natural outbreaks of cholera, or it may be produced by injecting healthy, susceptible pigs with one to two cubic centimeters of virus. A pig weighing from sixty to ninety pounds is usually used. The virus pigs should be carefully observed, and temperature records maintained. If susceptible pigs have been injected with a virulent virus there will be evidence of the disease in four to seven days, and from the seventh to the ninth day the temperature of the pig will probably range from 105 to 108 degrees Fahrenheit, and is then prepared for slaughter by thoroughly washing and applying some disinfectant to the skin of the venter surface of the body. In addition to these precautions the inferior cervical region is shayed. The entire pig is shrouded with moist, antiseptic gauze to prevent any particles of dust from dropping into the vessels used in collecting the virus. The vessels are severed, and the blood is collected in a sterile vessel and the fibrin whipped and removed; the remainder of the blood is filtered through gauze, and constitutes the virus blood. The virus pig is then autopsied, and if lesions of cholera are not found, or if lesions of other diseases are found, the collected virus blood is discarded. The collection of field virus requires the same precaution.

Hyperimmunizing may be accomplished by the intraperitoneal, intravenous, or intramuscular injections of virus. The quantity of virus employed depends upon the method used, that is, the slow or quick method. For the intravenous and intramuscular methods five cubic centimeters of virus are used to the pound weight of the hog that is being hyperimmunized. This quantity is divided and given in two injections in the slow process and as a single injection in the quick process. In the intravenous method the injection is made in an ear vein after properly cleaning and

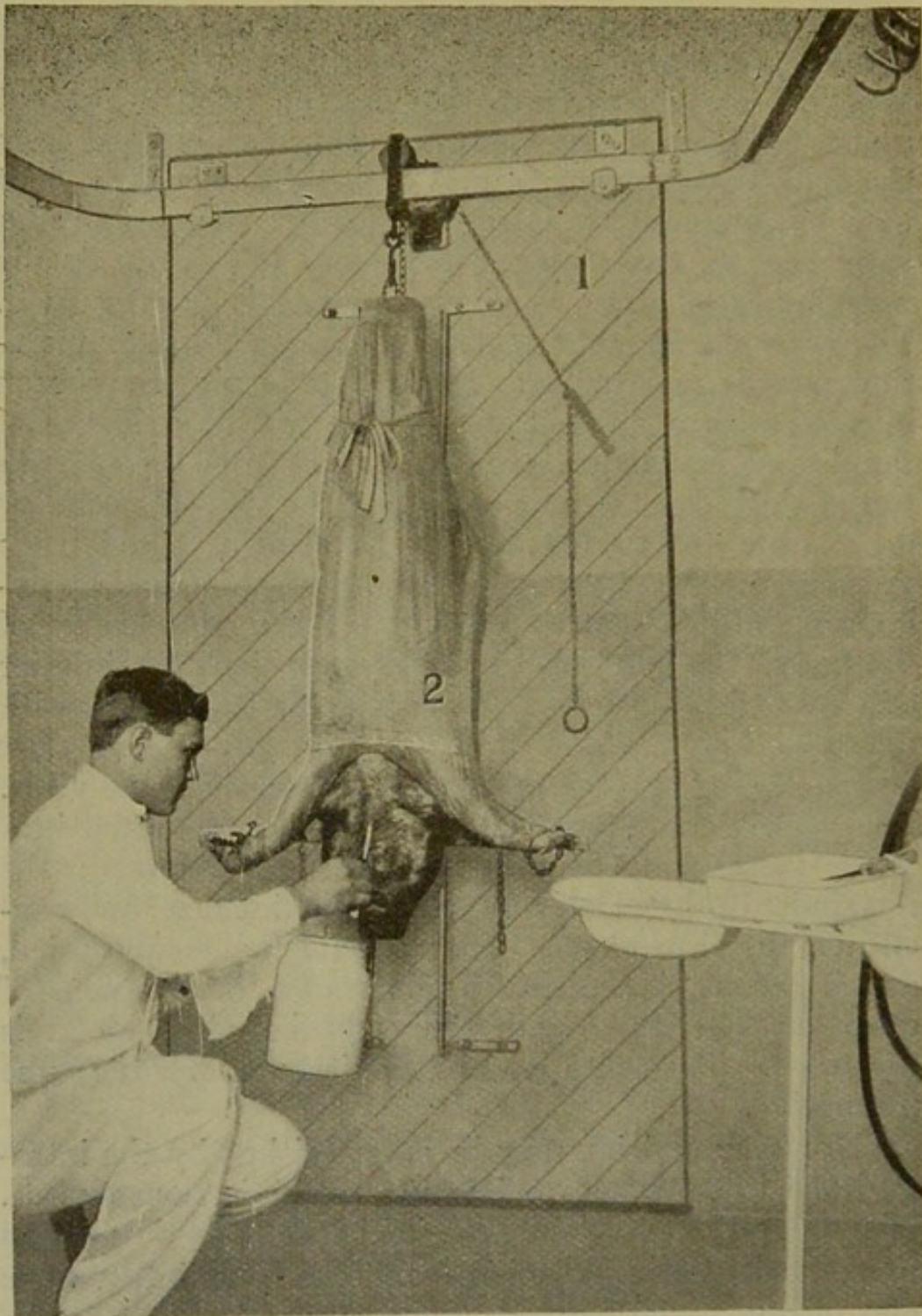


Fig. 19.—VIRUS BLEEDING ROOM.

1. Revolving door upon which the pig is secured and cleaned. The door is then turned, which brings the pig into the bleeding room.
2. shrouded pig.

securing the animal. Various devices are used in making the injection. The principle involved is to force the virus into the vein slowly. The virus should be near the body temperature when injected. In the intra-muscular method the virus is injected in the interstices between the muscle bundles, selecting two, three, or four locations, as the inner thigh muscles and the subscapular region. The intraperitoneal injection is made by passing a long needle through the abdominal parietes into the peritoneal cavity.

The hyperimmunes are kept in clean, sanitary pens and a temperature record maintained in order that the producer may know when the reaction is over. When the temperature assumes the normal the blood contains the antibodies. Two methods of bleeding hyperimmunes are in use—the slaughter method and tail bleeding. By the slaughter method practically all of the blood is obtained. By the tail-bleeding process from two to four bleedings are made, and the swine are re-hyperimmunized, and after the reaction they are used for bleeding. Sometimes the hyperimmune is tail bled for one, two, or three times and then slaughtered. Each method has some advantages and some disadvantages. The slaughter method is the most rapid—in other words, more serum can be produced in a given length of time than by tail bleeding. Tail bleeding is the most economical method of producing serum, and antiseptic precautions can be carried out more effectually.

Proper equipment is required for either process, and the instruments, bottles, and other utensils used must be sterile and the environment must be conducive to asepsis.

The blood obtained from hyperimmune swine is whipped, the fibrin being removed and the remaining portion of the blood filtered through gauze. When obtained by the slaughter method, the blood from each hog is kept separately until the carcass is autopsied and the absence of cholera and other diseases is demonstrated. The blood may also be kept in one container. Centrifugation of the blood is being practiced by some producers,

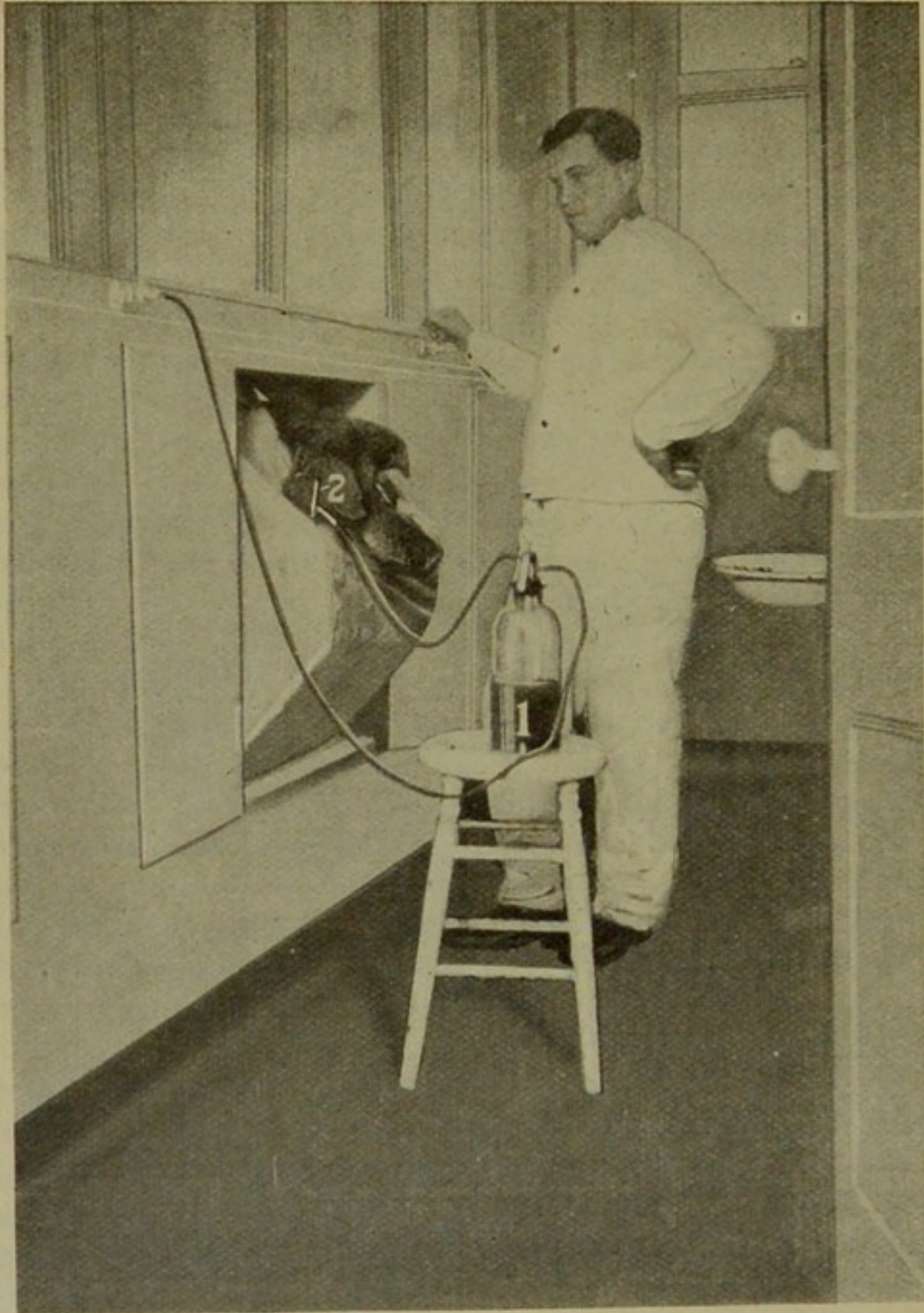


Fig. 20.—HYPERIMMUNIZING ROOM.

1. Virus container showing attachment to pressure tank. 2. needle inserted into the ear vein.

and this should be encouraged, as a cleaner product and one that is more easily injected is produced. The blood obtained from hyperimmune swine by either process is preserved by adding a small percentage of phenol or trikresol and properly sealed and placed in storage at a temperature of about 50 degrees Fahrenheit. Before the serum is used it is tested. First, second, third, and fourth bleedings from different hyperimmunes, or the blood from different hyperimmunes obtained by slaughtering, are mixed up to quantities of 80,000 cubic centimeters. This amount constitutes a series, and therefore each series is a composite serum. For a test sample a proportionate quantity is taken from each separate quantity that makes up a series. The sample should be obtained immediately after bleeding, thus obviating reopening of the bottles.

For the test eight healthy, susceptible pigs, weighing from sixty to ninety pounds each, are selected. These pigs are maintained in four separate pens of two each. The test is made as follows: Each of the eight pigs is injected with two cubic centimeters of virus; pigs No. 1 and No. 2 receive twenty-five cubic centimeters of serum; pigs Nos. 3 and 4 receive twenty cubic centimeters of serum; pigs No. 5 and 6 receive fifteen cubic centimeters of serum; and pigs Nos. 7 and 8 receive the virus only. Pigs Nos. 7 and 8 are designated check pigs, and they should show visible symptoms and die of typical cholera within twelve to eighteen days. A temperature record is maintained for twenty days, and from observing this record the virulency of the virus and the potency of the serum can in a measure be determined. The following chart is the record of a serum test: (See p. 198.)

This test is not absolute, but it is of value as an indicator. The test should be repeated if the following conditions arise. First, if the check pigs should not show any evidence of cholera within ten to fifteen days; second, if the check pigs or any of the other six should show a constant high temperature beginning on the second, third, or fourth day after the test begins; third, if either

RECORD OF SERUM TEST

Date Begun _____ 19____
 Date Ended _____ 19____ Quantity Tested _____
 Virus Used, Lot No. _____ Series _____

	DESCRIPTION				TEMPERATURES									
	Tag No.	Sex	Wt.	5/30 Temp.	5/31	6/1	6+2	6+3	6/4	6/5	6/6	6/8	6/9	6/10
25 Cc. Serum	89	F	84	2.4	2.6	2.2	2.4	3.0	3.0	2.4	2.0	1.4	1.4	1.4
2 Cc. Virus	90	M	88	1.4	2.0	1.6	1.8	1.8	2.0	1.8	2.2	2.0	2.2	2.0
20 Cc. Serum	91	M	77	2.6	2.0	2.4	2.2	2.8	3.1	4.2	3.2	2.8	3.0	3.2
2 Cc. Virus	92	F	87	3.8	3.2	2.8	2.7	2.0	2.4	2.4	2.1	2.2	2.1	2.2
15 Cc. Serum	93	F	70	2.4	3.0	2.2	2.0	2.6	2.4	2.3	2.4	1.8	2.6	1.6
2 Cc. Virus	94	M	81	2.8	3.2	2.8	2.4	2.6	2.5	2.6	3.0	2.6	2.4	2.6
2 Cc. Virus	95	F	45	3.6	3.4	3.6	3.4	4.6	5.4	4.8	5.2	4.0	4.8	5.2
2 Cc. Virus	96	M	47	3.2	4.0	3.2	3.4	3.6	3.7	4.2	4.0	6.4	6.2	6.0

RECORD OF SERUM TESTS—Continued

DAYS								POST MORTEM LESIONS							
6/11	6/12	6/13	6/14	6/15	6/16	6/17	6/18	Inguinal	Sub-Lumbar	Spleen	Mesenteric	Gastro-Hepatic	Kidney	Bronchial	Lungs
						Skin	Sub-max								
1.6	1.4	1.2	1.0	98.6	1.0	1.2	98.4								
2.2	2.0	1.8	1.3	1.2	1.4	1.6	1.4								
3.4	3.0	2.8	2.5	2.2	2.0	2.0	2.6								
2.0	2.2	2.4	2.0	2.2	2.2	2.4	2.2								
2.2	2.0	2.3	2.1	2.4	2.6	2.6	1.3								
2.8	2.6	2.8	2.5	2.6	2.8	2.6	2.2								
5.4	5.6	5.8	5.1	5.2	5.4	died 5.8	M	M	M	M	M	M	M	S	S
6.2	6.0	5.4	5.0	5.0	5.2	5.6	S	S	M	M	M	M	M	M	M

Key to Lesions: S—Slight. M—Well Marked. E—Extensive.

PLATE II.





Fig. 1

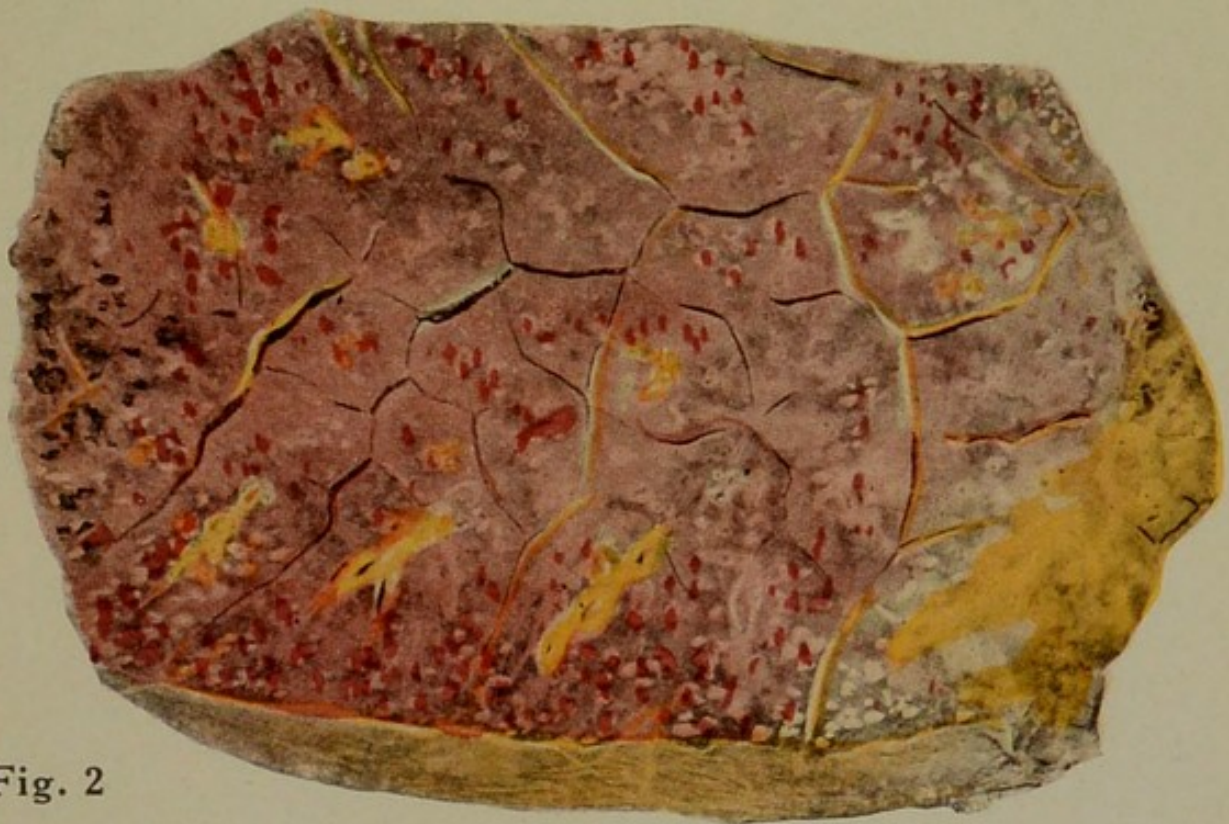

Fig. 2

FIG. 1. Thrombosis of the liver, showing red and white thrombi and thrombi in which decolorization is just taking place.

FIG. 2. Lung showing hemorrhagic areas due to hog cholera.



of the first four pigs should die of cholera during the time of the test.

The serum that has been tested and in which the two check pigs have died of cholera and the first six pigs have shown no visible illness nor any constant rise of temperature is ready for mixing and bottling, after which it is ready for use. The laboratory for mixing and bottling must be properly constructed in order that contamination of the serum may be reduced to a minimum and the necessary equipment, such as sterilizers, must be provided.

For mixing the serum a container must be selected that can be sterilized and from which the serum can be bottled.

After thoroughly mixing the serum constituting a series it is withdrawn into sterile bottles, the size of which will be determined by the demand. The bottles are properly sealed, labeled, and wrapped, and until needed put back in storage at a temperature not to exceed 50 degrees Fahrenheit.

The foregoing description is the general method of production of anti-hog-cholera serum. Many little factors that are of considerable importance have not been enumerated. The accompanying illustrations may convey some idea of the problems of the production of this product. The production of anti-hog-cholera serum has become of such vast importance to the swine industry of the country that Congress has provided means for its regulations in order that a potent serum may be obtained.

The following report of the committee on Uniform Methods for the Control of Hog Cholera was adopted by the United States Live Stock Sanitary Association in Chicago, December, 1913, and is a brief statement of the requirements for serum production:

Serum Production

Location of buildings.

Location to be such that surroundings will not interfere with sanitary production and that their operation will not contaminate surrounding areas.

Construction of buildings.

The construction of buildings to be of material that will permit of daily cleaning and disinfection, stone, brick, tile, and concrete being especially recommended.

Arrangement of plant.

1. The arrangement and equipment of buildings to be such as to insure the production of a pure and uncontaminated product.

2. Swine to be kept in separate buildings located a sufficient distance from the building containing the bleeding (either virus or serum) and hyperimmunizing rooms and in which swine are to be placed for the latter purpose only.




Fig. 21.—SERUM CENTRIFUGING ROOM.

1. A ten-quart centrifuge. 2. a four-quart centrifuge.

3. The serum bleeding room, the virus bleeding room, and the hyperimmunizing room to be separate and distinct rooms.

4. The preparation of serum, and the preparation of virus from the whole blood, to be operations conducted in separate and distinct rooms without direct communication with each other or with the foregoing not larger than an opening which will permit the transfer of receptacles containing the freshly drawn blood, and to be used for no other purpose.

5. Separate washing and sterilizing rooms to be provided.

6. The prepared serum and virus to be stored in properly cooled rooms.

7. Swine kept for virus production and the testing of serum to be properly isolated so as to reduce to a minimum the danger of spreading infection. Separate and distinct feed rooms to be provided for such animals.

8. Mortuary, crematory, abattoir, and desiccating or rendering plant operated for utilizing the waste products of the establishment to be located so as to prevent contamination from this source.

9. Necessary dressing and toilet rooms, properly equipped and located, to be provided. Also bottling and packing rooms.

10. Provision for the sanitary disposal of all manure, offal and debris.

Operation.

1. The operation of serum plants to be under the direct supervision of a competent veterinarian or other professional man whose training and experience have fitted him for this work.

2. Prohibition of the sale of serum and virus produced from animals affected with any contagious disease other than hog cholera and of any contaminated serum or virus.

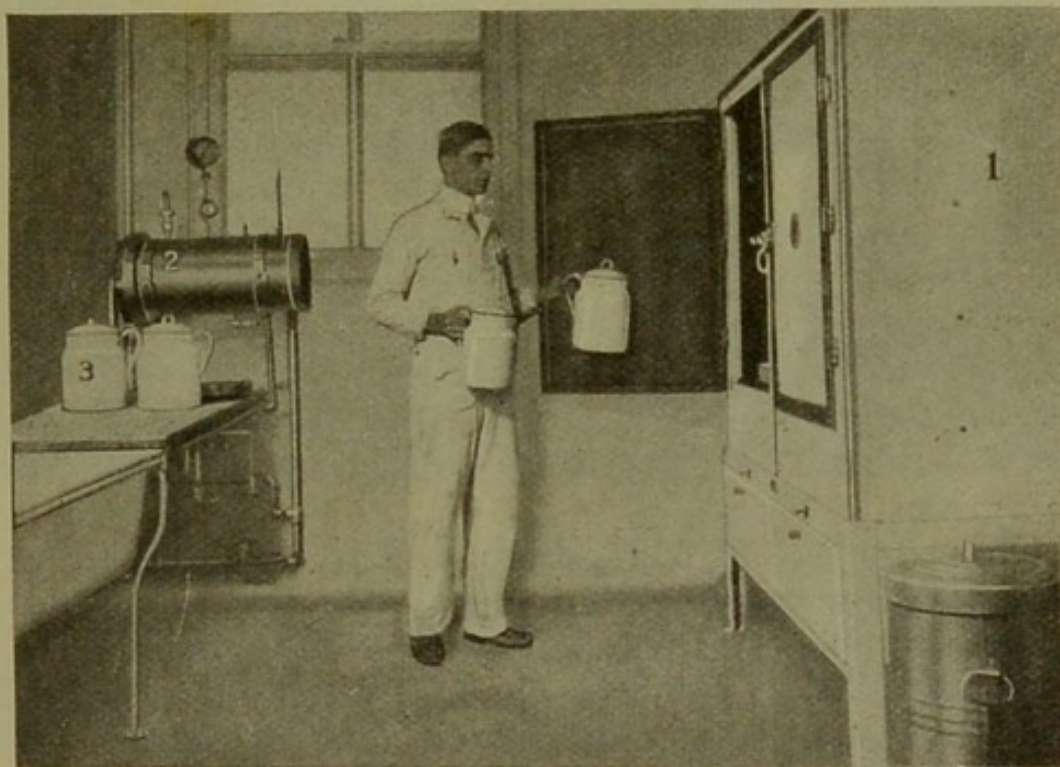


Fig. 22.—STERILIZING ROOM.

1. Electric sterilizer. 2. autoclave. 3. type of utensil used for collecting blood.

3. Provision requiring full and complete records of all steps in the manufacture and test of serum or virus.

4. The label on the container of serum or virus to show the true name of the product, the name or number of the manufacturer, the date of preparation, or the date after which the manufacture no longer guarantees the product, and a serial number to identify the product with the records of the establishment.

Two general methods are utilized in the immunization of swine with anti-hog-cholera serum—the serum alone method and the simultaneous method.

The exact method of administering serum has been freely discussed at various associations, and numerous articles have appeared in various publications. The operator must always provide clean and sterile instruments. It is true that the instruments become contaminated as soon as used, but at least two needles should be provided in order that one may be placed in a disinfecting solution while the other is in use. The syringe should be sterilized by boiling after being used for a few hours or after a herd has been immunized, before using it on another herd. The serum and virus should be injected deeply into the muscle in order to insure rapid absorption. Bad results frequently are the result of failure of absorption of the serum or virus that has been injected just beneath the skin in the subcutaneous fat. Swine that are in filthy, muddy pens should not be injected because of the probability of infection in the needle wounds, and swine that have quantities of mud or filth upon their bodies should not be injected. All swine that are injected should be reasonably clean, the point of injection should be painted with tincture of iodine, and the skin should be pinched after withdrawing the needle to prevent leakage.

The serum-alone method produces an immunity for a period of from one week to three months, but it does not entail any danger of infecting and producing cholera in a cholera-free herd and establishing new centers of cholera in a community free of the disease. By the proper use of serum alone in communities where there are only a few centers, cholera could be efficiently controlled. In such cases the infected herd and all surrounding herds should be immunized and if necessary the process could be repeated six weeks later. This method of control is not as applicable when several counties of a state, or the entire state, is infected. Serum alone, when given in large doses, is of considerable value in the incubation period of the disease before the animals show visible symptoms but after the temperature has risen. The judicious use of serum in such cases has saved as high as

eighty or ninety percent of the exposed herd. The serum alone is recommended for immunizing pregnant sows, because the simultaneous method frequently produces abortion. This method should also be used to immunize swine that are to be introduced into healthy, susceptible herds.

The dose of the serum in the serum-alone treatment should not be less than thirty cubic centimeters for each hundred-pound live weight of hog.

The simultaneous method is used more extensively




Fig. 23.—CHOLERA-IMMUNE HOGS.

There is a firm at the Stock Yards in Chicago manufacturing anti-hog cholera serum that makes a business of vaccinating hogs, that are to be kept in the Yards, at \$1.00 per hundred pounds and guaranteeing the owners against loss. These hogs are kept in the Yards from three weeks to two months and are driven about from pen to pen to clean up the feed left by other animals. They are of course continually exposed to virulent infection.

than the serum alone, because it produces a longer immunity. The dose of serum used in the simultaneous method should be fifty percent more than the dose in the serum-alone method. The serum and virus must be introduced separately in different parts of the body.

This method may be used successfully in exposed herds, especially in those swine that do not show a high temperature. But the virus should not be given to hogs that are showing visible signs of cholera.

The one serious disadvantage of the simultaneous method is the fact that infection is introduced. Good

authorities claim that a hog immunized by the simultaneous method does not eliminate the virus unless he dies of the disease, but this statement has not been clearly proved. Even though the virus is eliminated only in case of fatal illness of the immunized hog, the procedure is dangerous to say the least. The extensive epizootic of hog cholera in Iowa and adjoining states in 1913 bears the earmarks of the results of infection from simultaneous immunization.

To say the least, the use of the simultaneous method is contrary to good sanitation.

A so-called double method has been advocated by some for the prevention of cholera. It consists of the serum-alone immunization, followed ten days later by the simultaneous method. This method is quite efficient, but is rather expensive.

In time, the application of serum in the control of hog cholera will be rationally adjusted, and this, combined with the proper enforcement of efficient sanitary regulations, will result in diminishing the losses from this disease, and the swine industry may then be profitably pursued.

SWINE PLAGUE

Swine plague is a specific infectious disease caused by the *Bacillus suisepiticus* and is characterized, except in the septicemic form, by a catarrhal and necrotic pneumonia, with or without a fibrinous pleurisy.

The existence of this disease is doubted by some good authorities. In various sections of the United States a disease of swine, primarily confined to the lung and pleura and in its manifestations distinct from cholera, has been observed. The same disease has been identified in various other countries by other investigators. This disease is not so fatal, neither is it so widespread, as cholera. It may occur sporadically or enzootically, but it rarely assumes an epizootic form. The percentage of losses in affected herds varies from one percent to seventy percent.

Etiology.—The cause of swine plague is the *Bacillus suisepiticus*. This microorganism is a representative of

the hemorrhagic septicemia group. The *Bacillus suisepiticus* is a short, bipolar-staining, polymorphic, nonmotile organism, and does not form spores. The organism grows readily on practically all culture media, aëroically or anaëroically. It does not liquefy gelatine or coagulate milk, and is not stained by Gram's method.

Its vitality is prolonged for from five to fifteen days in soil, feces, and water when not exposed to sunlight, but is destroyed in two or three days by desiccation, and is easily destroyed by weak antiseptics. The organism is killed in twenty minutes by a temperature of fifty-eight degrees Centigrade.

Fowls, rabbits, and guinea pigs are susceptible to the pathogenic action of these organisms. The virulence of the *Bacillus suisepiticus* is quite variable and is likely to vary with suddenness. Intrapulmonary injections into swine usually produce multiple catarrhal pneumonia succeeded by necrotic pneumonia.

Source of infection.—The *Bacillus suisepiticus*, like the other representatives of this group, are widespread. They are frequently found in the respiratory passages of normal swine. Their virulence is variable, and it seems plausible that some predisposing condition must exist in the swine that become affected, or the organism suddenly, for some reason unexplained, becomes sufficiently virulent to produce the disease. In the most severe outbreaks it appears that the virulent organisms are transmitted from the diseased to the susceptible swine, or at least the disease becomes enzoötic in a very short time.

Channel of entrance.—The usual channel of entrance is by way of the respiratory organs, although it is possible that the organism may be successfully introduced through the digestive tract or skin.

Lesions.—The very acute disease is septicemic in form and is characterized by petechial hemorrhages in the skin and in the serous and mucous membranes. There may also be some enlargement of the lymph nodes and of the spleen. The usual form of the disease is characterized by catarrhal pneumonia, different areas of the lung show-

ing different stages of progress of the disease, such as congestion, red hepatization, gray hepatization, and later necrosis in which the necrotic material may be liquid or caseous. As a result of the variation of the progress of the disease in different areas the affected lung has a marbled or mottled appearance. There are some interlobular infiltrations; the bronchial and mediastinal glands may contain hemorrhages or necrotic centers; the pleura is usually affected with a fibrinous pleurisy with or without adhesions. In the more chronic cases the necrotic foci in the lung become more numerous and there may be a purulent or septic pleurisy due to the discharge into the pleural cavity of the necrotic pulmonary centers. There will be a diffuse redness of the skin.

Swine plague is frequently associated with hog cholera, and then the various lesions characterizing that disease will be present also, all of the lesions being variously modified.

Symptoms.—The period of incubation, at least in artificially infected cases, is of short duration, rarely exceeding two days. The septicemic type is ushered in suddenly with a high temperature, though it rarely exceeds 105 degrees Fahrenheit, accompanied by inappetence, weakness, and little tendency to move. The blush of the skin due to hyperemia may be observed. This form is rapidly fatal, the course rarely exceeding twelve hours.

The ordinary form of swine plague is evidenced by the usual symptoms of pneumonia, such as short, dry, spasmodic cough, dyspnea, temperature up to 105 degrees Fahrenheit, a disposition on the part of the affected animals frequently to sit on their haunches like a dog, mucous or mucopurulent nasal discharge, diminished appetite and finally cessation of appetite, and usually constipation. As the disease progresses, breathing becomes more difficult and there is extreme weakness and emaciation if the affected animals live long enough. The blush of the skin is usually present, and there may be conjunctivitis. The acute form usually terminates fatally

in about one week, but more rarely the disease becomes chronic.

The chronic form is evidenced by spasmodic cough, temperature of about 104 degrees Fahrenheit, poor appetite, emaciation, and weakness, the animals usually dying of exhaustion in from four to eight weeks.

Diagnosis.—The diagnosis of swine plague is attended with considerable difficulty. The septicemic form can be distinguished from the uncomplicated septicemic form of hog cholera only by the demonstration in the blood of the *Bacillus suisepiticus* or the presence of hog-cholera virus by the production of hog cholera by inoculation with the filtered blood.

From the pulmonary form of hog cholera the usual form of swine plague is differentiated only by autopsy. The lung lesions in hog cholera consist of a typical croupous pneumonia, but in swine plague they consist of a catarrhal pneumonia and, in the later stages, of necrosis. Pleuritic lesions are frequently present in swine plague.

Verminous pneumonia can be differentiated from swine plague by the chronicity of the attack, the wheezing respiration, and the demonstration on autopsy of the *Strongylus paradoxus*.

Catarrhal pneumonia is differentiated from swine plague by the fact that the former disease occurs only in young pigs and is sporadic, and rarely are the necrotic centers typical of swine plague found in the lung. Pleuritic complications are also the exception in catarrhal pneumonia.

Treatment.—Prevention by the enforcement of sanitary regulations is much more effective than curative treatment. The disease appears to be favored by dry weather, which usually insures dusty pens. Wetting of the pens with water or some dilute disinfectant prevents or diminishes the spread of the disease.

The use of a bacterin made from the *Bacillus suisepiticus*, tried out in a few herds, has not given uniformly good results, but this method is worthy of further trial and it is possible that a polyvalent bacterin prepared

from different strains of the different species of the representatives of the hemorrhagic septicemic group would be more efficient.

Immunization by means of a serum prepared by repeated injections of a horse with cultures of the *Bacillus suisepiticus* has been found partially successful, but the immunity thus produced was apparently of short duration. This method of immunization will probably not come into general use.

NECROBACILLOSIS

Necrobacillosis is a name for a group of diseased conditions caused by the *Bacillus necrophorus* and characterized by inflammation and necrosis. This condition is of common occurrence in one form or other in various locations in the United States and in other countries. The state of Colorado has suffered extensive losses from necrobacillosis; in fact, according to Glover, the losses from this disease in that state prior to 1912 were greater than the losses from cholera. The disease occurs sporadically, enzoötically, and rarely as an epizootic.

Etiology.—The *Bacillus necrophorus* is the cause of necrobacillosis. This microorganism is universally distributed, though the intestinal tract of swine may be its natural habitat. The *Bacillus necrophorus* is pleomorphic, but usually occurs in long threads in cultures and in the invaded tissues. It contains granules, particularly in old cultures. It is nonmotile and does not form spores. It is a strict anaërope and grows well in serum agar, bouillon, and milk. A pungent, disagreeable odor is evolved from the cultures, and may also be recognized in the lesions. It stains readily with practically all of the aniline dyes but not with Gram's stain.

The *Bacillus necrophorus* produces disease by products that it elaborates and eliminates into the tissue. This microorganism is pathogenic for practically all animals; but as a rule it is only a secondary invader, the tissue resistance having been diminished by previous disease process or by injury. Inoculations of cultures of the

Bacillus necrophorus produces necrosis, or abscess formation, in cattle, sheep, swine, and horses.

Source of infection.—The *Bacillus necrophorus* inhabits the digestive tube of swine and, less frequently, the digestive tube of other animals; therefore the microorganism is found in the feces of practically all animals. Soil, yards, pens, floors—in fact, practically all of the surroundings—easily become contaminated with fecal matter, and the disease may be obtained from anything that has been contaminated with feces. Infection is usually indirect, although the *Bacillus necrophorus* may be transmitted from an affected to a healthy animal by contact.

Channel of entrance.—This infective agent may be successfully introduced into the susceptible swine in food or drink by way of the mouth, upon inhaled dust particles by way of the respiratory organs, or it may be introduced through abrasions of the skin, and, more rarely, into the genital organs during copulation.

Lesions.—The *Bacillus necrophorus* is capable of invading practically any tissue of the body, and the lesions produced so closely resemble each other that one general description will suffice. The lesion consists of a coagulation necrosis, the necrotic material later becoming caseated. The local lesion has a tendency to become larger, due to the infiltration of the surrounding tissue with the products of the *Bacillus necrophorus*. The infection, and therefore the lesions, may occur elsewhere in the body, due to metastasis. There may be general emaciation due to absorption of the products of the *Bacillus necrophorus*, and tissue destruction.

The local specific lesion is a sharply circumscribed yellowish or brownish area containing a homogeneous, dry, mealy, or cheese-like substance from which a pungent and disagreeable odor emanates. Microscopic examination of a section of one of these areas reveals a central mass of tissue débris composed of disintegrating and destroyed cells which do not stain. Surrounding the necrotic area is a zone made up of leukocytes, damaged

tissue cells, and considerable numbers of *Bacillus necrophorus* filaments arranged in bundles. The surrounding tissue evidences a severe reaction by hyperemia, and the presence of large numbers of leukocytes and a few *Bacilli necrophorus*.

Necrobacillosis assumes many different forms, the most common of which are necrotic stomatitis, enteritis, rhinitis, pneumonia, hepatitis, splenitis, vaginitis, and dermatitis.

Necrotic Stomatitis

Necrotic stomatitis is probably the most common form of necrobacillosis. It is of frequent occurrence in suckling pigs.

Lesions and symptoms.—The inflammation usually begins at the margins of the gums. The successive changes in the affected areas are as follows. The surface is red or bluish red, becomes tumefied, is very sensitive, and bleeds easily. Two or three days later the area becomes yellowish white or even brown in color and of a mushy consistency, and usually sloughs, leaving an eroded surface which is covered by a coagulated necrotic tissue and appears as a diphtheritic membrane. The surrounding tissue becomes red, tumefied, and sensitive. The disease process gradually extends and ultimately becomes confluent, forming large eroded areas. A similar process frequently affects the lips simultaneously.

The affected pigs frequently attempt to nurse, but the gums are so sensitive that they obtain little nourishment. Pigs may transmit the disease to the teats of their mother by nursing. There is salivation and champing of the teeth. Upon inspection the foregoing lesions are observed and a peculiar disagreeable odor is also noted which may permeate the air and be recognized at a considerable distance. As the disease progresses the discharged saliva becomes bloody and contains shreds of tissue.

The course of this disease varies from a few days in the acute form to several weeks in the chronic form.

Diagnosis.—The identification of necrotic stomatitis is not difficult if the typical necrotic lesions are observed and the peculiar offensive odor is recognized.

Treatment.—In the early stages the treatment of the cases may be successful, but in the advanced stages the disease usually proves fatal regardless of treatment. The most successful treatment consists in washing the oral cavity and applying upon the eroded areas one-percent solutions of silver nitrate or three- to five-percent solutions of zinc chlorid. Local treatment should be repeated frequently.

Necrotic Enteritis

This is frequently a sequel to necrotic stomatitis, the infection passing along the digestive tube in the patches of sloughed necrotic tissue or directly from the intestinal content. Necrotic enteritis is relatively common in swine. It frequently accompanies hog cholera.

Lesions.—The lesions of necrotic enteritis are most common in the mucous membrane of the intestine near the ileocecal orifice. The lesion is very similar to that of necrotic stomatitis, except that here the necrotic tissue usually remains intact and becomes coagulated and mealy or caseous. This adhering pseudomembrane may occur in small, scattered, circumscribed areas, or practically the entire mucous membrane may be involved. Microscopically the surface epithelia in the affected areas are found disintegrated and commingled with the coagulated débris upon the mucous surface.

Symptoms.—This condition frequently exists to a limited degree without manifestation of any symptoms. In the cases where the lesions are more extensive there is indigestion, colicky pains, and diarrhea. Later the appetite may be diminished or the desire for food may cease; the animals become unthrifty, emaciated, and weak. The course varies with the intensity of the disease; it may run a rapid course or it may become chronic. It is rarely fatal.

Treatment.—Proper dieting and the provision of good sanitary quarters must first be considered. The use of castor oil to clean the bowel of offending material is a good practice. Intestinal antiseptics, too, may be used to good advantage.

Necrotic Rhinitis

This condition is usually associated with necrosis of the snout and frequently also of the lips, and is of rather common occurrence in small pigs. It is one of the conditions that constitutes the disease called sniffles. Sniffles also includes catarrhal rhinitis, particularly those cases in which deformity of the snout and nasal cavities occurs,

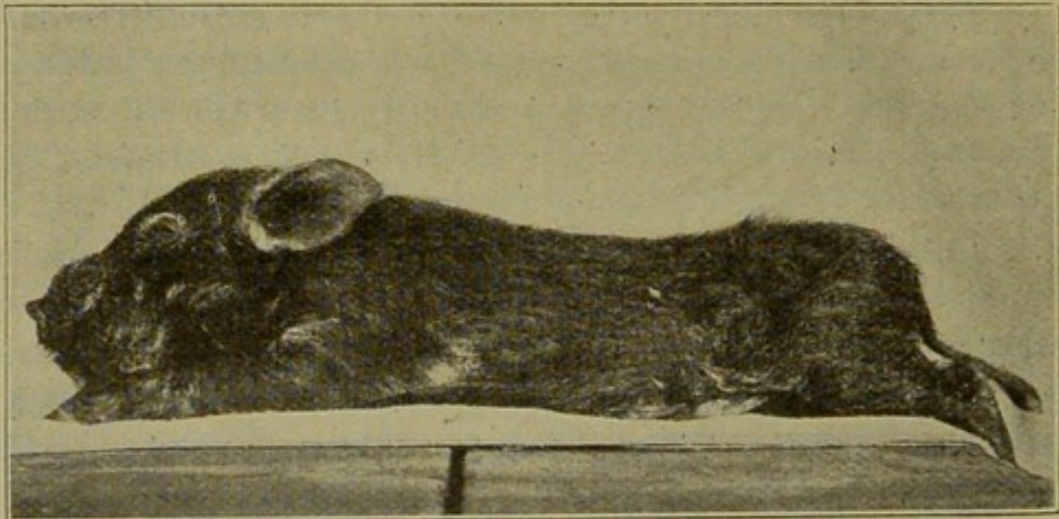


Fig. 24.—NECROBACILLOSIS.

and those cases of rickets in which there is involvement of the nasal and facial bones, causing more or less deformity.

Lesions.—Necrobacillosis of the schneiderian mucous membrane and the snout is characterized by the same lesions that are characteristic of necrotic stomatitis, except that here bone tissue is frequently involved, resulting in fibrinous proliferation and deformity of the parts.

Symptoms.—The affected animals have a tendency to root considerably in their food, but they eat little. The characteristic symptom consists of a peculiar blowing noise. The animals sneeze, and occasionally expel

bloody material containing shreds of tissue. The snout becomes enlarged and the face bulging, this condition frequently being called an elephant head.

Treatment.—It is not possible to efficiently treat these cases because of the difficulty of applying medicaments to the lesion and further because of the destructive changes in the bones of the nose and face.

Necrotic Pneumonia

Necrotic pneumonia is frequently an associated condition of necrotic rhinitis, the infection taking place by the inhalation of necrotic particles from the nose.

Lesions.—The same general coagulation necrosis type of lesions that characterizes necrobacillosis are observed also in necrotic pneumonia.

Symptoms.—Manifestations of the disease are similar to those of croupous pneumonia, though evidence of septic intoxication is more pronounced than in the latter. The very offensive odor of the expired air characterizes pulmonary necrobacillosis.

Treatment.—Treatment other than providing good, nourishing food and sanitary surroundings is of little or no avail.

Necrotic Hepatitis

Hepatic necrobacillosis is not of common occurrence, but some cases have been observed. It is usually secondary to necrotic enteritis, the infection passing through the portal system and metastasizing in the liver.

Lesions.—The lesions consist of sharply circumscribed grayish-white areas varying in size from that of a pinhead to a silver dollar. These areas may be surrounded by a fibrous capsule. The density or consistency of the lesion depends upon its age. It may be of the same consistency as the surrounding liver, it may be dry and mealy, or, if the animal recovers, it may become calcareous. These areas may not cause any irregularity in the size or shape of the liver or the lesion may assume the nodular form, the nodules projecting from the surface of the liver. The surface nodules have a raised border

and a depressed center, and are quite characteristic in appearance.

Symptoms.—No definite symptoms have been attributed to hepatic necrobacillosis other than general digestive derangement. These cases are diagnosed at autopsy.

Treatment.—The location of the lesions and the nature of the process practically eliminate the possibility of successful treatment.

Necrotic Splenitis

Splenic necrosis is a rather common condition in swine. It may be caused by other agencies than the *Bacillus necrophorus*, but from investigations thus far conducted it appears that the most frequent cause of necrosis of the spleen is the *Bacillus necrophorus*. This condition is commonly associated with the use of a contaminated hog-cholera virus. The infection is carried in the blood to the spleen.

Lesions.—The necrotic centers in the spleen are usually encapsulated, the density of the capsule varying with the length of duration of the process. As a rule, the centers are in the form of nodules. They are of a grayish-white color and usually have a depressed center and a raised border. In size these foci vary from masses half an inch in diameter to irregular masses from one to three inches in diameter. There may be only a few centers, but usually there are many; in some instances so numerous are they that it is difficult to identify any normal splenic tissue. The non-encapsulated lesions are dirty-white centers and give the appearance of having been painted in the splenic tissue.

Symptoms are indistinct, and treatment cannot be applied.

Vaginal Vulvar and Preputial Necrosis

Necrotic vaginitis and vulvitis occurs, but is not prevalent. Infection probably gains entrance through abrasions produced at the time of parturition or copulation or, more rarely, by means of accidental traumatic

wounds. The lesions consist of tumefaction, redness, and sensitiveness, followed by necrosis. The necrotic tissue may become desiccated and slough, or it may be converted into a mushy mass. The erosion of the vulva may destroy the vulvar tissue and even the anal tissue. Dense masses of fibrous tissue usually develop in the

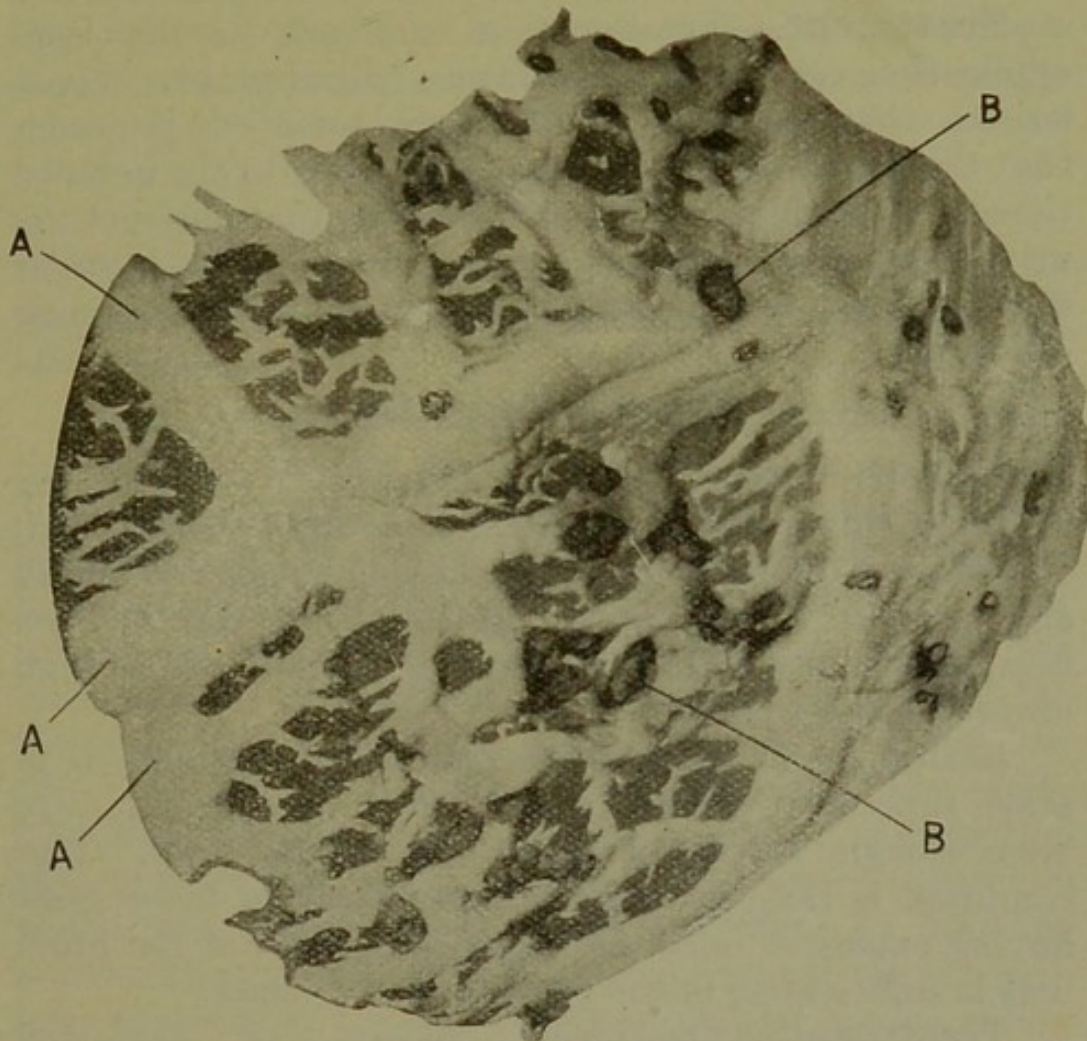


Fig. 25.—FAT NECROSIS (Omentum).
A. Normal fat. B. areas of necrosis.

perinecrotic zone, which later cicatrizes and produces various distortions of the vulvo-anal structures.

Infection of the prepuce may gain entrance through abrasions produced by inflammation that has resulted from irritation from urine, screw worms, or similar causes. Infection may also be favored by traumatic injuries of various kinds. The lesions are of the same

general nature as those observed in vulvitis. The prepuce occasionally becomes entirely destroyed, and sometimes the penis becomes involved.

The vulvar and preputial lesions sometimes interfere with, and even inhibit urination, resulting in retention of urine. In such cases in the male the sheath may become enormously distended with urine.

Treatment.—Treatment is confined to the local application of some penetrating disinfectant. Those lesions that become necrotic are removed in order that the disinfectant may have free access to the invaded tissue. Adhesions and other conditions that obstruct the urine should be corrected, at least temporarily, in order that the urine may be voided and thus uremic poisoning prevented.

Necrotic Dermatitis

Necrotic dermatitis, aside from the type affecting the lips, vulva, and prepuce, is sometimes encountered. It is of most frequent occurrence in young pigs, and affects any portion of the body. Infection of the *Bacillus necrophorus* into the skin is probably possible only through abrasions and wounds.

Lesions.—The lesions are practically the same as in other superficial necrobacillosis. Not infrequently large areas slough, leaving irregular denuded surfaces. This condition is frequently fatal, particularly in those cases having extensive infection where absorption of the products is sufficient to insure systemic disturbance.

Treatment.—Treatment consists of removing necrotic tissue and applying some antiseptic that will readily penetrate the infected area. The treatment must be persistent, as relief cannot be obtained from one application.

Unusual Forms of Necrobacillosis

Necrobacillosis sometimes occurs in the various structures of the eye. This is a serious condition, as the agents used in combating the *Bacillus necrophorus* have to be used in such concentration that they are injurious

to the eye. The usual outcome of ocular necrobacillosis is destruction of the eye, and if both eyes are involved the animal becomes blind and usually has to be destroyed.

Necrobacillosis as a sequel of castration has been previously discussed (See p. 120).

Necrobacillosis is a disease that may affect practically any and all tissues of swine and is of considerable economic importance. The most common forms of the disease are necrotic stomatitis and enteritis, and necrosis of the sheath.

TUBERCULOSIS

Tuberculosis is a specific infective disease caused by the tubercle bacillus and characterized by the formation of tubercles.

History.—Tuberculosis has been recognized from the remotest time in the history of man as a prevalent disease of mankind. In 1689 the tubercle was identified by Morton as the typical lesion of tuberculosis. Various investigators have given additional knowledge on the subject of tuberculosis. In 1865 Villemin proved the infectiousness of the disease, while Koch discovered the tubercle bacillus in 1882, thus establishing firmly the theory of the infectiousness of tuberculosis. The study of tuberculosis has been advanced and its recognition clinically has been made possible by the use of tuberculin which was discovered by Koch in 1890. In 1901 he startled the scientific world by announcing at the tuberculosis congress in London that human and bovine tuberculosis were separate and distinct diseases, a statement that was responsible for the organization of different scientific bodies that, after careful investigation, reported that although there may be some slight difference between the tubercle of human and bovine origin, the disease produced is the same and that the disease is inter-transmissible between animals and man.

Occurrence.—Tuberculosis is becoming very prevalent among swine. This is due to the fact that the dairying industry is becoming more extensive and the byprod-

ucts of milk are used for swine feed. A relatively large percentage of dairy cattle is tuberculous, and the infection gains entrance to the milk on filth that is contaminated with infected discharges, such as saliva and feces. The organism may also be eliminated direct from the mammary gland into the milk.

Swine from some sections of the United States have been found by experience to be so extensively tuberculous that some packers will buy them only subject to post-mortem inspection.

In Germany from 2.46 to 2.81 percent of swine slaughtered at abattoirs were condemned on account of tuberculosis. The disease is very prevalent in Belgium, France, Norway, and Sweden, and porcine tuberculosis is a common disease in the British Isles. According to the annual report of the Bureau of Animal Industry for 1911, 29,920,260 carcasses of swine were inspected in abattoirs, and of that number 31,517 carcasses and 870,361 parts were condemned on account of tuberculosis. The disease is becoming more extensive in swine in the United States and should receive more consideration than it does, for the economic loss annually is enormous.

Etiology.—The cause of tuberculosis is the tubercle bacillus or the *Bacillus* of Koch. It is a rod-shaped organism from 1.5 to 4 microns long and .3 to .5 micron in width, and is usually curved or slightly bent. It may contain granules or the body may be uniform. It is nonmotile and does not form spores. This organism is covered with a waxlike substance which renders it more difficult to stain than ordinary bacteria, but after the organism has been stained, which can be accomplished by applying steaming carbolfuchsin for five minutes, it retains the stain even when subjected to the action of acids; for this reason it has been called an acid-fast bacterium. It is an aerobe, and grows with relative slowness. It grows luxuriantly in egg albumen culture medium, and fairly well on glycerine agar and in glycerine bouillon. Tubercle bacilli from different sources manifest different cultural characteristics, and on this basis some

PLATE III.

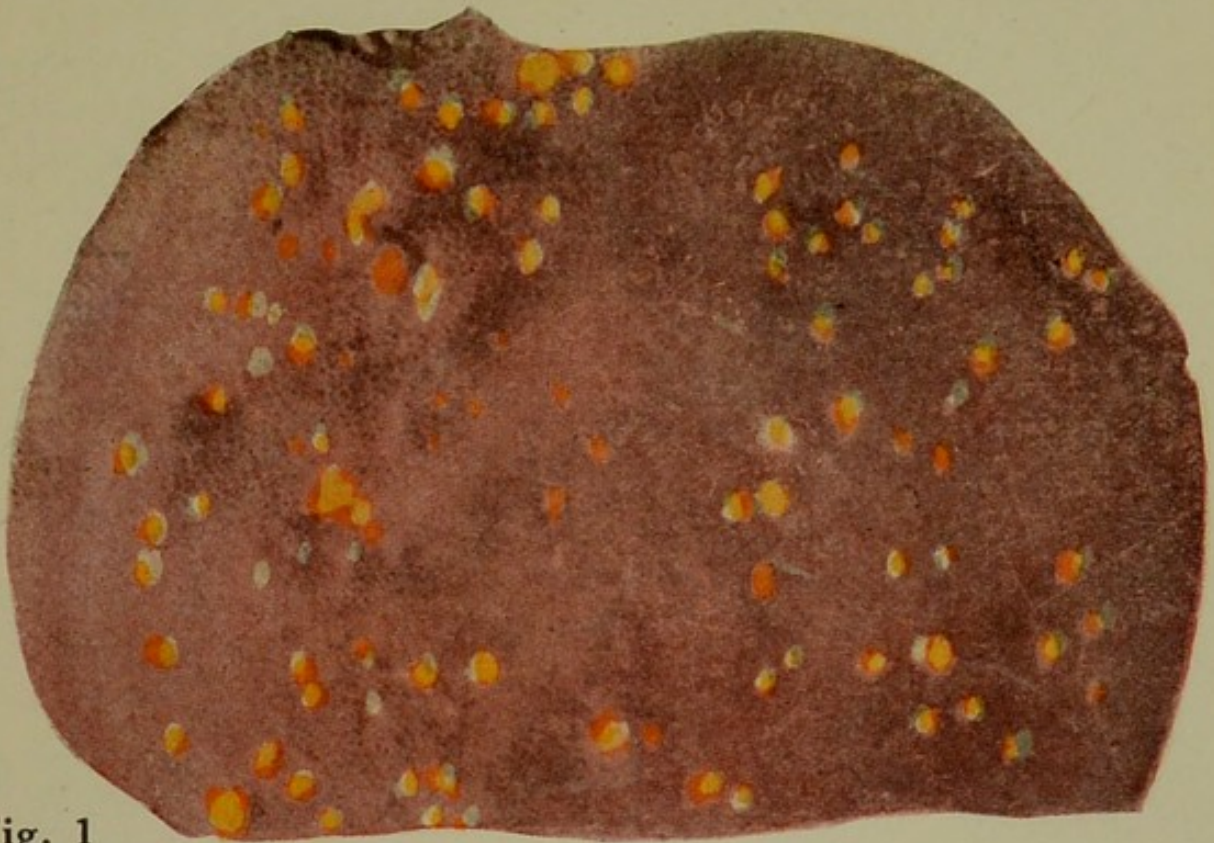

Fig. 1



Fig. 2

Fig. 1. A typical tuberculous liver.

Fig. 2. Vertebrae showing tuberculous bone lesions.

THE UNIVERSITY OF CHICAGO
LIBRARY

have claimed four varieties of tubercle bacilli, namely, human, bovine, avian, and reptilian. The bovine and human types have been encountered in swine.

The tubercle bacilli are very resistant to external injurious influences. This resistance is probably due to the waxy coat they possess. Direct sunlight destroys them when freely exposed for twenty to thirty minutes, but they retain their vitality and virulence for from ten to twenty days when exposed to diffuse daylight. When desiccated and not exposed to light they may retain their virulence for four months or even longer. In decomposing tubercular tissues they remain virulent for a long time. In milk they retain virulence for ten days. Dry heat at 212 degrees Fahrenheit destroys them in one hour; moist heat at the boiling temperature will destroy them in fifteen minutes. They are also destroyed by chemical disinfectants, the length of time for exposure depending upon the concentration of solution and the nature of the tissue or discharge incorporating the bacilli. Gastric juice does not destroy the tubercle bacilli, and bile has little or no injurious effect upon them.

The inoculation of healthy, susceptible animals with virulent bacilli produces tuberculosis, the extent of the lesions produced depending upon the virulence of the bacilli injected and upon the resistance of the inoculated animal.

Source of infection.—Tubercle bacilli are eliminated from the affected animals, at least when there are open lesions in organs, the secretions or excretions of which pass to the outside world. Thus the tubercle bacilli are eliminated in the feces from animals having tubercular ulcers of the intestinal mucosa. Open tuberculous lesions of the respiratory tract would permit of the elimination of the tubercle bacilli in the discharge from the air tubes and also in the feces, for the chances are that the pharynx would become contaminated by the pulmonary or tracheal discharge and this infection would be carried with food or drink and ultimately pass from the body in the feces. Tubercle bacilli from lesions

in the liver or pancreas may also be eliminated in the feces.

Tubercle bacilli from open tubercular lesions of the urogenital organs are eliminated in the urine, seminal fluid, or other discharges from these organs. Infection is directly eliminated from open, cutaneous, tuberculous lesions, and tubercle bacilli may be eliminated in the milk, especially if tuberculous lesions exist in the mammary gland.

The dissemination of tubercle bacilli in the body and the possibility of their elimination through any channel is facilitated by leukocytes. Thus tubercle bacilli in the lung may be incorporated and retained by leukocytes that are later eliminated by the mammary cells, and the milk become infected even though the mammary gland contain no tuberculous lesions.

From the foregoing it is evident that any of the discharges of tuberculous animals may contain the tubercle bacilli. In the United States and in practically all other countries tuberculosis of cattle is prevalent, particularly among cattle used for dairy purposes.

The most frequent source of porcine tuberculosis is from tuberculous cattle. Swine become infected from infected cow's milk, feces, nasal discharges, and the carcasses of tuberculous cattle that are given them for food. A limited number of swine become infected from garbage that contains the human tubercle bacilli. This has been especially observed in swine fed upon garbage from tuberculosis sanitariums, or hotels. An occasional case of uterine, ovarian, or testicular tuberculosis is the result of direct infection by copulation. It is possible that infection may be transmitted in the exhaled air from infected to healthy swine.

Channels of entrance.—The most frequent channel of entrance of the tubercle bacilli in swine is the digestive tube, the infection being introduced in food or water. An occasional case may become infected by the inhalation of the bacilli and by direct transmission through the genital organs. Mammary tuberculosis may be the result

of cutaneous infection or it may be transmitted from elsewhere in the body.

The transmission of the tubercle bacilli from the mother to the fetus is possible but it is of rare occurrence. But a weakened condition or susceptibility to the disease may and frequently is transmitted from the mother to the fetus.

Lesions.—The typical initial lesion of tuberculosis is the tubercle which has been aptly defined as a nonvascular nodule composed of leukocytes, endothelial, giant and connective tissue cells, with a tendency for the central part of the nodule to undergo necrosis. There




Fig. 26.—TUBERCULOSIS OF THE TONGUE.

A. Normal muscle. B. tuberculous lesions. This is a rare condition in swine.

may be slight variation in the tubercle in different animals, due to variation of susceptibility of the animal and variation of the virulency of the infecting bacilli. The typical lesion may also be materially modified by secondary lesions. Tuberculous lesions may occur in any tissue or organ, but lymphoid tissue is most frequently affected.

The tubercle bacilli and their products are the causative factors in the formation of a tubercle. Having lodged in a tissue favorable for their growth and development, the bacilli begin to multiply and to eliminate products that stimulate the surrounding connective tissue and endothelial cells to increase in number, and at the

same time exert a positive chemotactic action upon the leukocytes. In swine there is a very marked chemotactic action and limited stimulation of connective tissue. The typical porcine tuberculosis tubercle is largely composed of leukocytes and has little fibrous tissue.

Tubercles grow because of the increased accumulation of leukocytes and the formation of a small quantity of fibrous tissue. The tubercle contains no blood vessels; that is, it is nonvascular, although in the early stages there may be a hyperemic zone around the tubercle. This hyperemic zone is the result of irritation in the tissue,

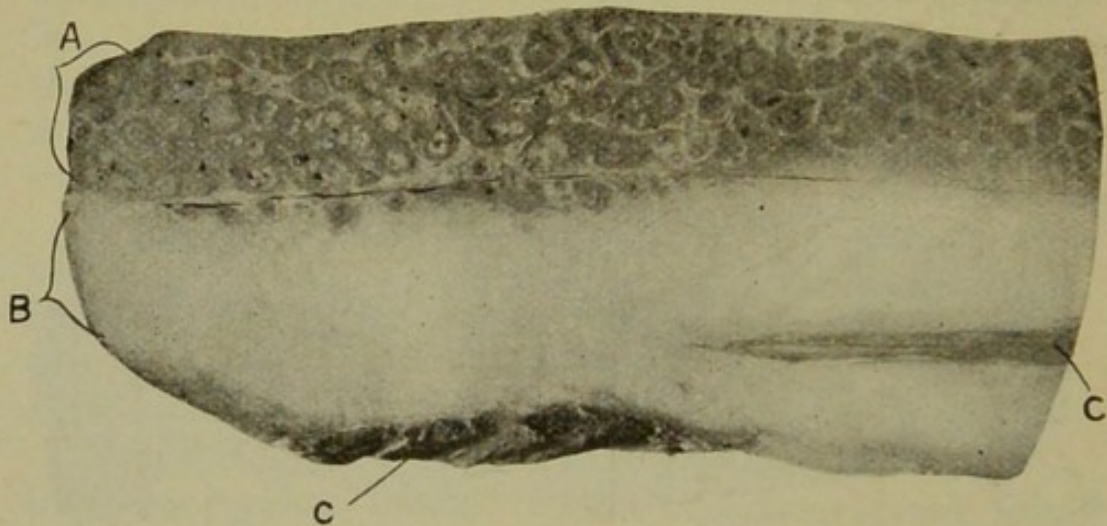


Fig. 27.—TUBERCULOSIS OF THE SKIN.

A. The skin showing caseo-calcareous lesions. B. subcutaneous fat. C. muscle.

the tubercle formation causing a tissue reaction. As the tubercle becomes larger, due to the accumulation of leukocytes on the margin, the central part begins to degenerate.

Porcine tubercular lesions are characterized by enlargement of lymphatic glands, the formation of tubercles of variable sizes in or upon serous membranes and within the substance of glandular organs, bones, and other connective tissues. The tubercles produce increased density of invaded soft tissues and are, therefore, easily detected except in very recent infection. The tubercular nodules in the early stages present about the same color as the surface of the tissue invaded. In sectioning the

tubercle the central portion is caseous and slightly yellow, or fibrous and white. Sometimes there is a combination of both conditions, and occasionally the tubercles contain calcareous granules. The central portion of porcine tubercles rarely contains liquefied necrotic tissue.

Microscopically, porcine tubercular lesions are always cellular in the beginning, the cellular tubercles being fairly constant in structure, regardless of the tissue in which they occur. The center is at first represented by a mass of lymphoid cells, the other cellular elements occurring as the tubercle develops.

Necrosis, or fibrosis, succeeds the cellular stage in the porcine tubercular lesion. Necrosis of tubercles is probably the result of the activity of virulent bacteria or the low resistance of the infected animal. The necrotic center may be surrounded by a cellular zone (lymphoid and endothelial cells), or it may be surrounded by fibroblasts. The necrotic material is invariably caseated and later becomes calcified.

Fibrous lesions vary from the formation of small quantities of fibrous tissue to dense fibrous centers. They are probably produced by bacteria of low virulence, or occur in animals having a marked resistance. The central portion of the fibrous lesion may become calcified.

The so-called arbor vitæ gland is a fibrous center in which the fibrous tissue is arranged similarly to the trunk and branches of a tree, hence the name. In the hog, this lesion is observed in the cervical lymph nodes. The *Bacterium tuberculosis* has been demonstrated in about thirty per cent of arbor vitæ glands.

The lesions of porcine tuberculosis are in brief either cellular, necrotic, and calcified tubercles, or cellular, fibrous, and calcified tubercles. The lesion is always nonvascular, as in other animals.

Tubercular lesions are most common in the digestive viscera. The liver and spleen frequently contain caseous nodules.

Pulmonary porcine tuberculosis manifests itself either by a few or many cheesy foci or by a few large centers.

There may be a general caseous pneumonia associated with more or less pleurisy.

Tubercular involvement of the nervous tissue occurs in swine, but is relatively rare. One case has been observed in which a tubercular center occurred in the cerebral tissue. Tuberculosis of the meninges may be local and circumscribed or diffuse and quite general.

Osseous tuberculosis is of common occurrence in swine. It is found especially in the vertebræ.

Symptoms.—Tuberculosis is essentially a chronic disease. The onset is usually so insidious that no abnormality is suspected, and the usual clinical examination of swine is not sufficient to predicate a diagnosis because the symptoms are so indistinct. Lymph-gland involvements result in tumefaction. The enlarged glands are not pathognomonic of tuberculosis.

Tubercular invasion of the digestive organs produces indigestion. The digestive derangements develop slowly and usually only in young pigs. They become unthrifty and emaciated as the disease progresses.

Pulmonary tuberculosis is evidenced by a dry, short, suppressed cough and by some difficulty of breathing. The cough becomes more aggravated, and the animals become weak and thin and have a rough coat.

Tuberculosis of the brain, or meninges, is not common and the symptoms evidenced will depend upon the location of the lesion.

Osseous tuberculosis is associated with interference of locomotion and tumefaction of the affected bone.

The length of the course of tuberculosis is variable. In young pigs it may produce fatal termination in from two to three months after the onset. Older swine rarely die of tuberculosis, as the disease assumes a chronic form in them and they are usually marketed before the disease has manifested itself clinically.

Diagnosis.—The clinical diagnosis of this disease is practically impossible without the use of the tuberculin test. The lesions may be identified and the disease can therefore be recognized by autopsy.

PLATE IV.

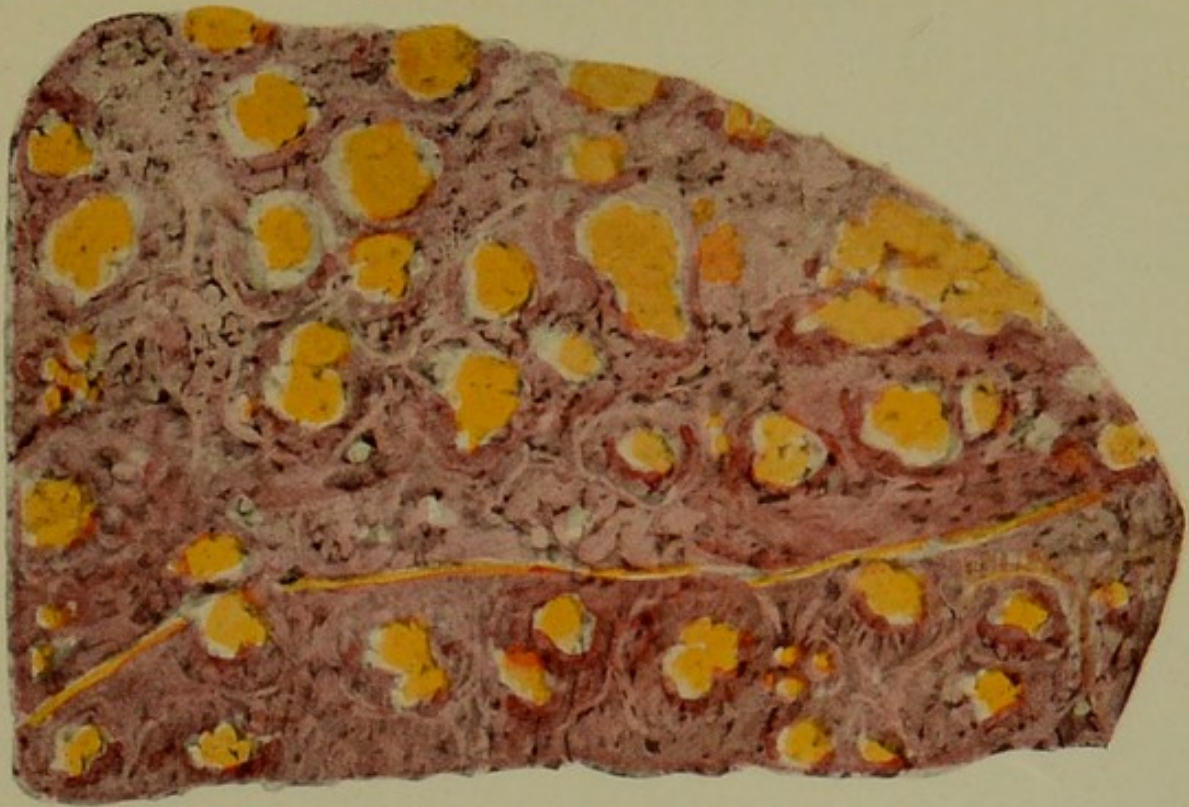


Fig. 1



Fig. 2

FIG. 1. Spleen showing calcified tubercles surrounded by hyperemic margins.

FIG. 2. Lung showing areas of normal tissue, areas of red hepatization and caseo-calcareous, tubercular areas.



The intradermal tuberculin test is most applicable to swine. This test is made by the injection into the dermis at the base of the ear of from three to five minims of ordinary tuberculin.* The reaction consists of a dense swelling at the point of injection and becomes most prominent on the second or third day after injection.

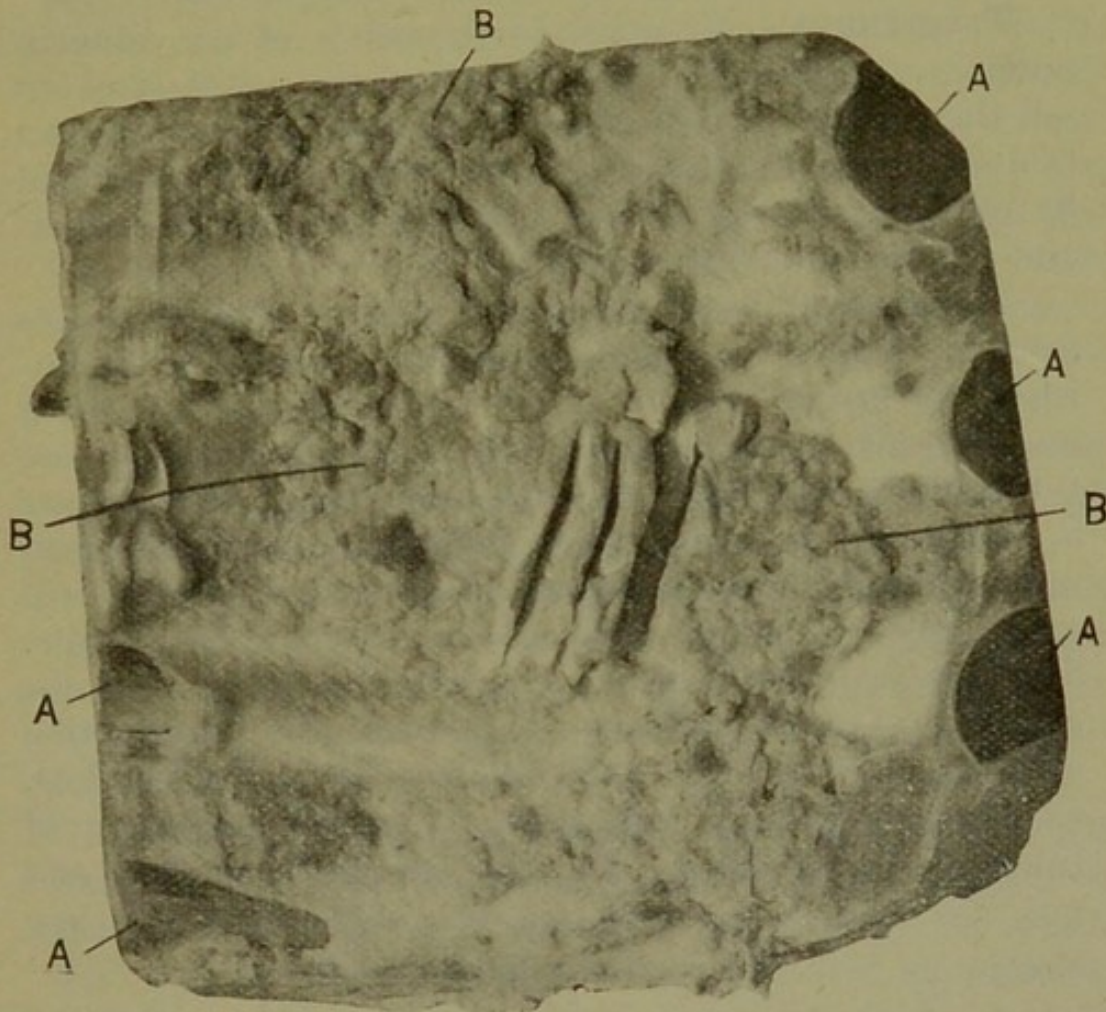


Fig. 28.—TUBERCULOSIS OF THE PLEURA.
A. Rib. B. masses of tubercles.

The subcutaneous tuberculin test may be used, but it is not as applicable to swine as it is to cattle. The ophthalmic test may also be employed in swine.

Microscopic examination may be made of the various discharges for the purpose of identifying the tubercle

*The Bureau of Animal Industry have issued an order that all swine used for tail bleeders in serum production must be tested with especially prepared intradermal tuberculin. The object of this order is not clear, as the ordinary tuberculin is as efficient as special intradermal tuberculin,

bacilli. In making this test it must be remembered that there are other acid-fast bacteria and further that the absence of tubercle bacilli in the preparations examined is not positive proof of the absence of the disease.

Animal inoculations may be resorted to, particularly in cases in which no tuberculin test has been made and there is a dispute as to the nature of the lesions found.

Treatment.—Curative treatment is of no value in porcine tuberculosis. The only rational method is to sell the affected swine subject to the post-mortem inspection findings. In this way some value will be obtained by the original owner, there will be no loss to the packer, and no danger to the consumer.

Tuberculosis is a preventable disease and the losses from it could be avoided, or at least materially diminished, by proper control of tuberculosis in cattle. With our present farm methods the eradication of porcine tuberculosis cannot be accomplished until the disease is eradicated in cattle. The judicious use of skimmed milk, including pasteurizing milk from suspected cows, will materially diminish tuberculosis in milk-fed swine. The tuberculin testing of steers or other cattle and the elimination of all reactors will prevent the introduction of tuberculosis in swine that follow cattle in the feed lots. Cooking of garbage will prevent the dissemination of tuberculosis to swine. Denver garbage is cooked and fed to swine, the infection of tuberculosis and hog cholera as well is thus eliminated.

OMPHALOPHLEBITIS, PYEMIC ARTHRITIS (NAVEL ILL)

This is an acute infectious disease of recently farrowed pigs characterized by inflammation of the umbilical tissues and suppurative arthritis.

Navel or joint ill has prevailed more or less extensively since the dawn of history. In some years this disease is responsible for the loss of a large percentage of the young pigs produced in certain communities. The disease

occurs enzoötically and as an epizoötic, sporadic cases being rare.

Etiology.—This condition is caused by infection, but the specific exciting cause has not been positively identified. The *Staphylococcus pyogenes aureus* has been isolated from the lesions and was apparently present in practically a pure culture. A *Streptococcus* appears to be the exciting cause in some cases, and in other cases the colon bacillus or some of its derivatives have been identified. *Bacillus pyocyaneus* sometimes causes this condition. The young animals are predisposed to the various types of infection by filthy surroundings and improper care. Some breeders claim that if the sows are permitted to farrow in clean quarters, and are maintained and fed in the proper way, that the pigs will not contract this disease.

There is evidence of the transmission of the disease *in utero* from the dam to the foal in horses, but such evidence has not been obtained in swine.

The infection gains entrance through the thrombi in the umbilical vessels. The infecting organisms extend in the thrombus, ultimately reaching the blood stream, by means of which they are disseminated throughout the body.

Lesions.—The manifestations of this disease are variable and depend upon the number and virulency of the infecting organism and their location in the body. The typical lesions consist of omphalitis and suppurative arthritis. Inflammation of the umbilical vessels may be limited or there may be an accumulation of pus, the inflammation being a typical suppuration and abscess formation. The lesions of the joints are variable. There may be a mild synovitis with limited or extensive infiltration and tumefaction of the structures surrounding the synovial membrane, in which cases the synovial membrane is injected and tumefied. There is an increased amount of fluid and it will be turbid and perhaps contain flakes of coagulated material. In other instances the synovial membrane will be distended with accumulated

pus and surrounding tissues may also be infiltrated with pus.

Metastatic abscesses may occur in various organs, as in the liver and spleen. If the infection extend to the bladder there will also be a purulent cystitis.

Symptoms.—The symptoms usually appear in the first week of life, although they may occur in the second or third week after farrowing. The affected pigs will be lame and indisposed to move. On examination one or more of the articulations are found to be swollen and sensitive, the tarsal joints being most frequently involved. There may be diarrhea. The course of the disease is usually brief, the pigs as a rule dying on the second or third day.

Treatment.—Curative treatment is of little value. The disease may be prevented by providing clean pens and keeping them clean before and after farrowing.

SPASMS OF THE DIAPHRAGM (THUMPS)

Thumps is a condition caused by violent contractions of the diaphragm, and is relatively common in small pigs.

Etiology.—This condition is apparently due to some interference of the diaphragm, and is usually associated with overloading of the stomach or insufficient exercise.

Symptoms.—There is a sudden jerking of the flanks. This symptom is very prominent when it occurs in a pig that is standing quietly, and there may be an accompanying sound that is quite distinct. There is an irregularity in the frequency of the contractions; sometimes they occur in rapid succession, followed by a period of apparently a normal condition, then another series of contractions. Exercise and a full stomach aggravate the condition. The pig may become weak and emaciated. The course of the disease varies from one week to two or three months.

Treatment.—Good nourishing food and plenty of exercise are usually sufficient to correct spasms of the diaphragm. Small doses of from two to three drops of tincture of opium, administered with oil, will usually give temporary relief.

Rabies

Rabies occurs in swine, but is not prevalent. It may occur enzoötically, but is much more likely to affect only one animal, or few animals at most, in any one locality.

Etiology.—Rabies is caused by a virus, but the exact nature of this virus has not been determined more than that it is filterable. Recently it has been successfully cultivated.

Source and manner of infection.—The usual source of rabies in swine is from an infected animal, usually a dog. Rabid dogs meandering through the country occasionally attack swine, biting and thus infecting them.

Lesions.—Gross lesions are absent in swine that have died of rabies. Foreign substances may be found in the stomach, but swine have a habit of consuming almost anything and therefore foreign bodies in the stomach has little significance. Microscopically, Negri bodies are found in the cells of the amnion horn, and also in the cells of the cerebellar cortex. These bodies are the same in swine as in other animals.

Symptoms.—Affected swine usually become excitable and show sexual desire, and they may become vicious and attack other animals or man. They have a depraved appetite, or there may be inappetence. These symptoms will become more aggravated for two or three days, then the animal becomes depressed and paralysis of various groups of muscles appears. The affected animals may be depressed from the beginning, soon evidence more or less of paralysis, and finally assume a comatose state prior to death.

Diagnosis.—Diagnosis cannot be made positive by clinical examination, although if the history shows contact with a rabid animal from ten days to four weeks before the symptoms appeared one could diagnose the case as suspected rabies. A positive diagnosis can be made only by the finding of Negri bodies by microscopic examination, or the reproduction of the disease by inocu-

lation of a laboratory animal with a small quantity of the brain tissue of the animal in question.

Treatment.—Curative treatment has always been considered futile. Recently the use of quinine has, according to reports, given good results in cases of rabies in dogs. Other investigators have failed to obtain beneficial results from the use of quinine in experimentally inoculated cases of rabies. If valuable animals are known to have been bitten by a rabid dog it may be given the Pasteur treatment and thus the development of the disease prevented.

Foot and Mouth Disease. (Aphthæ Epizooticæ)

This is an acute, infectious, transmissible disease, primarily affecting cattle and sheep. It also affects hogs, goats, more rarely horses, dogs and other animals.

This disease is quite prevalent in some European countries and it has appeared in the United States on six different occasions: In 1870, 1880, 1884, 1902, 1908 and 1914.

Etiology.—Foot-and-mouth disease is produced by one of the so-called filterable viruses, which up to the present time has not been successfully cultivated outside of the animal body. The virus exists especially in the serous fluids of the vesicles in the mouth, from which it gains entrance to the saliva and thus to the soil and food from the salivary secretions. The vesicular lesions are also found on the feet and thus the virus also gains entrance to soil, bedding and food, from which other animals can easily obtain infection. There appears to be little doubt but what the virus is eliminated from the body in all excretions. The exact length of time the virus will retain its vitality outside of the animal body has not been determined, but it has been observed that infection will persist in buildings that have not been disinfected for several months. Some outbreaks of this disease have been apparently traced to contaminated hay, that had not been in contact with diseased animals for three months or more. Thus infection may be obtained from

food, infected premises, hides and in the various animal serums.

In the 1914 outbreak in the United States several centers of infection were undoubtedly established through the use of anti-hog cholera serum that had been made from infected hogs. This latter source is of considerable importance and should entail careful inspection upon the part of the government employes to prevent a distribution of the disease by this means.

The usual channel of entrance of infection is through the abrasion of the buccal mucous membrane, but in hogs the infection is more frequently affected through abrasion of the skin in an interdigital space or around the superior part of the hoof. Such abrasions are no doubt of very common occurrence as they can easily be produced by stubs, sticks and splinters which are very common in the pens where hogs are maintained. Infection can also be introduced upon food stuff, especially by milk from affected cows and thus gain entrance to the lesions to abrasions in the mouth, and as before stated infection may be introduced in serum. Some authorities are of the opinion that the disease may be carried from farm to farm by birds and other carrion animals and thus an absolute quarantine should be maintained on all infected premises.

Lesions.—Foot-and-mouth disease assumes two forms, benign and malignant. As a rule hogs are not as seriously affected with this disease as are cattle, a subacute or benign form being most prevalent in these animals. The principal manifestation of this disease consists of vesicles which develop around the coronary band and in the interdigital spaces. One or more feet may be involved and these vesicles vary in size from a grain of wheat to a pea, and are usually of short duration. The surface of the epithelium ruptures and later desquamates, leaving a denuded surface. The surrounded surface becomes tumefied and hypersensitive. Similar lesions may also be found on the skin of the snout and less frequently upon the buccal mucous membrane. If

the animals are maintained in clean quarters the simple uncomplicated lesions will heal in from ten days to three weeks. If the animals are maintained in muddy, filthy pens secondary infections frequently arise and the hoof may slough and the animals die of septic infection. Very rarely a general vesiculo-papular eruption may occur on large areas of the skin.

Symptoms.—The most pronounced symptoms of foot-and-mouth disease in hogs consist in lameness; the principal lesions being found on the feet. The animals have a disinclination to move and because of the soreness tend to assume a decubital position. If the animals are forced to move they will probably walk upon their toes. The lesions in various stages of progress may be observed at this time by inspection. If the disease is of a virulent type there will be systemic disturbances consisting of rise of temperature, inappetence, listlessness or dullness. If the buccal mucous membrane is involved, there will be more or less of salivation and disinclination to eat.

Course and Prognosis.—This disease usually runs its course in from one to three weeks, although it may progress for a longer period. The disease is ordinarily not fatal if uncomplicated in the hogs, although the financial value of the animals is considerably depreciated because of the fact that they rapidly emaciate.

Treatment.—Thus far no treatment has been found that will curtail the course of the disease. Animals that have had the disease possess an immunity for a short time, probably not longer than six months or a year. The disease is of such a destructive nature in so far as the value of the animals is concerned, that it has always been considered advisable to destroy the animals and disinfect the premises along with the proper disposal of the carcasses to insure destruction of all available virus.

Because of the extent of the 1914 outbreak in the United States, it is possible that new centers of the disease may make its appearance at almost any time and veterinarians should familiarize themselves with this disease.

INDEX

- Actinomycosis of the skin153
- Actinomycosis sequel to castration123
- Albuminuria108
- Amyloid changes in the liver 58
- Anemia161
- Anemia of the stomach... 22
- Ascariasis of the liver.. 67
- Ascaris suum..... 47
- Ascites 71
- Atelectasis 84
- Bacillus coli communis...178
- Bacillus necrophorus10, 185, 208
- Bacillus of koch.....218
- Bacillus suispestifer.....171
- Bacillus suissepticus.....204
- Belladonna poisoning..... 41
- Bladder, calculi in.....114
- Bladder, dilatation of...113
- Bladder, malformations of112
- Bladder, tumors of.....116
- Blood161
- Blood vessels.....160
- Botryomyces sequel to Castration122
- Bronchial tubes..... 80
- Bronchial tubes, stenosis of 80
- Bronchitis 81
- Bronchitis, verminous.... 82
- Bulbo-urethral glands...117
- Calculi, cystis.....114
- Calculi, renal.....102
- Campomyia macellaria123, 153
- Castration, actinomycosis sequel to.....123
- Castration, botryomyces sequel to.....122
- Castration, hemorrhage from119
- Castration, infection sequel to.....120
- Castration, parasite infestation123
- Castration, sequels to....119
- Catarrh, infectious nasal. 77
- Caustic soda poisoning... 39
- Caustic potash poisoning. 39
- Cerebral hyperemia.....167
- Cheilitis 9
- Cholelithiasis 59
- Chorea166
- Circulatory organs.....159
- Cirrhosis-sclerosis 64
- Cloudy swelling of the liver 57
- Coccidiosis of the liver... 66
- Cocklebur poisoning..... 40
- Congestion of the kidneys102
- Cotton-seed meal poisoning 44
- Cowper's glands.....117
- Cryptogamic poisoning... 43
- Cysticercosis of the liver.. 70
- Cysticercosis of the muscles144
- Cysticercus cellulosæ.....167, 144
- Cystitis115
- Cystitis, catarrhal.....115
- Cystitis, purulent.....115
- Cysts, dontigerous.....127
- Cysts, dermoid.....127
- Cysts, ovarian.....126
- Delirium163
- Demodex folliculorum....157
- Dermatitis granulosa....152
- Dermatitis, necrotic.....216
- Diaphragm, spasms of...228
- Diarrhea in sucklings... 45
- Digestive system, the.... 9
- Dilatation, acute gastric.. 27
- Dilatation, chronic gastric 28
- Dilatation of the bladder.113

- Dilatation of the esophagus 18
 Dilatation of the intestines 34
 Dilatation of the stomach 27
 Distomatosis 67
 Echinococcosis of the liver 69
 Eclampsia dentition.....166
 Eczema151
 Edema of the lungs..... 85
 Emesis 22
 Emphysema of the intestines 34
 Emphysema of the lungs. 85
 Endocarditis160
 Enteritis 35
 Enteritis, necrotic.....211
 Enteritis, acute catarrhal. 35
 Enteritis, chronic catarrhal 36
 Enteritis, croupous and diphtheritic 37
 Enteritis, toxic..... 38
 Enterorrhagia 31
 Epididymitis118
 Epilepsy165
 Epistaxis 75
 Erythema149
 Esophagitis 20
 Esophagostoma dentatum 49
 Esophagus, dilatation of.. 18
 Esophagus, malformations of 17
 Esophagus, perforation of 19
 Esophagus, stenosis of... 18
 Esophagus, tumors of... 20
 Fallopian tubes.....127
 Fatty changes in the heart159
 Fatty changes in the liver 57
 Fatty changes of the kidneys101
 Fatty degeneration of muscle136
 Feet, sore.....135
 Female reproductive organs125
 Fleas infestation.....154
 Foot and mouth disease..230
 Foreign bodies in the liver 54
 Foreign bodies in the stomach 21
 Freezing150
 Gall-stones 59
 Garbage poisoning..... 42
 Gastritis 24
 Gastritis, catarrhal..... 24
 Gastritis, chronic..... 27
 Gastritis, croupous..... 25
 Gastritis, phlegmonous... 26
 Gastritis, toxic..... 38
 Gastro-enteritis, toxic.... 38
 Gigantorhynchus hirudinaceus 52
 Glossitis 11
 Glycogenic infiltration of the liver..... 58
 Heart, fatty changes in..159
 Heart, hemorrhage of...159
 Heart, parasites of.....160
 Heart, tumors of.....160
 Heart stroke.....164
 Hematemesis 23
 Hematuria112
 Hemorrhage after castration119
 Hemorrhage of the heart.159
 Hemorrhage of the intestines 31
 Hemorrhage of the kidneys100
 Hemorrhage of the lungs 86
 Hemorrhage of the ovary.125
 Hemorrhage of the skin..150
 Hemorrhage of the stomach 23
 Hemorrhage, uterine....128
 Hemothorax 95
 Hemotopinus suis.....154
 Hepatitis 61
 Hepatitis, acute interstitial 63
 Hepatitis, acute parenchymatous 62
 Hepatitis, chronic interstitial 64
 Hepatitis, necrotic.....213
 Hepatitis, suppurative... 62
 Hog cholera.....169
 Hog cholera, interstate shipment of.....190
 Hydronephrosis 99
 Hydrothorax 94
 Hyperemia, cerebral.....167
 Hyperemia, hepatic active 61
 Hyperemia, hepatic passive 60
 Hypermia, hepatic portal 61

- Hyperemia of the liver... 60
 Hyperemia of the stomach 24
 Hypertrophy of the spleen162
 Icterus 56
 Infection sequel to castration120
 Infectious diseases.....169
 Injuries to the peritoneum 71
 Injuries to the uterus....127
 Intestines, dilatation of.. 34
 Intestines, emphysema of 34
 Intestines, hemorrhage of 31
 Intestines, malformations of 31
 Intestines, obstruction of. 33
 Intestines, parasites of... 46
 Intestines, tumors of..... 53
 Kidneys 99
 Kidneys, calculi in.....102
 Kidneys, congestion of...102
 Kidneys, fatty changes of101
 Kidneys, hemorrhage of..100
 Kidneys, malformations of 99
 Kidneys, parasites of...110
 Kidneys, tumors of.....110
 Laryngitis 79
 Larynx, tumors of..... 79
 Leukemia161
 Lightning stroke.....165
 Lips, malformations of... 9
 Lips, tumors of..... 11
 Liver 54
 Liver, amyloid changes in 58
 Liver, ascaridiasis of..... 67
 Liver, cloudy swelling of 57
 Liver, coccidiosis of..... 66
 Liver, cysticercosis of.... 70
 Liver, distomatosis of.... 67
 Liver, echinococcosis of.. 69
 Liver, fatty changes in... 57
 Liver, foreign bodies in.. 54
 Liver, glycogenic infiltration of..... 58
 Liver, malformations of.. 54
 Liver, parasites of..... 66
 Liver, rupture of..... 55
 Liver, stephanurosis of... 66
 Liver, tumors of..... 65
 Locomotion, organs of...135
 Lousiness154
 Lungs, edema of..... 85
 Lungs, emphysema of.... 85
 Lungs, hemorrhage of... 86
 Lungs, parasites of..... 94
 Lungs, tumors of..... 94
 Male generative organs..117
 Malformations of the bladder112
 Malformations of the esophagus 17
 Malformations of the intestines 31
 Malformations of the kidneys 99
 Malformations of the lips 9
 Malformations of the liver 54
 Malformations of the ovary125
 Malformations of the stomach 21
 Malformations of the trachea 80
 Malformations of the ureters112
 Malformations of the uterus127
 Mammary glands.....130
 Mammary glands, tumors of133
 Mammitis130
 Mammitis, actinomycotic.132
 Mammitis, botryomycotic.131
 Mammitis, tuberculous...132
 Mange155
 Mange, demodetic.....157
 Mange, sarcoptic.....155
 Measles, pork.....144
 Metritis128
 Metritis, purulent.....128
 Metritis, septic.....128
 Mold poisoning..... 43
 Mouth 12
 Muscles, cysticercosis of..144
 Muscles, fatty degeneration of.....136
 Muscles, trichinosis of...142
 Muscles, tumors of.....147
 Nasal catarrh..... 77
 Navel ill.....226
 Necrobacillosis208
 Necrobacillosis of the intestines211
 Necrobacillosis of the liver213

- Necrobacillosis of the lungs213
 Necrobacillosis of the nose212
 Necrobacillosis of the prepuce214
 Necrobacillosis of the skin153, 216
 Necrobacillosis of the spleen214
 Necrobacillosis of the stomach210
 Necrobacillosis of the vagina214
 Necrobacillosis of the vulva214
 Necrobacillosis, unusual forms of.....216
 Necrosis of the spleen....161
 Nephritis103
 Nephritis, acute interstitial105
 Nephritis, acute parenchymatous103
 Nephritis, chronic.....106
 Nephritis, chronic interstitial106
 Nephritis, purulent.....105
 Nervous system, parasites of167
 Nervous system, the....163
 Nose 75
 Nose, bleeding..... 75
 Nose, tumors of..... 78
 Omphalophlebitis226
 Oophoritis125
 Orchitis118
 Ornithodoros megnini....158
 Osteomalacia140
 Osteomyelitis, purulent...141
 Ovarian cysts.....126
 Ovary, hemorrhage of...125
 Ovary, malformations of.125
 Ovary, tumors of.....127
 Pancreas 70
 Para-cholera171
 Paralysis of the pharynx 17
 Parasites, *Ascaris suum*33, 47
 Parasites, *Campylobacter macellaria*123, 153
 Parasites, *Cysticercus cellulosæ*167, 144
 Parasites, *Demodex folliculorum*157
 Parasites, *Esophagostoma dentatum* 49
 Parasites following castration123
 Parasites, *Gigantorhynchus hirudinaceus*..31, 52
 Parasites, *Hemotopinus suis*154
 Parasites of the heart....160
 Parasites of the intestines 46
 Parasites of the kidneys..110
 Parasites of the liver.... 66
 Parasites of the lungs... 94
 Parasites of the nervous system167
 Parasites of the peritoneum 73
 Parasites of the skin....153
 Parasites of the stomach.. 30
 Parasites of the tongue.. 12
 Parasites, *Ornithodoros megnini*158
 Parasites, *Sarcocystis mierscheri*147
 Parasites, *Tænia marginata* 70
 Parasites, *Tænia solium*..144
 Parasites, *Trichinella spiralis* 52
 Parasites, *Trichocephalus crenatus* 50
 Parotiditis 15
 Penis124
 Perforation of the esophagus 19
 Peritoneum 71
 Peritoneum, injuries to... 71
 Peritoneum, parasites of.. 73
 Peritoneum, tumors of... 73
 Peritonitis 72
 Pharyngitis 16
 Pharynx 16
 Pharynx, paralysis of.... 17
 Pharynx, tumors of..... 17
 Phosphorous poisoning... 40
 Phthiriasis154
 Pericarditis159
 Pleura 94
 Pleura, tumors of..... 98
 Pleurisy 96
 Pleurisy, acute..... 96
 Pleurisy, chronic..... 97

- Pneumonia 87
 Pneumonia, necrotic.....213
 Pneumonia, catarrhal..... 88
 Pneumonia, chronic inter-
 stitial 93
 Pneumonia, croupous..... 89
 Pneumonia, gangrenous or
 septic 91
 Pneumonia, purulent..... 90
 Pneumonia, verminous... 82
 Pneumothorax 96
 Poisoning, belladonna... 41
 Poisoning, caustic potash. 39
 Poisoning, caustic, soda.. 39
 Poisoning, cocklebur..... 40
 P o i s o n i n g, cotton-seed
 meal 44
 Poisoning, cryptogamic... 43
 Poisoning, garbage..... 42
 Poisoning, mold..... 43
 Poisoning, phosphorous... 40
 Poisoning, ptomain..... 43
 Poisoning, sodium chlorid 38
 Poisoning, Xanthium can-
 adense 40
 Preputial necrosis.....214
 Prostate gland.....117
 Ptomain poisoning..... 43
 Pyelonephritis108
 Pyemic arthritis.....226
 Rabies229
 Rachitis138
 Respiratory system, the.. 75
 Rheumatism, articular...137
 Rheumatism, muscular...136
 Rhinitis 76
 Rhinitis, necrotic.....212
 Rickets138
 Ringworm infestation...158
 Rupture of the liver..... 55
 Sarcocystis mierscheri...147
 Sarcosporidiosis146
 Schistosis labii..... 9
 Scours in sucklings..... 45
 Scrotal hernia.....123
 Scurvy 15
 Serum production.....199
 Skin, actinomycosis of...153
 Skin, freezing of.....150
 Skin, hemorrhage of.....150
 Skin, necrobacillosis of...153
 Skin, parasites of.....153
 Skin, the.....149
 Skin, tumors of.....153
 Sodium chlorid poisoning. 38
 Spirochæta suis.....172, 178
 Spleen161
 Spleen, hypertrophy of..162
 Spleen, necrosis of.....161
 Spleen, tumors of.....162
 Splenitis, necrotic.....214
 Stenosis of the bronchial
 tubes 80
 Stenosis of the esophagus 18
 Stenosis of the trachea... 80
 Stephanurosis of the liver 66
 Stomach, anemia of..... 22
 Stomach, dilatation of... 27
 Stomach, foreign bodies in 21
 Stomach, hemorrhage of.. 23
 Stomach, hyperemia of... 24
 Stomach, malformati o n s
 of 21
 Stomach, parasites of... 30
 Stomach, tumors of..... 29
 Stomach, ulcers of..... 23
 Stomatitis 13
 Stomatitis, necrotic.....210
 Stricture of the urethra..116
 Sunburn149
 Sunstroke164
 Swine plague.....204
 Tænia marginata..... 70
 Tænia solium.....144
 Testicles117
 Testicles, tumors of.....119
 Thread worm infestation.158
 Thumps228
 Tick infestation.....158
 Tongue 11
 Tongue, parasites of.... 12
 Tongue, tumors of..... 12
 Tonsilitis 15
 Trachea, malformations of 80
 Trachea, stenosis of..... 80
 Trachea, tumors of..... 80
 Tracheitis 80
 Trichinella spiralis..... 52
 Trichinosis142
 Trichocephalus crenatus.. 50
 Tubercle bacillus.....218
 Tuberculosis217
 Tumors of the bladder...116
 Tumors of the esophagus 20
 Tumors of the heart.....160
 Tumors of the intestines.. 53
 Tumors of the kidneys...110
 Tumors of the larynx.... 79

- | | | | |
|---------------------------|-----|----------------------------|-----|
| Tumors of the lips..... | 11 | Uremia | 109 |
| Tumors of the liver..... | 65 | Ureters, malformations | |
| Tumors of the lungs..... | 94 | of | 112 |
| Tumors of the mammary | | Urethra | 116 |
| glands | 133 | Urethra, stricture of..... | 116 |
| Tumors of the muscles... | 147 | Urethritis | 117 |
| Tumors of the nose..... | 78 | Uro-genital system, the.. | 99 |
| Tumors of the ovary..... | 127 | Urticaria | 151 |
| Tumors of the peritoneum | 73 | Uterine hemorrhage..... | 128 |
| Tumors of the pharynx.. | 17 | Uterus, injuries to..... | 127 |
| Tumors of the pleura.... | 98 | Uterus, malformations of. | 127 |
| Tumors of the skin..... | 153 | Uterus, tumors of..... | 129 |
| Tumors of the spleen.... | 162 | Vagina | 129 |
| Tumors of the stomach.. | 29 | Vaginitis, necrotic..... | 214 |
| Tumors of the testicles.. | 119 | Viciousness | 163 |
| Tumors of the tongue.... | 12 | Vomition | 22 |
| Tumors of the trachea... | 80 | Vulva | 130 |
| Tumors of the uterus.... | 129 | Vulvitis, necrotic..... | 214 |
| Ulcers of the stomach.... | 23 | Xanthium canadense..... | 40 |
| Ulcers, peptic..... | 23 | | |



