

Surgical diseases of the dog and cat : with chapters on anaesthetics and obstetrics / [Sir Frederick Thomas George Hobday].

Contributors

Hobday, Frederick T. G. Sir, 1870-1939.

Hobday, Frederick T. G. Sir, 1870-1939. Canine and feline surgery.

Publication/Creation

London : Baillière, Tindall and Cox, 1906.

Persistent URL

<https://wellcomecollection.org/works/p4mwqkwj>

License and attribution

Conditions of use: it is possible this item is protected by copyright and/or related rights. You are free to use this item in any way that is permitted by the copyright and related rights legislation that applies to your use. For other uses you need to obtain permission from the rights-holder(s).

SURGICAL DISEASES
OF
THE DOG AND CAT
AND ANAESTHETICS

F. HOBDAY

SECOND EDITION



22101894045

Med

K52318


9/12/05
10/6 vet


M. xx. v

20/h

SURGICAL DISEASES OF THE DOG
AND CAT







A Canine Operating-room.

SURGICAL DISEASES OF THE DOG AND CAT

WITH CHAPTERS ON
ANÆSTHETICS AND OBSTETRICS


(SECOND EDITION OF 'CANINE AND FELINE
SURGERY')

BY

FREDERICK T. G. HOBDAY, F.R.C.V.S., F.R.S.E.

MEMBER OF THE BOARD OF EXAMINERS OF THE ROYAL COLLEGE OF VETERINARY SURGEONS;
LATE PROFESSOR IN THE ROYAL VETERINARY COLLEGE, LONDON; CONSULTING VETERINARY
SURGEON TO THE BRITISH BULLDOG AND THE GRIFFON BRUXELLOIS CLUBS; HONORARY
VETERINARY SURGEON TO THE LADIES' KENNEL ASSOCIATION, THE FOX-TERRIER
CLUB, ETC., ETC.

SECOND EDITION, REVISED AND ENLARGED



LONDON
BAILLIÈRE, TINDALL AND COX
8 HENRIETTA STREET, COVENT GARDEN

1906

[All rights reserved]

7 170285

WELLCOME INSTITUTE LIBRARY	
Coll.	welMOMec
Call	
No.	✓

TO

D'ARCY POWER, Esq.,

M.A., M.B. (Oxon.), F.R.C.S., F.S.A.,
SURGEON TO ST. BARTHOLOMEW'S HOSPITAL, AND LATE LECTURER ON HISTOLOGY AT
THE ROYAL VETERINARY COLLEGE, LONDON,

THIS BOOK IS DEDICATED

AS A SLIGHT TOKEN OF THE AUTHOR'S DEEPEST GRATITUDE



Dr. Louis Sambon has always
the kindest wishes & most
profound respect of the Author
Fred. H. Hobday.

PREFACE TO THE SECOND EDITION

THE reception accorded to the first edition has proved that a small text-book of the kind was distinctly wanted, and in presenting a second and enlarged edition the author regrets that illness and other causes have allowed the first to remain so long out of print.

By the request of numerous friends, the work has been enlarged to include symptoms and general details of treatment other than that which may be described as purely surgical, although the original idea of the author to keep the book as a handy manual for the final-year student has still been adhered to.

The introduction of antiseptics has revolutionized all the old-fashioned ideas, and has benefited the animal world to almost as great an extent as that of man.

It is true that we have not quite the same advantages as our *confrères* in human surgical practice, but it is astonishing what can be done by strict attention to the principles introduced by the discoveries of Pasteur, and applied to surgery by the teachings of Lister.

Operations which only a few years ago were looked upon beforehand with dread are now done every day, and owners of pet animals have learned to appreciate the value of modern antiseptic methods almost as much as the members of the profession themselves.

For much help and advice in the revision of the proofs I

am indebted to Mr. D'Arcy Power, M.A., M.B., F.R.C.S., and to Professor MacFadyean, M.B., B.Sc., M.R.C.V.S. To Mr. Reginald Waud, artist, and to Mr. R. E. Holding, veterinary draughtsman, for sketches too numerous to specify individually, and to Messrs. Hooper and Berry, of Kensington, for much patience in photographing the many and often refractory patients, I owe much thanks.

To Messrs. D. Crole, T. Angwin, and T. Duncan, all M.R.C.V.S., to Messrs. Arnold and Sons, and to others whose names are mentioned in the text, I am also indebted for many specimens or fresh sketches, without which it would have been impossible to illustrate the work to anything like its present extent.

If the publication of this volume will only advance in the slightest degree the application of modern surgical principles for the benefit of the suffering animal world, the wishes of the author will be more than gratified.

F. H.

10, SILVER STREET,
KENSINGTON, W.
November, 1905.

PREFACE TO THE FIRST EDITION

DURING my experience in the Free Out-patients' Department of the Royal Veterinary College I have often thought that a small text-book containing directions with regard to surgical operations upon canine and feline patients would be appreciated by the students engaged in the daily work of the Clinique for small animals, and perhaps also by the busy practitioner. It is with the idea of supplying these directions in as concise a manner as possible that this little manual has been written.


The major portion of the work has already appeared as a series of articles in the *Journal of Comparative Pathology and Therapeutics*, to the editor of which, Professor MacFadyean, I am particularly indebted for much help in revising the proofs, and for many suggestions.

To Messrs. Arnold and Sons, Messrs. Kröhne and Sesse-mann, and Mr. B. Kühn, I am obliged for the loan of drawings of instruments and appliances.

Almost all the operations herein described have been performed in the Clinique during the past seven years, and the ultimate results have been carefully noted as far as possible and summarized. References are given to where the individual cases may be found in detail.

F. H.

ROYAL VETERINARY COLLEGE,
LONDON, N.W.,
May, 1900.



CONTENTS

CHAPTER I

	PAGES
GENERAL RULES FOR TREATMENT OF THE PATIENT BEFORE AND AFTER A SURGICAL OPERATION - - -	1—6

CHAPTER II

ANTISEPTIC PREPARATION OF INSTRUMENTS, DRAINAGE-TUBES, SUTURE MATERIAL, SPONGES, ETC. - - -	7—13
--	------

CHAPTER III

METHODS OF SECURING - - - - -	14—22
-------------------------------	-------

CHAPTER IV

THE ADMINISTRATION OF ANÆSTHETICS (LOCAL AND GENERAL)	23—46
Local Anæsthetics - - - - -	24
General Anæsthetics - - - - -	29
Morphia and Chloral - - - - -	45

CHAPTER V

ACCIDENTAL AND OPERATION WOUNDS ; CONTUSIONS -	47—58
--	-------

CHAPTER VI

ABSCESS, CYST, SINUS, FISTULA, AND POLYPUS - -	59—65
--	-------

CHAPTER VII

TUMOUR, INFLAMMATORY NEW GROWTH, GRANULOMA	66—76
--	-------

CHAPTER VIII

THE EAR - - - - -	77—87
Examination of the Interior before, and Application of Dress- ings after, an Operation - - - - -	77
Polypi, Tumours, and Enlarged Ceruminous Glands - -	78
Hæmatoma or Tumefied Flap - - - - -	79

	PAGES
Amputation of the Ear-flap or a Portion of it - - - - -	83
Cropping - - - - -	83
Operations to Cause the Ears to Droop - - - - -	85
Tumours - - - - -	87

CHAPTER IX

OPERATIONS ON THE SKULL, FACE, LIPS, AND NOSTRILS	88—100
Trephining - - - - -	88
Tumours on the Nose - - - - -	89
Tumours and Polypi in the Nostrils - - - - -	90
Other Foreign Bodies in the Nostrils - - - - -	92
Hare-lip and Cleft Palate - - - - -	92
Rodent Ulcer of the Lip - - - - -	96
Pus in the Antrum - - - - -	97
Tumours - - - - -	99

CHAPTER X

THE EYE AND EYELIDS - - - - -	101—122
Examination for, and removal of, Foreign Bodies - - - - -	102
Pterygium or Dermoid Growths on the Cornea - - - - -	102
Dropsy of the Eyeball (Hydrops Oculi) - - - - -	104
Wounds and Ulcers of the Cornea - - - - -	105
Staphyloma - - - - -	106
Strabismus, or Squint - - - - -	107
Cataract - - - - -	109
Excision of the Eyeball - - - - -	111
Protrusion or Paralysis of the Membrana Nictitans - - - - -	114
Displacement or Tumefaction of the Orbital Gland - - - - -	116
Entropion and Trichiasis - - - - -	117
Ectropion - - - - -	120
Tumours - - - - -	121

CHAPTER XI

OPERATIONS ON THE MOUTH, PHARYNX, TONGUE, AND TEETH	123—139
Examination - - - - -	123
Removal of Foreign Bodies - - - - -	124
Ranula - - - - -	126
Scarification of the Tongue - - - - -	127
Amputation of the Tongue or a Portion of it - - - - -	128
Hare-lip and Cleft Palate - - - - -	130
Tumours - - - - -	130
Papilloma or Wart - - - - -	130
Sarcoma or Carcinoma - - - - -	133
Epulis - - - - -	135

CONTENTS

XV

PAGES

Scaling and Cleaning the Teeth	-	-	-	-	135
Extraction of Teeth	-	-	-	-	136
Insertion of False Teeth	-	-	-	-	137
us in the Antrum	-	-	-	-	139

CHAPTER XII

THE THROAT AND NECK	-	-	-	-	140—150
Choking	-	-	-	-	140
Passing the Probang	-	-	-	-	142
Œsophagotomy	-	-	-	-	143
Tracheotomy	-	-	-	-	145
Foreign Bodies around the Neck	-	-	-	-	147
Tumours	-	-	-	-	148
Dislocation of the Neck	-	-	-	-	150

CHAPTER XIII

THE THORACIC AND ABDOMINAL WALLS	-	-	-	-	151—165
Accidental Injuries involving the Thorax	-	-	-	-	151
Violent Contusions	-	-	-	-	151
Punctured Wounds	-	-	-	-	151
Fractured Ribs	-	-	-	-	152
Paracentesis Thoracis (Tapping the Chest)	-	-	-	-	153
Tumours of the Chest Wall	-	-	-	-	155
Paracentesis Abdominis (Tapping the Abdomen)	-	-	-	-	156
Laparotomy	-	-	-	-	158
Accidental Injuries involving the Abdomen	-	-	-	-	160
Gunshot Wounds	-	-	-	-	161
External Violence and Contusions	-	-	-	-	162
Acute Suppurative Peritonitis	-	-	-	-	163
Tumours of the Abdominal Wall and Mammary Glands	-	-	-	-	165

CHAPTER XIV

THE STOMACH AND INTESTINES	-	-	-	-	166—202
Aids to Diagnosis	-	-	-	-	166
Colic	-	-	-	-	168
Puncture of the Stomach or Bowel	-	-	-	-	171
Foreign Bodies in the Stomach	-	-	-	-	171
Gastrotomy	-	-	-	-	177
Gastric Ulcer	-	-	-	-	178
Foreign Bodies in the Lower Part of the Œsophagus	-	-	-	-	178
Gastrectomy or Gastrostomy	-	-	-	-	179
Intussusception of the Intestine	-	-	-	-	180
Fæcal Impaction of the Intestine	-	-	-	-	183
Foreign Bodies in the Intestine	-	-	-	-	186
Enterotomy	-	-	-	-	188

	PAGES
Enterectomy and Anastomosis of the Intestine - - - - -	190
Volvulus - - - - -	198
Stricture of the Bowel - - - - -	198
Strangulation of the Intestine - - - - -	199
Meckel's Diverticulum - - - - -	199
Peritoneal Bands - - - - -	199
Tumours of the Stomach and Intestine - - - - -	199
Appendicitis and Typhlitis - - - - -	200

CHAPTER XV

DISEASES OF THE RECTUM AND ANAL REGION - - -	203—217
Prolapse of the Anus and Bowel - - - - -	203
Reduction and Minor Operative Interference - - - - -	207
Gersuny's Wax Operation - - - - -	209
Proctopexia, or Ventrifixation of the Bowel - - - - -	210
Amputation of the Prolapsed Portion - - - - -	211
Imperforate Anus - - - - -	213
Cloaca - - - - -	213
Hæmorrhoids or Piles - - - - -	214
Fistula of the Anus - - - - -	215
Obstruction of the Anal Glands - - - - -	216
Rectal and Anal Tumours - - - - -	217

CHAPTER XVI

OPERATIONS ON THE OMENTUM, LIVER, SPLEEN, AND PAN- CREAS - - - - -	218—223
The Omentum - - - - -	218
The Liver - - - - -	218
The Spleen - - - - -	220
Removal of Tumours from the Abdominal Organs - - - - -	222

CHAPTER XVII

HERNIA - - - - -	224—238
The Main Principles of Surgical Treatment - - - - -	224
Umbilical Hernia - - - - -	225
Abdominal (or Ventral) Hernia - - - - -	227
Inguinal Hernia - - - - -	228
Scrotal Hernia - - - - -	232
Perineal Hernia - - - - -	234
Femoral Hernia - - - - -	237

CHAPTER XVIII

THE URINARY ORGANS - - - - -	239—265
Examination of the Urethra and Bladder; Passing the Catheter - - - - -	239
Imperforate Urethra or Vagina - - - - -	240

CONTENTS

xvii

	PAGES
Calculi in the Urethra - - - - -	241
Stricture of the Urethra - - - - -	247
Prolapse of the Urethra - - - - -	248
Renal Calculus - - - - -	248
Hernia, Prolapse, and Rupture of the Bladder - - - - -	251
Tumours - - - - -	253
Calculus of the Bladder - - - - -	255
The Prostate Gland - - - - -	263

CHAPTER XIX

THE MALE GENERATIVE ORGANS - - - - -	266—287
Tumours on the Penis and Prepuce - - - - -	266
Wounds of the Prepuce - - - - -	270
Foreign Bodies around, or Fracture of, the Penis - - - - -	271
Phimosis - - - - -	273
Paraphimosis - - - - -	274
Tumours of the Testis - - - - -	275
Castration - - - - -	276
Cryptorchids - - - - -	280
Hermaphrodites - - - - -	283
Torsion of the Cord - - - - -	286

CHAPTER XX

THE FEMALE GENERATIVE ORGANS - - - - -	288—305
Examination - - - - -	288
Prolapsed Vagina - - - - -	289
Malignant Tumours - - - - -	291
Benign Tumours - - - - -	292
Nymphomania - - - - -	293
Hysteria, Oöphorectomy, and Ovariectomy - - - - -	294
Purulent Metritis - - - - -	298
Hysterectomy - - - - -	299
Hysterotomy - - - - -	304
Stricture - - - - -	305

CHAPTER XXI

DIFFICULT PARTURITION - - - - -	306—323
Maternal Dystokia - - - - -	306
Foetal Dystokia - - - - -	310
Accidents, etc. - - - - -	315
Treatment of the Mother and Puppies or Kitten - - - - -	318
Malformations - - - - -	323

CHAPTER XXII

	PAGES
THE LIMBS AND TAIL - - - - -	324—356
Dislocations - - - - -	- 324
Fractures - - - - -	- 332
Amputations - - - - -	- 341
Overgrown Nails - - - - -	- 349
Tenotomy and Suture of Tendon - - - - -	- 351
Foreign Bodies - - - - -	- 352

CHAPTER XXIII

VALUE OF THE RÖENTGEN RAYS IN DIAGNOSIS - - - - -	357—362
INDEX - - - - -	363—366

LIST OF ILLUSTRATIONS

FIG.	PAGE
Frontispiece : A Canine Operating-room.	
1. Animals' Thermometer (Author's Pattern) - - - - -	5
2. Canine Thermometer, showing Fever Markings (Author's Pattern) - - - - -	5
3. Instrument Sterilizer - - - - -	8
4. Instrument Cabinet - - - - -	9
5. Glass Ligature Bottle (Clarke's) - - - - -	11
6. Photograph of Dog held for safe Examination - - - - -	15
7. A Clove Hitch applied - - - - -	16
8. A Piece of Tape applied as a Muzzle - - - - -	16
9. A Clove Hitch ready for Application - - - - -	17
10. The Author's Pattern of Hobbles - - - - -	17
11. Improvised Hobbles - - - - -	18
12. The Author's Pattern of Operating Table - - - - -	18
13. Key Hobbles looped ready for Application - - - - -	19
14. A Dog fixed with Hobbles on an Ordinary Table in the 'Abdominal' Position - - - - -	19
15. A Dog fixed on the Operating Table in the 'Dorsal' Position - - - - -	20
16. Gray's Operating Rack attached to an Ordinary Table, with a Cat fixed in the 'Abdominal' Position - - - - -	21
17. Ether Spray Apparatus - - - - -	24
18. Glass Tube containing Ethyl Chloride ready for Application - - - - -	25
19. Drop-bottle for the Administration of a General Anæsthetic - - - - -	31
20. Wire Muzzle Mask - - - - -	32
21. The Author's Anæsthetic Inhaler (First Pattern) - - - - -	33
22. Junker's Inhaler (Kröhne and Sesemann's Pattern) - - - - -	34
23. The Author's Second Design of Inhaler - - - - -	35
24. The Author's Third Pattern of Inhaler showing another Form of Mask - - - - -	36
25. An Electrical Motor Pump for the Administration of Anæsthetic Vapour (Author's Pattern) - - - - -	37
26. Antidote Drop-tube and Bottle for Hydrocyanic Acid - - - - -	42
27. Elizabethan Collar - - - - -	48
28. Insufflator for the Application of Dry Dressings - - - - -	50
29. Artery Forceps of Different Patterns - - - - -	51

FIG.		PAGE
30.	A 'Surgical' Knot - - - - -	53
31.	A 'Granny' Knot - - - - -	53
32.	Aluminium Suture Button (Pugh's) - - - - -	54
33.	Different Patterns of Sutures - - - - -	55
34.	Needle-holder (Macphail's) - - - - -	56
35.	Wire Suture Needles (Reeks') - - - - -	57
36.	Abscess Knife (Syme's and Paget's Blades) - - - - -	60
37.	Exploring Trocar and Cannula - - - - -	61
38.	Dalmatian with Cyst in the Submaxillary Space - - - - -	62
39.	Director and Blunt Needle combined - - - - -	62
40.	Curette or Volkmann's Spoon - - - - -	64
41.	Photomicrograph of Carcinoma - - - - -	68
42.	Inoperable Sarcoma of the Neck - - - - -	70
43.	Photomicrograph of a Round-celled Sarcoma - - - - -	71
44.	A Lipoma with Distinct Pedicle - - - - -	72
45.	Blunt Tumour Hook or Retractor - - - - -	73
46.	Écraseur (Farmer Miles' Pattern) - - - - -	74
47.	A Large Lipoma, Inoperable, owing to its Extent and Large Size - - - - -	75
48.	Microphotograph of a Granuloma - - - - -	76
49.	Kramer's Speculum - - - - -	77
50.	Avery's Speculum - - - - -	78
51.	Papillomatous Growths in Dog's Ear - - - - -	79
52.	Hæmatoma of the Ear-flap before and after Operation - - - - -	80
53.	A Simple Many-tailed Bandage for the Ears, cut out of a Piece of Calico - - - - -	81
54.	Natural Carriage of Ears - - - - -	84
55.	Dog of same Breed which has been cropped - - - - -	84
56.	Ugly Ears, one being pricked up and the other carried properly - - - - -	86
57.	The same Dog after Operation - - - - -	86
58.	Boarhound with Malformed Ear (Congenital) - - - - -	86
59.	The same after Operation - - - - -	86
60.	Trephine - - - - -	88
61.	Granuloma of the Nose - - - - -	89
62.	Cat with Polypus of the Right Nostril - - - - -	90
63.	Polypus Snare (Blake's) - - - - -	91
64.	An Inoperable Case of Single Hare-lip in a Griffon - - - - -	93
65.	A Bulldog, Three Years old, with Single Median Hare-lip, but no Cleft Palate - - - - -	93
66.	A Bulldog Puppy, Five Months old, with Unilateral Hare-lip and Cleft Palate, before Operation - - - - -	94
67.	The same Puppy after Operation - - - - -	94
68.	Malformed Bull-puppy with Double Hare-lip and Cleft Palate - - - - -	95
69.	The Usual Situation of the Discharge - - - - -	98
70.	Left Upper Fourth Premolar, showing Result of Fracture and Inflammation of the Fangs - - - - -	99
71.	Photograph showing Eye-shade in Position - - - - -	101
72.	Mongrel with Dermoid Growth on Cornea of the Eye - - - - -	103

FIG.		PAGE
73.	Eye (from Fig. 72) magnified to show Dermoid Growth on the Cornea - - - - -	103
74.	Fox-terrier with Dropsy of the Eyeball and Glaucoma - - -	104
75.	Bowman's Eye Speculum - - - - -	105
76.	Collie with Internal Squint of Each Eye - - - - -	107
77.	Strabismus Hook (Walton's) - - - - -	108
78.	Graefe's Cataract Knife - - - - -	110
79.	Graefe's Cystotome and Curette - - - - -	110
80.	Pug-dog with a False Eye (Left One) of Vulcanite - - -	111
81.	A Cat fitted with a Glass Eye (Left One) - - - - -	112
82.	Patterns of Glass Eyes for Dogs and Cats - - - - -	113
83.	Japanese Spaniel before a Glass Eye was inserted - - -	114
84.	The same with Glass Eye <i>in situ</i> - - - - -	114
85.	Cat with Paralysis of the Membranæ - - - - -	115
86.	A Displaced and Tumefied Orbital Gland - - - - -	116
87.	Entropion and Trichiasis of the Left Eyelid - - - - -	118
88.	Sketch showing Elliptical Piece removed from each Eyelid affected with Entropion - - - - -	119
89.	Sketch showing V-shaped Incision for the Relief of Ectropion -	120
90.	Photograph of Carcinoma of the Orbit of a Dog - - - - -	121
91.	Photograph of Carcinoma of the Orbit of a Cat - - - - -	121
92.	Mouth Speculum (Author's Pattern) - - - - -	124
93.	Mouth Speculum (Gray's Pattern) - - - - -	124
94.	Portion of Sheep's Femur which had been longitudinally fixed for Two Days on the Molar Teeth of a Collie - - -	125
95.	Half a Sheep's Pelvic Bone which had become fixed on Fox-terrier's Lower Jaw - - - - -	125
96.	Cat with Ranula - - - - -	127
97.	Throat Forceps - - - - -	128
98.	Squamous-cell Carcinoma of the Tongue of a Cat - - - - -	128
99.	Apparatus by which a Dog which had lost Half its Tongue could drink Water - - - - -	129
100.	Mouth of Terrier, smothered with Warts (Papillomata) on the Tongue and Buccal Mucous Membrane - - - - -	130
101.	Head of Pug showing Warty Growths at Seat of Inoculation on Right Upper Lip - - - - -	131
102.	Carcinoma of the Pharynx and Cervical Glands of a Terrier -	133
103.	Endothelioma, perforating the Palate, of a Great Dane -	133
104.	Deformity of the Face due to Carcinoma of the Lips - - -	134
105.	Scaling Instruments of Different Patterns - - - - -	136
106.	Different Patterns of Tooth Forceps - - - - -	137
107.	Set of False Teeth made for an Aged Collie - - - - -	138
108.	Set of False Teeth made for an Aged Schipperke - - - -	138
109.	An Aged Schipperke Dog with Set of False Teeth <i>in situ</i> -	138
110.	An Aged Collie whose Loss of Incisors was satisfactorily replaced with Gold by American Bridge Work - - -	138
111.	A Kitten's Larynx transfixed by a Needle - - - - -	140

FIG.		PAGE
112.	Carcinoma of the Œsophagus in a Cat - - -	141
113.	Two Patterns of Probang - - -	142
114.	A Lacerated Wound in the Œsophagus caused by the Continued Presence of a Foreign Body - - -	144
115.	Two Patterns of Tracheotomy-tube - - -	145
116.	Collie Pup with Tracheotomy-tube <i>in situ</i> - - -	146
117.	Yorkshire Terrier from the Subcutaneous Tissue of whose Neck an Indiarubber Ring was removed - - -	148
118.	Pointer Bitch with Myxoma of the Neck - - -	149
119.	Bull-terrier with Dislocated Neck - - -	149
120.	Trocars and Cannulæ: Various Sizes (nested) - - -	154
121.	Tumour (weighing 2½ pounds) attached to the Sternum - - -	156
122.	Cross-bred Mastiff with Dropsy of the Abdomen (Ascites) - - -	157
122a.	Sites of Incision for Various Operations - <i>To face p.</i>	158
123.	Adenoma-carcinoma of the Mammary Gland - - -	164
124.	A Bitch with Large Mammary Tumours - - -	165
125.	Skiagraph of a Lady's Hatpin in the Œsophagus and Stomach of a Kitten - - -	173
126.	Photograph of a Sheepdog Ten Days after Operation, from whose Stomach a Rubber Ball was removed by Gastrotomy - - -	175
127.	Site of Incision in the Abdominal Wall, Ten Days after Operation, through which a Rubber Ball was removed from the Stomach - - -	177
128.	Intussusception of the Intestine - - -	181
129.	A Cat's Intestine with a Piece of Sewing Tape passing from Stomach to Rectum - - -	187
130.	Bowel Clamp (Makins) - - -	189
131.	Murphy's Button and Mayo Robson's Bobbin - - -	191
132.	Two Hairpins clamped on the Intestine in Position for Operation - - -	192
133.	The Hairpins tied in Apposition, with some of the Sutures <i>in situ</i> - - -	193
134.	Cones with Sutures and Needles attached - - -	195
135.	Mode of Insertion of Cone - - -	196
136.	Operation half completed (Dog's Bowel) - - -	197
137.	<i>Post-mortem</i> Specimen of a Cat showing Enormously Enlarged Kidneys - - -	200
138.	A Case of Perityphlitis and Ulceration of the Bowel - - -	201
139.	Cæcum of a Bull Bitch distended from Inflammation of the Interior - - -	202
140.	Prolapse of the Bowel - - -	206
141.	Suture of the Bowel to the Abdominal Wall - - -	211
142.	Anal Adenomata - - -	217
143.	Inoperable Sarcomata of the Liver in the Abdomen of an Irish Terrier Dog - - -	219
144.	Tumours (Sarcomata) of the Spleen - - -	221
145.	Umbilical Hernia (Front and Lateral Views) - - -	226

LIST OF ILLUSTRATIONS

xxiii

FIG.	PAGE
146. Tumours in Inguinal Region (for comparison with next figure)	230
147. Inguinal Hernia - - - - -	230
148. A Double Inguinal Hernia fixed in a Suitable Position for Operation - - - - -	231
149. Hernia Bistoury - - - - -	231
150. A Pug-dog with Scrotal Hernia - - - - -	232
151. An Aged Yorkshire Terrier with Scrotal Hernia - - - - -	233
152. An Aged Dachshund with Perineal Hernia (Omentum) - - - - -	235
153. Perineal Hernia in a Collie - - - - -	236
154. Catheter inserted into the Bladder, illustrating a Perineal Hernia which had been opened and found a Fistula - - - - -	237
155. Curved Hernia Needles (MacEwen's) for suturing the Inguinal Ring - - - - -	238
156. Flexible Metal Sound - - - - -	239
157. Usual Position of Incision in Urethrotomy - - - - -	242
158. Urethral Forceps - - - - -	246
159. Kidney Calculi <i>in situ</i> - - - - -	249
160. Small Renal Calculi - - - - -	250
161. Pedunculated Tumour of the Bladder - - - - -	254
162. Bladder Calculi <i>in situ</i> - - - - -	256
163. Shapes of Bladder Calculi - - - - -	257
164. Site of Incision for Suprapubic Lithotomy - - - - -	258
165. Perineal or Posterior Pubic Lithotritry - - - - -	259
166. Lithotrite - - - - -	260
167. Urethral Dilator - - - - -	261
168. Thompson's Evacuator - - - - -	262
169. Suppurating Prostate Gland - - - - -	264
170. Carcinoma of the Prepuce - - - - -	267
171. Contagious Venereal Growths on the Penis - - - - -	268
172. Wound in the Prepuce - - - - -	271
173. Malformation of the Prepuce and Penis - - - - -	274
174. Sarcoma of the Testicle - - - - -	276
175. Method of holding Cat for Castration - - - - -	277
176. Fox-terrier with Ectopic Testicle - - - - -	278
177. Wire-haired Terrier with Ectopic Testicle - - - - -	279
178. Dissection of a Cryptorchid - - - - -	282
179. Hermaphrodite Puppy - - - - -	284
180. Dissection of Hermaphrodite - - - - -	285
181. Tumour of Undescended Testicle - - - - -	286
182. Vaginal Speculum - - - - -	288
183. Prolapse of the Vagina - - - - -	289
184. Contagious Venereal Tumours of the Vagina - - - - -	291
185. Fibromas of the Vagina - - - - -	293
186. Diseased Uterus and Ovary - - - - -	295
187. Prolapse of the Uterus - - - - -	300
188. Bull Bitch after Ovaro-hysterectomy - - - - -	301
189. Myoma of the Uterus - - - - -	302

FIG.	PAGE
190. Sarcomas of the Pelvis and Ovaries - - -	303
191. Spaniel Bitch after Hysterectomy - - -	307
192. Group of Puppies saved by Hysterectomy - - -	310
193. A Monstrosity - - - - -	311
194. A Monstrosity - - - - -	312
195. Parturition Forceps - - - - -	314
196. Puppy sucking from a Feeding-bottle - - -	319
197. Ward's Foster-mother - - - - -	320
198. Tee's Foster-mother - - - - -	321
199. A Bulldog saved by Ovaro-hysterectomy - - -	322
200. Collie Dog with Dislocated Wrists - - -	324
201. Collie Dog with Leather Splints applied - - -	325
202 and 203. Dislocation of the Elbow - - -	327
204 and 205. Dislocation of the Patella - - -	328
206 and 207. Malformed Patella Joints - - -	329
208. Dislocation of the Pollux (Skiagraph) - - -	330
209. A Cyst in the Spinal Cord - - - - -	331
210. Dislocation of the Tail-bones (Skiagraph) - - -	332
211 and 212. Fracture of Both Fore-legs - - -	333
213. Fracture of the Wrist - - - - -	334
214. A Badly-set Wrist - - - - -	334
215. A Swollen Foot - - - - -	335
216. Comparison between Two Femurs - - - - -	336
217. Cat with Fractured Leg - - - - -	337
218. Fractured Shoulder - - - - -	338
219. Fracture of Each Humerus - - - - -	339
220. Comminuted Fracture of a Digit (Skiagraph) - - -	340
221. Amputation Saw - - - - -	341
222. Fractured Leg - - - - -	342
223. Artificial Limbs - - - - -	343
224. Amputation of Both Fore-legs - - - - -	344
225 to 230. False Legs applied - - - - -	344-347
231. Pug with Overgrown Nails - - - - -	350
232. Nail Forceps - - - - -	350
233. Severed Gastrocnemius Tendon - - - - -	352
234. Skiagraph of Cat's Leg with Foreign Body - - -	353
235. Serous Cysts - - - - -	355
236. An Inflammatory New Growth - - - - -	356
237 and 238. Skiagraphs of Fractures - - - - -	358
239. Skiagraph of Comminuted Fracture - - - - -	359
240. Skiagraph of Pelvis - - - - -	361
241. Skiagraph of a Dog's Normal Stifle Joint - - -	362

CANINE AND FELINE SURGERY

CHAPTER I

GENERAL RULES FOR TREATMENT OF THE PATIENT BEFORE AND AFTER A SURGICAL OPERATION

WHEREVER possible, it is better, though not absolutely necessary, that the patient should be prepared some time before passing through the ordeals of anæsthetization and operation. If the animal has been recently removed from its owner and placed amongst fresh surroundings, such as the infirmary of the operator, it is always wise, when possible, to allow it to get accustomed to the strange place and attendants, and to make sure that the dog or cat has a good appetite and is feeding well. If there is fever, catarrh, or other sign of ill-health, the operation, unless the case is an urgent one, should be postponed. The action of the bowels and kidneys should be watched, and if the former are at all constipated, a dose of laxative medicine about twenty-four hours, or an enema about two hours, before operating is a wise precaution. The laxative chosen, however, should not be one which will cause nausea, griping, or loss of appetite. Castor-oil or liquorice are suitable, and for the enema either warm water and soap, or glycerine and water, answer the purpose well.

Where an abdominal operation involving the stomach or intestine is anticipated, and the condition of the patient will

allow it, some intestinal antiseptic (such as chinosol, izal, calomel, carbolic acid, β -naphthol, etc.) should be administered every four or six hours for three or four consecutive days previously.

Immediately before some operations it is necessary to repeat the enema and to withdraw the urine by the aid of a catheter. A light meal of finely-divided solid food or a quantity of beef-tea or milk is advisable about seven or eight hours before anæsthetization. Vomiting during, or when recovering from, the application of chloroform, so frequently met with in human patients under similar conditions, is very rare in the dog and cat. The author has only met with it in eight or ten instances out of more than a thousand closely recorded administrations of chloroform (see Chapter IV.). It is generally due to the presence of solid food in the stomach.

After an operation under anæsthesia the patient should be put in a quiet place where there is plenty of fresh air, and allowed to recover. The eyes, nostrils, and mouth should be sponged with cold water, care being taken that none of it gets into the back of the mouth. On no account should stimulants or other fluids be administered in any quantity down the throat until recovery has taken place, as some of it is likely to find its way into the trachea and lungs. When the animal is able to lap voluntarily, a little cold water may be allowed, but solid food should not be given for at least an hour. A clean place, attention to hygiene and diet, together with antiseptic dressings as often as necessary, will complete the directions to bring about restoration to health.

Preparatory Treatment of the Site of Incision.

The **antiseptic** treatment is the *only* one which is admissible in modern surgery. All instruments, the patient, the operator, the operating-table, and all surroundings, must be considered as dirty until they have been treated antiseptically and

rendered surgically clean. It is only by this method that one can hope to get an uninterrupted series of successful results.

All hair from the site of operation and the contiguous parts should be removed a short time before operating, by the aid of scissors or clipping machines and a razor, the skin being thoroughly scrubbed for fully two minutes with soap and hot water containing some disinfectant, then again for two minutes with ether, spirit, or ether soap to remove all grease and sebaceous material, and afterwards swabbed with an antiseptic of reliable strength. Turpentine, which is sometimes used in human surgery, is not permissible, as it acts as a violent irritant to the skin of the dog and cat. A pad of wadding soaked in some antiseptic, and carefully kept in position over the site for an hour before the operation commences, completes the process by which the parts are rendered surgically clean.

If a preliminary dressing cannot be applied, owing to the situation of the wound, the temper of the animal, or some other cause, the antiseptic chosen and the cleansing process must be applied with extra thoroughness and care at the time of operating. *The use of the razor is absolutely essential to bring about a continuous series of primary wound unions without pus formation. This primary union can, however, be assured in more than 90 per cent. of cases if only the operator will take the care to be surgically clean.* This statement is based upon the results of careful records taken upon more than a thousand wounds in veterinary patients.¹

The choice of an antiseptic must rest with the operator. Probably those which are in most common and general use for surgical purposes are solutions of carbolic acid, lysol, creolin (each of which is used in from 1 to 2 per cent. solutions with water), corrosive sublimate (1 in 1,000 parts),

¹ *Veterinary Record*, vol. xv., p. 685. (Proceedings of the Central Veterinary Medical Society.)

chinosol (1 in 1,000 to 1 in 500), boracic acid (5 to 10 grains to the ounce), and biniodide of mercury (1 in 1,000 solution, being aided by the addition of a little more than an equal amount of potassium iodide).

Of these, boracic acid is particularly selected for wounds on the cornea of the eye; solutions of carbolic acid, lysol, creolin, and perchloride of mercury, must be used with the greatest care when operating on small dogs or cats, as toxic symptoms sometimes ensue even when these drugs are applied only to a small area.¹

As an illustration of this the following case is worth remark. The patient, a female cat in an emaciated condition, was placed on the operating-table for laparotomy, the object being to remove a cork which could be distinctly felt to be present in the intestine. A 5 per cent. solution of carbolic acid was used to disinfect the site of operation after the hair had been shaved off, and also for the instruments. A little was also used to wipe the edges of the bowel wound and to disinfect the peritoneum in one place where it became soiled. The solution was, however, used sparingly, but before the operation was completed symptoms of carbolic acid poisoning had commenced, the voluntary muscular system was twitching violently, and the temperature became subnormal. Antidotal measures were adopted, but within two hours after the completion of the operation the patient was dead.

Solution of biniodide of mercury has advantages over that of the perchloride, in that no precipitate is formed when it becomes mixed with blood, and it does not combine with albumin. Many of these antiseptics can now be purchased in the convenient form of tabloids, tablets, or soloids, one of which dissolved in a certain quantity (usually a pint or a quart) makes a lotion of the requisite strength in a few moments.

After trials of various antiseptics, those usually chosen by the author have been ether soap and creolin for the operator's hands and the preliminary washing of the patient, and chinosol for the final cleansing.

¹ *Journal of Comparative Pathology and Therapeutics*, vol. x., p. 361; *idem*, vol. ix., p. 1.

Value of the Thermometer after Operations.

Indications that a septic infection is already present or that one has taken place after an operation are suspected by the general dulness of the patient, loss of appetite, haggard facial expression, a thready or almost imperceptible pulse, and a rise of temperature.

The thermometer is one of the most valuable aids to a diagnosis of septic infection, although it must not be forgotten that a very little excitement will in a few moments cause the temperature of a healthy dog or cat to become raised even as much as one or two degrees.

In order to test this point, the author made a large number of observations on dogs, cats, and other animals.¹ From a series made upon over 200 dogs, the normal average rectal temperature worked out at 101.5° F., and from a series made upon forty-one cats the average

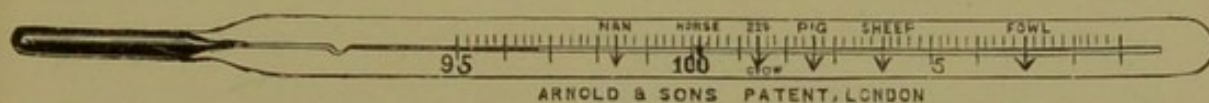


Fig. 1.—Animals' Thermometer (Author's Pattern).

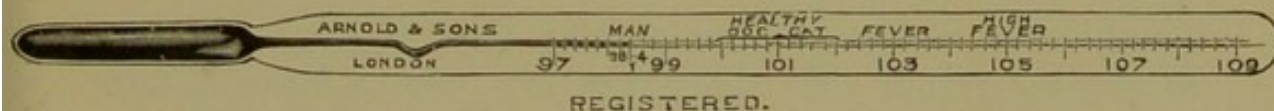


Fig. 2.—Canine Thermometer, showing Fever Markings (Author's Pattern).

was 101.7° F. It was a perfectly easy matter, by merely causing the animal to struggle, to obtain a rise of temperature of a degree (and even more) within three minutes, so that this fact, in an excitable animal, must not be lost sight of.

The normal temperature of the dog and cat, at rest and in health, ranges between 100° and 102° F., depending a little upon the age, condition, temperament of the animal, and also whether the temperature was taken after food, prolonged rest or exercise, and at what time of the day.

¹ *Journal of Comparative Pathology and Therapeutics*, vol. ix., p. 301; Schafer's 'Text-book of Physiology,' vol. i., p. 790 *et seq.*

Young animals have a higher temperature than old ones; when well fed the body is slightly warmer than when the animal is emaciated; certain diseased conditions made a very appreciable difference, and the surroundings and presence of companions also act as extraneous influences. Œstrum and various other things must also be taken into account. Exceptions to this rule will occasionally be met with, but for general purposes the above may be taken as the normal average range.

CHAPTER II.

ANTISEPTIC PREPARATION OF INSTRUMENTS, DRAINAGE-TUBES, SUTURE MATERIAL, SPONGES, ETC.

BEFORE entering upon a surgical operation, it is essential that the operator bestows care upon the instruments which he is about to use. For the majority of operations the following instruments will suffice, and they should as far as possible be made entirely of metal, those which are jointed being so constructed that they can be taken to pieces: Several scalpels, director, forceps, scissors (straight and curved), two or three pairs of artery forceps, a probe, and needles of various shapes and sizes. For special operations, of course, others, such as *écraseurs*, *bistouries*, *tenotomes*, *hernia needles*, etc., are required. The nickel plating of parts which can be so treated is also an advantage, both as regards cleanliness and for the sake of appearance.

One of the most important secrets of the successful healing of a surgical wound consists in seeing that injurious germs are not introduced by means of the instruments and sutures, and it is very essential that both shall be first rendered aseptic. This can be readily attained by boiling for about ten minutes in some form of **sterilizer** (for which purpose an ordinary clean saucepan or fish-kettle can be suitably improvised), or by placing them for at least half an hour previous to use in an antiseptic solution of reliable strength. Rust is prevented by adding a piece of washing soda, about an ounce in weight, to an ordinary fish-kettle full of water. To merely

plunge them in an antiseptic solution, as is frequently done, about a minute before operating is of no value at all, and is apt to bring discredit on principles which, when carried out properly, have been the means of saving many thousands of valuable lives.

For the antiseptic solutions, trays or dishes made of glass, earthenware, or metal are the best. A clean pie-dish or an enamelled iron bowl can be improvised for the purpose very well.

The solutions usually chosen are those already mentioned

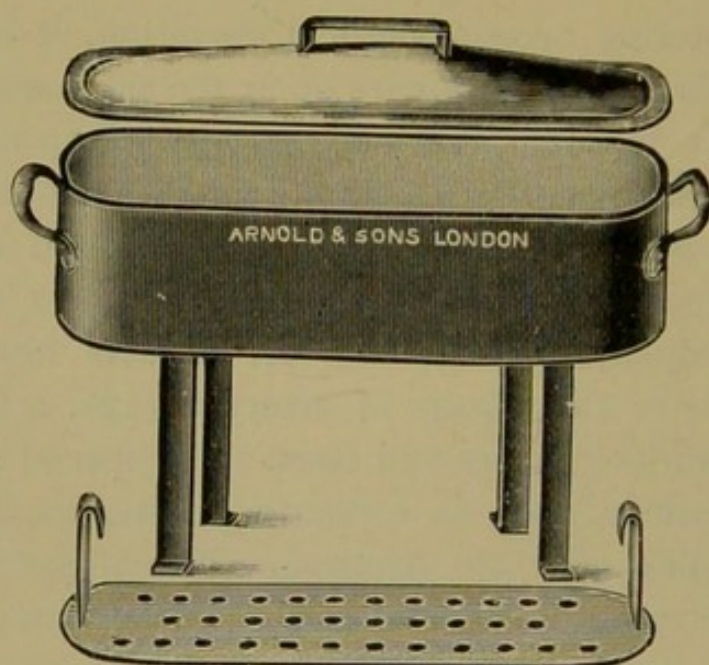


Fig. 3.—Instrument Sterilizer.

when dealing with the preparation of the site of incision; most of them have some minor disadvantages, although the advantages far outweigh these. For instance, solution of lysol makes the handles slippery to take hold of, and has an astringent effect on some operators' hands. Solutions of chinisol, biniodide of mercury, and corrosive sublimate discolour the steel; solutions of creolin are opaque and hide the instruments; and each of them has more or less action upon the edge of the blade. During the

operation the greatest care must be taken that the instruments do not come in contact with anything which has not been thoroughly cleansed and rendered aseptic, and when finished with they should be carefully cleaned in very hot water, dried, and put in a dry, clean place until required for future use.

Instrument cabinets, with tight-fitting doors to exclude dust, and with glass shelves, can now be obtained at a com-

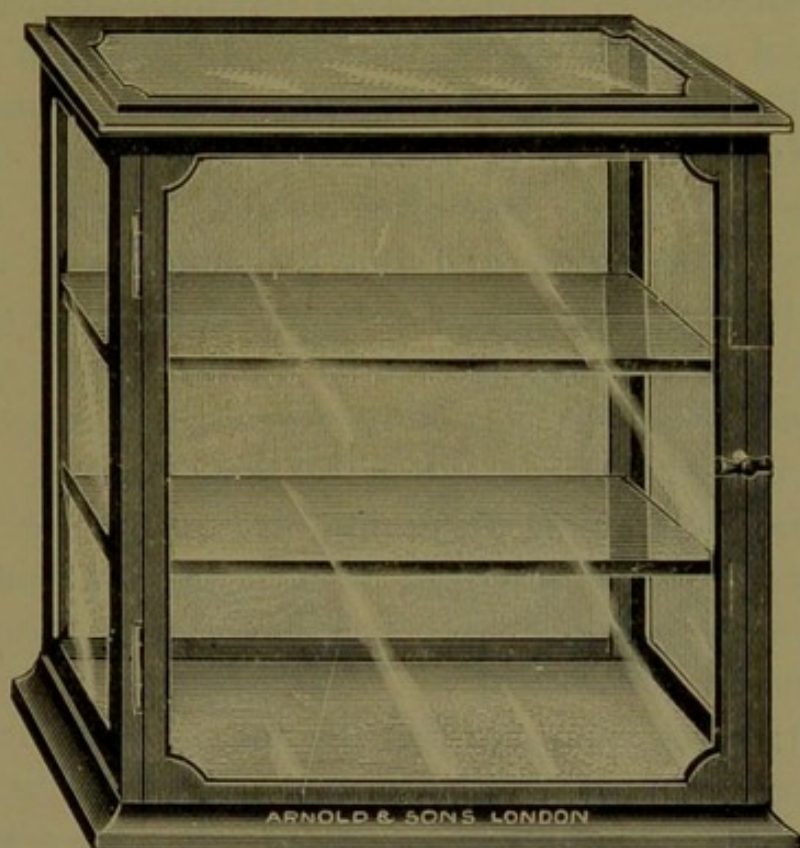


Fig. 4.—Instrument Cabinet.

paratively small cost, and if placed in a dry situation nothing further is necessary than to lay the instruments inside.

In the event of the absence of a proper cabinet, the instruments should be wrapped in clean lint or wadding and put in a thoroughly dry and dust-proof place.

Preparation of Silk and Wire.—Silk and wire for suture purposes should be clean and carefully boiled for at least ten or fifteen minutes in plain water (if soda is added the silk

becomes brittle) before use, or placed for at least half an hour in some reliable antiseptic solution. Silk is conveniently prepared in various sizes known as 00, 0, 1, 2, 3, 4, etc., and can be kept ready for immediate use by being wound on glass reels and kept in glass-stoppered bottles.

Catgut and kangaroo tendons will not bear boiling; they require lengthened immersion in antiseptic solution, and, to be thoroughly sterile, a proper method of preparation. Mr. C. B. Lockwood, F.R.C.S.,¹ speaks very highly of the sterile property of catgut prepared according to Esmarch's² directions, which are as follows: 'The ordinary commercial catgut, Nos. 1 to 3, is vigorously cleansed with a brush in soft soap and water, and after washing in pure water is wound on glass spools and laid in bichloride of mercury solution (1 to 1,000) for twelve hours; then in an alcoholic (1 to 200) solution of bichloride for twelve hours; and it is finally preserved dry in tightly-closed glass vessels. Just before it is used it is laid in a vessel filled with an alcoholic (1 to 2,000) solution of bichloride of mercury.' A simpler and more recently described French method consists in soaking it for a week in *lini iodi*, and this is stated to be quite satisfactory.

Catgut, ready prepared by the above or some similar method, can be purchased at a reasonable price, being conveniently arranged in dust-proof bottles in such a way that the gut is kept in the solution until a portion of it is required, and then only that portion is exposed which is to be used. If in oil, it should be well washed with ether or soaked in a strong antiseptic for some hours before using.

Silkworm gut or fishing gut is especially valuable because it does not possess capillary properties. It is to be obtained in different sizes, and is readily sterilized by boiling.

¹ 'Aseptic Surgery,' p. 180.

² 'The Surgeon's Handbook,' translated by Curtis, 1888, p. 15.

Drainage-tubes, either of glass, metal, or rubber, are readily sterilized by boiling and afterwards being immersed in an antiseptic solution. The chief trouble with our patients is to keep the tubes clean when in position, and in reality the less they are used the better, a plug or tent of antiseptic cotton-wool being usually an efficient substitute.

Sponges are very useful for the purpose of soaking up blood, etc., when operating ; but as it necessitates a lengthy and troublesome process to cleanse and render them sterile, it is the wisest plan to avoid their use whenever it is desired that immediate union shall take place. To be rendered

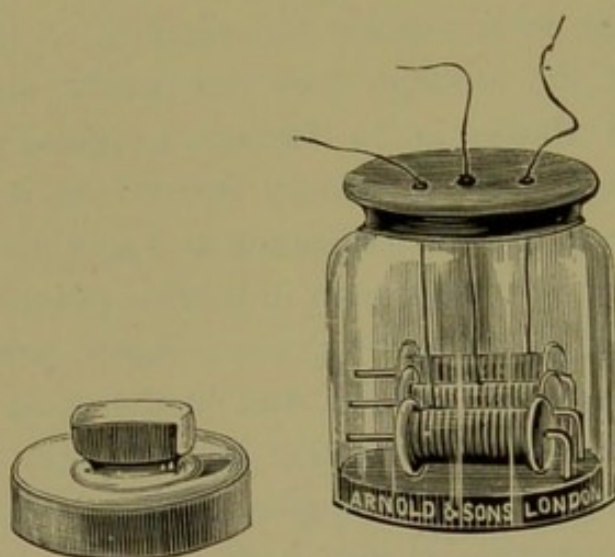


Fig. 5.—Glass Ligature Bottle (Clarke's).

aseptic they have to pass through a complicated process of washing and soaking in solutions of hydrochloric acid, boiled water, soda, sulphurous acid, boiled water again, and lastly some antiseptic lotion.¹

Tampons of cotton-wool or swabs which have been boiled for about ten or fifteen minutes and afterwards placed in a reliable antiseptic solution are much better, and, as they are cheap, they can be used freely. They are made either by merely screwing up some absorbent cotton-wool into little balls, or, better still, by stitching or tying small pieces of

¹ 'Aseptic Surgery,' C. B. Lockwood, p. 184.

clean gauze around small masses of wadding. If required to be used dry, they can be sterilized by being placed in a glass-stoppered jar and kept in an autoclave, or even an ordinary oven, at a temperature of 160° C. for about an hour.

Preparation of the Operator's Hands.

This part has been placed second to that of the treatment of the instruments, because in these days of aseptic and antiseptic surgery it seems hardly necessary to say that the operator should pay particular attention to the condition of his hands, nails, etc.

If an excuse is necessary for alluding to the subject, it must be that the student does not easily understand the importance of always going through a regular routine before operating. Again, in veterinary operations it is not at all times possible to get the assistance and spotless surroundings which accompany the surgeon in human practice.

The operator in veterinary practice has to attend personally to the securing of the animal, and in doing so is compelled to touch parts of the latter's body which are far from clean according to bacteriological ideas. Before operating, the hands, particularly the nails, should be thoroughly soaked and scrubbed for five minutes with soap and hot water (containing some antiseptic) by the aid of a clean nail-brush, again with ether, spirit, or ether soap, and then held for some minutes in some clean antiseptic solution. In abdominal and some of the more serious operations the operator cannot be too scrupulously careful. During the operation care must be taken not to touch anything which has not been rendered aseptic, and if by accident this is done the hands must be again carefully disinfected before touching either the wound or the instruments. The wound should be touched with the fingers as little as possible. The choice of the antiseptic must be left to the operator, care always

being taken to make it of sufficient strength. Any of those mentioned in the previous paragraphs are suitable, the only precautions necessary being taken in the cases of carbolic acid, lysol, and creolin, which have an irritant effect on the hands of some surgeons, especially when the solution is concentrated.

CHAPTER III

METHODS OF SECURING

IN securing canine or feline patients, the principal objects of the operator are to place the patient in the safest and best possible position for the operation to be done, and at the same time to insure the minimum amount of risk for his assistants and himself. Especial care on behalf of the operator or his assistants must always be taken where an animal is known to be vicious, and on behalf of the patient when the latter is known to be nervous, fat, or aged, particularly in those breeds (such as pugs, bulldogs, Blenheim spaniels, etc.) where the nasal bones are short and depressed, as sudden death from asphyxia has been known to occur. With a quiet animal the head and eyes can be examined by allowing an assistant to hold the patient while the operator lightly grips the throat between the thumb and the forefinger of the one hand, pushing them firmly under the angles of the jaws, the other hand being placed on the top of the head (Fig. 6); all attempts at biting are thus prevented by pressing the head and jaws between the two hands. When the animal is at all inclined to be vicious, the plan to adopt is to request the owner to grip the patient firmly by the back of the neck, whilst the operator places a tape round the jaws in such a manner as to keep them tightly closed. This tape is best affixed in the form of the clove hitch, having the loose ends underneath, and afterwards passing them under the ears to tie in a bow at the back of the poll.

These loose ends should not be tied round the neck or throat, on account of the danger of strangulation. Another method of securing the mouth is to pass the tape twice round the jaws and tie once on the top of the nasal bones, twisting the two loose ends several times round one another and fixing them to a leather collar previously placed around the neck (Fig. 8).

The **clove hitch** (Fig. 7), however, is undoubtedly the better method, as it is very easy to apply, effectually keeps



Fig. 6.—Photograph of Dog held for Safe Examination.

the jaws closed, and can be removed at a moment's notice by simply applying traction to either one end or the other. The method by which it is made is difficult to describe, although it can be readily demonstrated with a piece of cord or tape. Two loops are made in reverse directions and folded on each other so that they fall as illustrated in Fig. 9.

Having thus prevented the animal from biting, the next step is to fix the patient in such a position as will be most

convenient for the performance of the operation, and at the same time give the minimum amount of risk of injury. For minor operations, such as the lancing of some abscesses, etc.,




Fig. 7.—A Clove Hitch applied.

all that is necessary is to get an assistant to hold the dog or cat, but for prolonged or delicate operations it is always



Fig. 8.—A Piece of Tape applied as a Muzzle.

best to secure the animal by the aid of hobbles or a proper operating-table.

Portable hobbles are made, consisting of clamps which can

be placed anywhere on the edge of an ordinary kitchen or saddle-room table, a tape to pass round each leg, and adjustable sliding cords by which the length may be graduated as

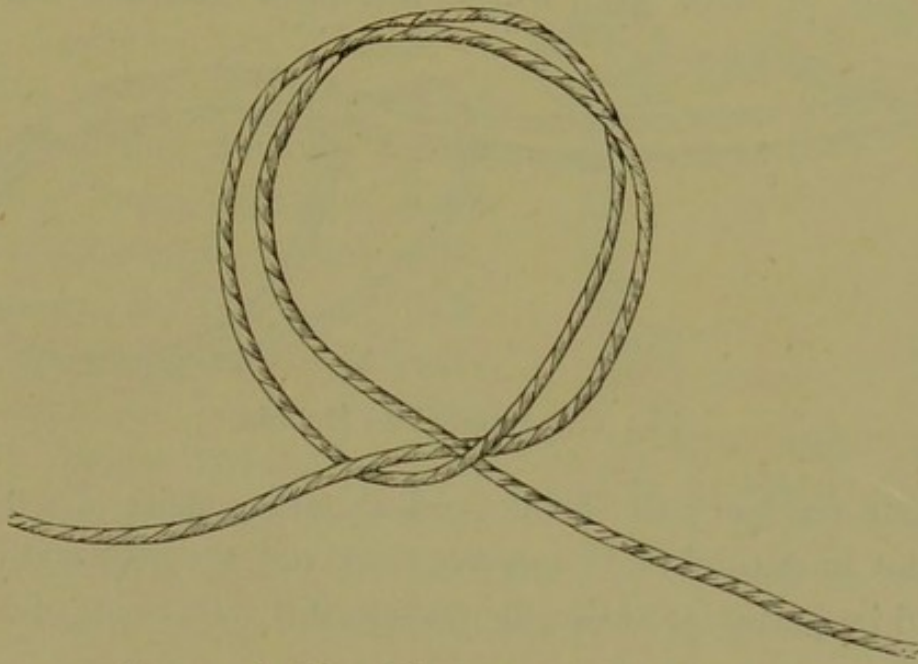


Fig. 9.—A Clove Hitch ready for Application.

much as is thought requisite (Fig. 10). Hobbles can be improvised by doubling four long pieces of tape in each case so as to make a slip-noose in the centre (Fig. 11), and

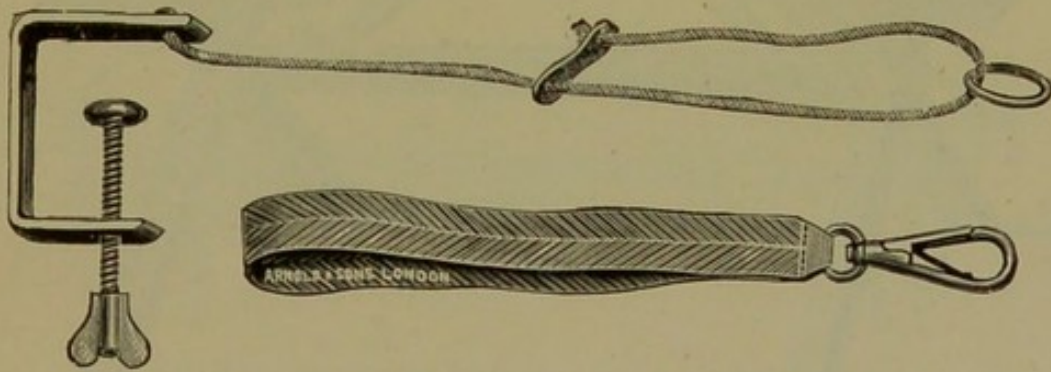


Fig. 10.—The Author's Pattern of Hobbler.

then fixing the loose ends to the legs of an ordinary kitchen or saddle-room table, or to nails or hooks driven in the edge of the table.

An operation-table is almost essential in every large canine

practice, and even where only a moderate amount of canine work is done its advantages cannot be overestimated. The top should be made of some hard wood, such as pitch pine, oak, elm, or teak, etc., which will bear constant washing

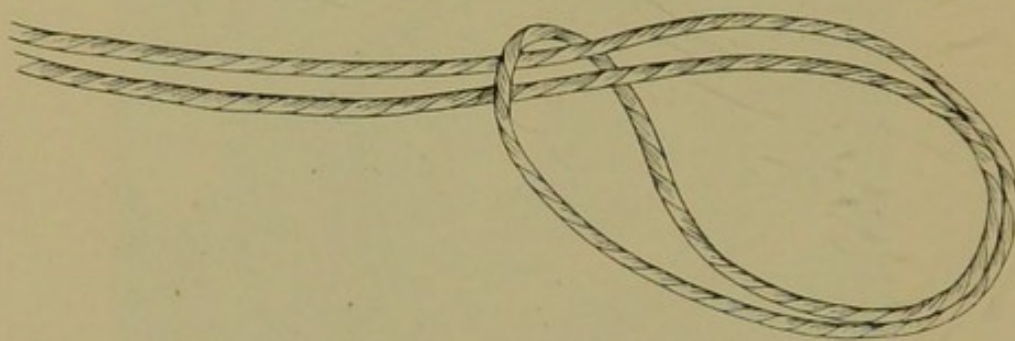


Fig. 11.—Improvised Hobble.

without tendency to shrink, and should consist of a board about 1 inch thick. If expense were not a consideration, it would be better for antiseptic reasons if it were made of metal,




Fig. 12.—The Author's Pattern of Operating Table.

glass, or some such absolutely impermeable material, and a trough or metal tray can be arranged underneath to carry off the superfluous fluid. The measurements of the top, to take

all classes of dogs, are about $5\frac{1}{2}$ by $2\frac{1}{2}$ feet. The front is improved by making the edge in the form of a semicircle, as this sometimes affords an advantage when operating upon the parts which overhang it.

The keyholes are placed in parallel rows at intervals of about 3 inches, the long part of the hole being made to point towards the centre of the table, as shown in Fig. 12. The keys which fit into these holes are made of brass or other metal, being shaped like a solid key, but having a shoulder or rim running just underneath the loop in order to prevent

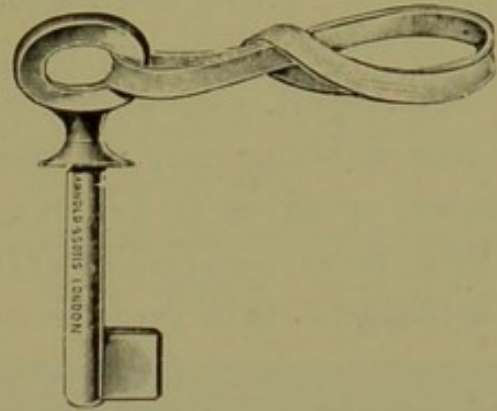


Fig. 13.—Key Hobble looped ready for Application.

them from passing too far into the hole in the board. The

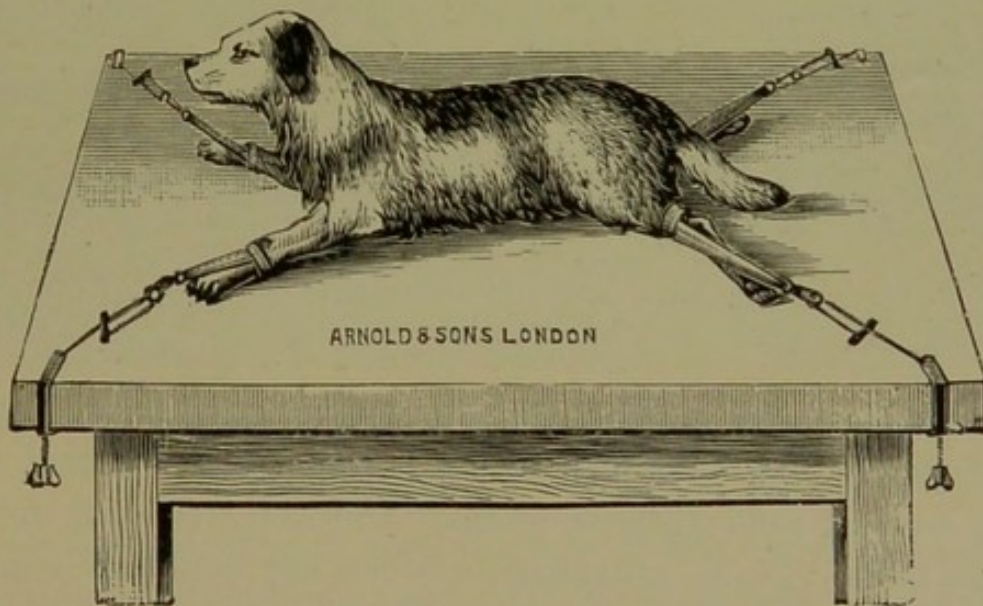


Fig. 14.—A Dog fixed with Hobbles on an Ordinary Table in the 'Abdominal' Position.

hobble consists simply of a piece of tape passing through the ring on the key, the two ends being stitched firmly together.

The method of securing an animal is first to place the clove hitch on the jaws as previously described, then a hobble

tightly round each leg (in the fore-legs above the carpus or elbow, and in the hind-legs above the tarsus) ; secure the fore-legs first by passing the keys through two of the holes in the table and giving them a twist, then the hind-hobbles in the same way, pulling the hind-legs down together. With very large dogs it is sometimes also a good plan to pass a piece of stout webbing over the back and loins and tie it under the table, or an extra key may be made use of on either side. With a cat, on account of the facility with which this animal withdraws its limbs from restraint, thin tape is advisable for

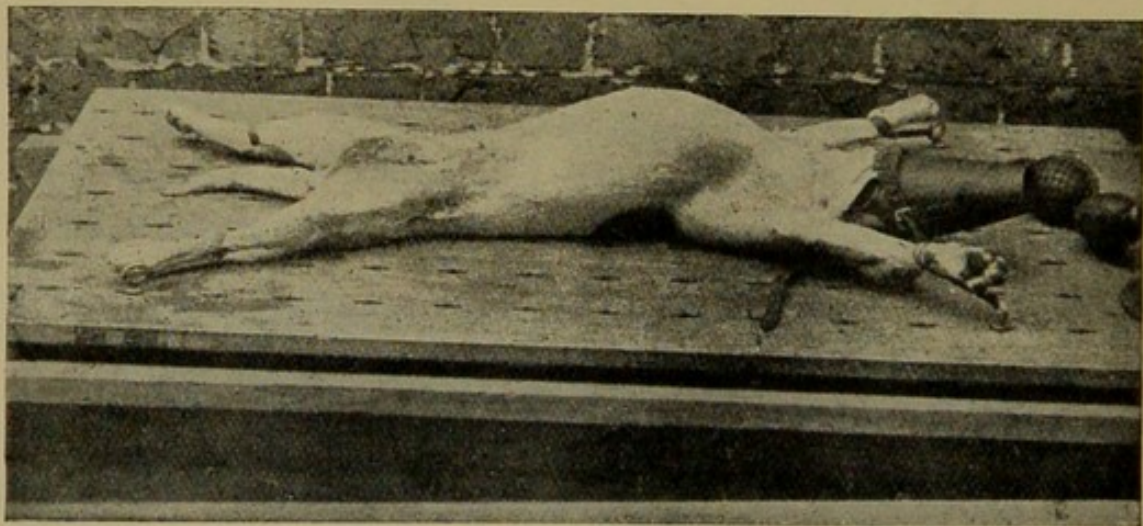


Fig. 15.—A Dog fixed on the Operating table in the 'Dorsal' Position.

the hobbles, and it should be drawn very tight just above each paw. The chief precaution to take is to see that the legs are just sufficiently wide apart and well stretched out to allow of no violent struggling. When the hobbling is done properly, it is astonishing with what ease an animal can be controlled. This places the patient flat on its abdomen, and for convenience will be referred to, when speaking of positions for operative purposes, as the **abdominal** one.

When it is necessary to operate upon the abdomen or under parts of the body, the animal is turned upon its back and fixed in a similar way, extra care, however, being here

taken with the fore-limbs, so as not to stretch them out too tightly, and thus injure the muscles attaching the fore-limb to the chest. This will for descriptive purposes be termed the **dorsal** position.

For operations on the sides or flank the animal can readily be laid on either side. These will be referred to in the text as the right and left **lateral** positions respectively.

Since this pattern of table has been introduced into general use, more than 8,000 animals have, to the author's knowledge




Fig. 16.—Gray's Operating rack attached to an Ordinary Table, with a Cat fixed in the 'Abdominal' Position.

alone, been secured in one or other of the above-mentioned positions without accident. It is especially convenient because, by means of the key hobbles and keyholes, a patient can be extended and a limb brought forward or retracted in whatever position may be desired.

Another pattern of operating-table has been described by Mr. B. P. Godfray,¹ in which the legs are secured by tape hobbles to the ends of the table, but in addition the body is

¹ *Veterinarian*, December, 1896.

held in position by three straps which pass through slits in the table surface and are buckled round the neck, chest, and loins respectively.

Mr. Henry Gray has devised a very ingenious operating-rack which is portable and can be fitted to any ordinary kitchen or saddle-room table. It consists of a couple of bars, which are held in position by clamps, and between these the animal (after being hobbled) is extended either in a dorsal or abdominal position as required (Fig. 16).

After an operation, and in some diseases, it is sometimes desirable to secure a patient's legs in some such way that it is unable to scratch the parts. This can easily be done by hobbling with pieces of tape, a short piece of which is tied around each hind-leg above the hock; or two pieces are used, a fore and a hind leg being connected.

CHAPTER IV

THE ADMINISTRATION OF ANÆSTHETICS (LOCAL AND GENERAL)

General Remarks.

ANÆSTHETICS are medicinal agents which produce unconsciousness to pain, and they are used for this purpose very largely when performing operations. They are of very great value on humane grounds, and also on account of the convenience they afford to the operator. They cause relaxation of muscular tissues in some cases (such as herniæ), and allow delicate operations to be conducted with much greater care and precision, when the animal is perfectly still, than could be adopted with a struggling, violent patient. They are divided into two classes, viz., local and general.

By the term **local** anæsthetic is understood 'an agent which removes sensation from the parts to which, or contiguous to which, it is applied.'

Under this heading, for surgical use, come such agents as cold water, ice, ether, ethyl-chloride, anestile, cocaine, eucaine, holocaine, stovaine, and orthoform.

By the term **general** anæsthetic is understood a 'medicinal agent which acts upon the higher centres to produce a complete loss of consciousness in the whole body of the animal to which it is administered.'

Under this heading, for surgical use, come such preparations as chloroform, ether, the A.C.E. and other mixtures.

Morphia, subcutaneously injected, and chloral administered

either as draught, intravenously, or by enema, are largely made use of on the Continent as narcotizing agents to keep the patient quiet and to deaden pain.

Local Anæsthetics.

Taking the local anæsthetics first, anæsthesia produced by the first five agents mentioned (*viz.*, cold water, ice, ether, anæstle, and ethyl chloride) depends chiefly upon the amount and intensity of the cold produced.

Cold water and **ice** have a very transient effect, and are only suitable for trivial operations, such as the lancing of

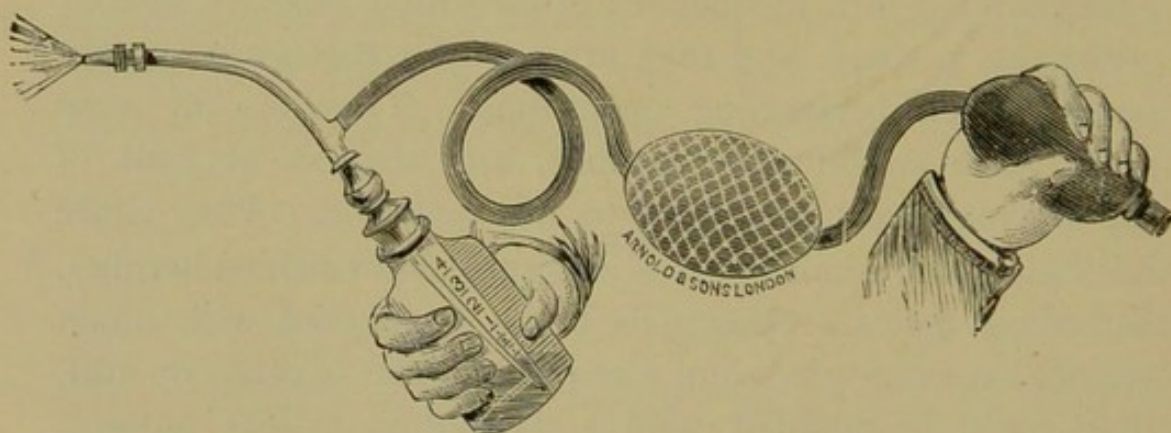


Fig. 17.—Ether Spray Apparatus.

abscesses or the removal of small superficial tumours. In order to act efficiently, they must be applied for a few minutes directly to the part upon which the operation is to be performed.

In **ether** and **ethyl chloride** we have drugs by the aid of which the parts are artificially frozen, and thus deprived of sensation. Ether is applied with a spray, as first introduced into human medical practice by the late Sir B. W. Richardson, M.D.

The parts to be anæsthetized should have the hair removed by shaving, and be then rendered aseptic and as dry as possible, the ether being forced out of the bottle by the

rubber bellows, and falling directly in the form of a very fine spray on the required spot.

Ethyl chloride and **anestile**, which are also applied in the form of a spray, are sold in a very portable and neat form in small glass or metal vessels (see Fig. 18).

They are applied directly to the spot at which anæsthesia is to be produced by merely removing the metal cap from the end and holding the bottle in the warm hand.

These three agents are also best suited for minor operations, such as the lancing of abscesses, the anæsthetizing of the skin, or the removal of small superficial tumours, and are not readily applied to thick muscular tissues where a

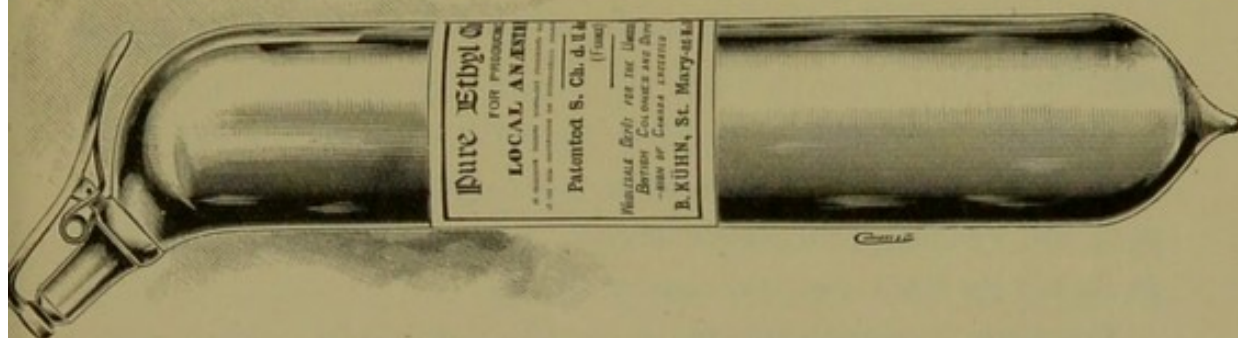


Fig. 18.—Glass Tube containing Ethyl Chloride ready for Application.

considerable amount of dissection has to be done; the reasons being that, if a thin layer only be frozen, the warm blood (when the incision is made) prevents the further application of the anæsthetic, whilst if the whole mass be frozen first it is difficult to cut, and there is the danger of necrosis as a sequel.

As a general rule, anæsthesia is produced when the skin has turned white; this occurs in from half a minute to a minute and a half, and the effect lasts for about two minutes.¹ Care must be taken not to keep the parts frozen for too long a time, or necrosis may follow.

¹ *Journal of Comparative Pathology and Therapeutics*, vol. ix., p. 227.

The above-mentioned agents have the advantage over other drugs of not being in any way absorbed so as to produce toxic effects, unless inhaled through the respiratory passages, and even in that case plenty of warning would be given by the patient.

For operations on the cornea of the eye they are not suitable, on account of the amount of irritation set up.

We now come to cocaine, eucaine, holocaine, and orthoform, which owe their special function to their power of paralyzing nerve terminals in the tissues to which they are applied.

Cocaine is a vegetable alkaloid obtained from the leaves of the coca plant, whilst **eucaine** is a chemical preparation possessing exactly the same formula.

The hydrochlorate of each is the salt generally made use of.

Both of them are toxic, even in very small doses, and great care has to be exercised in their use ; they are readily absorbed into the system from subcutaneous, serous, or mucous surfaces, particularly from the first named.

Cocaine hydrochlorate is readily soluble in cold or warm water, but decomposes on boiling ; the solutions made use of vary from 1 to 10 per cent. It should always be made fresh when required, as even after a few days the efficacy of the solution is not to be relied upon. If it is absolutely necessary to keep it in solution, a small quantity of either salicylic or boracic acid added to it will help to preserve it for a longer time.

After an injection complete local anæsthesia is produced in from three to five minutes, and lasts about twenty or twenty-five minutes ; its effect is manifested around the seat of injection for a space of from half an inch to $1\frac{1}{2}$ inches, so that where a large incision or large tumour is concerned injections must be made in several places. Superficially it can be used to deaden pain when painted on parts (such as

the under surface of the abdomen and thighs) where the skin is thin, but on the thicker parts its external use on the unbroken skin is not encouraging. On the cornea of the eye its effect is splendidly shown in from one to three minutes.

Eucaine hydrochlorate, when used alone, does not give such good or rapid anæsthetic results as cocaine, except when applied to the cornea. It is, however, slightly cheaper than cocaine; a solution of it can be boiled, and thus rendered sterile, without altering its anæsthetic power, and the toxic dose is a little larger. When anæsthesia is produced, too, the effect lasts longer than that of cocaine. A mixture of the two in equal proportions is very useful, as by it can be produced the better and more rapid anæsthetic effect of the cocaine, and at the same time the more prolonged anæsthesia and greater security from toxic symptoms which follow the use of eucaine. *In order to be on the safe side, the operator should never allow more than one-tenth of a grain of either cocaine or eucaine for each pound of the live body-weight of the patient to be absorbed into the system at one time.*

These results were arrived at as the result of a large number of carefully recorded observations on surgical and other patients, the investigation being undertaken on account of the numerous mishaps which were continually occurring from the injudicious use of these drugs.¹

Holocaine,² like eucaine, is a chemical preparation, and is used in the form of the hydrochlorate. It is antiseptic, and does not decompose on boiling. A few drops of a 1 per cent. solution cause, when applied to the cornea, a temporary burning sensation, which passes off in a few

¹ *Journal of Comparative Pathology and Therapeutics*, vol. viii., p. 20, vol. x., p. 80.

² *British Medical Journal Epitome*, 1898, p. 99; *Year Book of Treatment for 1898*, pp. 158, 368, 454.

seconds, and is immediately followed by a local anæsthesia lasting from about twelve to fifteen minutes. It is not suitable for hypodermic injection, or for use over any extent of surface, as it is more toxic than cocaine, producing symptoms resembling those of strychnine. The chief advantage which it is claimed to possess over cocaine or eucaine is that local anæsthesia is produced in ophthalmic cases without causing any intra-ocular tension or congestion of vessels in the neighbourhood to which it is applied.

Orthoform,¹ a local anæsthetic which has been introduced recently, is very valuable for wounds, mucous surfaces, and places where the skin is abraded. From a canine surgical point of view it is mainly of value in the treatment of wounds that are painful, and, dissolved in collodion in the proportion of 1 to 8, as an application for hermetically sealing an operation wound. For the latter purpose it is most valuable, especially for the closing of such wounds as are made during an abdominal operation. Before application, after the sutures have been inserted, the wound is thoroughly dried and the mixture painted on with a camel-hair brush. Its local anæsthetic effect is well marked, and continues for periods lasting even as long as thirty-six hours; in addition, orthoform is non-poisonous, and can be used over large abraded surfaces with perfect safety. The author has used it in several hundred cases as a dressing for hermetically sealing operation wounds without bandaging, and in no case where the wound was aseptic has the animal evinced irritation or attempted to interfere with the sutures; in instances of painful wounds, too, orthoform has proved equally valuable, when used alone or mixed in varying proportions with starch or boracic acid.

Having thus disposed of the **local**, we have next to consider the **general** anæsthetics—*i.e.*, those which produce

¹ *British Medical Journal Epitome*, 1898, p. 79; *Lancet*, November 6, 1897.

complete loss of consciousness in the whole of the body by their action upon the higher cerebral centres. Of these the best are chloroform, ether, and the A.C.E. and A.E.C. mixtures. They are used for major operations, and in cases, such as reduction of herniæ, where it is desirable to relax various tissues. Morphia and chloral must also be considered here.

General Anæsthetics.

The Choice of a General Anæsthetic.—*Chloroform is the ideal anæsthetic to choose for the average adult dog.* It is much more pleasant to taste than ether, does not produce so much salivation, the stage of excitement is less, and that of anæsthesia more prolonged, besides which the after nauseating effects are by no means so well marked. *If given slowly in a proper manner and sufficiently diluted, the risk to adult canine patients is very slight.* In the cat, however, and in the young of very delicate breeds of dogs, greater care must be exercised, and it is safer for an unskilled anæsthetist to choose either ether or the A.C.E. mixture. The last-named consists of a mixture of 1 part of alcohol, 2 parts of chloroform, and 3 parts of ether. These opinions are based on the fact that (mainly by inexperienced students in the Out-patients' Free Clinic of the London Veterinary College) chloroform was administered during five consecutive years by the pattern of inhaler shown in Fig. 21 to more than 1,200 consecutive canine patients with only five fatalities, four of which were satisfactorily accounted for on post-mortem examination; in the fifth case, unfortunately, no post-mortem was made. As, however, the latter was a pug, I was not altogether surprised, this breed of dog being usually risky to anæsthetize on account of the shape of the nose. The operations were of all kinds, some very trivial and some very severe, the animals not being (except in a very few instances) in any way prepared or selected, whilst they were of all ages, sizes, breeds, and conditions. The periods of

anæsthesia varied from a few minutes to four hours.¹ Of the five fatalities, two patients were pugs, and another a very old fox terrier ; the latter was found to be the subject of a generalized tuberculosis, which involved very extensively both the heart and pericardium. In the case of the first pug the animal was aged and very nervous, and death was due to rupture of a large abdominal vessel whilst struggling in the stage of excitement. In cats 120 consecutive cases were chloroformed with three deaths—a much larger proportion. Since these experiences we have used A.C.E. mixture or ether for all short-nosed delicate breeds of dog and for cats, up to the present, with satisfactory results in over 200 cases.

Indications for Especial Care in the Use of General Anæsthetics.—Extra care must always be exercised in very young animals, those of delicate breeds, those which are very fat, and those suffering from any respiratory or cardiac trouble.

Any impediment to the respiratory functions must always be looked upon with especial caution ; with regard to some cardiac affections, it is worth noting that, in five or six instances in the Clinic, dogs whose post-mortem examinations, when made shortly afterwards, revealed large vegetations on the valves of the heart, had taken chloroform for a prolonged period without showing the slightest sign of danger.

Preparation of the Patient.—It is a good plan, although by no means absolutely essential, to diet the animal carefully for one or two days, and to allow only a small fluid meal about four or five hours previous to the administration of the anæsthetic.

It is not necessary to make use, as is sometimes recommended, of subcutaneous injections of atropine or morphia

¹ *Journal of Comparative Pathology and Therapeutics*, vol. viii., p. 287, vol. xi., p. 114, vol. xiii. ; *Veterinary Record*, vol. ix., p. 284, vol. x., p. 163.

a short time before anæsthetizing, or to administer either ammoniacal or alcoholic stimulants. In fact, from observations made in order to test this point, the author is inclined to consider that when morphia and atropine (or either) are previously used, the result is rather to increase than diminish the risk.

Method of Fixing the Patient.—The object in fixing must be to place the animal in such a manner, first, that the organs contained in the thorax are allowed full play, and, secondly, that relief from restraint can be effected at a moment's notice. *These points are very important, and, in fact, absolutely essential.*

The safest position is undoubtedly that which is described in the chapter on methods of securing as the 'abdominal' one, the patient being anæsthetized in this position, and afterwards turned about as required to suit the convenience of the operator.

If the animal is merely held in the arms of an assistant, care must be taken not to compress the chest in any way nor hinder the breathing during the stage of struggling which usually precedes anæsthesia.

Methods of Administration, Apparatus, etc.—There are two chief methods of administering general anæsthetics. One is known as the 'open' method, and the other 'administration by the aid of an inhaler.'

For the **open** method, the best and safest results can be attained by the aid of an ordinary wire muzzle, a thin duster, and a drop-bottle; or, in place of the duster, a piece of thin flannel or calico may be previously sewn around that part of the patient's muzzle which covers the nostrils and lips.




Fig. 19. — Drop-bottle for the Administration of a General Anæsthetic.

The secret of success with chloroform is to allow plenty of air, and only just a sufficiency of well-diluted chloroform vapour for the purpose required. The duster must on no account be folded upon itself, one thickness of the cloth being ample, and the anæsthetic applied *gradually* from the drop-bottle.

The wire muzzle is useful, because it forms a framework upon which to rest the duster, and protects the face from the irritant effects of any chloroform which would otherwise come in contact with the skin or eyes. For small animals an improvised apparatus can be made by placing a piece of blotting-paper or cotton-wool soaked in chloroform at the

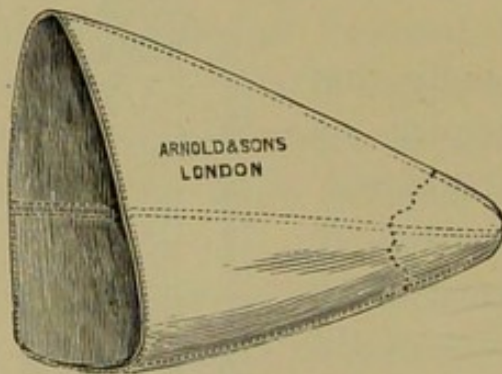


Fig. 20.—Wire Muzzle Mask.

bottom of a tumbler or gallipot, and holding it to the animal's nose; or the animal may be placed under a bell-jar, or in an air-tight box with a glass lid, into which there is placed cotton-wool or some material soaked in the anæsthetic.

The two latter methods, however, require great care, and are not very convenient for prolonged operations.

The **inhalers** suitable for canine work are of three chief patterns, varying somewhat in their construction and in the amount of vapour which they give off.

The advantages of an inhaler are, that only the vapour comes in contact with the patient's nostrils (there being thus no fear of irritant effects), the anæsthetic is well mixed with air in tolerably constant proportions before being breathed, the amount allowed can be adjusted with great delicacy, and the risk of overdose is thus minimized; the quantity, too, of chloroform used is considerably less, as the amount wasted is exceedingly small.

The first apparatus is so devised that it allows 6 or 8

drachms of chloroform to be placed in the bottle ; by means of the bellows a current of air is sucked over the surface of the anæsthetic, the mixed vapour being forced onwards into the mask (Fig. 21).

When 8 drachms are in the bottle and the temperature of the air about 60° F., each full compression of the bellows sends over chloroform vapour well mixed with air in the proportion of about 1·9 to 2 per cent.¹ In order to produce anæsthesia, the bellows must be worked as hard as possible,

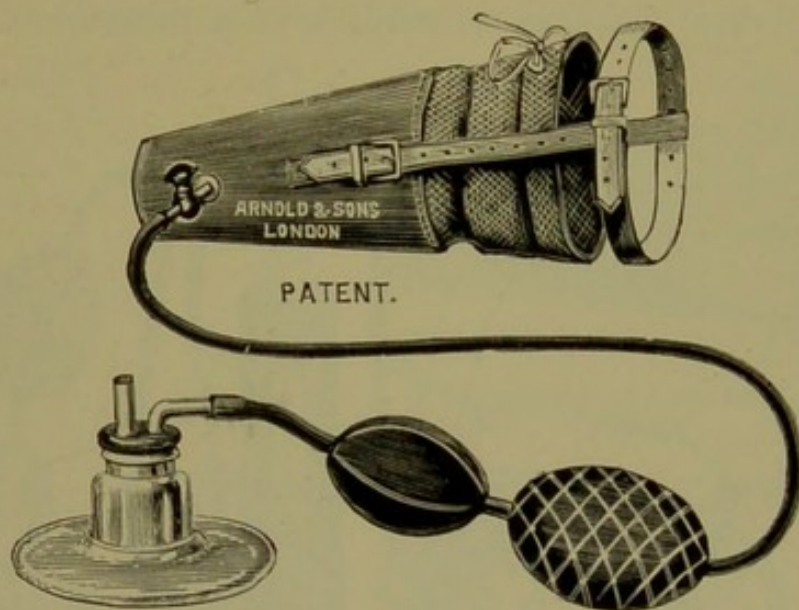


Fig. 21.—The Author's Anæsthetic Inhaler (First Pattern).²

the end of the mask being closed at the discretion of the anæsthetist.

With strong dogs of the larger breeds it is sometimes necessary to assist anæsthesia by placing a little chloroform on wadding in the end of the mask. For very delicate or young animals the vapour can be very much more diluted, either by putting less chloroform in the bottle, by only partially compressing the ball, by regulating the amount

¹ For the accurate demonstration of this percentage by Dr. Waller's dosimetric method, I am indebted to Mr. W. L. Symes, M.R.C.S.

² This pattern of inhaler is the one preferred by the author for patients up to the size of a large terrier, and for continuous use in larger dogs when once the patient is anæsthetized.

admitted by means of the tap, or by leaving the end of the mask uncovered.

The second pattern, known as Junker's, which has been modified to suit the smaller animals by Messrs. Kröhne and Sesemann, allows a stream of air to be forced through a quantity of chloroform, and so sends into the mask the vapour of air and chloroform mixed (Fig. 22).

With this it has been estimated that (at a temperature of 62° F.), with 8 drachms of chloroform in the bottle, each full compression of the bellows sends over a mixture of chloro-

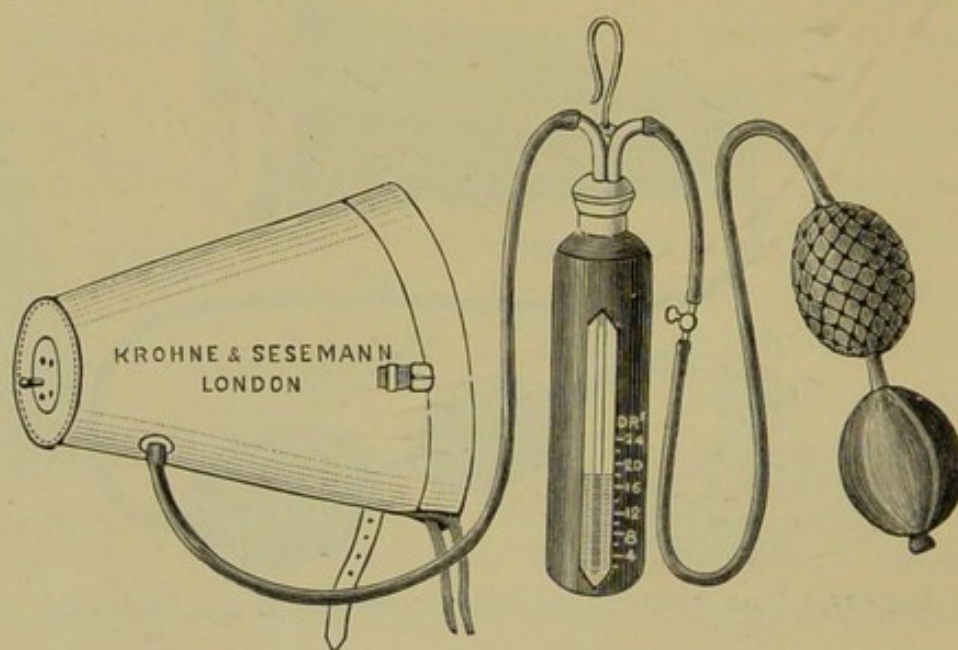


Fig. 22.—Junker's Inhaler (Kröhne and Sesemann's Pattern).

form vapour and air, which may contain as much as 10 per cent.

This apparatus is suitable for large dogs, but with small ones and cats great care must be exercised, or an overdose may easily be given. When used for these animals, the bellows must not be compressed to their fullest extent, and the end of the mask must be left open.

The anæsthetist should commence by pressing the ball very lightly, and not to more than about one-sixth of its extent, the pressure being gradually increased until sufficient vapour has been given to produce anæsthesia.

The third pattern of apparatus plays a medium part between the other two, as its object is to force a current of air over the surface of the chloroform (Fig. 23).

The vapour sent over is stronger than that of the first pattern, but less concentrated than that of Junker's.

Two other modifications, suitable for hospitals or infirmaries where operations are constantly being performed, consist in an arrangement whereby all pumping by means of the bellows is done away with, in one pattern by means of a cylinder of compressed air, with a regulating valve, attached

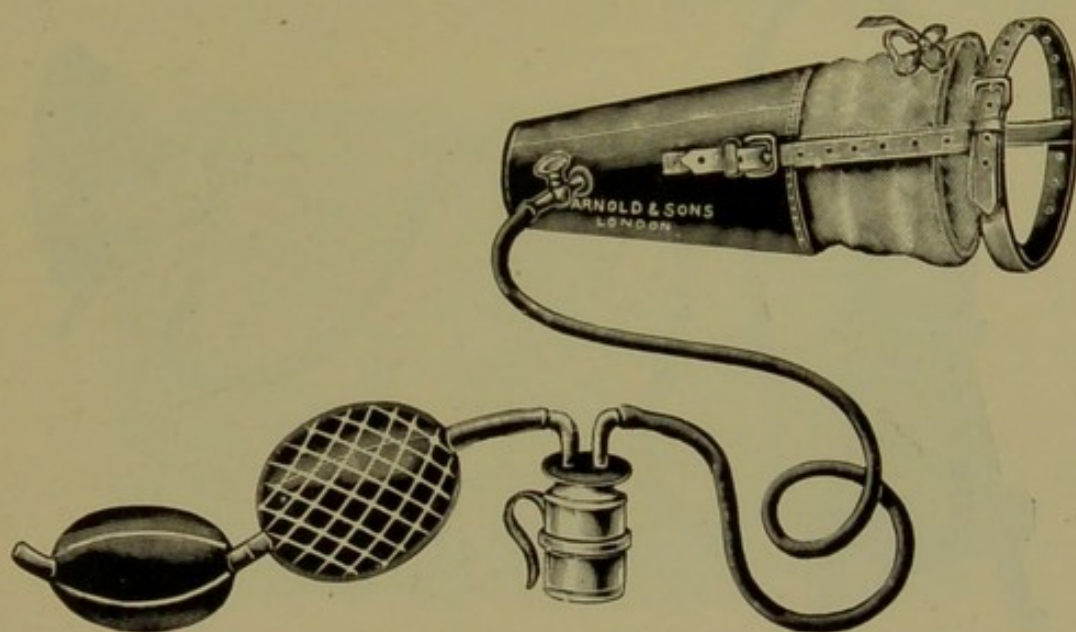


Fig. 23.—The Author's Second Design of Inhaler.

to the bottle in such a way that the current (when turned on) passes either over or through the chloroform, and so forces the mixed vapour onwards into the mask (Fig. 24); and in a second pattern by means of a small electrical motor-pump arrangement, whereby air is either sucked or forced automatically, the supply of electricity being obtained either from a small battery (D) or by direct attachment (E) to the main current (Fig. 25).

Whichever inhaler is used, care must be taken to produce anæsthesia slowly, and to administer the vapour as regularly and steadily as possible. The average length of time required

in which to produce the safe stage of unconsciousness for a cat or small dog is from one to two minutes; for a dog the size of a terrier, about three or four minutes; and for the larger breeds, six or eight minutes.

Stages of Chloroform or Ether Anæsthesia.—During the process of complete anæsthetization an animal passes through four stages. The first one is a stage of surprise and alarm, during which the patient sometimes holds its breath as if unwilling to receive the strong vapour. This is especially

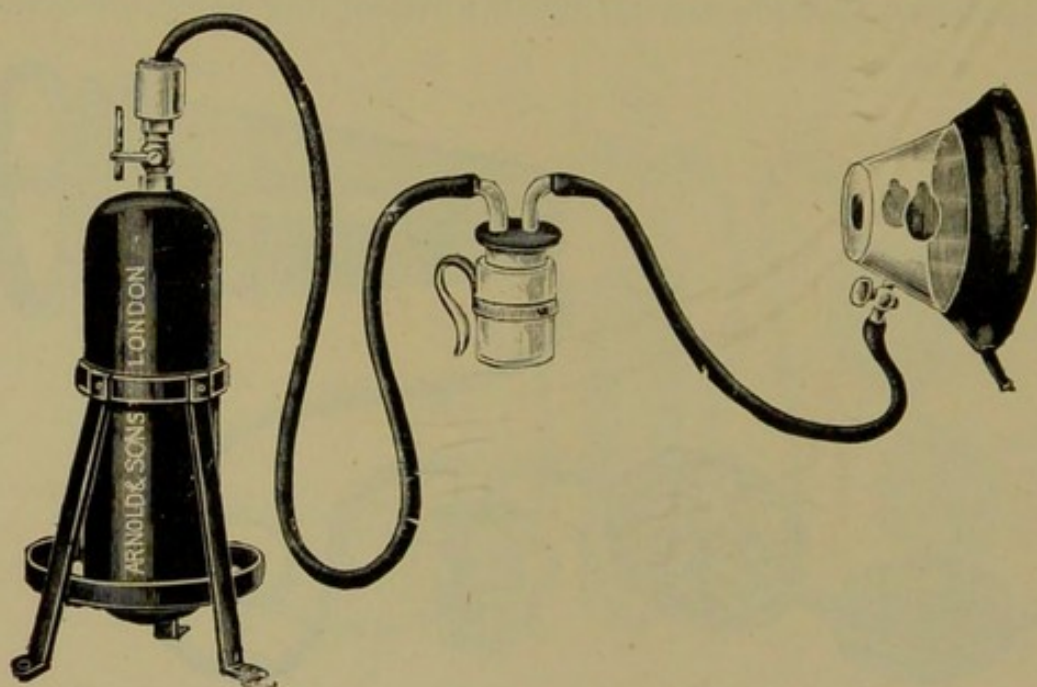


Fig. 24.—The Author's Third Pattern of Inhaler showing another Form of Mask.

noticeable in cats and rabbits, and care must be taken to allow the respirations to become regular before proceeding. The second stage is one of excitement during which the animal is in a semi-conscious state, and appears in an almost frenzied condition, yelping and struggling violently, and often involuntarily relaxing the sphincters of the rectum and bladder. After this we get the third or safe anæsthetic stage, in which the animal is ready for the operation; and lastly the fourth or dangerous stage, in which there is risk of permanently paralyzing one or more of the great vital centres.

When the anæsthetic is administered very gradually, it is often possible to cause the animal to pass into the third stage without becoming in any way frenzied or excited; one can frequently succeed in quietly anæsthetizing small dogs whilst they are held in the arms of the owner, without being secured in any way and without any struggling, the animal passing tranquilly into the stage of unconsciousness.

The first signs of the approach of the stage of **safe anæsthesia** are that the struggling becomes less, the efforts being weaker, and the tail becomes limp; then the hind-quarters




Fig. 25.—An Electrical Motor Pump for the Administration of Anæsthetic Vapour (Author's Pattern).

A, Chloroform bottle; B, pump; C, switch; D, battery; E, for connection with the main current; F, canine mask.

become powerless, and ultimately the head cannot be raised. When the whole body is totally limp and respirations are regular the operation should be performed. Dilatation of the pupil of the eye, especially in the cat, is always well marked, and is by no means, as stated by some, a sign of danger. To maintain the patient in this stage with safety, the anæsthetic must be carefully administered in *small* quantities from time to time at discretion, and it is a good plan to release the animal from restraint as much as possible

in order to be thoroughly prepared to administer antidotes in case of accidents. An animal may be kept in this stage for any reasonable length of time. The longest period in which the author has kept a dog under chloroform has been four hours, but very few of the operations of daily practice require an anæsthesia of more than half an hour.

Signs of Danger.—*The anæsthetist must devote his whole time and attention to his work, and not be watching the operator.* He must note particularly the efforts of respiration; should these become weak, shallow, irregular, or in any way spasmodic, or should they cease suddenly, the mask must be at once removed and antidotal measures adopted. The pulse is not such a good guide to danger, but extra care must be taken if it become irregular, jerky, intermittent, or feeble. The temperature of the body must be taken into consideration in very prolonged operations, the effect of the anæsthetic, combined with the stillness of the body, causing a fall below normal. This should never be allowed to get below 95° F. Another sign which is dangerous is a convulsive twitching of the extremities, especially marked in the paws of the hind-legs, and in the cat it invariably means death if the hairs of the coat suddenly turn the wrong way.

The respiration, however, is the chief, and also the easiest, thing to watch.

Out of an experience of a very large number of dogs and cats destroyed with chloroform gradually administered, in fully 95 per cent. the respiration has perceptibly been the first to fail. Occasionally the heart has appeared to cease first, or the two have appeared to stop together, this being particularly noticed when the vapour was rapidly administered in a concentrated form and insufficiently diluted with air, but in each case where the thorax was at once opened the heart was still perceptibly beating.¹ The phonendoscope, an instrument devised particularly for listening to chest sounds, is of great service in demonstrating these points.

¹ *Journal of Comparative Pathology and Therapeutics*, vol. viii., p. 287, ol. xi., p. 101.

Remedial Measures and Antidotes.

In all cases where general anæsthesia is practised antidotes should be placed beforehand in a position where they can be obtained and used at a moment's notice. Strong ammonia and Scheele's hydrocyanic acid are the best in the author's experience.

Upon the first signs of danger, at once tear off the mask and remove all restraint; carry the patient carefully into the fresh, cool air, place in a horizontal position, lowering the head slightly in such a way that the lumen of the trachea is not at all lessened; open the mouth, withdraw the tongue, either with the fingers or forceps, continually pulling it forward in a jerky manner; apply a full medicinal dose of Scheele's acid to the back of the tongue, the vapour of strong ammonia to the nostrils, and immediately commence **artificial respiration**.

The latter can be done in several ways. We may copy the method known in human practice as Sylvester's, which consists in placing the patient on its back and slowly endeavouring to imitate normal respiratory movements by extending the fore-limbs well over the head, and then pressing the elbows and bent limbs against the sides of the thorax.

A second, which appears to bring greater success in the dog and cat, consists in laying the animal on the right side and emptying the thorax by means of a number of short, sharp efforts, the natural elasticity of the ribs causing the chest to expand again.

Whichever way is adopted, the mouth at the same time should be held open and the tongue drawn well forward by short, sharp jerks, in order to raise the larynx and allow as free a passage as possible for the entrance and exit of air.

A third method, which will cause the lungs to be filled, is performed by taking hold of each elbow and jerking the body upwards into the air several times. This is certainly a very

effective method of filling the thorax, but there is always danger of rupturing some large abdominal vessel in fat animals, and in the large and weightier breeds it cannot always be managed.

A fourth method, which sometimes brings success, is to force air or stimulant vapour (such as that of amyl nitrite) by means of a special form of bellows (Higginson's enema syringe can be improvised for the purpose) up the nostrils, and so into the lungs. This is done in a jerky manner, and the air is then forced out again with a succession of short, sharp compressions on the ribs.

In practising any of these ways care must be exercised, as rupture of the liver or mesenteric artery is an occasional sequel to performing artificial respiration too energetically, especially in fat and aged animals.

Recovery will sometimes follow **simple inversion** or swinging the animal round by the hind-legs, these acts being performed with the idea of causing a flow of blood to the head and thus relieving the over-congested heart. These methods are, however, open to the objection that they tend to diminish the capacity of the chest by throwing the weight of the abdominal organs against the diaphragm.

Cold affusions to the head and chest, and striking the body with a wet cloth, are also recommended, but certainly must not be trusted to alone.

Tracheotomy is sometimes advisable, but in cases of this kind, where whatever is done must be done immediately, this operation is often a matter of difficulty, especially in the smaller and long-haired breeds.

Venesection has been practised, but cannot be relied on.

The **medicinal antidotes** found to be of the most value are: strong ammonia vapour, amyl nitrite, hydrocyanic acid (Scheele's), and subcutaneous injections of ether, saline solution, or strychnine.

Whatever antidote is chosen, it is obvious that the chances

of success are enormously increased if the agent can be administered before respiration actually ceases. If this could always be done, the proportion of deaths during anæsthetization in the dog and cat would be infinitesimal.

Since chloroform is an agent which destroys life by paralyzing either the respiratory or cardiac centres, and sometimes both apparently at once, the objects sought for in an antidote are those which will act as a stimulant and restorative to either or both. It is important, then, that the anæsthetist shall select the one which seems most nearly to fulfil these objects.

In **ammonia vapour**, such as is evolved from liq. ammon. fort., we have an agent whose therapeutic actions are those of a general stimulant, both respiratory and cardiac; but we dare not give it in the form of a draught, because the patient is unable to swallow, and we cannot inject it hypodermically, on account of its slowness of absorption and irritant action, whilst its intravenous injection is difficult, so that it is usually given in the form of a vapour inhalation. It is needless to remark that the respiratory apparatus must be artificially induced to work if it has ceased to do so, in order that the effect of the vapour may be shown on the body. This is sometimes a source of difficulty, and when once the respiratory organs have recommenced to work, the vapour must not be too suddenly applied, or the reaction is apt to be too severe. It must be used at intervals with discretion, holding the bottle under the patient's nostrils for a few moments and then withdrawing it.

With **amyl nitrite** the chief action is that of a cardiac stimulant, and it has the advantages of being non-irritant and readily absorbed from mucous surfaces, so that it can be administered on the tongue. The necessary dose, too, is very small, and it can be given undiluted. For the dog or cat about one-quarter of a minim for each pound of the body-weight is a fair average dose.

Hydrocyanic acid¹ first suggested itself as an antidote to chloroform whilst watching the powerful respiratory efforts which it so rapidly causes when given to produce toxic effects, and when used as an antidote the object must be to give just sufficient to attain a temporary stimulating effect

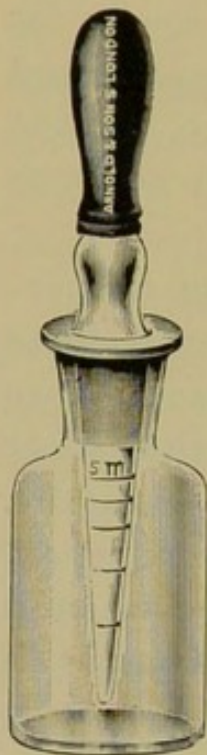


Fig. 26.—Antidote Drop-tube and Bottle for Hydrocyanic Acid.

on the respiratory centre without causing overstimulation and consequent arrest. Its rapidity of action is unquestionable, and it can be given either subcutaneously or by the mouth. With the former there are no local irritant effects as a sequel; and with the latter there is no danger of any entering the trachea and producing choking, because the dose is so small. The method of administration which is advised consists in placing a small quantity by the aid of a drop-tube on the back of the tongue, from whence it is absorbed readily by the moist mucous membrane. A full medicinal dose should be given, Scheele's acid acting quicker than that of the British Pharmacopœia strength, although, of course, it must be used with greater caution, one reason being that the evanescent vapour is drawn into the lungs by the performance of artificial respiration, and is thus more rapidly absorbed into the system.

Hydrocyanic acid is of especial value because it not only stimulates the respiratory centre to recommence if once it has ceased, but if given in full medicinal doses it maintains the breathing until it is able to look after itself, and at the same time, by the deep inspirations produced, it causes the entrance of a large amount of fresh air into the system. Its effects, too, on the heart-beats is beneficial. The dose recommended, of Scheele's strength, to be placed on the

¹ *Journal of Comparative Pathology and Therapeutics*, vol. xi., p. 101; *Lancet*, January 1, 1898.

tongue averages about one-eighth of a minim for each pound of body-weight (see Fig. 26). Subcutaneous injection of ether is advised on account of its rapidity of absorption and powerful action as a general and diffusible stimulant. Saline solution (1 ounce of sodium chloride to the pint of distilled water) has certain action upon the blood-plasma which assists the engorged and enfeebled heart to recover itself. It acts more rapidly when heated to a temperature of from about 105° to 110° F. before being injected.

Strychnine is used because it is a respiratory stimulant, but its action is decidedly slower than that of hydrocyanic acid, and besides that there is always the great risk of over-dosage, as in order to get rapid antidotal action a full dose must be given, and dogs and cats seem to have most peculiar individual susceptibilities to this drug.

With students as amateur anæsthetists we have had, in the Free Out-patients' Clinic, many opportunities of trying each of these different methods and agents, and the plan which we have found to yield **the best results** has been to immediately release from all restraint, clear the nostrils and throat of mucus, draw the tongue well forward in a jerky manner, apply artificial respiration by the second method described, as quickly as possible place a few drops of Scheele's hydrocyanic acid on the back of the tongue, and cautiously apply ammonia vapour to the nostrils.

Symptoms of Recovery, Bad Omens, etc.

After respiration has actually ceased, the good signs to be looked for when resuscitative measures are being adopted are :

Recommencement of respiration, the efforts becoming gradually more regular ; increase in force and regularity of the heart's action ; side-to-side movements of the lower jaw and voluntary retraction of the tongue ; moaning or yelping ; and movements of the head, ears, or limbs.

When breathing has recommenced, artificial respiration should be carefully continued until the patient is well out of danger, or, if this precaution is not followed out, the breathing may again cease and death ensue.

When an animal is recovering, plenty of time should be allowed to elapse before fluid restoratives or foods are administered forcibly by the mouth, as there is danger of some of the material getting into the trachea and causing choking or pneumonia; care must also be taken, particularly when dealing with the cat, to avoid being bitten, as sometimes an animal when recovering will involuntarily make a vicious bite at any object near its mouth, and not uncloze the teeth until forcibly made to do so.

Bad omens are to be gathered from relaxation, during the stage of danger, of the sphincters of the bladder and rectum; erection of the hairs of the coat, especially well marked in the cat; stoppage of the heart, and no sign of returning animation after five minutes' continuous and careful attempt at resuscitation; stertorous breathing, breathing which becomes suddenly short and sharp or prolonged and slow—*i.e.*, any sudden deviation from the condition when the patient appeared to be in a satisfactory state. Hope should not be given up for at least ten minutes after respiration has ceased, and, above all, never so long as the heart is beating. In several instances we have observed from two and a half to four minutes to elapse before there was any sign of a return to life.

In case of a fatal termination, a post-mortem examination should always be made where possible, as this often gives a satisfactory explanation of the cause of death.

Differences between the Administration of Chloroform, Ether, and A.C.E. Mixture.

When desirous of using ether, either by the open method or with the aid of an inhaler, air must be excluded to a very much larger extent than when chloroform is chosen.

The mixed vapour should consist of fully 70 per cent. of ether, whereas with chloroform the proportion admitted even for a large dog need not in the majority of cases be more than 1 in 1,000, and for very young animals and those of the smaller and more delicate breeds 1 in 3,000 or 1 in 4,000 parts of air is not too small a percentage, especially at the commencement.

If using a wire muzzle and towel, the latter should be folded two or three times after the anæsthetic has been put on it, and the ether allowed to flow much more rapidly from the drop-bottle or measure; with an inhaler air must be excluded at the end of the mask as much as possible, always, of course, at the discretion of the anæsthetist. With this drug the stage of excitement is longer, and that of anæsthesia shorter, than where chloroform is used.

The A.C.E. mixture is particularly useful for small, delicate dogs and cats. With it there is not so much risk of producing dangerous symptoms as when chloroform alone is used by an inexperienced anæsthetist, and the mixture does not produce so much salivation as when ether alone is used; besides which, the stage of anæsthesia lasts longer, and that of excitement is shorter, than when ether is used. It thus occupies a middle place between chloroform and ether.

Morphia.

Morphia, as an adjunct to surgical work, is used to a much greater extent on the Continent than in England. It is classed as a narcotic rather than as an anæsthetic, and

although it certainly deadens pain for minor operations, it does not do away with it altogether, as is the case with chloroform and ether. It is distinctly a useful aid, in that the dazed, stupid condition in which the patient is put renders it more tractable and easily managed. Some dogs will vomit and pass fæces or urine within a few minutes of its administration, and remain dull and stupid for a long time afterwards, whilst others will tolerate exceedingly large doses without any bad effect. Compared with man, the dog is extraordinarily insusceptible to morphia.

From a tenth of a grain to a grain, depending upon the size of the patient, is a fair range of dose. It is sometimes given in smaller doses, about a thirtieth to a tenth of a grain, subcutaneously, about twenty minutes or half an hour before the administration of chloroform.

Chloral.

This drug, given by the mouth, by intravenous or rectal injection, has not found much favour in England as a surgical anæsthetic. The intravenous method of administration in a small animal like a dog or cat has too many risks attached to it to ever become popular to the general practitioner. Given by the mouth or *per rectum*, it should be well mixed beforehand with mucilage, on account of its irritating effect upon the mucous surface with which it is brought in contact.

According to Kaufmann,¹ the anæsthetic dose averages about 4 grammes, and the toxic dose from 8 to 16 grammes, depending, of course, upon the size of the dog.

¹ 'Traité de Thérapeutique Vétérinaire.'

CHAPTER V

ACCIDENTAL AND OPERATION WOUNDS ; CONTUSIONS

A 'WOUND' is defined as 'a solution of continuity of parts naturally united' (Hoblyn), whilst the term 'contusion' is given to the result of violent contact with some blunt article, the tissues being bruised, but the skin not broken.

Wounds may legitimately be divided under two headings—viz., accidental and surgical or operative—the latter being always intentionally produced by the instruments of the surgeon, and therefore much easier to deal with from an antiseptic point of view than the former, because they are clean cut, and are made with clean instruments.

Accidental wounds in dogs and cats are frequently met with, and the most common causes are from fighting, from gun accidents, and from violent contact with sticks, stones, wheels of vehicles, sharp palings, etc. They may be lacerated, punctured, incised, or contused, the names explaining themselves, and, lastly, the term 'gunshot' is applied to any inflicted with a gun or rifle.

Accidental Wounds.

In the dog and cat accidental wounds, as a rule, heal very well when properly attended to and the animal is prevented from causing undue irritation by constant licking. In the cat, particularly, this licking of the wound is often a source of trouble and greatly retards healing, owing to the roughness of the tongue. The chief principles to observe are those

of thorough cleanliness, the careful removal of all foreign bodies, the application as often as necessary of some antiseptic dressing, and the avoidance of all sources of irritation. The deeply-rooted idea that the constant application of a dog's tongue to a wound is beneficial may now be relegated to a past age. *If antiseptic treatment can be, and is, properly carried out, an animal will not lick its wounds. It is the presence of pus which accounts for the irritation.*

The application of saliva and the constant irritation of the tongue will keep a wound open for a much longer time than would be the case if this was prevented by thorough surgical

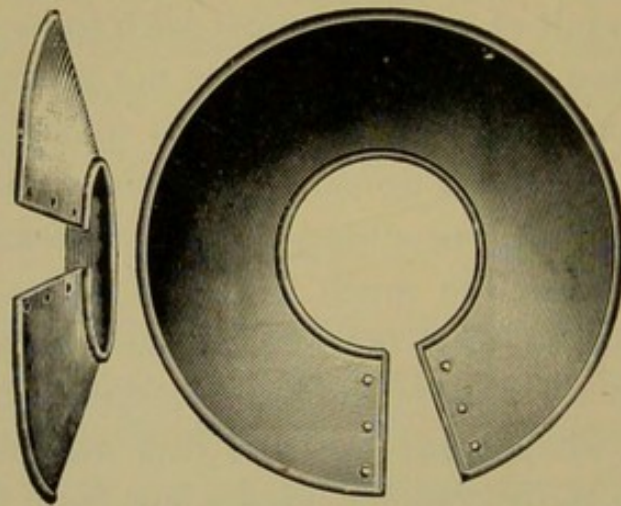


Fig. 27.—Elizabethan Collar.

cleanliness. This can be readily demonstrated when opportunity offers to treat two wounds on the same animal, one being treated with antiseptic precautions, and the other left to the care of the animal itself. The former will heal much quicker, and also leave less scar tissue afterwards.

The hair at the edges of a wound should always be removed either by being clipped close with scissors, or, better still, by shaving, the wound and its surroundings being thoroughly cleansed with soap and water, and dressed with antiseptics.

The advantage given by the use of the razor cannot be too strongly emphasized.

All blood-clots and foreign bodies should be removed from

between the edges, the latter being drawn together by sutures, and then bandaged or not at the discretion of the surgeon. Dusty materials, such as sawdust, powdered cork, peat-moss, etc., should particularly be avoided as kennel bedding whilst wounds are being treated.

For the detection of foreign bodies a probe is essential, and for their removal either a pair of forceps, a curette, or Volkmann's spoon (Fig. 40) may be required. The latter is especially valuable where bone has been injured. The presence of a dirty foreign body causes formation of pus, sets up continual irritation, and must be removed before healing can take place. If by chance it is an aseptic foreign body, it may become encapsuled. As an everyday illustration of the latter, one has the sequel to the use of silkworm gut as suture material to the muscular layer of the abdominal wall after laparotomy. It can readily be found surrounded by a thickening of the tissues if a *post-mortem* examination is made on the patient even two or three years afterwards.

When the skin is very tight over any place, or where a lot of it has been accidentally torn out or intentionally excised, and it is still desirable to unite the edges, an operation known as **Cherry's operation** is performed. This consists in making a fresh incision longitudinally through the skin on each side of the original wound in such a way that the tension on the original edges is removed; they can thus be brought together and the sutures will not be pulled apart. One thus leaves three scars to heal instead of only one, but the result is usually quite satisfactory. A case related on p. 270 (Fig. 172) shows a typical instance in which it was utilized successfully, and the operation for cleft palate is done in this way.

When it is not considered advisable to draw the edges together, and the wound is left open, the thorough application of antiseptics must be resorted to, either by application on clean wadding or with a syringe. Syringes should be

made of some material (such as glass or metal) which can be rigorously cleaned ; boiling is the easiest plan, and one which renders them absolutely sterile.

Antiseptic powders are applied usually by being dusted on the parts with the aid of a piece of wadding, or, if at all deep-seated, by means of an insufflator (see Fig. 28).

The list of fluid antiseptics commonly used for wounds is the same as that already mentioned when speaking of those used for the site of incision (see p. 2). Dry antiseptics include such agents as boracic acid, zinc oxide, iodoform, thioform, tannoform, chinosol, starch, alum, tannic acid, etc., either alone or mixed in various proportions. Those that



Fig. 28.—Insufflator for the Application of Dry Dressings.

are at all toxic, such as iodoform, must be used with great caution, as absorption may take place, and particularly if they are applied to a part which the animal can reach with its tongue, as poisonous effects have been known to ensue.

Operation Wounds.

After cleansing, applying sutures, and thoroughly drying with aseptic cotton-wool, an invaluable dressing is formed either by iodoform and collodion (1 to 10 or 12), or orthoform and collodion (1 to 8 or 10). Both these mixtures allay irritation and protect the wound effectually until complete union has taken place, if it is aseptic and does not become accidentally infected. As they will not adhere properly unless the surface is thoroughly dried, this may be hastened

¹ *Veterinary Record*, vol. xiv., p. 262.

by swabbing with ether and allowing rapid evaporation to take place afterwards. If the collodion dressing is not at hand, some antiseptic gauze, lint, or wadding may be fixed over the spot by means of strapping plaster or a bandage. Given, however, an aseptic operation wound, a clean place in which to put the patient afterwards, and the careful and thorough application of the collodion dressing,

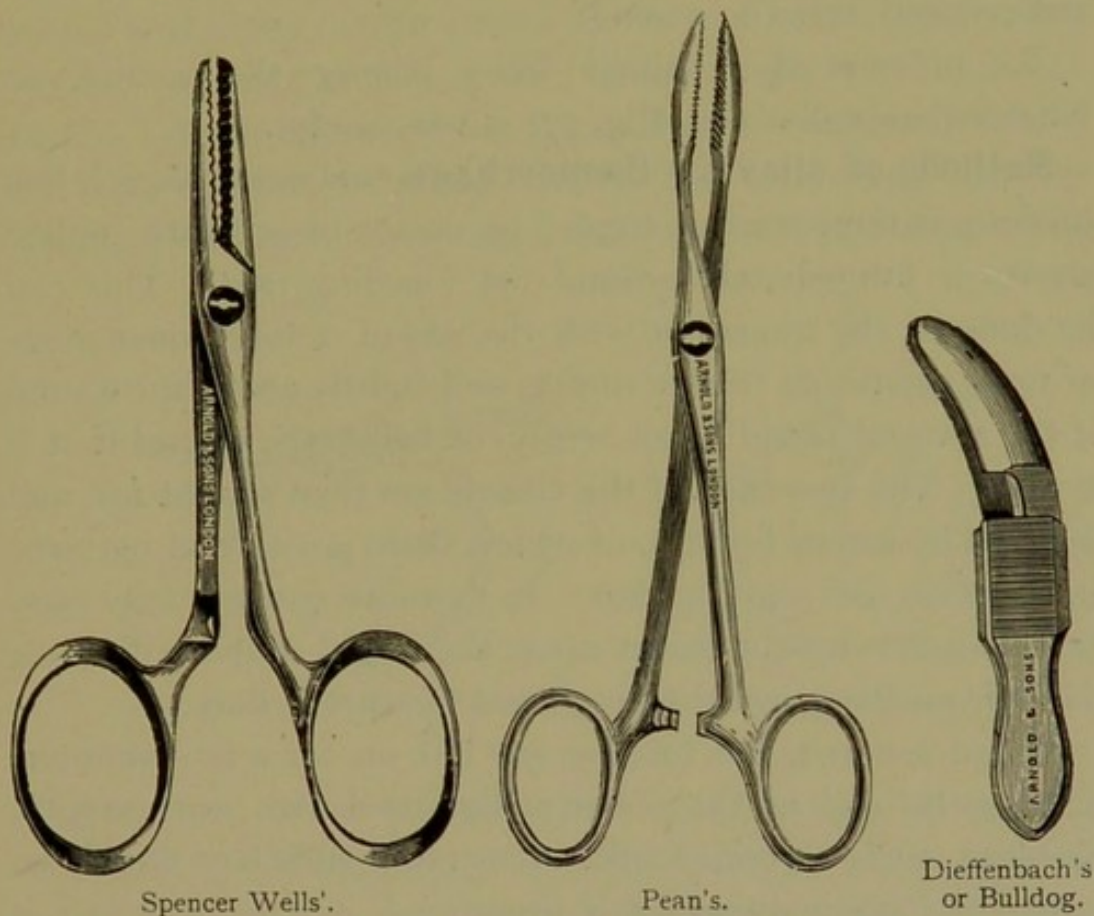


Fig. 29.—Artery Forceps of Different Patterns.

the operator may rely (even in animals) upon over 90 per cent. of primary unions. As a rule there is no need to touch the wound again until it is time to remove the sutures. This is done in from three days to a week. The author bases this statement on observations taken upon more than 1,000 surgical wounds.¹

¹ *Veterinary Record*, May 2, 1903 (Proceedings of the Central Veterinary Medical Society).

Möller¹ recommends a wound gelatine which has the advantage of adhering equally well to moist or dry surfaces. It is prepared by soaking ordinary sheet gelatine in a sufficient quantity of a 1 per cent. sublimate solution to cover it. After it has become quite soft it is melted by gentle heat, and a quantity of glycerine equal to one-tenth of the dry gelatine added. When required for use it is melted over a slow fire and painted over the wound.

To prevent the animal from licking the wound, an Elizabethan collar (see Fig. 27) is very useful.

Methods of allaying Hæmorrhage.—Hæmorrhage, when profuse, is temporarily arrested by means of pressure applied above or immediately around the bleeding part. This can be done by the fingers or with the aid of a tourniquet made of tape, elastic, or rubber tubing tied tightly above the wound if the severed vessel be an artery, or below the wound if it is a vein. The two ends of the vessels are then sought for, and secured by artery forceps, of which there are several patterns in common use (see Fig. 29). In extreme cases it may even be necessary to cut down upon the vessel a short distance away from the original wound, and ligature it here.

When secured, the forceps are left on for a few minutes, or else the end of the vessel is ligatured with some aseptic material, such as boiled silk. It is often sufficient merely to twist the forceps round a few times.

Small hæmorrhages can be checked by the direct application of styptics, such as perchloride of iron, adrenalin, tannic acid, tannoform, etc.

The Suturing of Wounds.—Various forms of sutures are used for drawing together the edges of wounds, the two chief divisions being the 'interrupted' and the 'continuous.'

The principal subdivisions of interrupted sutures are: simple interrupted, pin, button, or quill sutures, Lembert, and Czerny-Lembert.

¹ Möller's 'Veterinary Surgery' (Dollar's translation), p. 2.

The principal continuous sutures are: simple continuous, furrier's, Halsted's, and the purse, draw-string or tobacco-pouch.

The materials used are: silk, horsehair, wire, catgut, kangaroo or reindeer tendon, silkworm gut, and linen thread. Each of these can be obtained in various sizes.

Whatever material is used must first be rendered aseptic, or pus will form in the suture holes and retard the healing process. Catgut and kangaroo tendon, especially the latter, do not become absorbed for a considerable length of time, and are valuable in cases where it is required that the sutures shall remain in for a long period; thick silk and

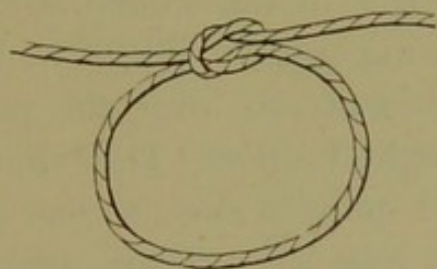


Fig. 30.—A 'Surgical' Knot.

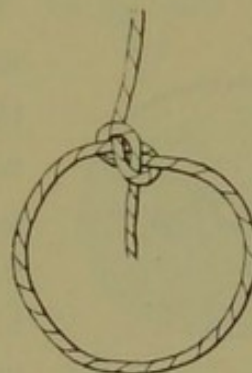


Fig. 31.—A 'Granny' Knot.

silkworm gut never become absorbed (usually they become encysted), and silkworm gut is particularly good for suturing the abdominal wall, because it does not possess capillarity. This lessens the chance of infection from the exterior.

Simple interrupted sutures are those in which each suture is complete in itself, and entirely separated from the others. They are made by passing the needle and suture material through the edges of the wound, and tying the suture carefully in some form of knot which is not liable to slip. The best patterns of knot for this purpose are variously known as a 'surgical,' 'Staffordshire,' or 'reef' knot, and is so arranged that when completed the loose ends fall opposite to one another at right angles to the wound, and directly over the

suture itself. The knot may be left directly in the centre, or, what is probably a better plan, because it causes less irritation, pulled to one side. When the loose ends fall in the same line as the wound and at right angles to the suture, the knot is apt to slip or give way; this is termed a 'granny' knot (see Fig. 31).

Simple interrupted sutures are suitable for many kinds of surgical work, and should be inserted from a quarter to half an inch apart.

Pin sutures are not so commonly used in the surgery of the dog and cat as in that of the larger animals. They cause irritation, and are too easily removed by the teeth or claws, leaving the edges of the wound lacerated and torn. They

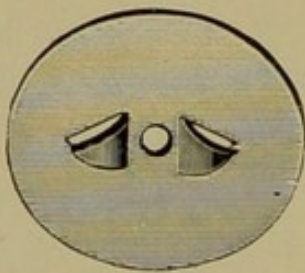


Fig. 32.—Aluminium Suture Button (Pugh's).

are made by passing clean pins through the two edges of the wound, and afterward twisting aseptic silk, tow, hair, or some such material, over the pin in a figure-of-eight fashion. They should not be inserted quite so close to one another as in the case of ordinary interrupted sutures.

Button sutures are particularly useful for large wounds, where the edges are thin and apt to tear away. In making them, button-shaped pieces of bone metal (or some such hard, easily cleansed material) are used, the suture being passed through the edges of the wound, then through a hole in the button on the opposite side, and fastened in some way suitable to the particular pattern used.

Quill sutures are similar in principle to button sutures, with the exception that an ordinary quill or piece of wood of that shape is fixed on either side of the edges of the wound by the silk or thread. They are suitable for similar wounds to those in which the button suture is applicable.

Lembert's sutures (see Fig. 33) are used when suturing the stomach, intestine, bladder, or uterus. They are made

by passing interrupted sutures about a tenth of an inch apart, and the same distance from the edges of the wound, through the serous, muscular, and submucous coats only, great care being taken to avoid puncturing the internal or mucous coat, and to tuck the edges in, so as to bring the two serous surfaces well into contact with one another. Small round milliner's needles are the best ones to use when inserting these sutures; if a flat or bayonet-pointed needle is used the sutures are apt to tear out. The object is to arrange the in-contact surfaces

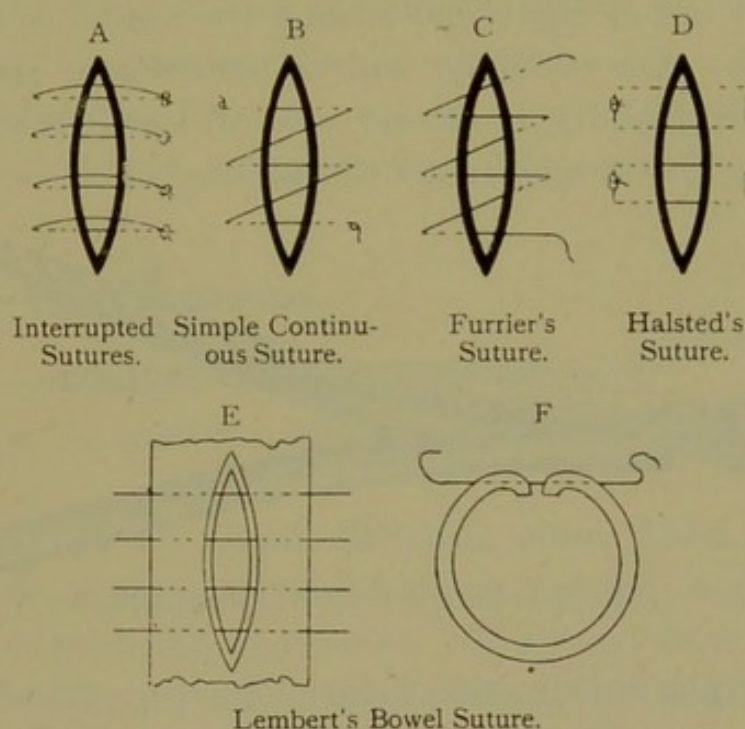


Fig. 33.—Different Patterns of Sutures.

so that the two edges to be sutured together consist only of *serous* membrane. Adhesions with the surrounding parts are not then so likely to form, and union is rapid. Particular care must be taken to do this carefully; if any fluid escapes from the intestine into the abdomen peritonitis is sure to ensue.

In the case of a long incision there is always a little 'pucker' at each end which must be carefully sutured over, and in closing a small circular aperture, the 'draw-string' or 'tobacco-pouch' pattern, which passes in and out and around

the opening, is the best. With a large circular wound it is often necessary to convert it into an elliptical shape before drawing it together with interrupted sutures.

The **Czerny-Lembert suture** is used as a double safeguard to prevent leakage after some internal viscus has been opened. It consists of two rows, the first of which passes through the mucous coat (or it may pass through all three) close to the extreme edge of the wound. Other sutures of Lembert pattern are then passed over it, thus burying it completely out of sight, and closing the wound as effectually as possible. Occasionally, with a large viscus such as the stomach or bladder, a second row of Lembert's sutures is placed over the first as an additional safeguard.

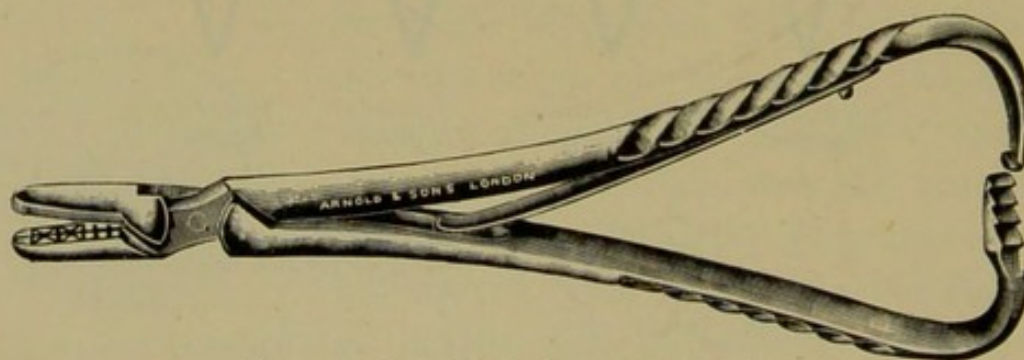


Fig. 34.— Needle-holder (Macphail's).

The **simple continuous suture** (see Fig. 33) requires no explanation; it is particularly used for suturing the peritoneum where considered necessary after abdominal operations, and for the skin where the sutures are only intended to be temporary, and where the wound is to be reopened.

The **furrier's suture** (see Fig. 33) is not a suitable one where quick healing is desired, as the suture material passes between the edges of the wound, thus causing irritation and preventing immediate union.

Halsted's suture (see Fig. 33) is very useful for some wounds, and is made by passing the suture through the wound, then returning it and tying off on the proximal side so as to make a square-headed suture. It is especially useful

in the suture of divided muscles and tendons. Care must be taken that it is not drawn so tight as to wrinkle the skin, or healing will be retarded, and the cicatrix will be uneven and prominent.

The **purse, draw-string, or tobacco-pouch suture** is made by pressing a continuous suture through the tissues in an 'in-and-out' manner, like a draw-string is placed round the neck of a purse or bag, the ends being then drawn tight and tied. It is used under certain conditions to contract the orifice of the anus, and in the intestine when performing an anastomosis by means of Murphy's button.

The **needles** (see Fig. 35) used for suture purposes are of various sizes, shapes, and patterns. They may be straight,




Fig. 35.—Wire Suture Needles (Reeks').

curved, half curved, round, flattened either from above to below or from side to side, bayonet-pointed, with chisel-shaped ends or merely sharpened. They may or may not be fixed in a handle, according to the fancy of the operator and the kind of work required of them.

For carrying wire, an improved pattern is that designed by Mr. H. C. Reeks, which has a tubular end and two hollow spaces, so arranged that the wire falls into a slot prepared for it, and does not in any way interfere with the passing of the sutures.

A needle-holder, of which there are several patterns, is a useful accessory; a pair of Spencer Wells' artery forceps forms a fairly efficient substitute.

Bandaging.

It is sometimes necessary to bandage a wound, and different forms of bandages are used for different parts of the body. For the limbs an ordinary roll bandage, either broad or narrow, is suitable. Tape forms one of the best materials for a narrow bandage, especially when a wound of the digits has to be attended to, and it can be purchased in different widths. For the body the roller bandage, especially a broad one, is again useful, and if inclined to slip over the hind-quarters it must be attached to a collar placed round the neck.

A convenient body bandage can be made out of a broad piece of linen by cutting holes through which the legs are passed, and sewing up or tying the edges with tapes along the centre of the back. Holes are made in the neighbourhood of the penis or vagina and anus in order to prevent soiling, and pleats are taken in where requisite in order to make it comfortable and fit tight to the body.

For the ears a many-tailed bandage is useful; it is readily made by taking a piece of linen of sufficient size to cover the head and ears, tearing or cutting it at the edges (or affixing tapes), and tying each opposite end underneath the neck or jaw (Fig. 53).

CHAPTER VI

ABSCESS, CYST, SINUS, FISTULA, AND POLYPUS

Abscess.

Definition.—An abscess may be defined as a circumscribed area containing pus. It may occur in any part of the body, and is a common sequel to a violent blow or to the introduction of some foreign body, such as a needle, fish-bone, piece of wood, etc.

Symptoms.—With an ordinary abscess there is a good deal of heat and tenderness on pressure; this is followed by a swelling which is soft on palpation, fluctuating, and less painful. If not interfered with, this occasionally becomes absorbed, but it is much more likely to burst and leave a nasty jagged wound.

A 'cold' or 'chronic' abscess is also met with, the encapsuled pus being surrounded by very much thickened walls, and the exterior may or may not be painful on pressure.

The surgeon must be careful not to confound it with a hernia or a cyst. The introduction of a knife into the former would be especially serious if the operator was not prepared for such a contingency.

Treatment.—Hot fomentations or poultices, with sedative lotions to ease the pain, should be applied until the swelling is ready for operative interference. When just ripe the abscess should be lanced in its softest and most dependent part, the

blade of the knife being protected by the fingers (or by some tow or wadding wrapped round it) from entering too deeply, and the cutting action made in a direction away from the animal's body. This operation, which is a very simple one, requires the aid of a sharp scalpel or lancet, the pattern of blades known as Syme's or Paget's being especially adapted for the purpose (Fig. 36). A bold incision should be made, sufficiently large to enable the interior to be thoroughly cleansed and examined after the contents have been evacuated. Care must always be exercised in the region of the throat or other dangerous situations.

If there is doubt about the contents, an exploratory puncture may be made with a fine trocar and cannula (Fig. 37) or an exploring needle. The latter consists of a needle with a fixed handle, and having a groove down one



Fig. 36.—Abscess Knife (Syme's and Paget's Blades).

side of the blade, the groove being for the purpose of retaining a small quantity of the contents, in order that the nature of them may be examined before deciding whether the swelling is to be lanced or not. If pus is found the operation of opening the abscess should be proceeded with without further delay.

The *Prognosis* is good, and the wound is afterwards treated with antiseptics, either applied in the form of fluid injections or dry powder, a drainage-tube or 'tent' of antiseptic material being inserted for a few days in order to insure free drainage. If necessary, a local anæsthetic may be used over the spot where the incision is to be made, anesthetic, ethyl chloride, or the ether spray, being easy of application and very effective.

Serous Effusion.

The term 'serous abscess' is sometimes applied to a circumscribed collection of serum under the skin. It is a fluctuating swelling, and cannot always be differentiated externally from a true abscess. It usually follows as a sequel to a violent blow, and generally contains a blood-clot or piece of bruised muscle tissue. The treatment is exactly the same as with an ordinary abscess. An exploring trocar or grooved needle, used cautiously, is very useful as an additional aid to an exact diagnosis.

Cysts.

Definition.—A cyst may be defined as a soft, fluctuating, non-purulent swelling containing a fluid or semi-gelatinous

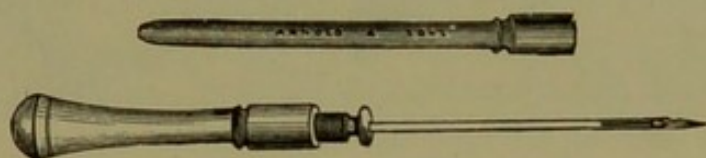


Fig. 37.—Exploring Trocar and Cannula.

material which is secreted by the lining membrane which surrounds it. It is sometimes due to the dilatation of an obstructed duct, but is more often the result of degeneration of the gland, as is shown by the microscopical examination of the cyst wall and contents.

Diagnosis.—It is sometimes difficult to distinguish between a cyst and an abscess, as both fluctuate under the fingers; the chief distinguishing features are the absence of heat and pain in the former, and the comparative slowness with which it forms. A cyst, too, has well and sharply defined edges (see Fig. 38).

Treatment.—The removal of a cyst is best effected by carefully and *completely* dissecting around its external wall, and so endeavouring to remove it in its entirety without

evacuating the contents. A director, to insert between the skin and cyst wall, is of the greatest service in these cases to enable the operator to avoid incising the cyst itself, and thus remove it intact. In some cases, however, the contents,

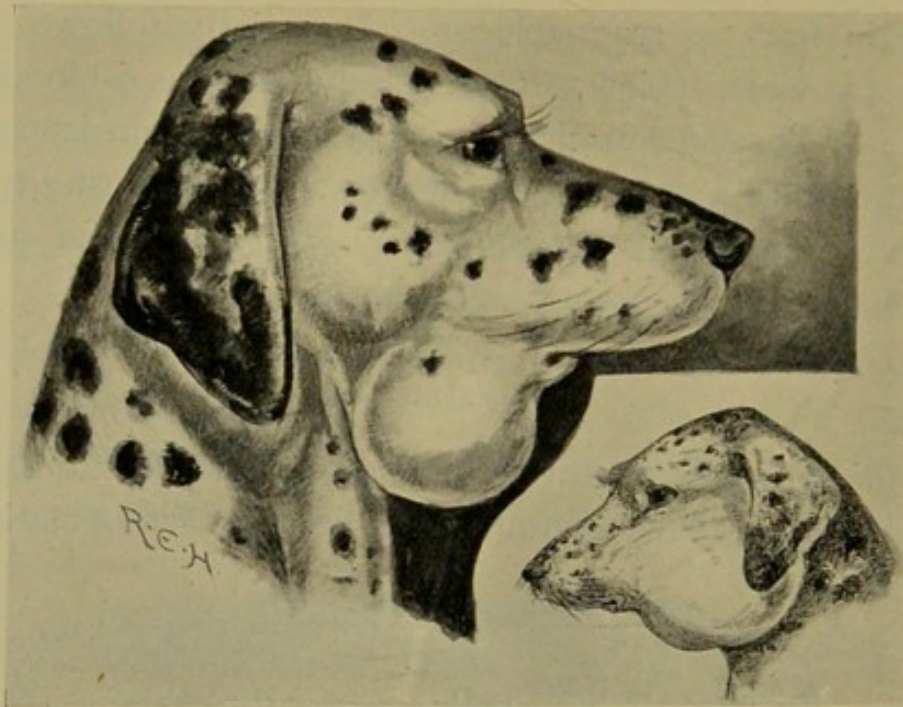


Fig. 38.—Dalmatian with Cyst in the Submaxillary Space.
The figure on the right is an abscess of the face and cheek for comparison.

or a portion of them, must first be allowed to escape, on account of lessening the risk of injuring surrounding structures, *but care must always be taken to remove the whole of the surrounding membrane. If this precaution be neglected, the cyst*



Fig. 39.—Director and Blunt Needle combined.

is apt to form again and refill. The contents are usually a semi-fluid, gelatinous material.

Cysts may be met with in various parts of the body, but particularly in the intermaxillary space, where their complete obliteration is often a matter of great difficulty on account

of the proximity to large vessels. In this situation it may attain such a size as to interfere with respiration, and even threaten asphyxia. They are also common between the digits, where they sometimes cause great pain and lameness (see Fig. 235).

Should it be impossible to dissect out the cyst wall, the interior should be freely curetted, and afterwards dressed with pure tincture of iodine.

An interesting and unusual situation in the spinal column is illustrated by Fig. 209.

Sinuses.

By a sinus is understood a wound which has 'pocketed' or 'burrowed' a certain depth into the surrounding tissues. It may have more than one opening communicating with the outside, and there may be more than one sinus communicating with the same wound.

Treatment.—The first thing necessary in dealing with a sinuous wound is to ascertain its depth and the exact direction in which it goes. For this purpose a probe, usually made of metal or whalebone, is carefully inserted into the orifice and passed inwards as far as possible. This must be done in a very delicate manner, especially in the case of wounds in the neighbourhood of joints or of any vital organs. One must not forget that it may reveal the presence of a foreign body. Having ascertained the depth, if it is thought desirable to open it up and so make a clean exposed wound, a director (Fig. 39) is inserted, and the whole length laid open by means of a sharp or blunt pointed bistoury, the granulation tissue being scraped away with a Volkmann's spoon. It is sometimes possible to dissect out the whole sinus.

If, instead of laying the sinus open, it is considered desirable to scrape the interior, this is done by the aid of a curette or Volkmann's spoon (Fig. 40). Frequently the

walls have become indurated, and, in addition to the scraping, it may be necessary to destroy them with caustics or astringents before healing can be accomplished.

Curettes are made in different sizes, and the spoon-shaped part may have its edge sharp or blunt.

Fistulæ.

Definition.—A fistula is a wound which has existed for some time, communicating between a mucous surface and the exterior. It is most commonly met with in the dog and cat in connection with the mouth, anus, parotid gland, and stomach.

Diagnosis.—To be sure whether one is dealing with a true fistula or merely a sinus, the patient should be put under



Fig. 40.—Curette or Volkmann's Spoon.

observation for a short time, and the discharge noted; a probe should be carefully passed, and a blunt director introduced to collect some of the contents of the interior.

Treatment.—This is sometimes tedious, although if persevered in will generally bring success. The lining membrane will probably have become indurated, and will need cautious removal before the edges can be persuaded to unite. The possible presence of some foreign body, too, must not be overlooked, and, if present, its removal should be the first consideration. Caustics, astringents, and antiseptics are then used at the discretion of the surgeon. It is quite impossible to lay down any specific treatment which will cure all fistulæ.

Ulcer.

The term 'ulcer' is given to a wound which shows no tendency to heal. As a rule its edges are ragged, raw, and sore.

Treatment.—Cleanse and apply antiseptics carefully and frequently. If these efforts are unavailing, the edges should be excised for some distance around, the incisions being made in the healthy tissues; the edges are then drawn together, and the parts treated as in the case of a healthy wound (see p. 50).

Polypi.

A polypus consists of a smooth, rounded growth with a well-defined pedicle, and it usually springs from some mucous surface, such as the vagina, bladder, ear, or nostril. Frequently in the latter situation these tumours are multiple, and give a lot of trouble on this account (see p. 90). On account of their pedicle, they are removed with facility if only they happen to be in an accessible situation. The so-called polypi of the nostrils are frequently granulation tissue, and associated with disease of the underlying bone.

CHAPTER VII

TUMOUR, INFLAMMATORY NEW GROWTH, GRANULOMA

Tumour.

‘A TRUE tumour or neoplasm is an abnormal non-inflammatory new growth, composed of newly-formed histological elements, and not the result of a mere transformation of pre-existing normal tissues. Inflammatory new tissue may simulate a neoplasm in being very circumscribed, but inflammatory new tissue is composed solely of connective tissue and bloodvessels (occasionally bone). On the other hand, a great variety of elements (connective tissue, bone, cartilage, muscle, gland-cells, etc.) are found in the neoplasmata’ (MacFadyean).

Surgical Diagnosis.—Tumours must be carefully differentiated from other swellings, such as those of inflammatory new growth, herniæ, cysts, and abscesses. From the former the diagnosis can often only be made by the aid of the microscope, as to all external appearances it looks like a tumour (see Fig. 236); from the last three the diagnosis is made by palpation with the fingers and by the general history as gleaned from the owner. As a rule tumours form painlessly—at all events until they attain a certain size. Many of them have definite outlines, whilst some appear to become imperceptibly blended with the surrounding tissues. In the dog and cat they frequently attain an enormous size. They may appear in any region of the body, either externally or internally, and be malignant or benign, single or multiple.

The varieties which are **malignant** are carcinoma, sarcoma, and some species of adenoma.

Amongst the **benign** are some adenomas, angioma, chondroma, fibroma, glioma, lipoma, melanoma, myxoma, myoma, osteoma, odontoma, psammoma, and papilloma.

The use of the terms **single** and **multiple** depends solely upon whether one or more happens to be present.

Malignant Tumours.

Carcinoma.—This variety of tumour, commonly spoken of as **cancer**, is one of the most dangerous and rapidly malignant of any which the surgeon is called upon to treat. Its most common situations are the glands of the throat and larynx, the mammary gland, and the orbit, although it is by no means exclusively met with in these regions (see pp. 121 and 133). It is almost exclusively confined to adult or old age, and grows in connection with the epithelial tissues, speedily infecting the neighbouring lymphatic glands.

In an article on the subject of the occurrence of cancer in the domesticated animals,¹ Professor MacFadyean reported that he had been able to diagnose microscopically eighteen cases of true carcinoma from specimens taken from the dog and cat, and amongst these one was from the mammary gland, four were from the throat or neck, and five were from the anus.

The author, in a communication made before the members of the Laryngological Society,² and in a paper read before the members of the Central Veterinary Medical Society in 1905, demonstrated the histories of a number of cases from the dog and cat, five of which had come under his personal observation within six months. Four of these occurred in the larynx and pharynx, two in the orbit, and one in the œsophagus. The ages of the patients averaged about eight years. In every case the diagnosis was microscopically confirmed either by Professor MacFadyean or by Drs. Bashford and Murray, of the Imperial Cancer Research Association.³

¹ *Journal of Comparative Pathology and Therapeutics*, vol. xii., p. 137.

² *Proceedings of the Laryngological Society*, November 4, 1904; *Veterinary Journal*, January, 1905.

³ *Veterinary Record*, vol. xvii. p. 694.

The *Clinical Diagnosis* can only be suspected by the fact that the tumour is hard to the touch, has not especially well-defined edges on every side, and has grown very rapidly since its increase in size was first observed. The patient, too, shows signs of emaciation, and secondary growths may be visible in the contiguous lymphatic glands.

If the region of the mouth is affected (as shown by the

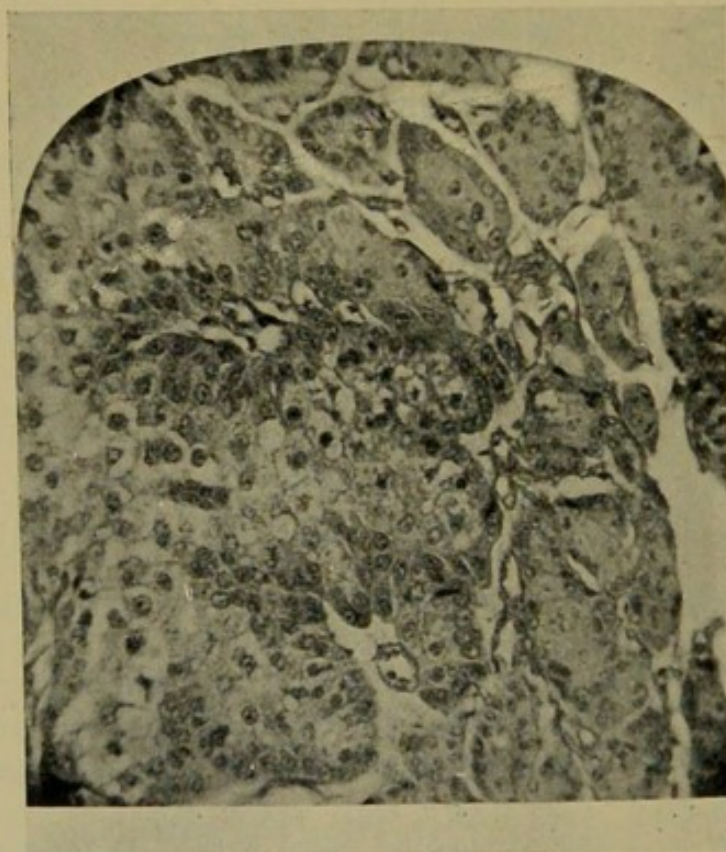


Fig. 41.—Photomicrograph of Carcinoma.¹

cases sketched in Figs. 102 and 103), the symptoms shown will be fairly distinctive. The patient becomes capricious in appetite on account of the soreness caused by the presence of food in the pharynx, and the act of feeding sets up considerable salivation, the food being taken down in gulps. After an attempt to take solid food, the animal wears a most haggard expression of countenance and holds the head down

¹ For this specimen, taken from the prepuce of the foxhound illustrated in Fig. 170, I am indebted to Professors Mettam and Wooldridge.

in a dejected manner. Examination of the interior of the mouth and throat with a speculum may at this stage reveal a red, angry-looking tumour growth on the gums, or a nasty jagged ulcerating sore at the back of the fauces, close by the tonsil. The left side seems to be the one most commonly affected, although the right is by no means exempt. External examination will now reveal a swollen condition of the larynx and cervical glands on the affected side, a state of affairs which may have escaped the owner's observation if the dog or cat is of the long-coated variety.

Pressure upon either lesion causes pain, and the ulcer in the mouth has on more than one occasion been diagnosed and treated as due to an injury such as would be produced by a bone or stick across the fauces (see Figs. 102 and 103). If a small piece of the tumour can be excised and submitted to an expert pathologist, the diagnosis can be speedily verified.

If humane counsels do not prevail with the owner, the patient gradually wastes away, and becomes a mere skeleton. This latter remark applies ultimately to all cases of cancer, whether the tumour is in the throat or some other region.

If in the œsophagus or on the tongue (see Fig. 98), the dysphagia is equally well marked, and the patient can only swallow fluid foods. The cat whose œsophagus is photographed in Fig. 112 was kept alive for nearly three months on milk alone. The case was exceptionally interesting, partly because of the situation of the growth, and partly because the history given when the patient was brought was that it had a bone in the throat.

The **sarcomata** are tumours growing from the connective tissues. They do not so commonly affect the neighbouring lymphatic glands as the carcinomata, but they are equally as troublesome to deal with on grounds of malignancy, and often attain an enormous size in the dog and cat. They occur in almost all situations of the body, especially in the

mammæ, testes, liver, and lungs, and when once sarcoma has been definitely diagnosed the practitioner may with certainty give a prognosis that his patient has not very long to live. Secondary growths are usual, and these may be very numerous and of very large size (see Figs. 42 and 123).

Adenoma.—This variety of tumour sometimes grows to an enormous size in the tissues of the dog and cat, and is frequently very malignant. When it contains sarcomatous

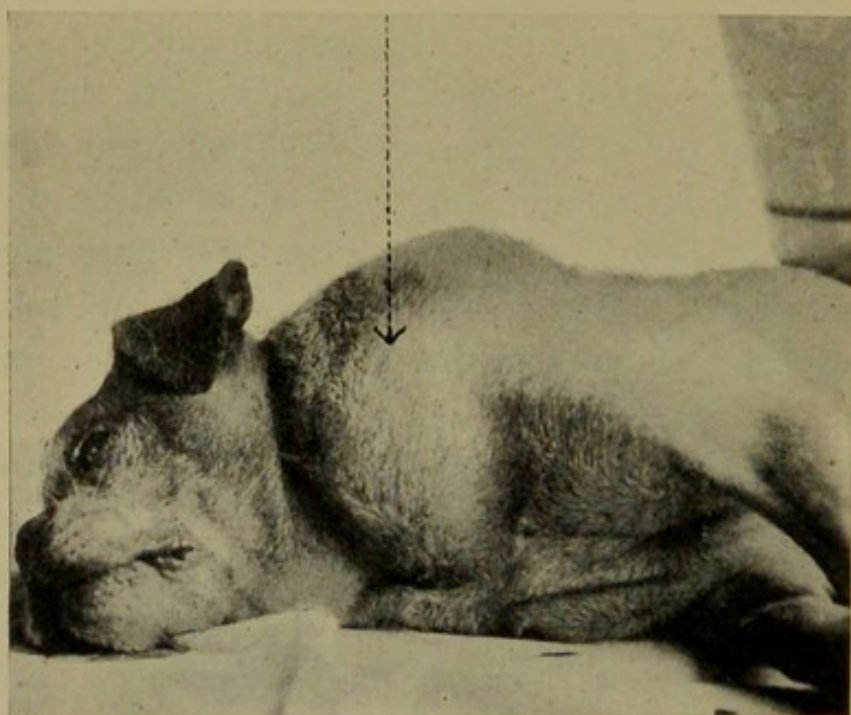


Fig. 42.—Inoperable Sarcoma of the Neck.¹

elements it is then termed an **adeno-sarcoma**. It may be cystic and may occur in any situation of the body, but is most commonly met with in the region of some glandular structure, especially the mammary and anal glands.

It is usually very vascular, and when operating there are numerous large arteries and veins, which should be carefully ligatured before being cut across.

It has been discovered in the brain (see p. 100).

¹ For this photograph I am indebted to Professors Mettam and Wooldridge.

Benign Tumours.

Some **adenomas** come under this heading, as their removal is followed by no attempt at recurrence.

An **angioma** is a tumour largely composed of dilated bloodvessels. On account of its great vascularity, it is often exceedingly troublesome to deal with, and all vessels must be carefully ligatured before or during the operation.

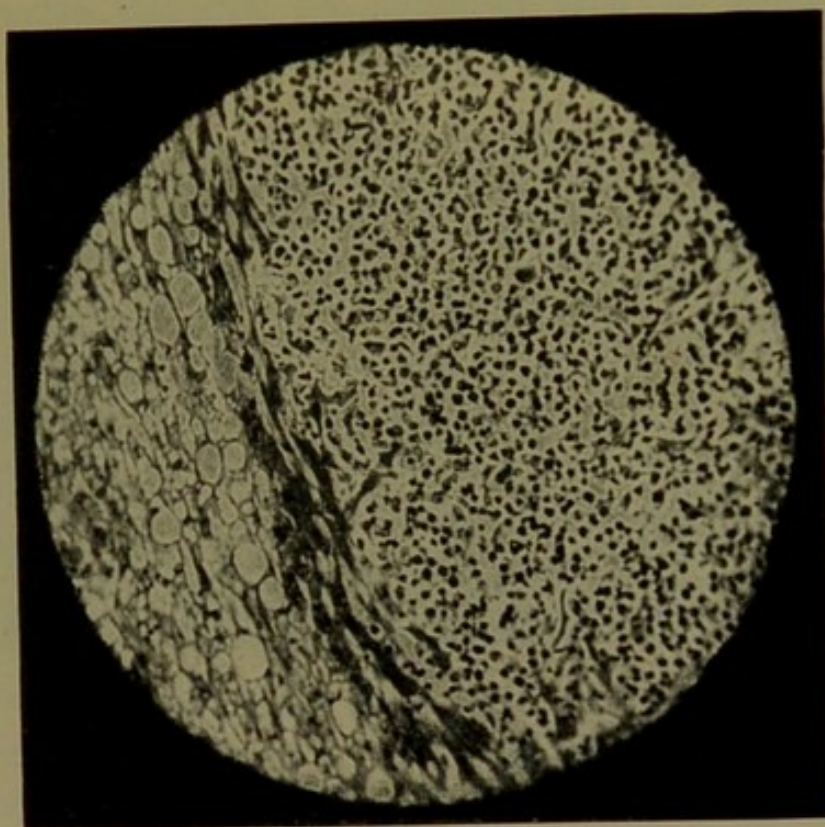


Fig. 43.—Photomicrograph of a Round-celled Sarcoma.¹

Chondroma is composed of cartilaginous structures, and may be met with in the region of the mammary gland and testicle or in the neighbourhood of bones and joints.

Fibroma is probably the most typical of the non-malignant growths. It is met with on any part of the body, especially between the claws, in the mammary gland, and on the legs.

¹ For this photograph, taken from the small intestine of a cat, I am indebted to the Imperial Cancer Research Association.

Composed mainly of fibrous tissue, they are hard to the touch and are usually well circumscribed. Before they become adherent to the skin or surrounding tissues their surgical removal is generally an easy matter.

They are very apt to be multiple, and may exist in large numbers on a single patient.

Glioma is the name given to a rare form of tumour occasionally found in the brain or spinal cord.

Lipomata, or fatty tumours, are harmless except when (as in the figure on p. 75) they grow to an enormous size

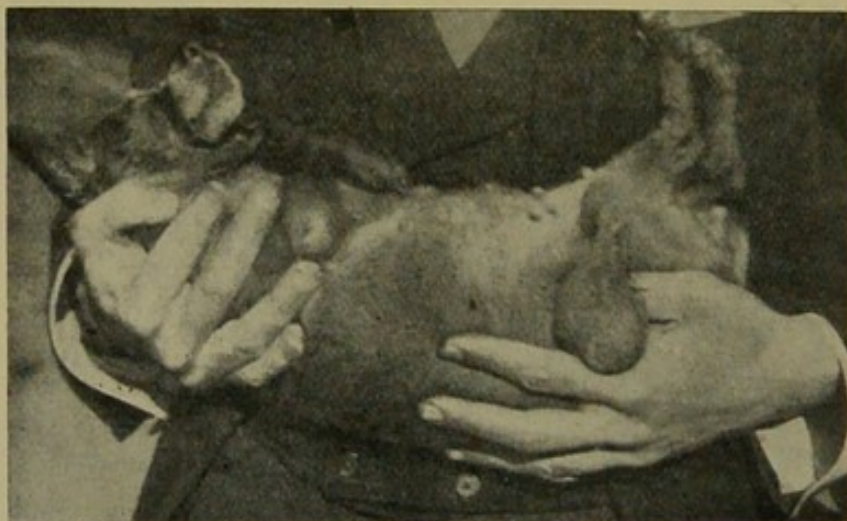

Fig. 44.—A Lipoma with Distinct Pedicle.

and interfere with the general convenience or utility of the patient. They may exist in great numbers all over the body, or in some such favourite situation as the buttock. They may possess a definite pedicle, rendering their removal by ligature and scalpel an easy matter.

They are diagnosed by their soft, flabby touch; their outline is well defined, and they are generally freely movable under the skin unless ulceration or adhesion has already taken place.

Melanoma is the name given to a dark-coloured tumour which is very frequently seen on the skin of black dogs or those which have some pigment in their coats.

Myxoma is the name given to a soft, fluctuating tumour composed of connective-tissue cells embedded in a mucoid groundwork. It may occur anywhere where connective tissue exists normally.

A **myoma**, or muscle tumour, is so called because in structure it resembles non-striated muscular tissue. It is most commonly met with in connection with the subcutaneous tissues and the uterus (see p. 302).

Osteomata are formed of bone tissue, and are met with in connection with bone or cartilage. Occasionally, in the bitch and cat, they are found in the mammary gland.

The **psammoma** is very rarely met with in the dog and cat, and occurs only in the brain. Its presence can only be suspected by the symptoms shown by the patient, but its certain diagnosis can only be made after a post-mortem



Fig. 45.—Blunt Tumour Hook or Retractor.

examination. It is located in such a situation that its successful removal by surgical procedure is impossible.

Papillomata, or warts, are a variety of tumour commonly met with in the dog and cat. They may occur almost anywhere, and are particularly met with on the skin, in the mouth, and even in the trachea. The mouth and tongue of the dog have been known to be completely covered with them, so closely are they sometimes packed together (see Fig. 100). In this situation they are contagious, and may even interfere with the act of feeding (see p. 130).

In addition to the above tumours, there are those which partake of the nature of more than one class; for example, we may get an **osteo-sarcoma**, **osteo-chondroma**, **adenocarcinoma**, etc.

Treatment.—In the case of malignant growths, the benefit

afforded by operative interference can only be temporary. With the benign varieties, a certain prognosis can be given that they will not recur if completely removed.

In doubtful cases, though, the aid of the microscope, or, better still, the opinion of an expert pathologist, should be sought.

Whatever the variety, **the principles of removal** by surgical methods are the same. In those which have a distinct pedicle, a ligature of silk, catgut, horsehair, or some such material, may be tied firmly around this part, and the tumour removed at once with a sharp knife, or the ligature may be allowed to remain on for two or three days before removal. Many lipomas and papillomas can be removed in this way.

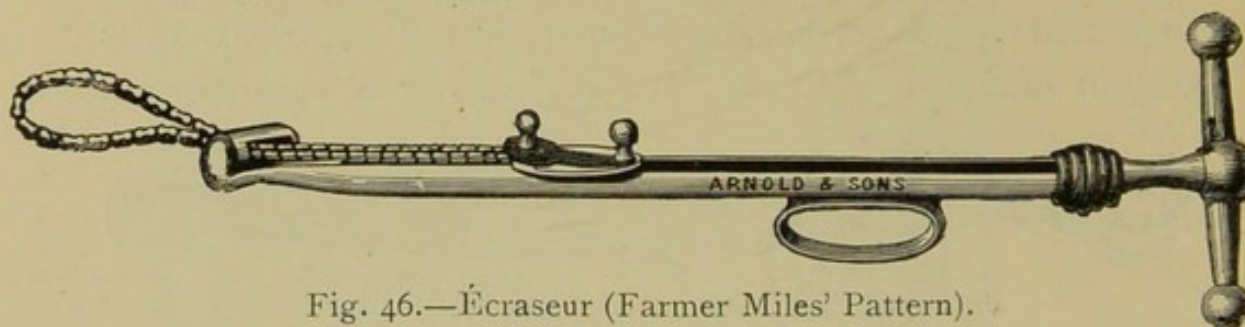


Fig. 46.—Écraseur (Farmer Miles' Pattern).

In some cases resort is made to the actual cautery and clamp, or the *écraseur* may be used. When the latter instrument is employed, the skin should first be cut through, as, if it be left, the traction on this caused by the chain or wire gives excessive pain unless an anæsthetic is used, and in addition damages the edges somewhat severely.

In removing large tumours, the hair over the line of incision is removed by shaving, the parts being thoroughly cleansed and washed with some antiseptic (see p. 2), and an incision made over what is thought to be the most convenient part. Cutaneous hæmorrhage is arrested by the application of artery forceps (for which purpose the Spencer Wells or bulldog patterns are the most convenient), and the skin carefully dissected off around the growth, the latter being raised by a tumour hook or by passing a needle and

strong silk through it in order to make a loop to take hold of.

Having kept the parts neatly cleansed with tampons of aseptic cotton-wool, and taken up the vessels wherever necessary with artery forceps, the tumour should be carefully dissected to its base. Here, as a rule, will be found the main blood-supply, which needs to be secured either by a ligature or by torsion before removal, in order to prevent hæmorrhage. The scalpel readily completes the removal,




Fig. 47.—A Large Lipoma, Inoperable, owing to its Extent and Large Size.

or if the *écraseur* is to be employed, the chain is now put on and tightened very slowly until excision is complete. The edges of the skin are trimmed and sutured, a drainage-tube inserted in position if considered necessary, and the parts treated antiseptically as an ordinary surgical wound (see p. 50).

It must not be forgotten that some tumours, although not malignant, cannot be surgically removed, owing to their large size and the amount of cutaneous and other tissue which would be involved.

Fig. 47 is an illustration of this, the tumours (large lipomas) extending almost the entire length of the chest wall.

The patient (a mongrel fox terrier) weighed $51\frac{1}{2}$ pounds, and two lipomas weighing respectively 8 pounds and 2 pounds were removed on *post-mortem* examination. The larger one measured $22\frac{1}{4}$ by $25\frac{1}{4}$ inches, and the smaller one $13\frac{1}{2}$ by $16\frac{1}{4}$ inches.

Granuloma.

The term **granuloma** indicates a bacterial tumour, not a neoplasm, and the growth is formed of granulation tissue

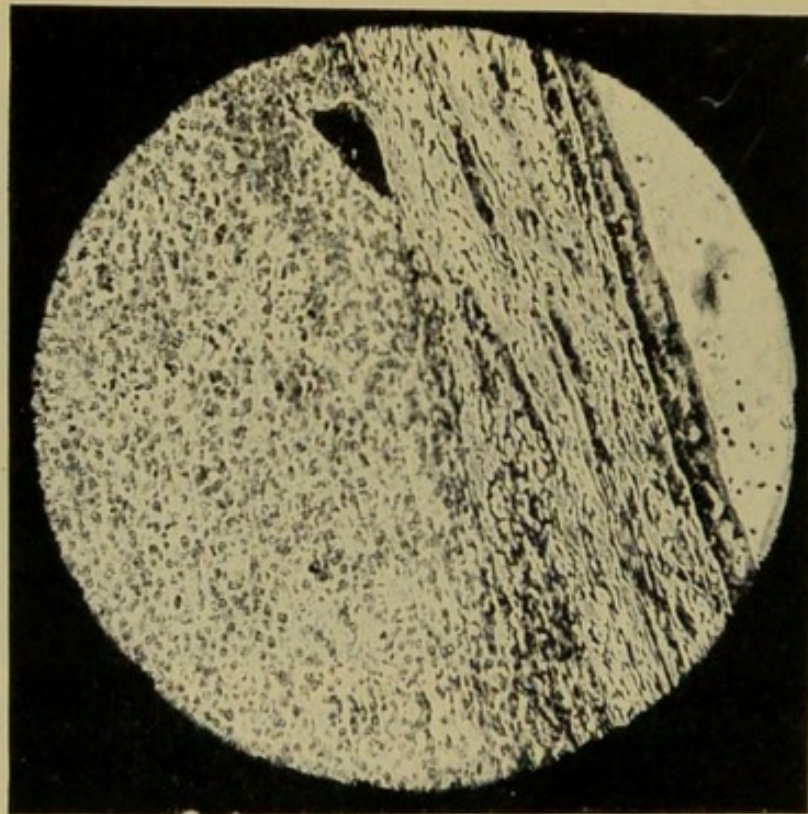


Fig. 48.—Microphotograph of a Granuloma.¹

due to the irritation produced by some specific organism, such as that of tuberculosis, glanders, actinomycosis, and others (such as the contagious venereal tumours alluded to on pp. 171 and 291), of which the organism has not yet been discovered. With most granulomata the specific disease can be transmitted by subcutaneous transplantation of diseased tissue or by scarification of, and application to, mucous surfaces.

¹ For this I am indebted to the Imperial Cancer Research Fund.

CHAPTER VIII

THE EAR

Examination of the Interior before, and Application of Dressings after, an Operation.

A CURSORY examination of the interior of the ear can be made with the fingers, but a speculum of some pattern or other is always an advantage, as also is an electric lamp, as by their aid foreign bodies are more likely to be discovered and dressings can be more easily applied and any irritant matter more readily removed. There are several patterns




Fig. 49.—Kramer's Speculum.

of speculum which are convenient for canine work, the two most useful being Kramer's and Avery's (Figs. 49 and 50).

Dressings may be applied on wadding by the aid of a slender pair of forceps or on the end of a fine probe; for fluids a syringe with a curved and protected nozzle has been devised, or an ear sponge can be used, whilst for powders, after the cavity has been rendered thoroughly dry, an insufflator (Fig. 28) is very useful.

Whatever method is adopted, dressings for the interior

should always be applied as gently as possible, because, especially when wounded or irritated, it is extremely sensitive.

It is worth while to note here that a dog which is totally deaf is disqualified from competition (or from receiving a prize if awarded) in any show held under Kennel Club rules.

Polypi, Tumours, and Enlarged Ceruminous Glands.

Symptoms.—Abnormal growths in the ear are not uncommon in dogs and cats, and cause a good deal of irritation to the patient. The animal shakes its head, frequently holds it on one side, rubs the affected ear on the ground, constantly scratches the base of the ear and yells or moans with pain. Deafness is a common sequel.

Operation.—If the growth has a pedicle, its removal is best effected with curette, a ligature or fine *écraseur*, the parts being painted with cocaine. In other cases, under a general

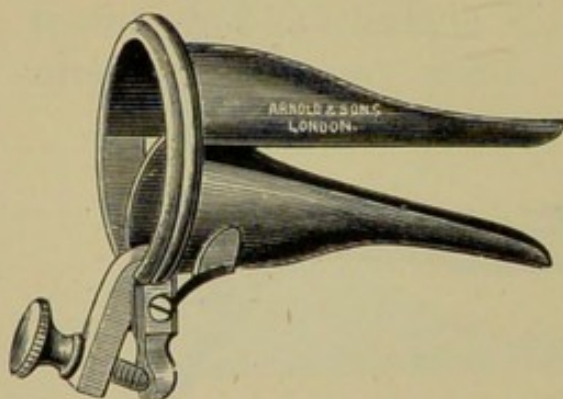


Fig. 50.—Avery's Speculum.

anæsthetic, the scalpel or a pair of curved scissors must be used, hæmorrhage being checked by the application of tampons of cotton-wool soaked in some styptic salt (as perchloride of iron solution or adrenalin) and pressure; or the root may be touched with the point of a fine

thermo-cautery. Subsequent treatment must be left to the discretion of the operator, as frequently these growths are very troublesome, and they (or others of the same variety) reappear larger than ever after a few months, being either malignant or multiple in character. This is especially the case with papillomas and enlarged ceruminous glands, and it is not uncommon for so much constitutional disturbance to be caused that the most humane course to adopt is painlessly to destroy the patient. In an ordinary case, to carefully

cleanse the ear with chinosol solution or some other anti-septic, and then to thoroughly dry it afterwards, is all that is necessary.

Hæmatoma or Tumefied Flap.

Symptoms.—This condition, sometimes spoken of as serous cyst, abscess, or blood tumour of the ear, is especially common in long lop-eared dogs, although it is also frequently

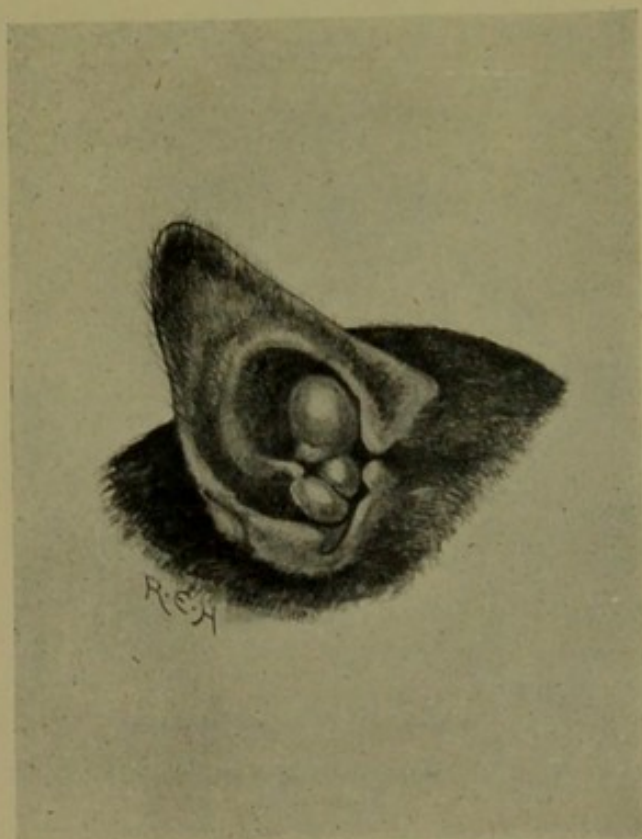


Fig. 51.—Papillomatous Growths in Dog's Ear.

seen in those with prick ears and in cats. It is generally due to some injury, and sometimes follows canker as a result of repeated bruising from the shaking of the ears and constant rubbing or scratching. The patient shakes his head and gives short yells of pain when the ear strikes the head, or will hold the head on one side so that the injured ear becomes pendulous.

Examination of the ear-flap reveals a soft fluctuating

swelling on the under surface. In its early stages this is exceedingly tender to pressure, but after it has existed for some days, unless repeatedly bruised, this tenderness passes off. It may be only the size of half a filbert, or it may extend the whole length of the ear. If left without treatment the fluid may become absorbed, but the ear is usually left deformed and crinkled. Even when treatment is adopted, this untoward sequel sometimes follows.

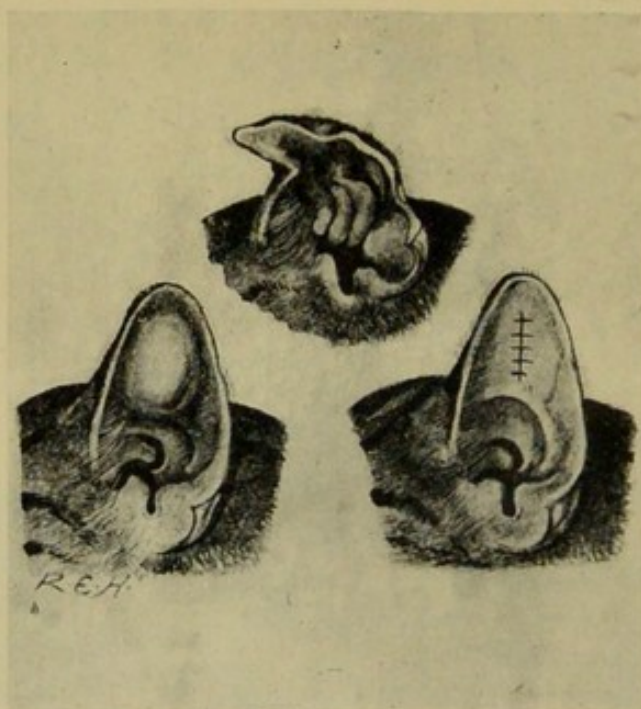


Fig. 52.—Hæmatoma of the Ear-flap before and after Operation.

The top figure shows the crinkled appearance which often occurs if no operation is performed.

Operation.—A common method of treatment consists in merely lancing the under surface of the ear-flap, carefully pressing out its contents, and treating the wound antiseptically. Some practitioners excise a large triangular or elliptical piece from the under surface, and afterwards insert a plug of cotton-wool or tow, in order to prevent too rapid healing by keeping the edges of the wound apart, or inject concentrated solutions of iodine.

Another method consists in inserting a seton tape through the swollen under part, and so endeavouring to keep up a

continual drainage until all the fluid has escaped, and a certain amount of adhesion has taken place between the skin and cartilage.

A third operation,¹ which seems to give by far the best and quickest result, is performed as follows: The ear is carefully washed and dried with antiseptic precautions (see p. 2), the hair being shaved off, and a plug of dry wadding

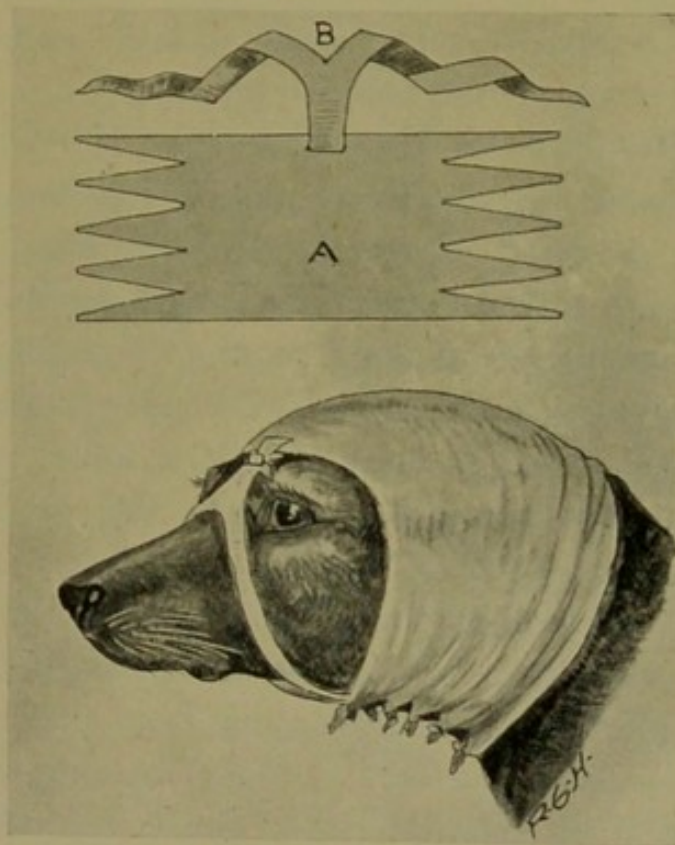


Fig. 53.—A Simple Many-tailed Bandage for the Ears, cut out of a Piece of Calico.

placed in the aural orifice; the parts are painted with a 10 per cent. solution of cocaine (or the animal is anæsthetized), and a good longitudinal incision made in the under surface. Every particle of clot or fluid is then most carefully removed, and the edges and interior of the wound are dried with aseptic wadding. In almost every case a shred of bruised

¹ This operation was first suggested to me by my colleague, Professor M'Queen.

tissue is to be found. Suture material is passed at intervals of about a quarter of an inch right through the flap from above to below, across the incision and again to the upper surface, upon which each suture is tied in a surgical knot. The object of this is to produce a firm pressure on the internal surfaces, and at the same time to bring the edges of the incision in contact with each other. This having been completed, and the parts again carefully dried, the whole ear is placed in a pad of aseptic wadding and bandaged firmly to the head; a cap or net placed over this is of advantage if the animal attempts to remove it.

After-treatment consists in examining the wound once or twice daily, pressing out any fluid which may be present, carefully drying and bandaging again with aseptic wadding.

The average length of time required to effect a cure is about ten days; in some cases the bandage can be left off within a week, in other cases it will be found necessary to keep up the treatment for a fortnight, or even three weeks.

Whichever method of operating is adopted, it will always be found of advantage in the dog to utilize the bandage or ear-cap in order to protect the animal from shaking the head and again bruising the ear. Proper caps or nets for the purpose can be purchased, but an improvised one can readily be made from a piece of linen and a few pieces of tape, which tie underneath the throat and jaw, a hole being made for the other ear to pass through, as this materially assists in keeping the cap in position (Fig. 53).

In the cat this is not absolutely necessary, as the comparatively short, upstanding ears of this animal do not allow of the flap being injured so readily as that of the dog when the head is shaken; even here, however, a bandage or cap is often useful, as it gives a certain amount of protection against scratching and rubbing. In applying a bandage, care must be taken that it is not put on too tightly, or necrosis of

the extremity of the flap will ensue through interference with the circulation.

In some cases the flap is bandaged flat on to the cheek; in others it is laid back over the forehead or poll; when recovery is protracted, it is a wise plan to alternate between the two.

The sequel mostly to be feared is a permanent thickening or shrinking, and consequent deformity of the flap of the ear.

Amputation of the Ear-flap or a Portion of it.

This operation is sometimes necessary when the ear gets severely injured or has on it ulcerating wounds which cannot be made to heal. Sometimes the continual bruising caused by the animal shaking the ears when suffering from neglected canker will render amputation of the edges absolutely necessary before healing can be effected. A general anæsthetic is used, and the offending parts are removed either with a sharp pair of scissors or by the aid of a scalpel and some solid substance (such as a clean block of wood) upon which the ear is laid.

Cropping.

Cropping, by which is understood the clipping of the ears in such a way that the natural droop is entirely done away with, and a 'prick' ear substituted, used to be done regularly in several breeds, especially the Great Dane, griffon, bull-terrier, and black-and-tan varieties. It was merely a mutilation due to the dictates of fashion, and the revised rules of the Kennel Club, which came into force on July 1, 1903, did a great deal towards abolishing this unnecessary cruelty.

By Rule 6, 'A dog shall be disqualified from winning a prize, or from receiving one if awarded, at any show held under Kennel Club rules . . . if it be proved to the committee of the show "that if any cutting, piercing, breaking by force, or any kind of operation or act which destroys tissues

of the ear, or alters their natural conformation or carriage, or shortens the tail, or alters the natural formation of the dog, or any part thereof, has been practised, or any other thing that has been done to deceive, except in cases of necessary operation certified to the satisfaction of the Kennel Club Committee.”

Previous to the passing of the above rule, one on the same subject had come into force on August 16, 1901, and the one in force at the present time is as follows :

‘ No dog cropped after April 9, 1898, and no dog born after March 31, 1895, nor Irish terrier born after December 31, 1889, can, if cropped, win a prize at any show held under Kennel Club rules. This rule shall not apply to rounding of foxhounds and harriers.’



Fig. 54.—Natural Carriage of Ears.



Fig. 55.—Dog of same Breed which has been cropped.

The operation is, however, sometimes done in dogs other than those used for show purposes, when one or both ears have become so badly lacerated or ulcerated that removal of a large portion of either flap is necessary. The after-deformity is not so great when they are made symmetrical.

Operation.—To make them equal, a piece of cardboard is cut of the required shape and laid on the injured flaps. Under chloroform and strict antiseptic precautions (see p. 2), the lacerated portion is trimmed off with sharp, strong scissors along the margins of the cardboard, and the other

is served in the same way. When doing the latter, the piece of cardboard is merely reversed and laid alongside the other ear. Care must be taken not to forget this, or the effect will be very far from what is desired.

In days gone by, when the cropping of dogs' ears was not considered a cruel and unfashionable operation, the usual method adopted was to fix a metal clamp of the required shape, to the ear-flap, the projecting parts being removed with a sharp scalpel or razor. In harriers and foxhounds the ears are sometimes shortened or rounded off with a specially shaped instrument known as a 'rounding iron.'

After-treatment.—Any cartilage which protrudes should be carefully snipped off, the parts being treated antiseptically until healed.

The ears should be kept as still, and as free from all sources of irritation, as possible.

Deafness, so commonly met with in bull-terriers as a congenital defect, is attributed by some authorities to this operation.

Operations to Cause the Ears to Droop.

When performed on a dog with the object of improving appearances for show purposes this operation is illegal, and would therefore not be done by a professional man, but it is of the greatest importance that he should be acquainted with the manner in which it is done; in order that, when called as an expert, he may know where to look for evidences of this form of 'faking' having been practised.¹

The object desired is a proper carriage of the ears in a certain direction, varying slightly with the breed of dog. Some animals, for example, have 'prick' ears when the ears should droop; to effect this 'droop' temporarily, pieces of leather or weights are affixed, or the ear is fixed to the cheek by some adhesive substance such as cobbler's wax. Flat

¹ See quotation from the Kennel Club rule on p. 83.

gelatine discs or sticky 'sweets' are sometimes sufficient. Absence or disarrangement of hair on the surface of the ear gives rise to suspicion of this having been done. To effect



Fig. 56. — Ugly Ears, one being pricked up and the other carried properly.



Fig. 57. — The same Dog after Operation.

a permanent droop, the cartilage is nicked in one or two selected places (or perhaps the entire length) on its under surface, care being taken not to wound the upper skin.



Fig. 58. — Boarhound with Malformed Ear (Congenital).



Fig. 59. — The same after Operation.

Close examination of the under surface will reveal a scar or several scars, the cicatrised tissue being whiter than the other part.

The cartilage may be weakened by being subcutaneously cut halfway through, the ear then falling by its own weight beyond the incised spot. This in a month or less leaves practically no trace, but at the same time is not always successfully done, as it requires expert and delicate manipulation. A hot knitting-needle or skewer is sometimes manipulated in a similar way.

Another method adopted consists in incising the skin at the edge of the upper surface almost at the base of the ear; a fine probe-pointed bistoury, the blade of which is introduced flatwise, is then inserted subcutaneously, and has its sharp edge drawn across the muscle which is pulling the ear in the objectionable direction. When neatly done either of these is very difficult, and in some cases quite impossible, to detect; as even if a small scar is found, it may readily be passed over as being due to a bite or other injury.

Congenital malformations of the ear are not uncommon, and, if placed (as in Fig. 58) so that the orifice is open and can admit dust, dirt, and other foreign bodies, will give rise to considerable irritation and pain. This must of necessity be rectified, or, as was the case in the boarhound illustrated above, the animal will suffer constant annoyance. In this particular instance the patient was continually shaking its ears and holding the head on one side, as if suffering from earache. In fact, it had contracted the habit of carrying the head in a crooked fashion. The result of the operation was in every way satisfactory.

Tumours.

Tumours on the ear-flaps are not very common. A papilloma or fibroma is occasionally met with, and can be readily removed by excision under the usual antiseptic and anæsthetic precautions (see pp. 2 and 23). Those of the interior of the ear have already been dealt with (p. 78).

CHAPTER IX

OPERATIONS ON THE SKULL, FACE, LIPS, AND NOSTRILS

Trephining.

THE operation of trephining the skull, nostrils, or face is occasionally resorted to after severe injuries, in order to

remove foreign material from underneath or to raise depressed pieces of bone. It is also of value in some dental cases.

The *instruments* required are a sharp scalpel, dissecting forceps, artery forceps, a curved piece of metal to use as an elevator, a small -sized trephine (Fig. 60), and a strong gimlet.

Operation.—The animal is secured in the

abdominal position and anæsthetized, the hair having been previously removed by shaving from the seat of operation and the parts thoroughly disinfected. A crucial or T-shaped incision is made over the spot, and all tissues between that and

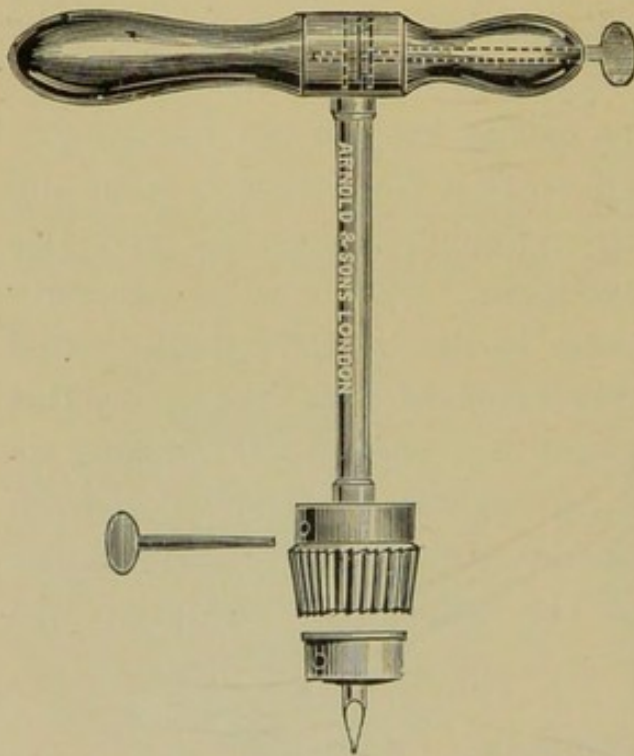


Fig. 60.—Trephine.

the bone carefully removed by cutting or scraping. A hole, intended for the insertion of the central pin, is bored with a gimlet in the middle of the spot to be operated upon, and the trephine applied. This instrument is worked steadily and carefully to and fro in a rotatory manner with gentle pressure until it is felt to have almost penetrated the bone. One side is then slightly depressed in order to cause the piece of bone in the trephine to become elevated on one side, and so attach itself to the instrument when the latter is



Fig. 61.—Granuloma of the Nose.

withdrawn, instead of falling into the cavity underneath. The foreign body is then sought for, or the purpose of the operation accomplished, the skin afterwards being sutured over the part, and the whole covered with antiseptic dressings (see p. 3) and bandaged, or left open, according to the discretion of the operator.

Tumours on the Nose.

Tumours on the outside of the nose are not common, but they are occasionally met with, as is shown by Fig. 61.

Treatment.—They are treated like tumours in other situa-

tions, but if malignant, as was the case here, the patient should be put painlessly away in the lethal chamber.

The subject of the illustration, a female cat aged four years, had been in the owner's possession for two and a half years, and had apparently had good health until about six weeks before it was taken to the veterinary hospital of Mr. A. H. Towne, M.R.C.V.S. The owner stated that he had then observed a small swelling, which was now rapidly becoming larger, and causing the cat to be greatly disfigured. Feeling sure of its malignancy, the lethal chamber was advised as the most humane course, and the body was afterwards sent to the Cancer Research Association. Dr. Bashford reported that the growth microscopically had the characters of a granuloma, and that it was readily transplanted into other cats, growing with great rapidity (*Veterinary Journal*, May, 1905).




Fig. 62.—Cat with Polypus of the Right Nostril.
The small sketch shows the actual specimen, natural size.

Tumours and Polypi in the Nostrils.

Symptoms.—There may be a watery discharge, the animal sneezes constantly, snuffles during respiration, and becomes distressed after exertion or when excited. In some cases small pink rounded bodies can be seen near the nasal orifices; these are the polypi.

Operation.—On account of the narrowness of the nostrils, the removal of the polypi is often a matter of great difficulty, and the bone forceps or trephine may have to be made use of. General anæsthesia is attended with risk, although of great advantage, because the operation is a very painful one and requires delicate manipulation. Adrenalin and cocaine in solution, injected into the nostrils or applied with a brush, are effectual in most cases. The former acts as an astringent to the bloodvessels, and the latter as a local anæsthetic. The polypi are generally multiple, and are removed either with a snare or by ligature. If both these are impossible to apply, they may be destroyed with a fine electric cautery, or the nostril may be trephined or split with fine bone forceps.

The *Prognosis* should always be guarded, because, as a

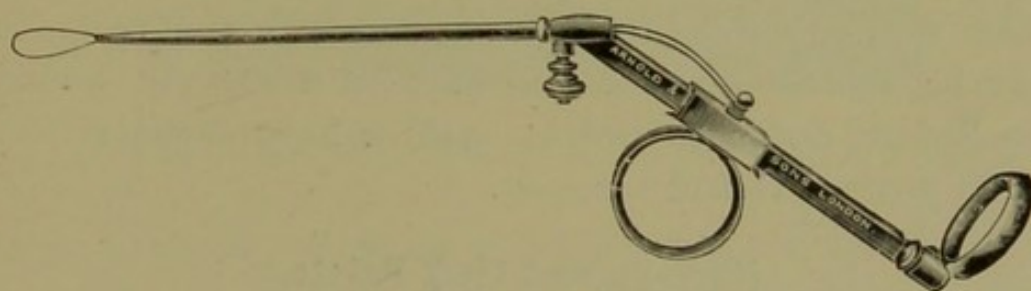


Fig. 63.—Polypus Snare (Blake's).

general rule, the removal of one polypus merely makes room for another to take its place. An operation is, however, worth a trial in all cases, because there is always the chance that the polypus which can be seen is quite alone, as happened to be the case in the subject of the illustration. In this instance the polypus had (Fig. 62) quite a long pedicle, and the snare removed it intact right at the root; there was no evidence of recrudescence nor of any others six months later.

After-treatment.—The nostrils in severe cases should be syringed with solution of adrenalin two or three times daily for a week or ten days.

Other Foreign Bodies in the Nostrils.

A parasite (the *Pentastoma tænoides*) is sometimes found lodged in the dog's nostril, and foreign bodies, such as a barley-corn, a blade of rib-grass, or a splinter of wood, have been removed on numerous occasions.

Symptoms.—Constant sneezing; the patient rubs its nostril on the ground or with one or both paws, and in other ways shows irritation of the part. Occasionally a little streak of blood will be seen after a violent effort at expulsion, and if the symptoms are not alleviated the mucous exudation becomes thick and stringy.

Treatment.—Explore the nostrils as far up as possible with the aid of a speculum and electric lamp. If the foreign body is in sight, it must be removed by a fine pair of forceps, either with or without the aid of cocaine. If a parasite, one may be able to reach it this way, or it may be forcibly expelled by errhines, such as snuff or liquor ammon. fort., which produce violent sneezing.

Hare-lip and Cleft Palate.

These deformities frequently occur together in the same patient, although they may exist separately. They are congenital malformations, and constitute very grave defects. They are especially common in the short-nosed breeds, particularly bulldogs, griffons, and Japanese, and usually attributed to in-and-in breeding. The author has on several occasions seen as many as three and four (usually the biggest and best) pups so affected in one litter. In the kitten a cleft palate is of more common occurrence than a hare-lip.

Symptoms.—The presence of a hare-lip alone may be looked upon merely as a disfigurement, and unless very extensive, and thus preventing the puppy from catching hold, need not necessarily deprive its possessor of the power of feeding; but a puppy or a kitten with a cleft palate cannot, as a rule,

form the vacuum in the mouth which is necessary to enable it to swallow the mother's milk, and so has to be artificially

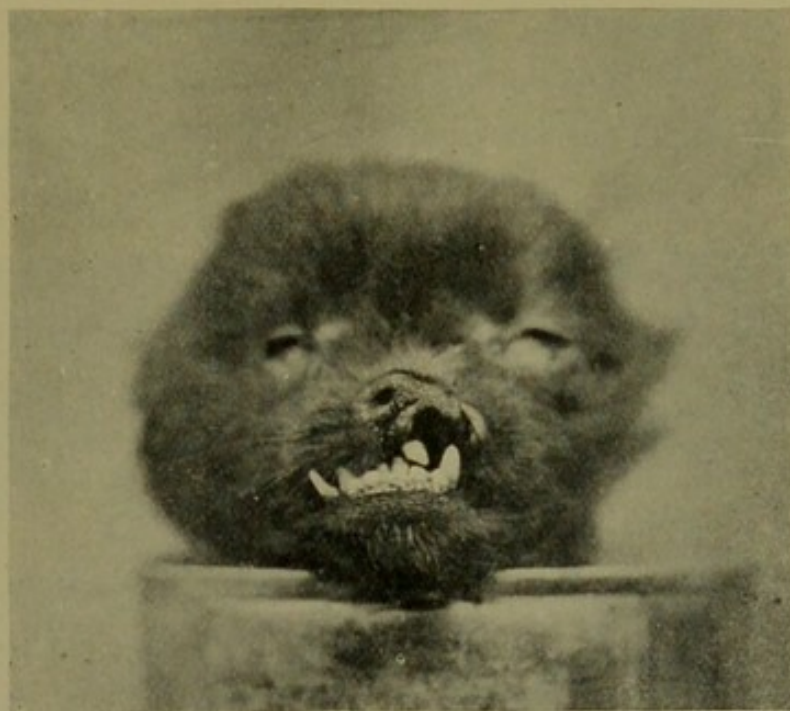

Fig. 64.—An Inoperable Case of Single Hare-lip in a Griffon.

fed. The milk returns down the nostrils, and to enable the animal to get sufficient nutriment the teat of the feeding-bottle used should be sufficiently large to fill (and reach to the back of) the mouth. A hare-lip may be double (Fig. 68) or single (Fig. 66), and the cleft in a palate may be wide or narrow; the latter may only exist in the anterior or posterior portion of the mouth, or it may extend the whole length. A small cleft is, naturally, more easily dealt with than a large one, and one existing only in the anterior portion of the mouth much less serious than one at the back. As a rule, unless successfully operated upon, if the cleft is at all



Fig. 65.—A Bulldog, Three Years old, with Single Median Hare-lip, but no Cleft Palate.

extensive, a puppy or kitten with this defect dies within three or four days of starvation.

Operation for Hare-lip.—To operate on a hare-lip, either cocaine or chloroform anæsthesia may be employed, the patient being secured in the abdominal position. With a sharp scalpel or scissors the edges of the cleft are scarified until they bleed, or a portion of them is cut away. The mucous mem-

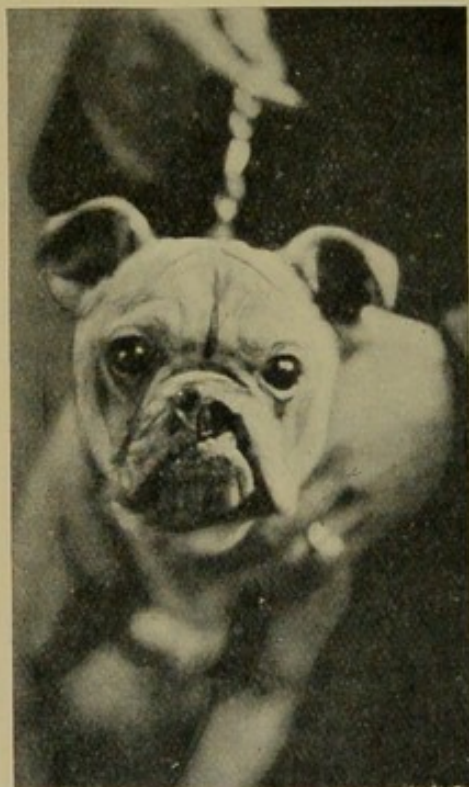

Fig. 66.—A Bulldog Puppy, Five Months old, with Unilateral Hare-lip and Cleft Palate, before Operation.




Fig. 67.—The same Puppy after Operation.

brane uniting the under surface of the lip to the gum is then dissected away until the lip is so loose that no tension will be put on the sutures, and the raw edges are united with sutures. For the latter some material, such as silk, catgut, soft wire, or kangaroo tendon, of fair thickness is preferable, as a good deal of swelling occurs, and the patient is apt to lick the parts freely. If either silkworm gut or thin silk is used, it is apt to cut its way through the tissues before

union has taken place. Should this occur, the wound must be stitched up again as soon as possible, and one need not immediately despair of a successful result, for the lip of the patient shown in Fig. 67 was sutured three times before the wound united. It may be necessary to extract a canine or other projecting tooth if this interferes with healing. In some cases this is absolutely necessary to a successful result, and it was done in the subject of the illustration.

A coating of orthoform (or iodoform) and collodion completes the operation. To prevent removal of the sutures,

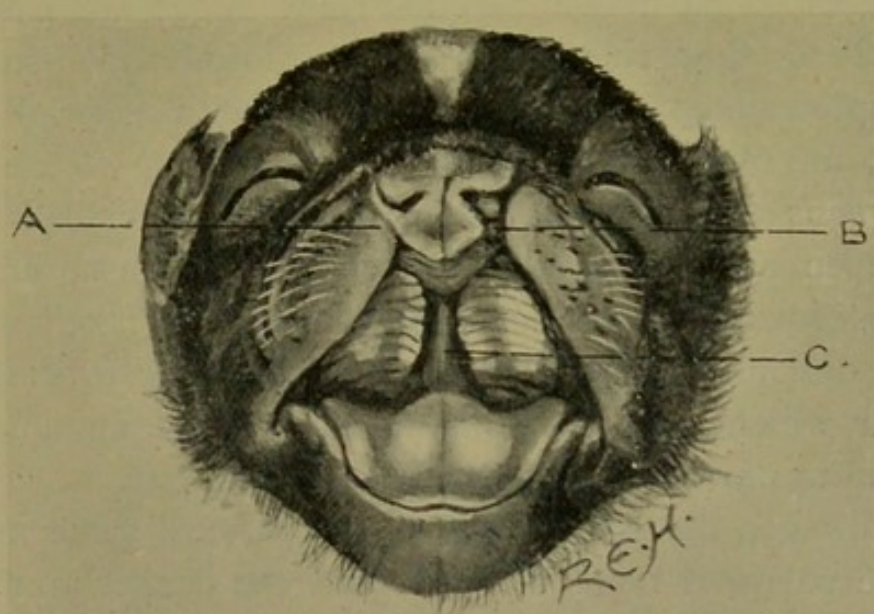


Fig. 68.—Malformed Bull-puppy with Double Hare-lip (A and B) and Cleft Palate (C).

the animal must be closely watched for a while, and the legs may be hobbled by means of pieces of tape or bandage material passed round the waist and back, or an Elizabethan collar may be put on (see Fig. 27).

The *results* are excellent in a large proportion of cases, whether the operation is done immediately after birth, or, as in the case of the bulldog shown in Fig. 67, when the animal is several months old.

Operation for Cleft Palate.—A cleft palate is much more troublesome to deal with than a hare-lip. If only a very

narrow slit, the edges may be scarified and allowed to heal by granulation, but if there is some perceptible space to be closed sutures must be inserted. On account of the friability of the mucous membrane in puppies and kittens, this is sometimes difficult, as the stitches readily tear out.

Cocaine is applied and the mouth held open. An incision is made longitudinally on either side parallel with the cleft, and a sufficient amount of the palate is separated from the bone with the end of a fine blunt curved pair of scissors (care being taken not to remove it at the top or bottom) to enable the edges to be drawn together; the edges are pared or scraped so that they present a uniformly raw surface; interrupted silk sutures are then inserted with a special palate needle, and tied in the usual way.

Prognosis should always be guarded. The accidents liable to happen are that fatal hæmorrhage may ensue and the portion of palate may be torn completely off. There is always a little difficulty about tying the sutures, owing to the small space in which one must work and the delicate manipulation required to prevent the sutures from tearing out.

If, however, the patient can be reared until some months old, the palate is much tougher, and the danger from this latter contingency much less.

It is astonishing, too, to what extent a cleft palate may exist without the owner's attention having been drawn to it. The author had one instance in a cat, eighteen months old and in excellent condition, in which the cleft was directly in the centre of the palate, elliptical in shape, and about the size of a melon-seed. This had not been observed until about a month before it was brought for operation, the result of the latter being quite satisfactory.

Rodent Ulcer of the Lip.

This is not infrequently seen in the cat, the under surface of the upper lip being most commonly affected. It is usually supposed to have its origin in the bite from a rat or another cat, and if neglected will develop into a nasty, hard, ulcerating

sore with a dark necrotic centre, this becoming a great disfigurement to the animal. Its chances of healing are greatly retarded because it is in a part which is not kept dry, and is, in addition, continually rubbed either by food or with the teeth and tongue.

Treatment.—Anæsthetize with cocaine and thoroughly scrape with a sharp curette or the point of a scalpel; then paint three times a day with pure tincture of iodine for three or four days, and afterwards paint with iodine lotion (1 to 8 of water). Internally administer potassium iodide. If, after two or three weeks, medicinal treatment fails, a more extensive operation must be performed. The edges of the ulcer must be cut away for some little distance around the diseased portion, the parts being drawn together with sutures, or treated as an open wound at discretion.

Prognosis should always be very guarded, as although the patient may appear to recover and keep right, even for three or four months, relapses are common.

Pus in the Antrum.

Every now and again one is brought in contact with a case of what appears to be an abscess in the face, a purulent discharge appearing a short distance below the inner canthus of the eye. In the early stages the animal shakes its head, rubs its face on the ground, and shows pain on external pressure. If unfamiliar with the cause, the wound is treated antiseptically, and will probably heal, but in a week or two the discharge breaks out again, and is as bad as ever. The true cause of the mischief lies in the antrum at the root of the fourth premolar of the upper jaw, and until this is extracted no permanent cure may be expected. Occasionally the tooth behind this has to be removed as well.

Instruments.—A pair of molar forceps, probe, mouth-gag, and small syringe.

Operation.—Secure the patient in the abdominal position, shave and cleanse around the wound, anæsthetize with chloroform, and instruct an assistant to steady the head whilst the operator takes a firm grip of the jaw in one hand and applies the molar forceps with the other. The points of the latter are pushed well up under the gums in order to get a good grip, the tooth is loosened by a twist of the wrist and extracted whole. Badly fitting forceps or a slip may cause the tooth to break; the fangs must be extracted if possible,

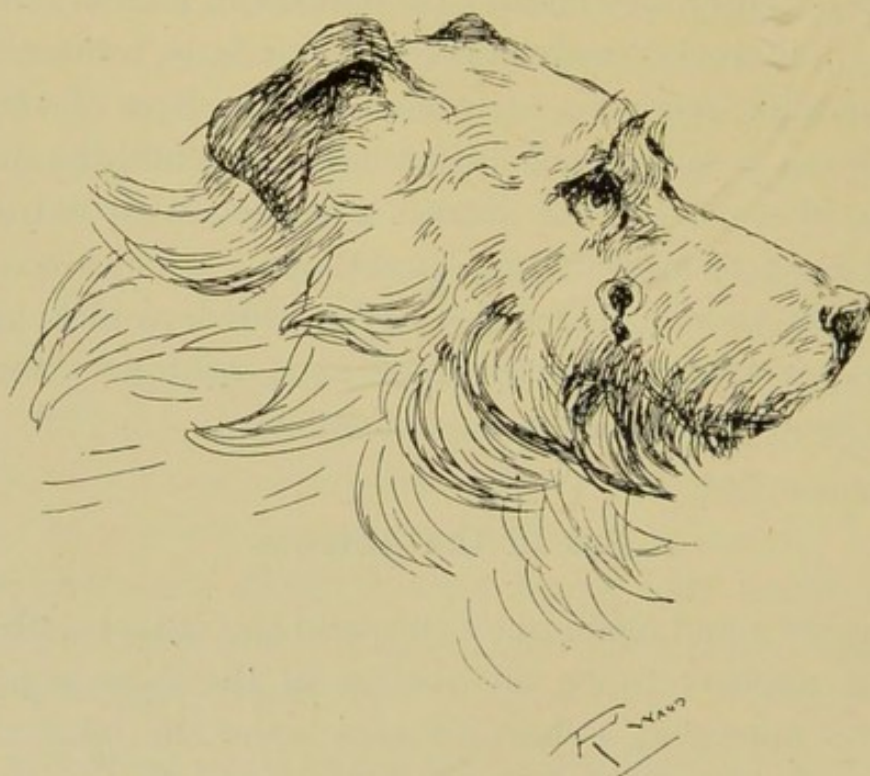


Fig. 69.—The Usual Situation of the Discharge.

although, so long as there is a communication large enough to admit a probe between the antrum and the mouth, the result is generally satisfactory.

After extraction a probe is passed through from above to below, and a good dependent orifice made. When the patient has recovered from the anæsthetic, the wound is thoroughly syringed from above to below with some antiseptic solution, and as a rule no further treatment is required. In some cases it is wise to use the syringe two or three times a day

during the next few days, and to keep the wound open, but as a general rule this is not necessary.

The illustration (Fig. 70) here shown represents the left upper fourth premolar extracted from a small Welsh terrier, the subject of pus in the antrum, for the sketch and technical description of which I am indebted to Mr. Charles Tomes, F.R.C.S. (author of 'Dental Anatomy').

'The crown of the tooth presents nothing unusual, and has been exposed to little wear. All three roots show signs of inflammation of some standing, and are reduced by absorption consequent upon the inflammation. The outer external root, seen to the left of the figure, is not much shortened, but its apical portion is thinned down so that it terminates in a sharp point. The antero-internal root, imperfectly seen behind the other in the figure, is more shortened, and terminates in a sharp-edged crater, very characteristic of absorption. The posterior root at the right of the figure is more interesting; it is thinned, shortened and roughened by absorption, and two cracks run across it—the upper one widely open, and the lower one with its edges in apposition. These edges have been attacked by absorption, and to some extent excavated and rounded. There is not the least doubt that the incomplete fracture of the root took place weeks, and probably a good many months, before it was extracted. The probable history is that the dog broke the root partly through in biting a bone, and that the irritation caused by the fracture set up absorption, not only in the damaged root, but also, to a less extent, in the other two undamaged roots, the periosteum of which may well have suffered minor injury by the wrench. Probably the tooth pulp was killed by, or died subsequently to, the accident, though this cannot be ascertained from the specimen. Its death and decomposition would account for the suppuration above its root.'¹

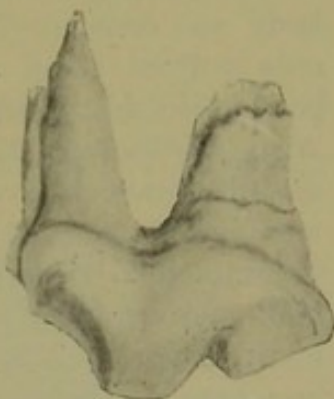


Fig. 70.—Left Upper Fourth Premolar, showing Result of Fracture and Inflammation of the Fangs.

Tumours.

Tumours of the brain of the dog are rare, and their satisfactory removal whilst the patient is alive is usually a

¹ *Veterinary Journal*, vol. lx., p. 137.

matter of impossibility. Their presence gives rise to symptoms which vary in accordance with the part of the brain substance upon which they cause pressure. Adenoma and sarcoma have each been recorded.

In the *Journal of Comparative Pathology*, vol. x., p. 75, Professor Penberthy records a case of tumour about the size of a walnut in the right lateral ventricle of an aged bulldog, and attached only to the vessels of the plexus choroides. This, upon examination by Professor McFadyean, proved to be an adenoma. The patient appeared silly, could see fairly well, but was somewhat deaf. The dog was dull and listless, the pupils were dilated, and, although the appetite was good, the body was emaciated. These symptoms came on suddenly, and were only noticed about a fortnight before admission into hospital. The patient was destroyed. In a second case, translated for the *Veterinary News and Bulletin* (November 12, 1904) from *Annales Belges*, M. Hebraut records a case occurring in a dog of eight years of age, which had for two months been affected with cerebral symptoms, characterized by difficulty in locomotion. The patient had difficulty in rising, and staggered on his hind-quarters, catching up one hind-leg suddenly and then falling lame on it, dragging it along. He ran up against obstacles, and did not appear to see them; knee jerks were exaggerated. Later the dog became partly paralyzed, and kept turning to the right. The patient was destroyed, and a post-mortem revealed a small hard tumour, the size of a small pea, on the right side of the base of the cerebellum, and adherent to the pia mater. On microscopical examination it proved to be a sarcoma.

CHAPTER X

THE EYE AND EYELIDS

AFTER many operations on the eye, avoidance of light is essential for a certain period, and a shade, such as is shown



Fig. 71.—Photograph showing Eye-shade in Position.

in Fig. 71, is worn. It is easy to make, and should consist of some black or dark material, such as silk or alpaca, and the patient soon becomes used to its presence. If it is

necessary to keep it at some distance from the orbit, the framework of an ordinary wire or leather muzzle can be utilized to give the requisite support.

Examination for, and removal of, Foreign Bodies.

The removal of foreign bodies from the eye can be accomplished quite painlessly under the influence of cocaine, eucaïne, or a mixture of the two. A small quantity of a 2 to 4 per cent. solution, applied with a camel-hair brush, will produce a very effectual anæsthesia in from one to three minutes. The eyelids are then separated with the fingers or by the aid of a speculum, the foreign body being sought for, and, when found, removed either with forceps, a blunt probe, or some sharp instrument, the choice of which must be determined by the operator. In using anything sharp, great care must be taken that the instrument is held in such a way that the cornea will not be injured if the patient unexpectedly moves. A few drops of castor-oil are of great assistance as a lubricant, and, in order to give the eye absolute rest afterwards, it is a wise plan to put the patient in a darkened room or enforce the wearing of an eye-shade for a few days.

Pterygium or Dermoid Growths on the Cornea.

Symptoms.—If the hairs turn in there is a watery discharge from the eye ; irritation and perhaps a nebula on the cornea. The growth is usually congenital and easily seen.

Operation.—Anæsthetize in the usual way with cocaine or eucaïne, and carefully dissect off the growth with a small and very sharp scalpel or razor and forceps. It is rarely of permanent value to merely pluck out the hairs, as they almost invariably reappear and cause more irritation than before.

In operating upon dermoid growths, very great care has to be exercised in order to avoid rupturing the cornea. Some-

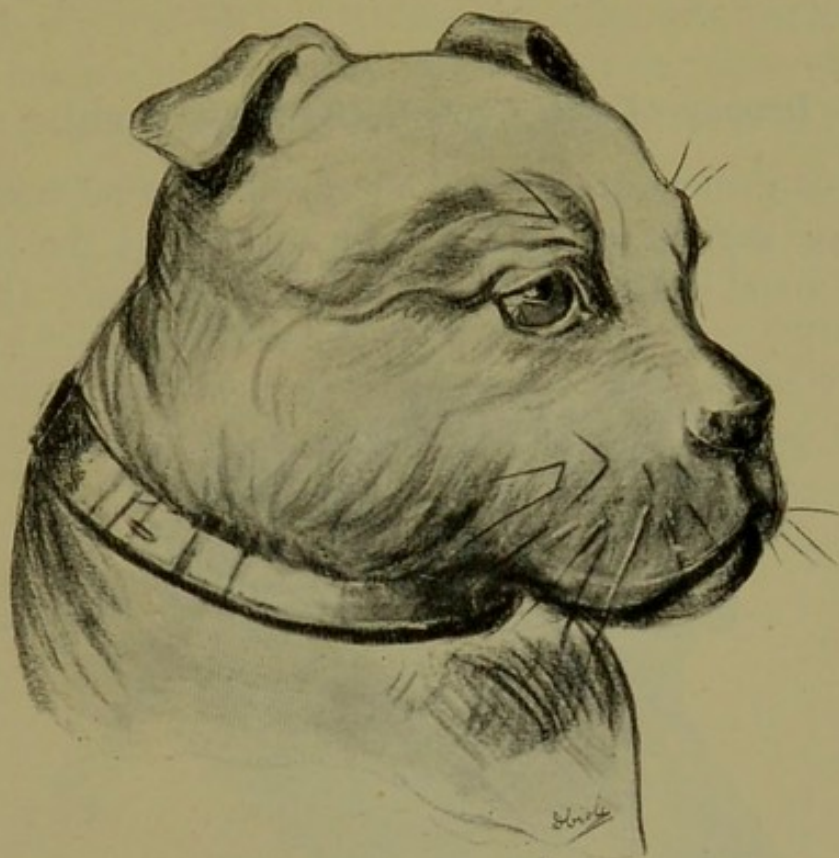

Fig. 72.—Mongrel with Dermoid Growth on Cornea of the Eye.

times the growth is very vascular, and gives trouble on account of hæmorrhage, in which cases cold compresses wrung out in boracic solution (from 5 to 10 grains to the ounce) should be applied. Occasionally the hairs will be found on the membrana.

After-treatment. — Keep the patient in a darkened room or kennel, and apply antiseptic lotion (chinosol gr. ss. to ʒi. or zinci sulph. gr. i. to ʒi.) two or three times a day.

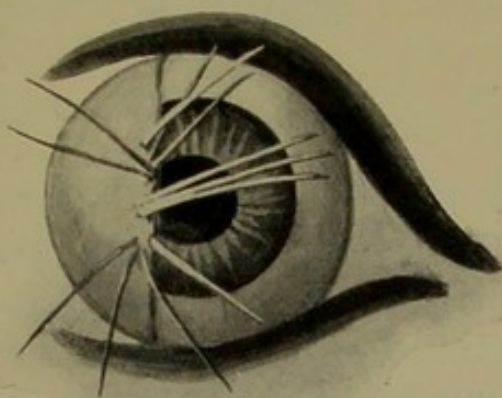


Fig. 73.—Eye (from Fig. 72) magnified to show Dermoid Growth on the Cornea.

The *Prognosis* is excellent if the patient may completely lose all traces of the defect, unless the latter has been very extensive.

Dropsy of the Eyeball (Hydrops Oculi).

An enlargement of one or both eyeballs is sometimes seen in the dog and cat, being due to an increase in the amount of fluid found in the anterior chamber of the eye. As a rule

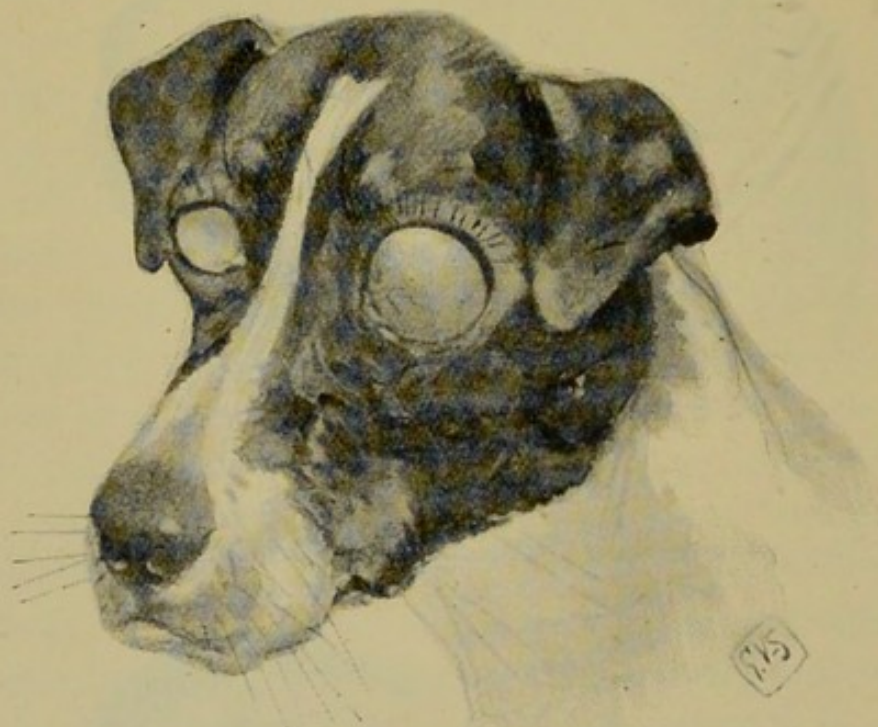

Fig. 74.—Fox-terrier with Dropsy of the Eyeball and Glaucoma.¹

This patient had also an inverted lens.

its progress is gradual, and the patient does not suffer any great inconvenience or pain; the eyesight, however, becomes impaired, and, on this account and the prominent position of the cornea, the latter is more prone to injury.

Treatment.—Tapping of the cornea (see next page), together with the internal administration of potassium iodide,

¹ For this photograph I am indebted to Mr. H. Gray, M.R.C.V.S.

may be tried ; but as a rule the relief given is only temporary, and the operation has to be repeated at frequent intervals. Excision of the whole organ is the only other alternative when the animal seems in pain or the eyeball becomes seriously injured through violently running against some hard substance (see p. III).

Wounds and Ulcers of the Cornea.

Causes and Symptoms—Medicinal Treatment—Operation.—The operation of tapping the cornea is very useful in some cases of staphyloma and ulceration where healing is prolonged. It may also be tried for dropsy of the eyeball, but as a rule the relief is only temporary. It is simple,

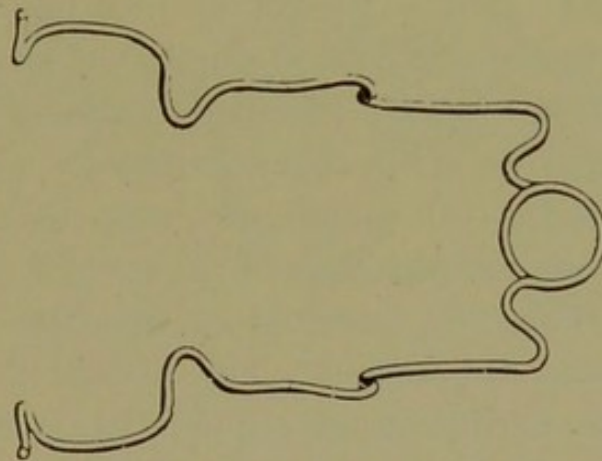


Fig. 75.—Bowman's Eye Speculum.

and, if done carefully under aseptic precautions, need give rise to no bad results; the object is to relieve the tension produced on the cornea by the aqueous humour, and thus to facilitate the commencement of the healing process. It may have to be done two or three times at short intervals. After the thorough application of cocaine or eucaine solution and some solution of boracic acid or chinosol as an antiseptic, the patient's head is held firmly by an assistant, and the lids forced gently apart by the forefinger and thumb or by a speculum. The operator then plunges a bayonet-pointed or broad-bladed needle through the cornea at its outer margin,

and, whilst the thin part of the blade of the needle is in the wound, applies gentle pressure upon the eyeball so as to force out a quantity of the aqueous humour. The needle is withdrawn, and the cornea carefully wiped with boric acid solution. Care must be taken to keep the needle in a direction approximately parallel with the cornea, and to avoid injuring the other side of the eyeball, the lens, or the iris.

Prognosis.—If done antiseptically the operator need not fear a bad result, and the effect on the ulcer, owing to the temporary relief of tension, is sometimes very gratifying.

Staphyloma.

Symptoms and Causes.—By this term is understood a protrusion of the aqueous humour through a wound of the cornea, the whole bearing some resemblance to a small grape.

It may occur from a direct injury or as a sequel to some debilitating disease. It sometimes gives rise to great pain, and may result in complete loss of the eyeball.

Treatment.—The first essential is that the patient shall be put in a darkened kennel. The eyeball is cleansed and fomented, some astringent and sedative lotion (such as zinci sulph. grs. i.-ii., liq. opii sed. ʒi., aq. ad ʒi.) being applied; or the staphyloma may at once be cauterized with nitrate of silver, and afterwards treated as above.

In regard to surgical interference, the protruding portion may be ligatured, and for this purpose a thread of fine silk is passed over the staphyloma, drawn sufficiently tight to act as a ligature without cutting into the protruding part, and left in that position for one or two days, when the staphyloma is excised.

Previous to the operation the eyeball is prepared by the application of a solution of some antiseptic and local anæsthetic. It is often a matter of difficulty in our patients to keep the ligature in position. In very persistent cases benefit

is also derived from allowing the escape of some of the aqueous humour by the operation of tapping the cornea already described.

Strabismus, or Squint.

Symptoms.—This deformity is not very common in veterinary patients. The eyeball may be drawn outwards (external

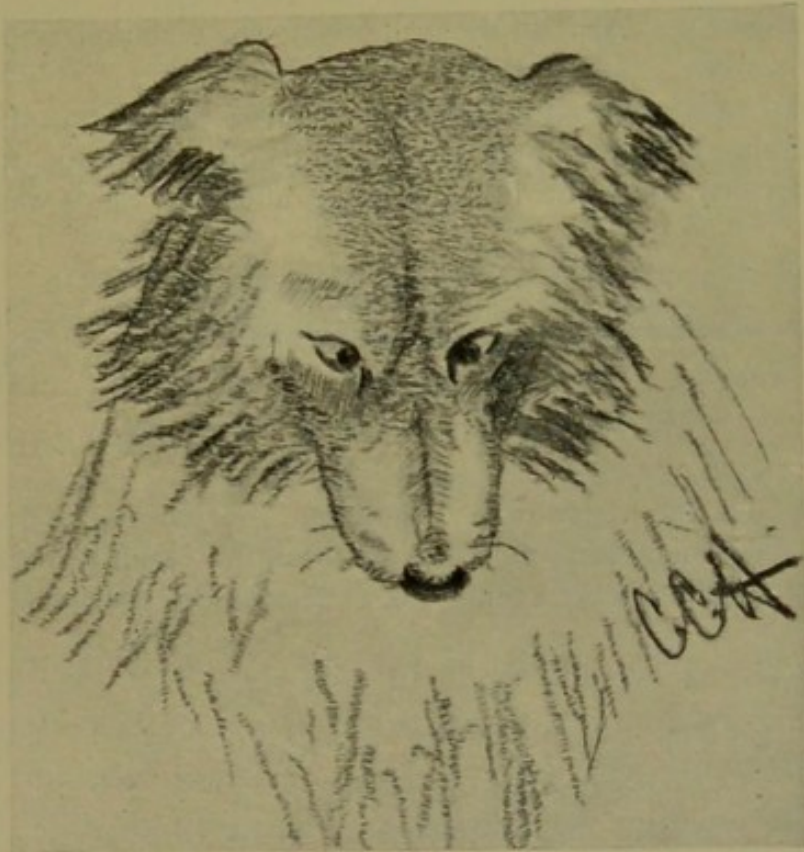

Fig. 76.—Collie with Internal Squint of Each Eye.¹

strabismus) or inwards (internal strabismus), either of which, if well marked, may interfere with vision, the patient appearing to hesitate when hurrying along or when suddenly brought amongst a number of objects.

The subject of the illustration came under observation in the Free Out-Patients' Department in March, 1895,² the animal being a very fat collie

¹ For this sketch (made from a photograph taken at the time) I am indebted to Mr. C. C. Abram, M.R.C.V.S.

² *Journal of Comparative Pathology and Therapeutics*, vol. viii., p. 250 ; *Veterinary Record*, vol. vii., p. 688.

dog with a well-marked internal squint in each eye, the pupils appearing to be looking at the nose all the time. The appearance of the animal's face was most ludicrous (see Fig. 76). The deformity was congenital, the animal being then about three years old. No defect of vision had been observed until during the last three months, when the owner stated that the dog appeared to see imperfectly, and when crossing a crowded thoroughfare had been almost run over on one or two occasions; this latter fact led him to seek professional advice. As the result of operation the condition of one eye was decidedly ameliorated, but in the other there was not much alteration; the animal, however, became restored to usefulness as a drover's dog, and the owner noticed a marked improvement in the way it went about its work.

A second case came under observation in October, 1901, the patient being a well-bred retriever pup, seven months old. This, too, was a congenital deformity, only the left eye being affected; there was internal



Fig. 77.—Strabismus Hook (Walton's).

strabismus, and the vision was defective. The internal rectus muscle was cut and the membrana nictitans removed, the result being a marked improvement, although the eyeball never became quite normal.

Operation.—The operation for the relief of strabismus is not a difficult one, although it requires a certain delicacy of manipulation of the instruments. Either local or general anæsthesia may be used, the latter being preferable, because the head can be kept perfectly still. The object in operating is to divide the muscle, either the external or internal rectus, which is producing the squint. A speculum is applied to the eyelids, and the conjunctiva at the canthus carefully incised with a pair of fine scissors; a fine blunt hook is passed underneath the rectus muscle, which is divided as near as possible to its insertion into the eyeball.

It may also be advantageous, when operating upon the inside, first to remove the membrana nictitans. The eyeball is then pulled outwards or inwards, as the case may be, as far as possible.

After-treatment consists in the daily application of some non-irritant antiseptic solution, such as boracic acid (10 grains to the ounce) or chinosol ($\frac{1}{2}$ grain to the ounce).

The *prognosis* as to complete return to normal appearance must be guarded, as frequently the improvement is only temporary.

Cataract.

Symptoms.—Although usually a disease of old age, this is by no means a rule without exception, as the author has seen it in canine patients five and nine months old respectively, and others have also made the same observation. A cataract is defined as an opacity of the lens, and the first sign of its appearance is a dulness or shiny, pearly appearance of this portion of the eyeball. It may follow severe ophthalmia, and occasionally comes as a sequel to some debilitating disease.

Operation.—Operative treatment for cataract does not give such successful results in veterinary patients as in those of the human surgeon. A very guarded prognosis should always be given, as, although the result may be a restoration to partial vision, it more often leads to disappointment. In the human subject the sight may after the operation be still further improved by spectacles, but in the dog, although these adjuncts have been affixed, there are certain difficulties to be overcome which prevent their general application. The object sought after is the removal of the opacity of the lens.

There are several methods of operating, two of which will be described here. A general anæsthetic is advisable, as it is essential that the patient shall keep perfectly still. The eye, the pupil of which has been dilated with atropine, is carefully disinfected with boric acid, perchloride of mercury, or chinosol solution, and a speculum inserted to keep the lids apart. In the first operation an instrument termed a cysti-

tome is passed into the anterior chamber at the margin of the cornea in the direction of the lens, which it scratches several times in such a way as to lacerate its capsule. This procedure may have to be repeated two or three times at intervals of a month or six weeks, the lens itself ultimately undergoing a process of absorption.

The second operation consists in the removal of the entire



Fig. 78.—Graefe's Cataract Knife.

lens. A special pattern of knife (usually Sichel's or Graefe's) is used in order to puncture the cornea, an entrance being effected on its conjunctival margin, and the point pushed through some distance further along, the intervening portion of cornea, together with a thin slice of the conjunctiva, being incised. The aqueous humour is allowed to escape, and the capsule of the lens is scratched with a cystitome as described above; gentle pressure with the finger and thumb is put

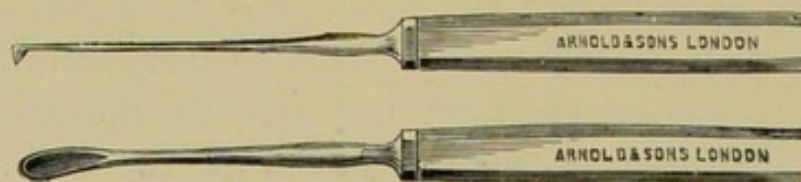


Fig. 79.—Graefe's Cystitome and Curette.

upon the eyeball, and by the aid of a cataract spoon or curette the lens is slowly and carefully forced out through the corneal orifice. More antiseptic lotion is then applied, the eyelids being kept closed and covered with an antiseptic pad.

After-treatment consists in keeping the patient in a darkened kennel, and as quiet as possible, for about a fortnight or so, the antiseptic pad being changed once or twice a day.

It is worth while to note here that a dog which is totally blind is disqualified from competition (or from receiving a prize if awarded) in any show held under Kennel Club rules.

Excision of the Eyeball.

This severe course is usually avoided as long as possible, but it becomes absolutely necessary in certain diseased conditions of the eyeball, such as some cases of injury,

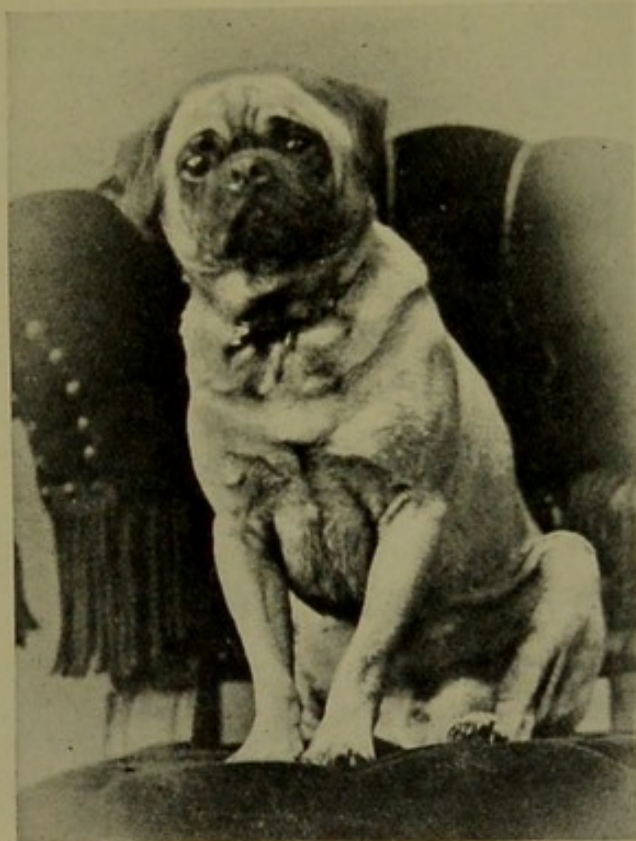

Fig. 80.—Pug-dog with a False Eye (Left One) of Vulcanite.¹

ulceration, dropsy, or tumours. It is very rarely necessary, however, in veterinary patients to remove a diseased eyeball solely on the pretext that the disease (whatever it may be) shall not extend to the other eye.

Operation.—As this operation is a very painful one, some general anæsthetic should always be chosen, except in cases where the eyeball has been forced out of the socket and the

¹ For this photograph I am indebted to Mr. T. Hibbard, M.R.C.V.S.

posterior portion is exposed. In such instances solution of cocaine (5 to 10 per cent.) answers very well. After having applied the anæsthetic, the eyeball itself and its surroundings are washed with some non-irritant antiseptic. The only instruments absolutely necessary are a fine scalpel (or a pair of blunt-pointed curved scissors) and forceps, with a sharp hook

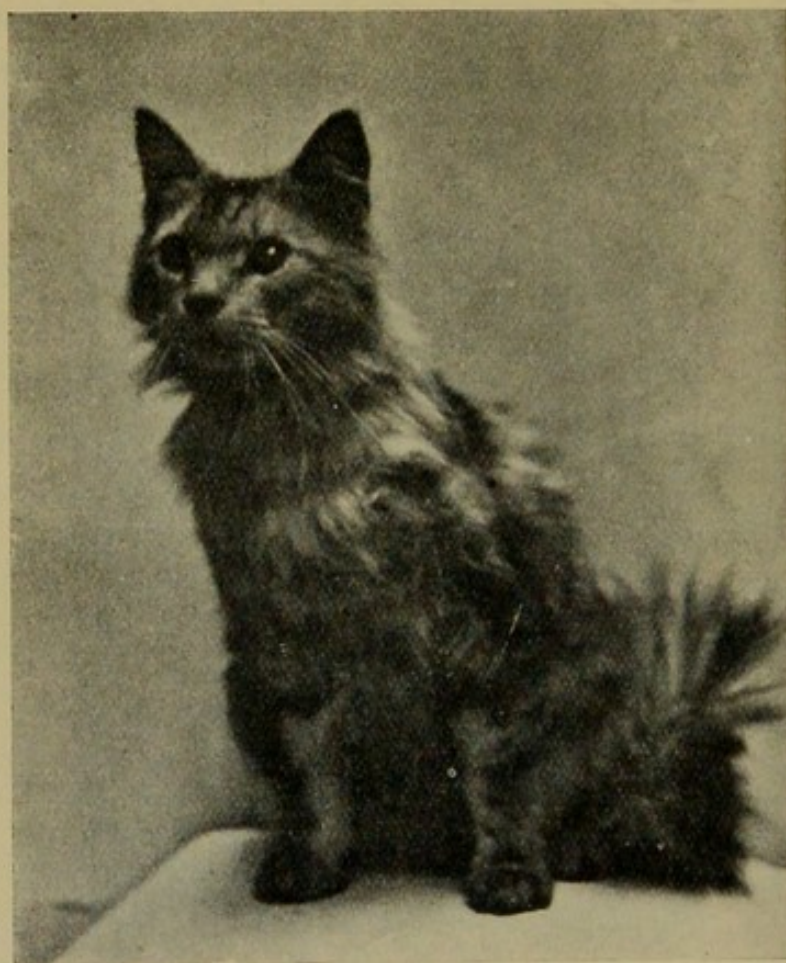

Fig. 81.—A Cat fitted with a Glass Eye (Left One).¹

or pair of toothed forceps to seize the eyeball with; the latter can be improvised by a needle and silk which is passed through the structures of the eyeball and tied in the form of a loop. A wire speculum is also of advantage.

The lids are held apart and the conjunctiva is divided along its upper and lower borders, the eyeball is pulled out,

¹ For this I am indebted to Professor Dunstan, F.R.C.V.S., F.R.S.E.

and the recti muscles are divided with scissors or scalpel as low down as possible; the eyeball is then pulled upon or made to protrude, and the last structures to be cut are the optic nerve and vessels at the back of the orbit. Care must be taken to clear out the cavity as neatly as possible.

A solution of some styptic, such as adrenalin or liq. ferri perchlor., is applied on a pad of wadding, the after-treatment consisting merely in the application of antiseptics, a bandage being used where it can be kept on.

False eyes of glass, celluloid, vulcanite, etc., of the necessary

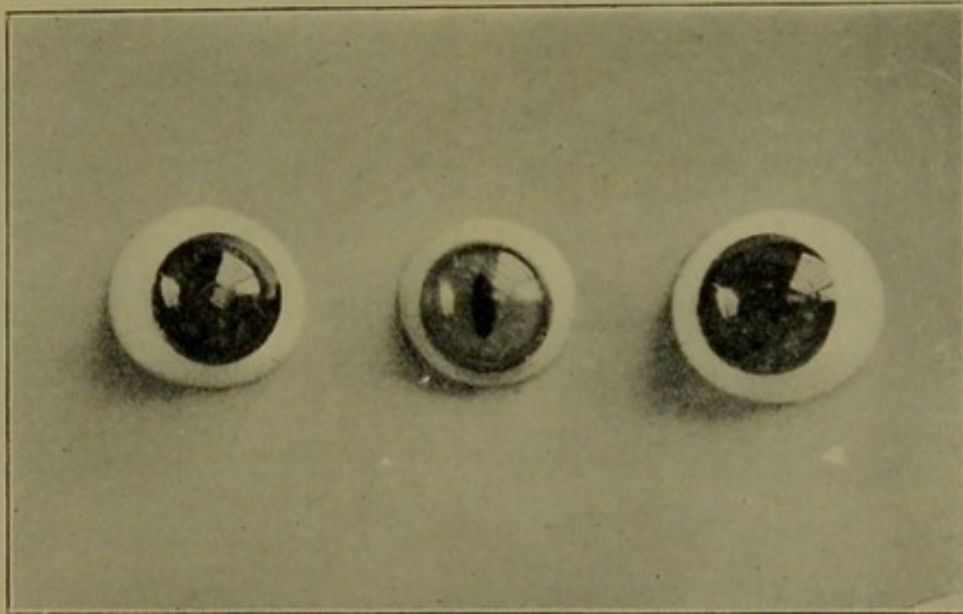


Fig. 82.—Patterns of Glass Eyes for Dogs and Cats.

colour and size can be obtained through an instrument-maker or a naturalist, some having a hollow posterior surface, and others being solid. The choice must be made in accordance with the condition of the orbit; sometimes granulations occur and almost completely fill up the cavity, in which case an eye with a hollow back is not so likely to cause irritation. The false eye should not be inserted for at least three or four months after the eyeball has been removed, in order to allow for complete healing, and also for a certain amount of contraction of the orbit which usually takes place. For a few

days immediately following its first insertion the artificial eye should only be allowed to remain for about an hour or so, the time being gradually extended. In all cases it is necessary to remove it each evening for cleansing purposes, as if left in altogether it causes a watery, catarrhal, or even purulent, discharge. The improvement in the appearance of the animal when the false eye is inserted is very great.



Fig. 83.—Japanese Spaniel before a Glass Eye was inserted.



Fig. 84.—The same with Glass Eye *in situ*.

Protrusion or Paralysis of the Membrana Nictitans.

This may be the result of an accident, such as a scratch from a cat, a tear with a nail, or some such injury; or it may occur as a sequel to an illness.

Symptoms.—It is not uncommon, especially after some debilitating diseases, for one or both of the membranæ to become paralyzed and to protrude over the eyeball, sometimes to such an extent as to cause considerable irritation to the patient and to interfere with vision. As the animal becomes convalescent this may right itself, and it is always well to try the effect of a course of quinine and iron or other tonics

before resorting to operative interference. If, however, they have not returned to their natural position in three or four weeks, and they are a source of annoyance, they should be removed. Occasionally, too, the membrana becomes swollen and afterwards thickened, or it may be the seat of a tumour.

Operation.—Having secured the patient, cause the head to be held as still as possible in a convenient position for the operation. Paint the upper and lower surfaces of the mem-



Fig. 85.—Cat with Paralysis of the Membranæ.

brana to be removed with some suitable local anæsthetic; allow time for this to act, secure the membrana firmly with a pair of forceps (or by passing a fine silk thread through it), and excise with a small pair of curved scissors or sharp scalpel as close to the inner canthus as possible. The slight hæmorrhage which follows is easily arrested by the application of a cold wet compress or a solution of adrenalin, and no bad sequelæ need be feared. In several cases which were kept under close observation for three or four years, the

animals did not in any way appear to be inconvenienced by the removal of their membranæ.¹

Displacement or Tumefaction of the Orbital Gland.

It is not infrequent, especially with a puppy, for an accident to happen to a glandular structure which is situated in the inner canthus immediately underneath the membrana

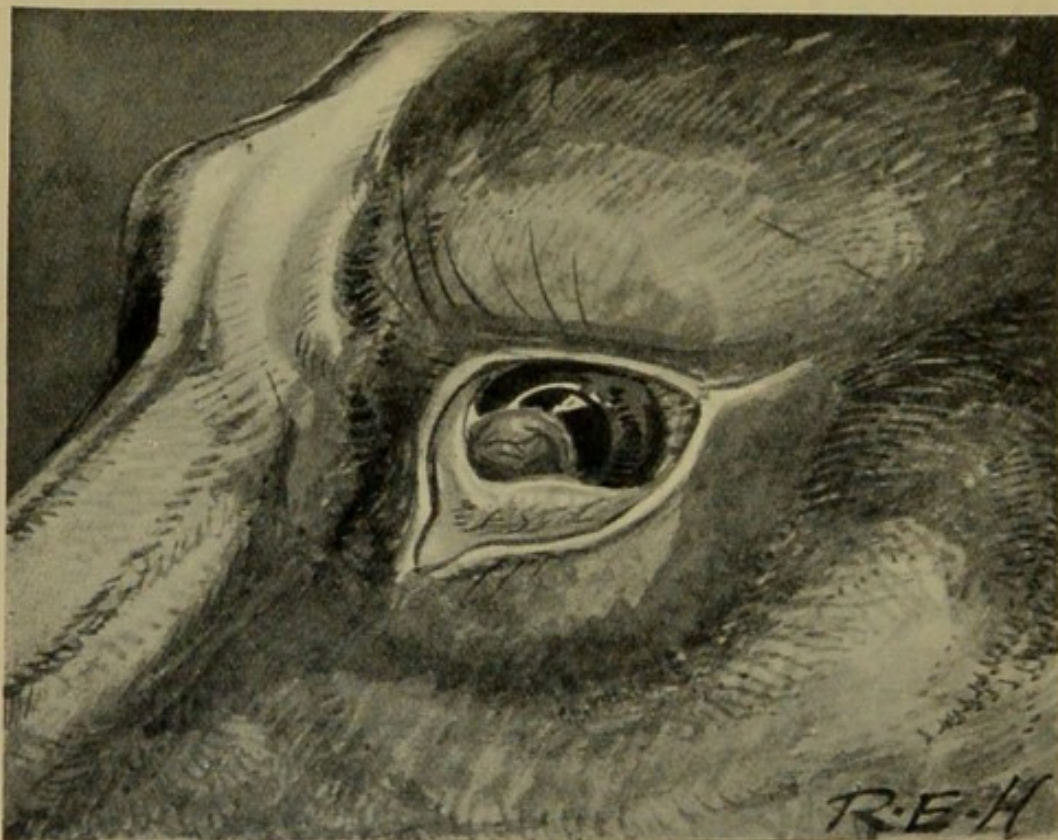


Fig. 86.—A Displaced and Tumefied Orbital Gland.

nictitans. It becomes everted, swollen, and comes into view as illustrated in Fig. 86.

The *Symptoms* are that the animal is continually pawing at the affected spot on account of the annoyance caused, and an examination reveals a reddish-coloured sac-like body, about the size of a pea, protruding from within the membrana.

¹ *Journal of Comparative Pathology and Therapeutics*, vol. viii., p. 248 ; *Veterinarian*, vol. lxvii., p. 337.

Treatment.—If discovered within a few moments after it has become displaced and its return can be accomplished, this should be done, and a mild astringent lotion (such as zinc sulphate, 1 or 2 grains to the ounce) applied for a few days.

If medicinal treatment fails, the parts should be painted with cocaine or some local anæsthetic, and excised with a pair of sharp scissors.

Prognosis is excellent, and the application for a few days of a mild antiseptic completes the cure.

Entropion and Trichiasis.

The term 'entropion' is given to a condition in which the edges of the eyelids turn inwards; the term 'trichiasis' is applied when the eyelashes turn inwards; frequently both conditions are present at the same time (districhiasis).

Symptoms.—Both conditions are usually congenital, and may, if not relieved, give rise to opacity of the cornea and total blindness from the constant irritation produced. Even in mild cases there is usually an objectionable watery or mucous discharge, which is more abundant the first thing in the morning, and the patient frequently irritates the eye by rubbing it against the ground or with its paw.

Operation.—The patient should be secured in the abdominal position, and the head held firmly by an assistant. The hair is removed as closely as possible from the external surface of the eyelid by shaving, and the parts are then anæsthetized with cocaine, or the animal is placed under the influence of some general anæsthetic. An elliptical piece of the offending eyelid is then removed either with a pair of scissors or a scalpel, great care being taken to remove only the skin, and not to injure the mucous membrane lining the lid. The wound is then sutured with fine silk, catgut, or silkworm gut covered with

collodion or orthoform and collodion,¹ and treated as an ordinary small surgical wound (see p. 50); when only a very small piece is taken out, there is no absolute necessity for the insertion of the sutures. The only unfavourable sequelæ to be feared are when an ugly sore occurs as the result of



Fig. 87.—Entropion and Trichiasis of the Left Eyelid.

The diagram above shows how the intorted lashes irritate the cornea.

continual rubbing or scratching,² or when too great an ellipse is made and the eyelid becomes a little everted; neither is, however, of anything more than minor importance. A second

¹ Iodoform and collodion is temporarily irritating when applied so near the eyeball, and for this reason is to be avoided, as the patient may (on this account) immediately rub out the sutures and make an ugly-looking wound.

² *Journal of Comparative Pathology and Therapeutics*, vol. viii., p. 247.

method of operating which is sometimes adopted consists in the application of a red-hot needle or wire to the eyelid, the resulting contraction and scar causing the skin of the eyelid to be shortened. In cases of trichiasis it is sometimes necessary, in addition to the above operation, to pluck out the offending hairs by the roots; this is done with a pair of tightly-closing forceps with broad points. This alone, however, is rarely more than a mere temporary measure.

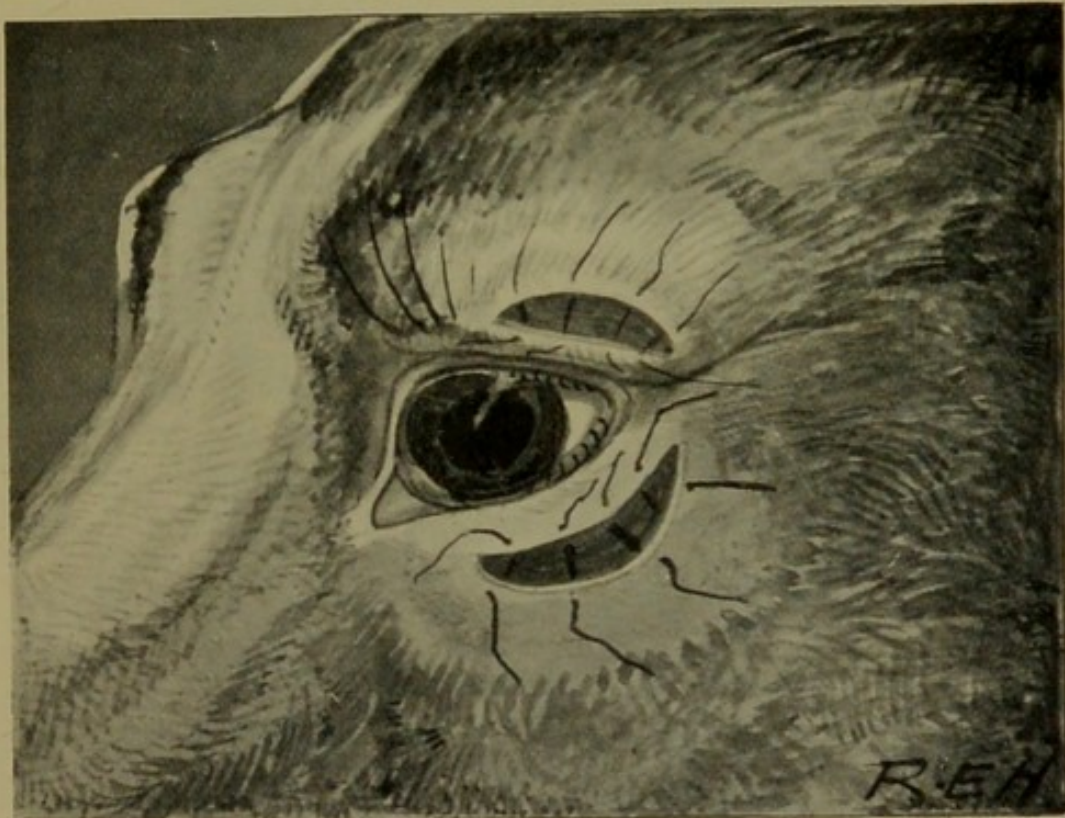


Fig. 88.—Sketch showing Elliptical Piece removed from each Eyelid affected with Entropion.

A third and simpler method than either, and one which sometimes gives a satisfactory result, consists in slitting the outer and inner canthus (or the outer one alone) under cocaine, and then pulling the cartilage of the deformed lid outwards away from the eyeball. If a piece of the cartilage projects, it may be cut off. In slight cases of entropion this has the desired effect. The wound is kept clean with some antiseptic, and soon heals.

Ectropion.

This term is applied when the eyelids turn outwards, exposing the conjunctival mucous membrane; it is a much more rare condition than entropion or trichiasis.

Operation.—It can be treated by the removal of a V-shaped piece of the eyelid, the incision being carried through the whole thickness of the lid, more of the mucous than of the cutaneous surface being excised. The wound is then care-

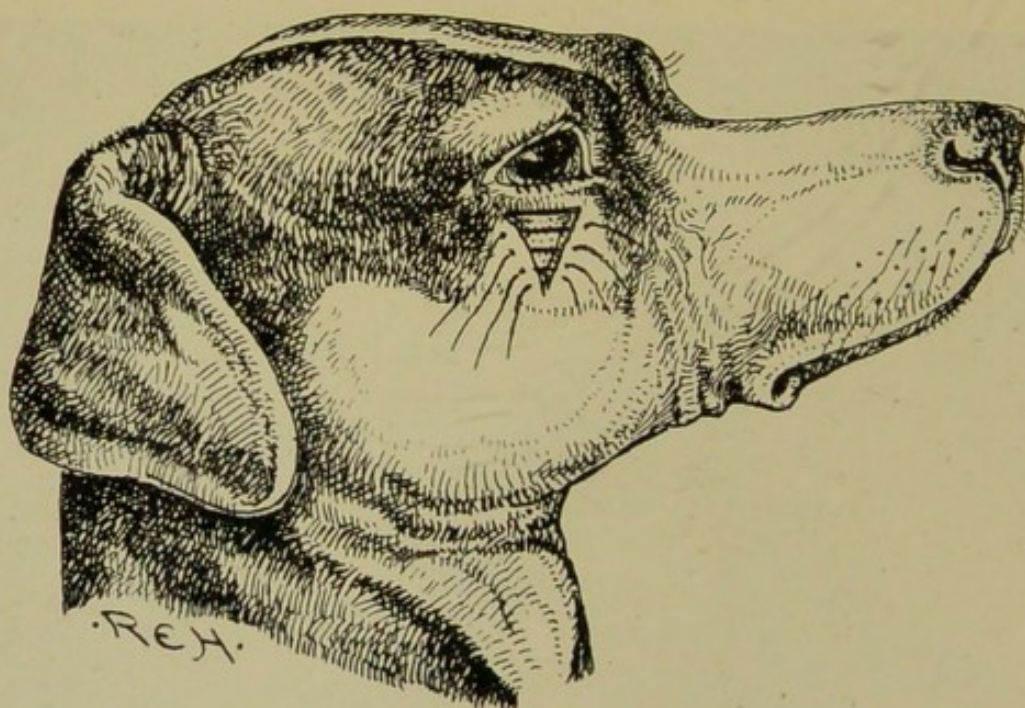


Fig. 89.—Sketch showing V-shaped Incision for the Relief of Ectropion.

fully sutured and treated antiseptically. Another method of treatment consists in the application of the galvanic cautery to the mucous surface in fine lines, a bone spatula being used to protect the eyeball itself; the object is to cause contraction of the mucous membrane by the formation of cicatricial tissue.

Mr. H. Gray has successfully effected the same result by crystals of copper sulphate applied, under cocaine, transversely to the mucous membrane. Immediately after application any excess of the caustic is carefully washed off. It causes swelling and removes a small portion of mucous tissue.

Tumours.

Probably the most common tumours of the orbital cavity are papilloma, sarcoma, and carcinoma. Each of the last

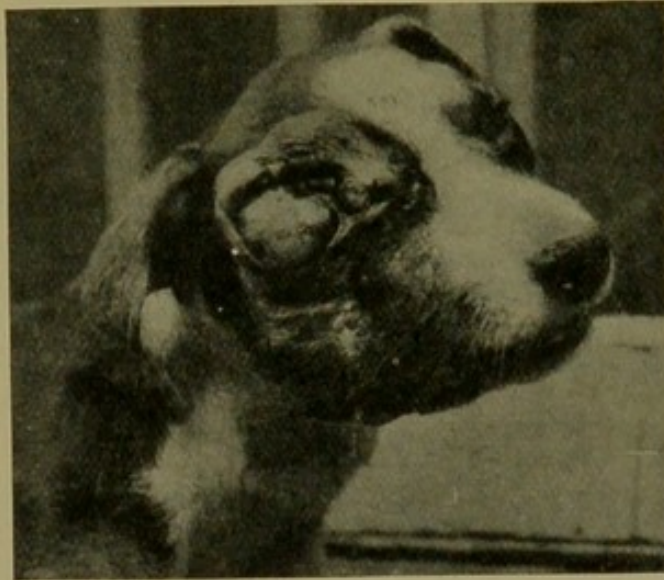

Fig. 90.—Photograph of Carcinoma of the Orbit of a Dog.¹




Fig. 91.—Photograph of Carcinoma of the Orbit of a Cat.¹

¹ *Veterinary Record*, vol. xvii., p. 694 (Proceedings of the Central Veterinary Medical Society).

two are malignant and practically inoperable. Surgical interference only causes them to grow more rapidly. The most humane course to adopt is to destroy the victims painlessly as soon as the diagnosis is established beyond all question. In each of the two animals illustrated (Figs. 90 and 91) the nature of the tumour was confirmed by Professor McFadyean. An attempt at removal was made by the owner's special request in the case of the dog, but its malignancy speedily reasserted itself. The cat's orbit was not interfered with, and grew to the extent illustrated within about three months.

CHAPTER XI

OPERATIONS ON THE MOUTH, PHARYNX, TONGUE, AND TEETH

Examination.

FOR a superficial examination, a good view can readily be obtained in canine patients by placing the finger and thumb of the right hand over the upper jaw in such a way as to press the loose, pendulous skin of the upper lip inwards between the molar teeth; the left hand serves the lower jaw in a similar manner, and the two are then drawn gently apart so as to expose the interior. So long as the lips are held in this way a dog cannot bite the fingers of the person conducting the examination, without first biting its own buccal membrane.

The under surface of the lips can be examined in most cases without difficulty, but in an animal of uncertain temper it is always a wise precaution to first put on an ordinary tape muzzle. Where a prolonged examination is necessary, it facilitates matters very much if the patient is placed on an operating-table in the abdominal position, and the services of some form of mouth speculum are called into requisition. The accompanying figures (Figs. 92 and 93) show different patterns, their method of use hardly needing any explanation.

A tongue depressor is very useful to hold that organ out of the way; the handle of a teaspoon or a tablespoon improvises very well for this purpose.

Gentle traction applied to two pieces of tape, one looped or tied round the upper jaw, and one round the lower, is also very effectual, the upper jaw being kept as a fixed point.

For the cat, if neither an operating-table nor a set of hobbles is at hand, the best plan is to wrap the animal's body in a roller towel or strong cloth, in such a way as to just leave the head exposed. The mouth may then be opened in one of the ways mentioned above, but if attempting to open it with the fingers alone, the best plan is to secure the upper

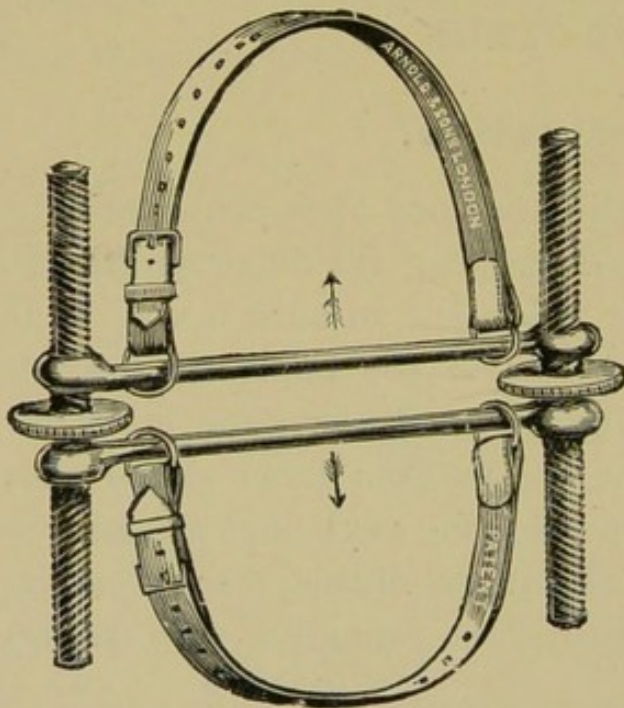


Fig. 92.—Mouth Speculum (Author's Pattern).

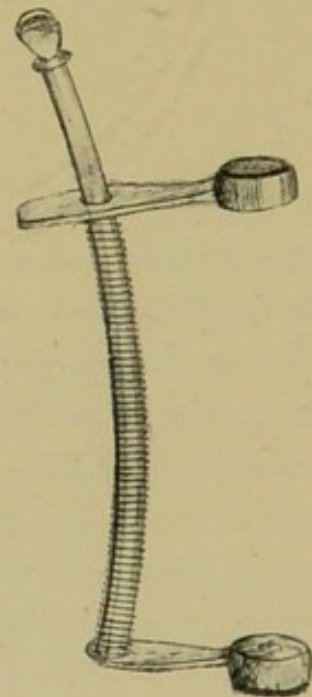


Fig. 93.—Mouth Speculum (Gray's Pattern).

jaw firmly with one hand and depress the lower jaw by pressing the ball of the thumb on the top of the lower incisor teeth or by taking hold of the hair below the symphysis of the jaw.

Removal of Foreign Bodies.

The choice of an instrument for the purpose must depend somewhat upon the foreign body itself; the most common ones met with are bones and needles. A strong pair of curved throat forceps (Fig. 97) will do in the majority of

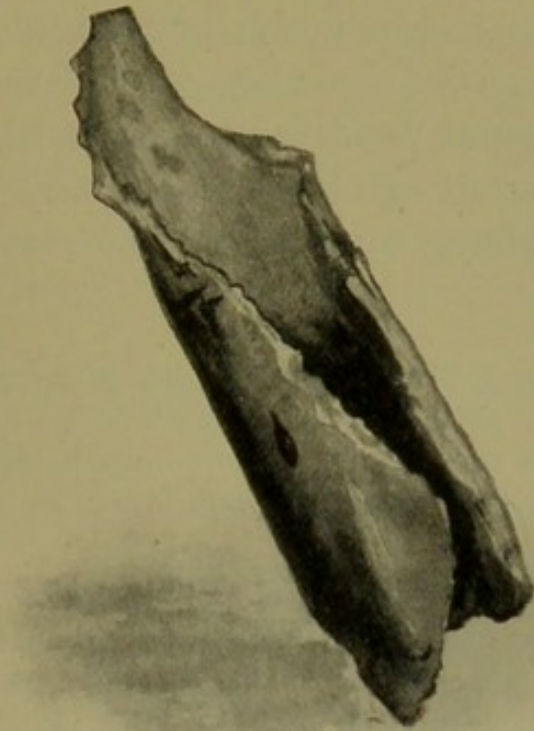


Fig. 94.—Portion of Sheep's Femur which had been longitudinally fixed for Two Days on the Molar Teeth of a Collie. (Natural size.)

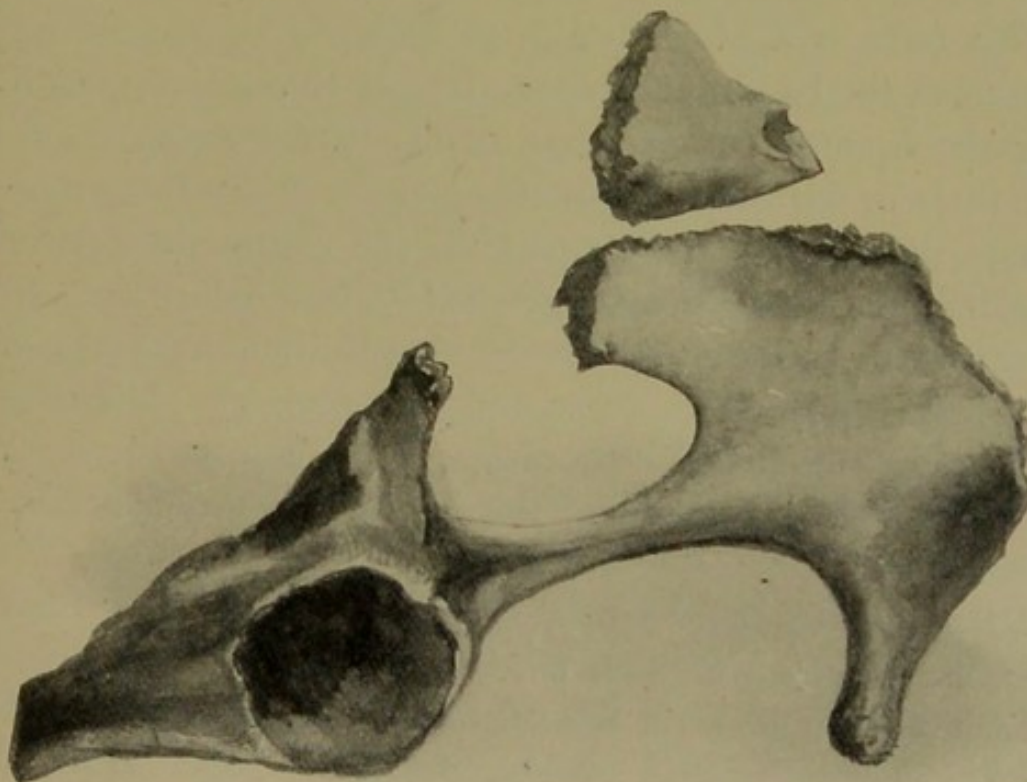


Fig. 95.—Half a Sheep's Pelvic Bone which had become fixed on Fox-terrier's Lower Jaw.

cases, being applied when the mouth is held open. Sharp pieces of bone frequently get wedged across the mouth, each end becoming inserted between the molars, and occasionally the hollow shaft of a long bone becomes fixed longitudinally on the molars, causing the mouth to be propped open (see Fig. 94).

The illustration shown in Fig. 95 is that of half the pelvis of a sheep. A fox-terrier had, in endeavouring to crack it, forced his lower jaw through the obturator foramen, and it had become so tightly wedged that a piece had to be sawn out before the animal could be released.

When removing a needle, care must always be taken to see in which direction the point has entered, as neglect of this precaution may lead to the breaking of the needle and unnecessary laceration of the mucous membrane.

Ranula.

This term is applied to a large bleb-like swelling which appears at the lateral or under surface of the tongue, usually near the frenum. It may come within a few days, or may take three or four days to become of such a size that attention is drawn to it. It is painful, and causes the patient considerable inconvenience, producing free salivation. In some cases it becomes of such size that the mouth is propped open. It is due to cystic degeneration, or perhaps to blocking, and consequent enlargement, of one of the mucous glands of the mouth. The contents of the swelling are a thick, glairy mucous fluid.

Operation.—By the aid of a speculum the mouth is fixed open, the tongue being drawn to one side or so arranged as to place the ranula in the most suitable situation for removal. The swollen sac is then punctured with a scalpel or sharp pair of scissors, the whole of the wall being dissected away as closely as possible. Great care must be exercised about

this latter point, because if any portion is left the ranula will reappear after a short interval.¹

After-treatment consists in washing out the mouth several times a day with some astringent and antiseptic collutorium, such as that of alum (5 to 10 grains to 1 ounce), chinosol (half a grain to the ounce), or boracic acid (10 grains to the ounce).

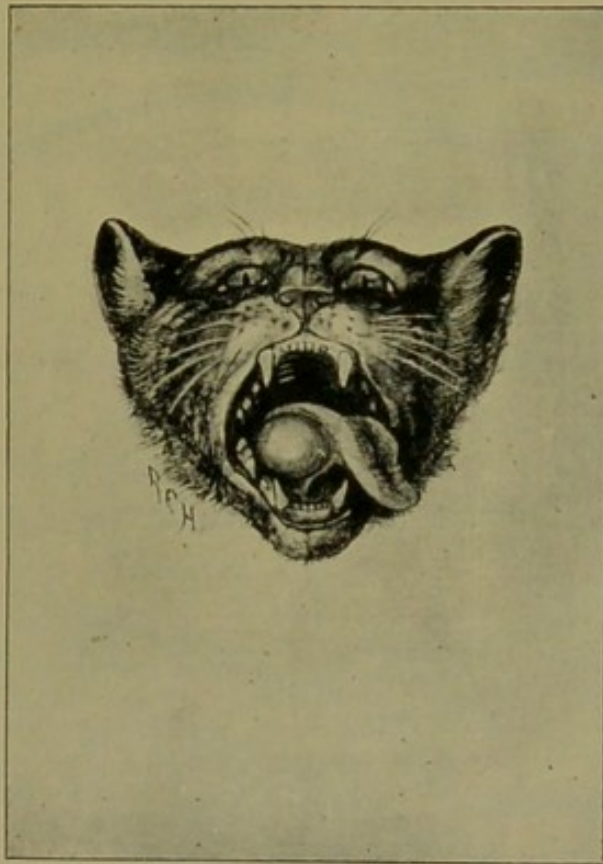


Fig. 96.—Cat with Ranula.

Scarification of the Tongue.

This treatment is advisable in some cases of glossitis, and consists in scarifying the tongue freely but not deeply in a longitudinal direction in several places. The under or lateral surfaces are usually chosen, and the operation is performed with a small gum lancet or scalpel, the blade being protected from entering too deeply by being wrapped with cotton-wool or tow.

¹ *Journal of Comparative Pathology and Therapeutics*, vol. x., p. 358 ; *Veterinary Journal*, vol. lx., p. 333 (Ridler and Hobday).

Amputation of the Tongue or a Portion of it.

This operation is only undertaken as a last resource, as a dog or cat which has lost a large piece of its tongue has difficulty both in eating and drinking. If the tip and edges are necrotic (a condition which is not infrequently seen in




Fig. 97.—Throat Forceps.

patients suffering from epizootic gastritis), these parts can be readily removed with a pair of scissors or sharp scalpel, being first seized with an ordinary pair of toothed or vulsellum forceps. If a large portion has to be removed,

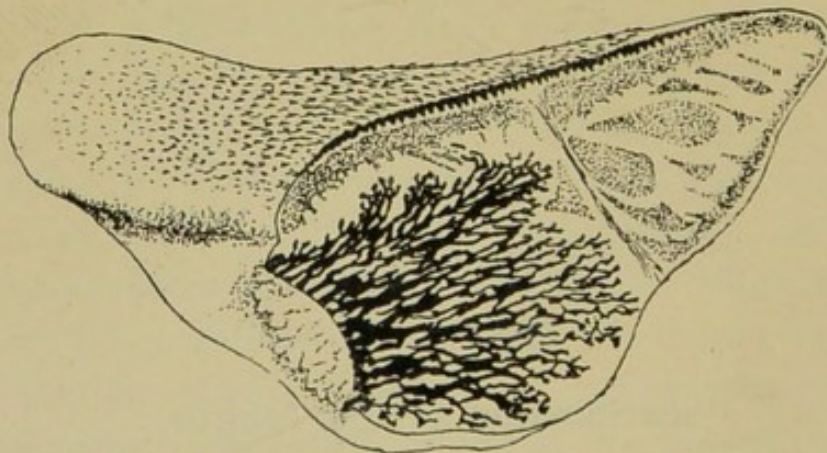


Fig. 98.—Squamous-cell Carcinoma of the Tongue of a Cat.

Transverse section through the ulcerated surface of the growth on the anterior half of the tongue. The columns of epithelial cells are shown in black.¹

chloroform should be administered. When the animal is deeply under its influence, a speculum is inserted and the tongue is drawn well forward by forceps, the mucous

¹ For this sketch I am indebted to Dr. Murray, of the Cancer Research Association.

membrane and external muscles are snipped slowly through with blunt-pointed scissors, the bloodvessels being taken up as they are severed, and a double thick silk ligature is passed through the centre of the remaining portion and tied off on either side; the parts below this are then excised. A small *écraseur*, worked very slowly, answers the same purpose, or the double ligature may be dispensed with in a small tongue, the lingual artery being secured and twisted with forceps. Care must always be taken to keep the head in a horizontal or dependent position, in order that blood may not run down the larynx and trachea, and the help of a good assistant is invaluable to watch this point.

After-treatment consists in the frequent application of some antiseptic, such as solution of permanganate of potash, chinosol, or boric acid.

As mentioned above, a dog which has lost a large portion of its tongue has considerable difficulty in drinking, and may even be unable to exist at all without artificial aid. It can readily be understood that it will be harder for the patient to obtain liquids when the head is dependent than when the mouth is raised. Thus, it would be easier to drink from a running tap than from a saucer on the floor. Fig. 99 is

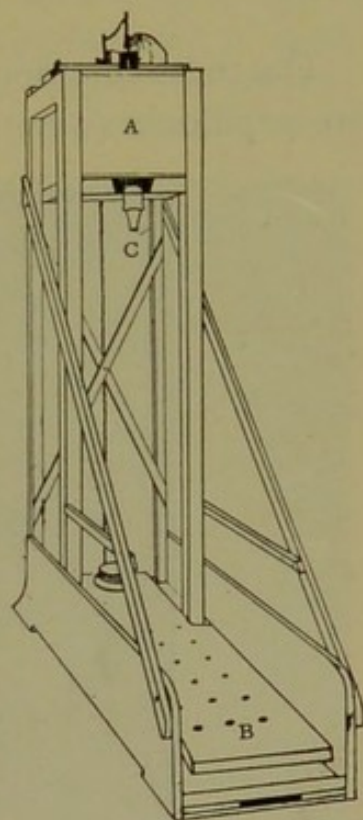


Fig. 99.—Apparatus by which a Dog which had lost Half its Tongue could drink Water.

the sketch of a very ingenious contrivance which was made by an owner for a favourite dog, half of whose tongue had necrosed and been amputated, and by which the animal was enabled to gratify his thirst whenever it wished. It consisted of a small water-tank (A) with an exit in the bottom closed by a valve. The latter was connected by a wire lever arrangement with a

platform (B). When the dog placed his weight on this platform, the valve was raised, and the water trickled down through the spout (C). The intelligent animal soon learnt to put his mouth to this, and used to utilize the apparatus whenever he wished to drink.¹

Hare-lip and Cleft Palate.

For a description of the operations for these conditions, see p. 94.

Tumours.

The most common varieties of tumours found in the mouth are papilloma (wart), carcinoma (cancer), and sarcoma.



Fig. 100.—Mouth of Terrier, smothered with Warts (Papillomata) on the Tongue and Buccal Mucous Membrane.²

Papilloma or Wart.—These are often multiple, so much so as to almost completely cover the tongue and mucous membrane of the lips (see Fig. 100). That they are contagious has been demonstrated by a series of experimental observations,³

¹ For the sketch of this apparatus and the accompanying history I am indebted to Mr. Cyril F. Jackson, Hon. Secretary to the British Bulldog Club.

² For this photograph I am indebted to Mr. Philip Vincent, M.R.C.V.S.

³ *Journal of Comparative Pathology and Therapeutics*, vol. xi., p. 341 (McFadyean and Hobday).

and it has been for a long time well known that when once they appear amongst large kennels of puppies (such as foxhounds) they spread with great rapidity. This is probably owing to the habit puppies have, when playing, of catching hold of one another's mouths. A scratch or small abrasion of the mucous membrane is necessary for infection.

The main details of the observations alluded to are as follows: On August 13, 1898, the cut surface of a wart, just excised with sterile instruments from the buccal mucous membrane of a young foxhound, in which the lining membrane of the mouth was absolutely covered with growths, was used to rub a small area of abraded mucous membrane on the right upper lip of each of three dogs—a pug and two fox-terriers. Nothing was noticed for about a month, when in each of the terriers a very small growth began to show itself.

After six weeks a minute elevation was observed on the scarified spot on the pug. In the two fox-terriers the papillomata continued to increase until about June 10, when they had attained an appearance identical with those of the natural warts in the

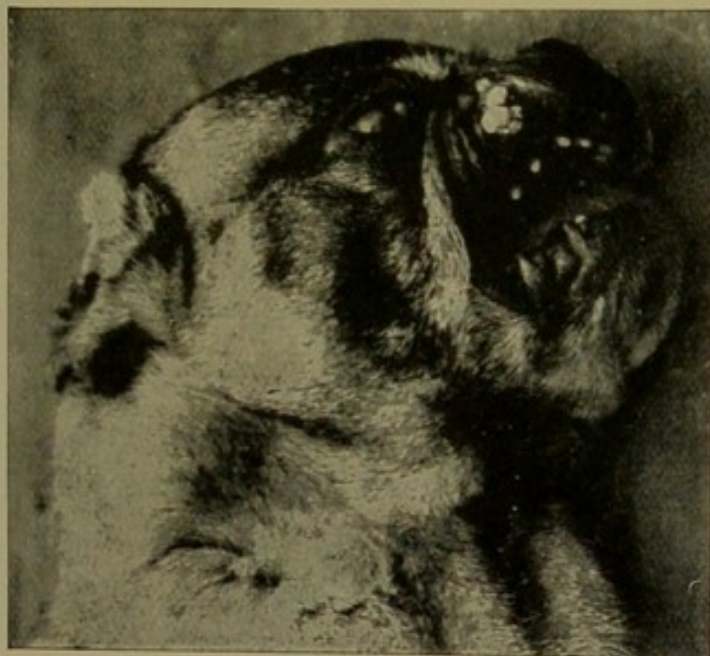

Fig. 101.—Head of Pug showing Warty Growths at Seat of Inoculation on Right Upper Lip.

mouth of the foxhound. They remained like this for about a week and then began to shrink, and by the 28th had almost entirely disappeared. The warts on the lip of the pug grew rather more slowly. On June 30, when the animal was destroyed by chloroform, they had the size and appearance shown in Fig. 101. On June 30 one of the experimental warts was snipped off with sterile scissors and gently rubbed over a small area of scarified mucous membrane on the left side of the upper lip of each of the same fox-terriers and on both sides of the upper lip of a bull-terrier. Papillomata formed at the scarified spot on each side of the bull-terrier's lip; they were perceptible on August 2, and grew until about the 26th, and by September 6 had almost entirely disappeared. In

the fox-terriers there was no result, and it was surmised that possibly the first attack had conferred some degree of immunity.

In another observation a typically natural wart was excised with sterile instruments from the tongue of a fox-terrier, and rubbed gently on a small area of abraded mucous membrane on the upper lip of a retriever pup and on the lower lip of the previously mentioned bull-terrier. On October 7 a warty growth was visible on the retriever's lip, but no growth formed on the lower lip of the previously infected bull-terrier.

In a further series a piece of the warty growth was excised from the retriever puppy, and applied gently to an abraded portion of mucous membrane on the upper lip of an adult retriever dog and of a sheep dog respectively. Six weeks later there was a perceptible growth on the lip of each dog; these passed through the usual course and finally disappeared.

These experiments conclusively proved that the common papillomata of the dog's mouth are transmissible, and they support the clinical evidence in favour of contagion being the common cause of such growths. They also show that without any treatment whatever such papillomata may disappear by a process of gradual shrinking and absorption, and they suggest the thought that the credit claimed for some methods of treatment may be undeserved. Lastly, the experiments indicate that after disappearance of a first crop of papillomata the animal is left in a measure protected against a second infection of the same kind.

A saturated solution of tannic acid applied two or three times a day for several consecutive days sometimes obviates entirely any surgical interference; medicinal means are always worth a trial, especially in those cases in which there are a large number of the tumours. Complete disappearance will sometimes follow the use of liquor arsenicalis and salicylic acid (or salicylate of soda) internally in full medicinal doses, this being given regularly and persistently for about a month or six weeks.

Operation.—In cases where only one or two warts are present, the best plan is to remove them by a silk ligature, which is applied to the base and left *in situ* for three days. The knife or scissors may be used, but there is always the danger that the blood which follows may infect a fresh spot. Where there are a large number, if drugs have failed, they must be ligatured in batches at the discretion of the operator. A small electric or benzine cautery is also very useful for those whose pedicle can be reached.

After-treatment consists merely in the application of a little antiseptic lotion (boric acid, chinosol, or permanganate of potash) several times a day.

Sarcoma or Carcinoma—*Symptoms*.—As a general rule the first signs will merely be a capricious appetite and difficulty in swallowing, the animal appearing to have a very sore throat. There is salivation, and, after the trouble has existed

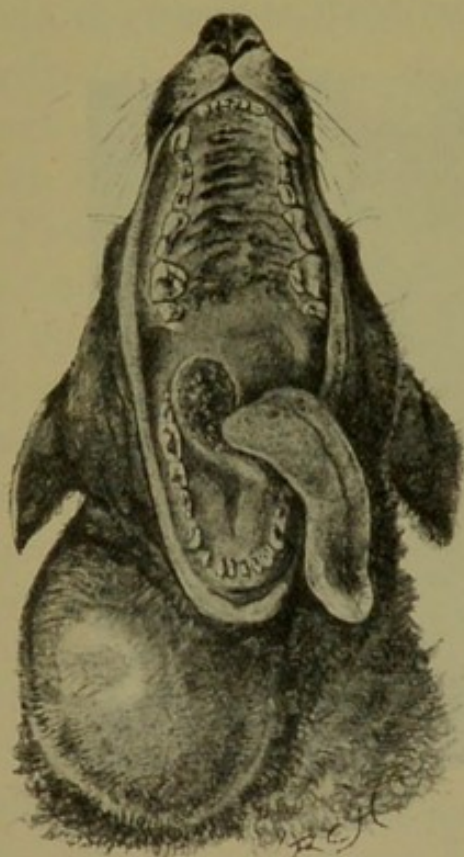

Fig. 102. — Carcinoma of the Pharynx and Cervical Glands of a Terrier.

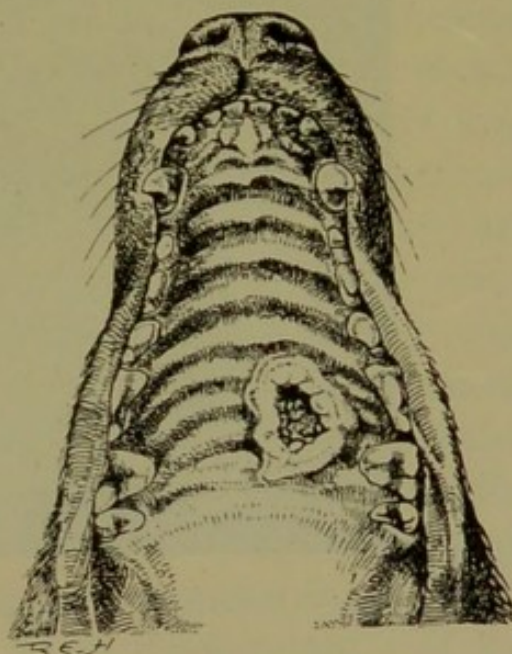


Fig. 103. — Endothelioma perforating the Palate of a Great Dane.

for a few weeks, a gradual emaciation of the body will be observed. It is not uncommon upon discovering a sore at the back of the mouth, such as is illustrated in Fig. 102, for a diagnosis to be made of an injury from a sharp bone or a piece of stick. This had been actually done in each of the cases from which Figs. 102 and 103 were sketched. All doubt on this question can be set aside if the wound has a ragged, ulcerated appearance, shows no tendency to heal after careful

application of antiseptics, and the cervical glands become enlarged. In the Great Dane patient (Fig. 103) the palate bones had become perforated.

Cancer may always be considered in animals as well as in man to be mainly a disease of old or adult age, and this fact, too, is of value as an aid to diagnosis. In a paper (illustrated by a number of sketches, photographs, and actual specimens) read before the Central Veterinary Medical Society in April,




Fig. 104.—Deformity of the Face due to Carcinoma of the Lips.

1905,¹ and the discussion which followed, practically in every case the affected patients had averaged in age from eight to fifteen years. Professor McFadyean, in an article upon 'The Occurrence of Cancer in the Lower Animals,' summarizing from a list of some forty-nine tabulated cases, also drew attention to the fact that the individuals attacked were nearly always middle aged or old.²

Treatment.—When microscopical examination, at the hands of an expert pathologist, has verified the suspicion of the

¹ *Veterinary Record*, vol. xvii., p. 694.

² *Journal of Comparative Pathology and Therapeutics*, vol. xii., p. 137.

surgeon that the tumour present in the mouth is either sarcoma or carcinoma (cancer), the sooner the poor beast is painlessly destroyed the better. They may be recognised by the malignancy of the growth, the rapidity of its spread after it has once fairly started, its fœtor when once ulceration has commenced, and an enlargement of the contiguous lymphatic glands.

In the case illustrated in Fig. 104, Professor McFadyean verified the diagnosis; the face was terribly deformed, the teeth were loose (several had disappeared), and it was only with difficulty that the patient could feed at all.

Epulis.—This name is given to a hard, smooth periosteal tumour which appears on the gums at the edge of the alveoli of the teeth. There may be only one, or the tumours may be numerous. Sometimes they are benign in character, looking almost like a fibroma, but occasionally they are malignant, and they may cause much inconvenience when feeding, especially if they are multiple. Unless causing pain, they are best left alone. If it is necessary to remove them, this can be done with a ligature or by the aid of a scalpel or scissors, the slight hæmorrhage which follows being readily stanchd by any styptic, such as adrenalin or perchloride of iron. Occasionally the root will contain bony material, and the bone forceps or saw have to be requisitioned. If, by recurring, they prove to be malignant, operative measures will only afford relief for a time.

Polypus.—This condition has been recorded in the Eustachian tube of a cat.¹ It was in a position which was quite inoperable.

Scaling and Cleaning the Teeth.

Removal of tartar from the teeth is frequently necessary in old animals, both in the dog and cat, in order to keep the breath from becoming offensive, and in some instances, when

¹ *Journal of Comparative Pathology*, vol. x., p. 178 (P. J. Howard, M.R.C.V.S.).

neglected, tartar has been known to collect in such quantity as to prevent the animal from closing its mouth, and to cause a great deal of pain.

Operation.—Scaling is performed by the aid of certain steel instruments specially designed for the purpose; there are numerous shapes for use in human dentistry, but, for all ordinary purposes, in canine practice two, or at most three, patterns, will be found sufficient (see Fig. 105). The method of application consists in securing the patient's mouth with a tape muzzle, obtaining the services of an assistant to hold

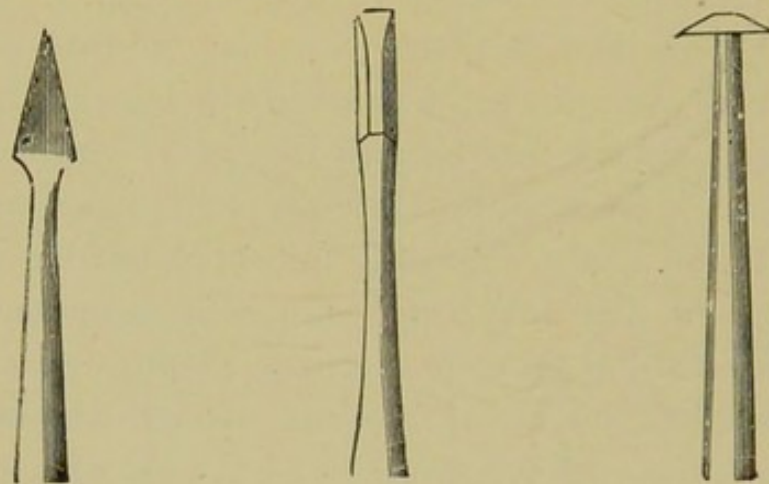


Fig. 105.—Scaling Instruments of Different Patterns.

the head, and removing the tartar around the teeth by the firm and steady application of one or other of the instruments close up under the gum, the scaler being drawn towards the crown of the tooth. When the interior is affected, a speculum must be used. As a rule the tartar shells off quite easily. The teeth are then cleansed by the application of some tooth-powder or mouth-wash on cotton-wool or on an ordinary tooth-brush.

Extraction of Teeth.

In extracting a tooth, care must always be taken to get a firm grip as far up the fang as possible, pushing the points of the forceps well under the gum into the alveolar cavity. The offending organ is then loosened in its socket

by a few lateral movements, and withdrawn by being pulled in a direction which is continuous with the fang or fangs. If pulled in a direction out of this straight line, unless the tooth is very loose, the crown is apt to be broken off. Canines are probably the most difficult to extract, and milk-teeth always require very delicate handling, or they will break off and a portion be left in the gum. A mouth speculum may or may not have to be used, depending upon the position and condition of the tooth to be extracted.

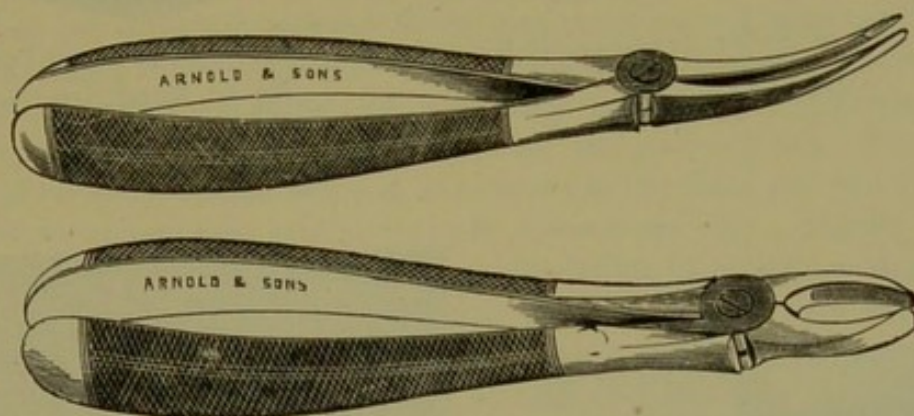


Fig. 106.—Different Patterns of Tooth Forceps.

When a general anæsthetic is administered, care must be taken that neither blood nor any other foreign body finds its way down the trachea.

Insertion of False Teeth.

This has been twice successfully attempted.¹

The first subject was an aged Schipperke (see Fig. 109), whose teeth had almost all disappeared. The only remaining ones were four canines, the four carnassial molars, and a few very loose incisors. The latter were extracted, and impressions taken of the mouth. A set of false teeth was made, and fitted in with springs and wires in the same way as in human dentistry. Most of this had to be done under chloroform, as the patient was very intractable.

Twenty-four teeth only were used (six incisors, six molars and pre-molars in each jaw), it not being thought worth while to restore the small

¹ *Journal of Comparative Pathology and Therapeutics*, vol. x., pp. 294 and 362 (Mosely and Hobday).




Fig. 107.—Set of False Teeth made for an Aged Collie.

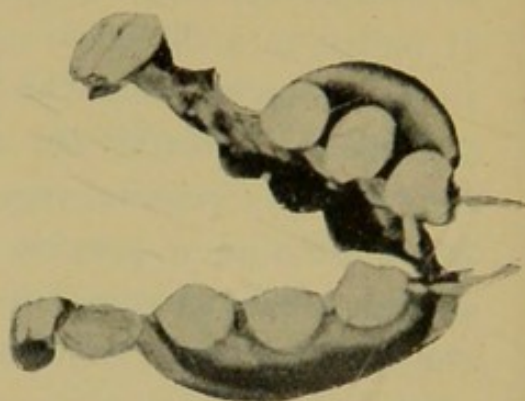


Fig. 108.—Set of False Teeth made for an Aged Schipperke.



Fig. 109.—An Aged Schipperke Dog with Set of False Teeth *in situ*.

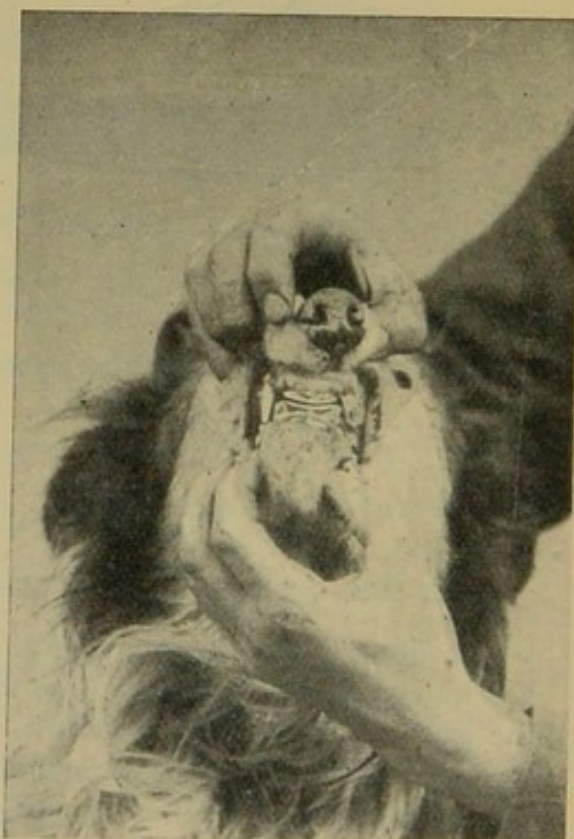

Fig. 110.—An Aged Collie whose Loss of Incisors was satisfactorily replaced with Gold by American Bridge Work.

molars at the back of the mouth. They were ground down to the proper size and shape from the smallest human incisors made of Ash's porcelain. The cutting edges were protected by thin platinum-foil, upon which gold solder was fused, as this gave an efficient edge and considerably lessened the risk of breakage of the porcelain.

The animal tore the meat off a mutton chop, and crunched the upper portion of the bone, very shortly after they had been put in, whereas before this it had taken nothing but liquid or finely-cut food. For the first few days they caused discomfort, much in the same way as is experienced by the human subject when commencing to wear a set of false teeth, and the animal on numerous occasions successfully removed them with his paws. They were therefore firmly wired in, but after a week or ten days they settled down into position, and, after some subsequent slight alterations, were worn regularly for about eighteen months, being removed each night, cleansed, and replaced the following day. The dog improved in coat and condition, and got quite fat. Unluckily, he was stolen, the teeth being in the mouth at the time, and lost sight of.

The second patient was a very old collie from whose mouth all the incisors had disappeared, the canines still being firm and good, and all the molars, with one exception, being present. Plates were made and the missing teeth replaced, but owing to the length of the mouth and some peculiarities of the molars it was difficult to make them fit in so firmly that the dog could not get them out with his paw. The plate therefore was abandoned, and American bridge work substituted, a strong bar of gold being placed between the canines on each jaw to take the place of the missing incisors. This was riveted in each case to the canine, and thus held firmly in position. The result was an unqualified success, and the patient improved wonderfully in condition afterwards. Previous to the insertion of the 'bridge,' the gums had appeared very sore, and on several occasions the dog was seen to give up the task of trying to eat dry biscuit or bones. In fact, for some time previously his owner had been administering only soft food on this account. With the gold substitute covering the gums this difficulty did not exist, and both bones and dry biscuit were attacked with eagerness.

Pus in the Antrum.

For this the upper fourth premolar is extracted (for details see p. 97).

CHAPTER XII

THE THROAT AND NECK

Choking.

UNFORTUNATELY, it is no uncommon thing for the surgeon to be called in to a dog or cat whose greediness has resulted

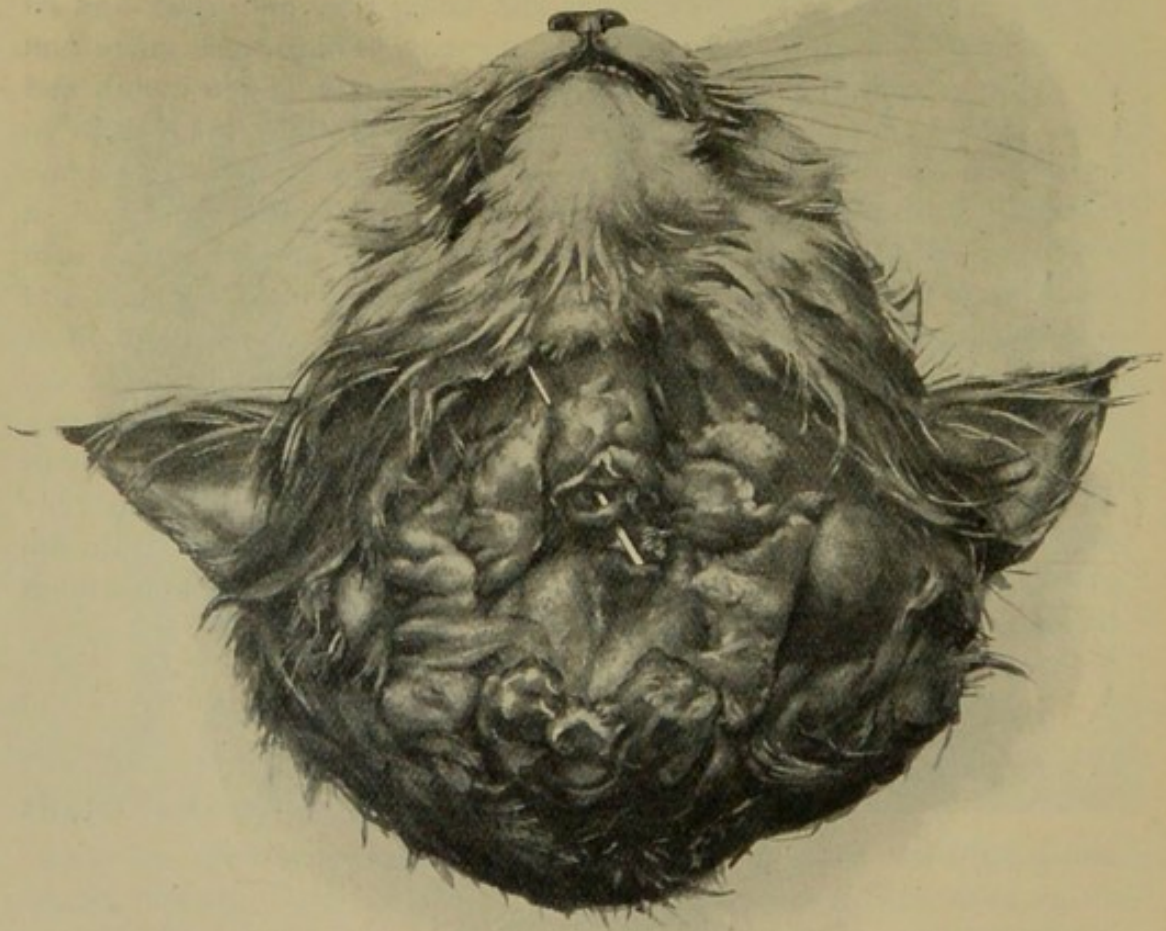


Fig. 111.—A Kitten's Larynx transfixed by a Needle.

in a fit of choking. The most common foreign bodies are bones, needles, and pieces of wood. If external manipulation will not bring about the desired result, and the foreign body cannot be moved one way or the other, a probang must be passed. The gulping actions of the patient and the evident distress, with return of food down the nostrils when attempting to swallow, are the chief symptoms manifest.

Fig. 111 is a sketch made from a kitten. A needle had become transfixed across the larynx. The patient was continually gulping, and the probang was passed several times without giving relief. Eventually the animal died, and the needle was discovered on *post-mortem* examination.

Fig. 112 shows a case of carcinoma of the œsophagus, the patient being a cat eight years old, and observed by the owner to have difficulty in swallowing.

Knowing the frequency with which these animals get a foreign body in the throat and œsophagus, a probang was passed. This could distinctly be felt to pass over a fixed and hardened body in the gullet, both when going down and when being withdrawn. A growth of some kind was diagnosed, and, as the owner did not wish for an operation, the patient was painlessly destroyed. The *post-mortem* examination revealed the condition of things illustrated in Fig. 112, the specimen being sent to Drs. Bashford and Murray, of the Imperial Cancer Research Fund, and discovered, upon microscopical examination, to be true epithelioma of the squamous-celled variety.

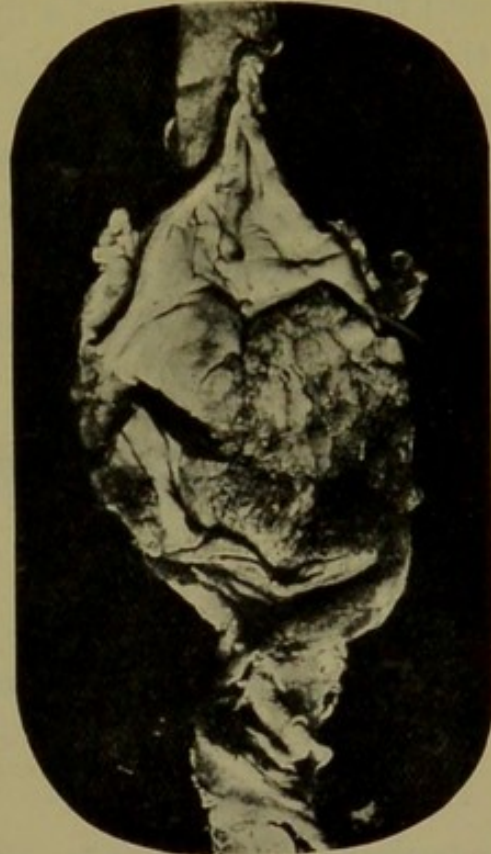

Fig. 112—Carcinoma of the
Œsophagus in a Cat.¹

¹ Proceedings of the Central Veterinary Medical Society, *Veterinary Record*, March, 1905.

Passing the Probang.

A probang is passed whenever a foreign body is suspected in the throat or œsophagus out of reach of the forceps. The mouth is fixed open with a speculum (see Fig. 49), whilst the probang, after being carefully lubricated and the stilette twisted a little so as to compress and stiffen the horsehair portion, is passed lightly and carefully down the œsophagus, care being taken that it does not enter the trachea and so cause asphyxia. If the foreign body is a large one, such as a piece of bone or gristle, gentle and continuous pressure must be applied. On no account must undue force be exerted, or laceration and rupture of the

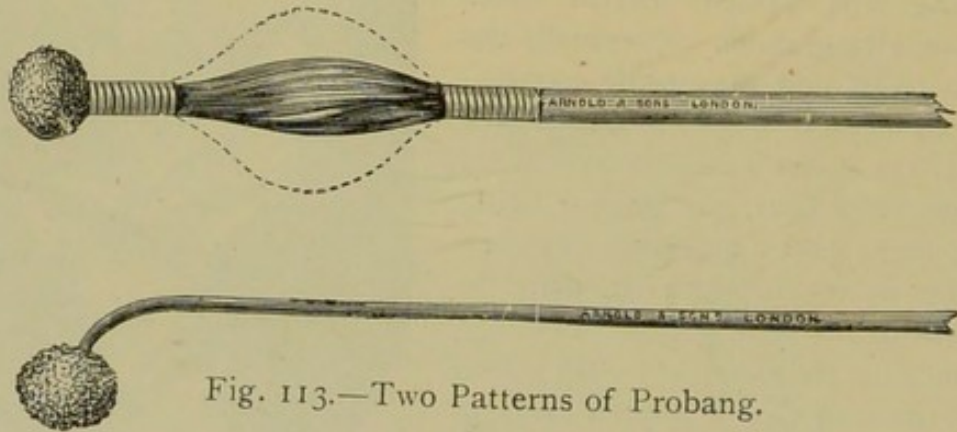


Fig. 113.—Two Patterns of Probang.

œsophagus may result. This unfortunate incident may already have occurred from constant pressure or friction of the foreign body before the patient is brought for treatment, the probang meeting with no opposition, and passing through the wound in the œsophagus into the chest or surrounding tissues (see Fig. 114). If the obstruction is a small one, it may either be forced onwards or withdrawn with the probang. Needles and fish-bones are often removed in this latter way, becoming fixed either in the sponge at the extremity or in the horsehair brush portion.

Before being withdrawn, the handle of the stilette is pulled upwards out of its socket, and, if thought necessary to stiffen it, slightly twisted. It is then taken out and examined, or it

may be passed gently up and down the œsophagus for a few times. Probangs are made of different sizes, and especial care must be taken to use a sufficiently small one, as otherwise the œsophagus is apt to become injured when violent pressure is put upon it. In inserting it, too, there is occasionally difficulty in guiding it past the larynx.

Œsophagotomy.

When a foreign body becomes so firmly lodged in the œsophagus that it cannot be moved by forceps or probang, the œsophagus must be incised. If this is not done, ulceration and rupture may take place, or the foreign body may cause dilatation and form a pouch for itself, the result usually being great pain, emaciation, and ultimately death. The most common seats at which obstructions occur are just before the gullet passes into the thorax, and in the thoracic portion just before the œsophagus passes through the diaphragm. In the latter case it is sometimes necessary to perform gastrotomy (see p. 177), and, by the aid of a pair of thin forceps passed through the cardiac orifice of the stomach, to reach the foreign body from behind.

In one case the author removed the foreign body (a large, irregularly-shaped piece of gristle which could not be reached from above) from a fox-terrier bitch, seven months old, which had been in great pain for some days, and was very thin and weak. The probang could distinctly locate the obstruction, and, as the latter could not be felt at all by digital examination of the outside of the neck or chest, it was plain that whatever was there was fixed in the thorax between the first two ribs (through which it had passed) and the foramen sinistrum of the diaphragm, through which it could not pass.

Unluckily, considerable ulceration had already taken place, and whilst withdrawing the piece of gristle, rupture of the aorta took place. Death speedily ensued, a *post-mortem* examination revealing intense inflammation and extensive ulceration of the œsophagus for fully an inch above the cardiac orifice. (*Journal of Comparative Pathology and Therapeutics*, vol. xii., p. 262.)

In the case illustrated by Fig. 114, and reported by Mr. H. G. Simpson

to the *Veterinary Record* (vol. xv., p. 265), the patient, an Aberdeen terrier, was admitted to hospital with symptoms of choking. A probang

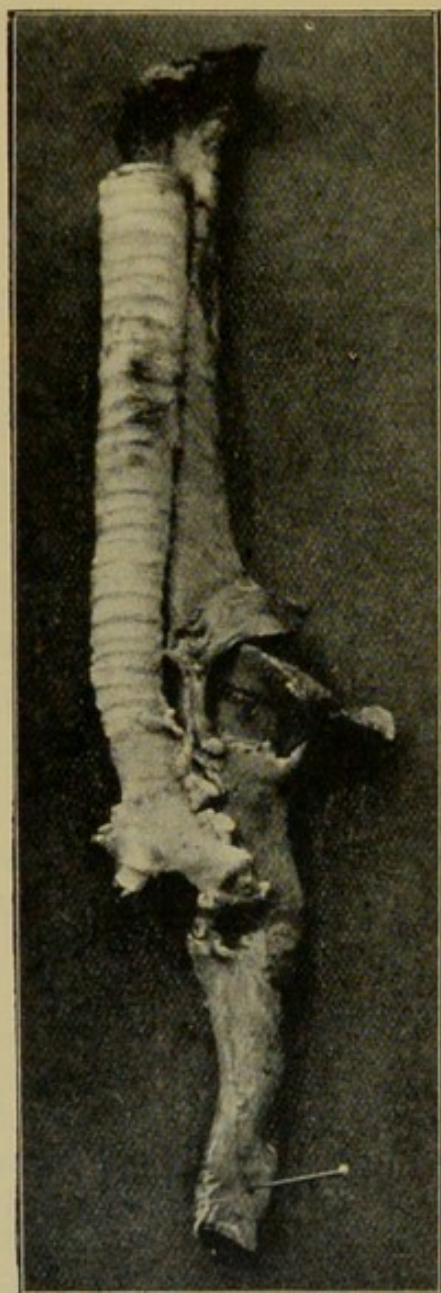


Fig. 114.—A Lacerated Wound in the Œsophagus caused by the Continued Presence of a Foreign Body.¹

was passed without meeting with any apparent obstruction, and a portion of some medicine which was administered was retained. The animal, however, suffered great pain, and died about twenty-four hours later. *Post-mortem* examination revealed a jagged piece of bone, which had ulcerated through the Œsophagus in that portion which is contained within the thorax. The probang had evidently passed through this hole directly into the chest, and this would account for the fact that it met with no opposition on its passage down.

Operation.—Place the patient on the operating-table in the dorsal position, with the neck well extended so as to expose the throat. Anæsthetize with some local anæsthetic (cocaine or ethyl chloride answers admirably), and incise the skin directly over the obstruction well to the left side. Apply pressure forceps to allay hæmorrhage, push aside any vessels in the vicinity, and expose the Œsophagus. This organ is then incised longitudinally by a clean, bold cut, and the foreign body removed with forceps. At this stage vomiting sometimes occurs.

The wound and surrounding parts are then thoroughly cleansed and disinfected, and the Œsophagus is sutured through all the coats at the same time,

¹ For this photograph I am indebted to the *Veterinary Record*.

the muscles and skin being then closed separately, and the whole covered with some antiseptic.

After-treatment consists in that usually applied to a wound (see p. 50), whilst particular attention is paid to diet. Milk or soups containing small quantities of some non-irritant antiseptic, such as boric acid or dilute chinosol, may be given during the first three or four days, or rectal feeding may be resorted to entirely. When commencing again with solid food, this should be cut up very small and given as




Fig. 115.—Two Patterns of Tracheotomy-tube.

slowly as possible. The bad sequelæ to be feared are tardiness of healing, the formation of an abscess, and ultimate formation of a stricture or fistula; but on the whole, if antiseptic measures are rigorously attended to, reports show that the results are very satisfactory.¹

Tracheotomy.

This operation is performed to relieve asphyxia caused by acute laryngitis or pharyngitis, by the presence of some foreign body in the pharynx or larynx or around the neck

¹ *Journal of Comparative Pathology and Therapeutics*, vol. x., p. 358 ; *Veterinary Record*, vol. xiv., p. 262.

(see Fig. 117), and in some cases if dangerous symptoms become manifested during the administration of some general anæsthetic or during the catarrhal stages of distemper or some other disease.

The prognosis is usually good, particularly in cases where the tube is only to be worn for a short time.




Fig. 116.—Collie Pup with Tracheotomy-tube *in situ*.¹

Operation.—The patient is placed in the dorsal position, with the head well thrown back, and the skin of the neck is made as tense as possible. After the usual antiseptic precautions an incision, is made in the upper third of the neck about an inch below the larynx, at a spot where the trachea can be felt most superficially. The latter is picked up with a

¹ For this photograph I am indebted to Mr. F. C. Gillard, M.R.C.V.S.

sharp curved hook or bent needle and thread, and an elliptical or circular piece excised to make a hole sufficiently large for the insertion of the tube. The tube—which may be made of silver-plated metal, aluminium, celluloid, or vulcanite—is then placed in the trachea and fixed in position.

For temporary purposes a piece of bent glass tubing, held in position by tapes tied around the patient's neck, improvises very well.¹

The subject of the illustration (Fig. 116) was a collie pup, apparently dying from asphyxia owing to the presence of thick mucus in the nostrils; and, in fact, the animal was said by the owner to be already dead. The tube was hurriedly inserted, artificial respiration was applied, and restoratives were administered, the patient making an excellent recovery. The tube was worn only for a few days.

Foreign Bodies around the Neck.

It is by no means uncommon for the practitioner to be consulted with reference to a curiously regular and continuous wound round the neck. The animal may be showing pain, and trying to rend the part with its paws, or this stage may have passed off. In extreme cases the respiration may be distressed. Numerous instances have been met with in which the cause of the trouble has been an indiarubber ring or a piece of thread or twine (especially the first named), which has been slipped on the neck by children, and remained undetected until it has completely buried itself under the skin.² A rabbit-snare has on more than one occasion been known to be completely buried in the skin of a cat before the animal became sufficiently ill to attract attention.

In the case illustrated (Fig. 117), the rubber ring depicted (actual size) was completely buried except in two or three small ulcerating spots, and the pressure on the trachea had already progressed to such an extent that

¹ *Journal of Comparative Pathology and Therapeutics*, vol. ix., p. 155.

² *Ibid.*, vol. x., p. 362.

each respiration produced a whistling sound, and the dog fell over from semi-asphyxia when excited in the slightest degree. After removal of the ring the patient ultimately recovered.

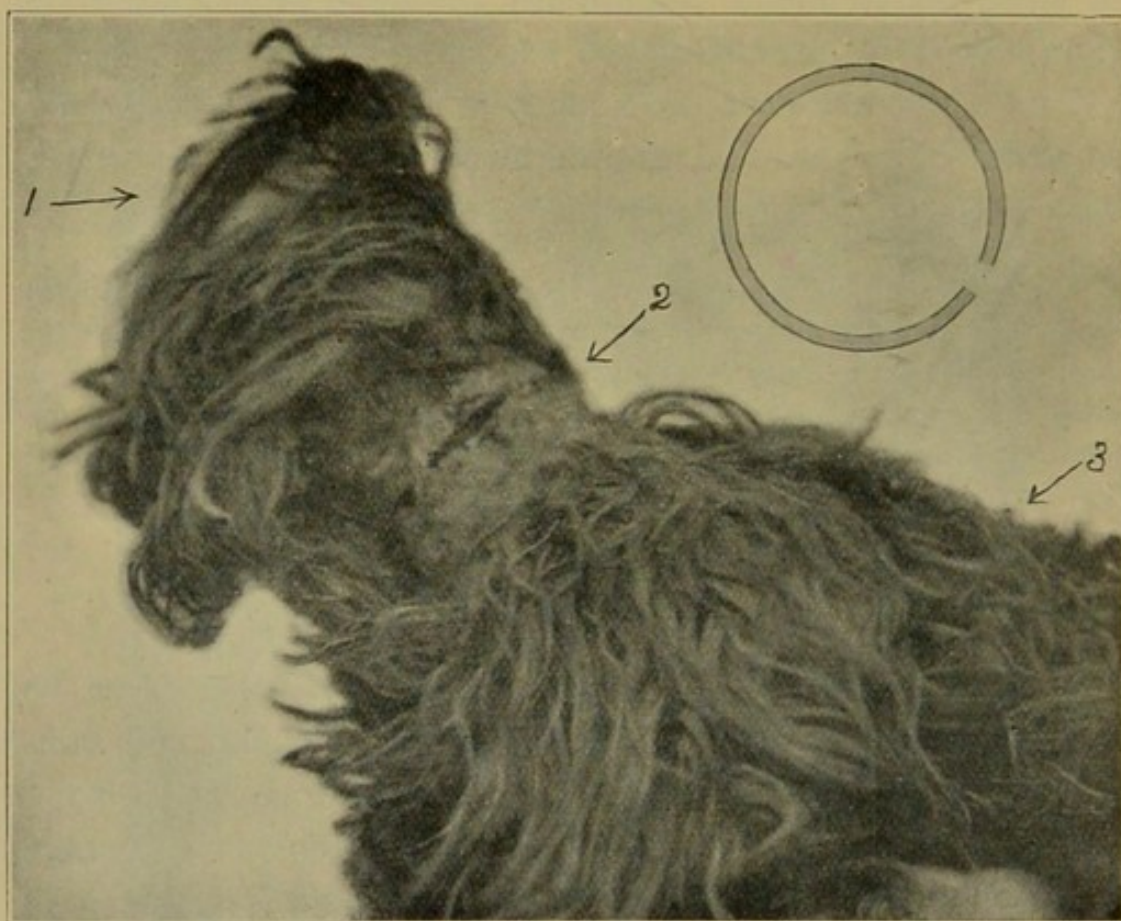


Fig. 117.—Yorkshire Terrier from the Subcutaneous Tissue of whose Neck an Indiarubber Ring (actual size shown here) was removed.¹

1, Dog's head ; 2, wound in neck caused by the ring ; 3, dog's back.

Tumours.

The chief varieties of tumour met with in this region are sarcoma, carcinoma, fibroma, myxoma.

For particulars regarding their removal, see p. 74.

¹ *Journal of Comparative Pathology and Therapeutics*, vol. xv., p. 268 (Broad and Hobday).



Fig. 118.—Pointer Bitch with Myxoma of the Neck.



Fig. 119.—Bull-terrier with Dislocated Neck.¹

¹ For this photograph I am indebted to Mr. F. Moreton-Wallis M.R.C.V.S.

Dislocation of the Neck.

This accident is, fortunately, not commonly met with. It is usually the result of a sudden wrench or of direct violence, and may cause instant death.

The patient carries its head on one side, and expresses pain when an attempt is made to straighten it. Reduction under chloroform by careful manual manipulation is the only remedy which can be advised if it is the owner's wish to have the attempt made. Warning should, however, be given that there is considerable danger attached to the procedure, especially if the dislocation has existed for some time. The sooner the attempt is made after the accident has occurred, the better the chances of success. A skiagraph is of great assistance in determining the exact extent of the lesion.

The patient whose photograph appears above was injured whilst 'ratting,' and was quite lively and well in health afterwards, and could walk all right, but when running would fall over. Reduction was attempted under chloroform, but terminated fatally.

CHAPTER XIII

THE THORACIC AND ABDOMINAL WALLS

Accidental Injuries involving the Thorax.

CONTUSIONS and punctured wounds of the thoracic wall are frequently met with in the dog and cat, being caused by direct violence from such things as the toe of a boot, sticks, stones, wheels of vehicles, bites of other animals, or contact with spiked railings. Fractures are not as frequent as one might expect, owing to the wonderful elasticity of the ribs in these animals.

Violent contusions cause stiffness and pain, and may give rise to a pleurisy. They are treated by hot fomentations and sedative or absorbent lotions, complications (such as abscesses, etc.) being treated as they arise.

Punctured wounds should be treated antiseptically and sutured as soon as possible, the patient being kept in a clean place and perfectly quiet. The prognosis given must always be guarded, although the result need by no means of necessity be fatal. Lacerations from vicious bites in this direction are sometimes of a terrible nature, leaving only one course open, viz., the destruction of the patient; but punctured wounds from palings may be so small as to be missed unless the skin is carefully denuded of hair before giving an opinion. Air enters the thorax (this condition being termed *pneumothorax*), and the lung on that side collapses to a more or less extent,

but the animal may live for some time after a very extensive injury, and may even ultimately recover.

A lurcher dog brought for treatment, suffering from injuries the result of a fight rather more than a quarter of an hour before, had the left shoulder almost completely torn away, the thoracic muscles being frightfully lacerated, and the heart and lungs exposed to view. The patient was perfectly conscious, but successful remedial measures were impossible, and a dose of hydrocyanic acid terminated its sufferings.

A fox-terrier dog,¹ two or three years old, had a punctured wound of the lower part of the thorax, between the fifth and sixth (or six and seventh) ribs on the right side, the result of contact with spiked palings. The lung was not collapsed, and with each inspiration came into view. The wound was cleansed thoroughly, sutured, and treated antiseptically, the patient making an excellent recovery. The skin wound measured 3 inches in length, and the wound through the thoracic muscles into the chest cavity was rather more than half an inch in length.

When pus forms in the pleural cavity the condition is termed *empyema*. Its treatment in canine and feline patients, unless localized to a slight area, is practically hopeless.

Fractured ribs are often not easily diagnosed, and that the last rib is a 'floating' rib is a point which must not be lost sight of, as its unattached extremity has frequently been mistaken for a fracture. The fracture can only be detected by the pain exhibited upon manual examination, or by sounds of crepitus, and is suspected by the history given and the intense disinclination to move exhibited by the patient. Respiration, too, may be hurried and painful.

Treatment consists in the tight application of a sheet of cotton-wool and a rolled bandage around the ribs, in order to afford them as much rest as possible, and to keep them in position. This should be allowed to stay on for a fortnight or three weeks, the patient being kept quiet and dieted sparingly and frequently on food which does not distend the stomach, which is laxative in character.

¹ *Journal of Comparative Pathology and Therapeutics*, vol. ix., p. 153.

Paracentesis Thoracis (Tapping the Chest).

The accumulation of fluid in the chest can usually be traced as a sequel to an attack of pleurisy, although in many cases no acute symptoms of the disease have been observed by the owner. It is equally commonly met with in the dog and cat.

Symptoms.—The patient is noticed to be dull, capricious in appetite, and to have lately become very much emaciated; exercise or other exertion causes distress and great lassitude, the respiration being distinctly laboured, and a line from the last rib diagonally along the tucked-up flank (the so-called 'pleuritic ridge') is well seen in short-haired dogs. The temperature is not usually high, and may even be normal or sub-normal.

Occasionally the appetite will remain ravenous even until a very late stage in the disease, and death may occur suddenly without any preliminary warning. The operation of exploring the chest is done to verify the diagnosis of fluid, and effect its removal when found to be present.

Operation.—Unless absolutely necessary, it is not advisable to fix the patient before performing this operation, but merely to have the animal quietly held in the standing position. Any pressure on the throat or chest is dangerous, and death is very apt to ensue suddenly from asphyxia if the patient struggles or falls heavily to the ground. Carefully shave the hair from and disinfect (see p. 2) a spot about an inch above and behind the point of the elbow on the right side; a fine trocar and cannula, which have been boiled, are introduced subcutaneously for a short distance, and the point turned in between two of the ribs (usually the sixth and seventh or seventh and eighth; see Fig. 122). The trocar is then withdrawn and the cannula inserted as far as necessary, the fluid contents of the chest being allowed to escape slowly. Any material blocking the end of the cannula and retarding the

flow must be removed by the careful reintroduction of the trocar or a sterilized blunt probe.

The left side may or may not, at the discretion of the operator, be punctured in the same way. On this side, when choosing the site of puncture, the portion of chest wall immediately over the heart-beat must be avoided, the trocar being inserted very cautiously just through the pleura in a slanting direction, and then withdrawn, the rest of the puncture being made with the blunt cannula.

The author has seen one of the heart ventricles accidentally punctured, the blood spurting out with each heart-beat. The patient was kept under close observation afterwards for a week, and appeared to suffer no inconvenience.




Fig. 120.—Trocars and Cannulae : Various Sizes (nested).

Symptoms of collapse must be watched for, and the amount of fluid withdrawn left entirely to the discretion of the operator. The author's opinion is that as much as possible should be withdrawn unless signs of syncope appear, as it is practically impossible to entirely empty the dog's chest, on account of its shape.

Solution of iodine, chinosol, adrenalin chloride, or some antiseptic may, or may not, be injected, after which the cannula is carefully and slowly withdrawn.

The seat of puncture is dried with aseptic cotton-wool, and covered with iodoform (or orthoform) and collodion.

Of these, adrenalin chloride is the one with which the most favourable results have been recorded. It was first advocated in the treatment of erosive effusions by Dr. Barr, of Liverpool, in 1903, and Drs. Plant and

Steele have confirmed its value in human patients (*British Medical Journal*, July 15, 1905). Reading of the recoveries obtained in human practice, the author was induced to try it in veterinary patients, the result being to confirm its beneficial effects. The method of using is to withdraw as much of the fluid as possible, and inject from half a drachm to a drachm of adrenalin chloride (1 in 1,000), diluted with from two drachms to two ounces of sterilized water, before the cannula is withdrawn. The wound is sealed with collodion, and the exterior of the chest or abdominal wall is massaged to spread the fluid about as much as possible. It is supposed that the beneficial results attained are due to the property which adrenalin chloride possesses, when added to the serous exudation, of causing rapid coagulation, with immediate formation of flakes or bands of lymph.

Prognosis.—If done with antiseptic precautions, exploration of the chest with a fine trocar and cannula may be resorted to again and again without fear.

Although cases do occasionally receive permanent benefit,¹ the prognosis must always be guarded, as the relief given may only be temporary, and very often more fluid is formed and has to be removed within a few weeks. Potassium iodide administered internally is said to have a beneficial effect in preventing the re-formation of fluid, and in aiding the absorption of any that may be left, quinine and strychnine being also recommended to give tone to the system; but cases of complete recovery are few and far between. Life may certainly be prolonged for some months by repeated tapping, and if recovery does take place, the patient should be carefully looked after for a long time.

Tumours of the Chest Wall.

The chest wall, in common with other parts of the body surfaces, is apt to be the site of tumour growths, and at times these grow to enormous size, as shown in Figs. 47 and 122.

The patient (Fig. 121) was an adult fox-terrier, male, with a huge tumour hanging from a little to the right of the middle line in the pectoral region. The surface was bosselated and almost warty in appearance; contact with the ground had caused a few suppurating sores, but other-

¹ *Veterinary Journal*, November, 1905 (R. Lewis Green, M.R.C.V.S.).

wise the external surface was intact, and the dog did not seem in pain. Chloroform was administered, and the growth, when excised, weighed about two and a half pounds.¹

Treatment is as already described (p. 74).

Paracentesis Abdominis (Tapping the Abdomen).

The operation is performed to remove fluid from the abdominal cavity. This condition is most commonly met

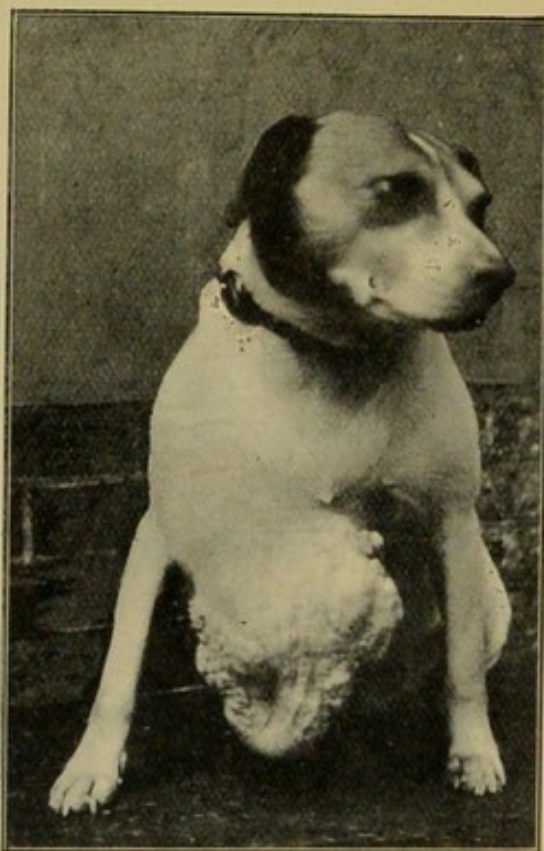

Fig. 121.—Tumour (weighing 2½ pounds) attached to the Sternum.

with in old dogs (although this is by no means a constant rule), and is generally associated with some disease of the peritoneum or, more frequently, cirrhosis of the liver and kidneys. Sarcoma and other tumours of the liver are sometimes seen in dropsical patients.

Operation.—The best situation to choose for this operation is the linea alba, or as close to it as possible, an inch or so

¹ *Veterinary Journal*, March, 1905 (R. G. Haskell, M.R.C.V.S.).

behind the umbilicus. The patient is fixed on its side, and after the removal of the hair and thorough disinfection of the part a small trocar and cannula are introduced subcutaneously for about half an inch, and turned cautiously into the abdomen; the stilette is then immediately withdrawn. Care must be taken with the abdominal wall, so as not to injure any of the abdominal organs. The method of procedure

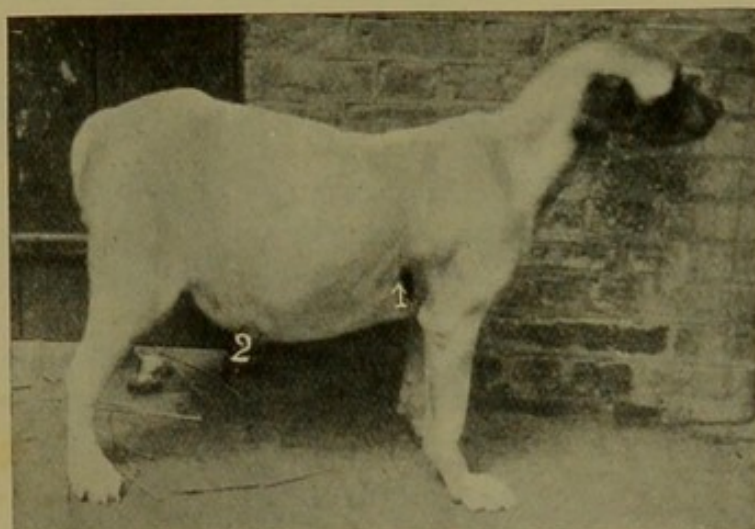


Fig. 122.—Cross-bred Mastiff with Dropsy of the Abdomen (Ascites).

1, Site of paracentesis thoracis operation; 2, site of paracentesis abdominis operation.

afterwards is the same as already described in the preceding paragraph (paracentesis thoracis), the maximum amount of adrenalin being injected; very large quantities are sometimes removed.¹

The subject of the illustration (Fig. 122) was a mongrel mastiff, five and a half years old, with a history that the owner had observed a gradual increase in the size of the abdomen during the past four months. On June 2, 1899, paracentesis abdominis was performed, and 5½ gallons of fluid were removed, some warm chinosol lotion being injected up the cannula afterwards. The relief afforded to the patient was immediately obvious, and no further operation was necessary for some four months, although at this period (October) there was some evidence which appeared to point to the fact that the abdomen was slowly refilling.

¹ *Journal of Comparative Pathology and Therapeutics*, vol. xii., p. 262.

Prognosis must be guarded, but the prospects are much better than in the case of removal of fluid from the chest. The life of the patient may be saved for a much longer time, and occasionally permanent benefit results, as the following cases show :

In consultation with Mr. Charles Taylor, M.R.C.V.S., a French poodle bitch, four years old, which had recently developed ascites shortly after rearing a litter of puppies, was operated upon. A large quantity of fluid was withdrawn, and the bitch was put on iodide of potassium twice a day. The fluid showed no signs of recurrence, and the patient made an excellent and permanent recovery, remaining in the same owner's possession for some time afterwards.¹

Mr. R. Gillard,² M.R.C.V.S., records a case of permanent recovery in a wire-haired fox-terrier, male, aged four years, from whose abdomen 1½ pints was removed on the first occasion, and a further quantity on a second occasion.

'F.R.C.V.S.' also reports in the *Veterinary Record* (November 12, 1904) a case of permanent recovery after withdrawal of fluid from a six-year-old fox-terrier dog.

Laparotomy.

This consists in opening the abdominal cavity either with a view to exploring³ or operating upon some of its internal organs, the removal of foreign bodies, for dystokia, or as a treatment for ascites and tubercular peritonitis.⁴ On the day preceding any major abdominal operation, the patient should be bathed and the site of incision (together with some distance around it) shaved and disinfected as directed on p. 50. No solid food should be given for about twelve hours before, although a little milk or beef-tea may be taken.

Operation.—Administer a general anæsthetic (see p. 23), with the patient in the abdominal position, and then turn the animal over on to its back, fixing it there with hobbles, the limbs being well extended. Rigidly disinfect again and incise the skin in the median line, the actual situation

¹ *Veterinary Journal*, vol. lx., p. 125.

² *Ibid.*

³ *Veterinary Record*, September, 1900.

⁴ Watson Cheyne, *British Medical Journal*, December 23, 1899.

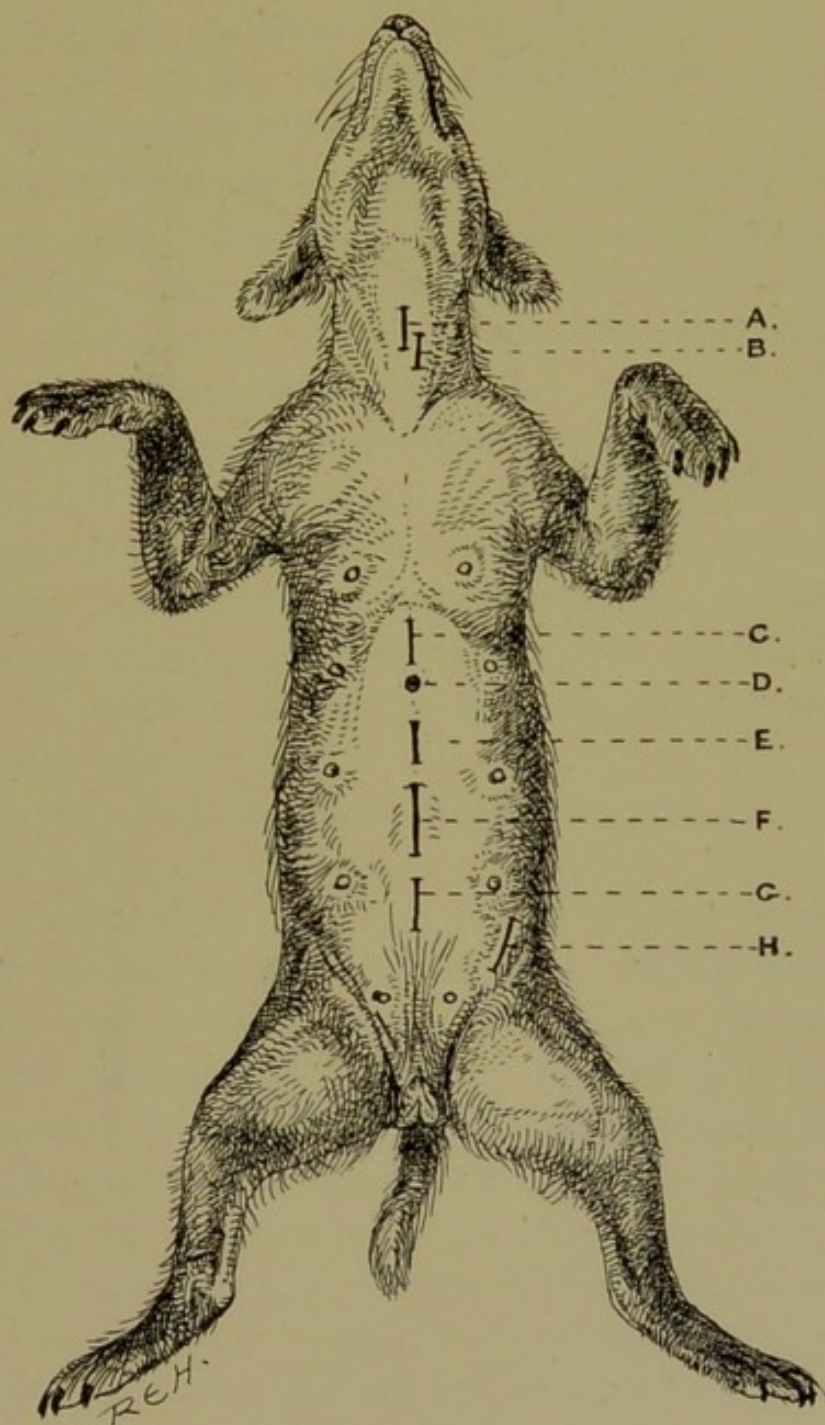



Fig. 122a.—Sites of Incision for Various Operations.

A, tracheotomy; B, œsophagotomy; C, gastrotomy; D, umbilical hernia; E, exploratory laparotomy, oöphorectomy, and ovariectomy; F, ovaro-hysterectomy and hysterotomy (Cæsarean section); G, suprapubic lithotomy (female); H, inguinal hernia.

[To face p. 158.]



chosen depending upon which organ is to be operated upon. Carefully arrest all hæmorrhage either with artery forceps or tampons of aseptic wadding, puncture the peritoneum, insert a director, and with the aid of a scalpel or scissors make an incision of the required length.

After doing whatever is necessary to the internal organs, remove all blood from the neighbourhood of the wound, suture the peritoneum with fine silk, and the muscles with silk, and the skin with silkworm gut. The peritoneum and muscles may be taken together, and some practitioners suture all three layers (peritoneum, muscles, and skin) at once, but this method cannot be as safe as if they are taken separately. A continuous suture may be used for the peritoneum, but interrupted sutures are unquestionably the best for the muscles and skin, as, if septic infection takes place, it is necessary to remove one or two for the cleansing and dressing of the wound.

The sutures should be placed close; if far apart a piece of omentum is apt to protrude, and the bowel may follow it. About a third of an inch is a fair distance. In order to complete the operation, the exterior is carefully dried with ether and aseptic wadding and covered with iodoform (or orthoform) and collodion, as already directed on p. 50.

Occasionally in large dogs, where a long incision has been made, a bandage is useful over this to give support to the edges of the wound; but in the majority of cases this is not necessary, and only forms a source of annoyance and irritation to the patient. Care must be taken to keep the animal perfectly quiet and on low diet for about ten days, and on no account to allow it to go up and down steps or to jump from a height. Neglect of these precautions is liable to lead to the reopening of the wound and escape of the intestines. Water should also be allowed sparingly, and care should be taken, above all, to avoid any food or admixture of foods which might produce vomiting. Such a

misfortune would be very likely to cause tension upon the sutures, and even rupture, protrusion of intestine, and death.

In two instances which came under the author's personal observation this accident occurred. A retriever dog, upon which laparotomy had been successfully performed five days before, was surreptitiously given a hearty meal by its owner, with the result that the abdominal sutures burst open and the intestines escaped; and in a second case a very valuable bull bitch lost her life a week after laparotomy, when all danger seemed past, by vomiting violently after an injudicious meal.

Prognosis is excellent, provided rigid attention is paid to antisepsis; and as a general rule, beyond the removal of the cutaneous sutures four or five days later, the wound requires no further attention. Hernia may result in about 4 or 5 per cent. of cases, but is generally traceable to some neglect of detail, and now and then a buried silkworm gut suture gives rise to irritation, and requires to be removed.

The median line is preferable wherever it can be conveniently used, because (1) there is less tissue to cut through; (2) less hæmorrhage, the bloodvessels here being few and small; (3) if infection takes place and pus collects in the abdomen, it has a better chance of draining away; and (4) healing is very rapid, provided that septic infection does not take place. In fact, union by first intention can generally be assured.¹

Accidental Injuries involving the Abdomen.

Small animals are continually receiving injuries to the abdomen, especially from being kicked or struck violently, from the wheels of motor-cars and other vehicles, gun accidents, and from contact with spiked palings. The last-named is apt to inflict an ugly wound, through which the omentum and intestines may make their exit. The prognosis

¹ The conclusions arrived at in this chapter are the result of an experience of more than 380 carefully recorded abdominal sections in dogs or cats, in the majority of which union of the abdominal wound was obtained by first intention.

of such cases must always be grave on account of septic dangers; but numerous instances of recovery are on record, and the owner should certainly be encouraged to make some attempt to save the patient's life. The prolapsed organ should be returned and held in place by the hand covered with a clean handkerchief or other cloth, until an assistant can adjust something to act as a temporary retention bandage. The sooner skilled professional aid is obtained, the better the chance of success. The patient should be put on the operating-table and chloroformed, the parts thoroughly washed with warm antiseptic and returned, the external orifice being sutured as described for laparotomy (see p. 159). If the gut is, or has, been exposed, a careful search should first be made for perforations, and these closed by Lembert's sutures (see p. 54). In the case of omentum, the protruding portion had better be removed altogether, as this lessens the chance of infection, and the absence of even a large piece of it will not be of vital consequence to the patient (see p. 218).

A greyhound, four years old, attempted to clear some spiked railings near Hyde Park, and became impaled on the top, staying there until released by friendly hands. When lifted down, it was seen that a bunch of intestine as large as a cocoanut had escaped. The owner, a lady, holding a handkerchief over the wound and the protruding bowel, had the patient carefully lifted into a cab, and arrived at the infirmary within ten minutes after the accident. The dog was placed on the operating-table in the dorsal position and chloroformed; the intestines, visibly soiled, were carefully washed with warm chinosol solution (1 grain to the ounce), and returned to the abdomen; the edges of the wound being similarly treated and then sutured in separate layers with silkworm gut. The patient gave very little further trouble, and made an excellent recovery.

With **gunshot wounds** of the abdomen, if extensive but not yet fatal, the patient is usually in such agony that it is better to destroy the animal as speedily as possible. If slight, it is questionable whether it is wise to interfere surgically beyond the application of antiseptic external dressings (see p. 50), rest, and the dietary prescribed on p. 160. It must be

left to the discretion of the surgeon as to whether the gut is sufficiently injured to necessitate laparotomy (see p. 158), repair of the bowel injuries (see p. 189), and surgical or antiseptic treatment of the interior.

In cases of **external violence and contusions**, without the presence of a visible wound, such immediate contingencies as the rupture of some internal organ or internal vessel must be thought of, especially when the patient appears in a state of collapse, and peritonitis is apt to ensue as a sequel. The stomach and liver are commonly ruptured. In either case it is quite a forlorn hope, especially if a lot of food has escaped into the abdomen. Laparotomy (see p. 158) should be performed without delay, and an examination made; the rupture being sought for, and if possible repaired, by sutures, all food being carefully removed and the peritoneum thoroughly irrigated with antiseptic solution. Ruptured vessels must be sought for in the same way and ligatured, all blood in the peritoneum being carefully removed with antiseptic irrigation. This is a very troublesome procedure, on account of the small space and cramped conditions in which the operator has to work; but it is possible, and occasionally will be the means of saving a valuable life.

Contusions alone cause great pain and stiffness, and may even lead to peritonitis. An animal which has been injured by being run over, even although at the time it may not seem very much hurt, should be dieted carefully and receive a little gentle laxative medicine, being kept quiet and under observation for at least three or four days.

In cases in which there is great pain, laxative and cooling medicine (such as calomel or magnesium sulphate) should be given internally, and the parts treated externally with refrigerant and sedative lotions (such as lead and opium, or arnica and spirit, etc.

If an abscess or hæmatoma forms, it must be treated as already directed (see p. 59), being lanced with particular care

to examine first for hernia, and to see that the knife does not open the abdomen.

Acute Suppurative Peritonitis.

Pus in the abdomen, when floating about freely and not encapsuled, of necessity sets up a peritonitis, and if not removed is fatal. This condition may cause death within three or four days, or the patient may live for several weeks after the operation or injury which has been its source of origin.

Symptoms.—In *acute* suppurative peritonitis the temperature rises three or four degrees, respiration is accelerated, the pulse is quick and wiry, the abdomen is tender on pressure, the eye is abnormally bright, the mucous membranes are very hot and feverish, and the animal vomits, refuses food, and is dull. Death may take place within forty-eight hours, being preceded by coldness of the surface and extremities and coma. In the *chronic* form the disease may progress unsuspected until near the finish, the patient eating food a little capriciously, but appearing normal in other ways. The thermometer is the best guide, but even that is uncertain in the dog and cat, as the least excitement and exertion will cause variations (see p. 5).

In either condition the previous history is always worth the most careful consideration.

Operation.—The only chance of escape from death lies in the removal of the purulent fluid, and the only prospect of doing this effectually lies in surgery. When the peritoneum is invaded, laparotomy should be done without delay (see p. 158), and the sooner it is done the better for the chance of success, the abdomen being carefully irrigated (not swabbed, as this removes the lining cells) with warm non-irritating antiseptic solution (such as chinosol, a grain to the ounce). Sterilized saline solution (a teaspoonful to a pint of distilled water) employed at a slightly higher temperature than that

of the body (about 105°) is also employed for the purpose, on account of its restorative effect.

Before completing the sutures, a large - sized rubber drainage-tube is left in position between the last two, the whole being covered with an antiseptic pad and bandage. Any pus collecting in this tube must be carefully sucked out with a syringe two or three times a day. This tube is removed as soon as the collection of pus has ceased, being replaced by an antiseptic 'tent' or 'plug.'

After-treatment.—Day and night attention by a skilled canine nurse, if one can be obtained. Small doses of stimu-

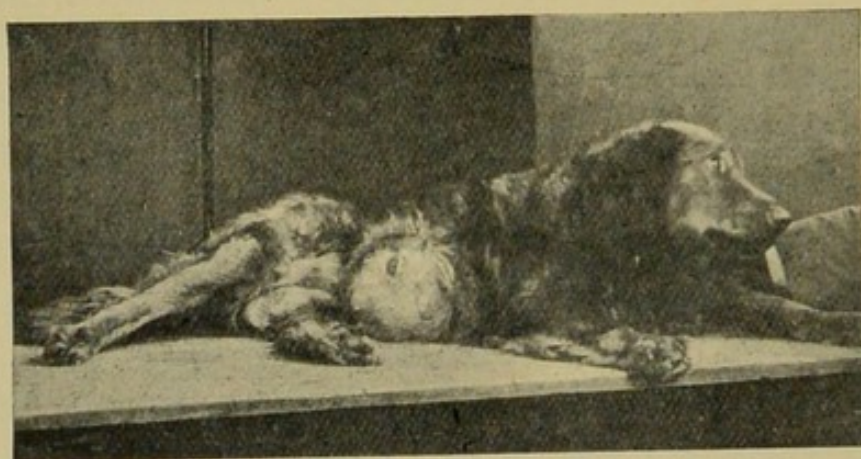


Fig. 123.—Adeno-carcinoma of the Mammary Gland.¹

lants in beef-tea, milk, Benger's Food, or other nutrients at intervals, varying from every half-hour to every four hours at discretion. Subcutaneous injections of brandy or ether, and nutrient rectal suppositories or enemas, are also valuable.

Prognosis.—This must always be very grave. As a rule with acute suppurative peritonitis death takes place before the surgical measures which have been adopted can take effect, and it is only when the purulent area is a small one at the time of its discovery that experience teaches the operator to hope for a successful issue. With a localized peritonitis

¹ For this photograph I am indebted to the Cancer Research Association.

confined to the pelvic region, or within a few inches of an operation or accidental wound, there is always more hope than with the diffused variety.

Tumours of the Abdominal Wall and Mammary Glands.

Tumours of the exterior of the abdomen are very common, especially in the region of the mammary gland, and frequently they attain an enormous size. The chief varieties are those of sarcoma or adenoma, but osteoma, chondroma, fibroma, and carcinoma are also seen; and one must not forget that in a bitch whose milk has been allowed to accumulate and




Fig. 124.—A Bitch with large Mammary Tumours.¹

remain in the mamma, indurated portions of gland, which feel very like tumour tissue, are met with.

The *Treatment* is the same as for tumours in other parts of the body (see p. 74), and one must not forget that, as a rule, mammary tumours are very muscular, so that particular attention must be paid to avoid hæmorrhage by taking up the vessels as they appear.

In making a diagnosis one must bear in mind the similarity in appearance in some cases (Figs. 146 and 147) of mammary tumours and inguinal hernia, so that an operation should not be undertaken until after a very careful examination.

¹ For this photograph I am indebted to Mr. A. S. Hodgkins.

CHAPTER XIV

THE STOMACH AND INTESTINES

Aids to Diagnosis.

IN veterinary patients there is often an especial difficulty in making an *exact* diagnosis as to the cause, etc., of stomach and bowel trouble ; unfortunately, our patients cannot so definitely reply to our queries as can the human patient to the surgeon. At the same time, there are many symptoms and signs which are unmistakable, and in animals, such as the dog and cat, which have comparatively small, thin bodies, we are frequently able to definitely locate and diagnose the nature of the offending obstruction.

A thorough and searching manual or digital examination should always be made, and the patient's symptoms and general condition taken carefully into consideration, before an operation is decided upon, together with the history prior to and during the attack, as related by the owner.

The **history** cannot always be accurately relied upon, and one should always be prepared to discount points upon which the owner is not absolutely certain, or which are related only upon conjecture. The habits of the dog, especially in relation to a propensity for picking up stones, etc., and any previous attacks in consequence, should be especially inquired into ; and in the case of a kitten the tendency to play with cords, and to swallow bits of cotton, hair, etc., must not be forgotten. Any previous attacks of a like character, the

suddenness or otherwise of the symptoms (indicating acute or chronic trouble), and the passing of intestinal parasites (especially of the round worm, *Ascaris marginata*, in puppies), all materially assist one in making a diagnosis.

The **general condition** must always be carefully considered, more especially from the point of view of the operator and the success of the operation. If the patient is already moribund, it is not fair to blame the operation for an unsuccessful result. In bowel obstruction, especially impaction from faecal matter, toxic absorption may already have taken place and gained such headway that its effect cannot be overtaken. In obstruction from any cause, the general prostration and weakness which, of necessity, takes place from pain, and inability to take or retain food, are important factors, *and the earlier surgical aid is called in (if medicinal means seem likely to be ineffectual), the better the chance of the patient.* In these days, too, thanks to Lister and Pasteur and the antiseptic methods they have introduced, the surgery of the abdomen has taken its proper place with all other major operations, and abdominal section a comparatively common operation.

The **symptoms** have particularly to be watched. Colic is more commonly present in the earlier stages and before obstruction is complete, whilst vomiting, haggard countenance, and continual straining, with no result, may indicate complete stoppage.

For the **examination** of a dog or cat suffering from obstruction of the bowels, the patient should be placed on a table or chair at a height convenient for manipulation. After the general appearance has been noted, the pulse and temperature should be taken ; if possible, before excitement has changed their character (see p. 5). Clammy mucous membranes, a quick, almost imperceptible pulse, and a temperature which is over 104·5° F. or below 99° F. are exceedingly bad signs.

The patient is then muzzled or securely held by the head,

and the abdomen palpated between the hands or fingers. This is best done in small animals by placing the left hand firmly on the spine, whilst the right one, with outstretched fingers turned upwards on one side and the thumb on the other, passes carefully along the under surface of the abdomen from before to behind in an endeavour accurately to locate and diagnose the cause of the pain and obstruction. In the larger breeds both hands must be used, one being passed along each side.

In small patients with some kinds of swallowed foreign body, the aid of the **Röntgen Rays** may be satisfactorily invoked (see pp. 173 and 357).

Preparation of the Patient.—Where circumstances will allow it, the patient, in addition to the usual preparation for an operation (see p. 1), should three or four times a day receive doses of some internal antiseptic. Of these, chinosol, carbolic acid, izal, salol, calomel, or β -naphthol are amongst those most commonly selected.

Colic.

Patients, especially canine, are frequent sufferers from abdominal pain. Cases are met with most commonly, perhaps, in puppies, but adults are by no means exempt. The causes are various, the commonest being flatulent distension of the stomach or bowel, the presence of round worms (*Ascaris marginata*) and foreign bodies, violent and irritant poisons, hernia, intussusception; and a strangulation of the gut by fibrous bands, Meckel's diverticulum, or volvulus.

Symptoms.—Sudden seizure, continual yelping which cannot be quietened, raised temperature, quickened pulse, and distended abdomen, the animal crawling away to hide itself, and laying flat on its belly on a cold surface between the spasms, but changing about from place to place to try to get relief during the seizures.

Vomiting, especially if the dog takes food (which it will

sometimes do between the fits of pain), may occur, the presence of food decidedly aggravating the pain. Eventually, if no relief is given, excessive prostration ensues, and the patient dies.

Treatment.—Medicinal agents should be resorted to first, unless a certain diagnosis has been made which makes this course to be considered useless. If worms or some foreign body be suspected in the stomach, a dose of apomorphine should be given to cause vomiting and an attempt to get rid of the cause of the irritation. Otherwise hot flannels or compresses covered with mackintosh cloths should be applied externally, and an enema, together with medicinal agents (ether, ammonia, turpentine, opium, chlorodyne, bismuth, or castor-oil, etc., depending upon what the diagnosis has been) given by the mouth. Should relief not be afforded by these within three or four hours, and the abdomen is still much distended, the stomach or intestine may be punctured (see p. 171); failing ease from this, an exploratory laparotomy (see p. 158) should certainly be done without further delay. Even if no possible cause for the colic is found, the operator need not despair of a successful issue; for in a number of cases the opening of the abdomen alone has caused relief from vomiting and violent pain,¹ and, so far as the operation itself is concerned, no great alarm need be felt if strict attention has been paid to antiseptic precautions. Peritonitis, that bugbear of old-fashioned surgery, is, comparatively speaking, a rare sequel to laparotomy performed under antiseptic precautions, even when dogs and cats are the patients.²

Five consecutive cases upon the result of which the above assertion was first made are worth briefly recording. In each patient there was more or less acute abdominal pain, the history obtainable being either none at all or else of a swallowed foreign body.

¹ *Journal of Comparative Pathology*, vol. xii., p. 259.

² *Veterinary Record*, vol. xiii., p. 142.

CASE 1.—October, 1898. Dalmatian dog, two years old, the subject of persistent vomiting for the past three weeks. The dog was very thin, and could neither retain fluids nor solids. As no drugs gave permanent relief, it was thought that there must be some foreign body present, and an exploratory laparotomy was done under chloroform. By some misfortune the animal escaped from hospital, and was ultimately found three days later at the Dogs' Home; it then ate greedily and retained any food. The wound healed by first intention, and the patient was sent home, remaining quite well until January of 1899. Between January and April several similar attacks occurred, these being temporarily relieved by doses of orthoform. In April, after an especially severe attack, the owner had the dog destroyed. *Post-mortem* examination revealed nothing to account for the symptoms.

CASE 2.—December 1, 1898. A cat, fifteen months old, had for about ten weeks suffered from occasional fits of abdominal pain and great prostration. An exploratory laparotomy revealed no visible cause, but the patient recovered well, and afterwards had no return of the symptoms.

CASE 3.—December 1, 1899. Fox-terrier, male, six years old. The owner said the animal had swallowed a meat-skewer. Being a little sceptical at the time, we treated the dog with medicines for a week, but at the end of that time, as there was great debility and partial paralysis of the hind-legs, we thought that probably the owner was right in saying that a meat-skewer had been swallowed. An exploratory laparotomy was made, but no foreign body was found. The wound healed by first intention, the sutures being removed on the third day, and the patient was sent home on December 6. Reinspection was made at intervals during the next three months, but there was no return of the symptoms.

CASE 4.—May 19, 1899. Retriever, male, nine years old, supposed to have swallowed a solid rubber ball. There was excessive abdominal pain, vomiting, no fæces had been passed for three days, and the dog seemed very weak and ill. An exploratory laparotomy revealed nothing. Until the 22nd the dog appeared very dull, but on this date suddenly brightened up and began to feed. Diet was given sparingly, and it was arranged for the owner to remove the animal home on the 29th. Unfortunately, on the 28th the owner came to see how things were progressing, and, with mistaken kindness, gave the dog a heavy meal of a food of which he was especially fond.

The result was that violent peristalsis was caused, the abdominal wound was torn open, and the intestines escaped. A dose of poison was at once given, as veterinary help was not accessible at the time.

CASE 5.—July 13, 1900. Fox-terrier, male, four years old, in acute abdominal pain for several days. Various drugs were unsuccessfully tried, and, feeling sure that some foreign body must be present, an exploratory laparotomy was performed. Nothing was discovered, but the pain ceased at once; recovery was uneventful, and the patient was

discharged from hospital on the 20th. With the exception of a buried suture abscess some months afterwards, the patient had no return of the colicky pain.

Puncture of the stomach or bowel must be done with all attention to antiseptic precautions, as already described (see pp. 2 and 158), the site of operation being shaved and disinfected, whilst the trocar and cannula is boiled. This instrument (see Fig. 120) should be of small size, an ordinary exploring needle (see Fig. 36) answering very well, and is inserted under local anæsthesia (ethyl chloride or anæsthe answer splendidly) through the skin over the most distended spot, and directly into the stomach or bowel. For the stomach, the instrument is inserted on the right side, about an inch behind the last rib, and pointed forwards very cautiously so as to avoid the liver or diaphragm. The safest plan is, as soon as the skin has been penetrated, to withdraw the point of the trocar within the cannula, and explore with the blunt end of this for the distended organ. This will yield on pressure, whereas the liver and diaphragm each offer a solid resistance. Puncture of the stomach is followed by a rush of gas when the stilette is withdrawn. The usual place chosen for bowel puncture is either high up in the flank, about midway between the last rib, the sacrum, and the lumbar vertebræ, or about an inch on one side or other of the median line. When the gas present has escaped the instrument is removed, the operator carefully pushing the skin away from him towards the abdomen as the stilette is pulled out.

Foreign Bodies in the Stomach.

Meat-skewers, hatpins, sticks, pins, needles, nails, tacks, beads, stones, corks, coins, rubber or wooden balls, etc., are swallowed by both dogs and cats, especially the former, and at times give rise to a good deal of trouble, which necessitates surgical interference.

Gastrotomy, too, is occasionally necessary for the removal

of a foreign body firmly impacted in the lower portion of the œsophagus, when it cannot be removed from above (see p. 178), and for the excision of ulcers from the stomach wall.

Skewers are not at all infrequently met with by the canine practitioner in London and large towns where the horse-flesh used for dog and cat food is sold in thin slices held together by a wooden skewer. A greedy animal will sometimes bolt the lot intact, especially if there is another dog near; and the author has removed the offending article from the region of the flank close under the thigh (showing that it must have found its way down the intestine), as well as from between the posterior ribs over the stomach.

Broken pieces of stick have frequently been removed from the stomach or œsophagus. The author has in his possession the end of a candle-rod, $5\frac{1}{2}$ inches long, removed from the œsophageal region of a St. Bernard dog, by Mr. J. Blakeway, F.R.C.V.S.¹ Sticks are usually swallowed by puppies or as the result of an accident.

Stones are often involuntarily swallowed by dogs as a result of the habit which some people have of throwing a stone for a dog to fetch. Sometimes a very large number will be taken, and the author knew of one instance in which an Aberdeen terrier had swallowed no less than 114, mostly sharp flint-stones. The animal showed an arched back, and was, as might be expected, very dull and depressed, but eventually passed them all and made an excellent recovery. In another instance a dog was seen to swallow a peculiar shaped stone on December 13, and the same stone was vomited back in the owner's presence on February 12 following.

Hatpins have been most commonly met with in kittens. P. J. Simpson recorded one $4\frac{1}{2}$ inches long (*Veterinary Record*, vol. xv., p. 409), and J. McCall also recorded one of $7\frac{1}{2}$ inches long (*Veterinary Record*),² each of which was

¹ *Veterinary Journal*, vol. lxi., p. 26.

² Vol. xiv., p. 766.

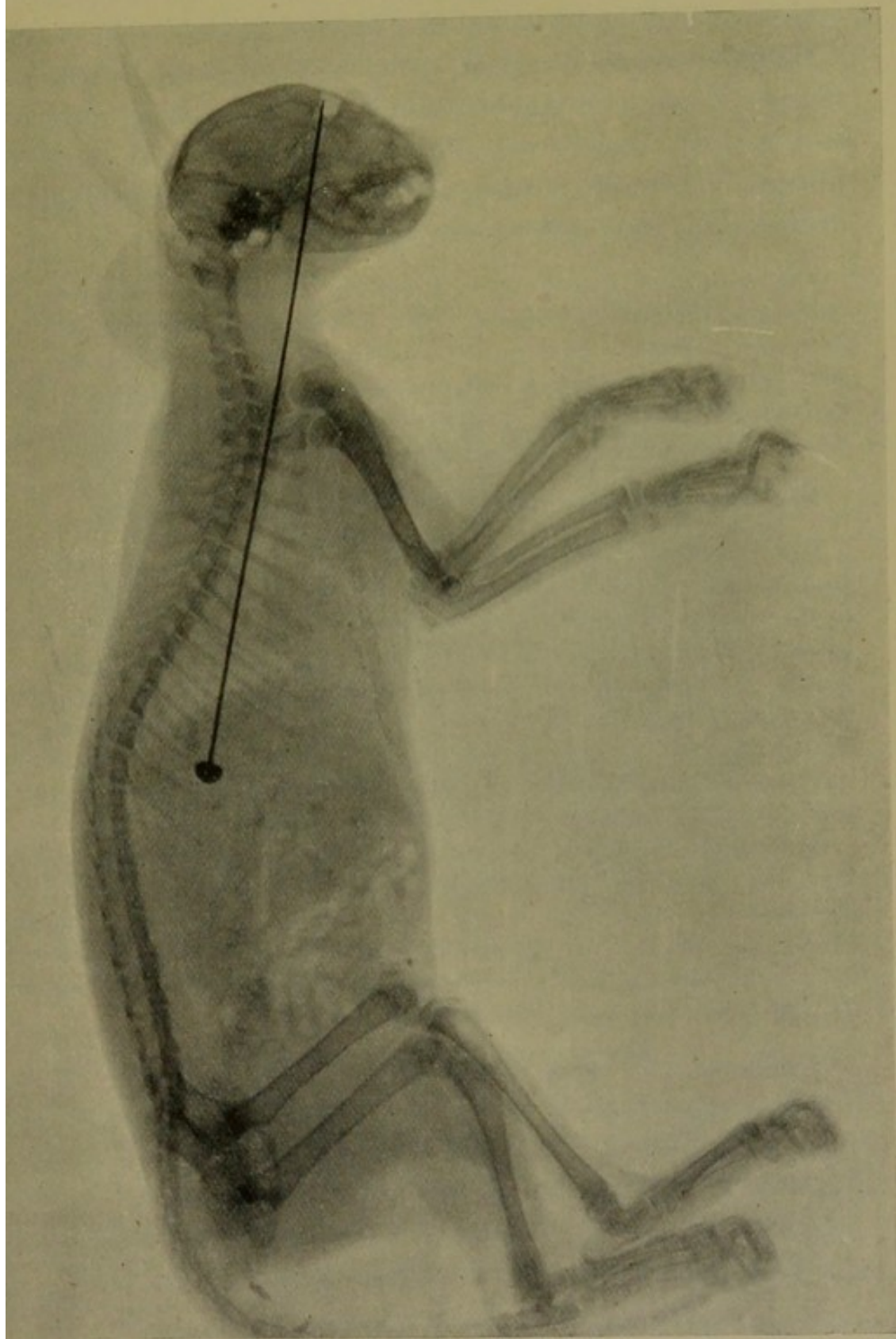


Fig. 125.—Skiagraph of a Lady's Hatpin in the Esophagus and Stomach of a Kitten.¹

¹ For this I am indebted to Mr. T. Wooff, M.R.C.V.S.

successfully removed; whilst Fig. 125 shows the skiagraph of a kitten which had swallowed a lady's hatpin 6 inches long.

Coins and such small articles are readily swallowed. Copper coins undergo corrosion in the stomach or intestine, and in time cause serious illness and death if not removed. Silver coins merely tarnish, and, unless they cause mechanical obstruction, need give rise to no alarm.

The author on one occasion found, on *post-mortem* (made for the purpose by the owner's request), a two-shilling piece which the dog had been seen to swallow five years previously. It had made a sac for itself in a portion of the stomach wall, and, beyond being tarnished, was quite undamaged; nor had it given the patient any inconvenience, the animal being fat and well when destroyed by a dose of hydrocyanic acid.

Of other foreign bodies the variety may be legion.

Mr. S. Bennett (*Veterinary Journal*, vol. lx., p. 318) has recorded a case in which a fish-hook was found in the rectum of a cat. Mr. F. Spencer has recorded an instance of the greater portion of a lamb's foot passed *per anum*, with the hair still on it (*Veterinary Record*, vol. xv., p. 409); and the author on one occasion discovered a valuable diamond collar stud which the owner had missed and suspected his dog of swallowing. The patient depicted in the photographs (Figs. 126 and 127) was operated upon by Mr. W. H. Chase, the dog having swallowed a hard composition cricket-ball when playing with some children.¹

Professor Udrischi, of Bucharest, successfully removed a lady's hairpin from the stomach of a kitten, the article having accidentally slipped down the patient's throat whilst it was being used as an improvised tongue depressor.² Mr. A. S. Hodgkins has recorded a piece of lead pipe $\frac{3}{8}$ inch thick, 2 inches long, and $1\frac{1}{2}$ ounces in weight, vomited from the stomach of a toy Yorkshire, only 7 pounds weight herself.³

Symptoms.—In many instances the patient has shown no illness whatever until, in the case of a hatpin or skewer, an abscess swelling has been observed under the skin. The most common situation in which this is met with is the right or left side, between some of the last ribs, the œsophageal region, and the flank (from an inch to 2 inches above the linea alba).

¹ *Journal of Comparative Pathology and Therapeutics*, September, 1902.

² *Veterinary News*, July, 1905 (translated from *Archiva Veterinaria*).

³ *Veterinary Record*, vol., xiv., p. 147.

As a rule some history can be obtained, either that the patient has been seen to swallow the suspected foreign body, or that the animal is in the habit of swallowing such things; but this is not to be too definitely relied upon unless accompanied by certain symptoms, as on more than one occasion a dog has been operated upon in a vain endeavour to recover some object which has been discovered on the owner's premises a few days later.

The chief signs exhibited are: attempts at vomiting, dis-



Fig. 126.—Photograph of a Sheep Dog, Ten Days after Operation, from whose Stomach a Rubber Ball was removed by Gastrotomy.¹

inclination to feed, general dulness and depression; in a later stage, unthriftiness of the coat, irregularity of the bowels, blood in the motions, and progressive emaciation.

Treatment.—For small bodies, such as nails or fish-hooks, some dietary of the 'stodgy' variety, which will surround the foreign body and gradually pass it along the intestine, is required. Suet pudding, if the animal will take it, is

¹ For Figs. 126 and 127 I am indebted to Mr. C. S. Simpson, veterinary student.

very effectual ; the cat will generally take this if mixed with a little fish, and to the ordinary house-dog it is not unacceptable when hungry. For a foreign body which is not sharp, some emetic (apomorphine is the quickest and best) will often cause its reappearance, and if this is ineffectual a dose of castor-oil should be administered. With skewers, hatpins, or needles, if the patient is not suffering any apparent inconvenience, the wiser plan is to await developments, as the point will in a few days make its way to the surface, causing an abscess. When this is lanced, the foreign body is grasped and withdrawn. The head of such a substance as a lady's hatpin may either be cut off close and allowed to fall back into the stomach or intestine (where it will soon be got rid of), or the orifice carefully enlarged and the head withdrawn. The former is preferable. As a rule adhesion has already taken place between the internal organ and the peritoneum, and, if the abscess cavity is carefully cleansed, the patient makes a rapid and permanent recovery.

One must not forget that there is an element of risk of death from peritonitis, and the alternative to put before the owner is that of an immediate operation ; but it is really wonderful how little inconvenience is sometimes shown to the presence of wounds caused by meat-skewers and hatpins in the stomach, even when no antiseptic or surgical measures are taken. During the past few years quite a number of practitioners (Wolsterholme, Perryman, Brooksbanks, Tutt, R. Gillard,¹ Woodruff,² Mayall, and others)³ have recorded cases in which foreign bodies have been carried for a length of time in the stomach of the dog or cat, without causing any more alarming symptom than the formation of an abscess in the side. At the same time, the practitioner

¹ *Veterinary Record*, vol. vii., pp. 187, 295 ; vol. x., p. 206 ; vol. xi., pp. 376, 434.

² *The Veterinary Student*, vol. i., No. 2, p. 2.

³ *Journal of Comparative Pathology and Therapeutics*, vol. viii., p. 254 ; vol. x., p. 360.

not infrequently discovers one of these bodies, on post-mortem, to have been the cause of death.

One must not necessarily expect to see needles which have been swallowed come out in any one particular spot, as their wandering habits are, when once inside the body of a dog or a cat, as great as they are in that of the human individual.

The *Operation*, technically known as **gastrotomy**, is per-

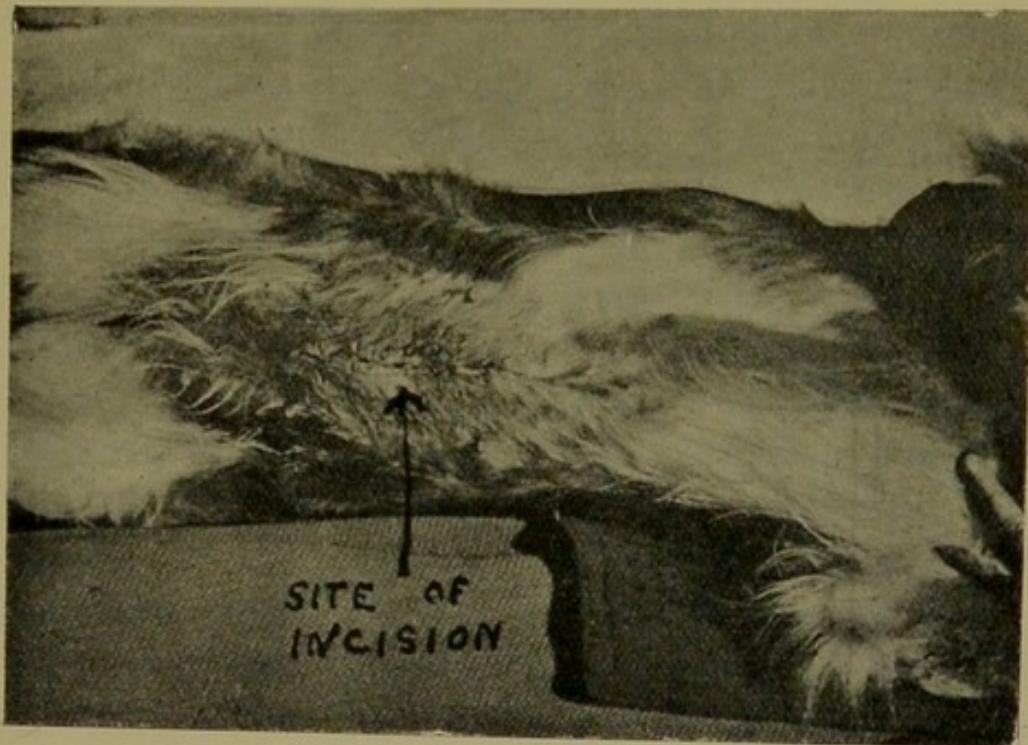


Fig. 127.—Site of Incision in the Abdominal Wall, Ten Days after Operation, through which a Rubber Ball was removed from the Stomach.

formed as follows: The patient is prepared and laparotomy performed as already described (see p. 158), the site of incision being the median line, from 2 to 3 inches below the cartilage of the sternum.

The stomach is drawn up outside the abdominal wall as far as possible, resting on a piece of sterilized mackintosh or jaconet (which has been slit to receive and protect it), and carefully packed and surrounded with lint or boiled

cloths, the foreign body being sought for and brought close up against a portion of the wall where the bloodvessels are small or absent, and an incision made directly over it. Usually, as soon as the stomach is punctured, a certain amount of gas rushes out, and, as it may carry fluid contents with it, this should be guarded against by making a preliminary puncture with a fine trocar and cannula. Should any fluid escape, it must immediately be caught before it can reach the peritoneum.

The foreign body is extracted, the internal edges of the wound carefully cleansed with antiseptic solution, and a close row of silk Czerny-Lembert or Lembert (see p. 55) sutures inserted with a small, round, milliner's needle. The first row passes through all three coats, the second row being of Lembert's pattern and inserted through the serous and muscular coats only, about a sixth or a fourth of an inch from the edges of the wound, so that they act as a double protection against the exit of fluid. Particular care must be taken to close the small 'pucker' which is left at either end of the wound.

With a **gastric ulcer** the chief trouble lies in the difficulty of making an accurate diagnosis; the operative procedure consists in making an elliptical incision so as to remove all the necrosed edge, and drawing the sound portions of the wall together as already described. The abdominal cavity must be carefully examined for any material which may have escaped, this being thoroughly removed with antiseptic swabs.

Foreign bodies in the lower part of the œsophagus usually consist of large pieces of bone, gristle, etc., which have been greedily swallowed, and which cannot enter the cardiac orifice of the stomach, and cannot be pushed down with the probang or brought up by an emetic (see p. 142). In one case we were successful in removing a very large piece of gristle by means of a strong slender pair of dressing

forceps passed up the œsophagus through the stomach wall when all attempts to move it with the probang had failed.¹ The removal of any foreign body from here must always be done as gently as possible, otherwise the pneumogastric nerves, which pass through this opening in the diaphragm, may be seriously injured, and the result may even be fatal. The method of opening the stomach and closing the wound is as already described.

After-treatment consists in keeping the patient as quiet as possible, allowing nothing but a little water, or milk and water, containing boric acid, during the first forty-eight hours, nutrient enemas of beef-tea or mutton broth, or suppositories, being given *per rectum* every four or six hours at discretion. On the third day a little milk, Plasmon, Benger's Food, or beef-extract by the mouth may be allowed in addition, and at the end of the fifth or sixth day some finely minced raw meat or cooked fish. Care must be taken during the first fortnight that the stomach never becomes distended, on account of the risk of tearing out the sutures.

Prognosis.—The prognosis must always be guarded, as the operation is a major one; but if the diagnosis is certain, and the patient not too debilitated, it ought certainly to be adopted if medicinal treatment has failed and the animal's life is perceptibly in danger.

The operations of removal of the stomach or a portion of it (**gastrectomy**), or **gastrostomy**, the making of a permanent fistula in it, are hardly likely to be performed in every-day veterinary surgery, it being by far the most humane plan painlessly to destroy a patient needing either. That each is now possible has been demonstrated repeatedly in human surgery (chiefly for cancer), the patients' lives being prolonged thereby, but the author is not aware of any record of this dreaded disease in the stomach of the dog or cat.

¹ *Journal of Comparative Pathology and Therapeutics*, vol. xii., p. 262.

Gastrectomy is done in the case of a malignant growth affecting the stomach, the diseased part being excised and the healthy portions united by Lembert's or Czerny-Lembert's sutures.

In gastrostomy the stomach is opened and a fistula, through which food is passed, permanently established.

Intussusception of the Intestine.

This condition, a 'telescoping' or 'invagination' of one portion of intestine into another, is most commonly met with in young animals, although adults are by no means exempt. It is produced as a sequel to the violent peristalsis set up by some irritant, such as indigestible food or the presence of worms. As regards situation, the commonest varieties are the ileo-cæcal and the enteric. In the former the ileum is invaginated into the colon, the intussusception extending as far as the ileo-cæcal valve, and it may even go so far as to protrude through the anus to the extent of 5 or 6 inches (see p. 106).

Fig. 140 is an illustration of this. The patient, a valuable bull puppy, aged three months, was supposed to be suffering from prolapse of the rectum, but upon closer examination this was found to be the small intestine, as when returned the intussusception could still be distinctly felt at the end of the finger. Laparotomy was performed, an intussusception of the ileum 8 inches long was reduced, and the patient made an excellent recovery.¹

With the enteric variety the small intestine is protruded into a portion of itself.

Sometimes a number of puppies in the same kennel will suffer about the same time, and unless a *post-mortem* is made the cause will be inexplicable.

The specimen shown in Fig. 128 was a portion of the small intestine of a Chow-chow puppy, eight weeks old, and in the kennel from which it

¹ *Veterinary Record*, vol. xvii., p. 493.

came the owner had lost no less than four within a week, the *post-mortem* revealing an intussusception in each case, the puppies being from four different litters.¹

Symptoms.—The patient may or may not show signs of colic, but is continually straining when at exercise and endeavouring to pass a motion, but only a little fluid or dark, blood-stained mucus comes away even after the most violent efforts. Food will not be refused at the commencement, and will be retained for a while, but after the existence of the lesion for a few hours vomiting occurs if it is taken. The eyes are bright, and the patient withdraws out of sight

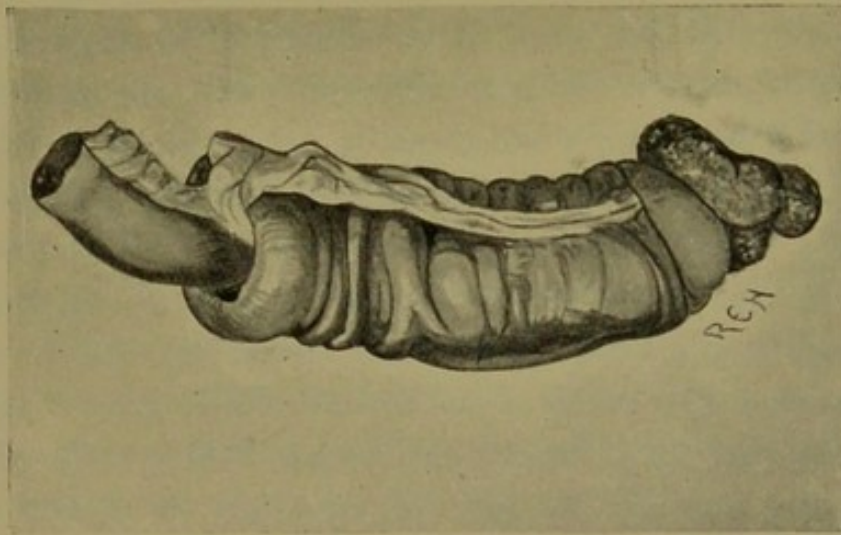


Fig. 128.—Intussusception of the Intestine.

as much as possible, and away from its companions, remaining abnormally quiet except when straining. Sometimes the membranes are icteric and jaundice is a complication. Examination of the exterior of the abdomen between the fingers and thumb, or the fingers of both hands, readily reveals a sausage-shaped swelling in thin patients; but in fat animals this is not so readily detected, although after the lapse of some hours the abdominal wall will become less tense; it is always a good plan to make frequent examinations.

¹ Miss Aleen Cust, *Veterinary Record*, 1904.

The swelling is not tender on pressure in the early stages, nor is the abdominal wall sore.

When the diagnosis is made, the sooner an operation is performed the better the chance of success. Purgatives and other medicines are generally returned as soon as administered.

The inflation of the bowel with warm enemata may be tried, a long tube, passing as far up the gut as possible, being used; but undoubtedly the surest and safest method of reduction lies in the application of modern surgery.

It is true that now and again sloughing of the intussuscepted gut will occur, firm adhesion of the serous edges having taken place, and the 'cast' of bowel will be passed *per anum*; but the process is a comparatively slow one, the animal is in pain until it has happened, there is great risk of stricture as a sequel, and there is also great risk that the gangrene and peritonitis which must accompany the process may extend and cause the death of the patient. Ulceration, too, may occur, and then a fatal termination would be certain.

Operation.—The surgical method of affording relief consists in the performance of laparotomy (see p. 158) and the replacement of the gut into its natural situation by means of the fingers.¹ If the intussusception is of recent origin, this can be done without any difficulty, but if it has existed for some time adhesions will have formed, and the outlook is much more serious. If these adhesions can be broken down without materially injuring the bowel wall, this should be done; if not, the whole piece must be excised (see Enterectomy, p. 190).

Prognosis.—The prognosis of an uncomplicated case is excellent if the operation has not been delayed too long. It is, of course, serious if enterectomy has become necessary.

After-treatment.—It is very important that the bowels

¹ *Journal of Comparative Pathology and Therapeutics*, vol. xii., p. 261 ; *Veterinary Record*, vol. xvii., p. 493.

should be kept as quiet as possible for some days, and to insure this the patient should receive doses of opium either by the mouth or in the form of suppository. The dietary and other treatment should be as described on p. 179, exercise and excitement of any kind being forbidden.

Fæcal Impaction of the Intestine.

Obstinate constipation and impaction of the intestine by hardened fæces are very common troubles in the dog and cat, especially those of unclean habits and belonging to inattentive owners. The administration of laxative or purgative medicine and the use of the enema syringe are usually sufficient to put matters right, but occasionally surgical aid has to be invoked. A very obstinate impaction of the intestine is particularly met with in the shooting breeds of dogs, although by no means solely confined to these varieties, being caused by over-indulgence in game and rabbit bones. These, matted together with hair or fur, form a hard, bony mass which it is extremely difficult to dislodge.

In two cases met with by the author, the animals (retrievers) had passed no fæces for at least three weeks.¹

The obstruction usually occurs in the colon, and it may extend upwards for a considerable distance into the small intestine. In one of the retrievers above mentioned, fully a foot of intestine was involved by a mass as hard as a stone, the small intestine in front being enormously dilated and full of semi-fluid fæculent material.

Symptoms.—The patient becomes dull, refuses food, vomits occasionally, and is observed to strain continually in an attempt to pass fæces, the effort being utterly ineffectual and accompanied by pain. After an attempt the poor beast will look around at its flanks and stand rigidly still, looking

¹ *Journal of Comparative Pathology and Therapeutics*, vol. xii., p. 261 (Dunstan and Hobday).

up when spoken to with a most appealing glance in its eyes, and showing the greatest disinclination to move. The coat is unthrifty, and after a week or ten days the dog becomes emaciated and perceptibly weak. Palpation reveals great tenderness of the abdominal walls, especially on pressure, and the presence of a hard, swollen mass can be detected. On examination *per rectum* the mass can generally be felt, and the surgeon must guard against being scratched by the spicules of bone, which are sometimes as sharp as needles.

Operation.—Surgical aid is rendered after all efforts to remove the impaction by medicines given by mouth or rectum have failed. The simplest plan consists in the injection of melted lard or warm oil *per rectum*, and the removal of as much as possible, bit by bit, with the fingers or a blunt spoon or curette. This can generally be done to a certain extent, but often the lump is out of reach and matters become more serious. Laparotomy (see p. 158) must be performed, and the obstructed bowel massaged and kneaded gently but firmly, until its contents break up into fragments of sufficiently small size to be passed on into the rectum; they are then removed by an assistant.

The process of kneading must be done very patiently with the ends of the fingers and thumb, great care being taken to avoid injury from the nails; it is a good plan to try first at one end and then at the other, gradually working towards the centre, or any place that feels softer than its surroundings.

A second plan consists in opening the bowel and removing the obstruction in that way (see Enterotomy, p. 188), the operation being rendered more risky than in an ordinary case on account of the large accumulation of fluid fæculent matter and the lax, debilitated condition of the serous and muscular coats of the intestine, the latter in particular rendering the insertion of sutures without tearing a matter of very careful and delicate manipulation.

Enterectomy and subsequent anastomosis (see p. 190) offer

another solution to be adopted at the discretion of the surgeon.

Prognosis.—The prognosis when the hardened fæces can be removed by the spoon alone is good, the only after-treatment necessary being the injection for a few days of some emollient antiseptics, such as chinosol and oil, or chinosol, glycerine, and water. When the case has progressed so far that laparotomy, enterotomy, or enterectomy have become necessary, the prognosis is grave, because, as a rule, the patient is debilitated from inability to take proper nourishment and from absorption of septic materials. Death from collapse may occur within a few hours afterwards, and in one case met with death occurred suddenly four days afterwards from invagination and strangulation of the bowel, a large piece of the healthy portion having pushed its way into the dilated portion where the obstruction had existed before the latter had had time to contract and recover its tone and normal size. At the same time, the operation is the one which gives the patient the best chance of recovery, and the author has known it to be successful in two very typical instances, in each of which the dogs had enormous masses of concretion which had been accumulating for many days.¹ The bowel of one patient (an Aberdeen terrier) was perseveringly massaged for fully three-quarters of an hour before the whole mass could be broken down and removed.

After-treatment.—It is sometimes most difficult to get the bowel to recover its normal tone. The case above mentioned, in which invagination occurred four days after operation, is an instance of this.

For the first twenty-four hours the patient, when the bowel has not been opened, should receive a little dilute brandy and some preparation of strychnine in milk, Benger's Food, Plasmon, or some farinaceous food, every four hours, and the

¹ *Journal of Comparative Pathology and Therapeutics*, vol. xii., p. 261; *Veterinary Record*, vol. xvii., p. 492.

quantity should be small, whether taken voluntarily or administered. On the third day the dose of strychnine can be increased, and this should be continued until convalescence is well established. Rectal feeding by suppository or enema may be added at discretion, and an enema administered if there is no action of the bowels.

When convalescence has perceptibly commenced, recovery is usually rapid.

For instructions as to after-treatment when the bowel has been opened, see p. 179.

Foreign Bodies in the Intestine.

Sticks, pieces of wood, stones, corks, balls, coins, nails, sponge, hair (especially in Persian cats), cotton (particularly in kittens), tape, and other foreign bodies, are frequently met with in the intestines of the dog and cat, and sometimes give rise to irritation, inflammation, and even perforation, peritonitis, and death, without of necessity causing complete obstruction of the bowels. Sometimes they are in very large quantities, and the author knew of one instance in which 114 stones were passed, at intervals extending over two days, by an Aberdeen terrier.

Corks are very commonly met with in cats, and are a frequent source of death from obstruction of the gut, the offending body usually being half a wine-bottle cork or a portion of one of a large medicine-bottle size. Pieces of sponge, too, are not uncommon, being soaked in fat and generally given with malicious intention. Both these substances swell when they have been soaking in the intestinal juices for a few hours.

Probably one of the most extraordinary cases ever met with is illustrated in Fig. 129, and was recorded by Mr. T. G. Heatley, M.R.C.V.S., in the *Veterinary Journal* for May, 1905. The patient, a Persian cat, aged two years, swallowed a long piece of ordinary sewing tape, and, as might be expected, became very ill in consequence. Four days before

death it was noticed by the owner to be dull and out of sorts, refusing all food, attempting to vomit, and occasionally lapping a little cold water. When brought to Mr. Heatley saliva was hanging from the mouth, the cat could scarcely stand, and was rapidly becoming comatose; death took place the same evening, and a *post-mortem* examination revealed the bowels to be slightly congested externally, and with a curious puckered appearance. About 3 inches of the tape projected into the stomach through the pyloric orifice, and the remainder had worked its way to within 5 inches of the anus.

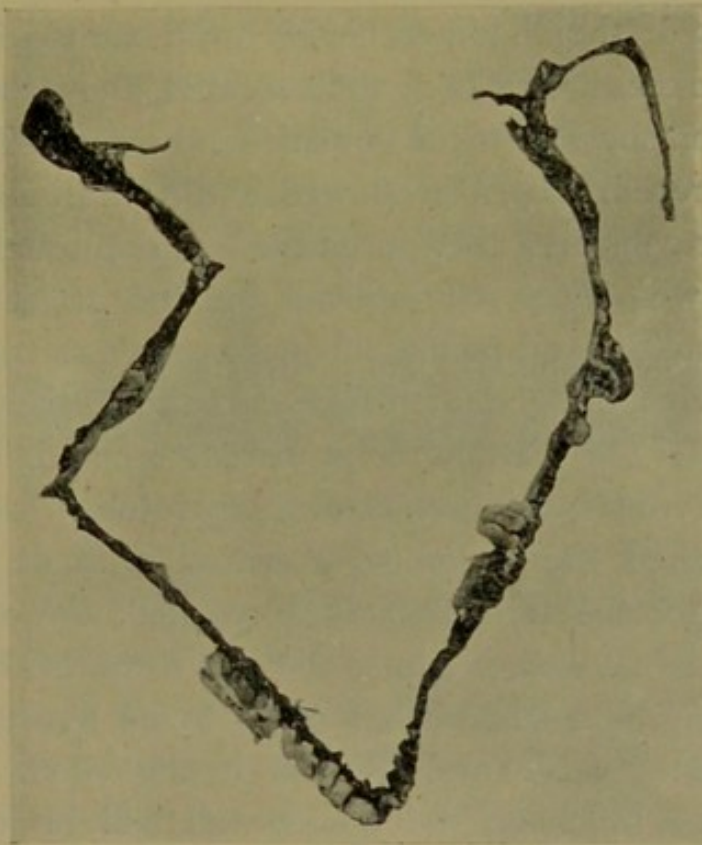


Fig. 129.—A Cat's Intestine with a Piece of Sewing Tape passing from Stomach to Rectum.

Symptoms.—In some cases where a sharp body has been swallowed, no signs of illness are exhibited until the foreign body appears on the surface; but where a blunt article is the cause we get dulness, capricious appetite (the patient will look for food, but refuse to eat when it is brought, or only take a little and leave the remainder), occasional colic of a more or less violent character, and a tendency to hide in a quiet place; efforts to pass *fæces* result in diarrhœa or a

small quantity of blood-stained mucus. In the early stages the temperature may be raised; in the later stages it becomes subnormal. The eyes and face have a curious, anxious expression. After some days the body becomes emaciated, fits of vomiting occur, and the patient is greatly prostrated. In cats this stage is often reached before the patient is brought to the practitioner, and it is usually too late to save the animal's life.

Palpation of the abdomen between the hands will in many cases enable the foreign body to be located, and its removal by medicinal or surgical means must then be decided upon. If it has only recently been swallowed, and from its size, etc., the practitioner considers that purgatives, external manipulation, or enemas, will effect its removal, and the patient seems in no immediate danger, medicinal means may be tried; otherwise the earlier the abdomen is opened the better.

Operation.—The patient is prepared, secured, and anæsthetized, in the same way as for laparotomy (see p. 158). Having opened the abdomen, a search is made along the intestine until the foreign body is reached, and an attempt is then made to pass it along the gut towards the rectum, where it may be seized with forceps by an assistant. This must be done very carefully, as, if the agent has been in one place for long, the bowel wall will be very much weakened and is easily torn. If this can be accomplished, the abdominal wall is sutured, and a prognosis of success is almost assured. If this is not possible, the gut must be opened, this operation being technically known as **enterotomy**. Or it may be even necessary to excise a portion, this being termed **enterectomy**, the cut ends being united afterwards.

Enterotomy.

The portion of intestine containing the foreign body is brought into view through a slit or hole in a piece of macintosh or jaconet cloth, which has been boiled and soaked in anti-

septic, and an attempt made to move it into a spot where the wall is still healthy. The site of incision having been decided upon, the material within the gut is gently but firmly squeezed above and below for about half an inch or an inch, and the bowel clamped to prevent its return, and so prevent exit of infective matter when the incision is made.

For this purpose clamps (see Fig. 130) can be used, although pieces of rubber tubing held tightly around the bowel with artery forceps improvise very well, or (Maunsell's suggestion) safety-pins padded with sponge or wadding.

The bowel is then carefully packed around with boiled aseptic lint or wadding, an incision made in the longitudinal direction in the least congested part, as far away

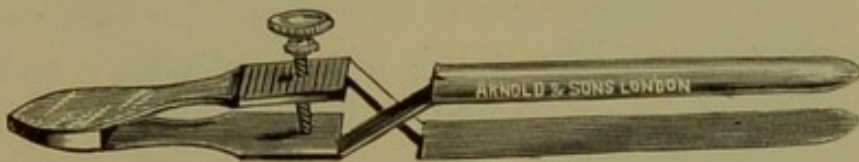


Fig. 130.—Bowel Clamp (Makins).

from the mesenteric attachment as possible, and the obstructing substance extracted.

The edges of the wound and the intestine above and below as far as the clamped portion are thoroughly cleansed and disinfected, Lembert's or Czerny-Lembert's sutures (see p. 55) are inserted, and the wound in the abdominal wall treated as after an ordinary laparotomy (see p. 158).

Prognosis and After-treatment.—Careful dieting, as already described after gastrotomy (see p. 179). If the patient has not already become exhausted, the prognosis, although always grave, may be considered hopeful.

Interesting cases of recovery after operation have been reported by Vennerholm¹ and Pauer.² In Vennerholm's case the foreign body was

¹ *Veterinary Record*, vol. x., p. 327 (Mayall's translation).

² *Ibid.*, vol. xii., p. 110.

situated in the rectum, whilst Pauer removed a stone from the upper part of the bowel near the stomach. To add to the interest of the latter case, a careful *post-mortem* examination was made when the dog died (from another ailment) five years later, and the scar could distinctly be seen, although otherwise the bowel was quite normal.

Enterectomy and Anastomosis of the Intestine (Enterorrhaphy).

In certain cases in which the bowel has become gangrenous or injured, owing usually to the presence of a foreign body or some other cause, the only chance of saving the patient's life depends upon the excision of the diseased portion and the union of the cut ends. The former is technically termed **enterectomy**, and the reunion of the cut ends **enterorrhaphy**. These operations, although, of course, very serious ones, have now regularly taken their places in human surgery, and that it can be successfully performed in healthy dogs and cats has been demonstrated many times.¹ The chief difficulty in veterinary practice seems to be to make a sufficiently accurate diagnosis early enough—*i.e.*, before gangrene and septic peritonitis have set in or the patient has become exhausted. In the author's experience² the results, although not altogether without success, have not been good, but in most cases the patient was very much exhausted when brought for treatment.

For an enterectomy the preliminary preparations are the same as for laparotomy and enterotomy (see pp. 158 and 188); for the intestinal anastomosis careful suturing alone may be done, or resort may be had to certain mechanical aids, such as those afforded by cones, discs, buttons, bobbins, etc., made of metal, decalcified bone, carrot, turnip, potato, etc.

The abdomen is opened in the usual way in the median line or flank, according to the position of the obstruction, and the offending portion of intestine sought for and withdrawn,

¹ *Journal of Comparative Medicine and Veterinary Archives* (Cecil French), 1902, p. 162. *Lancet*, October, 1897 (Martyn Jordan).

² *Veterinary Record* (Ridler and Hobday).

being pulled through a hole in a mackintosh or jaconet cloth (which has been carefully boiled), soaked in warm antiseptic, and packed around with antiseptic lint or wadding. The contents of the bowel are forced back by pressure with the fingers and thumb for about 2 inches above and below the diseased part and clamped. Special instruments are designed for the purpose; they can be improvised by fixing pieces of rubber tubing around the gut, or (Maunsell's suggestion) by safety-pins padded with sponge or wadding.

The mesentery is incised in the shape of an inverted V, and the branches of the mesenteric artery actually supplying

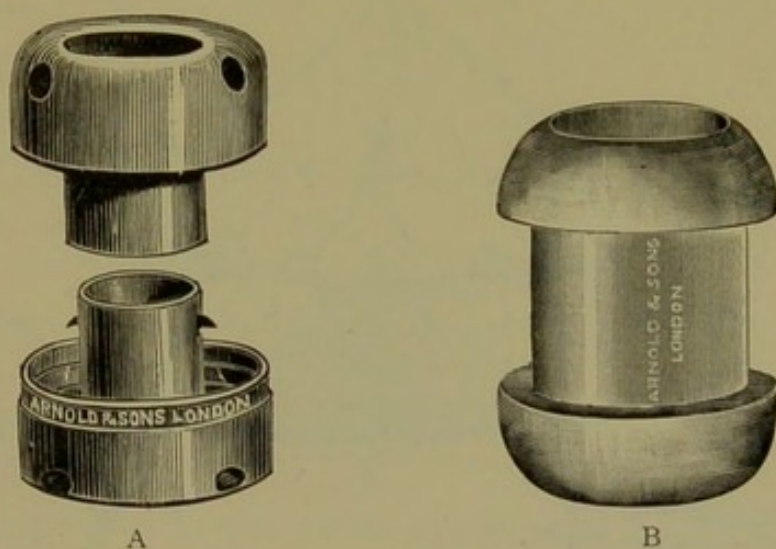


Fig. 131.—A, Murphy's Button; B, Mayo Robson's Bobbin.

the region to be excised are taken up with pressure forceps and ligatured, it being recollected that the collateral branches of these are few in number, and that therefore as few as possible of the main branches must be interfered with. The bowel is cut through with scissors held at right angles to its lumen, and the latter is swabbed out as far as the clamps with wadding soaked in some fluid antiseptic. The two serous surfaces are brought into contact by interrupted sutures of Lembert's pattern (see p. 55), inserted about a tenth of an inch from the edge and an eighth or a tenth of an inch apart, particular care being taken not to penetrate the

mucous coat of the bowel, and to tuck the edges in neatly. A very fine round needle and silk No. o or oo should be used.

Mr. Cecil French, D.V.S., of Washington, has originated a very ingenious and practical scheme by which two hairpins are utilized to facilitate anastomosis. By this method two hairpins are taken and bent to the shape shown in Fig. 132,

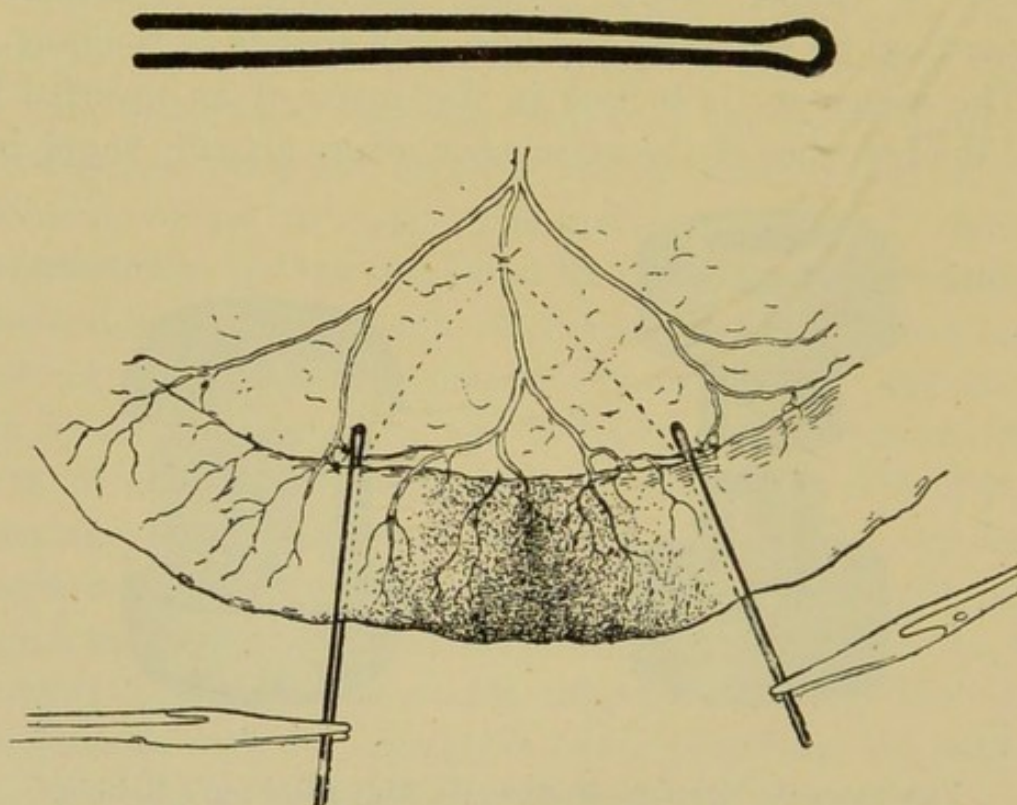


Fig. 132.—Two Hairpins clamped on the Intestine in Position for Operation.

three or four pairs of pressure forceps being necessary to act as clamps.

French recommends¹ a No. 8 or No. 9 size of milliners' needle, and No. 2 size of black sewing silk. Great care is taken that no mesenteric vessels are obliterated other than those supplying the area of intestine it is intended to remove. The area to be resected is carefully mapped out, the mesen-

¹ *Journal of Comparative Medicine and Veterinary Archives*, 1902, p. 162.

teric vessels secured by ligature by means of a curved needle and fine silk, and the anastomosing loops running near the mesenteric attachment are secured at a point level with the proposed line of resection. One prong of the hairpin is passed through the mesentery at the upper point of resection, and, together with its fellow, is brought transversely across the gut. The two are clamped together, as in Fig. 133. The intervening portion of intestine is severed with a scalpel quite close to the clamped prongs of the pin, and a wedge-shaped portion of mesentery also removed. The two

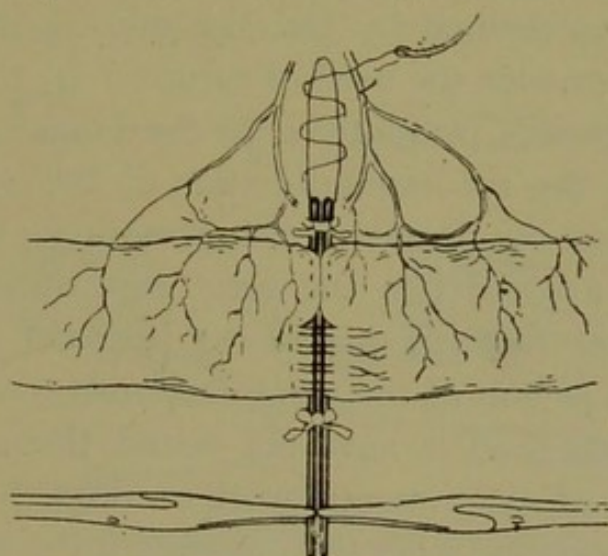


Fig. 133.—The Hairpins tied in Apposition, with some of the Sutures *in situ*.

hairpins are then tied or clamped tightly together, and sutures placed on one side, starting at the mesenteric attachment. The bowel is turned over, and the sutures applied in the same manner on the other side. The pins are then untied or unclamped, and severed at their bent ends with bone or wire cutting forceps and withdrawn, one prong at a time. The remaining openings are closed with one stitch each, particular care being exercised that the margin is properly turned in at the mesenteric attachment. Finally the incision in the mesentery is closed by a continuous suture.

French records that he operated experimentally upon six different animals with five completely successful results. In

the sixth case the patient was only five weeks old, and succumbed to obstruction of the gut from formation of adhesions between the line of coalescence and a portion of the bowel wall immediately beyond, this giving rise to an acute curvature of the gut.

Of the various **mechanical devices** for facilitating the anastomosis of the divided ends of the intestine after enterectomy, the metallic button invented by Murphy of Chicago (see Fig. 131) is probably the one which has attracted the most notice amongst surgeons during the past few years. The advantages claimed by Dr. Murphy are that—(1) the button dispenses with the need of sutures; (2) the possibility of non-apposition is prevented; (3) the danger of sloughing is avoided; (4) the too rapid digestion of the catgut sutures is prevented; (5) the operation being more rapid, prolonged anaesthesia is avoided; (6) the great ease of the operation renders the instrument as safe in the hands of the everyday practitioner as in that of the most dexterous specialist.'

All who have used it have not found these advantages. After a course of experimental work on dogs, Jordan speaks of 'the danger arising from the presence of the large metallic button, and the risk of gangrene spreading further than is necessary, in Murphy's operation.' Harrison Cripps¹ speaks very strongly against its use in human surgery, his experience leading him to directly opposite conclusions to those of Murphy, whereas others speak very highly in its favour.

It is placed and fixed in position as follows: A continuous running thread is passed in and out completely around each end of the intestine in a manner similar to the 'puckering string' or 'draw string' of a bag; the male half of the button is placed in the distal end of the bowel, and the female half in the proximal end, being held there by an assistant; the silk is then drawn up around each stem of the button and tied securely. The two halves are steadily and firmly

¹ 'Ovariectomy and Abdominal Surgery,' p. 281.

pressed together, so that the two serous surfaces of the intestine come in direct contact. In from a week to a fortnight sloughing occurs of the parts included within the button, and the latter is passed through the bowel, union of the two serous surfaces having occurred in the meantime.

Jordan,¹ in India, performed enterectomy experimentally upon fifty-nine pariah dogs by various methods, the one which gave the greatest percentage of success being as follows: Two hollow cylinders, each three-quarters of an inch long, were made either from the decalcified femora of geese or turkeys, or from fresh carrots, turnips, or potatoes,

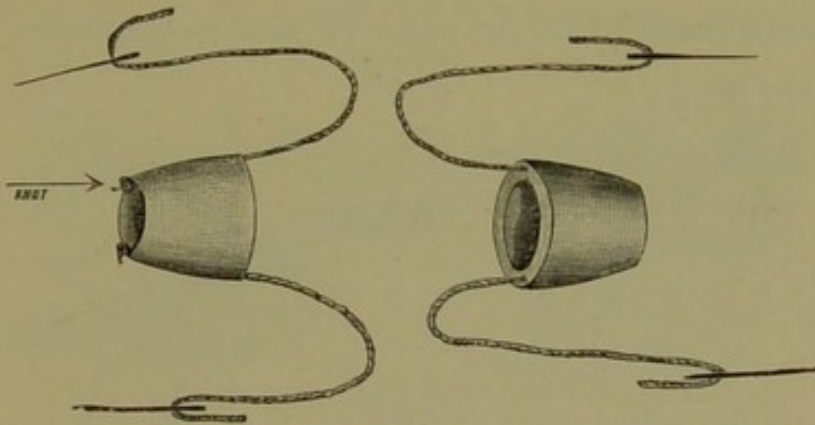


Fig. 134.—Cones with Sutures and Needles attached.²

and bevelled off at one end so as to form a hollow truncated cone, the apex being less than, and the base the diameter of, the lumen of the bowel. Each cone was furnished with two sutures, which were passed through its wall from the apex to the base, one on each side, a big knot at the apical end preventing the suture from being pulled through the cone. The apex was then inserted, and the 'cone sutures' passed through all the layers of the bowel an eighth of an inch from the cut margin, one at the mesenteric attachment, and the other at the opposite side of the gut. The other cone being similarly passed, an assistant approximated the ends of the bowel, and the corresponding pairs of sutures were tied moderately

¹ *Lancet*, October, 1897, p. 1098.

² For this and the following two figures I am indebted to the *Lancet*.

tightly. The ends of the sutures were cut as short as possible. The cut ends of the gut were thus fixed in contact, slight inversion of the ends occurring at the sutures. A continuous 'double turned' suture (see Fig. 134) was now commenced on the under surface of the bowel about one-third of an inch from the mesenteric attachment; especial care was paid to the first four stitches to insure that the knot of the 'cone sutures' was buried beneath the line of the continuous suture, the needles here being inserted a little farther from the cut margins. The assistant, holding the bowel at the apex of each 'cone' between the thumb and fingers, kept the cut ends of the gut in view (other-

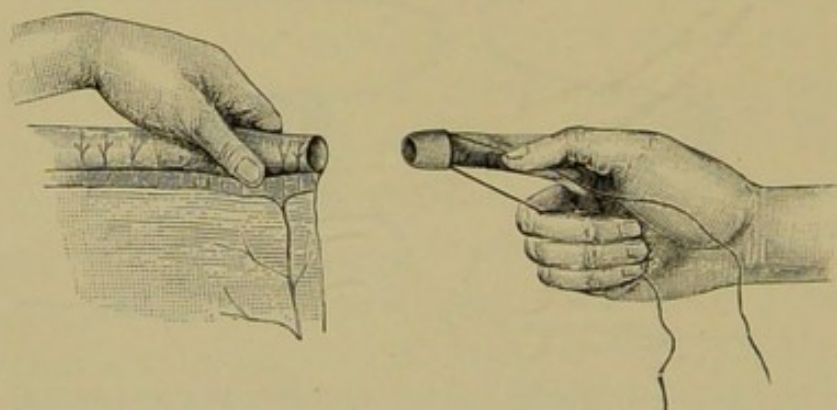


Fig. 135.—Mode of Insertion of Cone.

wise excessive inversion occurred during the suturing), and gradually rotated the bowel back to its original position as the suturing proceeded. Especial care must be taken to bury the 'cone suture' knots, or peritonitis is apt to ensue. As each 'double turn' (see Fig. 134) of the continuous suture was in process of being tightened, the assistant, with the closed blades of a pair of scissors applied on the flat, or other instrument, inverted the margins of the bowel, and kept them so until the double turn was drawn sufficiently tight to invert them permanently. When the gut had been sutured all round, the two ends of the suture were tied with a reef-knot; the bowel was carefully cleansed and the line of resection inspected, to insure that the edges were everywhere

inverted. The mesentery was drawn together with a continuous suture. The gut was then bathed in hot antiseptic water and returned, the abdominal wall being treated as already described for an ordinary laparotomy.

Thirty-two dogs were operated upon by this method, pieces of from 4 to 13 inches being excised. Only two deaths occurred, and one of these might reasonably be attributed to other causes than the enterectomy. It must not,

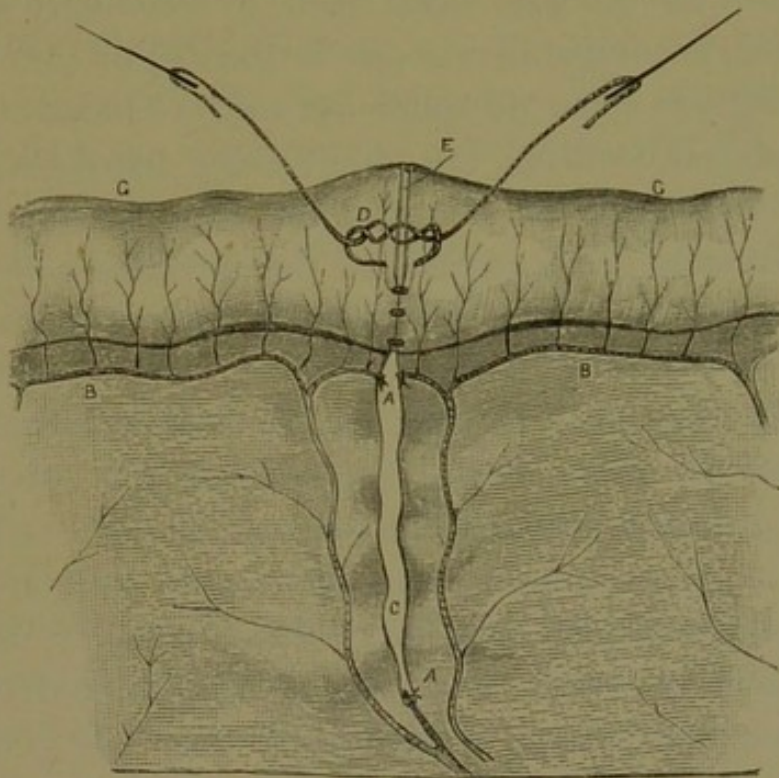


Fig. 136.—Operation half completed (Dog's Bowel).

AA, Arteries ligatured ; BB, arterial loops ; C, gap in mesentery ; D, double turn ; E, cut margins of gut ; GG, gut.

however, be forgotten that these were comparatively healthy animals, none of them suffering at the time from disease of the intestine.

The sequelæ as reported were excellent, the animals afterwards rapidly putting on flesh ; but Mr. Jordan does not appear to have kept them under observation for more than about six months to see whether or not stricture resulted.

The after-treatment consisted in the above cases in dieting

with milk for the first two days, the dogs being allowed as much as they would drink. For the next four days minced meat and boiled rice were substituted, and they were then allowed to eat anything.

Prognosis and After-treatment.—This is already described on p. 179.

Volvulus.

Torsion of the intestine upon itself, so commonly met with in the horse, is comparatively rare in the dog or cat.

The *Symptoms* come on suddenly, and are those of violent pain, occasional vomiting, the patient being distressed, and the abdomen distended. If not operated upon, strangulation of the bloodvessels and gangrene of the intestine will precede death, the animal being out of pain when this has taken place.

It may be surmised to exist by the history given by the owner, and by the negative evidence of the existence of direct obstruction, intussusception, etc., whilst its certainty can only be demonstrated by an exploratory laparotomy (see p. 158), which should be done without delay if medicinal agents (such as ether, ammonia, opium, chlorodyne, etc.) fail to give relief within a reasonable time. If volvulus is found, an attempt should be made to untwist it. If this is impossible, an enterectomy may be done (see p. 190), or the patient may be painlessly destroyed by a dose of Scheele's hydrocyanic acid administered intra-thoracically before consciousness returns.

Stricture of the Bowel.

Occurring most frequently in the rectum, the only remedy for this condition lies in enterectomy (see p. 190), but, as it is usually associated with other conditions, it is generally the most humane course to put the patient painlessly away.¹

¹ *Journal of Comparative Pathology and Therapeutics*, vol. x., p. 173.

Strangulation of the Intestine.

This condition may be caused by volvulus, hernia, or through the presence of peritoneal bands or of a Meckel's diverticulum.

The two former are described elsewhere (pp. 198 and 224) in detail; the latter are rarely recorded, although possibly they are sometimes overlooked. The author has met with two distinct instances.

Meckel's diverticulum is a congenital abnormality occurring as a fibrous cord with one end attached to the lower end of the mesentery of the ileum, and the other end floating loose in the abdomen for about an inch or more. It is really an abnormal condition of the omphalo-mesenteric duct, which, instead of lying close to the peritoneal wall and becoming entirely obliterated, has become detached. The free end becomes adherent to the abdominal wall, or even the gut itself, and if there is a portion of intestine enclosed within the loop, as the gut grows it becomes impinged upon and strangulated.

Peritoneal bands may be caused by detached pieces of omentum, the constant drag upon them during peristalsis causing them to become cord-like, or as a sequel to an old peritonitis.

The *Symptoms* and *Treatment* are as already described above (see Volvulus), and it is only by an exploratory laparotomy that their presence can be discovered.

Tumours of the Stomach and Intestines.

Tumours of the stomach and intestine of the dog and cat are not common. Carcinomata and sarcomata¹ (Fig. 41) are occasionally met with, but even these malignant growths, so frequently seen in the stomach or lower bowel of man, are very rare in this situation in the dog and cat, although occasionally the testicles and ovaries are affected (see pp. 276

¹ *Journal of Comparative Pathology and Therapeutics*, vol. x., p. 173.

and 295). Knowing the tendency of dogs towards obesity, one might have expected that lipomata, such as have



Fig. 137.—*Post-mortem* Specimen of a Cat showing Enormously Enlarged Kidneys.¹

been recorded in the horse, would have been found, but even these are only noteworthy by their absence.

In the cat the extreme mobility of the kidneys must not be forgotten, and these organs (especially if enlarged, as in Fig. 137) have on more than one occasion been diagnosed as tumours, and laparotomy has been performed with the object of removing them. Their situation and shape, together with a few days' observation of the patient, are the chief aids to diagnosis, but that the

shape may become distorted and misleading is well illustrated in the photograph.

Appendicitis and Typhlitis.

Appendicitis, to which so much attention has recently been drawn in human surgery, is an impossible disease in the dog or cat, on account of the absence of the appendix from these animals, and **colotomy**, the operation by which an artificial communication is made between the lower bowel and the outside of the body, needs but a passing remark here, as (except experimentally) it would not be performed

¹ For this photograph I am indebted to Mr. H. G. Simpson, F.R.C.V.S.

on either a canine or feline patient. The lethal chamber would be a more humane and preferable termination.

The case illustrated in Fig. 138 was that of a mastiff, aged about twelve years, whose history was that the appetite and general health had been variable and the bowels irregular for about two months. When brought under treatment the temperature was 103° F., pulse 146, the extremities

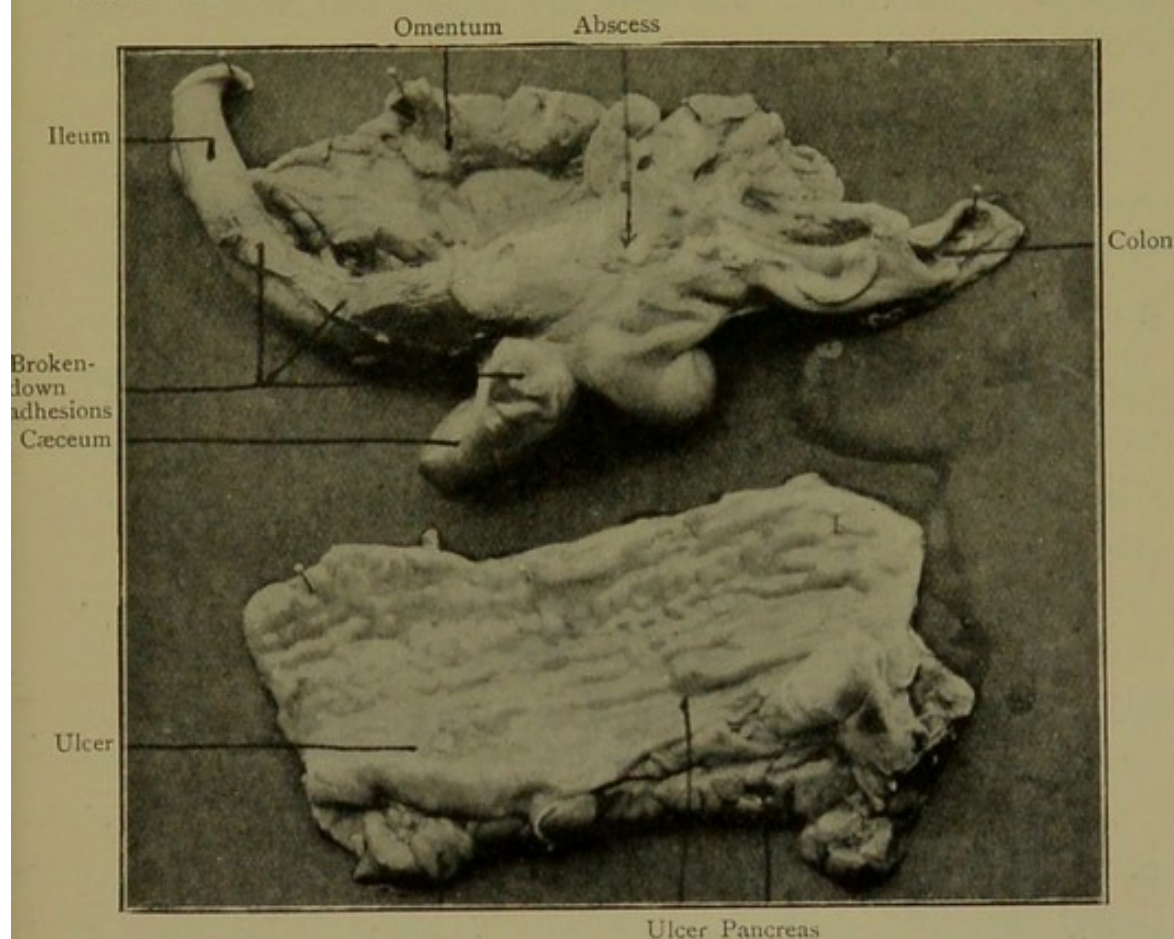


Fig. 138.—A Case of Perityphlitis and Ulceration of the Bowel.¹

The upper specimen is the ileo-cæcal region, the lower specimen is a portion of duodenum.

cold, and all the symptoms of general collapse. Vomition had occurred several times, but no tenderness of the abdomen was discoverable by external manipulation. Coma set in, and death occurred about thirty-six hours afterwards, a *post-mortem* examination revealing extensive perityphlitis with ulcers in the duodenum and ileum, in the latter of which one had perforated, thus allowing the intestinal contents to escape into the abdominal cavity.¹

Typhlitis is, however, tolerably frequently met with, the *Symptoms* shown being those of acute abdominal pain,

¹ *Journal of Comparative Pathology and Therapeutics*, vol. xviii., p. 75 (G. H. Livesey).

the patient being unable to get rest and ease for long in any position.

Colicky pain will be especially shown after food has been taken, and may be so severe as to cause continual yelping, moaning, or screaming. Pressure on the posterior part of the abdomen between the fingers and thumb causes evidence of soreness, and in some cases the swollen cæcum can distinctly be detected.

Treatment may be medicinal or surgical. The former consists in the administration of the usual sedatives, together with a dose of castor oil to clear out all irritants from the gut, and a dose of morphia subcutaneously may be requisite. If the pain is not eased within twelve hours, laparotomy (see

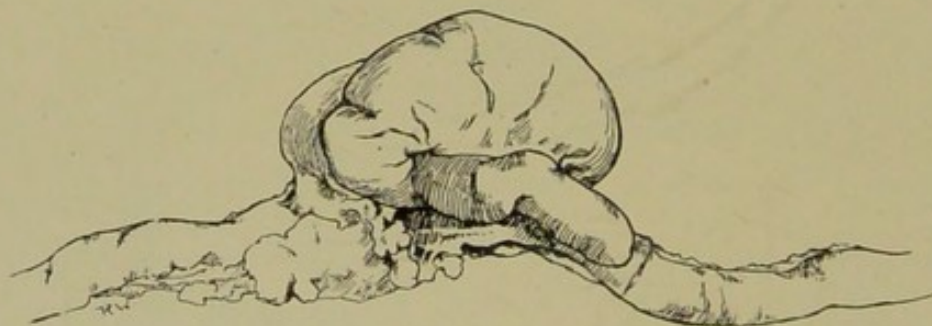


Fig. 139.—Cæcum of a Bull Bitch distended from Inflammation of the Interior.

p. 158) should be performed, and the cæcum and surrounding bowel carefully massaged between the finger and thumb, in order to macerate the contents, which are often in a semi-solid, thick condition. Collection of gas (the cæcum is usually much distended) can also be got rid of by this means.

After-treatment is as already described on p. 179, and for several weeks afterwards no bones or very indigestible food should be given.

Torsion of the Stomach has been recorded twice. It is rare, and is not a condition which can be diagnosed except by exploratory laparotomy.¹ It causes acute pain and collapse, with death in a very short time.

¹ *Veterinary Record*, vol. ix., p. 449 (Wallmann and Kitt, Mayall's translation).

CHAPTER XV

DISEASES OF THE RECTUM AND ANAL REGION

Prolapse of the Anus and Bowel.

THIS condition is most commonly met with in young dogs and cats, although adults are by no means exempt. The protrusion usually consists of everted rectum, but occasionally of ileum or colon; the latter is much more serious to replace, and necessitates an abdominal operation to put matters right, as it generally accompanies an intussusception. In such a case the sooner this is done, before adhesions take place, the better for the chances of success (see p. 180).

Prolapsus Ani.

Symptoms.—In slight cases the mucous membrane of the anus alone is visible, appearing after defæcation as a small red protrusion. It is most common in old, fat dogs, and usually accompanies a visibly relaxed condition of the exterior of the anus.

Medicinal Treatment consists in an attempt to get the patient into good general condition. In a fat dog a diet of lean meat (raw for preference), given regularly and restricted in amount, together with medicinal doses of iodide of potassium and plenty of exercise, is the best; and, after the superfluous flesh has been reduced, a course of tonic medicine. Astringent lotion (alum, tannic acid or lead) should also be

applied to the anus, and cold astringent injections administered twice or three times a day *per rectum*.

For a dog merely debilitated, this condition must be overcome by a course of hæmatinic or general tonic medicine and local astringents.

Should these measures fail, operative measures must be resorted to.

Operations.—Knowing, from observations made upon the healing of wounds, that the cicatrix which eventually forms occupies less space than did the original tissue, the surgeon makes use of this knowledge in regions where such a course is possible. The stricture which frequently forms after certain operations upon the œsophagus, bowel, or urethra is an illustration of this. The operations for entropion (see p. 119) and this operation upon the relaxed anus are instances in which the cicatricial tissue can be satisfactorily made use of.

The patient should be fed only on milk or sloppy diet for two or three days, getting nothing whatever (if of a hardy breed) for twenty-four hours previous to the ordeal; in the case of toy dogs, cats and delicate animals, however, a small saucerful of milk or beef-tea may be given about six or eight hours beforehand. A warm boric acid (grs. x to ʒi.) or chinosol (gr. ss. to ʒi.) enema is administered, a cocaine suppository is inserted, and about an hour later the patient placed in the abdominal position (see p. 19) on the operating-table. The parts round the anus, hind-quarters and tail are carefully shaved and prepared antiseptically (see p. 2); a finger is passed into the rectum, and the relaxed mucous membrane withdrawn. The anal orifice is painted outside and inside with a 5 per cent. solution of cocaine, and, with a pair of sharp scissors, two or three superficial elliptical wounds, from a third of an inch to an inch long, in the longitudinal axis, are made just where the skin and mucous membrane join. These are afterwards

treated antiseptically by iodoform or other suppositories and lotions, the dog or cat receiving opium for two or three days, and restricted milk or beef-tea diet for a week, in order to give the anus as little work as possible.

Gersuny's Wax Operation (see p. 209) is also of value in these cases, the sterilized paraffin melting at 105° being injected subcutaneously, and in the submucous tissue, near the anus, in such a way that pillars are formed which mechanically obstruct and tighten this orifice.

Prolapsus Recti.

Sometimes the prolapse is met with in a puppy in apparently good health, but, as a rule, it occurs after (or during) some debilitating illness and suddenly; the animal, apparently all right a few moments beforehand, now having an inch or more in view. Constipation, diarrhœa, hemorrhoids, any rectal irritation and the consequent straining, are prevailing causes.

Symptoms.—The patient withdraws from the society of its companions, and is quieter than normal; the floor where it has lain down is blood-stained, the hind-quarters also, and it resents interference with the region of the tail. Examination of the region reveals the prolapsed gut in a more or less congested, and perhaps lacerated, condition. If not attended to, it becomes in a few hours intensely swollen, livid, and acutely painful. If neglected altogether, death is apt to take place either from shock, collapse, or septic absorption; or adhesion may take place at the anal ring, the part below being constricted and ultimately sloughing away. If the patient is seen in the act of defæcation or attempted defæcation, the gut will be protruded and retracted as straining takes place and ceases again. After these efforts the animal looks round at the affected part.

If observed within an hour or so, the bowel is readily

returned by a little manipulation, and now is the time to differentiate between rectum and small intestine. When it is the former, a digital examination reveals the interior to be perfectly smooth, the walls being relaxed and in their normal place again. When one has to deal with an intussusception and prolapse of the bowel above the rectum, the rounded edges of the intussuscepted portion will be felt at the fingertip, just out of reach, and the end of the finger can be

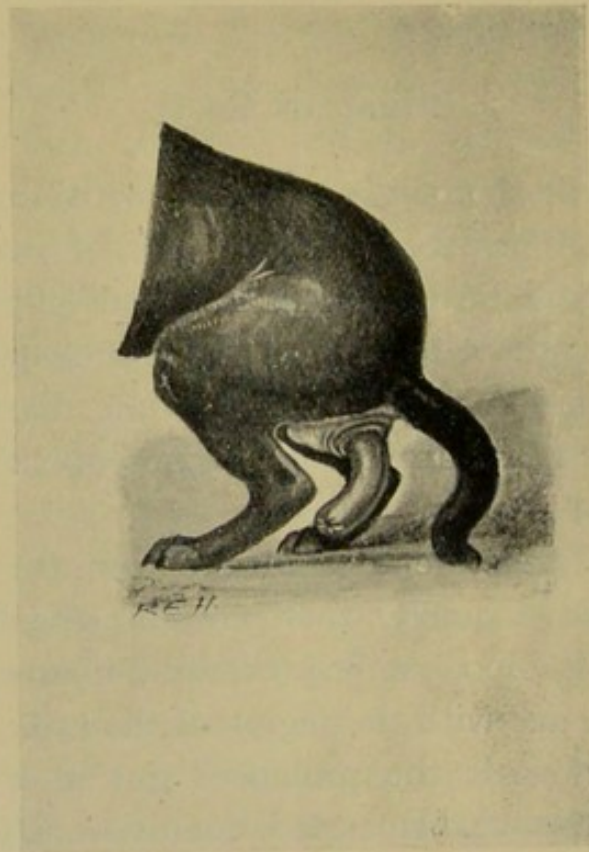


Fig. 140.—Prolapse of the Bowel.

distinctly passed into a pouch between the interior of the rectal wall and this piece of gut.

As a rule, too, in the case of a prolapsed rectum, when returned, the bowel will remain *in situ* for some hours, and often permanently, whereas in the case of an intussusception and prolapse of the small intestine, the gut will be protruded immediately the patient moves a few yards—*i.e.*, of course, if no mechanical means are taken to prevent it.

Reduction and Minor Operative Interference.—If seen soon after the trouble has occurred, the patient should be muzzled and put on a table of convenient height, the protruding parts carefully washed with soap and water and warm antiseptic (the hair around the anus being removed with the scissors or razor), anæsthetized with a 5 per cent. solution of cocaine (see p. 26), and gradually kneaded and manipulated with the ends of the fingers until it is returned. Care must be taken that the mucous membrane, which becomes very friable if prolonged exposure has taken place, is not damaged by the finger-nails; carbolic oil or vaseline are useful adjuncts, and a thin cloth soaked in antiseptic forms a useful protective, besides distributing the pressure over a larger surface. When the parts are very swollen and hard to the touch, either hot fomentations to relax the parts, or cold applications (such as ice) to the gut to act as an astringent, are advisable. The former are preferable when the case is seen early and the parts have not become lacerated. When they have become friable, cold water or ice should be used, as after their application the mucous surface becomes stronger and better able to bear the pressure which must, of necessity, be put upon it. It is astonishing how readily, after continuous fomentation for half an hour or even less, the tissues of the anus and bowel will relax, and enable the operator, by careful manipulation, to return an apparently hopeless prolapse. It is always wise, too, before finally resorting to the use of the scalpel, to chloroform the patient; as this effectually overcomes the resistance offered both by the voluntary movements of the animal itself and the spasm of the anus. The kneading is done with the ends of the fingers and thumbs of both hands, commencing with the extremity of the prolapse, gradually turning the edges into the lumen until only about an inch remains outside, when the anus itself is also manipulated, and with a final push the whole will disappear from view.

The middle finger is then inserted as far as possible, and the interior of the rectum adjusted, a morphia suppository inserted, and one or more stitches put across the anus. If preferred, the draw-string or tobacco-pouch suture (as recommended by Müller),¹ made by passing tape or stout silk suture material in an 'in-and-out' manner through the skin around the anal orifice, may be inserted (see p. 56). These are left *in situ* for a week or so. Stockfleth² advises a similar procedure for constricting the rectum, by placing pins at intervals around the anus and uniting them with threads.

Pessaries introduced into the rectum usually do more harm than good, and act as a continual source of irritation.

The chief trouble to be dealt with is the straining which takes place afterwards and causes a return of the prolapse. This is to be guarded against by keeping the animal as quiet as possible, resort being had to the medicinal use of opium by the mouth or rectum, the latter in the form of suppository. Diet should consist of milk or beef-tea for about a week, and the patient must be kept under observation for some time, as it is a trouble which is very apt to occur again even after two or three months. The author had one case in which the rectum was prolapsed and returned fourteen times before the owner consented to further operative measures. A course of nerve tonics such as strychnine or arsenic, together with attention to the state of the bowels to prevent constipation and the administration of regular meals and exercise, should be commenced after the active symptoms have subsided.

Major Operations.—In cases of recurrent prolapse the animal becomes a continual care and nuisance, and one or other of the following operations may be done:

1. Gersuny's operation, made popular in this country in human surgery by Mr. Stephen Paget,³ which consists in

¹ 'Diseases of the Dog' (Glass's translation), p. 73.

² *Idem.*

³ *Lancet.*

narrowing the lumen of the lower bowel and anal orifice by the subcutaneous injection of sterilized wax.

2. Proctopexia, or ventrifixation of the bowel—*i.e.*, laparotomy and the fixation of the bowel to the abdominal wall by sutures.

3. Amputation.

In each case the most careful attention to antiseptic precautions (see p. 21) must be observed to insure success, and provided this is done a tolerably satisfactory prognosis may be given. Amputation is the most serious of the three, but even with this the result is good if the patient has not become too weak to stand the operation.

Gersuny's Wax Operation.—The patient is placed on the operating-table in the abdominal position and chloroformed, the lower bowel having been washed out by an antiseptic enema (warm boric acid or chinosol solution). The operator then allows the rectum to be prolapsed as far as it will come down (even assisting in the process with the finger) on to a sterilized mackintosh cloth or piece of jaconet, where it is carefully cleansed. The wax to be used (a special variety of white paraffin wax melting at 105° , properly sterilized, and put up in convenient-sized, wide-mouthed bottles) has previously been melted by placing it in a bowl of hot water, and is now drawn up into a sterilized syringe. A thermometer is placed in the water to guard against scalding, as the heat at which it should actually be injected is just above that at which the wax melts. A fold of the mucous membrane of the bowel is picked up between the finger and thumb in a longitudinal direction, the needle is inserted, and the wax slowly injected. During the process, to prevent clogging in the needle, an assistant covers this with a hot swab; as soon as the injection is completed, this is changed to ice-cold water, which is poured over the pillar of wax thus formed in order to make it 'set.' The process is repeated two, three, or perhaps four times, pillars of wax being formed on opposite

sides of the bowel in such a way that (when returned), if straining takes place, these approach one another and mechanically prevent eversion. After as much has been inserted as is deemed sufficient to effect the required purpose, the still prolapsed and everted gut is carefully manipulated between the fingers and gradually returned, the middle finger being inserted to adjust the mucous membrane.

In doing this operation, care must be taken to puncture the mucous membrane in as few places as possible, the wax having an unpleasant habit of escaping freely through the tiniest hole. The operator, too, must always be prepared to guide the fluid wax in the proper direction, and to mould it into the required shape.¹

The author has had the opportunity of testing Gersuny's method on five most troublesome cases of prolapse, all the patients being bull-dogs. In one case the bowel had been prolapsed no less than fourteen times, in a second eight or nine times, and in a third the owner had periodically had to have it returned during a period of three months. In each instance pessaries and sutures of various patterns (interrupted and tobacco-pouch) had temporarily kept the bowel up, but eventually it always protruded again. In every case a successful and permanent result was attained.

Proctopexia, or Ventrifixation of the Bowel.—When a prolapse takes place again and again, and no adhesions have formed, laparotomy is performed in the median line (see p. 158), and the bowel drawn inwards and fixed to the abdominal wall. Several catgut or kangaroo tendon sutures are used, being passed through the mesentery and abdominal muscles whilst the bowel is held away from the direction of the pelvis. Catgut and kangaroo tendon are better than fine silk as suture material, because they take longer to become absorbed, and so allow more time for firm adhesion to take place; silkworm gut would soon tear its way out.

After the sutures have been inserted, the abdominal wound

¹ *Veterinary Record*, 1904. (Proceedings of the Liverpool University Veterinary Medical Society.)

is closed and the patient carefully dieted, as already described, opium being given for the first forty-eight hours.

Mr. H. Gray¹ and Professor Liénaux² (*Annales de Méd. Vét.*) have each reported a successful case treated in this way, and the subject of the illustration (Fig. 141) was a bull puppy, operated upon by the author in conjunction with Mr. F. H. Ridler, M.R.C.V.S., for persistent prolapse of the ileum through the anus. When laparotomy was performed an extensive intussusception was discovered. This was reduced; the bowel was sutured to the abdominal wall as already described, the patient making a satisfactory and permanent recovery.

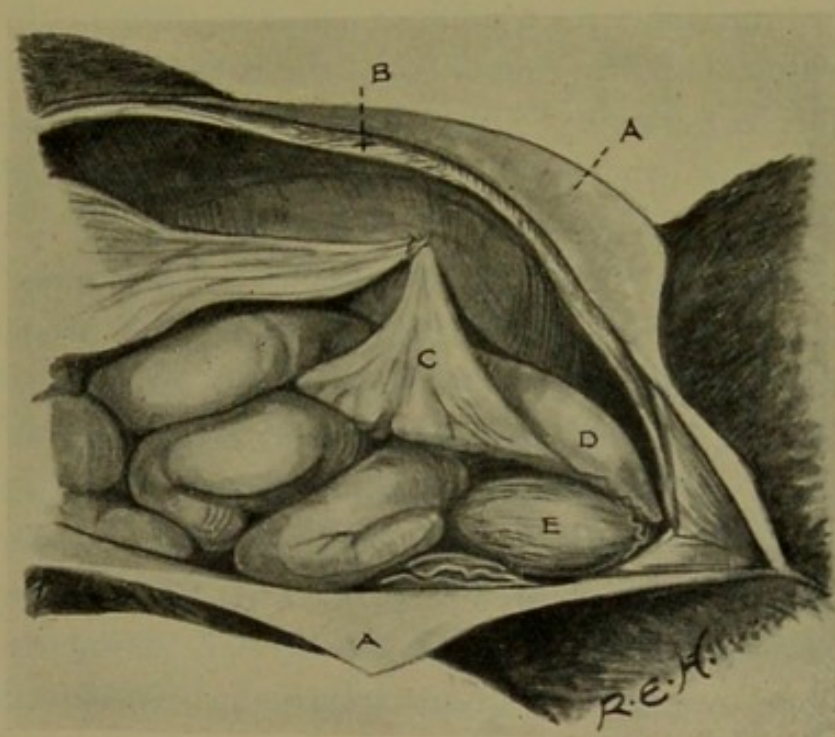


Fig. 141.—Suture of the Bowel to the Abdominal Wall.

AA, Skin; B, abdominal muscles; C, mesentery; D, rectum; E, bladder.

Amputation of the Prolapsed Portion.—When the rectum has been out for some days, and adhesions have taken place, it is often impossible to return it, and amputation must be practised. The patient is placed on the operating-table in the abdominal position (see p. 19), the anal region is carefully shaved and disinfected, and antiseptics are thoroughly applied to the exterior and interior of

¹ *Veterinary Journal*.

² *Ibid.*

the rectum, the prolapsed portion resting on a piece of sterilized mackintosh. Cocaine or general anæsthesia (see p. 23) may be used. A round metal sound or probe (an ordinary clinical thermometer case answers very well) is inserted into the lumen of the rectum, and half a dozen interrupted silk sutures are passed through the bowel downwards on to this and back again with a curved needle close to the skin of the anal orifice, in order to prevent the intestine from completely disappearing into the abdomen when the inverted portion is cut off. A circular incision is then made with a sharp scalpel halfway round *below* the sutures; more sutures are then inserted close to the sphincter to unite the cut edges firmly, and the other half is then excised and treated in the same way.

After-treatment.—The patient should be kept quiet for ten days, on a milk diet only for the first week, the bowels being kept as still as possible. Doses of opium are useful for the first two days, but suppositories should be avoided at first in the majority of cases, as the rectum should be kept as empty as possible. The anus should be kept clean by the use of antiseptics. Sawdust, broken cork, peat moss, or any dusty bedding, should be avoided in the kennel, as, indeed, in any case where a wound is under treatment. A stricture may follow, but this is not usual, and as a rule a good result follows.

In one case which came under the author's observation, a bull terrier, about eighteen months old, was brought in for treatment, with an everted rectum which had been in that condition for two days. It had been replaced and kept in position by sutures which eventually gave way. It was excised under chloroform, about 2 inches being removed. Opium was administered internally, and the patient kept as quiet as possible. This was February 25, 1897. On March 9 a further portion, about an inch in extent, became prolapsed, and was excised under cocaine, and on March 23 a still further portion of about half an inch under a mixture of cocaine and eucaine. About ten minutes afterwards the dog strained and put out quite 5 inches of intestine through the anal opening. This was returned, the anus sutured across, and 30 grains of cannabis indica extract

administered. On the next day a further 10 grains of cannabis extract was given, the animal straining occasionally, but not sufficient to expel the gut. After this date matters progressed favourably and the dog made a good recovery.¹

Imperforate Anus.

This condition is congenital, and is occasionally met with in the newly-born puppy or kitten, there being no visible anal opening. It may not be observed at once, the author having had one case in which the animal was three days old before the owner noticed anything wrong. In this instance there was a distinct subcutaneous bulging of the perinæum, indicating the presence of a rectum full of material which could not escape.

Symptoms.—Beyond not seeming to thrive, there is nothing to indicate this condition on the part of the patient. An examination is the only method of detection.

Operation.—This is easy if a rectum is present, and consists simply in making an incision through the skin in the position where the anus ought to be, cutting a small circular piece out so as to separate the two edges of the wound, opening the rectum, drawing it into the wound, and suturing it there. If the intestine is otherwise normal, a satisfactory termination may be looked for.

In the case alluded to above, all that was necessary was to incise the skin and cauterize the edges in order to prevent union until normal defæcation was established. The patient progressed quite satisfactorily.

Cloaca.

By this is indicated a congenital (or accidental) malformation of females by which the anus and vagina have a common external orifice. If there is enough material present, plastic surgery may be tried; and in cases where it is the result of an accident, the sooner sutures are inserted and the part

¹ *Journal of Comparative Pathology and Therapeutics*, vol. x., p. 174; *Veterinary Record*, vol. x., p. 213.

treated antiseptically, the better. In the newly-born puppy or kitten, it is better in most cases to leave the animal until the tissues become larger and stronger before attempting operative interference.

Hæmorrhoids or Piles.

A dilated and very troublesome varicose condition of the veins around and just within the anus is not infrequent in fat old dogs, especially pugs, and gives rise to a good deal of pain and irritation, especially when fæces are passed, and when the animal is at all constipated.

Symptoms.—The patient is continually licking the parts and rubbing along the ground. The anal surface frequently appears moist and swollen, and the fæces may be streaked with blood.

Treatment.—Attention should be paid to the state of the bowels, mild doses of cascara, sulphur or other laxatives being given regularly, whilst locally the parts must be kept clean and dressed with hazeline lotion (1 to 8 or 10), or with extract of hamamelis made into an ointment. The B.P. ointment of galls and opium is also a valuable remedy. If the piles are 'internal'—*i.e.*, inside the rectum—these medicaments must be so inserted that they come into direct contact with the dilated veins, and their administration must be carried out frequently during the day.

Should medicinal treatment prove ineffectual, operative measures must be adopted.

Operation.—The piles should be picked up one at a time with forceps, and either ligatured by passing a curved needle and silk around them, the intervening portion being excised, or clamped and removed with the actual cautery at dull red heat.

If they are to be ligatured, it is best to form a groove at the base of each by cutting around it with a pair of blunt-pointed scissors, the incision being deeper on the cutaneous

than on the mucous aspect. The ligature should be of floss silk, which has been thoroughly well boiled to make it sterile. In every case the anus should be thoroughly stretched by the introduction of the forefingers of the two hands of the surgeon until the contraction of the sphincter is entirely overcome.

After-treatment.—After the operation the patient should be kept without food for twenty-four hours, and during the next three or four days should only receive milk, beef-tea or other sloppy diet in sparing quantities. Doses of opium should be given two or three times daily, the object being to keep the bowels at rest. On the third or fourth day a dose of oil and a warm enema can be given if the patient has had no action of the bowels and seems uncomfortable. Locally the parts must be kept clean and dressed with some antiseptic.

Fistula of the Anus.

True fistula of the anus is comparatively rare in the dog or cat; enlarged anal glands and other discharging sinuses in this region are not uncommonly confounded with it. Foreign bodies, such as needles and sharp pieces of bone, are the usual cause, and even fish-hooks have been discovered in the rectum. Careful examination should always be made by passing a blunt-pointed probe up the suspected fistula, and at the same time feeling for the internal orifice with one finger in the rectum. The probe must be passed very carefully, and not in any way forced, as there may be several sinuses, some of them being blind ones. A rectal speculum (Fig. 182) and electric lamp are of value for thorough examination, and in many cases when anæsthesia is complete a considerable portion of rectum may be everted.

Symptoms.—The patient is continually attempting to reach the anal region with the tongue, or drags its hind-quarters along the ground, exhibiting signs of great irritation and

pain. The parts are very painful on manipulation and during defæcation, especially if constipation is present.

Operation.—Treatment consists in opening up each sinus freely with a director and bistoury, and carefully curetting the walls (or treating them cautiously with some caustic to destroy their indurated lining), and afterwards applying antiseptics in the same way as to a sinuous wound.

Prognosis.—In cases where ulceration of the bowel has not taken place, the wound generally heals up and brings about a satisfactory termination, although progress may be slow. Either a local or general anæsthetic should always be used.

Obstruction of the Anal Glands.

The anal glands are two sac-like pouches, lined with mucous membrane, situated one on either side of the rectum, and opening into the latter by orifices which are to be found just inside the anus. They frequently become filled with purulent or semi-solid sebaceous material which cannot escape, and give rise to symptoms of irritation and annoyance on the part of the animal.

Symptoms.—The patient will be continually licking the anal region or rubbing it along the ground. Examination reveals that the parts are sore, perhaps visibly swollen, and often ulcerated. Defæcation, too, especially if constipation is present, is painful.

Operation.—Temporary relief can be given by the application of pressure, the finger being introduced into the rectum and the contents of the glands evacuated, but as a rule they refill in a very short time.

An hour before operating the rectum should be emptied by a warm glycerine and boric acid enema.

The parts should be painted with a 5 per cent. cocaine solution or a general anæsthetic administered (see p. 23), and the glands freely opened from the outside about a third or

half an inch from the sphincter of the anus, with a Symes' knife or fine scalpel. The interior is then scraped with a small sharp curette (see Fig. 40), and the whole of the secreting lining destroyed. The parts are then treated antiseptically like an ordinary wound.

Prognosis.—If the operator has shaved around the part and otherwise practised antiseptic precautions, he may safely promise a complete and rapid recovery. The author has



Fig. 142.—Anal Adenomata.¹

never seen or heard of a bad result in consequence of the complete obliteration of one or both anal glands.

Rectal and Anal Tumours.

These are treated, where possible, as already described (see p. 66). Unfortunately, they are often of a malignant nature, the chief varieties being anal adenomata in connection with the anal glands, fibromata in very fat, unhealthy dogs, and carcinomata of the rectum.

¹ For this photograph I am indebted to Professors Mettam and Wooldridge.

CHAPTER XVI

OPERATIONS ON THE OMENTUM, LIVER, SPLEEN, AND PANCREAS

The Omentum.

THE omentum is frequently involved in cases of hernia, and may even be the only organ found in the sac. In wounds of the lower portion of the abdominal wall it is very apt to be the first to protrude. In appearance it looks like a white fatty mass. If there is any difficulty about returning it, or if it is at all in the way or soiled, the protruding portion may be excised without the slightest fear. In fact, if it is at all soiled, this is by far the safer plan, as it is a structure which does not readily lend itself to antiseptic cleansing.

In one case which came under the author's observation the whole of the omentum was removed, and the patient did not seem in any way to suffer from its disappearance.

Operation.—Under the usual antiseptic precautions (see p. 158) any vessels in the line of excision are secured by ligature, the parts below are removed either by scissors or scalpel, and the remainder returned into the abdomen. The abdominal wall is then treated as already described under laparotomy.

The Liver.

Practically, the surgery of the liver in the dog and cat is confined to the occasional removal of a tumour which has

sufficient pedicle to permit of this procedure.¹ Even this had better be done with a clamp and the actual cautery (a heated scalpel does well), as the liver tissue is so vascular and friable that it does not lend itself well to the application of sutures. If a rupture is only suspected and the symptoms are not

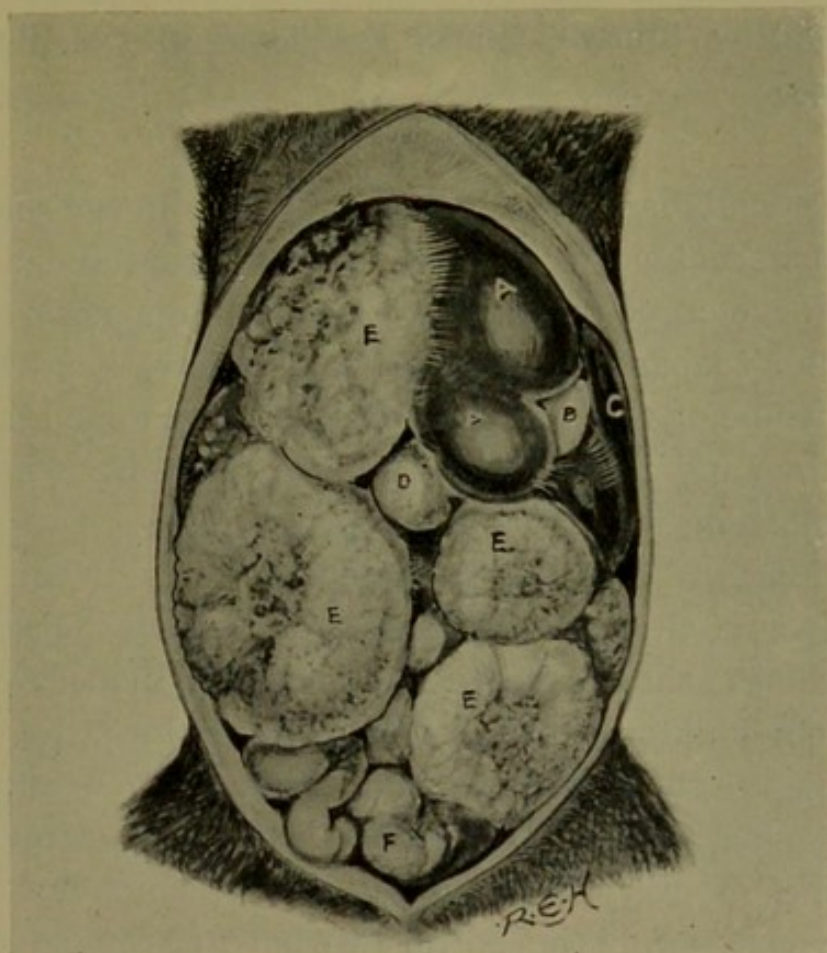


Fig. 143.—Inoperable Sarcomata of the Liver in the Abdomen of an Irish Terrier Dog.

A, C, Liver tissue ; B, gall-bladder ; D, stomach ; EEE, sarcomata ; F, intestine.

urgent, rest and hæmostatic medicine internally is the best course to adopt. Some of the tumours attached to the liver are of enormous size, and in time almost fill up the abdomen, giving to the bitch or female cat the appearance of pregnancy, and to the male that of ascites, from

¹ *Journal of Comparative Pathology and Therapeutics*, vol. xi., p. 251 (Nelder and Hobday).

each of which a careful distinction must be made. Sarcoma is the commonest variety, and, on account of its malignancy, it is questionable whether the most humane plan when this tumour is discovered, even if no others are in sight, is not to destroy the patient painlessly before consciousness returns. Sometimes the liver will be almost entirely destroyed by tumour tissue, as shown in the illustration (Fig. 143).

The Spleen.

Occasionally large tumours are met with in the spleen, and during external violence it may be badly ruptured, and fatal hæmorrhage ensue if it is left. A certain diagnosis can only be made by laparotomy and internal observation. Removal of the whole of the organ is always a serious operation, both at the time and as regards its sequel, death from marasmus often following within twelve months.

Mr. Martyn Jordan has, however, shown by an experimental research into the effects of partial excision upon healthy dogs that excellent results can be obtained.

The chief untoward results to be looked for at the time of operating are those of death from hæmorrhage or shock; the former must be guarded against by careful clamping and ligaturing of every vessel along the splenic omentum or those which supply the portion to be excised, and to avoid the latter the operation should be performed as rapidly as possible, hypodermic injections of stimulants being at hand for immediate use if required.

Operation—Splenectomy.—For extirpation of the whole organ, the patient is prepared, secured, and operated upon as in an ordinary laparotomy (see p. 158), the incision being made on or near to the median line, about an inch behind the sternum. The spleen is then sought for and brought as much out of the orifice as necessary, each vessel, however small, being clamped or ligatured in two places before being cut through, after which the organ is removed.

In six cases in which Mr. Jordan removed the whole spleen, 'all the dogs suffered greatly from shock, and there were three deaths,' one being from marasmus and two from shock.

For partial excision Jordan recommends the following method of continuous ligature, by which he obtained a practically bloodless section: 'A long needle threaded with fairly coarse silk twist $1\frac{1}{2}$ feet long is inserted on the inner

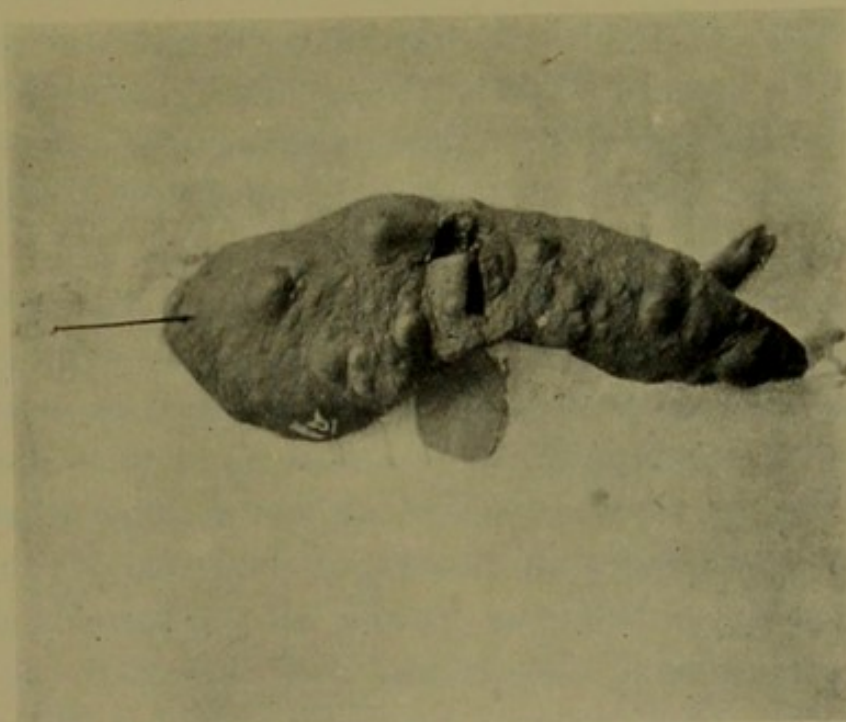


Fig. 144.—Tumours (Sarcomata) of the Spleen.¹

or under surface about half an inch from the edge or border, and passed through the thickness of the spleen, emerging on the outer or upper surface about the same distance from the edge; the ligature is drawn through until the ends are equal; the free end is brought up round the border of the spleen, and a double turn made with the two ends and drawn as tightly as possible, this turn being kept over the exit of the needle. The needle is then passed back through the

¹ This spleen was removed on *post mortem* from the pug-dog illustrated in Fig. 42, and the case was quite a hopeless one.

spleen on the occluded side of the organ, as close to the line of ligature as possible, and an eighth of an inch from the edge or border side of the turn; this being done in order that the next loop shall include the spleen where the needle has previously passed through, so that any oozing along this track shall be stopped when the loop was drawn tight. The needle is then repassed through the spleen from the under to the upper surface half an inch further on, and a double turn again taken and drawn tight. Continuing in this way, the spleen is traversed. A reef-knot is then tied and the ends cut short. The occluded end of the spleen is then cut through close to the line of the ligature.'

Interrupted, instead of continuous, interlaced ligatures are sometimes used.

Prognosis. — Following out his method of continuous ligature, Jordan had twenty-one successes out of twenty-two cases, the animals being Indian pariah dogs varying in ages from a month upwards. In nineteen of them the lower half of the spleen was excised without a single fatality or noticeable disturbance afterwards; in the remaining three, in which the upper half was excised, all the animals showed great constitutional disturbance, and one death occurred from shock. This authority concludes that it is the removal of the upper half of the spleen which is full of danger, on account of the risk of shock and after-hæmorrhage, and that it is much more difficult to operate upon than the lower half.

Removal of Tumours from the Abdominal Organs.

Diagnosis of tumours of the abdominal organs can usually be made with certainty in thin emaciated patients, but in fat animals it is often a matter of difficulty. The liver and spleen, and the uterus and ovaries in the case of the bitch, are the organs most commonly affected (see pp. 218 and 295),

and of these the uterine and ovarian are the most successfully dealt with.

Tumours of the liver are especially vascular, and their removal is accompanied by hæmorrhage.

In all cases the principles of operation are the same. Rigid antiseptic precautions must be adopted, and laparotomy performed under anæsthesia; the tumour is then sought for, and removed by ligature and the knife, or whatever way is deemed advisable by the operator, in order to get as little hæmorrhage as possible, the abdominal wound being sutured and treated in the usual way.

Sarcomata have been the most common variety met with in the author's experience.

CHAPTER XVII

HERNIA

A **hernia** (or **rupture**, as it is more commonly termed) consists of the protrusion of an organ, or portion of an organ, out of its normal situation, through an opening in the surrounding tissues.

As a general rule, when speaking of hernia, it is understood that the organs of the abdomen are referred to, although a hernia of brain substance or other parts of the body substance may occur, and quite correctly be described under this heading.

General Remarks.—The varieties most commonly seen in the dog and cat are umbilical, abdominal (or ventral), and inguinal. Scrotal, perineal, and femoral are met with, but are comparatively rare. Care must be taken to differentiate between tumours and abscesses, occurring in these regions, and hernia. In some cases this is by no means an easy matter, even to those who have had considerable experience. In hernial sacs one must endeavour to trace the form of the herniated organs by careful manipulation between the finger and thumb, and if there is any doubt about the matter, the patient should be again examined after a course of purgative medicine and fasting.

The main principles of surgical treatment are the same in all cases, and consist in the return of the organs to their normal situation and the adoption of the steps necessary to retain them there. In all cases the patient

should be carefully prepared as already described (p. 2). If a general anæsthetic is used (see p. 29), the patient is placed on the operating-table in the abdominal posture (Fig. 14), and afterwards turned on its back or side as the operator may consider the most convenient. If a local anæsthetic (see p. 24) is sufficient, the animal is at once placed in the most convenient position for the performance of the operation, and the anæsthetic applied. Rigid antiseptic precautions (see p. 7) are always necessary with regard to instruments, the parts to be incised, and the operator's fingers.

If the internal organs are at all adherent, the greatest care must be taken to prevent injuring them with the scalpel.

The author had one case of ventral hernia in a cat in which this accident occurred, the small intestine being cut transversely for fully seven-eighths of its circumference. A number of worms (*Ascaris mystax*) were removed from the interior of the bowel, the gut was carefully cleansed with chinosol solution and sutured with silk (Lembert's pattern), and the patient made an excellent recovery.¹

Instruments required.—These consist of two sharp scalpels, a director, probe, blunt-pointed scissors, two pairs of dissecting forceps, two or three pairs of Spencer Wells' artery forceps, two curved and two half-curved needles, silk and silkworm gut.

In addition, a hernia bistoury, a pair of MacEwen's needles (Fig. 155), and for perineal hernia, if the distended bladder is suspected to be present, a small exploring trocar and cannula, are useful adjuncts.

Umbilical Hernia.

This condition consists of a swelling at the umbilicus: it may be soft and fluctuating, in which case it is generally reducible, the umbilical ring being plainly defined; or it may be irreducible from adhesions or because the umbilical ring has contracted since the mass was extruded. In the latter

¹ Ridler and Hobday, *Veterinary Record*, 1901.

case it usually feels hard to the touch, and the contents consist of omentum alone. When the bowel is present there is danger of strangulation.

The hernia may vary in size from that of a pea to half an orange, and is frequently congenital; severance of the umbilical cord, either by the bitch or the canine accoucheur, too close to the umbilicus will also cause this trouble. It is

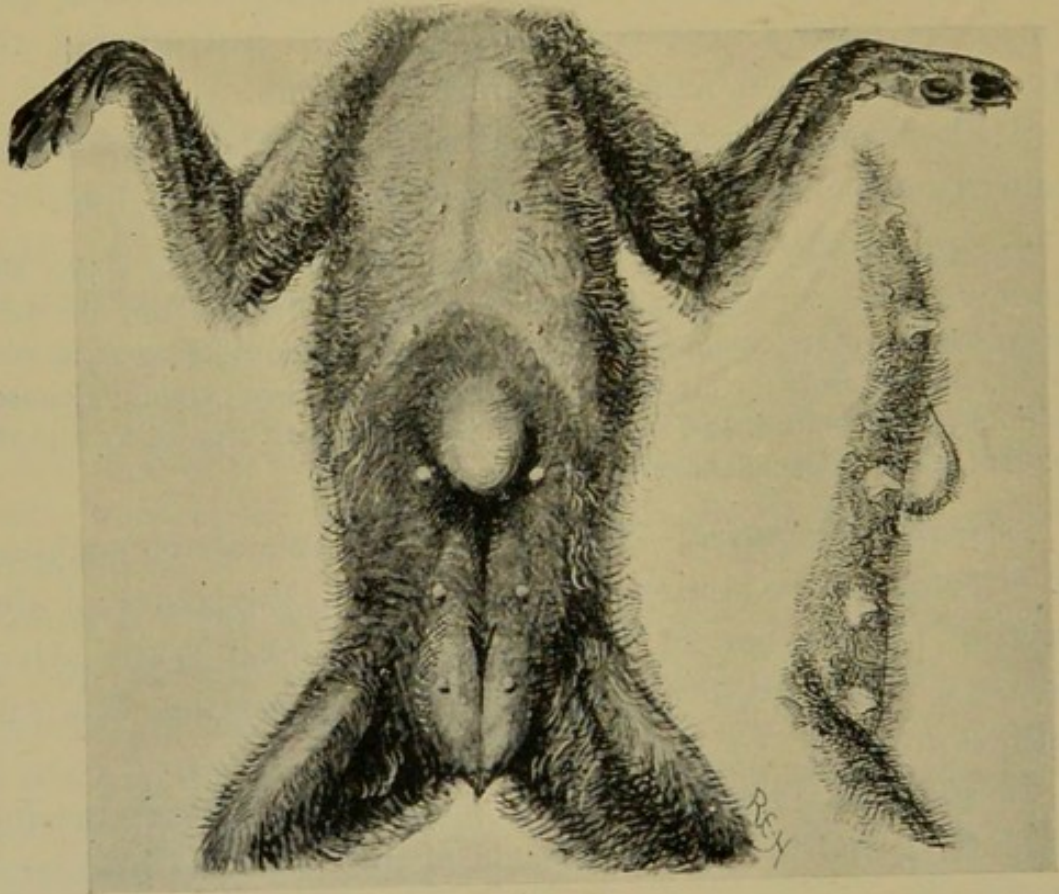


Fig. 145.—Umbilical Hernia (Front and Lateral Views).

commonly met with in all breeds, particularly pure-bred bulldogs, Japanese and St. Bernards.

Coughing or struggling will cause the hernial sac to become suddenly very tense and distended.

In the bitch intended for breeding purposes, the presence of an umbilical hernia is more serious than in the dog, and there is no doubt that the tendency is hereditary. In both sexes, if the hernia is of any size, steps should be taken

to reduce the abnormality, especially in the more active breeds, as the skin over the rupture is always very thin, and it has only to become lacerated in order to expose the abdominal organs, and possibly give rise to a fatal peritonitis. Continual lying on the skin of the abdomen is apt to cause ulceration of the skin and subsequent adhesions of the contents to the sac. Occasionally, as the patient reaches one or two years of age and the tissues become stronger, the hernia will disappear, or will become so reduced in size as to give no cause for anxiety.

Treatment.—A small hernia may be reduced by the aid of a rounded strip of cork affixed over the swelling by strips of plaster. In a quiet puppy this is well worth a trial. If that fails, the radical operation will usually bring about a complete and permanent cure.

The skin is shaved, scrubbed, and carefully incised directly over the centre of the swelling by the aid of a scalpel and director. The contents of the sac are returned into the abdomen, all adhesions to the edges of the ring being broken down. The edges of the dilated umbilical ring are refreshed so as to give a raw surface and drawn together with silk or gut sutures, the skin sutured with silkworm gut, and the wound coated with collodion and iodoform (or orthoform).

Sometimes a simple solution of the difficulty consists in excising a portion of the omentum and returning the remainder into the abdomen before suturing the ring as mentioned above.

Abdominal (or Ventral) Hernia.

The term 'ventral (or abdominal) hernia' is applied to a protrusion of some of the internal organs through a hole in the abdominal wall in some situation other than the umbilical, inguinal, perineal, scrotal or femoral regions. It may be of large size, and can generally be traced to some injury, such as

a kick or violent blow. Sometimes it occurs as a sequel to an operation on the belly wall.

The contents of the sac may consist of any of the abdominal organs, especially the intestine, which is apt to become strangulated if the neck of the sac is at all constricted. It consists of a soft, fluctuating swelling which is readily distinguished from tumour tissue by the impression given to the finger-tips.

Treatment.—A general anæsthetic is much the safest and most convenient for this, as any struggling on the part of the patient is apt to cause protrusion, and consequent risk of soiling, of the contained organs.

Under strict antiseptic precautions (see p. 2), the skin and sac wall are incised with scalpel and director, the contents returned into the abdomen (care being taken to see that all adhesions are broken down), the edges of the muscles are lightly scraped and freshened up, and the edges of the rupture are drawn together. If it is possible to secure the peritoneum, three layers of sutures are inserted: the first, of fine silk, through the peritoneal coat; the second, of silk or catgut, through the muscle; and the skin with silkworm gut. If the peritoneum cannot be sutured separately, care must be taken to pass the silk or gut sutures through it when suturing the muscular layer. The resulting cicatrix is stronger. A layer of collodion and iodoform or orthoform (see Laparotomy, p. 158) hermetically seals the wound, and, if the rent has been a large one, it may become necessary to affix a bandage to give support for a time. The silk sutures become buried and absorbed in time, whilst the silkworm gut is removed in about a week or ten days.

Inguinal Hernia.

Inguinal hernia is common in bitches which have already borne young, and is not infrequent in maiden animals. Between the years 1896 and 1900 alone, the author met with

nine cases in females which had never been mated by the dog; in one puppy, a Pekinese only three weeks old, there was a double inguinal hernia, each side being quite as large as a walnut and easily reducible. It is most frequently met with on the left side. As a rule, in these cases, the contents of the sac consist of one or both horns of the uterus; frequently in addition one finds intestine and omentum.

In one case met with in April, 1896,¹ a small Manchester terrier bitch, with a double inguinal hernia, had in the right sac a portion of the small intestine, the pancreas, omentum, bladder, right horn of the uterus, the cæcum, and even a portion of the rectum.

Sometimes a single horn of the uterus is found to be herniated in each inguinal region, and occasionally one or two foetuses are present.

In another instance met with by the author, a fox-terrier bitch was operated upon for an inguinal hernia containing a pregnant horn. The foetus was removed, and the horn afterwards excised, the animal suffering so little disturbance that she gave birth to a puppy in the ordinary way seventeen days later.²

It is diagnosed by palpation with the finger-tips, the patient being turned on her back and held loosely by the hind-legs whilst the diagnosis is made. Care must be taken not to mistake cystic adenomata or other tumours in the inguinal region for a hernia (see Figs. 146 and 147).

Treatment.—Chloroform is by far the best anæsthetic to employ, as it is so essential that the patient shall be perfectly still.

An attempt should always be made to reduce the hernia by gentle pressure under a general anæsthetic when the parts are thoroughly relaxed. Whether this can be effected or not, the skin is prepared antiseptically (see p. 2), and an incision is made through the skin directly over the hernial sac, care being taken not to penetrate this, and, if possible, to avoid

¹ *Journal of Comparative Pathology and Therapeutics*, vol. x., p. 171.

² *Ibid.*, vol. viii., p. 153.

making an opening into the peritoneum. If the organs have not been returned, another attempt may now be successful,




Fig. 146.—Tumours in Inguinal Region (for comparison with next figure).

particularly if the exterior of the sac be carefully separated from the surrounding skin by means of a scalpel handle or



Fig. 147.—Inguinal Hernia.

some blunt instrument. The extremity of the sac is seized with a pair of pressure forceps—Spencer Wells' or Pean's pattern of artery forceps (see Fig. 29) answer admirably—and

the sac itself twisted slowly until it forms a kind of pedicle, around which a ligature of aseptic silk or gut can be placed. The lower portion of the sac is then cut off, and the external wound sutured and treated on aseptic lines. If very much dilated, the inguinal ring should also have several sutures drawn across it.

In some cases of inguinal hernia, however, the sac has to

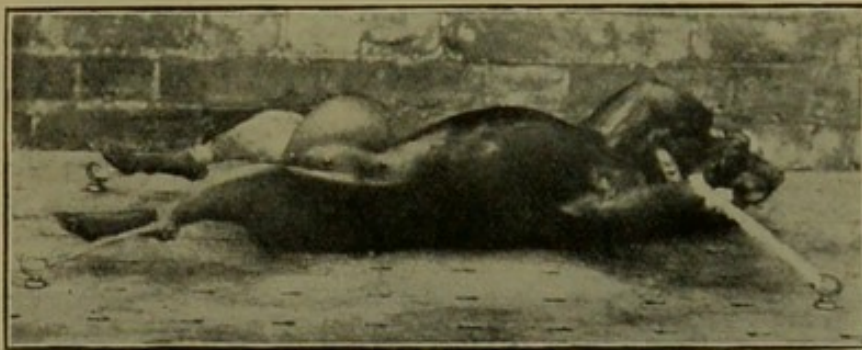


Fig. 148.—A Double Inguinal Hernia fixed in a Suitable Position for Operation.

be opened and its contents exposed before reduction can be effected. The greatest care must now be used to avoid septic infection. After the organs have been returned, the inguinal canal must be sutured with silk or catgut, a pressure pad of aseptic wadding being applied or not according to discretion,



Fig. 149.—Hernia Bistoury.

and the external wound sutured with silkworm gut and covered with iodoform collodion.

At times it is found necessary to incise the inguinal ring before the organs can be returned, and for this purpose a special bistoury with only a very small portion of its edge sharpened is cautiously used. At other times some portion of the herniated organs, particularly in the case of omentum

or uterus, has to be excised; this is best done with the scalpel after applying a ligature, the stump being sutured to the inguinal ring or returned into the abdominal cavity.

The decision as to whether a bandage should be applied here or not must be left to the operator's discretion: in some cases it is necessary; in other cases, where the patient is of an irritable temperament or the weather is very warm, it is apt to do more harm than good.

Scrotal Hernia.

Fortunately this condition is not very common, as when met with it is most troublesome to permanently relieve,

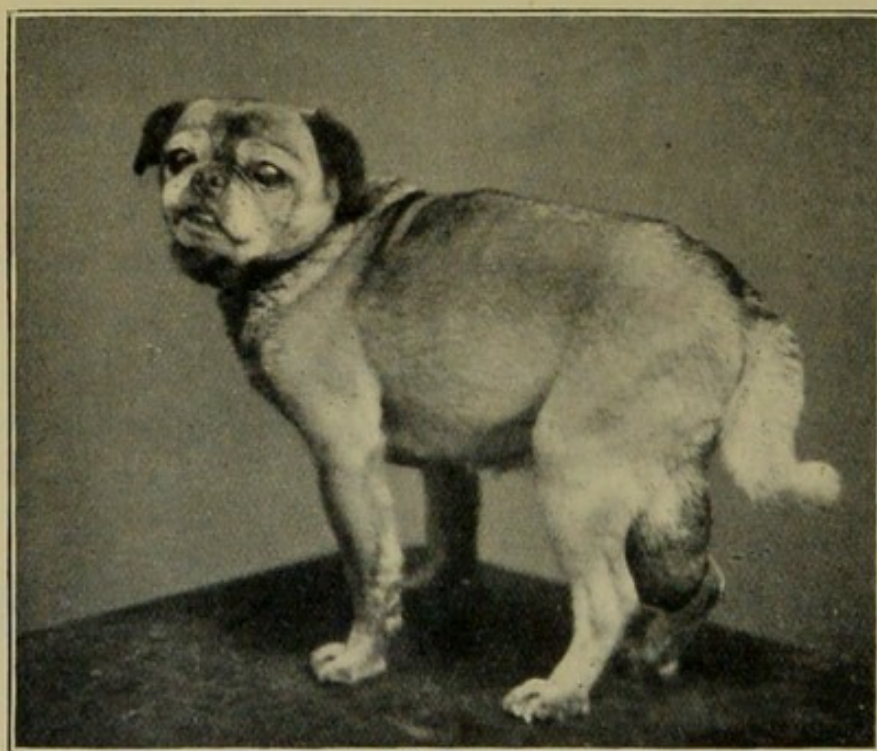


Fig. 150.—A Pug-dog with Scrotal Hernia.

unless castration is allowed to be performed at the same time. It consists of a swelling, usually reducible in the scrotum, the hernial sac containing a loop of omentum or intestine. It is a very serious condition if intestine is present, as at any time the accumulation of food material may cause

the bowel to become so much enlarged that it becomes incarcerated, and would lead to gangrene of the bowel and septicæmia if unrelieved.

Operation.—If castration is done matters are greatly simplified, as the prolapsed intestine is carefully returned under chloroform (the usual antiseptic precautions having been adopted), and an incision made into the scrotum down as far

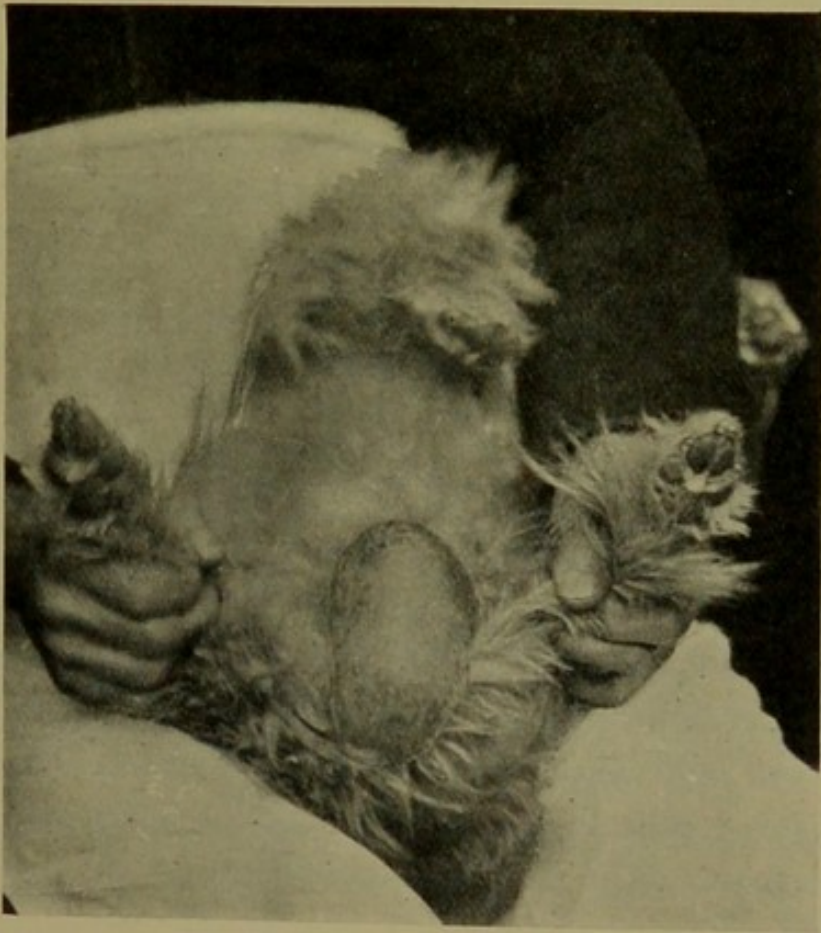

Fig. 151.—An Aged Yorkshire Terrier with Scrotal Hernia.¹

as the tunica vaginalis testis. At this stage the sac is clearly stripped from the surrounding tissues, and a silk ligature fixed around it above the testicle. The part below is excised, the abdominal cavity not being opened. The skin is sutured with silkworm gut, and covered with iodoform and collodion in the usual way.

¹ For this photograph I am indebted to Mr. H. Gray, M.R.C.V.S.

Another method consists in opening the sac, ligaturing the cord with aseptic silk as high up as possible, removing the testicle, and closely suturing the end of the sac, the skin being stitched and dressed afterwards in the usual way. Occasionally the intestine can be returned and the canal drawn together with sutures so that the neck of the sac is too narrow to admit the prolapsed gut again, and yet does not press upon the vessels or other structures of the cord.

If castration is not to be practised, and the hernia keeps returning after being repeatedly reduced, laparotomy may be performed, the herniated intestine withdrawn and sutured to the abdominal wall (see p. 211).

Perineal Hernia.

This occurs as a soft swelling at the side of the anus; it is not so common as the inguinal or umbilical varieties.

The herniated organs are usually omentum or bowel, and the bladder is not infrequently included. The author has met with five such cases within a comparatively short time. If the latter is present, it is of considerable danger to the patient, and may cause retention of urine and excessive pain. Under such conditions the urine must be withdrawn either by the catheter or, if that is impossible, by a fine trocar and cannula.

In the case of the dachshund, represented by the photograph in Fig. 152, the omentum was the only organ herniated, and the patient lived to a good old age, suffering no pain, but merely a certain amount of inconvenience.

Fig. 153 represents a perineal hernia in an aged collie, which contained the bladder and a certain amount of omentum. The bladder used to become distended, causing great pain, and the urine was drawn away on numerous occasions with a catheter. On five separate occasions, however, this was impossible, and a fine exploring trocar and cannula was used, with most excellent results. It was an impossible case upon which to attempt the radical cure.

Operation.—On account of the horizontal position of the patient, it is often difficult to perform a radical cure, and if the animal is in no apparent danger (particularly if the contents are only omentum), it is better not to interfere surgically. The only precaution necessary is to keep the patient under occasional observation and avoid constipation.

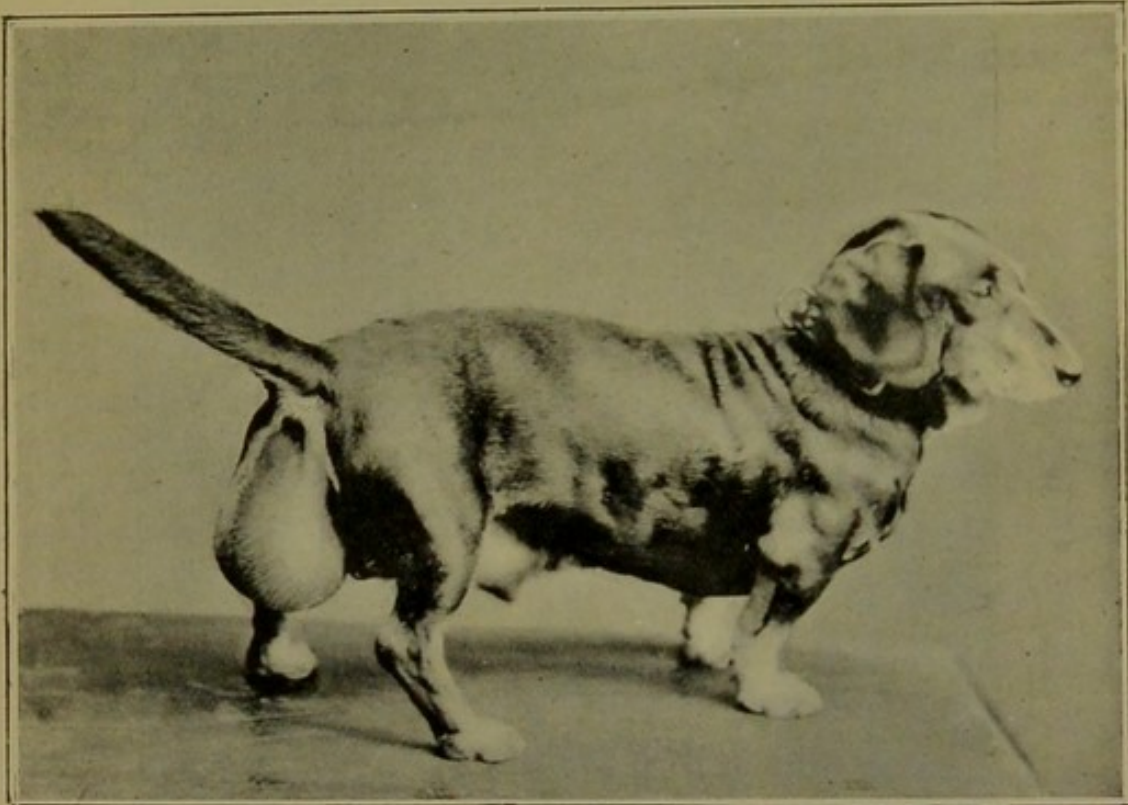


Fig. 152.—An Aged Dachshund with Perineal Hernia (Omentum).¹

If, however, the bladder is herniated, something should be done.

Three courses are open: In a case such as that shown in Fig. 152, the sac may be opened, the protruding omentum ligatured and excised, the bowel returned, and the skin excised (if very pendulous) and sutured in the usual way;² secondly, laparotomy may be performed, the contents withdrawn into the abdomen, and the sac sutured to

¹ For this photograph I am indebted to Mr. S. E. Holman, M.R.C.V.S.

² *Journal of Comparative Pathology and Therapeutics*, vol. xii., p. 260.

the abdominal wall (see Fig. 141); or, thirdly, the hernial sac may be dissected out, ligatured and excised, and the stump sutured to the peritoneal wall. The ring is then closed with interrupted sutures.

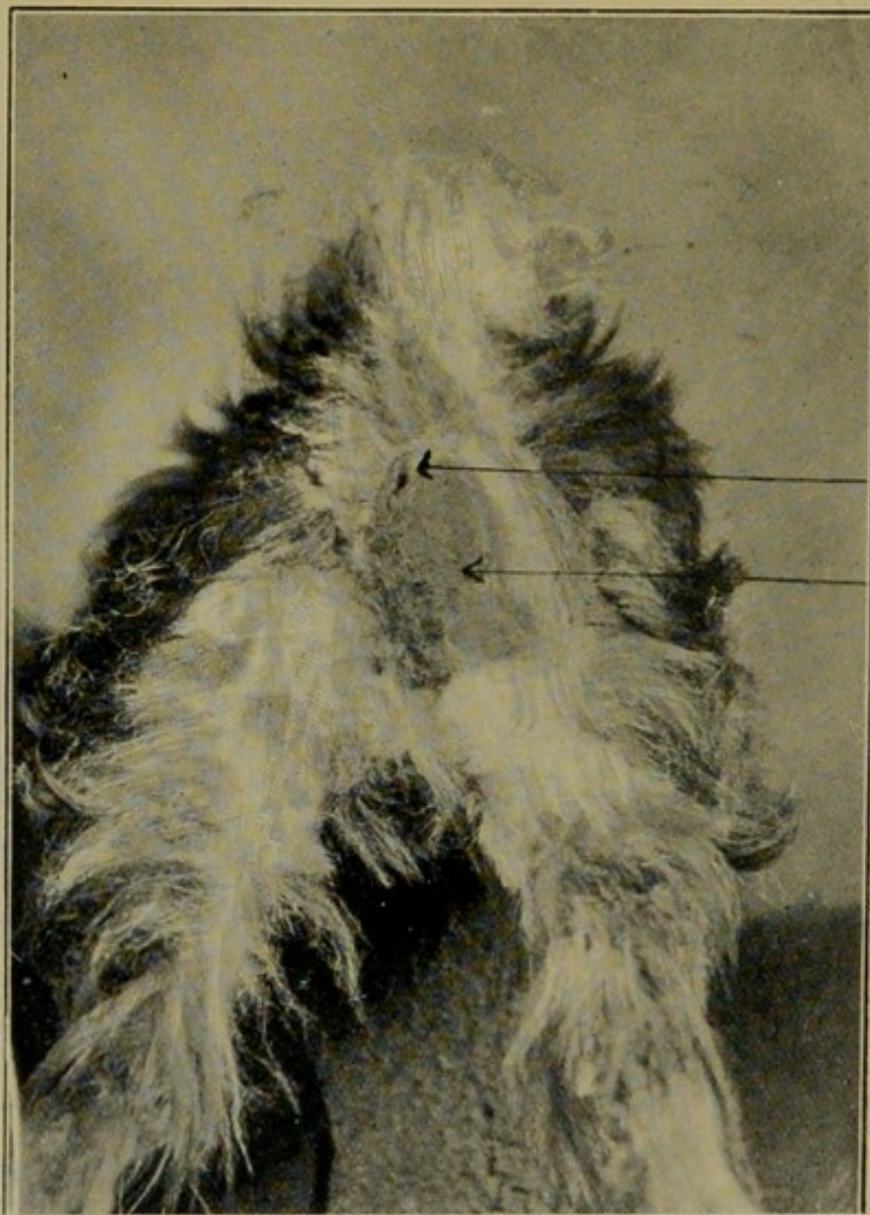


Fig. 153.—Perineal Hernia in a Collie.

The bladder was herniated, and was punctured on five separate occasions, with excellent temporary results.

Fig. 154 illustrates a case in which a perineal hernia had caused great pain and formed a fistula. The bladder was opened, and for eleven days urine escaped through this orifice, the normal passage being blocked by a purulent swelling of the urethra. Under antiseptic treatment the

wound healed, and the patient made an excellent recovery. The perineal hernia, however, remained, as the owner did not desire any further operation, the fundus of the bladder adhering to the wall of the sac.

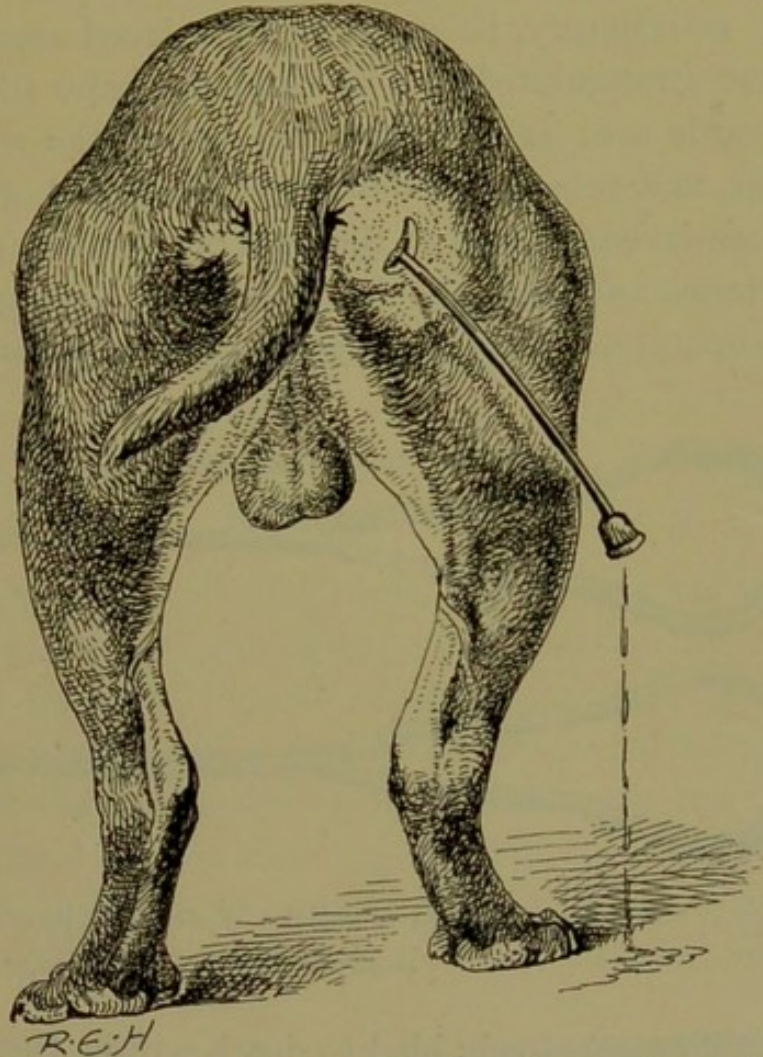


Fig. 154.—Catheter inserted into the Bladder, illustrating a Perineal Hernia which had been opened and formed a Fistula.

Femoral Hernia.

This hernia is of such extremely rare occurrence as to only merit a passing allusion to it. According to Müller,¹ it is occasionally seen after fractures of the pelvis, occurring as a soft painful swelling in the inner fascia of the thigh. The principles of operation are the same as with other herniæ, very great care being necessary on account of the close proximity and size of the bloodvessels in this region.

¹ 'Diseases of the Dog' (Glasse's translation).

Prognosis and Sequelæ.

The sequelæ of the operative treatment of hernia are as a rule satisfactory, provided the displaced organs have not become strangulated. The chief mishaps likely to occur afterwards are: (1) Violent removal of the sutures by the patient, and subsequent descent of the bowel or other organ. (2) Hæmorrhage either at the time of operating or afterwards. All arteries and veins should be ligatured during the progress of the operation. Two of the author's most promising patients

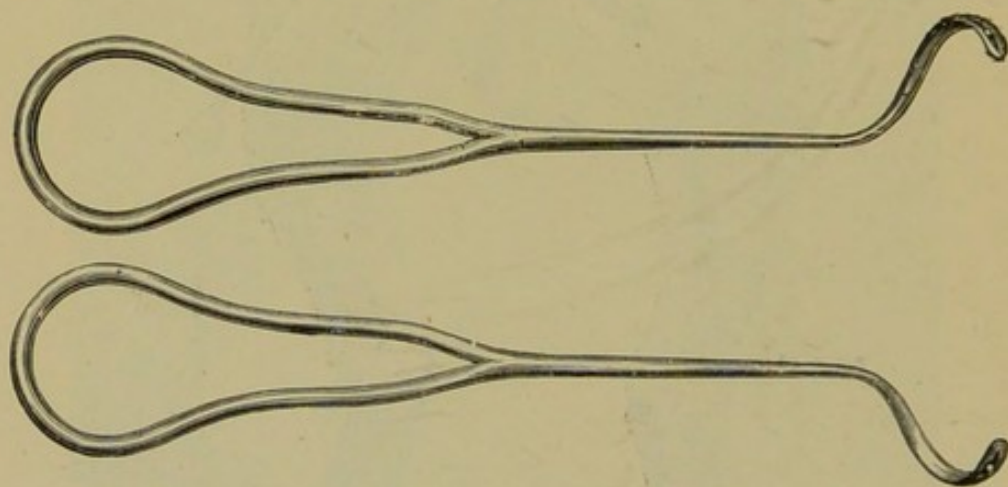


Fig. 155.—Curved Hernia Needles (MacEwen's) for suturing the Inguinal Ring.

(inguinal cases) slowly bled to death within three days after the operation, from uncontrollable hæmorrhage due to injury to some veins at the time of operating. (3) Peritonitis, which can only be avoided by absolutely following out the principles and details of aseptic surgery.

These statements are based upon the notes made upon forty-four consecutive cases,¹ of which twenty-five were inguinal, ten umbilical, two abdominal, two scrotal, and five perineal.

¹ *Veterinarian*, March, 1896; *Journal of Comparative Pathology and Therapeutics*, vol. viii., p. 151, vol. x., p. 170; *Veterinary Record*, vol. x., p. 282.

CHAPTER XVIII

THE URINARY ORGANS

Examination of the Urethra and Bladder; Passing the Catheter.

IN the male the bone of the penis, which is furrowed to allow of the passage of the urinary fluid, makes the choice of a sound or catheter of small calibre a necessity. In fact, in cats and in puppies of some of the very small toy breeds the passage of the instrument through this furrow is a matter of impossibility. To examine the urethra and bladder for stricture or for calculi and other foreign bodies, a catheter, bougie, or flexible metal sound, is used. Catheters and




Fig. 156.—Flexible Metal Sound.

bougies are made in sizes, known according to the diameter, as Nos. $\frac{1}{2}$ to 12. For canine and feline work Nos. $\frac{1}{2}$ to 5 answer in the majority of cases.

The metal sound is of especial value when a calculus is present, as, when its extremity strikes the hard stone, a distinct 'jar' is communicated to the operator's fingers.

In the female of the larger breeds the instrument can be passed whilst the animal is standing, but in the smaller ones

it is often of advantage to place the patient in the dorsal position, and introduce a speculum (Figs. 49 or 182) as an aid to finding the urethral entrance. The catheter, which in the female may be gum elastic or metal instrument, is guided gently by the forefinger into the orifice of the urethra, this being found as a small opening on the floor of the vagina, and carefully introduced in a slightly downward and backward direction into the bladder.

To pass the catheter in the male, the animal should be placed on its back or side, the operator having both hands free to manipulate the instrument and penis. The penis is forced gently but firmly out of the prepuce, the latter being pushed back at the same time, and the catheter carefully introduced into the urethra. Gentle pressure is then exerted, and the catheter slowly passed into the bladder. Sometimes resistance is met with when the instrument reaches the perineal arch, but this can be readily overcome by withdrawing the stylet for a short distance, and thus allowing the more flexible cannula to go forward by itself.

Having thus introduced the catheter into the bladder, the only remaining procedure is to carefully withdraw the stylet and allow the urine to come away.

Attention must always be paid to the cleanliness of the catheter, and, before being introduced, the instrument should be lubricated with some antiseptic, such as pure vaseline, boracic acid ointment, or oil containing some antiseptic, the parts of the animal being also well washed with soap and water.

Imperforate Urethra or Vagina.

An imperforate urethra or vagina is occasionally met with in the newly-born puppy or kitten. It is readily discovered upon careful examination, although, unless looked for, it may not cause sufficient inconvenience or discomfort for some days, or even weeks. Its presence may be suspected by an

abnormal distension of the abdomen of the patient, and moans or cries indicative of pain or discomfort.

In one case met with by the author¹ the patient was a female kitten, six weeks old. Its bladder was distended, and could be felt without difficulty through the abdominal wall, whilst the urethral orifice was entirely absent, the opening being replaced by a very thin skin, the exterior being moist owing to the presence of urine in the vaginal passage. The urine appeared to filter slowly through this.

When an incision was made with a lancet, the urine flowed out with a rush. The edges of the wound were cauterized (with nitrate of silver) to prevent them from uniting too quickly, and the animal made an excellent recovery.

Operation.—If the obstruction is due to a severe malformation, the probability is that the most humane course would be to kill the animal painlessly. It must be left to the discretion of the operator to say whether an operation would be likely to give permanent success or not.

If the stoppage occurs at the extremity, and is merely due to a fold of skin, an incision with a scalpel will give immediate relief. Precautions must be taken to prevent union of the edges of the wound, either by making a fairly large orifice or by the application of some caustic.

Calculi in the Urethra.

In the dog and cat, particularly in the male animals, small calculi are frequently met with in the urethral canal. They cause acute pain during their passage through the urethra, and frequently give rise to cystitis, and even rupture of the bladder. The obstruction may be due to one stone alone, to gravel (especially in the cat), or to many small calculi following one after the other. They vary in size up to that of a pea, and may be rounded or uneven on their external surface. In the bitch they may be much larger.

* ¹ *Journal of Comparative Pathology and Therapeutics*, vol. ix., p. 155.

In one instance the author removed eleven calculi at one urethrotomy operation, the patient being a St. Bernard dog whose owner had unfortunately allowed the case to progress so far before surgical aid was called in that the extremity of the penis was gangrenous.

On each of two other occasions the author counted more than fifty small calculi in the urethra and bladder.

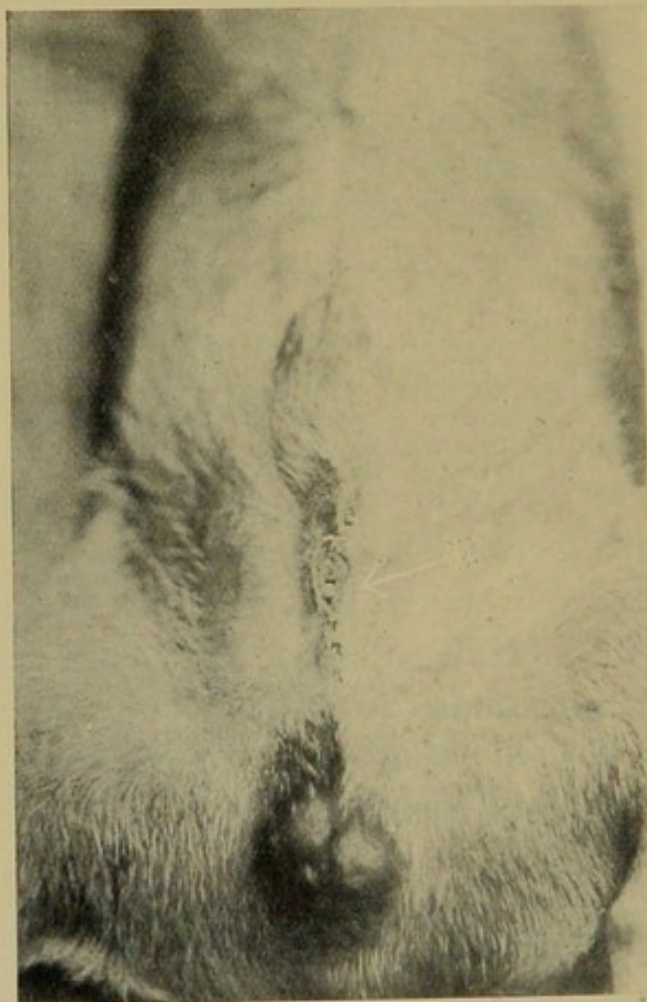

Fig. 157.—Usual Position of Incision in Urethrotomy, with Two Calculi *in situ*.

On account of the short and comparatively elastic urethra of the female, it is not common for calculi to lodge there, but occasionally such cases are met with. Gray¹ has recorded one instance in which eight were discovered to be present in the urethra of an aged female terrier. It may occur at almost any age, but is more common in the adult or aged

¹ *Journal of Comparative Pathology and Therapeutics*, vol. x., p. 88.

than in puppies or kittens. In cats it is more frequently seen in the castrated male than in the uncastrated animal.

Symptoms.—The animal is restless, appearing dull and uneasy, looking at the flanks, and making frequent long but ineffectual attempts to pass his urine. A few drops may come away, these being of a dark colour or blood-stained, and during the act of attempting to micturate the pleading expression of the eyes and anxious features give distinct evidence of the pain produced. When approached, the patient will wait until touched before moving from its position. In the case of the dog the animal may raise its leg in the usual normal manner, or stoop down like a bitch; and in the cat the penis protrudes to its fullest extent, the extremity moving jerkily with the efforts produced. If neglected for more than twenty-four hours, the distended bladder can be readily felt as a large, hard, pear-shaped body by manipulation through the abdominal wall. This manipulation must be done between the thumb and fingers very cautiously, as otherwise, if too much pressure is put upon it, the bladder can readily be ruptured. If relief can be brought about at this stage, the urine is practically normal in colour, but, of course, increased in quantity. After twenty-four or thirty-six hours' enforced retention it becomes of a darker colour, and possesses a strong ammoniacal odour, ultimately becoming coffee-coloured and fœtid.

The stone can readily be diagnosed when an attempt is made to pass the catheter or sound, as it forms an obstruction which prevents the instrument from going beyond a certain point. In the majority of cases the calculi become lodged in that portion of the canal which runs through the os penis or immediately behind that bone. Occasionally it will be found nearer the entrance to the bladder, and in the cat the gravel may be at the extreme end of the penis, near its orifice. Sometimes the catheter can be so manipulated as to dislodge the stone, when, if it is not of too large

a size, it may be washed out of the urethra with the next outflow of urine. In large dogs a pair of long thin urethral forceps can be passed up the urethra, and the stone crushed or removed intact, but this is rendered impossible in small patients on account of the narrowness of the groove in the bone of the penis. It is always worth while, before deciding upon urethrotomy, to try whether manipulation and careful pressure upon the bladder between the ball of the thumb and the fingers will not remove the obstruction. This is especially the case in the cat, and the end of the urethra should first be carefully squeezed and picked out. For this purpose, on account of the small size of the opening, a fine probe or a thin wire (such as the stylet of the catheter), if used cautiously, improvises very well.

If, by mischance, during manipulation the bladder does rupture, the operator has warning of it in the sudden collapse, and perhaps attempt at vomiting, of the patient. Immediately previous to that he has probably heard or felt it go, the bursting making a distinct 'popping' sound, and the collapse of the structure in the hand being very sudden. In the event of such an accident, the only chance lies in immediate laparotomy (see p. 158), suture of the rent in the bladder wall (see p. 259), and careful swabbing out of the abdominal cavity with antiseptics. The chance of success, on account of the patient's condition, is a very slender one; otherwise, under healthy circumstances, the bladder wall heals well when sutured, and even if urine does escape into the abdomen, a fatal result does not necessarily follow (see p. 297).

Operation.—If external manipulation fails to give relief, and the above-mentioned accident has not occurred, the surgeon must choose between puncture of the bladder or urethrotomy.

Puncture of the Bladder.—This operation is most commonly done in cats and the smaller varieties of dogs in which it is impossible to pass the catheter. It is performed

in order to evacuate the contents of the bladder when this organ is over-distended. In addition to over-distension from the presence of calculi, this condition may arise from any excessive pressure on the neck of the bladder, such as is met with in perineal hernia (see Fig. 153).

The most convenient situation for operating is a spot in the *linea alba* from about 1 to 3 inches (depending chiefly upon the size of the animal) behind the brim of the pelvis, the object being to pierce the bladder in a part where it is tense and yet fairly close to the neck. The patient is very gently placed on the back or side, the bladder being grasped carefully but firmly through the walls of the abdomen with one hand, and held as near the seat of operation as possible. Having carefully shaved off the hair, under antiseptic precautions a trocar and cannula (which should be of a fine bore) are inserted subcutaneously for a short distance, and then directly into the bladder. The trocar is withdrawn and the urine allowed to escape. After-treatment consists in withdrawing the cannula carefully, drying the surface of the wound and covering it with iodoform (or orthoform) and collodion.

It is risky to administer a general anæsthetic in the majority of these cases, or even to fix the patient firmly, because, if the bladder is much distended, rupture or sudden collapse is apt to occur during the struggling; the author has seen this happen in three instances. As regards sequelæ, in so far as the operation itself is concerned, if antiseptic precautions are observed, no evil results need be feared. It can be depended upon to give great relief, and, if the patient is not too much exhausted or the cause of the distension is not some permanent obstruction in the urethra or neck of the bladder, the benefit is usually immediate and permanent.

By way of illustrating the slight element of risk when the bladder is punctured under strict antiseptic conditions, attention may be drawn to the patient in Fig. 153. The operation was performed five times within

three months, the result being on each occasion to give instant relief. In several other patients, too, the author has punctured the bladder three or four times, and the histories of the patients have been followed for several years afterwards.

Even in cats with the urethra apparently blocked with gravel which could not be sufficiently removed to enable the urine to flow away, if the end of the passage is cleaned out as much as possible, and the bladder punctured, in by far the majority of instances the patients will presently pass urine voluntarily. The explanation of this is that the relief of the pressure from behind the obstruction alters the position of some of the gravel and, instead of being one semi-solid blocked-up mass, it becomes converted into small particles which are washed away by the time the bladder is

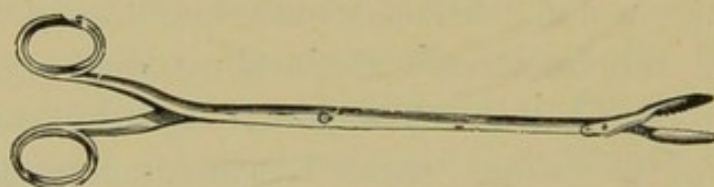


Fig. 158.—Urethral Forceps.

again full enough to be evacuated. The muscles, too, are put at rest as their tonic contraction is relaxed.

Urethrotomy.—For this operation in the male the dorsal position (Fig. 15) is the best, but struggling must be avoided as much as possible, on account of the risk of rupturing the bladder. A local or general anæsthetic is made use of, the parts are thoroughly cleaned with some antiseptic, and a catheter is passed up the urethra as far as the obstruction. An incision is made in the median line directly over the calculus (see Fig. 162), which is then removed together with any others within reach, and the parts are thoroughly washed with a fluid antiseptic. The catheter should be passed right into the bladder to make sure that the passage is clear, and the bladder itself washed out with a solution of some non-irritating antiseptic, such as chinosol (gr. ss. to ʒi.) or boracic

acid (grs. x. to ʒi.). In some cases it is a wise plan to leave the cannula of the catheter *in situ* for some hours after the operation. The wound itself is treated with antiseptics in the usual manner.

If only small, it is better to suture and cover with iodoform and collodion; but if of some length, a small orifice should be left for drainage, as otherwise the urine will find its way through and disturb all the sutures. In any case it does not much matter, and many operators advise using no sutures at all, but treating the place as an open wound.

In the female the shorter urethral canal does not offer quite so many difficulties. A calculus lodged in it can sometimes be grasped and crushed or withdrawn by a pair of fine forceps, or if necessary a fine blunt-pointed tenotome or Paget knife may be used to enlarge the orifice. Material assistance in removing calculi from the urethra of the bitch can often be obtained by manipulation with the fingers through the rectum and vagina.

The *Prognosis* of these cases is excellent except where the patient has been left until almost in a state of collapse before surgical aid is attempted. The internal administration of bladder and urethral sedatives, such as urotropin, hyoscyamus, buchu, pearl-barley-water, etc., afterwards are useful aids to convalescence. The chief dangers in the future are those of stricture or the presence of another stone which may escape from the bladder.

Stricture of the Urethra.

This condition is liable to follow any operation involving cutting into, or other injury of, the mucous membrane of the urethra of either male or female. To avoid its formation, a patient whose urethra has been the subject of operation should be brought at least once a week or once a fortnight to the surgeon for some months afterwards (at his discretion), in order that a bougie or catheter may be passed and the

urethra kept open; the instrument should remain there about ten minutes. The size of catheter is small at first, being gradually increased. In cases where adhesions have to be forcibly broken down, the instrument should be passed twice, or even three times, a day for a time, plenty of oil or vaseline being used as a lubricant. If it is impossible to break down the stricture, an orifice may be made behind the bone of the penis, and kept open by the insertion of a catheter; but this can only, in the case of the dog, be looked upon as a temporary matter, and unless there is some urgent reason for keeping the patient alive, it had much better be painlessly put away.

Prolapse of the Urethra.

This condition, although rare, has been observed in the bitch, the mucous membrane of the urethra itself becoming much relaxed and protruding below the urethral orifice into the vaginal passage. It is sometimes very troublesome to treat.

In a small French bull bitch which came under the author's observation there was fully $1\frac{1}{2}$ inches prolapsed.

Operation.—The prolapsed portion is returned with some smooth object, such as a clean thermometer-case or a catheter of sufficient calibre, an astringent injection of alum (or tannic acid) and opium diluted with water being used two or three times a day at the operator's discretion for a week or ten days. Internally the patient should receive quinine or other tonics, and absolute rest should be prescribed.

Renal Calculus; Nephrolithotomy; Nephrectomy.

Although calculi of the kidney are by no means common, they are not infrequently met with by those who have a large number of canine patients to deal with. As a general rule,

they are not diagnosed until the *post-mortem* examination is made, and it is the difficulty of making a certain diagnosis which is at present so hard to overcome.

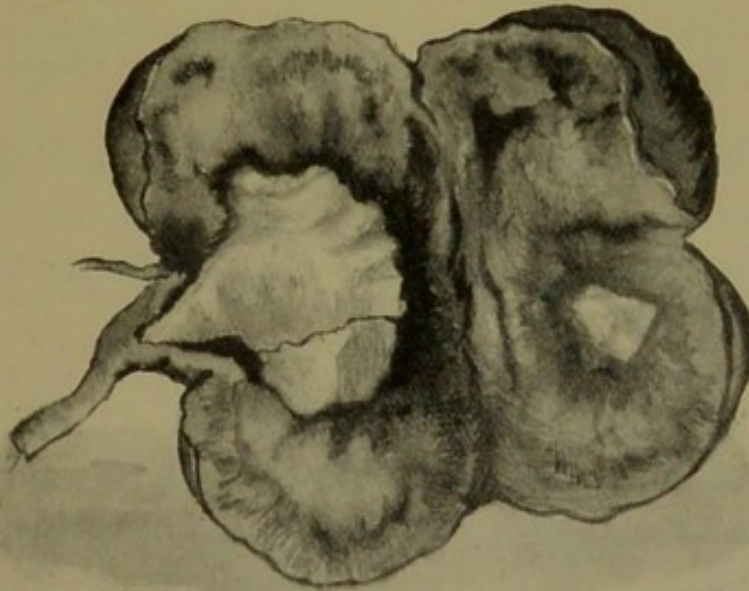
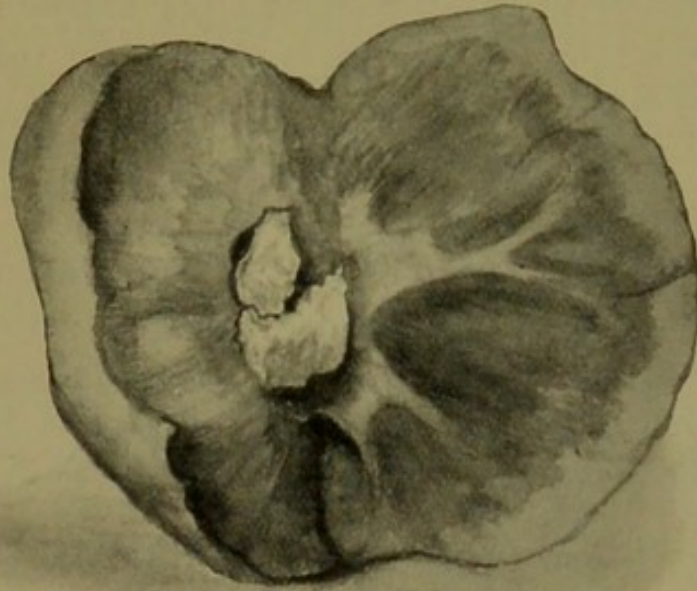


Fig. 159.—Kidneys cut open to show Calculi *in situ*.

(The patient from whom these kidneys were taken was only four years old.)

In the patient from which the kidneys shown in the above sketch were taken, the animal (a bulldog) was only four years old, and showed no signs whatever of kidney trouble, dying from pneumonia.

By the term **nephrolithotomy** is indicated the operation of cutting into the kidney in order to remove a stone. A laparotomy is performed in the usual way in the flank on the side suspected to be affected, and the kidney is exposed to view. As a rule, the calculus is situated in the pelvis. An incision is made directly down on to it, it is removed, and the wound is drawn together with fine sutures. The peritoneal wound is treated in the usual way.

Nephrectomy (removal of the kidney) has been performed many times experimentally on healthy animals, and in human surgery it has taken its place amongst the useful operations. In canine practice, in addition to the difficulty of diagnosing a tumour, calculus, or other disease of the kidney



Fig. 160.— Small Renal Calculi showing Two of the Shapes assumed.

necessitating its removal, we have the fact that (in the case of calculus at all events), as a rule, when one kidney is affected the other has generally become affected before professional aid has been sought.

In thin animals the kidney can be removed by an incision made in the median line, and this gives a little advantage when uncertainty exists as to which is the diseased side. In larger patients an incision is made in the flank just below the lumbar region. The operation is not difficult; the kidney is carefully separated from its situation under the loins, two silk ligatures are passed round its pedicle, and an incision is made between them. The peritoneal wound is sutured and treated in the usual way.

Hernia of the Bladder.

The bladder sometimes passes backwards through the bony pelvis and becomes involved in a perineal hernia (see p. 236). It is apt to have serious consequences for the patient when the bladder becomes distended (as in dogs of clean habits when kept for too long a time in the house without a chance of passing urine), because the animal may not be able to voluntarily exercise sufficient pressure on the bladder wall to overcome the resistance offered by the 'kink' in the bladder neck. The bladder in a severe perineal hernia is so placed that it cannot be acted upon by the abdominal muscles. Fig. 153 was a case of this kind, and the urine had repeatedly to be withdrawn by a trocar and cannula (see p. 61). Under such a condition an operation becomes a necessity.

Operation.—Under general anæsthesia and strict antiseptic precautions, laparotomy is performed either in the median line (in the bitch) or about an inch on one side of the prepuce (in the dog). The bladder is withdrawn and carefully sutured to the abdominal wall either with silk or catgut (see p. 211).

Prolapse of the Bladder.

This condition, which might legitimately be included under the above heading of 'hernia,' is occasionally met with in the bitch, the bladder becoming everted through the relaxed and enlarged urethral opening.

Rupture of the Bladder ; Washing out the Interior.

This accident may occur during an operation, or from over-distension due to obstruction of the urethra from some tumour growth,¹ and subsequent cystitis; or as the result of violent injury, such as that caused by a blow or the wheel of a vehicle. It has also been known to occur when

¹ *Journal of Comparative Pathology and Therapeutics*, vol. xi., p. 50.

the interior of the bladder is being washed out for acute cystitis, the bladder wall being very easily torn, and usually with a large jagged rent which it is almost impossible to suture with any chance of permanent success.

For **washing out the bladder** a double-channel catheter should be used wherever possible, but, on account of the small lumen of the urethra in all except the larger breeds, this is impossible in the male animal. It is, however, possible in many breeds in the bitch. A solution of chinosol (gr. ss. to ʒi.) or boric acid (grs. v.-x. to ʒi.) to which a little belladonna or opium has been added acts well as a sedative and antiseptic, being injected by a syringe with a fine nozzle attached to the catheter. The bladder should be distended to about one half its normal size when full, and then emptied, the process being repeated once or twice daily at the surgeon's discretion. It is emptied by very gentle pressure through the abdominal wall. If it is ruptured during this process the operator hears a distinct 'popping' sound, and the patient may vomit or immediately collapse.

That the escape of normal urine into the abdominal cavity is not necessarily followed by peritonitis or death is illustrated by the following case:¹

An Irish terrier bitch, eighteen months old, was the subject of an oöphorectomy, and whilst making the incision in the abdominal wall the bladder (which was enormously distended) was incised. A quantity of urine made its escape into the abdomen. This was swabbed up as completely as possible, and the edges of the wound drawn together with three sutures. The oöphorectomy was completed, and the patient made an uneventful recovery.

Operation.—Under an anæsthetic and strict antiseptic precautions, laparotomy is performed (see p. 158)—on the median line in the bitch, just over the pelvic region, or in the dog at one side or other of the prepuce. Where the

¹ *Journal of Comparative Pathology and Therapeutics*, vol. xii., p. 263 (Ridler and Hobday).

bladder is distended, the operator can, if he prefers it, open the abdomen in the male immediately in front of the extremity of the prepuce. The advantage of this is that there is less hæmorrhage, as there is practically no muscle tissue to cut through.

The bladder is exposed and brought through the incision on to a piece of boiled lint, jaconet, mackintosh, or some such material, and the lower part tightly packed. The rupture is sought for and sutured (Lembert's pattern) with silk (see p. 55), the abdomen very carefully swabbed out with some antiseptic solution, and the wound of the abdominal wall covered with iodoform colloid, etc., as already described (p. 50).

Tumours of the Bladder.

Of these, the most commonly met with are papilloma, sarcoma, and carcinoma. Others are myxoma and fibroma. They may occur outside the bladder, and have adhesions or connections with surrounding structures, or be found inside, growing on the mucous membrane. In the latter case, after a certain time has elapsed, they have a villous or fungoid appearance, and bleed on the slightest touch.

Symptoms.—In the early stage the only symptom noticed is hæmaturia, the urine being blood-stained. This is presently followed by pain whenever urine is passed, the bladder being irritable, and the act of urination more frequent. In the last stages the patient becomes emaciated through pain and want of rest, and the urine may be fœtid or purulent.

Diagnosis is aided by the use of a sound (Fig. 156) or catheter, the tumour (if sufficiently large) being felt as a soft, spongy body resisting the progress of the sound inside the bladder. If small, however, this cannot be detected. A rectal examination should always be made.

Treatment.—Before resorting to surgical aid medicinal remedies may be tried. The bladder should be washed out with a solution of non-irritating antiseptic, such as adrenalin,

boric acid, saline solution, Condyl's fluid, or chinosol, containing a little sedative, such as belladonna or opium, and internal bladder sedatives (such as urotropine or hyoscyamus),

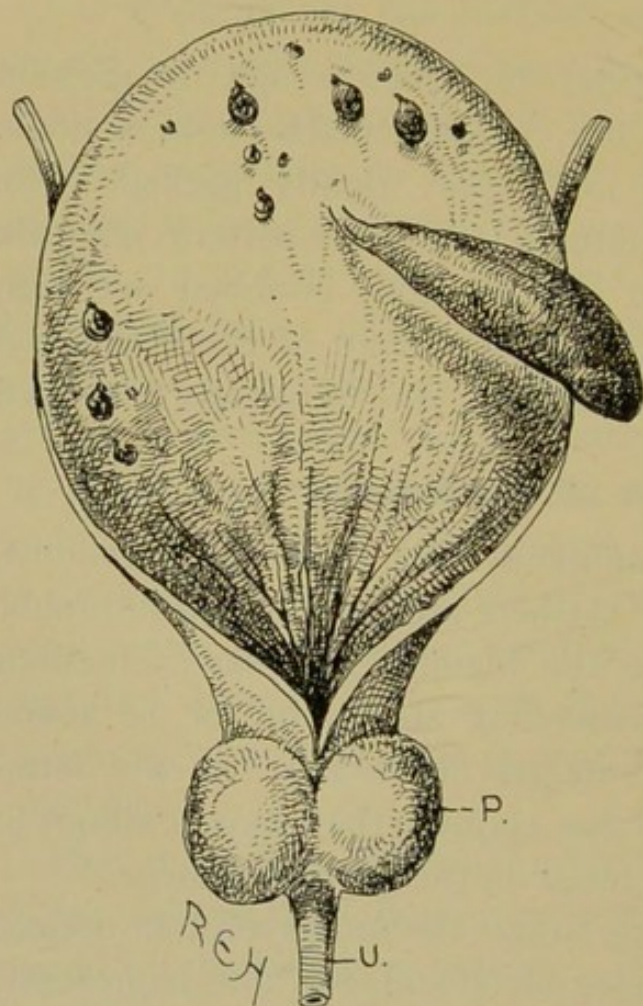


Fig. 161.—Pedunculated Tumour of the Bladder.¹

Prognosis should be extremely guarded, and, before commencing the operation the surgeon should obtain the owner's permission to painlessly put the patient away before consciousness returns, if the case seems hopeless.

Rievel reports a case² in a pointer in which a large round-celled

¹ The specimen from which this sketch was made was taken from a Yorkshire terrier, male, about six years old, and proved on microscopical examination by Professor McFadyean to be a mucoid polypus.

² *Veterinary Record*, vol. xiii., p. 724 (*Berliner Thierärztl. Woch.*, Mayall's translation).

or astringents and antiseptics (such as ergot or buchu), administered by the mouth.

When these appear to be valueless, the only chance (a remote one with most tumours) lies in an operation.

Operation. — Suprapubic lithotomy is performed (see p. 257), the bladder is exposed, and if the growth is external, it is removed if possible. If internal, the bladder is opened and the growth removed by scalpel and curette, the bladder being sutured and after-treatment adopted as described on p. 259.

sarcoma was present in the abdomen, occupying the body and neck of the bladder and extending to the umbilicus, about twenty other growths being present in the pelvic and lumbar region. The case was quite inoperable.

Cystitis ; Calculus, or Stone, in the Bladder.

Cystitis, or inflammation of the bladder, may proceed from various causes which give rise to irritation of the mucous membrane lining the interior. Tumours (especially papilloma and carcinoma) are occasionally met with, septic organisms may gain access through the passing of a dirty catheter and other causes, overdoses of certain medicines (such as cantharides), or the presence of a calculus or a number of calculi, may be at the root of the mischief.

There may be only one stone present (as in specimen No. 3, Fig. 163), or there may be a very large number. The author has known one instance in which no less than eighty-four stones were counted in this situation.

Calculi are most commonly met with in old, or at all events adult, animals, but even young ones are not exempt. They are as frequently met with in the cat as the dog, especially the castrated male. Bitches seem to be more predisposed than dogs, and the stones certainly attain larger size in the former.

The *Symptoms* which first draw the owner's attention to the animal are a continual restlessness and constant attempts at urination, during which efforts only a few drops are passed. This may be discoloured or blood-stained, but the presence of blood is by no means a necessary aid to diagnosis, as this depends entirely upon whether the mucous membrane of the bladder has become abraded or not. If matters are allowed to proceed further, great pain is evinced, the appetite is capricious, and the patient is feverish and becomes emaciated.

Examination should be made through the abdominal walls

with the fingers or *per rectum*, and a catheter or metal sound (see Fig. 156) should be passed into the bladder. With this instrument a distinct 'jar' and a metallic 'click' can be felt when it strikes against the calculus. When a calculus

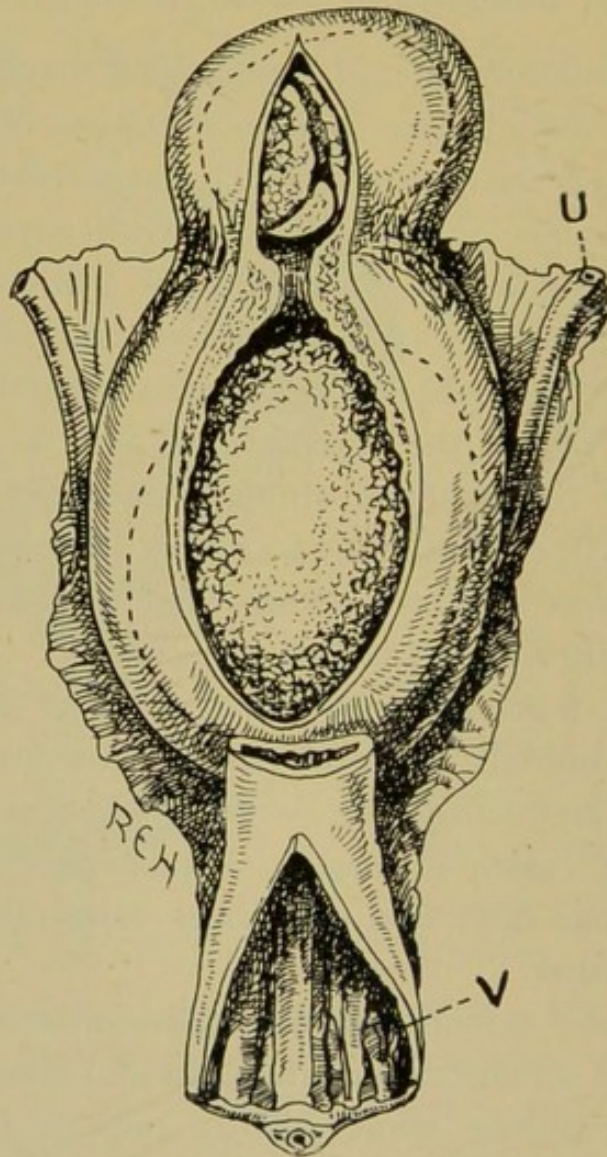


Fig. 162.—Bladder Calculi *in situ*.

U, Ureter; V, vagina.

has been discovered, surgical treatment is the only one which gives a chance of permanent success. For cystitis due to other conditions the cause itself must be discovered and treated. If septic organisms are suspected, the bladder must be washed out (see p. 252), and urotropin, buchu, creolin,

cresosote, carbolic acid, hyposulphite of soda, or other such urinary disinfectant agents, administered by the mouth.

Urotropine and hyoscyamus stand high in therapeutic value as bladder sedatives and diuretics, whilst potassium bicarbonate and other alkalies are useful agents. Tincture of cantharides in small medicinal doses gives immediate relief in some cases of hæmaturia, whilst pearl-barley-water or linseed-tea are useful fluid demulcents.

Operations.—The diagnosis having been made with certainty, either a **lithotomy** or a **lithotrity (litholapaxy)** may be performed, the surgeon having the choice of two situations in which to operate.

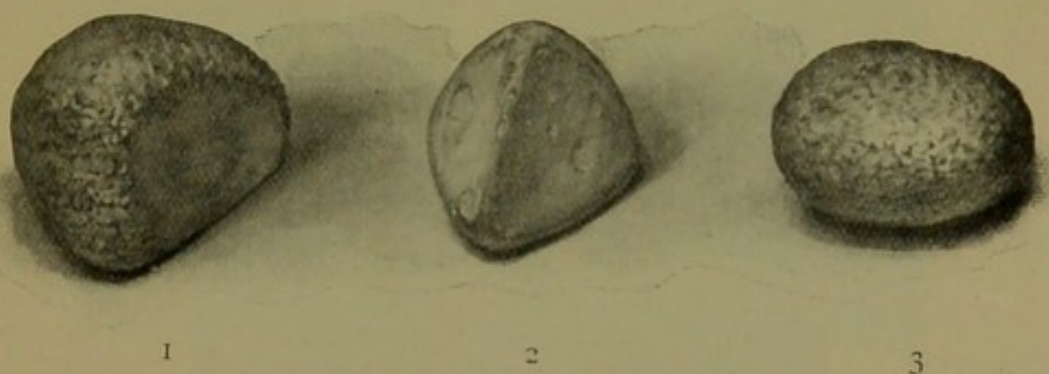


Fig. 163.—Shapes assumed by Calculi in the Bladder.

In either dog or bitch the bladder can be reached from the suprapubic region, or in the former the incision may be made in the perineum, and in the latter the stone can often be extracted through the urethral orifice, and so into the vagina.

The term 'lithotomy' is used when the bladder is incised and the stone or stones extracted whole, and the term 'lithotrity' when the calculi are first crushed or broken up into fragments before being removed through the urethra.

Suprapubic lithotomy is performed as follows: After the bladder has been emptied with a catheter, and carefully washed out with solution of chinosol, boric acid, or some

other antiseptic, the patient is anæsthetized and placed in the dorsal position, laparotomy being performed as already described. The site of the cutaneous incision in the male is either in the median line immediately in front of the penis, or else in the flank a little to the right or left of that organ, and in the female in the median line immediately in front of the edge of the pelvis.

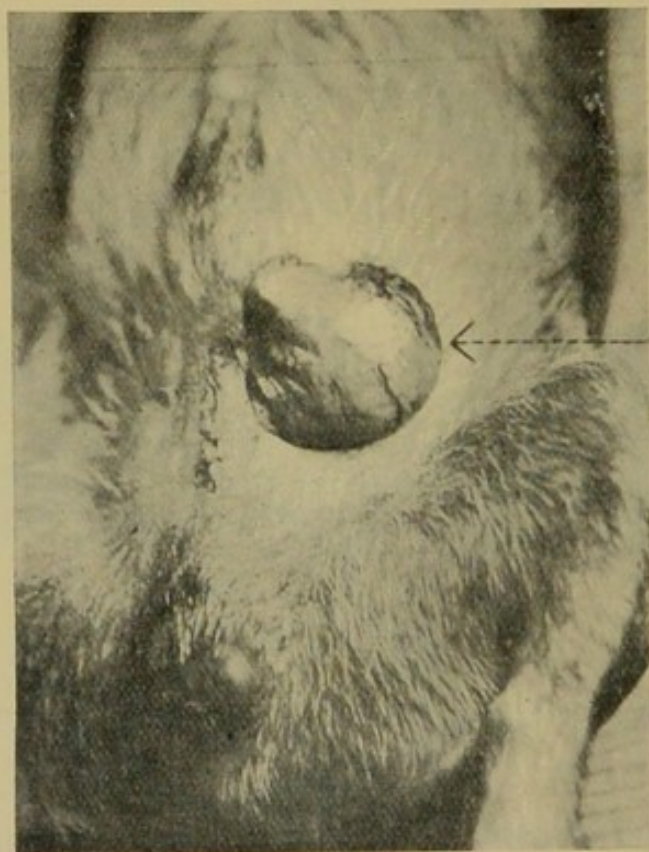

Fig. 164.—The Bladder exposed to show the Site of Incision for Supra-pubic Lithotomy in the Male.

The bladder is carefully raised and drawn into the wound, where it is packed round with aseptic lint, and, if considered necessary, held in position by a loop of silk passed through its muscular and serous coats, but not through the mucous membrane. A longitudinal incision is made down its centre in the least vascular portion, as near as possible directly over the stone. This is carefully removed with forceps, after having been first broken up with a litho-

trite, if of very large size. If, as is not uncommon, it is adherent to the interior, care must be taken to loosen it very gently from its attachments. If a number of small stones are present, they must be removed with a blunt scoop or forceps. The interior is then carefully washed or swabbed out with some trustworthy non-irritant antiseptic (such as boric acid or chinosol), and the edges drawn together with silk sutures of Lembert's pattern (see p. 55). In four cases¹ in which we have sewn up wounds of the bladder, Lembert's

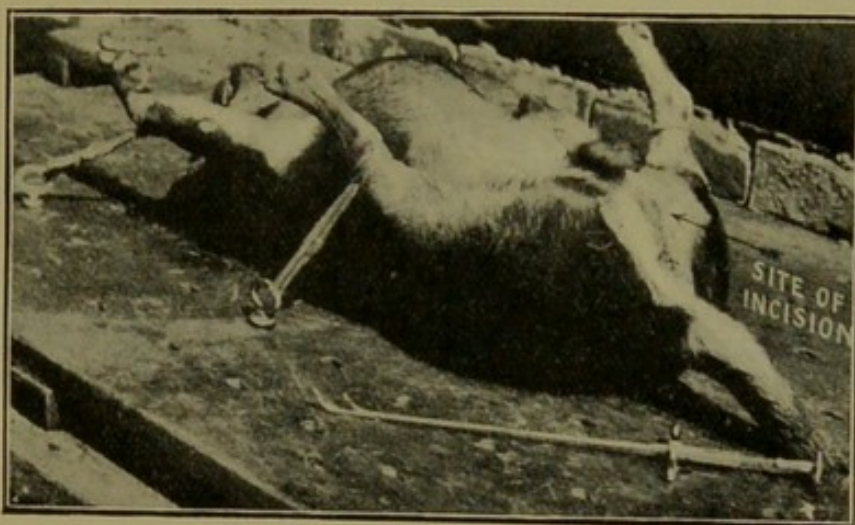


Fig. 165.—A Dog secured for Perineal or Posterior Pubic Lithotripsy.

sutures of silkworm gut were used, but silk is undoubtedly better, as it becomes absorbed in time. Some operators suture through the whole of the coats at once in the ordinary way with interrupted sutures, but it is better that there shall be no foreign body protruding into the interior of the bladder, as it is apt to form a nucleus for future deposit. As a rule, the wound in the bladder heals by first intention, and there is no need to insert a drainage-tube if antiseptic precautions have been rigidly carried out.

In the cases illustrated in Fig. 163, No. 3 was the only stone present, the patient being a whippet four years old. The operation, a supra-

¹ *Journal of Comparative Pathology and Therapeutics*, vol. xii., p. 263.

pubic lithotomy, passed off quite satisfactorily, the bladder and abdominal wounds being each sutured without drainage and healing by first intention, the external sutures being removed on the ninth day afterwards.¹

Nos. 1 and 2 illustrate the facets which form from the friction produced when one stone is continually rubbing against another. In the one instance there were three stones, and in the other five, present.

In **lithotrity** the abdomen is not opened, the stone or stones being reached through the urethra. In the male, after anæsthesia has been established, the animal is fixed on the operating-table in the position illustrated in the photograph, the hind-legs being drawn forward so as to efficiently expose the seat of operation, which has already been shaved and rendered thoroughly aseptic. The urine having been previously drawn off, and the catheter left in position in order to define clearly the outline of the urethra, an incision



Fig. 166.—Lithotrite.

is made directly on to this in the perineal region, about midway between the testes and the anus. An aperture of sufficient size to introduce the lithotrite is made in the urethra, and the catheter steadily withdrawn. The curved end of the lithotrite is introduced, passed round the pelvic border, and into the bladder. Search is made for the calculus, which must be manipulated until it is firmly fixed between the jaws of the instrument, when steady pressure is exerted upon it in order to break it up into small pieces, care being taken not to include the mucous membrane of the bladder. Some of the larger pieces may require a second application. The fragments are then got rid of, either by forceps or by continual irrigation with an antiseptic fluid, such as solution

¹ *Veterinary Record*. Proceedings of the Central Veterinary Medical Society (Garry and Hobday).

of chinosol or boric acid, after the introduction of an evacuating catheter into the bladder. The wound is then sutured, the urethra itself with fine silk, and the muscles and skin separately, the whole being covered with iodoform or orthoform and collodion. In small patients it is sometimes impossible to suture the urethra, and even in the larger ones some operators prefer to merely suture the skin and muscles. Where the animal is of a quiet disposition, a catheter or drainage-tube may be left in the urethra for two or three days with advantage; but if it gives rise to irritation, and consequent continual efforts to lick the parts, its continued use is best avoided. If the wound is not sutured, it must be kept clean and treated antiseptically.

In the bitch, the vaginal method is one which has given

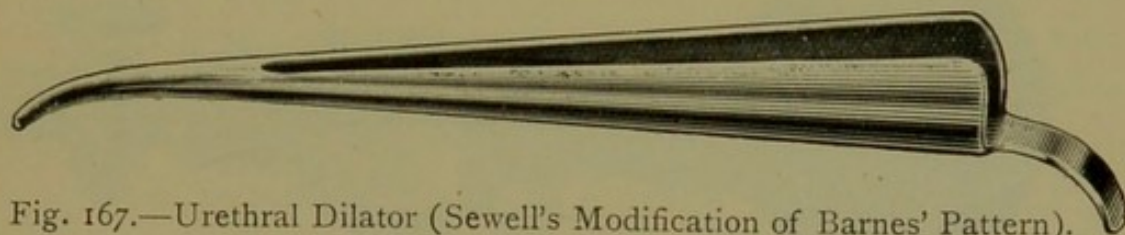


Fig. 167.—Urethral Dilator (Sewell's Modification of Barnes' Pattern).

excellent results in cases where the patient is of sufficient size to allow it to be done. The method of fixing is the same as already described for urethral lithotomy in the male.

A conical-shaped dilating speculum—Avery's or Kramer's answer well (see Figs. 50 and 182)—is forced into the vagina to dilate the passage as much as possible, then withdrawn, and a urethral dilator (Fig. 167) pressed into the urethra until the latter is sufficiently large to admit the little finger. This is withdrawn, and replaced by a small pair of stone-crushing forceps (a pair of small parturition forceps improvise well when the calculus is to be removed without crushing) or a lithotrite, which is passed directly on to the stone in the bladder. Care is taken to make sure that the mucous membrane of the bladder is not included, and the stone is broken up into small pieces. The pieces are then removed by means

of a special catheter and an evacuator (Fig. 168). If the urethra can be sufficiently dilated the stone may be removed intact. The urethra may even be incised, a director and fine bistoury with blunt point being used for the operation.

Mr. A. J. Sewell¹ records one case in which he was able to remove a stone about the size of a hazel-nut, without breaking it, after enlarging the urethra with a small bistoury.

Mr. H. Gray² had a similar experience with a very fat, small fox-terrier bitch, ten years old, digital examination *per vaginam* revealing a calculus

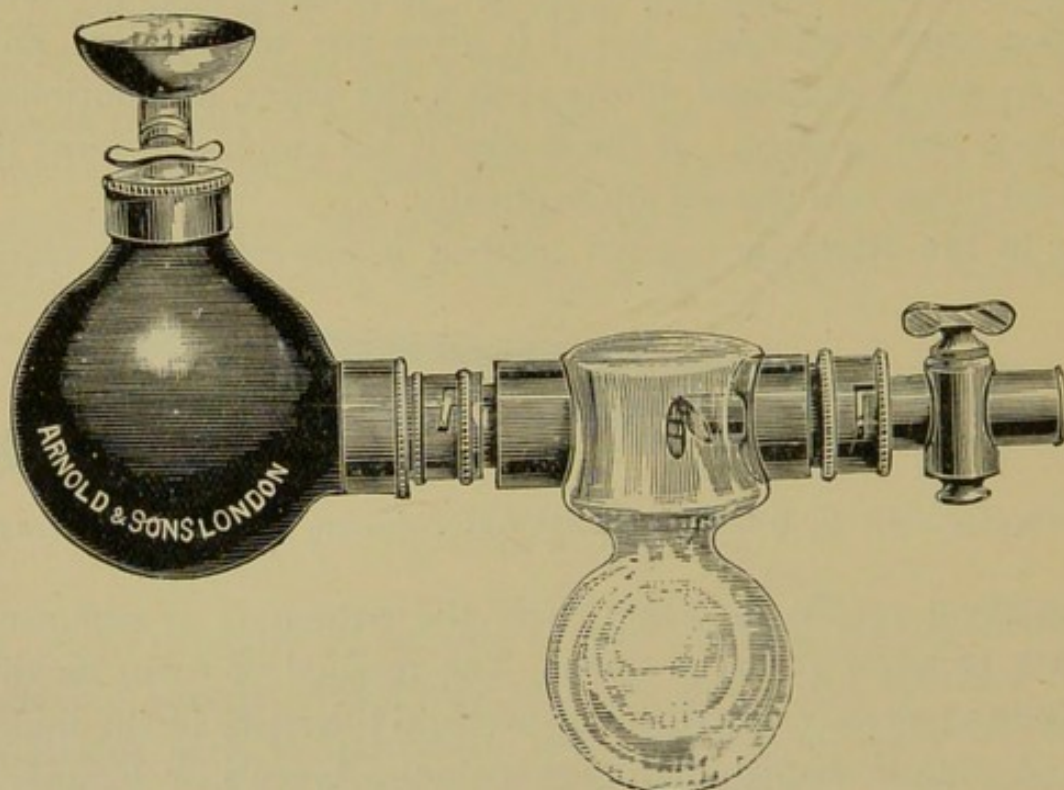


Fig. 168.—Thompson's Evacuator.

as large as a marble in the urethra, and upon manipulating it with one finger in the rectum and one in the vagina, seven small calculi, each about the size of a tare, shot out. The large calculus could not be extracted until the urethra had had a vertical incision made down upon it.

After-treatment must depend a little upon the progress made. Diet should be of an easily digestible character and sparing in quantity, the supply of fluids being limited for the first three or four days.

¹ *Veterinary Record*, vol. xi., p. 510.

² *Journal of Comparative Pathology and Therapeutics*, vol. x., p. 87.

If a little urine finds its way through the urethral wound in the male, extra care must be taken as regards cleanliness, but no alarm need be felt so long as the lower part remains open. If much pain is shown, morphia should be given hypodermically, or some sedative to the mucous membrane of the bladder (such as urotropine or hyoscyamus) administered by the mouth. A little blood may possibly be passed with the urine during the first few days after the operation, but that need cause no anxiety.

The Prostate Gland.

The prostate gland is situated on the neck of the bladder, and in old dogs is apt to become enlarged, and, by causing pressure on the urethra, give rise to pain and obstruct the flow of urine. It may even suppurate, and ultimately give rise to septicæmia, or the abscess may burst into the abdominal cavity and set up peritonitis.

It can be felt *per rectum* as a two-lobed body, about 1 or 2 inches from the anus. When enlarged or causing trouble, pressure upon it will give rise to pain.

Symptoms.—The pain arising from this condition is often excessive, the patient refusing to move, and when forced to do so walking with a straddling gait, looking very anxious, not eating food, and having difficulty in passing urine. It is this latter symptom which makes one suspect the trouble. Examination *per rectum*, or even pressure in the perineal and pelvic region, will cause pain.

Treatment.—If this is the first attack, medicinal remedies may be tried. Warm opiate enemas should be administered, a full dose of physic given, and urotropine, hyoscyamus, or other urinary sedatives given internally. If the patient has been attacked before, removal of one or both testicles (as first suggested by White of Philadelphia in 1894 for human patients) should be at once undertaken (see Castration,

p. 276). The result is excellent, an improvement being manifested almost at once. This, too, is permanent.¹

The following three cases are illustrative of the benefit which results from castration in these cases :

CASE I.—The patient, a toy black and tan terrier, about four years old, suffered from strangury, the urine being very scanty in amount, and only passed with great difficulty. An unsuccessful attempt was made to pass

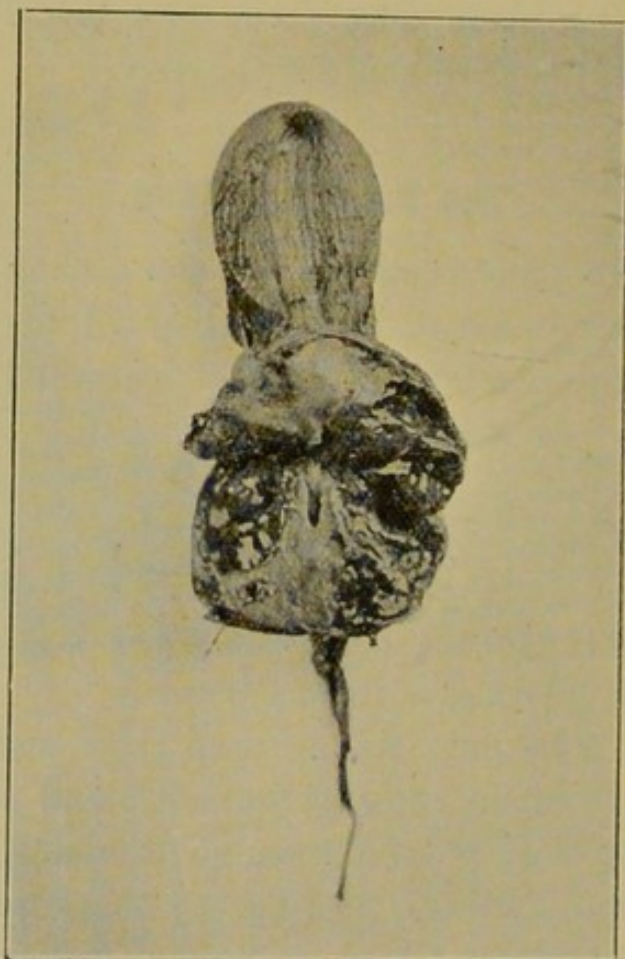


Fig. 169.—An Enlarged Suppurating Prostate Gland, taken from an Irish Terrier, Seven Years old, suffering from Perineal Hernia, in which it was included.

the catheter, and a rectal examination revealed a distinct enlargement of the prostate gland. Castration was performed under chloroform, and six days later urination was free and regular, and the catheter could be passed without any trouble. The prostate, too, was perceptibly less. Within three weeks it had become of quite normal size, and there was no return of the symptoms.

¹ W. M. Scott, *Veterinarian*, June, 1897; Hobday, *Journal of Comparative Pathology and Therapeutics*, vol. ix., p. 336.

CASE 2.—A collie, nine years old, was brought for treatment on account of a peculiar straddling gait of the hind-legs, inability to walk more than about 10 yards without resting, difficulty in rising after lying down, and pain when pressure was applied to the loins and flank. The latter was probably due to over-distension of the bladder, as when urination was attempted a certain amount of difficulty was experienced at the commencement, this being followed by the passage of an abnormally large quantity. Rectal examination revealed an enlarged prostate gland. Castration was performed under chloroform, and ten days later the improvement was most marked, the urine being passed easily, and the prostate very perceptibly less. The improvement was permanent.

CASE 3.—A Dandie Dinmont, about eleven years old, was brought with a history of difficulty in urination, straddling gait, and evident pain when passing urine. The prostate was enormously enlarged, and painful on pressure. After castration relief was shown within three days, the urinary flow was unimpeded, and progress to recovery uneventful. The patient was kept under close observation for more than two years afterwards, and there was no evidence of relapse.

CHAPTER XIX

THE MALE GENERATIVE ORGANS

Tumours on the Penis and Prepuce.

ON the exterior of the prepuce, especially in black-coloured dogs, one frequently finds small pedunculated tumours. These are usually melanotic, and belong to the variety of either the adenoma, fibroma, or papilloma; they are easily removed either by ligature or scalpel. The preputial tissue may also be infected with carcinoma and sarcoma.

Inside the prepuce and on the mucous surface of the penis one meets with another variety, the infective venereal tumour, which is indistinguishable, microscopically, from a sarcoma.¹ It appears to be most commonly met with in the bulldog variety, and the author has also seen it in St. Bernards, terriers, poodles, and pugs, although there is no reason why it should be confined to these breeds.

In the bulldog breed several kennels have been almost ruined, and it had worked such ravages amongst the stud dogs and bitches that, in 1903, the Committee of the British Bulldog Club found it necessary to issue a circular to all the members, warning them against mating dogs and bitches until both sexes had been carefully examined. It is *very*

¹ G. Bellingham Smith and J. W. Washbourn, *Journal of Comparative Pathology and Therapeutics*, vol. xi., p. 41. Report of the Imperial Cancer Research Fund, 1905, Part II., p. 33.

contagious, and capable of being communicated from dog to bitch, and *vice versâ*, during copulation.

Three histories mentioned by Smith and Washbourn are particularly typical and worth recording in detail, as they illustrate the extreme contagiousness of the growths.

From January to June, 1894, dog A was mated with twelve bitches, eleven of whom became infected. Examination of the dog revealed a growth on the penis, just behind the corona. The bitches were of various

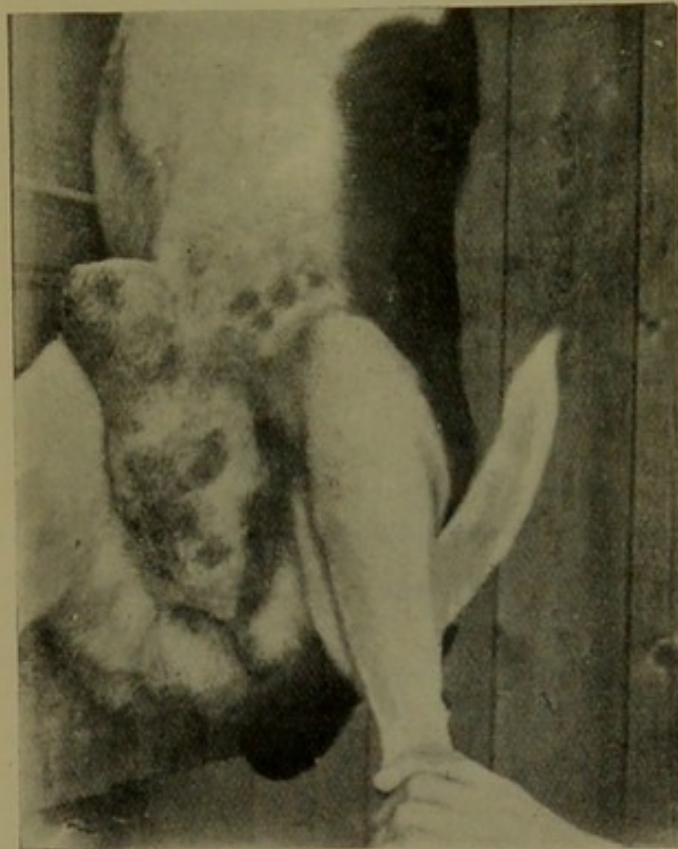


Fig. 170.—Carcinoma of the Prepuce in a Foxhound.¹

ages, the younger being less severely affected than the older. Three, the oldest and most severely affected, had to be killed. Another dog which served three of the affected bitches caught the infection, developed a growth, and before this was noticed mated with two healthy bitches, one of whom became contaminated.

In another kennel and another breed entirely, five bitches were served by a certain dog, and all became affected with vaginal growths. One of these bitches was subsequently served by another dog, and, in spite of

¹ For this photograph I am indebted to Professors Mettam and Wooldridge.

every precaution being taken in the way of frequent washing of the penis after coitus with antiseptic lotions, a number of small growths made their appearance on the penis.

An examination can be made by stripping the prepuce, or sheath, downwards over the root of the penis, steadily, and to the extreme end. In a healthy dog this rarely causes any

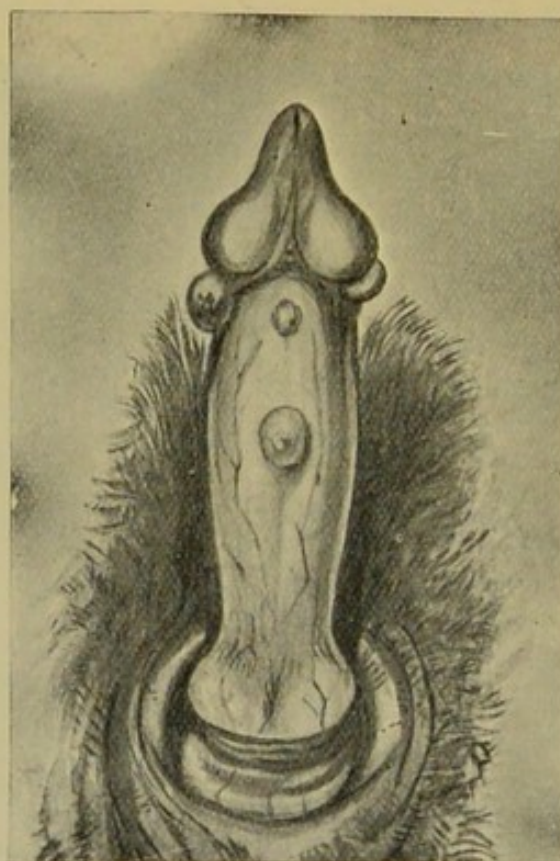


Fig. 171.—Penis of Bulldog with Contagious Venereal Tumours of about Two Months' Growth.

pain, and the mucous surface of the penis presents an even appearance and is of a light pink colour.

The infective tumours, if present, appear as small yellowish-white raised patches about the size of a mustard-seed, or (if further advanced) as well-defined growths either on the sides or end of the penis, or at the extreme base, where they look like clusters of unhealthy masses, which readily bleed when touched. Both are very serious—the former because they are liable to infect, high up, the generative passage of

the bitch during coition, and the latter because of the difficulty of access for the purpose of complete surgical removal from the dog.

One can usually surmise with approximate correctness, from an examination of an affected bitch, what has been the situation of the tumour on the penis of the dog from whom she received the infection.

Symptoms.—Unless the owner of the stud dog is cautious, or has some reason for making an examination, the disease may have existed for some months without his attention being drawn to it. The only suspicious symptoms evinced are that there may be hæmorrhage after service, the dog may refuse to act, or (especially if it is close to the urethral orifice) the patient may show pain when urinating.

Smith and Washbourn thus describe one case in which they were able to watch the progress of the disease on the penis of a dog from its commencement.

Within a week of infection the growths appeared as small glistening elevations, about the size of millet-seeds, mostly transparent but sometimes blood-stained. They looked like vesicles, but on pricking them they proved to be solid. One was removed, and on microscopical examination showed the same structure as the more advanced growths. At the end of two months they were still small, but were more solid in appearance. At the end of six months two of the growths had considerably increased in size, and were about half an inch in diameter, while the remainder had disappeared. In a year the growths had further increased in size, and had assumed the usual lobulated appearance.

Operation.—The patient is secured in the lateral or dorsal position, and the penis exposed and washed with disinfectant. The tumours and surrounding mucous membranes are painted with a 5 per cent. solution of cocaine, and allowed to remain for three or four minutes till anæsthetized. The growth is then picked up with forceps and snipped off with sharp scissors, *the operator taking particular care to excise sufficient of the surrounding mucous membrane to clear the edges of the tumour.* This precaution is essential, and if it can be done that particular growth will not return. If a portion of it is

left a recurrence may be expected. The wound is then treated antiseptically, and afterwards left alone. As a rule it gives no further trouble. Another, and more bloodless, method of removal consists in the application of a ligature around the base of the tumour, this being then allowed to drop off, or being removed with scissors on the second day afterwards. In very severe cases only a certain number should be removed at the one operation, the mucous membrane being allowed to heal before more are taken away, and the parts daily treated with some non-irritant antiseptic lotion. Large wounds may advantageously be drawn together with fine silk sutures. The patient should be examined every week or ten days for at least two months before being declared free and used at stud.

Wounds of the Prepuce.

Occasionally, as in Fig. 172, a dog will become injured, from contact with barbed wire and other causes, in the region of the prepuce, and considerable difficulty is encountered in promoting healing. In the particular case here alluded to, the patient, a bright little Yorkshire terrier, had received an injury about three months before, and the penis could not be prevented from protruding through the wound.¹

The edges of the orifice had by this time become hardened and half healed over. Various devices, such as the application of a bandage, the insertion of sutures between the mucous surface of the penis and the interior of the prepuce, the freshening up of the edges, and the resuturing of the wound, etc., were adopted, but without any permanent degree of success. As a last resort **Cherry's operation** (see p. 49) was tried, and the result was in every way gratifying.

¹ G. Reddish and F. Hobday, *Veterinary Journal*, vol. lx., p. 338.

Foreign Bodies around, or Fracture of, the Penis.

Occasionally, for mere mischief or spite, an indiarubber ring will be placed around the penis of the dog. If not removed, it will find its way into the soft tissue, and in a very short time cause gangrene of the end of the organ from a stoppage of the blood-supply.

Again, a piece of twine or cotton has been discovered



Fig. 172.—Photograph of Wound in the Prepuce, with Penis protruding therefrom.

placed around the penis, usually done maliciously during the act of copulation, when the dog is powerless to reach the miscreant with his teeth. This, too, if not discovered and removed, will cause excessive pain, and, ultimately, gangrene of the end of the penis.

The state of affairs can only be suspected by the apparent pain of the dog, the animal's actions drawing attention to

the fact of something being wrong in that direction. Occasionally, from an accident, such as is occasioned by a violent blow or during a fight with another dog, the penis will become lacerated and the bone even fractured, and amputation will be necessary. Gangrene of the extremity is also met with as the result of calculi in the urethra.

The *Symptoms* shown are those of great constitutional pain, inability to pass urine properly, hæmorrhage from the urethra, continual licking of the parts, and, if gangrene has already taken place, a very nasty fœtid odour.

Treatment.—The first thing to do is to detect and remove the cause. If it is a piece of thread or string, or an elastic band, this must be cut off, the parts being afterwards fomented and treated with antiseptic, sedative, or astringent lotion. Calculi in the urethra can be detected by the aid of a metal sound or catheter, and must then be removed (p. 241). If gangrene has proceeded to such an extent that recovery of the extremity is hopeless, amputation must be practised.

The *Operation* of **Amputation** is performed with the aid of a scalpel, forceps, and saw, a rubber or tape ligature being previously placed above to control hæmorrhage. A catheter is passed into the urethra, a circular incision is made through the fleshy portion (the patient, of course, being anæsthetized), the urethra is, if possible, dissected out from the interior of the groove in the bone and laid back, and a saw is used to complete the excision. In the cat amputation is occasionally done unintentionally by the amateur castrator, and a painful death is the usual sequel.

After-treatment.—The parts must be kept clean with antiseptics, and the urethral orifice kept open by passing the catheter twice a day for a fortnight or three weeks, and after that at intervals of once a week or so until the operator is sure that all danger of stricture has passed.

Mr. F. J. Taylor, M.R.C.V.S. (*Veterinary Record*, vol. xvi., p. 505), has recorded an interesting case of this operation in a fox-terrier, the animal having had the penis bone fractured when fighting. The bone was amputated at about its centre, and the patient was alive eighteen months afterwards and apparently suffering no inconvenience from the loss of the organ.

Phimosis.

By this term is meant a constricted condition of the end of the prepuce, whereby the penis cannot be exposed. It is occasionally met with in puppies, and is nearly always congenital. It causes the animal a great deal of annoyance, especially as it grows older, and is apt to cause irritability and pain. The only remedy lies in surgical interference, which may take the form of either a simple incision or a circumcision.

Sometimes a congenital malformation or arrest of development will be met with, such as is shown in Fig. 173, in which the end of the prepuce is closed, and the penis finds its exit through an abnormal opening some little distance from the place. Such a case would require a combination of the second operation detailed below and Cherry's operation (p. 49).

In this case, recorded by Professor Taylor in the *Veterinary Record* (vol. xv., p. 447), there was an oval slit, through which the penis protruded, in the prepuce, and a few hairs were growing on the corpora cavernosa. In front of this slit there was a fold of skin representing the end of the prepuce, but there was no apparent orifice. The scrotum only contained one testicle.

Operations—1. *Simple Incision*.—With the patient hobbled or held in the dorsal position, a longitudinal or V-shaped incision is made of sufficient length to allow of the protrusion of the penis. The edges are cauterized in order to retard healing, and, if sufficient has been cut out, the wound gives no further anxiety.

2. *Circumcision*.—In this operation the end of the prepuce

is stretched tightly, and a circular incision is made around it with a sharp scalpel, or the end may be cut off with scissors. The chief precaution to take here is not to remove too much, as if this is done the penis will protrude afterwards

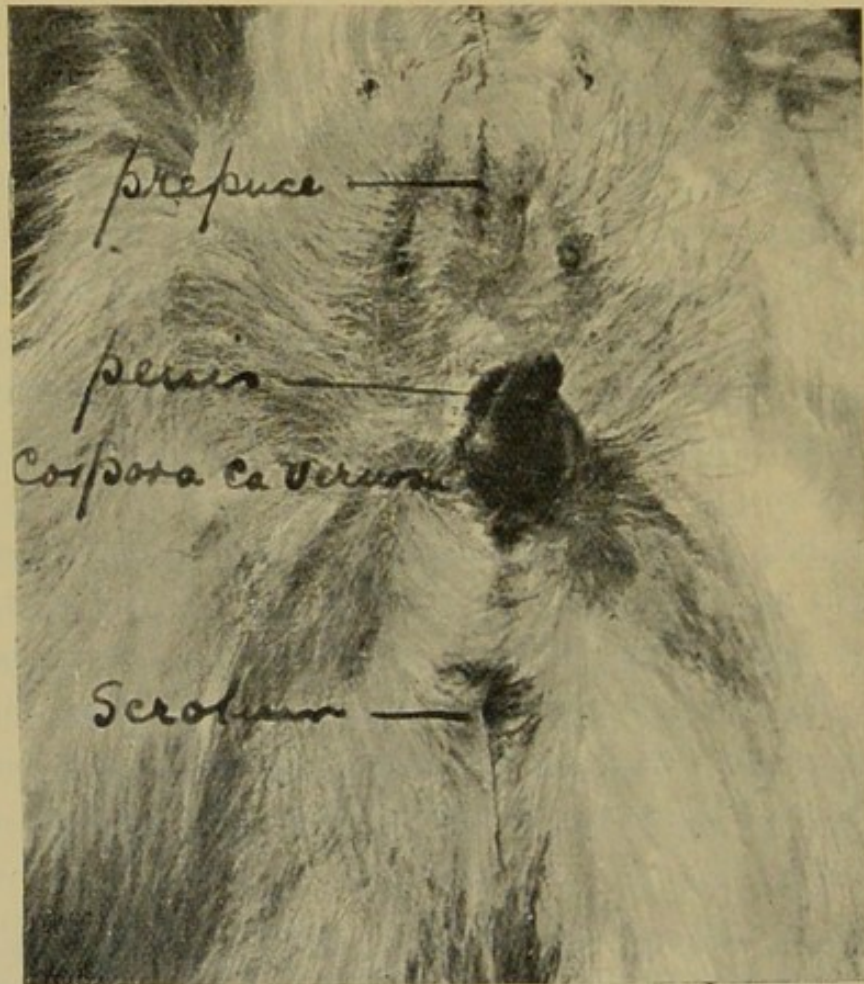

Fig. 173.—Congenital Malformation of the Prepuce and Penis.¹

in a very unsightly and objectionable manner, besides running risks of injury, the last state of the patient being thus worse than the first.

Paraphimosis.

This condition is the opposite of that of 'phimosis,' being one in which the glans penis is so swollen that the

¹ For this photograph I am indebted to the *Veterinary Record*.

prepuce cannot be drawn over it. It may appear very suddenly without any apparent cause, and, unless relieved, exist for sufficient time to cause the end of the penis to assume an alarming size and colour. Before resorting to operative measures, the application of ice or refrigerant lotions may be tried, attempts being made by gentle and steady pressure of the balls of the two thumbs to induce the glans to return, the fingers at the same time trying to raise the prepuce at the sides so as to cover it. This generally succeeds, but failing relief this way surgical measures must be resorted to.

Operations—1. *Scarification*.—This is done very lightly, and in fact consists, more properly speaking, of a number of small punctures with a needle or the point of a fine scalpel. When this has been done, gentle pressure, as already described, should again be tried.

2. *Incision of the Prepuce*.—This is done with a sharp scalpel or bistoury, but should only be performed when the other operation has failed.

Tumours of the Testis.

A chronically enlarged condition of the testis is sometimes seen in old dogs as the result of an orchitis. This condition is usually traceable to some injury, and the testis attains a certain size in a few days, after a period of rapid inflammation and acute pain.

Of tumours, sarcoma and carcinoma are the most common in this region, and they occur in testes which are retained in the abdomen as well as those in the scrotum. Generally to be seen in middle-aged or old dogs, they will grow to a very large size within a few weeks, and the tumour will, in time, displace the whole of the normal testicular tissue. During their period of formation they sometimes cause acute pain and cachexia.

The *Treatment* consists in complete removal by the operation of castration.

Castration.

This operation is performed in the cat and dog, especially the former, in order to keep the animals from wandering; also in certain diseased conditions, such as orchitis, sarcoma or other tumour of the testicle, and enlargement of the prostate gland; and in cats in order to diminish the unpleasant odour possessed by the urine.

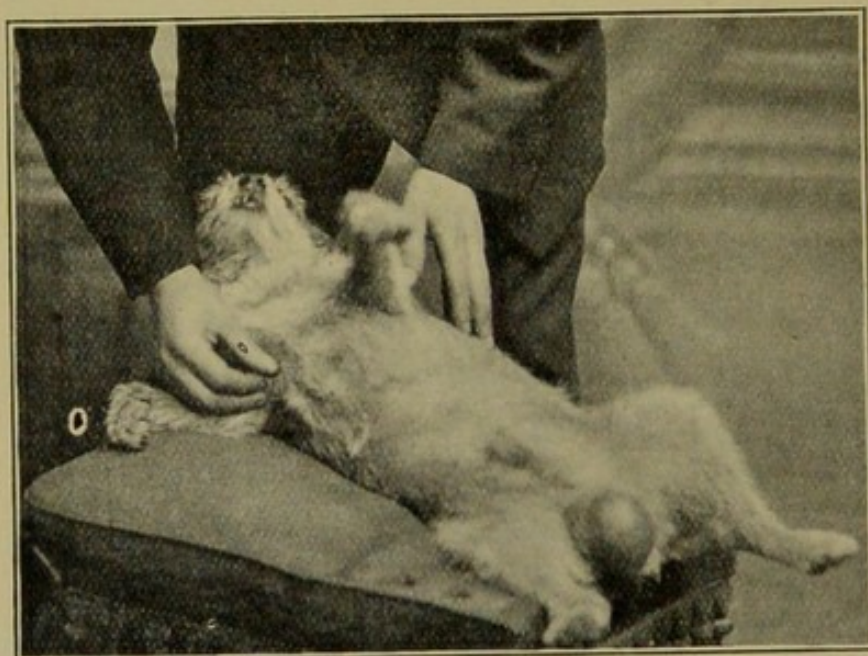

Fig. 174.—Aged Irish Terrier with Sarcoma of the Testicle.¹

Preparation and Method of Securing.—Although the operation should be done under an anæsthetic, this is not always employed, as the procedure is very simple and completed within a few seconds. Before making the incisions the hair should be clipped or shaved off, and an antiseptic used, particularly in the varieties of cats which have long hair; neglect of these precautions has been known to lead to septicæmia and death. The dorsal position on the operating-

¹ For the photographs of Figs. 174, 176, and 177, I am indebted to Mr. Henry Gray, M.R.C.V.S.

table is the most convenient. A cat, when no anæsthetic is used, may either be rolled up in an ordinary towel (care being taken not to cause suffocation), with the parts to be operated upon left exposed, or held by an assistant as shown in the photograph (Fig. 175). An old-fashioned and very effectual way used to be to put the animal head downwards in a top-boot or the sleeve of an overcoat.

In the method illustrated in Fig. 175, the cat is lifted up by the shoulders, the fore and hind limbs on each side being

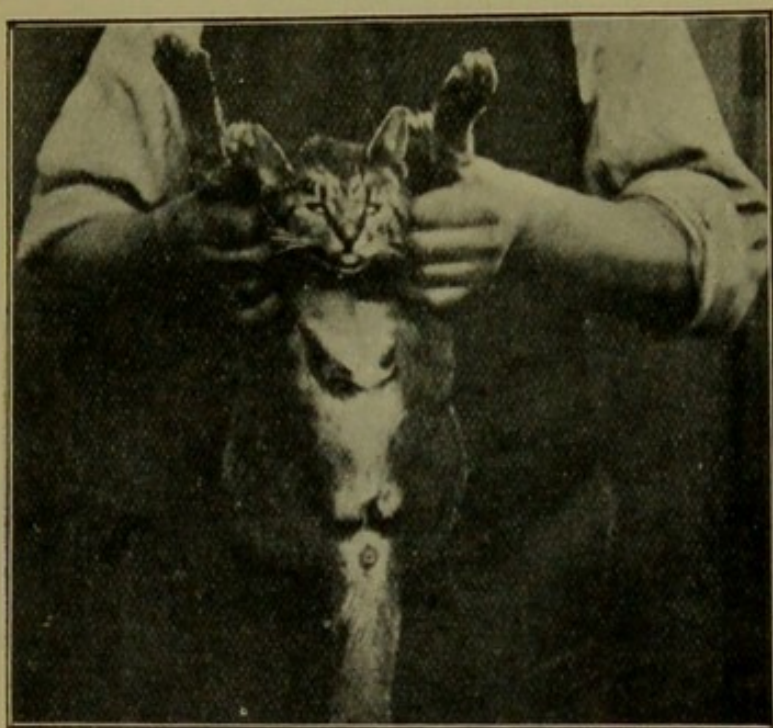


Fig. 175.—Method of holding Cat for Castration.

crossed over one another and grasped tightly. The first fingers are then crossed under the throat, and the thumbs are pressed firmly at the back of the head in such a way that the cat cannot get its mouth down, or even sideways, to use its teeth. The tail is pulled out of the way, and the hind-legs are held widely apart. The operator should never stand immediately behind the patient, as the animal is apt to eject a stream of odoriferous urine in that direction.

The *Operation* is performed as follows: An incision is

made over each testicle separately, the organ is withdrawn, and the cord is twisted several times and slowly scraped through. Another method commonly adopted is to employ traction on the cord until it gives way; with either of these methods the hæmorrhage is very slight. The surgeon should always be careful not to leave pieces of the cord protruding from the wounds, as if this is done the projecting piece becomes indurated, and causes pain and irritation, especially in cats. It may even lead to death.

In old dogs, those of large breeds, and those which have




Fig. 176.—Aged Fox-terrier with Ectopic Right Testicle and Orchitis, the Left One being normally placed in the Scrotum.

diseased conditions of the cord, more care must be taken. For these cases an anæsthetic should always be administered, as the operation is necessarily to some extent prolonged. The testicle is exposed in the usual way, and removed either by slow scraping after twisting the cord several times, by excision after the application of an aseptic ligature, by an emasculator, by the clamp and iron, or by torsion forceps and clamp. Each method is good in its way, and the choice must be left to the discretion of the operator.

When aseptic precautions have been rigidly adopted, the scrotal wound may be sutured and covered with iodoform or

orthoform and collodion, the sutures being removed in four or five days. To prevent the animal from licking the wound, the device known as an Elizabethan collar (Fig. 27), made of some stiff material such as wood, leather, or tin, is very useful.

If asepsis has not been properly carried out, the best plan is not to suture, but to treat the part as an open wound,



Fig. 177.—Aged Wire-haired Terrier with Ectopic Left Testicle and Chronic Orchitis.

antiseptics being freely applied two or three times a day. Exercise is always beneficial, and the prognosis is favourable in most cases. The chief precautions to take are: In the dog, to guard against hæmorrhage either at the time or afterward; in the cat, carefully to clip off the hair before making the incisions, to avoid asphyxiating the animal when holding it, and to be careful not to excise the penis by mistake. When the latter is done, death invariably ensues.

It is worth while to note here that by the rules of the Kennel Club a castrated dog, or one which has in any way been improperly tampered with, is disqualified from competition, or from receiving a prize if awarded.

Cryptorchids.

Retention of the testicle is not at all of uncommon occurrence in the dog and cat, and when the term 'cryptorchid' is used it is understood that the animal to whom it is applied has one, or perhaps both, hidden from view.

If one is out of sight and the other present in the scrotum, the animal is said to be a unilateral cryptorchid, or monorchid; if neither can be seen nor felt, the term bilateral or double cryptorchid is applied. Amongst the agricultural community such an animal is commonly spoken of as a 'rig.' Occasionally a condition is met with in which no testes are, or ever have been, present at all. Such an animal is technically known as an 'anorchid.'

Heredity.—There is no doubt that there is a hereditary tendency for a cryptorchid sire to propagate males with a like defect, although this is not of so much importance in multiparous animals as in those, like the equine tribe, who usually only have one at each birth. At the same time, it is a point worth thinking about when considering the value of a dog for stud purposes. It is highly probable, too, that atavism plays some part in propagating the malformation, as a bitch descended from a sire whose scrotum only possessed one testicle is very likely to transmit that defect amongst a certain proportion of her progeny, even although she has been mated with a perfectly normal sire.

Power of Procreation.—This is a point of the utmost importance, and disputed opinions upon it have led to many law cases in the canine world. The dispute usually arises as to whether a dog possessing misplaced testicles is or is not a stud dog. The author's experience is that when one

testicle is well down in the scrotum the animal *may* be valuable as a stock-getter; if, however, both are in the inguinal region and neither in the scrotum, the probability is greatly against the procreation of stock, although the dog or cat may mate satisfactorily. Finally, if neither testicle can be seen or felt—*i.e.*, if both testes are in the abdomen—the prospect of the dog becoming a sire is exceedingly remote—in fact, practically *nil*.

When examined microscopically after removal, it is not rare to find spermatozoa in testicles which have remained in the lower part of the inguinal canal, but in those taken from the upper part and in those taken from the abdomen this is exceptional. Fertility, however, depends upon many things, including the number and state of maturity of the spermatozoa; the actual presence, therefore, of a few specimens in the semen removed from a testicle does not necessarily imply power to propagate species.

Retained testicles in the dog or cat, as is also the case with the human subject and with the horse, are liable to disease, and it is not infrequent to find them enlarged and affected with carcinoma or sarcoma.

In this connection the following case reported by Mr. W. Pauer, M.R.C.V.S. (*Veterinary Record*, vol. xvii., p. 88), is of interest:

The subject, a deer-hound, about nine years old, had had trouble in passing *fæces* for about twelve months, and during the latter part of the time the rectum had to be emptied artificially every other day. Examination revealed this organ to be dilated so that a round mass of *fæces* collected about the size of an orange. Any attempt to defæcate caused the patient excessive pain.

Manipulation and examination of the abdomen revealed a hard, round body, the size of a pullet's egg, distinctly loose in the interior; and as a further examination revealed the absence of one testicle from the scrotum. I concluded that this enlargement was the missing testis. On account of the rectal trouble the dog was destroyed, and a *post-mortem* examination revealed the right testicle to be within the abdomen, cystic and very much enlarged. It weighed 2 ounces, and was examined microscopically by Professor McFadyean, who stated that it was carcinomatous. The spermatic cord was twisted about eight times around itself, with the vein

so distended that it presented a corkscrew-like appearance. The left testicle was undeveloped, and only weighed 2 drachms.

Mr. Pauer considered that the pain caused when pressure such as is caused during the act of defæcation was put upon the diseased testicle had been the original cause of the dilatation of the rectum, the dog

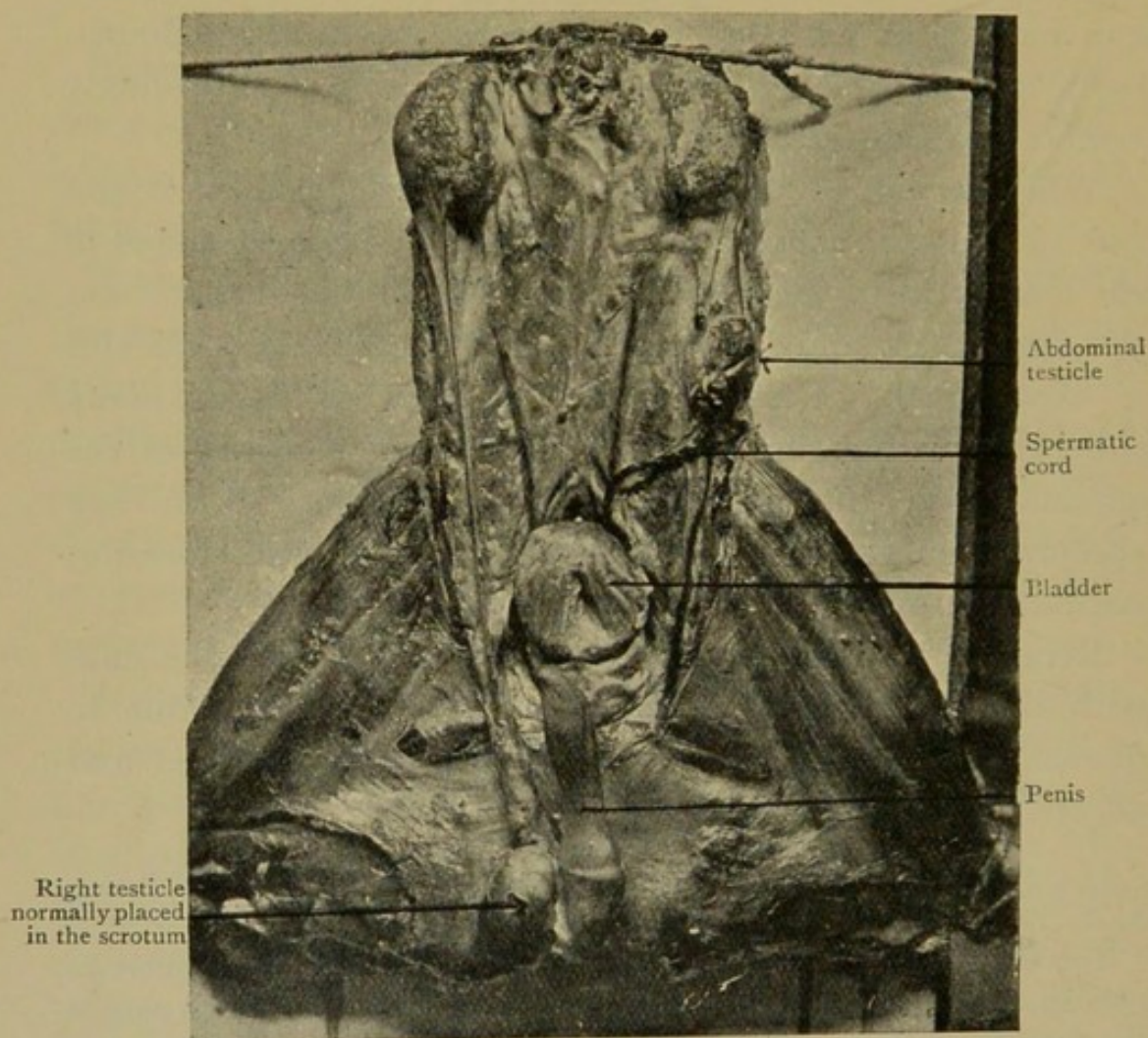


Fig. 178.—Anatomical Arrangement of the Testicles in a Cryptorchid Dog (Fox-terrier).¹

avoiding the attempt to pass a motion as long as possible, and thus causing the rectum to enlarge.

Another instance is reported on p. 286 (Torsion of the Cord).

Operation.—The necessity for operation may arise from the wandering habits of the dog, or perhaps from a dis-

¹ For this photograph and dissection I am indebted to Professor Dunstan, F.R.C.V.S., F.R.S.E.

puted argument as to whether a dog has been castrated or not.

In one instance in which the author was called upon to decide, the patient, an Irish terrier, had been sold by one man to another for two guineas, the purchaser discovering the absence of testicles about a week later. He returned the dog and demanded his money back. The vendor, who had bred the dog and knew that no operation had been performed, refused to return the purchase-money, and at this stage, at the request of the vendor's veterinary surgeon, the author was called upon to decide. An operation was agreed to, laparotomy was performed, and the missing testicles were discovered in the sublumbar region. The patient made a rapid recovery.

On account of the smaller size of the inguinal canal, unless the misplaced organs happen to be close at hand, the best method of reaching them is to perform laparotomy and remove them through the abdominal wound.¹ If they can be felt in the inguinal region the operation merely becomes a modified castration. Under a general anæsthetic and with the usual antiseptic precautions (p. 2), an incision is made in the median line immediately in front of the prepuce. The operator inserts his middle finger and searches in the lumbar and pelvic regions for the missing testicles, withdrawing each one in turn, and excising it after the application of a boiled silk ligature. The abdominal wound is then sutured and treated as already described (see Laparotomy, p. 158).

Hermaphrodites.

Sometimes a dog or cat is seen possessing organs of generation which partake partly of the shape and character of the male and partly of the female. To this freak of Nature the term 'hermaphrodite' is applied.

Such animals are quite incapable of propagating their species, although they may be able to effect coition, and on this account they are apt to become troublesome.

¹ *Veterinary Record*, vol. xii., p. 298.

The patient from whom Figs. 179 and 180 were made became objectionable on account of the persistent protrusion of an abortive penis (or enlarged clitoris), which was successfully amputated.

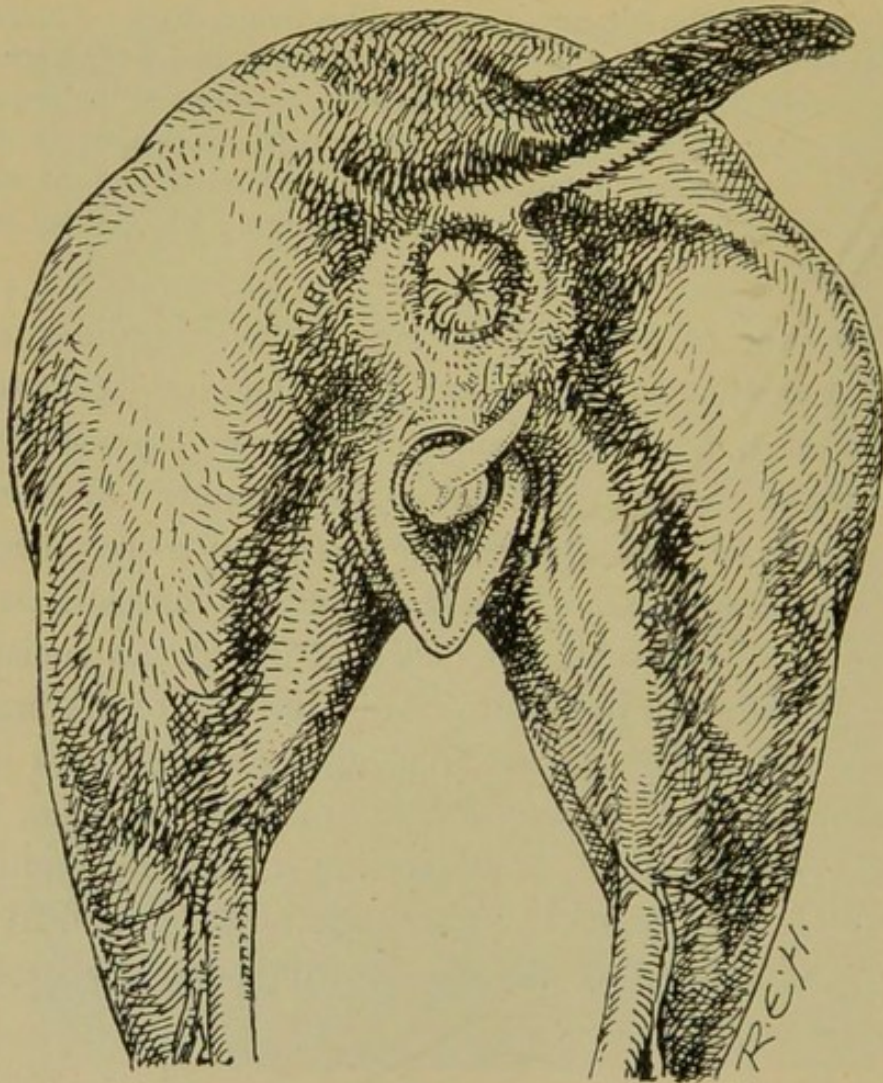


Fig. 179.—Sketch taken from the Hind Parts of a Hermaphrodite Pug Puppy Five Months old.

Castration or ovariectomy may be decided upon, the final decision depending upon the condition discovered when it is seen what state of things is revealed by an exploratory laparotomy.¹

¹ *Veterinary Journal*, June, 1905, p. 313 (Craig and Hobday).

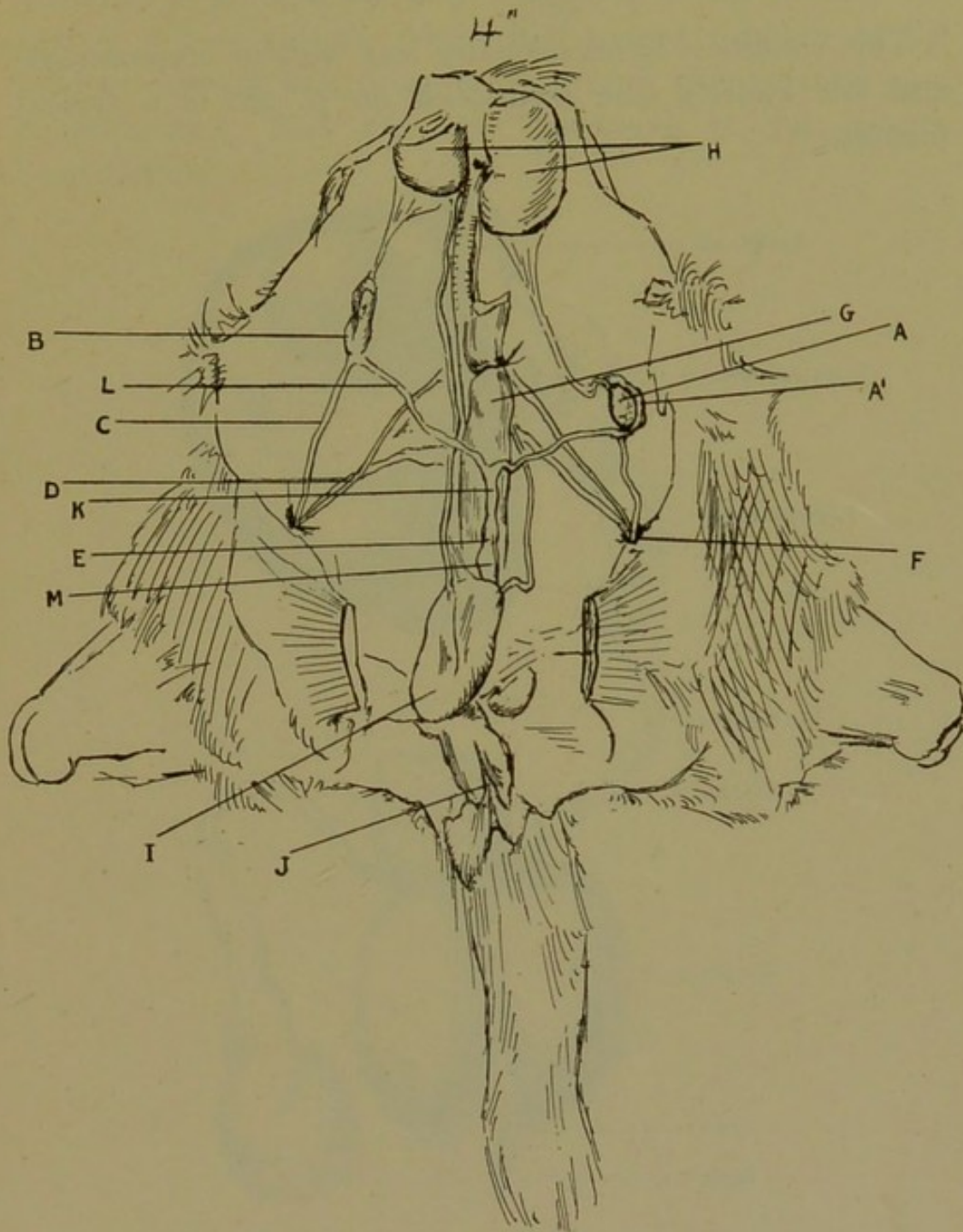


Fig. 180.—Dissection of the Internal Generative Organs of the Pug
Puppy illustrated in Fig. 179.

A, Left testicle; A', epididymis; B, right testicle; C, gubernaculum testis; D, femoral vessels; E, os uteri; F, internal abdominal ring; G, rectum; H, kidneys; I, urinary bladder (reflected); J, vulval opening; K, body of uterus; L, cornu; M, vagina.

Torsion of the Cord.

This condition is occasionally met with in cryptorchids, and Mr. Pauer's case mentioned on p. 281 is a typical instance.

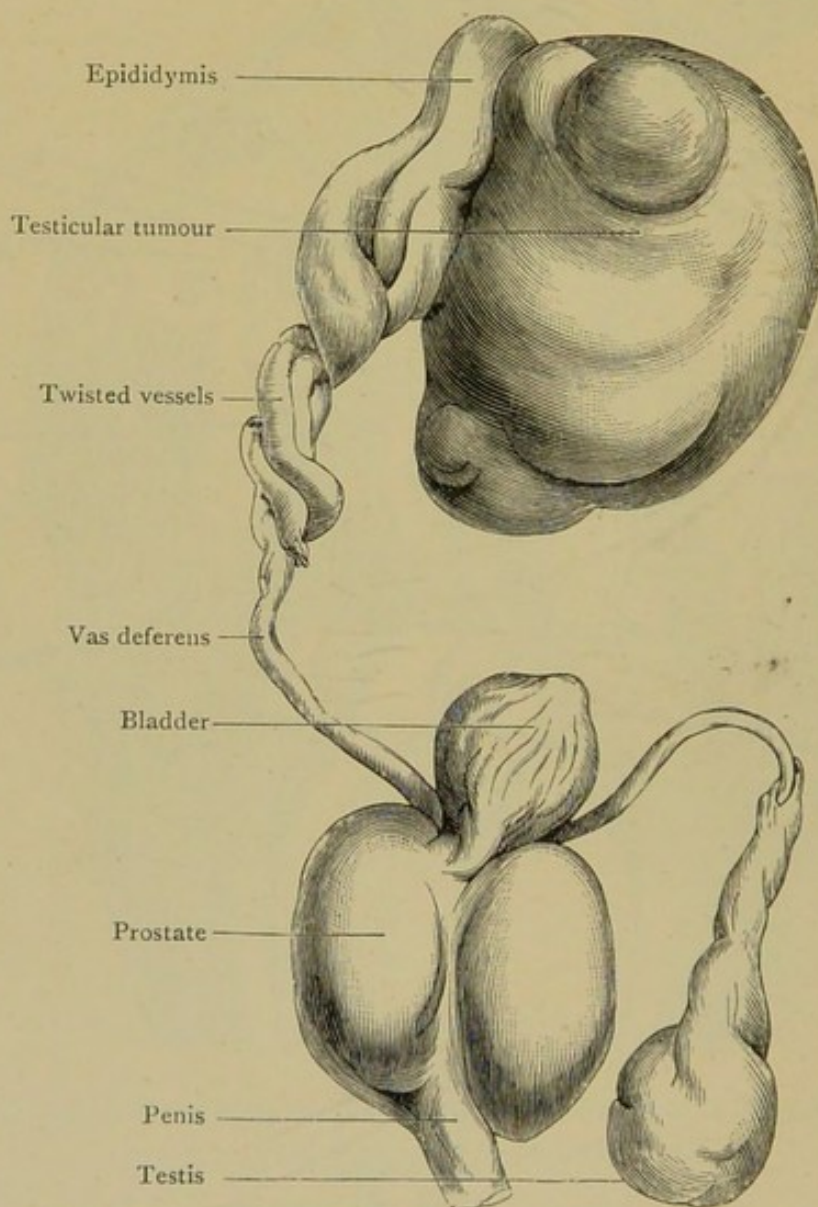


Fig. 181.—Tumour of a Pug Dog's undescended Testis which had undergone Axial Rotation (J. Bland Sutton).¹

Mr. J. Bland Sutton, F.R.C.S., has also recorded a case in the *Medico-Chirurgical Transactions* for 1892 (p. 257)

¹ 'Surgical Diseases of the Ovaries' (second edition).

in which there was retention of the right testis in the abdomen of an aged pug dog. This organ had become the seat of a new growth, which had caused rotation of the cord two and a half times on itself and strangulation as a consequence. This was only discovered on *post-mortem* examination.

CHAPTER XX

THE FEMALE GENERATIVE ORGANS

Examination of the Prepuce or Vagina, and Removal of Foreign Bodies.

THE interior of the prepuce or vagina can be examined for some distance from its orifice by the aid of the fingers or by the insertion of a speculum of similar design to one of those already described for the ear or rectum (see Figs. 49 and 50). The female can be examined in the standing posture, unless very restless, in which case the dorsal position on the

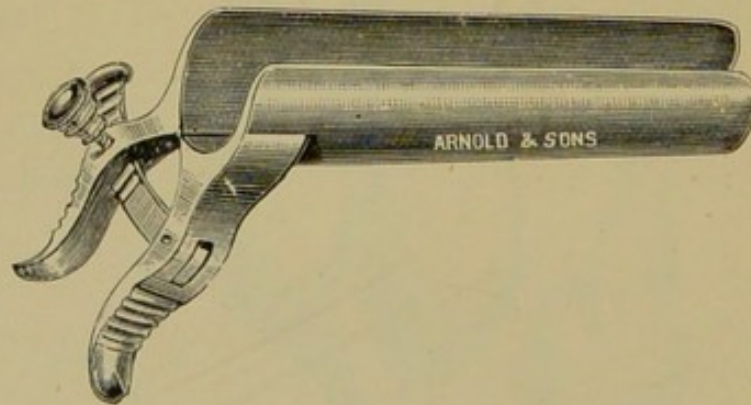


Fig. 182.—Vaginal Speculum.

operating-table, with the hind-legs raised and held over the body, will be found to be the most convenient; whilst in the case of the male the animal should be held or fixed on its back, with the hind-legs spread well apart. A small electric lamp is an exceedingly useful adjunct.

Foreign bodies other than tumours are removed by the

aid of forceps. Tumours are often a source of great trouble, and some varieties are contagious and recur very rapidly (see p. 291).

Prolapsed Vagina.

Frequently, especially during the period of œstrum and after parturition, especially when a bitch is out of condition, the vaginal mucous membrane becomes relaxed, and in some

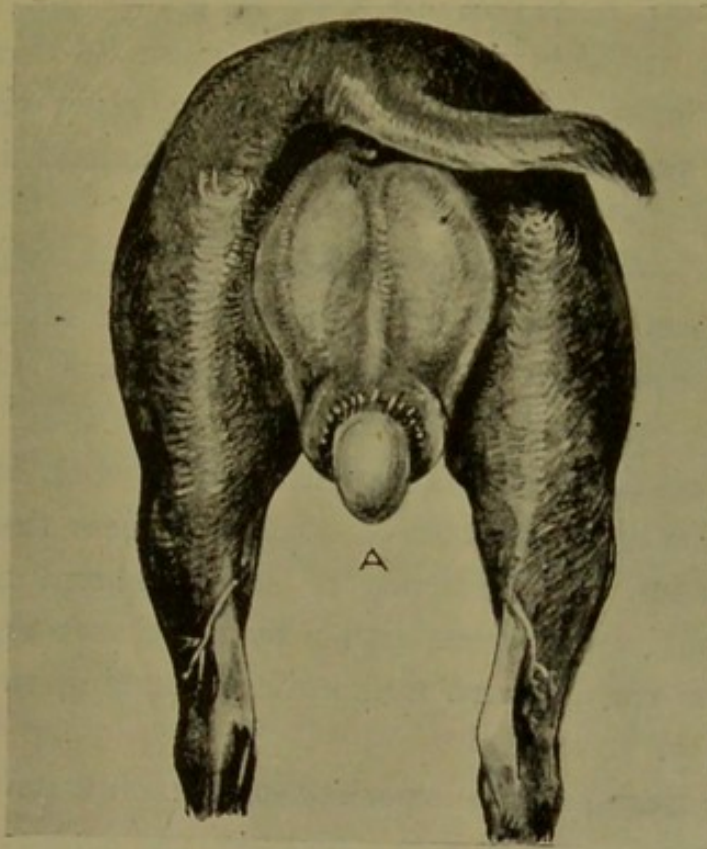


Fig. 183.—Prolapse of the Vagina.

cases will protrude from the vulva for a considerable distance. It is a serious condition in brood-bitches, as it often interferes with mating, and also with the passage of the pups at time of birth. It is particularly noticeable when the animal lies down. To look at, in the first instance, it is like a small, white, shiny rubber or celluloid ball, varying in size from a filbert to an orange, or even, in the larger breeds, to a cocoanut. If neglected, the surface which protrudes from the vulva will become hardened and corrugated or wrinkled in appearance.

It is then a great detriment and disfigurement, and measures should be taken to put it right as soon as possible.

In some cases it is worth while to try various remedies, such as the application of a pessary and sutures, together with the injection of solution of alum, tannin, or other internal astringents, before resorting to amputation, the object being to get recovery without injuring the vaginal walls. When, however, all hope of permanent return has been given up, the prolapsed parts must be excised. The operation is not difficult, and rarely gives rise to bad sequelæ if performed properly and the animal is not very much exhausted.

Operation.—The patient is secured on the operating-table in the abdominal position, or may be held securely in the standing posture by an assistant. The parts, having been thoroughly syringed and cleansed with some antiseptic solution, are dried carefully with cotton-wool, and painted with a 5 per cent. solution of cocaine (unless the patient is already under the influence of some general anæsthetic). Amputation is performed either by the clamp and iron, the *écraseur*, or the ligature and knife, according to the will of the operator.

Judging from several experiences of each way, the ligature seems to be the best if it can be used, the *écraseur* being the least preferable, on account of the amount of laceration caused. In all cases care must be taken not to include the opening of the urethra in the part excised.

After-treatment consists in plugging the vagina with wadding, or syringing with solution of liq. ferri perchlor. and water or adrenalin until hæmorrhage has ceased, and afterwards using an antiseptic solution as long as may be considered necessary. The latter is of some considerable importance, as if neglected or unable to be properly performed, owing to the animal being very refractory or vicious, a septic infection may take place up the urethra, involving

the bladder, reaching the kidneys by way of the ureters, and, ultimately causing the death of the patient. The author has known two such instances.

Mr. H. Gray obtained permanent success in one case¹ by performing laparotomy, applying traction to the uterus from within the abdomen, thus replacing the prolapsed part, and attaching it to the abdominal wall with sutures.

Malignant Tumours of the Vagina.

In the vagina of the bitch one frequently meets with a species of ulcerating contagious venereal tumour which is communicable to the male when the animals are used for stud purposes.² If neglected, these tumours grow very large, causing an offensive, fœtid, and continuous discharge. To effect their removal, the knife and curette must be used freely, the parts having been anæsthetized by cocaine solution or the animal placed under chloroform (see Chapter IV.). If imperfectly removed, the return of the growth is usually rapid, and the animal may become valueless for breeding purposes; as a rule, an old dog will not mate with a bitch suffering from these tumours. Their vascularity is much increased at time of œstrum.³

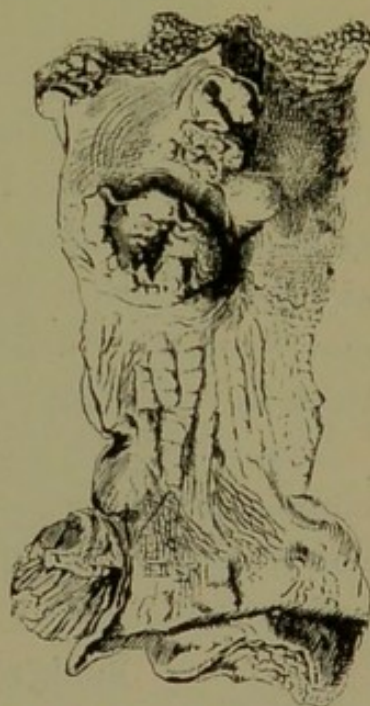

Fig. 184.—Vagina Split open to show Contagious Venereal Tumours.²

Operation.—For their permanent removal it is essential that an area of mucous membrane shall be excised around the edges of the growth. This is done under an

¹ Unrecorded.

² Smith and Washbourn, *Journal of Comparative Pathology and Therapeutics*, vol. xi., p. 41.

³ This tumour is indistinguishable in microscopical structure from a sarcoma, and is now classified as a granuloma (Report of the Imperial Cancer Research Fund, Part II., 1905).

anæsthetic by the aid of scalpel or scissors and forceps, a pair of pressure forceps being of material assistance in gripping the growth and the vagina itself being held open with a speculum (see Fig. 182).

A sharp curette (Fig. 40) may afterwards be applied with advantage. The hæmorrhage is controlled as already described (p. 52), and the *After-treatment* consists in the application of antiseptics.

If the growth happens to be near the vulva, it can often be permanently removed at one operation, but if higher up, and involving the os uteri, it may be a matter of impossibility.

Prognosis.—The prognosis of a complete and permanent cure must be very guarded.¹ The author has known death to ensue from inflammation of the bladder, owing to the retention of urine consequent upon a swollen condition of the mucous membrane around the urethral orifice. Septic infection may also take place, organisms finding their way up the urethra into the bladder, and so to the ureters and kidneys, and after severe excision of a large area a stricture may form, so constricting the vagina that the bitch is of no value for breeding purposes (see p. 305).

The return of the growth can be very much retarded if oöphorectomy (see p. 294) is performed in addition to the curetting;² these operations, however, should be done on separate occasions.

Benign Tumours of the Vagina.

Fibromata are met with in this situation, and as they are sometimes multiple and attain a very large size, they give rise to serious inconvenience, and may even cause emaciation and death. They are not contagious, but after a time ulcerate, and cause an offensive, semi-purulent discharge.

The *Diagnosis* can readily be made by a digital examina-

¹ These tumours have caused such serious losses amongst valuable brood bitches that the British Bulldog Club have issued a circular to its members warning them of its contagious character.

² *Veterinary Record*, vol. x., p. 30.

tion, and to the touch they present a smooth, hard, lobulated surface, which is readily distinguishable (even when ulceration has commenced) from the contagious venereal granuloma.

Operation.—The only chance of successful removal lies in complete excision, and this is done by the aid of a speculum, scalpel, forceps, and scissors, the patient being put under an anæsthetic.

After-treatment consists in the application of an antiseptic

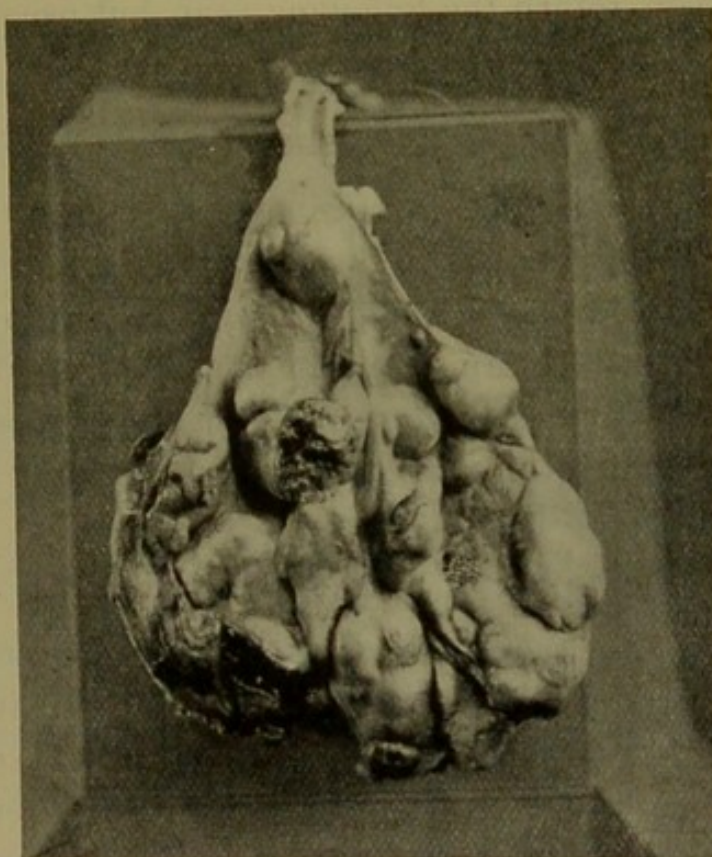


Fig. 185.—Multiple Fibromata (weighing six ounces) of the Vagina.¹

douche; and the *Prognosis* must, as with the granuloma, be guarded, especially in a bitch intended to be used again for breeding purposes.

Nymphomania.

By this term is understood a condition of persistent œstrum. It is not infrequently met with in cats, and occasionally in old bitches, the animal rarely becoming

¹ *Veterinary Journal*, vol. lx., p. 255 (F. Aulton and F. Hobday).

pregnant, and, every few weeks, being a constant source of annoyance and trouble. It usually depends upon some irritable, congested condition of the ovary or uterus.

The remedy consists in the operation of **ovariotomy** or **ovaro-hysterectomy**, if, after fair trial, sedative drugs, such as bromides, fail to act satisfactorily. Sometimes, especially in middle-aged bitches and cats, the beneficial results are not seen until after the 'rutting' season has passed, and they may even return the following year, but usually, if they do, it is to a much less degree.

Hysteria.

This condition is met with in nervous bitches and cats, especially during period of œstrum, the patient becoming very excitable and uncontrollable. Fits, resembling epilepsy, may be noticed. Treatment consists in keeping the patient as quiet as possible and under the influence of bromides, but if these fail, **ovariotomy** or **ovaro-hysterectomy** should be performed.

Oöphorectomy and Ovariotomy.

This operation, commonly spoken of as 'spaying,' is performed for certain diseased conditions of the genital organs, and also in healthy subjects, with the object of preventing pregnancy and œstrum. Its effect upon the latter is by no means absolutely certain, as upon several occasions we have observed signs of œstrum in bitches and cats whose ovaries have been wholly removed, the animals even copulating with the male.¹ Messrs. Leeney, P. J. Simpson, and Cecil French have also observed the same.² The term **oöphorectomy** is applied to the operation when the ovaries are healthy, and the term **ovariotomy** when they are diseased.

Animals may be operated upon at any age, but from six to

¹ *Veterinary Record*, vol. xii., p. 15.

² *Veterinary Journal*, vol. xxxi., p. 11; *idem.*, vol. lx., p. 31; *Journal of Comparative Medicine*; and *Veterinary Archives*, 1900.

twelve months for the bitch, and from three to nine months for the cat, seem to be the most favourable.

Operation.—Having previously had the abdominal wall around the seat of incision carefully cleansed and shaved, a pad of antiseptic material is put over the part and the animal placed on the operating-table to be anæsthetized; when unconscious the patient is turned over and fixed on its back, with the limbs well spread apart. The antiseptic pad

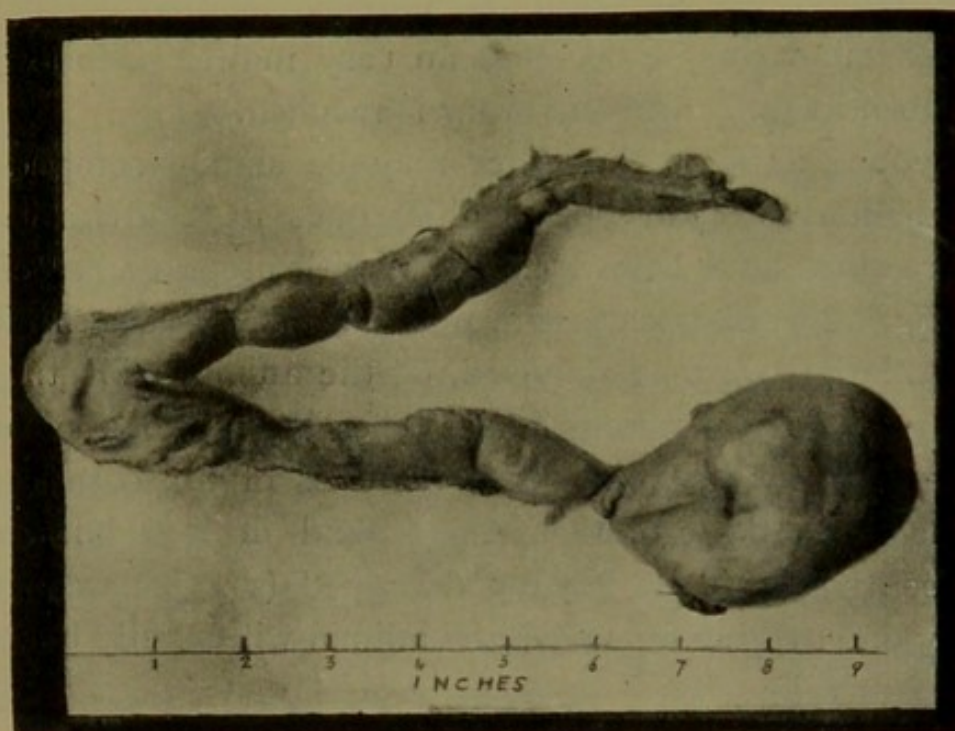


Fig. 186.—Diseased Uterus and Ovary removed by Operation from a Bull Bitch.

The horns were full of pus. The right ovary was normal and weighed 8 grains; the left one was diseased and weighed $2\frac{3}{4}$ ounces.

is removed, the skin being lightly scrubbed with ether and again washed with antiseptic lotion. A longitudinal incision of from about half an inch to an inch long is made through the skin and muscular tissue on or close to the median line just behind the umbilicus, all bloodvessels being carefully taken up with artery forceps before the peritoneum is pierced. The latter is done with the point of a scalpel, the incision being completed with the aid of a director. At this stage a blunt probe or flexible catheter may be inserted by an

assistant into the vagina, if the operator has not had much previous experience; this generally penetrates as far as the os uteri, occasionally passing into one of the cornua, and acts as a guide. The operator introduces the fore or middle finger of his right hand, or a blunt hook, into the abdomen, keeping it close to the abdominal wall and pushing the intestines on one side, the object being to find one of the cornua or the body of the uterus in which is contained the probe which an assistant is moving cautiously about. Having found this, it becomes an easy matter to follow up each horn in turn until the ovary is reached.

In young animals the latter may be simply scraped off with a blunt scalpel, but in older ones it is advisable to ligature above and below the ovary with aseptic silk before excising. In either case care must be taken to see that the whole of the ovary is removed, or the animal will still be liable to become pregnant,¹ thus defeating one of the main objects of the operation. The cut ends of the cornua are returned into the abdomen, the wound in the abdominal wall being treated as already described (see Laparotomy). If only one ovary is removed, the animal will readily become pregnant again.

As an instance of pregnancy when a small piece of ovarian tissue is left, on one occasion the author snipped off each ovary with sharp scissors as closely as possible, without injuring the Fallopian tubes or the attachment of the uterine horns to the lumbar peritoneum, or using any ligatures. Apparently every particle of ovarian tissue was removed so far as the naked eye could see, but in reality a microscopical portion in each case must have been left, as within three months the patient, a cat, had two kittens. Laparotomy was performed a second time, and it was found that the ovarian tissue had already become regenerated, on one side to the size of a pea, and on the other to the size of a horse-bean. Both were cystic. They were removed, this time after the application of a ligature, and the patient did well.

The results are excellent² if antiseptic precautions are

¹ *Veterinary Record*, vol. xii., p. 15.

² *Journal of Comparative Pathology and Therapeutics*, vol. x., p. 175, vol. xi., p. 254; *Veterinary Record*, vol. xii., p. 14.

observed. The chief **unfavourable sequelæ** to be feared are those of shock, peritonitis, descent of the bowels, hernia, and persistent disinclination to feed. The first and last mentioned have sometimes given rise to anxiety, especially in cats, several patients having refused to feed, although apparently all right in every other particular, and *post-mortem* examinations have given no clue as to the cause of death. Iodoform powder and other dressings which are at all poisonous should be avoided for wounds on small dogs and cats, and we have had opportunity to prove that iodoform dressings are toxic. Peritonitis can be avoided by rigid attention to antiseptic precautions, and by putting the animals in a clean place after the operation. This assertion is made upon the carefully recorded results of more than 250 consecutive oöphorectomies or ovariectomies in the bitch, in no single instance of which did death occur from peritonitis or any other cause. To avoid hernia and descent of the bowels, the patient should be kept quiet, and not be allowed to jump from any height, or go up and down steps, for two or three weeks after the operation.

One cat patient unexpectedly developed most peculiar and vicious maniacal propensities immediately after the operation, and ultimately became paralyzed in the hind-quarters, a *post-mortem* examination revealing nothing whatever to account for death. With cats one can never give so confident a prognosis as to the sequel as with a bitch.

By way of illustrating how little disturbance the operation causes when done under chloroform and antiseptic precautions, the following case (No. 54 of a series published in the *Veterinary Record* for July 8, 1899) is worth recording. An Irish terrier, aged eighteen months, in œstrum, had the urinary bladder very much distended at the time of operating, and, by an unfortunate slip of the scalpel, this organ was incised. A quantity of urine escaped into the abdominal cavity, being afterwards soaked up with antiseptic wadding, and the bladder wound was closed by three Lembert's sutures. The oöphorectomy was proceeded with and finished in the usual way. The cutaneous wound healed by first intention, the sutures being removed four days later. An absolutely

uneventful recovery took place, and the patient was sent home a week later. Three or four days after her arrival home she was still observed to be in œstrum, and even allowed the dog to line her twice—this notwithstanding the fact, of which I am absolutely sure, that ligatures were placed well above and below each ovary and every particle of these organs removed. Of course, no pregnancy or further sequel of that kind resulted.

It is worth while to mention here that a spayed bitch, or one which has in any way been improperly tampered with, is disqualified from competition (or from receiving a prize if awarded) in any show held under Kennel Club rules.

Purulent Metritis.

In bitches and cats which have bred once and not again, and occasionally in virgin animals, the internal lining membrane of the uterine horns becomes diseased, and the horns themselves (or one of them) are distended with a foetid purulent fluid.

The *Symptoms* shown are that the animal appears dull and listless, and the appetite is capricious, whilst at intervals a glairy, sticky, intermittent discharge comes from the vagina. This is noticed by the male, who constantly draws attention to it. As matters progress, the discharge becomes more profuse and very offensive, the bitch or cat leaving a stain wherever she has lain or sat down. At a still later stage there is very great disinclination to move—in fact, a state of stupidity; and during the intervals between the discharging periods, whilst the fluid is collecting, the abdomen is distended.

Diagnosis can be assisted by palpation of the uterus through the abdominal wall.

Treatment.—As a general rule, all treatment, beyond that of the surgical removal of the entire uterus (hysterectomy), or the ovaries and uterus (ovaro-hysterectomy), is futile except as a palliative measure.

Injectations of warm antiseptic fluids, such as boracic acid,

Condy's fluid, or chinosol, may be tried, the system being kept up with iron and other tonics. The chief difficulty to be contended with is that the os uteri is generally so far closed that no enema nozzle, not even a probe or catheter, can be passed through it. This can be obviated to some extent by the use of extract of belladonna smeared around the os, and by warm continuous injections for about ten minutes before the attempt is made to insert the enema-tube.

It is almost impossible, even in a large dog, to cleanse the interior of each horn so completely that the fluid will not accumulate again. Ovaro-hysterectomy, as below mentioned, should be advised in the early stages, and if the patient is not already much emaciated and in a state of collapse, a favourable *Prognosis* may be given.¹

Hysterectomy and Ovaro-hysterectomy.

By the term **hysterectomy** is meant the removal of the entire uterus, and the term **ovaro-hysterectomy** is employed when the ovaries are also included.

This operation is occasionally performed upon a healthy animal for the same purpose as oöphorectomy, with equally satisfactory results; it is necessary in those cases of purulent metritis in which the uterus becomes filled with foetid fluid (see above). It is also valuable in cases of dystokia,² or where dystokia is to be feared, as when the female of some small breed has become pregnant by the male of some larger variety. In the latter cases, if the patient has not become exhausted by labour pains, the results are excellent—indeed, so satisfactory that the author usually advises that it shall be performed as soon as pregnancy is assured in all cases in which the bitch is not required for stud

¹ *Veterinary Record*, February, 1901 (Ridler and Hobday).

² Torsion of the pregnant uterus is occasionally met with. Such a case has been recorded by M. Bonnet in the *Journal de Lyons* for January 31, 1905 (translated in the *Veterinary News*, April 29, 1905).

purposes. It gives her a much better chance than if matters are left until parturition actually commences.¹

Prolapse of one or both uterine horns into a hernial sac is quite common, and it sometimes happens that this organ may have to be removed; the horn may even be pregnant and strangulated. In the latter case, of course, it must either be returned into the abdomen or excised (see p. 229).

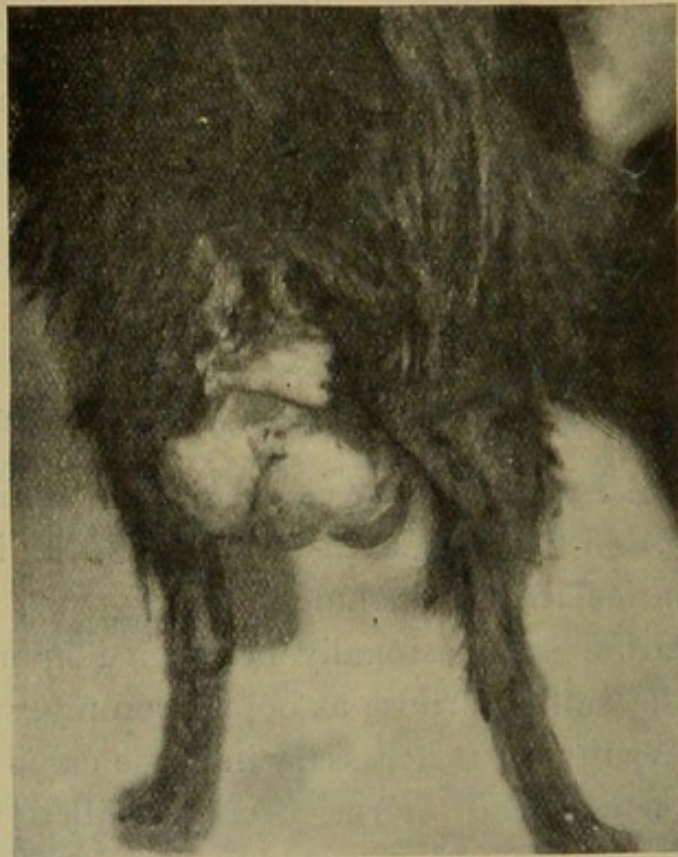

Fig. 187.—Prolapse of both Uterine Horns after Parturition.

Prolapse, too, may occur through the vagina after parturition, one or both horns 'coming down.'

Fig. 187 is an illustration of this, the patient, a toy Pomeranian, having both horns prolapsed as depicted in the photograph. Each was ligatured separately and excised, the bitch making an uninterrupted recovery.

Fig. 188 illustrates a bull bitch patient, taken six months after the operation, from which a puppy, the last of seven, could not be removed *per*

¹ *Journal of Comparative Pathology and Therapeutics*, vol. x., p. 176, vol. xi., p. 252; *Veterinary Record*, vol. xi., pp. 463, 652; H. Simpson, *Veterinary Record*, vol. xiii., p. 370; G. H. Golding, *Veterinary Record*, vol. xi., p. 462.

vaginam, the foetus being out of reach in the extremity of one uterine horn. Progress after the operation was quite uneventful.

Fig. 191, a Blenheim spaniel, was six years old before mating was allowed to take place, and the pelvic bones were quite unyielding, the vaginal passage being exceptionally small. In conjunction with Mr. G. Parr, F.R.C.V.S., the author performed ovaro-hysterectomy of the pregnant uterus, and the patient made an uninterrupted recovery. The puppies were all dead at the time of operation.

In another case, the patient, a toy Manchester terrier, had been clandestinely mated by a large fox-terrier, and after six weeks' pregnancy



Fig. 188.—Bull Bitch upon which Ovario-hysterectomy was performed for Dystokia.

(Photograph taken about six months after operation).

was so uncomfortable and distended as to appear almost ready to burst. Had matters been allowed to progress, she must inevitably have died before the time for parturition had arrived, and, as matters proved afterwards, it would have been a physical impossibility for the puppies to have been passed. Ovario-hysterectomy was performed, the wound healed by first intention, and recovery was quite uneventful, the patient being shown to the members of the Central Veterinary Medical Society¹ five days later, and sent home within a week.

¹ *Veterinary Record* (Proceedings of the Central Veterinary Medical Association).

Tumours of the uterus are not common in the bitch or cat, but now and again they are met with. Some varieties (such as myoma, see Fig. 189) can be excised, and the patient may live for years afterwards; whilst others, such as sarcoma (see Fig. 190), are malignant, and the most humane course is, to destroy the patient painlessly as soon as this fact is assured. Sometimes these tumours attain an enormous size.

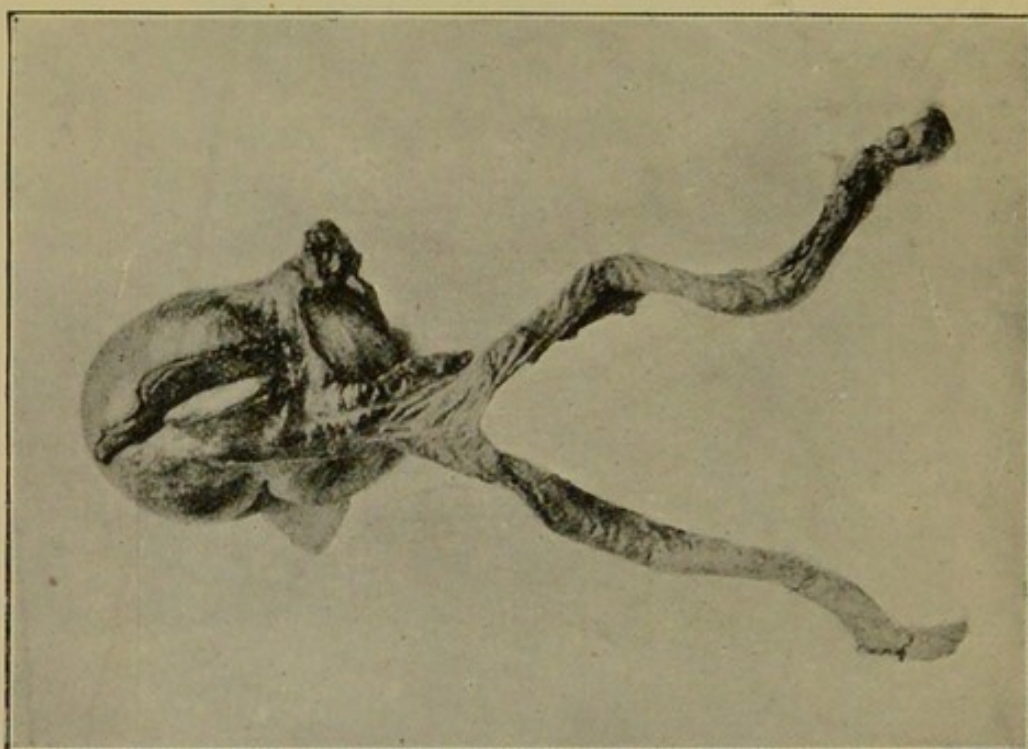


Fig. 189.—Myoma of the body of the Uterus of a Retriever Bitch.¹

Professor Penberthy has recorded an instance where an aged collie was found on *post-mortem* examination to have an oedematous fibroma of the uterus weighing 19½ pounds.²

Fig. 189 was photographed from the uterus of a retriever bitch, nine years old. The animal was thought by the owner to be pregnant.³

Operation.—The patient is prepared in the same manner as for oöphorectomy, the incision in the abdomen being of

¹ *Journal of Comparative Pathology and Therapeutics*, vol. x., p. 73.

² *Ibid.*, September, 1902 (G. H. Williams and F. Hobday).

³ This condition was not discovered until after death, although a tumour was diagnosed.

sufficient size to allow the gravid uterus (if this condition is present) to be withdrawn. Two catgut or boiled silk ligatures are placed above each ovary, and two others around the body of the uterus just below the junction of the two horns. The uterus and its contents are lifted out of the abdomen on to a boiled and sterilized cloth, the ligatures effectually preventing any of the contents from escaping into the peritoneal cavity and excised bodily. The stump of the uterus is carefully disinfected and returned into the abdomen. It is not

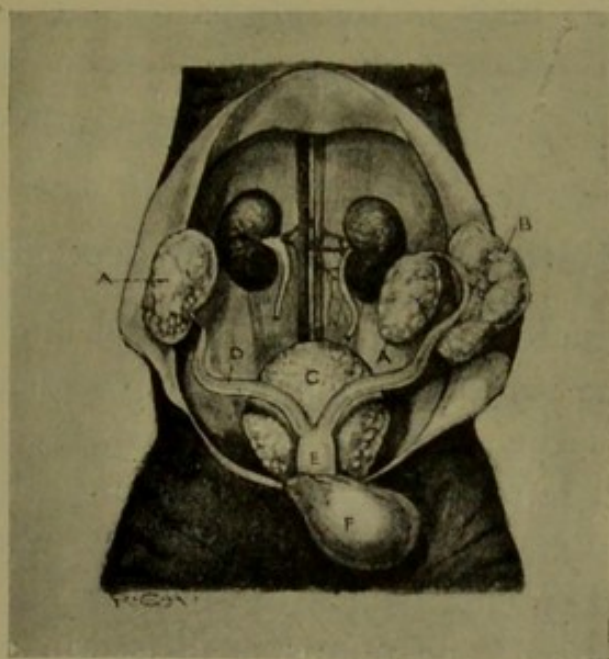


Fig. 190.—Inoperable Malignant Tumours (Sarcoma) of the Pelvis and Ovaries of a Cat.¹

necessary to in any way fix the stump to the external wound. The external wound is sutured and treated exactly as already described (see Laparotomy).

As after oöphorectomy, œstrum has been observed and mating has been allowed even when the two ovaries and the whole of the uterus as far as just above the junction of the horns with the body have been cleanly taken away beyond any possibility of question.

It is not always necessary to take both horns away; and if

¹ For this specimen I am indebted to Mr. Lionel Stroud, F.R.C.V.S. (*Veterinary Journal*, vol. lx., p. 317).

one can be saved and left intact, the bitch will still remain able to procreate her species.

In cases of purulent metritis (see p. 298), this operation gives good results if the patient is not emaciated and exhausted, or septic intoxication has not already commenced. In operating, particular care must be taken to avoid puncturing the uterus or allowing any of its contents to fall into the abdomen. The cut ends must be disinfected with the greatest care. The ligatures are put well above each ovary and around the body of the uterus respectively, two being used for each before making the incision between them. Fig. 186 shows a diseased uterus and appendages removed in this way.

Hysterotomy (Cæsarean Section).

In this operation the uterus is incised and the contents removed. The subject is prepared in the same way as for oöphorectomy, the abdomen being incised and the uterus exposed. The latter organ is then drawn to the edge of the wound or withdrawn altogether from the abdomen, being placed on a warm cloth which has been boiled or otherwise rendered aseptic. The uterus is incised in a longitudinal direction, the situation chosen being one as free from blood-vessels as possible, and the foetus or foetuses (with the placentæ) are removed. After their withdrawal the interior of the womb must be swabbed out with antiseptic solution, particularly near the wound. The edges of the latter are then drawn together by two, or in some cases three, rows of silk or catgut sutures: the first row consists of silk or catgut, and is passed right through the wall of the uterus; the second and third are made of silk or fine catgut and are of Lembert's pattern, thus completely burying the first row, and so lessening the risk of septic infection. When more than one foetus is present, an attempt should be made to extract them all through the one opening, because if the womb has to be

incised in several places the danger is materially increased. The abdominal walls and skin are sutured and treated as in laparotomy.

The **chief sequelæ** to be dreaded are collapse and peritonitis, and the percentage of successes is very low compared with those of hysterectomy. Successful cases have, however, been recorded, pregnancy afterwards taking place, and successful delivery being effected without difficulty.¹

Stricture.

Stricture of the vagina may be a congenital malformation, but it is much more frequently met with as a sequel to severe operative measures for the removal of vaginal growths. In examining a brood bitch for purchase, it is one of the principal things to be sought for; it can readily be detected by digital examination.

Treatment. — Preventive treatment, after surgical interference with the vagina, consists in the passage of the finger (or some blunt, rounded instrument of convenient size) once or twice a day, at the operator's discretion, for a month or six weeks, so as to keep the orifice dilated until healing has completely taken place.

When the stricture is already present, it must be forcibly broken down under local (or general) anæsthesia, and for this purpose digital manipulation, first with one finger and then with another, is often successful. An instrument like an ordinary glove-finger stretcher (in fact this article improvises very well) is inserted and the stricture gradually but firmly broken down. Care must be taken to keep it from re-forming by continual daily use of the instrument for a prolonged period.

¹ Mathis, *Journal of Comparative Pathology and Therapeutics*, vol. ii., p. 277; Laithwood, *idem.*, vol. xii., p. 335.

CHAPTER XXI

DIFFICULT PARTURITION (DYSTOKIA)

ON account of the frequent necessity for surgical interference at time of labour, no book on canine or feline surgery could be considered to be complete without a reference to the above subject.

Difficulty in getting rid of the foetus at time of accouchement is apt to be met with in all breeds of dogs and cats. Those which have short square heads, such as bulldogs and Japanese, are an especial source of trouble; terriers, greyhounds, borzois, and those breeds whose puppies have long, wedge-shaped heads which gradually dilate the pelvis, stand a much better chance of passing through the ordeal without assistance.

The comparatively short fore-legs and heavy shoulders of the bull puppy are continually in the way, and are a frequent cause of dystokia.

The difficulties may be directly due to some defect on the part of the bitch, in which it is termed **maternal** dystokia; or on the part of the puppy, in which the case is said to be one of **foetal** dystokia.

Maternal Dystokia.

The principal causes of maternal dystokia are—

1. A pelvis which will not in any way dilate, or which is malformed from accident or disease.

2. Some obstruction in the vaginal passage, such as a tumour, polypus, stricture, or a prolapse of the vaginal mucous membrane.

3. Uterine inertia.

4. Exhaustion.

In the case of a pelvis which refuses to dilate, there is apt to be great trouble in effecting delivery. This condition is, as a rule, only met with in bitches or cats of middle or old age, whose pelvis has never been dilated by a litter of puppies whilst young, and in some cases it is an utter



Fig. 191.—Photograph of Spaniel Bitch taken Six Weeks after Hysterectomy.

impossibility to withdraw the puppies by the natural passage, or to reach and crush them so that they can be extracted piecemeal. The only remedy lies in the operation of hysterectomy (see p. 299).

The little Blenheim bitch illustrated in Fig. 191 was the subject of this trouble. She was not bred from until six years of age, and at the time of

accouchement it was found impossible to withdraw the puppies through the pelvis owing to the rigidity of that organ. In consultation with Mr. George Parr, F.R.C.V.S., ovaro-hysterectomy was performed, four abnormally large puppies were removed, and the bitch made an excellent recovery. The puppies were dead at the time of removal.

Malformation of the pelvis may be due to some disease, such as rickets, or to some injury, such as is inflicted when an animal has been run over. If the side of the pelvic girdle has been badly crushed, even although union of the bones may take place, the callus which results may project into the passage, and so narrow its lumen and cause a serious obstruction.

The most common varieties of growth in the vagina are granuloma, which is contagious and malignant, and fibroma, which is benign, but may be multiple and of enormous size. The former may be suspected by continued hæmorrhage after the passage of each puppy, and it may sometimes be sufficiently large to necessitate removal of a portion before the pup can be taken away. Either variety can be readily detected by digital examination, and any doubt as to the pathology can be set at rest, if necessary, by the microscopical examination of an expert.

Each has been alluded to more fully in a previous chapter (p. 291).

Polypus may attain sufficient size to interfere with parturition, but its removal is easily effected on account of its thin pedicle (see p. 65). On first sight it is excusable to confound this with a **prolapse of the vaginal mucous membrane**, but a careful examination will soon differentiate between them, and this is especially necessary, as in the former case immediate surgical interference may be the better plan; in the latter, except under very exceptional circumstances, it is wise to wait until some weeks after parturition before operating (see p. 298).

A bitch known to have a **stricture of the vagina** is always a cause of anxiety at these times, and this defect may

necessitate to be remedied before the first pup can be delivered. This is especially the case in the bulldog and other short-nosed breeds, the wedge shape of the head of the longer-nosed varieties being much more likely to force their way through. In dealing with a stricture, it is better to avoid the use of the knife if possible, the stricture being forcibly broken down with the fingers or with a specially-designed speculum or pair of forceps. Further details of surgical treatment are given on p. 305.

Uterine inertia is a most troublesome condition to deal with, and the tendency is unquestionably hereditary. It is most commonly met with in bitches with heavy litters, and in those whose puppies, through accidental or other causes, have died *in utero*. It sometimes happens that there are no labour pains at all, or it may be that two or three puppies have been safely delivered, and the labour pains have then entirely ceased. In such cases no time should be lost in using every endeavour to get the puppies away. Ergotine (gr. $\frac{1}{10}$ to gr. i.) should be given hypodermically, or the liquid extract of ergot (℥x. to ʒi.) given by the mouth, and repeated in half an hour, and then every hour for three or four times. The flanks and abdomen should be massaged, and hot solution of some non-irritating antiseptic (such as boracic acid, grs. v. to ʒi.) injected into the uterus in order to stimulate contraction. Attempts may be made with long forceps to reach a foetus, but this must always be done very cautiously, as there is great risk of including the wall of the uterus in the forceps. If after five or six hours (or some reasonable time, determined at the discretion of the practitioner in charge of the case), no labour pains can be induced and no puppies can be got away, the only course open in order to save the bitch lies in laparotomy. Sometimes this will be all that is necessary, manipulation with the hand being sufficient to pass the foetus towards the pelvic outlet; but in other cases either Cæsarean section

or ovaro-hysterectomy will have to be performed (see pp. 299, 304).

Exhaustion of the mother is to be treated much on the same lines as a case of uterine inertia, with the addition of the frequent internal administration of brandy or other stimulant in beef-tea, Plasmon, milk, Benger's or other fluid food. Ether may also be given hypodermically. If the mother is very much exhausted, and there is a wish to save




Fig. 192.—A Group of Puppies, Three Months Old, saved by Hysterectomy.¹

the young ones, no delay should be made about operating, either Cæsarean section or ovaro-hysterectomy being resorted to at once.

Fœtal Dystokia.

Fœtal dystokia may be caused by—

1. An abnormally large puppy.
2. Some malformation of the pup (a monstrosity).
3. An unnatural presentation of the pup.

¹ For this photograph I am indebted to Mr. W. J. Pegg.

4. Two puppies may try to enter the body of the uterus, one from either horn, at the same time, and become tightly wedged together, thus blocking up the passage and preventing either from advancing.

It is easy to understand, without much explanation, that any of the above causes would, merely on mechanical grounds, give rise to trouble. In toy breeds especially, trouble from

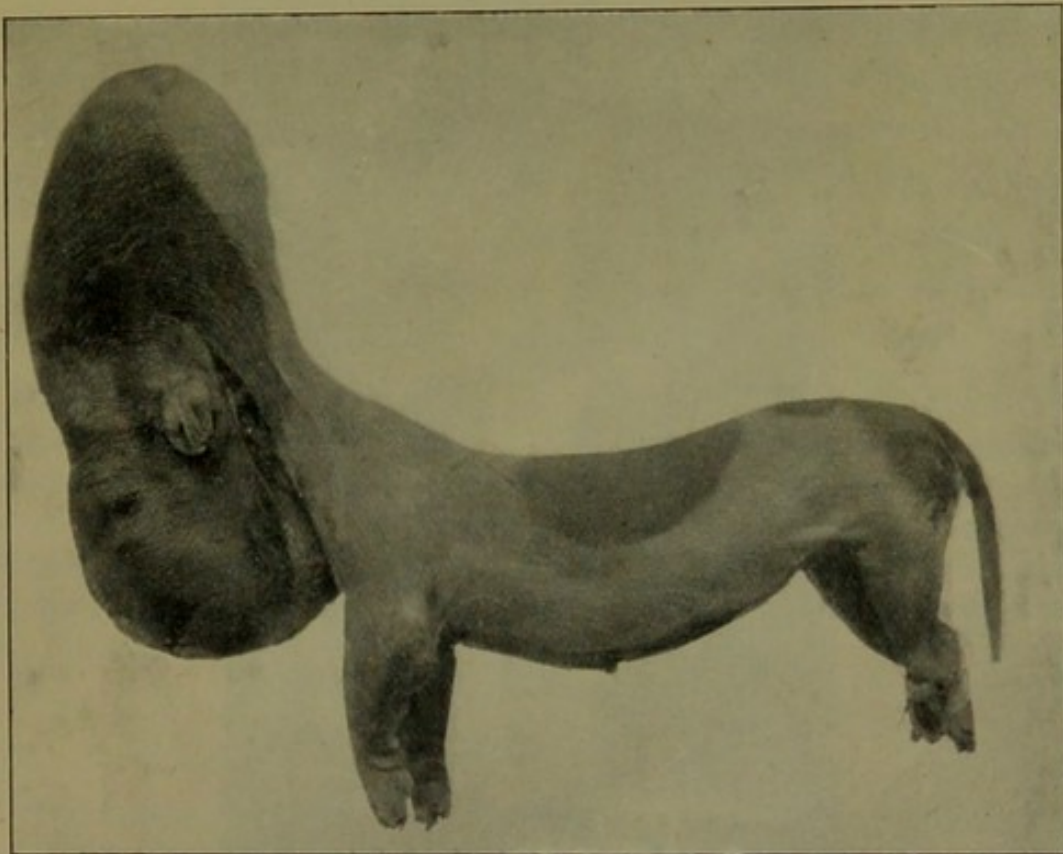


Fig. 193.—A Monstrosity removed from a Blenheim Spaniel.¹

an abnormally large foetus is frequent, and this contingency is more to be feared when there are only one or two pups than when the mother has a large number.

Of unnatural presentations, the worst is one in which the back or loins alone can be touched, and it requires considerable patience and delicacy of manipulation to get over this difficulty. At times it is impossible even by embryotomy,

¹ For this photograph I am indebted to Mr. Ernest Perry, M.R.C.V.S.

and the only choice lies between ovaro-hysterectomy or Cæsarean section and the lethal chamber.

To come naturally the pup's forelegs and head should come first, the former (in breeds whose fore-legs are suffi-



Fig. 194.—A Monstrosity removed from a Fox-terrier.

ciently long to allow it) projecting to a level with, or slightly in advance of, the nose. It is easy to comprehend why a wedge-shaped head, such as that of a fox-terrier or greyhound, gives so little trouble when compared with that of the bulldog, Japanese, or similar breeds with short squat faces.

The same applies in cats, the common house cat causing far less anxiety on this account than the highly-bred Persian.

Breech presentations are usually dealt with successfully, but, on account of resistance of the hair and the absence of the gradual dilatation of the pelvis which the nose and head cause, they are apt to be a source of trouble, and to necessitate professional aid.

Monstrosities of all kinds, from twin monsters with six or eight legs, and perhaps double bodies, to merely dropsical skulls, are frequently met with, and one must not forget that it is by no means impossible to have two puppies at once, either completely or partially, in the body of the womb. Careful examination should therefore always be made, as far as is possible in the limited space at disposal, before excessive force is used to drag on a projecting limb.

The illustration shown in Fig. 194 was reported in the *Veterinary Record* for September 15, 1900, by Mr. A. S. Hodgkins, and represented one of a fox-terrier litter. The hanging lump was attached to the navel of a well-developed male puppy, and consisted of a peculiar torpedo-shaped portion of the body, with two well-developed feet of a second puppy. The little animal lived for twenty-four hours, and was then destroyed.

Principles of Treatment.

The main principles of treatment consist in the application of a knowledge of the anatomical relations of the parts, an infinity of patience, and great delicacy of manipulation both of the fingers and of instruments. It is really astonishing how much can be done with the patient and persistent application of one or two fingers, and how a case which has seemed almost hopeless at the commencement will be successfully negotiated within half an hour.

In regard to **instruments**, it is a matter for congratulation, both to the owner of a favourite dog or cat in parturition trouble and also to the poor beast itself, that the day has gone past when the only instrument the obstetrician could

produce would be either a common button-hook or a pair of dressing forceps, each, oftener than not, in such a rusty and filthy condition that their use simply courted death from septicæmia. The modern veterinary surgeon has an excellent selection to choose from. The author has had exceptional opportunities for testing a number of English, French, and German patterns of forceps and hooks, and Fig. 195 illustrates a fair selection.

All joints should be made so that they can take apart for cleaning purposes, and the most ready and safe way of doing

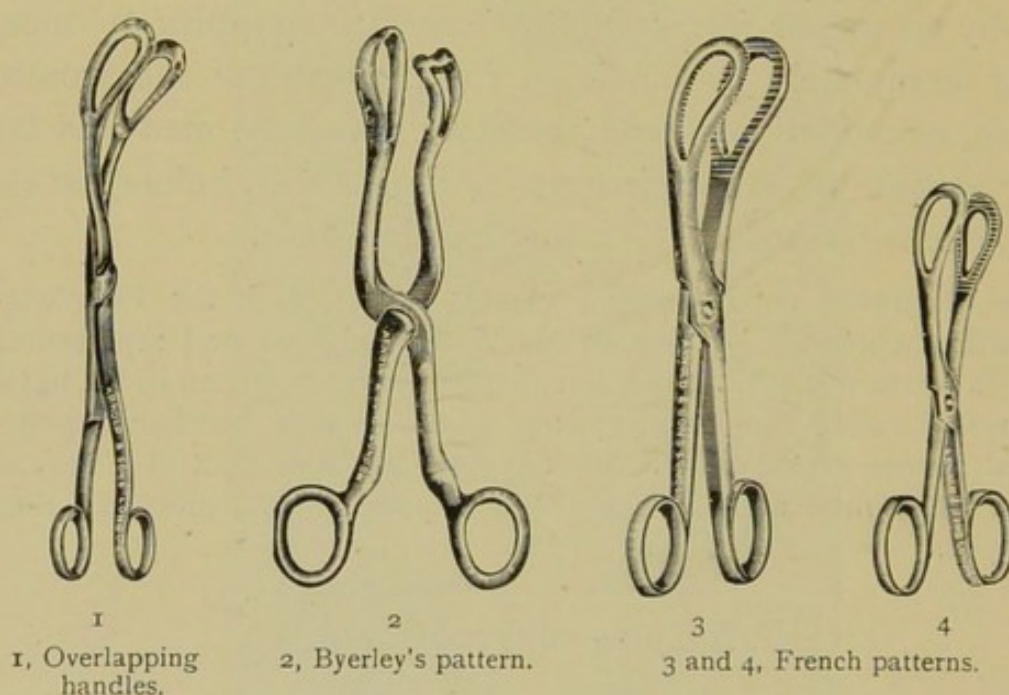


Fig. 195.—Various Patterns of Parturition Forceps.

this is to boil for three or four minutes in clean water, or water to which a little bicarbonate of soda has been added. Parturition instruments should always be boiled or otherwise rendered aseptic immediately before and after use, and the obstetrician cannot be too careful upon this point.

In selecting forceps, care should be taken not to choose a joint which causes the handles to overlap, as if this occurs the mucous membrane of the floor or roof of the vagina (relaxed as it is at these times) is apt to become included, and it may even be seriously pinched or torn.

In using any pattern of forceps, the greatest care should always be taken to see that nothing is included which is not intended for withdrawal; it is usually possible to make sure upon this point with the fingers before applying traction.

The chief secrets of success lie in the use of care and patience, the use of forceps at discretion, and strict application of antiseptic methods.

In regard to the latter, not only should the operator carefully attend to his instruments and his own hands, but he should also carefully cleanse (clipping hair away when necessary) the labia and hinder parts of his patient before proceeding to make an examination of the interior.

Accidents and Untoward Sequelæ.

The most common dangers to be feared are those of septicæmia, prolapse of the vagina, and even of the body or cornua of the uterus; and rupture of, or other injury to, the womb during the removal of the fœtuses. Prolapse of the vagina and uterus have already been dealt with on pp. 289 and 300.

Injury to the womb must be guarded against by the most delicate manipulation of the forceps and fingers, with the recollection that it is by no means impossible to pass the forceps right through this organ, and even to drag the whole of it away through the vagina. This contingency must be especially guarded against when using forceps (such as those marked in Fig. 195) with overlapping joints. The mucous membrane of the vagina is very sensitive, and, as a rule, when a portion of it becomes pinched the patient will give expression to the violent pain which is being caused. Rupture of the uterus is followed by acute pain and vomiting, the patient's face having a most anxious and haggard expression. One must not forget that when any attempt is made to syringe the uterus under such conditions the fluid finds its way into the abdominal cavity. Should the obstetrician have the ill-

luck to have to deal with such a case, and be perfectly sure about the diagnosis, he should perform laparotomy without delay, either sewing up the rent in the uterus as already described on p. 304, or removing the whole womb (see p. 299). The prognosis in such a case is very grave. Bitches and cats quickly succumb to an injury of this kind when inflicted at time of parturition.

Septicæmia, or blood-poisoning, is a trouble which the canine surgeon is, unluckily, only too frequently brought in contact with. There is no doubt that in the pre-antiseptic days want of cleanliness and attention to surgical details accounted for a great deal of this, but the work of Pasteur and Lister has altered all that. At the same time, in obstetric work, as well as in any other surgical procedures, one must be careful to work with clean hands and sterile instruments, and also to cleanse the parts of the patient which have become soiled by the vaginal discharges.

Septic infection may originate from external or internal sources, and, to avoid some of the former, care must be taken to boil or otherwise disinfect all instruments before use. A syringe which has been used to disinfect the womb of a case of purulent metritis must be *thoroughly* disinfected if it is intended to use it subsequently on a healthy case.

In removing a puppy or kitten piecemeal, the projecting bones often scratch the mucous membrane, and thus afford a means of inlet for septic organisms. *The slightest abrasion of the uterine or vaginal mucous surface, particularly in the case of the bitch, is always a source of very grave danger.*

Placentæ or portions of placentæ which may be retained are a frequent source of septicæmia; when left behind they decompose very quickly, and will cause death in from two to four or five days. The placentæ should be counted whenever possible, and each should be removed as soon after the foetus as it can be managed. Frequently a placenta will be retained for a while, and two will come away together when the next

fœtus arrives, and one must not forget that many bitches will eat these organs (which are commonly spoken of as 'after-births') as soon as they appear, thus accounting for their mysterious disappearance.

Retained puppies quickly decompose when once death has taken place, and septicæmia is nearly always the result, although occasionally mummification is observed.

The *Symptoms* shown are that the patient is dull, refusing food or vomiting painfully when any has been taken; the temperature is raised to 103° , 104° , or even 106° , and the whole expression is haggard and miserable. There may also be continual attempts at micturition, and the vaginal mucous membrane is very hot and of a nasty livid colour; there is a blackish-green foetid discharge from the vulva, and pressure on either side of the abdomen causes some of this fluid to be ejected. The abdominal walls are very tender, and the patient groans when any pressure is applied. In the later stages the patient becomes semi-comatose, and usually dies very quietly.

Prognosis is not hopeful, although *Treatment* should not be neglected on this account. The sooner it is commenced, the better. Quinine should be given internally together with stimulants, such as brandy, and some preparation of ammonia or ether. If unable to be retained they must be administered hypodermically, and the strength kept up by nutrient enemata or suppositories.

Uterine injections of some warm, non-irritating antiseptic, such as chinosol ($\frac{1}{2}$ to 1 grain to the ounce), permanganate of potash (2 to 4 grains to the ounce), or biniodide of mercury (1 in 1,000 to 2,000), should be given every one or two hours, and in the early stages of a septicæmia this course is sometimes successful in bringing away the decomposing placenta which has been the cause of the mischief.

In cases of this kind the syringe must be inserted and used gently, care being taken not to distend the uterus

too much, as the walls are very easily ruptured when decomposition has set in. Higginson's enema, with a long uterine tube, is the best pattern to use, a few syringefuls being inserted, and then ejected by gentle pressure exercised over the abdominal walls, a small quantity ultimately being left for the patient herself to eject or retain as she pleases.

If the patient survives the fifth day after parturition, there is usually a fair prospect of recovery, although the period of convalescence is often prolonged. Good nursing, good food, and a course of tonics are necessary to complete the cure.

Treatment of the Mother during and after Difficult Labour.

As the duration of continuous labour pains may be anything from a few minutes to twenty-four, or even forty-eight, hours, the mother is, naturally, very liable to become exhausted. In such case she should be fed continually every hour (or in some cases every half-hour) with easily-digested fluid food, such as Brand's Essence, Bovinine, Bovril, beef-tea, Plasmon, milk, Benger's Food, arrowroot, or something which is equally readily assimilated, and at discretion a little brandy or other stimulant may be added. Only a small quantity should be given at a time, as a full stomach would be liable to induce vomiting. For several days after, when all goes on well, the diet should consist mainly of fluids, a bitch with a lot of puppies being fed about every four hours. Meat may be given, but not in any great quantity, the food being confined to those things most likely to increase the secretion of milk. Good nursing is essential throughout, and a warm, dry place should always be chosen for the whelping kennel.

Treatment of the Puppies or Kittens.

If the mother is alive and able and willing to rear and look after the young ones, the owner cannot do better than to leave them entirely to her care. If she has too many to

rear them all herself, a foster-mother should be obtained without delay. Another bitch or cat may be chosen, or one or other of the patterns of artificial foster-mothers now on the market may be purchased. In obtaining a natural foster-mother the owner should be quite sure that she is rearing puppies of approximately the same age as those about to be put to her, and in purchasing an animal for this purpose should insist upon one or more of the puppies or kittens

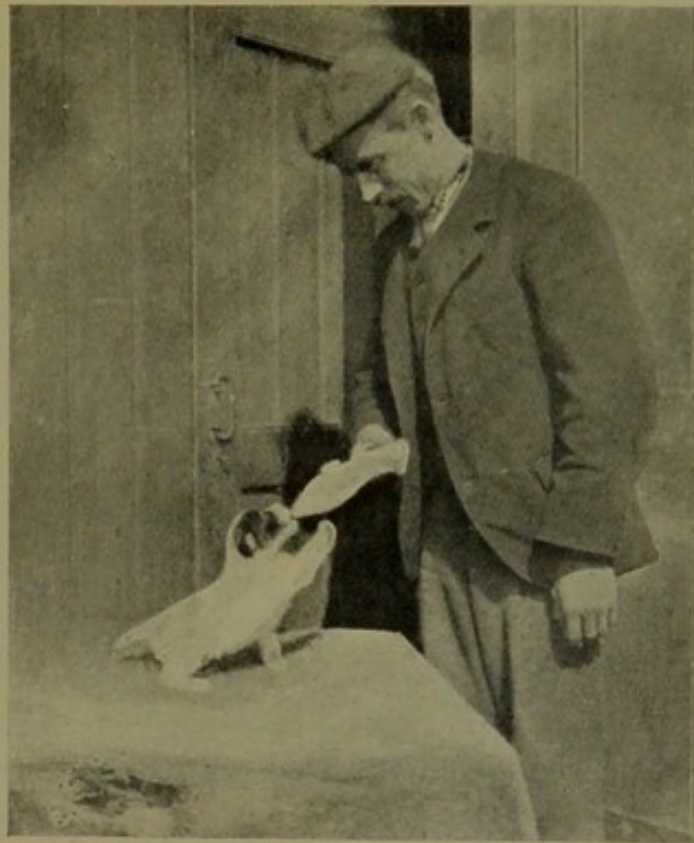

Fig. 196.—Puppy sucking from a Feeding-bottle.¹

being sent at the same time. Neglect of this precaution often gives rise to great disappointment, and not infrequently the death of a valuable litter. A newly-born puppy or kitten may usually with safety be put to a bitch or cat which has had its young ones within three or four days, but after this time there is a certain amount of risk that the milk may not agree with the new-comer, and may cause diarrhœa or other intestinal complication.

¹ For this photograph I am indebted to Dr. C. Grindrod.

A foster-mother, too, should always be carefully inspected for mange, distemper, or other contagious disease before being admitted into a kennel where there are valuable dogs. Neglect of this precaution has on numerous occasions intro-

duced disease and caused most terrible losses.

It should not be forgotten that a cat will often bring up puppies, and that they make the very best of foster-mothers for the small and toy breeds of dogs.

Having obtained the foster-mother, the next thing to be done is to get her to take to the offspring, and to do this she should be fed, made as comfortable as possible, and allowed to settle down quietly if she has come from a distance, the new puppies or kittens being placed with her for the first time at night amongst her own, several of whom it is wiser to keep.

The puppies or kittens for two or three hours after birth need warmth

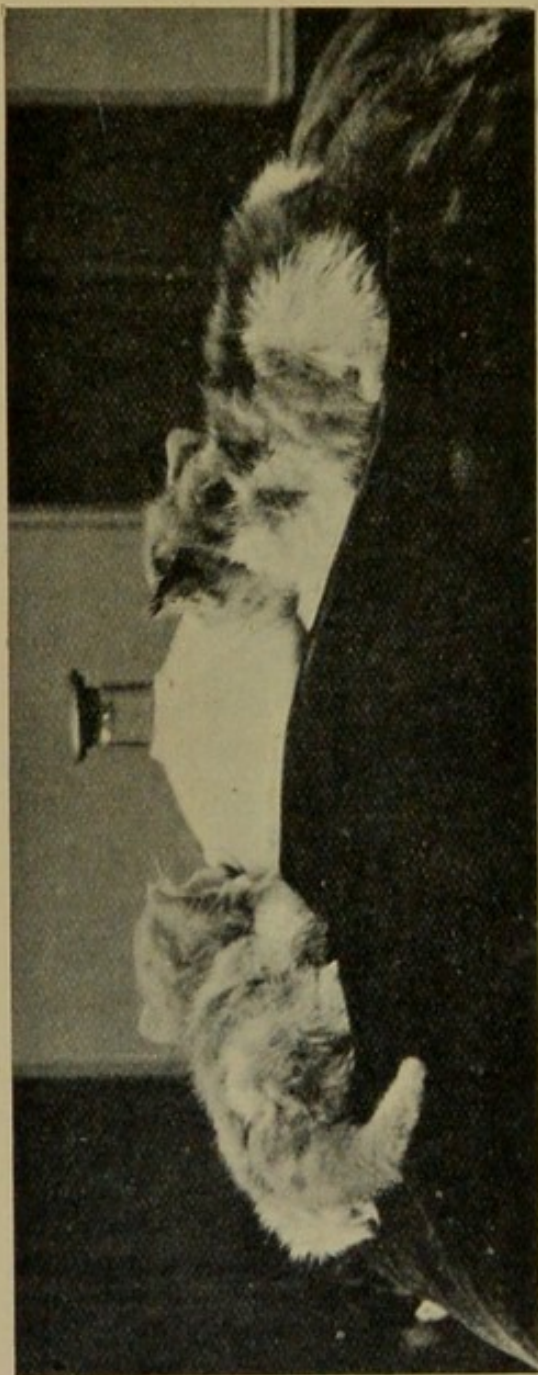


Fig. 197.—Ward's Artificial Foster-mother.

even more than food. It is the custom with some well-known breeders always to remove the pups as they are born, to dry them and place them in flannel in a basket in front of a

fire until the last of the litter has arrived; they are then given to the mother. This is a matter which must always be left to the discretion of the accoucheur, and depends somewhat upon the individual temperament of the bitch. Certainly in some cases, especially with bull-bitches and others which are often clumsy mothers, it is a wise plan to temporarily remove each puppy after the bitch has licked and fondled it, and not to leave them all with her until she has settled down and has completed her period of labour. Otherwise she will either crush some of them or allow them to become cold and neglected.




Fig. 198.—Tee's Artificial Foster-mother.

When all are born, the sooner they commence to suck the teats, the better. Some puppies take to it instinctively, whereas with others a good deal of patience and persevering effort is required to get them to make a start. The pup's mouth should be held against a teat, and a little milk squeezed out over the lips; if they are not imperfectly formed, a little perseverance usually brings about the desired end, and when once they have started, as a rule, there is no great trouble about inducing them to continue.

Some very ingenious foster-mothers have been devised for puppies and kittens, and for those who have the time to devote to a litter they undoubtedly give a chance of saving life when a natural foster-mother cannot be obtained. Cow's milk and water, cow's or goat's milk undiluted, or condensed milk, are all used, as are also various infants' foods with success. It should be given lukewarm, and care must be taken to keep the vessels scrupulously sweet and clean.




Fig. 199.—'Woodcote Consolation,' a Bulldog saved by Ovario-hysterectomy and reared artificially.¹

Many puppies have been reared by food administered through a teat and piece of glass tubing (a drop-tube such as is used universally to refill a fountain pen being very efficient) or given with a small teaspoon; but whichever way is chosen, those who undertake to artificially rear puppies should know beforehand that for a month at least the post is no *sinecure*.

¹ For this photograph I am indebted to Mr. W. J. Pegg.

When they are about a month old the pups will begin to lap for themselves (or before that if reared by hand), and they may then have a little bread and milk or other solid food.

Malformations of the Offspring.

The chief of these are hare-lip, cleft palate, and imperforate anus or urethra.

In examining newly-born puppies or kittens these should all be looked for.

Hare-lip alone is often curable (see p. 94), and the pup may be operated upon at once, or, better still, be left until three or four months old. Cleft palate is more troublesome, and if very extensive the pup usually dies from inanition within two or three days. If only slight, and the animal is able to suck, an operation may be done when the tissues are stronger (see Fig. 66).

Imperforate anus or urethra are remediable (see p. 213). Malformations which amount to monstrosities must be dealt with at the discretion of the surgeon and the owner. As a rule, these freaks of nature settle the question for themselves by living only for a few hours.

CHAPTER XXII

THE LIMBS AND TAIL

Dislocations.

A DISLOCATION is distinguished from a fracture by the fact of the swelling occurring at a joint, the absence of crepitus, and, as a rule also, of violent pain during movement. The



Fig. 200.—Photograph of an Aged Collie with Dislocation of Both Wrists.

limb is also perceptibly shorter than the other. The most common dislocations met with are those of the shoulder, elbow, stifle, and toe-joints. They are most frequently seen in

young dogs, and are most troublesome conditions to deal with on account of the tendency to relapse after reduction has been effected. The prospects of cure are much better if treatment is adopted immediately after the injury has occurred.

The *principles of Treatment* are as follows: Chloroform or some general anæsthetic is of service in severe cases because it relaxes the tissues, and because after reduction it



Fig. 201.—The same Dog as in Fig. 200, with Leather Splints applied.

is easier to keep the parts in their proper places until external supports are affixed to keep them in position. The patient is placed in a lateral posture on the operating-table, three legs being fixed, and the injured one placed in the most convenient position for the application of traction. An assistant takes a firm hold above the dislocation; the operator then grips the limb just below the injury with one hand, and employs steady traction in whichever direction he deems necessary to replace the affected parts in their normal situa-

tion; at the same time with the fingers and thumb of the other hand he endeavours to adjust the joint. In old-standing cases a successful result is often impossible, but in recent ones reduction can generally be effected. The most difficult task is to retain the parts in position, and the attempt to do this frequently ends in failure. Bandages and strappings of different kinds covered with gum, plaster of Paris, starch, some preparations of pitch, etc., are most commonly used, but the difficulty is to get them to fit closely without causing gangrene, and especially with the elbow-joint. Poroplastic felt, cardboard, brown paper moulded to the limb, are each sometimes used with success, but with each the prognosis as to a complete cure should always be guarded.

Dislocation of the Shoulder.—This accident is very apt to occur in racing dogs, or when a dog or cat jumps or falls from a height, and is caught by the leg or gets hung up by the claws. The shoulder-joint becomes perceptibly enlarged and temporarily inflamed, the leg being carried and shorter than the other during progression.

In reducing this, a broad bandage or handkerchief passed under the axilla and firmly held by an assistant is of material assistance, whilst the operator applies traction on the limb with one hand, and with the other endeavours to replace the joint into its natural position.

It is almost an impossibility permanently to reduce a shoulder dislocation if it has been neglected for two or three weeks.

Dislocation of the Elbow.—This dislocation is particularly seen in toy black and tan terriers, and it appears to be congenital in many instances. The puppy will in some cases be quite unable to get its paws on the ground, walking on the sides of its wrists, and looking very much like a kangaroo. It is often a congenital malformation due to want of development either of the summit of the olecranon or the grooves between which it should fit.

Painless reduction is easily effected, but it is a matter of impossibility to keep the bones in place.



Fig. 202.—The Attitude assumed when the Elbow is Dislocated.

In one very troublesome elbow dislocation which occurred in a toy Manchester terrier, the author attained a successful result, so far [as the dislocation was concerned, by wiring the radius and ulna into place, but the patient never satisfactorily regained full use of the leg. Under chloroform and strict anti-septic precautions, holes were made through the radius and ulna with a fine gimlet. Fine wire was

passed through these, and the skin wound treated in the ordinary way.¹

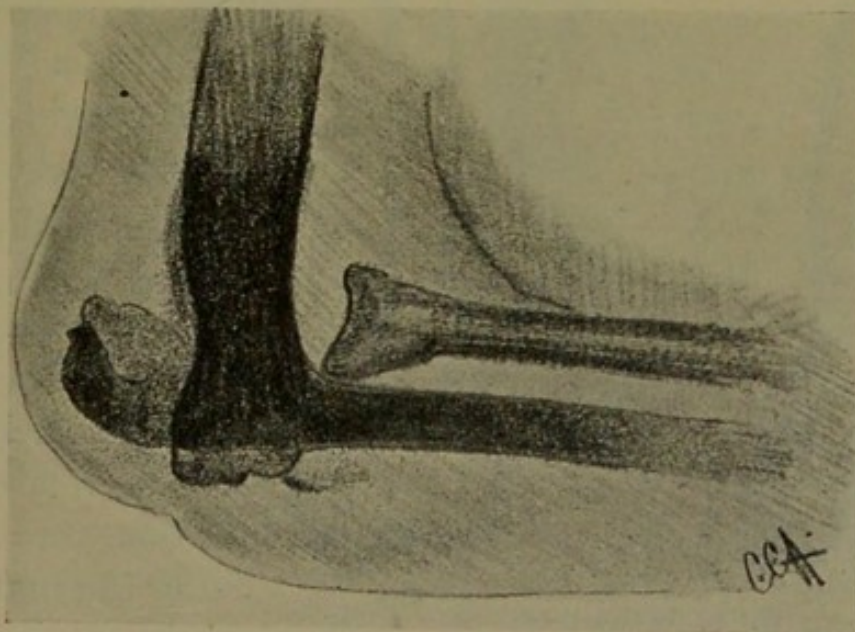


Fig. 203.—Skiagraph of an Elbow Dislocation.²

¹ *Veterinary Record*, vol. xii., p. 344.

² For this I am indebted to Messrs. Rotherham and Singleton, M.R.C.V.S.

Dislocation of the Stifle.—The patella is very frequently displaced, the bulldog and Japanese breeds being, in the

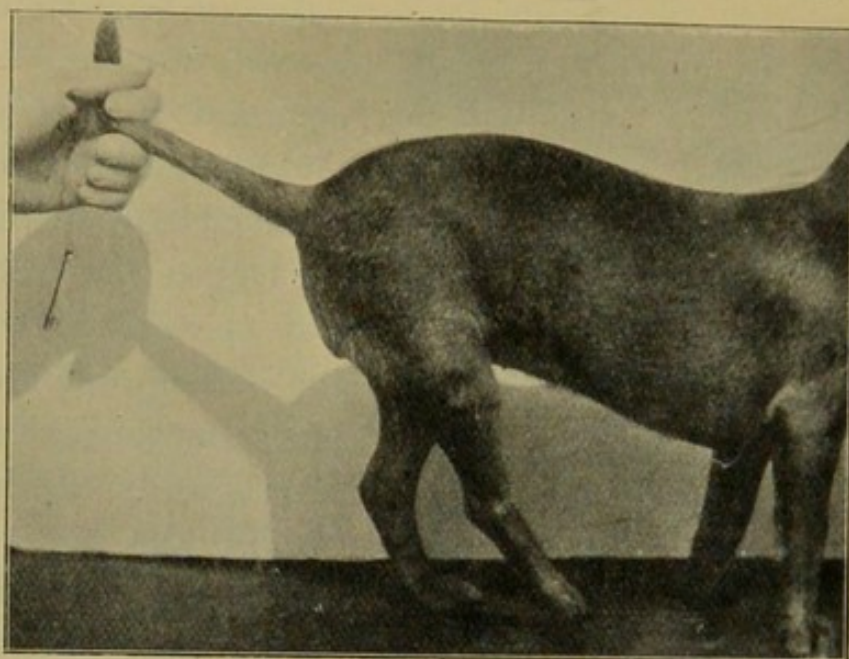


Fig. 204.—Position assumed when the Patella is Dislocated (Plosz).

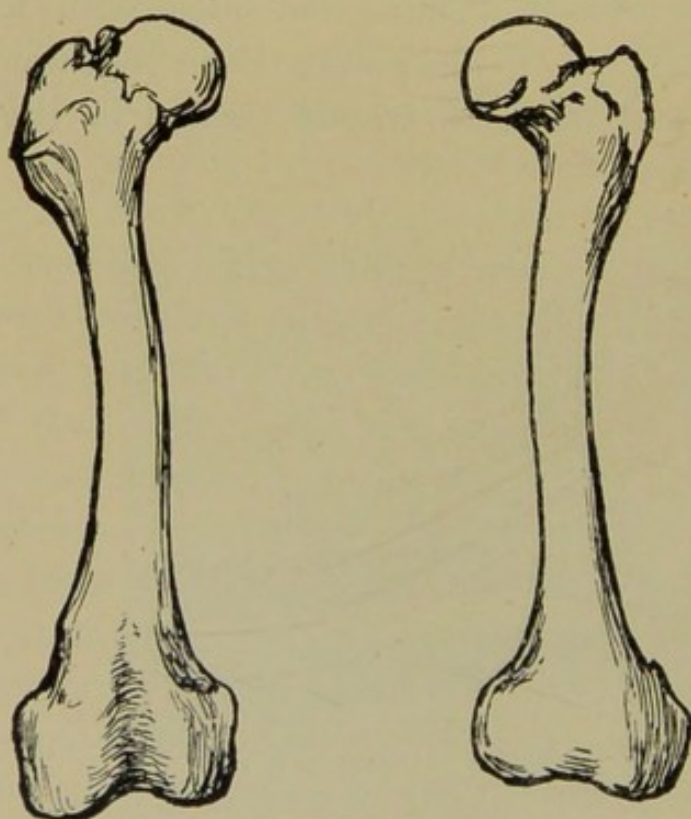


Fig. 205.—Healthy and Undeveloped Femur of a Japanese Puppy which had a Dislocated Patella, showing Entire Absence of the Internal Ridge.¹

author's experience, especially susceptible. As a rule the bone is displaced inwards, and in puppies one cause is a want of development of the internal ridge of the lower end of the femur.¹

The patella can be readily replaced, but it is extremely difficult to retain it in position. In a puppy, if the internal ridge at the base of the femur can be felt, or

¹ *Veterinary Journal*, May, 1905 (Craig and Hobday).

in an adult dog in whom the dislocation has just occurred, it is always worth while to try the effect of a gum or plaster bandage. This is put on whilst the leg is extended forwards, the patient being afterwards kept completely at rest for some weeks.

Prognosis should be guarded even under the most favourable circumstances.

Dislocation of the Toe-joints.—This is most commonly

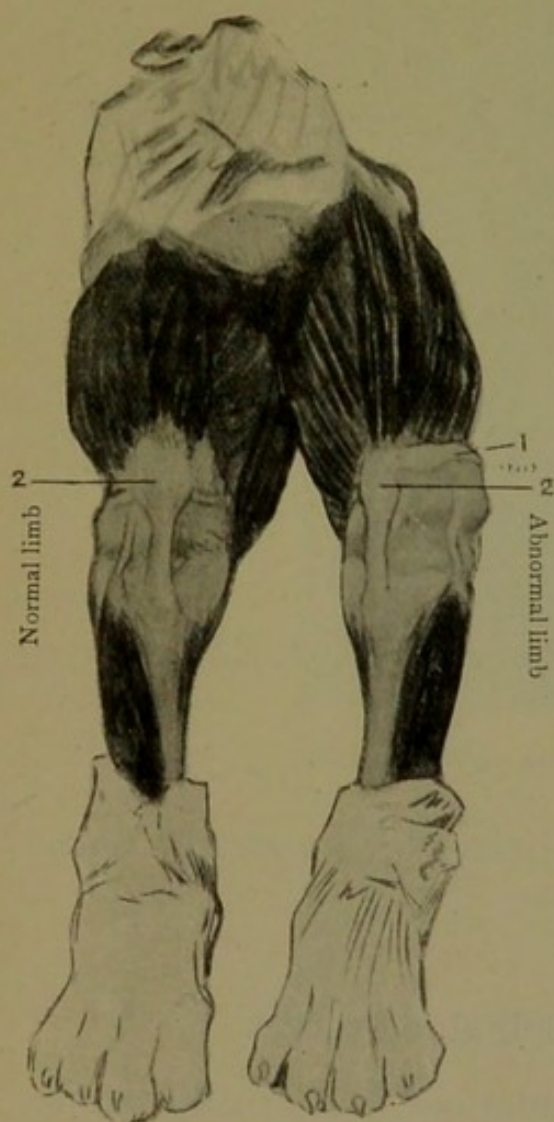


Fig. 206.—Congenital Malformation of the Patella Joint in a Bull Puppy.¹

Dissection showing the muscles and patellar ligaments. 1, External lateral patellar ligaments; 2, patella.

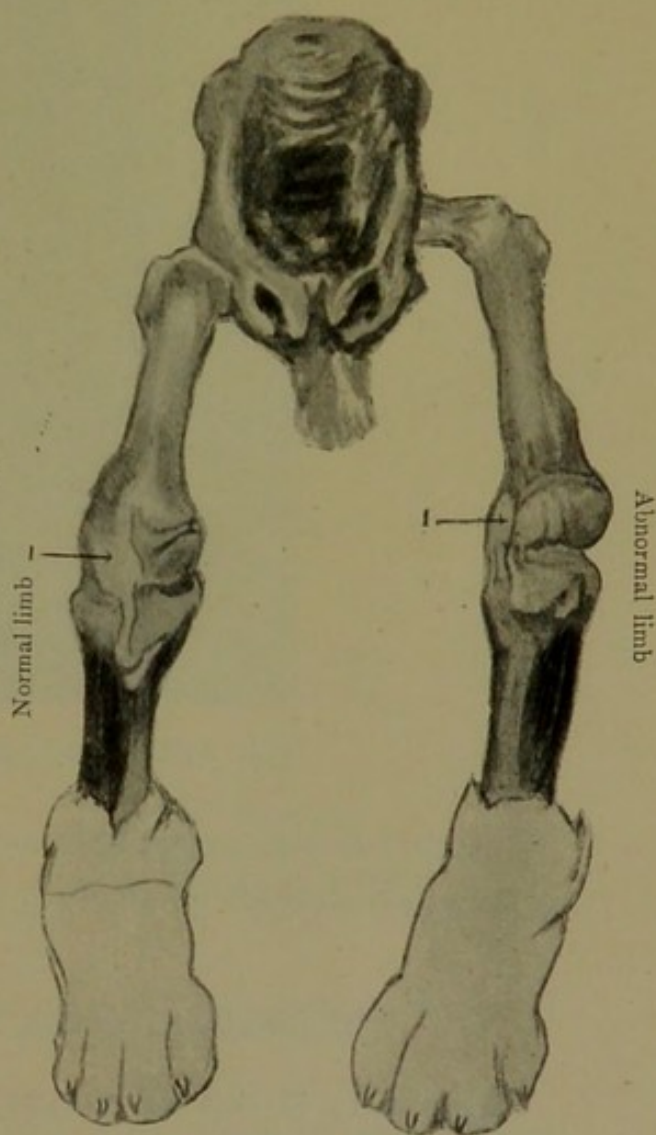


Fig. 207.—Congenital Malformation of the Patella Joint in a Bull Puppy.¹

Dissection showing the normal and malformed bones. 1, Patella, showing position in the normal and abnormal limbs respectively.

¹ *Veterinary Journal*, May, 1905 (Craig and Hobday).

seen in greyhounds and other sporting dogs, and is usually caused by the animal catching its toe in some way in the ground. It is readily reduced by traction and manipulation if discovered at once, the foot being bandaged and the patient kept at rest for a time afterwards.

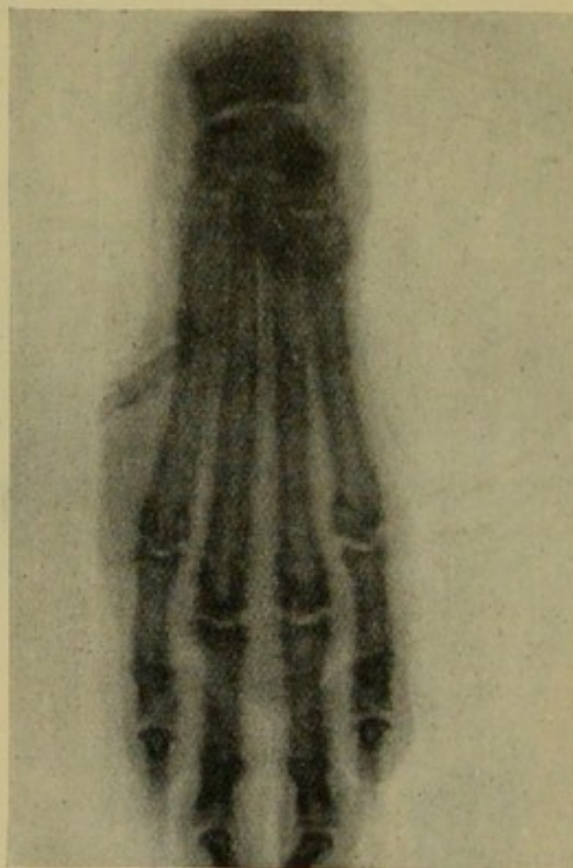


Fig. 208.—Dislocation of the Pollux.

If reduction is impossible and the dog is uselessly lame, amputation should be effected.

Dislocation of the Spinal Vertebrae.

This injury is not an uncommon one, and usually occurs from a sudden twist such as is caused when an animal unexpectedly loses its balance and falls from a height.

The subject of the illustration, an Aberdeen terrier, male, about five years old, jumped out of a trap whilst the vehicle was going along at the rate of some ten miles an hour. He fell heavily, and immediately became paralyzed in the hind parts. There was retention of urine for forty-eight

hours and loss of sensation for some three or four months. The loins were fomented and treated with sedative lotions, and in about a fortnight the dog recovered power of the sphincters, but the hind legs remained paralyzed and became spastic. There were increased knee and ankle jerks and foot clonus, but the scrotal reflex could not be obtained during the subsequent eighteen months. Prolonged periods of regular treatment with strychnine, arsenic, and iodide of potassium respectively, with external massage, were carried out, but beyond occasionally being able

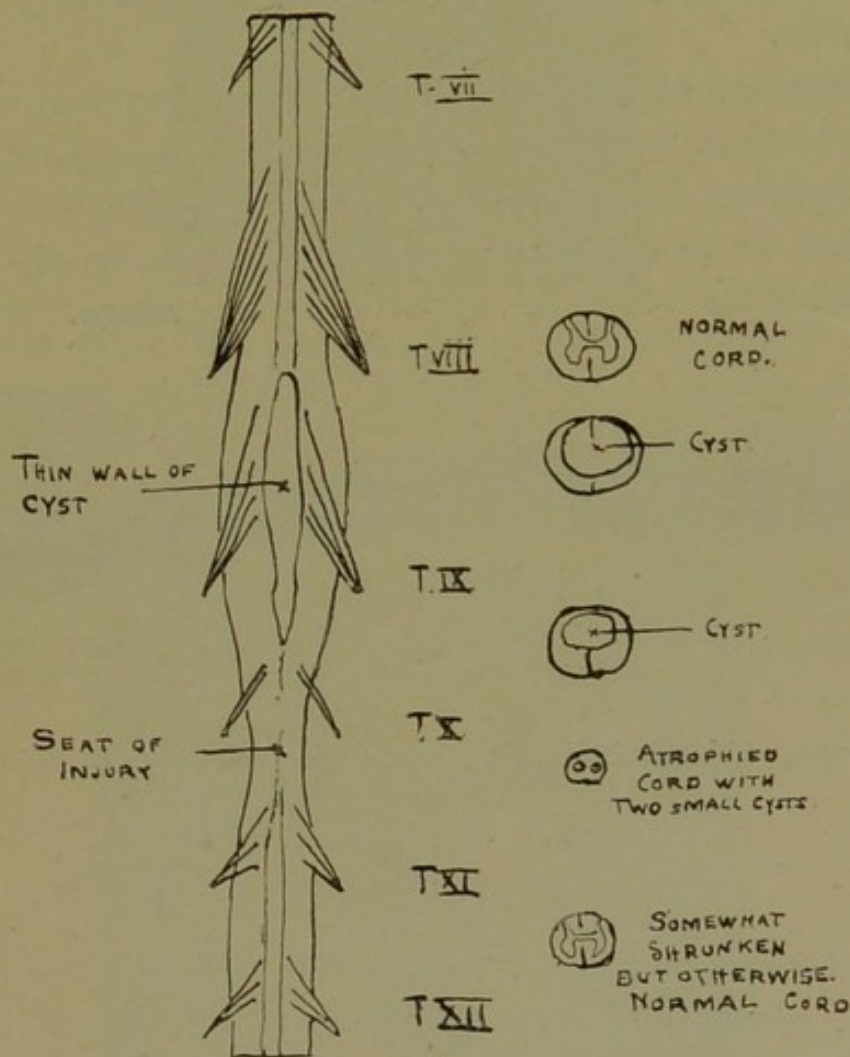


Fig. 209.—Spinal Cord, showing a Cyst at the Level of the Ninth Thoracic Segment.

to stand for a few seconds or to walk a few steps, no improvement resulted. As might be expected, at times abrasions were shown on the skin of the legs. A skiagraph was taken, but did not afford any real assistance to a more accurate diagnosis, and after eighteen months the patient was painlessly put away in the lethal chamber.

The *post-mortem* examination (made by Dr. F. E. Batten) revealed a displacement between the ninth and tenth thoracic vertebræ, without any

actual fracture of bone, and at the level of the ninth vertebræ there was a cyst measuring about 1 inch in length by $\frac{1}{4}$ inch at its maximum diameter, this being the result of an intramedullary hæmorrhage.¹

Treatment.—If diagnosed at once an attempt may be made, under anæsthesia, to reduce the dislocation, but in all cases the owner should be warned that there is a risk of sudden collapse, and also that the attempt may be unsuccessful.

Dislocation of the Tail.—This accident is mostly met with in greyhounds, whippets, or an animal of some such slender, delicate breed with a long tail. It can generally be reduced if attended to soon after the accident has occurred, and the tail should for a time be supported by a bandage.

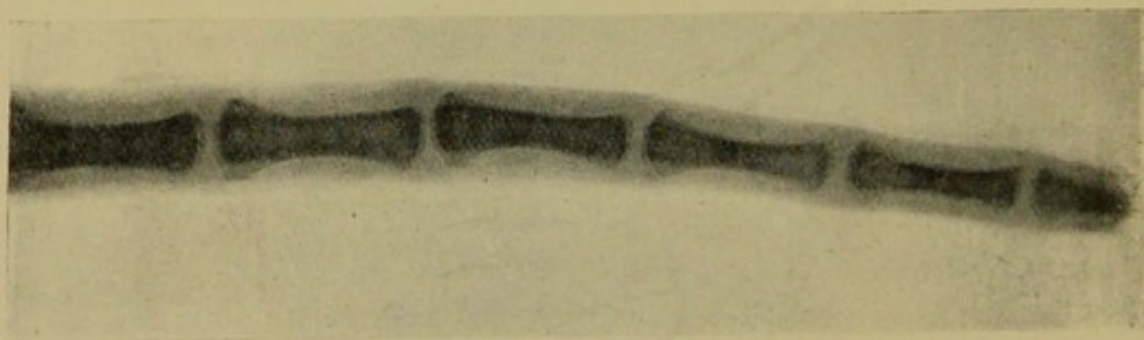


Fig. 210.—Skiagraph showing Dislocation of the Tail Bones in a Greyhound.²

Fractures.

Fractures are termed **simple** when there is no external wound, **compound** when the ends of the broken bone are in communication with the air, **comminuted** when the bone is broken into several fragments (see Fig. 213), and **complicated** when there is serious injury to some nerve, artery, or other important structure in the vicinity. The term **greenstick** is applied to a fracture such as frequently occurs in puppies or kittens, in which the bone is bent and only partially fractured.

¹ *Veterinary Journal*, vol. lx., p. 273 (Mower White and Hobday).

² For this skiagraph I am indebted to Mr. A. S. Hodgkins.

Reduction.—In a simple fracture reduction is effected and the ends brought into apposition by grasping the limb



Fig. 211.—Photo showing Characteristic Attitude when Both Fore-legs are broken.

firmly with one hand above the seat of injury, and bringing the lower portion into position with the other hand, the



Fig. 212.—Another Canine Patient with Both Fore-legs broken.

animal being held firmly by an assistant or placed under the influence of a general anæsthetic. The divided ends are

then maintained in place by the application of bandages and splints, the latter being made of wood, metal, leather, card-




Fig. 213.—A Deerhound with a Severely Fractured (Comminuted) Arm and Wrist.¹

board, or poroplastic felt. In order to prevent chafing of the skin, the limb is first covered with lint, wadding,

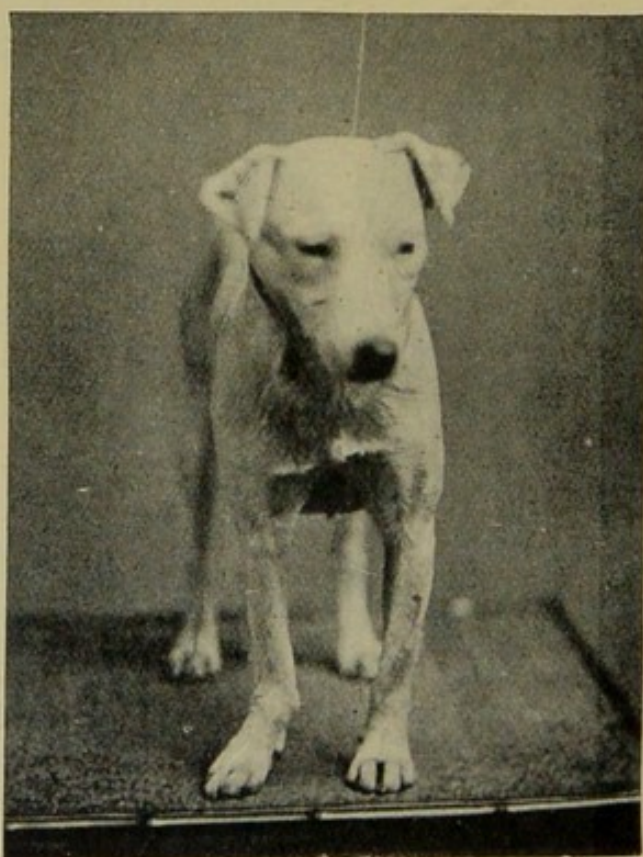

Fig. 214.—A Malformed Wrist after Reduction and Imperfect Setting.

or a bandage, especial attention being paid to all bony prominences; the splints (also carefully protected) are then

¹ For this photograph I am indebted to Mr. W. Stuart, M.R.C.V.S.

laid on in such a way as to keep the limb rigid. One or two narrow bandages which have been smeared with solution of gum, glue, pitch, starch, or plaster of Paris, are then neatly wound round the whole. Gum is particularly valuable on account of the objection the animal shows to attempting to bite it off. Solutions of those substances should be made thick, care being taken that the external bandage dries and is hard before the patient is allowed to put the limb to the ground. It is always a wise precaution, if the severity of the



Fig. 215.—Swelling of the Foot due to Too Tight a Bandage.

case needs a tight bandage, to include the foot, as if this organ is left free, and circulation is impeded above it, the toes may become swollen and, if not attended to, gangrenous (see Fig. 215).

With a **compound** fracture, particularly in the cat, much difficulty is often experienced; in many cases the quickest way to recovery is to amputate the limb at once, above the seat of injury (see p. 341). When an attempt is made to treat it

otherwise, the wound is carefully cleansed with an antiseptic and dried thoroughly, a bandage and splints being applied as for a simple fracture, but a window being left in it in order that the wound may be dressed; this 'window' can be formed by placing a pill-box lid over the wound when bandaging, and afterwards removing it by cutting out the parts above with scissors. Particular care must be taken to

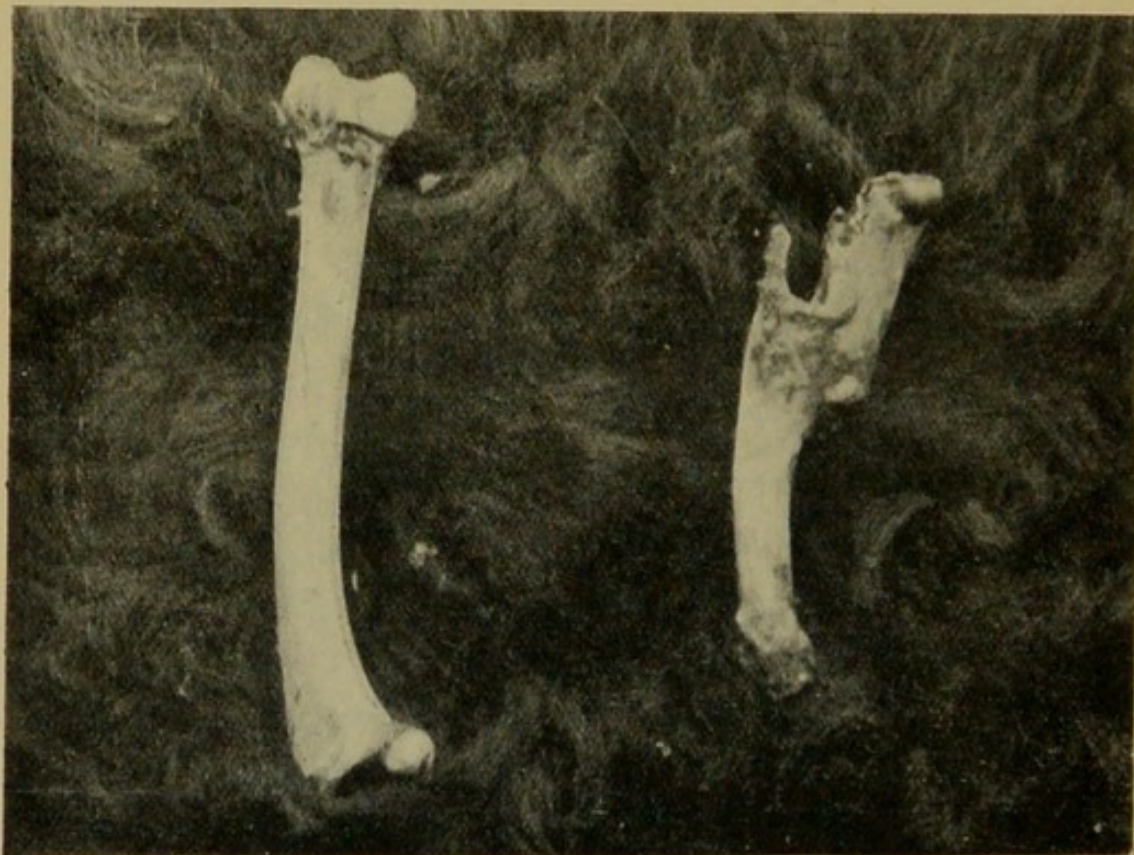

Fig. 216.—Comparison between a Femur which has set naturally (and badly) after Fracture, and the Normal Bone of the Other Leg.¹

dress the wound frequently, and to see that none of the discharge runs downwards underneath the bandage.

Fractures of the ribs are treated by placing a broad bandage around the chest and abdomen as tightly as possible without causing too much inconvenience to the patient.

Fractures of the jaw necessitate a special splint cut or moulded to the required shape, and kept in position by tape

¹ For this photograph I am indebted to Mr. Ernest Perry, M.R.C.V.S.

or a wire muzzle,¹ the patient being fed artificially by mouth or rectum on liquid nourishment.

Fractures of the tail are treated in a similar manner to those of the limbs, the bones being replaced in position, and particular care being taken that the bandage is not put on too tight.

Fractures in the region of the **shoulder, pelvis, and hip,**

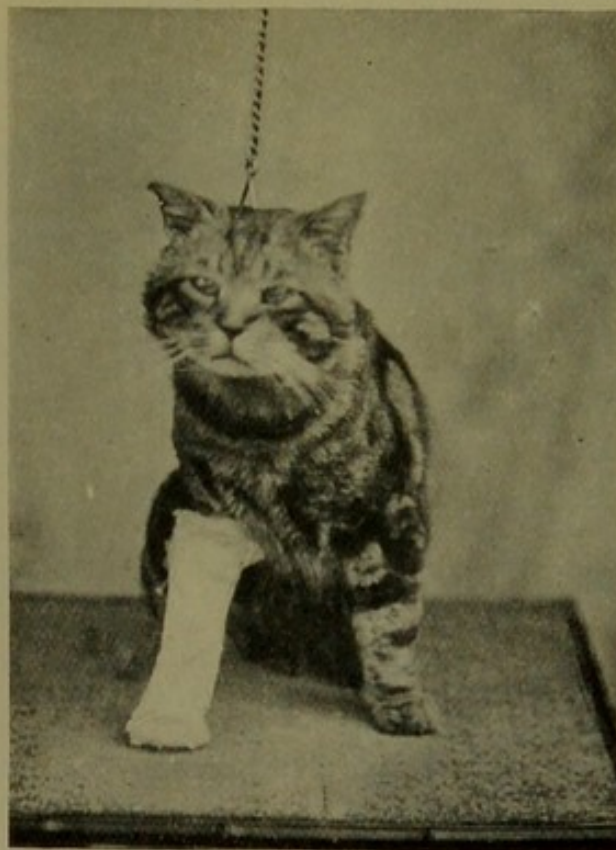


Fig. 217.—Cat with Fractured Radius bandaged in Plaster of Paris.

when too high for bandaging, may be treated by the application of a 'charge' or plaster, consisting of some such mixture as—Resin, one part; Venice turpentine, three parts; ordinary pitch, five parts; put on with a spatula whilst hot. The layers may or may not be interspersed with tow cut up very fine. The exterior should always be covered with a piece of calico or some material to prevent it from sticking to the ground when the animal lies down.

¹ Hodgkins, *Veterinarian*, vol. lxix., p. 902; T. F. Prime, *Veterinary Journal*, vol. lx., p. 311.

The time for which a permanent bandage requires to remain in position varies from three to six weeks. The patient should be kept as quiet as possible, on no account being allowed to run up and down steps or to jump from any height. The callus, or bony lump, which forms at the seat of union may be so large as to interfere with progression. This should be painted with iodine (see Fig. 238). The principal **untoward sequelæ** to be feared are—



Fig. 218.—Bandage applied to Fractured Shoulder.

1. That the limb may not be straight afterwards (see Fig. 214). This frequently happens when the bandage is not sufficiently stiff and the patient attempts to bear weight on it too soon. In refractory patients it may be difficult to avoid.

2. That union may not take place, or that the union may be a fibrous instead of a bony one. The latter condition gives rise to what is termed a **false joint**, and it not infrequently

happens after comminuted fractures or when the injury has not been attended to during the first few days. The internal administration of phosphate of lime in the form of syr. phosphat. co. and lime-water is beneficial.

3. Gangrene, owing to severe injury to the principal vessels or to the bandage having been put on too tightly or insufficiently padded. A fœtid, sickly smell from the

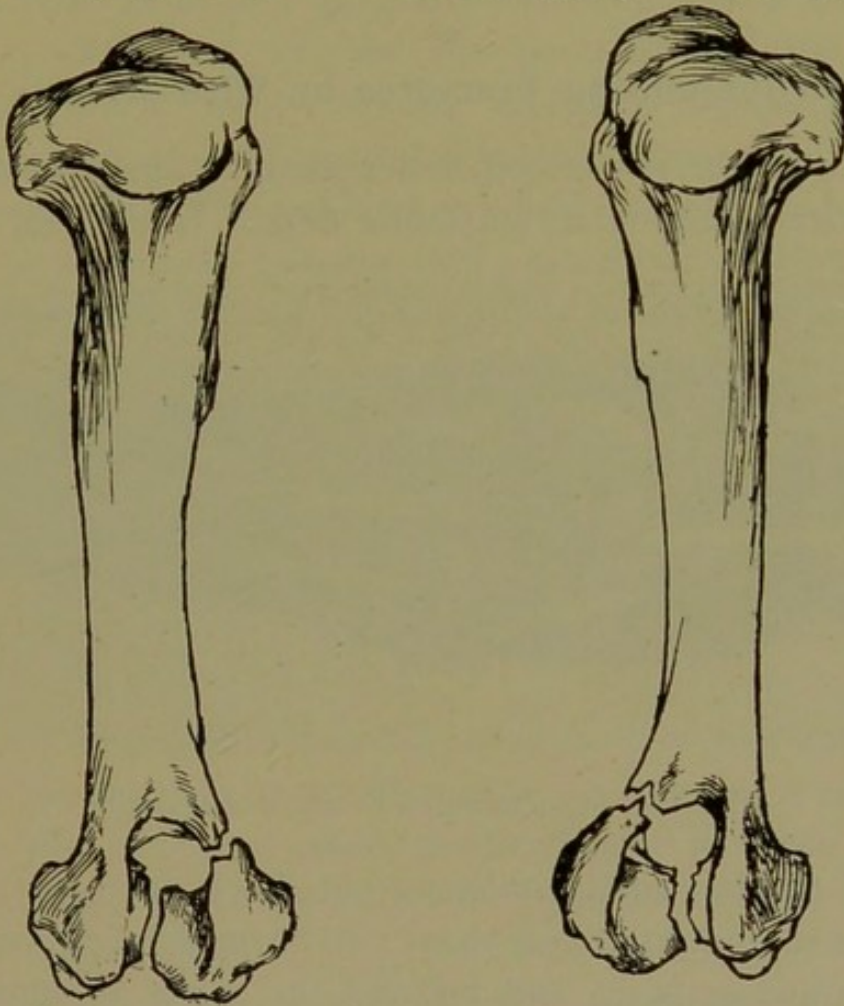


Fig. 219.—Fracture of Lower End of Each Humerus.¹

bandaged leg, and continual uneasiness and attempts at licking on the part of the patient, must always give rise to suspicion of this, and the bandage should at once be removed and the wound treated antiseptically.

4. Chafing or wounding of the tissues from rubbing on the hard edges during progression or other movement.

¹ For this specimen I am indebted to Mr. Snaith, M.R.C.V.S. (*Veterinary Journal*, vol. lxi., p. 13).

5. Septicæmia, especially in compound fractures.

In the event of a false joint forming, in cases of gangrene and septicæmia, and in some instances of compound fracture, it often happens that amputation (see p. 341) offers the only chance of a successful issue.

With a false joint the operation of wiring or pegging the bones together is worth a trial.

Operation for uniting Fractures by Wire or Bone Pegs.

This must be performed under general anæsthesia, and with strict attention to antiseptic details (see p. 2). The

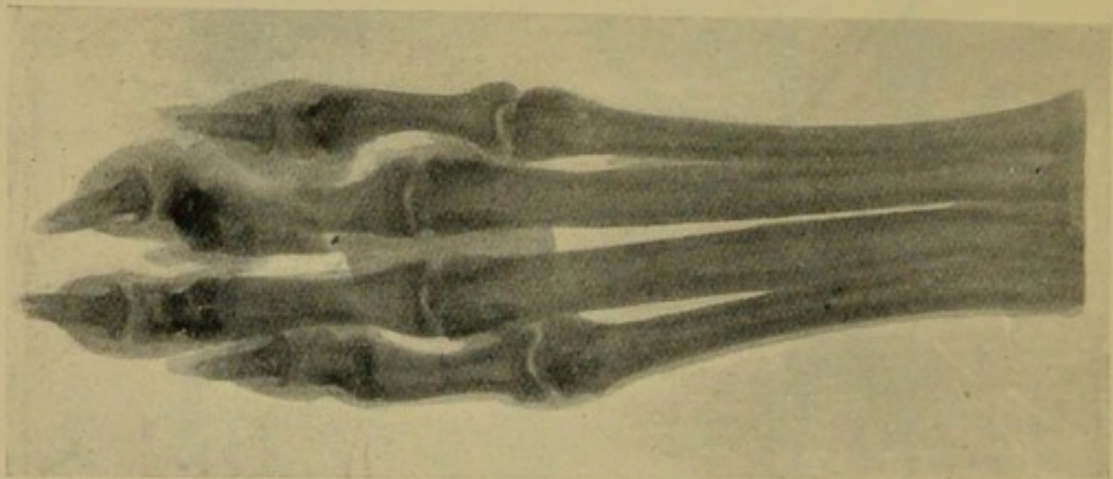


Fig. 220.—Comminuted Fracture of a Digit.¹

ends of the fractured bones are cut down upon, all fibrous union is carefully scraped away, two or more holes are bored with an awl or brace and bit, and the pieces are united by flexible silver wire or specially prepared peg splints. The author has had one successful result in a small toy dog by using strong silkworm gut. The site of operation is then covered up and the skin sutured and covered with iodoform colloid, the leg being fixed in a splint and bandaged.

The *Prognosis* is hopeful, especially in cases in which the false joint has not been in existence for very long. If the

¹ For other skiagraphs illustrating fractures, see Chapter XXIII.

operation has been done antiseptically, the bandage and splint need not be removed for a week, by which time the wound will have healed.¹ The support of the splint is, however, necessary for at least a month or six weeks.

Amputation of a Limb.

For this operation a general anæsthetic should always be given. Wherever possible, the parts around the site of incision are carefully shaved, cleansed, disinfected, and bandaged a couple of hours before the animal is secured for the operation. The position in which the patient is placed must be arranged according to the discretion of the operator.

In cases where one leg is injured, it is a good plan to secure the three sound legs with hobbles, and instruct an

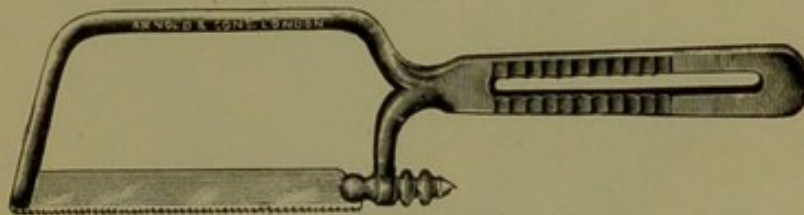


Fig. 221.—Amputation Saw.

assistant to gently, but firmly, keep hold of the injured one above the seat of the accident until anæsthesia is complete. When this has taken place, the bandage is removed and the injured leg placed on a cloth which has been boiled or otherwise rendered aseptic.

Operation.—After having placed a tourniquet of tape or elastic above the seat of operation, the skin is pulled downwards as far as possible and incised with a sharp-pointed scalpel or long thin-bladed amputation knife. The incision may be either circular or flap-shaped, the latter being the one which has given the best results. The circular incision is made with one sweep of the knife all around the limb, the flap method being done by incising the skin in the form of a **U** (see Fig. 222). The skin is pushed back, and

¹ *Journal of Comparative Medicine and Veterinary Archives*, November, 1900 (Cecil French, D.V.S.).

the muscles are treated similarly, being dissected off the bone so as to expose the latter as high up as possible. The bone is then removed with a saw.

If a sharp-bladed amputation knife or catlin is used, the point is thrust through the skin and muscles alternately

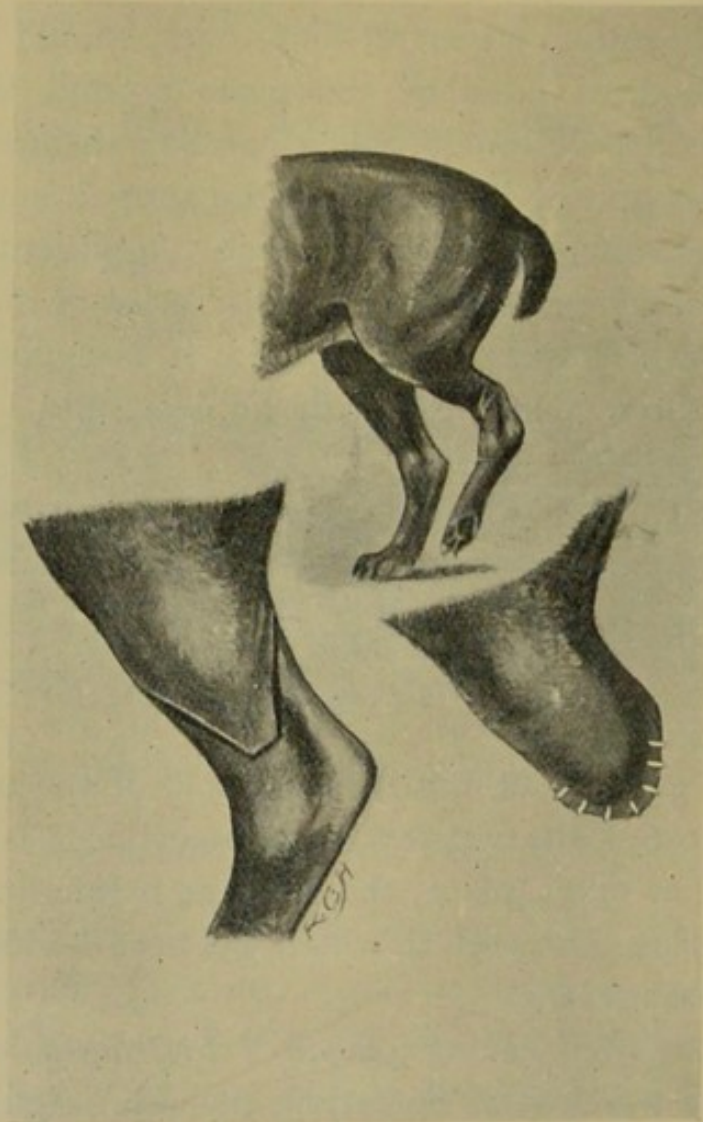

Fig. 222.—A Fractured Leg, the Flap Incision, and the Sutured Flap after Amputation.

on each side of the leg, and the flap made by two rapid downward incisions.

The vessels are sought for and twisted or ligatured; the edges of the wound are drawn together with boiled silk or aseptic catgut, the muscles and skin being sutured separately,

the latter with silkworm gut, and afterwards covered with iodoform colloid and a bandage.

After-treatment consists in carefully keeping the parts clean by the aid of antiseptics and bandages, or, if the stump is too short for these to be put on, the wound may be covered with iodoform collodion only. The stitches should be removed about the fourth or fifth day, or sooner if it is suspected that pus is present.

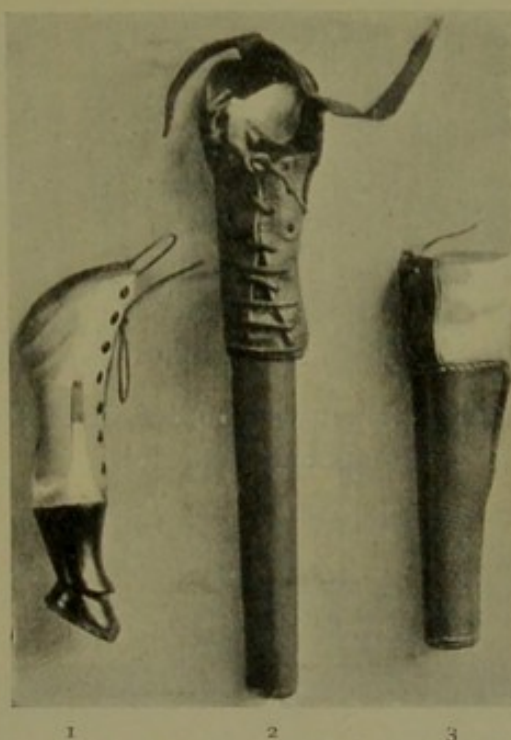


Fig. 223.—Patterns of Artificial Limb.

1, Of chamois leather and vulcanite, with silver side-supports; 2, of leather with a wooden stump; 3, made entirely of leather.

False legs consisting merely of a plain leather socket (Figs. 228, 230), or a more elaborate arrangement of silver, rubber, chamois leather and vulcanite, as shown in Fig. 223, can be fitted afterwards; but it is astonishing to see how soon an animal can reconcile itself to the loss of a limb, and how well it soon learns to walk about on the remaining three.

Fig. 224 was a very severe case. The animal, a valuable whippet, had a severe compound fracture of both fore-legs, and, owing to improper bandaging, gangrene set in. Amputation was performed, the wounds

healing perfectly within ten days. The animal soon learnt to hop about like a kangaroo, has lived for several years since, and has been used many times as a stud-dog. Three sets of artificial legs were made, but the dog refused to wear them.¹



Fig. 224.—Valuable Whippet with both Fore-legs amputated after Compound Fracture.



Fig. 225.—Sheep-dog with False Leg made of Leather, with a Wooden Stump.²

¹ *Journal of Comparative Pathology and Therapeutics*, vol. x., p. 362.

² For this I am indebted to Mr. G. Ellis, M.R.C.V.S.



Fig. 226.—Blenheim Spaniel after Amputation ; with False Leg and Imitation Paw.¹



Fig. 227.—The Same, with False Leg and Paw affixed.¹

¹ For Figs. 226 and 227 I am indebted to Mr. Frank Leigh, F.R.C.V.S. (*Veterinary Journal*, June, 1905).

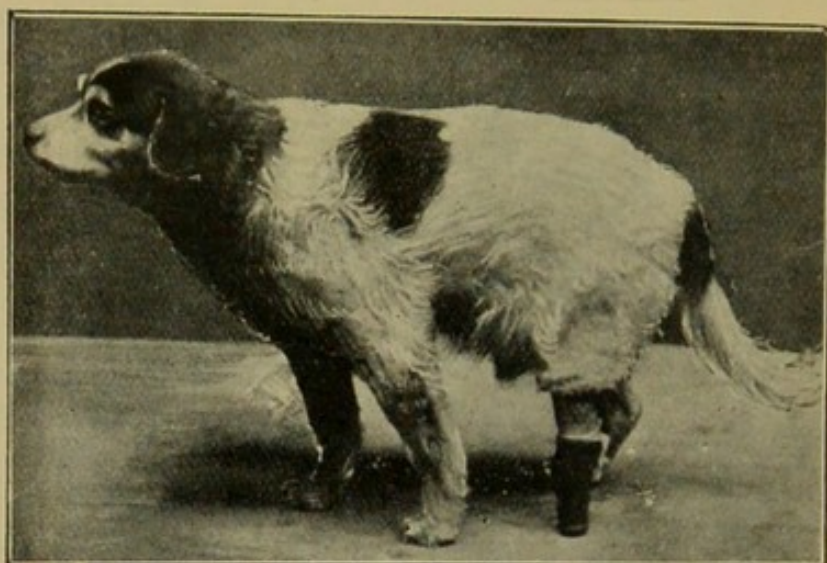

Fig. 228.—A Cheap Pattern of Plain Leather False Leg.



Fig. 229.—An Artificial Limb of Silver and Vulcanite, with Complete Flexible Joint and False Paw.¹

¹ *Veterinarian*, vol. lxviii., p. 400.

Amputation of the Tail.

This is necessary in some cases of tumours and other injuries to the tail, especially in the larger breeds of dogs, such as boarhounds, St. Bernards, greyhounds, etc.; and in cats, in which the end of the tail will frequently get much irritated and inflamed. In fact, it is often an impossibility



Fig. 230.—Artificial Limb of Leather.

to get the wound to heal, an ulcer forming time after time just as the surgeon thinks he has attained success.

The original injury is usually caused by some violent injury, such as a crush in a door, the tail being trampled upon, or continual wagging and banging against furniture, etc.

By Kennel Club Rules the tails of dogs of the following breeds may be shortened without the animals being rendered liable to disqualification :

'Spaniels (except Irish Water), Fox Terriers, Irish Terriers, Welsh Terriers, Airedale Terriers, Old English Sheep-dogs, Poodles, Toy Spaniels, Yorkshire Terriers, Schipperkes, Griffon Bruxellois, or such varieties of foreign dogs as the Committee may from time to time determine.'

Operation.—In puppies this is very simple, the tail merely being snipped off with a pair of scissors when they are a few days old. Special forceps or blunted nippers can also be got which draw the tendons from under the coccygeal surface, and so cause the animal to carry its tail higher. The old-fashioned method of performing this was by biting the tail off with the teeth.

In full-grown dogs it is performed in a similar manner to that described for amputation of a limb (see p. 341), the flap method giving the most successful results. When performed antiseptically at the root of the tail, healing usually takes place by primary union; but when performed near the extremity, the healing process is apt to be very slow, and much retarded by the action of the animal in licking or biting the parts, or by banging the tail against the walls, floor, etc. It is better to amputate at a joint rather than to go through one of the coccygeal bones.

After-treatment.—With adult dogs of the larger breeds, in order to prevent undue irritation by the tail being banged against the external surroundings, the patient should be tied to the centre of a rope placed across the middle of a loose-box or large room, sufficient length of rope being allowed for the animal to lie down without its being able to reach the hind quarters. Another plan adopted is to place a strap round the loins or ribs, and another round the neck, a stick being firmly fixed between the two in such a way that the body cannot be bent, or the tail itself may be ensheathed in a case of leather or tin. The Elizabethan collar (Fig. 27) is also useful here.

Very often, especially in large breeds, such as boarhounds

and St. Bernards, a great deal of trouble is experienced, and all methods adopted to preserve the tail are unavailing, amputation at the root having to be resorted to before healing can be effected.

Amputation of Dew-claws.

In some dogs the dew-claws are continually becoming injured, and require to be amputated. Sometimes the nail has no bony attachment, being united to the limb merely by a piece of skin.

Operation.—After shaving off the hair and thoroughly cleansing the part with antiseptics, the claw, if only attached by skin, is snipped off with a strong pair of scissors, and the edges of the skin united by sutures. When there is a distinct bony union, the skin is drawn down towards the nail and incised by a circular sweep; it is then pushed back, and the protruding bone removed as high up as possible. The skin is sutured and the wound treated antiseptically.

In the majority of cases a local anæsthetic is all that is necessary, and for securing on the operating-table the abdominal position (Fig. 14) is the most convenient.

By the Kennel Club rules the removal of dew-claws is permissible in any breed, and does not constitute 'faking.'

Overgrown or Ingrowing Nails.

In dogs that have insufficient exercise it is common to find the nails very long, the animal suffering a good deal of pain, and becoming lame, and even deformed, in consequence. The dew-claws in particular, if neglected, grow to considerable length, and often curl round so that the points become embedded in the flesh.

Operation.—By merely cutting a portion off they are shortened with instruments similar in pattern to bone forceps or wire nippers (Fig. 232). The instruments should always be applied in a vertical direction, not transversely, as there

is less danger of splitting the nail. The claws should not be cut too short, or they will bleed and remain sore for

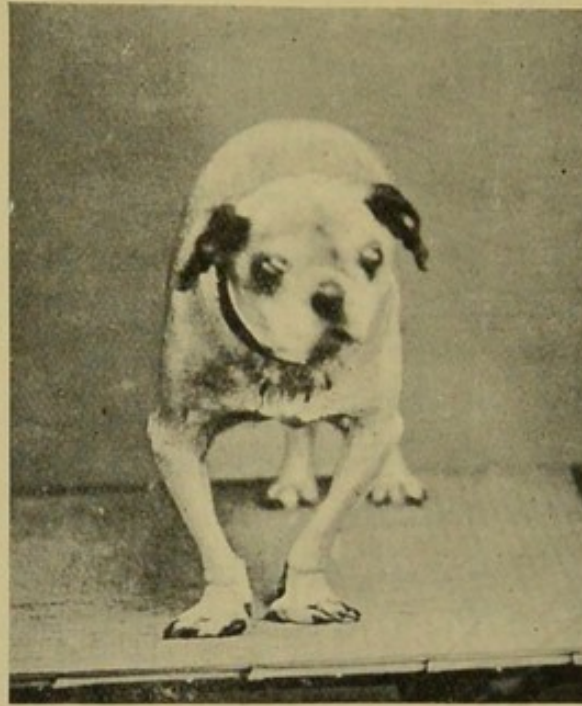

Fig. 231.—Pug-dog with Dislocated Wrists and Overgrown Nails through Inability to take Exercise.

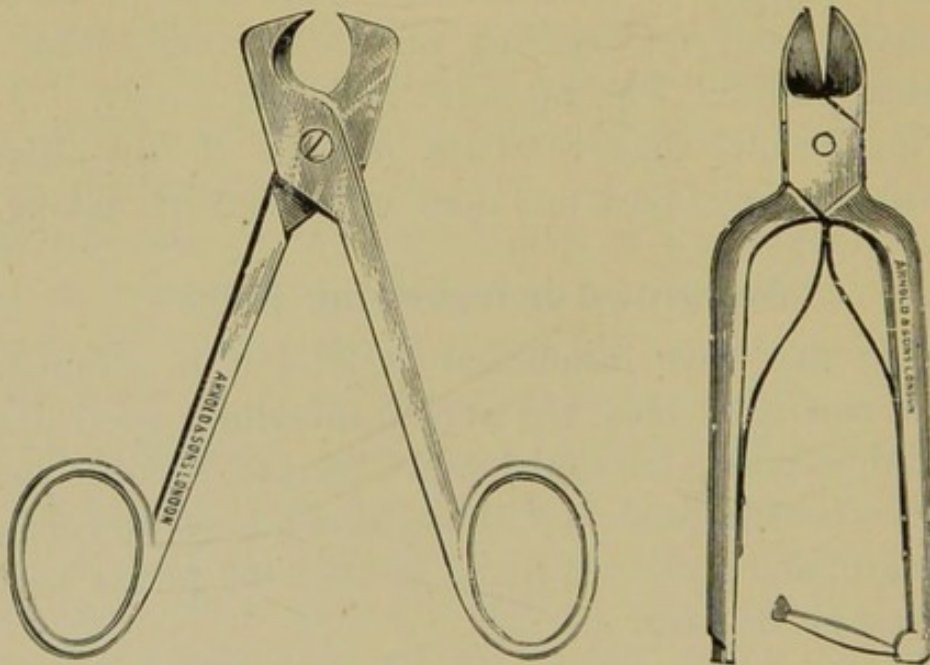


Fig. 232.—Two Patterns of Nail Forceps.

several days; when cut to the sensitive structures, the application of fomentations containing some sedative or antiseptic drug is beneficial.

Tenotomy.

A contracted condition of one or more tendons in connection with a paw is occasionally met with, the paw being deformed and the animal lame in consequence. This can be remedied by tenotomy, performed at the most convenient and superficial place of whatever tendon is contracted.

Operation.—An anæsthetic is used, the parts are shaved, and strict attention paid to antiseptic precautions, the patient being secured on its side or back. An incision is made through the skin at the side of the tendon, and a blunt-pointed tenotome is introduced flatwise above or below the tendon whilst the leg is flexed; the cutting edge is turned towards the tendon, the leg is straightened, and the tendon cautiously cut through. Care must always be taken not to wound any of the blood-vessels and not to cut through the skin at the other side or back of the tendon, on account of the trouble which is likely to ensue from excessive granulations. The wound is then sutured and covered with iodoform collodion and a bandage. The results are usually very satisfactory although occasionally contraction will again take place.

The most common situations for tenotomy are just above and behind the carpus and the under surface of the deformed toe.

Suture of Divided Tendon.

After severe injuries, especially wounds and cuts on the legs, some of the tendons are frequently found to be severed. Unless the divided ends are reunited the animal is apt to become a permanent cripple.

Operation.—Under an anæsthetic and strict antiseptic precautions, the ends must be carefully sought for and brought into apposition, being first lightly scraped or roughened. They are then united by fine sutures of catgut or silkworm gut, the latter being the most suitable, as they remain in position for years without becoming absorbed. Antiseptic dressings are applied to the wound, and the limb

must be so fixed by splints and bandage that no strain is put upon the tendon for some weeks, until firm union has taken place. Occasionally, although such cases must be comparatively rare, a ruptured tendon will be met with when there is no external wound of the skin.

The author had an interesting instance of this in a fox-terrier dog whose gastrocnemius tendon was found to be completely divided, without any history whatever of injury. The animal exhibited no sign of pain, but walked on its tarsus like a rabbit. Under chloroform and with antiseptic precautions an incision was made through the skin, the divided ends of




Fig. 233.—Attitude assumed when the Gastrocnemius Tendon is severed.¹

the tendon being scraped, brought into apposition, and sutured with silk-worm gut. After-treatment was as described above, and the result was a perfect and permanent success.²

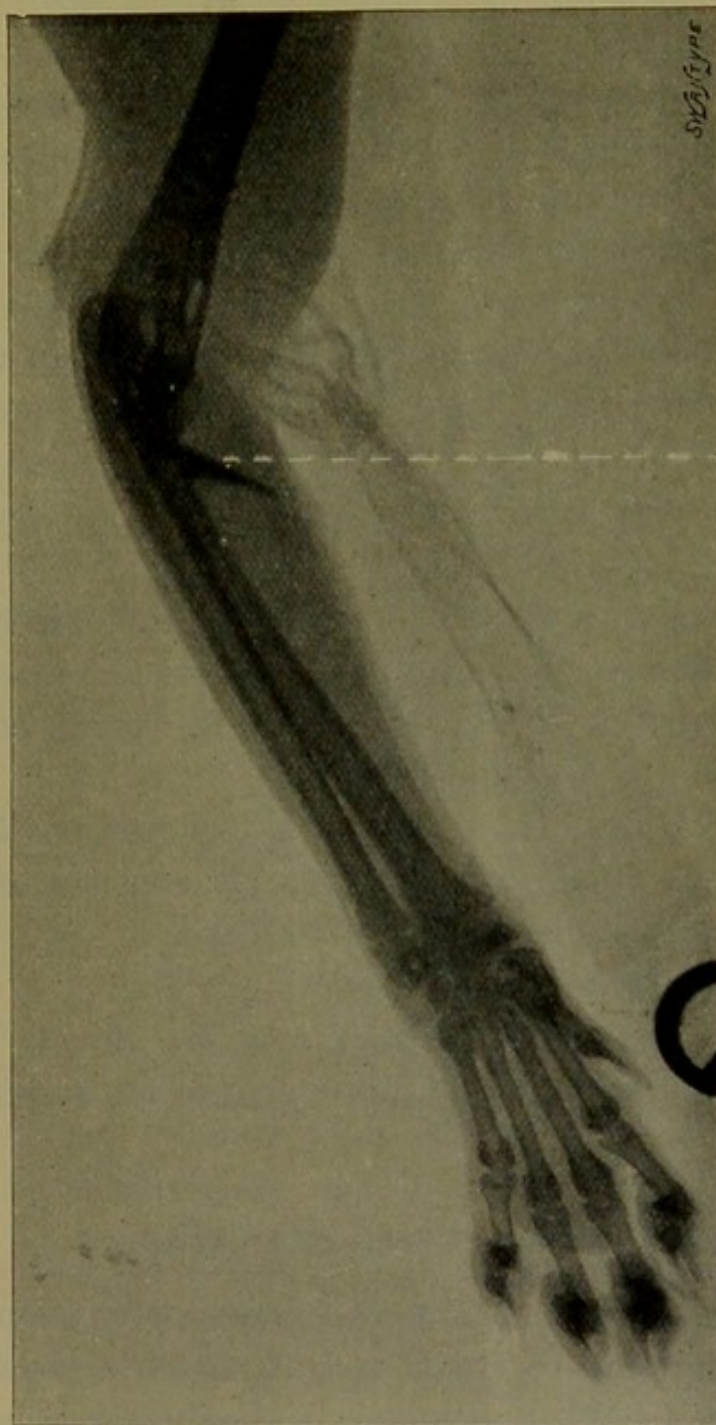
Foreign Bodies in or around the Limbs and Feet.

It is astonishing what curious foreign bodies are occasionally discovered in or around the limbs. Those which are most commonly found embedded in the tissues consist of

¹ For this photograph I am indebted to Professor Plosz of the Buda Pesth Veterinary College.

² *Veterinary Record*, vol. xii., p. 310 (Brown and Hobday).

such things as small pieces of sharp metal, such as wire or steel, needles, pins, bullets, slugs, splinters of wood, etc.,



Foreign body which proved, when removed, to be half the extremity of a pen-nib.

Fig. 234.—Skiagraph of Cat's Leg containing a Foreign Body in the Soft Textures a little below the Elbow-joint.¹

and, if interfering with any of the locomotory muscles, will cause intense pain and lameness. They may give rise to

¹ *Journal of Comparative Pathology and Therapeutics*, vol. ix., p. 59.

no visible evidence of their presence, or an abscess may form and some of the above causes thus be suspected. They must then be sought for by manual or digital examination and removed.

In doubtful cases, with suitable patients, the application of the Röntgen rays will usually decide the position and prospects of surgical removal in a few moments.

In the case of foreign bodies *around* the limb, such things as rubber rings and pieces of string or cotton are the most common, and it is astonishing how they gain access to the part. The portion of a rabbit wire snare is not infrequently met with in the cat. For the rubber ring children are usually blamed, the article being slipped on in play and forgotten.

The *Symptoms* shown are lameness or a continual irritation of the part, the dog or cat constantly licking it, and a swollen area (like that shown in Fig. 215) below the point of constriction, the latter being concentric.

Operation.—The first thing to do is accurately to locate the foreign body, then find out what it consists of and remove it with scalpel or scissors and forceps.

The wound is afterwards treated antiseptically.

It sometimes happens that gangrene has already commenced, and the limb may even have to be amputated (see p. 341).

Serous Cysts between the Claws.

This condition is one which the canine practitioner is frequently called upon to treat, and at times it gives rise to a good deal of trouble on account of the intense lameness caused and the persistence with which the swellings recur. It used to be thought to be most commonly seen in sporting dogs, such as spaniels, etc., whose lives are spent largely in the fields; but in the author's experience it has been equally met with in bulldogs, St. Bernards, and other breeds. The

patient from which the sketch was made was a Bedlington terrier, and rarely went out of London.

The *Symptoms* shown are that the dog is continually licking or nibbling at the affected spot between the claws and there may also be lameness. Examination reveals either a redness of the part or a bleb-like swelling, which is tense and fluctuating. It may or may not be painful to the touch.

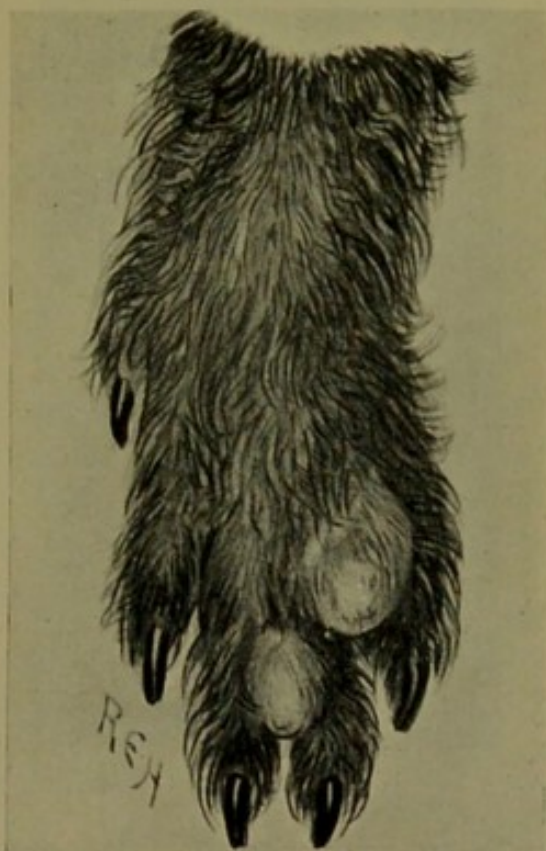

Fig. 235.—Serous Cysts between the Claws.

Treatment.—Complete excision of the whole cyst wall and entire removal of the internal lining with a small sharp curette (see p. 64) is the most effectual treatment, the wound afterwards being treated antiseptically. Occasionally a free incision, to allow complete drainage, will answer, the interior being cauterized with silver nitrate; but it is not so effectual as a complete curettage for preventing recurrence.

The *Prognosis* may be considered good, although occasionally a second operation may be required.

Tumours.

Tumours are occasionally met with between the claws, the fibroma being the most common variety.

The most common tumours of the limbs are the fibroma, lipoma, and sarcoma. Their treatment has already been described (p. 66).



Fig. 236.—An Inflammatory New Growth on the Carpus.

Inflammatory new growths are also met with, being indistinguishable from tumour tissue, except by microscopical examination.

Wounds.

Wounds of the limb are very common, but their treatment does not materially differ from those of wounds in any other part of the body. Sometimes there is a little difficulty in obtaining a satisfactory union in the case of a wound of the digits or pad, but, as a general rule, by perseverance with antiseptic applications, and by taking means to prevent the dog from continually licking and thus irritating the place, healing can be effected.

CHAPTER XXIII

VALUE OF THE RÖNTGEN RAYS IN DIAGNOSIS

THE discovery of Professor Röntgen has proved of very considerable practical value in surgical practice, not only in the field of human surgery, but also in that of the animal world. Of veterinary patients there is none to which it can be so exactly and easily applied as in the case of the dog and cat. The small and convenient size of these animals, together with the safety with which they can be secured and anæsthetized (if required), make them ideal subjects for X-ray work; whilst the comparatively small cost of a skiagraph and the tolerably general distribution of Röntgen-ray appliances in the larger towns has made the application of this aid to a more certain diagnosis within the reach of most veterinary surgeons who have cases about whose exact lesions there is room for doubt.¹

Of course, *all* doubtful diagnoses cannot be tested by the use of the screen or the taking of a skiagraph, and the aid of the technical expert should always be sought to explain to those who use it for the first time the normal and abnormal appearances of the photographic record; but, as the cases here illustrated will show, in certain lesions the exact mischief can be demonstrated beyond all possibility of doubt. That the person upon whom the diagnosis depends must be

¹ *Journal of Comparative Pathology and Therapeutics*, vol. ix., pp. 58 and 337.

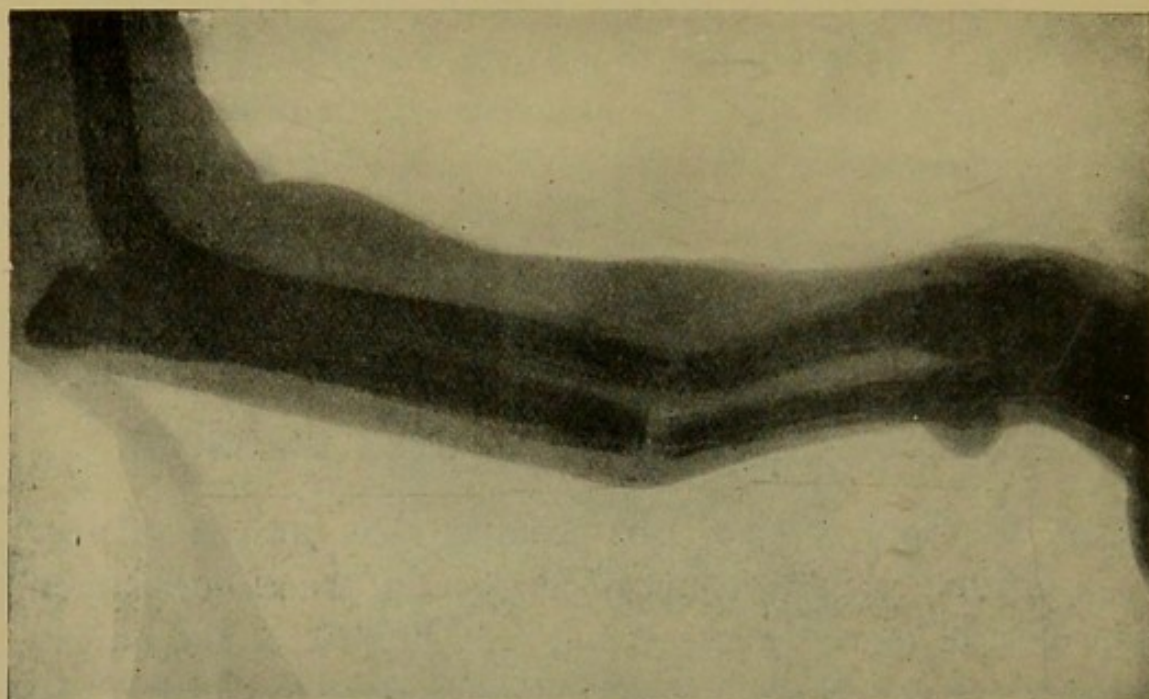


Fig. 237.—Fractured Radius and Ulna before Reduction.

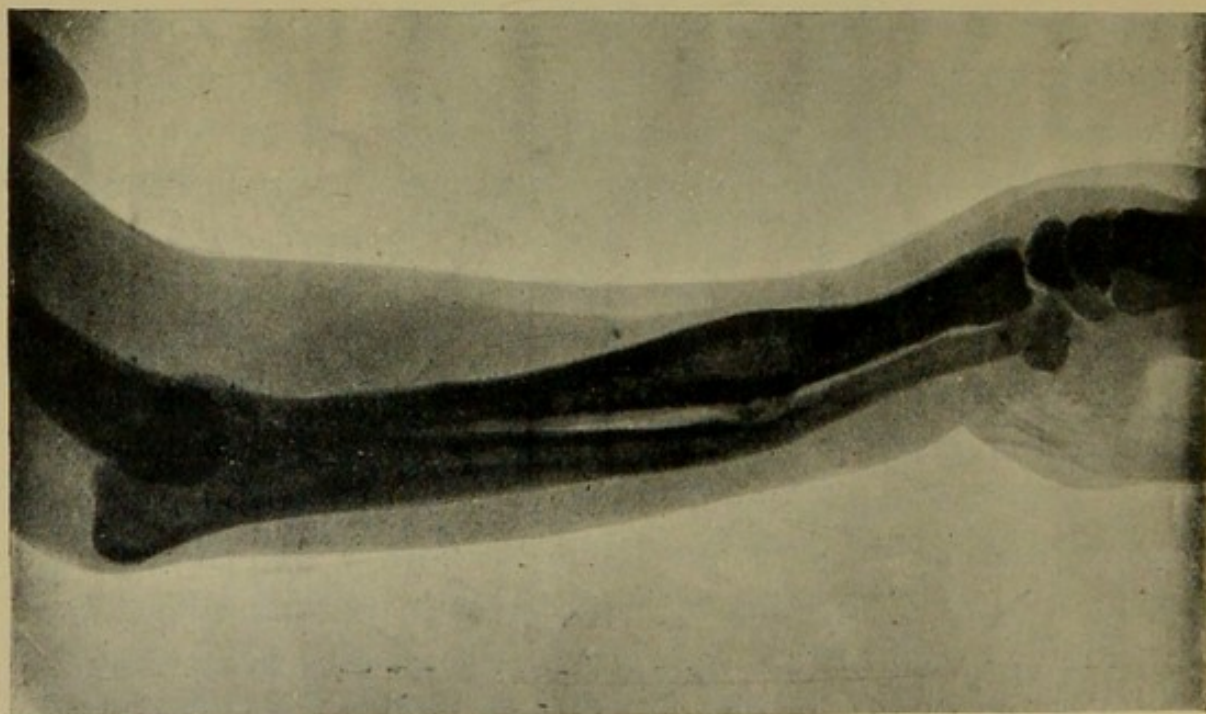


Fig. 238.—The Same after Reduction, showing the Callus.¹

¹For Figs. 237 and 238 I am indebted to Professor Dunstan, F.R.C.V.S., F.R.S.E.

thoroughly acquainted with the anatomical structures in the part which is being exposed goes without saying ; in fact, to sum up, in any case sufficiently obscure to need the X-ray application the veterinary surgeon should accept all the aid he can obtain from the reading of the signs shown on the plate, as interpreted by the technical expert, before giving his client a decided and definite opinion.

To those who for the first time work with an animal, there are certain points which do not so specifically apply to human patients to be taken into consideration. For example, it is sometimes difficult to make a cat or dog understand

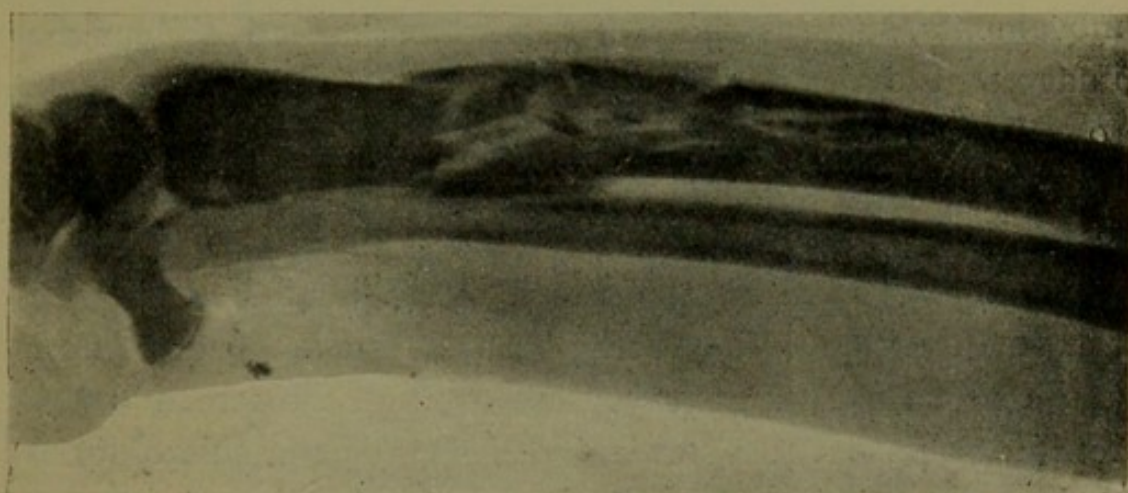


Fig. 239.—Comminuted Fracture of the Radius of a Dog.¹

that the crackling noise which accompanies the electrical discharges need not be considered a cause for fright or alarm, and in the case of a nervous patient hobbles, such as are used for an ordinary surgical operation, may have to be applied. This can sometimes be obviated by allowing the apparatus to work within a short distance of the patient for a few minutes before the plate is exposed, and by the presence of the owner holding and talking to the animal. Of late years this difficulty has largely been done away with by the improved methods introduced for shortening the exposure,

¹ For this skiagraph I am indebted to Mr. A. S. Hodgkins.

which can now be reduced to a very few seconds for any other than the thicker parts of the body. Again, one must not forget that the hairs of the coat are naturally attracted by the electricity, and this will produce a pricking sensation, or even a distinct shock if the tube is brought too close. This point is especially to be thought of in curly-coated or long-coated dogs whose coats project a slight distance outwards from the body. As a general rule it will be found that the tube can be satisfactorily placed about six inches away, whilst the part of which a skiagraph is wanted is laid flat directly on the plate or film. For making exposures of the body itself, the operator must not forget that any continuous movements, such as those of respiration, are apt to blur the image on the photographic plate or film; and if it is possible to utilize a fluorescent screen in these cases, matters are often simplified considerably. The time of exposure can also be considerably diminished by using an intensifying film.

The fluorescent screen is placed in immediate contact with the sensitive film, and the whole enveloped in opaque paper and exposed so that the rays pass through the screen before reaching the sensitive surface. As regards the suitability of different body tissues or abnormalities for X-ray work, injuries of the bony structures are more clearly demonstrable than those of the softer parts, and with a 10 to 12 inch coil and a good interrupter, such as the 'mercury jet,' the exposure needed for the limbs only averages about three seconds. For the deeper-seated bones, such as the vertebræ and pelvis, about twelve seconds' exposure is sufficient for any ordinarily thin muscular dog, such as a terrier or greyhound. For obese patients or some large breed, such as a St. Bernard, a few seconds more must be allowed.

Shots, bullets, or foreign bodies of metallic origin are not so difficult to locate as stones or calculi. Early pregnancy is not easily demonstrated even in the cat, whose abdominal walls are thin and easily penetrated.

Kittens not infrequently play with ladies' hatpins, and, when once the head has got into the throat, speedily swallow the whole pin. Fig. 125 is an illustration of a kitten which was brought with such a history as the above. The skiagraph was the result of sixty seconds' exposure.

Fig. 234 is that of a kitten with a piece of steel, which proved to be half the extremity of a pen-nib, which had

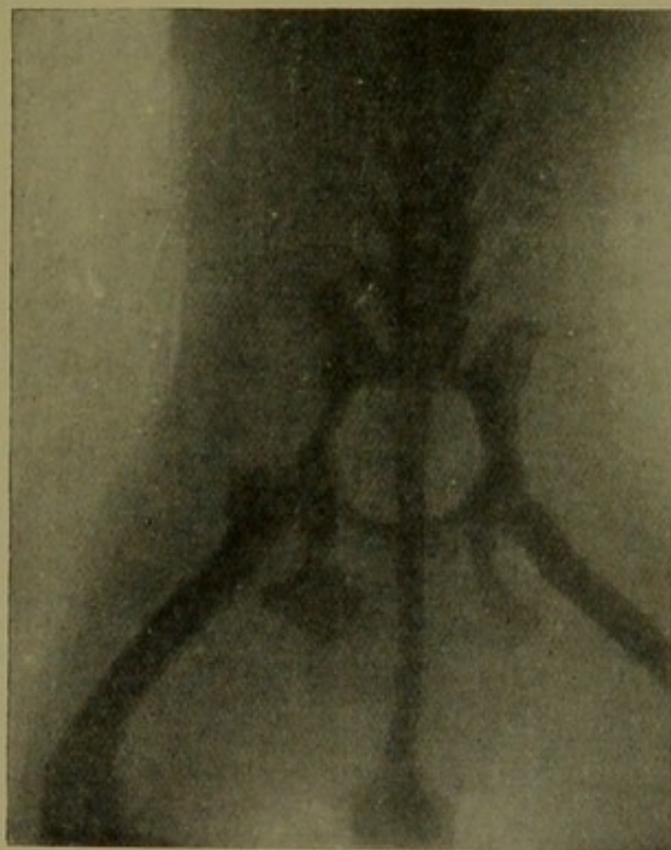


Fig. 240.—Skiagraph of Pelvis of a Toy Bull Bitch, showing Normal Pelvis.

penetrated the muscles near the elbow and produced lameness. It was extracted, and the patient did well.

Fig. 210 shows a dislocation of one of the bones of the tail, the patient being a greyhound, and the lesion the result of violence.

The patient, the skiagraph of whose pelvis appears in Fig. 240 was a toy bull bitch, the subject of a controversy, and was said to have a deformed pelvis, the owner having been dissuaded from using her as a brood-bitch on this

account. Being very anxious to settle the question beyond all doubt, a skiagraph was taken, the pelvis demonstrated as quite normal, and the bitch has since had a fine litter of puppies, without the slightest trouble or assistance at time of parturition.

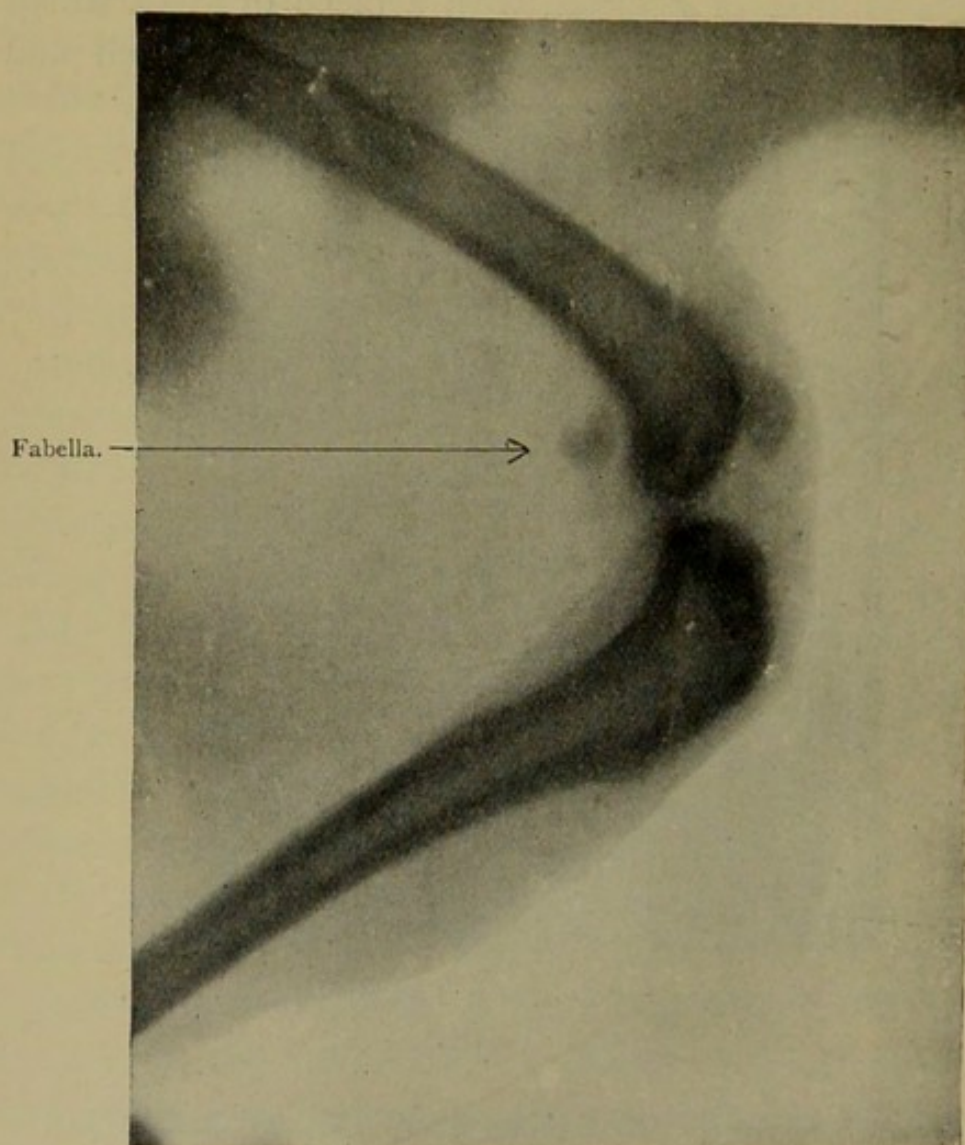


Fig. 241.—Skiagraph of a Dog's Normal Stifle Joint.

Figs. 220 and 239 show severe fractures of the radius and a digit respectively, the comminuted condition of the former being particularly well illustrated.¹

¹ I am indebted to Mr. A. E. Isenthal for many courtesies extended on numerous occasions when the X rays were applied to canine or feline patients and in connection with this chapter.

INDEX

- ABDOMEN, operations of the, 151
 Abdominal hernia, 227
 position, 20
 Abscess, 59
 A.C.E. mixture, 45
 Adeno-carcinoma, 73
 Adenoma, 71, 217
 Amputation of dew-claws, 349
 of ear-flap, 83
 of a limb, 342
 of rectum, 211
 Anæsthetics, 23
 Anal glands, 216
 Anestile, 25
 Angioma, 71
 Animal thermometer, 5
 Antidotes, 39
 Antiseptic, choice of an, 3
 Antrum, pus in the, 97
 Anus, diseases of the, 203
 Appendicitis, 200
 Artery forceps, 51
 Artificial legs, 343
 Ascites, 157
 Avery's speculum, 78

 Bandages, 57, 81
 Benign tumours, 71, 293
 Bladder, diseases of the, 239
 Bobbin, Mayo Robson's, 191
 Bowel clamp, 189
 operations on the, 166
 prolapse of the, 206
 Bowman's eye speculum, 105
 Button sutures, 54
 Murphy's, 191

 Cæsarean section, 304
 Calculi, bladder, 255
 kidney, 249
 urethral, 241
 Callus, 358
 Canine thermometer, 5
 Carbolic acid, danger of, 4
 Carcinoma (cancer), 67, 68, 121, 133
 Castration, 276
 Cataract, 109

 Catgut, 10
 Catheter, passing the, 239
 Cherry's operation, 49
 Chloral, 46
 Chloroform, 29
 Choking, 140
 Chondroma, 71
 Cleft palate, 92
 Cloaca, 213
 Clove hitch, 17
 Cocaine, 26
 Coins in the stomach, 174
 Colic, 168
 Compound fracture, 335
 Continuous sutures, 55
 Cornea, ulcers and wounds of the,
 105
 Cotton-wool, 11
 Cropping, 83
 Cryptorchids, 280
 Curette, 64
 Cyst, 61, 331
 Cystitis, 255
 Cystitome, 110
 Czerny-Lembert sutures, 55

 Dermoid growth, 102
 Dew-claws, amputation of the, 349
 Digit, fracture of a, 340
 Dilators, 261, 288
 Director, 62
 Dislocations, 324
 Districhiasis, 117
 Dorsal position, 21
 Drainage-tubes, 11
 Draw-string suture, 57
 Dropsy of the eyeball, 104
 Dystokia, 306

 Ear, diseases of the, 77
 Ectropion, 120
 Elbow, dislocation of the, 326
 Elizabethan collar, 48
 Enterectomy, enterorrhaphy, 190
 Enterotomy, 188
 Entropion, 117
 Epulis, 135

- Ether, 24
 Ethyl chloride, 25
 Evacuator, Thompson's, 262
 Eucaïne, 27
 Excision of the eyeball, 111
 Exploring trocar, 61
 Extraction of teeth, 137
 Eyelids, diseases of the, 101
 Eyes, diseases of the, 101
 Eyeshade, 101

 Face, operations on the, 88
 False legs, 343
 teeth, 138
 Female generative organs, 288
 Femoral hernia, 237
 Femur, fracture of the, 326
 undeveloped, 329
 Fibroma, 71
 Fistula, 64, 215
 Flap incision, 342
 Forceps, artery, 51
 parturition, 314
 Foreign bodies in the stomach, 171
 in the intestine, 178
 Foster-mother, 320, 321
 Fractures, 332
 Furrier's suture, 55

 Gastrectomy and gastrostomy, 179
 Gastric ulcer, 178
 Gastrotomy, 177
 Generative organs, operations on
 the, 264
 Gersuny's wax operation, 205
 Glass eyes, 113
 Glaucoma, 104
 Glioma, 72
 Godfray's operating-table, 21
 Graefe's cataract knife, 110
 Granny knot, 53
 Granuloma, 76, 89
 Gray's operating-rack, 21
 Gunshot wounds, 161

 Hæmatoma, 79
 Hæmorrhage, 52
 Hæmorrhoids, 214
 Halsted's suture, 55
 Hands, preparation of the, 12
 Hare-lip, 92
 Hatpins in the digestive tube, 172,
 173
 Hermaphrodites, 283
 Hernia, 224
 Hip, fractures of the, 337
 Hobbles, 17
 Holocaine, 27
 Humerus, fractures of the, 339

 Hysterectomy, 299
 Hysteria, 294
 Hysterotomy, 304

 Impaction of the intestine, 183
 Imperforate anus, 213
 urethra or vagina, 240
 Incision, 2
 Inertia, uterine, 309
 Inflammatory growth, 66, 356
 Ingrowing nails, 349
 Inguinal hernia, 228
 Inhalers, anæsthetic, 33
 Insufflator, 50
 Interrupted sutures, 55
 Intestine, foreign bodies in the, 186
 tumours of the, 200
 Intussusception, 180

 Jaw, fractures of the, 336
 Junker's inhaler, 34

 Kangaroo tendon, 10
 Kittens, treatment of, 318
 Knot, surgical and granny, 53
 Kramer's speculum, 77

 Laparotomy, 158
 Lateral position, 21
 Legs, artificial, 343
 Lembert sutures, 54
 Limbs, operations on the, 324
 Lipoma, 72
 Lips, operations on the, 88
 Lithotomy, suprapubic, 257
 Lithotrite, 260
 Liver, diseases of the, 218
 Lotions, 363

 Makins' bowel clamp, 189
 Male generative organs, 264
 Malformations of the offspring, 323
 Malformed ear, 86
 wrist, 334
 Malignant tumours, 67
 Mammary glands, 165
 Mask, chloroform, 32
 Mayo Robson's bobbin, 191
 Meckel's diverticulum, 199
 Melanoma, 72
 Membrana nictitans, 114
 Methods of securing, 14
 Metritis, 298
 Monstrosities, 311, 312
 Morphia, 45
 Mother, treatment of the, 318
 Mouth, operations on the, 123
 Murphy's button, 191
 Myoma, 73, 303
 Myxoma, 73

- Nails, overgrown, 349
 Nasal polypus, 90
 Neck, dislocation of the, 150
 foreign bodies round the, 147
 operations on the, 140
 Needles, 57
 Nephrolithotomy, nephrectomy,
 248
 Normal temperature, 5
 Nostrils, operations on the, 88
 Nymphomania, 293

 Œsophagotomy, 143
 Oöphorectomy, 294
 Omentum, operations on the, 218
 Operation hobbles, 17
 to make ears droop, 85
 rack, 21
 table, 18
 Orbital gland, 116
 Orthoform, 28
 Osteoma, 73
 Osteo-sarcoma and osteo-chon-
 droma, 73
 Ovariectomy, 294
 Ovaro-hysterectomy, 299
 Overgrown nails, 349

 Pancreas, operations on the, 218
 Papilloma, 73, 130
 Paracentesis abdominis, 156
 thoracis, 153
 Paralyzed membrana, 115
 Paraphimosis, 274
 Patella, dislocation of the, 328
 Pean's forceps, 51
 Pegs for bony union, 340
 Pelvis, fracture of the, 337
 skiagraph of the, 361
 Penis, operation on the, 266
 Perineal hernia, 234
 Peritoneal bands, 199
 Peritonitis, 163
 Perityphlitis, 201
 Pharynx, operation on the, 123
 Phimosis, 273
 Piles, 214
 Pin sutures, 54
 Pollux, dislocation of the, 330
 Polypi, 65, 90
 Premolar, fracture of, 99
 Preparation of the patient, 2
 Prepuce, operations on the, 266
 Probang, passing the, 142
 Proctopexia, 210
 Prolapse of the anus and bowel,
 203
 of the urethra, 248
 of the vagina, 289
 Prostate gland, 263

 Psammoma, 73
 Pterygium, 102
 Puppy, treatment of the, 318
 Purulent metritis, 298
 Pus in the antrum, 97
 in the uterus, 298

 Quill sutures, 94

 Radius, fracture of the, 359
 Ramula, 126
 Recti, prolapsus, 205
 Rectum, operations on the, 203
 Reduction of fractures, 333
 Reeks' suture needle, 57
 Renal calculus, 248
 Rodent ulcer, 96
 Röntgen rays, 357

 Sarcoma, 69, 133, 219, 303
 Saw, amputation, 341
 Scaling teeth, 135
 Scarification of the tongue, 127
 Scrotal hernia, 232
 Securing, methods of, 14
 Septicæmia, 316
 Serous effusion, 61
 of the claws, 354
 Shoulder dislocation, 326
 Silk, 11
 Silkworm gut, 10
 Sinus, 63
 Site of incision, preparation of, 2
 Skewers in the stomach or intes-
 tines, 172
 Skiagraphs, 173, 330, 332, 340, 353,
 358, 359, 361
 Skull, operations on the, 88
 Snare, polypus, 91
 Sound, flexible metal, 248
 Speculum, Kramer's, 77
 Avery's, 78
 Spencer Wells' forceps, 51
 Spleen, operations on the, 218
 Sponges, 11
 Squint, 107
 Staphyloma, 106
 Sterilizer, 7
 Stomach, operations on the, 166
 foreign bodies in the, 171
 sticks in the, 172
 tumours in the, 199
 Stones in the stomach or bowel,
 172
 Stovaine, 23
 Strabismus, 107
 Strangulation of the intestine, 198
 Stricture, 198, 247, 305, 308
 Suprapubic lithotomy, 257
 Suture material, 11

- Sutures, various, 55
 Suturing of wounds, 52
 Swabs, 11
 Tail, amputation of the, 347
 dislocation of the, 332
 fracture of the, 337
 operations on the, 324
 Tampons, 11
 Tape in intestine, 187
 Teeth, 123
 Tendon, suture of divided, 351
 Tenotomy, 351
 Testis, tumours of the, 275
 Thermometer, 5
 Thompson's evacuator, 262
 Thorax, operations on the, 151
 Throat, operations on the, 140
 Tight bandage, 335
 Tobacco-pouch suture, 56
 Toe-joints, 331
 Tongue, operations on the, 123
 Torsion of the cord, 286
 of the intestine, 198
 of the stomach, 202
 Tracheotomy, 145
 Treatment of the patient, 1
 Trichiasis, 117
 Trocar and cannula, 61
 Tumefied flap, 79
 Tumour, 66
 Tumours of the abdomen, 222
 of the abdominal walls, 165
 of the anus, 217
 of the bladder, 253
 of the brain, 99
 of the chest wall, 155
 of the ear, 87
 of the eye, 121
 Tumours of the limbs, 356
 of the liver, 219
 of the mouth, 130
 of the nose, 89, 90
 of the ovaries, 295
 of the penis, 268
 of the rectum, 217
 of the stomach and intestines,
 199
 of the testicle, 275
 of the throat, 148
 of the uterus, 302
 of the vagina, 291, 293
 Typhlitis, 200
 Ulcer, 64, 96
 Umbilical hernia, 225
 Urethra, calculi in the, 241
 imperforate, 240
 Urinary organs, operation on the,
 239
 Uterine inertia, 309
 Uterus, pus in the, 298
 excision of the, 299
 tumours of the, 302
 Vagina, imperforate, 240
 prolapse of the, 289
 tumours of the, 291, 292
 Venereal tumours, 266, 291
 Ventral hernia, 227
 Ventrifixation of the bowel, 210
 Vertebrae, dislocation of the, 330
 Volkmann's spoon, 64
 Volvulus, 198
 Wax operation, Gersuny's, 205
 Wire, suture, 9
 Wounds, 47

THE END



Baillière, Tindall and Cox, 8, Henrietta Street, Covent Garden

