

**The comparative anatomy of the domesticated animals / [John McFadyean].**

**Contributors**

McFadyean, John, Sir, 1853-1941.

**Publication/Creation**

Edinburgh : Johnston, [1887]

**Persistent URL**

<https://wellcomecollection.org/works/nrz6tjqa>

**License and attribution**

This work has been identified as being free of known restrictions under copyright law, including all related and neighbouring rights and is being made available under the Creative Commons, Public Domain Mark.

You can copy, modify, distribute and perform the work, even for commercial purposes, without asking permission.



Wellcome Collection  
183 Euston Road  
London NW1 2BE UK  
T +44 (0)20 7611 8722  
E [library@wellcomecollection.org](mailto:library@wellcomecollection.org)  
<https://wellcomecollection.org>

THE  
COMPARATIVE ANATOMY  
OF THE  
DOMESTICATED ANIMALS  

---

PART I.

---

OSTEOLOGY AND ARTHROLOGY.


HENRY KIMPTON  
Medical Bookseller,  
SPECIALIST IN OSTEOLOGY,  
2, HIGH HOLBORN,  
LONDON, W.C.



22101895099

Med  
K52731





THE  
COMPARATIVE ANATOMY  
OF THE  
DOMESTICATED ANIMALS

---

PART I.  
OSTEOLOGY AND ARTHROLOGY.

---

BY

J. M'FADYEAN, M.B., C.M., B.Sc., F.R.S.E.

MEMBER OF THE ROYAL COLLEGE OF VETERINARY SURGEONS,  
LECTURER ON ANATOMY AT THE ROYAL (DICK'S) VETERINARY COLLEGE, EDINBURGH.



W. & A. K. JOHNSTON,  
EDINBURGH AND LONDON.

*All rights reserved.*]

[1887]

J. H. Frank

Veterinary Student

32895 7

1893



32874

WELLCOME INSTITUTE LIBRARY	
Coll.	weIMOmec
Call	
No.	✓

## NOTE.



THE Publishers are induced to issue the First Part of this Work in advance of the remainder, in order to meet the requirements of junior students of anatomy under the recent regulations regarding the veterinary examinations.

Part II., comprising the remaining sections of the Work, will shortly be published, and may be ordered through any Bookseller.



# CONTENTS.

—:O:—


	PAGE.		PAGE.
INTRODUCTION . . . . .	3	Humerus of Horse . . . . .	109
CLASSIFICATION OF ANIMALS . . . . .	5	Radius of Horse . . . . .	112
SECTION I.—OSTEOLOGY.		Ulna of Horse . . . . .	114
General Properties of Bone . . . . .	11	Carpus of Horse . . . . .	115
Minute structure of Bone . . . . .	15	Metacarpus of Horse . . . . .	118
Development of Bones . . . . .	18	Sesamoids of Horse . . . . .	121
The Vertebral Column . . . . .	22	First Phalanx of Horse . . . . .	122
Cervical Vertebrae of Horse . . . . .	25	Second Phalanx of Horse . . . . .	123
Dorsal Vertebrae of Horse . . . . .	31	Third Phalanx of Horse . . . . .	124
Lumbar Vertebrae of Horse . . . . .	34	Navicular of Horse . . . . .	126
Sacral Vertebrae of Horse . . . . .	36	Skeleton of Fore Limb of Ox . . . . .	127
Coccygeal Vertebrae of Horse . . . . .	38	Skeleton of Fore Limb of Sheep . . . . .	131
Vertebral Column of Ox . . . . .	40	Skeleton of Fore Limb of Pig . . . . .	131
Vertebral Column of Pig . . . . .	42	Skeleton of Fore Limb of Dog . . . . .	133
Vertebral Column of Dog . . . . .	43	Skeleton of Fore Limb of Cat . . . . .	137
Vertebral Column of Cat . . . . .	45	Innominate Bone of Horse . . . . .	137
Ribs of the Horse . . . . .	45	Pelvis of Horse . . . . .	141
Sternum of the Horse . . . . .	48	Femur of Horse . . . . .	142
Thorax of the Horse . . . . .	49	Patella of Horse . . . . .	145
Thorax of the Ox, Sheep, and Pig . . . . .	50	Tibia of Horse . . . . .	145
Thorax of the Dog and Cat . . . . .	51	Fibula of Horse . . . . .	148
Occipital Bone of Horse . . . . .	52	Tarsus of Horse . . . . .	149
Parietal Bone of Horse . . . . .	53	Metatarsus of Horse . . . . .	152
Interparietal Bone of Horse . . . . .	54	Skeleton of Hind Limb of Ox . . . . .	156
Sphenoid Bone of Horse . . . . .	55	Skeleton of Hind Limb of Sheep . . . . .	158
Frontal Bone of Horse . . . . .	58	Skeleton of Hind Limb of Pig . . . . .	159
Temporal Bone of Horse . . . . .	59	Skeleton of Hind Limb of Dog . . . . .	161
Ethmoid Bone of Horse . . . . .	64	Skeleton of Hind Limb of Cat . . . . .	164
Pterygoid Bone of Horse . . . . .	66	Skeleton of Fowl . . . . .	164
Palatine Bone of Horse . . . . .	66	SECTION II.—ARTHROLOGY.	
Superior Maxilla of Horse . . . . .	67	Classification of Joints . . . . .	167
Lachrymal Bone of Horse . . . . .	69	Articulations of Vertebral Column of Horse . . . . .	171
Malar Bone of Horse . . . . .	70	Temporo-maxillary Articulation of Horse . . . . .	176
Nasal Bone of Horse . . . . .	70	Articulations of Hyoid Bone of Horse . . . . .	177
Premaxilla of Horse . . . . .	71	Articulations of Ribs of Horse . . . . .	179
Vomer Bone of Horse . . . . .	72	Comparative Anatomy of Joints of Trunk . . . . .	181
Turbinated Bones of Horse . . . . .	73	Shoulder Joint of Horse . . . . .	182
Inferior Maxilla of Horse . . . . .	74	Elbow Joint of Horse . . . . .	183
Hyoid Bone of Horse . . . . .	76	Knee Joint of Horse . . . . .	185
Cranium of Horse . . . . .	78	Fetlock Joint of Horse . . . . .	188
Temporal Fossæ of Horse . . . . .	79	Pastern Joint of Horse . . . . .	191
Orbits of Horse . . . . .	80	Coffin Joint of Horse . . . . .	192
Nasal Fossæ of Horse . . . . .	80	Comparative Anatomy of Joints of Fore Limb . . . . .	192
Air Sinuses of Skull of Horse . . . . .	81	Sacro-iliac Joint of Horse . . . . .	194
Foramina of Skull of Horse . . . . .	83	Hip Joint of Horse . . . . .	196
Morphology of Skull of Horse . . . . .	88	Stifle Joint of Horse . . . . .	197
Skull of Ox . . . . .	89	Hock Joint of Horse . . . . .	202
Skull of Sheep . . . . .	94	Comparative Anatomy of Joints of Hind Limb . . . . .	206
Skull of Pig . . . . .	97		
Skull of Dog . . . . .	101		
Skull of Cat . . . . .	105		
Scapula of Horse . . . . .	106		


ILLUSTRATIONS.<sup>1</sup>

FIG.	PAGE.	FIG.	PAGE.
1. Skeleton of Horse . . . ( <i>Bendz</i> )	2	48. Skull of Horse, transverse section . . .	73
2. Skeleton of Cow . . . ( <i>Bendz</i> )	5	49. Inferior Maxilla of Horse . . .	75
3. Skeleton of Pig . . . ( <i>Bendz</i> )	6	50. Hyoid Bone of Horse . . .	77
4. Skeleton of Dog . . . ( <i>Bendz</i> )	7	51. Orbital Hiatus of Horse's Skull . . .	85
5. Skeleton of Goose . . . ( <i>Franck</i> )	10	52. Skull of Ox, antero-lateral view . . .	90
6. Vertical Section of Long Bone . . .	12	53. Horn and Horn-core of Ox . . .	91
7. Transverse Section of Long Bone, magnified . . . ( <i>Leyh</i> )	15	54. Skull of Ox, posterior view . . .	92
8. Vertical Section of Long Bone, magnified . . . ( <i>Leyh</i> )	16	55. Inferior Maxilla of Ox . . .	94
9. Lacuna and Bone Cell, magnified . . . ( <i>Franck</i> )	17	56. Skull of Sheep, front view . . .	95
10. Femur of Young Pig . . .	19	57. Skull of Sheep, posterior view . . .	96
11. First Dorsal Vertebra of Horse . . .	23	58. Skull of Pig, lateral view . . .	98
12. Cervical Vertebrae of Horse . . .	25	59. Skull of Pig, posterior view . . .	100
13. Fifth Cervical Vertebra of Horse . . .	26	60. Skull of Dog, front view . . .	102
14. Sixth Cervical Vertebra of Horse . . .	27	61. Skull of Dog, posterior view . . .	103
15. Seventh Cervical Vertebra of Horse . . .	28	62. Inferior Maxilla of Dog . . .	105
16. Atlas of Horse . . .	28	63. Scapula of Horse, outer surface . . .	107
17. Axis of Horse, antero-lateral view . . .	30	64. Scapula of Horse, inner surface . . .	108
18. Axis of Horse, postero-lateral view . . .	30	65. Humerus of Horse, antero-lateral view . . .	109
19. Dorsal Vertebra of Horse, front view . . .	32	66. Humerus of Horse, postero-lateral view . . .	111
20. Dorsal vertebra of Horse, side view . . .	32	67. Radius and Ulna of Horse, front view . . .	112
21. First Dorsal Vertebra of Horse . . .	33	68. Radius and Ulna of Horse, posterior view . . .	114
22. Last Dorsal Vertebra of Horse . . .	34	69. Carpus of Horse, front view . . .	116
23. Lumbar Vertebra of Horse, front view . . .	35	70. Carpus of Horse, antero-lateral view . . .	117
24. Lumbar Vertebra of Horse, hinder aspect . . .	35	71. Metacarpal and Sesamoid Bones of Horse . . .	119
25. Sacrum of Horse, antero-lateral view . . .	36	72. Large Metacarpal of Horse, front view . . .	121
26. Sacrum of Horse, inferior surface . . .	37	73. First Phalanx of Horse, front view . . .	123
27. Coccygeal Vertebrae of Horse ( <i>Franck</i> ) . . .	38	74. First Phalanx of Horse, posterior view . . .	123
28. Atlas of Ox . . .	40	75. Second Phalanx of Horse, front view . . .	124
29. Axis of Ox . . .	40	76. Second Phalanx of Horse, posterior view . . .	124
30. Fourth Cervical Vertebra of Ox . . .	40	77. Third Phalanx of Horse, postero-lateral view . . .	125
31. Sacrum of Ox . . .	41	78. Third Phalanx of Horse, inferior aspect . . .	125
32. Cervical Vertebra of Pig . . .	42	79. Navicular Bone of Horse, front view . . .	127
33. Atlas of Pig . . .	43	80. Navicular Bone of Horse, posterior view . . .	127
34. Axis of Pig . . .	43	81. Scapula of Ox, outer aspect . . .	128
35. Atlas of Dog . . .	44	82. Scapula of Ox, inner aspect . . .	128
36. Axis of Dog . . .	44	83. Humerus of Ox, outer aspect . . .	129
37. Lumbar Vertebra of Dog . . .	44	84. Humerus of Ox, inner aspect . . .	129
38. Sacrum of Dog . . .	44	85. Radius and Ulna of Ox, outer aspect . . .	130
39. Rib of Horse, inside view . . .	46	86. Radius and Ulna of Ox, inner aspect . . .	130
40. Rib of Horse, outside view . . .	46	87. Manus of Ox, anterior aspect ( <i>Bendz</i> ) . . .	130
41. Sternum of Horse . . .	48	88. Manus of Ox, posterior aspect ( <i>Bendz</i> ) . . .	130
42. Sternum of Ox . . . ( <i>Bendz</i> )	50		
43. Sternum of Pig . . . ( <i>Bendz</i> )	51		
44. Sternum of Dog . . . ( <i>Bendz</i> )	51		
45. Skull of Horse, anterior view . . .	56		
46. Skull of Horse, posterior view . . .	62		
47. Skull of Horse, mesial section . . .	64		

<sup>1</sup> Except where otherwise stated the illustrations are original.

FIG.	PAGE.	FIG.	PAGE.
89. Scapula of Pig, outer aspect . . .	131	121. Innominate Bone of Pig . . .	159
90. Scapula of Pig, inner aspect . . .	131	122. Femur of Pig, outer aspect . . .	160
91. Humerus of Pig, outer aspect . . .	132	123. Femur of Pig, inner aspect . . .	160
92. Humerus of Pig, inner aspect . . .	132	124. Tibia and Fibula of Pig, outer aspect . . .	161
93. Radius and Ulna of Pig, outer aspect . . .	132	125. Tibia and Fibula of Pig, inner aspect . . .	161
94. Radius and Ulna of Pig, inner aspect . . .	132	126. Pes of Pig, posterior aspect (Bendz) . . .	161
95. Manus of Pig, anterior aspect (Bendz) . . .	133	127. Innominate Bone of Dog, inferior aspect . . .	162
96. Scapula of Dog, outer aspect . . .	134	128. Femur of Dog, outer aspect . . .	162
97. Scapula of Dog, inner aspect . . .	134	129. Femur of Dog, inner aspect . . .	162
98. Humerus of Dog, outer aspect . . .	134	130. Tibia and Fibula of Dog, outer aspect . . .	163
99. Humerus of Dog, inner aspect . . .	134	131. Tibia and Fibula of Dog, inner aspect . . .	163
100. Radius and Ulna of Dog, outer aspect . . .	135	132. Pes of Dog, posterior aspect (Bendz) . . .	163
101. Radius and Ulna of Dog, inner aspect . . .	135	133. Intervertebral Joints of Horse . . .	172
102. Manus of Dog, posterior aspect (Bendz) . . .	136	134. Ligamentum Nuchæ of Horse (Chauveau) . . .	173
103. Innominate Bone of Horse, outer aspect . . .	138	135. Intervertebral Joints of Horse (Leyh) . . .	175
104. Innominate Bone of Horse, inferior aspect . . .	140	136. Temporo-Maxillary Joint of Horse (Leyh) . . .	176
105. Femur of Horse, anterior aspect . . .	142	137. Costo-central Joints of Horse (Leyh) . . .	179
106. Femur of Horse, posterior aspect . . .	144	138. Costo-vertebral Joints of Horse . . .	179
107. Patella of Horse, posterior aspect . . .	145	139. Shoulder Joint of Horse (Franck) . . .	182
108. Tibia and Fibula of Horse, antero-external aspect . . .	146	140. Elbow Joint of Horse (Leyh) . . .	183
109. Tibia and Fibula of Horse, posterior aspect . . .	147	141. Carpus of Horse (Franck) . . .	185
110. Tarsus of Horse, antero-external aspect . . .	149	142. Fetlock Joint of Horse (Leyh) . . .	189
111. Tarsus of Horse, postero-internal aspect . . .	151	143. Manus of Horse (Leyh) . . .	190
112. Metatarsal Bones of Horse, anterior aspect . . .	153	144. Pelvis of Horse (Chauveau) . . .	195
113. Metatarsal Bones of Horse, posterior aspect . . .	153	145. Pelvis of Horse (Leyh) . . .	196
114. Pelvic Bones of Ox . . .	155	146. Hip Joint of Horse (Leyh) . . .	197
115. Femur of Ox, outer aspect . . .	156	147. Stifle Joint of Horse, antero-lateral view . . .	198
116. Femur of Ox, inner aspect . . .	156	148. Stifle Joint of Horse, posterior view . . .	199
117. Tibia of Ox, outer aspect . . .	157	149. Stifle Joint of Horse, mesial section . . .	200
118. Tibia of Ox, inner aspect . . .	157	150. Hock Joint of Horse, front view . . .	202
119. Pes of Ox, inner aspect (Bendz) . . .	158	151. Hock Joint of Horse, posterior view . . .	204
120. Pes of Ox, anterior aspect (Bendz) . . .	158		





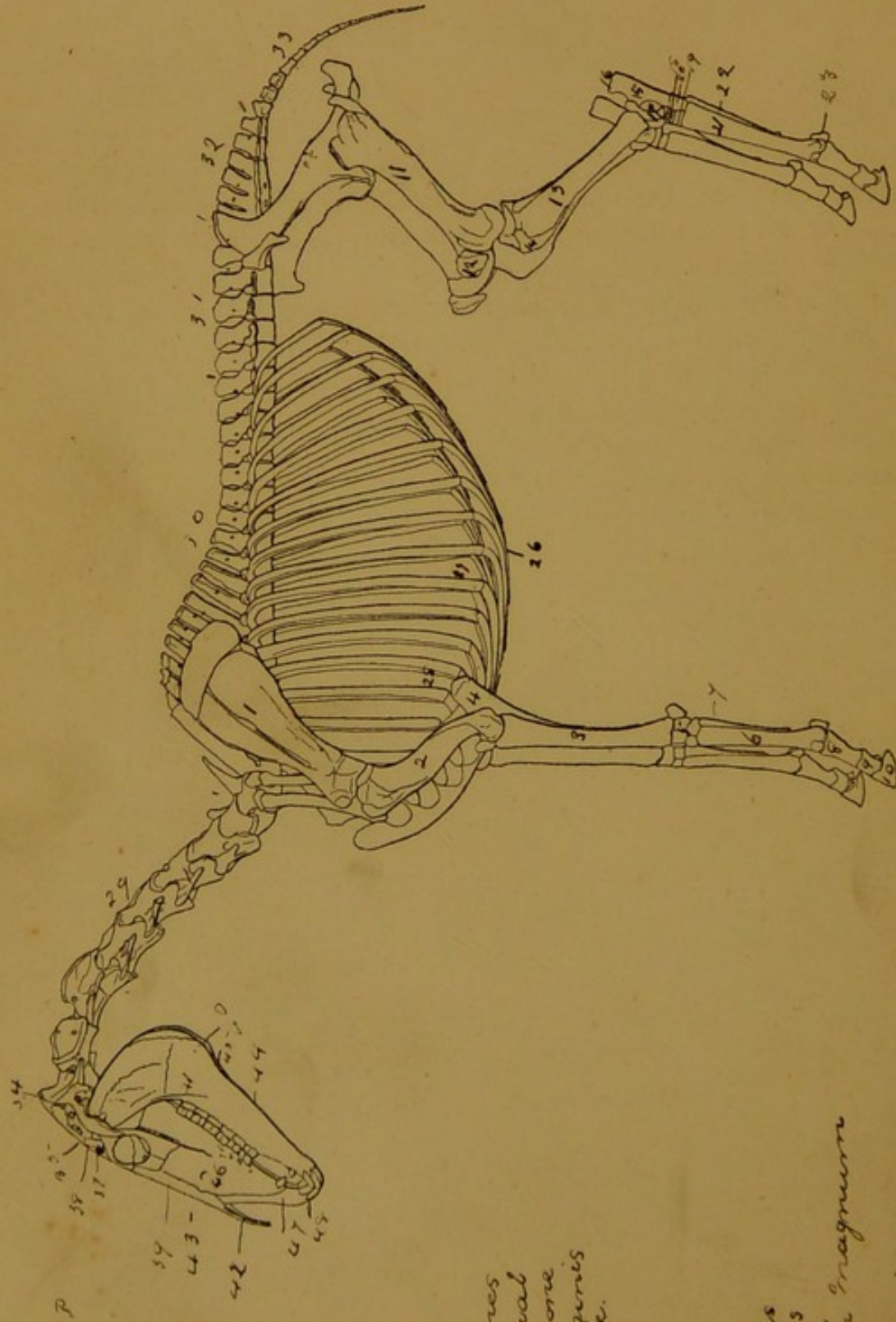


FIG. 1.—SKELETON OF THE HORSE.

Scapula

Humerus

Radius

Ulna

Carpus Bones

Metacarpal

Splint Bone

Os. Supraglenoid

Os. Coronoid

Os. Radialis

Femur

Patella

Tibia

Fibula

Os. Calcis

Tuber. Calcis

Os. Astragalus

Scapulo

Cubito

Cuboid

Metatarsal

Small Metatarsal

Sesamoid

Os. Supraglenoid

Os. Coronoid

Os. Radialis

26. Sternum
27. Asternal Ribs
28. Sternal Ribs
29. Cervical
30. Vertebral
31. Dorsal Vert.
32. Lumbar Vert.
33. Sacral Vert.
34. Caudal Vert.
35. Os. Sacral Bone
36. Interparietal Bone
37. Parietal Bone
38. Squamosal Bone
39. Process. Same
40. Frontal Bone
41. Maxillary Bone
42. Nasal Bone
43. Peak
44. Premax. Bone
45. Supercil
46. Maxillary
47. Ridge
48. Infra-orbital
49. Foramen
50. Frontal Bone
51. Incisor
52. Foramen

## INTRODUCTION.

---

**Anatomy**, in its most comprehensive sense, embraces all that relates to the structure of vitalised objects. It is thus an important branch of **Biology**, and it resolves itself naturally into two primary sections, viz., **Zootomy**, or the anatomy of animals, and **Phytotomy**, or the anatomy of plants.

Zootomy comprises two subsections—special anatomy and comparative anatomy. **Special Anatomy** is applied exclusively to the investigation of the structure of a particular species of animal. **Comparative Anatomy**, on the other hand, brings under observation the structure of different species of animals, in order to trace their points of resemblance.

Special Anatomy itself comprises several subdivisions. Thus, when it is concerned with the elementary cells and tissues of which the various organs of the body are built up, it is termed **Histology**. Again, when it traces the succession of forms exhibited by the individual, from the date of conception to the period of adult life, it is called **Developmental** or **Embryological Anatomy**. Lastly, when it groups together facts relating to structure, in order to discover the natural laws that determine the form of different parts of the body, it is designated **Morphological Anatomy**.

There are two distinct ways in which the special anatomy of an animal may be prosecuted. In the first of these ways the different groups, or systems, as they are called, of similar organs are studied separately, and in the order in which we would naturally proceed had we the power to build up an animal. Thus, under this method the system of bones falls to be first studied, since these form the framework of the body; the joints and ligaments by which these bones are connected come next in order, and so on. This is termed **Systematic** or **Descriptive Anatomy**.

Under the second method the different structures are investigated in the order of their position in the same part of the body, that is to say, in the order in which they would present themselves in the course of a dissection. This constitutes **Topographical Anatomy**.

In the one case, then, the investigation proceeds by synthetical, and

in the other by analytical, methods. Under the systematic method we learn the structure of an animal by building it up; under the topographical method we arrive at the same object by taking it to pieces.

Whoever would become a skilled anatomist must follow both of these methods. To the beginner the systematic method is the simpler and more natural. By it he can most readily master the general plan of structure, and perceive in the various organs the adaptation of structure to function. By the topographical pursuit of anatomy the student becomes familiar with the exact form and connections of the objects that compose each particular region of the body, and he thus acquires the knowledge that is indispensable in the practice of medicine and of surgery.

In the following pages the systematic method is followed in describing the anatomy of the common domesticated animals of this country.

THE COMPARATIVE ANATOMY  
OF THE  
COMMON DOMESTICATED ANIMALS.

---

POSITION OF THE DOMESTICATED ANIMALS  
IN THE ANIMAL KINGDOM.

THE common domesticated animals of this country all belong to the *Vertebrate* sub-kingdom. The distinguishing features of this group, the highest in point of organization of all the great divisions of the animal kingdom, are as follows.

The mesial plane of the body is traversed in early life by an un-

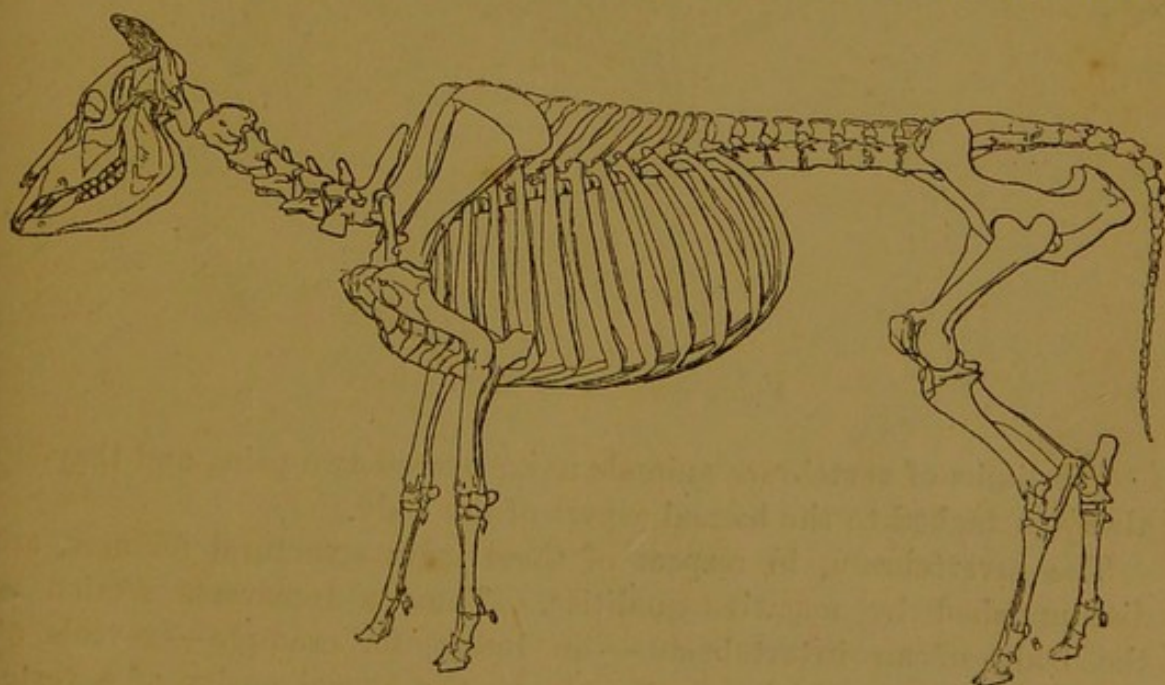


FIG. 2.—SKELETON OF THE COW.

jointed cartilaginous rod—the so-called **chorda dorsalis**, or **notochord**. In the lowest vertebrate forms (*amphioxus*) this rod persists in an almost unmodified condition throughout life. In the great majority of the vertebrata, however, the notochord soon becomes replaced by a chain of cartilaginous elements, or *vertebræ*. These are developed by

segmentation of the tissue surrounding the notochord, and they constitute the so-called **vertebral column**, from which the name of the sub-kingdom is derived. The separate elements of the column may remain in great part cartilaginous throughout life, but in all the higher vertebrata the primitive cartilage is almost entirely replaced by bone.

A transverse section of the trunk of a vertebrate animal reveals two cavities, the notochord or the more highly developed vertebral column lying in the partition between the two. The upper or dorsal cavity is tubular in form, and it contains the central axis (brain and spinal cord) of the cerebro-spinal nervous system. It is therefore termed the **neural canal**. The lower or ventral cavity contains the alimentary canal, the heart, and in general also a double gangliated cord forming the central axis of the so-called sympathetic nervous system. In contradistinction to the neural canal, this cavity is termed **hæmal**, since it contains the heart and great blood-vessels.

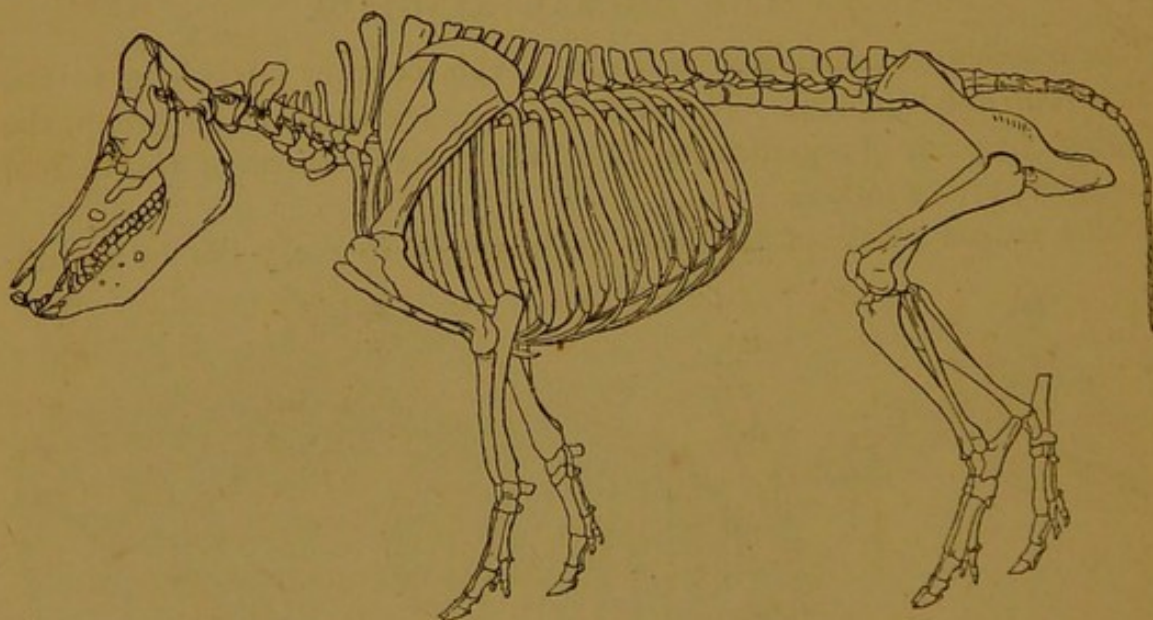


FIG. 3.—SKELETON OF THE FIG.

The limbs of vertebrate animals never exceed two pairs, and they are always attached to the hæmal aspect of the body.

The invertebrata, in respect of these main structural features, are distinguished by negative qualities. Thus, a transverse section of the body of an invertebrate — an insect, for example — reveals at most one cavity, which corresponds to the hæmal cavity of a vertebrate, and contains the alimentary canal and the central nervous system. The neural canal and the cerebro-spinal nervous system are entirely unrepresented. Except in the larval state of one group (*Tunicata*), no structure corresponding to the notochord or vertebral column is found in any of the invertebrata.

The nervous system of the invertebrata corresponds to the vertebrate

sympathetic system, but it is ventrally placed, whereas the latter system is dorsal in position.

The limbs of the invertebrata are frequently numerous, and they are attached to that side of the body on which the central axis of the nervous system lies.

The vertebrate sub-kingdom is divided into the following five classes, the last two of which include the ordinary domesticated animals:—

- (1) Fishes (*Pisces*).
- (2) Amphibians (*Amphibia*).
- (3) Reptiles (*Reptilia*).
- (4) Birds (*Aves*).
- (5) Mammals (*Mammalia*.)

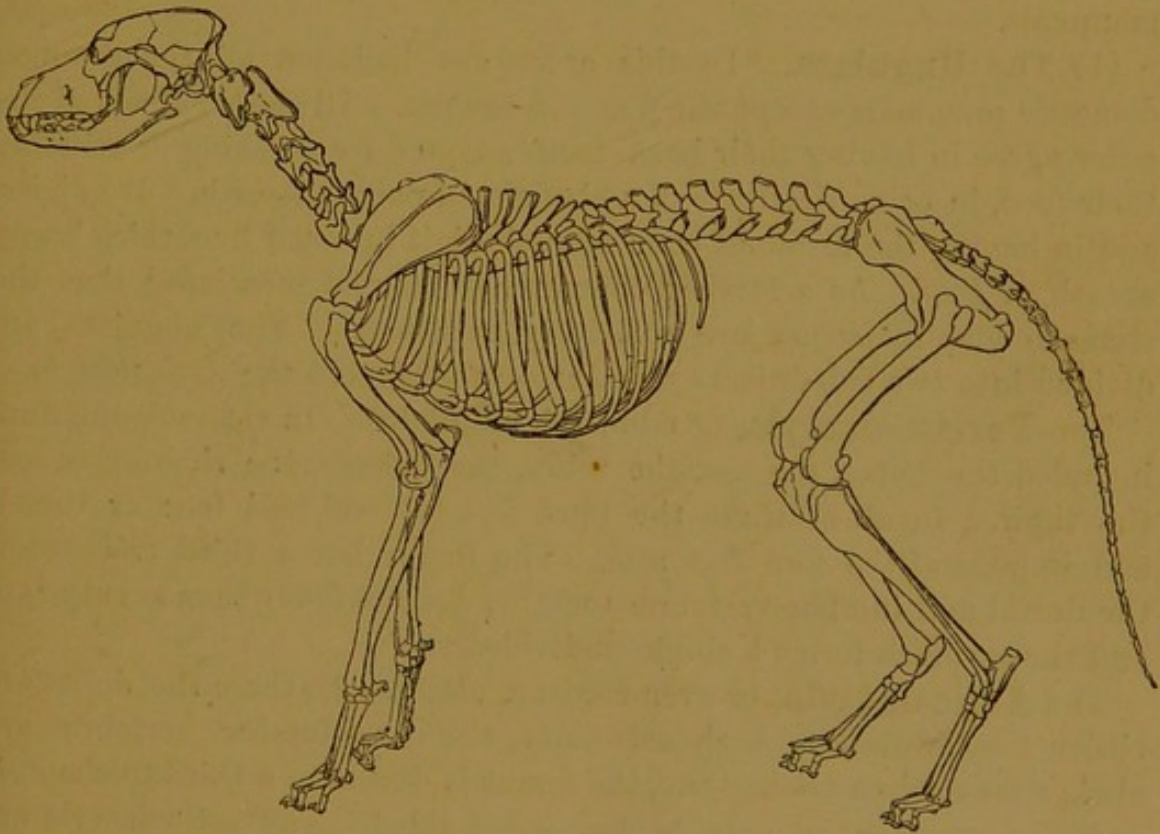


FIG. 4.—SKELETON OF THE DOG.

**Characters of the class, Aves.** The aves may be defined as “air-breathing, warm-blooded vertebrata, which have epidermal appendages of the structure of feathers, and which are always oviparous.” They resemble the mammalia in being air-breathing and warm-blooded, and in having a four-chambered heart; but their closest affinities are with the reptilia, with which they agree in having a single occipital condyle, the ankle-joint in the middle of the tarsus, a single auditory ossicle, and oval nucleated red blood corpuscles.

Existing birds are divided by Huxley into two orders, viz., the Ratitæ and the Carinatae. The **Ratitæ** comprises the ostriches, emeus, and

cassowaries, in which the sternum is flat or raft-like. In the **Carinatae**, which includes all other existing birds, the sternum is provided with a pronounced mesial ridge or keel for the attachment of the pectoral muscles.

**Characters of the class, Mammalia.** The mammalia may be defined as air-breathing, warm-blooded, viviparous<sup>1</sup> vertebrates, with epidermal appendages in the form of hairs, and which nourish their young for a variable period after birth on the secretion of special glands termed the mammary glands. They differ further from the aves in the possession of a perfect diaphragm, two occipital condyles, non-nucleated red corpuscles, and a corpus callosum.

The existing mammalia are divided into a great many (thirteen, *Huxley*) orders, but the following two include all the ordinary domestic mammals.

(1) The **Ungulata**. In this order are included all the common domestic mammals except the dog and the cat. All the members of the order agree in having their back teeth adapted for crushing or grinding their food, in being destitute of a clavicle, in never possessing five digits, and in having the terminal bone of each digit invested by a thick horny sheath or *hoof*. As a further character it may be mentioned that the stomach and intestines are relatively capacious. The ungulata are divided into two sub-orders—the *Perisso-dactyla* and the *Artio-dactyla*.

The **Perisso-dactyla**, or odd-toed ungulates. In this sub-order are included the horse, the ass, the zebra, the quagga, the rhinoceros, and the tapir. In all of these the hind feet are odd-toed (one or three), and in general the fore feet also. The femur has a third trochanter, the dorsal and lumbar vertebræ together are not fewer than twenty-two, and the stomach forms a single undivided sac.

The **Artio-dactyla**, or even-toed ungulates. In these the digits are either two or four in each extremity, the dorso-lumbar vertebræ are always fewer than twenty-two, the femur is devoid of a third trochanter, and the stomach is more or less sub-divided. The artio-dactyla are divided into the *Ruminantia*, and the *Non-Ruminantia*.

The **Ruminantia**. This group includes the ox, the sheep, the goat, the camel, and all other animals that ruminate or chew the cud. In these animals the stomach comprises three or four compartments, the front of the upper jaw is devoid of teeth, and bilaterally paired horns are usually present.

The **Non-Ruminantia**. In this group are included the pig, the peccary, the hippopotamus, etc. These ungulates do not chew the cud, the stomach is simpler than in the ruminantia, the front of the upper jaw carries teeth, and when horns are present, as in the rhinoceros, they are mesially placed.

<sup>1</sup> Oviparous in *Ornithorhynchus*.

(2) The **Carnivora**. This order includes the dog, the cat, the seal, the walrus, and the great majority of the terrestrial beasts of prey. In all the members of the order canine, incisor, and molar teeth are present, and the canines are always distinguishable from the other teeth by their size and form. The back teeth are more or less adapted for cutting or tearing an animal diet. Clavicles are absent or rudimentary, the scaphoid and semilunar bones of the carpus are fused together, and the extremity of each digit is provided with a claw. The stomach is simple, and the capacity of the intestines relatively small.

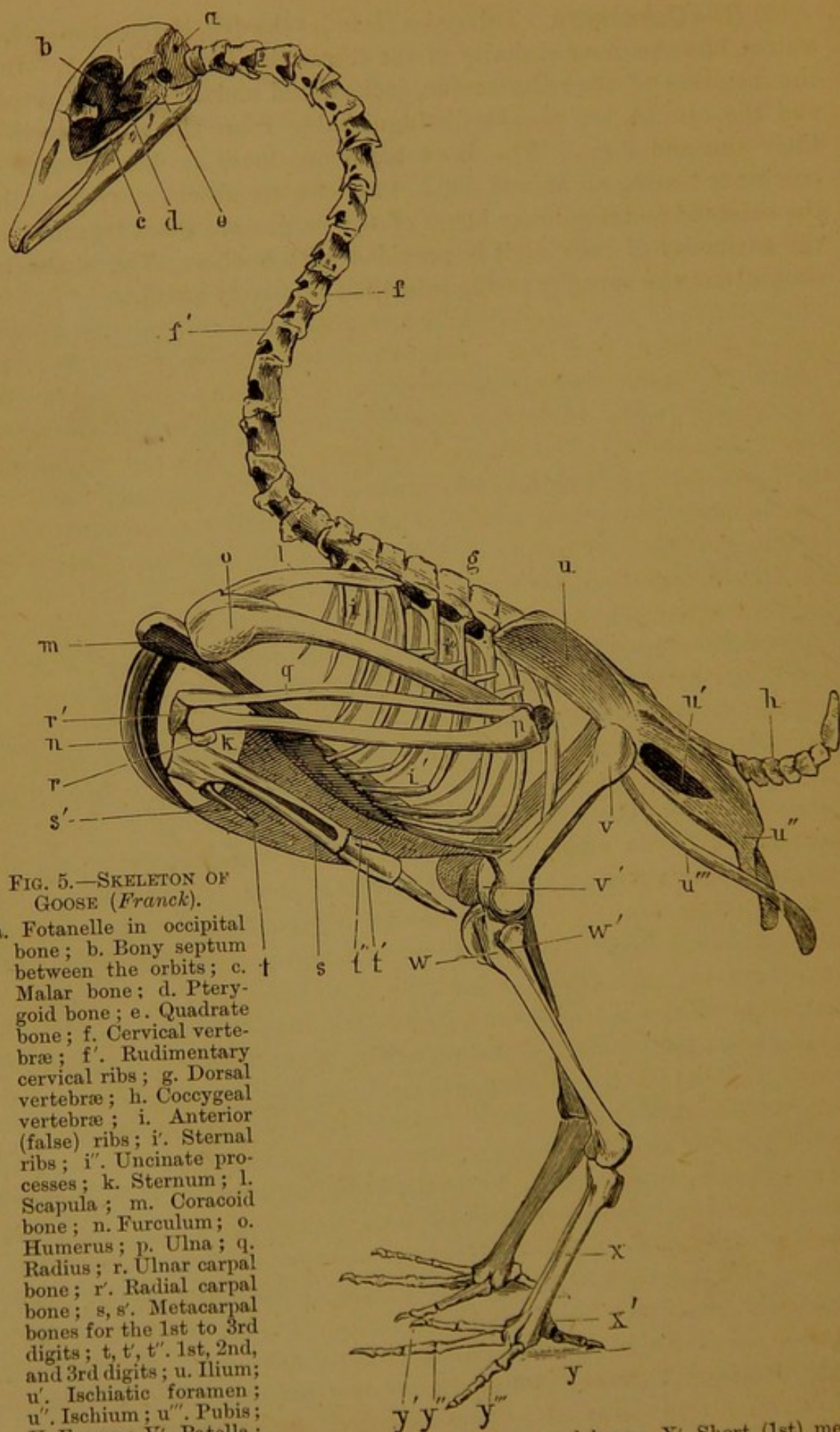


FIG. 5.—SKELETON OF  
GOOSE (*Franck*).

- a. Fontanelle in occipital bone; b. Bony septum between the orbits; c. Malar bone; d. Pterygoid bone; e. Quadrate bone; f. Cervical vertebrae; f'. Rudimentary cervical ribs; g. Dorsal vertebrae; h. Coccygeal vertebrae; i. Anterior (false) ribs; i'. Sternal ribs; i''. Uncinate processes; k. Sternum; l. Scapula; m. Coracoid bone; n. Furculum; o. Humerus; p. Ulna; q. Radius; r. Ulnar carpal bone; r'. Radial carpal bone; s, s'. Metacarpal bones for the 1st to 3rd digits; t, t', t''. 1st, 2nd, and 3rd digits; u. Ilium; u'. Ischiatic foramen; u''. Ischium; u'''. Pubis; v. Femur; v'. Patella; w. Tibio-tarsal bone; w'. Fibula; x. Tarso-metatarsal bone; x'. Short (1st) metatarsal bone; y-y'''. The four toes.

## SECTION I.

### OSTEOLOGY.

#### GENERAL CONSIDERATIONS REGARDING THE BONES.

THE study of the bones is termed osteology. In a systematic treatise the bones are naturally the first organs to be considered, since they form the framework of the body. Before proceeding to the detailed description of the individual bones, it is desirable to devote some space to the consideration of the bones in general.

It is customary to divide the bones according to their general shape into four classes.

(1) **Long Bones.** A long bone may be defined as one that possesses a medullary or marrow cavity. In general they are notably extended in one dimension, so that their length considerably exceeds their breadth or thickness. In every long bone there are recognised a central part termed the **shaft** or **diaphysis**, and two extremities termed the **epiphyses**. The shaft is a hollow bony cylinder surrounding the **medullary cavity**, which in the recent state is occupied by the medulla or marrow. The long bones are found exclusively in the limbs, and their form specially adapts them for bearing weight, for, with a given amount of material to be made into a pillar or support, the maximum strength is obtained when that material is made into the form of a hollow cylinder. Examples are—the humerus, the radius, the femur, and the tibia.

Some bones, although notably extended in one dimension, are yet devoid of a medullary cavity, and hence do not strictly conform to the definition of a long bone. An example is furnished by the ribs, and these are sometimes regarded as forming a separate class termed **elongated bones**. In some cases, however, the absence of a medullary cavity in bones of an elongated form is due to arrest of development. The splint bones and the fibula of the horse, for example, are in reality aborted long bones.

(2) **Flat or Tabular Bones.** The bones of this class are extended in two dimensions in excess of the third, and they are therefore more or less plate-like. This flattening of bones may have for its object either

to give an increase of surface for the attachment of muscles, as with the scapula, or to afford protection to subjacent structures, as in the case of the parietal and frontal bones of the cranium or brain-case.

(3) **Short Bones.** The bones of this class are all of comparatively small size, and they generally approach the cubical in form. Examples are furnished by the bones of the carpus and tarsus. These collections of short bones play an important part, for, by multiplying joints, they serve to distribute weight and pressure, and thus diminish the risk of injury from concussion.

(4) **Irregular Bones.** These bones, as the name of the class implies, are of very irregular shapes, their irregularity being due to the projections or processes that stud them. The majority of them are mesially placed, and are therefore symmetrical in themselves and unpaired, while most of the bones of the other classes are paired bones, there being one of each on either side of the body. The vertebræ are examples of irregular bones.

A section through almost any bone of the body reveals that two varieties of bone texture enter into its composition. These are termed respectively *compact* and *cancellated* tissue of bone.

**Compact tissue** is dense and close-grained. It forms an outer shell of varying thickness in all the bones. In long bones it occurs in greatest amount in the shaft, the centre of which is composed almost exclusively of this variety of tissue. As it is traced away from the centre of the shaft, its thickness gradually diminishes, until over the extremities of the bone it forms a mere

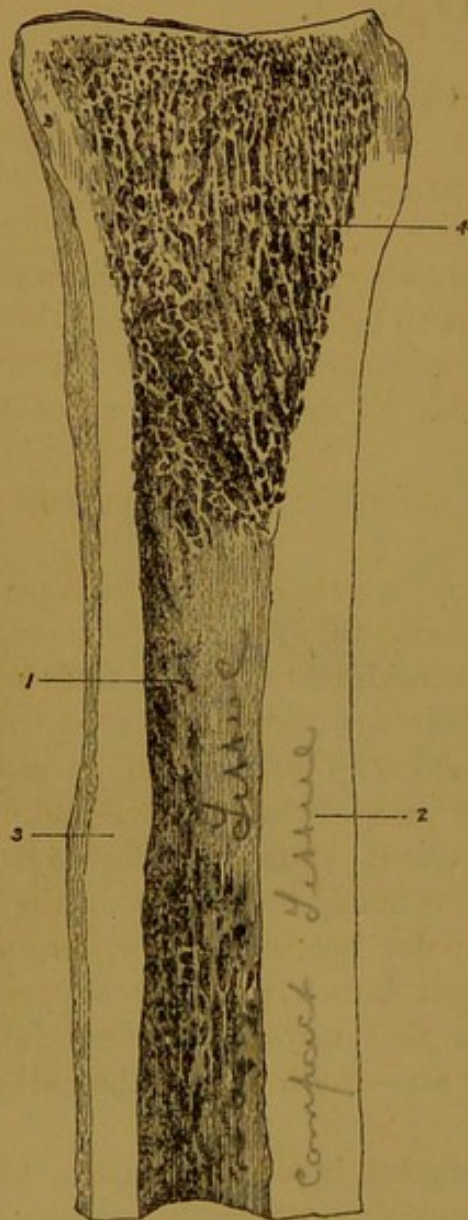


FIG. 6.—VERTICAL SECTION OF UPPER HALF OF LARGE METACARPAL BONE.

1. Medullary cavity ; 2. Thick layer of compact tissue on front of shaft ; 3. Somewhat thinner layer on posterior aspect of shaft ; 4. Mass of cancellated tissue at upper extremity.

shell enclosing a mass of cancellated tissue. Compact tissue, it need hardly be said, is strong and resistant, and hence it is found aggregated in positions where there is the greatest strain on the bone. In illustration of this, it ought to be observed that not only is the compact

tissue thickest towards the centre of the shaft (where the bone would be most likely to give way under pressure), but that it is of unequal thickness on the two sides of the shaft. Thus, in the case of the large metacarpal bone of the fore limb, the layer on the front of the shaft is greater than that behind, and there is a greater thickness on the inside than on the outside, in correspondence with the lines along which the weight of the body chiefly falls. In the other classes of bones the thickness of the outer shell of compact tissue varies in an irregular manner, but it never attains the proportion seen in the shaft of long bones.

**Cancellated or spongy tissue** is light and porous in appearance. On close inspection it is seen to be composed of a multitude of little intersecting osseous plates and bars, surrounding spaces that are filled in the fresh bone by red marrow. In a long bone there is scarcely any cancellated tissue at the centre of the shaft, but towards the ends of the marrow cavity it forms a lining of increasing thickness for the compact tissue, and it forms nearly the total mass of the expanded extremities of the bone. This variety of bone texture is much less resistant than the compact, but from its lightness it is well adapted for giving to the epiphyses the expansion that is necessary to confer stability on the joints, without unnecessarily adding to the weight of the bones.

In the flat bones a varying thickness of cancellated tissue nearly always intervenes between the two layers of compact bone, but at some points the cancellated tissue may be very sparing in amount, or even entirely absent. The main mass of short and irregular bones is formed by cancellated tissue, always, however, with an enveloping shell of compact bone.

In the bones composing the roof and lateral walls of the cranium or brain cavity the compact and cancellated tissue are arranged in a way that calls for special notice. These bones are composed of three layers of different density, viz., (1) an outer layer of compact bone of moderate density, (2) a middle layer of cancellated tissue, here termed **diploe**, and (3) an inner layer of compact bone, so dense and hard that the name *tabula vitrea* or glassy layer has been conferred upon it. Hence the bony skull-cap has been not inaptly compared to a triple covering of "wood outside, porcelain inside, and soft leather between the two."<sup>1</sup> In this arrangement there is apparent an admirable provision for lessening the risk of injury to the brain from blows delivered over the skull.

**Physical Properties** of bone. Bones are of a whitish colour, with a tinge of yellow unless they have been artificially bleached. When exposed in the living body the white is tinged with bluish pink, from the blood contained in the vessels of the bone.

Bone tissue is hard and resistant, these properties being indispensable

<sup>1</sup> Holden's "Human Osteology."

in objects that are to be used for support, or for the protection of delicate parts. At the same time even the hardest bones of the skeleton possess some degree of elasticity and toughness. The latter qualities are much more marked in some bones than in others. The ribs are the most elastic bones in the body, and a tolerably powerful bow may be made with one of them taken from a large horse. The pliability and elasticity of the limb bones is of the greatest importance, for shocks and jars are thereby broken, and the liability to fracture is greatly diminished. The elasticity of the ribs tends to bring them back to their original position when the muscles of inspiration cease to act, and thus, apart from muscular action, the air is driven out of the chest.

**Chemical Composition** of bone. Bone tissue is composed of animal and earthy matter intimately combined in the proportions indicated in the subjoined analysis.<sup>1</sup>

*Composition of the bones of oxen.*

Animal matter . . . . .	30·58
Phosphate of lime . . . . .	57·67
Carbonate of lime . . . . .	6·99
Fluoride of calcium . . . . .	2·69
Phosphate of magnesia . . . . .	2·07

---

100·00

In round numbers there are therefore about thirty parts by weight of animal matter to seventy of earthy matter in the bones of oxen. The composition of bones from any of the other domestic animals is practically identical with that shown in the above table, save that in the case of fowls' bones the proportion of phosphate of lime is somewhat higher. The chief physical properties of bones are largely dependent upon the proper admixture of their earthy and animal matter. To the inorganic or earthy salts are due the hardness, rigidity, and strength of bones; while, on the other hand, some degree of pliability and elasticity is conferred upon them by the animal matter.

By burning a bone in an open fire the whole of the animal matter is consumed, and a white chalky skeleton of the original bone is left. In the process of combustion the bone loses about one-third of its weight, and it becomes completely deprived of its elasticity. By prolonged boiling of bones the animal matter can be extracted in the form of gelatine.

By steeping a bone in a dilute solution of hydrochloric acid, the whole of the earthy salts can be dissolved out, the bone in the process losing about two-thirds of its weight. At the same time the rigidity and weight-supporting power of the bone are lost, and it becomes supple and pliable.

<sup>1</sup> Bloxam's "Chemistry."

In the bones of young animals and in certain diseased states (rickets and mollities ossium) the rigidity of the bones is greatly diminished, and they become permanently distorted under the weight of the body or the traction of the muscles attached to them. In old animals, on the other hand, and also in some pathological conditions, the elasticity of the bones is markedly diminished, and their liability to fracture greatly increased. These differences in the physical properties of bone are generally ascribed to a disturbance of the proper proportion in which the animal and earthy ingredients are combined in a state of health, but in part they may be due to variations in the relative amounts of compact and cancellated tissue, an excess of the former rendering the bones more brittle, while an undue preponderance of cancellated tissue would tend to make them more yielding.

## MINUTE STRUCTURE OF BONE.

When the outer surface of the shaft of a macerated and dried long bone is examined with a pocket-lens, it shows a great many point-like openings, which are the mouths of fine canals of the compact tissue. These are the so-called **Haversian canals**, which permeate the entire thickness of the shaft. The direction of the main canals is longitudinal, but the ends of adjacent canals are connected by oblique or transverse branches. The outermost canals of the shaft open by one mouth on the free surface, while the deepest open in the same way into the medullary cavity, or into one of the spaces of the cancellated tissue.

In a magnified transverse section of dried bone the compact tissue is seen to be arranged in the form of complete or imperfect rings, or **lamellæ**. A variable number of such rings encircle in a concentric manner the mouth of each cut Haversian canal. These are the so-called **Haversian lamellæ**, and each canal with its encircling lamellæ constitutes a **Haversian system**.

In the angular spaces left between adjacent Haversian systems, there are other lamellæ that look like fragments of larger systems. These are the so-called **ground** or **interstitial lamellæ**. Lastly, at the exterior of the shaft of a long bone a variable number of **peripheral lamellæ** may be disposed parallel to the surface.

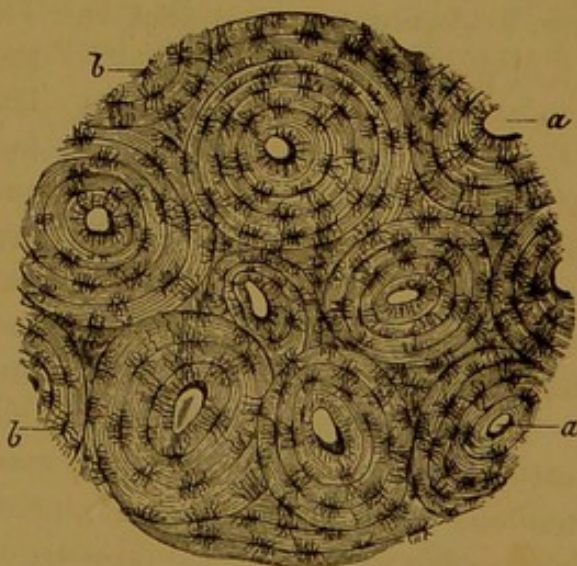


FIG. 7.—TRANSVERSE SECTION FROM LARGE METACARPAL BONE OF HORSE (*Leyh*).  
*a.* Haversian canals, around which are the Haversian lamellæ; *b.* lacunæ with their canaliculi. Between the Haversian systems are seen some ground lamellæ.

The matrix or ground substance of a bone lamella is a fine fibrous reticulum, impregnated with lime salts. Here and there calcified nail-like processes pass from the surface inwards through a number of lamellæ, which they appear to bolt together. These are the **perforating fibres** of Sharpey.

In a transverse section of dried bone viewed under the microscope

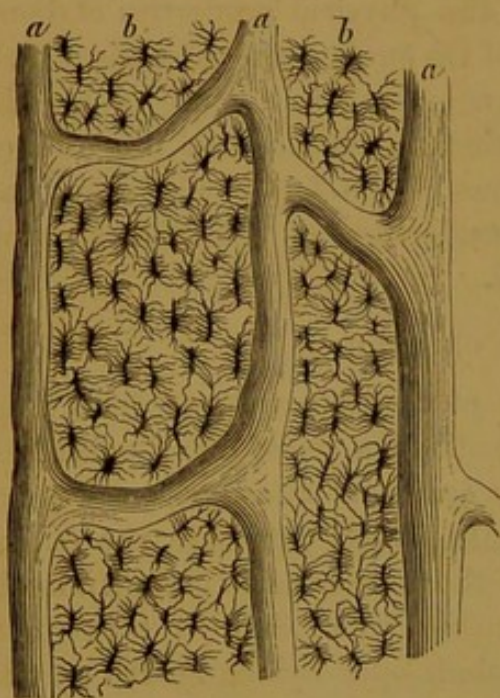


FIG. 8.—VERTICAL SECTION FROM THE MACERATED LARGE METACARPAL BONE OF A HORSE (*Leyh*).

a. Haversian canals; b. lacunæ with their canaliculi.

by transmitted light, a number of dark spots are seen along the lines of apposition of adjacent lamellæ. These are the **lacunæ**, which in reality are empty spaces in the macerated and dried bone.

Numerous fine **canaliculi** radiate from each lacuna, and, piercing the lamellæ, unite with like canals from the neighbouring lacunæ of the same system. The central canaliculi from the innermost row of lacunæ in a Haversian system open into the Haversian canal.

The structure of cancellated tissue differs from that just described chiefly in the absence of Haversian canals.

The thin intersecting bars and plates are composed of irregular groups of lamellæ, with intervening rows of lacunæ and canaliculi, the innermost of which open into the cancellous spaces. The honey-comb cavities of spongy tissue are termed **Haversian spaces**.

The foregoing description applies to the structure of a macerated and dried bone, but such a bone has been deprived of a number of highly important soft structures, which must now be considered.

**The Periosteum.** This is a thin membrane which invests the outer surface of a bone everywhere except at articular surfaces and where tendons are attached. It comprises (1) a dense *outer layer* of fibrous connective tissue, and (2) an *inner* or *osteogenetic layer*, composed of more loosely arranged connective tissue bundles, with numerous cells. These cells are most abundant in young growing bone, in which they may be seen to form a continuous layer on the surface of newly formed lamellæ. Since these cells are directly concerned in the formation of new bone, they are termed **osteoblasts**.

The periosteum is a vascular membrane, its deeper layer especially containing numerous capillary blood-vessels. From the vessels of the periosteum a fine branch passes into the open mouth of each Haversian canal, carrying with it a delicate prolongation from the osteogenetic layer.

The **Bone Cells.** In the fresh bones the lacunæ are not empty spaces. Each is occupied by a nucleated protoplasmic cell, from the periphery of which slender branching processes pass into the canaliculi. These are the so-called bone cells.

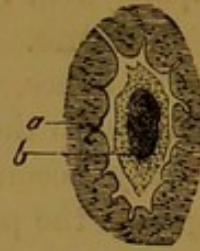


FIG. 9.—FROM THE FRESH ETHMOID BONE OF A MOUSE (*Franck*).

a. Bone matrix around a lacuna;  
b. nucleated bone cell.

The **Marrow.** There are two varieties of marrow—yellow and red. **Yellow marrow** is found in the medullary canal of long bones. It is composed principally of groups of fat cells supported by delicate vascular connective tissue. Interspersed through it are a few proper marrow cells. **Red marrow** is the vascular substance found in the spaces of cancellated tissue. It contains few or no fat cells, and it is of a reddish tint. The most abundant elements in it are the so-called **marrow cells**, which in size and appearance resemble a white corpuscle of the blood. Scattered among these are other cells, conspicuous from their large size and the numerous nuclei that they contain. These are the **giant cells** or **myeloplaxes**. In some situations the red marrow contains also faintly coloured nucleated cells that have been regarded as transitional forms between marrow cells and red blood corpuscles.

The delicate vascular tissue lying on the surface of the trabeculæ of cancellated tissue, and lining the medullary cavity, is sometimes termed the **endosteum**, but it cannot be detached as a distinct membrane like the periosteum.

The **Vessels of Bone.** Bones are highly vascular. As already mentioned, each Haversian canal contains a delicate vessel—capillary or vein. These are in communication outwardly with the periosteal vessels, and inwardly with the vessels of the medulla. Numerous fine vessels ramify on the surface of the trabeculæ of the cancellated tissue, and pass into the red marrow. At the extremities of some of the long bones there are numerous large foramina for the passage of vessels. Some of these transmit arteries, but the majority of them give exit to large veins returning blood from the cancellated tissue. The shaft of each long bone is penetrated by a considerable artery, misnamed the **nutrient artery**. This vessel ought to be termed the *medullary artery*, since it is chiefly expended in supplying the vessels of the yellow marrow. A satellite vein runs in company with the nutrient artery.

**Lymphatic vessels** form a network in the periosteum. Each Haversian canal contains one or two lymphatic vessels in company with the blood-vessel. These Haversian lymphatic vessels are in communication with the canaliculi and lacunæ, which thus serve as a series of

irrigating canals for each Haversian system. Lymphatic vessels also run in company with the blood-vessels of the marrow.

**Nerves of Bone.** Both compact and cancellated tissue, and also the marrow of bones, contain nerve fibres, which, however, appear to appertain chiefly to the blood-vessels of these textures. A considerable nerve generally accompanies the nutrient artery, and finer filaments enter along with the periosteal vessels.

#### DEVELOPMENT OF BONES.

In the foetus the future elements of the skeleton are composed either of cartilage or of connective tissue, and subsequently, by a gradual process termed **ossification**, this cartilage or connective tissue is *replaced* by bone. The great majority of the bones were first laid down as cartilage; but in the case of the flat bones of the face and of the roof and lateral walls of the cranial cavity, ossification took place in sheets of connective tissue. A distinction has accordingly been drawn between **intra-cartilaginous** and **intra-membranous ossification**, but the process is essentially the same in both cases.

The process of ossification does not take place simultaneously all over the cartilaginous or membranous representative of a future bone. On the contrary, it begins at one or more points, from which it extends until the entire soft tissue has been replaced by bone. These points are known as **centres of ossification**. In a fully developed long bone there are always three such centres, one of which appears about the middle of its length, while the other two are situated in the extremities. The process of ossification proceeding from the centrally placed nucleus towards either extremity leads to the production of the bony shaft, or **diaphysis**. In the same way, at either extremity a larger or smaller piece of bone, termed an **epiphysis**, is formed from the other two centres. Eventually the process initiated towards the centre of the shaft meets that which began in the extremities, and the ossification of the bone is then complete. To these three chief centres of a long bone a variable number of others may be added for the ossification of its outstanding parts or processes.

It follows from what has just been said, that, until the process of ossification has been completed, a macerated long bone will resolve itself into three or more distinct pieces, which separate owing to the destruction of the as yet unossified cartilage. In Fig. 10, the narrow lines of persisting cartilage indicate the diaphysis, the two epiphyses, and a fourth piece—the great trochanter, each of which had a separate centre of ossification. In a few months more the intervening layers of cartilage would have disappeared, and the ossification of the bone would have been complete. In flat, short, and irregular bones the process is essentially the same, but the number of nuclei, although

determinate for each individual bone, is more variable than in the class of long bones.

**Intra-cartilaginous ossification.** In the shaft of a long bone, the first step in the process of ossification consists in the formation of irregular intercommunicating spaces in the hyaline cartilage at the so-called centre of ossification. These spaces or **cartilage channels** are occupied by processes derived from the deep layer of the perichondrium—the membrane that invests the cartilage. The perichondrium is similar in structure to the periosteum already described, its deeper layer being identical with the osteogenetic layer of that membrane. The tissue filling the cartilage channels is therefore rich in blood-vessels and in osteoblasts. This initial stage of ossification has been termed **Chondroporosis** (*Klein*).

In the next stage the place of the cartilage channels is taken by larger and more irregular spaces—the **primary marrow cavities**, which are occupied by **primary marrow**. These primary marrow cavities are produced by extension of the preceding cartilage channels, and their contents are derived from the inward-growing processes of the perichondrium, that is to say, they contain blood-vessels and osteoblast cells. The walls of the primary marrow cavities are formed by trabeculæ of unabsorbed cartilage, which, as if to strengthen the part, become calcified.

The cells of the primary marrow now arrange themselves as a continuous layer on the calcified cartilage trabeculæ, and assume a true osteogenetic function. Around each cell there is formed a zone of material which is at first soft and fibrous. This material speedily becomes hardened by the deposition of lime salts in it, and in this way the matrix of new bone is formed. Each osteoblast, which has in the meantime become branched, is thus enclosed in a space of the newly formed matrix. The space is a bone lacuna with its canaliculi, and the included osteoblast persists as a bone cell. As the formation of bone on the surface of the calcified cartilage trabeculæ proceeds, the trabeculæ themselves gradually become absorbed. In this manner the

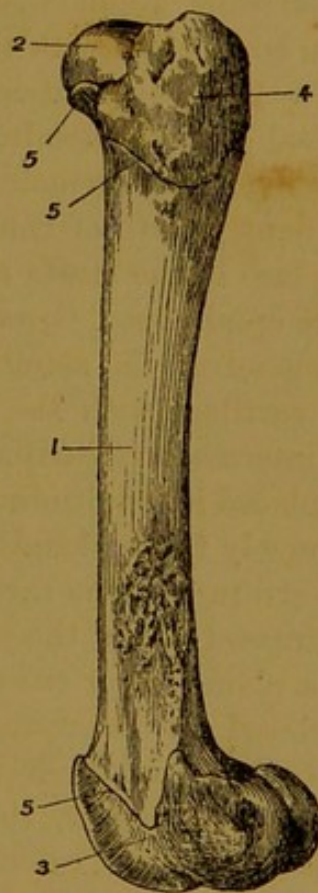


FIG. 10.—FEMUR OF A YOUNG PIG.

1. Diaphysis; 2. Upper Epiphysis;
3. Lower Epiphysis; 4. Great Trochanter;
5. Lines of intermediary cartilage.

original cartilage becomes replaced by cancellated bone tissue, the remnants of the primary marrow persisting as the red marrow of the new bone.

The miniature shaft of spongy bone which in the first instance takes the place of the original cartilage is not a permanent structure. By absorption of the trabeculae towards its interior, a small marrow canal is formed in it, and this continues to grow by absorption of the surrounding spongy bone. Hence, before birth the whole of the first formed endo-chondral bone of the shaft has disappeared in the formation of the medullary canal. But while this is being effected the thickness of the shaft is being augmented by the intra-membranous formation of new bone in connection with the deep layer of the periosteum.

By a process identical with that just described small epiphyses composed of endo-chondral bone are formed at the ends of the shaft, from which they remain separated by a stratum of cartilage. The subsequent growth of the bone in length, both before and after birth, takes place in the strata of cartilage interposed between the diaphysis and the epiphyses. Growth takes place in this cartilage, and new bone (endo-chondral) is simultaneously formed at the plane of junction of the cartilage with the end of the already osseous shaft. The cells of the intermediary cartilage assume a more or less regular arrangement, being placed in longitudinal rows, with the long axis of each cell directed transversely to the length of the bone. Near the plane of ossification a thin stratum of the cartilage becomes more transparent by reason of the increased size of the cartilage lacunae. By absorption of the matrix along a plane nearer the shaft, the cartilage lacunae become opened up, and placed in intercommunication, the cartilage cells themselves disappearing, and their places being taken by osteoblasts and blood-vessels. Still deeper, the trabecular remains of the cartilage matrix become completely calcified. Osteoblasts arrange themselves on the surface of these calcified trabeculae, and clothe them with new bone. Finally, in a deeper plane complete absorption of the calcified trabeculae is effected, and new bone takes their place.

As long as an intermediary cartilage is present at one or both ends of the shaft of a long bone, a possibility of the growth in length of that bone exists, through the steps just described. At a period which differs not only for the individual bones, but also for the opposite ends of the same bone, the process of ossification overtakes the process of growth in the intermediary cartilage, which accordingly disappears. The epiphysis and diaphysis are then consolidated, and growth in length arrested.

**Intra-membranous ossification.** After the whole of the cartilaginous shaft has been replaced by endo-chondral bone, it continues to grow in thickness by an addition of new bone to its outer surface.

This new bone is formed in connection with the deep layer of the periosteum, and it is therefore intra-membranous. Through the agency of the osteoblast cells of that layer, new spongy bone is formed. Subsequently the Haversian spaces of this bone become enlarged by absorption of some of its trabeculae (osteoporosis). At a still later date the marrow cells lying on the trabeculae of this spongy bone take on an osteoblastic function, and thus a lamella of new bone, with lacunae, canaliculi, and included bone cells, is formed. Successive layers of osteoblasts behaving in the same way gradually narrow a Haversian space, and convert it into a Haversian canal. In this manner the periosteal bone, which is at first spongy, becomes converted into compact tissue. The remains of the trabeculae of the first-formed spongy bone persist as the interstitial or ground lamellae of the compact substance.

Ossification in the case of the so-called membrane bones, such as the tabular bones of the skull, is a process identical with the formation of periosteal bone. Moreover, it is apparent that intra-membranous and intra-cartilaginous ossification are essentially similar processes. In both cases the active agents of bone formation are osteoblast cells, derived originally from the osteogenetic layer of the perichondrium or periosteum. In the one case the process is direct; in the other a miniature model of the future bone is laid down in cartilage, and this cartilage is piecemeal removed and *replaced* by bone, not *converted* into bone.

In the foregoing description of the process of bone formation, reference has more than once been made to an opposite process of bone absorption. In the case of a long bone, the whole of the first-formed endo-chondral bone of the shaft soon disappears in the hollowing out of the medullary canal. Moreover, well into the period of adult life a steady absorption of bone takes place immediately around this cavity, to compensate for the constant deposit of new periosteal bone on the surface of the shaft. The compact tissue of the deeper part of the shaft first returns by absorption to the condition of spongy bone, and then even the trabeculae of this spongy bone are themselves removed. These and all other instances of bone absorption appear to be brought about by the agency of special cells, termed from their function **osteoclasts**. In a similar manner the absorption of cartilage which necessarily takes place in the formation of endo-chondral bone is effected by **chondroclasts**.

These osteoclasts and chondroclasts are identical with the already described myeloplaxes of red marrow. They are multinucleated giant-cells. In a microscopic section of bone such cells may be seen in pits or spaces which appear to have been eroded by their agency. These pits are known as **Howship's lacunae**. It ought to be stated, however, that other giant-cells, identical in appearance with osteoclasts, appear to discharge a bone-forming function.

## THE SKELETON.

The framework of relatively hard textures, serving for the support and protection of the softer and more delicate parts of an animal, constitutes its **skeleton**. In the case of the adult horse or other domesticated animal, the skeleton is the connected framework formed by the bones, with the addition at a few points of certain elements which retain the structure of cartilage. This framework is embedded within the softer parts of the body, and it is therefore termed an **endo-skeleton**. Such a skeleton in a more or less complete form is found throughout the *vertebrate* sub-kingdom. Among the *invertebrata*, on the other hand, the skeleton is very commonly placed superficially to the softer parts, as is the case in the lobster, for example; and a protective framework of this type is termed an **exo-skeleton**. Occasionally a bone is found detached from the general framework and embedded in some soft organ. To this the term **splanchno-skeleton** is applied, examples of which are furnished among the domesticated animals by the *os cordis* in the heart of the ox, and the *os penis* of the dog.

The skeleton of a horse or other mammal comprises an **axial** portion, forming the bony framework of the head, trunk, and tail, and an **appendicular** portion, belonging to the limbs.

## THE VERTEBRAL COLUMN.

The fundamental part of the axial skeleton is the vertebral column or back-bone. This consists of a flexible chain of bones extending along the mesial plane of the animal, towards its dorsal aspect. At its anterior end the vertebral column is jointed to the skeleton of the head, while posteriorly it is prolonged beyond the trunk to form the skeleton of the tail.

The component bones of the vertebral column are termed **vertebræ**, and the number of such bones varies considerably in different species of animals.

The back-bone comprises five regions or groups of **vertebræ**, viz., **cervical**, **dorsal**, **lumbar**, **sacral**, and **coccygeal** or **caudal**. Speaking generally, it may be said that these belong respectively to the neck, back, loins, croup, and tail. Save in the case of the sacral region, the individual **vertebræ** remain freely movable, the adjacent bones being united by a fibro-elastic substance. In the sacral region, however, the **vertebræ** of the adult animal are rigidly and continuously fused together, and form what would popularly be regarded as a single bone.

The **vertebræ** of the same region have, in general, a close resemblance to one another, but the **vertebræ** of different regions exhibit very considerable differences of size and shape. Notwithstanding this latter fact, all the bones of the vertebral column are constructed after a common plan, and the diversity of shape exhibited by bones from

different regions is produced in most cases by variations in the size or form of the component parts of what may be called a typical vertebra. In other instances diversity of shape is due to the total suppression of some of these parts. A typical vertebra comprises a *body*, an *arch*, and certain *processes*.

The **body** or **centrum** is the fundamental part of the vertebra, and the other parts are grouped around it. In general it has the form of a solid rod or prism, but occasionally it is so short as to be disc-like. In most cases the anterior end of the centrum is more or less rounded or convex, while the opposite extremity is correspondingly concave. The convex anterior end of one vertebra is adapted to the concave posterior end of the vertebra in front, and the opposed surfaces are united by the so-called *intervertebral substance*. This material forms a very strong bond of union between the adjacent vertebræ, while at the same time it permits some degree of movement between them. The lower aspect of the centrum may be variously shaped, being sometimes rounded, and at others flat or ridged. Its upper surface is flattened, and it forms the floor of the spinal canal.

The **arch** of the vertebra is so named from its shape. It is superposed to the centrum, and with the latter it completes a short tube termed the **neural ring** of the vertebra. The entire series of neural rings of the vertebral column makes up the **neural** or **spinal canal**, in which the spinal cord is lodged. Each half of an arch comprises two portions, viz., a pedicle and a lamina. The **pedicle**, which forms the side of the arch, is an approximately vertical plate of bone, attached below to the side of the upper face of the centrum, and blended with the lamina superiorly. The **laminæ**, 1. Centrum; 2. The posterior notch in the pedicle; 3. The lamina; 4. Placed in the neural ring; 5. The anterior oblique process; 6. Posterior ditto; 7. The transverse process; 8. The neural spine; 9. The inferior spine.

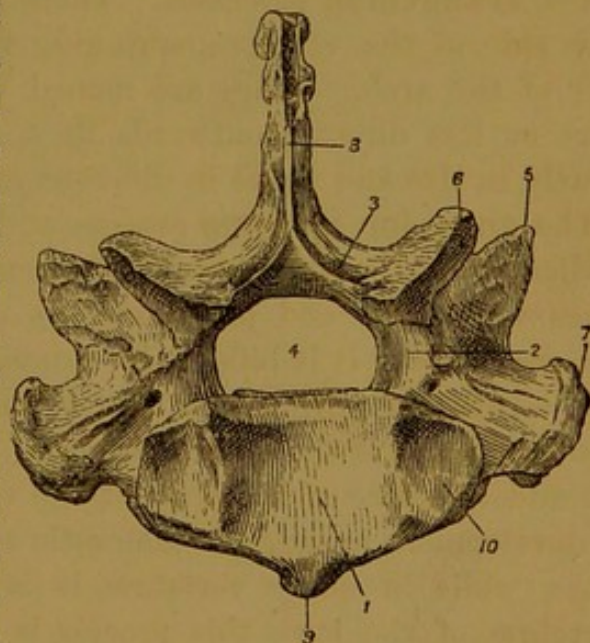


FIG. 11.—POSTERIOR VIEW OF FIRST DORSAL VERTEBRA OF HORSE.

the same side, while inwardly it is fused on the mesial plane, and at a more or less open angle, with the opposite lamina. The anterior and posterior edges of each pedicle exhibit in most vertebræ a semicircular out-cut termed a **notch**. When the vertebræ are in position, the anterior notch of one vertebra is opposed to the posterior notch of the

bone immediately in front, and the two together circumscribe a hole termed the **intervertebral foramen**. These foramina permit the outward passage of the nerves arising from the spinal cord, and they at the same time transmit the arteries and veins passing to and from the cord.

The **processes** of a vertebra are much more inconstant in their presence, and more variable in size and shape in the different regions of the spine, than the centrum and arch. The following are the chief of these processes.

The **oblique** or **articular** processes (*zygapophyses*). There are generally four of these. Two of them are placed on the anterior and two on the hinder edge of the arch. The anterior pair present smooth articular surfaces, which have an upward direction, and which, when adjacent vertebræ are in position, meet and are overlapped by the posterior pair of the vertebra immediately in front, the direction of the latter pair being downwards. In the natural state these surfaces are covered by articular cartilage. The joints which they form permit considerable freedom of movement between adjacent vertebræ, and yet, from the overlapping of the bones, they do not diminish the strength of the bony column.

The **transverse** processes. There are generally two of these, one on each side of the vertebra, springing from the body or from the lower part of the arch. They are named transverse from their proceeding more or less directly outwards in a lateral direction, and they vary greatly in size and shape in different regions of the spine.

The **superior spinous** process or **neural spine**. This is a single median process projecting upwards from the arch. The process is sometimes very large and prominent, at other times scarcely observable, and occasionally it is bifid at its summit.

The **inferior spinous** process (*hypapophysis*). This is more inconstant than any of the other processes. It is situated on the middle of the under surface of the body of the vertebra, and in its highest degree of development among the domestic animals it has the form of a mere ridge, while in many vertebræ it is totally absent. In the lumbar vertebræ of the hare this process is very prominent, exceeding in size the neural spine.

**Development of the Vertebræ.** Like the majority of the other bones of the skeleton, the vertebræ are in the fœtus blocked out in cartilage. In nearly all of the vertebræ ossification proceeds from three main centres, one of which is for the greater part of the body, while each of the other two serves for one half of the arch, and a small portion of the body adjacent to the foot of the arch. A thin disc-like epiphysis at each end of the body has a separate nucleus of ossification. In some cases the neural spine and the transverse processes have separate centres of ossification, while at other times they ossify by extension from

the arch or body. In either case the tips of these processes remain for a long time cartilaginous, and they in general ultimately ossify as little epiphyses with separate centres of ossification. The oblique processes ossify as integral portions of the arch, and the inferior spinous process as a part of the centrum.

#### THE VERTEBRAL COLUMN OF THE HORSE.

The number of bones in each region of the vertebral column of the horse is indicated in the following formula, each region being denoted by its initial letter :—**C**<sub>7</sub>, **D**<sub>18</sub>, **L**<sub>6</sub>, **S**<sub>5</sub>, **C**<sub>18 to 20</sub>.

The **Cervical Vertebrae**. The cervical vertebrae are seven in number, and they form the skeleton of the neck. They receive numerical designations, as *first*, *second*, etc., but the first two and the last receive additional names, the first being termed the *atlas*, the second the *axis*, or *vertebra dentata*, and the seventh the *vertebra prominens*.

The **Third, Fourth, and Fifth Vertebrae**. The **bodies** of these vertebrae, when compared with those of other regions, are distinguished by their length. The inferior aspect of the body carries mesially the **inferior spine**. This has the form of a sharp ridge becoming increasingly prominent as it is traced towards its posterior end, which is blunt and tubercular. The lateral surfaces of the body are slightly concave, and carry some rough lines which, with the inferior spine, give attachment to fibres of the longus colli muscle. The upper surface of the body is flattened, and forms part of the floor of the spinal canal. It shows a central, level, smooth area, constricted in the middle of its length, and giving attachment to the superior common ligament of the vertebrae. On each side of this area, close to the pedicle, the upper surface of the body is depressed lengthways, forming

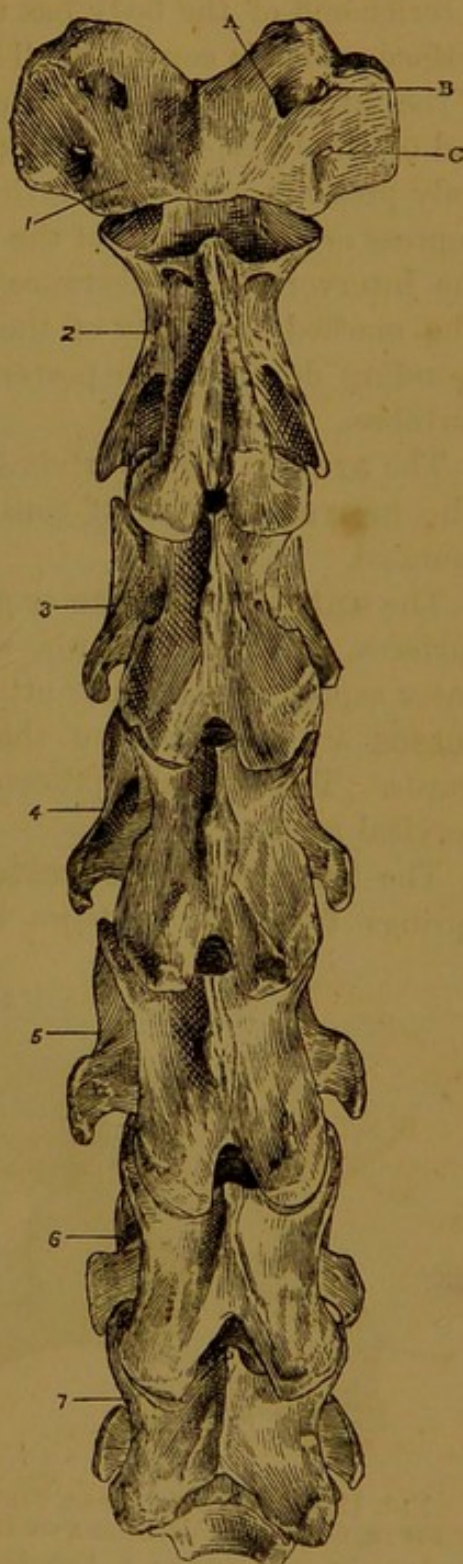


FIG. 12.—CERVICAL VERTEBRÆ OF HORSE SEEN FROM ABOVE.

A. Antero-internal foramen of atlas ; B. Antero-external foramen ; C. Posterior foramen.

1. The atlas ; 2. The axis ; 3, 4, 5, and 6. The corresponding vertebrae ; 7. The vertebra prominens.

a shallow groove which lodges the spinal veins. In these grooves are seen some foramina for the passage of the vessels of the bone. The anterior end of the body has the form of a projecting, smooth, articular surface, which is convex in all directions, and which, through the medium of the intervertebral substance, is most intimately united to the posterior end of the body of the preceding vertebra. The posterior end of the body presents a smooth, articular, rather deep cavity, which is like the impress or counterpart of the anterior articular surface. It is united by the intervertebral substance to the body of the succeeding vertebra. The marked convexity of the anterior end of the body, and the corresponding depth of the posterior end, are characteristic of the cervical vertebræ.

The **arch** in these vertebræ is strong, and the **notches** are very deep. The **neural ring** is of considerable calibre, and its roof is smoothly rounded.

The **anterior oblique** or **articular processes** are extensive smooth surfaces, directed upwards and inwards, and slightly rough on their outer aspect for muscular attachment. The **posterior articular processes** are similar, save that they are directed downwards and outwards. The articular processes attain their largest dimensions in the cervical region.

The **transverse processes**. Each of these is perforated where it springs from the vertebra by a foramen—the **vertebral foramen**, through which the vertebral vessels and nerve pass on their course up the neck. Or, to describe the process otherwise, it may be said that it springs from the side of the vertebra by two roots, one from the side of the body, and the other from the lower part of the arch, the vertebral foramen being included between these two roots. The vertebral foramen (which must not be confounded with the *intervertebral* foramen formed by contiguous notches) is peculiar to the vertebræ of the neck. Outwardly each transverse process possesses an anterior and a posterior division. The former projects obliquely downwards and forwards, while the latter, which is shorter and more tuberous, has an opposite direction. The transverse processes of these vertebræ are of medium size as compared with other regions, and they serve to give attachment to the muscles of the neck.

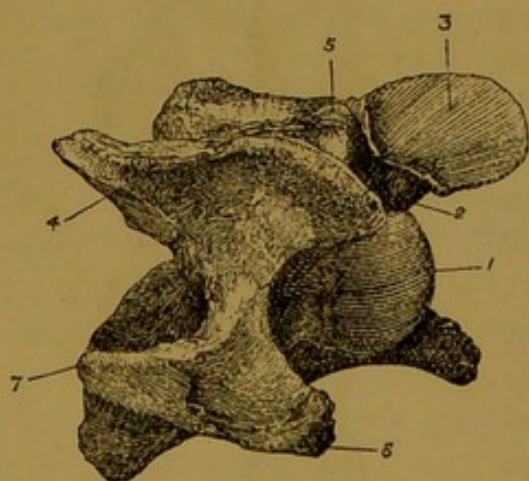


FIG. 13.—ANTERO-LATERAL VIEW OF FIFTH CERVICAL VERTEBRA OF HORSE.

1. Anterior end of body ; 2. Anterior notch ;
3. Anterior oblique process ; 4. Posterior oblique process ; 5. Neural spine ; 6 and 7. Anterior and posterior divisions of transverse process.

The **superior spinous process**, or **neural spine**, has the form of a low rough ridge, narrow in front, and gradually diminishing in height, but increasing in breadth, as it passes backwards. It serves for muscular and ligamentous attachment, and, as compared with its size in other regions, the process is very slightly developed in these vertebræ.

Although the three vertebræ now being considered are very similar in appearance, still they are distinguishable. The body is longest in the third and shortest in the fifth. The outside width of the arch is least in the third, and greatest in the fifth. In the case of the third vertebra, a plate of bone continuous with the posterior oblique process is continued horizontally forwards to near the middle of the arch; in the fifth this plate reaches quite forwards to the anterior oblique process; and in the fourth the plate is of intermediate length, a notch being left between its anterior end and the anterior oblique process. In the third bone the extreme anterior points of the transverse processes, anterior oblique processes, and body lie nearly in the same plane, so that the bone rests at once on these five points when placed head downwards on a table. When the other two bones are similarly placed, they touch by the oblique and transverse processes, but the anterior end of the body remains a little distance above the surface of the table.

The **Sixth Cervical Vertebra** has a trifid **transverse process**, the superadded division being a plate-like part which projects below the level of the body at its hinder end. In other respects this bone has a close family resemblance to the three vertebræ already described, but it is shorter and broader, and its **inferior spine** is less prominent.

The **Seventh Cervical Vertebra** is specially distinguished by having a small, and undivided, **transverse process**, by the absence of the **vertebral foramen**, by the height of its **neural spine**, and by the presence of a semicircular concave **capitular cavity** at each side of the posterior end of the body. This super-

added articular surface, together with a similar depression on the front of the first dorsal vertebra, forms a cup-shaped cavity for the head of the first rib. The **neural spine** of this vertebra is a triangular flattened plate with a slight forward inclination, and about an inch and a half high. It is from the greater height of the process

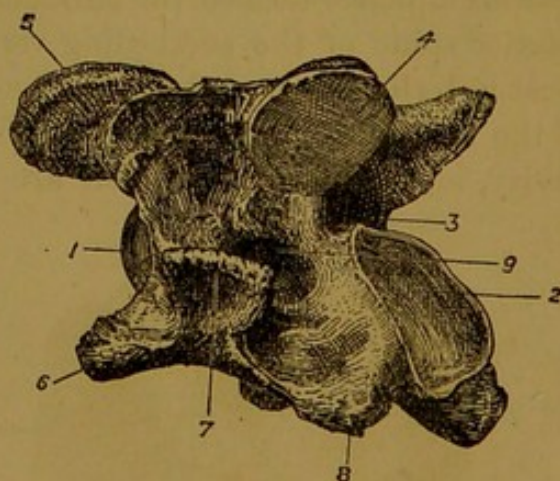


FIG. 14.—POSTERO-LATERAL VIEW OF SIXTH CERVICAL VERTEBRA OF HORSE.

1. Anterior end of body ; 2. Posterior end of body ; 3. Posterior notch ; 4. Posterior oblique process ; 5. Anterior oblique process ; 6, 7, 8. The three divisions of the transverse process ; 9. Vertebral foramen.

that this bone receives the additional name of **vertebra prominens**. The seventh vertebra is shorter but broader than the preceding bones, its **notches** are very large, and its **inferior spine** has the form of a mesially divided tubercle. Finally, it may be remarked that this bone,

in its size and shape, shows considerable resemblance to the vertebræ of the dorsal region.

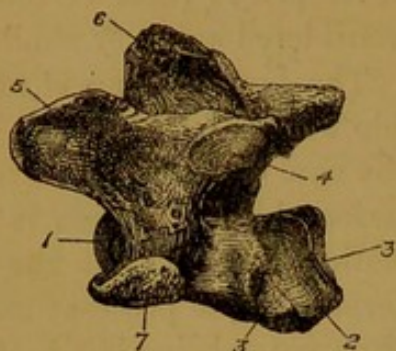


FIG. 15.—POSTERO-LATERAL VIEW OF SEVENTH CERVICAL VERTEBRA OF HORSE.

1. Anterior end of body ; 2. Posterior end of body ; 3. Capitular surface ; 4. Posterior oblique process ; 5. Anterior oblique process ; 6. Neural spine ; 7. Transverse process.

The **Atlas**<sup>1</sup> or **First Cervical Vertebra**. This bone and its successor in the cervical series depart very considerably from what has already been described as the typical conformation of a vertebra, being specially modified in order to form the joints that permit the head to move freely on the anterior end of the vertebral column. The atlas does not possess a body, and it may be best described as having the

form of a **ring** or short tube, to which is affixed on each side a considerable plate of bone termed the **wing**.

The exterior of the ring shows on its under aspect a mesially placed obtuse eminence termed the **tubercle** of the atlas. This represents the inferior spine of the succeeding vertebræ, and it gives insertion to the most anterior fibres of the longus colli muscle. Outwardly, at the side of the ring, and bounded partly by the wing, there is an irregular oval cavity, at the bottom of which are seen three holes or foramina. The

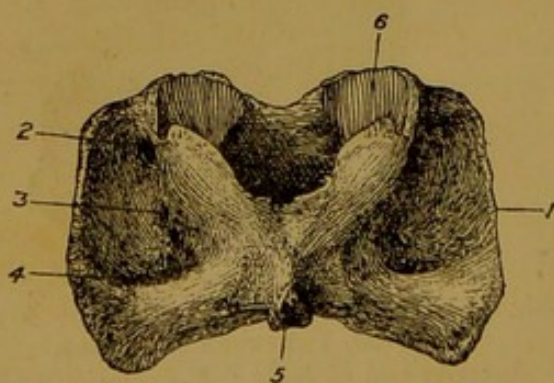


FIG. 16.—UNDER ASPECT OF THE ATLAS OF HORSE.

1. Edge of wing ; 2. Antero-external foramen ; 3. Unnamed foramen perforating ring ; 4. Posterior foramen ; 5. Tubercle ; 6. Cavity for occipital condyle.

central and smallest of these is unnamed. It passes through the thickness of the ring, into the neural canal, and it transmits a vein. The anterior hole is the **antero-external foramen**, and the hindmost of the three is the **posterior foramen**. These will be observed again in connection with the wing itself.

The upper aspect of the ring is somewhat dome-shaped, and mesially it is roughened in the position of the neural spine of other vertebræ. Close to the anterior

<sup>1</sup> The special name of atlas was applied to this bone in human anatomy because in man it supports the head, as Atlas in Greek mythology was supposed to support the world.

edge of this surface two small foramina are sometimes found perforating the thickness of the ring.

The interior or **neural ring** of the atlas is of large calibre—larger than in any other vertebra. Superiorly it is comparatively smooth, while on each side it is irregularly depressed, and shows the inward opening of the unnamed foramen already referred to in connection with the under aspect of the exterior. Above and in front of that is a much larger opening—the **antero-internal foramen**. The inferior portion of the inner surface of the ring is rough in its anterior half, to which the odontoid ligament is attached. Behind that the surface is smooth and articular for the odontoid process of the next vertebra.

The anterior edge of the ring of the atlas is notched mesially above and below. On each side it presents a deep **articular cavity**, for a condyle of the occipital bone of the skull. This cavity is compounded of an upper and a lower facet, and circumscribed by a sharp edge with a deep notch outwardly between the two facets. In the recent state these articular surfaces are covered by articular cartilage, and they form synovial joints with the occipital condyles.

The posterior edge of the atlas is sharp and non-articular in its upper third. Beneath that on each side it shows an extensive undulated smooth surface, for articulation with the next bone. The right and left articular surfaces are continuous with each other across the mesial plane, and they are also continuous with the articular part already described in connection with the interior of the ring. These, like all the other articular surfaces of the atlas, form synovial joints, this being a feature that distinguishes the atlas from all the other vertebræ.

The **wings**, or **alæ**, of the atlas represent the transverse processes of other vertebræ. Each is a nearly flat but slightly inclined plate of bone, attached inwardly to the lateral aspect of the ring, and terminated outwardly by a thick rough edge. This edge, which slopes obliquely downwards and backwards, is placed almost immediately under the skin, and it forms a prominence which can be both seen and felt in the living horse. It gives attachment to certain muscles of the head and neck. In connection with each wing (Fig. 12, p. 25) three foramina are to be observed, though only two of these pass actually through the wing. The first two of these foramina are placed together towards the forepart of the wing, and they are connected by a short gutter. The outermost of the two is the **antero-external foramen**, the other is the **antero-internal foramen** of the atlas. The former represents the anterior notch of succeeding vertebra, and it transmits the first spinal nerve and the cerebro-spinal artery. The antero-external foramen gives passage to the inferior division of the first spinal nerve, and to the occipital vessels. The third foramen found in connection with the wing pierces it towards its posterior part. It is termed the **posterior foramen** of the atlas,

and it gives passage to the retrograde or anastomotic branch of the occipital artery.

The **Axis, Vertebra Dentata, or Second Cervical Vertebra.** The second of these designations is conferred upon this bone from a tooth-like process which it possesses in the human subject. It receives the name of axis because the atlas, carrying with it the head, rotates around this same tooth-like process.

The **body** of the axis is longer than that of any other vertebra. Anteriorly the body carries the **odontoid process**, so called from its tooth-like shape in human anatomy. The upper surface of this process, which is slightly concave from side to side, is rough, and it shows a shallow pit on each side of a central eminence. The odontoid ligament is attached to this surface. The inferior surface, which is convex from side to side, is smooth and articular. The upper and lower surfaces of the process are separated by a sharp convex and slightly notched edge. The body also carries anteriorly, on each side of the root of the odontoid process, an extensive articular surface, convex from above to below, and slightly concave from side to side. These surfaces blend with the lower

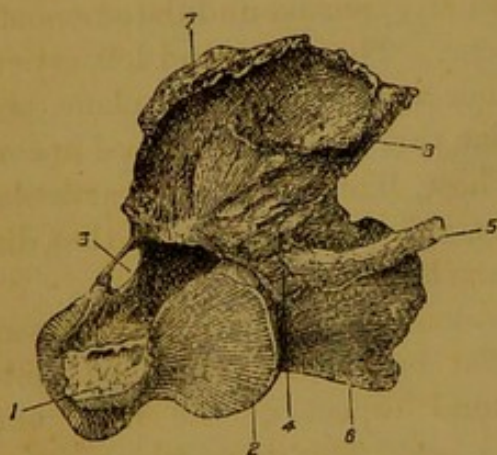


FIG. 17.—ANTERO-LATERAL VIEW OF THE AXIS OF HORSE.

1. Odontoid process ; 2. Articular surface at side of same ; 3. Foramen representing the anterior notch ; 4. Vertebral foramen ; 5. Transverse process ; 6. Inferior spine ; 7. Superior spine ; 8. Posterior oblique process.

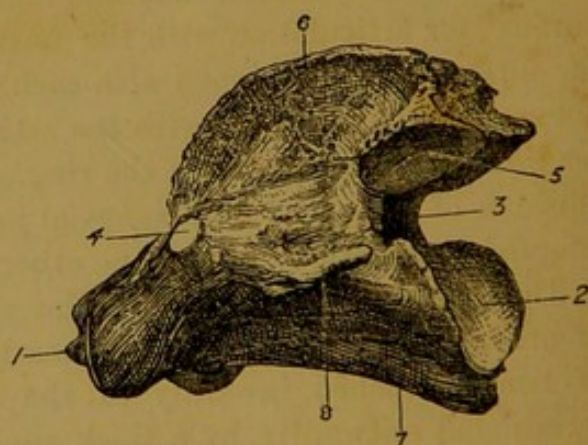


FIG. 18.—POSTERO-LATERAL VIEW OF THE AXIS OF HORSE.

1. Odontoid process ; 2. Posterior end of body ; 3. Posterior notch ; 4. Foramen representing anterior notch ; 5. Posterior oblique process ; 6. Superior spine ; 7. Inferior spine ; 8. Transverse process.

surface of the odontoid process, and the whole articulate with the surfaces already described in connection with the atlas.

The upper and lower surfaces and the posterior end of the body have a close similarity to the same parts in the succeeding vertebræ of the series.

The **pedicle** presents posteriorly the usual **notch**, but the place of

the anterior notch is taken by a large oval foramen. The **neural ring** is of rather small calibre.

The posterior pair of oblique or **articular processes** resemble these of the succeeding bones, and are placed on the hinder edge of the arch. No oblique processes are carried by the anterior edge of the arch, the articular facets flanking the root of the odontoid process compensating for the absence of the anterior oblique processes of this vertebra.

The **transverse processes**, which are smaller than in any of the other cervical vertebræ, are undivided and directed backwards. The usual **vertebral foramen** perforates their root.

The **superior spine** is a very strong process which completely covers the arch. Its upper edge, single and narrow in front, is divided in its posterior two-thirds into two rough divergent ridges, each of which joins the upper aspect of the oblique process of its own side, and serves to give attachment to one of the lamellæ of the ligamentum nuchæ.

The **inferior spine**, as in the immediately succeeding bones, is a sharp ridge ending posteriorly in a tubercle.

[**Development of the atlas and axis.** The arch of the atlas—that is, the upper two-thirds of its ring—is ossified from two lateral centres corresponding to those of other vertebræ. The cartilage which in the fœtus completes the ring inferiorly ossifies from two lateral centres, but these speedily coalesce. A supplementary nucleus appears on each side for the edge of the wing and the undulated articular facet on the posterior aspect of the ring.

The axis ossifies from the usual centres, but to these are added two separate centres for the odontoid process and the facets at its base. The odontoid process is regarded as the displaced body of the atlas, and in the lowest group of mammals (the *ornithodelphia*) it remains for a long time or for life as a separate bone.]

The **Dorsal Vertebræ**. The vertebræ of this region, eighteen<sup>1</sup> in number, are named dorsal from their position in the back. They are also appropriately called *costal* vertebræ, since they carry the ribs.

The **body** of a dorsal vertebra is very short compared with that of a cervical vertebra. The anterior end of the body is less convex, and the posterior cavity shallower, than in the region of the neck. Here, as in all the intercentral joints behind the axis, the bodies of adjacent bones are united by the intervertebral substance. At each side of the articular end of the body, before and behind, there is a little concave articular surface, termed the **capitular surface**. When adjacent vertebræ are in position the posterior of these facets on each side is opposed to the anterior facet of the next bone, and there is thus formed, with the aid of the intervertebral substance between the two bones, a cup-shaped cavity for articulation with the *capitulum* or *head* of a rib. The **notches** are smaller than in the cervical region. The posterior pair are considerably deeper than the anterior, and in the bones at the end of the series they are frequently converted

<sup>1</sup> Occasionally the number is one more or fewer than eighteen.

into foramina. The **neural ring** is slightly depressed from above to below. The **articular processes** occupy the same position on the arch as in the neck, but they are much smaller than in that region. The **transverse processes** are small and single. Each carries on its

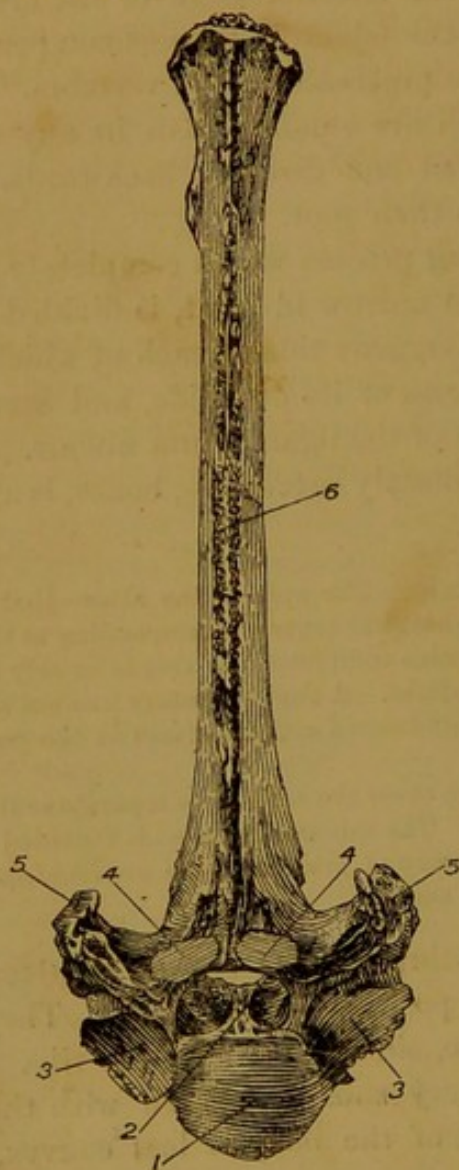


FIG. 19.—FRONT VIEW OF ONE OF THE ANTERIOR DORSAL VERTEBRÆ OF HORSE.

1. Anterior end of body; 2. Neural ring; 3. Anterior capitular surface; 4. Anterior oblique process; 5. Transverse process; 6. Superior spinous process.

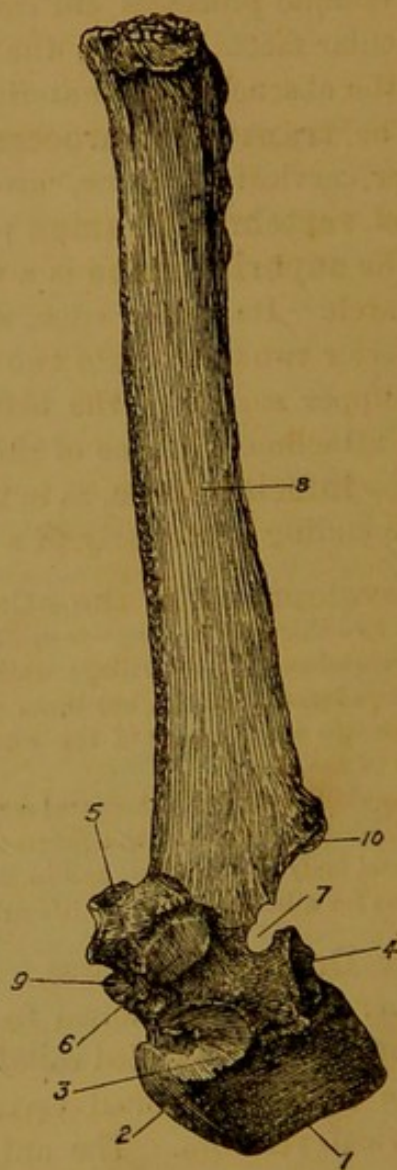


FIG. 20.—SIDE VIEW OF ONE OF THE ANTERIOR DORSAL VERTEBRÆ OF HORSE.

1. Inferior spine; 2. Anterior end of body; 3. Anterior capitular surface; 4. Posterior capitular surface; 5. Transverse process; 6. Its tubercular surface; 7. Posterior notch; 8. Superior spine; 9. Anterior oblique process; 10. Posterior oblique process.

outer aspect a smooth facet for articulation with the *tubercle* of a rib, and termed therefore the **tubercular surface**. The presence of this facet is characteristic of the dorsal vertebrae. The **superior spinous process** is of great size. Each is a flattened bar of bone, the anterior edge of which is thin and sharp, while the posterior is thick and grooved. The **inferior spinous process** can hardly be said to exist in the

dorsal region, being represented at the most by a sharp ridge on the middle of the lower aspect of the body.

The foregoing description applies to the dorsal vertebræ as a series, but among themselves they vary considerably, particularly as regards the degree of development of some of their processes. Thus, it is observed that the facets for articulation with the heads of the ribs diminish in depth and extent from the first to the last vertebra. From the first bone to the ninth or tenth the oblique or articular processes diminish rapidly in size, and those of opposite sides approach each other on the arch. Behind the tenth vertebra the anterior articular processes tend to become concave from side to side, the posterior pair being correspondingly convex. The transverse processes diminish in size from the first to the last, and the tubercular facets likewise diminish in extent. In the case of the last three or four bones, the anterior capitular facet is confluent with the tubercular facet. On examination of the series of dorsal vertebræ, it is observed that in the anterior members of the series the transverse processes show a slight tendency to be divided into two parts. This becomes more and more pronounced until in the last four or five bones the division is complete, each transverse process consisting of an outer portion bearing the facet for the tubercle of the rib, and an inner portion (*metapophysis*)<sup>1</sup> which has retreated so as to surmount the anterior articular process. The superior spinous processes diminish in length both forwards and backwards from the fourth, which is the longest. The second is a little broader than the first, and the succeeding processes diminish in breadth to about the ninth, from which point they again increase in breadth to the last. Their summits are broad and tuberosus from the third to about the tenth. The remainder have their summits compressed from side to side. These processes as far as the fifteenth have a backward inclination, which is most marked in the first four or five. The sixteenth is vertical, and the last two are slightly inclined forwards.

### The First Dorsal Vertebra

has a decided resemblance to the last cervical. The oblique and trans-

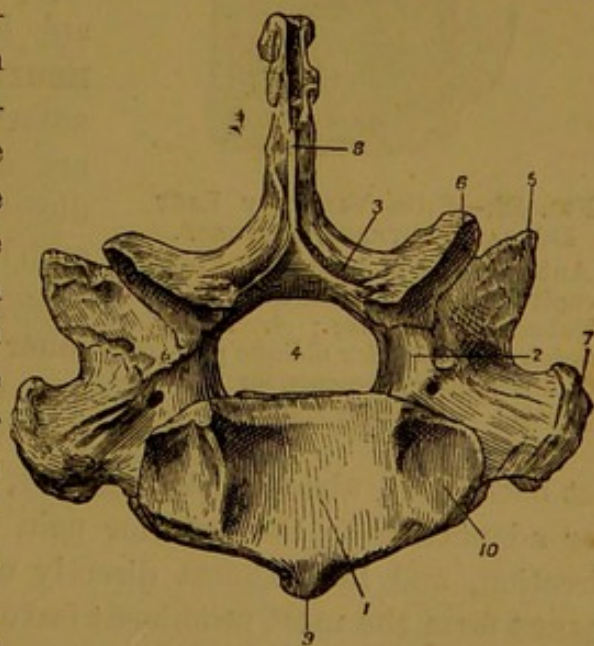


FIG. 21.—POSTERIOR VIEW OF FIRST DORSAL VERTEBRA OF HORSE.

1. Centrum; 2. The posterior notch in the pedicle; 3. The lamina; 4. Placed in the neural ring; 5. The anterior oblique process; 6. Posterior ditto; 7. The transverse process; 8. The neural spine; 9. The inferior spine; 10. Capitular surface.

<sup>1</sup> Mammillary process of human anatomy.

verse processes, and notches are large as compared with those of succeeding bones. The superior spinous process is comparatively short (about three inches long), pointed at its summit, and slightly curved backwards.

The **Second Dorsal Vertebra** has a superior spinous process six or seven inches long and pointed at its summit.

The **Eighteenth Dorsal Vertebra** is distinguished by the absence of the posterior capitular surfaces. Moreover, this bone and a few others at the end of the series exhibit in all their parts except their transverse processes a decided family resemblance to the lumbar vertebræ.

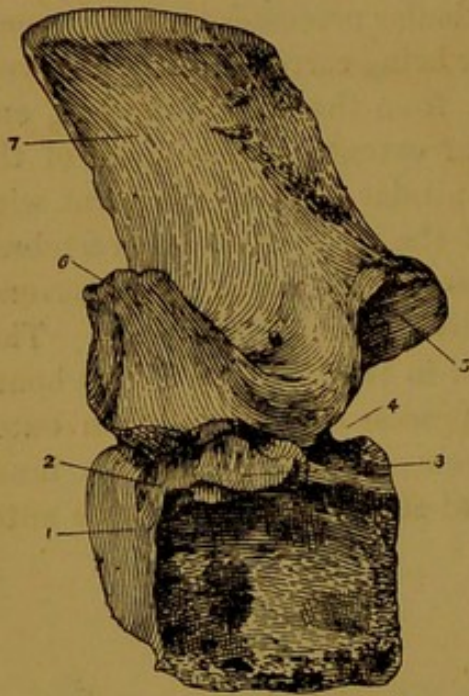


FIG. 22.—SIDE VIEW OF LAST DORSAL VERTEBRA OF HORSE.

1. Anterior end of body ; 2. Anterior capitular surface, confluent with 3. Tubercular surface ; 4. Posterior notch ; 5. Posterior oblique process ; 6. Mammillary process, or metapophysis ; 7. Superior spine.

The **Lumbar Vertebræ**. This region comprises six bones.<sup>1</sup> Their **bodies** are intermediate in length between the centra of the cervical and dorsal regions. As in the dorsal region, the anterior end of the body is but slightly convex, and the concavity of the posterior end is correspondingly shallow. The posterior **notches** are larger than the anterior. The **neural ring** is nearly circular. The anterior pair of **articular processes** are concave from side to side, and directed inwards. On its outer side each bears an obtuse muscular eminence (*metapophysis*) lying in series with the inner division of the transverse process of the last dorsal vertebræ. The posterior pair of articular processes pro-

ject backwards, almost close together, from the hinder edge of the arch. For adaptation to the anterior pair, they are convex in the transverse direction, and look almost directly outwards. The **transverse processes** form the most prominent feature in a lumbar vertebra. Each of these is a relatively enormous plate of bone, flattened from above to below, and projecting outwards nearly at right angles to the body. Each process is approximately horizontal in position, but it has a slight downward curve towards its free extremity. The large size of the transverse processes of the lumbar region is co-related with the great size and strength of the muscles of the loins. The **superior spinous process** is a broad flattened plate, about the same height as the neural spine of the last dorsal vertebræ. Its summit forms a thick rough edge, and the

<sup>1</sup> In the ass, and occasionally in the horse, only five.

whole process has a slight forward inclination. The **inferior spinous**

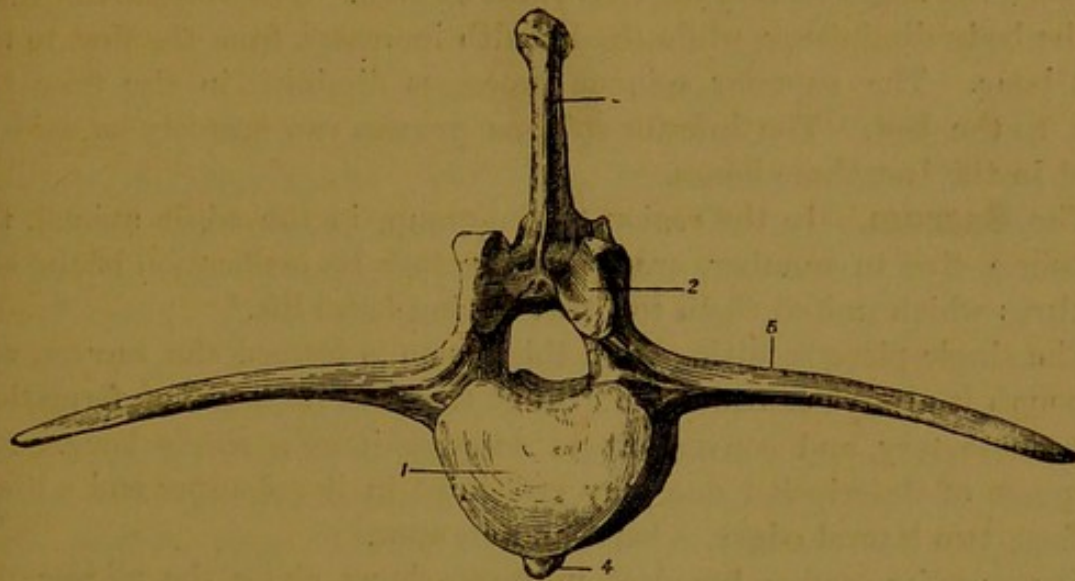


FIG. 23.—FRONT VIEW OF ONE OF THE ANTERIOR LUMBAR VERTEBRÆ OF HORSE.

- 1 Anterior end of body ; 2. Anterior oblique process ; 3, Superior spine ;  
4. Inferior spine ; 5. Transverse process.

**process** is represented by a mesial rough ridge on the under aspect of the body.

**Special characters of the lumbar vertebræ.** The transverse pro-

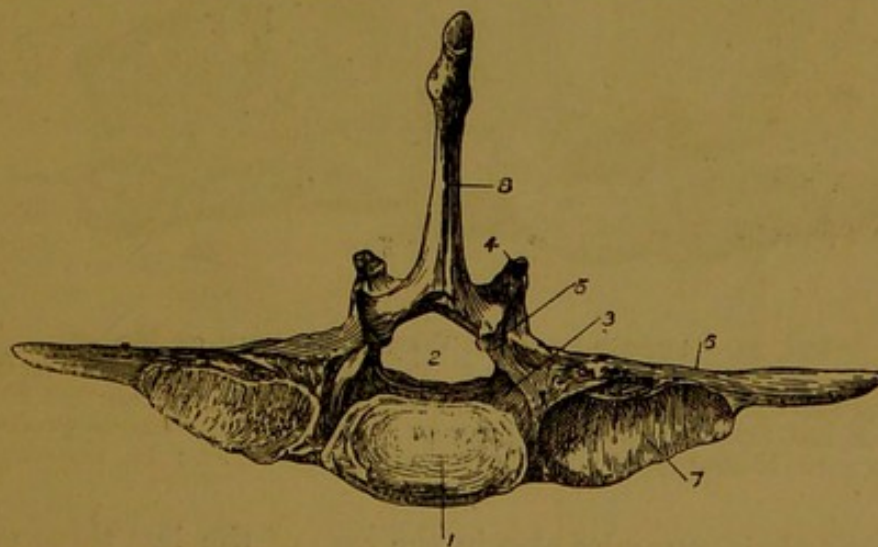


FIG. 24.—HINDER ASPECT OF LAST LUMBAR VERTEBRA OF HORSE.

1. Posterior end of body ; 2. Neural ring ; 3. Posterior notch ; 4. Anterior oblique process ; 5. Posterior oblique process ; 6. Transverse process ; 7. Articular surface of the same ; 8. Superior spine.

cesses are longest in the second and third, and shortest in the last. The process projects nearly at right angles to the body in the third, while the first two are inclined slightly backwards, and the last three more pronouncedly in the opposite direction. The thickness of the process is greatest in the last two bones, which are further distinguished by the presence of an articular facet on each edge of the process. One such facet is found on the hinder edge of the fourth bone. By means of these

facets additional joints are formed between the last three bones, and between the last bone and the base of the sacrum. The vertical thickness of the body diminishes, while the breadth increases, from the first to the last bone. The superior spinous processes diminish in size from the first to the last. The inferior spinous process can scarcely be said to exist in the last three bones.

The **Sacrum**. In the region of the croup, in the adult animal, the vertebræ, five in number, are fused together by ossification of the soft textures which united them together during foetal life.<sup>1</sup>

The single piece resulting from this fusion is termed the *sacrum*, and although it always continues to exhibit traces of its mode of formation, it is customary and convenient to describe it as a single bone. For purposes of description one may recognise in it an upper and a lower surface, two lateral edges, a base, and an apex.

The *superior surface*, broadest in front, shows along the middle line the **superior spinous processes** of the five sacral vertebræ. These are more or less completely fused at their bases, and in old animals

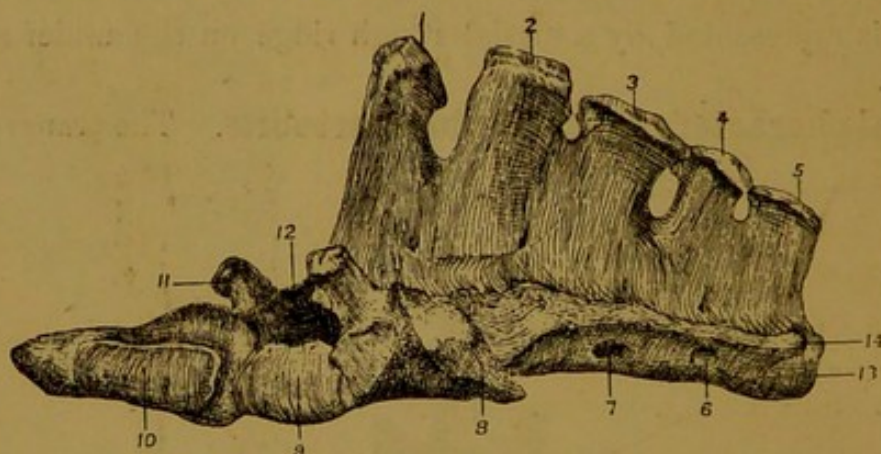


FIG. 25.—ANTERO-LATERAL VIEW OF SACRUM OF HORSE.

1-5. Superior spinous processes; 6 and 7. Two of the inferior sacral foramina; 8. Auricular facet; 9. Anterior end of first sacral centrum; 10. Surface for articulation with last lumbar transverse process; 11. Anterior oblique process of first vertebra; 12. Neural canal; 13. Centrum of last vertebra; 14. Transverse process of same.

frequently at their summits also in the case of the last three segments. The summits of these processes are tuberos, and generally bifid, except the first, which is sharper. The first two are of nearly equal height, and the succeeding processes become progressively shorter. At the bases of the fused spines on each side there are four foramina—the **superior sacral foramina**, corresponding to the intervertebral foramina of other regions.

The *inferior surface*, also broadest in front, is smooth, and it forms the greater part of the roof of the pelvic cavity. It is slightly arched in the longitudinal direction, and it shows four faint transverse lines,

<sup>1</sup> The bones of this region are therefore termed *false* vertebræ.

indicating the lines of fusion of the five originally distinct sacral centra. At the extremities of these lines are placed the **inferior sacral foramina**, four on each side. These diminish in size from the first to the last, and they represent intervertebral foramina.

The *lateral edges*. Each of these bears towards its anterior end the so-called **auricular facet**. This constitutes a somewhat rough surface, bevelled so as to look upwards and outwards, for articulation with the innominate bone. Internal to the auricular facet a rough area serves for the attachment of the sacro-iliac ligament. Behind the auricular facet the lateral edge is somewhat sharp, and here the sacro-sciatic and inferior ilio-sacral ligaments are attached.

The *base*, or anterior extremity of the sacrum, is in reality the anterior aspect of the first sacral vertebra. It shows centrally the entrance to the **neural ring** of that vertebra, and on each side of the anterior edge of its **arch** there is an **articular process**, similar in form to the anterior articular processes of the lumbar vertebrae. The edge of the **pedicle** shows on each side the usual **notch**. Below the entrance to the neural canal lies the anterior end of the first sacral **centrum**, in the shape of a slightly convex articular surface, which is united to the hinder end of the body of the last lumbar vertebra by the usual intervertebral substance. On either side of this surface there is another of somewhat similar shape. These latter form synovial joints with the like facets on the posterior edge of the last lumbar

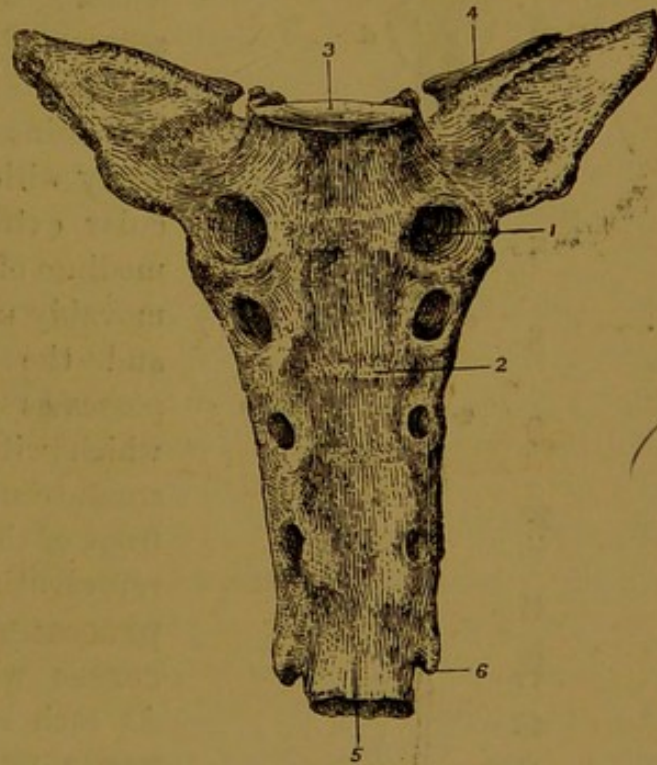


FIG. 26.—INFERIOR SURFACE OF SACRUM OF HORSE.

1. An inferior sacral foramen ; 2. Line indicating junction of second and third vertebrae ; 3. Anterior end of first centrum ; 4. Surface for articulation with last lumbar transverse process ; 5. Centrum of last vertebra ; 6. Transverse process of same.

transverse process. Between the central facet and these lateral facets there is a **notch** lying in series with the inferior sacral foramina.

The *apex*, or posterior extremity of the sacrum, is formed by the hinder aspect of the last sacral segment. On it there is recognised the **neural ring** of that bone, triangular in outline and much reduced in size. Above that there is seen the hinder edge of the last **neural**

**spine**, and below the neural ring the nearly flat posterior end of the last sacral **centrum**, which is movably united by intervertebral substance to the first coccygeal bone. At each side of this articular surface there is a little backward-projecting process representing the **transverse process** of the last sacral vertebra, but the arch is destitute of any oblique or articular processes.

#### The Coccygeal Vertebræ.

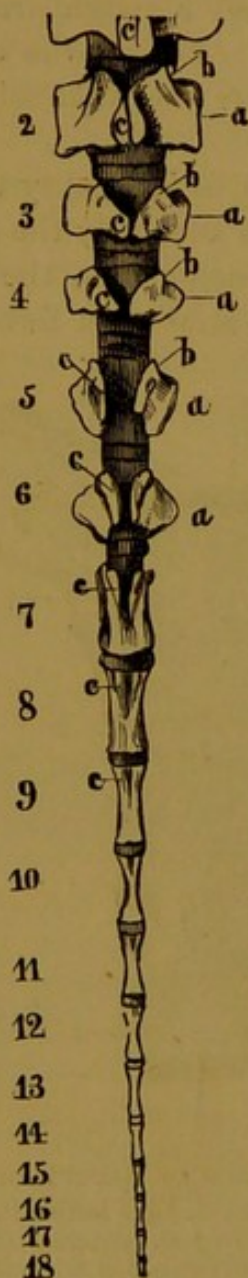


FIG. 27.—COCYGEAL VERTEBRÆ OF HORSE (*Leyh*).

The numerals 1 to 18 indicate the separate vertebrae; *a a*. Transverse processes; *b b*. Articular or mammillary processes; *c c*. Laminae.

This region comprises all the movable vertebrae behind the sacrum. The number of bones included within it is in most cases eighteen, but it is not rare to find one or two more or fewer than that number. The bones of the series steadily diminish in size from the first to the last.

The **first** in size and appearance has a close resemblance to the last sacral segment, to which in the middle-aged animal it is not infrequently united by ossification. It possesses a short **body** with flat or slightly convex articular extremities, which, through the medium of intervertebral substance, are movably united to the sacrum in front and the second bone behind. It possesses also a rudimentary **arch**, which with the body circumscribes a small triangular **neural ring**. On the front of the arch are small projections representing the anterior **articular processes**, or the **mammillary processes** which these carry outwardly. At each side there is a small **transverse process**, and the arch is surmounted in the mesial plane by a rudimentary **superior spinous process**.

In the **second** and **third** bones the parts just enumerated as being present in the first are still recognisable, but in a more degenerate form.

In the **fourth** bone the **laminæ** of the arch fail to meet in the mesial

plane, and the **neural ring** is therefore incomplete above.

In the succeeding bones the neural ring is represented by a mere groove on the upper aspect of the body, while the processes become

gradually reduced in size. In the last seven or eight bones the arch and processes are altogether suppressed, and only the centra remain. Each of these is a little rod of bone, constricted in its middle like an hour-glass, and slightly rounded at its extremities. Throughout the entire series the adjacent ends of these centra are united by thin discs of intervertebral substance.

A number of the anterior coccygeal vertebræ carry at the anterior end of the under aspect of the body two small processes between which the middle coccygeal artery runs.

#### THE VERTEBRAL COLUMN AS A WHOLE.

In the articulated vertebral column the entire series of vertebral centra forms a long flexible rod, which describes a **succession of curves** in the mesial plane of the body. Thus, the cervical region in the ordinary posture of the animal at rest is slightly arched, so as to be concave on its lower aspect. Towards the junction of the cervical and dorsal regions, however, the bony column is curved in the opposite direction, being concave above. The remainder of the dorsal region and the lumbar region are disposed in almost the same straight line. The sacrum, again, is slightly arched, forming on its under aspect a concavity which is continued by the bones of the coccygeal region when the tail hangs in its ordinary position.

The **calibre** of the neural canal is greatest of all in the atlas. Very much smaller in the succeeding bones, it again increases considerably in the last three cervical and first two dorsal vertebræ. Behind that it again diminishes in size, until at the middle of the back the calibre of the canal is less than at any anterior point. In the region of the loins the calibre again increases as far as the last or second last bone, from which point it rapidly diminishes, until it loses its character of a complete canal about the fourth coccygeal bone. The ample capacity of the ring of the atlas permits free movement of the occipito-atlantal and atlanto-axial joints without danger of injury to the delicate spinal cord. The increased calibre of the canal at the junction of the neck and back and in the loins is co-related with the larger size of the cord, and the freer movements of the intervertebral joints, at these points.

On tracing the modification of size and form of the various processes throughout the column, it is observed that the oblique or **articular processes** attain their maximum size in the neck. In the back they are greatly reduced in size, and hardly visible in the articulated spine. In the last dorsal bones, however, and in the loins, these processes become more conspicuous, from the mammillary process carried by the anterior pair on their outer aspect.

The **neural spines**, except in the axis, are of inconsiderable size in the neck. In the back, however, they form the most prominent feature

of the bones, and determine by their length the height of the *withers*. Throughout the lumbar region these processes still continue prominent, in the sacral region they become progressively smaller, and they finally disappear in the anterior part of the coccygeal region.

The **transverse processes** form strong rugged projections in the cervical region. In the back they are greatly reduced in size, but are specially distinguished by the articular facet which each carries for the tubercle of a rib. In the loins, the great size of these processes forms the main feature of the region. In the sacrum the separate transverse processes are not distinguishable, and in the tail they exist only in the anterior members of the series, and in a degenerate form.

The **inferior spinous processes** attain their maximum size in the cervical region, and behind that they become less and less prominent.

#### THE VERTEBRAL COLUMN OF THE OX.

The ordinary number of vertebræ present in the spine of the ox is represented in the formula  $C_7D_{13}L_6S_5C_{18-20}$ .

**Cervical Vertebræ.** These bones from the second to the sixth have shorter bodies than in the horse. Viewed from above, they are wider, a continuous plate of bone uniting the anterior and posterior articular processes on the same side. The transverse process consists of an upper tubercular division and a lower more plate-like part, the latter being very large in the sixth bone. The neural spine is a short thick rod, better developed than in the horse, and more inclined forwards. In the second vertebra the summit of the process is bifid. These processes increase in length from the second to the sixth bone. The inferior spine is very similar to that of the horse. It is nearly absent in the sixth bone.

**Atlas.** The wings of this bone are more horizontal than in the horse. The posterior foramen is absent. As in the horse, a short furrow unites the antero-external

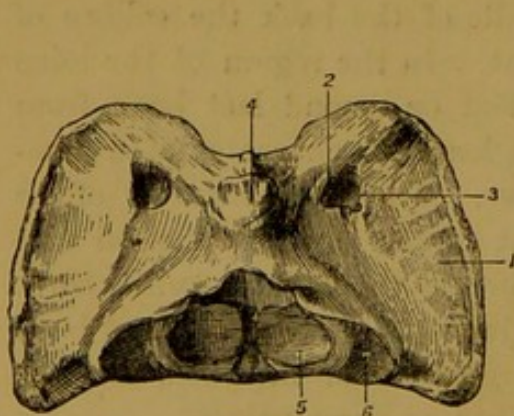


FIG. 28.—ATLAS OF OX, VIEWED FROM ABOVE.

1. Wing; 2. Antero-internal foramen; 3. Antero-external foramen; 4. Eminence in position of neural spine; 5. Articular surface for odontoid process; 6. Surface for articulation with facet at base of odontoid process.

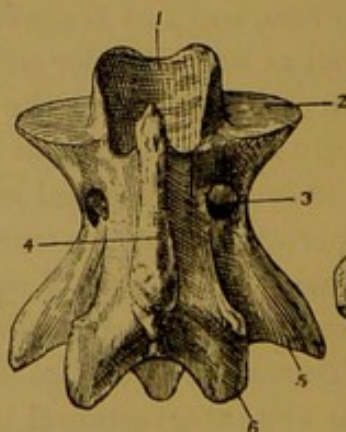


FIG. 29.—AXIS OF OX, VIEWED FROM ABOVE.

1. Odontoid process; 2. Facet at base of same; 3. Intervertebral foramen (converted notch); 4. Neural spine; 5. Transverse process; 6. Posterior oblique process.

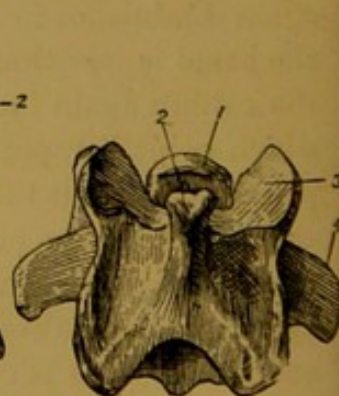


FIG. 30.—FOURTH CERVICAL VERTEBRA OF OX, VIEWED FROM ABOVE.

1. Anterior end of body; 2. Neural spine; 3. Anterior oblique process; 4. Transverse process.

and antero-internal foramina, and from the middle of this furrow a third small foramen passes into the neural ring. A fourth and smaller foramen perforates the wing a little behind the furrow, but this opening may be absent on one or both sides. The

eminence in the position of the neural spine is more prominent than in the horse. The tubercle or inferior spine on the other hand is scarcely so large. The hinder edge of the ring carries on its upper half a central and two lateral slight notches. The facets on this edge for articulation with the axis are flatter than in the horse.

**Axis.** The body of this bone is relatively shorter than in the horse. The odontoid process is shorter, less pointed, and more spout-like on its upper aspect. The prominent collar of bone that underlies it is not notched mesially, and the articular surface on each side of it is flatter. The neural spine is undivided, and less massive than in the horse. The transverse process is stronger.

**Vertebra Prominens.** The neural spine of this bone is much larger than in the horse, having in a moderate sized animal a height of from three to four inches. It possesses no inferior spine.

**Dorsal Vertebrae.** The bodies of these bones are longer than in the horse. The neural spines are broader, and their posterior edge is narrower. The first five spines are nearly equal in length and in breadth. Behind the fifth they diminish steadily in length to the last. With the exception of the last, they are all inclined backwards, the degree of inclination being very marked in the middle members of the series. Except in the last four or five bones, the articular facet of the transverse process is saddle-shaped, being convex in the vertical and concave in the horizontal direction. The inferior spine is even less developed than in the horse. In all or nearly all of the dorsal region the intervertebral foramina are double, the posterior notch being represented by a complete foramen.

**Lumbar Vertebrae.** The body is longer than in the horse. The transverse processes are also longer and more slender. They do not form articulations among themselves, nor does the last articulate with the sacrum. The superior spines are broader but shorter than in the horse. All the centra are ridged inferiorly.

**Sacrum.** The sacrum of the ox is more arched than that of the horse. The neural spines are shorter and completely fused together. The superior foramina are smaller, the inferior larger. There are no facets on the base of the bone for articulation with the last lumbar transverse process. The lower face of the bone is traversed mesially by a longitudinal furrow for the middle sacral artery.

**Coccygeal Vertebrae.** The caudal vertebrae of the ox are proportionally larger than those of the horse, and their processes are better developed. A complete arch is present in the first four or five bones, which possess also distinct though small anterior oblique processes. In the first nine or ten bones, distinct rudiments of the transverse processes are present. About as far as the twelfth vertebra, two small processes are developed in front on the lower face of each centrum. The middle coccygeal artery runs between these processes.

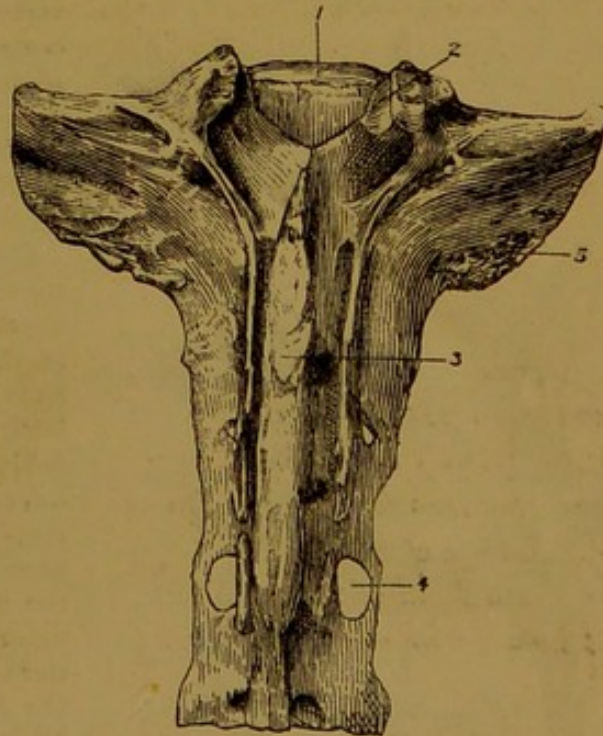


FIG. 31.—SACRUM OF OX, VIEWED FROM ABOVE.

1. Centrum of first sacral vertebra; 2. Anterior oblique process of same; 3. Fused neural spines; 4. Sacral foramen; 5. Auricular facet.

#### THE VERTEBRAL COLUMN OF THE SHEEP.

The spinal formula of the sheep may be stated as  $C_7D_{13}L_6S_4C_{18}$ . It is to be observed, however, that not rarely there are seven lumbar vertebrae, and that the

number of coccygeal bones varies greatly with the breed, the extreme numbers being three and twenty-four (*Nathusius*).

**Cervical Vertebrae.** Except in respect of size, these bones resemble very closely those of the ox. In the third and fourth, however, the transverse process is shaped more like that of the horse. In the third bone the neural spine is small, and throughout the series the inferior spines are not so prominent as in the larger ruminant.

**Atlas.** This bone is very similar to that of the ox. The eminences in the position of the superior and inferior spinous processes are not so well developed. The upper half of the ring is not so deeply notched on either its anterior or its posterior edge.

**Axis.** The neural spine is not so high as in the ox, but the transverse processes are longer than in that animal.

**Dorsal Vertebrae.** These bones present the closest resemblance to the same bones of the ox. It may be remarked, however, that the edges of the neural spines are straighter, and that the posterior notches are only exceptionally converted into foramina.

**Lumbar Vertebrae.** In all of these bones the transverse processes have a slight forward inclination. In other respects they are like those of the ox.

**Sacrum.** The lower surface of this bone differs from that of the ox in being distinctly convex in the transverse direction, and in the absence of a mesial longitudinal furrow.

**Coccygeal Vertebrae.** Similar to those of the ox, but devoid of processes on their lower face.

#### THE VERTEBRAL COLUMN OF THE PIG.

The number of bones in the vertebral column of the pig is denoted in the formula  $C_7D_{14}L_{6 \text{ or } 7}S_4C_{20-23}$ . In rare cases there may be as many as seventeen dorsal

vertebrae. In the domestic pig six is the most common number of lumbar bones. When seven are present, the last of them is generally derived from the sacral region, which in that case possesses only three vertebrae. In the wild pig the normal number of lumbar vertebrae is five.

**Cervical Vertebrae.** The centra of these bones are relatively shorter than in any of the other domestic animals. The ends of the centra are also flatter, the anterior end being even slightly depressed. The laminae are very narrow from before to behind, and consequently a considerable inter-annular space is left in the articulated spine between adjacent arches. The oblique processes are much more inclined than in the horse. A bar of bone perforated by a supernumerary foramen connects the anterior oblique process to the upper division of the transverse process on the same side. The superadded foramen gives passage to the superior primary division of the spinal nerve. The neural spine is thicker and more prominent than in the horse, and inclined forwards. The inferior spine is altogether absent. The transverse process consists of an upper short tubercle-like division, and a lower plate-like part. The latter is directed downwards; and the right and left divisions

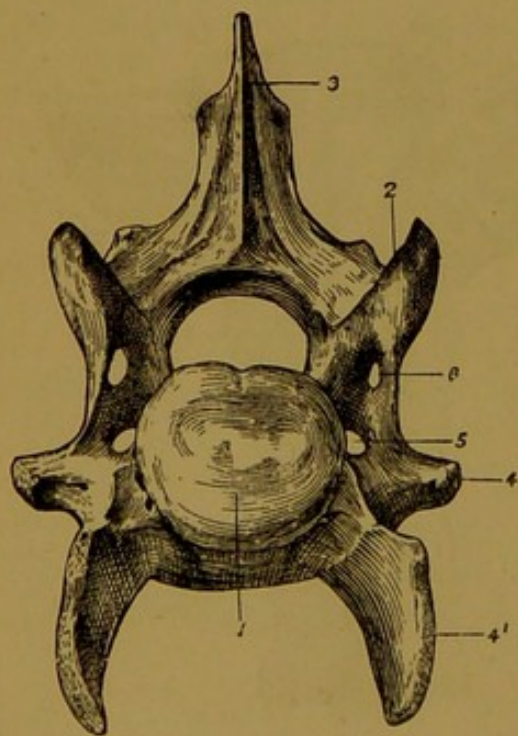


FIG. 32.—CERVICAL VERTEBRA OF PIG (Front View).

1. Centrum; 2. Anterior oblique process;
3. Neural spine; 4 4'. Upper and lower divisions of transverse process; 5. Vertebral foramen; 6. Supernumerary foramen.

together with the lower surface of the body, give to the inferior aspect of the vertebra the form of a deep well-defined groove.

**Atlas.** The wings are almost horizontal. The posterior foramen perforates the wing from its hinder edge to its lower surface. The upper surface of the ring is very convex.

**Axis.** The odontoid process is short, conical, and constricted at its base. The

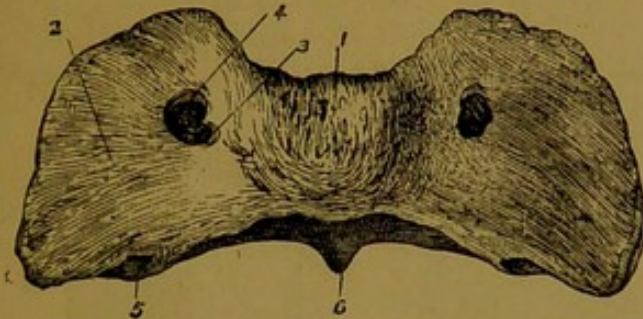


FIG. 33.—ATLAS OF PIG, VIEWED FROM ABOVE.

1. Ring; 2. Wing; 3. Antero-internal foramen.  
4. Antero-external foramen; 5. Posterior foramen; 6. Tubercle or inferior spine.

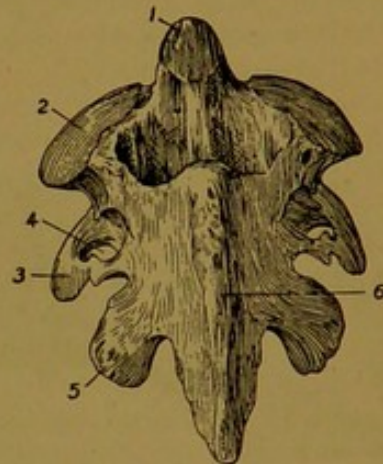


FIG. 34.—AXIS OF PIG, VIEWED FROM ABOVE.

1. Odontoid process; 2. Anterior articular surface; 3. Transverse process; 4. Vertebral foramen; 5. Posterior oblique process; 6. Neural spine.

articular facets on either side of it are disjoined from it, and distinctly convex in all directions. The transverse process is small, undivided, and perforated by a large vertebral foramen. The neural spine is very high and undivided.

**Vertebra Prominens.** The neural spine of this bone is nearly as long as that of the immediately succeeding dorsal vertebrae.

**Dorsal Vertebrae.** The dorsal vertebrae of the pig have most resemblance to those of the ruminant. The extremities of the centra are flatter than in the horse. In the last four bones the anterior capitular facet is confluent with the tubercular facet. These bones possess *mammillary* processes, and *accessory* processes are carried by the hinder edge of the arch. A supernumerary foramen perforates the root of the transverse process, and the intervertebral foramina are usually double as in the ox. The neural spines are relatively long and flat.

**Lumbar Vertebrae.** These bones form no inter-transverse joints. The transverse processes are perforated at the base by a supernumerary foramen. The intervertebral foramina in the anterior bones are sometimes double.

**Sacrum.** The four vertebrae of this region remain distinct for a longer period than in the other domestic animals. Large interannular spaces are left between the adjacent arches. The auricular facets are nearly vertical, and the neural spines are reduced to the condition of a slight crest.

**Coccygeal Vertebrae.** The first four or five bones possess both anterior and posterior articular processes.

#### THE VERTEBRAL COLUMN OF THE DOG.

The spinal formula of the dog is  $C_7D_{13}L_7S_3C_{18-22}$ .

**Cervical Vertebrae.** Save in respect of size, these vertebrae resemble most closely the corresponding bones of the horse. The ends of the centra, however, are flatter than in the horse, the neural spines are better developed, and the laminae are broader. The transverse measurement of the bones diminishes from the third to the last.

**Atlas.** This bone is narrow from before to behind. The upper surface of the ring presents no eminence in the position of the neural spine. The wings are prominent, nearly horizontal, and produced farther backwards than in the other domestic animals.

The antero-external foramen is represented by a notch. The articular surfaces on the posterior aspect of the ring are concave.

**Axis.** The odontoid process is bluntly conical, and directed slightly upwards. It

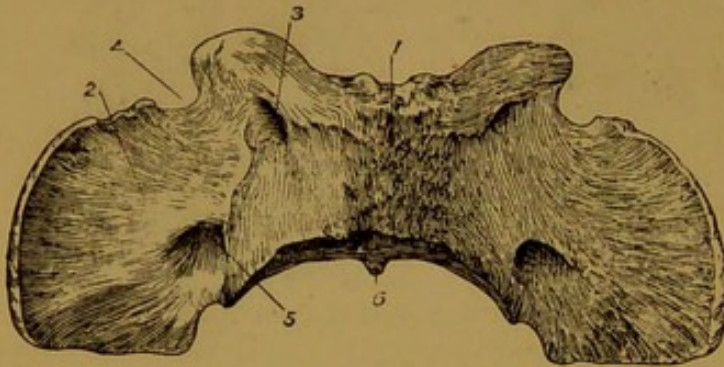


FIG. 35.—ATLAS OF DOG, VIEWED FROM ABOVE.

1. Ring; 2. Wing; 3. Antero-internal foramen;
4. Notch representing antero-external foramen;
5. Posterior foramen; 6. Tubercle or inferior spine.

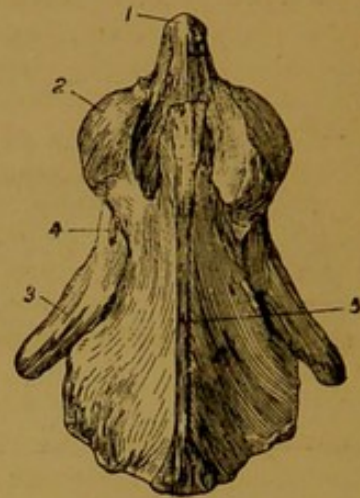


FIG. 36.—AXIS OF DOG, VIEWED FROM ABOVE.

1. Odontoid process; 2. Articular surface at base of same;
3. Transverse process; 4. Vertebral foramen; 5. Neural spine.

resembles most the same process of the pig, but it is longer, and not constricted at its base. The facets on either side of it are distinctly convex in all directions, as in the pig. The neural spine is of great size, but undivided. Anteriorly it projects so far as to over-

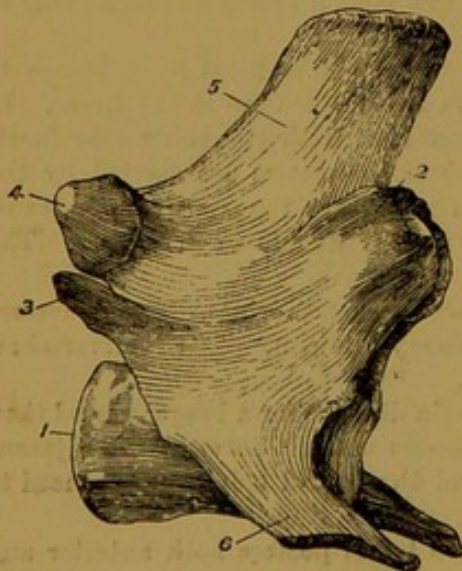


FIG. 37.—LUMBAR VERTEBRA OF DOG (Lateral View).

1. Posterior end of body; 2. Mammillary process; 3. Accessory process;
4. Posterior oblique process; 5. Neural spine; 6. Transverse process.

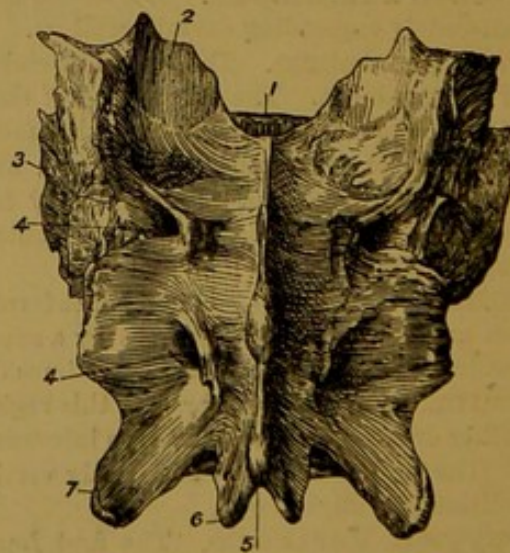


FIG. 38.—SACRUM OF DOG, VIEWED FROM ABOVE.

1. Body of first sacral vertebra; 2. Anterior oblique process of same; 3. Auricular facet;
4. Superior sacral foramina; 5. Neural spine, and 6. Posterior oblique process of last sacral vertebra.

hang the ring of the atlas. The anterior notch is never converted into a foramen. The transverse processes project farther backwards than in the horse.

**Dorsal Vertebrae.** These have most resemblance to the same bones of the horse,

but the neural spines are narrower and thicker on their posterior edge. The posterior capitular facet is absent in the last three bones.

**Lumbar Vertebrae.** These bones are relatively large, and their processes are well developed. The ends of the centra are flatter than in the horse. On its outer side the anterior oblique process carries a distinct *mammillary* process, and a slender pointed *accessory* process projects backwards and upwards from the hinder edge of the arch. The transverse processes are strong and inclined downwards and forwards. No inter-transverse joints are formed.

**Sacrum.** The sacrum of the dog is short, and the three vertebrae that compose it are early anchylosed. Its lower surface is very concave in the antero-posterior direction. The neural spines are short, and fused together throughout their whole extent. The auricular facet is more vertical than in the horse.

**Coccygeal Vertebrae.** The anterior bones of this region in the dog are less degenerate in form than in the horse. The first three or four have all the parts of a typical vertebra distinctly developed, and their oblique processes form synovial joints.

#### THE VERTEBRAL COLUMN OF THE CAT.

The cat has in each region of its spine the same number of vertebrae as the dog.

As in other species, the number of coccygeal bones varies with the breed and with the individual. Most commonly they are about twenty, but only four are present in the Manx breed.

**Atlas.** The under part of the ring is very narrow. The notch representing the antero-external foramen is deeper than in the dog, and the posterior foramen opens on the hinder edge of the wing, as in the pig.

**Axis.** The odontoid process is longer and more slender than in the dog, and the neural spine carries a slight point at its posterior end.

The other cervical vertebrae closely resemble the same bones of the dog, save that the seventh has no capitular surface for articulation with the first rib.

**Dorsal Vertebrae.** Very similar in form to those of the dog. The first has the capitular cavity large enough to receive the entire head of the first rib. The posterior capitular cavity is absent in the last three bones.

**Lumbar Vertebrae.** As in the dog, these bones are strong and rugged. *Mammillary* and *accessory* processes are well developed, and the transverse processes are much inclined downwards.

**Sacrum.** This differs in no important respect from the same bone of the dog.

**Coccygeal Vertebrae.** In the first six or seven, rudiments of all the parts of a typical vertebra are present, and as far as the eighth a complete neural ring is formed. From the second to about the tenth vertebra, small Y-shaped *chevron bones* are articulated beneath each inter-central joint.

#### THE THORAX.

The skeleton of the thorax comprises, besides the dorsal vertebrae already described, the sternum, the ribs, and the costal cartilages.

#### THE RIBS OF THE HORSE.

The ribs of the horse number eighteen pairs, each vertebra of the dorsal region carrying a rib on either side. Each rib is an elongated, more or less curved, and highly elastic bone; articulated to the spine by its upper extremity, and prolonged at its lower extremity by a rod of cartilage termed a costal cartilage. The part of a rib where the curve is most acute is termed the *angle*, but this is not well marked in any of the ribs of the horse. For descriptive purposes there may be recognised in a rib two surfaces, two edges, and two extremities.

The *outer* surface is convex in its length in all of the ribs. It is also convex in the transverse direction, but in the anterior half of the series

this surface presents a shallow wide groove anteriorly. It shows, especially in the neighbourhood of the angle, some slight ridges for muscular attachment.

The *inner* surface is concave in its length, and flattened in the transverse direction. It is smoother than the external surface, and in the living animal it is lined by the *pleura*.

The *anterior* edge of the rib is concave. In the anterior half of the series it is thin and sharp, but in the remainder of the ribs it is thick and rounded.

The *posterior* edge is convex and thick. On its inner aspect it presents a groove which begins at its upper extremity and extends for a variable distance down the bone. The intercostal vessels descend in this groove. The edges of the ribs give attachment to the intercostal muscles, which in the recent state fill up the intercostal spaces and complete the chest-wall.

The upper extremity of each rib is compounded of the *head*, the *neck*, and the *tubercle*.

The **head**, or *capitulum*, is a hemispherical articular process, divided (in all the

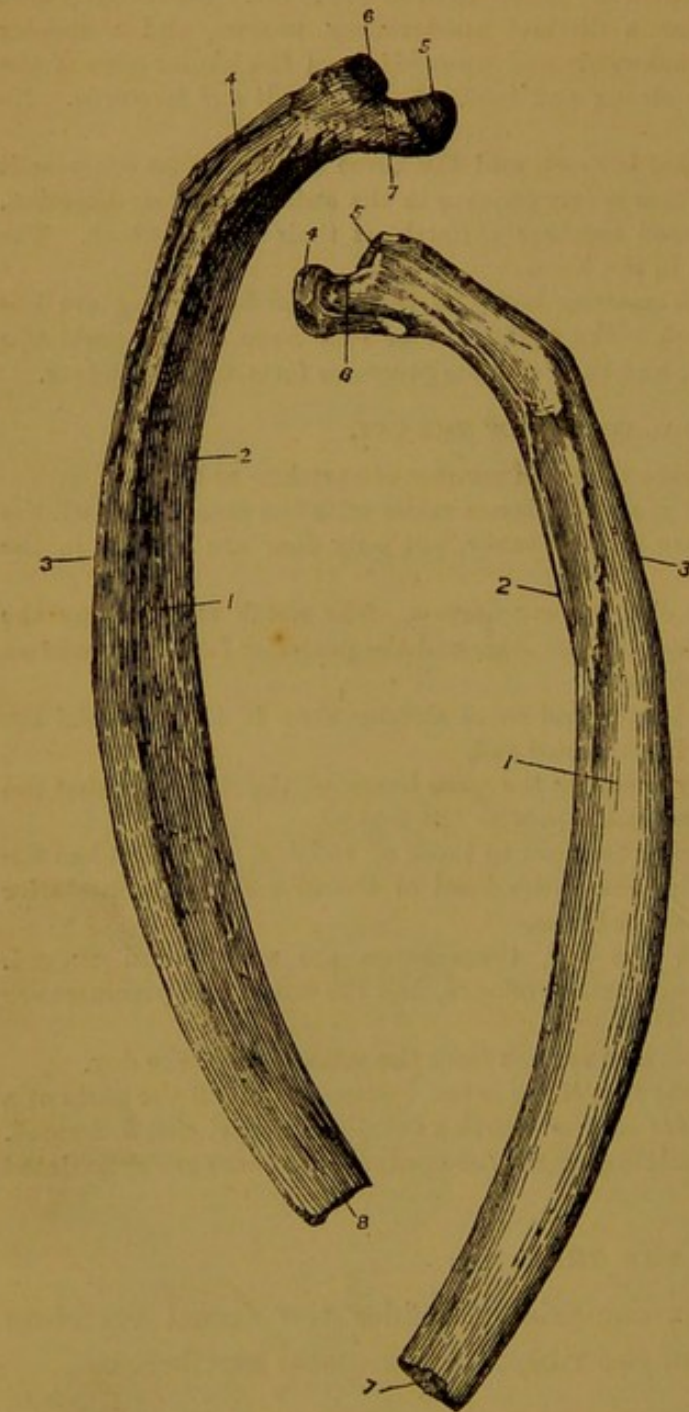


FIG. 39.

FIG. 40.

FIG. 39.—SIXTH LEFT RIB OF HORSE (Inside View).

1. Inner surface; 2. Anterior edge; 3. Posterior edge; 4. Groove for intercostal vessels; 5. Head; 6. Tubercle; 7. Neck; 8. Lower end.

FIG. 40.—SAME BONE AS FIG. 39 (Outside View).

1. Outer surface; 2. Anterior edge; 3. Posterior edge; 4. Head; 5. Tubercle; 6. Neck; 7. Lower end.

ribs except the first) by a groove into an anterior and a posterior facet. It is received into one of the hemispherical cavities already described in

connection with the bodies of the dorsal vertebræ, and it thus articulates with the bodies of two dorsal vertebræ, except in the case of the first rib, the head of which articulates with the last cervical and first dorsal vertebra. The groove which divides the head into two facets gives attachment to the interarticular ligament of the costo-central joint. The **neck** of the rib is a constricted portion immediately below the head. It is roughened outwardly for ligamentous attachment. The **tubercle** is separated from the head by the neck. It carries a nearly flat surface for articulation with the transverse process of a dorsal vertebra. As already said, the head of each rib articulates with the bodies of two vertebræ, and the tubercle articulates with the transverse process of the posterior one of these vertebræ. Outwardly the tubercle is roughened for muscular attachment.

The *lower extremity* of each rib is slightly encavated for articulation with its cartilage.

**Costal Cartilages.** The ribs are prolonged inferiorly by the so-called costal cartilages. Each of these is a more or less rounded rod of hyaline cartilage, which, in the case of the eight anterior ribs, articulates by its distal end with the side of the sternum. These ribs are therefore termed **sternal**. The remaining ten pairs of ribs are termed **asternal**, since their cartilages do not articulate with the sternum. The cartilage of each of these is closely bound for nearly its entire length to its predecessor in the series.<sup>1</sup> In the young subject the costal cartilages are entirely composed of hyaline cartilage, but with advancing age they become more or less calcified by the deposition of lime salts.

**Special characters of the ribs and cartilages.** The first rib is the shortest and the least curved. It has the largest head and tubercle, and the former is undivided. Its outer surface and anterior edge carry some imprints for the attachment of the scalenus muscle. It is further distinguished by the presence of two smooth markings on its anterior edge, the higher of these being the impress of the dorsal roots of the brachial plexus, while the lower marks the point at which the axillary vessels emerge from the chest.

In the case of the other ribs the head and tubercle diminish in size from the first to the last. In the last three or four ribs the posterior articular facet of the head is confluent with the facet of the tubercle. The curvature of the ribs progressively increases from the first to the last. The length of the ribs diminishes in passing forwards and backwards from the ninth, which is the longest; and their breadth diminishes in the same way in passing forwards and backwards from the sixth.

The ninth rib has the longest cartilage, and the first has the shortest.

<sup>1</sup> In some animals one or more of the costal cartilages at the end of the series project freely into the abdominal wall, and are unconnected with the preceding cartilage. The ribs to which these cartilages belong are then termed *floating ribs*.

The cartilages of the sternal ribs are shorter and thicker than these of the asternal ribs, and their distal ends are blunt for articulation with the sternum, while the distal ends of the asternal cartilages are pointed. The cartilage of the first rib differs from all the others in articulating on the mesial plane with its fellow of the opposite side.

**Development.** Each rib ossifies from three centres, viz., one for the head, another for the tubercle, and the third for the remainder of the bone.

#### THE STERNUM OF THE HORSE.

The sternum, or breast-bone as it is popularly called, is a mesially-placed segmented structure, forming the floor of the chest, and suspended to the dorsal vertebræ by means of the ribs. Although described as a single bone, it in reality comprises a number of originally distinct osseous segments, or *sternæbræ*, and throughout life a considerable portion of it retains its primitive cartilaginous structure. The sternum of the horse is distinctly canoe-shaped, and it may be described as possessing three surfaces, three edges, and two extremities.

The *superior surface* has the form of a very elongated isosceles triangle with the base behind. It forms the floor of the thorax.

The *lateral surfaces* (right and left) are more extensive than the preceding. Each presents near its upper edge a series of articular depressions, seven in number, for the cartilages of the sternal ribs from the second to the eighth. The first four of these depressions are vertically elongated, and separated by considerable intervals, but the remaining three are more circular in outline, and clustered together. Beneath the line of these articular cavities each lateral face affords attachment to the pectoral muscles.

The *supero-lateral edges* (right and left) separate the superior and

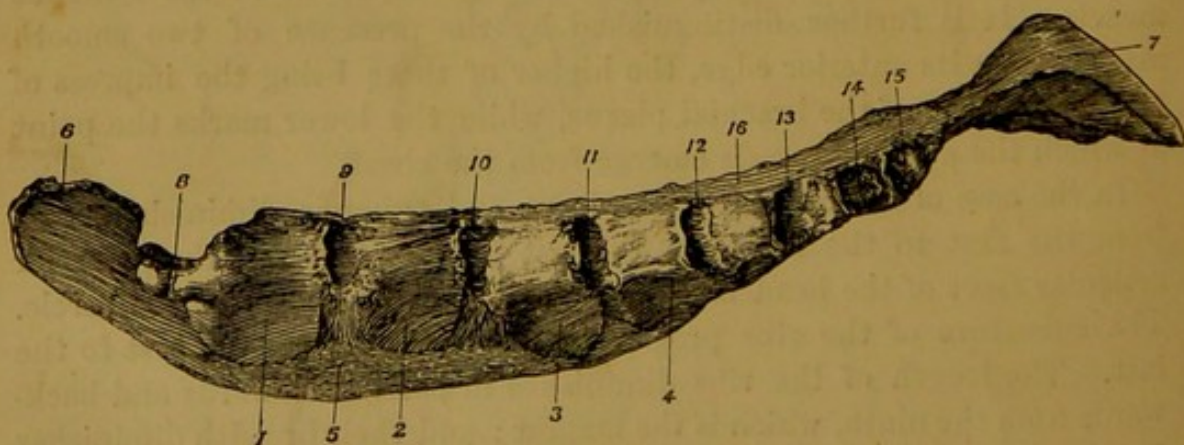


FIG. 41.—STERNUM OF HORSE, VIEWED FROM THE LEFT SIDE.

1, 2, 3, and 4. The first four osseous segments or *sternæbræ*; 5. Persisting cartilage; 6. Pre-sternal or cariniform cartilage; 7. Xiphoid or ensiform cartilage; 8. Notch for first pair of ribs; 9 to 15. Cavities for remaining seven sternal ribs of left side; 16. Upper surface.

lateral surfaces. In the recent state each is traversed by a fibrous cord.

The *inferior edge* is convex, narrow, and blunt. It may be distinctly felt in the living animal.

The *anterior extremity* of the sternum is entirely cartilaginous, forming a marked prominence termed the **presternal** or **cariniform cartilage**. This process presents right and left faces and an inferior edge continuous with the like parts of the body of the sternum, and an upper edge with a wide semi-circular notch for articulation with the cartilages of the first pair of ribs. The presternal cartilage gives attachment to some of the muscles of the neck, and it can be felt in the living animal.

The *posterior extremity* of the sternum is formed by the **xiphoid** or **ensiform cartilage**. This is a thin, flexible, heart-shaped piece of cartilage, concave on its upper aspect, and convex on its lower. The diaphragm is inserted across the upper face of the cartilage close to its line of junction with the body of the sternum. The upper face of the cartilage thus forms part of the floor of the abdomen.

**Development.** As already stated, a considerable portion of the sternum never becomes ossified. In early life ossification commences in seven centres. The osseous pieces developed from the last two centres speedily become indistinguishably fused, but the remaining pieces remain for a long time or for life distinct and separated by persistent cartilage. Besides the presternal and xiphoid cartilages, a considerable portion adjoining the inferior edge remains cartilaginous. The first piece of the horse's sternum, together with the cariniform cartilage, forms the **presternum**, or **manubrium sterni** of human anatomy. The succeeding five pieces compose the **meso-sternum** or body; while the last piece, with its cartilaginous appendix, forms the **xiphisternum**. The first pair of costal cartilages articulate with the presternum, or first segment; the second pair at the point of junction of the presternum and meso-sternum; and the succeeding pairs at the points of junction of the remaining segments.

#### THE THORAX OR CHEST.

In the articulated skeleton the outlines of the thorax are mapped out by the dorsal vertebræ, the sternum, and the ribs with their costal cartilages. Together these circumscribe a cavity that has the form of a cone compressed laterally. What may be termed the *roof* of this cavity is formed by the bodies of the dorsal vertebræ, its *floor* is formed by the sternum, and its *lateral walls* by the ribs and their cartilages. The *apex* of the cone is placed anteriorly, and is represented by an elliptical opening, bounded laterally by the first pair of ribs, and completed above by the body of the first dorsal vertebra. The *base* of the cone slopes obliquely downwards and forwards, and is heart-shaped in outline. It is bounded superiorly by the body of the last dorsal vertebra, inferiorly by the hinder segment of the sternum, and on each

side by the last rib and the united cartilages of all the asternal ribs. In the living animal the base of the cavity is closed by the diaphragm; the apex is closed by the windpipe, gullet, blood-vessels, and other structures passing into or out of the chest; and the seventeen intercostal spaces on each side are closed by the intercostal muscles.

#### THORAX OF THE OX AND SHEEP.

**Ribs of the Ox.** The ox possesses thirteen pairs of ribs—eight sternal and five asternal. They are proportionally longer, broader, and less curved than in the horse. The neck is longer, and the tubercular facet is slightly concave. The sternal ribs, with the exception of the first, articulate with their respective cartilages in a synovial joint.

**Ribs of the Sheep.** These are very similar to the ribs of the larger ruminant, but all of them are consolidated with their cartilages as in the horse.

**Sternum of the Ox.** The sternum of the ox is compressed from above to below, presenting an upper and a lower surface. The former corresponds to the upper face of the horse's sternum, the latter to the combined lateral surfaces of that bone. It comprises seven segments or *sternebrae*, each of which has two lateral centres of ossification. The first piece or *manubrium sterni* has no presternal cartilage, and it is movably articulated to the second. The xiphoid cartilage is smaller than in the horse and more detached. On each side of the sternum there are eight cavities for articulation with the cartilages of the sternal ribs.

**Sternum of the Sheep.** Similar to that of the ox, save that the first piece is not movably united to the second.

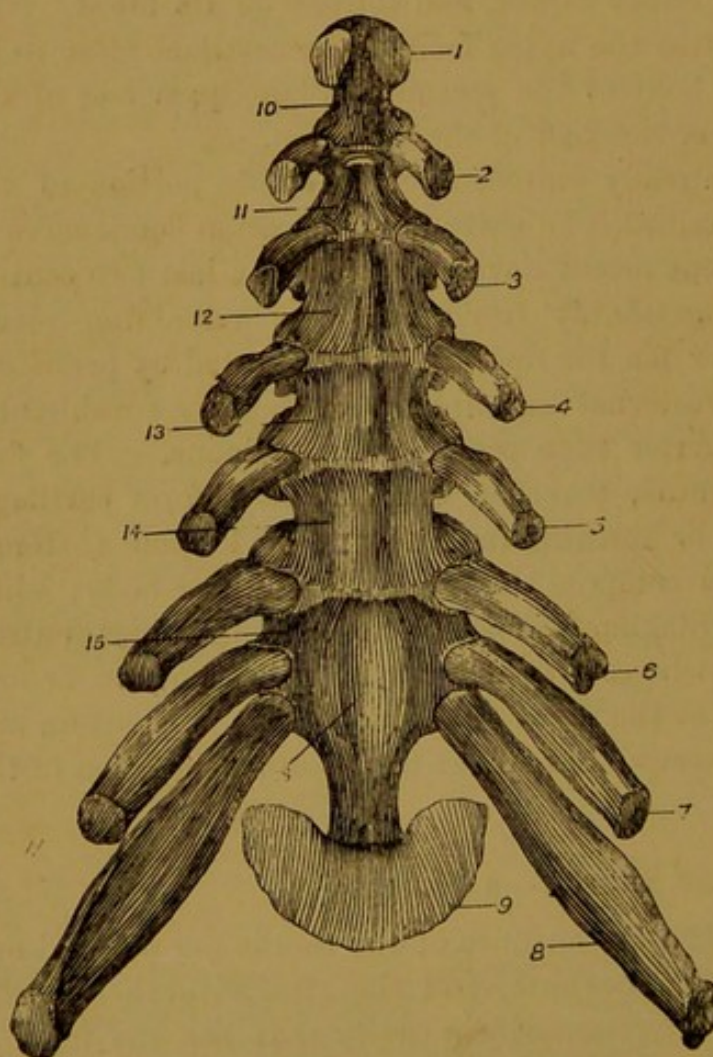


FIG 42.—STERNUM OF OX, VIEWED FROM ABOVE.

1. Surface on manubrium sterni for articulation with cartilage of first rib; 2 to 8. Cartilages of remaining sternal ribs; 9. Xiphoid cartilage; 10 to 16. The seven osseous segments or *sternebrae*.

fourteen pairs of ribs—seven sternal and seven asternal. Exceptionally there may be as many as seventeen pairs. They are somewhat similar to those of the ruminant, but more curved. The second, third, fourth, and fifth bones form movable joints with their cartilages.

**Sternum of the Pig.** The sternum of the pig comprises six pieces. It has most resemblance to that of the ruminant, but it is narrower, and the first segment

#### THORAX OF THE PIG.

##### Ribs of the Pig.

The pig has, in most cases,

carries a small presternal cartilage. As in the ox, the manubrium sterni is movably articulated to the second piece. The xiphoid cartilage is small and well detached.

## THORAX OF THE DOG AND CAT.

**Ribs.** In the dog and cat the ribs number thirteen pairs, of which nine are sternal. They are narrower and more curved than in the other domestic animals. The last is a

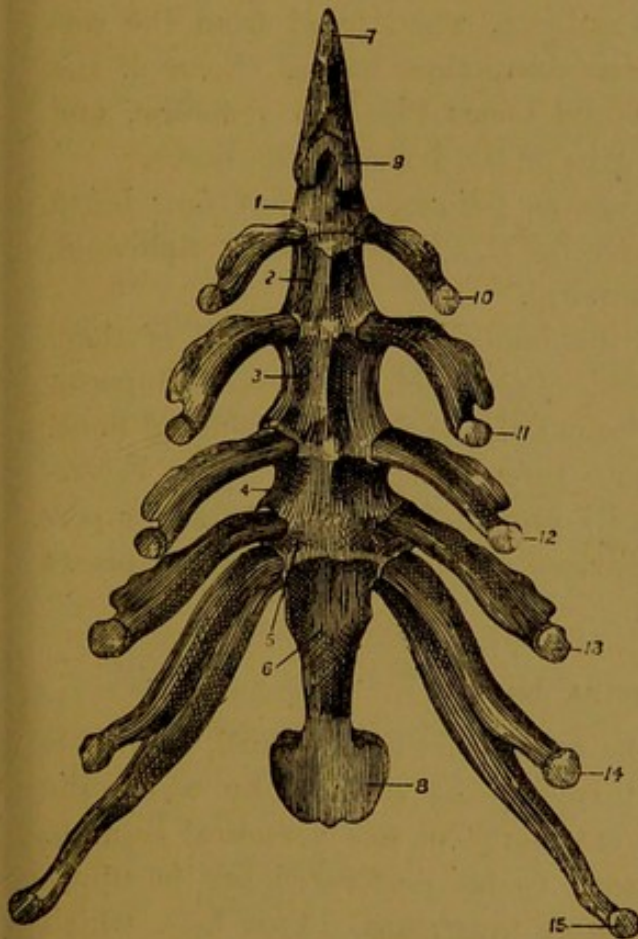


FIG. 43.—STERNUM OF PIG, VIEWED FROM ABOVE.  
1 to 6. The six sternbrae; 7. Presternal cartilage; 8. Xiphoid cartilage; 9. Surface for first costal cartilage; 10 to 15. Cartilages of remaining sternal ribs.

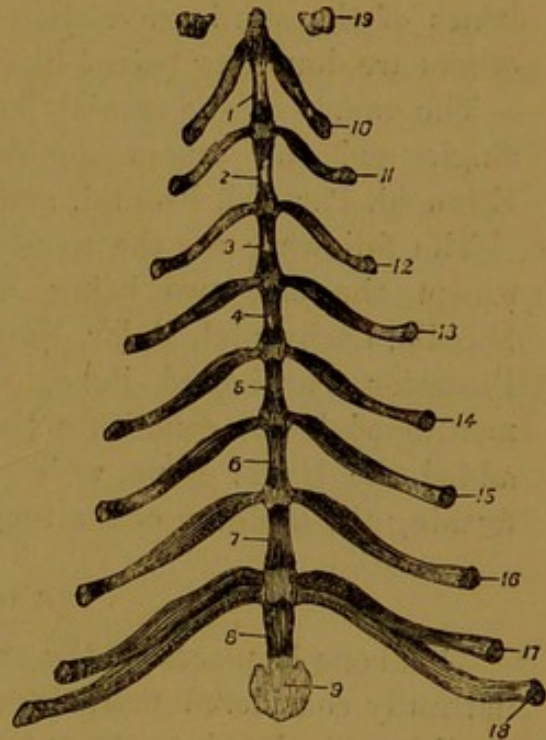


FIG. 44.—STERNUM OF DOG, VIEWED FROM ABOVE.  
1 to 8. The eight sternbrae; 9. Xiphoid cartilage; 10 to 18. Cartilages of sternal ribs; 19. Rudiment of clavicle.

*floating rib.* In the cat each of the last three bones articulates with but one vertebra, and the head is therefore undivided.

**Sternum.** There are eight pieces in the sternum of these animals. Each sternbra is slightly compressed from side to side, and constricted in its middle. The uniting cartilage between the segments persists as such until late life. The presternal cartilage is absent, and the xiphoid cartilage is small.

## THE HEAD.

The skeleton of the head, or skull, as it is commonly called, consists of two portions—the cranium and the face. The **cranium** is that part of the skull which encloses the brain; the **face** contains the cavities of the mouth and nose, and with the cranium completes on each side the orbit, or cavity for the eye. A great many distinct bones enter into the formation of the skull; and, with the exception of the lower jaw, adjacent bones are united by closely applied surfaces or edges, forming

synarthrodial joints. Moreover, it is only during early life that these joints are distinct, for with advancing age the soft uniting substance (cartilage or connective tissue) itself becomes ossified. Hence, in animals beyond middle age the limits of the various bones are almost entirely obliterated. For the study of the separate elements of the skull one must therefore take the head of a foal, preferably two or three months old. The skull of such a subject, when freed from the soft textures, can easily be resolved into its component bones. Some of the bones of the skull are median unpaired bones like the vertebræ, and others are double or paired like the ribs or the bones of the limbs.

The names of the cranial bones are as follows, the first four being single and the others double:—Occipital, Interparietal, Sphenoid, Ethmoid, Parietal, Frontal, and Temporal.

The following are the names of the bones of the face, all of them except the last two being double:—Pterygoid, Palatine, Superior Maxilla, Lachrymal, Malar, Nasal, Premaxilla, Anterior Turbinated Bone, Posterior Turbinated Bone, Vomer, Inferior Maxilla. The before-mentioned bones constitute the skull proper, but to these are super-added the Hyoid Bone, which comprises a number of separate pieces forming the skeleton of the tongue.

#### THE OCCIPITAL BONE.

This bone is placed at the extreme upper part of the skull,<sup>1</sup> and it is naturally considered first, since it furnishes the surfaces by which the skull is articulated to the anterior extremity of the vertebral column. When viewed from behind it is seen to be perforated at its upper part by a large opening—the **foramen magnum**. This hole, which is comparable to the neural ring of a vertebra, establishes a communication between the spinal canal and the cranial cavity. The spinal cord here joins the brain. On each side the foramen magnum is bounded by a convex articular process, termed the **condyle**, which is received into one of the articular cavities on the front of the atlas. Outwards from the condyle on each side a strong curved process—the **styloid** or **paramastoid process**—curves backwards and inwards. The styloid processes serve for muscular attachment. Between the condyle and the root of the styloid process on each side, a considerable hole, termed the **condyloid foramen**, opens. Beneath the foramen magnum a thick rod of bone—the **basilar process**—descends in a vertical direction to articulate by a truncated end with the body of the sphenoid. The outer surface of this process is convex from side to side, and just at its point of junction with the sphenoid it carries some tubercles for the attachment of the anterior straight muscles of the head. The inner or

<sup>1</sup> Throughout the description of the bones of the skull, the head is supposed to be placed with its long axis vertical.

cranial surface of the process is slightly depressed, and the medulla oblongata and pons Varolii rest on it. The lateral edges of the process are thin and sharp, and form the outer boundary of a very irregular opening termed the **foramen lacerum basis cranii**. In front of the foramen magnum there is a somewhat four-sided piece of bone, termed the **supra-occipital**, which for several months after birth remains distinct from the remainder of the bone. Anteriorly the supra-occipital is crossed by a prominent transverse and horizontal ridge, from which again a lateral ridge runs downwards and outwards on each side, to be continued on the temporal bone. The central horizontal portion of this ridge forms the highest point of the skull, and to the entire ridge the term **occipital** or **lambdoid crest** is applied. On the middle line of the supra-occipital, close behind the occipital crest, a small laterally compressed process serves for the attachment of the funicular part of the ligamentum nuchæ. A slight median crest is sometimes continued back from this process to the foramen magnum, on either side of which the bone is depressed and rough for muscular attachment. In front of the central part of the occipital crest, a small area of the supra-occipital looks directly forwards, and is articulated inferiorly with the interparietal. More outwardly the occipital articulates in succession with the parietal, squamous temporal, and petrous temporal, the surface of articulation for the last-named bone being continued on the root of the styloid process. The supra-occipital in the region of the crest is a very thick piece of bone, and it forms the vaulted roof of the cerebellar division of the cranial cavity.

**Development.** At birth the occipital is composed of four pieces, each of which develops from a separate centre of ossification. One of these forms the basilar process (*basi-occipital*). Two bound the foramen magnum laterally and anteriorly (*ex-occipitals*), each being composed of a condyle, a styloid process, and a small piece of bone bounding the foramen magnum in front. The fourth piece (*supra-occipital*) forms, as already described, the occipital crest, and the bone immediately behind it.

#### THE PARIETAL BONE.

The parietal bones are placed on the anterior aspect of the cranial cavity, immediately below the occipital crest. Each has the form of a thin, slightly curved plate of bone, possessing two surfaces and four edges.

The *anterior* or *outer surface* is convex, and for the greater part of its extent it enters into the formation of the temporal fossa, affording attachment to the fibres of the temporal muscle. At the infero-internal angle a small flat triangular area of this surface is excluded from the temporal fossa by a curved ridge which becomes increasingly prominent

with advancing age. Towards the outer edge a part of this surface is concealed in the articulated skull, being overlapped by the squamous temporal, with which it articulates by the dovetailing of numerous scaly processes. The before-mentioned ridge is continuous above with the sagittal crest.

The *posterior* or *inner surface* is concave, and it forms a considerable part of the roof or vault of the cranium, overlying the cerebral hemisphere. It is smooth and close-grained in texture, and it presents two series of markings, viz., (1) a number of ramifying narrow grooves marking the course of the meningeal arteries, and (2) numerous shallow pit-like or digital markings, which are the impressions of the cerebral convolutions. In the recent state this surface is lined by the dura mater, which serves as an internal periosteum to the bone.

The *inner edge*, which is thick and serrated in the whole of its extent, presents superiorly a deep square-cut notch for articulation with the interparietal. Below this notch the inner edge is opposed on the mesial plane to the same edge of the opposite bone, and in the adult skull the line of junction is raised outwardly into a prominent ridge—the **sagittal crest**—which separates the right and left temporal fossæ.

The *outer edge* is thin and sinuous. It articulates with the squamous temporal for nearly the whole of its extent, but the extreme upper part of it meets the wing of the upper division of the sphenoid.

The *lower edge* has an internal bevel in its outer half, and an external bevel in its inner half, and it articulates with the frontal bone.

The *upper edge* is articulated to the occipital and petrous temporal bones. It presents a well-defined groove which enters into the formation of the parieto-temporal conduit. This groove at first lies under cover of the upper edge, but in passing outwards it crosses so as to lie on the outer aspect of the edge. In the articulated skull the edge now under consideration projects into the cranial cavity, behind its line of articulation with the occipital and temporal bones, and gives attachment to a process of dura mater termed the tentorium cerebelli.

**Development.** Each parietal bone ossifies from a single centre.

#### THE INTERPARIETAL BONE.

This bone is also known as the *os triquetrum*, and the *Wormian bone*. It is mesially placed on the anterior aspect of the cranium, being wedged in between the parietal bones inferiorly and laterally, and the occipital bone above. It presents two surfaces and four edges.

The *outer surface* forms in the foal at birth a small four-sided flat area immediately below the occipital crest.

The *inner* or *cranial surface* carries a three-sided process of bone which projects freely into the cranial cavity like a small shelf or wall-bracket. This process is termed the **ossific tentorium** (*tentorium cerebelli osseum*),

and its lateral edges give attachment to the tentorium cerebelli of the dura mater, while its inferior edge, which is continuous with the mesial suture of the parietal bones, affords attachment to the falx cerebri. The upper face of the process is turned towards the cerebellum, and the lateral surfaces (right and left) are opposed to the cerebral hemispheres. Each of the latter faces presents a vascular depression for the transverse venous sinus.

The *upper edge* of the interparietal is thick and dentated for articulation with the occipital; the *lateral* and *inferior edges* are thinner, and more closely serrated for articulation with the parietals.

**Development.** The interparietal bone ossifies from two lateral centres.

#### THE SPHENOID BONE.

This bone is placed at the base of the skull, its central portion underlying the basilar process of the occipital. In the foal at birth, and for some months afterwards, it is composed of two pieces, as distinct from each other as are any of the other bones of the skull. For convenience these divisions may be described separately, the upper part, which lies next the occipital, being termed the post-sphenoid, and the lower part the pre-sphenoid.

The **Post-Sphenoid**. This division of the sphenoid is composed of a central portion, or body, and two pairs of processes—the wings, and the sub-sphenoidal processes.

The **body** or **basi-sphenoid** is a short cylinder of bone with square-cut or truncated *extremities*, the upper of which is joined by a thin layer of cartilage to the basilar process of the occipital, while the lower is united in the same way to the body of the pre-sphenoid. Its *posterior* or *outer surface* is convex from side to side, and furnished at its upper part with some tubercles for the attachment of the anterior straight muscles of the head. The *anterior* or *cranial surface* is flattened, with a faint depression in its lower half. This depression is termed the **pituitary fossa** or **sella turcica**, and it lodges the pituitary gland. The *edges* of the body have the wings attached to them.

The **wings**<sup>1</sup> project outwards and forwards on each side of the body. Each may be said to present two surfaces and four edges. The *posterior* or *outer surface* has attached to it inferiorly the sub-sphenoidal process. Inwardly, close to its junction with the body, a faint groove—the **vidian groove**—crosses it vertically. The *anterior* or *cranial surface* of the wing is smooth, and lined by dura mater. It presents outwardly a wide shallow depression for the uncinat convolution of the cerebrum. Internal and parallel to this there is a deep well-defined groove for the

<sup>1</sup> *Alæ majores* or *ali-sphenoids* of human anatomy.

superior maxillary division of the fifth nerve. To the outer side of this, between it and the depression for the uncinatè convolution, a narrow furrow marks the course of the fourth cranial nerve. Lastly, at the

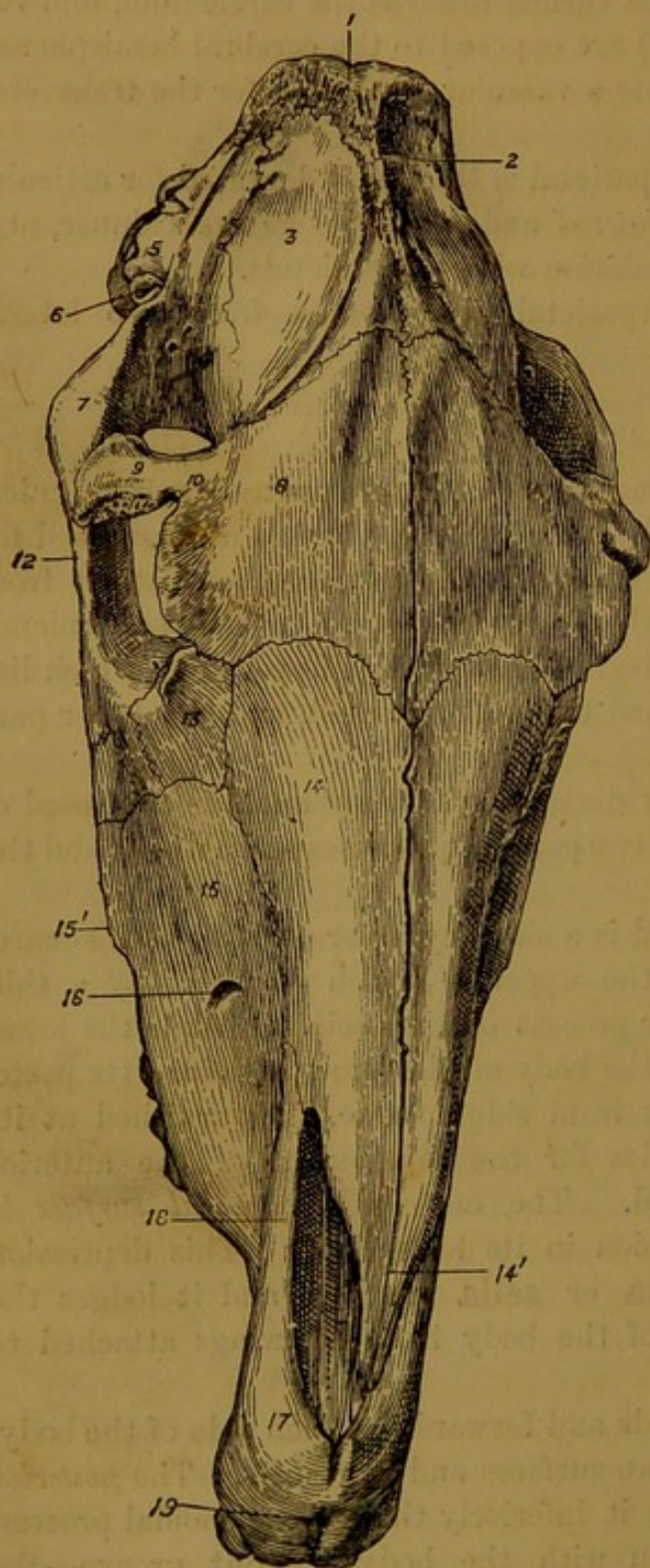


FIG. 45.—RIGHT ANTERIOR VIEW OF SKULL OF HORSE (Six Months Old).

1. Occipital bone ; 2. Interparietal bone ; 3. Parietal bone ; 4. Squamous temporal bone ; 5. Pyramidal process of same ; 6. Auditory process of petrous temporal ; 7. Zygomatic process of squamous temporal ; 8. Frontal bone ; 9. Its supra-orbital process ; 10. Supra-orbital foramen (notch) ; 11 and 12. Malar bone ; 13. Lachrymal bone ; 14. Nasal bone ; 14'. Nasal peak ; 15. Superior maxillary bone ; 15'. Its zygomatic ridge ; 16. Infra-orbital foramen ; 17. Premaxillary bone ; 18. Its nasal process ; 19. Incisor foramen.

extreme inner part of this surface, close to its junction with the body, a faint vertical impression is left by the cavernous sinus.

The *inner edge* of the wing is fused with the body. The *outer edge* is bevelled and scaly for articulation at its upper corner with the parietal, and for the rest of its extent with the squamous temporal. The *upper*

*edge* is free, forming the lower boundary of the foramen lacerum basis cranii. It presents three notches, viz., (1) an inner notch, close to the body, for the internal carotid artery; (2) a middle, for the inferior maxillary division of the fifth nerve; and (3) an outer, for the great meningeal artery. The *lower edge* of the wing is articulated to the wing of the pre-sphenoid. It presents the **foramen rotundum**, and by apposition with the pre-sphenoid it forms the **foramen lacerum orbitale** and the **pathetic foramen**.

The **sub-sphenoidal** or **pterygoid processes** project downwards and backwards from the lower part of the wings. At its base each is perforated by the **sub-sphenoidal canal** or **foramen**. The **temporal foramen**, for the anterior deep temporal artery, leads from the canal and opens above the lower edge of the wing. The point and anterior edge of the process articulate with the palatine bone, and by the inner side of its base it contracts a small articulation with the pterygoid bone.

The **Pre-sphenoid**. This division of the sphenoid comprises a body and two lateral wings.

The **body** is a short rod the *upper extremity* of which is truncated for articulation with the body of the post-sphenoid. The *lower extremity* is excavated, and divided by a perforated septum into two deep cavities which form part of the sphenoidal sinus. Anteriorly the septum is produced into a short projecting process, or *rostrum*, for articulation with the crista galli process of the ethmoid. The *posterior* or *outer surface* of the body is convex from side to side, porous, and concealed in its lower half by articulation with the vomer. Laterally it meets the palatine, and at the point of articulation a minute furrow continues the vidian groove from the post-sphenoid. The *anterior* or *cranial surface* is smooth and nearly flat in its lower two-thirds, where it supports the cerebral hemispheres. In its upper third it presents, at a lower level than the preceding, a smooth flat surface for the optic chiasma; and from either extremity of this a round foramen—the **optic foramen**—passes obliquely downwards and outwards to open externally near the junction of the body and the wing.

The *lateral edges* of the body are joined to the wings.

The **wings**.<sup>1</sup> Each of these presents two surfaces and a circumferent edge.

The *outer surface*, slightly convex, possesses an oblong part which is smooth and free on the inner wall of the orbit; but below and in front of this, forming three-fourths of the surface, the wing is rough and concealed by articulation with the orbital plate of the frontal bone. The *inner surface* is slightly concave, smooth, and furnished with some faint digital impressions left by the cerebral convolutions.

<sup>1</sup> *Alae minores* or *orbito-sphenoids* of human anatomy.

The *upper edge* of the wing is articulated to the wing of the post-sphenoid, and it presents grooves which complete the foramen lacerum orbitale and the pathetic foramen. The *outer edge* is convex and received into a cleft of the frontal bone. The *lower edge* is also articulated to the frontal bone, and it carries close to the body a notch, which, with a similar notch of the frontal, forms the **internal orbital foramen**. The *inner edge* is fused with the body.

**Development.** The post-sphenoid ossifies from three centres, one for the body, and one for each of the wings. The pre-sphenoid has two centres (*Baraldi*, quoted by *Franck*).

#### THE FRONTAL BONE.

This bone is placed on the front of the skull, on the limits of the cranium and face. It presents for consideration two surfaces and four edges, besides an orbital plate, and a supra-orbital process.

The *anterior* or *outer surface* of the bone is smooth and subcutaneous. In the foal at birth it is distinctly convex, but in the adult animal it is nearly flat. The *posterior surface* is divided into an upper and a lower part by a strong horizontal ridge. The upper or cranial part is convex and smooth, and it shows faint digital markings left by the cerebral convolutions. The lower part has the form of a cavity with irregular walls, and it forms part of the frontal sinus. Superiorly this cavity ascends so far between the outer and inner tables of the bone as to lie in front of the lower part of the cranial cavity. The before-mentioned horizontal ridge which divides this surface is articulated at its inner end to the crista galli process of the ethmoid, and for the rest of its extent with the cribriform plate of the same bone.

The *inner edge* of the frontal is denticulated above and plain below, and for the whole of its extent it is articulated to the same edge of the opposite bone. The *upper edge* is bevelled and scaly for articulation with the parietal. The *lower edge* has a wide outward bevel, and is scaly for articulation with the nasal bone inwardly and the lachrymal outwardly. The *outer edge* carries the orbital plate and the supra-orbital process.

The **supra-orbital process** is a short rod of bone, so named from its relation to the orbit. It stretches like a bridge between the frontal bone and the zygomatic arch, and forms an imperfect separation between the orbital cavity and the temporal fossa. It presents two surfaces, two edges, and two extremities.

The *upper surface* is smooth and convex. The *lower* or *orbital surface*, also smooth, is slightly depressed for the lachrymal gland.

The *upper edge* is concave in its length, and thick and rounded in the transverse direction. The *lower edge* is also concave in its length. It is sharper than the upper edge, and it forms the upper part of the orbital rim.

The *inner extremity* or *root* of the process is perforated close to the anterior edge by the **supra-orbital foramen**. At birth, and for some months thereafter, this foramen is represented by a notch, as in Fig. 45. The *outer extremity* is truncated for articulation with the zygomatic process of the squamous temporal.

The **orbital plate** of the frontal passes backwards from the main portion of the bone, at the inner side of the orbit. It possesses two surfaces and four edges.

The *outer* or *orbital surface* is concave and smooth, and it forms the greater part of the inner wall of the orbit. Superiorly, close to the root of the supra-orbital process, it shows a pit in the position of the fibrous loop through which the tendon of the superior oblique muscle of the eye is reflected. This pit is scarcely perceptible in the young skull.

The *inner surface* is divided into two portions by a continuation of the horizontal ridge already described in connection with the main mass of bone. The upper and larger of these is opposed to the outer surface of the wing of the pre-sphenoid, and anteriorly it is limited by a deep semi-circular cleft—the **incisura sphenoidalis**, into which in the adult skull the margin of the pre-sphenoidal wing is received. The lower portion is rough, and it enters into the formation of the frontal sinus.

The *anterior edge* of the orbital plate unites it to the main portion of the bone. The *posterior edge* is articulated to the pre-sphenoidal wing. It shows a deep oblong outcut occupied by that wing in the articulated skull, and beneath that a small notch which the wing converts into a complete foramen—the **internal orbital foramen**. The *upper edge* is thin, bevelled outwardly, and scaly for articulation with the squamous temporal. The *lower edge* is thin, convex, and articulated to the palatine, superior maxilla, and lachrymal bones.

**Development.** The frontal bone ossifies from a single centre.

#### THE TEMPORAL BONE.

At birth the temporal bone of the horse is composed of two distinct pieces, which are termed respectively the *squamous* and *petrous* portions.

The **Squamous Temporal**. This bone forms part of the lateral wall of the cranial cavity behind the parietal. It has the form of an ovoid slightly curved plate, to which are added two processes—the pyramidal process, and the zygomatic process. It may be described as possessing two surfaces and a circumferent edge.

The *outer surface* is convex and smooth, and for the most part it enters into the formation of the temporal fossa. In its upper half the zygomatic process is attached to it. The *inner surface* is concave and smooth towards its centre, where it appears on the inner surface of the cranial

wall, and is lined by the dura mater. Around this the inner surface is cut into numerous scaly processes for articulation with the parietal, frontal, and post-sphenoidal wing.

The *circumferent edge* is thin and scaly for articulation with these same bones, except at its upper part where it is joined to the pyramidal process.

The **pyramidal process** springs from the upper part of the circumferent edge. It is irregularly triangular in outline, with an inner and an outer surface, three edges and three angles.

The *outer surface* is crossed obliquely by a sharp ridge which continues the upper edge of the zygomatic process to the occipital crest, and marks here the limit of the temporal fossa.

The *inner surface* is applied to the petrous temporal, and it is crossed inferiorly by a groove, which the petrous temporal and parietal bones convert into a complete canal—the **parieto-temporal canal**.

The *posterior edge* of the process is concave, forming a bay for the external auditory process of the petrous temporal. The *upper edge* presents a central notch by which the mastoid artery enters the parieto-temporal canal. The *anterior edge* is perforated by several small foramina leading out from the parieto-temporal canal.

The *lower angle* of the process is that by which it is united to the body of the squamous temporal; the *supero-posterior angle* abuts against the mastoid process; and the *supero-anterior angle* touches the occipital bone.

The **zygomatic process**. This is a long curved process springing from the outer surface of the bone, and forming the outer boundary of the temporal fossa. It passes at first outwards, and then, forming a bend, it passes downwards to join the upper extremity of the malar bone. It may be described as possessing two surfaces, two edges, and two extremities.

The *inner* or *anterior surface* is smooth, and turned towards the temporal fossa. The *outer* or *posterior surface* carries close to its upper end an articular surface for the condyle of the lower jaw. This surface comprises three portions, viz., (1) a transversely elongated **glenoid cavity**, (2) in front of that a transversely elongated **condyle**, or **articular eminence**, and (3) behind the cavity a short nipple-like projection—the **post-glenoid process**. The inferior aspect of this process is articular, forming as it were the upper boundary of the glenoid cavity. The condyle of the inferior maxilla articulates with this surface through the medium of an inter-articular fibro-cartilage. Immediately above the post-glenoid process the lower orifice of the parieto-temporal canal is found.

The *anterior edge* of the zygomatic process is convex and thick. Immediately above its lower end it carries a rough surface for the

abutment of the supra-orbital process of the frontal. The *posterior edge* is concave and sharp.

The *upper extremity* is fused to the outer surface of the squamous temporal, from which it appears to arise by two roots. The **inferior root** is represented by the condyle. The **upper root** is separated from the lower by the glenoid fossa. It carries posteriorly the post-glenoid process, and superiorly it is prolonged by a sharp ridge which is continuous below with the anterior edge of the process, and above with the ridge already described on the outer surface of the pyramidal process. The *lower extremity* of the process is cut into a posterior bevel for articulation with the upper extremity of the malar bone, to the inner side of which it articulates with the superior maxilla.

**Development.** The squamous division of the temporal ossifies from a single centre.

The **Petrous Temporal**. This division of the temporal bone is so named from the stony hardness of its compact tissue. It is situated on the postero-lateral aspect of the skull, and it has the form of a four-sided pyramid, the base of which is turned downwards and backwards.

The *anterior surface*, the smallest of the four, is articulated outwardly to the upper edge of the parietal, and inwardly it is free and directed towards the cerebral division of the cranium. It forms the posterior boundary of the parieto-temporal canal.

The *posterior surface* is comparatively flat, and articulated to the occipital bone. It shows near its lower part a minute foramen by which the auricular branch of the vagus penetrates into the aqueduct of Fallopius.

The *outer surface* is concealed in the articulated skull, being overlapped by the pyramidal process of the squamous temporal. It is crossed by a groove for the mastoid artery.

The *inner surface* is smooth and free, forming part of the boundary of the cerebellar division of the cranium, and it presents some digital impressions. In its lower third it shows the **internal auditory meatus**, by which the seventh and eighth cranial nerves enter the bone. The bottom of the meatus shows inferiorly a foramen which is the beginning of the **aqueduct of Fallopius**, and for the rest of its extent it is perforated by numerous minute openings for the filaments of the eighth nerve. The seventh nerve enters the aqueduct. Behind the meatus, close to the hinder edge of this surface, there is a narrow slit-like opening—the **aquæductus cochleæ**; and above that again a larger slit—the **aquæductus vestibuli**.

These four surfaces are separated by four edges, of which two are anterior and two posterior (external and internal).

The *antero-internal edge* is sharp and slightly notched. The tentorium cerebelli is attached to it. The *antero-external edge* is short, thick, and

concealed by the pyramidal process of the squamous temporal. The *postero-internal* edge is comparatively sharp. It shows sometimes at its lower part a small depression for the petrous ganglion of the ninth cranial nerve.

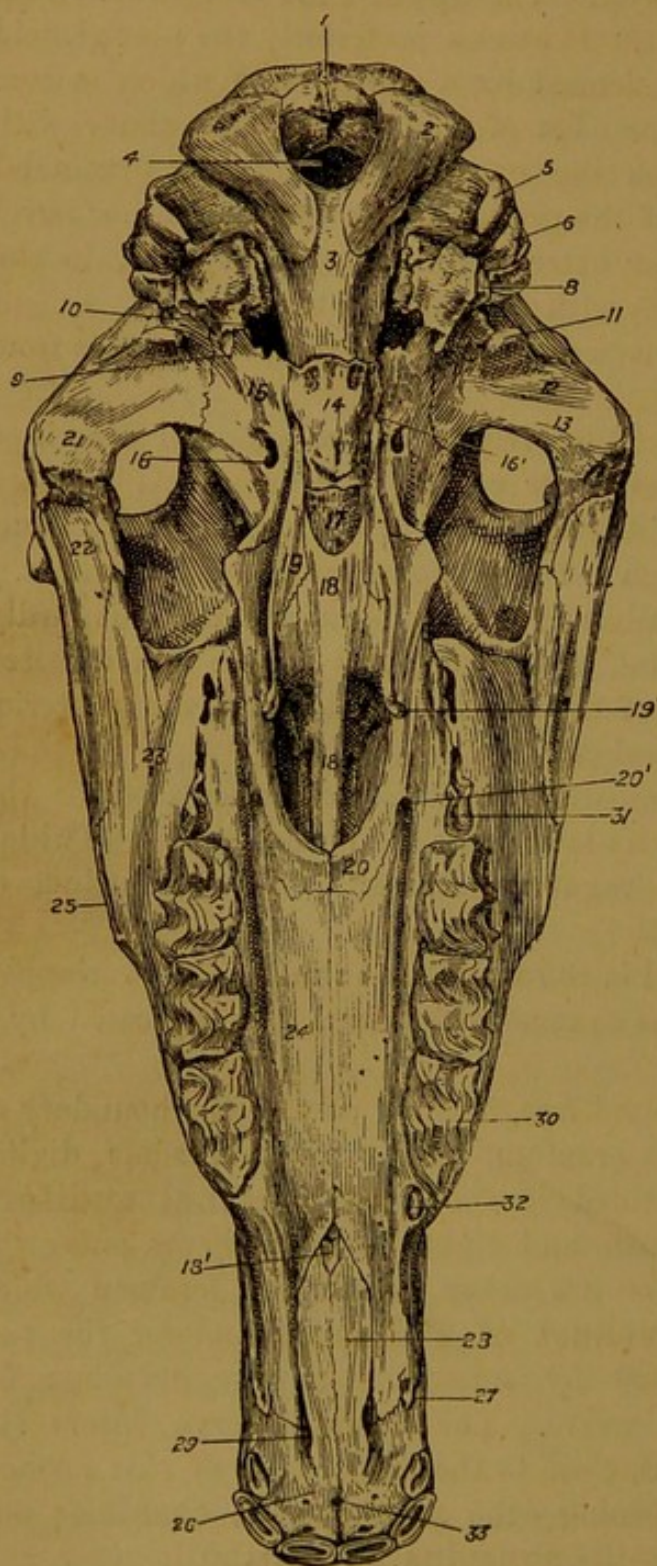


FIG. 46.—POSTERIOR VIEW OF SKULL OF HORSE (Six Months Old).

1. Occipital crest; 2. Condyle, and 3. Basilar process of occipital bone; 4. Foramen magnum; 5. Styloid process of occipital bone; 6. Mastoid process; 7. Auditory bulla; 8. Hyoid process, and 9. Styloid process of petrous temporal bone; 10. Foramen lacerum basis cranii; 11. Post-glenoid process, 12. Glenoid cavity, and 13. Articular eminence of squamous temporal bone; 14. Body of post-sphenoid; 15. Wing of same bone; 16. Sub-sphenoidal canal; 16'. Upper orifice of vidian canal; 17. Body of pre-sphenoid; 18. Vomer bone; 18'. Its lower extremity; 19. Pterygoid bone; 19'. Its hamular process; 20. Palatine bone; 20'. Posterior palatine foramen; 21. Zygomatic process of squamous temporal; 22. Malar bone; 23. Superior maxillary bone; 24. Its palatine plate; 25. Its zygomatic ridge; 26. Pre-maxillary bone; 27. Alveolus for temporary canine tooth; 28. Palatine process of pre-maxillary bone; 29. Incisor cleft; 30. First temporary molar tooth; 31. First permanent molar; 32. Wolf's tooth; 33. Incisor foramen.

The *postero-external* edge projects freely on the exterior of the articulated skull between the squamous temporal and occipital bones, and forms a ridge—the **mastoid crest**—which is continuous above with the occipital crest. Inferiorly the mastoid crest terminates in a blunt pro-

cess—the **mastoid process**—which lies immediately in front of the root of the styloid process of the occipital. Both crest and process serve for muscular attachment. About its centre this edge is notched for the mastoid artery.

The *apex* of the bone is directed upwards and forwards, and is included between the occipital and squamous temporal.

The *base* is free in the articulated skull, and it forms the outer boundary of the foramen lacerum basis cranii. Besides several important foramina, it carries the auditory process, the auditory bulla, the hyoid process, and the styloid process.

The **auditory process** is a short tube of bone which leads into the tympanum or middle ear—an irregular cavity in the petrous temporal bone. The annular cartilage at the root of the ear surrounds this process, and the tympanic membrane is stretched across it. The outer opening of the tube is the **external auditory meatus**. The direction of the tube is upwards, outwards, and forwards. In the foal at birth the process is very short, and incomplete on its upper aspect.

The **hyoid process** lies almost immediately behind the auditory process. It is a small plug-like rod of bone projecting downwards and backwards from a kind of sheath. It is united through the medium of a piece of cartilage to the great cornu of the hyoid bone.

The **auditory bulla**, or **mastoid protuberance**, is placed immediately behind the hyoid process. It is a large smooth boss with thin walls, its interior being honeycombed by air spaces in communication with the tympanum.

The **styloid process** is a slender spiculum of bone springing from the lowest point of the base, and projecting freely downwards and backwards. The tensor and levator palati muscles take origin from it.

The following openings and foramina occur on the base:—(1) The **stylo-mastoid foramen** is of considerable size, and situated between the mastoid process above and the hyoid process below. It is the outward opening of a curved canal—the **aquæductus Fallopii**—through which the seventh cranial nerve passes. The nerve obtains entrance to this canal at the bottom of the internal auditory meatus of the inner surface. (2) The **styloid foramen**, or **Glaserian fissure**, opens below the auditory process and above the root of the styloid process. It gives passage outwards to the chorda tympani nerve. (3) The **Eustachian orifice** is an irregular slit to the inner side of the root of the styloid process. It leads into the tympanum, and the cartilaginous Eustachian tube is inserted around it. (4) To the inner side of the Eustachian orifice a small foramen gives exit to the large and small superficial petrosal nerves.

**Development.** What has been described above as the petrous part of the temporal, ossifies from three chief centres, which lead respectively

to the formation of the so-called petrous, mastoid, and tympanic portions. The *tympanic part* comprises the auditory bulla and the styloid and auditory processes. It is comparatively late in uniting with the rest of the bone, its outlines being quite distinct at birth. The hyoid process (tympano-hyal), although closely connected with this part, ossifies from a special centre. The *mastoid part* comprises the crest and process of that name and part of the adjacent bone. At birth it is indistinguishably united with the *petrous part*, which forms the densest portion of the bone, and is the most important piece, in the sense that it contains the complicated internal ear, or labyrinth. The three portions together circumscribe the middle ear, or tympanum, in which there is developed a chain of small bones described in connection with the organ of hearing.

#### THE ETHMOID BONE.

This bone is mesially placed, and it comprises four parts, viz., a horizontal plate, a vertical plate, and two lateral masses.

The **Horizontal or Cribriform Plate.** This is a sieve-like plate of bone placed horizontally as a partition between the cranial cavity and the nasal fossæ. Its sieve-like character is due to numerous small perforations or foramina, through which the filaments of the olfactory nerves pass to reach the nasal mucous membrane. It possesses an upper and a lower surface and a circumferent edge.

The *upper or cranial surface* is mesially divided by the upper edge of the perpendicular plate. Each half is concave and porous in appearance,

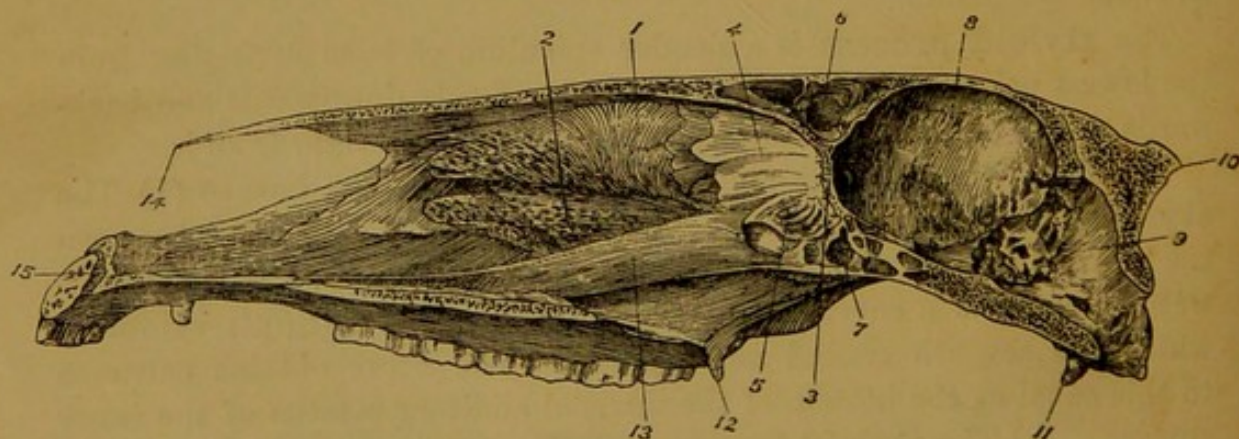


FIG. 47.—VERTICAL (ALMOST) MESIAL SECTION OF SKULL OF HORSE.

1. Anterior turbinated bone; 2. Posterior ditto; 3. Cribriform plate of ethmoid;
4. Perpendicular plate of ethmoid; 5. Lateral mass of ethmoid; 6. Frontal sinus;
7. Sphenoidal sinus; 8. Cerebral compartment of cranium; 9. Cerebellar compartment;
10. Occipital crest; 11. Styloid process of occipital bone; 12. Hamular process of pterygoid bone; 13. Vomer; 14. Nasal peak; 15. Incisor foramen.

and it forms the bottom of the olfactory fossa, in which the olfactory bulb is lodged. Besides the numerous small foramina for the olfactory nerves already mentioned, it shows at each side a larger foramen for the passage of the nasal branches of the ophthalmic artery and nerve.

The *lower or nasal surface* is convex, and concealed by the lateral masses, the cells of which are attached to it.

The *circumferent edge* of the horizontal plate is attached on each side to the frontal and pre-sphenoid bones.

The **Perpendicular Plate** is placed in the mesial plane of the head, and two surfaces and four edges may be recognised in it.

The *surfaces*, right and left, are free, and covered in the recent state by nasal mucous membrane. They form part of the inner wall of the nose.

The *anterior edge* is articulated to the mesial suture of the frontal bones. The *posterior edge* is received into the cleft of the vomer. The *upper edge* projects freely into the cranial cavity as a prominent crest—the **crista galli**—between the olfactory fossæ. Anteriorly the crista galli projects into the mesial suture of the frontal bones, and posteriorly it is articulated to the rostrum of the pre-sphenoid. The *lower edge* of the perpendicular plate is irregular, and continuous in the recent state with the septal cartilage of the nose.

The **Lateral Masses**. Each of these is a conical mass, base uppermost, attached to the under surface of the cribriform plate, and almost entirely filling up the extreme upper end of the nasal chamber. Each is composed of a number of small scrolls or convoluted shells of very fragile bone, arranged the one in front of the other. These are termed the **ethmoidal cells**, and they increase in size from behind to before, the most anterior one being much larger than any of the others.

The *inner surface* of the lateral mass is plane, and separated by a very narrow interval from the surface of the perpendicular plate. It shows the lateral contours of the ethmoidal cells, and the interspaces between them. The *outer surface* is convex, and directed towards the frontal and maxillary sinuses. It is covered by a smooth thin leaf of bone—the **lamina papyracea**—to whose inner surface the ethmoidal cells are attached. Below it is articulated to the palatine, superior maxilla, and anterior turbinated bone, and above to the frontal and pre-sphenoid.

The *base* of the lateral mass is united to the cribriform plate, while the *apex*, formed by the lower end of the largest cell, is a free rounded projection.

Air from the nasal chamber is admitted into the interior of the ethmoid cells by the interspaces on the inner surface of the lateral mass, but occasionally the cavity of some of the cells appears to be closed. In the recent state all these cells are invested by nasal mucous membrane.

**Development.** The ethmoid ossifies from three centres—two for the lateral masses, and one for the perpendicular and horizontal plates. Ossification is later in beginning here than in any of the surrounding bones, and at birth the horizontal and vertical plates are yet quite cartilaginous,

while the lateral masses are then partly ossified. The study of the ethmoid bone is thus rendered difficult; for, by the time it is fully ossified, the surrounding bones have become so firmly united that disarticulation cannot be effected.

#### THE PTERYGOID BONE.

This is a small slightly twisted strap-like bone, placed at the side of the guttural opening of the nose. It possesses two surfaces and two extremities.

The *inner surface* is smooth and covered by the mucous membrane of the pharynx.

The *outer surface* is articulated to the palatine, vomer, and sphenoid, and superiorly by contact with the last-named bone it converts the vidian groove into a complete canal—the **vidian canal**.

The *upper extremity* of the bone is pointed, and wedged in between the body of the pre-sphenoid and the root of the sub-sphenoidal process.

The *lower extremity* is free, slightly bent outwards, and pulley-like on its outer aspect. This constitutes the **hamular process**, round which the tendon of the tensor palati muscle is reflected.

**Development.** The pterygoid bone ossifies from a single centre.

#### THE PALATINE BONE.

The palatine bones lie one on each side of the pharyngeal opening of the nose, their lower extremities forming the extreme upper part of the hard palate, while their upper ends appear on the inner wall of the orbit. They are very irregular in shape, but for descriptive purposes each may be said to present two surfaces, two edges, and two extremities.

The *outer surface* is naturally divided into three areas, viz., (1) an *orbital* portion, placed superiorly, and appearing in the articulated skull as a smooth slightly convex surface on the inner wall of the orbit; (2) an *articular* portion, central in position, rough for articulation with the superior maxilla, and traversed by a groove which the last-named bone converts into a complete canal—the **palatine canal**; (3) a *palatine* portion, the smallest and most inferior of the three areas, and so named because it forms a narrow strip of the hard palate. This last area, it is to be observed, although considered a part of the external surface, looks directly backwards, as if the lower end of the bone had been twisted inwards.

The *inner or nasal surface* is for the most part smooth and covered by mucous membrane. It is placed on the limits of the nose and pharynx. In its upper and broader part it carries an articular surface for the pterygoid bone.

The *posterior edge* is rough in its upper third, forming the **palatine crest**. This crest is most prominent at its extremities, the upper of

which rests outwardly against the tip of the sub-sphenoidal process, while the lower supports inwardly the pterygoid bone just above its hamular process. In its lower two-thirds the posterior edge is smooth and rounded, and it here forms the upper edge of the hard palate. In its middle third this edge forms outwardly, by apposition with the superior maxilla, a narrow groove—the **staphylin groove**, for the artery and nerve of that name.

The *anterior edge* presents about its middle the round **spheno-palatine foramen**. Below this the edge is thin and denticulated for articulation with the ethmoid and superior maxilla. Above the foramen the edge divides so as to circumscribe a large elliptical cavity which enters into the formation of the sphenoidal sinus. The thin inner lip of this cavity is articulated to the vomer, and the outer lip to the frontal, pre-sphenoid, and superior maxilla.<sup>1</sup>

The *upper extremity* bears an elongated pit for articulation with the sub-sphenoidal process. The *lower extremity* is turned inwards to articulate by a narrow flat surface with the corresponding part of the opposite bone. This articulation lies on the mesial plane of the head, at the extreme upper part of the hard palate.

**Development.** The palatine bone ossifies from a single centre.

#### THE SUPERIOR MAXILLA.

With the exception of the inferior maxilla, this is the largest bone of the skull. It is situated on the lateral aspect of the face, and it carries the upper grinding teeth. For convenience of description it may be divided into a main portion or body, and a palatine plate.

The *body* possesses two surfaces, two edges, and two extremities.

The *outer or facial surface* is slightly concave in front and convex behind. A little above and in front of its centre it shows the **infra-orbital foramen**. Towards its posterior and upper part it is raised into a prominent ridge—the **super-maxillary or zygomatic ridge**.<sup>2</sup> The ridge is continued upwards by the hinder edge of the malar bone, in common with which it gives origin to the masseter muscle. Above the ridge a rough area of the outer surface is articulated to the malar bone.

The *inner or nasal surface* is markedly concave in the transverse direction, and it forms part of the lateral boundary of the nose. Near its anterior edge it is traversed vertically by a groove for the lachrymal duct. In the adult animal this groove is converted superiorly into a complete canal, which is continuous with a similar canal of the lachrymal bone. A little behind this groove a slight bony crest marks the line of attachment of the posterior turbinated bone. At the supero-

<sup>1</sup> In some skulls with the lachrymal also.

<sup>2</sup> Malar process of human anatomy.

anterior part of this surface the bone is excavated into a large irregular cavity, which forms part of the superior maxillary sinus. The palatine plate is attached to the lower two-thirds of this surface close to its posterior edge. Above the upper edge of the plate a rough scaly surface, traversed vertically by a groove, serves for articulation with the palatine bone. The vertical groove, by apposition with a like groove of the palatine bone, is converted into the **palatine canal**.

The *anterior edge* of the body is convex, thin, and scaly. It articulates in succession from below upwards with the nasal process of the premaxilla, the nasal bone, and the lachrymal bone.

The *hinder or alveolar edge* is excavated in the adult animal by six large alveoli for the grinding (pre-molar and molar) teeth, and occasionally by a small seventh alveolus for the so-called "wolf's tooth." Beneath the lowest alveolus this edge becomes narrow, forming part of the interdental space. Above the uppermost alveolus a rough mark—the **alveolar tuberosity**—serves for the attachment of the buccinator and depressor labii inferioris muscles.

The *lower extremity* of the bone is pointed. It articulates with the premaxilla, and by apposition with that bone it forms an alveolus for the canine tooth.

The *upper extremity* forms in the adult animal a great rounded boss—the **maxillary tuberosity** or **protuberance**, which is situated behind the floor of the orbit, and into which the cavity of the superior maxillary sinus extends. At birth the protuberance is but slightly developed, and it then contains the germs of the upper molars. Immediately to the outer side of the protuberance the upper extremity carries a pointed process, the **zygomatic process**, which is articulated outwardly to the malar, and by its summit to the zygomatic process of the squamous temporal. Inwardly the maxillary protuberance is articulated to the palatine bone, by apposition with which it forms the upper orifice of the palatine canal. In front it is insulated by a deep trench—the **maxillary hiatus**, which exhibits three foramina arranged in the form of a semicircle. (1) The **superior palatine foramen**, the most posterior of the three, is formed on the suture between the palatine bone and the protuberance. It is the upper orifice of the palatine canal, whose lower opening is found on the hard palate. (2) The **sphenopalatine foramen** is situated between the other two, and, as already described, it perforates the edge of the palatine bone. (3) The **superior maxillary foramen** is formed entirely in the bone now under consideration. It is the upper orifice of the **superior dental canal**, which traverses the bone to open below at the infra-orbital foramen. The thin plate of bone that bounds the maxillary hiatus in front is articulated to the lachrymal, frontal, and palatine bones.

The **palatine plate** is a shelf of bone springing from the inner surface

of the body, close to its alveolar edge. It forms a large part of the bony palate, and it may be described as possessing two surfaces and four edges.

The *anterior* or *nasal surface* forms part of the floor of the nose. It is a little rough; but in its lower two-thirds, close to its inner edge, it is traversed by a faint groove which marks the course of the canal or organ of Jacobson.

The *posterior* or *palatine surface* is smooth and nearly flat. It forms part of the roof of the mouth, and it shows a number of small foramina for the passage of blood-vessels. Close to its outer edge a vertical furrow—the **palatine groove**—descends along it. This furrow leads downwards from the lower orifice of the palatine canal, and it marks the position of the palato-labial artery and palatine nerve.

The *outer edge* of the palatine plate is fused to the body. The *inner edge* is slightly dentated for articulation with the same edge of the opposite plate, and the hinder edge of the vomer rests on the nasal aspect of this mesial suture. The *lower edge* slopes outwards and forms part of the outer boundary of the incisor cleft. The *upper edge* is scaly and articulated to the palatine bone.

**Development.** The superior maxilla is ossified from a single centre.

#### THE LACHRYMAL BONE.

This small bone is placed at the lower part of the orbit, and it offers for description two surfaces and a circumferent border.

The *outer surface* is sharply divided into a facial and an orbital portion by an edge which forms part of the orbital rim. The facial portion is irregularly pentagonal, and slightly convex. Near the orbital rim it bears in the adult animal a small tubercle—the **lachrymal tubercle**—for attachment of the orbicular muscle of the eyelids. The orbital portion is concave, and irregularly triangular with the point near the maxillary hiatus. It forms a large part of the floor of the orbit, and anteriorly, close to the rim, it is deeply depressed to form the **lachrymal fossa**, from the bottom of which the osseous lachrymal canal begins. The fossa lodges the lachrymal sac, and the canal transmits the first part of the lachrymal duct. Behind the lachrymal fossa a small pit marks the point of origin of the inferior oblique muscle of the eyeball.

The *inner surface* is concave, irregular, and crossed vertically by a ridge that indicates the course of the bony canal already mentioned. It forms part of the boundary of the frontal and superior maxillary sinuses.

The *circumferent edge* of the lachrymal is thin, and scaly or denticulated. It articulates in its lower portion with the superior maxilla, posteriorly with the malar, anteriorly with the nasal and frontal, and by the

posterior point of its orbital portion it again meets the superior maxilla.<sup>1</sup>

**Development.** It ossifies from a single centre.

#### THE MALAR BONE.

This small bone is placed immediately behind the lachrymal, and it meets the zygomatic process of the squamous temporal to complete the zygomatic arch. It may be described as possessing three surfaces, three edges, a base, and a summit.

The *outer* or *facial surface* is smooth, slightly convex, and, like the other surfaces, widest below. The *anterior* or *orbital surface* is smooth, and distinctly concave in its length. It forms part of the floor and outer wall of the orbit. The *posterior* or *articular surface* is for the most part engaged in articulating with the superior maxilla, but in part it enters into the formation of the superior maxillary sinus.

The *antero-external edge* is for the most part concave, and it forms part of the orbital rim. At its lower part it is straight and denticulated to meet the lachrymal. The *antero-internal edge*, also concave, is thin and articulated to the superior maxilla. The *posterior edge* is thick, nearly straight, and directly continuous below with the zygomatic ridge of the superior maxilla, in common with which it gives origin to the masseter muscle. The *base* of the bone forms its lowest point, and articulates with the superior maxilla. The *apex* is thin, pointed, and bevelled inwardly for articulation with the zygomatic process of the squamous temporal.

**Development.** The malar ossifies from a single centre.

#### THE NASAL BONE.

The nasal bones are placed on the anterior aspect of the face, one on each side of the mesial plane. They are named from their relationship to the nasal cavities, which they bound in front. Each bone has the form of a thin slightly curved plate of bone, with two surfaces, two edges, a base, and an apex.

The *outer* or *facial surface* is smooth, and convex from side to side. It is nearly straight in its length, but in some subjects it is very distinctly convex in its lower third.

The *inner* or *nasal surface* is concave from side to side. For the most part it enters into the formation of the nasal fossa, but supero-posteriorly it concurs in forming the frontal sinus. It is traversed lengthways by a thin ridge of bone placed nearer the outer than the inner edge. This ridge or crest marks the attachment of the anterior turbinated bone. Superiorly the ridge sends outwards a branch which forms the lower boundary of the area belonging to the frontal sinus.

<sup>1</sup> In some cases it articulates with the palatine also.

The *inner edge* is straight and opposed to the same edge of the opposite bone. In its lower third it is plain, and for the rest of its extent it is scaly or denticulated.

The *outer edge* is sinuous in outline. In its upper two-thirds it is thin, scaly, and articulated to the superior maxilla and premaxilla. About the junction of its middle and its lower third it presents a rounded notch, below which it is free and forms the edge of the **nasal peak**.

The *base* of the bone is convex, bevelled inwardly, and scaly for articulation with the frontal and lachrymal bones.

The *apex* lies beside the corresponding point of the opposite bone, with which it forms the free end of the nasal peak.

**Development.** Each nasal bone develops from a single centre of ossification.

#### THE PREMAXILLA.

The premaxillary bones are situated at the lower part of the face, and carry the incisor teeth. Each bone comprises a lower thick part or body, a nasal process, and a palatine process.

The **body** presents three surfaces. The *anterior* or *labial surface* is smooth, convex, and related to the upper lip. The *posterior* or *buccal surface* is smooth and slightly concave. It forms the extreme lower part of the hard palate. The *internal* or *articular surface* is flat, and articulated to the same surface of the opposite bone. It is traversed from back to front by a groove which, by apposition with a like groove on the opposite bone, forms a short passage termed the **incisor foramen**. The *inferior edge*, or that which separates the buccal and labial surfaces, is excavated in the adult animal by three sockets or **alveoli** for the incisor teeth. Above the outermost alveolus this edge is smooth and rounded for a short distance, forming the space between the outer incisor and the canine tooth.

The **nasal process** is the larger of the two processes, and it looks like an upward tapering prolongation of the body. It may be said to possess two surfaces, two edges, and two extremities. The *outer* or *facial surface* is smooth, rounded from side to side, and widest below. The *inner* or *nasal surface* is nearly co-extensive with the preceding. It is also smooth and convex in the transverse direction, and it forms a narrow strip of the lateral boundary of the nose. The *anterior edge* is free, smooth, and thick. A wide triangular gap separates it from the edge of the nasal peak. The *posterior edge* is scaly for articulation with the superior maxilla. At its lowest point it forms by articulation with the latter bone the alveolus for the permanent canine tooth.<sup>1</sup> The *lower extremity* of the nasal process is thick and joined to the body of the

<sup>1</sup> When a temporary or milk canine tooth is developed, its socket belongs exclusively to the superior maxilla.

bone. The *upper extremity* is pointed, and wedged in between the nasal bone in front and the superior maxilla behind.

The **palatine** process is shorter and more slender than the preceding, to the inner side of which it lies. It possesses two surfaces, two edges, and two extremities. The *anterior* or *nasal* surface is slightly ridged lengthways. It forms part of the floor of the nasal chamber. The *posterior* or *palatal surface* is flat and smooth, and it forms part of the hard palate. The *inner edge* is straight and dentated for articulation with the same edge of the palatine process of the opposite bone. The *outer edge* is slightly convex, and free, being separated from the nasal process and the superior maxilla by a narrow interval termed the **incisor** or **naso-palatine cleft**. The *lower extremity* is fused to the body, close to the mesial plane. The *upper extremity* is included between the lower end of the vomer and the palatine plate of the superior maxilla.

**Development.** The premaxilla ossifies from a single centre.

#### THE VOMER BONE.

This bone is placed on the mesial plane of the head, forming part of the partition between the right and left nasal chambers. It is composed of two thin strips of bone united by one edge so as to form a narrow deep gutter. It may be described as possessing two surfaces, two edges, and two extremities.

The *surfaces* (right and left) are broadest a little below the upper end of the bone. They are plane, and covered in the recent state by mucous membrane of the nose.

The *anterior edge* shows the gutter-like space already mentioned. Into this is received superiorly the hinder edge of the perpendicular plate of the ethmoid, and below that the same edge of the septal cartilage of the nose. The free margins of the plates that bound the gutter are very thin, and at the upper end of the bone each carries outwardly a narrow surface for articulation with the palatine and ethmoid bones. The *posterior edge* from its upper end to near its middle is narrow and smooth, and in the articulated skull it divides the guttural opening of the nose into a right and a left half. In its lower half the posterior edge is flat and rough for articulation with the nasal aspect of the mesial suture of the palatine and superior maxillary bones.

The *upper extremity* is flattened from before to behind, and opposed to the body of the pre-sphenoid, but in the dried skeleton a narrow interspace is left between the bones. Superiorly a wide notch is cut out of this extremity, and laterally it is articulated to the pterygoid.

The *lower extremity* is pointed, and it extends as far as the tips of the palatine processes of the premaxilla, with whose nasal aspect it articulates.

**Development.** The vomer ossifies from a single centre.

## THE TURBINATED BONES.

There are two of these bones on each side. In the articulated skull they are concealed within the nasal chamber, the extent of which they materially diminish. They are distinguished by the terms anterior and posterior.

The **Anterior** or **Ethmoidal Turbinated Bone**. This bone, viewed as a whole, is irregularly conical, but it may be described as possessing two surfaces, two edges, and two extremities.

The *inner surface* is smooth, slightly convex, and separated by a narrow interval from the septum nasi. The *outer surface* is attached along its anterior limit to the vertical crest already described in connection with the nasal bone. The *anterior edge* is rounded and separated from the nasal bone by a narrow interval—the **anterior meatus** of the nose. The *posterior edge*, also rounded, is separated by a similar interval—the **middle meatus**—from the posterior turbinated bone. The *upper extremity*, forming the base of the cone, is partly blended with the lateral mass of the ethmoid. The *lower extremity*, or *apex*, reaches to near the angle of meeting of the nasal

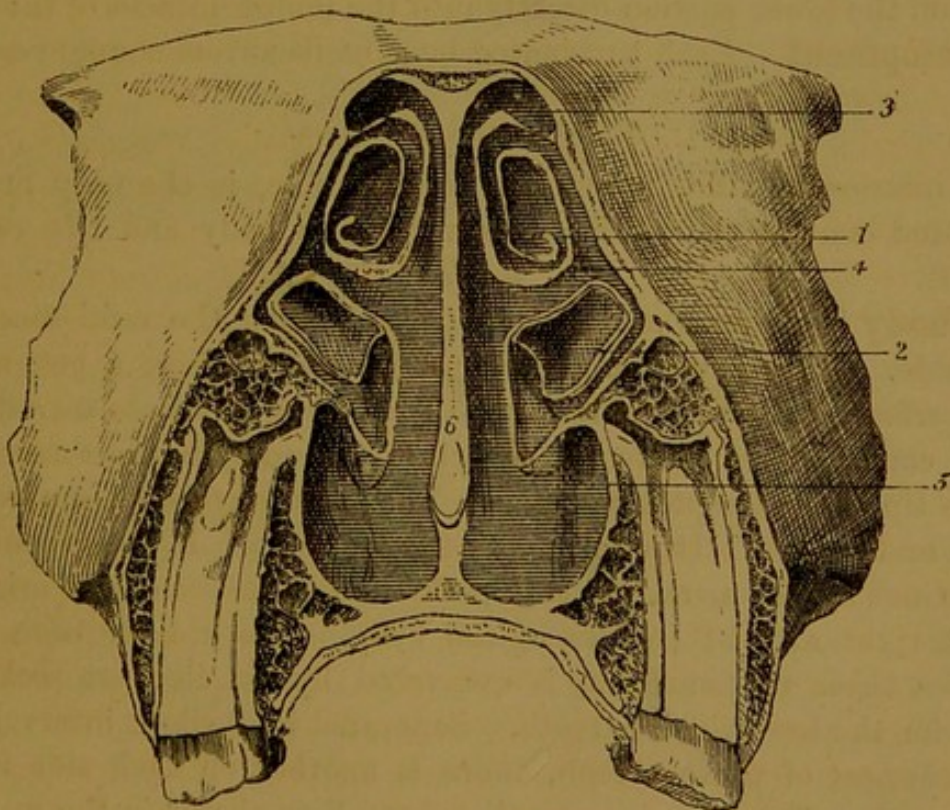


FIG. 48.—TRANSVERSE SECTION THROUGH THE NASAL CHAMBERS.

1. Anterior turbinated bone ; 2. Posterior turbinated bone ; 3. Anterior meatus ;  
4. Middle meatus ; 5. Posterior meatus ; 6. Septum nasi.

and premaxillary bones. In the recent state it is prolonged by cartilage to near the nostril.

The anterior turbinated bone is composed of a paper-like osseous

plate, fixed by its outer edge to the before-mentioned nasal crest, and rolled one and a half times on itself like a scroll. The first turn is made from the fixed edge backwards, as shown in Fig. 48. The curved space which the bone thus circumscribes is divided about its centre by a transverse septum. Above the septum the bone completes the frontal sinus, and its cavity opens into that sinus. Below the septum the cavity of the bone opens directly into the nasal chambers. The bone is invested on both its surfaces by mucous membrane.

The **Posterior** or **Maxillary Turbinated Bone**. This bone resembles in most respects the preceding, but it is considerably smaller. The middle meatus separates it from the anterior bone in front; and a similar but larger interval—the **posterior meatus**—separates its hinder edge from the floor of the nose. It is composed of a thin osseous plate attached by one edge to a crest of the superior maxilla, and rolled upon itself scrollwise. The first turn is made from the fixed edge forwards, or in a direction contrary to that of the anterior bone. Its upper part forms part of the boundary of the inferior maxillary sinus, and, as in the case of the anterior bone, its interior is partitioned by a transverse plate. The upper portion of its cavity opens into the inferior maxillary sinus, and the lower portion directly into the middle meatus of the nose.

**Development.** Each turbinated bone ossifies from a single centre.

#### THE INFERIOR MAXILLA.

The inferior maxilla, lower jaw, or mandible, is the only movably articulated bone of the skull. It comprises a body and two rami or branches.

The **body** is a single median piece from which the rami ascend on either side. It presents an anterior or buccal surface, a posterior or labial surface, and an alveolar edge. The *buccal surface* is smooth, and slightly concave. In the recent state it is covered by mucous membrane, and the tip of the tongue rests on it. The *labial surface* is comparatively smooth and convex. It is related to the lower lip. It shows a more or less distinct mesial mark, indicating the line of fusion of the originally distinct right and left halves of the body. The *alveolar edge*, which separates these two surfaces, is excavated by six close-set sockets or alveoli for the lower incisor teeth. Separated by a slight interval from the outermost of these alveoli, there is another on each side for the canine tooth. These canine alveoli are small or absent in the mare.

The **rami** diverge from one another like the limbs of the letter **V**, leaving between them a space termed the intermaxillary space. Each ramus is a somewhat elliptical plate, with a pronounced round bend a little above its middle.<sup>1</sup> The convex posterior edge of the curved part is

<sup>1</sup> The part of each branch between the angle and the body is sometimes termed the *horizontal ramus*; and the part above the angle, the *vertical ramus*.

termed the **angle** of the jaw. Each ramus may be said to present for description two surfaces, two edges, and two extremities.

The *outer surface* is widest at the angle, and it contracts towards either extremity. Below the angle it is slightly convex and smooth, but in its upper portion it carries a number of prominent rough lines for the attachment of the masseter muscle. At its lower end, close to the body, it presents a large foramen—the **mental foramen**, which opens outwards from the inferior dental canal.

The *inner surface* is co-extensive with the outer. Below the angle it is smooth and slightly depressed lengthways towards its middle. At its

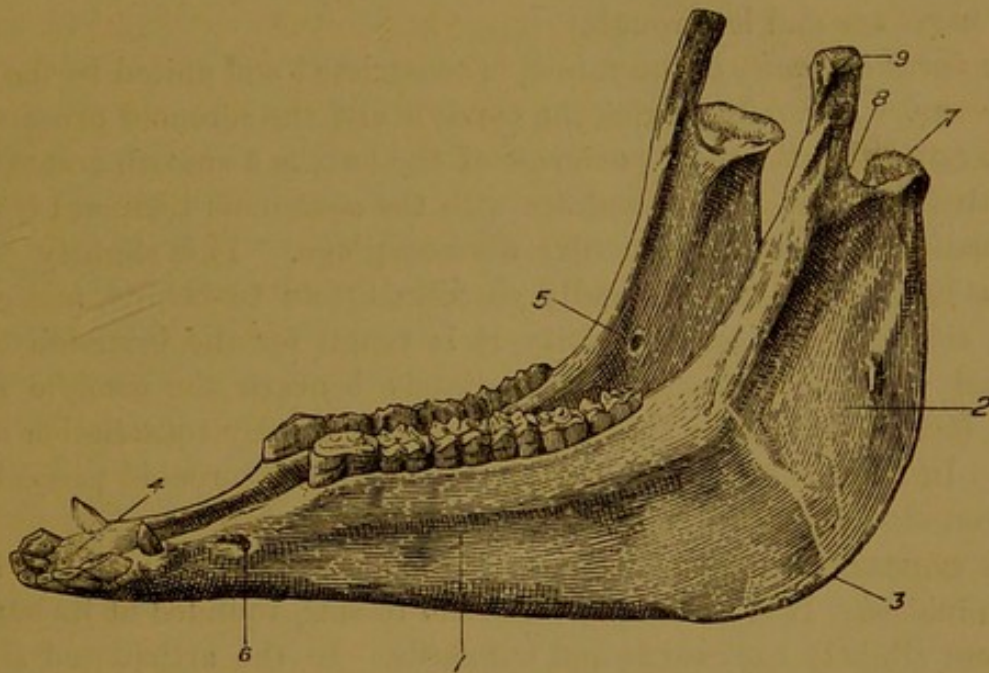


FIG. 49.—INFERIOR MAXILLA OF HORSE.

1. Horizontal ramus; 2. Vertical ramus; 3. Angle; 4. Body; 5. Inferior maxillary foramen; 6. Mental foramen; 7. Condyle; 8. Sigmoid notch; 9. Coronoid process.

junction with the body, close to the posterior edge, it presents a slight depression for the attachment of the genio-hyoideus and genio-glossus muscles. Sometimes a faint longitudinal line near the alveolar edge marks the attachment of the mylo-hyoid muscle. Above the angle it is markedly concave and rough for the attachment of the internal pterygoid muscle. A little in front of its mid point it shows the large **inferior maxillary foramen**. This is the upper orifice of the **inferior dental canal**, which descends through the ramus beneath the roots of the grinding teeth, and after opening outwards at the mental foramen is continued into the body under the canine and incisor teeth. At several points above the angle the ramus is composed entirely of compact tissue, and is so thin as to be translucent.

The *anterior* or *alveolar edge* is excavated below the level of the angle by the alveoli (six in number in the adult) for the lower grinding teeth.

In front of the lowest of these alveoli this edge forms a short interdental space. Above the angle it is thin and sharp, and immediately below the coronoid process of the upper extremity it is roughened for the attachment of the temporal muscle.

The *posterior edge* is thick and rounded below the angle in the young subject, but in old animals it is much narrower and sharper. The middle third of this part is roughened for the insertion of the lower tendon of the digastricus. The **angle** itself is broad and rough for muscular attachment, and immediately below it a smooth part indicates the point where the submaxillary vessels and the duct of the parotid gland turn round the bone. Above the angle the bone again becomes much narrower and less rough.

The *lower extremity* of the ramus is constricted and united to the body.

The *upper extremity* carries the condyle and the coronoid process.

The **condyle**, the most posterior of the two, is a smooth transversely elongated process. It articulates with the squamous temporal through the medium of an interarticular fibro-cartilage. It is slightly convex from side to side, and markedly so from before to behind, and on the under side of its inner extremity it is rough for the insertion of the external pterygoid muscle. Immediately beneath the condyle is the **neck**, but in the horse this is not marked by any constriction of the bone. In front the condyle is separated from the coronoid process by a deep rounded **sigmoid** or **corono-condyloid notch**.

The **coronoid process** surmounts the condyle by an inch and a half or two inches. It is flattened from side to side, rounded at its summit, and bent slightly backwards and outwards. In the articulated skull it projects into the temporal fossa, and it serves for the attachment of the temporal muscle.

**Development.** The inferior maxilla ossifies from two lateral centres, one for each ramus and the corresponding half of the body. At birth and for about two months afterwards the bone is composed of separable right and left halves, united along a mesial suture or symphysis of the body.

#### THE HYOID BONE.

The so-called hyoid bone comprises the following distinct osseous pieces.

The **body**, or *basi-hyal*, is a short transversely placed rod of bone around which the other pieces are grouped. Mesially the glossal process is solidly united with it in front. Each extremity of it carries superiorly a convex facet for articulation with the small cornu, and it is fused with the thyroid cornu behind.

The **glossal process**, or *glosso-hyal*, is a mesially placed rod, united to the body by its posterior end, while its anterior end is pointed and free.

The process is compressed from side to side, with a sharp upper and a blunt under edge. It is embedded in the root of the tongue, and it affords attachment to the mylo-hyoid, genio-hyoid, and great hyo-glossus muscles.

The **thyroid cornua**, or *thyro-hyals*. Each of these is a slightly curved bar of bone, united by its anterior extremity to the body, and by its posterior extremity to the superior cornu of the thyroid cartilage of the larynx.

In the adult animal the body, glossal process, and thyroid cornua are united to form a single piece having some resemblance to a spur, the glossal process representing the spur proper, and the combined body and thyroid cornua representing the fork for the heel.

The **small cornua**, or *cerato-hyals*. Each of these is a short rod of bone, which in the ordinary position of the head is directed obliquely upwards and forwards. Its lower extremity is furnished with a small cup-like facet for articulation with the body, while its upper extremity is blunt and united by intermediate fibro-cartilage to the lower end of the great cornu.

The **great cornua**, or *stylo-hyals*, are the largest pieces of the hyoid. Each is a long strap-shaped piece of bone, directed obliquely upwards and back-

wards from the small cornu to the base of the skull, and slightly curved in its length with the concavity outwards. When viewed in profile the bone has some resemblance to the human leg and foot, the latter part being represented by the upper extremity of the bone. It may be described as possessing two surfaces, two edges, and two extremities. The *outer surface* is smooth and narrowest below. The *inner surface* is co-extensive with the outer, and also smooth. The *lower extremity* is narrow, and united by fibro-cartilage to the small cornu. The *upper*

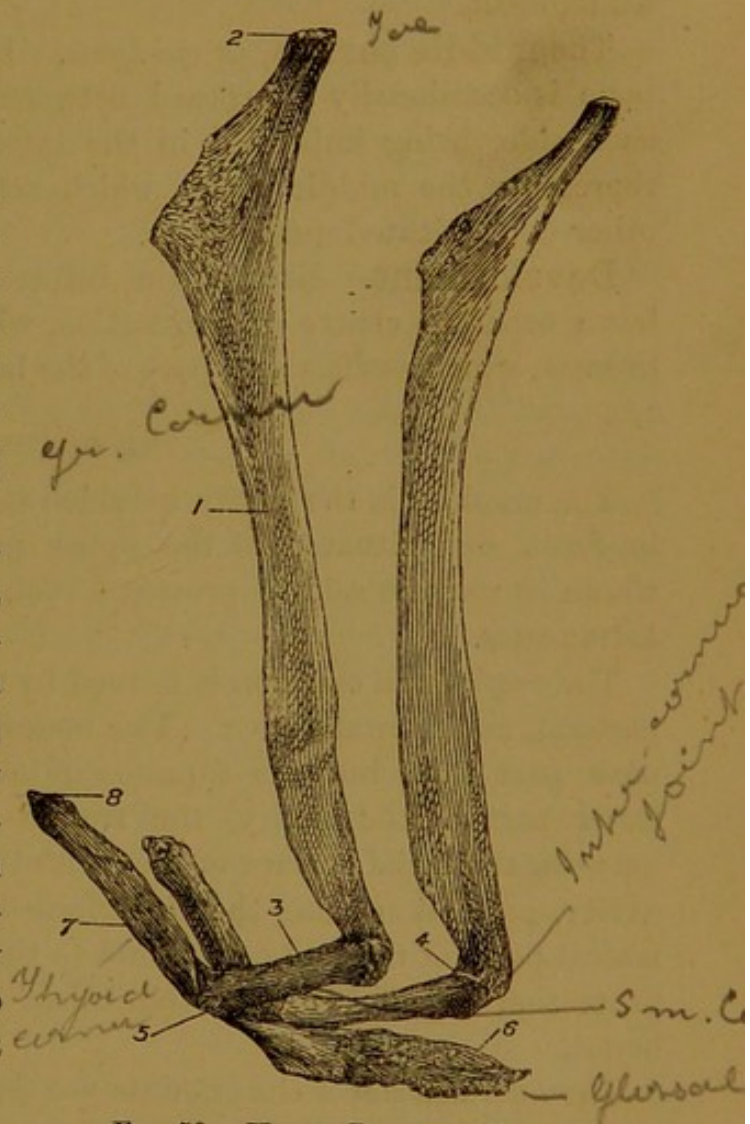


FIG. 50.—HYOID BONE OF HORSE.

1. Great cornu; 2. Toe-like point of same; 3. Small cornu; 4. Intercornual joint; 5. Joint between small cornu and body; 6. Glossal process; 7. Thyroid cornu; 8. Tip of same for articulation with thyroid cartilage.

*extremity* has, as already said, an outline like the human foot. The toe-like point is united by a short rod of fibro-cartilage to the hyoid process of the petrous temporal. The part representing the sole is separated from the styloid process of the occipital by a triangular interval which is filled up by the occipito-styloid muscle. This sole-like edge terminates posteriorly in a thickened "heel," and both are roughened for muscular attachment.

The **middle cornua**, or *epi-hyals*. In the horse a pea-like nucleus of bone is occasionally interposed between the great and small cornua on each side, being imbedded in the intermediate fibro-cartilage. This represents the middle cornu, which attains a much greater size in the other domesticated quadrupeds.

**Development.** Each of the before-described divisions of the hyoid has a separate centre of ossification, with the exception of the glossal process, which ossifies as a part of the body.

#### THE CRANIUM.

The cranium is the cavity in which the brain is lodged. It is ovoid in form, and situated in the upper part of the skull. Viewed as a whole, it may be said to present a roof, a floor, lateral walls, and two extremities.

The *roof* of the cranium is formed by the supra-occipital, interparietal, parietal, and frontal bones. The bones composing the roof are for the most part thin, but the supra-occipital is thick and strong. At the lower part of the cavity, the frontal sinuses are extended upwards between the facial surface of the frontal bone and the proper roof of the cavity, protection being thereby afforded to the underlying brain. The lateral parts of the roof correspond to the temporal fossæ, and here again protection is afforded by the thick temporal muscles clothing the bones.

The *lateral walls* of the cranium are formed by the occipital, temporal, parietal, and frontal bones. They pass without any line of demarcation into the roof and floor.

The *floor* is formed by the basilar process of the occipital, and the sphenoid bone. It is rugged and irregular, being perforated by foramina for the passage of cranial nerves and vessels. The bones of the cranial floor are thick as compared with the roof and walls; but notwithstanding this, a blow delivered over the roof may fracture the floor, where the bones are weakened by the numerous foramina that perforate them.

The *upper extremity* of the cavity is pierced by the foramen magnum, which puts the cranium and the spinal canal in free communication.

The *lower extremity* is closed by the cribriform plate of the ethmoid, which serves as a partition between the cranium and the nasal fossæ.

The cranium is partially subdivided even in the dry skull into three

compartments, viz., an upper or cerebellar, a middle or cerebral, and a lower or olfactory.

The **cerebellar compartment** underlies the vaulted supra-occipital, its floor being formed by the basilar process. It communicates superiorly through the foramen magnum with the neural ring of the atlas. Inferiorly the plane of separation between this and the cerebral compartment is indicated on the middle of the roof by the ossific tentorium, and on each side by a bony ledge formed by the parietal and petrous temporal bones. These bony projections indicate the attachments of the tentorium cerebelli, which in the recent state effects a more complete separation between the cerebral and cerebellar compartments. The cerebellum is the largest of the divisions of the brain herein contained; but the medulla oblongata and pons Varolii are also lodged here, resting on the basilar process of the occipital bone.

The **cerebral compartment** greatly exceeds the other two in size. Its floor is formed by the sphenoid, and its roof and lateral walls by the parietal, frontal, and squamous temporal. Superiorly it is separated in the manner previously indicated from the cerebellar compartment, and inferiorly the olfactory fossæ open freely off it. It is almost regularly oval in form, and it is occupied by the cerebrum, whose convolutions leave their impress in the shape of digital markings on the roof and walls of the cavity.

The **olfactory compartment** lies at the lower extremity of the cranium, and it is divided by the crista galli process into two well-defined oval pits—the **olfactory fossæ**. The floor of these pits is formed by the cribriform plate, and they accommodate the olfactory bulbs.

#### THE TEMPORAL FOSSÆ.

The temporal fossæ (right and left) occupy the anterior and lateral aspects of the cranium. They are the cavities for the lodgment of the temporalis muscles, and their size varies very greatly in different species of animals, in correspondence with the degree of development of these muscles. In the horse, as in other herbivora, they are of relatively small capacity, as compared with the great proportions that they attain in the dog and carnivorous animals in general.

Each fossa has the form of a wide and shallow spiral groove. In the upward direction it extends as far as the occipital crest, and here the right and left fossæ approach the mesial plane, being separated only by the sagittal crest.

This **sagittal crest** is a slight bony ridge developed on the middle line of what was in the foal the flat smooth outer surface of the interparietal bone. Superiorly it is prolonged to join the occipital crest, and inferiorly it reaches the interparietal suture. As the temporal fossæ

descend they deviate from one another, and pass outwards to become confounded with the orbital cavities. Inwardly each fossa is limited by a curved line that connects the sagittal crest to the upper edge of the supra-orbital process. Outwardly it is bounded by the zygomatic process of the squamous temporal, and by a sharp ridge continued from the upper root of that process to the occipital crest. The bones that form the fossa are the occipital, parietal, interparietal, frontal, and squamous temporal. The surface of these bones is slightly roughened for the attachment of the temporalis muscle. In its outer part the fossa presents a number of foramina leading out of the parieto-temporal canal.

#### THE ORBITS.

The orbits, or sockets for the eyes, are situated on the lateral aspect of the skull, towards the junction of the cranium and the face. Each cavity is cone shaped, the axis of the cavity being directed downwards, outwards, and slightly forwards from its apex to its base. In the dry skull the bony boundaries of the orbit are deficient posteriorly, so that the cavity is there quite open outwardly, and confounded superiorly with the temporal fossa. The *apex* of the orbit lies at the optic foramen. Its *base* is circumscribed by a circle of bone termed the **orbital rim**. The bones that enter into the formation of the rim are the lachrymal below, the frontal inwardly, the supraorbital process of the frontal above, and the tip of the zygomatic process of the squamous temporal and the malar bone outwardly. The bones that concur to form the *walls* of the orbit are those just mentioned, and in addition the palatine and sphenoid. The cavity of the orbit is much more perfectly circumscribed in the living animal, in which a strong fibrous membrane—the *ocular sheath*—completes it posteriorly, and isolates it from the temporal fossa. The interior of the orbit is for the most part smooth to permit the movements of the eyeball.

Superiorly, under the supraorbital process, a shallow pit marks the situation of the lachrymal gland. On the floor of the cavity the lachrymal bone presents the lachrymal fossa for the lodgment of the sac of the same name, and from the bottom of the fossa the bony tube for the lachrymal duct begins. Immediately behind the lachrymal fossa a little pit marks the origin of the inferior oblique muscle of the eye. On the inner side of the orbit, beneath the root of the supraorbital process, a slight depression of the orbital plate of the frontal marks the position of the fibrous loop for the play of the reflected tendon of the superior oblique muscle of the eye.

#### THE NASAL FOSSE.

The cavity of the nose is divided by a vertical mesial partition into right and left halves, termed the nasal fossæ. Each fossa is an elon-

gated tubular passage, which for descriptive purposes may be said to present a roof, a floor, lateral walls, and two extremities.

The *roof*, or anterior wall, is formed by the nasal and frontal bones. The *floor*, or posterior wall, is formed by the palatine, superior maxillary, and premaxillary bones, the opposite aspect of these same bones forming the bony palate. The *inner wall* is very imperfect in the dry skull. It is formed in part by the vomer, and superiorly by the perpendicular plate of the ethmoid; but below the lower edge of the plate the right and left fossæ are not separated in the skeleton. In the recent state the perpendicular plate is continued downwards and completed by the septal cartilage. The *outer wall* is formed by the superior maxillary, premaxillary, and nasal bones, and it is rendered very irregular by the anterior and posterior turbinated bones, which descend along it. These bones divide the nasal fossa into three narrow passages, termed respectively the anterior, middle, and posterior meatus. The **anterior meatus** lies in front of the anterior turbinated bone, the **middle meatus** between the two turbinated bones, and the **posterior meatus**, the largest of the three, between the nasal floor and the posterior turbinated bone. The osseous tube for the lachrymal duct opens into the middle meatus, and is continued downwards by a groove. At the upper part of this same meatus a narrow interspace between the two turbinated bones leads into the superior maxillary sinus.

The *lower extremity* of the nasal fossa is bounded by the nasal and premaxillary bones, and it opens into the outer air.

The *upper extremity* is closed towards the cranial cavity by the cribriform plate of the ethmoid, and further occluded by the lateral mass of the same bone. Below and behind the lateral mass the nasal fossa presents its guttural or pharyngeal opening. The right and left openings, or **superior nares**, as they are termed in opposition to the inferior nares, or nostrils proper, are separated by the hinder edge of the vomer, while each is bounded outwardly by the palatine and pterygoid bones.

#### THE AIR SINUSES OF THE SKULL.

The sinuses of the skull are large air spaces developed on the limits of the cranium and the face, and communicating directly or indirectly with the nose. They affect considerably the contour of the head, and add to its volume without materially increasing its weight. In the recent state they are lined by a continuation of the mucous membrane of the nose. The sinuses number four pairs, viz., sphenoidal, frontal, superior maxillary, and inferior maxillary. They are imperfectly developed in the foal's head at birth, and they continue to increase in size even after the period of adult life has been attained. The following description of them applies to the skull of a middle-aged subject.

The **sphenoidal sinus** is the smallest of the four. It consists of an

upper or sphenoidal part, and a lower or palatine part, which communicate with each other by a narrow aperture. The *sphenoidal part* consists of a variable number of loculi excavated in the body of the pre-sphenoid, and separated from the opposite sinus by a mesial perforated plate. The *palatine part* is bounded by the vomer, palatine, and lateral mass of the ethmoid, and it opens freely in front into the inner compartment of the superior maxillary sinus.

The **frontal sinus** is the second in point of size. It is bounded by the frontal, nasal, lachrymal, ethmoid, and anterior turbinated bones. In the upward direction it extends as far as a line drawn level with the upper edge of the supra-orbital process, so that it here lies in front of the lower end of the cranial cavity. A mesial plate forms a complete partition between the right and left sinuses. A thin bony septum extending between the lateral mass and the osseous tube for the lachrymal duct separates the frontal from the superior maxillary sinus, but a large nearly circular hole in this septum places the two sinuses in free communication.

The **superior maxillary sinus** is the largest of these cavities. It is bounded by the superior maxilla, lachrymal, malar, and ethmoid. It is imperfectly divided into an outer and an inner compartment by a bony ridge, whose free edge corresponds to the superior dental canal. Over this edge the two compartments communicate freely with one another. The *inner compartment* extends backwards and upwards beneath the floor of the orbit, and here the sphenoidal sinus opens into it. On its inner side it communicates with the frontal sinus by the large aperture previously mentioned. Towards its lower extremity it opens into the middle meatus of the nose by a narrow aperture between the two turbinated bones. The *outer compartment* extends beneath the orbit and into the maxillary protuberance. Inferiorly it is separated from the inferior maxillary sinus by a thin but imperforate horizontal plate, which in a medium-sized animal lies about an inch and a half above the lower end of the zygomatic ridge of the superior maxilla. The root of the uppermost molar tooth and in part that of the one next to it are seen in this compartment, invested by a thin layer of bone.

The **inferior maxillary sinus**. This cavity also comprises an outer and an inner compartment, which communicate freely over a bony ridge caused by the superior dental canal. The *outer compartment* lies directly below the corresponding compartment of the sinus last considered, from which, as before said, it is completely separated by a thin bony septum. The root of the third uppermost grinding tooth, and in part also the root of the tooth on either side of that, project into it. A horizontal line drawn about three-quarters of an inch below the lower extremity of the zygomatic ridge of the superior maxilla would indicate the lower limit of this compartment, which is formed entirely

in the bone last mentioned. The *inner compartment* is formed between the superior maxilla and the posterior turbinated bone. On the one hand it communicates with the outer compartment, and on the other with the middle meatus of the nose.

#### THE FORAMINA OF THE SKULL.

The **foramen magnum**. This is the largest foramen of the skull. It is nearly circular in outline, and it is formed entirely in the occipital bone, whose condyles bound it on either side. It transmits the spinal cord with its meningeal envelopes, the spinal roots of the 11th cranial nerve, the basilar artery, and some unnamed veins.

The **condyloid foramen** is also a perforation of the occipital bone, its outer opening being found at the bottom of a deep fossa between the condyle and the root of the styloid process. It gives passage to the 12th cranial nerve, a meningeal branch of the prevertebral artery, and the condyloid root of the occipital vein.

The **foramen lacerum basis cranii**. This in the dry skull is a large irregularly triangular gap in the floor of the cranium, bounded inwardly by the basilar process of the occipital, outwardly by the base of the petrous temporal, and below by the wing of the post-sphenoid. In the recent state it is in large measure closed by dense fibrous tissue or fibro-cartilage. At its upper angle an opening (*foramen lacerum posterius*) is left for the exit of the 9th, 10th, and 11th cranial nerves, and for the entrance of a meningeal twig of the prevertebral artery. At the lower edge of the gap now being considered three other foramina are left, these being bounded inferiorly by the notches previously described in connection with the wing of the post-sphenoid (page 57), and superiorly by the above-mentioned fibro-cartilage. The innermost of the three (*foramen lacerum medium*) gives passage to the internal carotid artery, the vidian nerve, the cranial branches of the sympathetic nerve, and the connecting branch between the cavernous sinus and the sub-sphenoidal sinus. The middle foramen (*foramen ovale*) is the largest of the three. It gives passage to the inferior maxillary division of the 5th cranial nerve. The outermost of the three foramina (*foramen spinosum*) lies just at the root of the styloid process of the petrous temporal, and it transmits the spheno-spinous or great meningeal artery.

The **parieto-temporal canal**. This canal begins as a groove at the base of the ossific tentorium of the interparietal bone. It is continued outwards as a groove between the occipital and parietal bones, being completed outwardly by the squamous temporal, but open towards the cavity of the cranium. Finally, in its outer third it is a complete canal between the petrous and squamous divisions of the temporal bone, its outward orifice being found above the post-glenoid process, and in front

of the auditory process. A vascular furrow on the outer surface of the petrous temporal passes under the pyramidal process of the squamous temporal, and conducts the mastoid artery into the canal. The transverse sinus of the dura mater passes along the entire length of the canal to issue at its outward opening.

The **internal auditory meatus** is found on the inner surface of the petrous temporal, and by it the 7th and 8th cranial nerves enter. The former is conducted through the bone by a curved canal—the **aqueduct of Fallopius**—to emerge again at the stylo-mastoid foramen. The 8th nerve is expended within the petrous temporal in supplying the labyrinth, or internal ear.

The **aquæductus cochleæ** is a slit-like opening behind the internal auditory meatus. Above that again is a somewhat larger orifice—the **aquæductus vestibuli**. These lead respectively to the cochlea and vestibule of the labyrinth, and they transmit small vessels to and from these parts.

The **stylo-mastoid foramen** opens between the mastoid process and the auditory bulla. As already stated, it is the outward opening of the aqueduct of Fallopius, and it gives passage to the 7th cranial nerve.

The **styloid foramen**, or **Glaserian fissure**, opens to the outer side of the root of the styloid process of the petrous temporal. It gives exit to the chorda tympani nerve—a branch detached from the 7th nerve in the aqueduct of Fallopius.

The **external auditory meatus** is the outward opening of a short tube—the auditory process of the petrous temporal—which in the articulated skull is situated between the post-glenoid and pyramidal processes of the squamous temporal. In the dried skull it leads down into the tympanum or middle ear, but in the recent state the membrana tympani is stretched across the bottom of the tube.

The **Eustachian opening** of the middle ear perforates the petrous temporal in front and slightly to the inner side of the root of the styloid process. It admits air from the Eustachian tube to the middle ear.

The superficial petrosal nerves issue from the petrous temporal a little to the inner side of the Eustachian opening, and the auricular branch of the vagus enters the aqueduct of Fallopius by a small foramen on the posterior surface of the same bone. The last-mentioned foramen cannot be seen in the articulated skull.

The **sub-sphenoidal canal**, or **pterygoid foramen**, perforates the root of the sub-sphenoidal or pterygoid process of the post-sphenoid bone, and gives downward passage to the internal maxillary artery. Its upper orifice is plainly seen a little outwards from the body of the post-sphenoid, but its lower opening lies under concealment of the lower edge of the wing of the same bone.

The **vidian canal** is a fine canal for the transmission of the nerve of the same name. Its upper orifice lies directly to the inner side of the sub-sphenoidal canal, and its lower forms one of the group of orbital foramina. The vidian groove leads down to its upper opening, and the canal itself is formed by the apposition of the sphenoid, pterygoid, and palatine bones.

At the back of the orbit a number of foramina are grouped together

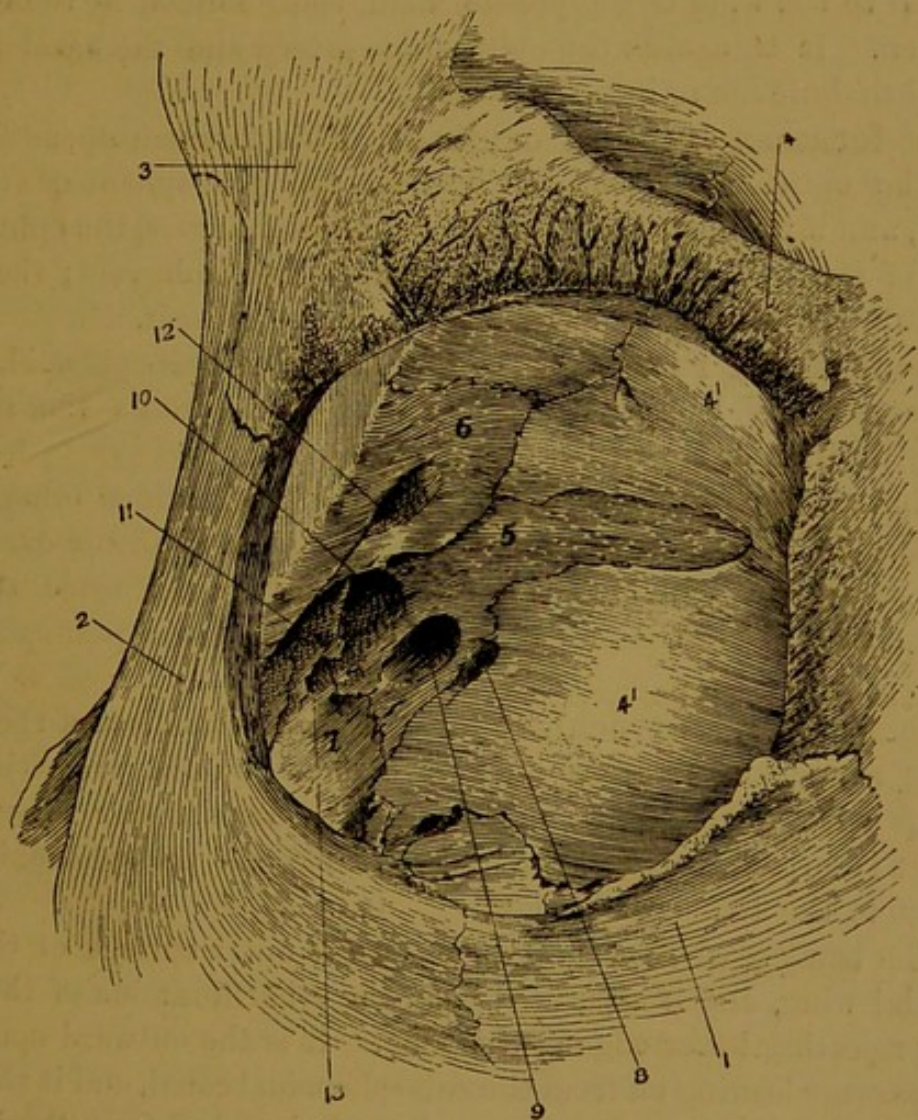


FIG. 51.—ORBITAL GROUP OF FORAMINA OF HORSE'S SKULL.

1. Lachrymal bone; 2. Malar bone; 3. Zygomatic process of squamous temporal;
4. Supra-orbital process of frontal bone; 4' 4'. Orbital plate of same; 5. Wing of pre-sphenoid; 6. Wing of post-sphenoid; 7. Palatine bone; 8. Internal orbital foramen; 9. Optic foramen; 10. Foramen lacerum orbitale; 11. Foramen rotundum behind which is the lower orifice of sub-sphenoidal canal; 12. Temporal foramen; 13. Lower orifice of vidian canal. The pathetic foramen, which by an oversight has no reference line in the figure, is seen below the temporal foramen. The line from the numeral 9 if prolonged would touch its edge.

to form what is sometimes termed the **orbital hiatus**, or the **orbital group** of foramina. They are eight in number, viz., the optic foramen, the internal orbital foramen, the foramen lacerum orbitale, the foramen

rotundum, the pathetic or trochlear foramen, the temporal foramen, and the lower openings of the sub-sphenoidal and vidian canals.

(1) The **optic foramen** is formed entirely in the pre-sphenoid bone, and it lies almost directly in the axis of the orbit. It is circular in form, and it gives outward passage to the optic or 2nd cranial nerve.

(2) The **internal orbital foramen** opens a little below and in front of the optic. It is situated on the suture uniting the orbital plate of the frontal to the wing of the pre-sphenoid, being formed by these bones in common. It transmits the ophthalmic artery and the nasal branch of the ophthalmic nerve into the cranium.

(3) The **foramen lacerum orbitale**. This foramen opens directly behind the optic. It is formed between the post-sphenoid and pre-sphenoid, and it transmits the 3rd and 6th cranial nerves, the ophthalmic division of the 5th cranial nerve, and the ophthalmic vein; the vessel passing into the cranium, and the nerves issuing from it.

(4) The **foramen rotundum** is formed in the post-sphenoid, and it opens immediately behind the preceding. It transmits the superior maxillary division of the 5th cranial nerve.

(5) The **sub-sphenoidal canal** has its lower orifice immediately behind the foramen rotundum. In the complete skull the distinction between these two openings cannot be clearly seen, since they lie under concealment of the projecting lower edge of the post-sphenoidal wing.

(6) The **pathetic or trochlear foramen** is the smallest of the group. It opens above the foramen lacerum orbitale, on the projecting edge of bone previously mentioned, or in some instances under concealment of it. It is formed between the post-sphenoid and pre-sphenoid, and it gives exit to the 4th cranial nerve.

(7) The **temporal foramen** opens on the outer surface of the post-sphenoidal wing, and is separated from the other foramina of the group by the projecting lower edge of the wing. It is the outward opening of a short passage leading off from the sub-sphenoidal canal, and it transmits the anterior deep temporal artery—a branch detached from the internal maxillary artery.

(8) The lower orifice of the **vidian canal** is found below the thin septum of bone separating the foramen rotundum from the foramen lacerum orbitale. It is formed at the point of meeting of the post-sphenoid, pre-sphenoid, and palatine bones, and it gives exit to the vidian nerve from the canal.

The **supra-orbital foramen** perforates the root of the supra-orbital process of the frontal bone, and gives upward passage to the artery and nerve of the same name.

The **olfactory foramina**. Under that name there may be included

(1) the numerous minute perforations of the cribriform plate of the ethmoid, giving passage to the filaments of the 1st cranial nerve, and (2) the single larger foramen at each side of the plate, which transmits the nasal branches of the ophthalmic artery and nerve into the nasal fossa.

The following three foramina, sometimes classed together as the **maxillary hiatus**, or the **maxillary group** of foramina, are situated behind the orbital floor, almost vertically under the before-described orbital group.

(1) The **superior palatine foramen**. The three foramina lie in the arc of a circle and this is the most posterior. It is formed in common by the palatine and superior maxillary bones, and it transmits the palato-labial artery and the palatine nerve into the palatine canal.

(2) The **spheno-palatine foramen** is placed between the other two. It is larger than the preceding, circular in shape, and pierced in the palatine bone. It transmits the spheno-palatine artery and nerve into the nasal chamber, and a vein of the same name out of it.

(3) The **superior maxillary foramen** is the most anterior of the three. It is formed entirely in the superior maxillary, but its outline cannot be very easily seen in the intact skull, since it lies in the depth of a deep trench that isolates the maxillary protuberance anteriorly. It transmits the superior dental artery and nerve into the canal of the same name, and the accompanying vein in the opposite direction.

The **lachrymal fossa** and **osseous lachrymal canal**. The fossa of this name occupies nearly the whole of the orbital surface of the lachrymal bone, and from the bottom of it the bony canal leads through the substance of the lachrymal bone, to be continued for a short distance in the superior maxilla. The inward opening of the canal is found on the nasal surface of the last-named bone, in the middle meatus of the nose, and it is continued down the bone by a groove. The fossa lodges the lachrymal sac, and the tube gives passage to the duct of the same name.

The **posterior palatine foramen** is found at the upper part of the bony palate, on the suture uniting the palatine and superior maxillary bones. It is continued down the palate by the palatine groove, and it gives downward passage to the palato-labial artery and the palatine nerve.

The **palatine canal**<sup>1</sup> is formed by the apposition of the palatine and superior maxillary bones. Its upper orifice is the superior palatine foramen of the maxillary group, and its lower the foramen last described. It transmits the palato-labial artery and the palatine nerve.

<sup>1</sup> Posterior palatine canal of human anatomy.

The **infra-orbital foramen** is found on the facial surface of the superior maxilla. It is the outward opening of a branch from the superior dental canal, and it gives exit to the infra-orbital nerves and a slender artery of the same name.

The **superior dental canal** conveys the vessels and nerves for the teeth of the upper jaw. The superior maxillary foramen of the maxillary hiatus is its upper opening, and the superior dental artery and nerve here enter it, while the vein of the same name issues from it. The canal descends in the superior maxilla above the roots of the grinding teeth, and, after throwing off a branch to open outwards at the infra-orbital foramen, it is continued into the premaxilla above the roots of the canine and incisor teeth.

The **incisor foramen**<sup>1</sup> is in reality a short mesially placed canal formed by the apposition of the right and left premaxillary bones. Its posterior opening is found at the lower end of the hard palate, and it transmits to the upper lip the labial vessel resulting from the fusion of the palato-labial arteries of opposite sides.

The **naso-palatine** or **incisor cleft**<sup>2</sup> is a slit-like opening on each side of the bony palate, bounded on its inner side by the palatine process of the premaxilla, and on its outer side by the nasal process of the same bone and by the superior maxilla. In the recent state it is closed by fibro-cartilage, into which the canal of Stenson passes from the nose.

The **inferior maxillary foramen** is found on the inner surface of the ramus of the lower jaw bone. It transmits the inferior dental artery and nerve into the canal of the same name, and the inferior dental vein in the opposite direction.

The **mental foramen** is found on the outer side of the ramus of the inferior maxilla, close to its junction with the body. It is the outward opening of a branch from the inferior dental canal, and it gives passage to the mental vessels and nerves.

The **inferior dental canal** conveys the vessels and nerves for the supply of the teeth of the lower jaw. Beginning at the inferior maxillary foramen, it descends through the ramus beneath the roots of the grinding teeth; and, after opening outwards at the mental foramen, it is continued into the body of the bone, to supply the canine and incisor teeth.

#### MORPHOLOGY OF THE SKULL.

When a comparison is instituted between the skeleton of the head and the axial skeleton of the trunk, a certain similarity of structure is observable. A segment of the axial skeleton when most completely developed, as in the region of the back for example,

<sup>1</sup> Two foramina—the foramina of Scarpa—represent this in the human subject.

<sup>2</sup> Foramen of Stenson of the human subject.

comprises (1) a central axis represented by the vertebral body; (2) a superior or neural arch, which completes on the upper aspect of the central axis a segment of the canal for the lodgment of the spinal cord; and (3) an inferior, hæmal, or visceral arch, here formed by a rib on each side, and completed below by a sternal segment. In the arrangement of the component bones of the cranial skeleton there is a suggested homological relationship with certain of the above-mentioned parts of a trunk segment. This is most obvious in the case of the occipital bone, the body or basilar process of which clearly lies in series with the vertebral centra, while its ex-occipital and supra-occipital parts stand to the basilar process in the relationship of a neural arch. Further it is not a far-fetched comparison to accept the condyloid foramen as the representative of an intervertebral foramen (which in the atlas and axis pierces the arch) and the styloid process as the homologue of a vertebral transverse process. Again, the postsphenoidal body may be taken to represent the centrum of another cranial segment, the arch of which is formed by the postsphenoidal wings and the parietal bones. In front of this the presphenoid and frontal bones make up a third cranial segment. Lastly, although the homology is by no means so clear as in the other instances, a fourth cranial segment may be recognised in the union of the ethmoid, frontal, and nasal bones.

It is thus easy to recognise in the arrangement of the cranial bones a resemblance to, if not an actual homology with, vertebræ. On the other hand, the skeleton of the face appears to be for the most part made up of greatly modified inferior or visceral arches. Thus the hyoid bone constitutes an arch not unlike one of the thoracic visceral arches, the stylo-hyal and cerato-hyal taking the place of a rib, and the basi-hyal representing a sternal segment. The lower jaw or mandible clearly represents another free visceral arch, and the thyro-hyals may possibly be a rudiment of a third. Finally, although the resemblance is much more obscure, the premaxillary bones, and the united pterygoid, palatine, and superior maxillary bones may represent other two of the visceral arches of the skull.

Although the majority of the elements of the cephalic skeleton may thus be looked upon as parts of peculiarly modified cranial vertebræ, or of their visceral arches, there are certainly other bones of the skull that have no corresponding parts in the trunk skeleton. The temporal bone, for example, is a special ossification developed as a protection to the organ of hearing.

#### THE SKULL OF THE OX.

**Occipital Bone.** In the ox this bone is confined to the supero-posterior part of the skull. It does not form the highest point of the skull, nor is it at all visible when the head is viewed directly from the front. As in the horse, it is primarily composed of four pieces, but the supra-occipital even before birth is united to the interparietal and parietal bones, whereas the basi-occipital and ex-occipitals remain separable during the first few months of extra-uterine life. The basilar process is shorter but broader than in the horse. Its outer surface is traversed mesially by a slight ridge, and furnished at its lower extremity with two pronounced muscular eminences. Its cranial surface is more depressed than in the horse. The condyles have a tolerably well-defined edge dividing their articular surfaces into an upper and a lower facet. The styloid processes are shorter, wider at the base, and more curved inwards at the tip than in the horse. Besides the usual foramen (*anterior condyloid* of human anatomy) for the passage of the twelfth cranial nerve, another opening (sometimes double) perforates the bone immediately in front of the condyle. This foramen (*posterior condyloid*), which is situated above and in front of the other, opens outwardly into the stylo-condyloid fossa, and inwardly into the cranium, and between these two points it leads into a venous canal which passes upwards and forwards to open on the interior of the skull, near the upper end of the parieto-temporal canal. The supra-occipital part shows on the middle of its outer face an obtuse eminence for the insertion of the ligamentum nuchæ. On its cranial aspect it presents a central depression, and at each lateral angle a groove for the lateral sinus.

**Interparietal Bone.** In the skull of the foetal calf this bone forms a separate element, which, indeed, as in the horse results from the fusion of two lateral pieces. Before birth, however, it fuses with the supra-occipital behind, and the two parietals in

front, the lines of junction being traceable for a longer period on the interior than on the exterior of the cranium. It differs notably from the same bone of the horse in that it does not carry any distinct ossific tentorium on its cranial aspect.

**Parietal Bones.** These bones differ altogether in form and position from the same bones of the horse. They are confined to the superior aspect of the skull, no more than their anterior edge being visible when the skull is viewed directly from the front. The right and left bones fuse much more promptly than in the horse, and, as already stated, they are also early united with the interparietal and supra-occipital. Each bone is bent to nearly a right angle, so as to present an upper horizontal part which unites with the same part of the opposite bone, and a lower vertical part that descends into the temporal fossa. The horizontal part of the united bones forms a flat plate, which lies behind a line joining the bases of the horn-cores of the frontal bones, and whose outer surface looks directly upwards. A semicircular line runs across this surface, and is continued backwards between the horizontal and vertical parts to join a ridge of the temporal bone. In the skull of the ox this ridge takes the place of the occipital or lambdoid crest of the horse. The vertical or temporal part of the parietal is slightly concave on its outer surface. It lies between the frontal and squamous temporal bones, being largely overlapped by the latter in the articulated skull. The parietal bone of the ox does not aid in forming the parieto-temporal canal,

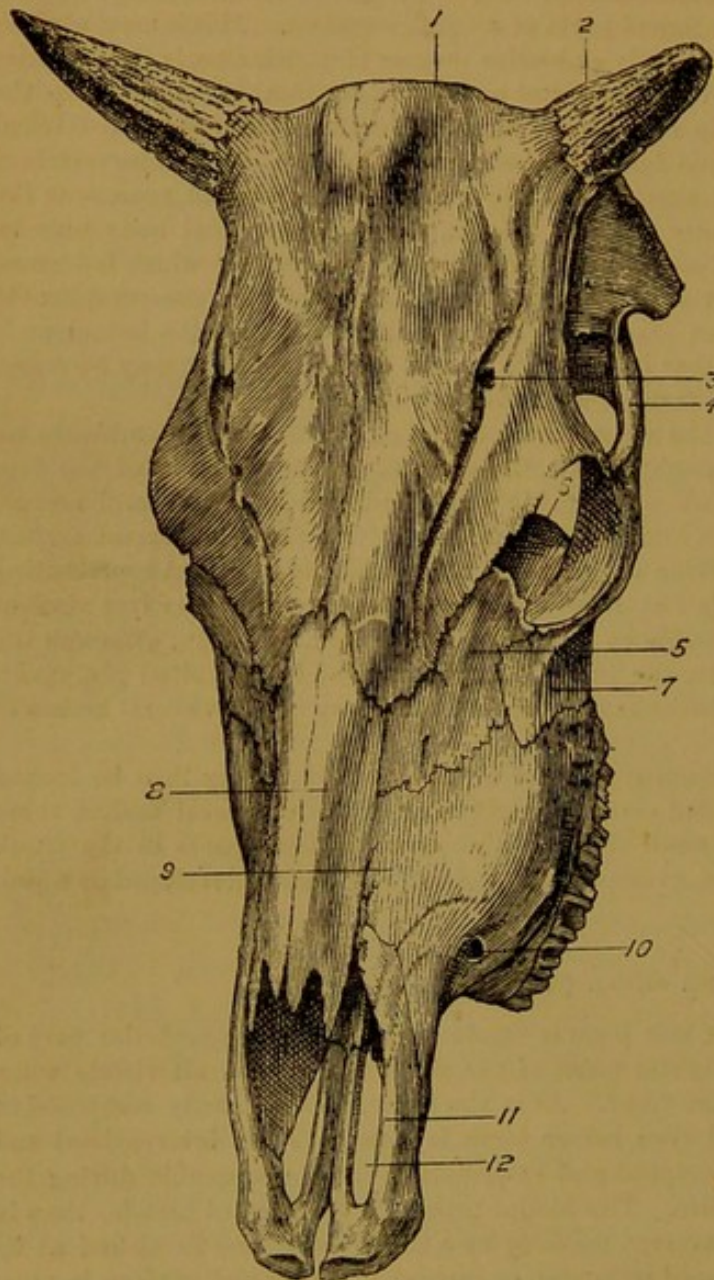


FIG. 52.—SKULL OF OX (Antero-Lateral View).

1. Frontal; 2. Horn-core; 3. Supra-orbital foramen; 4. Zygomatic process of squamous temporal; 5. Lacrymal; 6. Its post-orbital protuberance; 7. Malar; 8. Nasal; 9. Superior maxilla; 10. Infra-orbital foramen; 11. Premaxilla; 12. Incisor cleft.

and in the adult animal its outer and inner tables become widely separated by a backward extension of the frontal air sinus.

**Sphenoid Bone.** The body of the post-sphenoid shares in the formation of the strong muscular eminences already mentioned in connection with the basilar process of the occipital bone. The pituitary fossa is deep, and superiorly it is limited by a ragged projection corresponding to the posterior clinoid processes of the human subject. The wing of the post-sphenoid is pierced above its centre by a large *foramen ovale* for the passage of the inferior maxillary division of the fifth cranial nerve and the great meningeal or speno-spinous artery. This foramen takes the place of the middle and outer notches

of the upper edge of the wing in the horse. The inner or carotid notch is absent, its place being taken by a much smaller outcut for the vidian nerve. The sub-sphenoidal processes are thin laterally compressed plates, and the canal of the same name is absent. To the outer side of the root of the last-named process, a small canal perforates the bone to open on the pituitary fossa. It gives passage to a small artery. A single large foramen takes the place of the pathetic foramen, foramen rotundum, and foramen lacerum orbitale. The body of the pre-sphenoid is solid, or at most but slightly excavated to form the sphenoidal air sinus, and its wing takes no share in forming the internal orbital foramen.

**Frontal Bone.** The characteristic form of the skull of the ox is mainly due to the size and shape of this bone. It extends from the summit to a little below the middle of the anterior aspect of the skull, and the two bones together form the whole anterior boundary of the cranium. At its supero-external angle each bone carries in most breeds of cattle a large process termed the **horn-core** or **flint**, for the support of the horns. These processes are conical in shape and slightly curved. Their length and the degree of their curvature vary in the different breeds. The outer surface of the processes has a rough and porous aspect, and inwardly they are hollow, being excavated by a cavity in communication with the frontal sinus. Irregular bony septa subdivide the cavity into a variable number of intercommunicating spaces. In the so-called polled or hornless breeds, such as the Galloway and Aberdeen-Angus, the horn-cores are absent. The supra-orbital process is short, and its outer end articulates with the malar bone, instead of with the zygomatic process of the squamous temporal, as in the horse. The supra-orbital foramen deserves to be termed a canal. It is placed nearer the middle plane of the head, and its anterior orifice (sometimes double) opens into a vascular furrow,

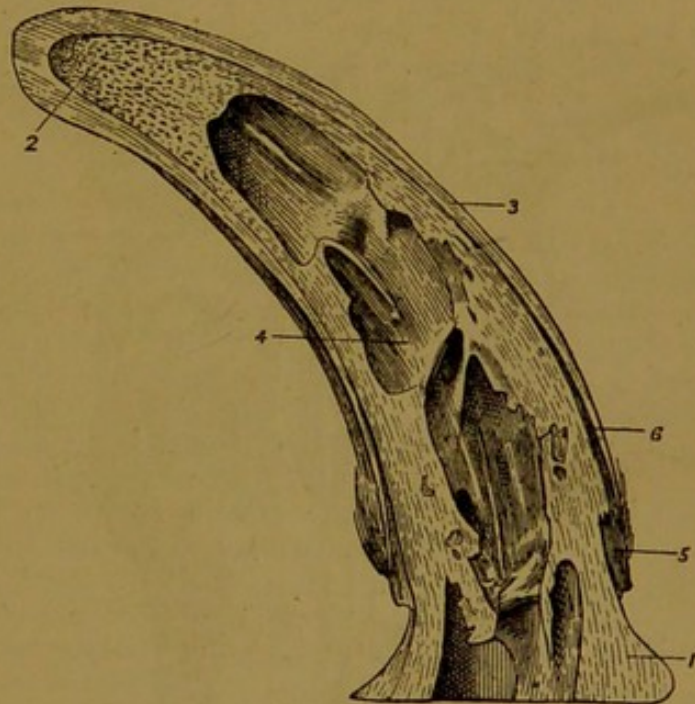


FIG. 53.—SECTION OF HORN AND HORN-CORE OF OX.

1. Base of horn-core; 2. Its tip; 3. Horn; 4. Cavity of horn-core; 5. Skin; 6. Soft texture between horn and core.

which is prolonged upwards towards the root of the horn-core, and downwards to near the lower end of the bone. Inferiorly the united frontal bones form a notch for the nasal bones—a connection the reverse of that found in the horse. The internal orbital foramen is formed entirely in the frontal bone. The frontal sinuses are of great size in the adult ox, reaching from near the level of the lower margin of the orbit to the summit of the head, and being prolonged into the horn-cores, the parietal, and interparietal bones, and even into the occipital. As a last feature of this bone in the ox, it may be mentioned that it does not articulate with the palatine.

**Temporal Bone.** In the ox, and in all the domestic animals except the horse, the squamous and temporal bones are speedily fused together. The zygomatic process articulates with the malar only, not with the frontal. The glenoid cavity is not so wide or deep as in the horse, but the condyle or articular eminence is more extensive. The post-glenoid process is smaller. The superior root of the zygoma bears immediately in front of the auditory process a blunt eminence that takes the place of the mastoid process of the petrous part in the horse. From this a ridge is continued upwards to join the ridge previously described on the parietal bone. The petrous part forms neither a mastoid crest nor a mastoid process. The tube of the auditory process is directed outwards and

slightly backwards. The hyoid process is smaller and more concealed. The auditory bulla is more compressed from side to side than in the horse, and it approaches so close to the edge of the basilar process as to render the foramen lacerum basis cranii a much smaller opening than in the horse. The styloid process is longer and thicker. The parieto-temporal canal is formed entirely between the squamous and petrous divisions of the temporal bone. Its upper orifice opens into the cranial cavity towards the point of articulation of the occipital, parietal, and temporal bones. At its lower end there are three openings, viz., one on either side of the post-glenoid process, and one in the temporal fossa.

**Ethmoid Bone.** The perpendicular plate is large, and the anterior cell of the lateral mass is so voluminous that it might be reckoned as a third turbinated bone.

**Pterygoid Bone.** This is a long, thin, strap-shaped bone. Its hinder edge, parallel to that of the opposite bone, forms nearly the whole of the lateral boundary of

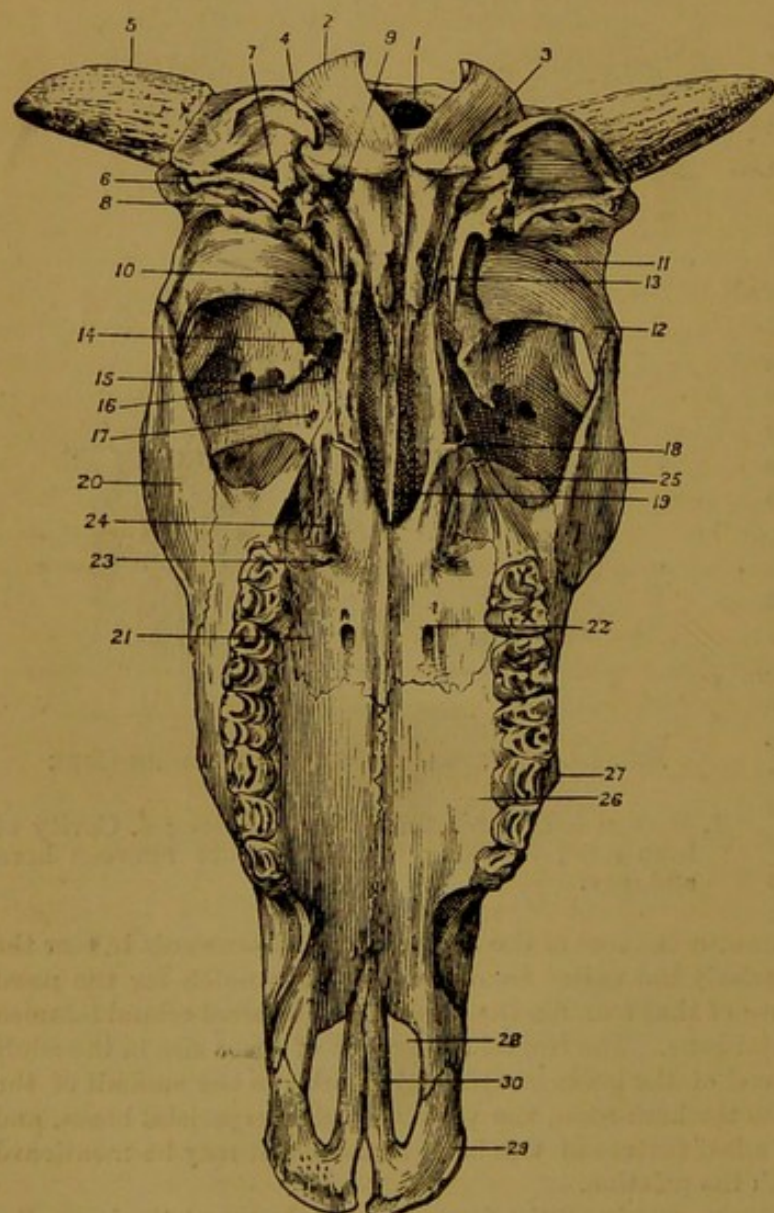


FIG. 54.—SKULL OF OX, VIEWED FROM BEHIND.

1. Foramen magnum; 2. Occipital condyle; 3. Basilar process; 4. Styloid process of occipital; 5. Horn-core; 6. External auditory meatus; 7. Stylo-mastoid foramen; 8. Outward opening of parieto-temporal canal; 9. Foramen lacerum posterius; 10. Foramen ovale; 11. Glenoid fossa; 12. Zygomatic process of squamous temporal; 13. Styloid process of petrous temporal; 14. Combined foramen rotundum and foramen lacerum orbitale; 15. Supra-orbital foramen; 16. Optic foramen; 17. Internal orbital foramen; 18. Hamular process of pterygoid; 19. Vomer; 20. Malar; 21. Palatine; 22. Posterior palatine foramen; 23. Superior palatine foramen; 24. Sphenopalatine foramen; 25. Lachrymal protuberance; 26. Superior maxilla; 27. Tubercle on facial surface of same; 28. Incisor cleft; 29. Premaxilla; 30. Its palatine process.

the pharyngeal opening of the nose. In front it closes a vacuity between the subsphenoidal process and the palatine bone.

**Palatine Bone.** This bone forms nearly one-third of the hard palate. The palatine canal is formed entirely in it, the lower orifice of the canal (posterior palatine foramen) being found towards the middle of the palatal surface of the bone. Above this there are generally two or three small **accessory palatine foramina** leading out of the canal. The outer edge of the palatal portion of the bone serves to

complete the alveolus for the uppermost molar tooth. The sphenopalatine foramen is a very large elliptical opening. The upper extremity of the bone is not excavated for the sphenoidal sinus, but the maxillary sinus is prolonged into its palatal part. In the ox this bone does not articulate with the frontal.

**Lachrymal Bone.** The facial part of this bone is much larger than in the horse, and the lachrymal tubercle is absent. The lachrymal fossa is small, and close to the orbital rim, which presents a deep notch. At the back of the orbit this bone forms a great **lachrymal protuberance**, into which the maxillary sinus is prolonged. This part of the bone is thin and paper-like, and hence, unless great care be exercised, it is very apt to be destroyed, exposing the interior of the maxillary sinus.

**Malar Bone.** This bone has a more extensive facial surface than in the horse. Its upper extremity is bifurcate, the anterior branch articulating with the supra-orbital process of the frontal, and the posterior branch with the zygomatic process of the squamous temporal.

**Superior Maxilla.** This bone is broader but shorter than in the horse. The zygomatic ridge is absent, its place being taken by a blunt eminence, and by a rough curved line which extends from this eminence to the facial surface of the malar. The infra-orbital canal is lower down than in the horse, opening at the level of the lowest grinding tooth. The zygomatic process is small, and the maxillary tuberosity absent. The palatine plate is hollow, the maxillary sinus being prolonged into it. The superior maxilla takes no share in forming the palatine canal, and it forms much less of the hard palate than in the horse.

**Nasal Bone.** This bone is both shorter and narrower than in the horse. Superiorly the right and left bones form a triangular projection indenting the frontal bones. The lower end of each bone is divided by a deep notch into an outer and an inner process, the latter being the larger. The inner processes lie together, and give to the nasal peak of the ox a trifid character. The nasal bones articulate with the frontal by a dentated suture, but their other connections are by plain edges (*harmonia suture*), and hence a slight force serves to detach them in the dry skull.

**Premaxilla.** The body of this bone is thin, compressed from before to behind, and destitute of alveoli, the upper incisor and canine teeth being absent in the ox. There is no incisor foramen, an interspace, open below, intervening between the bodies of the right and left bones. The naso-palatine cleft is a much wider opening than in the horse.

**Vomer.** In its upper part the vomer is a slender plate lying within the depth of the guttural opening of the nose. Beneath this it is free for a considerable distance, the bone being articulated to the lower two-thirds of the superior maxilla only. Hence in the dried skull of the ox the nasal fossæ are much more imperfectly separated than in the horse.

**Turbinated Bones.** The anterior bone is very much smaller than the posterior. It is thickest in its middle portion and pointed at both extremities. Its upper part is included between the roof of the nose and the great ethmoidal cell, which looks like a third turbinated bone. By its anterior edge it is attached to the nasal bone, and by its posterior edge it is closely applied to the lachrymal and frontal bones. The cavity which it circumscribes is thus completely shut off from the nose, but it communicates freely with the frontal sinus.

The posterior turbinated bone is of large size. It is fixed to the superior maxilla by a lamella of its outer face, and its anterior edge is rolled from this attachment forwards, while its posterior edge is rolled in the opposite direction. The cavity of the bone communicates in front of the above-mentioned lamella with the middle meatus of the nose, and behind the lamella with the posterior meatus, but it has no communication with the maxillary sinus. The posterior turbinated bone is late in ossifying to the superior maxilla. Both turbinated bones are less fragile in texture than the same bones of the horse.

**Inferior Maxilla.** Except in very old animals the right and left halves of this bone are not ossified at the symphysis. The body of the bone carries eight close-set alveoli for the cutting teeth, and the alveolar edge of each ramus is excavated by other six alveoli for the grinding teeth. Below the angle the hinder edge of the ramus is strongly convex, and the angle itself is less rounded than in the horse. The condyle is

saddle-shaped, being convex from before to behind, and concave from side to side. The coronoid process is long, broad, and strongly bent backwards and outwards.

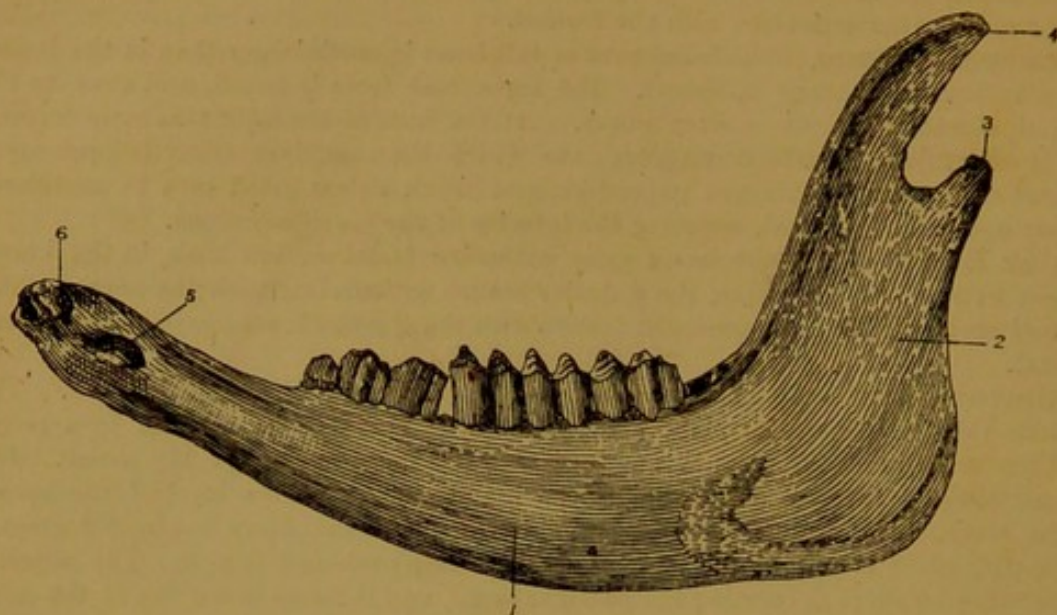


FIG. 55.—INFERIOR MAXILLA OF OX.

1. Outer surface of ramus; 2. Surface for attachment of masseter; 3. Condyle;  
4. Coronoid process; 5. Mental foramen; 6. Body.

**Hyoid Bone.** The glossal process is short and blunt. The thyro-hyals are not ossified to the body. The epi-hyal rivals the cerato-hyal in size.

**Skull of the Ox as a Whole.** The face is a little more bent upon the cranium than in the horse, the ox having a cranio-facial angle of about  $135^{\circ}$  ( $140^{\circ}$  in the horse). [The cranio-facial angle is found by drawing two lines on a vertical mesial section of the skull, one from the posterior margin of the foramen magnum to the lowest point of the cranial surface of the presphenoidal body, and the other from the latter point to the alveolar edge of the premaxilla.] The greatest difference, however, is found in connection with the anterior aspect of the cranium, viz., the greater breadth and flatness of the skull of the ox between the vertex and the orbits. This is due mainly to the relatively great size of the frontal bones, and to the enormous development of the frontal air sinuses. The wide separation thereby made between the outer and inner tables of the frontal and parietal bones masks the actual contour of the cranium in the ox. At the same time the temporal fossæ are altogether displaced from the anterior aspect of the skull, and thrust backwards to its sides. This greater breadth of the skull affects also its posterior aspect at and above the level of the glenoid fossa, the temporal bones and the basilar process being proportionally wider than in the horse. The reduced size of the foramen lacerum basis cranii and the presence of a large foramen ovale are other notable features of this region. The guttural opening of the nasal chamber is much more compressed laterally. The length of the hard palate is considerably greater than in the horse, and its transverse measurement is also greater. A horizontal line drawn through the upper edge of the bony palate of the horse passes through or below the uppermost molar, but in the ox such a line lies half an inch or more above that tooth.

#### THE SKULL OF THE SHEEP.

**Occipital Bone.** This bone in form and position differs less from the horse's occipital than does the same bone of the ox. It forms a transverse occipital crest, which, as in the horse, is the highest point of the skull. The condyles, styloid processes, and basilar process, on the other hand, resemble those of the ox, but the muscular eminences of the last-named process are higher up and further removed from the mesial plane. Another small eminence is found on either side close to the condyle. A posterior

condyloid foramen and a canal leading from it are present, as in the ox. The frontal sinus is never prolonged into the supra-occipital.

**Interparietal Bone.** Similar to that of the ox, save that the frontal sinus never invades it.

**Parietal Bone.** This bone fuses early with its fellow of the opposite side, and

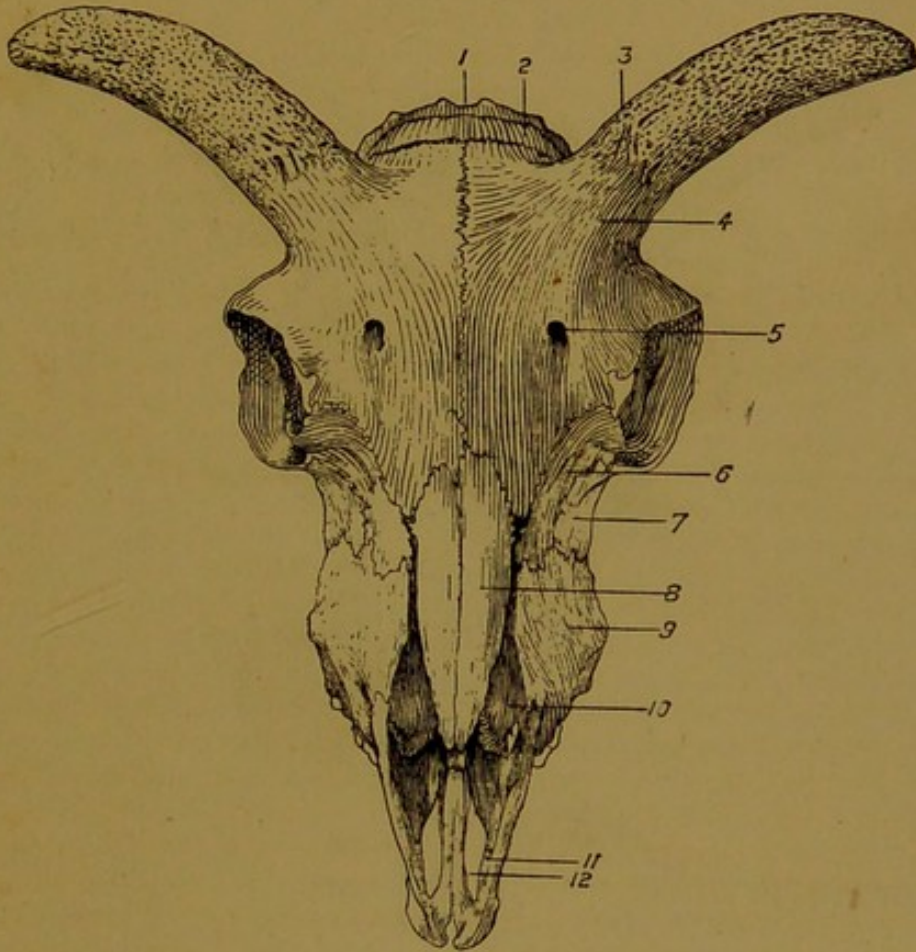


FIG. 56.—SKULL OF SHEEP (Front View).

1. Occipital; 2. Parietal; 3. Horn-core; 4. Frontal; 5. Supra-orbital foramen; 6. Lachrymal; 7. Malar; 8. Nasal; 9. Superior maxilla; 10. Posterior turbinated bone; 11. Premaxilla; 12. Incisor cleft.

with the interparietal, but the united bones remain for a long time distinct from the supra-occipital, the suture being evident in the young adult. The bone is bent in somewhat the same manner as in the ox, but the bend is not so abrupt. The superior part looks forwards and upwards, and is therefore visible from the front. The part that descends into the temporal fossa is slightly convex, whereas it is concave in the ox. The frontal sinus is never prolonged into the parietal, and the bone participates in the formation of the parieto-temporal canal. The parietal of the sheep is absolutely thicker than the same bone of the horse—a protection to the brain that was obviously necessary in an animal whose head is employed as a weapon of offence.

**Sphenoid Bone.** This bone is almost identical with that of the ox. The bony projection above the pituitary fossa (posterior clinoid processes) is even more prominent than in the ox. No sphenoidal sinus is ever developed.

**Frontal Bone.** This bone differs in only minor respects from that of the ox. It does not form the summit of the head. It is strongly convex at the level of the horn-core, its upper part having a forward and upward direction. The horn-cores vary in shape, size, and direction, according to the breed, being in some slightly spiral. The frontal sinus is relatively smaller. The vascular furrow into which the supra-orbital foramen opens does not extend above the foramen. In the hornless breeds the horn-cores are necessarily absent.

**Temporal Bone.** The tympanic part remains for a long time distinct from the petro-mastoid part. The fusion of the squamous and petrous portion is not so prompt as in the ox. The auditory bulla is larger, less compressed, and more closely applied to the basilar process than in the ox. The hyoid process is larger and less concealed. There is no ridge on the posterior aspect of the auditory process, which looks outwards and slightly

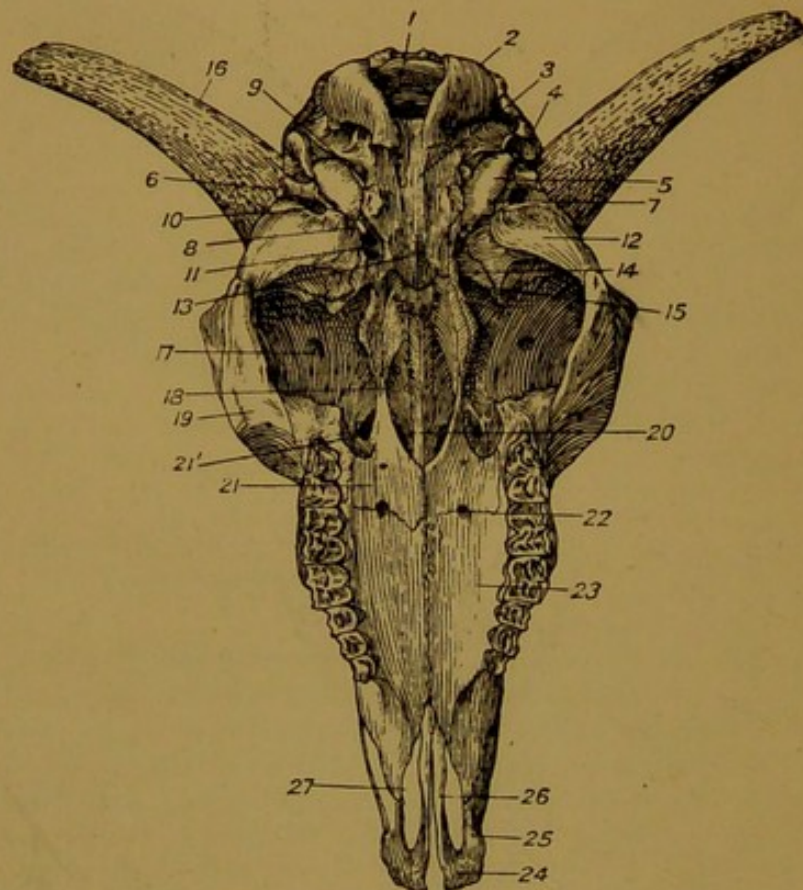


FIG. 57.—SKULL OF SHEEP, VIEWED FROM BEHIND.

1. Foramen magnum; 2. Occipital condyle; 3. Basilar process; 4. Styloid process of occipital; 5. Auditory bulla; 6. External auditory meatus; 7. Hyoid process; 8. Styloid process of petrous temporal; 9. Foramen lacerum posterius; 10. Outward opening of parieto-temporal canal; 11. Foramen ovale; 12. Glenoid fossa; 13. Body of post-sphenoid; 14. Wing of same; 15. Orbital hiatus; 16. Horn-core; 17. Supra-orbital foramen; 18. Hamular process of pterygoid; 19. Malar; 20. Vomer; 21. Palatine; 21'. Spheno-palatine foramen; 22. Posterior palatine foramen; 23. Superior maxilla; 24. Premaxilla; 25. Its nasal process; 26. Its palatine process; 27. Incisor cleft.

downwards. In other respects the temporal of the sheep is similar to that of the ox.

**Ethmoid Bone.** Similar to that of the ox.

**Pterygoid Bone.** This bone is somewhat shorter than in the large ruminant. Its hamular process is slender, pointed, and much curved upwards at its tip.

**Palatine Bone.** This bone resembles that of the ox in the considerable share that it takes in forming the bony palate. It differs, however, in that the palatine canal is not formed by it alone, but in conjunction with the superior maxilla, the posterior palatine foramen opening on the suture, as in the horse. Furthermore, the maxillary sinus is never prolonged into its palatal part, nor does its upper extremity form part of a sphenoidal sinus.

**Lachrymal Bone.** The facial surface of this bone is depressed to form with the assistance of the malar a distinct fossa. In other respects it resembles the same bone of the ox.

**Malar Bone.** Its facial part bears a more distinct ridge than in the ox, this ridge being connected by a curved line to the tubercle of the outer face of the superior maxilla. The upper extremity is bifurcate, as in the ox.

**Superior Maxilla.** Save in assisting to form the palatine canal, and in not having the maxillary sinus prolonged into its palatine plate, this bone resembles that of the larger ruminant. A narrow cleft isolates it from the nasal bone in the dry skull.

**Nasal Bone.** The nasal bone of the sheep does not articulate with the superior maxillary, a narrow interval in the dried skull separating the adjacent edges of these bones. Neither does it articulate with the nasal process of the premaxilla. The lower extremity of the bone is undivided, but the nasal peak is less acute than in the horse.

**Premaxilla.** This bone closely resembles that of the ox. The naso-palatine clefts are proportionally longer.

The **Vomer** and **Turbinated Bones** resemble those of the ox, but the anterior turbinated bone is not united to the nasal.

**Inferior Maxilla.** This bone bears a close resemblance to the same bone of the ox, but the posterior edge, from the body to the angle, is much less convex.

**Hyoid Bone.** The epi-hyal and cerato-hyal are of nearly equal size. The thyro-hyals are not ankylosed to the basi-hyal, and the latter has no glossal process.

**Skull of the Sheep as a Whole.** The sheep's skull resembles in most respects that of the larger ruminant. The axis of the face is even more bent upon the cranial axis than in the ox, the cranio-facial angle of the sheep measuring about 125°. The smaller size of the frontal sinuses causes the upper part of the skull to depart less from the form of the horse's cranium. Thus, the occipital crest still forms the culminating point of the skull, and the parietal bones are visible when the head is viewed directly from the front. The lateral position of the temporal fossæ, the size and prominence of the orbits, and the large dimensions of the hard palate are points of resemblance between the skull of the sheep and that of the ox.

#### THE SKULL OF THE PIG.

**Occipital Bone.** This bone forms the highest point of the head, but only the anterior edge of its supra-occipital part, which constitutes a prominent occipital crest, is visible when the skull is viewed directly from the front. The foramen magnum is compressed from side to side, and somewhat triangular. The basilar process is very broad superiorly, but narrower where it joins the sphenoid. It is traversed mesially by a slight ridge. The styloid processes are of great length, and project nearly straight backwards. The condyloid foramen is single, as in the horse, but further removed from the condyle, being placed close to the root of the styloid process. The supra-occipital unites with the parietals sooner than with the ex-occipitals. Its outer surface looks almost directly upwards, and on it two divergent ridges proceed from the foramen magnum to the extremities of the occipital crest. It has no eminence for the ligamentum nuchæ. The cranial surface shows close behind the line of junction with the parietals a furrow for the transverse sinus, but there is no ossific tentorium. In the adult pig the frontal sinus is prolonged into the supra-occipital.

**Interparietal Bone.** This element is absent in the skull of the pig.

**Parietal Bone.** In position this bone agrees with that of the horse, being situated on the anterior aspect of the skull, immediately below the occipital crest. In shape, however, it resembles the parietal of the ruminant. The right and left bones are early united together, and the combined bones then present a flat central plate which looks directly forwards, and two lateral slightly concave plates, each of which looks outwards, and forms the greater part of the temporal fossa. The central plate is separated on each side from the lateral plate by a prominent curved ridge extending between the occipital crest and the supra-orbital process of the frontal bone. These ridges correspond to the sagittal crest of the horse's skull and to the divergent ridges that descend from it. In the adult pig the outer and inner tables of the parietal are widely separated by an upward extension of the frontal sinus. No parieto-temporal canal is formed in the pig's skull.

**Sphenoid Bone.** The pituitary fossa resembles that of ruminants, being limited superiorly by a large downward projecting plate. The free corners of this process (posterior clinoid processes) form prominent projections. The sub-sphenoidal processes are very strong, flattened from above to below, and devoid of a sub-sphenoidal canal. There is no foramen ovale, this, as in the horse, being represented by a notch on the upper edge of the wing. The foramina of the orbital hiatus are similar to those of the

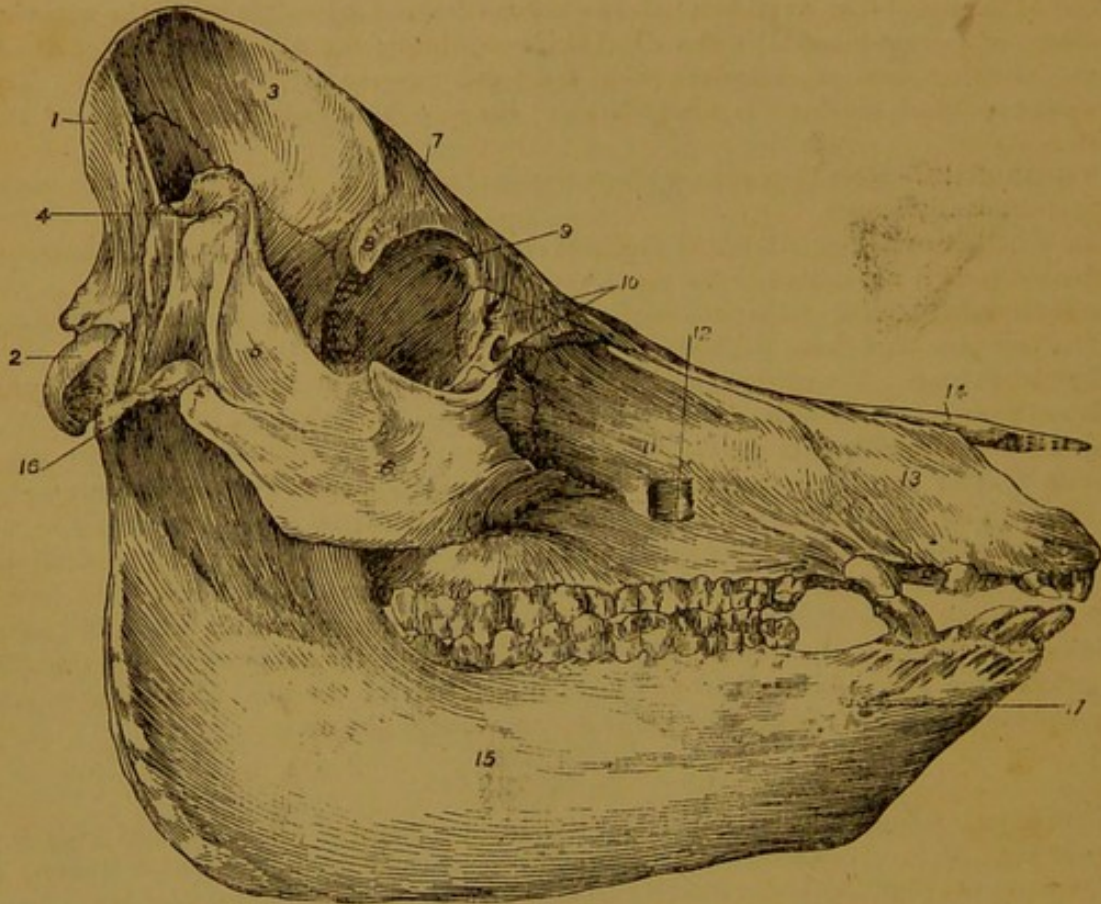


FIG. 58.—SKULL OF PIG (Lateral View).

1. Occipital; 2. Condyle of same; 3. Parietal; 4. External auditory meatus; 5. Zygomatic process of squamous temporal; 6. Malar; 7. Frontal; 8. Its supra-orbital process; 9. Supra-orbital foramen; 10. Lachrymal canals; 11. Superior maxilla; 12. Infra-orbital foramen; 13. Premaxilla; 14. Nasal; 15. Ramus of inferior maxilla; 16. Condyle of same; 17. Mental foramina.

ox. The wing of the pre-sphenoid articulates by suture with the frontal. In the adult pig the entire body of the sphenoid is excavated to form a sphenoidal sinus.

**Frontal Bone.** This bone is much smaller than in the ox, but larger than in the horse. In the wild pig its outer surface is nearly flat, but in the domesticated animal it is concave in the vertical direction, the concavity being most pronounced in the finer breeds. The supra-orbital process is short, pointed, and unconnected to the zygomatic arch in the dry skull. The so-called supra-orbital foramen is considerably removed from the root of that process, and opens almost level with the lower edge of the orbit. As in the ox, this opening is nearer the mesial plane than in the horse, and a vascular groove descends from it to the nasal bone. The internal orbital foramen is formed entirely in the orbital plate of the frontal, which, as already mentioned, is articulated by suture with the wing of the pre-sphenoid. The frontal bone of the pig articulates with the superior maxilla.

**Temporal Bone.** The tympanic part of the petrous temporal fuses at an early age with the squamous temporal, but the petrous part proper, or periotic, remains for a long time distinct. The mastoid part is very rudimentary, and is not visible on the exterior of the articulated skull. It forms a small scale-like process on the inner surface

of the squamous division. The auditory process is directed forwards and outwards. It is a much longer tube than in any of the other domesticated animals. A curved ridge runs backwards from the external auditory meatus to the auditory bulla. The auditory bulla, or mastoid protuberance, is much larger proportionally than in the horse or ruminant, and it projects to a marked extent backwards, below the root of the styloid process of the occipital. On its inner side it approaches but does not touch the edge of the basilar process, and the foramen lacerum basis cranii is very similar to that of the horse. The styloid process is represented by a scale-like ridge. The hyoid process, or tympano-hyal, is very slender and concealed at the bottom of a depression below the root of the styloid process of the occipital. To its outer side, in this same depression, there is seen the stylo-mastoid foramen. The glenoid fossa is of considerable extent in the vertical direction. It is shallow and directed upwards, while the condyle, or articular eminence, is relatively broader than in the horse, and directed backwards. The post-glenoid process is absent. The zygomatic process is very strong, and its lower end rests in a deep notch of the malar bone. From the most prominent point of its anterior border a sharp ridge of bone passes to the inner side of the external auditory meatus, and is continued backwards and upwards to the occipital crest, forming the postero-superior limit of the temporal fossa.

**Ethmoid Bone.** The cranial surface of the horizontal plate looks forwards and slightly upwards, lying in nearly the same plane as the basi-cranial axis. The lamina papyracea, or os planum, which envelopes outwardly the lateral mass, is visible on the exterior of the skull, appearing between the frontal, palatine, superior maxilla, and sphenoid, immediately above the maxillary hiatus.

**Pterygoid Bone.** This bone is less inclined than in the horse. Its anterior or upper end is broader, and the hamular process is less projecting.

**Palatine Bone.** This bone has a small orbital surface, but it forms more of the hard palate than in the horse, though somewhat less than in the ruminant. Its palatal portion is triangular with the point below, and the lower orifice of the palatine canal (posterior palatine canal) opens on the superior maxilla, the palatine taking no part in its formation. At each side of the pharyngeal opening of the nose the palatine carries a strong tubercle, against which the extremity of the sub-sphenoidal process rests outwardly, and the hamular process inwardly. As in the ox, the palatine bone does not articulate with the frontal.

**Lachrymal Bone.** The facial surface of this bone is larger than in the horse, though smaller than in the ox. It carries a short ridge or blunt tubercle. There are two osseous lachrymal canals, one of which has its orifice on the orbital rim, and the other on the facial surface a little below the rim. The orbital surface has a deep blind fossa marking the attachment of the inferior oblique muscle of the eyeball. A well-defined ridge, interrupted by a vascular furrow, traverses the orbital surface in the antero-posterior direction. The periorbital membrane, or ocular sheath, is attached to this ridge, and as much of the bone as lies to the outer side of the ridge is therefore excluded from the orbital cavity proper. The form of the facial surface of the lachrymal bone varies considerably in different breeds. In the wild pig and in the coarser races the lachrymo-frontal suture is much longer than the lachrymo-maxillary suture, but in the finer breeds the latter suture may equal or exceed the former in length. In the pig the lachrymal bone does not articulate with the nasal.

**Malar Bone.** The facial part of this bone is small. Its orbital surface which is also of small extent, is smooth, and groove-like. This surface is strictly speaking not orbital, for it is occupied by fat and vessels, and excluded from the orbit proper by the before-mentioned attachment of the ocular sheath to the orbital surface of the lachrymal. The zygomatic part is of great strength, and much more extensive than all the rest of the bone. Its upper extremity is deeply notched in front for the reception of the zygomatic process of the squamous temporal. It does not articulate with the supra-orbital process of the frontal.

**Superior Maxilla.** This bone is of large size in the pig. Its facial surface, which is concave, is perforated towards its centre by a large infra-orbital foramen. The zygomatic ridge is short but strong, forming a buttress-like support for the malar. The alveolar edge carries six or seven alveoli (in the adult) for the grinding teeth, the size

of these alveoli increasing from the lowest to the highest. At the lower extremity of this edge a large complete alveolus is excavated for the canine tooth. In the adult male the facial side of this alveolus is raised into a ridge. The maxillary protuberance and the alveolar tuberosity are absent. The zygomatic process is short but broad. The palatine plate is of great length. In the adult animal it is often more or less distinctly ridged

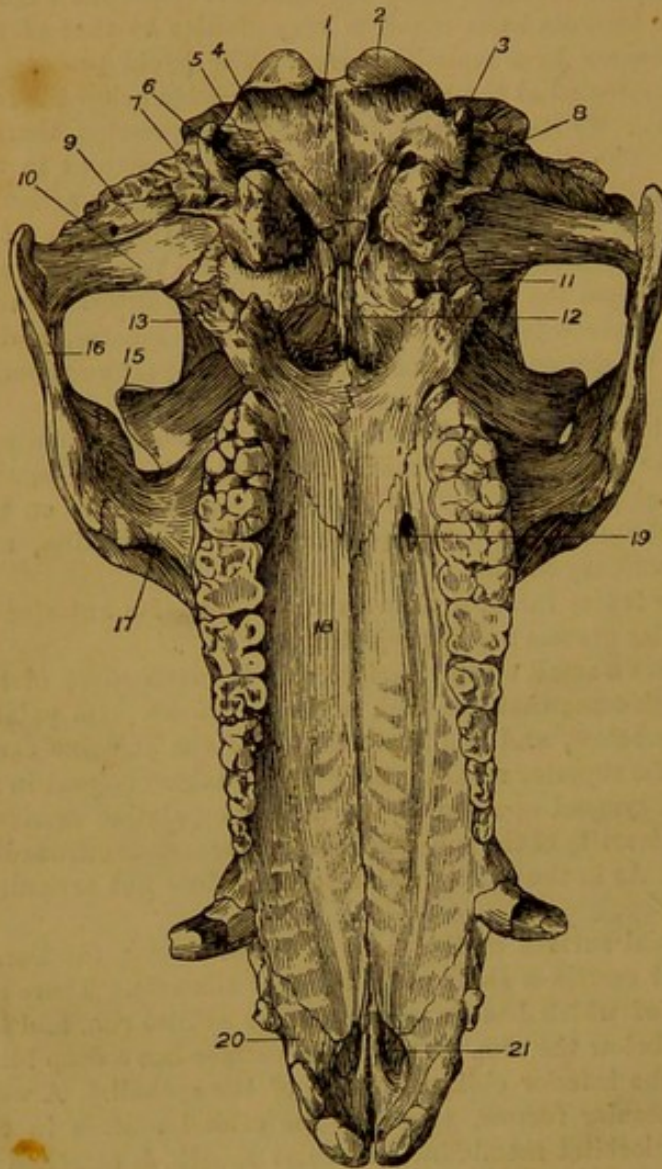


FIG. 59.—SKULL OF PIG, VIEWED FROM BEHIND.

1. Basilar process; 2. Condyle of occipital bone; 3. Styloid process of same; 4. Condylod foramen; 5. Foramen lacerum posterius; 6. Foramen lacerum medium; 7. Stylo-mastoid foramen; 8. Auditory bulla; 9. Glenoid fossa of squamous temporal; 10. Condyle of same; 11. Wing of post-sphenoid; 12. Vomer; 13. Trifid tubercle formed by palatine, sphenoid, and pterygoid bones; 14. Palatine; 15. Supra-orbital process; 16. Malar; 17. Zygomatic process of superior maxilla; 18. Palatine plate of same; 19. Posterior palatine foramen; 20. Pre-maxilla; 21. Incisor cleft.

shorter and stronger. The vascular groove descending from the supra-orbital foramen is continued for a short distance on the outer surface of this bone. The length and the degree of concavity of the outer surface of the nasal bones of the pig vary considerably with the breed, the bones being shortest and most concave in the finer races.

**Vomer.** This bone is of great length in the pig. Its upper end is small, and the free part of its hinder edge, where it separates the posterior nares, lies more deeply and

transversely, in correspondence with the palatine bars or ridges of the mucous membrane. The posterior palatine foramen opens on the upper part of this palatine plate the palatine canal being formed entirely in this bone. A palatine groove, less distinct than in the horse, is continued downwards from the foramen. The maxillary sinus is small, and it does not extend into the palatine plate. The sphenopalatine foramen is small, while the superior maxillary foramen and the superior dental canal are very large. In the pig this bone articulates with the frontal.

**Premaxilla.** The body and nasal process, especially the latter, are very strong in the pig. The body is excavated by three alveoli for the incisor teeth. Slight intervals separate these alveoli. The nasal process has a much longer articulation with the nasal bone than in the horse. The palatine process is shorter than in the horse. As in the ruminant, a narrow interval separates the bodies of the right and left bones, and therefore no incisor foramen is formed. The naso-palatine clefts are short but wide.

**Nasal Bone.** This bone is thicker and more solidly united to its fellow and to the surrounding bones than is the case in any of the other domestic animals. Its lower extremity is undivided, and the nasal peak is similar to that of the horse, save that it is

is sharper than in the horse. This edge has a very extensive articulation with the hard palate, the lower extremity of the bone reaching close to the body of the premaxilla.

**Turbinated Bones.** The anterior bone resembles that of the ruminant, but it is stronger, of greater length, and more firmly united to the nasal bone. It encloses a single undivided cavity, which communicates by a narrow opening with the upper part of the middle meatus, and near the same point with the frontal sinus. The posterior turbinated bone is larger than the anterior. It bears a close resemblance to the same bone of the ruminant, but its texture is stronger.

**Os Rostri, or Prenasal Bone.** This is a small osseous piece embedded in the snout, at the lower end of the septal cartilage of the nose, to which it is movably united. Its purpose is to strengthen the snout as a digging organ.

**Inferior Maxilla.** The right and left halves of this bone soon become ankylosed at the mesial suture of the body, as in the horse. The whole bone is relatively very large and strong. The alveoli for the molar teeth cause an inward projection or bulging of the ramus. Besides the mental foramen, several smaller accessory foramina open above it on the outer surface of the ramus. Two or three small foramina are also present on the labial surface of the body. The coronoid process is small and almost on a level with the condyle. The latter is convex in both directions, and of almost equal extent in the antero-posterior and transverse directions.

**Hyoid Bone.** The basi-hyal is small and devoid of a glossal process. The thyro-hyals are ankylosed to the basi-hyal. The cerato-hyals are short and united to the body by cartilage. The epi-hyals are represented by a yellow elastic ligament. The stylo-hyals exist for a long time as a rod of cartilage in which subsequently one or two osseous pieces are developed.

**Skull of the Pig as a Whole.** The face is a little less bent upon the cranium than in the horse, the pig having a cranio-facial angle of about  $148^{\circ}$ . The cranium bears a much greater proportion to the face than in the horse, owing to the greater development of the frontal sinuses. As in the ox, the actual contour of the cranial cavity is masked by these sinuses. The capacity of the cranium is relatively inferior to that of the horse. No sagittal crest is formed in the pig, and the temporal fossæ occupy only the lateral aspects of the cranium, the parietal bones forming a broad flat area between the fossæ. The orbits are small, and the rim incomplete above. Beneath the orbits the transverse measurement of the face is less than in the horse, owing to the smaller size of the maxillary sinuses. The face, like the cranium, has a characteristic four-sided form, a tolerably abrupt edge marking the line of articulation of the nasal bone with the superior maxilla and premaxilla. The inferior nares are situated almost at the lower extremity of the skull, and the nasal peak is short. The pharyngeal opening of the nasal chambers looks almost directly upwards. Its outline is more square than in the horse, and its bony boundaries are very strong. Lastly, the relatively enormous length of the bony palate is a very notable feature of the pig's skull. In the horse the hard palate measures somewhat less than one half of the length of the entire skull, whereas in the pig it forms two-thirds of the whole length. A horizontal line drawn through the upper edge of the hard palate falls some distance above the uppermost molar tooth.

#### THE SKULL OF THE DOG.

**Occipital Bone.** In position this bone agrees closely with that of the horse. It forms a transverse occipital or lambdoid crest, the mid-point of which is the summit of the skull. Before birth its supra-occipital part fuses with the interparietal element, which intrudes itself as a long narrow strip between the right and left parietal bones. The basilar process is short, broad, and furnished with a mesial ridge. The auditory bulla of the temporal bone abuts upon its edge, and between the two a short venous canal is formed. By the abutment of the bulla against the edge of the basilar process, the vacuity corresponding to the foramen lacerum basis cranii of the horse's skull is divided into an upper opening—the *foramen lacerum posterius*, and a lower opening—the *foramen lacerum medium*, or carotid foramen, the latter corresponding to the carotid notch of the horse's sphenoid. The before-mentioned venous canal opens superiorly into the depth of the foramen lacerum posterius, and inferiorly into the cranial cavity. Above the usual

condyloid foramen for the twelfth nerve, one or two other openings are present on the inner aspect of the condyle. These conduct to a venous canal, one branch of which leads to the foramen lacerum posterius, while the other opens into the cranium. The styloid processes are shorter eminences than in any of the other domesticated animals.

**Interparietal Bone.** As already stated, this bone fuses before birth with the supra-occipital. The ossific tentorium is of great size in the dog, and the parietal bones contribute largely to its formation. The

right and left parieto-temporal canals unite in the substance of this process. In the skull of adult dogs of the larger breeds the outer surface of the interparietal bone is taken up almost entirely in forming a strong sagittal crest, the sides of which give attachment to the temporal muscles. In young dogs, however, and throughout life in the smaller breeds, this surface forms no sagittal crest, and a broader or narrower area of the parietal bone intervenes on each side between it and the temporal fossa.

**Parietal Bone.** In position this bone corresponds exactly with that of the horse. It is also similar in shape, but it is relatively more extensive. In adult animals of the larger breeds its outer surface is almost entirely taken up in forming the temporal fossa, and mesially it forms a strong sagittal crest which materially increases the extent of these fossæ, and affords attachment to the powerful temporal muscles. In the smaller breeds, however, and in the young animal of all breeds, the parietal bone is traversed by a curved ridge which limits the temporal fossa, and cuts off inwardly a smooth area of variable breadth that takes no share in forming the fossa.

**Sphenoid Bone.** The wings of the post-sphenoid are much larger than those of the pre-sphenoid. The pituitary fossa is deeper than in the horse,

and limited above and below by clinoid processes. A sub-sphenoidal canal is present as in the horse, and the foramen rotundum opens into it. The pathetic foramen is absent, and a foramen ovale is present as in the ox.

**Frontal Bone.** The supra-orbital process is even smaller than in the pig. It has the form of a short blunt tubercle which does not reach the zygoma, and the orbital rim is therefore incomplete above. The supra-orbital foramen is absent. The internal orbital foramen is formed entirely in this bone. The frontal sinus is of considerable extent in the larger breeds, but it is rudimentary in the smaller races. As in the pig, the frontal bone articulates with the superior maxilla. In the larger breeds a considerable part of the outer surface of this bone enters into the formation of the temporal fossa, the temporal part and the facial part being separated by a prominent line connecting the supra-orbital process to the sagittal crest. In young animals, and in the small breeds at any age, this line is faint, and the temporal part of the bone is small.

**Temporal Bone.** The separate parts of this bone soon become ankylosed together. The zygomatic process forms a wide outward bend, leaving a capacious temporal fossa. It

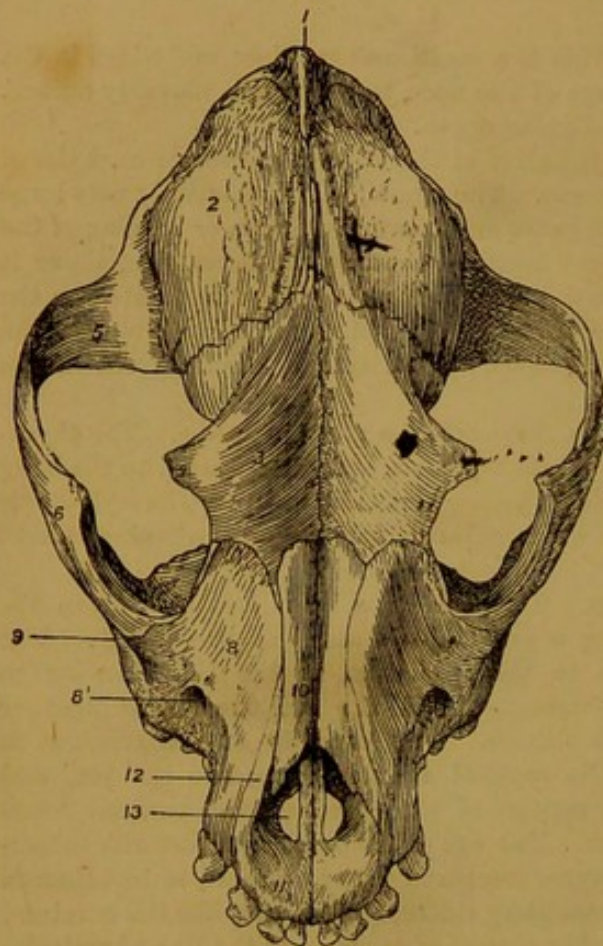


FIG. 60.—SKULL OF DOG (Front View).

1. Occipital crest; 2. Parietal; 3. Frontal;
4. Its supra-orbital process; 5. Zygomatic process of squamous temporal; 6. Malar; 8. Superior maxilla; 8'. Infra-orbital foramen;
9. Zygomatic process of superior maxilla; 10. Nasal; 11. Premaxilla; 12. Its nasal process;
13. Incisor foramen.

has a long articulation with the malar, but the supra-orbital process of the frontal and the zygomatic process of the superior maxilla do not reach it. There is an extensive glenoid cavity and a large post-glenoid process, but the condyle or articular eminence is absent. The mastoid portion of the bone is small. The auditory process is very short, and the external auditory meatus is large, and directed outwards and slightly upwards. The auditory bulla is of great size. It abuts closely against the basilar process of the occipital, a venous canal, as already mentioned, being formed between them. Immediately to the outer side of this venous passage, a second canal—the carotid canal—perforates the inner side of the bulla. Superiorly this canal begins at the foramen lacerum posterius, and inferiorly it ends at the carotid foramen, or foramen lacerum medium. The internal carotid artery passes through this canal. The styloid process is rudimentary. The hyoid process is also very small, and concealed at the bottom of a deep depression to the outer side of the articulation between the auditory bulla and the styloid process of the occipital. The stylo-mastoid foramen opens into the outer part of this same depression. The inner surface of the petrous temporal shows above the internal auditory meatus a deep blind depression for a process of the cerebellum. The antero-internal edge of the petrous part is sharp and prominent for the attachment of the tentorium cerebelli. Near its lower end this edge is perforated by a foramen through which the fifth cranial nerve passes forwards.

**Ethmoid Bone.** This bone is largely developed in the dog. The ethmoidal fossæ are very deep, and but slightly separated from each other, the crista galli process forming only a slight ridge. The cells of the lateral mass are large and numerous.

**Pterygoid Bone.** In the dog this bone is quadrangular in shape, being shorter but broader than in the horse. Its postero-superior angle carries a small upturned hamular process.

**Palatine Bone.** Both the palatine and the orbital part of this bone are larger than in the horse. The former furnishes nearly a third of the length of the hard palate. As in the horse, the posterior palatine foramen opens on the suture between the palatine and superior maxilla, but sometimes the palatine canal itself is formed entirely in the first of these bones. Two or three accessory palatine foramina perforate the bone above the main foramen. The palatine bone takes no share in forming the sphenoidal sinus.

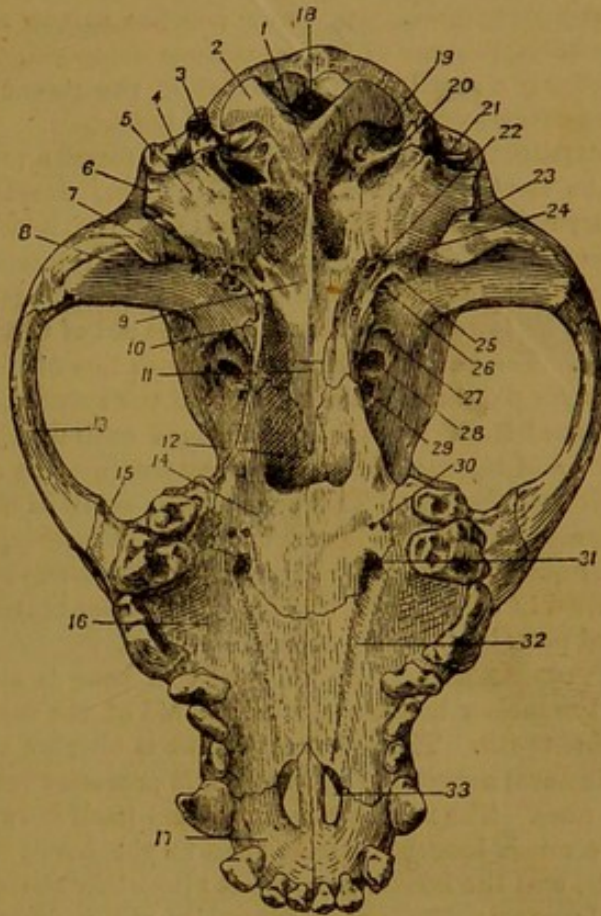


FIG. 61.—SKULL OF DOG, VIEWED FROM BEHIND.

1. Basilar process; 2. Condyle of occipital; 3. Styloid process of same; 4. Mastoid process of temporal; 5. Auditory bulla; 6. External auditory meatus; 7. Post-glenoid process; 8. Glenoid fossa; 9. Post-sphenoid; 10. Hamular process of pterygoid; 11. Pre-sphenoid; 12. Vomer; 13. Malar; 14. Palatine; 15. Zygomatic process of superior maxilla; 16. Palatine plate of same; 17. Premaxilla; 18. Foramen magnum; 19. Condylod foramen; 20. Foramen lacerum posterius; 21. Stylo-mastoid foramen; 22. Carotid foramen; 23. Outward opening of parieto-temporal canal; 24. Eustachian orifice; 25. Foramen ovale; 26. Upper orifice of sub-sphenoidal canal; 27. Lower orifice of same and foramen rotundum; 28. Foramen lacerum orbitale; 29. Optic foramen; 30. Accessory palatine foramina; 31. Posterior palatine foramen; 32. Palatine groove; 33. Incisor cleft.

**Lachrymal Bone.** In the dog this bone is almost entirely orbital, little more than its anterior edge entering into the formation of the face. The superior maxilla cuts it off from articulation with the nasal bone, but, on the other hand, it articulates constantly with the palatine.

**Malar Bone.** The facial part of this bone is very small, but the zygomatic part is greatly developed. Its upper end has a long anterior bevel for articulation with the zygomatic process of the squamous temporal. The orbital edge of the process carries superiorly a small tubercle, which in the recent state is connected by ligament to the supra-orbital process of the frontal bone.

**Superior Maxilla.** This bone forms a much larger proportion of the face than in the horse, its upper extremity being developed at the expense of the malar and lachrymal bones. The small size of the latter bone allows the superior maxilla to articulate with the frontal. There is a large centrally placed infra-orbital foramen, but the zygomatic ridge is absent. The alveolar edge carries alveoli for the six back teeth, and at its lower end it forms with the aid of the premaxilla a large socket for the canine tooth. The palatine plate forms much less of the hard palate than in the horse. The posterior palatine foramen opens on the suture between this bone and the palatine, but the canal itself is sometimes formed entirely in the palatine. The palatine groove is faint, and the maxillary sinus very small. The alveolar tuberosity is absent.

**Nasal Bone.** This bone is very small in the dog. In most breeds the upper end is narrower than the lower, but sometimes (Fig. 60) this relationship is reversed. The outer surface of the bone is more or less concave in its length, the concavity being most marked in the smaller breeds. The lower extremity exhibits a rounded notch, and the nasal peak is therefore absent.

**Premaxilla.** The body of this bone is strong. It is excavated by three alveoli for the incisor teeth, and with the aid of the superior maxilla it forms the socket for the canine tooth. The palatine process is shorter but stronger than in the horse, and on their nasal aspect the right and left processes form a groove for the septal cartilage of the nose. The nasal process intrudes itself between the superior maxilla and nasal bone for a much longer distance than in the horse. The naso-palatine clefts are short but wide, and the incisor foramen is altogether absent or very small.

**Vomer.** The upper extremity of this bone is narrow and deeply notched. The upper part of its hinder edge lies more in the depth of the pharyngeal orifice of the nose, which is therefore less distinctly divided than in the horse.

**Turbinated Bones.** The turbinated bones are more richly convoluted than in the horse. The anterior bone is less distinctly separated from the lateral mass of the ethmoid. The posterior bone is rolled in two opposite directions from its attached edge, as in the ox; but its main lamina carries secondary and tertiary lamellæ, which are again rolled upon themselves. The bones take no part in forming the frontal or maxillary sinuses.

**Inferior Maxilla.** Except in old animals, the right and left halves of this bone do not become ankylosed. The axis of the bone from the coronoid process to the lower extremity of the body forms only a slightly curved line. At its junction with the body the ramus is stronger than in the horse, and outwardly it carries two or three mental foramina. In the position of the angle, which would otherwise be indistinct, there is a strong backwardly directed process for the attachment of the masseter and internal pterygoid muscles. Above and in front of this the outer face of the ramus is deeply depressed for the attachment of the masseter. The condyle is elongated transversely, convex from before to behind, and slightly concave from side to side. The coronoid process is a relatively enormous plate of bone, standing much higher than the condyle, and rivalling the ramus in breadth. The corono-condyloid notch is not well marked. The alveolar edge of the ramus carries alveoli for the seven back teeth, and the body is excavated by four other alveoli for the canine tooth and the three incisors. There is scarcely any interdental space.

**Hyoid Bone.** The basi-hyal is elongated transversely and rod-like. The glossal process is absent, and the thyro-hyals are not ankylosed with the body. The epi-hyal is nearly equal in size to the stylo-hyal, and much larger than the cerato-hyal.

**Skull of the Dog as a Whole.** The cranio-facial angle of the dog's skull

measures about  $142^{\circ}$ . Contrary to what is the case in the horse, the cranial part of the skull rivals or exceeds the facial part in size. The reduction in the size of the facial part is most marked in the smaller breeds. The temporal fossæ are vastly more developed than in the horse, a feature which is characteristic of the carnivorous skull. As already mentioned, the right and left fossæ in the larger breeds approach the middle line in front, being separated only by the sagittal crest above. To further increase the capacity of

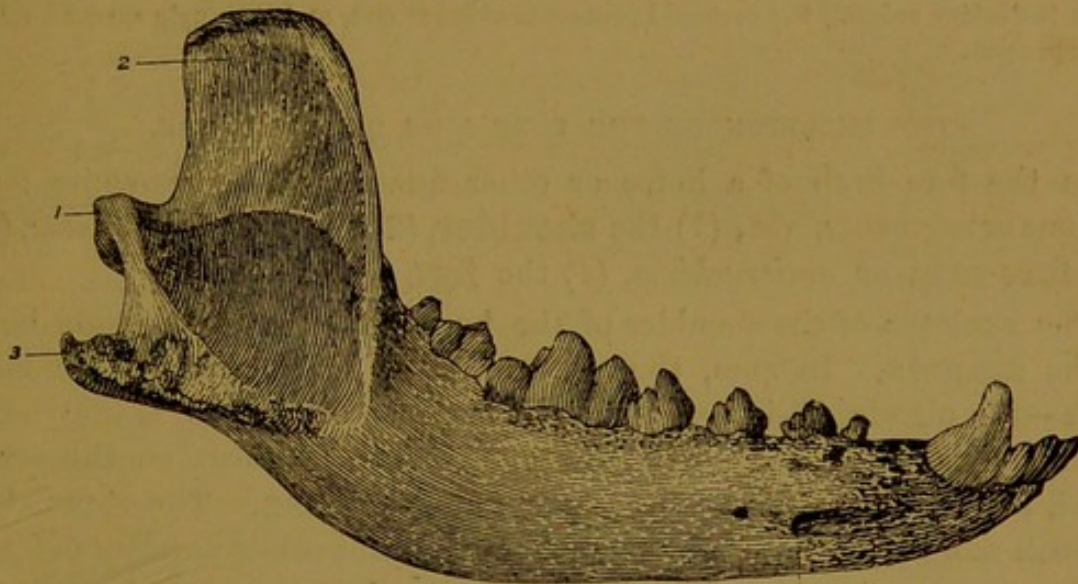


FIG. 62.—INFERIOR MAXILLA OF DOG.

1. Condyle ; 2. Coronoid process ; 3. Muscular process of angle ; 4. Mental foramen.

these fossæ, the zygomatic process of the squamous temporal takes a much wider sweep outwards than in the horse. In the bull-dog and related breeds the transverse measurement from one process to the other stands in relation to the long axis of the entire skull as 2 : 3 (almost as 2 : 5 in the horse). As in the pig, the orbital cavity in the dry skull communicates freely with the temporal fossa; the orbital rim, owing to the slight development of the supra-orbital process of the frontal, being incomplete above. The axis of the orbit has more of a forward and less of an outward direction than in the herbivorous orders. The frontal region is relatively smaller, owing to the small size of the frontal sinuses. Similarly, the lateral aspect of the face is more depressed on account of the slighter development of the maxillary sinuses. The breadth of the hard palate, more especially in the bull-dog and smaller breeds, is relatively greater than in the horse. A horizontal line drawn through the upper margin of the palate falls a little above the uppermost molar tooth. The posterior nares look almost directly upwards, and they are more compressed from before to behind than in the horse. The inferior nares on the other hand are more circular in outline than in the horse, and they are placed nearly at the lower extremity of the skull.

#### THE SKULL OF THE CAT.

The individual bones of the cat's skull resemble very closely the same bones of the dog. The entire skull is also very similar in form to the skull of a small dog. The cranio-facial angle in the cat measures about  $145^{\circ}$ . As compared with the horse or the ruminant, the cat exhibits a great reduction in the size of the facial part of the skull. Thus, in the skull of the horse the distance between the occipital crest and the lowest point of the frontal bone is almost equal to the distance between the latter point and the lower extremity of the premaxilla, whereas in the cat the first of these measurements is to the second almost as 3 : 1. The anterior aspect of the cat's skull forms in the vertical direction an almost regular curve or arch, the nasal bone having a slight forward convexity continuous with that of the frontal. The temporal fossa, as in other carnivorous animals, is large. The orbital rim is incomplete above, but the supra-orbital pro-

cess is better developed than in the dog. The orbit is relatively much larger than in any of the other domestic animals; and, as in the dog, its axis is directed well forwards. The cranial cavity is relatively capacious, and it has a large ossific tentorium, which belongs to the parietal bones. The auditory bullæ are still larger than in the dog. The bony palate is of small size, and its length is equalled by its transverse measurement at its upper part. Less than one-third of its mesial suture belongs to the superior maxillary bones. The ramus of the lower jaw is little curved and shorter than in the dog. As in the latter animal, the coronoid process is of great size, and the angle carries a muscular process.

#### THE SKELETON OF THE FORE LIMB OF THE HORSE.

In the fore limb of a horse or other quadruped we recognise four regions or segments, viz., (1) the **shoulder**, (2) the **arm** or *brachium*, (3) the **fore-arm** or *antibrachium*, (4) the **fore foot** or *manus*.

The skeleton of the shoulder of the horse is formed by a single bone—the **scapula**. In man, the cat, and some other animals, a second bone—the **clavicle**—is present. The skeleton of the arm is invariably formed by a single bone—the **humerus**. The fore-arm, on the other hand, includes two bones—the **radius** and the **ulna**. The manus has a much more complex skeleton than any of the other segments of the limb. It comprises three sets of bones, viz., (1) a group of short bones termed the **carpus**, (2) a number of approximately parallel long bones, termed the **metacarpus**, and (3) the **phalanges**, or skeleton of the digit.

#### THE SCAPULA.

The scapula, or shoulder blade, belongs to the class of flat bones. It occupies a movable position on the antero-lateral part of the thorax, and in the horse and other animals destitute of a clavicle it is connected to the axial skeleton by muscles only. The entire bone is somewhat triangular in outline, and its long axis is directed obliquely downwards and forwards. It may be described as possessing two surfaces, three edges, and three angles.

The *outer surface*, or *dorsum*, widest above, is traversed lengthways by a prominent ridge of bone—the **spine** of the scapula. This ridge attains its greatest height and prominence a little above its middle, where it carries a rough **tubercle** for the attachment of the trapezius muscle. Above the tubercle the spine gradually subsides in extending to the upper end of the bone. Below the tubercle the ridge has a blunt rough edge, and it terminates a few inches above the lower angle of the bone. This gradual subsidence of the spine is a notable feature in the scapula of the horse, for in many animals a larger or smaller *acromion process* prolongs the spine at its lower extremity.

The spine partitions the dorsum into two unequal divisions, which from their being slightly hollowed out, are known as *fossæ*. The division in front of the spine is termed the **supra-spinous fossa**, while

that behind it is the **infra-spinous fossa**. The area of the first of these is about half that of the other. The supra-spinous fossa is comparatively smooth, and occupied by the supraspinatus muscle. Just below the lower end of the spine, it shows some faint transverse grooves, which are the impress left by blood-vessels. The infra-spinous fossa is also for the most part smooth. It shows, however, some vascular impressions, and near the hinder edge and towards its lower end some slight muscular ridges. The **nutrient foramen** of the scapula is found in the inferior third of this fossa, about opposite the lower end of the spine. The infra-spinous fossa lodges the infraspinatus and teres minor muscles, the rough lines previously mentioned marking the attachment of the last-named muscle.

The *inner surface* or *venter* of the scapula is similar to the *dorsum* in extent and outline. Its lower two-thirds is taken up entirely in forming the shallow **subscapular fossa**, which lodges the subscapularis muscle. At its upper end this fossa extends with a tapering point to near the upper edge of the bone. In front of this prolongation of the fossa there is an extensive rough area, on which the levator anguli scapulæ and serratus magnus muscles are inserted, and behind the prolongation there is another somewhat similar area for the attachment of the last-named muscle. The subscapular fossa shows in its lower half a number of branching vascular impressions, which mark the course of branches of the subscapular artery.

The *anterior edge* of the bone is also appropriately termed the *coracoid edge*, since it is terminated inferiorly by the coracoid process. In its upper half this edge is convex, blunt, and rough, but in its lower half it is thin, smooth, and concave.

The *posterior edge*, also called the *glenoid edge*, because it conducts at its lower end to the glenoid cavity, is slightly concave. At its extreme

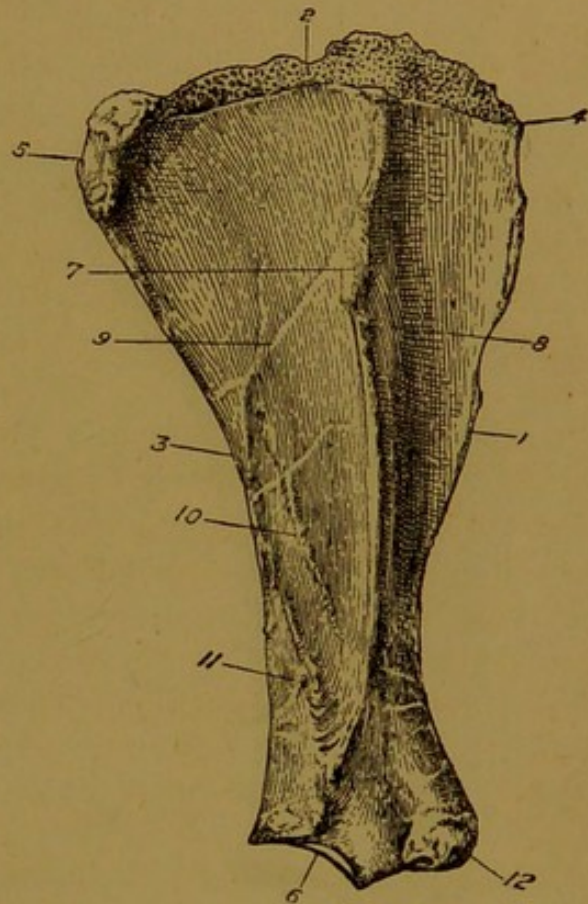


FIG. 63.—RIGHT SCAPULA OF HORSE  
(Outer Surface).

1. Coracoid edge; 2. Vertebral edge; 3. Glenoid edge; 4. Cervical angle; 5. Dorsal angle; 6. Glenoid fossa; 7. Tubercle of spine; 8. Supra-spinous fossa; 9. Infra-spinous fossa; 10. A muscular ridge; 11. Nutrient foramen; 12. Coracoid process.

upper part it is thick and tuberos, in its middle third it is thin and slightly grooved, and in its lower third it is again thick and slightly roughened. Several muscles of the shoulder take origin from this edge.

The *superior* or *vertebral edge* carries the **cartilage of prolongation**.

This is a thin flexible plate of cartilage representing a persistent or unossified part of the foetal cartilaginous scapula. The cartilage is smooth and convex on its upper free edge, and posteriorly it forms a rounded projection which extends beyond the line of the posterior edge of the scapula. The inner surface of the cartilage gives attachment to the rhomboideus muscle.

The *cervical angle* of the scapula, which separates the upper and anterior borders, is comparatively thin.

The *dorsal angle* is that which separates the superior from the posterior border. It is thick and tuberos.

The remaining angle is the *inferior* or *articular angle*. It carries the **glenoid cavity** and the **coracoid process**. The glenoid cavity is a shallow, oval, articular depression, which meets the head of the humerus in the shoulder joint. The rim of the cavity gives attachment to the

capsular ligament of the joint. It shows a notch at its antero-internal part, and at the diagonally opposite point it carries outwardly a small blunt tubercle from which some of the fibres of the *teres minor* arise. A very faint constriction, or **neck**, encircles the bone immediately above the glenoid cavity. The **coracoid<sup>1</sup> process** forms the anterior part of the lower angle of the scapula. It is an obtuse rough eminence with a projecting tubercle on its inner aspect. The *coraco-brachialis* muscle takes origin from this projection, and the remainder of the process gives origin to the *coraco-radialis* or *biceps* muscle. A broad well-defined groove, in which

<sup>1</sup> So named from its resemblance in human anatomy to a crow's beak.

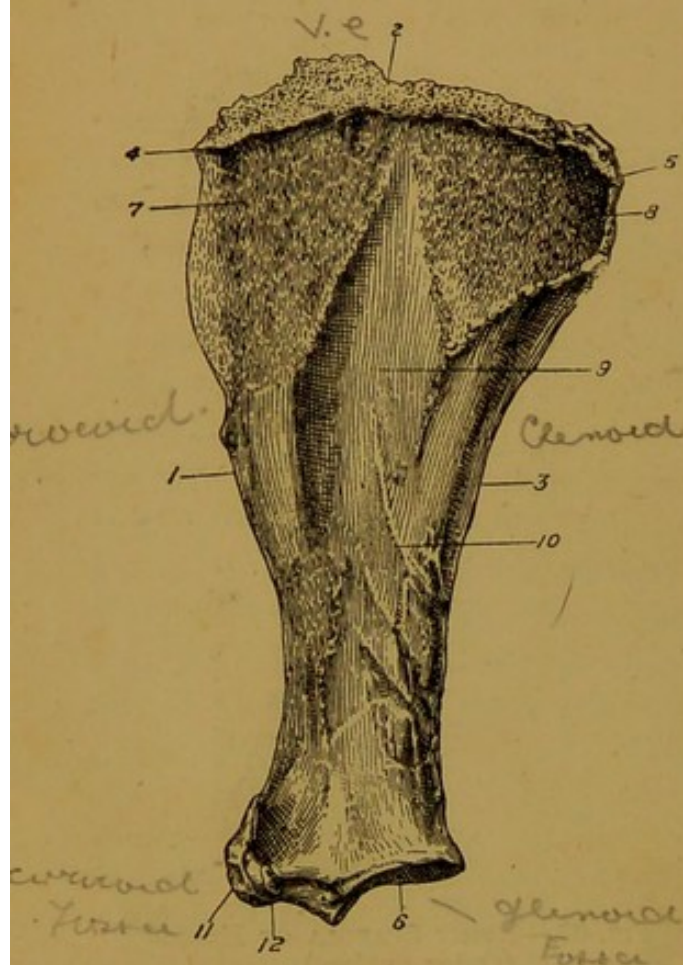


FIG. 64.—RIGHT SCAPULA OF HORSE  
(Inner Surface).

1. Coracoid edge; 2. Vertebral edge; 3. Glenoid edge; 4. Cervical angle; 5. Dorsal angle; 6. Glenoid fossa; 7 and 8. Surfaces for attachment of levator anguli scapulæ and serratus magnus muscles; 9. Subscapular fossa; 10. A vascular groove; 11. Coracoid process; 12. Nodule of same for coraco-brachialis muscle.

the tendon of the subscapularis muscle rests, separates the coracoid process from the glenoid cavity, on the inner aspect of the bone.

**Development.** The scapula ossifies from three centres. One of these appears about the middle of the primitive cartilage, and serves for the ossification of the greater part of the bone. A second centre belongs to the coracoid process, which is the homologue of the coracoid bone of the fowl and lower vertebrates. A third centre appears about the middle of the glenoid cavity.

#### THE HUMERUS.

The humerus, which belongs to the class of long bones, occupies an oblique position in the limb, its long axis being directed downwards and backwards between the shoulder and elbow joints. It possesses a *shaft* and two *extremities*.

The shaft, or *diaphysis*, may be described as possessing four surfaces.

The *anterior surface* is widest above, and narrowest towards its lower end. It is for the most part smooth, but in its middle third it carries some rough lines and markings for the attachment of the coraco-brachialis muscle.

The *inner surface* is rounded from side to side, and blended with the anterior and posterior surfaces. About the junction of its upper and its middle third it bears the **internal tubercle**—a rough slightly projecting area for the attachment of the tendons of the latissimus dorsi and teres major muscles. Lower down, in the inferior third of this surface, is the **nutrient foramen** of the bone.

The *posterior surface* is smooth, convex in the cross direction, and blended with the lateral surfaces.

The *external surface* has the form of a deep spiral groove, termed the **musculo-spiral groove** or **furrow of torsion**. It lodges the brachialis anticus muscle. At its upper end this groove encroaches on the posterior surface, and, after a spiral course downwards and forwards, it terminates towards the front of

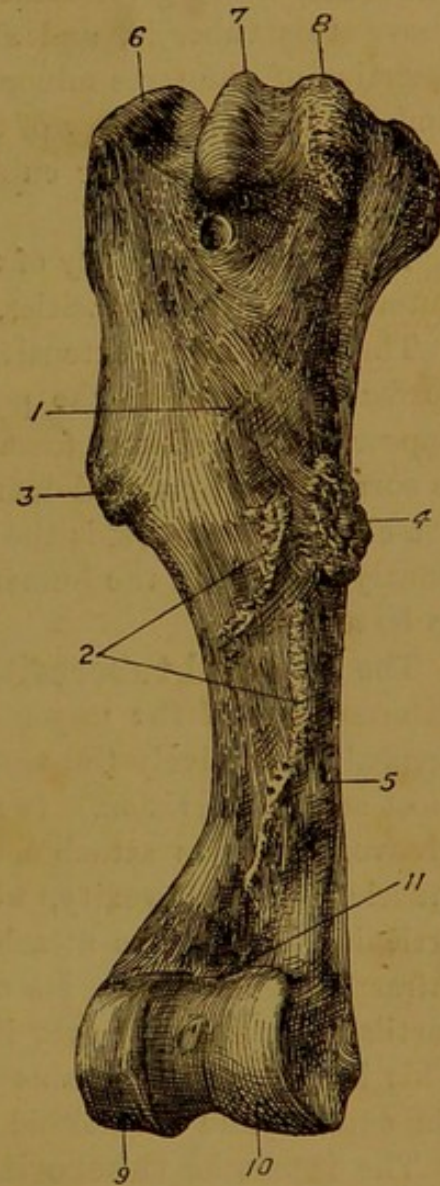


FIG. 65. — RIGHT HUMERUS OF HORSE (Antero-Internal View).

1. Anterior surface of shaft; 2. Markings for attachment of coraco-brachialis; 3. External tubercle; 4. Internal tubercle; 5. Nutrient foramen; 6. External tuberosity; 7. Mesial ridge of bicipital groove; 8. Internal tuberosity; 9. Outer, and 10. Inner part of lower articular surface; 11. Coronoid fossa.

the lower end of the shaft. From the anterior surface the groove is separated by a ridge which extends upwards from a little above the coronoid fossa. At its most prominent part, a little above the middle of the shaft, this ridge carries the **external** or **deltoid tubercle**, which gives attachment to the deltoid muscle. Immediately above this tubercle, and almost blended with it, is a nodule for the insertion of the teres minor muscle. From this nodule a curved line, limiting here the furrow of torsion, and giving origin to the middle head of the triceps extensor cubiti, extends backwards and upwards to the articular head.

The *superior extremity* of the humerus is compounded of the head, the outer and inner tuberosities, and the bicipital groove.

The **head** is an extensive, slightly convex, nearly circular articular surface, which forms the posterior part of the upper extremity. It is opposed to the glenoid fossa of the scapula in the shoulder joint, and it is surrounded by a well-defined edge, to which the capsular ligament is attached. The **neck** is the constriction beneath the head, but this is so faintly marked in the humerus of the horse that it might almost be said to be absent.

The **external tuberosity** is a muscular process placed at the antero-external part of the upper extremity. It is composed of two divisions, termed respectively the *summit* and the *convexity*. The summit is the most anterior division. It forms the external boundary of the bicipital groove, and gives attachment to the outer tendon of the supraspinatus muscle. The convexity, which lies directly to the outer side of the articular head, gives attachment inwardly to the inner tendon of the infraspinatus muscle. Its outer surface is smooth and covered by fibro-cartilage for the play over it of the outer tendon of the infraspinatus. This latter tendon obtains insertion into a rough oval mark between the summit and the deltoid tubercle.

The **internal tuberosity** is placed opposite to the outer. It comprises an anterior and a posterior division. The anterior division forms the inner boundary of the bicipital groove, and gives attachment at its highest point to the inner tendon of the supraspinatus, while outwardly the posterior deep pectoral muscle is inserted into it. The posterior division lies to the inner side of the articular head, and gives insertion to the tendon of the subscapularis muscle.

The **bicipital groove** is so named because the upper tendon of the biceps muscle plays over it. It is placed at the front of the upper extremity of the humerus, between the external and internal tuberosities. A prominent ridge divides it into an outer and an inner channel, the latter being slightly the larger, and the entire surface is covered in the recent state by fibro-cartilage to facilitate the play of the biceps tendon. Behind the bicipital groove and in front of the articular head there is

an area of bone showing a number of foramina for the passage of vessels belonging to the cancellated tissue of the bone.

The *lower extremity* of the humerus carries a pulley-like surface for articulation with the bones of the fore-arm. An obtuse ridge passes from front to back of this surface, and divides it into an outer and an inner portion. The outer portion, which is very much the smaller of the two, is faintly grooved like a pulley. It articulates with the radius. The inner division is also traversed by a pulley-like groove, which begins in front at the upper limit of the articular surface, and, after turning round the lower aspect of the surface, gains the olecranon fossa at the back of the bone. The greater part of this surface also articulates with the radius, but its posterior prolongation towards the olecranon fossa articulates with the ulna.

On the anterior aspect of the lower extremity, immediately above the articular surface, there is a well-marked pit—the **coronoid fossa**, which receives the coronoid process of the radius in extreme flexion of the elbow joint. To the outer side of this fossa there is a smaller rough pit which affords a common origin to the extensor metacarpi magnus and extensor pedis muscles.

Opposite to the coronoid fossa, at the back of the lower extremity, there is a much deeper cavity—the **olecranon fossa**, which receives the olecranon process of the ulna during complete extension of the elbow joint. Thick ridges, termed respectively the outer and inner condyles, bound the olecranon fossa on either side. The **outer condyle** has a sharp

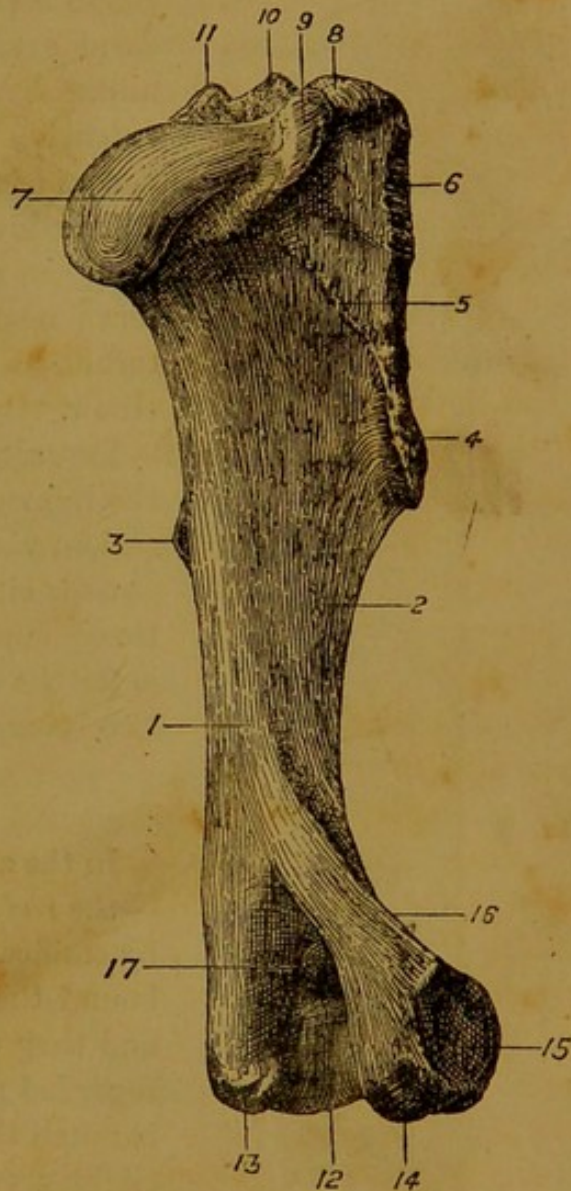


FIG. 66.—RIGHT HUMERUS OF HORSE  
(Postero-External View).

1. Posterior surface of shaft; 2. Musculo-spiral groove; 3. Internal tubercle; 4. External tubercle; 5. Ridge for middle head of triceps extensor cubiti; 6. Mark for outer tendon of infraspinatus; 7. Articular head; 8. Summit, and 9. Convexity of external tuberosity; 10. Mesial ridge of bicipital groove; 11. Internal tuberosity; 12. Lower articular surface; 13. Surface for origin of flexors of digit; 14. Surface for origin of external flexor of metacarpus; 15. Pit for external lateral ligament; 16. Anterior edge of outer condyle, for origin of extensor metacarpi magnus; 17. Olecranon fossa.

anterior edge, which forms here the outer boundary of the musculo-spiral groove, and gives origin to the extensor metacarpi magnus. At its lowest point the outer condyle shows a rough area for the origin of the flexor metacarpi externus. The **inner condyle** is terminated inferiorly by a similar but more extensive rough area for the origin of the flexors of the digit.

The lower extremity carries outwardly a deep pit, and inwardly a small tubercle, which serve respectively for attachment of the external and internal lateral ligaments of the elbow.

**Development.** Like other long bones, the humerus has three main centres of ossification, viz., a central one for the shaft, and one for either extremity. To these are added three supplementary centres, one of which is for the external tuberosity, while the other two belong to the outer and inner condyles.

#### THE RADIUS.

In the adult horse the bones of the fore-arm—the *radius* and the *ulna*—are rigidly united by ossification of the ligamentous fibres which bound them together in the young animal, and they thus form what would popularly be regarded as a single bone. The radius, which is much the larger of the two, is a long bone, slightly curved in its length, and extending in a nearly vertical direction from the elbow joint above to the carpus below. It possesses a *shaft* and *two extremities*.

The shaft of the radius, which is slightly curved with the convexity forwards, is flattened from before to behind, so as to present an anterior and a posterior surface separated on either side by rounded ill-defined edges.

The *anterior surface*, slightly convex in its length, and markedly convex in the cross direction, is for the most part smooth and covered by the extensor muscles of the meta-

carpus and digit. It shows on its inner side, a few inches below the upper extremity of the bone, a rough imprint for the insertion of the

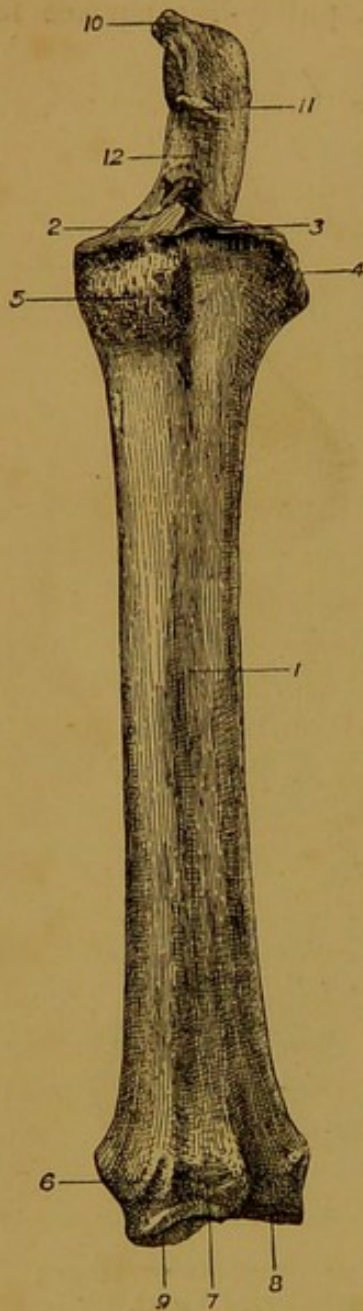


FIG. 67.—LEFT RADIUS AND ULNA OF HORSE (Front View).

1. Anterior surface of shaft of radius; 2. Its upper articular surface; 3. Coronoid process; 4. External tuberosity; 5. Bicipital tuberosity; 6. Groove for extensor metacarpi obliquus; 7. Groove for extensor metacarpi magnus; 8. Groove for extensor pedis; 9. Lower articular surface; 10. Summit of olecranon; 11. Beak of same; 12. Sigmoid cavity.

internal lateral ligament of the elbow joint, and immediately above this another mark for the tendon of the brachialis anticus muscle.

The *posterior surface*, slightly concave in its length, is nearly flat from side to side. On its lower third, and towards the outer edge of the surface, there is a rough elevation for attachment of the supracarpal band of the superficial flexor of the digit. Above this, and extending upwards along the outer edge of the surface, there is an elongated triangular area with the point below. To this area the ulna is united by ligamentous fibres in the young animal, and by ossification in the adult. Superiorly, a few inches below the upper end of the bone, this area is limited by a smooth transverse depression forming the anterior boundary of the **radio-ulnar arch**, through which the interosseous vessels of the fore-arm are transmitted. The **nutrient foramen** of the bone is placed at the lower limit of this smooth surface. Above the radio-ulnar arch the posterior surface is rough and irregular in its outer half. Here the radius and ulna are united by an interposed ligament, which in the very old animal is often ossified.

The *upper extremity* of the radius carries an articular surface that is like the mould or impression of the lower articular surface of the humerus. A well-defined edge encircles the articular surface, and at the middle of its anterior half it carries a slight projection—the **coronoid process**. Behind the main articular surface, and looking backwards, there are two small facets, which form synovial joints with like facets of the ulna. At either extremity of its transverse axis the upper end of the radius is prominent and rough for ligamentous and muscular attachment. At the antero-internal part of this extremity there is a rough round eminence—the **bicipital tuberosity**, to which the lower tendon of the biceps muscle is inserted.

The *lower extremity* of the radius is furnished with an articular surface compounded of several facets for articulation with the upper row of carpal bones. At either extremity of its transverse diameter it carries a prominent rough tuberosity for ligamentous attachment. The outer tuberosity has a vertical groove for the tendon of the extensor suffraginis muscle. On the anterior aspect of the bone, immediately above the articular surface, there are three distinct grooves. The inner one is the smallest, and it is directed obliquely downwards and inwards. It lodges the tendon of the extensor metacarpi obliquus. The middle groove is wide, and vertical in its direction, and it gives passage to the tendon of the extensor metacarpi magnus. The outermost groove resembles in size and direction the middle one, and it lodges the tendon of the extensor pedis. At the back of the lower extremity, immediately above the articular surface, the bone is pitted and irregular for ligamentous attachment.

**Development.** The radius possesses the three main centres of ossification common to long bones, viz., one for the shaft, and one for either extremity. A supplementary centre is present in the outer tuberosity of the lower extremity, which ought to be regarded as the distal end of the ulna.

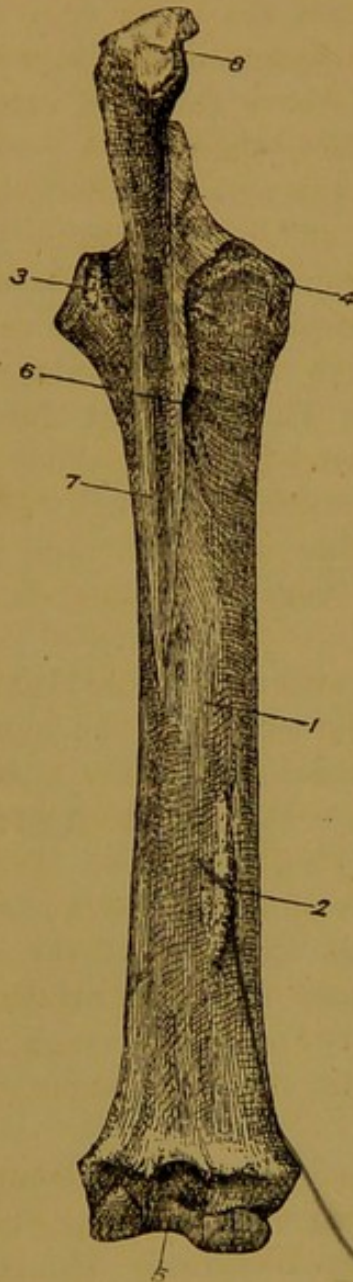


FIG. 68.—LEFT RADIUS AND ULNA OF HORSE (Posterior View).

1. Posterior surface of shaft of radius;
2. Rough mark for supra-carpal band of flexor perforatus; 3 and 4. Outer and inner tuberosities of upper extremity; 5. Lower articular surface;
6. Radio-ulnar arch; 7. Body of ulna; 8. Summit of olecranon.

#### THE ULNA.

One of the most remarkable features of the skeleton of the horse is the relatively small size of the ulna. In the human subject, for example, and in many other animals, the ulna is the larger of the two bones of the fore-arm, extending from the point of the elbow to the wrist or carpus. In man, moreover, the radius and ulna remain movable upon one another throughout life. In the horse, on the other hand, the ulna is a comparatively diminutive bone, rigidly fixed in adult life to the upper half of the radius. The ulna of the horse is in reality a long bone whose development has been arrested. It does not conform to the definition of a long bone, for it is destitute of a medullary canal. It may be described as possessing a body and two extremities.

The *body* is a three-sided piece of bone tapering towards its lowest point.

The *anterior surface* of the body is opposed to the outer part of the posterior surface of the radius. It presents a little below its upper end a smooth portion forming the posterior boundary of the **radio-ulnar arch**. Above and below the arch this surface is rough, and united to the radius by ligament.

As already stated, however, the ligamentous fibres below the radio-ulnar arch are invariably ossified in the adult, but it is only in late life that ossification invades the fibres uniting the bones above the arch. Sharp well-defined edges separate this anterior surface from the lateral surfaces.

The *lateral surfaces* are smooth, slightly convex, and separated from

each other by a round smooth edge. The inner surface is the more extensive of the two.

The *upper extremity* is made up of the olecranon process and the sigmoid cavity.

The **olecranon process** is a massive piece of bone, surpassing in weight all the rest of the ulna. It presents an outer convex and an inner concave surface, a posterior thick, round, and nearly straight edge, and an anterior edge which is concave and sharper. The latter edge terminates below in a projecting beak, which overhangs the sigmoid cavity, and which during extreme extension of the elbow-joint passes into the olecranon fossa of the humerus. The summit of the process forms the point of the elbow. It has the form of a rough tuberosity, and it gives insertion to the triceps extensor cubiti muscle.

The **sigmoid cavity** is a semicircular outcut below the anterior edge of the olecranon process, and above the anterior surface of the body. It is for the most part smooth for articulation with the lower extremity of the humerus. Immediately below the sigmoid cavity, and placed at the upper limit of the anterior surface of the body, there are two small facets, which form synovial joints with similar facets already described on the radius.

*Inferiorly* the ulna reaches to the lower third of the radius, where it terminates by a sharp point or by a minute nodular enlargement.

**Development.** The ulna as above described ossifies from two centres—one for the body, and one for the upper extremity. But, as already stated, the piece of bone which ossifies from a separate centre at the outer side of the lower extremity of the radius ought to be regarded as the lower end of the ulna.

#### THE BONES OF THE CARPUS.

The bones of the carpus of the horse are at the most eight in number, but in the majority of cases only seven are present. They are arranged in two rows or tiers, and all of them belong to the class of short bones. The names and relative positions of the bones in each row are shown below, the left side of the page corresponding to the inner side of the limb :—

Upper Row—Scaphoid, Semilunar, Cuneiform, Pisiform.

Lower Row—Trapezium, Trapezoid, Os Magnum, Unciform.

The bone which is only exceptionally present is the trapezium—the innermost bone of the lower row.

The **Scaphoid**. This is the largest bone of the upper row, and it is also the most regularly six-sided of all the bones of the carpus. The *upper surface* of the bone is undulated, smooth, and articular, and it responds entirely to the radius. The *inferior surface*, recognised by its smoothness as being also entirely articular, is convex in its anterior

half, and cupped in its posterior half. It responds to the os magnum and trapezoid. The *outer surface* presents two articular facets for the semilunar. For the remainder of its extent it is non-articular, and irregularly excavated for the attachment of an interosseous ligament. The remaining three surfaces—*anterior*, *inner*, and *posterior*—are non-articular. The scaphoid articulates with four bones, viz., the radius, semilunar, trapezoid, and os magnum.

The **Semilunar**, or **Lunar**. In point of size this is the second bone of the upper row. It may be recognised by its wedge shape. Its

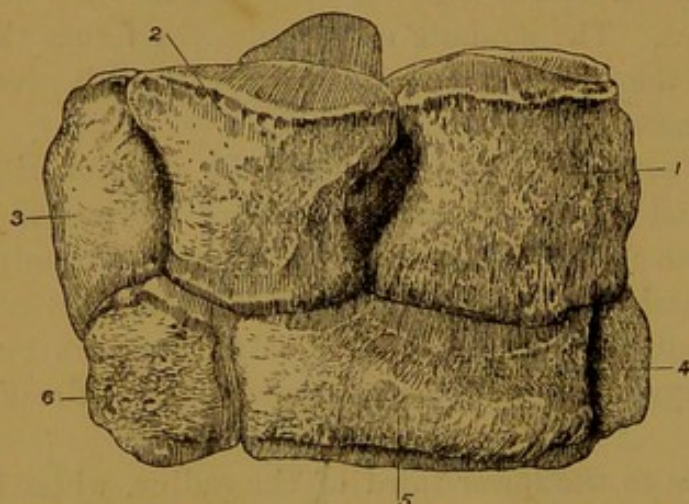


FIG. 69.—FRONT VIEW OF RIGHT CARPUS OF HORSE.  
1. Scaphoid ; 2. Semilunar ; 3. Cuneiform ; 4. Trapezoid ;  
5. Os magnum ; 6. Unciform.

*upper surface* is undulated, smooth, and articular, and it responds to the lower end of the radius. The *lower surface*, also smooth and articular, is slightly convex in front and concave behind. It articulates with the os magnum and unciform. The *lateral surfaces*—external and internal—present each two facets, the remainder of these surfaces being depressed and rough for

the attachment of interosseous ligaments. The facets on the inner of these surfaces respond to similar facets on the scaphoid, while those on the outer surface play the same part with regard to the cuneiform. The *anterior surface*, which is slightly convex, rough, and non-articular, forms the base of the wedge. The *posterior surface*, which represents the edge of the wedge, is rounded and non-articular. The semilunar articulates with five bones, viz., the radius, scaphoid, cuneiform, os magnum, and unciform.

The **Cuneiform**. This is the smallest bone of the upper row. It may be distinguished from all the other bones of the carpus by the shallow cup-like shape of its *upper surface*, which is smooth for articulation with the radius. The *lower surface*, entirely articular, is undulated, and responds to the unciform. The *inner surface* possesses two facets for articulation with the semilunar. The *anterior* and *outer surfaces* are blended, rough, and non-articular. The *posterior surface* is almost entirely articular, in the shape of a vertically elongated slightly concave facet for articulation with the pisiform. The cuneiform articulates with four bones, viz., the radius, semilunar, unciform, and pisiform.

The **Pisiform**. This bone is distinctly flattened and four-sided in

shape, and by that character it can easily be distinguished from the other bones of the carpus. Functionally it differs from the other members of the upper row, in that it is not a weight-bearing bone. It projects backwards at the outer side of the carpus, in order to afford increased leverage to the flexors of the metacarpus. The bone may be described as possessing two surfaces and four borders. The *inner surface* is concave, and it forms the outer boundary of the carpal sheath—the tubular passage through which the flexors of the digit pass at the back of the knee. The *outer surface* is slightly convex. It is crossed obliquely downwards and forwards by a furrow which lodges a tendon belonging to the flexor metacarpi externus. The *anterior border* of the bone carries two facets, the lower of which is convex and oval for articulation with the cuneiform, while the upper, which is concave and circular, responds to the lower end of the radius. The *upper, posterior, and lower borders* are rounded and non-articular. The pisiform articulates with two bones, viz., the radius and the cuneiform.

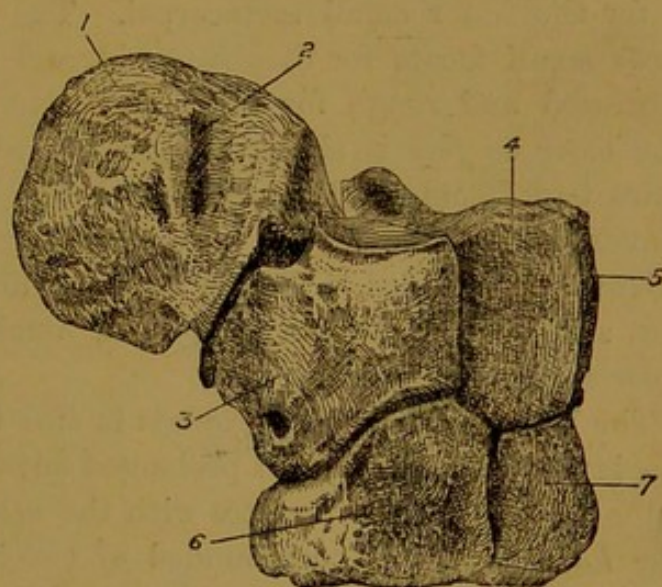


FIG. 70.—ANTERO-LATERAL VIEW OF RIGHT CARPUS OF HORSE.

1. Pisiform ; 2. Groove of same for tendon of flexor metacarpi externus ; 3. Cuneiform ; 4. Semilunar ; 5. Scaphoid ; 6. Unciform ; 7. Os magnum.

The **Trapezium**. When present this bone is of small dimensions, and articulated with the back of the trapezoid. It is rounded in form, and occasionally double the size of a common pea, though generally it is much smaller.

The **Trapezoid**. When the trapezium is absent, this is the smallest of the bones of the lower row. It more approaches the hemispherical in shape than any of the other bones of the carpus. The *upper surface* of the bone is convex, smooth, and articular, and it is prolonged so as to encroach upon the inner surface. It articulates with the scaphoid. The *lower surface*, also articular, is compounded of two facets, the anterior and larger of which is for the inner small metacarpal bone, while the other articulates with the large metacarpal. The *external surface* carries two or three facets for articulation with the os magnum, and for the rest of its extent it is rough for the attachment of an interosseous ligament. The *anterior, inner, and posterior surfaces* are blended so as to form one continuous convex surface. When the trapezium is present the posterior surface bears a small facet for articulation with that

bone. The trapezoid articulates with five bones, viz., the scaphoid, trapezium (inconstant), os magnum, large metacarpal, and inner small metacarpal.

The **Os magnum** greatly exceeds in size any of the other bones of the lower row. The scaphoid exceeds it in weight, but it is readily distinguished from that bone by its greater breadth. Its *upper surface* is compounded of two articular facets separated by a slight ridge. The inner facet articulates with the scaphoid, the outer with the semilunar. The *lower surface* is also entirely articular, and with the exception of a small bevelled facet at its antero-internal corner it is entirely taken up in articulating with the larger metacarpal bone. The small bevelled facet is for the inner small metacarpal. The *inner surface* carries two or three small facets for the trapezoid, and for the rest of its extent it is depressed and rough for the attachment of an interosseous ligament. The *outer surface* is similar to the preceding, but less extensive. It bears two facets for the unciform. The *anterior surface* is extensive, convex, and non-articular. The *posterior surface*, also non-articular, is narrow and rounded. The os magnum articulates with six bones, viz., the scaphoid, semilunar, trapezoid, unciform, large metacarpal, and inner small metacarpal.

The **Unciform** slightly exceeds in size the trapezoid. Its *upper surface* is smooth, convex, and prolonged outwards so as to encroach on the outer surface. It articulates with the semilunar and cuneiform bones. The *lower surface* is compounded of two bevelled facets separated by a slight ridge. The inner and larger of these articulates with the large metacarpal, while the other responds to the outer small metacarpal. The *inner surface* carries two facets for the os magnum, the intervening area affording attachment to an interosseous ligament. The *anterior surface* is slightly convex and non-articular. The *outer surface* is of small extent, being encroached upon by the upper surface. The *posterior surface* forms an obtuse nodular non-articular process. The unciform articulates with five bones, viz., the semilunar, cuneiform, os magnum, large metacarpal, and outer small metacarpal.

**Development.** Each of the bones of the carpus ossifies from a single centre.

#### THE METACARPUS.

The second segment of the manus is the *metacarpus*, the skeleton of which comprises the *metacarpal bones*. In the typical mammalian manus five metacarpal bones are present—one for each digit, as is the case with the human hand, or the fore foot of the dog. The metacarpus of the horse, however, exhibits a marked departure from the typical plan. Two of the five metacarpal bones with their digits are entirely suppressed. Of the remaining three, one only is present in a fully developed con-

dition, and carries a digit; the other two being small slender bones, unprovided with digits, and placed one on each side of the main bone. The last-mentioned bone is termed the *large metacarpal*, and it corresponds to the metacarpal bone that carries the middle finger of the human hand. The two rudimentary bones are termed respectively the *external* and the *internal small metacarpals*, and very commonly also they are called the *splint bones*. The internal bone is the homologue of the metacarpal bone carrying the fore-finger of the human hand, while the outer is the homologue of the metacarpal of the ring finger.

#### THE LARGE METACARPAL BONE.

This is a long bone, and it occupies a nearly vertical position between the carpus above and the fetlock below. Like other long bones it possesses a shaft and two extremities.

The *shaft* is slender compared to the great weight that it has to support, but in compensation for this it is composed almost entirely of compact tissue. It is semicylindrical in shape, and may be described as possessing two surfaces — anterior and posterior.

The *anterior surface* is convex and smoothly rounded from side to side.

The *posterior surface* is comparatively flat, and with the splint bones on either side it forms a shallow wide channel for the superior sesamoid ligament. This channel is for the most part smooth, but close to its upper end it is slightly roughened for the attachment of the before-mentioned ligament. Towards the junction of its upper and middle thirds it shows the **nutrient foramen** of the bone. On either side, beginning a little above the middle of the bone and extending upwards to the superior extremity, there is a narrow rough surface to which the splint bone is articulated.

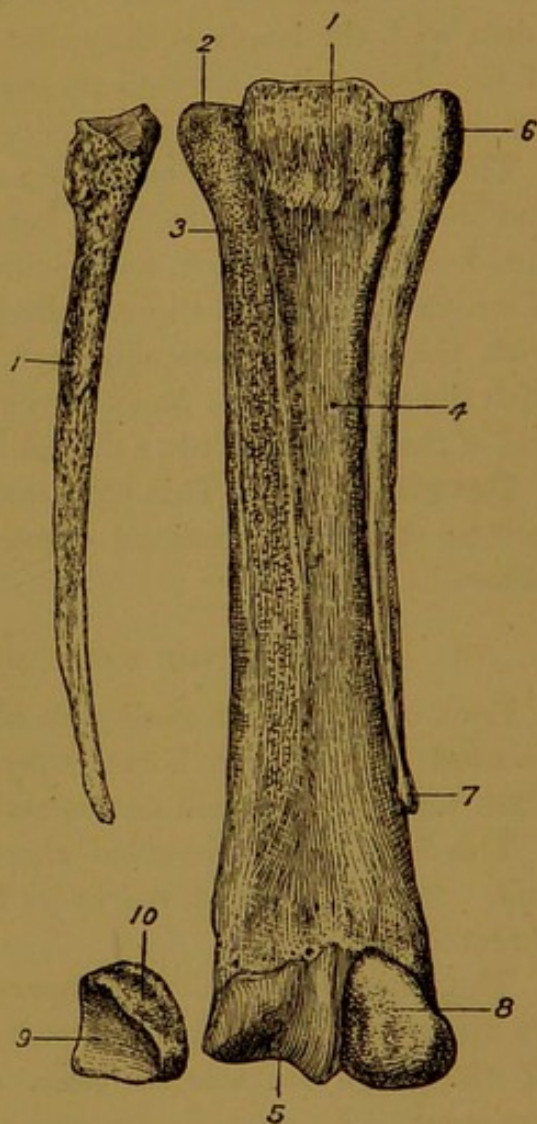


FIG. 71.—METACARPAL BONES AND SESAMOIDS OF RIGHT (OFF) LIMB OF HORSE.

1. Upper end of large metacarpal; 2. Facet for head of inner splint bone; 3. Synarthrodial surface for body of same bone; 4. Nutrient foramen; 5. Lower articular surface; 6. The head, and 7. The lower extremity or "button" of the outer splint bone; 8. Posterior surface of outer sesamoid; 9 and 10. Anterior and outer (excentric) surfaces of inner sesamoid; 11. Anterior or articular surface of inner splint bone.

The *upper extremity* carries an articular surface for the lower row of carpal bones. About three-fourths of this surface is for the os magnum, and one fourth, in the form of a sloping facet at the outer side, articulates with the unciform. The facet for the trapezoid, which is small and sometimes absent altogether, is situated at the postero-internal part of the area for the os magnum. At each side of the posterior aspect of the upper extremity, there are two small facets which form synovial joints with the heads of the splint bones. On the antero-internal aspect of this extremity, a rough projecting surface serves for the insertion of the extensor metacarpi magnus tendon.

The *lower extremity* carries an articular surface for the first phalanx and the sesamoid bones. An antero-posterior ridge traverses this surface from front to back, and divides it into two pulley-like articulations, of which the inner is slightly the larger. The sesamoid bones articulate with the extreme posterior part of this surface, and the first phalanx with the remainder. At either extremity of its transverse diameter, this end of the bone presents a digital depression for ligamentous attachment.

**Development.** This bone ossifies from two centres, one of which is for the shaft and proximal extremity, while the other is for the distal extremity.<sup>1</sup>

#### THE SMALL METACARPAL BONES.

Each of these is in reality an aborted long bone. Like the similarly aborted ulna of the horse, they are destitute of a medullary canal. Each may be described as possessing a body and two extremities.

The *body* is a three-sided slender rod of bone, tapering to its lower end. It is slightly curved in its length, with the concavity of the curve directed outwards.

The *anterior surface* is comparatively flat, and rough, except towards its lower part. The greater part of this surface is opposed to the back of the large metacarpal bone, and united to it by an interosseous ligament. In animals beyond middle age, however, this ligament is often wholly or in part ossified. For an inch or two above its lower end this surface is free, and separated by a narrow interval from the back of the large bone.

The *outer surface* is smooth, and slightly rounded from side to side.

The *inner surface* is the narrowest of the three. It helps to form the channel for the superior sesamoidean ligament, with whose edge it is in contact.

The *upper extremity*, or *head*, of each bone is relatively massive. Superiorly it carries an articular surface, composed of a single facet in

<sup>1</sup> According to Franck the proximal extremity has a separate nucleus, and forms an epiphysis which speedily unites with the shaft.

the case of the outer bone, and compounded of two facets in the case of the inner. By this surface the outer splint articulates with the unciform, and the inner with the trapezoid and os magnum. On its anterior aspect the head bears two small facets which meet and form synovial joints with similar surfaces already described on the back of the upper end of the large metacarpal bone. On its outer side the head is rough for muscular and ligamentous attachment.

The *lower extremity* forms a small nodular process sometimes termed the "button" of the splint bone. This normally stands out a little from the back of the large metacarpal, and may easily be felt in the living animal as a slightly movable process.

**Differences** between the two bones. The inner bone is generally the larger of the two, both in volume and in length. The articular surface of the proximal end is formed by a single facet in the case of the outer bone, but it is compounded of two facets in the case of the inner bone. The head of the outer bone has always two facets for articulation with the large metacarpal, but the inner bone has sometimes only one such facet.

**Development.** Each bone ossifies from a central nucleus. Sometimes the extremities ossify as epiphyses from separate centres.

#### THE SESAMOID BONES.

These small bones, two in each limb, are placed behind the lower extremity of the large metacarpal bone. They are developed in that position for the purpose of affording increased leverage to the flexors of the digit. They belong to the class of short bones, and each has the form of a three-sided pyramid.

The *anterior surface* is smooth and articular. It is concave in the vertical and convex in the transverse direction, and it articulates with the posterior part of the lower articular surface of the large metacarpal bone.

The *posterior surface*, slightly convex in both directions, is comparatively smooth. In the recent state this surface is covered by a layer of

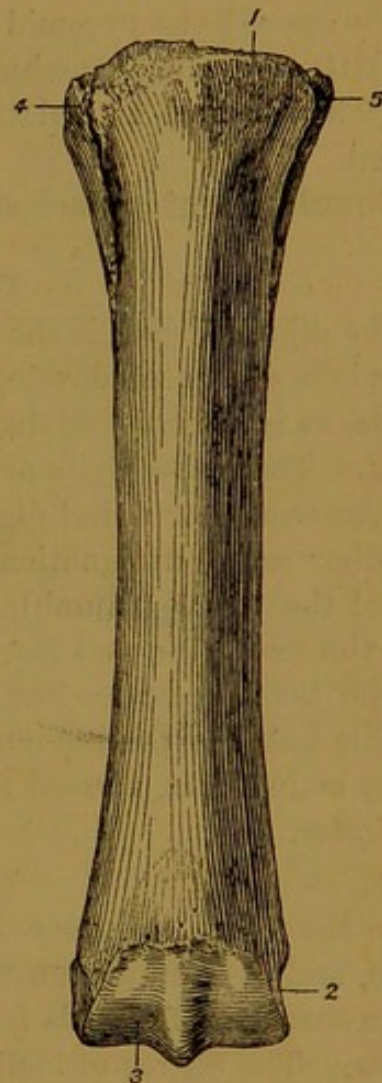


FIG. 72.—RIGHT METACARPAL BONE OF HORSE (Front View).

1. Surface for insertion of extensor metacarpi magnus; 2. Pit for attachment of lateral ligament; 3. Lower articular surface of large metacarpal; 4. Head of outer splint bone; 5. Head of inner splint bone.

fibro-cartilage, and with the same surface of the opposite sesamoid it forms a pulley-like groove for the gliding of the deep flexor tendon.

The *external surface* is grooved for the attachment of the great suspensory ligament of the fetlock joint. It is the narrowest of the three surfaces.

The *apex* of the pyramid is directed upwards and the *base* downwards, the latter affording attachment to the inferior sesamoidean ligaments.

Each sesamoid articulates with but one bone, viz., the large metacarpal.

**Development.** Each sesamoid ossifies from a single centre.

#### THE DIGITAL REGION.

The digital region is the terminal segment of the manus. In its most complete degree of development the mammalian manus comprises five digits, as is exemplified in the thumb and four fingers of the human hand. These five digits are distinguished by the numerals one to five, the innermost or radial digit being the 1st, and the outermost the 5th. Another set of designations is also applied to the digits, the 1st being called the *pollex* (thumb), the 2nd the *index*, the 3rd the *medius*, the 4th the *annularis*, and the 5th the *minimus*.

The horse possesses but one digit—the *medius*, corresponding to the middle finger of the human hand. The skeleton of this digit comprises three main bones, termed the *phalanges*, and a sesamoid bone, called the *navicular*.

#### THE FIRST PHALANX.

In the horse this bone is also called the *os suffraginis*. It is a long bone, and it occupies an oblique position in the limb, being directed downwards and forwards from the fetlock joint above to the pastern joint below. The degree of inclination varies considerably in different horses. When the slope is excessive, undue strain is thrown upon the tendons and ligaments at the back of the limb; and when, on the other hand, the bone is nearly upright, almost the entire weight of the animal is thrown upon the bones of the digit. The first phalanx has a four-sided shaft and two extremities.

The *anterior surface* of the shaft is comparatively smooth, and slightly rounded from side to side.

The *lateral surfaces*, also rounded, pass insensibly on either side into the anterior surface. Sometimes each exhibits about its centre a vascular impression left by the perpendicular artery.

The *posterior surface* is flattened, and in its upper two-thirds it carries a V-shaped area, which marks the attachment of the middle division of the inferior sesamoid ligament. The edge which separates the posterior from the lateral surface on each side is rough in its lower half for ligamentous attachment.

The *upper extremity* of the bone carries an articular surface that is like the mould or impress of the lower extremity of the large metacarpal bone, with which it articulates. It shows a deep antero-posterior groove,

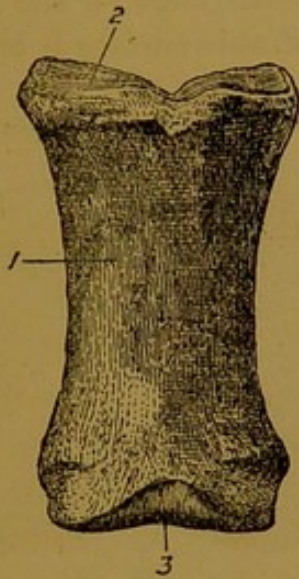


FIG. 73.—LEFT FIRST PHALANX OF HORSE (Front View).

1. Anterior surface of shaft; 2. Upper articular surface; 3. Lower articular surface.

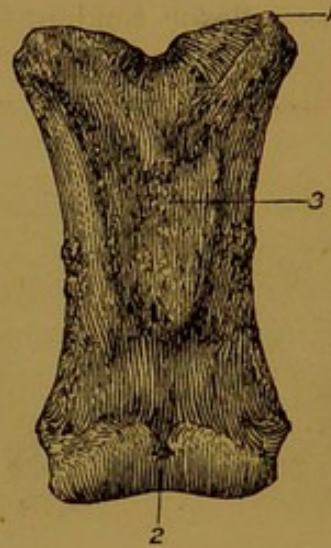


FIG. 74.—SAME BONE AS FIG. 73 (Posterior View).

1. Upper extremity; 2. Lower extremity; 3. Posterior surface of shaft.

and on each side of the groove a shallow articular cavity, the inner being slightly more extensive than the outer. The entire articular surface is somewhat four-sided in outline, and its posterior corners are supported by buttress-like tubercles of bone, which at the same time serve for the attachment of ligaments.

The *lower extremity* carries an articular surface to meet the second phalanx in the pastern joint. A shallow ill-defined groove traverses this surface from front to back, and divides it into two slightly convex areas, the inner of which is somewhat larger than the outer. At either side of the lower extremity of the bone there is a shallow oblique groove surmounted by a tubercle, these serving for ligamentous attachment.

**Development.** Like other long bones the first phalanx ossifies from three centres, one for the shaft and one for either extremity, but the lower epiphysis is consolidated with the shaft before birth.

#### THE SECOND PHALANX.

In the horse this bone receives the additional name of *os coronæ*. It does not possess a medullary canal, and is therefore classed along with the short bones. The bone is placed obliquely in the digit, its inclination corresponding with that of the first phalanx. It may be described as possessing six surfaces.

The *anterior surface* is slightly depressed, and widest in its transverse diameter.

The *posterior surface*, more extensive than the anterior, carries at its extreme upper part a transversely elongated projecting smooth area, which in the recent state is covered with fibro-cartilage for the passage of the deep flexor tendon. The remainder of this surface is compara-

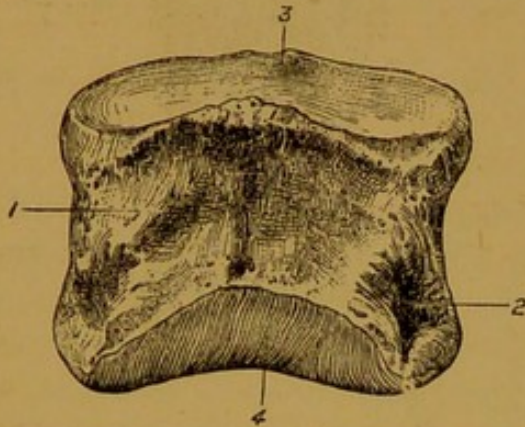


FIG. 75.—SECOND PHALANX OF HORSE  
(Front View).

1. Anterior surface; 2. Pit for ligamentous attachment; 3. Upper articular surface; 4. Lower articular surface.

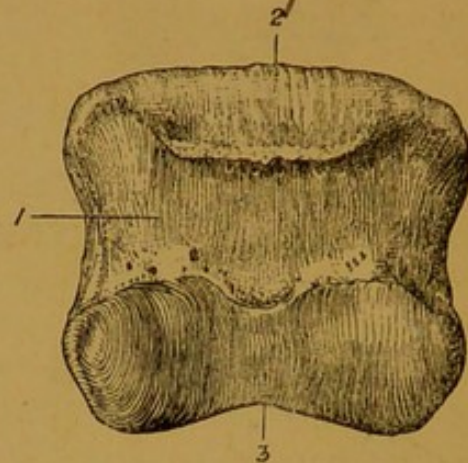


FIG. 76.—SAME BONE AS FIG. 75  
(Posterior View).

1. Posterior surface; 2. Projecting surface for passage of deep flexor tendon; 3. Lower articular surface.

tively smooth, and it presents a number of foramina for the passage of blood-vessels.

The *lateral surfaces* are rough and perforated by foramina, and at its lower part each carries a distinct pit for ligamentous attachment.

The *upper surface* is articular, and moulded on the lower extremity of the first phalanx. It presents two shallow cavities separated by an antero-posterior ridge, the inner cavity being slightly more extensive than the outer.

The *lower surface* is also articular, meeting the navicular bone and the third phalanx in the terminal joint of the limb. This surface resembles in form the lower extremity of the first phalanx, but is rather more extensive in the antero-posterior direction.

**Development.** The second phalanx ossifies from three centres, after the manner of a long bone, but the lower epiphysis very speedily fuses with the main part of the bone (*Franck*).

#### THE THIRD PHALANX.

In the horse this bone is also known as the *os pedis*, and the *coffin bone*. It is entirely included within the hoof, to which it bears some resemblance in shape. Its compact tissue is denser than that of any of the other bones of the skeleton with the exception of the petrous division of

the temporal bone. It belongs to the class of short bones, and for purposes of description there may be recognised in it three surfaces, and two lateral angles.

The *anterior* or *laminal surface* slopes downwards and forwards, and responds to the inner surface of the wall of the hoof. It is convex from side to side, and nearly straight from above to below. It is dotted over by numerous foramina of various sizes, the largest of which form a semicircle a little above the lower limit of the surface. In the vertical direction the surface is most extensive towards its centre, and it tapers gradually towards the angles of the bone. Like the other surfaces, it is nearly symmetrical on either side of the mesial plane of the digit. On either side of this surface, running horizontally forwards from each angle, there is a distinct groove—the **preplantar groove**, which terminates anteriorly in one of the larger foramina. In the recent state

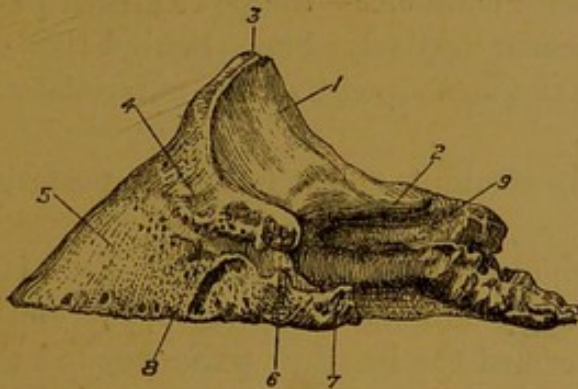


FIG. 77.—THIRD PHALANX OF HORSE  
(Postero-Lateral View).

1. Articular surface for second phalanx; 2. Facet for navicular bone; 3. Pyramidal process; 4. Pit for antero-lateral ligament; 5. Laminal surface; 6. Basilar process; 7. Retrossal process; 8. Preplantar groove; 9. Plantar groove.

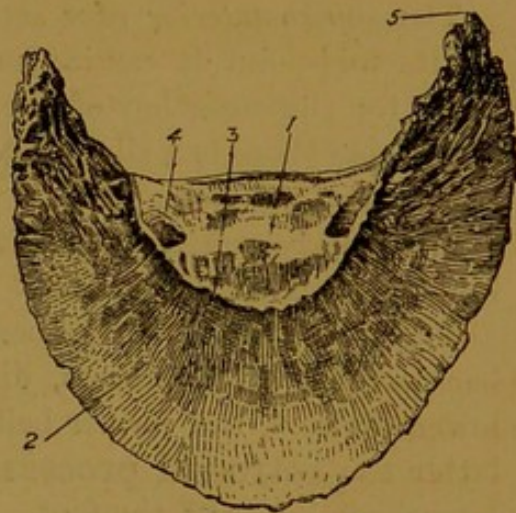


FIG. 78.—SAME BONE AS FIG. 77.

1. Tendinous surface; 2. Solar surface; 3. Semilunar crest; 4. Plantar foramen; 5. Wing.

this surface is clothed by the sensitive laminae, which unite it to the horny laminae of the wall of the hoof.

The *inferior surface* looks slightly backwards as well as downwards, and it is divided by a curved line—the **semilunar crest**—into an anterior and a posterior part. The anterior or *solar* portion is crescentic in shape, and slightly vaulted. It is comparatively smooth, more close-grained in texture than the anterior surface, and it responds to the upper surface of the horny sole. The posterior or *tendinous* division of this surface shows on each side a considerable foramen—the **plantar foramen**, to which the **plantar groove** conducts from the angle of the bone. The plantar foramina transmit the arteries of the same name

into the **semilunar sinus**—an excavation towards the centre of the bone in which the right and left arteries meet and anastomose. Between the plantar foramina and the semilunar crest, this surface is rough, and to the rough area and the crest itself the deep flexor tendon is inserted.

The *upper or articular surface* is for the most part moulded on the lower articular surface of the second phalanx. It presents two lateral shallow cavities separated by an ill-defined antero-posterior ridge, the inner cavity being a little more extensive than the outer. The extreme posterior part of this surface has the form of a transversely elongated nearly flat facet, for articulation with the navicular bone. The foregoing three surfaces are separated by three distinct edges.

The *inferior edge* is the most extensive of the three. It is sharp, convex, and slightly notched, and it separates the laminal and solar surfaces. The outer half of this edge is more convex than the inner.

The *supero-anterior edge* separates the articular and laminal surfaces. At its mid-point it carries an obtuse eminence—the **pyramidal process**, for the insertion of the extensor pedis tendon. Behind this on either side there is a slight pit, for the attachment of the antero-lateral ligament of the coffin-joint.

The *postero-superior edge* is nearly straight, and it forms the posterior limit of the articular surface.

The *lateral angles* of the bone are also termed the **wings**. Each is a backward directed process, divided by a notch into an upper and a lower division, the former being termed the **basilar process**, and the latter the **retrossal process**. The wings serve for the support of the lateral cartilages of the foot. In the old animal the notch separating the basilar and retrossal processes is generally converted into a foramen, through which the preplantar artery passes. In the old animal, moreover, the wings are increased in size by ossification of the adjacent edge of the lateral cartilage.

**Development.** The os pedis ossifies from two centres, one of which is for the articular surface, but this epiphysis fuses with the rest of the bone before birth (*Franck*).

#### THE NAVICULAR BONE.

This is a small shuttle-shaped bone placed behind the articulation between the second and third phalanges. It is elongated transversely, and it possesses two surfaces, two edges, and two extremities.

The *articular surface* of the bone, which may be recognised by its smoothness, is directed upwards and forwards to articulate with the hinder part of the lower articular surface of the second phalanx. For adaptation to that surface it is convex in its middle and concave on either side, the inner concavity being slightly larger than the outer.

The *tendinous surface* resembles the preceding in form, but it is broader and less smooth. It is directed downwards and backwards, and

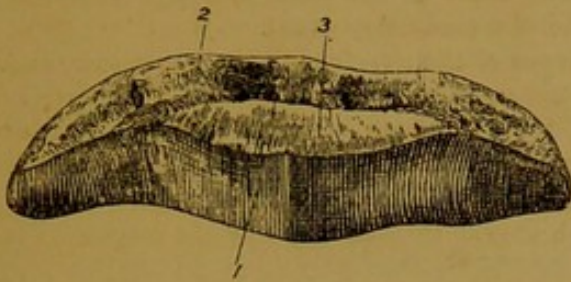


FIG. 79.—NAVICULAR BONE OF HORSE.  
(The bone is inverted and viewed from the front.)

1. Articular surface; 2. Grooved part of lower edge for attachment of interosseous ligament; 3. Facet for articulation with os pedis.

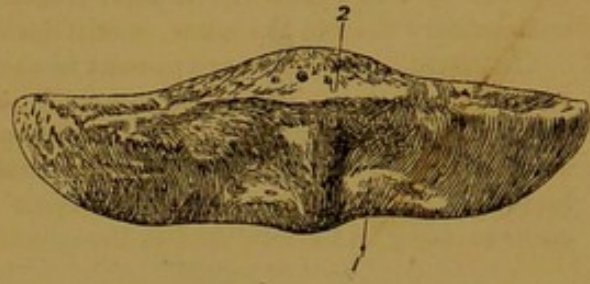


FIG. 80.—SAME BONE AS FIG. 79.  
1. Tendinous surface; 2. Upper edge; 3. Lower edge.

in the recent state it is covered by fibro-cartilage for the passage of the deep flexor tendon.

The *upper edge* is thick and grooved in its middle, but thinner towards its extremities, and it gives attachment to the postero-lateral ligaments of the coffin-joint.

The *lower edge* is composed of two portions, viz., an anterior articular portion, in the form of a transversely elongated flat facet for articulation with the os pedis; and a posterior grooved portion, perforated by numerous foramina, and affording attachment to the interosseous ligament of the coffin-joint.

The *extremities* of the bone are pointed.

**Development.** The bone ossifies from a single centre.

#### THE FORE LIMB OF THE OX.

**Scapula.** The vertebral border is longer than in the horse. The spine is placed nearer the anterior or coracoid edge, the breadth of the supraspinous fossa being to that of the infraspinous fossa as 1 : 3. At its lower end the spine is produced into a short but distinct acromion process. The subscapular fossa is shallow, and ill-defined at its upper end. The coracoid process is small and almost close to the glenoid cavity, which is larger and more circular than in the horse.

**Humerus.** The musculo-spiral groove is shallower than in the horse, and the external and internal tubercles are smaller. The nutrient foramen is on the posterior surface. The articular head is larger than in the horse, and the neck, though still indistinct, is better developed. The bicipital groove is undivided, and the summit of the external tuberosity is produced inwards so as to form half an arch over the groove. The olecranon and coronoid fossæ are deep, and the antero-posterior ridge of the lower articular surface is more prominent than in the horse.

**Radius.** This bone is proportionally shorter but broader than in the horse. The bicipital tuberosity is smaller, and the tendinous grooves at the lower end of the bone are indistinct. The upper articular surface has a deep antero-posterior groove.

**Ulna.** This bone is much better developed than in the horse. It has a massive olecranon process, and its shaft is as long as that of the radius, reaching to the carpus. Between the opposed bones a passage is left in the position of the radio-ulnar arch of the horse, and a smaller passage exists a few inches above the carpus. A groove along

the outer side of the line of union connects the upper and the lower passage. In the adult animal the two bones of the fore-arm are solidly ankylosed throughout the entire length of their surfaces of contact, save at their upper ends, where, as in the horse, they respond by two small diarthrodial facets. The shaft of the ulna, although much less rudimentary than in the horse, is still destitute of a medullary canal.

**Carpus.** Six bones are present in the carpus of the ox—four in the upper row, and two in the lower. The upper row comprises the same bones as are present in the horse. The scaphoid is proportionally smaller, and the semilunar larger. These two bones articulate with the radius, while the cuneiform articulates with both the bones of the fore-arm. The pisiform is much smaller than in the horse, devoid of a groove on its outer surface, and articulated to the cuneiform only. In the lower row the trapezium is

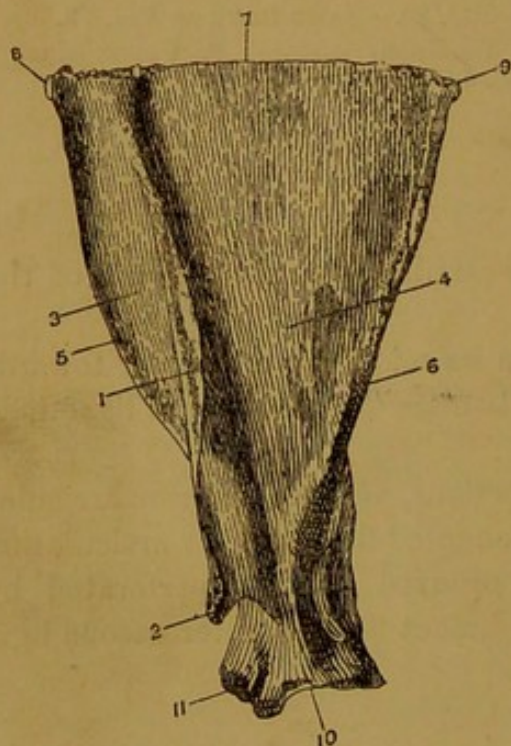


FIG. 81.—SCAPULA OF OX  
(Outer Surface).

1. Spine; 2. Acromion process; 3. Supraspinous fossa; 4. Infraspinous fossa; 5. Coracoid edge; 6. Glenoid edge; 7. Vertebral edge; 8. Cervical angle; 9. Dorsal angle; 10. Glenoid cavity; 11. Coracoid process.

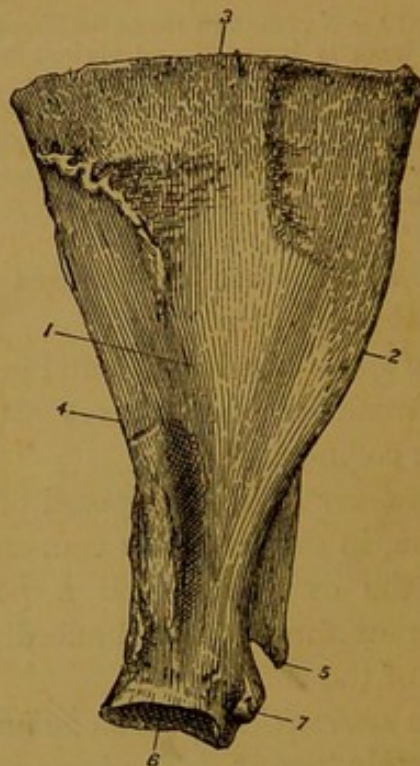


FIG. 82.—SCAPULA OF OX  
(Inner Surface).

1. Subscapular fossa; 2. Coracoid edge; 3. Vertebral edge; 4. Glenoid edge; 5. Acromion process; 6. Glenoid cavity; 7. Coracoid process.

unrepresented. The innermost and larger of the two bones present represents the combined trapezoid and os magnum. The unciform is larger than in the horse.

**Metacarpus.** In the adult ox this region comprises two bones, viz., a large metacarpal and an external splint bone. The large metacarpal presents some resemblance to the same bone of the horse. Its shaft is traversed on both its anterior and its posterior surface by a vertical furrow, and at either extremity of these furrows a canal passes through the thickness of the shaft. The medullary canal of the bone is divided lengthways by a bony septum whose edges correspond to the before-mentioned furrows. The lower extremity is divided by an antero-posterior cleft, each of the divisions having a likeness to the lower articular surface of the same bone of the horse. The inner division is slightly larger than the outer. The splint bone of the ox is short, and articulated to the large bone in the same position as the outer splint of the horse. Its head responds to the main bone by a small diarthrodial facet, but it does not as a rule contract any articulation with the unciform. The large metacarpal bone of the ox

represents the combined 3rd and 4th metacarpals of the human hand, and in foetal life the two bones are distinct and separate. The vertical furrows of the shaft, and the septum of the medullary canal indicate the lines of fusion. The splint bone represents the 5th metacarpal. The ox possesses four **sesamoids**. The outer and the inner pair articulate respectively with the outer and the inner division of the lower end of the large metacarpal. The inner pair are slightly larger than the outer, and the bones of the same pair articulate with each other by their contiguous edges.

**Digit.** The ox possesses four digits, corresponding to those of the human hand *minus* the thumb. Only two of these, representing the 3rd and 4th (medius and annularis), are weight-bearing digits; the other two are very rudimentary and placed behind the fetlock joint. The latter pair correspond to the 2nd and 5th (index and minimus) of the human hand. Each of the two main digits includes the same bones as are present in the single digit of the horse, but each of the smaller digits contains only two

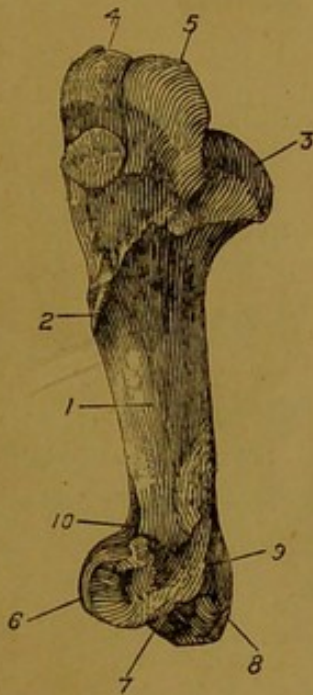


FIG. 83.—HUMERUS OF OX  
(Outer Aspect).

1. Musculo-spiral groove; 2. External tubercle; 3. Head; 4 and 5. Summit and convexity of external tuberosity; 6. Lower articular surface; 7. Outer condyle; 8. Inner condyle; 9. Olecranon fossa; 10. Coronoid fossa.

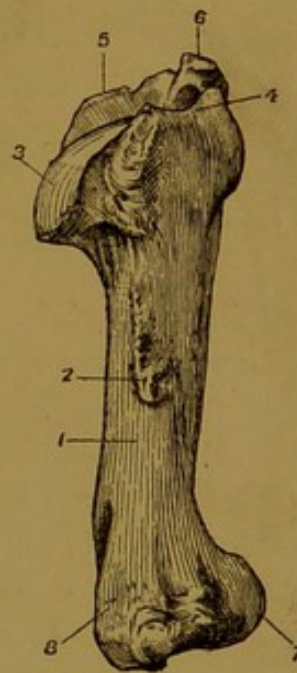


FIG. 84.—HUMERUS OF OX  
(Inner Aspect).

1. Internal surface of shaft; 2. Internal tubercle; 3. Head; 4. Internal tuberosity; 6. External tuberosity; 7. Lower articular surface; 8. Inner condyle.

bones, which represent aborted 2nd and 3rd phalanges. The following are the characters of the bones of the main digits.<sup>1</sup>

The **first phalanx** bears some resemblance to one half of the same bone of the horse (divided vertically). Its excentric side is convex and smooth, while the opposite side is flattened, and roughened posteriorly for ligamentous attachment. Both its extremities are divided by an antero-posterior groove, the excentric division being the larger of the two. Superiorly it articulates with the lower end of the large metacarpal bone.

The **second phalanx** is a little more than half of the length of the first, which it otherwise resembles. A small medullary canal is present in its centre. Its upper articular surface is divided unequally by an antero-posterior ridge.

<sup>1</sup> Each bone of the inner digit is slightly larger than the corresponding bone of the outer digit.

The **third phalanx** has a close resemblance to one half of the os pedis of the horse. Its laminal surface is rough, porous, and perforated by about a dozen foramina of considerable size. The largest of these, corresponding to the preplantar foramen of the horse, is close to the posterior angle. The mesial surface is flattened. The solar surface is but slightly concave, and it is perforated by two or three considerable foramina. No distinct semilunar crest is present, but a narrow area looking backwards between the articular and solar surfaces represents the tendinous surface of the horse's bone. The articular surface presents posteriorly a small nearly flat area for the navicular bone, and

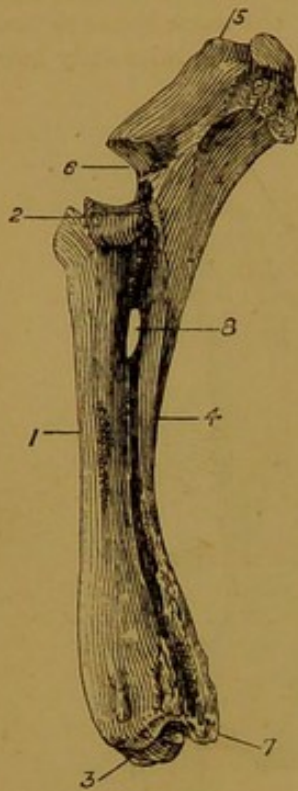


FIG. 85.

FIG. 85.—RADIUS AND ULNA OF OX  
(Outer Aspect).

1. Shaft of radius; 2 and 3. Upper and lower articular surfaces of same; 4. Shaft of ulna; 5. Olecranon process; 6. Sigmoid cavity; 7. Lower end of ulna; 8. Radio-ulnar arch.

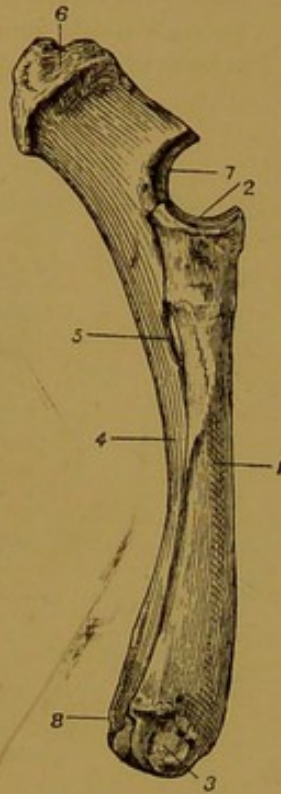


FIG. 86.

FIG. 86.—RADIUS AND ULNA OF OX  
(Inner Aspect).

5. Radio-ulnar arch; 6. Olecranon process; 7. Sigmoid cavity; 8. Lower end of ulna. The other references as in Fig. 85.

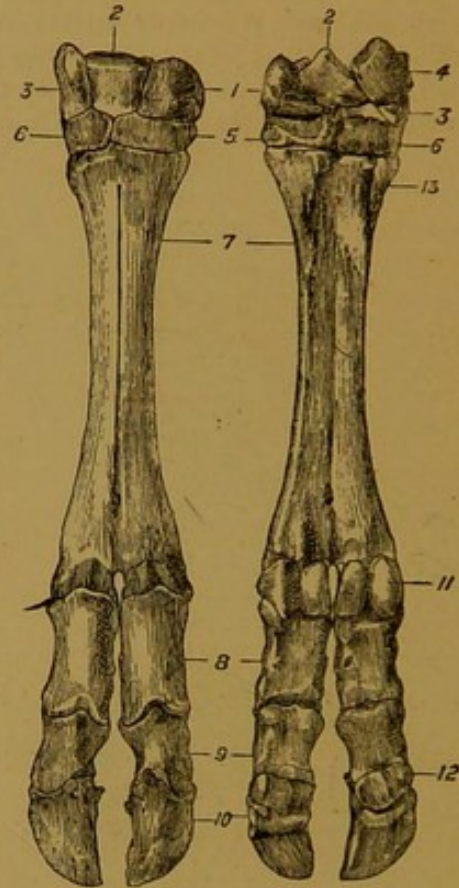


FIG. 87.

FIG. 87.—MANUS OF OX (Front View). FIG. 88.—POSTERIOR VIEW OF THE SAME.

1. Scaphoid; 2. Semilunar; 3. Cuneiform; 4. Pisiform; 5. Bone representing combined trapezoid and os magnum; 6. Unciform; 7. Large Metacarpal; 8, 9, and 10. The three phalanges; 11. Sesamoid; 12. Navicular; 13. Small (external) metacarpal.

for the rest of its extent it is moulded on the lower end of the second phalanx. The pyramidal process is small, and the pits present on either side of it in the horse are absent. Near its summit it is perforated by a foramen, and a much larger opening (taking the place of the plantar foramen of the horse) is found on its mesial aspect. These foramina conduct to a large vascular space in the interior of the bone. The wing of the horse's bone is represented by a short blunt process, which is sometimes divided by a minute notch into an upper and a lower part, corresponding to the basilar and retrorsal processes.

Each digit possesses a **navicular bone**, which is proportionally shorter and broader than the navicular of the horse.

#### THE FORE LIMB OF THE SHEEP.

**Scapula.** This bone is proportionally broader at its upper part than in the ox. On the other hand the *neck* is more distinctly marked. The acromion process is slightly smaller. In all other respects the bone bears the closest resemblance to the scapula of the ox.

**Humerus.** The musculo-spiral groove is scarcely so deep as in the ox. The external and internal tubercles are smaller, and the former is higher up on the shaft. The external tuberosity is less prominent, especially in its posterior half. The coronoid fossa is shallower.

**Radius and Ulna.** Except in point of size, these bones are almost identical with those of the ox. The ulna is rather more slender, and the radio-ulnar arch is larger. The union of the two bones is less intimate, the fibres of the interosseous ligament above the arch persisting as in the horse.

**Manus.** The bones of this region correspond almost exactly with those of the larger ruminant, but the splint bone is even less developed, and the two posterior rudimentary digits are generally devoid of phalanges.

#### THE FORE LIMB OF THE PIG.

**Scapula.** This bone is proportionally broad. The anterior or coracoid edge is markedly convex in its upper three-fourths. The spine is placed somewhat nearer the

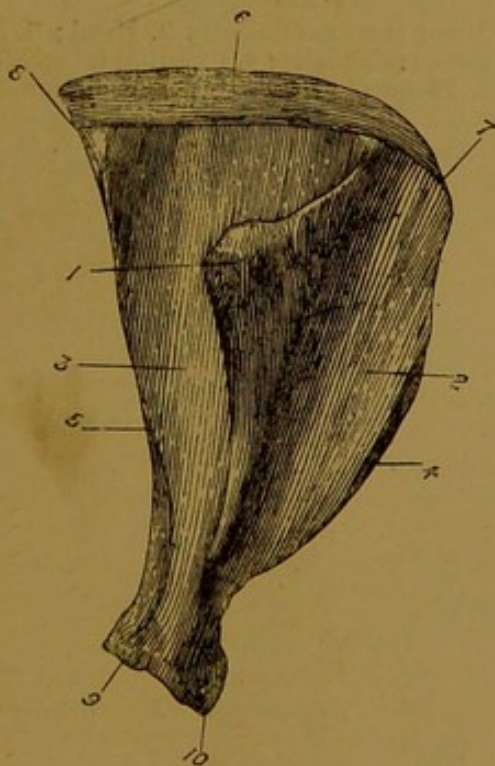


FIG. 89.—SCAPULA OF PIG  
(Outer Surface).

1. Spine; 2. Supraspinous fossa; 3. Infraspinous fossa; 4. Coracoid edge; 5. Glenoid edge; 6. Cartilage of prolongation; 7. Cervical angle; 8. Dorsal angle; 9. Glenoid cavity; 10. Coracoid process.

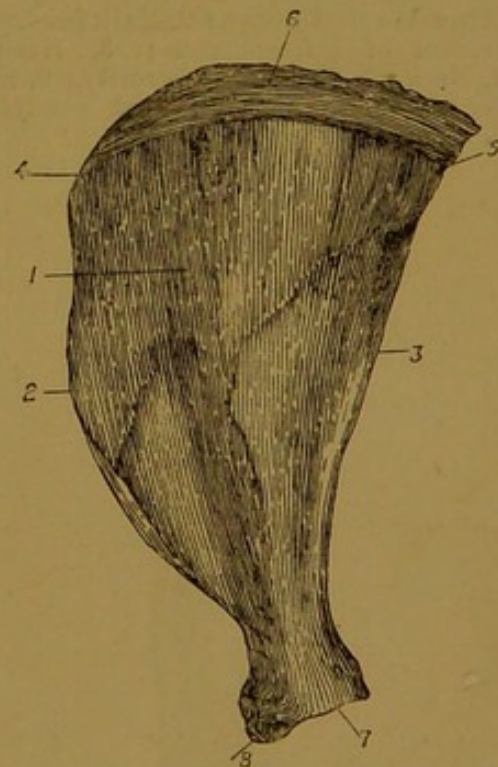


FIG. 90.—SCAPULA OF PIG  
(Inner Surface).

1. Ventral surface; 2. Coracoid edge; 3. Glenoid edge; 4. Cervical angle; 5. Dorsal angle; 6. Cartilage of prolongation; 7. Glenoid cavity; 8. Coracoid process.

middle of the dorsum than in the horse, and it has the form of a triangular plate the summit of which curves backwards over the infraspinous fossa. About two inches above

the glenoid cavity, the spine terminates in a minute nodule which represents an acromion process. The coracoid process is small and closely applied to the glenoid cavity, which

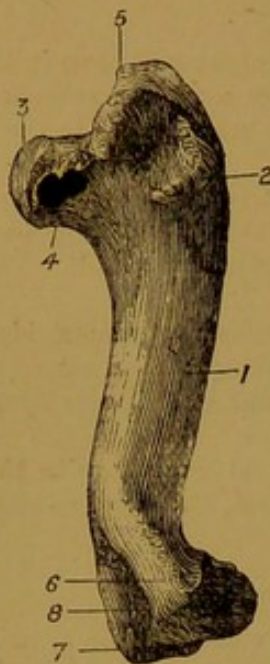

FIG. 91.—HUMERUS OF PIG  
(Outer Aspect).

1. Musculo-spiral groove; 2. Mark for outer tendon of infraspinatus; 3. Head; 4. Neck; 5. External tuberosity; 6. External condyle; 7. Internal condyle; 8. Olecranon fossa.

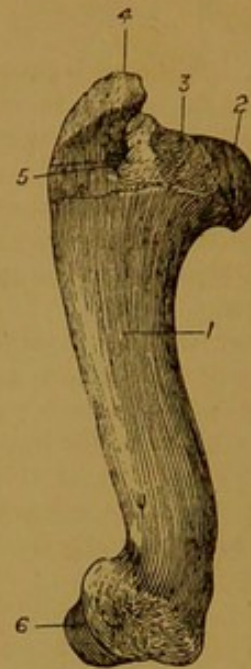


FIG. 92.—HUMERUS OF PIG  
(Inner Aspect).

1. Inner surface of shaft; 2. Head; 3. Internal tuberosity; 4. External tuberosity; 5. Bicipital groove; 6. Lower extremity.

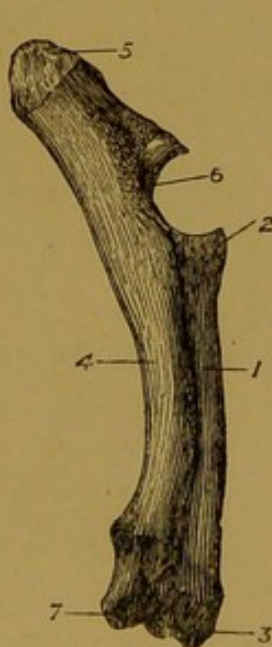


FIG. 93.—RADIUS AND ULNA OF PIG  
(Outer Aspect).

1. Shaft of radius; 2. Its upper end; 3. Its lower end; 4. Shaft of ulna; 5. Olecranon process; 6. Sigmoid cavity; 7. Lower end of ulna.

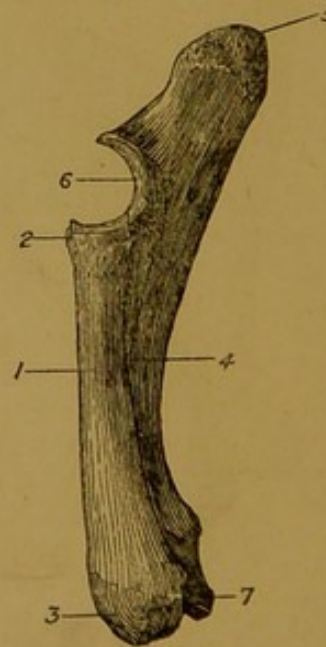


FIG. 94.—RADIUS AND ULNA OF PIG  
(Inner Aspect).

The references are the same as in the preceding figure.

is deeper than in the horse. Above the articular angle there is a well-marked constriction, or neck.

**Humerus.** This bone is distinctly curved in its length, so that its lateral profile resembles an italic *f* without the cross bar. The musculo-spiral groove is shallower than in the horse. The external or deltoid tubercle is small, and the internal tubercle is represented by a rough non-projecting mark. As in the ox, the nutrient foramen is on the posterior surface. The articular head is very convex, and beneath it there is a well-marked neck. The bicipital groove is undivided. The summit of the external tuberosity is very prominent, and produced inwards over the bicipital groove, which it thus almost converts into a complete foramen.

**Radius.** This bone is relatively short, but thick. In the articulated skeleton the greater part of its posterior surface is concealed by the ulna. The bicipital tuberosity is less distinct than in the horse.

**Ulna.** The ulna of the pig is a well-developed long bone, exceeding the radius in volume. It has a massive olecranon process, and its lower end reaches to the carpus, where it articulates with the cuneiform and pisiform bones. The shaft of the bone presents outer, inner, and anterior surfaces, the latter being closely applied to the back of the radius, to which it is united by an interosseous ligament. A single radio-ulnar arch is left in the same position as in the horse.

**Carpus.** Eight bones are present in the carpus of the pig—four in each row. The semilunar is larger than the scaphoid. These two bones articulate with the radius, the cuneiform articulates with both bones of the fore-arm, and the pisiform with the ulna. The trapezium is constantly present, in the form of a small conical bone articulated to the back of the trapezoid. The latter bone responds inferiorly to the two innermost metacarpals, the os magnum to the second innermost metacarpal, and the unciform to the two outermost metacarpals.

**Metacarpus.** The pig possesses four metacarpal bones. The central two of these are large and of nearly equal size, while the other two, disposed one on either side of the larger pair, are considerably smaller. The outer small bone represents the metacarpal of man's little finger, and the other three represent the metacarpals of the next three human fingers. Two small sesamoids articulate with the lower end of each metacarpal.

**Digits.** Each of the four metacarpals of the pig carries a digit. The central pair are large and of approximately equal size. The lateral digits—external and internal—are also about equal to each other in size, but considerably smaller than the central pair, and in ordinary circumstances they do not reach the ground. Each of the digits possesses the usual phalanges and a navicular bone, all of which resemble very closely the corresponding bones of the ox. These four digits of the pig correspond to the four fingers of man's hand, but the thumb is altogether absent in this animal.

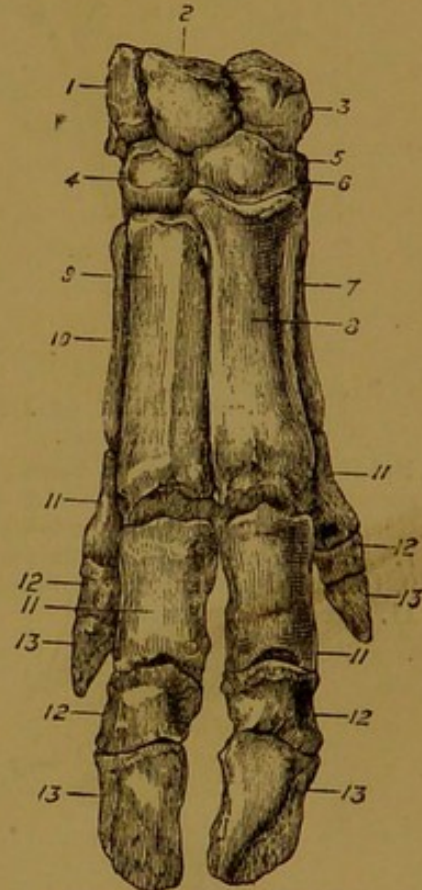


FIG. 95.—MANUS OF PIG  
(Front View).

1. Cuneiform; 2. Semilunar; 3. Scaphoid; 4. Unciform; 5. Os magnum; 6. Trapezoid; 7, 8, 9, and 10. The four metacarpal bones; 11, 12, 13. The three phalanges of each digit.

#### THE FORE LIMB OF THE DOG.

**Clavicle.** The collar bone of man is represented in the dog by a minute bone embedded in the muscles in front of the shoulder. Sometimes it is absent.

**Scapula.** This bone lacks the cartilage of prolongation. As in the pig, the coracoid or anterior edge is very convex in its upper three-fourths. The spine is near the middle of the dorsum, and the two fossæ are therefore of nearly equal size. It has no very distinct tubercle, but at its lower end it is produced into a short acromion process. The

subscapular fossa is shallow, and extended upwards to the vertebral border. The coracoid process is small, and closely applied to the glenoid cavity. At the lower end of the posterior edge, immediately above the glenoid cavity, there is a distinct tubercle.

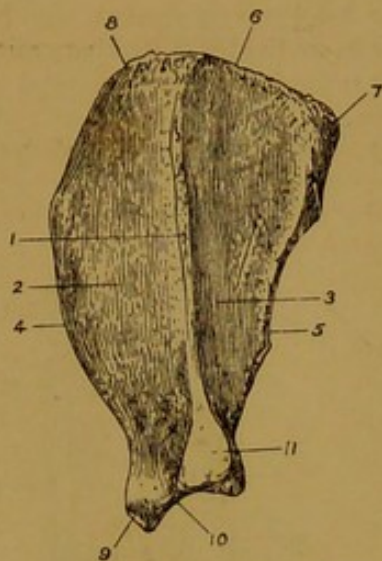


FIG. 96.—SCAPULA OF DOG  
(Outer Surface).

1. Spine; 2. Supraspinous fossa; 3. Infraspinous fossa; 4. Coracoid edge; 5. Glenoid edge; 6. Vertebral edge; 7. Dorsal angle; 8. Cervical angle; 9. Coracoid process; 10. Glenoid cavity; 11. Acromion process.

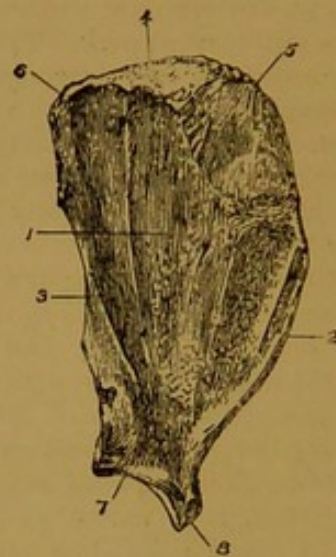


FIG. 97.—SCAPULA OF DOG  
(Inner Surface).

1. Ventral surface; 2. Coracoid edge; 3. Glenoid edge; 4. Vertebral edge; 5. Cervical angle; 6. Dorsal angle; 7. Glenoid cavity; 8. Coracoid process.

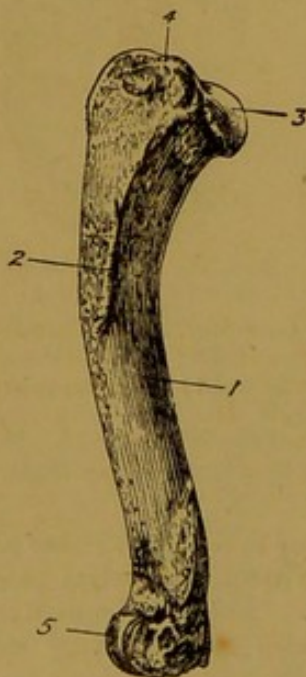


FIG. 98.—HUMERUS OF DOG  
(Outer Aspect).

1. Musculo-spiral groove; 2. Deltoid tubercle; 3. Head; 4. External tuberosity; 5. Lower extremity.

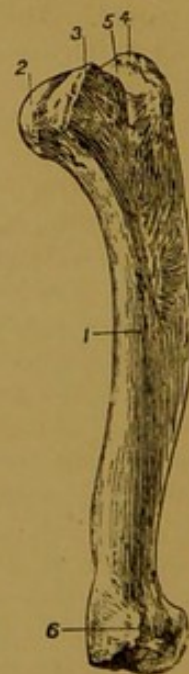

FIG. 99.—HUMERUS OF DOG  
(Inner Aspect).

1. Inner surface of shaft; 2. Head; 3. Internal tuberosity; 4. External tuberosity; 5. Bicipital groove; 6. Lower extremity.

**Humerus.** This bone is relatively long in the dog, and it resembles the pig's humerus in being curved like an italic *f*. The musculo-spiral groove is very much

shallower than in the horse. The deltoid or external tubercle is small, and a rough mark takes the place of the internal tubercle. The nutrient foramen is on the posterior surface. The articular head is more convex than in the horse, and the neck is better developed. The bicipital groove is undivided. The external tuberosity is small, and not distinctly divided into a summit and a convexity. The outer trochlea of the lower articular surface is only faintly grooved, and the coronoid and olecranon fossæ communicate by a large foramen.

**Radius.** The bones of the fore-arm are relatively long in the dog. The radius is much flattened from before to behind. The coronoid process is prominent, and the posterior edge of the upper extremity forms a convex articular surface for the ulna. The lower end of the bone has three distinct tendinous grooves, similar to those found on the front of the lower extremity of the horse's radius.

**Ulna.** As in the pig, this is a well-developed though somewhat slender long bone.

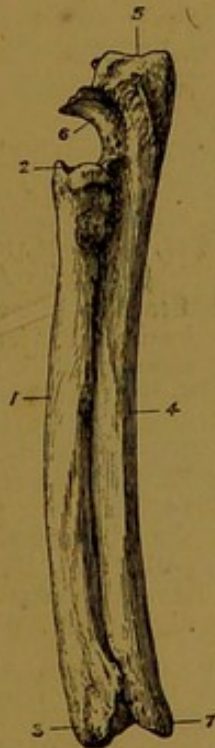


FIG. 100.—RADIUS AND ULNA OF DOG  
(Outer Aspect).

1. Shaft of radius; 2. Its upper end;
3. Its lower end; 4. Shaft of ulna;
5. Its olecranon process; 6. Its sigmoid cavity; 7. Its lower end.



FIG. 101.—RADIUS AND ULNA OF DOG  
(Inner Aspect).

References as in the preceding figure.

Beneath the sigmoid cavity it is articulated rather to the inner side of the head of the radius, and at its lower end it is similarly connected to the outer side of the radius. Between these two points a narrow interosseous space separates the shafts of the two bones. The lower end of the ulna articulates with the cuneiform and pisiform bones. The summit of the olecranon has a pulley-like groove.

**Carpus.** Seven bones are present in the carpus of the dog—three in the upper row and four in the lower. The reduction in the number of bones commonly present in the upper row is due to the fusion of the scaphoid and semilunar to form a single large bone. This bone articulates with the radius, the cuneiform articulates with both bones of the fore-arm, and the pisiform with the ulna. The pisiform has the shape of a short rod constricted in its middle. The cuneiform is remarkable in that it descends to the outer side of the unciform to contract an articulation with the outermost metacarpal. In the lower row the trapezium is invariably present, articulating with the 1st and 2nd meta-

carpals. The trapezoid articulates with the 2nd metacarpal; the os magnum, which is smaller than the unciform, articulates with the 3rd metacarpal and slightly with the 4th also; while the unciform articulates with the 4th and 5th metacarpals. On the inner side of the dog's carpus a small shot-like sesamoid bone is articulated to the scapholunar.

**Metacarpus.** Five bones are present in the metacarpus of the dog. The 1st or innermost of these is much the shortest, and the 3rd and 4th are the longest. The 2nd is only slightly shorter than the 3rd and 4th, and a little longer than the 5th, which is the thickest bone of the five. Superiorly the five bones articulate among themselves by diarthrodial facets, and in passing downwards they diverge slightly. The 1st bone has a pulley-like lower end, but the other bones have inferiorly a convex articular surface, divided in its posterior half by a slight mesial ridge. Each metacarpal carries two small sesamoids.

**Digits.** In the manus of the dog there are five digits, corresponding to those

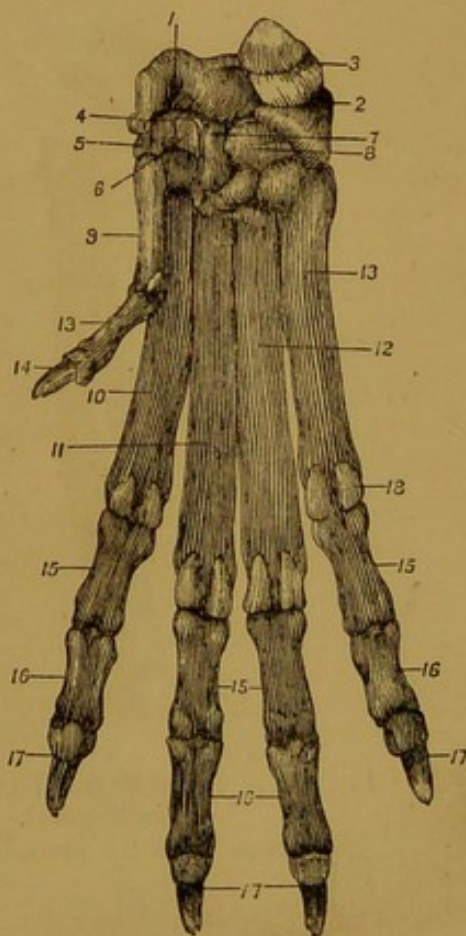


FIG. 102.—MANUS OF DOG  
(Posterior Aspect).

1. Scapho-lunar; 2. Cuneiform; 3. Pisiform; 4. Carpal sesamoid; 5. Trapezium; 6. Trapezoid; 7. Os magnum; 8. Unciform; 9-13. The five metacarpal bones; 13 (left side of figure)<sup>1</sup> and 14. The two phalanges of the innermost digit, or pollex; 15, 16, and 17. The three phalanges of the other digits; 18. Sesamoid.

<sup>1</sup> By an oversight the number 13 has been repeated in this figure.

of the human hand. The innermost of these, which is the homologue of the human thumb, possesses only two phalanges,<sup>1</sup> and in walking it does not come into contact with the ground. Of the other four digits the central pair (3rd and 4th) are a little longer than the one on either side. Each of the four weight-bearing digits possesses three phalanges, but no navicular bone is present. The first and second phalanges are diminutive long bones. The third phalanx is a small hook-like bone with a projecting collar of bone encircling its base. A projection of the under aspect of the base of this phalanx takes the place of a navicular bone.

As compared with the other regions of the limb, the manus of the dog is very short.

<sup>1</sup> The 1st phalanx of this digit is probably united to the lower end of its metacarpal bone.

## THE FORE LIMB OF THE CAT.

**Clavicle.** This bone is better developed in the cat than in any of the other ordinary domesticated mammals. It is still, however, a rudimentary bone, having the form of a slender rod, whose extremities are connected, by soft parts only, to the acromion process of the scapula and the manubrium sterni.

**Scapula.** This bone resembles the scapula of the dog, but the cervical angle is more rounded, the acromion process is larger, and the coracoid process is relatively long and hook-like. Immediately above the acromion process the spine gives off a backward projecting *metacromion*, only a rudiment of which is present in the scapula of the dog.

**Humerus.** This bone is relatively longer than the humerus of the dog. The olecranon and coronoid fossæ do not communicate. The inner condyloid ridge is perforated by a *supracondylar foramen*, through which the brachial artery and median nerve pass.

**Radius and Ulna.** These bones present a close resemblance to the same bones of the dog, save that they are proportionally longer and more slender.

**Manus.** Seven bones are present in the carpus, the scaphoid and semilunar, as in other carnivora, being fused. The pisiform bone articulates with the unciform as well as with the cuneiform. In the metacarpal and digital regions the same bones are present as in the dog. In the case of all the digits except the innermost or pollex, the terminal phalanx is ordinarily retracted, so as to lie on the outer side of the second phalanx. To permit this retraction of the terminal phalanx with its claw, the second phalanx presents a hollow on its outer side.

## THE SKELETON OF THE HIND LIMB OF THE HORSE.

The hind limb, like the fore, comprises four regions, viz., the **hip** or **haunch**, the **thigh**, the **leg**, and the **hind foot** or *pes*. The skeleton of the hip is formed by the **innominate bone**; the thigh contains a large main bone—the **femur**, and a floating or sesamoid bone termed the **patella**; the leg contains two bones—the **tibia** and the **fibula**; and the *pes* contains three sets of bones—the **tarsus**, the **metatarsus**, and the **phalanges**.

## THE INNOMINATE BONE.

This is a large, irregularly shaped bone which enters into the formation of the cavity of the pelvis. In foetal life it is composed of three distinct segments, which meet together around a large articular cavity called the **acetabulum**, or **cotyloid cavity**. These three segments are termed respectively the **ilium**, the **ischium**, and the **pubis**. Although in adult life the lines of junction of these originally distinct elements become obliterated, it is convenient to describe each element separately.

## THE ILIUM.

This is the largest of the three divisions of the innominate bone. It is irregular in shape, being expanded and flattened superiorly, and narrow and prismatic in its lower part. The latter portion is sometimes termed the **shaft** of the ilium. The bone may be described as possessing three surfaces, three edges, and two extremities.

The *gluteal surface* looks outwards and backwards. It is wide and concave above, narrow, and convex below. Its expanded portion is

comparatively smooth and covered by the middle gluteus muscle, while the narrow inferior third of the surface presents some rough lines and markings for the origin of the deep gluteus.

The *iliac surface* is directed forwards. Like the other surfaces it is widest above, and it is covered by the iliacus muscle. About the junction of its middle and lower thirds it shows a large **nutrient foramen**, and at the same place a smooth transverse impression left by the iliaco-femoral vessels. In the upper third of this surface a smaller and fainter impression is left by the ilio-lumbar vessels.

The *sacral or pelvic surface* is directed inwards towards the cavity of the pelvis. On its upper third it carries an **auricular facet**, which forms a joint with a like facet on the sacrum. Beneath this facet the surface is for the most part smooth, and faintly grooved longitudinally at its lower part for the obturator vessels and nerve. Above the auricular facet the bone is rough for ligamentous attachment.

The *cotyloid edge* of the bone conducts inferiorly to the cotyloid cavity, and separates the gluteal and iliac surfaces. It is concave, narrow above, and thick below.

FIG. 103.—RIGHT INNOMINATE BONE OF HORSE  
(View of External and Inferior Surfaces).

1. Gluteal surface of ilium; 1'. Markings for origin of deep gluteus muscle; 2. Crest; 3. Angle of the haunch; 4. Angle of the croup; 5. Ischiatic edge; 6. Pubic edge; 7. Superior ischiatic spine; 8. Cotyloid cavity; 9. Pit for outer head of rectus femoris; 10. External edge of ischium; 11. Tuber ischii; 12. Inferior ischiatic spine; 13. Lower surface of pubis; 14. Pubio-femoral groove; 15. Ischio-pubic symphysis.

the gluteal and sacral surfaces. It is markedly concave, and for the most part thin and sharp. In its lower part, above the cotyloid cavity, it is elevated and roughened outwardly, forming part of the superior ischiatic spine, to which the sacro-sciatic ligament is attached. About its middle this edge forms the anterior boundary of the great sacro-sciatic foramen.

The *pubic edge* is so named because it conducts inferiorly to the pubic

bone. It is also called the **ilio-pectineal line**. At the upper part of the ilium this edge is altogether effaced, the iliac and pelvic surfaces being there blended. In its lower third it presents the **ilio-pectineal eminence**, for the insertion of the *psoas parvus* muscle.

The *upper extremity* of the ilium has the form of an extensive edge, often termed the **crest** of the ilium, which terminates at either extremity in a prominent angle of bone. The inner angle, or **angle of the croup**,<sup>1</sup> is acute, and it forms a rough projection of bone which surmounts the sacral spines, and forms the highest point of the skeleton in the region of the croup. The outer angle, or **angle of the haunch**,<sup>2</sup> is formed by a massive piece of bone composed of four tuberosities arranged in pairs, two above and two below. This angle forms a more or less conspicuous surface prominence in the living animal. The crest as well as the before-mentioned angles are rough for muscular attachment.

The *lower extremity* of the ilium meets the os pubis and ischium in the cotyloid cavity. On its anterior aspect, immediately above the cavity, there are two pits, one on each side of the termination of the cotyloid edge of the bone. These give origin to the outer and inner heads of the *rectus femoris* muscle.

#### THE OS PUBIS.

This is the smallest of the three divisions of the innominate bone. It is placed at the anterior part of the floor of the pelvic cavity, and it possesses two surfaces, three edges, and three angles.

The *upper surface* is smooth and concave,<sup>3</sup> and the urinary bladder rests on it. The *lower surface* is slightly convex, and crossed by a groove which passes obliquely backwards and inwards to end in the cotyloid cavity. This is the **pubio-femoral groove**, for the lodgment of the ligament of the same name.

The *anterior edge* forms part of the inlet or brim of the pelvis. It is thin in its inner half, but outwardly it is thick and tuberos. The *inner edge* is opposed to the same edge of the opposite bone, forming the **pubic symphysis**. The *outer edge* is concave, and it forms the greater part of the inner boundary of the obturator foramen.

The *antero-external angle* meets the ilium and ischium in the cotyloid cavity. The *antero-internal angle* is opposed to the same angle of the opposite bone, at the anterior end of the symphysis. The *posterior angle* joins the ischium.

#### THE ISCHIUM.

This bone is flattened and four-sided, exhibiting two surfaces, four edges, and four angles.

Posterior superior spine of human anatomy.

<sup>2</sup> Anterior superior spine of human anatomy.

<sup>3</sup> In the young subject this surface is convex, and the whole bone is much thicker.

The *upper surface*, which forms the posterior part of the pelvic floor, is smooth and slightly concave. The *lower surface* is nearly flat, and it serves for the origin of the adductor muscles of the thigh.

The *anterior edge* forms the outer or posterior boundary of the obturator foramen. The *inner edge* is opposed to the opposite bone

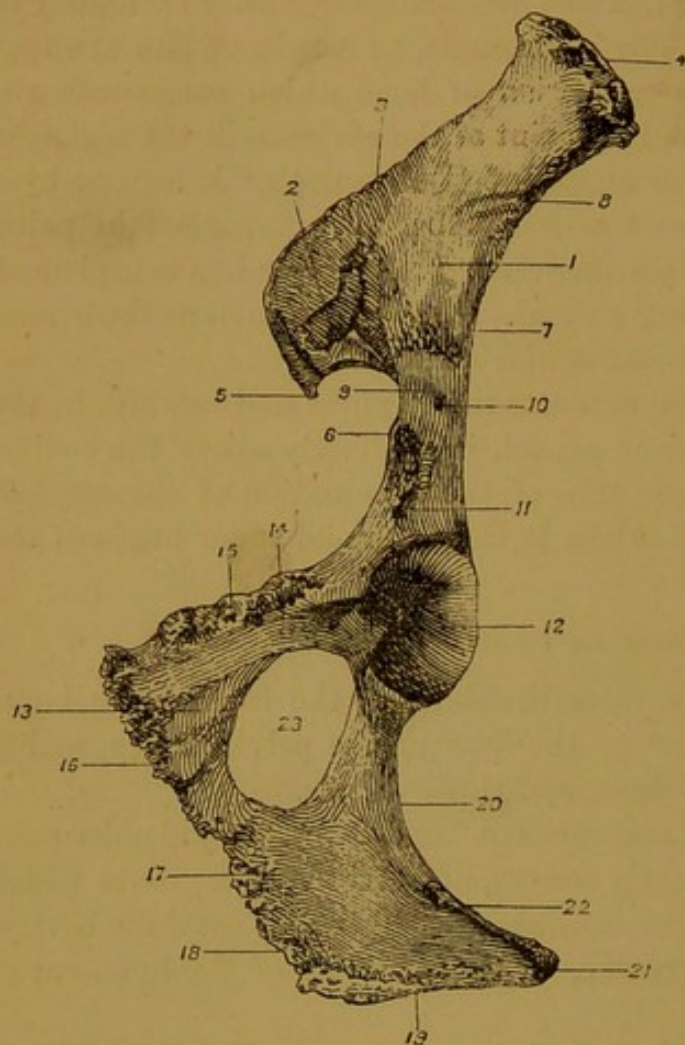


FIG. 104.—LEFT INNOMINATE BONE OF HORSE  
(Inferior Aspect).

1. Iliac surface of ilium; 2. Auricular facet; 3. Crest;
4. Angle of haunch; 5. Angle of croup; 6. Iliopectineal eminence; 7. Cotyloid edge; 8. Impression of ilio-lumbar vessels; 9. Groove for iliaco-femoral vessels; 10. Nutrient foramen; 11. Pit for inner head of rectus femoris; 12. Cotyloid cavity;
13. Lower surface of pubis; 14. Pubio-femoral groove; 15. Anterior edge of pubis; 16. Inner edge of same; 17. Lower surface of ischium; 18. Its inner edge; 19. Its posterior edge; 20. External edge; 21. Tuber ischii; 22. Inferior ischiatic spine;
23. Obturator foramen.

process—the **tuber ischii**—which may be felt in the living animal at the point of the hip. On its lower aspect the tuber carries a prominent ridge, the **inferior ischiatic spine**, to which the erector muscles of the penis are attached.

The **cotyloid cavity**, or **acetabulum**. This is a deep hemispherical

along the **ischiatric symphysis**. The *posterior edge* is thick and rough. It slopes inwards towards the same edge of the opposite bone, forming with it the **ischial arch**, which constitutes the inferior boundary of the pelvic outlet. The *outer edge* forms the lower boundary of the lesser sacro-sciatic foramen, and it is for the most part thick, smooth, and rounded for the passage of the common tendon of the obturator internus and pyramidalis muscles. At its anterior end it is elevated, sharp, and roughened outwardly, forming part of the **superior ischiatic spine**.

The *antero-internal angle* meets the os pubis, the *antero-external angle* joins the ilium and os pubis in the cotyloid cavity, the *postero-internal angle* is opposed to the same angle of the opposite side at the summit of the ischial arch, and the *postero-external angle* forms a thick rough

articular cavity, formed on the outer side of the innominate bone by the meeting of its three constituent pieces. The cavity receives the articular head of the femur in the hip joint. The rim of the cavity, to which the cotyloid ligament is attached, presents a wide interruption or notch inwardly. By this notch the pubio-femoral ligament enters the cavity. For the most part the cavity is smooth and articular, but from the notch of its rim a triangular rough non-articular part extends inwards to near its centre. This non-articular depression serves for the accommodation of the pubio-femoral ligament, and gives attachment inwardly to the round ligament of the hip joint.

The **obturator foramen**. This, which is called also the *thyroid foramen*, is a large opening on the floor of the pelvis, circumscribed by the ischial and pubic bones. It is oval in shape, with the long axis directed forwards and outwards. At its anterior extremity the obturator vessels and nerve pass through the foramen to reach the thigh.

**Development.** The innominate bone possesses three main centres of ossification, viz., one for each of its three segments. To these are added three supplementary centres—one for the crest of the ilium, a second for the tuber ischii, and a third which makes its appearance at the cotyloid cavity, at the point of meeting of the ilium, pubis, and ischium.

#### THE PELVIS.

The cavity of the pelvis is the most posterior of the three great visceral cavities of the body. In the living subject it has the form of a short tube, directly continuous in front with the abdominal cavity. In the skeleton the boundaries of the pelvis are imperfectly indicated by the innominate bone, the sacrum, and the first one or two coccygeal bones. The great vacuity which is present on each side between the lateral edge of the sacrum and the innominate bone is filled up in the recent state by the sacro-sciatic ligament. The plane of communication between the pelvis and the abdomen is termed the **brim** or **inlet** of the pelvis, and the posterior opening of the cavity is termed its **outlet**. The inlet is a complete bony circle, circumscribed by the base of the sacrum above, by the anterior margin of the pubic bones below, and by the ilio-pectineal line on each side. The inlet is nearly circular in outline, and it looks downwards and forwards. The outlet of the pelvis is indicated in the skeleton by the first two coccygeal bones above, and by the posterior edges of the ischial bones below. In the recent state it is completed laterally by the hinder edge of the sacro-sciatic ligament, which stretches on each side between the coccygeal bones above and the tuber ischii below. The outlet is considerably smaller than the inlet, and in shape it is ovoid with the broad

end below. The plane of the outlet is directed backwards and upwards, being nearly parallel to the plane of the inlet.

**Differences between the male and female pelvis.** Considerable differences are exhibited between the pelvis of the horse and that of the

mare, these differences depending upon the fact that in the parturient mare the foetus has to traverse the pelvic cavity. Speaking generally, it may be said that the breadth and capacity of the pelvis are much greater in the mare than in the horse. The distance measured between the cotyloid cavities, superior ischiatic spines, or ischial tuberosities of opposite sides is relatively greater in the mare than in the horse. The ischial arch is wider and more open, and the obturator foramina are larger and more circular in the mare. The floor of the pelvis is flatter in the mare, the ischia of opposite sides meeting at a more open angle.

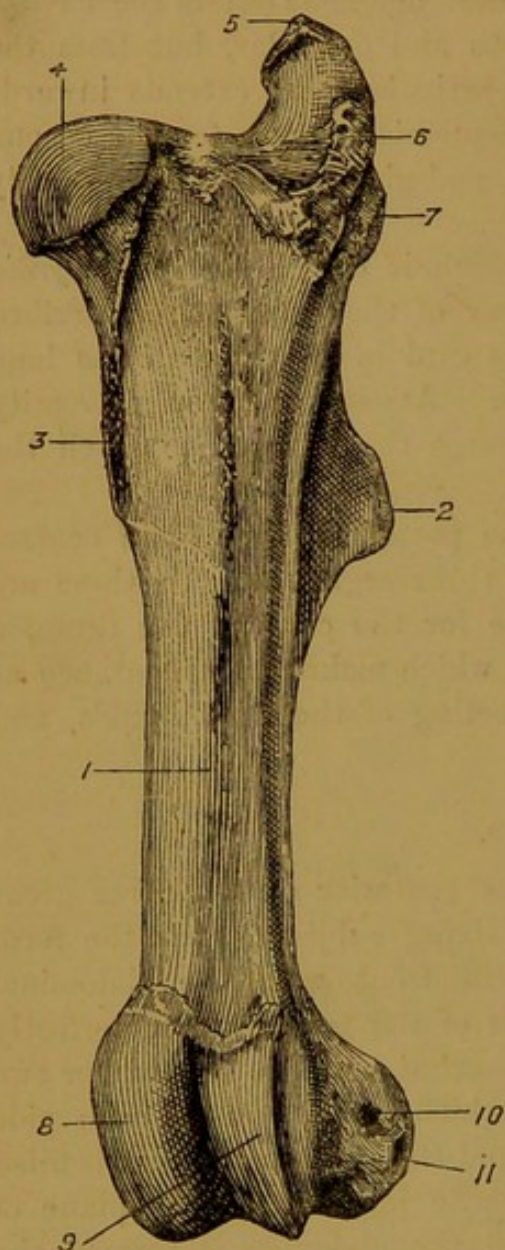


FIG. 105.—LEFT FEMUR OF HORSE (Anterior Aspect).

1. Anterior surface of shaft; 2. Third trochanter; 3. Internal or small trochanter; 4. Head; 5, 6, and 7. Summit, convexity, and crest of great trochanter; 8 and 9. Inner and outer lips of trochlea; 10. Pit on outer condyle for external lateral ligament of the stifle joint; 11. Pit for origin of popliteus.

#### THE FEMUR.

The femur is the most massive bone in the body. It is a long bone, and it occupies an oblique position in the limb, stretching downwards and forwards between the hip and stifle joints. Like other long bones, it possesses a shaft and two extremities.

The *anterior* and *lateral surfaces* of the shaft are blended so as to form one continuous smooth surface, convex in the transverse direction, and clothed by the quadriceps extensor cruris muscle.

The *posterior surface* is extensive, widest above, and flattened. It is

crossed obliquely downwards and outwards in its lower third by a smooth impression, which marks the course of the femoral blood-vessels. Immediately above this there is a four-sided rough area from which the

adductor muscles of the thigh take origin. Above this again, towards the inner edge of this surface, an oblique rough line or ridge serves for the attachment of the quadratus femoris muscle. At the same level, but towards the opposite side, and situated partly on the back of the third trochanter, there is a rough circular area to which the biceps femoris is attached.

The *inner edge* of this surface, or rather the edge which separates this from the inner surface, carries the **small** or **internal trochanter** in its upper third. This has the form of a thick rough projection, and it serves for the insertion of the iliacus and psoas magnus muscles. The **nutrient foramen** of the bone is found about the middle of this edge, and near the same point the pectineus is inserted into a rough impression. Still lower, immediately below the groove for the femoral vessels, this edge carries the **supra-condyloid crest**, from which the inner head of the gastrocnemius arises.

The *outer edge* carries, at nearly the same level as the inner trochanter, a strong forward-curved projection, termed the **third trochanter**.<sup>1</sup> The superficial gluteus muscle is inserted into the rough free edge of this process. At the lower part of this edge, opposite to the supra-condyloid crest, there is a deep rough pit—the **supra-condyloid fossa**. The flexor perforatus muscle arises from the bottom of the fossa, and the outer head of the gastrocnemius takes origin from its rough outer lip.

The *upper extremity* of the femur is made up of the articular head, and the great or external trochanter.

The **head** is a hemispherical articular process, which is received into the cotyloid cavity of the innominate bone. A deep non-articular triangular **sulcus** extends from near the centre to the inner edge of the head, and gives attachment to the pubio-femoral and round ligaments. A distinct line marking the attachment of the capsular ligament encircles the head, and beneath it the bone is slightly constricted, forming the **neck**.

The **great trochanter** lies to the outer side of the head, and in it there may be recognised three parts, viz., a summit, a convexity, and a crest. The **summit**, which is placed posteriorly, gives attachment to one of the tendons of the middle gluteus. In a medium-sized animal it surmounts the head by about two inches, and from it a prominent ridge—the **trochanteric ridge**—descends to near the third trochanter. The **trochanteric** or **digital fossa** lies immediately to the inner side of this ridge. The **convexity** lies in front of the summit, from which it is separated by a notch; and the **crest** is a strong ridge on the outer side of the convexity. In the recent state the convexity gives attachment inwardly to the deep gluteus, while its outer surface is incrustated with fibro-cartilage for the passage of the outer tendon of the middle

<sup>1</sup> Trochanter minor externus.

gluteus, which obtains insertion into the crest. Between the head and the great trochanter there is an area of bone perforated by numerous foramina for the passage of vessels belonging to the cancellated tissue of the bone.

The *lower extremity* of the femur is made up of the trochlea in front, and the condyles behind.

The **trochlea** is a pulley-like groove for articulation with the patella.

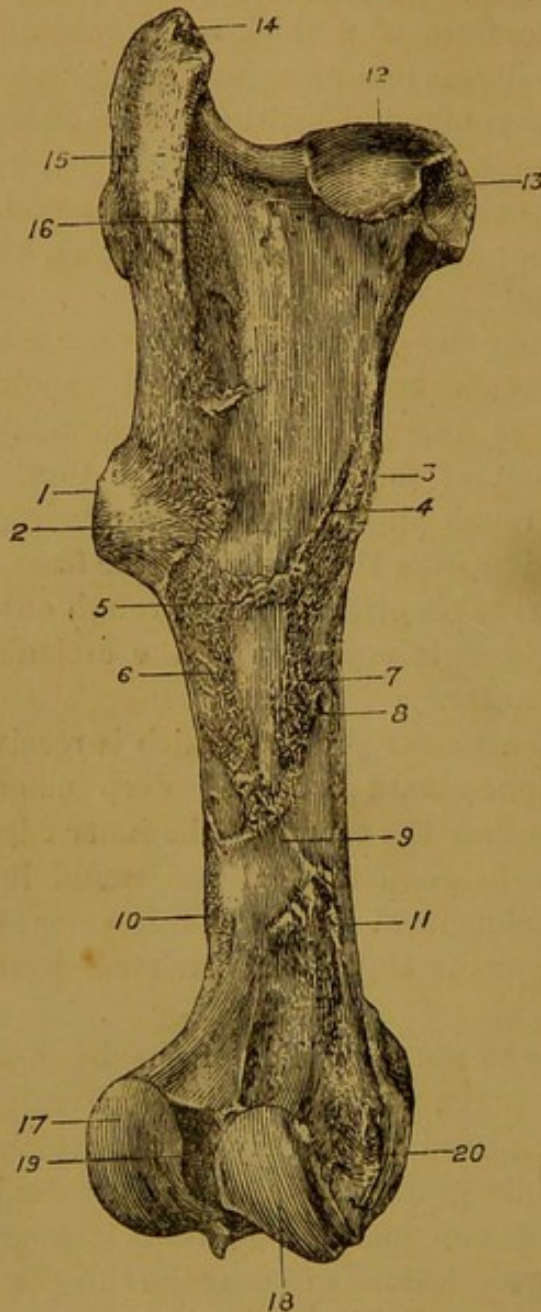


FIG. 106.—LEFT FEMUR  
OF HORSE  
(Posterior Aspect).

1. Third trochanter; 2. Mark for attachment of biceps femoris; 3. Internal or small trochanter; 4. Oblique line for quadratus femoris; 5 and 6. Markings for origin of small and great adductors of the thigh; 7. Point of insertion of pectineus; 8. Nutrient foramen; 9. Groove for femoral vessels; 10. Supracondyloid fossa; 11. Supracondyloid crest; 12. Head; 13. Pit for round and pubio-femoral ligaments; 14. Summit of great trochanter; 15. Trochanteric ridge; 16. Trochanteric or digital fossa; 17 and 18. Outer and inner condyles; 19. Intercondyloid groove; 20. Tubercle for internal lateral ligament of stifle joint.

The groove is nearly vertical in direction, and its inner lip is much more prominent than its outer. To the outer side of the extreme lower end of the outer lip, between it and the outer condyle, there is a well-marked pit for the common tendon of the extensor pedis and flexor metatarsi muscles.

The **condyles**—external and internal—are separated by a deep

**inter-condyloid groove**, which lodges the spine of the tibia and the crucial ligaments of the stifle joint. Each condyle is a convex ovoid articular process, for articulation with the upper extremity of the tibia. On its inner aspect the internal condyle carries a small eminence for the attachment of the internal lateral ligament of the stifle. The external condyle bears outwardly two small pits, the higher of which marks the attachment of the external lateral ligament, while the lower serves for the origin of the popliteus. At the posterior part of the inter-condyloid groove, close to the inner condyle, there is a digital pit for the attachment of one of the slips of the external semilunar cartilage; and opposite to this, close to the outer condyle, there is a larger pit for the attachment of the anterior crucial ligament.

**Development.** The femur, like other long bones, ossifies from three main centres—one for the shaft, and one for either extremity. To these a fourth centre is added for the great trochanter.

#### THE PATELLA.

This is a short bone articulating with the trochlea of the femur. It corresponds with the knee-cap of the human subject. It is not a weight-bearing bone, its function being to give increased lever power to the great extensor muscle of the leg. It presents for consideration three surfaces.

The *posterior surface* is entirely articular, and may be recognised by its smoothness. A ridge divides it into two lateral areas, both of which are grooved in the vertical direction. The central ridge slides in the groove of the femoral trochlea, and the lateral areas are adapted, though not very accurately, to the lips of the trochlea. The inner

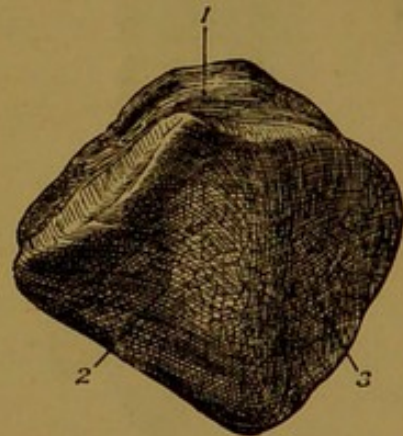


FIG. 107.—RIGHT PATELLA OF HORSE.

1. Superior surface; 2 and 3. Inner and outer areas of posterior or articular surface.

The inner lateral area is much more extensive than the outer, in correspondence with the larger size of the inner lip of the trochlea.

The *upper surface* is the smallest of the three. It is concave from before to behind, and slightly convex from side to side.

The *anterior surface* is the most extensive of the three. It is convex in all directions, and rough for muscular and ligamentous attachment.

**Development.** The patella ossifies from a single centre.

#### THE TIBIA.

The tibia is a long bone, and in size it greatly exceeds the fibula—the other bone of the leg. It occupies an oblique position in the limb,

extending downwards and backwards between the stifle and hock joints. It possesses a three-sided shaft, and two extremities.

The *external surface* of the shaft is widest above, and slightly spiral in its direction. At its upper part it looks almost directly outwards, but it gradually inclines towards the front of the bone, until at its lower end it looks directly forwards. It is concave above, convex in its middle, and nearly flat at its lower end. In the whole of its extent it is smooth, and clothed by the flexor metatarsi muscle.

The *outer surface* is wide above and narrow below. In its upper fourth it is rough for muscular attachment, but for the remainder of its extent it is smooth. This smooth part of the inner surface of the tibia is subcutaneous in position, and it corresponds to the "shin" of the human leg.

The *posterior surface* is flattened in the transverse direction. In its middle portion it is roughened by a number of vertical lines or ridges, which mark the origin of the deep flexor of the digit. In the upper third or more of this surface, and inclining inwards, there is a smooth triangular area covered by the popliteus muscle. The **nutrient foramen** is placed in the upper third of the bone, on the line of separation between the upper smooth area and the area carrying the rough lines. The lower third of this surface is smooth, and covered by the flexor muscles of the digit.

The foregoing surfaces are separated by three edges—an anterior and two lateral.

The *anterior edge* is very prominent and sharp in its upper third, con-

stituting the **tibial crest**. For the rest of its extent it is rounded and indistinct.

The *outer edge*, which is concave in its length, is opposed to the fibula to form an interosseous space—the **tibio-fibular arch**. The anterior

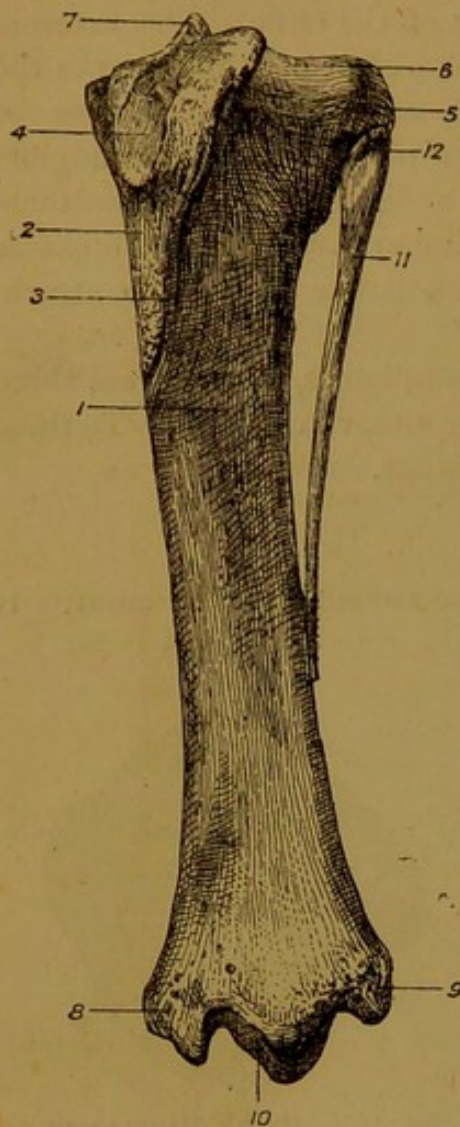


FIG. 108.—LEFT TIBIA AND FIBULA OF HORSE (Antero-External Aspect).

1. External surface of tibia; 2. Its internal surface; 3. Tibial crest; 4. Groove on anterior tuberosity for middle straight ligament of patella; 5. External tuberosity; 6. Groove for common tendon of extensor pedis and flexor metatarsi; 7. Tibial spine; 8. Internal malleolus; 9. External malleolus; 10. Lower articular surface of tibia; 11. Body of fibula; 12. Its head.

tibial vessels pass through the upper part of this space, and leave there a smooth impression on the outer edge of the bone.

The *inner edge* carries in its upper third a prominent tubercle for the attachment of the popliteus muscle.

The *upper extremity* is massive and compounded of three tuberosities—an anterior, and two lateral.

The **anterior tuberosity** is a non-articular process, continuous inferiorly with the tibial crest. It presents a vertical groove for the middle straight ligament of the patella. It is most prominent to the outer side of this groove, and between it and the outer tuberosity a deep notch is left for the passage of the common tendon of origin of the flexor metatarsi and extensor pedis muscles.

The **external tuberosity** carries superiorly a saddle-shaped articular surface, for articulation with the outer condyle of the femur. On its outer side it presents a rough depression for articulation with the head of the fibula.

The **internal tuberosity** carries superiorly a slightly undulated articular surface, which responds to the inner condyle of the femur, and which is prolonged on the inner surface of the tibial spine. On its posterior aspect the internal tuberosity bears a small tubercle for the attachment of the posterior crucial ligament. There is a marked want of adaptation between the articular surfaces of the tibial tuberosities and the corresponding condyles of the femur, but in the complete joint this is compensated for by the interposition of the semi-lunar cartilages.

The **tibial spine**. This is a peak-like process of bone situated near the centre of the upper extremity. On its inner side the spine is smooth, and continuous with the articular surface of the inner tuberosity. It

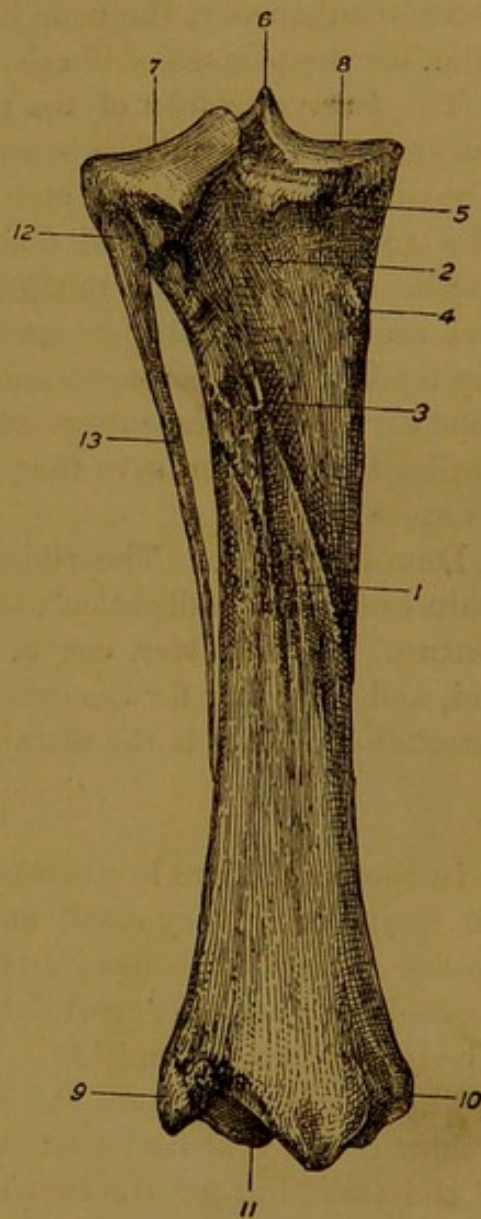


FIG. 109.—LEFT TIBIA AND FIBULA OF HORSE (Posterior Aspect).

1. Ridge on posterior surface of tibia for origin of flexor perforans;
2. Smooth area covered by popliteus;
3. Nutrient foramen;
4. Tubercle for popliteus;
5. Tubercle for posterior crucial ligament;
6. Tibial spine;
- 7 and 8. Articular surfaces of outer and inner tuberosities;
9. External malleolus;
10. Internal malleolus;
11. Lower articular surface of tibia;
- 12 and 13. Head and body of fibula.

presents to its outer side a pit for the attachment of the anterior crucial ligament.

Between the outer and inner tuberosities, and between these and the anterior tuberosity, the bone is rough and perforated by numerous foramina for the passage of blood-vessels belonging to the cancellated tissue.

The *lower extremity* of the tibia carries an articular surface for the astragalus. This surface is composed of two deep grooves, separated by a median articular ridge, and bounded on either side by the malleoli. The grooves are disposed obliquely, being directed forwards and outwards. The **external malleolus** is articular inwardly, and roughened and grooved vertically on its outer side. The groove gives passage to the tendon of the peroneus muscle, and on either side of the groove the bone serves for ligamentous attachment. The **internal malleolus** is similar to the outer, save that it is smaller, and destitute of a groove on its excentric side.

**Development.** The tibia as before described possesses the three main centres of ossification common to long bones, and two subsidiary centres. Of the latter, one is for the anterior tuberosity of the upper end, and the other for the external malleolus. In reality, however, the external malleolus is the distal end of the fibula.

#### THE FIBULA.

In the horse there is a marked disparity between the bones of the leg, the fibula being very small and slender. In size and shape it is not unlike the splint bones; and, like these, it is to be regarded as an aborted long bone, its medullary cavity being undeveloped. It possesses a body and two extremities.

The *body* is a styliform rod of bone, tapering to its lowest point. For a short distance at its lower end it is closely applied to the outer edge of the tibia, but for the remainder of its extent it is opposed to that edge so as to leave between them an elongated interosseous space—the **tibio-fibular arch**.

The *upper extremity* or **head** of the fibula is the thickest part of the bone. It presents an *inner surface*, flat and somewhat rough for articulation with the outer tuberosity of the tibia; an *outer surface*, which is slightly convex and affords attachment to the external lateral ligament of the stifle; and blunt *anterior* and *posterior edges*, the latter being the thicker of the two.

The *lower extremity* forms a sharp point, which reaches to the lower third of the tibia.

**Development.** The fibula as above described possesses two centres of ossification, one for the body, and another for the head. But, as already stated, the external malleolus of the tibia ought to be regarded as the distal epiphysis of the fibula.

## THE BONES OF THE TARSUS.

The tarsus comprises six short bones, named as follows:—*astragalus*, *os calcis*, *scaphoid*, *cuboid*, and *great* and *small cuneiform*<sup>1</sup> bones. These bones may be said to form two rows comparable to those of the carpus, the upper row comprising the astragalus and os calcis, and the lower the cuboid and two cuneiforms, while the scaphoid is interposed between the two rows on the inner side.

**The Astragalus.** This bone is of very irregular shape, but it may be described as possessing six surfaces. The *upper* and *anterior* surfaces are blended to form an articular surface for the lower end of the tibia. This surface is pulley-like, consisting of a median deep groove and two lateral rounded ridges; and it winds with a spiral twist downwards, forwards, and outwards, so as to make nearly half a turn round the bone. The *lower surface* is almost entirely articular, and it is slightly convex from before to behind. It articulates with the cuboid by a small bevelled facet at its outer side, and for the remainder of its extent with the scaphoid. A non-articular groove for the attachment of an interosseous ligament begins about the centre of this surface, and runs to the outer edge. The *posterior surface* is rugged and irregular. It carries three or four facets for articulation with the os calcis, and intervening rough areas for ligamentous attachment. The *lateral surfaces*—outer and inner—are non-articular, the former carrying a prominent blunt tuberosity, and the latter a shallow wide pit, to which ligaments are attached. The astragalus articulates with four bones, viz., the tibia, os calcis, scaphoid, and cuboid.

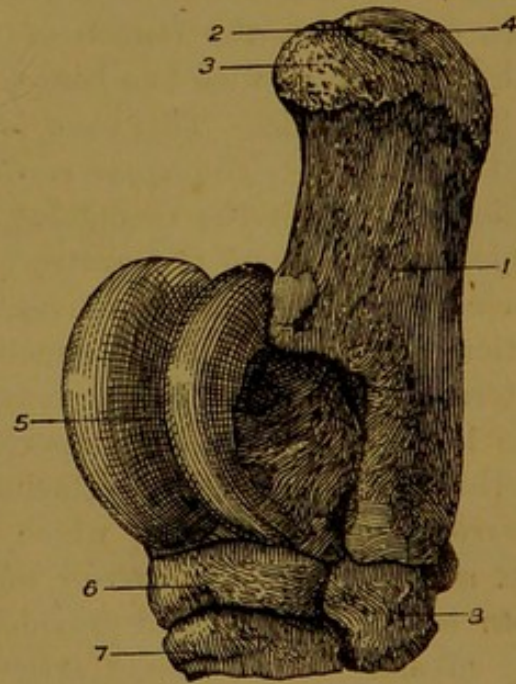


FIG. 110.—LEFT TARSUS OF HORSE (Antero-External Aspect).

1. Os calcis; 2, 3, and 4. Middle, anterior, and posterior areas of upper end of tuber calcis (*see text*); 5. Astragalus; 6. Scaphoid; 7. Cuneiform magnum; 8. Cuboid.

**The Os Calcis, or Calcaneum.** This bone also is of very irregular shape. It is made up of a body and a large process—the tuber calcis.

The **body**, which is placed inferiorly, presents a rugged *anterior surface*, moulded on the posterior surface of the astragalus, and provided with three or four facets for articulation with that bone. Between these

<sup>1</sup> The small cuneiform of the horse is formed by the fusion of two bones representing the inner and middle cuneiform bones of man.

facets the bone is rough for ligamentous attachment. *Inferiorly* the body carries a single elongated, slightly concave facet for articulation with the cuboid. *Superiorly* the body carries the tuber calcis, and to the outer side of the line of junction it bears a wide groove for the passage of the deep flexor muscle.

The **tuber calcis** forms the "point of the hock," a projection which corresponds to the heel of the human subject. The process is flattened from side to side, presenting an *outer surface* which is nearly plane, and an *inner surface* which is less extensive, and grooved so as to form the boundary of the tarsal sheath, for the transmission of the tendon of the deep flexor of the digit. The *anterior edge* of the tuber is short, rounded, and slightly concave in its length. The *posterior edge* is longer, thicker, and nearly straight, and in the recent state the calcaneo-metatarsal ligament is attached to it. The *upper extremity* of the tuber is slightly expanded. It shows three areas or markings, viz., (1) a middle depressed mark for the insertion of the gastrocnemius tendon, (2) an anterior convex area on which the above tendon rests during extreme flexion of the hock joint, and (3) a posterior smooth convex area over which the tendon of the flexor perforatus plays. The os calcis articulates with two bones, viz., the astragalus and cuboid.

The **Scaphoid**. This bone is flattened in shape, with two surfaces and four edges. The *upper surface* is slightly concave and smooth for articulation with the astragalus. It possesses a non-articular groove, which begins about the centre and is directed to the outer edge. The *lower surface* is slightly convex, and for the most part smooth. It articulates with the small cuneiform by a convex facet at its postero-internal corner, and for the remainder of its extent by two facets with the large cuneiform. A non-articular groove runs between the facets of this surface, affording attachment to interosseous ligaments. The *anterior* and *inner edges*, which are not distinctly separated, are convex and rough; the *posterior edge* is notched and irregular; and the *outer edge* is concave, and provided with two facets for articulation with the cuboid. The scaphoid articulates with four bones, viz., the astragalus, cuboid, and both cuneiforms.

The **Cuneiform magnum**.<sup>1</sup> This bone is somewhat similar in shape to the scaphoid, but it is more triangular in outline, and smaller. It presents two surfaces and three edges. The *upper surface* is slightly convex, and divided into two unequal facets by a transverse non-articular groove. It articulates with the scaphoid. The *lower surface* is very slightly convex. It presents a non-articular groove, which sometimes runs quite across it, and for the rest of its extent it articulates with the large metatarsal bone. The *anterior edge*, forming the base of the triangle, is convex, rough, and non-articular. The *outer edge* is con-

<sup>1</sup> External cuneiform of human anatomy.

cave, and furnished with two facets for articulation with the cuboid. The *inner edge*, slightly more concave than the outer, has one facet for articulation with the small cuneiform. The cuneiform magnum articulates with four bones,<sup>1</sup> viz., the scaphoid, small cuneiform, cuboid, and large metatarsal.

The **Cuneiform parvum** is much the smallest of the bones of the tarsus. It is very irregular in shape, but it may be described as possessing two surfaces, two edges, a base (or third edge), and an apex. The *inner surface* is convex and rough. The *outer surface* is concave, and provided with a backward projecting nodule. The *upper edge* carries a concave facet for articulation with the scaphoid. The *lower edge* bears a small flat facet anteriorly for articulation with the large metatarsal, and immediately behind that a larger concave facet for the inner small metatarsal. The *base* or *posterior edge* is rounded, non-articular, and produced inferiorly into a nodular projection. The *apex*, placed in front, carries outwardly a small facet for articulation with the large cuneiform. The cuneiform parvum articulates with four bones, viz., the scaphoid, large cuneiform, large metatarsal, and inner small metatarsal.

The **Cuboid**. This is the most regularly prismatic of all the tarsal bones. It is a six-sided bone, in shape not unlike a brick. The *upper surface* is slightly convex, and smooth for articulation with the astragalus and os calcis. The *lower surface* presents two facets in front and two behind, with an intervening non-articular groove. The outer facet of each pair articulates with the external small metatarsal, and the inner with the large metatarsal. The *inner surface* is articulated to the scaphoid and large cuneiform by four facets, two for each bone. The remainder of the surface is rough and non-articular, and it is provided with an antero-posterior groove, which in the articulated tarsus forms with the opposed scaphoid and cuneiform magnum a canal for the passage of the perforating metatarsal artery and an accompanying vein. The *anterior*, *outer*, and *posterior surfaces* are rough and non-articular. The cuboid articulates with six bones, viz., the astragalus, os calcis,

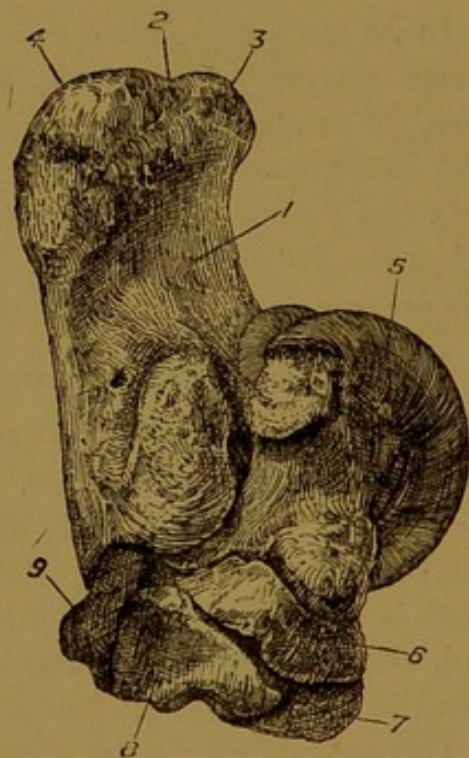


FIG. 111.—LEFT TARSUS OF HORSE (Postero-Internal Aspect).

8. Cuneiform parvum; 9. Cuboid. The other references are the same as in the preceding figure.

<sup>1</sup> In some hocks it has a fifth articulation, for the inner small metatarsal.

scaphoid, cuneiform magnum, large metatarsal, and external small metatarsal.

**Development** of the tarsal bones. The os calcis possesses two centres of ossification, one of which is for the summit of the tuber. The remaining bones, with the exception of the small cuneiform, ossify each from a single centre. The small cuneiform, however, ossifies from two distinct centres, each of which represents a separate bone, corresponding respectively to the inner and middle cuneiform bones of the human tarsus or that of the dog. Sometimes the fusion of the pieces resulting from these two centres does not take place, and the horse then possesses three distinct and separate cuneiform bones.

#### THE METATARSUS.

In its most complete form the mammalian metatarsus contains five bones, corresponding to the five bones of the metacarpus. Such is the case, for example, in the human foot. In the horse, however, the outer and inner bones are entirely suppressed; and, of the remaining three, only the central one is fully developed and carries a digit, the other two being slender and splint-like. These three bones are named respectively the *large metatarsal*, and the *outer* and *inner small metatarsals*.

#### THE LARGE METATARSAL BONE.

This is a long bone, and it extends in a nearly vertical direction between the hock and fetlock joints. In form it closely resembles the large metacarpal, but it is easily distinguished from that bone by its greater length,<sup>1</sup> and the more regularly cylindrical character of its shaft. The shaft is narrowest in its middle, and slightly expanded at its extremities, and, although nearly circular on section, it may, for purposes of description, be said to present four surfaces.

The *anterior surface* is convex and smooth, and it passes insensibly on either side into the lateral surfaces (outer and inner), which are also smooth and rounded from side to side. The *outer surface* shows a faint groove which begins at its upper end, and crosses it very obliquely downwards and backwards to disappear about the middle of the bone. This groove marks the course of the large metatarsal artery.

The *inner surface* shows at its upper end a shorter and fainter oblique groove for the inner metatarsal vein.

The *posterior surface* is flattened, and in its lower third it is smooth. At each side of this surface, in the upper two-thirds of the bone, there is a narrow rough surface, slightly widening as it ascends, for articulation with the small metatarsal bone. Between these surfaces the bone is smooth, forming with the splint bones a channel for the suspensory ligament of the fetlock. The **nutrient foramen** (sometimes double as

<sup>1</sup> In a medium-sized animal the metatarsal is about  $2\frac{1}{2}$  inches longer than the metacarpal.

in Fig. 113) is found on this surface, about the junction of its upper and middle thirds.

The *upper extremity* is terminated by an articular surface for the lower tarsal bones. Towards its outer side this surface presents two small facets for the cuboid, separated by a non-articular groove which extends inwards to the middle of the surface; at its postero-internal corner it carries one small facet for the cuneiform parvum; and for the remainder of its extent it articulates with the cuneiform magnum. On the posterior aspect of the upper extremity there are four small facets

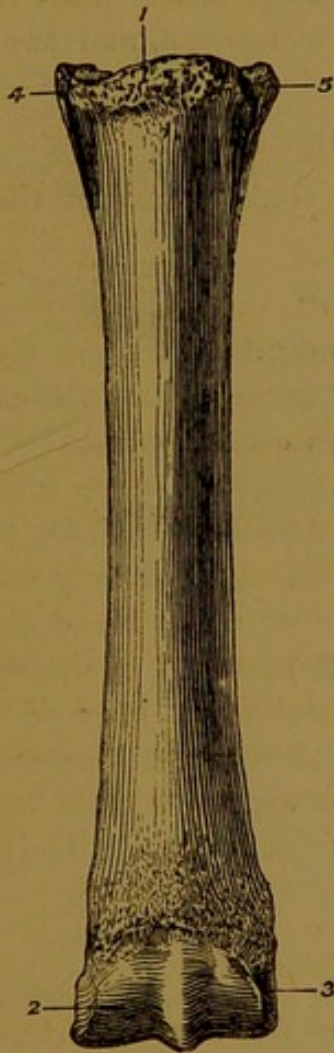


FIG. 112.—LEFT METATARSAL BONES OF HORSE (Front View).

1. Mark for tendon of flexor metatarsi;
2. Lower articular surface of large metatarsal;
3. Pit for external lateral ligament of fetlock;
- 4 and 5. Heads of inner and outer small metatarsal bones.

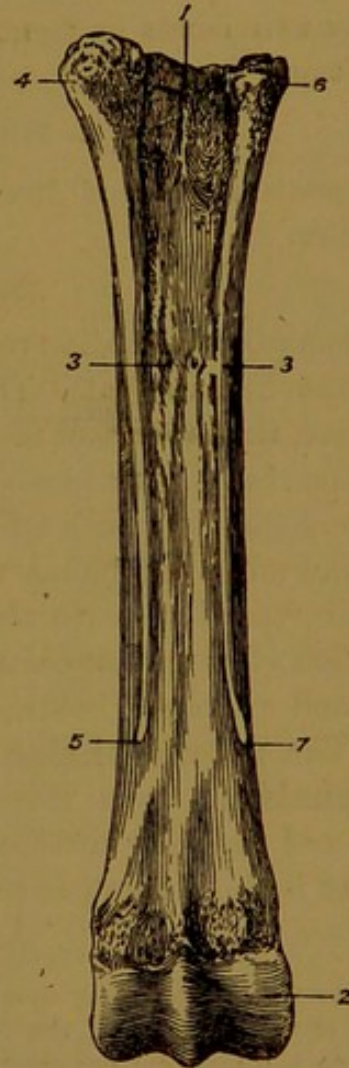


FIG. 113.—LEFT METATARSAL BONES OF HORSE (Posterior View).

1. Upper extremity of large metatarsal;
2. Inner division of lower articular surface of same bone;
- 3 3. Nutrient foramina (generally there is only one such foramen);
- 4 and 5. Head and "button" of outer small metatarsal;
- 6 and 7. The same parts of the inner small metatarsal.

in pairs, two on each side, these being for articulation with the heads of the small metatarsal bones. On the front of this extremity, but more to the inner than the outer side, a rough semi-circular ridge serves for the insertion of the flexor metatarsi muscle.

The *lower extremity* differs from the corresponding surface of the large metacarpal bone only in being larger, both in its transverse and its antero-posterior diameter. It articulates with the first phalanx and sesamoids.

#### THE SMALL METATARSAL BONES.

These bones closely resemble the splint bones of the fore limb. They are, however, longer, and their upper extremities are more massive. The outer bone is the larger of the two, particularly in respect of its head, which is provided with two facets in front for the large metatarsal, and two above for the cuboid. The head of the inner bone has similarly two facets in front for the large metatarsal, and two<sup>1</sup> above for the small cuneiform.

#### THE SESAMOID BONES.

The *sesamoid bones* of the hind limb are slightly smaller than those of the fore.

#### THE DIGITAL REGION.

The typical mammalian pes possesses five digits or toes, as is exemplified in the human foot. The toes are distinguished by the numerals one to five, the innermost toe or *hallux*, which corresponds to the thumb, being the 1st. The horse possesses but one hind digit or toe, viz., the homologue of man's middle toe. The bones of this digit are the same in number and names as those of the fore digit already described; and their resemblance to the latter is so close as to make a detailed description of them unnecessary. The **first phalanx** is shorter, wider above, and narrower below, than the corresponding bone of the fore limb. The **second phalanx** has a shorter transverse diameter. The **third phalanx**, when viewed from its solar aspect, is more pointed at the toe, and the solar surface is more concave or vaulted. The **navicular bone** is shorter and narrower.

#### PARALLELISM OF THE FORE AND HIND LIMBS.

In the case of almost every mammal a similarity or correspondence between certain segments of the skeleton of the fore limb, and other segments of the hind limb, is apparent to the most cursory observation. In no animal is this better illustrated than in the horse, for, as already seen, the resemblance between the digital skeleton of the fore and hind limbs is so close that one description serves for both. In the succeeding segments of the limbs (passing upwards) the correspondence of parts becomes more and more obscure, and hence some diversity of opinion yet prevails regarding the exact relationship of certain elements of the appendicular skeleton. The most generally accepted views are the following. As stated above, the strict correspondence of the digital region of the fore and hind limbs does not admit of any doubt. In pentadactyle (five-toed) animals the thumb corresponds to the great toe, the little finger to the little toe, and so on with the intermediate digits. In the case of animals in which some of the five digits have been suppressed, the relationship of the remaining digits may not be at once apparent; but an examination of the condition of these parts in the embryo, and

<sup>1</sup> Sometimes the head of the inner bone carries superiorly a third facet for the large cuneiform.

in the most nearly related species, generally leaves no doubt on the matter. The single anterior digit of the horse is strictly homotypical with the posterior digit, for the one is the representative of the middle finger of the human hand, and the other of the middle toe of the human foot.

That the great metacarpal bone is the homotype of the great metatarsal follows from what has just been said. So also, the outer and inner small metacarpal bones are respectively homotypical with the outer and inner small metatarsals.

The series of carpal bones is homotypical with the tarsal bones. The most probable relationship of the individual bones is indicated below.

CARPUS.				TARSUS.	
Scaphoid	}	.	.	astragalus.	
Semilunar				os calcis.	
Cuneiform	.	.	.	small cuneiform.	
Trapezium	}	.	.	great cuneiform.	
Trapezoid				cuboid.	
Os magnum	.	.	.		
Unciform	.	.	.		

The carpal pisiform is a sesamoid unrepresented in the tarsus, and, on the other hand,

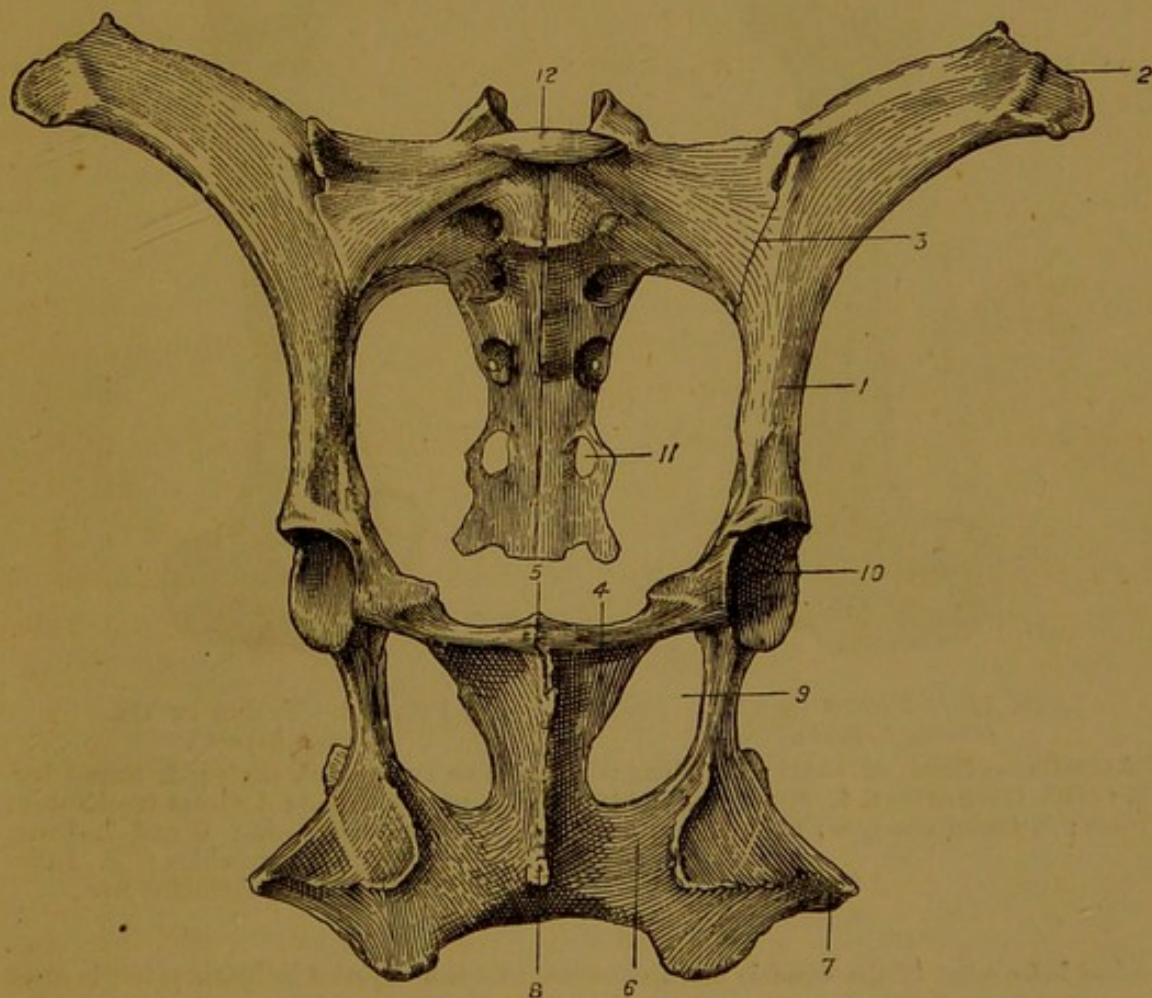


FIG. 114.—PELVIC BONES OF OX.

1. Shaft of ilium ; 2. Angle of the haunch ; 3. Sacro-iliac joint ; 4. Lower surface of pubic bone ; 5. Pubic symphysis ; 6. Lower surface of ischium ; 7. Tuber ischii ; 8. Bony ridge developed under symphysis ; 9. Obturator foramen ; 10. Cotyloid cavity ; 11. A sacral foramen ; 12. Anterior end of first sacral centrum.

the tarsal scaphoid is the representative of the *os centrale* of the carpus—a bone which is rarely present in mammals.

The radius is the homotype of the tibia, and the ulna of the fibula.

The humerus is the homotype of the femur, the inner side of the former corresponding with the outer side of the latter, these bones having been rotated in opposite directions from their original embryonic position.

The scapula is the homotype of the ilium, and the coracoid process (a separate bone in the lower vertebrates) of the ischium. The pubis is entirely unrepresented in the scapular girdle of the horse, but its homotype is found in the precoracoid and part of the epicoracoid of the lower vertebrates. Lastly, it may be mentioned that the clavicular element of the scapular girdle (absent in the horse) has no bony representative in the posterior extremity, but possibly Poupart's ligament may be homotypical with it.

#### THE HIND LIMB OF THE OX.

**Innominate Bone.** The gluteal surface of the ilium shows a faint longitudinal ridge in its lower part. The angle of the haunch is compounded of three tuberosities,

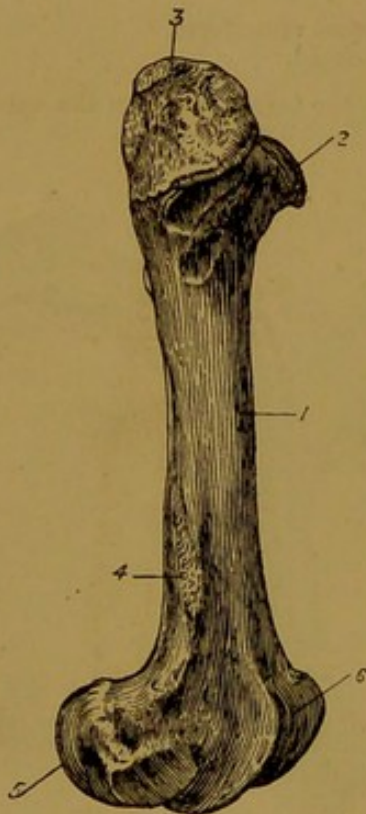


FIG. 115.—FEMUR OF OX  
(Outer Aspect).

1. Anterior surface of shaft; 2. Head; 3. Great trochanter; 4. Supracondyloid fossa; 5. Outer condyle; 6. Trochlea.

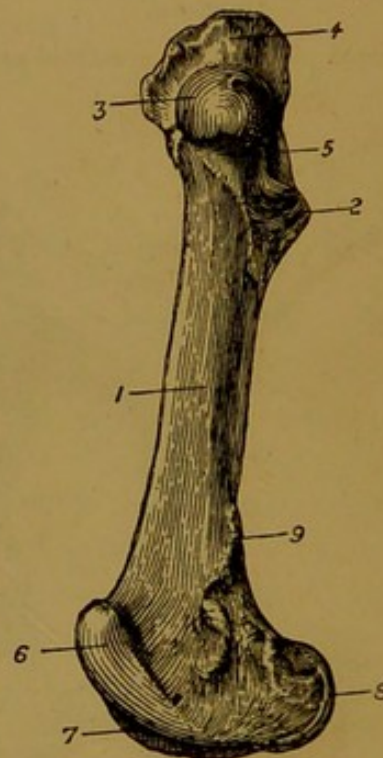


FIG. 116.—FEMUR OF OX  
(Inner Aspect).

1. Inner surface of shaft; 2. Small trochanter; 3. Head; 4. Great trochanter; 5. Trochanteric fossa; 6 and 7. Inner and outer lips of trochlea; 8. Inner condyle; 9. Supracondyloid crest.

the ischiatic edge of the bone is more concave, and the superior ischiatic spine is more elevated. A groove is present on the under surface of the pubic bone; but, unlike the pubio-femoral groove of the horse, it does not extend into the cotyloid cavity. The tuber ischii has the form of a large trifold process, and a strong curved muscular ridge is carried by the inferior surface of the ischium. The gap in the rim of the cotyloid cavity is much smaller than in the horse, and the rim is cut anteriorly by a small notch or a complete foramen. The obturator foramina are very large. The pubic and ischial bones of opposite sides join at a more acute angle than in the horse, and the pelvic floor is thus more basin-like. In the adult animal a strong bony ridge is developed on the under aspect of the ischio-pubic symphysis. Each half of this ridge has a separate centre of ossification.

**Femur.** The shaft is less massive, the posterior surface is narrower than in the horse, and the third trochanter is absent. The small or internal trochanter is higher up on the shaft, and the trochanteric ridge connects it to the great trochanter. The latter eminence is very massive, but it is not divided into a summit and a convexity. The head is smaller and more spherical, and the neck is better marked. The excavation for the round ligament is shallow, and almost centrally placed on the head. The supra-condyloid fossa is much shallower than in the horse. As in the latter animal, the inner lip of the femoral trochlea is much more prominent than the outer.

**Patella.** This bone is narrower than in the horse.

**Tibia.** This bone is proportionally shorter than in the horse, and the muscular ridges on the posterior surfaces are fewer in number, but they extend farther upwards. The anterior tuberosity of the upper end is devoid of a mesial furrow. The external tuberosity carries no facet for the head of the fibula. The notch between the anterior and

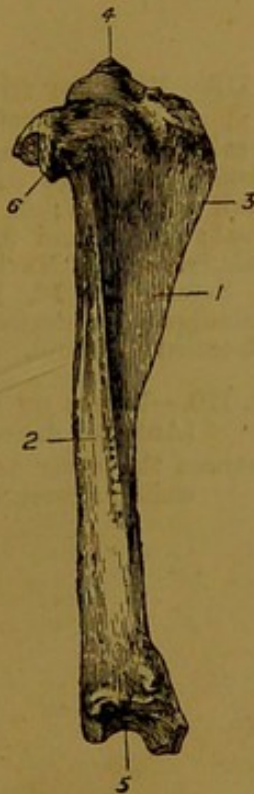


FIG. 117.—TIBIA OF OX  
(Outer Aspect).

- 1 and 2. External and posterior surfaces of shaft; 3. Tibial crest; 4. Tibial spine; 5. Lower articular surface of tibia; 6. Process representing head of fibula.

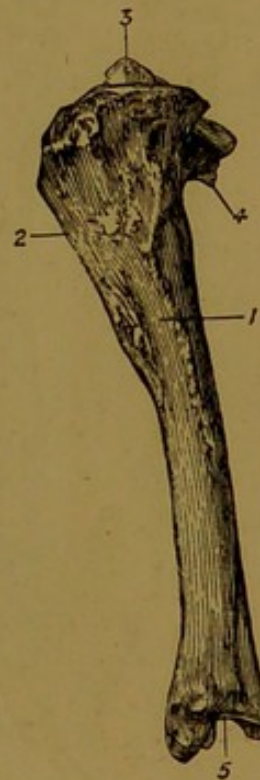

FIG. 118.—TIBIA OF OX  
(Inner Aspect).

1. Inner surface of shaft; 2. Tibial crest; 3. Tibial spine; 4. Process representing head of fibula; 5. Lower articular surface.

external tuberosities is much narrower than in the horse. The grooves of the lower articular surface have an antero-posterior direction, and the external malleolus is altogether separate from this bone.

**Fibula.** This bone is even more rudimentary than in the horse. In the young adult its shaft and upper extremity are represented by a fibrous cord extending between the external tuberosity of the upper end of the tibia and the external malleolus. The latter process is ossified as a separate bone, articulating with the astragalus, os calcis, and tibia. In the middle-aged subject the upper extremity of the fibula is also generally ossified, but ankylosed to the tibia.

**Tarsus.** Only five bones are present in the tarsus of the ox, viz., the astragalus, os calcis, two cuneiforms, and a bone representing the combined scaphoid and cuboid bones of the horse. The pulley-like surface by which the astragalus is articulated to the

tibia is vertically grooved. The lower surface of the same bone has a condyle outwardly and a trochlea inwardly for articulation with the scapho-cuboid. The tuber calcis is longer and more slender than in the horse, and its upper extremity is grooved for the flexor perforatus tendon. The scapho-cuboid bone extends completely across the tarsus, and it contracts articulations with all the other bones. The two cuneiforms correspond to the same bones of the horse, but the cuneiform parvum is smaller and more rounded.

**Metatarsus.** The ox possesses a large metatarsal representing the combined 3rd and 4th metatarsals of the human foot, and a small round flattened bone placed like a

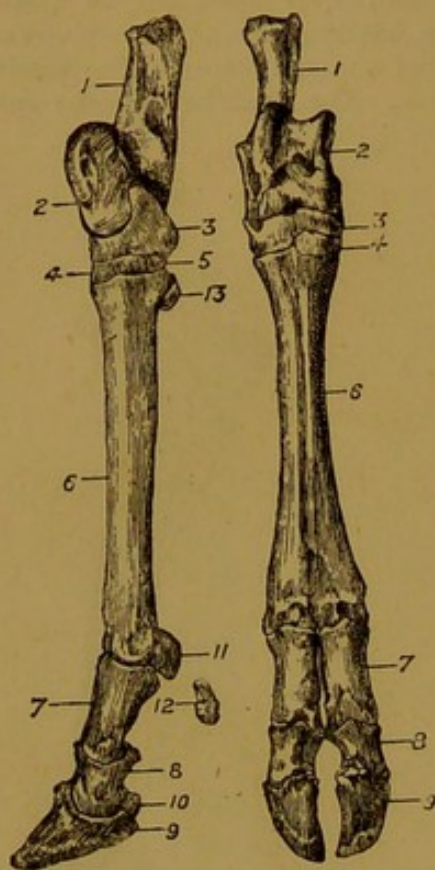


FIG. 119.

FIG. 120.

FIG. 119.—BONES OF THE PES OF OX (Inner Aspect).

1. Os calcis; 2. Astragalus; 3. Scapho-cuboid; 4. Large cuneiform; 5. Small cuneiform; 6. Large metatarsal; 7, 8, and 9. The three phalanges; 10. Navicular bone; 11. Sesamoid; 12. Rudimentary phalanges of posterior digits; 13. Sub-tarsal sesamoid.

FIG. 120.—BONES OF PES OF OX (Anterior Aspect).

References the same as in the preceding figure.

sesamoid on the inner side of the upper end of the large bone. This rudimentary bone may possibly represent the 2nd metatarsal. The large bone is somewhat similar to the corresponding bone of the fore extremity, but it is longer, and its shaft is distinctly four-sided. In the foetus the 3rd and 4th metatarsal bones are distinct and separate, and in the adult animal indications of their former independence are seen in mesial furrows of the shaft and a longitudinal septum of the medullary cavity.

**Digits.** The digital region of the hind limb presents the closest correspondence with the same segment of the fore extremity.

#### THE HIND LIMB OF THE SHEEP.

**Innominate Bone.** The gluteal surface of the ilium has a longitudinal ridge, as in the ox. The long axis of the ilium and that of the ischium form a nearly straight line. The crest is longer and more convex than in the larger ruminant, the angle of the haunch is less massive, and the superior ischiatic spine is less elevated. Anchylosis of the symphysis is late in occurring. In other respects the bone resembles that of the ox.

**Femur.** The great trochanter is on a level with the head, the supracondyloid fossa is very shallow, the crest of the same name is scarcely observable, and the lips of the trochlea are of nearly equal prominence.

**Tibia and Fibula.** The tibia is relatively longer than in the ox, and its shaft is

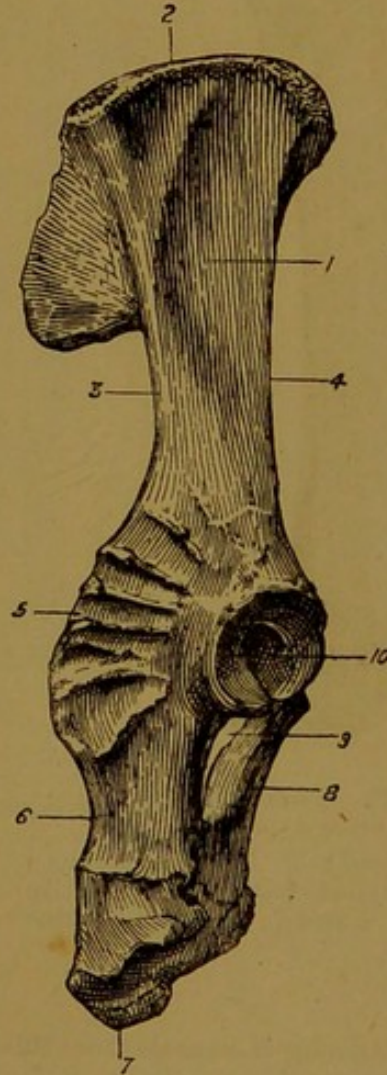
more rounded. Only the lower epiphysis, or external malleolus, of the fibula is ossified, this forming as in the ox a small bone disconnected from the lower end of the tibia.

**Pes.** The skeleton of this region is similar to that of the large ruminant, but the posterior rudimentary digits are either destitute of a skeleton, or possess only a single ossicle.

#### THE HIND LIMB OF THE FIG.

**Innominate Bone.** The gluteal surface of the ilium is traversed by a ridge extending between the crest and the superior ischiatic spine, and on either side of this ridge the gluteal surface is distinctly concave. The crest is long and markedly convex,

FIG. 121.—RIGHT  
INNOMINATE BONE OF FIG.  
1. Gluteal surface of ilium;  
2. Crest; 3. Ischiatic edge;  
4. Cotyloid edge; 5. Superior ischiatic spine; 6. Outer edge of ischium; 7. Tuber ischii; 8. Lower surface of pubis; 9. Obturator foramen; 10. Cotyloid cavity.



and the angle of the haunch is undivided. The superior ischiatic spine is elevated, and provided outwardly with prominent muscular ridges. The long axis of the ilium is almost in the same straight line as that of the ischium. The inferior ischiatic spine has the form of a rounded tubercle. The pubio-femoral groove is absent. The cotyloid cavity is very similar to that of the ruminant, but it is proportionally deeper. Anchylosis does not usually take place at the ischio-pubic symphysis.

**Femur.** The femur of the pig is proportionally longer than in the horse. The shaft is very similar to that of the ruminant, the third trochanter being absent, and the posterior surface narrower than in the horse. The internal trochanter is near the upper end of the bone. The great trochanter is undivided, and its highest point is almost on a level with the head. The latter is more spherical than in the horse, and its sulcus is small. The neck is very much better marked than in the horse or the ruminants. The trochanteric ridge is oblique. The supracondyloid fossa is shallow, and the crest of the same

name is scarcely observable. The lips of the femoral trochlea are of nearly equal prominence.

**Patella.** This bone is longer and narrower than in the horse.

**Tibia.** This bone is very similar to the tibia of the ruminant. Its posterior surface is almost smooth. The anterior tuberosity of the upper end has a shallow vertical furrow.

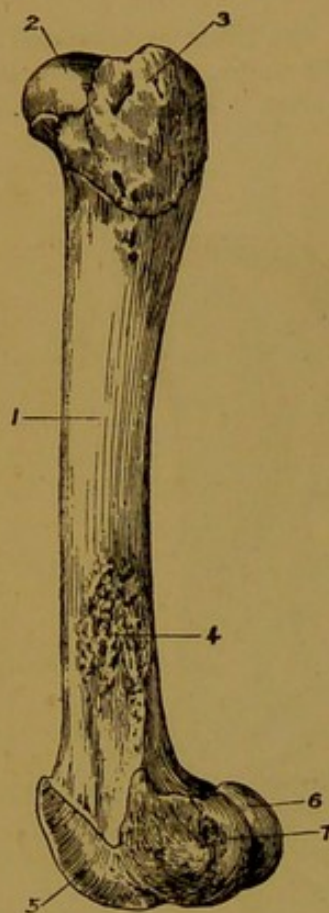


FIG. 122.—FEMUR OF PIG  
(Outer Aspect).

1. Shaft; 2. Head; 3. Great trochanter; 4. Supracondyloid fossa; 5. Outer lip of trochlea; 6 and 7. Inner and outer condyles.

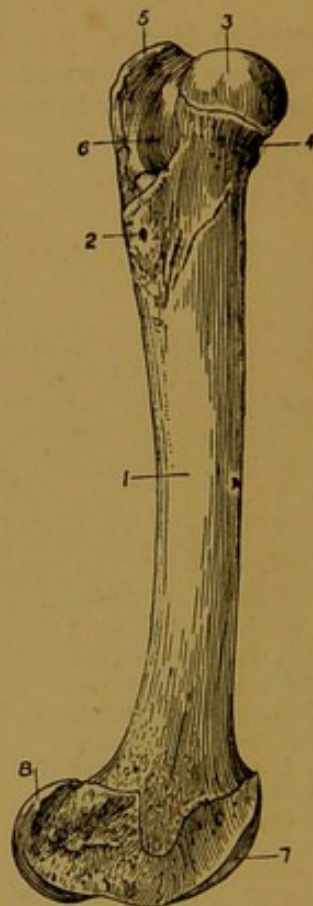


FIG. 123.—FEMUR OF PIG  
(Inner Aspect).

1. Inner surface of shaft; 2. Small trochanter; 3. Head; 4. Neck; 5. Great trochanter; 6. Trochanteric fossa; 7. Inner lip of trochlea; 8. Inner condyle.

The external malleolus is separate from this bone, and the grooves of the lower articular surface are antero-posterior in direction.

**Fibula.** The fibula of the pig is completely ossified throughout its whole extent. Its upper extremity or head articulates with the external tuberosity of the tibia in the same manner as in the horse. Its lower epiphysis (which corresponds to the external malleolus of the horse's tibia) is movably articulated to the astragalus and to the outer side of the lower end of the tibia. The shaft of the bone is thin and compressed, with a sharp anterior and a thicker posterior edge. Between the opposed shafts of the leg bones a wide interosseous space is left.

**Tarsus.** Seven bones are present in the tarsus of the pig, the small cuneiform of the horse being represented by two bones. The os calcis and astragalus are very similar to those of the ox. The lower articular surface of the latter bone has the form of a double trochlea for articulation with the scaphoid and cuboid. The cuboid bone is relatively large, and it articulates with the two outermost metatarsals. The three cuneiforms are distinguished as external, middle, and internal. The first of these is much the largest, and it articulates with the innermost of the two large metatarsals.

The middle cuneiform, which is much the smallest of the three, articulates with the two innermost metatarsals. The internal cuneiform also articulates with the two innermost metatarsals.

**Metatarsus.** The pig possesses four metatarsal bones resembling very closely the corresponding bones of the fore extremity. The central pair (3rd and 4th) are about equal in size, and much larger than the other two. The latter (2nd and 5th) are placed one behind each of the larger pair. These four metatarsal bones of the pig correspond

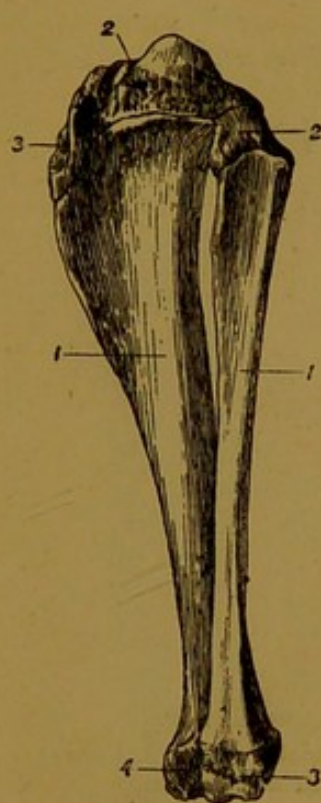


FIG. 124.—LEG BONES OF PIG (Outer Aspect).

1. (Left side of Fig.) Shaft of tibia; 2. Upper extremity; 3. Groove on anterior tuberosity; 4. Lower extremity; 1. (Right side of Fig.) Shaft of fibula; 2. Upper epiphysis; 3. External malleolus.

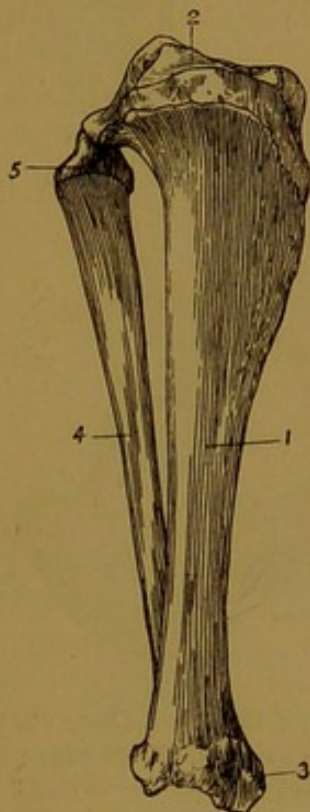


FIG. 125.—LEG BONES OF PIG (Inner Aspect).

1. Shaft of tibia; 2. Upper articular surface; 3. Internal malleolus; 4. Shaft of fibula; 5. Its upper epiphysis, or head.

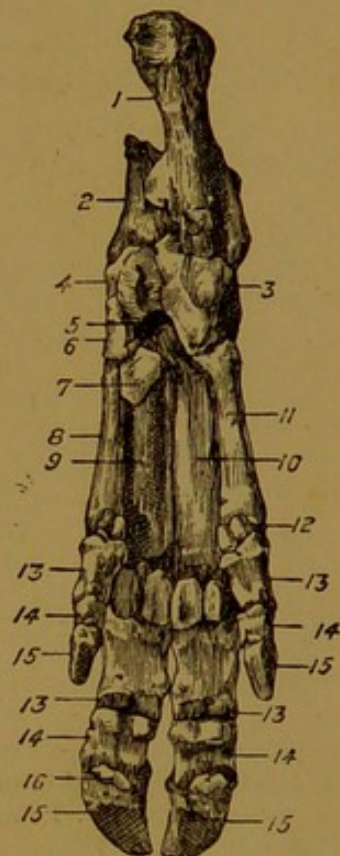

FIG. 126.—BONES OF PES OF PIG (Posterior Aspect).

1. Os calcis; 2. Astragalus; 3. Cuboid; 4. Scaphoid; 5. External cuneiform; 6. Internal cuneiform; 7. Subtarsal sesamoid; 8, 9, 10, and 11. The metatarsal bones; 12. A sesamoid bone; 13, 14, and 15. The three phalanges; 16. Navicular bone.

to the metatarsals of the human foot *minus* that which carries the great toe. A sesamoid bone articulated behind the upper end of the inner large metatarsal is sometimes regarded as a rudiment of the metatarsal bone of the great toe.

**Digits.** Four digits are present in the foot of the pig. These are homologous with the 2nd, 3rd, 4th, and 5th toes of the human foot, but the great toe (1st) is entirely suppressed in the pig. All the bones of this region present the closest resemblance to the corresponding bones of the fore limb.

#### THE HIND LIMB OF THE DOG.

**Innominate Bone.** The gluteal surface of the ilium is deeply depressed. The crest is very convex, and the angle of the croup is almost obliterated. The angle of the haunch carries an upper and a lower eminence, corresponding respectively to the anterior superior and anterior inferior spinous processes of human anatomy. The superior ischiatic spine

is less elevated than in the larger animals. The ilium and ischium join at a more open

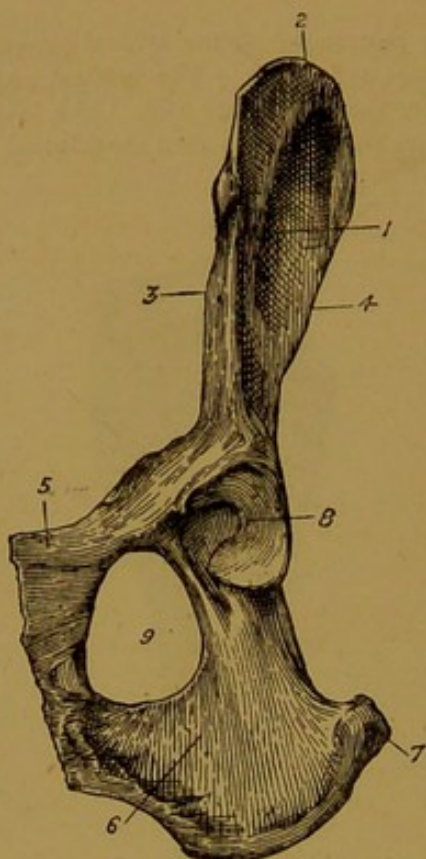


FIG. 127.—INNOMINATE BONE OF DOG, VIEWED FROM BELOW.

1. Gluteal surface of ilium; 2. Crest; 3. Pubic edge; 4. Ischiatic edge; 5. Pubis; 6. Ischium; 7. Tuber ischii; 8. Cotyloid cavity; 9. Obturator foramen.

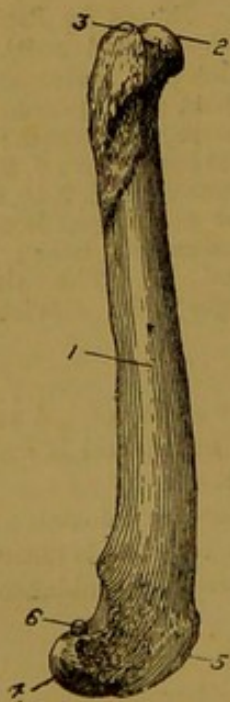


FIG. 128.

FIG. 128.—FEMUR OF DOG  
(Outer Aspect).

1. Shaft; 2. Head; 3. Great trochanter; 4. External condyle; 5. Trochlea; 6. Fabella.

FIG. 129.—FEMUR OF DOG  
(Inner Aspect).

1. Shaft; 2. Small trochanter; 3. Head; 4. Internal condyle; 5. Trochlea; 6. Fabella.



FIG. 129.

angle than in the horse. The pubio-femoral groove is absent. The tuber ischii is

undivided. The cotyloid cavity is deep. The ischial arch is of small extent. The transverse diameter of the pelvis is much greater behind than in front. Anchylosis at the ischio-pubic symphysis is later in occurring than in the horse.

**Femur.** This bone is proportionally of much greater length than in the larger domestic animals, and its shaft is more curved. The posterior surface is narrow, and bounded on either side by a rough line (*linea aspera* of man). The third trochanter is absent. The great trochanter is small, undivided, and on a lower level than the head. The latter is more spherical than in the horse, its ligamentous excavation is shallow, and the neck is well-marked. There is no supracondyloid fossa, and the lips of the trochlea are of equal height. On the posterior aspect of the lower extremity, immediately

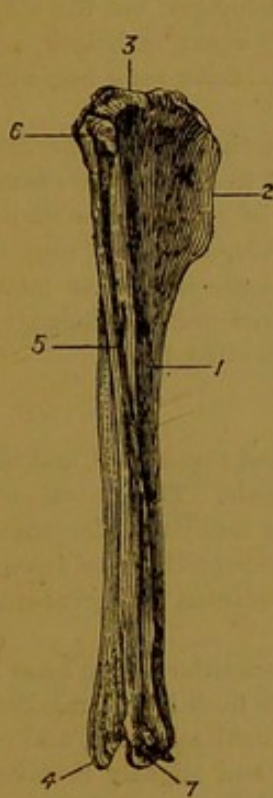


FIG. 130.—TIBIA AND FIBULA OF DOG (Outer Aspect).  
1. Shaft of tibia; 2. Its crest; 3. Its upper extremity; 4. Internal malleolus; 5. Shaft of fibula; 6. Its head; 7. External malleolus.

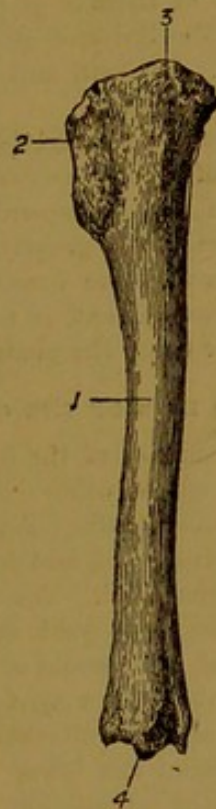


FIG. 131.—TIBIA OF DOG (Inner Aspect).  
1. Shaft; 2. Crest; 3. Upper extremity; 4. Lower extremity.

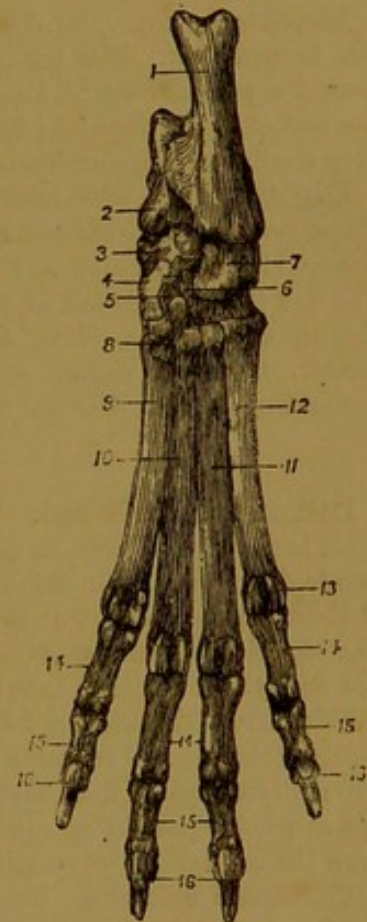


FIG. 132.—PES OF DOG (Posterior Aspect).  
1. Os calcis; 2. Astragalus; 3. Scaphoid; 4, 5, and 6. Inner, middle, and outer cuneiform bones; 7. Cuboid; 8, 9, 10, 11, and 12. The metatarsal bones (1st-5th); 13. Sesamoid; 14, 15, 16. The three phalanges.

above each condyle, there is a little circular flat facet for the **fabella**. Each of these is a little pisiform bone playing the part of a sesamoid to the head of the gastrocnemius.

**Patella.** This bone is narrow and vertically elongated.

**Tibia.** The leg bones of the dog are very long. The lower part of the shaft of the tibia is more rounded than in the horse. The anterior tuberosity of the upper end has no furrow, and the external malleolus is not united to the lower extremity. The articular furrows of the latter are antero-posterior in direction.

**Fibula.** The fibula of the dog is long and slender. Its upper extremity is articulated to the tibia in the usual position, and its lower extremity furnishes the external

malleolus, articulating with the astragalus and tibia. A wide interosseous space separates the shafts of the two bones in their upper half, but in the lower half of the leg the shafts are in contact and united by interosseous fibres.

**Tarsus.** Like the pig, the dog possesses seven tarsal bones. The upper end of the tuber calcis is grooved. The lower articular surface of the astragalus has the form of a convex *head*, or condyle, which is received into a cup-like cavity of the scaphoid. The cuboid is proportionally larger than in the horse, and it articulates with the two outermost (4th and 5th) metatarsals. Of the three cuneiforms the external is the largest, and the middle the smallest. The internal bone articulates with the two innermost (1st and 2nd) metatarsals, the middle with the 2nd metatarsal, and the external with the 2nd and 3rd metatarsals.

**Metatarsus.** The dog possesses five metatarsal bones, corresponding to those of the human foot. The 1st (innermost) of these is of pea-like dimensions, but the other four are well-developed long bones. The 3rd and 4th are nearly equal in length, and somewhat longer than the 2nd and 5th. In form and connections these four bones are very similar to the corresponding metacarpals.

**Digits.** Four well-developed digits are constantly present in the foot of the dog. These correspond to the outer four toes of the human foot. Each of them comprises bones almost identical in size and form with the corresponding bones of the anterior digits. The 1st (innermost) toe of the dog varies very greatly in its development. It may be absent, or represented by a single small bone connected by ligament to its metatarsal. In its maximum degree of development, it possesses three perfect phalanges resembling in form, but one half smaller than, the phalanges of the other toes.

#### THE HIND LIMB OF THE CAT.

**Innominate Bone.** The iliac surface of the ilium is almost suppressed, and the shaft is flatter and broader than in any of the other domestic animals. The gluteal surface is depressed, as in the dog; and the auricular facet is near the middle of the length of the sacral surface. The tuber ischii is rounded, and devoid of a spine on its lower aspect. The superior ischiatic spine is slightly developed. The obturator foramen is of great size, and ankylosis does not take place at the ischio-pubic symphysis.

**Femur.** The shaft is long, rounded, and devoid of a third trochanter. The head is nearly globular, and set on to the shaft at almost a right angle. The neck is well-marked. The supracondyloid fossa and crest are almost obliterated. The trochlea is wide, and its lips are sub-equal in prominence. Behind the lower extremity, and slightly removed from the condyles, two small pits serve for articulation with the *fabella*.

**Tibia and Fibula.** The leg bones of the cat are long. In the relative size of the two bones with regard to one another, and in their mode of union, they resemble closely the same bones of the dog.

**Pes.** The tarsus comprises seven bones very similar to those of the dog. There are four well-developed metatarsal bones and digits; but the 1st (innermost) metatarsal is, as in the dog, very rudimentary, and the corresponding digit is altogether absent.

#### THE SKELETON OF THE FOWL.

The osseous tissue of the fowl is for the most part dense and close-grained, and it is characterised chemically by a large proportion of phosphate of lime. Notwithstanding this, the entire skeleton is light as compared with that of the mammal, owing to the fact that the majority of the bones of the adult bird contain air instead of marrow.

**Vertebral column.** The cervical region is always relatively long in birds. It comprises thirteen bones in the common domestic fowl, twelve in the pigeon, fifteen in the duck, and eighteen in the goose. The atlas is small and ring-like; and the axis, as in mammals, possesses an odontoid process. In the succeeding bones the ends of the centra are saddle-shaped, the anterior extremity being convex in the vertical, and concave in the horizontal, direction; while the posterior extremity has the converse configuration. In a number of the posterior bones the transverse process is prolonged downwards and backwards by a slender rod, which has a special centre of ossification, and which is to be regarded as an aborted cervical rib.

The dorsal vertebræ number seven in the common fowl, the same in the pigeon, and nine in the goose and the duck. In the adult fowl they are generally anchylosed into a solid mass.

Behind the last dorsal vertebra, which is clearly distinguished from its successors by carrying a distinct rib, the spine of the bird is composed of a number of anchylosed vertebræ to which the term *sacrum* is applied. In the common fowl this portion of the spine comprises fourteen vertebræ, and of these probably four ought to be regarded as lumbar, five as sacral, and the remaining five as coccygeal (*Huxley*). The composite sacrum is anchylosed for its entire length to the ilium on each side.

Behind the so-called sacrum there are seven movable coccygeal vertebræ in the spine of the common fowl. The last of these, which is much larger than any of the others, is termed the ploughshare bone, or **pygostyle**. In reality it is formed by the fusion of two or more caudal vertebræ. It projects in an upward direction at the end of the vertebral column, and serves as a support for the tail feathers and the coccygeal oil-gland.

**Thorax.** The sternum of the fowl results from the fusion of five pieces, which have separate centres of ossification in the chick. The central of these, termed the **lophosteon**, is the main part of the bone. Its upper surface is concave, and its lower surface carries mesially a pronounced longitudinal ridge or keel. Each lateral edge is united to the pleurosteon and the metosteon; the anterior extremity bears a central *rostrum*, or *manubrium*, and its posterior extremity is produced backwards as a long *middle xiphoid process*.

The **pleurosteon** is united to the lateral edge of the lophosteon, and it articulates with the ribs. Anteriorly it is produced outwards, forwards, and upwards into the so-called *costal process*. The **metosteon** is attached to the postero-lateral corner of the lophosteon. It divides into an *outer* and an *inner xiphoid process*. In the recent state the deep notches between these, and between the latter and the middle xiphoid process, are closed by membrane.

The common fowl possesses seven pairs of ribs. Each rib comprises an upper segment (*vertebral rib*) corresponding to the osseous rib of the mammal, and a lower segment (*sternal rib*) homologous with the mammalian costal cartilage. Each rib, with the exception of the first and the last, carries near its upper end a short **uncinate process**. This passes backwards and upwards over the succeeding rib, to which it is connected by ligament.

**Skull.** The cranium of the fowl is composed of the same elements as are present in the mammalian cranium, save that there is no interparietal. The sutures uniting the various bones disappear much more promptly than in the mammal, the limits of the separate elements of the cranium being indistinguishable even when the young bird leaves the shell. The occipital bone has only one condyle, and in the goose and duck it presents on each side an unossified *fontanelle*, which appears as a foramen in the dry skull. The Eustachian orifices perforate the body of the sphenoid, and have a common opening on the under surface of the skull. The perpendicular plate of the ethmoid forms a large *interorbital septum*, which, however, is perforated so as to put the two orbits in communication.

The bones of the face are greatly modified as compared with the same bones of the mammalian skull. The premaxillary bones are very large, and form the chief support of the upper division of the beak. Each gives off an *ascending process* to the frontal bone, and a *palatine process* which unites with the palatine bones in passing along the middle of the palate. The nasal bones together with the premaxillæ circumscribe the anterior nares, which are placed near the base of the beak. Superiorly they are united to the frontal bones. The articulation of the ascending processes of the premaxillæ and the nasal bones with the frontals connects the beak to the cranium, but, owing to the slender character of this union, the upper jaw is permitted an appreciable degree of movement on the cranium. The superior maxillæ are small and slender. Each is united to the premaxilla in front, and to the jugal behind. The jugal (malar) bone has the form of a slender rod, united to the superior maxilla by its anterior end, while its opposite extremity articulates inwardly with the quadrate bone. The palatine bones bound the posterior nares on each side. Anteriorly they articulate with the superior maxillary and premaxillary bones, and posteriorly they meet the pterygoids. Each pterygoid bone

articulates by its inner end with the basi-sphenoid, the joint being a movable one; while its opposite end articulates with the quadrate bone. The **quadrate bone** is the homologue of the malleus of the mammal—one of the small bones of the middle ear. Its proximal end articulates with the sphenoid and temporal bones in a diarthrodial joint. Its distal end is similarly articulated to the inferior maxilla centrally, to the jugal outwardly, and to the pterygoid inwardly. Each ramus of the inferior maxilla results from the fusion of six pieces. The angle is produced backwards into a long curved process.

**Fore limb, or wing.** The skeleton of the shoulder is composed of three bones, viz., the scapula, the coracoid, and the furculum. The scapula is narrow, rod-like, and devoid of a spine. The **coracoid bone** is the homologue of the coracoid process of the mammalian scapula. It is a thick, strong bone, articulated inferiorly to the antero-lateral angle of the sternum, and superiorly to the scapula, coracoid, and humerus. The glenoid cavity is formed in common by the coracoid and scapula.

The **furculum**, or "mercy-thought," is a V-shaped bone, resulting from the fusion of the right and left clavicles with a median *interclavicle*. The angle of union carries a laterally compressed process—the **hypocleidium**, which is united by ligament to the manubrium sterni. The free end of each branch of the furculum meets the distal ends of the scapula and coracoid. The humerus of the fowl is a well-developed long bone. The articular head is compressed from before to behind, and articulated to the scapula and coracoid. The radius and ulna form the skeleton of the fore-arm, the latter being much the larger bone of the two.

The carpus comprises only two free bones, one radial and one ulnar. A piece of cartilage, representing the lower row, unites early with the metacarpus. The metacarpal region includes three bones, corresponding to the metacarpals of the thumb and two adjacent fingers of the human hand. The outer two of these bones are fused at their extremities, but a narrow interspace is left between their middle portions. The innermost (metacarpal of the thumb) is small, and united to the radial side of the proximal end of the 2nd bone.

Corresponding to the three metacarpals, the terminal segment of the limb possesses three digits—the pollex, index, and medius (1st, 2nd, and 3rd). The 2nd digit has three phalanges, and each of the other two has at most two phalanges.


**Hind limb.** The ilium is elongated, and ankylosed with the whole length of the so-called sacrum, and with the last dorsal vertebrae. The ischium lies to the outer side of the posterior half of the ilium. Behind the acetabulum a large foramen is left between the adjacent edges of the two bones. From the acetabulum the pubic bone passes backwards and downwards as a long slender bone, with an incurved free extremity. The floor of the fowl's pelvis is completed by membrane, but there is no pubic or ischiatic symphysis. The acetabulum is pierced by a large foramen.


The femur in its general form resembles the same bone of the mammal. Its distal end articulates with the fibula, as well as with the tibia and patella.

The fibula is an elongated slender bone, which in relative size and mode of union with the tibia, is not unlike the same bone of the horse. The tibia, or **tibio-tarsus**, is the main bone of the leg. Its distal end, which carries a pulley-like articular surface, is a separate cartilage in the embryo, and is the homologue of the mammalian artragalus.

The **tarso-metatarsus** succeeds the bone last described, there being in the fowl's skeleton no free tarsal bones. The tarso-metatarsal bone is a long bone resulting from the fusion of three metatarsal bones (2nd, 3rd, and 4th). Its proximal end is completed by a separate ossification representing the distal bones of the mammalian tarsus. A bony core for the horny spur, or *calcar*, is united to the inner side of the tarso-metatarsus. The 1st or innermost metatarsal is rudimentary, and united by ligament to the postero-internal aspect of the lower end of the tarso-metatarsus.

The ordinary number of digits present in the foot of the fowl is four (in the Dorking and some other breeds five). These digits are homologous with those of the human foot *minus* the little toe. The innermost digit is directed backwards and inwards, while the other three radiate in an anterior direction. The 1st (innermost) digit has two phalanges, the 2nd has three, the 3rd four, and the 4th five.





## SECTION II.

### ARTHROLOGY.

#### GENERAL CONSIDERATIONS REGARDING THE JOINTS.

THE study of the joints is termed **arthrology** (Gr. *αρθρον*, a joint). In anatomy the word joint, or articulation, is applied to the union of any two of the constituent pieces (bone or cartilage) of the skeleton, whether or not this union is a movable one. The term **syndesmology** is used almost synonymously with arthrology. Strictly speaking, it embraces only a study of the ligaments, which in almost every joint pass between the bones, and bind them together.

It is customary to arrange the joints in three great classes, as follows:—

(1) **Synarthrosis**. In this class the opposed surfaces or edges of the bones are united by a relatively thin layer of interposed connective tissue or cartilage. Consequently, in this class movement at the joint is inappreciable or altogether absent. The great majority of the synarthrodial joints are found in connection with the skull, in which all the joints save that between the upper and lower jaw are of this variety. The synarthrodial joints have been subdivided into four classes, viz., *sutura*, *harmonia*, *schindylesis*, and *synchondrosis*.

In the **sutura** the opposed edges of the bones are adapted to each other by a series of interlocking processes, the line of union in the intact joint having thus some resemblance to a seam. If these processes are fine and regular, like the teeth of a saw, the joint is termed a *sutura serrata*; if larger and less regular, a *sutura dentata*; and if the interlocking processes are thin and scale-like, a *sutura squamosa*.

The term **harmonia** is applied to synarthrodial joints in which the opposed edges are almost plane, and **schindylesis** to cases in which the edge of one bone is received into a fissure or cleft of another. In these subvarieties of the synarthrodia the uniting medium in the joint is connective tissue. In the remaining subdivision—**synchondrosis**, the opposed surfaces of the bones are united by cartilage.

It may be observed here that the soft tissue—cartilage or connective tissue—of synarthrodial joints is merely the remnant of the original

material in which ossification took place, and with advancing age even this remnant disappears by ossification. Naturally, in the case of the so-called cartilage bones the uniting medium is cartilage, as in the synchondrosis; while in the case of membrane bones it is connective tissue, as in the other subclasses of the synarthrodia.

The following table shows the various subdivisions of this class of joints.

Sutura	{	Serrata. <sup>1</sup>	Interfrontal.
		Dentata.	Interparietal.
		Squamosa.	Squamous temporal and parietal.
		Harmonia.	Internasal.
		Schindylesis.	Frontal and presphenoid.
		Synchondrosis.	Basi-sphenoid and occipital.

(2) **Amphiarthrosis.** In all joints of this class an appreciable degree of movement is permitted. The bony surfaces are connected by soft tissue—generally cartilage or fibro-cartilage, and the extent of movement permitted depends largely on the amount of this connecting material. The joints formed between the vertebral bodies, and that between the petrous temporal bone and the styloid cornu of the hyoid bone furnish examples of amphi-arthrodial joints.

(3) **Diarthrosis.** This is the largest and most important of the three great classes of joints. Functionally the joints of this group are distinguished by their greater freedom of movement, and structurally by the possession of a synovial membrane. The articular surfaces are here covered by a layer of hyaline cartilage, and maintained in apposition (but not united as in the two preceding classes) by ligaments passing from bone to bone around the joint. In each diarthrodial joint there is thus formed a potential, if not an actual, cavity, bounded at either extremity by the cartilage-covered articular surfaces, and completed elsewhere by ligaments, or occasionally by muscles passing in proximity to the articulation. This cavity is lined by the delicate synovial membrane, which secretes the synovia or joint-oil. It will be necessary to consider shortly the structure of articular cartilage, ligaments, and synovial membranes.

**Articular Cartilage** forms a thin layer over every bony surface entering into the formation of a diarthrodial joint. It comprises a hyaline matrix, with imbedded cartilage cells. The deeper cells are arranged in rows perpendicular to the free surface, in the most superficial part of the cartilage they are more closely packed and flattened out, their flat surfaces lying parallel to the free surface of the carti-

<sup>1</sup> The difference between serrated and dentated sutures is so slight that the distinction is scarcely worthy of being maintained.

lage. In the joints of adult animals the articular cartilage possesses a calcified layer connecting it to the bone.

**Ligaments** may be said to be of two kinds as regards their purpose or function. (1) The majority of them exert a *binding* or *restraining* action. Ligaments of this kind pass like inextensible bands between the bones composing the joint, maintaining the articular surfaces in more or less close apposition, and thus materially strengthening the articulation. In keeping with this function, these ligaments are generally somewhat cord-like in shape. In many cases they exert an important action in limiting or restraining the movement of the joint in some particular direction. (2) A second class of ligaments have for their main purpose to complete the cavity of the joint, and afford support to the synovial membrane or capsule, which lines their internal surface. Such ligaments are therefore termed *capsular*. When most developed they take the form of a thin membranous bag or sack completely surrounding the joint cavity between the articular surfaces. In other cases, while retaining their membranous form, they are less complete; and in a considerable number of joints they are entirely absent, the synovial membrane being then adherent to the deep aspect of the retaining ligaments, or to the adjacent muscles.

In most instances the ligaments are composed of white fibrous tissue, but some, such as the great ligamentum nuchæ, are composed of yellow elastic tissue.

The **Synovial Membrane** is the structure by which the synovia or joint-oil is secreted. It has a basis of vascular fibrous connective tissue, adherent to the inner surface of the capsular or other ligaments, or, exceptionally, obtaining support from the adjoining muscles. At the margin of the articular surfaces this connective tissue blends by a transition stage with the articular cartilage. The inner or free surface of the membrane is covered more or less completely by a layer of flattened endothelial cells. At the margin of the articular surfaces the synovial membrane may take the form of finger-like or villous processes projecting into the joint cavity. These so-called *synovial fringes* serve to increase the extent of the secreting surface, and, perhaps, to distribute the joint-oil over the margin of the cartilages. Immediately external to the synovial membrane, and elsewhere in close proximity to joints, there is frequently a considerable amount of fat, which serves as a sort of packing and protecting material, and in its semi-fluid state does not interfere with the movements of the joint. **Synovia** is the glairy, straw-coloured fluid which plays the part of a lubricant to the articular surfaces. Although somewhat oily in appearance, it contains only traces of fat, its glairy character being due to mucin and albumen.

Although the term "joint cavity" has more than once been used in the foregoing description, it ought to be observed that there is not

normally any actual cavity in a joint, in the sense of a space empty or occupied by air. Apart altogether from the binding action of the ligaments, atmospheric pressure plays an important part in maintaining the articular surfaces in apposition, and is of itself sufficient to prevent any great separation of the bones even under strong traction. When, during the movements of a joint, the articular surfaces are partly separated, and there is a tendency to the formation of a gap between them, atmospheric pressure drives in the soft structures in the neighbourhood, and thus prevents the formation of an empty space. In certain diseased states there is a hyper-secretion of fluid from the inner surface of the synovial membrane, and the joint may then come to possess a considerable cavity occupied by this fluid :—

Diarthrodial joints are subdivided into the following four classes. (1) An **enarthrosis** is a joint in which one of the articular surfaces has the form of a rounded head or ball, while the other is concave and more or less exactly moulded on the former. Such articulations are therefore also termed ball-and-socket joints, of which the hip and the shoulder form good examples. (2) A **ginglymus** or hinge joint is one in which, either from the form of the articular surfaces or the restraining action of the ligaments, movement is limited to flexion and extension. The elbow joint and the true hock joint are examples. (3) An **arthrodia** is a joint with nearly flat articular surfaces, the movement between which is of a gliding character. The small joints formed between the bones in the same row of the carpus are of this nature. (4) A **pivot joint** is an articulation in which one of the bones furnishes a pivot around which the other bone rotates. The joint between the atlas and the axis is of this nature.

For the sake of precision the various movements executed in joints are defined as follows :—

**Angular movements** are such as vary the size of the angle formed by the meeting of the two bones of a joint. If the effect of this movement is to diminish the size of the angle, the movement is termed **flexion**; if to increase it, **extension**. If the angular movement carries the distal bone of the joint away from the mesial plane of the body, it is termed **abduction**; and where it has the opposite effect, **adduction**.

**Circumduction** is the movement in which the shaft of the distal bone of the joint describes the surface of a cone (or the distal end of the same bone describes a circle).

**Rotation** is applied to the movement in which a bone, without change of place, turns round on axis passing through itself, or in which it revolves around a pivot furnished by the other bone of the joint.

**Gliding** is a sliding movement in which the opposed articular surfaces are displaced without rotation, circumduction, or angular variation of either of the bones.

## ARTICULATIONS OF THE VERTEBRAL COLUMN.

The intervertebral joints and ligaments from the axis to the sacrum are so closely alike that one description will suffice for the series. With the exception of the atlas, every vertebra in front of the sacrum forms three joints with the succeeding bone. The first of these is an **amphiarthrodial** articulation between the bodies, the hinder end of each centrum being firmly united to the anterior end of the next by a disc of fibro-cartilage. Above this intercentral joint the hinder edge of each arch forms with the anterior edge of the next two **diarthrodial** joints, one on each side. The articular surfaces for these are carried by the oblique or articular processes. Lastly, supernumerary joints are formed between the last three lumbar transverse processes, and between the last process and the sacrum. These joints are also of a diarthrodial character, but in old animals they are frequently ankylosed. For convenience of description, the various ligaments that connect the vertebræ may be divided into (1) those that consolidate the intercentral joints, (2) those that connect contiguous arches, and (3) those that connect the different processes.

(1) The intercentral joints are consolidated by the intervertebral discs, and by the superior and inferior common ligaments.

The **intervertebral discs**. Each disc is a thin plate of fibro-cartilage interposed between the concave hinder end of one centrum and the convex anterior end of the next. It is therefore convex on its anterior surface, and concave on the other. The discs are not of uniform thickness, those of the back being thinner than those of the neck or loins. Moreover, they are not uniform in texture, the outer part of each being considerably denser than its centre. The peripheral part of each disc is composed of concentric laminae of fibro-cartilage, alternating with laminae of fibrous tissue. In each layer the fibres pass obliquely between the two bones, and in successive layers the direction of the fibres is reversed. This part of the disc is dense and tough, and it forms an exceedingly strong bond of union between the centra. Towards its centre the disc becomes pulpy, soft, and elastic, and thus a greater freedom of movement between the two vertebræ is permitted. The pulpy central part of the disc is the slightly altered remnant of the foetal *chorda dorsalis*. In the dorsal region the discs concur in forming the cavities for the reception of the heads of the ribs. It is interesting to note that in the human subject these discs are absolutely thicker than in the horse, man's erect posture exposing his spine to greater risk of concussion, and requiring, to counteract this, the interposition of a thicker elastic cushion between the adjacent bones.

The **superior common ligament**. This is a riband-like, white, fibrous ligament extending along the floor of the spinal canal from the

sacrum to the axis, and intimately adherent to the bodies of the vertebræ and to the intervertebral discs, or (in the dorsal region) to the inter-

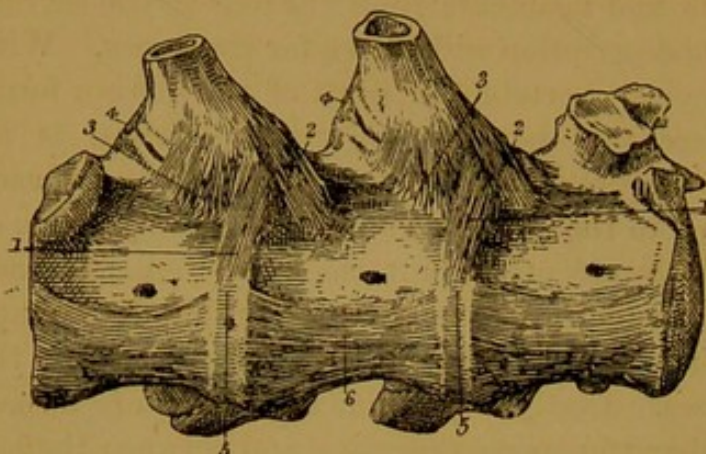


FIG. 133.—TWO INTERVERTEBRAL AND TWO COSTO-VERTEBRAL JOINTS OF THE HORSE, VIEWED FROM BELOW.

1. Attachment of the Costo-vertebral (stellate) ligament to intervertebral disc; 2 and 3. Attachments of the same ligament to the anterior and posterior vertebral bodies; 4. Posterior costo-transverse ligament; 5. Intervertebral disc, covered by 6. The inferior common ligament.

articular ligaments of the ribs. The edges of the ligament are scalloped, its breadth being greatest where it passes over an intervertebral disc, and least at the centre of the vertebra.

The **inferior common ligament** is a thin stratum of white fibres covering the inferior aspect of the vertebral centra, from the sacrum as far forwards as the 6th dorsal vertebra.

(2) The ligaments connecting the edges of adjacent arches are termed the **ligamenta subflava**. They serve to complete the spinal canal, being composed of fibres that pass from the hinder edge of one arch to the anterior edge of the next. They are composed of white fibrous tissue in the dorsal and lumbar regions, but of yellow elastic tissue in the neck.

(3) The ligaments connecting the vertebral processes are the capsular ligaments of the articular processes, the interspinous ligaments, and the supraspinous ligament, the latter being in the cervical region so peculiarly modified that it receives a special name—the *ligamentum nuchæ*.

The **capsular ligaments** are loose membranous sacs, enclosing the joints between the oblique or articular processes, and affording support by their inner face to the synovial membrane. They are composed of white fibrous tissue, except in the region of the neck, where they are yellow and elastic. The intertransverse joints of the last three lumbar vertebræ, and the joint between the last lumbar transverse process and the base of the sacrum have each a small capsular ligament of white fibrous tissue, for the support of the synovial membrane.

The **interspinous ligaments**. In the dorsal and lumbar regions these ligaments fill up the interspaces of the neural spines. The ligament of each space is composed of two distinct strata of white fibres—a right and a left. The fibres are directed obliquely downwards and backwards, being attached at either end to the edges of the spines. This oblique attachment of the fibres permits the separation of the spines during flexion of the vertebral column. In the cervical region each

interspinous ligament is composed of two narrow strips of yellow elastic tissue, attached at either end to a neural spine.

The **supraspinous ligament**. This is a dense cord of white fibrous tissue, extending along the tips of the neural spines from the sacrum to the 4th dorsal vertebra, where it becomes directly continuous with the funicular portion of the *ligamentum nuchæ*. Besides forming a strong bond of union between the neural spines that it covers, it affords attachment to several muscles of the back and loins.

The **ligamentum nuchæ** takes the place of the preceding ligament in the neck. It is composed of two portions—a funicular and a lamellar.

The *funicular* part has the form of two cords running side by side from the summit of the 4th dorsal spine (when it is continuous with the last described ligament) to the special tubercle on the occipital bone. The cords are composed of yellow elastic tissue, and when the ligament is relaxed they are slightly curved with the concavity upwards. Above the ligament, in the middle of the neck, there is developed a variable amount of yellow elastic tissue mixed with fat.

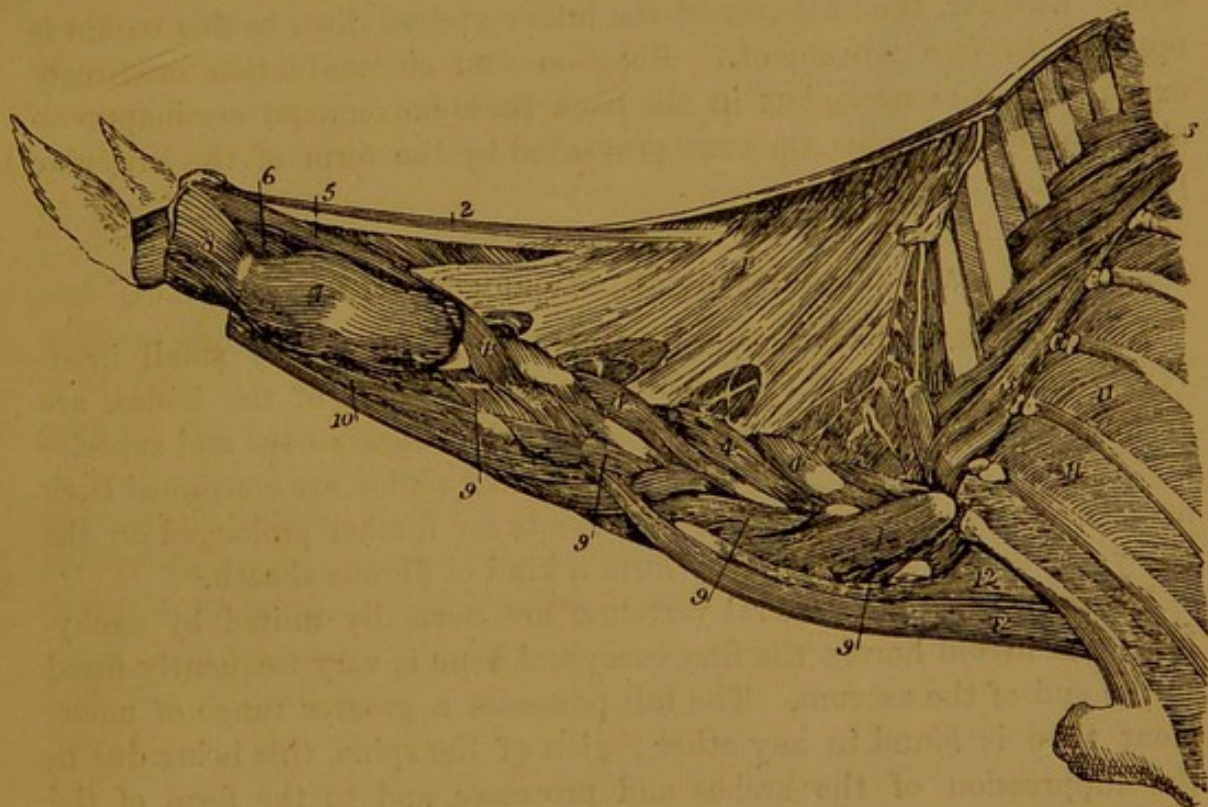


FIG. 134.—LIGAMENTUM NUCHÆ OF THE HORSE.

1. Lamellar portion; 2. Funicular portion.

The *lamellar* part is composed of a double (right and left) sheet of yellow elastic fibres attached superiorly to the spines of the 2nd and 3rd dorsal vertebræ, or to the under aspect of the funicular part, and extending obliquely downwards and forwards to become attached in bundles to the spines of the last six cervical vertebræ (not to the atlas).

The right and left layers are united by loose connective tissue. In its posterior part the fibres form an anastomosing network with open meshes, but in the anterior two-thirds of the ligament the lamellæ form a complete septum on the mesial plane of the neck.

This enormous mass of yellow elastic tissue affords a great assistance to the muscles of the neck in suspending the head, and in restoring it to position when it has been lowered.

**Movements.** The movements permitted in the part of the spine now being considered are not alike free in all the joints. Flexion and extension (movements in a vertical plane) and lateral inclination are executed with freedom in the cervical region, especially in its posterior part. In the lumbar region these movements are much more restricted, owing to the greater size and firmer union of the neural spines, the different form of the oblique processes, and the contact of the last lumbar transverse processes with each other and with the sacrum. In the dorsal region movement is even more hampered than in the loins, the ribs being the chief obstacle to lateral bending, and the size and firm connection of the neural spines preventing freedom of flexion and extension. Further, the thinness of the intervertebral discs in this region is opposed to free movement. Rotation and circumduction are freely executed in the neck, but in the back these movements are inappreciable, and in the loins they are prevented by the form of the articular processes.

#### ARTICULATIONS OF THE SACRUM AND COCCYX.

**Ligaments.** The coccygeal vertebræ are united by small intervertebral discs, which, for adaptation to the form of the bones, are slightly concave on both their surfaces. The supraspinous and superior and inferior common ligaments of the lumbar region are continued back on the sacrum, and these same ligaments are further prolonged on the coccygeal bones, for which they form a kind of fibrous sheath.

**Movements.** The sacral vertebræ are normally united by ankylosis, and in old horses the first coccygeal bone is very frequently fused to the end of the sacrum. The tail possesses a greater range of movement than is found in any other region of the spine, this being due to the suppression of the arches and processes, and to the form of the diminutive centra (convex on either end).

#### THE ATLANTO-AXIAL ARTICULATION.

This joint, formed between the atlas and the axis, possesses four ligaments.

The **odontoid ligament** is situated on the floor of the spinal canal. It has the form of a short flat band narrowest behind, where it is fixed

to the upper surface of the odontoid ligament, and widening out in front to be inserted across the floor of the atlas. On each side a thin bundle of fibres is continued forwards to become attached within the condyle of the occipital bone.

The **superior atlanto-axial ligament** represents the interspinous ligaments of the succeeding joints, and, like these, it is made up of two parallel bands of yellow elastic tissue, attached anteriorly to the upper aspect of the ring of the atlas, and posteriorly to the neural spine of the axis.

The **inferior atlanto-axial ligament** is a thin white fibrous band, fixed in front to the tubercle of the atlas, and behind to the inferior spine of the axis.

The **atlanto-axial interannular ligament** is membranous, attached to the hinder edge of the atlas, and to the anterior edge of the arch of the axis. It completes the spinal canal between the two bones, as the ligamenta subflava do in the case of the succeeding joints.

There is no special capsular ligament for this joint, the synovial membrane obtaining support from the odontoid ligament superiorly, the inferior ligament below, and the interannular ligament on each side.

**Movements.** This articulation ought to be regarded as appertaining to the head rather than to the neck, since it is here that the rotatory or side to side movements of the head are executed. In these movements the axis remains fixed, its odontoid process serving as a pivot around which the atlas, carrying with it the head, rotates.

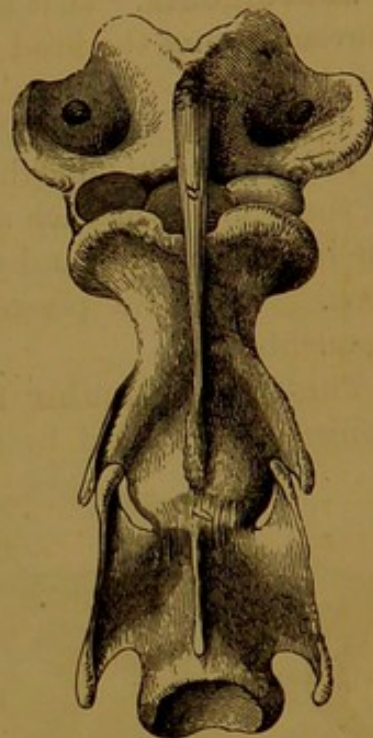

FIG. 135.—FIRST TWO INTER-VERTEBRAL JOINTS OF THE HORSE, VIEWED FROM BELOW.

a. Inferior atlanto-axial ligament; b. Intervertebral disc between axis and 3rd cervical vertebra.

#### THE OCCIPITO-ATLANTAL ARTICULATION.

This is a double articulation, comprising on each side a synovial joint between the occipital condyle and its receiving cavity on the front of the atlas. It possesses a single ligament with superior and lateral thickenings.

The **occipito-atlantal ligament** is membranous, attached in front to the upper and lower edges of the foramen magnum, and to the occipital bone outside the condyle, while posteriorly it is fixed to the anterior edge of the atlas. On the under aspect of the joint this ligament is thin, loose, and elastic. Superiorly it presents a number of fibres inter-

crossing like the letter X, and sometimes termed the *cruciform* ligament. On each side it is strengthened by a strong glistening bundle of fibres passing between the wing of the atlas and the styloid process of the occipital bone. These are sometimes designated the *styloid* ligaments. Each synovial membrane is supported outwardly by the occipito-atlantal ligament, and inwardly by the dura mater and the occipital prolongation of the odontoid ligament.

**Movements.** It is at this joint that flexion and extension (nodding movements) of the head on the spine are executed.

#### TEMPORO-MAXILLARY ARTICULATION.

This is the only diarthrodial joint formed in connection with the bones of the skull. On each side the joint is formed between the condyle of the inferior maxilla and the articular surface of the squamous temporal bone. The joint possesses an interarticular fibro-cartilage and three ligaments.

The **interarticular fibro-cartilage**. This is a fibro-cartilaginous meniscus interposed between the articular surfaces. Superiorly it is

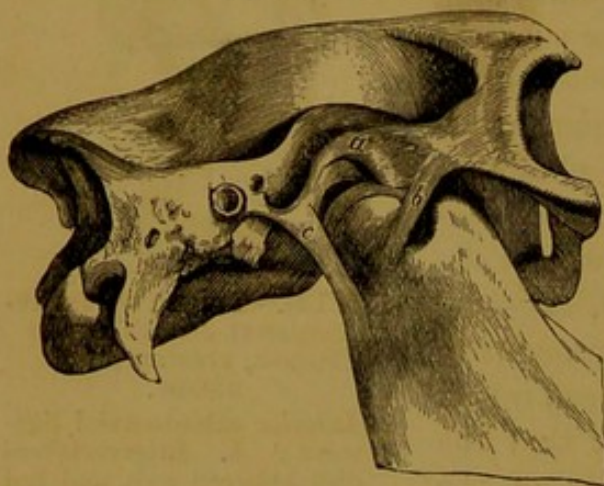


FIG. 136.—RIGHT TEMPORO-MAXILLARY JOINT OF HORSE.

a. Interarticular fibro-cartilage; b. External ligament; c. Posterior ligament.

adapted to the articular surface of the squamous temporal bone, and inferiorly it presents a cavity for the condyle of the inferior maxilla. The cartilage extends completely across the joint, its rim being adherent to the inner surface of the capsular ligament. There are thus in reality two distinct joints with separate synovial membranes, one between the cartilage and the temporal bone, and another between the cartilage and the maxillary condyle.

The **capsular ligament** envelops the joint, being attached around the temporal articular surface above, and around the maxillary condyle below. As already stated, the rim of the interarticular cartilage is united to the inner surface of the ligament.

The **posterior ligament** is a yellow elastic band, fixed by one extremity to the post-glenoid process, and by the other to the hinder edge of the lower jaw beneath the condyle.

The **external ligament** is a short white band of fibres scarcely distinct from the capsular ligament. It is fixed superiorly to the lower edge of the zygoma, and inferiorly to the outer aspect of the lower jaw, below the condyle.

**Movements.** In the shut mouth the condyle of the lower jaw underlies the glenoid fossa of the squamous temporal bone, from which it is separated by the meniscus. In opening the mouth the lower jaw is depressed by rotation of the condyles round a horizontal axis passing through both joints (right and left). At the same time that this movement is executed between the condyle and the lower surface of the meniscus, the latter is itself carried forwards by gliding on the temporal articular surface, until, when the mouth is fully open, the condyle of the lower jaw underlies the same process of the temporal bone. By an inverse movement the mouth is shut. When the above-mentioned sliding movement between the meniscus and the temporal surface is executed without depression of the lower jaw, the latter is protracted until the lower incisors come to lie altogether in front of the upper; and when this movement is executed on one side only, the inferior maxilla is carried to the opposite side, and a grinding action is communicated to the molar teeth.

## ARTICULATIONS OF THE HYOID BONE.

In connection with the hyoid bone three joints are formed on each side, viz., the basi-cornual joint between the body and the small cornu, the intercornual joint between the small and great cornua, and the temporo-hyoideal joint between the great cornu and the petrous temporal bone.

The **Basi-cornual Articulation.** This joint is formed between the shallow articular cup carried by the lower end of the small cornu (ceratohyal) and the convex articular facet of the body. The connection is a diarthrodial one, the joint being provided with a small **capsular ligament**, lined inwardly by a synovial membrane.

The **Inter-cornual Articulation.** This is an amphiarthrodial union, the adjacent extremities of the small and the great cornu being united by **intermediate cartilage**, in which there is sometimes embedded a pea-like nucleus of bone, representing the middle cornu or epihyal.

The **Temporo-hyoideal Articulation** is another amphiarthrodial joint, the toe-like part of the upper end of the great cornu being united to the hyoid process of the temporal bone through the medium of a **cylinder of fibro-cartilage** about half an inch in length.

**Movements.** The movements executed in these joints are of the nature of flexion and extension, the hyoid bone, carrying with it the root of the tongue and the larynx, moving backwards and forwards. These movements are brought into play during the act of swallowing. Of the three joints, the temporo-hyoideal articulation possesses the greatest range of movement, and the intercornual articulation the least.

## THE SYNARTHRODIAL JOINTS OF THE SKULL.

As has already been stated, all the intrinsic joints of the skull, with the exception of that between the lower jaw and the squamous temporal, are of a synarthrodial character. At birth and for a short time afterwards all of these joints are distinct, but in an old skull the entire series of bones (with the before-mentioned exception) are united by ankylosis, that is to say, the process of ossification eventually converts the last remnant of intervening cartilage or connective tissue into bone. In the case of the cranium the sutures of the interparietal bone are the first to become obliterated, and in succession all the other cranial joints are similarly effaced, until by the sixth year the brain cavity is a rigid bony case.<sup>1</sup> By the tenth year the facial sutures are similarly obliterated, save that the greater part of the internasal joint persists throughout life as a harmonia suture.

The purpose of the synarthrodial joints of the skull is not to permit of movement between the adjacent bones, as is the case with the other joints of the skeleton, but to make provision for the growth of the bones, and for the necessary expansion of the various cavities of the head, in keeping with the growth of their contained organs. In the case of the cranium, for example, as long as the suture between the opposite parietal and frontal bones persists, growth takes place in the intervening connective tissue. At the same time the process of ossification is advancing into this newly formed connective tissue at the margins of the bones, which thus grow in breadth. The interparietal and interfrontal sutures thus make provision for the expansion of the cranial cavity in the transverse direction. Similarly, the sutures that lie on the lateral aspect of the cranium, between the parietal and frontal bones anteriorly and the temporal and sphenoid bones behind, provide for its expansion in the antero-posterior direction. But provision has to be made for growth of the cranial cavity in length also, and that is found in the various transverse sutures, such as those that connect the occipital to the underlying bones, and those between the parietal and frontal bones. By the time the animal has reached the age of six years the brain has attained its full growth, and the last of the sutures disappears. In a precisely similar way the facial sutures provide for the expansion of the air sinuses and the cavities of the orbits, nose, and mouth.

After what has already been said, a detailed description of the various synarthrodial joints of the head is not necessary. It only remains to be added that, while in most cases the separate articulations are named simply from the bones that enter into their formation, such as temporo-sphenoidal, fronto-nasal, internasal, etc., a few receive special designations borrowed from human anatomy. Thus, the interparietal is also

<sup>1</sup> Even in old age the petrous temporal bone does not fuse completely with the surrounding bones.

termed the **sagittal** suture; the fronto-parietal, the **coronal** suture; and the occipito-parietal, the **lambdoidal** suture.

## ARTICULATIONS OF THE RIBS.

In connection with the ribs four series of joints are formed, viz.; (1) the costo-central articulations between the vertebral bodies and the heads of the ribs, (2) the costo-transverse articulations, between the tubercles of the ribs and the dorsal transverse processes, (3) the chondro-costal articulations, between the ribs and their prolonging cartilages, and (4) the chondro-sternal articulations, between the sternum and the cartilages of the first eight ribs on each side.

(1) The **Costo-central Articulations**. In these joints the head of the rib is received into a shallow cup formed by two adjacent vertebral centra and the disc that unites them. Each joint possesses two ligaments, viz., costo-vertebral and inter-articular. The **costo-vertebral** or *stellate* ligament is placed beneath the joint. Its fibres are attached on the one hand to the rib just below its articular head, and on the other to the bodies of the two vertebræ and the intermediate disc. The **interarticular ligament** is fixed to the groove dividing the head of the rib into two facets. It passes inwards across the floor of the spinal canal, being united to the upper edge of the intervertebral disc, and covered by the superior common ligament; and on the mesial plane of the body it becomes continuous with the corresponding ligament of the opposite rib, detaching a few fibres forward to end on the vertebral centrum. It is absent in the case of the first rib. The first costo-central joint has

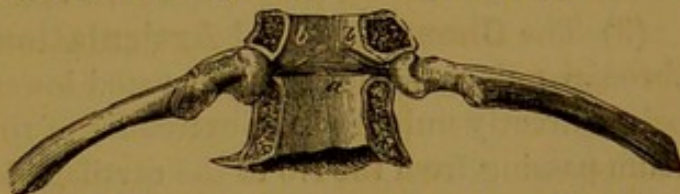

FIG. 137.—COSTO-CENTRAL JOINTS OF HORSE.

The preparation is viewed from above, the arches of the vertebræ having been sawn off, and the superior common ligament removed.

a. Interarticular ligament; b b. Slips of the same passing to the anterior vertebra.

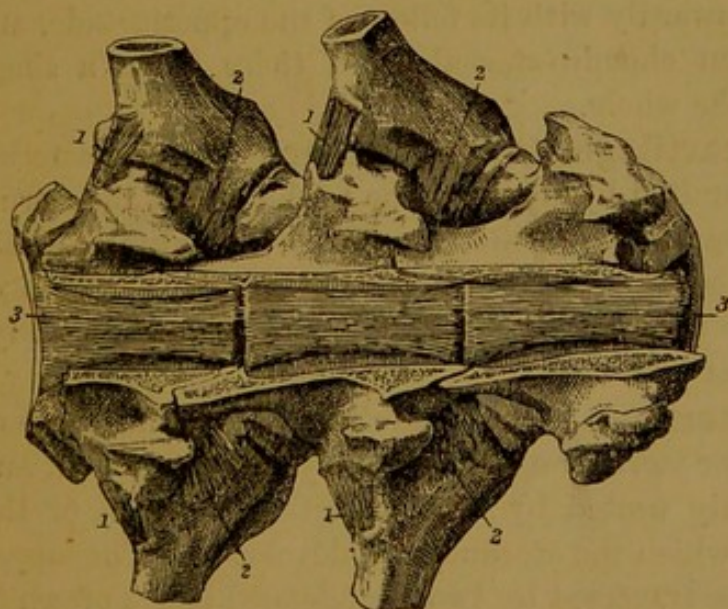


FIG. 138.—TWO COSTO-VERTEBRAL JOINTS OF HORSE, VIEWED FROM ABOVE.

The arches of the vertebræ have been removed.

1. Posterior costo-transverse ligament; 2. Anterior costo-transverse ligament; 3, 3. Superior common ligament.

is absent in the case of the first rib. The first costo-central joint has

only one synovial membrane, but all the remaining joints of the series possess two small synovial membranes, separated from each other by the interarticular ligament.

(2) The **Costo-transverse Articulations**. These are the joints formed between the costal tubercles and the vertebral transverse processes. Each possesses two ligaments—an anterior and a posterior. The **anterior costo-transverse ligament** connects the antero-inferior aspect of the transverse process to the neck of the rib. The **posterior costo-transverse ligament** stretches across the supero-posterior aspect of the joint, being attached inwardly to the transverse process, and outwardly to the rib just below its tubercle. The last two or three costo-transverse joints do not possess a special synovial membrane, the posterior costo-central sac being prolonged to supply them, but each of the other joints of the series has its own proper synovial sac.

(3) The **Chondro-costal Articulations**. This is a kind of synarthrodial union, the slightly excavated lower end of the rib receiving, and being directly united to, the extremity of the costal cartilage. The periosteum passing from the rib to the cartilage helps to consolidate the union.

(4) The **Chondro-sternal Articulations**. These are the diarthrodial joints formed between the sternum and the cartilages of the first eight ribs. Each joint, with the exception of the first, possesses a synovial membrane and a **capsular ligament**. This ligament is thicker above and below than laterally, and the thickenings are sometimes designated the **superior** and **inferior costo-sternal ligaments**. The first costal cartilage is articulated inwardly with its fellow of the opposite side, and forms with it a common chondro-sternal joint, there being a single synovial membrane for the whole.

**Union of the costal cartilages to one another.** The first asternal cartilage (9th) is firmly united by fibrous tissue to the last of the sternal cartilages, and it is further bound to the lower face of the xiphoid cartilage by a small band—the **chondro-xiphoid ligament**. The tip of each succeeding cartilage is united by elastic fibres to the posterior edge of the cartilage in front of it.

**Ligaments of the sternum.** In the adult horse the last two or three osseous segments, or sternobræ, are generally fused together, and the remainder are rigidly united by thin persisting portions of the primitive cartilage from which the sternum was developed. The upper surface of the sternum is traversed by two well-defined bands of white fibres, one on each side. These **suprasternal fibrous bands** are confounded anteriorly, and posteriorly they diverge and lose themselves on the upper face of the sternum.

**Movements of the ribs.** The costal movements are of great importance in respiration. During the act of inspiration each rib is rotated outwards and forwards, as if it were hinged on an axis passing

through its head and the sternal end of its cartilage. There is thus a simultaneous rotation in the costo-central and chondro-sternal joints, the effect being to move the mid point of each rib outwards and forwards from the corresponding point of the opposite rib. In this way the transverse diameter of the chest, measured between any two opposite ribs, is lengthened, and the thoracic capacity is thereby greatly increased. During the act of expiration each rib returns to its original position by moving in the opposite direction. In each of these respiratory movements the tubercle of the rib glides on the facet of the transverse process, moving in a circle whose centre is the costo-central joint. The movement is precisely of the same nature in the whole series of ribs, but it is not of the same extent, the range of motion increasing from the first rib to the last. The anterior or sternal ribs are hampered in their movements by the overlying fore limb, and by the nature of their connection with the sternum. Besides, being but slightly arched, their rotation has little effect in removing their mid point from the mesial plane of the chest. On the other hand, the asternal ribs are not under cover of the shoulder, their lower extremities have greater play, and being much curved their rotation has a powerful effect in widening the chest.

## COMPARATIVE.

**Ligamentum Nuchæ.** The degree of development of this ligament varies greatly in different species of animals, depending (1) on the weight of the head, and (2) on the length of the neck.

In the **ox** it is even better developed than in the horse, the head in the former species being relatively heavier, although the neck is shorter. In the ox the funicular part has a disposition resembling that of the horse. The anterior portion of the lamellar part has three strong insertions into the neural spines of the 2nd, 3rd, and 4th cervical vertebræ. The fibres of the posterior half of the lamellar part, which is much thinner than the anterior half, take origin from the anterior edge of the first dorsal spine and from the funicular part, and end on the neural spines of the last three cervical vertebræ.

In the **dog** the lamellar portion is suppressed, and the funicular part is rudimentary, having the form of a slender cord extending between the axis and the first dorsal vertebra.

In the **pig** and **cat** the ligament is still more rudimentary, being represented merely by a thin superficial fibrous raphe, and a few strands of fibrous tissue on the mesial plane of the neck.

**Interspinous Ligaments.** In the **cat** these ligaments are replaced by interspinous muscles throughout the neck, back, and loins. In the **dog** similar muscles are found replacing these ligaments in the neck.

**Odontoid Ligament.** In the **pig**, **dog**, and **cat**, the odontoid ligament has a right and a left division, which are attached anteriorly within the occipital condyles. The atlas is provided with a *transverse ligament*, which passes above the odontoid process, and retains it in position. A small synovial bursa is developed between the ligament and the process.

**Occipito-atlantal Joint.** In the last-mentioned animals there is only one synovial membrane for this articulation, and in the carnivora it communicates with the atlanto-axial capsule.

**Temporo-maxillary Joint.** In the **ox** the various movements permitted in this joint are even more free than in the horse. In the **pig** lateral movements are very restricted, but antero-posterior movements (protraction and retraction) are very free. In

the **dog** the only movements executed are elevation and depression. In the last-named animal the interarticular fibro-cartilage is very thin, and the posterior ligament is absent.

**Chondro-costal Joints.** In the **ox** all the sternal ribs except the first are articulated to their cartilages by a diarthrodial joint, provided with strong capsular fibres. Rudimentary joints of the same nature are also formed in the case of some of the asternal ribs. In the **pig** similar joints are formed between the 2nd, 3rd, 4th, and 5th ribs and their cartilages.

**Intersternal Joints.** In the **ox** and **pig** the first segment of the sternum (manubrium sterni) is articulated to the second by a diarthrodial joint. The joint is enclosed by strong capsular fibres, and the movements permitted are of the nature of abduction and adduction, that is to say, the manubrium may be bent slightly to the right or to the left.

#### THE SHOULDER JOINT.

This important joint is formed between the glenoid fossa of the scapula and the articular head of the humerus. Notwithstanding its great size, it possesses only one ligament.

**Capsular ligament.** This is a typical ligament of its class, having the form of a double-mouthed sac, one mouth being attached around the rim of the glenoid cavity, and the other at the periphery of the head of the humerus. The ligament is for the most part thin, loose, and membranous, but it is strengthened anteriorly by two bundles of fibres which start from the coracoid process and diverge to become attached to the outer and inner tuberosities. A large pad of fat is interposed in front of the joint between the ligament and the tendon of the biceps; and posteriorly the small scapulo-humeral muscle passes vertically over the ligament, on which some of its fibre seems to end. Inwardly the ligament is lined by the synovial membrane.

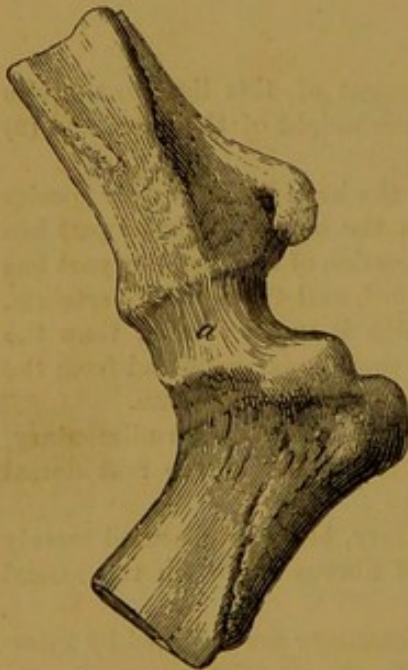


FIG. 139.—SHOULDER JOINT OF HORSE, SHOWING (a) THE CAPSULAR LIGAMENT.

The ligament has been punctured, permitting separation of the articular surfaces.

tends to keep the bones in contact.

**Movements.** The shoulder joint is a typical enarthrosis, possessing considerable freedom of movement, and admitting of flexion, extension, abduction, adduction, circumduction, and rotation. The greatest range of movement is in the antero-posterior direction (flexion and extension).

In the horse, as compared with the human subject, the movement of abduction is greatly restricted by the much lower attachment of the pectoral muscles, which in a manner bind the arm and forearm to the chest wall.

It is important to notice in this connection the absence of any joint between the scapula and the trunk skeleton, such as is afforded by the intermediation of the clavicle in man. Nevertheless, the muscular attachments of the scapula permit it to move freely on the wall of the chest. When a horse raises his fore limb from the ground, as a preparation for carrying it forwards, the scapula rocks on the thorax, its articular angle being carried upwards and forwards (thus making room for the extension of the humerus), while its dorsal angle in the same degree is carried downwards and backwards. When the extended limb is brought into contact with the ground, and receives the weight of the body, a rocking movement in the opposite direction restores the scapula to its original obliquity. In the ordinary standing posture the average inclination of the scapula to the horizon is  $60^\circ$ , and that of the humerus  $50^\circ$  to  $55^\circ$ , the value of the scapulo-humeral angle being  $110^\circ$  to  $115^\circ$ .<sup>1</sup>

#### THE ELBOW JOINT.

This is the joint formed between the distal end of the humerus on the one hand, and the upper articular surface of the radius together with the sigmoid cavity of the olecranon on the other. It possesses three ligaments.

The **external lateral ligament** is a short, strong cord of white fibres, fixed superiorly to a depression on the outer side of the distal end of the humerus and to the ridge which forms the lower boundary of the musculo-spiral groove, and inferiorly to the external tuberosity at the upper end of the radius.

The **internal lateral ligament**, longer but more slender than the preceding, is fixed above to a small eminence on the inner side of the distal end of the humerus. Inferiorly its most superficial and longest fibres are attached to the inner edge of the radius a little below the level of the bicipital tuberosity,<sup>2</sup> while its deeper fibres, more or less distinct from the preceding, are attached to the internal tuberosity

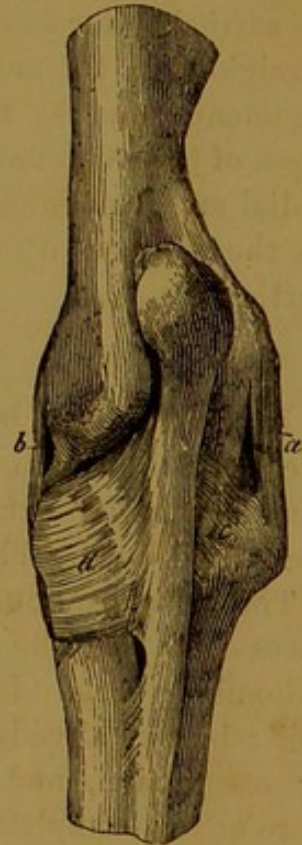


FIG. 140.—RIGHT ELBOW JOINT OF HORSE, VIEWED FROM BEHIND.

a. External lateral ligament; b. Internal lateral ligament; c and d. Arciform ligaments.

<sup>1</sup> The values assigned to the articular angles in this work are based upon the very careful measurements of M. Goubaux (*L'Exterieur du Cheval*).

<sup>2</sup> According to Franck the superficial part of this ligament frequently contains muscular fibres at its lower end, and ought to be regarded as an undeveloped pronator teres muscle.

of the radius. At its lower attachment the ligament is confounded behind with the inner arciform ligament, and in front with the anterior ligament and the biceps tendon.

The **anterior ligament** is membranous and irregularly four-sided. It is placed on the anterior aspect of the joint, being attached to the humerus above, to the radius below, and to the lateral ligament on each side. Its posterior face is lined by the synovial membrane of the joint. Behind the lateral ligaments the synovial membrane lines the tendons of the flexors of the metacarpus and the superficial and deep flexors of the digit, and a pouch of it ascends into the olecranon fossa, where a pad of fat separates it from the anconeus muscle.

**Movements.** The elbow joint is a typical ginglymus, the only movements being flexion and extension. Other movements are prevented by the form of the articular surfaces, and by the strong lateral ligaments. In flexion the bones of the fore-arm do not move in the plane of the humerus, but deviate a little outwards. Extension cannot be carried so far as to bring the arm and fore-arm bones into the same straight line, the movement being arrested by the tension of the lateral ligaments, and by the passage of the beak of the olecranon into the fossa of the same name. In the ordinary standing posture the humero-radial angle measures  $140^{\circ}$  to  $145^{\circ}$ , the humerus having an inclination to the horizon of  $50^{\circ}$  to  $55^{\circ}$ , and the radius being approximately vertical.

#### THE RADIO-ULNAR ARTICULATION.

In adult life the bones of the fore-arm are anchylosed together from the radio-ulnar arch downwards. Above the arch their opposed surfaces remain distinct until advanced age, and in this position the bones are united by the following three ligaments:—

The **interosseous ligament** is composed of short, strong, white fibres occupying the narrow interspace between the two bones above the radio-ulnar arch. In the foal the bones are similarly united below the arch; but, as already stated, this part of the ligament soon disappears by ossification, and in very old subjects the upper portion is also more or less completely converted into bone.

The **arciform ligaments**, outer and inner, are composed of glistening white fibres passing transversely on each side from the edge of the ulna above the radio-ulnar arch to the back of the radius, and blending in part with the lateral ligaments of the elbow joint.

**Movements.** The movements permitted between the radius and ulna in the horse are quite inappreciable, notwithstanding that the bones respond at the upper limit of their contact by two small diarthrodial facets. These, however, are not provided with special synovial membranes, but are supplied in connection with the synovial membrane

of the elbow joint. The suppression of movement between the bones of the fore-arm is one of the most striking peculiarities of the horse's limb. In man the bones move freely upon one another, permitting the palm of the hand to be turned either downwards (pronation) or upwards (supination), but in the horse the manus is fixed in the condition of pronation.

#### THE KNEE JOINT.

This is a composite articulation comprising three main joints, viz.—(1) the radio-carpal joint, between the distal end of the radius and the upper row of carpal bones; (2) the inter-carpal joint, between the two rows of carpal bones; and (3) the carpo-metacarpal joint, between the lower row of the carpus and the proximal ends of the metacarpal bones. But besides these we have in each tier of the carpus the subsidiary joints between the adjacent bones. The most convenient method of studying the numerous ligaments is to group them together according as they belong specially to one or other of these articulations, leaving to the last such as are in a manner common to the whole series of joints.

**Ligaments of the upper row.** Of these three are **anterior** and three **interosseous**. The anterior ligaments are flat short bands of white fibres passing transversely between the adjacent bones. The one connecting the scaphoid and semilunar, and that between the latter and the cuneiform, are strictly speaking anterior, and are covered by the anterior common ligament; but the third ligament, which connects the pisiform to the cuneiform, is placed on the outer aspect of the carpus. The three interosseous ligaments are composed of short fibres connecting the contiguous surfaces of the bones. The ligament passing between the pisiform and cuneiform bones is less distinctly interosseous than the other two, being placed on the posterior aspect of the carpus, under cover of the posterior common ligament.

**Ligaments of the lower row.** The three constant bones of this tier are connected by two **anterior** and two **interosseous** ligaments, similarly disposed to those of the upper row.

**Radio-carpal ligaments.** There are three of these. The strongest is a thick cord that stretches obliquely downwards and inwards between the radius and the scaphoid, on the posterior aspect of the carpus. The

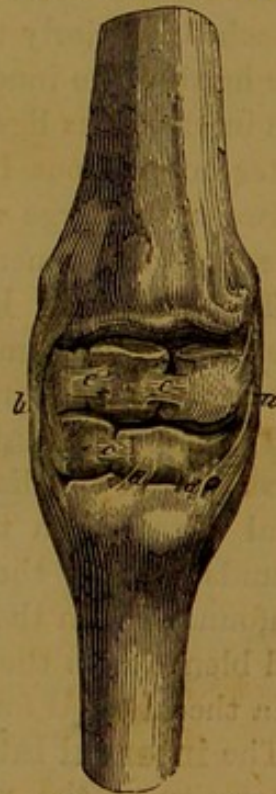

FIG. 141.—RIGHT CARPUS OF HORSE, VIEWED FROM THE FRONT.

a. Internal lateral ligament; b. External lateral ligament; c. Anterior ligaments of the two rows; d d. Anterior ligament (double) uniting the os magnum to the large metacarpal bone.

second is a very slender ligament which is fixed to the radius beneath the preceding, and passes downwards to be attached to the semilunar and the interosseous ligament between the cuneiform and pisiform bones. The third is situated on the outer aspect of the joint, where it connects the radius and the upper border of the pisiform.

The **Inter-carpal ligaments** are also three in number. One of them connects the scaphoid to the magnum and trapezoid, and another joins the cuneiform and magnum, both of these being situated on the posterior aspect of the carpus. The third ligament, the strongest of the three, is situated on the outer side of the joint, its fibres being fixed superiorly to the pisiform, and inferiorly to the unciform and the head of the outer small metacarpal bone.

The **Carpo-metacarpal ligaments**. These are four in number—two **anterior** and two **interosseous**. The first of the anterior ligaments is composed of two separate slips connecting the magnum to the large metacarpal bone, and the second passes between the unciform and the head of the outer splint bone. The inner interosseous ligament is attached inferiorly to the interstice between the large metacarpal and the head of the inner splint bone, and superiorly it is confounded with the interosseous ligament between the trapezoid and os magnum. The outer interosseous ligament passes in like manner from the interstice between the large metacarpal and the outer splint bone to join the interosseous ligament between the os magnum and unciform.

The **Common ligaments of the carpus**. The following four ligaments are common, in the sense that they serve to consolidate each of the three main articulations of the carpus.

The **external lateral ligament** is fixed superiorly to the external tuberosity of the distal end of the radius. Its longest and most superficial fibres reach the head of the outer splint bone, while its deeper strands end on the cuneiform and unciform bones. Anteriorly it is confounded with the anterior common ligament, and inferiorly it covers and blends with the outermost inter-carpal ligament. It is perforated by a thecal canal for the extensor suffraginis tendon.

The **internal lateral ligament** is fixed superiorly to the internal tuberosity of the radius, and inferiorly to the heads of the large and inner small metacarpal bones, furnishing slips as it passes over the carpus to the scaphoid, magnum, and trapezoid bones. It blends in front and behind with the anterior and posterior common ligaments.

The **anterior common ligament** is a membranous four-sided structure, fixed superiorly to the radius and inferiorly to the large metacarpal bone, while laterally it blends with the lateral ligaments. Its deep face is partly adherent to the carpal bones or their anterior ligaments, and partly it is lined by synovial membrane. The tendons

of the extensor pedis and extensors of the metacarpus play over its superficial face, where they are provided with synovial bursæ.

The **posterior common ligament** is much stronger than the preceding. Placed on the posterior aspect of the carpus, it is fixed to the radius above and to the large metacarpal bone below. Its inner edge blends with the internal lateral ligament, and its outer edge mixes its fibres with the outermost intercarpal ligament. Its anterior face is closely attached to the carpal bones over which it passes, and posteriorly it presents a smooth face covered by the synovial bursa of the carpal sheath, to facilitate the gliding of the flexor perforans tendon. Inferiorly this ligament appears to be directly continued to form the so-called *subcarpal* ligament, which reinforces the perforans tendon below the carpus.

**Synovial membranes of the carpus.** There are three carpal synovial membranes, corresponding to the three main joints. The **radio-carpal** synovial membrane facilitates the movements between the radius and the bones of the upper row, and descends between the latter bones as far as their interosseous ligaments. The **inter-carpal** synovial membrane similarly belongs to the articulation between the two tiers, but it is also insinuated above and below between the bones of the same row as far as their interosseous ligaments. Between the os magnum and the unciform this membrane communicates with the next. The **carpo-metacarpal** synovial membrane belongs specially to the articulation between the lower row and the metacarpus. At the same time it ascends between the bones of the lower row as far as their interosseous ligaments, and dips down to supply the joints between the large metacarpal and the heads of the splint bones.

**Movements of the carpus.** The radio-carpal and inter-carpal articulations are ginglymoid joints, and when flexion and extension are executed at the carpus both of these joints participate in the movement. In the ordinary standing posture the long axis of the carpus and metacarpus is in a straight line with the axis of the fore-arm, that is to say, it is approximately vertical. When the carpus is flexed, the distal part of the limb is carried freely backwards, a gap being formed in front between the radius and the upper row, and between the two rows. Provision is made for this in the disposition of the ligaments, the special ligaments of these joints being placed behind and laterally, so as to present no obstacle to the necessary separation of the bones in front. With the same object the anterior common ligament is loose in the extended carpus. During extension, movement is arrested as soon as the metacarpus is brought into line with the fore-arm. Further movement in this direction is prevented by the strong posterior common ligament, and by the special radio-carpal and inter-carpal ligaments, which are for the most part placed behind these joints. Owing to the slight obliquity

of the radio-carpal and inter-carpal joints the metacarpus and digit during flexion deviate a little outwards from the plane of the fore-arm bones. In the extended carpus movements of abduction and adduction are impossible owing to the tension of the strong lateral ligaments, but when the joint is flexed these ligaments are relaxed, and slight abduction and adduction movements are possible.

The carpo-metacarpal joint is of the nature of an arthrosis, the motion being of a gliding character, and very restricted. It does not participate to an appreciable degree in the movement of flexion, which is resisted by the anterior and interosseous ligaments special to this joint.

Lastly, it remains to be said that the small gliding joints formed between adjacent bones in each row of the carpus, although not contributing to the main movements executed at the knee, are nevertheless of great importance, for they tend to distribute pressure in the joint, and thus obviate the bad effects which would have been likely to result from concussion, had each row been a single osseous piece.

#### THE INTER-METACARPAL ARTICULATIONS.

Each splint bone is united to the large metacarpal bone (1) by a small diarthrodial articulation between their proximal extremities, and (2) by a synarthrodial union which fixes the body of the splint bone to the postero-lateral aspect of the large metacarpal. The diarthrodial joint is lubricated by a process of the carpo-metacarpal synovial membrane, and it does not possess any special ligaments. The synarthrodial union is effected by means of an **interosseous ligament**, composed of short fibres cementing the opposed bony surfaces. In animals above middle age this ligament is very frequently ossified, and the splint bones are then inseparably connected to the main bone of the metacarpus. Normally, however, the splint bone for an inch or two above the "button" of its lower extremity stands out a little from the back of the large metacarpal, and the loose interosseous fibres there persist, and permit on pressure some slight movement of the terminal part of the splint bone. The only other movement permitted between the large and small metacarpal bones is an inappreciable gliding action between the diarthrodial facets of their upper ends.

#### THE FETLOCK JOINT.

This is technically termed the metacarpo-phalangeal articulation, and the bones that enter into its formation are the large metacarpal, the first phalanx, and the sesamoids. The two sesamoids are first connected together, and they are then fixed to the back of the first phalanx, whose articular surface they thus increase and adapt more accurately to the distal end of the large metacarpal bone. The ligaments connected with the joint may therefore be naturally divided into: (1) those that

unite the sesamoids together and to the first phalanx, and (2) those that serve to attach these united bones to the lower end of the large metacarpal. The ligaments of the first class are: an intersesamoidean ligament, a pair of lateral sesamoid ligaments, and three inferior sesamoid ligaments.

The **intersesamoid ligament** closely unites the two sesamoid bones together. It is dense and fibro-cartilaginous in texture, and concurs with the posterior face of the sesamoids to form the pulley-like groove for the flexor perforans tendon.

The **lateral sesamoid ligaments** (outer and inner) are composed of transverse fibres uniting each sesamoid to the corresponding side of the upper end of the first phalanx.

The **inferior sesamoid ligaments** are three in number, viz., superficial, middle, and deep. The **superficial** ligament is ribband-like, and slightly broader above than below. Superiorly it is attached to the bases of the sesamoids, and inferiorly to the complementary fibro-cartilage of the second phalanx. The **middle** ligament comprises a central and two lateral bundles of fibres. The lateral

bundles are attached to the converging lines on the posterior surface of the first phalanx, and superiorly they diverge to become inserted each into the base of the corresponding sesamoid. The central bundle ascends vertically between the before-described lateral bundles, being fixed inferiorly to the posterior surface of the first phalanx above the apex of its V-shaped area, and superiorly to the bases of the sesamoids. The **deep** ligament consists of a few short fibres disposed like the letter X, and fixed on the one hand to the posterior surface of the first phalanx near its upper limit, and on the other to the base of the sesamoids.

The second series of ligaments of this joint are: two lateral ligaments, an anterior ligament, and a superior sesamoidean or suspensory ligament.

The **lateral ligaments** (outer and inner) of the fetlock joint comprise (1) a superficial fasciculus, whose fibres pass vertically from the lower end of the large metacarpal bone to the upper end of the first phalanx, and (2) a deep fasciculus of oblique fibres fixed beneath the preceding to the lateral pit of the lower end of the large metacarpal, and radiating to be attached to the side of the sesamoid and the upper end of the first phalanx.

The **anterior ligament** is a membranous four-sided structure which encloses the joint in front of the lateral ligaments, and whose deep face

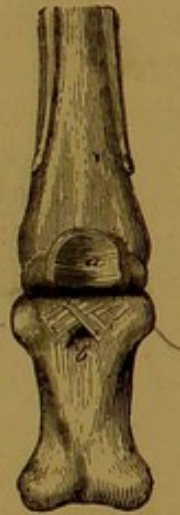

FIG. 142.—FETLOCK JOINT OF HORSE, VIEWED FROM BEHIND.  
a. Intersesamoid ligament; b. Deep inferior sesamoid ligament.

serves for the support of the synovial membrane. It is fixed to the large metacarpal above, to the first phalanx below, and to the lateral ligament on each side. The extensor pedis tendon plays over its anterior face, a small synovial bursa being interposed.

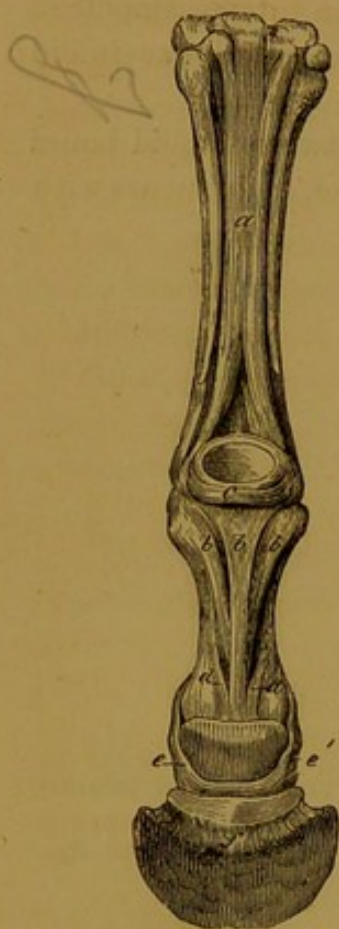


FIG. 143.—LEFT MANUS of HORSE, VIEWED FROM BEHIND.

*a.* Suspensory ligament; *b.* (central letter). Superficial inferior sesamoid ligament; *b b.* (lateral letters). Lateral bundles of the middle inferior sesamoid ligament; *d.* The innermost slips of the glenoidal fibro-cartilage of the pastern joint; *e.* Postero-lateral ligaments of the coffin joint.

The **superior sesamoid** or **suspensory ligament**. The main part of this ligament has the form of a strong riband, and is lodged in the channel formed by the three metacarpal bones. Superiorly the fibres of this riband have a double origin (1) from the lower row of carpal bones, and (2) from the upper end of the large metacarpal bone. A few inches above the sesamoids the ligament bifurcates, the branches diverging to gain the lateral aspect of the sesamoid bones. Here a considerable part of each branch terminates, the remainder being continued as a narrow flat band which crosses obliquely downwards and forwards over the side of the fetlock joint to gain the anterior aspect of the first phalanx, where it joins the extensor pedis tendon, ultimately becoming inserted on the pyramidal process of the os pedis. This ligament, while mainly composed of white fibrous tissue, invariably contains some bundles of striped muscular fibres. It is, in fact, the representative of one of the plantar interosseous muscles of the human hand.

The **synovial membrane** of the fetlock joint is supported in front by the anterior ligament, and laterally by the lateral ligaments. Posteriorly it is supported under the sesamoid bones by the deep inferior sesamoid ligament; but above these bones it is unsupported, and hence when distended it first shows itself here, in front of the branches of the suspensory ligament.

**Movements.** The only movements executed in the fetlock joint are flexion and extension. In an animal with well-formed or moderately oblique pasterns, the axis of the digit in the ordinary standing posture slopes downwards and forwards at an angle of about  $60^\circ$  with the horizon (about  $65^\circ$  in the case of the hind limb). The metacarpus being approximately vertical, there is thus formed in front of the fetlock an angle of about  $150^\circ$ . The first effect of flexion is to obliterate this angle by bringing the two rays of the joint into the same straight

line, and when carried further a progressively diminishing angle is formed behind the joint. This backward movement is very free, but it is finally arrested by the obstacle that the sesamoids and the adjacent soft structures offer to the complete closing of the angle. The movement of extension is freely permitted until the normal anterior angle of  $150^\circ$  is formed, but further movement in that direction is strongly resisted by the suspensory ligament. That ligament, indeed, may be described as a powerful brace or stay to prevent over-extension of the fetlock joint. In the extended joint abduction and adduction are prevented by tension of the lateral ligaments, but when the joint is fully flexed slight lateral movements can be effected by manipulation.

[In the first part of this section flexion was defined as the movement that diminishes the angle formed by the meeting of the two bones of a joint. But in the case of the fetlock and some other joints, at different phases of movement of the inferior ray an angle is formed on both aspects of the joint. It would be most logical in the case of the fetlock to apply the word extension to the backward movement of the digit, for, as already stated, in a state of rest the angle of the joint lies in front, and the first effect of the backward movement of the digit is to increase that angle. Nevertheless it is customary to call the backward movement flexion, probably because the posterior angle is the most variable one. Where, in such cases as this, the movement of extension is carried so far as to bring the two rays of the joint into a straight line, any further movement, which would have for effect to form a new angle on the opposite side of the joint, may be distinguished as *over-extension*.]

#### THE PASTERN JOINT.

This joint, technically termed the first interphalangeal articulation, is formed between the distal end of the first and the proximal end of the second phalanx. The lower articular surface is extended by a complementary fibro-cartilage, and the joint possesses two lateral ligaments.

The **complementary or glenoidal fibro-cartilage**. This is a piece of fibro-cartilage fixed along the posterior edge of the upper articular surface of the second phalanx. Three fibrous slips pass from it on each side, and become attached to the first phalanx. The innermost of these slips is fixed near the middle of the lateral edge of the first phalanx, and the other two are inserted beneath the first, near the lower end of the bone.<sup>1</sup> The superficial inferior sesamoid ligament is attached to the mid point of the complementary cartilage, and the terminal insertion of the flexor perforatus tendon is blended with it at either extremity.

The **lateral ligaments** (outer and inner) are fixed superiorly to the lateral aspect of the lower end of the first phalanx, and inferiorly to the side of the second phalanx. Some of the fibres of each ligament are prolonged downwards and backwards to form part of the postero-lateral ligament of the next joint.

<sup>1</sup> It would perhaps be better to describe these fibrous slips as posterior ligaments of the pastern joint.

**Synovial membrane.** This is supported in front by the extensor pedis tendon, which here plays the part of an anterior ligament. On each side it is supported by the lateral ligament, and posteriorly it lines the complementary fibro-cartilage, and is prolonged upwards as a pouch behind the lower extremity of the first phalanx.

**Movements.** The only movements executed in this joint are flexion and extension. In the limb at rest the second phalanx has almost the same inclination as the first. The backward movement of the second phalanx (flexion) is freely permitted, but it is impossible to carry the movement of extension much beyond the point at which the first and second phalanges are in the same straight line, this movement (over-extension) being resisted by the fibrous slips of the complementary cartilage, and by the superficial inferior sesamoid ligament.

#### THE COFFIN JOINT.

This, the second interphalangeal joint, has three bones entering into its formation, viz., the second and third phalanges and the navicular bone. The navicular bone is in a manner complementary to the terminal phalanx, these two together furnishing the lower articular surface. For this purpose they are firmly united by an interosseous ligament, and they are then connected to the second phalanx by two pairs of ligaments—antero-lateral and postero-lateral.

The **interosseous ligament** is composed of short fibres passing from the lower border of the navicular bone to the tendinous surface of the os pedis, behind its articular surface.

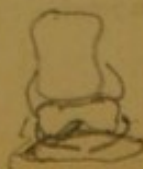The **antero-lateral ligaments.** Each of these passes from the side of the second phalanx to be attached to the excavation at the side of the pyramidal process of the os pedis.

The **postero-lateral ligaments.** In part each of these ligaments appears to be the continuation of the lateral ligament of the pastern joint, and the remainder of its fibres are attached superiorly to the side of the second phalanx. After an oblique course downwards and backwards, the ligament ends on the upper edge of the navicular bone. From the extremity of the latter bone some fibres pass to be attached to the wing of the os pedis and the inner surface of the lateral cartilage.

**Movements.** The only movements permitted in this joint are flexion and extension, the extent of these movements being somewhat less than in the preceding articulation.

#### COMPARATIVE.

**Shoulder Joint.** In the **pig, dog, and cat**, the rim of the glenoid cavity is encircled by a rudimentary glenoid cartilage. In these animals the synovial membrane of the joint is in communication with that which favours the play of the biceps tendon in the bicipital groove.



**Elbow Joint.** In the **ox** this joint differs but little from that of the horse. It may be remarked, however, that the union between the two bones of the fore-arm is even more intimate than in the horse, the interosseous ligament being normally ossified in adult life throughout the whole of its extent.

In the **pig** the radius and ulna are rigidly united by interosseous fibres, which are so short and strong as to prevent any appreciable movement between the two bones.

In the **dog** and **cat**, the radius and ulna are articulated together by a diarthrodial joint at either extremity, and between these two points they are separated by a narrow interspace occupied by an interosseous ligament. The proximal joint possesses an *orbicular ligament*, which passes transversely in front of the head of the radius, to blend outwardly with the external lateral ligament of the elbow joint. The head of the radius is thus closely maintained in contact with the articular surface of the ulna, but is allowed to rotate freely within the ring bounded by the ulnar articular surface behind and the orbicular ligament in front. In the ordinary position of the paw, that is, when its palmar or flexor aspect looks backwards or downwards, the radio-ulnar joint is said to be in a condition of *pronation*. When the flexor surface of the manus is turned inwards, as when the animal holds anything between its fore-paws, the condition is termed *supination*. To bring about this latter position the radial head rotates within the orbicular ligament, while the distal end of the bone, carrying with it the paw, is rotated slightly outwards around the lower end of the ulna.

**Carpus.** There are of course manifold minor differences exhibited by the carpal ligaments in the different domestic animals, in correspondence with the variations of the bones forming the joint. The general plan, however, is similar in all. As regards movements, it may be observed that abduction and adduction are much more free in the **carnivora** than in the other domestic animals.

**Inter-metacarpal Joints.** In the **ox** the rudimentary metacarpal is articulated to the main bone in the position of the horse's outer splint bone, a process of the carpo-metacarpal synovial membrane supplying the joint. The small bone is more movable than the splint bones of the horse, and it seldom or never becomes ankylosed to the main bone.

In the **pig** and in the **carnivora** small diarthrodial joints are formed between the proximal ends of the adjacent metacarpal bones, permitting, in the latter animals especially, distinct movement. The bones are connected by interosseous fibres, and by the insertion of the anterior and posterior carpal ligaments on the heads of the metacarpal bones.

**Fetlock Joint.** There are two metacarpo-phalangeal articulations in the **ruminants**, one for each digit. Besides an intersesamoid ligament between the two sesamoids of the same digit, there is an additional ligament between the mesial sesamoids of the two digits. A *superior interdigital ligament* composed of intercrossed fibres connects the opposed surfaces of the first phalanges of the two digits. There are four inferior sesamoid ligaments in each digit. Two of these are lateral bands connecting the sesamoids to the upper end of the first phalanx. The other two are intercrossed like the deep ligament of the horse. The most interesting difference in this region is found in connection with the superior sesamoidean or suspensory ligament. As has already been stated, this ligament in the horse invariably contains some muscular fibres, and it ought to be regarded as an altered interosseous muscle. In the case of the **ox** the true nature of the ligament is much more evident, the muscular tissue, in the young subject especially, being so abundant that the structure might with equal propriety be described with the muscles. Occupying the same position as in the horse, the ligament divides about the middle of the metacarpus into an anterior and a posterior portion. The posterior division is a flat broad band which bifurcates, each branch uniting with the flexor perforatus behind the fetlock to form a ring for the passage of the flexor perforans tendon. The anterior division resolves itself into six bands, four of which pass to the four sesamoids of the two digits. The band passing to the two outer sesamoids detaches an oblique slip to join the proper extensor tendon of the digit, after the manner of the horse's ligament. The remaining two bands of the anterior division are much more slender and less muscular than the preceding. Passing into the cleft which divides the

lower end of the large metacarpal, they become confounded with each other, and are continued downwards and forwards between the first phalanges. Here they separate, each joining the proper extensor tendon of its own digit. The other ligaments of this joint closely resemble the same ligaments of the horse.

In the **pig** and the **carnivora** each metacarpo-phalangeal articulation has its own proper ligaments, which in a general way resemble those of the ruminant. The inferior sesamoid ligament is composed merely of two intercrossed bundles. The anterior ligament has a small nucleus of bone in it, which plays the part of a sesamoid to one of the divisions of the common extensor of the digit. The place of the suspensory ligament is taken by distinct interosseous muscles, which will be described in the next section.

**The Inter-phalangeal Joints.** In the **ox** the complementary or glenoidal cartilage of the os coronæ has only two slips attaching it to the first phalanx. In addition to the antero-lateral and postero-lateral ligaments found in the horse, the terminal joint of the limb is provided with an anterior elastic ligament. Further in ruminants an inferior interdigital ligament connects the opposed ends of the navicular bones and the inner surface of the terminal phalanges of the two digits. A strong band of fibres passes downwards from each after-claw or rudimentary digit to end on the second phalanx.

In the **carnivora** the last inter-phalangeal joint is provided with an elastic ligament which acts as a retractor of the claw. This ligament, which is much stronger in the dog than the cat, is attached by its proximal end to the outer side of the lower end of the second phalanx, and by its opposite end to the front of the terminal phalanx, above the root of the claw.

#### THE SACRO-ILIAC ARTICULATION.

This is the joint formed between the auricular facet of the sacrum and the corresponding articular surface of the ilium. Only one ligament—sacro-iliac—passes in close relation to the joint, but it is convenient to describe here three other ligaments which pass between the sacrum and the innominate bone. These are the sacro-sciatic ligament and the superior and inferior ilio-sacral ligaments.

The **sacro-iliac ligament** is composed of short strong white fibres that pass between the sacrum and the ilium in close relation to the articular surfaces. It comprises an upper and a lower portion, the former being much the stronger of the two. This ligament is the chief bond of connection between the spine and the innominate bone.

The **sacro-sciatic ligament.** This large, membranous ligament forms the greater part of the lateral boundary of the pelvis. It is irregularly four-sided in form. Its upper edge is fixed to the lateral edge of the sacrum and to the transverse processes of the first one or two coccygeal bones; its lower edge is attached to the superior ischiatic spine and to the tuber ischii, and between these points it forms the upper boundary of the small sacro-sciatic foramen; its anterior edge is short, and forms the posterior boundary of the great sacro-sciatic foramen; its posterior edge, much more extensive than the anterior, is thin, ill-defined, and united to the coccygeal origin of the semi-membranosus muscle. The outer surface of the ligament is crossed by the great sciatic nerve, and its inner surface is lined anteriorly by peritoneum. The *great sacro-sciatic foramen* is an elliptical opening on the

lateral wall of the pelvis, limited by this ligament behind, and by the ischiatic edge of the ilium in front. It gives passage to the gluteal nerves and vessels and the great sciatic nerve. The *small sacro-sciatic foramen* is a second opening in the pelvic wall, bounded by the sacro-sciatic ligament above, and by the ischial bone below. It transmits the common tendon of the obturator internus and pyriformis, and the nerves to these muscles.

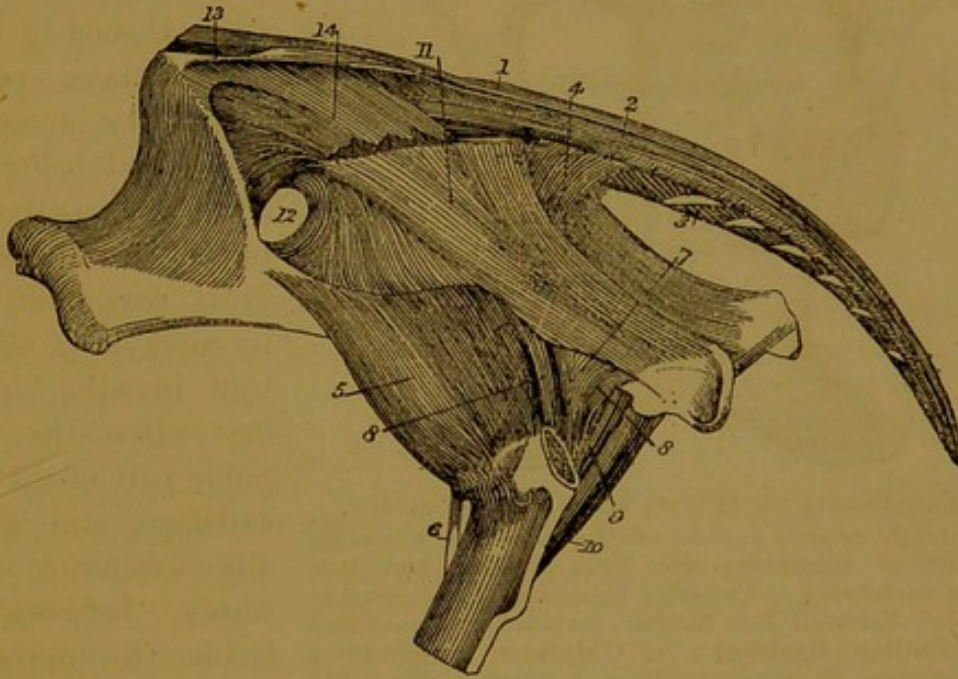


FIG. 144.—PELVIS OF HORSE, VIEWED FROM THE SIDE.

11. Sacro-sciatic ligament; 12. Great sacro-sciatic foramen; 13. Superior ilio-sacral ligament; 14. Inferior ilio-sacral ligament.

The **superior ilio-sacral ligament** has the form of a cord passing obliquely between the internal angle of the ilium (angle of the croup) and the summits of the sacral spines.

The **inferior ilio-sacral ligament** is membranous and triangular. Its anterior edge is fixed to the upper part of the ischiatic border of the ilium; its lower edge is attached to the lateral border of the sacrum; and its posterior or upper edge is ill-defined, being continuous with the fascia investing the coccygeal muscles.

**Movements.** The sacro-iliac joint is a diarthrodial one, inasmuch as it possesses a rudimentary synovial membrane. It is, however, a joint in which only very restricted movement is permitted, as is indicated by the nature of the articular surfaces, which lack the smooth and polished character commonly found in diarthrodial joints. But if it is a comparatively immobile joint, it is at the same time a remarkably strong one, its stability being secured mainly by the sacro-iliac ligament.

## THE ISCHIO-PUBIC SYMPHYSIS.

The right and left innominate bones meet together along the mesial plane of the body, and, in the foal, the inner edge of each ischial and

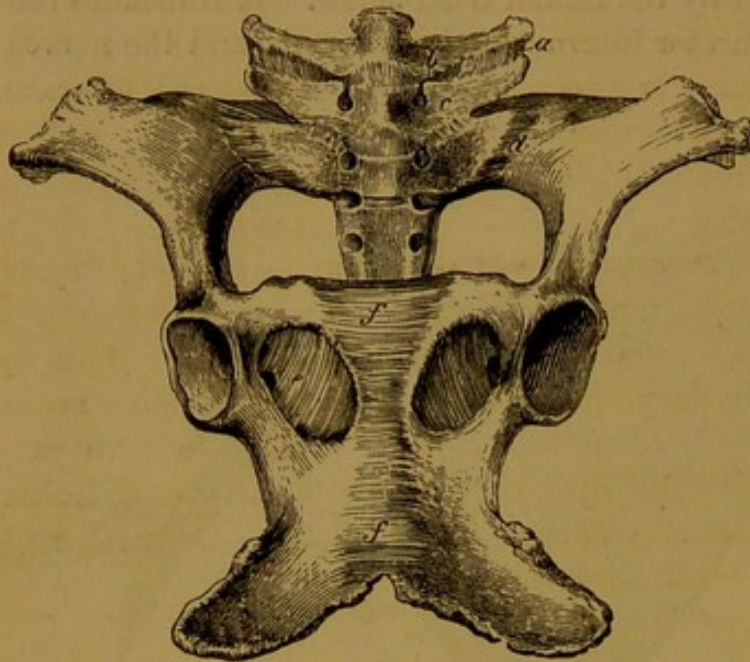


FIG. 145.—PELVIS OF HORSE, VIEWED FROM BELOW.

- a.* An intertransverse muscle of the loins; *b.* Capsular ligament of intertransverse joint between last two lumbar vertebrae; *c.* Capsular ligament of corresponding joint between last lumbar vertebra and sacrum; *d.* Sacro-iliac ligament; *e.* Obturator membrane; *f.* Transverse ligamentous fibres beneath ischio-pubic symphysis.

pubic bone is united to its fellow of the opposite side by a thin stratum of fibro-cartilage. The union is further strengthened by transverse fibres passing across the symphysis above and below. In adult animals the symphysis is always in great part obliterated by ankylosis, ossification invading in the first place the interpubic part of the fibro-cartilage, and gradually extending backwards between the ischia. No appreciable movement is permitted at the symphysis.

There may here be noticed the **obturator membrane**, a thin stratum of fibrous tissue which extends across the foramen of the same name, leaving anteriorly a passage for the obturator vessels and nerves in their descent to the thigh.

## THE HIP JOINT.

The hip or coxo-femoral joint is formed between the head of the femur and the cotyloid cavity of the innominate bone. The joint possesses four ligaments, viz., cotyloid, round, pubio-femoral, and capsular.

The **cotyloid ligament** is a ring of fibro-cartilage fixed to the margin of the acetabulum, which it serves to deepen. Inwardly the ligament bridges over the gap in the rim of the cavity, which it thus converts into a foramen for the passage of the pubio-femoral ligament. This part of the ring is sometimes termed the *transverse ligament*.

The **round ligament** (*ligamentum teres*) is a short, strong cord, fixed superiorly to the non-articular depression of the acetabulum, and inferiorly to the sulcus on the head of the femur.

The **pubio-femoral ligament** is peculiar to the *Equidæ*. It derives its fibres from the (opposite) prepubic tendon of the abdominal muscles, the right and left ligaments intercrossing in front of the pubes as they pass obliquely backwards and outwards towards the acetabulum. Each ligament enters this cavity by passing through the notch of its rim, over the so-called transverse ligament, and it terminates in the sulcus of the head of the femur, close to the point of attachment of the round ligament. Before it enters the joint it lies in the pubio-femoral groove on the lower surface of the pubic bone, where it perforates the origin of the pectineus muscle.

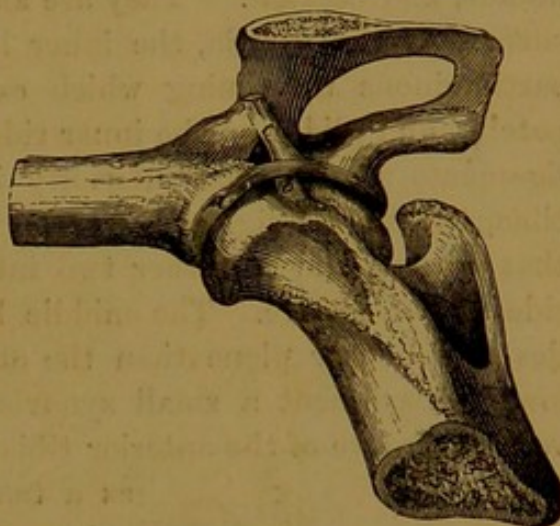


FIG. 146.—RIGHT HIP JOINT OF HORSE, VIEWED FROM BELOW AND IN FRONT.  
a. Cotyloid ligament; b. Round ligament;  
c. Pubio-femoral ligament.

The **capsular ligament** has the form of a double-mouthed sack, attached on the one hand to the rim of the cotyloid cavity and to the cotyloid ligament, and on the other hand to the line that circumscribes the head of the femur. The sack is thinnest on the inner and posterior aspects of the joint, and thickest in front, where it is strengthened by an oblique band of fibres (ilio-femoral ligament of man). The inner surface of the ligament is everywhere lined by the synovial membrane.

The **synovial membrane** lines the deep face of the capsular ligament, and invests the pubio-femoral and round ligaments in the interior of the joint.

**Movements.** The hip joint is a typical enarthrosis, and in the horse it possesses a greater range of movement than any other articulation of the limbs. When the horse stands squarely on his four limbs, the ilio-femoral angle measures from  $110^{\circ}$  to  $115^{\circ}$ , the inclination of the femur being about  $80^{\circ}$ , and that of the ilium from  $30^{\circ}$  to  $35^{\circ}$ . In flexion the femur is carried forwards, this movement being executed with great freedom. In extension the femur moves back to its original inclination, and it may even be carried so far as to efface the normal anterior angle, and form a new angle behind the joint. Abduction is considerably restricted in the horse by the pubio-femoral ligament, which that movement tends to put upon the stretch.

#### THE STIFLE JOINT.

The stifle joint corresponds to the knee of the human subject. The bones that enter into its formation are the femur, the tibia, and the patella. In reality it comprises two articulations, viz. (1) that between

the patella and the femoral trochlea, and (2) that between the femur and the tibia.

(1) The **Femoro-patellar joint** possesses three straight ligaments, a capsular ligament, and two lateral ligaments.

The **straight patellar ligaments** are distinguished as *external*, *middle*, and *internal*. They are all attached superiorly to the anterior surface of the patella, the inner ligament being provided with a fibro-cartilaginous thickening which extends the articular surface of the patella, and glides on the inner ridge of the femoral trochlea. All three ligaments are inserted inferiorly into the anterior tuberosity of the tibia, the middle ligament to the lower part of the vertical groove of that process, and the other two into its most prominent part on either side of the groove. The middle ligament, imbedded in a pad of fat, lies on a deeper plane than the other two, and immediately above its lower attachment a small synovial bursa favours its gliding in the vertical groove of the anterior tibial tuberosity. These ligaments serve

as a tendon of insertion to the quadriceps extensor cruris muscle, transmitting its action to the tibia.

The **capsular ligament** is loose and membranous. It is attached around the margins of the articular surfaces.

The **lateral patellar ligaments** are two thin flat bands scarcely distinct from the capsular ligament. Each passes from the lateral aspect (outer or inner) of the femur to the corresponding edge of the patella.

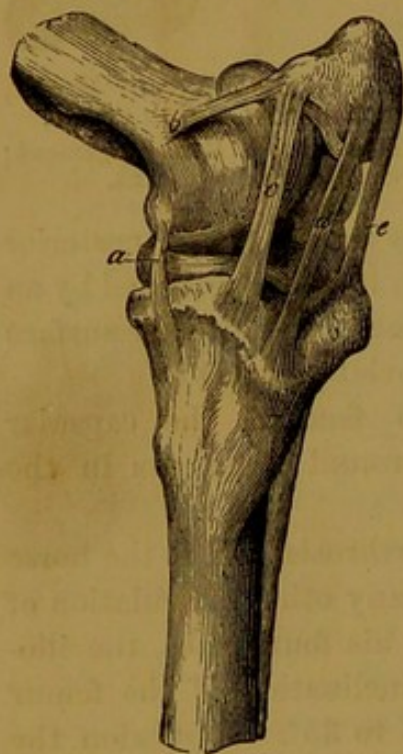The **synovial membrane** lines the deep face of the capsular ligament, and when distended it forms an upward protrusion between the femur and the quadriceps muscle. Inferiorly it is in contact with the synovial membranes of the femoro-tibial joint, and it generally communicates with them by one or two small openings.

FIG. 147.—LEFT STIFLE JOINT OF HORSE (Antero-lateral View).

a. Internal lateral tibio-fibular ligament; b. Internal lateral patellar ligament; c d e. Inner, middle, and outer straight patellar ligaments.

(2) The **Femoro-tibial ligaments** are two lateral, two crucial, and a posterior. Besides these the joint is provided with two interarticular fibro-cartilages.

The **interarticular or semilunar fibro-cartilages**. These are two crescentic or sickle-shaped pieces of fibro-cartilage interposed between the condyles of the femur and the articular surface of the tibia. The convex margin of each is turned outwards, and is much thicker than the concave edge, which is so thin as to be translucent. The lower surface



of each is flattened to rest on the tibia, while the upper surface is hollowed to embrace the femoral condyle. The cartilages are maintained in position as follows:—The anterior extremity of the inner fibro-cartilage is fixed into an excavation in front of the tibial spine, while its posterior extremity is similarly fixed behind the spine. The outer cartilage is fixed by its anterior extremity in front of the spine, while its posterior extremity is bifid, having an upper slip inserted into a depression at the posterior part of the intercondyloid groove, and a lower into the rim of the tibial articular surface. These slips of insertion are sometimes termed the **coronary ligaments**, three of which belong to the outer, and two to the inner, fibro-cartilage.

The **lateral ligaments**. These are strong fibrous cords, placed one on each side of the joint. The *external* ligament is fixed above to the higher of the two pits on the external condyle of the femur, covering the origin of the popliteus muscle from the lower pit. It descends over the external tuberosity of the tibia, a synovial bursa being interposed, and is inserted into the head of the fibula. The *internal* ligament is longer and more slender than the preceding. It is fixed above to a small tubercle on the inner condyle, plays over the edge of the tibial articular surface, and is inserted into the internal tuberosity of the tibia.

The **crucial ligaments**. These two ligaments are lodged in the intercondyloid groove. They are strong, fibrous cords crossing each other like the limbs of the letter X. They are distinguished as anterior and posterior. The *anterior*, the more external of the two, is attached superiorly to the intercondyloid groove, and to the external condyle of the femur where it bounds that groove. Its fibres, which have a slightly spiral arrangement, extend downwards, and forwards to be inserted into the tibial spine. The *posterior* ligament is longer than the anterior, and is fixed superiorly to the intercondyloid groove and inner condyle. It extends downwards and backwards to be fixed to a special tubercle on the back of the tibia, below the rim of its articular surface.

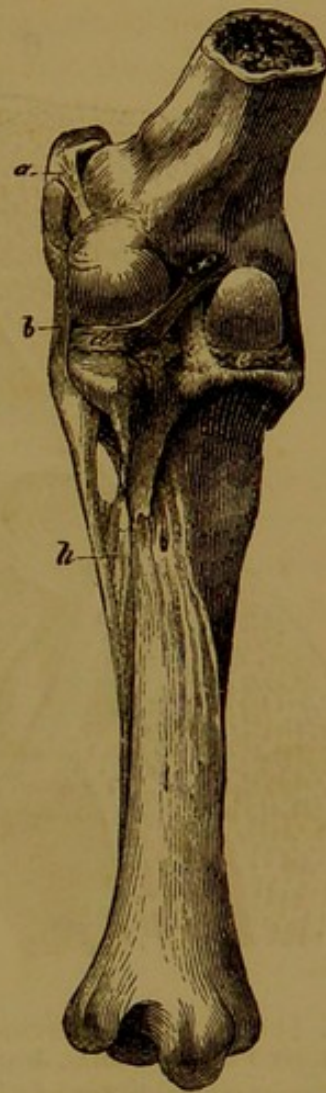


FIG. 148.—LEFT STIFLE JOINT OF HORSE, VIEWED FROM BEHIND.

- a. Outer lateral patellar ligament; b. Outer lateral tibio-fibular ligament; c. Posterior crucial ligament; d and e. Outer and inner interarticular fibro-cartilages; f and g. Posterior coronary ligaments of outer fibro-cartilage; h. Tibio-fibular interosseous ligament.

The **posterior ligament** is membranous in character, and it serves to close in the joint on its posterior aspect, and to give support there to

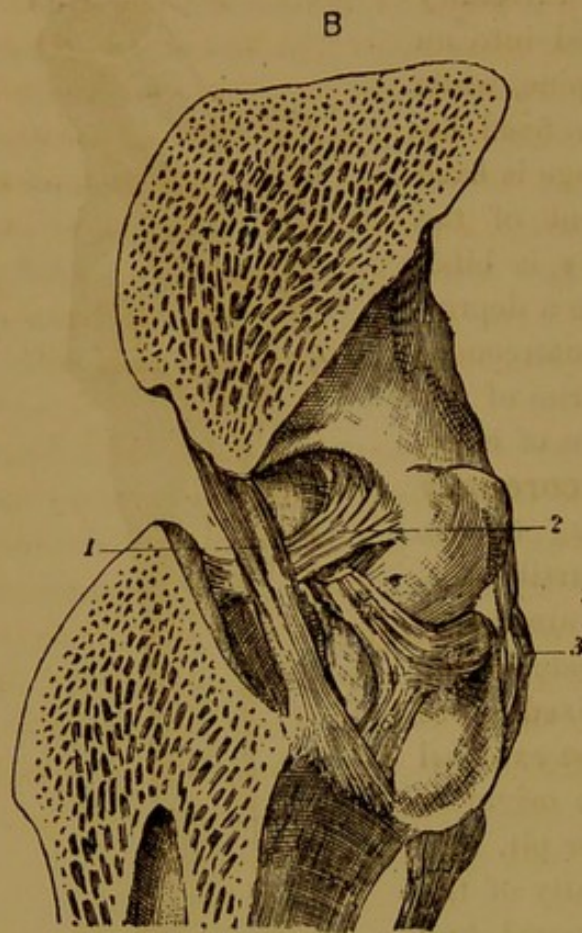


FIG. 149.—ANTERO-POSTERIOR SECTION OF RIGHT FEMORO-TIBIAL JOINT OF HORSE.

1. Posterior crucial ligament; 2. Anterior crucial ligament; 3. External lateral ligament; 4. Outer interarticular fibro-cartilage; 5 and 6. Its posterior coronary ligaments.

its synovial membranes. It is attached superiorly across the back of the femur above its condyles, below it is attached to the tibia just below the margin of its articular surface, and on either side it is partly adherent to the lateral ligament. Its deep face is adherent to the interarticular cartilages and to the posterior crucial ligament, and is lined elsewhere by synovial membrane.

### Synovial membranes.

The femoro-tibial articulation is in reality a double joint—one for each femoral condyle and the opposed tibial surface, and each of these joints possesses a synovial membrane. The two membranes are separated from one another by the crucial ligaments, while behind and at the sides they line the posterior and lateral ligaments. In front they are in contact with the synovial

capsule of the femoro-patellar joint, and separated from the patellar straight ligaments by a pad of fat. As already stated, they generally communicate with the femoro-patellar membrane. These synovial membranes invest the semilunar cartilages, and the outer one covers also the tendon of origin of the popliteus and the common tendon of the flexor metatarsi and extensor pedis muscles.

**Movements.** The femoro-tibial articulation is of a ginglymoid nature, its movements being almost confined to flexion and extension. When a horse stands squarely, the articular angle (behind the joint) measures from  $145^{\circ}$  to  $150^{\circ}$ , the femur sloping downwards and forwards at an angle of  $80^{\circ}$  with the horizon, and the tibia having an opposite inclination of  $65^{\circ}$  to  $70^{\circ}$ . In progression the joint is first flexed to clear the foot of the ground, this action coinciding with flexion of the hip joint. When the thigh has been raised and carried sufficiently forwards

by this flexion of the hip, extension of the stifle comes into play, and carries the distal part of the limb forwards. The act of flexion is very free, since, with the exception of the posterior crucial, all the femoro-tibial ligaments are relaxed by that movement. Extension cannot be carried so far as to bring the thigh and leg bones into the same straight line, the movement being arrested by tension of the lateral and anterior crucial ligaments. In this position of the joint these same ligaments completely prevent any lateral or rotatory movements of the tibia, but such movements can be executed to a slight extent when the joint is flexed. During extension the semilunar cartilages are moved forward, being, as it were, squeezed out of place, and during flexion they return to their original position.

The movements of the patella on the femoral trochlea take place simultaneously with the flexion and extension movements between the femur and the tibia. The patella is made to ascend on the trochlea when the quadriceps muscle contracts—an action which necessarily entails the extension of the leg, since the straight patellar ligaments are inserted into the tibia. For the same reason, when the leg is flexed the patella is made to descend again on the trochlea. These movements of the patella are a combination of gliding with *co-aptation*, that is to say, while the bone moves up or down as a whole, successive areas of its articular surface come into contact with the femoral trochlea.

#### TIBIO-FIBULAR ARTICULATION.

The head of the fibula is articulated to the outer tuberosity of the tibia, forming an obscure diarthrodial joint. Short, strong, **peripheral fibres** pass between the two bones, and bind them very closely together. Beneath this point the bones have a synarthrodial union, a membranous **interosseous ligament** connecting them together, and filling up the tibio-fibular arch. This ligament is perforated superiorly by the anterior tibial vessels, and just above the aperture for their transmission the fibres of the ligament are disposed in opposite directions, like the limbs of the letter X. Beneath the tibio-fibular arch, where the slender body of the fibula comes into contact with the outer edge of the tibia, the bones are united by short **interosseous fibres**; and from the lower end of the fibula a **round cord** of fibres is continued to the external malleolus of the tibia. In reality this cord represents an unossified part of the shaft of the fibula, and as already stated (p. 148), the external malleolus is the lower epiphysis of the same bone.

No appreciable movements are executed between the tibia and the fibula of the horse. In keeping with this, the articular surface of the head of the fibula, and the facet of the tibia to which it is opposed, lack the smooth polished character of diarthrodial surfaces in general.

## THE HOCK JOINT.

This, like the knee, is not a simple joint, but a complex series of joints, to which appertain a great many distinct ligaments. The simplest and most systematic order of study for these ligaments is to take first those that bind together the several tarsal bones, proceeding in imagination to build up the tarsus out of its separate elements, and to leave until the last the ligaments that are common to the whole tarsus, and those that unite the tarsus, as thus built up, to the lower end of the tibia.

The **intercunean ligament** is interosseous in position, and, as its name expresses, it unites the large and small cuneiform bones.

The **scaphoido-cunean ligament** is also interosseous. It unites the scaphoid to the large cuneiform, its short fibres being inserted into the non-articular or excavated parts on the opposed surfaces of the two bones.

The **cuboido-scaphoid ligaments** are two—an anterior and an interosseous. The *anterior* ligament is of small size, and passes between the cuboid and the scaphoid, above the entrance to the vascular canal by which the perforating metatarsal artery passes through the hock. The *interosseous* ligament connects the opposed surfaces of the two bones, forming, as it were, the roof of the same canal.

The **cuboido-cunean ligaments** are also two—an anterior and an interosseous. The *anterior* ligament passes between the two bones on the anterior aspect of the hock, below the entrance to the above-mentioned vascular canal. The *interosseous* ligament unites the bones where they are opposed to one another in the interior of the hock.

The **calcaneo-astragaloid ligaments**, as the name expresses, unite the os calcis and the astragalus. They

are four in number—a superior, two lateral, and an interosseous. The *superior* ligament is composed of short fibres connecting the bones above

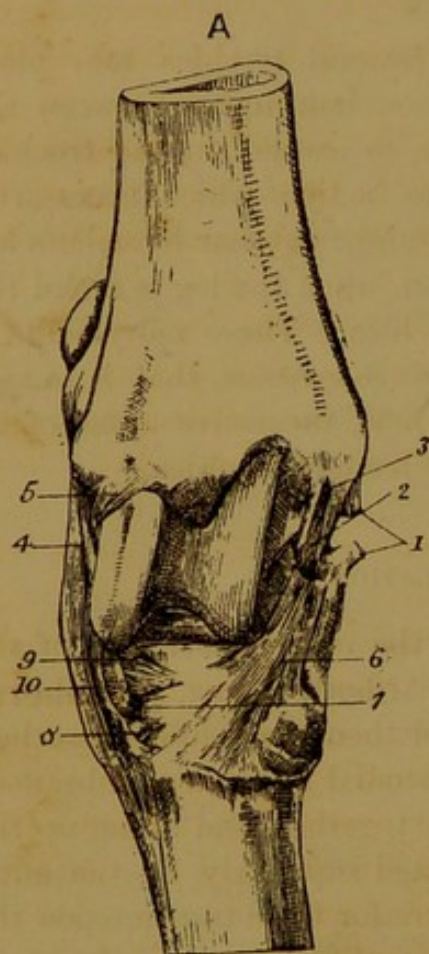


FIG. 150.—RIGHT TARSUS OF HORSE, VIEWED FROM THE FRONT.

- 1, 2, and 3.—Superficial, middle, and deep divisions of internal lateral ligament; 4 and 5. Superficial and deep divisions of the external lateral ligament; 6. Astragalo-metatarsal ligament; 7. Canal for perforating metatarsal artery; 8. Anterior cuboido-cunean ligament; 9. Anterior cuboido-scaphoid ligament; 10. Cuboid insertion of the flexor metatarsi.

their surfaces of contact, the *lateral* ligaments pass between them on each side, while the *interosseous* ligament is buried between the two bones, being implanted into the rough areas between their articular facets.

The preceding ligaments serve to bind the tarsal bones into two sets, the upper set comprising the os calcis and astragalus, and the lower the cuboid, scaphoid, and cuneiform bones. The next four ligaments may be viewed as intended to bind these two sets to each other, though, with the exception of the first, they at the same time unite the tarsus to the metatarsal bones.

The **astragalo-scaphoid ligament** is an interosseous ligament completely concealed while the bones are in position. It is composed of short fibres closely uniting the lower surface of the astragalus to the upper surface of the scaphoid, being attached to the non-articular depressions of these surfaces.

The **calcaneo-metatarsal ligament**. This strong ligament is situated at the back of the hock, being attached to the hinder edge of the tuber calcis, to the cuboid, and the head of the outer small metatarsal bone.

The **astragalo-metatarsal ligament** is situated on the antero-internal aspect of the tarsus. Its fibres are attached superiorly to the inner surface of the astragalus, from which its fibres radiated downwards and forwards to end on scaphoid, cuneiform magnum, and large metatarsal bone.

The **tarso-metatarsal ligament** is placed behind the tarsus. It forms a thick layer of fibrous tissue, closely adherent to the tarsal bones, and to the heads of the metatarsal bones. Its inner edge blends with the internal lateral ligament of the tibia-tarsal joint, and its outer with the calcaneo-metatarsal ligament. The anterior face of the ligament, where not adherent to the bones, is lined by synovial membrane, and its posterior face is overspread by the synovial membrane of the tarsal sheath. Inferiorly this ligament is continued as the *subtarsal* ligament, or check band of the flexor perforans tendon.

The following four ligaments are **tibio-tarsal**, that is to say, they belong specially to the joint formed between the tibia and the tarsus, or, to speak more precisely, between the tibia and the astragalus.

The **external lateral ligament** consists of a superficial and a deep fasciculus, which are intercrossed. The *superficial* division, which is much the larger of the two, is fixed superiorly to the posterior part of the external malleolus, and inferiorly its fibres end on the astragalus, os calcis, cuboid, large metatarsal, and outer small metatarsal. It is perforated by a thecal canal for the passage of the peroneus tendon. The *deep* bundle of fibres extends downwards and backwards from its point of attachment to the forepart of the external malleolus, and it ends by distinct slips on the astragalus and the os calcis.

The **internal lateral ligament** comprises three sets of fibres, which may be distinguished as superficial, middle, and deep. The *superficial* division, the largest of the three, is fixed superiorly to the internal malleolus, from which point its fibres descend over the inner side of the tarsus, ending on the astragalus, scaphoid, large and small cuneiforms, and large and inner small metatarsal bones. The *middle* division is attached, beneath the preceding, to the internal malleolus, and inferiorly it ends on the astragalus and os calcis. The *deep* division is a slender bundle of fibres stretching between the internal malleolus and the astragalus, under cover of the middle fasciculus.

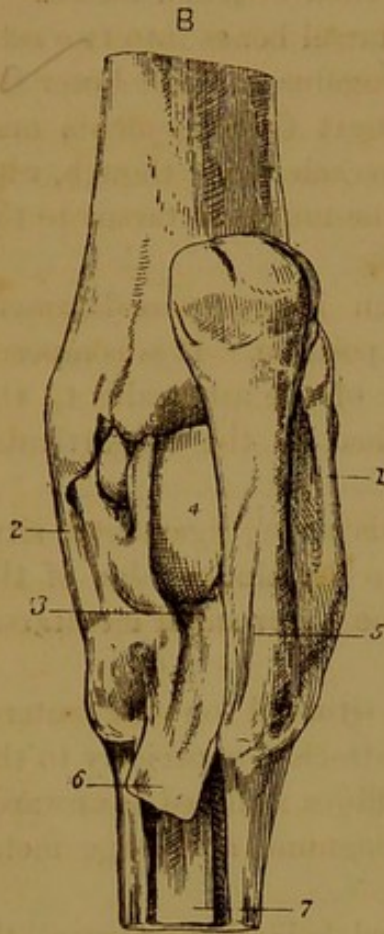


FIG. 151.—RIGHT TARSUS OF HORSE, VIEWED FROM BEHIND.

1. External lateral ligament;
2. Internal lateral ligament;
3. Tarso-metatarsal ligament;
4. Fibro-cartilaginous thickening of posterior ligament;
5. Calcaneo-metatarsal ligament;
6. Subtarsal ligament;
7. Suspensory ligament.

The **anterior ligament** is a membranous capsular ligament designed to enclose the tibio-astragaloid joint in front, and give support by its deep face to the synovial membrane. It is fixed above to the tibia, and below to the astragalus, scaphoid, and cuneiform magnum, blending in part with the astragalo-metatarsal ligament. On either side it blends with the lateral ligaments. The anterior or superficial face of the ligament is related to the anterior tibial vessels and to the flexor metatarsi and extensor pedis tendons. These tendons afford it support, except at its antero-internal part, where, consequently, it is bulged out as a "bog-spavin" when there is an excess of fluid in the joint.

The **posterior ligament** is somewhat similar in form and purpose to the preceding, completing the tibio-astragaloid joint posteriorly. It is fixed to the tibia above, to the astragalus below, and to the lateral ligaments at the sides. Its anterior face is lined by the synovial membrane of the joint, while its posterior surface is overspread by the synovial membrane of the tarsal sheath. It presents a fibro-cartilaginous thickening for the play of the perforans tendon. This tendon affords support to the ligament, and resists to some extent its backward distension; but when there is a great excess of fluid in the joint, the ligament yields, and is pushed out on either side of the tendon, above the before-mentioned fibro-cartilaginous thickening.

**Synovial membranes.** There are three principal synovial capsules

in the tarsus, viz. (1) tibio-tarsal, (2) inter-tarsal, and (3) tarso-metatarsal. The **tibio-tarsal** synovial membrane is the largest and most important. It lubricates the joint between the tibia and the astragalus, being supported by the anterior, posterior, and lateral ligaments of that articulation. It sends a prolongation to supply the upper two calcaneo-astragaloid facets, and it communicates with the next capsule. The **inter-tarsal** synovial membrane lubricates the joint formed between the os calcis and astragalus as representing the upper row of tarsal bones, and the cuboid and scaphoid as representing the lower. It is prolonged above to supply the two lower calcaneo-astragaloid facets, and below to lubricate the anterior cuboido-scaphoid articulation. The **tarso-metatarsal** synovial membrane belongs specially to the articulation between the cuboid and cuneiform bones above and the metatarsal bones below. It also supplies the articulations between the large and small metatarsal bones, the articulation between the two cuneiforms, and the anterior articulation between the cuboid and the large cuneiform. A fourth synovial membrane, which may be termed the **scaphoido-cunean** synovial membrane, lubricates the joint between the scaphoid and great cuneiform, and sends prolongations to the posterior articulations between the cuboid and these two bones.

**Movements.** The only important joint in the hock, as regards the range of its movement, is the tibio-astragaloid articulation, sometimes termed the true hock-joint. It is a typical ginglymus, the only movements permitted being flexion and extension. When the horse stands squarely on his four legs, the tibio-tarsal angle measures from  $155^{\circ}$  to  $160^{\circ}$ , the inclination of the tibia being  $65^{\circ}$  to  $70^{\circ}$ , and the tarsus and metatarsus being approximately vertical. During flexion the pes is carried forwards; and, owing to the oblique character of the pulley of the astragalus, the metatarsal bones do not move in the plane of the tibia, but deviate a little outwards. This movement is very free, and may be carried so far as to close the normal articular angle. The movement of extension cannot be carried so far as to obliterate this angle by bringing the leg and metatarsus into line, this being prevented by tension of the lateral ligaments. These same ligaments, coupled with the form of the articular surfaces, effectually prevent lateral or rotatory movements in the joint.

The movements permitted in the other tarsal articulations are of a very restricted character, consisting merely in a slight gliding movement between the opposed surfaces. As in the knee these small joints play an important rôle in distributing and equalising pressure in the joint.

It is unnecessary to describe the remaining articulations of the hind

limb, these resembling in the closest manner the corresponding joints of the anterior member.

## COMPARATIVE.

**Hip Joint.** As already stated, the pubio-femoral ligament is not present in any of the domestic species save the horse and the ass. Its absence permits a greater range to the movement of abduction, as is exemplified by the force and ease with which a cow can kick in the lateral direction.

**Stifle Joint.** In the **sheep, pig, and carnivora** there is only one straight patellar ligament, and a single synovial membrane for the femoro-patellar and femoro-tibial articulations. In the **dog** the two interarticular fibro-cartilages are connected anteriorly, and the articulations between the femoral condyles and the fabellæ are supplied by the common synovial membrane of the joint.

**Tibio-fibular Articulations.** These joints are absent in the **ruminants**. In the **carnivora** the leg bones are articulated by a diarthrodial joint at either extremity, while their shafts are united by an interosseous ligament. In the **pig** the disposition is the same, save that the superior union is a kind of amphiarthrosis, the articular surfaces being united by an interosseous ligament.

**Hock Joint.** Of all the domestic animals the horse is the one in which the movements at the tarsus are most restricted. This applies more particularly to the secondary articulations of the tarsus, such as the calcaneo-astragaloid and astragalo-scaphoid joints, in which, in the other species, the facets are less flat, and therefore more favourable for movement.



