

Arteria uterina ovarica : the utero-ovarian artery, or, the genital vascular circle, anatomy and physiology, with their application in diagnosis and surgical intervention / Byron Robinson.

Contributors

Robinson, Byron 1857?-1910.

Publication/Creation

Chicago : E. H. Colegrove, 1903.

Persistent URL

<https://wellcomecollection.org/works/dzjs8g2u>

License and attribution

Conditions of use: it is possible this item is protected by copyright and/or related rights. You are free to use this item in any way that is permitted by the copyright and related rights legislation that applies to your use. For other uses you need to obtain permission from the rights-holder(s).

**wellcome
collection**

Wellcome Collection
183 Euston Road
London NW1 2BE UK
T +44 (0)20 7611 8722
E library@wellcomecollection.org
<https://wellcomecollection.org>


THE UTERO-OVARIAN ARTERY

BYRON ROBINSON



22500559749

Med
K44258



UNIVERSITY OF LONDON
G. W. MEDICAL
LONDON
24.12.1903

Col -

Arteria Uterina Ovarica e. #7

Quain 10-
Anat. 475-2

THE UTERO-OVARIAN ARTERY

OR

The Genital Vascular Circle

Anatomy and Physiology, with their Application
in Diagnosis and Surgical Intervention.

BYRON ROBINSON, B. S., M. D.
CHICAGO, ILL.

Author of "PRACTICAL INTESTINAL SURGERY," "LANDMARKS IN GYNECOLOGY,"
"LIFE-SIZED CHART OF THE SYMPATHETIC," "ABDOMINAL BRAIN,"
"COLPOPERINEORRHAPHY AND THE STRUCTURES INVOLVED," "THE URETER," "GYNECOLOGIC
CHARTS OF GENITAL CIRCULATION."

The object of research is the benefit it may confer
and not merely to know the truth.

Chicago, Ill.
E. H. COLEGROVE,

1903



COPYRIGHTED BY
BYRON ROBINSON,
1903.

10881944

WELLCOME INSTITUTE LIBRARY	
Coll.	WelMCmac
Coll.	
No.	NP

PREFACE.

The following monograph is presented to the medical profession in the hope that it will contribute to the progress of medical science. The data on which the monograph is based were secured through fifteen years of experimental research and many years as a gynecologist. There is practically so far no recognized literature on the arteria uterina ovarica except the four excellent essays by Jules Broeckheart, 1892; Semmy Davidson, 1892; Wilhelm Nagel, 1897, and Pierre Fredet, 1899. Other short valuable contributions had previously appeared in anatomic works. M. J. Weber, 1830, presented a fairly well executed illustration of a pregnant uterus. In 1839 M. J. Bourgery presented a good cut of the circulation of a puerperal uterus one-half life size, drawn by N. H. Jacob. In 1864 the remarkable anatomy of Hubert Luschka appeared, noting new views on the arteria uterina ovarica. In 1870 the epoch making work on the arteria ovarica of Joseph Hyrtl appeared. It was based on corrosion anatomy and will stand forever as a monument of industry. Jacob Henle's excellent work on this artery was published in 1876. The latest work on *this subject* is from the Prince of German anatomists, W. Waldeyer, "Das Becken" (The Pelvis) 1899. Soligoux published an instructive but very short article in 1901. The Surgeon General's catalogue does not mention this artery. Numerous dissections, injections and corrosion anatomy aided by the X-ray has enabled me to confer additional points of interest on the arteria uterina ovarica. The most accurate anatomic methods are secured by the use of celloidine or paraffin and acid e. g., HNO_3 , *corrosion anatomy*.

The arteria uterina ovarica (spiral segment) with a part of the abdominal aorta, common iliac and internal iliac was published some years ago as the "circle of Byron Robinson."

As new features we present the utility of the genital vascular circle in surgical intervention on the tractus genitalis. On account of the mobility and capacity for extension of the genital vascular circle, the internal genitals may pass to the diaphragm (as in pregnancy) or be drawn through the pudendum with traction forceps for palpation, inspection or repair without loss of integrity. The genital vascular circle has more utility in medicine than the circle of Willis (1622-1675) which doubtless by its volume governs cerebral phenomena.

For the purpose of defunctionating the tractus genitalis as regards reproduction and menstruation without ablation of organs or ligation of arteries we present the operation of endometrectomy and partial myomectomy. In this monograph so far as I am aware is presented for the first time a description of

the genital vascular circle, the important arterial cervical loop which is so frequently ligated in surgical intervention on the tractus genitalis. The ovarian vascular circle, the lateral cervical triangles, a constant artery of the ligamentum latum and the bifurcations of the arteria uterina ovarica are also presented for consideration. Besides the cervical vascular zone the four oligemic (exsanguinated) uterine zones, the proximal middle and distal arterio-ureteral crossings, anatomic landmarks, useful in diagnosis and surgical work, are noted. Labor in comparative anatomy demonstrates that the genital vascular circle is the same in animals and man. The accompanying illustrations demonstrate the genital vascular circle not only in man but guinea-pig, dog, cat, rabbit, leopard, cow, sheep, pig, horse, monkey and baboon. The genital vascular circle of higher erect apes resembles almost exactly that of man as will be noted in the cut of the golden faced baboon (*cyno-cephalus*).

The carnivora, cat, herbivora, cow, soliped, horse, present a circle exactly resembling that of man but with the addition of a large vaginal arterial branch from the pudic anastomosing with the uterine making in quadrupeds a quadrupedal genital vascular arch while in man a tripedal genital vascular arch exists. The utero-ovarian vascular arc courses the closest to the genitals, i. e., it has the shortest rami laterales genitales in the cat (*carnivora*) while in the dog and rabbit the genital vascular arch courses the most distant from the uterus, i. e., has the longest rami laterales genitales. The guinea pig possesses the most circular form of the genital vascular circle. Many observations will be found included in the description of the cuts as the direct demonstration of the view may be there observed.

The monograph will be accompanied by illustrations representing the different phases in the life of the genital vascular circle facilitating surgical procedures and the explanation of its age and functional relations.

Much time has been spent in securing accurate and reliable illustrations from nature. The labor in producing the illustrations has many times exceeded that of the text. Repetition occurs in the book due, however, to the fact that each chapter is practically complete in itself and also that the vast functional changes in the utero-ovarian artery—as in gestation—calls for an extra chapter of observation.

The accurate and excellent X-ray work of the extended investigation on the arteria uterina ovarica was performed in Dr. Harry P. Pratt's X-ray and electro-therapeutic Laboratory, for which I am indebted.

I wish to present my thanks to the following persons who assisted me in the investigation of this subject: Drs. Robert Gregg, Elizabeth Brady, William E. Holland, Ida Schell, Prof. W. A. Evans, Rodney Ludlow, S. Josephine McCollum, Savage, Jones, E. C. Fortner, O'Byrne and F. Harris.

April, 1903.

THE AUTHOR.

THIS MONOGRAPH IS DEDICATED TO
DR. HENRY T. BYFORD,
IN RECOGNITION OF HIS EMINENT SERVICES
IN GYNECOLOGY.




Fig. 1—Half-tone puerperal uterus 5 days post partum and 1 day post mortem. About half life size. Age 24. Primipara.

Death was due to traumatism of instrumental delivery followed by extra peritoneal sepsis, as no peritonitis was visible at the autopsy. This uterus was injected in situ with celloidin and vermilion; several days later it was injected with red lead and starch. It was taken in Dr. Pratt's X-ray and electro-therapeutic laboratory and magnified as a so-called bromide plate and photographed. The artist, Dr. Scholer, strengthened the defective outlines of the vessels by the pen.

This specimen shows a typical genital vascular circle; e. g., an extended or straight pelvic floor (1, 2, 3, 4) and uterine (4, 5, 6,) segment an ovarian vascular circle (6, 7, 9,—6, 8, 9). The oviducal segment (6, 7, 9,—6, 8, 9,) is rich in rami laterales. These vessels to the ovary (38) show exceedingly well. This cut presents the usual typical 3 rami laterales oviductus arising from the ramus oviductus. It presents the evidence that the arteria ligamenti lati number (34), is an established and constant vessel. Observe the ovarian arcs and arcades. On the right side the cervical loop persists like a twisted rope. On the left side the ovarian vascular circle is divided at 9 by a connecting vessel at the point where it crosses the ureter. A similar affair appears on the right side. A wire distinctly visible in the cut (20, 19), was passed through each ureter.

It will be noted that the distal cervical arteries are limited in number, which is due to the trauma of the obstetrical forceps occluding the vessels luman to such a degree that complete injection was not possible. The tripodal genital arch is plain in this illustration; i. e., internal iliac, 17, common iliac and aorta, 12.

The ovarian segment of the circle (from 10 to 12) was completed by employing that of a pregnant subject, 3 months pregnant. It appears that the oligemic uterine zones are obliterated from the maximum distention of uterine vessels. Observe the beautiful rich oviducal circulation with its 3 rami laterales oviductus (31, 32, 33) and how far distalward it appears to be removed from the fundus of the uterus. 40, 40 shows the fine rich blood supply to the oviducal pavilion. The bromide plate was magnified 30x30 inches and the artist strengthened the arterial lines with the aid of a strong magnifying lens in order that the cut should be true to nature. With all the care employed many small vessels escaped being brought in evidence. For numbers see general description page.

For out see viii.

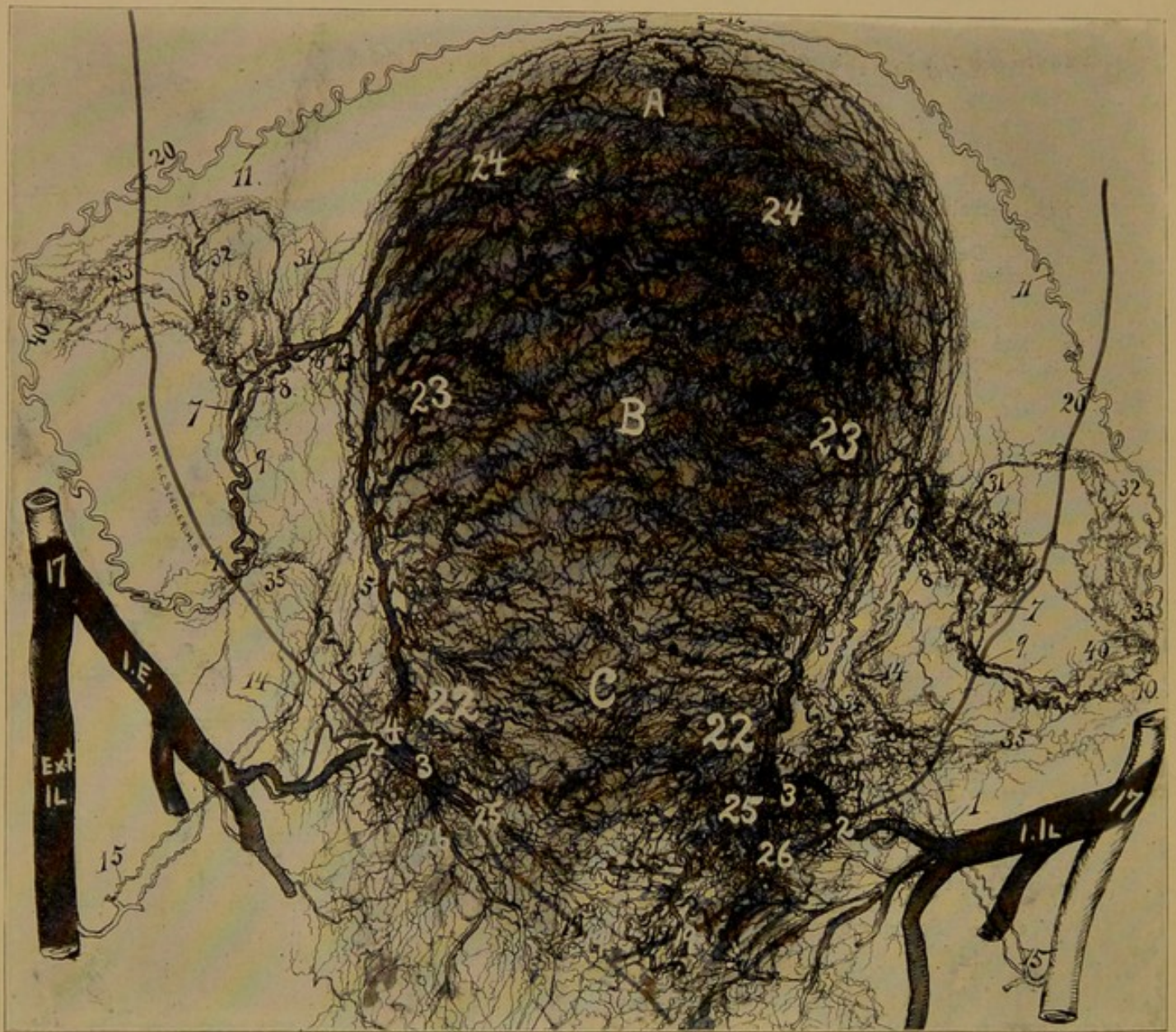

Fig. 1—Half-tone illustration from an X-ray of the circulation of a puerperal uterus 5 days post partum, presenting the utero-ovarian artery or genital vascular circle (1, 2, 3, 4, 5, 6, 7-8, 9, 10, 11, 12).

For description see front of this page.

CHAPTER I.
ARTERIA UTERINA OVARICA—THE UTERO-OVARIAN ARTERY—
THE SPIRAL SEGMENT OF THE GENITAL VASCULAR
CIRCLE.

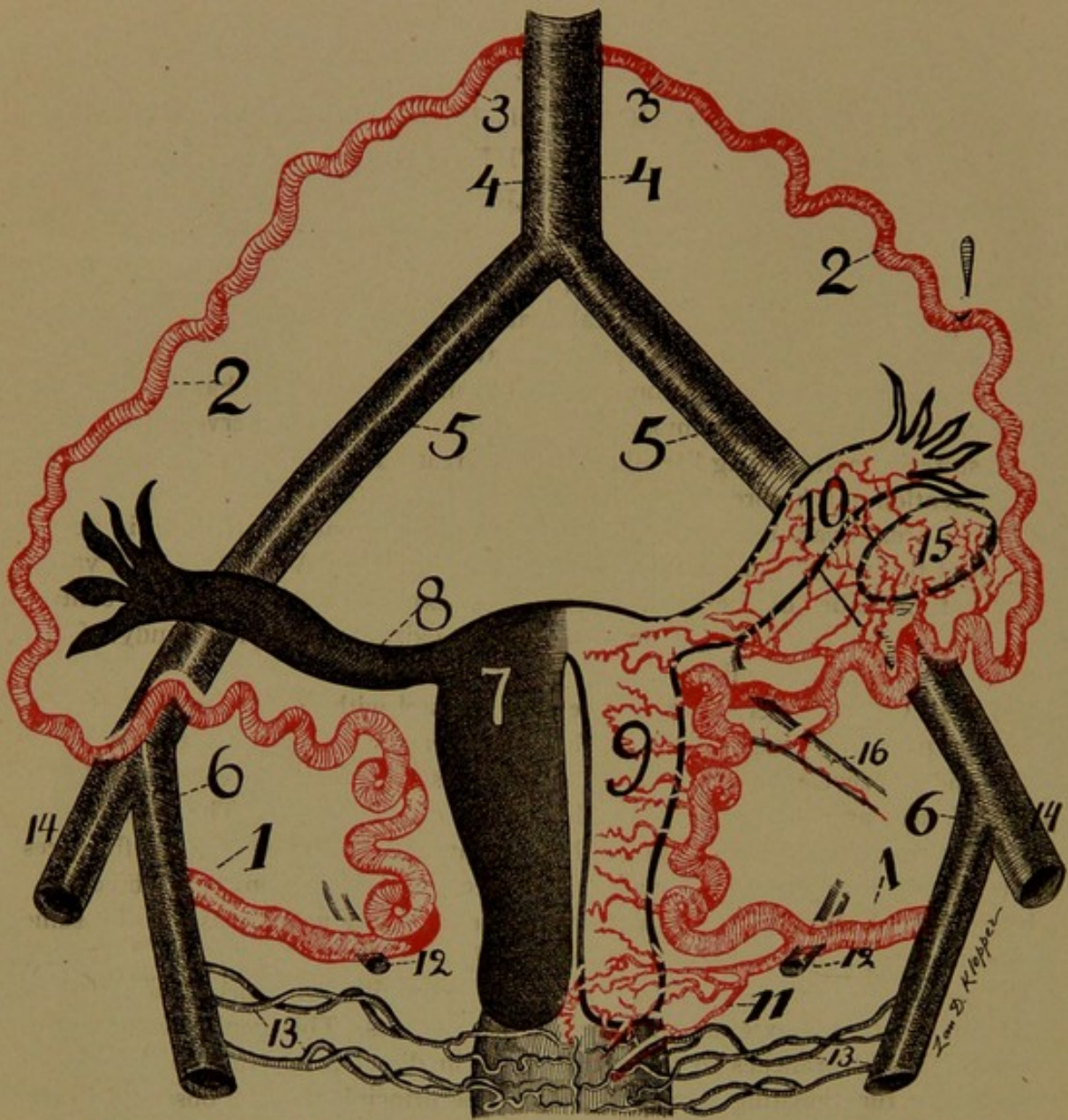
GENERAL REMARKS.

Surgery is the mother of practical anatomy. Since hysterectomy has become a recognized, useful operation, physicians have studied with care and detail the utero-ovarian artery. Hysterectomy, as well as ureteral relations, has dignified the utero-ovarian into the most important of arteries. Surgical intervention—which lessen suffering and prolong life—has made it great. Even anatomists did not pay much attention to it before the epoch of hysterectomy. The profound modification which the utero-ovarian artery experiences both locally and functionally in development of the genitals, makes it an object of rare interest. A wide range of variations and anomalies of the spiral arterial loop explains the existence of contradictory opinions. So far as I am aware there exists no complete study of the vessels of the internal genitals.

I shall view the utero-ovarian artery as a vessel with a triple origin.

The primitive anastomosis of the utero-ovarian occurred in the Wolffian body, and by development the distal organs passed into the greater and lesser pelvis of man and the higher apes, due to the erect attitude. The anastomosis may have resulted in modification of the primitive plan as noted in the differences in its course in animals and man. It is necessary to demonstrate objectively whether modifications exist, or whether in the adult the anastomosis is the same as in the fetus, and according to a general plan.

The utero-ovarian artery is an arcade, the extremities of which arise from the abdominal aorta, the external and internal iliac arteries. This genital vascular arc sends off lateral branches to the genital tract in direct proportion to the importance of the functioning segments. The same principle may be observed in the arcs and arcades of the *vasa intestini tenuis*. Several views as regards the location of anastomosis of the utero-ovarian artery may be considered, viz: First, that the anastomosis occurs at the ovary; second, that it occurs at the point of exit of the cervico-vaginal artery; and third, that it takes place at the utero-oviducal angle; but practically none of these views is tenable, because the utero-ovarian artery is a persistent arcade of the Wolffian body. As regards the three original, persistent anastomotic branches of the genital vascular circle forming the utero-ovarian artery from the Wolffian body, the uterine was carried during development distally into the pelvis from the Wolffian in the direction of the internal iliac; the artery of the round ligament was carried distally in the direction of the external iliac, while the ovarian artery retained its original position near the kidney.



THE UTERO-OVARIAN ARTERY—THE CIRCLE OF BYRON ROBINSON.*

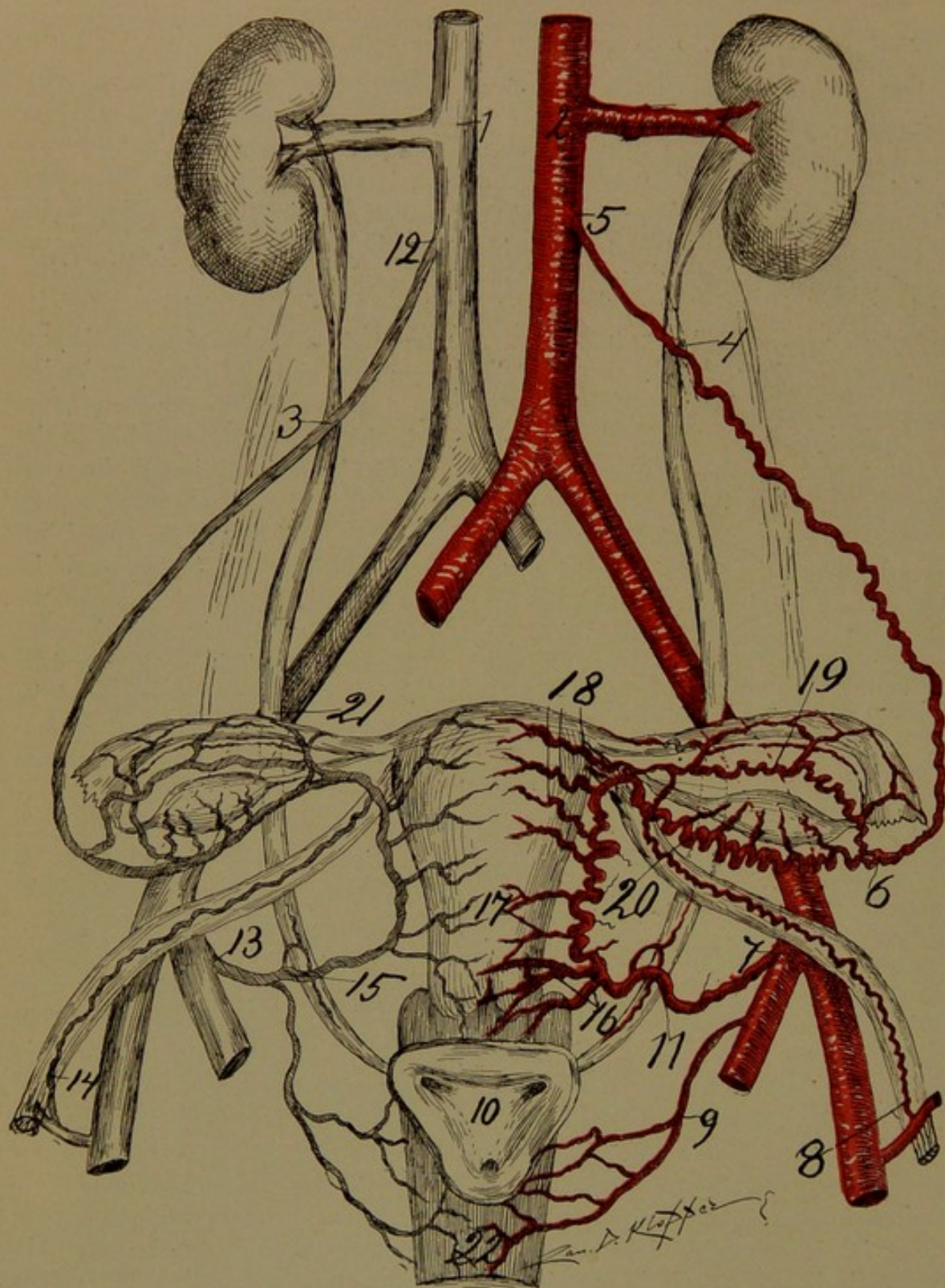
Fig. 2—1, 2, 3, the utero-ovarian artery, the spiral segment of the genital vascular circle; 4, the aorta; 5, the common and 6, the internal iliacs, the straight segment of the genital circle.

* Dr. Wm. E. Holland—American Journal Surgery and Gynecology—December, 1900).

This disposition of the arteries is plainly seen in comparative dissections of lower animals, the distal and proximal extremities of the utero-ovarian arc being quite near together.

The uterus receives blood from three sources: (a) abdominal aorta, (b) hypogastric, and (c) epigastric inferior. Hence, the exact directions of currents and space supplied by each of the three arches are not precisely fixed, as is shown by injections. From the dissection of lower animals it appears that the artery of the round ligament is simply a persistent median branch of the Wolffian body. In general, the typical internal genital blood-supply consists of prominent lateral branches issuing from the spiral segment of the genital vascular circle, especially at the cervix, fundus and ovary, with pavilion (sphincters or divisions of genitals). The spiral segment of the genital vascular circle is located along the lateral borders of the genitals, more or less removed from them and hence allowing varied motions to different segments of the same. In dogs and rabbits the utero-ovarian artery is widely distant from the genitals; in the cat it is close; while in the human it is at a moderate distance, say one-third of an inch. Injected, dissected specimens in man and lower animals appear to prove that the three persistent branches of the Wolffian body are the uterine, ovarian, and that of the round ligament, producing a typical tripod vascular arch. A logical conclusion would be that the ovarian branch supplies the ovary and the uterine branch supplies the uterus; while the round ligament is supplied by its own branch, with variations for developmental changes, especially attitude. The internal genitals are irrigated by the rami laterales of the utero-ovarian spiral segment and not by the trunk of the same. Injections in comparative anatomy demonstrate that the original anastomosis of the Wolffian body, or the primitive plan of the genital circulation, is not destroyed in adults.

The investigations of the utero-ovarian artery should be carried on through fetal life, childhood, puberty and the gestative, puerperal and senescent stages. It must be remembered that the character of injections alters the conditions of the genital vascular circle, especially the spiral segment with its lateral branches. Vast changes may be observed during injection and more arise later. The uterine artery is not so elastic as the myometrium, and hence after expulsion the rapid contraction of the myometrium forces the utero-ovarian artery into loops. The most important plan of study of the uterine artery (aside from comparison of animals) is the embryologic development, because no distinction of sex exists for three months. At the third month, the ovary and testicle become macroscopically distinguishable. Comparative anatomy shows that the spiral segment of the utero-ovarian circle possesses lateral branches for the internal genital tract—as in bicornuate uteri—dog, cow, cat, rabbit, pig, etc. There are three kinds of anastomosis in the genitals, viz:—longitudinal, perpendicular and transverse. The longitudinal anastomosis is much less than the transverse and exists chiefly at the uterine border. All rami laterales intercommunicate; hence, one ligature does not produce hemostasis because the arteriæ uterinæ form an extensive vascular network. The branches of the utero-ovarian artery may be almost equal in volume to the trunk from which they spring. The utero-ovarian artery can be injected through the umbilical, the aorta, the femoral artery, or the ramus ligamenti teretis (limited). It is difficult of inspection on account of its treble origin.



THE PLAN OF THE GENITAL CIRCULATION.

Fig. 3—Its relation to the ureter. 1, vena cava; 2, aorta; 3 and 4, proximal arterio-ureteral crossing, also the apex of the author's uretero-venous triangles, formed by the ureter, renal, vena cava and ovarian veins; 5, origin of the ovarian arterial segment; 6, end of ovarian segment; 7, origin of the uterine artery; 8, origin of the artery of round ligament; 9, vaginal artery; 10, vesical trigone; 11, distal arterio-ureteral crossing; 12, exit of ovarian vein in vena cava; 13, exit of uterine

vein; 14, exit of vein of round ligament; 15, distal uretero-venous crossing; 16, cervico-vaginal artery (note large size); 17, lateral corporeal uterine arteries (note small size); 18, fundal arteries; 19, ramus oviductus; 20, ramus ovarii; 21, middle arterio-ureteral crossing (at the flexura iliac ureteris); 22, vagina. The right side of the figure is arterial, showing the spiral segment of the genital circle (viz: 5, 6 and 7). The left side is the venous segment of the genital circle (viz: 12 and 13). Note that the spiral segment of the genital circle lies entirely ventral to the ureter which it crosses three times, intimately at 4 and 11. The segments of the spiral part of the genital circle are:—7 to 16, is the pelvic floor segment; 16, to the utero-oviducal angle is the uterine segment. From the utero-oviducal angle to 6 is the oviducal segment and from 6 to 5 is the ovarian segment.

The utero-ovarian is a single non-divisible artery, on account of its full macroscopic or stovepipe method of anastomosis. It has a treble origin, viz:—the ovarian segment arises from the anterior surface of the abdominal aorta close to the renal artery. The uterine segment arises from the anterior branch of the internal iliac artery (hypogastric) in the lesser pelvis. The artery of the round ligaments arises from the deep epigastric (inferior). I use the term utero-ovarian for the segments as the names are established in medical literature and the designations are perhaps more significant than any other. The utero-ovarian artery is the spiral segment of the genital vascular circle or the circle of the author.

A knowledge of the spiral segment of the utero-ovarian vascular circle demonstrates that it is always in accord with the state of the internal genitals.

A knowledge of the spiral segment of the utero-ovarian vascular circle is of the highest utility in gynecology and obstetrics, because this segment is accessible for surgical and medical measures.

The spiral segment is the small non-developed quiescent portion in childhood, the portion which rapidly springs into enlarged activity at puberty; a large, long and very tortuous portion in gestation, and again the quiescent and atrophic portion in senility. The internal genitals (the uterus, oviducts, ovaries) at puberty are supplied with a wonderful wealth and a luxuriant richness of blood, both macroscopically and microscopically, especially during the functioning crisis. The spiral segment rests in a vast mobile areolar bed, loosely connected with no organ except the uterus, ovary and peritoneum.

The utero-ovarian is a paired genital artery. Its treble origin from the aorta is due to development from the Wolffian body, which is located in the lumbar region. Gradually, with developmental changes and the assumption of the erect attitude, the genitals pass distalward into the lesser pelvis. The ovarian end of the utero-ovarian artery maintained its primitive location, while the uterine end shifted distalward from the erect attitude, into the lesser pelvis. A third end—that of the round ligament—moved distalward with the external iliac. The artery of the round ligament also shifted to the internal abdominal ring. The anastomosis between the uterine and the ovarian segments and that of the round ligament is so perfect that the beginning or ending of any segment cannot be located. The same is true in all the animals which I have examined.

It is not merely capillary; it is full arterial anastomosis. The macroscopic or stovepipe method of anastomosis in the utero-ovarian artery is a common factor in the body, as I will show in the accompanying cuts. The superior and inferior mesenteric arteries, with their numerous macroscopic or full anastomotic circles,

arcs and arcades, beautifully illustrate this condition. The gastro-hepatic vascular circle composed of the gastric, hepatic and pyloric arteries, and the circle of Willis are also good illustrations. See page 79.

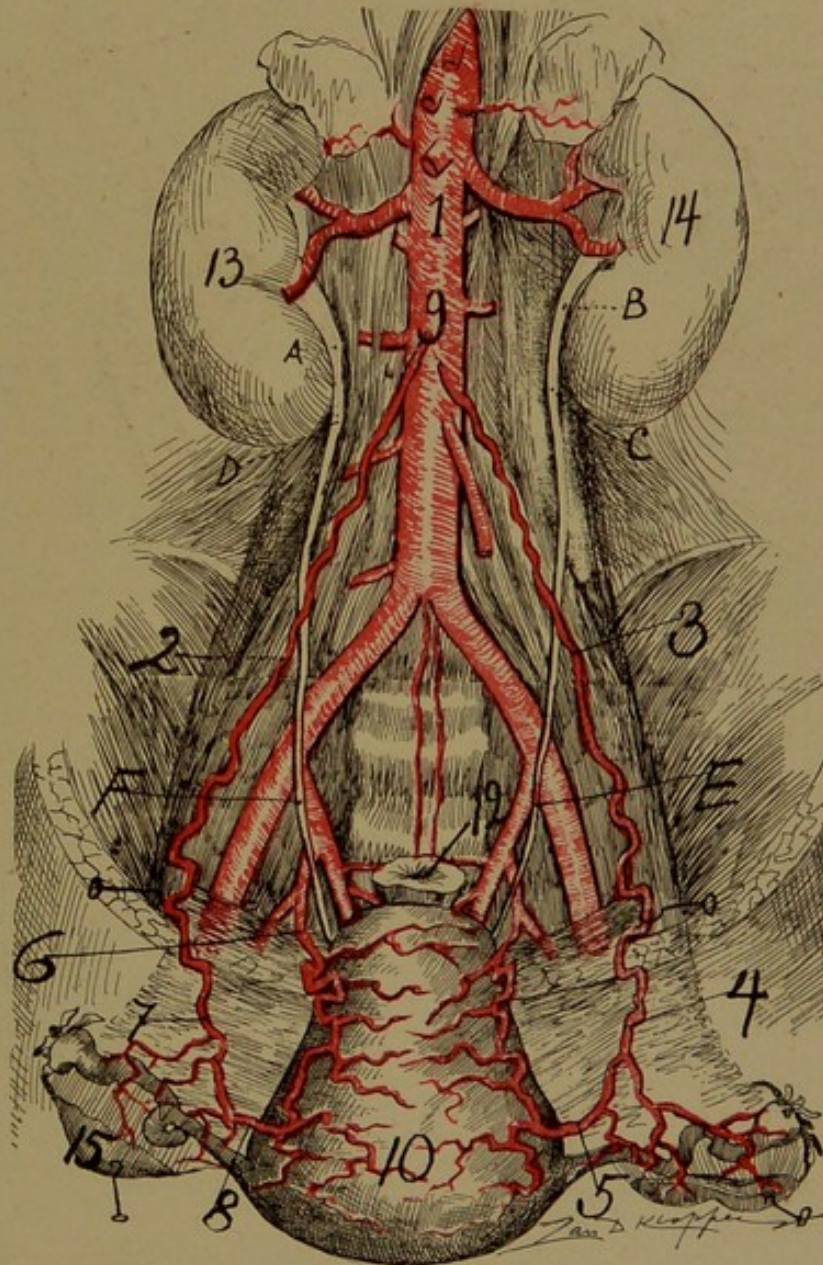
The utero-ovarian artery is much longer than the distance between its origins. The spiral segment of the genital circle being considerably longer than the distance between its origins, and having the genital tract attached well toward the middle periphery of the spiral segment, enables the internal genitals to pass proximally to the diaphragm, as in pregnancy. Moreover, the internal genital tract can be drawn with the traction forceps distally through the vagina, where inspection, palpation, vascular ligation and medical and surgical interventions may be practiced at leisure. In dogs, in the dried specimens, the spiral segment of the genital circle measures three to five times the length of the distance between the two origins of the utero-ovarian artery. In woman the length of the spiral segment is about three times the distance between its two origins. In the cow the distance between the two origins is not three inches. In the horse the utero-ovarian arises as two trunks—the large ovarian and uterine. There is also a large vaginal which anastomoses, stovepipe-like with the uterine. The dissections demonstrate a wide variation in the trunk and its rami laterales. The typical blood-supply of a mammal's uterus is at the cervix (same as man's, cervico-vaginal), at the fundus uteri (man, rami fundi), and at the ovary (with pavilion). This accords with the function and functioning segment of the genital tract. In all animals dissected I found that the strongest and longest rami laterales tended toward the point of gestation (placental site), i. e., toward the fundus in man, ape, and the more erect monkey, while in animals with bicornuate uteri, cow, dog, sheep, cat, they tend toward the uterine horns where gestation occurs (placental site).

Through the major course of the utero-ovarian artery it gives origin to small, fine branches, which become adherent to and supply the walls of the numerous accompanying large adjacent veins. The utero-ovarian artery supplies the uterus with blood from three sources, insuring triple nourishment. This enables any segment of the internal genital tract (uterus or oviduct), as in the intestinal tract, to concentrate the blood-current at any required point, e. g., wherever gestation may begin (intra and extrauterine). The utero-ovarian artery lies close to two genital segments, viz:—the uterus and ovary. The remaining portion of the genital tract—the vagina and oviduct—receives its branches—the vaginal and oviductal—at long distances from the utero-ovarian. The utero-ovarian artery is an effectual genital support.

The hypogastric pedicle, with its cord, is the most effective means of uterine fixation. The cord contains artery, vein, nerves and connective tissues. It shows its supporting power by the fact that in its absence, as in bilateral castration, the uterus passes distalward; also in sacropubic hernia. During pregnancy or internal genital stimulation, the spiral segment of the utero-ovarian vascular circle experiences wonderful changes, enormous development. In the dog, cat and rabbit, the rami laterales uteri appear to be elongated three times the original length at the several points of gestation.

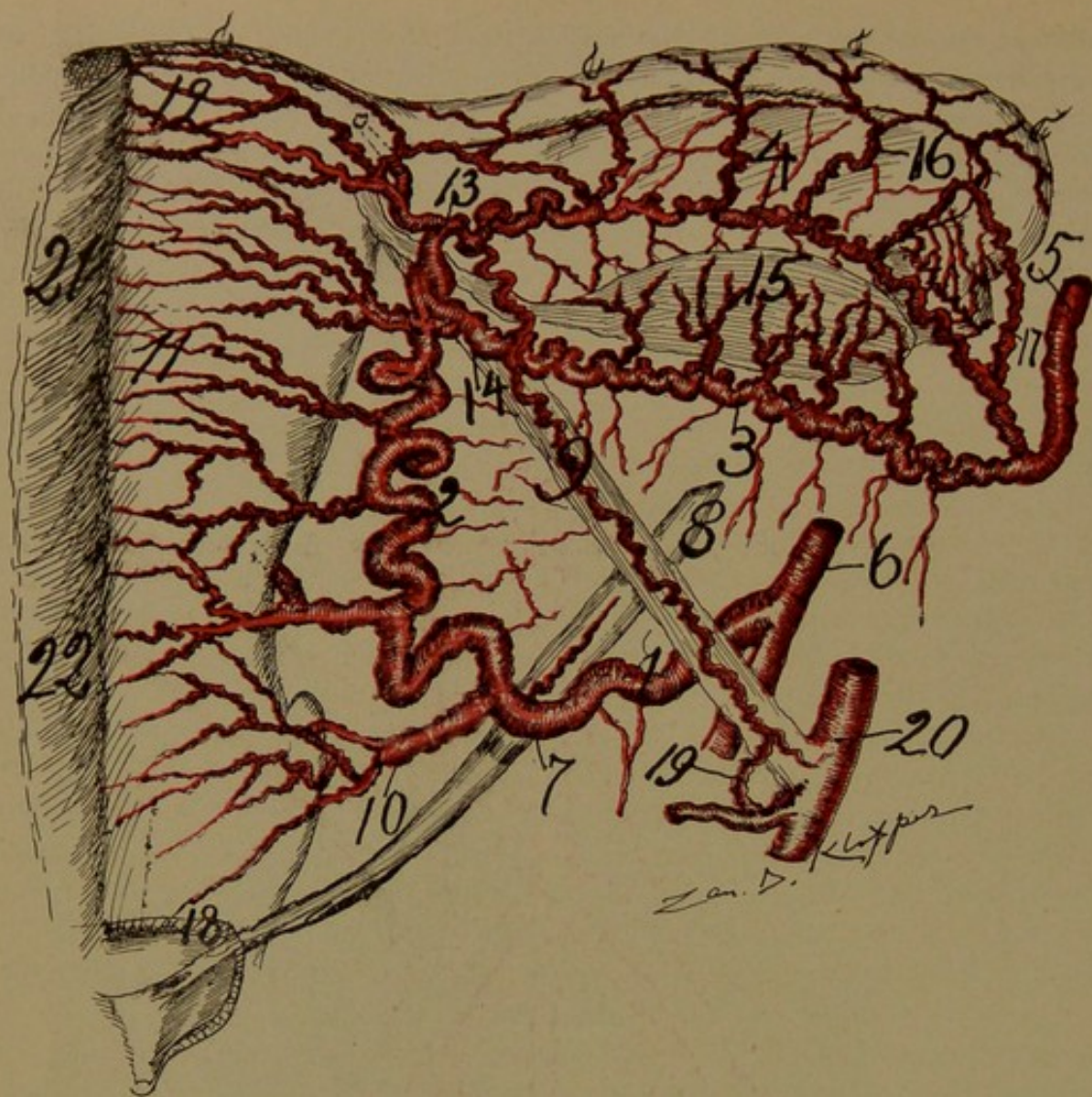
The spiral segment of the genital circle is difficult to investigate on account

of limited records and material, and also on account of the profound modifications of the artery at different epochs and functional crises of life. Besides, anomalies in its evolutionary development explain differences of views. It requires laborious research to clear up its obscurities, and the artery is still in the stage of research. The relation of the utero-ovarian artery to adjacent structures, as the vagina, cervix, uterus, ureter, ovary and oviduct, modern surgery has dignified into profound importance. It varies in distribution and course. The interesting subject of varying function of the proximal and distal segments of the uterus, may



THE UTERO-OVARIAN VASCULAR CIRCLE.

Fig. 4—Illustrates the genital circle in a child a year old. 1, aorta; 2 and 3, the proximal arterio-ureteral crossing; 4 and 5, portions of the spiral segment; 9, 2, 7, 8 and 6, is the whole spiral segment; 10, posterior uterine surface; 12, rectum; 13 and 14, kidneys; 15, ovary; E and F, middle arterio-ureteral crossing. Note that the spiral segment of the artery is only slightly tortuous in a child. Gestation completely develops the utero-ovarian artery.



THE UTERO-OVARIAN VASCULAR CIRCLE.

Fig. 5.—Woman, 50 (anterior view). I first made a careful dissection and later drew the vessels and branches as accurately as possible after it was dried. Mr. Klopper, my artist, made the drawing after this model. The uterus was about double the normal size from the existence of sarcoma in the endometrium which caused the arteries to be about the size of a 3 months' pregnancy. 1, uterine (pelvic floor segment); 2, uterine segment; 3, ovarian; and 4, oviducal branches of the oviducal segment; 5, fragment of ovarian segment; 6, internal iliac artery; 7, distal arterio-ureteral crossing at which point the uterine artery gives off the arteria ureterica distal; 8, ureter; 9, artery of round ligament; 10, cervico-vaginal artery; 11, lateral corporeal uterine branch; 12, fundal branches; 13, oviducal branch; 14, ovarian branch; 15, ovary receiving 5 (helicine) branches; 16, lateral oviducal branches; 18, mouth of ureter; 19, round ligament branch, from epigastric; 20, external iliac; 21 and 22, the superficial wall of the uterus dissected off to show the vessels. Senile atrophy has not begun in the spiral artery. Note how far the artery is located from the uterus. It is similar to that of the dog, rabbit and pig.

be studied by investigating the uterine artery during the gestative and puerperal states. The results of such studies, which, however, require vast material, will no doubt explain how the myometrium acts with such precision with its automatic living ligatures to control hemorrhage.

The utero-ovarian artery is spiral in its entire course and looped in local parts. It passes through a rich, yielding, mobile bed of connective tissue, which

accounts for its capacity for safe, rapid and extensive movements in all directions. It is accompanied by the rich plexus of vagino-utero-ovarian veins—the plexus pampiniformis. The extensive mobility of its bed explains the numerous and useful operations in which it is involved. The utero-ovarian artery crosses ventral to (above) the ureter three times. The pelvic floor segment crosses ventral and proximal to the ureter, making what I shall term the distal arterio-ureteral crossing. The ovarian segment crosses the ureter anterior or ventral (front) forming the proximal arterio-ureteral crossing. The proximal arterio-ureteral crossing (where the vasa ovarica cross anterior to the ureter) forms the apex of the uretero-venous triangles of the author (bounded by the ureter, renal and ovarian veins). The entire spiral segment of the utero-ovarian vascular circles lies anterior or ventral to the ureter. However, the ureter passes through or penetrates the genital vascular circle. In dogs, the pelvic segment of the uterine artery passes distal (under) the ureter (opposite to that of man). In most dogs the ovarian segment passes ventral to the ureter. However, the ureter penetrates or passes through the genital vascular circle in dogs similar to that of man. The most important topographic landmark in the pelvis is the point where the uterine artery crosses proximal and ventral to (over) the ureter—the distal arterio-ureteral crossing. The most important segment of the utero-ovarian artery is what I shall term the cervical loop. It is the internal portion of the pelvic floor segment and lies between the distal arterio-ureteral crossing and the lateral cervical border. It is ligated in the chief forms of hysterectomy.

The utero-ovarian artery possesses considerable variation, especially in its rami laterales of the uterine and euiductal segments. Since the artery lies in its entire course in a more or less mobile and yielding bed its mobility is remarkable. Its most important relation to any organ except the internal genitals is to the ureter, which is also capable of liberal motion in its rich areolar bed.

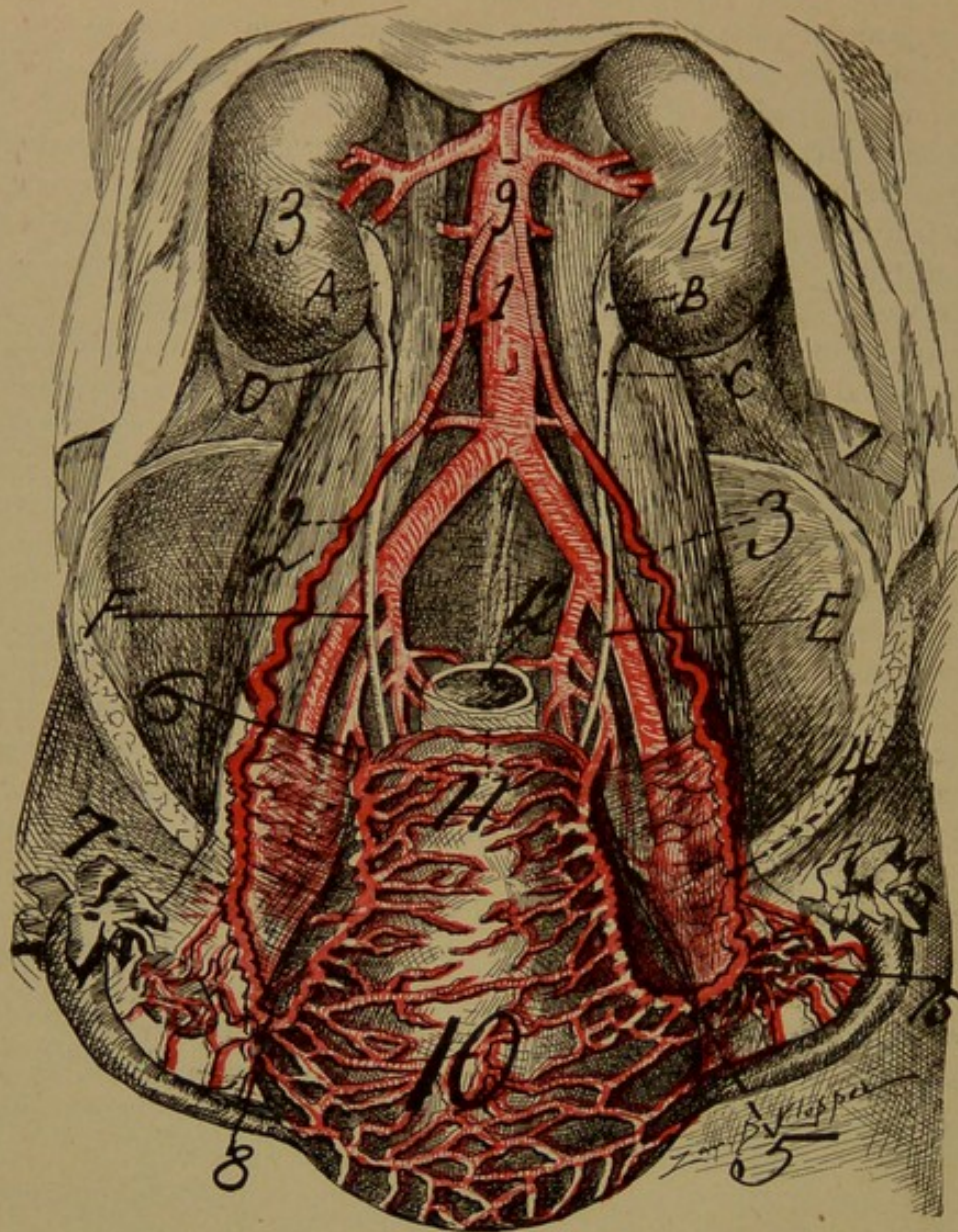
Hard and fast lines in the division of the utero-ovarian artery, as regards segments, cannot be made, as the segments vary and glide imperceptibly into each other.

THE OBJECTIVE PLAN OF THE UTERO-OVARIAN ARTERY.

It is to nourish trebly sure the genital tract (vagina, uterus, oviduct, and ovary) with blood from three sources. The anastomosis not only liberally unites the triple arterial origins of each side, but unites in close union in the median line the bilateral genital blood-supply. Since all rami laterales genitales intercommunicate, a fetus can be equally well nourished on any locality of the corporeal endometrium (or even in the oviduct, endosalpinx). The typical blood-supply of the internal genitals consists of a grand vascular arcade of triple origin, from the periphery of which lateral arteries are emitted, especially at the cervix, fundus, ovary and pavilion.

For convenience of description and for the purpose of emphasizing the importance of the physiologic and topographic relations of the spiral segment of the utero-ovarian vascular circle, I have divided it into five segments: 1. Pelvic floor. 2. Uterine. 3. Oviducal. 4. Ovarian. 5. The segment of the round ligament.

The view here advocated is that the vascular arcs and arcades which con-



THE UTERO-OVARIAN VASCULAR CIRCLE.

Fig. 6—Illustrates the genital circle pregnant about 3 months. 1, aorta; 2 and 3, ovarian segment near proximal arterio-ureteral crossing; 9, 2, 7, 8 and 6 show spiral segment of the genital vascular circle on the left at 3 months gestation; 10 and 11 shows the median anastomoses of the two lateral uterine surfaces; 12, rectum; 15, lateral ovarian branches. In pregnancy the spiral segment becomes more spiral and looped, thicker and of greater volume and completely developed at the end of the first gestation. Note the three arterio-ureteral crossings at 2, F and 6.

stitute the adult utero-ovarian grand arcade was originally found in the Wolffian body. Our claim is that the distal feet of the vascular arcs of the Wolffian body have during the assumption of the erect attitude gradually passed distalward as the internal iliac (uterine) and external iliac (artery of round ligament). This process I followed through many quadrupeds. In the cow the distance between the origins of the uterine and ovarian artery is about 3 inches apart, while the length of the utero-ovarian, the spiral segment, is 48 inches, i. e., 16 times the

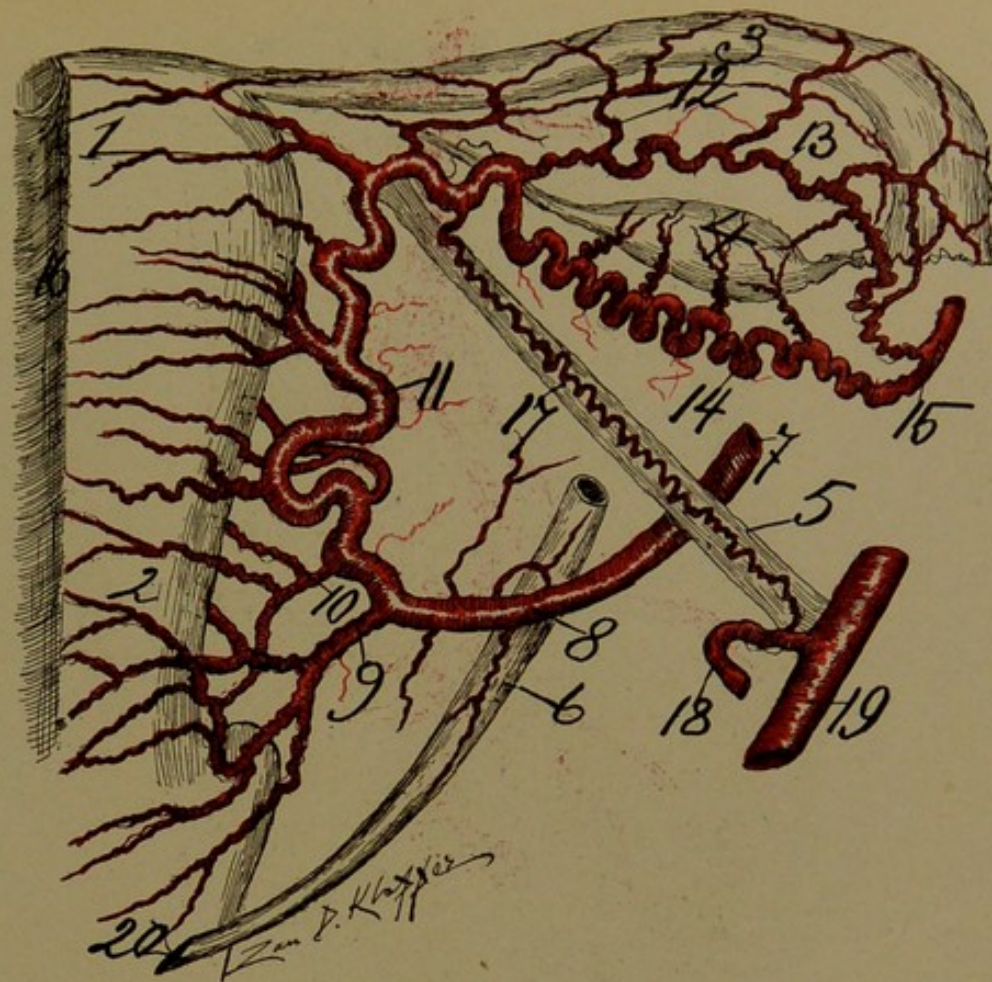


Fig. 7—Oviducal Segment 13, 14, makes the ovarian circle which surrounds the ovary. Pelvic floor segment 9 to 7, uterine segment 10, 11 to utero-oviducal angle. Drawn from a subject about 60 years old. Atrophic ramus fundus 1, ramus cervicis 2, rami laterales oviductus 3, ovaries receiving its helicine arteries from the ramus ovarii 4, artery of round ligament arising distal to ovarian vascular cord 5, ureter receiving its ramus ureteris 6, uterine artery 7, distal arterio-ureteral crossing 8, cervico-vaginal 9, cervical 10, uterine segment 11, rami laterales of the ramus oviductus 12, ramus oviductus 13, ramus ovarii 14, fragment of ovarian segment 15, peritoneum of the uterus dissected and turned medianward 16, round ligament artery 17, deep epigastric 18, external iliac 19. Note distance of the artery from the uterus and oviduct and its atrophic lateral branches. The ramus ovarii alone retains its marked spirality.

length of the distance between their origins. In the horse the ovarian and the uterine—utero-ovarian—may arise together, i. e., from a common trunk from the aorta; however, there is a uterine proper located more distalward which arises generally from the iliacs which makes it practically resemble that of man. The distance between the origins of the uterine and ovarian arteries in the horse may be three inches. The monkey resembles man very closely.

Dogs of 15 pounds measures about 3 inches between the origins of the ovarian and uterine arteries while the spiral segment (utero-ovarian) of the genital circle measures about 12 inches. In women of 125 pounds the distance between the origins of the ovarian and uterine arteries measures about six inches, while the spiral segment (utero-ovarian) of the genital vascular circle measures about 18 inches. In other words, the spiral segment of the genital vascular circle in

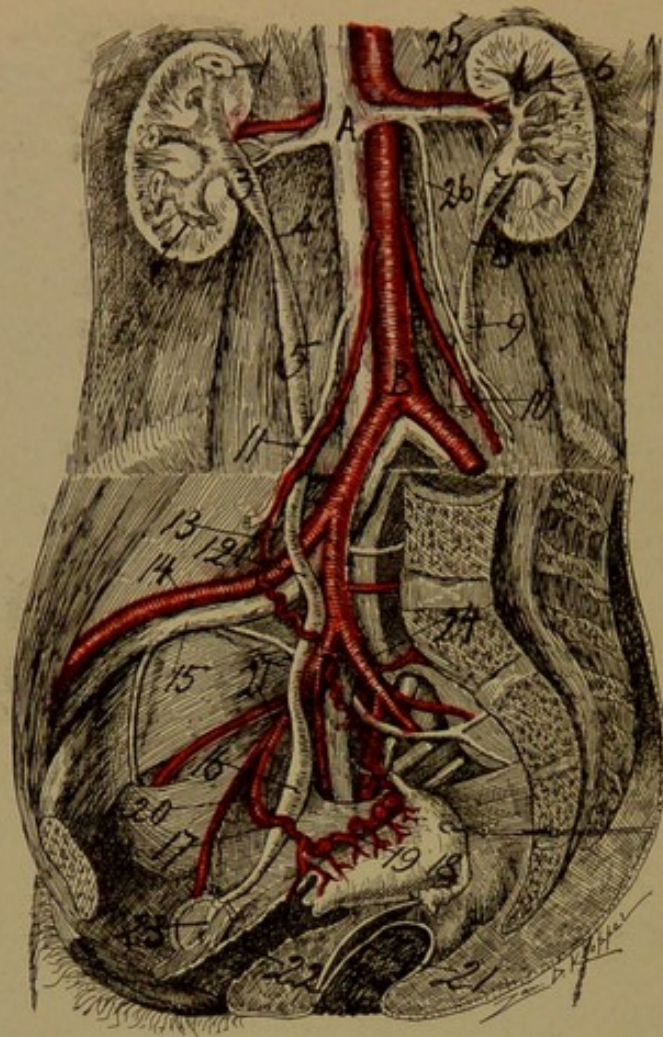


Fig. 8—Topography of ureter and blood vessels of lateral pelvic wall and dorsal abdominal wall, with especial reference to the utero-ovarian artery. The cut illustrates the relations of the ureter and the spiral segment of the genital vascular circle. The upper portion of the cut represents a front view while the under part of the cut represents a side view. It shows the proximal (11), middle (iliac) and distal (17) arterio-ureteral crossing. The spindle of the ureters are shown closely adjacent to the emission of the arteria ureterica, proximal and distal. In this drawing a suggestion from Holl is employed. The genital circle and the ureter are shown in their relation: 1, kidney; 3 and 7, ureteral pelvis; 4 and 8, proximal ureteral isthmus; 5 and 9, proximal ureteral spindle; 6, ureteral calices; 10 and 11, proximal arterio-ureteral crossing; 12, middle arterio-ureteral crossing; 13, ovarian segment; 14 and 15, external iliac vessels; 16, pelvic ureteral spindle; 17, distal arterio-ureteral crossing; 18, left oviduct; 19, uterus; 20, pelvic segment of uterine artery divided by the ureter; 22, vagina; 23, ureteral orificial slit opening into bladder; 24, posterior branch of internal iliac; 25, renal vein receiving the ovarian vein; 26, 9, 26, 25, 7, uretero-venous triangle.

man and animals is three times the length of the straight segment of the genital vascular circle.

On these anatomic data, rests the capacity of wide range of motion and utility of the spiral segment in surgery.

In a pig of 200 pounds, the distance between the two origins is two inches, while the length of the spiral segment of the genital vascular circle is twelve inches. In the spiral segment of the genital vascular circle the difference between man and quadrupeds lies in the greater length of the ovarian segment in man, due to the distalward passing of the ovary from the erect attitude.

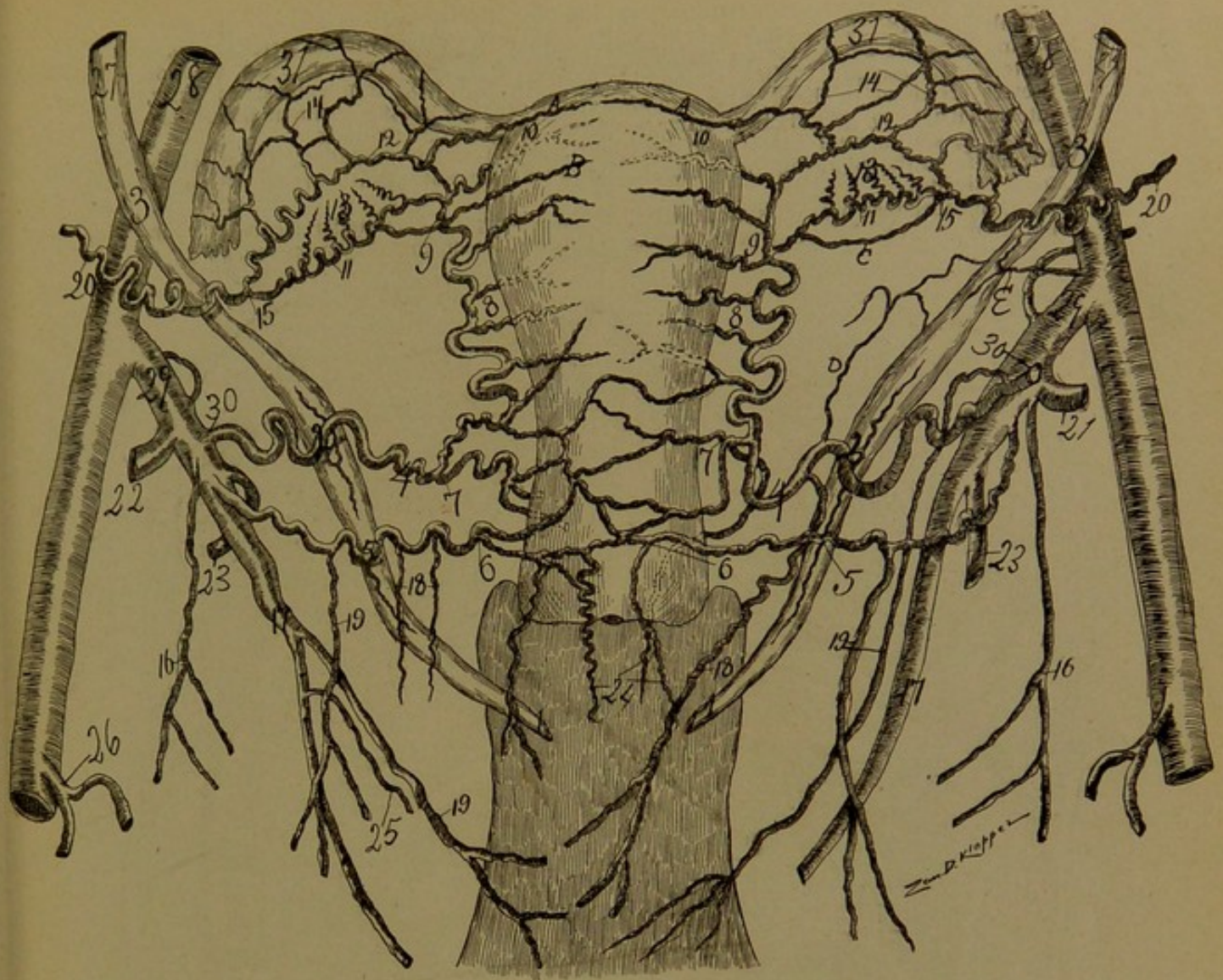


Fig. 9—Accessory cervical artery arising from the hypogastric. The ureteral relations are shown.

This interesting drawing was taken from a subject about 55 years old. I injected the arteries and uterus of the specimen with red lead and starch after removing the kidneys, uterus, bladder, aorta, common and internal iliac with the internal genitals and vagina—all intact to secure perfect filling of the genital vascular circle and ureters; 1, 1, vesicle orifice of ureter, 2, 2, distal arterio-ureteral crossing and (2) point of origin of distal arteria ureterica which supplies the Pelvic-ureteral spindle; 2, 2, arterio-ureteral loop; 2, 2, distal ureteral spindle; 4, 4, cervical loop or internal portion of the pelvic floor segment; 5, 5, points to the 2nd (accessory) distal arterio-ureteral crossing, at which a 2nd (accessory) distal arteria ureterica is emitted. 6, 6 2nd (accessory) cervical loop or internal portion of the pelvic segment. Note that this 2nd uterine or (accessory) cervical artery, though originating from the same location on the hypogastric is less tortuous than the 1st uterine artery. 5, 5, 6, 6 indicate the distal bifurcations of the utero-ovarian artery.

Note the confusion of anastomosis produced by the additional cervical artery. 7, 7 cervical artery from uterine, or cervical loop. 8, 8 rami laterales uteri (dotted ones pass to dorsal uterine surface). 9, 9 middle bifurcation of the utero-ovarian artery or the division point between the uterine and oviduct segment.

Note that the ramus ovarii (9, 11, 15) and the ramus oviductus (9, 12, 15) do not spring from the same point on the uterine segment; 10, 10 rami fundi; 11, 11 ramus ovarii, from which emerge the rami laterales ovarii; (13, 13, short helicine arteries) 12, 12 ramus oviductus, from which emerge the rami laterales oviductus, (14, 14); 13, 13, rami laterales ovarii; 14, 14, rami laterales oviductus. 15, beginning of ovarian segment and ending of oviducal segment. It is at the point of anastomoses of the ramus oviductus and ramus ovarii 9, 11, 12, 15 the ovarian

vascular circle, 16,16 hypogastric artery emitting the two vesicle arteries 17,17 internal pudic 18, 18. The 2nd (accessory) cervical emitting vaginal arteries, 19,19 vaginal arteries 20,20 ovarian segment. 21 and 22, superior gluteal, 23,23, inferior gluteal. 24 Azygos vaginæ. 25 middle hemorrhoidal; 26, deep epigastric; 27,27, ureters proximal to the middle arterio-ureteral crossing; 28,28 common iliac, 29,29 internal iliac. 30, 30, origin of primary uterine artery, 31,31 oviducts.

A A, shows rami fundi from the right and left ramus oviductus. B, a ramus fundus from the right ramus ovarii. C shows an extra anastomatic arc in the ramus ovarii sinistra.

This specimen was dissected and sketched with great care under alcohol. I am indebted to Prof. W. A. Evans for the courtesy of securing this specimen.

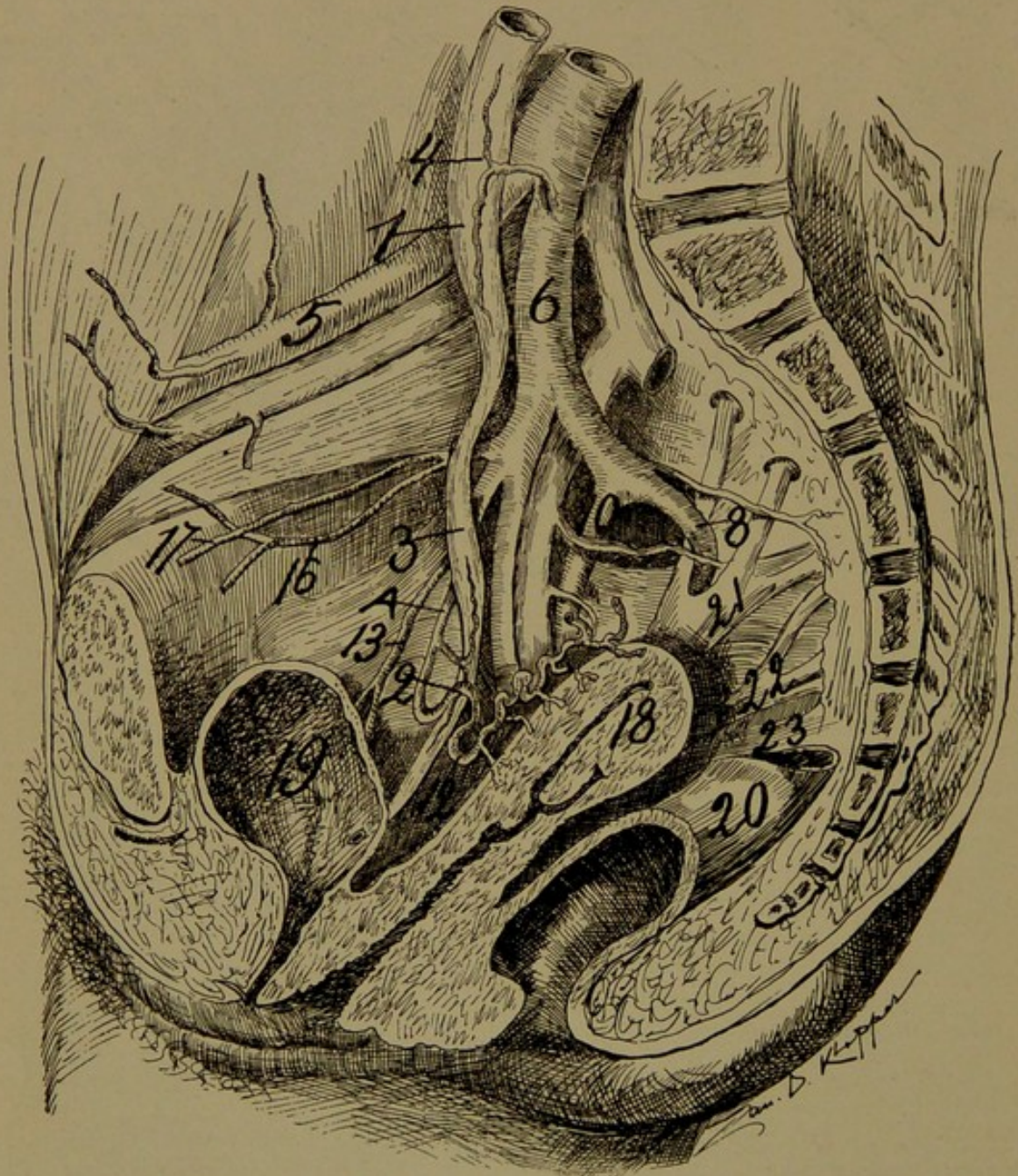


Fig. 10—Shows a right lateral view of the relations of the ureter and pelvic floor segment of the utero-ovarian artery in a sexually active adult. It is fairly typically. 2, distal arterio-ureteral crossing; 2, arterio-ureteral loop. Note that the distal arteria ureterica is emitted proximal to the distal arterio-ureteral crossing and supplies (pelvic) ureteral spindle; 5, external iliac; 6, internal iliac; 8, superior gluteal;

10, inferior gluteal; 12, *cervical loop* or internal portion of the pelvic floor segment. 13, vesicle artery, 16, obturator 17, hypogastric 18, uterus 19, bladder 20, rectum 21, 22, 23, sacral plexus. A. External portion of the pelvic floor segment with its relations to the ureter, showing a not unusual arterial curve, with its concavity proximalward.

Observe how a traction forceps placed on the cervix would extend, unfold, the cervical loop (12) so that it could be ligated without wounding the ureter. Besides, observe how in Pratt's operation the rami laterals uteri may be severed without severing the uterine segment of the utero-ovarian artery.

From the presentation of this cut to exsanguinate any of the pelvic viscera for malignancy, as the urinary (ventral pelvic viscera), genital (middle pelvic viscera) or rectum (dorsal pelvic viscera), it would be necessary to ligate the internal iliac (6). The internal iliac is so irregular in origin, number and distribution of its branches that no definite territory can be exsanguinated without sacrificing all the branches of the internal iliac.

In this cut a suggestion from Mendelsohn is employed.

BIFURCATIONS OF THE UTERO-OVARIAN ARTERY.

The bifurcations of the utero-ovarian artery occur at significant locations of the genital tract (sphincters and angles) and form important topographic landmarks as regards physiology, anatomy and surgery. I shall divide these bifurcations into one distal, one proximal and two medial; the medial being those at the utero-oviducal angle and at the origin of the round ligament.

1. The distal bifurcation of the utero-ovarian artery [*bifurcatio arteriæ uterinæ distal* (Waldeyer)] occurs in the pelvic floor segment, adjacent to the distal arterio-ureteral crossing. This point is located at the junction of the internal and middle third of the pelvic floor segment or about midway between the uterus and pelvic wall. It marks the point of division (sphincters) of the external genital (vagina and pudendum) from the internal genitals (uterus, oviducts and ovaries). Practically the cervico-vaginal artery supplies the external genitals (the vagina). It passes distalward as all other vaginal arteries. The emission of the cervico-vaginal artery marks the most distal point of the genital vascular circle. The cervico-vaginal artery originates internal to the arterio-ureteral loop and nearly always from the internal portion of the pelvic floor segment. In hysterectomy per vaginam it is almost always this artery which gives rise to slow but persistent hemorrhage because during the operation it is torn and its powerful coats contract immediately and mainly check the hemorrhage for a while, but not being included in the ligature or clamp later dilates, causing serious, if not fatal, hemorrhage. The distal bifurcation of the utero-ovarian artery forms an acute angle with the main trunk.

2. The proximal bifurcation of the utero-ovarian artery (*bifurcatio arteriæ-ovaricæ proximal*) occurs at the distal end of the ovarian segments. It marks the location of the ovary and proximal end of the oviducal sphincter. The artery here divides in two branches to supply the oviduct and ovary forming the oviducal segment. The angle made by this bifurcation is an acute one. It is at the point where an additional vascular arc, the *ramus oviductus*, originates to maintain the oviduct, due to the interpolation of the ovary. This bifurcation marks not only the ovary but the proximal end of the oviduct (sphincter).

3. The middle bifurcation of the utero-ovarian artery (*bifurcatio arteriæ uterinæ medial*) consists of two factors: (a) the division of the uterine segment at the utero-oviducal angle forming the *ramus oviductus* and *ramus ovarii*; (b)

the bifurcation of the ramus oviductus forming the ramus oviductus and the ramus ligamenti teretis or the segment of the round ligament. These two arterial bifurcations mark a significant point (sphincter oviductus distal) in the internal genitals the utero-oviducal angle which is divided by the round ligament noting the division between uterus and oviduct. The sphincter oviductus distal is also located here. In the human and in the dog the anatomy is similar in this respect.

As is easily observed in injecting the pregnant uterine artery it is capable of enormous distension of the lumen without rupture, with vast capacity for retraction of its walls by forcing the fluid later into the rami laterals and their capillaries. The typical winding or looped course of the utero-ovarian artery is especially observable in the injected ovarian segment of the four-months pregnant cow. Here the loops are so large and abundant as to represent the figure of 8. The injection forced vigorously may distend and distort the rami laterales as may be seen in the X-ray specimens.

The study of the uterine artery is incomplete because it has not always been considered as important as it is to-day. Up to the present the study of the artery is only in its extraperitoneal passage and its relations to the ureter for surgical objects. The difficulty of injection of its fine spiral tortuous branches, profound modifications, anomalies and changes in development make the utero-ovarian artery difficult for complete investigation and study. Besides appropriate material to demonstrate bifurcational and quiescent conditions of the utero-ovarian artery is everywhere limited. Corrosion anatomy is the most accurate but the most difficult on account of the fragile condition of the vast vascular net work. The X-ray is the last and one of the best aids in demonstrating the details of the utero-ovarian artery and its branches. On account of its thick walls and spiral course it does not show the shadow of the X-ray so well, being more difficult to inject than a straight artery with thinner walls.

ANASTOMOSIS OF THE UTERO-OVARIAN ARTERY.

Anastomosis in the genitals is both macroscopic and microscopic. It exists in the resting uterus to a certain degree, but is extensive in the pregnant one.

1. The transverse anastomoses cause the arteries to communicate from both sides bilaterally. The strongest transverse anastomoses are found subperitoneally on the posterior surface, and there is one especially developed near the fundus.
2. A vertical, perpendicular, anastomosis which solidly rebind superimposed branches of the cervix, corpus and fundus. They unite the superficial vessels along the border of the uterus. They are sometimes so well developed at the fundus as to displace the principal trunk, (uterine segment).
3. A dorso-ventral (antero-posterior) anastomosis which forms connected and solid the various vascular planes of the uterus.

The typical anastomosis occurs in a cow's uterus where the arteries pass to the uterus and dichotomously divide the two peripheries of the one anastomosing with the two peripheries of the other absolutely surrounding the uterus with a vascular circle analogous to that in the intestine. Besides the longitudinal anastomoses of the rami laterales, especially along the lateral borders, of the uterus,

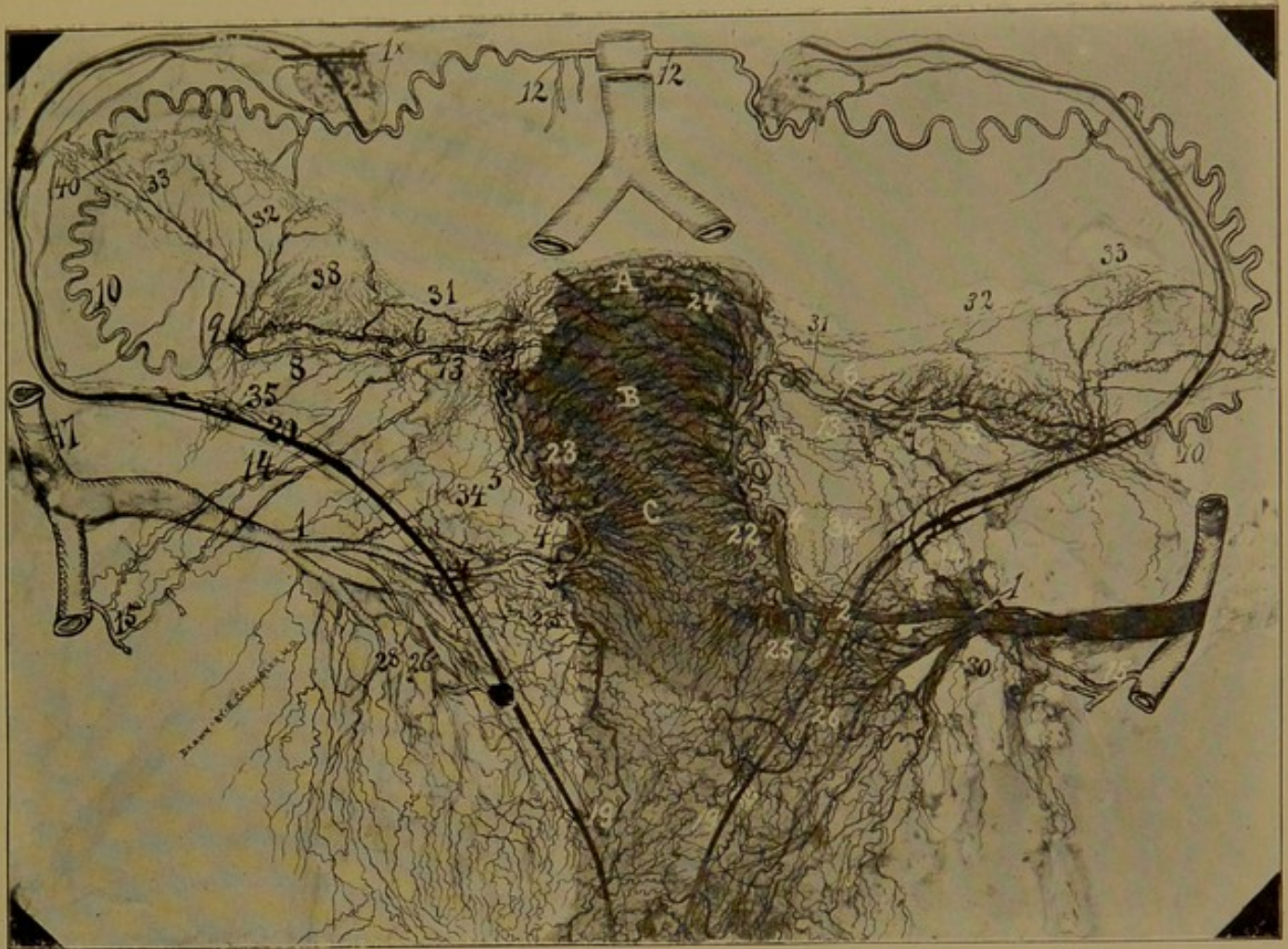



Fig. 11—Multipara, 36 years of age. This specimen was injected after removal from the body with celloidin and vermilion, which filled the smaller vessels and several days later when the alcohol and ether were evaporated it was reinjected with red lead and starch, which practically filled the larger vessels. It presents a rich vascular supply along the pelvic floor (1, 2, 3, 4,) uterine (4, 5, 6,) and oviducal (6, 7, 9—6, 8, 9) segments. The ovarian vascular circle (6, 7, 9—6, 8, 9) shows bilaterally and is luxuriantly rich in vessels. The genitals having experienced gestation the arteria arterina ovarica with its rami laterales have arrived at maximum development. Hence this half tone demonstrates that not only the segments of the utero-ovarian artery (pelvic floor, uterine, oviducal and ovarian) but especially the arteries of the ligamentum latum (34 and 35) and the rich lateral branches of the oviducal segment are evident.

It is peculiar that the ramus oviductus (6, 8, 9) emitting its rami laterales oviductus (31, 32, 33) appears larger in this illustration than the ramus ovarii (6, 7, 9). The ramus ovarii is almost always larger than the ramus oviductus. The uterine segment (4, 5, 6,) is markedly spiral. The rami laterales ovarii (38, 38) are numerous. The magnified cut with lens shows distinctly that some of the rami laterales ovarii arise from the ramus oviductus.

The vaginal arteries (25, 25, 26, 26,) are very large. Observe that at the cervix the arteries assume two different directions, one set passing distalward on the cervix and vagina while the other set passes proximalward on the corpus. The ramus cervicis is large and powerful at birth and it persists large and strong after the climacterium as is demonstrated by the well preserved cervical epithelium in senescence; e. g., women of 60 years and still more advanced. The large size of the cervical and vaginal arteries of pueritas is the reason of the large size of the cervix, while the large size of the fundus in adult sexual life is accounted for by the large size of the rami fundi. A wire was passed through each ureter from the distal ureteral orifice to proximal ureteral calyces. Its outline with that of the ureter may be plainly noted in cut. The arterial segment removed from the aorta allowed the origins of the ovarian segments to be forced toward the uterus, thus lessening the size of the X-ray plate. The central longitudinal oligemic uterine zone (A, B, C,) appears to be almost obliterated from complete filling of uterine vessels. The pelvic floor segment presents no loops (cervical and arterio-ureteral) because it is forcibly extended. For numbers see general description page 32.



as in the cow, transverse on the ventral (anterior) and dorsal (posterior) uterine surface and vertically along the center of the uterus.

There is, fourth, an undefined or irregular anastomosis on the ventral, anterior and dorsal posterior surface of the uterus only observed in the injected pregnant uterus by the X-ray or by accurate dissection. This anastomosis consists of rather small arteries uniting points of circulation of wide or short distances from each other. This fourth form of anastomosis may be termed perpendicular or vertical, which unites the superficial and deep set of rami laterales.

Some older authors have attempted to show that the utero-ovarian artery anastomoses at the cervix, utero-oviducal angle or at the ovary, i. e., at the three points of usual bifurcation or at the important land marks of the genitals (sphincter), cervix, utero-oviducal angle (sphincter oviductus uteri) or at the oviducal pole of the ovary (sphincter oviductus proximal). These views of the anastomosis are untenable, as the utero-ovarian artery is one grand indivisible macroscopic vascular arcade originating in the Wolffian body. All the lateral branches of the utero-ovarian artery anastomose with each other forming not only a solid unilateral, but a solid bilateral arterial network, a great arterial anastomic system, which irrigates the genitals and their supports.

The anastomosis in the horse, deer and cow (ungulates) has an additional vessel over that of man. There is the ovarian which arises from the aorta and assumes a course similar to that of man; the uterine (of man) which arises from the internal iliac (umbilical) which passes chiefly to the horn of the uterus supplying it by dividing dichotomously, one vascular arm passing to one side and the other passing to the other side of the uterus. In this case there is a distinct vascu-

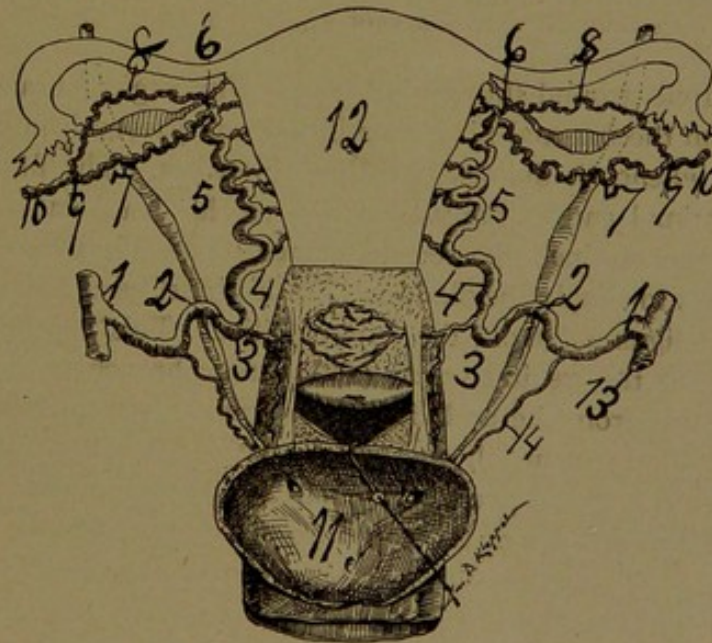


Fig. 12—A diagram to illustrate the relations of the ureter, utero-ovarian artery and cervix. 1, origin of uterine artery; 2, arterio-ureteral loop; 3, cervical loop; 4, level of internal os.; 5, 2, 3, 4, Pelvic floor segment; 4, 5, 6, Uterine segment; 6, 8, 9—6, 7, 9, ovarian vascular circle; 10, ovarian segment; 11, trigone; 12, uterus. The vagina is incised transversely to expose the cervix. 13, internal iliac; 14, vaginal.

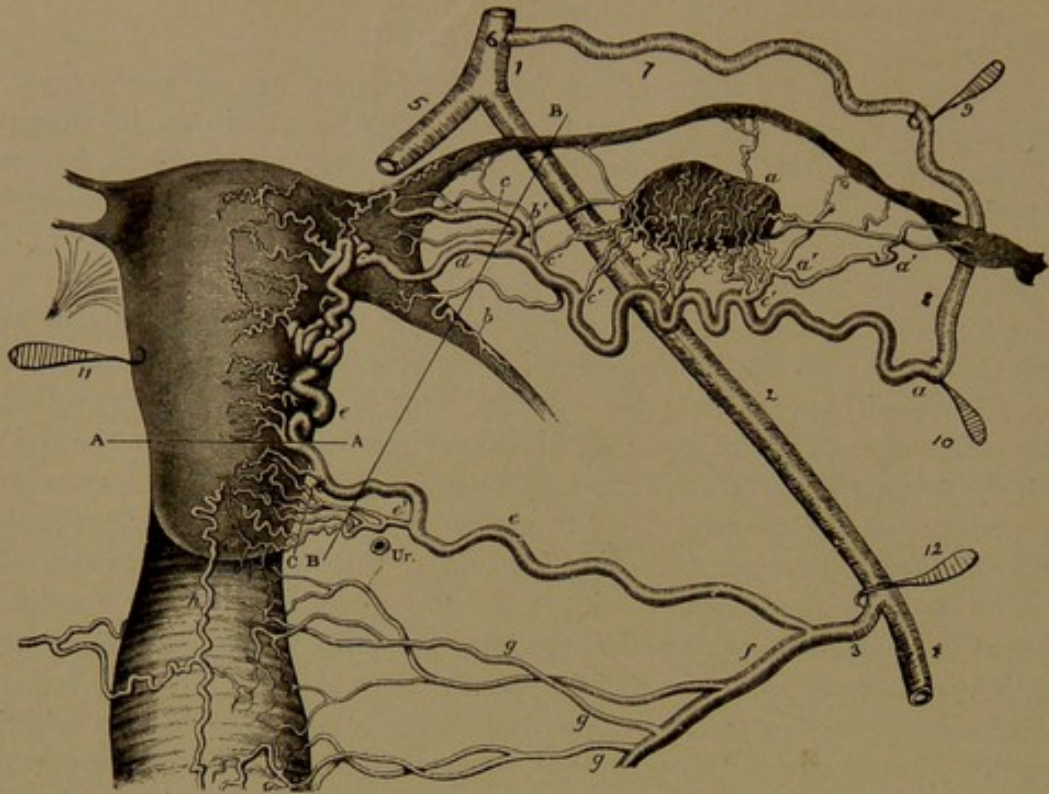
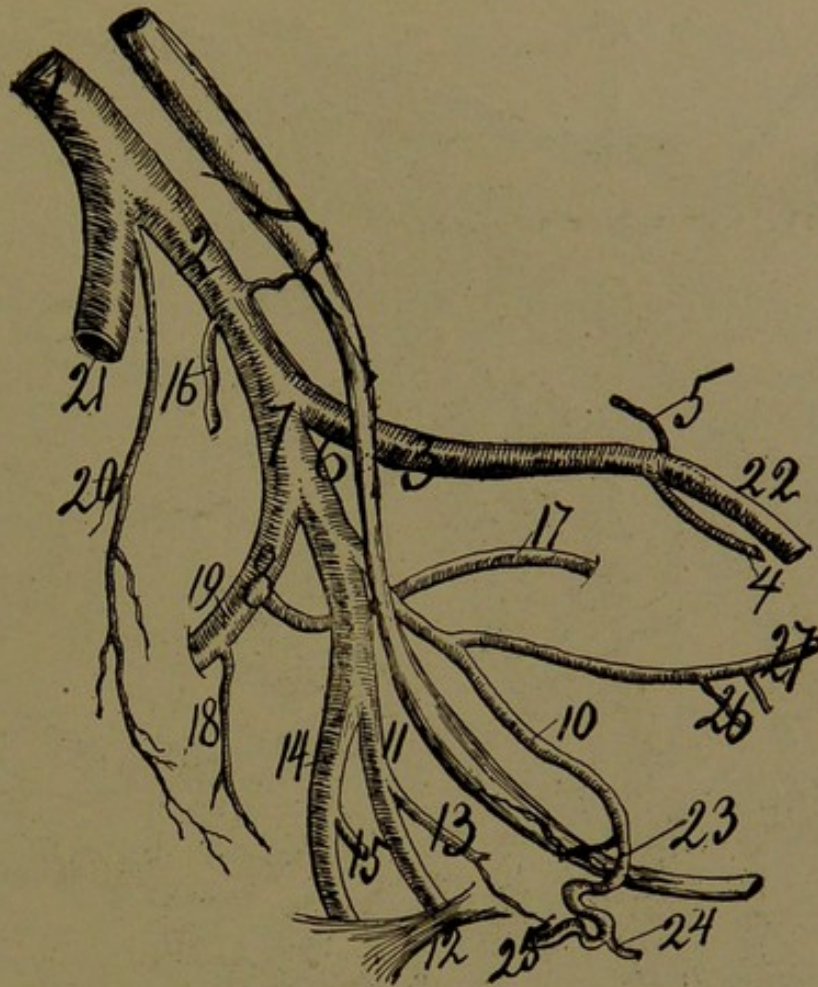


Fig. 13—The utero-ovarian vascular circle modified from Hyrtl by completing the genital vascular circle 1, 2, 12. The straight portion of it, genital circle 3, E, E, d, a, 9, 7, 6. The spiral portion of the genital circle. Ur. Ureter. C, C, fanshaped expansion of the cervical artery. g, g, g. 3 vaginal arteries, all arising from the internal iliac. In this case the ovarian vascular circle is completed by the aid of the anastomoses of the rami laterales ovarii. B, B, shows the line of structure included in the ligatures for the usual hysterectomy. h, arteria azygos vaginæ. b, artery of round ligament.

lar anastomatic circle around the uterine horn. The vaginal branch arises distal to the uterine from the internal iliac (umbilical) and passes distally to the vagina and the bladder, whence it divides into three branches. The first passes proximally on the proximal end of the vagina and on the distal end of the uterus to anastomose with the uterine; the second branch passes distalward on the vagina and the third passes to supply the bladder. To this must be added a fourth branch, that of the round ligament from the external iliac. This anastomoses with the trunk arteries along the genital tract. These four branches, the ovarian from the aorta, the uterine from the umbilical, the vaginal from the umbilical, and the branch of the round ligament, all anastomose with each other, forming arcs and arcades. They form a grand genital vascular arcade of immense dimensions, resembling the arcs and arcades of the vasa intestini tenuis of man.



TOPOGRAPHY OF URETER AND ARTERIES ON LEFT PELVIC WALL.
ESPECIALLY THE PELVIC FLOOR SEGMENT OF THE UTERO-
OVARIAN.

Fig. 14—Note the topography of the ureter (left) with the internal iliac artery and its branches; 2, common iliac; 3, external iliac; 4, obturator; 5, circumflex iliac; 6, bifurcation of common iliac with its relation to the ureter; 7, trunk of internal iliac; 8, superior gluteal at origin of obturator, 17; 10, uterine; 11, internal pudic; 12, internal pudic; 13, vaginal; 15, hæmorrhoidal; 14, inferior gluteal; 16, ilio-lumbar opposite the origin of the arteria ureterica (medium); 18, lateral sacral; 19, superior gluteal; 20, middle sacral; 21, right common iliac; 22, external iliac; 23, arterio-ureteral crossings with arteria ureterica (distal); 24, cervico-vaginal; 25, uterine; 26, superior and inferior vesicles; 27, arteria hypogastrica. Note arterio-ureteral and cervical loops.

THE HISTORY OF METHODS IN DEMONSTRATING THE ARTERIA
UTERINA OVARICA WITH ITS RAMI LATERALES.

Vascular anatomy, especially that of the uterus, cannot be completely studied without the aid of artificial technique. Technical art has aided in the study of vascular anatomy; (1) by the use of the injecting syringe (von Graef) with colored or uncolored fluids; (2) by injecting colored or uncolored solid material; (3) by injecting liquid material which subsequently hardened, as wax (Swammerdam) and plaster of paris; (4) by injecting material which would resist acids, as wax (Swammerdam) and subsequently allowing acids to corrode the tissue from the wax form in the vessels; (5) by injecting liquid metals in the vessels,

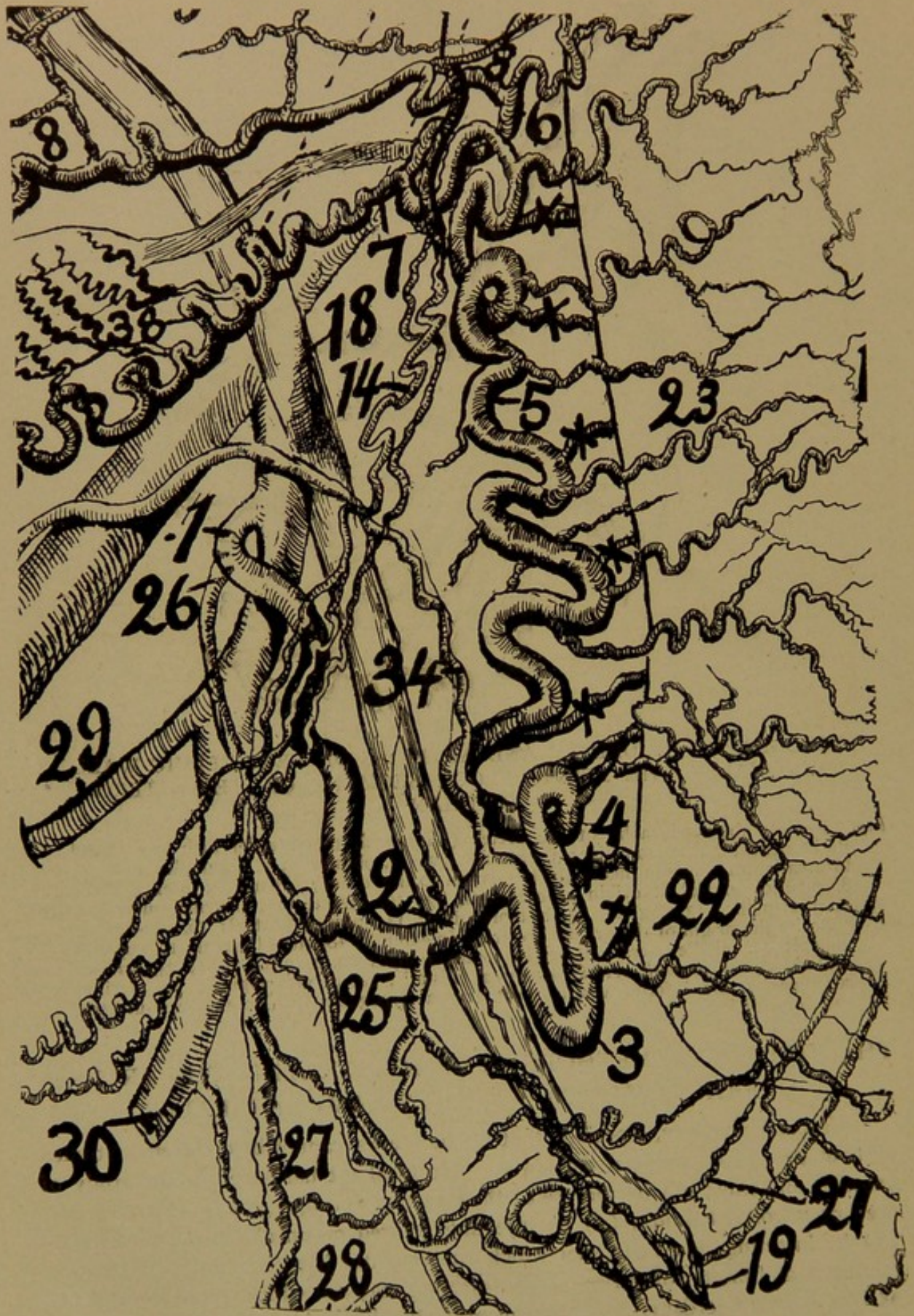
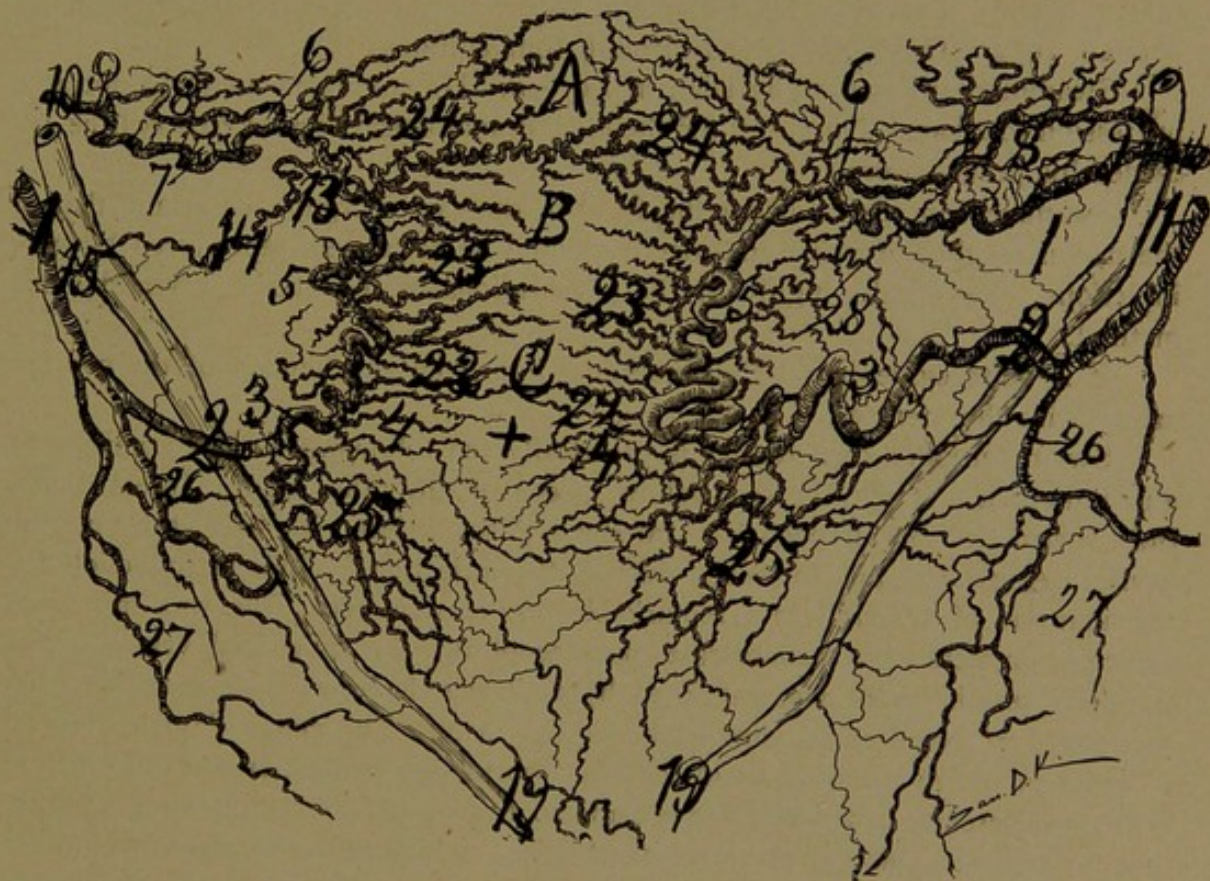

Fig. 15. For description see page 23.

Fig. 15—A dissection I made from a uterus pregnant several months, injected in situ with red lead and starch.

- 1, 2, 3, 4, pelvic floor segment.
- 4, 5, 6, uterine segment.
- 1, 2, external portion of pelvic floor segment.
- 2, 3, 4, internal portion of pelvic floor segment, or the cervical loop.
- 2, distal arteria ureteral crossing.
- 2, arterio-ureteral loop.
- 2, distal arteria ureterica.
- 6, middle bifurcation of the utero-ovarian artery.
- 6, 8, ramus oviductus.
- 6, 7, ramus ovarii.
- 14 to 30, round ligament segment.
- 18, ureter crossing common ilica (middle arterio ureteral crossing).
- 19, distal or vesical end of ureter.
- 22, cervico-veginal artery dividing dichotomously, producing a lateral cervical oligemic zone which saves woman from hemorrhage in lateral cervical lacerations.
- 23, rami laterales corporis.
- 25 and 26, vaginal arteries.
- 27, 28, vesical arteries.
- 29, obturator artery.
- 30, pudic.



AN X-RAY.

Fig. 16—Multipara about 50 years of age with bilateral ovarian cysts as large as cocoa nuts. 1, 2, 3, 4, pelvic floor segment, 4, 5, 6, uterine segment, and 6, 7, 8, 9, oviducal segment of utero-ovarian artery; 22, 22, rami laterales cervicis; 23, 23, rami laterales corporis; 24, 24, rami laterales fundi; 25, 26, arteria vaginalis; 27, arteria vesicæ; 13, 14, 15, arteria ligamenti teretis; 19, 19, ureter, distal orifices. The rami corporis are atrophied, while the rami fundi are strong and large maintained by the large ovarian cysts. A, B, C, longitudinal exsanguinated zone.

which subsequently hardened (as mercury) and then boiling the specimen until the tissues fall away from the metal form of the vessels (Bidloo); (6) by the X-ray (Roentgen).

REGNERUS DE GRAEF (1641-1673).

De Graef introduced the method of injecting the blood vessels with a syringe. He injected the spermatic vessels with mercury. He used colored water injections in order to demonstrate that the injected fluid could be forced from the arteries through the capillaries into the veins, thus confirming Harvey's theory, which doubtless still had hard opponents. It can at once be seen what a great step in anatomic progress this proved. Unfortunately this noted worker and benefactor died at the age of 33, the same age at which the rarely gifted genius, M. Bichet, laid down his work.

SWAMMERDAM (1637-1680).

Johannes Swammerdam introduced wax injections for anatomic purposes. This was the foundation of accurate modern anatomic dissections and a great step in anatomic progress. He was the founder of comparative anatomy. The most important work of Swammerdam, for our purpose, is his "*Miraculum naturæ S. uteri muliebris fabrica.*" The miracle of nature or the structure of the uterus of woman, 1672. This book passed through four editions.

Swammerdam was a physician in Leyden. He cultivated anatomy not as a profession to make a living, but for the love of anatomical science. In skill he exceeded his predecessors.

Swammerdam claimed that the form of the cavity organs, especially that of the uterus or that of veins and arteries, could be accurately reproduced by wax injections. He speaks highly of the preparations of the uterine artery by this method.

It is quite evident that Swammerdam knew the anastomosis of the ovarian artery with the uterine.

Swammerdam's own receipt is practically the following: "Take white wax and liquefy it. It may be red, yellow, green or any other color. Inject it into the spermatic or hypogastric artery. Also inject it into the uterine cavity. Allow no air to enter during the injection." This introduction for the anatomy of vessels was a remarkable progressive step. The wax injections sufficed completely to demonstrate macroscopically the superficial vessels. For the deep vessels of the visceral parenchyma it was defective because tedious dissections were required to completely expose them. The classic Hyrtle claimed from an extensive research of old anatomic works that Swammerdam was also the father of corrosive anatomy. He became so engrossed in scientific medical study that he neglected his private medical practice. This neglect angered his father, who cut off his support of his son. The father's abandonment caused Swammerdam to experience a period of considerable privation, which unfortunately disturbed his health, both physically and mentally. In 1675 his father died, leaving him an adequate fortune, but it was too late to retrieve his health. Swammerdam became a hypochondriac and mentally disturbed. He joined a mystic religious sect, headed by Antoinette Bourignon. Becoming financially poor and mentally unbalanced, he died in poverty at Amsterdam in 1680.

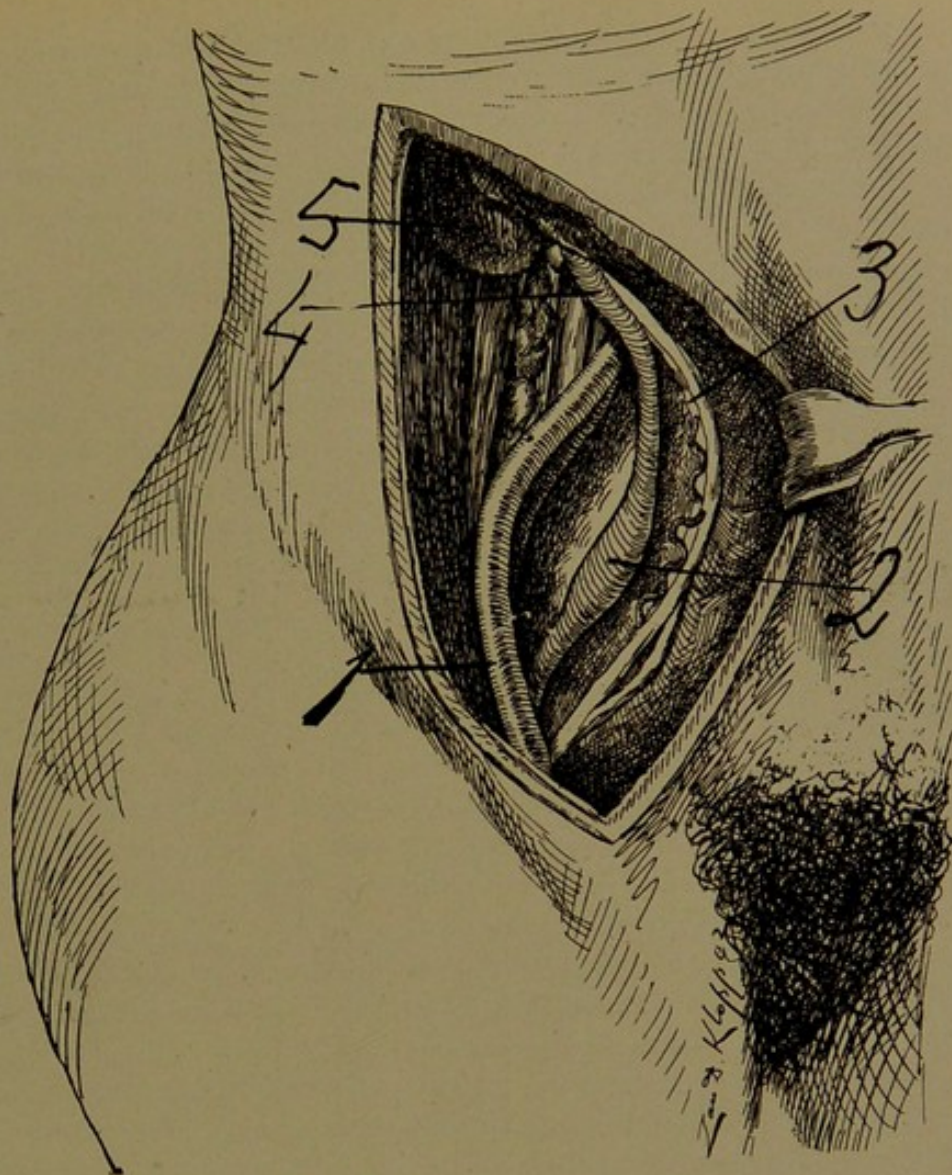


Fig. 17—Presents the lumbar ureteral spindle exposed in the lateral abdominal region while in the erect attitude. 1. Arteria iliaca communis. 2. Lumbar ureteral spindle. 3. Vasa-ovarica. 4. Pars infrarenalis ureteris. 5. Kidney. The vasa-ovarica are forced ventralward with the Peritoneum and ureter. In this cut a suggestion from Drs. Tandler and Halban is used.

Thus perished, at the age of 43, the physician who first saw the arterial anastomosis of the uterus through wax injections.

FRIEDERIC RUYSCH (1638-1731).

Ruysch was born at The Hague and died at Amsterdam at the age of 93. He was the secret vender of injected anatomic specimens. He made and sold anatomic museums. He employed the corrosive anatomy, as is shown by his cuts. He was a predecessor of Barnum in his ability to arrange for exposition shows of his ornamental anatomic specimens and museums. It is reported that he made large sums of money by his secret methods of injections, which were likely corrosive anatomy. His methods might not have been exactly the same as practiced to-day. He may have used the boiling process as well as corroding by acid. Ruysch

was professor of anatomy at Amsterdam. Although of a mercenary tendency, yet he gave a great impulse to anatomic research in various directions. His elegant anatomic museums, adorned with ornamental specimens of exquisite perfection, excited popular interest and widely extended anatomic knowledge. Ruysch was a genius in the technique of anatomic preparations as well as a celebrated anatomist.

The table in his "Thesauris Anatomicis Ruyschii" are specimens of rare art. The eight tables represent drawings of viscera, embryos injected, vascular trees, injections of various portions of the body, and, finally, grave scenes and mummies. Ruysch wrote his first work on the lymphatics in 1665 and 63 years later, 1728, appeared his last work, which was written in his ninety-first year and dedicated to the Academy of Paris when he was nominated as a member. That Ruysch learned the method of injecting organs by stiffened masses from Swammerdam may be inferred from a paragraph on the muscles of the uterus in Ruysch's work as well as the kind of injecting materials used.

GOTFRIED BIDLOO.

Bidloo was professor of surgery and anatomy in Leyden. He introduced metal anatomic injections for ducts and vessels. After the injections the specimen was boiled to destroy the tissue when from its strength it could, unlike the fragile corroded specimen, be preserved and used for teaching demonstrations. Bidloo published an "Anatomia humani corporis" with 105 tables, at Amsterdam in 1685. The engravings of these tables was performed by the master hand of Wilhelm de Lairese. These beautiful plates, with the large book, are a model of industry. Three copper tables were subsequently sold to the English publisher of William Cowper's work, "The Anatomy of Human Bodies," Oxford, 1697. Cowper committed the plagiarism of publishing the tables as his own, staining the honor of an otherwise useful life in anatomic research. Metal injections, invented by Bidloo, are useful only in large ducts or vessels. The question of priority of discovery of metal injections in anatomy proved a continuous polemic between Ruysch and Bidloo.

JOHANN NATHANIEL LIEBERKÜHN (1711-1756.)

What is understood to-day by corrosion anatomy was introduced by Lieberkühn. It consists of injecting the vessels of viscera or other structures with some form of material that resists mineral acids, after which the parenchyma or tissues are corroded by mineral acid. For example, the uterus is injected with wax, celloidin, after which it is placed in acid (HCl) until the Parenchyma Tissues are corroded, leaving the injected wax, which occupies the original position and form of the uterine vessels. Lieberkühn made the corrosion anatomy preparation permanent by a process of secondarily replacing the fragile wax from the vessels by a solid metal form (as silver). For convenience of material, ease of execution and prominent demonstration, the kidney is generally the organ sought in corrosion anatomy. Most of the anatomic European museums which contain collections of Lieberkühn's corrosion methods possess a model of the arteria renales. The modern master in corrosion anatomy was Joseph Hyrtl of Vienna, whose testimony was published in a very rare monograph in 1873.

Fig. 18.—Leopard, 100 pounds. X-ray. This specimen I secured through the professional courtesy of Prof. W. A. Evans and Dr. Wayne I. Stillman, who had performed Caesarian section on the animal, removing two cubs some 10 hours previous to death. I injected the specimen in situ. The two cubs were in the left uterine horn the rich vascular network of which is noted in the cut. The left horn is drawn proximalward. For numbers see general description page 82 P. S. ureter. Observe that the uterine segment as in the cut is closely in contact with uterus and uterine horns.

The form and distribution of vessels in the parenchyma of viscera is demonstrated by corrosion anatomy.

The arteria uterina ovarica with its rami laterales can be beautifully demonstrated by injecting the vessels with melted paraffin, after which the specimen is placed in HCl or HNO₃ several days—until the tissues are corroded from the solid paraffin whence the vessels will appear accurate in position. Corrosion anatomy of the visceral vessels is the most accurate and instructive of all forms of anatomy.

THE UTILITY OF THE GENITAL VASCULAR CIRCLE OR CIRCLE OF AUTHOR.

The greatness of any thing depends on its usefulness to man. Definition. The genital vascular circle consists of two segments: 1, the spiral segment which is the arteria uterina ovarica; 2, a straight segment, the part of the abdominal aorta distal to the origin of the ovarian segment, the common iliac artery and the internal iliac artery to the point of origin of the arteria uterina.

The spiral segment of the genital vascular circle accommodates the rapid changes of position and volume of the uterus. It shows that the internal genitals are supplied by a vascular circle similar to that of the circle of Willis. The uterus, oviduct and ovary may be extirpated per vaginam without severing any segment of the utero-ovarian vascular circle, as demonstrated by Dr. E. H. Pratt, of Chicago. The author has also followed this method. The rami laterales to uterus and oviduct and ovary will need severing, but hemorrhage may be arrested by small pressure forceps, without a ligature. The mobility and distensibility of the spiral segment of the utero-ovarian vascular circle enables the gynecologist to draw the uterus, oviduct and ovary into the vagina with traction forceps, where the organs may be inspected, palpated, treated and ligatures may be applied at leisure. One of the great principles of vaginal extirpation of the genitals rests on the anatomic fact that the spiral segment of the utero-ovarian vascular circle will yield and elongate sufficiently to draw the uterus oviduct and ovary into the vagina for inspection and palpation, for repair or for removal or application of ligatures.

In vaginal hysterectomy, by not severing the genital circle, cutting off only the rami laterales which nourish the uterus, the whole ligamentum latum and its contents, the oviducts and ovaries are left in situ and intact as perfectly, normally nourished as before the operation.

This method will leave the central sexual organ of woman—the ovaries—absolutely normal in blood, lymph and nerve supply. No anatomic and physiologic disturbance will arise except in the checking of the regular uterine menstruation and reproduction.

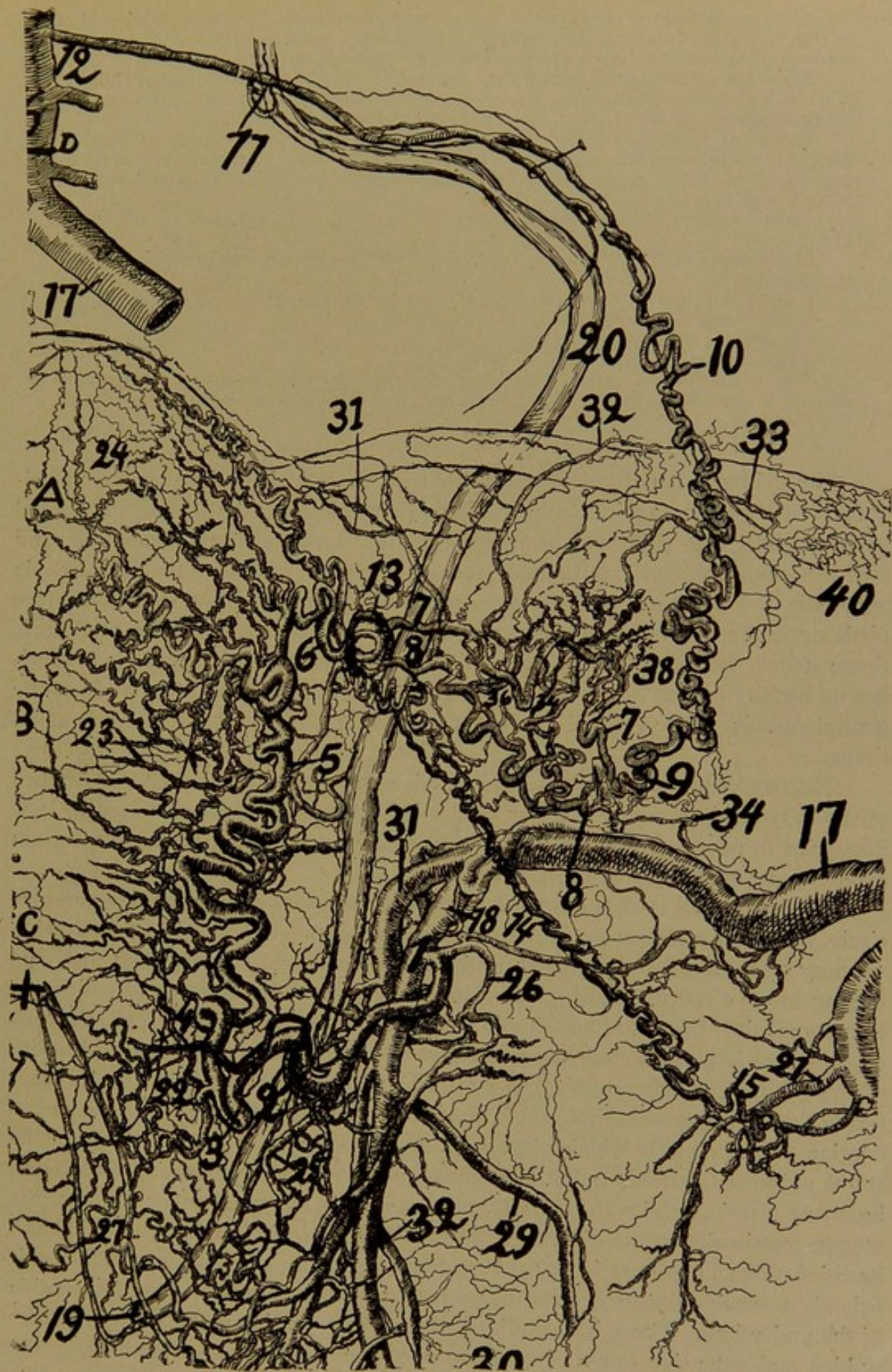


Fig. 19. For description see page 30.

Fig. 19.—A reproduction of an X-ray of a uterus pregnant several months. I injected it *in situ* at the post-mortem with red lead and starch. It shows well the *pelvic floor segment* of the utero-ovarian vascular circle, or circle of the author.

Divisions of the spiral segment of the circle: (1) *Pelvic floor segment*, 1, 2, 3, 4; (2) uterine segment, 4, 5, 6; (3) oviducal segment, 6, 7-7, 9; 6, 8-8, 9; (4) ovarian segment, 9, 10, 11, 12; (5) round ligament segment, 13, 14, 15.

Important locations of the spiral segment: Arterio-ureteral loop, 2; cervical loop, 3; arterio-ureteral crossings; distal, 2; middle, 18; proximal, 11; cervico-vaginal artery, 22; oligemic zones: (a) central longitudinal axis, (b) lateral cervical border, and (c) fundus.

Spiral segment (utero-ovarian artery), 1, 2, 3, 4, 5, 6, 7-7, 8-8, 9, 10, 11, 12 (13, 14, 15).

Straight segment of the circle, abdominal aorta, common and internal iliac, 16, 17, 18.

Lateral arteries: Uterus, 22, 23, 24; oviduct, 31, 32, 33; ovary, 34, 36, 38.

Cervico-vaginal artery, 22.

Ureter, 20, 19.

Vaginal arteries, 25, 26.

The utero-ovarian vascular circle or circle of the author is here represented without a personal equation. It is an X-ray, and therefore an exact representation from nature.

The oviducts, a part of the menstrual organ (which is the uterus and oviducts), may perform their regular periodic rhythmic function because the genital vascular circle may still pass through its monthly cycle of engorgement, the rami laterales oviductus and rami laterales ovarii being still intact. The genital circle left undivided will allow the ovaries—organs of progressive function from before birth until the ovarian tissue is worn out—to functionate normally until their tissue stroma yields to senile processes. The universal rule of surgery is to sacrifice no healthy organs or tissue. The suggestions brought about by a study of the genital vascular circle will aid to prevent sacrificing genital organs or even genital tissue.

Thomas Willis (1622-1673), an English anatomist and philosopher, described at the base of the brain a vascular circle which has since borne his name. It is important in neurology, as the variation in blood supply to the brain, to a certain extent, governs many cerebral phenomena.

In what I shall term the genital vascular circle, or the utero-ovarian vascular circle, we have a vastly more important circle, as work involving the utero-ovarian vascular circle is of much greater utility in medicine and surgery than that pertaining to the circle of Willis. The value of research work is the good which can be accomplished by it, and not simply the knowledge of the facts. Research work on these two important circles demonstrates the fact of the greater practical utility of the genital vascular circle. The straight segment of the circle does not, practically, concern gynecologists. It is the tortuous or spiral segment of the utero-ovarian vascular circle which plays such an important role in gynecology. The spiral segment consists of the anastomosed tortuous uterine, ovarian and round ligament arteries. The tortuous segment allows wide range of motion to the uterus, proximally to the diaphragm, laterally to the lateral abdominal walls, and its chief utility in surgery is that this tortuous segment can be drawn distally sufficiently to enable the surgeon to ligate both uterine and ovarian arteries outside of the pudendum. The spiral condition of the utero-ovarian vascular circle allows sudden and extensive range of movements of the uterus as in pregnancy, in the activity of bodily movements and in the use of traction forceps on the uterus. The

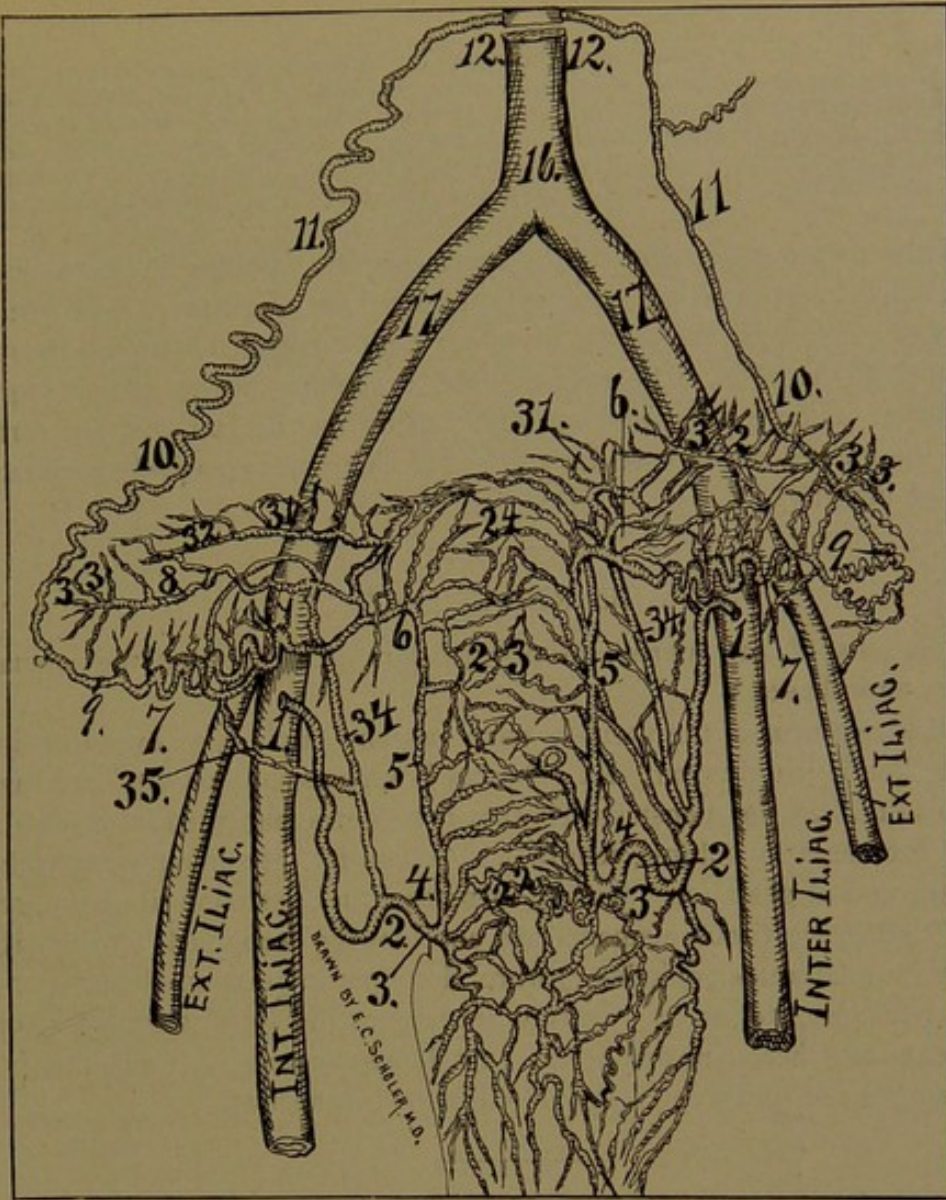


Fig. 20.—Infant one day old. Ventral view. Reverse of Fig. (21). In this case the genital vascular circle is complete as 9, 10, 11, 12. 16, Aorta. 17, common iliacs. Observe that Fig. (21) has vastly more vessels on the dorsal surface than the same uterus has on the ventral surface. 34 and 35, arteries of ligamentum latum, forming arcs and arcades in ligamentum latum especially adjacent to the ovaries. In this specimen the arteria ligamenti teretis became fractured and destroyed during working. Note the peculiar form of circulation on the ventral uterine wall as compared with that on the dorsal (Fig. 21). The uterine segment (4, 5, 6,) is straight extended as it is during gestation. Observe the arteria azygos vaginae on ventral vaginal wall. The umbilical or internal iliac is larger than the external iliac. Note that the left ovarian segment is quite straight (9, 10, 11, 12,) while the right (9, 10, 11, 12,) is quite spiral. The ovarian vascular circle is evident, the vaginal branches are so rich that they cannot all be drawn. Also the lens presents more branches to the ovary than can be placed. In the infant the cervix and vagina are supplied richly out of all proportion to the other segments of the tractus genitalis and the arteries are also very large, hence the large size of the cervix in pueritas. Practically its cervico-corporeal oligemic zone is the separation of the rich vaginal vascular leash which is directed distalward on the vagina and the lesser vascular leash which is directed proximalward on the corpus uteri.

The dorsal surface of the uterus in man is supplied with 25 per cent or one-quarter more blood than the ventral, as is shown at birth, and in adult by corrosion anatomy. The dorsal rami laterales uterii are decidedly transverse. The ventral rami laterales are directed more proximalward and distalward. The cervix is the

point where the rami laterales have their great turning point; — uterine pass proximal (spiral), — vaginal pass distalward (straight). The chief large vessels course on or near the uterine surface and they send perpendicular branches through the endometrium, which finally end in leashes or tufts like the vaginals. The rami laterales fundi, corporis, and to a less degree vaginales, end in tufts, leashes or tufts like a cat-o'-nine-tails. Celloidin with vermilion is the best injection for fine vessels.

capacity of the tortuous segment of the utero-ovarian vascular circle to elongate is its chief value to gynecologic surgery, especially per vaginam. With the traction forceps one can draw the uterus distalward sufficiently to ligate all its vessels at leisure outside the body. The future route for pelvic surgery is per vaginam, and the facility of its accomplishment rests chiefly on the fact that the tortuous segment of the utero-ovarian vascular circle will elongate extensively without suffering loss of integrity.

AGE RELATIONS.

Age relations of the utero-ovarian vascular circle subjects the woman to sexual crises and phases.

The spiral segment of the utero-ovarian vascular circle is an organ of limited life. In pueritas it is quiescent. At pubertas it springs into activity, increases in size and spirality. In the menstrual rhythm it becomes engorged with blood. In gestation it increases in volume, length and tortuosity, becoming completely developed at the end of gestation. During menstrual and gestation life its muscular, elastic and connective tissue elements are enormously developed, so that, if any of its larger rami laterales genitales rupture, these predominating elements at once contract, if not close, its lumen. During senescence the spiral segment atrophies in all its coats and becomes non-spiral. Its lumen lessens, it walls calcify and it again assumes the quiescent stage of childhood—pueritas.

THE UTERO-OVARIAN VASCULAR CIRCLE.

GENERAL DESCRIPTION.

The following general description applies to the illustrations in the monograph except otherwise indicated.

The X-ray work was performed for me in Dr. Harry Pratt's X-ray and electro-therapeutic laboratory. It was magnified by Dr. Wm. E. Holland for the artist, Mr. Zan D. Klopper, to follow as a model, except otherwise noted.

The general methods of preparing the specimens were to inject in situ at the autopsy or after removal. The specimens were injected with red lead (Triplumbic Tetroxide, Pb_3O_4) and starch, paraffin or celloidin, mixed with vermilion (cinabar, red sulphite of mercury, mercuric sulphide $Hg S$). The specimens injected with red lead were X-rayed. Those injected with vermilion, celloidin or paraffin were X-rayed and corroded in nitric acid (HNO_3).

I shall divide the genital circle, or utero-ovarian artery, into five segments, of which a concise description will be here presented, based on (a), local structures and functions; (b), bifurcations of the utero-ovarian artery; (c), for convenience of description and signification.

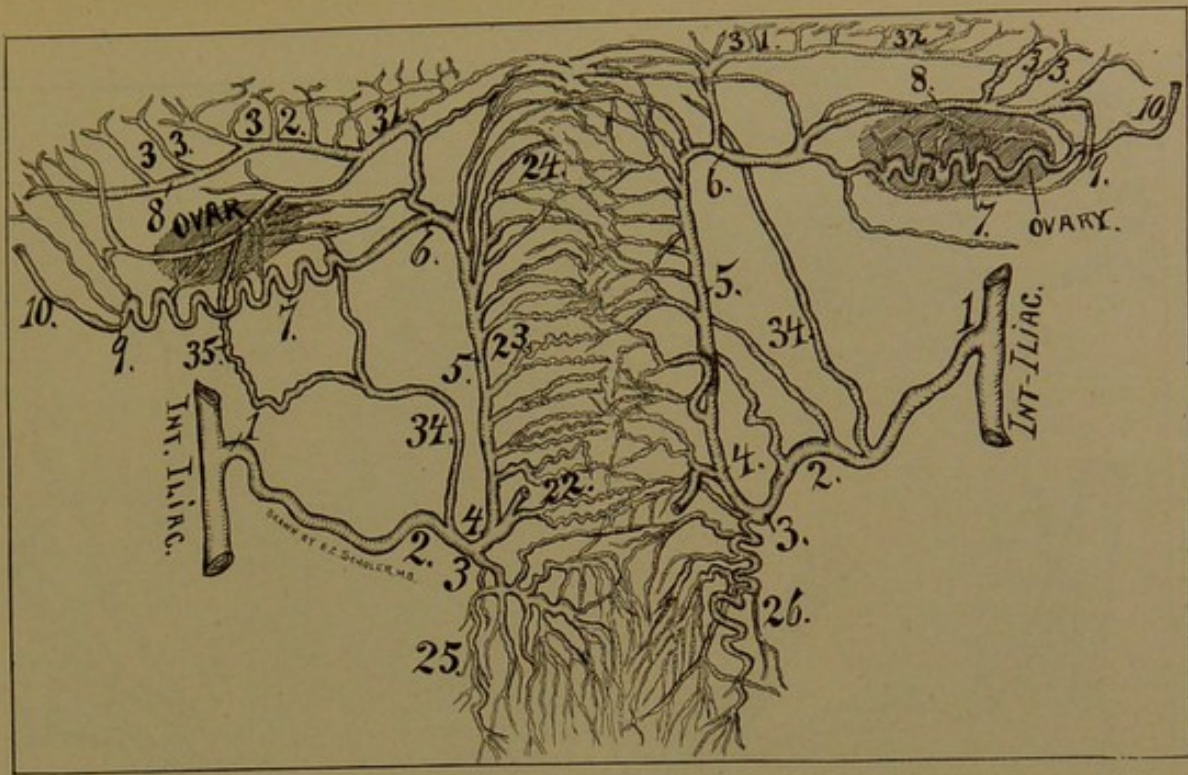


Fig. 21—Infant one day old injected with celloidin and vermilion (Hgs.) *in situ*. It was subsequently removed and placed in Nitric acid 30 per cent, water 70 per cent, for two weeks, when the tissues were corroded—dorsal view. It was drawn while lying in 90 per cent water and 10 per cent glycerine by the aid of a lens magnifying some 10 diameters. Observe how the vaginal arteries pass distalward. Note the large cervico-vaginal (22) bifurcated, one branch passing dorsal and the other ventral to cervix. 34, artery of ligamentum latum; 35, subovarian arcade. The vaginal arteries divide dichotomously and are so rich that they can not be drawn. Tuftlike branches exist on the terminal vaginal arteries. The infant's uterus teaches that the uterus is distinctly a double organ with double circulation. The aid of the magnifying lens demonstrates that the circulation in the fundus and corpus consists first of an independent circulation of each half as shown by the rami corporis and rami fundi passing almost to the middle line whence they curve toward the lateral uterine border, second a relatively limited number from one lateral half coalesces with those of the other. If one looks longitudinally through the uterus from fundus toward the cervix as it stands in the fluid the circulation presents itself as double, one vascular circular tube on each side of the center of the uterus resembling exactly a double barreled shot gun. The corroded specimen demonstrates that the large arteries pass near the external surface of the uterus not far from the peritoneum. The rami uteri end in the endometrium in terminal tufts resembling the ending of arteries in the mucosa intestinalis. In the infant's uterus the dorsal surface presents one-fourth more blood supply than the ventral. Also the rami uteri dorsalis are arranged more parallel and transverse than the ventral. The rami uteri ventralis course more in the direction of the longitudinal axis of the uterus than of the dorsal wall. Observe the direction of the arteriæ vaginae (25 and 26) as distalward. The rami corporis (23) are directed horizontally. The rami fundi (24) are directed primalward. The ureters were injected with melted paraffin and presented typical bilateral constrictions and dilations.

They passed close to the cervix and symmetrical on each side, producing the typical arterial ureteral loop (2, 2). Observe the large arteria ligamentum latum (34). The ovarian vascular circle is easily observed.

The genital vascular circle, or utero-ovarian artery, consists of (1) a straight segment, viz: (a), the abdominal aorta; (b), common iliac, and (c), the internal iliac. (2) The spiral segment, viz: the five segments, (a); pelvic floor, (b); uterine, (c); oviducal (d); ovarian and that of (e), the round ligament.

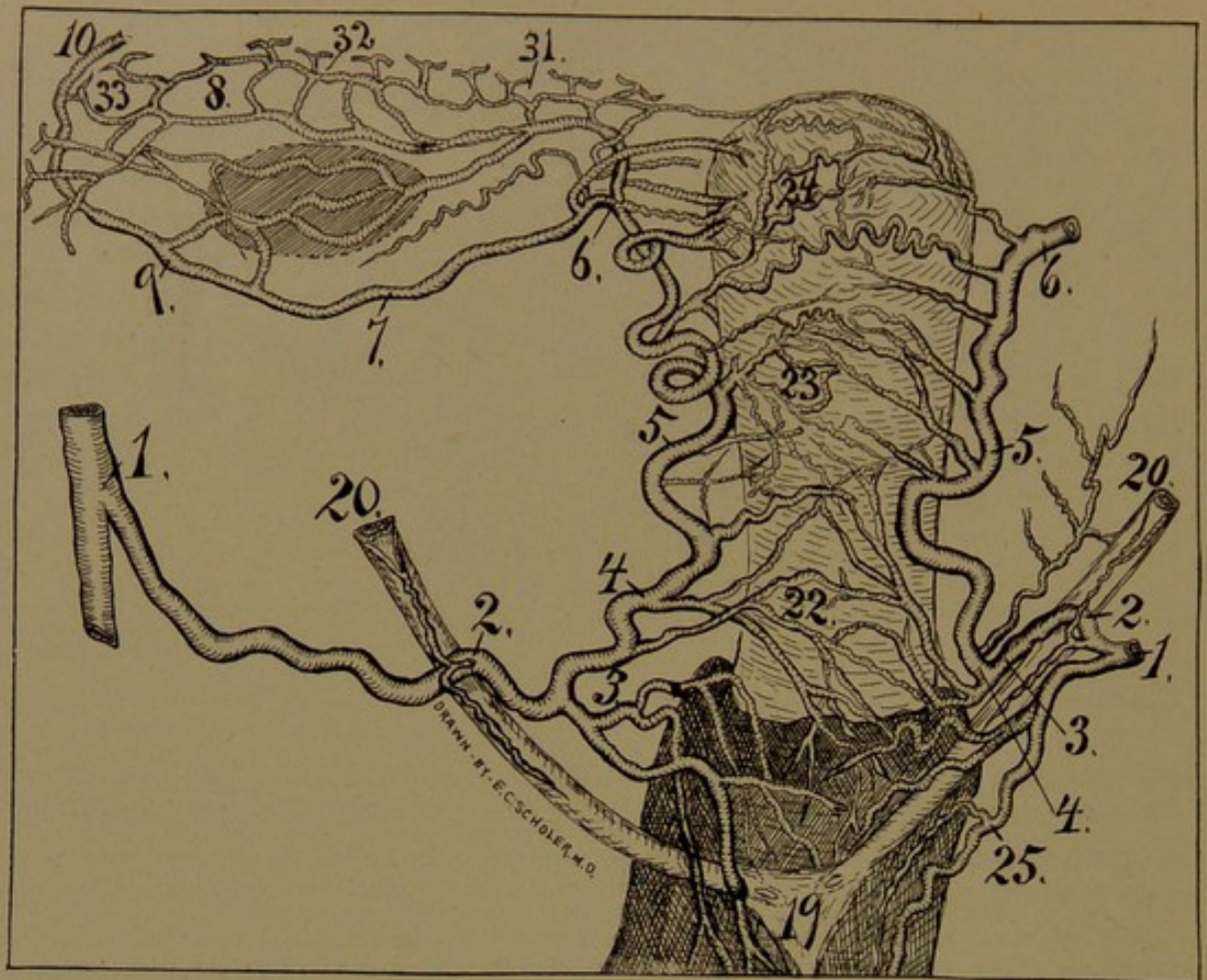

Fig. 22—Subject 46 years of age injected with celloidin and vermilion (Hg. S) and corroded in nitric acid 30 per cent and water 70 per cent. The ureters were injected with melted paraffin. Ventral view. The specimen after careful washing is preserved in 90 per cent water with 10 per cent glycerine. It was carefully drawn while floating in the fluid by the aid of a large magnifying lens. (X) 1, origin of uterine artery from internal iliac. 2, distal arterio-ureteral crossing with an arterio-ureteral loop and arteria ureterica distal. 3, Cervical loop 4, point where uterine arteries arrive at cervix. 5, uterine segment of utero-ovarian artery. 6, bifurcatio arteria uterinæ medial or middle bifurcation where the uterine segment divides into ramus oviductus (6, 8, 9,) ramus ovarii (6, 7, 9) and rami fundi (24). 10, ovarian segment 31, 32, 33 branches to oviduct. 22, ramus cervicis at the bifurcatio arteriæ uterinæ or distal bifurcation of uterine artery, 23 rami corporis; 20, ureter; 19 vesical trigone; 25 and 26 vaginal arteries. This specimen presents a loop of the uterine segment lying on the ventral surface of the uterus. Note that at (22) some of the more distal branches supply uterine territory proximal to their usual region. This specimen presents an unusual arrangement of the cervical branches as well as of the oviduct segment. The ovarian vascular circle is plainly evident.

THE PELVIC FLOOR SEGMENT. { 1, 2, 3, 4. 1, 2, 3, 4.

This segment extends from the origin of the utero-ovarian artery in the hypogastric artery to the level of the internal os uteri. This is the surgical segment dignified into importance by (a), the arterio-ureteral loop (2); (b), the distal arterio-ureteral crossing (2); (c), the cervical loop (3); (d), the distal bifurcation (22) of the utero-ovarian artery; (e), the utero-cervico-arterial triangle, or the lateral cervical triangle (2, 19, 4); (f), the cervico-vaginal artery (22); and

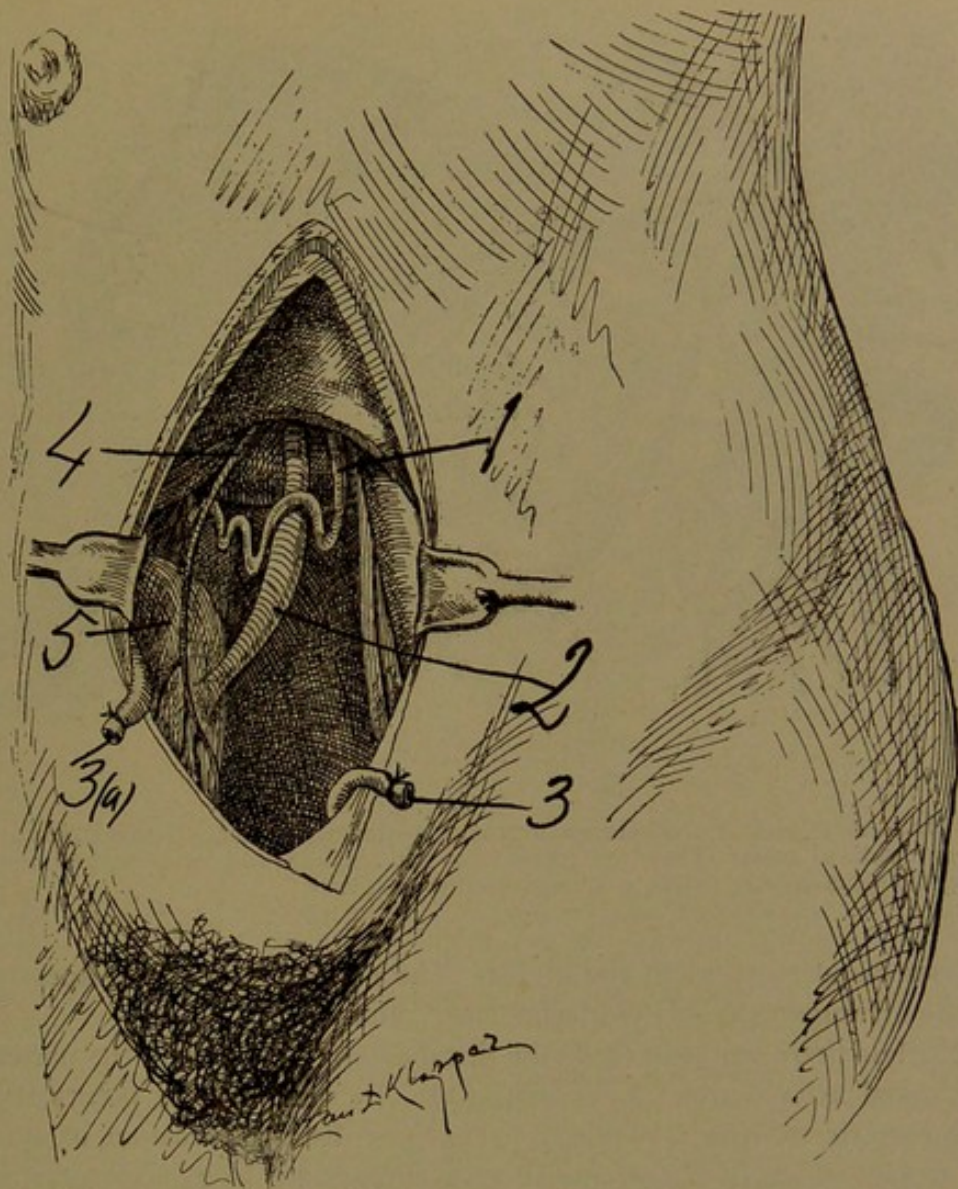


Fig. 23.—Ureter and uterine artery in erect attitude exposed. 1. Arteria uterina with its arterio-ureteral crossing on the ureter and the cervical loop between the uterus and ureter. 2. Pelvic ureteral spindle. 3 and 3 (a). Arteria hypogastrica. 4. Arteria vesicalis superior. 5. Vesica urinaria. In this drawing a suggestion from Drs. Tandler and Halban is employed.

(g), the arteria ureterica distal (at 2). I shall divide the pelvic floor segment by means of the ureter in the external portion (1 to 2) (external two-thirds, about two inches), and internal portion (2 to 4) (internal one-third, about one inch). In the 3 months' pregnant case the pelvic floor segment is exactly four inches in length and divided equally, in the middle, by the ureter (20, 19 at 2). The *cervical loop* (3), in this case, is two inches in length. It enlarges and unfolds during gestation. In the long cervical loop (3), which enables the operator to avoid wounding the ureter in hysterectomy, saving many women from suffering and death. The pelvic floor segment crosses proximal to (above) the ureter (20, 19 at 2), so that in pregnancy the proximal-ward movements of the uterus may not kink and obstruct both the artery and ureter. In the dog, cat, rabbit, cow, pig and sheep, my dried and wet specimens show that the uterine artery, unlike in

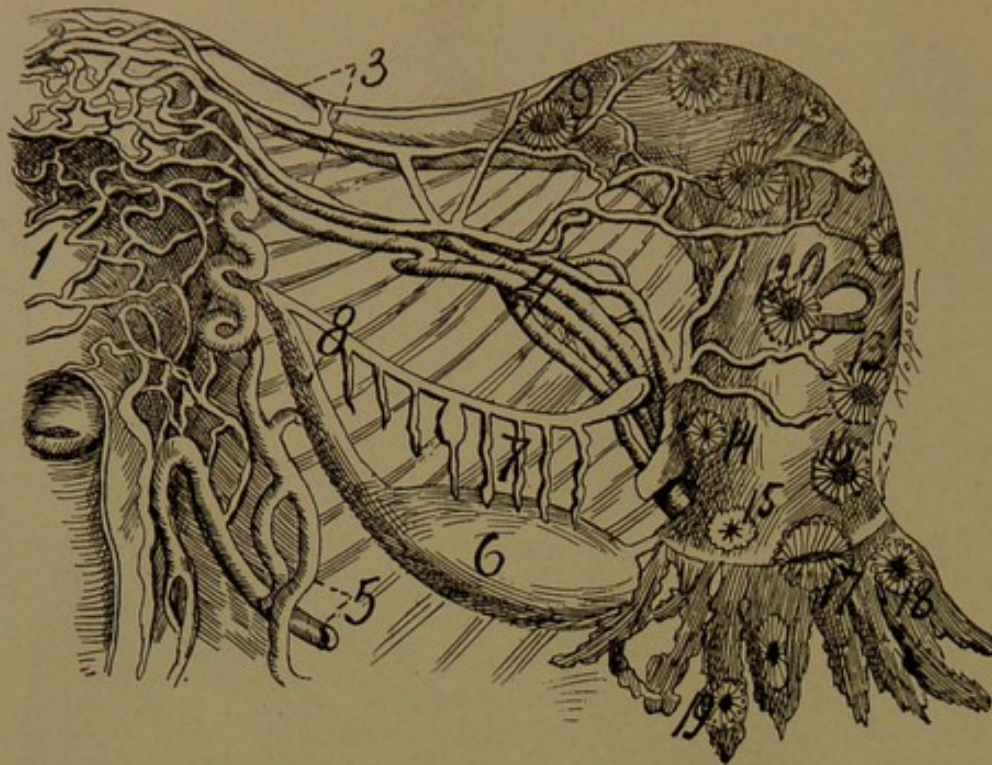


Fig. 24—The venous and arterial circulation of the internal genitals. Dorsal view. Accessory oviducal ostia. They are located on the ampulla and oviducal pavilion; 9, 10, 14, 18, 19, accessory ostia; 4, 5, vasa uterina; 6, ovary.

man, passes distal to (under) the ureter. The monkey and higher apes resemble man in the arrangements of the uterine artery and ureter.

The pelvic floor segment sends the distal arteria ureterica to the ureter at the point of distal arterio-ureteral crossing (2). In this segment occurs the distal bifurcatio arteria uterinæ (Waldeyer) (22), or distal bifurcation of the utero-ovarian artery, which is of extreme surgical importance in hysterectomy and certain cervical lacerations.

The lateral cervical triangle (2, 19, 4), located on the lateral cervical border, is composed of the ureter as a base (two inches, 2 to 19), the cervical loop (3) as one side (one inch), and the distance from the lateral border of the internal os uteri (4) to the vesicle orifice of the ureter (19) for the other side (one and one-half inches). This triangle is of extreme importance in vaginal hysterectomy as one of its sides, the cervical loop must be ligated. The pelvic segment lies in a vast bed of loose connective tissue in the base of the ligamentum latum, is extensively mobile, slightly spiral but strongly looped, it loops the ureter, lies in a vast venous plexus and sends branches to the cervix, vagina, ureter and adjacent structures. The cross (+) indicates that a ramus lateralis uteri passes to the posterior surface of the uterus.

The cervico-vaginal artery (22) divides before it reaches the cervical border in two branches; one supplying the posterior and the other the anterior cervical wall, which makes a vascular boot-jack angle on the lateral cervical border and a consequent exsanguinated lateral cervical zone. This bloodless zone explains why women in labor with lateral cervical lacerations do not die from hemorrhage.

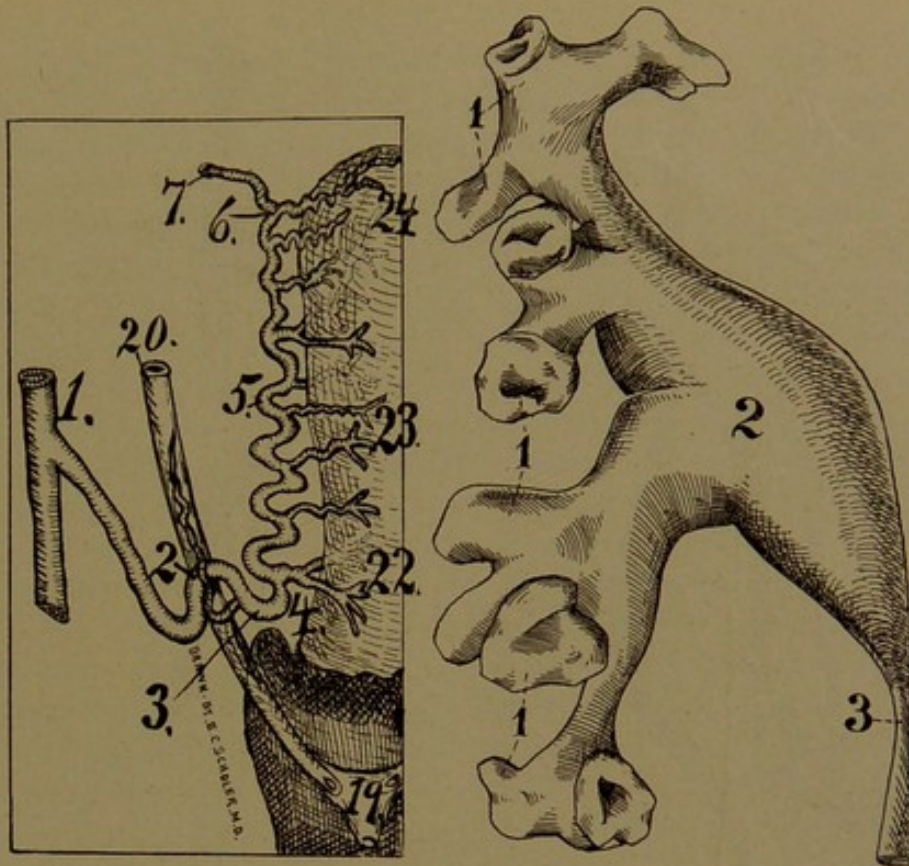


Fig. 25.—The cut at left is that of a woman 46 years of age. The internal iliac was injected after the specimen was removed from the body with celloidin and the ureter with melted paraffin. It was corroded in hydrochloric acid. During the washing the fine vessels broke away. This cut presents several distinct matters. It shows the arterio-ureteral loop (2) with its arteria ureterica distal. A distinct cervical loop (3) appears. The ramus cervicis (22) originating at (4) divides dichotomously one branch passing to the dorsal and the other to the ventral wall of the cervix one ramus uteri immediately proximal to (5) divides dichotomously one branch passing to the dorsal and the other ventral uterine wall. All other rami uteri except one originate as one branch from the uterine segment and pass entirely to the ventral or dorsal uterine wall. The ramus cervicis always divides dichotomously supplying a dorsal and ventral cervical branch. 20, ureter, 19, distal ureteral surface and trigone. Observe that this specimen shows marked regularity of the rami laterales uteri. (1) to (2) is the external portion while (2) to (4) is the internal portion (*cervical loop*) of the pelvic floor segment at the utero-ovarian artery. The ureter divides the pelvic floor segment at the junction of its middle and internal thirds. Note spiralty of rami fundi (24). The cervical artery (22), straight or extended. The cut at right is a paraffin cast of the left kidney of a woman 46 years of age. It was corroded in acid. (1, 1, 1), calyces two or four armed according to base of view. Number of calyces eleven (2) well developed rounded pelvis (3), distinct proximal ureteral isthmus.

Anterior-posterior cervical lacerations bleed vigorously because one or both of the boat-jack vascular arms of the cervical artery becomes torn.

THE UTERINE SEGMENT. { 4, 5, 6. 4, 5, 6.

This segment passes in a sinuous winding course along the lateral uterine border between the blades of the ligamentum latum from the os uteri internum (4) to the utero-oviducal angle (6). It is located about one-third of an inch from the myometrium, lying in a rich bed of connective tissue. It sends off the rami laterales uteri to the cervix (22), corpus (23), and fundus (24), each of which

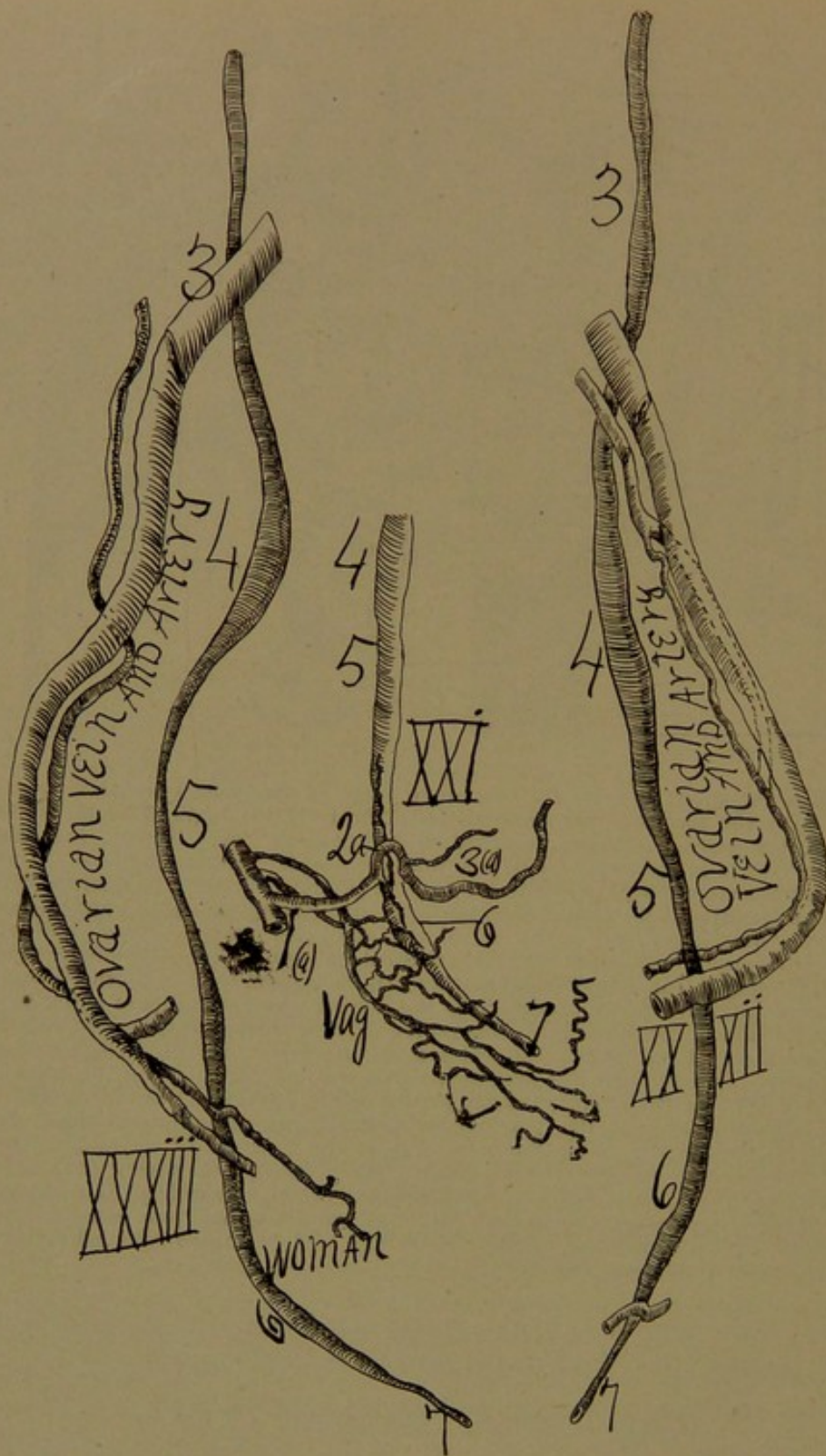


Fig. 26—Nos. XXXII and XXXIII, middle-aged woman with prominent ureteral spindles. XXXIII has three pelvic ureteral spindles. XXI, distal end of female ureter with relations to arteria uterina (1 (a), 2 (a), 3 (a)) and arteriæ vaginales (Vag.), two spindles (4) and (6) pronounced. XXXII the ovarian artery and vein are shown in relation to ureter, (3) proximal arterio ureteral crossing.

This specimen was injected with red lead and starch after removal from the body and X-rayed.

differs in characteristics. The rami laterales to the cervix (22) divide dichotomously, supplying the anterior and posterior cervical wall, making a triangular lateral oligemic (exsanguinated) cervical zone between the vascular arms of the cervical ramus. Those to the corpus (23) and fundus (24) are destined either for the posterior or anterior corporeal or fundal wall, producing a longitudinal and fundal oligemic (exsanguinated) zone. The pregnant uterus has about 20 rami laterales uteri, in general the larger in size and number pass to the posterior uterine wall. The uterine segment practically begins at the bifurcatio arteria uterinæ distal (22) and ends at the bifurcatic arteria uterinæ medial (6). This segment is always spiral and looped, but more straight in advanced pregnant distention. The uterine segment lies in a mobile bed of connective tissue and almost concealed in a vast plexus of veins. There is ample distance between the uterine segment and the uterus (myometrium) to sever the rami laterales uteri without severing the uterine artery (genital circle). In other words, the uterus can be removed without cutting the utero-ovarian artery or the genital circle (Pratt's operation). There are almost always three large rami laterales uteri, viz: the cervico-vaginal (22) to the cervix, second, the ramus at the level of the ligamentum ovarii (near 6) passing to the junction of the corpus and fundus, and third, a ramus at the level of the oviducal angle (24), chiefly posterior passing to the fundus. Of the rami laterales uteri, those to the cervix (22) (long and large) pass distalward at an acute angle, those to the corpus (23) (short and small) pass at a right angle, while those to the fundus (24) (long and large) pass proximalward at an acute angle from the uterine segment. The rami laterales uteri are always spiral and anastomose with their opposite fellows, which is transverse anastomosis (A. B. C). they anastomose with their adjacent fellows, which is longitudinal anastomosis (A, B, C), especially at the lateral uterine border, and the three superimposed vascular strata of the perimetrium, myometrium and endometrium anastomose with each other, which is a perpendicular anastomosis making the uterine circulation compact and solid. A. B, C shows the location of both longitudinal and transverse anastomoses. In pregnant subjects, as shown in my experience, fluid injected in the common iliac artery on one side rapidly passes in large quantities to the common iliac artery of the opposite side. The cervix and fundus sit in circular vascular zones. The topography and distribution of the rami laterales uteri present three oligemic (exsanguinated) zones, viz: central longitudinal, lateral cervical and fundal, all of profound signification and importance in gynecological surgery. The author's operation of endometrectomy and partial myomectomy is based on the oligemic (exsanguinated) central longitudinal zone.

THE OVIDUCAL SEGMENT. $\left\{ \begin{array}{l} 6, 7-7, 9. \\ 6, 8-8, 9. \end{array} \right.$

This segment extends from the utero-oviducal angle (6) to the external pole of the ovary or to the distal end of the ovarian segment (9). The oviducal segment consists of two branches, namely, the ramus oviductus (6, 8-8, 9), and the ramus ovarii (8, 7-7, 9). The oviducal segment presents what I shall term the *ovarian vascular circle* (6, 7-7, 9. 6, 8-8, 9), which is composed of the ramus ovarii and ramus oviductus, which unite internal (6) and external (9) to the

ovary. In this subject both branches send long (36 and 34) and short (38) helicine arteries to the ovary. The oviducal segment ends and begins where its two branches anastomose (6 and 9). The oviducal segment emits rami laterales ovari (36) and rami laterales oviductus (31, 32 and 33). It begins at the bifurcatio arteriæ uterinæ medial (6) and ends at the bifurcatio arteriæ uterinæ proximal (9) and is generally accompanied by two veins. By severing the lateral branches (31, 32, 33) of the ramus oviductus close to the oviduct one can remove the oviduct without cutting the genital vascular circle or the ramus oviductus. By severing the lateral branches (38) of the ramus ovarii the ovary can be removed without cutting the ramus ovarii or the genital vascular circle.

In the present pregnant case the ovarian vascular circle (6, 7—7, 9 and 6, 8—8, 9) is extremely well developed and prominent on both sides. It is one of the original Wolffian vascular arches. The rule is that the ramus ovarii sends five short very spiral helicine branches (38) to the ovary and the ramus oviductus sends three long sinuous helicine branches (34 and 36) to the ovary and three large long sinuous branches (31, 32 and 33) to the oviduct. It has a phenomenal development during pregnancy in man and animals.

The oviducal ampulla, receptaculum seminis, is attended by an enormous blood supply (33 and 40).

THE OVARIAN SEGMENT. { 9, 10, 11 and 12. 9, 10, 11 and 12.

This segment extends from the oviducal pole (9) of the ovary to the aorta near the origin of the renal artery (12). In this segment is found the proximal arterio-ureteral crossing (11) with the proximal arteria ureterica. The ovarian segment begins at the proximal bifurcation of the utero-ovarian artery, Bifurcatio arteriæ uterinæ proximal (9), and ends at the original location of the Wolffian body along the aorta (12). From the proximal arterio-ureteral crossing (11) the ovarian segment passes close to and externally parallel with the ureter (20, 19) as far as the ligamentum suspensorium ovarii (9). In its course it sends several branches to the ureter, peritoneum and adjacent structures, but especially strong branches to the ligamentum suspensorium ovarii (35 and 34), where numerous additional arches and branches may be recognized in pregnant subjects. It is very spiral in its distal portion but straight from its origin in the aorta to the proximal arterio-ureteral crossing (11). It develops rapidly during gestation in man and animals. The ovarian segment lies in a vast bed of connective tissue and possesses extensive mobility.

THE ROUND LIGAMENT SEGMENT. { 13, 14 and 15. 13, 14 and 15.

This segment extends from the deep epigastric (21) to the ramus oviducts near the utero-oviducal angle (6). It lies in the center of the ligamentum rotundum uteri and is very tortuous. It begins practically at the middle bifurcation of the utero-ovarian artery, bifurcatio arteria uterinæ medial (6), and ends* in the deep epigastric artery (21). It has a wonderful development and tortuous course during gestation. At its origin from the deep epigastric (21) it may be by two branches, which dwindle to one or two in the middle of the round ligament (14).

It rises from the ramus oviductus (13 and 8) frequently also by two branches, one of which passes to the uterine fundus along the round ligament. At both extreme ends it is strongly looped. In its middle it is more straight. It is not easy to decide the direction of the blood in the round ligament segment.

In the middle of the round ligament the blood current is very feeble in the resting genitals. This segment is best injected through the common iliac or femoral, however it can be injected from any point of the utero-ovarian artery. It should be ligated in hysterectomy.

GENERAL.

The utero-ovarian artery consists of a tripedal arch, the feet of which are located one on the internal iliac (uterine 1), a second at the deep epigastric (that of the round ligament 15), and a third foot (the ovarian) on the anterior surface of the aorta near the renal artery (12). The vascular arches of the genitals were originally formed in the Wolffian body, and two of its feet moved distalward on the iliacs due to the erect attitude. The utero-ovarian artery is subject to age relations and passes through sexual crises and sexual phases; i. e., (a) the phase of foetal and childhood life (pueritas); (b) the crisis or puberty (pubertas); (c) the crisis of menstruation; (d) the crisis of gestation; (e) the phase of menopause, and (f) the phase of senescence.

The spiral segment of the genital vascular circle consists of a grand arch formed in the Wolffian body and from which emerges rami laterales genitales to nourish the genital tract. The utility of the spiral segment of the genital vascular circle consists in its capacity to allow sudden and extensive genital movements in all directions, but especially proximalward during gestation and distalward during surgical intervention. The spiral segment of the resting genitals is sufficiently long and mobile to allow the genitals to be drawn by traction forceps into the pudendum for inspection, palpation and vascular ligation, treatment and partial or general removal. The spiral segment is dignified by gynecological surgery into the most important of all arteries from its frequent and important uses and its relation to the genitals and ureter (distal, 2, and proximal, 11, arterio-ureteral crossings). It lies ventral to the ureter. It can be injected from any point in its course. The genital vascular circle is almost identically the same in man and lower animals, except in bovine, soliped, carnivora, which possess an extra anastomotic genital arch through the addition by anastomosis of the larger vaginal artery. In the horse the aortic or pudic gives off one branch, which later divides into the uterine and ovarian, thus forming the utero-ovarian or genital vascular circle of the author. It is a grand arcade formed in the Wolffian body.

All the rami laterales uteri anastomose with each other. The spiral segment of the genital vascular circle may be ligated (Gottschack-Martin operation, independently suggested by Dorsey) at any point bilaterally at the same time without gangrene. The result is atrophy of the genital parts whose blood supply is cut off by the ligature. There is a special system of fine arterial branches passing from the utero-ovarian artery to the vast venous plexuses of the genital tract.

The utero-ovarian artery appears to me to treble itself during gestation, which would make the uterus receive six times more blood during the gestating than the resting state.

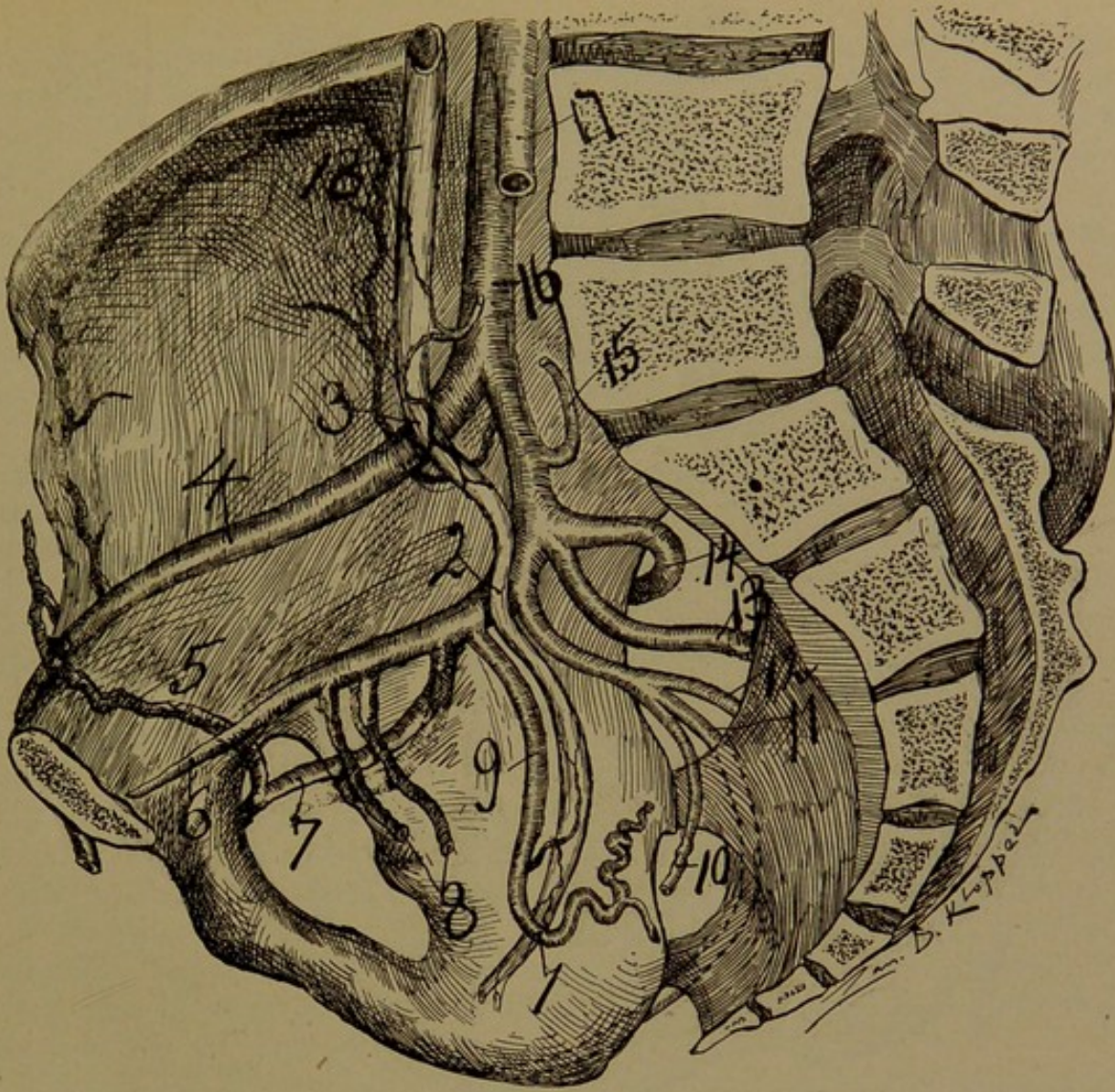


Fig. 28—Right lateral view of pelvis showing the arterial and ureteral relations. Drawn from dissected subject about 55, in which I placed the vessels as accurately as possible, after which Mr Zan Klopper, my artist, finished from the model. 1, arterio-ureteral crossing (distal), showing arterio-ureteral loop and cervical loop; 2, point where ureter crosses anterior trunk of internal iliac; 3, middle arterio-ureteral crossing; 4, external iliac; 5, artery connecting obturator and external iliac; 6, hypogastric; 7, obturator; 8, superior and inferior vesicle; 9, uterine artery lying parallel with ureter and sending off the arteria ureterica (distal); 10, middle hæmorrhoidal; 11, internal pudic; 12, anomalous branch; 13, inferior gluteal; 14, superior gluteal; 15, lateral sacral; 16, common iliac at point where arteria ureterica (medium) passes to ureter; 18, proximal ureteral spindle. Note pelvic ureteral spindle.

The reason that woman does not bleed to death at labor and from uterine (cervical) lacerations is because of the oligemic (exsanguinated) uterine vascular zones, and especially because the vessels lie surrounded by the meshes of muscular bundles, which act like living ligatures in checking hemorrhage.

The solid and compact anastomoses of the entire lateral branches to the uterus (bilateral) and oviduct (unilateral) enables the uterus or oviduct to entice and direct the main blood current to any point of the endometrium or endosalpinx, which may be stimulated or irritated, as in pregnancy or tumors. Hence, whether

an ovum becomes fixed to the endometrium or endosalpinx the arrangement of the blood apparatus of the uterus and oviduct is so compact in anastomosis that the chief stream tends to wherever the gestating point is located. The solid anastomoses of the utero-oviducal apparatus explains the fact that the ovum thrives so vigorously in the oviduct.

In all animals I dissected with regard to the utero-ovarian artery, man, monkey, ape, cow, sheep, horse, dog, cat, pig, bear, guinea pig, rat, rabbit, I found that the largest and strongest of all rami laterales uteri tended toward and supplied the usual point of gestation as the fundus in man, ape and monkey, and the cornua uteri in lower animals.

It is an error to attempt to locate the point of anastomosis of the utero-ovarian artery as it is a single indivisible grand arcade. The utero-ovarian artery sends branches to the ligamentum latum, mesosalpinx, peritoneum, ureter and tissue adjacent to its course.

The ovarian segment with the ovarian vein forms the uretero-venous triangle (author). This uretero-venous triangle is a constant structure and is composed of the ureter on the external side, the renal vein on the proximal side, and the vena cava and ovarian vein on the internal side. The apex of the right uretero-venous triangle extends more distalward than the left and may extend distal to the iliac crest.

The longitudinal oligemic (exsanguinated) zone, located in the central longitudinal axis of the uterus, allows the uterus to be bisected longitudinally with but slight capillary hemorrhage. It would perhaps not be fatal in the resting uterus.

The lateral cervical oligemic (exsanguinated) zone allows lateral cervical laceration with limited non-fatal hemorrhage. The fundal oligemic (exsanguinated) zone, the usual location of uterine myomata, allows myomectomy with limited and non-fatal hemorrhage.

27, 28, vesicle arteries; 29, obturator; 30, internal pudic; 31 (left side), superior gluteal; 32 (left side), inferior gluteal.

34 and 35 arteries of ligamentum latum and subovarian arcades, represent vascular arches formed in the Wolffian body, which present additional proof that all the arches of the genital vascular circle arose in this body.

40 shows the vast network of blood vessels supplying the oviducal ampulla. D shows where a section of the aorta has been removed to shorten it (to lessen the size of the cut). The Latin (+) cross is placed at the location of the internal os.

16, aorta; 17, common iliac; 18, internal iliac; 19, distal end of ureter; 20, middle of ureter; 22, 23, 24, rami laterales uteri; 25 and 26, vaginal arteries; 30, hypogastric artery; 31, 32, 33, rami oviductus; 36, branches from the ramus oviductus to ovary; 38, rami ovarii; 40, branches to pavilion; 41, external iliac; 45, renal artery; 46, dorsal branch of renal artery; 47, ventral branch of renal artery; 48, adrenal branch; 49, phrenic branch; 50, artery to renal capsule; 57, connection between ovarian segment and renal arteries; 53, hypogastric artery.

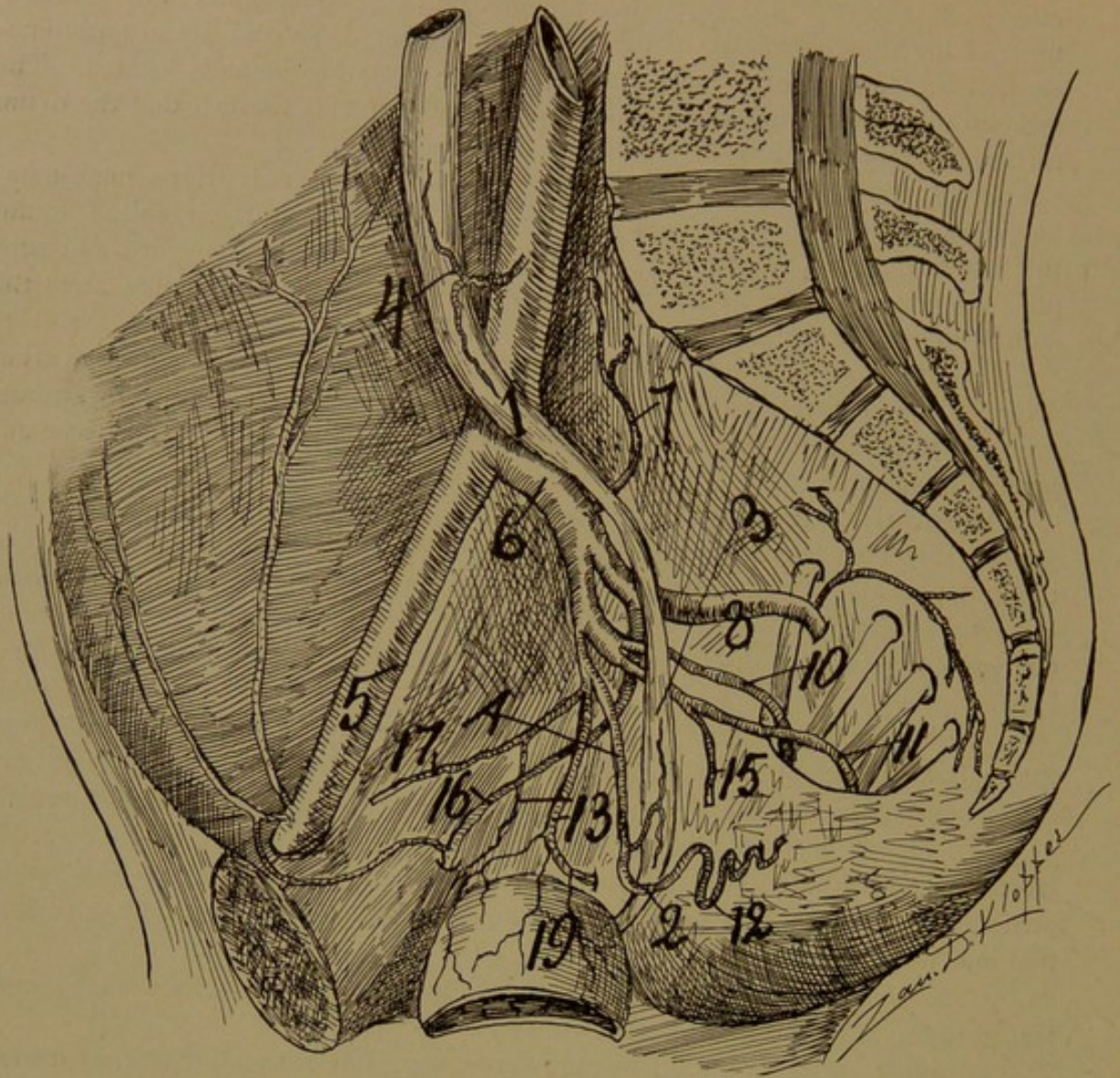


Fig. 30.—Illustrates a right view of the pelvis to show the relations of the pelvic floor segment of the utero-ovarian artery to the ureter; also the divisions and distributions of internal iliac.—1. The middle arterio-ureteral crossing (entirely on the common iliac); 2. The distal arterio-ureteral crossing from which entirely proximal springs the distal arterio-ureterica, T-shaped; 3. Distal or pelvic spindle of the ureter (urinal reservoir); 4. The middle arteria ureterica arising from the common iliac, T-shaped, also proximal or lumbar ureteral spindle (urinal reservoir); 5. External iliac; 6. Internal iliac; 7. The ileolumbalis; 8. Superior gluteal; 10. Inferior gluteal; 11. Internal pudic; 12. Cervical loop or internal portion of pelvic floor segment; 13. Vesicle arteries; 15. Middle hæmorrhoidal; 16. Obturator; 17. Hypogastric; 19. Bladder.

Observe that the ureter courses posterior, dorsal, to the internal iliac in this case, and that A (the external portion of the pelvic floor segment) makes its usual dorsally looped concavity. The branches of the internal iliac vary in number, size, and distribution, while also the ureter varies in its course as regards the internal (and external iliac); hence scarcely do any two cadavers present exactly similar relations of ureter and pelvic floor segment of the utero-ovarian artery.

I sketched this drawing carefully at my dissection, so that it represents approximately exact anatomic data. In this figure the anterior trunk of the internal iliac is not sufficient in length to place a double ligature for the purpose of exsanguinating the pelvic viscera supplied by the anterior division of the internal iliac. Hence, here the only safe method for pelvic visceral exsanguination (as for malignancy) would be to dissect away the ureter and ligate the trunk of the internal iliac.

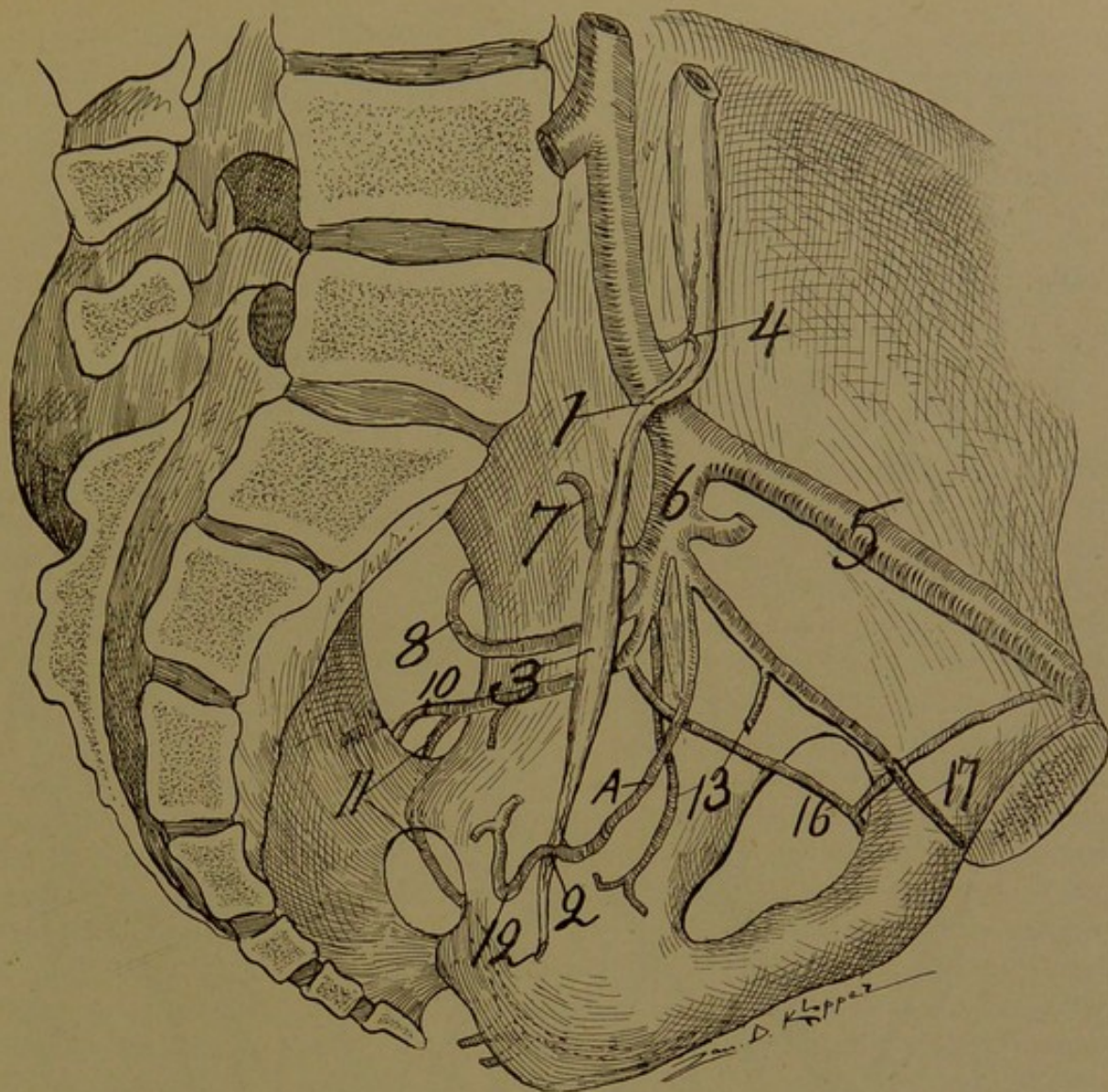


Fig. 31—Illustrates a left lateral view of the pelvis to demonstrate the relations of the ureter and pelvic floor segment of the utero-ovarian artery; also the divisions and distributions of the internal iliac. I sketched this drawing from my own dissection.—1. Middle arterio-ureteral crossing; 2. Distal arterio-ureteral crossing, at which point is emitted the distal arteria ureterica, T-shaped. 3. Pelvic (distal) ureteral spindle (urinal reservoir); 4. Arteria ureterica media, T-shaped, and supplying the lumbar ureteral spindle (urinal reservoir); 5. External iliac; 6. Internal iliac; 7. Ileolumbar; 8. Superior gluteal; 10. Inferior gluteal; 11. Internal pudic; 12. Cervical loop or internal portion of pelvic floor segment; 13. Vesicle arteries; 16. Obturator; 17. Hypogastric. The distal arterio-ureteral crossing and distal end of the ureter drawn well dorsalward, but the sketch was made from a cadaver lying on the back with empty rectum and bladder. A. Pelvic floor segment of the utero-ovarian artery. Note in this drawing that the ureter crosses the common iliac and passes entirely dorsal to the internal iliac. Observe the whorled condition of the branches of the internal iliac. In this case no definite pelvic visceral territory could be exsanguinated by ligature except the whole pelvic viscera, as only the trunk of the internal iliac could be ligated.

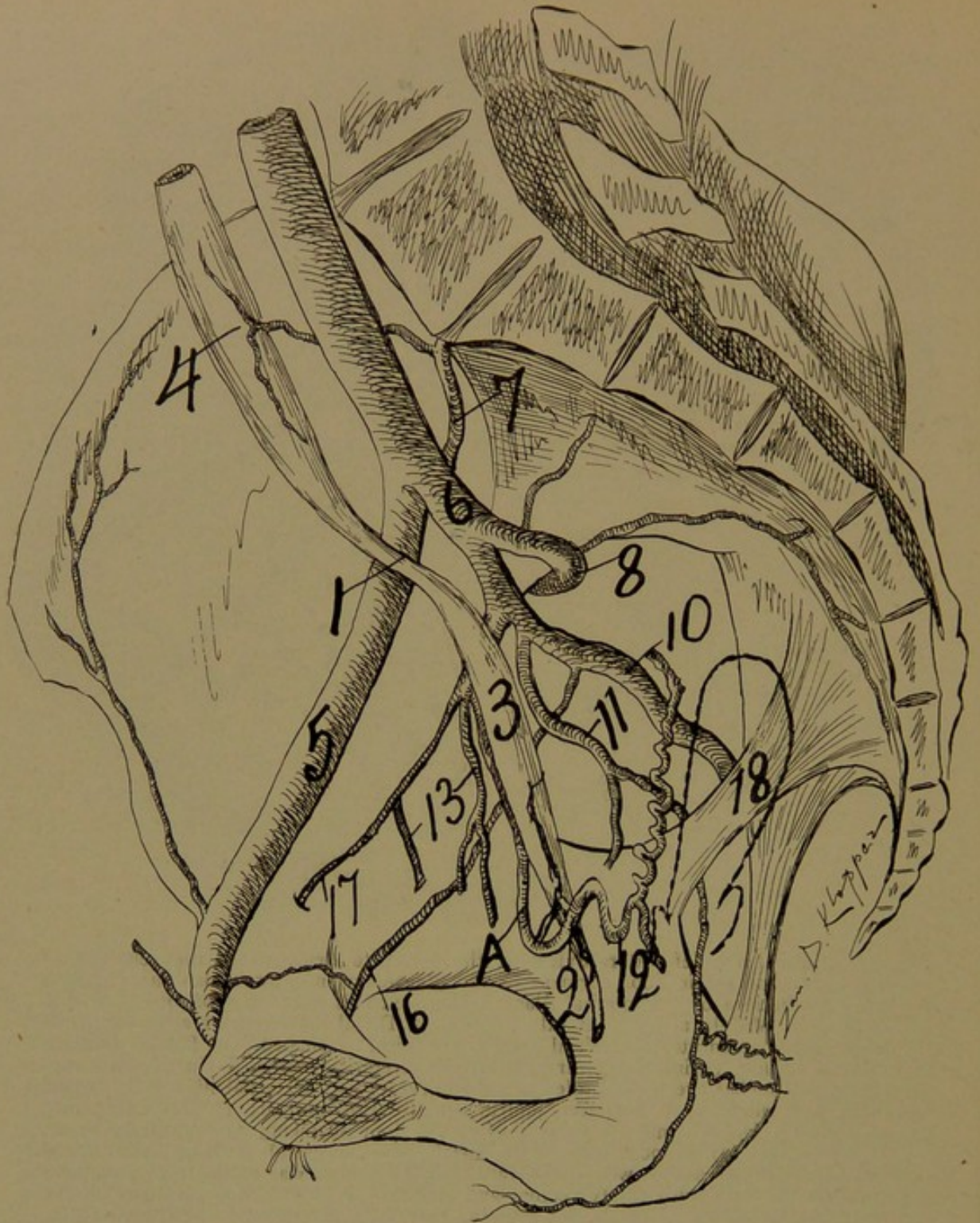


Fig. 32—Illustrates a right lateral view of the pelvis to demonstrate the relations of the ureter to the pelvic floor segment of the utero-ovarian artery; also the divisions and distributions of the internal iliac.—1. Middle arterio-ureteral crossing; 2. Distal arterio-ureteral crossing with its distal arteria ureterica and arterio-ureteral loop; 3. Pelvic (main distal) ureteral spindle (urinal reservoir); 4. Arteria ureterica media springing from the ileolumbar (7); 5. External iliac; 6. Internal iliac. The uterine segment of the utero-ovarian artery is shown from its distal bifurcations to 10. 8. Superior gluteal; 10. Inferior gluteal; 11. Internal pudic, which also emits the middle hæmorrhoidal; 12. Cervical loop of internal portion of the pelvic floor segment of the utero-ovarian artery; 13. Vesicle arteries; 16. Obturator; 17. Hypogastric; 18. Outline of uterus. This drawing I sketched from a dissection. Observe that the ureter crosses the external iliac and lies ventral to the internal iliac. A.

Pelvic floor segment of the utero-ovarian artery which lies parallel and in contact with the ureter for two inches. It shows the usual curve with the dorsal concavity.

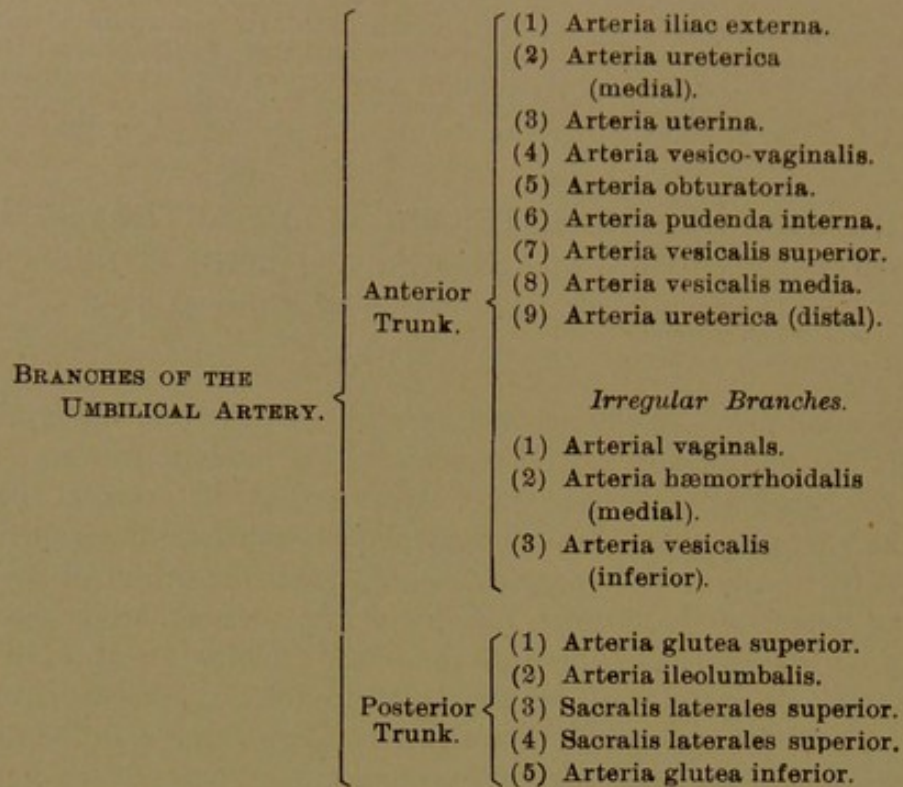
From noting this cut, it is evident that no definite territory of the pelvic viscera, anterior, central, or posterior pelvic viscera can be definitely exsanguinated without sacrificing all the branches of the trunk of the internal iliac; 6, the internal iliac is insufficient in length to apply a double ligature. In this case the pudic and obturator arise from the inferior gluteal. The origin, number, and distribution of the branches of the internal iliac are uncertain, as are also the relations of the ureter.

THE UMBILICAL, OR THE INTERNAL ILIAC ARTERY; THE DISTRIBUTION OF ITS BRANCHES, AND THE ZONES OF EXSANGUINATION RESULTING FROM ITS DELIGATION.

The umbilical artery in the new-born extends patent from the origin of the external iliac to the umbilicus. The segment of the umbilical artery, which is known as the hypogastric, extends from the origin of the external iliac to the origin of the internal pudic. This segment remains patent throughout life. The segment of the umbilical artery, which extends from the origin of the internal pudic to the fundus of the bladder, remains partially patent, while the segment extending from the fundus of the bladder to the umbilicus atrophies to a white, impervious cord. With the new-born before the eye the two umbilical arteries pass in contact with the lateral borders of the bladder to converge with the urachus at the umbilicus. In adults these atrophied structures are known as the ligamentum vesico-umbilicale laterale. The obliterated remains of the alantoid, or partially atrophic and impervious urachus, are known as the ligamentum umbilicale medium. In the new-born the hypogastric artery cannot be said to exist, as it is merged into the umbilical. However, with the assumption of extra-uterine life: (a) the segment of the umbilical artery extending from the umbilicus to the fundus of the bladder immediately ceases function and slowly obliterates into a white fibrous cord with a considerable sheath of connective tissue. This we will call the *umbilical segment* of the umbilical artery; (b) the segment of the umbilical artery extending from the summit of the bladder to the origin of the internal pudic partially ceases its function. It emits one or two vesical arteries. This we will call the *vesical segment* of the umbilical artery; (c) the segment of the umbilical artery extending from the origin of the internal pudic to the origin of the external iliac is the arteria hypogastrica, and the only portion which remains fully patent in the adult. This we will call the *hypogastric segment* of the umbilical artery, and, according to the present method of anatomic instruction, the arteria uterina is a branch of the arteria hypogastrica. The arteria uterina in the new-born can be injected through the umbilical. This description applies only where the internal iliac has a typical division.

The numerous variations and atypical distributions of the branches of the internal iliac may be noted in some of the accompanying illustrations drawn from my dissections of female subjects.

BRANCHES OF UMBILICAL ARTERY.



The division in the internal and external iliac arteries generally occurs at the level of the lumbosacral joint. The trunk of the internal iliac precedes a variable distance previous to the origin of its peripheral branches. The main branches originate from the trunk of the internal iliac at the proximal border of the foramen ischiadicum major. The length of the trunk in my dissections varied from one-half to one and one-half inches (Jastschinski, from one-half to two and one-quarter inches). Frequently the trunk is so short that two ligatures could not be applied without severing the artery between them. The internal iliac divides into two branches—an anterior (ventral) and a posterior (dorsal). The anterior branch passes ventrally to divide into a variable number, one of which is the pelvic floor segment of the utero-ovarian artery.

The dissections showed that the internal may be a trunk of about one-half inch, and presents a point from which a whorl of arterial branches originate. The *posterior branch* passes dorsally, and usually consists of the superior gluteal, ilio-lumbar inferior gluteal, and lateral sacral arteries.

The *anterior branch* of the internal iliac is the chief one of interest to the gynæcologist, as from it arises the uterine artery. The chief variation exists in the anterior branch, which mainly consists in the varying origin, length, distribution, and size of its branches. If one adopts a typical scheme, and attempts to draw the consecutive dissections by it, he will find a lack of definite arrangements in the branches in the anterior trunk.

The branches of the internal iliac that remain fairly constant are the superior vesicals and the uterine, in the anterior trunk. However, the origin of the uterine is variable, in 30 per cent. of subjects arising from the pudic. The inferior gluteal,

puhic, and especially the vaginales, are quite variable. In my dissections the variations extended to the different sides of the same individual.

In the posterior trunk the superior gluteal was constant in every subject dissected. In all dissections, one fact stands prominent, namely, the variability in size, origin, and divisions of the anterior branch of the internal iliac artery. It is rarely of surgical length, and having once ligated it one does not know with certainty what territory is exsanguinated. The pelvic floor segment of the utero-ovarian artery (the uterine) can be ligated at any point, internal or external to the ureter, as far as its origin. But the variability of the branches of the anterior trunk compels the operator to sacrifice all the branches by ligating the trunk to exsanguinate with certainty any single territory. The operator must remember the uncertain length and numerous anomalies of the anterior trunk. The internal iliac artery at its origin rests in a groove with the psoas muscle to the external side and the common iliac vein posterior and internal. It crosses the external common iliac vein and proceeds into the lesser pelvis in company with the internal iliac vein. The vessel lies immediately beneath the peritoneum, and hence can be easily approached.

A very important matter in regard to the internal iliac artery is that the ureter lies in close relation with it from origin to division. In some cases the ureter lies in actual contact with the whole length of the artery. The ureter usually lies in close relation with the anterior branch of the internal iliac artery as far as the origin of the uterine, along which it courses, mainly parallel and frequently in actual contact to the *distal arterio-ureteral crossing*. In some cases the ureter must be dissected not only from the internal iliac artery, but from the external two-thirds of the pelvic floor segment of the utero-ovarian artery. Toldt's Atlas contains very accurate cuts in regard to the relation of the ureter and uterine artery, with which must be mentioned the excellent monographs on the uterine artery of Drs. W. Nagel, Jules Broeckaert, Semmy Davidsohn, and Pierre Fredet.

In some cases where the uterine artery arises well ventrally from the umbilical, the ureter may lie one-quarter to one-half inch distal to the internal iliac. The ureter thus forms the hypotenuse of a triangle of which the base is the umbilical and the side is the uterine artery. Variations of divisions and origins in the anterior branch of the internal iliac produces varied relations with the ureter. Dissections show that neither the internal iliac artery nor the ureter are constant in location or in relation to each other. Besides, the artery and ureter are not fixed in relations to any intraperitoneal structure.

The surgical importance lies in the intraperitoneal relations of the uterine (and internal iliac) with the ureter. Though the uterine artery and ureter are not bound together in the same subperitoneal sheath, yet, when in close relations, which is frequently the case, they move together to some extent in the general subperitoneal bed.

Practically, the umbilical artery or the internal iliac of English anatomic textbooks is of supreme importance as regards its topographic relations in the pelvic viscera. For example, the internal iliac artery supplies three systems of viscera in the pelvis, viz: (1) *Ventrally* in the pelvis lies an important segment of the tractus urinarius as the distal end of the ureter, the bladder, and the urethra, which

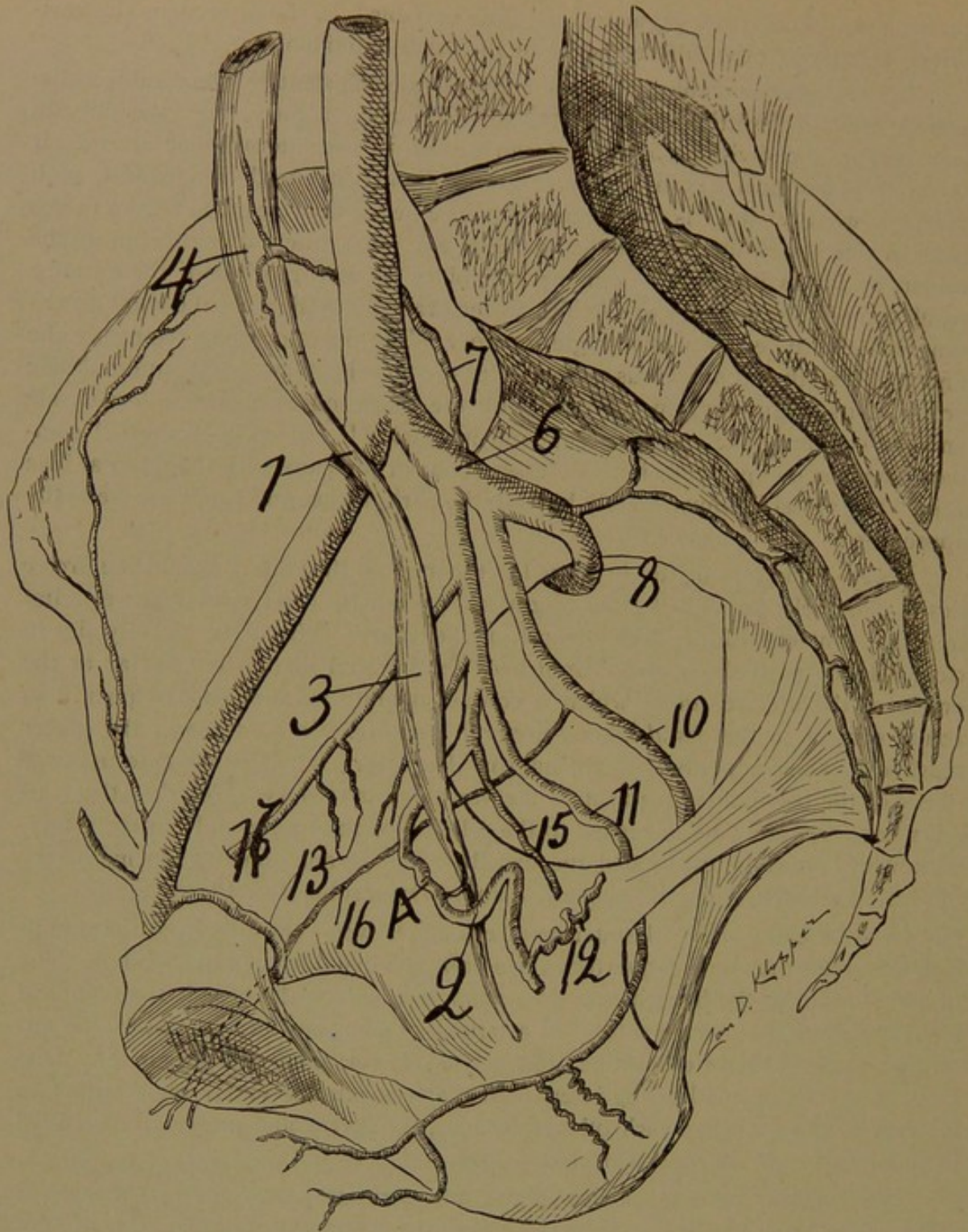


Fig. 33—Illustrates a right view of the pelvis to demonstrate the relations of the ureter to the pelvic floor segment of the utero-ovarian artery; also the divisions and distributions of the internal iliac.—1. Middle arterio-ureteral crossing; 2. Distal arterio-ureteral crossing with the distal arteria ureterica and the arterio-ureteral loop. 3. The distal or pelvic ureteral spindle (urinal reservoir); 4. The middle arteria ureterica springing from the internal iliac; 6. Internal iliac; 7. Ileolumbar supplying the ureter at 4; 8. Superior gluteal; 10. Inferior gluteal; 11. Internal pudic; 12. *Cervical loop* or internal portion of the pelvic floor segment of the utero-ovarian artery. 13. Vesicle arteries; 15. Vaginal and perhaps middle hæmorrhoidal from uterine; 16. Obturator; 17. Hypogastric. I drew the ureteral and vascular relations from a dissection. Observe that the ureter crosses the common iliac and lies anterior, ventral, to the internal iliac, 6. Note that the obturator arises from the

inferior gluteal. Note that the uterine arises from the pudic with its usual curve and its proximal concavity. In this case the anterior branch of the internal iliac is long enough to ligate without disturbing the posterior. The ligation would exsanguinate bladder and internal and external genitals, as it would include the internal pudic. However, the obturator arises from the inferior gluteal, and would not be disturbed.

The irregularity in origin, size, number, and distribution of the branches of the internal iliac is a striking factor in attempting to exsanguinate any definite territory of the anterior, central, or posterior pelvic viscera by ligature.

are supplied mainly by the vesical arteries. (2) In the *center* of the pelvis lies the tractus genitalis, as the uterus, oviducts, and ovaries, which are chiefly supplied by the utero-ovarian artery. (3) *Dorsally* in the pelvis lies a segment of the tractus intestinalis, as the rectum practically supplied by the middle and inferior hæmorrhoidal vessels.

The *first factor* of importance as regards the internal iliac artery is the possibility of exsanguinating definitely any or all of the pelvic viscera by ligature. The *second factor* presented is opportunity to ligate with certainty any one of its branches without damage to adjacent structures as the ureter.

The *third factor* is that certain branches (as the utero-ovarian) present at their periphery of bilateral anastomoses limited oligemic (exsanguinated) zones, which may be utilized in surgery without ligature or clamp, *e. g.*, the longitudinal central axis of the uterus, the fundus, and the lateral cervical borders present oligemic (exsanguinated) zones supplied by arterioles or capillary vessels only. The final utility of the internal iliac artery to the surgeon will depend on whether the artery has a constant distribution which would enable the operator to exsanguinate by ligature with precision any or all the pelvic viscera.

Unfortunately, the distribution of the branches of the internal iliac is irregular; and hence the operator cannot exsanguinate by ligature with certainty any definite pelvic visceral area. The only ligature which will accomplish this is the one which will exsanguinate all the pelvic viscera, *i. e.*, a ligature on the trunk of the internal iliac.

The great and painstaking work of S. Jastschinski (*International Monatschrift für Anatomie und Physiologie*, Bd. viii, 1891), who dissected 1034 half pelves, has demonstrated for all time the irregularity in size, origin, and peripheral distribution of the internal iliac artery. Pryor dissected seven subjects, and the author has dissected over twenty subjects for the purpose of observation of size, origin, and distribution of the internal iliac artery. I found great variations in every one of my subjects.

The object of knowing exactly the origin, distribution, and topographic relations of the internal iliac artery is to remove all adjacent disease in operative procedures, or to starve what tissues cannot be removed by its vascular ligation.

There is no certainty in exsanguinating definite pelvic fields by ligature of the anterior branch of the internal iliac. By ligating the internal iliac trunk only two more important definite branches will be sacrificed, *viz.*, the gluteal superior and inferior.

By ligating the internal iliac trunk, the uterus, bladder, and vagina are directly exsanguinated, and become indirectly supplied by the superior hæmorrhoid and some small branches ventrally located. Atrophy, starvation, and more or less necrosis of tissue will undoubtedly occur; yet it is the only and last chance in pelvic visceral malignancy.

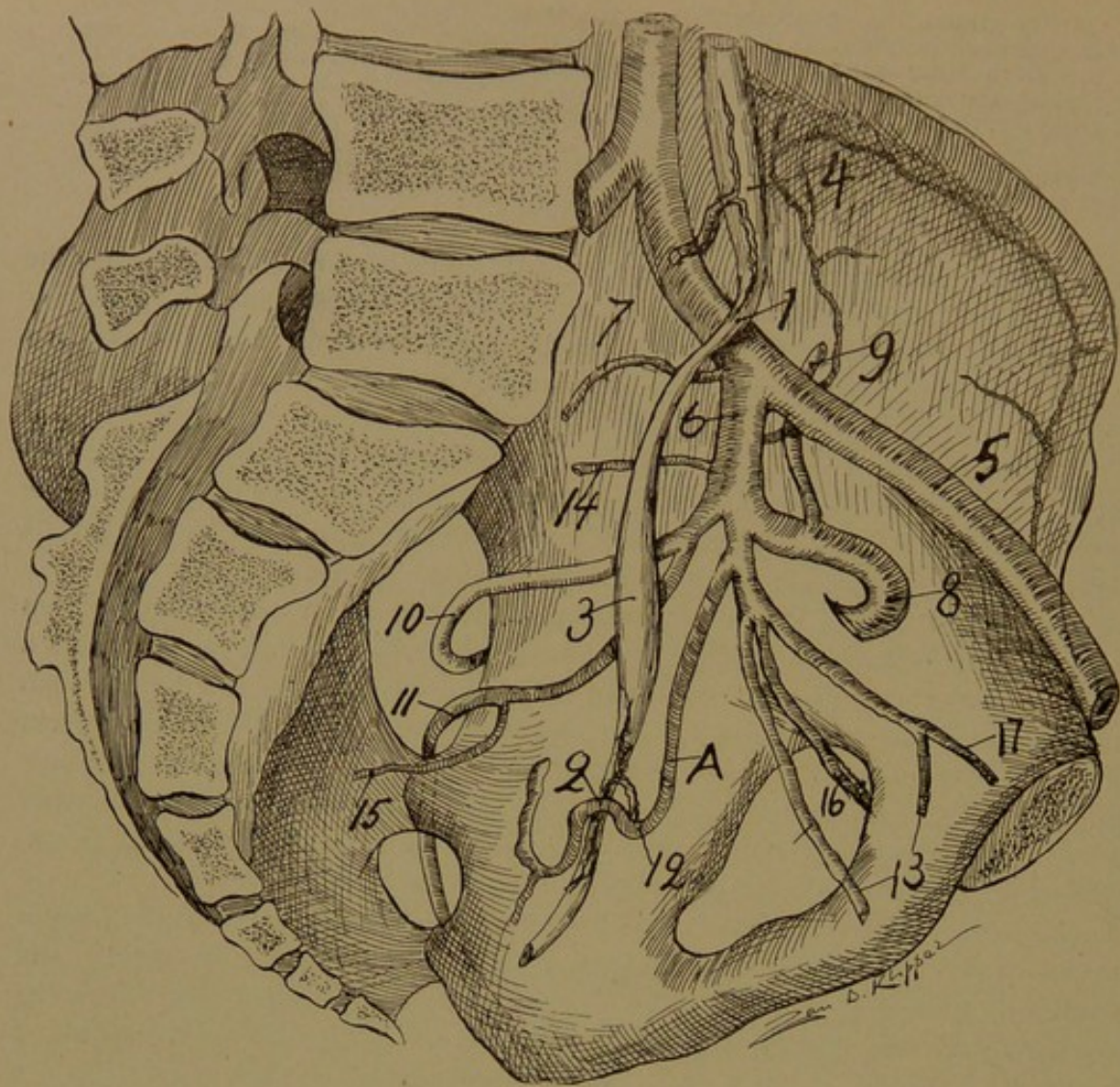


Fig. 34—Illustrates a left lateral view of the pelvis to demonstrate the relations of the ureter and pelvic floor segment of the utero-ovarian artery, and also the territories of the pelvic viscera which can be exsanguinated by ligatures of the branches of the internal iliac trunk. It also demonstrates the division and distribution of the internal iliac.—1. Middle arterio-ureteral crossing; 2. Distal arterio-ureteral crossing with the distal T-shaped arteria ureterica emerging closely adjacent as well as the arterio-ureteral loop; 3. Pelvic (distal) ureteral spindle (urinal reservoir); 4. Middle arteria ureterica supplying the proximal (lumbar) ureteral spindle (urinal reservoir); 5. External iliac; 6. Internal iliac; 7. A sacral artery; 8. Superior gluteal; 9. Ileolumbalis; 10. Inferior gluteal; 11. Internal pudic; 12. Cervical loop (the number 12 should be dorsal to the ureter); 13. Vesicle arteries; 14. A sacral; 15. Middle hæmorrhoidal; 16. Obturator; 17. Hypogastric. It is plainly evident from a careful personal dissection, that no definite area of pelvic viscera can be exsanguinated by ligation of branches of the internal iliac on account of the irregularity of the origin, number, and distribution of the branches of the trunk of the internal iliac. The trunk alone through ligation will exsanguinate definite viscera. Observe that the ureter crosses the common iliac, courses dorsal to the internal iliac, and quite parallel to A, the pelvic floor segment of the utero-ovarian artery.

Ligating the pelvic floor segment of the utero-ovarian artery near its origin might include the internal pudic; and, besides, ligating the uterine arteries does not exsanguinate the bladder, rectum, or vagina. The chief origins of the uterine artery are first from the umbilical (hypogastric) or from the internal pudic.

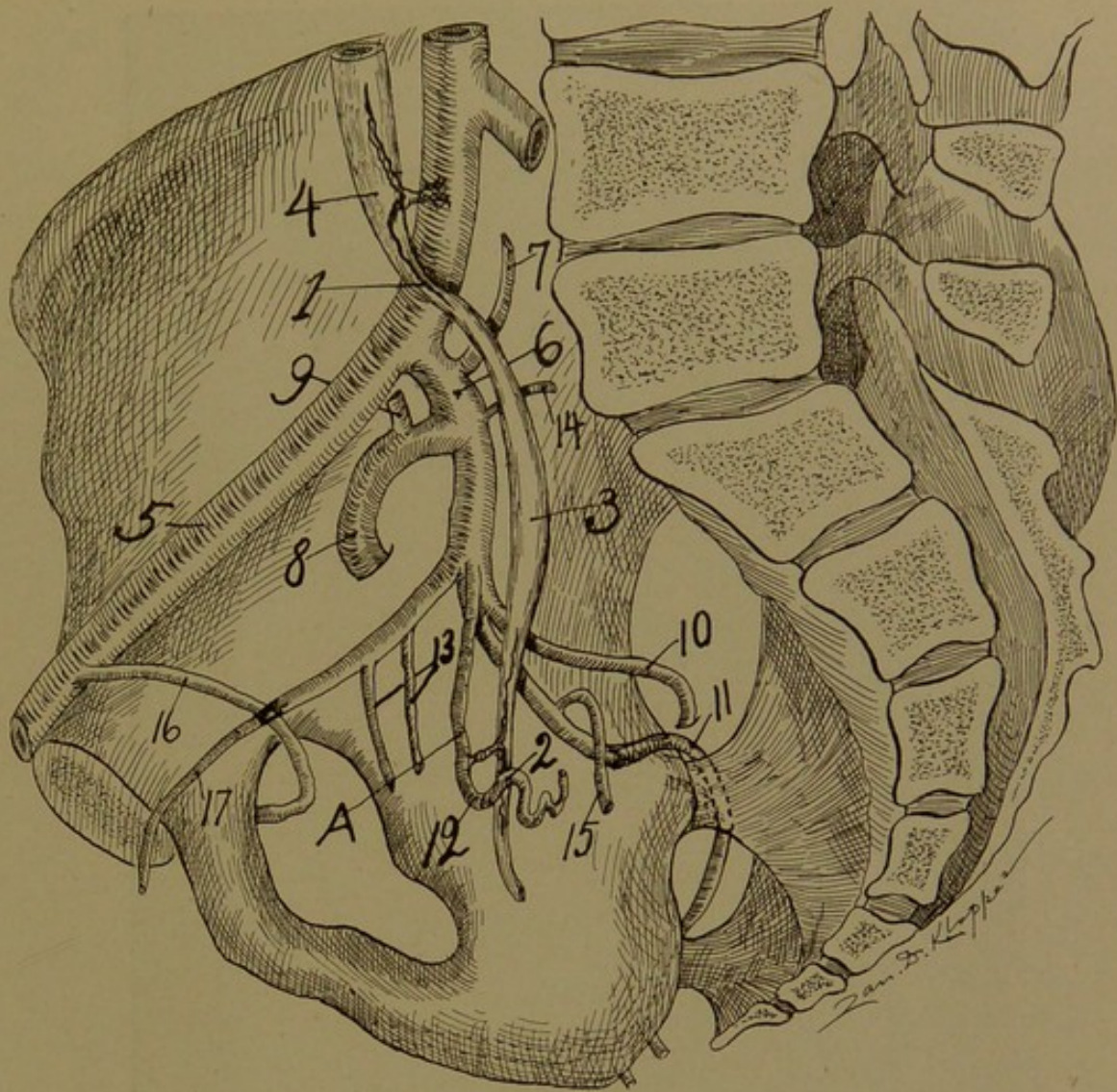


Fig. 35—A cut to illustrate the right wall of the pelvis in order to demonstrate vascular and ureteral relations as well as to what pelvic visceral territories may be exsanguinated by ligations of branches or trunk of the internal iliac. It also demonstrates the divisions and distribution of the internal iliac. In this cut the sacrum is preserved to show additional relations.—1. Middle arterio-ureteral crossing; 2. Distal arterio-ureteral crossing with its arterio-ureteral loop and distal arteria ureterica; 3. Pelvic or distal ureteral spindle (urinal reservoir); 4. Arteria ureterica media supplying the proximal or lumbar spindle (urinal reservoir); 6. Internal iliac; 7. Ileolumbar; 8. Superior gluteal; 9. Ileolumbar; 10. Inferior gluteal; 11. Internal pudic; 12. Cervical loop or internal portion of the pelvic floor segment of the utero-ovarian artery; (12 should be median to the ureter); 13. Vesicle arteries; 16. Obturator; 17. Hypogastric.

This cut shows that on account of the irregularity of origin, number, and distribution of the branches of the internal iliac no definite pelvic visceral territory can be exsanguinated without ligating the trunk of the internal iliac, and thus sacrificing all of its branches. Note that in this case the ureter crosses the common iliac, courses dorsal to the internal iliac parallel on a curve and in contact, and finally passes parallel to the uterine for a little over an inch.

One could ligate the vessels in this case and save the superior gluteal. A. The uterine in this case is short on account of the peculiar trunk of the internal iliac separating the origins of the superior and inferior gluteals by a long stretch.

Number 12 should be on the median side of the ureter; 15. Middle hæmorrhoidal. A. The pelvic floor segment of the utero-ovarian artery in this cut is the shortest of all the dissections, of which this is a careful drawing sketched from the subject *in situ* with ureter filled by red lead and starch.

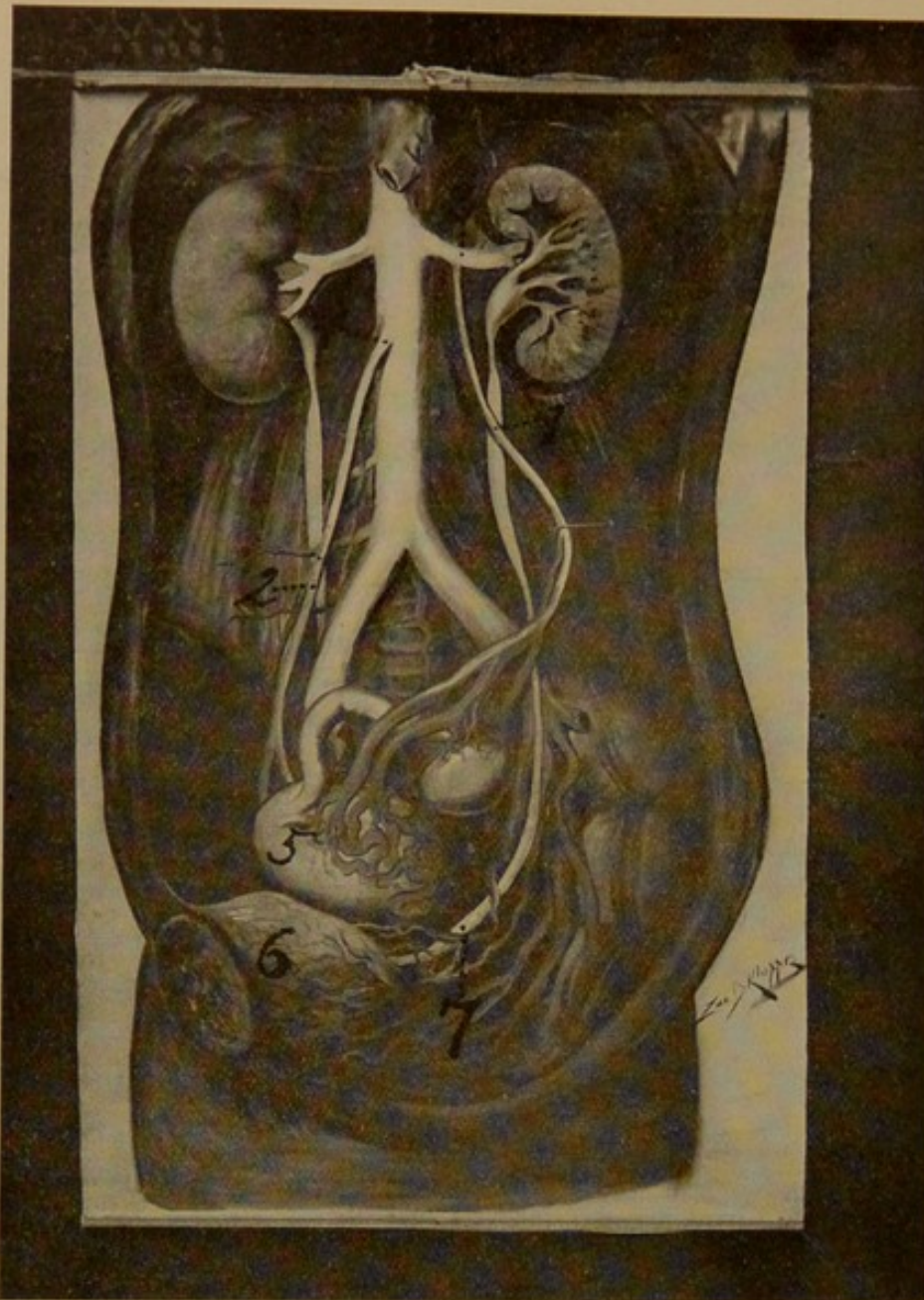
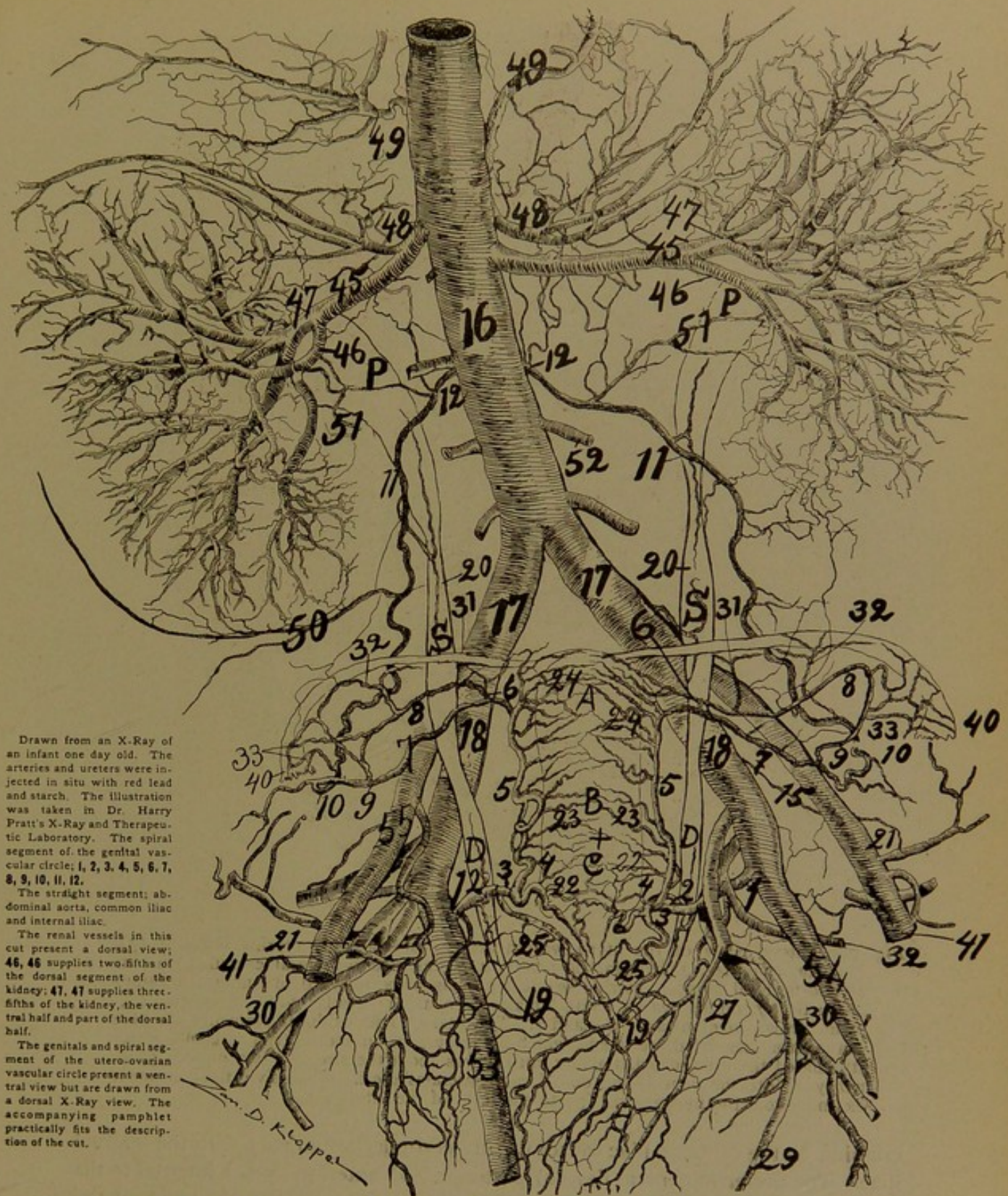


Fig. 36—Illustrates the relation of the ureters to veins. 1 is where the left ovarian vein crosses the ureter; 2, where the right ovarian vein crosses the ureter. 1 and 2 stand at the apex of the uretero-venous triangles or the triangles of the author. 3, origin of left and 4, origin of right ovarian veins; 5, uterus; 6, bladder; 7 is the pelvic segment of the ureter passing through the great venous plexuses.

The relations of the ureters are important to the great iliac vessels over which they pass to course along the pelvic wall and floor to the bladder. In general, the right ureter crosses the vessels more distal than the left, and also the angle for the right ureter, *flexura iliaca ureteris*, is greater than the left. On account of the right ureter crossing the iliac vessels more distal, one observes more frequently the right ureter on the arteria iliaca externa and the left ureter on the arteria iliaca communis. Whatever the division points of the arteria iliaca communis, the rule is that the right ureter crosses more distal and the left more proximal, hence the left ureter lies nearer the median line than the right. This variation of the ureteral



Drawn from an X-Ray of an infant one day old. The arteries and ureters were injected in situ with red lead and starch. The illustration was taken in Dr. Harry Pratt's X-Ray and Therapeutic Laboratory. The spiral segment of the genital vascular circle; 1, 2, 3, 4, 5, 6, 7, 8, 9, 10, 11, 12.

The straight segment; abdominal aorta, common iliac and internal iliac.

The renal vessels in this cut present a dorsal view; 46, 46 supplies two-fifths of the dorsal segment of the kidney; 47, 47 supplies three-fifths of the kidney, the ventral half and part of the dorsal half.

The genitals and spiral segment of the utero-ovarian vascular circle present a ventral view but are drawn from a dorsal X-Ray view. The accompanying pamphlet practically fits the description of the cut.

The Utero-Ovarian Vascular Circle. (The Circle of Byron Robinson)

Fig. 37—Infant one day old. Demonstrating the longitudinal oligemic uterine zone. (A, B, C.) Also the lateral cervical and fundal oligemic uterine zones. For numbers see general description page 82

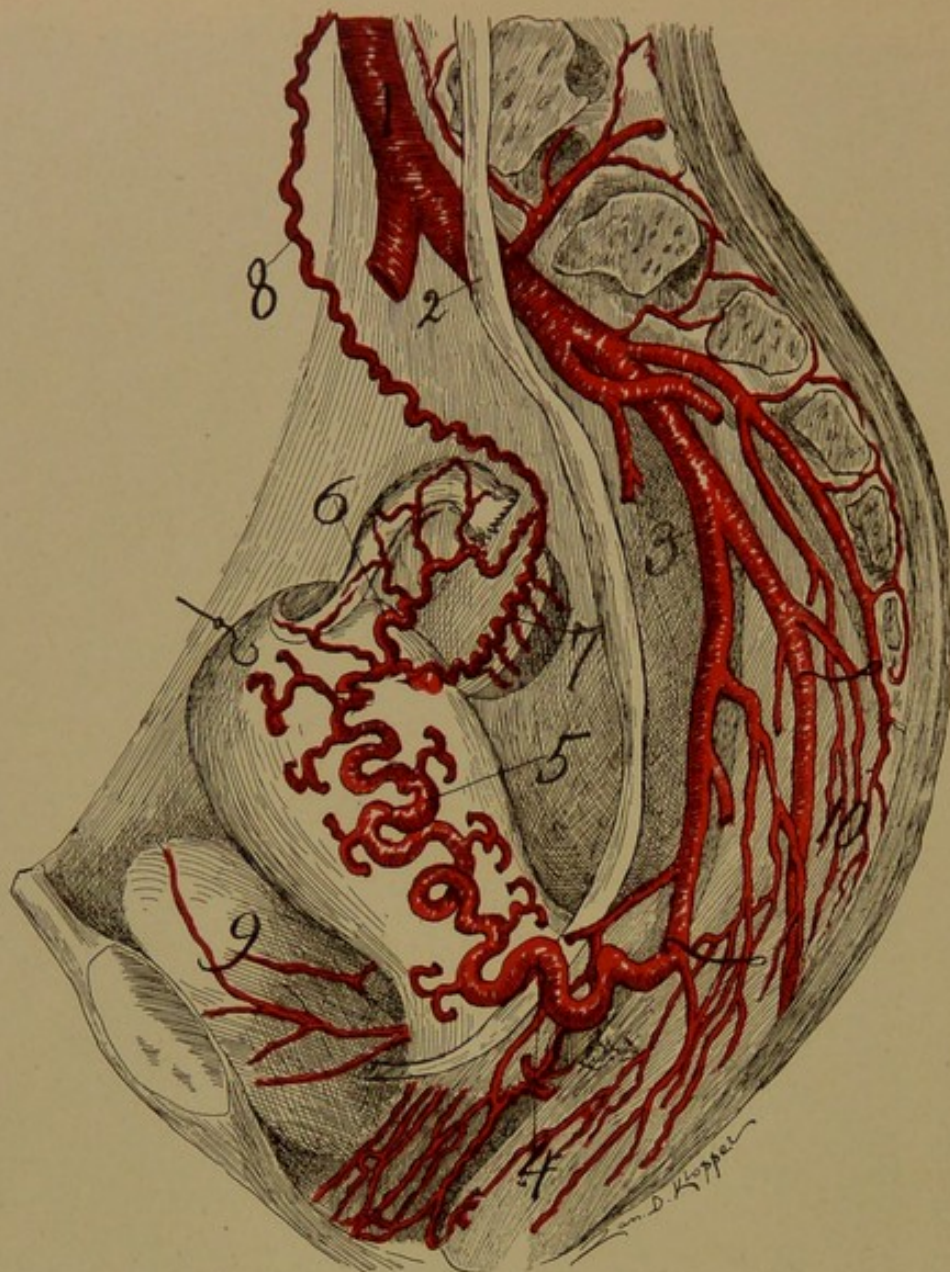


Fig. 38—Lateral view of the utero-ovarian artery, especially its uterine segment (5), 1, aorta, 2, ureter, 3, hypogastric artery, 4, distal arterio-ureteral crossing with its arterio-ureteral loop; 5, uterine segment passing proximalward to fundus; 6, ramus oviductus; 7, ramus ovarii; 6 and 7 make the ovarian vascular circle; 8 ovarian segment, drawn medianward; 9 bladder. The uterine and oviducal segments are here drawn from my dried specimens, which on account of an endometrial sarcoma, which stimulated the utero-ovarian artery until it was about the size of a two months pregnancy. Note the ventral and dorsal rami laterales uteri. The pelvic floor segment extends from the hypogastric (3) to the level of the internal os.

crossing on the common iliac causes the ureteral relations to vary with the internal iliac. The ureter in general lies (*a*) posterior, (*b*) anterior, or (*c*) internal to the internal iliac artery, which should be remembered when ligating the trunk of the internal iliac. The variations of the relations of the ureter to the arteries is due to the variation of the divisions of the abdominal aorta, the common and internal iliacs. The trunk of the internal iliac or hypogastric is short (one-half to one and one-half inches). It is not so large as the external iliac. The direction of the

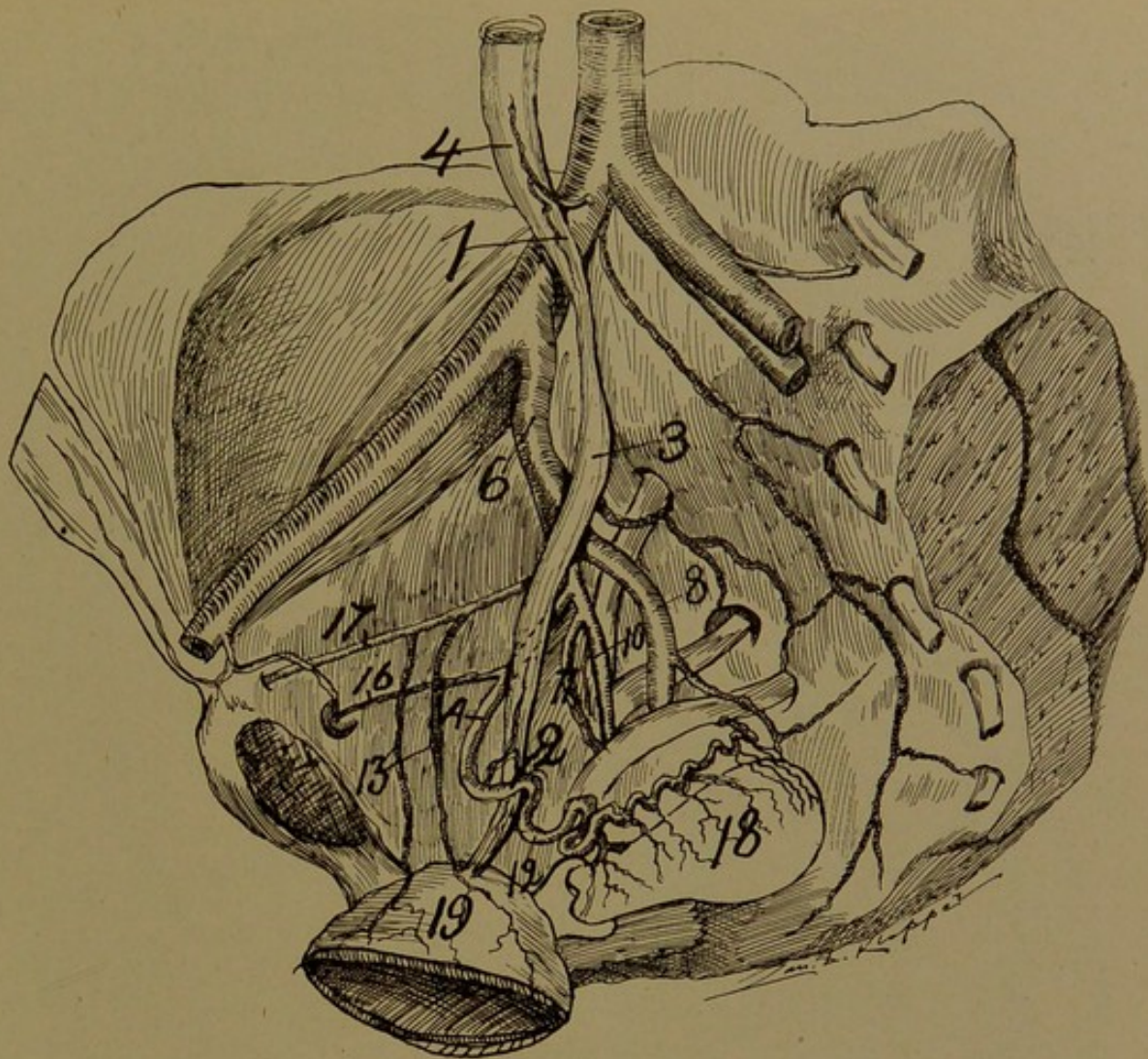


Fig. 39—A cut to illustrate the right wall of the pelvis in order to demonstrate vascular and ureteral relations as well as to what pelvic visceral territories may be exsanguinated by ligations of branches or trunk of the internal iliac. It shows the division and distribution of the internal iliac. In this cut the sacrum is preserved to show further relations.—1. Middle arterio-ureteral crossing; 2. Distal arterio-ureteral crossing with its arterio-ureteral loop and distal arteria ureterica. 3. Pelvic distal ureteral spindle (urinal reservoir); 4. Arteria ureterica media supplying the proximal or lumbar spindle (urinal reservoir); 6. Internal iliac; 8. Superior gluteal; 10. Inferior gluteal; 11. Internal pudic; 12. *Cervical loop* or internal portion of the pelvic floor segment of the utero-ovarian artery; 13. Vesicle arteries; 16. Obturator; 17. Hypogastric; 18. Uterus with uterine segment and rami laterales uteri in typical blood supply; 19. Bladder.

This cut shows that on account of the irregularity of origin, number, and distribution of the branches of the internal iliac no definite pelvic visceral territory can be exsanguinated without ligating the trunk of the internal iliac, and thus sacrificing all of its branches.

Note that the ureter crosses the common iliac, courses dorsal to the internal iliac, and does not lie parallel to the pelvic floor segment of the utero-ovarian artery. The ureter crosses the uterine artery twice in this cut, once ventral and once dorsal to A., the uterine artery. In such cases the ureter is easily dissected from the artery. A. Pelvic floor segment of the utero-ovarian artery with the usual curve, convexity proximalward.

internal iliac is distalward and dorsalward on the proximal circumference of the great sacrosciatic foramen. Its proximal end lies on the medial psoas surface and also on the sacro-iliac articulation.

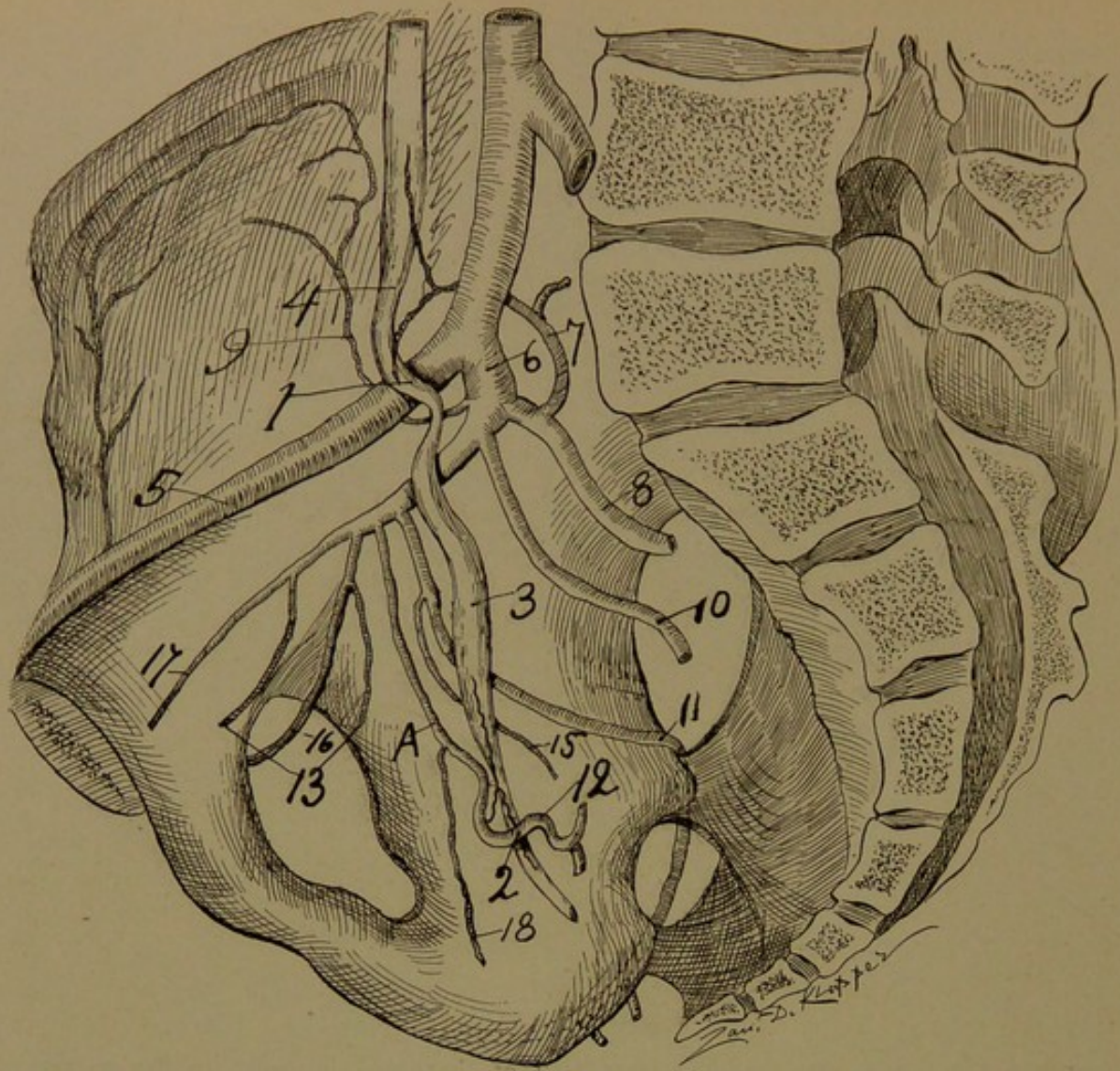


Fig. 40—A cut to illustrate the right wall of the pelvis in order to demonstrate vascular and ureteral relations as well as to what pelvic viscera territories may be exsanguinated by ligations of branches or trunk of the internal iliac. It also demonstrates the division and the distribution of internal iliac. In this cut the sacrum is preserved to show further relations.—1. Middle arterio-ureteral crossing; 2. Distal arterio-ureteral crossing with its arterio-ureteral loop and distal arteria ureterica; 3. Pelvic distal ureteral spindle (urinal reservoir); 4. Arteria ureterica media supplying the proximal or lumbar spindle (urinal reservoir); 6. Internal iliac; 7. Ileolumbar; 8. Superior gluteal; 9. Ileolumbar; 10. Inferior gluteal; 11. Internal pudic; 12. Cervical loop or internal portion of the pelvic floor segment of the utero-ovarian artery; 13. Vesicle arteries; 16. Obturator; 17. Hypogastric; 18. Vaginal.

This is an interesting sketch from my personal dissection of a woman about fifty-five. The arteries were well injected, and I injected red lead and starch in the ureter; all were dissected and drawn *in situ*.

Note that one vesicle originates from the hypogastric and one from the obturator. The trunk of the internal iliac is so short that it would be difficult to ligate. Hence, again, this cut shows that on account of the irregularity of origin, number, and distribution of the branches of the internal iliac no definite pelvic visceral territory can be exsanguinated without ligating the internal iliac, and thus sacrificing all of its branches.

Note the kink or short bend that occurs in the ureter between the internal iliac and external iliac vessels. Observe that this ureter crosses the external iliac, courses anterior to the trunk of the internal iliac and dorsal to the pudic. The ureter lies parallel to the pelvic floor segment of the utero-ovarian artery for two inches. A. Pelvic floor segment of the utero-ovarian artery with scarcely any curve, parallel for two inches to the ureter, but not in contact.

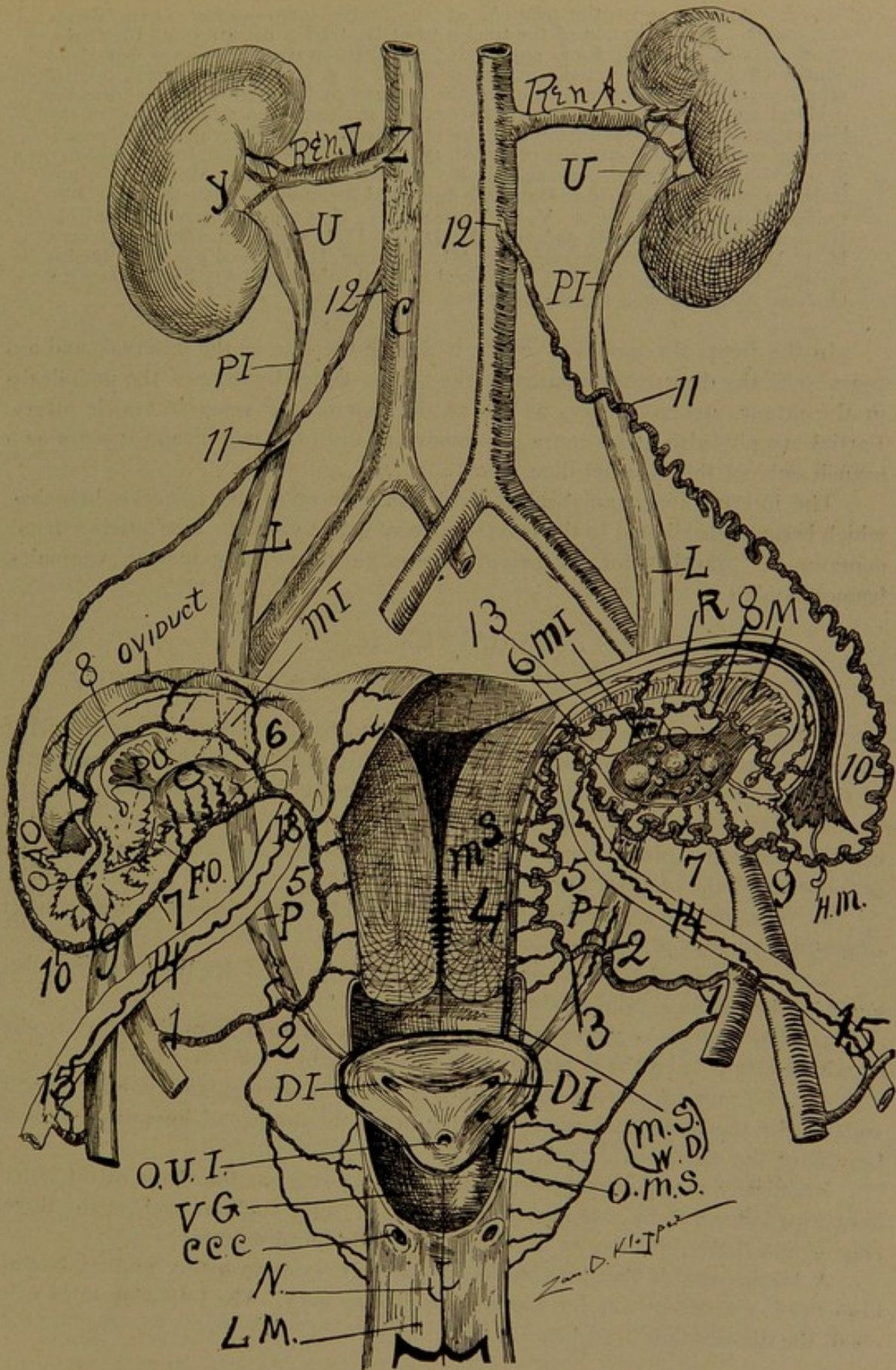


Fig. 41. For description see page 62.

Fig. 41—A cut to illustrate the relations of the ureter, utero-ovarian artery, cervix and vagina. An illustration of the tractus genitalis, tractus urinarius and their relations. 1, 2, 3, 4, pelvic floor, segment of the utero-ovarian artery, divided about equally by 2, its distal arterio-ureteral crossing; 4, 5, 6, uterine segment; 6, 7, 9, ramus ovarii; 6, 8, 9, ramus oviductus, the oviducal and ovarian branches form the oviducal segment; 9, 10, 11 and 12, its ovarian segment; 4, 6 and 9 represent the bifurcations of the spiral segment of the utero-ovarian vascular circle or bifurcatio arteriae uterinae distal media et proximal, 13, 14 and 15, round ligament segment; 11, proximal arterio-ureteral crossing. H. M., Hydatid of Morgani. M., Paraovarium. R. MS, Duct of paraovarium, Gartner's duct (it is the mesonephritic duct) O MS., Orifice of mesonephritic duct. V. G., Vagina. C. C. C., Corpus cavernosum clitoridis. N., nymphae. L. M., Labia pudendi. DL, DL., O. U. I., Orificium urethra internum. M. I., Middle arterio-ureteral crossing. MI., Ovarium. U., Ureteral pelvis. L., lumbar spindle. P., Pelvic spindle. P. I., Proximal ureteral isthmus. F. O., Fimbria ovarica. O. A. O., Orificium abdominalis oviductus. C., Vena cava.

In the foetus the umbilical artery is double the size of the external, and appears to be the direct continuation of the aorta. After ligation of the umbilicalis in the infant, atrophy occurs as far as the exit of the superior vesicle artery. Partial atrophy also arises more proximalward until the umbilicalis appears as a branch only of the external iliac.

The internal iliac, umbilicalis, divides into anterior and posterior branches, which become distributed to the pelvic wall and pelvic viscera. The anterior trunk contains the branches for the pelvic viscera, as the vesicles, uterine, vaginales, hæmorrhoidals.

CHAPTER II.

GENERAL DIVISION OF THE UTERO-OVARIAN ARTERY.

For convenience of anatomic description and for the purpose of emphasizing the importance of the physiologic and topographic relations of the spiral segment of the utero-ovarian vascular circle I have made the following division:

1. *The pelvic floor segment* of the utero-ovarian artery arises from the anterior division of the internal iliac in the lesser pelvis, and terminates at the lateral border of the os uteri internum.
2. *The uterine segment* of the genital vascular circle begins at the os uteri internum and ends at the utero-oviducal angle.
3. *The oviducal segment* of the spiral artery passes from the utero-oviducal angle to the oviducal pole of the ovary.
4. *The ovarian segment* of the genital artery extends from the ovary to the proximal origin from the aorta adjacent to the renal.
5. *The round ligament segment* arises from the deep epigastric inferior and ends at the utero-oviducal angle near the origin of the round ligament. It is a branch of the ramus oviductus.

Practically the spiral segment of the genital circle has the shape of the letter S or of a brace and bit. It presents an acute or right angle at each of the three origins and three right angles in the course of the spiral segment.

A knowledge of the distribution of the utero-ovarian artery and its lateral branches is a first requisite for successful pelvic surgery. The following table will recall the distributing branches.

Segments of the Utero-Ovarian Artery and their branches.	1. The Pelvic Floor Segment	{ a, rami ligamentali lati b, ramus ureteris (distal) b, rami vesicales d, ramus cervico-vaginalis
	2. Uterine Segment	{ a, rami cervicis b, rami corporis c, rami fundi d, rami legamenti lati
	3. Oviducal Segment	{ a, ramus fundi b, rami oviductus c, ramus ovarii d, ramus ligamenti teretis e, rami ligamenti lati f, rami mesonephros g, rami meso-ovicuctus
	4. Ovarian Segment	{ a, rami ovarii b, rami oviductus c, ramus ureteris (proximal) d, rami peritonei
	5. Round Ligament Segment	{ ramus ligamenti teretis

The following table of comparative measurements will assist in the consideration of the segments. The measurements were taken from my personal dissected specimens both wet and dry. They are fairly accurate and can be confirmed on the still preserved specimens.

THE FOLLOWING TABLE OF COMPARATIVE MEASUREMENTS WILL ASSIST IN THE CONSIDERATION OF THE SEGMENTS. THE MEASUREMENTS WERE TAKEN FROM MY PERSONALLY DISSECTED SPECIMENS, BOTH WET AND DRY. THEY ARE FAIRLY ACCURATE AND CAN BE CONFIRMED ON THE STILL PRESERVED SPECIMENS.

The length of the segments of the utero-ovarian artery in man, cat, dog, cow, pig, horse, guinea-pig and rabbit. Also distance between origins of uterine and ovarian in same.

ANIMAL	PELVIC FLOOR SEGMENT	UTERINE SEGMENT	OVIDUCAL SEGMENT	OVARIAN SEGMENT	ROUND LIGAMENT	DISTANCE BETWEEN ORIGINS	LENGTH OF URETER
1 Dog 6 lbs.	2 inches	6 inches	1 inches	2 inches		2 1/4 inches	5 inches
2 Dog 15 lbs.	2 1/2 "	6 1/2 "	1 1/2 "	2 3/4 "		3 "	6 "
3 Dog 12 lbs.	3 "	6 "	3/4 "	3 "		2 3/4 "	5 "
4. Dog 12 lbs.	2 1/2 "	6 "	1 "	3 "		2 "	6 "
5. Puppy 2 lbs.	1 1/4 "	3 "	1/2 "	1 3/4 "		3/4 "	3 "
Average of 10 lb. Dog.	2 1/2 "	6 "	1 "	2 1/2 "		2 "	5 "
6. Guinea Pig 2 lb.	1 "	2 1/2 "	1/2 "	1 1/2 "		2 "	3 "
7 Cat 6 lbs.	1 1/2 "	6 "	3/4 "	2 1/2 "		2 "	3 1/4 "
8. Cat 5 lbs.	1 1/2 "	3 "	1/2 "	2 1/2 "		2 1/4 "	4 "
9 Cat 10 lbs.	2 "	7 "	1 "	3 1/2 "		3 "	5 "
10 Cat 8 lbs.	1 1/4 "	5 "	1 "	4 "		3 "	5 "
11. Cat 4 lbs.	1 1/2 "	4 "	3/4 "	2 1/4 "		2 "	4 "
Average of 6 lb. Cat	1 1/2 "	5 "	1 "	3 "		2 1/2 "	4 "
12. Rabbit 8 lbs.	1 "	4 "	1 "	2 "		1 "	5 "
13 Rabbit 3 lbs.	3/4 "	4 "	1 "	1 3/4 "		1 "	3 1/2 "
14. Rabbit 4 lbs.	3/4 "	6 "	1 1/2 "	2 1/4 "		1 "	5 "
Average of 5 lb. Rabbit	1 "	5 "	1 "	2 "		1 "	4 "
15 Average of 125 lb. Woman	3 "	2 "	3 "	10 "	5 inches	6 "	10 "
16. Cow of perhaps 600 lbs.	8 "	27 "	8 "	15 "		24 1/4 "	24 "
17. Pig.	2 "	6 "	2 "	3 "		1 1/2 "	10 "
18. Cow.	4 "	12 "	3 "	14 "		4 "	26 "
19. Horse 700 lbs.	8 "	12 "	5 "	7 "		3 "	28 "

In No. 18 multipara cow the single uterus was 5 inches in length, the uterine horn 8 inches, and the oviduct 6 inches in length. In this cow both utero-ovarian segments of the utero-ovarian artery arose from the (inferior) posterior mesenteries. In No. 17, multipara pig, the single uterus was 5, the uterine horn 15, and the oviduct 5 inches each in length. In this pig both ovarians arose at the same level and 1 inch proximal to origin of (inferior) posterior mesenteric artery.

1 THE PELVIC FLOOR SEGMENT OF THE UTERO-OVARIAN ARTERY.

The pelvic floor segment extends from its origin, the anterior branch of the internal iliac, to its destination, the os uteri internum. The whole segment is generally about three inches in length. The pelvic floor segment lies about one and a half inches on the lateral wall and about one-half its length (one and a half inches) in the base of the ligamentum latum in an extensive bed of connective tissue considerably removed from the peritoneum, and hence very mobile. The ureter and the pelvic floor segment lie parallel for one to two inches, and in close contact with the peritoneum (hence with limited mobility). This segment passes proximal, ventral or anterior to the ureter. It courses lateralward and distal to the ovary along the border of the fossa ovarica immediately proximal to the ureter. The uterine artery lies nearer the lateral pelvic wall, while the ureter lies nearer the peritoneum and more median. About one and a half inches from its origin the uterine artery enters the base of the ligamentum latum, thence assuming a median, horizontal direction toward the uterus and bladder. Since the artery lay in its beginning externally lateral to the ureter, it must cross it to gain the border of the uterus. For a short distance (one to two inches) the uterine artery and ureter frequently assume a course parallel to each other, but soon the uterine artery assumes a course directing itself ventralward, thence medianward, and finally proximalward, while the ureter assumes a course distalward, thence medianward. With a strong ventral, median and proximal deviation of the uterine artery and a dorsal deviation of the ureter, both course through the pelvis, ending one to two inches from each other.

This segment extends from the origin of the utero-ovarian artery in the hypogastric to the level of the internal os. This is the surgical segment dignified into importance by the arterio-ureteral loop (2), the distal arterio-ureteral crossing (2), the cervical loop (3), as well as the distal bifurcation (22) of the utero-ovarian artery and the arteria ureterica distal, besides the lateral cervical triangle (4, 2, 19). Also the cervico-vaginal artery and the chief artery of the ligamentum latum arises from it.

I shall divide the pelvic floor segment in the resting uterus by means of the ureter into the external portion (external two-thirds, about two inches) and internal portion (internal one-third, about one inch). In the chart here presented of a three months pregnant uterus, the pelvic floor segment is four inches long and divided exactly in the middle by the ureter. The *cervical* loop in a pregnant case of three months is two inches in length. It is the long cervical loop which enables the operator to avoid wounding the ureter in hysterectomy, saving many women from suffering and death. The pelvic floor segment crosses proximal to (above)

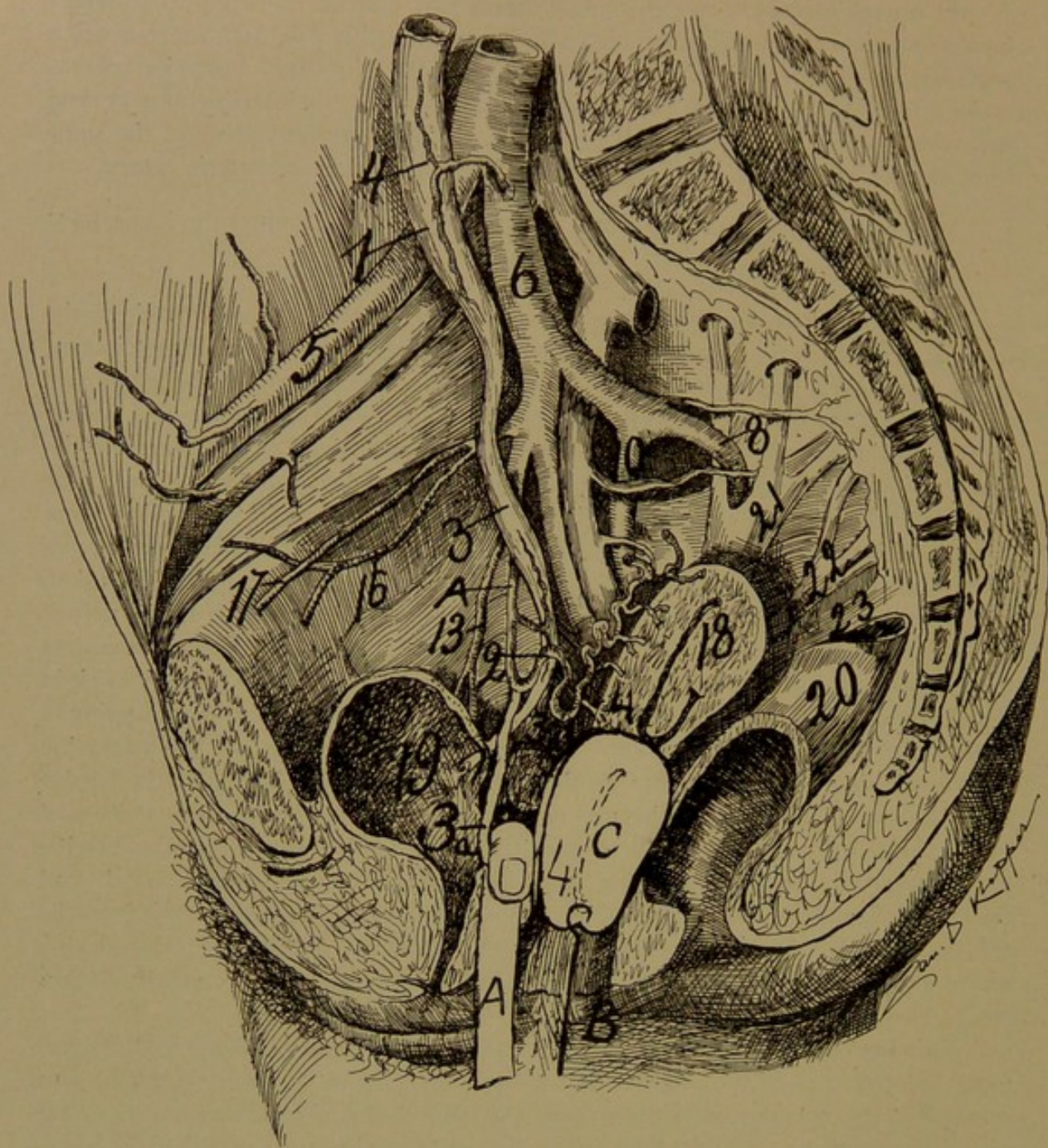


Fig. 42—A cut to illustrate the cervical loop and lateral cervical triangle during operation. The cervical loop (2, 3, 4). The lateral cervical triangle (2, 3, 4; 2, 19; 4, 19). The cervical (2, 3, 4) loop is drawn distalward by the finger (A) becoming, 3a, ready for ligation. c is the uterus drawn distalward in the vagina by traction forceps. B, traction forcep. 1, middle arterio-ureteral crossing; 2, distal arterio-ureteral crossing; 3, cervical loop (also distal ureteral spindle); 4, internal os; 5, external, and 6, internal iliac; 8, superior gluteal; 10, inferior gluteal; 13, vesicle arteries; 16, hypogastric; 17, obturator; 18, uterus; 19, bladder at vesicle orifice; 20, rectum; 21, 22, 23, sacral plexus; A, pelvic floor segment of the utero-ovarian artery with its usual concavity dorsalward. Observe that the situation of the ureters and trigone remain the same during the operation.

the ureter, so that in pregnancy the proximalward movements of the uterus may not kink and obstruct the artery and ureter. It sends the distal arteria ureterica to the ureter at the point of distal arterio-ureteral crossing. In this segment occurs the distal bifurcatio arteriæ uterinæ (Waldeyer), or distal bifurcation of the utero-ovarian artery, which is of extreme surgical importance in hysterectomy.

DIVISIONS OF THE PELVIC FLOOR SEGMENT.

I shall adopt as the most natural and practical division of the pelvic floor segment the distal arterio-ureteral crossing. The part of the pelvic floor segment external to the ureter could be called the *external portion*, or external two-thirds, while the part internal to the ureter could be called the *internal portion*, or internal one-third. In short, it could well be named the *cervical loop*.

Other authors have employed different divisions, as *parietal, descending, intra-ligamentous, horizontal, ligamentum teres, intermediary*, etc., but gynecologic surgery demands a natural division of practical importance, hence I have assumed the ureter or the distal arterio-ureteral crossing as the landmark of separation between the internal (one-third) and external (two-thirds) portions of the pelvic floor segment.

The distal arterio-ureteral crossing, though varying within wide anatomic limits, is more constant than any other available or practical landmark, as the ligamentum latum, which varies considerable in physiology (pregnancy) and in pathology (myomata) and intra-ligamentary cysts.

GENERAL.

The pelvic floor segment from its hypogastric origin lies in contact with the lateral pelvic wall for two inches (more or less); however, it leaves the pelvic wall and turns medianward in the base of the extensive bed of connective tissue in the ligamentum latum. In some cases the arteria uterina leaves the lateral pelvic wall at a short distance from its hypogastric origin, whence it traverses the parametrium at considerable distance proximal to the pelvic floor, arriving at the uterus proximal to the internal os. In such cases the cervico-vaginal artery is apt to be very large. The uterine artery at its origin forms an acute angle with the hypogastric (umbilical). The pelvic floor segment may form a right angle at its junction with the uterine segment; however, dissections and the X-ray present varied degrees to the angle.

The pelvic floor segment is divided by the ligamentum latum uteri in two segments. About one and a half inches from its origin the artery begins to leave the lateral pelvic wall and enter the lateral base of the ligamentum latum, whence it courses closely to and superior to the ureter to reach the lateral cervical border. In some cases the distal arterio-ureteral crossing forms quite a fixum punctum by being bound firmly together through connective tissue and the distal arteria ureterica. When traction forceps draw the cervix distalward the ureter passes distalward less rapidly than the artery, which then forms a more prominent loop about the ureter and the cervical loop unfolds. However, by the degree of traction on the cervix which brings the cervix in the pudendum the uterine artery begins to pass distalward faster than the ureter, and this fact lengthens the distance between artery and ureter, allowing safer ligation of the artery. The cervix and vaginal

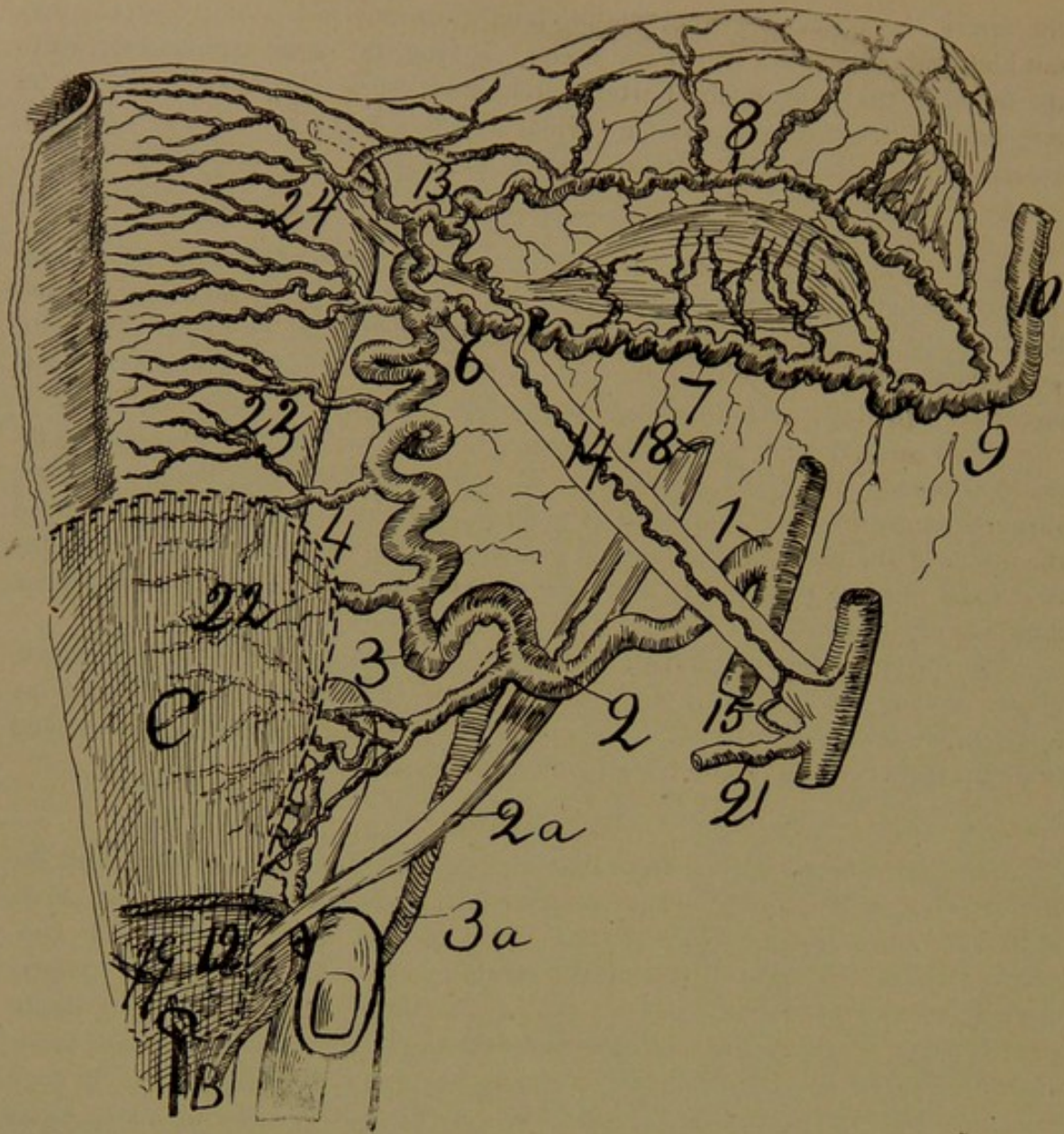


Fig. 43—A cut to illustrate the cervical loop (2, 3, 4) and lateral cervical triangle (2, 4, 19) normally and during operation reversed. The cervical loop (2, 3, 4). The lateral cervical triangle (2, 19; 2, 3, 4; 4, 19). 1, origin of pelvic floor segment; 2, distal arteria ureteral crossing (also arterio-ureteral loop and distal arteria ureterica); 3, cervical loop; 4, internal os; 5, uterine segment; 6, middle bifurcation of the utero-ovarian artery; 7, ramus ovarii; 8, ramus oviductus; 9, junction of oviducal and ovarian segments (also proximal bifurcation of utero-ovarian artery); 10, ovarian segment; 19, vesicle orifice of ureter; 22, ramus cervicis; 23, ramus corporis; 24, rami fundi; 31, 32, 33, oviduct; A, finger hooked around the cervical loop; B, traction forceps drawing the left half of the uterus distalward into the vagina; C, traction forceps drawing the uterus into vagina; 13, 14, 15, round ligament segment; 21, deep epigastric. Observe that the ureters and trigone remain in situ, normally during the operation, especially after the uterus and bladder are separated from each other. This is easily noted in figure 42.

median side of the lateral cervical triangle shortens, and the arterial side, the cervical loop, unfolds and lengthens.

In some bodies, by careful measurement, the ureters come not only parallel, but in actual contact with the uterine artery, for three inches. In such case (ovaries hardened by formalin and about sixty years old) the pelvic floor segment measured four inches from origin to os internum. In one case, 54 years of age, the arteria interina measured 5 inches from origin to internal os. The distal arteria ureterica passed from the uterine artery midway between the os uteri internum and its origin, giving a T-shaped artery to the ureter, one branch passing distalward and the stronger branch passing proximalward. The vaginal arteries supply the distal end of the ureter. In one case old and hardened by formalin, and hence the elevation of the pelvic floor segment; the actual distal arterio-ureteral crossing occurred about one inch from the uterus. But since the ureter and artery were parallel for three inches and age had changed the anatomy by atrophy, it should be considered that where the artery of the ureter was given off was the original distal arterio-ureteral crossing, *i. e.*, exactly midway on the artery between the internal os and its origin. The ureter passed two-thirds of an inch from the cervix uteri.

Sometimes the distal arterio-ureteral crossing is located about two-thirds of an inch from the lateral borders of the cervix uteri, but the cervical loop may be long or short in such case. The reason that the ureter is not more frequently ligated in vaginal hysterectomy is because the traction forceps draws the uterus distalward while the ureters practically remain *in situ*, and hence elongates the distance between the ureter and the cervix uteri. The areolar bed (base of ligamentum latum uteri) in which the pelvic segment lies being the most extensive of any, allows the most rapid and wide range of movements. From the lateral pelvic wall, at least after the uterine artery enters the base of the ligamentum latum, it pursues almost a horizontal course to the os uteri internum (pars supravaginalis cervicis). The pelvic floor segment lies in an extensive bed of connective tissue, and can be forced out of its course for surgical and physiological purposes. At its origin it lies close to the hypogastric vessel and obturator arteries and against the lateral pelvic wall proximal to the ischial spine, and covered by little more than by the peritoneum. It begins at the anterior branch of the hypogastric artery on the lateral pelvic wall.

The uterine artery passes, first, distalward, and second medialward in a curve, first closely in contact with the peritoneum (for one and a half inches), secondly through the base of the ligamentum latum (for one and a half inches), and proximal ventral to the ureter (forming the distal arterio-ureteral crossing) to gain access to the level of the os uteri internum. It sends branches to the ureter, cervix, bladder, vagina and ligamentum latum.

The uterine artery springs from the hypogastric, and generally lies in contact with its ventro-lateral border for some distance. It lies externally lateral from the ureter and parallel to it. Practically the pelvic floor segment is a surgical segment of the first import in regard to its own ligation and relation to the ureter. The uterine artery is palpable in the pelvic floor segment in the non-gravid, gravid and myomatous state of the uterus. The distal arterio-ureteral

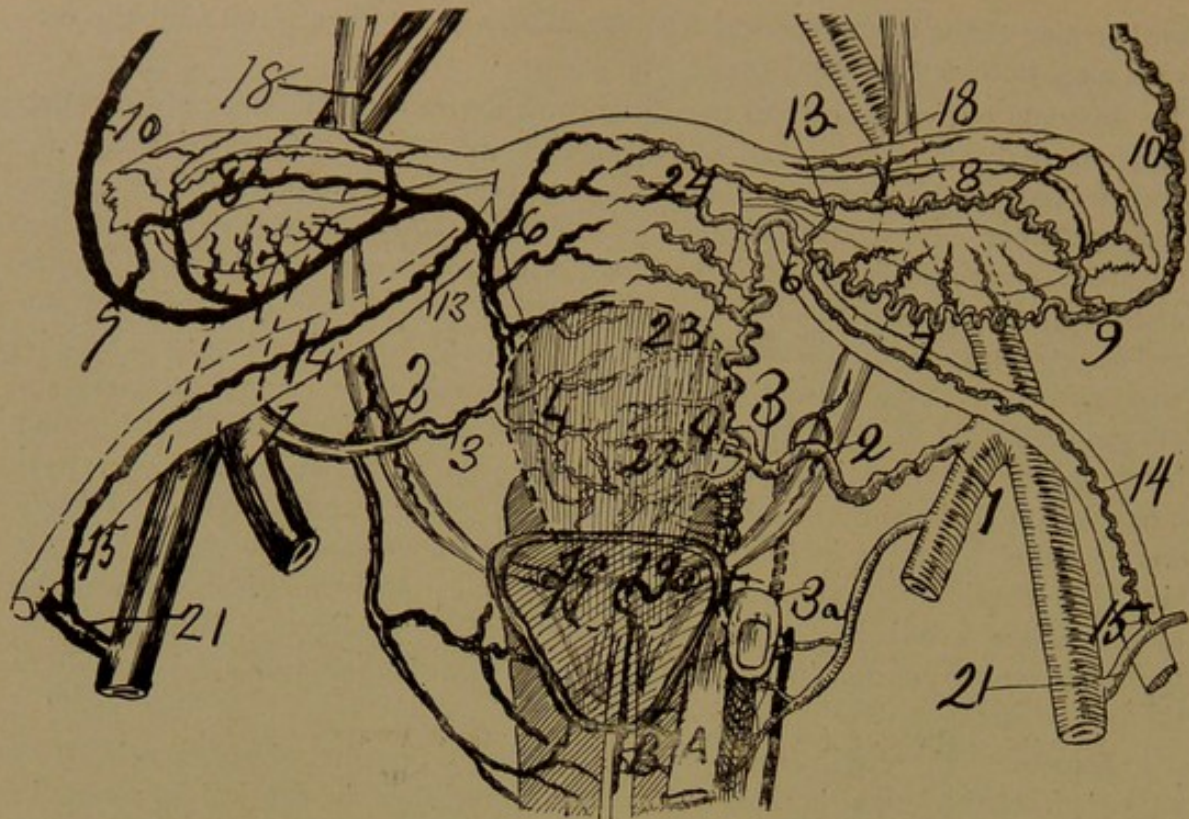


Fig. 44—A figure to illustrate the cervical loop and lateral cervical triangle normally and during operation reversed. The cervical loop (2, 3, 4). The lateral cervical triangle (2, 19; 2, 3, 4; 4, 19). 1, origin of the pelvic floor segment; 2, distal arterio-ureteral crossing (also arterio-ureteral loop and distal arteria ureterica); 3, cervical loop; 4, internal os; 5, uterine segment; 6, middle bifurcation of the utero-ovarian artery; 7, ramii ovarii; 8, ramus oviductus; 9, junction of oviducal and ovarian segments (also proximal bifurcation of utero-ovarian artery); 10, ovarian segment; 19, vesicle orifice of ureter; 22, ramus cervicis; 23, ramus corporis; 24, rami fundi; 31, 32, 33, oviduct; A, finger hooked around the cervical loop; B, traction forceps drawing the uterus distalward into the vagina. This cut shows the veins on one side (right) and the arteries on the other side (left). The cervical loop (2, 3, 4) normal becomes (2, 3, a, 19) reversed by drawing the uterus distalward in the vagina. Note that the normal site of the ureters and trigone remains during hysterectomy.

crossing, the most important topographical landmark in the pelvis, is located at the summit of the dome of the pelvic ureteral curve,

The distal arterio-ureteral crossing is practically midway between the uterine border and the lateral pelvic wall. In other words, the ureter divides the pelvic segment in two unequal portions, with the longer external to the ureter.

The pelvic floor segment has a distally directed, descending and a horizontally directed portion. It possesses a curve with its concavity proximalward. The pelvic segment might be divided in two portions, viz: (1) a parietal portion, fixed and quite intimately connected with the peritoneum; (2) a mobile or non-peritoneal portion, which traverses the base of the ligamentum latum. The second or non-peritoneal portion, the cervical loop, is of exceeding importance on account of its relation with the ureter, the distal arterio-ureteral crossing and its ligation in hysterectomy. It has more intimate connection with the rectum of quadrupeds than that of bipeds.

The pelvic floor segment has an age and functional relation. There is the quiescent, non-tortuous stage of fetal and childhood life; the completed sinuous

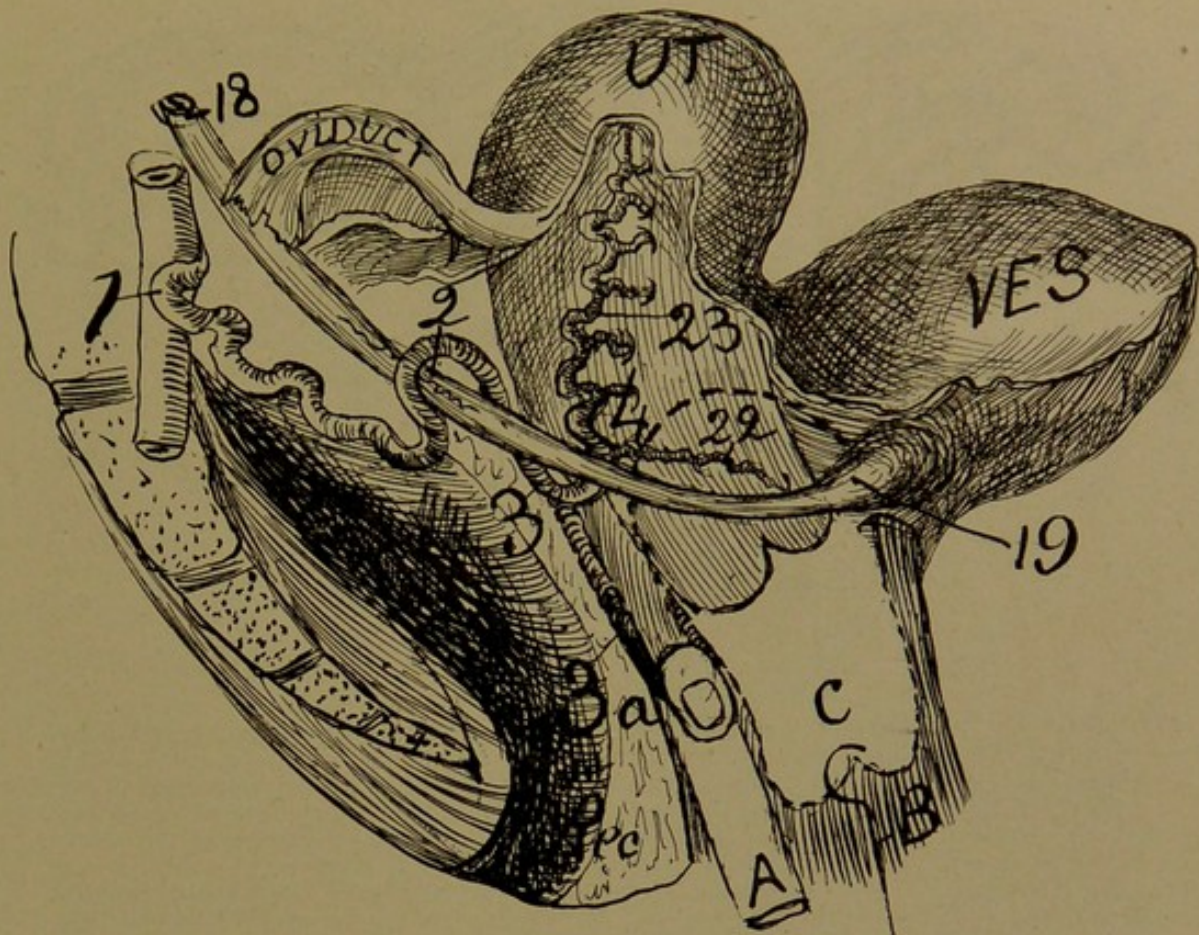


Fig. 45—A cut to illustrate the lateral cervical triangle (2, 4, 19) normally and reversed during operation. The finger is around the cervical loop (2, 3a, 4). The lateral cervical triangle is formed by 2, the distal arterio-ureteral crossing; (4) the internal os and (19) the vesicle orifice of the ureter. The cervical loop (2, 3, 4) forms the proximal side, the ureter (2, 19) forms the distal side and the lateral border of the cervix and vagina (4 to 19) forms the median side of the lateral cervical triangle. 3a shows the cervical loop forming the distal instead of the proximal side of the cervical triangle, which is reversed during vaginal hysterectomy. 1, origin of the pelvic floor segment of the utero-ovarian artery; 2, the distal arterio-ureteral crossing (also the ureteral loop and distal arteria ureterica). 3, cervical loop; 4, internal os; 19, ureter penetrating bladder wall; 22, ramus cervicis; 23, rami corporis; UT, uterus; ves, bladder; A, finger hooked around the cervical loop 3a; B, traction forceps; c, the uterus drawn distalward in the vagina; Rec, rectum.

development of reproduction life; the changes of size, length, caliber, spirality, and position in gestation; the changing volume in menstruation and the senile atrophy—change in size and position—of old age.

In childhood the pelvic floor segment passes well proximalward in the ligamentum latum, but passes well distalward in the pelvis and base of the ligamentum latum in adult sexual life, and again to recede proximalward in senility.

The pelvic floor segment of the utero-ovarian artery is of vast medical and surgical importance, because it contains:

1. The distal arterio ureteral crossing.
2. *The cervical loop.*
3. The arterio-ureteral loop.
4. The distal bifurcation of the utero-ovarian artery.
5. The distal arteria ureterica.

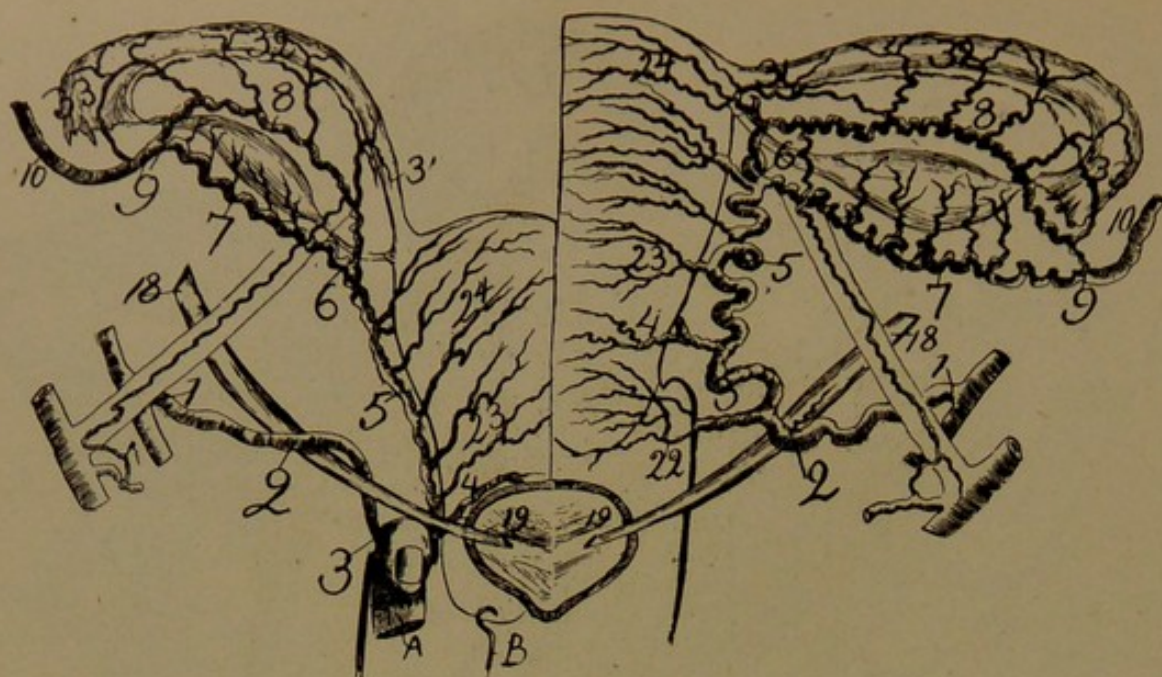


Fig. 46—A cut to illustrate the lateral cervical triangle reversed during operation by drawing the cervical loop distalward (2, 3, 4). The cervical loop (2, 3, 4). The lateral cervical triangle (2, 19; 2, 3, 4; 4, 19). 1, origin of pelvic floor segment; 2, distal arterio-ureteral crossing (also arterio-ureteral loop and distal arteria ureterica; 3, cervical loop; 4, internal os; 5, uterine segment; 6, middle bifurcation of the utero-ovarian artery); 7, ramus ovarii; 8, ramus oviductus; 9, junction of oviducal and ovarian segments (also proximal bifurcation of utero-ovarian artery); 10, ovarian segment; 19, vesicle orifice of ureter; 22, ramus cervicis; 23, ramus corporis; 24, rami fundi; 31, 32, 33, oviduct; A, finger hooked around the cervical loop; B, traction forceps drawing the right half of the uterus distalward in the vagina. Note that the normal position of the ureters and trigone remains while the operation proceeds.

ARTERIAL BRANCHES OF THE PELVIC FLOOR SEGMENT.

Ordinary dissections of the pelvic floor segment after careful injections of red material to make the arterial branches macroscopically visible reveal 4 parts, viz: (a) branches distributed to adjacent structures—rami ligamentilati; (b) branches to the ureter—ramus ureteris, distal, or arteria ureterica, distal; (c) branches to the cervix and the vagina—ramus cervico-vaginalis, and branches to the bladder—rami vesicales.

The X-ray on well injected uteri, especially of the pregnant, shows a vast network of vascular anastomoses in the pelvic floor segment, and numerous branches never before known or even suspected. The chief anatomic fact to which to call attention in the circulation of the pelvic floor segment is the numerous branches which it emits and the richness of their anastomoses. The first branches are to immediately adjacent structures.

ARTERIAL BRANCHES OF THE PELVIC FLOOR SEGMENT OF THE UTERO-OVARIAN ARTERY.

I shall divide the pelvic floor segment in two divisions, internal portion, or cervical loop and external portion which are separated by the ureter. The distal arterio-ureteral crossing where the ureter passes dorsal to the arteria uterina is

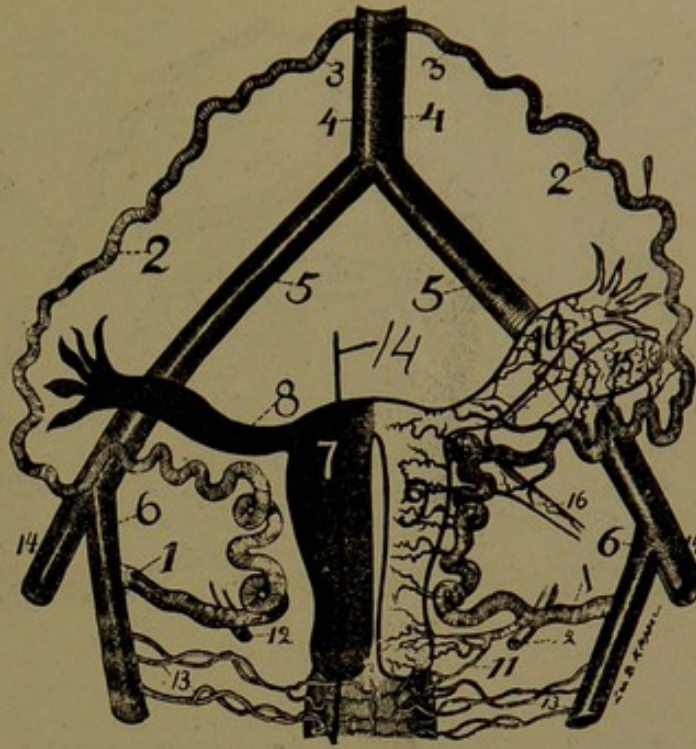


Fig. 47—1, 2, 3, the spiral segment of the genital vascular circle, the left side has no rami laterales genitalis. 4, 5, 6 the straight segment of the circles. 9 notes rami laterales uteri. 10 notes rami laterales oviductis. 15 notes rami laterales ovarii. 11 cervico vaginal artery. 12 ureter dorsal to uterine artery. Here it can be noted that the uterus oviducts and ovary could be removed by severing the rami laterales genitalis only (9, 10, 15). The author's operation (endometrectomy and partial myomectomy) incises the uterus in the line 14, after which the lateral segment of the uterus is sutured dorso-ventral.

the most important landmark in the pelvis; it is the grand crossing of the pelvis. A. The Cervical loop or internal portion of the pelvic floor segment extends from the distal arterio-ureteral crossing to the internal os. It is the most important of all arterial loops, being ligated in most forms of hysterectomy. It is described elsewhere. (Page 81.)

B. THE EXTERNAL PORTION OF THE PELVIC FLOOR SEGMENT.

It extends from the distal arterio-ureteral crossing to the origin from the hypogastric. It is the external two-thirds of the pelvic floor segment. The external portion descends externally parallel to the ureter, is non or slightly sinuous, and emits several small, fine branches. It is in a limited bed of connective tissue and closely associated with the peritoneum. It lies practically against the pelvic wall, in contact with the hypogastric artery. From the origin of the artery to the distal ureteral crossing, practically none or few macroscopical branches are emitted.

The parietal or descending portion of the pelvic floor segment in general courses first distalward $1\frac{1}{2}$ inches, more or less, and is slightly sinuous at its origin. The X-ray shows several small branches arising from this parietal or descending portion. It does not lie in the ligamentum latum. It lies parallel and internal to the ureter for about $1\frac{1}{2}$ inches. The ureter is first in front, and finally

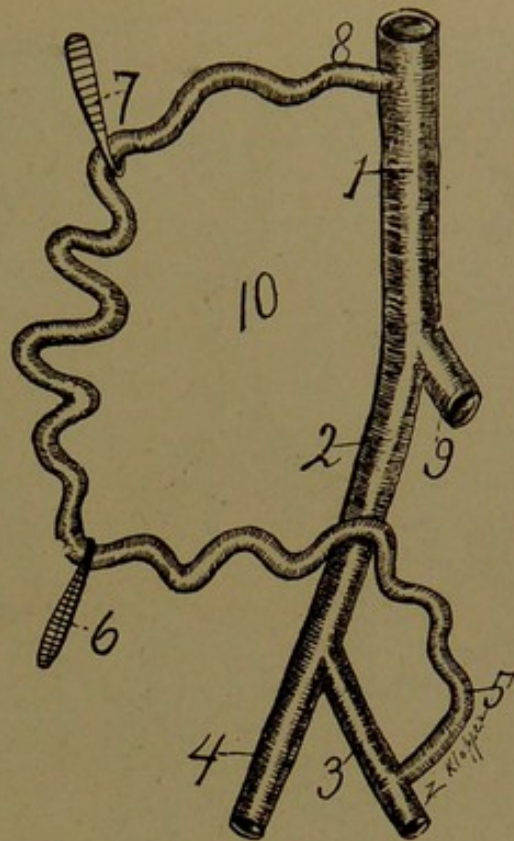


Fig. 49—The genital vascular circle. 1, abdominal aorta; 2, common iliac artery; 3, internal iliac artery; 1, 2 and 3 is the straight segment of the circle; 5, 6, 7 and 8 represents the spiral segments of the circle held in position by hooks. In this cut, free from complications, may be easily discerned the utility of the spiral segment of the circle in wide ranges of motion; 10, is the interior of the circle.

proximal. A second arteria vaginalis arises from the vesicle, or may arise from the pudenda internis, which may be termed the artera vaginalis medial. The distal end of the vagina is supplied by the arteria pudenda externis. In some of my X-ray specimens three vaginal arteries would arise from the pelvic floor segment of the utero-ovarian artery, the most external arising from the uterine almost exactly at its origin.

The arteriae vaginales of both sides agree in neither number, size nor direction. Transverse and longitudinal anastomosis occur in the arteriae vaginales similar to that of the arteriæ uterinæ. Loop and spiral conditions occur in the proximal vaginal arteries, especially those supplying the fornices, but fail in distal vaginal arteries. In the bovine and soliped a vaginal artery springs from the pudic, and strongly anastomoses with the utero-ovarian, producing a fourth foot to the genital vascular circle.

THE ARTERIO-URETERAL LOOP.

It consists of a curve or loop of the artery which embraces the ureter. The arterio-ureteral loop of the pelvic floor segment lies at the point of division of its external and internal portions. It varies in size; however, it is frequently long enough to more than encircle the whole ureter. The coils of this loop may make the artery appear to pass dorsal to the ureter. This loop crosses the artery

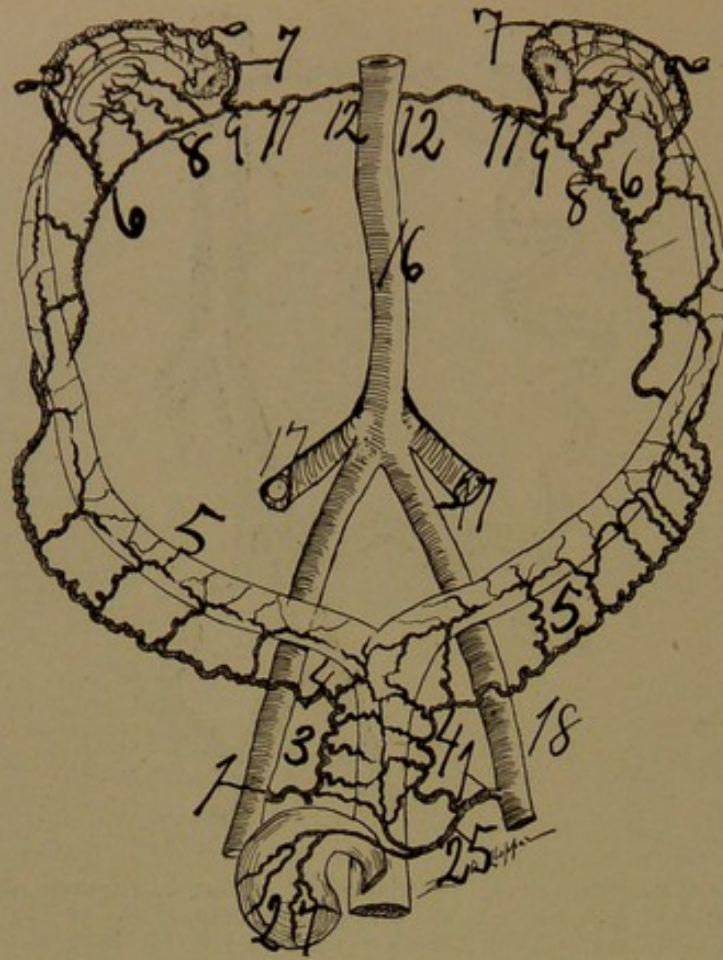


Fig. 50—Shows the genital circle of author in a guinea pig. 1, 3, 4, pelvic floor segment; 5, 6, uterine segment; 6, 7, 9 and 6, 8, 9 the oviducal segment; 9, 10, 11, the ovarian segment. The genital vascular circle or circle of author is the same in all mammals.

like an italic letter *x*, or at varying angles. The longer the arterio-ureteral loop the safer the vaginal hysterectomy, as the traction forceps can draw the internal portion of the pelvic floor segment more distalward when the more distant from the distal arterio-ureteral crossing, allowing safe ligation. Though the arterio-ureteral loop is bound in a vast connective tissue bed, and the ureter resides in a similar bed, with a considerable sized artery connecting the arterial loop and the ureter, yet there is liberal motion between the arterial loop and the ureter, for the artery at the distal arterio crossing is quite long. However, at the distal arterio-ureteral crossing the ureter is frequently inclosed in a loop of the uterine artery, which is located closely to the vaginal fornix.

The arterio-ureteral loop is located at the lateral border of, and lies in contact with the vaginal fornix. The space between the arterio-ureteral loop and the vagina is filled with dense cellular tissue, in which the ureter takes its course and the cervico-vaginal and vesical arterial branches traverse.

This loop is, perhaps, due to the erect attitude, as the uterus (genitals) pass distalward more rapid than the bladder, hence the pelvic segment becomes looped over the ureter like a rubber tube over a wire.

RAMI LIGAMENTI LATI.

The lateral branches, which are small, fine branched spiral twigs, distributed to the adjacent veins, peritoneum the base of the ligamentum latum and the space between the latter and the hypogastric artery. The rami ligamenti lati are several small, tortuous branches which supply the adjacent segment of the ligamentum latum. Dissections, corrosion, anatomy and X-ray on the injected uterus shows two constant arteries of considerable size which arises from the pelvic floor segment and supplies the mesometrium. See No. 34 in cuts anastomosing with the extra arcs and arcades of the oviducal segment. I shall call the large one the artery of the ligamentum latum.

RAMI VESICALES.

Rami vesicales, which are branches to supply the dorsal surface of the bladder. In dogs, one branch divides supplying vagina and bladder, vesico-vaginal. The vesical branches pass off from the internal portion at or near the origin of the cervico vaginal, to supply the vagina and bladder. Whatever be their point of origin, they supply the ventral vaginal dorsal and distal vesical wall. They surround the distal end of the ureter and lateral vaginal fornices. Dissections and the X-ray shows on the pregnant that the internal portion of the pelvic floor segment or the cervical loop may present the artery doubled on itself like a twisted rope and projecting distalward between the cervix and distal arterio-ureteral crossing.

The vesical and vaginal branches anastomose with the cervico vaginal, and hence will cause some hemorrhage in vaginal hysterectomy. However, since the cervical branches generally rapidly diminish in volume the anastomosis is weak, preventing serious hemorrhage.

THE DISTAL ARTERIO-URETERAL CROSSING.

This occurs generally at an acute angle with the uterine artery proximal (over) or ventral to the ureter. It is located midway between the lateral cervical border and the lateral pelvic wall. Since the pelvic floor segment of the utero-ovarian artery is longer than the distance between the lateral cervical border and the lateral pelvic wall, I shall assume that the distal arterio-ureteral crossing is located more accurately at the junction of the internal and middle thirds of the pelvic floor segment of the utero-ovarian artery. Also to still further mark this crossing the ureter is frequently embraced by a loop of the artery, the arterio-ureteral loop. Besides the significant distal arteria ureterica is given off at this point. It is the grand crossing of the pelvis.

At the distal arterio-ureteral crossing the arteria uterina passes proximal ventral (over) the ureter. In the erect attitude of man and ape this is necessary in order that during pregnancy the widely distal genitals lying in the pelvis may pass widely proximalward without kinking the ureter and uterine artery. If the uterine artery passed distal, dorsal (below) to the ureter when the uterus passed proximalward or ascended the uterine artery and ureter would produce a kink, bend, in each other and compromise both. In man and ape (erect) the bladder is a widely distal pelvic organ.

In quadrupeds (I examined the dog, cat, rabbit, cow, pig, horse, leopard, bear,

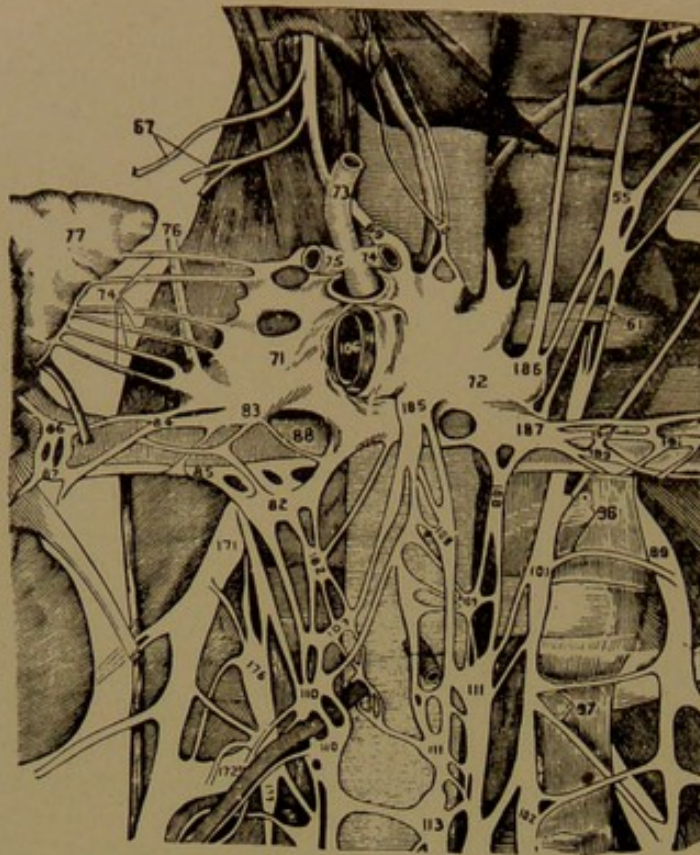


Fig. 51—Ganglion Coeliacum. Abdominal brain (71 and 72) presenting the large nerve supply which it emits along the ovarian segment of the utero-ovarian artery. 110, ovarian of ovarian segment.

sheep, etc.) the uterine artery passes dorsal, distal to, the ureter. From this anatomic fact no kinking of the ureter or uterine artery arises in pregnancy, because the genitals and bladder are practically not distal pelvic organs in quadrupeds. In quadrupeds the genitals and bladder ascend, pass proximalward together during pregnancy. When the uterine artery crosses ventral (proximal) to the ureter it gives off a T-shaped artery to the ureter (arteria ureterica). This arterial branch aids with extensive adjacent connective tissue to bind the ureter and uterine artery into a fixed point of vast significance in gynecology. This distal arterio-ureteral crossing, though a *fixum puntum*, is relatively mobile in the adjacent bed.

It is mobile in its bed of connective tissue, and besides it moves with adjacent mobile viscera. Its mobility is adjustable for physiologic and surgical purposes.

The distal arterio-ureteral crossing exists in two distinct shapes with intervening grades. The most frequent shape of the distal arterio-ureteral crossing is that of the italic letter *x*. The other distinct shape is that of a latin cross (+). The shape of the crossing depends on the parallelism of artery and ureter. When the uterine artery descends a certain curve with its convexity ventral it meets the ureter more or less at right angles. The distal arterio-ureteral crossing occurs on an average of two-thirds of an inch from the lateral border of the cervix, but the cervical loop, internal portion of the pelvic floor segment, will average one

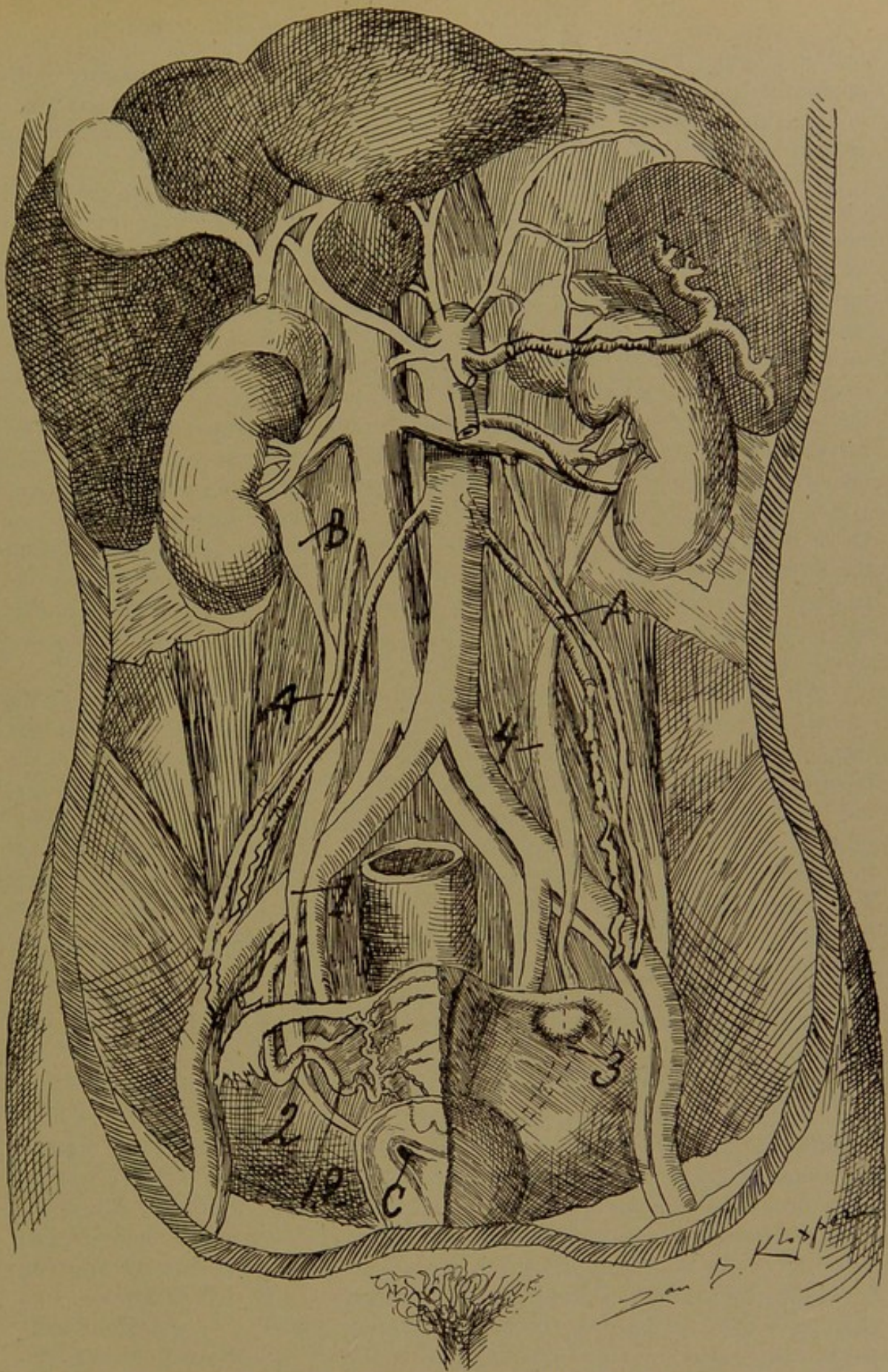


Fig. 52—View of the utero-ovarian artery and ureter on the dorsal wall.
 A.A. Proximal arterio-ureteral crossing presenting uretero-venous triangle of author. B, ureteral pelvis. 4, lumbar ureteral spindle. 3, pelvic ureteral. 2, arterio-ureteral loop. 12, cervical loop. C, distal ureteral orifice.

inch in length. The dangerous arterio-ureteral crossing in surgery is that which approaches the nearest to the uterus. This will arise in multipara, hypertrophic myometritis, myomata, gestation and malignant growths. In short, any uterine enlargement makes the crossing approach close to the uterus.

The distal arterio-ureteral crossing may be very oblique, and the artery and ureter may remain in contact. Sometimes they remain parallel for from one to one and one-half, or even two inches. The artery may ride the ureter with a short or long loop. Though the distal arterio-ureteral crossing may lie two-thirds or one-half inch from the lateral border of the cervix, yet drawing the cervix distalward by traction forceps may show the internal portion of the pelvic floor segment, the cervical loop, to be almost two inches by unfolding, which is ample length to ligate and avoid wounding the ureter. Practically the safety in ligating the uterine artery without compromising the ureter consists in separating the uterus from the bladder and passing the index finger between the cervix and bladder. This forces the ureter lateralward and proximalward and the uterine artery (cervical loop) distalward presenting ample space for clamp or ligature. Of course vigorous use of the traction forceps is an essential for the safety of the ureter, as the cervix with the uterine artery is much more mobile than the trigone and ureters, hence the traction forceps draws the cervical loop, the internal portion of the pelvic floor segment of the uterine artery distalward, separating the cervical loop of the uterine artery widely from the ureter.

At the distal arterio-ureteral crossing the ureters lying at a level of the internal os about two and one-half to three inches distant from each other and the crossing lies about one inch from the internal os, or midway between the lateral cervical border and lateral pelvic wall. The distal arterio-ureteral crossing is located about one inch from the entrance of the ureter in the bladder wall, or two inches from the vesicle-ureteral orifice. After the ureter passes distal to the crossing it curves medialward, approaching closer to the cervix and vagina, and ends in the vesical mucosa as an oval mucus slit about one inch from its opposite fellow. The space between the arterio-ureteral crossing and the cervical border is filled with large tortuous venous rootlets, whose trunks surround the ureter on all sides and veins, ureter and uterine artery are all bound in strong connective tissue so that the preparation of single parts require time and prudence.

The relation of the ureter to blood vessels which require ligation is important, especially because they are not fixed, but mobile. The most significant landmark in the pelvis is the distal arterio-ureteral crossing; this is also the most important practical surgical point in the pelvic floor segment. Besides, at this point occurs the arterio-ureteral loop and cervical loop which aid surgery by elongating the artery, allowing space for ligation. The ureter is the most dangerously exposed to the surgeon's knife at its distal arterio-ureteral crossing. This most important topographic pelvic landmark can be forced laterally from the uterus to some extent to avoid the knife or ligature. The significant acute angled distal arterio-ureteral crossing lies on a level with the os uteri internum, and about two-thirds of an inch lateralward. The ureter ends on the anterior vaginal wall, about one inch from the internal termination of the pelvic floor

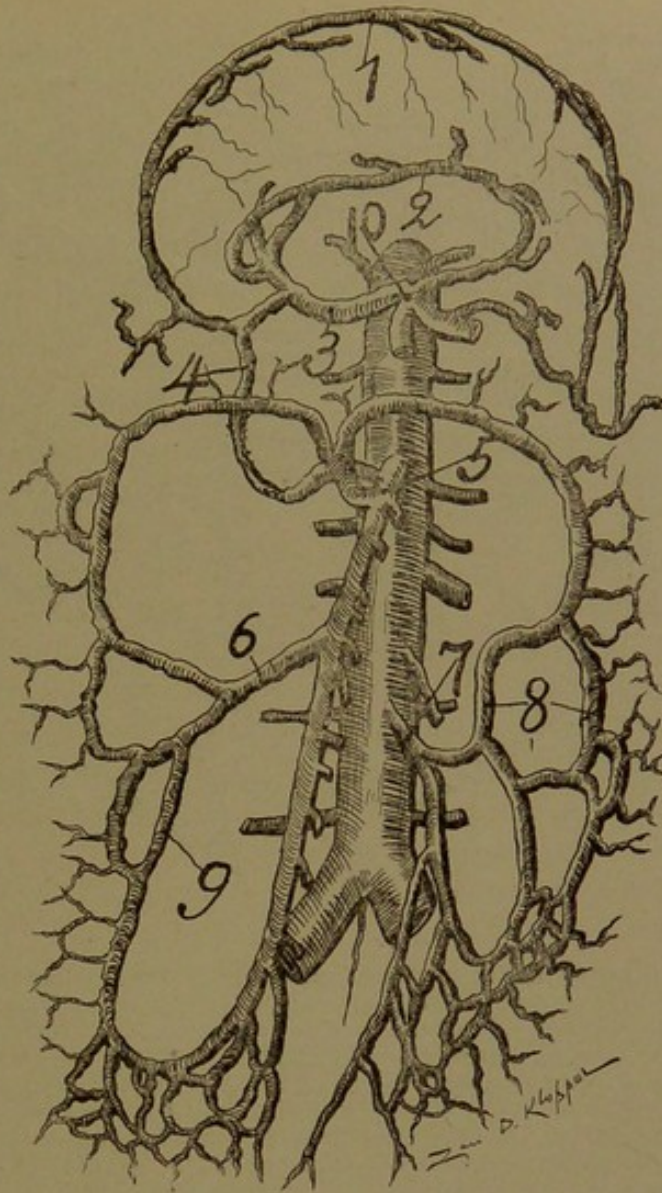


Fig. 53—Illustrates the anastomoses of the blood vessels of the tractus intestinales with its arcs and arcades. It is analogous to the compact, solid, anastomosis of the arcs and arcades of the utero-ovarian or genital vascular circle. 10 the arcs and arcades of the coeliac axis become united by anastomosis to the arcs and arcades of the great trunks of the superior (5) and inferior (7) mesenteric by means of (4) the Pancreatico duodenalis superior and inferior.

1. Gastro-epiploica dextra and sinistra anastomosed. 2, Gastric and pyloric anastomosed. 3, Hepatic. 4, Pancreatico duodenalis superior and inferior anastomosed. 7, inferior mesenteric artery with, 8, its arcs and arcades anastomosing with 6 and 9, arcs of the superior mesenteric at 5.

The arcs and arcades of the palmer arches are also analogous to the compact and solid anastomoses of the utero-ovarian artery or genital vascular circle.

segment. At the origin the external portion of the pelvic floor segment is in direct contact with the ureter. The ureter is in intimate contact with both the internal and external portion, but especially the external portion of the pelvic floor segment. The ureter passes through the pelvis obliquely. However the anatomic fact that the distal end of the ureter diverges distalward, and the internal end of the pelvic floor segment diverges proximalward, makes it fortunate for the patient's safety in surgical procedures, as this diverging of the artery and ureter enables the operator to ligate the artery without damaging the ureter.

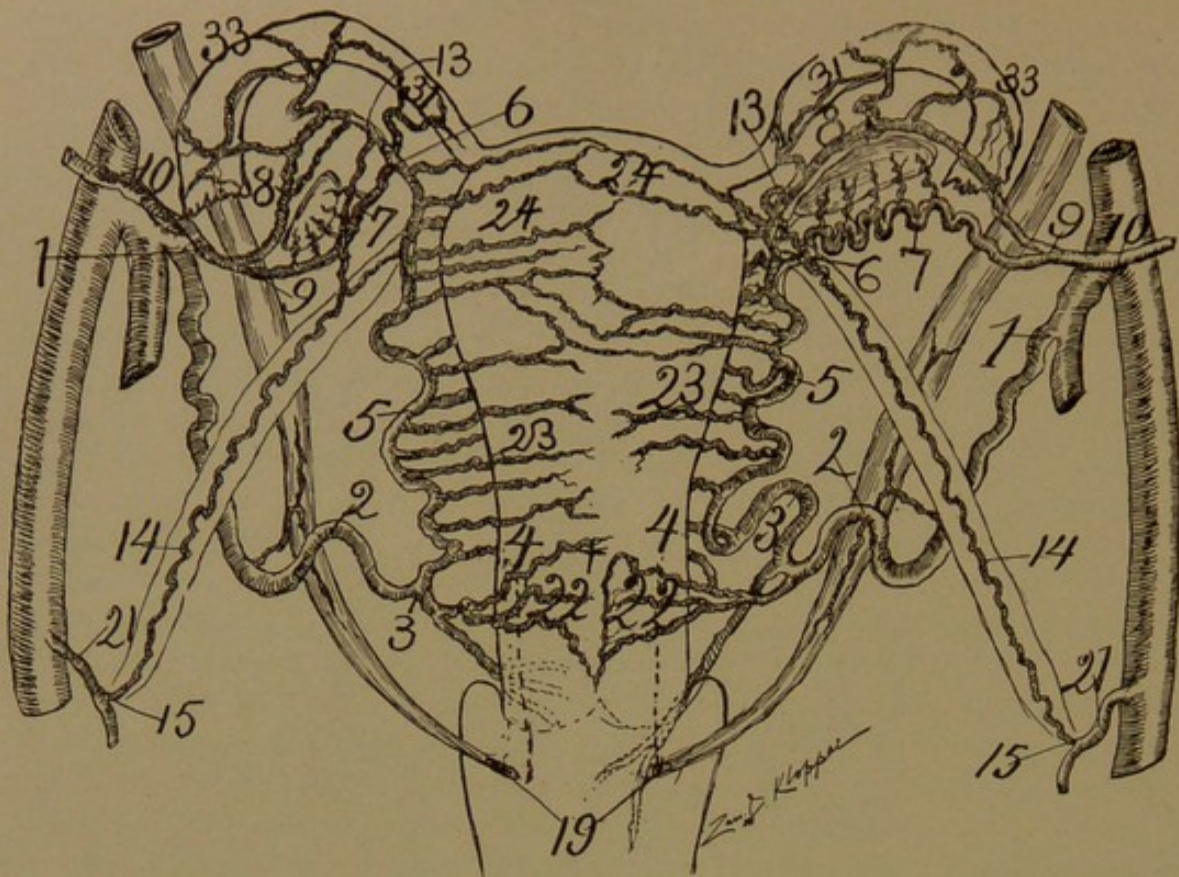


Fig. 54—This cut I dissected under alcohol from a subject of 55 and carefully placed each artery in position according to the dissected specimen. The subject had 3 myomata in the fundus and side of the uterus, hence note the irregularity in arterial supply to the uterus, as this uterus was well along in senility. The large and irregular arterial uterine supply was entirely kept prominent by the stimulating influence of the myomata. In the exact location of the myomata the rami laterales uteri were strong and numerous, like a pregnancy where no myomata existed and natural senescence progressed and the blank white spaces on the uterine surface show that the senescence rami laterales uteri were so atrophied that the fine injecting fluid would not penetrate them. The myomata on the left were chiefly located in the posterior wall of the uterus and the rami laterales uteri posterior were the ones still large and vigorous, while the corresponding anterior rami laterales uteri were too small to receive injecting fluid (see white space on anterior surface of uterus to left). Hence uterine myomata stimulate circulation in the myometrium similar to pregnancy. Also myomata will preserve and increase locally the size of the rami laterales uteri entirely beyond adult sexual life. The external portion of the pelvic floor segment was 2 inches. The internal portion of the pelvic floor segment, the cervical loop, was 1 inch. Note that the ramus vaginalis arises proximal to the ramus cervicis (left side) while on the right side the cervical and vaginal arise from one trunk—the cervico-vaginal.

The dotted lines show the arteria vaginalis passing dorsal to the vagina; 1, 2, 3, 4, pelvic floor segment of utero-ovarian artery (3 inches); 1, 2, external portion of pelvic floor segment (2 inches); 2, 3, 4, cervical loop internal portion of pelvic floor segment (1 inch); 2, distal arterio-ureteral crossing; 2, distal arteria ureterica; 2, arterio-ureteral loop; 3, cervical loop; 4, os uteri internum, the point of junction of pelvic floor and uterine segment; 5 uterine segment of utero ovarian artery; 6, junction of uterine and oviducal segments of utero-ovarian artery, also middle bifurcation of the utero-ovarian artery; 6, 7, 9, ramus ovarii, and 6, 8, 9, ramus oviductus, 8, i, e, the oviducal segment and the ovarian vascular circle; 10, ovarian segment of utero-ovarian artery; 13, 14, 15, round ligament segment of utero-ovarian artery (one end arises from the ramus oviductus and the other from the arteria epigastric inferior 21); 19, 19, vesicle or distal orifice of ureter; 22, ramus cervicis; 23, rami corporis; 24, rami fundi; 2, 4, 9, lateral cervical triangle.

The variations of the rami laterales genitals occurs mainly at the genital sphincters, viz.: a, internal (and external) os uteri; b, sphincter oviductus uterinæ

(utero-oviducal angle); c, sphincter oviductus fibræ. The points of the genitals to which the greater number and largest rami laterales tend are: a, the fundus uteri, and b, the ovary, and these show the least variation of the rami laterales genitales.

The oviducal segment is the most variable of the 5 segments of the utero-ovarian artery. All the rami laterales genitales show a wave form or rolling-like winding course. Many show a definite spiral or tortuous course and in multipara they may present coiled collections, which is observed in the puerperal cow or pig.

The spiral rami laterales genitales are all (so far as I can estimate) rotated from left to right. Hyrtl noted this. The rotations of the utero-ovarian artery apparently assume either right or left spirulation.

It shows the relation of the uterus to the ureters, utero-ovarian artery and the author's cervical loop.

The distal arterio-ureteral crossing is practically midway between the cervical border and the lateral pelvic wall. In other words, the ureter divides the pelvic floor segment in two parts with the longer external to the ureter.

SUMMARY IN REGARD TO THE DISTAL ARTERIO-URETERAL CROSSING.

The distal arterio-ureteral crossing is important, because, a, it is the most important topographic landmark in the pelvis; b, it is adjustable from its mobility from physiologic and surgical purposes; c, at this point the ureter is surrounded by an arterial loop (the arterio-ureteral loop); d, it is the grand crossing of the pelvis; e, from this point the distal arteria ureterica passes T-shaped to the ureter. It divides the pelvic floor segment in an external portion and an internal portion, or the cervical loop; g, it forms the external angle of the lateral cervical triangle; h, it is located in a vast bed of areolar tissue, and in the midst of a rich plexuses of large veins; i, it is a fixum punctum, but is still very mobile with adjacent structures.

THE CERVICAL LOOP.

The cervical loop extends from the distal arterio-ureteral crossing to the level of the os uteri internum.

This important landmark of the internal portion of the pelvic floor segment of the utero-ovarian artery is what I term the cervical loop. The importance and utility of this loop has been forced upon us by modern gynecologic surgery. My dissections, corrosion anatomy, vaginal hysterectomy and X-ray work has taught me its usefulness in avoiding damage to the ureter by ligature or clamp.

Old anatomists, as Bourguery and Jacobs (1840), Henle (1860), Hyrtl (1860), Pourier (1895), saw this loop, but not being practical surgeons and hysterectomy not being yet in vogue, did not realize its great value in enabling the surgeon to avoid injuring the ureter through extending, unfolding by drawing the uterus into the pudendum with traction forceps.

Dr. W. Nagel, the only eminent gynecologist I can find referring to it, simply says that he saw it in one of his cases as a loop of the arteria uterina median to the ureter. Physicians observed it simply as a loop of the uterine artery. I consider the cervical loop as the most important of all arterial loops.

The cervical loop is located at the lateral border of and lies in contact with the vaginal fonix. The space between the distal arterio-ureteral crossing and the vagina is filled with dense cellular tissue, in which the ureter takes its course and the cervico-vaginal and vesical arterial branches traverse.

This loop is perhaps due to the erect attitude, as the uterus (genitals) pass distalward more rapid than the bladder, hence the pelvic segment becomes looped over the ureter like a rubber tube over a wire.

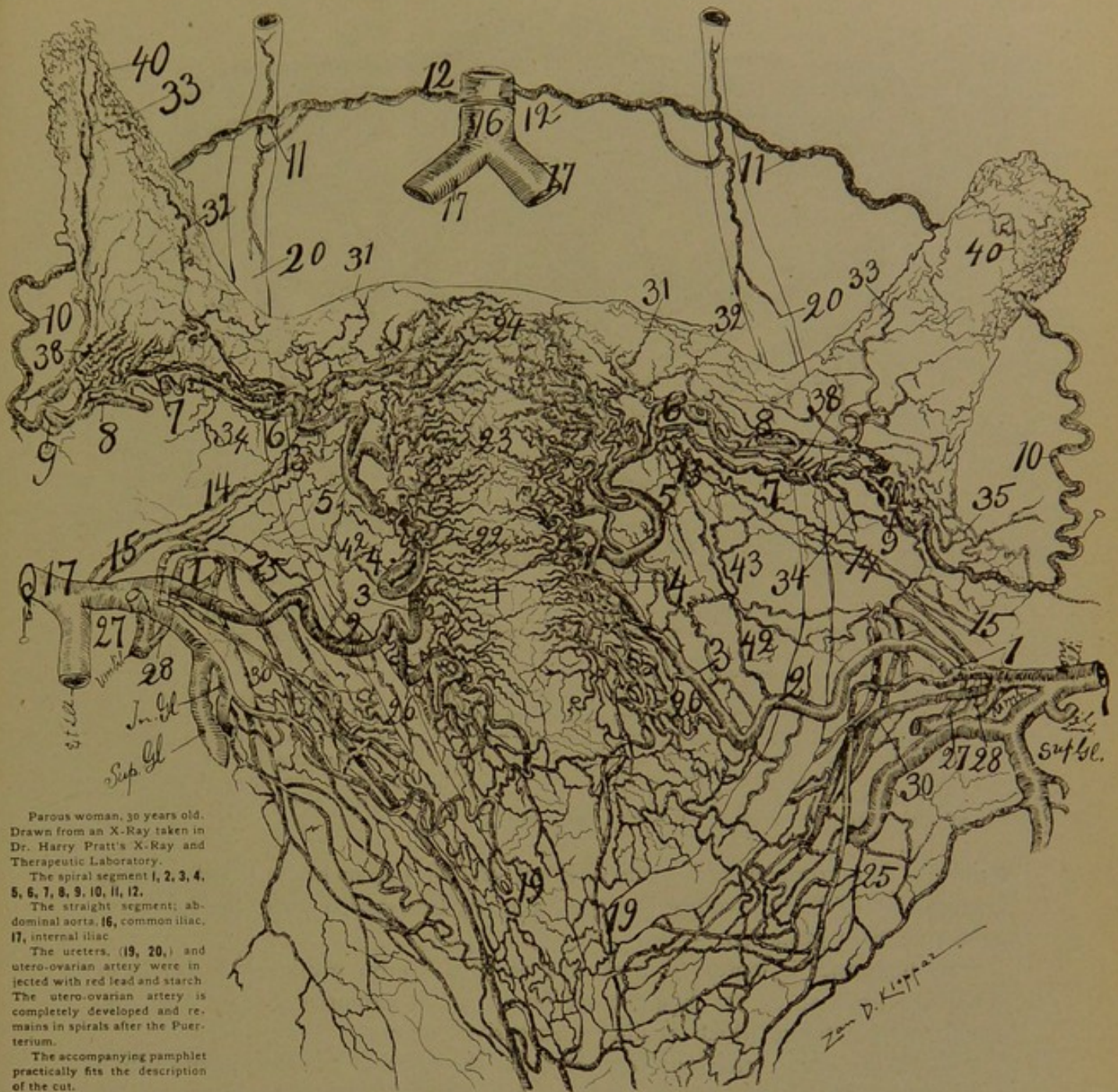
It exists in a spiral or tortuous state, which may be unfolded or extended for physiologic, anatomic or surgical purposes.

In vaginal hysterectomy the uterus should be drawn distalward, from the arterio-ureteral crossing, being allowed by the extent of the cervical loop, because the artery is much longer than the distance between the cervix and the distal arterio-ureteral crossing. This affords ample space to ligate the artery entirely free from the ureter and distal to it. However, what makes the distal arterio-ureteral crossing so adjustable laterally, which is the all-important factor in gynecological surgery, is due to what I shall name the cervical loop of the uterine artery, or the loop of the internal portion of the pelvic floor segment of the utero-ovarian artery. The gynecologist may observe this loop while performing vaginal hysterectomy. A well injected uterus, especially if pregnant two or three months, will demonstrate a considerable sized arterial loop projecting distalward between the lateral cervical border and the ureter at the distal arterio-ureteral crossing. The length of this cervical loop enables the gynecologist to force the distal arterio-ureteral crossing lateralward, and to draw the uterus distalward, allowing ample space to ligate the uterine artery internal to the ureter. Practically the cervical loop is ligated distal to the ureter. The exaggerated length of the loop is well observed during the use of the traction forceps on the uterus, and during its ligation with the index finger around it. The traction forcep forces the uterus distalward into the vulva. This unfolds, extends and draws the cervical loop into a straight line, but the distal arterio-ureteral crossing remains in situ, hence, again the excessive length of the cervical loop of the internal portion of the pelvic floor segment of the utero-ovarian artery enables the gynecologist to avoid ligating or wounding the ureter.

Little is found in medical literature on what I term the cervical loop of the uterine artery, as practically the utero-ovarian artery itself has no literature, yet the cervical loop is plain in vaginal hysterectomy, in dissections, and in the exact non-personal equation of the X-ray. The loop is excellently observed in corrosion anatomy. The descending arm of the cervical loop passes distalward along the internal and posterior border of the ureter, while the ascending arm of the loop passes proximalward along the lateral border of the vaginal fornix and cervix. During pregnancy the cervical loop doubles in length and size in the first three months.

The cervical loop has marked age and functional relations.

In fetal life and childhood it is short, small and straight. At puberty it springs into active life, becoming flexed and large. At the menstrual period it enlarges, its pulse beat is vigorous and it elongates. In gestation it enormously develops, trebles in length and caliber, shows a mighty cervical loop—in the form of two spiral arms, which fill the space between the lateral cervical border and the ureter, and during the later part of gestation the cervical loop extends, unfolds proximalward, becoming almost a straight line. In senility it atrophies.



Parous woman, 30 years old.
 Drawn from an X-Ray taken in
 Dr. Harry Pratt's X-Ray and
 Therapeutic Laboratory.

The spiral segment, 1, 2, 3, 4,
 5, 6, 7, 8, 9, 10, 11, 12.

The straight segment; ab-
 dominal aorta, 16, common iliac,
 17, internal iliac

The ureters, (19, 20,) and
 utero-ovarian artery were in-
 jected with red lead and starch
 The utero-ovarian artery is
 completely developed and re-
 mains in spirals after the Puer-
 terium.

The accompanying pamphlet
 practically fits the description
 of the cut.

The Utero-Ovarian Vascular Circle. (The Circle of Byron Robinson.)

Fig. 55—22, 23 and 24, represents the central longitudinal oligemic zone of the uterus in a multipara, 32 years old. 4, 5, 6 is the uterine segment of the utero-ovarian artery. (For numbers see general description page :2).

shortens in length, decreases in caliber, thickens, calcifies in its walls, and again becomes almost straight in outline, losing its flexuosity, as in childhood.

It extends from the distal arterio-ureteral crossing to the lateral border of the os uteri internum. It is an exceeding important vessel in gynecology, on account of its frequent ligation. It is the internal one-third of the pelvic floor

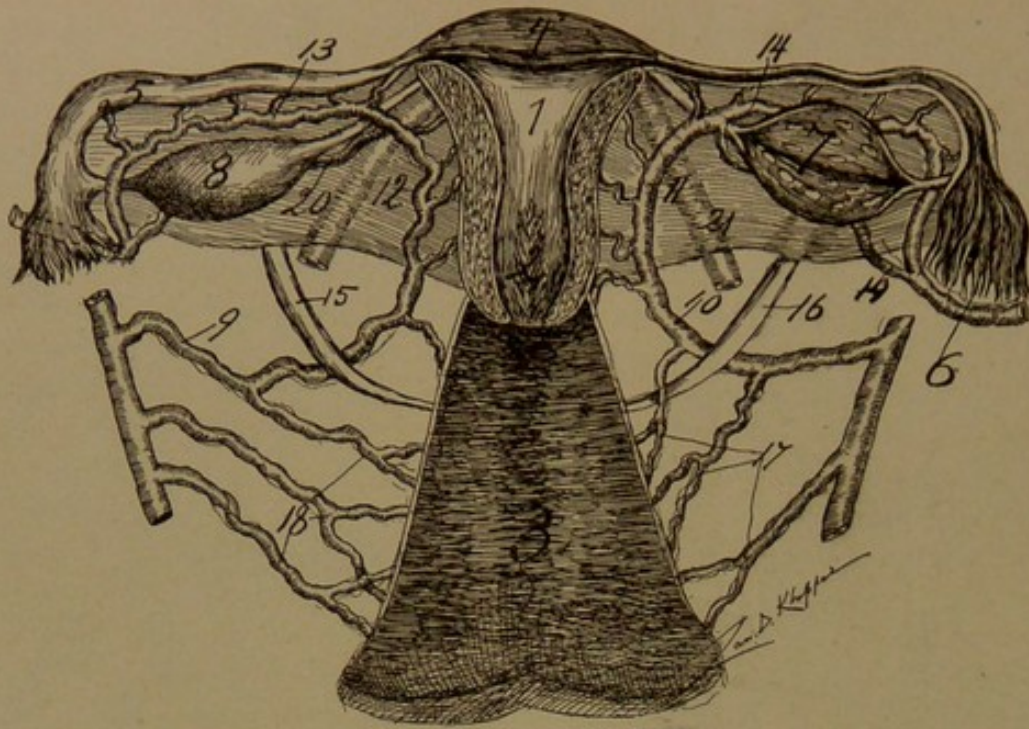


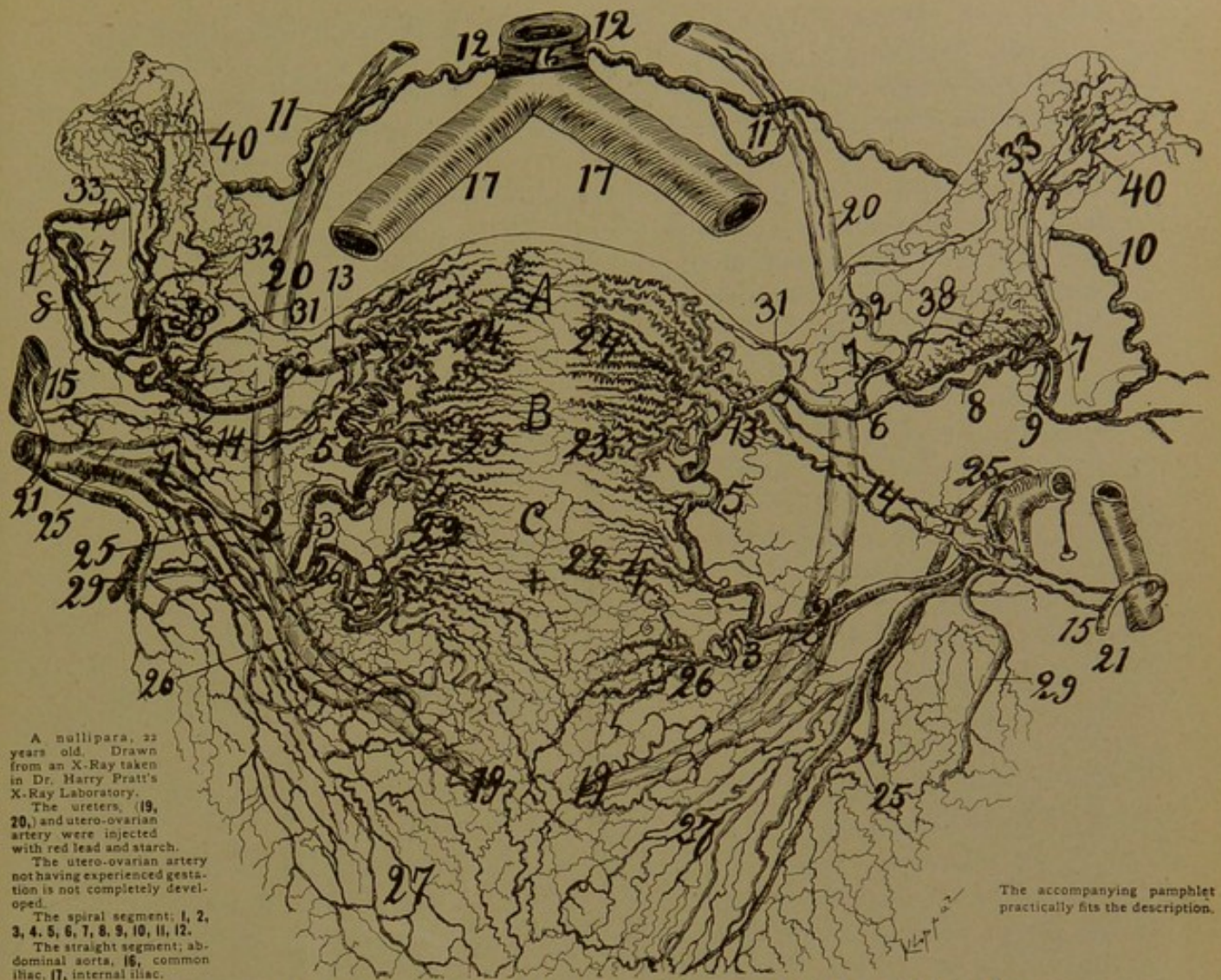
Fig. 56—Dorsal view of the circulation of the internal genitals with the dorsal blades of the mesometrium dissected, also the dorsal half of the uterus removed 1, cavum uteri; 2, cavum cervicis; 3, cavum vaginae; 4, fundus uteri; 5, oviduct; 6, oviducal pavilion; 7 and 8, ovaries; 9 and 10, pelvic floor segments of utero-ovarian artery; 11 and 12, uterine segments; 13 and 14, oviducal segments. On the left side 13 is the ramus oviductus and 20, is the ramus ovarii, on the right side 14 is the ramus oviductus and 19 the ramus ovarii. On each side the ovary lies within the ovarian vascular circle. 15 and 16 the spindles of the pelvic ureter coursing dorsal to the pelvic floor segment of the utero-ovarian artery. 17 and 18 the three arteries vaginalis on each side. On the right two vaginalis arise from the uterine, on the left two vaginalis arise from the hypogastric.

segment. It is from one to one and one-half, or even two inches in length, slightly flexuous in childhood, senility and the nullipara, but very flexuous in the multipara and early gestation.

Its flexuosity is increased in myoma or other uterine growths. It lies at or partly in the base of the ligamentum latum in an extensive bed of yielding, elastic, areolar tissue which facilitates extensive motion.

From the distal arterio-ureteral crossing the internal portion mounts proximalward over the lateral vaginal fornix, after which it departs slightly from the cervix and lateralward, and passes proximalward again to the distal portion of the corpus. In some cases it makes a distinct circular loop at the os uteri internum (see Figs. 55, 67, 99 and 106).

The abundant strong white connective tissue, fibres, bands and planes which surround the cervical loop, or the internal portion of the pelvic floor, are so intimately interwoven about the spiral cords of the artery that it will not easily elongate in a straight line without complete removal by dissection of the areolar tissue. The cervical loop, internal portion of the pelvic floor segment, sends off some very important branches. The cervical loop or horizontal, subligamentary portion, of the pelvic floor segment extends from the descending portion to the lateral border of the cervix. Practically the artery does not lie within the blades



The Utero-Ovarian Vascular Circle. (The Circle of Byron Robinson.)

Fig. 57—A, B, C, represents the central longitudinal oligemic zone of the uterus in a 22-year-old nullipara. 4, 5, 6, the uterine segment of uterine artery. 22, 23 and 24, rami laterales uteri. (For numbers see general description page 52).

of the ligamentum latum. Hence the horizontal portion of the pelvic floor segment should not be termed the intra-ligamentary portion.

The cervical loop, the internal portion of the pelvic floor segment, is the most mobile and free part of the utero-ovarian artery, besides being practically the chief surgical segment. Dissections and the X-ray show that the cervical loop terminates about one-fifth to two-thirds of an inch from the lateral border of the os uteri internum in a vast bed of white cellular tissue (whence by cervical lacerations infective germs gain access, producing cellulitis, and consequent vascular compromises). The cervical loop crosses the lateral vaginal fornix by mounting proximally over it.

In dissections and X-rays and corrosion anatomy I found a branch about the size of the distal arteria ureterica, springing from the pelvic floor segment

immediately internal to the distal arterio-ureteral crossing. It is very large, especially (see Nos. 34 and 35 in Figs.) making extra-vascular arches with the oviducal segment. It supplies the mesometrium. This is its chief artery of the ligamentum latum. Except the cervico-vaginal and the above branch the cervical loop lying between the distal arterio-ureteral crossing and the lateral cervical border sends off only very fine spiral twigs to the mesometrium. The cervico-vaginal branch courses to the lateral border of the cervix, thence distalward on the vagina, dividing in several branches which pass to the anterior and posterior surfaces of the cervix, in order either to end there or to pass to the anterior and posterior vaginal walls.

In the ligamentary portion the cervical loop is accompanied by large adjacent veins which being injected obscure the artery. It is here surrounded by a resisting envelope of cellular tissue; the same as surrounds the branches of hypogastric. It is this connective tissue condensed, difficult to dissect, which fills the space between the blades of the ligamentum latum.

The intra-ligamentary portion is crossed by the ureter. It lies in the base of the ligamentum latum.

SUMMARY IN REGARD TO THE CERVICAL LOOP.

1. The cervical loop extends from the distal arterio-ureteral crossing to the level of the os uteri internum.
2. It is the most important of all arterial loops.
3. The cervical loop exists in a spiral or potential state, which may be unfolded or extended for physiologic, anatomic or surgical purposes.
4. Its average length in nullipara is one inch; in multipara, one and one-half inches; at three months' gestation it is over two inches. In the late months of pregnancy the cervical loop is approxiated or extended, by the distending uterus.
5. In almost all adults the cervical loop or internal portion of the pelvic floor segment can be stretched or extended to two inches in length by careful traction with forceps and the finger.
6. The cervical loop is the chief surgical segment of the utero-ovarian artery, and is ligated or clamped in all operations for pan-hysterectomy, except in Pratt's operation and the method used by the author (endometrectomy and partial myomectomy).
7. The cervical loop has a descending and an ascending arm which lie mainly in contact, or may twist spirally about each other in early pregnancy.
8. The cervical loop (one inch) forms with the ureter externally (one and one-half inches) and the lateral border of the cervix and vagina to the ureteral vesicle orifice (one and one-half),
9. a urtero-arterio cervical triangle, or, in short, the lateral cervical triangle, which is significant in all pan-hysterectomies as the base of this triangle, is the cervical loop which must be ligated.
10. The cervical loop is plain in dissections in hysterectomy, especially vaginal and prominent in X-rays injected with finely divided metals and starch, as well as in corrosion anatomy.

11. In the first three months of gestation it appears to more than double itself.

12. The cervical loop emits the important cervico-vaginal artery, besides one large and several smaller ones to the adjacent structures and mesometrium. A vaginal may arise from it.

13. The cervical loop is flexuous, and its arms may assume a cork-screw spiral. It lies in a vast loose areolar bed, allowing safe motion, sudden or gradual.

14. The length of the cervical loop in hysterectomy saves subjects from damage to the ureter by the traction forceps drawing the cervix distalward, unfolding, extending the cervical loop so that the finger can hook the loop distal to the ureter before ligating it.

15. The cervical loop changes its size, shape, length and position during age and functional relations. It passes through the quiescent phase of fetal and childhood life, the crises of puberty, menstruation, gestation puerperium and of senility.

16. In nullipara it may project a short distance distal to the ureter. In multipara it may project distal to the ureter as far as the os uteri externum. At three months gestation it projects distal to the os externum uteri. In childhood and fetal life the cervical loop most frequently passes proximal to the ureter.

17. Both cervical loops bilaterally may be ligated simultaneously without gangrene (Gattschack-Martin operation).

18. In the multipara the loop generally rests against the lateral fornix; in childhood and senility it passes proximal to the vaginal fornix; in the first three months of pregnancy it passes distal to the vaginal fornix, and almost entirely fills the space between the lateral cervical border and ureter.

THE LATERAL CERVICAL TRIANGLE.

(Uretero-Arterio-Cervical Triangle.)

This triangle is bounded externally (in the resting uterus) by the ureter ($1\frac{1}{2}$ inches), proximally by the cervical loop (1 inch) and internally by the lateral borders of the cervix and vagina ($1\frac{1}{2}$) from os internum to the vesicle orifice of the ureter.

The cervical loop or internal portion of the pelvic floor segment with the ureter and lateral cervical vaginal border forms what I shall term the uretero-arterio-cervical triangle or shortly the lateral cervical triangle. The cervical triangle like the cervical loop is of vast import in hysterectomy.

In every vaginal or abdominal hysterectomy the lateral cervical triangle must be penetrated in order to ligate the cervical loop which is the proximal side of the lateral cervical triangle. In performing vaginal hysterectomy the proximal side of the triangle, the cervical loop (2, 3, 4), and the distal side of the triangle, the ureter (2, 19), become reversed, i. e., they take each the place of the other.

Normally the cervical loop (2, 3, 4), is proximal and the ureter (2, 19) is distal, when the cervix is drawn by traction forceps into the vagina the ureter remains in situ, while the cervical loop gradually passes distal to the ureter until one can pass the index finger through the reversed cervical triangle with the index finger. In Pratt's operation of hysterectomy without ligation of the utero-ovarian

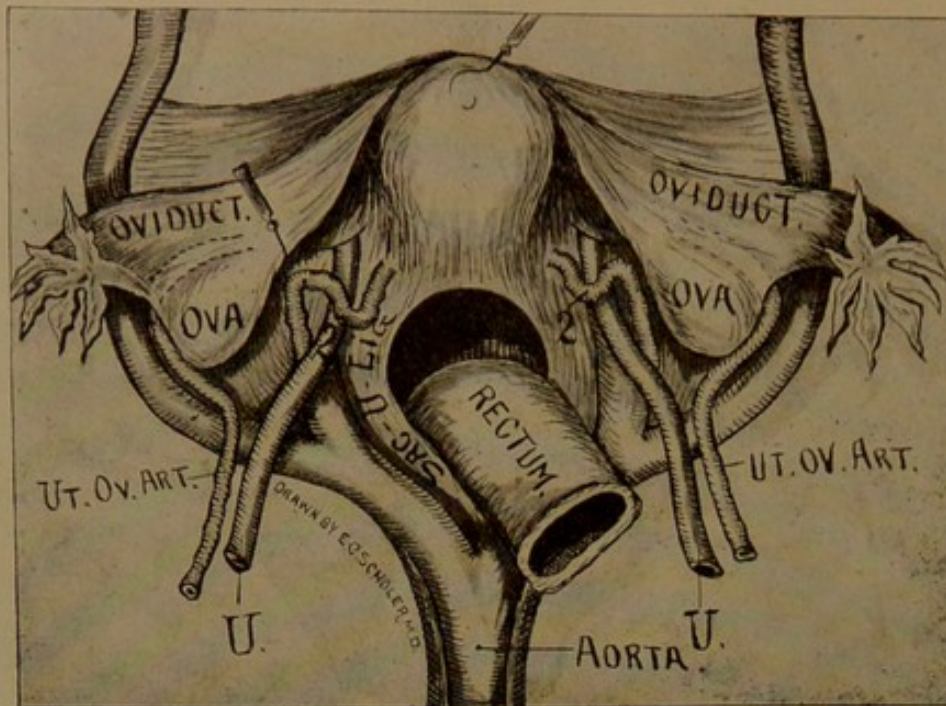


Fig. 58—This half-tone illustration presents a dorsal view of the internal genitals. Ureter passing distal to the uterine artery and enfolded by the (2) arterio-ureteral loop. In this drawing a suggestion from Altu Cheff was employed.

artery the lateral cervical triangle is simply penetrated at the median border (or cervico-vaginal border). In the author's operation of endometrectomy and partial myometrectomy the cervical loop and the ureter are not disturbed.

These anatomic data can be noted in the normally located and the reversed condition of the lateral cervical triangle in the accompanying cuts. The safety in performing vaginal hysterectomy lies in the penetration of the lateral cervical triangle close to the median border (cervical and vaginal border) from the dorsal or ventral surface and also in forcing lateralward the distal arterio-ureteral crossing, (2). Of course vast additional safety is added by a long cervical loop (2, 3, 4). During vaginal hysterectomy the chief practice consists in perforating the reversed lateral cervical triangle from the dorsal surface the lateral cervical triangle (2, 19, 4) is not penetrated or opened. Not only the long cervical loop (2, 3, 4) aids in vaginal hysterectomy but also the capacity of the spiral segment of the utero-ovarian artery to elongate distalward by means of the traction forceps fixed to the cervix.

RAMUS LATERALIS CERVICIS.

(The Cervico-Vaginal Artery. (See page 103.)

THE DEMONSTRATIONS OF THE CIRCULATION OF THE INTERNAL GENITALS FROM EXPERIMENTS WITH INJECTIONS BY THE X-RAY AND CORROSION ANATOMY.

Experiment No. 1. Celloidin holding vermilion (Hgs) in fine suspension was injected through the left internal iliac artery of a puerperal uterus in situ, five

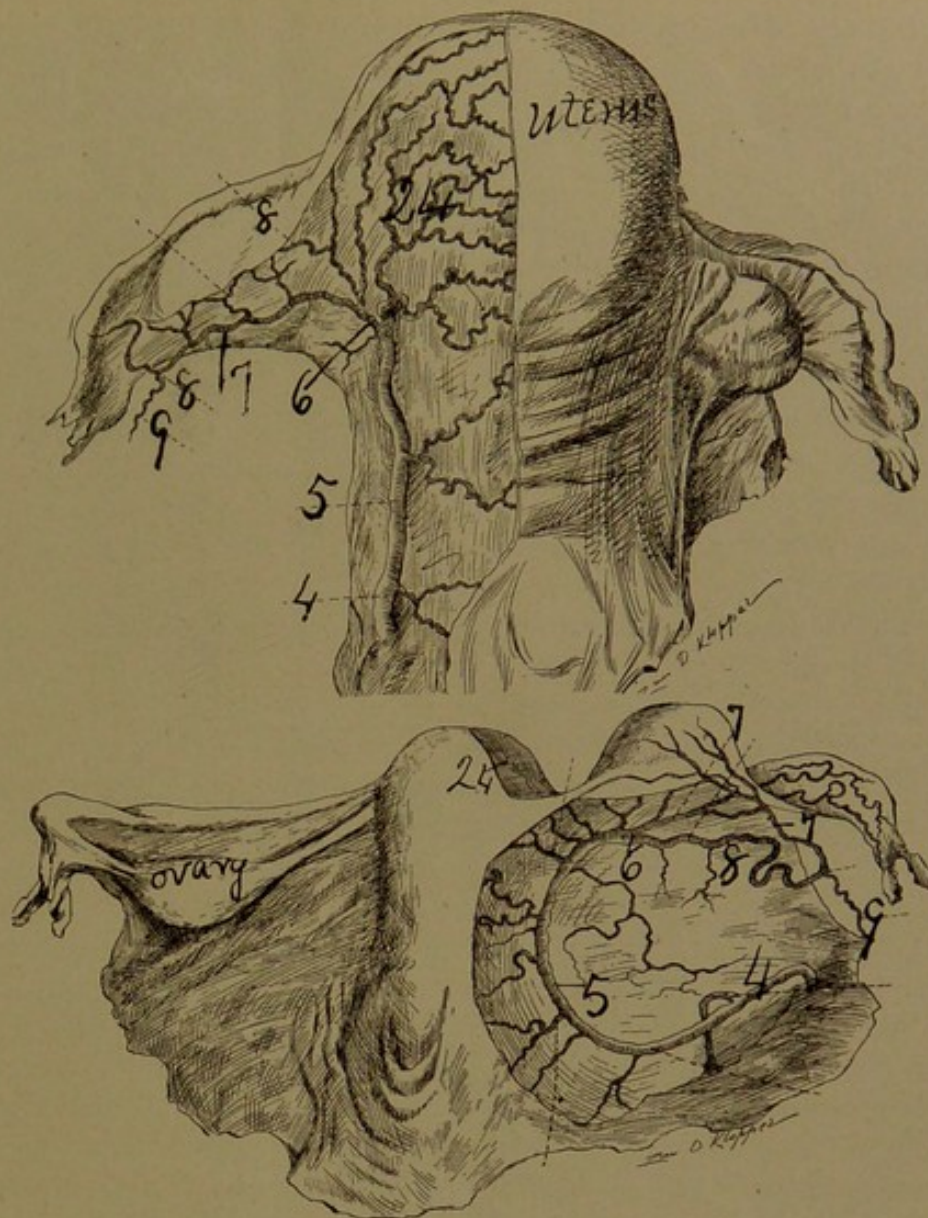


Fig. 59.—(Jules Broeckaert)—Upper cut. The internal genitals after parturition. 4, arteria vesico-vaginalis; 5, uterine segment, extended; 6, division of uterine segment in oviducal segment and fundal branches; 7, 8, 9, oviducal segment; 24, rami fundi. Lower cut, organs of girl 17 years old. 4 to 5, pelvic floor segment; 5 to 6, uterine segment; 6, 8, 9—6, 7, 9, oviducal segment.

days postpartum and twelve hours postmortem. Two minutes later the solution passed through the uterus into the common iliac artery, through the abdominal aorta, appearing in the periphery of the superior and inferior mesenteric arteries. Also it passed distalward in the right external and internal iliac arteries.

The segment of the round ligament became injected. In this subject the vessels of the internal genitals could not be completely distended without first ligating the right common and external iliac arteries. In other words, one could inject numerous organs of the body proximal and distal to the genitals by forcing the fluid into the left internal iliac artery and through the uterine vessels to the opposite side. The eye could easily observe the wave of the distending vessels as the injecting fluid passed from one side of the uterus to the other. Though

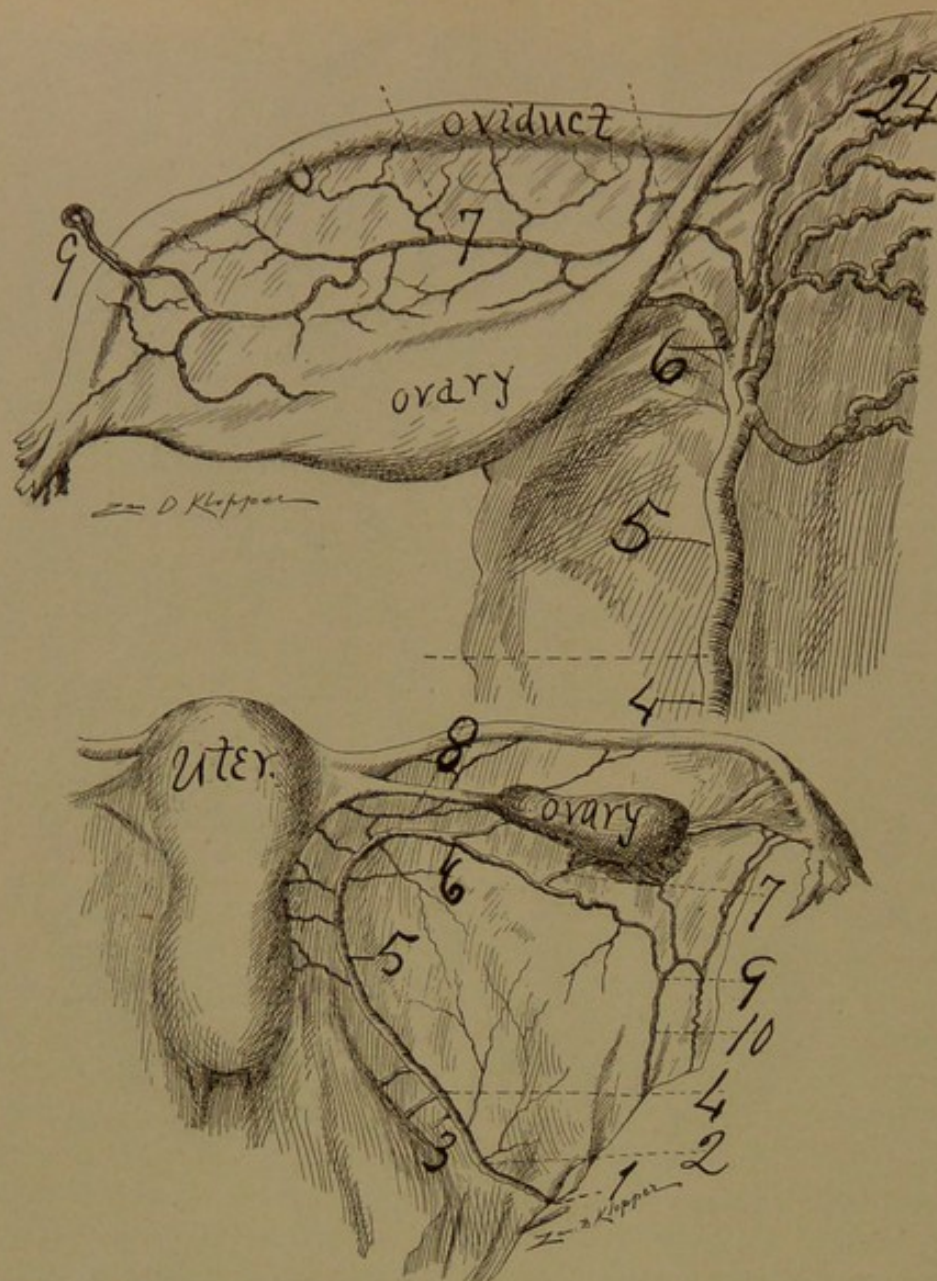


Fig. 60—(Jules Broeckaert)—Upper cut. Same as upper cut of figure 59 enlarged and prepared on right side; 4, 5, 6, uterine segment extended; 6, 7, 9, oviducal segment; 24, rami fundi. Lower cut, child 7 years old. 1, origin of uterine; 2, artery of ligamentum latum; 3, vaginal arteries; 5, uterine segment; 6, 8, 9—6, 7, 9, oviducal segment; 10, ovarian segment.

the entire vessels of both sides of the genitals could be partially distended by injections through one internal iliac artery, however, to completely distend all the vessels of the genitals one should inject the uterus bilaterally through both internal iliacs, as was distinctly demonstrated in this subject. The transverse anastomosis in the recently delivered uterus is extremely free—sufficiently free, I should judge, to partially inject the vessels of the entire body. Also dissections, the X-ray and corrosion anatomy demonstrate that the longitudinal and perpendicular anastomoses are profoundly free.

Experiment No. 2. I removed the nulliparous uterus from the body of a subject 31 years old, ligated all severed arteries except the internal iliacs on both

sides. Injections in the uterine vessels of one side passed within one minute into the vessels of the opposite side as the distending vessels of the uterine segment, oviducal segment and ovarian segment with their rami laterales demonstrated. The transverse anastomosis of this nulliparous uterus was quite free but comparatively less free than the recent puerperal uterus.

Experiment No. 3. An injection of red lead and starch in the right common iliac artery rapidly passed through a 22-year-old nulliparous uterus appearing in considerable quantities in the left common iliac artery within a minute. The transverse anastomosis of this uterus was more free than that of No. 2. The ligation of the left common iliac artery was required for complete distension of the bilateral uterine vessels.

Experiment No. 4. An injection of red lead and starch in the right common iliac artery of a puerperal uterus in situ six hours postpartum and five hours post-mortem, appeared in the left common iliac and abdominal aorta in large quantities within one minute. In fact, the bilateral arteries of the genitals in this case could not be completely distended without first clamping the common and external iliac of the opposite side. Practically we could almost completely inject the vessels of the uterus bilaterally from one of the internal iliac arteries if a ligature was placed on the opposite common and external iliac arteries. This experiment on a non-septic normally contracted puerperal uterus demonstrated beautifully the transverse anastomosis of the uterus in the pregnant state. The rami laterales genitales could be observed distending under the eye, especially in the mesosalpinx (oviducal segment).

Experiment No. 5. An injection of celloidin and vermilion in the right common iliac artery passed through a puerperal uterus in situ (pregnant three months), six days postpartum and three hours postmortem in abundant quantities, appearing in the opposite common iliac, ovarian segment and abdominal aorta within one minute. This subject showed that the transverse anastomosis in the uterus is extensive at three months' gestation. The ligation of the iliacs was requisite to completely distend the genital vessels bilaterally from one internal iliac. During the injections of the pregnant uterus (post partum) the transverse and longitudinal anastomoses could be observed developing under the eye. The red lead and starch or celloidin injection may be observed distending the superficial rami laterales uteri. The uterus becoming more erect as the vessels expand. The arteries of the nullipara presents some elasticity, the multipara presents more elasticity, but the arteries of the recent puerperal uterus presents wonderful elasticity. As one slowly but persistently injects the recent puerperal uterus the larger arteries especially may be observed not only gradually distending but passing through spiral movements. The moment the distending or injecting force crosses the lumen of the arteries rapidly elastically contract while the arterial coils attempt to reassume their original position.

Experiment No. 6. I experimented on animals, dog, cat, rabbit, cow, horse, sheep, demonstrating that the rami laterales genitales solidly and compactly anastomosed in the nulliparous, pregnant and puerperal uterus. The nulliparous anastomosis is much finer than that of the multiparous. The pregnant uterus presents free and extensive anastomoses.

Experiment No. 7. Uterus of multipara, 36 years old. I removed at autopsy

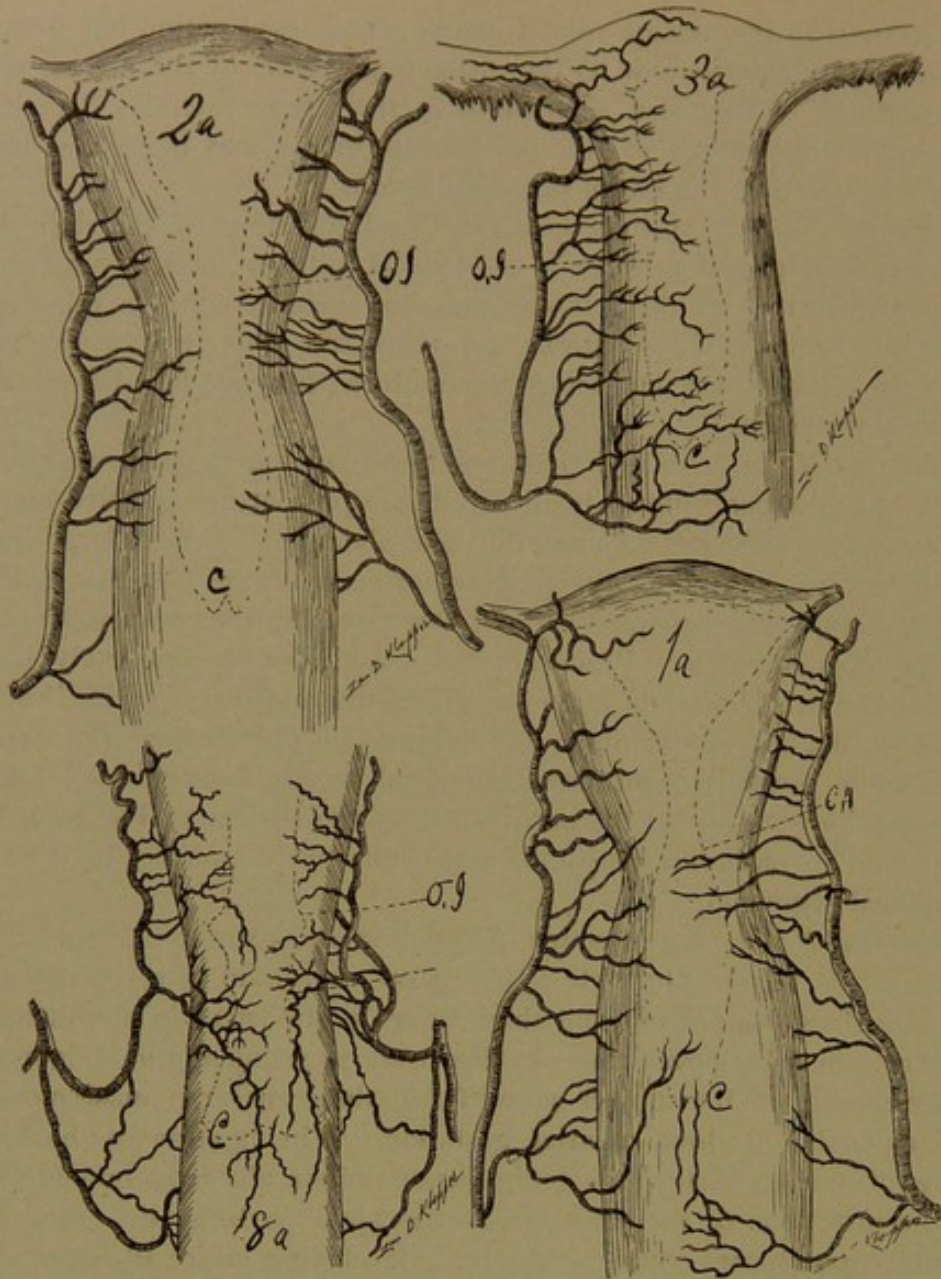

Fig. 61—(Semmy Davidsohn)—1a arteria uterina ventral surface, non-pregnant branches of right arteria uterina. A strong artery passes to the vagina, through ventral branch extending to the cervix, the dorsal branch passes to the dorsal vaginal wall close to the internal os; 4 arteries arise to supply the cervix. At the level of the internal os two more branches pass to the corpus uteri. Besides 7 more branches pass to the corpus and fundus. Branches of left arteria uterina. There are two vaginal arteries, both passing to the ventral vaginal surface the distal one multiple, branched sends a branch to the ventral wall of the cervix. 5 cervical arteries exist. 8 rami laterales are present. 2 a Dorsal view; reverse of 1 a. The comparison of 1 a ventral surface reversed presenting 2 a the dorsal surface shows that the dorsal surface is supplied with a greater amount of blood. 3, a ventral view non-pregnant. Right arteria uterina present strong branch passes to the distal cervix and proximal vagina. 4 cervical arteries exist. 8, branches pass to corpus and fundus. 8a, Puerperal uterus 25 years of age, death from tuberculosis 3 days post partum. Ventral view. Branches of right arteria uterina; a strong vaginal passes to the dorsal vaginal wall, anastomoses with the haemorrhoidalis media and extends on the cervix. Before this vessel reaches the vagina two smaller vaginal branches springs from a common trunk to supply the proximal vagina. The ramus cervicis is large, divides dichotomously supplying the dorsal and ventral cervical wall passing well ventrally and distally. Also 7 rami laterales uteri exist.

and all arteries ligated except the right and left internal iliacs. Injections of celloidin and mercuric sulphide in the left internal iliac artery appeared in two minutes in the opposite side, rapidly passing through rami laterales uteri of both sides, quickly appearing in the ramus oviductus and ramus ovarii, and the rami ligament segments as well as the ovarian segments presented distension by the red injection. With heavy pressure and relaxation on the syringe one could observe the extensive distension and contraction of the vast genital vascular net work. The elastic power of the arteria uterina ovarica was very apparent in this multipara of 36 years of age.

Experiment No. 8. Several uteri of different ages were injected with paraffin of celloidin and subsequently placed in 50 per cent HNO_3 for some two or three weeks, when the parenchymatous and connective tissue were corroded, leaving a most beautiful and accurate mold of the circulation of the internal genitals. After careful washing one can observe that the circulation of the internal genitals are solidly and compactly anastomosed transversely, longitudinally and perpendicularly. The celloidin with vermilion produces the best form of injection to distend the numerous finer genital vessels, and if the specimen be slowly corroded with HNO_3 , and carefully washed with very slight disturbance, one can observe with a free-hand lens the most perfect form of vascular anastomoses—transverse, longitudinal and perpendicular. Also the beautiful, fine tuft-like ending of the vessels in the endometrium. The corrosion anatomy is the most instructive and accurate of all forms of anatomy. It demonstrates what no other methods can effect. The corrosion anatomy is especially excellent in demonstrating accurately the circulation of infant uteri. It shows that the child's cervix uteri is large because the cervical vessels are large, and that the child's uterine fundus is small because the vessels are small. The corrosion anatomy demonstrates that the corpus and fundus of adults are large because the vessels supplying them are large.

Experiment No. 9. The common iliac and external iliac (right and left) of a woman 58 were ligated in situ. Celloidin mixed with vermilion was forced in the right common iliac and in one-half minute the red fluid passed through to left side, through both round ligaments, both deep epigastrics, both ovarian segments into abdominal aorta into the renals, some passing into intestinal. The X-ray of this specimen demonstrated excellently the anatomic fact that the rami laterales corporis are the first to disappear, atrophy in senescence. The skiagraph presented them as small, short lines only, while the rami fundi were quite well preserved, but the ramus cervicis showed advanced atrophy of senescence.

Experiment No. 10. Numerous human uteri of all ages; also numerous animal uteri of different ages, were injected with fluid suspending metal in fine division and X-rayed. The skiagraph demonstrated distinct, solid and compact anastomoses in the internal genitals. In other words, all rami laterales genitales communicate with each other like a wire net work. Irritation at any point of the genital vascular net work (as endometrium, endosalpinx) would entice the blood stream from all rami laterales genitales toward it. This makes oviducal gestation develop like uterine gestation. Injections of the internal genitals, X-rays and corrosion anatomy of man and animals, demonstrate that their vessels are solidly

and compactly anastomosed in all directions. Practically the genitals present no end arteries like the kidney, liver, spleen. The uterus presents transverse longitudinal and perpendicular anastomoses.

1. THE OLIGEMIC UTERINE ZONE (ZONA UTERINA OLIGEMICA).
2. ANASTOMOSIS OF RAMI LATERALES.
3. UTILITY OF THE OLIGEMIC (EXSANGUINATED) UTERINE ZONES.

1. An oligemic uterine zone is an area of few blood vessels and little blood. The oligemic uterine zones were studied through the aid of the X-ray, corrosion anatomy, colored injections and dissections. The accompanying cuts will demonstrate this better than a description in words. An oligemic or practically bloodless zone of the uterus is a territory which is supplied almost entirely by capillaries or arterioles. It is an area which incised in the resting uterus would not cause fatal hemorrhage. The line of coalescence on the bilateral territory of the rami laterales uteri, the divergence of the rami laterales uteri from the uterine trunk segment or the separation of the rami laterales uteri is what constitutes the oligemic zones.

The oligemic uterine zones are due to (a) defective or limited bilateral coalescence of the rami laterales uteri; (b) to dichotomous divisions of the rami laterales uteri; (c) to the separation of the rami laterales uteri.

Surgically, or practically, the resting uterus is oligemic, almost bloodless or exsanguinated in the center of its longitudinal axis, at the lateral cervical borders, at the central fundus, and in the ventral and dorsal territory between the ramus cervicis and distal ramus corporis.

A and B. The Bilateral Oligemic Zones. (ZONA BILATERALIS OLIGEMICA CERVICIS.)

The most important oligemic uterine zone is found on the lateral borders of the cervix, due to the dichotomous divisions of the ramus cervicis uteri. This zone is frequently lacerated in parturition or instrumentation, but if the ramus cervicis or one of the larger divisions is not ruptured the hemorrhage is limited.

As may be excellently observed in corrosion anatomy, the ramus lateralis cervicis or cervico-vaginal artery bifurcates, divides before it arrives at the border of the cervix into a dorsal branch and a ventral branch which supply the ventral and dorsal cervical wall. In the bilateral bootjack angles formed by the bifurcations of the cervical arteries the borders of the cervix projects and is supplied by a limited quantity of blood. In the usual lateral cervical laceration which occurs in one or both these vascular bootjack angles, the haemorrhage is practically nothing, unless the laceration is so extensive as to rupture one of the arterial cervical arms. If the laceration be dorso-ventral in the cervix the hemorrhage may be considerable.

C. THE CENTRAL LONGITUDINAL UTERINE ZONE. (ZONA UTERINA CENTRALIS LONGITUDINALIS OLIGEMICA.)

This oligemic zone lies in the central longitudinal axis of the uterus at the junction of the lateral anastomoses of the rami laterales uteri. In the resting uterus this zone can be dissected longitudinally with non-fatal hemorrhage. Uterine bisection would be dangerous in the menstruating uterus, and no doubt fatal

in the gestating or puerperal uterus. This is the most useful oligemic zone in surgical intervention on the uterus. The author's operation of endometrectomy and partial myometrectomy is founded on this zone. Myomata may be extirpated from this zone.

D. THE FUNDAL OLIGEMIC UTERINE ZONE. ZONA UTERINA OLIGEMICA FUDI.

This zone is an oval-shaped space situated on the proximal central fundus. It is due to the dorso-ventral deviation of the rami laterales fundi. It is especially useful in Cæsarean section and bisection, in myomectomy and in transverse or dorso-ventral bisection of the uterine fundus.

E. THE CERVICO-CORPORAL OLIGEMIC ZONE, ZONA OLIGEMICA CERVICI ET CORPORIS UTERI.

This oligemic or practically bloodless territory is located at the junction of cervix and corpus uteri. It lies between the ramus cervicis uteri and the distal corporis uteri. It is due to the separation of the ramus cervicis and distal ramus corporis uteri. It is most distinct during gestation. It is useful in longitudinal bisection of the uterus, in amputation of the uterus at the os uteri internum, per vaginam or per abdomen or in myomectomy.

2. ANASTOMOSIS OF THE RAMI LATERALES UTERI.

The uterine anastomosis is not only transverse and perpendicular, but longitudinally, especially of the uterine border. This is equally pronounced in the proximal lateral vaginal wall, as is excellently observed in my dried specimen of the dog. During pregnancy the arterial system of the internal genitals (especially that of the uterus) experiences an enormous development highly manifest in the rami laterales uteri.

If the anastomosis between the lateral halves of the uterus becomes gross, or large, as described by some authors, especially Luschka, it may be due to defective development. The analogy of the anastomosis in the right and left half of the thyroid gland as compared to the uterus is now untenable, as its anastomosis is less than in the uterus.

The arterial anastomosis of the lateral halves of the resting uterus in the middle line is very fine, resembling the capillary blood supply of other median coalescing e. g., abdominal wall and perineum. The lateral halves of the uterus coalesce from Miller's (pronephritic) ducts, and hence the anastomosis of the lateral uterine halves is a late acquisition. The uterus does not possess end arteries like the kidney. It is doubtful whether fatal hemorrhages would occur in a longitudinal bisected normal resting uterus. However, by injecting the uterus post partum six days, and pregnant about ten weeks, through the right common iliac abundant quantities of the injected fluid was found in the left common iliac a few minutes later. The longitudinal anastomosis, most marked at the lateral uterine borders, is practically only visible in pregnant uteri in the middle line. The most perfect forms of anastomosis, longitudinal, transverse and perpendicular, may be observed in a pregnant cow. The various arterial layers in the myometrial, endometrial and perimetrial strata are anastomosed by perpendicular connecting branches. The two lateral uterine halves anastomose by transverse branches. The superimposed muscular layers of the uterus are united

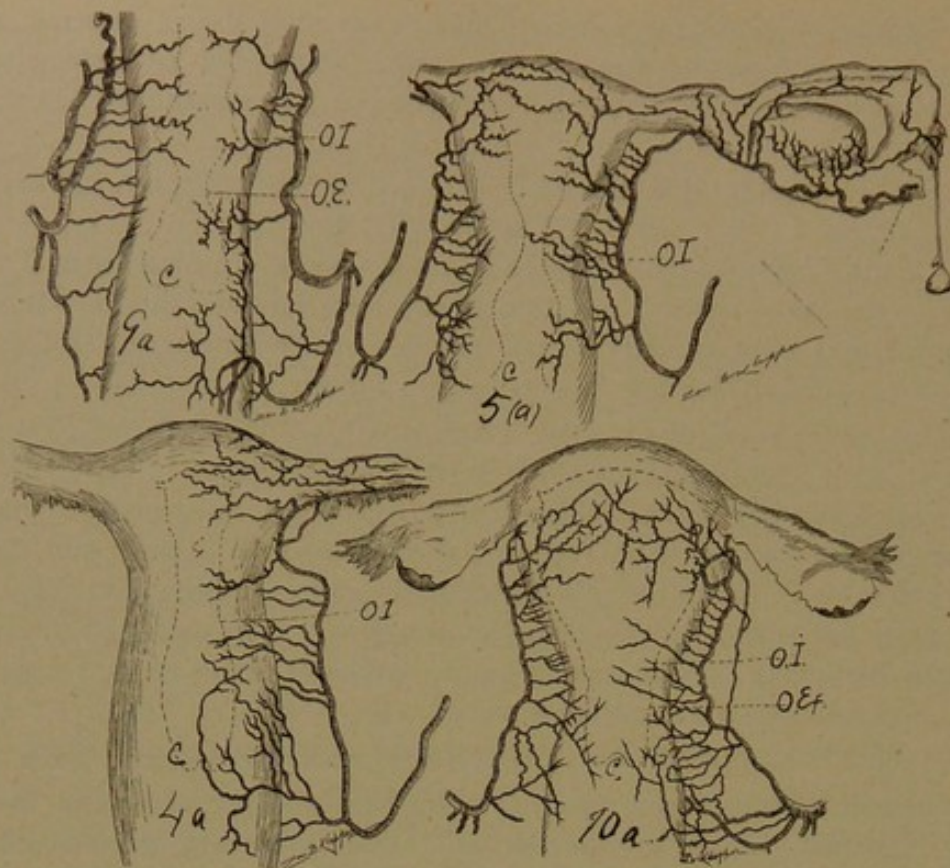


Fig. 62—9a, dorsal view, the reverse of 8a, in figure 61. Branches of left arteria uterina, one branch courses to vagina after it has given a small one to the cervix. The uterine segment divides itself in two branches of equal caliber. It sends two arteries to the cervix and 8 branches to corpus and fundus. 4 a, Dorsal view, the reverse of 3 a, in figure 61 non-pregnant. Right arteria uterina present only. Large cervical, dividing dichotomously. 5, cervical arteries exist, 7 branches pass to corpus and fundus. In this cut the connection of the uterine segment with the oviducal segment is shown. 5 a, uterus with the left oviduct and ovary and styled hydatid, ventral view non-pregnant. Right arteria uterina. There is one large cervical multiple divided and two smaller ones. At the level of the internal os the uterine segment divides into two equal branches, the dorsal branch, passing to anastomose with the oviducal while the ventral branch passes to supply the uterus. 6 rami laterales supply corpus and fundus. Left arteria uterina One large distal cervical divides into 3 end branches supplying the distal cervix. Two small proximal cervical arteries exist. The uterine segment then divides into two equal branches the ventral branch supplies the ventral wall of the uterus with 10 rami uteri. The dorsal branch supplies the dorsal uterine with 6 rami uteri and then passes lateralward to become the oviducal segment. An ovarian vascular circle exists. 10 a Puerperal uterus, 31 years old. IV-Para. Death 24 hours post partum due to peritonitis from gall bladder perforation. 7th month of gestation. Ventral view. Left arteria uterina; 3 large vaginals, supplying the vagina and anastomosing with the cervical. There are 3 cervical vessels, about a dozen rami uteri also exist. The right as shown in the cut; conditions are about the same Lateral view of arterio-ureteral loop.

by perpendicular branches, while longitudinal connecting branches unite the rami laterales uteri. The arteries of the cervix at the lateral uterine border anastomose freely with those of the corpus. The circulation of the uterus is solidly and compactly anastomosed in all directions and hence an ovum may be implanted at any point of the endometrium whence it can call or induce blood currents from all points to the uterus. Since all rami laterales uteri or oviductus are similarly anastomosed, an ovum implanted on the endosalpinx may call blood from all points supplied by rami laterales genitales.

3. THE UTILITY OF THE OLIGEMIC (EXSANGUINATED) UTERINE ZONES.

A knowledge of oligemic or practically exsanguinated uterine zones is useful in indicating localities of appropriate surgical intervention. A knowledge of the various bloodless or practically exsanguinated zones of the uterus is of vast surgical interest. Its value is observed in longitudinal median division of the uterus and in myomectomy. It gives choice of surgical attack on the uterus. Bloodless surgical incising on the uterus should be directed: a, in the center of the longitudinal axis; b, transversely on the fundus as the long axis, with dorso-ventral, as the short axis; c, transversely on the corpus, fundus and cervix between and parallel to the rami laterales uteri; d, the lateral borders of the cervix are practically bloodless zones, as is observed in the numerous bilateral cervical lacerations during parturition and instrumentation with slight hemorrhage.

The author's operation of endometrectomy, with partial removal of the central myometrium, is based on the anatomic fact that the central longitudinal axis of the uterus is oligemic, or practically a bloodless or exsanguinated zone, only bilateral capillary anastomosis existing in the resting uterus. Hence the resting uterus may be boldly bisected longitudinally, the endometrium removed, and as much myometrium removed as considered desirable, after which the bilateral uterine segments may be sutured separately, suture dorso-ventrally for the control of capillary oozing hemorrhage.

The rami laterales uteri are practically arranged in transverse planes, hence to enucleate a myoma it is necessary only to incise the corpus, fundus and cervix transversely.

CHAPTER III. THE UTERINE SEGMENT.

I shall divide the utero-ovarian artery into five segments, viz.: (a) Pelvic floor (1, 2, 3, 4); (b) uterine (4, 5, 6); (c) oviducal (6, 7-7, 9); (6, 8-8, 9) (d) ovarian (9, 10, 11, 12), and (e) that of the round ligament (13, 14, 15). (See cuts.)

The uterine segment of the utero-ovarian artery extends in a tortuous spiral course from the internal os uteri along the lateral uterine border to the utero-oviducal angle. Its chief characteristics are: (a) spiral form; (b) it lies in a bed of limited areolar tissue; (c) it originates a number of lateral arteries which supplies the different segments of the uterus and anastomoses with their opposite fellows as well as supplying the ligamentum latum; (d) it is not imbedded in the myometrium; (e) it is extremely spiral, especially during pregnancy and in multipara; (f) it is surrounded and interwoven by a rich network of veins. The artery lies in an areolar bed, amply sufficient for all necessary movements. The uterine segment is about $1\frac{1}{2}$ to 2 inches in length. It courses proximal toward the fundus between the blades of the ligament. The uterine artery on the lateral border of the uterus is more intimately connective with the myometrium after gestation on account of the more complete development and lateral expansion of the myometrium and looped condition of the artery. It is thick walled and second to the ramus ovarii only in its spirality.

The uterine segment of the utero-ovarian artery lies the closest to the genital tract—in fact its loops may be in actual contact with the myometrium. Approximately at the junction of the proximal and middle thirds of the uterus or at the origin of the ligamentum ovarii a division of the uterine segment occurs, making: (a) a ramus fundus; (b) a ramus oviductus, and (c) a ramus ovarii. This is what I shall term its bifurcatio uterinae media, or middle bifurcation of the utero-ovarian artery. The artery from its cervico-vaginal branch maintains almost a uniform caliber to this point where its 3 divisions lessen its lumen. The same phenomenal division arises in the dog and cat. The uterine segment lies practically in the cellular tissue (parametrium) of the ligamentum latum, hence the great mobility of the artery without loss of its anatomic bed or its integrity. This explains why there is so little bleeding in hysterectomy by holding the scissors close to the body of the uterus when cutting, as only the small lateral branches are severed. The artery lies in an areolar bed, and does not penetrate the myometrium. In nullipara and especially in multipara, where the uterine loops are increased, sometimes certain spirals of the uterine artery lie close to the ventral or dorsal surface of the uterus and such loops are liable to become severed if the uterus and uterine artery are not well drawn apart. Perhaps Sautier of Constance (1822) performed his vaginal hysterectomy without considerable hemorrhage by simply keeping the scissors or scalpel close to the uterus and severing the small lateral arteries only. The author's operation of endometrectomy and partial myomectomy avoids all chances of severing the uterine segment by keeping the scissors in the center or entirely within the myometrium in hysterectomy. As the uterine arterial segment lies closer to the myometrium in multipara the scissors in the author's operation should pass through the myometrium to the median line or center of uterus. The typical uterus has an especially vascular supply (rami laterales uteri) at the cervix, corpus and fundus. The large fundal and cervical arteries resemble each other in size, length and angle of departure from the uterine segment. From the os uteri internum the artery passes between the blades of the ligamentum latum toward the fundus uteri along the lateral border of the uterus to the utero-oviducal angle. It courses spirally through the perimetrium in contact with the myometrium but does not penetrate it. It sends 8 to 22 lateral branches to the ventral and dorsal surfaces of the uterus and ligamentum latum.

In dissection a great contrast exists between the uterine artery imbedded in the abundant connective tissue between the blades of the ligamentum latum, where it is difficult to expose by dissection, and its branches in the myometrium, where only muscles surrounds them where it is easy to expose them by dissection.

Just previous to the division of the uterine segment into oviducal and ovarian branches the trunk partially ceases the spiral state and at once assumes a liberal looped condition, after which it divides into ovarian, oviducal, fundal and that of the round ligament. The fundal or proximal rami laterales uteri are longer and more spiral than those of the distal cervix uteri. Approximately each ramus lateralis cervicis branches dichotomously to supply the ventral and dorsal surfaces of the cervix. In general each ramus lateralis uteri arises independently from the uterine segment and is destined either for the ventral or dorsal uterine wall.

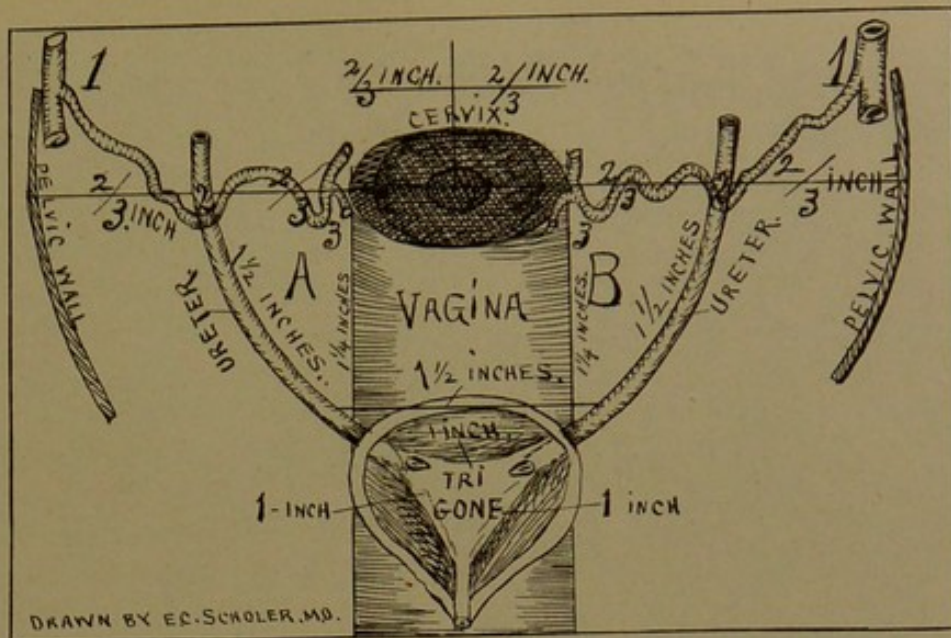


Fig. 63—A cut to illustrate the topographical proportions of the pelvic floor segment of the utero-ovarian artery to the ureter cervix, vagina and bladder. We have represented for convenience the pelvis as 4 inches transversely and divided it into 6 segmental spaces of two-thirds of an inch each. For example it is two-thirds of an inch from the lateral pelvic wall to the distal arterio-ureteral crossing (2) and from the distal arterio-ureteral crossing to the lateral border of the cervix it is two-thirds of an inch. Besides from the point of arrival of the uterine artery near the lateral cervical border to the median line of the uterus it is another two-thirds of an inch. Hence there are three segments of two-thirds of an inch from the center of the uterus to the lateral pelvic wall. The most important point of division being the distal arterio-ureteral crossing. A and B are placed within the lateral cervical triangle or the uretero-arterio-cervical triangle. Otherwise the cut explains itself.

The rami laterales uteri are in general distributed in 3 beds, viz.: 1, subperitonæal; 2, submucous; 3, myometrial. Rich anastomosis exists among the arterial layers.

The proximal end of the uterine segment divides so uncertain as to size, number and location that the ligamentum teretis uteri cannot be used as a standard of reference; however, the uterine segment generally passes dorsal and lateral to the ligamentum rotundum uteri before it divides in the ramus oviductus and ramus ovarii.

The course of the uterine segment is never straight, always more or less winding from pueritas to senescence. The winding course is the most pronounced in functioning sexual life, especially at full development after gestation. The uterine segment varies considerably as to the location of its bifurcations (bifurcatio arteriæ uterinæ distal, proximal or medial), and also the proximal fundal arteries vary with the bifurcatio arteriæ uterinæ medial. The arteries at the fundus and cervix (sphincters) expand similarly, like a fan. A knowledge of the distribution of the cervical, corporal and fundal arteries is requisite for successful surgery on the uterus.

THE BRANCHES OF THE UTERINE SEGMENT.

For convenience of description in practical and surgical gynæcology I shall divide the rami laterales uteri into 3 divisions, viz.: Those of the cervix, which are large, straight, non-parallel and long; those of the corpus, which are small,

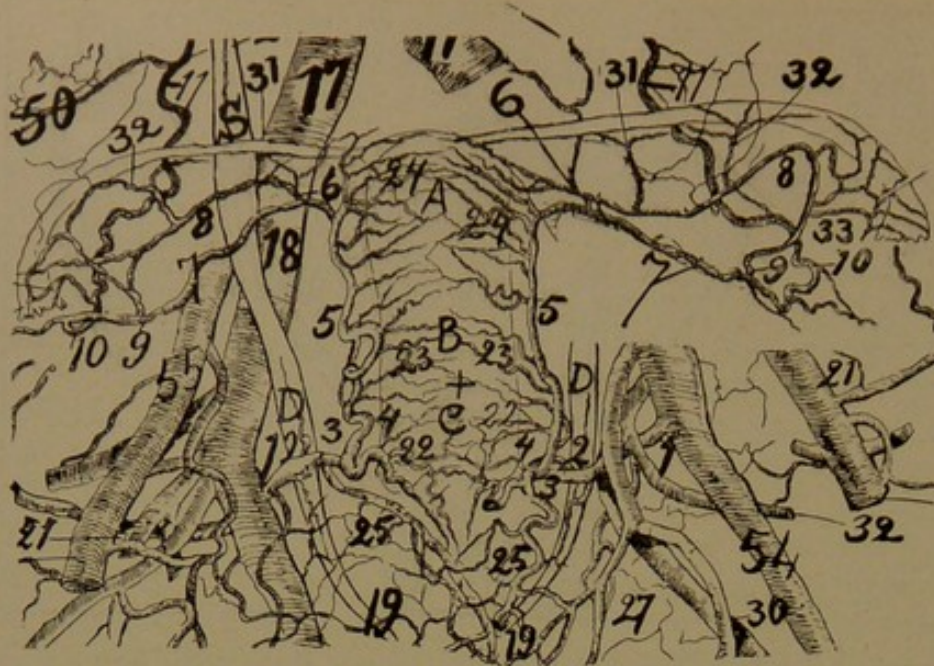

Fig. 64—Ovarian vascular circle of an infant one day old (6, 7, 9.—6, 8, 9) (6, 8, 9) ramus oviductus, (6, 7, 9,) ramus ovarii. Oviducal Segment (6, 8, 9—6, 7, 9.), drawn from an X-ray of an infant one day old. The subject was injected with starch and red lead and an X-ray taken in Dr. Pratt's X-ray laboratory. The bilateral ovarian vascular circle—6, 8, 9; 6, 7, 9, 9, 10, 11 the ovarian segment of the utero-ovarian artery; 1, 2, 3, 4 pelvic floor segment; 4 5 6 uterine segment.

spiral, parallel and short, and those of the fundus, which are large, spiral, parallel and long. The lateral uterine arteries are 1, branches of the uterine segment, which pass horizontally and uniformly to the different segments of the uterus, both on the ventral and dorsal surfaces.

Practically there are three distinct peripheral territories of the uterine segment, viz.: ramus fundis, ramus oviductus, and ramus ovarii. Accidental distribution by defective development may arise.

The spiral lateral branches which pass to the myometrium should be divided into two sets, viz.: (a) the superficial, and (b) the deep set. The superficial set of arteries send branches to nourish the longitudinal subserous muscular layer as well as the perimetrium. The superficial arteries become particularly large and tortuous during gestation and present, macroscopically, anastomoses between the lateral halves of the uterus. The macroscopic anastomoses between the lateral halves of the uterus is beautifully seen in a dog immediately and for 4 weeks post partum. The deep set of lateral arteries supply the myometrium and also form a rich plexus in the endometrium.

The superficial rami laterales are more tortuous than those of the deeper set. The strongest ramus lateralis is located at the utero-oviducal angle in the dorsal myometrium. It penetrates the dorsal uterine wall to the median line with slight diminution of its size to anastomose with its opposite fellow. This large vigorously spouting artery is easily observed in the author's operation of central hysterectomy (endometrectomy).

The lateral arteries of the uterus are eight to twenty-two in number, supplying the segments of the uterus almost equidistant according to size and function. The lateral arteries form a rich plexus near the myometrial surface which, during

gestation (see cuts), becomes enormously enlarged, resembling a cirroid aneurism. The spiral lateral uterine arteries traverse the myometrium transversely and chiefly perpendicular to its surface, hence the blood current in the uterus runs transversely to the long axis. This anatomic data indicate that each uterine segment is independently supplied with blood, so that a ligature could be placed completely around the uterus without destroying the circulation of the segments proximally or distally. This independent blood supply to each segment prevents atrophy of the uterus at points of flexion. The rami laterales uteri are more spiral, looped and larger in the proximal than the distal end of the uterus. The lateral branches with the most loops and spirals are located at the utero-oviducal angle and in general belong to the rami fundi. The uterus receives blood from the uterine artery only, *i. e.*, from the arteria uterina ovarica. The less spiral branches of the cervix are located deeply in the muscle or the cervical myometrium, and when torn in parturition the muscular bundles act as living ligatures to check the hemorrhage.

The uterus is the most vascular portion of the genitals, except the ovary, having the longest, largest and most numerous rami laterales. The uterus is nourished by vessels similarly arranged to those for the tractus intestinalis. The blood current in the oviduct, uterus and ovary is not always definite or constant in its direction, as they are supplied by lateral branches from an arterial arc unit., the blood globules now coursing in one direction, now in another. The plan of the rami laterales uteri is in general similar to the typical arrangement found in the cow, *viz.*: that separate branches arising from the trunk are destined from the ventral dorsal surface of the uterus. Exceptions to this rule arise, especially at the cervix, which I observed in corrosion anatomy. The rami laterales at the proximal and distal ends of the uterus are long, while at the middle they are short. The uterine segment is entirely intraligamentary, lying about one-quarter to one-half inch from the myometrial border.

The principal lateral branches of the uterine segment lie immediately under the external longitudinal muscular layer, the muscularis subserosum. The rami laterales spring from the uterine segment in two methods, *viz.*: 1, the branch which supplies the ventral and dorsal uterine surface arises generally independently from the uterine segment; 2, the branches may arise as a common trunk dividing dichotomously to the ventral and dorsal internal surface. The dorsal uterine surface contains more numerous and larger rami laterales than the ventral surfaces, as is especially noted in the infant and pregnant uterus. The rami laterales uteri pass especially voluminous to the cervix and fundus, leaving a limited blood zone for the corpus. The cervix and fundus are nourished by larger and longer branches from a wider distance, while the corpus is supplied by smaller branches from a shorter distance.

The increase of the caliber in the lateral uterine arteries during gestation is more apparent than real. It is the thickening and whitening of the wall, the lengthening and the consequent spiral or looped winding of the artery, which makes it appear so large. While performing the author's operation it is plain that there are three especially large lateral uterine arteries, *viz.*: 1, one in the utero-oviducal angle; 2, one about the level of the ligamentum ovarii, and, 3, one

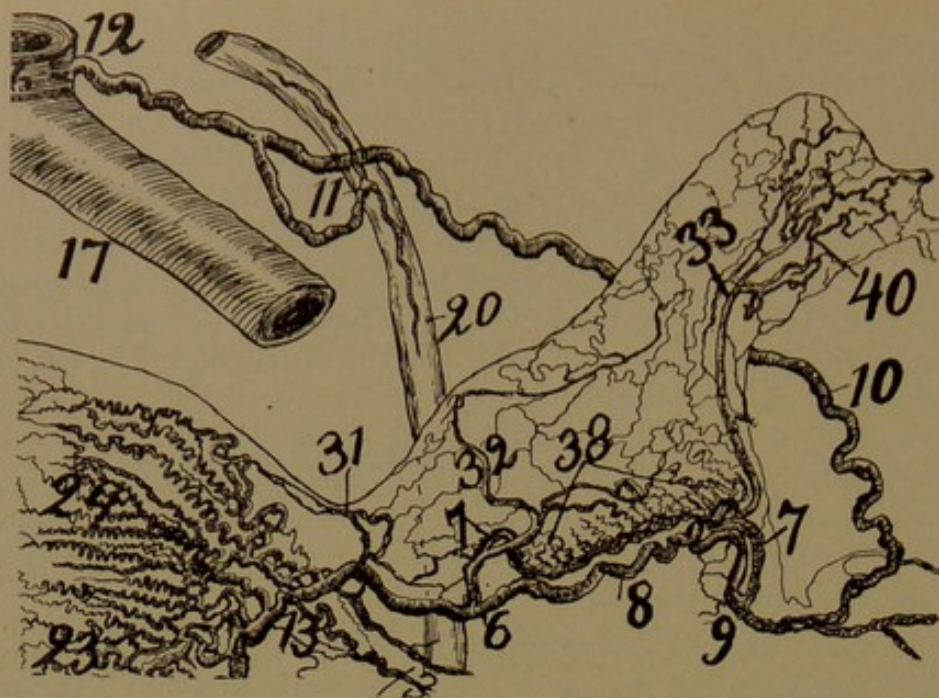


Fig. 65—Ovarian vascular circle of multipara 22 years old (6, 8, 9,—6, 7, 9)—Oviducal Segment 6, 7; 7, 9; 6, 8, 9 and 13. Drawn from an X-ray taken in Dr. Pratt's X-ray laboratory. 9, 10, 11 ovarian segment; 6, 7—7, 8 ramus ovarii (with some eight rami laterales ovarii); 6, 8, 9 ramus oviductus (with three rami laterales oviductus); 20 ureter; 13 is the round ligament segment severed. Note the wealth of blood supply to the proximal extremity of its oviduct, (40).

to the os uteri internum. The lateral uterine arteries are larger on the dorsal than on the ventral uterine surface, as is noted in corrosion anatomy. This anatomic fact is macroscopically demonstrated while removing the center of the corpus uteri by observing the volume of the blood jets from the vessels.

Finally this segment passes in a sinuous winding course between the blades on the ligamentum latum from the os uteri internum to the utero-oviducal angle. It is about one-third of an inch from the myometrium lying in a rich bed of connective tissue. Occasionally a loop of the uterine segment may lie in contact with the ventral uterine surface (see cuts Nos. 22 and 99), or extend widely lateral in the ligamentum latum. It sends off the rami laterales uteri to the cervix, corpus and fundus, each of which differ in characteristics.

The rami laterales to the cervix divide dichotomously, supplying the ventral and dorsal cervical wall, making a lateral oligemic (exsanguinated) cervical zone. Those to the corpus and fundus are destined either for the dorsal or ventral corporeal or fundal wall, producing a longitudinal and fundal oligemic (exsanguinated) zone.

Cut No. 19 has (twenty-two) rami laterales uteri. The uterine segment practically begins at the bifurcatio arteria uterinæ distal and ends at the bifurcatio arteria uterinæ medial.

The rami ligamenti lati are small branches except the constant large artery of the ligamentum latum, supplying that part of the broad ligament adjacent to the lateral border of the uterus. They are fine and numerous, as shown in my dried specimens, corrosion anatomy and the X-ray.

THE DISTANCE OF THE UTERINE SEGMENT FROM THE UTERUS.

In multipara the uterine artery, after being dissected free, will be found about one-half inch from the uterine border. In childhood and senility this distance is increased. Toward the end of gestation the uterine segment is stretched to almost a straight line. In ten weeks' gestation the cervical loop alone is two inches long. The spirality of the uterine segment is slight in childhood life, increased rapidly at puberty, completely developed by gestation, finally straightened out and atrophied in senility.

The distance of the uterine segment from the uterine border is long in childhood life, the shortest during and subsequent to gestation and again the distance of childhood life is exceeded in senility. The uterine segment is closer to the corpus than to the cervix or fundus.

The fact that pan-hysterectomy can be performed with non-fatal hemorrhages without clamp or ligature (Pratt operation) is due to the fact that the uterine artery may remain a fraction of an inch from the uterine lateral border, and the operator need sever the rami laterales uteri only. However, one must be on guard to avoid severing the occasional long loops of the uterine artery which may lie in contact with the dorsal, but especially the ventral, uterine surface.

The uterine segment gradually approaches the myometrium from childhood until the menopause, after which from myometrial and arterial atrophy it again recedes in the ligamentum latum as in childhood.

The uterine segment remains about one-third of an inch from the border of the uterus in nullipara, less in multipara, but is more distant before puberty and in senility. However, one must not only be on guard for arterial loops lying against the ventral or dorsal uterine surface, but occasionally the artery is held against the uterus by muscular bundles of the myometrium; *i. e.*, it may lie practically within the myometrium. The uterine segment lies the most distant from the lateral border of the uterus during senility. The important anatomic fact that the arteria uterine lies at a distinct distance from the uterine border explains why the uterus may be extirpated without severing the main artery or genital vascular circle. The rami laterales uteri alone need severing, which can be done without clamp or ligature. The scalpal or scissors must incise the rami laterales uteri close to the myometrium, and by traction forceps the rami laterales are put on the stretch presenting the opportunity.

The uterine segment courses along the lateral border of the uterus in a winding course at variable distance, according to age and functional relations.

* RAMUS LATERALIS CERVICIS.

(The Cervico-Vaginal Artery.)

The cervico-vaginal artery arises from the arterio-ureteral loop at the distal arterio-ureteral crossing (it may be to the right or left of this point, or more frequently from the cervical loop). The cervico-vaginal artery varies in size and sometimes it is so large that Waldeyer termed it the *bifurcatio arteria uterinæ*. It may arise by two trunks instead of one. The cervico-vaginal artery is the principal or largest branch of the pelvic floor segment. It courses distally on the lateral cervical border, dividing into several branches from which some pass to the ventral and dorsal cervical wall and either there to end or to pass more distalward

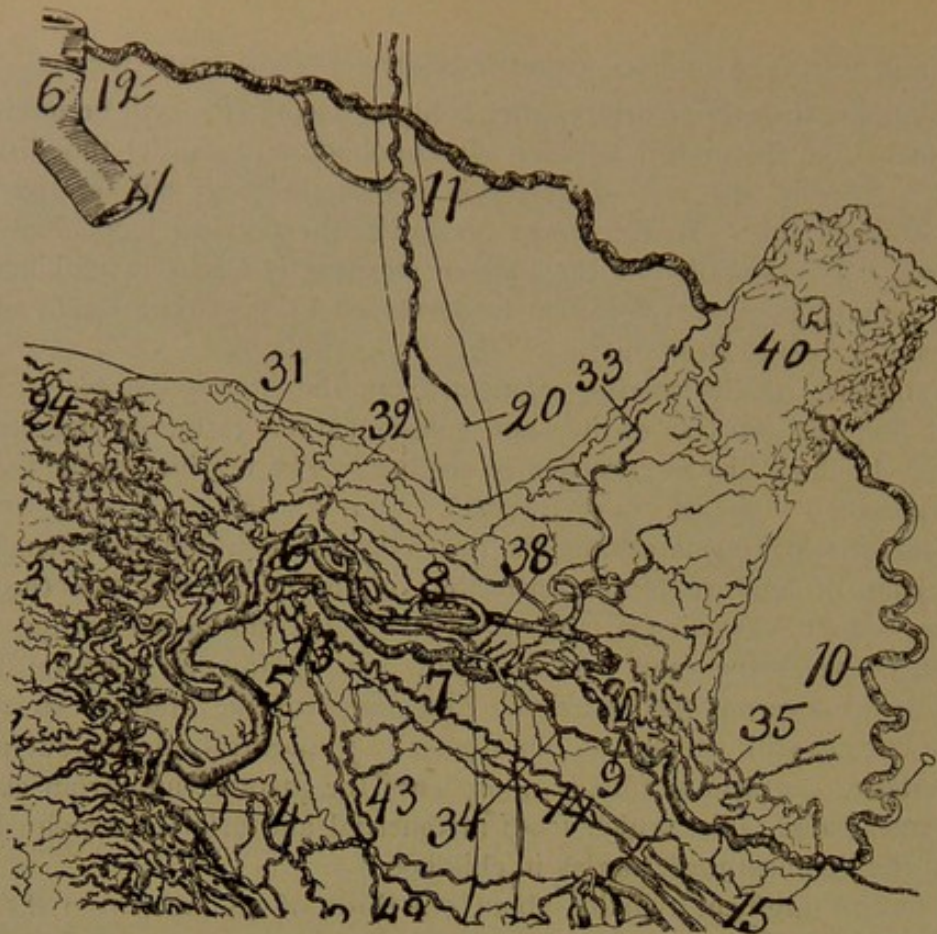


Fig. 66—Ovarian vascular circle of a multipara, 32 years old (6, 7, 9—6, 7, 9.). (6, 8, 9) ramus oviductus (6, 7, 9.) ramus ovarii. The oviducal segment 6, 8; 8, 9; 6, 7, 9. Drawn from an X-ray taken in Dr. Pratt's X-ray and therapeutic laboratory. 6, 7, 7 ramus ovarii (presenting four rami laterales ovarii); 6, 8, 8, 9 ramus oviductus (with three rami laterales oviductus); 9, 10, 11 ovarian segment; 4, 5, 6 uterine segment; 13, 14, 15 round ligament segment; 20 ureter; 43 and 34 extravascular arcades.

to supply the ventral dorsal and lateral vaginal walls while other branches pass directly to the vaginal wall. The X-ray and corrosion anatomy of the pregnant uterus shows that the cervico-vaginal artery also supplies the distal end of the ureter. It divides rapidly into branches which supply the cervix, vagina and base of the bladder. The cervico-vaginal branches three or four in number join the cervix and lateral vaginal fornix at quite uniform distances from each other. In performing vaginal hysterectomy the hemorrhage from the dorsal vaginal fornix is greater than that from the ventral, hence, the cervico-vaginal artery sends larger branches to the dorsal surface of the cervix and vaginal fornix. In the median line of the cervix in vaginal hysterectomy, the hemorrhage is practically nothing (hence capillary) but it is free if severed at the lateral cervical borders, and the cervical branches not being included in the ligatures may produce dangerous and even fatal hemorrhage. The cervical lateral branches lie **closer together than those of the body**. In dogs, my dried specimens show half a dozen cervical branches corresponding to that of the human quite equal in size and at uniform distances from each other. The important distal arterio-ureteral crossing, the cervical loop and the significant cervico-vaginal branch **divide the pelvic segment into three practical topographical landmarks for surgical intervention.**

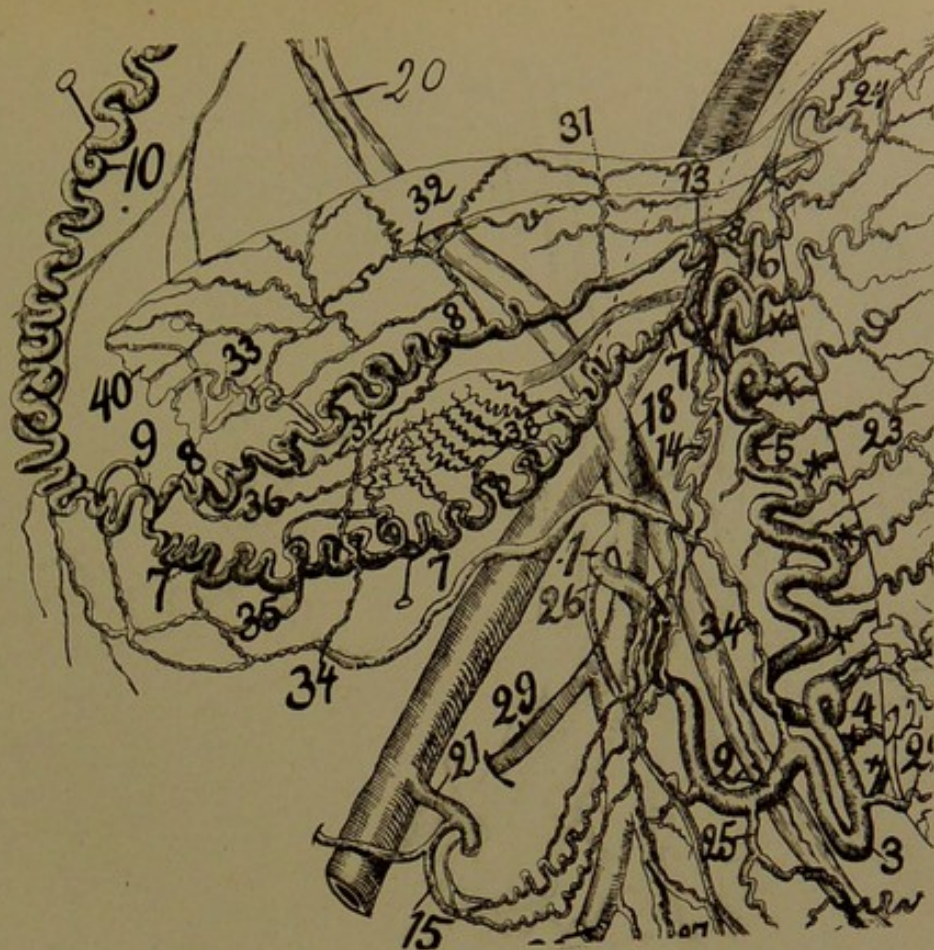


Fig. 67—Oviducal Segment 6, 8-8, 9; 6, 7-7, 9+13, 14, 15. A dissection of the right side (oviducal segment) of the utero-ovarian artery from a subject pregnant three months. It was injected from the right common iliac and dissected under alcohol. Spiral segment (utero ovarian artery) 1, 2, 3, 4, 5, 6, 7-7, 8-8, 9, 10, 11, 12-13, 14, 15; straight segment; abdominal aorta; common and internal iliac. Divisions of the spiral segment: (1) Pelvic floor segment 1, 2, 3, 4; (2) uterine segment 4, 5, 6; (3) oviducal segment 6, 7-7, 9-6, 8-8, 9; (4) ovarian segment 9, 10 to abdominal aorta; (5) round ligament 15, 14, 15; rami laterales uteri 22, 23, 24; rami laterales oviductus 31, 32, 33; rami laterales ovarii, 38; extraovarian arcades 34, 35, 36; cervico-vaginal artery, 2; ureter 20, 18, 2; vaginal arteries 25, 26. Important locations of the spiral segment: Arterio-ureteral loop 2; cervical loop 3; arterio-ureteral crossing 2, 18; cervico-vaginal artery 22; exsanguinated zones (a) central longitudinal axis, (b) lateral cervical border, and (c) fundus. Rami laterals oviductus longi (long helicines) 34, 36; rami laterales ovarii (short helicines) 38. The oviducal segment practically forms what I term the "ovarian vascular circle") 6, 8-8, 9; 6, 7-7, 9.

The accident which arises to the cervical branch, is laceration in parturition or during operations. In any case of laceration of the cervical branch, its thick walls rapidly control and check the hemorrhage, thus saving many lives. Besides, the cervical branches course among strong muscular bundles which, like living **elastic ligatures**, control the lumen of the vessels. The accidents which occur at the distal arterio-ureteral crossing are penetrating wounds of the ureter or obstructions (especially by clamps or ligatures). As regards the distal arterio-ureteral crossing, it lies in a vast bed of areolar tissue and therefore is very mobile, hence the location of this gynecological landmark can be changed by force and controlled by inspection and ligature applied at any point of the pelvic floor segment. The pelvic floor segment occasionally presents at the distal arterio-ureteral crossing an arterio-ureteral loop which may be sufficiently long to pass dorsal to the

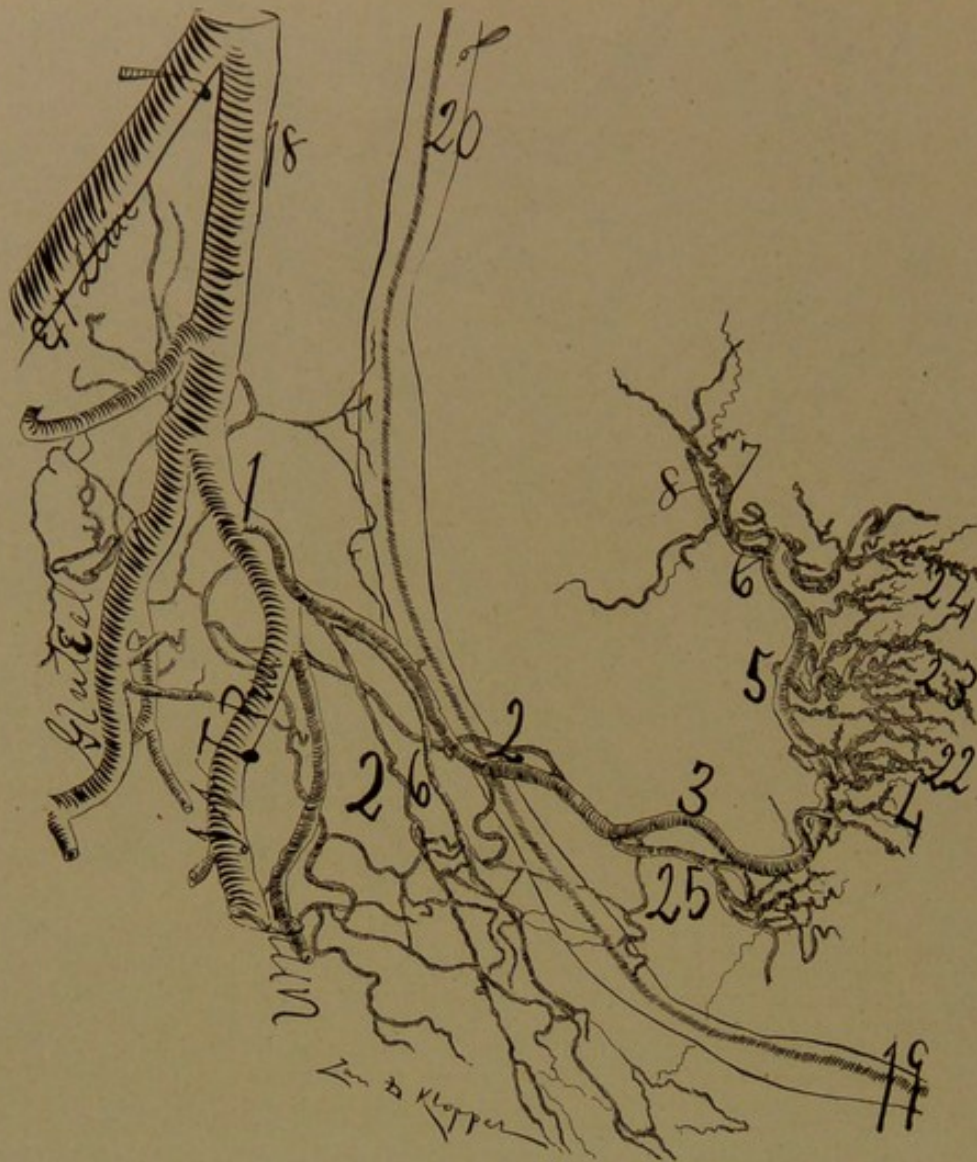

Fig. 68—Subject 23 years old. The uterus was injected in situ. The right side failed in filling. It was injected with celloidin and vermilion and later red lead and starch. It represents excellently the cluster of arteries supplying the uterine fundus. The subject being a nullipara, the utero-ovarian artery is incompletely developed, as may be observed in the small ramus cervicis (22) and small ramu corporis (23). The fundal arteries (24) are incompletely developed. For numbers see general description page 32.

ureter, thus complicating and endangering ureteral ligation unless the loop be unfolded. It might appear to some that the pelvic segment of the utero-ovarian artery makes practically two divisions when an especially large cervico-vaginal branch arises. This view should not be entertained as the cervico-vaginal artery is only a branch, not a division, of the pelvic floor segment. Besides, branches which supply the vagina, as the cervico-vaginal practically does, are characterized by surprising volume. They also join to form the ventral and dorsal azygos artery of the vagina. The medial anastomosis of the opposite cervico-vaginal arteries to form the arteria azygos vaginæ is the most beautifully shown in the injected uterus of a pregnant cow.

As to a single arterial circle (circulus arteriosus Huguieri) at the internal

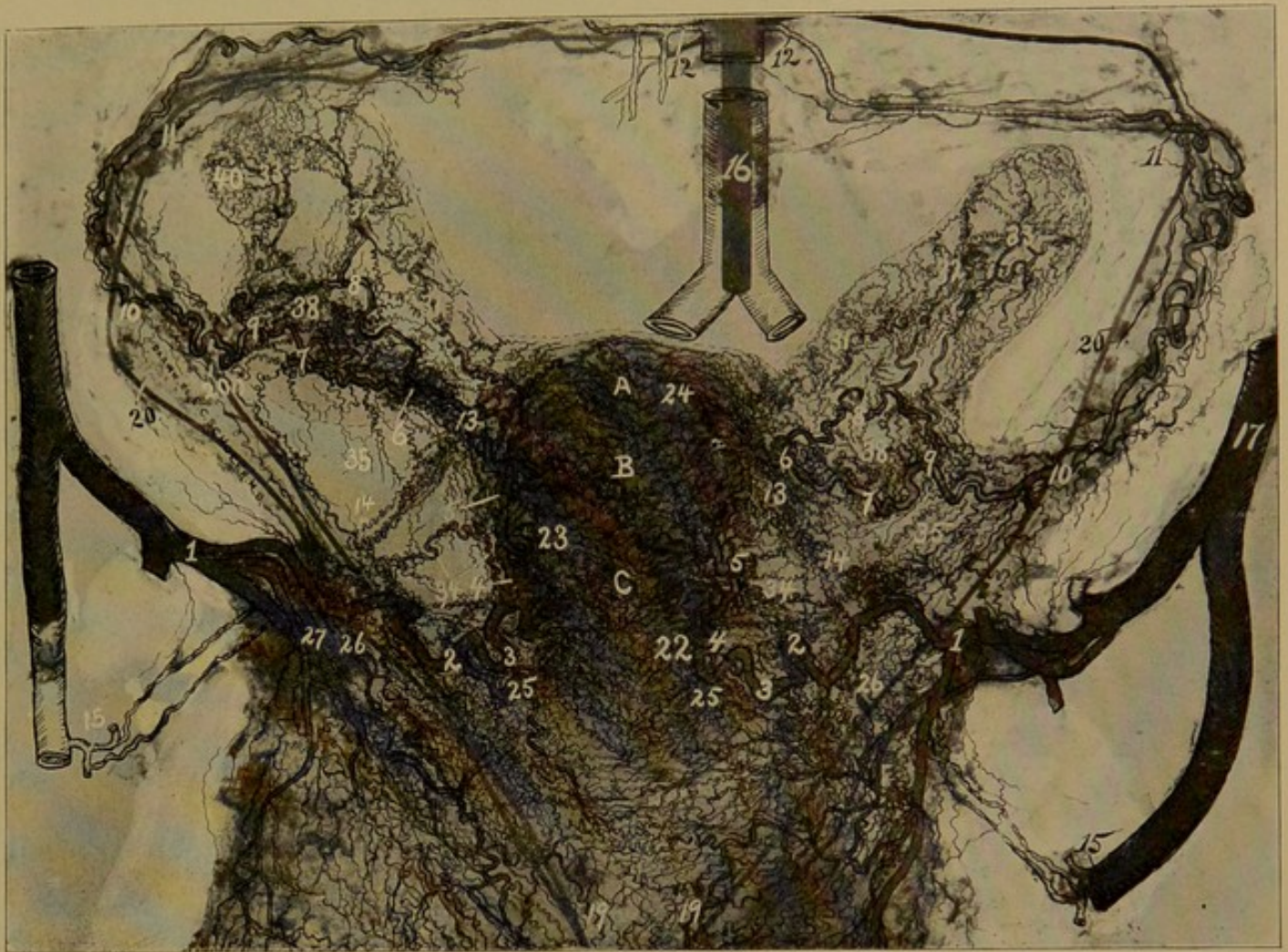


Fig. 69—Half-tone illustrations of a multipara (?) 31 years old. About half life size. This uterus was removed from the body, injected first with celloidin, some days later with red lead and starch, after which it was X-rayed and the arterial lines fixed by a bromide plate. 1, 12 and 15 represents the feet of the tripodal genital arch. The oviducal (6, to 9) supply is clearly brought out, as well as the ovarian vascular circle (6, 8, 9,—6, 7, 9) on each side. Observe at the cervix (4) that the arterial vessels assume different directions, viz: one set passes distalward on the cervix and vagina and the other set passes proximalward on the corpus. A wire was introduced into each ureter as noted in cut and the ureter outlined, showing its pelvis and calices. On the right side there is a double ureter noted by the two wires in the cut. The pelvic floor segment (1, 2, 3, 4) of the utero-ovarian artery shows its loops, especially the cervical loop (3, 3,) and on each side is the arterio-ureteral loop (2, 2,). The vessels which I have termed the artery of the ligamentum latum (34) is here marked, but more distinct in the specimen than the cut. The excised segment of the abdominal aorta with a metal rod in its lumen is marked in the cut and shows that while the specimen was X-rayed the origin of the ovarian artery was forced toward the uterus. The vaginal arteries (25, 25,) are very large and long. The central longitudinal oligemic uterine zone (A, B, C,) is not very evident from the complete injection of all uterine vessels. This specimen, though a reported nullipara and hence with incompletely developed genital arteries, presents a splendid injection with such an abundant vascular supply that I think that it is a multipara. For numbers see general description page 32. I am indebted to Dr. Fred Harris for this specimen.



os uteri, I cannot confirm in my dissections of well injected subjects, neither did Huguier claim it. This view was forced into Huguier's writing by other authors. It is true a fine visible anastomotic network of arteries covers the ventral and dorsal surface of the os uteri, but I can find no single, definite arterial circle. It might be claimed that this so-called *coronary artery of the cervix* consisted simply in the anastomotic macroscopic or stove-pipe union of one or two of the largest cervico-vaginal arteries with their opposite fellows. However, it is so indefinite as to be of little importance in the practice of gynecology. It may better be said that the cervix is surrounded by an oval, vascular zone of finely anastomotized arteries, but a single circular artery of the cervix is doubtful. The cervico-vaginal artery, a branch of the uterine from the cervical loop at the distal arterio-ureteral crossing, passes horizontally medianward to meet the uterus at a right angle.

At some distance from the cervix the cervico-vaginal artery divides into a ventral and dorsal branch which supply the ventral and dorsal surfaces of the cervix and vagina. This leaves an oligemic (exsanguinated) zone on the lateral cervical border, which anatomic fact explains why woman in labor with the ordinary bilateral cervical laceration is afflicted with so little hemorrhage. However, if the cervical laceration be ventral or dorsal one of the arms of the vascular boot-jack angle formed by the bifurcation of the cervico-vaginal artery will be ruptured and severe hemorrhage result.

The peripheries of the cervico-vaginal artery have the shape of a fan. The peripheries of the fan-shaped cervical arteries anastomose freely on the center of the ventral and dorsal surfaces of the vagina, cervix and uterus. The cervical artery connects the vesicle circulation with that of the vagina and uterus. The *ramus cervico-vaginalis* arising immediately adjacent to the distal arterio-ureteral crossing (it may be right or left) is the most important branch in practice because of its frequent laceration in parturition. It supplies the cervix, vaginal fornices, distal end of ureter and base of the bladder. It generally belongs to the internal portion of the pelvic floor segment, but however, may arise from the external portion.

It is well to remember that the ventral group of vesicle and vaginal branches anastomose with the cervico-vaginal and are very voluminous, distributing themselves to the ventral vaginal fornix at the fundus of the bladder and to the distal end of the ureter which applies itself on the ventral proximal vaginal surface. The X-ray and corrosion anatomy alone can show the richness of this blood supply as dissections destroy it before it can be viewed.

The dorsal group of branches from the vesico-vaginal is small and thin, supplying the dorsal vaginal fornix and cervix.

The small branches which go to the neck are remarkable for length and flexuosity. Before arriving at the neck they divide themselves into flexuous branches which supply the ventral and dorsal cervical surfaces.

The cervical arteries accommodate themselves to rapid and extensive cervical dilatations at delivery without losing their integrity.

The lymphatics accommodate themselves similarly to the neck by contracting into clusters on the lateral borders of the neck. The vaginal fornices are supplied

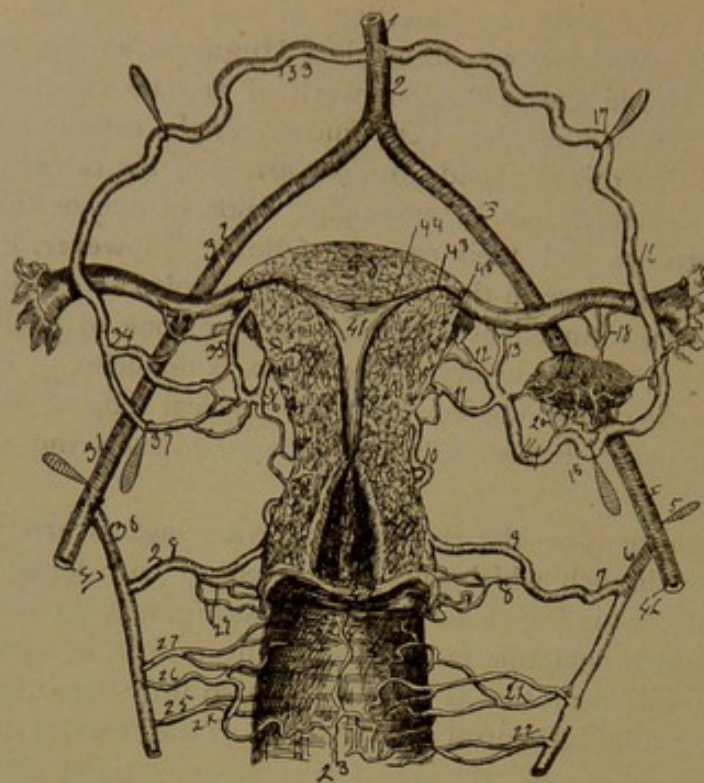


Fig. 70—This is a cut to illustrate the utero-ovarian vascular circle, the straight and spiral segments. 1, the abdominal aorta; 2, same below the origin of ovarian; 3 and 4, common iliac; 5, hook drawing laterally the common iliac at the origin of the internal iliac; 6, internal iliac; 7, uterine, as well as 9, 10, 11 and 12; 8, cervico-vaginal; 13 and 18, branches to the oviduct; 14, 15, 16 and 17, main ovarian artery; 20, ovarian branches; 21 and 22, vaginal branches (2 to 5); 23 and 24, vaginal azygos; 25, 26 and 27, right vaginal branches; 29, cervico-vaginal branches; 28, uterine artery; 30, internal iliac; 31 and 32, common iliac; 33, 34 and 37, ovarian artery; 35 and 36, uterine; 38, fundus; 39, corporeal myometrium; 40, cervical myometrium; 41, cavum uteri; 42, margin of the os externum; 43, junction of the intra-mural segment of oviduct with the proximal end of the uterine horn; 44, distal end of orificum uterinum (base of cone); 45, point of exit of oviduct from lateral border of the uterus; 46, external iliac (left); 47, right external iliac.

by the cervico-vaginal, but the vaginal furnish also vesicle and ureteral branches. The vaginal anastomose proximally with the cervical and corporal and distally with the pudic, thus producing a combined anastomoses of the external and internal genitals from oviducal pavilion to pudendum.

The cervical vessels are situated at first beneath the external muscular layer and penetrate the vaginal fornices by a large number of distributing vessels. The proximal cervical are located transversely while the distal vessels obliquely, in order to reach their destination. The cervix is relatively slightly vascular. The cervical branches, noted for the thickness of their walls, and the development of their internal tunic, distribute themselves in the constituent layers of the cervix. The arteries of the cervix penetrate the cervical myometrium at an oblique angle and not at uniform distances from each other. They divide in ventral and dorsal branches which anastomose with their opposite fellows in the median surfaces of the cervix thus actually surrounding the surface of the cervix with a circular vascular zone. There exist, a partial central longitudinal oligemie (exsanguinated) cervical zone which accounts for the slight hemorrhage in some dorso-ventral cervical lacerations. The cervical artery divides dichotomously and




Fig. 71—Transverse sections of the multiparous uterus, demonstrating the circulation in each segment. It shows the lateral cervical oligemic zone, due to the vascular bootjack angle, formed by the dichotomous division of the ramus cervicis uteri. It presents the longitudinal central oligemic zone. I, cervix and 10, fundus. 9 shows dichotomous division of ramus lateralis fundus—one branch supplying the dorsal and one the ventral uterine wall.

presents a bootjack angle at each lateral cervical border. Some cervical branches are in plexuses and are located superficially on the surface. They join their opposite fellows. In a word, the cervix is surrounded by its own arteries.

Huguier never mentioned a circle at the cervix; that was attributed to him.

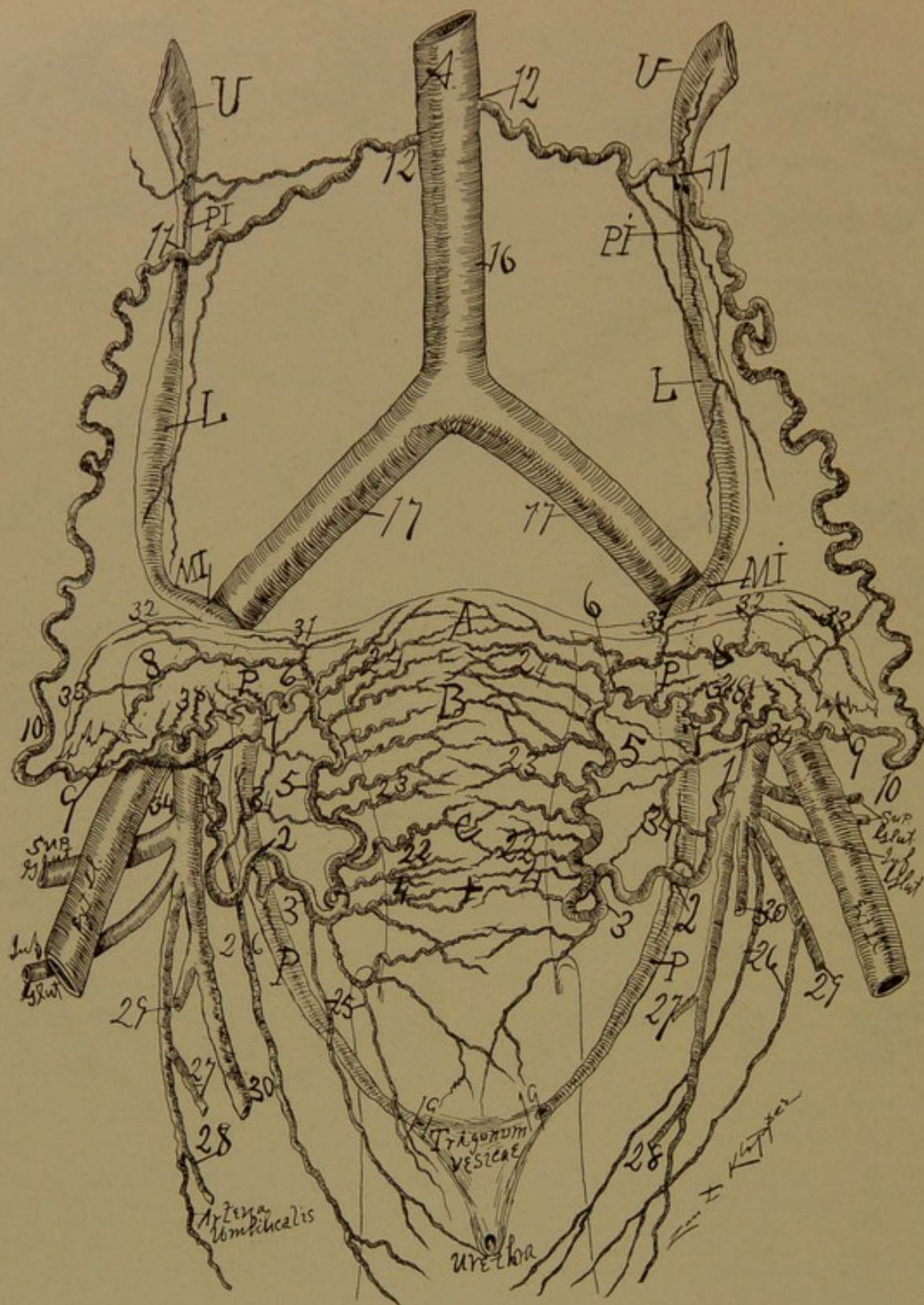


Fig. 72—Is a cut produced by dissection under alcohol after an X-ray had been taken. Subject about forty-five years. Ureteral spindles and isthmuses distinct and in usual location. 1, 2, 3, 4, 5, 6, 7, 8, 9, 10, 11, 12, spiral segment of the utero-ovarian or genital vascular circle. The important proximal (11) and distal (2) arterio-ureteral crossing as well as the cervical loop (2, 3, 4), may be observed. L, lumbar and P, pelvic spindle. For numbers see general description page 82

However, a vascular zone exists sometimes distinctly macroscopically in the human and distinctly in the cow. The X-ray as well as corrosion anatomy shows it plainly. The arteries of the cervix are located chiefly in the superficial layers of the cervical myometrium. At the cervix the arteries are less sinuous than in the corpus or fundus and not parallel. The arteries of the cervix are long, resembling those of the fundus.

The cervico-vaginal artery anastomoses with the rami laterales uteri on the same and opposite sides of the uterus which is quite evident in the injections of pregnant uteri (man and animals). In many cases (woman, dog, cat) one of the cervico-vaginal branches bends suddenly at a right or acute angle and passes distalward on the ventral or dorsal vaginal wall anastomosing with right and left transverse vaginal branches to form the arteria azygos vaginæ, which is excellently observed in injected pregnant specimens. The dorsal arteria azygos vaginæ, the larger, ends in the fossa navicularis, musculus bulbo-cavernosus and perhaps in the pudendo-vaginal gland.

The cervico-vaginal arteries are one or two in number slightly flexuous and quickly divide, penetrating the cervix at the point of vaginal insertion. They are constant, localized, special, large emissions from the genital circle, perhaps for sphincterial purposes. The reason an infant's cervix is large is because the cervical artery is large.

The cervico-vaginal arteries pass especially distalward dividing and subdividing in a typical manner and aiding their opposite fellows to form the cervico-vaginal azygos artery, well seen in injected pregnant subjects. Between the arteries of the cervix and corpus, however, much less between those of the fundus, there is a transverse zone of limited blood supply. It is an oligemic (exsanguinated) uterine zone. The cervico-vaginal artery divides before reaching its destination in the ventral and dorsal branches, leaving between them a triangle, an oligemic zone space which is filled with fine white connective tissue. There is one large lateral uterine branch on the level of the os uteri internum, well seen in carefully dissected and corroded uteri.

The ventral azygos vaginæ, the smaller, form anastomotic connections with the lateral cervico-vaginal arteries and also with the vaginal arteries ending on the ventro-vaginal wall on the urethra. The arteries of the vagina, especially those of the vaginal fornices, possess spirality, particularly noticeable during gestation.

The cervical arteries, unlike those of the corpus and fundus, arise from the main trunk as a single branch and divide *dichotomously* to supply the ventral and dorsal wall of the cervix.

The safety of woman in labor with the usual lateral cervical laceration depends on two factors, viz.: (a) When the cervico-vaginal artery arrives near the lateral border of the cervix it bifurcates, forming a vascular, bootjack angle, which allows the two arterial branches to pass one dorsal and the other ventral to the cervix, leaving an oligemic (exsanguinated) zone on the lateral cervical border. Besides, the lateral cervical laceration does not usually rupture either the ventral or dorsal arm of the cervico-vaginal artery, but tears through the lateral oligemic zone of the cervix. This vascular, bootjack angle of the cervico-vaginal artery on each side of the cervix makes the cervix surrounded by a vascular oval, formed by vigorous central and dorsal cervical transverse vascular an-

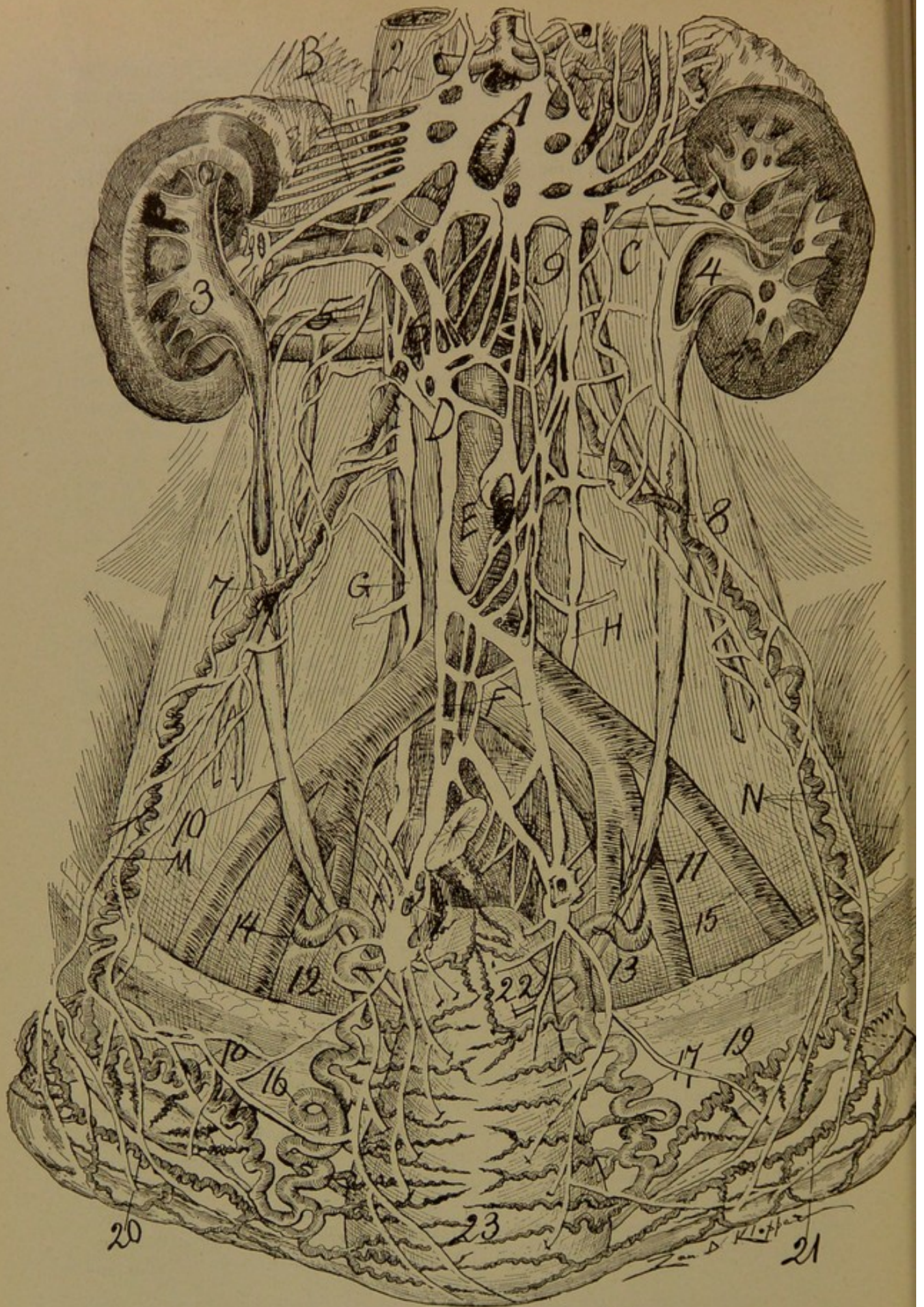


Fig. 73. For description see page 115.

Fig. 73—Represents the circle of author with sympathetic nerve, with course of ureters and central longitudinal oligemic uterine zone (23) of a subject pregnant about 3 months. Uterus is drawn distalward in order to expose its dorsal surface. Subject, about 49. I carefully dissected both sides, drew the vessels in accurate relation, and Mr. Klopper finished the drawing from the model. The ureters were distended with air through the vesical opening, showing a proximal and distal spindle—1, vena cava; 2, aorta; 3 and 4, ureteral pelvis; 5, exit of right ovarian vein; 6, origin of ovarian artery (both from accessory renals); 7 and 8, proximal arterio-ureteral crossing with arteria-ureterica; this is the apex of the author's uretero venous triangles; 9, exit of left ovarian vein; 10, ureter crossing external iliac (this point I shall term the median arterio-ureteral crossing or flexura iliaco-ureteris); 11, ureter crossing internal iliac; 12 and 13, distal arterio-ureteral crossing; 14 and 15, origin of uterine artery; 16 and 17, uterine segment; 18 and 19, ovarian branch; 20 and 21, oviduct branch of oviduct segment; 22, cervix points to cervico-vaginal artery; 23, fundus among the rami fundi.

Sympathetic nerve—A, abdominal brain; B, 5 adrenal nerves; C, renal ganglia; D, renal and ovarian ganglion; E, ganglion around inferior hypogastric plexus passing into pelvis; F, mesenteric artery; G and H, lateral lumbar ganglia; M and N, nerves of about the ovarian segment of the genital circle. Note ganglia each side of the cervix.

6, 7, 20, 16 and 14 right, while 15, 17 (19 and 20), 8 to origin of ovarian artery constitutes the spiral segment of the genital circle.

astomosis. It is analogous to the vascular oval which surrounds the fundus. If the cervical laceration occur in a ventral or dorsal direction in the cervix serious hemorrhage will occur because one of the ventral or dorsal cervical arms of the vascular, bootjack angle is torn. How often do we see this ventro-dorsal laceration in rapid delivery before full cervical dilation. (b) The branches of the vascular, bootjack angle pass through or between the muscular bundles of the cervical myometrium which act like living elastic ligatures on the blood vessels and hence when torn, the hemorrhage is checked by muscular contraction.

Dissections, corrosion anatomy and X-rays demonstrate that there is a constant ramus cervicis which divides dichotomously, one branch supplying the dorsal and the other the ventral wall of the cervix.

The ventral and dorsal cervical branch expanding like a fan, richly anastomose in the center with their opposite fellows producing what I shall term the *circular cervical vascular zone*. The central transverse anastomosis of the cervical vascular zone is so fine, capillary, that medial division of the cervix longitudinally produces very little, practically no hemorrhage.

The transverse cervical anastomosis is not so strong or large in volume as in the corpus or especially the fundus. The vessels of the ramus cervicis are closer together and less spiral than those of the corpus or fundus. The vertical anastomosis of the cervix is not so numerous in the cervix as in the corpus or fundus.

By reason of the extension of the uterine segment through distention of the myometrium in pregnancy, cervical branches may be displaced, becoming suppliers of the distal end of the corpus.

The cervix is supplied with arteries less in number, spirality and uniformity than the corpus or fundus.

The relations of the arterial divisions to the cervix indicate that during gestation, the cervix unfolds and the branches become more widely separated supplying the distal end of the corpus. When one notes in detail the arteries of a non-gravid cervix and a gravid cervix, it would appear that the non-gravid cervix has the greatest number as announced by Dr. Semmy Davidsohn, but this is owing to the extensive unfolding that the cervix experiences during gestation.

The cervix receives its blood supply direct from the utero-ovarian arc exactly as does the corpus and fundus.

The reason that non-fatal hemorrhage occurs at the numerous lateral cervical lacerations from parturition and menstruation is because the ramus cervicis divides dichotomously on arriving at the lateral cervical border, one branch supplying the dorsal and the other the ventral cervical wall. This dichotomous division of the cervical artery makes a vascular boot-jack angle on the lateral cervical border and an oligemic zone in the lateral cervical wall, which being lacerated, produces capillary bleeding only. However, if one or both of the vascular arms of the boot-jack angle becomes torn hemorrhage becomes immediately dangerous on account of vascular channels, the oblique cervical lacerations are always bloody. Hence the most important oligemic (exsanguinated)—or bloodless zones of the uterus are: (a) *The lateral cervical border*; (b), *the central longitudinal axis*; (c), *the fundal*; (d), *the inter-rami laterales uteri* and (e), a limited zone between cervix and corpus.

If the cervical vessel be severed within the cervical myometrium, the muscular and elastic bundles grasp the vessel like a living elastic ligature. If the vascular cervical oval be severed external to the myometrium; i. e., in the parametrium, it bleeds freely. In lacerations of the cervical vascular arm the powerful muscular and elastic elements in the ramus cervicis saves many lives by rapid contraction. The tissues or coats of the cervical artery are remarkably thick, and when severed or especially torn, the lumen is rapidly closed by muscular and elastic contraction. The muscular and elastic coats of the genital arteries are generally strong, particularly in such animals as the bovine and pig, e. g., it is difficult to inject a nullipara cow, pig, dog, horse or sheep.

In longitudinal bisection of the cervix there is practically no hemorrhage.

CONCLUSIONS IN REGARD TO THE RAMUS CERVICIS.

1. There is a bilateral oligemic (exsanguinated) zone of the cervix. As a result of the vascular boot-jack angle on each side of the cervix, a bilateral cervical oligemic zone exists. These zones are located at the usual points of bilateral cervical laceration and hence save women from hemorrhage during parturition.

2. There is a cervical circular vascular zone. The cervix is surrounded by an oval vascular zone which is widest in the median line of the cervix.

3. There is practically a medial longitudinal oligemic cervical zone, Median longitudinal cervical incisions or lacerations are practically bloodless and non-dangerous.

4. The oblique cervical laceration is dangerous. The dangerous cervical laceration or incision is the oblique one which severs the cervical vascular arms between the dichotomous division of the ramus cervicis and the median longitudinal cervical line.

5. Practically the only dangerous cervical laceration is the one which severs a vascular cervical arm external to the cervical myometrium.

6. The cervix of pueritas is large on account of the remarkable size of the cervico vaginal artery.

RAMI LATERALES CORPORIS.

The lateral branches of the corpus are short and small. Shortly after they originate they penetrate the myometrium and, like those of the cervix, rapidly diminish in volume. The branches on the ventral and dorsal surface of the corpus are relatively small, especially in the center. The arteries of cervix and corpus may interchange position according to the condition of the uterus, e. g., in advanced pregnancy the corpus may appropriate some of the cervical branches.

In pregnancy the cervix may receive only one or two branches. The others go to the corpus. The distal uterine segment in pregnancy is hence formed at the expense of the cervix. The arteries of the corpus arrange themselves at once in the central vascular strata. They spread out like a fan, furnishing two orders of branches, the one supplying the superficial subserous strata, coursing parallel near the surface, the other, or deep, vastly more numerous, pass practically perpendicular to the endometrium, where they form plexuses. The vessels form richer plexuses the nearer they approach the endometrium. They end in the endometrium similarly to those on the proximal vaginal vault, *i. e.*, in terminal tufts. In the endometrium they form two beautiful networks, *viz.*: one sub-epithelial, the other periglandular. The arteries of the corpus penetrate at once the myometrium. The arteries of the corpus, both short and small, penetrate the myometrium practically at right angles and at uniform distance from each other. In general the uterine arteries supplying the corpus uteri enlarge in gestation much more than those which supply the cervix uteri. The lateral arteries of the corpus uteri are spiral in shape, thick walled, anastomose with each other, and to a limited degree with their fellows of the opposite side.

The large middle lateral uterine artery lies in the dorsal myometrial surface on a level with the ovarian ligament and ejects a strong stream of blood on being severed. On inspection after injection it is found to be a strong branch. My experience on removing the center of the uterus in numerous patients and injected specimens has repeatedly confirmed this anatomic fact.

In the corpus and fundus the general rule is that these rami laterales uteri do not divide dichotomously, but the branches which are designed for the ventral or dorsal uterine surfaces pass directly from the uterine segment or trunk to their destinations. Exceptions to this general rule occurred in my own dissections, but especially in corrosion anatomy. The rami laterales of the corpus, two to five in number, are much more spiral than those of the cervix, emerge from the trunk of the uterine artery at right angles, and enter the corpus at right angles and parallel to each other. They are smaller than those of the cervix or fundus and are the first rami laterales in intimate contact with the peritoneum forming the ligamentum latum. They pass chiefly to the lateral uterine surface or border, penetrating the corpus dividing and extending to the endometrium, where they almost lose all spirality.

In age relations the rami laterales corporis are the last of the rami laterales uteri to appear, and the first to disappear. Corrosion anatomy and the X-ray demonstrate this distinctly.

RAMI LATERALES FUNDI.

The blood supply to the fundus consists of one large or several smaller branches which course either from the uterine segment or oviducal segments.

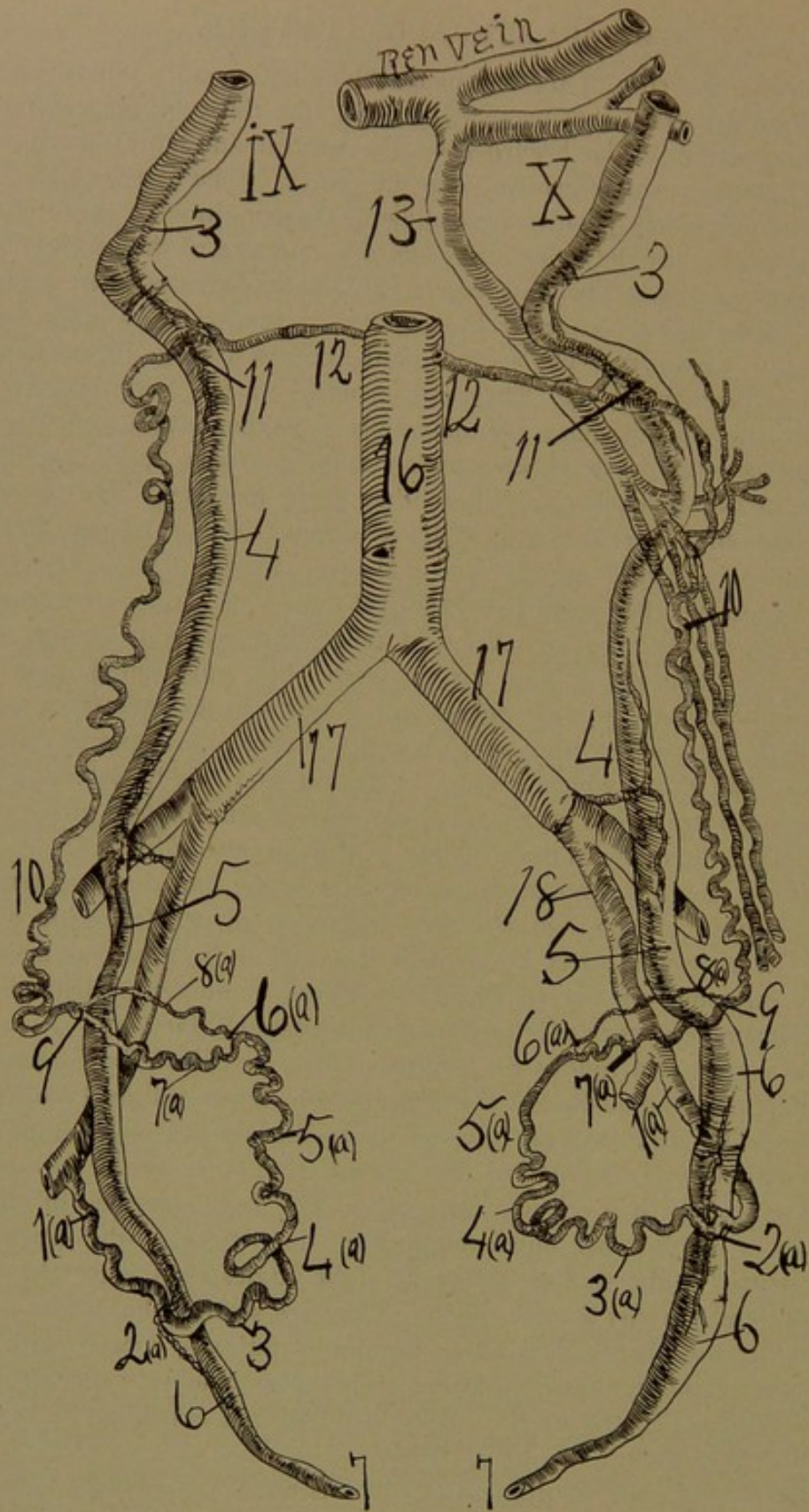


Fig. 74—An X-ray. Ureter in relation to utero-ovarian vascular circle, 1 (a), 2 (a), 3 (a), 4 (a), 5 (a), 6 (a), 7 (a), 8 (a), 9, 10, 11, 12. At 2 (a) the distal arterio-ureteral crossing the distal arteria ureterica passes from the arteria uterina to supply the ureter. IX and X from the same subject. At 11, the proximal arterio-ureteral crossing, the ovarian segment emits the proximal arteria ureterica to supply the

ureter, the arteria ureterica having age and functional relations, its lateral branches will also possess age and functional relations, consequently the walls of the ureter at the arterio-ureteral crossing will possess age and functional relations, and hence suffer in nourishment and dilate in climacterium and senescence. The ureters show different sized dilatations and sphincters in this subject. Both ureters cross the external and internal iliacs at the middle arterio-ureteral crossings, which of course will show no recognizable age and functional relations. 13, Ovarian vein. No. X presents the uretero-venous triangle of the author by means of the ovarian vein (13, II), ureter (II, 3, to kidney), and the renal vein. X shows wide spindle dilatations. 6 (a), 8 (a), 9—6 (a), 7 (a), 9, ovarian vascular circle.

The general rule is that the main fundal branch arises at the middle bifurcation of the arteria uterina ovarica. Frequently it arises from the oviducal. It is very tortuous, supplies the fundus of the uterus, and anastomoses with its fellow of the opposite side. Practically this artery is a lateral branch of the oviducal artery (ramus oviductus lateralis). Sometimes, when the ramus fundi of the uterine segment is single, it may be a large artery with a vigorous blood current. The rami fundi possess very similar spiral and looped conditions with the ovarian.

The arteries of the fundus are located extensively under the subserous muscularis. However, they penetrate to the endometrium, forming a vast capillary network, and perhaps the chief location is about the center of the myometrium. The arteries of the fundus are large, spiral and tortuous. The fundal cluster of arteries in general comes from the uterine segment. However, some may come from the ramus oviductus. The recurrent ramus fundi is well arranged for distension during gestation, as it aptly fits the expanding uterus.

The strong rami fundi, so pronounced during gestation and marked during menstrual life, is already sufficiently large in the new born to be noticeable, in my specimen of two hours' old.

All fundal branches from the oviducal segment may be considered as recurrent arteries displaced by development. The recurrent fundal artery may be one and strong, more frequently double or several, which subdivide and supply the fundus which is the great vascular region of the uterus—the location of placental insertion. This fundal bundle may furnish one or more branches for the oviducal isthmus. The fundal arteries are in clusters, sinuous, tortuous and parallel to each other.

The rami fundi, two to five in number, are unique. They may arise from the trunk of the uterine artery or chiefly from the ramus oviductus as separate branches, and course spiral and parallel to each other, without losing much if any of their caliber until they anastomose with their opposite fellows. The artery may arise as a single large trunk from the uterine segment and quickly subdivide, resembling a bouquet of branches which traverse the fundus spirally quite equidistant and closely parallel. The rami fundi are generally long branches emerging from the uterine trunk at acute angles and at a wide distance from the fundus, entering it also at an acute angle.

The fundal branches anastomose longitudinally, but especially transversely, by numerous divisions on the ventral and dorsal uterine surfaces. However, at the central portion of the proximal end of the fundus a limited blood area, or oligemic uterine zone, exists, showing slight anastomosis. The angle of bifurcation of the uterine segment into the ramus oviductus and ramus ovarii is acute, like that of the cervico-vaginal, with the pelvic floor segment.

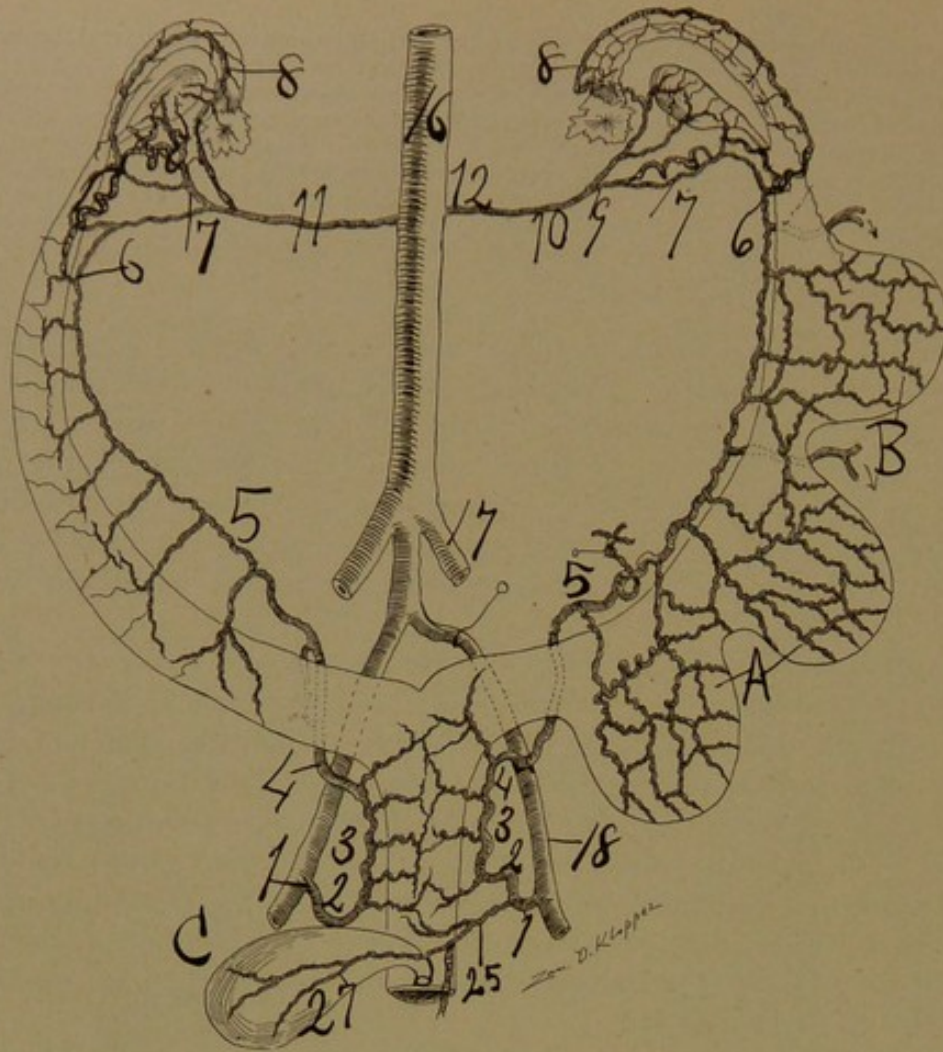


Fig. 75—Rabbit. Drawn from dried specimen which was injected in situ with red lead and starch. The subject was well advanced in gestation, 3 foetuses being found in one uterine horn. 1 to 2 represents the spiral portion of the genital vascular circle. The trunk of the uterine artery is widely removed from the uterine horns. Some of the rami laterales uteri (e. g. at 5) are very long. There is a distinct utero-ovarian vascular circle (6, 7, 9; 6, 8, 9). 25 vesico-vaginal arises as one trunk. C. Bladder. In the rabbit as in all other animals injected and examined the ramus oviductus course closely adjacent and parallel to the oviduct emitting rami laterales oviductus at quite regular intervals. In the rabbit as in many mammals the internal (18) and external (17) iliacs arise as separate branches from the aortic trunk. The ovarian segment (9, 10, 12), enters the aorta at right angles as it does in many quadrupeds. In erect animals (ape, man) it enters or emerges from the aorta at acute angles. At points of gestation in the rabbit the rami laterales uteri are plainly macroscopically enlarged over rami laterales uteri not actually engaged in supplying the placental sites. The ureter passes ventral to the uterine artery in rabbit the opposite of that in man.

The rami fundi course almost parallel with the proximal border of the fundus and stand in many fold transverse and longitudinal anastomosis. This rich anastomosis was plainly noted in my case of sarcoma in the uterus of eight weeks gestation, and especially of the puerperal uterus four hours, five days postmortem. The uterus of the first case equaled in size and condition ten weeks' gestation. In another case, where a myoma existed on the fundus, the rami fundi, five in number, equalled in size and richness a two months' pregnancy.

In partial vaginal hysterectomy, in the author's operation where only the

center of the uterus is removed, there are two to three large, distinct lateral uterine arteries, which on being severed squirt large quantities of blood. The proximal one, located on the dorsal uterine surface, no doubt corresponds to the largest ramus fundi. The largest and strongest volume of blood springs from the lateral uterine artery, which lies on a level with the utero-oviducal angle. It corresponds to the ramus oviductus or ramus fundi, which may balance each other in size. It may be stated that the uterine segment terminates by dividing into the ramus fundi, ramus oviductus, ramus ovarii and ramus ligamentiteretis. However, in my dissections it frequently occurred that the ramus oviductus sent recurrent arteries to the fundus. This is the case bilaterally in the puerperal four hours postpartem uterus. Also in the five days postpartem puerperal uterus. The fundal cluster of arteries supplying the placental site often resembles an oak tree with its numerous tortuous, sinuous branches.

See Figs. 68, 89.

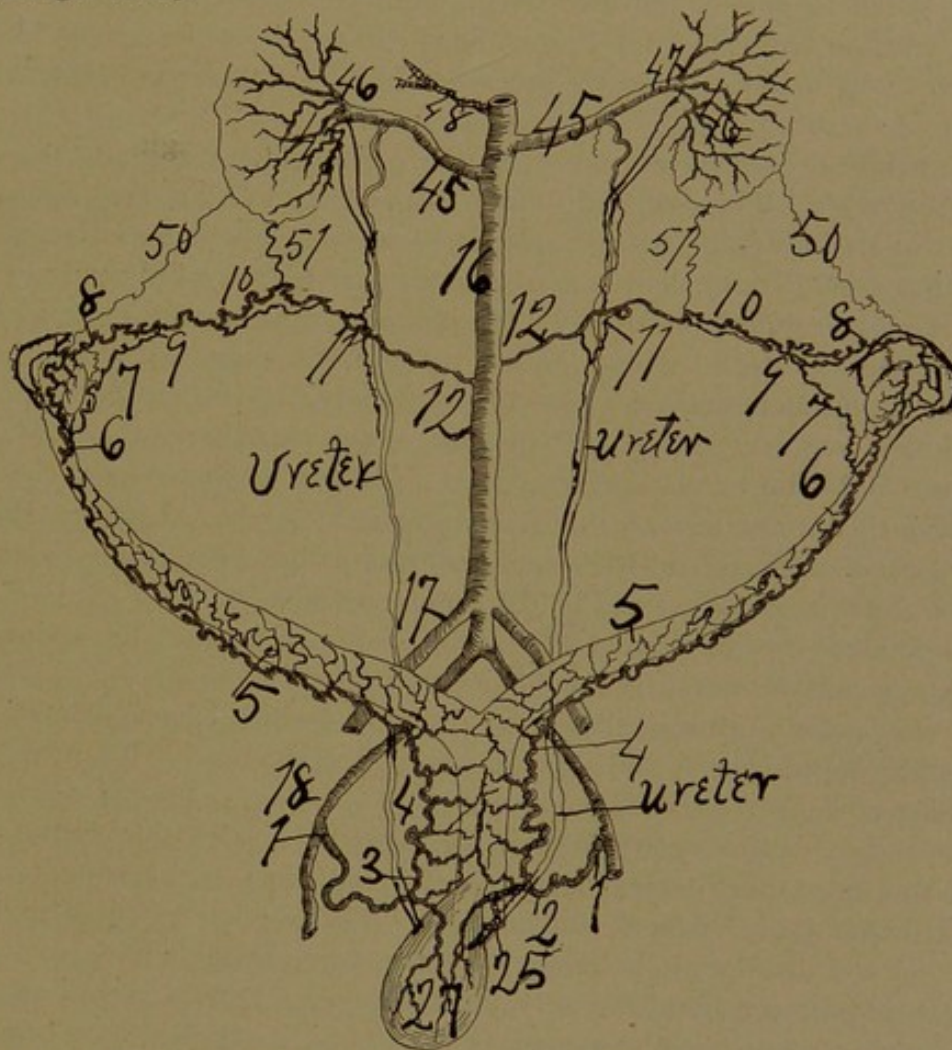


Fig. 76—Cat. Drawn from dried specimen, which was injected in situ. The genital vascular circle can be excellently demonstrated in the cat. Its characteristics are: It lies closely adjacent to the uterus and uterine horn, has numerous rami laterales uteri which are quite spiral and short. The ureter passes ventral to the uterine in cat—the opposite of that in man. In all animals examined the ovarian segment passes ventral to the ureter with a very few exceptions especially in the dog. There is a distinct ovarian vascular circle (6, 7, 9; 6, 8, 9). The ovarian segment enters the aorta with an acute angle proximally, exactly opposite to that in erect animals (ape, man). The proximal arteria ureterina is strong in cat. The renal artery as in man possesses a small dorsal (46) and large ventral branch (47). For numbers see general description page 32.

CHAPTER IV.

THE OVIDUCAL SEGMENT OF THE UTERO-OVARIAN ARTERY.

GENERAL REMARKS.

According to my injected, corroded, dried and X-rayed specimens the oviducal segment of the utero-ovarian artery is divided into three branches, viz: (a) Ramus oviductus, which courses between the blades of the mesosalpinx to supply the oviduct with rami laterales and anastomoses with the ovarian segment at the oviducal pole of the ovary. (b) Ramus ovarii, which courses along the distal border of the ligamentum proprium ovarii between the blades of the ligamentum latum to supply the ovary with rami laterales whence it anastomoses with the ovarian segment. (c) Ramus ligamenti teretis, which arises, in general, from the ramus oviductus and traverses the middle of the round ligament to its origin from the deep epigastric (external iliac).

The oviducal segment extends from the utero-oviducal angle to the external pole of the ovary. This segment begins at the bifurcatio arteriæ uterinæ media and ends at the bifurcatio arteria uterinæ proximal. The oviducal segment presents, what I shall term, the ovarian vascular circle, which is composed of the ramus ovarii and ramus oviductus. The three branches of the oviducal segment emit rami laterales to the oviduct, ovary, mesosalpinx, mesometrium and mesonephros, ligamentum teres uteri, and all are solidly and compactly anastomosed. The oviducal segment offers, perhaps, the widest variation of any of the five segments of the utero-ovarian artery. I dissected, corroded and X-rayed no subject which did not possess the ovarian vascular circle. However, the classic Hyrtl reported subjects which showed only one main artery in the oviducal segment and, of course, that would be the ramus ovarii.

Dissections, corrosions and the X-ray demonstrate that the oviducal segment shows considerable variation in its anastomotic outlines.

1. The general form of the oviducal segment which I have adopted, consists of a distinct ramus ovarii and a distinct ramus oviductus. This form makes a distinct macroscopic ovarian vascular circle.

2. A secondary form of the oviducal segment is where the ramus ovarii is distinct and large, but the ramus oviductus is indistinct, its anastomotic network is represented by an indefinite anastomosis. The ovarian vascular circle is not macroscopically distinct by the ramus oviductus being a single line.

In both forms the oviducal ampulla and pavilion receive each a macroscopic ramus, but the isthmus in the secondary form may be supplied by a branch from the ramus recurrens fundi. In the first form of anastomosis in the oviducal segment, *i. e.*, with a distinct macroscopic ovarian vascular circle, the ramus oviductus and the ramus ovarii are of almost uniform caliber, but the ramus ovarii is always the larger in caliber and the most spiral in outline, and is, undoubtedly, a segment of the original utero-ovarian vascular circle of the Wolffian body. In some cases the ramus oviductus is extremely short, but the rami laterales oviductus are prac-

tically long and large. In such cases the ovarian vascular circle is disproportionately small in diameter. Also the ramus oviductus may pass distal or proximal to the ramus ovarii. (See Figs.)

In the second form the ramus ovarii is of equal caliber with the adjacent parts of the utero-ovarian artery, *i. e.*, it is a segment of the great genital arcade and gradually glides proximally into the ovarian segment and distally into the uterine segment. In this form the ramus oviductus is a secondary branch in size and spirality and is not sufficiently prominent in caliber to demonstrate by gross dissections a distinct macroscopic ovarian vascular circle. Of course, the rami laterales oviductus solidly anastomose and produce always a continuous microscopic anastomotic ramus oviductus and thus completing the ovarian vascular circle. In some of such cases the anastomosis is very irregular and requires thorough injections and excellent light to trace the lines of anastomosis in the mesosalpinx.

Perhaps, in the vast majority of subjects the oviducal segment consists of a ramus ovarii and a ramus oviductus forming an ovarian vascular circle which emits rami laterales ovarii from its periphery, the ramus oviductus (long helicine) and ramus ovarii (short helicine).

The main lateral branches of the oviducal segment are directed to important and complicated functioning organs, *viz.*: (a) The ovary, the central sexual organ of woman; (b) the oviduct (a sphincter), the important reproductive ova transporter and one of the two macroscopic intraperitoneal organs; (c) the oviducal ampulla, the receptaculum seminis, or depot of conception, and (d) the oviducal isthmus (a sphincter).

The ramus ovarii and the ramus oviductus may be anastomosed by branches of considerable size passing from one to the other.

Also the round ligament segment may be anastomosed by macroscopic branches with the ramus oviductus or ramus ovarii, or with both. The oviducal segment passes lateralward from the uterine border distal to the ligamentum ovarii proprium in the mesometrium and mesosalpinx. At the distal end of the oviducal segment the utero-ovarian artery is remarkable for its strongly looped condition. The general rule is that at the point where the utero-ovarian artery leaves the lateral border of the uterus it emits one or more rami fundi; one branch of which passes along the distal oviducal border, the ramus oviductus, and one branch along the distal border of the ligamentum ovarii proprium. The oviducal branches coalesce at the oviducal pavilion, *i. e.*, in the ligamentum suspensorium ovarii to form the ovarian segment. Frequently, extravascular arcs and arcades exist at the distal end of the ovarian segment or in the ligamentum suspensorium ovarii, both in man and animals, especially in the cow.

The chief vessels in size and length of the rami laterales oviductus pass to the oviducal fimbria and ampulla, where they become distributed in numerous fine branches to each fimbria, whence it anastomoses as a fine vascular network with similar fine branches from the distal end of the ovarian segment.

A curious feature in regard to the oviducal segment is that at its beginning and at its ending it is remarkably looped, *i. e.*, at the utero oviducal angle and the ligamentum suspensorium ovarii, or oviducal pavilion.

The term, helicine arteries, signifies spiral, tendril-like, short vessels emitted

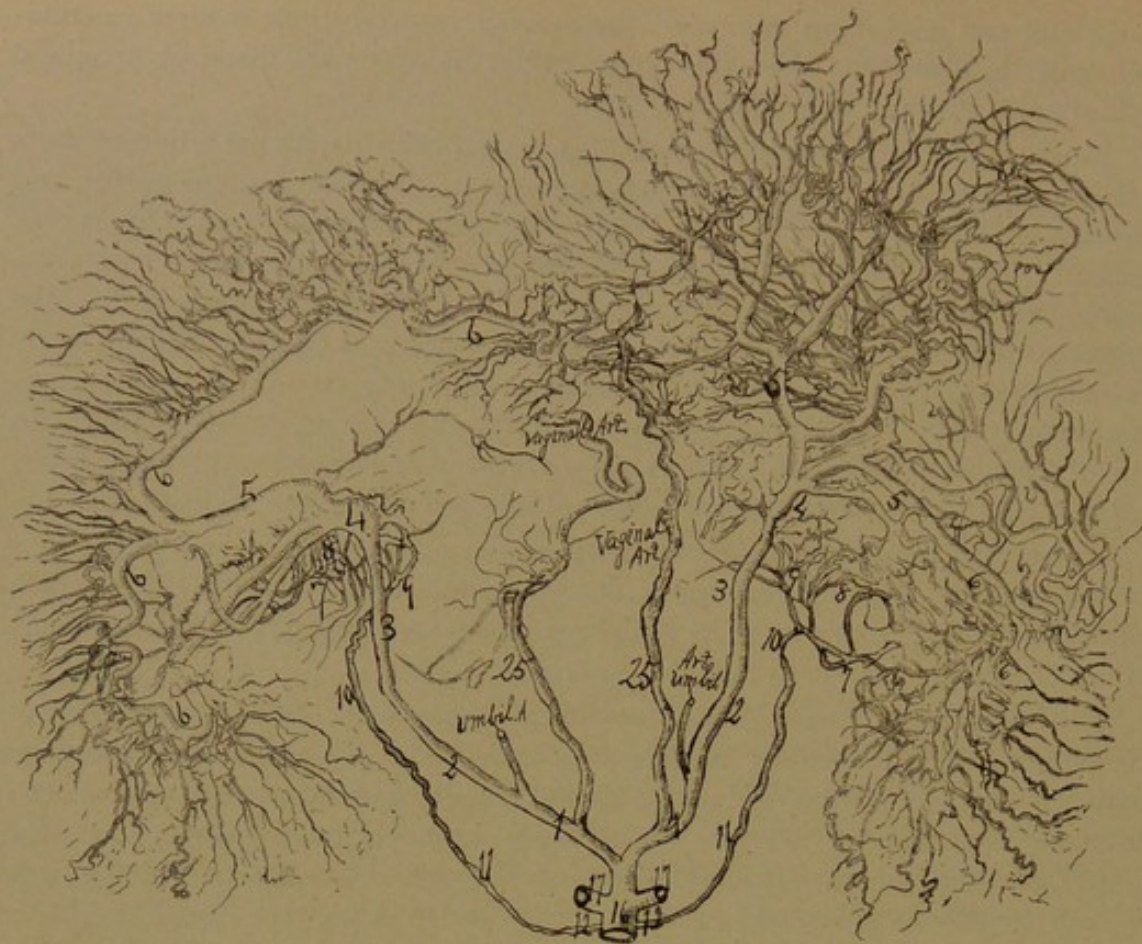

Fig. 77—Fig. X-ray. Injected with red lead and starch outside of body. The multiparous pig has an enormous genital circulation. The genital vascular circle resembles that of the sheep and cow in possessing a large, strong vaginal and uterine artery with profound anastomoses. The X-ray model was followed rather lightly to make the outlines of the vessels clear and distinct in such a vast mesh work. Dr. Wm. E. Holland executed the drawing after the X-ray model. The walls of the utero-ovarian artery in the pig are so thick and strong that it is difficult to completely fill them. For numbers see general description page 32.

from the larger branches; this term was introduced by that prince of anatomists, Johannes Mueller—(1801-1858).

The investigations of this article show from Nature that the oviducal segment is a vascular circle. The subjects injected, corroded, dissected and X-rayed, are:

- | | |
|--------------------------------------|--|
| 1. Three infants a few days old. | 2. A nullipara 22 years old. |
| 3. A multipara 30 years old. | 4. A parous subject pregnant 3 months. |
| 5. A parous subject 55 years old. | 6. A parous subject 60 years old. |
| 7. A puerperal subject 24 years old. | 8. A puerperal subject 27 years old. |
| 9. A nullipara 31 years old. | 10. A multipara 36 years old. |
| 11. A multipara 23 years old. | 12. A multipara 53 years old. |

This, with other material, establishes the idea of an *ovarian vascular circle in the oviducal segment*.

THE RAMUS OVARII.

This constitutes the principal artery of the ovary. It enters the ligamentum latum, courses parallel to the distal border of the ligamentum ovarii proprium

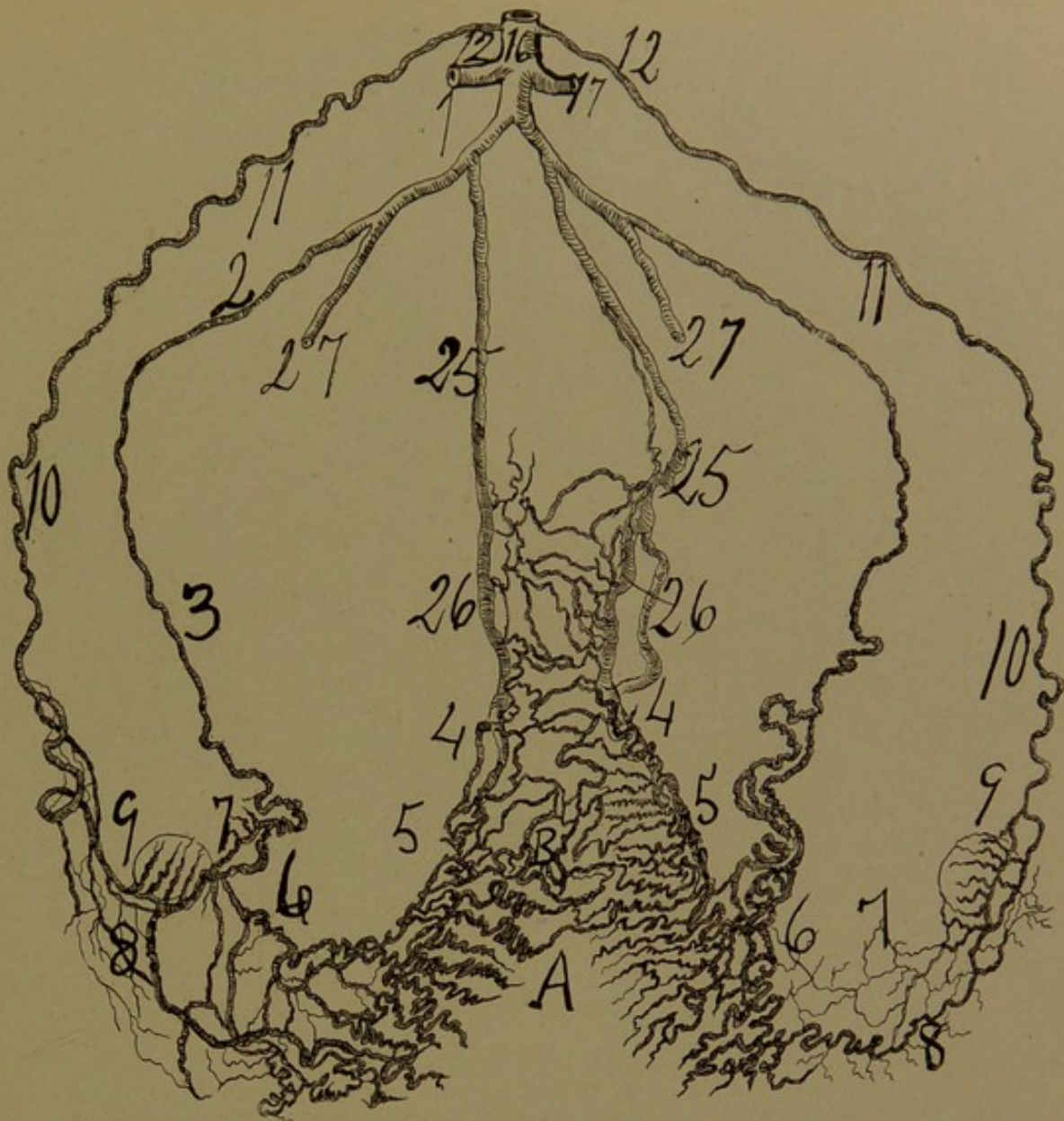


Fig. 78—Sheep. Multipara, X-ray. The specimen was injected after removal from the body. The genital vascular circle is typical and perfect. The sheep has notably a large vaginal which profoundly anastomoses with the uterine. A. B. Longitudinal oligemic uterine zone. For numbers see general description page 32.

and passes along the mesovarial border to the distal pole of the ovary to coalesce with the ramus oviductus, at which point the ovarian segment begins. The *ramus ovarii* is the division of the oviducal segment which passes to the ovary, after which it joins with the ramus oviductus to anastomose with the ovarian segment. It extends in a remarkably spiral-looped course from the utero-oviducal angle and traverses between the blades of the ligamentum latum. In my injected, dissected, corroded, X-rayed and dried specimens, the ramus ovarii of the oviducal segment is considerably the larger artery, conveying a powerful blood-stream. It is practically the artery of the ovary. It sends five to seven branches, rami laterales ovarii, to the ovary, which divide dichotomously and assume a wonderfully tortuous and looped course.

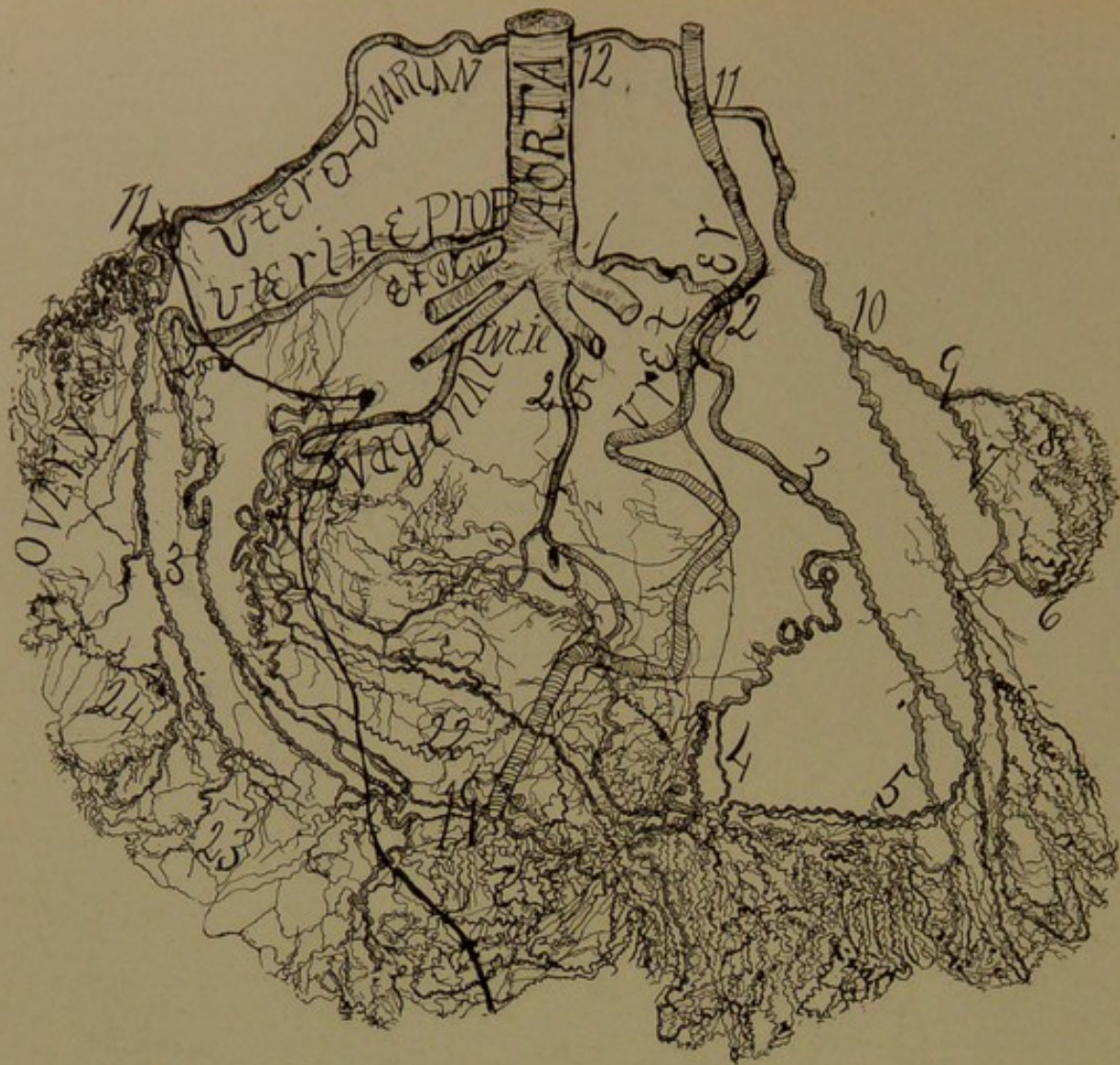


Fig. 79—Horse X-ray. This specimen was made from 3 specimens, two being X-rayed, viz.: Two specimens injected after removal from the boily while a third I injected in situ in an animal, perhaps 20 years old. The genital vascular circle of the horse is a quadrupedal arch, while man's genital circle possesses a tripedal arch. The ovarian segment is very large in a horse, as well as the vaginal. The genital vascular circle of a horse resembles almost exactly that of the deer, sheep, cow and pig. The ovarian segment (a voluminous vessel) arises from the abdominal aorta and quickly divides into a large ovarian to supply the ovary and oviduct and a small uterine to supply the horns of the uterus anastomosing with the uterine proper. The uterine proper (in our subject arose from the left external iliac on the left side and from the aorta on the right side), a comparatively long, slender vessel, passes to the uterine horns, anastomosing with the utero-ovarian and the large recurrent vaginal from the internal pudic. The artery of round ligaments is not drawn.

For numbers in cut see general description page 32

The characteristics in the genital vascular circle of a horse are, a large ovarian artery supplying very large ovaries and small oviducts. It divides into two branches generally called utero-ovarian. It sends a large branch to the great uterine horns to anastomose with the uterine proper, which anastomoses richly with the powerful recurrent vaginal. As regards age relations of the genitals at 18 years old the rami laterales genitales can scarcely be injected from atrophy, while considerable portions of the trunk of the genital circle fails to receive the injecting mass.

I am indebted for the specimens of the horse to the professional courtesy of the veterinary surgeons, Prof. Jos. Hughes, M. R. C. V. S., and Prof. Ed. Merillat. Dr. Wm. E. Holland executed the drawings after the X-ray model.

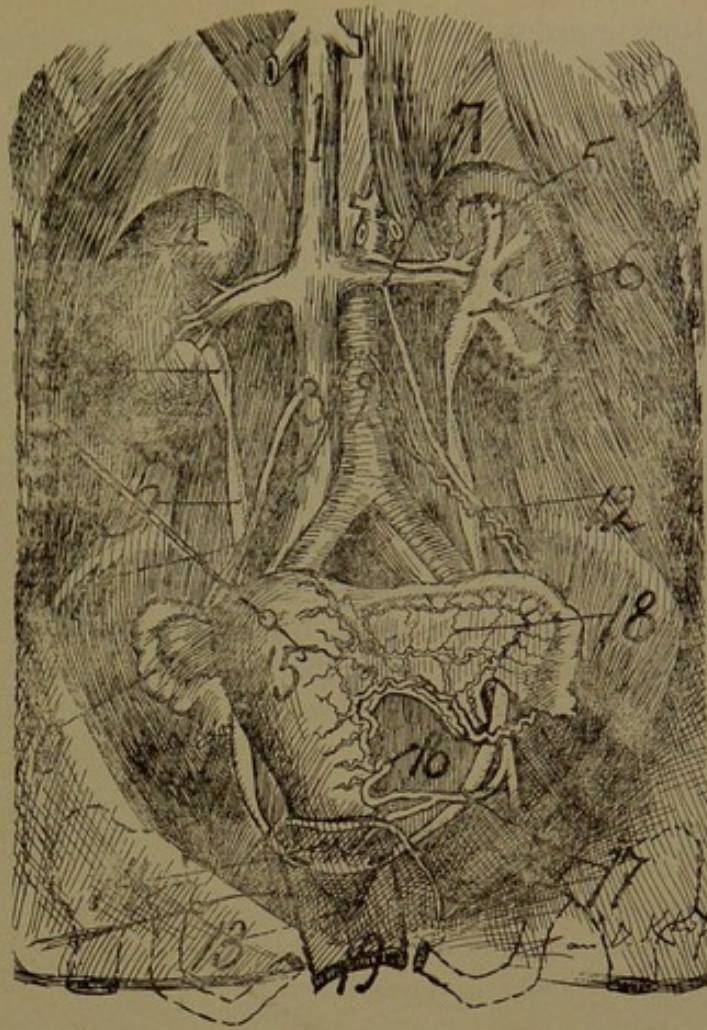

Fig. 80—An illustration of the utero-ovarian artery to the ureter, cervix and vagina 2, aorta from which arises the ovarian segment, 12, 11, proximal arterio-ureteral crossing. 18, oviducal segment. 17, distal arterio-ureteral crossing. 4, vesical trigone. 19, vagina. The ureter presents spindles.

The ramus ovarii is practically of uniform size and caliber throughout its course. It remains at a short distance from the ovary in the mesovarium. There is sometimes an extraovarian arcade from which may pass one or more short helicine arteries to the ovary. The ramus ovarii sends direct or recurrent branches to the ligamentum ovarii proprii.

The medial, or internal ramus lateralis of the ovary, may arise from the uterine segment. The ramus ovarii sends external lateral branches to the ovary. Since the ovary is an important gland, it has diverted the blood from various sources to itself, robbing the ramus oviductus and ramus ovarii as well as the uterine segment. The ramus ovarii, a branch of the oviducal segment as a whole, is the most spiral or looped of all the segments of the utero-ovarian artery. However, to the strong spiral state of the ramus ovarii must be added a prominent looped condition. In size and volume the ramus ovarii is the largest branch of the oviducal segment and appears to be the original direct continuation between the ovarian and uterine segments of the utero-ovarian artery, or of the genital vascular circle, as it is one grand arcade with no point of anatomic or macroscopic

division. The ramus ovarii is most spiral and looped at its proximal ends, *i. e.*, at the point where it emits the rami laterales ovarii, and adjacent to its proximal coalescence with the ramus oviductus. To the dissector familiar with the genital circulation it would appear, macroscopically, that the ramus ovarii is a distinct continuation and a segment of the original utero-ovarian vascular arch formed in the Wolffian body.

The branches of the ramus ovarii are: (a) The rami laterales ovarii, the short helicine, or tendril-like arteries. The branches pass, in a marked spiral state, in a converging or radiating direction to the substance of the ovary through the mesovarium. The ovarian branches, spiral, looped and large, lie close together like a thick bed of veins, and this gave origin to the term *Zona vasculosa* of the ovary. The vessels pass to the ovarian follicles around which they form a rich vascular zone or network in which the vessels have lost the spiral state. The rami laterales ovarii arise as a single trunk and quickly divide dichotomously previous to entering the ovarian substance. The rami laterales ovarii preserve a remarkably spiral course from their origin to their destination in the ovary, *i. e.*, to the ovarian follicles where they form the follicular vascular zone in an extended state. After the dichotomous division the spirality increases. The rami laterales ovarii vary in number, generally from four to seven. It appears that the spiral windings of the ovarian branches first lose this state in the theca folliculi.

(b) *Rami ligamenti lati*, small, fine spiral twigs which supply the mesometrium and mesosalpinx.

(c) *Rami mesonephros*, supplying the mesonephritic rests.

(d) *Extravascular arcs and arcades*, which are located in the region of the ovary and ligamentum suspensorium ovarii.

RAMUS OVIDUCTUS.

The ramus oviductus is the principal artery of the oviduct; it is the middle salpingian; it passes from the utero-oviducal angle lateralward ventral, in front of the ovarian ligament and between blades of the mesosalpinx as far as the oviducal pavilion. It is slightly sinuous medially, internally, from half an inch to one and a half inches, the lateral segment being quite spiral; it remains a finger's breadth distal to the oviducal border and passes dorsal to the mesonephron, to which it furnishes branches; it supplies the oviduct and mesosalpinx; its lateral branches increase in number until it reaches the pavilion, where it anastomoses with the ovarian segment; its branches may be spread out on the pavilion, subdividing on the fringes and, finally, unites itself to several ramifications from the ovarian segment.

The ramus oviductus is an artery of a less tortuous state and manifest less in genital function than the uterine segment. It lies in the limited transparent cellular tissue between the blades of the mesosalpinx; it courses sinuously parallel to the oviduct, about one inch distal to its border and passes posterior to the mesonephros; it is generally accompanied by two veins. The branches of the oviducal segment are:

1. *Rami laterales oviductus*, which in general are three in number: (a) One branch passes to the oviduct about an inch from its distal end; (b) another practically supplies the oviducal ampulla, and (c) a third supplies the oviducal

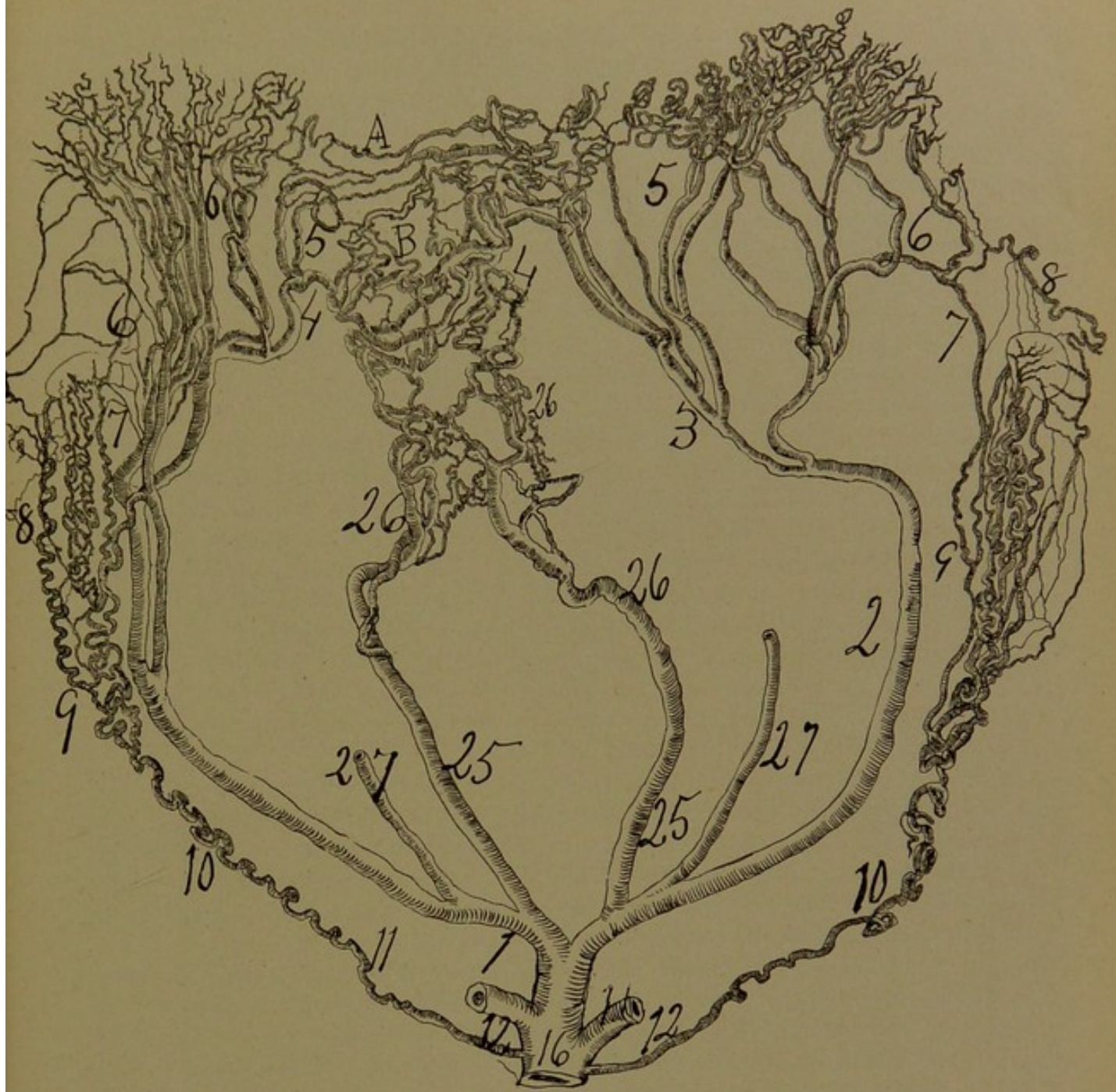

Fig. 81—An X-ray of a pregnant cow. The specimen was injected after removal from the body with red lead and starch. It presents the utero-ovarian vascular circle to be the same as that of mammals. It differs from man and ape in that it possesses a very large vaginal (25 and 26) which forms extensive anastomoses with the uterine (1, 2, 3, 4, 5 and 6). A. B. longitudinal oligemic uterine zone. The ovaries in cow, as in the horse, are supplied by large blood vessels and enormous quantities of blood while the uterus for its large size has disproportionately less. It reverses the condition found in man where the uterus receives disproportionately the larger quantity of blood while the uterus in cow and horse is far less in extent than that of man and apes. If one injects the uterus of a cow or that of man from two different points at the same time it will be found difficult to decide the direction of the (blood) current—as the anastomoses is so solid and compact that the blood current appears to course in various directions, depending on the direction (enticing placenta) of the force. There can be little doubt that the blood in some vessels of the internal genitals at one time course in one direction and at another time in an opposite direction in the same vessels.

pavilion. It may be remarked that the oviducal pavilion is so richly supplied by numerous fine vessels from this artery that some have thought it possessed erectile tissue, a theory at present abandoned. The three main rami laterales oviductus—proximal, middle and distal, previous to arriving at the oviduct bifurcate, the resulting twigs are directed, some to the right and some to the left to anastomose with each other. From this anastomosis results arterial arcs and arcades in the mesosalpinx which supply the distal, middle and proximal segments of the oviduct. It resembles in a smaller scale, however, the arterial arcs and arcades of the vasa intestini tenuis in the mesenteron. The ramus oviductus is of uniform caliber from end to end.

The *distal lateral* branch of the oviducal segment anastomoses with the ramus fundi, the *proximal lateral* branch with the ovarian segment indicating that the utero-ovarian artery is designed to supply the whole of Miller's duct, the vagina, uterus, oviduct and ovaries. Considerable interest is attached to the proximal lateral branch or proximal ramus lateralis oviductus of the oviducal segment as it supplies in a rich and luxuriant manner the oviducal ampulla and pavilion—the receptaculum seminis, or probable depot of conception. This proximal lateral branch of the oviduct is divided into numerous spiral terminal twigs, each fringe of the pavilion being liberally and richly supplied by them. The major oviduco-ovarian fringe also receives a wealthy supply from the same source. In some cases the ramus ovarii sends a branch or branches to anastomose with the proximal lateral branches of the oviducal segment, still more enriching the blood supply to the oviducal pavilion. The oviducal artery preserves a slight spiral but sinuous course.

Not infrequently the ramus oviductus sends off a recurrent branch which supplies the distal end of the oviductus isthmus and the uterine fundus. The oviducal pavilion is so well supplied by the vast numbers of fine arterioles that under the x-ray they resemble villous tufts in each one of the fimbria of the pavilion (see Figs.). From general dissection the ramus fundi belongs to the rami laterales uteri and not to the ramus oviductus.

2. *Rami laterales ovarii longi* are generally three small sinuous branches passing from the ramus oviductus to the ovary and extraovarian arcades.

3. *Rami mesosalpinx* are quite small vessels supplying the mesosalpinx.

4. *Rami mesonephros* are minute branches passing to the mesonephros.

The x-ray specimens demonstrate that the ramus ovarii and ramus oviductus may cross and recross each other, showing no definite or fixed position as regards the mesometrium.

The ramus oviductus traverses between the blades of the mesosalpinx at a considerable distance from the distal border of the oviduct. This resembles that of the dog. In the cat it lies against the uterine horn. In well-injected infants one can count three long helicine arteries passing from the ramus oviductus to the ovary. They are scarcely spiral, simply flexuous. The ramus oviductus sends chiefly three large rami laterales to the oviduct—to the isthmus, ampulla and pavilion. However, in some cases one or more long, large branches pass to the ligamentum latum from it. Small rami laterales oviductus pass to supply the mesosalpinx. The branch to the pavilion is often large and rich in fine divisions. In general, the rami laterales oviductus pass at right angles from the ramus

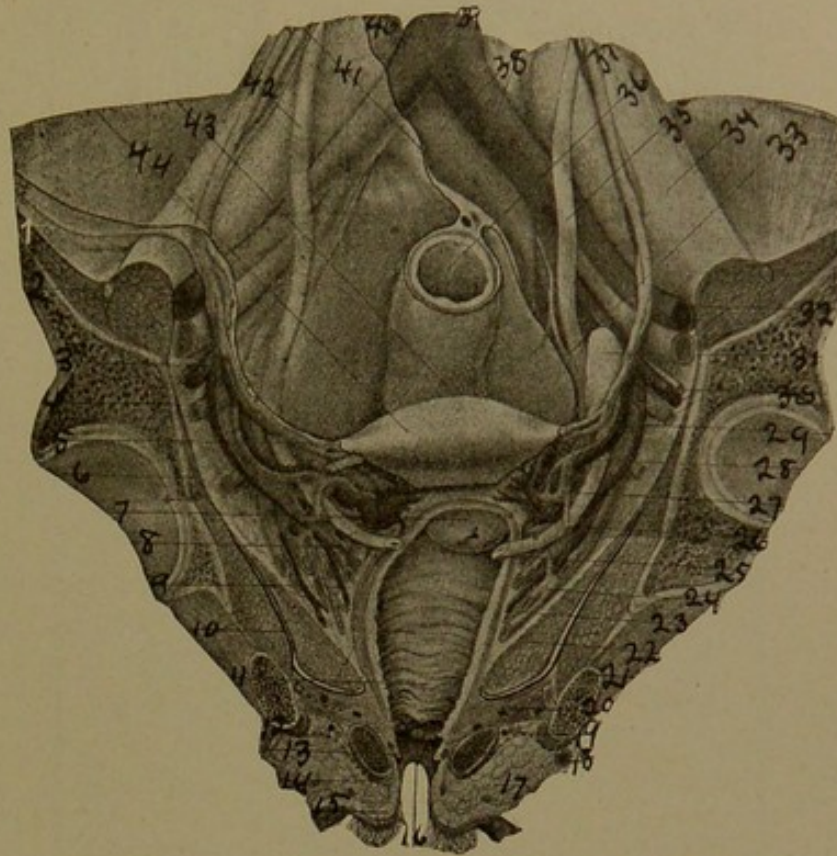


Fig. 82—A cut to illustrate the relations of the ureter, utero-ovarian artery, cervix and vagina. (Waldeyer.) 8 and 25 ureters. 27 and 6 uterine arteries passing ventral to ureters.

oviductus to meet the anterior and posterior faces of the oviduct at right angles, forming on those faces an anastomotic vascular network, especially on the ampulla and pavilion.

Ramus oviductus constitutes the numerous vessels which may pass to the ampulla, pavilion, fimbria ovarian, isthmus, ovary, mesosalpinx and mesometrium. The subperitoneal branches of the oviducal artery are very rich in fine anastomoses.

The rami laterales of the oviducal segment, like all the rami laterales genitales, form an anastomosing network of notable compactness and solidity.

The ramus oviductus is located ventral, anterior, to the ramus ovarii.

The rami laterales oviductus are more flexuous than the ramus oviductus. The rami laterales peritonei issuing from the ramus oviductus are very rich.

In a well-injected spare mesosalpinx one can easily observe the ramus oviductus in size and outline.

THE ROUND LIGAMENT SEGMENT.

Ramus Ligamenti Teretis.

This is a large, very spiral division of the oviducal segment. It passes through the ligamentum rotundum in a marked tortuous state to anastomose with the deep epigastric (external iliac) artery. The anastomoses of the artery of the round ligament with the deep epigastric is an additional blood supply to the internal genitals beyond the utero-ovarian artery.

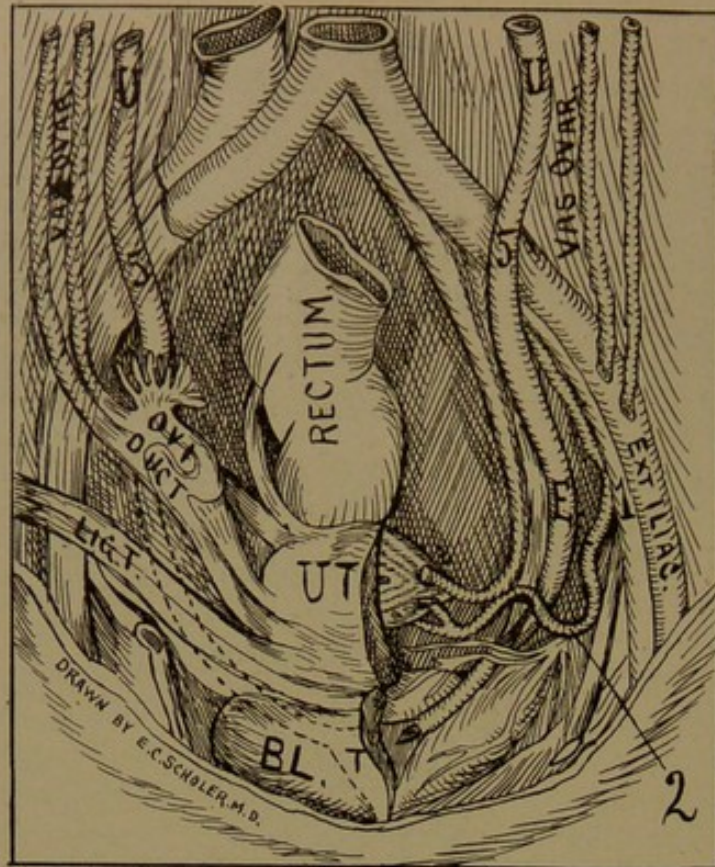


Fig. 83—Ventral view, relation of arteria uterina and ureter to genitals; 2, arterio-ureteral loop U, 5, e. ureter. 5 middle arterio-ureteral crossing. U. T. uterus divided.

The artery of the round ligament is sufficiently large to require a ligation in hysterectomy. It is not easy to decide in which direction blood flows in the artery of the round ligament at its uterine end, from the fact that the middle portion of the artery is the most feeble and smallest in caliber; also, from this fact the origin and destination is obscure; I shall designate the deep epigastric as the origin. The ramus ligamenti teretis arises from the deep epigastric, or by a secondary root of the ileo-circumflex and one branch descends in the inguinal canal, but the chief branch passes tortuously through the center of the round ligament; it is quite flexuous, or rather looped.

In anastomoses with the ramus oviductus it communicates with the inferior epigastric, furnishing a direct route from the mammary glands to the uterus for the sympathetic nerves to manifest the sympathetic phenomena between the uterus and mammary glands.

The segment of the round ligament is very feeble in blood current in the middle portion; at the epigastric end the circulation is quite vigorous.

The segment arises from the deep epigastric generally by one branch or by two, which unite and pass into the center of the round ligament; after entering this ligament it quickly divides, first into two branches, and, as it passes toward the uterus, a third branch is given off. The three branches course in a very sinuous, looped condition in the center of the round ligament for about two inches, whence they dwindle into one central looped branch.

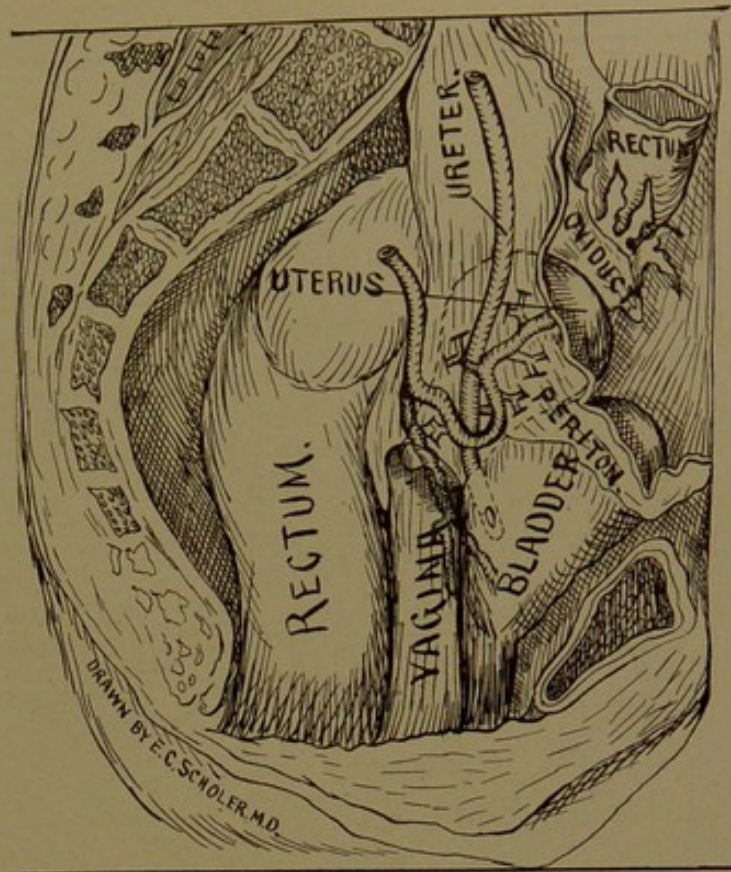


Fig. 84—An illustration of the lateral view of the arterio-ureteral loop with ureter, vagina and cervix. The peritoneum is dissected away from the organs in order to expose the relations of artery and ureter.

The uterine end arises chiefly from the ramus oviductus as a single branch or more seldom from the ramus ovarii, still less frequently it may arise from the common trunk of the oviducal segment, immediately previous to its division into ramus oviductus and ramus ovarii; it soon divides into two branches, one of which, the smaller, passes to the origin of the round ligament on the fundus of the uterus; the other, the main trunk, passes to the round ligament when it immediately makes four to six loops which lie close to each other; it then emits one or two branches which course sinuously parallel with the main trunk for one and a half inches, whence they dwindle into one tortuous branch lying in the center of the round ligament meeting the distal portion from the deep epigastric. The proximal and distal ends of the round ligament segment consists of a central tortuous trunk with one or two accompanying parallel, looped branches; the central portion consists of a single looped trunk lying in the center of the ligament. The proximal and distal ends are larger calibered, while the middle portion is small calibered and can only conduct a feeble stream, even in the pregnant state.

By injecting the round ligament segment during gestation many smaller arteries spring in view that are not seen during the resting state, they are too fine to receive the injection fluid. It would appear that the arc composing the round ligament segment is gradually fading out of existence, especially in the middle portion. Since the middle portion of this segment is very small in caliber

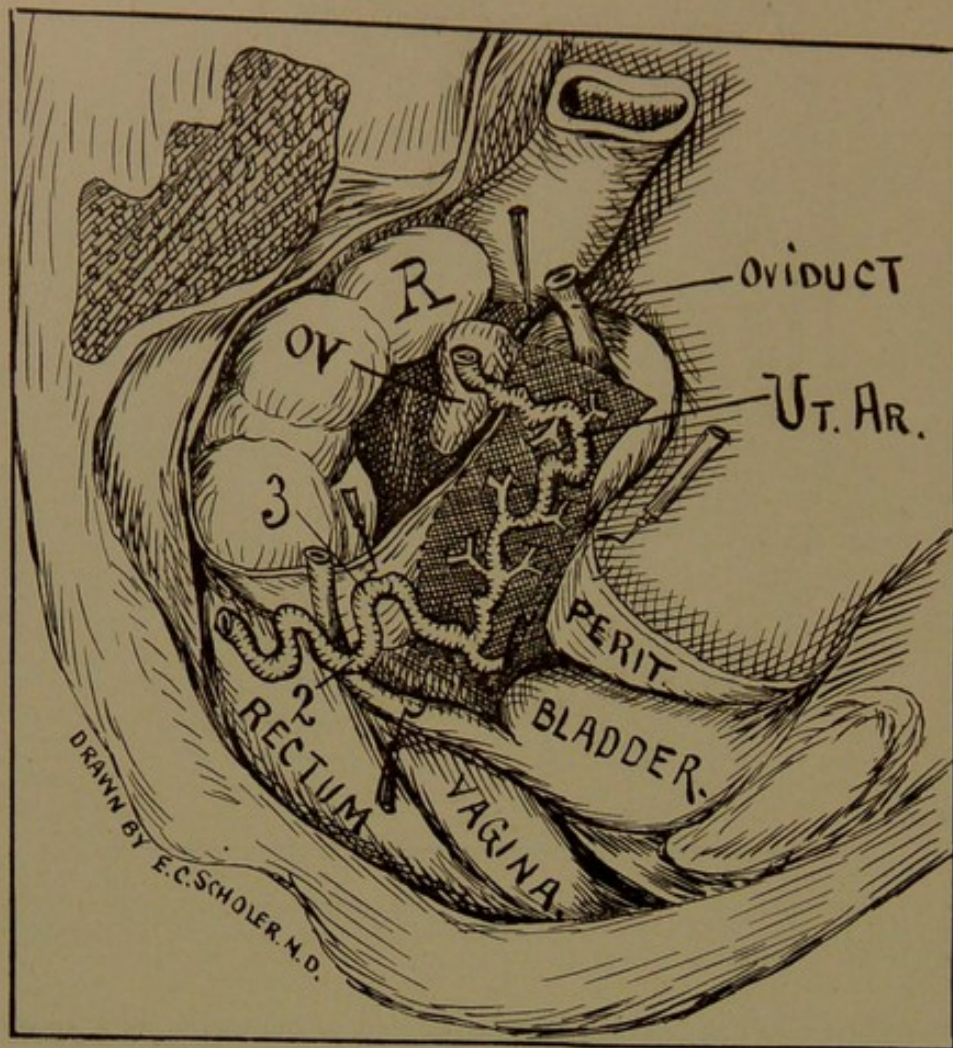


Fig. 85—Lateral view of uterus, with uterine segment; 2, arterio-ureteral loop; 3, cervical loop. Ut. Ar. Uterine artery. In figures 83, 84, 85, suggestions from Zuckerkandle were employed.

the blood current is very feeble in the resting state, making it difficult to decide the direction of the blood current in the segment. The round ligament is feebly supplied in the resting uterus, and even in the puerperal uterus, and hence does not give a large supply.

SUMMARY OF THE OVIDUCAL SEGMENT OF THE UTERO-OVARIAN ARTERY.

1. *The ramus ovarii* is the chief artery of the ovary—emitting generally five to seven lateral branches (*rami laterales ovarii*) to supply the ovary.
2. *The ramus oviductus* is the chief artery of the oviduct—emitting generally three lateral branches (*rami laterales oviductus*) to supply the oviduct.
3. The oviducal segment is practically a vascular circle, which I term the *ovarian vascular circle*.
4. The oviducal segment begins at the utero-oviducal angle and terminates at the distal extremity of the ovarian segment.
5. In size and spirality the *ramus ovarii* is the main artery of the oviducal segment. It is, perhaps, the original genital vascular arch of the Wolffian body.
6. The *ramus ovarii* emits the five short helicines, and the *ramus oviductus* emits the three long helicines to the ovary.

7. All the helicine, or tendril-like, arteries are spiral and practically parallel to each other.

8. The ramus ovarii is located at the distal border of the ligamentum ovarii proprium and mesovarium and between the blades of the mesometrium.

9. The ramus oviductus is located between the blades of mesosalpinx about one inch from the distal border of the oviduct.

10. There exists in the region of the ovary extravascular arcs and arcades which may anastomose with several or all of the five segments of the utero-ovarian artery, indicating the *wide extent* of ovarian blood supply.

11. The oviduct may be extirpated by severing the lateral branches (rami laterales oviductus), only leaving *in situ*, unsevered, the ramus oviductus and ramus ovarii.

12. The ovary may be extirpated by severing the lateral branches (rami laterales ovarii), only leaving *in situ*, unsevered, the ramus ovarii and oviductus.

13. In short, the ovary or oviduct may be extirpated without severing either branch of the oviducal segment.

14. The ovary (a progressively functioning organ), having less-marked age and functional relations than the uterus and oviducts (the menstrual organ—a periodically functioning organ), the oviducal segment will have less marked age and functional relations than the uterine segment.

15. The oviducal segment, since it almost entirely supplies the ovary from the periphery of its vascular circle, is practically the segment of the ovary.

16. The oviducal segment begins at the middle and ends at the proximal bifurcations of the utero-ovarian artery, both bifurcating ends vary as to location and appearance, hence the size of the ovarian vascular circle varies within wide limits.

17. All the rami laterales of the oviducal segment form a solid, compact anastomoses throughout the entire mesosalpinx and mesometrium, so that at any point of the oviduct (oviducal gestation), ovary (ovulation), the mesometrium (tumors) stimulation, may entice the chief volume of blood to one point.

18. The ramus ovarii and ramus oviductus are practically of uniform caliber from beginning to end.

The ramus ovarii sometimes forms one extraovarian arcade which may emit none, some or practically all the arteries of the ovary, rami laterales ovarii.

The utility of the extraovarian arcs and arcades is to supply, doubly sure, the ovary, the essential central sexual organ of women with a rich supply of blood. The extraovarian vascular arcs indicate the significance of the ovary in the animal economy. From my dissections, corrosion anatomy and X-rays the largest branch forming the extra-ovarian arcs and arcades is that arising from the pelvic floor segment immediately internal to the distal arterio-ureteral crossing (No. 34). This is the artery of the ligamentum latum.

Finally, the significance and importance of the ovary is predicated by the anatomic data that the ovarian vascular arcs and arcades are solidly and compactly anastomosed to every segment of the utero-ovarian artery.

This is an ultimate proof of my original claim that the genital vascular system, with its arcs and arcades, was primitively formed in the Wolffian body and have simply traveled distalward into the lesser pelvis from erect attitude.

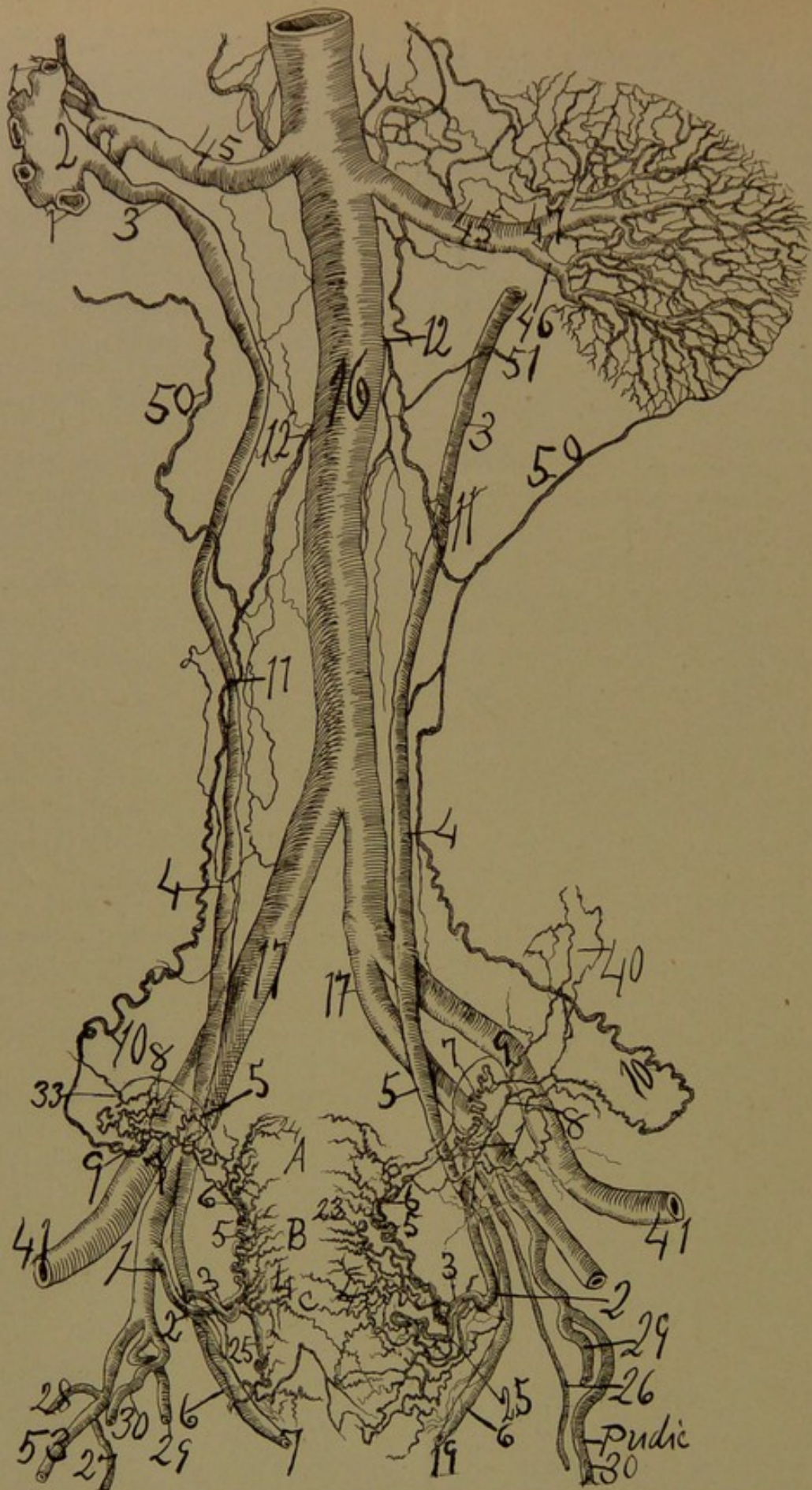

Fig. 86—Baboon, weight 25 pounds. (Golden faced, cynocephalus). The specimen was injected in situ with red lead and starch. It was X-rayed and followed as a model by Mr. Zan D. Klopper. The utero-ovarian artery in the baboon resembles precisely that of man. For designation of the number of the cut see general description page 32

AGE RELATIONS OF THE OVIDUCAL SEGMENT.

The age relation of the ovary is much less than that of the oviduct and uterus. The age relations of the ovary is not so marked as that of the menstrual organ (uterus and oviduct) because the ovary begins to ovulate before birth and it ovulates until the ovarian tissue is practically worn out in the sixties. The menstrual organ (uterus and oviduct) is an organ of limited life with definite age relations, hence its blood supply varies markedly at different periods and functions of life.

Since the ovary is exacerbated only at puberty when the utero-ovarian artery springs mightily into active and functional life, the ramus ovarii may not be expected to present such phenomenal age relations as the ramus oviductus. Yet, since the ramus ovarii and ramus oviductus are branches of a single trunk, the ovarian segment, it is difficult to discriminate age relations more in one segment of the utero-ovarian artery than in another. Hence, we will ascribe the following age relations to the oviducal segment, viz.: (a) Pueritas, childhood life, the quiescent phase; (b) pubertas, the developing crisis; (c) menstruation, a functional crisis; (d) gestation, a functional crisis; (e) puerperium, a functional crisis; (f) climacterium, a crisis in the cessation of function when nerve radiations are readjusted, and (g) senescence, a return to the quiescent phase of childhood.

THE OVARIAN VASCULAR CIRCLE.

In this article attention is called to the almost constant macroscopic vascular arterial circle or vascular oval found in the mesosalpinx and ligamentum latum. It is formed by the ramus oviductus medially (proximally) and ramus ovarii externally (distally) which converge laterally at the oviducal pavilion and medially at the utero-oviducal angle while the branches may be widely separated in the center of the vascular circle. The periphery of the ovarian vascular circle, *i. e.*, the ramus oviductus and ramus ovarii may lie practically parallel or pass over each other. This ovarian vascular circle prevails generally among lower animals. The ovary is the central organ of this vascular circle. In some cases the circle is six to eight inches in circumference, which is composed of the ramus oviductus and ramus ovarii each being three to four inches in length. The oviducal segment is practically a vascular circle, however, oval shaped in the living. This vascular circle begins at the utero-oviducal angle, the middle bifurcation of the utero-ovarian artery and ends at the pavilion, the proximal bifurcation of the ovarian segment or the reverse. The circle constitutes practically the whole of the oviducal segment of the utero-ovarian artery.

The oviduct or ovary can be removed without severing the ovarian vascular circle by clipping the mesosalpinx close to the oviduct or the mesovarium close to the ovary. The ovary is the central organ of this vascular circle and is fed by the long helicine arteries from the ramus oviductus and the short helicine arteries from the ramus ovarii emitted from the periphery of the circle. This should, therefore, be called the vascular circle of the ovary as it lies in the center and is fed from the peripheries.

The oviducal segment has the shape of an arterial ellipse, a vascular circle, from the periphery of which emerges lateral branches to supply the ovary, oviduct and adjacent structures as the mesonephros, mesometrium. The oviducal seg-

ment divides practically into three branches to supply the oviduct (*rami laterales oviductus*), ovary (*rami laterales ovarii*) and round ligament (*ramus ligamenti teritis*). The mesosalpinx and mesometrium and mesonephros being supplied by fine lateral branches, *rami ligamenti lati* and *rami mesonephros*. The uterine and oviducal segments generally form a right angle with each other at their junction, near the origin of the round or ovarian ligament.

Of the three almost constant branches of the oviducal segment the *ramus ovarii* is most spiral and looped, is much longer than the distance between its origins, while the *ramus oviductus* is scarcely spiral at all at its distal end, slightly flexuous, but not looped, at its proximal end. The branch of the round ligament is very flexuous and spiral and in pregnancy is looped apparently four times its length during the resting state. The location of the division or middle bifurcation of the uterine segment into the oviducal segment is very variable. The oviducal segment furnishes the artery to the oviduct, which courses in a spiral state horizontally laterward between the blades of the mesosalpinx and emits the *rami laterales oviductus*.

BRANCHES OF THE OVARIAN VASCULAR CIRCLE.

Helicine Arteries.

a. The long helicine (rami laterales ovarii longi).

The *ramus oviductus* may send two or three lateral ovarian branches (long helicine) which are longer than the short helicine from the *ramus ovarii*. The long ovarian helicine arteries from the *ramus oviductus* to the ovary at the first arise as non-spiral until they approach the external pole of the ovary. The long ovarian arteries (helicine) from the *ramus oviductus* stand in contradistinction to the short ovarian (helicine) arteries from the *ramus ovarii*. In the child I have found three long non-flexuous arteries from the *ramus oviductus* to the ovary. The long helicine arteries (three generally) from the *ramus oviductus* show some spirality but chiefly flexuosities. Besides the general half-dozen short helicine arteries destined for the ovary from the *ramus ovarii* and the generally three long helicine arteries destined for the ovary from the *ramus ovarii* I found irregular branches not exactly alike in each individual, supplying the extra ovarian arches. These irregular branches may make one or more arcs and arcades, in the *ligamentum latum* (see charts Nos. 34 and 35). I found similar irregular loops, arcs and branches in the cow, dog, cat and rabbit.

b. The short helicine (rami laterales ovarii brevis).

The short helicine arteries (generally five to seven) arising from the *ramus ovarii*, showed a marked spirality. Both long and short helicine arteries converge as they approach the ovary. They divide dichotomously. The sow shows five short helicine arteries from end divisions of the ovarian segment. In the cow the ovary is supplied directly from the ovarian segment without the intervention of lateral branches. The (five to seven) short helicine arteries (*rami laterales ovarii*) converge as they pass through the mesovarian to the ovary. The x-ray shows quite regularly four to five in number in man. The *ramus ovarii* gives origin to helicine arteries of which the most external anastomose with the *ramus oviductus* or the ovarian segment. The helicine arteries are practically all parallel. The *ramus ovarii* founds a sub-ovarian arcade which may emit nearly all the *rami laterales ovarii*.

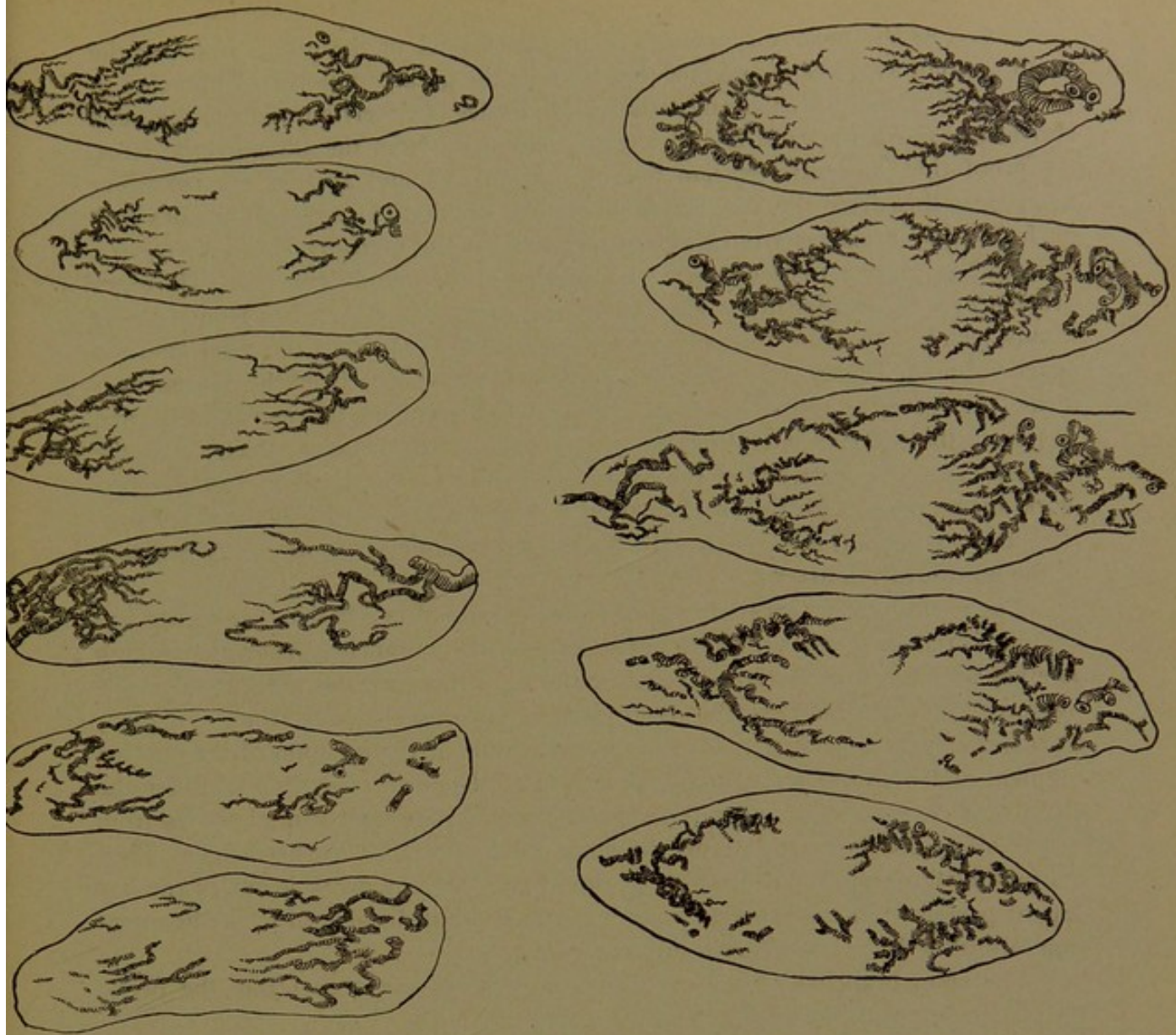

Fig. 87—An X-ray of transverse sections of a nulliparous uterus 22 years of age. 11, sections extending from cervix to fundus. The first cervical section begins at the upper left hand corner of cut. The last lower right hand cut is the fundus. The specimen was injected with red lead and starch.

c. Rami Laterales Oviductus.

The arteries which supply the oviducts are generally three in number, viz.: one large one supplying the pavilion and proximal ampulla. An artery of less dimension supplying the junction of isthmus and ampulla. Finally, a third artery of still smaller size which supplies isthmus oviductus.

d. Extra Ovarian Arcs and Arcades.

In the region of the ovary there exists a variable number of extra vascular arches especially belonging to the ramus ovarii. These extra vascular arches are located in the ligamentum latum and ligamentum suspensorium ovarii. The ovary is the last organ developed in the Wolffian body, and hence its vascular arcs and arcades are more persistent, consequently, when the important sexual gland, the ovary, passed distalward due to erect attitude, the persistent vascular arcs were transported with it to the lesser pelvis. I shall adopt the term *extra ovarian vas-*

cular arcs, as the most appropriate. The significance of the ramus ovarii in the extra ovarian arcs lies in the fact that it emits the greater number of branches to form the arcs, that the chief anastomoses of arcades is closely adjacent to the same and nearly all of the rami laterales ovarii may arise from the extra-ovarian arcs. As proof that the extra-ovarian or sub-ovarian arcs and arcades are persistent vascular arches from the Wolffian body we can say that the arcs and arcades may be formed by branches from the five segments of the utero-ovarian artery, viz.: Pelvic floor, uterine, oviducal, ovarian, and that of the round ligament. The extra ovarian arcs or arcades in my dissections were formed by branches from (a) the ramus ovarii, (b) from the pelvic floor (segment), (c) from the rami laterales ovarii (short helicine), (d) from the ramus oviductus; (e) from the ovarian segment, (f) from the round ligament segment, (g) from the uterine segment, and (h) from the external lateral ovarian and proximal long helicine which forms the extensive vascular network at the oviducal pavilion. The pavilion vascular network anastomoses with the extra ovarian arcs and arcades. Thus the extra ovarian arcs are solidly and compactly bound by anastomoses with every segment of the utero-ovarian artery.

The extra ovarian arcs and arcades may consist of one branch producing one vascular circle or arcades through anastomosis of many branches producing as high as eight vascular arcades through anastomosis. These arcades are located in the ligamentum latum between the ovary and ligamentum suspensorium. In other words, the extra ovarian arcades are located mainly at the junction of the ovarian segment and oviducal segment in the region of the ovary. I shall consider the extra-ovarian arcs and arcades as simply additional persistent genital arches from the Wolffian body due to late development and importance of the ovary. They are practically located in the region of the ovary. As the ovary is one of the last organs perfected in the Wolffian body it carried with it distalward to the ligamentum latum the last formed arcs and arcades.

The chief branches of the extra ovarian arcades are:—one from the pelvic floor segment, and one from its ramus ovarii.

The best way to realize the richness of the blood supply to the ligamentum latum, ovary and oviduct is to inject with red material the utero-ovarian artery of a very spare subject (man or animal) and then hold the injected membrane (better dried) between the eye and the sunlight, when a luxuriant blood supply may be observed. Subsequently, a more wealthy blood supply may be observed in the same ligamentum latum by placing it after drying, in balsam, when the opaque tissue of the ligamentum will be cleared, exposing fields of innumerable fine vessels.

The X-ray of a well-injected spare ligamentum latum shows a luxuriant blood supply superior to all other methods. Spare dogs and other animals show rich blood supply in the ligamentum latum and adjacent structures when well injected with red material and dried. The fine spiral ramifying vessels of the ligamentum latum may be noted coursing parallel and transverse to the surface of the oviduct, resembling those of the enteron and especially converging toward the ampulla and pavilion, forming luxuriant and rich vascular network. The exposure of the branches of the oviducal segment is the most certain with well injected X-ray specimens.

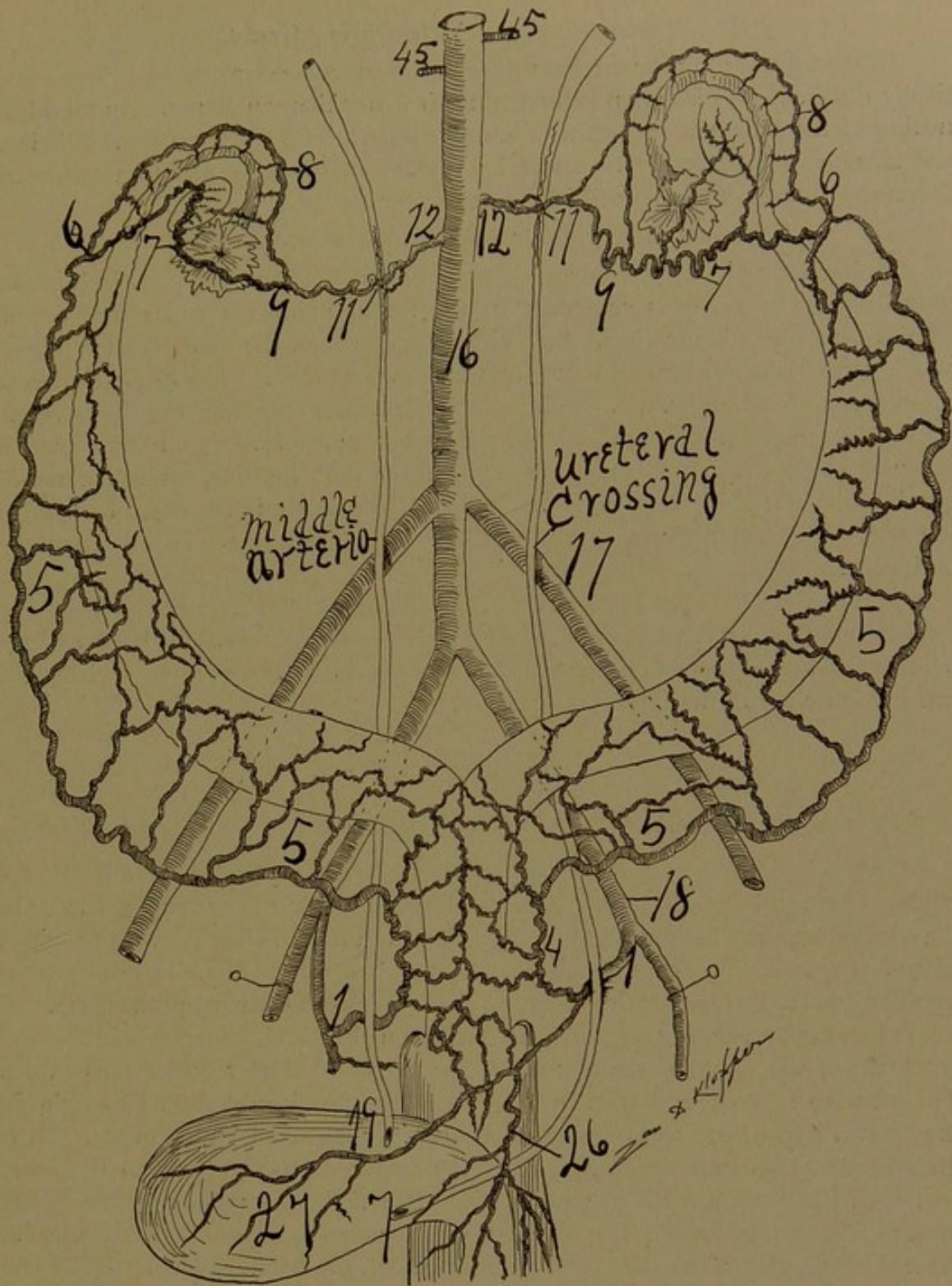


Fig. 88—Dog. The utero-ovarian vascular circle drawn from a dried specimen injected in situ. The special characteristic is that the trunk of the utero-ovarian artery lies at considerable distance from the uterus and its horns. The oviducal segment also lies at quite a distance from the oviduct. In other words the rami laterales genitales in a dog are remarkably long while in the cat they are very short. There is a distinct ovarian vascular circle 6, 8, 9; 6, 7, 9. The vesical (27) and vaginal (26) arise as a single trunk. The ureter lies ventral to the pelvic floor segment (1 to 4) see general description, page 82.

The Ovarian Vascular Circle During Gestation.

In the advanced pregnant state the ovarian vascular circle is large and beautifully distinct. A dissection demonstrates it better than an X-ray. In the illustration of the pregnant subject it is quite distinct. The long and short helicines are large and distinct. The short helicines were well likened to tendrils by Johannes Mueller, for they coil in markedly spiral states.

Summary in Regard to the Ovarian Vascular Circle.

In the vast majority of subjects there is a distinct ovarian vascular circle. The ovarian vascular circle is composed of the ramus oviductus and ramus ovarii. The ovarian circle is practically the oviducal segment of the utero-ovarian artery, and is located in the ligamentum latum and mesosalpinx. The circle begins at the utero-oviducal angle, *i. e.*, at the middle bifurcation, and ends at the pavilion, *i. e.*, at the proximal bifurcation of the utero-ovarian artery. In a typical ovarian vascular circle the ramus oviductus emits three long helicine, while the ramus ovarii emits five short helicine to the ovary. The ovary is the central organ of the ovarian vascular circle, which nourishes it by emitting branches from the periphery.

The ovarian vascular circle (the oviducal segment) allows the oviduct to be removed without severing it by incising the mesosalpinx close to the border of the oviduct. The ovary may be extirpated without severing the circle by incising the mesovarian close to the hilus.

CHAPTER V.

THE OVARIAN SEGMENT OF THE UTERO-OVARIAN ARTERY.

This segment extends from the bifurcatio arteriæ uterinæ proximal (the oviducal pole of the ovary), to the aorta, near the origin of the renal artery. In the ovarian segment is found the proximal arterio-ureteral crossing with proximal arteria ureterica. The ovarian segment begins at the proximal bifurcatio arteriæ uterinæ, and ends at the original location of the Wolffian body along the aorta.

The ovarian segment begins at its origin on the ventral surface of the aorta and ends at the external coalescence of the ramus oviductus and ramus ovarii. This ovarian segment traverses in a spiral course proximally from its origin on the ventral part of the aorta, immediately distal to the renal, to the ovary. It is directed distalward and lateralward, lying beneath the peritoneum on the inner border of the psoas muscle, in an extensive areolar bed. It passes ventral to the ureter. Thus the whole spiral segment of the utero-ovarian vascular circle lies ventral to the ureter, but the ureter passes through the genital vascular circle and ventral to the straight segment of the genital circle (aorta, com. iliac, int. iliac).

At the margin of the pelvis the ovarian segment curves medianward, enters the ligamentum latum, constituting an essential part of the ligamentum suspensorium ovarii, and anastomoses with the oviducal segment completing the spiral segment of the utero-ovarian vascular circle. It is accompanied by the ovarian veins, and the vasa ovarica crossing the ureter forms the proximal arterio-ureteral crossing. The reason the ovarian segment is so long is that the genitals passed distalward on assuming the erect attitude. It accompanies the ureter to the sacro-

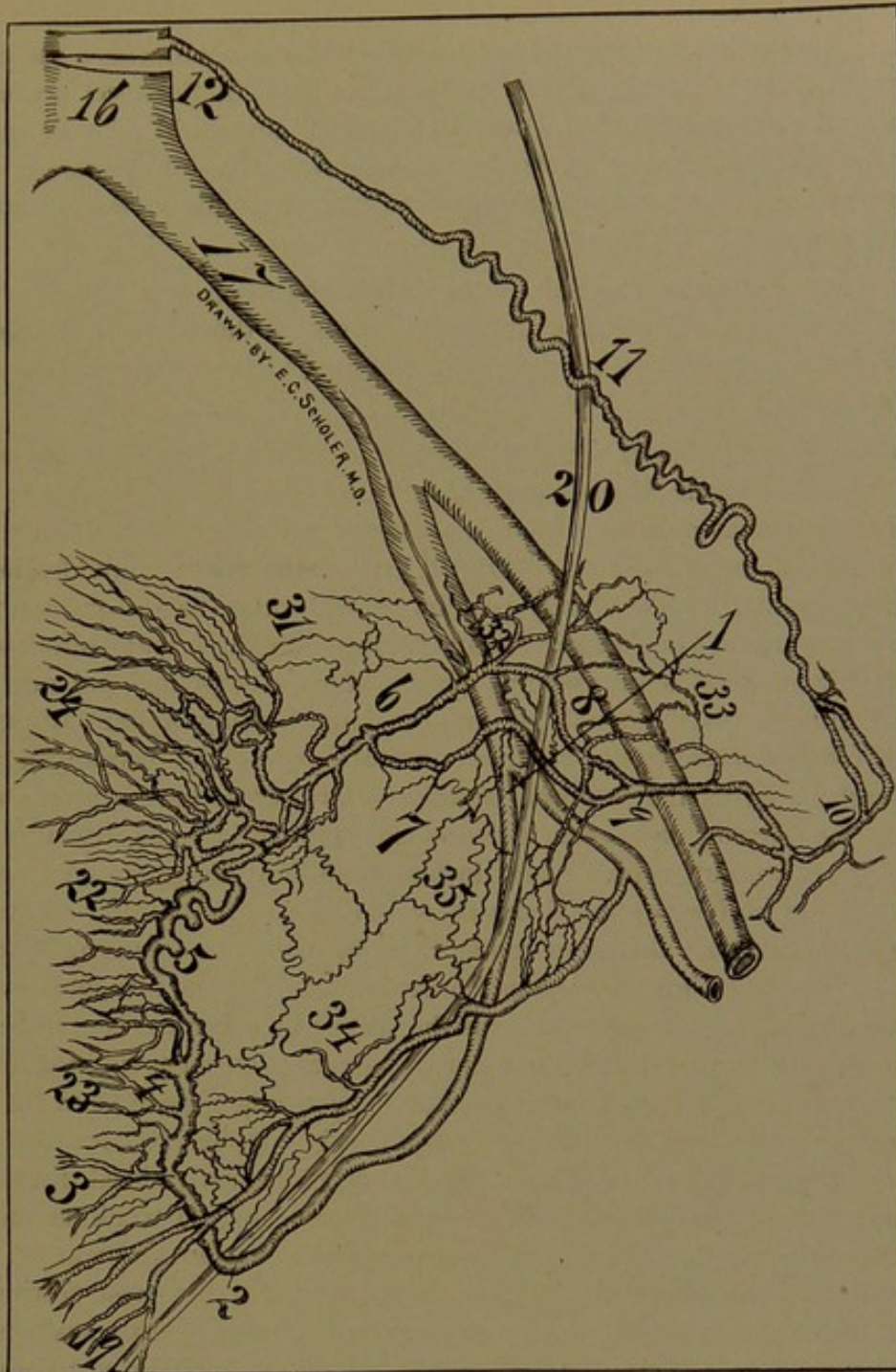


Fig. 89. Subject 53 years of age, showing the utero-ovarian artery remarkably large in the post climacterium. The genitals were injected in situ. The uterus possessed a large cervix with large cervical branches. The fundus was large with also large arteries. The corpus was small with small arteries. The corpori laterales uteri appear late in pubertas and disappear early in the climacterium. The arteria uterina was 3 inches long from its origin to the distal artero-ureteral crossing and 2 inches from the crossing to the uterine border; i. e., the pelvic floor segment was 5 inches in length. The os uteri internum as demonstrated by corrosion anatomy is the point where the rami laterales genitales make one of their great diverging angles, i. e., the rami laterales corporis and fundus pass proximalward while the rami laterales cervicis and vaginales pass distalward. Note that the ureter passes ventral to the uterine artery proximally, while it passes dorsal to it more distalward; i. e., at the distal artero-ureteral crossing.

The vascularity of this subject's internal genitals is well preserved. The ovarian vascular circle (6, 8, 9—6, 7, 9) is small but distinct. The artery of the ligamentum latum (34) and extra ovarian arcs and arcades (35) are distinct. The uterine segment (4, 5, 6) is still spiral at 53 years old. The subject was a multipara having had 6 children. A wire was passed through the ureter as noted in cut. For numbers see general description page 32.

iliac joint. The genitals originally were located at the point where the ovarian artery springs from the aorta and in man's assumption of the erect attitude the genitals passed distalward into the pelvis elongating the spiral ovarian segment. The right ovarian segment lies on the distal vena cava for a short distance. When well injected almost the entire ovarian segment may be plainly viewed through the dorsal peritoneum.

The arteria ureterica proximal, or the ramus ureteris proximal, of the utero-ovarian artery is a branch which supplies the ureter, at the point of crossing, the proximal arterio-ureteral crossing and is located at the apex of the uretero-venous triangle (author).

The ovarian artery arises from the aorta, and after passing one inch laterally distant it emits a branch which passes parallel to the main trunk as far as the ureter, whence it anastomoses with the proximal arteria uterica emitted at the proximal arterio-ureteral crossing. After it crosses the ureter it divides into two main branches, which course closely parallel to each other as far as ligamentum suspensorium ovarii. The smaller branch divides into three main terminal divisions at the ligamentum suspensorium ovarii, which it supplies, and one of the branches reunites with the trunk of the ovarian, forming a kind of vascular arcade. From the aorta to the proximal ureteral crossing the ovarian segment is almost straight. From the proximal arterio-ureteral crossing the artery rapidly increases in its spirality and when it enters the ligamentum suspensorium ovarii it assumes its maximum spirality and looped condition, being bound in a loose mobile bed of connective tissue. From the proximal arterio-ureteral crossing the ovarian segment courses, almost in contact and parallel to the external border of the ureter as far as the ligamentum suspensorium ovarii. The intimate or distant relationship of the ovarian segment with the ureter in its entire course bears an individual variation. Generally the ureter and ovarian segment lie in contact, or as far as one-half inch distant from each other. It would appear from the X-ray and subsequent dissections that the ureter is not only supplied by an artery at the proximal arterio-ureteral crossing, but also the large branch emitted distal to the crossing and coursing parallel to both ureter and main ovarian trunk, supplies the ureter with additional branches. The course of the ovarian segment is: after coalescence of the ramus oviductus and ramus ovarii in the mesometrium and ligamentum infundibulo pelvicum it passes through the ligamentum suspensorium ovarii, constituting an essential part of it over the pelvic brim, proximalward, on the ventral surface of the psoas muscle ventral to the ureter (forming the proximal arterio-ureteral crossing), to its origin from the aorta adjacent to the renal artery. It may send branches to the ovary, pavilion, ureter and mesosalpinx. The artery passes dorsal to the sigmoid on the left side and dorsal to the distal end of the enteron and coecum on the right side. The X-ray, as well as dissections of the pregnant uterus, demonstrates that the ovarian segment at its distal end emits numerous smaller and larger branches to the mesometrium and ligamentum suspensorium ovarii, as well as adjacent structures, aiding to form the extra-ovarian arcs and arcades. The exact point of external coalescence of the ramus oviductus and ramus ovarii, the demarcation between the oviducal segment and ovarian segment, is variable as well as the location of the external poles of the

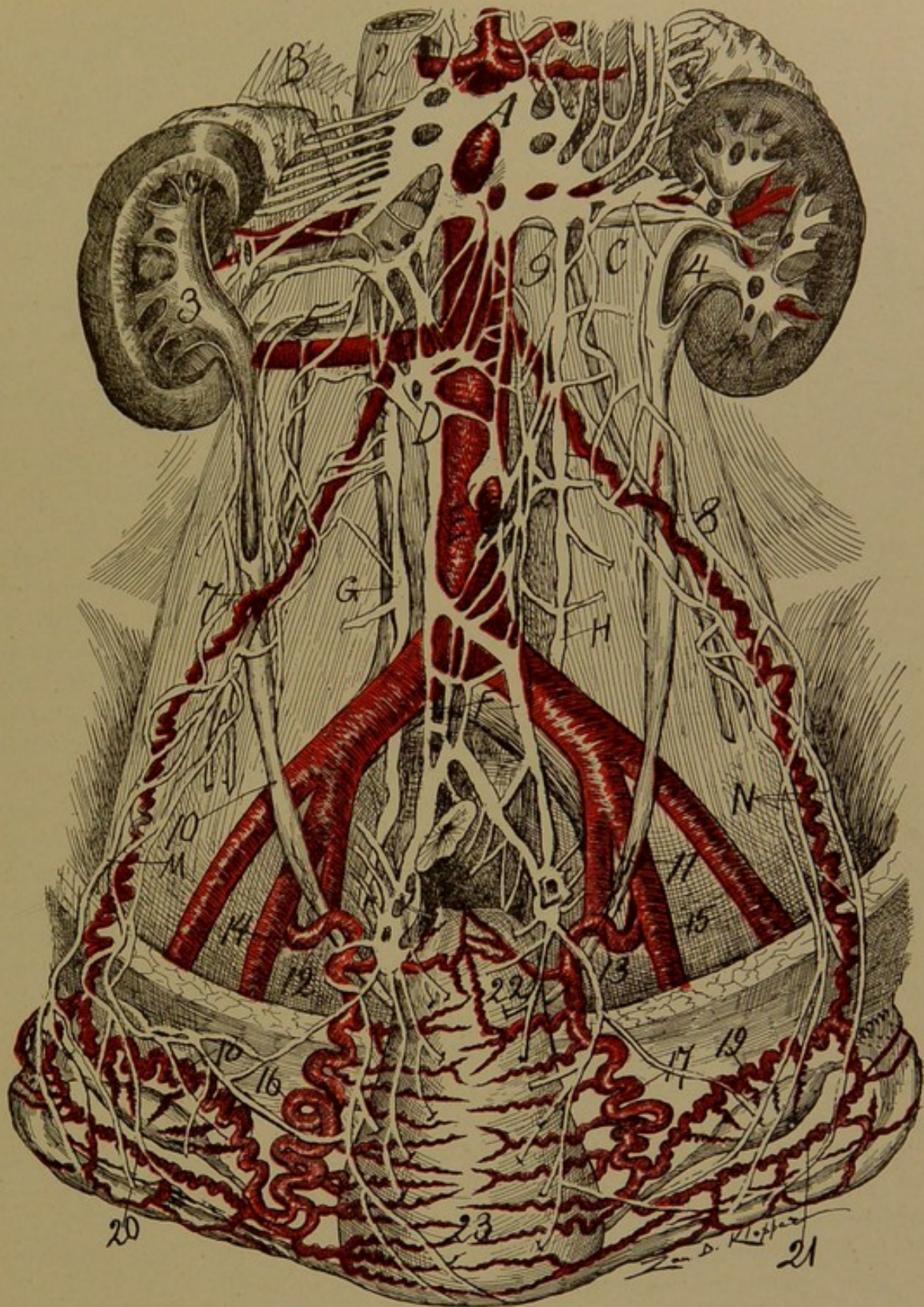


Fig. 90—Subject pregnant about 3 months. This cut presents the genital vascular circle with the fundus of the uterus drawn distalward. The sympathetic nerve accompanies the genital vascular circle. The central oligemic uterine zone is apparent. For general description see page 32 and Fig. 73.

ovary. No fast and hard lines can be established as regards the exact limits of the two segments. The ovarian segment forms an acute angle with the aorta in man. In most animals the angle is acute. In the rabbit, cat, leopard and dog it is a right angle.

The oviducal segment forms a right angle with the ovarian segment at their junction. It is impossible to fix the precise point of anastomosis of the utero-ovarian artery, as they insensibly glide into each other. At first the ovarian segment is practically straight, later more distally it is flexuous, which exists in all ages. It is always spiral at its distal end. It is the most flexuous and spiral in pregnancy. At the external pole of the ovary it divides into the ramus oviductus and ramus ovarii. The ovarian segment increases relatively the greater in pregnancy as was distinctly shown by my animal experiments. The ovarian artery is larger at the ovary than at its origin from the aorta. At its origin from the aorta in man and all animals examined it is straight for some distance. It forms a rod or cordon of vessels and a peritoneal ridge. Its smallest caliber is at its proximal end. Its spirality is approximately fixed by a venous plexus. The veins are nearly straight. The whole artery is surgically accessible. Its mobility is limited. It sends few branches to adjacent tissue. This artery emits a number of branches to the ligamentum latum. The oviduct and ovary are partially suspended and supported by the ovarian segment. It is the essential infundibulo-pelvic ligament. Myomata in the uterus show increase in the ovarian segment. It shows a mighty development in gestation, especially in the early half, both in man and animals. The most excellent example of an ovarian segment is found in the pregnant cow, which being well-injected, is very large. The largest and strongest ovarian segment I found in the horse.

In such cases renal anomalies would likely be present and collateral circulation established. Barthol cites a case with the two ovarian segments absent in a woman who had only one kidney and four supra-renal capsules. The ovarian segments may arise from a common trunk from the aorta. They may be emitted from the aorta at different levels. They may arise from the superior mesenteric. Absence of one ovarian segment is reported as not rare; however, I have never observed such a case.

The X-ray and corrosion anatomy shows distinctly the ovarian segment emitting branches to anastomose with branches of the renal arteries. This proves absolutely my original proposition that the original vascular arches of the genitals were formed in the Wolffian body. Since the kidney originated from the Wolffian body its vessels should be anastomosed with vascular branches of the genitals, which is the anatomic fact. The branches of the distal end of the ovarian segment assume a recurrent course in consequence of the shifting of their place of origin due to elongation of the segment. The distal end of the ovarian segment crosses ventral to the arteria iliaca externa.

The ovarian segment gives branches to the lymph nodes, and adjacent cellular tissue. One branch of considerable size supplies to the renal capsule and was termed by Von Haller *adiposa Ima*.

The left ovarian segment is subperitoneal and visible in its entire course. The right ovarian segment is concealed by the root of the mesenterium and ap-

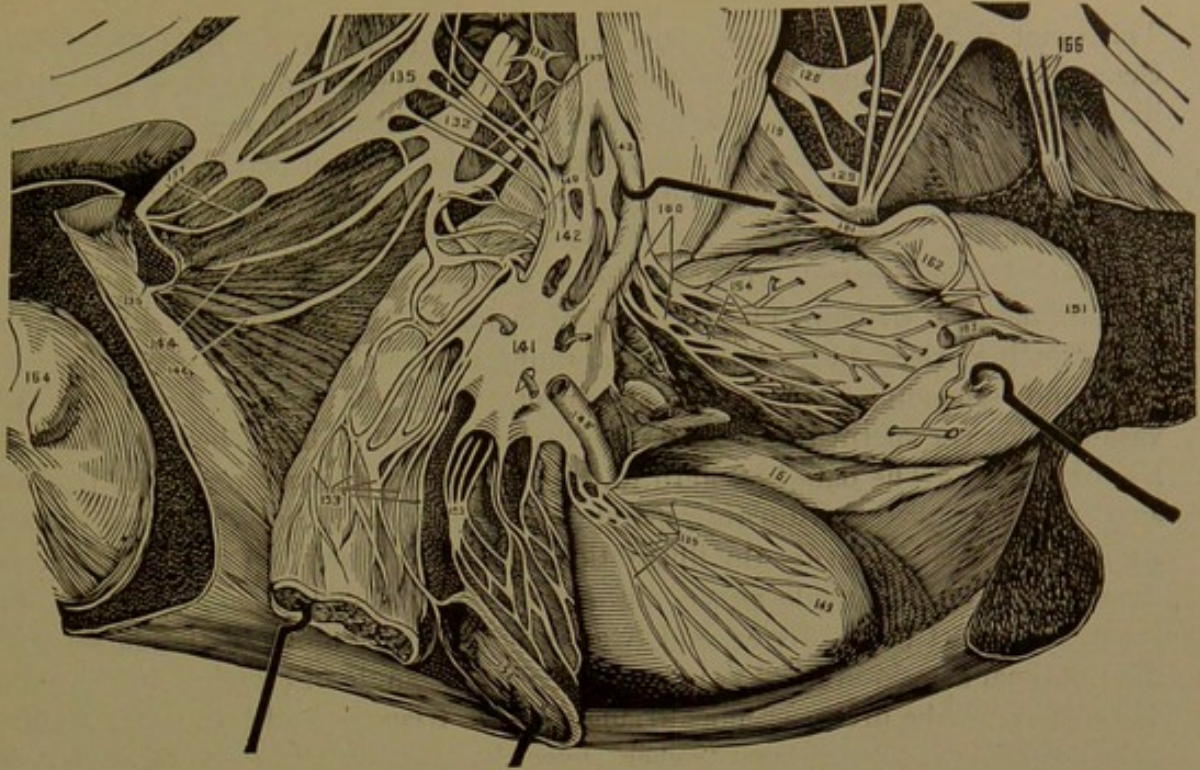


Fig. 91—Ganglion pelvicum—pelvic brain (1 and 2)—which innervates the utero-ovarian artery and uterus. This subject was a spare one and I dissected it with care under alcohol. It presents an abundant nerve supply. It is the great reorganizing center for the internal genitals.

pears subperitoneal in its distal portion only. In woman the distal segment of the ovarian segments passes through the thick strong ligamentum suspensorium ovarii and from it at this point radiate many small branches. In the cow this same ligament is large, muscular and strong, receiving radiating branches. Sometimes the right ovarian segment may arise from the right renal or an accessory right renal. Sometimes in the dog the ovarian segment passes dorsal to the ureter, and from the indefinite accounts in human anatomies it is likely that occasionally the ovarian segment passes dorsal to the ureter in man. This would be an accident of development in the Wolffian body, *i. e.*, the chief genital vascular arc passed dorsal to the ureter instead of ventral, as in the normal condition.

The right ovarian segment crosses the ventral surface of the vena cava, in contact, and at an acute angle. It also crosses in contact with the ventral surface of the ureter at an acute angle, which I term the proximal arterio-ureteral crossing, at which point the ovarian segment emits the proximal arteria ureterica. The right colic arteries (branches of the superior mesenteries) cross ventral to the ovarian segment as well as the distal end of the ileum.

The left ovarian segment is crossed ventrally by the left colic artery (branch of the inferior mesenteric).

THE PROXIMAL ARTERIO-URETERAL CROSSING.

The ovarian segment crosses ventral to and in contact with the ureter. The proximal arterio-ureteral crossing is always an acute angle in man. In dog, cat and rabbit it may be a right angle. The location of the proximal arterio-ureteral crossing lies at the apex of the uretero-venous triangle or triangle of the author.

This point varies from a short space distal to the kidney, to the right iliac fossa. Generally the proximal arterio-ureteral crossing occurs proximal to the crista iliaca and the right arterio-ureteral crossing is more distally located than the left. The vasa ovarica must cross the ureter because the ureteral pelvic or renal pyramids were originally developed external to the origin of the vasa ovarica. Where and how or the exact location and relations of the vasa ovarica and ureter at the proximal arterio-ureteral crossings shows a noteworthy variation of assertions among anatomic writers. The variation of claims as to the proximal arterio-ureteral crossing arises chiefly from not separating the female from the male anatomic data, and, secondly, from inexact statements, e. g., the anatomist will say the vasa-ovarica (or spermatica) crosses the ureter without adding whether it be ventral or dorsal. The data in regard to the ovarian and spermatic vessels, females and males, should be distinctly separate. However, it is nearly always a male subject which is chosen for the illustrations, yet every observing anatomist knows that the male and female vessels differ materially in course, in relation to the psoas, in respect to the ureter, and from difference in contour of the dorsal wall the proximal arterio-ureteral crossings differ in the angle of crossing and location of the apex of the uretero-venous triangle or the triangle of the author. Rudinger says that the ureter runs "ueber" over the vasa ovarica. However, all of Rudinger's cuts show the vasa ovarica ventral to the ureter. In man I saw no subject where the vasa ovarica coursed dorsal to the ureter. Gegenbauer says the vasa ovarica crossed the ureter toward the inlet of the smaller pelvis. On account of the position of the dissected body (lying on the dorsum) the words over and under have unfortunately been employed instead of ventral and dorsal. This explains the varied statements from noted anatomists as Luschka, Henke, Rudinger, Cruveilhier. Also many contradictory statements occur in the development of any subject. From dissections of the Wolffian body it would appear that the proximal arterio-ureteral crossing should be well toward the kidney rather than toward the lesser pelvis. In woman the ureter distal to the proximal arterio-ureteral crossing lies medial to the vasa ovarica. The proximal arterio-ureteral crossing, in general, varies in location from the distal margin of the renal hilum to the brim of the lesser pelvis.

RAMUS URETERIS OR ARTERIA URETERICA MEDIAL.

At or near the point on the arteria iliaca communis, or on the arteria iliaca externa or interna, there arises a branch which passes to supply the ureter. Thorough injection and careful dissection is required, as the artery is easily ruptured.

RAMUS URETERIS OR ARTERIA URETERICA PROXIMAL.

The proximal arterio-ureteral crossing is located where the vasa ovarica pass ventral to the ureter on the lateral dorsal wall. The location varies from the distal margin of the renal hilus to the brim of the pelvis. The arteria ureterica is a constant T-shaped vessel which supplies the ureter, coursing both proximalward or distalward on the ureter.

The ureter is nourished from two points of the spiral-segment, viz.: At the distal and proximal arterio-ureteral crossings, and from the straight segment at the middle arterio-ureteral crossing.

Spiral segment (utero-ovarian artery), 1, 2, 3, 4, 5, 6, 7-7', 6-8, 9, 10, 11, 12, 13, 14, 15.
 Straight segment abdominal aorta, 16. Common iliac, 17, and internal iliac, 18.

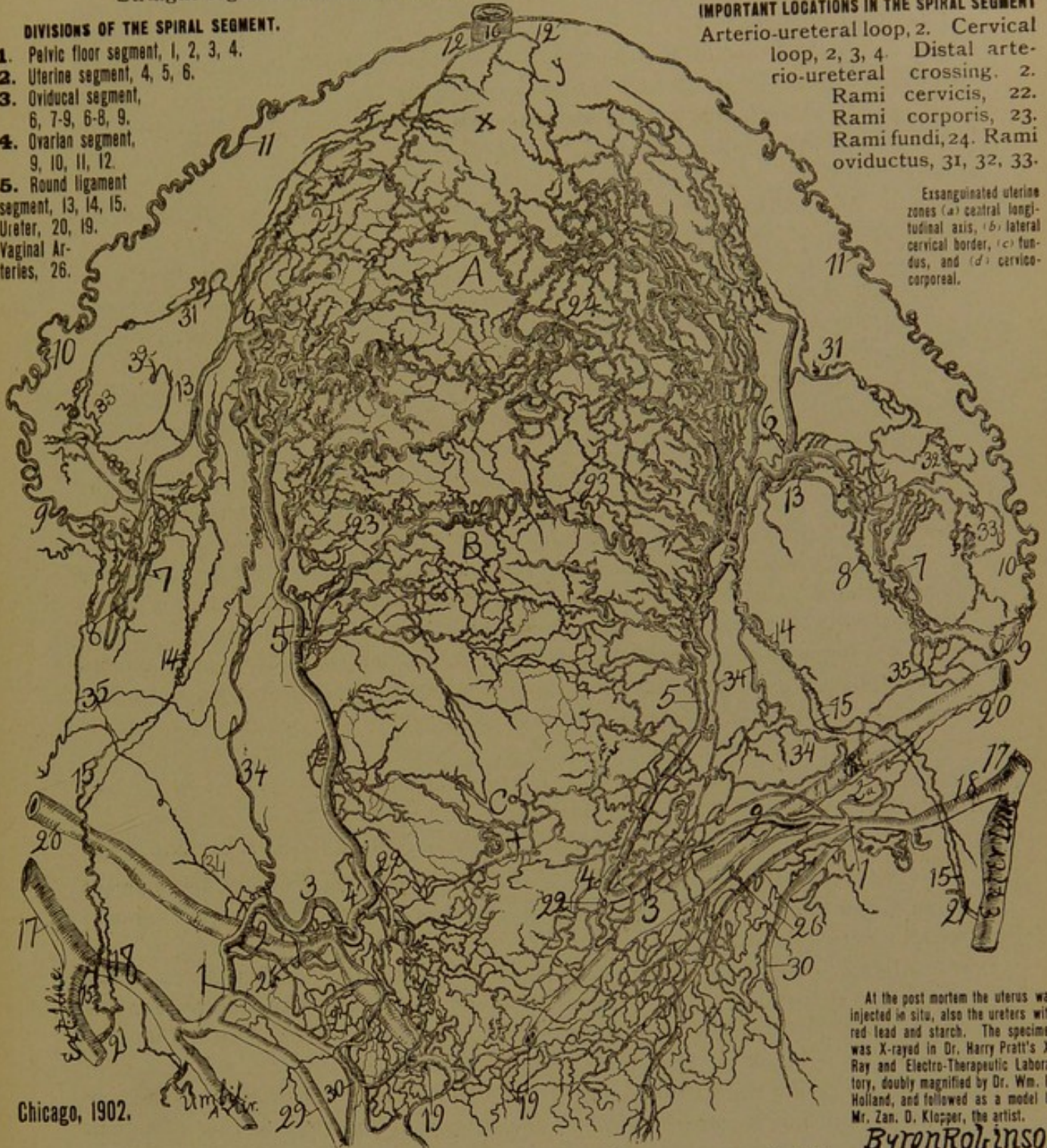DIVISIONS OF THE SPIRAL SEGMENT.

1. Pelvic floor segment, 1, 2, 3, 4.
2. Uterine segment, 4, 5, 6.
3. Oviducal segment, 6, 7-9, 6-8, 9.
4. Ovarian segment, 9, 10, 11, 12.
5. Round ligament segment, 13, 14, 15.
- Ureter, 20, 19.
- Vaginal Arteries, 26.

IMPORTANT LOCATIONS IN THE SPIRAL SEGMENT

- Arterio-ureteral loop, 2. Cervical loop, 2, 3, 4. Distal arterio-ureteral crossing, 2. Rami cervicis, 22. Rami corporis, 23. Rami fundi, 24. Rami oviductus, 31, 32, 33.

Exsanguinated uterine zones (a) central longitudinal axis, (b) lateral cervical border, (c) fundus, and (d) cervico-corporal.



At the post mortem the uterus was injected in situ, also the ureters with red lead and starch. The specimen was X-rayed in Dr. Harry Pratt's X-Ray and Electro-Therapeutic Laboratory, doubly magnified by Dr. Wm. E. Holland, and followed as a model by Mr. Zan. D. Klopper, the artist.

Byron Robinson.

Arterial Circulation of the Puerperal Uterus.

Four Hours Post Partum— $\frac{1}{2}$ Life Size.

Illustrating the Utero-Ovarian Vascular Circle (the Circle of Byron Robinson).

Fig. 92.—Death was induced by invagination of the uterus immediately following parturition due to atrophy of the fundus by reason of the dragging of a large powerful omental and peritoneal band in consequence of a ventral hysteropexy performed four years previously.

The ovarian segment of the utero-ovarian artery experiences marked age and functional relations :

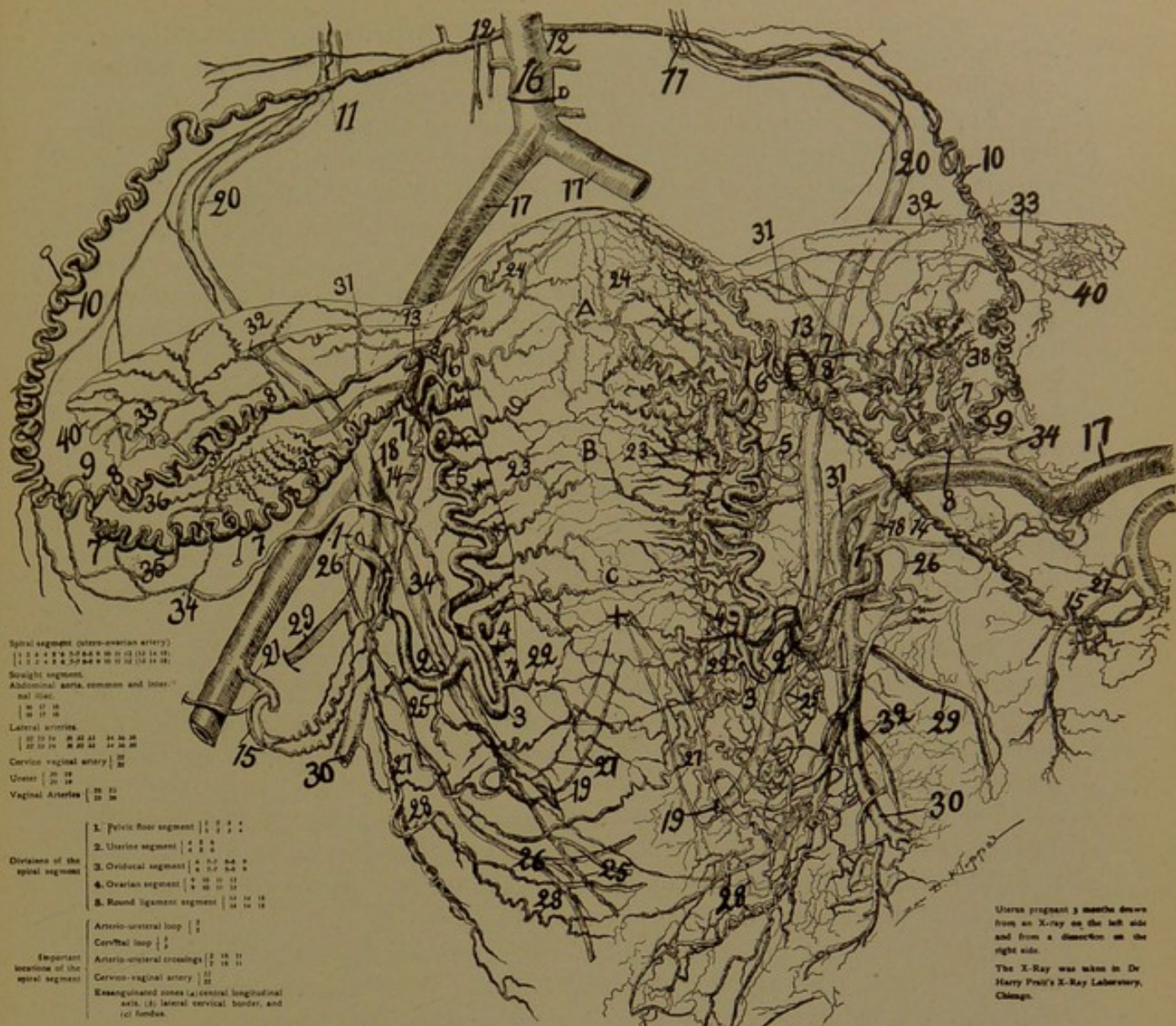1. *In Pueritas* (1 to 12 years)—It is non-developed, quiescent. Slightly spiral. Parenchymatous cells (muscle, elastic) limited.
2. *In Pubertas* (12 to 15 years), crisis—It rapidly springs into active life. Its caliber and spirals increase. Its parenchymatous (elastic muscular) cells develop.
3. *In Menstruation* (15 to 48 years), crisis—Its caliber and spirals become still further increased, muscle and elastic cells grow.
4. *In Gestation* (9 months), crisis—Its caliber and spirals become rapidly increased, especially in the first half of gestation. The ovarian segment becomes completely developed in gestation. The parenchymatous cells (muscle and elastic) develop rapidly.
5. *In Puerperium* (3 to 5 months)—The ovarian segment is thrown in a coiled condition from shortening its length. It experiences involution. Its spirals are now the greatest in life.
6. *In Climacterium* (45 to 48 years), crisis—Arterio-sclerosis begins atrophy of parenchymatous cells (muscle and elastic) and proliferation of connective tissue cells. Spirals and caliber decrease.
7. *In Senescence* (48 years until life ends), quiescence, the arterio-sclerosis is active and calcification may arise. Extensive pathologic degeneration of parenchymatous cells (muscle and elastic) occurs with proliferation connective tissue cells. The ovarian segment diminishes in its caliber and spirals and becomes straight again as in pueritas. The segment of the ureter supplied by the arteria ureterica proximal degenerates and dilates.

CHAPTER VI.

THE UTERO-OVARIAN ARTERY DURING GESTATION.

The utero-ovarian artery experiences during gestation a mighty development from origin to origin. The portion of special development is the uterine segment with its rami laterales uteri.

Should oviducal gestation occur similar excessive development arises in the oviducal segment with its rami laterales oviductus. The objects required for this study are the advanced pregnant and recently delivered uterus. In this investigation I have employed the uterus of man, monkey, baboon, ape, dog, cat, cow, sheep, pig, rabbit, deer, guinea pig, leopard and horse. All these animals show a similar and mighty development of the utero-ovarian artery during gestation. Because of the structural relations of the uterine and oviducal segments in man it is difficult to observe distinct local differentiations on any single segment of the utero-ovarian artery during gestation. In animals on account of structural relations, distinct localized differentiations in the course of the utero-ovarian artery may be observed during gestation; e. g., in the long uterine segment of the pig, dog, cat and rabbit it is plainly evident that there is a more mighty development of the rami laterales uteri at the location of gestation than at other points.



The Utero-Ovarian Vascular Circle. (THE CIRCLE OF BYRON ROBINSON)

Fig. 93—Represents the central longitudinal exsanguinated uterine zone A, B, C. Uterus pregnant 3 months, age 32 years. At 22 the lateral cervical oligemic zone is observed, formed by the dichotomous divisions of the ramus cervicis, one branch passing dorsal to the cervix and the other ventral to the cervix. 22. It makes a distinct vascular bootjack angle. The left side of the uterus was dissected, while the right was X-rayed. 4, 5, 6, the uterine segment of the utero-ovarian artery. 19, 19 distal orifices, of uterus. Cervical loop (2, 3, 4). Ovarian vascular circle (6, 8, 9—6, 7, 9). For numbers see general description page 32.

Human pregnant and recently delivered uteri for inspection, X-ray, corrosion anatomy and dissection, are everywhere limited. Ample material, however, of the domestic animals may be obtained from the slaughter-house and other places. Since the utero-ovarian vascular circle in animals is practically if not exactly similar to that of man and higher apes, the main factors of development in circulation are the same in animals and man during gestation.

The preparation by dissection of the numerous arteries of a pregnant uterus and the several layers of the same is a tedious and time-robbing process. However, the treasures of nature yield to labor alone and are rich in rewards.

The pregnant uterus should be injected with red lead and starch through the aorta proximal to the kidneys or through the external iliac distal to the deep epigastric. The red lead will cast a shadow by the X-ray which will enable the dissector to conform to the plan of direction of the rami laterales uteri. Both the X-ray and the dissection demonstrates the uterine segment, passing in a winding course on each lateral border of the uterus. They show that the trunk or uterine segment does not lie in the myometrium, but at a variable distance from it, differing according to the animal species, in the ligamentum latum. In its winding course along the lateral uterine border the uterine segment gives off continuously lateral branches both to the uterus, ligamentum latum and mesosalpinx. The rami laterales uteri arise from the trunk or uterine segment by two methods, viz.: (a) each lateral branch springs independently from the trunk and is destined for the ventral or dorsal wall of the uterus especially found in the corpus and fundus; (b) each lateral branch springs from the trunk of the artery and subsequently divides dichotomously, to supply the anterior and posterior surface of the uterus especially found in the cervix.

The general rule of origin of the rami laterales uteri is to arise independently from the uterine trunk or segment and to be destined either for the ventral or dorsal uterine wall. In the cows as a rule they arise as a single branch from the uterine and divide dichotomously, the branches supplying the ventral and dorsal uterine wall as in the enteron.

The dorsal uterine wall receives more and larger branches than the ventral. In fact, as shown in the exact X-ray of the pregnant uterus, confirmed by dissections, the main division of the uterine segment supplies the dorsal uterine wall well toward the fundus, the usual placental site.

Are there more rami laterales uteri in the gestating than in the resting adult uterus? I think the number is the same in both. Well injected pregnant uteri show through the X-ray vastly more lateral branches than dissections. Injections in pregnant uteri show more lateral branches than injections in resting uteri because in resting uteri the injection fluid cannot be made to penetrate the very fine spiral thick walled arterioles. The gestating and consequently expanding uterus may shift and modify the rami laterales uteri, especially those of the cervix.

The claim made by Soemmerring that a uterus which had experienced the puerperium could be distinguished from a nulliparous uterus cannot be presumed, as myomata or other uterine irritation may produce similar effects as gestation. Neither can the statement of the same distinguished author that any ramus lateralis uteri exceeds the trunk of the uterine segment be accepted in any of my dissections. The rami laterales uteri vary very much in size and number not only in individuals but on the different sides of the same individuals. Greater numbers and larger vessels nourish the dorsal uterine wall. In one case of nearly three months' pregnancy which I dissected on the right side I counted sixteen rami laterales uteri, besides the cervico-vaginal, and ten of them passed to the dorsal and six to the ventral uterine wall. Most of the dorsal rami laterales uteri were larger than the ventral.

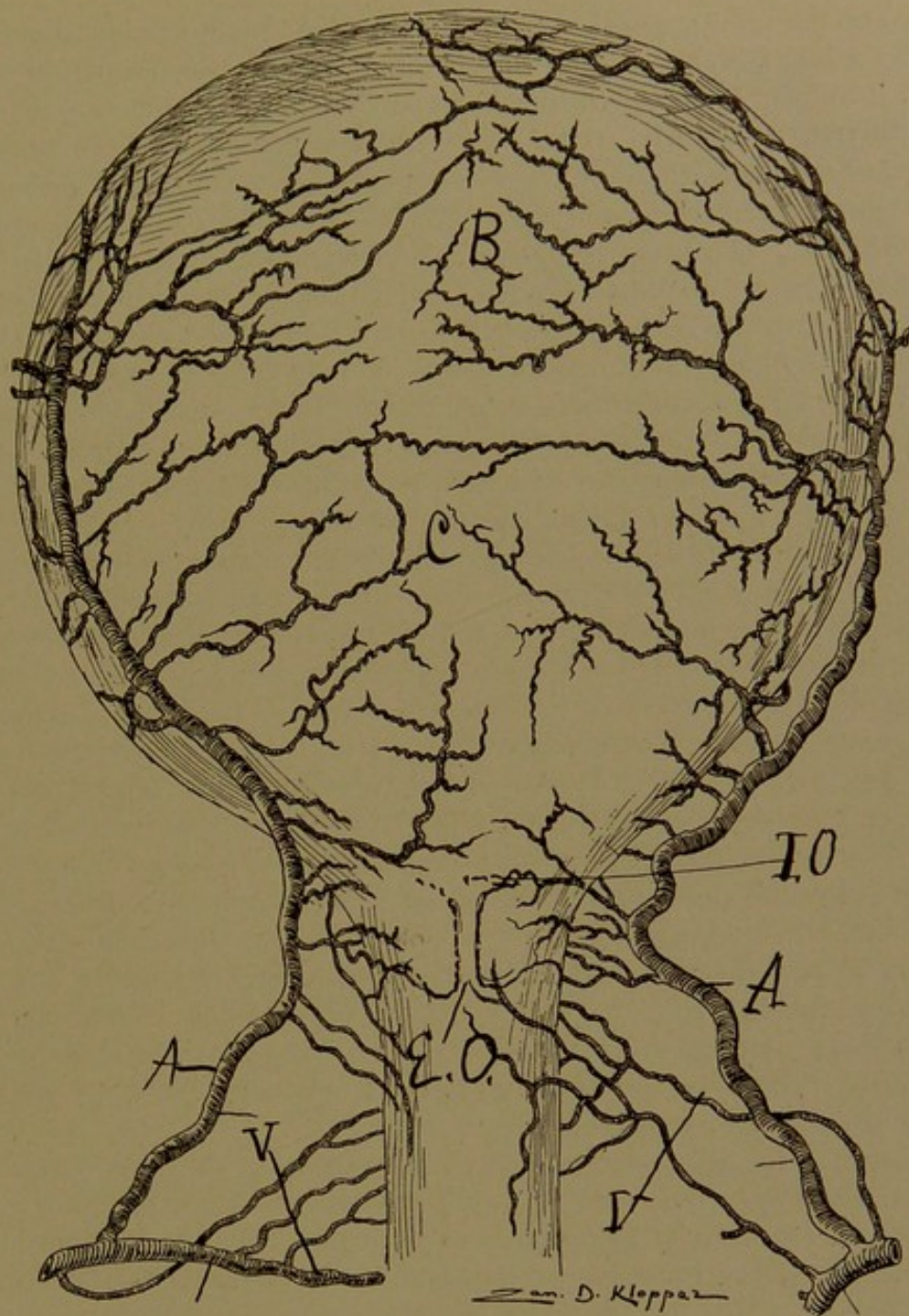


Fig. 94—(Dr. Semmy Davidsohn)—Half natural size. Puerperal uterus of a 31-year old. IV—Para, perforation of the biliary passage by hepatic calculus followed by a parturition at the 7th gestative month. Peritonitis and death 24 hours post partum. Ventral view. Two, respectively 3 arteria vaginales spring on each side from the arteria hypogastrica right from the arteria uterina. On the right 2 smaller vaginal arteries pass to the os externum. On the corresponding place, left, there is one artery for the cervix and vagina. The left cervix is further supplied by 2 small vaginales, while the right has one large one of several divisions. The ventral uterine surface is supplied by an anastomosing arterial net work. Immediately proximal to the internal os 2 arteries pass in the substance of the uterus and still more proximal ward 2 considerable sized ones to the dorsal segment of the corpus. Left, four arteries may be noted supplying the corpus, the strongest supplying the dorsal wall of the uterus. Observe that the arteria uterina bilaterally is almost straight, while the rami laterales uteri are spiral.

Some of the rami laterales uteri, especially those of the cervix and fundus, divide like a fan, *i. e.*, one branch will divide at its periphery into three smaller ones. It is difficult to decide whether such peripheral divisions always supply the same or different myometrial strata. X-rays of my specimens, as well as those of P. Fredet on uterine sections cut transverse to the longitudinal axis, demonstrate that the several peripheral branches of the lateral ramus may supply different myometrial strata. Unfortunately the ventro-dorsal X-ray does not allow one to differentiate between rami laterales uteri which supply the ventral and dorsal uterine wall. However, personal dissections on a uterus after an X-ray aids very much in unfolding the plan of distribution of the rami laterales uteri.

I have observed in different dissections of uteri that a ramus lateralis uteri not infrequently springs distally to but supply segments of the uterus proximal to other rami, *i. e.*, they cross each other. I have never seen the reverse except in the cervix. In other words, a ramus laterales uteri may supply a segment of the uterus entirely proximal to the one above it, or the reverse in the cervix. In pregnancy of three months the rami laterales uteri may be three-quarters to one inch long between the uterine segment and the lateral borders of the uterus.

The number of rami laterales uteri are very variable, not only in different individuals, but on different sides of the same uterus. In a well-injected pregnant uterus the X-ray will demonstrate over twenty. If one attempts to dissect the same generally one-quarter is lost. I have personally tried this process under favorable circumstances, and when the X-ray shows twenty to twenty-two rami-laterales on one side, dissections on the other shows about sixteen.

At the placental site a strong network of blood vessels are visible. This is because, first, the vessels at the placental site are especially developed, which though not so prominent in man, is plainly demonstrated in animals, *e. g.*, dog, cat, pig, cow, rabbit. Second, because the smaller arterioles of the uterus are capable of being injected during gestation, from increase in caliber. My observation convinced me that the vessels at the placental site are not only developed more in animals but also in man than adjacent ones.

In gestation the whole arteria uterina ovarica from the very origin of its tripedal arch to the periphery of its rami laterales genitales experiences a peculiarly great development in both man and animals. However, it is in animals that the rich, localized, excessive development of the vessels at the placental site can be observed. Also the long uterine horn of the cat, rabbit, dog, pig, cow, etc., enables one to note the difference of development between the general development of the utero-ovarian artery and its localized development at the placental site. A curious feature in pregnancy is that each foot (ovarian, aorta) (uterine, internal iliac) and round ligament artery (external iliac) of the tripedal arch enlarges from its exact origin to its anastomotic termination without producing marked enlargement of the arteries from which they arise (aorta, internal and external iliacs).

THE SIZE OF THE UTERO-OVARIAN ARTERY IN GESTATION.

The utero-ovarian artery increases in length during gestation. According to my observations it increases three times over the resting state. A treble increase would make the uterus during pregnancy receive six times the quantity of blood that it receives during the resting state. In the lower animals the increase

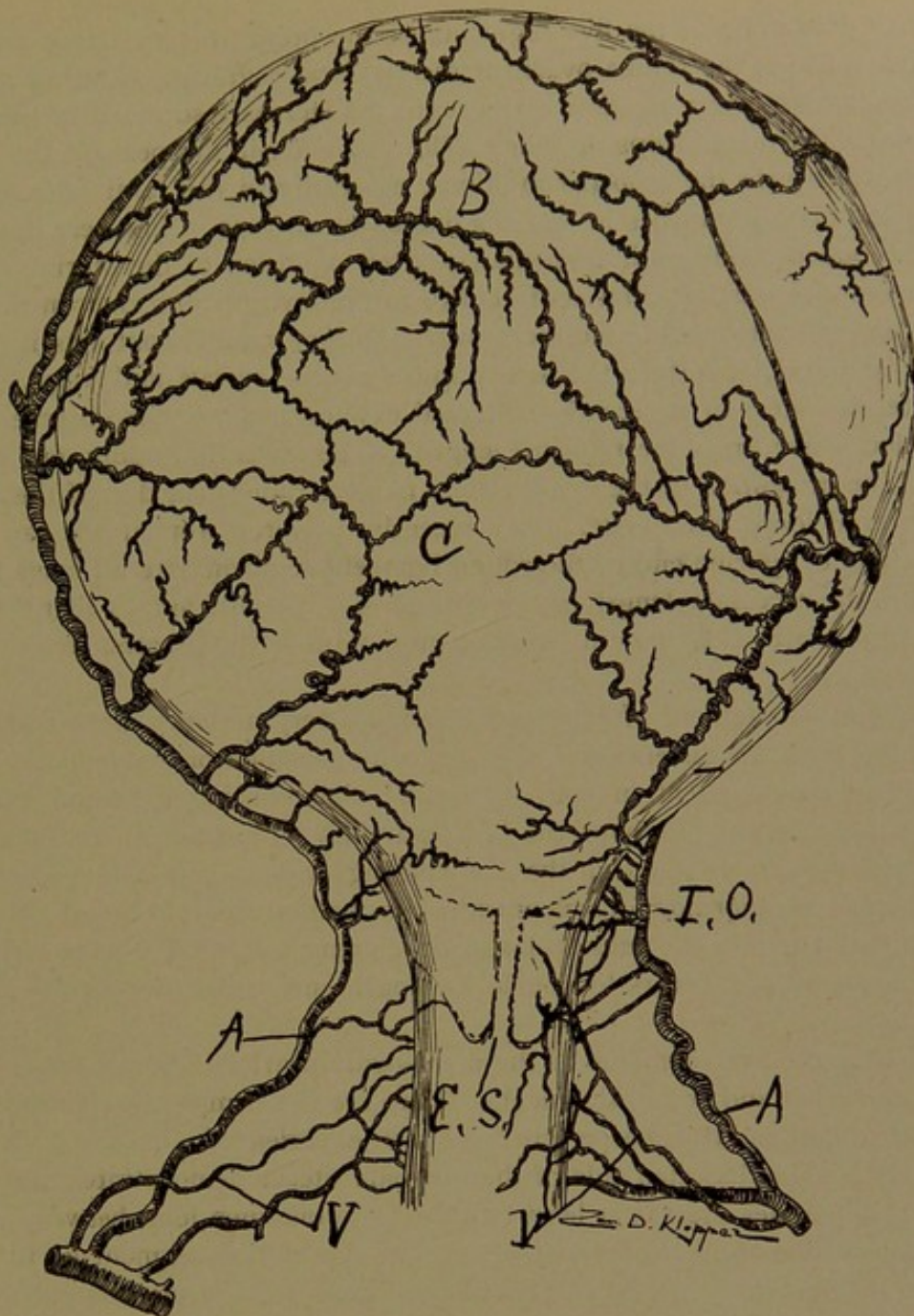


Fig. 95—(Dr. Semmy Davidsohn)—Fig 95 is a dorsal view of Fig. 94. Observe that the rami laterales uteri on the dorsal uterine wall are larger than those on the ventral uterine wall.

of the utero-ovarian during gestation is fully treble or greater than that of man. This is especially marked in multiple gestation as the pig, dog, leopard and rabbit. In the cow the increase of the utero-ovarian artery during gestation is enormous, relatively greater than that in man. However, the cow's genitals are relatively larger than those of man.

THE APPEARANCE OF THE UTERO-OVARIAN ARTERY DURING GESTATION.

The terms employed to describe the state of the utero-ovarian artery during gestation are: Spiral, tortuous, winding, coiled tendril shape, sinuous or looped. The terms spiral and looped are perhaps the most appropriate and accurate. In

pregnancy every one of the five segments of the utero-ovarian artery are spiral. The most spiral is the ramus ovarii of the oviducal segment. During gestation the utero-ovarian artery in some of its segments increases so much in length that it becomes thrown into loops or coils. The cow and pig are perhaps the best examples to illustrate the looped conditions, especially in the rami laterales uteri, where some of the branches lie in coils like so much rope. The best time to observe the looped condition is immediately after expulsion of the uterine contents, as there is more elasticity and contractility in the myometrium than in the utero-ovarian artery, hence, while the utero-ovarian artery rapidly contracts it does not contract so rapid, therefore the artery must assume spirals and loops. In the rami laterales uteri of a recently delivered cow or pig one can observe coils of arterial loops five times the required length. The loops lie in piles, one over the other. The involution of the myometrium is more rapid than that of the arteries, hence arterial loops must arise. In a recently delivered woman one can note in the proximal or uterine end of the round ligament segment arterial loops three to four times the necessary length of the structures. It would appear that the corporeal, but especially fundal rami laterales uteri acquire the greatest length during gestation.

The uterine segment of the utero-ovarian artery assumes more and more a straight line with the distention of the uterus by gestation or myomata.

The ovarian segment in both man and animal during gestation assumes a mighty development. Perhaps the best examples of prominent development of the ovarian segment is found in the cow and pig, which, by injection after expulsion, assumes an enormous development. In women the portion of the uterine segment that assumes the most colossal development is what I have termed the cervical loop, which appears to double its length and caliber during the first half of gestation.

I shall make five segments of the utero-ovarian artery; pelvic floor, uterine, oviducal, ovarian and round ligament. They are not completely developed until normal gestation and the puerperium have been experienced. Not only the X-ray side (left) but the dissected side of the pregnant uterus demonstrates that though each ramus laterales uteri is at least two-thirds to one inch long between myometrium and uterine trunk, some of the loops of the uterine segment lie in contact either on the ventral or dorsal surface of the uterus. This suggests extreme care in attempting to extirpate the uterus by severing the rami laterales uteri only (Pratt's method). If the uterus be not continually drawn distalward by traction forceps tension, such lateral projecting uterine segment loops may become severed. In the height of gestation a mere segment of a spiral becomes a considerable loop.

During gestation the spirals in all the arteries of the utero-ovarian system are increased, but so also is the myometrial surface, and hence the increase of spiral in the vessels is only relative. Looping of any portions of the utero-ovarian artery occurs in general where the uterus is subject to the greatest distension during gestation, as at the fundus and uterine end of the round ligament segment, also at the distal segment of the corpus and cervix.

Dissections and the X-ray demonstrate that the entire uterus is supplied by rami laterales which pass directly from the uterine segment. In the ordering of

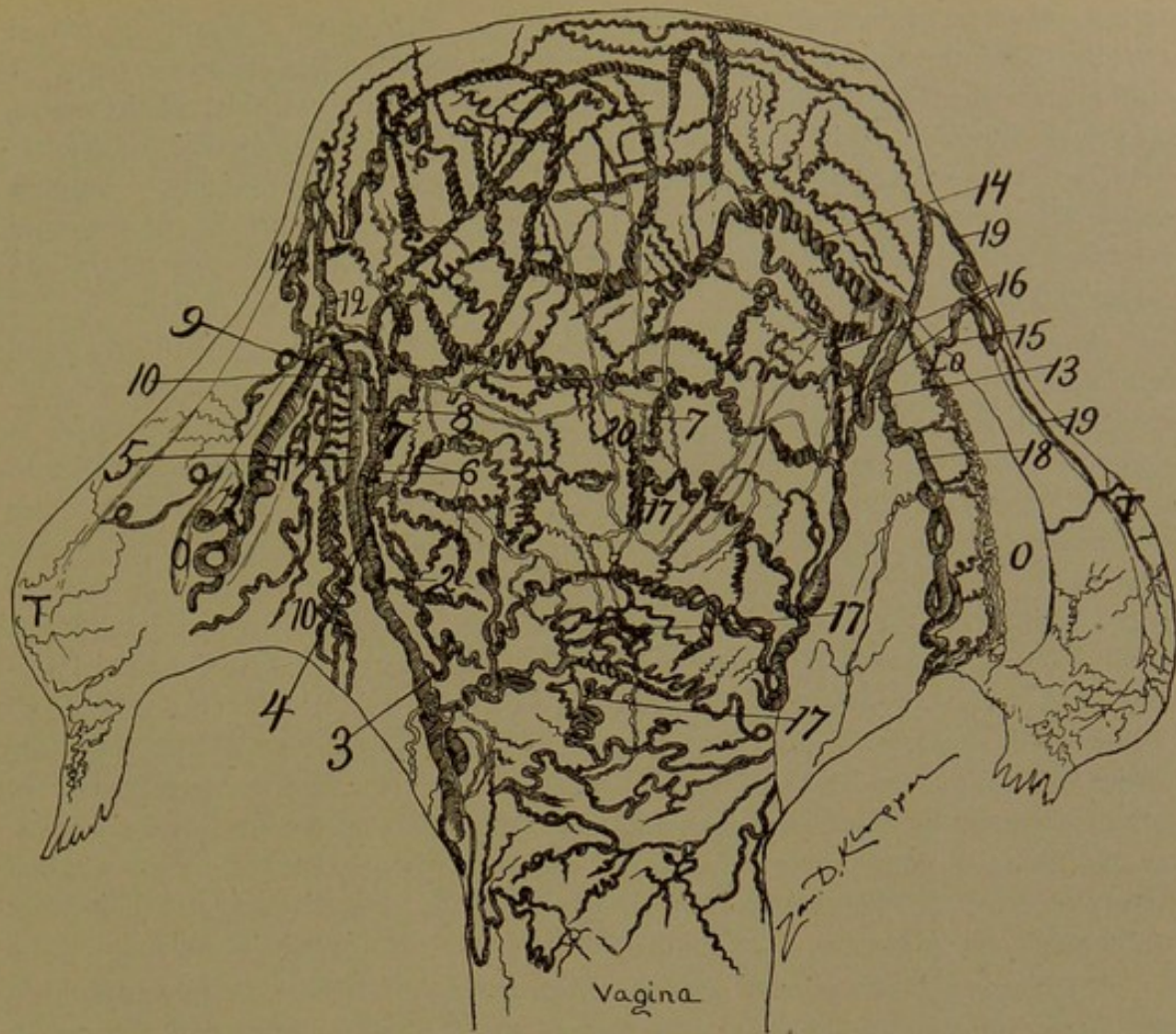


Fig. 96—(Dr. Wilhelm Nagel)—34 years. II—Para. Uterus 6 hrs. post partum, with injected arteries, dorsal view. O, o, ovarium, t, t, oviduct, l, o, ligamentum ovarium propria. 10, arteria ligamentum teretis sinistra. 15, arteria ligamentum teretis dextra. 11, arteria ovarica sinistra. 18, arteria ovarica, oviductus dextra. 19, ramus oviductus dextra. The dorsal wall contains larger arteries and more in number than the ventral wall. Thus the dorsal wall contains 7 long rami laterales uteri, right. Left side, the arteria uterina divides in 2 main branches, 4 and 5, at about the junction of the ligamentum ovarian with the uterus. 4 is the stronger of 2 temini arterial divisions (4, 5) of the left arteria uterina. The strong rami laterales uteri divide fork-like as 7, 8 and 9, which spread their numerous branches over the corpus and fundus and anastomose with the rami laterales uteri dextra. The weaker end branch (5) of the left side divides into three branches, of which 10, spiral shape, passes along the ligamentum rotundum uteri, while the second branch (11) becomes the ramus ovarii, and the third branch (12) becomes the ramus oviductus. On the right the arteria uterina divides into three end branches (13, 14, 14), (14, 14), ramus fundus uteri, 13, ramus, t, ramus oviductus 19, ramus ovarii, 15, arteria ligamenti teretis dextra. The transverse, longitudinal and perpendicular anastomosis is well shown in this excellent dissection. The smaller rami laterales uteri present a superficial net work. The larger rami laterales uteri present a net work in the central portion of the myometrium.

the rami laterales uteri I could not observe that the fixation and reflection of the peritoneum on the ventral and dorsal surface had any influence.

In a common work by Benckiser and Hofmeier, 1886, it is claimed chiefly by Hofmeier that the distal third of the uterus is supplied by very few rami laterales, but that the real blood supply of the uterus begins first where the peritoneum

reflects itself from the anterior surface of the uterus. In other words the proximal two-thirds of the uterus is the part which receives the main blood currents. I could not confirm Hofmeier's labors. In all my cases the distal third of the uterus was well supplied with rami laterales. Were Hofmeier's defective injections? The X-ray does not agree with Hofmeier's nor does corrosion anatomy. Another explanation may aid; in my injections of the uterus if any portion of the rami laterales failed to fill it was generally the distal ones or those of the cervix and distal end of the corpus.

These anatomic data are doubtless due to the angle of emergence of the rami laterales uteri. The chief injecting current passes through the pelvic floor segment of the utero-ovarian artery and the proximal rami laterales uteri pass off at an acute angle facilitating their prompt filling while the rami laterales of the distal corpus and cervix emerge at an exactly opposite acute angle, making their filling by injection more difficult. Again the pelvic floor segment is frequently severed very short, and when the injecting canula is inserted in the artery it is liable to pass beyond the distal emerging rami laterales uteri whence the distal rami will receive only that part of the injection secured by anastomoses of the rami laterales uteri. By this defect in injection one is liable to overlook the non-injected distal rami laterales uteri. Also the distal rami laterales uteri are frequently limited in number and hence large. Besides the cervix and distal corpus may be supplied chiefly by distalward coursing rami laterales from the level of the corpus. In my X-ray specimen, here presented, it will be observed that the cervico-vaginal artery supplies a wide range both distalward and proximalward, and if it were overlooked the false view of no distal rami laterales uteri would be evident.

Dr. Semmy Davidsohn of Hanover, Germany, in an excellent monograph on the arteria uterina and the distal uterine segment, 1892, claimed that the cervix of the puerperal and non-gravid uterus is supplied by more arterial branches than the pregnant uterus. This, Davidsohn claimed, rested on unfolding of the proximal and of the cervix during gestation. My observations have been opposed to those of Dr. Davidsohn.

Some obstetricians claim that the deficient number of rami laterales on the distal end of the uterus is necessary to explain the non-haemorrhage in placenta praevia, because after delivery in placenta praevia the distal uterine segment remains slack, non-contracted, with scarcely any hemorrhage. Why is there no haemorrhage in the puerperium of placenta praevia?

The answer is because the rami laterales course deeply in the meshes of muscular bundles which, after the expulsion of the uterine contents, contract like elastic or living muscular ligatures occluding uterine vessels. The large uterus becomes immediately small by contraction of the numerous muscular bundles which tightly grasp the arteries like a sphincter which rests in a contracted state.

Why is there so little haemorrhage after deep lateral cervical laceration?

First.—Because of the myometrical muscular bundles and second the elastic living ligatures, always on guarded tension even in a state of rest. Third, because the cervico vaginal artery divides dichotomously on the lateral border of the cervix in order that its vascular arms may surround and embrace the cervix. The cervical artery makes a vascular boot-jack angle on each lateral

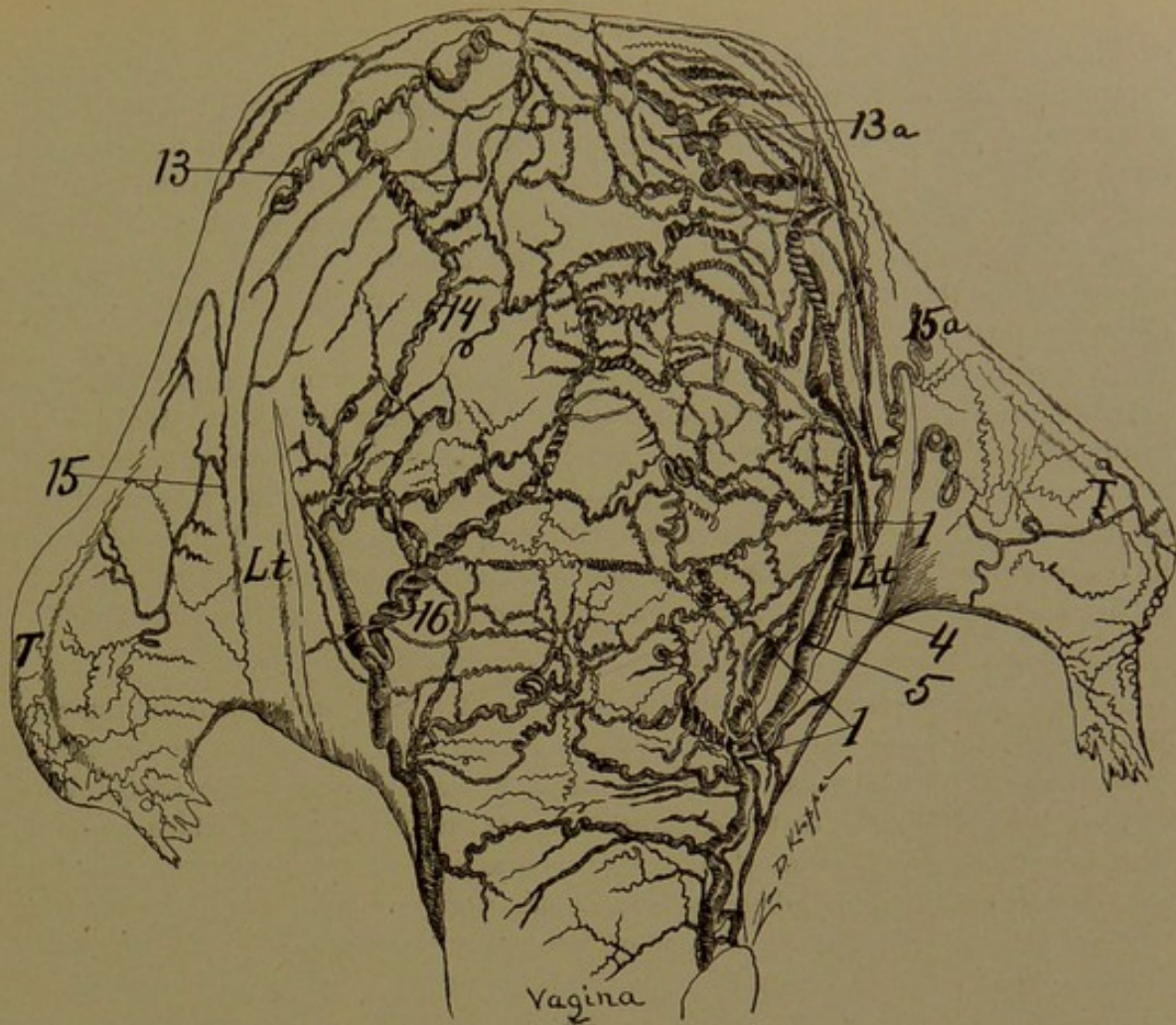


Fig. 97—(Dr. Wm. Nagel)—Uterus 6 hrs. post partum. Ventral, view of figure 96. Observe that the rami laterales uteri are less in size and number on the ventral surface than on the dorsal surface; the longitudinal and transverse anastomosis is evident.

cervical border and hence deep lateral cervical lacerations may occur without tearing vessels of any considerable size.

Second.—A large vascular stratum in the myometrium, the zona vascularis. These vessels visible to the naked eye course in extensive sheaths of white connective tissue. They form the chief vascular strata of the uterus.

Third.—There is a very fine, but very extensive vascular stratum in the endometrium. The three vascular strata, subserous, myometrial and endometrial, are solidly and compactly anastomosed by perpendicular vessels.

My X-ray cuts of pregnant uteri are excellent illustrations of the vascular bootjack angle or dichotomous division of the cervical artery on each lateral cervical border. The largest vascular arm of the cervico vaginal artery supplies the dorsal surface and also courses well proximalward on the uterus. It requires the actual dissection of the pregnant or puerperal uterus to indelibly impress on the mind that vast numbers of rami laterales uteri, the thousands of vessels, are surrounded by thousands of muscular rings (sphincters) and elastic fibers which are eternally on guard as muscular and elastic, living ligatures, controlling by constant tension the blood currents. Also after the expulsion of the uterine contents the rami laterales of the distal uterus, namely the cervix and distal end

of the corpus, becomes remarkably looped or coiled, which is due to the rapid contraction of the myometrium throwing the vessels into loops. The looped combination itself aids in controlling the blood because the loops lie clamped between the elastic fibers and muscular bundles which are always on tension. If one dissects the loops and coils carefully out of the surrounding white connective tissue it must appear plain that the elastic and connective tissue aids remarkably in preserving the looped condition of the artery, hence aids in controlling the blood stream.

From my dissections on numerous uteri, from X-rays on pregnant and non-pregnant uteri, and from corrosion anatomy, it appears to me that there is no distinct distal uterine segment based merely on the supply of rami laterales uteri.

During the state of rest the injected segment of the round ligament shows some exceeding fine lateral branches. During gestation the well injected round ligament artery shows numerous good sized lateral branches which not only supply the round ligament but also the adjacent structures, as the peritonium.

VASCULAR ANASTOMOSES IN THE PREGNANT UTERUS.

The anastomoses of the bilateral rami laterales uteri are numerous, intimate and extensive. This form of anastomosis renders the circulation in the uterus solid, compact and universal, insuring the immediate direction of a vast volume of blood to any location of the endometrium (or endosalpinx) on which an ovum may be attached. This anastomoses resembles the vast anastomoses found in the vasa intestina tenius where at a moment's notice of local enteronic irritation by food an immediate strong volume of blood may be directed to incite to motion and secretion local segments of the enteron or active digestion. The utility of any anastomotic circulation is its concentrative availability for immediate use at any required locality.

The compact anastomotic circulation of the oviducal segment enables the blood volume to concentrate itself at any locality (especially at the receptaculum seminis) of the endosalpinx that may be the seat of an attached ovum. The facility with which great blood currents in the uterus are directed toward points of local irritation or stimulation doubtless accounts for the rapid and persistent growths of myoma and malignancy.

The methods of vascular anastomosis in the pregnant uterus are accomplished by 3 directions, viz.: transverse, perpendicular and longitudinal. The vessels of the uterine anastomosis are very tortuous to the final terminals.

VASCULAR STRATA.

The pregnant uterus has: *First*, a well-developed subserous vascular layer easily followed by gross dissection. The vessels are very tortuous and when the peritoneum is torn from the myometrium they follow the serous coat. They lie in a limited bed of connective tissue.

TRANSVERSE ANASTOMOSIS.

Transverse anastomosis is the method by which the peripheries of the bilateral rami laterales uteri are limited in the (coalesced) median line. I injected a pregnant uterus through the right common iliac artery and in two minutes abundant quantities of the injected material was found in the left common iliac. (I injected the right and left common iliac veins and the fluid streamed

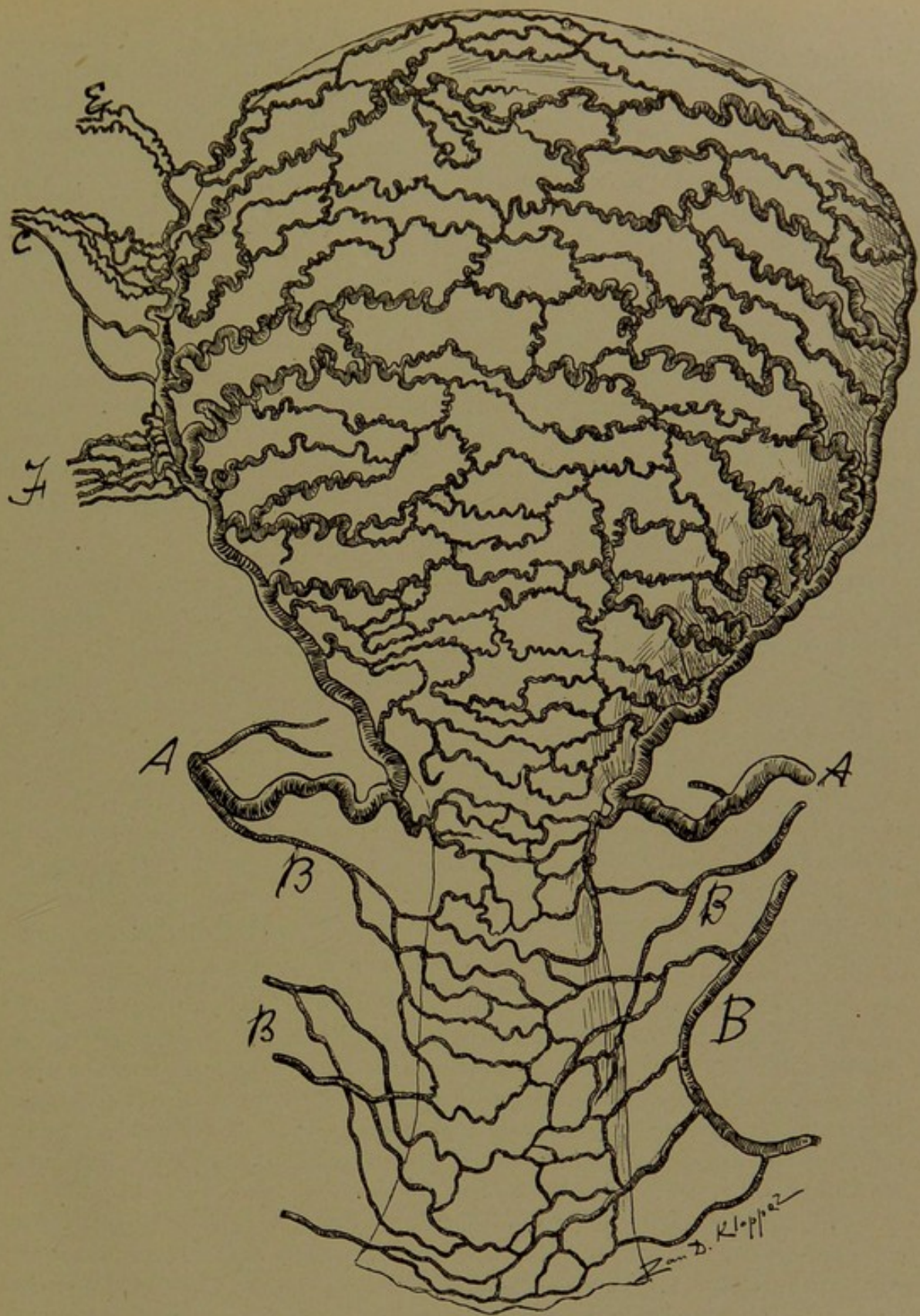


Fig. 98—(J. Hyrtl, 1873)—The arterial circulation of a pregnant uterus. Ventral view. The arteria uterina was injected with wax and subsequently the uterine tissue was corroded with acid. A, A.-arteria uterina. The principal trunks are less spiral, the parenchymatous branches (ramilaterales uteri) are strongly spiral. Observe transverse and longitudinal anastomoses. B, B, arteriæ vaginales are non-spiral. c, arteria ovarica. d, double anastomosis of same with the uterina. e, branch to oviduct. f, plexus to finger thick ligamentum rotundum uteri.

in large visible currents from one side to the other, filling bilaterally the utero-ovarian veins). This demonstrates that the transverse anastomosis of the uterus in pregnancy is very free, being formed by macroscopic vessels easily dissected and viewed in its plan, especially by a corrosion anatomy.

The transverse anastomosis representing the chief rami laterales uteri lie subserous and intra-myometrial. In the proximal portion of the uterus the anastomotic branches lie more centrally in the myometrium while in the distal portion of the uterus they lie more superficially external.

In general the arterial anastomotic vascular strata lie toward the center of the myometrium corresponding to the great zone vascularis. The region of especially intimate transverse anastomosis exists in the uterine fundus and proximal end of the corpus. Both gross dissection and the X-ray, but generally corrosion anatomy, demonstrate extensive transverse anastomosis in the proximal half of the uterus practically enclosed in the myometrium. In the cervix and distal end of the corpus the anastomotic strata lacks the numerous fine vessels and besides the stratum lies quite superficially in the corpus and cervix, in fact the anastomotic stratum approaches more and more the myometrial surface as it extends distalward on the uterus and vagina.

In animals as the cow, pig, dog, leopard and cat the cervical transverse anastomosis resemble that of man. The transverse anastomosis of the uterine horns is strong and large. The typical anastomosis is noted in the cow's uterine horns where the rami laterales uteri divide dichotomously, one branch supplying one side, ventral, of the horn and the other supplying the opposite, dorsal, resembling exactly the blood supply of the enteron.

The several vascular strata present different degrees of size in vessels and size of anastomotic network. There is the subperitoneal stratum of small calibered vessel and wide anastomotic network. The central myometrial stratum, layer, of large vessels and smaller-sized anastomotic mesh work and the endometrial stratum of fine, small calibered vessels and small size anastomotic mesh work.

THE LONGITUDINAL ANASTOMOSIS.

The X-ray of a pregnant uterus well injected with red lead and starch presents a solid and compact longitudinal anastomosis of the rami laterales uteri. It appears to me to be more extensive than that of the transverse. The strongest longitudinal anastomoses exists near the lateral borders of the uterus. In the center of the uterus the anastomoses are numerous, but the caliber of the vessels is smaller.


The different vascular strata in the longitudinal anastomoses present different sized vessels and meshes. The subperitoneal vessels are of small caliber and wire mesh work. The central myometrial stratum (*Zona vascularis*) presents large vessels with smaller anastomotic mesh work. In dissecting the pregnant uterus this can be easily recognized by the brighter color of the smaller caliber vessels and wide mesh work of the same. The endometrial anastomotic mesh work, as shown by corrosion anatomy, is extensive, but its vessels and mesh work are fine and small.

The longitudinal anastomosis may differ considerable on each side of the

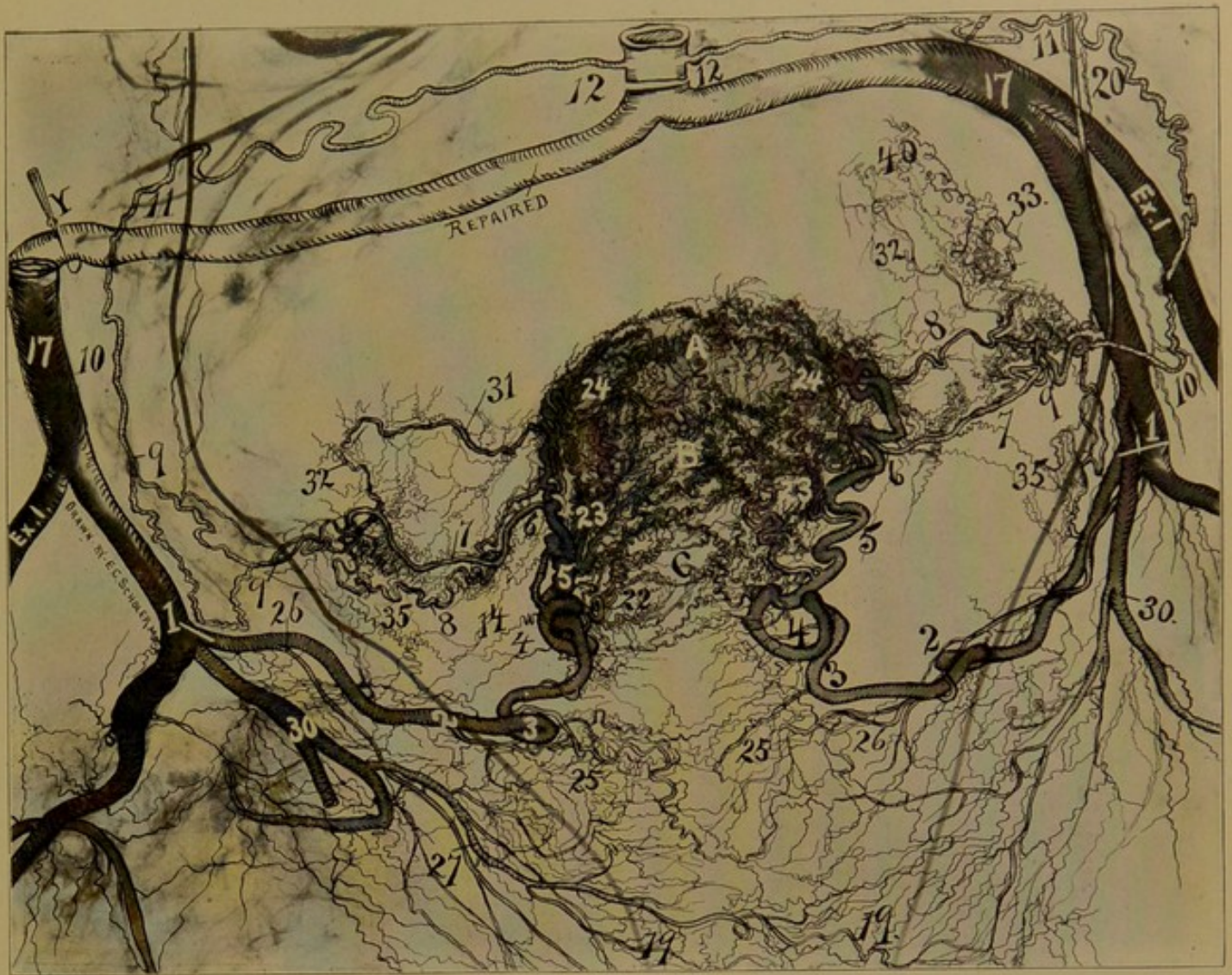

Fig. 99—Represents a subject 53 years of age with multinodular myomata in the uterine wall. The specimen was injected after removal from the body with red lead and starch. It was X-rayed and a bromide illustration was produced. Dr. Scholer, the artist, strengthened some of the weaker and repaired some of the defective shadows of vessels. The fact to observe is that, although this subject is 53 years of age, the presence of uterine myomata has so stimulated the arteria uterina that it is actually larger than is usual at 35 years of age. For size of vessels it resembles a pregnant uterus at 5 months. Note the loops of the uterine segment (4, 5, 6) and the distinct pelvic floor segment (1, 2, 3, 4). The ureters are marked by a wire (black line) which passed through them. The fact that the presence of uterine myomata stimulates the utero-ovarian artery to large size resembling that of gestation accounts for the continued and excessive hemorrhages of subjects possessing them. The cervical loop is very long and large on each side. The oviducal and ovarian segment are not so prominent as the pelvic floor and uterine segments. Observe that the smaller finer rami laterales uteri usually noted in active sexual life are not present, especially in the cervix. Also observe that rami laterales uteri on the left 4 and on the right 5 are very prominent, large and strong; these supply directly the large uterine myomata. This specimen resembles that containing the sarcoma of the endometrium in which the utero-ovarian artery was stimulated to the dimensions noted at the end of a 3 months' gestation. For numbers see general description page 82.

In gestation the utero-ovarian artery rapidly increases in length and volume, however, on account of the expanding uterus the arterial coils become unfolded, extended. In uterine myomata the uterus has similar irritation as in gestation, but the uterus remains small, and hence when the artery increases in volume and length it is compelled to coil in various directions, as noted in this beautiful X-ray half-tone.



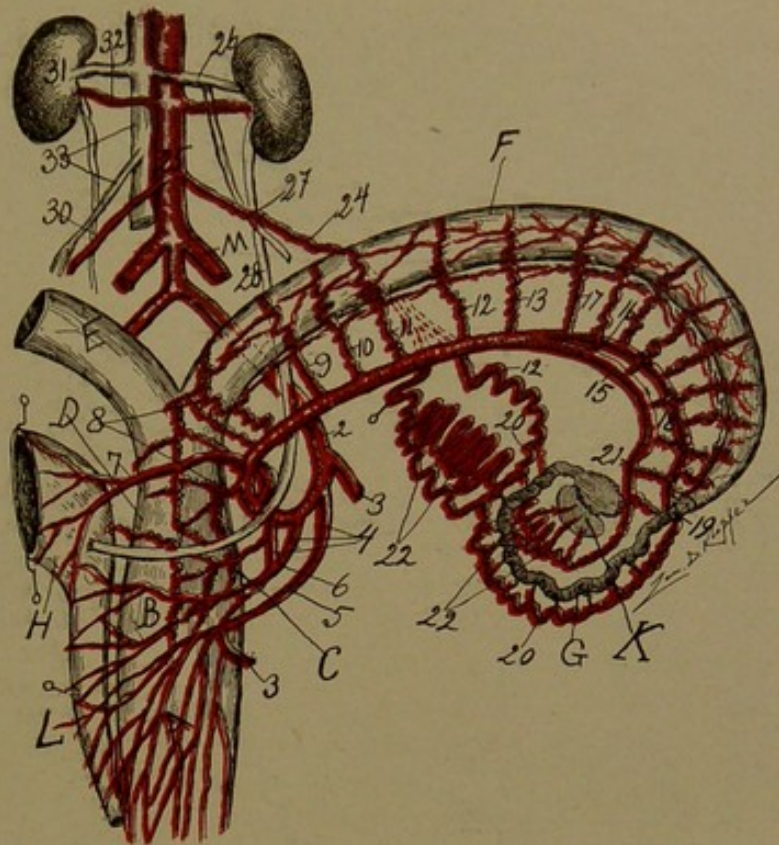


Fig. 100—Utero-ovarian artery of dog. A, vagina; B, cervix; C, line dividing cervix and vagina; D, corpus uteri; E, right uterine horn; F, left uterine horn; G, oviduct; H, bladder held by hooks; L, urethra (the bladder vagina and urethra were widely distended with air and divided to show exact circulation). K, ovary in a widely distended peritoneal pouch.

Ovarian segment 3 inches.

1, origin of uterine artery; 2, same before rectal branch is given off; 3, rectal branch; 4, 5, vaginal arteries which unite into two. Practically there is one large vaginal artery and one small. The smaller, 6, is a vesico vaginal artery. The multipara dogs in the dried specimens shows elegant transverse and longitudinal anastomosis with tortuous arteries at the vaginal fornices and posterior vaginal wall. 7, is the large vesicle arteries with 7 branches; 8, shows the 5 cervical and coporeal branches; 9, 10, 11, 12, 13, rami lateralis from uterine (horn) segment. 15, 16, are the divisions of the uterine (horn) segment into oviducal (16) and ovarian (15) branches. After the division into oviducal and ovarian branches the uterine horn is supplied by both branches (by rami laterales) as far as the origin of the oviduct, 17, 18, rami laterales from the oviduct (about 7, and ovarian branches (about 6). 19, points were the uterine born; branch passes into the oviducal; 20, 20, 21, is the ovarian branch which passes to join the ovarian segment, 22, 22, 22, are the 3 divisions of the ovarian segment which after two divisions of the ovarian segment which supply the ovary anastomose with the ovarian branch (21) of the uterine segment while the 3rd. branch of the ovarian segment (22), anastomoses with the oviducal branch (16) of the uterine segment. The ovary has 3 strongly spiral branches (rami ovarii), 23, 23, hooks drawing on the ovarian segment (24) which arises from the anterior surface of the aorta close to the renal artery. (25). 26, points to the origin of the ovarian (left) vein from the left renal vein. 27, is the apex of the uretéro-venous triangle. 28, ureter, which courses proximal (ventral) to the uterine artery at 29. At the proximal ureterio-arterial crossing the ureter may be anterior or posterior to the ovarian artery (In I dog at 27, the ureter was ventral to the ovarian artery). Note that at the distal arterio-ureteral crossing the ureter is ventral to the uterine artery—the opposite to that of man.

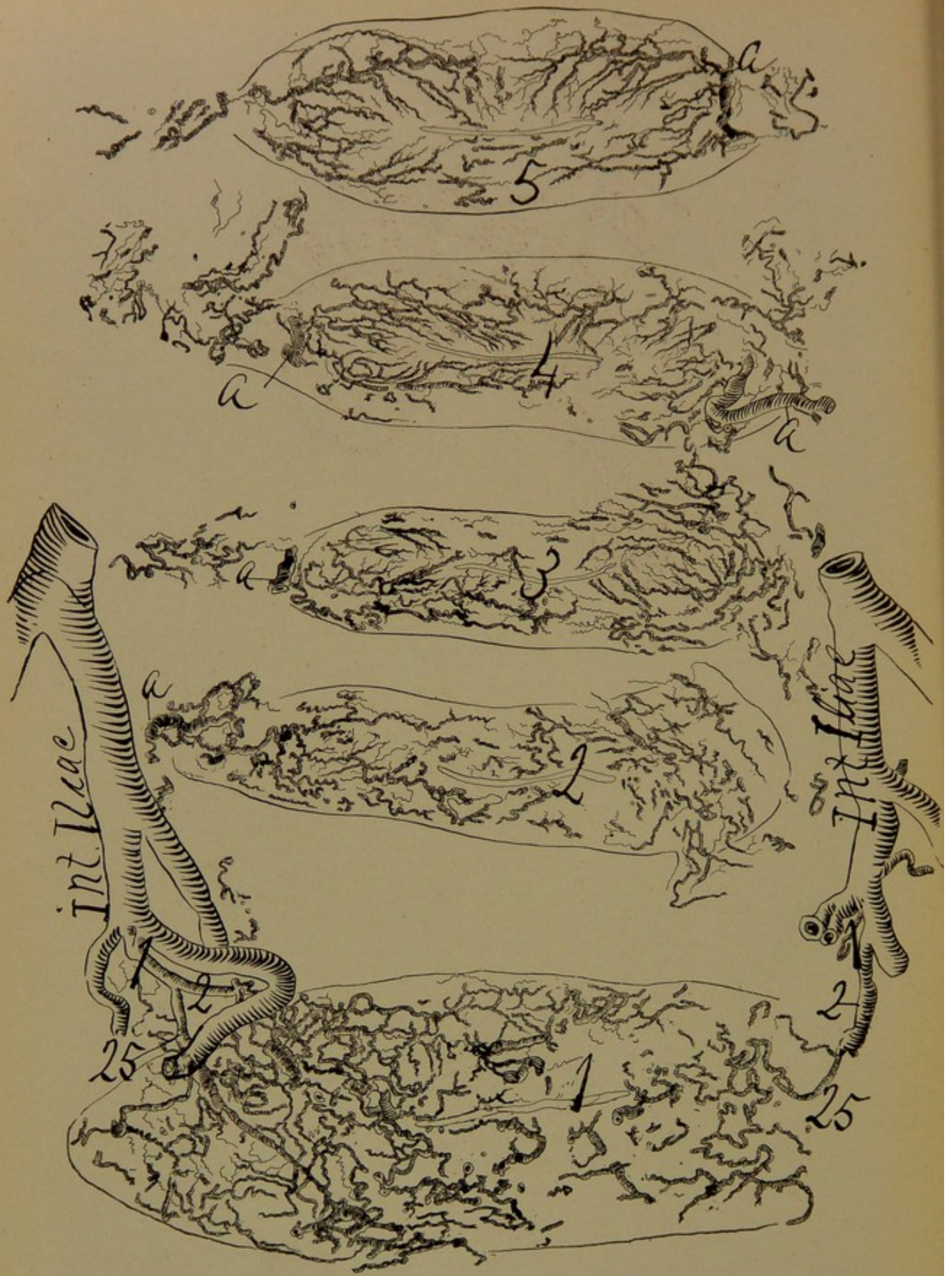

Fig. 101. For description see page 167.

Fig. 101—Transverse sections of a puerperal uterus from cervix to fundus 5 days post partum, to demonstrate the perpendicular anastomosis. The uterus was injected in situ with celloidin and vermilion. It presents a rich anastomosis in the myometrium. The 18 cross sections were about $\frac{1}{2}$ inch in thickness.

Sections 1 to 5 represent chiefly the cervix. However, section 1 is practically that of the vaginal fornices and it is connected by the uterine artery, 1 and 2 and by the vaginal, 25. In section 2 at a (the uterine artery) the dichotomous division forming the bootjack vascular angle, is well shown. The perpendicular anastomosis in the cervical myometrium is not so pronounced as in the corporeal myometrium.

same uterus. The most extensive longitudinal anastomoses exist toward the proximal end of the uterus. The myometrium contains the chief vessels, the main large branches constituting the transverse and longitudinal anastomoses.

PERPENDICULAR ANASTOMOSIS.

The perpendicular anastomosis of the rami laterales uteri consists of short vessels which unite the various planes of the vascular strata in a compact and solid general vascular network. By this method the 3 quite distinct layers of vascular network are connected viz.: the subserous, the myometrial and the endometrial. The superimposed vascular strata of the uterus are consolidated for functional purposes. The myometrium of course contains the chief rami laterales uteri and hence the strongest anastomoses—transverse, longitudinal or perpendicular. The most typical perpendicular anastomosis exists in the cow, pig and dog. The only accurate method to demonstrate the perpendicular anastomoses is by corrosion anatomy.

THE OVIDUCAL SEGMENT

experiences similar mighty development in pregnancy with the rami laterales uteri.

(a) The ramus oviductus mightily enlarged courses through the mesosalpinx emitting, in general, its 3 rami laterales oviductus as far as the oviducal pavilion where it joins with the ramus ovarii to form the distal end of the ovarian segment. It is flexuous but very slightly spiral. In well injected pregnant specimens vessels appear to pass from the ramus oviductus which were not visible in the resting uterus by the best kind of injections. It sends 2 to 3 long, large, sinuous, helicine arteries to the ovary.

(b) The ramus ovarii still larger and far more tortuous than the ramus oviductus courses along the distal border of the ligamentum ovarii, to which it emits branches, to the mesovarium where it again sends off 5 to 6 beautiful exceedingly spiral looped and dichotomously divided arteries. The ramus ovarii ends at its junction or anastomosis with the ramus oviductus at or near the oviducal pavilion.

THE OVARIAN VASCULAR CIRCLE.

The ramus oviductus and the ramus ovarii form about the ovary a beautiful vascular circle. In life it is of an oval shape, of some 3 inches in diameter. One end of the vascular oval begins at the origin of the ligamentum ovarii and the other end is found at the oviducal pavilion. The X-ray shows this beautifully, but dissection is still more impressive, yet nothing equals its corrosion anatomy. In the midst of this ovarian vascular circle lies the ovary supplied by some 3 long slightly spiral helicine arteries from the ramus oviductus and 5 to 7 short spiral

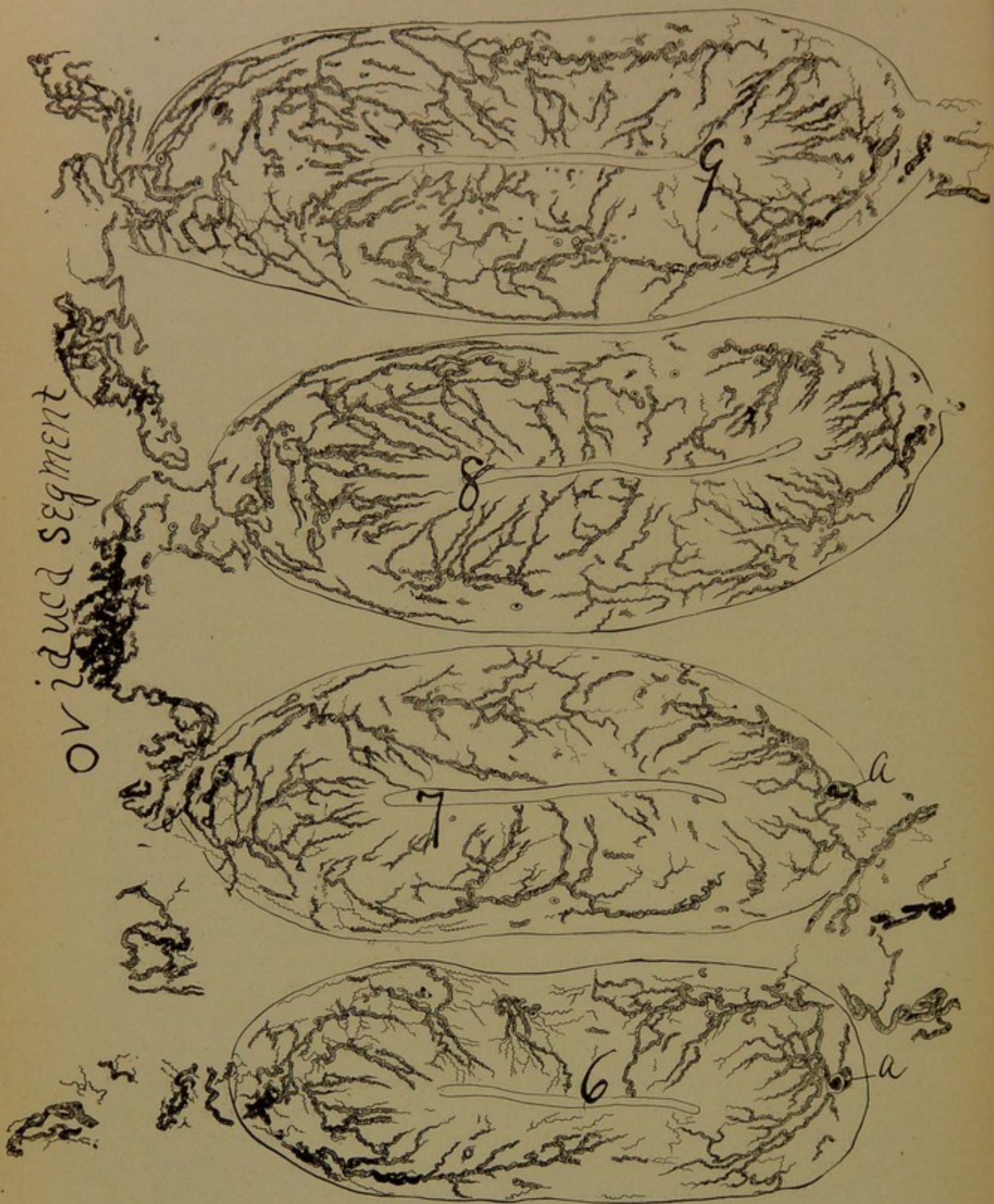


Fig. 102. For description see page 171.

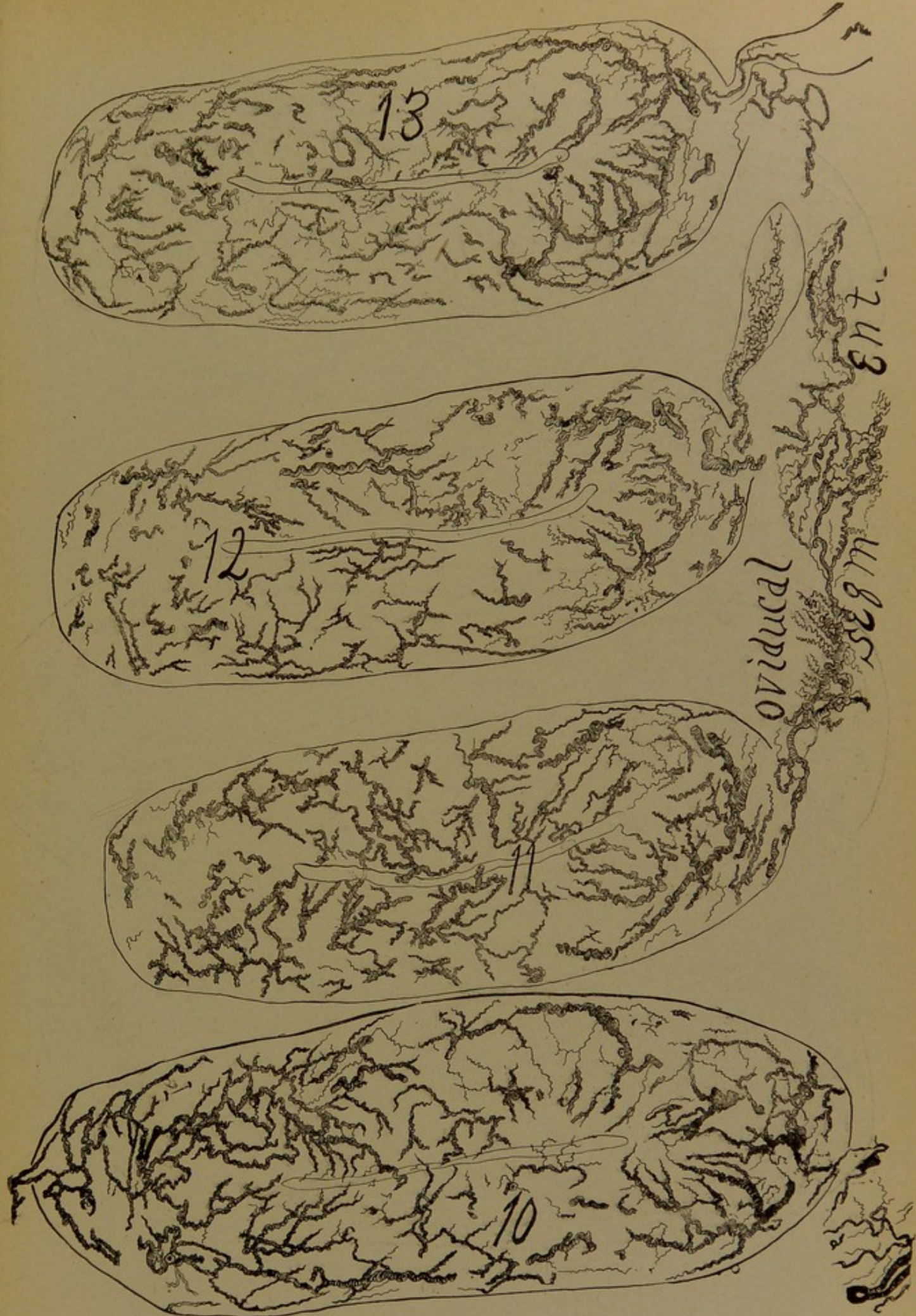


Fig. 103 For description see page 171.

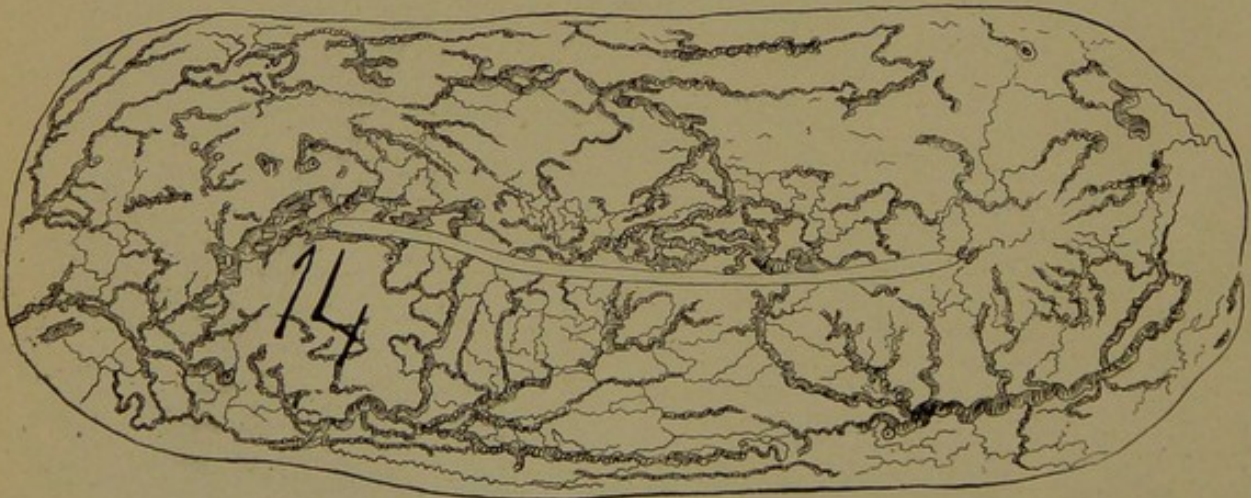
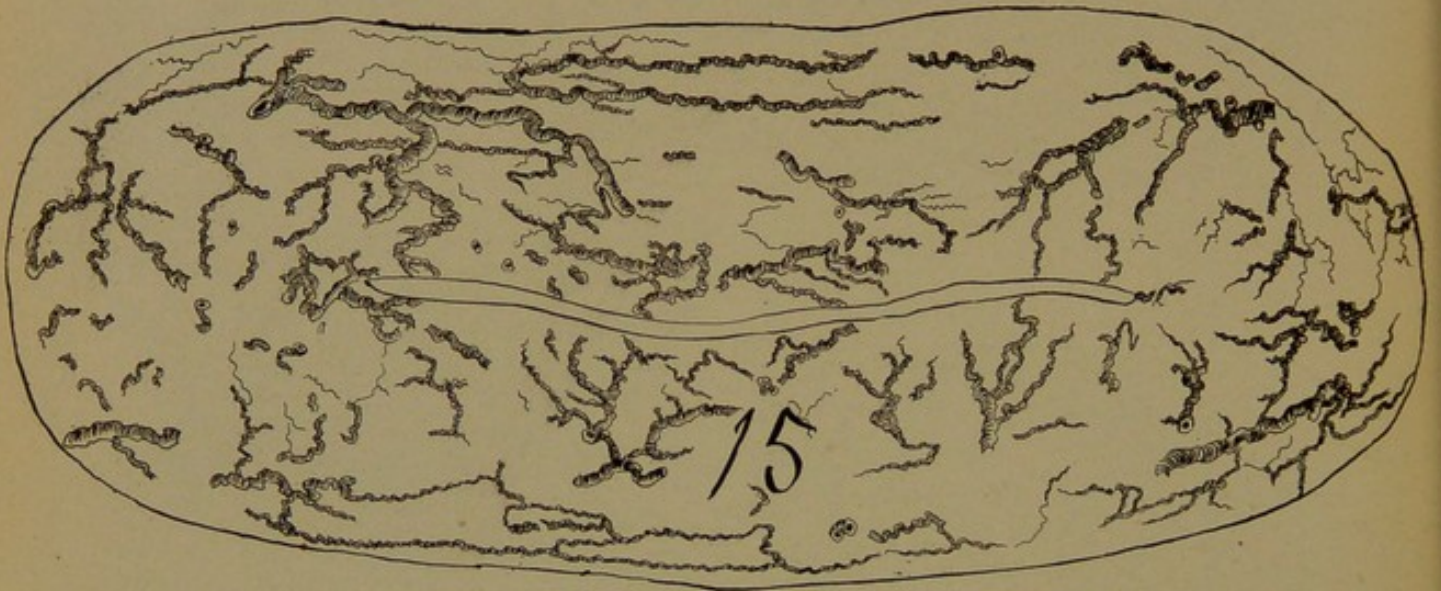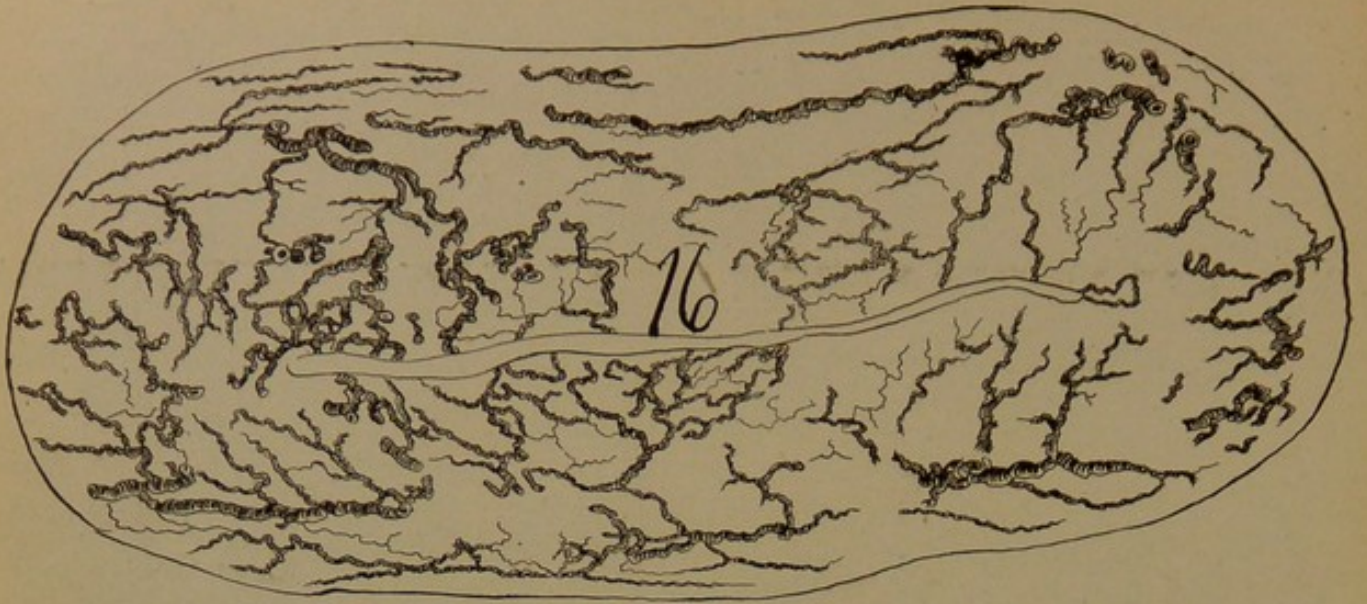


Fig 104 For description see page 171.

Fig. 102—Sections 6, 7, 8, 9, represent the distal corpus uteri. The perpendicular anastomosis becomes pronounced, especially in Section 8, the vessels coursing parallel. A rich oviducal segment presents which I extended parallel to the uterus in the X-ray in order to save space.

Note that the chief large arteries course near the myometrial surface.

Fig. 103—Sections 10, 11, 12 and 13, encroaching on the fundus, present a tortuous perpendicular anastomosis. It is especially rich in 10 on the left side in the Placental site.

Fig. 104—Sections 14, 15, 16 represent the circulation in the fundus, i. e., the segment of the uterus proximal to the insertion of the distal extremities of the oviducts. Section 14 shows the last segment at its Placental site, rich in large vessels. Especially adjacent to the endometrium. Note in these sections the long straight course of some vessels immediately adjacent to the myometrial surface.

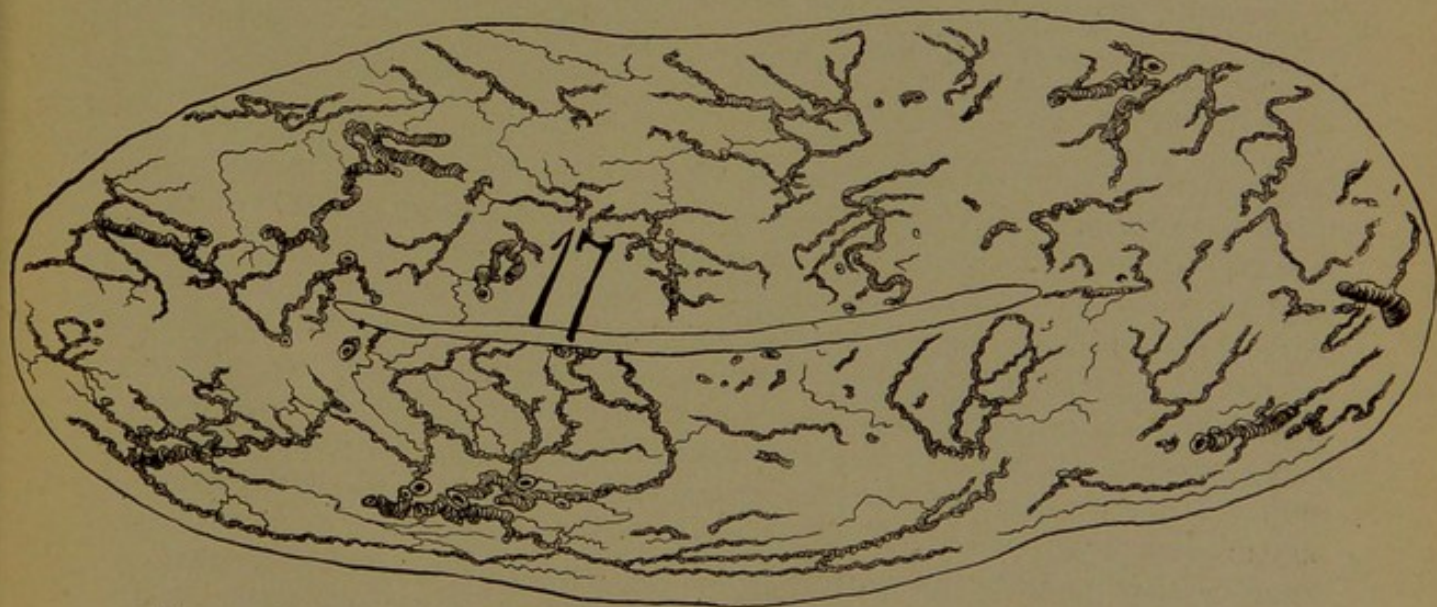
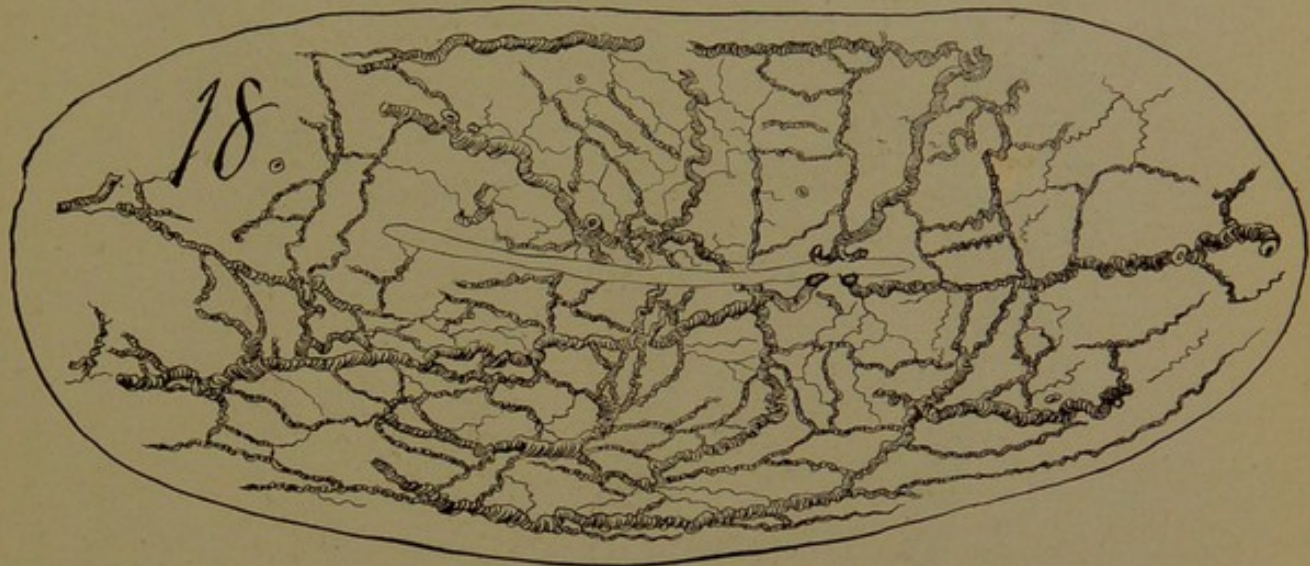


Fig. 105—Sections 17, 18, represent the extreme proximal fundus with its peculiar anastomosis in the form of an oval ——— an oval oligemic uterine zone. Section 17 shows pronounced perpendicular anastomosis, while this characteristic is changed in section 18 to a radiating form.

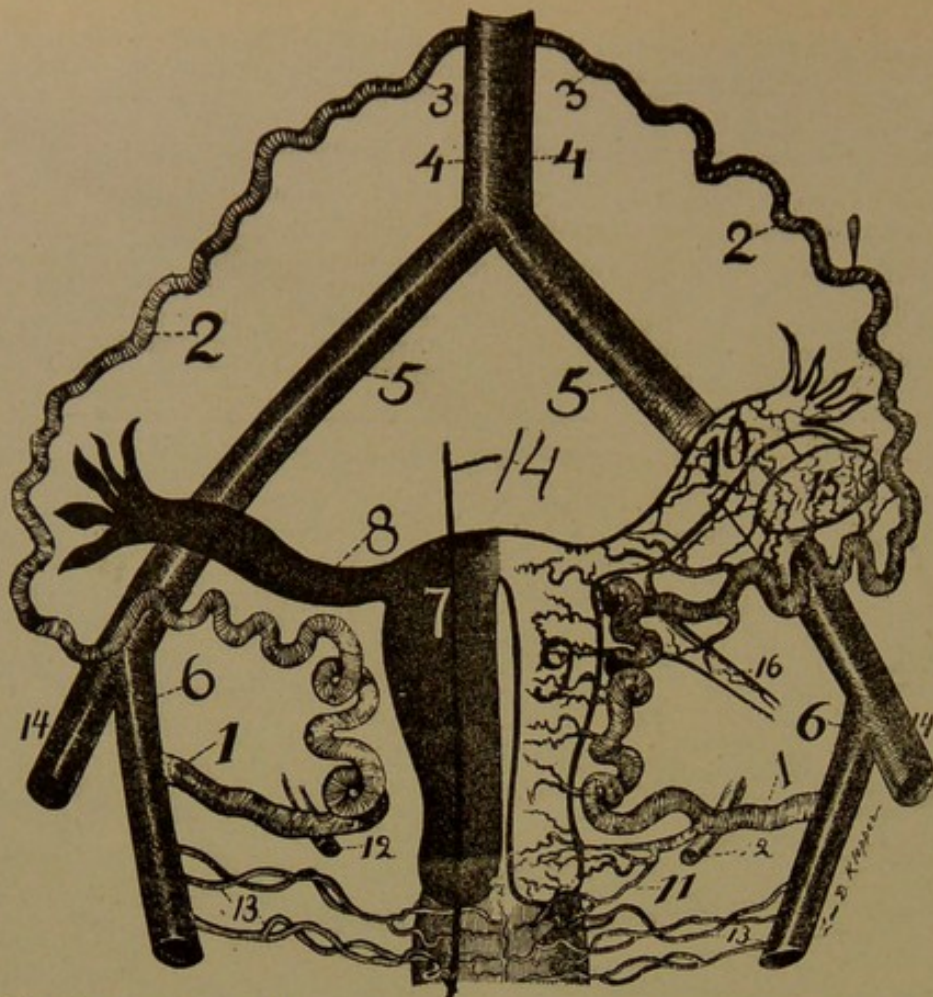


Fig. 106—The Circle of Byron Robinson. To illustrate the author's operation of endometrectomy and myometrectomy, 1, 2 and 3, the spiral segment of the circle without lateral arteries; 1, 2 and 3, the spiral segment of the circle (utero-ovarian) with horizontal and lateral arteries; 9, the uterine lateral or horizontal arteries; 10, the oviducal lateral arteries (as well as the ovarian); 11, the important cervico-vaginal arteries; 12, ureter; 13, vaginal arteries; 4, abdominal; 5, common iliac, and 6, internal iliac arteries; 4, 5 and 6, the straight segment of the circle. Note the capacity of the spiral segment of the circle (1, 2 and 3) to move distalward or proximalward. Also observe that the uterus, oviducts and ovaries can be removed without severing the spiral segment of the circle. All that require severing are the lateral arteries—9 and 10. The line marked 7 and 14 shows the line of incision longitudinally through the uterus to perform the author's operation.

helicine arteries from the ramus ovarii. The short helicine are very spiral, tortuous and even piled up in coiled loops. They converge as they course through the mesovarium. They divide dichotomously at some distance from their origin or at about the point where they arrive at the ovary. Curious enough the most external short helicine artery sends a strong branch to unite with a branch from the ramus oviductus whence it supplies the oviducal pavilion. In one of my dissections of a pregnant uterus the most external branch to the ovary sent off a strong branch which united with a strong branch from the pelvic floor segment emitted at the point of the distal arterio-ureteral crossing. In the ligamentum suspensorium ovarii the ramus ovarii and ramus oviductus unite to form the distal ovarian segment and at this point the arteries emit several irregular branches to adjacent structures. The oviducal segment is not completely developed until gestation has been accomplished.

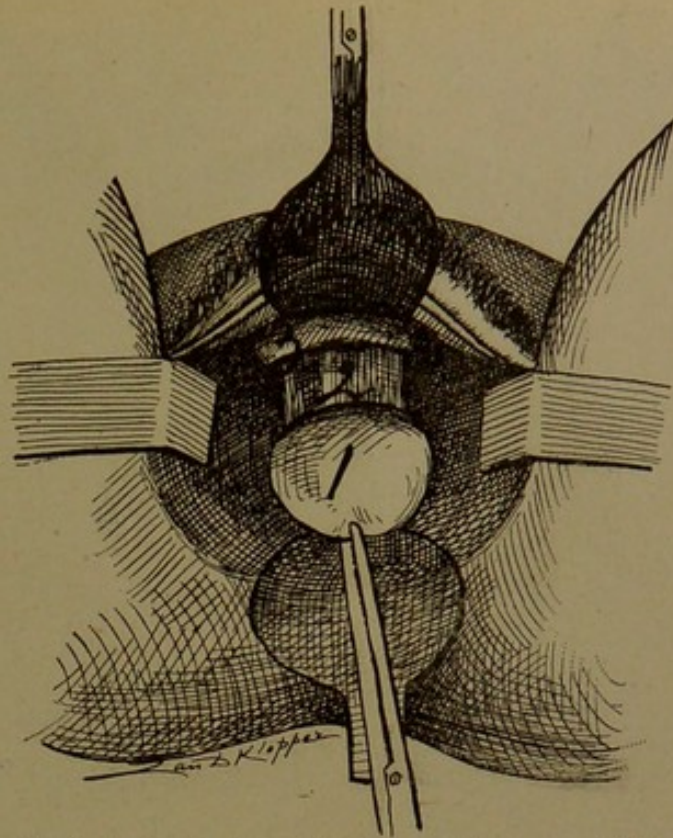


Fig. 107—Illustrates the first step in the author's operation, except that at present I do not incise the lateral vaginal fornices; 1, cervix with traction forceps. 2, cervical neck denuded. 3, vagina with introduced Sim's speculum.

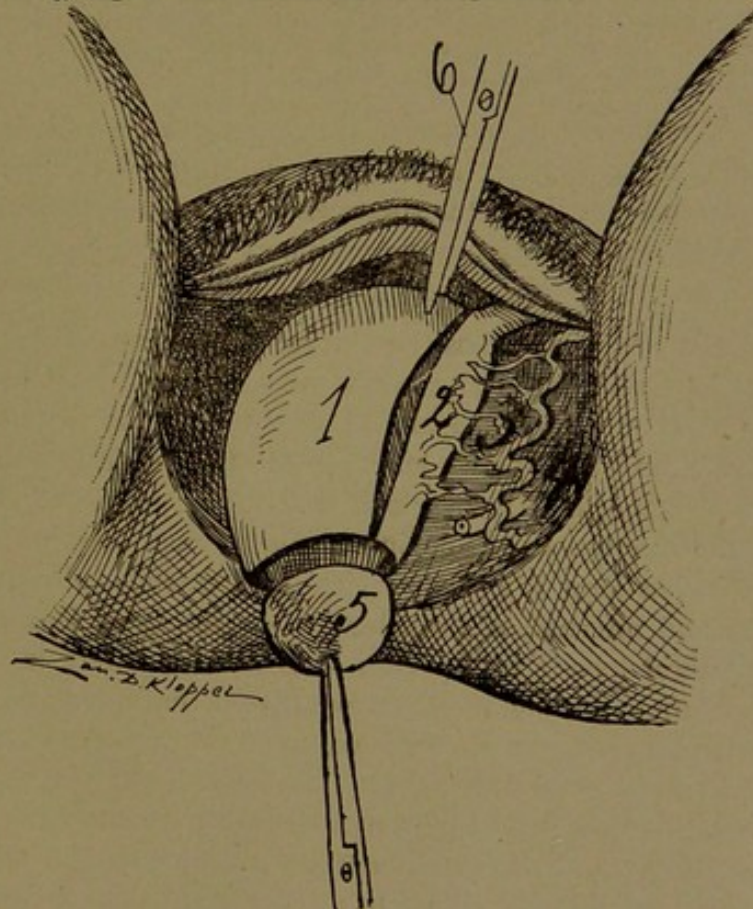


Fig. 108—Shows the lateral segment; of the uterus; (2) severed from the uterus (1); 3, lateral uterine arteries; 4, ligamentum latum; 5, cervix.

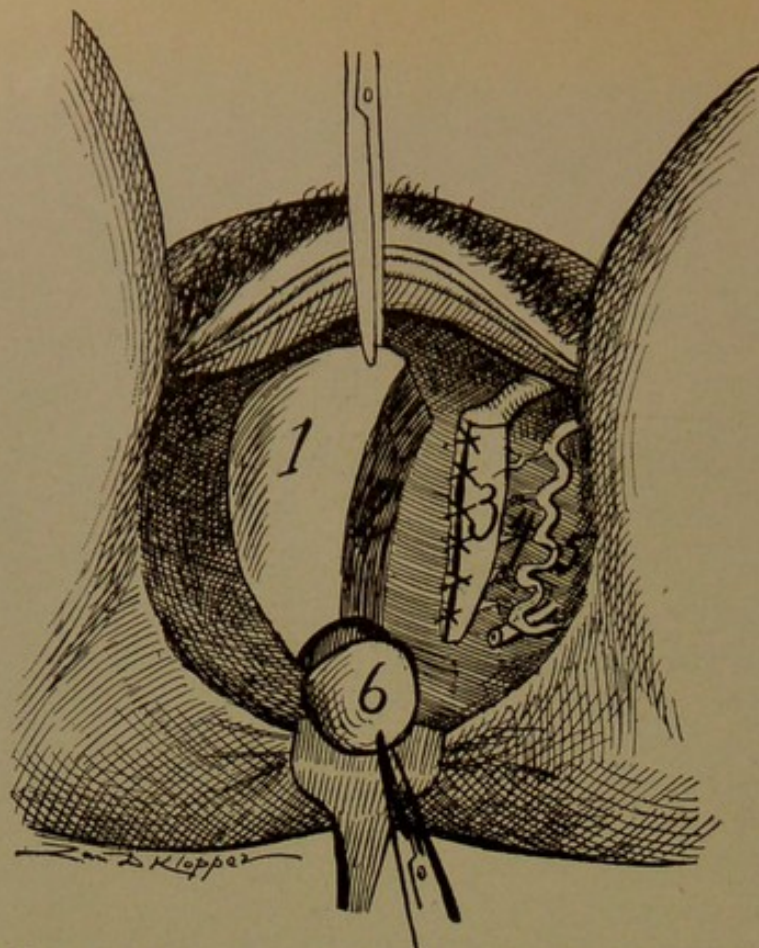


Fig. 109—Shows the severed lateral uterine segment closed in by sutures; 1, uterus; 2, external uterine tissue from which the lateral uterine segment was taken; 3, lateral uterine segment; 4, lateral uterine arteries; 5, ligamentum latum between 4 and 5 the uterine artery. More distally lies the ureter.

Both oviducal rami, ramus oviductus and ramus ovarii emit lateral branches to the mesosalpinx, mesometrium, ligamentum ovarii, oviduct, mesonephros, and ovary, and in well injected pregnant specimens present a beautiful rich vascular field extending in all directions from the periphery of the ovarian vascular circle.

THE CERVICAL LOOP.

The cervical loop is of the most significant importance in gynecology, especially in vaginal hysterectomy. In a pelvis of a woman pregnant 10 weeks the distal arterio-ureteral crossing was almost exactly midway between the lateral cervical border and the lateral pelvic wall. As to the pelvic floor segment of the utero-ovarian artery, it was 4 inches long, i. e., from origin in the hypogastric to the level of the internal os. The important cervical loop in this same case was exactly two inches long, i. e., the cervical loop extended distalward from the ureteral crossing and internal os (which were on the same level) precisely one inch. In this cervical loop 1 to 2 inches long lies the safety in vaginal or abdominal hysterectomy. In one case of dangerous haemorrhage from uterine sarcoma while ligating the pelvic floor segment of the utero-ovarian artery I found the cervical loop $1\frac{1}{2}$ inches long. The uterus was perhaps 20 per cent. larger than normal. In dissecting multipara I have frequently found the cervical loop over an inch long, and not infrequently $1\frac{1}{2}$ inches long. The largest cervical loop I found in dissection was in a 10 weeks' pregnancy where it was slightly over 2 inches in length.

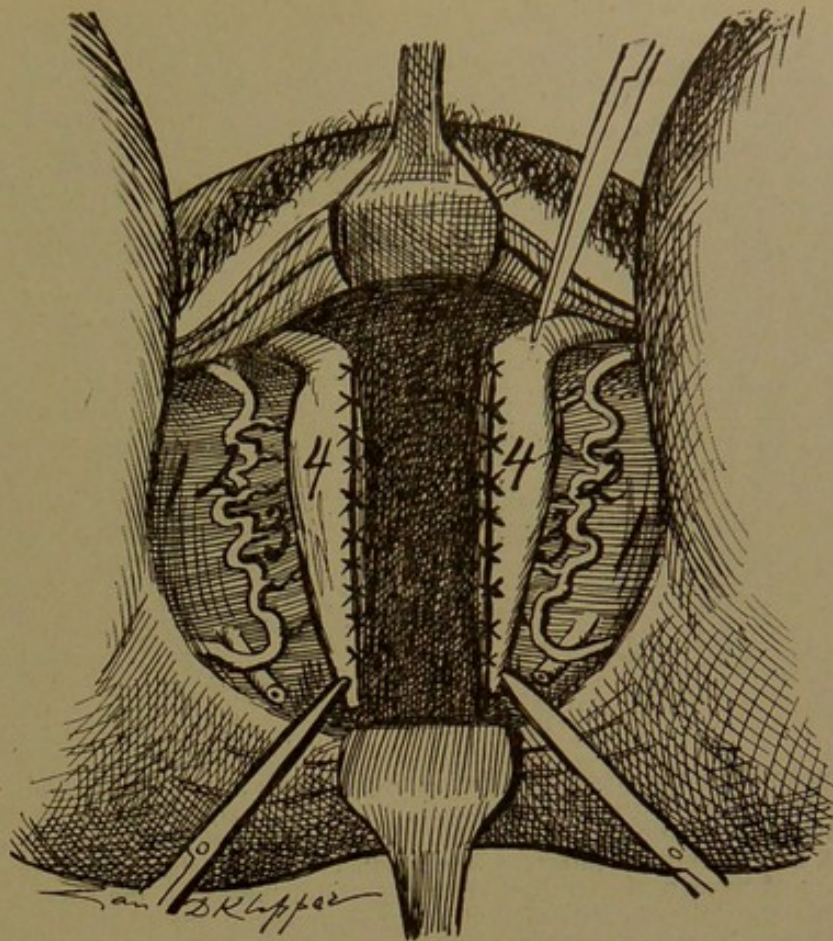


Fig. 110—Shows the lateral uterine segments severed and closed by sutures dorso-ventrally. The endometrium and myometrium are practically removed. 4, lateral uterine segments. 3, ligamentum latum or mesometrium. 2, arteria uterina. Traction forceps and specula fixing the parts for exposition.

The gynecologist alone and especially the one who dissects can fully realize the great value and safety rendered in operative procedures by the wonderful cervical loop against ureteral lesions—obstructions and punctures. Every gynecological operator should become familiar with the topography of the cervical loop.

The cervical loop appears to possess dominant age relations, for during sexual life it is well developed, and enormously large during early pregnancy, gradually becoming unfolded with the enlarging and proximal movement of the uterus. The cervical loop is relatively small in pueritas and absolutely small in senescence.

The descending and ascending limbs of the cervical loop lie in contact vertically or the two limbs twist about each other like a corkscrew. When the uterus is drawn distalward by traction forceps the ascending arms of the loop become unfolded and directed distalward, allowing ample room for arterial ligation.

AGE AND FUNCTIONAL RELATIONS.

The utero-ovarian artery is subject to marked age and functional relations. In *pueritas* (quiescent phase) the artery is in a state of quietude. It is small, almost straight, slightly spiral or looped and difficult to inject. In *Pubertas* (Crisis) it springs into vigorous activity and rapidly develops, becoming longer, larger and markedly spiral and looped. In *menstruation* (Crisis) it increases in length, vol-

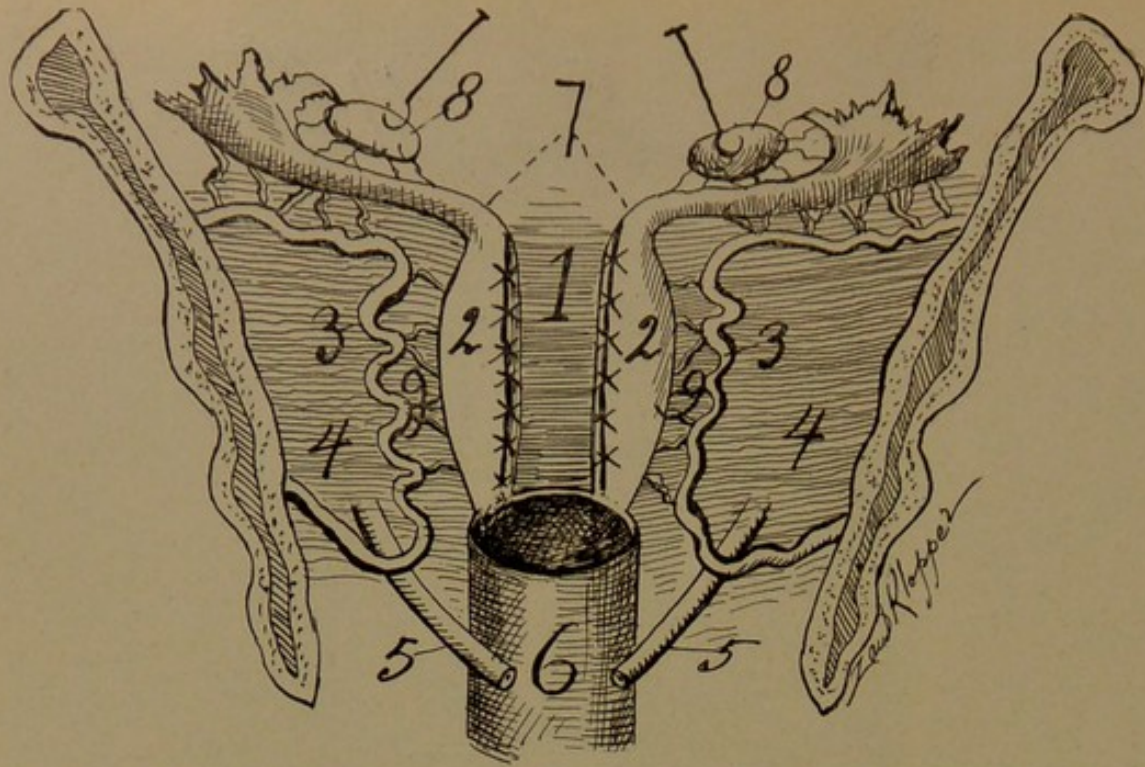


Fig. 111—Is a cut to show the organs in relation to the pelvis after the operation. Notice that the mechanism of the internal genitals is but relatively slightly disturbed. 1st the lateral segments of the uterus with the lateral arteries are intact. 2, the vascular apparatus is almost entirely intact; 3, the oviducts are not changed; 4, the central sexual organs of woman, the ovaries, are left perfectly intact; 5, the nervous system of the genitals especially the pelvic brain is not wounded; 6, the endometrium with a part of the myometrium is removed; 7, it is the most conservative and yet radical operation which can be performed on the genitals.

ume, spiral and looped condition. In *Gestation* (Crisis) it experiences a mighty development from origin to origin. It trebles in volume of blood. Its length, lumen, loops and spiral condition rapidly increased and it becomes completely developed. In *Puerperium* (Crisis) it experiences a marked involution. The artery being unable to contract after delivery as rapidly as the elastic fibers and muscular bundles of the myometrium. It is forced into spirals and coils. It is completely developed. In the *Climacterium* (Crisis) its congestions and decongestions, periodic hyperaemia gradually ceases. Arterio-sclerosis gradually rises. Oostitis physiologica occurs. Its lumen and length and spirality lessens. In *Senescence* (Quiescence) the artery atrophies. It becomes arterio sclerotic and calcification rises. Its length, lumen and spirality lessen. Hyperaemia does not arise and it becomes quiescent. It has returned to its state of pueritas. No study of the vascular part of an organ is complete without the aid of corrosion anatomy which presents with beautiful accuracy all the forms and conditions of the vessels.

A NEW METHOD OF PERFORMING HYSTERECTOMY. (Endometrectomy and Partial Myometrectomy.)

For some two years I have been practising a new method of performing hysterectomy. At least it is new so far as I am aware. Some five years ago Dr. E. H. Pratt, of Chicago, introduced an operation in which he extirpated the uterus by severing the lateral uterine and the lateral oviducal arteries. This can be

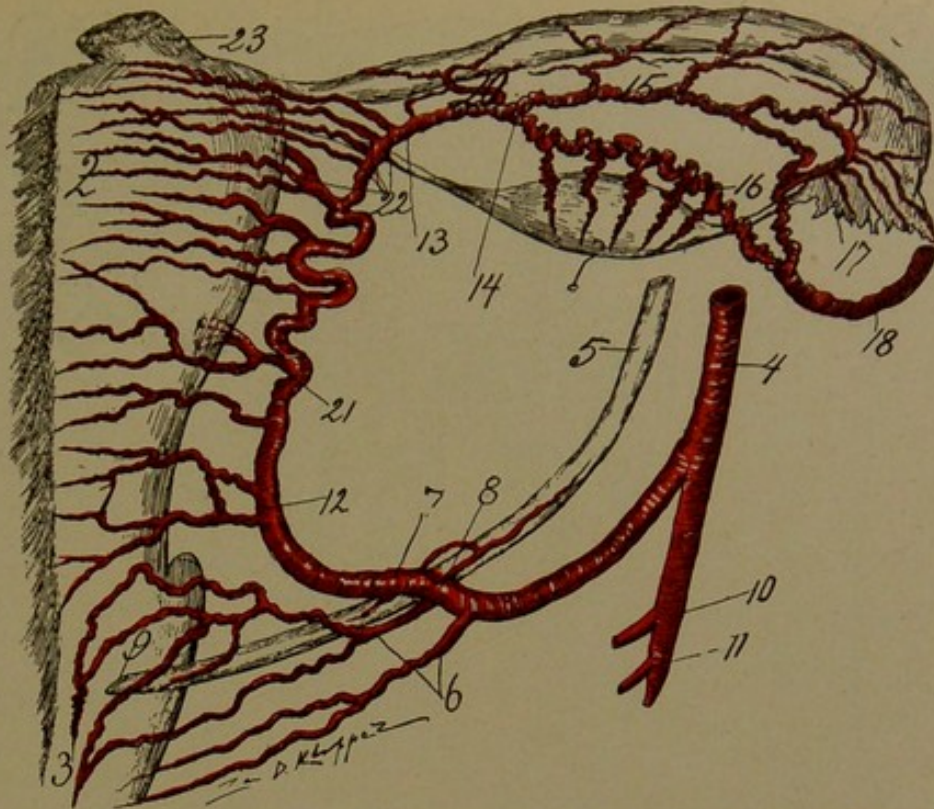


Fig. 112—Ovarian vascular circle 14, 16, 18 and 14, 15, 17, 18. Oviducal segment 14, 16 and 14, 15, 17. Uterine segment 12, 21, 22. Pelvic floor segment 12 to origin of uterine. Woman, aged about 55 years; front view. I carefully dissected the vessels, drawing them in accurate relations, after which model Mr. Kloppe drew. A myoma about the size of a pigeon's egg existed on the fundus, the pedicle 23; this tumor made the five fundal arteries remain very large. Cervico-vaginal, 1, lateral corporeal branches 2, very large vaginal branches (arterio azygos vaginæ) 3, hypogastric 4, ureter distal 5, vaginal arteries 6, distal arterio-ureteral crossing 7, arteria ureterica distal 8, ureteral opening 9, branches from hypogastric 10 and 11, exit of cervico-vaginal 12, uterine segment immediately before it divides into the oviducal branch (14) and ovarian branch (16) 13, point of division of uterine segment 14, rami laterales oviductus 17, 20, ovarian segment 18, lateral corporeal branch which divides dichotomously, sending a branch to anterior and posterior uterine surface 21, rami fundi 22. The corporeal and cervical branches were atrophied, the vaginal arteries were not. The fundal branches were enlarged from myomatous irritation.

performed without the application of clamp or ligature. However, in many cases the subsequent hemorrhage is very vigorous—as occurred in my own experience. I therefore determined to try another method.

I noticed (a well known fact) that on dissection of the uterus the nearer one approaches the median line of the uterus the smaller becomes the lateral spiral uterine arteries, and consequently the less the hemorrhage. In fact it appears to me that the median line of the non-pregnant uterus presents capillary anastomosis only—not macroscopic anastomosis. It is doubtful whether a woman would suffer fatal hemorrhage if the uterus was bisected longitudinally and abandoned without clamps or ligatures. From these careful dissections I began the longitudinal excisions of medial segments of the uterus and suturing the exposed surfaces of the segments by antero-posterior sutures. In actual practice it is very evident that the least hemorrhage occurs the nearer the longitudinally cutting plane passes to the median uterine line. The best result in this operation appears to occur when about one-fourth of the lateral segment of the uterus remains.

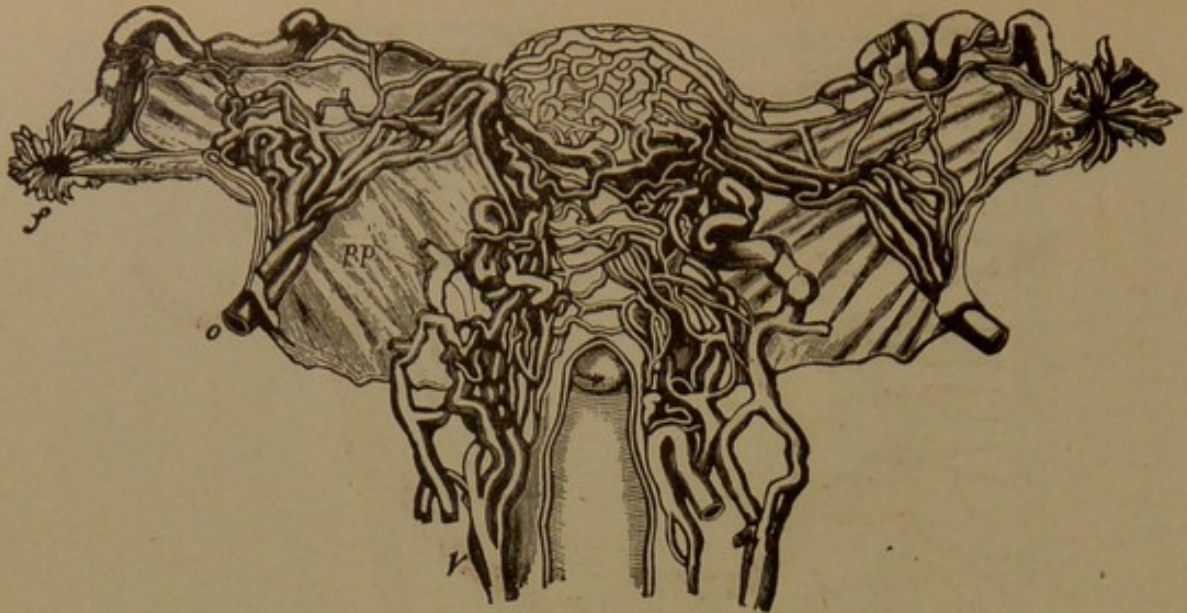


Fig. 113—Luschka. Venous supply of the ovary, oviducts, uterus and vagina.

In this operation the utero-ovarian artery (the genital circle) is not severed or ligatured. The ligamentum latum and its contents (the oviducts, ovaries, the lymphatics, nerves, mesonephros and elemental tissues) are left intact.

The oviducts are not removed. The ovaries, the essential central sexual organs of woman, are left undisturbed. The non-removal of the ovaries will preserve sexual integrity and prevent precipitate menopause or neurosis.

It is the most conservative of any known gynecologic operation which will arrest the three great genital functions of woman—menstruation, abortion and labor. The object of the operation is to arrest function in cases made ill by repeated infection, that is, cases of recurrent pelvic peritonitis.

It may be asked, in what cases is this operation applicable? In general, I would say in nearly all cases, except malignancy, in which it is desired to remove the uterus. It is applicable in pyosalpinx and in myoma of the uterus. It is sufficient in pyosalpinx to break up oviducal adhesions and puncture the pyosalpinx for drainage and remove the center of the uterus. The pyosalpinx will recover and the oviduct remain intact, serving the purpose of a non-functioning organ.

TECHNIC.

The technic of the operation consists in drawing the uterus distalward with a traction forcep and with a pair of scissors or knife incise the anterior and posterior vaginal fornices.

With the index finger separate the bladder and rectum from the uterine surfaces. The lateral vaginal fornices are not incised. With a pair of scissors clip off about one-fourth of the lateral segment of the uterus from cervix to fundus. After which suture the posterior and anterior edges of the severed uterine segment together, in closing all exposed uterine tissue. The operator can suture as the clipping is performed, so that hemorrhage will be limited. The method I pursue is to clip with the scissors from cervix to just above the internal os on both sides and immediately suture the surfaces with silkworm gut. I then seize the uterine fundus with traction forceps and draw it into the vagina, when I

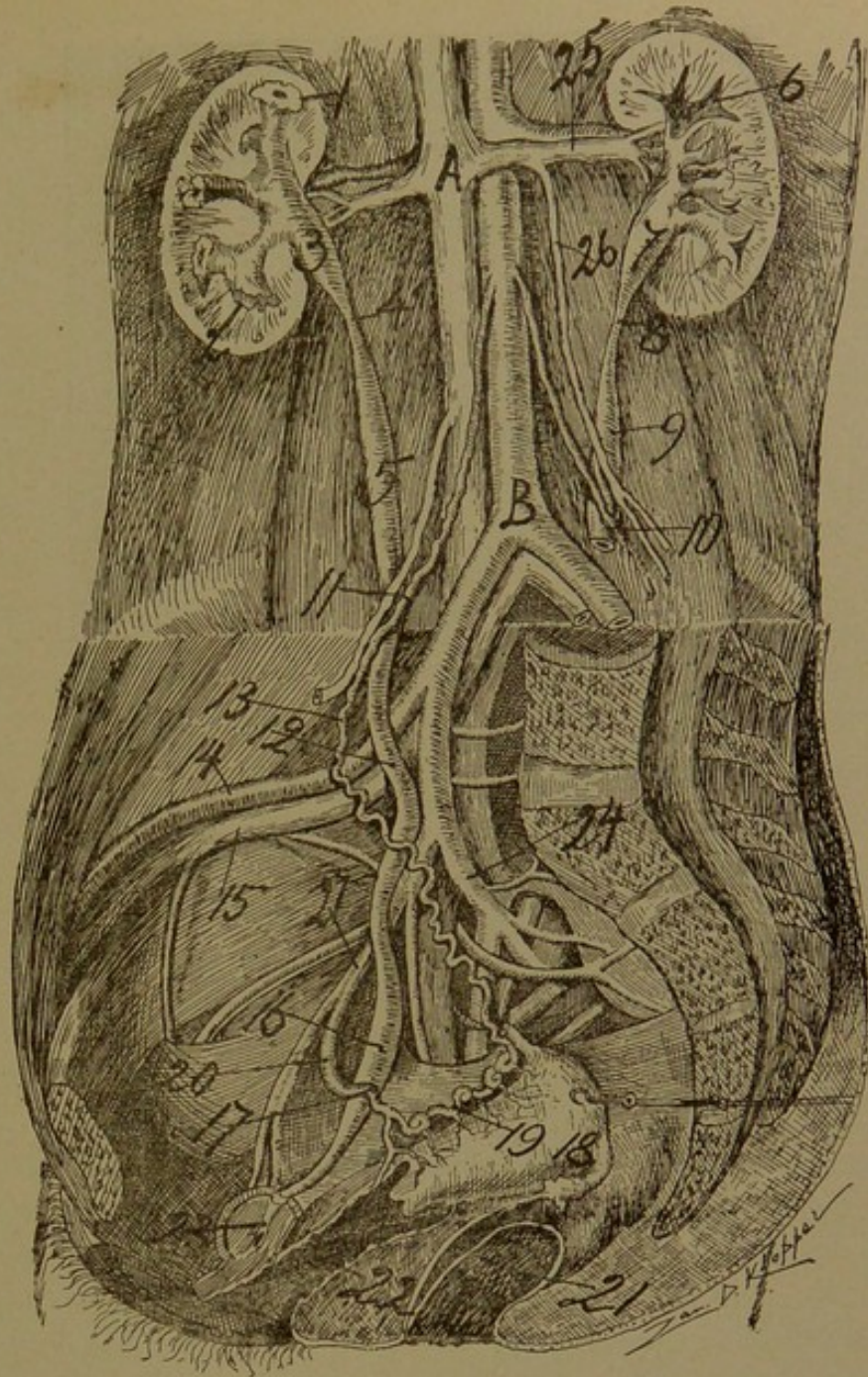


Fig. 114—The cut illustrates the relations of the uterus and the spiral segment of the genital circle. The upper portion of the cut represents a front view, while the under part of the cut represents a side view. It shows the proximal (II), middle (iliac) and distal (17) arterio-ureteral crossing. The spindle shape and curves of the ureters are shown. In this drawing a suggestion from Holl is employed. The genital circle and the ureter are shown in their relation, 1, kidney; 3 and 7, ureteral pelvis; 4 and 8, proximal ureteral isthmus; 5 and 9, proximal ureteral spindle; 6, ureteral calices; 10 and 11, proximal arterio-ureteral crossing; 12, middle arterio-ureteral crossing; 13, 14, 15, external iliac vessels; 16, pelvic ureteral spindle; 17, distal arterio-ureteral crossing; 18, left oviduct; 19, uterus; 20, pelvic segment of uterine artery divided by the ureter; 21, vagina; 22, ureteral orifice slit opening into bladder; 23, posterior branch of internal iliac; 24, renal vein receiving the ovarian vein; 25, 26, 9, 26, 25, 7 uretero-venous triangle. A suggestion from Holl is employed in this cut.

begin to sever the lateral uterine segments from fundus toward cervix, and continuously suture the uterine surfaces with silk worm gut until I meet the sutures

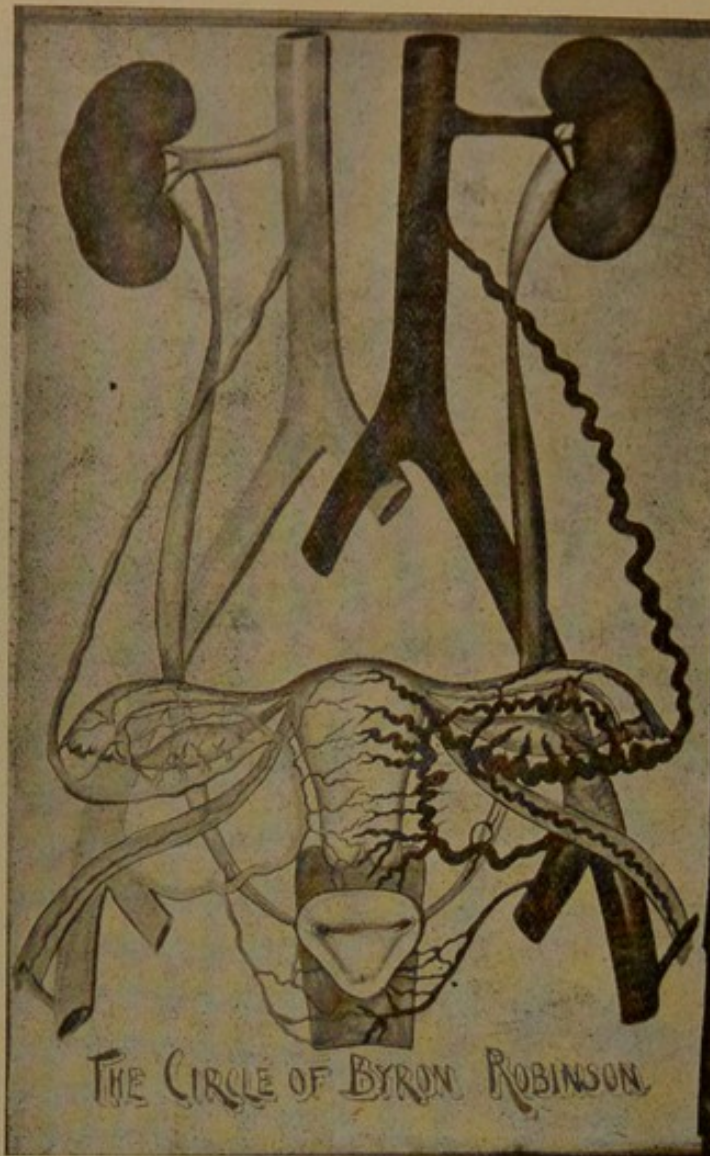

Fig. 115—Plan of tractus genitalis and tractus urinarius with relation to the genital vascular circle.

previously applied to the cervical end of the uterus. When finished no exposed cut uterine surface is exposed. Peritoneum covers all the remaining segments of the uterus, as the cuts will demonstrate.

The ligatures tried were cat-gut, silk, linen, and finally the one we use is the silkworm gut, which we remove about the tenth day, either with or without narcosis.

Two years' trial with this operation has given very satisfactory results. The uterine segments shrink or atrophy perhaps 25 per cent, menstruation ceases, and as a rule no neurotic menopause arises. The pyosalpinx (evacuated) recovers and the patients present excellent conditions.

In some cases I note on the tenth to twelfth day that the non-removed uterine segments become fixed by plastic adhesions to the vaginal vault and adjacent peritoneum. This allows opportunity to break them up and thus free the intact uterine segments.

I present this operation as a conservative procedure, yet sufficiently radical

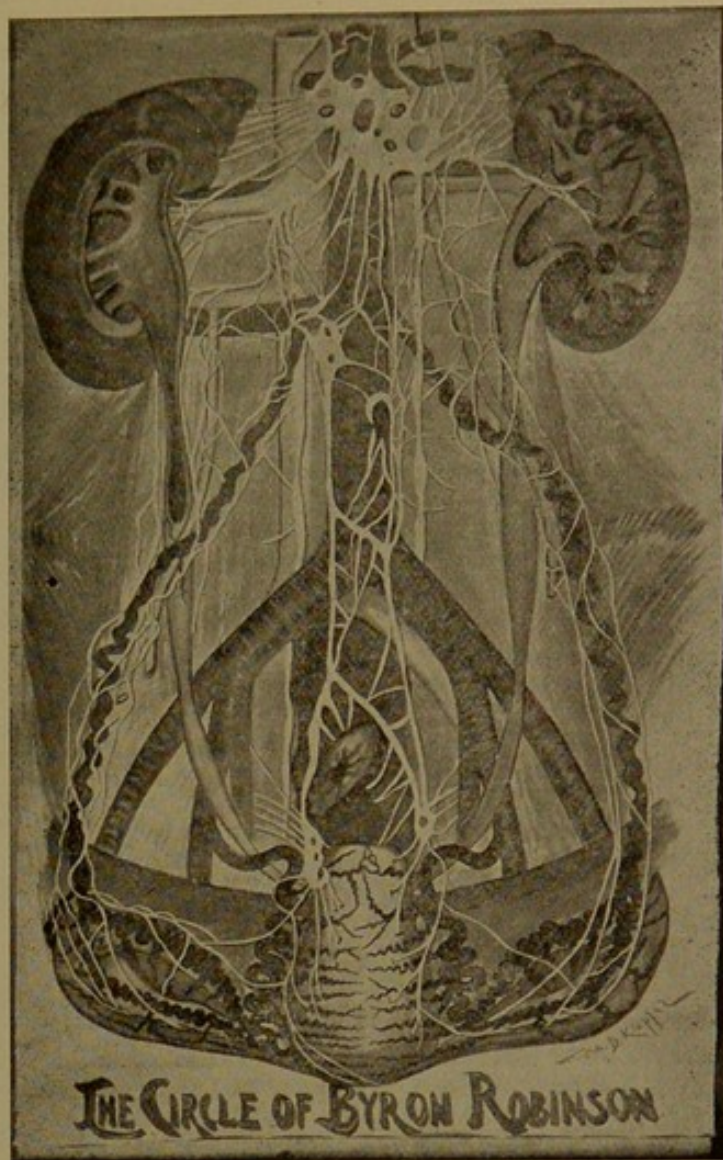


Fig. 116—Plan of tractus genitalis, urinarius and sympatheticus with genital vascular circle pregnant 3 months.

to arrest function (menstruation, abortion and labor); by the opportunity for drainage, cure the diseased oviducts and ovaries. The lateral vaginal fornices are not disturbed. In this operation the ureters and bladder are quite safe. The patient has lost the center of the uterus only. The special conservative features of the operation are that the utero-ovarian vascular circle is not severed, the ovaries, oviducts and ligamentum latum with nerves and vessels are left entirely intact. In short, no unnecessary tissue is sacrificed.

My injections of the utero-ovarian artery with X-ray applications has demonstrated that there are three oligemic (exsanguinated zones) or areas in the uterus, viz.: one in the longitudinal axis of the uterus, one at the fundus, and one at the lateral borders of the cervix. These oligemic (exsanguinated) zones allow valuable surgical application and based on this principle I later began to bisect the uterus, exsect the endometrium with sufficient myometrium to allow me to unite the anterior and posterior edges or flaps of the uterus. The final operation therefore may be called endometrectomy.

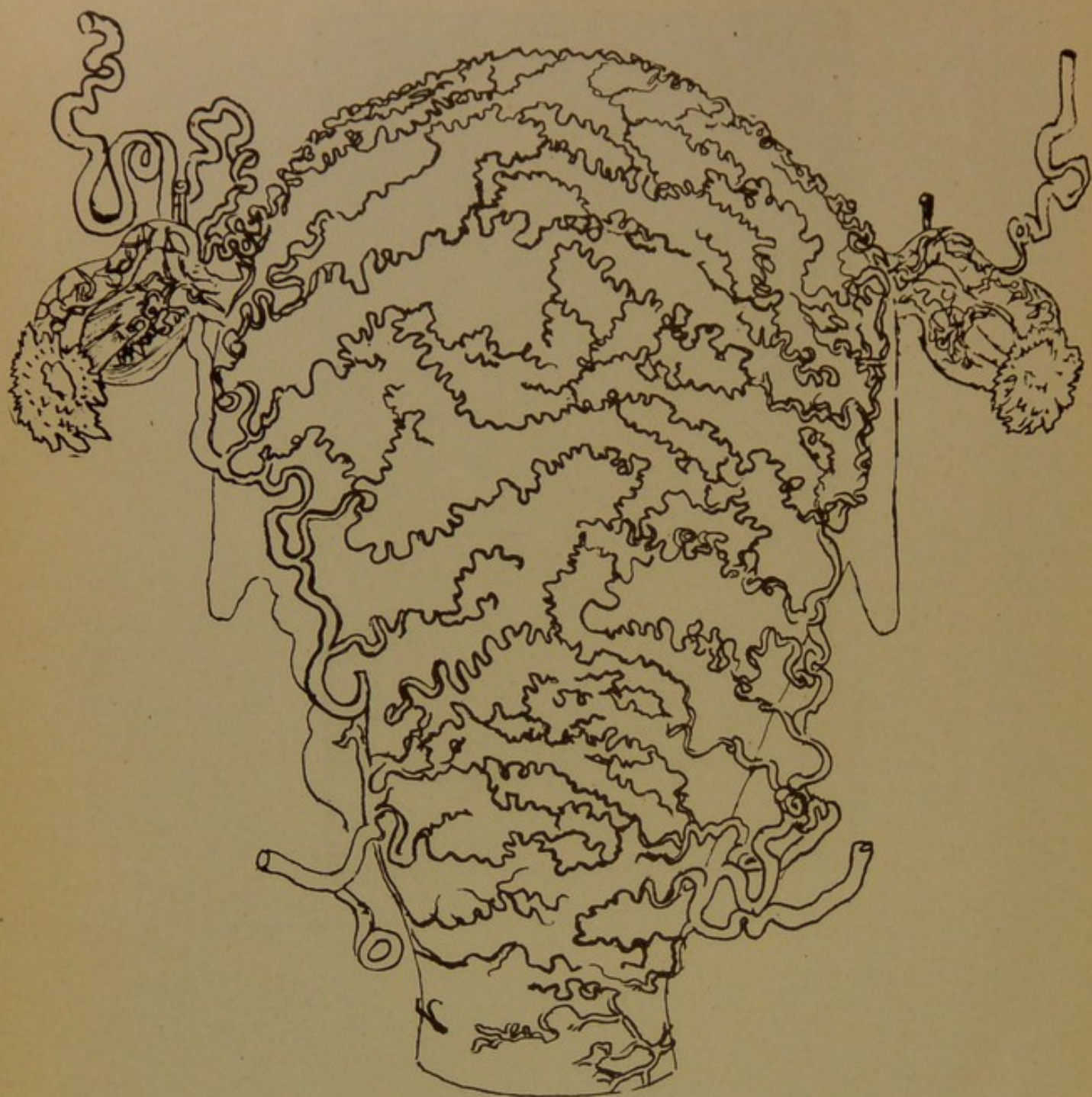

Fig. 117. Arteries of Uterus at the end of gestation
From Bourguery & Jacob: *Anat. de l'Homme* v. 5, 1839.
By C. de Coppono.







