

**Illustrations of the gross morbid anatomy of the brain in the insane : A selection of seventy-five plates showing the pathological conditions found in post-mortem examinations of the brain in mental diseases / by I.W. Blackburn, M.D., pathologist to the Government Hospital for the Insane, Washington, D.C.**

**Contributors**

Blackburn, I. W. 1851-1911.  
Saint Elizabeths Hospital (Washington, D.C.)

**Publication/Creation**

Washington : Govt. Print. Off, 1908.

**Persistent URL**

<https://wellcomecollection.org/works/rdqhsdam>

**License and attribution**

Conditions of use: it is possible this item is protected by copyright and/or related rights. You are free to use this item in any way that is permitted by the copyright and related rights legislation that applies to your use. For other uses you need to obtain permission from the rights-holder(s).



Wellcome Collection  
183 Euston Road  
London NW1 2BE UK  
T +44 (0)20 7611 8722  
E [library@wellcomecollection.org](mailto:library@wellcomecollection.org)  
<https://wellcomecollection.org>



/34288



22900381148

Med  
K33858

BLOOMSBURY HOSPITAL

MEDICAL LIBRARY

*Police from the ...  
... of the ...*

BOOKED DATE 1908-11-11  
RECEIVED LIBRARY





ILLUSTRATIONS  
OF THE  
GROSS MORBID ANATOMY OF THE BRAIN  
IN THE INSANE

---

A SELECTION OF SEVENTY-FIVE PLATES SHOWING THE PATHOLOGICAL  
CONDITIONS FOUND IN POST-MORTEM EXAMINATIONS  
OF THE BRAIN IN MENTAL DISEASES

S. 16  
f. 7

BY

I. W. BLACKBURN, M. D.

*Pathologist to the Government Hospital for the Insane, Washington, D. C.; Professor of  
Morbidity Anatomy in the Medical Department of the University of Georgetown,  
and in the Department of Medicine of the George Washington  
University, Washington, D. C.*



WASHINGTON  
GOVERNMENT PRINTING OFFICE  
1908

MEDICAL LIBRARY  
BLOOMINGDALE HOSPITAL  
NEW YORK

14219



336492 / 34288


WELLCOME INSTITUTE LIBRARY	
Coll.	weIMOmec
Call	
No.	WL

WELLCOME INSTITUTE  
LIBRARY

## CONTENTS.

---

	Page.
Letters of transmittal.....	vii
Introduction.....	1
Arteriosclerosis and other vascular conditions.....	6
Arteriosclerotic cerebral softenings.....	28
Hemorrhages.....	48
Atrophy of the brain.....	58
Meningo-encephalitis—Paresis.....	86
Hydrocephalic states.....	92
Meningeal conditions.....	110
Cerebral compressions.....	128
Sclerotic conditions.....	132
Intracranial and brain tumors .....	148



Digitized by the Internet Archive  
in 2016

<https://archive.org/details/b2805359x>

## ILLUSTRATIONS.

	Page.
PLATE I. Dissection of the basal arteries in arteriosclerosis.....	6
II. Dissection of the cerebral arteries in arteriosclerosis.....	8
III. The arteries at the base of the brain in advanced calcareous arteriosclerosis.....	10
IV. A dissection of the sclerotic arteries of the mesial surface and the insula, etc.....	12
V. Dissection of the cerebral arteries, showing an anomalous circle of Willis, etc.....	14
VI. Aneurisms of the basal arteries and an anomalous anterior choroid artery of the left side.....	16
VII. The base of the brain showing arteriosclerosis and anomalous arteries.....	18
VIII. The base of a brain showing arteriosclerosis.....	20
IX. The base of the brain showing arteriosclerosis of the small vessel type.....	22
X. The base of a brain showing arteriosclerosis.....	24
XI. Dissection showing the distribution of the anterior cerebral arteries and the distribution of a large median anterior cerebral artery.....	26
XII. A large arteriosclerotic softening of the left hemisphere.....	28
XIII. A large arteriosclerotic softening of the left hemisphere.....	30
XIV. Left half of brain with multiple cortical softenings due to arteriosclerosis.....	32
XV. The base of the brain showing arteriosclerosis of the basal vessels and softening from obstruction of the right posterior cerebral artery.....	34
XVI. A horizontal section of a brain showing central softenings from arteriosclerosis.....	36
XVII. A horizontal section of a brain showing central arteriosclerotic softenings.....	38
XVIII. A horizontal section of a brain showing syphilitic softenings of the interior and the cortex..	40
XIX. Horizontal section of a brain showing cicatricial central softenings.....	42
XX. The superior aspect of the brain in a case of thrombotic softening affecting the whole left hemisphere.....	44
XXI. Arteriosclerotic softenings of cerebrum.....	46
XXII. A brain the seat of a large hemorrhage causing left hemiplegia.....	48
XXIII. A horizontal section of a brain showing hemorrhage in the right basal ganglia.....	50
XXIV. Cerebral hemorrhage destroying the right internal capsule and the nucleus lentiformis.....	52
XXV. Horizontal section of a brain which had been the seat of a hemorrhage.....	54
XXVI. Horizontal section of a brain showing the effects of a former hemorrhage.....	56
XXVII. The left hemisphere in a case of extreme cerebral atrophy.....	58
XXVIII. The superior surface of a brain from a case of senile dementia with numerous cortical softenings due to arteriosclerosis.....	60
XXIX. Extreme atrophy of frontal regions of the brain.....	62
XXX. The superior surface of the cerebrum, showing atrophy; the fissures are artificially separated...	64
XXXI. The superior surface of a brain in chronic dementia with cerebral atrophy.....	66
XXXII. The superior aspect of the brain in a case of chronic dementia with atrophy.....	68
XXXIII. Mesial surface of the right hemiencephalon in chronic melancholia.....	70
XXXIV. Superior surface of the brain showing arteriosclerotic devastations of the cortex.....	72
XXXV. A dissection showing the basal arteries and the atrophy of the brain in the region of the insula.	74
XXXVI. Horizontal section of a brain from a case of senile dementia.....	76
XXXVII. A horizontal section of a brain of syphilitic dementia.....	78
XXXVIII. Brain of a case of senile dementia in a patient aged 99 years.....	80
XXXIX. Lateral surface of the left hemiencephalon in a case of chronic melancholia.....	82
XL. The superior surface of the brain in chronic mania.....	84
XLI. The effects of removal of the pia in paresis.....	86

	Page.
PLATE XLII. The left hemisphere in a case of paresis with flaking of the cortex.....	88
XLIII. The right hemiencephalon in a case of paresis.....	90
XLIV. Brain showing chronic internal hydrocephalus.....	92
XLV. Chronic acquired internal hydrocephalus.....	94
XLVI. Chronic acquired internal hydrocephalus.....	96
XLVII. A case of chronic acquired circumscribed internal hydrocephalus.....	98
XLVIII. Transverse section of the brain showing chronic internal hydrocephalus, probably congenital.	100
XLIX. Horizontal section of a brain from a case of senile dementia with ventricular dilatation. ....	102
L. A case of chronic congenital internal hydrocephalus.....	104
LI. A case of chronic congenital internal hydrocephalus. Interior of basal portion.....	106
LII. A case of chronic congenital internal hydrocephalus. Interior of upper portion.....	108
LIII. Superior surface of a brain showing leptomenigitis.....	110
LIV. The inferior surface of a brain showing leptomenigitis.....	112
LV. A brain showing chronic meningeal thickening and atrophy consequent upon bullet wound of the head.....	114
LVI. The right hemiencephalon from a case of acute mania.....	116
LVII. The superior aspect of the brain in a case of extreme meningeal hyperæmia with chronic cedema.....	118
LVIII. The superior aspect of a brain from a case of extreme atrophy in the terminal dementia of melancholia.....	120
LIX. Superior surface of the brain showing engorgement of the pial veins.....	122
LX. View of the brain in a case of meningo-encephalitis of childhood, with arrest of development of the brain. Photographed with a brain of normal size and weight.....	124
LXI. Views of the brain in a case of meningo-encephalitis of childhood, with arrest of development of the brain.....	126
LXII. The superior surface of a brain compressed by accumulation of subdural fluid.....	128
LXIII. The superior aspect of a brain showing compression of the left hemisphere by a hæmatoma of the dura.....	130
LXIV. Right hemisphere of a case of atrophic sclerosis in epilepsy.....	132
LXV. The superior surface of a brain with localized sclerosis of the left frontal lobe.....	134
LXVI. A case of sclerosis of a portion of the right hemisphere in epilepsy.....	136
LXVII. Sclerosis of a portion of the right hemisphere in epilepsy.....	138
LXVIII. Mesial view of the left hemisphere showing absence of the septum pellucidum.....	140
LXIX. Horizontal section of a brain without a septum pellucidum.....	142
LXX. Horizontal section of a brain made on a level with the junction of the fornix with the callosum.	144
LXXI. Horizontal section of a brain from a case of dementia præcox.....	146
LXXII. Section of brain showing glioma of the left frontal lobe.....	148
LXXIII. Plate showing a tumor of the dura penetrating the brain.....	150
LXXIV. Mesial surface of the left hemiencephalon, showing cavity left in the brain after enucleation of the tumor of the dura shown on Plate LXXIII.....	152
LXXV. Tumor of the dura penetrating the brain.....	154

## LETTERS OF TRANSMITTAL.

---

GOVERNMENT HOSPITAL FOR THE INSANE,

*Washington, D. C., June 11, 1908.*

SIR: I have the honor to transmit herewith, for publication, a work on the Gross Morbid Anatomy of the Brain in the Insane, prepared by Dr. I. W. Blackburn, pathologist to this hospital.

Very respectfully,

WM. A. WHITE,

*Superintendent.*

The SECRETARY OF THE INTERIOR.

GOVERNMENT HOSPITAL FOR THE INSANE,

*Washington, D. C., June 11, 1908.*

SIR: I have the honor to submit to you the work on the Gross Morbid Anatomy of the Brain in the Insane, prepared under your permission and direction. The work consists of 75 plates illustrating the pathological conditions met with in post-mortem examinations of the brain in the insane, together with a brief descriptive text and an introduction. The plates are selected from the photographs of pathological subjects which form the hospital collection, now numbering several hundred.

Trusting that the work may meet with your approval, and with sincere thanks for your assistance and support, I am,

Very respectfully,

I. W. BLACKBURN, M. D.,

*Pathologist.*

Dr. WILLIAM A. WHITE,

*Superintendent Government Hospital for the Insane.*



# GROSS MORBID ANATOMY OF THE BRAIN IN THE INSANE

By I. W. BLACKBURN, M. D.

## INTRODUCTION.

In the preparation of this work the aim has been to furnish accurate photographic representations of the gross changes which may be met with in post-mortem examinations of the brains of the insane. Comparatively few general practitioners of medicine have any degree of familiarity with the common pathological conditions affecting the brains of the insane, and to this class the work will appeal rather than to the neuro-pathologist.

Fresh specimens—or the next best, museum specimens—are not easily accessible; therefore the representations of these pathological conditions by photography and by photographic reproductions seems to be the natural means which suggests itself, and the present work is an effort in that direction. The ideal way to represent pictorially the gross appearances of a specimen is to accurately color the picture after nature, which requires high artistic skill and great expenditure of time, while the cost of reproduction in color precludes this method. Fortunately, many of the gross changes in the brain are morphological, and depend little upon color; such are well shown in black and white.

The technical difficulties in preparing the photographs were many, and only overcome, at least in a measure, by many trials and much laborious effort. It was finally concluded that the best method was to partly fix or harden the specimen, usually in formalin, place it momentarily in alcohol, and, after allowing the surface to dry to prevent glistening, to photograph it directly by means of a vertical camera. Fresh specimens containing much blood, or those which have preserved their color in Kaiserling, do not photograph so well, as even with orthochromatic plates the reds and yellows take too dark and the details are obscure. After the photograph is made, if satisfactory, it is ready for reproduction; if details require to be elaborated, a bromide enlargement is made on crayon paper, and on this the artist works, having constant reference to the museum specimen as a guide to his work. The bromide picture is then rephotographed for reproduction by any of the mechanical processes.

Though exact topography of anatomical points may not in all cases be secured, it is thought that by careful fixing to avoid distortion, care in the dissection and preparation of the specimens, equally careful manipulation of the lighting and other photographic details, all of which was under personal supervision, these errors are reduced to the minimum. The photograph has its limitations compared with drawing, in that it is impossible to change the picture materially and any diagrammatic representation is impossible; but, on the other hand, errors in drawing are avoided, and by the crayon retouching the picture may be strengthened and photographic defects may be corrected.

The collection of pathological specimens from which the photographs were made has extended over many years, and are selected from observations in 2,350 autopsies. Some of the specimens are quite rare, but the majority are representative of conditions which may occur at any time in autopsies among the insane. An endeavor has been made to give examples of most of the common changes found in the adult insane, as, on account of the few children among our patients, pathological conditions occurring more frequently in children of the defective class are hard to secure and are not well represented in the collection.

Following the classification of the lesions rather than the mental diseases, the plates have been arranged with this regard as far as possible. This is not always easy to do, and certain morbid conditions will be found to merge with others. In most instances the pathological condition is easily recognized, but may be made more evident by comparison; therefore, for the purpose of contrast I have occasionally introduced certain more normal pictures where they may best serve this purpose.

It will, of course, be understood that the lesions represented in no sense are to be considered as showing the essential morbid anatomy of any form of mental disease, except general paralysis and possibly senile dementia and arteriosclerotic dementia. In many instances the lesions found are simply accidental and may occur in any form of insanity or even in the sane. Senile and arteriosclerotic changes may supervene in any form of chronic insanity, and some of the changes are the results rather than the essential underlying condition or causation. There are, however, certain conditions which are naturally associated with mental failure, such as extreme atrophy, chronic œdema, advanced arterial disease, and the results of former hemorrhages; these may be regarded as explanatory of mental deterioration in general.

The mental diseases represented are many of them given under the older classification, and it has been thought best not to change these diagnoses. Almost all the common forms of mental affections are given a place; certainly all which may show gross lesions other than accidental. The pathological conditions represented are arteriosclerosis, cerebral softenings, hemorrhages, atrophies, paresis or meningo-encephalitis, hydrocephalic states, meningeal conditions, cerebral compressions, sclerotic conditions, and intracranial and brain tumors. A few plates represent comparatively normal brains in dementia præcox, etc., introduced for comparison and contrast.

Localization of the special senses, an extremely interesting but difficult matter among the insane, has only incidentally been referred to, though when lesions have been found in areas of known functions the clinical histories are often confirmatory. Often, however, the localization is confused by a multiplicity of lesions, and the consequent mental deterioration makes the observations extremely unsatisfactory. The localization of motor functions in the cortex and the abolition of muscular movements in lesions of the internal capsule are more easily determined and many examples occur.

It is to be regretted that the limitations of the work will not permit of more extended reference to the clinical histories, as only the prominent clinical manifestations and the form of mental disease could be given. The preliminary data given will sometimes be found to bear an important relation to the specimen, which will be readily appreciated.

An apology for the brevity of the descriptions is perhaps in order, though in most instances the plates are self-explanatory. It was also thought best not to disfigure the pictures by leaders or other indicators, and outlines such as used by some authors were impracticable. To those who are familiar with the anatomy of the brain it is hoped that this omission may not be vitally important.

To the authorities to whose generosity I owe the publication of the work, and to Dr. William A. White, Superintendent, whose encouragement and support made its preparation possible, I tender my sincere thanks; and in this connection I would not forget our honored former superintendents, to whose memory I am ever grateful for their assistance and guidance in my work. To my colleagues and all who have aided me directly or indirectly I am thankful, and to William M. Keeler, the hospital photographer, I am under many obligations for the care and skill which made the photographs so important a feature of the work.

GOVERNMENT HOSPITAL FOR THE INSANE,

*Washington, D. C., June 10, 1908.*



---

---

PLATE I.

---

---

PLATE I.

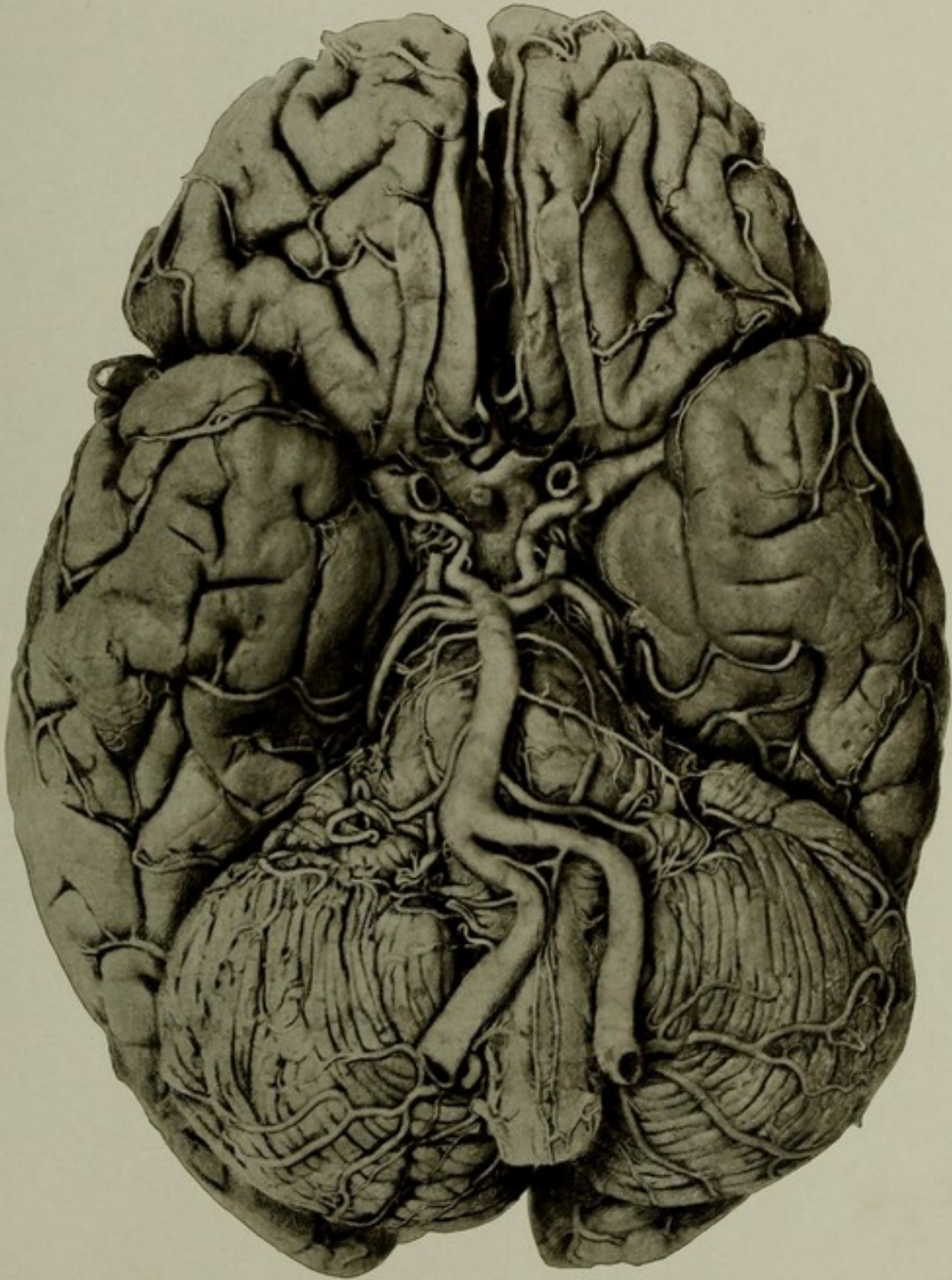
AUTOPSY No. 1672.

DISSECTION OF THE BASAL ARTERIES—ARTERIOSCLEROSIS.

Case 6604. J. N.; male; aged 58; colored; laborer; nativity, Georgia. Mental disease, epileptic insanity; duration, over eight years.

The patient had chronic disease of the cardiac valves, slight arteriosclerotic interstitial nephritis, and sclerosis and distortion of the cerebral arteries, with a small softening in the white matter of the occipital lobe.

The picture shows a dissection of the basal arteries made by removing the arachno-pia, leaving the vessels *in situ*. Portions of all the vessels are shown, and the arterial disease, as well as the developmental anomalies present. Both posterior communicating arteries are enlarged, and there is a double superior cerebellar on the right side. The extreme tortuosity of the anterior inferior cerebellar artery of the right side is noteworthy.



DISSECTION OF THE BASAL ARTERIES—ARTERIOSCLEROSIS.



---

---

PLATE II.

---

---

## PLATE II.

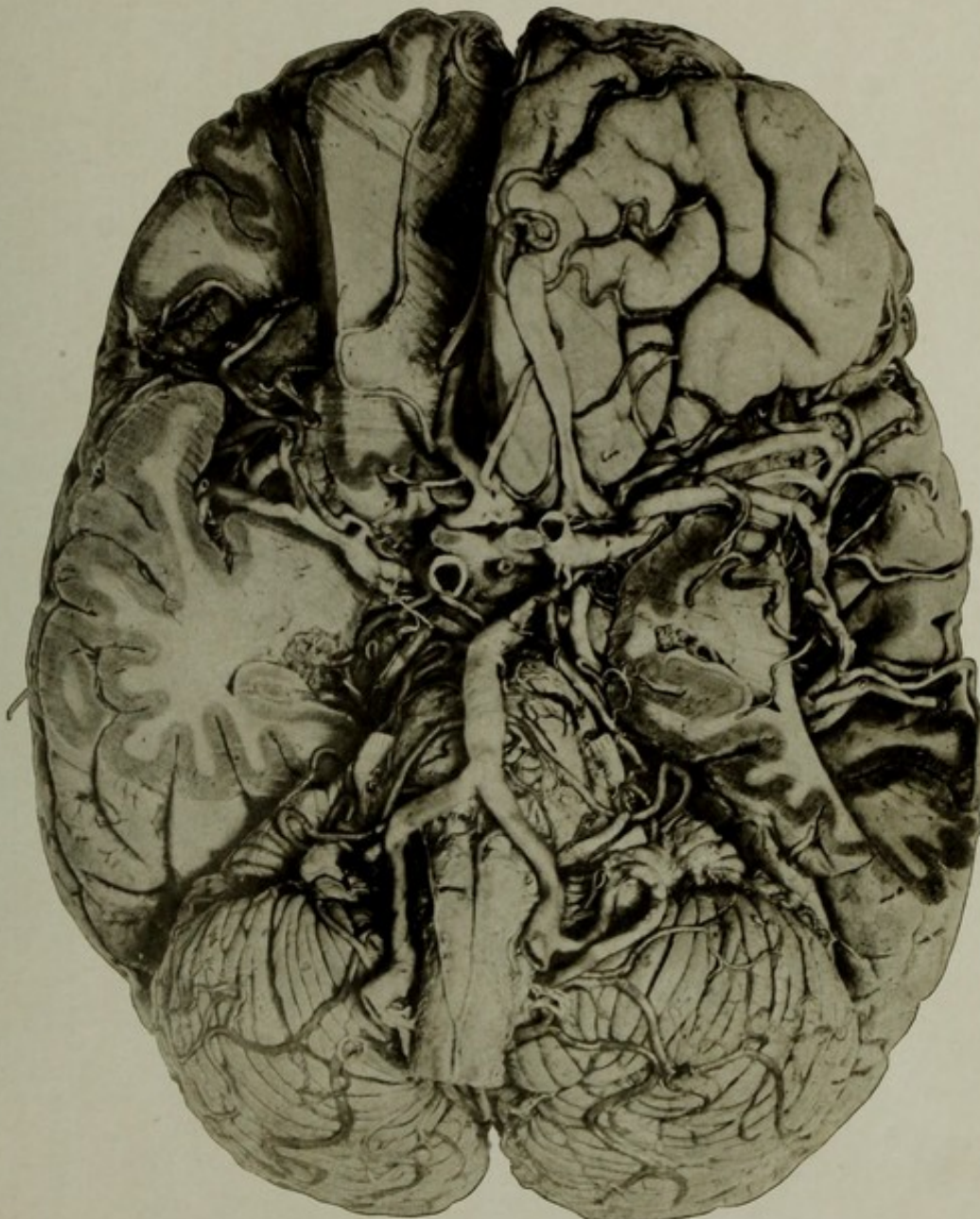
AUTOPSY No. 1925.

### DISSECTION OF THE CEREBRAL ARTERIES—ARTERIOSCLEROSIS.

Case 1311. T. McD.; male; aged 83; white; occupation unknown; nativity, Pennsylvania. Mental disease, chronic mania.

The arteries of the brain were very atheromatous, distorted, and curved. Weight of brain, 1,250 grams. The heart was hypertrophied, and the valves of the left side showed some chronic thickening. The kidneys were primarily contracted, but the left contained some pus deposits, a condition secondary to purulent cystitis.

The picture shows a dissection of the cerebral arteries made by removing portions of the brain which normally obstruct the view. Portions of all of the principal cerebral arteries are seen, including the anterior choroid arteries, that of the right side being visible from its origin to its destination in the choroid plexus of the descending horn of the right lateral ventricle. There are a few anomalies of minor importance. The extreme distortion and curvature of the arteries consequent upon senile arteriosclerosis are readily seen.



DISSECTION OF THE BASAL ARTERIES—ARTERIOSCLEROSIS.



---

---

PLATE III.

§

### PLATE III.

AUTOPSY No. 1719.

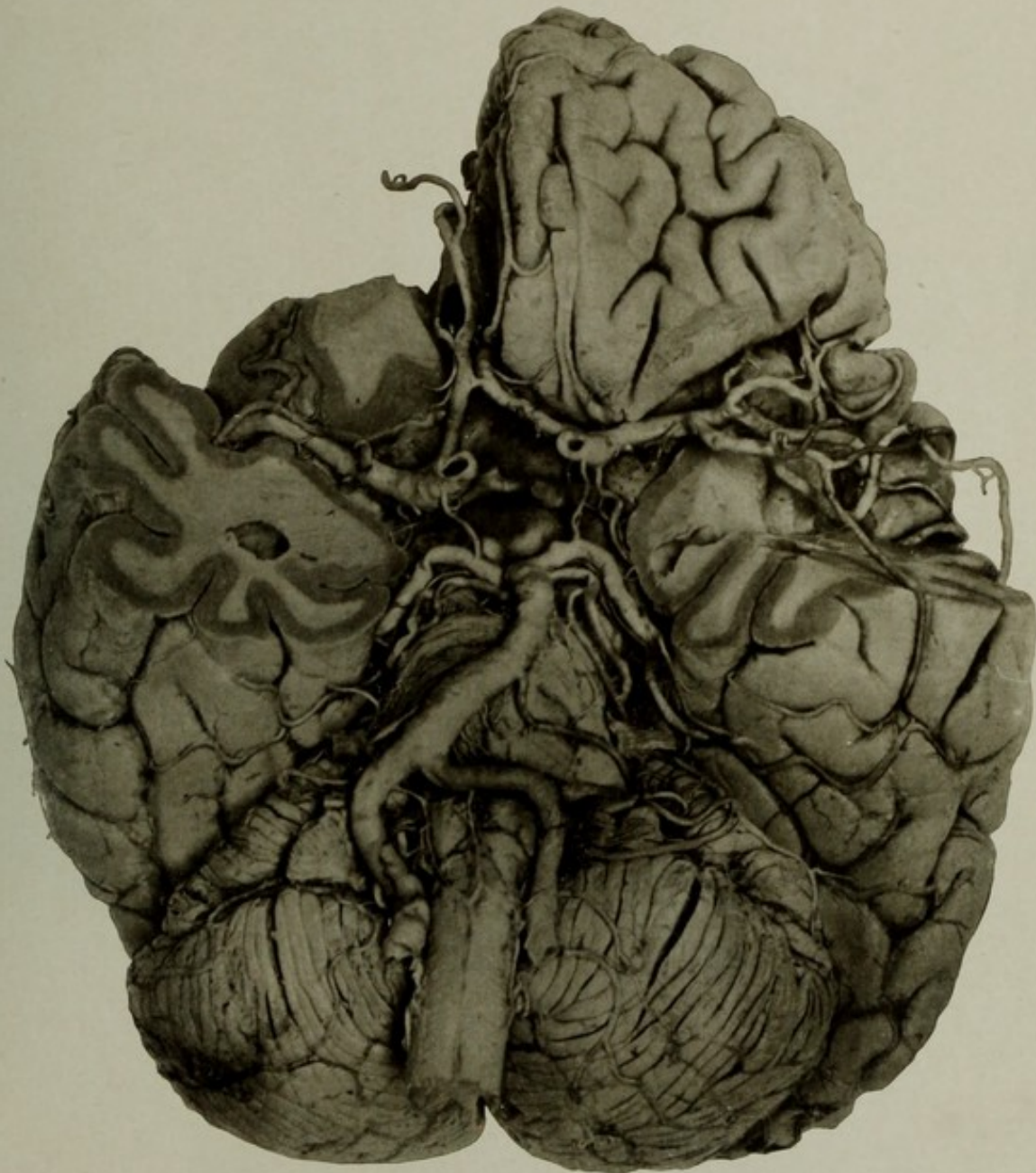
THE ARTERIES AT THE BASE OF THE BRAIN IN ADVANCED CALCAREOUS ARTERIOSCLEROSIS.

Case 13662. F. F. S.; aged 77; white; farmer; nativity, Pennsylvania. Mental disease, senile dementia.

Brain: Weight, 1,200 grams. Arteries at the base extremely sclerotic, distorted, and calcified. Great atrophy of the convolutions. The arteries were dissected free of the pia arachnoid and left *in situ*. The calcareous patches give a nodular appearance to the vessel walls, and the extreme distortion of the principal trunks are well shown. Parts which would obstruct the view are cut away.

The heart weighed 595 grams. Slight enlargement of the tricuspid orifice. Some chronic disease of the left valves. Coronary arteries and the aorta were sclerotic.

The associated conditions of other organs were cystitis and pyelo-nephritis, cholelithiasis, chronic ulcerative colitis, and two large hemorrhagic infarctions resulting from thrombosis of the splenic artery, which was very atheromatous, tortuous, and much calcified.



THE ARTERIES AT THE BASE OF THE BRAIN IN ADVANCED CALCAREOUS  
ARTERIOSCLEROSIS.



---

---

PLATE IV.

---

---

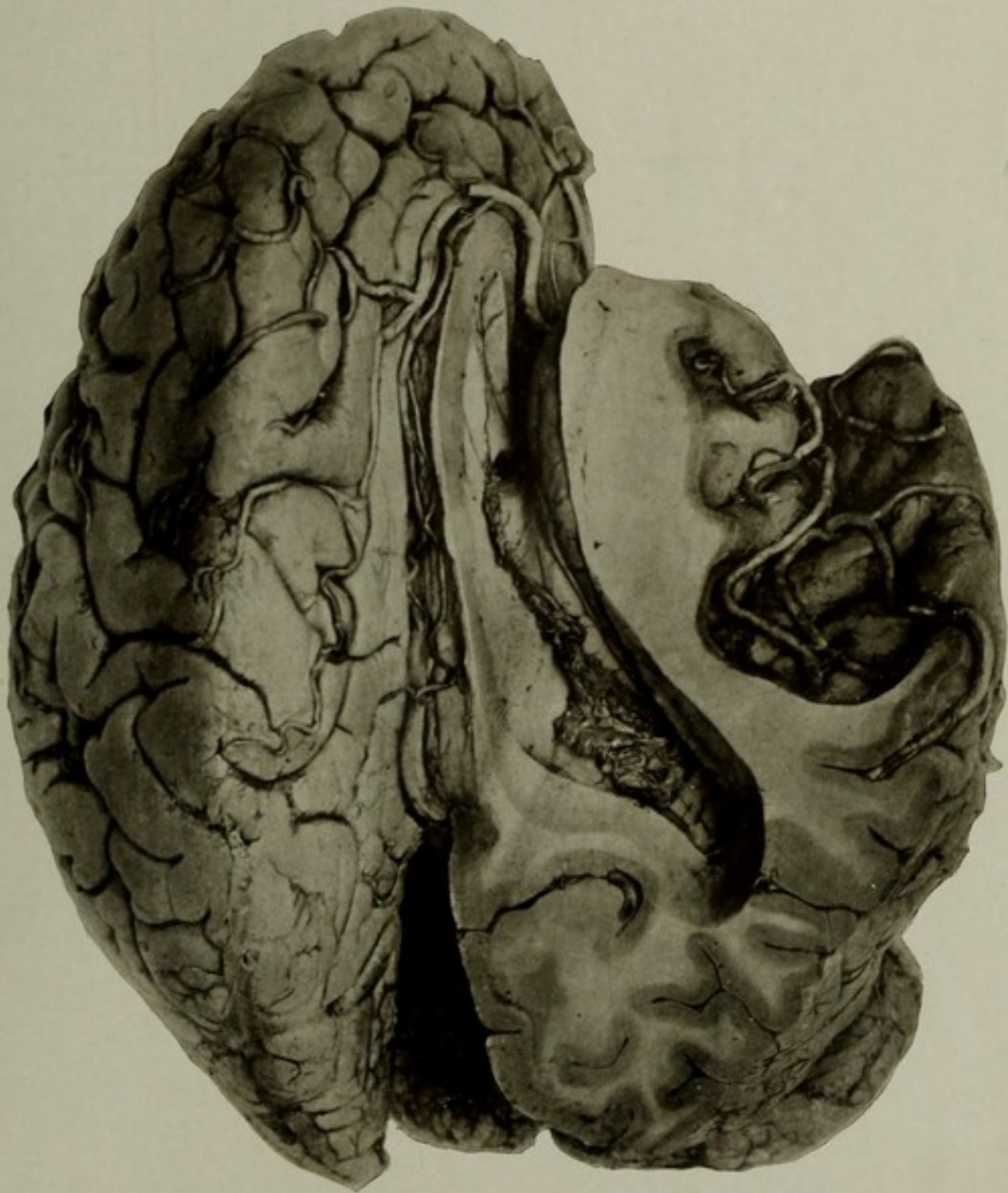
PLATE IV.

AUTOPSY No. 1719*a*.

A DISSECTION OF SCLEROTIC ARTERIES OF THE MESIAL SURFACE AND THE INSULA, ETC.

Case 13662. F. F. S.; aged 77; white; farmer; nativity, Pennsylvania. Mental disease, senile dementia.

This picture shows the terminal distribution of the anterior cerebral artery of the left side after removal of the overlying arachno-pia, the insular and temporal branches of the middle cerebral artery after cutting away the overlying brain, and the parts within the right lateral ventricle after removing the roof and the right side of the callosum. The tortuous condition and the patches of arteriosclerosis of the smaller arteries are particularly well shown in the vessels of the insula.



A DISSECTION OF SCLEROTIC ARTERIES OF THE MESIAL SURFACE AND THE  
INSULA, ETC.



---

---

PLATE V.

---

---

## PLATE V.

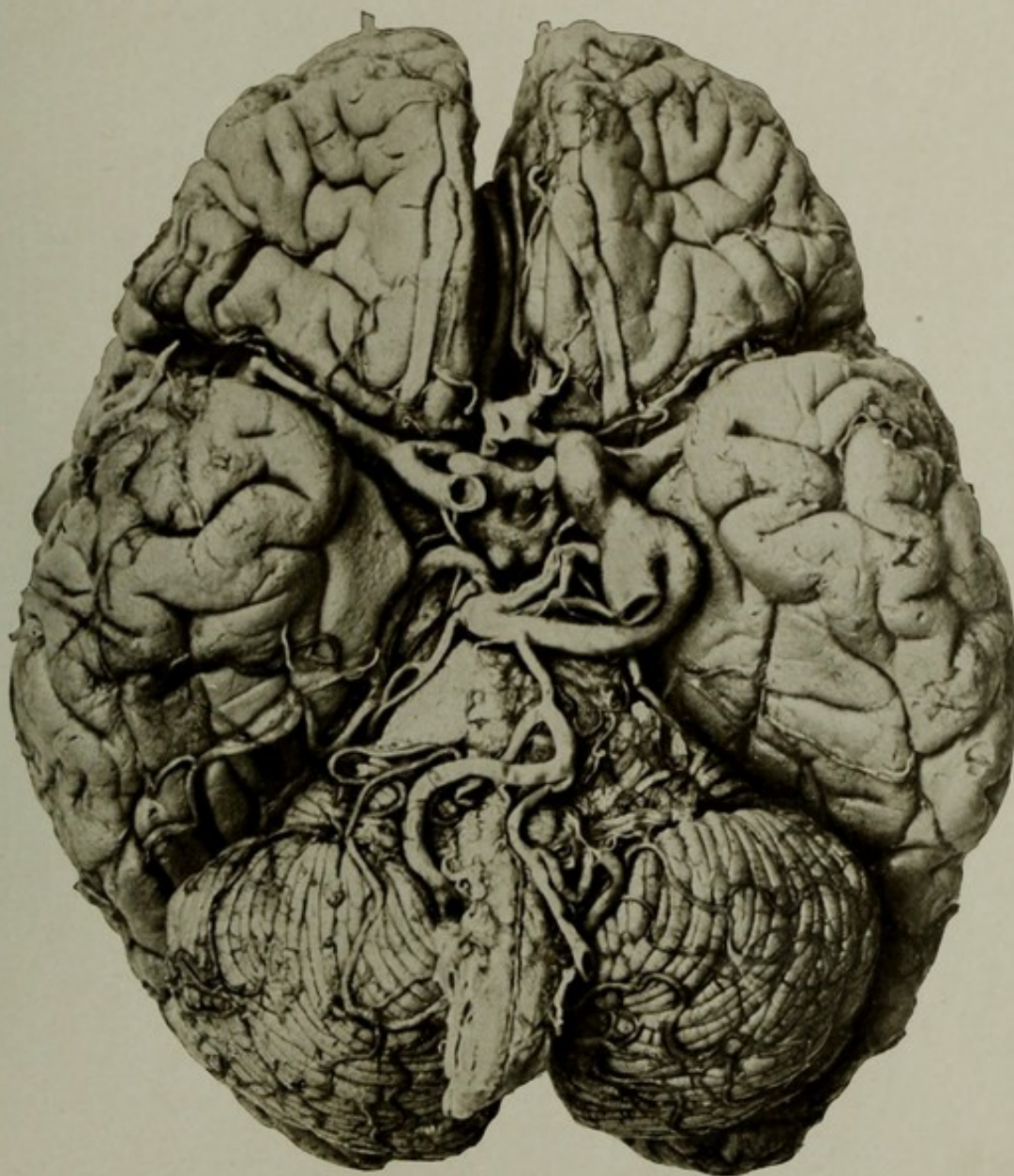
AUTOPSY No. 1926.

### DISSECTION OF THE CEREBRAL ARTERIES, SHOWING AN ANOMALOUS CIRCLE OF WILLIS.

Case 13646. A. C.; male; aged 78; white; soldier; nativity, Ohio. Mental disease, senile dementia; duration, uncertain. Partial autopsy; only the brain examined.

The picture shows a dissection of the cerebral arteries at the base, revealing advanced arteriosclerosis and a number of rare developmental anomalies of the arteries, the most noteworthy being an anastomotic branch of large size arising from the left internal carotid and joining the basilar, which it equals in size. The anterior communicating artery is double; the right anterior inferior cerebellar artery supplies both the anterior and inferior cerebellar branches; the left anterior inferior cerebellar artery is absent, and the left posterior inferior cerebellar artery is unusually large and furnishes branches which take the place of the absent anterior cerebellar. Other deviations from the normal, of minor importance, are present.

NOTE.—This case has been reported in detail in "Anomalies of the encephalic arteries among the insane," by I. W. Blackburn, M. D., *Journal of Comparative Neurology and Psychology*, November 6, 1907.



DISSECTION OF THE CEREBRAL ARTERIES, SHOWING AN ANOMALOUS CIRCLE OF WILLIS.



---

---

PLATE VI.

---

---

(15)

47078—08—3

PLATE VI.

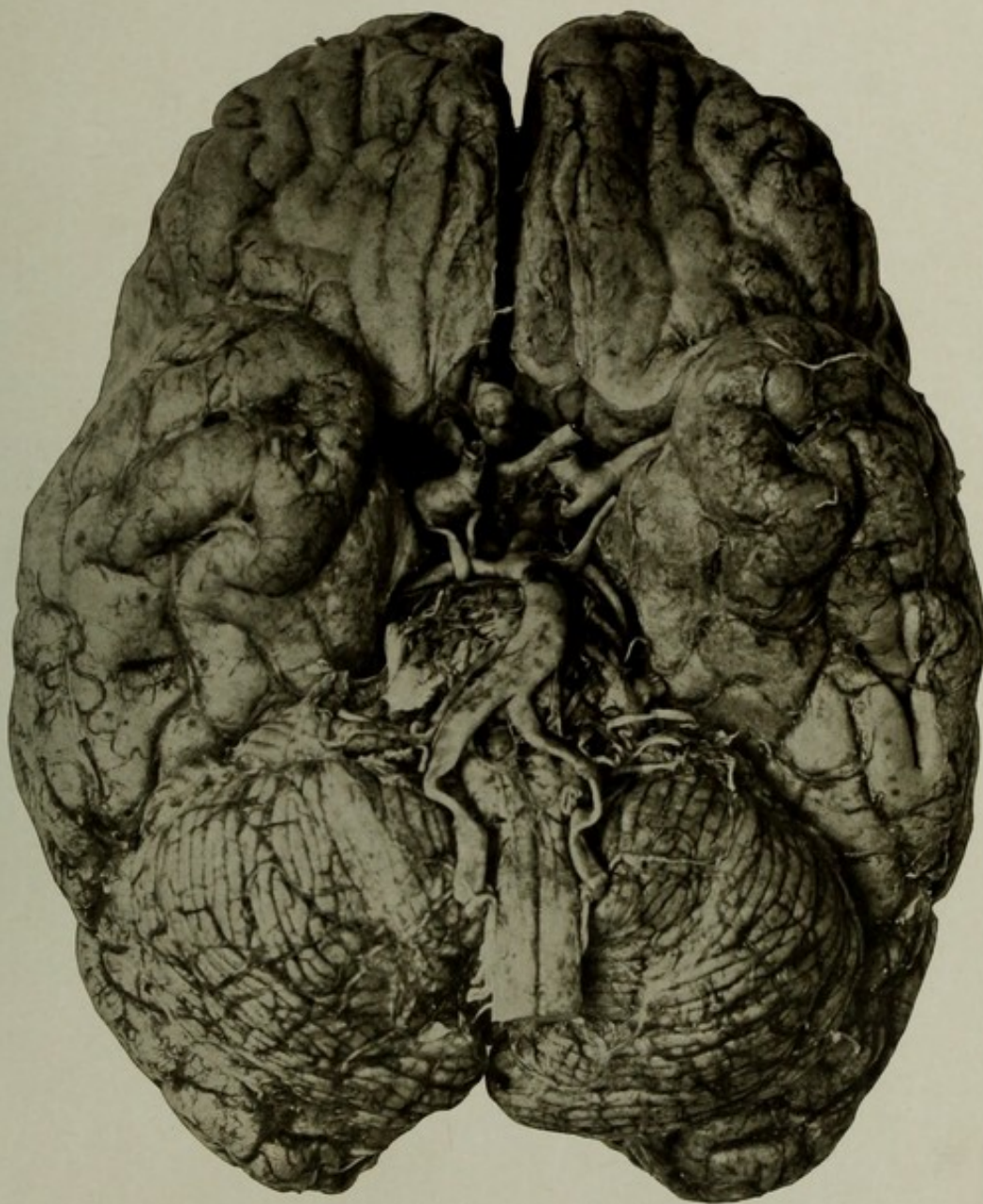
AUTOPSY No. 2163.

ANEURISMS OF THE BASAL ARTERIES AND AN ANOMALOUS ANTERIOR CHOROID ARTERY OF THE  
LEFT SIDE.

Case 15977. A. H. S.; aged 68; male; white; nativity, Kentucky. Mental disease, senile dementia.

Brain: Weight, 1,320 grams. Much atrophied and the leptomeninges opaque. The arteries are somewhat sclerotic and are distorted, dilated, and curved. The left anterior choroid artery is large and lies at first deep in the hippocampal fissure, whence it emerges and forms the parieto-occipital and the calcarine arteries. The posterior cerebral artery is distributed mainly to the inferior surface of the temporal lobe. The right carotid artery at its division into its main branches is dilated into an aneurism; a slight dilatation of the left exists at the same situation. At the junction of the right anterior cerebral with the anterior communicating artery is an aneurism about one-fourth of an inch in diameter.

Other pathological findings are of no importance in this connection.



ANEURISMS OF THE BASAL ARTERIES AND AN ANOMALOUS ANTERIOR CHOROID ARTERY OF THE LEFT SIDE.



---

---

PLATE VII.

---

---

## PLATE VII.

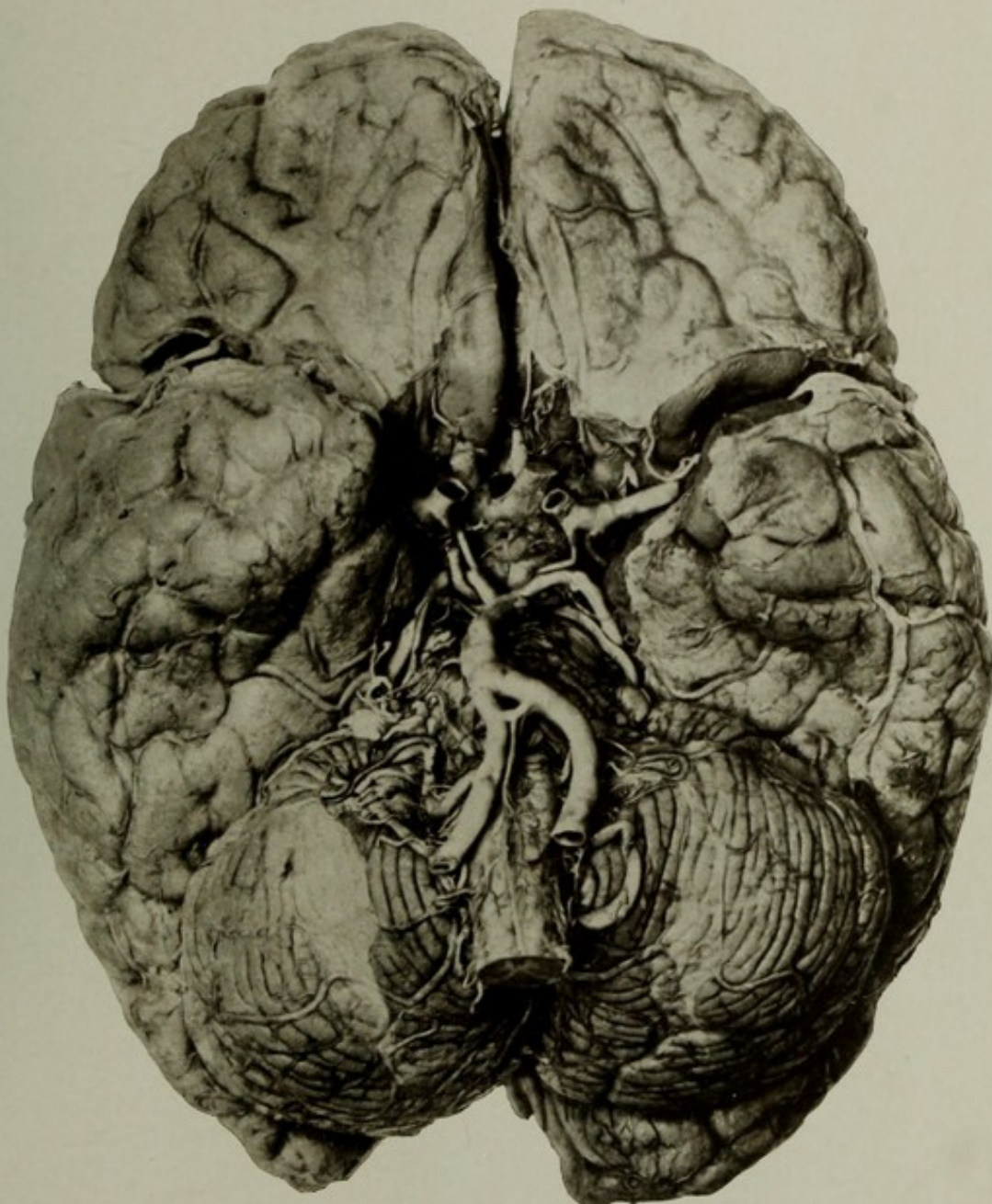
AUTOPSY No. 2094.

THE BASE OF THE BRAIN, SHOWING ARTERIOSCLEROSIS AND ANOMALOUS ARTERIES.

Case 2854. S. S. T.; aged 68; male; white; nativity, Illinois. Mental disease, chronic mania.

The picture shows the basal arteries after removal of the arachnoid and some dissection of the pia to show the smaller vessels. The tortuosity and irregularity of the sclerotic arteries are well shown, and in the right carotid a blood clot fills the lumen. There is marked curvature of the cerebellar arteries, and the vertebrals and the basilar are curved, the convexity of the latter being toward the right. The anomalous condition of the arteries consists of a connecting artery of large size connecting the two vertebrals and giving origin to the anterior spinal artery. Weight of brain, 1,390 grams.

Other pathological conditions bore no relation to the condition of the brain. The patient died of cystitis and pyelonephritis, consequent to prostatic enlargement.



THE BASE OF THE BRAIN, SHOWING ARTERIOSCLEROSIS AND ANOMALOUS ARTERIES.



---

---

PLATE VIII.

---

---

## PLATE VIII.

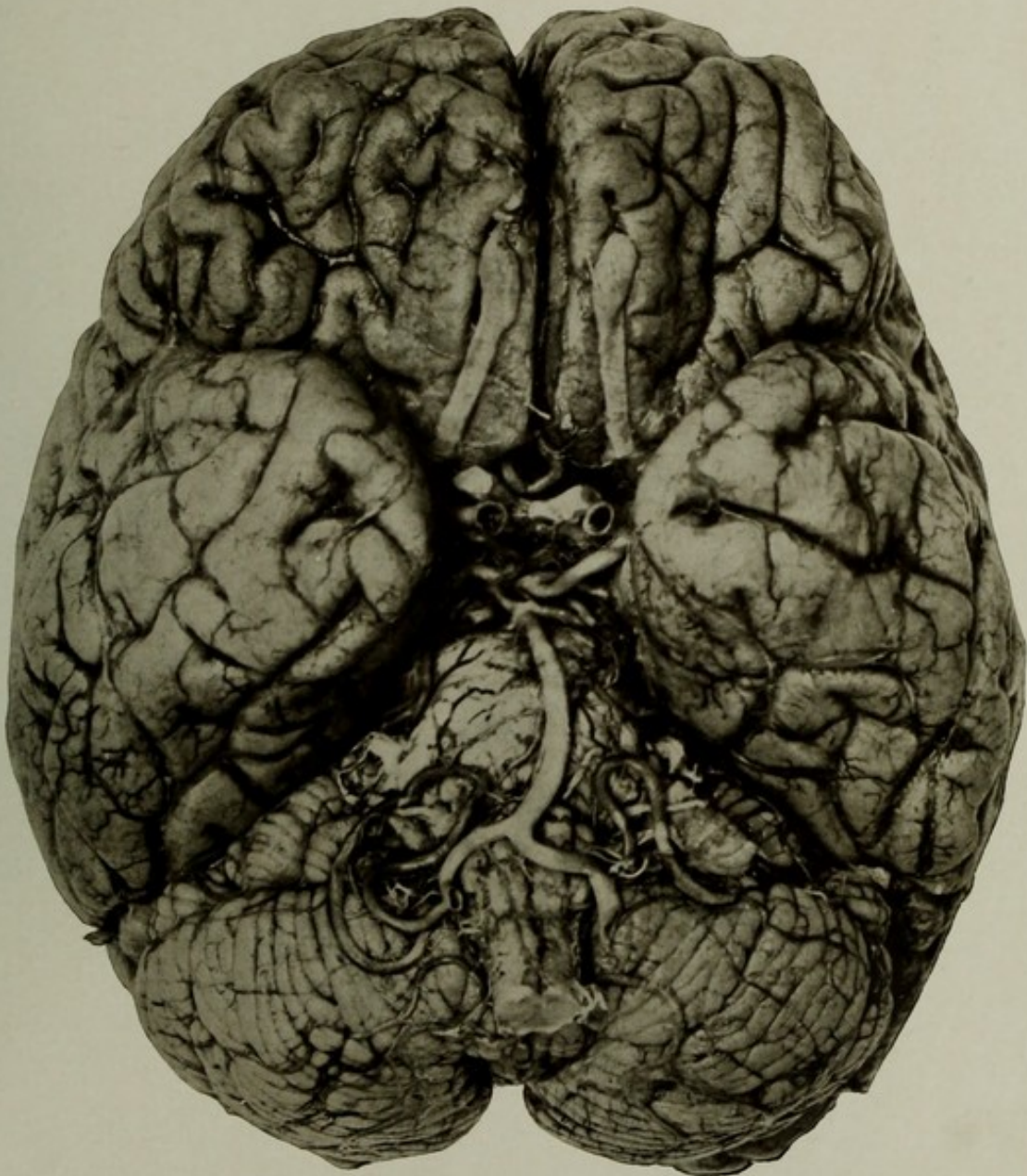
AUTOPSY No. 2057.

### THE BASE OF A BRAIN SHOWING ARTERIOSCLEROSIS.

Case 8783. A. K.; aged 77; white; late soldier; nativity, Germany. Mental disease, chronic melancholia.

Brain: Weight, 1,150 grams. Arteries at the base dilated and sclerotic. Both posterior communicating arteries were greatly enlarged and furnished the blood supply to the posterior cerebral regions, as the posterior cerebral arteries were abnormally small at their origin from the basilar. The superior cerebellar arteries were rather large, the anterior inferior cerebellar arteries being practically absent or represented by very small branches. The posterior inferior cerebellar arteries were large, extremely tortuous, and took the place of the anterior inferior cerebellar vessels as well. The right vertebral artery was disproportionately small and the left was the size of the basilar. The latter was curved, with its convexity toward the left. The right anterior cerebral artery was large and sent the main blood supply to the opposite territory through a large anterior communicating, the opposite artery being small.

The condition of the other organs is unimportant in this connection.



THE BASE OF A BRAIN SHOWING ARTERIOSCLEROSIS.



---

---

PLATE IX.

---

---

PLATE IX.

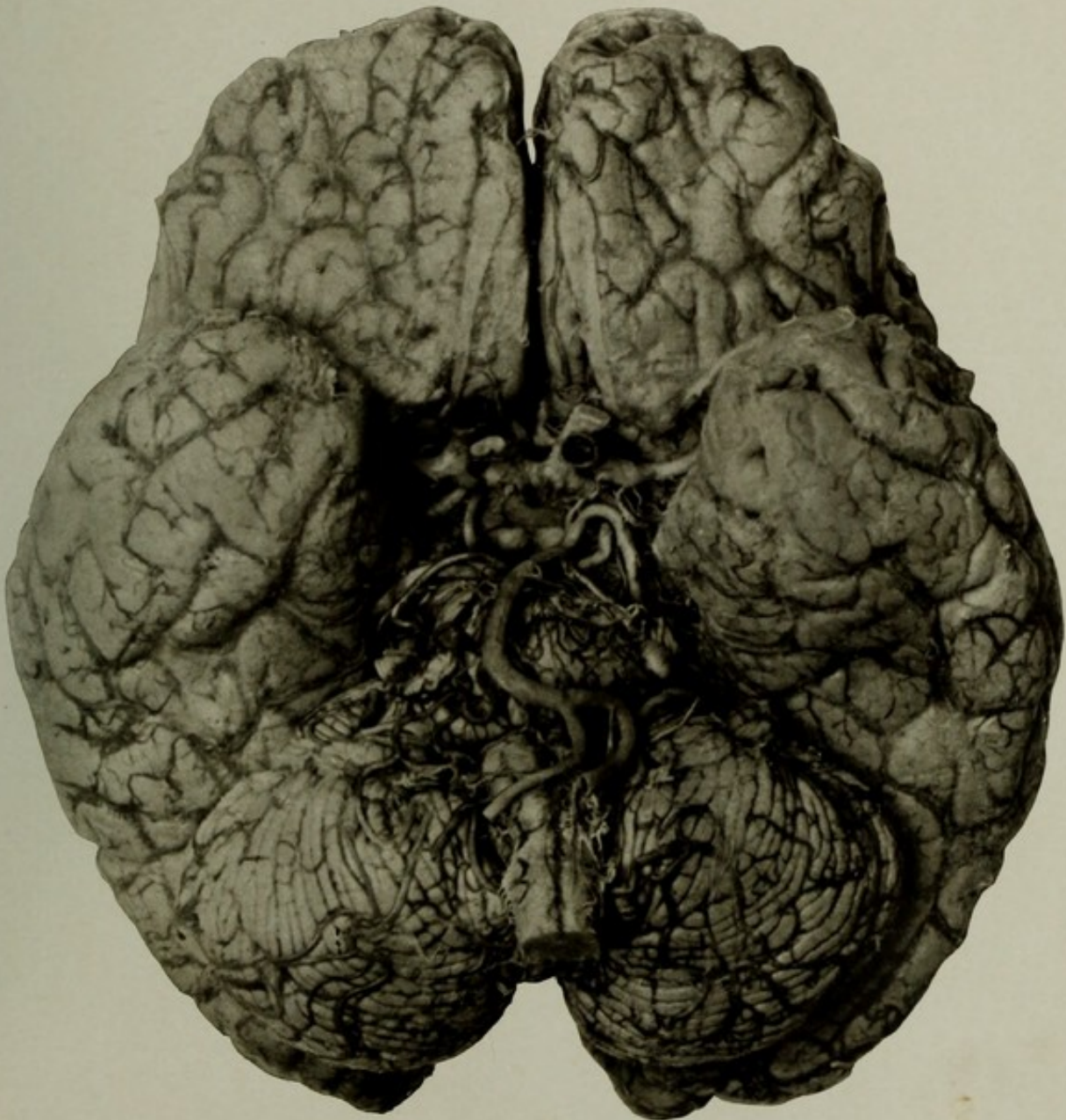
AUTOPSY No. 2091.

THE BASE OF THE BRAIN, SHOWING ARTERIOSCLEROSIS OF THE SMALL VESSEL TYPE.

Case 9142. A. M.; aged 81; male; white; nativity, Germany. Mental disease, senile dementia.

Brain: Weight, 1,200 grams. Much shrinkage of brain and *œdema ex vacuo* of pia. The arteries show only slight rigidity and opacity, but are greatly curved. This is especially noticeable in the basilar and vertebral arteries, the former being greatly bent, with its convexity toward the right. In both internal carotid arteries are recent dark clots completely filling the lumen. These are not true ante-mortem thrombi, being formed either shortly before or after death.

A noticeable feature of this picture is the extreme relative breadth of the brain compared with its antero-posterior diameter—a characteristic of many German brains.



THE BASE OF THE BRAIN, SHOWING ARTERIOSCLEROSIS OF THE SMALL VESSEL TYPE.



---

---

PLATE X.

---

---

(23)

PLATE X.

AUTOPSY No. 2042.

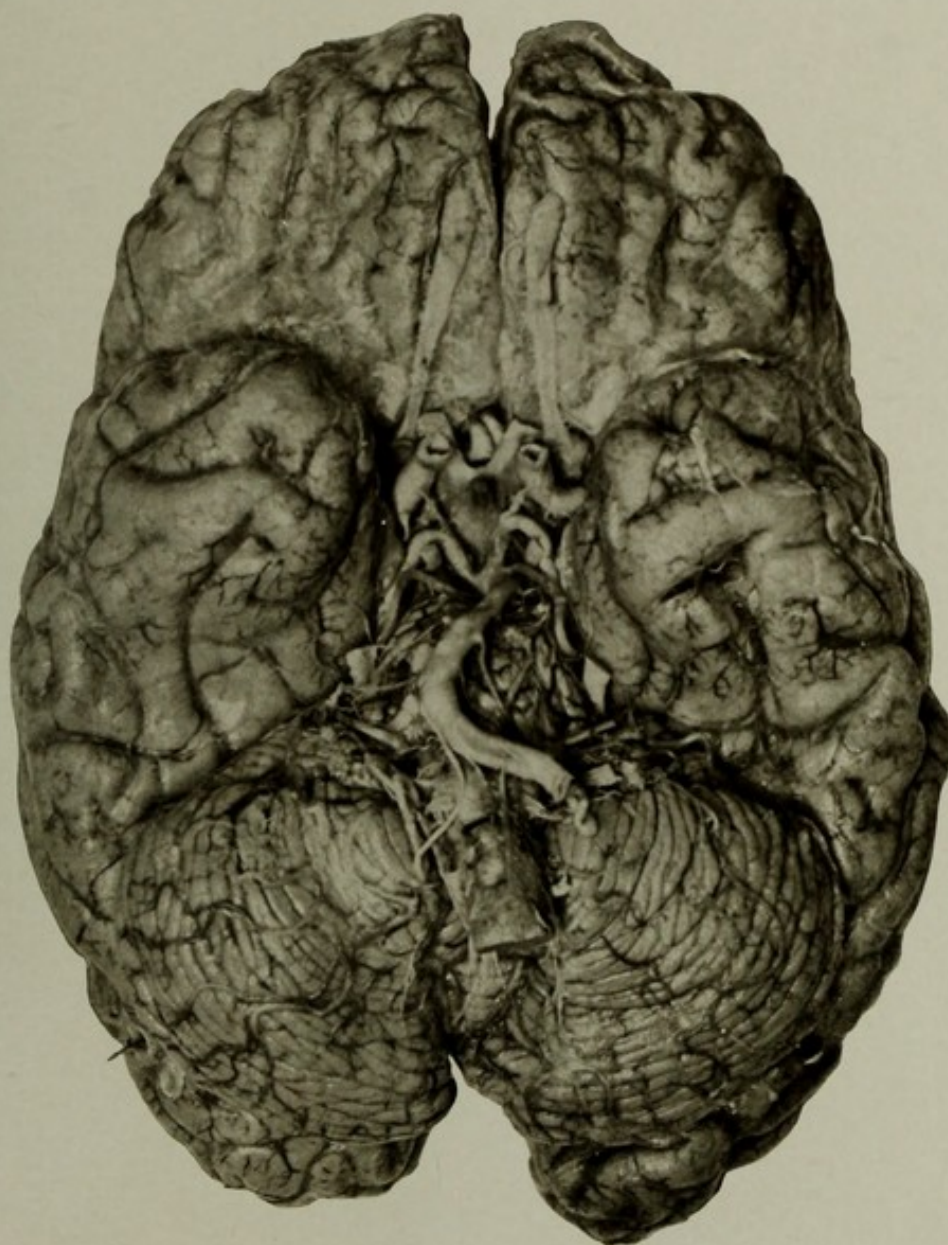
THE BASE OF A BRAIN SHOWING ARTERIOSCLEROSIS.

Case 7106. A. I.; aged 63; white; nativity, Germany. Mental disease when admitted, acute mania; now arteriosclerotic terminal dementia.

Synopsis of autopsy: Brain weight, 1,150 grams. Convolutions much shrunken over the whole brain. Arteries at the base showed advanced arteriosclerosis and distortion. The left vertebral artery was unusually large, passing without change of caliber into the basilar; the right was very small, almost impervious, and the posterior inferior cerebellar, which was of normal size, formed the main continuation of the cervical portion of the vertebral vessel. The anterior spinal artery arose from the left vertebral, and the left anterior inferior cerebellar artery came off the basilar much above its usual position. The basilar was strongly curved, with its convexity to the right; the superior cerebellar and the posterior cerebral arteries were much distorted.

The skull cap showed some nodular exostoses externally; the dura was adherent and showed a faint neo-membrane over the inner surface of the convexity.

The lungs contained numerous miliary catarrhal tubercles. The cæcal end of the colon was dislocated and the small bowel occupied the right iliac fossa in its stead.



THE BASE OF A BRAIN SHOWING ARTERIOSCLEROSIS.



---

---

PLATE XI.

---

---

## PLATE XI.

AUTOPSY No. 2269.

### DISSECTION SHOWING THE DISTRIBUTION OF THE ANTERIOR CEREBRAL ARTERIES AND THE DISTRIBUTION OF A LARGE MEDIAN ANTERIOR CEREBRAL ARTERY.

Case 11766. A. C.; aged 67; male; colored; nativity, Virginia. Mental disease, senile dementia; duration, seven years. Death from exhaustion and pulmonary hypostasis.

Skull thick and dense. Dura adherent to the bone.

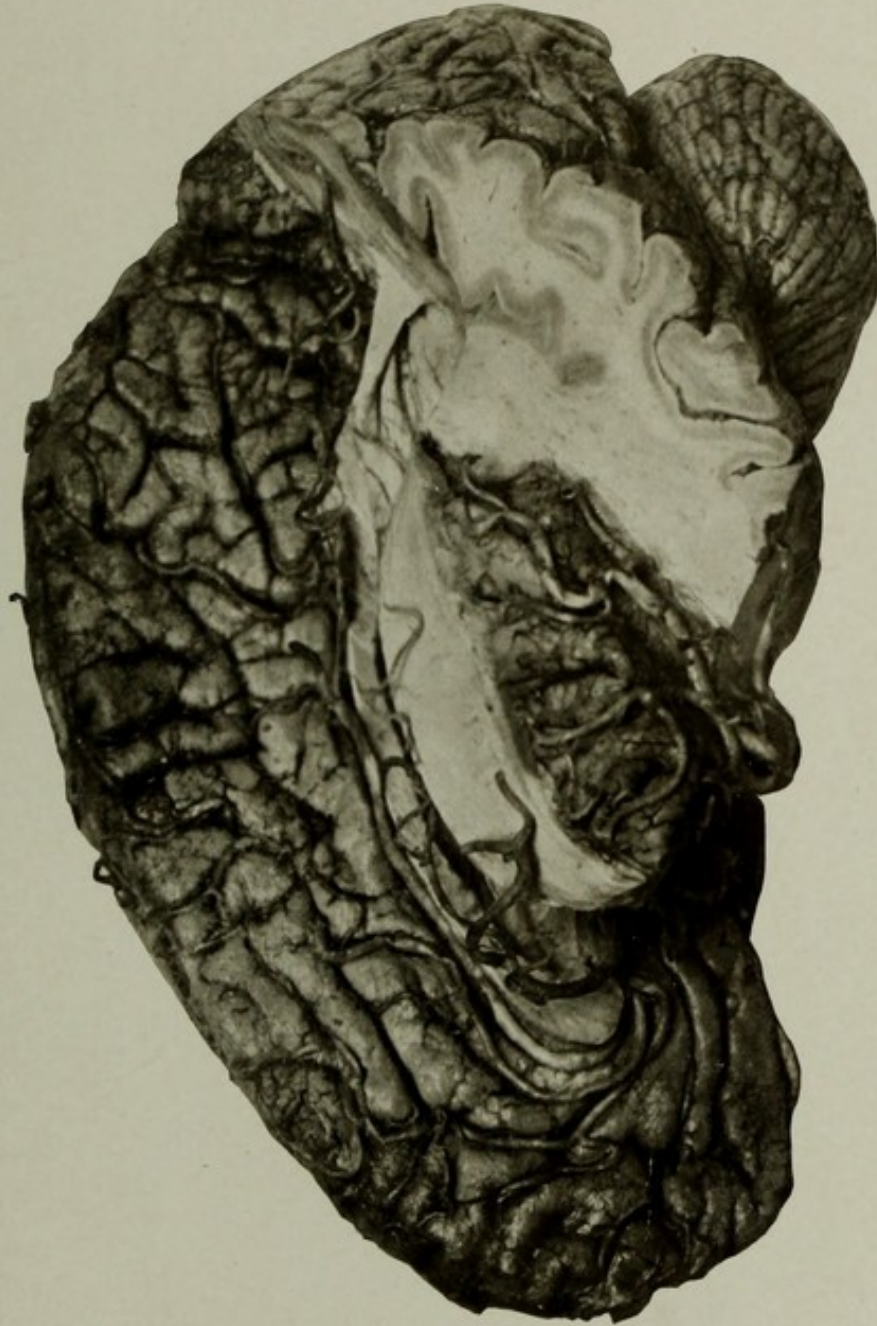Brain: Weight, 1,240 grams. Considerable degree of shrinkage; convolutions much cut up by secondary fissures. No gross lesions. A large median anterior cerebral artery was found arising from the anterior communicating artery. The vessel curved around the genu callosi and continued backward along the corpus callosum to a point opposite the paracentral lobule, where it divided into four equal large branches which supply the paracentral and quadrate lobules of the two sides. The two true anterior cerebral arteries were somewhat smaller than the abnormal vessel and were distributed to the anterior portion of the medial surfaces. The picture shows the upper part of the anomalous artery left *in situ*, while the left hemisphere is partly cut away. The arteries distributed to the left hemisphere are partly cut away and in part left free. The left insula is left intact, with the arteries of the Sylvian system left *in situ*. They are seen to be enlarged and tortuous, showing a moderate degree of senile arteriosclerosis. Some slight disproportion in the size of the vertebrals and the inferior cerebellar arteries. A small cortical softening on right orbital surface.

Lungs hypostatic. Heart increased in weight; the valves of the left side and the tricuspid are incompetent. Kidneys a little contracted. Other organs practically normal.

NOTE.—The median anterior cerebral artery—*arteria termatica* of Wilder—is found in a small percentage of cases. It quite commonly divides into branches which supply the two adjoining medial surfaces of the paracentral and quadrate lobules. It is not uncommon for one of the true anterior cerebral arteries to send a branch to the opposite hemisphere; and sometimes only one anterior cerebral is developed into a large callosal trunk with branches to both surfaces, while the opposite vessel is only distributed to the anterior part of its own hemisphere.

GROSS MORBID ANATOMY OF THE BRAIN IN THE INSANE.

PLATE XI.



DISSECTION SHOWING THE DISTRIBUTION OF THE ANTERIOR CEREBRAL ARTERIES AND THE  
DISTRIBUTION OF A LARGE MEDIAN ANTERIOR CEREBRAL ARTERY.



---

---

PLATE XII.

---

---

## PLATE XII.

AUTOPSY No. 310.

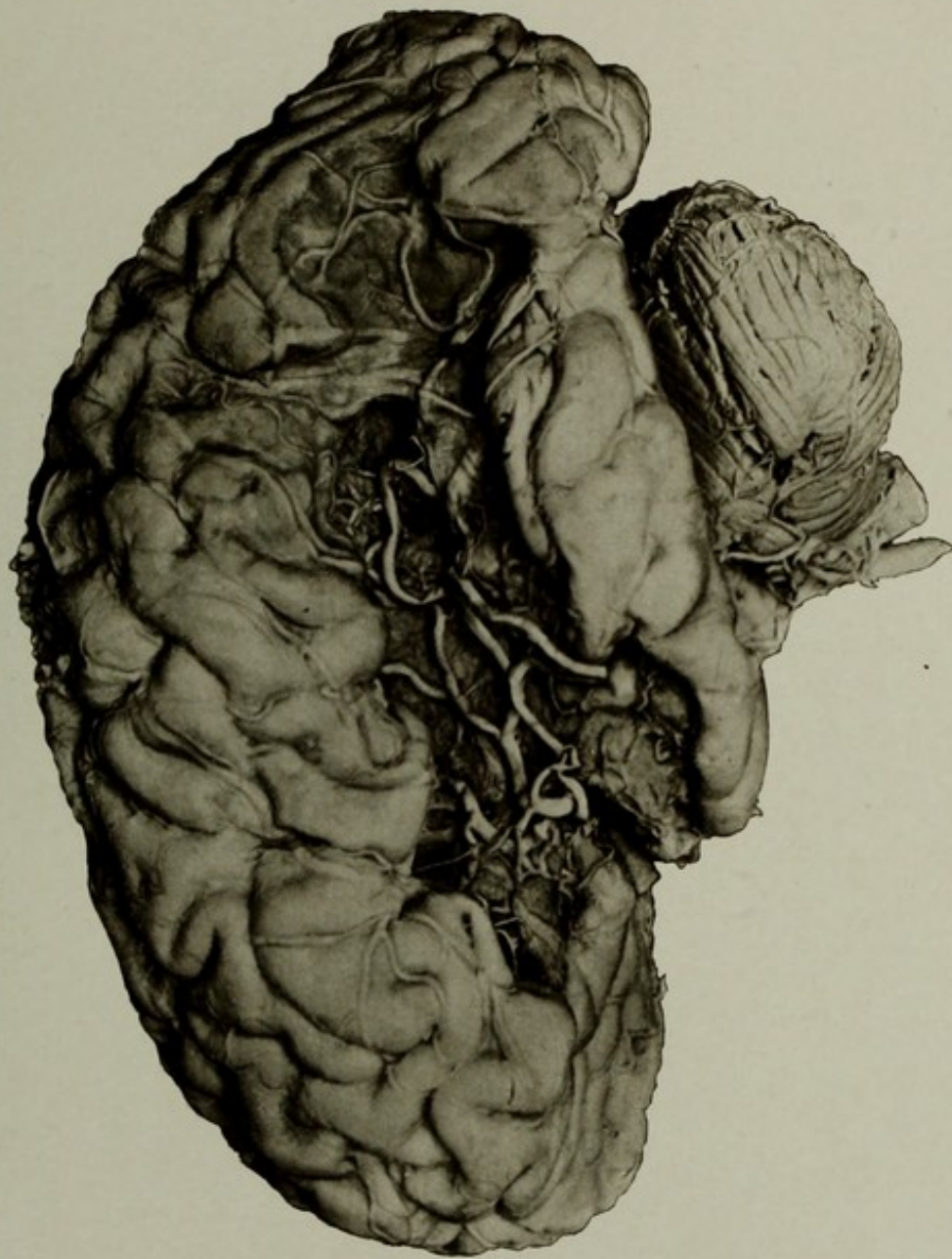
### A LARGE ARTERIOSCLEROTIC SOFTENING OF THE LEFT HEMISPHERE.

Case 7173. W. C.; aged 66; male; white; former soldier; nativity, Ireland. Mental disease, chronic dementia. Patient had right hemiplegia, aphasia, and was extremely demented.

Synopsis of autopsy: The brain was generally atrophied. Weight of right hemiencephalon, 22½ ounces (637 grams); the left, 19 ounces (538 grams). On the left side a large softening, with loss of substance, had involved the third frontal convolution, the insula, lower ends of the central gyri, inferior parietal lobule, the outer surface of the occipital lobe, and the greater part of the superior and middle temporal convolutions. The arteries were sclerotic and calcified at the base, and a thrombotic obstruction of the middle cerebral artery of the left side had doubtless caused the softening. The principal branches of the vessel, in the fresh condition containing blood, are seen lying, apparently well preserved, at the bottom of the necrotic cavity. The fact that the arteries were so well preserved and pervious suggests that the cause may have been thrombosis with reestablishment of the arterial circulation.

GROSS MORBID ANATOMY OF THE BRAIN IN THE INSANE.

PLATE XII.



A LARGE ARTERIOSCLEROTIC SOFTENING OF THE LEFT HEMISPHERE.



---

---

PLATE XIII.

---

---

PLATE XIII.

AUTOPSY No. 1517.

A LARGE ARTERIOSCLEROTIC SOFTENING OF LEFT HEMISPHERE.

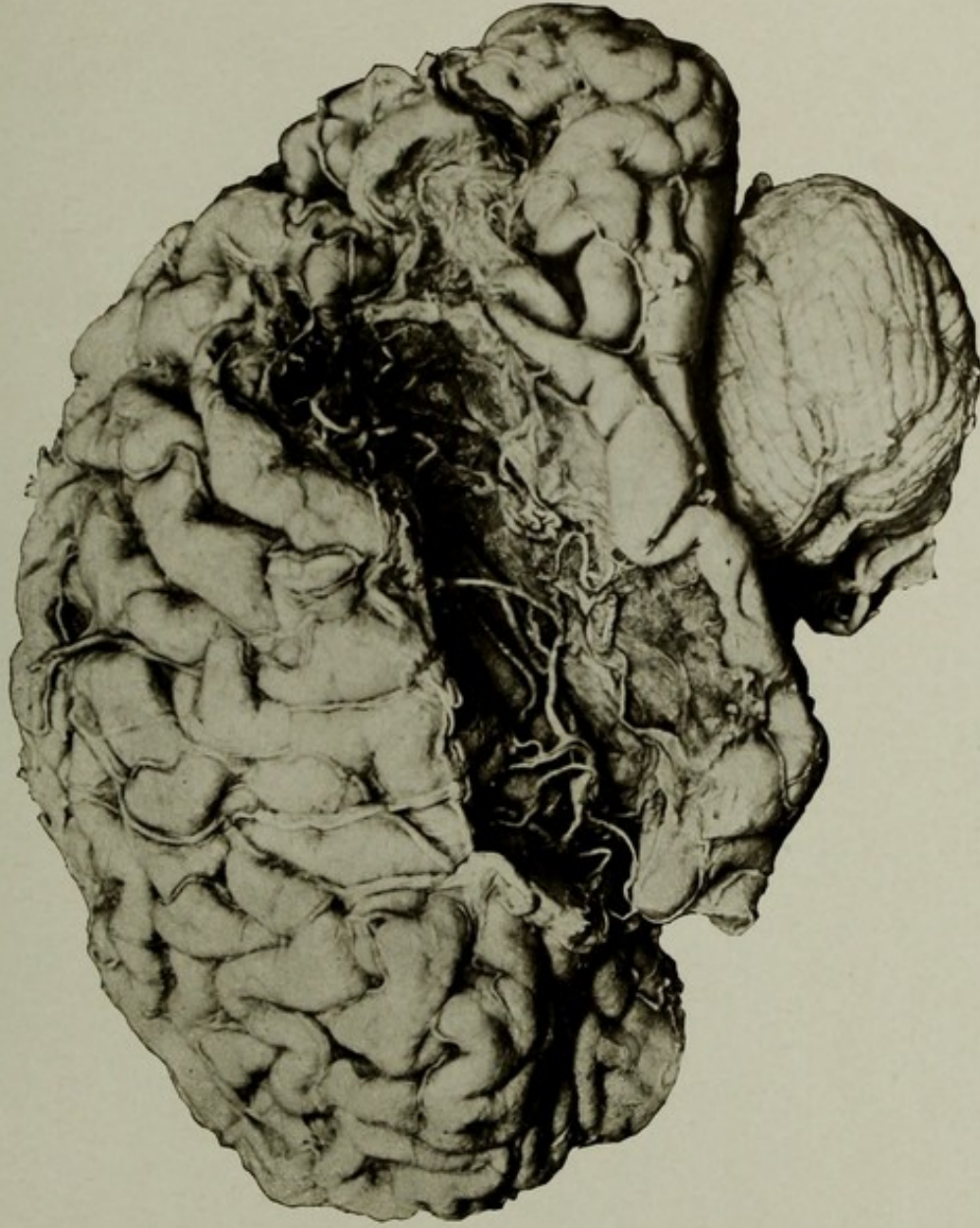
Case 10290. S. McF.; aged 83; white; male; wheelwright; nativity, Kentucky. Mental disease, senile dementia; duration, three years. Clinical history of advanced dementia.

Synopsis of autopsy: Skull unusually thin; sutures obliterated; dura adherent to the bone.

Brain: Weight of right half, 600 grams; left, 500 grams. The convolutions were generally atrophied; organ soft and œdematous; ventricles dilated. On the left side a large softening, with loss of substance, involved the greater part of the inferior parietal lobule, the first, second, and third temporal gyri, and the outer portion of the occipital lobe. The third frontal convolution, the central gyri, and the anterior portion of the insula had escaped injury. The obstructed arteries may still be seen lying at the bottom of the cavity, and in the recent condition they contained blood, though of no functional value. On the right side the lower portion of the cuneus and the upper part of the lingual and fusiform gyri were softened. The arteries at the base were sclerotic and calcareous, and the softenings were doubtless secondary to the vascular disease.

GROSS MORBID ANATOMY OF THE BRAIN IN THE INSANE.

PLATE XIII.



A LARGE ARTERIOSCLEROTIC SOFTENING OF LEFT HEMISPHERE.



---

---

PLATE XIV.

---

---

## PLATE XIV.

AUTOPSY No. 1601.

LEFT HALF BRAIN WITH MULTIPLE CORTICAL SOFTENINGS DUE TO ARTERIOSCLEROSIS.

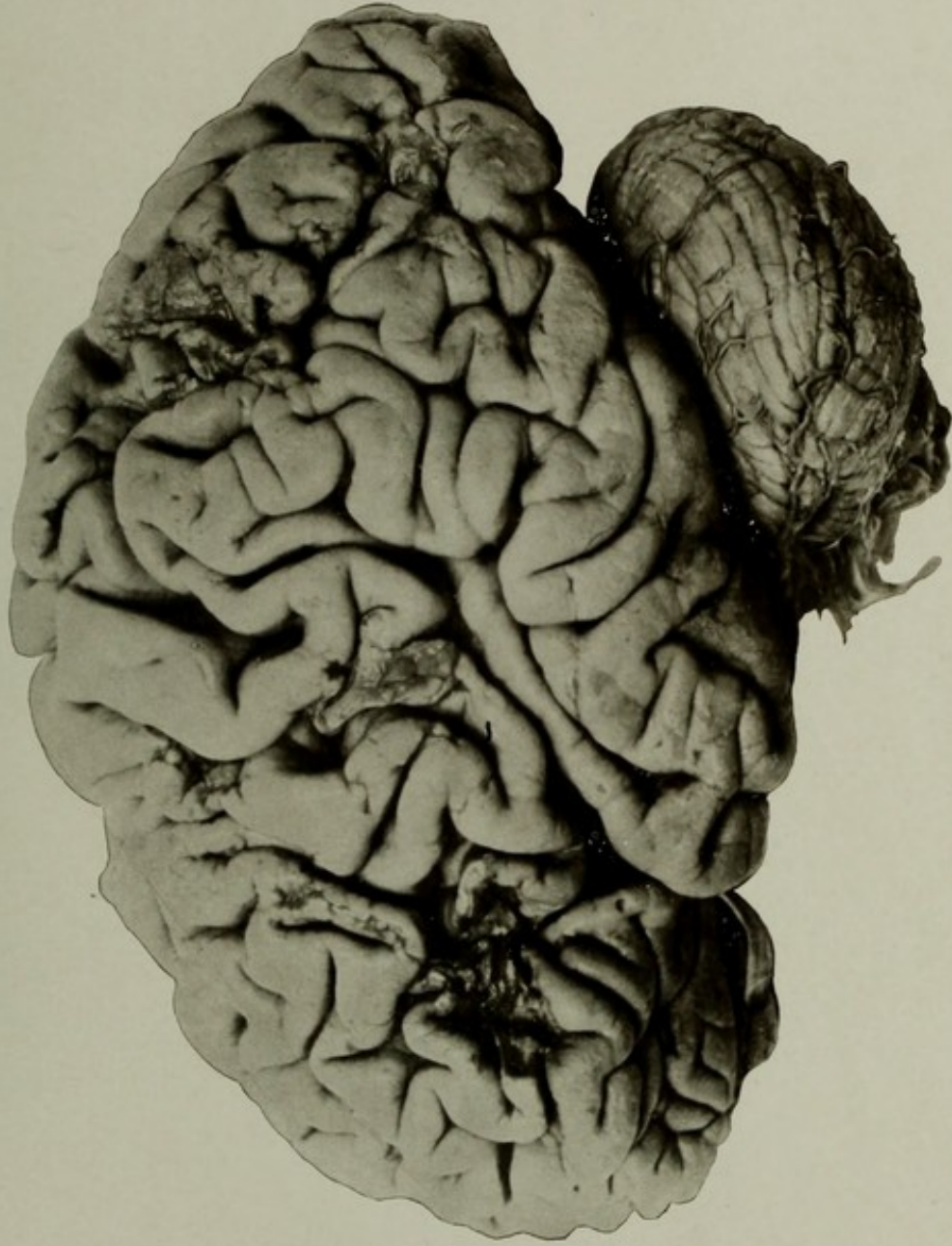
Case 9549. D. K.; aged 72; white; late soldier; nativity, Ireland. Mental disease, senile dementia. History of cardiac asthma and general muscular enfeeblement and ataxic aphasia.

Synopsis of autopsy: The brain weighed 1,100 grams. On the left hemisphere there were cortical softenings, with contraction and puckering of adjoining gyri, affecting the third frontal, middle frontal, upper part of the anterior central and lower part of the posterior central convolutions, a large area in the superior parietal lobule, and the outer surface of the occipital lobe and posterior part of the temporal lobe. Softenings were also found in the basal ganglia of this side, and on the right side a softening involved the head of the caudate nucleus and the adjoining anterior limb of the internal capsule. The brain showed general atrophy and œdema; arteries sclerotic and calcified.

The patient had chronic interstitial myocarditis, due to disease of the coronary arteries, to which was attributed the asthmatic attacks, but there was no valvular disease which could have led to embolism; therefore the softenings were believed to be the result of the vascular disease.

GROSS MORBID ANATOMY OF THE BRAIN IN THE INSANE.

PLATE XIV.



LEFT HALF BRAIN WITH MULTIPLE CORTICAL SOFTENINGS DUE TO ARTERIOSCLEROSIS.



---

---

PLATE XV.

---

---

PLATE XV.

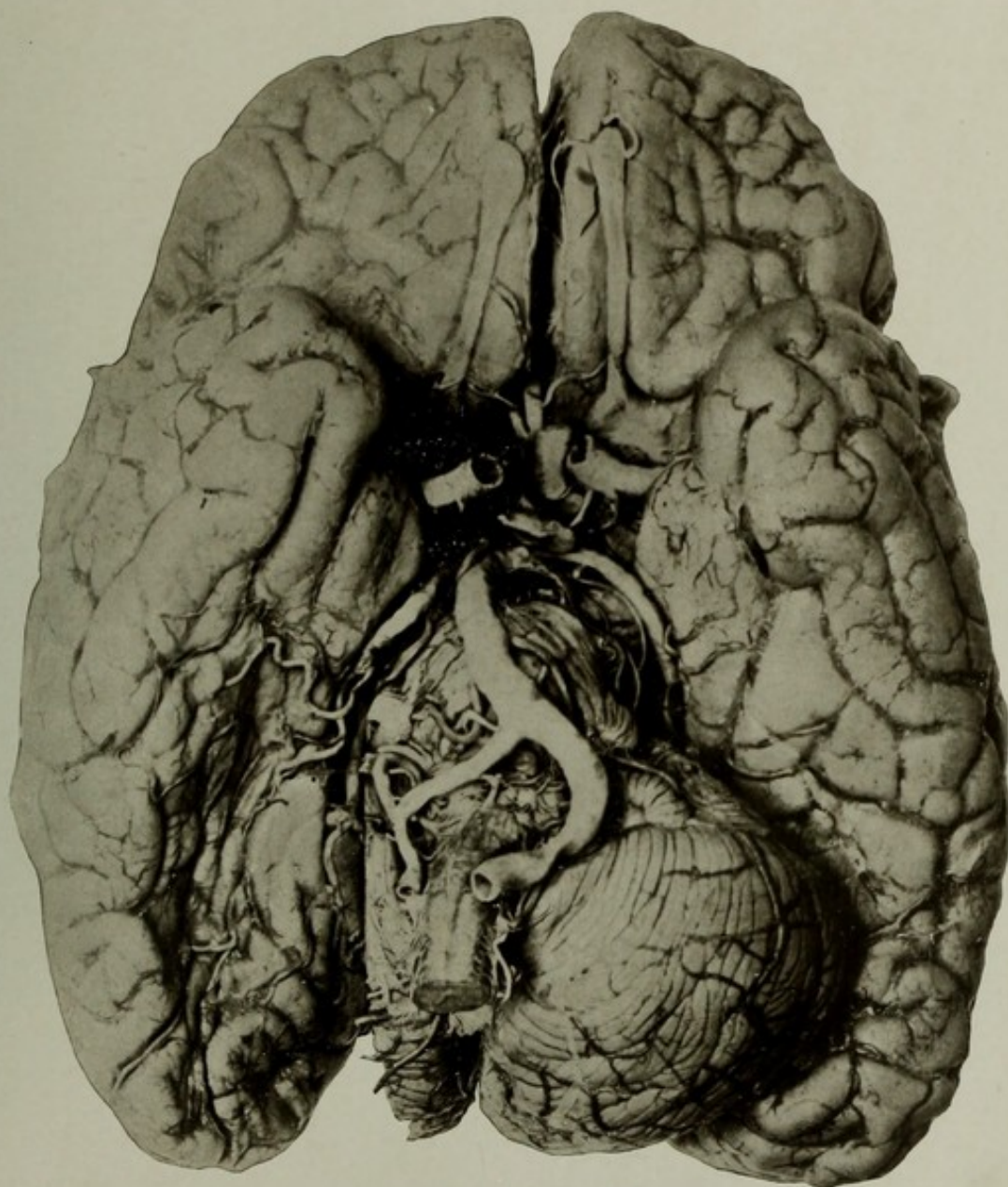
AUTOPSY No. 2089.

THE BASE OF THE BRAIN, SHOWING ARTERIOSCLEROSIS OF THE BASAL VESSELS AND SOFTENING FROM OBSTRUCTION OF THE RIGHT POSTERIOR CEREBRAL ARTERY.

Case 15546. M. J.; aged 85; female; colored; married; nativity, United States. Mental disease, senile dementia.

Brain: Weight, 1,030 grams. The picture shows marked arteriosclerosis of the basal arteries and a large softening of the base of the right hemisphere, involving the whole of the fusiform lobule, the adjoining convolutions, and the extremity of the occipital lobe. To show the extent of this softening and to show the disease of the posterior cerebral artery upon which it was dependent, the right hemisphere of the cerebellum has been cut away. There is a decided disproportion in the size of the two vertebral arteries, and the greatest degree of arteriosclerosis is noted in these and in the basilar artery. The genu of the callosum was softened, and there was great shrinkage of the brain over the convexity.

The kidneys were granular; the arteries of the body in general were sclerotic. The mucous membrane of the urinary bladder showed chronic catarrh.



THE BASE OF THE BRAIN, SHOWING ARTERIOSCLEROSIS OF THE BASAL VESSELS AND SOFTENING FROM OBSTRUCTION OF THE RIGHT POSTERIOR CEREBRAL ARTERY.



---

---

PLATE XVI.

---

---

## PLATE XVI.

AUTOPSY No. 2063.

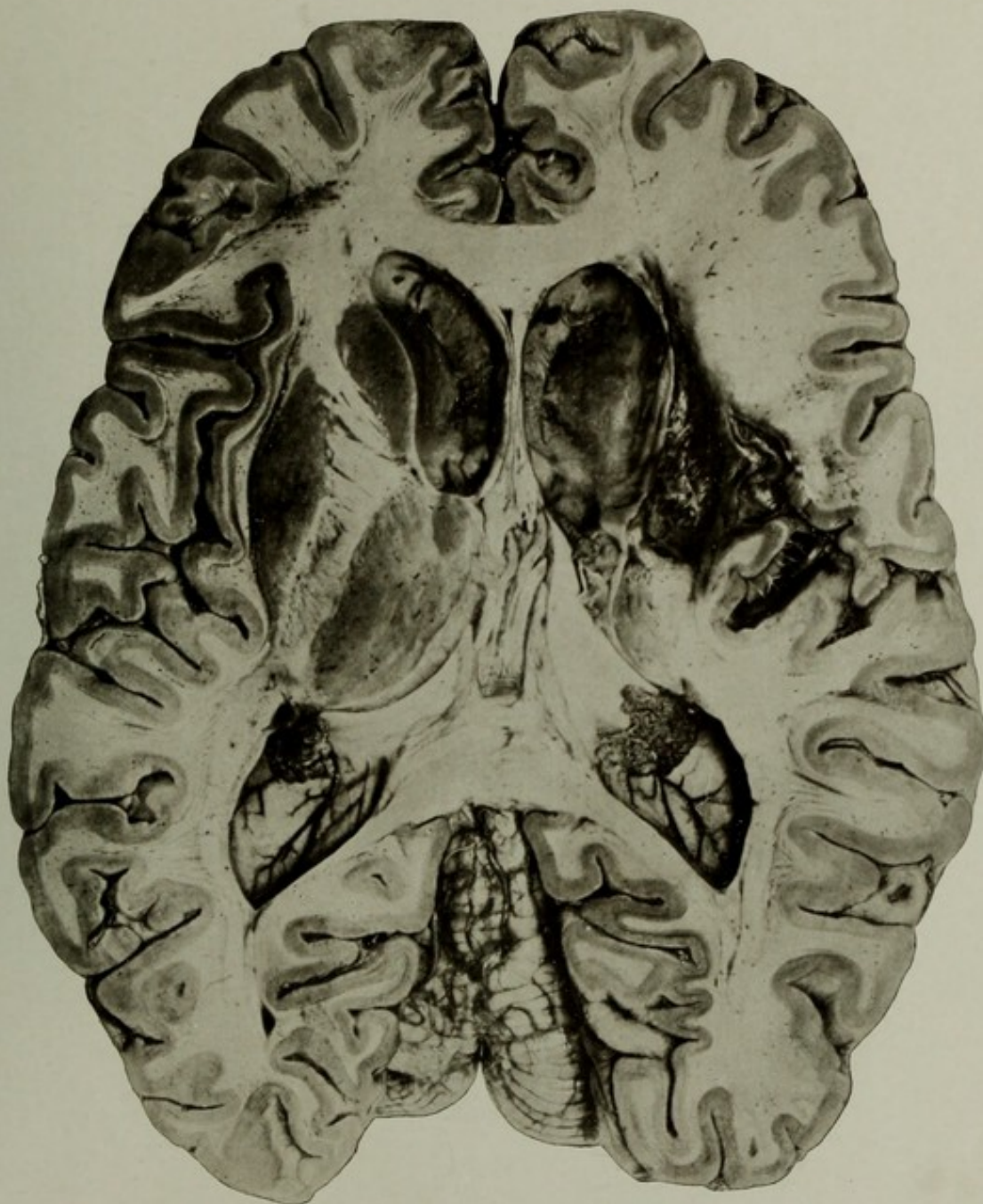A HORIZONTAL SECTION OF A BRAIN SHOWING CENTRAL SOFTENINGS FROM ARTERIOSCLEROSIS.

Case 15068. J. B. C.; aged 66; white; farmer; nativity, Ohio. Mental disease, organic dementia; senile arteriosclerosis.

Synopsis of autopsy: Senile gangrene of three toes of left foot.

Brain: Weight, 1,290 grams. Organ moderately shrunken over the whole convexity. Arteries sclerotic and calcareous. Section showed the tissue œdematous and soft; ventricles dilated; on the right side a large softening extended from the anterior portion of the insular gyri through to the ventricle, involving in its course nearly the whole of the lenticular nucleus, the capsules, and the head of the caudate. The posterior limb of the internal capsule and the thalamus were involved, but to a less degree, the posterior two-thirds of the former being fairly preserved. On the left side the ganglia and capsules were intact. The left vertebral artery was very small, the right unusually large, and entered without change of caliber into the basilar. The right anterior cerebral artery was small at its origin, and the left was correspondingly large, furnishing the main blood supply to the opposite region through an enlarged anterior communicating artery.

The other organs showed nothing of importance except a generalized arteriosclerosis.



A HORIZONTAL SECTION OF A BRAIN SHOWING CENTRAL SOFTENINGS  
FROM ARTERIOSCLEROSIS.



---

---

PLATE XVII.

---

---

## PLATE XVII.

AUTOPSY No. 2104.

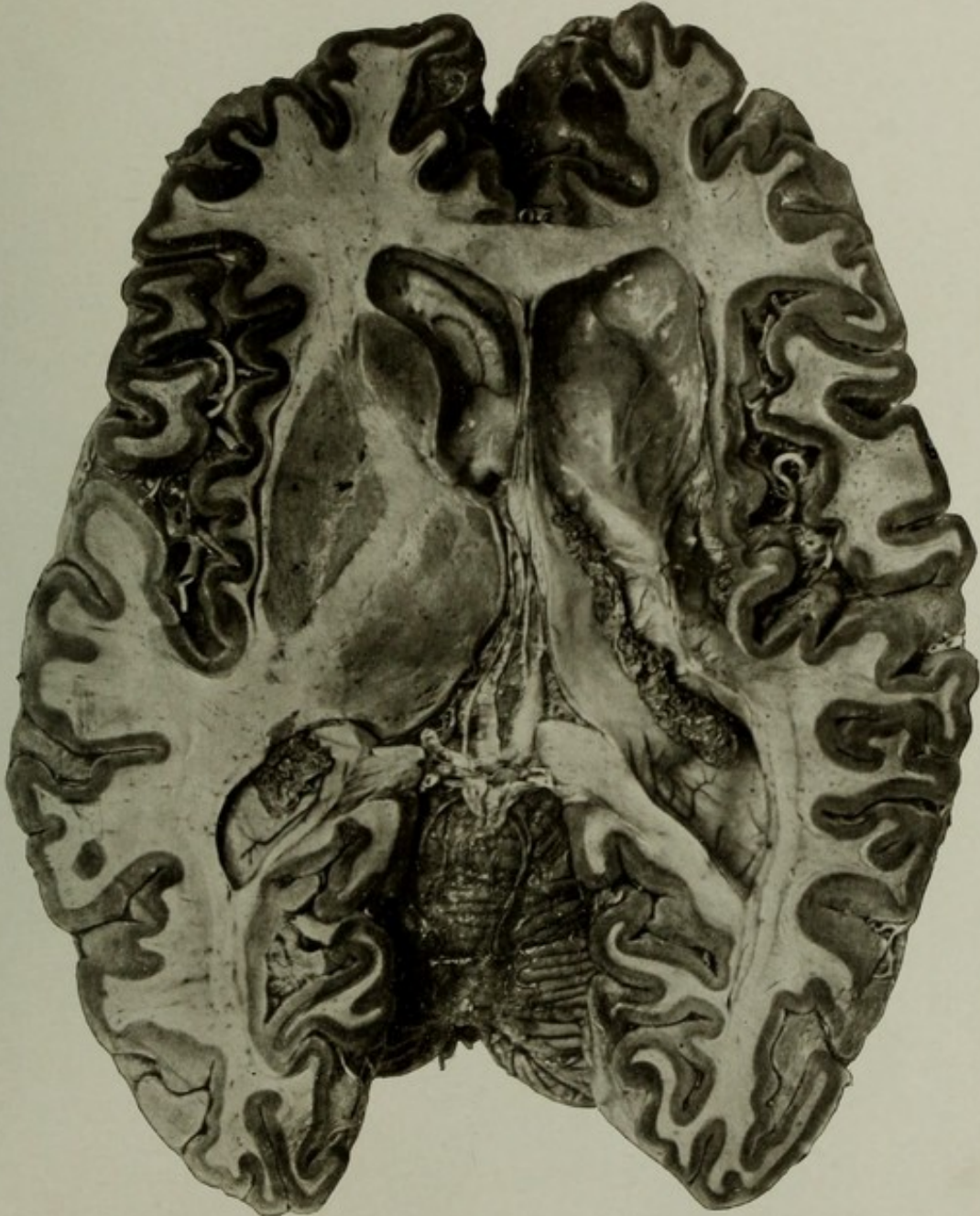
A HORIZONTAL SECTION OF BRAIN SHOWING CENTRAL ARTERIOSCLEROTIC SOFTENINGS.

Case 14246. A. S.; aged 63; male; white; soldier; nativity, United States. Mental disease, organic dementia.

Brain: Weight, 1,210 grams. Arteriosclerosis; brain shrunken and œdematous. A large chronic softening, revealed by horizontal section, was found to involve the insular cortex, white substance of the insula, the claustrum, external capsule, lenticular nucleus, the internal capsule, the outer portion of the head of the caudate nucleus, and almost the whole thalamus. The ventricles were considerably dilated.

Other pathological conditions were cardiac aneurism from interstitial myocarditis, chronic disease of the aortic and mitral valves, hypertrophy and dilatation of heart, and relative incompetency of tricuspid valve. Other pathological findings of no importance in this connection.

The patient had long suffered from left hemiplegia, attributed to cerebral hemorrhage, but there were no evidences of former hemorrhage, the lesion being destructive arteriosclerotic softenings.



A HORIZONTAL SECTION OF BRAIN SHOWING CENTRAL ARTERIOSCLEROTIC SOFTENINGS.



---

---

PLATE XVIII.

---

---

(39)

47078—08—6

## PLATE XVIII.

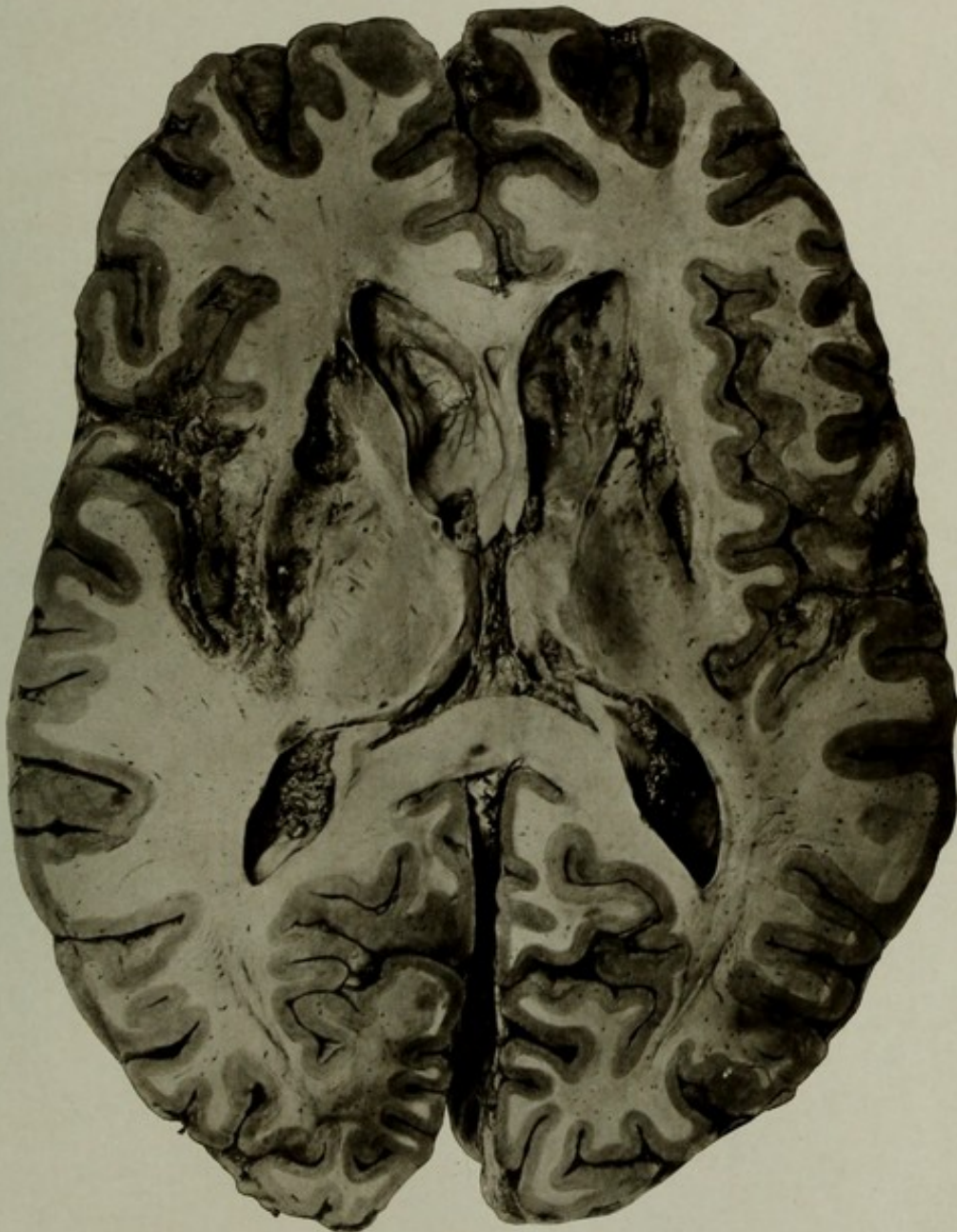### AUTOPSY No. 1961.

#### A HORIZONTAL SECTION OF A BRAIN SHOWING SYPHILITIC SOFTENINGS OF THE INTERIOR AND CORTEX.

Case 14124. J. S.; aged 30; white; soldier; nativity, United States. Mental disease, syphilitic dementia with right hemiplegia and aphasia.

Synopsis of autopsy: Brain weight, 1,730 grams. The organ showed softenings involving the posterior portion of the left frontal lobe, lower ends of the central gyri, lower part of the inferior parietal lobule, and the whole of the insula and the overlying opercula. On the right side a similar softening affected the lower part of the inferior parietal lobule and part of the supramarginal gyrus. On section, the softenings of the left side were found to involve the insula, external capsule, lenticular nucleus, a part of the anterior limb, and a portion of the posterior part of the posterior limb of the internal capsule. On the right side the head of the caudate and the whole of the lenticular nucleus and the anterior limb of the internal capsule were destroyed. The arteries at the base showed syphilitic arteriosclerosis.

Multiple gummata of the liver and depressed and pigmented dermal scars were further evidences of the nature of the softenings.



A HORIZONTAL SECTION OF A BRAIN SHOWING SYPHILITIC SOFTENINGS  
OF THE INTERIOR AND CORTEX.



---

---

PLATE XIX.

---

---

## PLATE XIX.

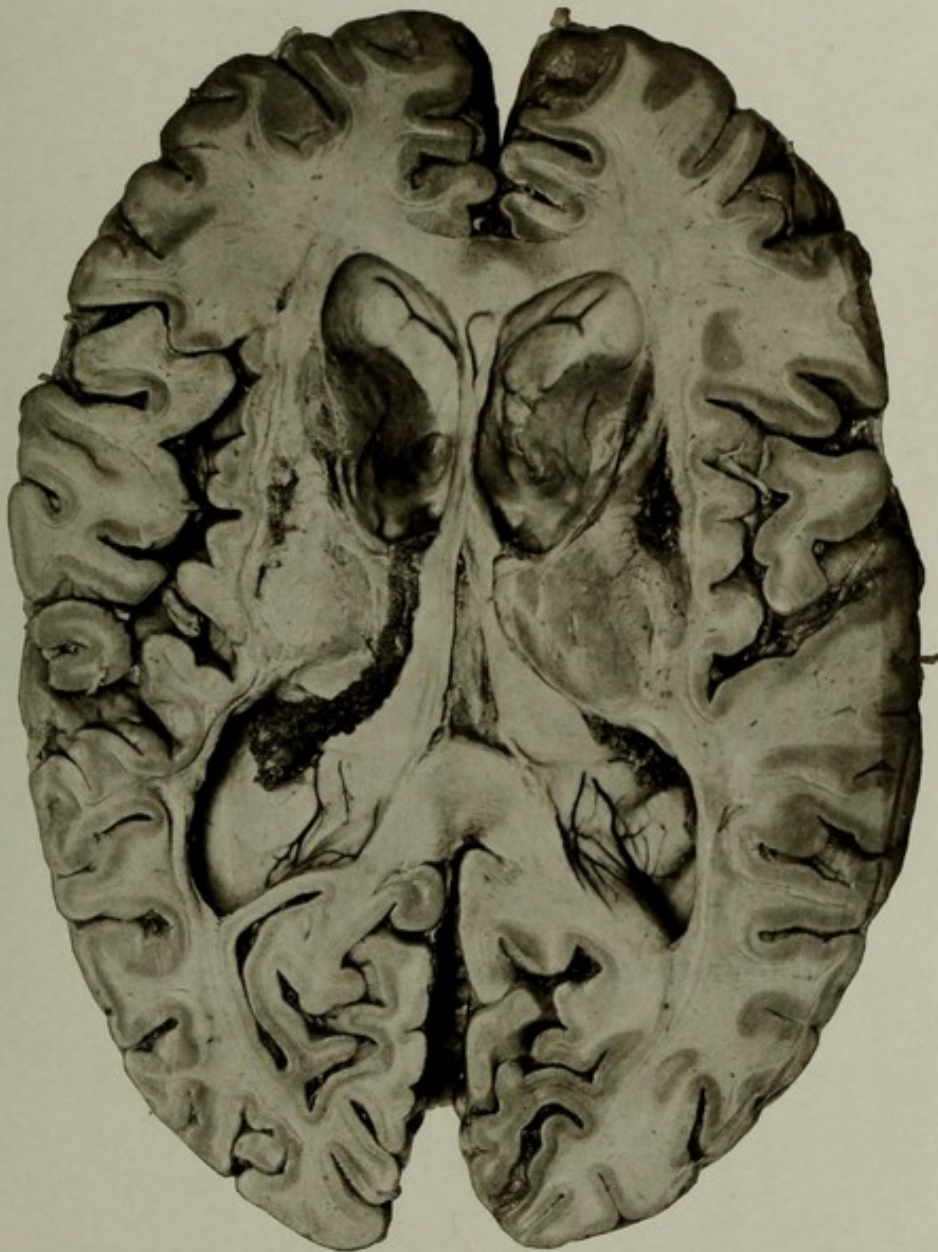AUTOPSY No. 2080.

### A HORIZONTAL SECTION OF A BRAIN SHOWING CIEATRICIAL CENTRAL SOFTENINGS.

Case 15070. R. F.; aged 68; white; soldier; nativity, Ohio. Mental disease, post-paralytic dementia; aphasia.

Brain: Weight, 1,400 grams. Arteries at the base very atheromatous; right posterior communicating artery large; both anterior cerebellar arteries very small. Brain generally atrophied. Cortical softening in the anterior extremity of the left temporal lobe and in the posterior portion of the insular face of the same lobe. Section showed dilatation of the ventricles. On the left side a softening was found, involving the lenticular nucleus, the genual portion of the internal capsule, and the head of the caudate. On the right side almost the same condition existed, with possibly a little less involvement of the facial bundle of the capsule and more destruction of the head of the nucleus caudatus.

A strangulation of the colon was found, caused by the small bowel and its mesentery passing over and above the hepatic flexure of the colon. This portion of the colon had been dislocated and was held to the anterior parieties of the abdomen by a fibrous band. The bulk of the small intestine lay in the right iliac fossa; its vessels were deeply engorged.



A HORIZONTAL SECTION OF A BRAIN SHOWING CICATRICAL CENTRAL SOFTENINGS.



---

---

PLATE XX.

---

---

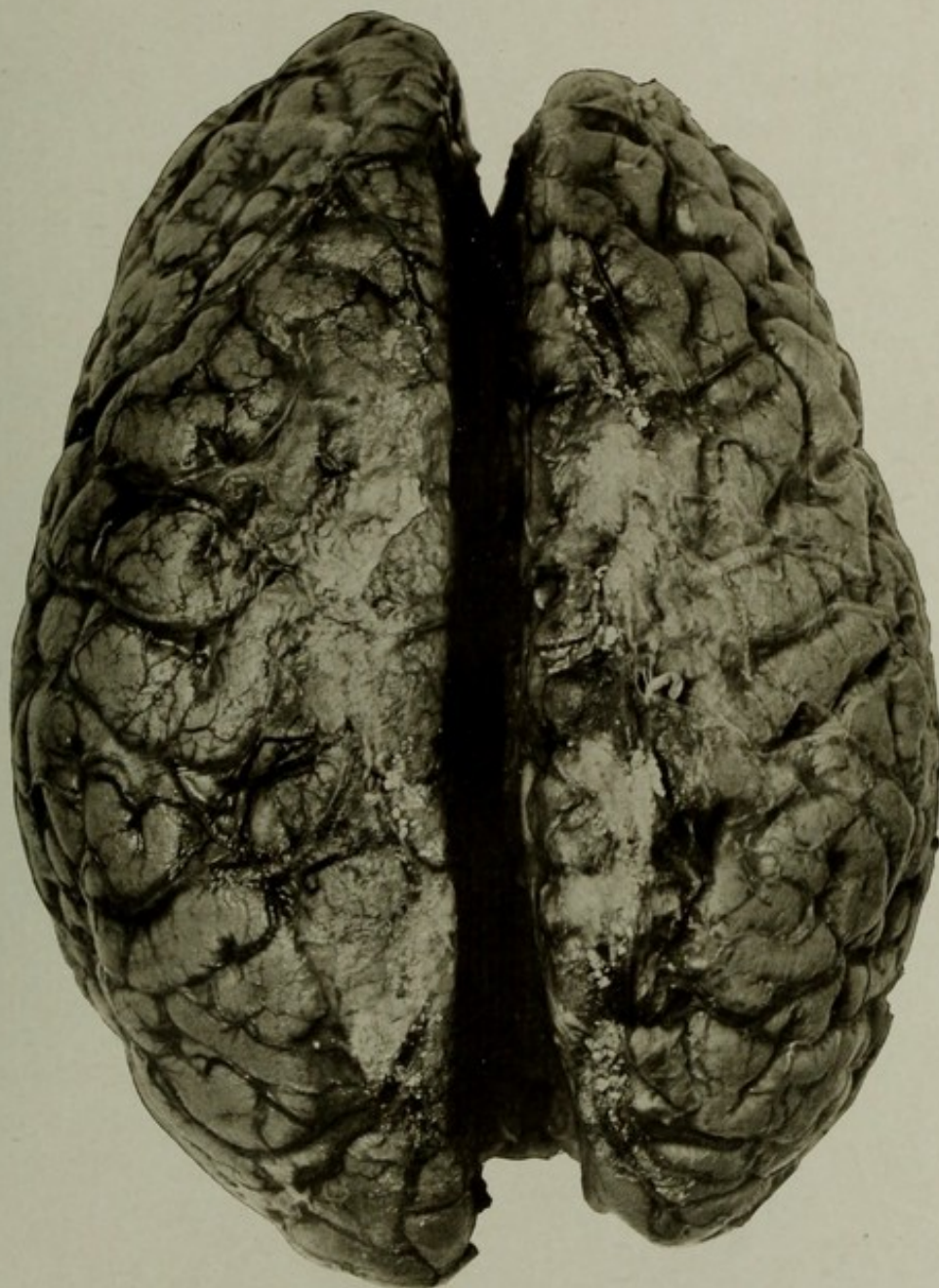
(PLATE XX.)

AUTOPSY No. 1909.

THE SUPERIOR ASPECT OF THE BRAIN IN A CASE OF THROMBOTIC SOFTENING AFFECTING THE WHOLE LEFT HEMISPHERE.

Case 9060. O. B.; aged 69; white; female; nativity, United States. Mental disease, chronic melancholia. Clinical history showed that she had a general convulsion, followed by right hemiplegia, six days before her death. She did not recover complete consciousness, and another convulsion occurred the next day. After this she remained semicomatose, gradually deepening into complete coma two days before death occurred.

Brain weight, 1,200 grams. Arteries at the base markedly sclerotic and tortuous. Both posterior communicating arteries large, and the left furnished the main blood supply to the posterior cerebral area, as the posterior cerebral artery was practically obliterated by disease at its origin from the basilar. A clot had formed in the upper end of the left carotid, cutting off the supply from all the vessels arising from this carotid, and the anterior communicating artery was obliterated by disease. The left hemisphere was thus deprived of blood and had undergone acute softening. The hemisphere was swollen, dark red, soft, and the veins were deeply engorged. The right hemisphere showed some atrophy and some venous engorgement. The pia over the convexity was thick and opaque.



THE SUPERIOR ASPECT OF THE BRAIN IN A CASE OF THROMBOTIC  
SOFTENING AFFECTING THE WHOLE LEFT HEMISPHERE.



---

---

PLATE XXI.

---

---

## PLATE XXI.

AUTOPSY No. 2150.

### ARTERIOSCLEROTIC SOFTENINGS OF CEREBRUM AND CEREBELLUM.

Case 8928. J. S.; aged 63; female; white; nativity, United States. Mental disease, acute mania on admission; duration, thirteen years. The patient became markedly demented. She had a sensation of falling and would scream for help. She had marked contraction of the extremities; some paralysis of the left side. Large abdominal tumor of the left side of the abdomen, found at the autopsy to be an enlarged spleen. The patient had been blind for some time.

Brain: Weight, 1,050 grams. Great general atrophy of the brain, with *œdema ex vacuo* of the pia mater. Veins were prominent and overfilled; some were partially obstructed by thrombi. The arteries at the base were sclerotic and the following obstructions existed: Both posterior cerebral arteries were obstructed as they curved around the crura, and as a result softenings were found at the distribution of all of their principal branches. On the right side the lingual and fusiform lobules were extremely softened. This area included the subcalcarine gyrus and the whole cuneus, and extended through to the posterior horn. On the left side the lingual gyrus and the cuneus were greatly softened, but the latter was still distinguishable. A large softening was found on the outer surface of the left occipital lobe. Section of the cerebrum showed no softenings of the basal nuclei nor capsules. The softenings noted above were found to extend through to the lining of the ventricles, and the softenings of the left cuneus were more extensive than noted on the surface. The left hemisphere of the cerebellum showed a large softening of the posterior border and another on its under surface, both of which extended deeply into the white matter. The right hemisphere showed a somewhat acute softening of the posterior border. These softenings were due to obstructions of the left posterior inferior cerebellar artery; on the right side there was some obstruction of the branches of the right posterior inferior cerebellar artery.

The right lung showed some old tuberculous deposits and a recent eruption of miliary tubercles; a small gangrenous cavity in right lower lobe.

Heart showed some sclerosis of its arteries; some fibrosis of papillary muscles.

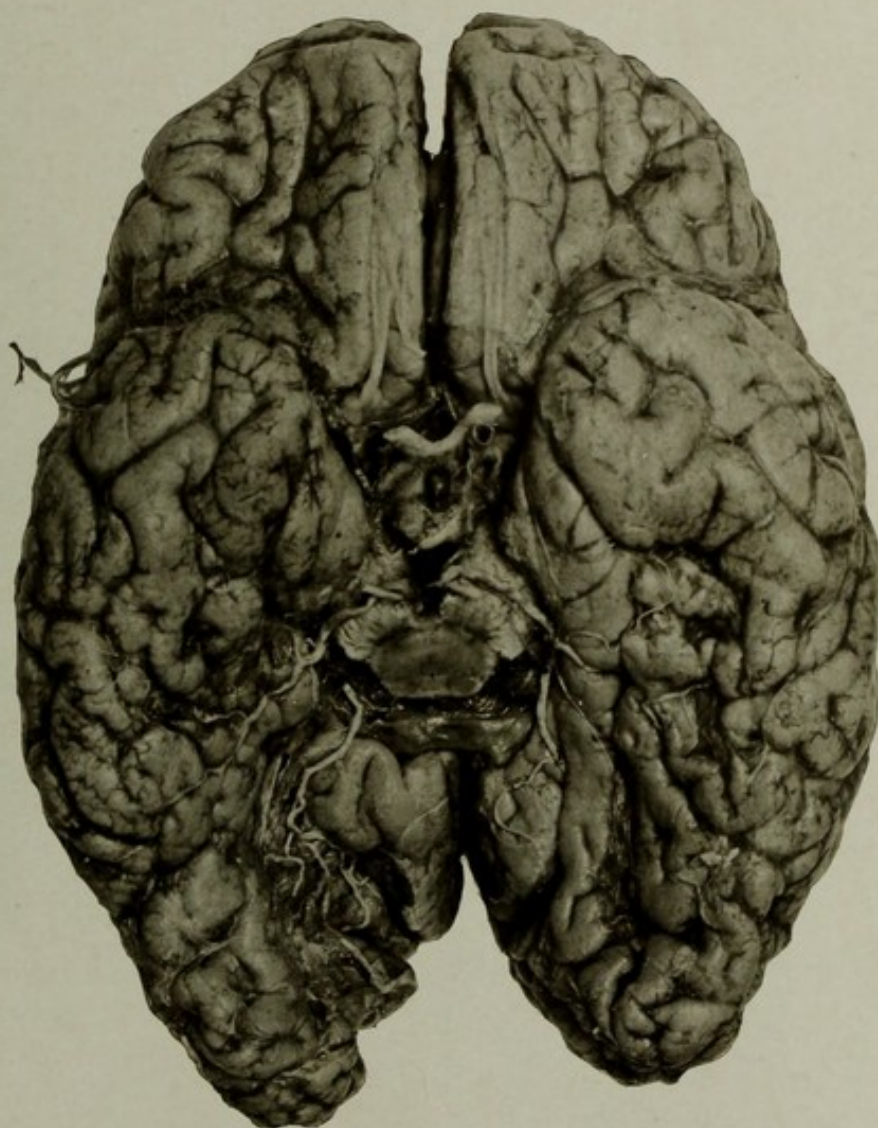
Spleen: Organ greatly enlarged; weight, 690 grams.

Kidneys: Some interstitial changes; pelvis of left contained two large calculi.

Liver: Weight, 90 grams. Nutmeg appearance of tissue; small mass of encysted calculi in gall bladder.

Appendix vermiformis situated behind the cæcum.

Two small leiomyomata in the uterus.



ARTERIOSCLEROTIC SOFTENINGS OF CEREBRUM.



---

---

PLATE XXII.

---

---

PLATE XXII.

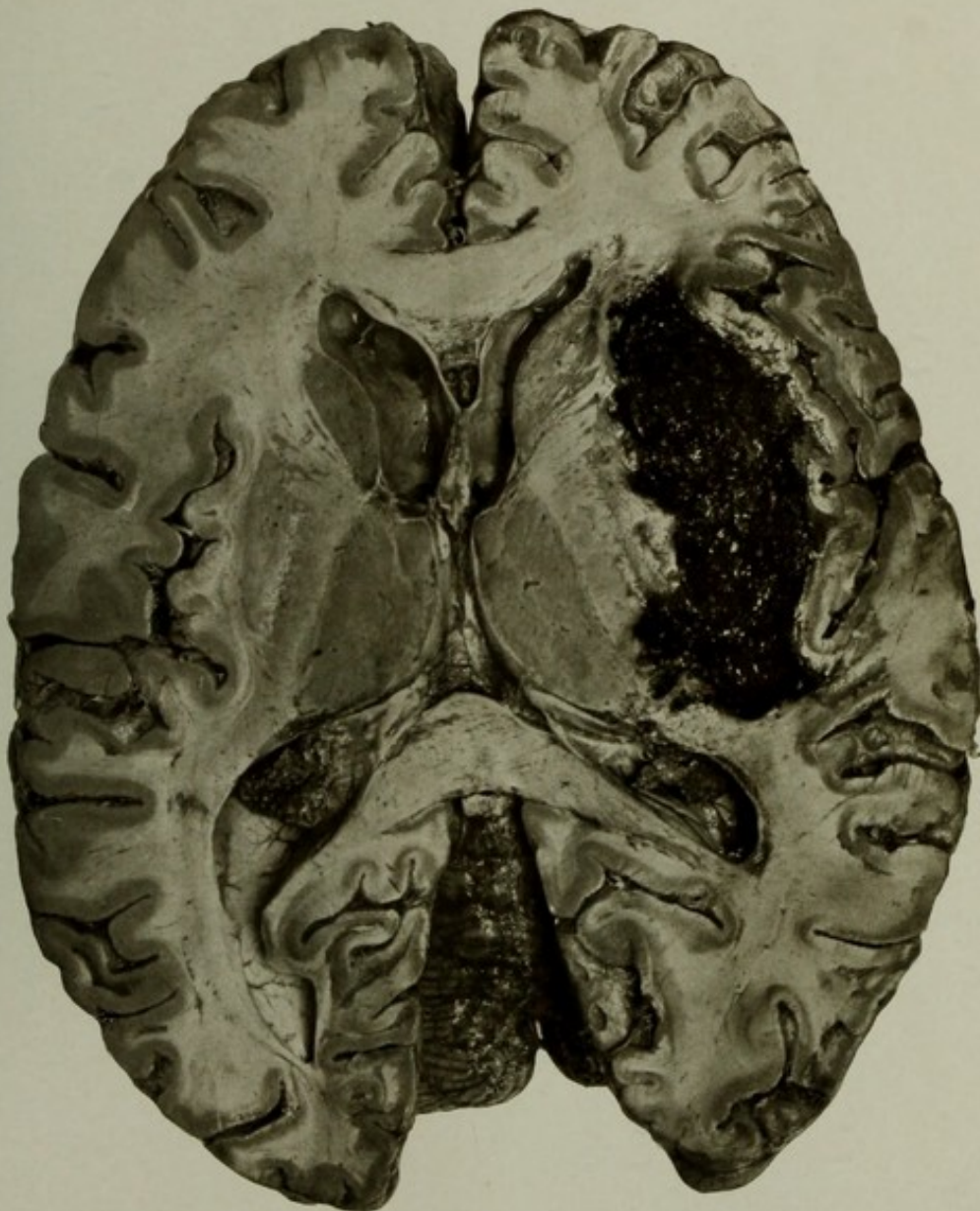
AUTOPSY No. 2054.

A BRAIN THE SEAT OF A LARGE HEMORRHAGE, CAUSING LEFT HEMIPLEGIA.

Case 13085. J. K.; aged 69; white; soldier; nativity, New York. Mental disease, chronic melancholia. An attack of apoplexy, with complete left hemiplegia, five days before death.

Brain: Weight, 1,400 grams. Vessels sclerotic; left vertebral artery represented by a mere threadlike vessel. Incision showed a large hemorrhage on the right side, between the insula and the basal ganglia. A remnant of the lenticular nucleus is still distinguishable and the greater part of the internal capsule is still seen. The hemorrhage had torn across the capsule at the posterior and anterior extremities; how much greater the destruction was at other levels could not be shown in the picture. The right side is seen to be intact. The displacement of the basal ganglia, an enlarged pseudocele, and several small foci of softening in the white substance are clearly shown, and to some extent the flattening out of the sulci and gyri of the right side by the pressure of the clot.

Nothing of importance was found in the other organs, except cardiac valvular disease and hypertrophy and a large Meckel's diverticulum.



A BRAIN THE SEAT OF A LARGE HEMORRHAGE, CAUSING LEFT HEMIPLEGIA.



---

---

PLATE XXIII.

---

---

## PLATE XXIII.

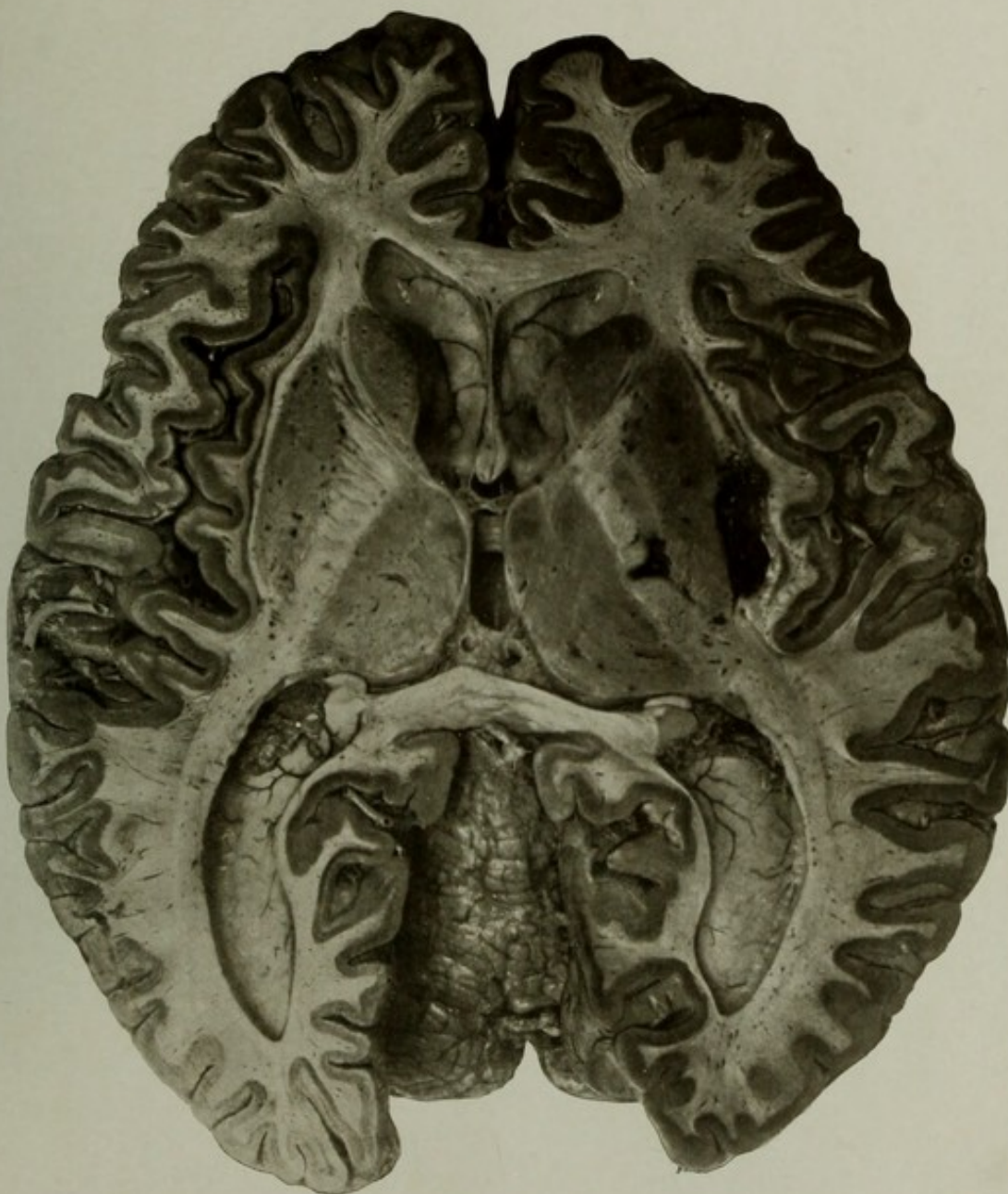
AUTOPSY No. 2037.

A HORIZONTAL SECTION OF A BRAIN SHOWING HEMORRHAGE IN THE RIGHT BASAL GANGLIA.

Case 13488. M. G.; aged 74; white; soldier; nativity, Switzerland. Mental disease, chronic melancholia with senility and dementia. Cerebral hemorrhage twenty-four hours before death.

Brain: Weight, 1,350 grams. Organ much shrunk over the anterior portion of the frontal lobes. Incision showed a hemorrhage on the right side, between the posterior portion of the external capsule and the lenticular nucleus, separating the two structures about  $1\frac{1}{2}$  centimeters. Rupture had taken place through the lenticular nucleus into the middle of the posterior limb of the internal capsule, and a few small foci of hemorrhage were found in the lenticular nucleus around the vessels. Large perivascular spaces in the basal ganglia and capsules. The ventricles were moderately enlarged. The arteries were sclerotic.

The skull was quite irregular on the outer surface, and the diploe was deeply congested and the tables thin over the posterior frontal and parietal regions. In these places the bone was easily penetrated with the knife. The heart weighed 400 grams; left auriculo-ventricular ring calcified; left valves thickened; aorta atheromatous. Kidneys slightly contracted. Other organs presented nothing important.



A HORIZONTAL SECTION OF A BRAIN SHOWING HEMORRHAGE IN THE RIGHT BASAL GANGLIA.



---

---

PLATE XXIV.

---

---

PLATE XXIV.

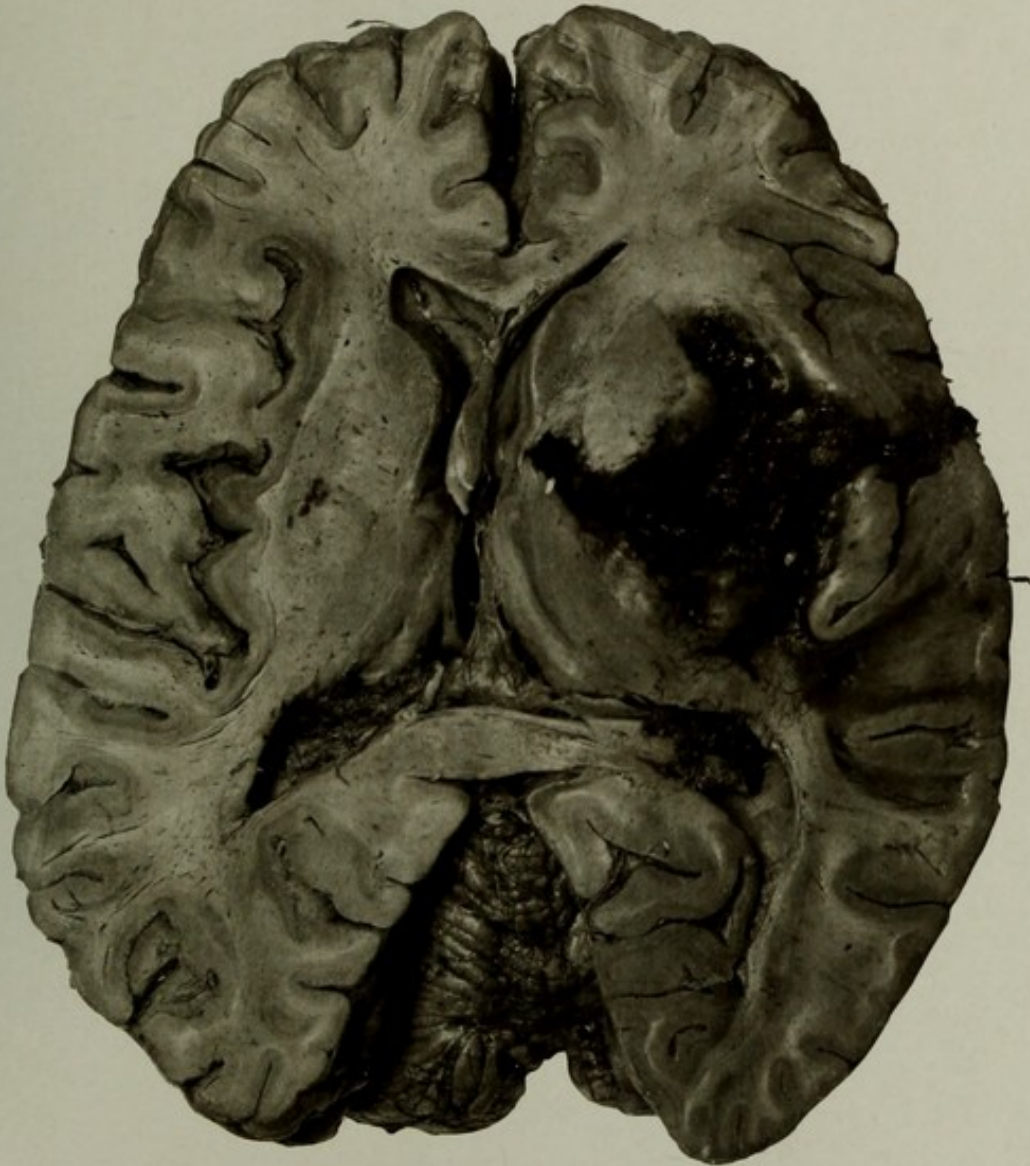AUTOPSY No. 2114.

CEREBRAL HEMORRHAGE DESTROYING THE RIGHT INTERNAL CAPSULE AND THE NUCLEUS LENTIFORMIS.

Case 5929. C. A. J.; aged 56; male; white; soldier; nativity, Germany. Mental disease, chronic mania. The patient had a cerebral hemorrhage two days before death. Paralysis of left side; able to talk until coma supervened.

Brain: Weight, 1,510 grams. Extensive subpial effusion of blood over right side, pons, interpeduncular space, and superior surface of cerebellum. Convolutions of right side flattened against the dura. Section showed a large hemorrhage on the right side, which had completely destroyed the nucleus lentiformis, posterior limb of internal capsule, external capsule, claustrum, and had torn through the insular cortex, escaping into the Sylvian fissure. It had *not* penetrated into the ventricular cavity. On the left side a small softening was found in the nucleus lentiformis and some small perivascular softenings. The arteries were sclerotic and tortuous, and some minor anomalies were found.

The other organs were not all normal, but presented no important conditions.



CEREBRAL HEMORRHAGE DESTROYING THE RIGHT INTERNAL CAPSULE AND  
THE NUCLEUS LENTIFORMIS.



---

---

PLATE XXV.

---

---

PLATE XXV.

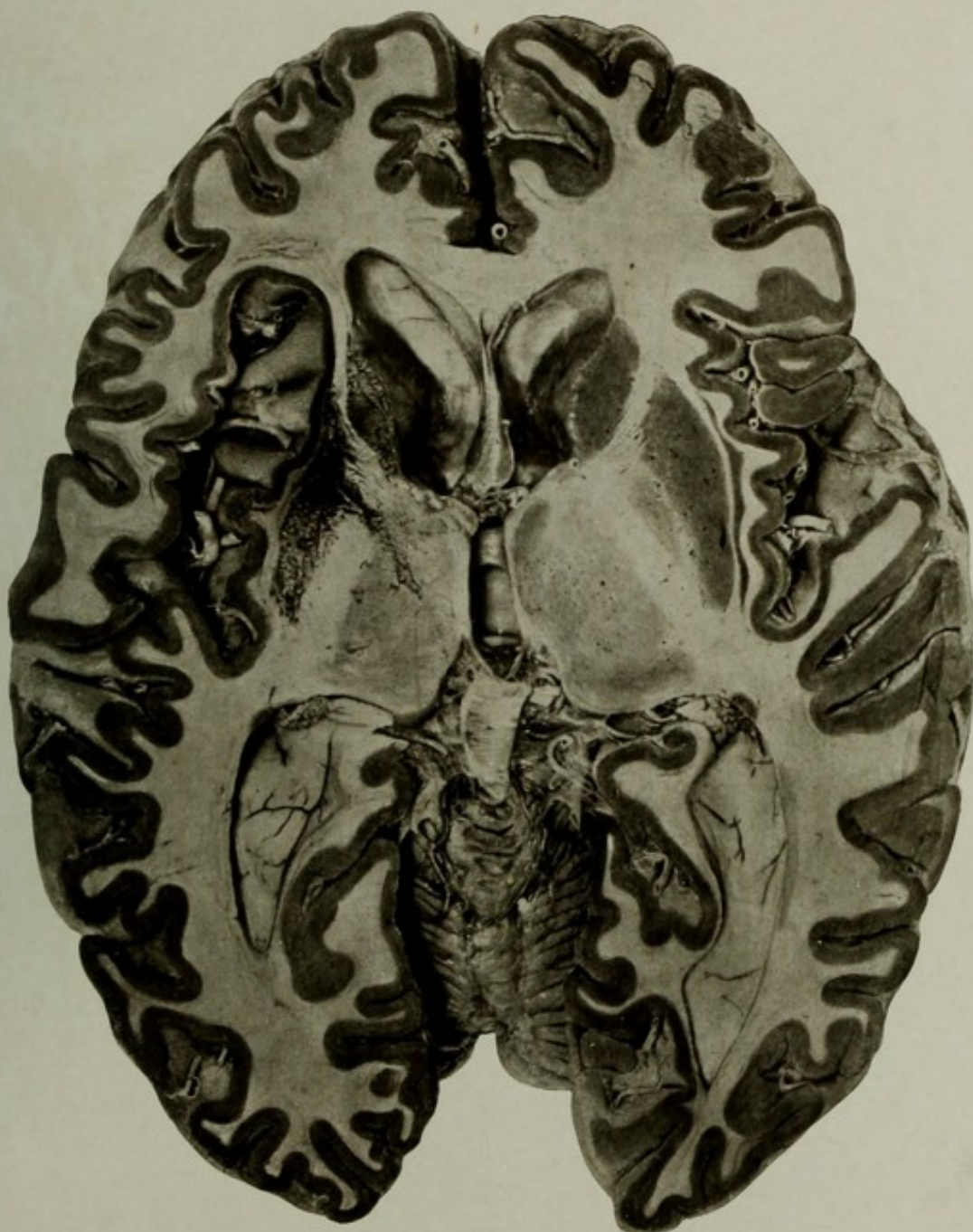
AUTOPSY No. 1486.

HORIZONTAL SECTION OF A BRAIN WHICH HAD BEEN THE SEAT OF A HEMORRHAGE.

Case 10726. E. A. J.; aged 77; white; female; nativity, Virginia. Mental disease, organic dementia. Clinical history of a hemorrhage ten years before death, causing aphasia and hemiplegia, both of which symptoms improved.

Brain: Not weighed. The organ presented the general appearance of a senile brain. Arteries at the base sclerotic; convolutions generally shrunken; no gross lesions of the cortex.

The picture shows the lesion situated on the left side, involving in softening and loss of substance the lenticularis, the claustrum, external capsule, and the white matter of the insula. The posterior two-thirds of the posterior limb of the internal capsule seem to be intact; a softening crosses the tract just behind the genual bundle and affects the thalamus, and the anterior limb is slightly encroached upon. The intact condition of those structures on the right side furnishes a good standard for comparison.



HORIZONTAL SECTION OF A BRAIN WHICH HAD BEEN THE SEAT OF A HEMORRHAGE.



---

---

PLATE XXVI.

---

---

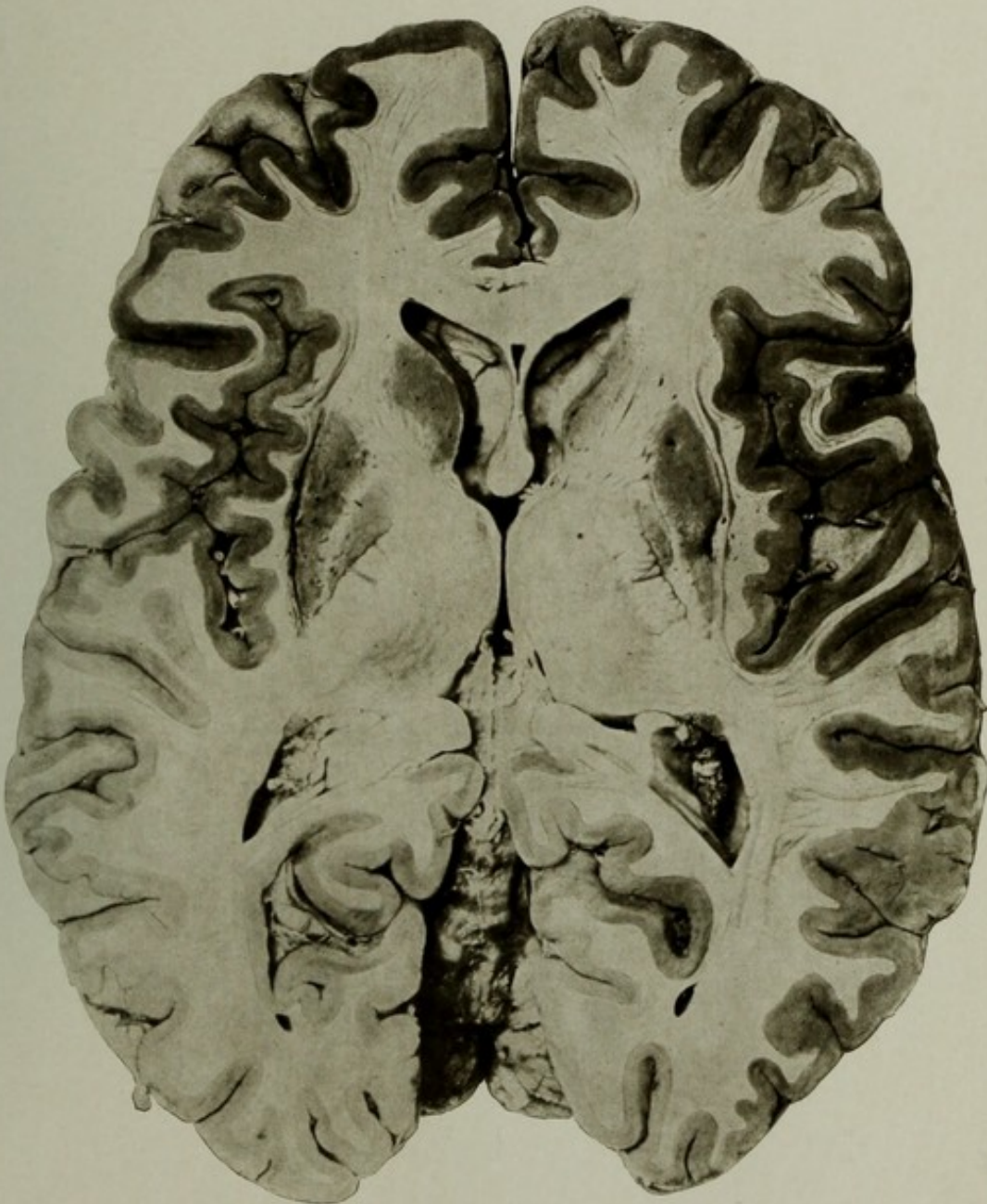PLATE XXVI.

AUTOPSY No. 1969.

HORIZONTAL SECTION OF A BRAIN SHOWING THE EFFECTS OF FORMER HEMORRHAGE.

Case 11960. B. W.; aged 60; male; white; soldier; nativity, Kentucky. Mental disease, chronic epileptic dementia. Clinical history of right-sided hemiplegia, with aphasia, about three years before death. The patient gradually regained the use of the right arm and, to a less degree, that of the right leg, and his speech distinctly improved. Finally he had a renewed attack of paralysis, but no additional speech disturbance; in this attack death occurred.

The picture shows a narrow line of loss of substance and a small cavity to the outer side of the left lenticular nucleus. Careful examination will show that this loss of tissue includes the external capsule and the claustrum. In the fresh condition this lesion had a yellow-ocher color, indicative of former hemorrhage, and the structures absent were probably destroyed at the time or by secondary softening. The lenticularis and internal capsule are intact, except two bands of acute softening which cross the latter and were probably the lesions causing the recent attack. On the right side a small hemorrhagic softening is seen, affecting the lenticular nucleus and the adjoining external capsule.



HORIZONTAL SECTION OF A BRAIN SHOWING THE EFFECTS OF FORMER HEMORRHAGE.



---

PLATE XXVII.

---

## PLATE XXVII.

AUTOPSY No. 1322.

### THE LEFT HEMISPHERE IN A CASE OF EXTREME CEREBRAL ATROPHY.

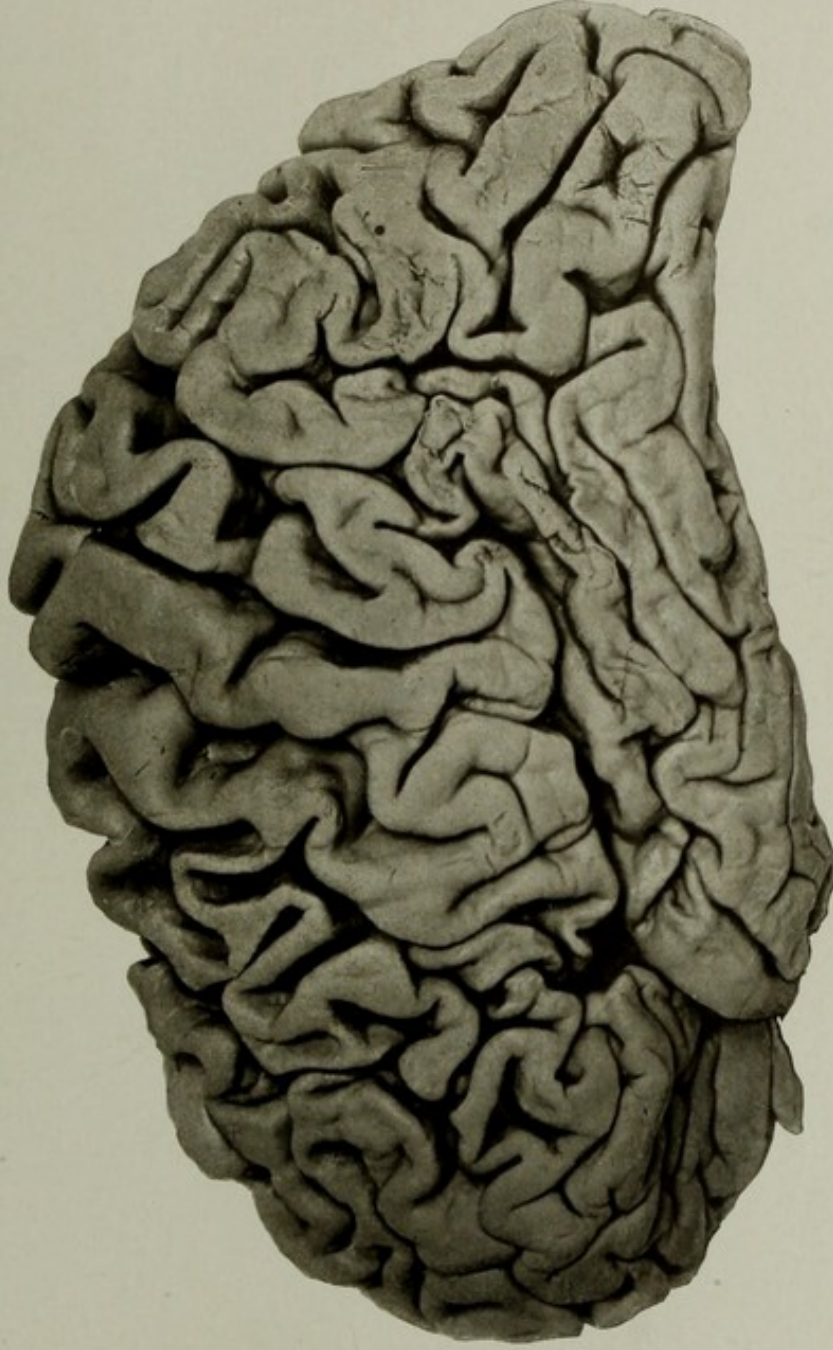Case 8719. J. H.; aged 54; white; soldier; nativity, Massachusetts. Mental disease, chronic dementia; duration, nine years. The patient had been operated upon for some supposed localized brain disease. The predominating symptoms were extreme dementia, but without definite paralysis; loss of hearing; memory poor.

Synopsis of autopsy: Skull thick and dense; deficiency of bone on the left side at the inferior posterior angle of the left parietal bone, about  $1\frac{3}{4}$  by 1 inch in diameters and roughly oval in shape. Dura generally thick and adherent to bone, and at the site of the bone lesion dura, pia, and cortex were adherent together.

Brain: Weight, 1,091 grams. The left hemiencephalon weighed about 15 grams less than the right. Extreme atrophy of the frontal region and the anterior temporal poles; the central regions better preserved on both sides. On the right side the anterior portion of the temporal lobe was softened, and on the left the posterior portion of the temporal lobe and the adjoining part of the inferior parietal lobule was softened, corresponding with the lesion of the skull above mentioned. There were no central softenings. The arteries were sclerotic and distorted, though not to a great degree.

GROSS MORBID ANATOMY OF THE BRAIN IN THE INSANE.

PLATE XXVII.



THE LEFT HEMISPHERE IN A CASE OF EXTREME CEREBRAL ATROPHY.



---

---

PLATE XXVIII.

---

---

PLATE XXVIII.

AUTOPSY No. 572.

THE SUPERIOR SURFACE OF A BRAIN FROM A CASE OF SENILE DEMENTIA WITH NUMEROUS CORTICAL SOFTENINGS, DUE TO ARTERIOSCLEROSIS.

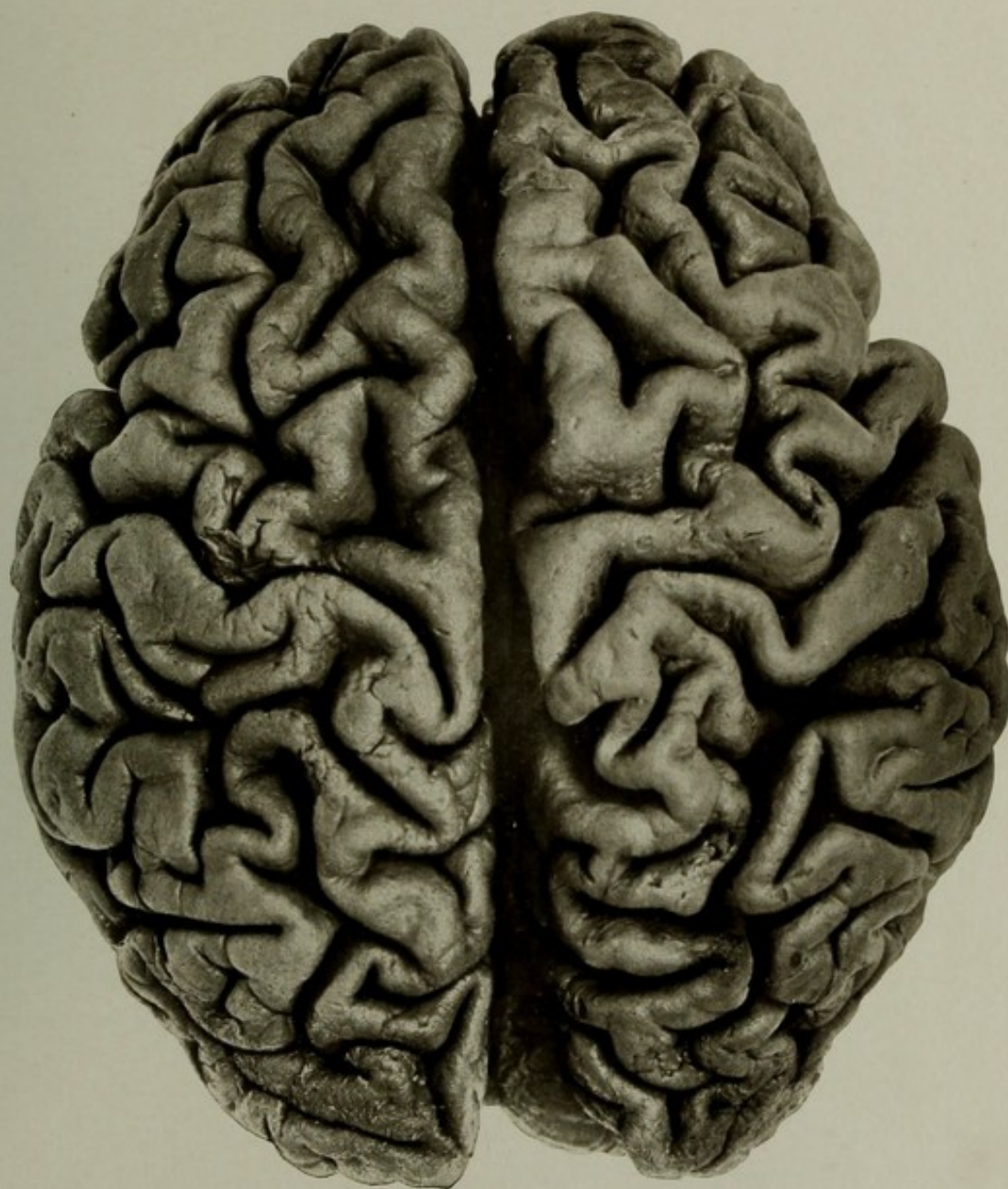
Case 7100. J. H.; aged 82; white; soldier; nativity, Switzerland. Mental disease, senile dementia. Right brachial monoplegia, and incoordination of muscular movements.

Brain: Weight, 970 grams. Extreme general atrophy of the whole brain. Pia opaque; cerebral veins tortuous and engorged; the arteries sclerotic and calcareous. The posterior communicating arteries were only connected to the posterior cerebral vessels by impervious threadlike cords. All the parts at the base were markedly atrophied. On removal of the pia, after hardening in Müller's fluid, a number of small cortical softenings, with puckering of the surface, were found over various parts of the brain, and the atrophy and widening of the sulci are well shown. A softening of the arm center in the left precentral gyrus is noteworthy.

The heart showed advanced calcareous disease of the left valves. Kidneys were contracted—arteriosclerotic interstitial nephritis. Liver weighed 900 grams. It was atrophied and there was some cirrhosis.

Other organs showed nothing of importance.

NOTE.—I think the shape and size of the brain are better preserved by hardening in Muller's fluid than in formalin, and the color does not interfere much with photography.



THE SUPERIOR SURFACE OF A BRAIN FROM A CASE OF SENILE DEMENTIA WITH  
NUMEROUS CORTICAL SOFTENINGS, DUE TO ARTERIOSCLEROSIS.



---

---

PLATE XXIX.

---

---

PLATE XXIX.

AUTOPSY No. 972.

EXTREME ATROPHY OF FRONTAL REGIONS OF THE BRAIN.

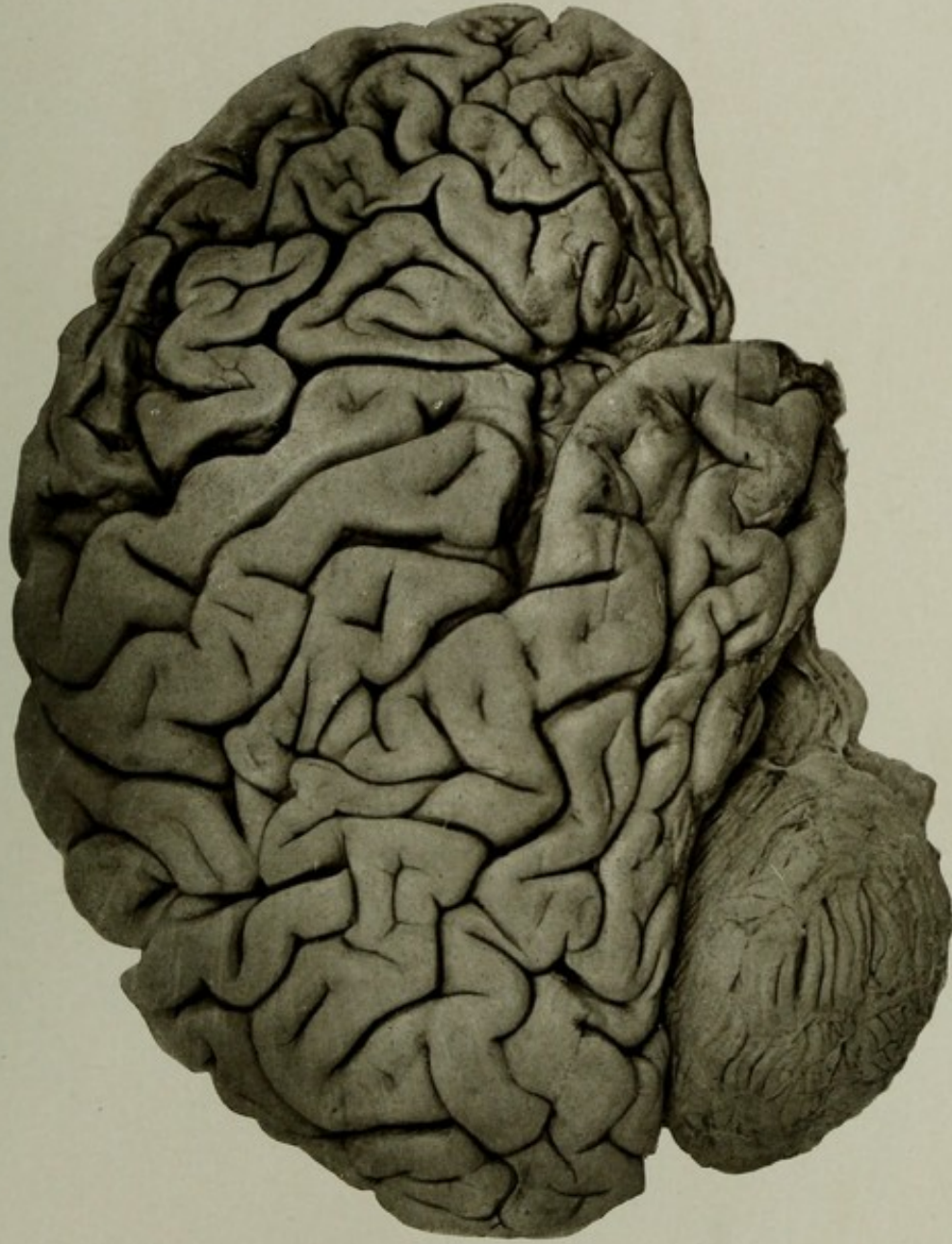
Case 8397. J. V.; aged 65; male; white; soldier; nativity, Pennsylvania. Mental disease, chronic dementia; duration, three years.

Skull a little thicker than usual in the frontal regions. Dura adherent to bone.

Brain: Weight of left hemiencephalon, 553 grams; right, 503 grams. Pia mater oedematous, faintly opaque over convexity. Arteries at the base sclerotic; smaller branches not diseased. On the left side there was marked atrophy of the frontal lobe anterior to the precentral gyrus, except a small part of the base of the middle frontal gyrus. On the right side the whole frontal lobe in front of the precentral gyrus, the anterior part of the paracentral lobule, and posterior portion of the gyrus cinguli were greatly atrophied. Other areas of atrophy were found in the right gyrus angularis, the middle and inferior temporal gyri, and the anterior pole of the temporal lobe. Removal of the pia from the atrophied regions showed that the brain tissue was soft, brownish in color, and the fissures were collapsed and the gyri flattened. Incision into the basal ganglia showed numerous softenings of small size, but no destruction of the capsules on either side. The ventricles were greatly dilated; parts in the interior very soft. The preservation of the motor areas and the capsules accounts for the absence of paralysis, while there was almost complete dementia.

GROSS MORBID ANATOMY OF THE BRAIN IN THE INSANE.

PLATE XXIX.



EXTREME ATROPHY OF FRONTAL REGIONS OF THE BRAIN.



---

---

PLATE XXX.

---

---

PLATE XXX .

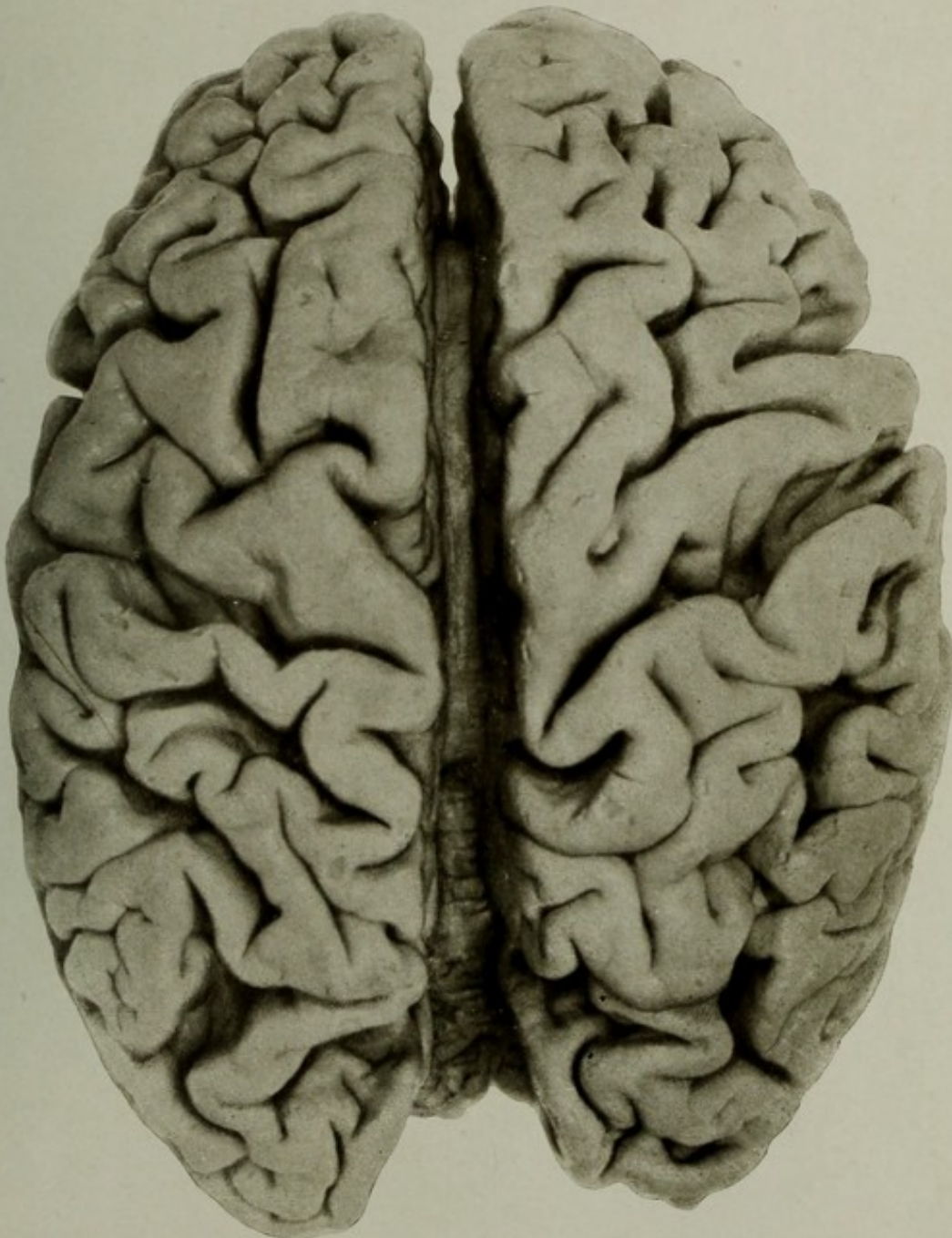AUTOPSY No. 1805.

THE SUPERIOR SURFACE OF THE CEREBRUM, SHOWING ATROPHY; THE FISSURES ARE ARTIFICIALLY SEPARATED.

Case 14180. E. J. H.; aged 77; male; white; nativity, United States. Mental disease, senile dementia.

The brain weighed 1,220 grams. Pia very œdematous; convolutions greatly shrunken. Arteries at the base sclerotic and calcareous. The lung showed hypostatic pneumonia, and a small abscess cavity in the right. Chronic disease of the aortic and mitral valves. Chronic contraction of the kidneys, with recent pus deposits. Bladder hypertrophied and slightly catarrhal. Prostate gland enlarged.

The photograph was made after the principal fissures had been carefully separated and kept so by packing lightly with absorbent cotton until the brain hardened, the design being to make an anatomico-pathological specimen. The two hemispheres are separated, showing the callosum and cerebellum in the depth of the median fissure.



THE SUPERIOR SURFACE OF THE CEREBRUM, SHOWING ATROPHY; THE FISSURES ARE ARTIFICIALLY SEPARATED.



---

---

PLATE XXXI.

---

---

## PLATE XXXI.

AUTOPSY No. 1921.

### THE SUPERIOR SURFACE OF A BRAIN OF CHRONIC DEMENTIA WITH CEREBRAL ATROPHY.

Case 11540. C. K.; aged 68; white; soldier; nativity, Germany. Mental disease, chronic dementia.

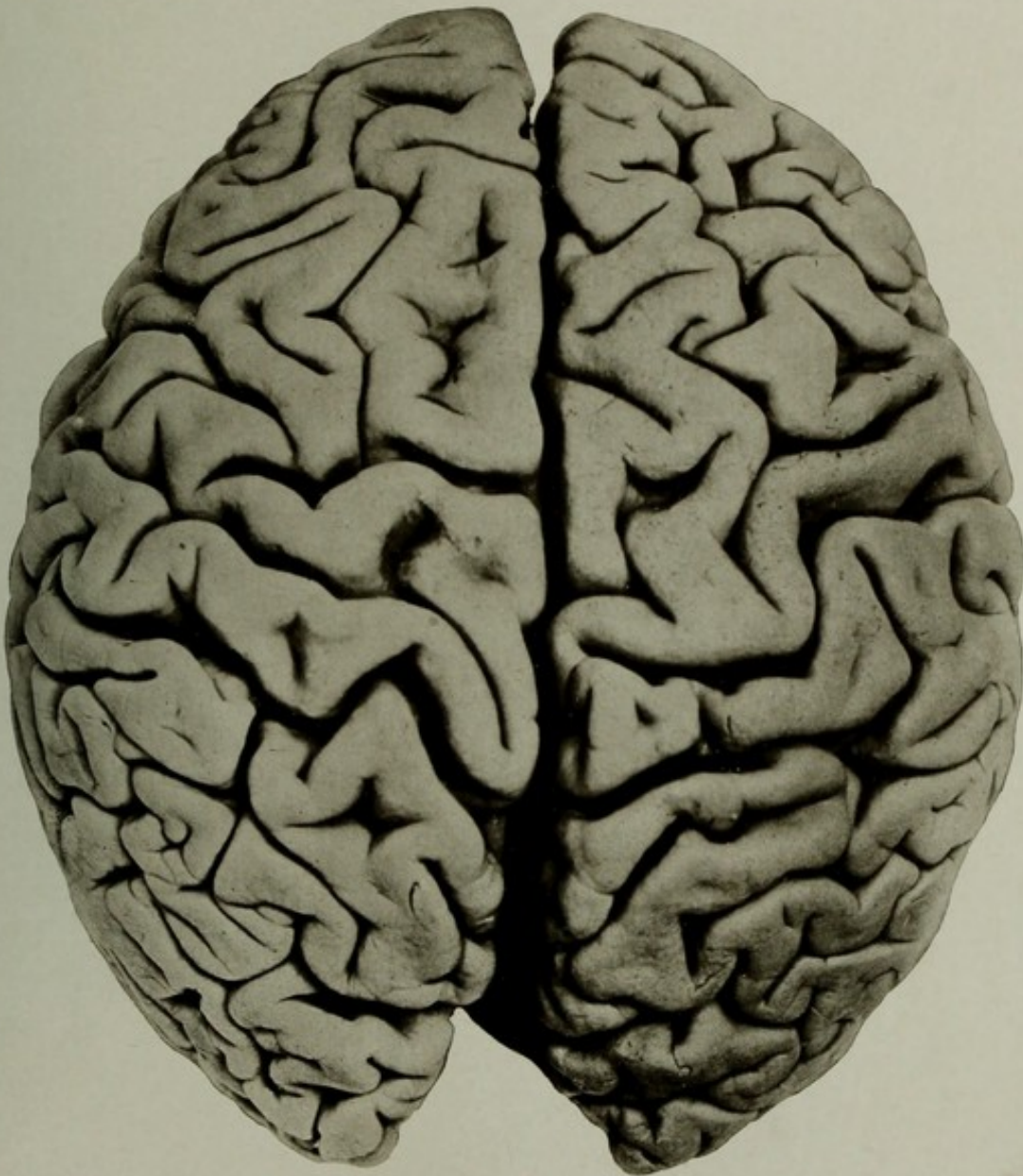Brain: Weight, 1,000 grams. Pia mater slightly opaque; arteries a little dilated, but otherwise normal; convolutions greatly shrunken over the whole convexity. Brain pale and œdematous.

The heart showed some patches of epicardial thickening. Valves of left side thickened and calcareous. Kidneys showed same areas of interstitial change. Stomach slightly dilated; walls thin.

The cause of the atrophy of the brain was not clearly explained by either the general condition or the state of the vessels.

The picture shows the shape of the encephalon quite well preserved, the head being the brachycephalic type frequently met with in Germans. It may be contrasted with brains like No. 1940, Plate XL, and compared with No. 572, Plate XXVIII.

NOTE.—The patient had sustained a fracture of the right radius, and later, one of the neck of the right femur. He became very feeble and markedly emaciated, and had toward the end of life some cystitis.



THE SUPERIOR SURFACE OF A BRAIN OF CHRONIC DEMENTIA WITH CEREBRAL ATROPHY.



---

---

PLATE XXXII.

---

---

PLATE XXXII.

AUTOPSY No. 1861.

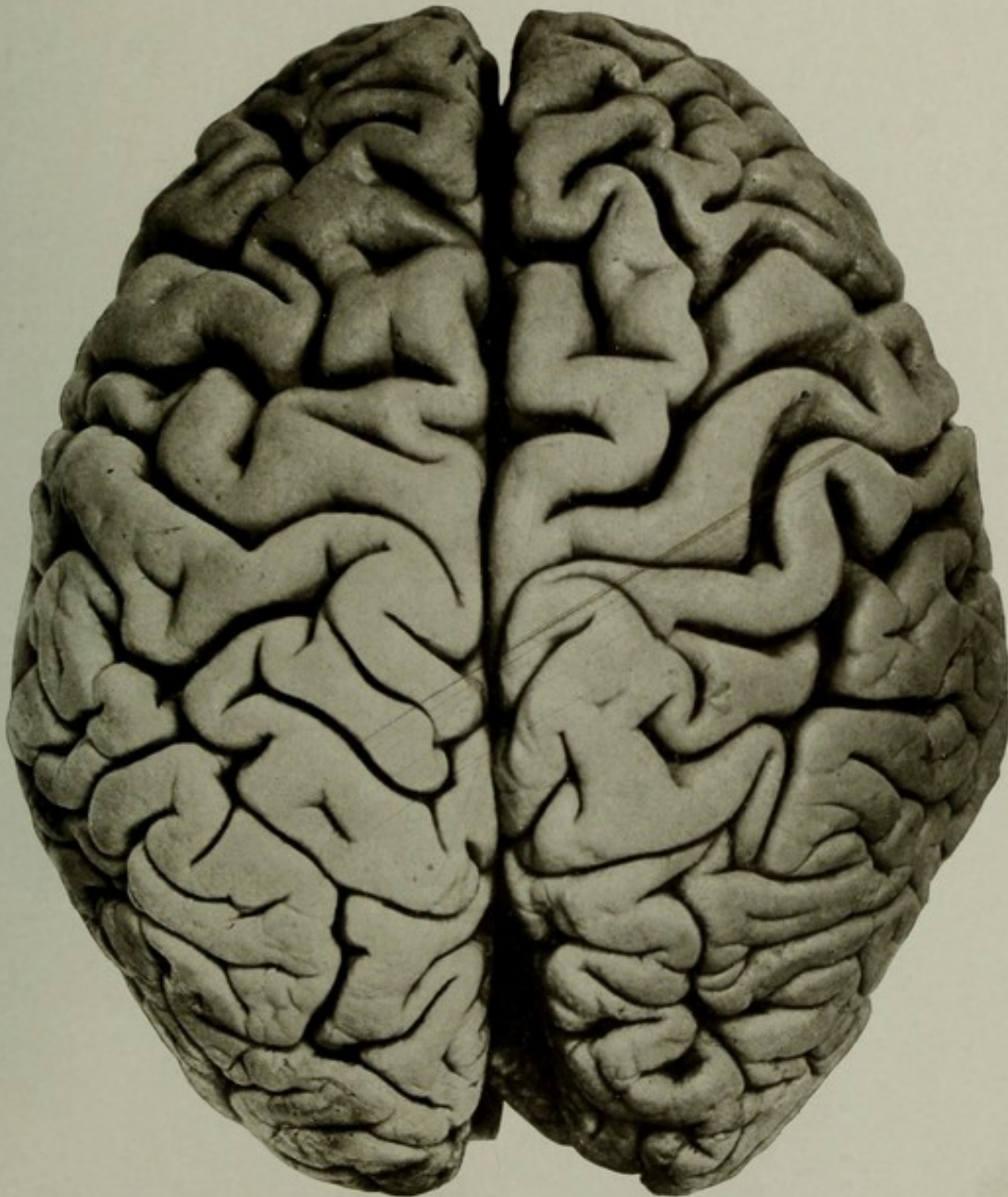THE SUPERIOR ASPECT OF THE BRAIN IN A CASE OF CHRONIC DEMENTIA WITH ATROPHY.

Case 14235. G. B.; aged 79; white; soldier; nativity, Germany. Mental disease, chronic dementia. Clinical history of advanced dementia; general enfeeblement; facial erysipelas.

Brain: Weight, 1,180 grams. The organ showed marked atrophy, especially of the anterior portions of the frontal lobes. The arteries were atheromatous in patches, but not markedly sclerotic for a man of the patient's age. The pia was easily removed, filled with serum, and the veins were moderately full of blood. The picture shows some widening of the sulci over the whole surface, but the shrinkage of the convolutions is most noticeable in the frontal regions. The brachycephalic type of brain characteristic of the race may be recognized in the picture.

The heart was moderately enlarged; slight thickening of left valves. Aorta atheromatous, especially at the lower end.

Kidneys showed some interstitial change. The liver was slightly granular on the surface, and the gall bladder contained numerous small calculi.



THE SUPERIOR ASPECT OF THE BRAIN IN A CASE OF CHRONIC DEMENTIA  
WITH ATROPHY.



---

---

PLATE XXXIII.

---

---

PLATE XXXIII.

AUTOPSY No. 1793.

MESIAL SURFACE OF THE RIGHT HEMIENEPHALON IN CHRONIC MELANCHOLIA.

Case 13814. W. G.; aged 60; white; farrier; nativity, United States. Mental disease, chronic melancholia.

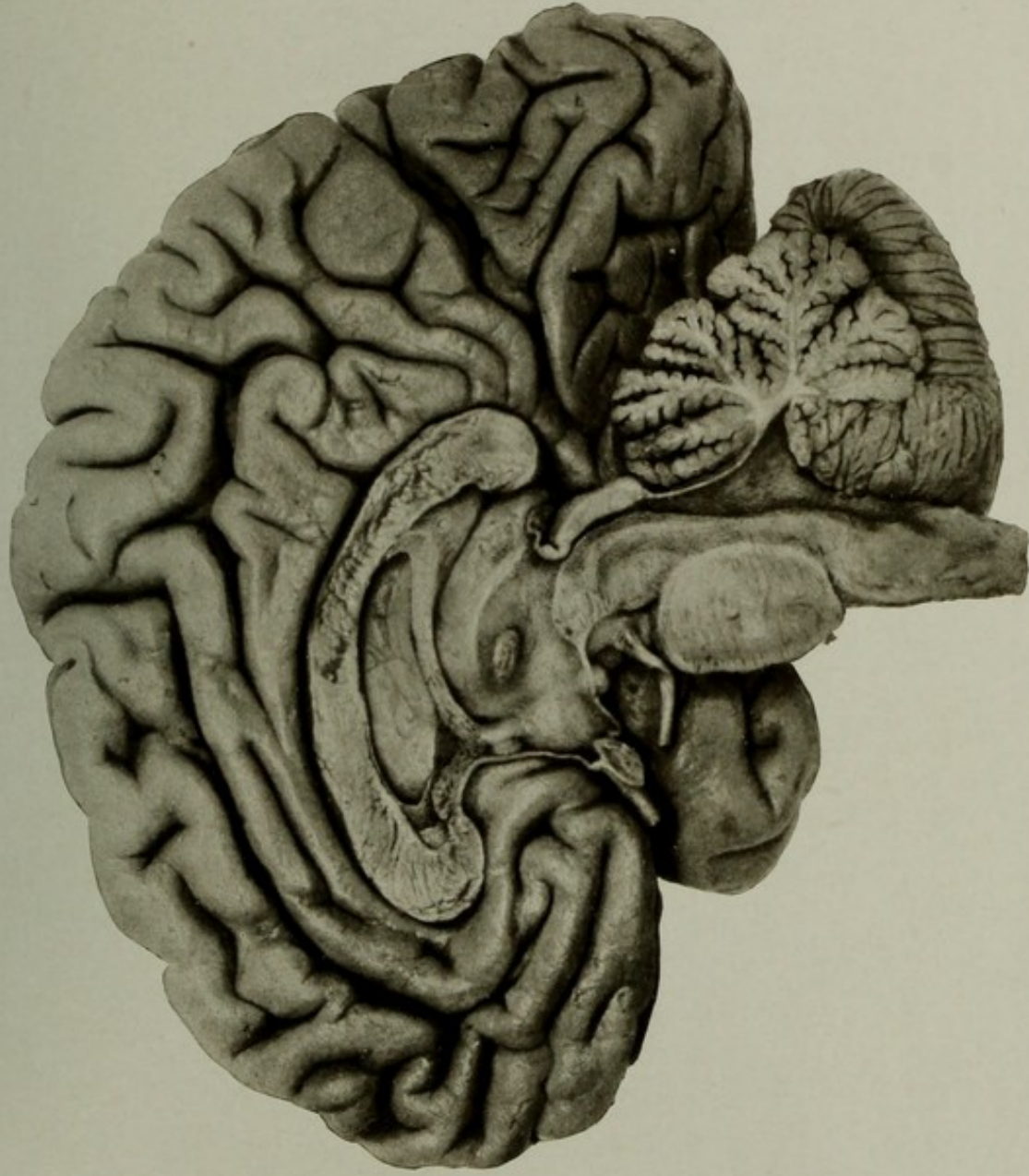Brain: Weight, 1,270 grams. Arteries not diseased; pia normal; considerable degree of atrophy of the anterior portions. No lesions in the interior.

Heart: Weight, 510 grams. Chronic disease of left valves and interstitial myocarditis affecting the anterior wall of the left ventricle.

The kidneys showed some interstitial change and the liver some cirrhosis.

The picture is mainly of anatomical value, the only pathological feature being some atrophy of the brain anterior to the paracentral lobule. The section cut away part of the septum pellucidum and exposed the ganglia of the right lateral ventricle. Portions of both sides of the septum are seen remaining anteriorly, and the cavity of the septum pellucidum is thus indicated. The other parts of the picture are self-explanatory.

The picture shows the advantage of this method of work for anatomical illustrations.



MESIAL SURFACE OF THE RIGHT HEMICEPHALON IN CHRONIC MELANCHOLIA.



---

---

PLATE XXXIV.

---

---

(71)

47078—08—10

## PLATE XXXIV.

AUTOPSY No. 2132.

### SUPERIOR SURFACE OF THE BRAIN, SHOWING ARTERIOSCLEROTIC DEVASTATIONS OF THE CORTEX.

Case 9965. C. A.; aged 74; male; colored; nativity, Virginia. Mental disease, chronic melancholia, with arteriosclerotic terminal dementia. The patient had right hemiplegia since his admission in July, 1896; had contractures of right arm and leg. Death occurred October 14, 1906, from cystitis.

Skull unusually thick, being 2 centimeters in average thickness in the frontal region. Numerous nodular exostoses on inner surface of frontal bone. Dura firmly adherent.

Brain: Weight, 1,140 grams. Marked arteriosclerosis and some minor anomalies. On the left side the brain was much atrophied and the surface was puckered and nodular. There was marked shrinkage and sclerosis of the lower third of the left postcentral gyrus, all of the precentral gyrus, all of the superior frontal gyrus of this side, the insula, and the anterior two-thirds of the mesial surface of the same side. Cortical softenings were found in the left paracentral lobule, the middle of the precentral gyrus, and in the depth of the central fissure. On the right side there was some sclerotic atrophy over the whole frontal lobe, but much less than on the left. The whole brain was much shrunken and the sulci were widened. Section of the brain showed no softenings involving the capsules nor basal ganglia, but both were small and shrunken on the left side, presenting a marked contrast with those structures on the right. The case seemed to be one of cortical origin solely.

The lungs showed some old tuberculous foci, and the lower lobes of both were solidified by hypostatic pneumonia.

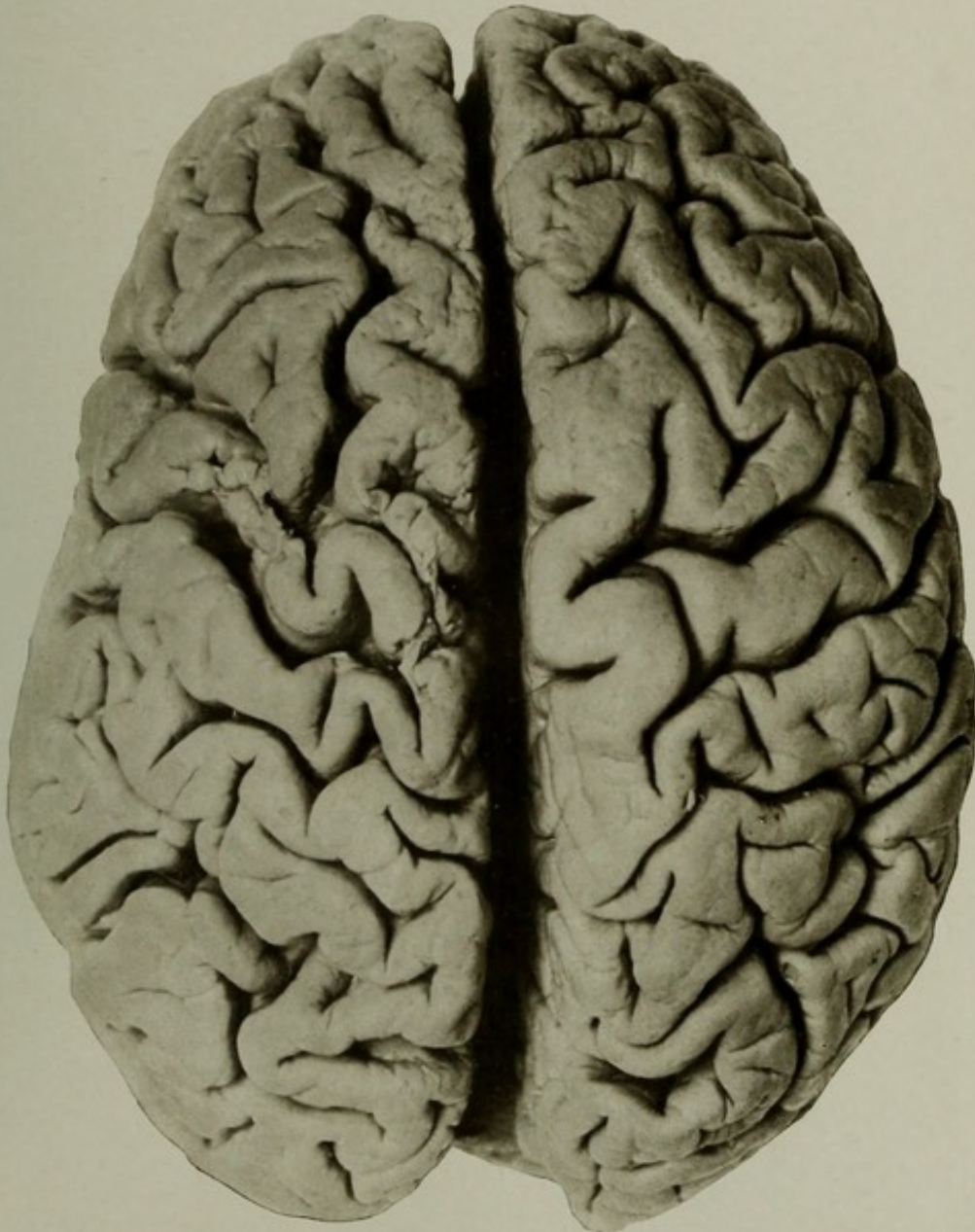Heart: Some chronic valvular disease.

Kidneys showed some contraction; pelvis of right, catarrhal.

Bladder showed adhesion of the fundus to the adjoining peritoneum by plastic adhesions; mucous membrane thickened and ulcerated. Middle lobe of prostate gland enlarged.

The liver showed passive hyperæmia.

Other organs presented nothing worthy of note.



SUPERIOR SURFACE OF THE BRAIN, SHOWING ARTERIOSCLEROTIC DEVASTATIONS OF THE CORTEX.



---

---

PLATE XXXV.

---

---

PLATE XXXV.

AUTOPSY No. 1990.

A DISSECTION SHOWING THE BASAL ARTERIES AND THE ATROPHY OF THE BRAIN IN THE REGION  
OF THE INSULÆ.

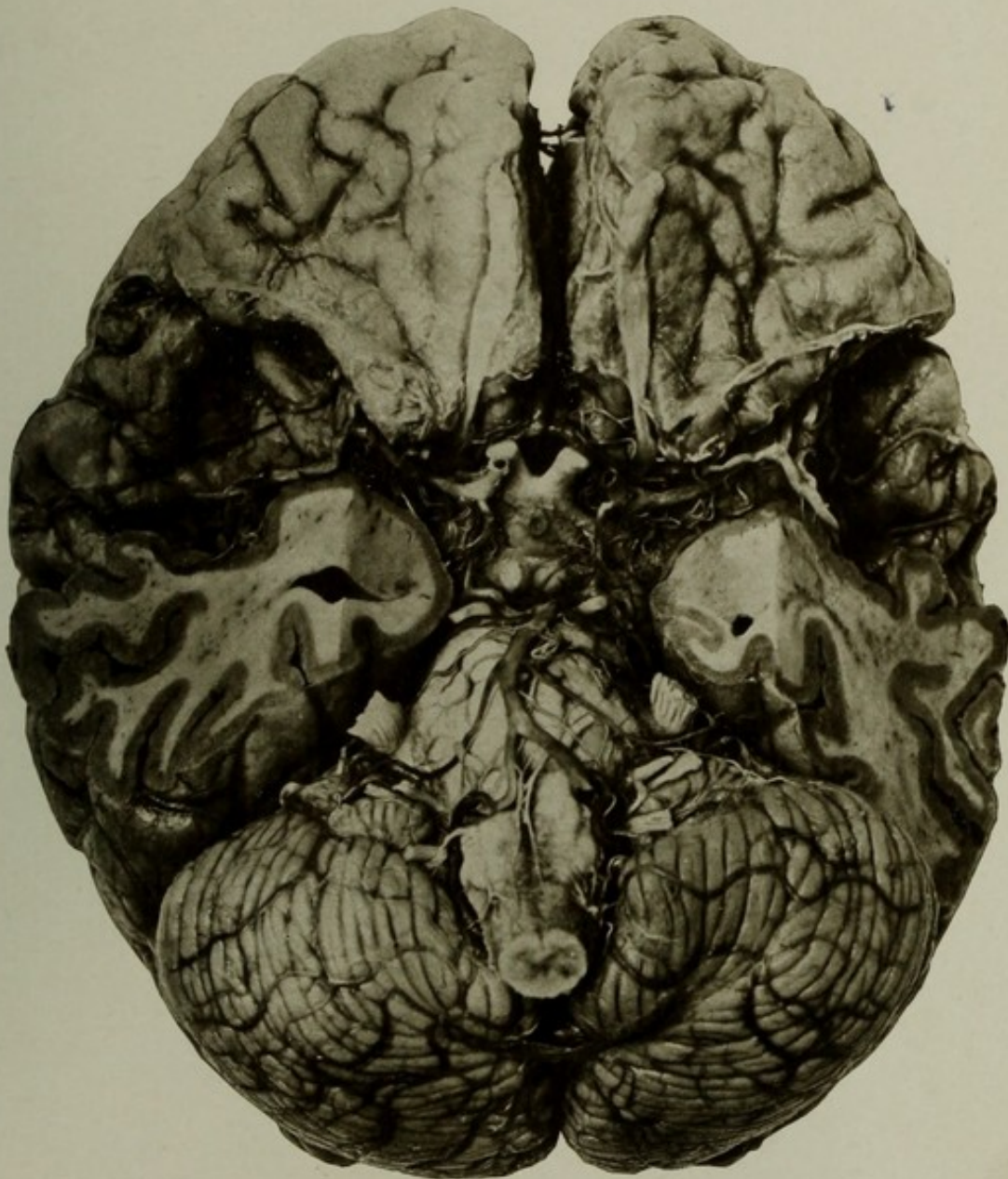Case 14645. B. A.; age 26; female; colored; nativity, United States. Mental disease, acute mania; physical condition, paresis and ataxia, due to extreme cerebral atrophy of unknown origin.

The brain weighed 990 grams. Pia slightly cloudy; cortex dark from hyperæmia; great atrophy of entire brain, more marked in the region of the insula and opercula and the anterior portion of the frontal lobe. The arteries at the base showed slight opacity in patches and were unusually small; right vertebral artery very small and practically obliterated.

Other organs showed nothing of importance.

The picture shows a dissection of the basal arteries made by removing the arachno-pia and cutting away the temporal poles. The arteries are thus exposed and unusual atrophy of the insular regions is demonstrated. The circle of Willis is seen in its entirety, and the internal nutrient arteries, the anterior choroid vessels, and the pontine vessels are all distinguishable with the aid of slight magnification. The cranial nerves have all been preserved.

The cerebral atrophy is noticeable anteriorly. It is possible that the unusually small vessels and the cerebral atrophy are anatomical evidences of congenital maldevelopment rather than acquired disease.



A DISSECTION SHOWING THE BASAL ARTERIES AND THE ATROPHY OF THE BRAIN  
IN THE REGION OF THE INSULÆ.



---

---

PLATE XXXVI.

---

---

## PLATE XXXVI.

AUTOPSY No. 1956.

### HORIZONTAL SECTION OF A BRAIN FROM A CASE OF SENILE DEMENTIA.

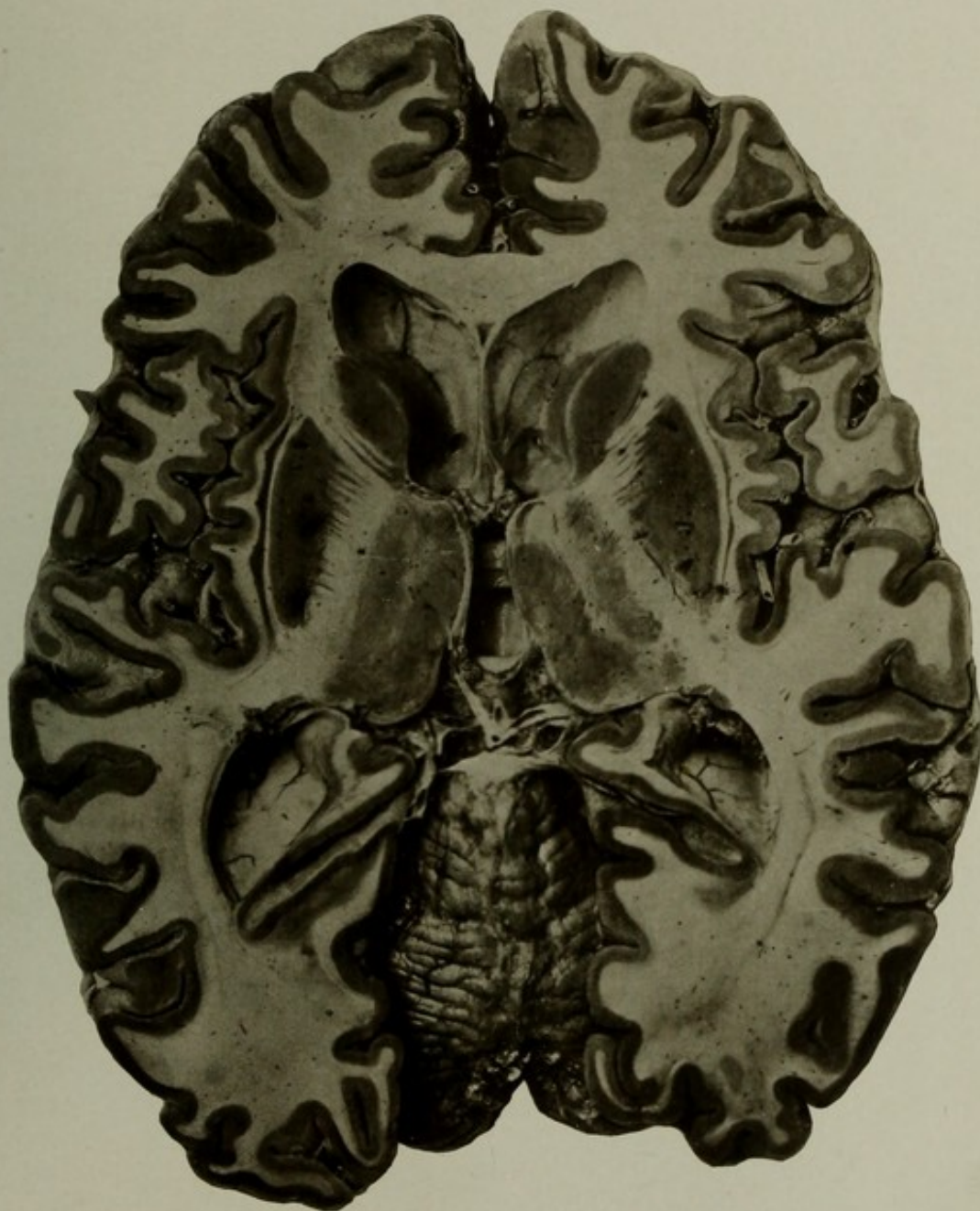Case 12526. T. S.; aged 79; white; soldier; nativity, Ireland. Mental disease, senile dementia. Clinical history of cardiac valvular disease, with hypertrophy.

Brain: Weight, 1,210 grams. Cerebro-spinal fluid greatly increased; convolutions atrophied; pia œdematous and opaque; arteries at the base showed some opaque patches and were somewhat dilated and tortuous.

The picture shows a horizontal section made on a line with the summit of the cerebellum and passing through the basal ganglia and the capsules in a position most favorable to show their relations. In addition to the anatomical points shown, the enlarged perivascular spaces surrounding the central nutrient vessels are very well seen. The ventricles are moderately enlarged, and the atrophy of the convolutions and the thalami is very apparent. The massa intermedia is preserved and may be seen stretching across the third ventricle.

The heart weighed 420 grams. The tricuspid valve was incompetent; mitral and aortic valves thickened and calcareous; muscular papillæ fibrous. Kidney showed passive congestion. Liver tissue presented nutmeg mottling; capsule adherent to the diaphragm.

NOTE.—This was a fresh section afterwards hardened. In some respects these are preferable to sections made after hardening. The slight wrinkling sometimes shows remarkably well the direction of certain fibers—for example, those of the optic radiations.



HORIZONTAL SECTION OF A BRAIN FROM A CASE OF SENILE DEMENTIA.



---

---

PLATE XXXVII.

---

---

PLATE XXXVII.

AUTOPSY No. 2051.

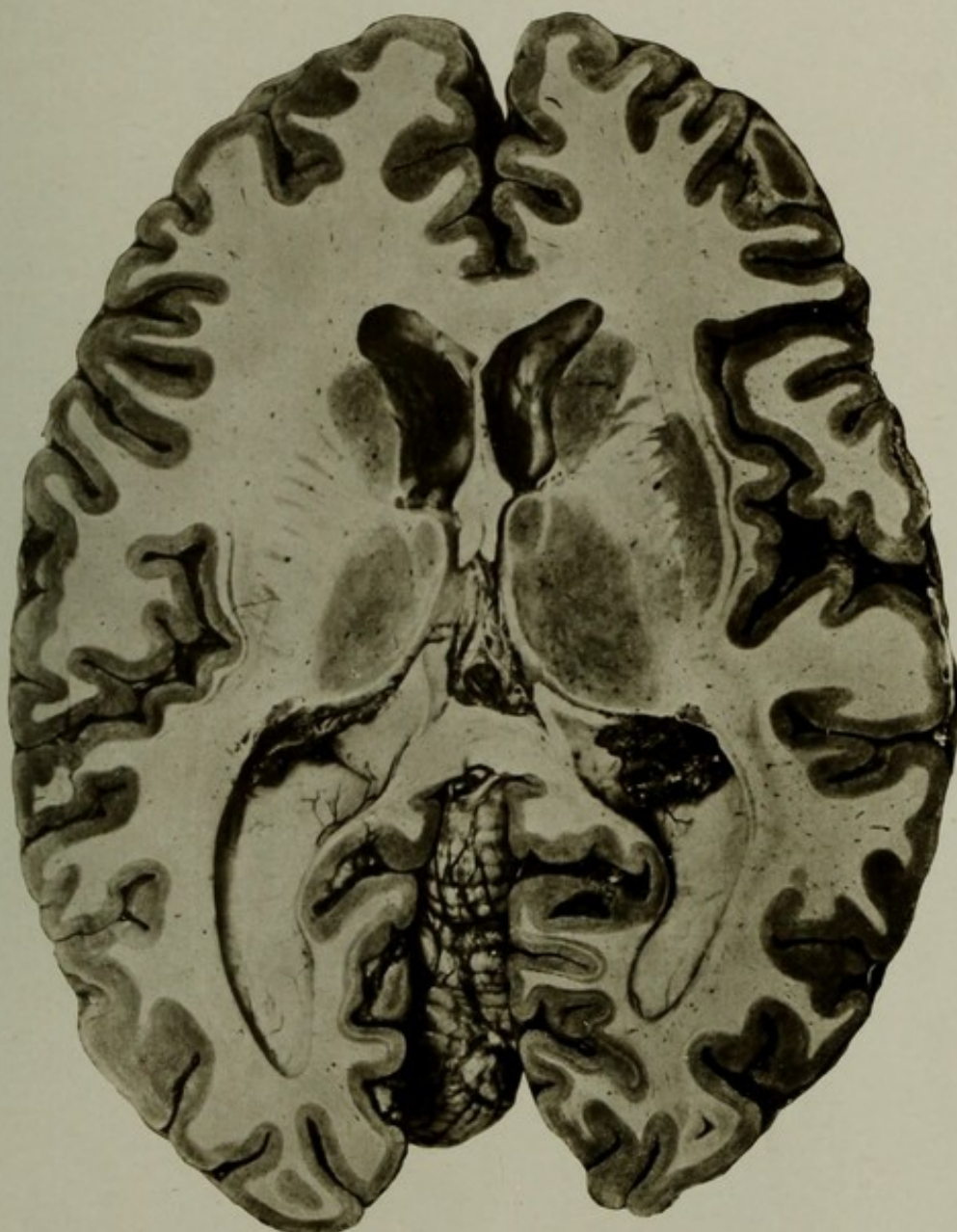
A HORIZONTAL SECTION OF A BRAIN OF SYPHILITIC DEMENTIA.

Case 15663. G. H.; aged 29; white; female; nativity, United States. Mental disease, dementia, attributed to syphilis. The patient died of general exhaustion and infectious nephritis.

Brain: Weight, 1,140 grams. Some atrophy of the frontal regions; tissue œdematous and the ventricles a little enlarged. The cerebral arteries were normal.

The picture shows a very slight deviation from the normal and is mainly of anatomical value. On the right side the section is a little lower than the left and gives a good view of the basal ganglia and capsules. The section is markedly clear in detail and may be contrasted with the chronic and senile cases.

The kidneys were enlarged, the cortex swollen and grayish; pyramids dark by contrast. The liver showed some adhesions of capsule to the diaphragm and some passive hyperæmia. Cyst of right ovary the size of a walnut.



A HORIZONTAL SECTION OF A BRAIN OF SYPHILITIC DEMENTIA.



---

---

PLATE XXXVIII.

---

---

(79)

## PLATE XXXVIII.

AUTOPSY No. 1588.

### BRAIN OF A CASE OF SENILE DEMENTIA IN A PATIENT AGED 99 YEARS.

Case 11844. M. W.; aged 99; female; white; nativity, Maryland. Mental disease, senile dementia of approximately twenty years' duration.

Brain: Weight, 1,135 grams. The organ was greatly atrophied over the whole convexity. Pia œdematous and loose; vessels curved and elongated and showed a few opaque patches of atheroma. No gross lesions in the interior except a small softening in the lenticular nucleus of the left side.

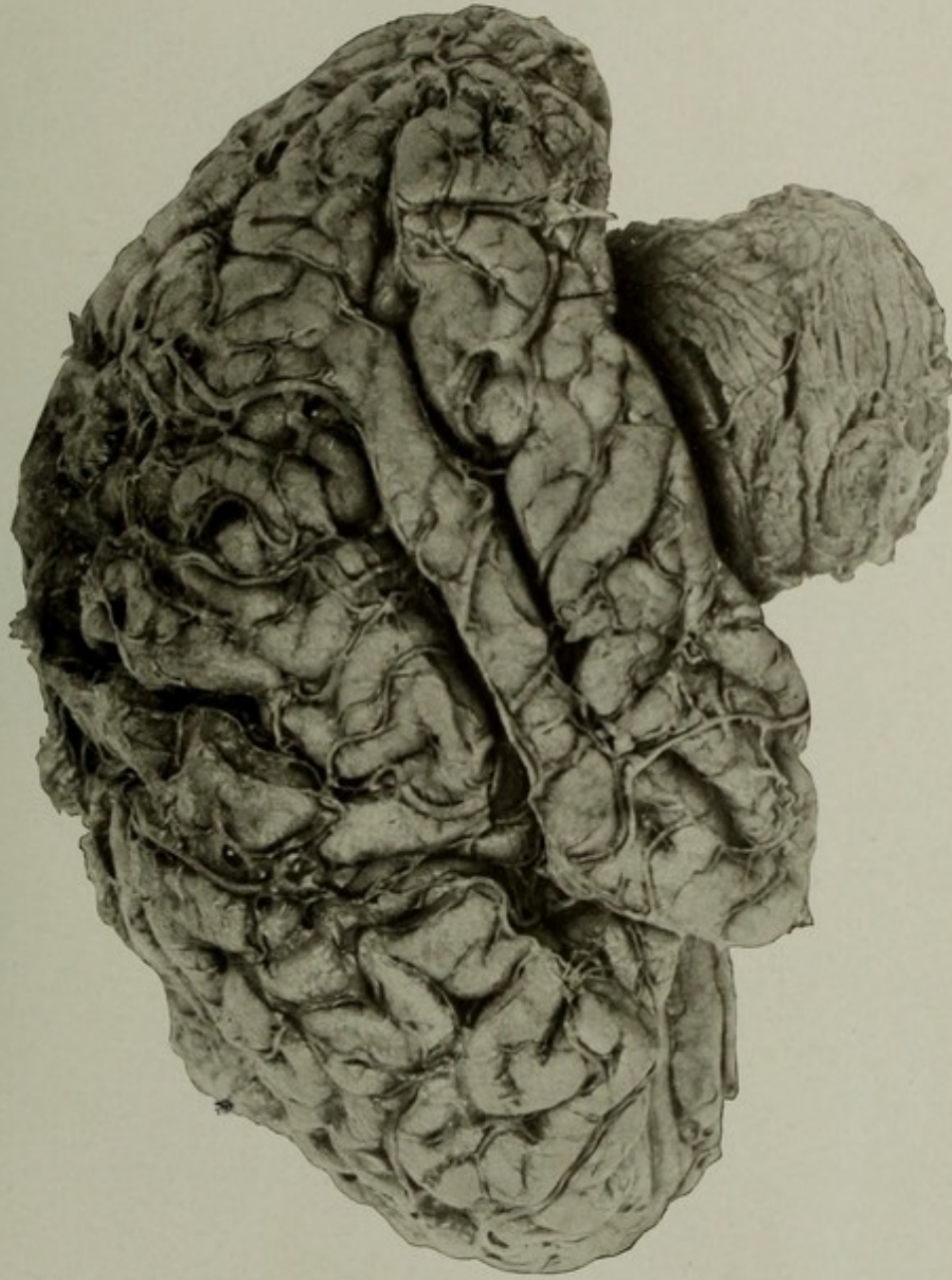The picture shows the extreme shrinkage of the convolutions and the tortuosity of the arteries and veins. The photograph was taken after the brain was hardened, and therefore the looseness of the pia is more perceptible than in the fresh condition. The cerebellum is out of proper position, but the atrophy of this part is well shown.

The skull was a little thicker than normal, and on the inner surface of the bone on the left side were some irregular exostoses; the dura was firmly adherent to the bone.

The lungs showed pneumonic consolidation affecting the whole of the lower lobe and the lower part of the upper lobe of the left lung, and slight hypostasis of right lung.

GROSS MORBID ANATOMY OF THE BRAIN IN THE INSANE.

PLATE XXXVIII.



BRAIN OF A CASE OF SENILE DEMENTIA IN A PATIENT AGED 99 YEARS.



---

---

PLATE XXXIX.

---

---

## PLATE XXXIX.

AUTOPSY No. 2265.

### LATERAL SURFACE OF THE LEFT HEMIENKEPHALON IN A CASE OF CHRONIC MELANCHOLIA.

Case 12079. B. D.; aged 74½; white; male; nativity, Germany. Mental disease, chronic hallucinatory melancholia; duration, seven years. The patient had been blind and deaf for the two years previous to his death. There was a progressive mental deterioration for some time. Patient found dead in his bed in the morning.

Brain: Weight, 1,290 grams. There was a thin neomembrane of internal pachymeningitis over the convexity of the dura. Pia mater cloudy over the convexity; very slight shrinkage of the brain. Arteries showed some minor anomalies, and were slightly sclerotic. Ventricles normal.

The picture was introduced for comparison with the cases of cerebral atrophy. Though the patient was well advanced in years, the cerebral arteries were nearly normal and the brain but slightly shrunken. The weight was about 113 grams less than the normal average, but it did not show so much reduction. There were also no gross lesions to account for the loss of sight and hearing, so that these affections must have been peripheral.

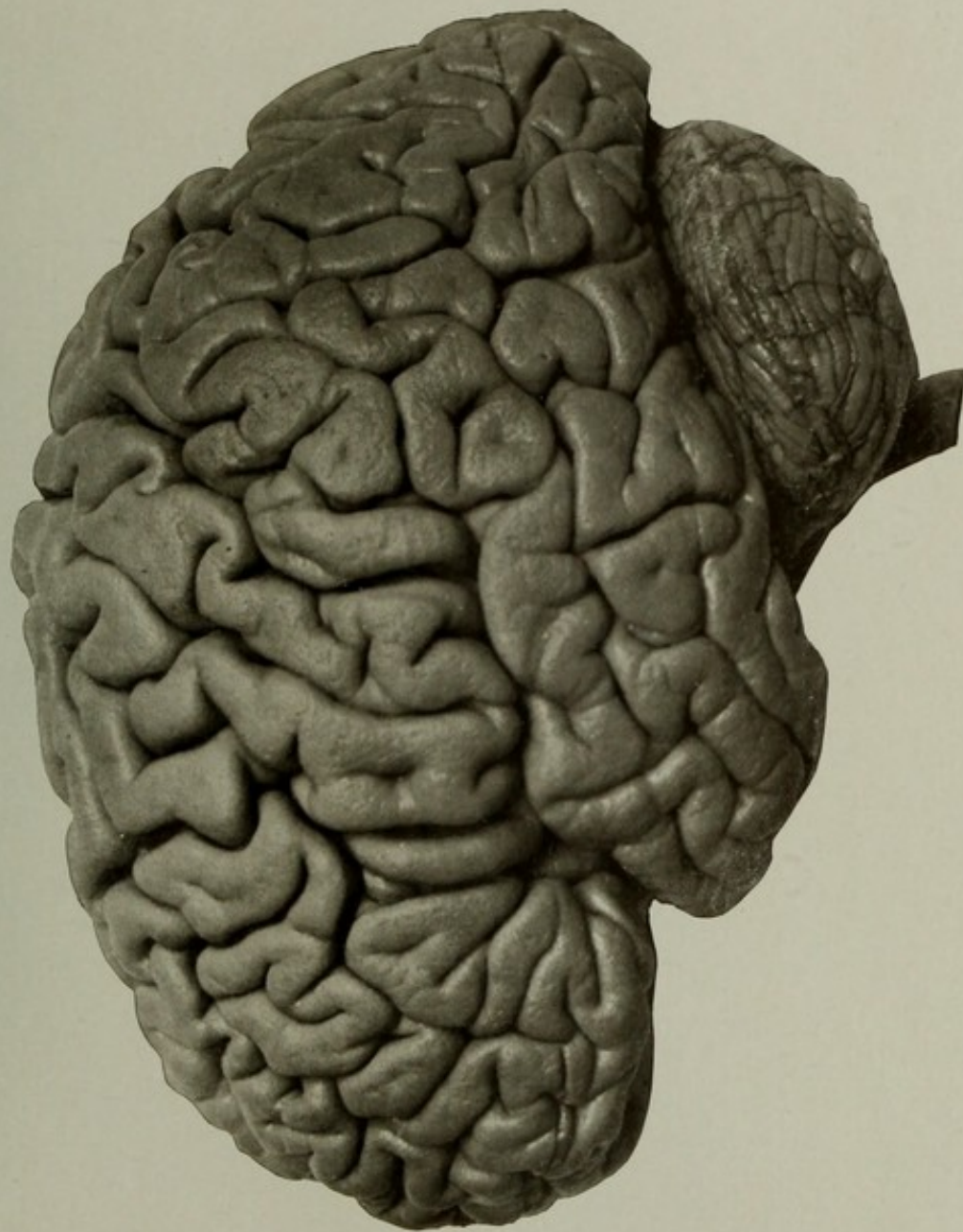
The heart valves were all competent, except some slight sclerosis of the mitral, with some thickening, and slight thickening of the aortic valves. Weight of heart, 330 grams. Slight atheroma of the abdominal portion of the aorta.

The stomach was greatly dilated and the mucous membrane mammillated; walls thin. Transverse colon was elongated and dilated.

The cause of death was obscure, but the conclusion was reached that it must have been acute gastric dilatation, with cardiac paralysis, as the clinical history showed that the heart was functionally disturbed.

GROSS MORBID ANATOMY OF THE BRAIN IN THE INSANE.

PLATE XXXIX.



LATERAL SURFACE OF THE LEFT HEMIENCEPHALON IN A CASE OF CHRONIC MELANCHOLIA.



---

---

PLATE XL.

---

---

PLATE XL.

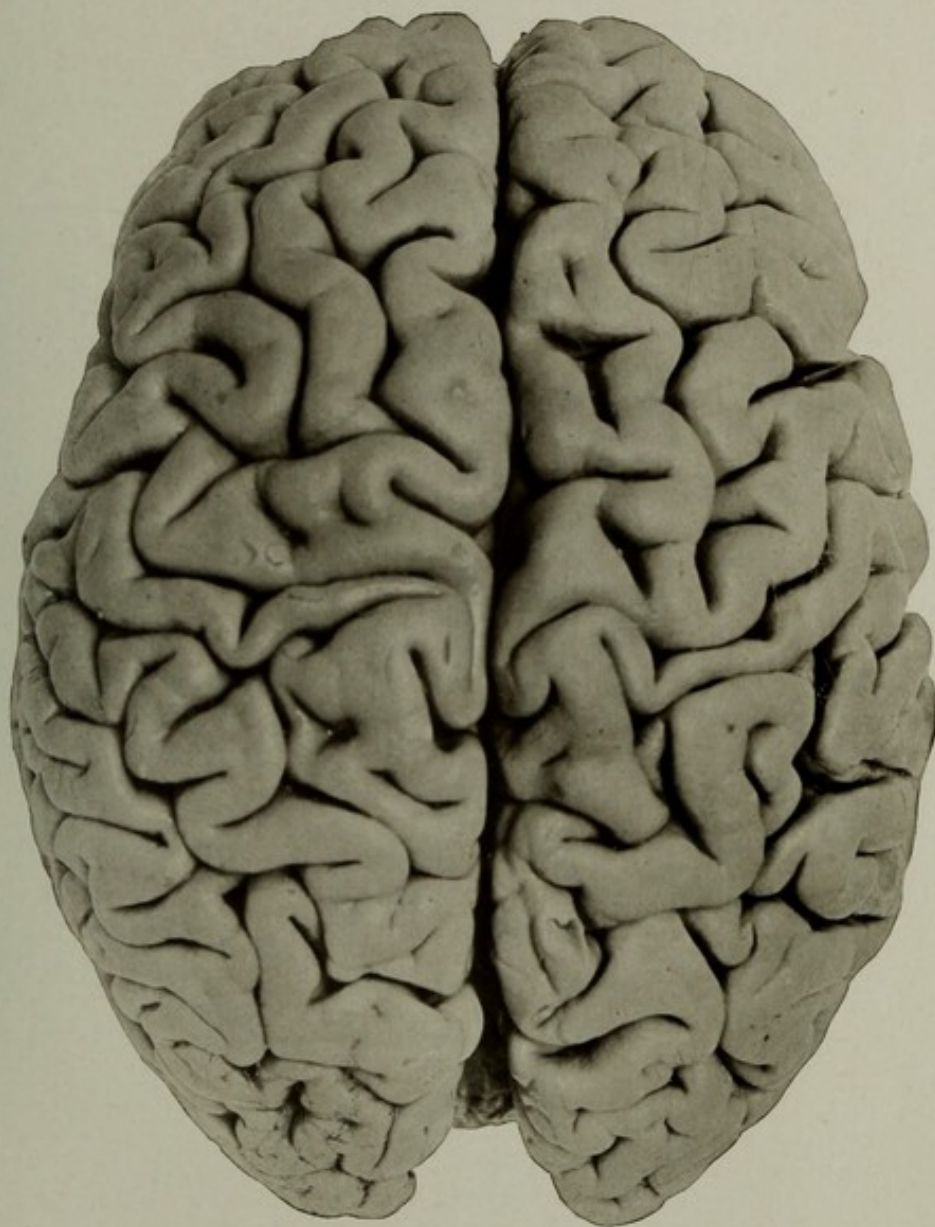
AUTOPSY No. 1940.

THE SUPERIOR SURFACE OF THE BRAIN IN CHRONIC MANIA.

Case 2878. L. McN.; aged 60; white; male; nativity, Ireland. Mental disease, chronic mania.

The brain showed slight œdema of the pia and a little separation of the convolutions. A few patches of atheroma in the cerebral arteries at the base. The lungs showed some chronic tubercular lesions in the left and some tubercular cavities in the right, in one of which a rupture of a vessel had caused fatal pulmonary hemorrhage.

The picture shows the superior surface of the brain apparently normal. It may be contrasted with No. 1805, Plate XXX, which shows senile atrophy in a man aged 77 years.



THE SUPERIOR SURFACE OF THE BRAIN IN CHRONIC MANIA.



---

---

PLATE XLI.

---

---

PLATE XLI.

AUTOPSY No. 1693.

THE EFFECTS OF REMOVAL OF THE PIA IN PARESIS.

Case 12545. J. V. B.; aged 25; white; soldier; nativity, Maryland. Mental disease, paresis, of about two years' duration. Brain affection said to be due to injury to spine, but of this the history was indefinite. Symptom-complex of paresis typical; occasionally epileptiform convulsions, more severe in the upper extremities; these were followed by transitory increase of the paralytic symptoms.

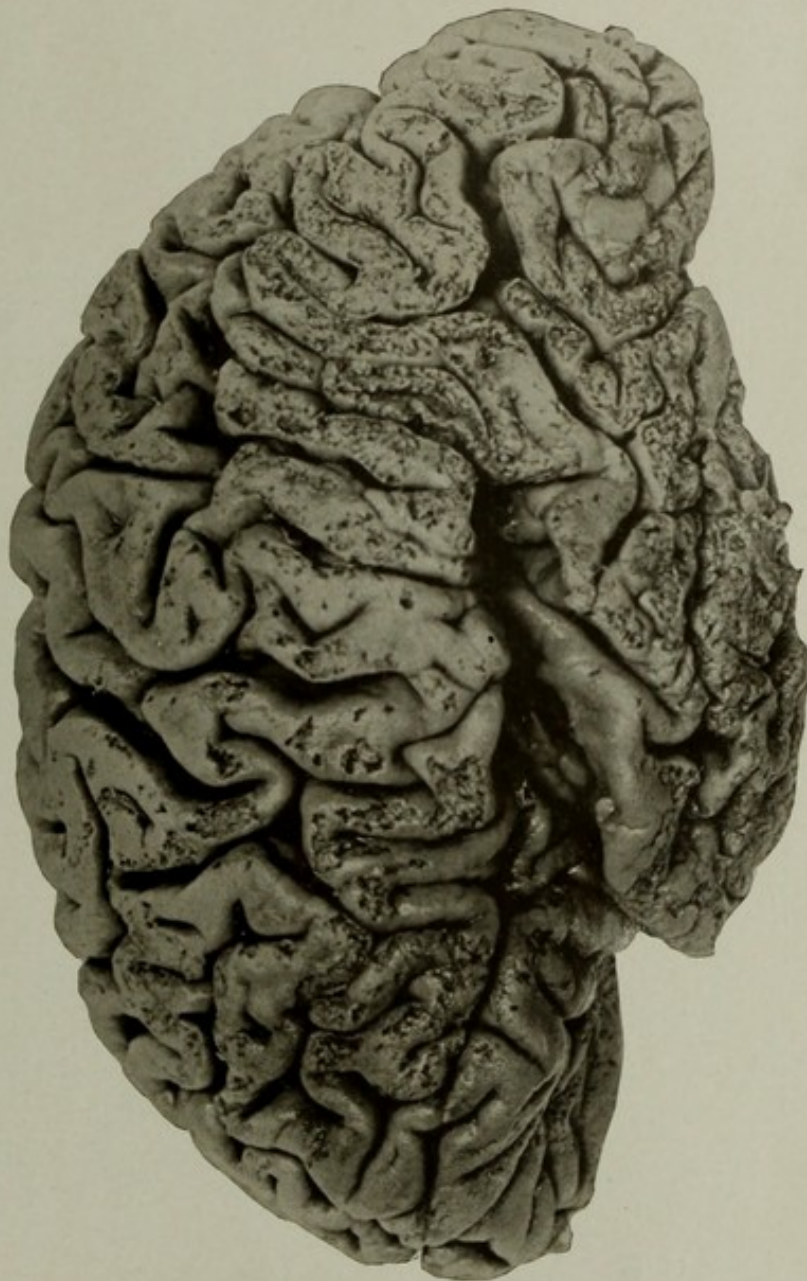
Synopsis of autopsy: Calvaria thin; persistent frontal suture; dura normal.

Brain weighed 1,200 grams. Subarachnoid fluid much increased; convolutions atrophied; brain substance œdematous and soft. Gray matter everywhere had a dark violaceous gray hue; white substance on section dripped with moisture. The ventricles slightly dilated, the ependyma granular, especially in the fourth.

Removal of the pia showed almost universal adhesions and typical decortication of the upper layers, perhaps most marked over the inferior parietal lobule and the temporal lobe and least over the superior central regions. The large arteries at the base showed no appreciable disease.

GROSS MORBID ANATOMY OF THE BRAIN IN THE INSANE.

PLATE XLI.



THE EFFECTS OF REMOVAL OF THE PIA IN PARESIS.



---

---

PLATE XLII.

---

---

## PLATE XLII.

AUTOPSY No. 1695.

THE LEFT HEMISPHERE IN A CASE OF PARESIS WITH FLAKING OF THE CORTEX.

Case 12739. L. V. B.; aged 61; white; piano tuner; nativity, Germany. Mental disease, paresis; duration, one and a half years.

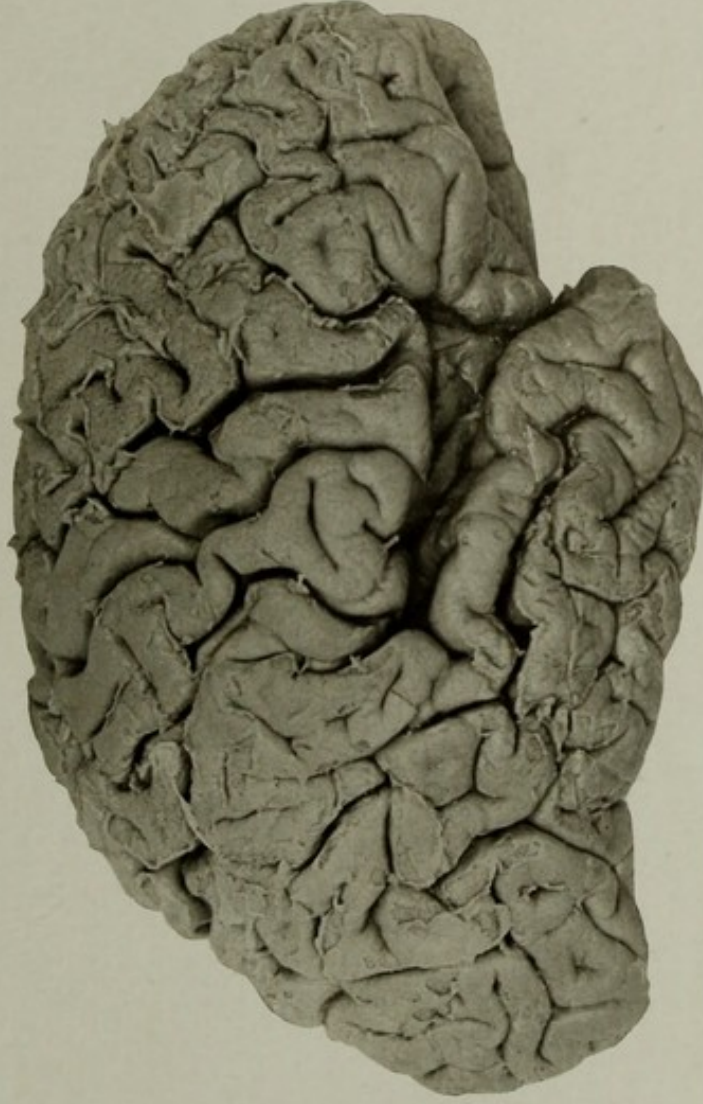
The clinical history a typical symptom-complex of paresis; supposed cause, alcoholism (?).

Synopsis of the autopsy: Brain weight, 1,240 grams. The arachno-pia was thick and opaque over the convexity and the anterior portions of the mesial surfaces. The subarachnoid exudate over the convexity was somewhat opaque and patchy in character. Veins moderately full of blood; arteries apparently normal. The frontal lobes were adherent below by their mesial surfaces, and there were universal adhesions to the cortex, resulting in the removal of the outer layers of the cortex with the pia. The gray substance everywhere was darker than normal and soft. The ventricles were normal in size; ependyma granulated.

Some old tubercular lesions at apices of lungs, and a hypostatic condition posteriorly. Other organs showed no important pathological conditions.

GROSS MORBID ANATOMY OF THE BRAIN IN THE INSANE.

PLATE XLII.



THE LEFT HEMISPHERE IN A CASE OF PARESIS WITH FLAKING OF THE CORTEX.



---

---

PLATE XLIII.

---

---

## PLATE XLIII.

AUTOPSY No. 2068.

### THE RIGHT HEMIENEPHALON IN A CASE OF PARESIS.

Case 14172. A. H.; aged 37; male; colored; laborer; nativity, Maryland Mental disease, paresis. Symptoms characteristic of the disease. Died in epileptiform convulsions.

Brain: Weight, 1,140 grams. Arachno-pia cloudy and œdematous. Some shrinkage of the convolutions over the convexity. The arteries showed slight opacity in patches; right vertebral artery small; the left as large as the basilar, both posterior communicating arteries were rather larger than normal. Ventricles dilated and granulated.

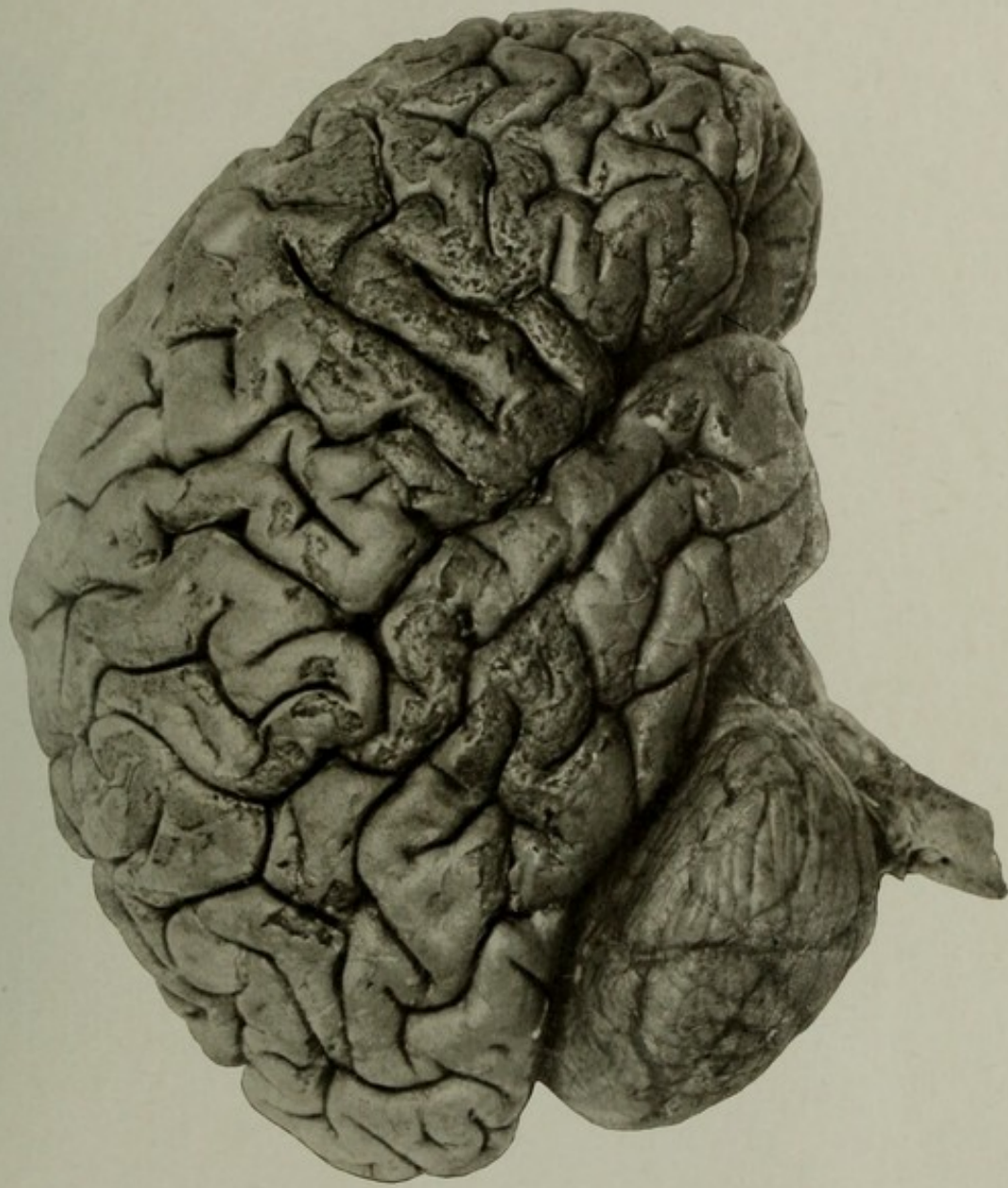
The picture shows that adhesions of the pia to the cortex were found almost everywhere, but were more marked over the frontal lobes. The gray matter was darker than normal. Section of the organ showed œdema and widening of the perivascular spaces, giving in some places almost a cribriform appearance to the tissue.

The other organs presented nothing of importance in this connection.

The microscope in this case showed typical conditions such as are found in paresis.

GROSS MORBID ANATOMY OF THE BRAIN IN THE INSANE.

PLATE XLIII.



THE RIGHT HEMICEPHALON IN A CASE OF PARESIS.



---

---

PLATE XLIV.

---

---

## PLATE XLIV.

AUTOPSY No. 1502.

### BRAIN SHOWING CHRONIC INTERNAL HYDROCEPHALUS.

Case 2281. J. H.; aged 57; male; white; nativity, Germany. Mental disease, chronic dementia; duration, thirty-five years.

Skull was very thin, almost oval in outline; sutures partly obliterated.

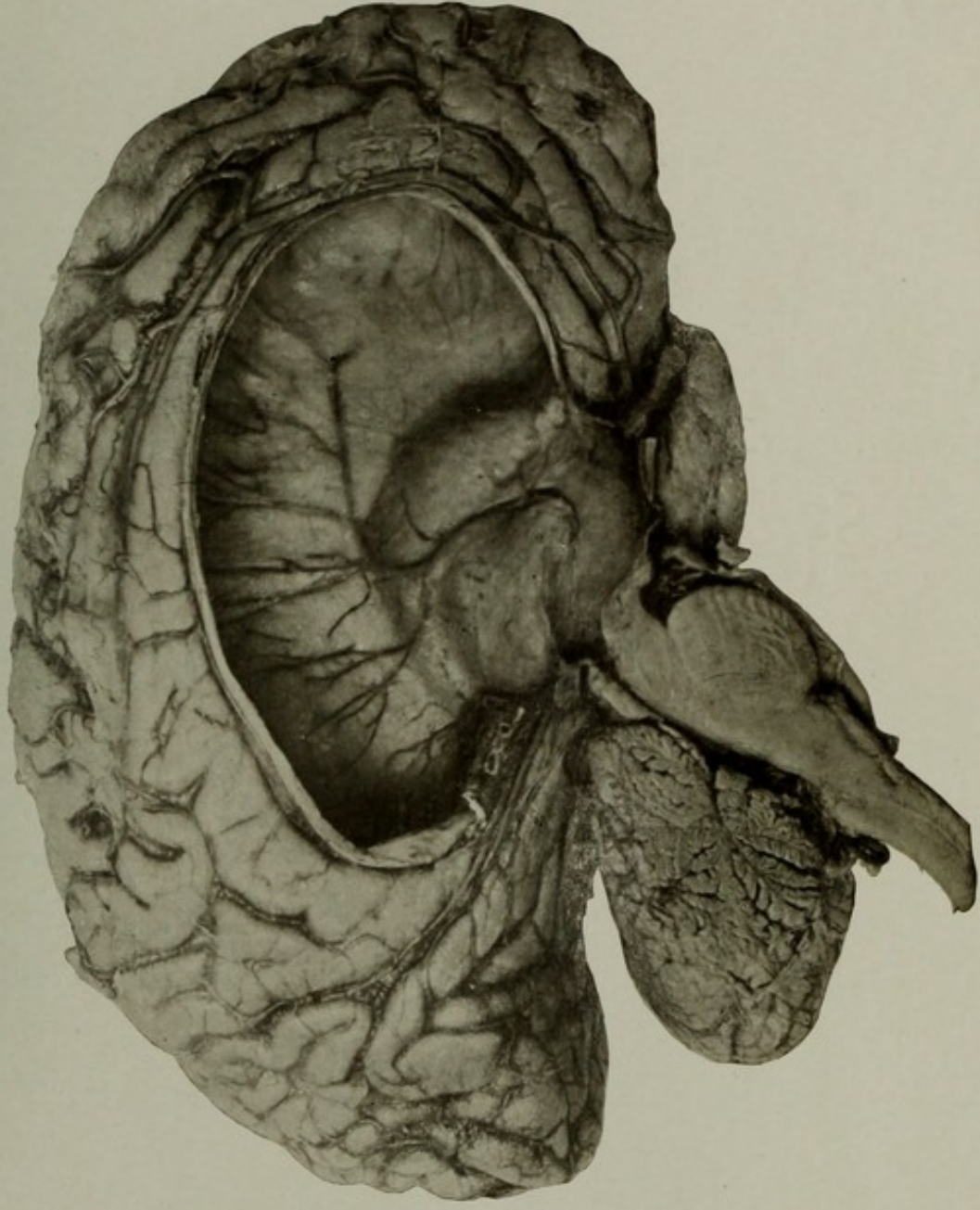
Brain weighed 1,040 grams; each half the same. On opening the ventricular cavity a large quantity of fluid escaped and the cerebrum collapsed. The ventricular cavities were greatly enlarged, especially the lateral ventricles. The callosum was greatly thinned, in some places consisting of little more than the ependyma and pia. Basal ganglia not much flattened. Foramen interventriculare greatly enlarged; fornix and septum much atrophied, and the latter was in some places deficient, so that the ventricular cavities were in direct communication. The third and fourth ventricles were only slightly dilated; the intraventricular veins, especially the striate veins, were enlarged and prominent. The brain mantle was in some places not over one-half centimeter in thickness; convolutions atrophied, but not flattened; nor were the sulci obliterated, as in the chronic congenital form of hydrocephalus. Arteries at the base not diseased.

The condition of other organs not important in this connection.

The picture shows most of the pathological conditions above given, and gives a good view of the relative size of the ventricle, as the picture is taken somewhat less than natural size. The cavity was lightly packed with cotton before hardening, but some flattening of the small parts occurred; these have been corrected in the finished picture.

GROSS MORBID ANATOMY OF THE BRAIN IN THE INSANE.

PLATE XLIV.



BRAIN SHOWING CHRONIC INTERNAL HYDROCEPHALUS.



---

---

PLATE XLV.

---

---

## PLATE XLV.

AUTOPSY No. 1900.

### CHRONIC ACQUIRED INTERNAL HYDROCEPHALUS.

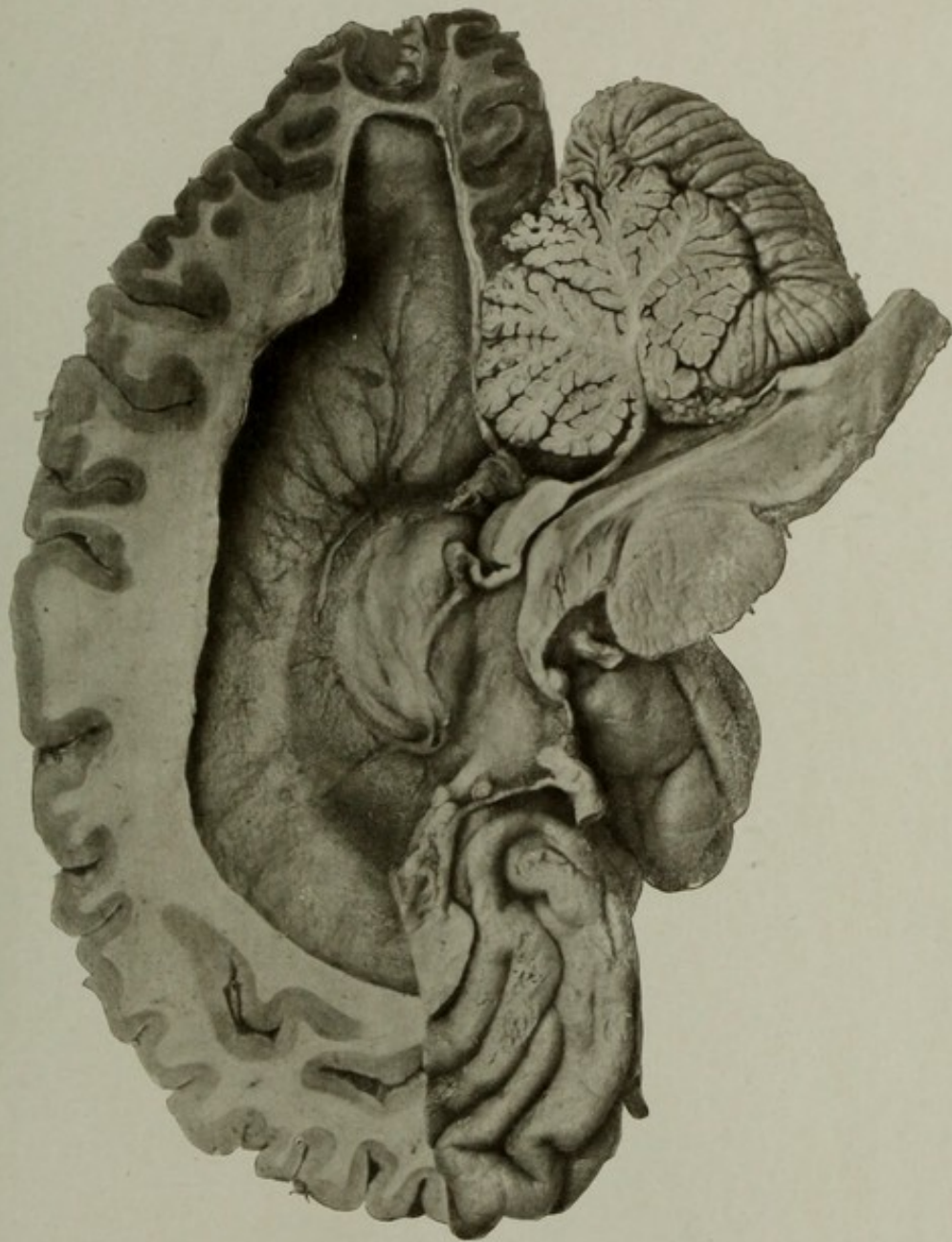
Case 13210. F. T.; male; aged 79; white; nativity, Germany; occupation, varnisher. Mental disease, senile dementia.

The brain was much atrophied, especially over the mesial surface of the frontal lobes. Ventricles dilated. Some sclerosis of cerebral arteries. Associated pathological conditions were ankylosis of the fourth, fifth, and sixth cervical vertebræ, slight chronic disease of the cardiac valves, and some interstitial change in the kidneys.

The picture shows a mesial section of the brain and the dilated right lateral ventricle, exposed by a vertical cut made about  $1\frac{1}{2}$  cubic centimeters outside of the median edge of the hemisphere and removing this piece by a horizontal cut in the frontal region after having cut the piece free posteriorly. The size of the ventricle, the dilated branch of the striate vein, and the caudate nucleus are well shown. The section of the cerebellum is a fortunate one, showing all the divisions of the vermis and an unusually good section of the inferior medullary velum. The massa intermedia was absent, as it frequently is in extreme enlargement of the ventricles.

GROSS MORBID ANATOMY OF THE BRAIN IN THE INSANE.

PLATE XLV.



CHRONIC ACQUIRED INTERNAL HYDROCEPHALUS.



---

---

PLATE XLVI.

---

---

PLATE XLVI.

AUTOPSY No. 714.

CHRONIC ACQUIRED INTERNAL HYDROCEPHALUS.

Case 7656. J. P. M.; aged 60; male; white; married; nativity, Ireland. Mental disease, chronic dementia; duration, seven years. The cause of death was acute colitis and tuberculous ulceration of the ileum.

Skull very thin; antero-posterior diameter, 21.5 centimeters; transverse, 16 centimeters. Shape symmetrical; sutures all distinct. Dura normal.

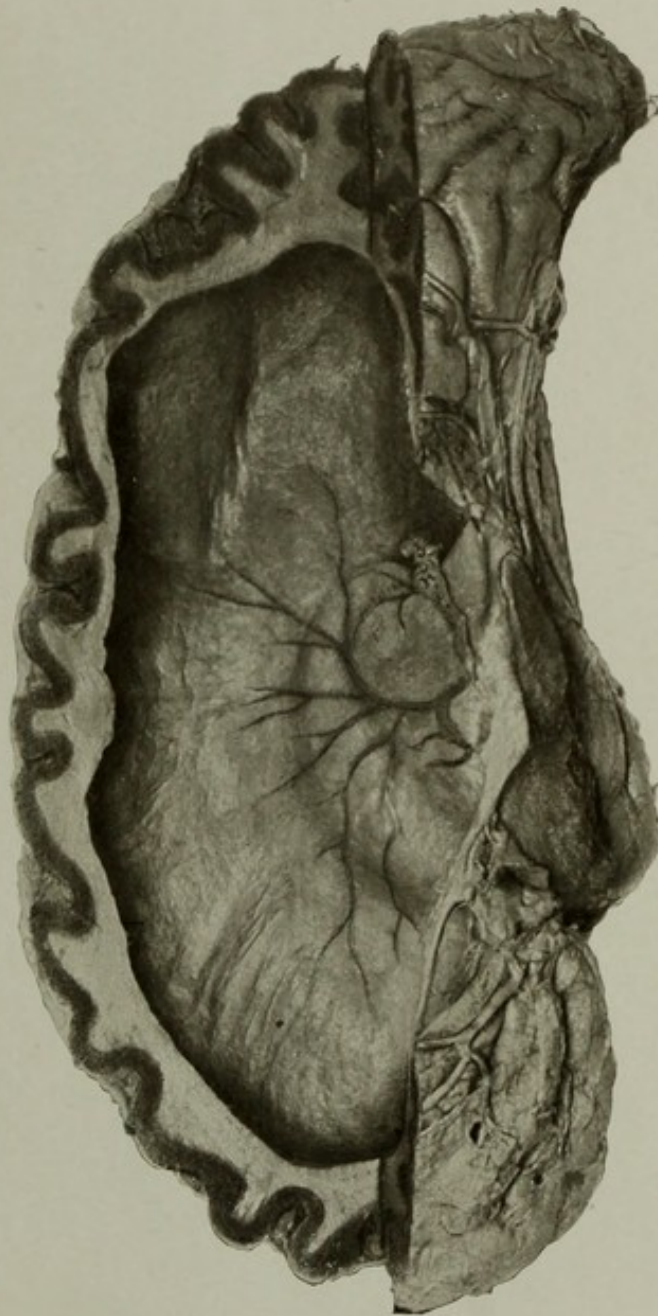
Brain: Weight, 1,386 grams. The ventricles contained 577 cubic centimeters of fluid; they were greatly dilated; septum pellucidum thinned and almost destroyed; fornix thinned; foramen interventriculare enlarged; callosum very thin; anterior commissure exposed for about 1 centimeter; third ventricle enlarged; massa intermedia had disappeared. The velum interpositum was thickened; ependyma thickened; the ventricular veins somewhat prominent. Several small arteriosclerotic softenings in the caudate nuclei. The gyri on the convexity showed some flattening from increased pressure.

The ileum showed several chronic tuberculous ulcers and adhesions of the serous surface. The large intestine showed the usual lesions of acute colitis.

The condition of the other organs was unimportant.

GROSS MORBID ANATOMY OF THE BRAIN IN THE INSANE.

PLATE XLVI.



CHRONIC ACQUIRED INTERNAL HYDROCEPHALUS.



---

---

PLATE XLVII.

---

---

PLATE XLVII.

AUTOPSY No. 606.

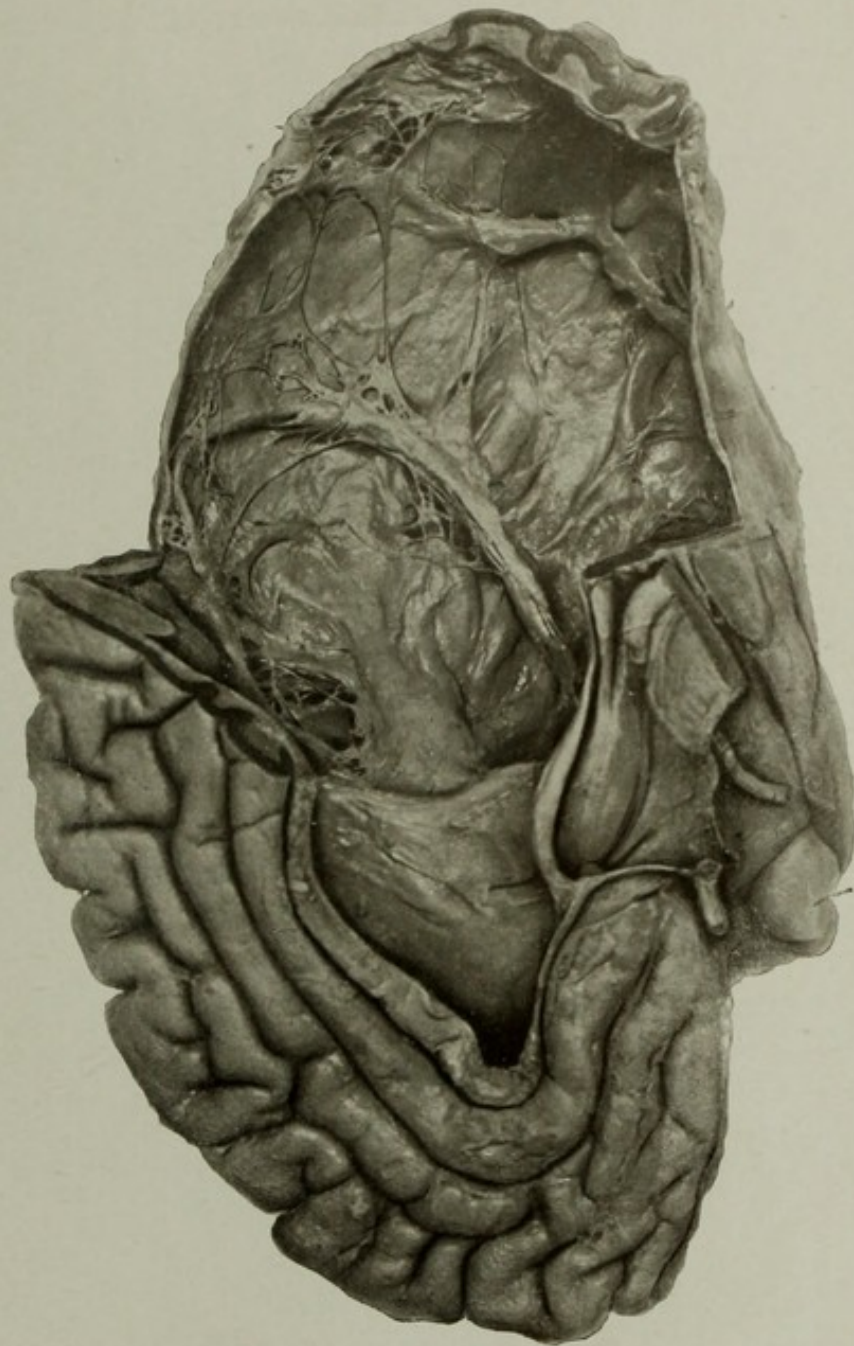
A CASE OF CHRONIC ACQUIRED CIRCUMSCRIBED INTERNAL HYDROCEPHALUS.

Case 3282. J. G.; aged 52; white; male; soldier; nativity, Ireland. Mental disease chronic epileptic insanity; duration, twenty-five and one-half years.

Brain: Weight of left half, 610 grams; the right half, 368.5 grams. The right hemisphere was occupied by a large cyst like accumulation of clear fluid, measuring, together with the contents of the ventricles, 385 cubic centimeters. The dilatation involved nearly all of the parietal, temporal, and occipital lobes, and the brain substance over this region was very thin. The cavity communicated with the ventricle by a large opening in the posterior portion; the inner wall of the cavity was covered by shreds of atrophied brain tissue, and the course of some of the principal fissures could be seen. The brain externally showed some flattening of the convolutions over both sides, though the ventricle of the left side was only moderately dilated. The brain tissue was soft, cortex rather dark, a few small softenings in the caudate nuclei, and slight arteriosclerosis. The fornix, septum pellucidum, and other internal parts of the brain seemed normal.

GROSS MORBID ANATOMY OF THE BRAIN IN THE INSANE.

PLATE XLVII.



A CASE OF CHRONIC ACQUIRED CIRCUMSCRIBED INTERNAL HYDROCEPHALUS.



---

---

PLATE XLVIII.

---

---

(99)

PLATE XLVIII.

AUTOPSY No. 1628.

TRANSVERSE SECTION OF THE BRAIN, SHOWING CHRONIC INTERNAL HYDROCEPHALUS, PROBABLY CONGENITAL.

Case 13081. E. V. C.; aged 59; male; white; soldier; nativity, United States. Mental disease, senile dementia. The clinical symptoms were a simple form of dementia, supposed to be presenile. Death from traumatic pleuritis.

Skull thin; frontal suture still persistent, somewhat enlarged.

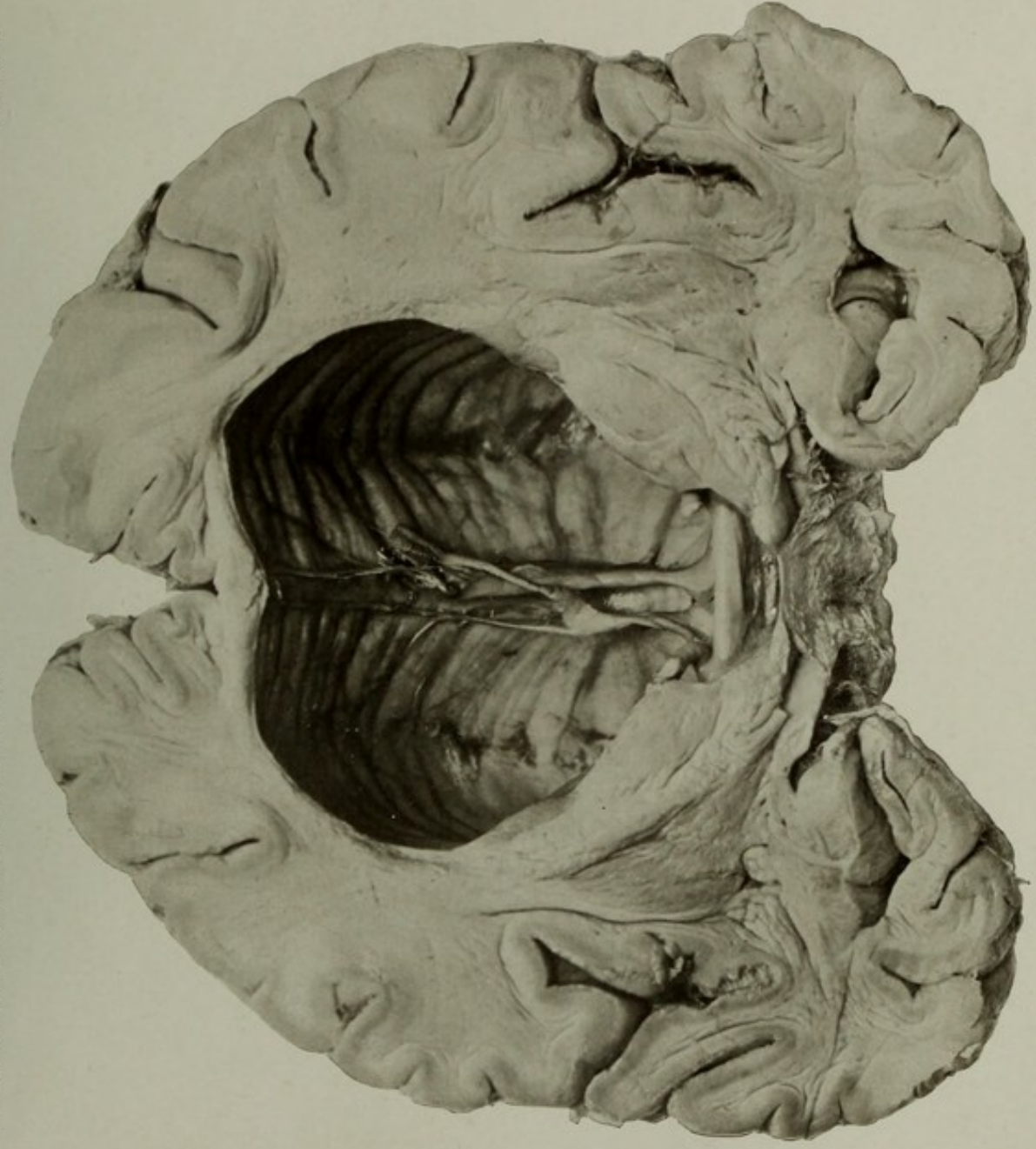
Brain: Weight when emptied, 1,560 grams; ventricles contained 340 cubic centimeters of fluid. Convolutions not appreciably flattened; arteries normal. Ventricles dilated; callosum thinned; anterior white commissure exposed for about 2 centimeters of its length; massa intermedia gone; anterior columns of the fornix elongated and cordlike; septum pellucidum thin and represented by some ragged strands. The basal ganglia were flattened, the third ventricle enlarged, and the tuber cinereum was bulged downward.

The patient had a large number of rib fractures, some old and healed, some recent and partially displaced. From these fractures an acute pleuritis had developed, and the lungs were partly solidified by pneumonic exudate. No cause was discovered for the rib fractures, except that the ribs were unusually fragile.

Other organs presented nothing of importance.

GROSS MORBID ANATOMY OF THE BRAIN IN THE INSANE.

PLATE XLVIII.



TRANSVERSE SECTION OF THE BRAIN, SHOWING CHRONIC INTERNAL HYDROCEPHALUS, PROBABLY CONGENITAL.



---

---

PLATE XLIX.

---

---

(101)

PLATE XLIX.

AUTOPSY No. 1934.

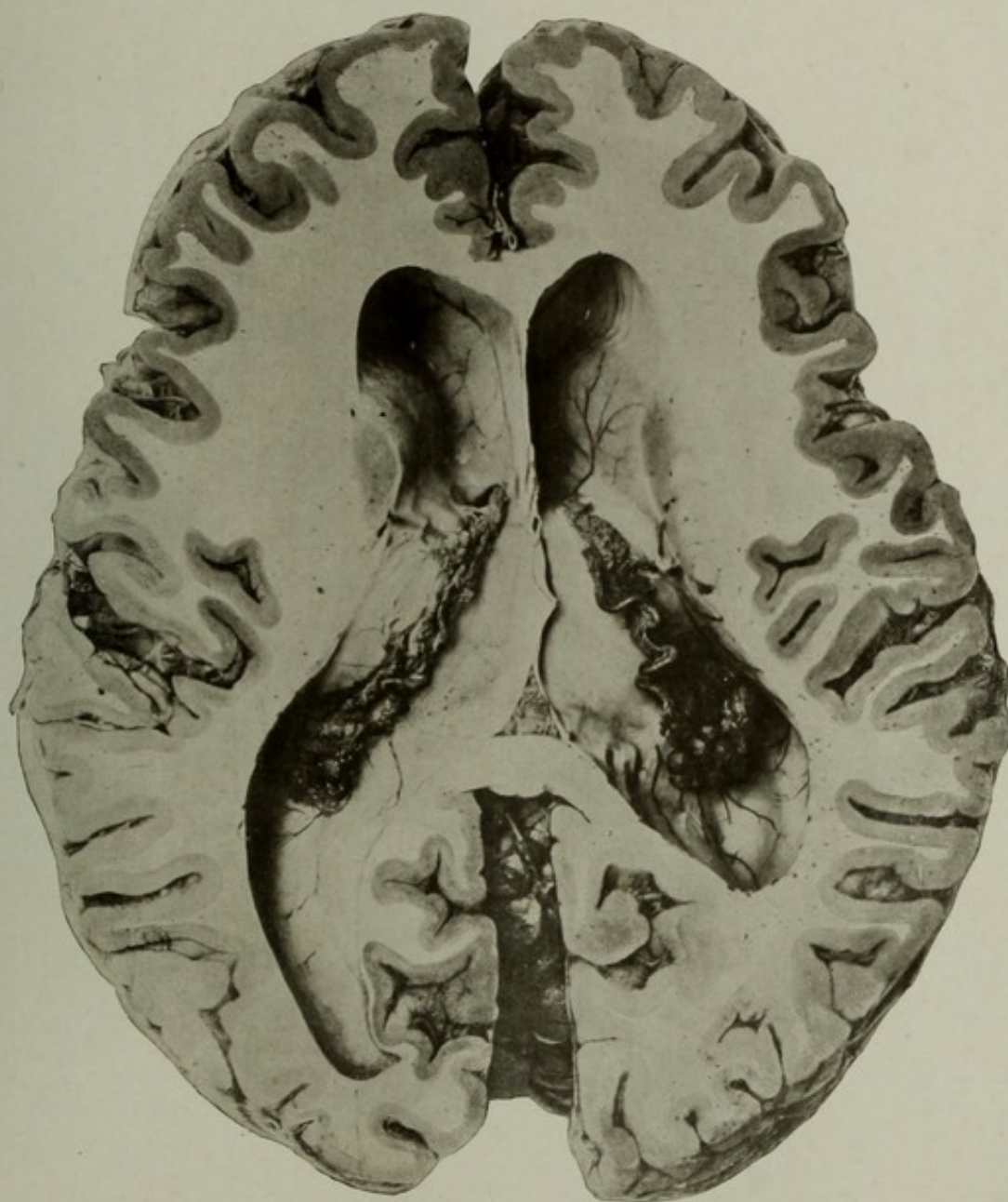
HORIZONTAL SECTION OF A BRAIN FROM A CASE OF SENILE DEMENTIA WITH VENTRICULAR DILATATION.

Case 12341. A. J. B.; aged 74; white; soldier; nativity, Ohio. Mental disease, senile dementia. Terminal pneumonia and cardiac weakness terminated life.

Brain: Weight, 1,210 grams. Convolutions extremely shrunken and the parts at the base atrophied. The arteries contained numerous patches of atheroma. Pia loose and œdematous; veins moderately full of blood.

The picture shows the surface atrophy in the outline and in the widely separated gyri. The ventricles are dilated, especially the posterior horn of the left lateral, which reaches far into the occipital lobe. The tæniæ fornicis are thinned and their edges are covered by the borders of the enlarged choroid plexuses. The enlarged and tortuous choroid vein is especially well seen on the right, and a cluster of grapelike cysts of the plexus are seen near the entrance of the inferior horn of the ventricle. The thinned septum pellucidum and the edge of the fornix where it joins the callosum are evidences of pressure atrophy. A small triangular opening accidentally made through the corpus fornicis reveals the underlying tela chorioidea ventriculi tertii.

The condition of the other organs was not important in this connection.



HORIZONTAL SECTION OF A BRAIN FROM A CASE OF SENILE DEMENTIA WITH VENTRICULAR DILATATION.



---

---

PLATE L.

---

---

47078—08—14

(103)

## PLATE L.

AUTOPSY No. 2187.

### A CASE OF CHRONIC CONGENITAL INTERNAL HYDROCEPHALUS.

Case 11547. L. P.; aged 60; male; white; single; nativity, District of Columbia. Mental disease, imbecility.

The patient had at one time considerable intelligence. He had some musical ability, some education, and could converse with ordinary facility on current topics. Later in life he became deeply demented, physically helpless, blind, and partially deaf. He had some spasticity of the lower limbs and beginning contractures of knee and hip. He never had convulsive attacks, and aside from the brain disease his health had always been fair.

The skull measured in circumference 70.5 centimeters; biparietal diameter, 19.6 centimeters; and from ophtyon to maximum occipital point, 23.3 centimeters. The skull was unusually thick for a hydrocephalic, measuring an average of 1.6 centimeters in the frontal regions. Dura mater not abnormally adherent.

Brain: Weight when emptied, 1,240 grams. It contained 2,400 cubic centimeters of fluid. Over the frontal regions of brain the gyri and sulci were fairly distinct, but over the posterior regions the configuration was lost and the brain mantle was converted into a smooth bag of fluid, the walls of which were, in places, not over 0.4 of a centimeter in thickness. Section showed that the dilatation of the ventricles was principally posteriorly, a fair degree of thickness persisting in the frontal regions. In the interior it was found that the posterior and lateral horns of the ventricles were practically merged into one, the septum pellucidum was lost, basal ganglia were flattened, and the choroid plexuses were pale and flattened. On the right side, where the section passed a little lower, the caudate and lenticular nuclei and the internal capsule were still distinguishable. The callosum was very thin and separated from the fornix; the velum interpositum still present; third and fourth ventricles slightly dilated.

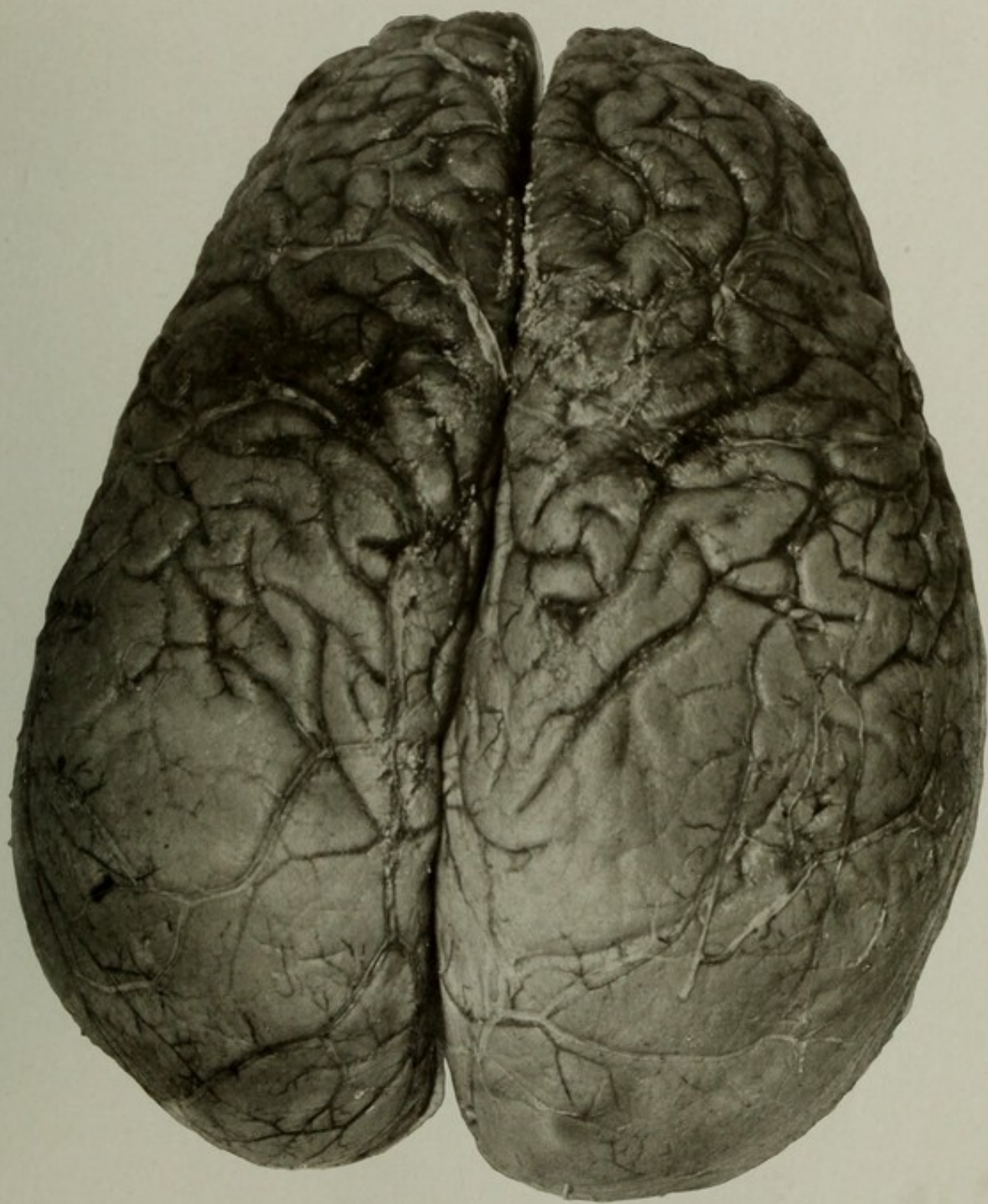
The relatively better preservation of the frontal lobes was noticeable on section, and the cortex over this part of the brain was of normal thickness. In fact, the whole extent of the cortex was fairly well preserved, the extreme dilatation being at the expense of the white matter.

The basal view showed a disproportion between the cerebellum and the cerebrum, some thickening of the arachnoid, normal arteries, and the optic nerves shrunken and grayish in color.

The other organs showed nothing of interest in this connection.

The chief interest in this case was the preservation of a degree of intellect, doubtless correlated with the better preservation of the frontal lobes, the thickness of the skull, and the preservation of an almost normal shape of the face.

This picture shows the superior surface of the convexity. Additional illustrations of this case are given on Plates LI and LII.



A CASE OF CHRONIC CONGENITAL INTERNAL HYDROCEPHALUS.



---

---

PLATE LI.

---

---

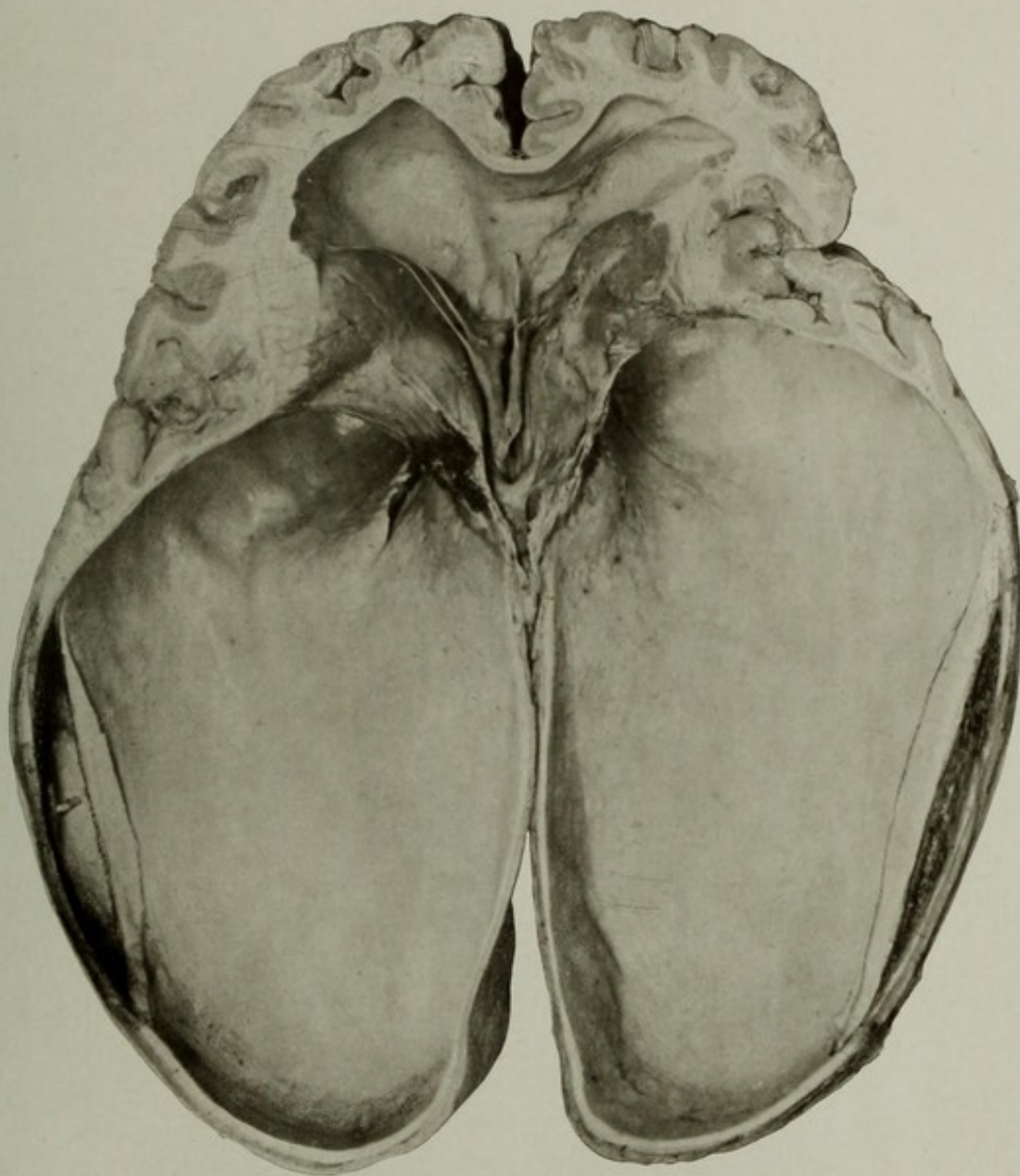
PLATE LI.

AUTOPSY No. 2187A.

A CASE OF CHRONIC CONGENITAL INTERNAL HYDROCEPHALUS INTERIOR OF BASAL PORTION.

Case 11547. A view of the lower part of the interior of the brain. The thickened ependyma and the white matter have separated to some extent from the cortex.

A general discussion of this case is given on page 104.



A CASE OF CHRONIC CONGENITAL INTERNAL HYDROCEPHALUS.  
Interior of basal portion.



---

---

PLATE LII.

---

---

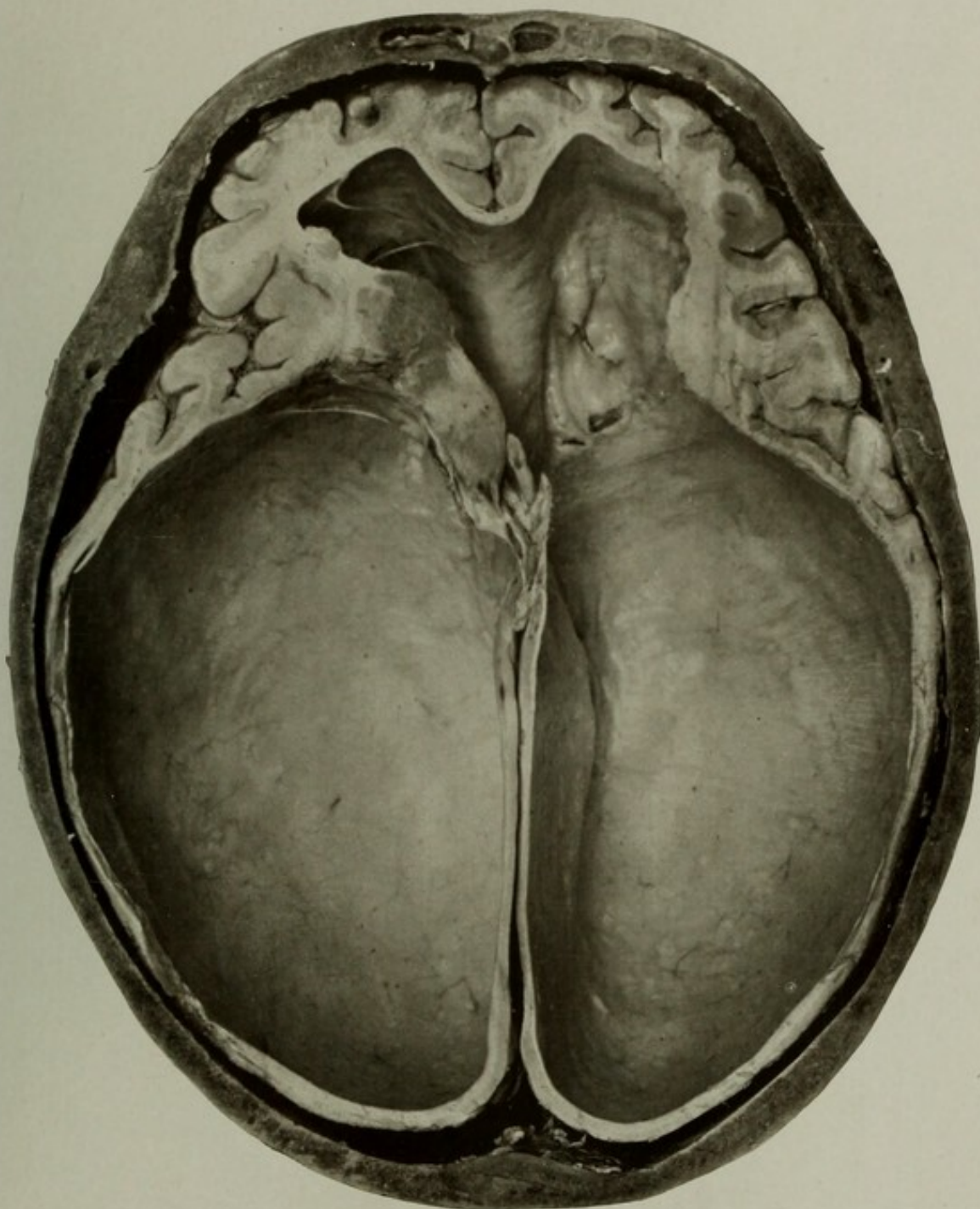
PLATE LII.

AUTOPSY No. 2187B.

A CASE OF CHRONIC CONGENITAL INTERNAL HYDROCEPHALUS INTERIOR OF UPPER PORTION.

Case 11547. Interior view of the upper portion of the brain within the calvaria. The relatively thick cut edge of the skull bone may be seen. The dura has been removed.

A general discussion of this case is given on page 104.



A CASE OF CHRONIC CONGENITAL INTERNAL HYDROCEPHALUS.  
Interior of upper portion.



---

---

PLATE LIII.

---

---

PLATE LIII.

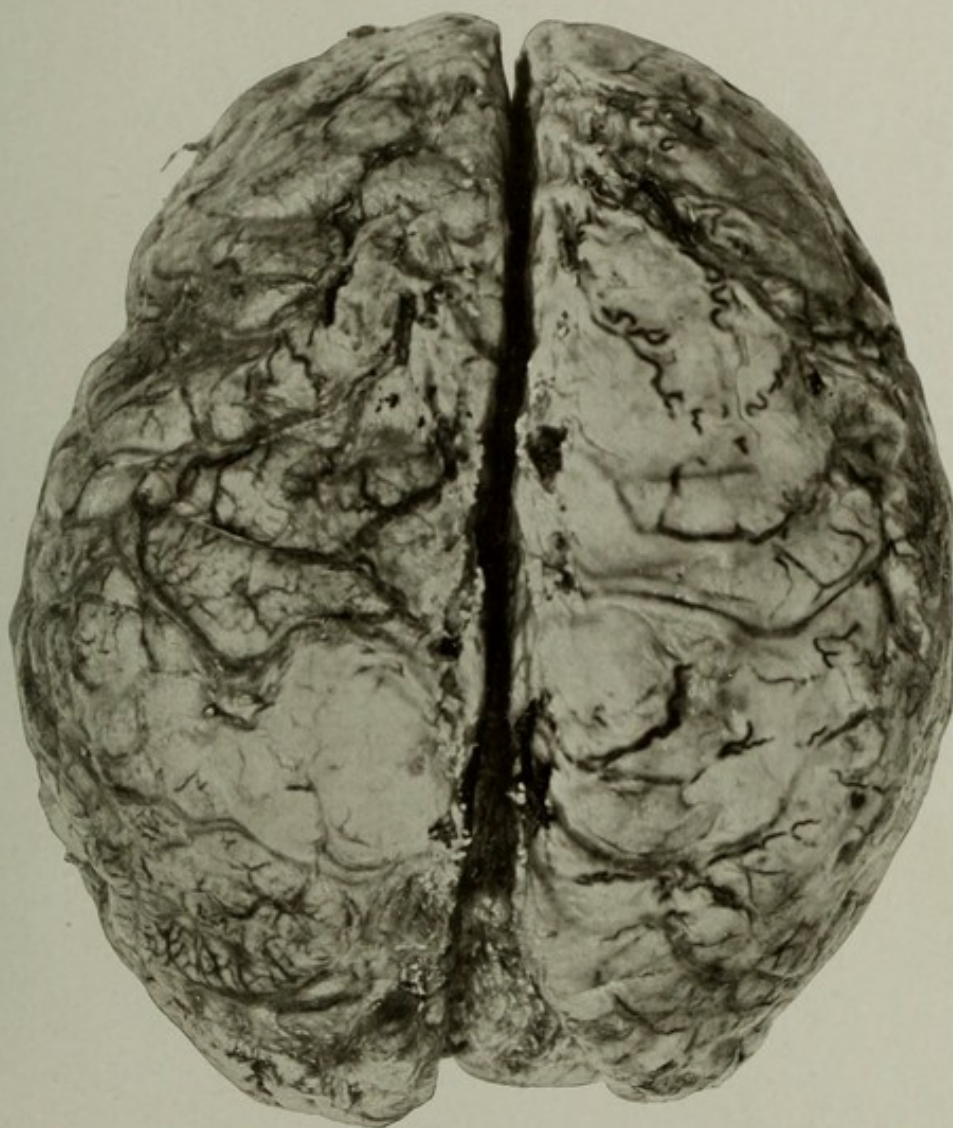
AUTOPSY No. 1700.

THE SUPERIOR SURFACE OF A BRAIN SHOWING LEPTOMENINGITIS.

Case 2744. E. B.; aged 68; female; white; nativity, Germany. Mental disease, chronic mania.

Synopsis of autopsy: On opening the dura a neomembrane of pachymeningitis interna was found over the portion of the dura covering the convexity, and over the whole extent of the pia was a subarachnoid sero-purulent exudate. Adhesions had formed between the inflamed arachno-pia and the neomembrane. The brain weighed 960 grams. The pia over almost the whole convexity was thick, with a yellowish-white exudate in its meshes. The greatest intensity of the condition was over the anterior lobes, the right convexity, and in the vicinity of the chiasma. The arteries were apparently normal on the convexity, but at the base there was some sclerosis and the right vertebral artery was small and partially obstructed; the veins were prominent and showed as dark tortuous lines over the yellowish-white exudate.

An additional illustration of this case is given on Plate LIV.



THE SUPERIOR SURFACE OF A BRAIN SHOWING LEPTOMENINGITIS.



---

---

PLATE LIV.

---

---

PLATE LIV.

AUTOPSY No. 1700A.

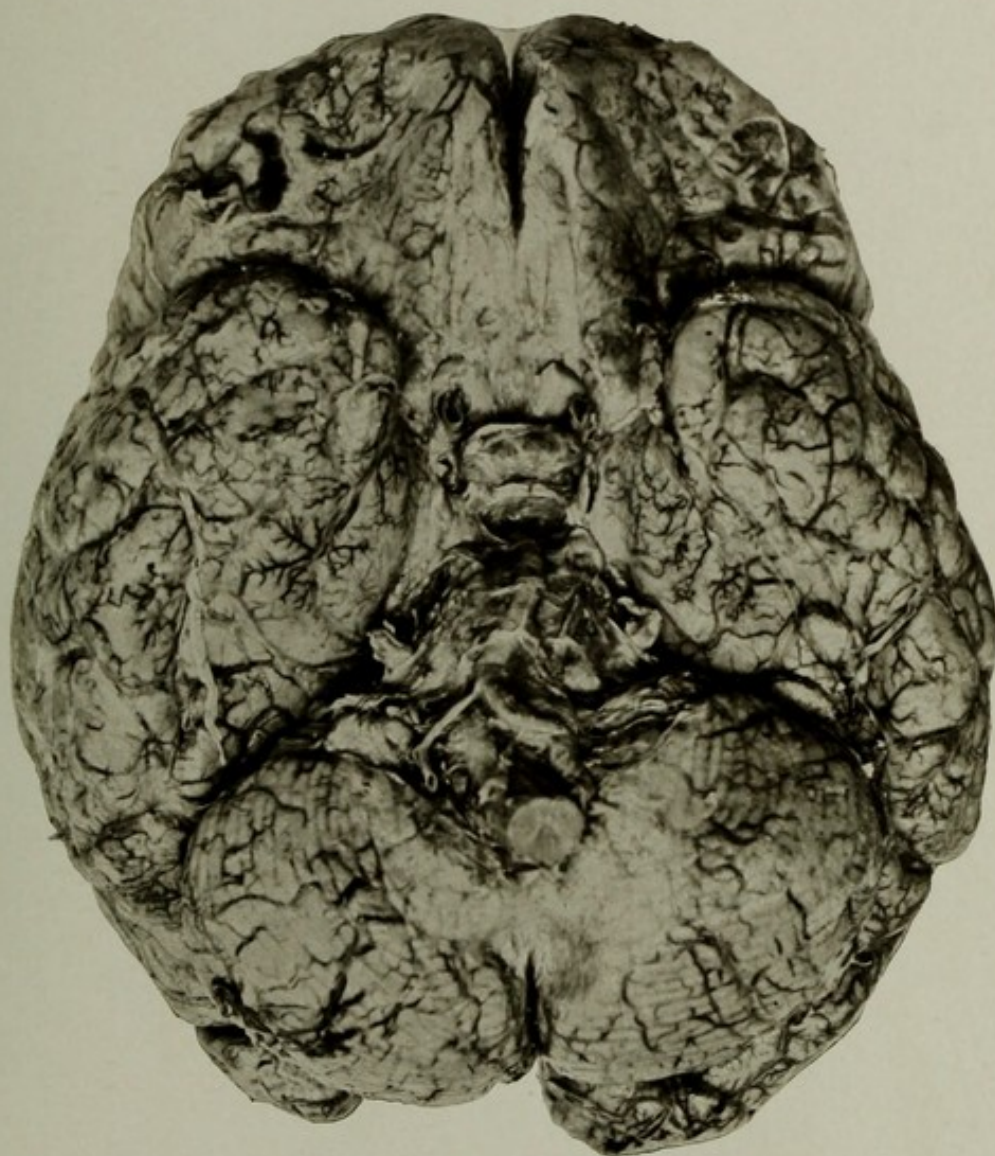
THE INFERIOR SURFACE OF A BRAIN SHOWING LEPTOMENINGITIS.

Case 2744. This plate shows the base of the same brain with the prominent veins and the thickened pia and arachnoid.

The lungs showed solidification of the whole lower lobe of the left and some remains of chronic tuberculosis of the apices. The kidneys showed slight evidences of swelling and probably parenchymatous inflammation.

Other organs presented nothing important.

A general discussion of this case is given on page 110.



THE INFERIOR SURFACE OF A BRAIN SHOWING LEPTOMENINGITIS.



---

---

PLATE LV.

---

---

PLATE LV.

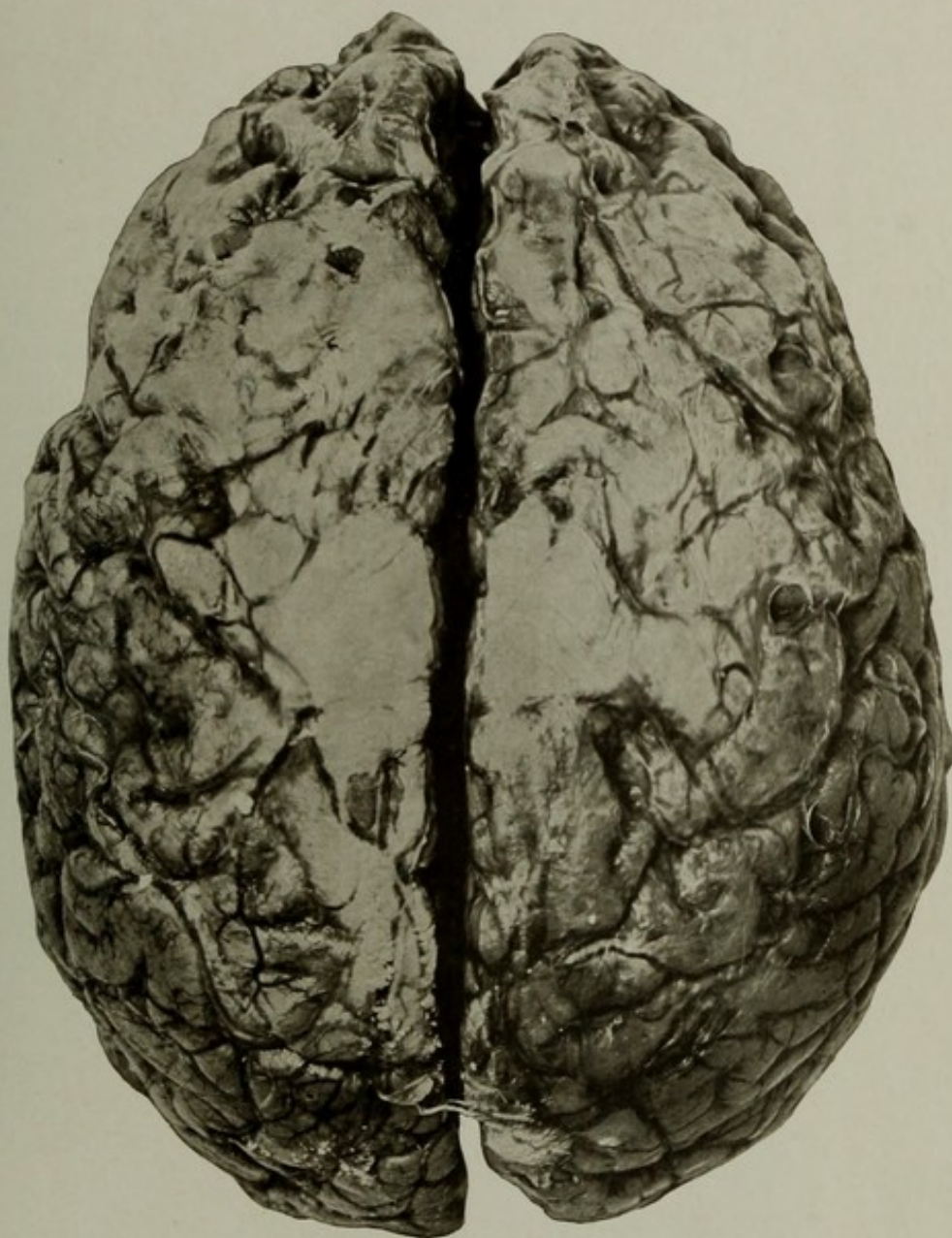
AUTOPSY No. 1941.

A BRAIN SHOWING CHRONIC MENINGEAL THICKENING AND ATROPHY CONSEQUENT UPON BULLET WOUND OF HEAD.

Case 13937. J. K.; aged 67; white; cooper; nativity, Ohio. Mental disease, chronic dementia. Clinical history of advanced dementia, delusions, and extreme muscular enfeeblement.

Brain: Weight, 1,080 grams. Arteries atheromatous and calcified; softenings found in the base of the right occipital and temporal lobes, on the external surface of the left occipital lobe, and temporal lobe. Brain excessively atrophied over the convexity, pia arachnoid much thickened over the fronto-parietal convexity, and the membrane was raised by large subpial effusions. Cerebellum, pons, and medulla were much shrunken. (It was noted that the large softening of the brain on the left side was situated beneath the site of the wound of the scalp. The picture does not show the softenings of the cortex.)

The condition of the other organs was not of any special importance in this connection. The kidneys showed some interstitial changes, there was some interstitial myocarditis, and there were some old tubercular lesions of the apices of the lungs.



A BRAIN SHOWING CHRONIC MENINGEAL THICKENING AND ATROPHY  
CONSEQUENT UPON BULLET WOUND OF HEAD.



---

---

PLATE LVI.

---

---

PLATE LVI.

AUTOPSY No. 1847.

THE RIGHT HEMIENEPHALON FROM A CASE OF ACUTE MANIA.

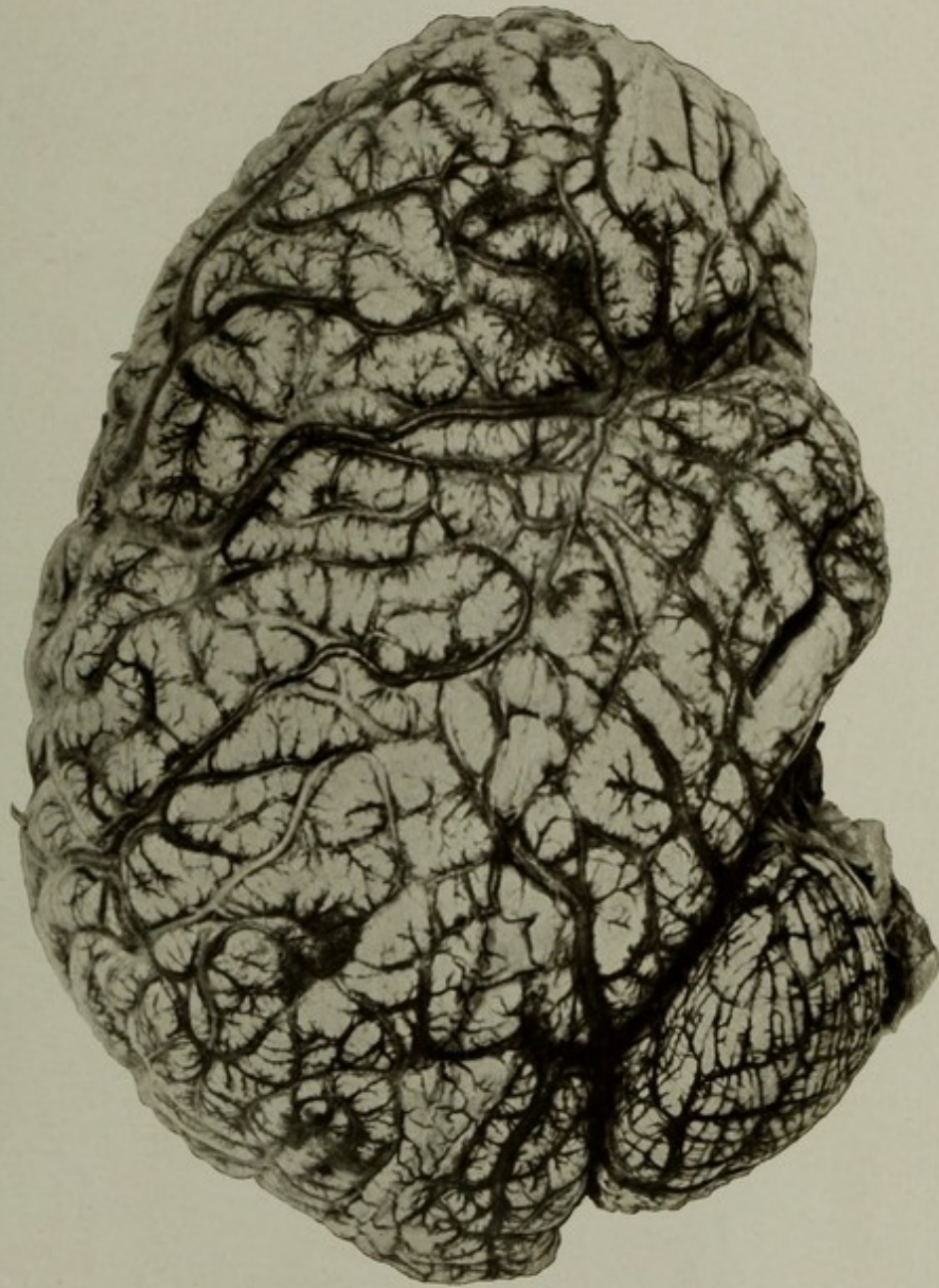Case 14420. A. F.; aged 20; colored; laborer; nativity, District of Columbia. Mental disease, acute mania. The clinical history shows that the patient suffered from intense maniacal excitement, which lasted from his admission four days, until his death occurred.

Synopsis of autopsy: Brain, weight of each half, 790 grams, or 1,580 grams for the whole encephalon. The whole brain was most intensely hyperæmic, every vessel visible to the naked eye was filled with blood, and the gray matter presented a deep purplish hue. The white matter had a pinkish hue, and the whole brain was œdematous and soft. It was found to be impossible to remove the pia without lacerating the cortex, but there were no other signs of meningo-encephalitis. The pia, aside from the intense hyperæmia, did not show any signs of inflammation.

The lungs showed acute caseous tuberculous masses, and the bronchi were full of mucopurulent secretions. The kidneys and liver were intensely hyperæmic. No cause could be discovered for the condition except the suggestion of some acute toxæmia, possibly tubercular.

GROSS MORBID ANATOMY OF THE BRAIN IN THE INSANE.

PLATE LVI.



THE RIGHT HEMICEPHALON FROM A CASE OF ACUTE MANIA.



---

---

PLATE LVII.

---

---

## PLATE LVII.

AUTOPSY No. 1995.

### THE SUPERIOR ASPECT OF THE BRAIN IN A CASE OF EXTREME MENINGEAL HYPERÆMIA WITH CHRONIC ŒDEMA.

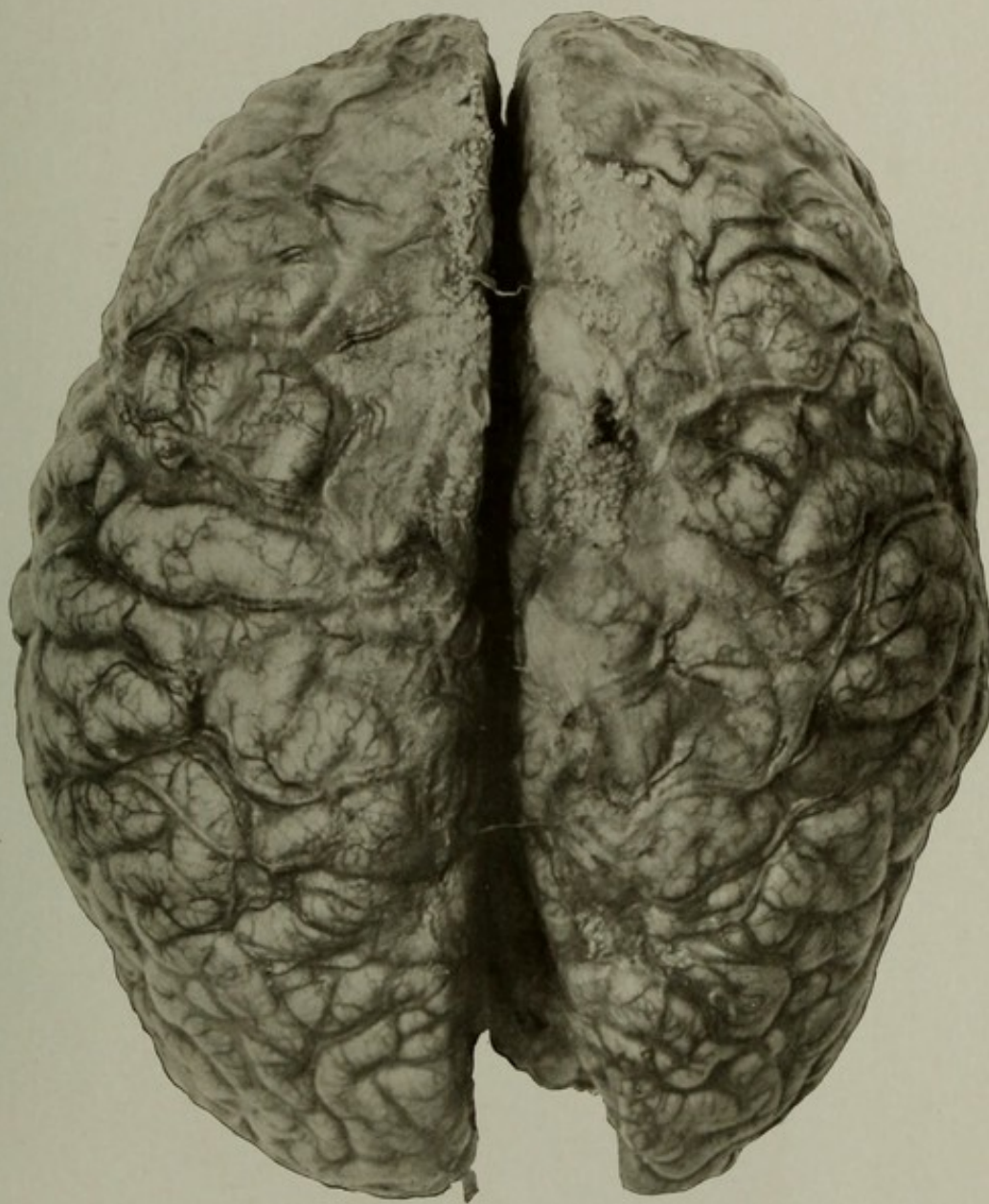
Case 8102. A. W.; aged 32; white; soldier; nativity, California. Mental disease, chronic melancholia. Extreme restlessness; did not sleep well; mental excitement.

Brain: Weight, 1,280 grams. The pia mater over the whole convexity was opaque, thickened, and cedematous. The veins were deeply engorged, and the gray matter everywhere was reddened and soft. The arteries were not diseased. Cerebellum deeply hyperæmic and its veins and arteries full of blood. Though the pia was not removed, a considerable degree of shrinkage was noted in the frontal regions.

The liver, spleen, and kidneys were congested, due doubtless to disease and incompetency of the tricuspid valve. Other cardiac valves were normal.

Stomach showed the effects of chronic catarrh, and the solitary follicles of the small intestine were enlarged.

NOTE.—The symptoms were those of cerebral hyperæmia with prostration, and some gastrointestinal irritation which occasioned vomiting.



THE SUPERIOR ASPECT OF THE BRAIN IN A CASE OF EXTREME MENINGEAL  
HYPERÆMIA WITH CHRONIC ŒDEMA.



---

---

PLATE LVIII.

---

---

(119)

PLATE LVIII.

AUTOPSY No. 2069.

THE SUPERIOR ASPECT OF A BRAIN FROM A CASE OF EXTREME ATROPHY IN THE TERMINAL DEMENTIA OF MELANCHOLIA.

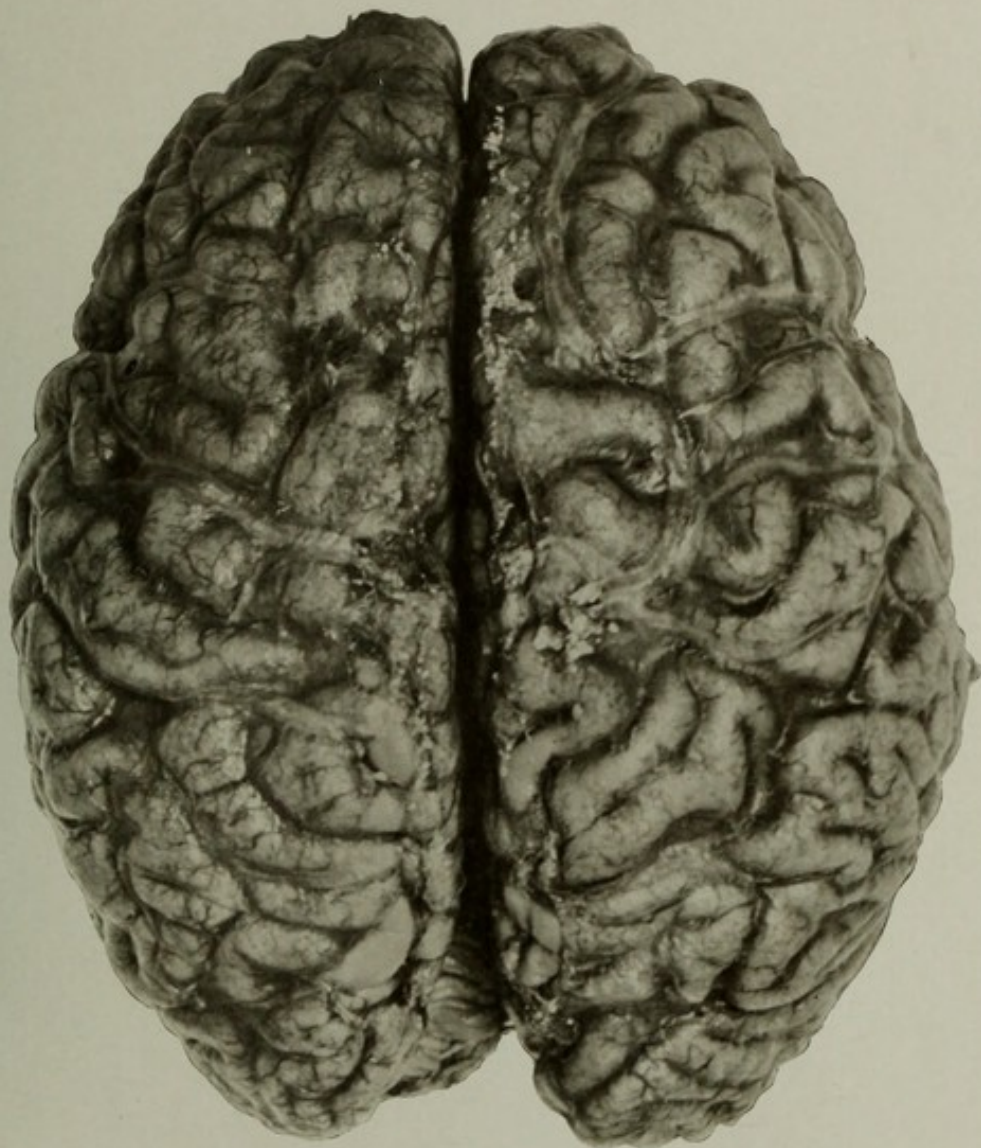
Case 4850. F. B.; aged 78; female; colored; nativity, Maryland. Mental disease, melancholia with arteriosclerotic terminal dementia; duration, twenty-six years. Pulmonary, and more or less generalized tuberculosis.

Synopsis of autopsy: Brain weighed 910 grams. The organ was much shrunken and the pia contained a large accumulation of subarachnoid fluid. The cerebral arteries were small, distorted, and sclerotic. The inferior cerebellar artery of right side came off in common with the anterior cerebellar.

The picture shows the general atrophy of the convolutions, and the large cerebral veins. Those of the right side are unusual in arrangement.

The lungs showed old tubercular lesions with recent auto-infection of the remainder of the lungs. The peritoneum, Fallopian tubes, and kidneys were tubercular, and the tubes and uterus were filled with pus.

Heart small, some thickening of left valves, and the aorta contained a few patches of atheroma.



THE SUPERIOR ASPECT OF A BRAIN FROM A CASE OF EXTREME ATROPHY  
IN THE TERMINAL DEMENTIA OF MELANCHOLIA.



---

---

PLATE LIX.

---

---

PLATE LIX.

AUTOPSY No. 2126.

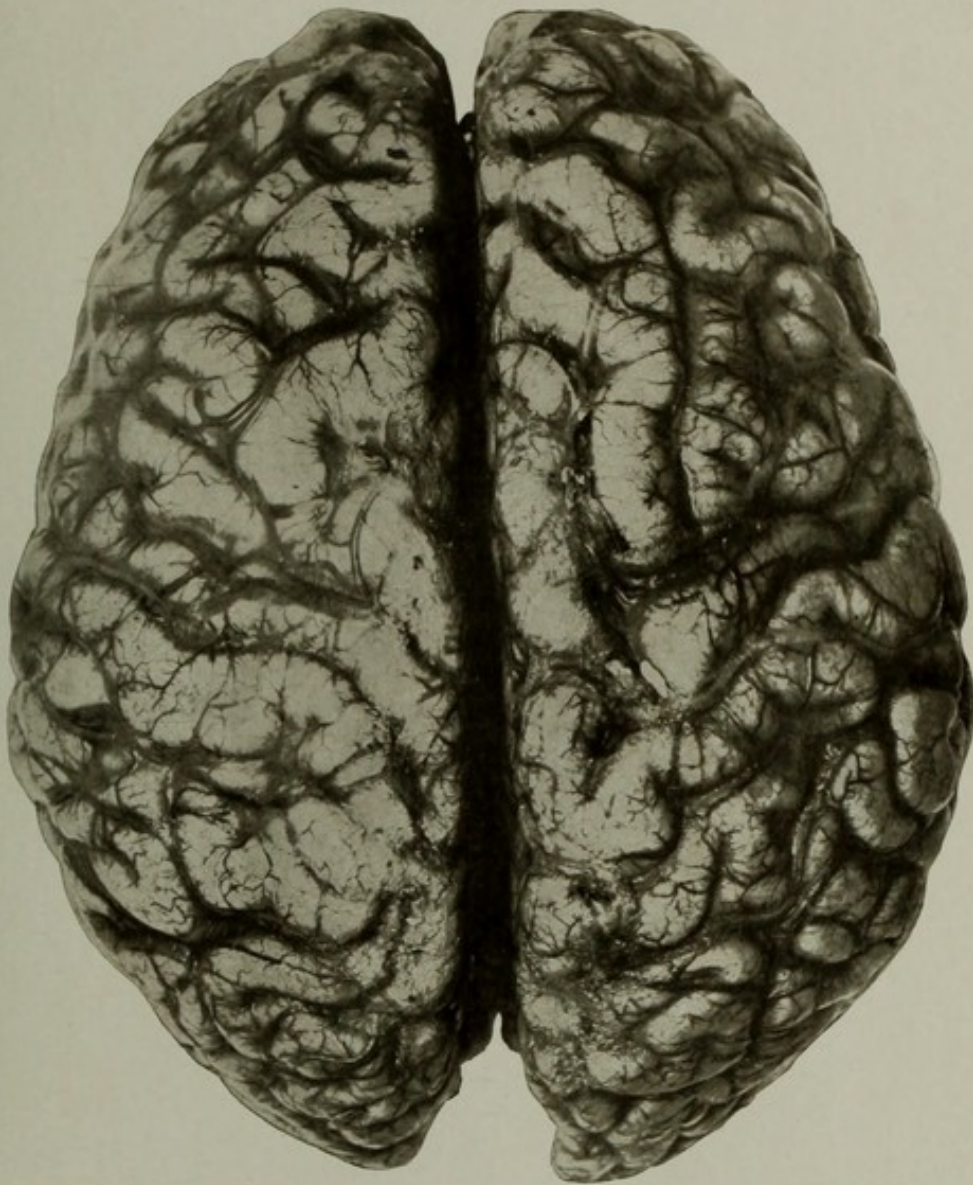
SUPERIOR SURFACE OF THE BRAIN, SHOWING ENGORGEMENT OF THE PIAL VEINS.

Case 15040. M. T.; aged 21; female; colored; nativity, District of Columbia. Mental disease, dementia præcox; duration, nine months. The patient had several maniacal attacks simulating manic-depressive insanity.

Brain: Weight, 1,340 grams—above the average for adult females, which is 1,247 grams. There was, however, slight atrophy of the convexity, probably due to the general wasting of the body. With the exception of this slight shrinkage and overfullness of the veins the brain was absolutely normal in appearance, and the picture is introduced to contrast with the cases of meningeal disease, extreme atrophy, and disease of the vessels.

The lungs showed gangrenous areas, cavities, and pneumonic consolidation.

Other organs showed nothing abnormal to unaided eye.



SUPERIOR SURFACE OF THE BRAIN, SHOWING ENGORGEMENT OF THE  
PIAL VEINS.



---

---

PLATE LX.

---

---

## PLATE LX.

AUTOPSY NOS. 2183 AND 2240.

VIEW OF THE BRAIN IN A CASE OF MENINGO-ENCEPHALITIS OF CHILDHOOD, WITH ARREST OF DEVELOPMENT OF THE BRAIN. PHOTOGRAPHED WITH A BRAIN OF NORMAL SIZE AND WEIGHT.

Case 15217. M. C. H.; aged 16; female; white; nativity, United States. Mental disease, imbecility (?). The duration was uncertain. Patient had convulsions; was blind; unable to talk; had marked contractures of upper and lower extremities.

Skull moderately thick; nearly elliptical in shape; tables were thin and hard; diploe abundant. Frontal sinuses enlarged; greatest thickness of frontal bone about  $1\frac{1}{2}$  centimeters. Sagittal suture partly obliterated. Dura not adherent to bone and otherwise normal. Cerebro-spinal fluid increased.

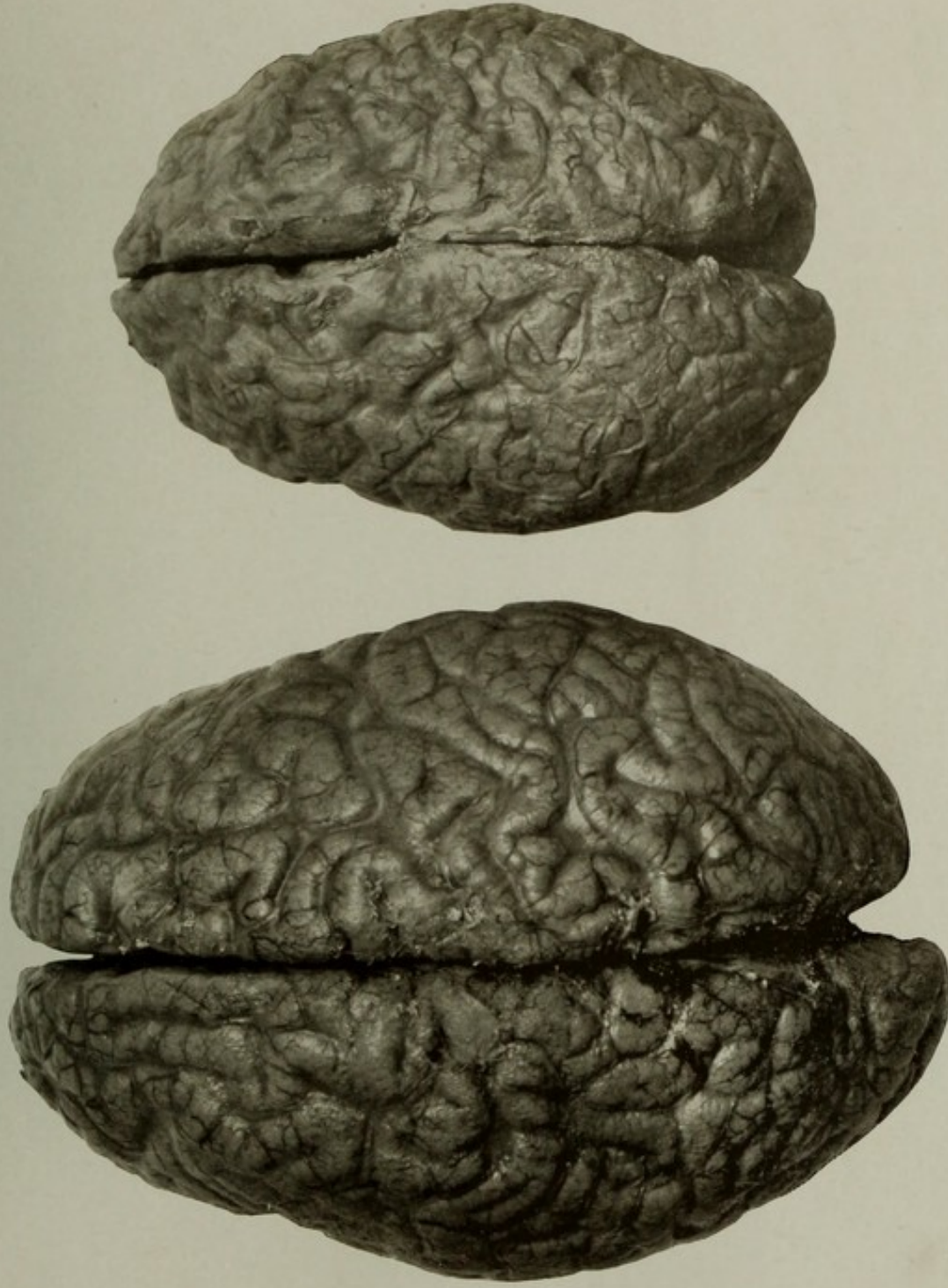
Brain: Weight, 720 grams; the right hemisphere somewhat smaller than the left. The organ was everywhere greatly shrunken, the insulæ partly exposed. Pia opaque and thick, with whitish lines along the veins. Vessels moderately full of blood; arteries normal. The pia arachnoid was thick around the isthmus encephali. The basal parts of the brain were much atrophied; no loss of substance from gross lesions. No special conditions present in the optic centers, tracts, nor optic nerves, except possibly some rigidity of the free portions. The cerebellum was doubtless somewhat smaller than normal, but it was relatively large compared with the cerebrum. Over the superior and posterior parts the pia was thick, opaque, and œdematous. The conclusion reached was that the patient had an attack of meningo-encephalitis in childhood which permanently impaired the development of the brain.

Superior surface of the brain, showing the pial opacity and thickening and the cerebral atrophy. The brain of No. 2183 is photographed with one from a case of dementia præcox (No. 2240), of about the normal size and weight, 1,480 grams, and showing no evidence of disease to the naked eye.

An additional illustration of this case is given on Plate LXI.

GROSS MORBID ANATOMY OF THE BRAIN IN THE INSANE.

PLATE LX.



VIEW OF THE BRAIN IN A CASE OF MENINGO-ENCEPHALITIS OF CHILDHOOD, WITH ARREST OF DEVELOPMENT OF THE BRAIN, PHOTOGRAPHED WITH A BRAIN OF NORMAL SIZE AND WEIGHT.



---

---

PLATE LXI.

---

---

PLATE LXI.

AUTOPSY No. 2183A.

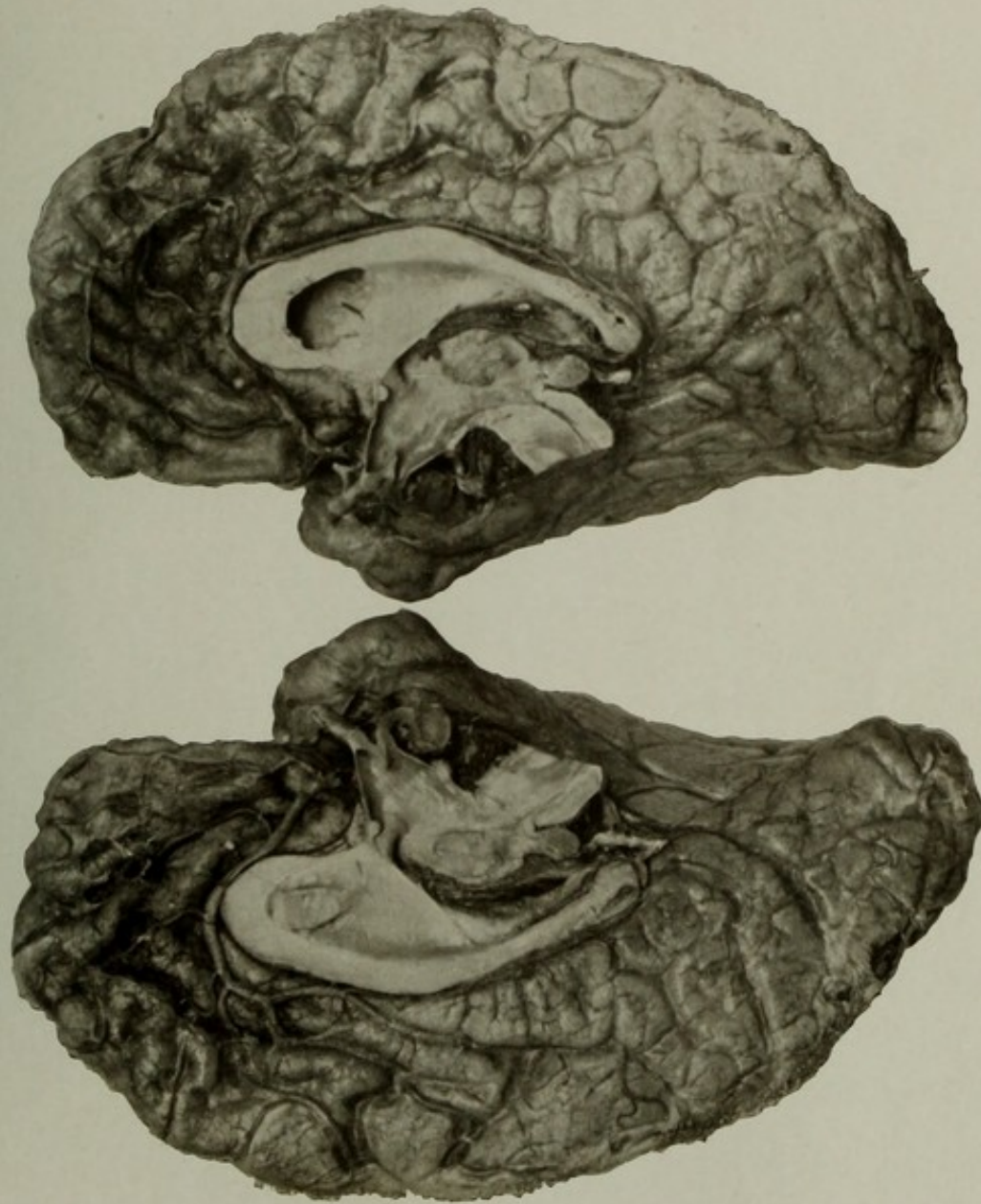
VIEWS OF THE BRAIN IN A CASE OF MENINGO-ENCEPHALITIS OF CHILDHOOD, WITH ARREST OF  
DEVELOPMENT OF THE BRAIN.

Case 15217. Views of the hemispheres of this brain divided in the median line to show  
the atrophy of the mesial surfaces.

A general discussion of this case is given on page 124.

GROSS MORBID ANATOMY OF THE BRAIN IN THE INSANE.

PLATE LXI.



VIEWS OF THE BRAIN IN A CASE OF MENINGO-ENCEPHALITIS OF CHILDHOOD, WITH ARREST OF DEVELOPMENT OF THE BRAIN.



---

---

PLATE LXII.

---

---

(127)

## PLATE LXII.

AUTOPSY No. 1946.

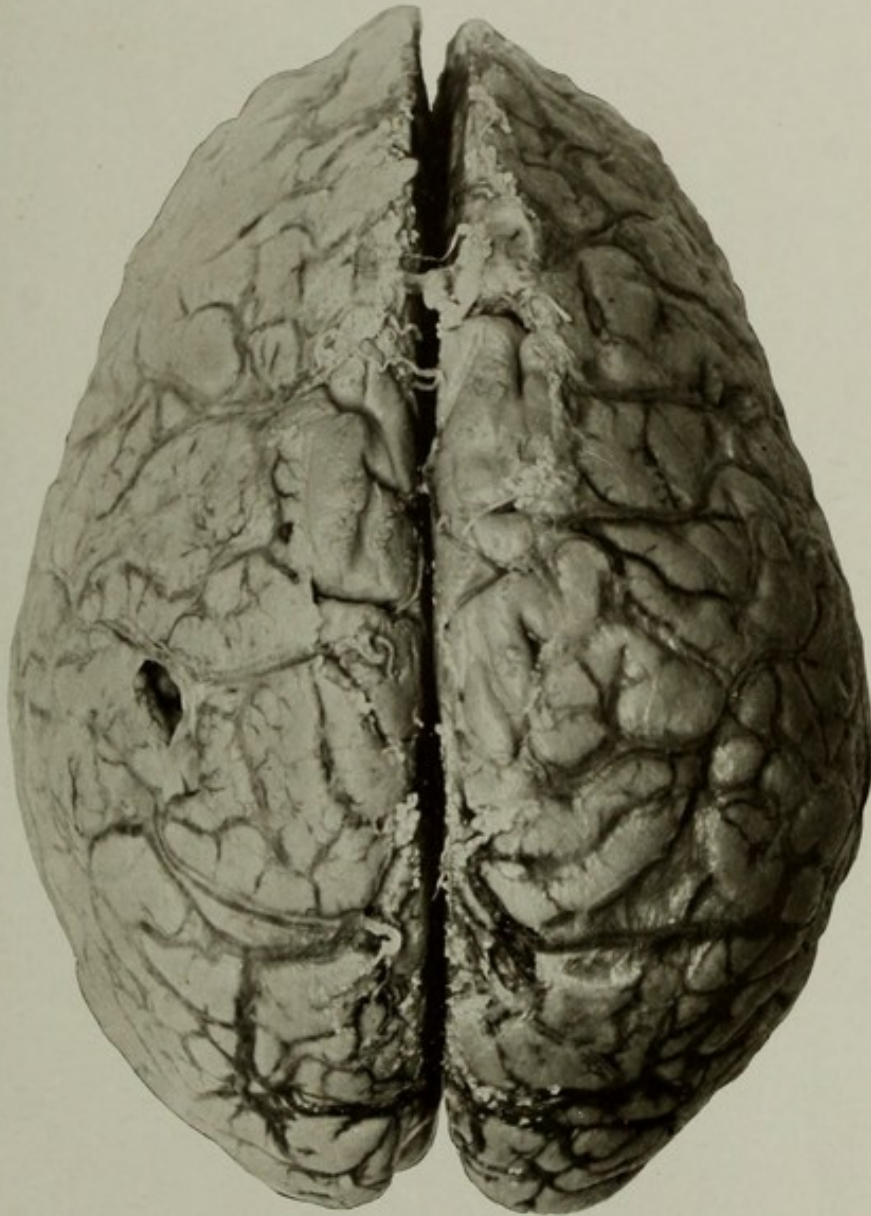
### THE SUPERIOR SURFACE OF A BRAIN COMPRESSED BY ACCUMULATION OF SUBDURAL FLUID.

Case 15022. L. A.; aged 56; female; colored; nativity, United States. Mental disease, organic dementia. Patient had choreiform movements of the extremities.

Skull fairly thick and dense; sutures partly obliterated. On opening the subdural cavity 210 cubic centimeters of clear fluid escaped, and it was seen that the brain was greatly compressed, especially anteriorly. There was but little evidence of gaping of the sulci, and the convolutions were actually flattened on the surface and pressed against the falx. The brain weighed only 800 grams. The arachno-pia showed marked opacity over the convexity and in the vicinity of the chiasma and interpeduncular space. The pituitary body was about four times its normal size. The veins over the convexity were quite distinct, and some were bordered by whitish lines. The arteries showed no abnormal conditions. Careful examination of the dura failed to reveal any pathological condition except adhesions to the bone, slight thickening, and rather large Pacchionian granulations.

The cause which led to the subdural effusion must therefore be undecided.

Other organs presented nothing important.



THE SUPERIOR SURFACE OF A BRAIN COMPRESSED BY ACCUMULATION  
OF SUBDURAL FLUID.



---

---

PLATE LXIII.

---

---

PLATE LXIII.

AUTOPSY No. 2006.

THE SUPERIOR ASPECT OF A BRAIN SHOWING COMPRESSION OF THE LEFT HEMISPHERE BY A  
HÆMATOMA OF THE DURA.

Case 10287. J. G.; aged 69; white; soldier; nativity, Switzerland. Mental disease on admission, acute dementia, from organic disease of brain. Patient lived about eight years after admission; had convulsions; became more demented, and finally the right side became paralyzed, and toward the end he was stuporous and died in coma.

Brain and dura: On the left side a bulky hæmatoma, about an inch in thickness, occupied the dura over the convexity and greatly compressed the hemisphere. The tumor consisted of at least two well-defined layers, between which the recent hemorrhage which had caused the paralysis had occurred. No membrane could be demonstrated on the falx nor the right side.

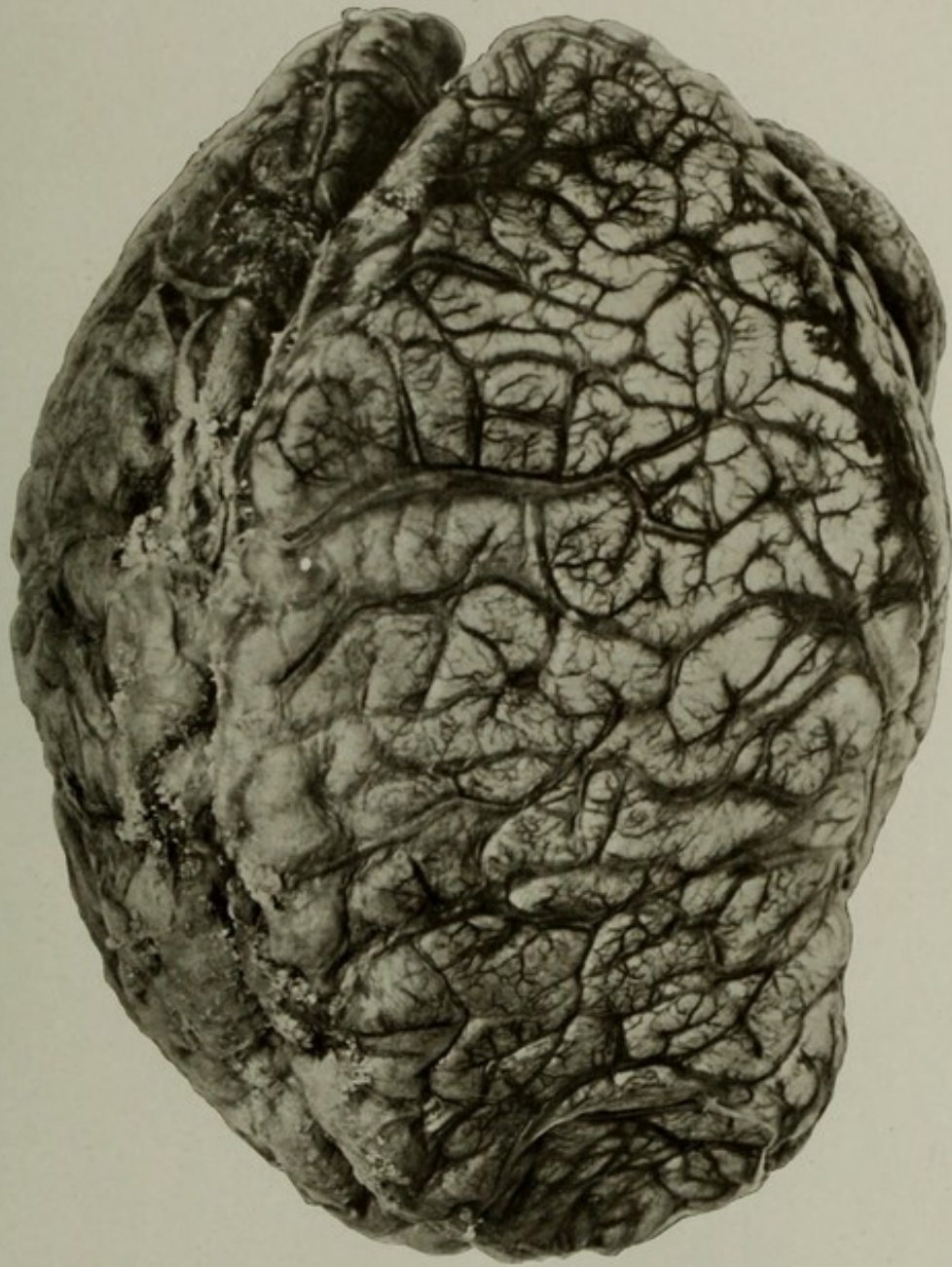The brain showed marked compression, especially over the anterior portions of the convexity. The veins were engorged even where pressure was greatest. Some opacity and thickening of the pia arachnoid over the superior portions of the convexity, and the convolutions showed some shrinkage. Some patches of arteriosclerosis in the basal vessels.

Some chronic disease of the cardiac valves, especially the aortic segments.

In the picture an attempt was made to show the distortion of the left hemisphere by the pressure of the hæmatoma. The flattening of the convexity is fairly well shown, especially the deep depression of the extreme frontal end of the hemisphere. A feature to be noticed is the engorgement of the cerebral veins, notwithstanding the great degree of pressure. This fullness of the veins must be mechanical, though the mode of production is not clear.

GROSS MORBID ANATOMY OF THE BRAIN IN THE INSANE.

PLATE LXIII.



THE SUPERIOR ASPECT OF A BRAIN SHOWING COMPRESSION OF THE LEFT HEMISPHERE BY A  
HÆMATOMA OF THE DURA.



---

---

PLATE LXIV.

---

---

PLATE LXIV.

AUTOPSY No. 229.

THE RIGHT HEMISPHERE OF A CASE OF ATROPHIC SCLEROSIS IN EPILEPSY.

Case 6860. J. H.; aged 45; male; farmer; nativity, United States. Mental disease, chronic epileptic dementia; duration, three and one-half years.

Synopsis of autopsy: Skull dense; dura adherent over inner table. Some local thickening of the bone at the two sides of the frontal bone and the upper and anterior part of the parietal bones.

Brain: Weight, 1,141 grams. The pia mater was opaque and thickened over the superior portions of the brain; veins engorged. Great shrinkage of the convolutions over the greater part of the convexity except the Sylvian regions and the anterior portions of the temporal lobes. On the mesial surfaces the shrinkage was not marked, and the basal surface showed none of the characteristic shrinkage and puckering. The cerebral arteries showed some patches of opacity in the larger trunks.

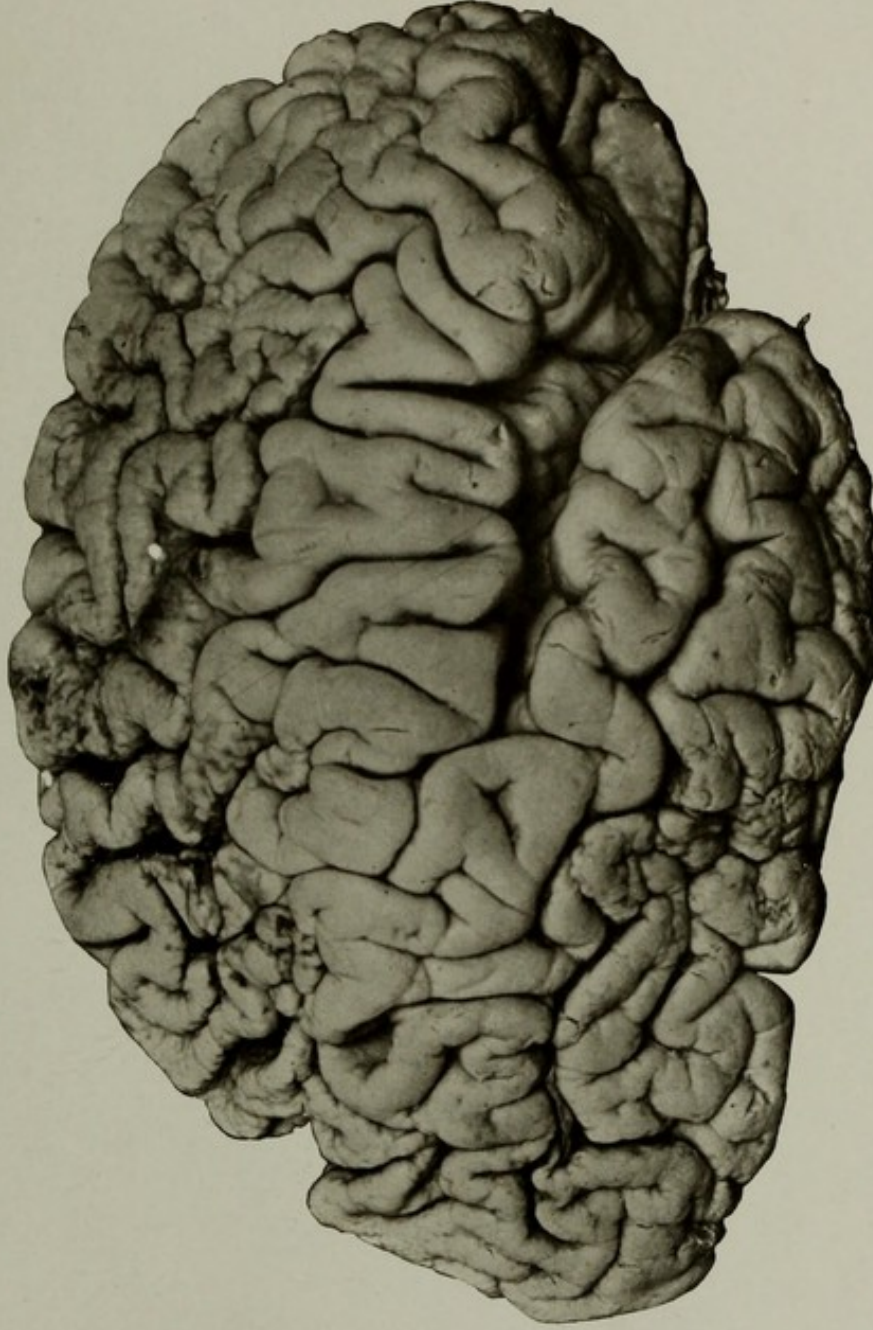
The condition of the most affected region is hard to describe. Morphologically the surface suggested that of the surface of the liver in cirrhosis. There was marked puckering of the surface, some brownish staining of the pits or depressions, and a general shrinkage of the affected gyri. The microscope showed multiple small softened areas, with some accompanying sclerosis.

Heart. Weight, 436 grams. Some thickening of left valves and mitral incompetence.

Kidneys showed advanced chronic interstitial nephritis.

GROSS MORBID ANATOMY OF THE BRAIN IN THE INSANE.

PLATE LXIV.



THE RIGHT HEMISPHERE OF A CASE OF ATROPHIC SCLEROSIS IN EPILEPSY.



---

---

PLATE LXV.

---

---

PLATE LXV.

AUTOPSY No. 1951.

THE SUPERIOR SURFACE OF A BRAIN WITH LOCALIZED SCLEROSIS OF LEFT FRONTAL LOBE.

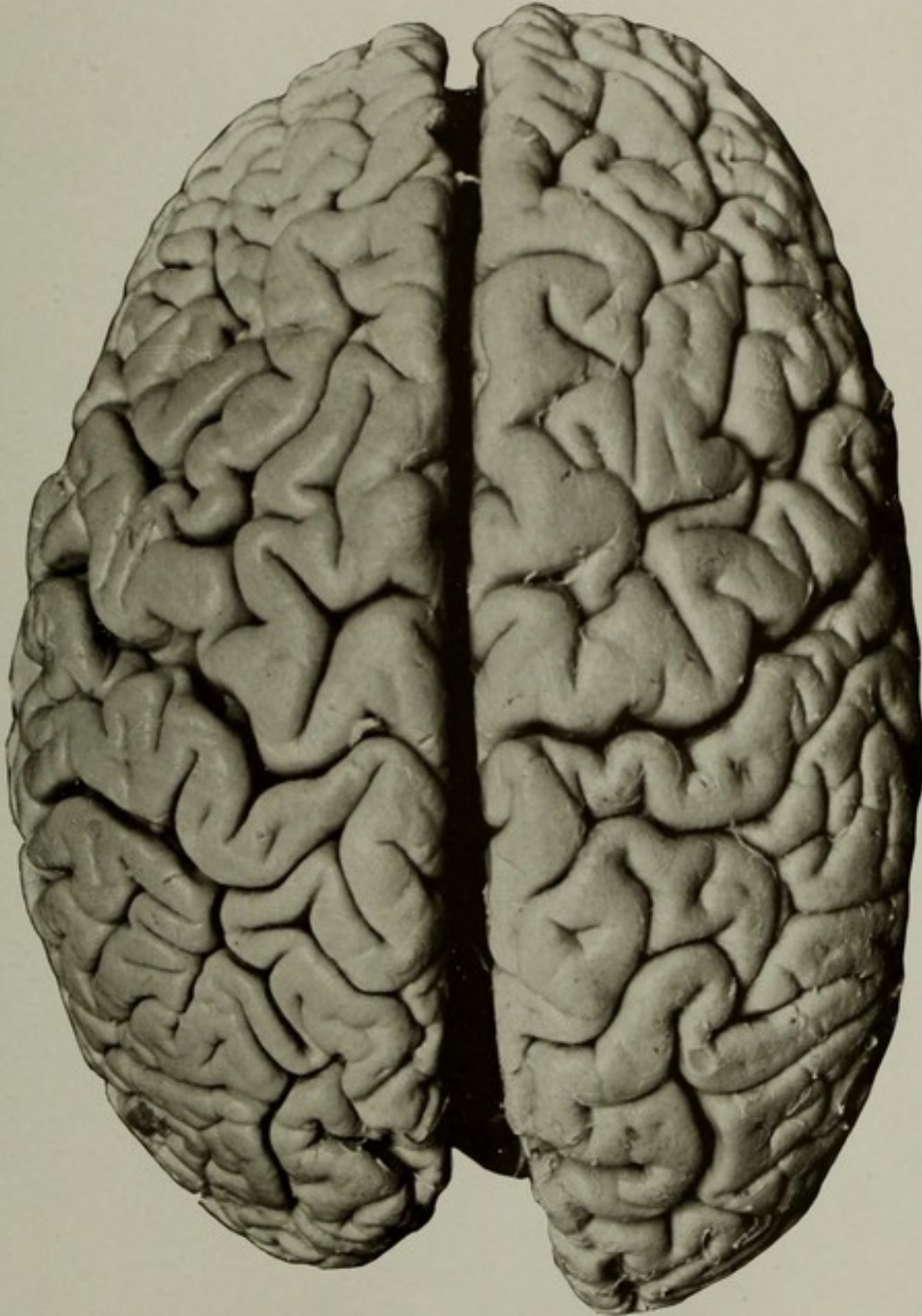
Case 4547. F. L.; aged 46; female; colored; nativity, United States. Mental disease, chronic epileptic dementia. The history shows progressive dementia; extreme contractures of legs; epileptic attacks infrequent; bedsores finally developed.

Cranium: The skull thick in frontal regions and rough and irregular on the inner surface; frontal sinuses enlarged and filled with greenish pus. Some small masses of bone in the dura.

Brain: Weight, 1,110 grams. Vessels at the base not diseased; pia nonadherent; brain moderately shrunken generally, and a region in the middle of the convex surface of the frontal lobe was markedly indurated and slightly puckered, but there were no adhesions of the pia to the cortex.

The picture shows decided disproportion between the two hemispheres, and on the outer surface of the left frontal lobe the regions of sclerosis may be seen. On the right side the hemisphere is fairly normal in appearance.

The other organs showed nothing of special importance except some catarrh of the urinary bladder.



THE SUPERIOR SURFACE OF A BRAIN WITH LOCALIZED SCLEROSIS OF  
LEFT FRONTAL LOBE.



---

---

PLATE LXVI.

---

---

(135)

## PLATE LXVI.

AUTOPSY No. 897.

### A CASE OF SCLEROSIS OF A PORTION OF THE RIGHT HEMISPHERE IN EPILEPSY.

Case 8670. H. M. B.; aged 47; male; white; soldier; nativity, Indiana. Mental disease, chronic epileptic dementia; duration, thirty years. The history in this case is meager, and aside from the fact of typical epilepsy of long duration, but with sufficient intelligence to serve as a soldier in the civil war, and no noticeable physical impairment, we have nothing definite. Death due to organic brain disease.

Skull of fairly normal shape and size, but dense and the sutures indistinct in inner table. Dura slightly adherent to bone.

Brain: Weight of right hemisphere, 517.4 grams; left, 545.6 grams; cerebellum, pons, and medulla, 184 grams. Arteries at base small, but otherwise normal; brain pale; slight general shrinkage. On the right side a large puckered and nodular depression existed in the supra-Sylvian region. The lesion involved the bases of the middle and inferior frontal gyri, the lower two-thirds of the central gyri, the whole of the supramarginal gyrus, a portion of the inferior parietal lobule, and extended on to the insula. There was some overhanging of the surrounding brain, showing that the lesion was of long standing, probably developmental. The pia mater was not adherent over the lesion, though mechanically hard to remove from the deeper portions of the affected sulci. The vessels of this region showed nothing to which the alteration could be traced. On the left side were several small cortical softenings not easily explained. No lesions in capsules nor basal ganglia. There seemed to be slight atrophy of crus and pons on the right side. Spinal cord normal to naked eye.

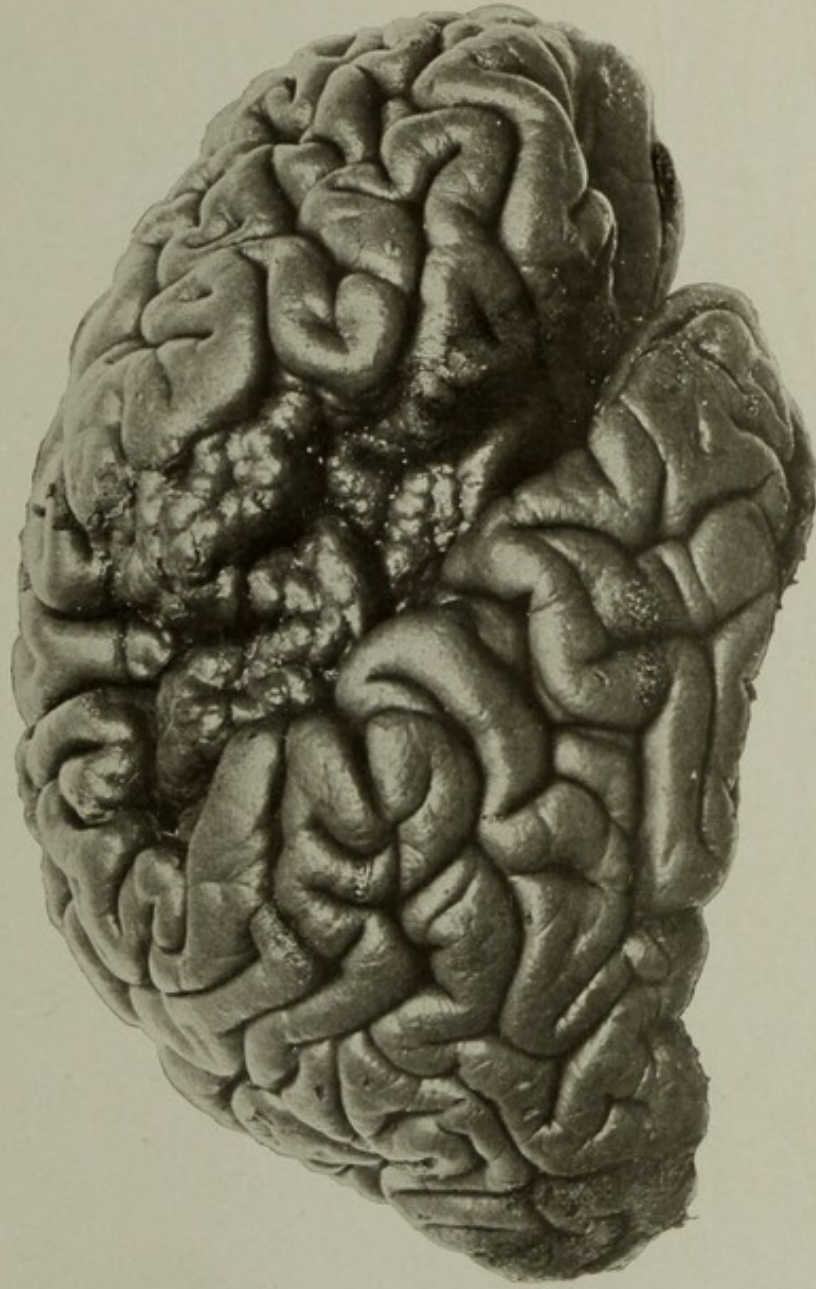
Heart: Slight hypertrophy and valvular disease, with incompetency.

Other organs were practically normal.

NOTE.—This specimen, occurring in an epileptic, was almost identical macroscopically and microscopically with that of No. 2283, Plate LXVII. The patients were nearly the same age, and in each the disease was of long duration. It is probable that in both cases the sclerosis was of a developmental type and the anatomical basis of the epilepsy.

GROSS MORBID ANATOMY OF THE BRAIN IN THE INSANE.

PLATE LXVI.



A CASE OF SCLEROSIS OF A PORTION OF THE RIGHT HEMISPHERE IN EPILEPSY.



---

---

PLATE LXVII.

---

---

(137)

PLATE LXVII.

AUTOPSY No. 2283.

SCLEROSIS OF A PORTION OF THE RIGHT HEMISPHERE IN EPILEPSY.

Case 10008. F. B.; aged 45; male; colored; nativity, Maryland. Mental disease, chronic epileptic insanity; duration of disease, since admission, ten years. The patient had frequent and severe convulsions, followed by excitement, during which he was combative and threatening. The patient's mother stated that he had no convulsions before he was 23 years old. Death due to injury to head during an epileptic seizure.

Brain: Weight, 1,355 grams. Some subpial hemorrhage, with laceration of the brain cortex over the right temporal lobe and a small softening, with loss of substance, on the outer surface of the right temporal pole. In the region of the right Sylvian fissure was a large depression, over which the cortex presented a nodular puckered appearance. On removal of the pia, which was not unusually adherent to the lesion, the condition was found to involve the posterior half of the superior temporal gyrus, the whole of the supramarginal gyrus, and extended forward into the base of the third frontal gyrus and upward into the lower ends of the central gyri, especially the postcentral gyrus. It also extended into the inferior parietal lobule and encroached to a slight extent upon the insula. Around the edge of the lesion the normal brain substance overhung the affected area. The arteries of the Sylvian region presented nothing abnormal in development and the vessels were not diseased. There were some minor anomalies of the arteries at the base and slight sclerosis of the intracranial portions of the carotids.

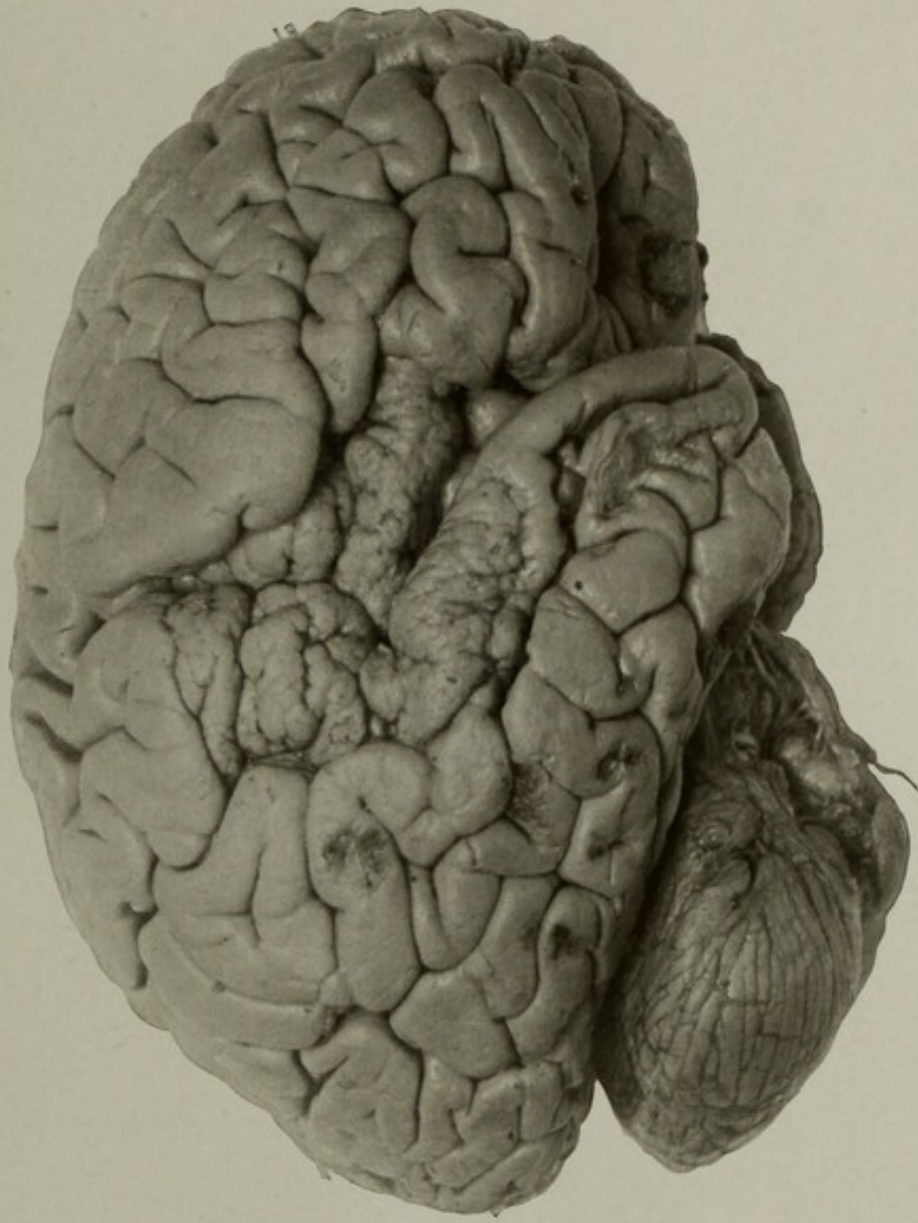
The cranium showed an irregular fracture extending from the petrous portion of the temporal bone to near the apex of the lambdoid suture, produced by a fall during a convulsion.

With the exception of intense passive hyperæmia the other organs were practically normal.

The lesion found is not infrequently met with in epileptics. It belongs to the class known as the scleroses and may affect almost any part of the brain. It would seem that these lesions are in some instances developmental defects. The microscope shows almost complete absence of nerve cells in the depressed regions and an irregular arrangement of these elements in the projecting nodules or granulations. (See Nos. 229, 897, and 1951, Plates LXIV, LXVI, and LXV.)

GROSS MORBID ANATOMY OF THE BRAIN IN THE INSANE.

PLATE LXVII.



SCLEROSIS OF A PORTION OF THE RIGHT HEMISPHERE IN EPILEPSY.



---

---

PLATE LXVIII.

---

---

PLATE LXVIII.

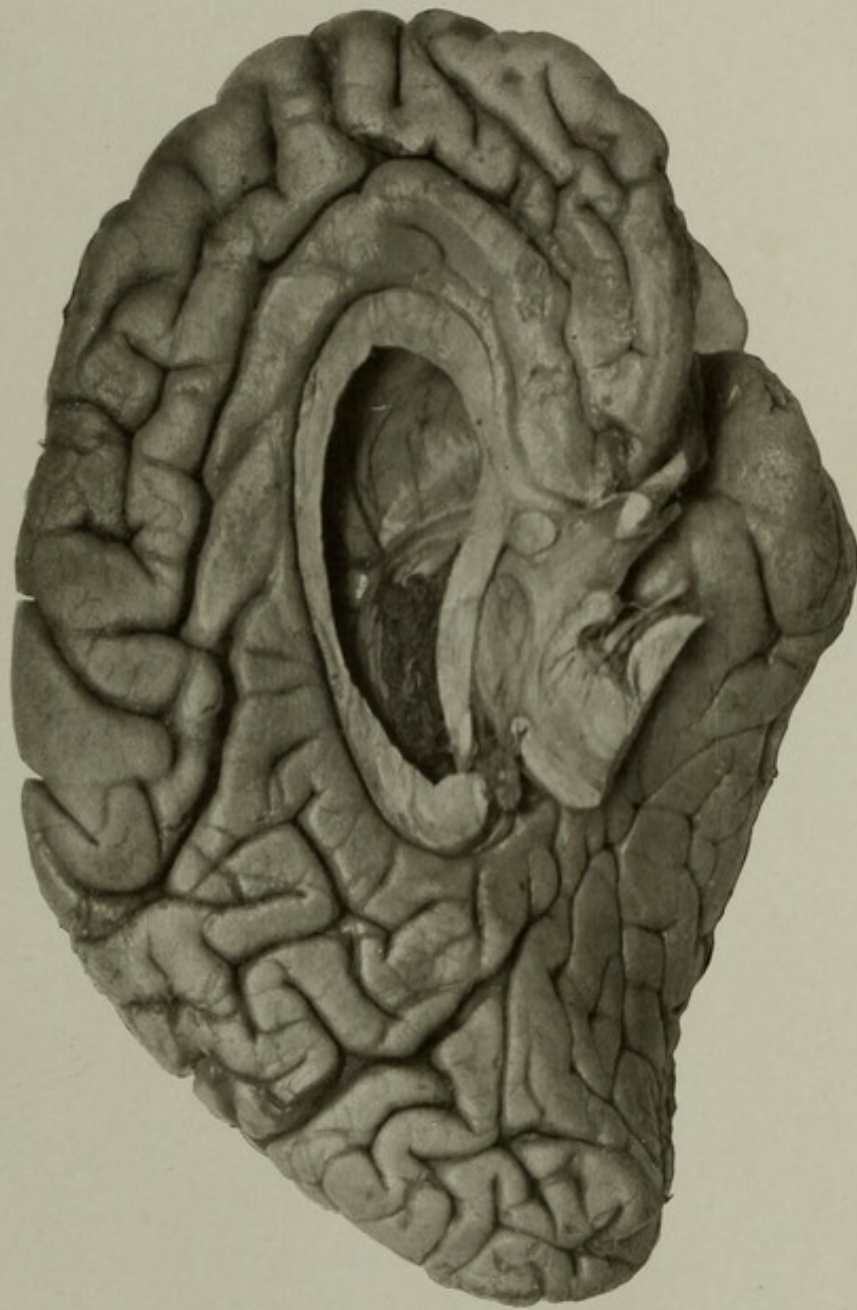
AUTOPSY No. 2283A.

MESIAL VIEW OF THE LEFT HEMISPHERE, SHOWING ABSENCE OF THE SEPTUM PELLUCIDUM.

This developmental defect occurred in the same case as the sclerosis of the right hemisphere, and while it probably had no direct connection with the latter it is some indication of a defective formation of the brain. There was no trace of the septum, but the fornix itself appeared normal and the ventricles were not abnormally enlarged. The picture presents no other points of interest except an unusual calcarine fissure and an unusually prominent mesial extent of the central fissure. (See No. 1949, Plate LXIX.)

GROSS MORBID ANATOMY OF THE BRAIN IN THE INSANE.

PLATE LXVIII.



MESIAL VIEW OF THE LEFT HEMISPHERE, SHOWING ABSENCE OF THE SEPTUM PELLUCIDUM.



---

---

PLATE LXIX.

---

---

## PLATE LXIX.

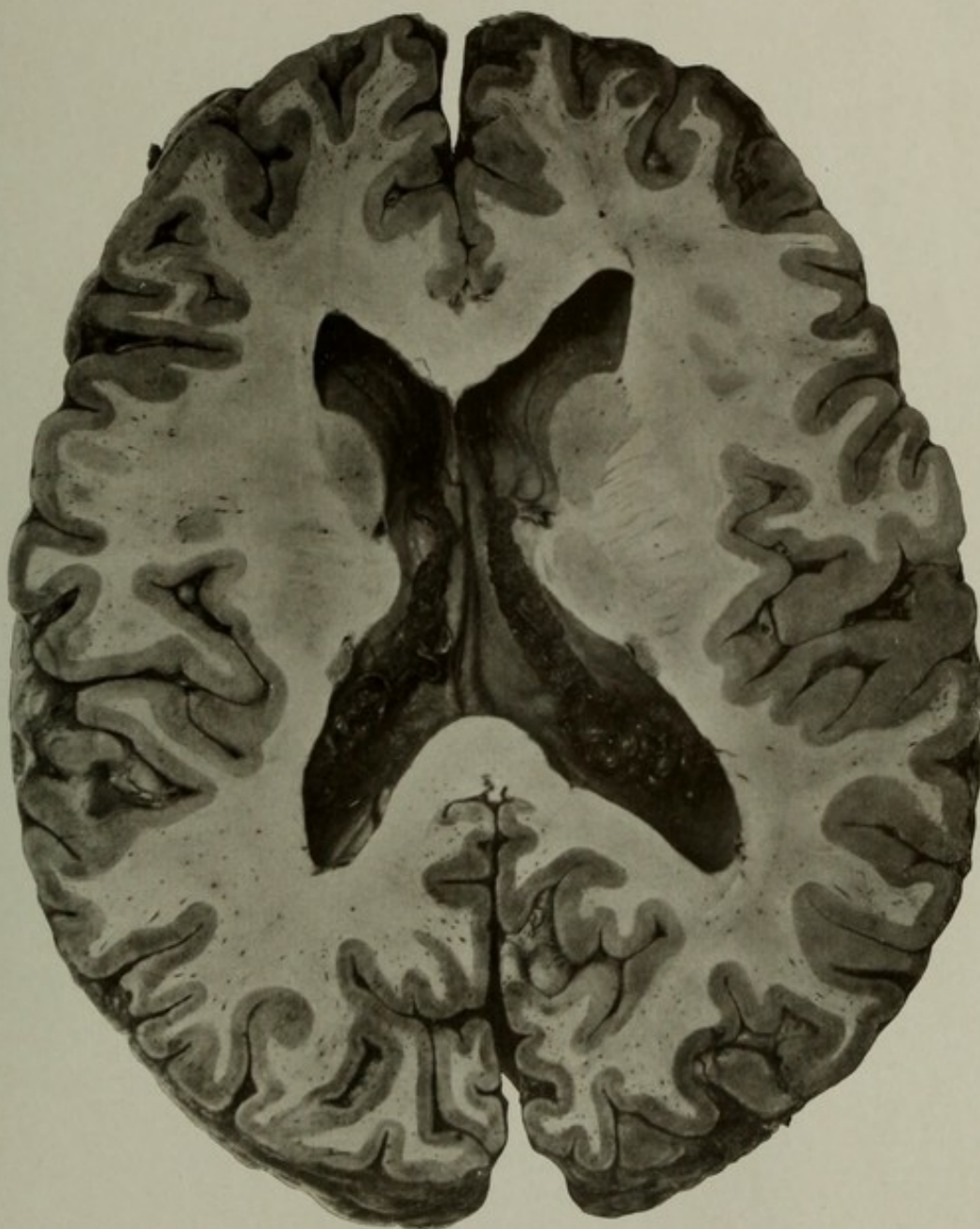
AUTOPSY No. 1949.

### HORIZONTAL SECTION OF A BRAIN WITHOUT A SEPTUM PELLUCIDUM.

Case 5191. C. S.; aged 54; male; white; convict; nativity, New York. Mental disease, chronic mania.

The brain weighed 1,320 grams. Some œdema of pia; slight shrinkage of convolutions of frontal lobes. Vessels not diseased. Section of brain made after hardening showed absence of septum. The condition of other organs unimportant in this connection.

The photograph shows the lower portion of the cerebrum divided horizontally. The upper part showed the under side of the callosum with two antero-posterior ribs, indicating the remains of the septum, and two small filaments, scarcely visible, which connected these with the corpus fornicis. The lower portion gives a view of the fornix without the vertical connection with the callosum. The tæniæ fornicis, plexuses, and two thick bundles anterior to the foramen inter-ventricular show the remains of this system, and a sharp ridge which curves upward and appears as a spine on the anterior portion of the callosum represents the trace of the septum. Grapelike cysts of the plexuses are indistinctly seen in the posterior horns of the ventricles.



HORIZONTAL SECTION OF A BRAIN WITHOUT A SEPTUM PELLUCIDUM.



---

---

PLATE LXX.

---

---

(143)

PLATE LXX.

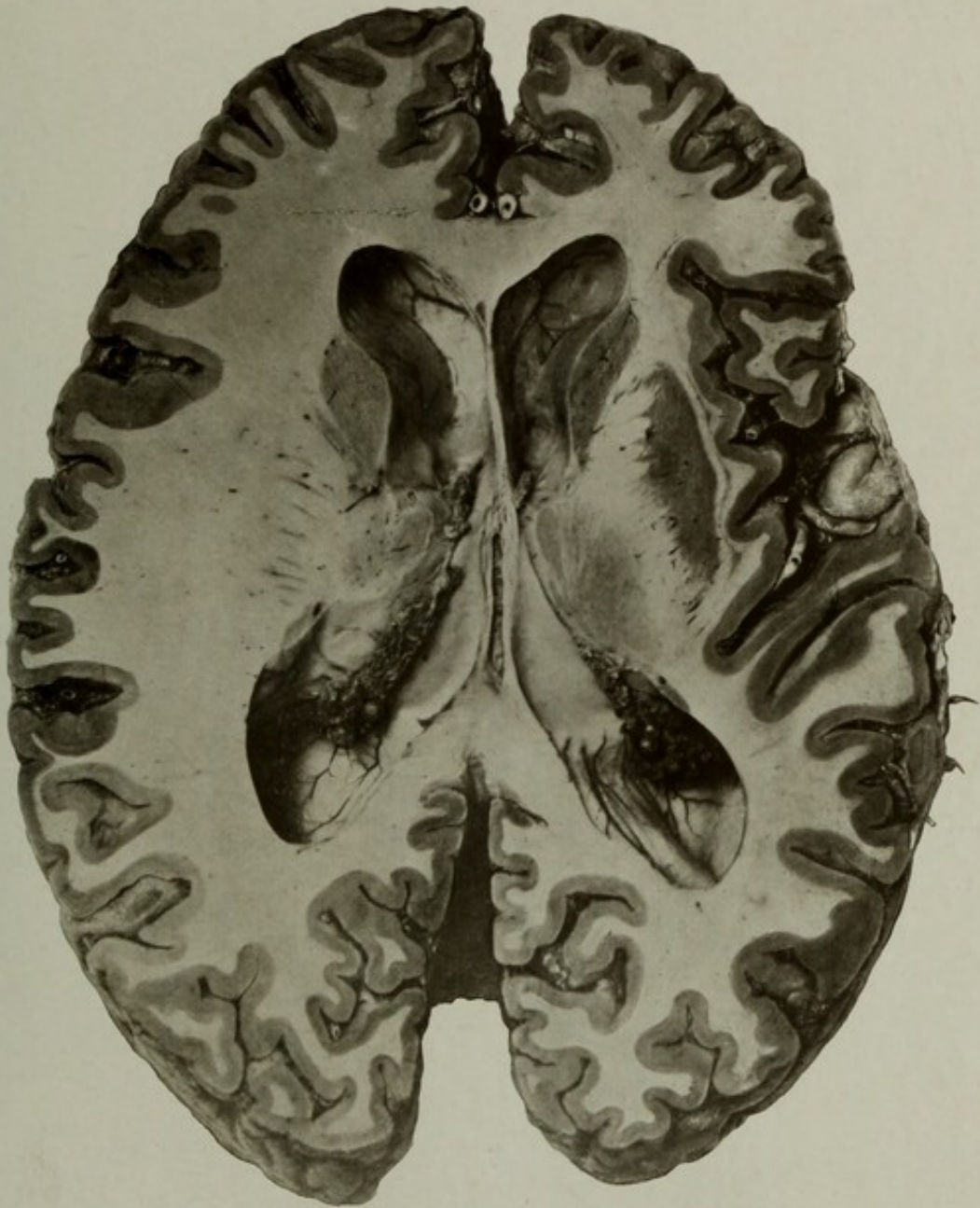
AUTOPSY No. 1964.

HORIZONTAL SECTION OF A BRAIN MADE ON A LEVEL OF THE JUNCTION OF THE FORNIX WITH  
THE CALLOSUM.

Case 3855. P. F.; aged 57; male; white; nativity, Ireland. Mental disease, manic-depressive insanity; duration, two months.

The brain weighed 1,310 grams. There appeared to be scarcely distinguishable atrophy of the convolutions and some arteriosclerosis of the cerebral vessels; otherwise the brain showed no gross lesions. Heart enlarged; weight, 490 grams. Incompetency of auriculo-ventricular valves; ante-mortem clot in right ventricle.

The picture shows a section made on about the same level as No. 1949, Plate LXIX, and with this specimen it may be compared. It presents no pathological alterations of importance and is mainly an anatomical study. A few small cysts of the choroid plexuses are seen near the entrance to the descending horns of the lateral ventricles.



HORIZONTAL SECTION OF A BRAIN MADE ON A LEVEL OF THE JUNCTION OF THE FORNIX WITH THE CALLOSUM.



---

---

PLATE LXXI.

---

---

PLATE LXXI.

AUTOPSY No. 1967.

HORIZONTAL SECTION OF A BRAIN FROM A CASE OF DEMENTIA PRÆCOX.

Case 14476. J. W. W.; aged 20; colored; male; nativity, District of Columbia. Mental disease, dementia præcox. Advanced pulmonary tuberculosis, and death from hemorrhage.

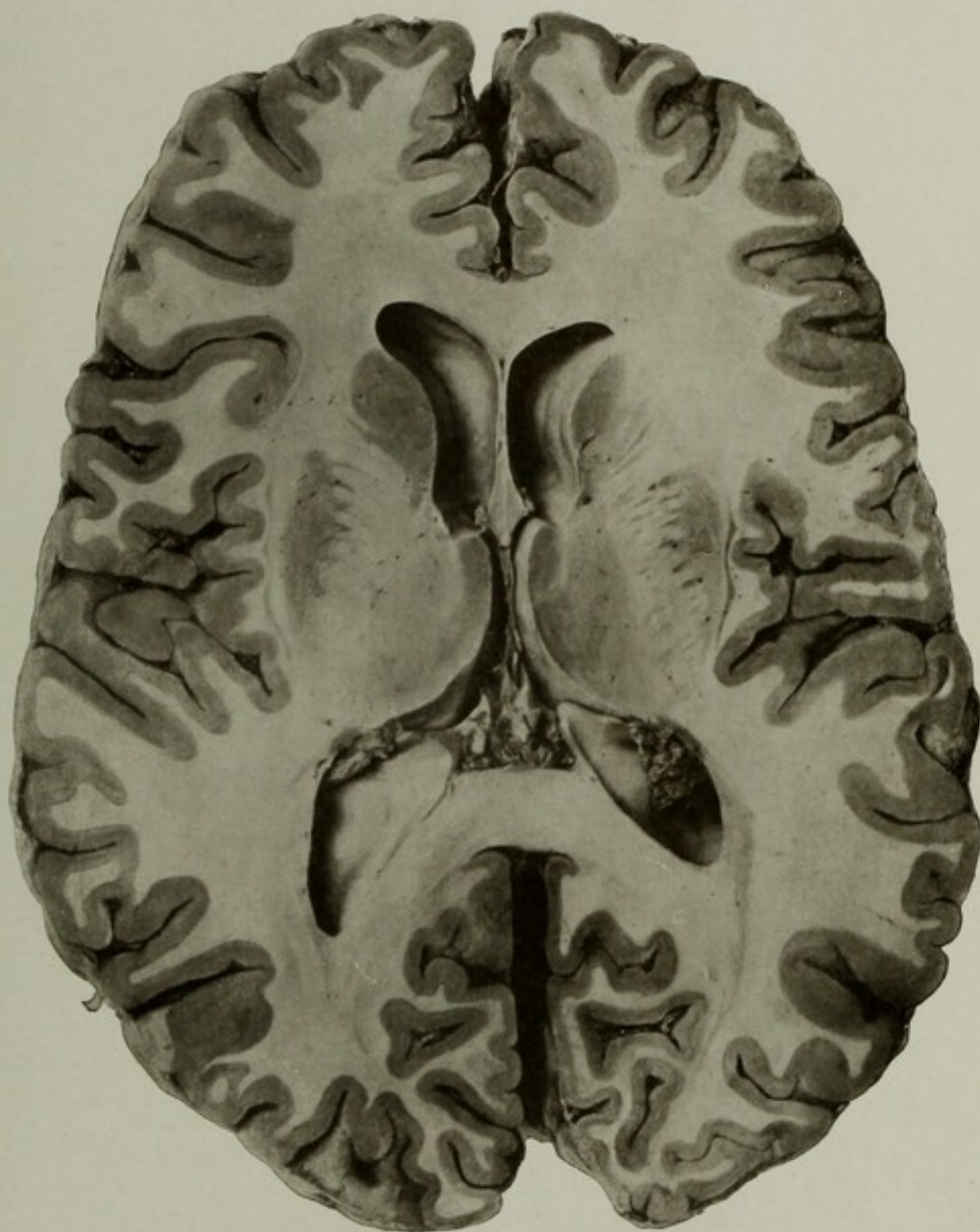
Brain: Weight, 1,400 grams. Very slight shrinkage on the surface and faint cloudiness of the pia arachnoid. Arteries normal.

The picture is chiefly of anatomical interest, no pathological alteration being apparent. It is introduced mainly to contrast with Nos. 1934, 1956, Plate XLIX, XXXVI, and others, showing abnormal conditions, and to show the normal condition of the septum pellucidum.

The lungs were in an advanced stage of destructive tuberculosis, and in the small intestine were a number of tubercular ulcers.

Kidneys showed a slight degree of parenchymatous nephritis.

Other organs presented nothing abnormal.



HORIZONTAL SECTION OF A BRAIN FROM A CASE OF DEMENTIA PRÆCOX.



---

---

PLATE LXXII.

---

---

PLATE LXXII.

AUTOPSY No. 1619.

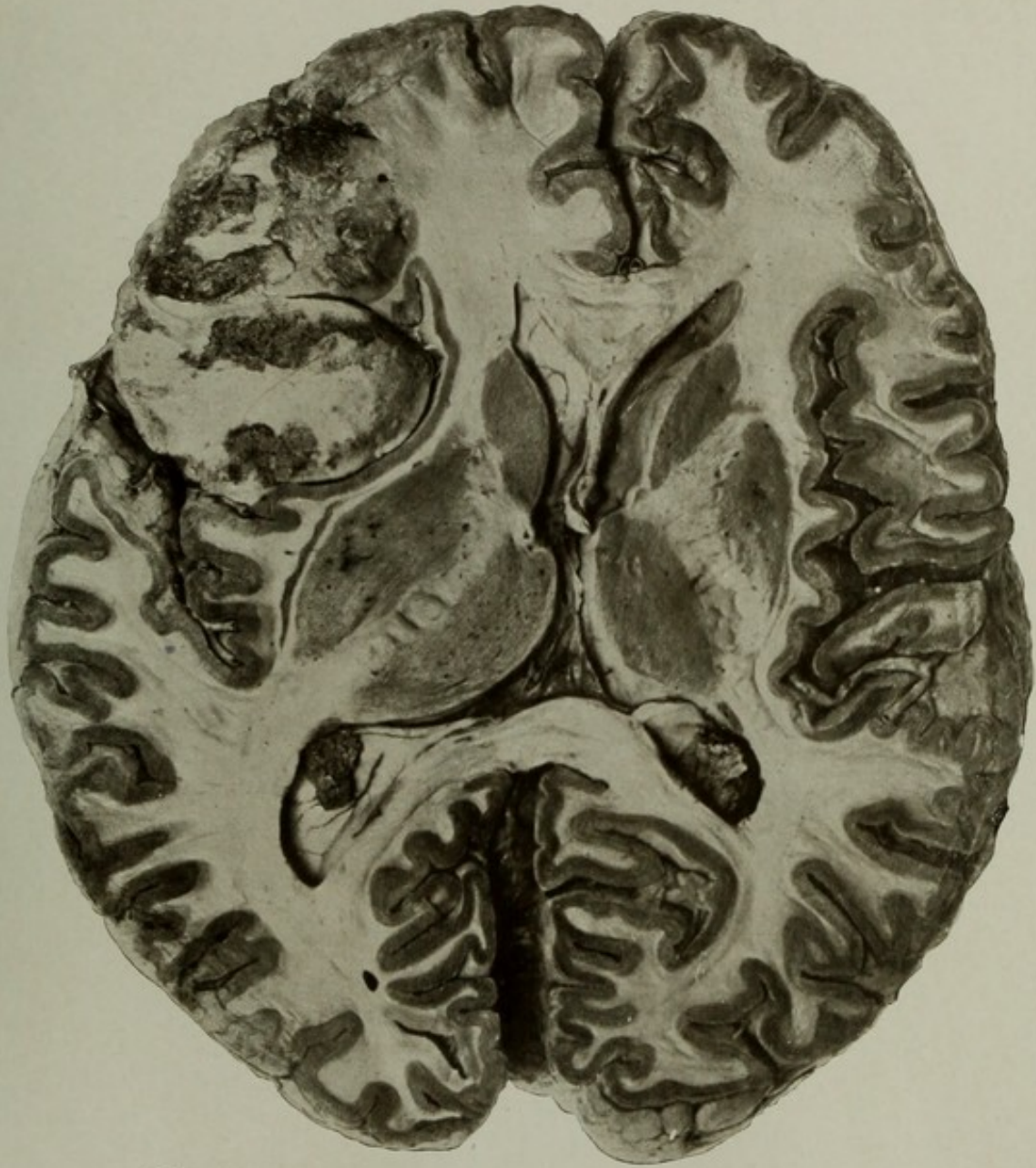SECTION OF BRAIN SHOWING GLIOMA OF LEFT FRONTAL LOBE.

Case 6328. W. L.; aged 49; soldier; white; nativity, Germany. Mental disease, dementia from tumor of brain.

Brain: Weight, 1,350 grams. Brain showed the effects of intracranial pressure, especially over the left frontal lobe. Case reported in 1902, "Intracranial Tumors Among the Insane."

The picture shows a large glioma occupying the left frontal lobe. Traces of the cortex and pia may be seen extending over the outer border of the tumor. The dark mottling is due to hemorrhage and degeneration of large areas within the tumor. The tumor has enlarged the frontal operculum and pressed backward and inward upon the insula, flattening out the anterior insular gyri, though the cortex is not destroyed. The basal ganglia are thrust inward and the septum pellucidum displaced to the right. The disproportion in size of the two frontal lobes is marked. In the left lenticular nucleus a small area of softening is seen and perivascular spaces around the central nutrient arteries are enlarged.

The arteries at the base showed patches of atheroma and were moderately dilated and curved. Brain tissue in the vicinity of the tumor markedly softened.



SECTION OF BRAIN SHOWING GLIOMA OF LEFT FRONTAL LOBE.



---

---

PLATE LXXIII.

---

---

PLATE LXXIII.

AUTOPSY No. 2113.

PLATE SHOWING A TUMOR OF THE DURA PENETRATING THE BRAIN.

Case 9119. M. T. S.; aged 45½; female; white; single; nativity, Denmark. Mental disease, paranoid form of dementia from tumor of the brain. The patient had fixed delusions of grandeur and of persecution; irritable; quarrelsome; finally she became much demented. She finally developed spastic paralysis of right arm and leg; reflexes exaggerated; right pupil responded sluggishly to light; retinae normal. She had no convulsions, no headache nor vomiting, and there was no evidence of optic neuritis.

An operation for relief of pressure upon the motor area of left side was performed. Intracranial pressure was found, but no growth presented at the seat of operation, and the wound was closed. Twenty-four days after the operation the patient died, and a tumor was found at the autopsy, just above the site of the opening in the skull.

Skull thick and dense; shape symmetrical; sutures normal. Dura was abnormally adherent around the opening in the skull and at the vertex.

Brain: Weight of the left hemiencephalon with the tumor, 760 grams; after removal of the tumor, 690 grams; weight of the tumor, 70 grams; the right hemiencephalon weighed 610 grams, being considerably less in weight than the left.

The tumor, evidently originating in the dura, had penetrated the left hemisphere, carrying the pia mater with it, just in advance of the central fissure. By its growth the central gyri were greatly displaced backward and the precentral gyrus was greatly thinned. The tumor was roughly globular and measured on an average of about 5.5 centimeters in diameter. On opening the sinus a mass of the growth was found lying within it, thereby causing obstruction to the blood current and thrombosis. The tumor was believed to be a spindle-celled endothelial sarcoma of the dura—a decision afterwards verified by the microscope.

The lungs showed broncho-pneumonia with slight pleuritis. The kidneys were moderately granular and contracted. The uterus contained a few small leiomyomata. Other organs showed nothing important.

Superior view of the same brain showing the tumor *in situ*. A small portion of the dura is adherent to the tumor, the sinus is opened, and the small mass of the tumor is seen within it. The ragged area on the border of the left convexity is the mutilated surface of the brain, which was adherent to the overlying dura and scalp.

An additional illustration of this case is given on Plate LXXIV.

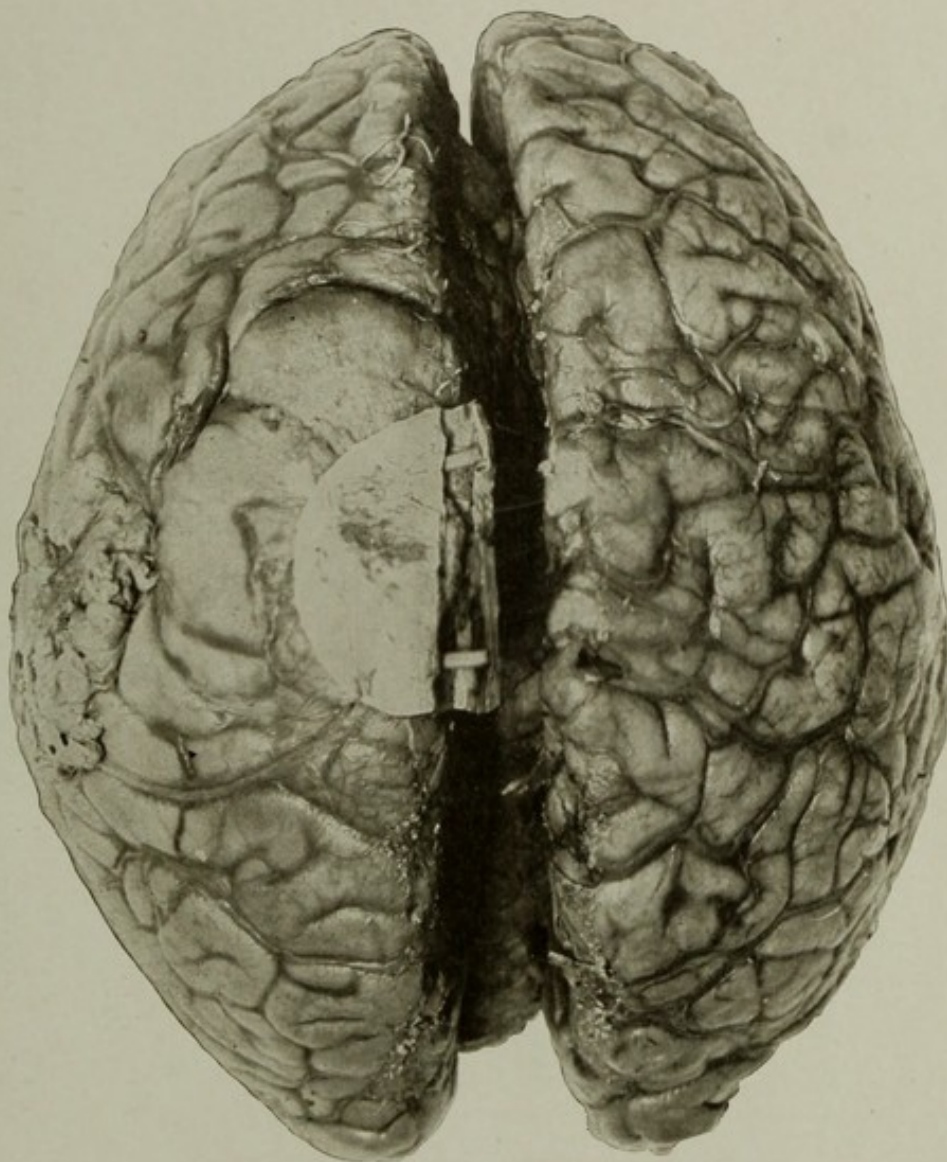


PLATE SHOWING A TUMOR OF THE DURA PENETRATING THE BRAIN.



---

---

PLATE LXXIV.

---

---

(151)

47078—08—20

PLATE LXXIV.

AUTOPSY No. 2113A.

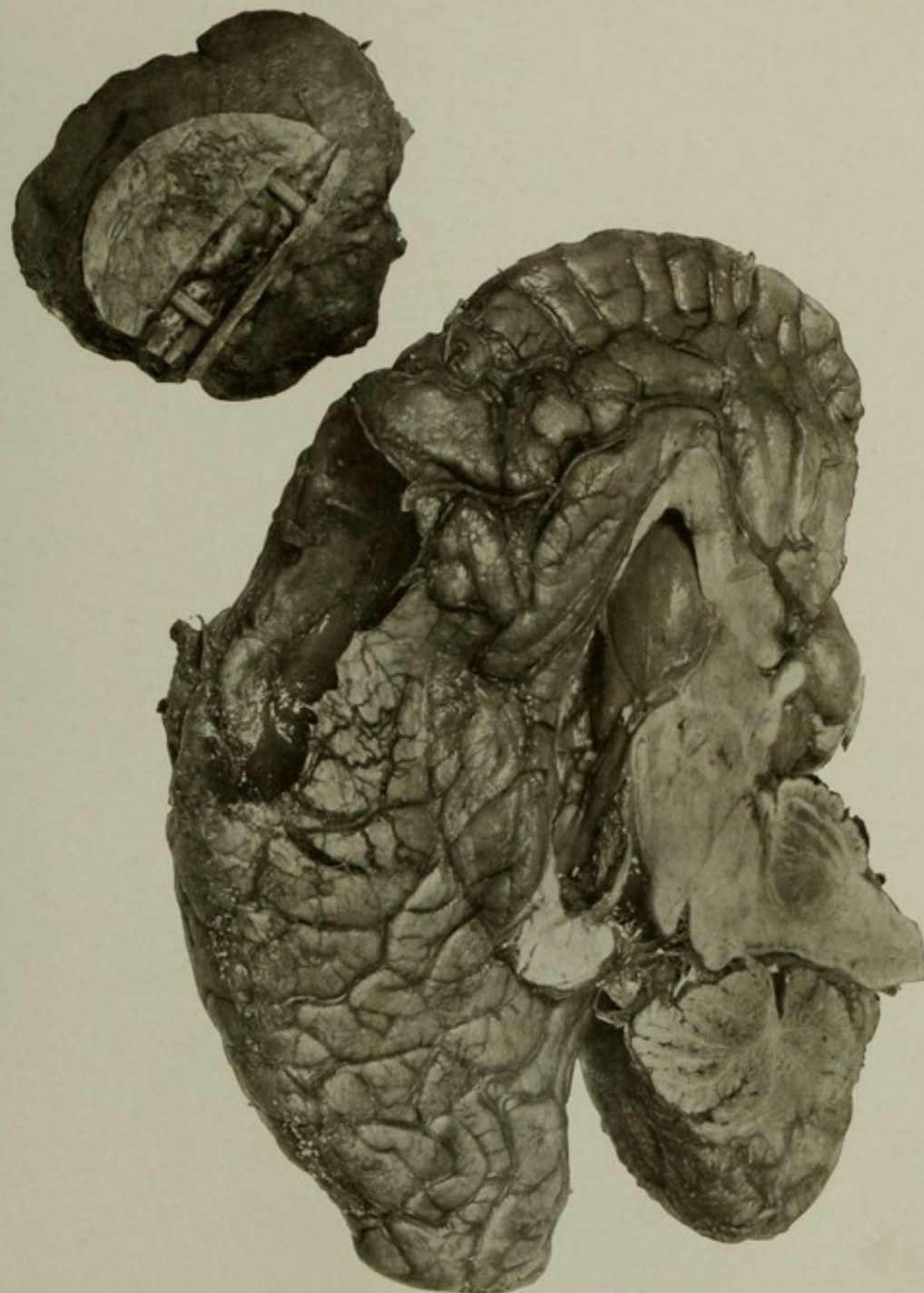
MESIAL SURFACE OF THE LEFT HEMIENEPHALON, SHOWING CAVITY LEFT IN THE BRAIN AFTER  
ENUCLEATION OF THE TUMOR OF THE DURA SHOWN ON PLATE LXXIII.

Case 9119. Showing the cavity left in the brain after enucleation of the tumor. The thin edges of the brain cavity, the engorged veins, and the lateral bulging of the brain beneath the falx are well shown. At the upper right of the plate is the tumor with its adherent dura. The sinus is kept open by two small slips of wood to show the tumor mass within it.

A general discussion of this case is given on page 150.

GROSS MORBID ANATOMY OF THE BRAIN IN THE INSANE.

PLATE LXXIV.



MESIAL SURFACE OF THE LEFT HEMICEPHALON, SHOWING CAVITY LEFT IN THE BRAIN AFTER ENUCLEATION OF THE TUMOR OF THE DURA SHOWN ON PLATE LXXIII.

WILLIAMS & WILKINS  
BLOOMINGDALE HOSPITAL  
MEDICAL LIBRARY

---

---

PLATE LXXV.

---

---

PLATE LXXV.

AUTOPSY No. 2011.

TUMOR OF THE DURA PENETRATING THE BRAIN.

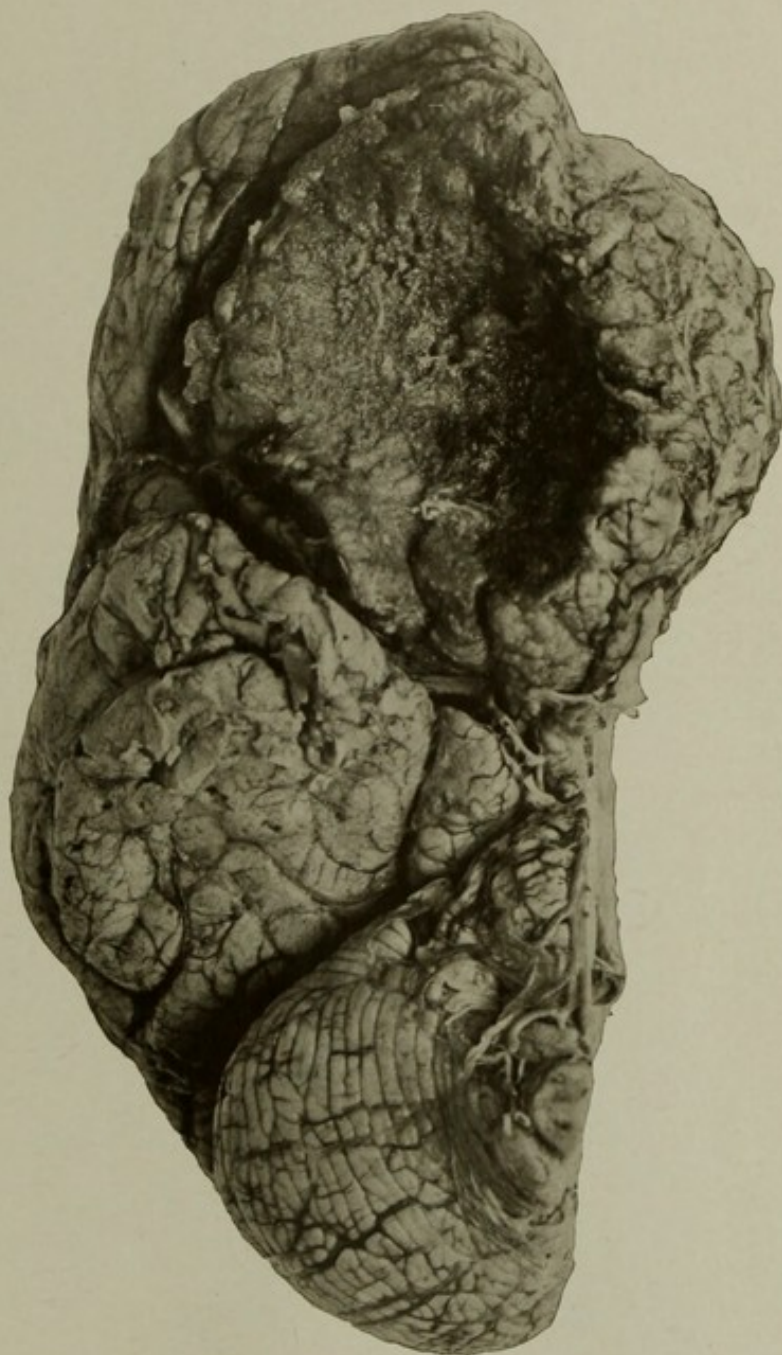
Case 14527. J. W.; aged 36; female; colored; nativity, United States. Mental disease, dementia from intracranial tumor.

The case was reported in the New York Medical Journal, April 7, 1906.

The picture here introduced is a basal view of the right hemisphere with the tumor *in situ*. The extent to which it invaded the opposite hemisphere is seen by the prominence beyond the median line. It was to a greater degree embedded in the right side, and the size of the growth and the displacement of the normal structures are well shown. The tumor was approximately 8 centimeters in diameter, was roughly spherical in shape, and weighed when enucleated 140 grams (nearly 5 ounces avoirdupois). Microscopic examination showed the growth to be a spindle-celled endothelial sarcoma, probably of dural origin.

(154)

O



TUMOR OF THE DURA PENETRATING THE BRAIN.



MEDICAL LIBRARY  
BLOOMINGDALE HOSPITAL  
WHITE PLAINS, N.Y.

WHITE PLAINS, N.Y.  
BLOOMINGDALE HOSPITAL  
MEDICAL LIBRARY



