

Proceedings of the fourteenth annual session of the Association of American Anatomists : held at Anatomical Laboratory of Johns Hopkins University, Baltimore, Md., December 27 and 28, 1900.

Contributors

Association of American Anatomists. Annual Session 1900 : Baltimore, Md.)

Publication/Creation

Washington, D.C. : Beresford, 1901.

Persistent URL

<https://wellcomecollection.org/works/dnn5phh5>

License and attribution

Conditions of use: it is possible this item is protected by copyright and/or related rights. You are free to use this item in any way that is permitted by the copyright and related rights legislation that applies to your use. For other uses you need to obtain permission from the rights-holder(s).

**wellcome
collection**

Wellcome Collection
183 Euston Road
London NW1 2BE UK
T +44 (0)20 7611 8722
E library@wellcomecollection.org
<https://wellcomecollection.org>

PROCEEDINGS
OF THE
FOURTEENTH ANNUAL SESSION

OF THE
Association
of
American **A**natomists,

HELD AT
ANATOMICAL LABORATORY OF
JOHNS HOPKINS UNIVERSITY, BALTIMORE, MD.,

DECEMBER 27 AND 28, 1900.

WASHINGTON, D. C.,
BERESFORD, PRINTER, 618 F STREET.
1901.

K7356

UNIVERSITY
COLLEGE
LONDON

WELLCOME INSTITUTE
LIBRARY

Coll.	WelM Omec
Coll.	
No.	RS

16964031

TABLE OF CONTENTS.

	PAGE.
PROCEEDINGS OF THE FOURTEENTH SESSION,	3
Constitution	11
Officers,	13
List of Members,	15
The Morphological Museum as an Educational Factor in the University System. Huntington,	27
The Value of the X-ray in the Study and Demonstration of Normal Anatomy. Corson,	43
The Levator Ani Muscle. Holmes,	47
The Use of Wet Specimens. Holmes,	50
Typical Forms of Shaft of Long Bones. Hrdlicka,	55
Contribution to the Osteology of Ribs. Hrdlicka,	61
Preliminary Report with Projection Drawings Illustrating the Topography of the Paracoeles in their Relation to the Surface of the Cerebrum and Cranium. Spitzka,	69
A Preliminary Communication of a Study of the Brains of Two Distinguished Physicians, Father and Son. Spitzka,	70
Preliminary Report of a Case of Cyclopia. Carmalt,	93
The Mesial Relations of the Inflected Fissure; Observations upon One Hundred Brains. Spitzka,	105
Method of Utilizing Frozen Sections for Class Demonstrations of Visceral Anatomy and Anatomy of the Epiphyses. Primrose,	116
A Contribution to the Fissural Integrality of the Paroccipital; Observations upon One Hundred Brains. Spitzka,	118
On the Teaching of the Normal Anatomy of the Central Nervous System of Human Beings to Large Classes of Medical Students. Barker and Kyes,	125
Note from Charles H. Ward,	138
The Lobule of the Lung. Miller,	139
The Epithelium of the Pleural Cavities. Miller,	139
Apparatus for Demonstrating the Circulation of the Blood. Stroud,	139
On the Occurrence of Tails in Man, with a description of the case reported by Dr. Watson. Harrison,	141
Discussion. Hrdlicka,	158
Bilateral Relations of the Cerebral Cortex. Mellus,	159
A New Carbon-Dioxide Freezing Microtome. Bardeen,	171
The Architecture of the Gall Bladder. Sudler,	177
On the Origin of the Lymphatics of the Liver. Mall,	185
Born's Method of Reconstruction by Means of Wax Plates as Used in the Anatomical Laboratory of the Johns Hopkins University. Bardeen,	193
Use of the Material of the Dissecting Room for Scientific Pur- poses. Bardeen,	203
On the Development of the Human Diaphragm. Mall,	213
The Intrinsic Blood-Vessels of the Kidney, and their Significance in Nephrotomy. Brödel,	251
Discussion. Holmes,	259



22500561736

7213

Med
K7356

PROCEEDINGS OF THE FOURTEENTH SESSION.

The fourteenth session of the Association of American Anatomists, meeting with the American Society of Naturalists and affiliated Societies in Baltimore, Md., was held in the Anatomical Laboratory of the Johns Hopkins University, Thursday and Friday, December 27 and 28, 1900.

The meeting was called to order, December 27 at 10.20 A. M., by President George S. Huntington.

The Executive Committee reported and recommended the names of the following candidates for membership: Armour, Bardeen, Campbell, Flint, Knower, Kyes, Paton, J. H. Smith, E. A. Spitzka, Sudler and Warren. [See list of members.] Also a recommendation that, at the discretion of the secretary, the first five "Proceedings," now out of print, should be reprinted. Also a recommendation that the Association endorse the proposition for the establishment of a psycho-physical laboratory in the Bureau of Education, Washington, D. C.

By unanimous consent the Secretary cast the ballot for the nominees for membership. The Association also authorized the Secretary to reprint the "Proceedings" as recommended. The recommendation to endorse the psycho-physical laboratory was not agreed to, and was referred to a committee to be appointed by the president to report at a future meeting. It was discussed unfavorably by Drs. Holmes and Hrdlicka.

The Secretary and Treasurer made the following report, for the year 1899-1900:

WASHINGTON, D. C., *December 22, 1900.*

TO THE MEMBERS OF THE

ASSOCIATION OF AMERICAN ANATOMISTS:

Your Secretary and Treasurer herewith submits his report for the year 1899-1900. A provisional report was made at the May meeting in this city.

The Proceedings of the twelfth and thirteenth sessions, held, respectively, in New Haven and Washington, were duly printed, bound together under one cover, as authorized at the May meeting, and have been distributed, leaving, however, a number of copies on hand which are available to members, and would be especially useful for presentation to libraries. The Secretary has also copies of the Proceedings from the sixth to eleventh, inclusive, which are similarly available.

The Secretary has had many requests, especially from libraries, for copies of the Proceedings from the first to fifth, inclusive, which are out of print. Two hundred copies of these, bound under one cover, can be printed for \$80.

In addition to the list of members there are thirty-three libraries and journals on the regular mailing list.

The financial exhibit is as follows: December 22, 1899, the Association was indebted to the Treasurer \$86.36 for monies advanced to pay certain expenses; during the year there has been paid for dues, \$465.75, and subscriptions to the *Journal of Anatomy and Physiology*, \$26.50; total receipts, \$492.25. The expenditures were: for postage, \$25.67; printing, \$144.92; stationery, \$1.25; items of express, telegram, copying, type-writing and drawing, \$14.43; due the Treasurer, \$86.36; subscriptions to *Journal of Anatomy and Physiology*, \$25.96; the Secretary's expenses at the New Haven meeting, \$14.19; the assessment of the Association for the same meeting, as its share of the entire expense of the affiliated societies, \$2.00; total expenditures, \$314.78. Leaving a balance in hand December 22, 1900, \$177.47.

The Treasurer would make the following remarks on this exhibit: It will be noticed how small an assessment is imposed on the Association for the expenses of the meetings with the affiliated societies and Naturalists—only \$2.00. The bill for the share of this Association in the expenses of the triennial Congress has not yet been rendered, but will probably be as much as in previous years, namely, nearly one hundred dollars. In addition to this, each member attending

the Congress is assessed five dollars, which he has to pay as an individual. The Secretary would ask the Association to consider the question whether it would not be more satisfactory to have an intercallary meeting with the Association for the Advancement of Science than triennially with the Congress. This would give us two meetings a year, like the Anthropological Section of that Association, which is now also to meet with the Naturalists and affiliated societies.

The members will observe that the difference between the subscriptions received for the *Journal of Anatomy and Physiology* and the expense of ordering the same is this year a balance of fifty-four cents in favor of the Association, a part of which must be debited to postage, showing that the cost to the subscriber and to the Association are nearly evenly balanced. The Secretary would therefore suggest that the arrangement continue by which subscribers may order through the Secretary's office.

At the close of the May meeting there were on the rolls 118 active, and 10 honorary members; total, 128. Since then we have lost Prof. Wm. Anderson, F. R. C. S., Eng., &c., Lecturer on Anatomy, St. Thomas' Hospital, London, an honorary member. Dr. Woods Hutchinson, late Professor of Comparative Pathology, &c., at University of Buffalo, has been dropped because the Secretary has been unable to establish any communication with him, and he is also in arrears for dues. Dr. A. L. T. Schäper has removed to Breslau, Germany, where he has been appointed a Professor in the University of that city. The membership is now, therefore, 116 active, 9 honorary members; total, 125. I may note in passing that 18 members are also members of the Society of Naturalists.

Seven members of this Association are in arrears for two years and five for three years; total arrearages \$225.00.

Respectfully submitted,

D. S. LAMB,
Secretary and Treasurer.

No reports were received from the Delegate to the Executive Committee of the triennial Congress of American Physicians and Surgeons, nor from the Committee on Anatomical

Peculiarities of the Negro, nor from the Committee on Table at Naples. Dr. Wilder, from the Committee on Anatomical Nomenclature, reported progress.

The President appointed a committee, consisting of Drs. Huber, Carmalt and Barker, to report nominations for Delegates to the Executive Committee of the Congress and a new member of the Executive Committee of this Association. Also a committee, consisting of Drs. Mall and Holmes, to audit the accounts of the Treasurer.

Dr. Huntington then read the Presidential address, subject: "The Morphological Museum, as an educational factor in the University system."

The following papers were also read:

Dr. Holmes, Philadelphia; "The use of wet specimens."

Dr. Chas. R. Bardeen, Baltimore: "Advantages and limits of the method of reconstruction with wax plates in anatomical and embryological investigations." Illustrated by specimens &c. Discussed by Drs. Huber, Minot, Barker, W. S. Miller and Huntington.

Dr. Bardeen: "Demonstration of a new freezing microtome."

Dr. Carmalt, New York City: "Specimen of cyclopia," with cast and photographs. Discussed by Dr. Minot.

Invitations were received from the Johns Hopkins, the University and Arundel Clubs, to the members of the Association, to avail themselves of the hospitalities of the club rooms.

The Association then took a recess for a luncheon, given by the Johns Hopkins University, in the Hospital building.

Reassembled at 2.20 P. M.

The following papers were then read.

Dr. Harrison, Baltimore: "A caudal appendage in a human infant." Illustrated by specimen and photographs. Discussed by Dr. Hrdlicka.

Dr. Hrdlicka, New York City: "Typical forms of shaft of

long bones other than the tibia." Illustrated by specimens and diagrams. Discussed by Drs. Huber and Huntington.

Dr. Hrdlicka: "Notes on the first and second ribs, and a demonstration of bicipital, bicaudal, notched and perforated ribs in man; also notes on articulation of ribs with each other." Illustrated by specimens. Discussed by Dr. Huntington.

Dr. Corson, of Savannah, Ga., not being able to be present, his paper, "The value of the X-ray in the study of normal anatomy," was read by Dr. Kerr, of Cornell University. Illustrated by photographs of the human membral epiphyses at the thirteenth year.

Dr. Huntington: "On the arrangement of the pectoral group and allied muscles in the Cynomorpha, with special reference to the human myological variations of this region." Illustrated by photographs.

Dr. Holmes: "The levator ani muscle." Discussed by Dr. Huntington.

Dr. Mall, Baltimore: "Development of human diaphragm." Illustrated by diagrams and specimens.

Dr. Stroud, of Cornell University, was unable to be present. A photograph sent by him showing "Apparatus for demonstrating the circulation of the blood," was passed around among the members.

Dr. Huntington: "Variations of the inferior cava." - Illustrated by photographs.

Dr. Mall: "The origin of the lymphatics of the liver." Illustrated by models. Discussed by Dr. Huber.

The Association then adjourned.

At 8 P. M., President Gilman, of Johns Hopkins University, made an address of welcome at McCoy Hall, followed by a lecture by Prof. Frank Russell, on "The Indians of the Southwest." Illustrated by lantern slides. And then a reception in the same hall to the visiting societies, by the University.

FRIDAY, DECEMBER 28TH.

The Association reassembled at 9.40 A. M. The Executive Committee reported favorably on the applications for membership of Drs. Pohlman and Hundee, of Cornell University, and the Secretary was directed to cast the ballot for them, and they were declared elected. [See list of members.]

The following papers were then read :

Dr. W. S. Miller, Madison, Wis.: "The lobule of the lung." Illustrated by models, diagrams and lantern slides. Discussed by Drs. Huntington and Huber.

Dr. Primrose, Toronto: "Frozen sections." Illustrated by lantern slides.

Dr. Miller: "Epithelium of pleural cavities." Illustrated by lantern slides.

E. A. Spitzka, New York City: "Preliminary report with projection drawings illustrating the topography of the paracœles in their relation to the surface of the cerebrum and cranium." Abstract. Illustrated by photographs and diagrams.

Mr. Spitzka: "Contribution to the question of fissural integrity of the paroccipital; observations on one hundred brains." Illustrated by drawings.

Mr. Spitzka: "The mesial relations of the inflected fissure; observations on one hundred brains." Illustrated by photographs and diagrams.

Mr. Spitzka: "The brains of two distinguished physicians, father and son; a comparative study of their fissures and gyres." Illustrated by drawings and photographs. Discussed by Drs. Lamb and Huntington.

Dr. Mellus, Baltimore: "Bilateral relations of the cerebral cortex." Illustrated by diagrams. Discussed by Dr. Barker.

Dr. Bardeen: "Methods of statistical study in the dissecting room with special reference to the peripheral nervous system." Illustrated by charts. Discussed by Dr. Huntington.

Dr. Harrison: "Wandering of the skin during development,

in relation to the distribution of cutaneous nerves." Illustrated by diagrams.

Mr. Max Brödel, Baltimore: "Intrinsic bloodvessels of the kidney and their significance in nephrotomy." Illustrated by specimens and diagrams. Discussed by Dr. Holmes.

Dr. T. S. Cullen, Baltimore: "Histology of the endometrium." Illustrated by specimens and drawings.

Dr. M. T. Sudler, Baltimore: "The architecture of the gall-bladder." Read by title.

Dr. Minot, Boston: "The classification of glands." Read by title.

Dr. Barker, Chicago: "Method of teaching the anatomy of the central nervous system to large classes of students." Read by title.

Dr. Huber, from the Nominating Committee, reported the following names: For the Executive Committee of the Association, Dr. Mall; for Delegate and Alternate to Executive Committee of the triennial Congress, Drs. Blake and Baker. On motion, the Secretary was directed to cast the ballot for these gentlemen, and they were elected.

Dr. Mall, of the Auditing Committee, reported the Treasurer's accounts correct. Report accepted.

On motion, the thanks of the Association were tendered to the University authorities, and especially the Medical School, for courtesies received.

The Association adjourned *sine die* at 1.40 P. M.

The following members were present at sometime during the meeting: Bardeen, Barker, Browning, Carmalt, Harrison, Holmes, Huber, Huntington, Hrdlicka, Kemp, Kerr, Knower, Lamb, Mall, Mellus, W. S. Miller, Minot, Paton, Piersol, Primrose, Holmes Smith, E. A. Spitzka, Sudler—total 23; besides Mr. Brödel and Dr. Cullen, of Johns Hopkins Medical School, who contributed papers, and also many visitors.

At 3 P. M., in McCoy Hall, the subject of "The attitude of the State toward scientific investigation" was discussed by the

following gentlemen : Prof. H. F. Osborn, Columbia University, New York City; Prof. W. B. Clark, Johns Hopkins University; L. O. Howard, Chief of Division of Entomology, and B. T. Galloway, Director of Plant Industry, both of the Agricultural Department, Washington, D. C., and W. T. Sedgwick, Massachusetts Institute of Technology.

At 7 P. M. a subscription dinner was given at "Hotel Rennert," followed by the annual address of the President of the American Society of Naturalists, Prof. E. B. Wilson.

CONSTITUTION.

SECTION 1. The name of the Society shall be the "ASSOCIATION OF AMERICAN ANATOMISTS."

SEC. 2. The Association shall have for its object the advancement of the anatomical sciences.

SEC. 3. The officers of the Association shall consist of a President, two Vice-Presidents, and a Secretary who shall also act as Treasurer.

SEC. 4. The officers shall be elected by ballot every two years.

SEC. 5. The management of the affairs of the Association shall be delegated to an Executive Committee, consisting of its President, Secretary and three other members.

SEC. 6. One member of the Executive Committee shall be elected annually.

SEC. 7. The Association shall meet annually, the time and place to be determined by the Executive Committee.

SEC. 8. Candidates for membership must be persons engaged in teaching or in investigation in the anatomical sciences, and shall be proposed in writing to the Executive Committee by two members. Each proposal shall be made at or before the first session of any regular meeting of the Association. The proposal shall state the official position or occupation of the candidate and the character of his investigations. The election shall take place by ballot in open meeting, a two-thirds vote being necessary. Honorary members may be elected from those, not Americans, who have distinguished themselves in anatomical research.

SEC. 9. The annual dues shall be five dollars. A member in arrears for dues for two years shall be dropped by the Secretary at the next succeeding meeting of the Association, but

may be restored on payment of arrears, at the discretion of the Executive Committee.

SEC. 10. The rulings of the Chairman shall be in accordance with "Robert's Rules of Order."

SEC. 11. Five members shall constitute a quorum for the transaction of business.

OFFICERS FOR THE YEAR 1900-1.

DR. GEO. S. HUNTINGTON, of New York City, - - - President.
 DR. F. H. GERRISH, of Portland, Me., - - - First Vice-President.
 DR. G. C. HUBER, of Ann Arbor, Mich., - - - Second Vice-President.
 DR. D. S. LAMB, of Washington, D. C., - - - Secretary and Treasurer.

DELEGATE TO EXECUTIVE COMMITTEE OF CONGRESS OF AMERICAN
PHYSICIANS AND SURGEONS 1900-3.

DR. J. A. BLAKE, of New York City.

ALTERNATE.

DR. FRANK BAKER, of Washington, D. C.

EXECUTIVE COMMITTEE.

DR. E. W. HOLMES, of Philadelphia, Pa.
 DR. C. S. MINOT, of Boston, Mass.
 DR. F. P. MALL, of Baltimore, Md.
and the
 PRESIDENT and SECRETARY, *ex officio*.

COMMITTEE ON ANATOMICAL NOMENCLATURE.

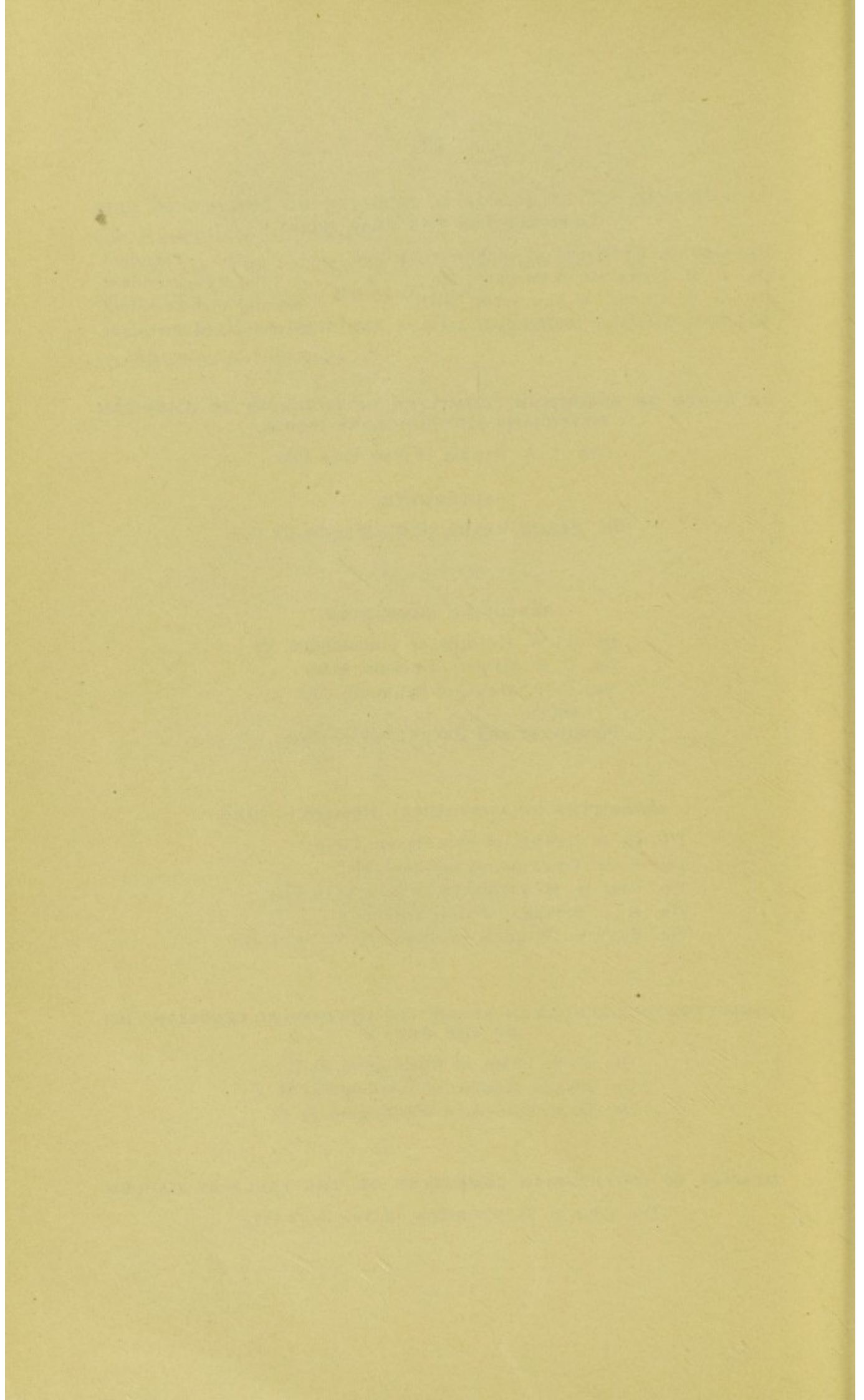
DR. H. B. FERRIS, of New Haven, Conn.
 DR. F. H. GERRISH, of Portland, Me.
 DR. GEO. S. HUNTINGTON, of New York City.
 DR. E. C. SPITZKA, of New York City.
 DR. BURT G. WILDER, of Ithaca, N. Y., *Secretary*.

COMMITTEE ON CIRCULAR IN REGARD TO ANATOMICAL PECULIARITIES
OF THE NEGRO.

DR. D. S. LAMB, of Washington, D. C.
 DR. FRANK BAKER, of Washington, D. C.
 DR. D. K. SHUTE, of Washington, D. C.

MEMBER OF SMITHSONIAN COMMITTEE ON THE TABLE AT NAPLES.

DR. GEO. S. HUNTINGTON, of New York City.



LIST OF MEMBERS.

HONORARY MEMBERS.

Cleland, John, M. D., LL.D., D. Sc., F. R. S. The University,
Glasgow, Scotland.

Regius Professor of Anatomy, University of Glasgow.

Cunningham, Daniel John, M. D., D. Sc., LL. D.

Professor of Anatomy and Chirurgery, University of Dublin, Ireland.

Duval, Mathias. 11 Cité Malesherbes, Rue des Martyrs, Paris,
France.

Professor of Histology, *Faculté de Médecine*; Member of the *Académie de Médecine*, Paris.

Gegenbaur, Karl. Heidelberg, Germany.

Professor of Anatomy, University of Heidelberg.

His, Wilhelm, M. D. Königstrasse 22, Leipzig, Germany.

Professor of Anatomy, University of Leipzig.

Koelliker, A. von. Würzburg, Germany.

Professor of Anatomy, University of Würzburg.

Macalister, Alexander, LL. D. (McGill University). Cambridge,
Eng.

Professor of Anatomy, University of Cambridge.

Ranvier, L. Paris, France.

Professor of General Anatomy, *Collège de France*; Member of the *Institute*
and *Académie de Médecine*, Paris.

Turner, Wm., M. B., F. R. C. S. Ed., M. R. C. S. Eng., D. Sc., LL. D.,
D. C. L. 6 Eton Terrace, Edinburgh, Scotland.

Professor of Anatomy, University of Edinburgh, and Royal Scottish Academy,
Edinburgh.

ACTIVE MEMBERS.

Allis, Ed. P., Jr. 54 Waverley Place, Milwaukee, Wis.

Associate Editor of "Journal of Morphology."

Armour, Donald John, A. B., M. B., M. R. C. P. L., F. R. C. S. E.
Chicago, Ill.

Instructor in Anatomy, Rush Medical College, University of Chicago.

- Baker, Frank, A. M., M. D., Ph. D. 1728 Columbia road,
Washington, D. C.
Professor of Anatomy, Medical Department, University of Georgetown,
Washington.
- Bardeen, Chas. R., M. D., Baltimore, Md.
Associate in Anatomy, Johns Hopkins University, Baltimore.
- Barker, Lewellys Franklin, M. B. Chicago, Ill.
Professor of Anatomy, University of Chicago.
- Bevan, Arthur Dean, M. D. 100 State st., Chicago, Ill.
Late Professor of Anatomy, now Associate Professor of Surgery, Rush Medical
College, Chicago.
- Blair, Vilray Papin, A. M., M. D. 319 North Grand ave., St.
Louis, Mo.
Instructor in Anatomy, Medical Department, Washington University, St Louis.
- Blake, Joseph Augustus, A. B., M. D., Ph. B. 601 Madison ave.
New York City.
Assistant Demonstrator of Anatomy, Medical Department, Columbia Uni-
versity, New York City.
- Bosher, Lewis C., M. D. 717 East Franklin st., Richmond, Va.
Late Professor of Anatomy, now Professor of Surgery and Clinical Lecturer
on Genito-Urinary Surgery and Venereal Diseases, Medical College of
Virginia, Richmond.
- Brewer, George Emerson, A. M., M. D. 68 West 46th st., New
York City.
Assistant Demonstrator of Anatomy, Medical Department, Columbia Univer-
sity, New York City.
- Brockway, Frederick John, A. B., M. D. 254 West 84th st., New
York City.
Assistant Demonstrator of Anatomy, Medical Department, Columbia Univer-
sity, New York City.
- Brooks, W. Allen, Jr., A. M. M. D. 167 Beacon st., Boston,
Mass.
Assistant in Anatomy, Harvard Medical School, Boston.
- Brown, Frank Irving, A. M., M. D. Pine near West High st., or
Box 205, South Portland, Me.
Instructor in Anatomy, Portland School for Medical Instruction.
- Browning, William, Ph. B., M. D. 54 Lefferts Place, Brooklyn,
N. Y.
Lecturer on Anatomy and Physiology of the Nervous System, Long Island
College Hospital, Brooklyn.
- Bryant, Joseph D., M. D. 54 West 36th st., New York City.
Professor of Surgery, University and Bellevue Hospital Medical College, New
York City.

- Campbell, Wm. Francis, A. B., M. D. 127 Lafayette ave., Brooklyn, N. Y.
 Demonstrator of Anatomy, Long Island College Hospital, Brooklyn.
- Carmalt, Churchill, A. B., M. D. 40 East 58th st., New York City.
 Assistant Demonstrator of Anatomy, Medical Department, Columbia University, New York City.
- Carr, William Phillips, M. D. 1103 13th st., nw., Washington, D. C.
 Professor of Physiology, Medical Department, Columbian University, Washington.
- Christian, Wm. Gay, M. D. Charlottesville, Va.
 Professor of Anatomy, Medical Department, University of Virginia, Charlottesville.
- Collins, Howard D., A. B., M. D. 119 East 35th st., New York City.
 Assistant Demonstrator of Anatomy, Medical Department, Columbia University, New York City.
- Conant, Wm. Merritt, M. D. 486 Commonwealth ave., Boston, Mass.
 Instructor in Anatomy, Harvard Medical School, Boston.
- Corson, Eugene Rollin, B. S., M. D. 11 Jones st., East, Savannah, Ga.
- Cotton, Clyde Ellsworth, M. D. 350 Jennings ave., Cleveland, O.
 Professor of Anatomy, Medical Department, University of Wooster, Cleveland.
- Coville, Luzerne, B. S., M. D. Ithaca, N. Y.
 Lecturer in and Demonstrator of Anatomy, Cornell University Medical College, Ithaca.
- Craig, Joseph Davis, A. M., M. D. 12 Ten Broeck st., Albany, N. Y.
 Adjunct Professor of Anatomy, Albany Medical College.
- Crary, George W., M. D. New York City.
 Assistant Demonstrator of Anatomy, Medical Department, Columbia University, New York City.
- Dawbarn, Robert H. MacKay, M. D. 105 West 74th st., New York City.
 Professor of Operative Surgery and Surgical Anatomy, New York Polyclinic College.
- Dercum, F. X., A. M., M. D., Ph. D. 1719 Walnut st., Philadelphia, Pa.
 Clinical Professor of Diseases of the Nervous System, Jefferson Medical College, Philadelphia.

- Dexter, Franklin, M. D. 148 Marlborough st., Boston, Mass.
Assistant Professor of Anatomy, Harvard Medical School, Boston.
- Dodson, John M., A. M., M. D. 1113 Venetian Building, Chicago, Ill.
Late Professor of Physiology and Demonstrator of Anatomy, now Professor of Medicine, Rush Medical College, Chicago.
- Dorsey, Geo. Amos, A. B., Ph. D. Chicago, Ill.
Acting Curator of Anthropology, Field Columbian Museum, Chicago.
- Duncan, J. T., M. B., M. D., C. M. 59 McCaul st., Toronto, Canada.
Professor of Anatomy, Ontario Medical College for Women, and Ontario Veterinary College, Toronto.
- Dwight, Thomas, A. M., M. D., LL. D. 235 Beacon st., Boston, Mass.
Parkman Professor of Anatomy, Harvard Medical School, Boston.
- Eccles, Robert G., M. D. 191 Dean st., Brooklyn, N. Y.
Professor of Organic Chemistry, Brooklyn College of Pharmacy.
- Ferris, Harry B., B. A., M. D. 317 Crown st., New Haven, Conn.
Assistant Professor of Anatomy, Medical Department, Yale University, New Haven.
- Flint, Joseph Marshall. Chicago, Ill.
Associate in Anatomy, University of Chicago.
- Foster, John Pierrepont Codrington, A. B., M. D. 109 College st., New Haven, Conn.
Lecturer on Anatomy, Yale School of Fine Arts, New Haven.
- Frost, Gilman DuBois, A. M., M. D. Hanover, N. H.
Professor of Anatomy, Medical Department, Dartmouth College, Hanover.
- Fry, Frank R., A. M., M. D. 3133 Pine st., St. Louis, Mo.
Professor of Diseases of the Nervous System, Medical Department, Washington University, St. Louis.
- Gage, Simon Henry, B. S. Ithaca, N. Y.
Professor of Anatomy, Histology and Embryology, Cornell University, Ithaca.
- Gallaudet, Bern Budd, A. M., M. D. 162 West 83d st., New York City.
Demonstrator of Anatomy, Medical Department, Columbia University, New York City.
- Garrigue, Evelyn, M. D. 18 West 103d st., New York City.
Late Demonstrator of Anatomy, Woman's Medical College and New York Infirmary, New York City.

- Gerrish, Frederick Henry, A. M., M. D. 675 Congress st., Portland, Me.
Professor of Anatomy, Bowdoin College, Brunswick, Me.
- Goodale, George Lincoln, A. M., M. D. 10 Craigie st., Cambridge, Mass.
Professor of Botany, and Director of the Botanic Garden, Harvard University, Cambridge.
- Hamann, Carl A., M. D. 744 Prospect st., Cleveland, O.
Professor of Anatomy, Medical Department, Western Reserve University, Cleveland
- Hamilton, Isaac B., M. D. Los Angeles, Cal.
Late Demonstrator of Anatomy, Medical College, University of Southern California, Los Angeles.
- Harrison, Ross Granville, B. A., Ph. D., M. D. Baltimore, Md.
Associate Professor of Anatomy, Johns Hopkins University, Baltimore.
- Haynes, Irving S., M. D. 1125 Madison ave., New York City.
Professor of Practical Anatomy, Cornell University Medical College, New York City.
- Heisler, John Clement, M. D. 3705 Powelton ave., Philadelphia, Pa.
Professor of Anatomy, Medico-Chirurgical College, Philadelphia.
- Hendee, Lawrence, M. D. Ithaca, N. Y.
Associate in Anatomy, Cornell University, Ithaca.
- Herrick, Charles Judson. Granville, Ohio.
Assistant Professor of Biology, Denison College, Granville; Associate Editor of "Journal of Comparative Neurology."
- Hewson, Addinell, A. M., M. D. 1508 Pine st., Philadelphia, Pa.
Demonstrator of Anatomy, Jefferson Medical College, Philadelphia.
- Holmes, Edmund Wales, A. B., M. D. 1930 Chestnut st., Philadelphia, Pa.
Demonstrator of Anatomy and Lecturer on Surgical Anatomy, University of Pennsylvania, Philadelphia.
- Hopkins, Grant Sherman, D. Sc. Ithaca, N. Y.
Assistant Professor of Anatomy, Cornell University, Ithaca.
- Hrdlicka, Ales, M. D. 106 East 71st st., New York City.
Associate in Anthropology, Pathological Institute of New York Hospitals, New York City.
- Huber, G. Carl, M. D. 333 East Ann st., Ann Arbor, Mich.
Junior Professor of Anatomy and Director of Histological Laboratory, University of Michigan, Ann Arbor.
- Huntington, George S., A. M., M. D. 50 East 73d st., New York City.
Professor of Anatomy, Medical Department, Columbia University, New York City.

- Hutchinson, Woods, A. M., M. D. Newberg, Oregon.
Late Professor of Comparative Pathology and Embryology, Medical Department, University of Buffalo, N. Y.
- Jayne, Horace, M. D. 1828 Chestnut st., Philadelphia, Pa.
Professor of Vertebrate Morphology, University of Pennsylvania, Philadelphia.
- Keiller, Wm., F. R. C. S. Ed., L. R. C. P. and S. Ed. 1601 31st st., Galveston, Texas.
Professor of Anatomy, Medical Department, University of Texas, Galveston.
- Kemp, George T., M. D., Ph. D. Urbana, Ill.
Late Associate Director, Department of Physiology and Experimental Therapeutics, Hoagland Laboratory, Brooklyn; now Professor of Physiology, University of Illinois, Urbana.
- Kerr, Abram Tucker, Jr., B. S., M. D. Ithaca, N. Y.
Assistant Professor of Anatomy, Cornell University, Ithaca.
- King, Alfred, A. B., M. D. 610 Congress st., Portland, Me.
Demonstrator of Anatomy, Bowdoin College, Brunswick, Me.
- Knower, Henry McElderry, A. B., Ph. D. Baltimore, Md.
Instructor in Anatomy, Johns Hopkins University, Baltimore.
- Kyes, Preston, A. M., M. D. Chicago, Ill.
Associate in Anatomy, University of Chicago.
- Lamb, Daniel Smith, A. M., M. D. 800 10th st., n. w., Washington, D. C.
Pathologist, Army Medical Museum; Professor of Anatomy, Medical Dept., Howard University, Washington.
- Langdon, Frank Warren, M. D. 5 Garfield Place, Cincinnati, O.
Professor of Nervous and Mental Diseases, Laurel Memorial Woman's Medical College, Cincinnati.
- Leidy, Joseph, Jr., A. M., M. D. 1319 Locust st., Philadelphia, Pa.
Late Assistant Demonstrator of Anatomy and Pathologic Histology, University of Pennsylvania, Philadelphia.
- Lewis, Wm. Evan, M. D. 409 East Fifth st., Cincinnati, O.
Professor of Descriptive and Surgical Anatomy, Cincinnati College of Medicine and Surgery.
- MacCarthy, John G., M. D. Montreal, Canada.
Lecturer on Anatomy, McGill University, Montreal.
- McClellan, George, M. D. 1352 Spruce st., Philadelphia, Pa.
Professor of Anatomy, Academy of Fine Arts, Philadelphia.
- McDonough, Edward James, A. B., M. D. 624 Congress st., Portland, Me.
Demonstrator of Histology, Bowdoin College, Brunswick, Me.

Mackenzie, R. Tait, B. A., M. D. 913 Dorchester st., Montreal,
Canada.

Senior Demonstrator of Anatomy, McGill University, Montreal.

McMurrich, James Playfair, A. M., Ph. D. 814 South Univer-
sity ave., Ann Arbor, Mich.

Professor of Anatomy, University of Michigan, Ann Arbor.

Mall, Franklin P., M. D. 1514 Bolton st., Baltimore, Md.

Professor of Anatomy, Johns Hopkins University, Baltimore.

Martin, Walton, Ph. B., M. D. 63 East 56th st., New York City.

Assistant Demonstrator of Anatomy, Medical Department, Columbia Univer-
sity, New York City.

Matas, Rudolph, M. D. 2255 St. Charles ave., New Orleans, La.

Late Demonstrator of Anatomy, now Professor of General and Clinical Sur-
gery, Medical Department, Tulane University; Instructor in Operative
and Clinical Surgery and Applied Anatomy, New Orleans Polyclinic.

Mathews, Wm. P., B. A., M. D. 1302 Bainbridge st., Manches-
ter, Va.

Demonstrator of Anatomy, Medical College of Virginia, Richmond, Va.

Matthews, Washington, M. D. Surgeon U. S. Army, (Retired.)
1262 N. H. ave., nw., Washington, D. C.

Mellus, E. Linden, M. D. 10 Chase st., East Baltimore, Md.

Fellow in Anatomy, Johns Hopkins University, Baltimore.

Miller, Clifton Meredith, M. D. 309 East Grace st., Richmond,
Va.

Demonstrator of Anatomy, Medical College of Virginia, Richmond.

Miller, Wm. S., M. D. 615 Lake st., Madison, Wis.

Assistant Professor of Vertebrate Anatomy, University of Wisconsin, Madison.

Minot, Charles Sedgwick, S. D. 688 Boylston st., Boston, Mass.

Professor of Histology and Human Embryology, Harvard Medical School,
Boston.

Mixter, Samuel Jason, B. S., M. D. 180 Marlborough st., Bos-
ton, Mass.

Late Demonstrator of Anatomy; Instructor in Surgery, Harvard Medical
School, Boston.

Moody, Mary Blair, M. D. Fair Haven Heights, New Haven,
Conn.

Moody, Robert Orton, B. S., M. D. Ithaca, N. Y.

Assistant in Anatomy, Cornell University, Ithaca.

Moran, John Francis, M. D. 2426 Pennsylvania ave., nw.,
Washington, D. C.

Late Demonstrator of Anatomy, Medical Department, University of Georgetown, Washington.

Morgan, James Dudley, A. B., M. D. 919 15th st., nw., Wash-
ington, D. C.

Late Demonstrator of Anatomy, University of Georgetown, Washington.

Munro, John Cummings, A. B., M. D. 173 Beacon st., Boston,
Mass.

Instructor in Surgery, Harvard Medical School, Boston.

Osborn, Henry Fairfield, D. Sc. New York City.

Da Costa Professor of Zoölogy, Columbia University; Curator of Vertebrate Palæontology, American Museum of Natural History, New York City.

Parkhill, Clayton, M. E., M. D. 245-6 Equitable Building,
Denver, Colorado.

Professor of Surgery, University of Colorado, Boulder, Col.

Parmenter, John, M. D. 519 Franklin st., Buffalo, N. Y.

Professor of Anatomy and Adjunct Professor of Clinical Surgery, University of Buffalo.

Paton, Stewart, A. B., M. D. 213 West Monument st., Balti-
more, Md.

Assistant in Clinical Neurology, Johns Hopkins University, Baltimore.

Piersol, George A., M. D. 4724 Chester ave., Philadelphia, Pa.

Professor of Anatomy, University of Pennsylvania, Philadelphia.

Pohlman, Augustus G., M. D. Ithaca, N. Y.

Assistant in Anatomy, Cornell University, Ithaca.

Primrose, Alexander, M. B., C. M. Edin., M. R. C. S. Eng. 100
College st., Toronto, Canada.

Professor of Anatomy, University of Toronto.

Reisinger, Emory Wm., M. D. 1209 13th st., nw., Washington,
D. C.

Demonstrator of Anatomy, University of Georgetown, Washington.

Reyburn, Robert, A. M., M. D. 714 13th st., nw., Washington,
D. C.

Late Professor of Anatomy, Medical Department, University of Georgetown;
Professor of Physiology, Medical Department, Howard University,
Washington.

Russell, Nelson S., M. D. Buffalo, N. Y.

Assistant in Anatomy, Medical Department, University of Buffalo.

Shepherd, Francis John, M. D., C. M. 152 Mansfield st., Mon-
treal, Canada.

Professor of Anatomy and Lecturer on Operative Surgery, McGill University,
Montreal.

- Shufeldt, Robert Wilson, M. D., C. M. Z. S., Assistant Surgeon,
U. S. A., (Retired.) 3221 School st., nw., Wash-
ington, D. C.
- Shute, Daniel Kerfoot, A. B., M. D. 1101 13th st., nw., Wash-
ington, D. C.
Professor of Anatomy, Medical Department, Columbian University, Wash-
ington.
- Small, Richard Dresser, A. B., M. D. 606 Congress st., Port-
land, Me.
Instructor in Anatomy, Portland School for Medical Instruction.
- Smith, Chas. Dennison, A. M., M. D. 126 Free st., Portland, Me.
Professor of Physiology, &c., Bowdoin College, Brunswick, Me., and Instructor
in Pathology and Bacteriology, Portland School for Medical Instruction.
- Smith, Eugene Alfred, M. D. 771 Ellicott st., Buffalo, N. Y.
Professor of Anatomy, Niagara University, Buffalo.
- Smith, John Holmes, M. D. 27 West Prescott st., Baltimore, Md.
Assistant Professor and Demonstrator of Anatomy, School of Medicine, Uni-
versity of Maryland, Baltimore.
- Souchon, Edmond, M. D. 135 Baronne st., New Orleans, La.
Professor of Anatomy and Clinical Surgery, Tulane University, New Orleans.
- Spitzka, Edward Anthony. 66 East 73d st., New York City. [MD, 1907
- Spitzka, E. C., M. D. 66 East 73d st., New York City.
Late Professor of Neuro Anatomy and Physiology, New York Post Graduate
Med. School; Editor "American Journal of Neurology and Psychiatry."
- Springle, John Anderson, M. D., C. M. 1237 Dorchester st.,
Montreal, Canada.
Lecturer on Anatomy, McGill University, Montreal.
- Stewart, George D., M. D. 130 East 36th st., New York City.
Lecturer on Anatomy, Bellevue Hospital Medical College, New York City.
- Stillman, Wm. Olin, A. M., M. D. 287 State st., Albany, N. Y.
- Stroud, Bert Brenette, B. S., D. Sc. Ithaca, N. Y.
Instructor in Physiology, Vertebrate Zoölogy and Neurology, Cornell Univer-
sity, Ithaca.
- Sudler, Merwin Tubman, S. B., Ph. D. Baltimore, Md.
Instructor in Anatomy, Johns Hopkins University, Baltimore.
- Terry, Robert James, M. D. 2726 Washington ave., St. Louis,
Mo.
Demonstrator of Anatomy, Missouri Medical College, St. Louis.

- Thompson, Millard Fillmore, D. D. S., M. D. 1113 Pennsylvania ave., nw., Washington, D. C.
Professor of Anatomy, Medical Department, National University, Washington
- Tupper, Paul Yoer, M. D. Linmar Building, St. Louis, Mo.
Professor of Applied Anatomy and Operative Surgery, Medical Department, Washington University, St. Louis.
- Tuttle, Albert Henry, M. Sc. Charlottesville, Va.
University of Virginia, Charlottesville.
- Vosburgh, Arthur S., A. B., M. D. 40 West 88th st., New York City.
Assistant Demonstrator of Anatomy, Medical Department, Columbia University, New York City.
- Ward, Charles Howell. 18 College ave., Rochester, N. Y.
Department of Human Anatomy, Ward's Natural Science Establishment, Rochester.
- Warren, John, A. B., M. D. Boston, Mass.
Assistant in Anatomy, Harvard Medical School, Boston.
- Weisse, Faneuil D., M. D. 46 West 20th st., New York City.
Late Professor of Anatomy, Medical Department, University of City of New York; Professor of Anatomy, New York College of Dentistry, New York City.
- West, Charles Ignatius, M. D. 602 K st., nw., Washington, D. C.
Demonstrator of Anatomy and Lecturer on Topographic Anatomy, Medical Department, Howard University, Washington.
- West, George William, M. D. 1102 14th st., nw., Washington, D. C.
Late Professor of Anatomy and Physiology, Medical Department, National University, Washington. Late Demonstrator of Anatomy, Medical College of Virginia, Richmond, Va.
- Wilder, Burt G., M. D., B. S. Ithaca, N. Y.
Professor of Neurology, Vertebrate Zoölogy and Physiology, and Curator of the Vertebrate Division of the Museum, Cornell University, Ithaca.
- Wilson, William Powell, B. S., D. Sc. 640 North 32d st., Philadelphia, Pa.
Professor of Pysiologic Botany, University of Pennsylvania, Philadelphia.
- Woodward, Wm. Creighton, M. D. 508 I st., nw., Washington, D. C.
Professor of Medical Jurisprudence, Medical Department, Georgetown University, Washington.
- Woolsey, George, A. B., M. D. 117 East 36th st., New York City.
Professor of Anatomy and Clinical Surgery, Cornell University Medical College, New York City.

GEOGRAPHICAL DISTRIBUTION OF MEMBERS.

New York,	39	New Hampshire,	1
District of Columbia,	12	Georgia,	1
Massachusetts,	9	Minnesota,	1
Pennsylvania,	9	Michigan,	1
Illinois,	8	Texas,	1
Maryland,	8	Colorado,	1
Maine,	6	California,	1
Canada,	6	Oregon,	1
Virginia,	5		
Ohio,	5	Germany,	3
Missouri,	4	France,	2
Connecticut,	3	Scotland,	2
Louisiana,	2	England,	1
Wisconsin,	2	Ireland,	1
U. S. Army,	2		

Total, 137 = 128 active, 9 honorary.

STATISTICAL DISTRIBUTION OF MEMBERS

1	New York	10
1	District of Columbia	10
1	Massachusetts	9
1	California	9
1	Illinois	8
1	Texas	8
1	Colorado	8
1	Ohio	8
1	Virginia	8
1	Georgia	8
1	Michigan	8
1	Wisconsin	8
1	Minnesota	8
1	Indiana	8
1	Missouri	8
1	Arizona	8
1	Florida	8
1	Alabama	8
1	South Carolina	8
1	Louisiana	8
1	Arkansas	8
1	Mississippi	8
1	West Virginia	8
1	Montgomery	8
1	Washington	8
1	Idaho	8
1	Utah	8
1	Wyoming	8
1	Nebraska	8
1	Kansas	8
1	Oklahoma	8
1	New Mexico	8
1	Alaska	8
1	Hawaii	8
1	Foreign	8
1	Total	100

Total 100 - 100 members

THE MORPHOLOGICAL MUSEUM AS AN EDUCATIONAL FACTOR IN THE UNIVERSITY SYSTEM.

BY DR. GEO. S. HUNTINGTON, NEW YORK CITY.

The educational value of the modern morphological museum has of late years received such general recognition that we may well regard its position as established in the university system. Not only do the departments of undergraduate instruction draw more and more extensively upon this portion of the university equipment for the illustration of courses and demonstrations, but the museum itself has assumed its proper relation to independent scientific research and to the investigation of biological problems. It has seemed to me desirable to present to this association—whose members are so largely both teachers of anatomy and investigators of the science—some account of the progress made during the last decade in museum work in the department of vertebrate morphology. More especially does it appear proper at this time to note the present stage of development of the modern anatomical museum, because we have, I think, reached a period at which we can look back over a series of busy years and gauge correctly the value of the results obtained, as well as forecast the probable future development of this work. Ten or fifteen years ago the morphological museum—established on lines of modern thought and research—existed in an embryonic form in only a few of our institutions of learning. From this period date a number of excellent monographs—in which the authors outline the plans of a proposed anatomical museum designed to meet the requirements demanded by the advance of the biological sciences—from the standpoint both of the teacher and the investigator. Prominent among these interesting publications are the following:

“Outlines for a Museum of Anatomy. Prepared for the Bureau of Education,” by R. W. Shufeldt. 1885.

“Die Aufgaben der anatomischen Institute,” by Professor A. Koelliker, 1884. An address delivered at the opening of the new anatomical institute in Würzburg on November 3, 1883.

"The Educational Museums of Vertebrates," an address before the Section of Biology of the American Association for the Advancement of Science, at Ann Arbor, August, 1885, by Professor B. G. Wilder.

"The Synthetic Museum of Comparative Anatomy as the Basis for a Comprehensive System of Research," by John A. Ryder, Professor of Comparative Embryology at the University of Pennsylvania, Philadelphia. 1893.

As I look over the list of these and other contributions to the literature of the anatomical museum I am tempted to characterize the period between 1885 and 1895 as the prophetic era, foreshadowing the establishment and recognition of the most essential and valuable aid to scientific anatomical instruction and research which our universities to-day possess. When we analyze the great and radical changes which our methods of morphological teaching have experienced since that time, we shall, I believe, agree that the demonstrative and objective instruction which has replaced so largely the old didactic lecture is intimately and organically connected with the evolution of the modern anatomical museum. It will perhaps best serve the purpose of my communication if in the following I confine myself to the facts as they are most familiar to me in the case of my own university, which, I believe, may fairly be taken as a concrete example of the general progress which has marked the period in question in the scientific institutes throughout our country.

The establishment of a museum of vertebrate comparative anatomy, on lines designed to illustrate and demonstrate to the fullest extent possible the morphological truths embodied in the doctrines of evolution, heredity and descent is an undertaking requiring years of careful and successful work before even a satisfactory beginning is made. The foundation of the museum at Columbia University was laid in 1889, and, while in many directions our progress has been rapid and the results gratifying, yet we feel that to-day but the outlines exist along which future growth is to take place.

I. PLAN AND SCOPE OF THE MUSEUM AND ITS RELATION TO ANATOMICAL INSTRUCTION.

I may in the first place call your attention to the general plan and purpose of the museum, in accordance with which the objects have been collected and prepared, and to the re-

lation existing between the museum and the undergraduate instruction in anatomy.

The following considerations present themselves:

1. The fundamental plan of the museum includes in the first place a general exposition of the vertebrate classes, whose purpose is to present the cardinal points in the anatomical structure of the great vertebrate classes and subclasses.

Each vertebrate class, subclass and order is represented by one or more typical forms in preparations illustrating as fully as possible the skeletal and locomotory apparatus, the circulatory and nervous systems, and the alimentary, respiratory and uro-genital tracts.

This display forms the guiding thread to the study of the individual forms—in respect to typical structures, *i. e.*, the fundamental anatomical characters of the mammal, bird, reptile, amphibian and fish are grouped together to afford a comprehensive view of the entire organism, from which starting point the detailed investigation of characteristic structures in their various modifications is to be followed through the series of species belonging to the *same class*.

To illustrate: the typical structure of the avian pectoral girdle is represented in the collection by the girdle of *Palamedea cornuta*, the horned screamer. It is here shown to contain three elements—the scapula, coracoid and furcula.

Turning to the corresponding series demonstrating the successive modifications of this structure, we find it as a link in the group devoted to the development of the vertebrate shoulder girdle. The various modifications in shape, extent and sternal attachment of the complete furcula are first illustrated, together with preparations of the membranous and ligamentous structures, which have a bearing on the general morphology of the episternal apparatus.

In the next place the avian girdle is found to pass from the type represented by *Palamedea*, in which all three skeletal elements are fully developed, to the intermediate condition seen in the toucan, where the furcula is developed as a bilateral structure, the two segments not fusing over the sternum, until we come to the brevipennate group of birds, of which *Dromæus* still has rudimentary anterior collar bones, whereas in *Struthio*, *Rhea* and *Casuaris* these have lost their identity by becoming fused with the scapula.

In the second place this division of the museum affords the

basis for broad comparison between the organizations of the different vertebrate classes. For example, the comparison of the entire anatomical system of a typical reptile, bird and mammal will show why reptiles and birds, although differing widely in structural detail, yet have sufficient general morphological characters in common, as against the mammal, to entitle them to be grouped under the single broad head of the Sauropsida.

Then, again, this portion of the museum is designed to elucidate the important problems of derivation of vertebrate sub-classes.

2. The second main division of the museum deals with the development, evolution and comparative structure of single organs and systems. The homologies in the different classes, and the modifications of the typical structures in each class, are here demonstrated as completely as possible. In many respects this portion of the work is educationally the most important. We draw most extensively upon it for our anatomical undergraduate instruction in the elucidation of problems in human morphology. I cannot take time in even superficially outlining the detailed development of this division of the anatomical museum. The enumeration of a few of the principal series must suffice.

I may instance the series dealing with the morphology of the alimentary tract, and especially the group devoted to the structure of the ileo-colic junction, cæcum, vermiform appendix and the allied segments of the large intestine. This series, including at present over 600 preparations, and beginning with type forms illustrating this portion of the alimentary canal in fishes, amphibia, reptiles and birds, passes to a complete demonstration of the structures in mammals, terminating with several specimens of the four anthropoid apes and leading up to the detailed study of the human cæcum and appendix, the numerous variations of which are all represented by one or more type specimens. In the same way the various forms of the stomach and the modifications of small and large intestine constitute a series of great morphological interest.

Other series deal with the vertebrate respiratory apparatus, especial stress being laid on the clear demonstration of the development, evolution and structure of the mammalian lung. Closely connected with this group is the serial exhibit dealing with the heart and circulatory system. Other series include

the nervous system, the genito-urinary tract, the pelvic and pectoral girdles, the mammalian temporal, periotic and tympanic bone, etc.

Special attention is given in this department of the museum to the demonstration of human anatomy. Eventually it is hoped that every portion of man's structure will be fully and exhaustively illustrated by perfect preparations. The museum should afford the medical student the opportunity of directly verifying his text-book information and should be a most valuable guide and aid to the practical anatomical study of the individual in the dissecting room. Moreover, many structures, as we all realize, are never fully examined or completely demonstrable to the student in the dissecting room. Aside from the individual differences in the cadaver in respect to development and state of preservation, and in the element of alteration of structure by diseased conditions, certain parts require special methods of preparation, such as the auditory apparatus; others necessitate for their exposition the sacrifice of surrounding structures to a degree not warranted by the practical requirement of getting the greatest amount of detail from the dissection of a single cadaver. Moreover, even the structures which are ordinarily fully examined and demonstrated in the dissecting room on the fresh subject, can be shown with great profit in the museum in various preparations by different methods. For example, the museum contains hardened situs preparations, organs hardened, distended and fenestrated, injection and corrosion preparations, etc., to illustrate fully the anatomical structure of each part and to enable the student to extend and amplify his observations on the cadaver.

Again, in connection with this department of the museum, I find it of distinct advantage to establish small comparative series designed to illustrate the development and normal anatomy, as well as the more important variations, of certain adult human conditions. These groups are accompanied by tablets, describing as fully as necessary the purpose of the exhibit, and drawings which emphasize the points at issue.

Thus, for example, under the heading of the cardinal sinus of the adult human heart—as part of the series exhibiting cardiac anatomy—the following group is placed with full explanatory text:

1. Heart and vascular system of *Raja ocellata*—various

preparations to show embryonic type of mammalian heart before septal division, ducts of Cuvier and symmetrical cardinal veins.

2. Heart of *Python molurus*—hardened and distended, with sections showing : (a) sinus venosus of right auricle ; (b) valves of sinus venosus and their relation to the Eustachian and Thebesian valves of the mammalian heart ; (c) pulmonary veins ; (d) persistent left precava.

3. Heart of *Struthio africanus*—injected, showing persistent avian left precava—with its relations to pericardium and coronary vein.

4. Ruminant heart (*Antelope cervicapra*)—mammalian type of normal persistence of left precava.

5. Series of normal human hearts—showing, in various preparations, coronary sinus, Thebesian and Eustachian valves—both foetal and adult.

6. Series of well-developed folds of Marshal in foetal and adult hearts.

7. As soon as obtained, the final member of this group will be added as a preparation showing the normal persistence of the left precava in the adult human subject.

Instances in which a similar limited and selected group of preparations may be with advantage established for the elucidation of special details in human anatomy could be almost indefinitely multiplied.

I have noted at random :

1. Development of axis and atlas.
2. Ligaments and tendons of shoulder joint.
3. Greater and lesser sciatic ligaments and relation to hamstring muscles and coccygeus.
4. Postcava and variations.
5. Carpus and tarsus.
6. Sacrum and vertebral variations.
7. Aortic arch and variations of primary branches.
8. Various myological problems.
9. The peritoneum.

The question as to the practical application of this educational material to the requirements of undergraduate instruction in anatomy deserves careful consideration from several points of view :

1. Primarily the museum should afford a consecutive and logical serial exhibition, arranged and administered in such a

manner that for both undergraduates and advanced students the preparations should be readily accessible and capable of being examined with only such restrictions as the safety of the object demands. The museum should be the reference library of the student in the widest sense, where the undergraduate can review and extend his anatomical knowledge on the hand of the actual object of his study, and where the advanced worker will find the necessary material in directing and supplementing his research in any given problem under investigation.

2. In the demonstrative teaching of the anatomical course the material of the museum in our experience can best be utilized in two ways :

a. It is our custom, in approaching any one of the large subdivisions of the course—such as the respiratory and circulatory system, the alimentary canal or genito-urinary tract—to devote a portion of the available time to a preliminary general consideration of the development, peculiarities of morphological structure and the physiological significance of the parts involved. For this purpose a judicious selection of a limited number of the museum preparations is made, and the objects are arranged in the form of a series, each number of which distinctly and forcibly illustrates a developmental stage or a significant and important structure or functional fact. It is necessary to limit the preparations thus selected in number to avoid confusion and superfluous expenditure of time, but it is surprising how clearly and convincingly the main broad lines of vertebrate development and evolution and the relation between structure and function can be brought out in a comparatively short series of selected preparations. Every teacher knows and appreciates the difference in the quality of instruction and its results between a demonstration of models and drawings, schematic or otherwise, and one referring directly to the natural object. The most important function of the museum, as an integral part of the educational system of the university, is exerted in supplying the material necessary for this kind of demonstrative teaching. Practically I find in the schematic blackboard sketch or the more carefully prepared colored chart a most valuable adjunct. The drawing should, however, be made directly from the actual preparation demonstrated and the student should have the opportunity of directly comparing both. In this way salient

points can be accentuated and the attention properly and immediately directed to the important facts which the preparation is designed to illustrate.

b. In connection with the class-room demonstration it is at times desirable to deal with general problems of vertebrate morphology from the higher standpoint which, on the hand of a more extensive series, affords a wider view of the structures concerned. I find that this can best be accomplished by a photographic lantern slide demonstration, in which a very considerable number of forms can be exhibited to the class in a comparatively short time. It has been our practice to photograph the preparations when finished, but before they are permanently mounted or included in the museum series. As a practical matter the best results are obtained by vertical exposure, the object being placed in suitable trays and covered by clear fluid—water or alcohol. In this way the disadvantage, resulting from the distortion and reflection of the jar containing the specimen when finally mounted, is obviated.

The resulting photograph forms part of the museum record and is useful in many ways. Properly labeled, it forms an excellent guide to the study of the preparation, and it can be used directly for reproduction in publications, or be made the basis of the drawing. Finally, as the completion of the series warrants it, the negatives yield a set of lantern slides which can be used in the teaching of the department as well as in extending the use of the museum material in other institutions.

3. The special courses in comparative anatomy and embryology, which are offered as optionals, electives, or for the higher university degrees, make demands which the museum should meet as fully as possible. In the first place, I find that the forms which can readily be obtained in numbers, and supplied to the students for their actual personal use in the laboratory courses, require in many cases comparison with allied types which, by reason of their rarity and value, can only be represented in the permanent collection of the museum. The courses can thus be extended and made infinitely more valuable and instructive. Again, every practical laboratory teacher will know the value of placing before the student a carefully and clearly executed preparation and reviewing the structures which he is to expose and determine for himself by the dissection of the fresh material on hand. This use of the museum is entirely apart from the valuable

and instructive deductions which a series of significant variations of normal structures will enable the student to make.

Moreover, in many respects the museum fulfills one of its most important practical functions in enabling the teacher to direct the student's attention, at the proper points in any laboratory course, to the corresponding structures and their modifications in selected preparations ranging throughout the entire vertebrate series. The broad and general application of the knowledge gained by the detailed study of any individual form can only by these means be impressed on the student, and it is thus that the anatomical museum accomplishes one of the main purposes of morphological study.

II. RELATION OF THE MUSEUM TO ORIGINAL RESEARCH AND ADVANCED STUDY.

Of equal importance with the value of the museum for undergraduate instruction is its influence in promoting original investigation and advanced morphological study. Its very existence carries this with it. It constantly opens up, in creating the nucleus around which the institution is to grow, lines of investigation and research which ultimately return their products to the museum as permanent records of the work accomplished, and thus prove sources of continual and valuable additions.

The museum in itself forms the basis for a progressive extension of morphological investigation. It accomplishes this in several directions. In the first place, the generalization of the structures presented by different types, which marks the central purpose of the institution, forms a circle from whose circumference at any point the line of a new and more extended investigation can be drawn. In fact, if the museum is to grow and develop according to its original intent, it is requisite that such enlargement should take place.

As the museum grows the vital questions of derivation and ancestry of forms must be investigated on the hand of constantly increasing material, which will open up points of view heretofore unattained. With each new accession to any group the capacity of the museum for extension of original thought and investigation increases. Any research opens at some point in its course side lines which may be of the utmost value. It is here that the immediate possibility of serial comparisons on a large scale afforded by the museum becomes of the

greatest importance. The museum represents in its complete condition a morphological reference depository. It functions in connection with the morphological library, but it possesses the inestimable advantage of presenting the actual objects instead of plates and descriptions, often at variance with each other, incorrect and incomplete in detail and failing to elucidate just the question which it is desired to solve.

In this sense the museum fulfills its highest functions, stimulating and directly promoting investigation and rendering such investigation fruitful and effective by contributing the series necessary for comparison and reference.

It may hardly be necessary to touch on the effect of this work on those who are engaged in it. It attracts men whom the university is glad to number among its students and graduates, and who in other institutions—as teachers and investigators—will reflect credit on their training. If from among the growing numbers of our medical students even a few are made to develop into scientific workers, I should yet hold those few—in their prospective value to the university and to science—as balancing the long list of medical graduates whom we annually send out at our commencement.

III. RELATION OF THE MUSEUM TO OTHER DEPARTMENTS OF THE UNIVERSITY.

There is scarcely a department of biological or medical instruction and investigation which is not in intimate relation with some portion of morphology, and which will not benefit by a connection with the museum and by access to its collections.

In physiology, the science dealing with the function of the machine which itself is the object of the study in morphology, the connection is obvious. But the tremendous advantage which will accrue to each of these sciences by closer mutual association, through the link of the comparative anatomical museum, can scarcely be estimated. Morphology offers in the series of modifications which different forms present in their structure, a field of nearly unlimited choice for the interpretation of the physiologist. The physiological study of an organ in a certain form—as the dog—may lead the investigator to certain results which apply in the first plan to the species examined. If now the morphology of the organ is accessible to the physiological investigator not only in a complete series

of the dog's own order, the Carnivora, but through the entire mammalian class, and beyond this limit, so as to include the homologous structures, in other vertebrate classes, the result of the investigation becomes potentially amplified to a corresponding degree.

The investigator can not only reason from analogy as to the results of similar experiments extended as far as deemed advisable through the vertebrate classes and orders, but he can also, guided by the morphology of the structure under consideration, select types which, from their anatomical configuration, promise unequivocal confirmation and extension of the results yielded by the first experiment. How frequently the success of an investigation depends on details of anatomical structure every physiologist will attest. It is often the question of the length of an arterial vessel without branches, or the arrangement of a duct, or the combination of several peripheral nerves. The museum of comparative morphology converts a hap-hazard search for a suitable form into one which will select the most desirable type with certainty.

In turn the generalized view of organized structure obtained in the comprehensive system of the museum will afford to the morphologist the aid which is to be found in the broad physiological interpretation of the modifications exhibited. Thus these two fundamental departments will be brought into closer contact with each other, a contact which cannot fail to redound equally to the benefit of both. I believe that a closer association of anatomy and physiology, such as is afforded by the link of the museum, is of very distinct advantage in undergraduate instruction. The modern development of science inevitably leads to a high degree of specialization, which naturally becomes apparent in the teaching of any department. The general advantage of this is obvious, provided touch is not lost with cognate branches.

The morphological museum preserves this vital connection between anatomy and physiology more than any other single factor in the university equipment. Moreover, the museum has important relations to the practical departments of medical teaching and to pathology. Nearly all important advances, especially in departments such as diseases of the eye and ear, the diseases of women, surgery in general and in its specialized branches, depend primarily on some morphological

question for their inception, rendering this or that proposed operative interference proper and advantageous, or interdicting it.

A museum which offers to the medical specialist not only the normal and variant human structures which constitute his field of work, but which enables him at the same time to examine the homologous parts of other vertebrates for the purpose of gaining clearer insight into obscure morphological conditions and the origin of aberrant formations, will certainly be an aid to practical advance which can be obtained by no other means. It is needless to point out further connections of a similar character, or to more than touch upon the line along which pathology and embryology meet, a line which is sufficiently extensive, but obscure because the assistance which vertebrate embryology can afford to the pathologist is only rarely attainable in the form which the museum proposes to offer, viz: complete sets of serial preparations. As the museum develops it is proposed to take successively certain portions of the subject, such as eye, ear, larynx, brain, genito-urinary tract, etc., and to develop these as fully as possible, demonstrating the results in the form of an exhibition to a selected number of scientific men who are directly interested in the matter as expert specialists. The importance of this feature of the museum work will thus be brought more particularly to the attention of those best able to judge of its value and to profit by the same. I have no doubt that from this class of men valuable work in investigation will be secured.

IV. UTILIZATION FOR THE PURPOSES OF THE MUSEUM OF THE MATERIAL OBTAINED FROM THE DISSECTING ROOM, AND REFERENCE COLLECTION IN OSTEOLOGY.

The question has at times been discussed whether the morphological museum should take its place in the university system as part of the departments of general biology and zoology, or as an integral division of the department of anatomy in the medical school. I am unhesitatingly of the latter opinion. Aside from the obvious relation to undergraduate medical instruction which I have attempted to outline above, the mere fact that man, the highest vertebrate of the series, forms the object of study in the medical curriculum, assigns to the morphological museum its logical place in the

university system. The human material necessary for the completion of the museum series is to be obtained from the supply of the medical school. The typical preparations are, of course, from specially selected subjects set apart for the purpose. Besides this, however, one of the important functions of the museum is to supervise the records of the dissecting room, to collect and arrange the statistical information afforded by the constantly repeated examination of the human body, to acquire for its own purposes the preparations which either illustrate normal structures unusually well or demonstrate important and significant variations. Part of this material is capable of direct incorporation in the museum series after removal from the cadaver and proper preparation. For other objects the method of plastic reproduction by means of casts is invaluable. This applies especially to the great group of myological variations. Not only are the objects bulky and not well adapted for preservation as moist specimens, but casts actually better serve the purposes of the museum in exhibition and instruction. In the comparative myological series, with which human muscular variations are necessarily brought into intimate relation, the method of plastic reproduction is an essential. The full utilization of rare and valuable animals requires this method because superficial structures must be removed before the deeper parts can be reached. As the superficial muscles are exposed casts of the different regions are taken in various positions. In the same way, by casting the deeper layers as they are successively reached, permanent records of the greatest value for myological study and reference are attained. The casts, together with the notes and drawings of the dissection, form a complete and readily accessible record far exceeding in value and accuracy any other method of illustration. Again, for example, in dealing with the development and modifications of the extremities in the vertebrate classes, each group is accompanied by casts of the entire hand and foot, forming, together with the preparations of the soft parts, muscles and ligaments and the skeleton of the extremities, a complete series. For purposes of instruction this method has proved itself very valuable. Thus a carefully prepared and hardened liver showing the natural surfaces and impressions, which are ordinarily lost in the organ removed from the body before hardening, and which are hence not ordinarily recognized, has been cast

and reproductions prepared in sufficient numbers to allow one to each student for personal examination during the demonstration of the organ to the class. This plan, when extended as purposed by the museum, will vastly add to the effect and value of our demonstrative teaching.

The development of the facilities for plastic reproduction of morphological objects enables the museum to enter into connection with other institutions for purposes of exchange and scientific intercourse.

In connection with the utilization of the human material for the museum I desire to mention briefly the Reference Collection in Osteology, as part of the plan of offering opportunities for extensive morphological and anthropological research. This collection includes :

1. The disarticulated skeletons of vertebrate animals.

These are kept in boxes, arranged like the books of a library, accurately catalogued and indexed, so that any desired skeleton can be immediately found and used. The collection is placed in the osteological laboratory. It is proposed to make the collection thoroughly representative, and to include sufficient individual specimens of each form to avoid erroneous deductions possibly based on unusual variations.

2. The department includes, in the second place, a reference collection of human bones, on a scale which renders possible a thorough comparative study in reference to racial character, variations, reversions, age and sex differentiations, etc. The collection is now approaching the limit which we originally designed for it, viz., 5,000 specimens of each of the bones of the human body, but will be extended beyond this point. I am gratified that this material has afforded one of our members, Dr. A. Hrdlicka, opportunity for some very interesting researches, some of which have already been presented to this Association, while his more recent results are to come before us at this meeting. The value of the collection is greatly increased by our system of record-keeping, which makes the material available for anthropological study in the widest sense. We obtain now, from the hospital records, the necessary data as to parentage, age, birthplace, etc., of each subject delivered at the college. These data are entered upon the record under a running number, which follows each bone on a lead tag through all stages of maceration and preparation until it is turned into the reference collection as finished. Conse-

quently this collection does not represent merely a catacomb of human bones indiscriminately packed together, but each bone, with its origin and history clearly indicated, becomes a member of a series available for scientific comparative work.

The same system is applied to all variations of the soft parts obtained from the dissecting room, and the variation collection of the general museum becomes in a like manner the means of promoting scientific inquiry into the causes and conditions at present operative in human evolution.

V. DEPARTMENTAL LIBRARY.

I may merely mention that a good working morphological library, containing the standard works and the more important current periodicals, forms part of the accessory equipment of the museum.

VI. LABELING AND CATALOGUE.

In conclusion I may briefly refer to the method of labeling and cataloguing the collection which we have found most useful.

The catalogue is divided into the *general* and *accession catalogue*. Each specimen as received is given an *accession number*. On the card slip, corresponding to the number in the accession catalogue, are entered all the data concerning the animal, as source of supply, date of receipt, weight of body and of individual parts, presumable age, sex, method of preparation, individual peculiarities, etc., and finally a complete list of the finished preparations derived from the animal as they are incorporated in the museum.

The general catalogue carries on each card the running number of the preparation and beneath the same the accession number of the animal from which the specimen is taken. It is thus possible, while avoiding needless repetition, to ascertain at once the details concerning any preparation by reference to the accession catalogue. The cards of the general catalogue are arranged in accordance with the serial exhibition of the museum. The running number of the general museum and the accession number appear on the label of each preparation. In addition the individual preparations carry two small disks of a bright color with a number. These are the complementary numbers of the preparation, referring it to some other group with which it is related, as well as indicating its position in its proper series. For example, the shoul-

der-girdle of the armadillo assumes its proper place in the series demonstrating the structure of this portion of the vertebrate skeleton, and is numbered accordingly on a green disk, so that its own place in the series is preserved, green being the color of that division of the museum which deals with the development of the pectoral and pelvic arches. If the armadillo's number in the series is 17, and an additional preparation enters the series next to it, it receives green number 17a, etc.

In addition to the green number a small red disk on the armadillo preparation carries a number which refers the preparation to its proper place in the series illustrating the general anatomy of the Edentates, red being the serial color of that division. So if it is desired to put together at once for comparison all the material contained in the museum for illustration of the Edentate type, every preparation carrying a red disk is taken out of its own series and the resulting group, when arranged in the sequence of the red numbers, forms the logical series treating of Edentate anatomy.

This plan makes every portion of the museum easily and at once accessible, and arranges the series in such a manner that each shall prove complementary to all the others.

By varying the shape of the colored labels and the character of the numerals sufficient range is obtained to meet all requirements.

In addition—as the series develop—more extensive type-written tablets are introduced, giving the general features of the group and indicating the purpose for which it was assembled.

Photographs and drawings of the preparations, carefully labeled, are used for indicating points of special importance, in such a manner that they can be readily identified in the actual preparation. These accessories prove of aid in the use of the museum for individual study and during informal demonstrations and conferences.

I have attempted to outline for your consideration the present status of the morphological museum and its relation to the system of the university. I am convinced that the practical value of the institution will continue to make itself more and more felt, and its general adoption and development will be one of the prominent features marking our educational and scientific progress during the next decade.

THE VALUE OF THE X-RAY IN THE STUDY AND DEMONSTRATION OF NORMAL ANATOMY.

BY DR. EUGENE R. CORSON, SAVANNAH, GEORGIA.

I have long felt that the X-ray would prove of value in certain lines of anatomical research, both human and comparative. Before we had the modern perfected coil and tube the value of the X-ray amounted to little, for only poor shadows of the bones were obtained; but, as the X-ray intensity became greater with a more perfect apparatus, the value of the method in the demonstration of normal anatomy was at once apparent. And as, without doubt, there is still much room for improvement of apparatus and technique, we can assuredly look for a still wider field of usefulness in the future. With the present X-ray efficiency at our disposal, its value is evident in the following lines of work.

1. In the study and demonstration of bone development, the growth of the epiphyses, the schema of their development, and the study of joints as joints, with their movements.
2. The demonstration of the internal structure of the bones
3. In the study and demonstration of the exact spacings and positions of the bones in the skeleton as a guide to its proper articulation and mounting. This would find its widest application in comparative osteology.
4. In the study and demonstration of the arteries on the cadaver where, properly injected, they can be skiagraphed in their absolute relations to other structures.

During this year I have devoted much time to the demonstration of bone development by this method, for it has a large practical bearing in its surgical application. Most of the skiagraphs which I present for your inspection have been reproduced in a paper which appeared in the November number of *Annals of Surgery*, on the membral epiphyses at the thirteenth year, and my excuse for showing you these prints is, that they are superior to the reproductions, and will give you a better idea of what we can expect from the X-ray findings. It is, perhaps, in this line of work that the X-ray will give us the greatest assistance, because we can really watch the bones grow, and there are many subtle problems of

bone development which may be solved in this way. Not only can we watch the successive steps in the growth and development of any one center of ossification, but we can get striking pictures of the several centers of ossific growth in the bones comprising a joint or member at the different stages of its progress towards perfected adult growth, that will enable us to take in this joint or member as a whole, a whole which will help to explain its parts.

• This has been especially brought home to me in the demonstration of the elbow joint, perhaps the most difficult one to understand in its development, the complete understanding of which may solve many riddles of bone growth. The skiagraph giving a coronal view of the elbow, shows us in a very beautiful way the entire schema of its development, and I know of no one figure in any anatomy which reveals more of this joint. A series of skiagraphs equally as good at the different years of growth would simply tell the whole story.

I have found in my work that an ossific center not bigger than a pin's head could be made out, provided the bone could be brought close to the plate. My experience is that a good negative offers much for careful study, and details almost microscopic can be brought out by a magnifying glass. In the print giving a coronal view of the elbow the entire course of the nutrient canal of the humerus can be traced, and even more perfectly in the negative.

In the study of joint movements I have attempted to show the value of the X-ray in my paper on the movements of the carpal bones and wrist. Of course the wrist lends itself especially to this method, but I am convinced that other joints can be studied in this way, and much definitely shown which is still in doubt.

In the best skiagraphs we get a skeleton of the skeleton, we get the inner trabeculation and bony structure; and in the skiagraphs of the bones themselves, the negatives are most beautiful and show as much as good sections of the bones. In the study of museum specimens, for example, which cannot be mutilated, the X-ray will give us all the internal structure. A skull so skiagraphed will show us all the sinuses and bone-structure at the base, all the inequalities of the inner surface, the diploic structure, and the grooves for the meningeal arteries. I show you such a skiagraph, one, by the way, which can be much improved upon, for it was done when I had less

experience in this work than I now have. In fact, on the living, we can get good outlines of all the sinuses, the *sella turcica* even, and thus measure the size of the *hypophysis cerebri*! A little thought will show us how certain other points of the skull can be made out on the living. We get thus a certain projection plan of the skull not obtained in any other way.

Another important feature of this work is the proper spacings and positions of the bones, revealed to us as they exist in the joints and in the groups of smaller bones, as in the carpus and tarsus. How many figures are given us in the textbooks where the bones are huddled together as in the articulated skeleton. In comparative osteology its value here must be even greater in giving us the true relations and arrangements of the bones, especially in the smaller animals, where the bones are so much smaller and their positions more difficult to estimate.

Another field but little worked up as yet, is the demonstration of the arteries, where the arterial trunks are injected with a substance which the X-ray can shadow. The Germans have done some work in this direction. We can get in this way skiagraphs of the arterial trunks, even up to the minutest arterioles, and in their exact relations to the bones, and even to tendinous and muscular landmarks, for much of the latter can be brought out by careful technique.

There is a certain mental drill associated with this work. From these bone-shadows the imagination is constantly building up mental pictures of the real bones. One is ever tallying the substance with the shadow. And these shadows are so different from the two-dimensional shadow of ordinary light. The X-ray shadow is a translucent one, so to speak. There is a perspective to the picture, and the bone shadows stand out like the real thing, with contrast, and depth, and the most delicate shading. The good negative is like an etching, and the better the negative the more this etching effect comes out in the print. My X-ray work has given me vivid mental pictures of the bones that I never had before. It has given a new interest to what had become familiar and commonplace.

As the acid eats out for us the earthy salts of the dead bone, leaving the animal matter, the X-ray eats out for us the an-

imal matter of the living bone, revealing the earthy framework in all its beautiful detail.

My friend, Prof. S. H. Gage, of Cornell University, had my prints made into transparencies for the stereopticon, and the pictures were brought out on the screen in a very striking way with all their detail and contrast, and I think it was the general opinion of those present that the demonstration of bone development at least could be made most instructive by this method. This subject does not enter much into the course in anatomy, and few students leave College with much knowledge of the subject, although it has a real practical bearing from a surgical standpoint. One or two lectures in the course so illustrated could be made most effective in a didactic way, and I have no doubt that this method will be so utilized.

THE LEVATOR ANI MUSCLE.

BY DR. EDMUND W. HOLMES, PHILADELPHIA.

If we trace the transversalis fascia downwards over the pelvic brim, we will find it continuous along the outer pelvic wall, in its attachments, to the margin of the sacrum and coccyx, to the tuber ischii and rami of the ischium and pubes, and anteriorly it spans the triangular space of the vesical triangle to join its fellow of the opposite side, subtending the subpubic membrane, forming the so-called posterior layer of the triangular ligament. Thus regarded, the fascia is wholly parietal, shutting out from the pelvic lumen the pyriformis, the obturator and the compressor urethrae muscles, and affording practically a mesial sheath for these muscles.

Internal to the fascia, on a line from the posterior surface of the crest of the pubes, to the spine of the ischium, our muscle arises from the face of this parietal fascia, from which also a fibrous leaflet projects proximal and distal to the levator ani, running downwards and inwards parallel to its muscular fibers, being called, respectively, the recto-vesical and anal fascias, but for our present purpose merely forming a sheath for this muscle, and in reality constituting the true supporting floor of the pelvic outlet.

The levator ani in its origin is unique. At its extremes, two small, bony points, and the rest, "the white line," all membranous. Powerful as its fibres are and important its function, I can think of exactly no such origin for any other muscle in the body. Its insertion also is fixed, only at the perineal center and the coccyx, while at the median raphé, movable, though counterbalanced by its fellow of the opposite side, and at the sphincters is as yielding as the soft viscera themselves.

Its peculiar attachments indicate a more varied function than its name implies, while its muscular layers are amply exercised, in affording a flexible floor for the pelvic viscera, which is influenced by each respiratory movement. In fact every practical operating gynecologist watches the breathing

movement of the perinaeum and feels the pulsation of the adjacent arteries, so that with the vascular beat and the respiratory rhythms at hand, he should not be entirely ignorant of the aetherized status of his patient.

The muscular fibers of the levator ani are distributed in a series of curves, arching downwards and inwards, those from the pubes extending posterior to the prostate. I cannot find that any part of this muscle is actually attached to this gland, only the fibrous sheaths coalescing, but the muscular fibers go behind it to conjoin with the opposite muscle, constituting a compressor as well as a levator prostatae. The radiations from the "white line" go directly to the perineal center and the sphincter ani, and to the sphincter vaginae in the female. We cannot trace muscular fibres to the walls of either of these canals, as again only the fibrous capsules are continuous. In fact, the upper edge of the levator ani can be traced to the edge of the sphincter ani, to that of the sphincter vaginae, the main support of both of these columns being the rectovesical fascia and not the muscle. In the interval between the prostate, rectum and coccyx and in the corresponding parts in the female, the levator ani meets its fellow of the opposite side.

The architectural plan of the pelvis is that of an ellipse; roughly speaking, the inlet and the outlet of the true pelvis may be regarded as two ovoids almost touching at the symphysis, widely separated by sacrum and coccyx behind, with "Carus" curve as the axis or stem.

The bladder with its urethra curves downwards and then forwards to emerge anteriorly; paralleled by the vagina, and then by the rectum, though later the anal canal curves away almost in the opposite direction.

The vagina was never intended to be a straight canal, but curves forward. In the erect posture, the weight of the abdominal viscera is thrown upon the symphysis and the upper circle of the bony arch, the fundus of bladder and uterus having a similar direction; the rectum curves parallel to the uterus following the hollow of the sacrum. The whole mechanism, I need hardly say, showing in the female, nature's intention to direct the foetal vertex under the pubic arch, the curve of the sacrum, the inclined plane of the pyriformis and of the obturator internus also having this tendency.

The fibers of the levator muscle are practically, therefore,

arranged in concentric layers, none of which are directly inserted into the vaginal or rectal walls.

The recto-vesical fascia which forms the proximal side of the muscular sheath blends with the fibrous coat of each canal. But the only direct interlacement of muscular fiber is with the sphincters.

By contraction the levator ani antagonizes the sphincter and thus opens the orifice of the vagina or rectum, while the remaining fibers attached to the median raphe, may in conjunction with its fellow, compress each canal and coapt the posterior to the anterior wall slightly, but such action must be very slight, it more likely acting as a tensor to the fascia. For this double function we find a sure sign—a double nerve supply—the inferior hemorrhoidal and the fourth sacral, and in further confirmation the latter nerve (fourth) supplies the compressor urethrae, which is also compressor in function. Similarly, as a result of its insertion into the vaginal sphincter, its fibers have only an indirect relation to the vaginal outlet by keeping the fascia tense, and to a slight degree coapting the posterior wall against the anterior. In parturition, therefore the vaginal sphincter tear is immaterial, but laceration of the supporting fascia a very serious matter.

The origin of our muscle being admitted, we concern ourselves, then, more particularly with its insertion. It would seem as if the authors are in error in asserting that the levator ani is inserted "into the lateral aspect of the prostate," "into the side of the rectum" or "into the walls of the vagina;" but, like its origin, the muscle is attached to a narrow linear insertion, the median raphe and the two sphincters. Probably through the fibers supplied by the inferior hemorrhoidal antagonizing the sphincters, at the same time rendering tense those inserted into the median raphe, while through these fibers encircling the bladder and prostate, or in the female the vagina, and supplied by the fourth sacral, it compresses these organs.

It is more a tensor of the fascia either at its origin or insertion, the fixed point being interchangeable, so that it should be called "tensor perinei" rather than "levator ani."

THE USE OF WET SPECIMENS.

BY DR. EDMUND W. HOLMES, PHILADELPHIA.

The purpose of this paper is not ultra scientific, but argumentative and evangelistic, because (1) among the general public and among many of our profession the great cry is practicability, *i. e.*, the doctor must be able to use that which he knows, and, knowing it, must be able quickly to transform it into gold; because (2) our medical schools are advocating the scientific idea—science and knowledge for its own sake—and, strangely enough, in the sectarianism of the laboratory are endeavoring to train their pupils to be scientific before they have been educated as physicians. We most thoroughly endorse the sentiments of Prof. Dwight, expressed at the last annual meeting in New Haven, in opposition to excessive student experimentation.

As a resultant of these two forces, our medical schools are getting away from their original intent of turning out practicing physicians, but in their stead are evolving one-sided specialists, which the tendency to laboratory and section teaching only seems to increase, by compelling men to choose a certain subject or two, which shall, perforce, occupy the greater part of their attention, to the disadvantage of the rest.

A good plan badly carried out is fatal to its efficiency, and laboratory or section work which (needlessly) tends to a narrow specialism in the undergraduate years, backed up by popular clamor for immature specialists and an undue desire for quick financial returns, is really worse than the old system of seven fundamental branches, of intelligent breadth of instruction, in *all* of which the graduate must be reasonably proficient.

From this attitude of utilitarianism and specialty has arisen a disregard of the fundamental branches and an impatience of the toil necessary for their acquirement, particularly in regard to human anatomy, which is ill concealed even by some in authority.

Let me quote two remarks that I have heard of as coming from two well known scientific anatomists—

(1) "There is nothing new in human anatomy; it is all in the books."

(2) "A man who has a book, a subject and a scalpel ought to be able to work it all out for himself"—

two as damnable heresies as ever were anathematized in a papal bull.

Following this has come a neglect of teaching method, so that in many instances the arrangements for instruction in anatomy are no better than they were twenty-five years ago.

One of the most obvious improvements is the teaching of anatomy in small sections, which has not been put in practice in the dissecting room for want of time, because the roster is overcrowded with subjects that belong more properly to the post graduate work and because it requires an increase in the corps of instructors.

Next to small numbers is the methodical apportionment of the work. There is no reason why on a certain day, in chemistry the class should work on certain elements, or in physiology on certain reactions, or in histology on certain tissues, while in dissecting it is a "hop scotch," "happy-go-lucky," "go as you please." If it were possible, we would not only assign the same dissection for the same section hour, but we would have the scalpels ply together, with the same unison as the violin bows in a well trained orchestra. If the task for the period is the deep fascia of the thigh, it would be a delight at the end of the hour to go around the room and see it thoroughly defined on every cadaver, with its subdivisions, its saphenous opening and the superficial veins and nerves lying neatly in view.

To be ahead of the assignment is a crime, to be behind is far better if it implies not sloth nor ignorance, the most careless students being the most rapid slashers.

Methodical and trim dissection implies a foreknowledge of the structures, exacting preparatory work at home; but it is difficult to impress the fact that the dissecting room is a laboratory and not a library alcove. Didactic reading should be done at home, the only use of the book here being in connection with the cadaver.

We would mark "absent" those who are away from their "part" for any considerable interval longer than to ask a

question, glance at a skeleton or examine briefly another dissection.

We would not allow students to cluster around tables not their own; it is usually an excuse to escape work.

Upon each subdivision, head, arms, &c., once a week a demonstration should be given showing the structures to be dissected out, and the assistant in charge should be expected to see that his students do that work, and may aid them individually, but should not in any way, by demonstration or otherwise, draw men from their work at other tables. In other words, the whole emphasis of the dissecting room should be upon the dissecting, and not upon the loafing, the telling of stories, the eating of lunch, or even the reading of anatomy. In place of the text book should far more usefully be provided the wet specimen and the explanation of the teacher. Further, as I have said elsewhere ("Medical Education," p. 10);

"Human bodies are too costly and too sacred to be used to teach novices the elementary principles of the dissecting art, such as how to take off skin or fascia, or how to clean up the insertion of a muscle. It can just as readily be done upon the cat or the rabbit. A student should not be allowed to touch a human cadaver till he knows how to dissect, and has been drilled upon a wet dissected (human) specimen to learn what to look for."

Knowing first, then, what to look for, the wet specimen of muscle, artery or joint should be kept continually before him as a pattern from which to work. We find a good dissection stimulates to good work; and upon being shown a structure clearly defined the student is the more ready to work it out for himself.

We all know it is not always possible to show everything on one part. This defect is also supplied by a wet subject; neither are the deeper connections given us at a glance, though they can well be indicated by the accessory dissection. Further, in the exhibition of deeper structures the more superficial must be cut away, but in the review they may be seen again in the permanent preparation.

At the conclusion of the dissecting period, several days should be devoted to review, when demonstrations may be given by all the table assistants, stopping at the point where the student "lays down upon the instructor;" such reviews

being imperatively on the cadaver and not "didactic" nor from the book.

One of the aggravations in a demonstrator's life is the *alumnus dissector*. He has graduated under the old regime; finds, to his sorrow, his weakness in anatomy, the lack of which there is nothing that he regrets more; so he comes back and says he has forgotten his anatomy (in reality he cannot forget it because he never knew it, if for no other reason than as a student he dissected the body only once, and no child could learn a simple puzzle that way), and declares he returns to his *Alma Mater* firmly determined to learn it—in a week. He "cares not for details and only wants the main facts." "How many parts can you give me?" "All you want!" "Well, send me up a leg." As he has taken a whole week off from practice to come to the city, he must see some of the performances of the theaters at night, and also some of the clinics by day, for of course by this time he is a specialist, having studied abroad six weeks, of which two were on the ocean.

After two days' work he becomes tired of the tedium of dissecting, and if he is allowed, he will ligate the arteries, amputate the extremities, and operate on the appendix, thereby precipitating an epidemic of similar operative procedures among the student body.

For such hurried practitioners we unqualifiedly recommend the wet specimen. With a book on applied anatomy, with the dissected subject before him, he can get ten times more practical benefit than he can by the hurried, untidy labors of his own hand.

Thus for both student, graduate and teacher the wet specimen is most admirable, enabling of rapid review upon a series of preparations far more elaborately and completely worked out than could possibly be accomplished by the individual not an expert.

In the average medical curriculum there are apt to be two great humbugs, the clinic and the dissecting room; that is, the large clinic where you see nothing, and the large dissecting class where you do nothing. If we were given the choice, with the average student, between a course of study upon the cadaver, with carefully prepared wet specimen, and the average hacked-up dissection, we would without hesitation recommend the former. Therefore for intelligent comprehension based on sound pedagogical principles, instruct your student first as to

what to find and where, "in the wet," and then careful, neat, systematized dissection cannot be done too often.

For the preservation of the wet specimens the cold storage is by far the best. Alcohol hardens them; a solution of chloral waterlogs them; formalin preparations favor mold as soon as the fluid is allowed to evaporate. Even the Kaiserling fluid permits of this if the specimen is not kept thoroughly immersed. But, outside of permanent jar preparations, those which are to be handled had better be kept in storage and can be thus used from year to year.

In the coming by and by, when the importance of the dissecting room is recognized, there will be a cold storage plant for this purpose adjacent to it. More and more, in the old museum, its musty jars will be relegated to desuetude, and specimens to be handled by the student will be abundant and within reach.

Human anatomy is the most difficult branch in the curriculum; the student entering without biologic training, and, perhaps, with it, is but a kindergartener, and should be taught at first as in the kindergarten, by models and specimens, taking apart and putting together, till he learns whereof he knows, and then he should dissect.

TYPICAL FORMS OF SHAFT OF LONG BONES.

BY DR. ALES HRDLICKA, OF NEW YORK CITY.

[Abstract.]

The paper presents the further results of the author's investigations of Prof. Huntington's osteological collection in the Medical Department of Columbia University, New York City. It deals with the variations in shape of the shaft of the long bones of the human skeleton and with classification of these shapes. The first part of these studies, dealing with the typical shapes of the shaft of the tibia, was presented before the Association in 1898.

There have been examined so far the long bones of 1,200 skeletons of whites, 40 skeletons of negroes and 100 skeletons of Indians.

Each variety of the long bones presents more than one typical shape of the shaft. The form is best differentiated at or near the middle of the bones, in adult individuals.

Variation in the shapes is greatest in the whites. There are considerable racial differences in the absolute as well as relative frequency of the different forms of shaft of the various bones; no one type, however, occurs exclusively in either of the three racial groups examined.

The bones of the lower extremity show somewhat more numerous differentiations of form than those of the upper extremity. Of the individual long bones the fibula shows the greatest variety of shapes; then follow, in the order named, the tibia, femur, humerus, ulna, radius.

Perfect representatives of the various types of form are found when larger collections of bones are examined; less perfect but clearly distinguishable types are more common. Besides these a considerable percentage of bones presents intermediary, and a smaller proportion combined, forms.

The fundamental form of shaft in all the long bones is the prismatic (No. 1). The outline of the cross-section of a shaft of this type approaches closely the equilateral triangle. This type of long bones is common in apes and, more or less modified, in lower mammals. The base of the prism is formed in

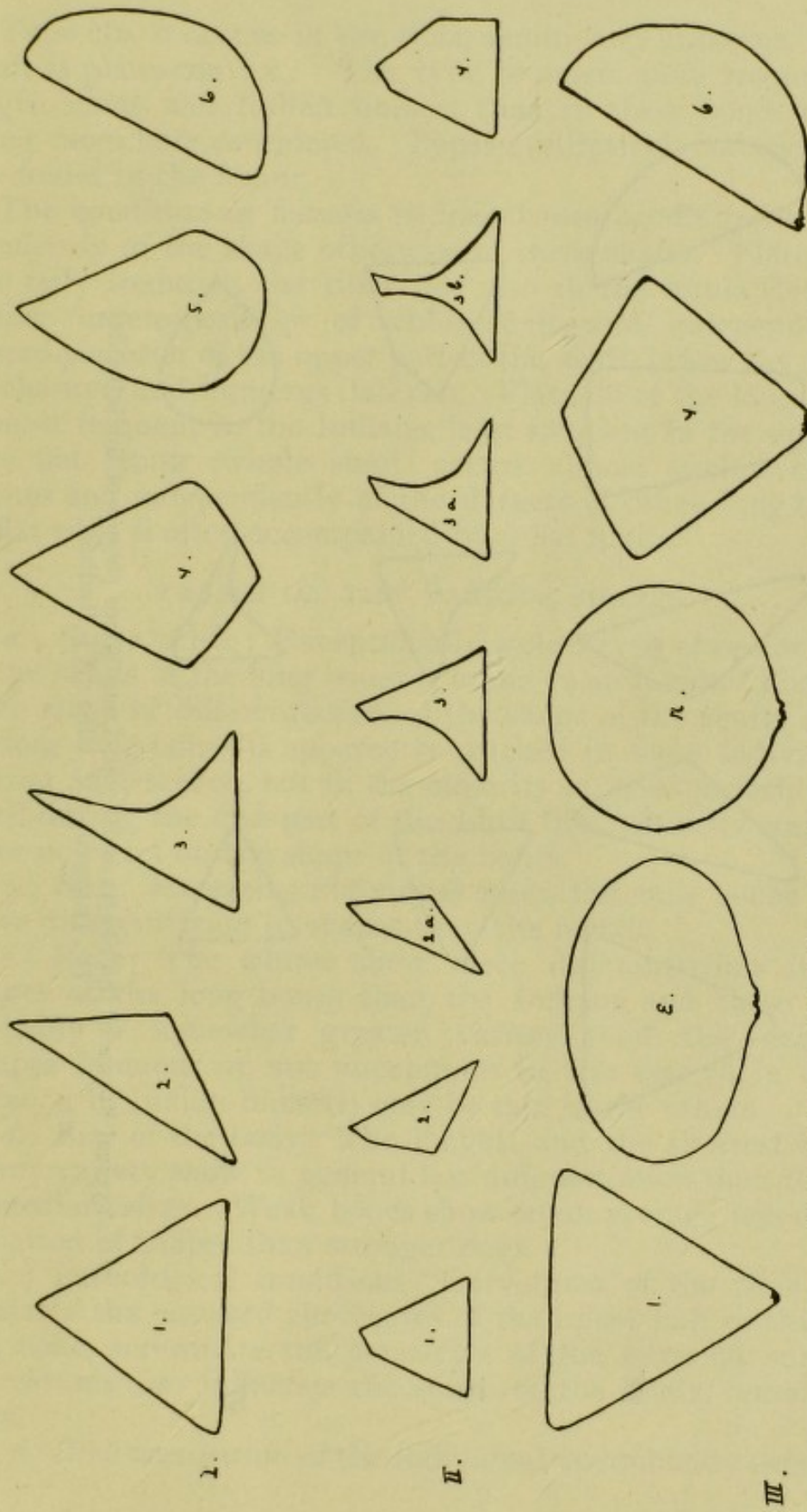
the tibia, fibula and humerus by the posterior; in the femur by the anterior; in ulna by the internal, and in radius by the external surface of the bone. In whites this type of shaft is most frequent in the humerus. In the fibula it is slightly modified by the anterior surface of the bone.

The nearest modifications of type 1 are types of shaft Nos. 2, 2*a*, and 4. Types 2 and 2*a* occur principally in the tibia, fibula and humerus; and are characterized by the obliquity of the posterior surface of the bone. Type 4 occurs in all the long bones, and is characterized by the presence of a distinct additional surface on the shaft. The formation of the surface differs in the various bones. In the tibia the additional surface results from a division into two, by a vertical ridge, of the posterior surface; in the fibula a duplication is observed on the external surface; in the femur it is the anterior, in the radius the external, and in the ulna the posterior surface, which occasionally, through the influence of a vertical ridge, shows a formation of a distinct additional plane; in the humerus, finally, a new, anterior surface results occasionally by the broadening out of the anterior border of the bone.

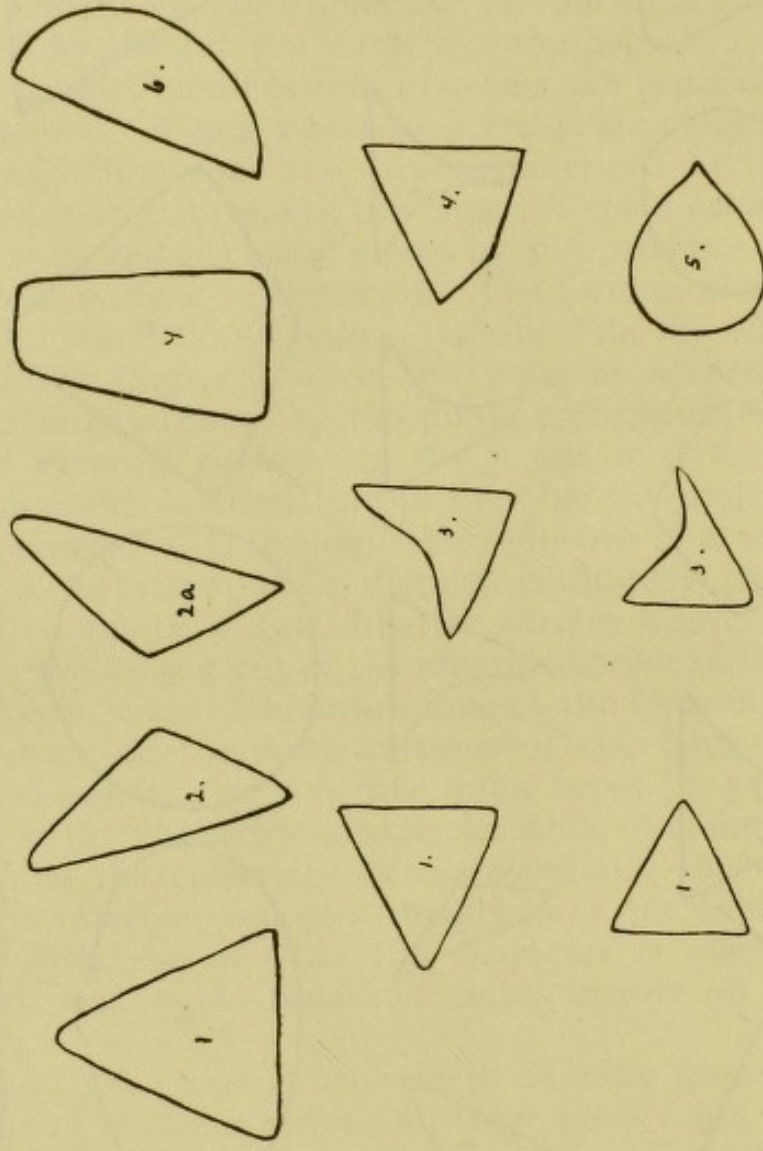
A special class of modifications of the form of the shaft is that where one or more surfaces of the bone show a pronounced concavity. We find such types (3, 3*a*, 3*b*,) particularly in the fibula, but also in the tibia, ulna and radius. In the fibula the concavity affects especially the external, but also the internal, and occasionally both the external and internal surfaces; in tibia the character is observed on the external and in the ulna and radius mainly on the anterior surface.

Types 5, 6, *e.* and *r.*, are widely differing forms of the shaft of some of the long bones; all these types have, nevertheless, two features in common, and that is an indistinctness or complete obliteration of one or more of the borders of the bone and marked convexity of two or all the surfaces. They approach more or less the infantile types of the bones.

Type 5 occurs occasionally in the tibia and frequently in the radius. It is marked by the convexity of the posterior tibial and external radial surface and by indistinctness of the internal and sometimes also the external border in the tibia and the anterior and posterior borders in the radius. In both bones, but particularly in the tibia, this type of form represents a deficiency in the differentiation of the bone.



Typical Forms of the Shafts of Human Long Bones (bones of the left side).
 I. Tibia ; II. Fibula ; III. Femur.



IV.

V.

VI.

Typical Forms of the Shafts of Human Long Bones (bones of the left side).
 IV. Humerus; V. Ulna; VI. Radius.

Type No. 6 occurs in the tibia, femur and humerus. The shaft is plano-convex. The type is much more frequent in negro tibiae and Indian humeri than in these bones in the other races here considered. Types *e* (elliptical) and *r* (round) are found in the femur.

The condition of flatness in long bones occurs quite independently of the shape otherwise of these shafts. Flatness is not only found in the tibia, but also in the fibula (lateral), femur (antero-posterior of whole shaft, and, independently, antero-posterior of the upper part of the shaft, below the minor trochanter) and humerus (lateral). Flatness of the long bones is most frequent in the Indians, least frequent in the negroes. The flat femur (whole shaft) occurs almost exclusively in whites and independently of the flatness of other long bones. A flat tibia is often accompanied by a flat fibula.

CAUSES OF THE VARIOUS SHAPES.

(*a.*) Stage of life: Exceptionally a clear type of one or more of the shafts of the long bones is found in an infant. The ultimate stage of differentiation of the shape of the shafts of the various long bones is apparently reached in some individuals during adolescence, but in the majority of cases probably not until during the first part of the adult life. Senility seems to have no effect on the shape of the bones.

(*b.*) Sex: Excepting individual cases, the male bones show more differentiation in shapes than the female.

(*c.*) Race: The whites show more differentiation in the shapes of the long bones than the Indians, and these show probably a somewhat greater variety than the negroes. Shapes frequent or not uncommon in one race (6 in negro tibiae, 4 in Indian humeri) may be rare in the others.

(*d.*) Size of the body: The longest and the shortest bones of any variety show in general less differentiation than the intermediary sizes. Weak bones show on an average less differentiation of shapes than stronger ones.

(*e.*) Pathological conditions: Curvatures of the tibia, particularly the outward curvatures of the upper half or third of the bone, accentuate the concavity of the external surface. Curvatures also influence the shape of the fibula, femur and ulna.

(*f.*) The occupation of the individual undoubtedly exercises

an influence on the shape of his bones. This subject, which is very complex, is under investigation.

(g.) The sum of the observations thus far concluded, points to the fact that the principal causes of the various shapes of the shafts of the long bones must be sought for, first, *in original differences in the attachment of the various muscles on the shafts*, and, second, *in an unequal development and work of these muscles during childhood and adolescence*. The original differences in attachment, some of which can be clearly demonstrated on the bones, will probably be shown to be partly hereditary, partly anomalous conditions. The manner in which the differently attached or differently developed muscles affect the shapes of bone must evidently be largely if not entirely mechanical.

Investigations continue in this direction as well as those concerning the concurrence of the different types.

The studies of the various forms of shaft of the human long bones lead to the following two generalizations:

(1.) The various forms of shafts represent possibilities of results of our present anatomical peculiarities and our present activities.

(2.) The greater range of variation of the forms in the whites than in the Indian or negro, corresponds to and is the result of the greater variation of activities among whites and probably also of inborn characters such as defects and surfects of muscle-insertions.

Investigations of the bones of whole families, or of persons related through much intermarriage or through some definite occupation practiced for several generations, are very desirable.

As to the tendency of the diversification of the forms of the shaft of the long bones, only possibilities can be spoken of. The variation of shapes may further increase. As to an evolution of any new type of skeleton, there can not be much expectation of such an event so long as activities diversify and mixture is great. Should, however, any definite class of activities continue to preponderate, either in some more isolated community or generally, it is logical to suppose that the type of bones most adapted, that is, presenting the least resistance, to those activities, would show a gradual augmentation.

CONTRIBUTION TO THE OSTEOLOGY OF RIBS.

BY DR. ALES HRDLICKA, OF NEW YORK CITY.

[Abstract.]

The material examined consists of 1,000 first, 1,200 second and 14,000 other ribs of Prof. Huntington's collection, and the ribs of numerous Indian skeletons in the American Museum of Natural History, New York City.

THE FIRST RIB.

(a.) This rib shows considerable differences both in size and shape. Two varieties of shape can be distinguished: the ribs of the first variety are nicely curved and almost semicircular in outline; the ribs of the second variety show in their course one or two distinct angles.

(b.) The "scalene" tubercle, or, rather, spine, was found as follows:

	<i>Per cent.</i>		<i>Per cent.</i>
Completely absent,	9.5	} Approximately,	30.0
Mere trace,	21.0		
Present, various sizes,	69.5	—Approximately,	70.0

In 2.0 per cent. of the ribs a distinct double spine was found.

The formation of the spine seems to be partly due to the mechanical effect of the contact of the subclavian artery with the first rib. The exact significance and formation of the spine needs further investigation.

(c.) On the superior surface of the first rib, near its sternal end, on or near its ventral border, there exists in 16.5 per cent. of the cases a distinct and occasionally prominent tuberosity, with an articular or, rather, a *contact* facet for the clavicle.

(d.) The cartilage of the first rib ossifies earlier than any other rib-cartilages; it also ossifies in another manner than most of these. In other ribs than the first, and possibly the second, the ossification of the cartilage proceeds, especially in one or both borders, on the surface, irregularly from one or a few points and the bone extends gradually over most of the

cartilage, showing none, or but very irregular interruptions or defects. On the cartilage of the first rib, the bone forms generally in more or less irregular, concentric segments. There are ordinarily three, four or five such segments, and they join by their serrated borders. Each segment may consist of several pieces of forming bone.

In rare cases the ossified cartilage of the first rib becomes united to the sternum; this process may possibly be influenced by some pathological condition.

(*e.*) A number of first ribs were found showing one or two pronounced deformities on their superior surfaces.

THE SECOND RIB.

(*a.*) The bone differs in size as well as shape. In shape there is a tendency to an angular form, the angle being situated at the tuberosity, but the modification is not as plain as in the first rib and not pronounced enough to constitute a distinct type of the second rib.

Pathological (rachitic) influences are more manifest on the second than on the first rib; they affect mostly the sternal extremity of the bone.

(*b.*) The tuberosity of the second rib is subject to much variation; it is almost absent in some and very pronounced in other specimens.

Anteriorly to the tuberosity, we find occasionally a more or less pronounced notch on the external border of the bone.

(*c.*) The ventral border of the second rib presents in some cases, in a location corresponding somewhat to that of the "scalene" tubercle on the first rib, one or two distinct small spines or tubercles. More frequently we find in this location a roughness or a dentation of the border.

RIBS BELOW THE SECOND.

In health, the fourth to tenth ribs show comparatively but little variation in form. The third rib, particularly its sternal half, is more subject to modifications. The eleventh and twelfth ribs differ much more in size than in shape. Occasionally the anterior extremity of one of the longer ribs will be unusually broad, or, again, tapering. In some cases a part of the inferior border of the rib shows an unusual development, and in others the head is much broadened.

The results of pathological (rachitis) and mechanical influ-

ences on the ribs from the third downward are quite frequent and apparent in whites; no deformities of this nature were found in the ribs of Indians.

NOTCHED RIBS.

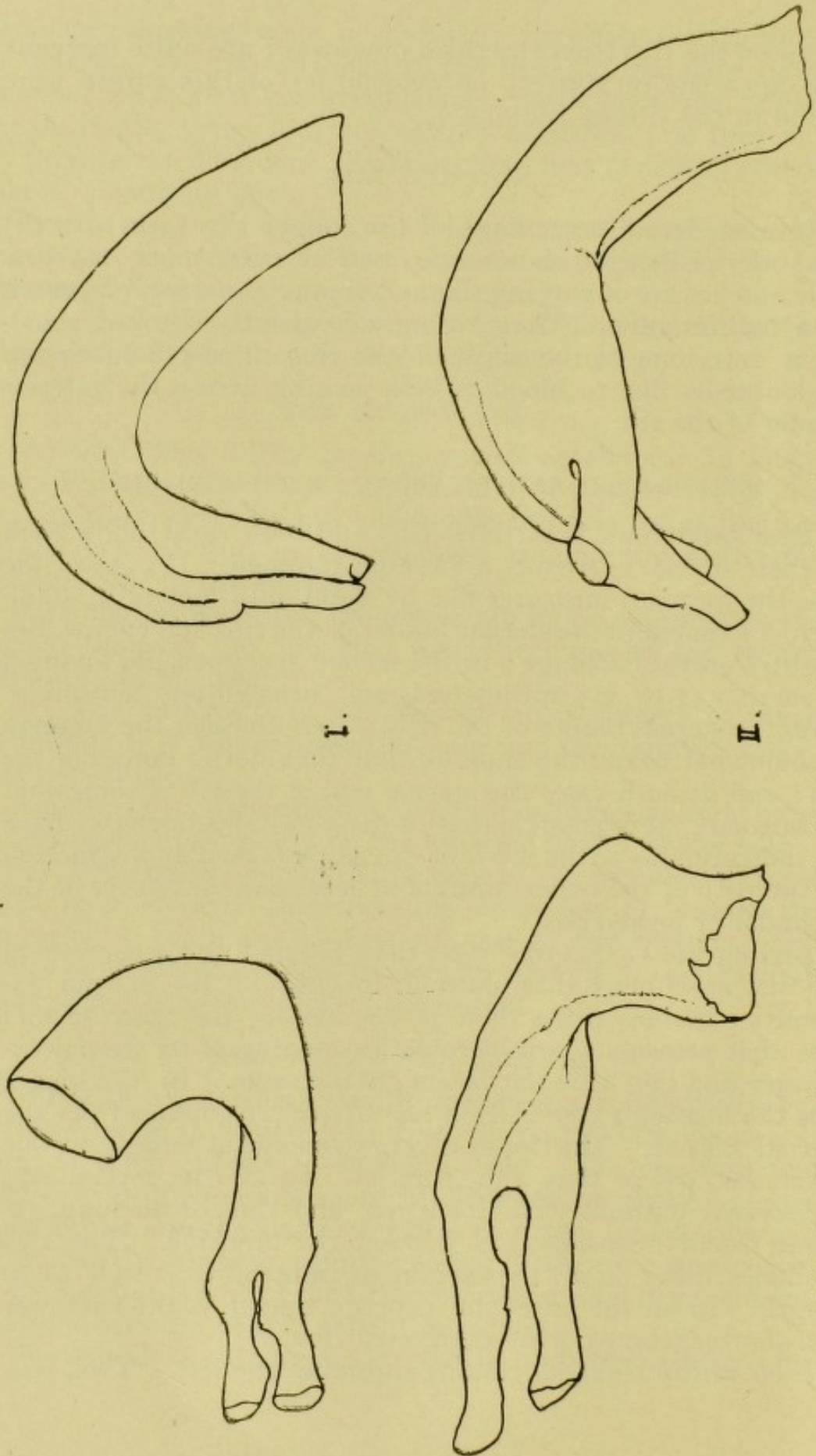
In a moderate percentage of the longer ribs (4th to 10th) the inferior border shows one, two or even more notches. The notches are of varying size and depth; some form as much as a half-foramen. They are most frequently situated somewhat anteriorly to the angle of the rib. These notches are undoubtedly due to blood vessels passing across the inferior border of the rib.

PERFORATED AND BICAUDAL OR FORKED RIBS.

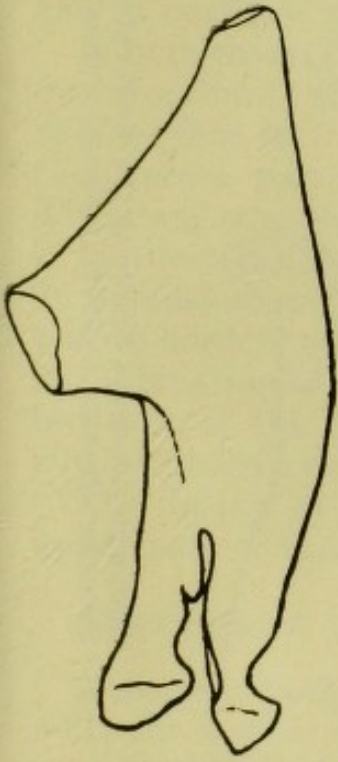
Two specimens, both third ribs and both right, show each in their sternal extremity a vascular foramen. In one of the ribs the foramen measures five by eight millimeters in diameter, is situated in the sternal border of the ribs and encroaches slightly on the cartilage; in the second specimen the foramen is smaller (2 by 3.5 millimeters) and situated one centimeter from the sternal border of the ribs. In both cases the foramen is somewhat nearer the superior than the inferior border of the rib; and in both cases the sternal end of the rib is somewhat broadened. It is possible that in these two specimens we have an indication as to the mode of causation (vascular obstruction in the path of the ossification) of at least some instances of the bicaudal or forked ribs.

Among the 14,000 ribs other than the first and second there are six specimens that show a forking of the sternal extremity; besides these there is one among the 1,200 second ribs that presents a considerable broadening of its sternal extremity and two articular facets on the same. In the longer ribs the forking extends from one to five centimeters from the sternal border. The forks diverge somewhat except in one specimen, where they run parallel. In all the forked ribs the sternal extremity is broadened, and this broadening extends usually considerably beyond the division. The two branches differ in all the specimens in breadth as well as in length. In all the cases the superior branch is the narrower and shorter (compare the perforated ribs).

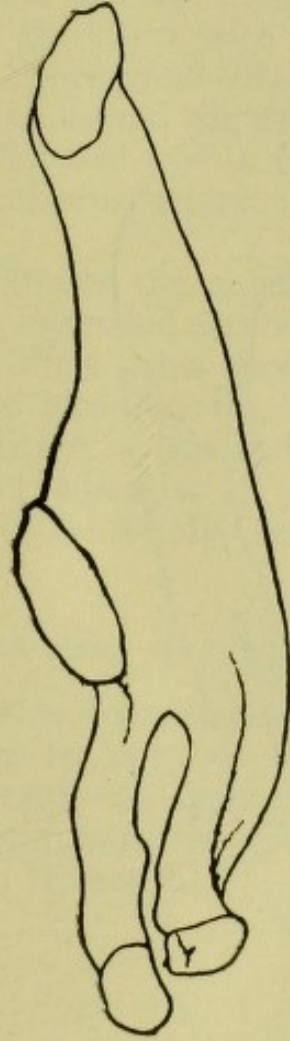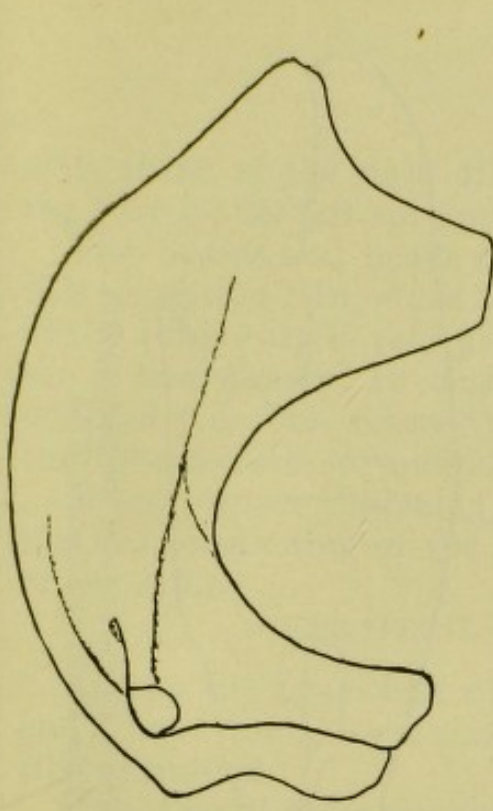
Four of the bicaudal ribs are right and one left. Two, pos-



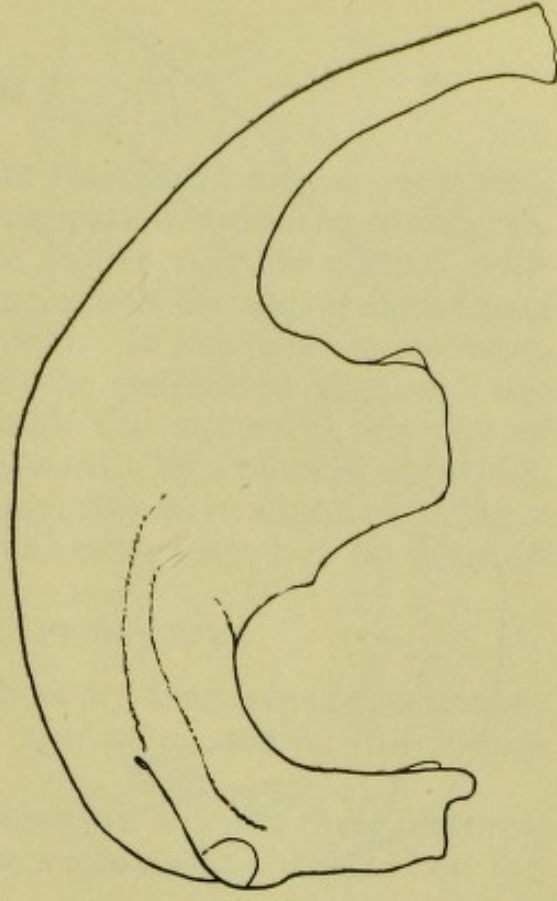
I. II. Specimens showing a Fusion of the distal extremity of a Cervical with the body of the First Rib.



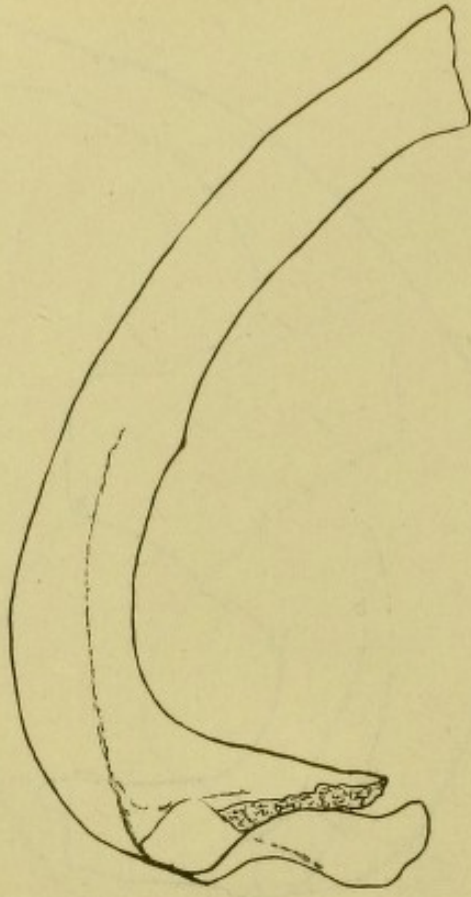
III.



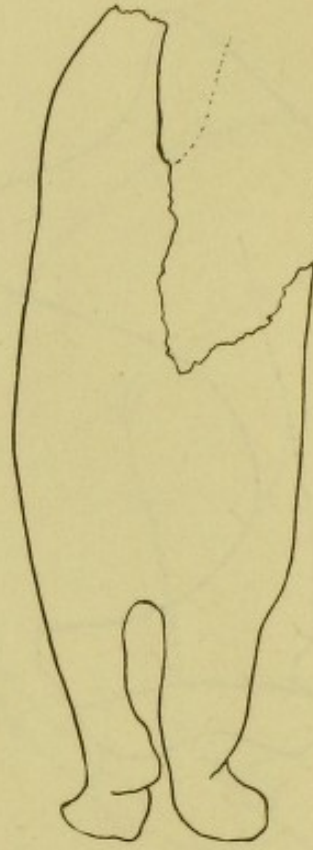
IV.



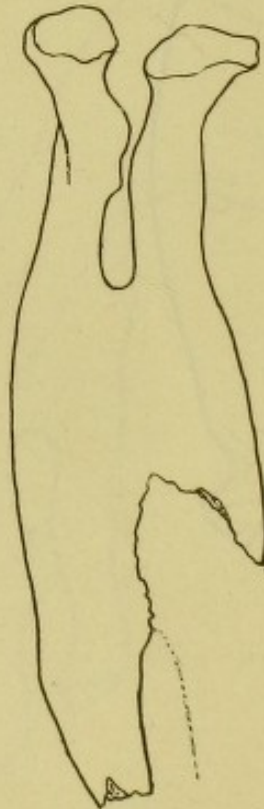
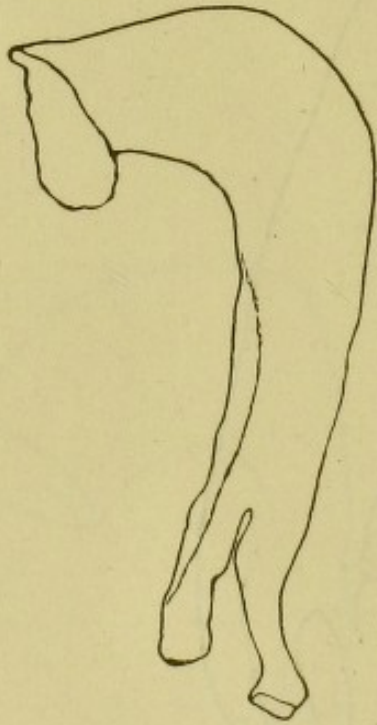
III. IV. Specimens showing a partial, marginal Fusion of the bodies of the First and Second Ribs.



V.



VI.



V. Specimen showing a Fusion of the distal extremity of the First with the body of the Second Rib.
VI. Specimen showing a partial, marginal Fusion of the bodies of the Third and Fourth Ribs.

sibly three, of the right ribs are the third ; one, at most two, the fourth ; the left specimen is apparently also the fourth rib.

The bodies and heads of the forked ribs are normal with this exception : In one of the specimens the non-articular part of the tuberosity is very prominent. In one (the same character is also present in both of the perforated ribs, and undoubtedly has no connection with the anomaly) this part of the tuberosity is surrounded outwardly by a marked exostosis.

Several upper thoracic (3d, 4th) ribs were found showing a marked broadening of the sternal extremity, but no division of the same.

BICIPITAL AND FUSED RIBS.

Among the 1,000 first ribs there are four joined specimens ; and I have found two similar specimens among the Indian ribs examined.

Only two of these six specimens are alike in their features, and five times out of the six the anomaly has occurred on the left side.

In two of the six cases we have a junction of a cervical with the first rib, in three a junction of the first with the second rib, and in one case a junction of the third with the fourth rib.

In both cases of the union of the cervical with the first, and in one of union of the first with the second rib, the more superior rib descends to the more inferior one and is fused with this ; the sternal part of these specimens shows no abnormality. These are true bicipital ribs.

In the remaining three specimens the anomaly consists in an extension and more or less extended fusion of the neighboring borders of the ribs. In these cases we have seemingly a combination of a bicipital and bicaudal rib ; the production, however, of the bicaudal condition in this and the variety of ribs previously described differs radically.

The fusion of ribs seems to be wholly restricted to the upper part of the thorax.

DIFFERENCES BETWEEN THE RIBS OF THE TWO SIDES.

A set of ribs from a skeleton is demonstrated. Beginning with the fourth rib, the bones on the two sides show very considerable differences in strength and shape of the body, not due to curvatures. The 11th and 12th ribs differ remarkably, the more superior ribs slightly, in length.

Less marked differences in the shape, strength and length of the ribs of the two sides are common in both undeformed and deformed thoraces.

ARTICULATIONS BETWEEN RIBS.

Occasionally, after a fracture of a rib, there is a development, from the callus, of a bony process which reaches to the adjoining rib, or meets a similar process sent from this, and the process and the rib or the two processes form an articulation.

In one instance, in the skeleton mentioned in the preceding paragraph, there are well developed articulations between four ribs on each side (8th to 11th) without there having been any fracture. The articular facets are slightly elevated; they are situated near the angle of the ribs, and have undoubtedly resulted from a close apposition and at least an occasional contact of the dorsal thirds of the bones.

FRACTURES OF THE RIBS.

Among the whites, fractures were found in four per thousand (1 in 125 skeletons) in the first rib; twenty per thousand (1 in 25 skeletons) in the second rib; and fifty per thousand (1 in each, or 3 in every third skeleton) in the ribs below the second. In Indians, fractures of ribs are very much more rare* (and the same seems to be the condition in the negro, but there were not enough negro ribs to permit a definite statement).

The fractures were:

Single in	77.4 ⁰ / ₁₀₀	(right, 39.4,	left, 38.0 ⁰ / ₁₀₀).
Double in	19.0 "	(right, 9.4,	left, 9.6 "
Triple in	3.2 "	(right, 1.6,	left, 1.6 "
Quadruple in	0.3 "	(right, 0.15,	left, 0.15 "

The situation of the single fractures was as follows:

In the head,	right, 0.3 ⁰ / ₁₀₀	left, — ⁰ / ₁₀₀
Between head and angle,	right, 2.9 "	left, 2.1 "
At the angle,	right, 8.4 "	left, 9.0 "
At or in the posterior third of body	} right, 21.0 "	left, 18.8 "
At or near middle,	right, 17.5 "	left, 26.0 "
At or near anterior third,	right, 21.5 "	left, 23.0 "
Near the sternal end,	right, 6.1 "	left, 3.5 "

Curvatures and pathological conditions of the ribs will be described later.

* Among 1480 ribs of the ancient cliff dwellers in Southern Utah, only four, or 2.7 per thousand were fractured.

PRELIMINARY REPORT WITH PROJECTION DRAWINGS, ILLUSTRATING THE TOPOGRAPHY OF THE PARACÆLES IN THEIR RELATION TO THE SURFACE OF THE CEREBRUM AND CRANIUM.

BY EDWARD A. SPITZKA, NEW YORK CITY.

(Illustrated by drawings.)

[Published in the *New York Medical Journal*, Vol. LXXIII, February 2, 1901.]

[Abstract.]

The operations of tapping, draining and injecting the paracœles, as the lateral ventricles are to be designated, have become recognized surgical procedures, both for diagnostic and therapeutic purposes. The mode of procedure, however, is yet far from technical completeness, and consequently these operations are not frequently resorted to, owing to the surgical risks and topographical uncertainties. The writer believed that reference plates giving reliable and clear representations of the cerebral and cranial relations of the paracœles were a desideratum. The otherwise excellent plates of Fraser, like most photographic plates, especially if composite, lack the clearness so essential for busy, practical men. A search of the literature made by the writer reveals three attempts essaying to depict such topography: by Poirier, in France, Wilson, in England, and Quain (source unknown). They are all unavailable for surgical use.

The results here offered are of a preliminary nature only, and so far are based upon the dissections of two heads of adults, for which material I am indebted to Prof. Huntington and Dr. B. B. Gallaudet, of the Medical Department of Columbia University.

For the illustrations the reader is referred to the fuller account published in the *N. Y. Med. Journal*, as cited above.

A PRELIMINARY COMMUNICATION OF A STUDY
OF THE BRAINS OF TWO DISTINGUISHED
PHYSICIANS, FATHER AND SON.*

BY EDWARD ANTHONY SPITZKA, OF NEW YORK CITY.

Student of Medicine, College of Physicians and Surgeons.

[Reprinted, with a few additions, from the *Philadelphia Medical Journal*,
April 6, 1901.]

To a great extent, the more recent studies of human brain anatomy may be termed one-sided, inasmuch as the numerous examinations made of individual cerebra were of such derived from criminals, lunatics, and other defectives, nay, most frequently from subjects whose life history and characteristics were and remained unknown, or were unworthy of record. On the other hand, the brains of public men of professional or scientific eminence, whose actions and attainments were "writ large upon the pages of history" are seldom obtainable. In the words of Wilder, this is "both illogical and unprofitable. * * * It is at once a reproach and an irreparable loss to science that the community has not yet been convinced that the preservation and study of one's brain is an honor to be coveted. Who can set a limit to the result that might have been attained from the examination of the brains of soldiers like Grant, Sherman and Sheridan; of preachers like Beecher, Brooks and Howard Crosby; of naturalists like Agassiz, Gray and Jeffries Wyman; of lawyers like Tilden, Conkling and Benjamin Butler. How long must science wait for a general sentiment such as is embodied in the declaration of an eminent historian, that science is as welcome to his brain as his old hat, and that he wishes he had ten of them."

To this day only a few brains of eminent men have been studied and described: among these may be mentioned that of Chauncey Wright, a philosophical writer; of George Grote,

* Read also, by invitation, before the Section on Anthropology and Psychology, New York Academy of Sciences, February 15, 1901. In view of a monographic study, the publication of which is contemplated, the writer refrains from an enumeration of those details essential to the latter and whose reproduction were unnecessarily repetitious.


the well-known historian of Greece ; Hugo Gylden, the astronomer ; Prof. von Helmholtz, physiologist and physicist ; Rudolf Lenz, violin virtuoso ; Prof. Carlo Giacomini, Gamba, Broca, Bertillon, Assezat, Asseline, Véron, Gauss, Fuchs, Dirichlet and perhaps a few others. The brain of Prof. Giacomini, recently studied (*Giornale della R. accademia de Torino*, August, 1900, pp. 737-808), is said to add a noteworthy item to the chapter of coincidences since it exhibited an anomaly which he himself was the first to describe, namely : *two central fissures*, and therefore a *gyrus Rolandicus*, so-called, upon the right side. Upon closer scrutiny of Prof. Sperino's descriptions and plates, it has become evident to the writer that the supposed second central is an unusually long and well marked post central fissure.

Still fewer brains of eminent women have been studied. One is that of Madam Sonya Kovalewski, the celebrated mathematician, and another is that of Laura Bridgman, who, though bereft of the powers of language, sight and hearing, displayed an intelligence and education of a remarkable degree. Kovalewski's brain, after being immersed in alcohol for four years, weighed 1,108 grams ; Retzius calculated the original weight to have been about 1,385 grams. (G. Retzius: *Biologische Untersuchungen, Neue Folge*, 1900, IX, pp. 1-16.) Laura Bridgman's brain weighed 1,389.5 grams after having been immersed in a two per cent. solution of potassium bichromate for about three months. Donaldson (*Amer. Jour. Psychology*, III, No. 3, 1890, p. 306,) thinks that the probable weight was somewhat over 1,200 grams.

In this view of the subject the writer ventures to assume that the presentation of the following preliminary account may not be uninteresting when it is learned that it is based on the examination of the brains of two eminent physicians, which have been "saved for scientific uses rather than wasted upon worms." But what is of especial importance and without precedent is that one is the descendant of the other, and furthermore, that their ancestors and several relatives of the same name had been for several generations physicians, chemists, engineers and architects, and that the ancestral history is marked by many meritorious achievements. The brains of which I speak are those of Dr. Edouard Seguin, and his son, Professor Edward C. Seguin, both of whom were distinguished for high scholarship and brilliant attainments.

BRIEF BIOGRAPHICAL SKETCHES.


The elder Seguin was born at Clamecy, Department of Nièvre, in France, on January 20, 1812. As I alluded to above, his ancestors for several generations were eminent as physicians, architects, etc., ranking at the head of their professions in the department. Dr. Édouard Seguin received a very thorough education at the college of Auxerre, and at that of St. Louis, in Paris. He then commenced the study of



DR. EDOUARD SEGUIN.

medicine with the celebrated Itard as preceptor, and was subsequently associated with Esquirol, the distinguished alienist and psychologist, in his investigations. The study of what is now known as arrested mental development began with Seguin's devotion of his young life and talents to the welfare of the idiot children at the Hospice de Bicêtre, and for over forty years he remained devoted to the cause he had made his

own. The works he published have been recognized as authorities to the present time. In this country he was the pioneer in advocating the introduction of the metric system, and he is equally noted for his contributions to the subject of medical thermometry. His son, Dr. Edward C. Seguin, departed this life so recently that it and his work are yet a fresh reminiscence. With the favoring ancestry already alluded to, it is not surprising that the younger Seguin should attain his



DR. EDWARD CONSTANT SEGUIN.

prominent position. Born in 1843, in Paris, and coming to the United States with his father in 1850, he received a public and high-school education in Cleveland, Ohio. In 1861 he began the study of medicine with his father and after a three years' course at the New York College of Physicians and Surgeons—showing his brilliant qualities even as a student—he graduated in 1864, being then only 21 years of age, and after

having at that early age served as a medical cadet in the regular army. Among other appointments which he received, was that of house physician at the New York Hospital. He developed a pulmonary trouble which was recovered from during a sojourn at Forts Craig and Selden, in New Mexico. From 1871 to 1885 he was lecturer at the College of Physicians and Surgeons on diseases of the nervous system and insanity. In 1873 he founded the clinic for nervous diseases in that college. He was a member of many societies in both hemispheres, and his contributions to the pathology and therapeutics of nervous disorders are especially valuable and rendered his position in the literature of the medical world a very prominent one. He will always be distinguished as one of the pioneers of American neurology. An indefatigable worker, his labors were all characterized by a methodicity which has become traditional among his friends and pupils. He died on February 19, 1898.

BRAIN OF DR. EDOUARD SEGUIN.

The elder Seguin's brain was removed within 24 hours after death by Dr. E. C. Spitzka, assisted by Dr. R. W. Amidon, on October 29, 1880. Its appearance and texture were normal, but there appeared to be a trifle less cerebrospinal fluid than usual. The brain-weight was recorded as 2 pounds, 12 ounces, 5½ drams, equivalent to 44.344 ounces or 1,257 grams. At the present time, after over 20 years' immersion in alcohol, this weight is reduced to 880 grams, the loss amounting to 377 grams, or 30 per cent. of the original weight.

The weights of the different parts of the brain* on December 3, 1900, were as follows:

Left hemicerebrum,	365 grams.
Right hemicerebrum,	367 grams.
Cerebellum,	84 grams.
Isthmus,	64 grams.
	<hr/>
Total,	880 grams.

* The division of the cerebral segments was not made strictly in accordance with Meynert's plan, but according to a modification which utilizes the ectal border of the optic tract, and the tænia thalami (ripa) as guides for a single simple incision; those of either side converge forward to meet in front of the chiasm; the usual cut through the callosum and lamina terminalis completes a trisection which leaves the prosencephalon and brain-axis separated as nearly the ideal as can be.

According to Marshall's tables the average brain-weight for a man of the height of 65 inches or under, and between the ages of 40 and 70, is 45.74 ounces (= 1,296 grams). It must not be forgotten, however, that the brain-weights of the French are somewhat less than those of the English which Marshall's figures represent; and if we remember that Dr. Edouard Seguin was about 64 inches in height and was in poor health for some time prior to his decease, his brain-weight of 1,257 grams cannot be said to deviate much from the normal figures, and, if anything, would point to the occurrence of some wasting of the brain-tissue from disease, or age, or both. Various estimates of Dr. Seguin's body-weight range between 125 and 145 pounds, giving ratios, as compared with the brain-weight, ranging between 1 : 45 and 1 : 52. The latter ratio was also found in the case of George Grote by Marshall, and was probably due to the same or similar causes.

BRAIN WEIGHTS OF EMINENT MEN.

[This table is only provisionally arranged, as a few of the figures have not yet been verified by the writer. The authorities for these weights have been omitted here, but will be fully supplied in the final report.]

Name.	Occupation.	Age.	Brain-weight.
Ivan Turgenieff.....	Poet and novelist.....	65	2,012
G. Cuvier.....	Naturalist.....	63	1,830
E. H. Olney.....	Mechanician and author...	59	1,816
E. H. Knight.....	Mechanician.....	54	1,813
von Bismarck.....	Statesman.....	83	1,807
Abercrombie.....	Physician.....	64	1,786
B. F. Butler.....	General and lawyer.....	74	1,758
— Olney.....	College professor.....	...	1,701
W. M. Thackeray.....	Humorist.....	62	1,658
Rudolf Lenz.....	Violin-virtuoso.....	?	1,636
John Goodsir.....	Anatomist.....	53	1,629
W. von Siemens.....	Physicist.....	68	1,600
F. B. W. v. Hermann.....	Economist.....	73	1,590
J. K. Ribbeck.....	(Industr.).....	61	1,580
K. Spurzheim.....	Phrenologist.....	56	1,559
J. Y. Simpson.....	Physician.....	59	1,531
P. G. Dirichlet.....	Mathematician.....	54	1,520
C. A. De Morny.....	Statesman.....	54	1,520
D. Webster.....	Statesman.....	70	1,518
John Campbell.....	Lord Chancellor.....	82	1,517
Chauncey Wright.....	Philosopher.....	45	1,517
— Schleich.....	Writer.....	56	1,503

Name.	Occupation.	Age.	Brain-weight.
Thos. Chalmers.....	Theologian.....	67	1,502
E. C. Seguin.....	Physician.....	55	1,502
von Helmholtz.....	Physiologist.....	73	1,500
Napoleon III.....	Sovereign.....	65	1,500
K. H. Fuchs.....	Pathologist.....	52	1,499
C. Giacomini.....	Anatomist.....	...	1,495
L. Agassiz.....	Naturalist.....	66	1,495
De Morgan.....	Mathematician.....	73	1,494
K. F. Gauss.....	Mathematician.....	78	1,492
— Babbage.....	Mathematician.....	79	1,488
K. von Pfeufer.....	Physician.....	63	1,488
Paul Broca.....	Anthropologist.....	56	1,484
Louis Asseline.....	Journalist.....	49	1,468
M. D. Skobeleff.....	General.....	39	1,457
C. H. E. Bischoff.....	Physician.....	79	1,452
J. A. H. Gylden.....	Astronomer.....	...	1,452
— Lamarque.....	General.....	63	1,449
F. R. von Kobell.....	Poet and geologist.....	79	1,445
— Dupuytren.....	Surgeon.....	58	1,437
Franz Schubert.....	Composer.....	70	1,420
A. Thorndyck Rice.....	Diplomat.....	35	1,418
J. E. Oliver.....	Mathematician.....	65	1,416
Melchior Meyr.....	Poet and philosopher.....	61	1,415
George Grote.....	Historian.....	75	1,410
J. Huber.....	Philosopher.....	49	1,409
J. Assezat.....	Journalist.....	45	1,408
— Bertillon.....	Anthropologist.....	62	1,398
W. Whewell.....	Philosopher.....	72	1,389
— Coudereau.....	Physician.....	50	1,378
H. T. von Schmid.....	Writer.....	65	1,374
J. G. J. Hermann.....	Philologist.....	76	1,370
K. F. Hermann.....	Archaeologist.....	51	1,358
von Schlagintweit.....	Explorer.....	51	1,352
J. von Liebig.....	Chemist.....	70	1,352
Ludwig II.....	Sovereign (insane).....	41	1,349
J. P. Failmerayer.....	Historian.....	71	1,349
J. H. Bennett.....	Physician.....	63	1,332
— Seizel.....	Sculptor.....	5(?)	1,312
R. E. Grant.....	Anatomist.....	80	1,290
Walt Whitman.....	Poet.....	72	1,282
Edouard Seguin.....	Physician.....	68	1,257
v. Lasaulx.....	Physician.....	57	1,250
E. Harless.....	Physiologist.....	42	1,238*
L. von Buhl.....	Physiologist.....	64	1,229
J. F. L. Hausmann.....	Mineralogist.....	77	1,226
I. von Döllinger.....	Physiologist.....	71	1,207*
F. J. Gall.....	Phrenologist.....	70	1,198
Léon Gambetta.....	Statesman.....	44	1,160*

* The weight of these brains when fresh will always remain unknown.

In the above list of brain-weights of eminent men compiled by the writer from various sources, Dr. Edouard Seg-

uin's position is rather a low one, but the idea that intellectuality always presupposes a heavy brain has long ago been demonstrated as groundless. Still, such a table has its value in showing that the maximum frequency of brain-weights of eminent men occupies a distinctly superior position as compared with those of ordinary individuals, and that the significance of brain-weight as an index of intellectual capacity must depend upon the proper collation of a sufficiently large number of cases, and the correlation of contributory and complicating factors.

Concerning the general form of the cerebrum the reader is reminded that during its immersion in alcohol for a score of years there has naturally been considerable shrinkage and flattening. Giving due allowance to this unavoidable distortion, its striking features can be enumerated as follows:

Marked development, with great breadth and fulness of the frontal lobes.

A great width and ample development of the parietal and temporal lobes.

Relatives smallness of the cuneus in both halves, especially the left.

General tortuosity of the fissures and gyres.

A full and ample development of the left insula, especially of its cephalic (anterior) portion, the insular pole being very fully developed, and far better than on the right side. A portion of the left preinsula is visible.

The sylvian cleft is more horizontally directed than in most brains. This approach to the horizontal is more marked on the left side, and is generally considered an important indication of superior development.

The left parietal and paroccipital fissures are separated while on the right side they are confluent. This arrangement is quite rare, having been found in 6 per cent. of cases by Wilder¹ and the writer.²

The fissures on the whole are characterized by their generally tortuous paths, by their great depth, and perhaps by a greater frequency in their deep interruptions by vadums and interdigitating subgyres. In general the gyres are neither of maximum nor minimum width; their size seeming to be determined by a tendency to crowd the greatest number—more or less regularly and evenly—into the available space. They are bold and massive, so that in spite of the intricate fissura-

tion the configurations of the brain are neither "overcrowded" nor "cramped-looking." There is that in the "physiognomy" of the brain as in the son's, which it is impossible to describe, otherwise than in terms the very use of which would suggest the having preconceived notions of a relation between structure and function, to say that it portrays the culture, refinement and intellectual capacity of its erstwhile owner when living.

The indices of the lobes* of the left hemicerebrum are :

Frontal index,	60.4
Parietal index,	22.2
Occipital index,	17.4

On the right hemicerebrum :

Frontal index,	58
Parietal index,	20.6
Occipital index,	21.4

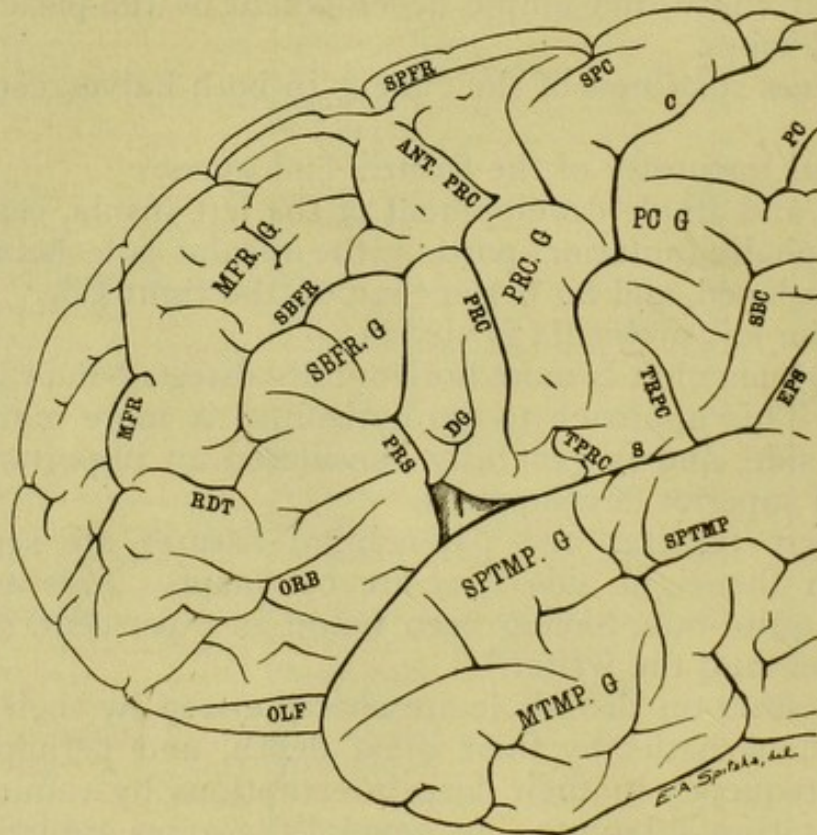


Fig. 1. Frontal portion of the left hemicerebrum of Edouard Seguin (father) showing exposed area of the preinsula, and also the well-developed opercula.

* These indices are measured along the dorsimesal border of the hemicerebrum, from pole to pole, and are expressed in terms regarding the entire length so measured as equivalent to 100.

These figures indicate in a measure the better development of the left frontal and parietal lobes.

The frontal gyres are the most complex of the entire brain, being particularly rich in their windings, though the parietal gyres are almost as rich in their development. The sub-frontal gyrus (Broca's convolution) of the left half is very well developed, as might be expected, in a right-handed individual with a left speech center. (See Fig. 1.)

Upon the left half the "intraparietal fissural complex" is remarkable in that all four of the so-called segments are distinctly separated from each other, a condition rarely observed and found by Cunningham³ in only four hemispheres out of sixty-two; once on the left, once on the right, and once on both halves. Mickle⁴ regards such bridging of the so-called

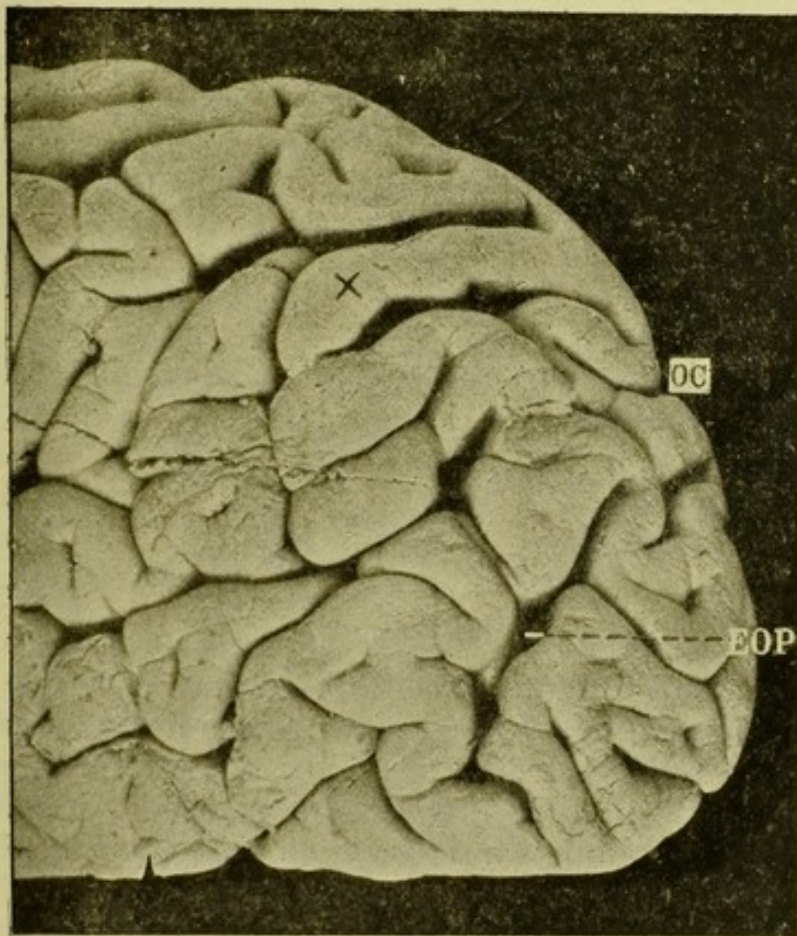


Fig. 2. Occipital portion of left hemisphere of Edouard Seguin (father) showing the remarkably distinct exoccipital fissure (EOP) as well as the paroccipital isthmus, marked by the cross (X). OC marks the occipital fissure. (Photograph by Dr. E. Leaming.)

"intraparietal sulcus" as a mark of superiority in brain evolution. The paroccipital fissure, which is of the true zygial type, is absolutely separated from the parietal fissure by a well-developed "paroccipital isthmus." (See Figs. 2 and 3.) Upon the right half there is a confluence of the corresponding fissures. This brain, therefore, presents an additional example of a rare arrangement hitherto unnoticed in the brains of moral and educated persons, at least so far as the writer knows. Of the six cases recorded by Wilder¹ there were three of unknown history, while the remaining three whose history was known, were insane, one a Swiss woman, one an engineer, and one a negro. The writer² has since found a similar arrangement in six of the one hundred brains of dissecting-room subjects, derived mainly from the pauper class dying in the municipal hospitals and charitable institutions.

As stated above, the occipital index on the left half is as 17.4 : 100, and on the right half as 21.4 : 100, according to Cunningham's method. This index averages 20.8 for human adult males, and 21.7 for females; and it increases as we descend to the anthropoids and apes. The following are Cunningham's figures :

Orang,	23.2
Chimpanzee,	24.2
Hamadryas,	29.5
Cynocephalus,	29.7
Mangaby,	30.5
Macaque,	31.
Cercopithecus,	32.9
Cebus,	33.1

It was recognized as being of considerable importance by even so early an observer as Gratiolet, and it would seem to indicate, other things being equal, that relative smallness of the cuneus, measured in this manner, signified superiority. Its exemplification upon the better developed left half of both of the Seguins' brains would seem to lend force to this hypothesis.

Notable for its extent and well-marked course is the exoccipital fissure on the left side. (Fig. 2.) It begins very near the zygon of the paroccipital, at its caudal part and separated from it by a narrow (3 millimeters) "deuxième pli de passage." Morphologically speaking, therefore, the fissure

falls into the first class of Wernicke's descriptions,⁵ a condition occurring normally in some apes. As the fissure passes ventrad a notable fact is the nature of the slope of its walls, which, as in the right half, incline distinctly caudomesad. It resembles a cleft rather than an ordinary fissure, and in its depths can be seen several interdigitating subgyres. As the fissure approaches the ventro-lateral border it takes an abrupt caudal direction and terminates just at the border. Around this end curves a narrow "quatrième pli de passage." The "troisième pli" may be any one of the several interdigitating subgyres alluded to above.

Upon the right half the "troisième pli" instead of being totally submerged, approaches to within seven millimeters of the surface and is capped by the lip of the poma (occipital operculum), so that it may properly be termed a subgyre. The exoccipital fissure consists, therefore, of two segments, a

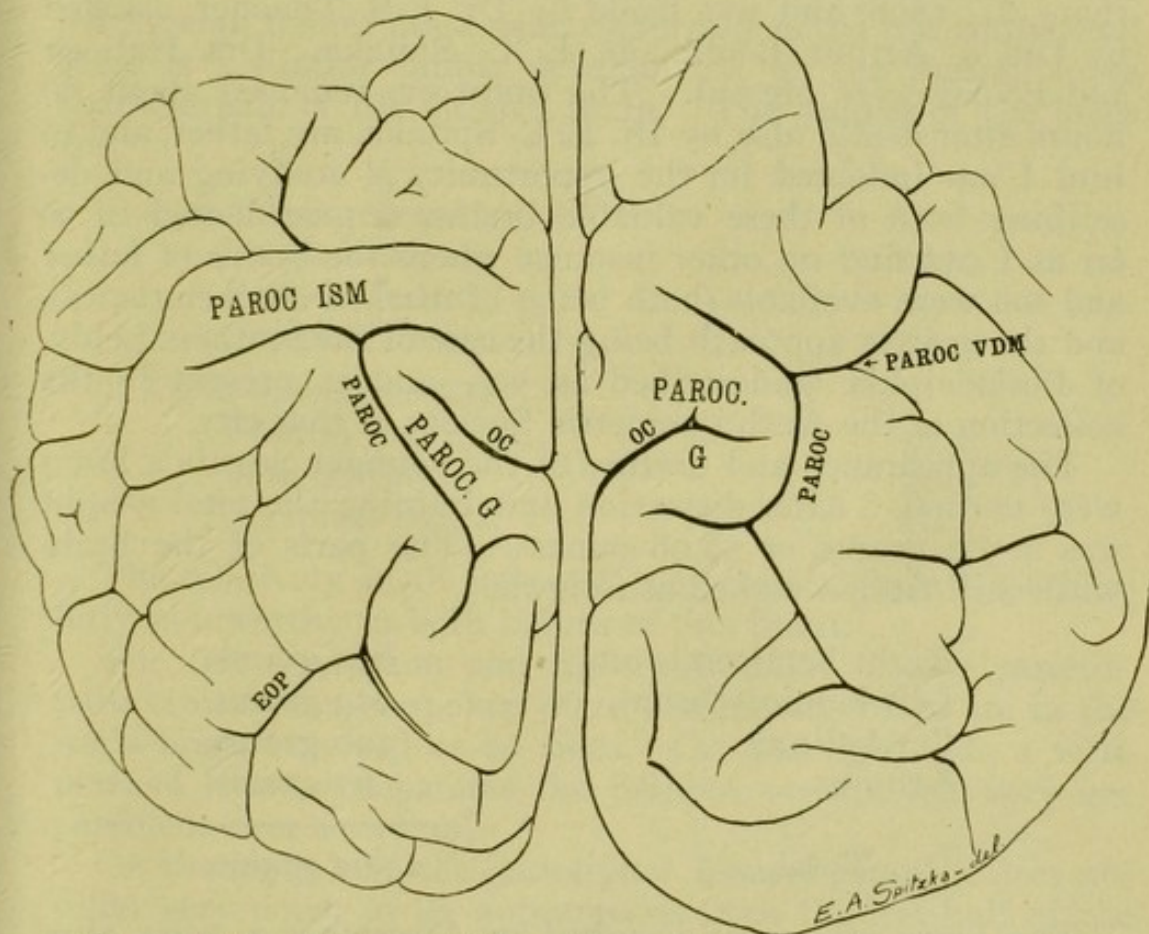


Fig. 3. View of the occipital regions of both hemispheres of Dr. Edouard Seguin (father). On the left a distinct paroccipital isthmus (PAROC. ISM.) separates the parietal from the paroccipital; on the right these fissures are confluent over a vadium at a depth of 11 millimeters.

superior (EOP') and an inferior (EOP''), superficially confluent with each other.

In both hemispheres the occipital lobe exhibits a distinct tendency to overlap the parietal gyres; the walls of the occipital fissure slope distinctly mesocaudad, suggesting the pomatic homology and derivation of the occipital lobe.

The insula on the left side is far better developed than its fellow on the right half, corroborating the statement made by Waldschmidt,⁶ that in educated men the left insula is "incomparably richer" in its development than the right. Upon close inspection, and by means of soundings made in the sylvian cleft, this redundancy is found to be most marked in the preinsular region.

BRAIN OF DR. EDWARD C. SEGUIN.

The autopsy upon the younger Seguin took place on February 21, 1898, and was made by Dr. J. S. Thacher, assisted by Drs. J. Arthur Booth and E. C. Spitzka. Drs. Hallock and Pooley were present. The brain was removed about 30 hours after death, also by Dr. E. C. Spitzka, my father, and to him I am indebted for the opportunity of studying and describing both of these valuable brains, unprecedented in so far as I can find no other instance where the brains of father and son were available (both being of marked characteristics), and the nearest approach being the case of the brothers Leidy, of Philadelphia, undescribed as yet—and at present in the collection of the Anthropometric Society of that city.

The appearance and texture of the younger Seguin's brain were normal. After dissection and draining the total weight was 1,502 grams, or 52.98 ounces. The parts of the brain while still fresh weighed as follows:

Right hemisphere,	.	.	642 grams.
Left hemisphere,	.	.	653 grams.
Cerebellum,	.	.	140 grams.
Isthmus,	.	.	67 grams.
			<hr/>
Total,	.	.	1,502 grams.

The brain was again weighed on December 3, 1900, after nearly three years' immersion in formaldehyde solution:

Right hemicerebrum,	555 grams.
Left hemicerebrum,	563 grams.
Cerebellum,	109 grams.
Isthmus,	57 grams.
	<hr/>
Total,	1,284 grams.

The loss in weight amounted to 218 grams, or 13 per cent. of the original weight.

This brain-weight (53 ounces in round numbers) is about 4 ounces, or about 125 grams above the average for one of Dr. E. C. Seguin's age and height, and his position in the list of brain-weights of eminent men is comparatively high.

Owing to the excellent preservative qualities of formaldehyde, this brain is only slightly flattened, and the shrinkage amounts to very little. As in the father's brain, there is a slight but unquestionable exposure of the left preinsula. The left sylvian fissure more nearly approaches the horizontal, and there is a similar ample development of the frontal lobes characteristic of the father's brain. The indices of the lobes are :

Left hemicerebrum :

Frontal index,	61
Parietal index,	23.6
Occipital index,	15.3

Right hemicerebrum :

Frontal index,	57.2
Parietal index,	26.3
Occipital index,	16.3

The relatively small index of the occipital lobe is particularly noteworthy in both halves of this brain.

The left separation and right continuity of the parietol-paroccipital fissures spoken of in the father's brain are in the son's brain reversed as to sides. On the right side a well-marked isthmus separates the fissures, on the left they are confluent over a vadum.

On the right half the exoccipital fissural complex does not differ very much in its appearances from the left half of the father's brain, except that the "troisième pli" is flush with the cerebral surface and not submerged.

The left insula, as in the father's, is far better developed

than the right, and the preinsular portion is so redundant that the surrounding opercular parts have been crowded apart and a small triangular portion of the insular pole is thus made visible upon the lateral aspect.

If one be permitted to indulge in such an expression I would say that the *physiognomy* of each of these brains reproduces that of the other, much as the outer physiognomy of their bearers did in life. By the metaphoric term "physiognomy" used in this connection, I mean the general feature of the arrangement, relations and molding of the convolutions, difficult to describe in so many words and renderable only through photographic or other reproduction, and even through these imperfectly. Every brain I have yet examined had its distinct features, as much distinct as the outer ones of its owner. One may distinguish brains resembling each other as a group, and as distinguishable from other groups as are different families and races of men. No more striking instance of a prevailing typical difference can be adduced than that of the Mongolian brains recently studied by Dercum and others. It were futile to attempt basing a discrimination on any single factor. It is the general physiognomy that seems to be so peculiar to the race, but by this I do not mean that given a certain brain an investigator could declare it to belong to such and such a race or sex. We are not advanced far enough for that yet, if we ever attain such a point; and how mistaken we may be in regard to the outer features I need not remind the reader. We are much like the traveler who merely touching the shores of a new land is struck by the, to him, strangely and strikingly uniform character of a new race—yet whose individuals are as distinguishable to their fellow tribesmen as that traveler's companions are to him.

Perhaps the most significant feature common to both brains is the exposure of the insula, and although this feature formed the theme of a special paper⁷ a brief summary thereof may not be out of place here.

Heretofore it was only in the brains of deaf-mutes, of negroes, of idiots, and of the defective classes generally, where the opercula are commonly atrophied, that the insula has been found visible. It was therefore regarded as an indication of inferior development. The brains of the Seguins, however, present the very reverse of low form or defective type. Nor are the opercular regions at all defective, though they fail

to come into typical apposition. The explanation of this anomaly is that the left preinsula is far better developed than its fellow on the right side, corroborating the findings of Waldschmidt (in 1887) upon the brains of two professors of the University of Freiburg. But in the Seguin brains this redundancy of development upon the left side is so pronounced, that the insula in a *quasi*-struggle to reach the general cerebral surface, has virtually thrust apart the opercula and made itself visible.

The interpretation of this exposure as due to the relative hypertrophy of the insula is sustained by the results of "soundings" taken at various points, and given in millimeters in the following table.

The terms pre-, medi-, and post-insular depth refer to the three points at which the Sylvian cleft was sounded, the pre-insular point being the junction of the Sylvian with its pre-sylvian ramus, the medi-insular point being at the middle of the course of the Sylvian, the post-insular being at the junction of the Sylvian cleft with its episylvian ramus.

DEPTHS OF THE SYLVIAN FISSURE IN THE FOUR HEMI-CEREBRUMS OF THE TWO SEGUINS.

EDOUARD SEGUIN (Father).

	Left.	Right.
Pre-insular depth,	11 mm.	18 mm.
Medi-insular "	22 "	22 "
Post-insular "	24 "	22 "

EDWARD C. SEGUIN (Son).

	Left.	Right.
Pre-insular depth,	7 mm.	15 mm.
Medi-insular "	20 "	23 "
Post-insular "	25 "	25 "

The conclusions naturally to be drawn from the above are that the causes potential in insular exposure must be discriminated or classified as follows:

Class 1.—In the highly intellectual (for example, the two Seguins), owing to the excessive growth and development of the left pre-insula, causing a displacement of the opercula, thrusting them apart, as it were, and even though the latter be very well developed.

Class 2.—In the defective, exposure of the pre-insula is due to deficient development of the opercula and because these fail to approach each other. In such cases the insula it-

self is, without a single exception in the series that I have studied, of inferior development, indicated not only by the soundings of the Sylvian cleft, but also by the flatness of configuration and lesser area of the insular cortex.

In the paper referred to, the writer said: "Among the reflections which occur in the course of such a study, is the possibility of some paternal influence exerted on the brain of the offspring under circumstances such as the following: Dr. Edouard Seguin (the father) was most actively engaged in the teaching of the idiot children at the Hospice de Bicêtre, wrote many treatises, and delivered many lectures upon the subject in the six years prior to the younger Seguin's birth. If physiological tendencies are transmitted from father to son, and if such transmission of function finds structural expression, one would expect it to be demonstrated where the circumstances are so favorable as here. Of course, all such statements are made tentatively; yet what would be a more natural conception when we view the circumstances, the visible evidences in the two brains, and the corroborative soundings of the Sylvian fissure of both sides. Both men were of high intellectual capacity; both were facile writers and speakers—if anything the son excelled the father; and both were polylinguists, speaking and writing three languages fluently. The teaching capacities of both men were remarkable, in the one case being especially devoted to the patient efforts required in the training of the feeble-minded, in the other developed in the highest degree in didactic lecturing and clinical teaching."

This unexpected exposure of the insula has been noted on both sides in the brain of Chauncey Wright, now in the care of Prof. Burt G. Wilder. In his Handbook article,⁸ written in 1889, Wilder called attention to the fact that possibly pressure may have caused sufficient displacement to artificially expose the insula. In a letter to me (March 12, 1901,) in response to a communication in which I suggested the explanation here advanced, Dr. Wilder states that probably the exposure of Wright's insula was also natural. This investigator proposes to review the matter as soon as he returns to Ithaca.

There are a number of facts which, naturally grouping themselves together, justify as a strong surmise, if not a scientific probability, this anticipation: that hereditarily transmitted and identifiable individualities in gyral disposition will be first satisfactorily determined in the region of the insula. To attempt sustaining this proposition by the experience of the

single case here presented were absurd; it simply points in the direction of the following logical chain—partly of obtained facts, partly of natural conclusions from these.

In a study made of heredity, whose results were placed at my disposal, covering the parentage and descent of individuals prominent in various fields of science, politics, art and handicraft, it is found that the cases where both father and son attained distinction sufficiently to merit place (in the biographical encyclopedias), in intellectual fields of labor, they had been of those in whom skilled motor innervations in their association with sensory impressions and registrations are prerequisites. Preeminently is this the case with two professions—that of the composer-musician and that of the philologist. As defects in speech are so likely to be repeated in a family line, it seems that its skilled employment by the ancestor is similarly reflected in the way of facile acquirability on the part of the descendant. Not unrelated may be the fact that among those recruited for the ranks of linguists of other than philologist parentage, there largely predominate those whose parents had emigrated or who were born on islands, in seaport towns or in lands where two dialects are spoken, not to mention those in whose families it has been the custom to maintain an ancient tongue for sacerdotal reasons.

The speech faculty in its intimate relations to thought-expression, to memory—in its reading-form to sight, in writing to manual muscular innervation, exquisitely hereditary as it is in life, and most accurately localizable in the ravages of disease, as shown after death, appears one whose transmission is most likely to be expressed by morphological signs—be they relative and quantitative or purely morphological—and these in and about the Island of Reil.

I have said that there exists a resemblance between the “physiognomies”—if I may use that term—of these brains. But if the various features of these specimens be separately analyzed and compared this resemblance becomes a striking one. The view that a coincidence of features in the brains of parent and child is due to an actual *transmission*, as that term is now understood, gains in plausibility in proportion as such features are marked or exceptional, and most so, as in the brains before us, where they approach the atypical.

The term *atypical* as here used is so in a morphological sense only, and not as equivalent to the sense of aberrant

atypy—heterotypy—found in grossly asymmetrical and pathological brains. Just as it is the simplest brains that are more symmetrical than the higher one, so the simplest arrangement of gyres is also the one which is most purely and symmetrically typical. With higher development, a certain degree of deviation from the type seems an inseparable accompaniment of the luxuriant development, contorted foldings, and deep as well as complicated fissuration, which represent a struggle for surface and expansion, in which the interests of neighboring formations often balance unevenly. This irregularity is regular even in its irregularity, however, of the surface only, and in this respect parallel to those perhaps not unrelated manifestations of the living organ of the mind, which in the shape of originality or ingenuity are often misapprehended and interpreted as evidence of unbalancing and eccentricity. It is because the simple mind has not breadth enough that it neither indulges in excursions into a field of original thought, nor understands such when indulged in by others. So it is because there is little rivalry of growth interests in an unexpansive organ that its simple gyres repose in the rough and comprehensible simplicity of the Bechuana folds.

“To certain minds fate narrow bounds has set,
In vain they try beyond those bounds to get.”

In reality all these qualities are but expressions of a strong individuality; and individuality is not conceivable otherwise than as an expansion beyond the average mediocrity,—expansion in the direction of deviation from that of the common rut.

In the case of the two Seguin brains it is safe to say that if they had been scattered among a hundred other brains, and these had been grouped according to the type of gyral disposition, they would have come together as the classification became finer and finer until ultimately they probably would have constituted a group by themselves.

The asymmetry of the halves of highly-developed brains must therefore form the basis for demonstrating hereditary transmission in the brains of parent and child before us; and it is for such unilateral features that we must search. They are present in sufficient number to establish the proposition, and while I am prepared to enumerate these at length, their presentation and discussion would require more space than it is my privilege to occupy. Briefly stated, the most important of these features common to both brains are:

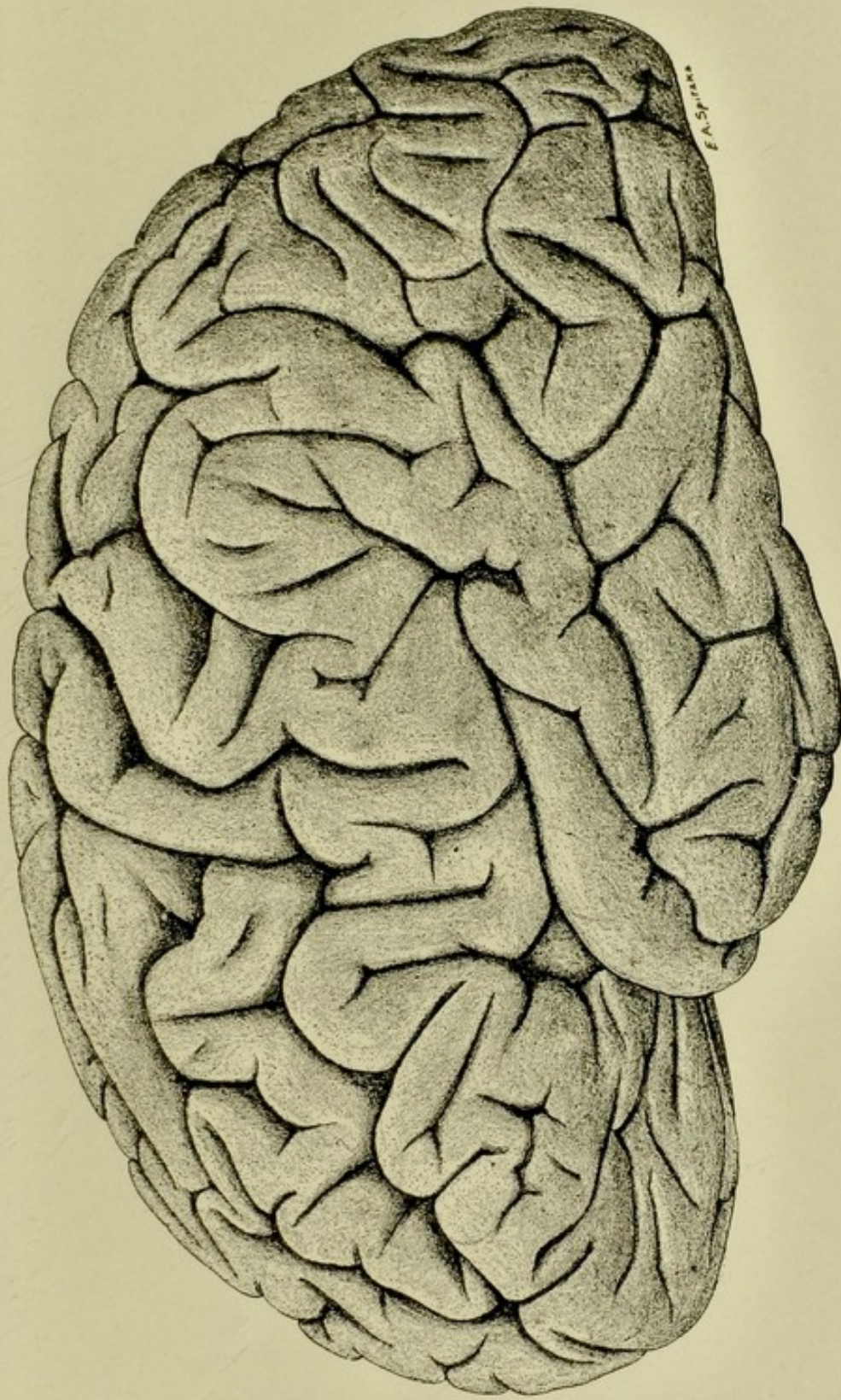



Fig. 4. Lateral view of the left hemicerebrum of Dr. Edward C. Seguin (son). Aside from the redundant development of the operculum, and the nearly horizontal course of the Sylvian fissure, the most striking feature is the visibility of the preinsula, whose summit approaches within 7 mm. of the cerebral surface. $\times .83$ natural size. From a drawing by the author.



The left insula exhibits an incomparably richer development than the right.

The left occipital index is smaller than the right.

The left frontal index is larger than the right.

The left subfrontal gyrus is larger than the right.

On both right operculums there is a single isolated fissure embraced by the limbs of the presylvian fissure.

The left medifrontal fissure is in two segments (in one case separated by a superficial isthmus, in the other by a slight vadum of 4 millimeters). Furthermore, the medifrontal is poorly represented on the right sides.

The left cephalic limb of the paracentral fissure is short; long on the right.

The left episylvian fissure, and also the hyposylvian are longer than on the right half.

The left fronto-marginal fissural segments are easily traced; they are absent on the right sides.

The left olfactory fissure is shorter than the right.

The left Sylvian fissure more nearly approaches the horizontal than does the right.

The existence of these and other facts give strong evidence of *direct hereditary transmission*. In addition, however, there are other interesting points of resemblance in attributing which to such transmission, one strange apparent difficulty is encountered, namely: their reversed position as to sides. This "crossed heredity," or the reproduction of unilateral asymmetrical peculiarities of one side in the father's brain upon the opposite side in the son's, would constitute an interesting chapter in itself. An enumeration of the facts in support of this mode of *crossed hereditary transmission* can only be briefly made here.

FATHER'S BRAIN.

I. Left parietal f. and paroccipital f. separated; continuous on right.

II. Postcalcarine f. bifurcated on right only.

III. Right occipitocalcarine angle = 70° ; left 60° (circa).

IV. Father's right "exoccipital complex" almost identical with son's left.

V. Left parietal f. joins supertemporal f. and intermedial f.

VI. Mode of junction of right medifrontal f. with orbitofrontal f. exactly as in son's left.

VII. Father's right half heavier.

SON'S BRAIN.

Left parietal f. and paroccipital f. continuous; separated on right.

Postcalcarine f. bifurcated on left only.

Right occipitocalcarine angle = 60° ; left = 70° (circa).

Son's left "exoccipital complex" almost identical with father's right.

Right parietal f. joins supertemporal f. and intermedial f.

Mode of junction of left medifrontal f. with orbitofrontal f. exactly as in father's right.

Son's left half heavier.

The last item is one to which I am not prepared to attach too much importance, for observations upon the weight of the halves of a dissected brain come within the range of error usually ascribed to the "personal equation."

The history of inheritable peculiarities, such as sex, polydactylism, abnormalities of the external ear, and the like, shows that the problematical mechanism of their transmission acts without regard to any other plan, in this respect, than that of "symmetry in asymmetry;" namely, it impresses the same or similar variation from the typical, if not on both sides, on either side alone, and indifferently as to correspondence with the one parentally involved.

Any declaratory explanation for the contralateral situation of the same or similar atypy in the brains of parent and child must rest on conjecture. The influences at work in molding organic forms are profoundly mysterious; particularly is this the case where symmetrical relations are in question. I need but refer to the possible relations of this fact to the more familiar ones just referred to, such as one-sided peculiarities of the pinna, the digits, or the orbits; and that these influences act contralaterally as well as unilaterally, and as harmoniously in their inversion as in those rare cases of complete transposition of the viscera. Let me instance an authentic case of maternal impression reported by Dr. W. L. Swift (*New York Medical Journal*, October 9, 1886, p. 407), where the birthmark not only repeated the original one-sided maternal impression, but was also duplicated, both sides of the body showing it. * * * Brown-Sequard demonstrated the hereditary transmissions of lesions in the nervous system of guinea-pigs, the change in the descendants often being bilateral where they had been unilateral in the animals experimented upon. (*Comptes rendus*, Vol. xciv, 627.) The deformities of "hammer-toe" and "syndactylism" may likewise exhibit unilateral, bilateral or even contralateral transmission. Lastly, I would allude to the mirror-like reproductions of physiological and pathological phenomena on opposite sides in certain forms of hysteria.

If such modes of transmission be wonderful and mysterious how much more so is that of the hereditary influences of which we speak. When we remember that we are dealing here with the one organ of the body that is so variable that no two individuals possess it exactly alike, so far as exter-

nal appearances are concerned, the importance of determining as nearly as possible the influences of heredity will be understood readily enough. More material of this kind, and extended observations upon this line are necessary before we can arrive at any satisfactory conception of the external appearances of this most important organ. Anatomists and scientists in general cannot urge too strongly upon their fellowmen and women the importance of bequeathing their brains to the uses of a science which might well regard such bequests, if not as invaluable as the legated brains once had been to their original owners, of the very highest one, such being indispensable to progress in psychological physiology.

For valuable aid and information cheerfully given while pursuing this study, the writer wishes to express his sincere thanks to Mrs. E. M. Seguin, and to Drs. J. Arthur Booth, E. Leaming, and Professor B. G. Wilder.

ABBREVIATIONS.

Fissures.

ANT. PRC.,	"Anterior precentral."
C.,	Central.
DG.,	Diagonal.
EOP.,	Exoccipital.
EPS.,	Episylvian.
MFR.,	Medifrontal.
OC.,	Occipital.
OLF.,	Olfactory.
PAROC.,	Paroccipital.
PAROC. VDM.,	Paroccipital vadium.
PRC.,	Precentral.
PRS.,	Presylvian.
RDT.,	Radiate.
S.,	Sylvian.
SBFR.,	Subfrontal.
SPC.,	Supercentral.
SPFR.,	Superfrontal.
SPTMP.,	Supertemporal.
TPRC.,	Transprecentral.
TRPC.,	Transpostcentral.

Gyres.

MFR. G.,	Medifrontal g.
MTMP. G.,	Meditemporal g.

PAROC. G.,	Paroccipital g.
PAROC. ISM.,	Paroccipital isthmus.
PC. G.,	Postcentral g.
PRC. G.,	Precentral g.
SBFR. G.,	Subfrontal g.
SPFR. G.,	Superfrontal g.
SPTMP. G.,	Supertemporal g.

REFERENCES.

¹ B. G. Wilder : Neurology Lecture Notes, Cornell University, 1899-1900, p. 28.

² E. A. Spitzka : "A contribution to the question of fissural integrality of the paroccipital; observations upon 100 brains." Proceedings of Association of American Anatomists, December, 1900. To be published in *Journal of Mental Pathology*.

³ D. J. Cunningham : "The intraparietal sulcus," pp. 135-155, *Journal of Anatomy and Physiology*, vol. xxiv.

⁴ W. Julius Mickle : "Brain forms in relation to mental status." *Journal of Mental Science*, January, 1897, p. 25.

⁵ C. Wernicke : *Lehrbuch der Gehirnkrankheiten*, 1881, p. 11.

⁶ Jul. Waldschmidt : "Beitrag zur Anatomie des Taubstummen Gehirns." *Allg. Zeitschrift f. Psychiatrie*, 1887, pp. 371-379.

⁷ E. A. Spitzka : "The redundancy of the preinsula in the brains of distinguished educated men." To be published in the current volume of the *Medical Record*.

⁸ B. G. Wilder : Brain, gross or macroscopic anatomy. *Reference Handbook of the Medical Sciences*. A. H. Buck, editor, viii, 1889. Also vol. ix. (Supplement.)

PRELIMINARY REPORT ON A CASE OF
CYCLOPIA.

BY DR. CHURCHILL CARMALT, NEW YORK CITY.

The Society of the Lying-In Hospital, of New York City, present through me, their representative, the following subject and its history, case number 20,484, in their records. No similar monster in records of 20,484 cases. Deformed foetus born at 36-7 weeks.

Father's history.—Russian Jew, 35 years old, tailor, small, rugged, very intelligent, ears prominent, and helix pointed. His father alive at 85; mother died in 70th year; no abnormality in either. Three brothers, two sisters and their six children have presented no abnormalities. He denies venereal disease and presents no evidence of syphilis or tuberculosis.

Mother's history.—Russian Jewess, 30 years old, large, stout woman with no marks of degeneracy or ill health. Mother and father over 70; both alive and normal. Three sisters and four brothers with seven children have had no abnormalities among them. She herself has borne 5 children in 10 years, one miscarriage at 8th month (4th pregnancy). One child died of measles, others alive and normal.

History of pregnancy.—Last child nursed while pregnant with foetus herewith presented. During, as nearly as the mother can remember, the second or early part of third month of this pregnancy, the mother, in a street brawl, was struck upon the abdomen. She "fainted away," in her own words, and was sick in bed a fortnight with small amount of vaginal hemorrhage; no medical attendance. Injured again in last two weeks of pregnancy. No evidence of syphilis or tuberculosis; no "maternal impression." She does not connect deformity of foetus with the injury.

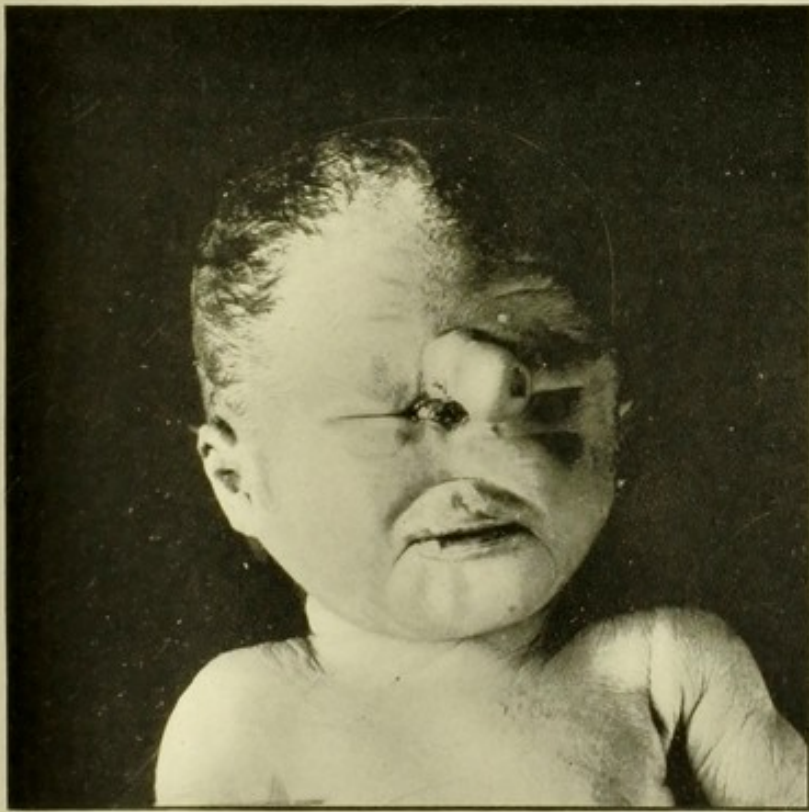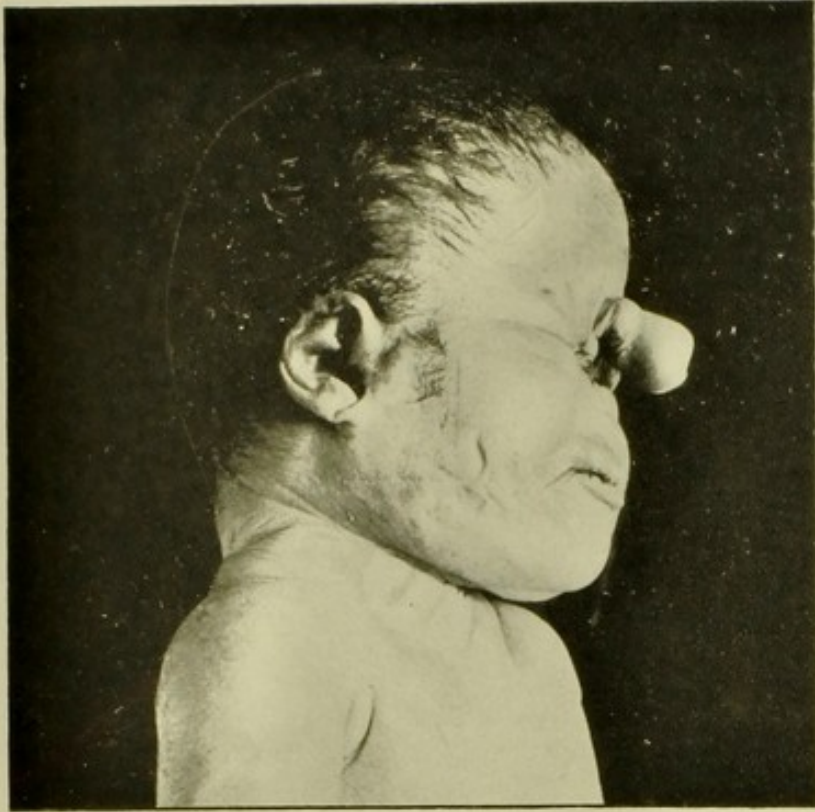
History of delivery.—Normal; vertex; L. O. A.; duration, 10 hours and 8 minutes; second stage lasted 1 hour. Placenta, normal; weight, 512 gm.; measurements, 18 cm. by 15 cm. by 2 cm. Blood vessels, normal; cord, 51 cm. long and normal. Membranes, normal, smooth, complete. Liquor amnii, moderate in amount. Primary respiration of child delayed;


artificial respiration was done and child dipped in hot and cold water alternately; breathing took place through the mouth. Heart sounds normal, beat regular. It lived 4 hours.

Appearance of child during life.—Weight, 2 kgm. 560 gm.; total length, 48 cm.; vertex coccygeal, 31 cm. Circumference of head: occipito mental, 33 cm.; occipito frontal, 29 cm. Diameters of head: occipito mental, 13 cm.; occipito-frontal, 9 cm.; bizygomatic, 8 cm.; bitemporal, 65 mm.; fronto-mental, 77 mm. Anus, perforate; meconium voided; urine voided. Sacral indentation, 1 cm. deep; testes undescended. Six fingers on both hands, origin from upper phalanx, little finger. Six toes on left foot, origin from upper phalanx, little toe.

General description of head and face.—Occipital, temporal, parietal and mental regions apparently normal; ears and jaw well developed. Frontal region normal with exception of mesial aspect or junction of superciliary ridges. From that point projects a tubercle with much the appearance of a penis, 5 cm. long by 15 mm. in diameter, the base slightly constricted. On the indented apex was a minute opening less than $\frac{1}{2}$ mm. in diameter from which exuded a watery fluid, drop by drop somewhat accelerated on pressure. This fluid contained some flat epithelial cells and fatty material much broken when examined. From the base of this tubercle on either side extended outward the eyebrows, normal in appearance, and well developed. Beneath this tubercle in the median line was a reddish mass looking like granulation tissue 2 cm. broad by 15 mm. longitudinally. It was enclosed on either side by eyelids with well developed eyelashes save on median junction of the upper and lower lids, which here seemed deficient. On separation of these lids at the outer canthi normally formed, appeared conjunctiva with sclera as far inward as the red median mass. The whole cleft was 4 cm. in width. Beneath the continuous single lower lid appeared a smooth skin surface to the vermilion border of the upper lip, which appeared normal, as did the mouth, dental ridges, hard and soft palates and uvula. A probe met an obstruction in the pharynx 2 cm. above the uvula, measured post-mortem.

After death the body was kept at normal room temperature in tenement house for six hours before it could be obtained, was then put in 4 per cent. solution of formaldehyde in water, 24 hours later was injected through umbilical vein with 1 per





cent. formaldehyde in water. Injection was not very successful, and entire body was then put in alcohol and formaldehyde, the strength of which I do not know. I then obtained the body, decapitated it and froze the head for a median section to mount. Head divided with saw $\frac{1}{2}$ mm. in width, 1 mm. approximately to left of median line.

Body then was examined. There was no sternalis muscle, as has been so frequently found by Dr. Shepard in anencephalic monsters, but from the axillary borders of both pectoral groups, a single muscular sheet extended backward enveloping the outer wall of the axilla to the axillary border of the latissimus dorsi, with fibrous arch from insertion of pectoralis major to insertion of latissimus dorsi. Through the arch passed the axillary vessels. The attachment was caudad to 5th, 6th and 7th ribs and fascia over intercostals. The nerve supply was from the external anterior thoracic, as has been pointed out by Dr. Shepard on this anomaly.

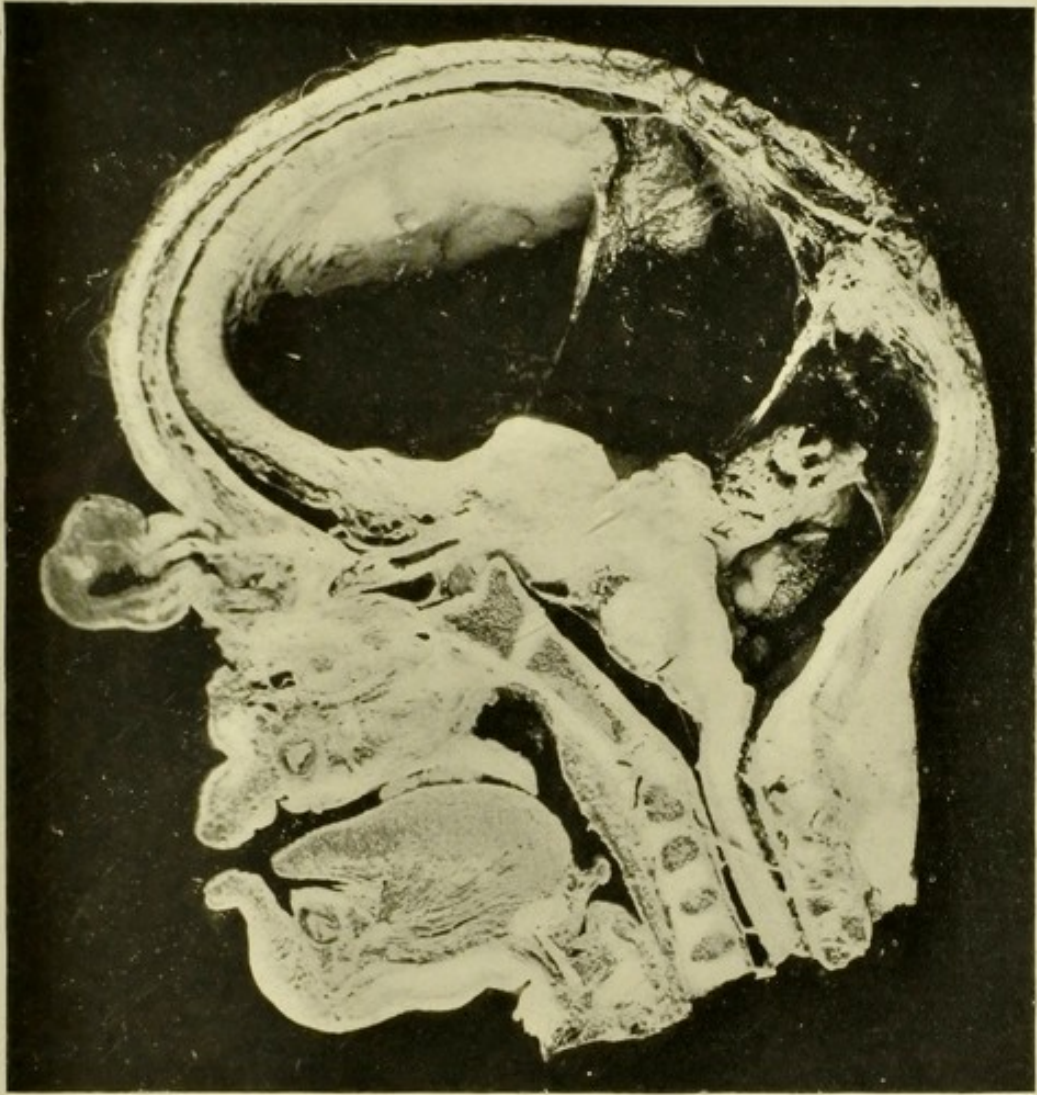
On removal of the sternum and costal cartilages, the thymus presented approximately normal as were the lungs, heart and great vessels. Lungs somewhat atelectatic. The thyroid body seemed somewhat large, 6 cm. by 5 cm. by 4 cm.; the lateral lobes embraced the trachea and oesophagus, impinging upon the vertebral column dorsally. Over right lobe of liver, beneath peritoneum of supero-external surface, was a large subperitoneal hemorrhage. Liver otherwise normal. Stomach normal save for attachment of omentum to transverse colon, which attachment had not taken place on left side for approximately 8 cm. Duodenum enclosed by peritoneum save for 4 cm., beneath attachment of mesocolon. Small intestines otherwise normal with exception of attachment of ileum to caecum shown in photograph, ileum passing behind caecum. Ascending and descending colon both have long mesenteric attachment, caecum is unrotated and appendix is on outer aspect of caecum, vessels and folds otherwise normal. Kidneys and adrenals normal, no hemorrhages within them; pancreas also normal. Right testis compressed by neighboring viscera into small triangular mass beneath right kidney, left testis just at outer ring, and not in scrotum. Ureters and bladder not dissected, but seem normal.


No extra muscles apparent to accessory fingers or toes.

Mesial section of skull and brain shown in photographs and diagram drawn by Mr. E. A. Spitzka from the dissected

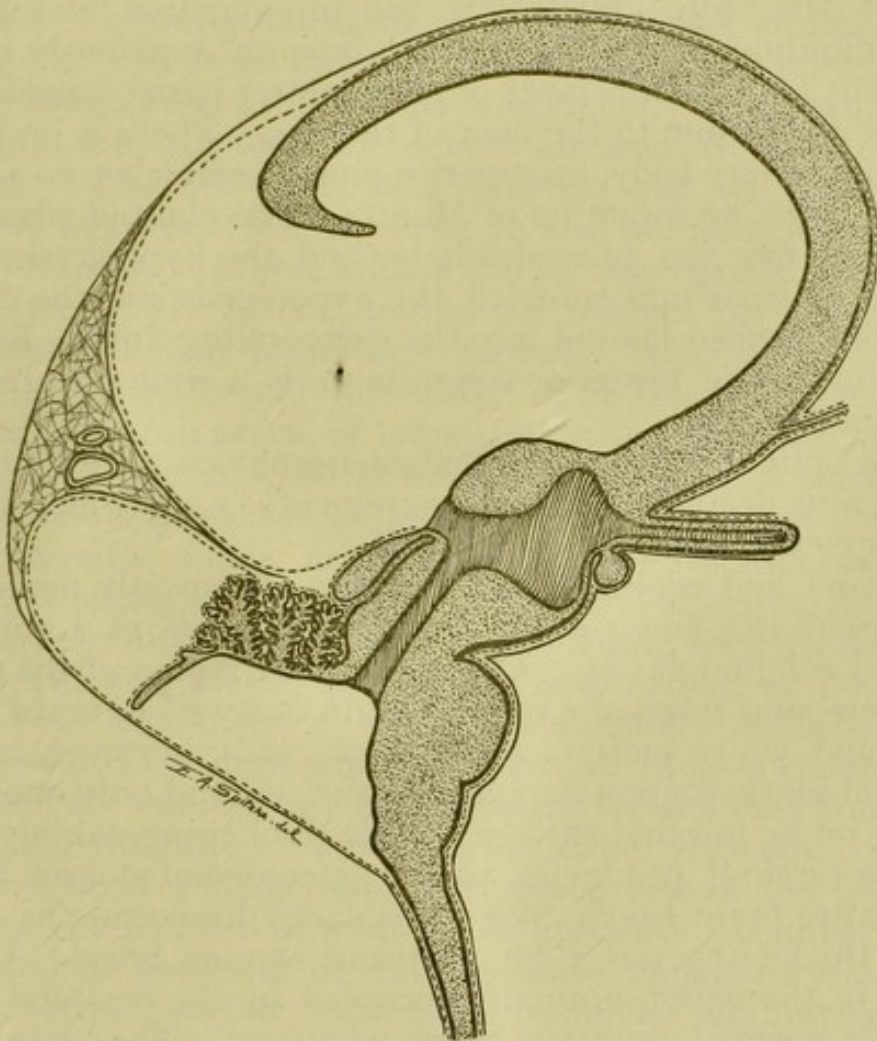
hemi-section. The latter is presented through his kindness. The skin, scalp and occipito frontalis are normal, as are the portions of parietal and occipital bones then apparent. There is no horizontal plate to frontal bone. The body of the ethmoid is represented by a small cartilaginous plate, through intervals in which pass two, possibly more, attenuated olfactory fibers. The basio-sphenoid is normal, but the sella turcica seems deficient anteriorly. Nasal bones are cartilaginous and misshapen, extending forward into protuberance, extending in front of lower end of frontal bone. Scattered bits of cartilage beneath the lower lid, irregularly separated by embryonal and irregularly-placed muscle fiber, seem to represent the unformed vomer, median plate of the ethmoid, the turbinate and palate bones. Tooth cavity normal in superior and inferior dental process. Spinal cord is normal in gross appearance. Inferior medullary velum is a thin veil between the peduncles of the flocculus. The nodulus is absent, or represented by the velum only. The metapore is a wide, open space uncovering the 4th ventricle. The small size of the cerebellar peduncles makes the floor of the 4th ventricle considerably larger than normal. The obex is ill defined.

In the floor of the 4th ventricle can be seen a well defined median sulcus, continuous with a dilated iter e tertio ad quartam ventriculam above and in front of it. The funiculi gracilis and cuneati are well developed and apparently normal. The cuneate tubercle of Schwalbe is enlarged as in all young human brains. The restiform bodies are poorly developed. The striae acusticae and eminentia teretes are very prominent. In consequence the superior and inferior foveae are very deep. The ligula is thick and well developed. The pons varolii of the mesencephalon is normal in gross appearance, but somewhat small. The iter is dilated evenly throughout its length (15 mm. in diameter), entering the third ventricle in relatively its normal position. The corpora quadrigemina, 20 mm. long, seem larger than normal and not differentiated in gross appearance into separate surface markings. Above the corpora quadrigemina is a flattened epiphysis, 10 mm. long by 1 mm. deep, over twice its normal size. A stalk passes cephalad from the epiphysis 1 mm., then ventrad and caudad to posterior commissure dorsad to entrance of iter to the 3d ventricle.





The cerebellum or eencephalon had a large hemorrhage over caudal and dorsal surfaces. The pia was much congested and the blood vessels seemed thickened. The lingula and superior medullary velum were normal. The lobulus centralis was small but normal in shape; its folia seemed normal. The sulcus post-centralis was well defined. The culmen monticula and its folia were also normal. The clivus was degenerate in form; its folia were diminutive. The sulcus preclivalis was well defined. The folium cacuminis was



represented by a thin layer of gray matter resting upon a thin stratum of white matter. This layer has become displaced in the specimen here presented. The horizontal sulcus was absent as were tuber valvulae pyramis, uvula and nodulus. Through the open space left by their absence are visible the flocculus, amygdala, lobi biventralis, lunatus anterior and posterior, gracilis, postero-inferior and postero-superior.

The 3d ventricle, of which the walls seemed in contact, the cavity not dilated, was 3 cm. long by 15 mm. deep. The thalami were united cephalad by an apparently enlarged middle commissure, which closed in cephalad and dorsad the anterior wall of this ventricle. Beneath this commissure and extending cephalad to it was a hollow stalk 2 cm. long, 1 cm. in diameter. This was the single or fused optic vesicles. At its mesial cephalal termination it divided into two hollow prolongations. Three mm. ventrad and caudad to the opening of the optic vesicle was the prolongation making the infundibulum, extending ventrad into an apparently normal hypophysis. A thin layer of gray matter passes caudad from the infundibulum to the floor of the iter. There is no fornix, no mammillary body, no superior pineal peduncles, no anterior commissure, no foramina of Monro. The choroid plexus did not penetrate the 3d ventricle beyond the hypophysis. The velum interpositum enfolded the hypophysis and the choroid plexus extended laterad into the surrounding fluid. Between the middle and posterior commissure is a wide opening into the space dorsad.

The optic thalami of the thalamencephalon were 2 cm. long by 15 mm. deep and (later measurement) 15 cm. wide, rounded and somewhat larger than normal.

Dorsad and cephalad to this brain, so far only moderately abnormal, is a single cyst, occupying the rest of a normally-shaped cerebral cavity. Cephalad in the region of the frontal and temporal lobes of a normal brain is a wall of brain tissue, gray and white matter, 2 cm. thick, with, however, no gyri or sulci marked upon its external surface, and only one thickening on its internal surface. This thickening, taking origin at the cerebral peduncles, passed laterad and dorsad around the entire brain cavity like a misplaced hippocampus major. This thickening was 3 cm. deep and 15 mm. broad. Caudad to it, in the region normally occupied by the occipital lobes, the pia covered no brain tissue whatever. The brain tissue in front was covered by congeries of blood vessels on both of its surfaces, which vessels are continuous with large vessels coursing over the occipital walls, to vessels in the folds of a nearly normal tentorium cerebelli.

Cephalad to the thalamencephalon, extending ventrad from this abortive prosencephalon (if it can so be called), extended a thin nerve fiber to the rudimentary ethmoid plate in front,

through which two fibers were found passing. This appeared to be a rudimentary olfactory tract.

On horizontal section, the optic stalk extending cephalad 2 cm., divided into two stalks, each 1 cm. long, terminating in a well developed eyeball, choroid, sclera, lens, and external conjunctiva with rudimentary retina, vitreous and cornea, behind the outer canthus of the single ophthalmic slit. Mesially interposed between it and its fellow were two layers of muscle (probably internal recti), surmounted in front by the mass of granulation tissue above mentioned, entirely concealing the eye from external inspection. The optic stalk had no connection with the mesencephalon. The 12th, 11th, 10th, 9th, 8th, 7th and 5th nerves all seemed normally developed. The 4th nerve was present, but its connection cephalad was lost. The 3d nerve, divided normally, supplied a normal levator palpebrae muscle and its fibers passed to muscle tissue irregularly placed around an eyeball of which the orbit was deficient posteriorly, mesially, superiorly, and degenerate externally and inferiorly. The frontal branch was normal. The 6th nerve, of large size, passed normally to a degenerate set of muscle fibers inferior to the levator palpebrae. The muscle appeared to be unattached at either end.

The mouth seems normal. Rathke's diverticulum has closed off normally, leaving a pharynx closed cephalad above normally opening Eustachian tubes. Tooth sockets, normal.

Von Häcker, in the *Archiv für mikr. Anat.* at Bonn, in 1897, Vol. XLIX, pp. 35-91, has elaborately described the microscopical findings, while C. Claus, in 1892-3, elaborately described the embryology and comparative anatomy from the Zoölogical Institute of Vienna, Vol. X, pp. 283-356. Smith and Parker, of Philadelphia, have given one of the best descriptions in English of a case. In literature I counted some two hundred instances of this anomaly and then ceased to count. It is, therefore, moderately common. Its interest lies in the fact that it pursues no known laws of variation; it is not a reversion to some animal; its findings are quite regular and much alike; its causation obscure, and its influence on form, the influence of anomaly in one part over anomaly in another part. This anomaly may throw light on the formation of the gyri and sulci, and the non-relation of cerebellar to cerebral gyri, or cerebellar gyri to other gyri in its substance.

In the specimen here presented the interest lies in the

hidden position of the eyeballs, and the few complications with other variations.

Dareste, with whom began most of our systematic knowledge of cyclopiian monsters, despite the earlier work of Geoffroy Saint-Hilaire, stated that its probable cause was pressure of the amniotic sac. In the case here presented, the amniotic fluid was sufficient at birth, and membranes carefully examined showed no old adhesions. Rudolph's case of placenta adherent to brow, with normally formed eyes and nose, would seem; unless this attachment was secondary, to disprove this assertion. Phisalix, a student of Dareste, thought a thrombus of the vessel passing into the cleft or constriction between the primary fore-brain and primary mid-brain, to be responsible for the condition. The vessels in this subject, although uninjected, seem normal so far as the dissection has gone.

Cleland thought a hydrops of the pineal body or epiphysis was regularly responsible for the condition. In this case the epiphysis was much enlarged, but certainly contained no collection of fluid as was described in Cleland's case.

Ahlfeld surmised that in some of his cases hydrocephalus was responsible for the condition occurring before the differentiation of the primary fore-brain, as seems confirmed in Rochi's case with twins. It cannot be denied that this may be possible, but many cases of apparently early hydrocephalus without this anomaly would lend doubt to such supposition. Kundrat has shown that there may be an absence of the olfactory lobes and nerves without as necessary corollary the deformity of cyclopia. No case of cyclopia seems to have occurred where these two cerebral vesicles were present even if the corpus callosum was deficient and the two halves were more or less fused, as in Knox's fourteen cases of imperfectly divided brains.

Von Hippel has shown that the eye may be single; fused with one lens, two imperfect halves; fused, with two pupils, two lenses and one globe, fusion of two eyes, or, as in this case, two eyes with single stalk and embryonal tissue between, or two eyes with separate tracts and only the union of the fronto-nasal process to indicate the condition.

In the Museum of the Presbyterian Hospital, of New York City, I have seen a well developed foetus of about the thirty-eighth week, a cyclops with fusion of two eyeballs on the mesial aspect. There is synotie as an additional abnormality

and deficient inferior mandibular process. In the Pathological Museum of the Medical Department of Columbia University, N. Y., I have seen a similar specimen, but the two pupils and lenses are in a single globe, and the synotie is more marked. These cases are exactly similar to the remarkably well described case of Smith & Parker, in Philadelphia, in 1884. Daresté maintained that cyclopia was common among pigs, while synotie was more common among sheep. Among references I have seen, however, it is quite as common among dogs, calves and sheep, as among pigs.

BIBLIOGRAPHY.

THEORIES OF CYCLOPISM.

Claus, C.—“Neue Beobachtungen über die Organisation und Entwicklung von Cyclops. Ein Beitrag zur Systematik der Cyclopiden.” *Arch. a. d. zool. Inst. d. Univ. Wien*, 1892-3, X, 283-356. 7 pl.

v. Häcker.—“Die Keimbahn von Cyclops; neue Beiträge zur Kenntniss der Geschlechtszellen-Sonderung.” *Arch. f. mikr. Anat.*, Bonn, 1897, XLIX, 35-91. 2 pl.

Rosenstein.—“Ueber Cyclophenbildung.” *Arch. f. path. Anat.*, etc., Berlin, 1853, VII, 532-540.

Daresté.—See below.

Tarenetski, A.—*Anatomija i istorija razvitija tsiklopii u chelovieka s primiehanijami o razvitii prostvich urodov voobtshe*. 8°. St. Petersburg, 1882. (Development of cyclops.)

Lubarsch & Ostertag Ergebnisse.

Taruffi.—“Un caso di ‘Cyclops dierhiuns’ nella specie umana.” *R. Accad. dell. scienze dell’ Istituto di Bologna*, Seduta del 10, III, 1895. (Nose above and below eye.)

Valenti, G.—“Sopra un caso di ciclopia nell’ uomo, notwole pei alcune anomalie concomitanti.” *Atti della Accad. med.-chir. di Perugia*, VI, p. 177, 1894.

Allan, R.—“Dissection of a human astomatous cyclops,” *Lancet*, London, 1848, I, 227.

Debierre, C.—“Sur un monstre cyclopéphalien du genre rhinencéphale.” *Compt. rend. Soc. de biol.*, Paris, 1886, 8s, III, 184-186.

CASES OF CYCLOPIA—STUDIED ANATOMICALLY.

Phisalix, C.—“Monstres Cyclopes.” *Jour. de l’ Anatomie et de la Physiologie*, Vol. XXV, 1889, pp. 67-105, Paris. (Dog, mare, sheep—three cases.)

Cleland.—“On the Brain in Cyclopians.” *Journ. of Anatomy and Physiology*, Vol. XII, 1877-78, p. 518. (Man, two pigs, lamb, dog.)

Förster.—“Die Missbildungen des Menschen.” Jena, 1865, p. 73.

Richter.—“Ueber Cyclopie, Archinencephalie und einblasiges Gehiren.” *Archiv. f. Psychiatrie*, Vol. XIX, pp. 545-546.

Ahlfeld.—*Missbildungen d. Menschen*. Abschn. II, 1882, Leipzig, pp. 277-282. (Five cases of Leipzig Museum, twenty-two cases of others.)

Panum.—*Nordisk medicinsk. Ark.*, Bd. I, No. 1; *Virchow u. Hirsch Jahresbericht*, 1869, S. 175. Also, 1878, *Virchow’s Archiv.*, LXXII, S. 289. (Two cases, human: 1, foetus 6 weeks old; 2, with spina bifida.)

- Rokitansky.—Handbuch der pathologischen Anatomie, 3 Auf., Bd. 1, S. 59. Abbildung Atlas, XLV, Fig. 1.
- Hecker und Buhl.—*Monatschrift für Geburtskunde*, Band 31, 1868, S. 430.
- Vrolik.—*Tabulae ad illustrandam embryogenesisin* (etc.). Leipsig, 1854. Taf. 26 and 53, Fig. 1 and 8; Taf. 54, Fig. 2 and 3. (Five cases.)
- Licetus, Fortunines.—*De Monstris* Amsterdam, 1665, p. 135.
- Schmid.—“Die Cyklopie” Inaug. Diss., Turici, 1838.
- Knape.—*Monstri humani maxime notabilis descriptio anatomica*. Inaug. Diss., Berlin, 1823, Tab. II, Fig. 1 and 2.
- Heyman & Meckel.—*Deutsches Archiv*, f. d. Phys., 1820, Bd. 6, p. 527.
- Jourdan.—“Description anatomique d'un cas de cyclopie.” Thèse de Paris, 1833.
- Lancereaux.—*Traité d'Anatomie pathologique*. Paris, 1875, p. 116.
- Walther.—“Ueber menschliche Monopsie und Cyklopie.” Inaug. Diss., Leipzig, 1845.
- Delle Chiaie.—“Istoria anatomico teratologica intorno ad una bambina rino-cephalo-monocola.” Napoli, 1840.
- Raddatz.—“De Cyklopie.” Inaug. Diss., Berlin, 1829.
- Ellis.—*Obstetrical Transactions*, Vol. VII, 1866, p. 162.
- Cruveilhier.—“Atlas der pathologischen Anatomie,” 33 Lieferung, Plate VI, Figs. 1 and 2.
- Hardy.—*Obstetrical Transactions*, Vol. IV, 1863, p. 215.
- Druys, Jacobus.—*Verhandelingen over het ampt der vroed-meesters en vroed-vrouwen*. Leiden, 1733, S. 194. (Twenty-two cases.)
- Buck's “Reference Handbook of the Medical Sciences.” Wm. Wood & Co., N. Y., 1886, Vol. III, p. 5; also Supplement, 1893, p. 583. (Specimen from Army Medical Museum at Washington. Skull preserved.)
- Rudolph.—“Monstrorum trium praeter naturam cum secundinis coalitorum disquisitio.” Tab. I, Berlin, 1829. (Placenta adherent to head; eyes distinct and bilateral.)
- Graefe, Saemisch.—*Handbuch der gesammten Augenheilkunde*, Bd. I, 2, p. 125.
- von Hippel, E.—“Graefe-Saemisch Handbuch,” 2d Edition. Leipsig, 1900, T. I, Bd. II. (References not among Ahlfeld's.)
- Huschke.—*Müller's Arch. f. Anat. u. Phys.*, 1832, pp. 1-48.
- Dursy.—“Zur Entwicklungsgesch. des Kopfes.” Tübingen, 1869.
- Sömmering.—*Abbildungen u. Beschreibungen einiger Misgeburten*. Mainz, 1791.
- Johnson.—*Dublin Quart. Jour.*, 1870, No. 90.
- Carus.—*Schmidt Jahr*, L. Bd., p. 266, 1841.
- Otto.—*Lehrbuch d. patholog. Anatomie*, Berlin, 1830, p. 457, Anm. 100.
- Walther, L.—*Jour. f. Chi. u. Augenheilk.* (v. Graefe u. Walther.) N. F., IV, Bd., p. 345.
- Schön.—*Handbuch der path. Anat. d. Auges*. Hamburg, 1828.
- Pennow.—“Fall von Cyclopie.” (Nach Nagel's Jahresb.), 1883.
- Bock.—“Beschreibung eines atypischen Cyclops.” *Klin. Monatsbl.*, S. 508, 1889.
- Nieden.—“Ueber Anophthalmia cyclopie.” *Arch. f. Augenheilk.*, XXII, S. 61, 1890.
- Dareste.—“Mode de formation de la cyclopie.” *Ann. d'ocul.*, CVI, p. 174, 1891.
- v. Monakow.—“Zur path. Entwicklung des Centralnervensystems.” *Naturf. vers. Frankfurt*, II; Theil II, Hälfte, S. 280, 1896.
- Gabrielides.—“Examen microsc. d'un oeil cyclope.” *Arch. d'Ophth.*, XVI, S. 627, 1896.
- Born.—“Die Kunstl. vereinigung lebender Teilstücke von Amphibienlarven.” *Arch. f. Entwicklungswech.*, III, 1897.
- v. Duyse.—“Pathogénie de la cyclope.” *Arch. d'Ophth.*, 1898.

Thoma.—Bruce's translation.—Text book of General Pathology, Vol. I, p. 218, 1896, London. Quoting: Kundrat.—Archinencephalie, Wien, 1882. *Wien med. Bl.*, 1882, p. 1395. (Absence of olfactory lobes and nerves.) Chiari.—*Prager Wochenschr.*, 1890.

GENERAL REFERENCES TO CYCLOPIA.

- Bateson.—Materials for the Study of Variation, p. 458.
 Dareste.—*Compt. Rendus*, Acad. d. sci., Paris, 1877, LXXXIV, p. 1038; 1880, XC, p. 191.
 Mackenzie.—Manual of Diseases of the Throat and Nose.
 Blok.—Weekblad von het Nederlandsch. *Tijd schr. voor. Geneeskunde*, XXX, 2d part, 414, Sept., 1894. Abstracted in Ballantyne.—Teratologia, London.
 Turner.—*Jour. Anat. and Phys.*, Vol. XII, Jan., 1878, part 2.
 Taruffi, C.—Storia della teratologia, 4 vols. 8°. Bologna, 1881-6.
 Meckel.—*Arch. f. Anat. u. Phys.*, 1826, p. 278 (?).
 Larcher.—"Cyclope, Cyclopie." *Dict. encycl. d. sci. méd.*, Paris, 1880, XXIV, pp. 538-545.
 Bardinet, M. A.—"Observations teratologiques." Vol. III, cyclocéphalie. 8°. Paris, 1839.
 Guerin, J.—Recherches sur les difformités congénitales chez les monstres, le fœtus et l'enfant. 8°. Paris, 1880-82.
 Princeteau.—Progrès de la tératologie depuis Isidore Geoffroy Saint-Hilaire. 8°. Paris, 1886.

DISSECTIONS OF HUMAN CYCLOPS.

- Allan, R.—"Dissection of a human astomatous cyclops." *Lancet*, London, 1848, I, 227.
 Bambaren.—Descripcion de un monstruo ciclocefaliano, del género de etmocéfalos. *Gac. med. de Lima*, 1860-61, V-VI, 125-128.
 Bramwell, B.—"Photographs of a case of cyclopean monstrosity." *Edinburgh Med. Jour.*, 1880-81, XXVI, 550.
 Burns.—Cyclopean monstrosity. *Boston M. and S. J.*, 1863, LXVIII, 513.
 Eustache, G.—"Etudes de tératologie humaine, fœtus cyclope et fœtus acéphale." *Arch. de tocol.* Paris, 1884, XI, 309, 326; also *Jour. d. sci. méd. de Lille*, 1884, VI, 473, 568.
 Francis.—*London Med. Gaz.*, 1844, XXXIV, 580.
 Galloupe.—*Boston M. and S. J.*, 1880, CII, 135, 495.
 Gosselin.—"Description d'un fœtus cyclope." *Comp. rend. soc. de biol.*, 1852. Paris, 1853, IV, 28.
 Guerdan.—*Monatschrift f. Geburtsk.*, X, p. 176, pl. I.
 Hall.—*Boston M. and S. Jour.*, 1861-2, LXV, 263.
 Hannover, A.—"Sur la structure du crâne humain dans l'anencéphalie, la cyclopie et la synotie et sur les rapports de ces monstruosités avec le cartilage primordial du crâne." (Abst. trans.) *Cong. périod. internat. d. sc. méd., compl. rend.*, 1884. Copenhagen, 1886, I. Sect. de path. gén., etc., 71-87.
 Gross.—Case in *Phila. Med. Times*, 1874-5, V, 481-485.
 Jahn, C. A. B.—"De Cyclopia." 8°. Berlin, 1860.
 Malherbe, A.—*Bull. soc. anat. de Paris*, 1879, LIV, 115-117.
 Roe.—*Dublin Q. J. M. S.*, 1871, LI, 146-149.
 Sappey.—*Compt. rend. soc. de biol.*, 1859. Paris, 1860, 3s., I, 46.
 Roché, L.—"Accouchement gémellaire; un des enfants cyclope; le deuxième hydrocéphale et bec de lièvre; difficulté de l'accouchement; description des deux enfants." *Bull. soc. med. d. l'Yonne*, 1870. Auxerre, 1872, XI, 42-50. 2 pl.

- Saussol.—“Un Monster cyclocéphalien rhinocéphale.” *Gaz. hebd. d. sc. med. de Montpel.*, 1886, VIII, 458.
 Scott, J.—“A monocular male foetus.” *Lancet*, London, 1862, I, 633.
 Smith & Parker.—*Am. Jour. Med. Sci.* Phila., 1882, LXXXIV, 132-140.
 Richter.—See above.
 Thompson.—*Tr. Obst. Soc. London* (1873), 1874, XV, 35-38.
 Wadsworth.—*Boston M. and S. J.*, 1875, XCII, 595.
 Wille, L.—“Ein Fall v. Missbildung des Grosshirnes.” *Arch. f. Psychiatrie*, Vol. X, p. 597, pl. VII.

CYCLOPIA IN ANIMALS.

- Gay, M.—Sopra un mostro ovino (Ciclope perostomo arnico). *Medicovet. Torino*, 1878, 5 s, I, 193-195.
 Gluge & Deroubaix.—“Observation d'un chien cyclope.” *Arch. de la méd. belge.* Bruxelles, 1840, III, 115-117.
 Magendie.—“Anatomie d'un chien cyclope et astome.” *Rev. méd. hist. et phil.* Paris, 1821, VI, 323-328.
 Meckel, A.—“Bemerkungen über einen Kalbscyklopen.” *Arch. f. anat. u. phys.* Leipzig, 1828, 159-166.
 Pigné.—“D'un chevreau cyclocéphale.” *Bull. soc. anat. de Paris*, 1841, XVI, 138.
 Wyman, J.—“Cyclopism in a pig.” *Boston Med. and Surg. Jour.*, 1858-9, LIX, 121.

CONGENITAL DIVISION OF THE NOSE.

- Riker.—*Atlanta Med. and Surg. Jour.*, 1878, p. 196.
 Bartholinus, Thomas.—*Hist. anatomicarum rariorum*, cent. I, hist. XXV.

OCCLUSION OF POSTERIOR NARES.

- Ronaldson.—*Edinburg Med. Jour.*, 1880, XXVI, 1035.

OCCLUSION OF ANTERIOR NARES.

- Smith.—*Med. Times and Gaz.* London, 1863, I, 320.
 Jarvis.—*N. Y. Med. Jour.*, XLVI, 536.

ABSENCE OF EYES.

- Landes.—*Med. Rec.* N. Y., Nov. 3, 1894.

OTHER ANOMALIES.

- Shepherd, F. J.—“The Musculus Sternalis and its occurrence in Anencephalous monsters.” *Jour. Anat. and Phys.* London, 1884-5, XIX, 311-319.
 Knox.—Incallosal Brains. *Glasgow Med. Jour.*, April 1875. (Fourteen cases.)

THE MESIAL RELATIONS OF THE INFLECTED
FISSURE. OBSERVATIONS UPON ONE
HUNDRED BRAINS.

BY EDWARD A. SPITZKA, NEW YORK CITY.

Student of Medicine, Medical Department, Columbia University.

[Reprinted, with revision, from the *New York Medical Journal*, January 5, 1901.]

Several cerebral morphologists have paid special attention to the so-called inflected fissure. Lussana of Padua first named it *solco inflesso*, while in America it was first noted by Professor Wilder¹, in 1885. The latter says of this fissure that it "indents the dorsi-mesal margin just cephalad of the pre-central fissure and paracentral lobule. In the brain exhibited (from an adult mulatto) it is particularly distinct, and is shown in the outline figure in the *New York Medical Journal*, February 23, 1884, Fig. 42. It seems to have been described by Lussana and Lemoigne (*Fisiologia dei centri nervosi encefalici*, Padova, 1871) under the name of *solco inflesso*; paronymized, in Latin this becomes *fissura inflecta*, and in English the *inflected fissure*."

More recently, Eberstaller², in his work *Das Stirnhirn*, gives to this fissure the long name *sulcus praecentralis medialis*, which Wilder³ considers a "needless and unwarranted change of names," an opinion with which critical students will agree. However, Eberstaller commits another error, more grave, perhaps, than the one Professor Wilder has unearthed, inasmuch as it has misled many writers and perpetrated a misinterpretation which has existed in our literature to the present day. His error consists in the identification of Lussana's⁴ and Wilder's inflected (or Eberstaller's *sulcus praecentralis medialis*) with the fissure named by Broca *incisure pré-ovale*, and by Schwalbe *sulcus paracentralis*.

On referring to the writings of Broca and Schwalbe, it becomes evident that the pre-oval incisure and paracentral sulcus of these two writers does not correspond to the so-called inflected, but that both designations refer to the cephalic limb of Wilder's paracentral, a ramus for which Eberstaller himself

suggests the name *preparacental*. Broca⁵ describes it as an "*incisure pré-ovale* de la scissure sous-frontale," and the wood-cut illustration which accompanies his article, renders his meaning absolutely clear. Schwalbe⁶ likewise represents this as a ramus of the calloso-marginal, in Fig. 339 of his *Lehrbuch*, and beside the clear and accurate description of his *sulcus paracentralis* as a cephalic limiting ramus (on page 541), he expressly identifies this fissure with Broca's *incisure pré-ovale* (in a foot-note, page 544). The various synonyms for this ramus may therefore be properly grouped as follows:

<i>Incisure pré-ovale</i> ,	.	Broca.
<i>Sulcus paracentralis</i> ,	.	Schwalbe.
<i>Sulcus praeparacentralis</i> ,	.	Eberstaller.
<i>Cephalic paracentral limb</i> ,	.	Wilder.

In only 9 per cent. of the brains examined by me did I find this limb separated from the paracentral, and usually it was confluent with the *supercallosal* (Fig. 2). In the event of separation the interposed isthmus was invariably very narrow and insignificant, and in no case did I observe that this cephalic ramus ever crossed the dorsimesal margin. On the other hand, the true inflected fissure always cuts across the margin to appear on both meson and dorsum, and only in rare instances, contrary to Eberstaller, is it confluent with the paracentral (or "calloso-marginal"). On this point Eberstaller seems to contradict himself, for, after stating that the *sulcus praecentralis medialis* is situated caudad—by the breadth of one gyrus—of his "*Anfangsstück der Pars posterior*" of the "subfrontal," he thereupon says that these two fissures anastomose in 55 per cent. of his cases. What error of observation or interpretation underlies the latter statement, I cannot say. However that may be, his comments upon Schwalbe's description are based upon a gross misinterpretation, as inconsistent as it is erroneous.

We are dealing, then, with two distinct fissures which have been erroneously identified with each other ever since Eberstaller's work gained its wide circulation. The inflected fissure was probably unknown to Schwalbe under any name whatsoever, and it is unrepresented upon Ecker's diagrams⁷.

Through the kindness of Professor Wilder I have been enabled to study the work of Lussana and Lemoigne⁴ in which the fissure, which forms the subject of this paper, was first designated. The fissure is shown in Figs. 174, 177, 178

and 179. It is designated *solco inflesso* in Fig. 177 and *Sc. inflessa* (*Sc.* stands for *Scissura*) in Fig. 179. The relations in Fig. 174 are substantially as in Fig. 1 of this article. In Figs. 177 and 179 it is placed cephalad of the supercentral, while in Fig. 178 it is a little caudad, *i. e.*, just cephalad of the central.

The designation "*solco inflesso*" does not appear in the text, though the fissure is evidently described in four lines on page 163. Freely translated, it reads:

"The caudal part ('pezzo posteriore T') of the superfrontal gyrus ('appendice anteriore') exhibits an inflection (φ) on the middle of its mesial face ('*ha una inflessione media-interna φ* ') by means of which this gyrus is readily identified on the dorsal aspect, in man as well as in ruminants."

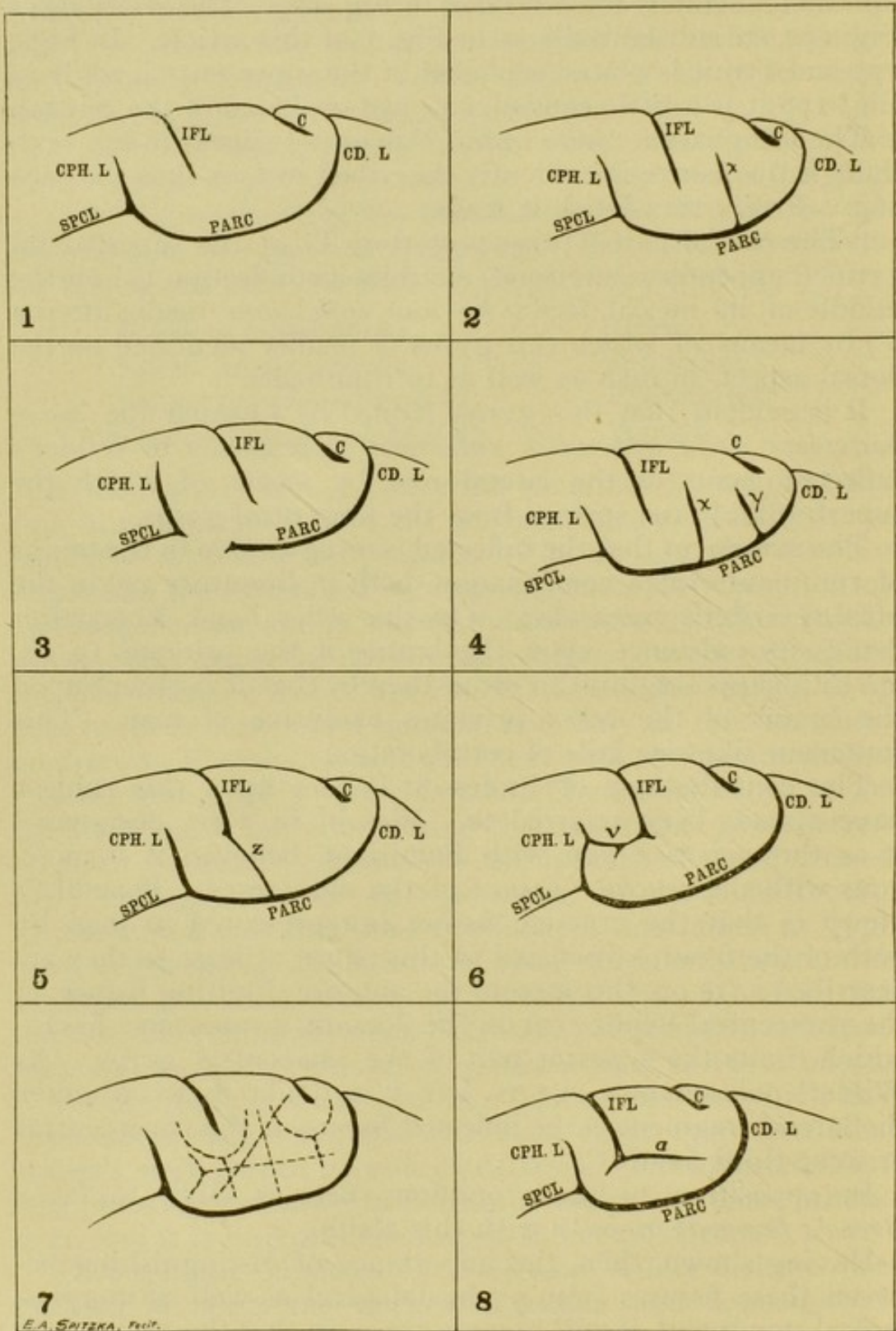
It is evident that this gyrus, named by Lussana the *pezzo posteriore della appendice anteriore*, corresponds to Wilder's inflected gyrus, or the lateral root, by means of which the superfrontal gyrus springs from the precentral gyrus.

The statement that the inflected is recognizable in the brains of ruminants lacks confirmation, both in literature and in the present writer's researches. On the other hand, Eberstaller denies its existence upon the brains of the primates (p. 65, *loc. cit.*), supposing him to mean thereby that it is absent upon the brains of the *other* primates, exclusive of man. This statement likewise fails of corroboration.

The contributions of Professor Wilder upon this subject have already been referred to. Flesch⁸ in 1885 designated it as the *x-fissure*, and with Familant⁹ believed it homologous with the *cruciate fissure* of the carnivores. Benedikt's view¹⁰ is that the cruciate fissure is represented in man by both of the fissures discussed in this paper, at least so they are described; (1) on the meson, the anterior limiting fissure of the paracentral lobule; (2) on the dorsum, a transverse fissure which limits the superior part of the pre-central gyrus. As Wilder³ pointed out, one is left "in doubt as to whether the lateral fragment is the inflected fissure or the supercentral or some third fissure."

In opposition to these opinions, Betz is said¹¹ to favor *Broca's pre-oval incisure* with this claim.

Having shown, then, the importance of distinguishing between these fissures from a physiological as well as morphological standpoint, it will become apparent that the anatomical relations of these fissures are of equal importance, and with



this view I carried on the researches which form the basis of this paper, in the anatomical laboratory of the Medical Department of Columbia University. I am indebted to Professor George S. Huntington and Dr. B. B. Gallaudet for their courteous permission to examine one hundred brains of dissecting-room subjects. The brains had been hardened in formalin and were in a good stage of preservation.

Among the various fissural schemas with which I am acquainted, Professor Wilder's¹² is the only one which places the inflected cephalad of the cephalic paracentral limb. Wilder's figure was based upon the brain of a mulatto described by him in the Handbook article, and in the *New York Medical Journal*, February 23, 1884. That this extraparacentral position of the inflected is an anomalous and rare one will be seen in the latter part of this paper.

The brains were divided into two series of fifty each. Series I consisted in a tabulation of both the dorsal and mesial relations of the inflected, while Series II was recorded by means of drawings taken *ad naturam*, as being better adapted for future study as well as being of great aid in the proposed schematization of the fissures of this region.

Table I expresses the mesial relations of both series. Table II shows the dorsal relations of the fissure in the first series. Its absence was symmetrical (*i. e.*, on both halves) in 6 brains, or three per cent., while it occurred 22 times on the left, and 18 times on the right half.

TABLE I.

	I Series.		II Series.		Totals.	
	Cases.	Pr. ct.	Cases.	Pr. ct.	Cases.	Pr. ct.
Number of inflected fissures.....	77		83		160	80
Cephalic limb confluent with PARC	70	91	76	91½	146	91¼
Cephalic limb separated from PARC.....	7	9	7	8½	14	8¾
<i>a.</i> left h.....	3	4	4	5	7	4½
<i>b.</i> right h.....	4	5	3	3½	7	4½
There is only one cephalic limb.....	50	64	51	62	101	63
<i>a.</i> left h.....	23	30	24	30	47	30
<i>b.</i> right h.....	27	34	27	32	54	33
There is one additional ramus caud. of IFL.....	16	21	19	23	35	22
<i>a.</i> left h.....	6	8	11	13	17	11
<i>b.</i> right h.....	10	13	8	10	18	12
There are several rami (unclassified)	4	5	6	7	10	6

In brief, it was found that in 40 hemicerebrums of the 200 examined, the inflected was wanting; in other words, the fissure was present in 80 per cent.

All further data are based upon the 160 hemicerebrums, in which the fissure was present, as equivalent to 100.

In ninety-one per cent. the inflected was situated in a plane *caudad of an unmistakable cephalic paracentral limb*, while in the remaining nine per cent., this limb had become separated from the main paracentral stem by a narrow isthmus or slight vadum. But in all cases the inflected was situated caudad of this limb, whether separated or confluent, or, in other words, *the inflected indented and lay partly within the paracentral gyrus (or oval lobule, as Broca prefers to call it)*. The reader will now understand the anomalous appearance of this region in Wilder's mulatto brain.

In sixty-three per cent. of all cases there was only one such limb or ramus, bounding the paracentral gyrus cephalad, as shown in Fig. 1; this arrangement occurred a little oftener upon the left half than upon the right.

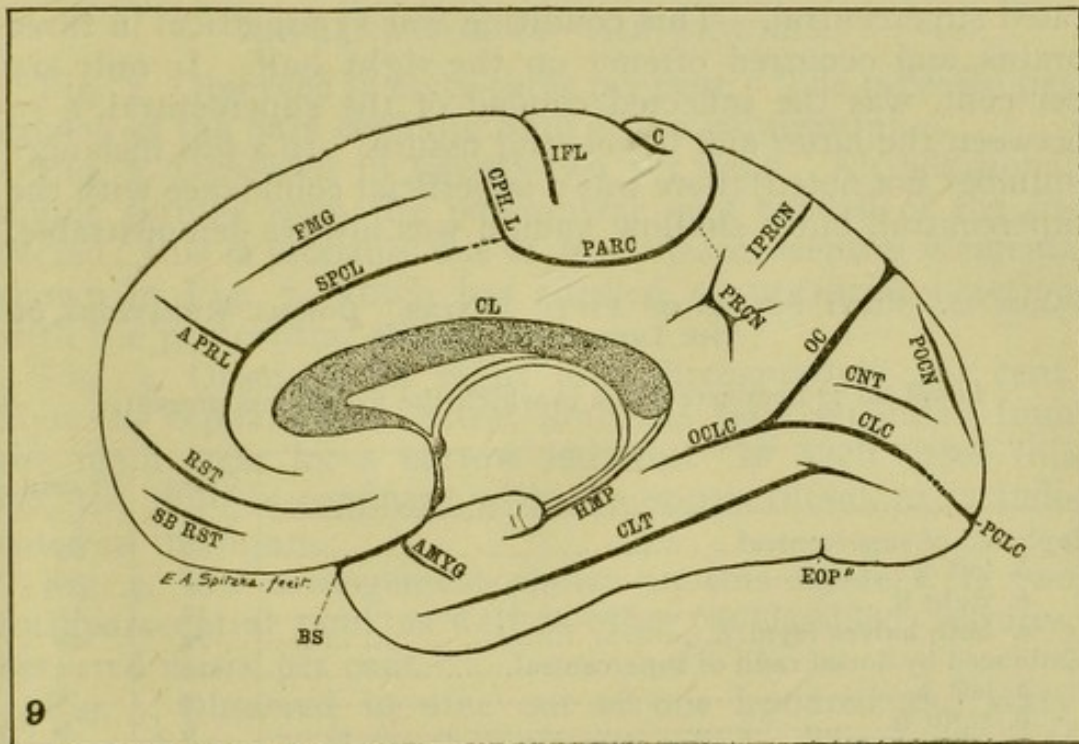
In twenty-two per cent. there was an additional ramus, *intraparacentral* in nature, and probably also in origin, situated just caudad of the inflected, between it and the central. Fig. 3 will show how at first glance such a ramus might be mistaken for the true cephalic limiting ramus, and one must be guided by its position with reference to the inflected, as well as by the size of the lobule thus marked off. This intraparacentral ramus may afford a possible explanation for the odd arrangement on Wilder's mulatto brain; the small paracentral gyre is limited cephalad by such a ramus, while the true cephalic limb failed to develop (see Wilder's Fig. 4,766, *Handbook*, Vol. VIII), so that the inflected fissure appears to lie wholly within the superfrontal gyrus. Fig. 4 is a copy.

In the remaining six per cent. the ramifications and disturbances of fissuration were so varied as not to allow readily of any classification. Sometimes there were two, or even three intraparacentral rami, or the paracentral itself was broken up into fissural segments.

As cited above, Eberstaller asserts that in fifty-five per cent. of his cases, the inflected (*s. præcentralis medialis*) anastomoses with the cephalic paracentral limb, or as he calls it, "*Anfangsstück der Pars posterior*," and "*s. præparacentralis*." I found such confluence *in only two* of the 160 hemicerebrums, both

being upon the left half. In nine other cases the inflected traversed the whole gyrus, effecting a conjunction with the paracentral stem; in all, eleven cases of junction, or seven per cent. In the comparison of these percentages with Eberstaller's figures, the question of racial peculiarity must be excluded, since the brains which were examined by me were derived from representatives of many different races, white and colored, male and female, and varying in ages from twenty to seventy.

In the large majority of the hemispheres examined, the inflected fissure ended upon the meson as well as upon the dorsum in a simple manner. In about sixteen per cent. it was observed that the mesial end joined some one of the *intraparacentral fissural elements*, giving the inflected a kind of



bifurcated appearance. These intraparacentral elements are of not a little importance. There appear to be at least five or six fairly definite types, and nearly every lobule is marked by one or several of these. The longitudinal one, first described by Betz¹³, and which is commonly bifurcated at one or the other end, is the furrow which is most common, and is *most* often joined by the inflected.

It were interesting to determine what relation exists, if any,

between the muscularity of the individual and the degree and kind of fissuration of the paracentral gyrus.

The importance of determining with accuracy the anatomical relations of this region is based largely upon the fact that the cortical distribution of the motor neurones presiding over the movements of the lower limb is essentially confined, on the meson at least, to the paracentral gyrus as Betz, Schwalbe, Broca appear to have understood it. (See the excellent figure in L. F. Barker's "Nervous System", Plate 1⁴.)

As indicated above, the dorsal relations of the inflected were also considered in the first series. In the great majority of cases (eighty per cent.) the inflected was situated cephalad of the supercentral. (See Table II.)

In thirteen per cent. it was observed to indent a well-defined *inflected gyre* (Wilder) embraced by the dorsal radii of a bifurcated supercentral. This condition was symmetrical in three brains, and occurred oftener on the right half. In only six per cent. was the inflected caudad of the supercentral, *i. e.*, between the latter and the central fissure. In a few instances (number not noted) there was a superficial confluence with the supercentral, but a shallow vadum was always demonstrable.

TABLE II.—FIRST SERIES OF FIFTY BRAINS. DORSAL RELATIONS OF THE INFLECTED FISSURE.

Based on 77 hemicerebrums in which the fissure was present.

	Cases.	Pr. cent.
Cephalad of supercentral.....	62	80
<i>a.</i> left h.....	30	39
<i>b.</i> right h.....	32	41
<i>c.</i> both halves (sym.).....	22	28
Embraced by dorsal radii of supercentral.....	10	13
<i>a.</i> left h.....	4	5
<i>b.</i> right h.....	6	8
<i>c.</i> both halves (sym.).....	3	4
Caudad of supercentral.....	5	7
<i>a.</i> left h.....	3	4
<i>b.</i> right h.....	2	3
<i>c.</i> both halves (sym.).....	1	1

Although Wilder's terminology has been generally employed in this article, there appears to be room for more discussion upon some of the terms. Broca¹⁵, Mickle¹⁶, and others consider *oval lobule* to be less objectionable than *paracentral*

lobule, or *gyrus*, because this structure is not really "paracentral." For the terms *cephalic paracentral limb* and *caudal paracentral limb*, we might very well adopt *preparacentral* and *postparacentral*, retaining the name *paracentral* for the longitudinal stem.

In Fig. 9 the writer presents a schema, provisional, of course, of the fissures upon the mesial surface. It is a modification of Wilder's well-known schema, the changes being based upon the newer features which have become known and more or less accepted within the last decade.

It remains for the writer to express his indebtedness to many valuable hints given by Professor Wilder in correspondence while engaged upon this work, and to Professor Huntington and Dr. Gallaudet for the exceptional opportunities which their material and aid afforded me.

EXPLANATION OF THE FIGURES.

Fig. 1. Observed in sixty-three per cent. The inflected lies caudad of the only cephalic limb of the paracentral.

Fig. 2. Observed in twenty-two per cent. An additional ramus springs from the paracentral, just caudad of the inflected; this is probably one of the intraparacentral elements shown in Fig. 7, which has effected a superficial junction with the paracentral stem.

Fig. 3. Observed in eight and three-quarters per cent. Here the cephalic paracentral limb has been separated from the main stem by a narrow isthmus. In such cases this isolated limb is confluent with the supercallosal, as is indicated in the figure.

Fig. 4. The arrangement shown in this figure, *i. e.*, two intraparacentral rami, as well as other (unclassified) features, occurred in six per cent.

Fig. 5. Observed in nine out of one hundred and sixty hemicerebrums. (Less than six per cent.) The junction of the inflected with the paracentral commonly took place by means of the element Z, generally shallow.

Fig. 6. Observed in only two hemicerebrums, or one and one-quarter per cent. Eberstaller claims to have found this junction in fifty-five per cent!

Fig. 7. This figure shows the intraparacentral fissural elements, of which the writer has so far found five more or less definite types. Almost any combination or variation of these

elements may be found, but the longitudinal seems to be the commonest constant furrow.

Fig. 8. This shows the inflected joining the longitudinal intraprecuneal element marked "a."

Fig. 9. This figure represents the writer's schema of the fissures of mesial surface of the hemiserebrum.

ABBREVIATIONS.

The abbreviations used are the same for all the figures.

AMYG.,	.	.	.	Amygdaline f.
APRL.,	.	.	.	"Ascending pre-limbic f."
BS.,	.	.	.	Basisylvian f.
C.,	.	.	.	Central f.
CD. L.,	.	.	.	Caudal limb of PARC.
CL.,	.	.	.	Callosal f.
CLC.,	.	.	.	Calcarine f.
CLI.,	.	.	.	Collateral f.
CNT.,	.	.	.	Cuneate f.
CPH. L.,	.	.	.	Cephalic limb of PARC.
EOP'',	.	.	.	Exoccipital ["Preoccipital"] f.
FMG.,	.	.	.	Frontomarginal f.
HMP.,	.	.	.	Hippocampal f.
IFL.,	.	.	.	Inflected f.
IPRCN.,	.	.	.	Intraprecuneal f.
OC.,	.	.	.	Occipital f.
OCLC.,	.	.	.	Occipitocalcarine fissural stem.
PARC.,	.	.	.	Paracentral f.
PCLC.,	.	.	.	Postcalcarine f.
POCN.,	.	.	.	Postcuneal f.
RRCN.,	.	.	.	Precuneal f.
RST.,	.	.	.	Rostral f.
SBRST.,	.	.	.	Subrostral f.
SPCL.,	.	.	.	Supercallosal f.

BIBLIOGRAPHICAL REFERENCES.

¹ B. G. Wilder. "On Two Little-known Cerebral Fissures, with Suggestions as to Fissural and Gyral Names." *Amer. Neur. Trans.*, 1885, *Jour. of Nerv. and Ment. Dis.*, XII, 1885, pp. 350-352. Abstr. in *Neurol. Centralbl.*, December 15, 1885.

² Oscar Eberstaller. *Das Stirnhirn, ein Beitrag zur Anatomie der Oberfläche des Grosshirns.* Wien und Leipzig, 1890.

³ B. G. Wilder. *Ref. Handbook of the Med. Sciences*, Supplement, p. 108 (1893).

⁴ Lussana et Lemoigne. "Fisiologia dei centri nervosi encefalici." Padua, 1871. 2 vols.

⁵ A. Broca. Anatomie descriptive des circonvolutions cérébrales. *Gaz. hebdom. de med. et de chir.*, XXVIII, 1891, pp. 28-29.

⁶ G. Schwalbe. *Lehrbuch der Neurologie*, p. 541. Erlangen, 1891.

⁷ A. Ecker. *Die Hirnwindungen des Menschen*. Braunschweig, 1869 and 1883.

⁸ M. Flesch. *Zur Casuistik anomaler Befunde an Gehirnen*, etc., *Arch. f. Psych.*, Vol. XVI, pp. 689-697. 1885.

⁹ V. Familant. *Beiträge zur Vergleichung der Hirnfurchen bei den Carnivoren und Primaten*. Bern, 1885.

¹⁰ M. Benedikt. *Jour. of Anat and Physiol.*, XXV, p. 213.

¹¹ W. J. Mickle, in article, "Brain-forms in relation to Mental Status," *Jour. of Mental Science*, July, 1896, p. 556, says, "—— a homology claimed by Betz for the sulcus spoken of as limiting the oval lobule in front." Mickle does not give the source of this information.

¹² B. G. Wilder. Fig. 4,768, *Ref. Handbook of the Med. Sciences*, Vol. VIII.

¹³ Betz. Nachweis zweier Gehirncentra. *Centralbl. f. d. Med. Wissensch.*, 1874. Nos. 38 and 39 (p. 595).

¹⁴ L. F. Barker. "The Nervous System." New York, 1899.

¹⁵ A. Broca. [See Note 5], pages 27 and 28.

¹⁶ W. J. Mickle [See Note 11], p. 556.

METHOD OF UTILIZING FROZEN SECTIONS FOR
CLASS DEMONSTRATIONS OF VISCERAL
ANATOMY AND ANATOMY OF
THE EPIPHYSES.

BY DR. A. PRIMROSE, TORONTO, CANADA.

The exhibition of lantern slides which was given before the Association of American Anatomists was that of a series of photographs made from sections through the trunk and extremities of children. The sections were prepared in a special manner so as to present a perfectly smooth surface with clear outlines of the various structures. These sections were photographed, and lantern plates made from the negatives. They were cut in sagittal, coronal and horizontal planes through the trunk, and in longitudinal and transverse directions through the extremities. The method adopted in the University of Toronto is that permanent preparations are made of the sections, which are mounted in flat dishes and thus exposed so that they are accessible to the students at any time in the Anatomical Department. The lantern demonstration of these sections is given from time to time at the close of a lecture. It proves to be a very useful adjunct to the ordinary methods of demonstration, and the student always has the opportunity of studying the actual sections in the dissecting room, the photograph of which is thrown upon the screen in the lecture theater. It is claimed that these photographs of actual sections are of much greater value from an educational standpoint than drawings reproduced from the sections.

My method of making the frozen sections referred to is as follows:

The subject must not be injected with alcohol, as that, of course, prevents freezing, but, if you wish, a colored injection may be thrown into the arteries. A wooden box is made, perforated with many holes so that water drains away from it readily. The subject is placed in the box and suspended in the position in which you wish to have it while cutting. The box must be sufficiently large to allow of about 18 inches of freezing mixture around the subject on all sides. The

freezing mixture is composed of ice and salt. The method I adopt for suspending the subject is as follows: An iron frame is made, rectangular in form and sufficiently long and broad to allow the subject to lie within it. My frame is 6 feet 6 inches long and 2 feet broad, and is supported at each end on iron supports 2 feet high. The frame must be strong enough to support the weight of the subject. A number of knobs are fastened to this iron frame. These knobs are separated 4 inches from one another all around the frame. A piece of ordinary factory cotton is used to suspend the subject, and this is readily tied to the knobs by strong twine. The value of this method is that one can readily obtain any degree of flexion of the head or of the spine or lower extremities by simply drawing upon the factory cotton and securing it to the knobs with the requisite amount of sagging in any one place to obtain the degree of flexion desired. The subject must remain in the box for about three days, when it ought to be frozen completely through and through. You then remove the subject from the box and cut it in the direction desired with an ordinary carpenter's saw. The sections should in no case be more than three-fourths of an inch in thickness. The section surface is cleaned off by pouring boiling water over it; thus all sawdust is removed, and it is then immediately immersed in alcohol of about 90 per cent. The sections should be left undisturbed in the *dirty* alcohol (for it becomes very "dirty") for a period of about two months at least, after which time they are taken out and thoroughly cleaned. They may subsequently be mounted in alcohol.

A CONTRIBUTION TO THE FISSURAL INTEGRALITY OF THE PAROCCIPITAL; OBSERVATIONS UPON ONE HUNDRED BRAINS.

BY EDWARD A. SPITZKA.

Student of Medicine, Medical Department, Columbia University.

I.

Chief among writers upon encephalic anatomy, Turner, Cunningham, Parker and Wilder, stand as exponents of several hypotheses concerning the status and origin of the paroccipital fissure. Turner¹ and Cunningham² consider it the *pars occipitalis* of an intraparietal complex composed of four factors. Wilder³ considers it a zygial fissural integer, his main point being its greatest depth at its middle, with no evidence of a transverse occipital at its caudal end more than at its cephalic, and with no approach to the parietal. Of more recent date is the work of Parker⁴. This author, taking into consideration the development of new conditions and pressure forces as cerebral growth continues, in a skull which assumes a more fixed and rigid shape, concludes that it is not a fissural integer at all, but merely a modification produced in the manner of connection of the originally confluent intraparietal and *fissura perpendicularis externa*, and that, for reasons pointed out by him, this so-called paroccipital is deepest at its middle point and gradually becomes shallower as it joins the intraparietal and backwardly displaced *fissura perpendicularis externa*.

The scope of this article does not permit me to go far into the details of Parker's argument, but I shall endeavor to give a brief account of his idea of the development of the fissure since it serves as the main basis for the present discussion.

I reproduce (Fig. 1) the conditions presented in the majority of the Simiadae, in diagrammatic form, and copied from A. J. Parker's Fig. 18. AB represents the intercerebral cleft; PO, the occipital ("parieto-occipital"); ip, the "intraparietal"; O', the exoccipital (*fiss. perp. externa*); P' and P² represent

the parietal and subparietal gyres, respectively, while O is the occipital lobe.

Now, as is well known, at some point near PO, but concealed within the depths of the fissure, "there develops in the monkeys, from its floor, a small bridging convolution"* and the external perpendicular fissure, O', is pushed backward just in proportion to the development of this gyrus. It is this gyrus which every one will recognize as Gratiolet's *première pli de passage*, attaining in man the dignity of a *paroccipital gyrus*, as it was first named by Professor Wilder.

We see, then, that Parker attaches some significance and value to the relative growth of this *pli de passage* in the subsequent formation of the paroccipital fissure and he advances the opinion (p. 336, *loc. cit.*) that all the *plis de passage* "are nothing but the posterior extremities of the occipito-frontal and occipito-temporal convolutions, which, checked in their development by the evolution of the occipital lobe in Primates, lie concealed in the majority of them by the overhanging operculum, whilst in the higher forms, through a renewed growth in this region, as we have seen in the case of the convolution 2 (Fig. 2 of this article) they finally reach the surface, displacing in their turn the operculum and pushing it backward."

The more one studies the morphology of the cerebral fissures and gyrus, the more apparent does the value of Gratiolet's *plis de passage* become, and it is to be regretted that Ecker⁵ should have rejected the name because they appeared to him to have no "justification in the human brain."

Parker does not proceed further in his very excellent argument though he might easily have done so and assigned an equally important rôle to the *deuxième pli de passage*. It is also evident that he considers the caudal rami (or the transverse piece called by Ecker the *S. occipitalis transversus*) as the human representative of a portion of the simian exoccipital.

If we take up the discussion at the point where Parker left it, it can be readily understood how a simultaneous up-growth of the *deuxième pli de passage* would serve to limit the ectal extension of such a paroccipital, always bearing in mind that it must be regarded as a segment of the simian exoccipital. The chief difficulty that we encounter then is that we have

* Parker, p. 321.

a zygon of variable length to deal with and one directed generally transversely to the course of the exoccipital fissure.

Let us assume that the growth of both the *première* and *deuxième plis de passage* takes place simultaneously; if we begin with the conditions as they exist in most of the simiadae, as in Fig. 1, such development will result in the isolation of a segment of the exoccipital situated between the two plis and forming the "proton" (anlage) for a paroccipital zygal fissure. Parker has shown (p. 335, *loc cit.*) how a combination of expansive forces and resisting forces controls the development of such zygal as well as of the triradiate and quadriradiate fissures, applying for this purpose the principles deduced by the eminent physicist Plateau⁶. In brief, he finds a stable equilibrium in the zygal form due to the apposition of four plastic spheres (Plateau's experiments were done by means of soap-bubbles floating on water or upon a glass plate). In the brain the four spheres which are here crowded together are represented in the following four elements:

- I. Première pli de passage.
- II. Deuxième pli de passage.
- III. Occipital lobe.
- IV. Parietal lobe.

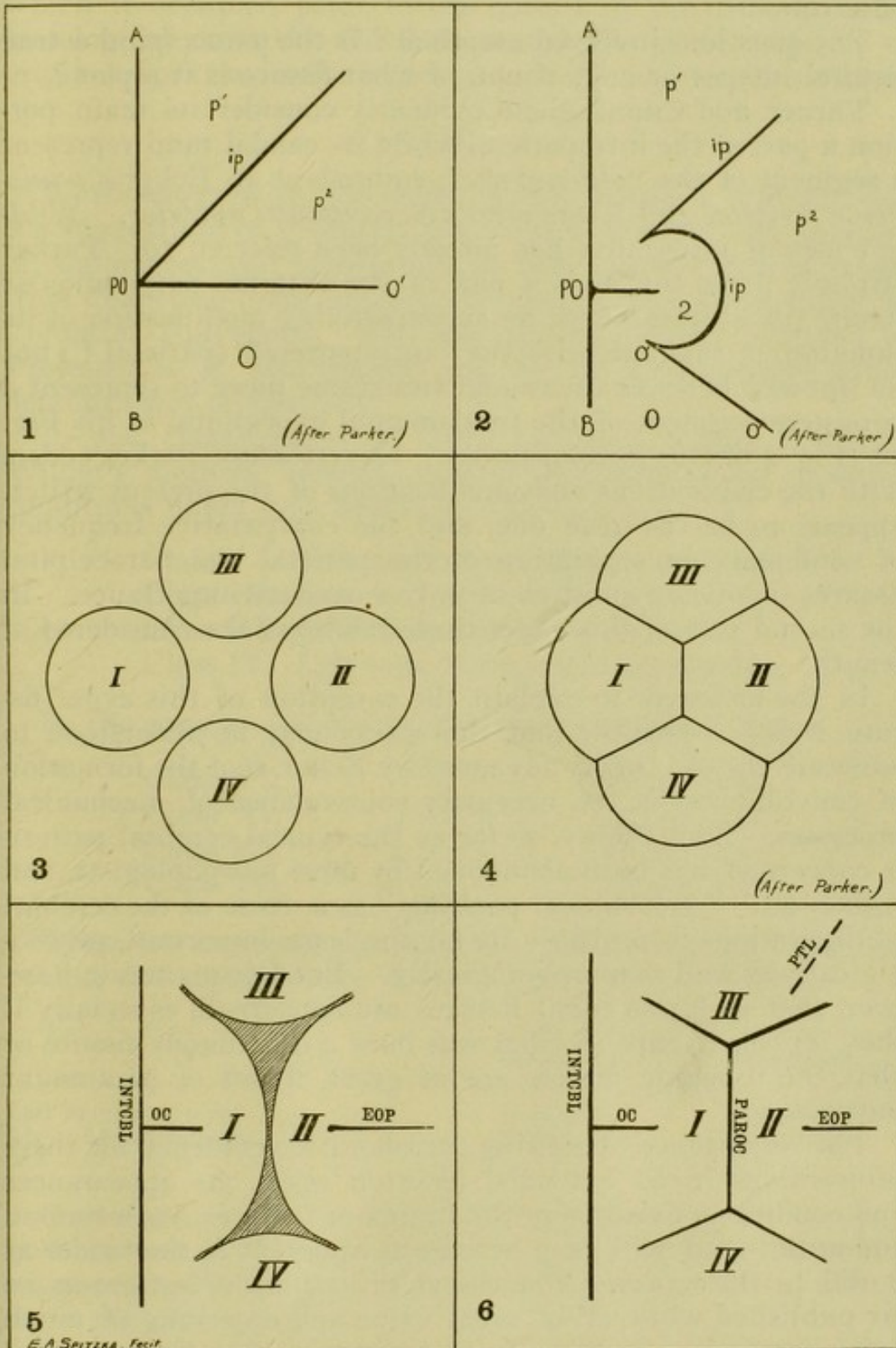
Development and growth takes place more forcibly and more rapidly on the part of elements I and II, and hence these crowd together before III and IV could, the result being a zygal fissure whose zygon or stem runs in a transverse direction to the course of the interrupted exoccipital. A rapid review of these developments resolves itself into the following:

First: An unbroken continuity of the mesial occipital with the exoccipital fissure, (as in most forms of Simiadae).

Second: A simultaneous up-growth of the *première* and *deuxième plis de passage* of Gratiolet, bridging the exoccipital and including between them a fissural segment of the exoccipital, forming the basis or *anlage* for the future paroccipital.

Third: An increased growth of these two *plis*, crowding upon each other while at the same time pushing apart the occipital and parietal lobar parts at this site, giving rise to the zygon or stem.

Fourth: The accompanying, though lesser, resistance of the parietal and occipital elements, situated cephalad and cau-



dad, giving rise to the rami and stipes of Professor Wilder's description.

The questions involved are, then : Is the paroccipital a true fissural integer or not ; if not, of what fissure is it a part ?

Turner and Cunningham evidently consider its main portion a part of the intraparietal while its caudal rami represent a segment of the "*Affenspalte*", equivalent to Ecker's *transverse occipital* and Eberstaller's *S. occipitalis anterior*. Wilder's idea of integrality has already been referred to. Parker strongly urges that it is a part of the external perpendicular fissure (exoccipital) with an accompanying modification of its junction, at that site, with the "intraparietal" (parietal f.) but he likewise believes the caudal transverse piece to represent a persistent segment of the fundamental exoccipital as his Fig. 19 (Fig. 2 of this article) shows. Nevertheless, Parker's idea, with the elaborations and modifications of the present writer, appears to be the true one, and the comparative frequency of confluence or separation of the parietal and paroccipital fissures involves a question of only secondary importance. In the second part of this paper these relations are considered at length.

In the endeavor to explain the causation of this zygial fissure, it is just possible that this writer may be understood to advocate the old theory advanced by Ecker, that the formation of convolutions is the necessary consequence of mechanical processes. This theory, so far as the typical cerebral pattern is concerned, has been abandoned by most morphologists, and rightly so. "Mechanical packing," as a cause of the cerebral configurations is probably by far the least important, physiologically as well as morphologically. But I do maintain, however, that so far as zygial fissures are concerned, especially if they represent gaps in what was once a continuous fissure or cleft, the dynamic factors are of great, if not of paramount importance.

The importance of seeking corroborative evidence for these propositions in an extended research upon the appearances and conditions existing in the brains of foetuses, both human and anthropoid, will have become as apparent to the reader as it did to the writer. The essays of various investigators so far published while all of great value and deserving of much praise, are still insufficient for accurate generalizations and deductions. However, macroscopic and developmental en-

cephalic anatomy promises to regain the important position which it occupied prior to the advent of the discoveries in histological methods which attracted the great majority of original workers in the latter part of the nineteenth century.

II.

While engaged in the study of this fissure, I followed out the suggestions of Professor Wilder and tabulated the number of confluences and separations in one hundred brains taken from dissecting-room subjects in the Medical Department of Columbia University. For this privilege I am indebted to Professor G. S. Huntington and Dr. B. B. Gallaudet, chief demonstrator of anatomy.

In the classification of these results I follow Professor Wilder's method, namely, that of distributing all possible conditions under four heads, as follows:

- Class I. Left continuity, right separation.
- Class II. Left and right continuity.
- Class III. Left and right separation.
- Class IV. Left separation, right continuity.

In the present researches the results obtained were:

Class I,	. . .	32 per cent.
Class II,	. . .	45 per cent.
Class III,	. . .	17 per cent.
Class IV,	. . .	6 per cent.

There is a continuity in sixty-four per cent. of all hemicerebrums, and separation in thirty-six per cent., as follows:

	Continuity.	Separation.
Left hemicerebrum.....	77 per cent.	23 per cent.
Right hemicerebrum.....	51 per cent.	49 per cent.

Continuity and separation were symmetrical (*i. e.*, upon both halves of the same brain) in sixty-two per cent., while asymmetrical conditions prevailed in the remaining thirty-eight per cent.

For convenience of comparison I present a table showing in the first column Professor Wilder's figures derived from

his "Lecture Notes for 1900"; in the second column those obtained by the writer.

	I.—B. G. WILDER.	II.—E. A. SPITZKA.
Class I.....	44 per cent.	32 per cent.
Class II.....	33 per cent.	45 per cent.
Class III.....	17 per cent.	17 per cent.
Class IV.....	6 per cent.	6 per cent.
Continuity (all cases).....	58 per cent.	64 per cent.
Separation (all cases).....	42 per cent.	36 per cent.
Left continuity.....	77 per cent.	77 per cent.
Left separation.....	23 per cent.	23 per cent.
Right continuity.....	39 per cent.	51 per cent.
Right separation.....	61 per cent.	49 per cent.
Symmetry	50 per cent.	62 per cent.
Asymmetry	50 per cent.	38 per cent.

It will be observed that in general the results are similar. The exceptional cases are an inversion of the percentages of classes I and II, a greater frequency of continuity in all cases (second column) and a greater frequency of symmetrical conditions, perhaps due to the average lower grade of the brains at my disposal.

BIBLIOGRAPHY.

¹ '66.—W. Turner: "The convolutions of the human cerebrum." Edinburgh, 1866.

² '90.—D. J. Cunningham: "The intraparietal sulcus," pp. 135-155, Vol. XXIV, *Journal of Anatomy and Physiology*.

³ '86.—B. G. Wilder: "The paroccipital,—a newly recognized fissural integer," pp. 301-315, Vol. XIII, *Journal of Nervous and Mental Disease*. Abstract in *Neurol. Centralbl.*, V., p. 501.

'96.—B. G. Wilder: "The paroccipital fissure; should it be recognized and so designated?" p. 69, *Proc. Assoc. Amer. Anat.* for 1896.

1900.—B. G. Wilder: "Further tabulations and interpretations of the paroccipital fissures," p. 14, *Proc. Assoc. Amer. Anat.* for 1900; also, "Lecture notes for 1900," Cornell University.

⁴ '96.—A. J. Parker: "Morphology of the cerebral convolutions, with special reference to the order of Primates," part 3, Vol. X, *Jour. of Acad. of Nat. Sciences*, of Philadelphia, 1896.

⁵ '83.—A. Ecker: "Hirnwindungen des menschen." Braunschweig, 1869 and 1883.

ON THE TEACHING OF THE NORMAL ANATOMY
OF THE CENTRAL NERVOUS SYSTEM OF
HUMAN BEINGS TO LARGE CLASSES
OF MEDICAL STUDENTS.

BY LEWELLYS F. BARKER, M. B., AND PRESTON KYES, M. D.

The writers had this past autumn to meet the problem of teaching 220 sophomore students the anatomy of the brain and spinal cord of human beings, in the absence of a sufficient amount of illustrative anatomical material, and with a corps of instructors of inadequate size. Less than twenty human brains were obtainable, and only four instructors, in addition to the lecturer, were available for laboratory teaching. The class was dealt with in the following way:

Two lectures were given weekly for three months. A few extra lectures were arranged for toward the end of the course. The lectures consisted of brief descriptions of the parts actually to be studied in the laboratory, accompanied by demonstrations of the parts and colored blackboard drawings. At the end of the courses, lectures upon the various conduction paths were given. The nomenclature employed was that of the B.N.A.

For the laboratory work two sessions of from one and a-half to two hours each were available weekly for each of the four sections into which the class was divided. An instructor was placed in charge of each laboratory section, and to make up for the lack of additional trained instructors, laboratory outlines were printed on library cards and distributed from time to time to each member of the class. No attempt was made to make one laboratory card correspond to one session of laboratory work. On the contrary, each card contained an outline of a certain portion of the course. This card was used until the corresponding portion of the work had been completed, a new card then being given out.

The number of brains, though small, was made to suffice, in that one brain was given to each twelve students. It was cut into four parts (1, right cerebral hemisphere; 2, left cerebral hemisphere; 3, cerebellum; 4, brain stem). Three students worked on each part, making drawings of the external form from different aspects, the parts being exchanged until each

of the twelve members of the group had made drawings of the naked-eye appearance of the whole external surface of the brain. Subsequently each brain was cut into a series of coronal sections at the levels indicated in the cards. Each of these sections was imbedded in a flat disk of plaster of paris and kept in a weak solution of formaline. These sections were distributed among the students, who drew them, the various sections being exchanged until each student had drawn all of them. The students were advised to use the lecture notes, an atlas (preferably Spalteholz' Toldt's), and a good text as guides to their laboratory work.

The most discouraging part of the course for the student was the drawing of the long series of coronal sections, especially through the region of the mid-brain, pons and medulla. During this period the student has to learn a large number of names for the various objects which are visible before he appreciates the significance of this knowledge for the conception of the nervous system in the three dimensions of space necessary for the proper understanding of the various conduction paths.

When the series of drawings had been completed lectures were given upon the various conduction paths, especially upon those of most importance to practical medical men, and the student was required to make diagrammatical sketches illustrating these various paths and the neurone systems composing them, relating each of the masses of nerve cells and each of the bundles of medullated axones to the structures which he had seen and drawn when passing through the series of coronal sections.

The following is the series of cards furnished each student, indicating the outline of the course as given :

OUTLINE NO. I.

SYSTEMA NERVORUM CENTRALE OF THE DOG.

Gross Study.

DIRECTIONS: Identify the following structures by a study of the projected animal :

<i>Syst. Nerv. Centrale.</i>	<i>Syst. Nerv. Periphericum.</i>	<i>Syst. Nerv. Sympathici.</i>
<i>Meninges</i>	<i>Nervi cerebrales</i>	<i>Truncus sympathicus</i>
<i>Cerebrum</i>	<i>Nervi spinales</i>	<i>Ganglia trunci sympathici</i>
<i>Cerebellum</i>	<i>Rami communicantes</i>	<i>Plexus sympathici</i>
<i>Medulla oblongata</i>		<i>Ganglia plexuum sympathicorum</i>
<i>Medulla spinalis</i>		

OUTLINE NO. 2.

SYSTEMA NERVORUM CENTRALE OF EMBRYO PIG.

Gross Study.

DIRECTIONS: Place the embryo flat on the abdomen with limbs extended. Make an incision in the mid-dorsal line the entire length of the animal. Dissect and remove the soft parts adjacent to the *columna vertebralis* working laterally from the median line.

Expose the *medulla spinalis* by removing the vertebral arches with forceps and scissors, taking care to avoid the underlying soft parts.

Expose the *encephalon* by removing the skull cap.

Draw the *systema nervorum centrale* as thus exposed with the *meninges* intact.

Attach to drawings the names of all visible structures mentioned in the nomenclature [B.N.A.].

Preserve the specimen in a four per cent. solution of formaldehyde.

OUTLINE NO. 3.

SYSTEMA NERVORUM CENTRALE OF EMBRYO PIG.

Gross Study.

Eviscerate the embryo through a median ventral incision. Note the chain of ganglia on either side of the *columna vertebralis*. Trace fibers from the ganglia through the body wall to the peripheral nerve trunks—*rami communicantes*. Note the extensive radiation of peripheral fibers from the ganglia. Draw three ganglia with their several connecting fibers.

With the embryo flat on the abdomen, expose the *nervi spinales* for a short distance beyond their exit from the *columna vertebralis*.

Dissect each *oculus* from its orbit, leaving it attached only to the *encephalon* by the *nervus opticus*.

Remove the *medulla spinalis* and *encephalon* intact after sectioning the peripheral attachments and laying open the *dura mater*.

Draw the ventral and lateral aspects of the system thus isolated.

Attach to drawings the names of all visible structures mentioned in the nomenclature [B.N.A.].

Preserve the specimen in a four per cent. solution of formaldehyde.

OUTLINE NO. 4.

ENCEPHALON OF MAN.

Gross Study.

Divide the human *encephalon* into four parts as follows:

Remove the *prosencephalon* by sectioning the *pedunculi cerebri*, and separate its symmetrical halves by division of the *corpus callosum*. Remove the *cerebellum* from the *rhombencephalon* by cutting the *brachia conjunctiva*, the *brachia pontis* and the *corpora restiformia*.

Make drawings of the isolated parts as follows:

1. *Prosencephalon*; median, lateral, dorsal and ventral aspects.
2. *Rhombencephalon* (minus the *cerebellum*); dorsal, ventral and lateral aspects.

3. *Cerebellum*; dorsal, ventral and anterior aspects.

Attach to drawings the names of all visible structures mentioned in the nomenclature [B.N.A.].

Preserve the specimens in a four per cent. solution of formaldehyde.

OUTLINE NO. 5.

ENCEPHALON OF MAN.

Gross Study.

DIRECTIONS: With the accompanying diagram as a guide, divide the *prosencephalon* into eight lamellae by transverse sections as follows:

Section I, to pass through the middle of the *lobus frontalis* immediately anterior to the *ventriculus lateralis* and the *genu corporis callosi*.

Section II, to pass through the anterior extremity of the *ventriculus lateralis* and the *caput nuclei caudati*.

Section III, to pass immediately posterior to the *commissura anterior*.

Section IV, to pass through the middle of the *thalamus*.

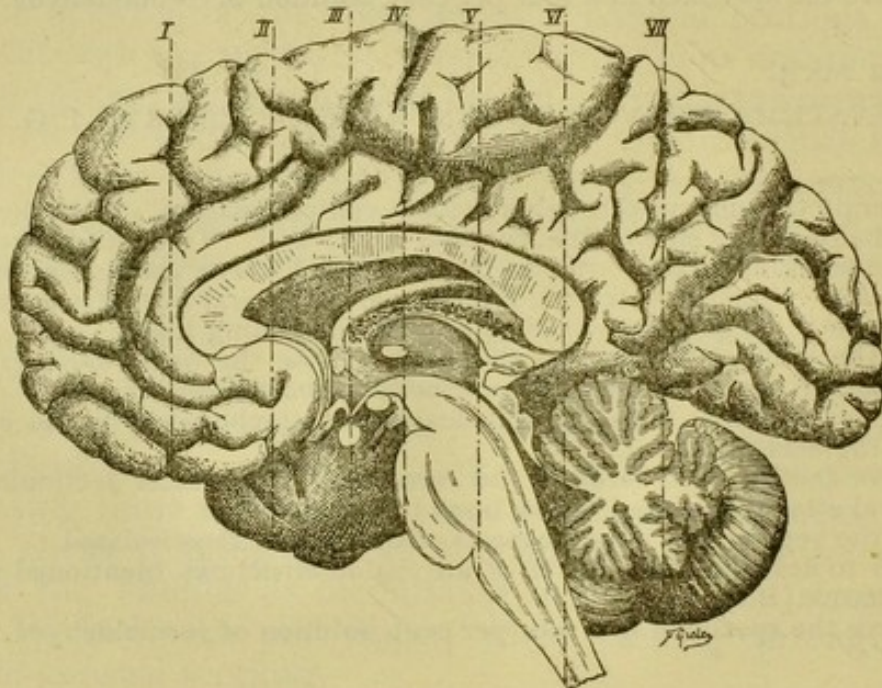
Section V, to pass through the *commissura posterior*.

Section VI, to pass through the *splenium corporis callosi*.

Section VII, to pass through the middle of the *lobus occipitalis*.

Refer to the diagram on the other side of this card.

Preserve the specimens in a four per cent. solution of formaldehyde.



OUTLINE NO. 6.

ENCEPHALON OF MAN.

Gross Study.

DIRECTIONS: Draw either of the coronal surfaces exposed by section I*, giving especial attention to the following structures:

<i>Substantia grisea</i>	<i>Gyrus frontalis superior</i>	<i>Sulcus frontalis inferior</i>
<i>Substantia alba</i>	<i>Sulcus frontalis superior</i>	<i>Gyrus frontalis inferior</i>
<i>Fissura longitudinalis cerebri</i>	<i>Gyrus frontalis medius</i>	<i>Sulcus olfactorius</i>

Draw either of the coronal surfaces exposed by section II*, giving especial attention to the following structures:

<i>Corpus callosum</i>	<i>Gyrus frontalis medius</i>	<i>Cornu anterius ventriculi lateralis</i>
<i>Fissura longitudinalis cerebri</i>	<i>Sulcus frontalis inferior</i>	<i>Septum pellucidum</i>
	<i>Gyrus frontalis inferior</i>	<i>Caput nuclei caudati</i>
<i>Sulcus corporis callosi</i>	<i>Fissura cerebri lateralis</i>	<i>Capsula interna</i>
<i>Gyrus cinguli</i>	<i>Lobus temporalis</i>	<i>Clastrum</i>
<i>Gyrus frontalis superior</i>	<i>Nervus opticus</i>	<i>Capsula</i>
<i>Sulcus frontalis superior</i>		

* Refer to Outline No. 5.

Attach to the drawings the names of all visible structures mentioned in the nomenclature [B.N.A.].

Preserve the specimens in a four per cent. solution of formaldehyde.

OUTLINE NO. 7.

ENCEPHALON OF MAN.

Gross Study.

DIRECTIONS: Draw either of the coronal surfaces exposed by section III*, giving especial attention to the following structures:

<i>Corpus callosum</i>	<i>Lobus temporalis</i>	<i>Substantia perforata anterior</i>
<i>Fissura longitudinalis cerebri</i>	<i>Gyrus temporalis superior</i>	<i>Ventriculus lateralis</i>
<i>Sulcus corporis callosi</i>	<i>Sulcus temporalis superior</i>	<i>Cornu anterius</i>
<i>Gyrus cinguli</i>	<i>Gyrus temporalis medius</i>	<i>Septum pellucidum</i>
<i>Sulcus cinguli</i>	<i>Sulcus temporalis medius</i>	<i>Columna fornicis</i>
<i>Gyrus frontalis superior</i>	<i>Gyrus temporalis inferior</i>	<i>Ventriculus tertius</i>
<i>Sulcus frontalis superior</i>	<i>Sulcus temporalis inferior</i>	<i>Commissura anterior</i>
<i>Gyrus frontalis medius</i>	<i>Gyrus fusiformis</i>	<i>Nucleus caudatus</i>
<i>Sulcus frontalis inferior</i>	<i>Fissura collateralis</i>	<i>Capsula interna</i>
<i>Gyrus frontalis inferior</i>	<i>Gyrus hippocampi</i>	<i>Globus pallidus</i>
<i>Fissura cerebri lateralis [Sylvii]</i>	<i>Uncus</i>	<i>Putamen</i>
<i>Gyri insulae</i>	<i>Nucleus amygdalae</i>	<i>Capsula externa</i>
	<i>Tractus opticus</i>	<i>Clastrum</i>
	<i>Infundibulum</i>	

Attach to the drawing the names of all visible structures mentioned in the nomenclature [B.N.A.].

Preserve the specimen in a four per cent. solution of formaldehyde.

OUTLINE NO. 8.

ENCEPHALON OF MAN.

Gross Study.

DIRECTIONS: Draw either of the coronal surfaces exposed by section IV*, giving especial attention to the following structures:

<i>Corpus callosum</i>	<i>Gyri insulae</i>	<i>Ventriculus lateralis</i>
<i>Fissura longitudinalis cerebri</i>	<i>Gyrus temporalis superior</i>	<i>Columna fornicis</i>
<i>Sulcus corporis callosi</i>	<i>Sulcus temporalis superior</i>	<i>Plexus chorioideus</i>
<i>Gyrus cinguli</i>	<i>Gyrus temporalis medius</i>	<i>Hippocampus</i>
<i>Sulcus cinguli</i>	<i>Sulcus temporalis medius</i>	<i>Ventriculus tertius</i>
<i>Gyrus frontalis superior</i>	<i>Gyrus temporalis inferior</i>	<i>Fossa interpeduncularis</i>
<i>Sulcus frontalis superior</i>	<i>Sulcus temporalis inferior</i>	<i>Nucleus caudatus</i>
<i>Gyrus frontalis medius</i>	<i>Gyrus fusiformis</i>	<i>Thalamus</i>
<i>Sulcus praecentralis</i>	<i>Fissura collateralis</i>	<i>Capsula interna</i>
<i>Gyrus centralis anterior</i>	<i>Gyrus hippocampi</i>	<i>Globus pallidus</i>
<i>Sulcus centralis</i>	<i>Sulcus hippocampi</i>	<i>Putamen</i>
<i>Gyrus centralis posterior</i>	<i>Uncus</i>	<i>Capsula externa</i>
<i>Fissura cerebri lateralis</i>	<i>Tractus opticus</i>	<i>Clastrum</i>
<i>Insula</i>	<i>Cauda nuclei caudati</i>	

Attach to the drawing the names of all visible structures mentioned in the nomenclature [B.N.A.].

Preserve the specimen in a four per cent. solution of formaldehyde.

* Refer to Outline No. 5.

OUTLINE NO. 9.

ENCEPHALON OF MAN.

Gross Study.

DIRECTIONS : Draw either of the coronal surfaces exposed by section V*, giving especial attention to the following structures :

<i>Corpus callosum</i>	<i>Gyrus temporalis medius</i>	<i>Hippocampus</i>
<i>Fissura longitudinalis cerebri</i>	<i>Sulcus temporalis medius</i>	<i>Plexus chorioideus</i>
<i>Sulcus corporis callosi</i>	<i>Gyrus temporalis inferior</i>	<i>Fornix</i>
<i>Gyrus cinguli</i>	<i>Sulcus temporalis inferior</i>	<i>Ventriculus tertius</i>
<i>Sulcus cinguli</i>	<i>Gyrus fusiformis</i>	<i>Commissura posterior</i>
<i>Gyrus centralis anterior</i>	<i>Fissura collateralis</i>	<i>Fossa interpeduncularis</i>
<i>Gyrus centralis posterior</i>	<i>Gyrus hippocampi</i>	<i>Striae medullaris</i>
<i>Fissura cerebri lateralis</i>	<i>Fissura hippocampi</i>	<i>Thalamus</i>
<i>Gyrus temporalis superior</i>	<i>Fascia dentata hippocampi</i>	<i>Capsula interna</i>
<i>Sulcus temporalis superior</i>	<i>Cauda nuclei caudati</i>	<i>Pedunculus cerebri</i>
	<i>Ventriculus lateralis</i>	

Attach to the drawing the names of all visible structures mentioned in the nomenclature [B.N.A.].

Preserve the specimen in a four per cent. solution of formaldehyde.

OUTLINE NO. 10.

ENCEPHALON OF MAN.

Gross Study.

DIRECTIONS : Draw either of the coronal surfaces exposed by section VI*, giving especial attention to the following structures :

<i>Corpus callosum</i>	<i>Lobulus parietalis inferior</i>	<i>Ventriculus lateralis</i>
<i>Fissura longitudinalis cerebri</i>	<i>Fissura cerebri lateralis</i>	<i>Cornu posterius</i>
<i>Radiatio corporis callosi</i>	<i>Gyrus temporalis superior</i>	<i>Bulbus cornu posterius</i>
<i>Sulcus corporis callosi</i>	<i>Sulcus temporalis superior</i>	<i>Calcar avis</i>
<i>Gyrus cinguli</i>	<i>Gyrus temporalis medius</i>	<i>Hippocampus</i>
<i>Sulcus cinguli</i>	<i>Sulcus temporalis medius</i>	<i>Tapetum</i>
<i>Gyrus centralis anterior</i>	<i>Gyrus temporalis inferior</i>	<i>Radiatio occipitothalamica</i>
<i>Gyrus centralis posterior</i>	<i>Sulcus temporalis inferior</i>	<i>Eminentia collateralis</i>
<i>Sulcus interparietalis</i>	<i>Gyrus fusiformis</i>	<i>Glomus chorioideum</i>
	<i>Fissura collateralis</i>	
	<i>Gyrus lingualis</i>	

Attach to the drawing the names of all visible structures mentioned in the nomenclature [B.N.A.].

Preserve the specimen in a four per cent. solution of formaldehyde.

OUTLINE NO. 11.

ENCEPHALON OF MAN.

Gross Study.

DIRECTIONS : Draw either of the coronal surfaces exposed by section VII*, giving especial attention to the following structures :

* Refer to Outline No. 5.

<i>Fissura longitudinalis cerebri</i>	<i>Sulcus temporalis medius</i>	<i>Glomus chorioideum</i>
<i>Lobulus parietalis superior</i>	<i>Gyrus temporalis inferior</i>	<i>Hippocampus</i>
<i>Sulcus interparietalis</i>	<i>Sulcus temporalis inferior</i>	<i>Calcar avis</i>
<i>Lobulus parietalis inferior</i>	<i>Gyrus fusiformis</i>	<i>Eminentia collateralis</i>
<i>Fissura cerebri lateralis</i>	<i>Fissura collateralis</i>	<i>Bulbus cornu posterioris</i>
<i>Gyrus temporalis superior</i>	<i>Gyrus lingualis</i>	<i>Tapetum</i>
<i>Sulcus temporalis superior</i>	<i>Fissura calcarina</i>	<i>Radiatio occipitohthalmica</i>
<i>Gyrus temporalis medius</i>	<i>Ventriculus lateralis</i>	
	<i>Cornu posterius</i>	

Attach to the drawing the names of all visible structures mentioned in the nomenclature [B.N.A.].

Preserve the specimen in a four per cent. solution of formaldehyde.

OUTLINE NO. 12.

ENCEPHALON OF MAN.

Gross Study.

DIRECTIONS: With the accompanying diagram as a guide, divide the *rhombencephalon* into nine lamellae by transverse sections as follows:

Section VIII to pass through the *colliculi superiores* of the *corpora quadrigemina* and the *pedunculi cerebri*.

Section IX to pass through the inferior portion of the *colliculi superiores* of the *corpora quadrigemina*.

Section X to pass through the *colliculi inferiores* of the *corpora quadrigemina*.

Section XI to pass through the principal motor nucleus of the *n. trigeminus*.

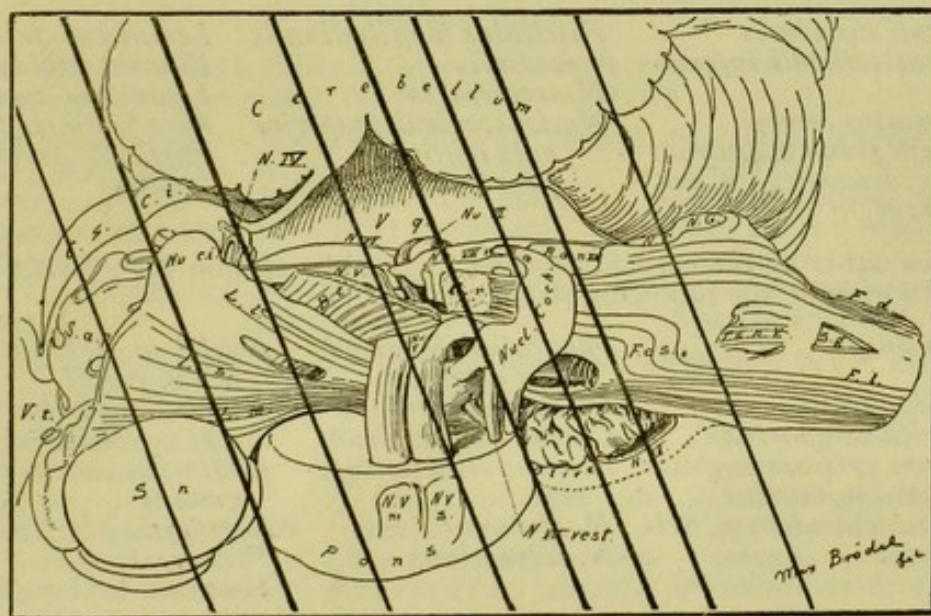
Section XII to pass through the area of entrance of the *n. cochleæ*

Section XIII to pass through the middle of the *nucleus olivaris inferior* and the *nucleus n. cochlearis dorsalis*.

Section XIV to pass through the spinal extremity of the *nucleus olivaris inferior*.

Section XV to pass through the level of the *decussatio lemniscorum*.

Preserve the specimen in a four per cent. solution of formaldehyde.



OUTLINE NO. 13.

ENCEPHALON OF MAN.

Gross Study.

DIRECTIONS: Draw either of the coronal surfaces exposed by section VIII*, giving especial attention to the following structures:

<i>Colliculi superiores</i>	<i>Decussatio tegmenti dor-</i>	<i>Basis pedunculi</i>
<i>Aqueductus cerebri</i>	<i>salis</i>	<i>Fasciculi cerebrospinales</i>
<i>Stratum griseum centrale</i>	<i>Nucleus n. oculomotorii</i>	<i>Fasciculus palliopontilis</i>
<i>Stratum album profun-</i>	<i>N. oculomotorius</i>	<i>(pars frontalis)</i>
<i>dum</i>	<i>Nucleus ruber</i>	<i>Fasciculus palliopontilis</i>
<i>Fasciculus longitudinalis</i>	<i>Lemniscus medialis</i>	<i>(pars temporooccipitalis)</i>
<i>medialis</i>	<i>Substantia nigra</i>	

Draw either of the coronal surfaces exposed by section IX*, giving especial attention to the following structures:

<i>Colliculi superiores</i>	<i>Decussatio tegmenti ven-</i>	<i>Nucleus lateralis superior</i>
<i>Aqueductus cerebri</i>	<i>tralis</i>	<i>[Flechsigi]</i>
<i>Stratum griseum centrale</i>	<i>Decussatio brachii con-</i>	<i>Lemniscus medialis</i>
<i>Stratum album profun-</i>	<i>junctivi</i>	<i>Substantia nigra</i>
<i>dum</i>	<i>Nucleus n. trochlearis</i>	<i>Pars basilaris pontis</i>
<i>Fasciculus longitudinalis</i>	<i>N. trochlearis</i>	<i>Fasciculi cerebrospinales</i>
<i>medialis</i>		

Attach to the drawings the names of all visible structures mentioned in the nomenclature [B.N.A.].

Preserve the specimens in a four per cent. solution of formaldehyde.

OUTLINE NO. 14.

ENCEPHALON OF MAN.

Gross Study.

DIRECTIONS: Draw either of the coronal surfaces exposed by section X*, giving especial attention to the following structures:

<i>Colliculi inferiores</i>	<i>Fasciculus longitudinalis</i>	<i>Lemniscus lateralis</i>
<i>Nucleus colliculi inferio-</i>	<i>medialis</i>	<i>Brachia conjunctiva</i>
<i>ris</i>	<i>N. trochlearis</i>	<i>Lemniscus medialis</i>
<i>Aqueductus cerebri</i>	<i>Nucleus centralis superior</i>	<i>Pars basilaris pontis</i>
<i>Stratum griseum centrale</i>	<i>pars centralis</i>	<i>Fasciculi cerebrospinales</i>
<i>Radix descendens n. tri-</i>	<i>pars lateralis</i>	<i>nales</i>
<i>gemini</i>		

Draw either of the coronal surfaces exposed by section XI*, giving especial attention to the following structures:

<i>Cerebellum</i>	<i>Fasciculus longitudi-</i>	<i>Nuclei motorii minores</i>
<i>Pons</i>	<i>nalis medialis</i>	<i>n. trigemini</i>
<i>Pars dorsalis</i>	<i>Lemniscus medialis</i>	<i>Nucleus motorius prin-</i>
<i>Ventriculus quartus</i>	<i>Corpus trapezoideum</i>	<i>ceps n. trigemini</i>
<i>Stratum griseum centrale</i>	<i>Nucleus olivaris supe-</i>	<i>Radix descendens n. tri-</i>
<i>Brachia conjunctiva</i>	<i>rior</i>	<i>gemini</i>
<i>Radix descendens n. tri-</i>	<i>N. abducens</i>	<i>Substantia gelatinosa</i>
<i>gemini</i>	<i>N. trigeminus</i>	<i>Pars basilaris</i>
		<i>Fasciculi cerebrospinales</i>

* Refer to Outline No. 12.

Attach to the drawings the names of all visible structures mentioned in the nomenclature [B.N.A.].

Preserve the specimens in a four per cent. solution of formaldehyde.

OUTLINE NO. 15.

ENCEPHALON OF MAN.

Gross Study.

DIRECTIONS : Draw either of the coronal surfaces exposed by section XII *, giving especial attention to the following structures :

<i>Cerebellum</i>	<i>N. glossopharyngeus</i>	<i>Nucleus n. cochleae ventralis</i>
<i>Medulla oblongata</i>	<i>N. vagus</i>	
<i>Ventriculus quartus</i>	<i>Nucleus n. vestibuli superior</i>	<i>Nucleus olivaris inferior</i>
<i>Brachia conjunctiva</i>		<i>Stratum interolivare lemnisci</i>
<i>Corpora restiformia</i>	<i>Nucleus n. vestibuli medialis</i>	<i>Radix descendens n. vestibuli</i>
<i>Fasciculus longitudinalis medialis</i>	<i>Tractus spinalis n. trigemini</i>	<i>Fasciculi cerebrospinales</i>
<i>Nucleus centralis inferior</i>		
<i>N. cochleae</i>	<i>Pedunculus flocculi</i>	

Draw either of the coronal surfaces exposed by section XIII *, giving especial attention to the following structures :

<i>Cerebellum</i>	<i>N. glossopharyngeus</i>	<i>Nucleus tractus solitarii</i>
<i>Medulla oblongata</i>	<i>N. vagus</i>	<i>Radix descendens n. vestibuli</i>
<i>Ventriculus quartus</i>	<i>N. hypoglossus</i>	
<i>Nucleus dentatus</i>	<i>Nucleus n. cochleae dorsalis</i>	<i>Stratum interolivare lemnisci</i>
<i>Corpora restiformia</i>	<i>Nucleus n. vestibuli medialis</i>	
<i>Fasciculus longitudinalis medialis</i>	<i>Pedunculus flocculi</i>	<i>Fasciculi cerebrospinales</i>
	<i>Nucleus olivaris inferior</i>	

Attach to the drawings the names of all visible structures mentioned in the nomenclature [B.N.A.].

Preserve the specimens in a four per cent. solution of formaldehyde.

OUTLINE NO. 16.

ENCEPHALON OF MAN.

Gross Study.

DIRECTIONS : Draw either of the coronal surfaces exposed by section XIV *, giving especial attention to the following structures :

<i>Medulla oblongata</i>	<i>Nucleus funiculi cuneati</i>	<i>Fasciculus longitudinalis medialis</i>
<i>Ventriculus quartus</i>	<i>N. glossopharyngeus</i>	
<i>Corpus restiforme</i>	<i>Fibrae arcuatae internae</i>	<i>Nucleus olivaris inferior</i>
<i>Nucleus n. hypoglossi</i>	<i>Substantia gelatinosa</i>	<i>Stratum interolivare lemnisci</i>
<i>N. hypoglossus</i>	<i>N. vagus</i>	
<i>Nucleus alae cinereae</i>	<i>Tractus spinalis n. trigemini</i>	<i>Fasciculi cerebrospinales</i>
	<i>Tractus solitarius</i>	<i>Nucleus arcuatus</i>

Draw either of the coronal surfaces exposed by section XV *, giving especial attention to the following structures :

<i>Medulla oblongata</i>	<i>Fibrae arcuatae externae</i>	<i>Tractus spinalis n. trigemini</i>
<i>Canalis centralis</i>		
<i>Fasciculus gracilis</i>	<i>Fibrae arcuatae internae</i>	<i>Substantia gelatinosa</i>
<i>Nucleus funiculi gracilis</i>		<i>Fasciculus cerebello-spinalis</i>
<i>Fasciculus cuneatus</i>	<i>Decussatio lemniscorum</i>	
<i>Nucleus funiculi cuneati</i>	<i>Fasciculus ventralis proprius</i>	<i>Fasciculi cerebrospinales</i>
<i>Nucleus commissuralis</i>		

* Refer to Outline No. 12.

Attach to the drawings the names of all visible structures mentioned in the nomenclature [B.N.A.].

Preserve the specimens in a four per cent. solution of formaldehyde.

OUTLINE NO. 17.

MEDULLA SPINALIS OF MAN.

Gross Study.

DIRECTIONS: Remove the *Meninges* of the *medulla spinalis*, leaving the proximal portion of the *nervi spinales* intact. Give especial attention to the following structures:

<i>Meninges</i>	<i>Medulla spinalis</i>	<i>Fissura mediana anterior</i>
<i>Dura mater spinalis</i>	<i>Pars cervicalis</i>	<i>Sulcus medianus posterior</i>
<i>Cavum subdurale</i>	<i>Intumescentia cervicalis</i>	<i>Sulcus lateralis anterior</i>
<i>Pia mater spinalis</i>	<i>Pars thoracalis</i>	<i>Sulcus lateralis posterior</i>
<i>Lig. denticulatum</i>	<i>Pars lumbalis</i>	<i>Sulcus intermedius posterior</i>
<i>Nervi spinales</i>	<i>Intumescentia lumbalis</i>	<i>(Sulcus intermedius anterior)</i>
<i>Radix anterior</i>	<i>Conus medullaris</i>	<i>Funiculus anterior</i>
<i>Radix posterior</i>	<i>Cauda equina</i>	<i>Funiculus lateralis</i>
<i>Ganglion spinale</i>	<i>Filum terminale</i>	<i>Funiculus posterior</i>

Draw the anterior, lateral and posterior aspects of the *intumescentia lumbalis* together with the portions of the *nervi spinales* dependent therefrom.

Attach to the drawings the names of all visible structures mentioned in the nomenclature [B.N.A.].

Preserve the specimens in a four per cent. solution of formaldehyde.

OUTLINE NO. 18.

MEDULLA SPINALIS OF MAN.

Gross Study.

DIRECTIONS: Divide the *medulla spinalis* into four segments by transverse sections as follows:

Section XVI to pass through the middle of the *intumescentia cervicalis*.

Section XVII to pass through the middle of the *pars thoracalis*.

Section XVIII to pass through the middle of the *intumescentia lumbalis*.

Draw the coronal surfaces thus exposed, giving especial attention to the following structures:

<i>Sulcus medianus posterior</i>	<i>Fasciculus anterolateralis superficialis</i>	<i>Substantia grisea centralis</i>
<i>Funiculus posterior</i>	<i>Fasciculus lateralis proprius</i>	<i>Commissura anterior alba</i>
<i>Fasciculus gracilis</i>		<i>Commissura anterior grisea</i>
<i>Sulcus intermedius posterior</i>	<i>Sulcus lateralis anterior</i>	<i>Commissura posterior</i>
	<i>Funiculus anterior</i>	<i>Columna anterior</i>
<i>Fasciculus cuneatus</i>	<i>Fasciculus cerebrospinalis anterior</i>	<i>Columna lateralis</i>
<i>Sulcus lateralis posterior</i>	<i>Fasciculus anterior proprius</i>	<i>Columna posterior</i>
<i>Funiculus lateralis</i>		<i>Apex columnae posterioris</i>
<i>Fasciculus cerebrospinalis lateralis</i>	<i>Fissura mediana anterior</i>	<i>Substantia gelatinosa</i>
<i>Fasciculus cerebellospinalis</i>	<i>Canalis centralis</i>	<i>Formatio reticularis</i>
		<i>(Nucleus dorsalis)</i>

Attach to the drawings the names of all visible structures mentioned in the nomenclature [B.N.A.].

Preserve the specimens in a four per cent. solution of formaldehyde.

OUTLINE NO. 19.

CONDUCTION PATHS.

Reconstruction.

DIRECTIONS: With the aid of the drawings already made, together with the lecture notes and descriptive texts, construct diagrams illustrating the following conduction paths and the neurone systems of which these paths are composed:

I. THE GENERAL SENSORY CONDUCTION PATHS FROM THE SKIN, MUSCLES, ETC., TO THE CEREBRAL CORTEX:

A. The Direct Path:

1. The neurones of the first order, or the peripheral spinal and cerebral sensory neurones.
2. The sensory neurones of the second order (with crossed axones), (*nuclei terminales, fibrae arcuatae internae, decussatio lemniscorum, stratum interolivare lemnisci, lemniscus medialis, thalamus*).
3. The sensory neurones of the third order, or thalamocortical neurones (*thalamus, capsula interna [pars occipitalis], corona radiata, gyri centrales*).

B. The Indirect Path by the Way of the Cerebellum:

1. The peripheral spinal and cerebral sensory neurones.
2. The spino-cerebella neurones.
 - (a) Direct cerebellar tract (*nucleus dorsalis, fasciculus cerebellospinalis, corpus restiforme, vermis*).
 - (b) Gowers' tract (*substantia grisea, medullae spinalis, fasciculus anterolateralis superficialis, vermis*).
3. The neurones whose axones constitute the *brachium conjunctivum* (*nucleus dentatus, brachium conjunctivum, decussatio brachii conjunctivi, nucleus ruber*).
4. The neurones extending from the *nucleus ruber* to the *pallium* (*nucleus ruber, capsula interna [pars occipitalis], gyri centrales, etc.*)

OUTLINE NO. 20.

CONDUCTION PATHS.

Reconstruction.

DIRECTIONS: With the aid of the drawings already made, together with the lecture notes and descriptive texts, construct diagrams illustrating the following conduction paths and the neurone systems of which these paths are composed:

II. THE OLFACTORY CONDUCTION PATH.

1. Peripheral olfactory neurones (*regio olfactoria nasi, nn. olfactorii, bulbus olfactorius*).
2. Central olfactory neurones (*bulbus olfactorius, tractus olfactorius, lobus frontalis and lobus temporalis [uncus]*).

III. THE VISUAL CONDUCTION PATH.

1. Peripheral visual neurones (dipolar cells of retina).
2. Central visual neurones.
 - (a) From the *retina* to the *corpus geniculatum laterale* (ganglion cells of *retina*, *n. opticus*, *chiasma opticum*, *tractus opticus*, *corpus geniculatum laterale*).
 - (b) From the *corpus geniculatum laterale* to the *lobus occipitalis* (*corpus geniculatum laterale*, *capsula interna* [*pars occipitalis*], *radiatio occipitohalamica* [*Gratioleti*], *cuneus*).
3. Neurones underlying optic reflexes.

IV. THE AUDITORY CONDUCTION PATH.

1. Peripheral auditory neurones (*organon spirale* [*Corti*], *ganglion spirale* [*Corti*], *n. cochleae*, *nuclei terminales*).
2. Central auditory neurones (*nucleus n. cochleae ventralis*, *nucleus n. cochleae dorsalis* [*tuberculum acusticum*], *corpus trapezoideum*, *striae medullares*, *superior olivary complex*, *lemniscus lateralis*, *nucleus lemnisci lateralis*, *nucleus colliculi inferioris*, *brachium quadrigeminum inferius*, *corpus geniculatum mediale*, *capsula interna* [*pars occipitalis*], *corona radiata*, *lobus temporalis* [*gyrus temp. sup.*, *gyri temp. transversi*]).

OUTLINE NO. 21.

CONDUCTION PATHS.

Reconstruction.

DIRECTIONS: With the aid of the drawings already made, together with the lecture notes and descriptive texts, construct diagrams illustrating the following conduction paths and the neurone systems of which these paths are composed:

V. THE GENERAL MOTOR CONDUCTION PATHS FROM THE CEREBRAL CORTEX TO THE MUSCLES.

A. Upper motor neurones (Cortico-nuclear motor neurones):

1. Those governing motor nuclei of origin of the cerebral nerves (*gyri centrales*, *corona radiata*, *capsula interna* [*pars occipitalis*], *basis pedunculi*, motor nuclei of *n. oculomotorius*, *n. trochlearis*, *n. trigeminus*, *n. abducens*, *n. facialis*, *n. glossopharyngeus*, *n. vagus*, *n. accessorius* and *n. hypoglossus*).
2. Those governing motor nuclei of origin of the spinal nerves (*gyri centrales* and *lobulus paracentralis*, *corona radiata*, *capsula interna* [*pars occipitalis*], *basis pedunculi*, *fasciculi longitudinales pontis*, *fasciculi pyramidales*, *decussatio pyramidum*, *fasciculus cerebrospinalis lateralis* and *fasciculus cerebrospinalis anterior*, *columna grisea anterior* [*cornu anterius*]).

B. Lower motor neurones (Nucleo-muscular neurones):

1. Those connecting the *mesencephalon* and *rhombencephalon* with muscles (motor nuclei of origin, roots and peripheral bundles pertaining to *n. oculomotorius*, *n. trochlearis*, *n. trigeminus*, *n. abducens*, *n. facialis*, *n. glossopharyngeus*, *n. vagus*, *n. accessorius*, *n. hypoglossus*).
2. Those connecting the *medulla spinalis* with muscles (motor nuclei of origin [*columna anterior*], anterior roots and peripheral bundles pertaining to *nn. cervicales*, *nn. thoracales*, *nn. lumbales*, *nn. sacrales*, *n. coccygeus*).

CONDUCTION PATHS.

Reconstruction.

DIRECTIONS: With the aid of the drawings already made, together with the lecture notes and descriptive texts, construct diagrams illustrating the following conduction paths and the neurone systems of which these paths are composed:

VI. THE CEREBRO-PONTO-CEREBELLAR PATHS.

A. Cerebro-cortico-pontal paths:

1. *Fasciculus palliopontilis* (*pars frontalis*), (feet of *gyri frontales*, *corona radiata*, *capsula interna* [*pars frontalis*], *basis pedunculi*, *fasciculi longitudinales pontis*, *nuclei pontis*).
2. *Fasciculus palliopontilis* (*pars occipitotemporalis*), (*lobus occipitalis* and *lobus temporalis*, *capsula interna*, *basis pedunculi*, *fasciculi longitudinalis pontis*, *nuclei pontis*).

B. Ponto-cerebellar path:

(*Nuclei pontis*, *brachia pontis*, *cortex cerebelli*).

VII. THE COMMISSURAL PATHS.

1. *Corpus callosum*.
2. *Commissura anterior cerebri*.
3. *Commissura hippocampi* (*Psalterium*).

VIII. THE ASSOCIATION PATHS.

A. Long paths:

1. *Cingulum* (*in gyrus fornicatus*).
2. *Fasciculus longitudinalis superior* (*lobus frontalis* and *lobus occipitalis*).

B. Short paths:

3. *Fasciculus uncinatus* (*uncus* and *lobus frontalis*).
4. *Fornix* (*hippocampus* and *substantia perforata anterior*).
5. *Tapetum* (*lobus frontalis* and *lobus occipitalis*).

The following additional outlines have been made out, and will be given in the course next year, the required material being prepared by a technical assistant:

SOPHOMORE NEUROLOGY.

OUTLINE NO. 16'.

ENCEPHALON OF MAN.

DIRECTIONS: Supplement the study of the fresh sections of the *pons* and the *medulla oblongata* by a study of corresponding sections of hardened tissue prepared according to the methods of Marchi and Weigert.

SOPHOMORE NEUROLOGY.

OUTLINE NO. 18'.

THE NEURONE AS A UNIT.

DIRECTIONS: Study the individual neurones in microscopic specimens prepared according to the methods of Golgi and Nissl.

Draw individual neurones as seen in the *cerebrum*, the *cerebellum*, the *medulla spinalis* and the *ganglia spinales*.

It is surprising how much students can be taught with the simple material prepared and presented in the way mentioned, and the results of the course have been so encouraging that the writers feel justified in recommending the adoption of similar methods in places where, owing to lack of time, laboratory facilities, material and a sufficient instructional force, more ideal courses in neurology cannot be given. A course of the nature outlined above is feasible in any medical school.

NOTE FROM CHARLES H. WARD.

ROCHESTER, N. Y., *December 23, 1900.*

I desire to inform you of the following facts concerning my paper on the Cranio-Mandibular Index, read at the Ithaca meeting December, 1897. The ratio between cranium and mandible suggested itself to me as of interest several years ago. Doctor J. Edward Line, of this city, then Editor of the *Odontographic Journal*, well posted on odontological matters, assured me, on inquiry, that, so far as he knew, no such comparison had been published.

The results of many hundreds of weighings were collected in my paper. The term Cranio-Mandibular naturally suggested itself as a good name for the proposed index. But on February 11, 1900, while glancing over a copy of the *American Anthropologist* of July 1891, a copy, by the way, whose leaves I cut as I read, I found on page 221 in an article by Doctor Robert Fletcher on "The New School of Criminal Anthropology," Orchanski had attempted to make a table showing the relation of the weight of the jaw to the cranium, or, as he terms it, the cranio-mandibular index.

THE LOBULE OF THE LUNG.

BY DR. W. S. MILLER, MADISON, WIS.

[Abstract.]

The term lobule as applied to the unit of the lung has been used in an exceedingly vague sense both by anatomists and pathologists. It is the purpose of the paper to give a definite meaning to the term.

THE EPITHELIUM OF THE PLEURAL CAVITIES.

BY DR. MILLER, MADISON, WIS.

[Abstract.]

Since the time of v. Recklinghausen and Oedmansson certain dark spots seen in many preparations of serous membranes stained by the silver-nitrate method have been called *stomata* and *stigmata*. Ludwig and Dybkowsky described such structures in the pleura. Muscatello has recently shown that such openings do not exist normally in the peritoneum. It is the purpose of the paper to show that they do not exist in the pleura when studied in the normal condition, and that they can be produced artificially at the pleasure of the investigator.

APPARATUS FOR DEMONSTRATING THE CIRCULATION OF THE BLOOD.

BY B. B. STROUD, B. S., D. SC., CORNELL UNIVERSITY.

The apparatus is an imitation of the actual blood vascular system. The heart, arteries, capillaries and veins are represented by a rubber bulb with valves, very elastic rubber tubing, capillary glass tubing and thinner rubber tubing. The bifurcation of arteries is shown in Y-shaped, of veins by U-shaped glass tubes. The circulation is continuous, as in the living body. Manometer tubes indicate the difference in pressure in arteries and veins.

The following papers (pp. 141 *et seq.*) having already been published in recent numbers of the Bulletin of the Johns Hopkins Hospital, are republished in the Proceedings. They were reprinted as a measure of economy from the forms of the Bulletin, Friedenwald Company, Printers, Baltimore, and this fact explains the slight differences in type, &c.

ON THE OCCURRENCE OF TAILS IN MAN, WITH A
DESCRIPTION OF THE CASE REPORTED BY DR.
WATSON.

BY ROSS GRANVILLE HARRISON, PH. D., M. D.,

Associate Professor of Anatomy, Johns Hopkins University.

Some years ago Bartels¹ gave an excellent *resumé* of our knowledge and beliefs concerning the occurrence of caudal appendages in man, showing that references to this peculiarity are to be found as far back as the writings of Pliny and Pausanias. Appended to Bartels' paper is a map, which shows the various lands supposed at one time or other to have been the haunts of human races with tails. These regions include not only widely distant portions of South America, Asia and Africa, but also the greater part of western Europe. While many of the statements cited by Bartels are to be classed as legendary, it is of interest to note how persistent and wide in range the belief in the existence of such races has been. The most remarkable stories have been told and have found credence; in these the significance of the caudal appendages has been variously interpreted. On the one hand, a tail has been considered a distinction of the highest degree, even a mark of divine descent, as in the case of the Ranas of Poorbunder;² on the other hand, it has usually been looked upon as a curse or a stigma of degradation.³

¹ M. Bartels: Die geschwänzten Menschen. Archiv f. Anthropol., Bd. xv, 1884.

² These were the rulers of the Jaitwa or Camari, one of the Rajpoot tribes. "They trace their descent from the monkey-god Hanuman, and confirm it by alleging the elongation of the spine of their princes, who bear the epithet 'Pooncheria, or the long-tailed Ranas of Saurashtra.'"—James Tod: Annals and Antiquities of Rajast'han, or the Central and Western Rajpoot States of India, vol. i, London 1829.

³ Bartels cites an instance of this in the stories regarding a certain

While careful investigation of the many travellers' stories has invariably given negative results regarding the existence of tailed races, so many individual instances of *homo caudatus* have been observed, that the popular belief in them has been kept alive without difficulty. With the growing interest shown by anatomists and anthropologists in the subject, the number of cases which have been reported has become considerable, and the fact that the human embryo at a certain period of development is provided with a tail-like appendage has lent color to the discussion of the question. Bartels in 1884 referred to one hundred and sixteen persons who had recorded observations upon tailed men. Of these, over sixty cases had been more or less completely described. In 1892 Schaeffer⁴ collected additional cases, adding in all twenty-five. Pyatnitski⁵ has also given an elaborate account of the subject, and still more recently Kohlbrugge,⁶ in connection with an admirable description of a very interesting case, has made valuable comparisons with previous work. From the United States five cases have, to my knowledge, been reported.⁷

community of tailed men in Turkestan. These were held in the utmost contempt by the other people, and were therefore condemned to constant inbreeding. They were referred to as "Kuju rukly Tatar," which in German is rendered "*Stinkendes Ungeziefer mit Schwänzen.*" The tail was supposed to be a special curse in that it hindered the possessor from sitting properly on his horse.

⁴ Oskar Schaeffer: Beitrag zur Aetiologie der Schwanzbildungen beim Menschen. Archiv f. Anthropol., Bd. xx, 1892.

⁵ I. S. Pyatnitski: On the Question of the Formation of a Tail in Man, and of Human Tails in General, according to Data from Literature and Personal Researches. Dissertation. St. Petersburg, 1893 (Russian).

⁶ J. H. F. Kohlbrugge: Schwanzbildung und Steissdrüse des Menschen und das Gesetz der Rükscklagsvererbung. Naturkundig Tijdschrift voor Nederlandsch-Indië, Deel lvii, 1898.

⁷ Dickinson: A Child with a Tail. Brooklyn Medical Journal, vol. viii, 1894.

Halsted Myers: A Caudal Appendage. Proceedings of the New York Pathological Society, (1893) 1894.

Julian Berry: Baby with a Tail. Memphis Medical Journal, vol. xiv, 1894.

A. Ecker: Der Steisshaarwirbel (vertex coccygeus), die Steissbeinplatte (glabella coccygea) und das Steissbeinrübchen (foveola coccygea),

Undoubtedly we have in these so-called tails a most heterogeneous collection of anomalies. Anything appended to the sacral or coccygeal region is described as a tail. Many do actually bear certain resemblances to the tails of lower animals, and have in fact been compared with a great variety of these. On the other hand, some are vesicular or of irregular shape and accompany the condition of *spina bifida*, while others are to be classed as teratomata or other tumors. A further very significant fact is that a large proportion of the cases have been complicated by the coexistence of *ectopia viscerum*, *hypospadia*, *atresia ani*, or deformities of the limbs, all of which are known to result from amniotic adhesions. This circumstance has led Schaeffer to the conclusion that human caudal appendages are always due to this cause.⁸

There are, however, a great many cases in which the anatomical relations of the tail are such as to indicate that it owes its existence to the persistence of at least part of the vestigial tail found in the human embryo. In some of these it seems that the coccyx extends down into the tail, though there is no good evidence that there is ever an increase over the normal number of coccygeal vertebræ in these instances. Under this latter head would come the majority of the adherent (*angewachsene*) tails described by Bartels,⁹ and also some cases in which the tail projects free from the trunk as, for instance, cases described by Braun,¹⁰ Ornstein,¹¹ and by Dick-

wahrscheinliche Ueberbleibsel embryonaler Formen, in der Steissbein-
gend beim ungeborenen, neugeborenen und erwachsenen Menschen.
Archiv f. Anthropol., Bd. xii, 1880. Ecker describes a case reported to
him in a letter from Dr. Neumayer, of Cincinnati.

Miller: Medical and Surgical Reporter, 1881. (Not accessible.)

⁸ Archiv f. Anthropol. Bd. xx, p. 219.

⁹ M. Bartels: Ueber Menschenschwänze. Archiv f. Anthropol., Bd.
xiii, 1881. In this paper Bartels classifies persistent tails, dividing them
into two main types, adherent and freely suspended (*freie*); of the latter
a number of subdivisions are made, between which, however, the distinc-
tion does not seem to me to be sharp.

¹⁰ M. Braun: Ueber rudimentäre Schwanzbildung bei einem erwach-
senen Menschen. Archiv. f. Anthropol., Bd. xiii, 1881.

¹¹ Ornstein: Schwanzbildung beim Menschen. Archiv f. Anthropol.,
Bd. xiii, 1881.

inson. The majority of the embryonic tails contain, however, no prolongation of the vertebral column but are classed as what Virchow¹² calls soft tails (*weiche Schwänze*).

DESCRIPTION OF CASE.

About a year ago Dr. Watson exhibited before the Johns Hopkins Hospital Medical Society a baby with a tail, which is an example of the last-named class.¹³ The tail was removed later, and through the kindness of Dr. Watson, who gave me the specimen as well as his notes of the case, I am enabled to make a fairly complete report on it, including a description of its histological structure.

The child, which was the third in the family, was a healthy, well-developed male. In its family history there is nothing which throws any light upon the case. Aside from the tail the baby presented only one other slight deformity, and that was in the four outer toes of the right foot. These toes were shorter than the normal ones of the left foot, their tips were turned up and the nails were small and thick. The phalanges of these toes were short and there were but two in each toe. The great toe of this foot was normally developed.

The tail appendage was attached in the mid-line about one centimeter below the tip of the coccyx. Examination of the sacro-coccygeal region showed a well marked *foveola coccygea* (Ecker) (Figs. 1 and 2), but owing to the extreme fineness of the hairs of this region, which to the unaided eye were quite invisible, it was impossible to distinguish any particular coccygeal bald spot or *glabella coccygea* (Ecker). Beginning a little to the right and below the *foveola* is a sharply defined groove, which runs obliquely downward and to the left between the buttocks and passes to the left of the root of the tail.

The appendage itself was of firm consistency, though con-

¹² R. Virchow: Schwanzbildung beim Menschen. Deutsche med. Wochenschr., 10. Jahrg., 1884.

¹³ W. T. Watson: Exhibition of a Three-months' Infant with a Caudal Appendage. Proc. J. H. H. Med. Soc. Johns Hopkins Hospital Bulletin, vol. xi, 1900.

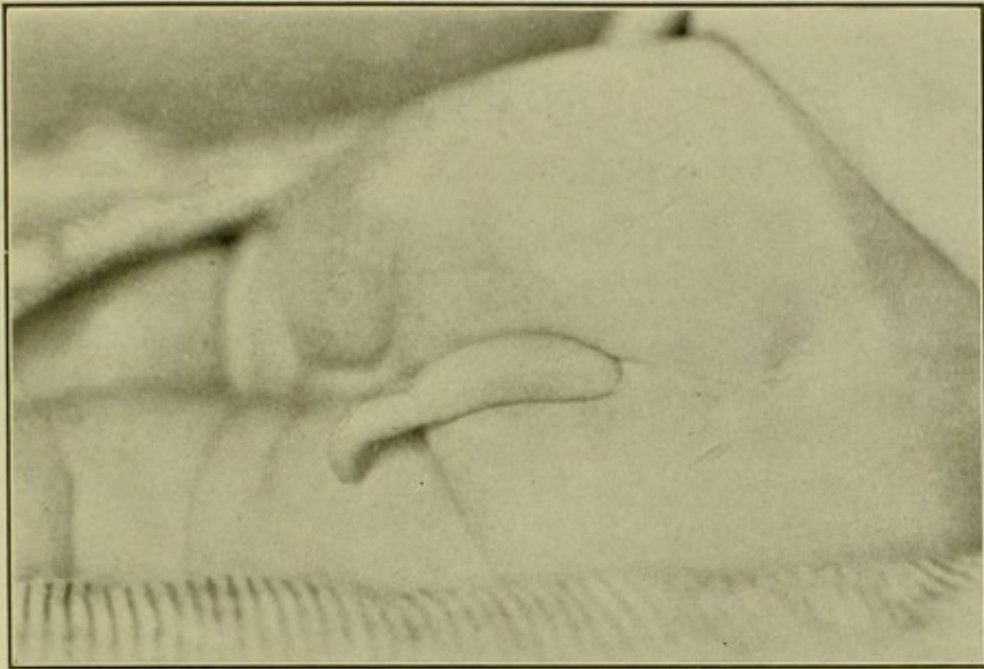


FIG. 1.—Photograph showing tail in extended condition.

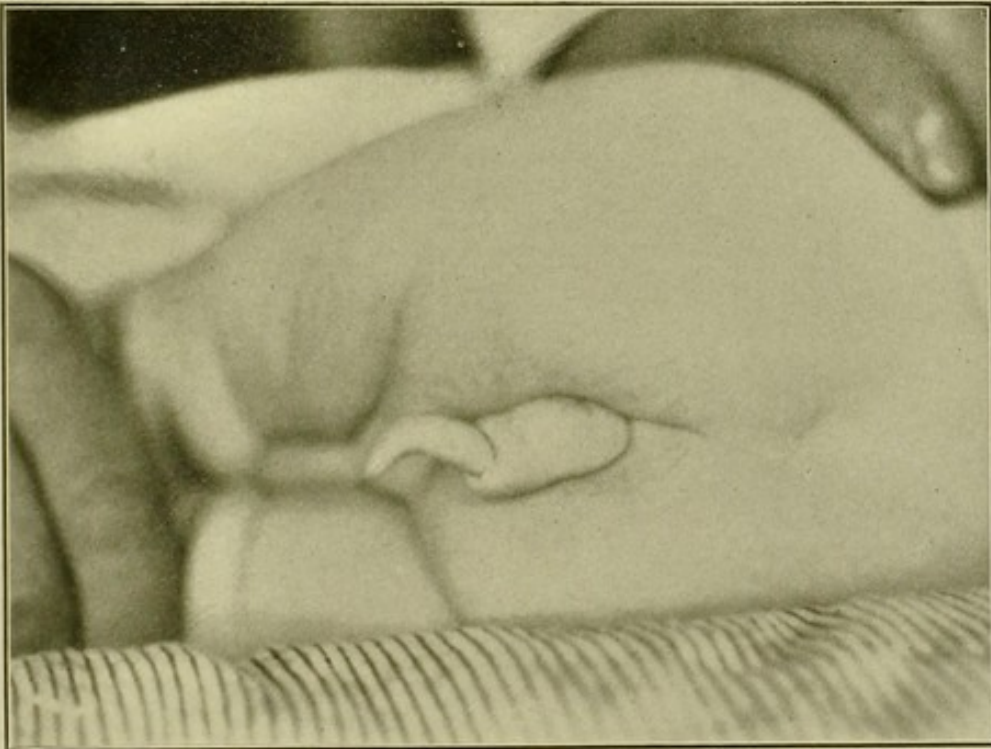



FIG. 2.—Photograph showing tail in state of contraction.



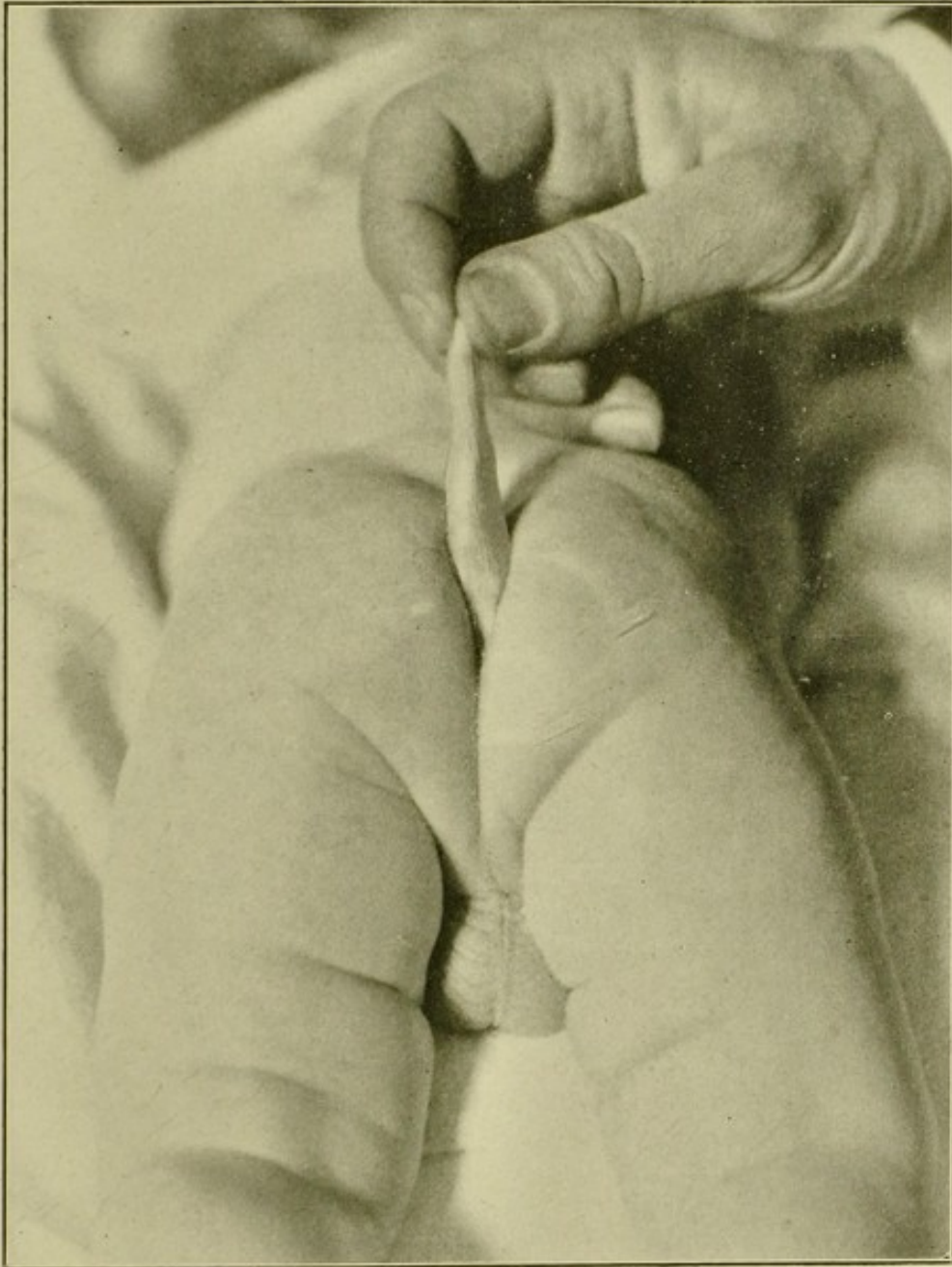



FIG. 3.—Photograph showing the ventral surface of tail.



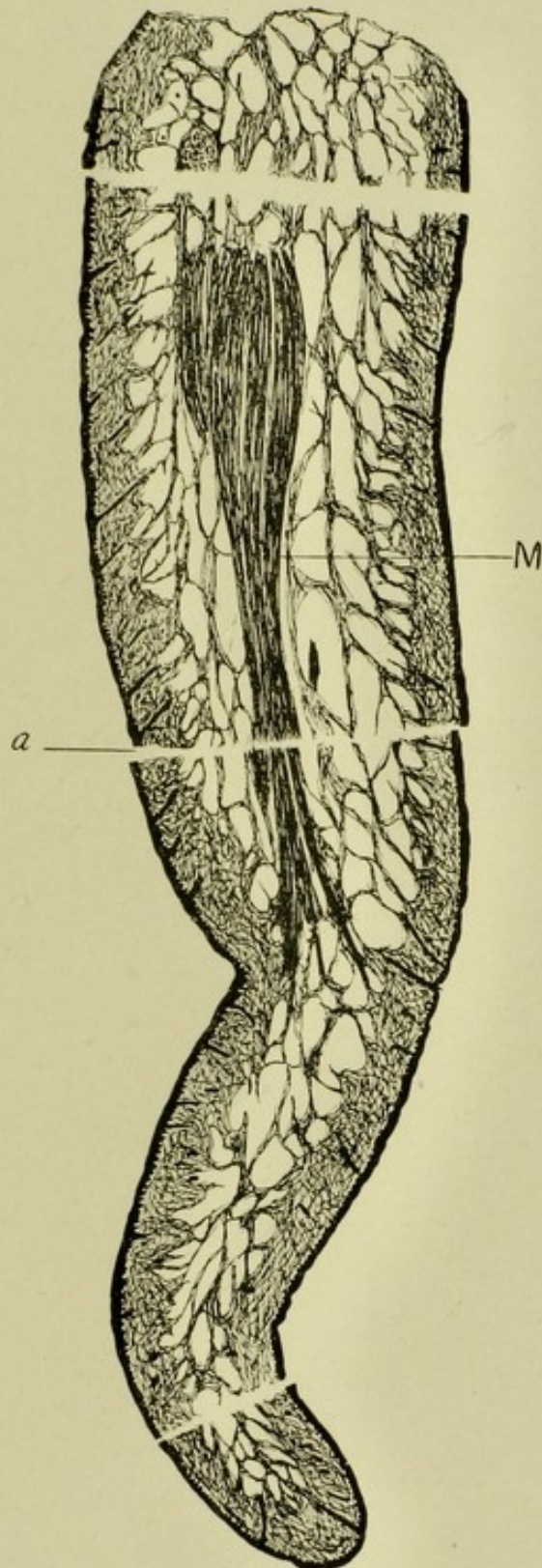



FIG. 4.—Frontal sections of tail, showing the arrangement of the muscle fibres (*M*).
a, Place from which the cross-section represented in Fig. 5 was taken. $\times 3$.



taining no bone. It was covered with normal skin, containing fine hairs, and was apparently well vascularized. Three distinct portions or segments could be made out. The basal piece was short and on the dorsal side scarcely marked off from the next following, except when the tail was in a state of contraction (Fig. 2). On the ventral side a transverse furrow separated it from the next portion. The middle segment had a length of 25 mm., was curved a little to the right and tapered somewhat towards its distal end, where the much more slender end-segment was attached. These two portions were separated by a constriction more marked on the left side. The terminal segment curved to the right and ventrally and ended in a rounded blunt extremity. On the whole, the tail gave an impression not unlike that of a pig's tail, a similarity which has been noted in a number of cases previously reported.

The hairs upon the tail, which were considerable in number, were plainly visible to the unaided eye. They pointed towards the tip, as could readily be confirmed by examination of longitudinal sections (Fig. 4). The convergence of the hairs towards the tip of the tail corresponds with the arrangement of the hairs in the coccygeal whorl (*vertex coccygeus* of Ecker), found in normal, *i. e.* tailless individuals, and supposed to be a vestige of the embryonic tail.

Two weeks after the birth of the child the tail was 4.4 cm. long; at the age of two months it had grown to 5 cm.; and at six months, when it was removed, it had attained the length of 7.0 cm., showing altogether a fairly rapid rate of growth.

The most remarkable characteristic of the tail was its movability. When at rest it would lie extended in the mid-line (Fig. 1), or bent over to one side upon the buttocks. The mother of the child said that she had seen the tail bent through an angle of 180° , its tip pointing towards the head. It must, however, have been brought into this position passively, for, as will be seen later, there was nothing in the arrangement of its muscles which could account for this. When the child was irritated, and cried or coughed, the tail would contract markedly. Between the basal and middle

segments but little movement was possible; the contraction of the muscles merely brought out the constriction between the two portions more plainly. Between the middle and distal segments the movement was considerable. The latter could be drawn in sharply, telescoping the middle segment, and at the same time flexion to the left side took place. During this action the middle segment became much shorter and thicker.

When the child was about six months old the tail was removed by Dr. Watson.¹⁴ The amputated appendage was put immediately into Zenker's fluid to harden. After it had been washed and kept in strong alcohol for some time it measured 5.3 cm. in length. It was then cut into four pieces with a sharp razor, and the pieces were imbedded in celloidin. Cross sections were cut at three different levels, near the base, proximal to the second joint, and near to the tip, as is indicated in Fig. 4. After a few transverse sections were cut off, the pieces were stuck together and reimbedded in celloidin for the purpose of cutting longitudinal sections of the whole.

From the study of sections it is seen that the skin covering the whole of the tail except a limited area on the ventral surface is of normal structure. The layers of the epidermis are easily distinguishable. The thickness of the skin varies somewhat. Near the base of the tail on the ventral side it is found to be quite 2 mm. thick, while on the dorsal surface of the same portion it is scarcely 1.5 mm. Further out, *i. e.* at the middle cut (Fig. 4, *a*), there is the same difference in thickness between skin of the ventral and dorsal surface (Fig. 5), although the skin is here not quite so thick as at the base. Near the tip the thickness throughout the whole

¹⁴ It seemed advisable to remove the tail, not only in order to accede to the wishes of the child's parents, who regarded its presence with chagrin, but also on more practical grounds. It looked as if the tail might become the seat of a troublesome intertrigo. Besides, its rate of growth was considerable, and it did not seem unlikely that the appendage might have later attained undue proportions, causing, as has been reported in several instances, considerable inconvenience in sitting. (See Lissner: Virchow's Archiv, Bd. 99, 1885.)

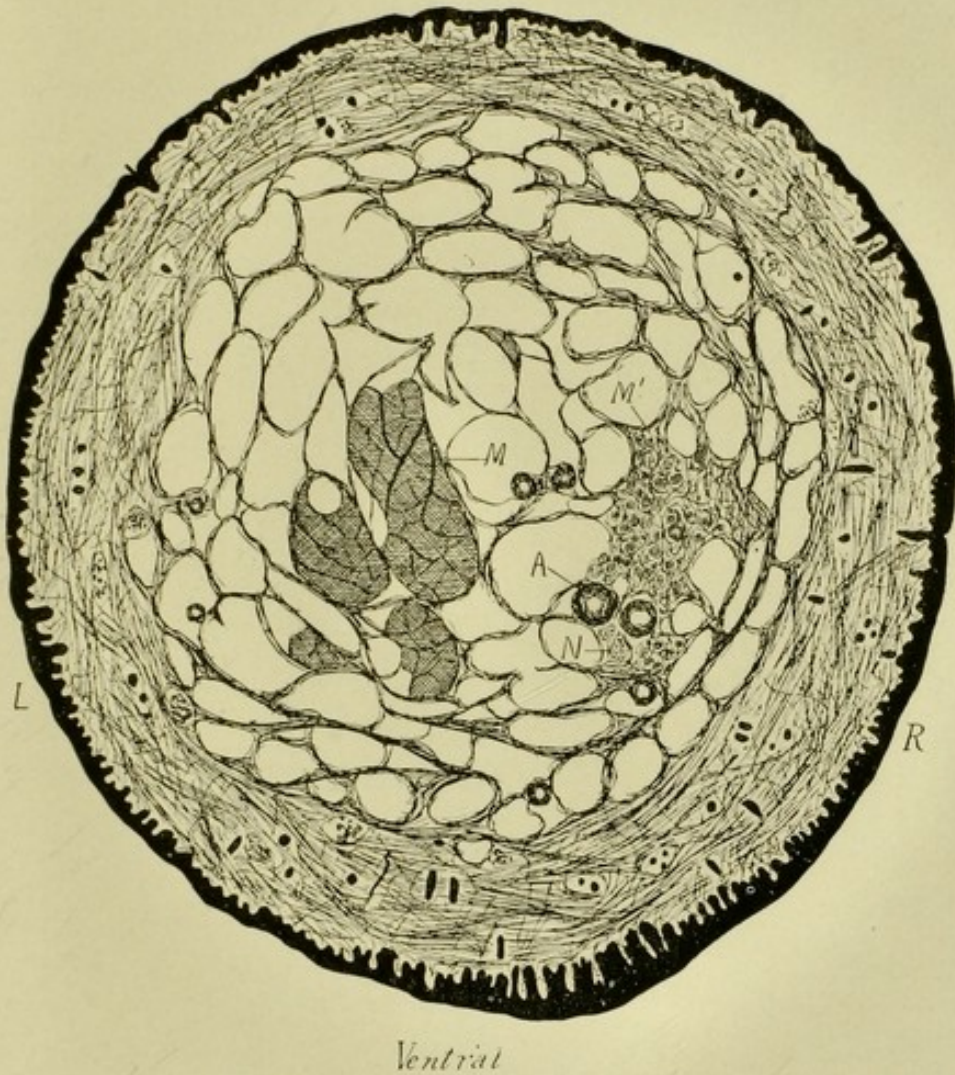



FIG. 5.—Cross-section through the middle of the tail (Fig. 4, a). *M*, muscle; *M'*, degenerating muscle; *A*, artery; *N*, nerve; *L* is placed on the left and *R* on the right of the appendage. $\times 9$.



circumference is nearly 1.5 mm. The greater thickness of the skin on the ventral side at the base is due principally to the epidermis, the corium being more nearly uniform throughout. In the thickened area the epidermal ridges extend down deep into the cutis, and the papillæ are very long and slender. The various integumentary organs, sweat glands, sebaceous glands and hairs, are numerous and of normal build. In longitudinal sections (Fig. 4) it may be very plainly seen that the hair follicles are obliquely inserted, the hair pointing towards the tip of the appendage. This is without exception the case in the proximal two-thirds of the tail, although the regular arrangement is somewhat disturbed at the crease where the distal and middle segments join, especially on the left side. The corium contains a very abundant supply of elastic fibres which may be readily demonstrated in sections stained by Weigert's method.

Beneath the skin the main bulk of the tail is made up of areolar tissue containing much fat. Blood-vessels, nerves, and striated muscle fibres are imbedded in this mass. There is no trace of anything like the medullary cord or of notochordal tissue, as Gerlach found in the tail of a fœtus of four months.

The voluntary muscle consists of a few bundles of fibres which take origin from the subcutaneous areolar tissue near the proximal end of the middle segment. They lie on the left side not far from the mid-line (Figs. 4 and 5), and run distally in parallel bundles diverging somewhat towards their insertion in the skin just beyond the joint between the middle and distal segments. The majority of the fibres are attached on the left side; a few, however, pass to the skin of the right side; and others are attached to the dorsal surface, and perhaps a few ventrally. The action of the muscle is thus clearly explained by its anatomical relations. There are no muscle fibres running between the trunk and the tail.

On the right side near the middle of the tail there are a few muscle fibres (Fig. 5, *M'*), but these are isolated in small bundles or as single fibres by a dense stroma of connective tissue. Moreover, nearly all of these fibres are in a state of

degeneration. The fibrils are less distinct than usual, and the nuclei may be found scattered throughout the substance of the fibres. The muscle is, in fact, in an advanced stage of simple atrophy.

No one of the blood-vessels stands out preëminently in size. The largest artery is on the left side, held in place by strong connective-tissue bundles. This may be seen in sections through the middle (Fig. 5, *A*), as well as through the base of the tail. There are several smaller vessels in the vicinity. Two small arteries are seen in the right dorsal quadrant near the centre and one just beneath the corium, to the left of the mid-line. The veins are small and inconspicuous. There is nothing to be seen of a tuft-like branching of the vessels as Virchow¹⁵ describes in one of his cases, nor is there anything resembling erectile tissue.¹⁶ There is, however, an abundant supply of blood-vessels in the corium.

A number of small nerve trunks (Fig. 5, *N*) run longitudinally in the areolar tissue of the appendage. The majority of these accompany blood-vessels.

Similar Cases.—While it is not practicable to enumerate here all of the similar cases which have hitherto been reported, there are some which for one reason or other are of especial interest. The tail of a Moï,¹⁷ ten years of age, which had attained the length of over twenty-five centimeters, is interesting on account of its size. Many of the cases have been described very briefly and only as regards external appearance. There are, however, a number of cases which have either been dissected or examined microscopically. These include Greve's case described by Virchow,¹⁸ and cases reported by Meyers,¹⁹ Vinogradow,²⁰ Rodenacker²¹ and Schebold-

¹⁵ Virchow's Archiv, Bd. 79, 1880.

¹⁶ Bartels: Archiv f. Anthropol., Bd. xv, p. 116.

¹⁷ Caudal Appendage in Man. (From the French of Étienne Rabaud, in "La Naturaliste.") Scientific American, vol. 50, 1889.

¹⁸ Virchow's Archiv, Bd. 79, 1880.

¹⁹ Proc. N. Y. Pathol. Soc., 1893.

²⁰ K. N. Vinogradow: On Human Tails. Vrach, vol. xv, 1894 (Russian).

²¹ G. Rodenacker: Ueber den Säugethierschwanz mit besonderer

ayeff,²² all of which agree with the present case in general structure but differ from it in the absence of muscle. In two other cases, however, described by Pyatnitzki²³ and Gerlach,²⁴ respectively, striated muscle fibres were found, and it is to be assumed that such tissue was present in Neumayer's case, for the tail in this instance could be excited to reflex contraction by stimulation of the sacral region. The complicated arrangement of the muscles found in some instances is associated with the occurrence of bone, as in the case described by Hennig and Rauber,²⁵ and especially in Kohlbrugge's case.²⁶ The tail described by Gerlach in a fœtus of 4.6 cm. also contained a continuation of the notochord, which has as yet never been seen in older subjects.

THE TAIL IN THE HUMAN EMBRYO.

The caudal region in human and other mammalian embryos has already been described by Ecker, His, Keibel, Fol, Braun and others. These accounts, while agreeing in the main, bring out considerable differences of opinion as to details. For this reason I give here a further description of the tail region in several human embryos. This I am enabled to do through the kindness of Dr. Mall, who placed at my disposal his fine collection of human embryos. Two specimens, fourteen and sixteen millimeters long respectively, were found to be especially adapted for this purpose, for it is at this stage that the tail reaches the highest point in its development. The study of these was greatly facilitated on account of their excellent state of preservation, and by the fact that they were cut into perfect series of sagittal sections.

Berücksichtigung der caudalen Anhänge des Menschen. Inaug.-Diss., Freiburg i. Br., 1898.

²² W. Scheboldayeff: Tailed Men. Zensk. Vrach, vol. vi, 1893 (Russian).

²³ Inaug.-Diss., St. Petersburg, 1893.

²⁴ L. Gerlach: Ein Fall von Schwanzbildung bei einem menschlichen Embryo., Morphol. Jahrb., Bd. vi, 1880.

²⁵ C. Hennig and A. Rauber: Ein neuer Fall von geschwänztem Menschen. Virchow's Archiv, Bd. 105, 1886.

²⁶ Natuurkund. Tijdschr. v. Ned. Indië, Deel. lvii, 1898.

Embryo 144. Greatest Length 14 mm.; Neck-Breech 12 mm.

—The tail of this embryo is marked off ventrally by a fold of epithelium which extends cranially from the anus, forming a shallow pit or crease between the anal prominence and the tail. This fold extends to the level of the cranial end of the thirty-third vertebra (Fig. 6), so that from this point on, *i. e.* distal to the third coccygeal vertebra, the caudal end of the embryo projects free from the trunk.

The vertebral column extends throughout but half the length of the tail, in which, therefore, a vertebral and non-vertebral portion may be distinguished.

The terminal portion of the tail or caudal filament is bent dorsally and inclined to the left side, and becoming rapidly thinner distally, ends in a slight knob-like enlargement, which is scarcely shown in the figure. The most conspicuous structure in the caudal filament is the medullary cord, which runs to the tip and there ends in a vesicular enlargement. The notochord and the terminal branches of the aorta and inferior vena cava also extend out into it though not so far as the medullary cord. The filament is supported by a diffuse mesenchymatous network, more concentrated in the ventral side just beneath the integument, which is perhaps an indication of the remains of the post-anal gut found in younger embryos.

Counting from the atlas down, it is clear that there are in all thirty-six vertebræ present, of which the distal seven belong to the coccygeal or caudal region. In the trunk, down through the sacral region, the vertebral bodies are composed of embryonic cartilage, which does not stain intensely. The intervertebral discs, owing to the greater concentration of the cells composing them, stand out in sections as deeply staining bands. Between the vertebral bodies and the discs there is a zone of cells, which stains more intensely than the cartilage and less so than the discs. In the well advanced vertebræ of the lumbar region the intermediate zone is thin and clearly forms a part of the perichondrium of the vertebral cartilages. Beginning with the first coccygeal vertebra this intermediate or perichondrial layer forms a thick pad, especi-

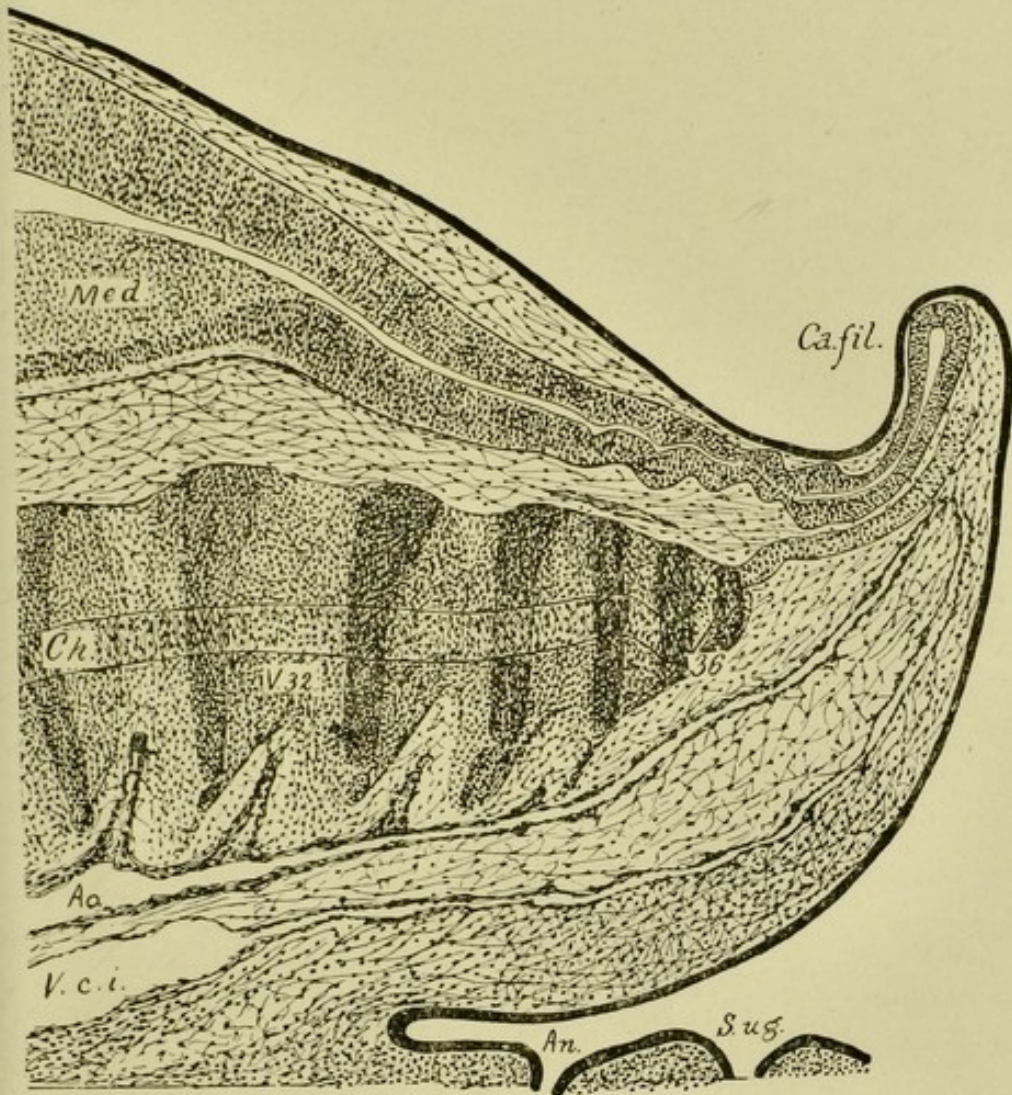



FIG. 6.—Caudal region of embryo of 14 mm. (No. 144 of Dr. Mall's collection), combined from several sagittal sections. *An.*, anus; *Ao.*, caudal aorta (*A. sacralis media*); *Ca. fil.*, caudal filament; *Ch.*, notochord; *Med.*, medullary cord; *S. ug.*, sinus urogenitalis; *V. 32*, third coccygeal vertebra; *36*, seventh coccygeal vertebra; *V. c. i.*, caudal portion of *vena cava inferior* (*V. sacralis media*). × 91.



ally on the distal surface of the disc. The vertebral body is here proportionately thin, showing itself merely as a lighter streak between the more deeply staining perichondrium of each end. In fact the bodies of the distal coccygeal vertebræ can hardly be spoken of as cartilaginous. In thickness (cranio-caudal) the vertebral bodies diminish steadily throughout the sacral and coccygeal regions, but there is very little diminution in the dorsoventral diameter until the thirty-fourth vertebra is reached. The last three diminish rapidly towards the tip. In the last two the discs are fully as thick as the vertebral bodies themselves. The distal surface of the vertebra is capped by a well marked disc. There is on each side of the intervertebral discs in the coccygeal region a small mass of deeply staining tissue, which projects ventrally and laterally. They are visible only in sections which pass to the side of the mid-line. They represent undoubtedly rudimentary hypapophyses or hæmal arches found in the caudal vertebræ of lower forms.

The spinal ganglia, not counting the ganglion of the hypoglossus, are thirty-three in number. In connection with the last a distinct ventral ramus arises and passes ventrally to the side of the vertebræ, bending distally; ventral to the vertebræ it joins a trunk from the next higher nerve. Its mode of ending is uncertain.

The number of muscle plates could not be made out clearly.

In the interval between the thirty-first and thirty-second vertebræ the medullary cord (*med.*) becomes suddenly attenuated into a *filum terminale*. There are apparently few or no neuroblasts beyond this point; the walls of the tube are made up of columnar epithelial cells. In the distal portion of the vertebral region and at the base of the caudal filament the cord takes a somewhat sinuous course. The central canal extends to the tip of the tail, where it ends in the slight enlargement mentioned above, the terminal ventricle.

The notochord (*ch.*) forms the axis of the vertebral bodies and discs, and in the proximal portion of the coccygeal region, as in the trunk, is almost straight. In the region of the last two or three vertebræ it is more tortuous. It leaves the

vertebral column near the dorsal surface of the last vertebral body and passes thence dorsally to the ventral side of the medullary cord, accompanying this nearly to the tip. In contrast to the vertebral portion, the terminal portion is scarcely differentiated and not well defined in the surrounding mesenchyme.

The continuation of the aorta (*ao.*), *i. e.* the *a. sacralis media*, at first ventral to the vertebræ, passes out into the caudal filament as an *a. caudalis*. From this are given off the segmental arteries, one for each vertebra down to and including the last or thirty-sixth. (The last two are not shown in the figure.) These pass up on each side of the vertebral bodies, but it is doubtful if the more distal ones are as yet fully open. In the same way the vena cava continues into the tail, as the *v. sacralis media* and the *v. caudalis*, which lies ventral and to the right of the artery. At their termination in the caudal filament the artery and the vein meet. The vein is of large calibre to the region of the thirty-second vertebra; here it narrows down very suddenly. There are numerous small blood-vessels throughout the mesenchyme of the tail.

Embryo 43. Greatest Length 16 mm.; Neck-Breech Length 14 mm.—The relations of the tail to the trunk are about the same as in the younger embryo first described, *i. e.* it is free from the thirty-third vertebra on.

The vertebral portion of the tail is longer, but the caudal filament is shorter and more shrunken. It bends sharply on itself to the dorsal side, almost through an angle of 180°.

Thirty-seven vertebræ are present, with possible indications of a thirty-eighth; eight of these belong beyond doubt to the coccygeal region. The thirty-fourth and thirty-fifth are partly fused in the middle. • The hypapophyses of each are distinct.

The spinal ganglia number thirty-two. The relations of the notochord, medullary cord and blood-vessels are the same as in the embryo first described. There is a slight irregularity in the notochord in the form of a process which extends ventrally into the substance of the thirty-sixth vertebra.

GENERAL CONSIDERATIONS.

Ecker²⁷ and His²⁸ were the first to give detailed descriptions of the caudal region of the human embryo. Their conclusions regarding its definition and ultimate development may be taken as the starting point in the discussion of the subject. The agreement reached by Ecker and His may be rendered in part as follows:²⁹ (1) The term "tail" may be applied only to that portion of the embryo which projects free beyond the cloaca. (2) The tail consists of a portion containing vertebræ and a portion without vertebræ (caudal filament). The latter contains only notochord and medullary cord. (3) Only the non-vertebral portion atrophies. The vertebral portion remains for some time as the coccygeal prominence (*Steisshöcker*), which, however, gradually disappears in consequence of the increase in the curvature of the sacrum and coccyx, and of the progressive development of the pelvic girdle and its musculature.

Two matters which have a bearing upon the morphological significance of the persisting caudal appendages in man are brought up in the above for consideration. The one concerns the structure of the tail in the human embryo in comparison with the tail in lower forms; the other is the nature and amount of regressive change which takes place in the human tail during development.

Regarding the first, Keibel³⁰ discovered an additional fact of importance in the presence of a post-anal gut in the human embryo. Braun's³¹ observations on the caudal filament of

²⁷ A. Ecker: *Archiv f. Anthropol.*, Bd. xii, 1880.

A. Ecker: *Besitzt der menschliche Embryo einen Schwanz?* *Archiv f. Anat. u. Physiol. anat. Abtheil.*, 1880.

²⁸ W. His: *Anatomie menschlicher Embryonen*, I, Leipzig, 1880.

W. His: *Ueber den Schwanztheil des menschlichen Embryo.* *Archiv f. Anat. u. Physiol. anat. Abtheil.*, 1880.

²⁹ A. Ecker: *Replik und compromissitze nebst Schlusserklärung von W. His.* *Archiv f. Anat. u. Physiol. anat. Abtheil.*, 1880.

³⁰ Fr. Keibel: *Ueber den Schwanz des menschlichen Embryo.* *Archiv f. Anat. u. Physiol. anat. Abtheil.*, 1891.

³¹ M. Braun: *Entwicklungsvorgänge am Schwanzende bei einigen Säugethieren mit Berücksichtigung der Verhältnisse beim Menschen.* *Archiv f. Anat. u. Phys. anat. Abtheil.*, 1882.

mammalian and bird embryos are of importance in showing that the caudal filament is of general occurrence and not a peculiarity of the human tail. Again, the occurrence of spinal nerves and ganglia in a number of the coccygeal segments, as shown by Fol,³² Phisalix³³ and Keibel, the continuation of the aorta and vena cava into the caudal filament, together with the presence of segmental arteries and the hypapophyses or rudimentary hæmal arches in all of the coccygeal segments as described in the present paper, show that the caudal region of the human embryo resembles that of other mammalian embryos in all respects except in size and in the number of its segments.

Concerning the regressive development of the tail considerable difference of opinion has been expressed. Rosenberg, who holds that, strictly speaking, the caudal rudiment in man is not the homologue of the tail of other animals, but is the result of a precocious growth of the medullary cord,³⁴ considers that the appendage disappears in consequence of the increase in volume of that end of the embryonic body and not through absorption. His,³⁵ in supporting Rosenberg, makes the statement that no reduction in the number of segments takes place during the development of the human embryo, but that the regressive changes are confined to the caudal filament; this view is confirmed in the agreement with Ecker. On the other hand, Fol and Phisalix find thirty-eight segments in embryos of 8-10 mm., with indications that sev-

³² H. Fol: Sur la queue de l'embryon humain. *Comptes Rendus*, T. 100, Paris, 1885.

³³ C. Phisalix: Étude d'un embryon humain de 10 millimètres. *Archives de Zool. Exp. et Gén.* II^me S., T. vi, 1888.

³⁴ E. Rosenberg: Ueber die Entwicklung der Wirbelsäule und das centrale carpi des Menschen. *Morphol. Jahrb.*, Bd. i, 1876. ". . . dass die Gestaltung des hinteren Leibesendes ebenfalls von dem Medullarrohr derart beeinflusst wird, dass letzteres, indem es in seinem Längenwachsthum dem der anderen, un der Zusammensetzung des hinteren Leibesendes Theilhabenden Bestandtheile vorseilt, an demselben einen Vorsprung erzeugt. . . ." p. 128.

³⁵ "Es werden demnach beim menschlichen Embryo keine überzähligen zur Rückbildung bestimmten Segmente angelegt." *Anatomie menschlicher Embryonen*, i, p. 92.

eral of these disappear through fusion in the course of development. Allowing for the possibility that these observers have counted in an occipital segment, there would be in embryos of this size at least thirty-seven trunk segments, which would correspond to thirty-six vertebræ. Keibel finds in an embryo of 8 mm. thirty-five trunk segments, together with a mass of unsegmented mesoderm, equaling two segments in length. Reckoning this as two instead of one segment, as Keibel does, we have again thirty-seven segments, corresponding to thirty-six vertebræ.

The following is an attempt to tabulate the number of segments found in embryos varying in length from 7.5 to 21.5 mm. With the exception of the last column the data are as recorded by the observers themselves. In the last column the number of vertebræ is given which would correspond to the total number of segments after certain changes have been made, such as deduction of occipital segments or addition of unsegmented mesoderm, which seemed justified by the descriptions of the authors.

Observer.	Length of embryo in mm.	Segments in mesoderm.	Spinal ganglia.	Vertebræ.	Corresponding number of vertebræ after allowing for corrections.
His	7.5	35	—	34	34
Keibel.....	8.0*	35 + unsegmented mesoderm.	—	—	36†
Fol.....	8.0-9.0	38	—	36	36
Phisalix	10.0	38	36	..	36
Keibel.....	11.5*	35 + unsegmented mesoderm.	34	35	36†
Fol	12.0	..	—	36	36
Harrison ...	14.0	..	33	36	36
Harrison ...	16	..	32	37	37
His	16.0	34	34
Rosenberg..	16.5	33	33
Fol	19.0	34	34
Rosenberg..	19.0	35	35
His	21.5	34	34

* Neck-breech measurement.

† Counting the terminal mesoderm as equivalent to two segments.

From this it may be seen that the number of vertebræ or their equivalent is fairly if not quite constant in embryos between eight and sixteen millimeters in length. We have, then, seven vertebræ in the embryonic tail at its highest period of development. The stages studied by His and by Rosenberg were either too young or too far advanced to show the maximum number of vertebræ. That the reduction takes place by fusion, as is maintained by Fol, is confirmed by the study of the embryos described above. In the older embryo (16 mm.), in which an exceptionally large number of segments was present, partial fusion between several of the adjacent vertebræ had taken place. In still older embryos, as seen in the table, the number of segments is inconstant; most probably this is due to the varying extent to which fusion has taken place, though it is possible that it may be due in part to a difference in the original number. As Steinbach³⁶ shows, the usual number of segments is thirty-four, *i. e.* five coccygeal, although the number may be less or, in rare instances, even increased by one.

The spinal ganglia of the caudal region, as Keibel has shown, also suffer reduction. There are never quite so many ganglia developed as vertebræ, and the last ones are always more or less rudimentary; but there are always more formed than persist in the adult. For instance, in an embryo of 10 mm. Phisalix described thirty-six ganglia; in an embryo of 11.5 mm. Keibel found thirty-four; in the embryo of 14 mm. described above there were thirty-three, and in the embryo of 16 mm. thirty-two, while in the adult there are but thirty-one. The segmental arteries of the distal caudal segments also become obliterated as development proceeds.

We conclude, then, with Keibel that, while as far as outward form is concerned the embryonic tail disappears largely as a result of the growth of the extremities and the gluteal region, a certain amount of regressive change takes place in the caudal appendage itself. This is manifest not only in the absorption of the caudal filament, as supposed by Ecker and

³⁶ E. Steinbach: Die zahl der Caudalwirbel beim Menschen. Inaug. Diss., Berlin, 1889.

His, but also in the reduction of all essential structures of the vertebral portion of the tail, *i. e.* the vertebræ, muscle segments, spinal ganglia and blood-vessels. It is interesting to note that in this tendency to reduction the resemblance between human and other mammalian tails also holds. The caudal filament, as Braun has shown, is present in other embryos and atrophies as development proceeds. The tendency to fusion of the distal vertebræ has been observed in the embryos of various long-tailed animals. And in short-tailed varieties, as Bonnet has shown, this tendency is merely accentuated.³⁷

The view that a great many of the anomalous caudal appendages found in man are, as stated in the beginning, due to the persistence of the embryonic tail, is warranted by the facts gathered both from the study of the former as well as of the latter. Many of the differences in form are explained by the hypothesis of Bartels that the embryonic tail may be arrested in any stage of its development. The soft or boneless tails are clearly not due to the multiplication of vertebræ or even to the persistence of all which are developed in the embryo, but, as His³⁸ first suggested, are to be regarded as persisting caudal filaments. The usual position of these appendages as well as their structure support this conclusion. The fact that they are not always attached exactly over the tip of the coccyx cannot be regarded as conflicting with this view, for, as has long been recognized, the curvature in the vertebral column, especially in the sacral and coccygeal regions, changes markedly during development, and the caudal filament not being firmly united to the tip of the coccyx might easily be shifted slightly in relation to the latter.

In the action of amniotic adhesions Schaeffer³⁹ has suggested a cause which may undoubtedly bring about the persistence of the caudal filament, for it is a fact that in many,

³⁷ R. Bonnet: Die stummelschwänzigen Hunde im Hinblick auf die Vererbung erworbener Eigenschaften. Zeigler's Beiträge z. path. Anat. u. allg. Pathol., Bd. iv, 1889.

³⁸ Anatomie menschlicher Embryonen, i, p. 95.

³⁹ Archiv f. Anthropol., Bd. xx, 1892, p. 219.

perhaps in a majority of the cases there are other evidences of such adhesions having been present, and, as Schaeffer points out, the caudal region, like other projecting portions of the embryo, is especially liable to stick to the amnion. The adhesions are to be regarded, however, merely as a factor which may induce the persistence of an otherwise transitory structure and it does not follow that such persistence is always the result of adhesions. On the contrary, we find in certain animals that the caudal filament normally persists. According to Braun, this is probably the origin of the tail-stump, composed of areolar tissue, found in *Inuus pithecus*, and similar appendages are also found sometimes in the Chimpanzee, as Rosenberg has described.

Dr. Hrdlicka stated that in examining seven hundred boys of the N. Y. Juvenile Asylum, he had found one with a little caudal appendage. The growth looked like the tip of the little finger protruding from beneath the skin and pointing downward. It was situated in the median furrow slightly above the end of the coccyx and was soft. No movement of the part was observed during the examination, soon after which the child was discharged and lost sight of.

BILATERAL RELATIONS OF THE CEREBRAL
CORTEX.

BY E. LINDON MELLUS, M. D.

(From the Anatomical Laboratory, Johns Hopkins University.)

In the study of the central nervous system it becomes more and more apparent that the statement that each cerebral hemisphere controls the opposite half of the body must be still further modified. It has long been recognized that certain movements were more or less bilateral; that is, equally controlled by each hemisphere. This is easily demonstrated by electrical stimulation of the cortex and, to a certain extent, the anatomical relations have been worked out. The bilateral representation of most facial movements would appear at first thought to be quite essential and anatomists held, long before it was demonstrated, that each of the motor nuclei in the pons and medulla was connected with its fellow of the opposite side by decussating fibres. Bilateral movement could thus be accounted for by simultaneous stimulation of the nuclei of both sides, but the results of some of the more recent investigations show that projection fibres run directly from the cortex of each hemisphere to the nuclei of both sides. This provides for simultaneous stimulation, while the fibres passing directly from one nucleus to the other may conserve the symmetrical discharge of energy.

The necessity for bilateral control of the limbs is not so evident, but the fibres of the so-called direct or uncrossed pyramidal tract in man and the finding of bilateral degeneration in the cord after unilateral lesion of the brain seemed to make it probable. For some time it was not possible to trace the course of this homolateral degeneration from the

brain to the cord, and various theories were brought forward to explain it. It was considered probable by some anatomists that the pyramidal tract divided at the decussation, some fibres passing to the lateral column of each side, while a portion remained in the anterior column as the direct tract; but in the absence of confirmation Sherrington's theory of "recrossed" fibres was generally accepted. Sherrington's conclusions were based upon experimental unilateral lesions on the brain of the monkey, in which he claimed that immediately below the decussation the degeneration was all on the opposite side of the cord, while at a still lower level degenerated fibres were found in both lateral columns. He thereupon assumed that all the degeneration crossed over in the decussation to the opposite side of the cord, but a portion crossed back at a lower level to the lateral column of the same side. The probable explanation of his mistake is that at the time of his observations the delicate methods in use in recent years were not known. Still the fact that he reported at the same time that fibres from the upper limb area of the cortex passed down the entire length of the cord, while fibres from the leg areas disappeared from the cord in the cervical and upper dorsal regions, would indicate that his preparations were handled or studied somewhat carelessly. It is rather curious that no one seems to have suggested that he had mixed up those cords.

Soon after the publication of Marchi's method of staining degenerated nervous tissue by osmic acid, Muratow undertook the study, by that method, of degenerations following lesions of the brain in the dog. He published the results of his observations in 1893¹ and clearly showed that in the dog the pyramidal tract divided at the decussation and a portion passed directly to the lateral column of the same side. I had been working with the same method tracing degenerations in the central nervous system of the monkey after very minute lesions of the cerebral cortex, and at the time of the appearance of Muratow's publication I had already accomplished the same results on the monkey, but to him undoubtedly

¹ Archiv für Anatomie und Entwicklungsgeschichte. 1893.

belongs the credit of priority. These results have since been confirmed by other investigators, and Dejerine and Thomas² and Risien Russell³ have proved the existence of the same conditions in man.

At the same time I was able to demonstrate the passage of fibres from the pyramid of one side directly to the motor nuclei of both sides in the pons and medulla.⁴

The following experiment enlarges still further the scope of bilateral representation and adds another to those paths already demonstrated by which one hemisphere may control more or less both halves of the body. It by no means stands alone, but is presented as the type of a considerable group which will be considered individually in a later publication.

On September 20, 1898, I operated in Mr. Victor Horsley's laboratory at University College, London, on a small but apparently healthy bonnet monkey (*Macacus sinicus*). The animal being etherized, the cortex of the left hemisphere was exposed under strict aseptic precautions, the centre for thumb movements determined by electrical stimulation and that portion of the cortex carefully excised. Care was taken not so much to remove every portion of cortical substance as to avoid injury to the underlying white matter. I therefore passed the knife under the cortex with the flat surface of the knife parallel to the convexity of the hemisphere, bringing it out at a right angle to the line of incision. Then lifting the cut edge with a pair of small forceps the excision was easily completed. The slight hemorrhage was controlled with hot saline solution, the wound closed with horsehair sutures and dressed with borated cotton smeared with collodion. This monkey got diarrhœa and died on the tenth day after the operation (September 30) of marasmus. The wound in the scalp had healed well and there was no trace of sepsis. The brain and cord were removed, kept for four days in formalin and then transferred to Müller. The brain

² Dejerine and Thomas. *Archives. de physiol. norm. et patholog.* 1896, No. 2. Review in *Neurologisches Centralblatt*, 1897, p. 503.

³ Risien Russell. *Brain*. Summer, 1898.

⁴ *Proc. Roy. Soc.* vol. 58.

was cut into thin segments in a plane nearly parallel to the occipital sulcus (Affenspalte), as shown in Figs. 1 and 2, and stained by the Marchi method. It was my endeavor to make the plane of section correspond as nearly as possible to the course of the projection fibres through the internal capsule.

DESCRIPTION OF THE LESION.

The portion of cortex removed was circular and about one cm. in diameter. About one-third of the area of the lesion was in the ascending parietal convolution and the other two-thirds in the ascending frontal. Its posterior extremity was about midway between the lowest portion of the interparietal sulcus and the fissure of Rolando, while its anterior boundary was the superior angle of the sulcus precentralis. The lowest portion of the lesion was very nearly opposite the lower extremity of the interparietal sulcus, and it extended upward to the superior frontal sulcus.^{4a} The lesion in the ascending frontal was much more shallow than in the ascending parietal and the entire cortical substance was removed only at that portion of the ascending parietal convolution nearest the centre of the lesion, close to the fissure of Rolando. It was at this point that uncomplicated flexion of the thumb was obtained on stimulation with a weak faradic current. The portion of cortex removed became thinner from the centre to the periphery of the lesion. In the hardened brain there was evidence of slight cerebral hernia, *i. e.* bulging of the brain into the opening in the skull, which accounts for the irregularity of contour in Fig. 3.

In Figs. 1 and 2 I have endeavored to show the distribution of association fibres to the external surface of the two hemispheres, the proximity of the oblique parallel lines to each other corresponding to the amount of degeneration found in the various convolutions. It was impossible to

^{4a} In Fig. 1 the lesion does not extend upward as far as it should. It is better represented in Fig. 3.

represent the comparative amount of degeneration so accurately in the outline drawings of transverse sections of the brain (Figs. 3 to 7 inclusive), because in so small a figure, in order to have the degeneration show at all, it was necessary to exaggerate. Degenerated fibres can be seen crossing in the corpus callosum in all the segments except "E," the most posterior. The distribution of association fibres to the convolutions of the two hemispheres is very nearly equal and quite symmetrical. It extends also upon the internal (mesial) surface of both hemispheres as far as the calloso-marginal fissure.

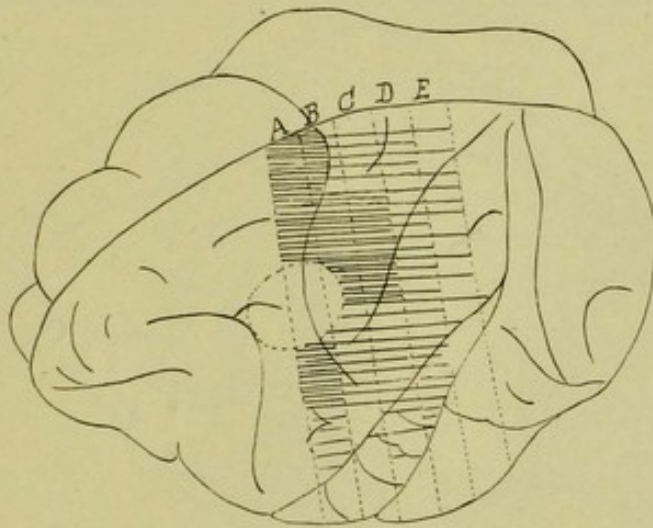


FIG. 1.

In two segments, C and D, the degeneration extends to the superior temporal convolution of both sides. The route taken by the degenerated fibres to reach the temporal lobe is the same in both hemispheres and is interesting. In section "B" (Fig. 4) a few degenerated fibres appear among the fibres passing to the superior temporal convolution just external to the thickened lower edge of the claustrum on both sides. In the segment posterior to this (Fig. 5) many degenerated fibres can be seen leaving the internal capsule, breaking through the thin inferior edge of the lenticular nucleus and passing below the claustrum to reach the superior temporal convolution. Some of these fibres probably terminate in the lateral geniculate body. Although no continuous

fibres could be traced from the internal capsule into the lateral geniculate body, it lies directly in the path of those running to the temporal lobe and there is considerable degeneration in this nucleus in both hemispheres. Still posterior to this (Fig. 6) degenerated fibres are passing between the islets of gray matter representing the prolongations of the putamen, while many others may be seen passing down among the fibres of the external capsule. The degenerated fibres in the superior temporal convolution are apparently continuous with both these tracts, the course of which is the same in both hemispheres.

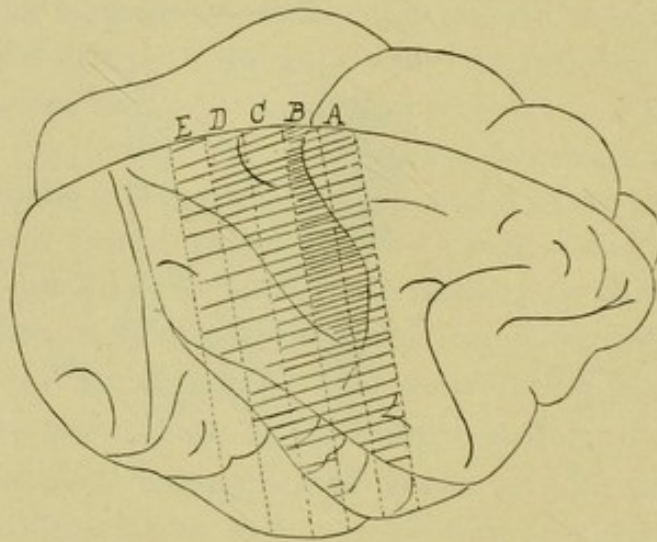


FIG. 2.

Taking into consideration the movements represented in that portion of the cortex removed, the distribution of association fibres is of especial interest. While the centre for *uncomplicated* movement of the thumb occupies but a small portion of the area removed, movements of the thumb as part of some associated movement or march may be obtained not only from every portion of that area but also from points considerably removed therefrom—even as far down the convexity of the brain as the lower extremity of the fissure of Rolando. It is a question of much interest whether this is brought about by means of association fibres or projection fibres passing directly from each of the widely separated cortical areas to the system of secondary neurons in the cervical

region of the cord. It is quite possible that complicated movements may be brought about in either or both ways. The great increase in cortical association tracts between monkey and man suggests the possibility of inconceivable degrees of association.

Looking upon the motor cortex as representing the centres for associated movements one would naturally expect to find projection fibres passing directly down through the capsule from that part of the cortex, giving rise to the movement. As I understand the significance of excitation experiments upon the cortex, the finding of a centre for the uncomplicated movement of the thumb only means that in the move-

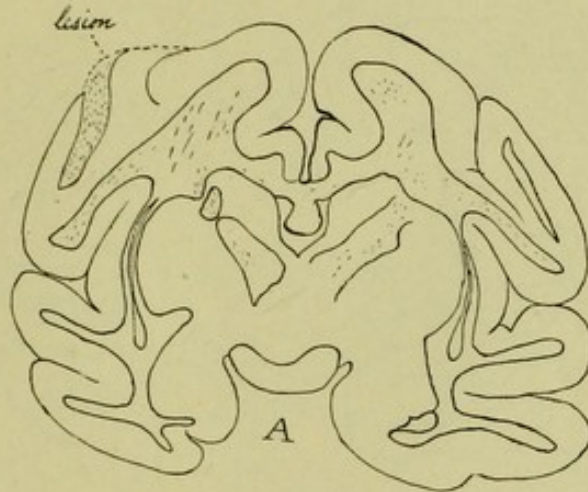


FIG. 3.

ment represented at that spot, the movement of the thumb (flexion or otherwise) is the first or initial movement of the march. If the stimulation is continued or increased the march is continued or completed unless interrupted by a general convulsion. Thus, if the anæsthesia is at just the right stage the gentlest stimulus only excites the first or initiatory movement of the march. In opposition to such a theory it may be urged that only one centre has been found in any single animal for such uncomplicated or initial movement, while many combinations are possible beginning with such movement. This would hardly render an entirely separate centre for each movement necessary, as they might all be grouped about the common centre.

In experimental destruction of small cortical areas in the monkey I have often traced projection fibres into the cervical region of the cord from portions of the facial area far removed from arm centres. Such fibres probably represent the conduction paths for impulses, giving rise to movements in which the arm is associated with facial movement. Such movements or actions are numerous in the monkey and increase as we go up in the scale. For example, in feeding, the monkey stretches out his arm, opens the hand to lay hold of the object, which he grasps and carries toward his already opening mouth. In this instance the extension of the arm is the initial movement, followed by extension of the thumb

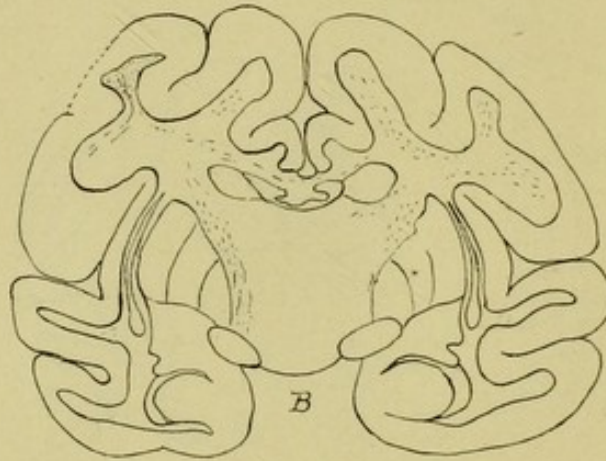


FIG. 4.

and fingers, then flexion, etc. Such a movement or march is of course much more complicated than any movement obtained by electrical stimulation of the cortex. But it must be assumed that the normal discharge of energy from the cells concerned in the cortical reflex, as a result of incoming sensations, is a very different affair from our experimental stimulation. Stimulation of the motor cortex with a weak faradic current gives rise to certain movements. Cut away the cortical cells and stimulate the cut ends of the projection fibres immediately beneath and you get the same result. Who can say these results are or are not brought about in the same way? Does the former experiment induce a discharge of energy from the cell or does the current passing through the

cell to the axis cylinder act exactly as in the other instance? However this may be we cannot safely assume that stimulation experiments disclose more than a hint of the functional activity of the cortex.

A study of the excitation experiments of Beevor and Horsley⁵ on the bonnet monkey shows that they obtained from the cortical area corresponding to the lesion in this experiment:

Movements of thumb of the opposite side; flexion, extension and adduction;

* Flexion and extension of the fingers, opposite side;

Movements of wrist, elbow and shoulder, opposite side;

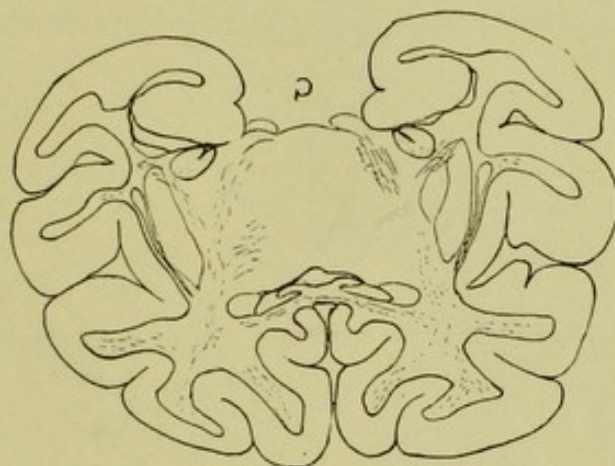


FIG. 5.

Closure of opposite eyelids;

Turning of the head to the opposite side;

Retraction and elevation of the corner of the mouth, opposite side;

Pouting, pursing and rolling in of the lips, more of the opposite side, but often bilateral;

Opening of both eyes and

Retraction of the head.

The last two were each observed only once in fifteen experiments. These movements were obtained from various points within the given area but in no single animal were they all observed, nor was any one of these movements obtained from

⁵ Beevor and Horsley, Phil. Trans. Royal Society, B. 1887 and 1894.

exactly the same point in all the animals experimented upon. Most were primary, though sometimes secondary or tertiary. No purely primary movement was observed of the elbow or the fingers.

On stimulation of the cortex of the orang outang the same investigators⁶ observed opening of the eyes and turning the head and eyes to the opposite side represented in the same area, or rather in that part of it anterior to the fissure of Rolando. This march, it will be seen, is also represented within this area in the Bonnet, though not so clearly brought out as in the latter. It is of especial interest in connection with the considerable degree of degeneration found, in the

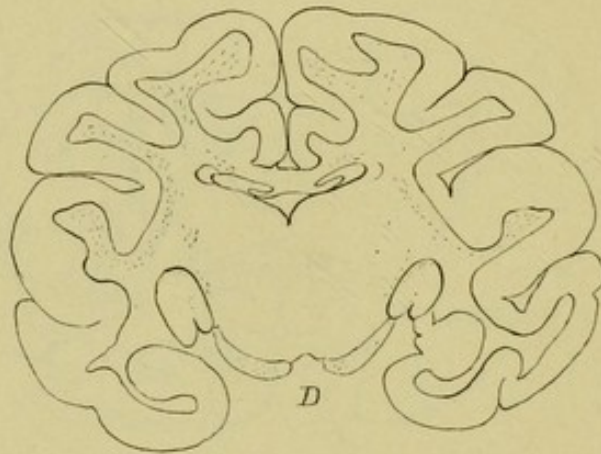


FIG. 6.

experiment here described, in the superior temporal convolution, now well established as the auditory centre. The association of this centre with that portion of the cortical area which controls the opening of the eyes followed by synchronous movement of the head and eyes would seem to be the anatomical basis of a cortical reflex of primary importance to self-preservation in all wild animals. It is also to be noted that the distribution of these fibres is quite bilateral. The fact that in this case they degenerate toward the auditory centre, instead of from it, may be urged against the supposition that these fibres are a link in this reflex, but the anatom-

⁶ Beevor and Horsley, Phil. Trans. Royal Society, B. 1890.

ical relations of the two centres are certainly intimate and direct.

The feature of special interest in this group of experiments is the large number of degenerate fibres passing from the area of the cortical lesion over the middle line in the corpus callosum and down the internal capsule of the opposite side.¹ With the exception of those fibres going to the superior temporal convolution of the opposite side, these fibres, in this experiment, all pass into the thalamus. In a few animals, in which practically the same area was extirpated, some of the degenerated fibres found in the internal capsule of the opposite side can be followed through the pons and medulla into the cervical region of the cord where they disappear.

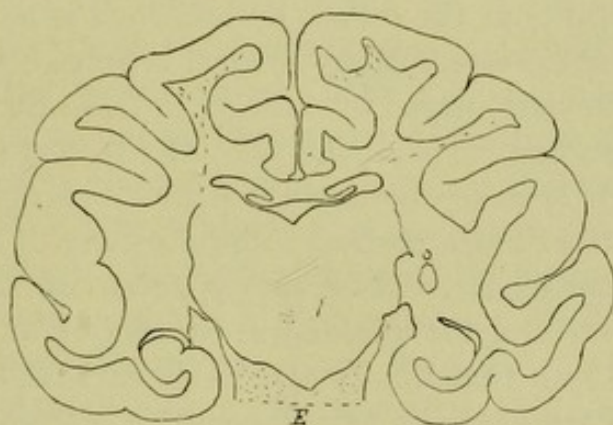


FIG. 7.

Nerve fibres within the central nervous system usually functionate in the direction of degeneration, but there is nothing in the character of the degeneration to suggest the character of the function. This can only be guessed at by the origin, course and termination of the fibres and what we know of the function of the areas and structures thus anatomically associated. Some of the projection fibres passing inward from the motor cortex clearly carry motor impulses, but it cannot be assumed that all do. A vast number of projection fibres arising in the motor cortex end in the

¹ The writer has found the same thing—degeneration in the internal capsule of both sides after unilateral lesion in the brain, in the dog. In the dog all the degeneration in the internal capsule of the opposite side ends in the thalamus.

thalamus; I think I may say in the thalamus of both sides. A careful study of the brains of a large number of animals, mostly monkeys, the subjects of experimental lesions of the cortex, leads me to conclude that this anatomical connection of each thalamus with the cortex of both hemispheres is most evident in those instances in which the area excised was that in which movements more or less bilateral are represented. These movements are mostly facial; such as are called into play in the expression of the emotions. May not this have some bearing on the function of the thalamus? It has been suggested that the thalamus is the centre for reflex or emotional movements.⁸ In unilateral facial palsy the escape of the emotional paths has long been a puzzle. According to present conceptions the cortex is concerned in all reflexes involving consciousness. Many cortical reflexes are purely voluntary. The part played by volition in those cortical reflexes termed emotional, such as the play of the features in facial expression, is open to discussion, but it can hardly be doubted that they are as much cortical reflexes as any of the so-called voluntary movements. The interposition of the thalamus in such an arc and the anatomical connection of each hemisphere with both thalami, as here demonstrated, may explain the play of the features as the result of emotion when voluntary movement is impossible. In many extensive lesions of the internal capsule fibres passing into the thalamus, even on the side of the lesion, might easily escape injury, even if bilateral control of the thalami were improbable.

As to the functions, other than motor, of projection fibres from the motor cortex, it is at least possible that some serve the purposes of inhibition, voluntary or otherwise. It seems altogether reasonable that voluntary inhibition of certain visual reflexes might be essential to holding the eyes fixed upon a given object. This is suggested as a possible explanation of the presence of degenerated fibres in the lateral geniculate bodies in this case (Figs. 5 and 6). There is certainly no reason why the reflex might not be inhibited in the geniculate body before it reaches the motor oculi nuclei.

⁸ Bechterew. *Leitungsbahnen im Gehirn und Rückenmark*. Zweite Auflage.

A NEW CARBON-DIOXIDE FREEZING MICROTOME.

BY CHARLES RUSSELL BARDEEN, M. D.,

Associate in Anatomy, The Johns Hopkins University, Baltimore.

The carbon-dioxide freezing microtomes in common use in pathological laboratories have several drawbacks. Of these the most serious are those due to the use of a rubber tube to connect the tank with the freezing stage. In addition to the annoyances due to the rubber tube the microtomes are so constructed as to utilize but a slight fraction of the heat absorption due to the expansion of the liquid carbon-dioxide. In order to obviate these drawbacks the microtome described below was devised. In the designing of the original machine I had the assistance of Mr. E. F. Northrup. In the construction of the present machine I am indebted to Bausch and Lomb, who manufacture it, for several modifications which have simplified the instrument and rendered it more useful.

Figure 1 shows the machine as it stands ready for use. It is made to screw directly upon the nozzle of the carbon-dioxide tank. The valve of the latter is utilized to control the escape of the gas into the freezing stage. When the microtome is screwed directly upon the carbon-dioxide tank it is necessary that the tank should lie in a horizontal position, on a table for instance, where it may be held in place by some simple clamp. On the other hand, if it is desired to connect the microtome to a tank placed in some other than the horizontal position an L-shaped piece of tubing may be screwed on the nozzle of the tank and the microtome on the other end of the L tube. The tank may then be placed in any position desired.

The axis and main support of the machine consists of a solid tube with a narrow lumen (*K-D*, Fig. 2). This axial

tube is united by a nut (*J*, Fig. 1 and Fig. 2) either to the nozzle of the tank or to the L-shaped tube mentioned above.

The machine is thus very readily attached.

On the top of the axial tube the freezing stage (*A*, Fig. 1, *A-C*, Fig. 2) is screwed. This stage piece consists of two




FIG. 1.

- A. Cover of freezing stage.
- B. Glass track for carrying knife.
- E. Spiral spring.
- F. Tubal base of knife-stage.
- I. Wheel.
- J. Nut for attaching axial tube to tank.
- M. Handle of tank-valve.
- N. Pointer.

parts, a base and a cover. The base is the part screwed into the upper end of the axial tube (*C*, Fig. 2). To this base the cover-piece is screwed (*A*, Fig. 2). Between the base of the stage and the axial tube is placed a thin brass plate (*D*, Fig. 2) with a very narrow aperture at its centre. Through this narrow aperture the carbon-dioxide escapes

into the lumen of the stage piece (C, Fig. 2). The difference in pressure on the two sides of the brass plate causes a very rapid expansion of gas between the cover and base of the

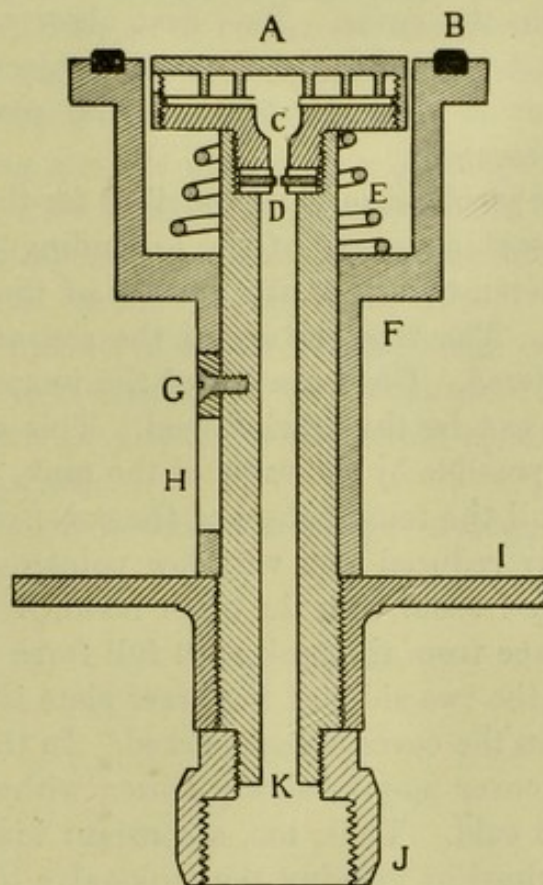


FIG. 2.

- A. Cover of freezing stage.
- B. Glass track for carrying-knife.
- C. Aperture in base of freezing stage.
- D. Aperture in thin brass plate.
- E. Spiral spring.
- F. Tubal base of knife stage.
- G. Check for limiting movements of knife-stage.
- H. Groove for G.
- I. Wheel.
- J. Nut for attaching axial tube to tank.
- K. Opening into lumen of axial tube.

freezing stage. The passage open for the escape of gas from the lumen of the base (C, Fig. 2) to the external world is in the form of a spiral passage which finally opens out through

the side of the cover, as shown in (Fig. 1, *A*). Between the cover and base of the freezing stage an asbestos washer is placed. The expanding gas therefore can absorb little heat from the base of the stage. Almost all heat absorption must take place from the cover. This heat absorption is greatly facilitated by the metallic spiral which projects down from the cover so as to give rise to the spiral passage through which the gas escapes.

Through the mechanism here described far the greater part of the heat-absorbing power of the expanding gas is utilized to lower the temperature of the surface of the cover of the freezing stage. The temperature of the rest of the machine is but little altered. Good control of the temperature of the freezing stage can be thus maintained. This control is farther rendered possible by the valve of the tank. If this valve is turned on full the temperature of the cover of the freezing stage is quickly reduced to a very low point. Tissue placed on it is quickly frozen. On the other hand, if the gas is not allowed to escape from the tank with full force the difference in pressure in the two sides of the brass plate is less and heat absorption from the cover is less marked. In this way tissues placed on the cover may be slowly frozen without subjecting them to severe cold. Thus, too, a constant low temperature may be maintained by opening the tank-valve to the required point.

The mechanism for controlling the thickness of the sections is equally simple. On the lower end of the axial tube a movable wheel (*I*, Fig. 1 and Fig. 2) is placed. This wheel moves up and down the axial tube on a screw thread cut twenty-five threads to the inch. A complete revolution of the wheel therefore raises or lowers it a millimeter. The margin of the wheel is divided into fifty spaces, each of which therefore represents twenty microns. A pointer (*N*, Fig. 1) serves to indicate the number of spaces passed in a partial revolution of the wheel and thus to show the thickness of the sections cut.


The knife-stage (*F-B*, Fig. 1 and Fig. 2) consists of a tubal base (*F*), which surrounds the axial tube and rests on the movable wheel; and of two flanges (*B*) which extend above

the freezing stage on each side for the support of the cutting blade. The base of the knife-stage is moved up the axial tube by screwing the wheel upwards. It is forced down the axial tube by the spring (*E*, Fig. 1 and Fig. 2) whenever the wheel is turned so as to be carried downwards. The flanges of the knife-stage support parallel glass tracks upon which the cutting blade is carried to and fro.

For cutting sections a razor or a plane or almost any good steel blade with a straight edge may be used.

The advantages of the machine are as follows:

1. But little carbon-dioxide is wasted.
2. The temperature of the freezing stage can be controlled.
3. Owing to the nature of its attachment to the tank it can be readily carried about. This should render it of especial value to surgeons.
4. Above all it is simple in design, strong, and unlikely to get out of order.



THE ARCHITECTURE OF THE GALL-BLADDER.

BY MERVIN T. SUDLER, PH. D., M. D.,

Instructor in Anatomy, Johns Hopkins University.

During the past few years the development of the surgery of the gall-bladder and ducts has increased the interest in their finer anatomy, and various investigations have been undertaken in order to add to our knowledge in regard to their structure. The lymphatics and finer blood-supply, however, do not seem to have had the same attention as the musculature and nerve supply; and so this paper deals more with this part of its structure and its histology than those which have been carefully considered in other papers.

The results mentioned here were obtained for the most part by the use of the gall-bladders of dogs and pigs. They were used because of their suitability and the ease with which they could be obtained. A limited number from cats and beeves were used also. The results thus obtained from fresh material were verified or refuted upon human gall-bladders as far as the limited supply and general bad condition of them allowed. Within a few hours after death the bile stains and macerates the tissues so that they are quite changed. The mucous membrane disappears entirely in from five to six hours after death; the nuclei and tissues under it refuse to stain, and it is impossible to obtain satisfactory results from any but the freshest material. For the histology small pieces hardened, distended and contracted in saturated corrosive sublimate solution yielded material that stained well and gave good pictures. For the connective-tissue elements the most striking picture was obtained by the use of Van Gieson's acid fuchsin and picric acid, but Weigert's elastic

fibre stain furnished the most accurate and delicate picture. For the blood-vessels ordinary carmine gelatin mass and lamp-black or cinnabar gelatin mass were all that were necessary. For the lymphatics a saturated aqueous solution of Prussian-blue proved to be the best, notwithstanding a careful trial of a number of more complicated and presumably better masses.

The thickness of the wall of the gall-bladder varies according to its state of distention. In an adult human subject it is from $\frac{3}{4}$ mm. thick in a state of distention to 2 mm. in a state of contraction. The distended gall-bladder of a newborn infant is nearly $\frac{3}{4}$ mm. thick. In the pig it may be from $\frac{3}{4}$ to 3 mm. thick, and in a dog of medium size from $\frac{1}{2}$ mm. to $1\frac{1}{2}$ mm. thick. The wall of the gall-bladder is made up of the following coats: 1. mucous; 2. fibro-muscular; 3. subserous and on the free part covered by peritoneum; 4. serous. The relative thickness of these coats can be seen in Fig. 6, which shows the gall-bladder of the dog contracted. The relations are essentially the same in man as in the dog.

The mucous layer is thrown into a series of folds from $\frac{1}{4}$ to $\frac{1}{3}$ mm. high in man. These folds of mucous membrane cover corresponding ridges of connective tissue of the fibro-muscular layer and contain an exceptionally rich capillary network. The irregular spaces surrounded by these folds are much larger at the fundus than at the duodenal end of the gall-bladder. In man the measurements in the distended gall-bladder are 3 mm. \times 5 mm. in the fundus and 1 mm. \times $\frac{1}{2}$ mm. or smaller near the beginning of the cystic duct. In the crypts formed by the folds solitary lymph follicles are found. These are more numerous in the dog than in the pig, and in this regard there seems to be a great deal of individual variation. The mucous layer is composed of simple columnar epithelium, which rests upon an incomplete muscularis mucosa. In the dog these cells are from 25-42 μ thick. These cells seem to secrete a thick mucous material but no goblet cells are present. R. Virchow (1), in an article published in 1857, finds fine fat-drops in the ends of these cells of the gall-bladder and ducts during or just after the absorption of chyle. These droplets gradually became larger

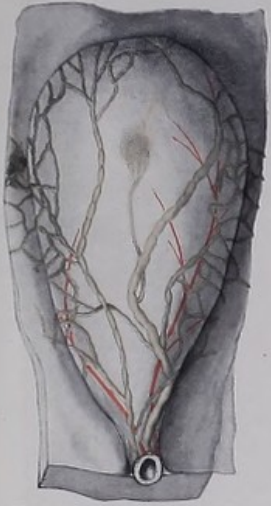

FIG. 1.—Gall-bladder of pig.

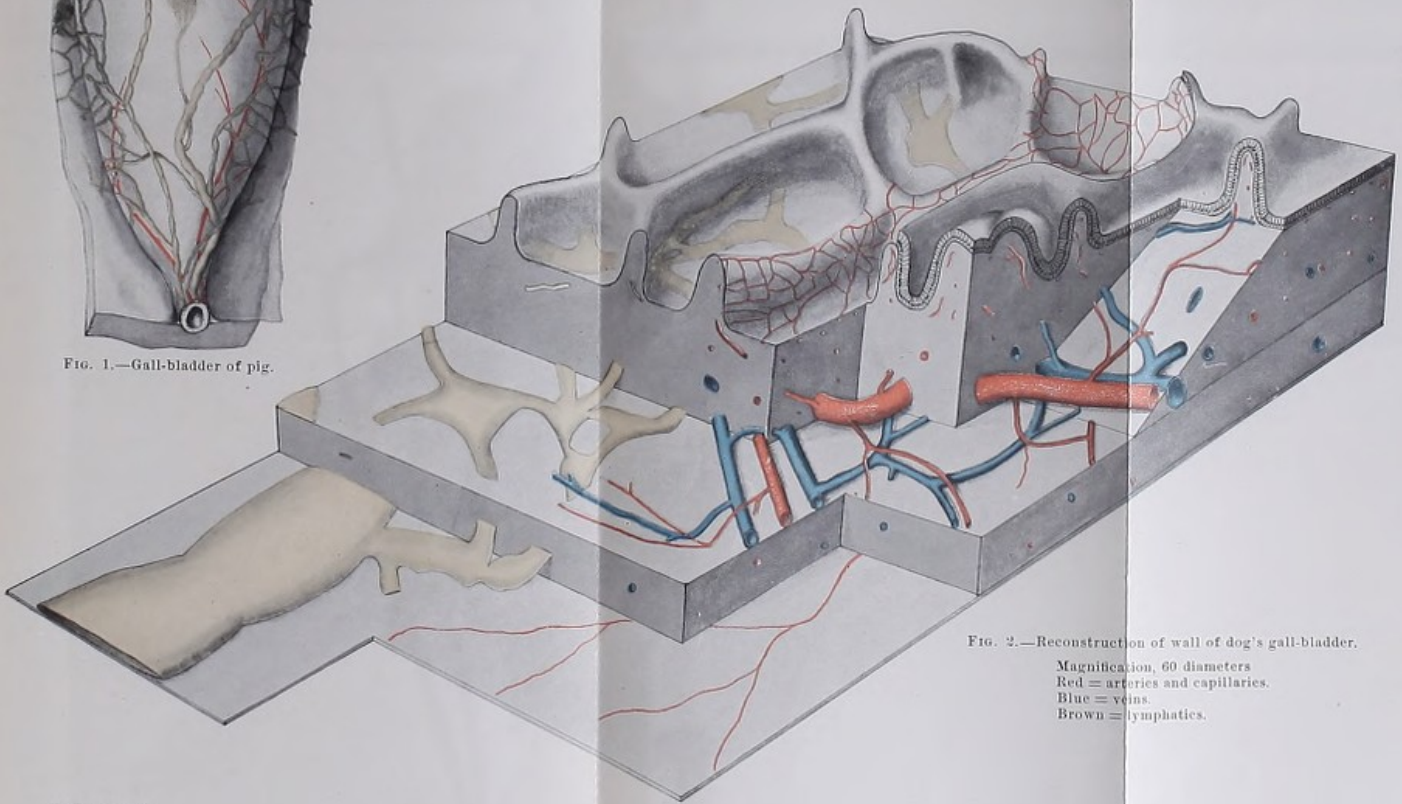



FIG. 2.—Reconstruction of wall of dog's gall-bladder.

Magnification, 60 diameters
Red = arteries and capillaries.
Blue = veins.
Brown = lymphatics.



and worked toward the base of the cell. He thought this fat had been lost from the liver in the secretion of the bile and was again picked up by these cells. Nothing was seen in my preparations to suggest this. Granules were often seen in the outer end or near the base of the cells, but these gave no reactions for fat. Belonging also to the mucous layer were the tubular glands. These were beautifully shown in specimens stained in gold chloride. There are few of them in the dog, but in the pig, and especially in the ox, they are quite numerous.

The fibro-muscular coat is composed of smooth muscle fibres and interlacing bands of connective tissue. The direction and arrangement of these fibres has been very carefully studied by Hendrickson (2). He concluded that in the gall-bladder there are no definite layers and that the bundles of fibres interlace in all directions with the greatest number tending toward a transverse direction. According to Doyon (3), the muscle fibres arrange themselves in two methods in different animals: 1. A network with rather rounded meshes. This arrangement is found in the guinea-pig. This fact has been corroborated by Ranvier. 2. The muscle fibres are arranged into bundles which form a number of principal directions more or less plainly marked out. This is found in the dog and cat, and means about the same as the description of Hendrickson. My preparations and sections lead me to agree with Hendrickson, with the possible exception that near the fundus in the dog there is an outer and rather definite longitudinal layer. See Fig. 6. The part of this layer near the mucous membrane is composed almost entirely of connective tissue with only a few muscle fibres scattered through it, the part directly under the epithelium forming a mucosa which, however, shades off gradually and is not sharply separated from the underlying tissue. It is in this region that the thickest plexus of capillaries and intrinsic lymph channels exists. The solitary lymph follicles, to which reference has already been made, are found also here just under the mucous membrane. Toward the subserous layer, on the contrary, the muscle fibres are collected into well developed bundles (especially so in the pig and ox) and the

connective tissue is correspondingly less. Elastic tissue occurs even here, however, varying in form from fine threads to coarse bands. It is especially abundant in the neighborhood of the blood-vessels. See Fig. 6. Unstriped muscle also exists in the larger gall-ducts, and at the point where the ductus communis joins the ductus pancreaticus it becomes modified into a sphincter. This has been found by Hendrickson in man, the dog and the rabbit, and also by Helly (4) in man, and Oddi (5) in man. The fibro-muscular layer contains the larger blood-vessels, which divide into branches and thus supply the other layers. See Figs. 2 and 6.

The subserous layer is composed of dense interwoven elastic tissue bands which contain comparatively few nuclei, and therefore few connective-tissue elements. These bands form an irregular mesh-work which is denser on the side toward the serous layer. This layer is poorly supplied with blood-vessels, although there is a well developed set of lymph channels which communicate with the large superficial vessels coming from the liver. By pulling the gall-bladder apart it is possible to divide it into two layers; the separation occurring at the junction of the subserous and fibro-muscular layers. By separating injected tissues in this manner a very pretty picture of the circulation in each part can be obtained distinct from the other.

The serous layer is present only on the part covered by peritoneum, *i. e.* the fundus, the inferior surface of the gall-bladder and the outer surface of the gall-ducts. It is composed of simple flat endothelial cells from 4-6 μ thick and adds but little strength to the organ. The larger lymphatic vessels from the liver and deeper layers of the gall-bladder run between it and the subserous layer.

Brewer (6) has described in a very careful manner the way the cystic artery reaches the gall-bladder in man and the variations one would find ordinarily. He found that in 50 subjects only 3 corresponded to the type described in textbooks of anatomy. It is possible to judge from this of the great amount of variation existing in its blood-supply. The largest artery after it has reached the gall-bladder is usually found, however, on its inferior surface and on the side toward

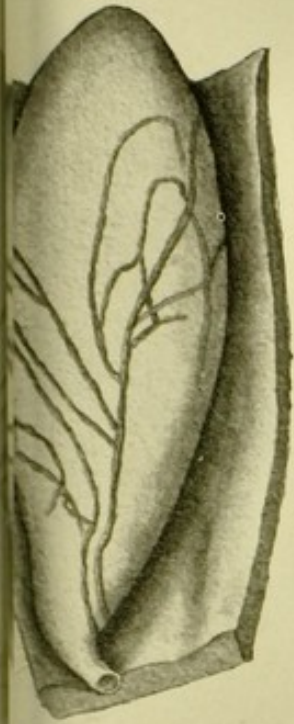

FIG. 3.

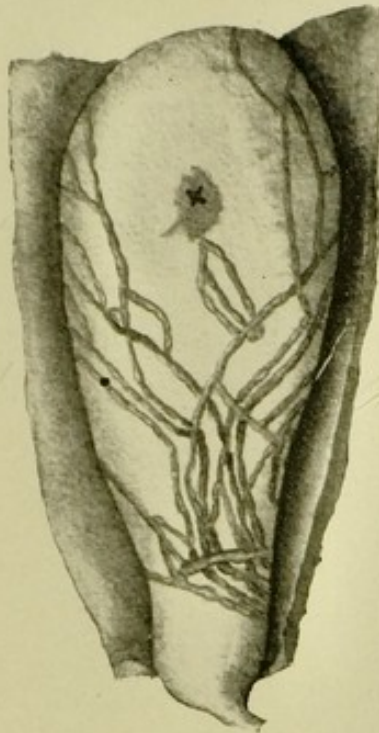


FIG. 4.

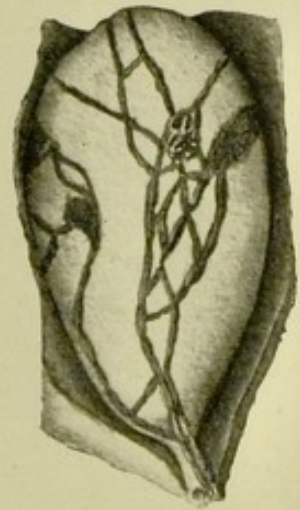


FIG. 5.

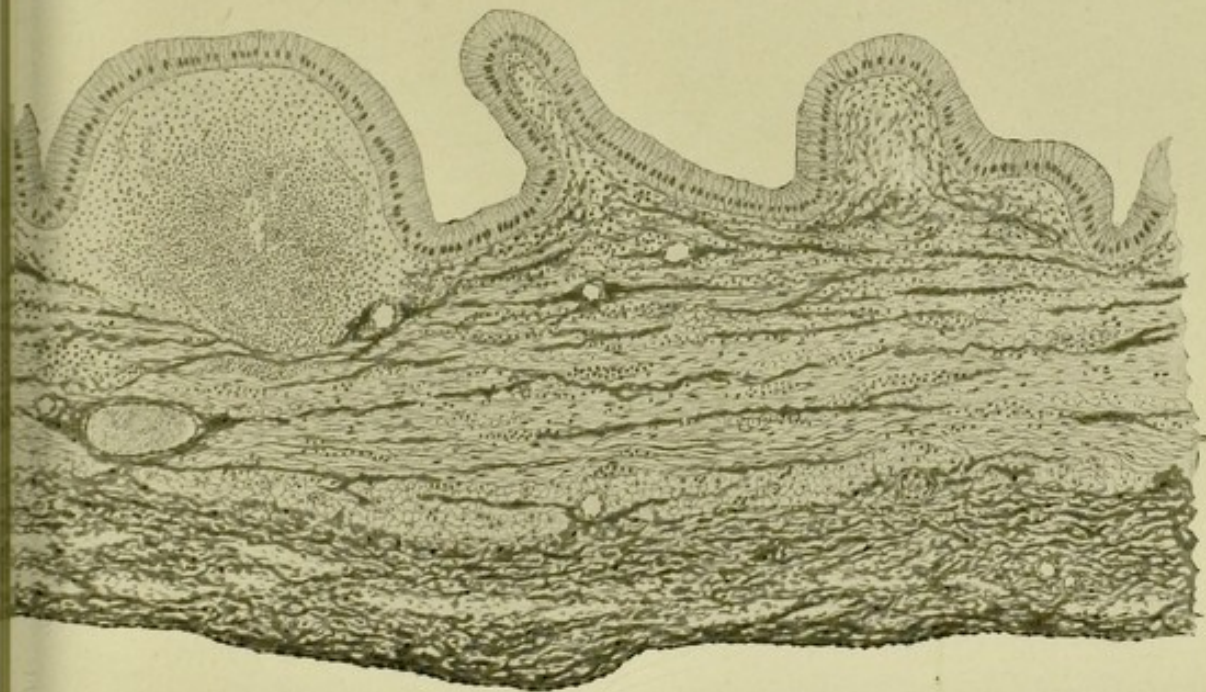



FIG. 6.



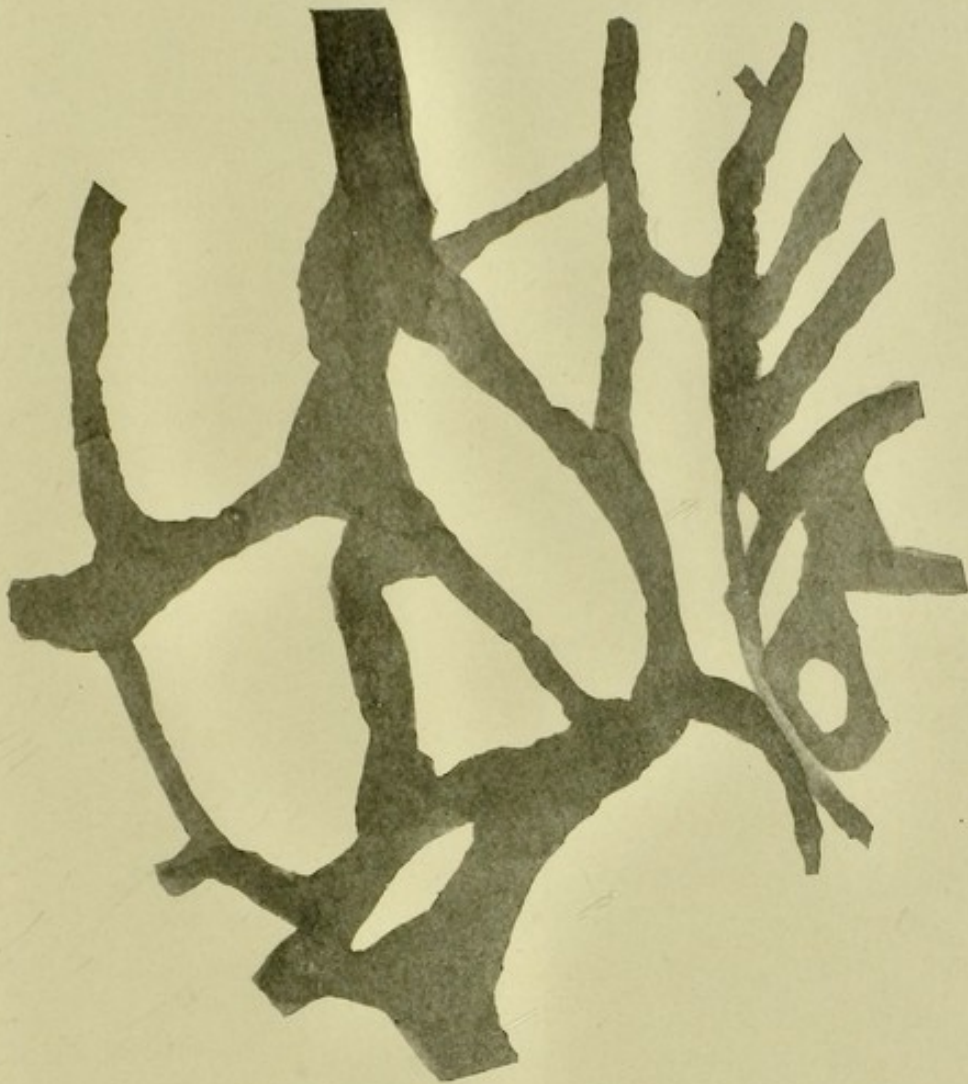


FIG. 7.

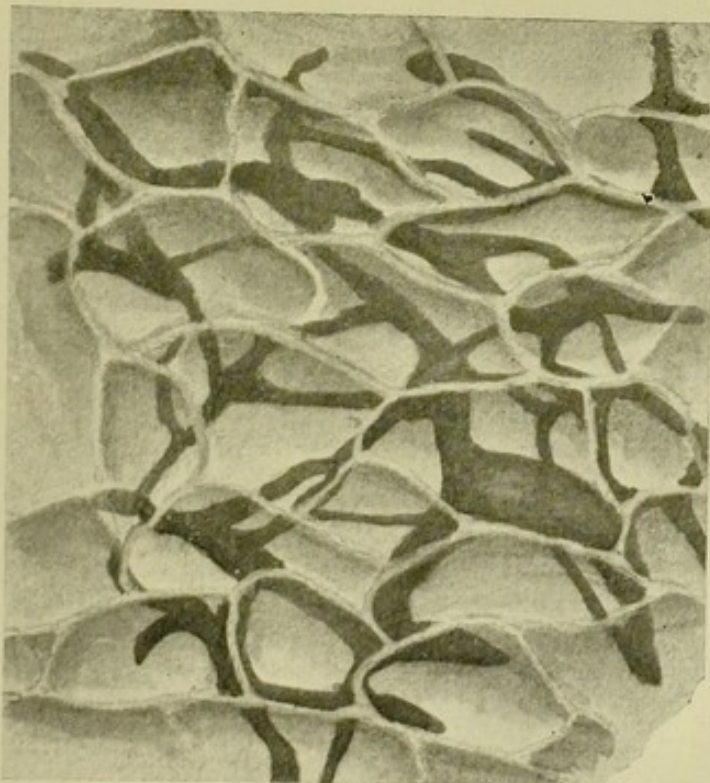



FIG. 8.



the middle line of the body. There also may be a smaller branch on the side away from the middle line. This is covered at first by peritoneum and then penetrates the outer part of the fibro-muscular layer and gives off the branches which supply the viscus. Most of the larger vessels are in the fibro-muscular layer near the dividing line between it and the subserous layer. See Fig. 6. If the needle of a hypodermic syringe be introduced into one of the smaller arteries and the mucous surface be watched while the fluid is slowly injected the arterioles and capillaries can be seen to be filled in areas about $2\frac{1}{2}$ mm. in diameter at a time from a single centrally placed artery. The capillaries under the mucous membrane are very numerous and in the folds the capillary network is especially thick. See Fig. 2. The blood from these is collected into the veins and returned to the larger and deeper lying ones accompanying the arteries.

The subserous layer has a comparatively poor blood-supply. The arteries are small and the capillaries widely separated. Some of the capillaries run out between this layer and the serous layer, and thus provide for the nourishment of the peritoneal covering. Some veins of considerable size are also found in this layer. On the surface of the gall-bladder in contact with the liver the veins communicate with the branches of the portal vein and the arteries in part come from the hepatic artery.

The large lymphatic vessels running over the gall-bladder bring lymph from the liver and the coats of the gall-bladder. They follow the inner side of the cystic duct and end in mesenteric lymph glands in the dog. In the pig and in man we have either one or two systems of the large lymph vessels. In almost all cases both are represented but the territory may not be equally large and there is wide variation in their method of distribution. In cross-section these vessels are always flattened although the degree of flattening varies with the completeness of the injection. Sappey (7) figures a mass of them running over the gall-bladder in a manner somewhat resembling Fig. 4, but he only mentions the fact that they bring in the lymph from the liver and deeper layers of the gall-bladder. In my preparations they run down eventually

on the inner side of the gall-bladder but there is usually a large vessel coming from the same side, but with the exception of one specimen figured in Plate 2, Fig. 4, which was believed to be pathological, are not as numerous as shown by Sappey.

In the subserous layer there is a network of lymph channels which empty into these larger vessels. See Fig. 7. This network is very irregular and the lymph channels vary markedly in size and shape. The picture of these lymphatics which seemed most normal was obtained by injecting carmine gelatin into the portal vein at a pressure of 80 mm. of mercury for fifteen minutes. This injects the lymphatics of the liver and in turn the larger ones over the gall-bladder, and finally these in the subserous coat in a more or less complete manner, but without any tearing or stretching of the vessels. In Fig. 2 they are represented as though the greater part lie simply on top of the subserous layer, while, as a matter of fact, they are scattered through it rather evenly.

The submucous sets of lymphatics are in the connective tissue just under the mucous membrane. However, they rarely run up into the connective-tissue folds but are at their lowest part or more frequently just at their base. The network is almost entirely absent in the denser muscular part. These were best seen by injecting aqueous Prussian-blue slowly under the mucous membrane and the injected portion was afterwards fixed and studied. In some cleared specimens the lymphatic vessels could be seen running up and joining the more superficial lymphatics of the subserous layer or directly one of the large superficial vessels as shown in Fig. 1. The lymphatic tissue belonging to this layer has already been described.

The nerve supply of the gall-bladder has been studied by Dogiel (8) and Huber (9) within recent years. The nerve supply is derived from two sources, viz., 1. the sympathetic system of ganglia and fibres connecting them, and 2. medullated fibres accompanying the large arteries. In regard to the distribution of the sympathetic fibres Huber suggests from the condition prevailing in other viscera that they supply the blood-vessels and smooth muscle of the coat. Doyon

thinks these are unable to act without receiving stimuli indirectly from the great splanchnic nerve. Dogiel has figured in a beautiful manner the kinds of cells found in the sympathetic ganglia and concludes that all the varieties found in the walls of the intestines occur here also. Quite a number of medullated fibres are also found near the large arteries. Both Huber and Dogiel have noted them. The former suggests that they are sensory fibres and are distributed to the mucous membrane. Their termination, however, has not yet been settled by direct observation.

REFERENCES.

(1) Rud. Virchow: "Ueber das Epithel der Gallenblase und über einen intermediären Stoffwechsel des Fettes." Virchow's Archiv, Bd. 11, H. 6, 1857.

(2) Wm. F. Hendrickson: "A study of the musculature of the entire extrahepatic biliary system, including that of the duodenal portion of the common bile-duct and of the sphincter." The Johns Hopkins Hospital Bulletin, vol. ix, 1898.

(3) Maurice Doyon: "Étude analytique des organs moteurs des voies biliares chez les vertébrés," Thèse sc. nat. Paris, 1894. An abstract of this article in Lehrbuch der Vergleich. Mikros. Anat. der Wirbeltiere, Albert Oppel, Jena, 1900.

(4) K. K. Helly: "Die Schliessmuskulatur an den Mündungen des Gallen und der Pankreasgänge." Arch. f. Mikros. Anat. Bd. 54, 1899.

(5) R. Oddi: "D'une disposition à sphincter speciale de l'ouverture du canal choledoque." Arch. Ital. de biol. T. 8, Fasc. 3.

(6) George Emerson Brewer: "Some observations upon the surgical anatomy of the gall-bladder and ducts." Contributions to the Science of Medicine by the Pupils of Wm. H. Welch, 1900.

(7) C. Sappey: Description des vaisseaux lymphatiques. Paris, 1885.

(8) A. S. Dogiel: Ueber den Bau der Ganglion in den

Geflechten des Darmes und der Gallenblase des Menschen und der Säugethiere. *Archiv f. Anat. u. Phys.*, 1899.

(9) G. Carl Huber: Observations on sensory nerve-fibres in visceral nerves, and on their modes of terminating. *Journal of Comparative Neurology*, vol. x, No. 2, 1900.

DESCRIPTION OF PLATES XXV-XXVI.

FIG. 1.—The gall-bladder of a pig; natural size. The lymphatics were injected by placing the needle just under the peritoneal covering of the liver near the edge of the gall-bladder at (*N*). The blurred mass in the centre represents the injection mass showing through and the lymphatic vessel coming up from the deeper layer to join the large superficial one. *N* = Needle of syringe.

FIG. 2.—Reconstruction of the wall of the partially contracted gall-bladder of a dog, magnified 60 times, showing the blood-vessels on the right and the lymphatic vessels on the left. Lymph follicles are shown on the right as two rounded eminences just under the epithelium. The vena comites shown is quite characteristic for the larger arteries. The large lymphatic vessel is shown partially collapsed.

FIG. 3.—Gall-bladder of adult man, showing superficial lymphatics. $\frac{1}{2}$ natural size.

FIG. 4.—Gall-bladder of man 19 years old, dead of chronic nephritis, showing the large superficial lymphatics. This gall-bladder gave evidence of having been through an inflammatory process, and so the lymphatics are probably abnormally numerous.

FIG. 5.—Gall-bladder of dog, showing the superficial lymphatic vessels. Natural size.

FIG. 6.—Section through the contracted gall-bladder of a dog, magnified 80 times, showing the arrangement into coats and the relations of the blood-vessels.

FIG. 7.—The lymphatics of the subserous layer of a dog. (Camera drawing.)

FIG. 8.—The lymphatics of the fibro-muscular layer of a dog, showing their relation to the folds on its surface. These folds are represented narrower and less complicated than in the specimen in order not to hide the lymphatics. (Outlines made with the aid of a camera.)

ON THE ORIGIN OF THE LYMPHATICS
IN THE LIVER.

BY FRANKLIN P. MALL,

Professor of Anatomy, Johns Hopkins University.

The origin of the lymphatics of the liver was first definitely determined by MacGillavry,¹ who studied this subject under the direction of Ludwig. Long before the work of MacGillavry it had been observed that ligation of the bile duct was followed by passage of bile over into the lymphatics, and the artificial filling of the lymphatics naturally followed by injecting a colored fluid into the bile duct. Sections of liver, in which the lymphatics had been filled with Prussian blue, or with asphalt, showed that the fluid injected into the bile ducts leaves them at the periphery of the lobule to enter spaces surrounding the blood capillaries, the so-called perivascular lymph spaces. These spaces communicate at the periphery of the lobule directly with the interlobular lymph channels. Frequently there is an extravasation of the injection mass into the blood capillaries of the lobule.

These observations were subsequently confirmed by numerous competent investigators, using the method employed by MacGillavry as well as that of direct injection of Prussian blue into the walls of the portal and hepatic veins. In successful injections made in this way it is found that the Prussian blue injected enters the lobule to encircle its blood capillaries.² Such injections, however, are always accompanied with numerous extravasations of the injected material into the tissues between the lobules, and often there is a secondary injection

¹ MacGillavry, Wiener Sitzungsber., 1864.

² Budge, Ludwig's Arbeiten, 1875.

into the blood capillaries of the lobule. This fact has raised an objection to the direct injection of the lymphatics from the bile capillaries. It appears more probable, the opponents say, that the extravasation of bile, or the injected material into the interlobular spaces, enters the lymphatic radicals of the capsule of Glisson, and from them the larger lymph channels and the perivascular spaces of the capillaries are filled. Furthermore the injected mass may pass from the pericapillary spaces directly into the capillaries, thus accounting for their frequent injection.

According to Fleischl,³ all the bile is taken up by the lymphatics after ligature of the bile duct, and in case the thoracic duct is also ligated no bile or only a trace of bile ever reaches the blood. The observation of Fleischl has been confirmed by Kunkel,⁴ Kufferath⁵ and Harley.⁶ It is extremely difficult to understand why the bile does not enter the blood capillaries in case it passes from the bile capillaries over into the perivascular spaces before it reaches the interlobular spaces after ligature of the bile duct. A further objection to the idea that the perivascular spaces first take up the bile, after ligature of the duct, is the fact that fluids injected into the bile duct pass with ease over into the lymphatics but only with difficulty into the bile capillaries. In all cases it appears as if the main origin of the lymphatics is at the periphery of the lobule and that the radicals communicate freely with the perivascular lymph spaces. Furthermore, it appears that the course the bile takes after ligature of the bile duct, or of a fluid injected into the bile duct in passing to the lymphatics, is between the lobules or at least at their extreme periphery. This idea is greatly strengthened since we know that the walls of the capillaries of the lobule are extremely porous, being composed of a dense layer of reticulum fibrils⁷ upon which lie the endothelial or Kupffer's cells. This layer of reticulum fibrils encircling each capillary

³ Fleischl, Ludwig's Arbeiten, 1874.

⁴ Kunkel, Ludwig's Arbeiten, 1875.

⁵ Kufferath, Arch. für Physiol., 1880.

⁶ Harley, Archiv für Physiol., 1893.

⁷ Kupffer, Arch. f. Mik. Anat., 54.

has been described from time to time by many investigators, and has been isolated by Oppel⁸ and by myself.⁹ Oppel obtained clear pictures of the connective tissue of the liver lobule by means of silver precipitation, while I employed Kühne's method of pancreatic digestion to remove the cells, followed by some intense stain like acid fuchsin. The nature of these fibrils is still under discussion but that matters little for the present communication. It is sufficient to know that the fibrils of reticulum form a basket-like membrane surrounding each capillary of the whole lobule, the interior of which is only partly lined by Kupffer's syncytial endothelial cells. The capillary walls then are very pervious, blood plasma passing easily from them out into the perivascular spaces to bathe the liver cells.

It is well known that a large quantity of lymph is constantly passing from the liver, much more than from any other organ. That this lymph comes directly from the blood is indicated by its high per cent of proteid matter, nearly that of the blood, and from two to three times that of the lymph from other parts of the body.

The course the lymph takes from the blood to the lymph radicals, *i. e.* its natural course, can easily be marked by injecting colored gelatin into any of the blood-vessels. I have usually found it most convenient to inject the gelatin into the portal vein, but it is just as easy to fill the lymphatics by injecting either the hepatic artery or hepatic vein. In all cases the colored fluid reaches the main lymph channels in the same way. The colored gelatin flows with great ease from the capillaries at the periphery of the lobule as well as from those around the sublobular vein into the lymphatics. After the lymphatics have all been filled it is well to inject a small quantity of fluid of different color into the blood-vessels. A much better method of making double injections is to mix red granules with a blue gelatin or blue granules with a red gelatin, the fenestrated lining membrane of the capillary acting is a sieve which allows the fluid to pass but

⁸ Oppel, Arch. Anz., 1890.

⁹ Mall, Abhandl. d. K. S. Ges. d. Wiss., xvii, 1891.

holds back the granules, as is the case with the blood when normal circulation is taking place.

If the portal vein is injected with Prussian-blue gelatin under a low pressure, it is found that in a few minutes the lymphatics are all filled with the blue mass. Livers injected in this way are best hardened in formalin and then cut by the freezing method, for alcohol causes the gelatin to shrink.

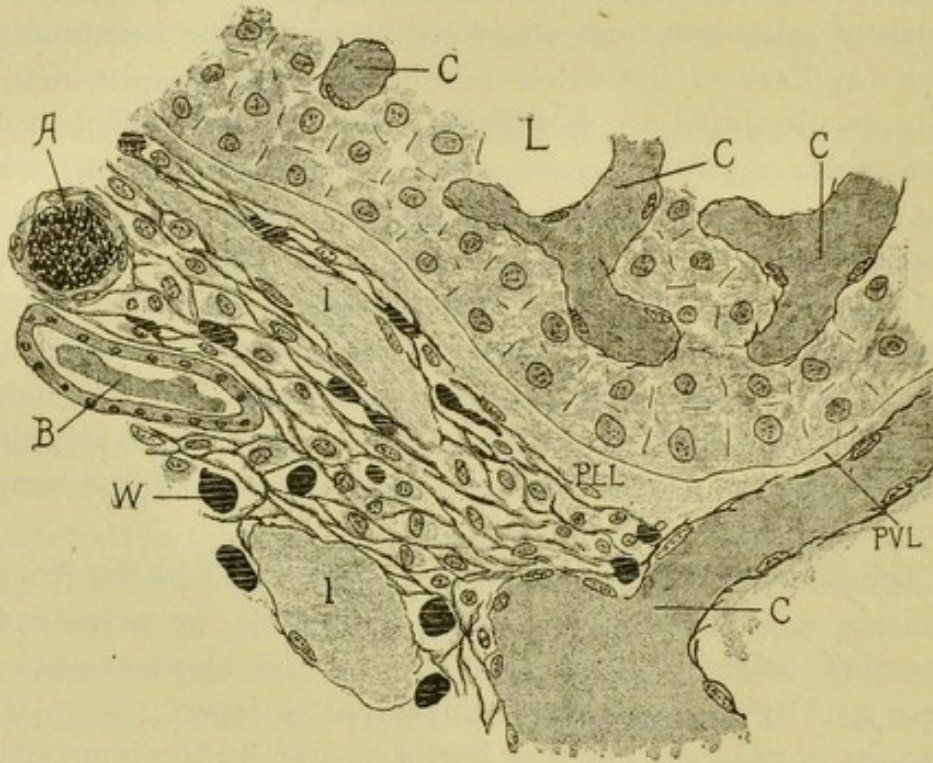


FIG. 1.—Section through the periphery of the liver lobule of a cat. The hepatic artery was injected with cinnabar gelatin, and the portal vein with Prussian-blue gelatin, stained with Van Gieson's stain. $\times 500$ L, lobule of liver; c, capillaries; a, artery; l, lymph vessel; pvl, times. perivascular lymph space; pll, perilobular lymph space; w, bundles of fibrils of white fibrous tissue.

Such sections show that the blue fluid has entered the lymphatics at the periphery of the lobule. More instructive are the specimens when the injection is stopped just as the first lymphatics are filled with the colored gelatin. By following the larger lymphatics back into the liver substance it is found that the interlobular connective tissue is entirely filled with blue where the lymphatics are injected, but only partly colored blue when they are not. In other words, the blue extra-

vasates from the periphery of the lobule, invades the connective tissue until it reaches the beginning of the lymphatics, when of course it is carried rapidly from the liver. The nearest course from the lobules to the lymphatics is between the lobule where the amount of connective tissue is small, so when colored fluid is beginning to enter lymph channels the tips of the capsule of Glisson are entirely colored, while larger portal spaces are encircled by a zone of the color. Furthermore it is found that in certain instances when the injection was not continued long enough the blue did not enter the lymphatics. In such specimens it is found that all the interlobular spaces are surrounded by a zone of colored gelatin which does not enter the main lymph channels.

A successful injection of the lymphatics is illustrated in the accompanying figure. The section was stained with Van Gieson's stain which gives a very satisfactory result. The granular blue enters the capillaries of the lobule, *c*, with ease, and from them the liquid blue is filtered through the capillary walls to enter the perivascular lymph space. This space communicates at the periphery of the lobule directly with a large lymph space between the liver cells and the capsule of Glisson, which I shall term the perilobular lymph space. These spaces in turn communicate with the lymph radicals.

Injection of the blood-vessels of the liver with aqueous Prussian blue fills the capillaries only, and in all cases it is shown that there are no capillaries between the periphery of the lobule and the interlobular connective tissue. The liver cells come directly against the capsule of Glisson. An injection of brief duration with blue gelatin soon fills the perilobular lymph spaces, so that it appears as if all groups of liver cells at the periphery of the lobule were separated from the interlobular connective tissue with capillaries. In case cinnabar granules are mixed with the blue a few of these granules are found in the perivascular and perilobular lymph spaces. The openings in the walls of the capillaries are large enough to allow a few of the smaller granules to pass through. As the injection is continued the blue invades the connective tissue spaces from the lymphatic radicals more and more until a lymph channel is reached, when of course it flows

rapidly from the liver. Were there a direct channel from the perilobular lymph spaces the blue should flow through it at once without further filtration through the interlobular connective tissue spaces. The course the cinnabar granules take also speaks against a direct channel between the perilobular lymph spaces and the interlobular lymph channels. A few of the granules enter the perilobular lymph spaces, but none of them reach the main lymph channels. All of my specimens without exception force me to the conclusion that there are no direct channels connecting the perivascular and perilobular lymph spaces with the lymphatics proper other than the ordinary spaces between the connective-tissue fibrils of the capsule of Glisson. These spaces, however, are relatively large, permitting of a rapid diffusion through them.

Interstitial injections into the walls of the interlobular veins naturally fill the surrounding lymphatic vessels, and when no valves are in the way the injected fluid passes to the origin of the vessels, or lacunæ, which are only in part lined with endothelial cells. From here the fluid passes through the main connective-tissue spaces to the periphery of the lobule into the perilobular and perivascular lymph spaces, and frequently from them into the blood capillaries. When the injection is made through the bile ducts I have always found that there is an extravasation of the fluid from these at the periphery of the lobule which immediately enters the lymph radicals, although the bile capillaries are often injected well into the lobule. The extravasation does not take place from the bile capillaries, only from the duct as it communicates with the capillaries; also it does not take place from the larger bile ducts. Such extravasations naturally are picked up by the lymphatics and are at once carried from the liver. If after ligature of the bile duct the bile enters the perivascular lymph space within the lobule it may still be carried to the lymphatics, as the direction of the current of lymph is constantly from the blood capillaries to the lymphatics.

It is well known that the liver cells arise from the embryonic bile ducts, and that in the further growth of the liver the bile ducts must elongate in order to adjust themselves

with the growing liver. Hendrickson¹⁰ has shown by staining the bile capillaries and ducts of the embryo's liver by Golgi's method that the tip of the primitive bile duct is added to by a coalescence of the bile capillaries at the periphery of the embryonic liver lobule. My own observation on the liver lobule after it is well formed is that whenever karyokinetic cell figures are present they are at the periphery of the liver lobule, *i. e.* at the junction of the bile capillary with the bile duct. It also appears that the vascular walls of the embryo are much more pervious than those of the adult, judging by the ease extravasation takes place when the blood-vessels of embryos are injected. This observation taken with that of the growth of the bile ducts may be an explanation why the extravasation of a fluid injected into the bile duct takes place at the periphery of the lobule. A further hint in this direction is the observation that it is easy to inject the lymphatics from the blood-vessels of an inflamed area. I have often seen the lymphatics of an inflamed intestine filled with blood, and upon injecting the blood-vessels found that the fluid readily entered the lymphatics.¹¹

That the capillaries of the liver communicate more freely with the lymphatics than do the bile ducts is proved by injecting the bile duct and the portal vein with fluids of different color under the same pressure at the same time. In all the experiments I made the fluid injected into the vein appeared in the lymphatics first. In many instances beautiful injections of the lymphatics were obtained from the vein while the fluid injected into the bile duct did not extravasate at all, showing at least that the veins communicate with the lymphatics much more freely than do the bile ducts.

The conclusions to be drawn from the above observations are (1) that the lymphatics of the liver arise from the perilobular lymph spaces and that these communicate directly with the perivascular lymph spaces; and (2) that the lymph reaches these spaces by a process of filtration through openings which are normally present in the capillary walls of the

¹⁰ Hendrickson, Johns Hopkins Hospital Bulletin, 1898.

¹¹ See also Sigmund Mayer, Anat. Anz., 1899.

liver. Furthermore, the fluid injected into the lymphatics from the bile duct leaves the duct as it enters the lobule and is at once taken up by the lymph radicals and perilobular lymph spaces, and from them extends, as a secondary injection, to the perivascular lymph spaces, and often into the blood capillaries of the lobule. The larger lymphatics accompanying the portal vein arise between the lobules near their bases, while those accompanying the hepatic vein do not arise within the lobule but around the larger sublobular veins.

BORN'S METHOD OF RECONSTRUCTION BY MEANS
OF WAX PLATES AS USED IN THE ANATOMI-
CAL LABORATORY OF THE JOHNS HOPKINS
UNIVERSITY.

BY CHARLES RUSSELL BARDEEN,

Associate in Anatomy, Johns Hopkins University.

The wax-plate method of reconstruction (Plattenmodellen methode) described by Born in 1876¹ has proved of great value in the study of the morphology of embryos. The method has received its most extensive application in the hands of Born, of His and of various pupils of these investigators. In general, however, it may be said, that the value of this method as an aid to the microscopic study of form has not been sufficiently appreciated.

In part this lack of a more general application of the method has been due to certain technical difficulties which tend to make it cumbersome and time-consuming. Yet by no other method can so accurate an idea be obtained of the form of those structures which from their minuteness or complexity of relation cannot well be dissected out.

Considerable application of the method has recently been made by different persons in this institution and each worker has contributed something towards making the method more effective.

As originally described by Born several steps are essential for the successful application of his method. These may be tabulated as follows:

¹ Morph. Jahrb. II; Arch. f. mikr. Anat., xxii, p. 584.

A. Preliminary steps.

1. Obtaining a good picture of the embryo or object to be reconstructed.

2. Hardening, staining and sectioning the object.

3. Drawing magnified enlargements of the sections or such parts of them as it is desired to reconstruct.

4. Preparation of the wax plates.

5. Transference of the image to the surface of the wax and cutting out the wax plates.

B. Constructing the model.

1. Piling the wax plates.

2. Removing parts not essential to the reconstruction desired and rounding off of the parts reconstructed.

3. Strengthening and finishing the model.

I shall consider these steps in the order named.

A. Preliminary steps.

1. Before proceeding to section the object to be reconstructed it is important to obtain good pictures of its external form. With such a picture at hand it is much easier to pile up the wax plates which represent the sections through the object. This is especially true when the object is symmetrical, as in the reconstruction of embryos, profile views of which are invaluable in this work. If the picture be enlarged to the magnification of the model desired a valuable control is furnished. A series of parallel lines may then be drawn through the picture to represent the planes through which the knife has passed in sectioning the embryo, so that the position of every plate is indicated.

For general purposes photography is undoubtedly the most convenient method of recording the gross external features of the object. If the object be very small as, for instance, an early human embryo, the camera may be so placed that the image in the negative is enlarged from two to four diameters. It is found that the most convenient way of photographing embryos is to place the camera with the axis in a vertical direction and the lens pointing downwards. A stand for holding the camera in this position and raising or lowering it is easily constructed. Ordinary lead shot seems to be

especially good for holding many small objects in the position in which it is desired to photograph them.

For detail in the distant as well as the proximal part of the object it is a great aid to make use of a stand capable of being raised without moving the object laterally. In this way, if the diaphragm be closed down so as to make the exposure a long one, the object may from time to time be brought slightly nearer to the lens of the camera, so that parts more distant are brought into sharp focus.

From the photographic plates thus obtained lantern slides are made or the negative itself is used to project the image at the required magnification upon a screen. Free-hand drawings are then traced on a paper upon which the image falls, or, if desired, bromide enlargements can be made. In this way accurate records can quickly be made of the external appearance of the object to be studied, yet no special talent for drawing is required. In the study of embryos the profile view is the most essential one, though others also prove of great value.

2. The only real essentials in the technique of obtaining serial sections of the object to be studied are that the series should be complete, the sections perfect and of uniform thickness. As pointed out by Born, the most convenient sections for this work are those from 20-40 microns in thickness. For sections of this thickness we have found alum cochineal to give uniformly the most satisfactory stain. It is important to know which side of the sections was uppermost during the cutting, so that in the subsequent reconstruction a true and not a mirror image of the object will be formed. For this reason it is well to make it a uniform practice to begin at the head when cutting transverse sections through an embryo, at the right side when cutting longitudinal vertical sections, and at the dorsal side when cutting horizontal sections and to label the sections in the order in which they have been cut.

3. For making drawings of the sections we have found that in general a projection apparatus is more convenient than a camera lucida unless the sections are small. Our projection apparatus is set up in a large dark room.

The illumination is received from an arc electric light or from a heliostat. An ordinary microscopic stand with the tube in a horizontal direction is used when the sections are small and a high magnification is desired. Eye piece and draw tube are usually removed and the objective is used as the magnifying lens. In case of larger sections a projection lens similar to that used for lantern slides is utilized.

The image is projected upon a screen which runs on a track. The screen can be moved toward or away from the microscope by means of windlass situated near by. In this way any desired magnification can be quickly obtained by using an appropriate lens and bringing the screen into the proper position.

The screen which I devised for our dark room has attached a leaf which can be lowered so as to form a drawing table and a mirror that can be placed at an angle of 45° over the table. In this way the image is projected on a horizontal surface so that tracing it is easier than when it is upon a vertical surface. In using an ordinary mirror a double image is projected but that from the surface of the mercury is so much brighter than that from the surface of the glass that no difficulty is experienced in drawing accurate outlines.

Fig. 1 illustrates the apparatus here in use.

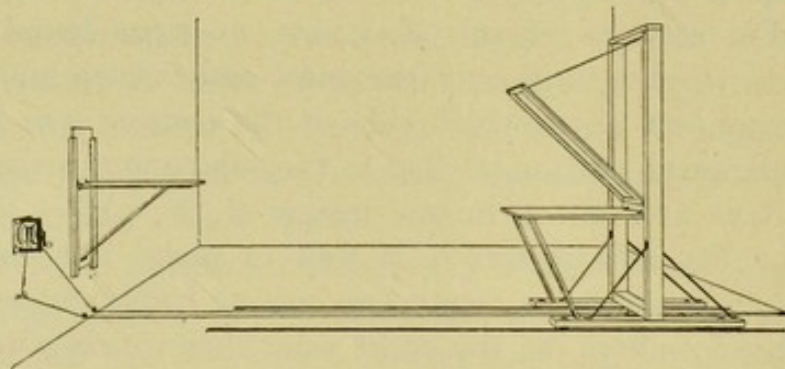


FIG. 1.—At the right the projection screen is shown in position on the track. The mirror is lowered to an angle of 45° and the drawing table is extended horizontally below this. At the left are shown the windlass used for moving the projection screen and the shelf used for holding the projection lantern.

In drawing pictures of the sections a careful outline of those main features which it is desired to bring out in the

reconstruction is the great essential. In addition it is often of value to distinguish by using pencils of various colors the different organs in structures as they appear in the section.

If desired, direct bromide enlargements can be made of the sections on the slides. This is the method preferred by His. The simpler method described above we have found, however, to be more convenient for general purposes.

The outline drawings may often be elaborated to any desired extent when the sections are subjected to careful microscopic study. It is a great help for the subsequent reconstruction to label, so far as possible, the various structures in the outlines of the sections before proceeding to the wax plates.

4. Much trouble in the preparation of the wax plates is to be saved by using plates of a uniform thickness and by making the magnification of the object under reconstruction correspond. The most convenient thickness for general use is 2 mm. Occasionally, for coarser work, 4 mm. plates have proved of value. It is very easy, with the apparatus above described, to make the ratio of the diameter of magnification of the drawings to the diameter of the sections equal to that of two millimetres to the thickness of the section. If plates 2 mm. thick be used and every section be drawn, sections 20 mm. thick = $1/50$ mm: must be magnified one hundred times. Or if desired, as is more often the case, every other section may be drawn at a magnification of fifty diameters.

For making the wax plates we have a large zinc pan with vertical sides. Its surface area is such that one kilogram of the wax mixture which we use will make a plate 1 mm. thick. The method of casting the plates is essentially that described by Born. Boiling water is run into the pan to the depth of several inches. On the surface of this the hot melted wax mixture is poured and quickly forms an even, smooth layer. Bubbles, which occasionally appear in the wax, may be quickly exploded by turning the flame of a Bunsen burner on the surface of the wax where they appear. As the wax plate cools it is necessary to free it from the sides of the pan by running a knife along the edge. Before the plates are perfectly cool they may readily be cut into smaller plates of any desired size.

The wax mixture in use here is composed of 950 parts of bees-wax and 50 parts of white rosin. Often, especially in summer, paraffin is added to give additional toughness. Black plates are made by adding lamp black to the melted wax, until after thorough stirring the mixture has become uniformly black. The amount by weight of wax necessary for a plate of a given size is obtained more easily by experimental trial than by calculation. A certain amount of wax becomes attached to the sides of the pan by surface tension, so that slightly more wax must be used than the amount one is likely to determine by calculation from the specific gravity of the wax and the size of the pan. On the other hand if a pan of a given size be used the amount of a given wax mixture necessary for making a plate of given thickness may be determined by a few trial castings.

The outlines are transferred to wax by means of red or blue tracing paper. The wax plates are then placed upon glass and are cut with a small, narrow knife and in a warm room.

B. Constructing the model.

1. The janitor can be trusted to trace the outline drawings on wax, to cut through the wax with a sharp knife where the outlines are traced and to make the preliminary piling. Usually two preliminary piles are made, one of that part of the wax plates which represent the sections and one of the wax plates themselves after removal of the parts representing the sections. From the former a positive, from the latter a hollow negative image of the original object is obtained. In this piling an enlarged picture of the object is of very great help. As originally suggested by Born, in case of symmetrical objects a surface outline may be drawn on card board and cut out, thus giving a fixed ridge against which to pile the plates. If but one side of any embryo is to be reconstructed from transverse sections it is of great help to cut each plate off sharply at the midline and to pile the plates against a profile outline of the embryo situated on a board which has been placed perpendicular to the plane in which the plates are piled. In case the reconstruction of some

internal organ is wanted it is usually of advantage to reconstruct at the same time the external form of the object, so that when the plates are piled the image they form may be compared with the picture of the original object. After getting the plates composing the positive image of the object into proper position, it is easy to trace two or three of its surface curves on paper or to represent them in wire and then to get the negative formed, as described above, into true shape. Plaster casts can then be made in this negative mould. The plaster casts, representing the external features of the original object, are very valuable to have at hand, while engaged in reconstructing the internal features from the wax plates.²

The method of making every fifth plate a black one has proved to be extremely valuable in arranging the wax plates. In this way it is easy at any time during the reconstruction of the model to count up and place any given section.

The method of reconstruction which I have found most convenient is as follows: After the plates are placed in proper position so that the external features of the object are accurately portrayed, I begin by taking off five plates from one side. The drawings of the sections I likewise have pinned together in groups of five in the same order in which the plates are piled. By going over the five finished drawings it is easy to obtain a good conception of the form of the structures represented in the block of five plates under consideration. I have at hand a paper of fine pins and these I press down through the various structures seen in section on the surface plate, and in such a direction that they will pass into the same structure in the sections below. When the parts of the plates which represent the structures to be reconstructed are thus firmly united by pins I remove the intervening portions of the wax plate with a pair of forceps. Thus, in a very short time, one is enabled to bring to light the form of the structures lying within the block of five sections. The pins hold the various bits of wax firmly in

² Many methods have been devised of piling plates according to special marks. The method devised by Wilson, *Zeitschrift für wissenschaftliche Mikroskopie*, xvii, 1900, page 177, seems a good one.

place and serve to strengthen the model in every way. When I feel satisfied with the appearance of the structures in the first block of five sections I proceed to the next and treat it in the same way. Those structures which are cut in both blocks of sections may at the same time be pinned together. After two or three blocks of sections have thus been piled up it is often well before adding another block of five sections to fuse them together with a hot knife and thoroughly to strengthen the reconstruction so far as it is completed. For strengthening piles of narrow strips of wax, representing sections through membranes and the like, a wire netting is of the greatest value. Perhaps the best form of wire netting for general purposes is a copper netting with 10 strands to the centimetre. The copper netting has no tendency to cause subsequent warping, as is the case with iron netting. The netting is heated in the flame of a Bunsen burner and is then applied to the surface which it is desired to strengthen. In case of narrow columns, such, for instance, as are formed in the reconstruction of blood-vessels and nerves, copper wire is of the greatest value. This can be heated and sunk in at one side and then fused over.

After the model is once well started the subsequent building up can proceed with great rapidity. Plates in blocks of five are added as described above until the model is finished. Of course a greater or less number of plates than five may be used to a block. In most of my work, however, I have found blocks of five, with a black plate on the surface of each block, to give the most satisfactory results.

In order to keep the various structures distinct during the reconstruction it is often of value to paint them with different colors, while the work proceeds. The various structures of a model built up as described may be removed as completed, or during the course of reconstruction, and then readily replaced. Pins are of great value in holding structures in place and for indicating where a structure removed must be replaced in order to regain its proper position.


If it is desired at any time to cut the model in a given direction the pins which hold the pieces of wax together may be readily cut with scissors.

3. I have mentioned methods by which the model is greatly strengthened during the course of reconstruction, the use of pins, of wire netting and of wire. All three means may be employed thoroughly to strengthen the model after the first rough reconstruction. The wire screening is then especially valuable. Of course it is possible to add free hand and with a good deal of accuracy structures which from their delicacy are difficult to model. This is true of blood-vessels, nerves and of fine membranes. The blood-vessels and nerves may be readily constructed by covering copper wire with wax, the membranes by covering a netting of narrow meshes with a thin coating of wax.

In rounding and smoothing up various structures in a model so as to give it a finished appearance, semi-melted wax applied with the fingers or with a spatula is of the greatest help.

The model is greatly protected in many ways by a thick coating of paint. Hot weather seems to have a far less detrimental effect on such models than on models unpainted.

We have found photography of great help not only in recording the condition of the finished model but also, at times, during the course of a reconstruction.



USE OF THE MATERIAL OF THE DISSECTING ROOM FOR SCIENTIFIC PURPOSES.

BY CHARLES RUSSELL BARDEEN, M. D.,

Associate in Anatomy, Johns Hopkins University.

Rosenberg, in a recent article,¹ has called attention to the opportunities that the dissecting room offers for scientific investigation. He gives an interesting summary of the various attempts that have been made to take advantage of these opportunities, and calls particular attention to the records obtained by Schwalbe at Strassburg, by Cunningham at Dublin, and by the Anatomical Society of Great Britain and Ireland.

It has seemed to me that the methods employed to utilize the material of the dissecting room and the work of the students for scientific purposes in Professor Mall's laboratory at the Johns Hopkins University, Baltimore, may prove of interest, possibly of value, to those engaged elsewhere in anatomical instruction.

The immense amount of study that has been given to the structure of the human body during the last four centuries renders it unlikely that the student's untrained eye and hand could be utilized to advantage in a search for unrecorded facts of gross structure even if time permitted him to delve in those little nooks and corners where the records are still incomplete. The very considerable amount of variation, however, which the individual bodies present in the structure, form and relationships of their various organs, offers a rich field for cultivation.

Since the time of Darwin much attention has been given to the study of variations in plants and animals. The greater

¹ *Morphologisches Jahrbuch*, 1895.

part of the attention, however, has been given to external features, to variation in size, color, and external form. Few studies have been made of the frequency of variation in the internal organs. Yet probably the body of no animal is

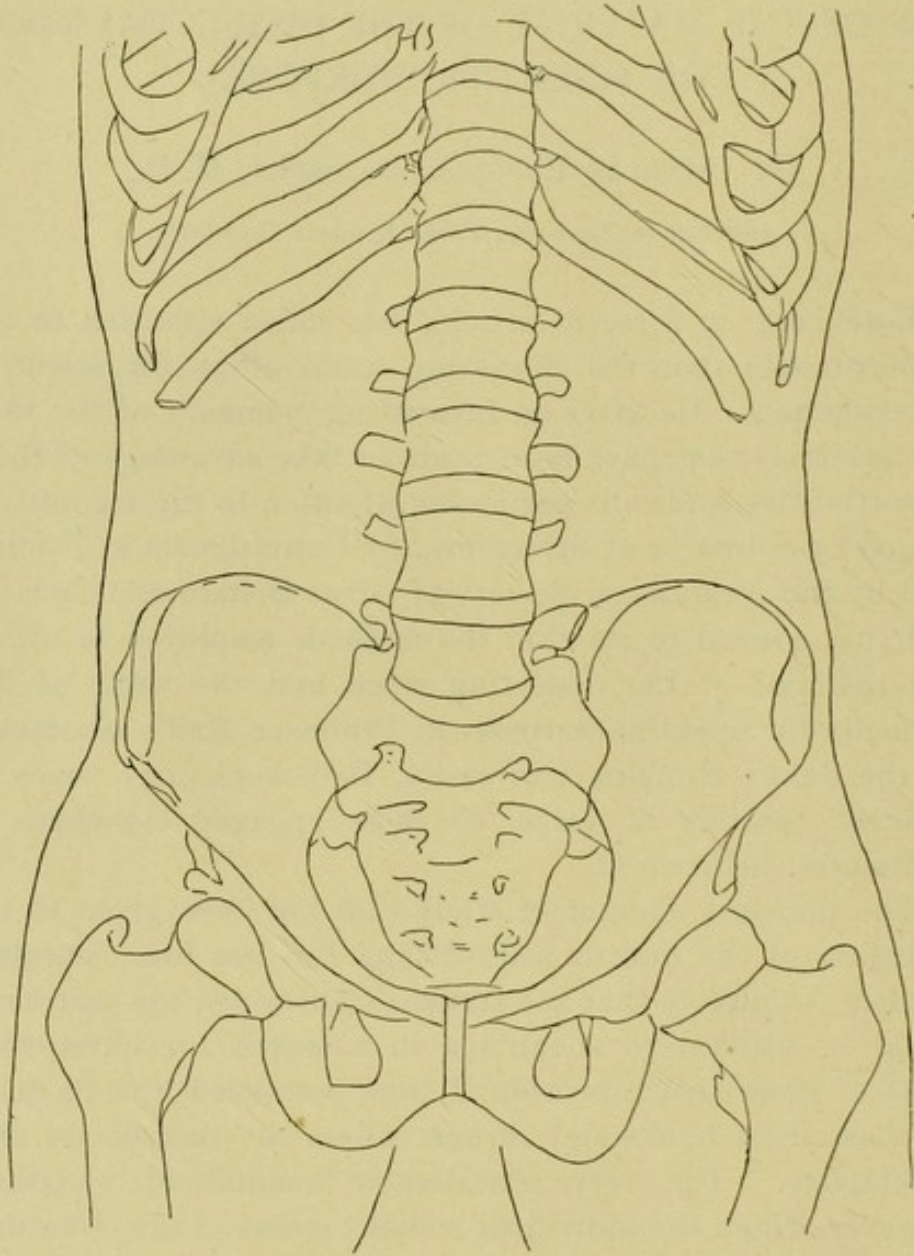


FIG. 1.

more suited to this study than that of man and none is studied with care by so great a number of individuals each year.

Until comparatively recently the variations brought to

light by the dissector have been recorded only when of an unusual nature. These observations, however, have been so numerous that we may assume that most of the variations likely to be brought to light have previously been recorded. While the limits of variation of the various organs of the body are thus fairly well understood, the frequency of variations has been determined but for few organs and for them only incompletely. The true "normal" or "most usual" is unknown. Henle, in his anatomy, pictured that as normal which his experience led him to think the most usual. Most of the other leading anatomists have done likewise. No two books, other than compilations from similar sources, give the same account of the normal form of the various organs. The great opportunity which the dissecting room offers is that of determining the curve of frequency of the various forms presented by bodily structures, and thus to make the normal a question of measurement rather than one of judgment. To render this possible, accurate records of the conditions found in each body must be made, of such a nature that they may be afterwards compared and reduced to tables.

The method of record thus becomes a question of paramount importance.

In the Anatomical Laboratory at the Johns Hopkins University the first attempts at making systematic records of conditions of structure revealed at the dissecting table were begun in the fall of 1895. It was determined to make a study of the variations in the distribution of the cranial and spinal nerves, especial attention being paid to the cervico-brachial and the lumbosacral plexuses. At the instigation of Professor Mall, Dr. A. W. Elting, at that time Assistant in Anatomy, prepared three record-charts, one for the nerves of the head, one for the nerves of the neck, arm and upper half of the thorax, and one for the lower half of the body. On these charts a record was made of the sex, color, and age, as well as of the nerve distribution in the body of the individual dissected. The scheme for recording the latter was as follows. On separate successive lines the numerical designation of a given cranial or spinal nerve was placed, followed by a list of the names of the nerves to which the given main

nerve trunk was assumed to contribute. In the preparation of this table the standard anatomies were consulted. A few lines from the "Cervicobrachial Chart" may suffice to make clear the general nature of this scheme:

C. VI. POST-BR. ANT-BR.—POST-THORACIC. SUBCLAVIUS. SUPRASCAP. COM. **C. VII.**

C. VII. POST-BR. ANT-BR.—EXT-ANT-THORACIC. COM-POST. CORD. **Outer Cord.** MUSC-CUT.—*Cor-brach. Biceps. Br-ant. Ant. Post.* OUTER-HEAD-MEDIAN.—*Ant-interos. Palm-cut. Thumb-br. 5 Digitals.*

C. VIII. POST-BR. ANT-BR. **Inner Cord. Post. Cord.** SUBSCAPS.—*Upper. Middle. Lower.* CIRCUMFLEX.—*Sup. Inf. Art.* MUSC. SPIRAL.—*Musc. Int-cut. Ext-up-cut-br. Ext-low-cut-br. Musc.* RADIAL.—*Ext-br. Int-brs. 4.* POST-INTEROS.—*Musc. Art.* COM. **D. I.**

The students were requested to compare carefully the nerves in the part dissected with the outline scheme, to underline the names of those nerves which were found to correspond with the scheme, to cross out the names of the nerves which did not thus correspond, and to insert these names in the proper place. Complex conditions, such for instance as are found in the cervicobrachial and the lumbosacral plexuses, were illustrated by diagrams drawn on the backs of the charts.

These outline schemes were well arranged and theoretically should have worked well. Yet they did not prove a success in the hands of the students. The suggestion induced by print seemed continually to lead the student into reading the scheme into his "part." The task of verifying the charts thus became a severe one. Another difficulty came from the fact that names can mean little so long as the "normal" is unknown. While the larger nerves are so constant in position that the names current in the text-books could be used without confusion it was found that many of the smaller nerves could be definitely recorded only by attaching a special definition to the name. The *iliohypogastric* and the *genitocrural* nerves may be mentioned as examples. The value of these earlier charts lies rather in the illustrative diagrams of the plexuses placed on the backs of the charts than in the records made on the tabulation schemes.

In the fall of 1897 I undertook the immediate supervision

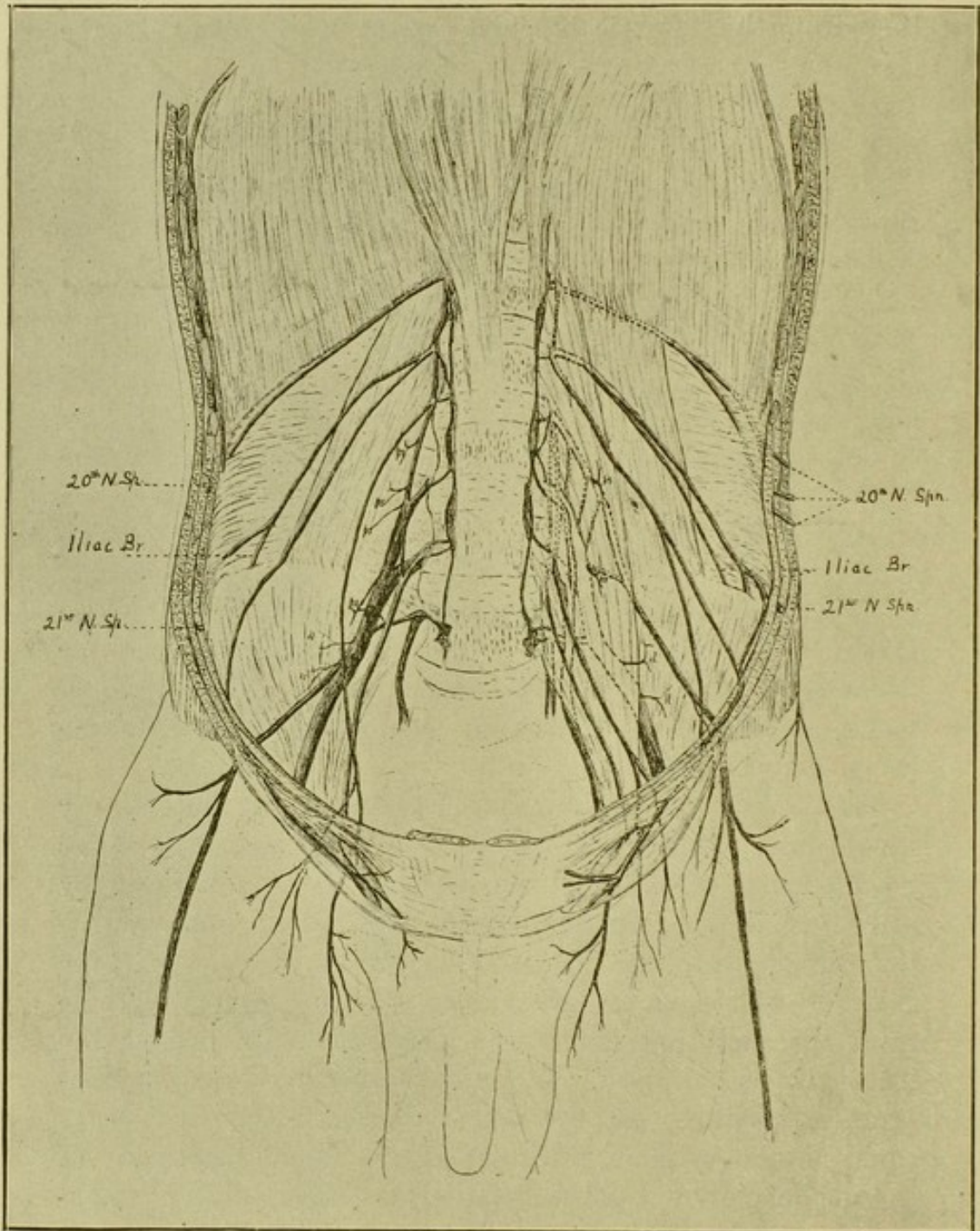


FIG. 3.

of these records. I discarded to a considerable extent the use of the printed schemes. The students were encouraged to record the distribution of the nerves by making free-hand diagrammatic sketches to illustrate the conditions found in the parts dissected. Many of the drawings thus made were well executed. Yet few of the students are sufficiently skillful draughtsmen to make even these simple sketches without a great expenditure of time. I therefore devised a set of simple outline diagrams on which the nerve distribution can be recorded. These diagrams are arranged for the various parts of the body. Thus there is one for the abdomen, which can be used either for the nerves of the abdominal walls or for the lumbar plexus (see Figs. 1-3); another for the nerves of the front of the thigh; one for the sacral plexus; one for the perineum; one for the back of the thigh, etc., in all 26 charts.² Separate charts are used for the right and left sides of the body.

In these diagrams the bones and the surface outline of the body after the removal of the skin and the superficial fascia are indicated by fine lines printed in brown ink. The scale of the charts varies from one-half to full life size, according to the region to be charted. In this way the general average proportions of the various parts of the body are furnished the student. Marked variations from these proportions can readily be indicated by changing the faint outlines of the skeletal scheme. After removing the skin from a given part of the body the student draws on the appropriate diagram the course of the superficial nerves as he finds them running in the fascia. When the muscles have been dissected out the nerve supply of the various muscles is charted. Muscles and other structures are drawn in to show the general relations of the nerves. The best records have been obtained when the student has attempted to record only a few simple conditions on a single chart. Thus in charting the nerves of the front of the thigh separate charts are used to record the distribution to the *sartorius* muscle, to the *rectus* muscle, to the *deep*

² These charts have been published in pamphlet form: "Outline Record Charts." The Johns Hopkins Press, Baltimore, 1900.

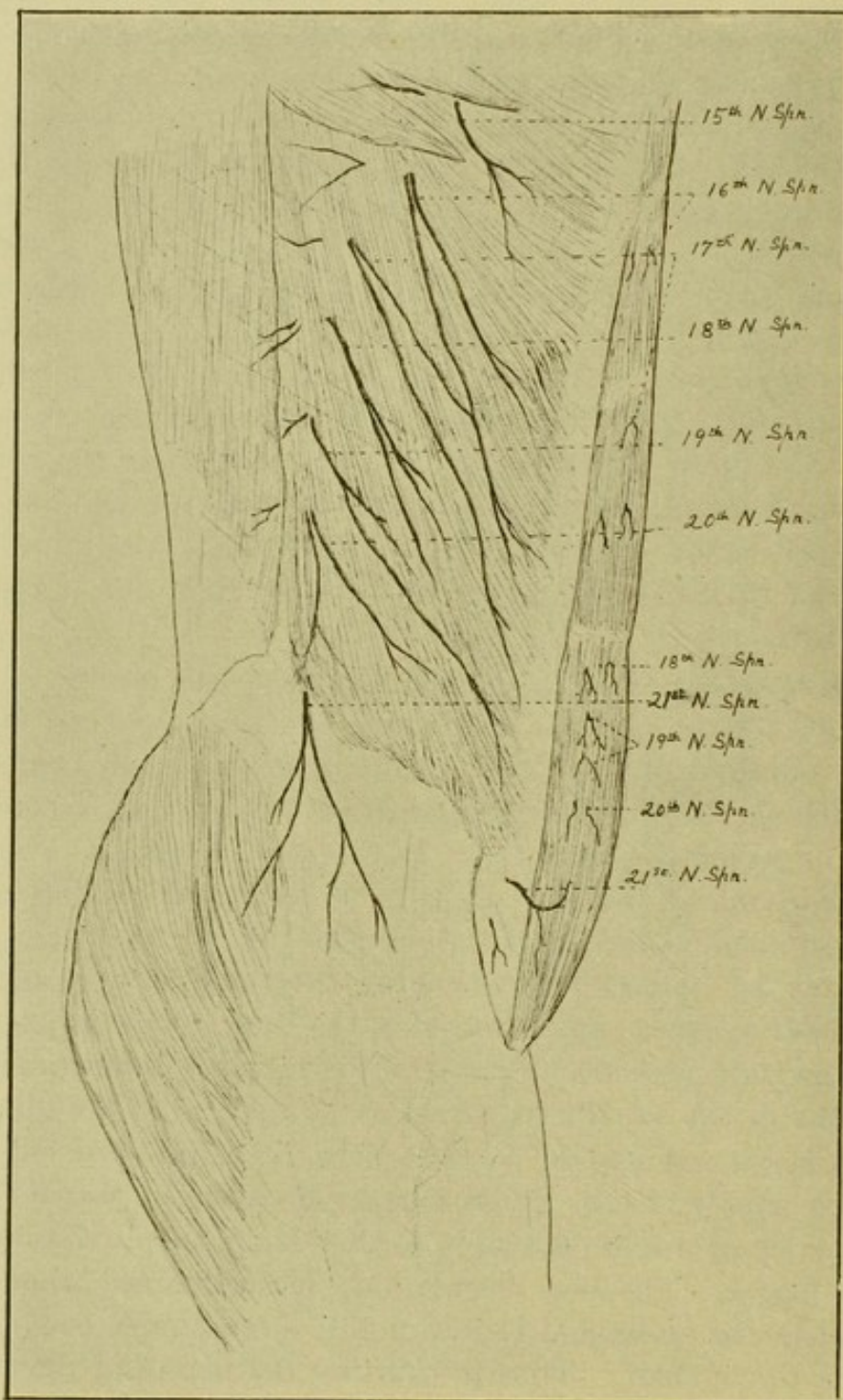


FIG. 4.

extensor muscles, to the *adductor longus* muscle and the *gracilis*, to the *adductor brevis* muscle, and to the *adductor magnus* and *external obturator* muscles.

To illustrate the method of using these charts a few examples may be given. Fig. 1 represents the outline diagram used for the abdomen and the lumbar region. Fig. 2 shows the distribution of the main ventral trunks of the abdominal nerves as dissected out and recorded by two students. Fig. 3 represents the lumbar plexuses and the distribution of the "border nerves" found in the same subject. The lateral branches of the abdominal nerves are shown in another chart (Fig. 4).

Of course one cannot hope to get from students the complete and accurate records which one could get by personal dissection. It is only rarely that perfectly satisfactory records are obtained of the peripheral distribution of all the nerves. On the other hand, it would be a physical impossibility by personal dissection to get the same number of records in the same space of time. Mistakes are more likely to be those of omission than of a positive nature. The student may destroy some fine nerve twig before it has been seen by an instructor, and thus it may escape record. The conditions that the average student finds and records are, however, of great value. Thus only may we hope to get that large number of records from which a curve of frequency may be determined.

In addition to the outline diagrams I have devised a simple printed scheme for keeping record of the race, sex, age, size, skeletal peculiarities and marked variations from the normal in the various organs of the body. This latter set of records is made out by the instructor who verifies the charts.

The verification of the charts is one of the most important features of the undertaking. Without careful verification by one man who gives his time in the dissecting room mainly, if not wholly, to this task the charts can be of little value.

Active co-operation on the part of all the instructors and of the students in the dissecting room is also essential.

The conditions which at present prevail in our medical department render it also perhaps more than usually easy to get the co-operation of the students in carrying out work of

this kind. The standards of admission to this school bring us a much more highly trained class of students than those usually found entering the average American medical school. On the other hand, the routine of a graded course, while inferior as a method of education to that freedom of choice which marks the German university, renders it much easier to win the co-operation of the students in this work. The number of students dissecting each year since the beginning of the undertaking has averaged about one hundred.

ON THE DEVELOPMENT OF THE HUMAN
DIAPHRAGM.¹

BY FRANKLIN P. MALL,

Professor of Anatomy, Johns Hopkins University.

In a paper on the development of the human cœlom, published several years ago, I was not able to give a detailed description of the separation of the body cavities from one another, because the specimens at my disposal did not include all the necessary stages. For that study I used 19 human embryos between 2 and 24 mm. long, in which various stages of the development of the body-cavities were shown, but a number of the important stages were missing.

During the past three years the collection of human embryos in the anatomical laboratory has grown very rapidly and all the missing stages for the study of the formation of the body-cavities have been supplied. The following table gives a list of these embryos. It will be seen from it that the series from 2 mm. upward is very complete with the exception of stages between 11 and 14 mm. long. Fortunately, the missing stages are not important. All the embryos given in this table are practically perfect, the imperfect ones having been excluded. The present study is based upon 15 embryos, only 3 of which are included in the 19 specimens considered in the earlier communication.

It has often been stated that the development of the diaphragm, especially in the human embryo, is one of the most difficult problems of embryology, partly because of the difficulty in obtaining the necessary specimens and

¹ Mall, *Jour. of Morph.*, vol. 12, 1897.

partly because there are no fixed points from which to calculate. In its development the whole diaphragm wanders from the head to the abdomen, passing by as well as modifying the structures and organs along the way. So, while von Baer recognized that the diaphragm wandered in its development, picking up its nerve in so doing, a fairly clear picture

TABLE OF EMBRYOS.

No.	Greatest length in mm.	Time between the beginning of the last period and the abortion.	Direction of the section.	From whom obtained.
XII.. . . .	2.1	41 days	Transverse	Dr. Ellis, Elkton, Md.
CLXIV . . .	3.5	...	"	Dr. MacCallum, Baltimore.
CXLVIII .	4.3	38 days	"	Dr. Hoen, Baltimore.
LXXVI... .	4.5	...	"	Dr. Mitchell, Chicago.
LXXX . . .	5	...	"	Dr. Branham, Baltimore.
CXXXVI .	5	56 days	Sagittal	Dr. Campbell, Halifax, N. S.
CXVI	6.5	55 days	"	Dr. Ryan, Springfield, Ill.
II	7	52 days	Transverse	Dr. C. O. Miller, Baltimore.
CXIII	8	...	Sagittal	Dr. Gray, Washington.
CLXIII ..	9	5 weeks	Transverse	Dr. Lamb, Washington.
CXIV	10	...	Sagittal	Dr. Gray, Washington.
CIX	11	...	Transverse	Dr. Cushing, Baltimore.
CXLIV . . .	14	...	Sagittal	Dr. Watson, Baltimore.
XLIII	16	...	"	Dr. Booker, Baltimore.
LXXIV... .	19	...	Transverse	Dr. Irving Miller, Baltimore.

of the whole process was not given until His studied carefully the development of the neck, heart, lungs and intestine. In his studies His recognized the *Anlage* of the diaphragm in a mass of tissue located with the heart amongst structures belonging to the head and containing within it the veins to the heart as well as the *Anlage* of the liver. This mass of

tissue His termed the septum transversum. His's studies were made upon the human embryo, mainly by the method of reconstruction, and shortly after they were published Uskow made a very careful study of the further growth of the septum transversum. Uskow recognized the great importance of two additional structures in the formation of the pericardium and adult diaphragm from the septum transversum; these he termed the *pleuro-pericardial membrane*, containing the phrenic nerve, and the *pillars* which form the dorsal ends of the diaphragm. The pillars of Uskow have been termed the *pleuro-peritoneal membranes* by Brachet, and as the latter term is more appropriate than the former I shall employ it in the present paper.

My own studies show that the pleuro-pericardial and pleuro-peritoneal membranes arise from a common structure, which extends from the lobe of the liver along the dorsal wall of the ductus Cuvieri to the dorsal attachment of the mesocardium. Later this structure grows towards the head to complete the pleuro-pericardial membrane and then towards the tail to complete the pleuro-peritoneal membrane. This structure, which I shall term the *pulmonary ridge*, is located in the sagittal plane of the body-cavity with cephalic and caudal horns on its dorsal side. The ductus Cuvieri lies between these horns (Fig. 29).

The purpose of this paper is to follow carefully the fate of the septum transversum and the origin and fate of the pulmonary ridge in the human embryo. In so doing it is of course necessary to consider the division of the body-cavity into the pericardial, pleural and peritoneal cavities. According to His, the body-cavity in early embryos is divided into the *Parietalhöhle* and *Rumpfhöhlen*. The communication between these spaces he has also termed the recessus parietalis. The parietal cavity from its earliest appearance contains the heart and is destined to form the pericardial cavity. I shall term it the pericardial cœlom. A portion of the recessus parietalis forms the pleural cavity; it surrounds the lung bud throughout its development and I shall term it the pleural cœlom. The remainder of the recessus parietalis to the origin of the liver has developed in it the liver and

stomach; this is added to the general peritoneal cavity and I shall term it the peritoneal cœlom. In the early embryos the whole cœlom lies far out of place; in Embryo XII nearly the entire cœlom lies in the region of the head and neck and in the further development of these parts the cœlom with the surrounding organs wanders away from the head to its permanent location. As long as the serous cavities arising from the cœlom are in the process of wandering and are not fully separated from one another I shall term them pleural, pericardial and peritoneal cœlom; when they are fully established I shall call them cavities.

In Embryo XII, Fig. 1, the cœlom of the embryo forms a free space encircling the heart and extending on either side of the body over the omphalo-mesenteric veins to the root of the umbilical vesicle. This canal of communication has developed within it the lung, stomach and liver, and throughout its earlier development it measures in length about one-fourth of that of the body (Embryos XII, CXLVIII, LXXVI, LXXX, II and CLXIII). The appearance of the lung and liver marks the subdivision of the cœlom into the pleural and peritoneal cœlom. With the development of the liver, lung and stomach the cœlom containing them gradually dilates until the embryo is about 9 mm. long, when the canal evaginates, so to speak, and turns the liver and stomach out into the general peritoneal cavity. The Wolffian body, which occupied the dorsal wall of this canal, gradually degenerates and the lung takes its place. From these statements it is readily inferred that the canal extending from the pericardial cœlom, His's recessus parietalis, gives rise to the pleural cœlom on its dorsal side and to the peritoneal cœlom on its ventral side. The line of division is formed by the pleuro-peritoneal membrane extending from the ductus Cuvieri to the adrenal.

The earliest embryo in my collection in which the septum transversum is well formed is No. XII, 2.1 mm. long, and about two weeks old.² The specimen is very valuable for the

² Different pictures of this embryo will be found in the *Journal of Morph.*, vol. 12; *His's Archiv*, 1897; *Johns Hopkins Hospital Bulletin*, 1898; and the *Welch Festschrift*, *Johns Hopkins Hospital Reports*, vol. 9.

study of the beginning of so many structures that it also becomes a good starting point for the study of the development of the diaphragm.

Figs. 1 and 2 give the external form and outline of the neural tube and alimentary canal drawn from a reconstruc-

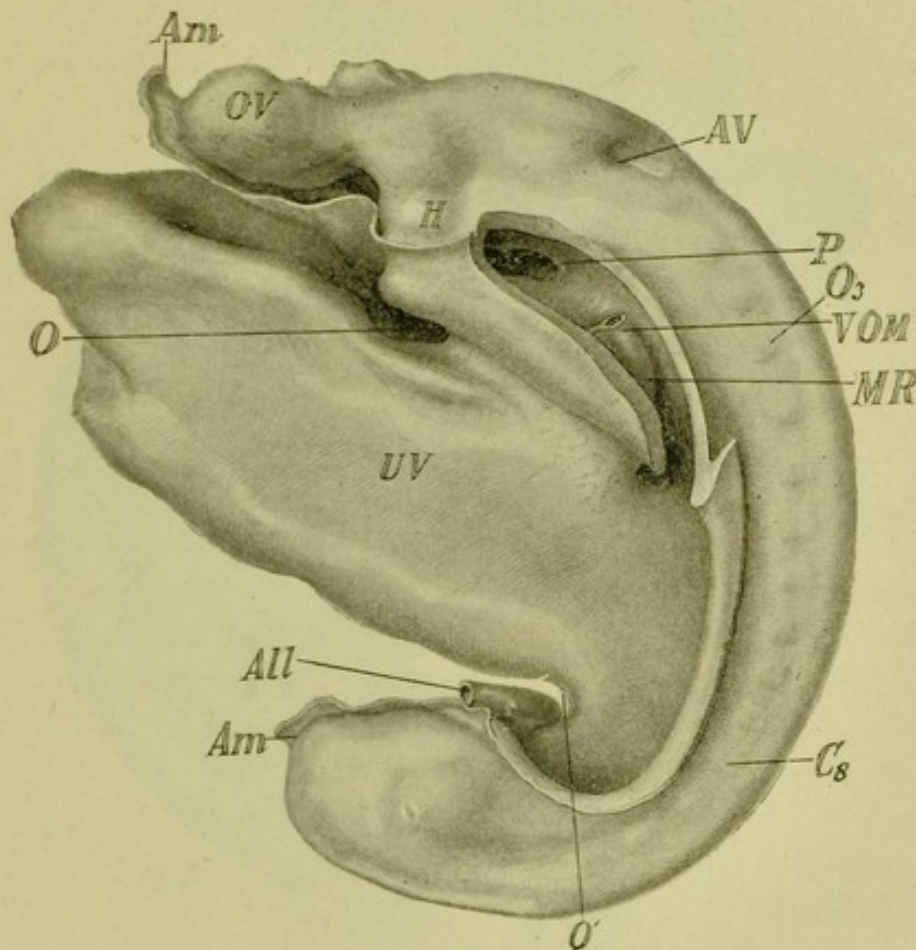


FIG. 1.—Profile reconstruction of the embryo 2.1 mm. long. No. XII \times 37 times; *am*, amni n; *ov*, optic vesicle; *av*, auditory vesicle; *uv*, umbilical vesicle; *h*, heart; *vom*, omphalo-mesenteric vein; *mr*, septum transversum; *o₃*, third occipital myotome; *C₈*, eighth cervical myotome.

tion. It is seen that the cœlom sends two canals into the head on either side of the neck which communicate with each other in the immediate neighborhood of the mouth. This U-shaped canal is separated from the exocœlom on its ventral side by a bridge of mesodermal tissue connecting the umbilical vesicle with the embryo at the juncture of the head with

the amnion. It follows that this bridge of mesodermal tissue, the septum transversum, is also U-shaped, as is shown in Figs. 1 and 2, *ST* and *MR*. It forms a portion of the ventral wall of the pericardial coelom and supports the omphalo-mesenteric and umbilical veins. Sections of it are shown in

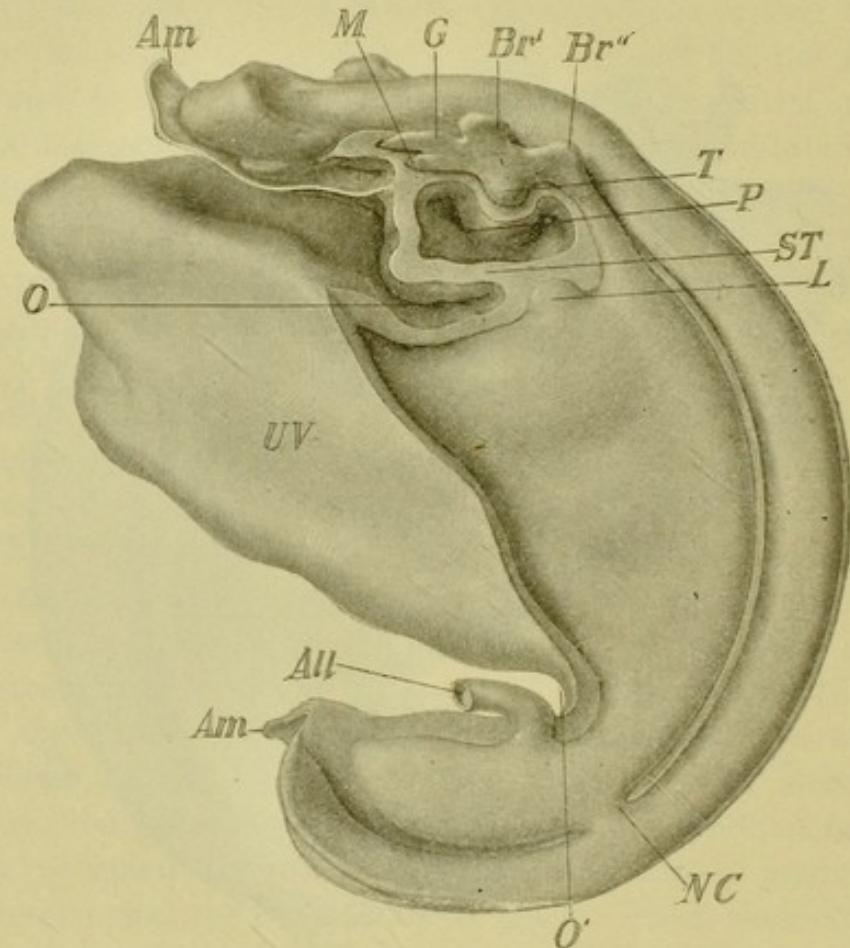


FIG. 2.—Partial dissection of the reconstruction of the embryo 2.1 mm. long. No. XII \times 37 times; *am*, amnion; *m*, mouth; *Br'*, *Br''*, first and second branchial pockets; *t*, thyroid; *p*, pericardial coelom; *st*, septum transversum; *l*, liver; *uv*, umbilical vesicle; *nc*, neurenteric canal.

Figs. 3, 4 and 5, which are from three sections through the head end of this embryo in the neighborhood of the first cervical myotome. The *Anlage* of the liver is shown in Fig. 4, which is located in this stage in a region belonging to the head.

Figs. 6 to 9 are from an embryo (CLXIV) slightly more

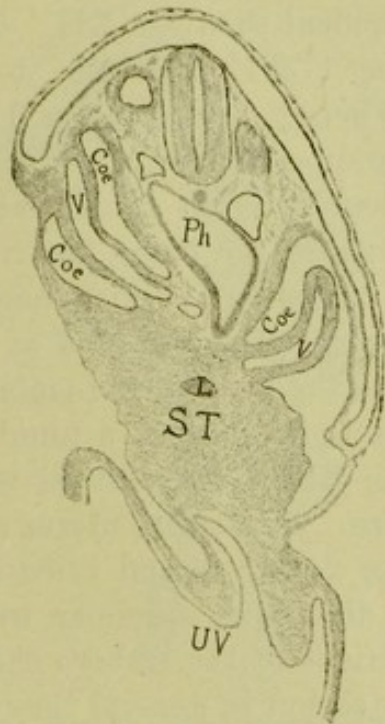


FIG. 3.—Section through the head of the embryo 2.1 mm. long. No. XII \times 50 times; *coe*, coelom; *ph*, pharynx; *l*, liver; *st*, septum transversum; *uv*, umbilical vesicle.

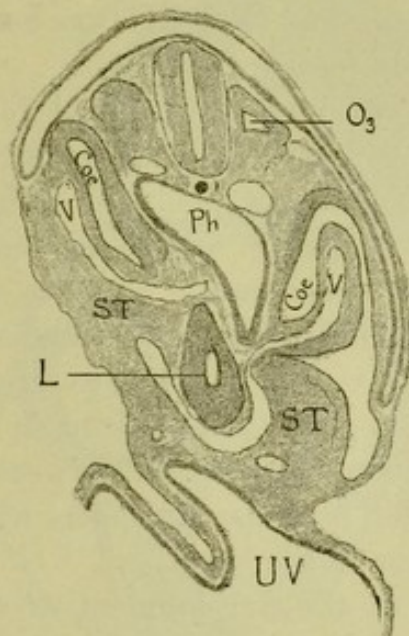


FIG. 4.—Section through the third occipital myotome of the embryo 2.1 mm. long. .04 mm. nearer the tail than Fig. 3 \times 50 times; *O*₃, third occipital myotome; *coe*, coelom; *v*, vein; *st*, septum transversum; *l*, liver; *ph*, pharynx; *uv*, umbilical vesicle.

advanced in development than No. XII. The embryo is from an ovum measuring 17 x 17 x 10 mm., found in the uterus at an autopsy. When the uterus was cut open the knife entered the ovum and possibly distorted the embryo, for when it came into my hands it was found that the embryo was floating in the cavity of the ovum but it was still adherent to its walls. This mechanical injury undoubtedly caused the body of the embryo to straighten and at the attachment of the umbilical vesicle the body of the embryo is bent towards the ventral side, as is the case in a number of the His embryos (for instance, BB). The ventral wall over the heart was also slightly torn. The entire uterus and ovum had been preserved on ice for 24 hours, and when it was given to me by Dr. MacCallum the entire specimen was placed in strong formalin. The sections of the embryo show that the tissues are slightly macerated but in general they are well preserved. The spinal cord is closed throughout its extent but the neuropore is still open. The thyroid gland, optic and otic vesicles, heart and veins, are but slightly more developed than in No. XII. If this embryo were curled up as No. XII it would measure from 2.5 to 3 mm., while if the two had been hardened in the same way (No. XII was hardened in alcohol) they would probably measure alike.

The figures given show the general relation as seen in Embryo XII with each of the structures but slightly advanced. The septum transversum is much the same as it is in XII, while the pericardial cœlom is pushed more to the ventral side of it and the diverticulum to form the liver is more marked. The umbilical vein has extended somewhat (Fig. 9) and the jugular vein has made its appearance (Fig. 7). The tissue of the septum transversum in the two embryos is formed of irregular round cells, between which there are numerous vessels, of irregular diameter, which communicate freely with the veins to the heart.

The next stage of the development of the septum transversum is found in an embryo 4.3 mm. long (CXLVII), obtained from Dr. Hoen.³ The specimen is perfect and normal,

³ A photograph of this embryo is given in the Welch Festschrift.

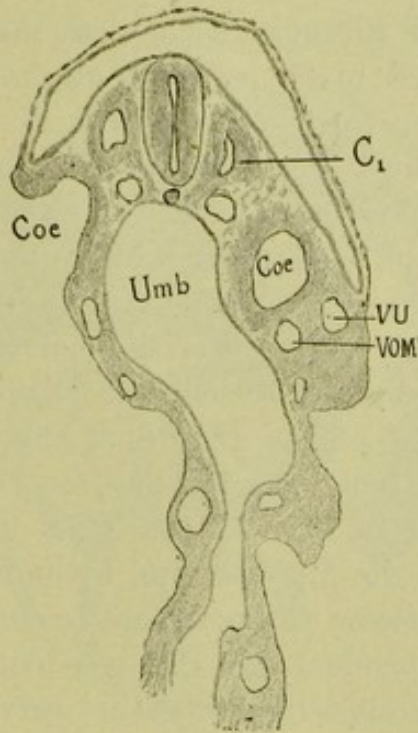


FIG. 5.—Section through the first cervical myotome of the embryo 2.1 mm. long, .23 mm. nearer the tail than Fig. 4 \times 50 times; *C*₁ first cervical myotome; *coe* coelom; *vu*, umbilical vein; *vom*, omphalo-mesenteric vein; *umb*, umbilical vesicle.

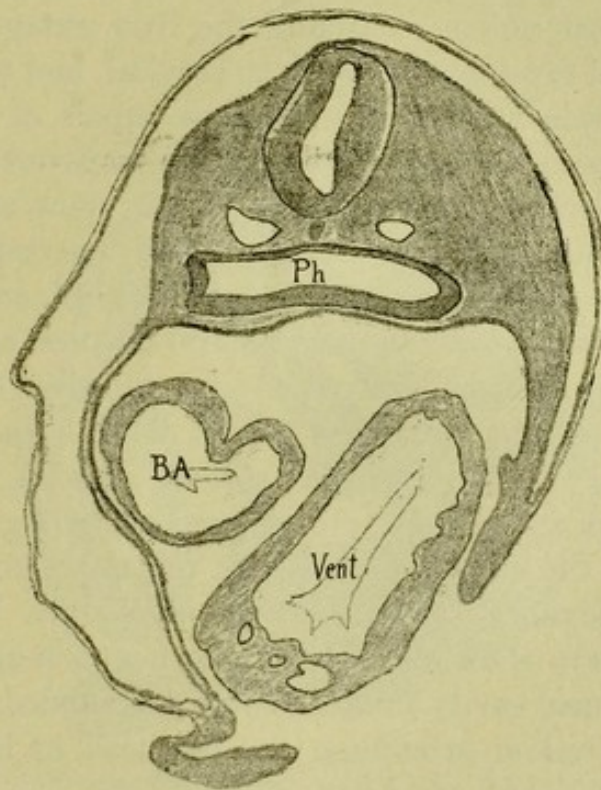


FIG. 6.—Section through the head of the embryo 3.5 mm. long. No. CLXIV \times 50 times; *ph*, pharynx; *ba*, bulbus aortae; *vent*, ventricle.

as it was obtained through mechanical means. The entire ovum was hardened in 80 per cent alcohol shortly after it was expelled from the uterus. This of course fixed the embryo in its natural shape, as was the case with No. XII. Both embryos are curved, but in the embryo 4.3 mm. long the branchial region occupies relatively more space than it does in the embryo 2.1 mm. long. In proportion to the length of the embryos this distance has increased 3 times. The pericardial cœlom has receded from the head in proportion to the increase of the growth of the branchial arches. In the embryo 2.1 mm. long the head end of the pericardial cœlom is opposite the otic vesicle, while in the embryo 4.3 mm. it is opposite the first occipital myotome. The point of communication between the peritoneal cœlom (encircling the liver) with the exocœlom has also receded. In the embryo 2.1 mm. long it is opposite the second cervical myotome; in embryo 4.3 mm. long opposite the second thoracic myotome (compare Figs. 1 and 10). His's embryo *Lr* (4.2 mm. long) is intermediate between the two embryos just compared. In *Lr* (see His's Atlas, Pls. IX and XI) the pericardial, pleural and peritoneal cœlom encircling the liver extends from the first occipital myotome to the sixth cervical, and the omphalo-mesenteric veins protrude into these canals of the cœlom. The liver has extended into the septum transversum but does not yet encircle the omphalo-mesenteric veins as it does in my embryo 4.3 mm. long. This detailed description is given to show the fate of the cœlom⁴ of the head and neck. It gives rise to the pericardial and pleural cavities, and that portion of the peritoneal cavity encircling the liver of the adult.

Sections of the embryo 4.3 mm. long (No. CXLVIII, Figs. 11 and 12) show the liver sprouts growing in all directions through the septum transversum, encircling and ramifying through the omphalo-mesenteric veins, making a condition slightly in advance of that in His's embryo *Lr*. The sections of this embryo show clearly that the heart, lungs, liver and lower peritoneal cavity arise in tissues surrounded by that portion of the cœlom extending into the head in Embryo XII.

⁴ Kopfhöhle; Halshöhle; Parietalhöhle and recessus parietalis.

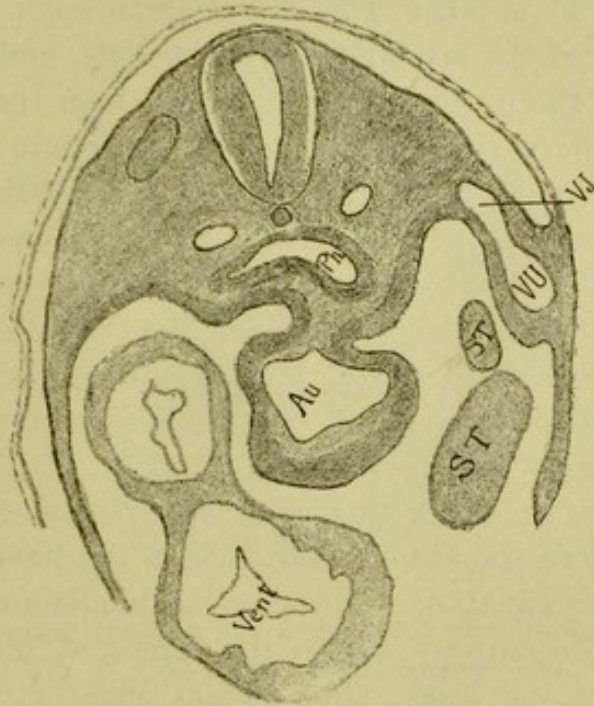


FIG. 7.—Section through the embryo 3.5 mm. long. .14 mm. nearer the tail than Fig. 6 \times 50 times; *ph*, pharynx; *au*, auricle; *vent*, ventricle; *st*, septum transversum; *vj*, jugular vein; *vu*, umbilical vein.

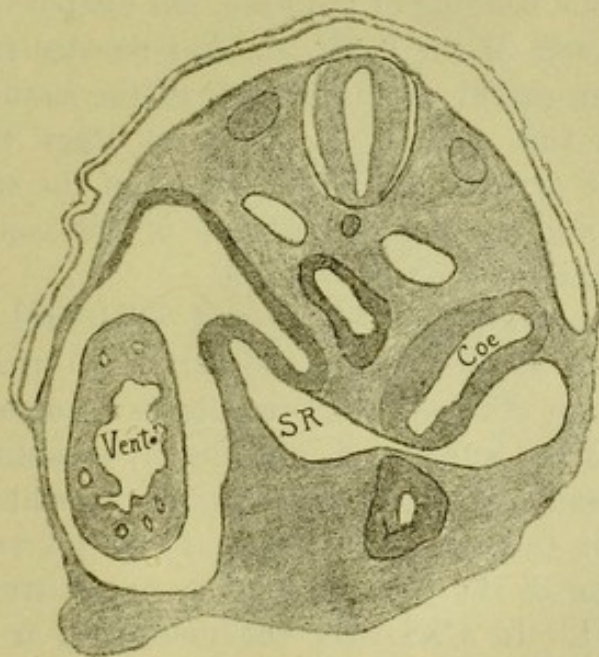


FIG. 8.—Section through the embryo 3.5 mm. long, .2 mm. nearer the tail than Fig. 7 \times 50 times; *l*, liver; *vent*, ventricle; *sr*, sinus reuniens; *coe*, coelom.

Fig. 1. Fig. 11 is taken from a section through a plane cutting the root of the arm and the otic vesicle, and can readily be placed in the outline, Fig. 10. It is seen that the lungs arise where the pericardial cœlom goes over into the pleural, *i. e.* high up in the region of the head. Immediately on the dorsal side of them is the beginning of the lesser peritoneal cavity, and the intestinal tube struck in this section is the stomach. All these structures lie on the cephalic side of the first cervical myotome. Projecting into the peritoneal cœlom, encircling and penetrating the omphalo-mesenteric veins are the projections of the liver, Figs. 11 and 12, *L*. The two lobes reach from the tip of the lungs and the foramen of Winslow to the point where the entodermal cells of the liver arise from the alimentary canal, or in this case the duodenum. The lobes of the liver lie entirely within the canals of the cœlom on either side of the head. The caudal ends of these cœlom canals have migrated from opposite the second cervical myotome in Embryo XII, Fig. 1, to opposite the second thoracic myotome in Embryo CXLVIII, Fig. 10. It has moved towards the tail eight segments, while the cephalic end of the canal, the pericardial cœlom, has been kinked over to correspond with the bending of the head, has dilated to correspond with the growth of the heart, and has receded from the otic vesicle to the extent of the growth of the branchial arches. We have in this embryo the necessary stage to locate the organs which arise in the neighborhood of the septum transversum, as well as to give the fate of the cœlom in their immediate neighborhood.

A stage somewhat in advance of CXLVIII is LXXVI. The embryo is slightly larger, measuring 4.5 mm. in greatest length. It was obtained from the uterus 7 hours after death. The entire ovum was placed immediately in absolute alcohol. It was impossible to obtain a picture of the embryo before it was cut, but the specimen proved to be an excellent one. The direction of the sections is more nearly transverse than in CXLVIII. In CXLVIII the neuropore is closed with a thickening of the epidermis just over the point of closure; the umbilical vein enters the liver and its direct connection with the ductus Cuvieri through the body wall is cut off.

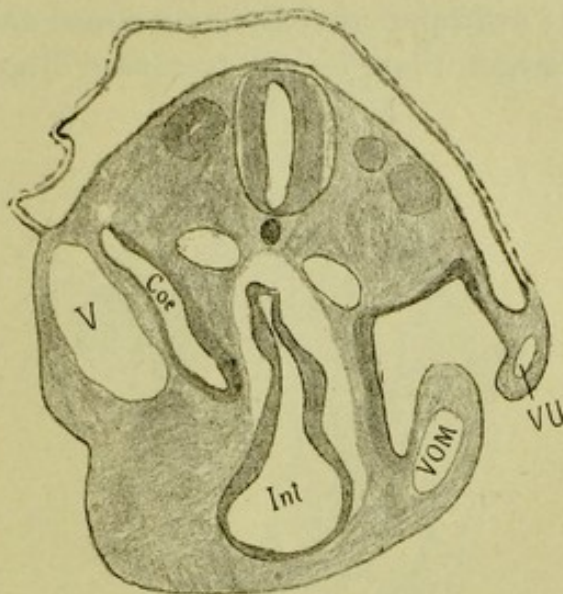


FIG. 9.—Section through the embryo 3.5 mm. long, .18 mm. nearer the tail than Fig. 8 \times 50 times; *coe*, coelom; *int*, intestine; *vom*, omphalo-mesenteric vein; *vu*, umbilical vein.

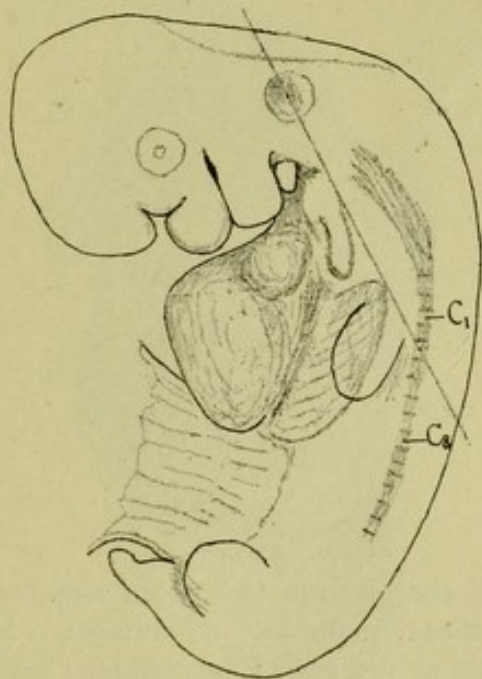


FIG. 10.—Outline of the embryo 4.3 mm. long. No. CXLVIII \times 15 times. *C*₁, first cervical myotome; *C*₈, eighth cervical myotome. The line indicates the direction of the sections.

In LXXVI the neuropore is completely closed and the embryo is somewhat larger than before (compare Figs. 13 and 14

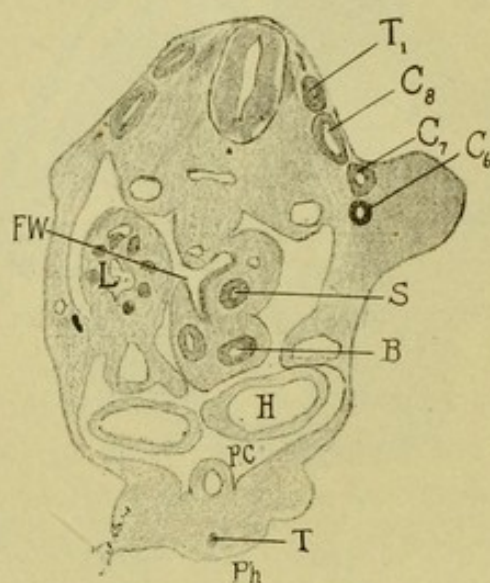


FIG. 11.—Section through the embryo 4.3 mm. long \times 25 times; T_1 , first thoracic myotome; C_6 , C_7 , and C_8 , cervical myotomes; s , stomach; fb , bronchus; h , heart; t , thyroid; pc , pericardial cavity; l , liver; fw , foramen of Winslow.

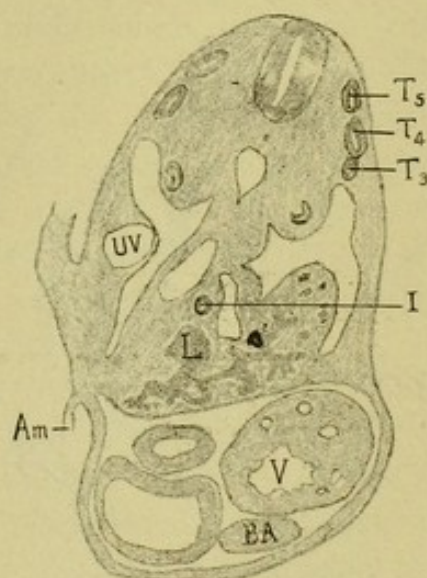


FIG. 12.—Section through the embryo 4.3 mm. long, .4 mm. deeper than Fig. 11 \times 25 times; t , thoracic myotomes; i , intestine; l , liver; v , ventricle; ba , bulb of the aorta; am , amnion; uv , umbilical vein.

with 11 and 12); the umbilical vein, however, communicates with the ductus Cuvieri through the body-wall on the left

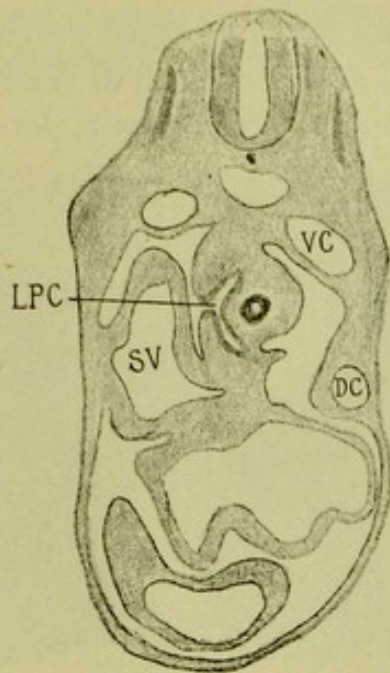


FIG. 13.—Section through the embryo 4.5 mm. long. No. LXXVI \times 25 times; *vc*, cardinal vein; *lpc*, lesser peritoneal cavity; *dc*, ductus Cuvieri; *sv*, sinus venosus.

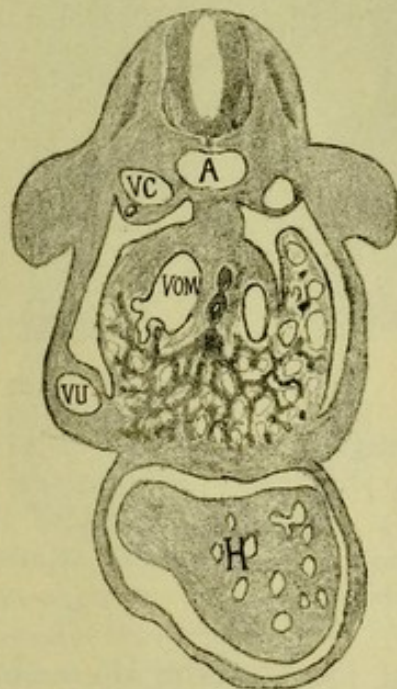


FIG. 14.—Section through the embryo 4.5 mm. long, .6 mm. deeper than Fig. 13 \times 25 times; *vc*, cardinal vein; *a*, aorta; *vom*, omphalomesenteric vein; *vu*, umbilical vein; *h*, heart.

side. This is an instance of retarded development of a part, as the left umbilical vein should have vanished by this time.

Fig. 13 gives a section through the foramen of Winslow immediately on the caudal side of the lung buds, as shown

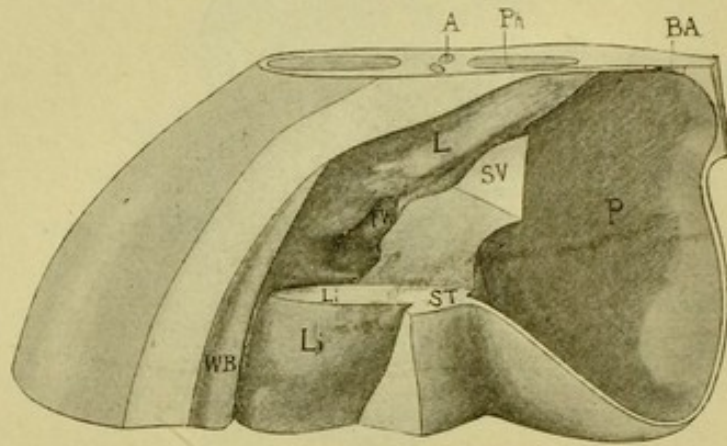


FIG. 15.

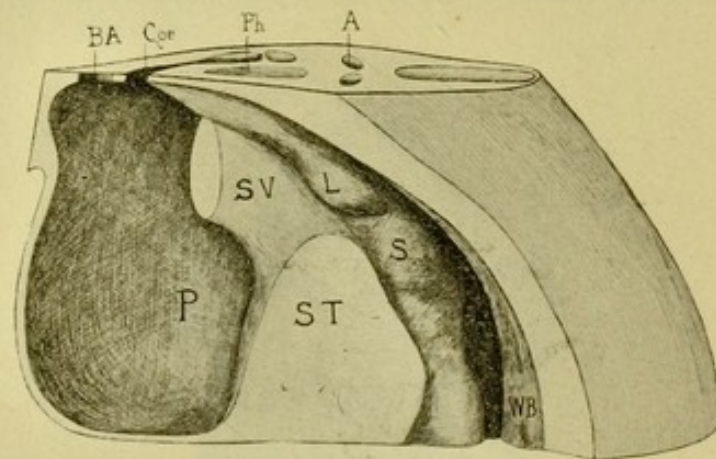


FIG. 16.

FIGS. 15 and 16.—Right and left views of a reconstruction of the embryo 4.5 mm. long \times 25 times; *a*, aorta; *ph*, pharynx; *ba*, bulbus aortae; *coe*, coelom; *p*, pericardial coelom; *l*, lung; *li*, liver; *Wb*, Wolffian body; *s*, stomach; *fw*, foramen of Winslow; *sv*, sinus venosus; *st*, septum transversum.

in a lateral view of the model of the embryo, Fig. 15. The septum transversum and liver have increased in quantity, as a comparison of the different figures will show. In this stage we have the extreme bending of the head, which throws

the heart to its most ventral point with the septum transversum about parallel with long axis of the embryo. The

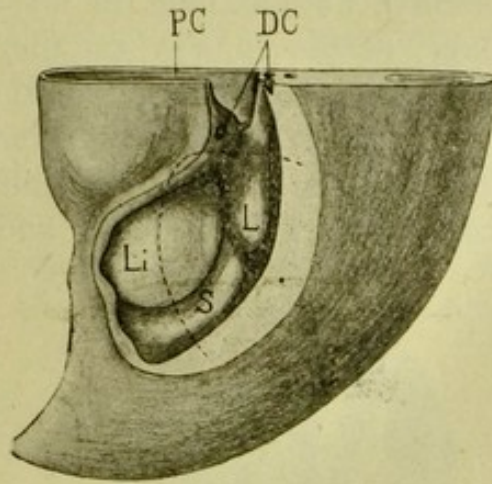


FIG. 17.—Lateral view of the reconstruction of an embryo 5 mm. long. No. LXXX \times 17 times; *l*, lung; *li*, liver; *s*, stomach; *dc*, ductus Cuvieri; *pc*, pericardial coelom which communicates fully with pleuro-peritoneal coelom.

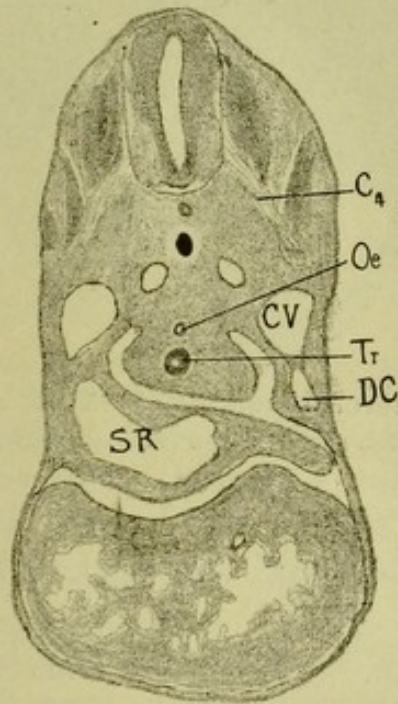


FIG. 18.—Section through the neck and heart of embryo LXXX \times 25 times; *C₄*, fourth cervical nerve; *cv*, cardinal vein; *dc*, ductus Cuvieri; *oe*, oesophagus; *tr*, trachea; *sr*, sinus reuniens.

position of the heart, lungs, liver and their relation to the coelom is much the same as in the younger embryo with the

exception of the lesser peritoneal cavity, which is now more to the caudal side of the lungs.

While in the embryo 4.3 mm. long the myotomes were well formed and hollow, in the embryo 4.5 they are solid and contain embryonic muscle fibres. The dorsal ganglia are also more developed. In the embryos 5 mm. long (LXXX and CXXXVI) the myotomes are still further differentiated with nerve trunks, composed of both dorsal and ventral roots,

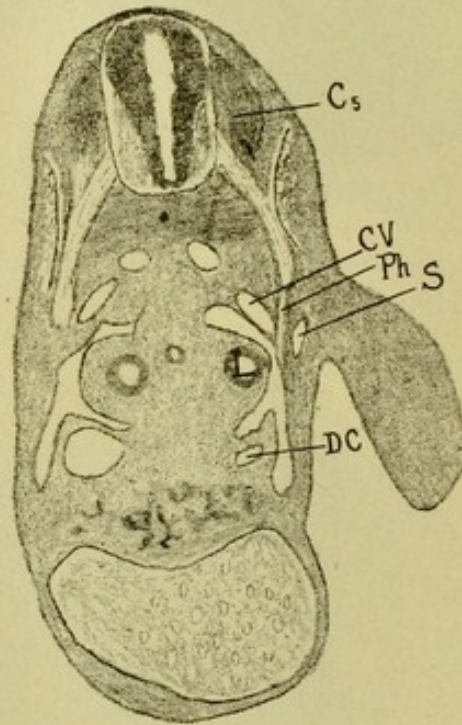


FIG. 19.—Section through embryo LXXX .22 mm. deeper than Fig. 18 \times 25 times; *C_s*, fifth cervical nerve; *cv*, cardinal vein; *s*, subclavian vein; *dc*, ductus Cuvieri; *l*, lung; *ph*, phrenic nerve.

which are growing into the body-walls of the embryo. Figs. 17-20 give the general form of this embryo, in reconstruction as well as in section. The septum transversum is not as perpendicular as in either younger or older stages (LXXVI and II), but in general this embryo is intermediate between them. A separation between the pericardial and pleural cœlom now begins to make its appearance by means of a constriction in its walls, the ductus Cuvieri encircling the cœlom at this point. The lung buds hang free into the pleural cœlom,

and the liver and stomach into the peritoneal cœlom. The ductus Cuvieri lies in a ridge of tissue encircling the canal of communication between the pericardial and pleural cœlom. In this embryo the ridge has no mesentery, as described by His (Fig. 18), but in sagittal sections of the same stage (CXXXVI) the mesentery is present. As yet there is no indication of a line of separation between the pleural and peritoneal cœlom in LXXX, but in CXXXVI there is an elevation on the dorsal wall of the pleural cœlom, Fig. 21, which encircles the lung and joins the dorsal end of the

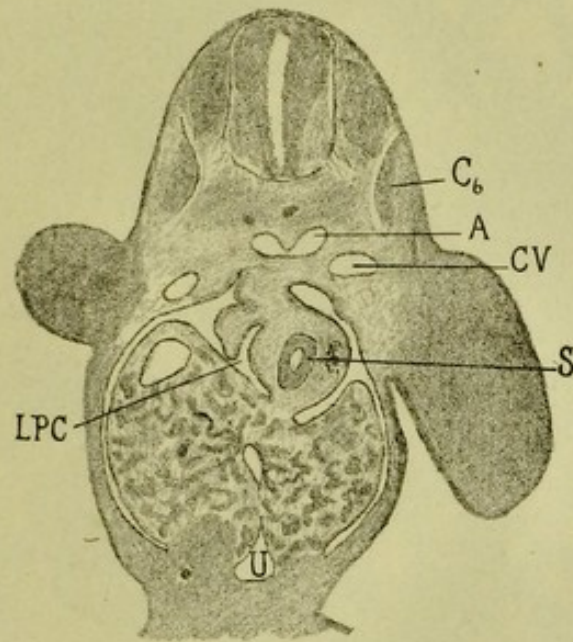


FIG. 20.—Section through embryo LXXX, .26 mm. deeper than Fig. 19 \times 25 times; *C₆*, sixth cervical myotome; *a*, aorta; *cv*, cardinal vein; *s*, stomach; *u*, umbilical vein; *lpc*, lower peritoneal cavity.

septum transversum. This is one of the pillars of Uskow or the beginning of a ridge which I shall term the *pulmonary ridge*.

Fig. 20, compared with Fig. 13, shows that the foramen of Winslow has moved more rapidly towards the tail than the heart. A section through it strikes the heart squarely in one case, while in the other it does not touch the heart but strikes the liver only. This is in part due to the direction of the section in the two specimens, and in part to the shifting of the foramen of Winslow with the recession of the

stomach. The cervical nerves are separated in No. LXXX with the exception of an anastomosis between the fourth and the fifth. From this point the phrenic nerve arises, Fig. 19, and passes to the lateral side of the parietal cœlom and lung. In a later stage it reaches the septum transversum through the pleuro-pericardial membrane of Uskow.

I have now followed the transformation of the relatively simple cœlom of the head and neck from the time it is well formed in an embryo of the end of the second week to the end of the third week. During this time the pericardial cœlom

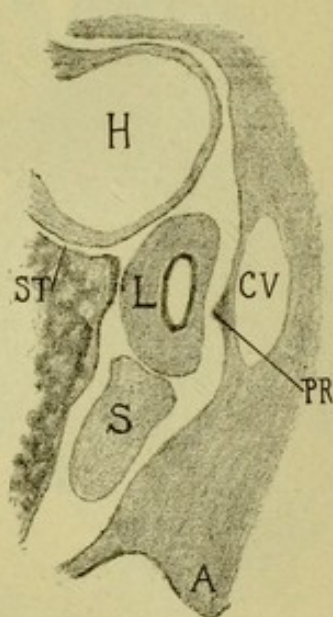


FIG. 21.—Sagittal section through an embryo, 5 mm. long. No. CXXXVI \times 25 times; *h*, heart; *cv*, cardinal vein; *st*, septum transversum; *l*, lung; *s*, stomach; *a*, arm; *pr*, pulmonary ridge.

has moved away from the head and the pericardial cavity is well outlined, but the membranes which divide the cœlom into pericardial, pleural and peritoneal spaces have not yet appeared. During the fourth week both of these membranes appear, but they are not well defined until the fifth week.

Fig. 22 is from a profile reconstruction of Embryo II, showing the relation of the organs to one another. A cast of the colon of this embryo is given in Fig. 23. The extreme ventral kinking of the heart is shown in this stage and from now on

it begins to sink more and more into the body as the liver recedes. The communication between the pericardial cœlom and the pleural cœlom is reduced to a narrow slit between the

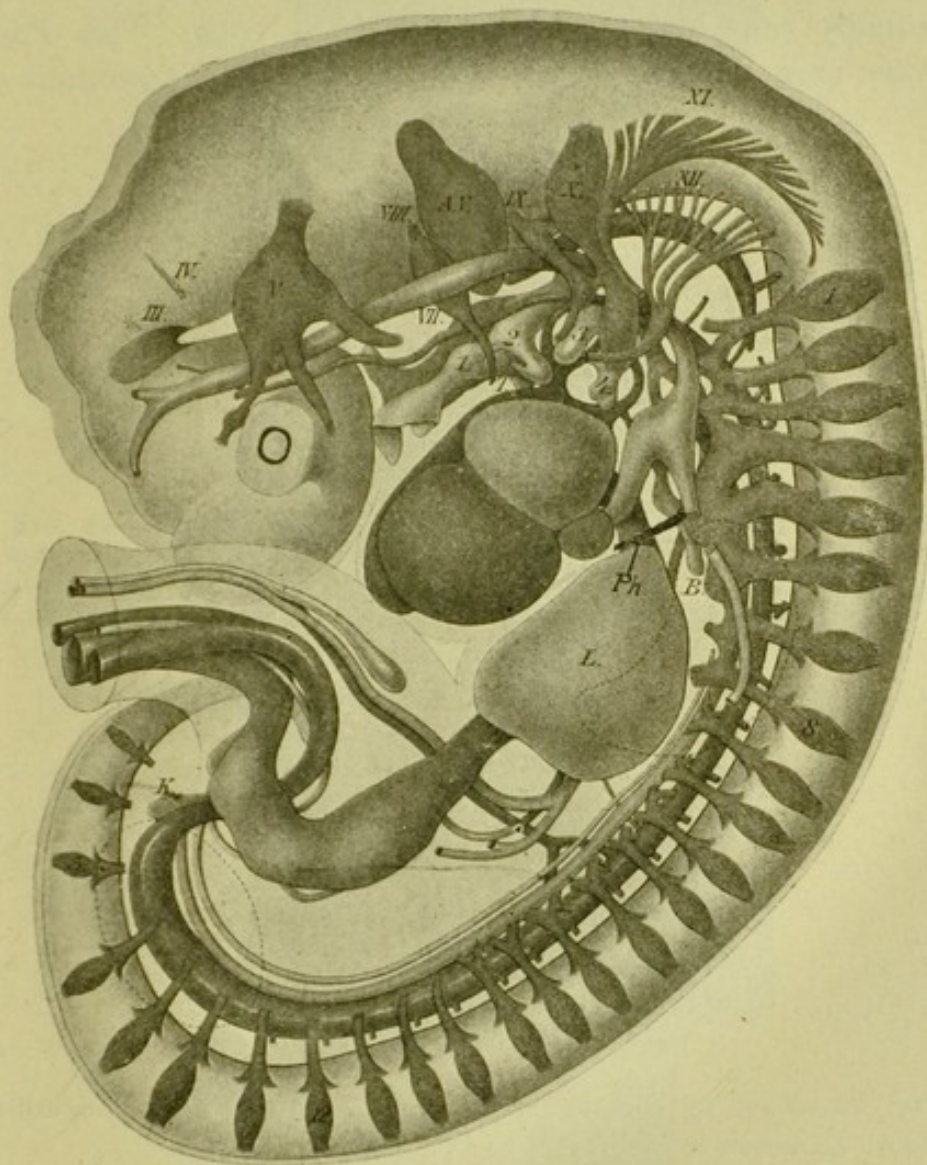


FIG. 22.—Reconstruction of embryo No. II \times 20 times; *B*, bronchus; *L*, liver; *Ph*, phrenic; 1, 2, 3, 4 branchial pouches.

cephalic end of the lung bud and the ductus Cuvieri. It appears as if a simple adhesion of the walls of the slit would complete the closure of the pericardial space. Fig. 24 is a section through this space, striking the seventh cervical myo-

tome and the tip of the phrenic nerve. It shows that the attachment of the ductus Cuvieri is no longer broad, as in embryo LXXX, but is narrow, forming a mesentery as described by His. On the dorsal side of the ductus there is a ridge which begins as the ductus projects into the cœlom and gradually runs over into the lobe of the liver. This ridge is very pronounced and is also well shown in the sections of

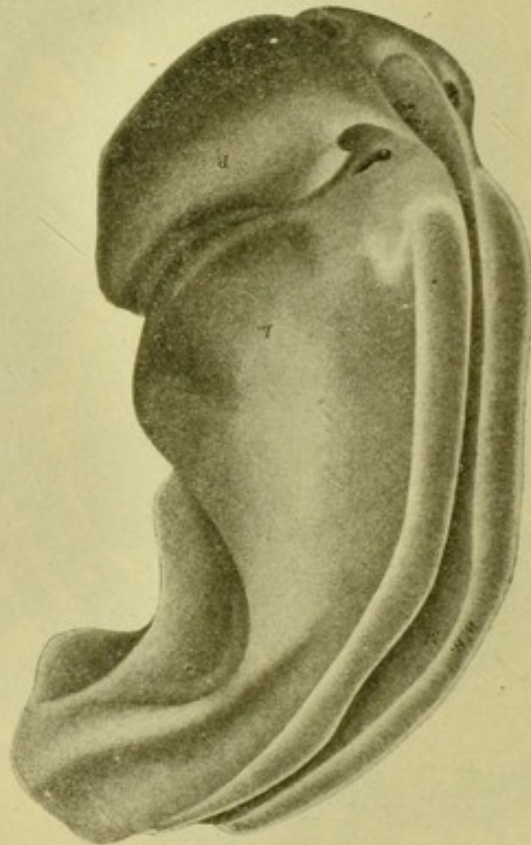


FIG. 23.—Cast of coelom of embryo II \times 20 times; *P*, pericardial coelom; *L*, coelom encircling to liver.

His's embryos, A and B, as given in his *Atlas*. The relation of this ridge to the phrenic nerve as well as its form in older embryos makes of it the *Anlage* of both the pleuro-pericardial and pleuro-peritoneal membranes. It lies in the sagittal plane of the cœlom and as it passes the region of the fourth and fifth cervical nerves receives into its substance the phrenic nerve which passes on the caudal side of the ductus Cuvieri.

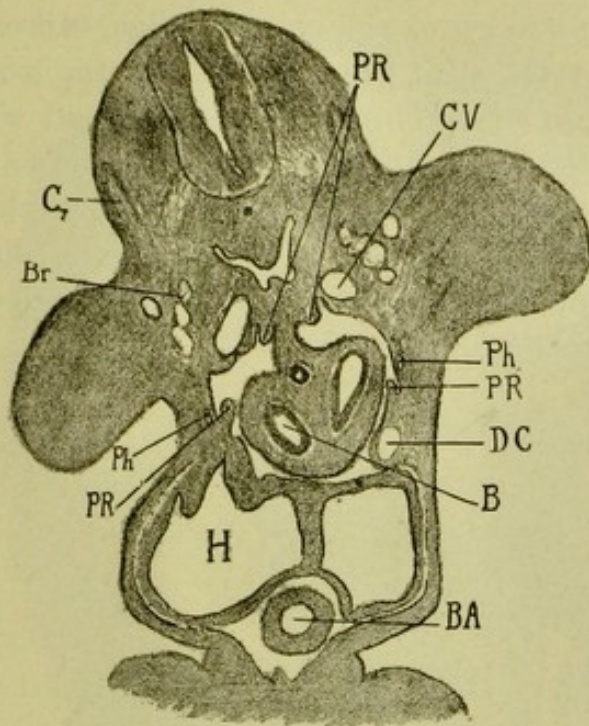


FIG. 24.—Section through the seventh cervical segment of the embryo 7 mm. long. No. II \times 25 times; *C*₇, seventh cervical myotome; *cv*, cardinal vein; *dc*, ductus Cuvieri; *br*, brachial plexus; *pr*, pulmonary ridge; *ph*, phrenic nerve; *b*, bronchus; *h*, heart; *ba*, bulbus aortae.

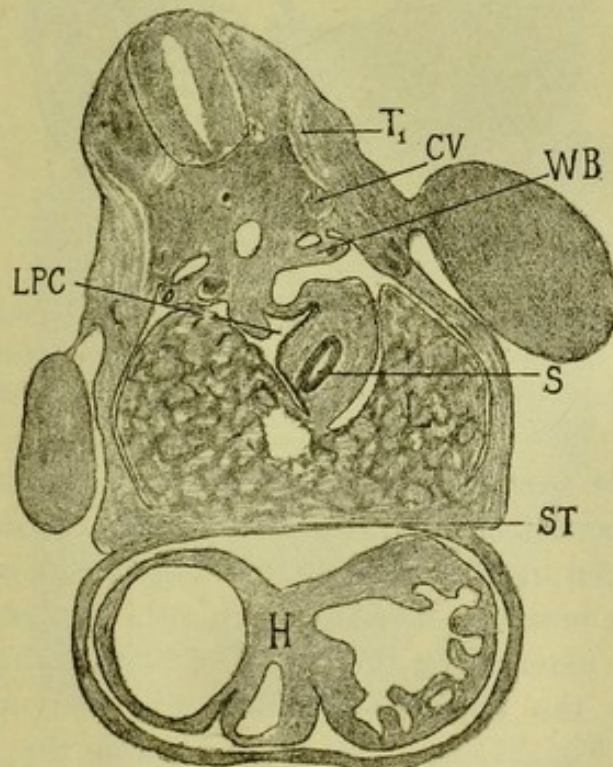


FIG. 25.—Section through the embryo 7 mm. long, .6 mm. deeper than Fig. 24 \times 25 times; *T*₁, first thoracic myotome; *cv*, cardinal vein; *wb*, Wolffian body; *s*, stomach; *lpc*, lesser peritoneal cavity; *l*, liver; *h*, heart; *st*, septum transversum.

Soon the lung bud grows against this ridge, causes it to bulge, and with the rotation of the liver towards the head the ridge is divided into two parts; (1) the cephalic end which retains the phrenic nerve and ductus Cuvieri and forms the pleuro-pericardial membrane, and (2) the caudal end which remains attached to the tip of the dorsal end of the septum transversum and the liver on the one hand, the body-wall on the other, to form the pleuro-peritoneal membrane.

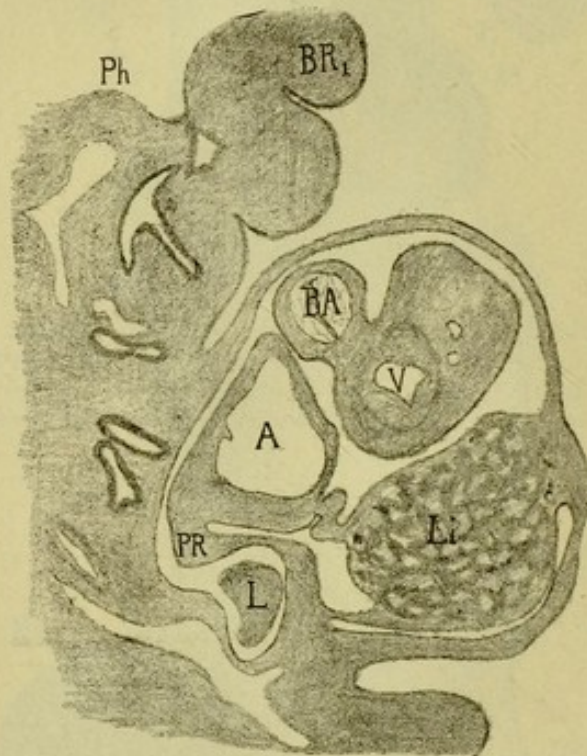


FIG. 26.—Sagittal section through the embryo 6.5 mm. long. No. CXVI \times 25 times; *ph*, pharynx; *br'*, first branchial arch; *ba*, bulbus aortae; *a*, auricle; *v*, ventricle; *l*, lung; *li*, liver; *pr*, pulmonary ridge.

Figs. 26-28 show this ridge in sagittal sections in Embryo CXVI, a specimen not quite as large as No. II, but somewhat more advanced in development. In Fig. 26 its cephalic end appears as a broad membrane which in a section nearer the middle line extends to the liver on the ventral side and accompanies the ductus Cuvieri to the body-wall on the dorsal side, Fig. 27, *pr*. Still more towards the midline the ridge ends as a decided elevation immediately to the caudal side of the tip of the lung.

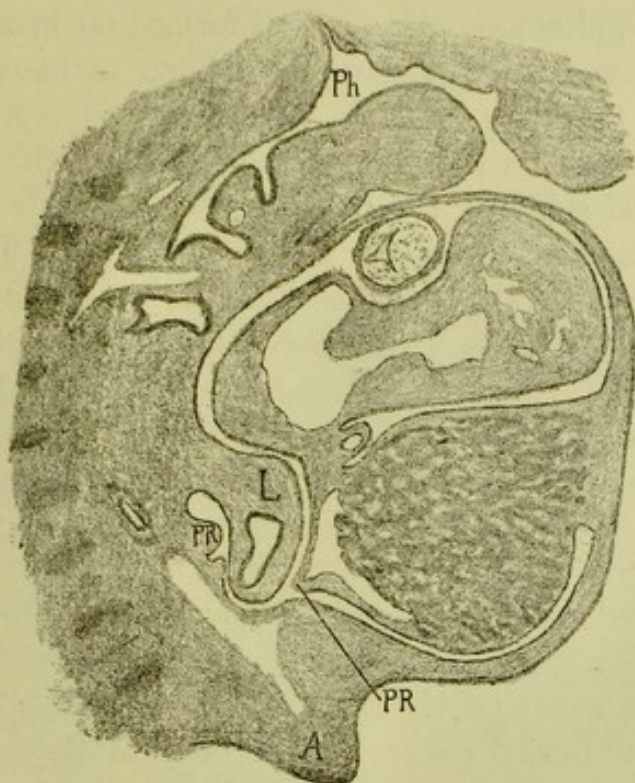


FIG. 27.—Section through the embryo 6.5 mm. long, .1 mm. deeper than Fig. 26 \times 25 times, *ph*, pharynx; *a*, arm; *pr*, pulmonary ridge; *l*, lung.

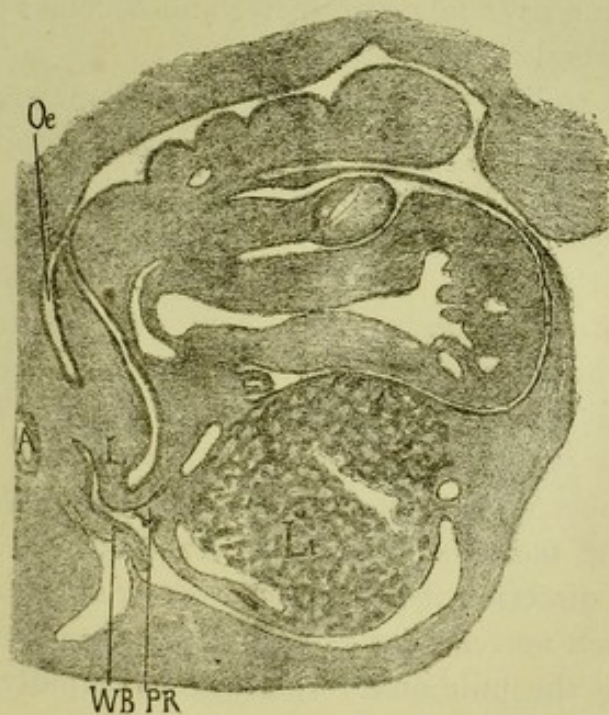


FIG. 28.—Section through the embryo 6.5 mm. long, .12 mm. deeper than Fig. 27 \times 25 times; *oe*, oesophagus; *a*, aorta; *l*, lung; *li*, liver; *Wb*, Wolffian body; *pr*, pulmonary ridge.

After the pulmonary ridge is well formed (as in Embryo II) it begins to widen at its dorsal end hand in hand with the rotation of the liver. Up to this time the septum transversum is parallel with the vertebral column, with the heart on its ventral side and the liver on its dorsal side projecting into the peritoneal cœlom, as shown in No. II. This condition was brought about at the time of the bending of the head when the viscera were forced towards the tail and into this position. The cephalic end of the pericardial cœlom is thus bent over the septum transversum but the main part of the head cœlom remained parallel with the spinal column on either side of the body. This process may be termed the rolling over of the heart.

In the next stage the heart rolls in a dorsal direction and the liver in a ventral direction. This process has already begun in embryo CLXIII and CXIII. In so doing the lung buds become buried deeper in the body of the embryo and the liver gradually changes its position from the dorsal side of the septum transversum to its ventral side. The septum transversum undergoes almost a half-revolution. The cœlom containing the liver lobe evaginates and becomes incorporated with the general abdominal cavity.

With the rolling of the heart the cœlom connecting the pericardial with the pleural space is kinked at the points of juncture between these cavities. At this point the duct of Cuvier enters the heart. Soon from its dorsal border the pulmonary ridge arises which is semicircular in form and reaches from the liver to the dorsal walls of the cœlom as described under Embryo II. It is shown in section in Fig. 24, and in a lateral reconstruction in Fig. 29. The pulmonary ridge is really an extension of the septum transversum from the lobes of the liver to the tip of the Wolffian body. As the heart moves in the dorsal direction and the liver in the ventral direction it is the dorsal end of the septum transversum which moves most rapidly in the direction of the tail. In so doing the pulmonary ridge grows rapidly and divides at its dorsal end into two membranes, one containing the duct of Cuvier and phrenic nerve, and the other still encircling the lung bud. In this division we have the beginnings of

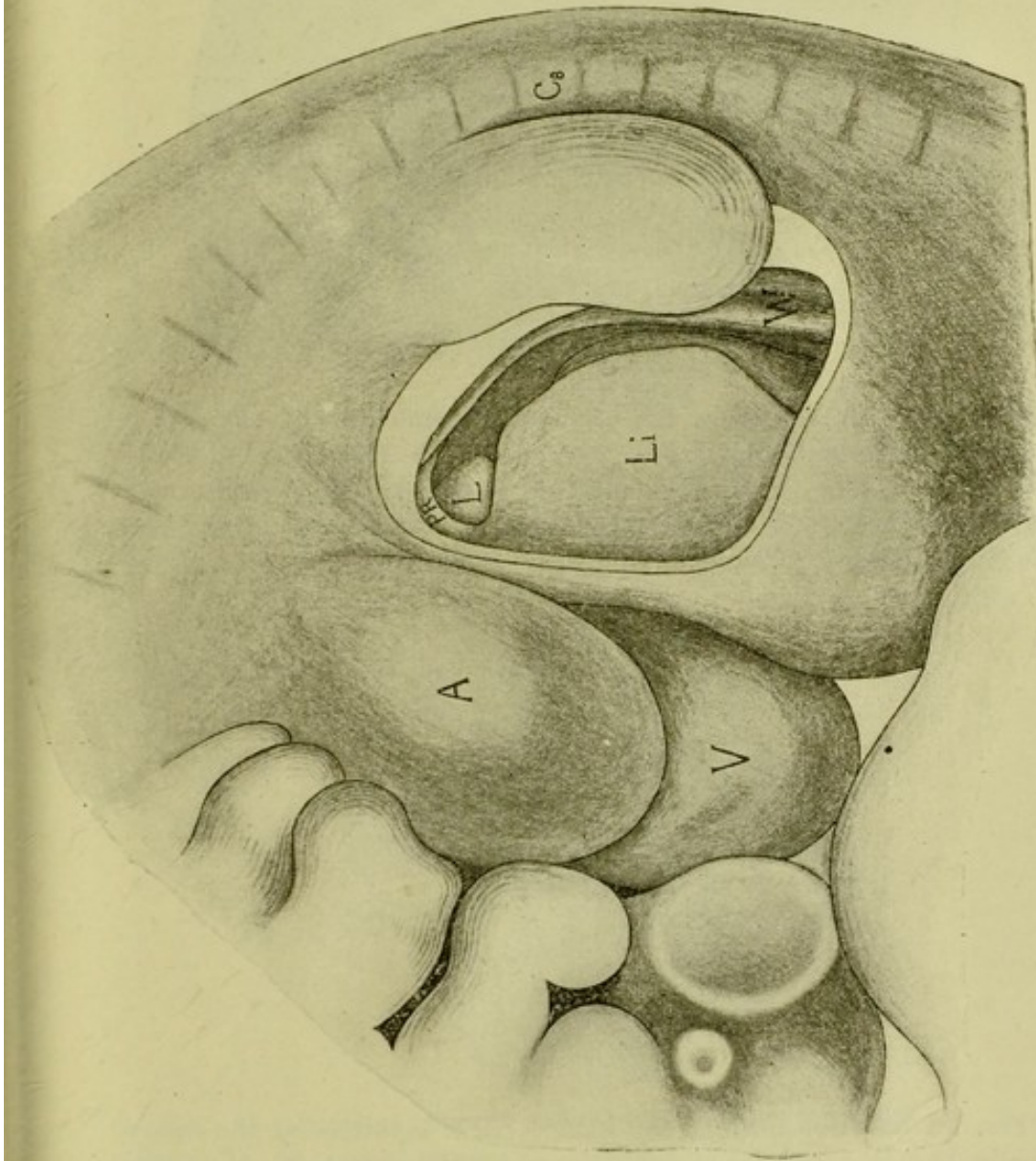


FIG. 29.—Lateral view of the pulmonary membrane and surrounding parts of the embryo 7 mm. long. No. II \times 30 times;
a, auricle; *v*, ventricle; *l*, lung; *li*, liver; *Wb*, Wolffian body; *pr*, pulmonary ridge; *Ca*, eighth cervical myotome.

the pleuro-pericardial membrane of Uskow, and the pleuro-peritoneal membrane of Brachet.

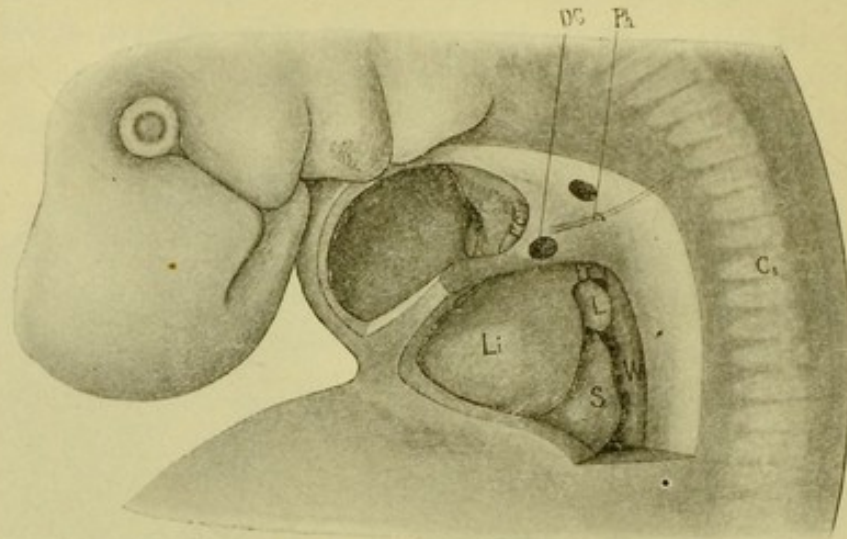


FIG. 30.—Lateral view of the pulmonary membrane and surrounding parts of the embryo 9 mm. long; No. CLXIII $\times 12\frac{1}{2}$ times, *C₈*, eighth cervical myotome; *li*, liver; *l*, lung; *s*, stomach; *Wb*, Wolffian body; *ph*, phrenic nerve; *pc*, pleuro-pericardial membrane; *pp*, pleuro-peritoneal membrane.

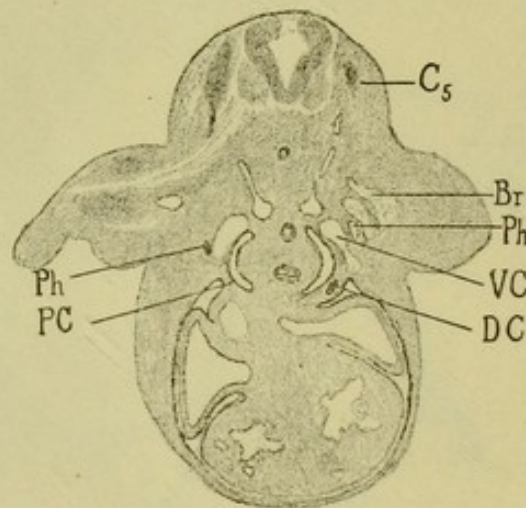


FIG. 31.—Section through the fifth cervical myotome of the embryo 9 mm. long, No. CLXIII $\times 12\frac{1}{2}$ times; *C₅*, fifth myotome; *vc*, cardinal vein; *dc*, ductus cuvieri; *br*, brachial plexus; *ph*, phrenic nerve; *pc*, cephalic end of the pulmonary ridge forming the beginning of the pleuro-pericardial membrane.

The pulmonary ridge is well formed in Embryo II. It appears as a ridge of tissue passing towards the head from

the lobe of the liver on the dorsal side of the ductus Cuvieri and then along the dorsal walls of the coelom to the mesocardium, where it ends in the pillars of Uskow. As the

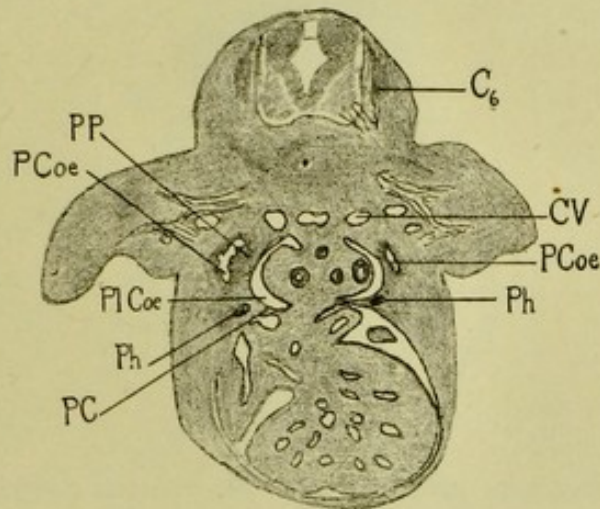


FIG. 32.—Section through the embryo 9 mm. long, .16 mm. deeper than Fig. 31 $\times 12\frac{1}{2}$ times; C_6 , sixth cervical myotome; cv , cardinal vein; ph , phrenic nerve; pc , pleuro-pericardial membrane; pp , pleuro-peritoneal membrane; $pl-coe$, pleural coelom; $p-coe$, peritoneal coelom.

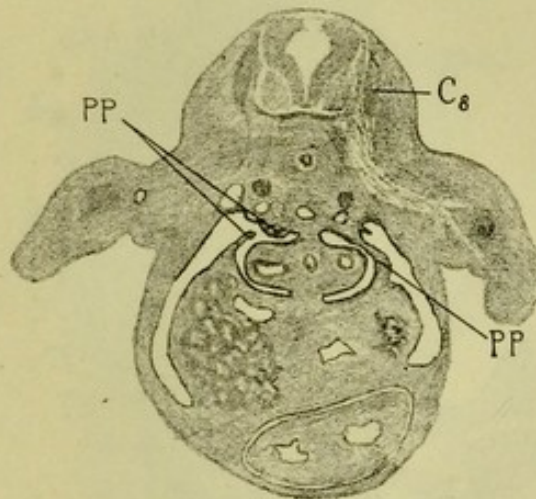


FIG. 33.—Section through the embryo 9 mm. long, .16 mm. deeper than Fig. 32 $\times 12\frac{1}{2}$ times; C_8 , eighth cervical nerve; pp , pleuro-peritoneal membrane.

embryo grows larger the ductus Cuvieri separates more and more from the lateral body-wall, and in a measure shifts into the pulmonary ridge, which at its most convex point grows in the form of a ridge towards the heart. This secondary ridge,

which is present in CLXIII, finally separates the pleural from the pericardial cavities and completes the pleuro-pericardial membrane.

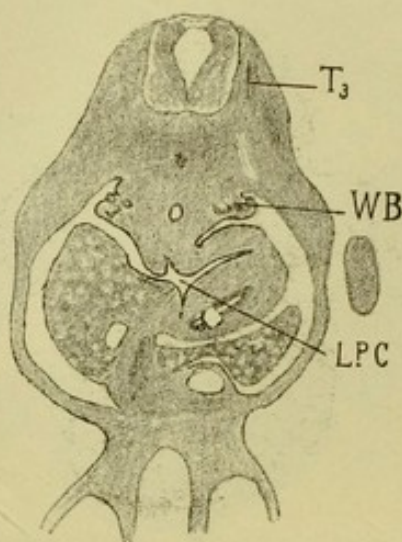


FIG. 34.—Section through the embryo 9 mm. long, .84 mm. deeper than Fig. 33 $\times 12\frac{1}{2}$ times; *T₃*, third thoracic myotome; *lpc*, lower peritoneal cavity; *Wb*, Wolffian body.

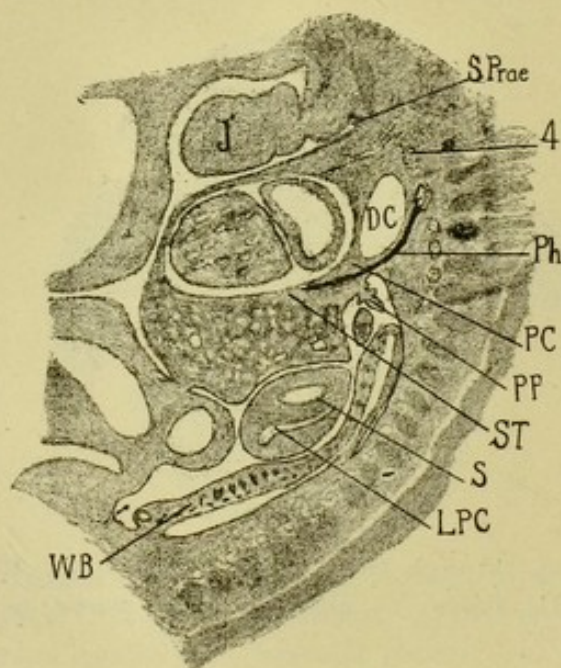


FIG. 35.—Sagittal section through the embryo 8 mm. long, No. CXIII $\times 10$ times; *j*, lower jaw; *s-prae*, sinus praecervicalis; *4*, fourth cervical nerve; *ph*, phrenic nerve; *st*, septum transversum; *dc*, ductus Cuvieri; *pc*, pleuro-pericardial membrane; *pp*, pleuro-peritoneal membrane; *l*, lung; *s*, stomach; *lpc*, lower peritoneal cavity; *Wb*, Wolffian body.

The pulmonary ridges from their beginning to their separation into the pleuro-pericardial and pleuro-peritoneal mem-

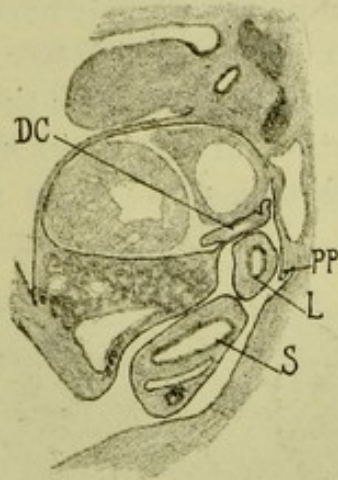


FIG. 36.—Section through the embryo 8 mm. long nearer the middle line than Fig. 35 $\times 10$ times; *dc*, ductus Cuvieri; *l*, lung; *s*, stomach; *pp*, pleuro-peritoneal membrane.

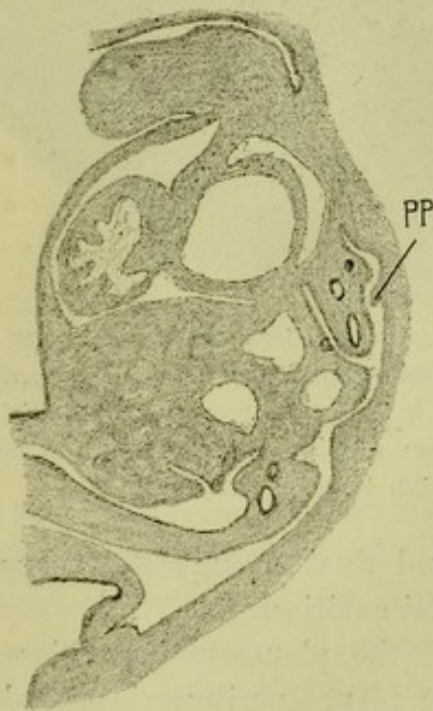


FIG. 37.—Sagittal section through the embryo 10 mm. long. No. CXIV $\times 10$ times; *pp*, pleuro-peritoneal membrane.

branes appear as two ears to the septum transversum, extending along the ducts of Cuvier in the sagittal plane of the

body and at right angles to the plane of the septum transversum. Judging by the relation of the phrenic nerve to the pulmonary ridge the portion of it on the dorsal side of the ductus Cuvieri containing the phrenic nerve, the portion containing the ductus Cuvieri, and the secondary ridge of the ventral side of the ductus Cuvieri, form the pleuro-pericardial membrane. The portion of the pulmonary ridge on the caudal side of the phrenic nerve gives rise to the pleuro-peritoneal membrane. In so doing it gradually shifts over

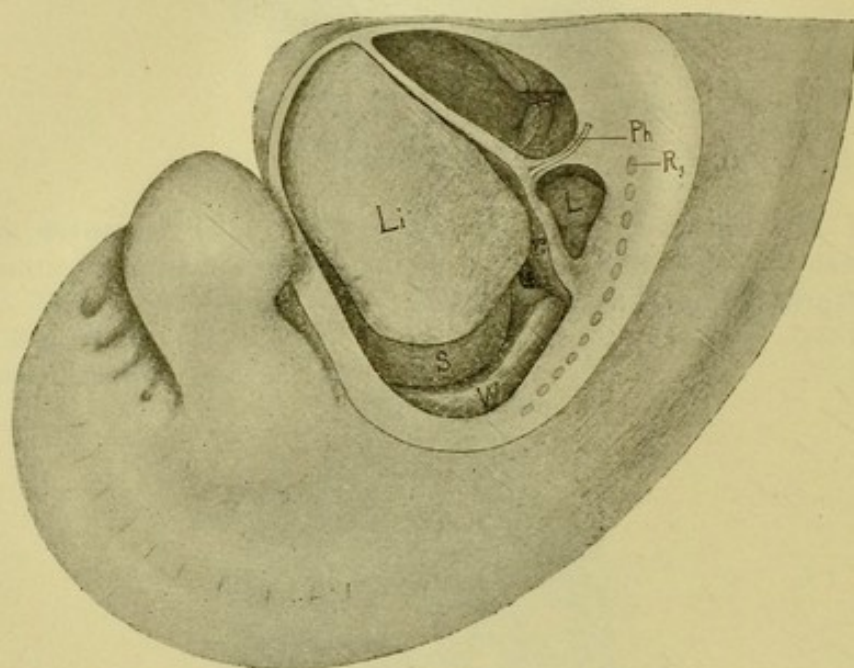


FIG. 38.—Lateral view of the embryo 11 mm. long, showing the pleuro-pericardial and pleuro-peritoneal membranes. No. CIX $\times 8\frac{1}{2}$ times; r_1 , first rib; l , lung; li , liver; ph , phrenic nerve in the pleuro-pericardial membrane; s , stomach; Wb , Wolffian body; pp , pleuro-peritoneal membrane which is not quite completed.

the lung buds and finally completely separates the pleural from the peritoneal cavities.

The growth of the pleuro-pericardial membrane towards the head and the pleuro-peritoneal towards the tail widens the dorsal projection of the septum transversum and into this wide base the lung burrows throwing the pleuro-pericardial membrane with the phrenic nerve to its medial side.

The fate of the pulmonary ridge is shown in Fig. 30, which is from Embryo CLXIII. Sections of this embryo are shown

in Figs. 31 to 34. They show again that the pulmonary ridge reaches from the ductus Cuvieri to the tip of the lung, and the phrenic nerve. It is readily seen from Figs. 30 and 32 how the phrenic nerve is pushed to its permanent position by the further rotation and recession of the septum transversum and liver, and the lateral growth of the lungs to encircle the heart.

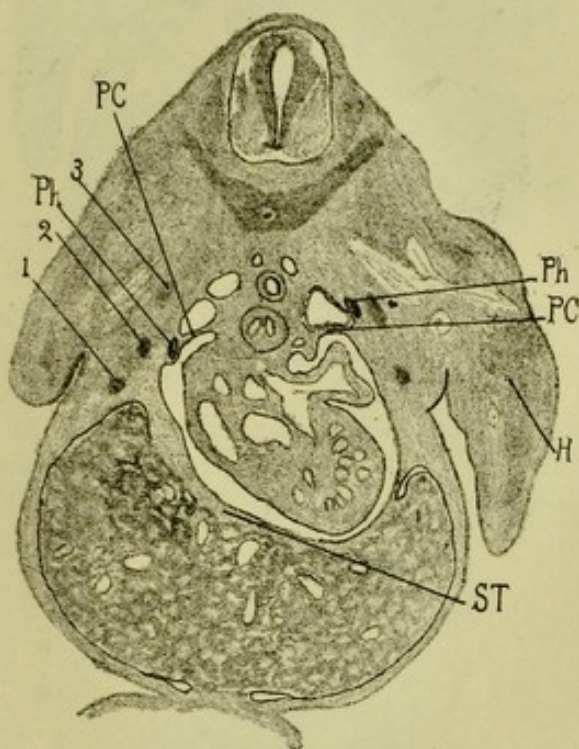


FIG. 39. — Section through the body of the embryo 11 mm. long. No. CIX \times 10 times; *ph*, phrenic nerve; *pc*, pleuro-pericardial membrane; *st*, septum transversum; *h*, humerus; 3, first rib; 2, second rib; 1, third rib.

Figs. 35 and 36 are from sagittal sections of Embryo CXIII, which is of the same stage as CLXIII. The phrenic nerve is shown throughout its whole course from the fifth cervical nerve to the pleuro-pericardial membrane. The nerve receives a second branch a few sections deeper from the sixth cervical which unites with the main trunk before it enters the pleuro-pericardial membrane. Hanging from the pleuro-pericardial membrane is a section of the pleuro-peritoneal, which in Fig. 36 unites with the dorsal wall of the coelom at the head end of the Wolffian body.

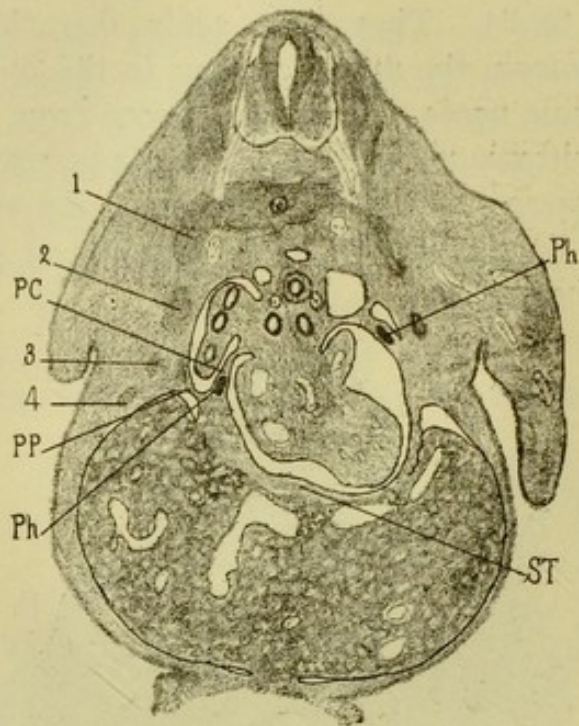


FIG. 40.—Section through the embryo 11 mm. long; .18 mm. deeper than Fig. 39 $\times 10$ times; *ph*, phrenic nerve; *st*, septum transversum; *pc*, pleuro-pericardial membrane; *pp*, pleuro-peritoneal membrane; *1*, *2*, *3*, *4*, ribs.

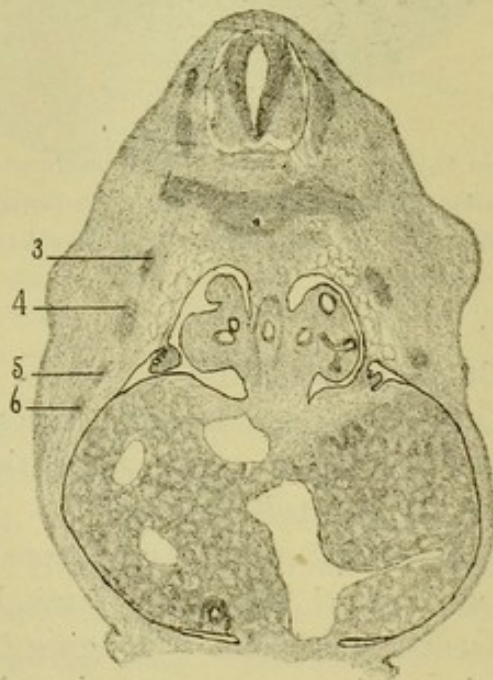


FIG. 41.—Section through the embryo 11 mm. long, .46 mm. deeper than Fig. 40 $\times 10$ times. The pleuro-peritoneal membrane is incomplete on one side, *3*, *4*, *5*, *6*, ribs.

About this time the portion of the pulmonary ridge destined to become the pleuro-pericardial membrane unites with the root of the lung bud and completely closes the pericardial cavity, Fig. 37. By this union the course of the ductus Cuvieri is from the body-wall to the heart through the pleuro-pericardial membrane, and the plane of the pleuro-pericardial membrane is practically that of the septum transversum, the two together being transverse to the body of the embryo.

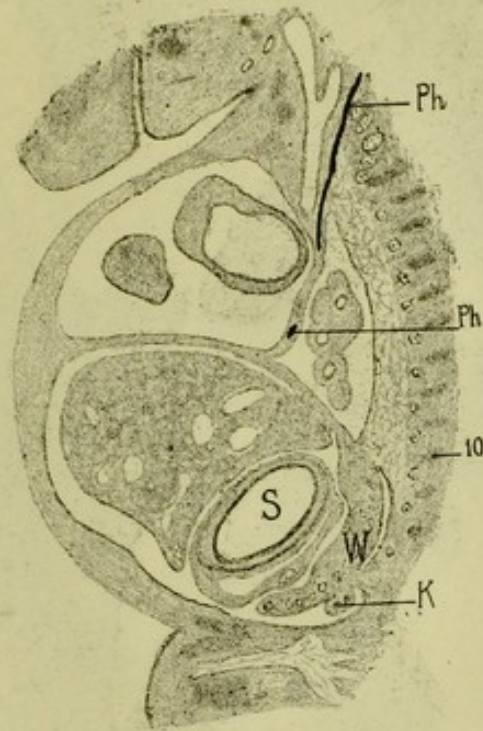


FIG. 42.—Sagittal section through the embryo 14 mm. long. No CXLIV \times 10 times, *ph*, phrenic nerve; *10*, tenth rib; *s*, stomach; *k* kidney; *W*, Wolffian body.

The phrenic nerve at this time is in the plane of the septum transversum and reaches its dorsal tip through its projection, the pleuro-pericardial membrane.

Immediately after the completion of the pleuro-pericardial membrane the rotation of the liver and septum transversum is accelerated, and by the time the embryo has grown to be 11 mm. long (CIX), the liver is practically in its adult position. The rapid rotation of the liver, especially at its dorsal end, has changed the relation of the planes between the

pleuro-pericardial membrane to the septum transversum from parallel to right angles. Now the septum transversum is in the plane of the pleuro-peritoneal membrane (Fig. 38). With the recession of the septum transversum, especially at its dorsal end, the evagination of the cœlom containing the

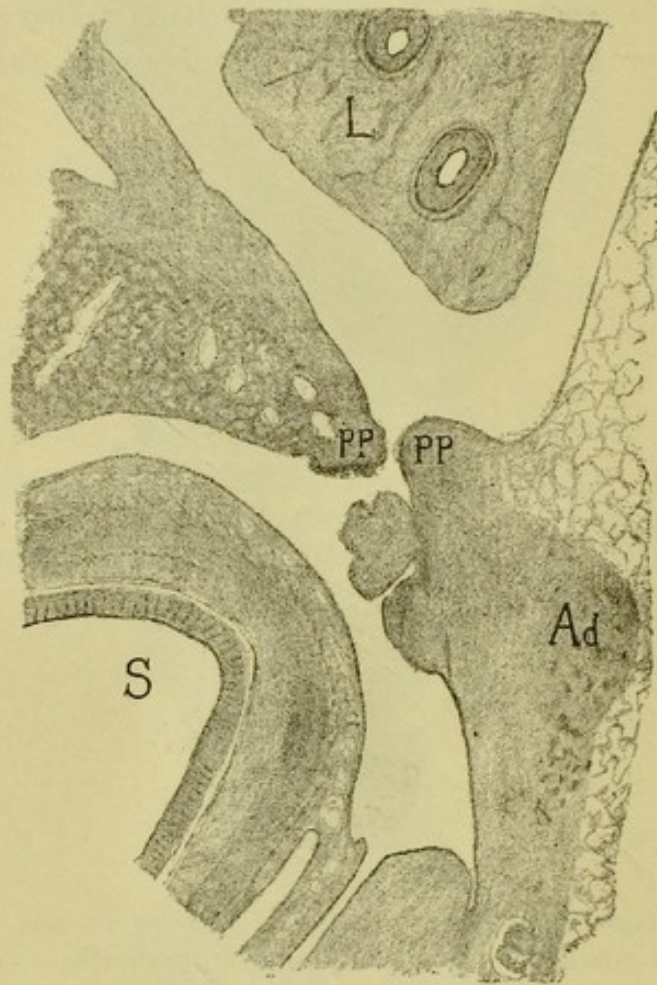


FIG. 43.—Section through the opening between the pleural and peritoneal cavities in the embryo 14 mm. long \times 50 times; *s*, stomach; *l*, lung; *pp*, pleuro-peritoneal membrane; *ad*, adrenal.

liver and stomach is complete, throwing them into the general peritoneal cavity.

Figs. 39, 40 and 41 are sections through the pleuro-pericardial and pleuro-peritoneal membranes of Embryo CIX, Fig. 38. They give the relation of the pleuro-pericardial and pleuro-peritoneal membranes to the surrounding structures. The heart is now in its permanent location in the thorax and

the liver is in the abdominal cavity. The septum transversum with its extension, the pleuro-peritoneal membrane, stretches across the body from the tips of the embryonic ribs. But in the thorax lie the lungs, and their further growth into the lateral walls of the embryo and septum transversum will make them encircle the heart, thereby enlarging the pleuro-pericardial membranes and changing position of the phrenic nerves.

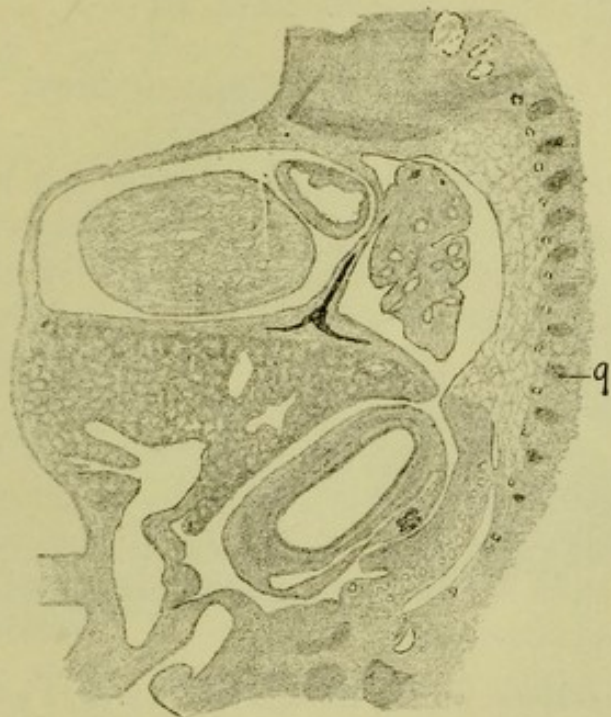


FIG. 44.—Sagittal section through the body of the embryo 16 mm. long. No. XLIII \times 10 times; *q*, ninth rib.

After the heart, lungs, liver and stomach are located in their permanent positions the pleuro-peritoneal membrane grows rapidly and soon closes the opening between the pleural and peritoneal cavities. Fig. 42 is from a section lateral to the opening showing the phrenic nerve throughout its greatest extent. In this specimen the marked growth is in the pleural cavity. Fig. 43 is from a section through the opening on a larger scale, including also the adrenal. A stage slightly more advanced is shown in Fig. 44. In this specimen, as in the one above, both pleural cavities communicate

with the peritoneal. In Embryo LXXIV, Fig. 45, the pleuro-peritoneal membrane is complete on the right side and incomplete on the left side. The reconstruction of this embryo shows that the opening is very large and extends from the seventh rib towards the tail. It may be an instance of retarded development, because in embryos 19 mm. long the membranes are as a rule complete on both sides of the body.

To what extent the permanent diaphragm is formed from the pleuro-peritoneal membrane it is difficult to determine

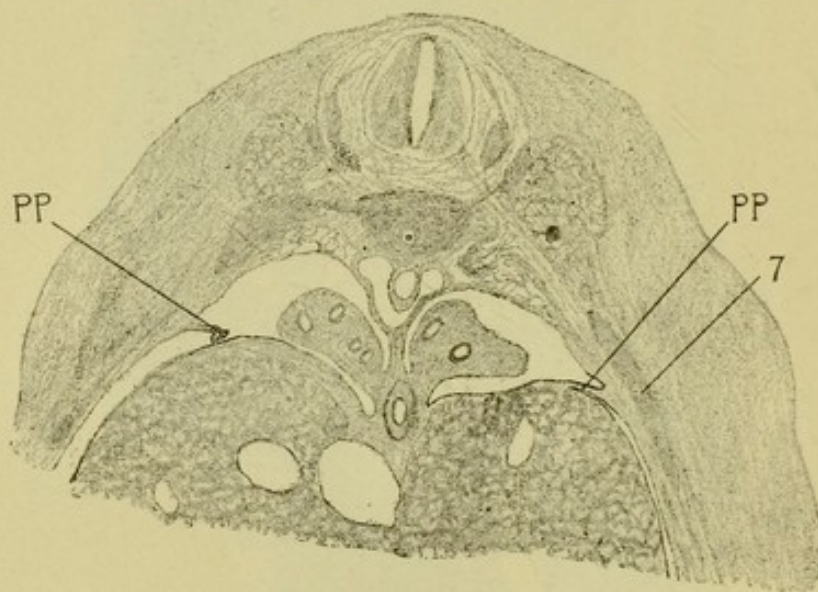


FIG. 45.—Transverse section through the embryo 14 mm. long. No. LXXIV \times 10 times; 7, seventh rib. The pleuro-peritoneal membrane; *pp*, is incomplete on one side.

Undoubtedly the portion of the diaphragm on the caudal and dorsal sides of the pleuro-pericardial membrane is formed from the pleuro-peritoneal membrane. That portion of the diaphragm on the cephalic side is formed from the septum transversum. But the diaphragm is greatly extended on the lateral sides of the heart after the embryo is 20 mm. long by the extension of the pleural cavities around it. It appears from the models that this portion of the diaphragm is also formed directly from the periphery of the septum transversum.

THE INTRINSIC BLOOD-VESSELS OF THE KIDNEY AND THEIR SIGNIFICANCE IN NEPHROTOMY.

BY MAX BRÖDEL.

[PRELIMINARY COMMUNICATION.¹]

In view of the enormous number of investigations of the different structures of the kidney recorded in the literature it seems strange that only scanty information exists on the actual course of the larger blood-vessels and their relation to the pelvis of the kidney. The normal and abnormal arrangement of the vessels at the hilum are well known and the microscopical pictures of the vessels in the cortex and pyramids are likewise thoroughly familiar to every student. But as to the actual form of the pelvis and the course and distribution of the larger vessels around its walls very vague ideas still prevail. It is evident that exact knowledge of the anatomy of this region would prove of the utmost importance to the surgeon in enabling him to open the pelvis of the kidney without running the risk of cutting large branches of the renal artery.

In order to study this region I made a large number (40) of celloidin injections of human kidneys. The injected

¹ Since this article was sent to press, I learned that Dr. William Keiller, of Galveston, Texas, has been following a similar line of research. His findings were embodied in a report to the Texas State Med. Soc., in whose Transactions for 1900 they appear. I have just received through the kindness of Dr. Keiller some of his specimens which substantiate many of the points brought forth in this paper, although the methods he employed differed essentially from mine. This being merely a preliminary communication precludes the possibility of discussing in detail Dr. Keiller's excellent work.

specimens were then digested² and the casts thus obtained, examined. Nearly thirty additional injected kidneys were not digested, but were cut into sections in various planes in order to control the results obtained by the method of digestion. Some of these sections were rendered translucent by the usual methods.

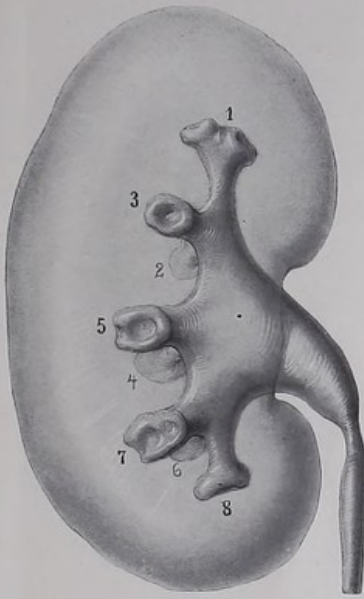
I made separate injections of the arteries, of the venous system and of the pelvis, combinations of any two out of three and finally triple injections. The great majority were of the last class. At first I confined my injections to kidneys which seemed normal so far as regarded form and size; later, after I had, in this way, determined the law according to which the vessels were grouped, I concentrated my attention upon abnormally shaped kidneys. The present paper will contain a short abstract of the main results of these studies. I shall confine myself to the description of the normal form and mention briefly only a few variations. A more elaborate communication will appear later.

The Pelvis of the Kidney.—From a surgical standpoint all forms of pelves may be classified under two main groups.

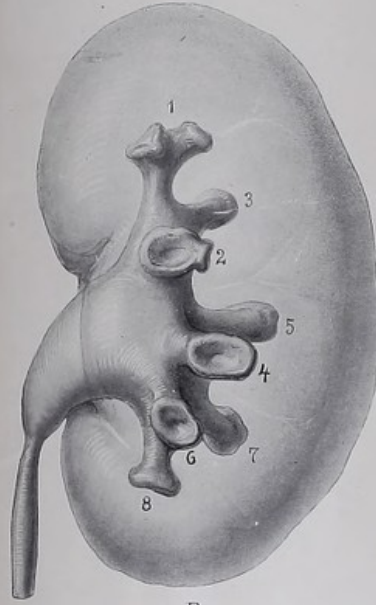
- (1) True pelves with major and minor calices.
- (2) Divided pelves, where there is no free communication possible between all of the calices inside of the kidney.

(1) *True Pelves.*—Fig. 1 shows the ideal form of a true pelvis. There are eight calices; the uppermost (1) and lowest (8) of which many have double papillæ. The remain-

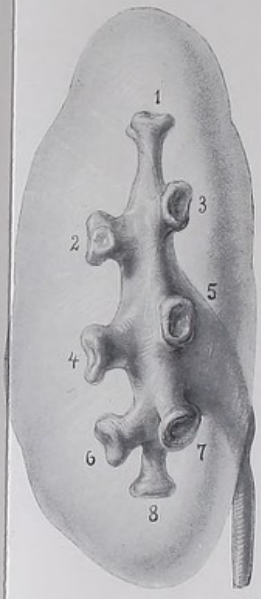
² I employed Schieferdecker's corrosion-method, slightly modified by Mixter and Mall. The procedure was as follows: The vessels and pelvis of the kidney were thoroughly washed out and then dehydrated with alcohol and ether. The arteries, veins and pelvis were then injected with cinnabar, Prussian blue and arsenic preparations of an alcohol and ether solution of celloidin, respectively. The kidney was then placed in a digesting fluid consisting of varying amounts of 1:3000 pepsin (Sharp & Dohme) dissolved in 0.3 per cent to 0.5 per cent of HCl. The process of digestion was completed in from three to four days to two weeks. When the substantia propria and the connective tissue of the kidney were completely dissolved, they were washed out with a gentle stream of water, leaving only the casts of the injected vessels and pelvis. The casts were preserved in glycerin to which a few drops of carbolic acid were added.



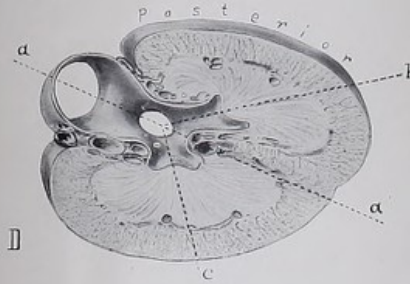
A



B



C




D

D. Transverse section through B viewed from above.

FIG. 1.—Left kidney drawn as though transparent, showing form and divisions of a true pelvis. The major calices are not very marked, the minor calices being situated directly upon the pelvis.

- A. Posterior view.
- B. Anterior view.
- C. Lateral view.



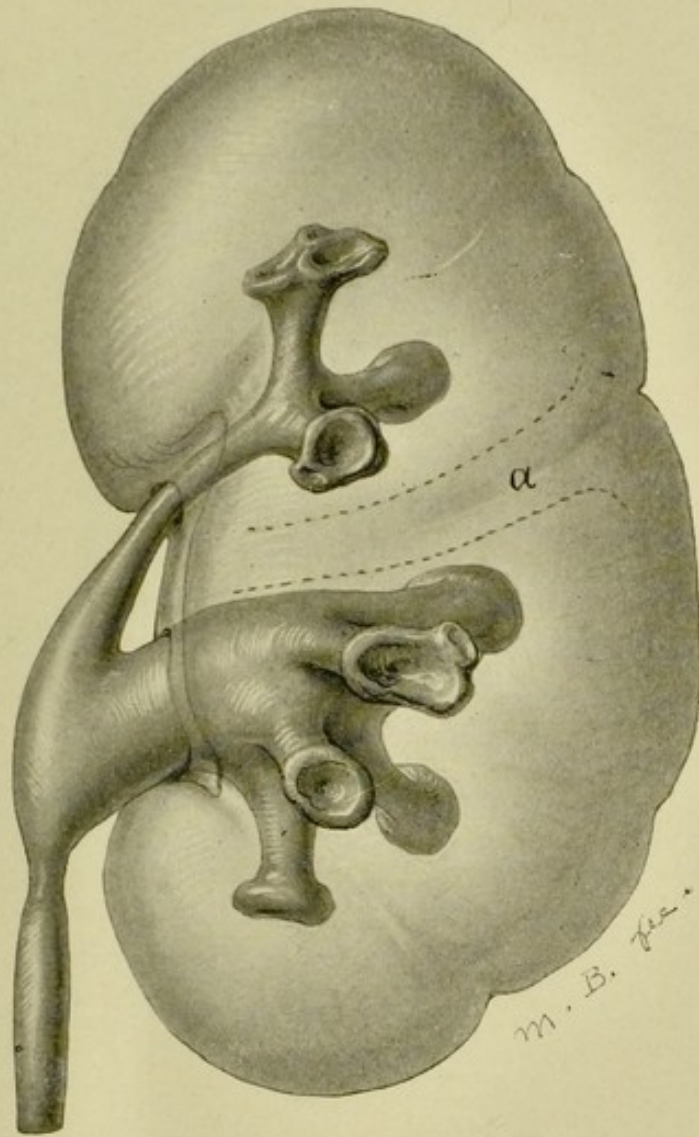

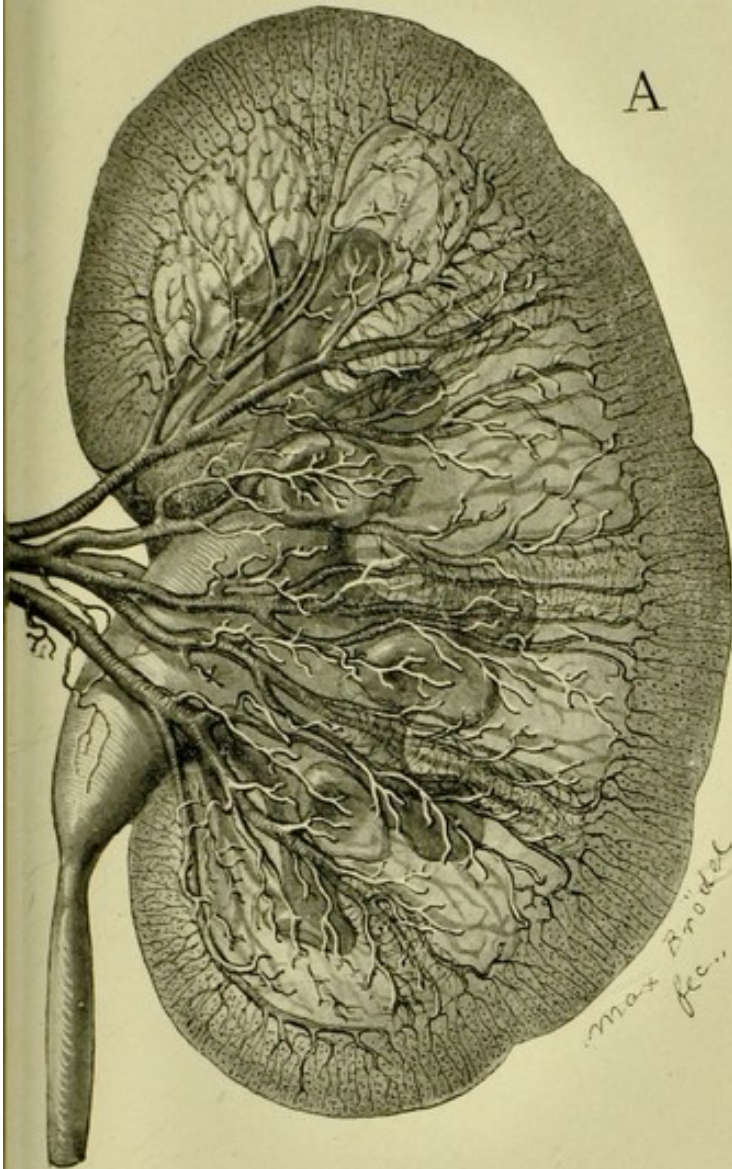


FIG. 2.—Left kidney with typical form of a divided pelvis. The two divisions of the pelvis are separated by an area of corticle substance (*a*) extending almost to the hilum. As a rule the upper division is narrow and has fewer calices than the lower. The division between the two branches of the pelvis is generally marked on the surface of the kidney by a deep depression.

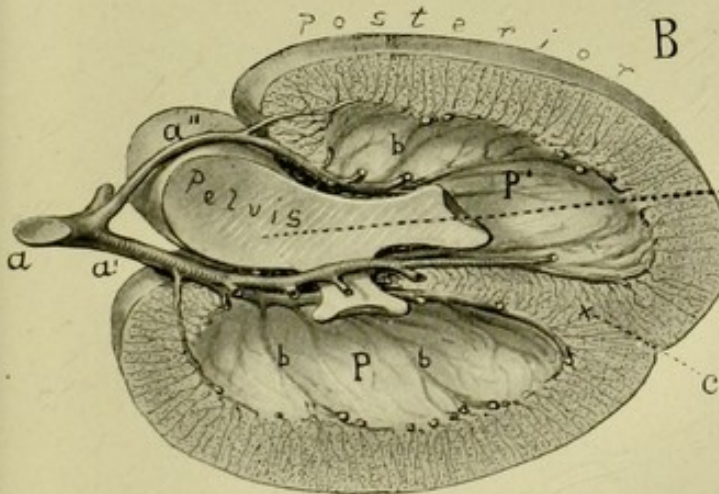




A


FIG. 3.—The renal artery and the distribution of its branches in relation to the pelvis.

A. Anterior view of a left kidney. There are 6 main branches seen entering the kidney substance. Only one of these (the third) passes posterior to the pelvis at the hilum, also small arteries coming from the upper and lower main branches are seen to pass posterior to the upper and lower calices. All the rest of the arteries pass anterior to the pelvis and its calices. The small branches to the cortex of the anterior portion of the kidney have not been drawn in order that the large branches and the pelvis might appear more distinctly.



B

B. Transverse section through the middle of the same kidney seen from above. The anterior branch of the artery supplies about $\frac{3}{4}$ of the kidney substance while the posterior branch supplies only $\frac{1}{4}$. The dotted line and arrow indicate the plane of arterial division.



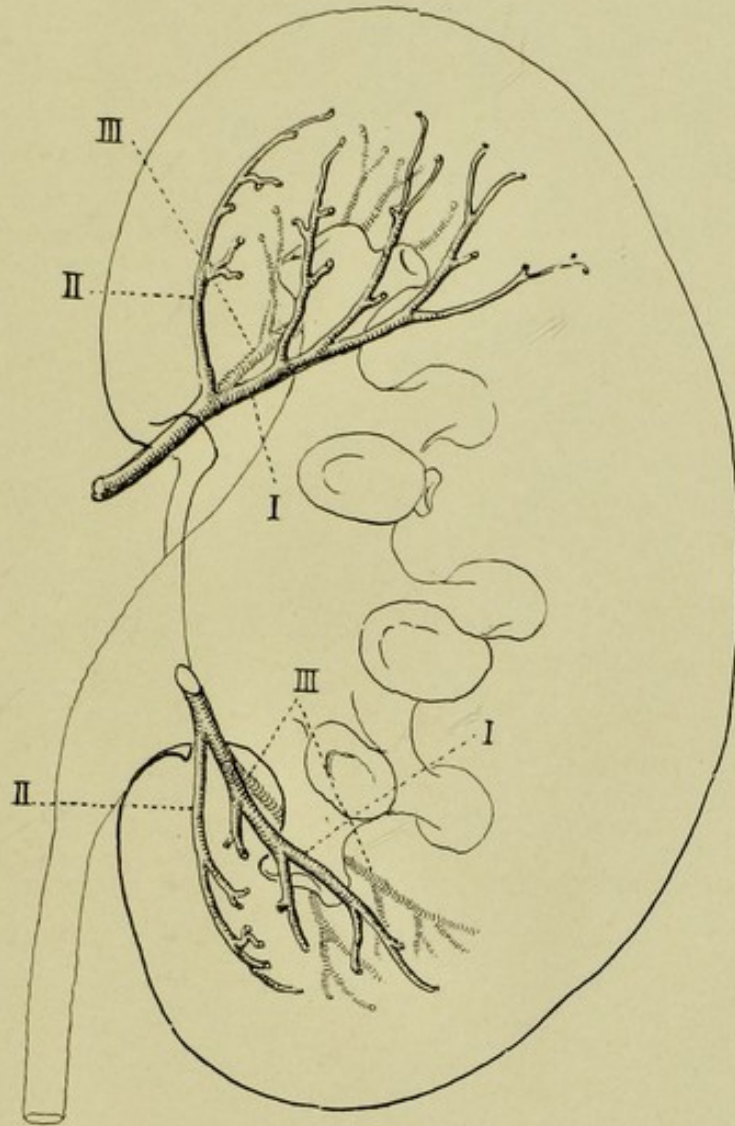



FIG. 4.—Arrangement of the arteries at the upper and lower pole. They come as single trunks from the main artery and run at an angle of 45° or more upward and downward to the vicinity of the major calices, where they divide into three branches.

- I. Anterior branch.
- II. Median branch.
- III. Posterior branch.

The anterior and posterior branches are as a rule much larger than the median.



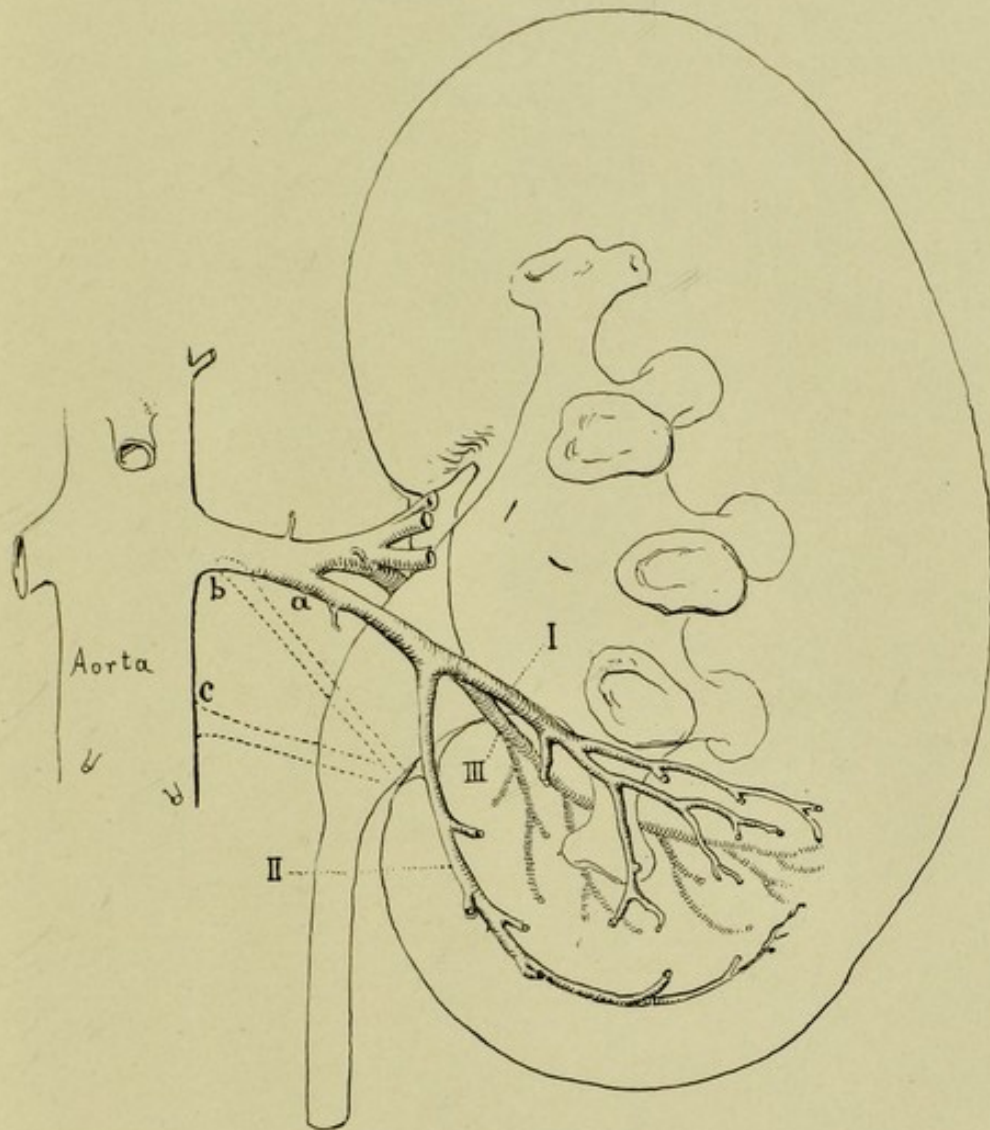

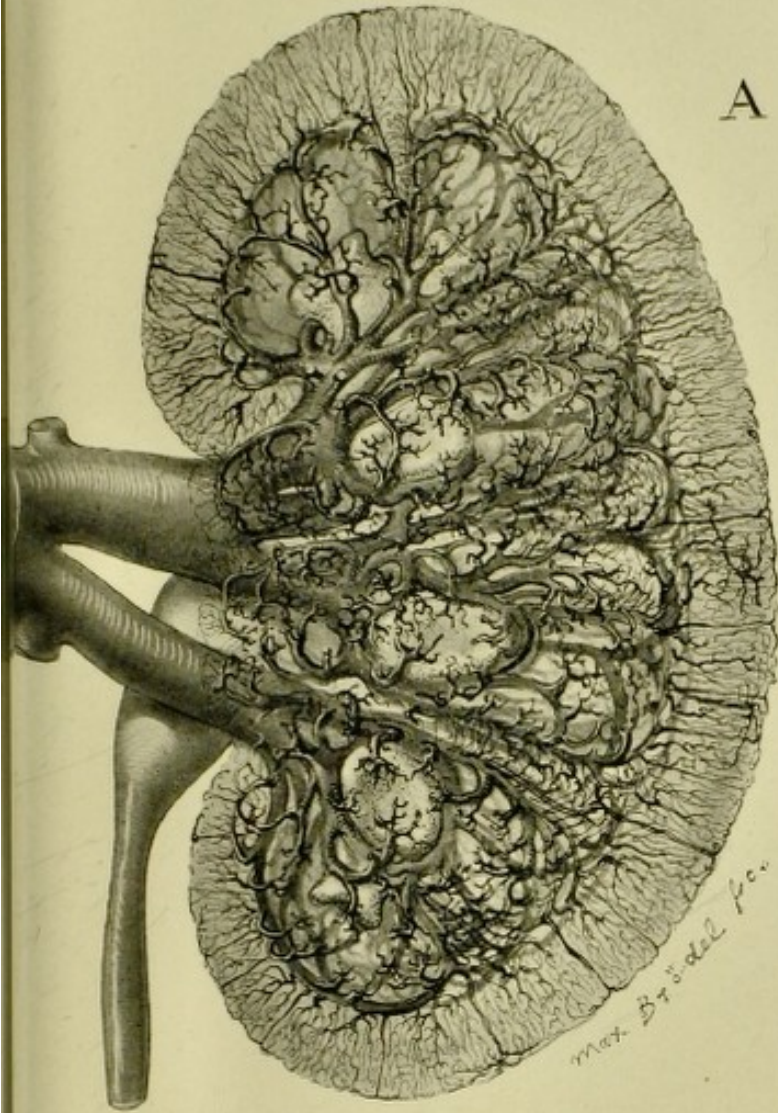


FIG. 5.—Variation of the median branch. This branch may be larger than usual and arise separately from the main artery at points *a* and *b*, or from aorta direct (*c*). It may be as large as the renal artery itself, in which case it gives off branches I and III or more. Such an arrangement of the arteries is as a rule associated with an abnormal form and position of the renal pelvis.

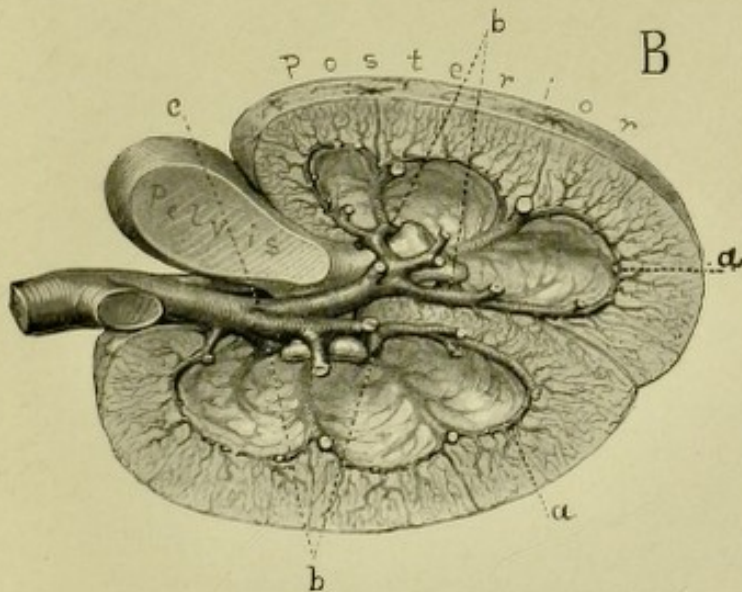




A


FIG. 6.—The renal vein and the relation of its branches to the pelvis of the kidney.

A. Anterior view of the left kidney. For the sake of clearness the small veins of the cortex of the anterior portion of the kidney have been omitted.



B

B. Transverse section seen from above. There is no collecting vein posterior to the pelvis; all the veins of the posterior region cross over to the anterior portion between the necks of the minor calices (*b*) to join the veins of the anterior region at a point indicated by *c*.



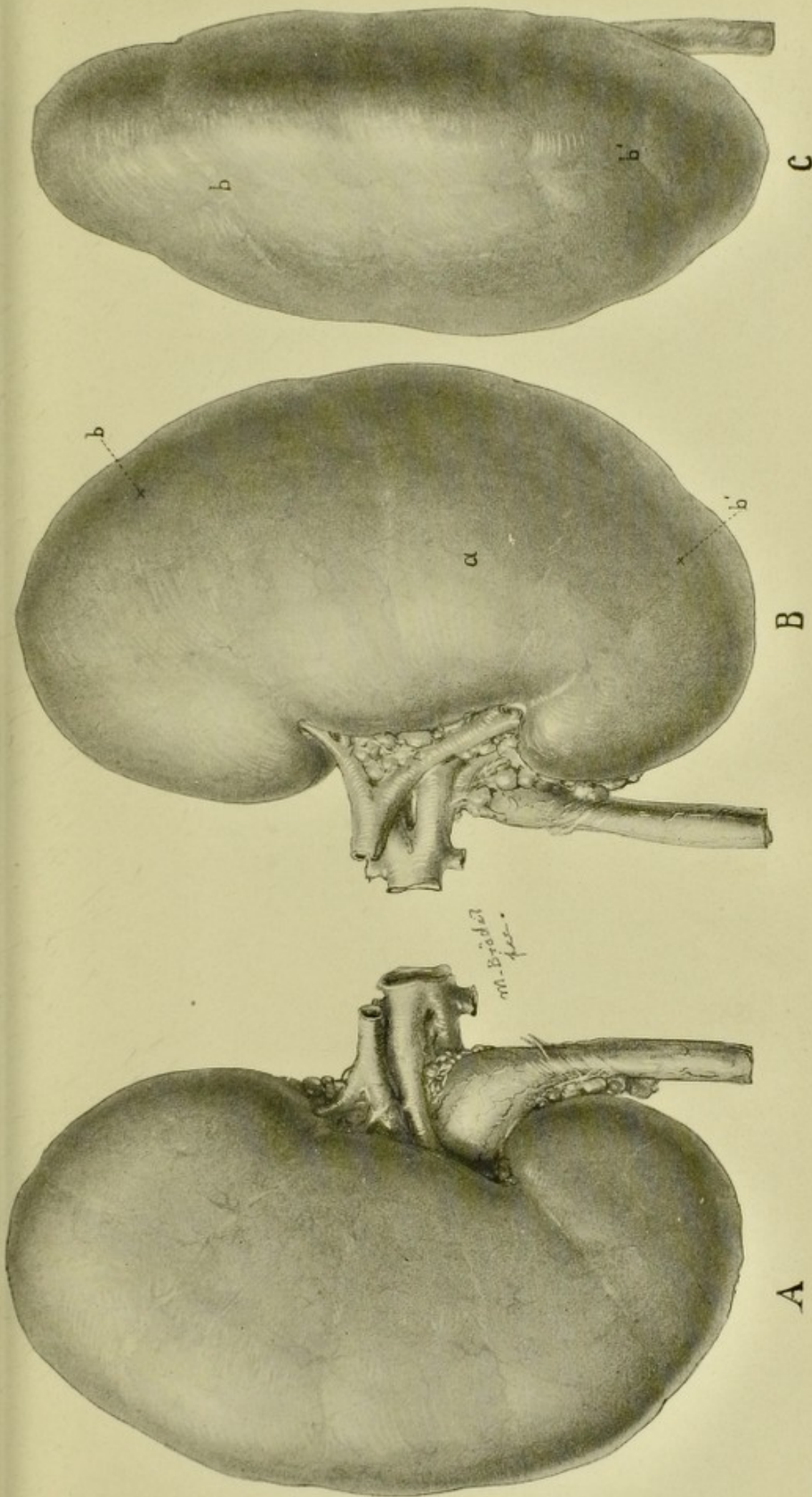



FIG. 7.—A normal left kidney. A. Posterior view.

B. Anterior view.

C. Lateral view.



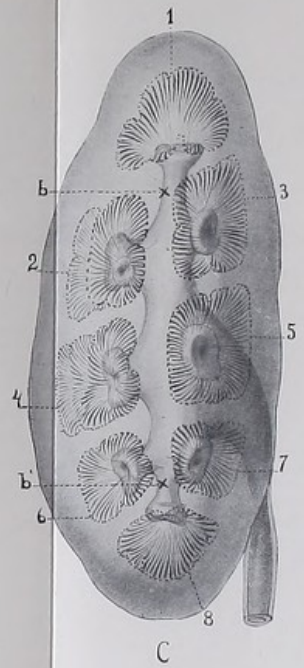
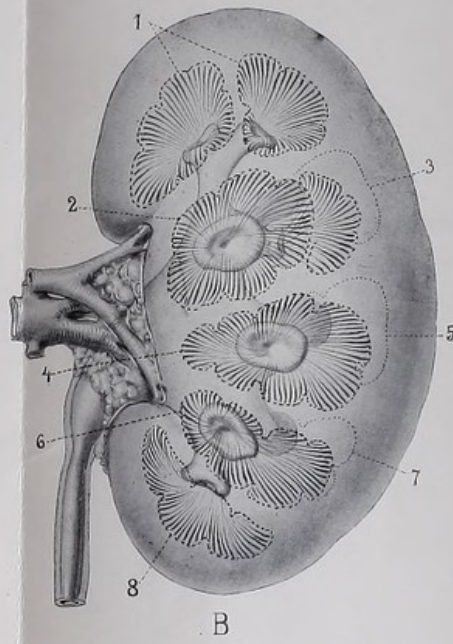
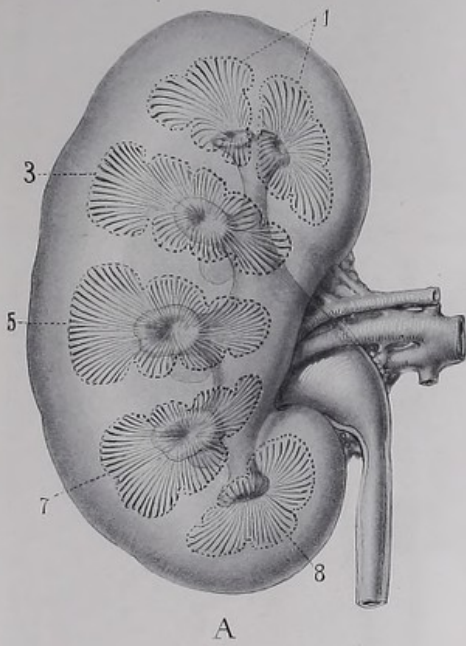
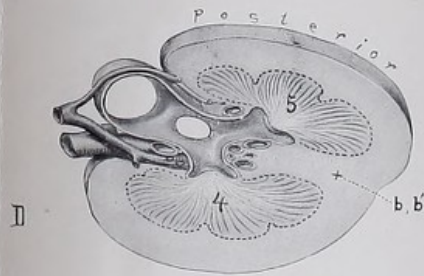



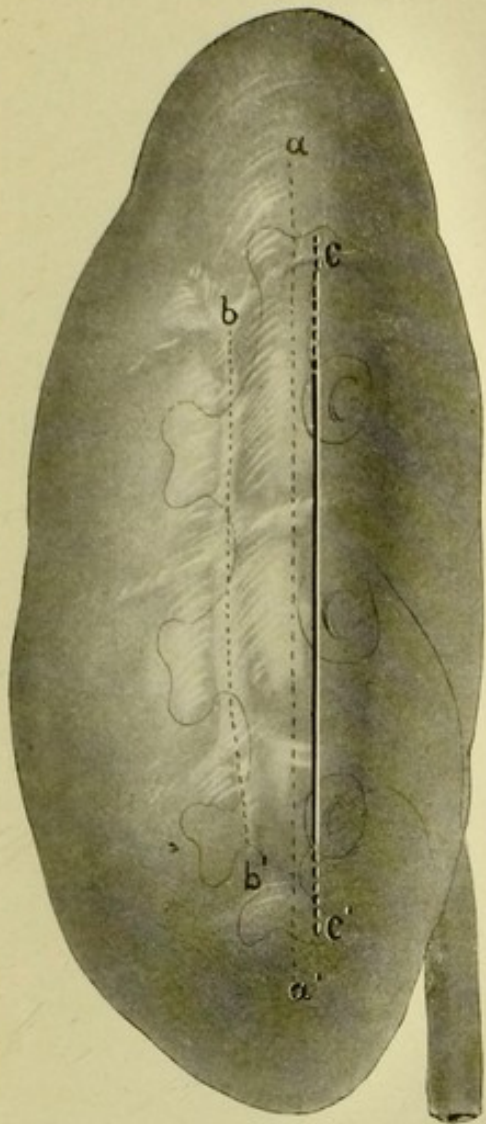
FIG. 8.—Same kidney as seen in Fig. 7 with a semi-schematic representation of the pyramids. The converging lines indicate the direction of the uriniferous tubules.

- A. Posterior region.
- B. Anterior region.
- C. Lateral view.



D. Transverse section through B seen from above.





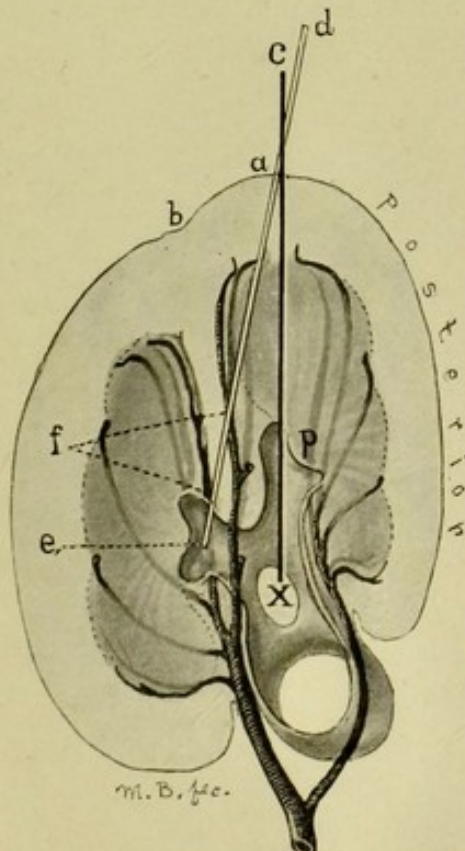
A

FIG. 9.—A. Lateral view of left kidney, showing the location of the most advantageous incision through the parenchyma in kidneys which have a normal arterial arrangement.

aa' Lateral convex border of kidney.

bb' Position of lateral column of cortical substance containing the vessels.


cc' Best incision.



B

B. *de* Incorrect direction of incision

cx Correct direction of incision.



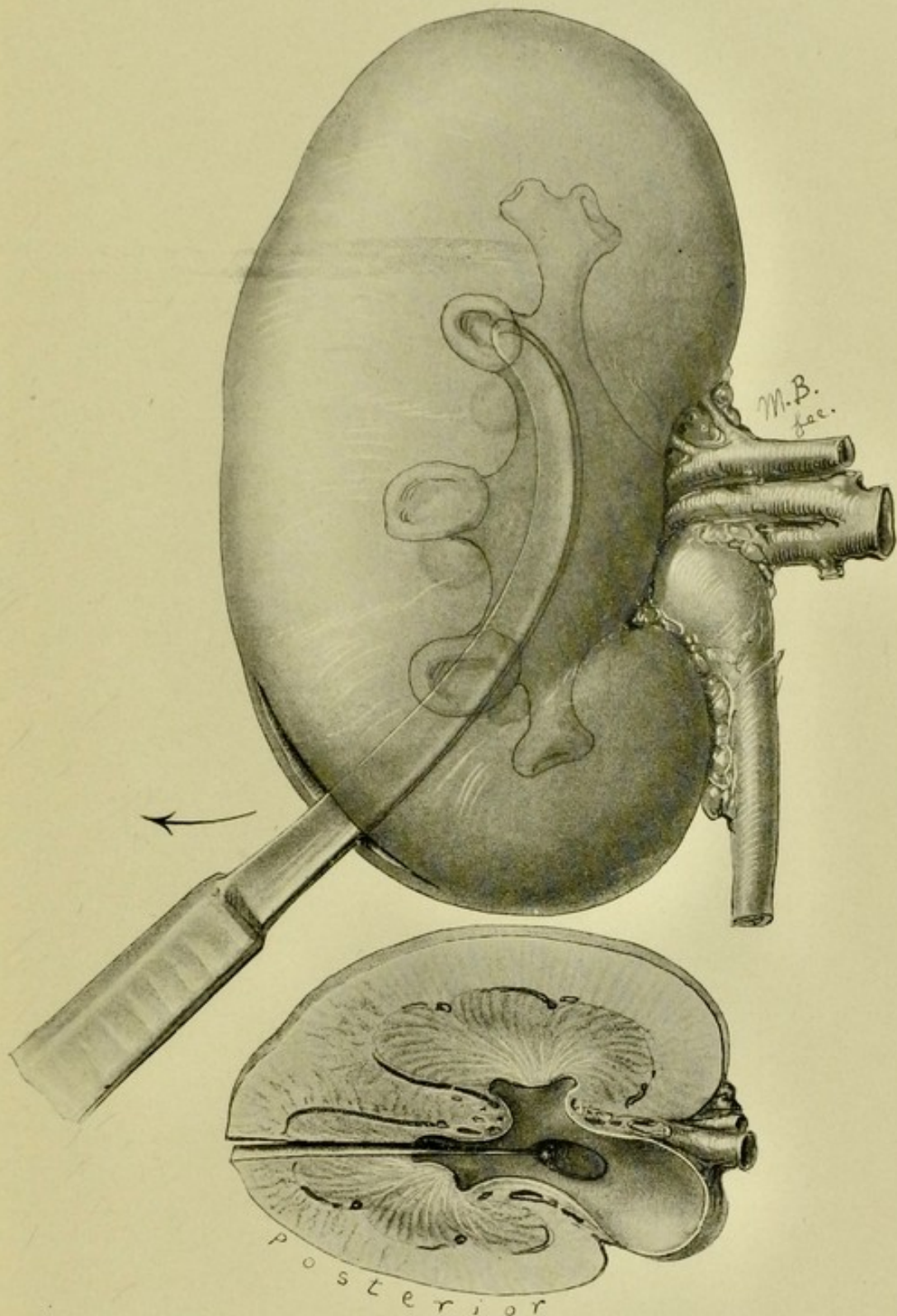



FIG. 10.—Posterior view of left kidney, showing method of exploring and opening the pelvis. The lower diagram indicates the direction of the incision in relation to the papillae of the posterior pyramids.



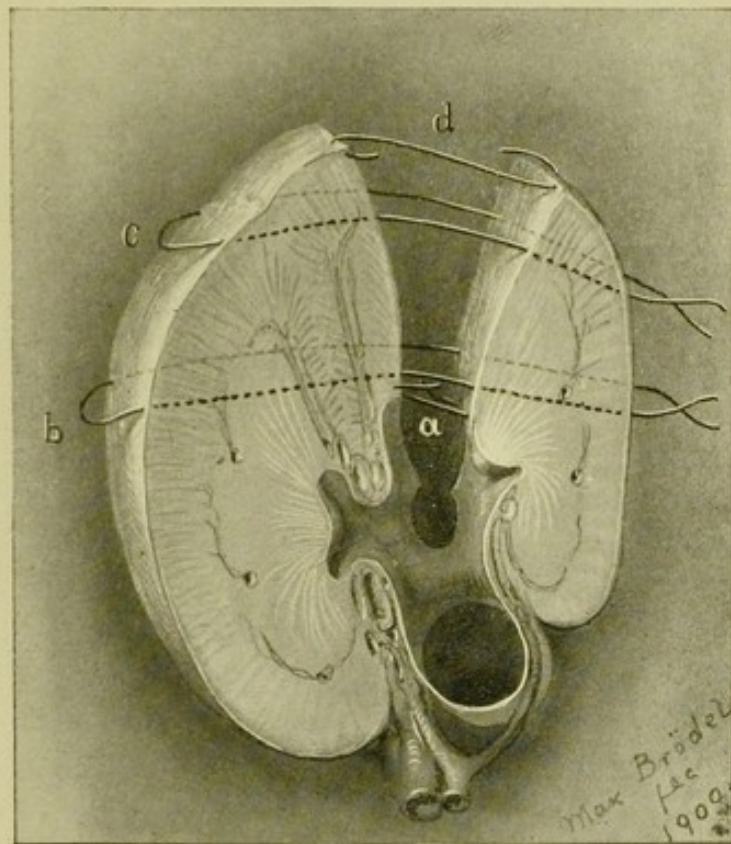



FIG. 11.—Imaginary transverse section through a kidney similar to Fig. 9 B, showing manner of placing the mattress sutures.



ing six calices stand upon the pelvis in a double row; an anterior, irregularly arranged (2, 4, 6) and a posterior, more regular, row (3, 5, 7).

The horizontal axis of the pelvis (Fig. 1 D, *a*, *a'*) runs from the posterior surface of the kidney obliquely through the organ to the outer third of its anterior surface and the two rows of calices leave this axis at almost equal angles. The posterior calices, therefore, point to a line just a little posterior to the lateral convex border of the kidney (*b*), while the anterior calices are directed straight forward into the convex anterior region of the organ (*c*). This form of the pelvis is, next to the distended pelvis, the most favorable for a surgical incision.

The great majority of pelves have well defined major calices, with a very narrow lumen, and owing to this condition it is often impossible to gain access to the minor calices and remote pockets through a surgical incision into the pelvis at the site of the hilum. Furthermore, this incision must be short, as there is a constant branch of the renal artery running downward over the posterior surface of the pelvis at the hilum.

The varieties of the ideal form are very numerous and will be described in detail in the fuller communication above referred to. All kidneys with a true pelvis have a smooth surface or moderate degree of lobulation, regular outline and, as a rule, a normal blood-supply.

(2) *Divided Pelves*.—Fig. 2 shows the typical form of a divided pelvis. Comparing it with Fig. 1 one finds that between calices 2, 3 and 4, 5 there is a zone of cortical substance (*a*), which extends to the hilum. It divides the upper part of the pelvis from the lower, and in the majority of cases the lower portion receives the greater number of calices. Although the number of calices in divided pelves may be eight, they are generally more numerous. In other respects the topography of these pelves is similar to that of the true pelves. A kidney with a divided pelvis, as a rule, preserves its fœtal lobulations and has an abnormal arterial circulation; the division between the individual sections of the pelvis is generally marked on the surface by an especially

deep groove, thus causing the appearance as though there were two separate kidneys, one on top of the other. Frequently they are indeed separate organs as far as their secretory function and their arterial circulation are concerned. The veins, however, collect, as a rule, in one single trunk. These conditions are readily understood by one who is familiar with the different stages of the development of the kidney, with its origin, its ascent from the pelvis to the lumbar region and finally the wandering in of the vessels.

The Renal Artery.—The renal artery divides at the hilum, as a rule, into four to five branches, the distribution of which, in relation to the pelvis, is such that three-fourths of the blood-supply is carried anteriorly, while one-fourth runs posteriorly. The relative size of the two systems may occasionally be $\frac{4}{5} : \frac{1}{5}$, $\frac{2}{3} : \frac{1}{3}$, but rarely $\frac{1}{2} : \frac{1}{2}$. The arteries are end-arteries in the strictest sense of the word and the branches of the anterior division never cross over to the posterior side, or *vice versa*. They do not anastomose with each other.³ The plane of division between the two arterial trees is indicated by the axes of the posterior row of calices (see Fig. 1 D b and Fig. 3 B arrow).

Fig. 3 B demonstrates this in a schematic way. The section is imagined as passing transversely through the middle of the kidney, as in the lower diagram in Fig. 1. The artery (a) sends a large branch (a') anteriorly and a small branch (a'') posteriorly. Both branches are seen running close to the pelvis and the calices up to the region of the papillæ, whence they send off fan-like branches (b) around the pyramids. The anterior branch (a') supplies the whole of the anterior pyramid (P) and the anterior portion of the pos-

³ To Hyrtl apparently is due the credit of having first mentioned the "natürliche Theilbarkeit der Niere," by which he means that in a corrosion specimen the two arterial systems are completely separated by the pelvis. He also affirms that this arrangement of the renal arteries is found "without exception in all mammalia from the whale to man." [Hyrtl, *Topographische Anatomie*. Wien, 1882. Bd. I, pg. 834.] Hyrtl's statement has unfortunately been overlooked and up to this date the text-books on anatomy and surgery make no mention of this anatomical fact, so important to the surgeon.

terior pyramid (P'), while the posterior branch (a'') supplies only the remaining portion of the posterior pyramid (P'). The arrow indicates the division between the two vascular trees. c represents a section of the long lateral column of cortical substance, which is situated between the anterior and posterior rows of pyramids P and P'.

The greater part of the arterial circulation of the kidney follows this system. The entire region from calices 2 to 7 has this arrangement. Around the uppermost (1) and lowest (8) calyx, however, the arteries have a somewhat different arrangement (Fig. 4). They are derived from the anterior group of vessels and run either as a single trunk, having a diameter of 2-3 mm., to the base of the major calyx, or divide before they reach the calyx into three branches, I, II, III. Branch I and branch III run courses similar to those of branches a' and a'' in Fig. 3 B, *i. e.* anteriorly and posteriorly to the calyx. It is obvious that their arrangement must prolong the arterial division, existing in the central portion of the kidney, upward and downward. Branch II may be short, as in Fig 3 A (upper pole), and vessels coming from branches I and III partially may take its place. Or it may be of considerable length, as in Fig. 5, where it makes a long sweep around the inner border of the pole. Branch II is the one that generally plays the rôle of the supernumerary artery; it may arise from the renal artery near its aortic origin (Fig. 5 *a* and *b*) or even from the aorta (Fig. 5 *c*); in the latter case it must be considered a supernumerary artery.

Although separate arteries are found in kidneys with smooth surfaces, they are much more frequently met with in those that have preserved their foetal lobulation. This abnormal arrangement of the arteries is, perhaps, the cause of the persistence of the lobulated form. When he meets with a kidney having a distinctly lobulated form, the operator may expect to find a long hilum with separate arteries and an abnormal renal pelvis.

The further course of the arteries, the irregularities that may occur and to what extent they affect the above described schema, will be dealt with in a fuller communication.

The Renal Vein.—Concerning the veins, I shall here record

only a few notes dealing with their more important characteristics.

While there is a complete arterial division in the plane connecting the posterior calices and terminating in the lateral half of the upper and lower calices, the veins follow quite a different arrangement. Around the bases of the pyramids they anastomose and form the familiar venous arches. They unite in large branches that run between the sides of the pyramids and the columns of Bertini to the necks of the calices, where they lie between the pyramid and the arterial branches. The thickness of these collecting veins accounts for the peculiar lobulated appearance of the base and sides of the pyramids (Fig. 6 B). Around the necks of the calices, both anteriorly and posteriorly, these veins form a second system of anastomoses (Fig. 6 B *b*) much shorter and thicker than that at the base of the pyramids (*a*). This appears as a number of thick loops or rings which fit like a collar around the necks of the calices. Nearly all the collected blood of the posterior region is carried anteriorly through these short thick stems, to join that of the anterior portion at the point indicated by *c*.

In comparing Figs. 3 and 6 one finds that an incision through the posterior row of calices would avoid all the arteries but would sever six of these collecting veins. As there remain, however, sufficient anastomoses at the upper and lower pole of the kidney, no serious consequence should follow an injury to these veins. The large veins at the hilum are generally described as being in front of the artery. This is, however, only the case in the neighborhood of the vena cava, while at the hilum and throughout the entire kidney the veins are usually situated between the arteries and the pelvis.

The Surface of the Kidney and its Relation to the Underlying Structures.—If one is thoroughly familiar with the kidney's surface it is a comparatively easy matter to determine the arrangement of the underlying structures; one can map out fairly accurately the position of the pyramids, of the columns of Bertini and of the calices; and as a consequence

the position of the plane of arterial division can also be determined. Let us consider briefly the principal landmarks.

The anterior surface (Fig. 7 B) of a normally shaped kidney is convex and has its greatest prominence at the lower portion at the point indicated by *a*. The posterior surface (A) is somewhat flattened. A lateral view of the organ (C) shows this very clearly; there is also rendered visible a depression (*b b'*), which indicates the position of the lateral column above referred to, or the line of division between the anterior and posterior rows of pyramids. This depression, however, by no means indicates the division between the arterial systems, as below it is situated the greatest number of large vessels contained in the kidney. This line (*b b'*) is therefore a most important landmark and in every nephrotomy should be thoroughly mapped out. The other depressions on the surface indicate the positions of the margins of the individual pyramids or subdivisions of such.

Fig. 8 shows the same kidney as Fig. 7, with its pyramids and calices schematically drawn. The posterior pyramids (A 3, 5, 7) are long and slender, while the anterior ones (B 2, 4, 6) are more rounded at their base, thicker and do not extend so far laterally as the posterior pyramids. Consequently, the line of division (D *b* and *b'*) between the pyramids leans more towards the anterior surface of the kidney, so that the anterior surface of the organ bulges, while the posterior is flat.

Between the pyramids are the columns of Bertini which carry the larger vessels. Fig. 8 C shows that these columns join in a longitudinal column (*b b'*), in which all of the largest vessels of the kidney (three-fourths of the arteries and all of the veins) are found (see also Figs. 3 and 6).

As was said before, in lobulated kidneys this column is indicated as a distinct depression on the surface. The capsule seems thickened along this line and frequently forms a whitish band, to which the perirenal fat appears to be more intimately attached than elsewhere.

Lobulation of varying degrees of distinctness is found in the great majority of cases. The trained eye can detect this lobulation in kidneys which a novice would pronounce per-

fectly smooth. Should, however, the kidney present not the slightest depression or lobulation, the arrangement of the large stellate veins of the capsule will still serve to sufficiently locate the limits of the pyramids and the position of the important lateral longitudinal column (*b b'*, Figs. 7 and 8). These veins are found to be more conspicuous and are arranged in rows along the lines where the foetal lobulation has been. (See Fig. 7.)

The Incision and Subsequent Suture.—The above described landmarks should suffice to guide the surgeon in making his incision so that the kidney can be readily opened between its anterior and posterior arterial branches.

Fig. 9 A shows the lateral view of the kidney; *a a'* represents a line showing the lateral convex border; *b b'* indicates the position of the lateral longitudinal column bearing the large vessels; *c c'* is the line along which an incision should be made. Diagram B shows the direction in which the knife should pass. An incision through the middle of the kidney (*d e*), would be inadvisable, inasmuch as it would cut through large vessels in region *f* and would fail to open the posterior calices. The proper direction is indicated by *c x*, the knife remaining in the posterior half of the kidney. The cut should be made anteriorly to the posterior papillæ (*p*) in order to avoid severing the collecting tubules of the posterior pyramids. It is advisable to palpate if possible the vessels and the pelvis at the hilum before making the incision, and if their arrangement is found to be normal, *i. e.* the pelvis at the posterior region of the hilum and the great majority of vessels anterior to the pelvis, then the above described procedure is applicable.

I wish to add a few suggestions as to the incision itself and also as to the subsequent suture.

A short incision is made into the lowermost posterior calyx if possible by means of blunt dissection (Fig. 1 A 7), and through this incision the pelvis is explored. In a collapsed state of the renal pelvis it may be difficult to enter one calyx. In such cases a moderate distention of the pelvis with sterile water or boric solution will facilitate the procedure considerably. If this short incision does not prove