

On aneurism and its cure by a new operation. / by James Wardrop.

Contributors

Wardrop, James, 1782-1869.
Royal College of Physicians of London

Publication/Creation

London : Longman, 1828.

Persistent URL

<https://wellcomecollection.org/works/fv9h5mvc>

Provider

Royal College of Physicians


License and attribution

This material has been provided by This material has been provided by Royal College of Physicians, London. The original may be consulted at Royal College of Physicians, London. where the originals may be consulted. This work has been identified as being free of known restrictions under copyright law, including all related and neighbouring rights and is being made available under the Creative Commons, Public Domain Mark.

You can copy, modify, distribute and perform the work, even for commercial purposes, without asking permission.



Wellcome Collection
183 Euston Road
London NW1 2BE UK
T +44 (0)20 7611 8722
E library@wellcomecollection.org
<https://wellcomecollection.org>





Digitized by the Internet Archive
in 2016

<https://archive.org/details/b28039774>

106/20.

In the Library of the
Royal College of Physicians
from the Author.

ON

ANEURISM, &c.

W. H. Johnson

Spec. Collection

University of Michigan

ANN ARBOR, MI.

106.2.

ON
ANEURISM,
AND
ITS CURE BY A NEW OPERATION,

DEDICATED BY PERMISSION TO THE KING,

BY
JAMES WARDROP,
✓
SURGEON TO HIS MAJESTY.



LONDON:
PRINTED FOR LONGMAN AND CO. PATERNOSTER-ROW,
BY WILLIAM NICOL, CLEVELAND-RROW, ST. JAMES'S.

1828.

ROYAL COLLEGE OF PHYSICIANS
LIBRARY

CLASS	616-13
ACCN.	19307
SOURCE	
DATE	

TO THE KING.

SIRE,

I venture to approach YOUR MAJESTY, for the purpose of expressing my deep sense of YOUR MAJESTY'S gracious condescension in permitting me to dedicate to YOUR MAJESTY my present Work.

In presenting this Volume to YOUR MAJESTY, I feel that I am laying it at the feet of a SOVEREIGN who has ever evinced an enlightened love for Science, and a lively interest in every pursuit, which has for its object the alleviation of human suffering.

That YOUR MAJESTY, with whose life the
welfare of the British Empire is so intimately
connected, may long reign, is the earnest
prayer of,

SIRE,

YOUR MAJESTY'S

Most dutiful subject,

And grateful servant,

JAMES WARDROP.

ADVERTISEMENT.

THIS Work is divided into four parts. The first contains a few observations on the Pathology of Aneurism, as more immediately connected with the new operation,—the second, a review of the operation of Hunter,—the third, a revival of the operation of Brasdor,—and the fourth, an account of the New operation ;—there is also an Appendix, containing some cases which could not be conveniently embodied in the work.

The materials which chiefly compose this volume have already been published in detailed parts ; but the great interest which the mode of operating here proposed for the cure of Aneurism, has excited on the continents of Europe and America, as well as in this

ADVERTISEMENT.

country, and the vast importance and increasing interest of the subject, have induced me to collect and arrange the various cases and explanatory remarks, with the hope that they may thus contribute more effectually to the improvement of the practical doctrines of the science of Medicine.

*Charles Street, St. James's Square,
November, 1828.*

CONTENTS.

Preliminary Observations on Aneurism.—

Aneurism a generic term—How they are formed, page 1—Hunter's experiments—Structure of the Sac—Of the Coagulum, page 2—Its vascularity not improbable—Hunter's observation on the internal clot, page 3—Aneurisms, where situated—"Bruit de soufflet," page 4—Mode of increase—Their situations—Mode of termination—Bursting—Spontaneous cure, page 5—Five modes of, page 7.

Treatment of Aneurism.—

Principles of treatment—Valsalva's system, page 8—Compression, page 9.

The Hunterian Operation.—

Old mode of operating, page 9—Anel's case—Principles of Hunter's operation, page 10—First adopted in popliteal Aneurism—In trunks of the first order—Effects of the operation—Languor of circulation—Coagulation of the blood, page 11—Anastomosing Arteries enlarge—Numbers of these—Observation of Sir Astley Cooper, page 12—Observation of the late Mr. Wilson—Circulation in the Sac after the operation, page 13—First observed by Sir Everard Home—Circulation continued in the Sac in two ways—Diminished force of circulation only necessary for coagulation, page 14—A new principle of operation established, page 15.

Revival of Brasdor's Operation.—

First published by Desault, page 15—First executed by Deschamps—Fatal result—Repeated by Sir Astley Cooper—Fatal result, page 16—Operation revived by the Author, page 17—Condemned by Mr. A. Burns,

CONTENTS.

page 18—Principle of Brasdor's operation—Compared with that of Hunter, page 19—Immediate diminution of the Aneurismal Tumor—The blood changes in its impetus, and coagulates—Tumor consolidates, page 20—Analogy, with the spontaneous process of cure, page 21—State of the blood when the artery is tied on the *cardiac* and on the *distal* side of an Aneurism, page 22—Comparative function of the ligature in these two situations, page 23.

First Case of Carotid Aneurism.—

Symptoms, page 24—Treatment—Brasdor's operation applicable, page 25—Operation—External incision—Exposition of the Artery, page 26—Its ligature—Immediate diminution of the Aneurismal Tumor, page 27—Subsequent changes—Discharge of the coagula by ulceration through the skin, page 28—Successful result of the operation, page 29.

Second Case of Carotid Aneurism.—

History of the case, page 29—Symptoms—Operation, page 30—Reports, page 33—Dissection, page 34.

Third Case of Carotid Aneurism.—

Symptoms, page 36—Diagnosis, page 38—Operation, page 39—Immediate diminution in the bulk of the Tumor, page 41—Reports, page 42—Hæmorrhage from the wound,—Cicatrization of the wound, page 43—Ulceration of cicatrix—Protrusion of a Fungus, page 44—Hæmorrhage from the wound—Fatal result—Dissection, page 45—Innominate healthy, page 46—*Cardiac* orifice of the Carotid closed—Sac filled with coagulum—Coats thickened—Artery ulcerated, page 47—Its *distal* orifice pervious, page 48.

Fourth Case of Carotid Aneurism.—

Symptoms, page 49—Operation, page 50—Sudden diminution of the Aneurism, page 52—Reports—Success of the operation.

CONTENTS.

Observations.—

Brasdor's operation established, page 53—Its application—Preferable to that of Hunter—Cause of the diminution of the Tumor, page 54—Hæmorrhage, two sources of, page 55—Retrograde motion of the blood—Important as regards the ligature, page 56—Limb, how nourished, page 57.

The New Operation.—

Rationale of Hunter's operation, page 57—Practical application of New operation in Aneurism of the Innominata, page 58—Neglect of Brasdor's operation—Too limited a view of its application—Views of the Author, page 59—Their practical utility—Coagulation, how affected in an Aneurism—Complete stoppage of the circulation in the Sac not necessary, page 60—A new principle of operating for Aneurism suggested by the Author, page 61—Necessary degree of diminution in the force of circulation not yet ascertained; probably very small, page 62—Coagulated lymph formed in every Aneurismal sac—Other effects of diminished impetus in the blood, page 63—How produced—Principle of the New operation illustrated, page 64—Application of the principle in Aneurisms of the Innominata, page 65—Illustrated by a Diagram, page 66.

Case of Aneurism of the Innominata treated by tying the Subclavian Artery.—

Tumor in the right side of the Neck, page 66—Change in the form of the Neck—And in the pulsation of the Carotid, page 67—State of the Thorax—General symptoms—History of the disease, page 68—Treatment—Operation—Subclavian Artery tied, page 69—External incisions—Supra-clavicular space exposed—Ligature placed on the artery, page 70—First effects of the operation—Relief in breathing—And in the head—Change in the Tumor—Reports, page 71—The Second Report

CONTENTS.

of this Case, page 72—Pulsation in the right Carotid returned, page 73—How this is to be explained, page 74—Ligature came away—The Third Report—A retrospect of the Case, page 75—State of amendment, page 77—The Fourth Report, page 78.

Concluding Observations.—

New operation, where applicable, page 82—Diagnosis of Aneurisms in the Neck, page 83—Diagnosis of Carotid Aneurism—Diagnosis of Aneurism of the Innominata, page 84—Diagnosis of Subclavian Aneurism—Diminished pulsation in the branches of an Aneurismal Artery—Difficulty of diagnosis of Aneurisms of the Neck, page 85—New Operation in Aneurisms of the Innominata—When to be adopted—One branch of the diseased trunk to be first tied, page 86—Carotid the most preferable, page 87—Or the branch which remains open—Conclusion, page 88.

Appendix.—

Case of Aneurism of the Innominata and root of the Carotid successfully treated by tying the Carotid Artery, by D. Evans, Esq. Surgeon at Belper, Derbyshire, page 93—Aneurism of the Innominata where the Carotid Artery was found obliterated, page 103—Aneurism of the Carotid Artery which had undergone a spontaneous cure, page 106—Aneurism of the Innominata and root of the Carotid and Subclavian Arteries, page 107.—Femoral Artery obliterated, and its place supplied by one enlarged vessel, page 117.

Explanation of the Plates.—

PRELIMINARY OBSERVATIONS

ON

ANEURISM.

ANEURISM has been used as a generic term, Aneurism a generic term. under which are comprehended many different diseases, which have no common character, except that they involve the arterial system. Thus the True, and False, the Varicose, and Anastomosing Aneurisms, all receive the same general title, although they differ essentially in their pathological character.

Aneurism, properly so called, which compre- How formed. hends the True and False aneurisms, is formed in two different ways.

The three tunics of the artery either yield and form an aneurismal swelling, or one or both of the internal tunics are ruptured by the impetus of the blood; the cellular coat of the vessel alone forms the parietes of the tumor, and prevents the effusion of blood into the surrounding parts.

Scarpa pointed out this last mode by which an aneurismal tumor is formed, but he conceived

that aneurisms arose only in that way. The dissections however, and observations of other pathologists, have clearly proved, that an aneurismal tumor may be formed without any rupture of the fibrous or inner coats, and merely by a dilatation of all the coats of the vessel.

When an aneurism is formed by a rupture of the internal and fibrous or middle coats, there is generally a transverse fissure found in the tube of the artery, and this is sometimes irregular or ragged; hence the dilatation of the cellular coat forms a tumor, which is more or less prominent.

Hunter's
experiments.

Endeavours have been made artificially to imitate the formation of an aneurism by experiments on animals. For this purpose John Hunter laid bare the carotid artery of a dog, and afterwards "skinned it with a knife even to transparency." No dilatation of the vessel took place. Three weeks afterwards the animal was killed, and the artery on which the experiment was made, in place of being dilated, where the external tunic had been detached, was found thickened by the inflammation and subsequent adhesion of the adjacent cellular structure.

Structure of
the sac.

Of the coa-
gulum.

In examining the sac of an aneurismal tumor, it is observed that the coats of the vessel are more or less thickened, and the cellular or external sheath is connected with, and adheres to the surrounding cellular structure. The aneurismal sac is more or less filled with coagulable lymph, and this lymph is always found formed in laminæ, these being

firmer the nearer they are to the coats of the sac.

The coagulum in an aneurismal sac sometimes adheres so closely to the internal tunic, that it is not improbable that there exists a vascular connection between them. There is no doubt, however, that this coagulable lymph, or at least the greater portion of it, is separated from the blood which circulates in the tumor, and is not effused from the surface of the internal membrane, in like manner as we observe lymph effused on the surface of inflamed serous membranes. It is not improbable, however, that some lymph may also be effused from the internal surface of the sac itself, and that such lymph, by its organization and intimate union with that deposited from the blood, may in time become an intermediate bond of living union between the coats of the sac and the mass of laminated coagulum.

This connection has not been accurately observed nor pointed out by pathological inquirers; yet it is a fact of much interest and importance, and in my opinion bears a strong analogy with that coagulum which is formed in an artery when a ligature has been placed upon it, and which is termed the internal clot. This coagulum intimately adheres to the sides of the vessel, at the place of the ligature, but its organization has never yet been with certainty demonstrated.

In one instance John Hunter injected the coats of an artery on which a ligature had been applied,

Its vascularity
not improbable.

Observation of
John Hunter.

and on examining the preparation, which still exists in his splendid Museum, there is a redness to be perceived in a portion of the coagulum. He states however in the catalogue, that he is doubtful whether the red color has been produced from injected vessels, or from effusion of the coloring matter.

The internal laminæ of the lymph in an aneurismal sac are sometimes covered with a coagulum of red blood, and at other times, when the process of consolidation of the sides of the sac has been completed, the coagulated mass has a distinct lining membrane which is smooth and polished, and in every respect resembles the lining membrane of a healthy artery.

Aneurisms
where situated.

Their form and
pulsation.

An aneurismal tumor, as may readily be supposed, is always found situated along the trajet of an artery. During the first stage its form is more or less rounded, accompanied with no discoloration of the skin, and to the touch it feels firm, and has a pulsation synchronous with that of the heart; the pulsations seem to result from dilatation of the sphere of the tumor, and not from any motion of elevation communicated to the mass.

"Bruit de
soufflet."

A peculiar whizzing sound accompanies this pulsation, which has been distinguished by the French, by the term "*bruit de soufflet*," from its resemblance to the sound made by a pair of bellows.

If the vessel be compressed between the tumor and the heart, the pulsation ceases, and is again renewed when the compression is removed.

As an aneurism enlarges, the pulsation of it becomes less and less sensible, and it ultimately communicates but a slight degree of noise when the hand is applied upon the surface. Neither can compression now diminish its volume.

The dilatation of an artery usually extends towards that side where there is the least resistance made by the contiguous parts. The artery will generally be found to continue to swell, in the direction in which it first began to tumefy, and the distal is found to be dilated more than that portion nearest the heart.

Aneurismal tumors are accompanied with a variety of uneasy sensations, arising from the peculiarities of their state as connected with particular nerves, or as being contiguous to particular veins.

Where aneurisms advance to their last stage, they terminate when the tumor adheres to a mucous surface either by bursting or sloughing, and they crack or ulcerate when in the serous surfaces, such as in the cavity of the pericardium or chest; or they may terminate by what is called a spontaneous cure.

It is particularly worthy of attention, in reference to the following remarks, that the reader should have a correct knowledge of the manner in which the spontaneous cures of aneurism are

Five modes of. effected. Now there are no less than five ways in which these may take place, though in all, the principle, which nature employs for the cure, is the same.

1st mode. The first of these is accomplished by the aneurismal sac being so strengthened and filled with coagulable lymph, that no fluid blood can pass into it, and of course all danger of rupture is prevented, whilst at the same time the original canal of the vessel remains pervious, and carries on the circulation.

2nd mode. An aneurism may undergo a spontaneous cure, by not only the sac being filled with coagulable lymph, but by the arterial canal being also obliterated.

3d mode. An aneurism may also be cured by the tumor acquiring such a size and position, that by pressing on the trunk of the artery above or below, the sides of the aneurism are thus brought into contact, and adhere. Such a case was first described by that enlightened pathologist Sir Everard Home, and similar cases have also been related by Scarpa.

4th mode. A spontaneous cure of aneurism has also been known to take place, where the whole circumference of the vessel has been dilated, the sac being filled up with coagulum, but leaving a canal in the midst of the tumor through which the blood continued to pass*.

5th mode. An aneurism may be cured by a process of sup-

* Vide Hodgson's excellent work on the diseases of the arteries.

puration taking place in the sac, after both it and the artery above and below the tumor have been filled with coagulum. In such a case the integuments ulcerate, and a great quantity of the coagulum is discharged through the opening which cannot be removed by the process of absorption.

Illustrations of these spontaneous processes by which an aneurism is cured, are given in the plates which accompany this work. See Appendix.

Treatment of Aneurism.

ANEURISM is a disease of so peculiar and dangerous a character, that its treatment must necessarily have engaged much of the attention of Surgeons. Accordingly we find, that at different periods, various methods have been promulgated by which the disease might be alleviated.

Principle of
Treatment.

The different modes which have been successively employed for the treatment of Aneurism, are all in strict imitation of those *natural* or *spontaneous* processes of cure which have been mentioned.

Valsalva's
system.

As it is the force of the circulation which causes the enlargement in an aneurismal tumor, as well as its ultimate rupture, and as the coagulating process, or the formation of laminated coagulable lymph within the sac proceeds more or less quickly; according as the force of the circulation is diminished; hence is to be explained the rationale of Valsalva's system of treatment, which he, as well as others since his time, have in many instances successfully adopted. Indeed depletion has in some cases been carried to a very great extent, and Valsalva recommended that blood should be removed by repeated bleedings, even until the patient is reduced to the last stage of weakness. Under such circumstances, the great languor of circulation which is induced, will enable the

coagulating process to go on, and thus the parietes of an aneurismal sac to be strengthened, so that a return of the natural force of the circulation will no longer cause an increase of the bulk of the tumor, but will be followed by its consolidation and gradual diminution.

Compression has also been employed for the Compression. cure of aneurism. It is not however very easy to conceive how pressure, applied to the aneurismal tumor itself, should cure it. It appears to me, that success in such cases of aneurism ought rather to be attributed to the pressure acting on the vessel above or below the tumor, rendering the circulation in it more languid, and thus contributing to the formation of coagulum, in like manner as in the other modes of treatment.

The Hunterian Operation.

As surgery improved, and as the insufficiency of these means became apparent, medical practitioners were emboldened, in favorable cases, to attempt an operation.

The method which they at first employed was Old mode of operating. to cut down into the aneurismal tumor, remove the coagula of blood, and then endeavour to tie the bleeding extremities of the vessel. This operation, independent of the great difficulty of its execution, gave rise to numerous bad consequences which in a great majority of cases terminated the life of the patient.

Anel's case.

Anel, to whom surgery is indebted for many valuable improvements, first conceived, in order to avoid the dangers of the operation then in common use, the idea of tying the diseased vessel above, or on the cardiac side of a popliteal aneurism.

This principle was not however established until the time of John Hunter, when that extraordinary man pointed out and executed the mode of operating, which has since been universally adopted, and which has justly been considered one of the greatest improvements in practical surgery.

Principle of
Hunter's
Operation.

The operation by Hunter consists in placing the ligature on the cardiac side of the tumor, but at a greater or less distance from it, thus not only avoiding all the difficulties and dangers of opening the sac, but also procuring a sound portion of the artery on which to apply the ligature.

Mr. Hunter was led to contemplate this principle, as particularly applicable to aneurisms of the popliteal artery, from the circumstance, that the old operation was here very difficult to accomplish, while the artery, at a considerable distance above the tumor, may be tied with great facility. The only circumstance which could have been argued against the propriety of this operation, was the danger of the limb not having a sufficient supply of blood, if the artery were obliterated high up in the thigh; but a multitude of facts gave Mr. Hunter assurance that the freedom of anastomosis which subsists between the branches

of the deep and superficial femoral arteries would be fully adequate to the nourishment of the limb.

Mr. Hunter established his principle of operating by tying the superficial femoral artery in cases of Popliteal aneurism; and though he failed in his first operations, yet the principle which he then established emboldened other Surgeons, more particularly those in this country, to act upon it, and hence, modern surgery has been enriched by a series of the most bold and splendid operations, whereby arterial trunks of the first order of magnitude have been successfully tied for the cure of aneurism.

Mr. Abernethy, upwards of 25 years ago, was thus emboldened to tie the trunk of the external iliac in an aneurism of the inguinal artery. The late Mr. Keate tied the subclavian artery for the cure of an axillary aneurism. Dr. Mott, of New York, applied a ligature to the Innominata. Sir Astley Cooper tied the carotid; and finally, the same distinguished Surgeon secured the Aorta itself.

When the Hunterian operation is performed, as I have already noticed, the changes which take place in the sac are similar to those which are observed when an aneurism undergoes a spontaneous cure. The circulation in the part of the vessel between the ligature and tumor, and also the current of blood in the tumor itself, is diminished. The blood being more or less in a state of rest, the coagulating process is allowed to proceed, the contents of the sac to consolidate, and the sides of the artery coalesce.

First adopted
in Popliteal
Aneurism.

In trunks of the
first order in
magnitude.

Effects of the
Operation.

Languor of
circulation.

Blood
coagulates.

It seems to be a law of nature, that whenever the circulation is directed into a new channel, the vessels in which the blood was originally carried, now being no longer of use, contract and become gradually obliterated. Of this, the obliteration of the ductus arteriosus and ductus venosus afford striking examples, as well as the changes in the umbilical artery and vein after birth.

Anastomosing
arteries enlarge.

Whilst this process is going forward in the tumor, the limb continues to be nourished by the enlargement of the anastomosing vessels. The enlargement of these to a certain extent takes place almost instantly after the trunk has been tied. I observed this in a child in whom I had secured the carotid artery. I could see the branches of the temporal and occipital underneath the delicate integument enlarging, and thus actively acquiring great additional vigour immediately after the operation.

Their number.

However necessary it may be that the calibre and activity of a considerable number of the anastomosing vessels should at first be increased in order to supply the limb with its due quantity of blood, dissections have proved, that ultimately the function of the vessel which had been tied was supplied by a very limited number of arteries, and those too nearly in the site of the original.

Sir A. Cooper's
Observation.

Med. and Chi-
rurg. Tr. vol. iv.
page 25.

Sir Astley Cooper amputated the thigh of a man on whom he had operated some years before for a popliteal aneurism, and he found an artery in the limb of equal magnitude, and apparently in the site of the femoral artery. "Hypothesis," says he,

“ would lead to a belief that anastamosing vessels would be numerous in proportion to the time which had elapsed from the operation, but the reverse of this is the fact; for at first many vessels convey the blood originally conducted by the principal artery; but gradually the number of these channels becomes diminished, and after a length of time, a few vessels conveniently situated for the new circulation become so much enlarged as to be capable of conveying an equal portion of blood to that which passed through the original trunk.”

The observations made by the late Mr. Wilson, also show how this process is accomplished, and how nature enlarges only one vessel, and that also nearly in the site of the divided one to supply its place. Mr. Wilson observed, that in a few hours after the division of a vessel on the sclerotica, one contiguous began to transmit red blood, gradually to enlarge, and in twenty four hours to acquire the bulk and assume apparently the site of the divided artery.

Mr. Wilson's
Observation in
his Lectures on
the Arteries, &c.

See also
Appendix.

When the Hunterian operation for the cure of aneurism was first contemplated, it was no doubt undertaken on the principle, that it would be followed by a *complete* stoppage of the circulation of the blood in the tumor. But in some of the cases operated upon by Mr. Hunter, and related by Sir E. Home in the Transactions of the Society for the Improvement of Medical and Chirurgical Knowledge, Sir Everard states, that the tumor in the ham continued to pulsate for a considerable time

Circulation in
the sac after the
Operation.

Sir Everard
Home's Obser-
vation.

after the ligature had been placed on the superficial femoral artery; and the important conclusion Sir Everard drew from that fact was, "that simply taking off the force of the circulation from the aneurismal artery is sufficient to effect a cure of the disease, or at least to put a stop to its progress, and to leave the parts in a situation from which the actions of the animal œconomy are capable of restoring them to their natural state."

Circulation
continued in
two ways.

Now, by subsequent observation it has been found, that the circulation through an aneurismal tumor has been continued after the trunk has been tied in two ways; the one, in consequence of some branch or branches passing from that portion of the vessel between the tumor and ligature continuing open and communicating by anastomosis with other trunks; the other by branches arising beyond the tumor anastomosing with other trunks. But in whatever mode the circulation has been kept up in the sac, the diminution in the force of circulation has been sooner or later sufficient to ensure the consolidation of the tumor, excepting in a few cases, and these have been in consequence of some unusual distribution of vessels, where the supply of blood into the tumor was so large as not to diminish the force of circulation to that degree necessary to admit of the process of coagulation.

Diminished
force of circula-
tion sufficient.

The knowledge of this fact, so distinctly stated by Sir E. Home, did not lead, however, to any practical inference, further than pointing out that

the circumstance of circulation in the tumor being carried on even after the artery was tied, ought not to be considered as an objection to Mr. Hunter's operation.

I shall however have occasion to point out the importance of this pathological fact, and to endeavour to demonstrate, that it enables us to establish a new principle for operating in aneurisms so situated, as hitherto to have been considered beyond the reach of art, and to which the Hunterian principle of operating is totally inapplicable.

Establishes a new principle of operation.

Revival of Brasdor's Operation.

Those aneurismal swellings so situated that the knife of the surgeon could not reach the vessel between the tumor and the heart, have hitherto been deemed incurable.

Brasdor indeed, a professor in the ancient school of surgery in Paris, upwards of forty years ago made a proposal in his lectures of another mode of operating for aneurism, which was to place a ligature on the aneurismal artery on the distal, in place of the cardiac side of the sac, as recommended by Hunter.

Boyer, Traité de Malad. Chir. Tom. ii.

Dessault was also in the habit of mentioning this proposal in his surgical lectures, and seemed to think that, in cases of aneurism where the situation of the tumor was such as to render the other operation impracticable, Brasdor's proposal might be worthy of trial. But this justly celebrated Surgeon never embraced any opportunity

Dessault first publishes Brasdor's proposal.

he may have had of putting the new operation to the test of experience.

Deschamps first
executed it.

Deschamps, however, his contemporary, executed this new operation of Brasdor's, though under the most unfavorable circumstances.

Case.

A man 60 years of age had, in the superior part of his thigh, an aneurism seventeen inches in circumference, and so situated that there was not above a finger's breadth between the tumor and Poupart's ligament. M. Deschamps obtained a consultation, and proposed to put a ligature on the artery *below* the tumor, hoping that the stagnation of the blood would cause it to coagulate.

Operation.

The operation was performed, but was tedious and difficult on account of the pulsations of the artery not being distinguished. The progress of the tumor had been very marked immediately previous to the operation, and it increased so much after it, that upon the fourth day rupture appeared at hand. It was then decided to adopt another operation, and to tie the artery according to the ordinary method, notwithstanding all the considerations which had formerly prevented its being done.

Result fatal.

Compression was made against the pubes; and after opening the aneurismal sac, two ligatures were placed, one above and the other below the opening in the artery; but the hemorrhagy was very great during the operation, and the patient died in eight hours.

Sir Astley
Cooper's case.

Sir Astley Cooper operated on the same principle

in a case of aneurism of the external iliac artery, which extended into the abdomen, so high as to render it impracticable to tie the artery on the cardiac side of the tumor. The femoral artery was therefore tied between the origins of the epigastric artery, and the profunda. The pulsation afterwards continued, but the tumor did not increase after the operation. The aneurism diminished so considerably, that it was conceived that if its diminution continued, it would then be possible to have the internal iliac artery tied on the cardiac side of the tumor. The aneurism however burst, and the patient died in consequence of the extravasation of blood, in the adjacent cellular membrane. Result fatal.

These were the only cases in which this mode of operating had been adopted from the time of its proposal by Brasdor, until about three years ago, when I had myself an opportunity in a case of aneurism at the root of the carotid artery, of putting it to the test of a fair trial. Operation revived by the Author.

Seventeen years ago I had seen, with my friend Dr. Monro, a patient who had an aneurism of the *arteria innominata*, and root of the carotid, and I was very anxious in this case to have tied the carotid artery, but the vessel had only been once secured at that period for the cure of aneurism, according to the Hunterian principle, so that the patient was left to his fate. The dissection afterwards however, shewed that it was an example of aneurism well calculated for the practice. See Appendix.

These cases seemed to me to be sufficient to prove the correctness of the principles of the original projector of this operation; and it is only to be wondered at how surgeons should not have long ago adopted it; and though some subsequent writers have advocated the propriety of the experiment, others attempted to throw it into ridicule.

See Appendix.

Brasdor's
operation con-
demned by Mr.
A. Burns.

"I cannot conceive," says Allan Burns, "a more futile idea than to suppose that such an operation could possibly tend to prevent the growth of an aneurismal sac: one might readily believe that it may, by preventing the blood from passing freely through the tumor, cause it to enlarge more rapidly than before. That it would occasion a firm coagulum of the contents of the aneurism, and consequently enlargement of the anastomosing branches; a diversion of blood from the tumor is what one would hardly expect, and least of all would any one imagine, that Dessault would have been the projector of such a doctrine, and Deschamps the first to put it to the test of experiment. In doing this, the latter had no reason to boast of his dexterity, nor could he say more of his success. Indeed, all circumstances considered, there is no point in the treatment of aneurism, which should be more decidedly reprobated than this: it is absurd in theory, and experience proves that it is ruinous in practice."

Surgical anatomy of the
head and neck,
by Allan Burns.

With regard to the principle on which the operation, as proposed by Brasdor, cures an aneurismal tumor, I would first observe, that the changes which such an operation produces both in the artery and sac, are precisely those which nature employs when she cures the disease by a spontaneous process.

Principle of
Brasdor's operation,

When, according to Hunter's method, a ligature is applied between the aneurism and the heart, the whole mass of blood contained between the ligature and tumor, as well as that in the tumor itself, suddenly ceases to circulate, whilst the ligature has to resist the impulse of the blood in the opposite portion of the vessel, until the internal clot and the adhesion of the sides of the vessel are sufficient to prevent hemorrhage. The blood in the tumor subsequently coagulates, and the diminution and consolidation of the aneurism, and its artery afterwards, take place more or less quickly.

Compared with
that of Hunter.

Now let us consider what will happen if the ligature be placed beyond, or on the *distal* side of the aneurismal tumor, and in a case where no branch either passes directly into the tumor or comes off from the trunk between the tumor and the ligature. No sooner is the ligature in such a case tied, and the usual course of circulation interrupted, than as after the Hunterian operation, the anastomosing vessels dilate and perform the function of the obliterated or obstructed trunk.

It might be expected that at the same moment

of tying the ligature, the resistance thus given to the circulation would cause an increased impetus in the vessel to propel its contents, not only against the ligature, but against the parietes of the tumor. But this increase of impetus we know can continue but for a very short time; for when a vessel is divided or tied, in a few hours branches of the divided trunk, which can only be supplied by anastomosis, freely carry on the circulation; and the cases in which this operation was performed, and where the tumor was large, prove that instead of increasing, in a few minutes after the vessel was tied beyond it, the swelling diminished, a circumstance which was ascertained by the skin covering it, which was tense and ready to burst, suddenly forming into wrinkles.

Immediate diminution of the tumor.

If the circulation be turned into a new channel, and if that channel completely fulfil the purpose, the sac with its contents, as well as the portion of artery extending between the aneurism and the ligature, and also the blood contained in it, will now be in a passive state; and though the blood will continue for a certain time to be influenced by the impulse of the circulation, carried on in that part of the vessel which passes into the tumor, still its motion must become not only languid, but its current irregular, a state which we know admits of its speedy coagulation.

The blood changes in its impetus and coagulates.

Whenever coagulation of the blood in the tumor does take place, then the cure of the aneurism may be said to be accomplished, the sac will

Consolidation of the tumor

contract, the coagulum will be absorbed, some portions in contiguity with the sac will become organized and consolidate, others if the quantity be very large, will escape by a process of ulceration through the skin, and ultimately a gradual coalescence of the tumor will thus take place.

Now all these phenomena, are precisely those which are to be observed during one of the modes Analogy with the spontaneous mode of cure. which nature employs in the spontaneous cure of aneurism. We observe that whenever the aneurism is so large, or so shaped that the circulation of blood in any part of it is altered in its course, or diminished in its impetus, then coagulation commences, and it proceeds until the cavity of the aneurism is obliterated. If the aneurismal tumor be of a moderate bulk, its contents are afterwards absorbed, and its parietes coalesce. But when the tumor is very large, nature removes some of the coagulum by producing an ulceration of the sac and superincumbent integuments, and thus evacuates such coagula as cannot be removed See Appendix and Plate. by the process of absorption; in such instances the artery is plugged up as in cases of mortification.

I may here observe with regard to the spontaneous cure of aneurism, that though nature cures this disease on certain principles, derived from the peculiar functions of the coats, as well as contents of the arteries, yet she diversifies her practical application of these means according to the place where the aneurism is situated, or

according to the peculiar form or bulk of the swelling.

State of the
blood when the
artery is tied on
the cardiac,

It is also worthy of consideration to compare the difference in the state of the blood contained in an aneurismal tumor when the ligature is placed on the *cardiac* or on the *distal* side of the tumor.

When on the cardiac side, the blood cannot make its escape, and cannot be pushed through the capillaries into the veins. It must remain in the sac, and must either be absorbed, or be evacuated by a process of inflammation and ulceration of the sac.

or distal side of
the aneurism.

When the ligature is placed on the distal side of the aneurism, as I have already stated, we know from experience, that there is immediately a diminution of the bulk of the tumor. The fluid-blood can find in such case a ready exit into the trunk from whence it came, and thus again passes into the circulation, in place of, as in the other case, having to pass through capillaries into veins,—and as nature immediately finds a new channel there is no more blood impelled into the tumor afterwards.

In the two first cases of carotid aneurism, where Sir Astley Cooper tied the carotid artery on the cardiac side of the tumor, both the patients died from an increase in its size, which took place after the operation. It would therefore seem that when the ligature is placed on the cardiac side of the tumor, it is not freed of its contents, but a congestion takes place of all the blood which may

be contained in it at the time of the operation ;
 whereas when a ligature is applied on the distal
 side of the aneurism, an immediate and permanent
 diminution of the tumor is effected. Sir Astley

Trans. of the
Med. and Ch.
Society, Vol. i.

Cooper states, when speaking of the case of carotid aneurism, where he tied the artery on the cardiac side of the tumor, " that the cause of her death was the inflammation of the aneurismal sac, and parts adjacent, by which the size of the tumor became increased so as to press on the pharynx, and prevent deglutition, and upon the larynx, so as to excite violent fits of coughing, and ultimately to impede respiration." This congestion and inflammation of the sac in cases of carotid aneurism, are serious evils attending the Hunterian operation, but are avoided when the artery is tied on the distal side of the tumor ; these effects would seem to prove that the action of the ligature was not merely mechanical but functional.

If the femoral artery be tied for a popliteal aneurism, the anastomosing vessels enlarge, not merely by an increased impulse, a tergo, but there is an effort of the vis medicatrix naturæ to supply the parts that have been deprived of their blood.

Perhaps it is not one of the least important advantages of Brasdor's mode of operating that the risk of secondary hemorrhage, will be greatly diminished. The ligature has here to perform
Comparative
functions of the
ligature.
 very different functions from what is required of it when placed between the tumor and the heart. Instead of being obliged to stem a strong current of blood until the internal coagulum is formed,

and sides of the artery adhere and are consolidated, it has to make resistance to such a current but for a few minutes, for the blood receiving a new direction, the circulation not only in the whole tumor becomes, almost immediately after the ligature is applied, extremely languid, as is proved in the diminution of the bulk of the swelling, but also the blood contained in the canal of the vessel between the ligature and tumor must cease to circulate and be immediately coagulated, form a complete barrier to any future circulation, and thus render any assistance from the ligature quite unnecessary. So much must this be the case, that if there was any useful purpose to serve by it, I conceive that a temporary ligature, in a case of this kind, would be particularly applicable.

*First Case of Carotid Aneurism.**

June, 1825.

Symptoms.

“ A female 75 years of age, having been for three months previously, afflicted with anomalous pains in the neck, and a difficulty in respiration for which she could not account, after a violent fit of coughing perceived a swelling on the right side of her neck, a little above the clavicle. When I saw her eight days afterwards, the tumor had all the characters of an Aneurism of the Carotid artery, and had become as large as a fist ; but was

* Case of Carotid Aneurism successfully treated by tying the artery beyond the tumor, by James Wardrop.—Extracted from the 13th volume of the Trans. of the Med. and Ch. Society. 1825.

so situated that it was quite impracticable to tie the vessel on the cardiac side of the tumor, so closely did it come in contact with the clavicle. The tumor continued to increase, and on the eleventh day after it was first observed it had acquired a formidable aspect, the skin covering the scapular portion having become very red and painful, the pulsation, which was very strong throughout the whole swelling, being here particularly so, See the Plate. the parietes feeling extremely thin, and as if ready to burst.

It was evident that the patient's life was now in the most imminent danger; and in this hopeless condition it forcibly struck me, that it might be highly expedient to tie the carotid artery beyond Treatment. the aneurism, in the hope that, by thus stemming the current of blood through the vessel, nature might establish a new channel to carry on the circulation, allow the blood in the tumor to coagulate, and the sac and vessel to contract and be obliterated, as take place after the Hunterian operation. Brasdor's operation applicable. There were circumstances which made this case particularly favourable for resorting to such a measure; the aneurism had been of short duration; the patient, though far advanced in years, had a healthy constitution, she was also of a tranquil disposition, and eager that something should be done for her relief. Besides, the diseased artery was most favorable for the proposed operation; for as no branches are sent off from the carotid artery until it divides into the external

and internal, the process of coagulation would not be interrupted by the continuance of circulation through collateral branches in immediate contiguity with the aneurism. The operation also appeared practicable in this instance, as the aneurism, though large, still left sufficient space for the application of a ligature between the tumor and the division of the artery.

Operation.

Under these impressions, and with the approbation of Dr. Veitch and Mr. Glen, Surgeon of Brompton, who attended the patient, I undertook the operation, and the result of which has, in my opinion, fully authorised the measure; and I trust the future experience of others will confirm its utility. The operation consisted in making an incision through the skin and cellular membrane, rather more than an inch and a half in length, commencing it immediately above the tumor, and extending it on the tracheal edge of the mastoid muscle, and in the direction of the carotid artery, taking care to avoid the large superficial veins.

External
incision.

Exposition of
the artery.

The subsequent part of the dissection was chiefly made with a silver knife, guided by the finger; and there was no particular difficulty in reaching the artery but what might have been anticipated, from its great depth, from the necessary limits of the incision, and from the numerous large veins which were to be avoided—particularly a branch that extended across the middle of the incision to the internal jugular, and consequently diminished the space in which the artery was to be

taken up. After a careful dissection, which was tedious from its being necessary to tear the attachments with the silver knife, the artery was so completely separated from the adjacent parts, that the point of the finger could be readily passed between the vessel and the vertebræ, and Mr. Bremner's needle, of which I have annexed a particular description,* was passed round the artery with great facility, taking care to avoid the par vagum, which was distinctly felt behind the finger. The vessel ^{Its ligature.} being previously ascertained to be healthy, one ligature was tied round it, as close to the tumor as the incision would admit, and the lips of the wound were stitched together by a suture, without any further dressings. The aneurismal tumor was covered with adhesive plaster, in order to protect the tender skin, and at the same time to keep up a certain degree of pressure.

I thought it probable that the resistance to the ^{Immediate diminution of the aneurism.} circulation, which the ligature would necessarily occasion, might, for a short while at least, after its application, be followed by an increase in the distention of the tumor; instead of which, however, there was an immediate *diminution* of its bulk, marked by a considerable corrugation of the skin at the base, as well as a decrease in its redness. The ligature of the artery did not seem to produce any change in the mental functions, or any unnatural feelings in the head; on the contrary, the patient passed the night after the operation more

* See the Appendix.

comfortably than previous to it, the tumor being accompanied with less uneasiness.

Subsequent
changes.

A progressive diminution in the bulk of the aneurism, and in the strength of its pulsations took place, so that on the fourth day after the operation it seemed to have diminished nearly one third in its bulk; the upper and tracheal portions had lost all pulsation, and only the scapular portion retained an obscure undulatory thrill. The integuments, which had lost their redness, now evidently became more inflamed, and during the fifth and sixth days there was a distinct increase in the size of the tumor, and it pulsated more strongly, which seemed partly owing to several severe fits of coughing. This apparently unfavorable change was, however, followed by a decided amendment; and eight days after the operation the swelling again began to diminish, and the pulsation became more obscure, so that on the fourteenth day it was not much larger than half its bulk at the time of the operation, and no pulsation could be detected in any portion of it; merely a slight vibration in some parts, which seemed to be produced by the pulsations of the contiguous vessels which were now enlarged, particularly the inferior thyroid artery.

Discharge of
coagula by
ulceration.

The redness of the skin, however, continued to increase, and that of the scapular portion of the tumor to become more and more of a purple colour, till, at last, ulceration commenced on the most prominent part. Several considerable-sized por-

tions of coagulated blood were discharged along with some healthy pus through the ulcerated opening; and on the twentieth day after the operation the ulceration of the integuments had closed, and nothing of the tumor remained, but some wrinkling of the skin, and a considerable degree of thickening of those parts on which the base of the tumor had rested. These continued to diminish, and at the end of the fifth week, from the time of the operation, the neck had nearly resumed its natural form, a slight degree of inequality only remaining; the ligature had come away, and the patient's general health, to the management of Successful result. which the greatest care had been bestowed, appeared now to be completely re-established.*

Second Case of Carotid Aneurism.†

"Dec. 2. E. B., ætat. 57, always enjoyed good History of the case. health till four years ago, when she was attacked with severe pains in the head, which terminated in a fit of apoplexy. By bleeding, the application of blisters, &c., however, she soon recovered. Two years afterwards she had a similar attack, and was ill for three weeks, but the same treatment being pursued she again was restored to

* Upwards of three years have elapsed since the above case was published, and the patient now continues to enjoy good health.

† Second case of Carotid Aneurism successfully treated by tying the artery beyond the aneurismatic tumor, by James Wardrop.—Extracted from the *Lancet*, vol. i. 1826.

perfect health. About six months since one of her companions accidentally observed a strong pulsation in her neck, which a surgeon discovered to be an aneurism of the right carotid artery, and proposed an operation, but the patient would not consent.

Symptoms.

A very strongly pulsating tumor is now visible on the right side of the neck, exactly under the sternocleido-mastoideus muscle, which appears much attenuated, and its two portions are somewhat parted. The pulsation extends from the clavicle about two inches upwards, and is much stronger at the superior than the inferior part of the tumor, which does not, seemingly, extend below the clavicle. It is fully two inches and a half in breadth; the external jugular vein is seen traversing the upper part of it, and is somewhat distended. The patient has had a hernia in the right groin for four years, and both her legs are œdematous, very tense, and painful. She complains of severe head-ache, and is unwilling to lie on her right side, because, when she does so, the pulsation of the tumor is increased, and is accompanied by much noise in the corresponding ear; sleeps little at night; appetite bad; thirst great; pulse natural in frequency, but with a slight thrill; bowels confined.

Operation.
Dec. 10, 1826.

Besides being bled at the arm, she was ordered some diuretic medicines. On the 10th, two grains of opium having been given in the morning, with the assistance of Mr. Lawrence, and in the pre-

sence of many practitioners, I tied the carotid artery at its emergence from beneath the omohyoideus muscle, and above the tumor. As the patient's neck was fat, the incision made in the integuments was not less than three inches in length; the rest of the operation was chiefly accomplished by means of a silver knife, and not above a tablespoonful of blood was lost. The ligature, formed of a portion of silk-worm gut, as recommended by Mr. Fielding,* was readily conveyed round the artery by Bremner's needle, and after being tied, both ends were cut away. The external wound was secured by two stitches, and a strap of adhesive plaster.

The patient felt no immediate effect from the operation, except a slight faintness; she walked up stairs unsupported, and sat some time in a chair, before she would get into bed.

The effect on the pulse was very remarkable, that of the right wrist being full and strong, while that of the left was comparatively small and feeble.

In the evening, the patient felt comfortable, complaining only of a dryness of the fauces, attributed to the opium she had taken. She was now ordered to have five grains of calomel.

Rested much better last night than she has
done for some time past; no headache; she feels
more lively than before the operation; coun-
tenance improved; pulsation in the tumor much

Report.
Dec. 11.

* See Trans. of Med. and Chir. Society of Edinburgh, vol. ii.

reduced, particularly in the tracheal portion. Pulsation of the opposite carotid increased in force. The adhesive plaster was taken away; wound adheres; no appearance of inflammation.

Dec. 12.

Pulse of the right arm continues much stronger than that of the left. Left carotid artery beats with increased force. Temporal artery of the right side can be felt, feebly pulsating. No perceptible change in the tumor since yesterday; whole wound appears to have completely adhered; no dressing required; no return of headache; health much improved: sat up and dressed herself, and is in excellent spirits. Tumor is easily diminished in bulk, by gentle pressure; but on its application, complained that the pain of the head returned. She experienced two slight attacks of faintness yesterday afternoon, with pain in the bowels. Bowels confined; to take some salts and senna immediately.

Dec. 13.

This morning she feels perfectly easy, the medicine having operated well; is quite free from all those pains in the head which troubled her previously to the operation, and she can lie down in bed on the left side without that feeling of suffocation which was formerly the consequence of it. The pulsation is now confined to the external part of the tumor, and on pressing it the pains are reproduced (for the time) in the head, with the same violence as formerly. The two stitches were removed, perfect adhesion having taken place.

Thursday, Dec. 21. The patient is entirely free from any uneasiness in the head; has an excellent appetite, and states, that in every respect she is "quite comfortable."

About three weeks after the operation she caught cold, and drank some spirits, after which she was seized with a violent cough, attended with fever; and it was observed that the tumor, which now remained in the neck, increased in bulk, and its pulsation became stronger. All these symptoms were relieved by a repetition of small bleedings, and she appeared to be convalescent. Three weeks after this, together with all the symptoms of hypertrophy of the heart indicated by a stethoscopic examination, there came on a considerable œdema of both legs; the swelling of the lower extremities continued to augment, notwithstanding the use of a variety of diuretics; but the secretion of urine was increased by small bleedings from the arm, and occasional cuppings. She died on the 23d March, never having complained of the swelling in her neck, or of any symptoms referrible to a disturbed circulation within the head, from the date of the operation, which was performed on the 10th of December.

Up to the day of her death, a tumor remained in her neck of about the bulk of an almond, which pulsated strongly, felt very thin in its coats, and its contents could be readily squeezed out of it, but returned rapidly when the pressure was removed.

Dissection.

Dissection.

“ The body was generally anasaruous, the lower extremities being swollen to twice their natural size. The tumor, which had existed in the neck during life, was not apparent after death. The arterial system being that to which our attention was particularly directed, the thorax was opened, and the teguments of the neck removed. The heart presented an unusual state of *hypertrophia* of both sides, being three times as large as natural. The serous membrane contained the usual quantity of serum found in similar cases, and appeared to have suffered from repeated attacks of inflammation, judging from the extent and thickness of the patches of organised lymph which had been previously effused from time to time. The aorta and arteria innominata presented nothing remarkable externally, but, internally, innumerable small yellow patches were observed, where ossific depositions had commenced. The muscles of the neck being removed, the arteria innominata, right subclavian, and carotid, were exposed. The carotid artery, immediately after its commencement, presented a manifest dilatation, which corresponded with the situation of the tumor that existed prior to death ; and the fact of the vessels being perfectly empty, and their walls collapsed, readily accounted for the swelling having disappeared. The length of the dilated portion, was

a little more than an inch. On examining the upper part of the artery, and replacing the teguments, so as to compare the relative positions of the cicatrix, (where the wound of the operation had been made,) and that of the vessel, both were found to be in exact correspondence; the line of the cicatrix obliquely crossing nearly at its centre, the line of the artery about half an inch below its bifurcation into the external and internal carotids. Intermediately between the cicatrix and the artery, the space was occupied by cellular tissue, condensed into a mass of apparently a fibrous structure. This substance intimately adhered not only to the artery, but also to the eighth pair of nerves. On slitting open the artery, the dilated portion was much thinner in its wall than the rest of the vessel. The internal surface presented numerous patches, or rather elevated flakes, of a yellow substance, but no cicatrix, or other appearance, could enable us to ascertain the precise point where the ligature had been applied. The carotid was completely pervious, as also were its several branches, with the exception of the superior thyroid, which was filled with a plug of organised lymph. It was also found that the vertebral artery, on the same side, was filled with a similar plug."

This dissection was conducted by Professor Bennett, of which, he drew up the above account.

*Third Case of Carotid Aneurism.**

Symptoms.

“ A female, about 49 years of age, of spare habit, and unhealthy appearance, consulted me early in the month of January last, on account of a swelling in the *right* side of the neck. On examining the part, I discovered a pulsatory tumor, situated immediately above the sternal end of the clavicle, being partly covered by the mastoid muscle; it possessed all the characters of an aneurismal swelling, and its pulsations, which were synchronous with the heart's beat, were so forcible, as to be visible even at some distance from the patient. The tumor appeared to be of the size of a large walnut; but on examining it with my fingers, I found that it was considerably larger, extending some way backward, and, as it were, issuing from out of the chest. With the exception of its lower part, the tumor was circumscribed, and its boundaries well-defined; pressure upon it occasioned considerable pain. The account which the patient gave me of the origin and progress of her disease, was as follows:—about two years ago, she received a sudden and violent shock to her feelings from a most painful domestic occurrence, and from that period she found, that on making any

* Case of Aneurism at the root of the Carotid, successfully treated by tying the artery above the aneurismal tumor, by James Lambert, Surgeon, Walworth.—Extracted from the *Lancet*, vol, xii, 1827.

bodily exertion, she had tremblings and palpitation of the heart. These symptoms went on gradually increasing, and at the time of her making application to me, had become so much aggravated, that she was incapable of pursuing her ordinary domestic employments. On walking hastily across the room, in the attempt to go up stairs, or under slight mental agitation, her heart became affected with violent palpitation, and the respiration was rendered difficult to a most distressing degree. When she attempted to stoop, she said that she felt a sensation of choking, as if something were pressing on the lower part of the windpipe and interrupting her breathing. The same sensation was also experienced on moving the right arm over the head. She complained of dryness in the throat, with occasional cough, excited by a sense of tickling in the trachea; her sleep was interrupted by frightful dreams; appetite was defective, and she had become much emaciated. There were no marked uneasy sensations in the head, but she complained of dimness of vision in the left eye, and this was much increased at those times when the circulation was hurried. On applying my hand over the præcordial region, I found the heart's impulse to be very great, so forcible, indeed, that it could be distinctly felt at any part of the chest; the pulse at each wrist was vibratory, as was also that of each carotid artery. The pulsations of the right common carotid artery, were apparent nearly throughout its whole extent

in the neck. With respect to the formation of the tumor, the patient stated, that she first perceived, some months ago, a beating or throbbing at the lower part of the neck; this symptom became gradually more evident, until at length a small tumor made its appearance, which by degrees attained the size, and presented the characters, I have described.

Diagnosis.

There could be no doubt that the disease was aneurismal, and apparently affecting the lower part of the right common carotid artery; but whether confined to that vessel, or extending into the *arteria innominata*, was to me a matter of conjecture, for I am free to confess that I know of no certain diagnostic marks, by which we can discriminate between aneurism at the root of the right carotid artery, and aneurism of the *arteria innominata*, presenting, as it usually does, a tumor at the lower part of the neck. This, however, is not of the moment which at first sight it appears to be; for, as I shall have occasion presently to remark, the operation of tying the artery above the tumor, is expedient in either case. It occurred to me, therefore, that the only chance which could be afforded to the patient was, that of applying a ligature to the artery above the tumor. The aneurism had been, according to her account, of some months standing; but it had increased more rapidly of late, and the symptoms had proportionally become more distressing, so that a fatal issue was to be anticipated speedily, unless some-

thing was done for her relief. Previous to the adoption of any measure, I thought it right to obtain the opinion of Sir Astley Cooper: this I did about a week after I had first seen the patient. Sir Astley Cooper discountenanced the operation, and remarked that "*it was aneurism by dilatation, which would not increase.*" I must acknowledge that I was not at all satisfied with this opinion, no sufficient reason being shown why the operation should not be undertaken, and I still adhered to my opinion respecting its expediency. Mr. Key, who saw the case at my request, thought that the arteria innominata was affected, and that the operation was, therefore, inadmissible. Similar opinions were entertained by Mr. B. Cooper and Mr. Callaway, who also saw the patient.

In this state of affairs, my own views of the case remaining unaltered, I requested the opinion of my friend Mr. Wakely, who visited the patient, and recommended the operation to be immediately performed, even admitting that the innominata was affected. I also consulted Mr. Wardrop, who, on examining the patient, unreservedly declared himself in favor of the operation; and, as the patient was now becoming uneasy at the delay, (upwards of a month having elapsed since I first saw her,) I fixed an early day for the performance of the operation. The tumor in the neck had visibly increased within the last fortnight, but the patient's general health had undergone some improvement under the exhibition of

Operation,
March 1827,

bitter infusions, with carbonate of soda, and attention to the state of the bowels.

On the first of March I undertook the operation, in the presence of Mr. Wardrop, Mr. B. Cooper, and Mr. Callaway. The steps which I pursued were nearly as follows: the patient being placed on a table with her head elevated, and slightly turned towards the left side, I commenced by making an incision through the skin and cellular membrane, of about three inches in length. The incision was made obliquely—that is, in the direction of the fibres of the mastoid muscle, and at a short distance to the inner side of its tracheal edge. I continued to dissect, layer by layer, gradually and cautiously, until I ascertained by my finger, that I was near upon the trunk of the artery, when I laid aside the scalpel, and used a silver knife. The process of separating and detaching the artery from its adjacent cellular membrane, by means of a blunt instrument, rendered this part of the operation tedious, but at length it was effectually accomplished, and the aneurismal needle (Bremner's) was passed round the artery. The vessel appeared to be unusually large, but, in my opinion, was not unhealthy; one ligature* was tied around it, the ends of which I cut close to the knot; the edges of the wound

* The ligature (which I employed at the suggestion of Mr. Wardrop) is known by the name of fisherman's silk; it is, I believe, a vegetable product.

were brought together by two sutures, and short strips of adhesive plaster.

I experienced no particular difficulty in performing the operation; there was a large superficial vein at the upper part of the incision, but this I took care to avoid, and there was very little blood lost. The edge of the internal jugular vein was seen, but it did not at all overlap the artery, nor was its distension upon expiration apparent, in the least degree; the descendens noni was within the sheath, and in front of the carotid artery; I took care to avoid including this in the ligature, and with respect to the nervus vagus, it was not seen during the operation. The part, at which the artery was secured, was immediately above where it is crossed by the omo-hyoideus muscle.

The patient underwent the operation with great fortitude: she became somewhat faint, however, towards its conclusion, and I allowed her to remain on the table upwards of an hour, before I attempted to remove her to bed. At this time she felt much nausea; and soon after she was placed in bed, vomiting occurred, with violent straining, tending, of course, very much to disturb the parts concerned in the operation. In the evening, as the stomach still continued in an irritable state, I ventured to administer twenty drops of the wine of opium, which had the effect of quieting the stomach.

Before proceeding further in the report of the progress of this case, I may remark that a dimi-

Diminution of
the bulk of
the tumor.

nution in the bulk of the aneurismal tumor was immediately apparent on the application of the ligature around the artery, and its pulsation was materially lessened.

Reports.

On the following day, I found that the patient had passed a comfortable night; the pulse at each wrist was moderate in quantity, but that of the right side was full and strong, as compared with the left. The heart's impulse was very moderate; and the patient, of her own accord, noticed to me that which constitutes an essential feature in her case; namely, that "the beating of the heart was gone." She did not even experience the palpitation after, or at the time she was retching violently, although such an exertion, prior to the operation, would undoubtedly have excited violent action in the heart. The ligature, did not produce any apparent ill-effects on the brain—the cerebral functions not being, in any degree, disturbed.

On the third day after the operation, I moved the dressings from the wound, and also took away the lower suture; the upper part of the wound had united by the adhesive process. The aneurismal tumor had so far subsided, that it was only evident to the eye, by a feeble pulsation at the part; and, on applying the finger, the tumor was felt to be much consolidated, and greatly reduced in size. The patient was, in every respect, doing well; and she remarked, that she now slept better than for two years past, not being disturbed by frightful dreams.

The patient went on well, and I was almost rid ^{Hæmorrhage from the wound.} of apprehension; when, upon visiting her on the morning of the tenth day after the operation, I found that there had been some bleeding from the wound, and the blood was observed to be of a red colour. About two or three drachms seemingly had escaped, and the patient remarked that it issued out suddenly, and she felt it trickling down her neck. The upper part of the wound, as I before noticed, had united; the lower part was suppurating freely, the matter discharged being of a healthy character.

As I saw the suppurative process must necessarily be set up in the lower part of the wound, I had during the last few days dressed it with short strips of adhesive plaster, lightly applied, and over these a poultice was put. But on the occurrence of the hæmorrhage I desisted from the use of the poultice, and applied a piece of linen rag, doubled and made wet with cold water, over the adhesive strips. I had the gratification of finding that the bleeding did not recur, and from this period the wound went on progressively healing. The relief which had been given to the patient now became very obvious, and she repeatedly expressed to me in the most grateful terms, her sense of the benefit resulting from the operation. Although I have at present for obvious reasons, restricted her from using much exertion, she can now bear moderate exercise without producing any of those distressing symptoms under which she laboured previously to

the operation. With respect to the swelling, it has entirely disappeared, and all that can be felt on passing the finger deeply down, is a small hard tumor having a very faint undulatory thrill."

Continuation of the Case.

Ulceration of
the cicatrix.

Fungus pro-
truded.

"Five weeks after the performance of the operation, the cicatrix ulcerated at its centre, and a small, shining, spongy granulation presented itself, which, in the course of a few days, became considerably raised above the level of the surrounding parts. I found much difficulty in subduing this fungous growth, for although I repeatedly used escharotics, it recurred again and again during the space of a fortnight, and proved a great source of annoyance, inasmuch as the patient was, in every other respect, perfectly well. Indeed, had she not been prevented by the occurrence of gout, which at one time attacked the stomach, producing violent vomiting, she would have gone into the country to visit her friends, being, as she herself stated, "in better health than she had been for many years past."

"I visited her on the 17th of April, and found, on looking at the neck, that there was still a luxuriant granulation in the centre of the cicatrix; it was not, however, much larger than the blunt end of a probe. I applied a small piece of lint and a strip of adhesive plaster to the part. It is worthy of remark, that the patient on this occasion complained

of uneasiness and tingling about the wound ; but there was nothing particular to be observed.

“ On the following day, April 18th, I was sent for ^{Hæmorrhage from the wound.} in haste, and on my arrival, found that the patient had lost a considerable quantity of blood from the wound in the neck. It was checked by the immediate application of wet cloths, on removing which, the bleeding did not recur, and the wound, I observed, differed but slightly from the appearance it presented on the previous day. I applied a dossil of lint with strips of adhesive plaster, and directed her to be kept in a state of perfect quietude. Notwithstanding, the patient had vomiting and violent retchings (nausea being at all times easily produced), there was no further bleeding from the wound during the day. The hæmorrhage however recurred on the following day, 19th, and occurred at intervals until the 23d, from which time, until the 30th of April, a period of eight days, it did not return. On the morning of the 1st of May the hæmorrhage returned, and with so much violence, that on my arrival, which was soon after its commencement, it was evident that the patient's dissolution was at hand. I endeavoured, in vain, ^{Fatal result.} to rally the almost exhausted vital powers ; she died at eleven o'clock in the forenoon.

“ The body was examined twenty-four hours after ^{Dissection.} death ; Mr. Callaway was present, and my friend Mr. Pilcher, lecturer on anatomy at the Webb-street school, who conducted the examination, has obliged me with the following memorandum of

the appearances observed on dissection. " Externally in the neck, no tumor was perceptible. More than half of the cicatrix resulting from the operation had ulcerated, leaving a glossy, sloughy-looking ulcer. Upon removing the sternum, the arch of the aorta, through the pericardium, appeared to be enlarged; having opened the pericardium, there was exposed a thin layer of fibrine, upon the investing portion (said to be common to rheumatic patients). The lungs and heart were perfectly healthy. The descending aorta, two axillary and two internal mammary arteries having been tied, coloured size was injected into the arch of the aorta, and the injection found its way through the wound in the neck. The right common carotid artery, internal jugular vein, nervus vagus, sheath, and surrounding cellular membrane were very firmly united, especially below the wound. Immediately under the lower half of the cicatrix, consequently a little below the external wound, there was ulceration extending through the platysma myoides, to the artery.

Innominate
healthy.

" Upon tracing the large vessels upwards from the heart, the arch of the aorta was found to be slightly, but not unusually enlarged; the arteria innominata externally, quite natural; when opened, a few small patches of curdy matter were seen under the lining membrane, an appearance common in subjects of this age. The right subclavian artery was perfectly healthy.

" At the root of the right common carotid

artery was a consolidated tumor, of a pyramidal shape, its base below and extending two inches up the artery, and was at its lower part about half an inch in breadth. A probe could not be passed upwards, from the arteria innominata, and water forcibly injected at this part would not pass, so completely and effectually closed was the lower part of the carotid artery. On making a longitudinal section of the tumor, we observed at its lower part a firm coagulum of blood, of about the size of a French olive; it accurately closed the opening at the base of the carotid, and it was this which afforded the resistance to the probe and injection of water passing upward from the arteria innominata. The coats of the artery where surrounding the coagulum, were thickened to about four times their natural size, and lined by a thin layer of fibrine. Above the coagulum the coats of the artery were thickened to the extent of at least six times their natural size, and in addition to a layer of fibrine closely adherent to the inner surface of the artery, and continuous with that surrounding the coagulum at the lower part of the tumor, there were three other layers of coagulated lymph. They were evidently adapted to the cylindrical shape of the vessel, and appeared to have been formed successively, thus gradually encroaching upon and at length obliterating the entire calibre of the artery. At the upper part of this thickened state of the artery, and just above the omo-hyoideus, where the ligature was applied,

Cardiac orifice
of the Carotid
closed.

Sac filled with
coagulum.

Coats thick-
ened.

Artery ulc-
erated.

Distal orifice
pervious.

was an ulcerated opening on the anterior and tracheal surface of the carotid artery, a quarter of an inch in length and rather less in breadth, covered by a coagulum of dark-coloured lymph, communicating with the opening in the integuments. The posterior surface of the artery, corresponding with the ulcerated opening on the anterior part, was covered with a coagulum, and on removing this the division of the internal and middle coat produced by the ligature was observed.—Above the ulcerated opening the carotid artery was pervious and healthy, with the exception of a few spots, resembling those observed in the arteria innominata; and there did not appear to have been any attempt made to effect obliteration. The superior thyroideal artery, given off a little higher than usual, was readily distended by throwing water into the arch of the aorta, which passing through the left carotid artery, regurgitated by means of anastomosing branches, through the right external, internal, and common carotid artery, and flowed out at the wound. The trunk of the superior thyroideal became *very* manifestly enlarged on injecting the water from the aorta."

*Fourth Case of Carotid Aneurism.**

“ Mary Covis, æt. 36, in March, 1826, observed a pulsating tumor about the size of a small hen’s egg, in the upper part of the lower third of the right side of the neck, corresponding to the situation of the carotid artery, which, to the present period, (Sept. 2, 1827) has progressively enlarged. A prominent tumor now extends from the clavicle on the right side, upwards to near the os hyoides, ^{Symptoms.} Sep. 2, 1827. pressing on the trachea, bearing it off to the opposite side, and passing under the sterno-mastoid muscle (which is stretched over it) to nearly an inch beyond its outer border. The integuments of this side of the neck, particularly in front of the tumor, are thin, shining, and loaded with varicose veins. The tumor is firm at its circumference, but soft in its centre, and by pressure its size can be diminished; it pulsates strongly, the throbs being synchronous with those of the left ventricle of the heart. The stethoscope indicates it to be purely aneurismal, and by this instrument the left side of the heart appears to be acting on an increased quantity of blood, with more force than natural. The poor woman is much emaciated, and her deglutition and respira-

* A Case where the right Carotid Artery was successfully tied at the distal side of a large Aneurismatic Tumor, by George Bush, M.D. Professor of Anatomy, New York.—Extracted from the *Lancet*, vol. i. 1828.

tion, which have been much impaired for some months, are now almost annihilated.

Sep. 6.

Dr. Clarke, physician to the forces; staff-surgeons Burton, Clarke, and Daun, with other officers of the medical staff, and most of the neighbouring practitioners, assembled this day; and, after considering the case, were of opinion that an operation would be fruitless, in consequence of the advanced stage of the disease; and moreover, from the magnitude of the tumor, it would be impossible to find the carotid artery.

Operation.
Sep. 11.

This morning, my medical friends wrote to me saying, "That as Covis had not swallowed any thing for the last nine days, her respiration was becoming more alarming, and her voice had almost failed her; added to her own supplications and the entreaties of her friends, they wished that I might now attempt to secure the carotid on the distal side of the aneurism." Accordingly, at three o'clock, P. M. I proceeded as follows:—The patient being placed on a table, with her head and shoulders slightly elevated, I endeavoured to gain as much space as possible, by bending her neck to the opposite side; but this I found totally impracticable, from the dreadful suffering and sense of immediate suffocation she experienced on the slightest attempt to accomplish this end; therefore, with her head rather inclined to the diseased side, I commenced an incision at the angle of the jaw, (which was very prominent), and carried it obliquely downwards and forwards

for two inches, in a direction corresponding to the anterior edge of the sterno-mastoid muscle, by which the external jugular vein was exposed, crossing the centre of the wound. Fearing troublesome hæmorrhage from its division, I included it within two ligatures, and then cut between them; the cervical fascia and platysma being dissected off, the anterior edge of the sternomastoid was readily brought into view, by the side of which lay a tortuous plexus of dilated veins; these being pushed off with the handle of the knife, I endeavoured to divaricate the lips of the wound with brass retractors, but from the tense state of the sterno-mastoid muscle I found it almost impossible, and the slightest attempt produced much pain and more laboured respiration, with swelling of the cervical veins, and from these difficulties, added to the great depth at which the carotid lay, in consequence of the magnitude of the tumor forcing all the parts out of their natural situation, I found it necessary to divide the integuments on the upper part of the tumor to the extent of an inch, and by this expedient I was enabled to lacerate the cellular tissue in the neighbourhood of the hyoides, which bone I at length reached, and found that it was situated between one and a half and two inches from the surface; then, by a little manipulation, I succeeded in pushing the tumor somewhat downwards, and to the opposite side; thus exposing the sheath of the vessels, which, when I had

removed the descendens noni to the outer side, was opened in the usual manner, but, as far as I could judge in the deep and bloody cavity, with the great impediment of an enormous internal jugular vein. The portion of the artery immediately above the aneurism was dilated, and not more than half an inch of its extremity appeared sound, on which, with a common silver probe, I placed a single silk ligature. The wound was lightly dressed, and the patient put to bed, not having been more than fifteen minutes on the table.

Sudden diminution of the tumor.

Immediately on the tightening of the ligature, Dr. Clarke observed that the tumor was more soft and less prominent than before the operation; and this, to those who heard the observation and myself was obvious enough. In the commencement of the case it may be read, that the poor woman had not swallowed any thing for nine days, that her respiration was particularly distressing, and that her voice had almost failed her; but the reader will not be a little surprised when I say, that before the wound was dressed, she swallowed nearly ten ounces of wine and water; and such was her relief, that she actually thanked me for the benefit I had conferred on her, and, if allowed, would have prolonged the conversation.

So far I have copied verbatim from notes taken as the circumstances occurred; but the operation being safely executed, a continuation of the details, after this manner, can be no more interesting,

and as long narrations never fail to exhaust the most studious, I have thought proper to condense the remainder of this case. Until the 14th day she required four small bleedings, to keep down arterial action, and ease pain of the right side of the heart; gentle enemata were employed to regulate her bowels; her respiration and deglutition rapidly improved; her food consisted of strong beef tea and jelly, and she had easy nights, without the slightest tendency to orthopnœa, from which she had suffered much previous to the operation; the tumor rapidly decreased, and its pulsations became more weak. The ligature was cast off on the 19th day, and the wound was healed on the 27th, at which period she left her bed, the tumor being reduced to one half its bulk, and almost free from pulsation.

Reports.
Sep. 14, 1827.

At the present time, April 19th, she is in perfect health; there is scarcely a remnant of the tumor, the inordinate action of the heart has ceased, and her respiration and deglutition are natural."

Success of the
operation.
April 19, 1828.

Observations.

The foregoing cases of Carotid Aneurism, seem to me to prove indisputably, that the future growth of an aneurismal tumor may be arrested, and its parietes consolidated, by placing a ligature on an artery on the *distal* side of the sac, when no branch intervenes between the sac and the ligature. An important practical point is thus established

Brasdor's
operation
established.

in the treatment of aneurism, and the utility of
 Its application. this mode of operating, is more particularly applicable to aneurisms in which the artery is so situated that it is impracticable to place a ligature on the cardiac side of the sac. Its application however, does not appear to me limited to such cases, being persuaded that future experience will confirm the observation I have already made, that the diminution of the tumor, from the ready escape of a quantity of its contents along the artery into the main trunk will, in many cases, render the operation of Brasdor preferable to that of Hunter, more particularly when the tumor is large, and likely to inflame after the circulation is interrupted through the sac; and also, as there is probably less risk of hemorrhage from the part of the vessel on which the ligature is applied in this, than in the Hunterian operation. The sudden diminution of the tumor which took place immediately on the application of the ligature on its distal side, was to me an unforeseen advantage of this operation; at first conceiving that there would be an increased impetus of blood against the parietes of the sac; and thus if the sides were very much attenuated, there would then be danger of the operation causing them to burst, or to become highly inflamed from the increased distension.

Preferable
to Hunter.

See page 27.

Cause of immediate diminution of the tumor.

But taking a simple mechanical view of the subject, such an effect need not have been anticipated; for supposing the arteries simple elastic

tubes, if a barrier or ligature be placed upon a vessel, say an inch beyond the point where it gives off a branch, almost instantly the fluid in that part of the canal will cease to circulate, and be nearly in a state of stagnation; the quantity of the fluid being also diminished in proportion to the degree of elasticity and collapse of the sides of the vessel. On this principle we can readily explain, indeed might have anticipated, the immediate diminution of an aneurismal tumor when a ligature is placed on the vessel on its distal side.

With regard to the hemorrhage which took See page 48.

place in the third case, it is important to remark, that the blood in this instance flowed from the *distal*, and not from the cardiac orifice of the artery; the aneurismal sac and portion of the vessel between it and the ligature being plugged up with coagulated lymph, and having become quite impervious. Is it not probable that hemorrhage has often taken place in like manner from the ulceration of the artery beyond the ligature after the Hunterian operation? And may not this explain the circumstance, not very unusual, of hemorrhages after such operations being sometimes so easily stopped, the motion of the blood being in such instances retrograde, coming from the distal orifice, and being supplied merely by the anastomosing capillaries or collateral branches passing into the artery beyond the ligature? And may not this be the reason why hemorrhages from arteries tied for the cure of aneurisms, are more

Hemorrhage,
two sources of.

frequent than after amputations? In the former, there is danger of bleeding from two orifices: would it therefore be preferable to apply two ligatures in operations for aneurism? Or how would a temporary ligature answer? for if an internal clot be formed only on one side of the ligature, and if the vessel is not divided by the ligature, then no bleeding can ensue.

Retrograde
motion of the
blood.

Independent of a knowledge of the fact, that hemorrhages take place from the orifice beyond the ligature, whether applied on the cardiac or distal side of an aneurism, the circumstance illustrates the change produced in the circulation of the blood when an arterial trunk is obstructed, and points out that it assumes a retrograde motion in the vessel beyond the ligature. This retrograde course of the blood in the portion of an artery between a ligature and the capillary arterial branches which anastomose with its ramifications, is a curious pathological fact, the branches of the obstructed vessel thus acquiring a power to transmit the blood in a direction opposite to its natural course.

Important as
regards the
ligature.

The circumstance, that there is a retrograde motion in the blood of an artery beyond a ligature, for at least a certain period, deserves mature consideration in devising the best means of placing ligatures on vessels, secondary bleeding from the distal being as likely to take place as from the cardiac orifice. Nature employs the same process, that of forming an internal clot to stop the bleed-

ing, whether it takes place from above or below the ligature; therefore it is necessary that a certain space intervene below the ligature and a branch, as well as above them, in order that an internal clot may be formed.

Thus when an artery is tied, there appears to be two processes employed for the subsequent nourishment of the limb. There is first a supply of blood into the obstructed branches by the anastomosing ramifications, and hence the blood's retrograde circulation; and there is subsequently, though the period is not known, an enlargement of one or more trunks near the obstructed one, as already mentioned, which trunks continue ever afterwards to nourish the limb, and in them the blood flows in its natural direction. These are all points of great interest, and well worthy the attention of future observers. I am not aware that they have hitherto been minutely investigated.

Limb, how
nourished.

See page 12.

The New Operation.

It is strange that a knowledge of the effects of the Hunterian operation on the contents of the sac in the aneurismal tumor, and more particularly an acquaintance with the spontaneous process of cure, should not have given a very different view of Brasdor's operation, and caused it to have been performed in aneurisms, where a vessel could be tied beyond the tumor, and thus diminish the

force, though it could not altogether obstruct the current of the blood in the sac.

Rationale of
Hunter's operation.

See page 14.

It had often been conceived, that for the cure of aneurism, according to the Hunterian principle of operating, it is requisite that the flow of blood through the aneurism should be entirely interrupted, in order to admit of the coagulation of the blood in the tumor. But as I have already shown, the observations of Sir Everard Home, as well as those of subsequent writers, have proved that this doctrine is erroneous, and that it is sufficient for the cure of an aneurism that the impetus of the blood through it be diminished, laminæ of coagulable lymph being then formed within the parietes of the sac.

Its practical
application in
the aneurism of
the innominata.

Admitting this view of the subject to be correct, and that both the process employed by nature, and the operation on the Hunterian principle, do not necessarily require a complete stoppage of the circulation of the blood in the tumor, for the cure of the disease, it seemed to me a rational practical inference to deduce from these facts, that in cases of aneurism of the Arteria Innominata, the progress of the disease might be arrested by tying its two great branches, the carotid and subclavian; and although a certain portion of blood would still continue to pass along the innominata to those branches of the subclavian on the cardiac side of the ligature, the ligature being necessarily placed on the subclavian artery after it emerges from

between the scaleni muscles, yet such would be the diminution of the impetus of the blood in the sac, that the process of thickening of its parietes would not only go on, and thus its future increase be prevented, but even a permanent obliteration of the aneurismal cavity would be accomplished.

When I first successfully applied a ligature on the distal side of an aneurism, I considered that I had established an important principle in the treatment of those aneurisms in which no ligature could be placed on the cardiac side of the tumor, and, at the same time, no branch intervene between that ligature and the heart.

Nearly fifty years had elapsed from the period when this operation was proposed by Brasdor, but in two instances only, excepting in those cases mentioned by me, it had never been performed, either in this country or on the continent of Europe; and although some writers on aneurism had advocated the principle of such an operation, yet the complete stoppage of the circulation was by all deemed a *sine qua non* to its success. Suitable cases for the operation, under such circumstances, must have therefore been extremely few; and this may perhaps be considered the reason why it has been so seldom practised. Many eminent surgeons argued not only against the probability of meeting with proper cases, but, as I have already mentioned, even denied the soundness of the principles on which it was founded.

Neglect of
Brasdor's operation.

From too limited a view
of its application.

The successful results however of the foregoing

Views of the
Author.

Their practical utility.

operations, together with discoveries from dissections, have led me to advance a step further, and I trust, that I shall now be enabled to communicate the knowledge of a principle for the cure of many aneurisms, which have hitherto been considered beyond the reach of art.

Coagulation, how effected in an aneurism.

Although, as I have already mentioned, some surgeons have considered, that in order to allow the process of coagulation to go on in an aneurism, it is necessary to put a complete stop to the circulation of the blood in the tumor, it is well known, and many instances are on record, where, after the femoral artery had been tied in cases of popliteal aneurism, the tumor for weeks, and even months, continued to pulsate, and yet the coagulation of the contents of the sac was ultimately established. A knowledge of this circumstance alone would, we might suppose, have led to the adoption of Brasdor's operation, in those aneurisms in which the circulation of the blood in the tumor could only be partially arrested; and thus would have led pathologists to inquire, what was the necessary degree to which the circulation in the tumor must be diminished, in order to admit of the coagulation of its contents.

Complete stoppage of circulation not necessary.

But by far the most interesting and conclusive arguments to elucidate the important point, which I am so desirous to establish for the cure of aneurism, are to be deduced from the observations which have been made on the spontaneous cure of the disease. And it is a curious circumstance,

that the natural or spontaneous process does not effect a cure on the principle of the Hunterian operation by completely arresting the passage of the blood into the sac, but is in strict conformity with the principle of the operation I am now endeavouring to establish,—that is, by the formation of a barrier in the artery beyond, or at the distal side of the aneurism.

In a case of aneurism of the innominata, Mr. See Appendix. Mackelcan found that nature had nearly completed a cure of the disease on this principle. The carotid artery was plugged up, and the large aneurismal swelling was filled with a coagulum, leaving only a comparatively small channel for the blood to pass into the subclavian artery. I have seen some cases, and several are on record, which illustrate the same important pathological fact, and prove beyond a doubt that blood can coagulate in an aneurism so as to strengthen the parietes of the sac, and ultimately fill its cavity, without the circulation through the sac being in the first instance either suddenly or entirely interrupted.

It was a knowledge of this fact that led me to perform the operation I am about to relate. In the patient, nature had already instituted a curative process, by diminishing the circulation in the carotid artery, and when I found this alone not sufficient to arrest the enlargement of the aneurism, I then determined on placing a ligature on the subclavian, and in so doing, conceived that I was

New principle
of operating
suggested by
the Author.]

Necessary diminution in the force of circulation not ascertained.

strictly imitating the process which nature herself had commenced. I was thus led to act on a new view in this operation, and was naturally induced to consider the important question, to what extent is it necessary to diminish the momentum of the circulation through an aneurism, before the blood contained in it will coagulate? If I were able to ascertain this, it is evident that I could at once point out with accuracy, those aneurisms in which it would be practicable to cure the disease by tying the artery, or arteries, at the distal side of the tumor. Now, in examining the cases where nature had performed a spontaneous cure, on the principle of forming by degrees a barrier to the circulation in the sac by an obstruction in the vessel beyond it, it appeared indisputable, that a process of coagulation in the aneurismal sac must have begun when the momentum of blood in it could have been but very slightly diminished, no more alteration having taken place in the circulation than what might be supposed to be the effect of an enlargement of the calibre of the arterial tube, at the diseased part; neither can it be supposed that the vessels which were obliterated, in the cases to which I allude, could have undergone any thing like a sudden or instantaneous obstruction; on the contrary, whatever the process may have been, the arteries seemed to have undergone a gradual obstruction, indicated by the slow diminution in the force of their pulsation. That a very moderate degree of diminution in the impetus

Probably very small.

of the blood of an aneurismal sac is adequate to allow the coagulating process of the contained blood to go on, seemed therefore to me proved from the pathological facts which I have now stated ; though still, the exact quantity necessary to effect this purpose remained a matter of conjecture.

In a practical point of view, this must be considered a subject of interesting inquiry; and, besides the phenomena already stated, I may also observe, that no circumstance appears to me more conclusive in pointing out this diminution to be very small, than laminated coagulable lymph being found within every aneurismal sac, of whatever size, and however recent in its formation, in which cases the change in the blood's motion must have been very trifling.

As a subject of pathological research, it is interesting to enquire how the coagulation of the blood should take place in the living body by a mere diminution of its momentum. This quality of blood is sometimes even essential for the preservation of life, as on it depends the process which nature employs in stopping hemorrhages, as well as in curing aneurisms, the languid state in the circulation produced by fainting, admitting the coagulating process of the blood to be effected in the divided vessel, or as it is called, the internal clot to be formed. It ought also to be recollected, that alterations in the blood's velocity are employed in the animal œconomy for the perform-

Coagulated
lymph in every
aneurism.

Other effects
of diminished
impetus.

ance of other functions ; and hence the manifest differences to be observed in the modes by which different arteries are distributed, how some are ramified, how some vary in length, how others vary in their course ; all these peculiarities assisting no doubt in performing a peculiar function, which can be no other than altering the velocity in the current of the blood before it arrives at the respective organs.

Principle of
new operation
illustrated

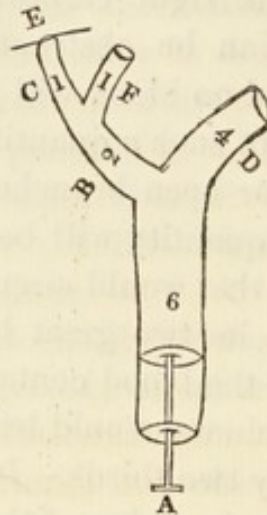
To render more intelligible the principle of this new mode of operating in aneurisms, let me suppose, by way of illustration, that the right carotid and subclavian arteries into which the innominate is divided, are of equal diameters ; it appears from those cases where the spontaneous cure had commenced in the aneurism of the innominate, that the closure of one of these great branches was not alone sufficient to allow of the complete consolidation of the tumor. Suppose therefore, that besides the carotid, the circulation through the subclavian artery was arrested at the point where it emerges from between the scaleni muscles, a very considerable diminution in the circulation of blood in the tumor would then be produced, and the arteria innominate, in place of having to transmit blood through the carotid and subclavian vessels, would only have to supply those branches of the subclavian which come off nearer the heart than the point where the ligature had necessarily been applied. Suppose, further, that these branches, which are usually four in number, when taken collectively are

equal in diameter to their trunk, it will then follow, that if the right carotid be impervious, and the subclavian be obstructed at the point already mentioned no blood will pass through the innominata, except such a quantity as is sufficient to supply the four open branches of the subclavian, and which quantity will be about one-third only of the mass that would circulate through the innominata were its two great branches not obstructed; hence, the blood contained in an aneurism of the innominata, would have its circulation diminished nearly two-thirds. It may be argued, that the four open branches of the subclavian will perform the function of the trunk which is shut up, and by their enlargement cause as much blood to flow through the innominata as used to pass before the ligature was applied.

Application of
the principle in
aneurisms of
the innominata.

But whatever be the site of the vessels which ultimately supply the place, and perform the function of the subclavian, it is quite evident, that in the first instance, the force of the current of blood is not directed exclusively into those branches of the subclavian which remain open between the cardiac side of the ligature and the innominata, but must be diffused into all the contiguous branches of the aorta in the ratio of their different sizes. And this reasoning is in strict conformity with the important observation of Sir Astley See page 12.
Cooper, already quoted, that though a few branches, and those too, near the site of an obliterated arterial trunk perform ultimately its functions, yet at first the circulation is carried on by numerous

branches. This may be illustrated by a simple diagram.



By a diagram.

Suppose the pressure of a syringe A to be 6, the impetus given to the fluid in B to be 2, in C to be 1, in F to be 1, and in D to be 4. Then if C be obstructed at E, the effect will be, that the whole of the impetus of C, will not be communicated to F alone, but will be diffused in the tubes F and D, in nearly the ratio of the squares of their diameters.

Thus, in place of the lost impetus of C passing into F, F will only receive about one-fifth of it, the other four-fifths passing into D.

*Case of Aneurism of the Arteria Innominata, treated by tying the Subclavian Artery.**

Tumor in the right side of the neck.

“On the right side of the neck of Mrs. Denmark, ætat. 45, there is observable an unnatural throbbing, which, when the hand is placed upon it, is

* Case of Aneurism of the Arteria Innominata treated by tying the Subclavian Artery, by James Wardrop. Extracted from the *Lancet*, vol. i. July, 1827.

found to be produced by a pulsating tumor of the size of a turkey's egg, whose base is situated under the upper portion of the sternum, while its apex emerges completely from the cavity of the chest, appearing in the neck at the tracheal side of the sterno-mastoid muscle. This tumor, though in some degree compressible, cannot be entirely emptied of its contents; its pulsations are vigorous, and synchronous with those of the heart. The strongest pressure applied to it will not stop the circulation of blood through the subclavian artery, although it diminishes the quantity which is transmitted by that vessel.

The neck itself presents a remarkable appearance, the right side being much less full and plump than the left. The left half, particularly in the situation of the sterno-mastoid muscle, being more prominent than natural, whilst, in the right side, there is a distinct hollow in the course of the carotid artery, the tracheal edge of the mastoid muscle being reflected inwards. No pulsation can be discovered in any of the branches of the right carotid artery, although they have been most minutely examined; but in those of the left, the circulation is extremely vigorous. A pulsation in the course of the trunk of the right carotid is very perceptible, but this does not seem to arise from circulation in that vessel, but from an impulse communicated by the tumor, a like pulsation being evident in every other part of the right side of the neck.

Change in the form of the neck.

In the pulsations of the carotids.

State of the
thorax.

She has no other complaints in her chest. The contents of the thorax, after a most minute and careful examination with the stethoscope, and by percussion, appeared to be in a healthy condition, except at the upper part of the sternum, on a confined space, under the clavicular edge of the sterno-mastoid muscle, where the bruit de soufflet can be heard. She experiences severe pains, extending through the left side of the head and neck, and a disagreeable sensation of throbbing in the tumor. She has at times great difficulty of respiration, which increases on the slightest motion to such a degree as to produce a sense of impending suffocation; she is obliged to use a high pillow. Her nights are very restless and disturbed; she sleeps but for short periods, and is often obliged to get out of bed. Her countenance bespeaks great anxiety; her complexion is pale and sallow; she has suffered considerable loss of flesh; the primæ viæ are natural.

General
Symptoms.

History of the
disease.

The disease commenced eleven months ago with difficulty of respiration, cough, and severe pains in the chest, head, and neck, which she considered to be rheumatic. About five months afterwards, she accidentally observed, when washing her neck, the pulsating tumor above the sternum, which very slowly but perceptibly increased. It was attended by a violent and distressing throbbing; in three months the tumor decidedly increased. Small bleedings were now frequently had recourse to; she took digitalis, was kept on a low

diet, and in a state of the most perfect quiet. This plan of treatment alleviated the severity of the symptoms, and seemed to stop the progress of the disease. The tumor, however, during the last three weeks has most rapidly increased in bulk, which has also been attended with a great increase in the difficulty of respiration, cough, distressing sense of suffocation, and violent throbbing in the tumor and neck. The integuments covering the apex of the swelling have within these few days become painful. A fortnight ago, Mr. Searle's ingenious instrument was applied to compress the humeral artery, in order to diminish the current of blood through the aneurismal tumor, but the patient could bear only for a short time the necessary pressure.

As there were no reasonable grounds to expect Treatment. that the distressing situation of this patient could be relieved by any further medical treatment, and as the aneurismal tumor had begun so rapidly to increase, it appeared to me a plausible measure to tie the subclavian artery, as the only chance of saving her life. Accordingly, on the sixth of Operation. July (1827), I performed the following operation. July 6, 1827.

The arm was placed downwards and back- Subclavian wards, and the head turned to the left side. I artery tied. found great advantage from placing a solid semi-cylindrical block of wood under the neck, for securing the head in a steady position. Two incisions were made through the integuments, one parallel to, and immediately above the clavicle

External
incisions.

fully four inches in length, and the other parallel with, and immediately above the edge of the clavicular portion of the mastoid muscle. These two incisions met at an angle upon that muscle close to its insertion in the clavicle; the superior termination of the incision extended close to the external jugular vein, which was not endangered. Instead of first dissecting back the skin, and then the platysma myoides and cervical fascia successively, I made the incision at once through these parts, safely guided in doing this by cutting down at once as deep as the fibres of the sterno-mastoid muscle. I was thus enabled by one dissection, to raise a triangular flap formed of skin, platysma myoides, and fascia. By this method, the supra-clavicular space was distinctly exposed, and the numerous veins and arteries were only once divided. I allowed the bleeding of these, which was by no means profuse, to cease, and it was not necessary to tie any of the divided vessels. The remaining part of the operation was performed with a blunt-edged silver knife, and so trifling was the hemorrhage, that every part concerned in the subsequent steps of the operation could be distinctly seen.

Supra-clavicular space exposed.

The fat which fills up the supra-clavicular cavity in which the subclavian artery lies, was pushed aside, and the deep fascia which extends between the omo-hyoideus muscle and the first rib, and which in this case was remarkably strong, was exposed. A single silk ligature of moderate

Ligature placed on the artery.

thickness was now tied round the vessel; the wound was closed by a few stitches and adhesive plaster. She endured the operation, which was completed in less than ten minutes, with the greatest fortitude. The pulse at the wrist ceased; no pulsation could be detected in the right carotid artery or its branches. She complained of a smarting pain in the wound for an hour. There was an immediate relief in her breathing, which now became free and tranquil, and this change was more striking, as during the preceding twenty-four hours, she had suffered an unusual degree of suffocating dyspnœa, during which her countenance was observed by her husband to be of a dark leaden colour, and to express much anxiety. The peculiar sensations which she complained of in her head were also removed. Although it could not be positively stated that the tumor perceptibly diminished, there was certainly no increase, and the patient herself distinctly expressed, that she felt a decided diminution in the strength of the beating, which was confirmed by my own observation. Since the operation has been performed, (which is now six days), she has not experienced the slightest pain in the wound, and there is little appearance of inflammation; the wound looks healthy, and discharges a small quantity of pus.

First effects of
the operation.

Relief in
breathing and
in the head.

Change in
the tumor.

Twenty-four hours after the operation a very slight pulsation could be observed at the wrist, which has continued without an increase of force;

Reports.

the temperature of the arm has not been altered, and she has had no numbness nor loss of power in it. The remarkable relief which she experienced in her breathing and in the throbbing of the tumor immediately after the operation, has been permanent; neither have the uneasy feelings in her head returned. She has continued to lie in the horizontal posture ever since the operation with perfect ease, and her breathing appears quite natural. She has also enjoyed a very refreshing night's sleep, of which she had long been deprived. The anxious character of her countenance has entirely subsided, and there only remains that appearance which belongs to a person who has undergone considerable depletion.

The operation has not been followed by any febrile excitement, and although the pulse continues rather more full and frequent than natural, the skin has remained cool and moist, the tongue clean, and the bowels perfectly regular."

*The Second Report.**

July 9, 1827. "I have stated in the former Report, that, immediately after the operation, this patient experienced a remarkable degree of relief, and that the peculiar sensations in her head were removed. Soon after she had been placed in bed, it was also evident that the pulsations of the aneurismal tumor had become much diminished in strength

* Extracted from the *Lancet*, vol. i. 1827.

and their impulse seemed to extend less high in the neck. She suffered no peculiar sensations in her arm; the pulse of the radial artery was imperceptible, and the heat of the limb did not seem to vary from the natural state. She had none of those sensations of tingling and numbness, which are usually felt after the main artery of a limb has been tied.

The day after the operation, a slight thrill was perceptible in the radial artery, which has not since increased much in volume, and the heat of the aneurismal limb had sunk below its natural temperature. All the distressing symptoms which formerly had harassed the patient, seemed to be rapidly disappearing. In this way she has gone on, gradually mending, without the occurrence of a single symptom requiring medical treatment, the wound having united completely by the first intention, except at the point where the ligature emerged. Her nights, which before the operation were passed in a state of restless inquietude, were now spent in the most refreshing slumbers. She expressed her satisfaction at her condition, which had become better than at any period since the commencement of her complaint.

On the ninth day, a pulsation became perceptible in the carotid artery, which gave rise to much speculation among the distinguished professional men who visited her during her recovery. Some of them were inclined to consider it owing to the inosculation of the vessel with those of the

Pulsation in
the right ca-
rotid returned.

How to be
explained.

opposite side, the blood thus arriving at the trunk from its extreme ramifications. This opinion seemed to be strengthened by the fact, that the pulsation was at first stronger in the temporal branch, than in the carotid itself. It appeared however to me, to be a more plausible way of accounting for this circumstance, by supposing that the aneurismal tumor, which formerly rose high in the neck, had previous to the operation compressed the carotid, and thus prevented the circulation of blood through it; but the swelling having now, by the effects of the ligature become greatly diminished, the pressure had ceased, and a free course now existed for the traject of the blood. This fact has been observed, and the opinion entertained, by former pathologists. Whatever explanation may appear the most likely, the occurrence itself cannot be at all regretted, since the tumor having subsequently continued gradually to diminish, it tends only to prove more completely the truth of those principles which I advanced, and from a knowledge of which the propriety of the operation was deduced; and although, had the vessel been altogether blocked up, the aneurismal tumor would by this time have completely disappeared, yet, even with the circulation of blood through the carotid, that end will in all probability ultimately arrive. Be that however as it may, the patient has been brought from a state of great suffering, to one of comfort, bordering on health.

On the 22d day after the operation, the ligature ^{Ligature come away.} came away, and the wound is now completely healed. The tumor is greatly reduced in size. She has no pain in her head, difficulty of breathing, cough, nor sense of suffocation. She can now walk out, and can even ascend stairs with comparative ease. She expresses the greatest gratitude, and considers that the operation has conferred on her incalculable benefit."

*The Third Report.**

In the beginning of August, immediately after ^{Dec. 5, 1827.} the last report was printed, and one month subsequent to the operation, Mrs. D. left London with the view of establishing, through the influence of open air, gentle exercise, and milk diet, the more complete recovery of her health, which from the time the operation was performed had ^{Retrospect of the case.} been gradually improving, so that at the period of her removal she had no complaint, except a great degree of weakness and emaciation, which, independent of the existence of the aneurism, might probably have been produced by the long confinement and rigid depletory treatment to which she had been previously subjected. The only appearances of the original disease which still remained, were a considerable degree of difficulty of respiration, much aggravated by walking, and a slight, scarcely perceptible pulsating enlargement,

* Extracted from the *Lancet*, vol. i. 1827.

situated immediately above the sterno-clavicular articulation. The distressing cough, sense of impending suffocation, severe pains in the neck and shoulder, the constant headach, and the tumor, which at the time the ligature was applied to the artery had attained the size of half a turkey's egg, had all now very nearly disappeared, the wound had healed, and indeed hardly a mark remained to point out the former existence of the aneurism.

Went to the country.

In this condition she went to the country, from which she derived immediate advantage. Her strength daily increased, the dyspnœa, in a corresponding degree diminished, and her general appearance improved perceptibly to those around her. In the course of a very short time she was able to walk out into the open air, a recreation which she had been entirely deprived of for many months, and the severity of the dyspnœa had now diminished so much, that she could ascend a staircase with comparative ease. About this period, (the end of August), the symptoms of her disease

Mr. Chapman's observation.

had so completely vanished, that Mr. Chapman, who examined her in the country with great accuracy, informed Mr. Lawrence, that unless he had previously been acquainted with the nature of the case, he could never have discovered that aneurism of any of the large vessels of the heart had ever existed.

Pulsation of the right carotid.

The pulsation of the right carotid artery was now distinct, though by no means so strong as that of the left. The right radial artery was

scarcely perceptible, while that of the left conveyed a peculiarly hard thrilling sensation. On application of the stethoscope to the thorax, the pulsations of the heart were found to be natural, but at the upper portion of the sternum, a slight impulse was experienced, as if arising from some considerable enlargement of the origin of the *arteria innominata*. This impulse was however scarcely to be discovered, except after the patient had been making any bodily exertion, or when her mind had been agitated by questions which seemed to excite a suspicion of the existence of any supposed danger. Her countenance had lost entirely that anxious expression which was formerly so observable; and indeed her whole appearance bespoke the enjoyment of tolerable, though feeble, health. About a fortnight ago, she was attacked after exposure to cold with a severe bronchitis, and a consequent return of the dyspnœa to a great degree, which rendered the abstraction of blood necessary; by means of which, and attention to diet, she has regained a nearly perfect state of health. On her return to town six weeks ago, it was found that not a vestige of the aneurismal tumor remained to mark its former position. The dislocation of the clavicle, described in my former report, no longer existed, and all the distressing symptoms of her alarming disease had completely vanished. She expressed herself comfortable and happy, and indeed seemed now to enjoy good, though feeble

Impulse above
the sternum.

Attacked with
bronchitis.

Her return
to London.

State of
amendment

health. A slight degree of dyspnœa was the only symptom of which she now complained."

*The Fourth Report.**

Second attack
of Bronchitis.

Severity of the
Symptoms.

Aneurismal
tumor not
changed.

" Soon after the date of the last report, Mrs. Denmark, without any cause, of which she is aware, was again attacked by a severe bronchitis, which, whether from increasing the disorder arising from the state of the coats of the aorta, or any impediment to the circulation of the blood which might exist from the closure of the subclavian artery, produced symptoms of an alarming character. On visiting her at this period, I found her, (the bronchitic affection having continued for two days,) labouring under a degree of dyspnœa so great, as entirely to prevent her lying down, and producing a most agonising sense of impending suffocation. She had a frequent cough, which was accompanied with copious expectoration of a frothy mucus. Her pulse was about 130, and wiry. Her skin was hot, and there was great general febrile derangement, inducing, towards midnight, high delirium. She did not suffer great pain, but complained much of the sensation of impending suffocation, which was accompanied with a slight difficulty in deglutition. There was also present slight œdema of the feet. On examination of the neck, no tumor could be found in the situation of the former aneurism, nor were the

* Extracted from the *Lancet*, vol. i. 1828.

pulsations of the aorta and heart more strongly felt than previous to the occurrence of this severe attack, nor, indeed, did any symptom appear to indicate that the disease in the vascular system had increased. The sense of impending suffocation was however so constant and severe, as to induce the patient to think that she could not survive many hours. Under these distressing circumstances, the line of practice to be pursued appeared to me evident. She was largely bled, ^{Treatment,} leeches were applied to the chest and feet, and she was kept constantly under the depressing effects of nauseating doses of the tartrate of antimony. During the course of the next day she was again twice largely bled, once cupped in the region of the sternum, and the action of the antimony was continued. From this treatment she experienced considerable relief; but during the course of the three succeeding days I found it necessary to repeat the venesection several times. She was now reduced to a weak condition; but although the pulse had sunk nearer to the natural standard, and the febrile action had greatly subsided, yet she still experienced a remarkable degree of difficult respiration, accompanied with the feeling of suffocation, which had so alarmed her. The cough was still very frequent, and accompanied with more copious expectoration. She was for the next week kept extremely low, and again bled, after which she began to revive a little, and her difficulty of breathing became considerably relieved;

but still it was so difficult that she was unable to lie down for any length of time, and always slept propped up in bed.

She continued in a very weak and precarious state for several weeks, during which time the difficulty of respiration frequently increased to such a degree, as to render the abstraction of blood necessary. For two months she was unable to rise out of bed, and during all that time was affected with a greater degree of difficult respiration, cough, and expectoration, than she had ever experienced, except at the commencement of the attack. At this period, to such a state of weakness and emaciation had she been reduced, that a near female friend, who came from a distance to see her, fainted the moment she beheld the altered condition of her person. She now however began gradually to recover, was able to sit out of bed, and her respiration became more free. She was still unable to sleep in the horizontal position. During the whole period of this severe illness, no appearance of any pulsating swelling could be discovered in the site of the former aneurism, nor did the aorta or the heart betray any symptom of increase of that disease, which, previous to the operation, I had suspected, and mentioned in the first Report. It ought here to be observed, that from the time of her return from the country, to the commencement of this attack, she had not been bled; and perhaps the cessation of an evacuation, to which she had long been habituated,

may have had some effect in producing the severe attack of bronchitis. I thought it therefore advisable, in order to prevent any recurrence of this complaint, to repeat the bleedings frequently, particularly as she was sensible that they afforded her great relief.

It is important to observe, that from the commencement of my attendance on this patient, she has now been bled above fifty times, to an extent at each operation seldom less than a pint of blood, and frequently to nearly double that quantity. Since the ligature of the artery, she has been restricted to about an ounce of solid meat daily, and twelve ounces of fluid. Besides these, however, she has frequently taken a very small quantity of bread and butter, and occasionally a little fruit.

Great extent
of bleeding.

The following is the present state of the patient:—She is more reduced in point of flesh than at the period of the last report, but this has evidently been owing to the attack of bronchitis, and the severe measures to which she has been subjected, for, within the last six weeks, she has regained her former appearance in a wonderful manner. The difficulty of respiration has greatly diminished, so much so, that she can now sleep in the natural position, and she is entirely free from the dreadful sensation of threatened suffocation. No tumor is perceptible in the situation of the former aneurism, but an unnatural feeling of hardness can be perceived at the root of the neck,

Aug. 8, 1828.

immediately above the sternum, arising, no doubt, from a condensation of the aneurismal tumor. The right carotid artery still pulsates, although not so strongly as the left; its pulsation corresponds to that of the heart, but its branch, the temporal artery, affords no indication of the circulation of blood; the right radial artery beats with about half the strength of the left. She suffers none of those pains in the regions of the neck, shoulder and back; nor has she, for a long time, experienced any of those severe head-achs which formerly gave her so much uneasiness; the œdema of the feet has entirely disappeared, and she takes exercise in the open air daily.

Sept. 9, 1828. The above report was drawn up a month ago, previous to her visit to the country, from which, in a letter received from her yesterday, she states that she is now in a better state of health than she has been for a long time."

Concluding Observations.

Whilst the principle of Brasdor's operation is fully established by the cases which have been described, it also appears to me, that the foregoing case of Mrs. Denmark, points out a new view of operating in another, and in a hitherto fatal class of aneurisms.

New operation, where applicable.

The cases of aneurism in which the Hunterian operation is not applicable, are chiefly those of the carotid and subclavian arteries, of the arteria

innominata, and of the iliac arteries, where the tumor is formed so near the heart, and has acquired such a bulk, as to render placing a ligature on the artery between the tumor and heart, an impracticable operation. It is in such cases, I conceive, that the new operation may be peculiarly applicable, a class which, from their formidable and hitherto untractable nature, have generally pursued a fatal course.

In the practical application of this new mode of operating for aneurism, it will be of great im-^{Diagnosis of aneurisms of the neck.} portance to form an accurate diagnosis of aneurismal swellings in the neck, those particularly at the roots of the carotid and subclavian arteries, as well as those of the arteria innominata. This is generally esteemed extremely difficult; and erroneous opinions have in several instances been formed as to the site of such tumors by most experienced surgeons. I apprehend, however, that the difficulty of distinguishing aneurisms of these arteries from one another, has chiefly arisen from the circumstance of their having all been considered incurable, at least by operation; and as far as general treatment has been concerned, the same system having been applicable to all of them, no one has even endeavoured to point out their diagnosis. From having had frequent opportunities of examining cases of this kind, since my attention was directed to this important subject, I think that aneurisms of these different vessels may generally be distinguished from one another;

and it may be observed that the diagnostic characters about to be pointed out, are chiefly derived from a consideration of the natural position of the vessels, and their relative situation to the surrounding parts.

Diagnosis of
aneurism of
the carotid.

When an aneurismal swelling is formed at the root of the Carotid, the tumefaction will first be perceived in the small triangular space, formed between the heads of the sternal and clavicular portions of the mastoid muscle, and when the tumor increases in bulk, it more or less displaces, or sometimes produces the absorption of a portion of either the one or the other of the heads of that muscle.

Of aneurism
of the arteria
innominata.

If the aneurismal swelling be formed in the Arteria Innominata, then, in place of its first making its appearance between the two heads of the mastoid muscle, at the bottom of which space lies the carotid artery, covered merely by a loose cellular structure and some fat, the tumor rises up from below the sternum, and on the tracheal edge of the sternal portion of the mastoid, at which place the innominata is most uncovered. The situation of the tumor, however, varies when the innominata is the seat of the disease, according to the part of the artery that is affected; as in the case of Gordon, where the rupture of the internal coat of the innominata being at the distal extremity of that vessel, and the other coats yielding in the direction of the impetus of the blood, the tumor took a diagonal

See Appendix.

direction between the lines of the carotid and subclavian, and thus first appeared in the triangular space on the acromial edge of the mastoid muscle.

Moreover, when the aneurism is formed in the Subclavian, then will the tumor rise on the cervical side of the clavicular portion of the mastoid, in the triangular space between that muscle and the trapezius, where, like the former vessels, it is covered only by some fat and condensed cellular membrane. It is indeed in these several spaces where the three different arterial trunks are most exposed, and where the superincumbent parts are of that nature which will most readily yield to the growth of the aneurismal swelling.

Of aneurism of the subclavian.

Another diagnostic mark in distinguishing the seat of the disease of these vessels, is the state of the pulsation in the branches of the subclavian and carotid arteries; the force of the pulse being usually diminished in the branches of a trunk affected with aneurism. Thus when the carotid is the seat of the disease, its branches only will have their pulsation affected; when the subclavian suffers the radial artery will pulsate with less force; and when the innominata, the circulation in the branches of both subclavian and carotid will be more or less influenced.

Diminished pulsation in the branches of an aneurismal artery.

I may also observe in conclusion, that as the aneurismal tumor acquires considerable bulk, the diagnosis will become more difficult, and the difficulty will, in many cases, arise from the circum-

Difficulty of diagnosis in aneurisms of the neck.

See the plates.

stance, that two or more of these vessels, and in many instances the arch of the aorta, are involved in the disease.

New operation in aneurisms of the Innominata.

It is in cases of aneurism of the Arteria Innominata, wherein I consider the operation of tying one, or both, of the branches of that vessel on the distal side of the tumor, likely to become an operation of great utility, and in an especial manner applicable.

When to be adopted.

In considering the application of this principle of operating in a case of aneurism of the innominata, the first important point of enquiry ought to be, whether blood continues to circulate both through the carotid and the subclavian arteries, or through only one of these divisions of the innominata? I have already stated that there were examples of aneurism of the innominata wherein nature had shut up the carotid, and thus had, in part, accomplished the consolidation of the sac.

When the aneurism has not attained so great a bulk as either to produce serious affections of the head or of the chest, or to threaten rupture, and when, under such circumstances, both the divisions of the innominata remain open, I would then be satisfied with adopting Valsalva's system of treatment, in the hope that, ultimately, one of the trunks might be obliterated.

One of the branches to be first tied.

Should, however, so favourable a change not ensue, the propriety of tying one of the divisions of the innominata is then to be considered;

and how far such treatment ought to be adopted in a patient whose case is in other respects hopeless, future experience, and an exact knowledge of the practical application of this principle of operating, can alone determine. I may here observe, that it will perhaps be a matter of no small difficulty to ascertain when one of these arterial trunks is obliterated, as I have with others been more than once deceived on this point. Conceiving that a want of pulsation was a sufficient indication of the closure of an artery, I formed an erroneous opinion in the case of Mrs. Denmark; and from the pulsation in the carotid and its branches not See page 67. being perceptible, I supposed that the canal was plugged up; but in a short time after a ligature was placed on the subclavian, I was surprised to find the pulsations of the carotid return, and ultimately resume their wonted vigour.

It is a fact demonstrated by dissection, and wor- Carotid the most preferable. thy of remark in contemplating such an operation, that when a spontaneous cure of aneurism of the innominata has been going on, nature has first shut up the carotid, so that in performing an operation for the cure of such an aneurism, it surely would be advisable to imitate nature in this respect, and to place the first ligature on the carotid, in preference to the subclavian. The advantage of this is obvious, for as no vessels pass from the carotid between the ligature and the sac, a greater diminution in the force of the circulation in the

tumor would follow than if the subclavian were tied, it not being practicable to apply a ligature on that vessel without leaving four large branches between the ligature and the sac. I have been taking for granted that the calibre of the carotid and subclavian is about equal.

When under these assumed circumstances the carotid has been tied, the propriety of afterwards placing a ligature on the subclavian, must be decided by the effects produced on the aneurism, as well as on the system of the patient.

Or the branch
which remains
open.

On the other hand, when in a case where either the carotid or subclavian is already obliterated by a spontaneous process of cure, then am I strongly impressed with the propriety of tying the vessel which remains open, all other circumstances being favourable. Of course no such operation would be advisable, when there was any reasonable prospect of the spontaneous curative process advancing; but if, notwithstanding the general treatment adopted, the tumor were decidedly to increase, I would not then hesitate to tie the open vessel.

Conclusion.

In advocating this principle of operating for aneurism, I am well aware that it has already been successfully practised and recommended by several intelligent surgeons: there are, however, many difficulties and prejudices to overcome, and the doctrines I have now brought forward will call forth warm discussion, and doubtless severe criticism. From this, however, science will derive an

important benefit: all the facts and arguments which may appear to refute my opinions, will be brought under review, and the profession will then be enabled to form a just opinion of the advantages, as well as of the unfavourable circumstances, attending the operation.

APPENDIX

important points: all the facts and arguments which may appear to refute my opinion will be brought under review; and the proposition will then be admitted to form a part of the opinion of the majority as well as of the minority. (Circumstances attending the operation of the law are not to be considered.)

The second point is, to consider the law as it stands, and to determine whether it is consistent with the principles of justice and equity, and whether it is consistent with the principles of the constitution. (Circumstances attending the operation of the law are not to be considered.)

The third point is, to consider the law as it stands, and to determine whether it is consistent with the principles of justice and equity, and whether it is consistent with the principles of the constitution. (Circumstances attending the operation of the law are not to be considered.)

The fourth point is, to consider the law as it stands, and to determine whether it is consistent with the principles of justice and equity, and whether it is consistent with the principles of the constitution. (Circumstances attending the operation of the law are not to be considered.)

The fifth point is, to consider the law as it stands, and to determine whether it is consistent with the principles of justice and equity, and whether it is consistent with the principles of the constitution. (Circumstances attending the operation of the law are not to be considered.)

The sixth point is, to consider the law as it stands, and to determine whether it is consistent with the principles of justice and equity, and whether it is consistent with the principles of the constitution. (Circumstances attending the operation of the law are not to be considered.)

The seventh point is, to consider the law as it stands, and to determine whether it is consistent with the principles of justice and equity, and whether it is consistent with the principles of the constitution. (Circumstances attending the operation of the law are not to be considered.)

The eighth point is, to consider the law as it stands, and to determine whether it is consistent with the principles of justice and equity, and whether it is consistent with the principles of the constitution. (Circumstances attending the operation of the law are not to be considered.)

The ninth point is, to consider the law as it stands, and to determine whether it is consistent with the principles of justice and equity, and whether it is consistent with the principles of the constitution. (Circumstances attending the operation of the law are not to be considered.)

The tenth point is, to consider the law as it stands, and to determine whether it is consistent with the principles of justice and equity, and whether it is consistent with the principles of the constitution. (Circumstances attending the operation of the law are not to be considered.)

The eleventh point is, to consider the law as it stands, and to determine whether it is consistent with the principles of justice and equity, and whether it is consistent with the principles of the constitution. (Circumstances attending the operation of the law are not to be considered.)

The twelfth point is, to consider the law as it stands, and to determine whether it is consistent with the principles of justice and equity, and whether it is consistent with the principles of the constitution. (Circumstances attending the operation of the law are not to be considered.)

APPENDIX.

*Aneurism of the Innominata and Root of the Carotid successfully treated by Tying the Carotid Artery. By D. EVANS, Esq. Surgeon at Belper, Derbyshire.**

AN outline of this case, politely communicated to me by Mr. Evans, was received too late to be printed in an earlier part of this work. I am here, however, enabled to insert a detailed and most interesting account of it, as published by himself; and I cannot help expressing the high gratification it affords me, to notice not only the success of the operation, but that it has been so promptly adopted by Mr. Evans, as well as by other provincial surgeons.

CASE.

“ William Hall, ætat. 30, a butcher and horse-dealer, an athletic and spirited young man, about five feet six inches high, has been accustomed to laborious exercise, frequently riding from 70 to 100 miles a day, and always enjoyed excellent health, until the appearance of the following symptoms :

About fourteen months ago he was affected with ^{Symptoms.} shortness of breath, troublesome cough, and tightness over the chest, after much exertion, especially

* Extracted from *The Lancet*, vol. i. Nov. 1828.

in walking fast up a hill. These symptoms continued until the 6th of March, when he had an attack of bronchitis. His expectoration was copious, consisting of mucus slightly streaked with blood, and his cough came on in violent paroxysms, which were followed by a sense of suffocation.

Appearance of
the tumor,
March 10,
1828.

On the 10th of March, after a fit of coughing, a soft pulsating tumor, about the size of a walnut, suddenly made its appearance behind, and extending a little above the right sterno-clavicular articulation, and covered, externally, by the sternal portion of the sterno-mastoid muscle. The tumor was greatly diminished by firm pressure, but could not be made entirely to disappear.

The pulsation of the tumor, which was synchronous with that of the heart, was increased in force by pressure upon the right subclavian artery, and was diminished, and sometimes completely arrested, by pressure upon the right carotid. The pulsations of the right carotid and subclavian arteries were stronger than those of the left; but there was no apparent difference in the pulsations of the radial arteries.

As soon as the tumor made its appearance, the cough and dyspnœa ceased to be troublesome, and his health was soon re-established. His chest sounded well upon percussion, and the respiratory murmur was distinctly heard all over it. No unnatural pulsation could be detected, by the use of the stethoscope, between the tumor and the heart. A loud and powerful pulsation was heard

over the tumor, unattended with any unusual sound.

In taking into consideration the situation of the tumor,—its sudden appearance, after a violent paroxysm of coughing, and its soft pulsating character, together with the symptoms above enumerated, little doubt could be entertained of its nature, and I concluded that the root of the carotid artery was chiefly the seat of the disease.

Considering this a favorable case for the operation lately revived, and so ably advocated by Mr. Wardrop, I was induced to obtain the opinion of two eminent surgeons in London respecting its propriety. Both, however, disapproving of the operation, it was determined, with the approbation of my friends Mr. Bennet, and Mr. Brown of Derby, that a fair trial should be made of Valsalva's plan of treating aneurisms.

Valsalva's
treatment
adopted.

The nature of the disease was fully explained to the patient, who, fortunately, was a man of strong sense and most determined resolution, and, from his avocations leading him to attend to the diseases of horses, there was no difficulty in making him comprehend the dangerous tendency of the disease. He therefore submitted to the proposed plan of treatment; and I cannot sufficiently admire the fortitude and cheerfulness with which he bore the long privation which it was necessary to enforce, and the implicit faith which he placed in the remedies adopted for his relief.

Commenced
April 3, 1828.

He was accordingly ordered to bed, to be bled to the extent of eight ounces every third day; his diet to consist of small quantities of gruel, broth, and tea. Small doses of digitalis were likewise administered. This plan of treatment was continued until the 13th of July. During the first month there appeared some little improvement; his pulse was frequently as low as 47 in the minute, the tumor became harder, its pulsation less forcible, and more remote; from which it was supposed that coagula might be forming. The blood hitherto had seemed perfectly healthy; and it was noticed that if the bleeding were delayed beyond the usual time, the symptoms were aggravated.

Symptoms
aggravated.

In the beginning of May a great alteration for the worse took place, which was supposed to be owing to his taking a small quantity of animal food. The blood, after each bleeding, now became buffed; pulse 80 in the minute; the tumor rapidly increased in the course of a few days, and became very painful upon pressure. Twenty leeches were applied without any relief. A few days afterwards a diarrhœa supervened: the inflammatory state of the tumor now abated, the pain ceased, and the swelling in some degree subsided. After this attack his pulse was never less frequent than 80 in the minute, although the same plan of treatment was rigidly adhered to.

Tumor in-
creases.

From this time until the 1st of July the tumor

remained stationary ; but from the latter date until the 20th he again got gradually worse ; the tumor increased, and now reached as high as the cricoid cartilage, and, by its pressure upon the trachea and œsophagus, partially impeded respiration and deglutition. His shirt-collar, which prior to his illness would button comfortably, could not now be made to meet by more than three inches ; his countenance became bleached ; pulse more feeble ; and it was evident that the lowering system had been carried as far as it could be done with safety.

Under these circumstances the operation was now recommended, as the only remaining chance. Operation recommended. Its advantages and disadvantages were fairly stated, and the chance of success, although small, made him anxious that it should be performed. Dr. Bent, of Derby, saw the patient on the 17th, and concurred in the propriety of the operation, as a last hope.

On the morning of the 22nd of July, the day proposed for the operation, the patient became so agitated, that the pulsation of the tumor of the heart and the large arteries, especially the abdominal aorta, was perceptible to the eye. The operation was performed in the presence of Messrs. Bennet and Brown, of Derby ; Mr. Ingle, of Ashby de la Zouch ; and Mr. Walne, of Chancery-lane.

In consequence of the tumor extending so high up the neck, there was some difficulty in getting down to the sheath of the carotid artery, which was opened to the extent of half an inch. The Performed, July 22, 1828.

artery appeared healthy, and was easily secured by a single ligature of strong silk. Immediately after tightening the ligature the pulsation in the different branches of the external carotid artery ceased, except a slight fluttering in the extreme branches of the temporal. The pulsation of the tumor continued without diminution.

Reports, July
23 and 24.

He went on well. The pulsation in the tumor was stronger than it was before the operation, and the pulsation of the right radial artery was observed to be more forcible than that of the left.

July 25.

He became feverish; pulse 120, and full; the right lip of the wound swollen and painful. Six ounces of blood were taken away from the arm, and a saline medicine administered. The blood was much buffed.

July 26.

Morning—Much better; pulse 92; stronger in the right radial artery than in the left; pulsation in the tumor still very forcible. Evening—The fever, and pain in the tumor, returned. He was again bled. Blood still buffed.

July 27.

Better again this morning. He was taken worse at nine o'clock in the evening. Pulse 100; delirious; anxious countenance, and sickness. No diminution in the size of the tumor.

July 28.

Much better, and continued so all day.

July 29.

At seven A. M. he was taken suddenly worse, and appeared to be dying; his countenance ghastly, and covered with perspiration; tracheal rattle, and inability to swallow. He appeared conscious, but could only speak in a whisper;

pulsation in the tumor still forcible ; the pulse in the right radial artery scarcely perceptible, whilst the left pulsated as strongly as it did the previous day. These symptoms were accompanied with a profuse ptyalism. He remained in this state for several hours, at the expiration of which time he rallied, and by the evening (with the exception of the salivation, which continued) he appeared quite as well as on the preceding day.

As he continued to improve from this period, it will not be necessary to enter into a daily report of the case ; I shall therefore content myself with noticing the most prominent symptoms which occurred.

One of the most remarkable was the obliteration of the arteries of the right arm and fore arm, Obliteration of the arteries of the arm. which was first observed in the arteries of the fore arm on the 29th of July, the eighth day after the operation, for until that day the arteries of the right arm pulsated with greater force than those of the left. The process of obliteration was attended with severe intermittent paroxysms of pain, chiefly felt in the course of the brachial and axillary arteries. The brachial artery, after its obliteration, was hard and painful to the touch, and felt very like an inflamed absorbent vessel. The right arm wasted, and became partially paralysed, Wasting of the arm. and continued to diminish for three weeks, at the expiration of which time several arterial anastomosing branches were observed pulsating on the back part of the arm. As these vessels enlarged,

the limb improved very slowly, not having yet (Oct. 19) perfectly acquired sensation, nor its muscles the power of obeying volition.

Wasting of the
right side of
the head and
face.

On the 11th day after the operation he was attacked with intermitting paroxysms of pain in the right side of the head and face, of the same character as the pain in the right arm, though not so violent: this pain ceased within a fortnight. The right side of the head and face became emaciated, and any one looking at him would immediately discover, that the right half of the face was much smaller than the left. The blood having since found its way into the temporal and facial arteries, the right side of the face is now nearly as plump as the left.

Ptyalism
excessive.

The ptyalism, which began on the 29th of July, continued until the middle of September, during which time he spat daily about a pint of saliva; a more generous diet, and a small quantity of ale, were then allowed, and the salivation subsided.

Pulsations of
the tumor diminish
in force.

Three weeks after the operation he was able to sit up to his meals. The first time that he got out of bed, he perceived that the whole of the right side was numbed, and weaker than the left. The pulsation in the tumor, which had hitherto been more powerful than it was before the artery was tied, now (August 15) began to diminish rapidly, and by the 23rd of August, the thirty-third day after the operation, had so much subsided, that it was doubtful whether it arose from

the passage of blood into the tumor, or from the impulse given to it by the subclavian artery beneath.

In five weeks after the operation, he was sufficiently recovered to be able to take daily exercise in a gig, or on horseback, and from this time he has continued to improve in health, without interruption.

The obliteration of the right brachial artery is now complete, and above the insertion of the latissimus dorsi the pulsation of the axillary artery can be easily felt. The pulse in the radial artery is scarcely perceptible; the right arm increases daily, but is yet far from being of the size of the left. Sensation and susceptibility of the influence of volition are more perfect on the whole of the right side of the body, but still that side is more feeble than the left. The tumor is hard and firm, and has diminished about one-third since the operation. By pressing it from above downwards, a feeble, deep-seated pulsation is felt, but in grasping the tumor and using lateral pressure no pulsation can be perceived.

Progress of
the cure.

On the 13th of October the wound was nearly healed; the ligature had not come away; and as it acted as a source of irritation to the small wound, it was cut off level with the skin.

The most peculiar features which this interesting case presented were—1st. The obliteration of the arteries of the right arm; 2nd. The profuse

Concluding
Observations.

salivation; 3rd. The disposition to paralysis of the whole of the right side of the body.

The two first symptoms commenced on the 8th day after the operation; and I think there can be little doubt that the obliteration of the arteries of the arm was accomplished by inflammation extending from the aneurismal sac to the internal membrane of the subclavian artery, and thence to the brachial artery. Might not the active obliteration of such large arteries as those of the arm and fore-arm, be the cause of the unpleasant train of symptoms which occurred on the 8th day after the operation? The salivation appeared to be connected with the state of the digestive apparatus; for as soon as ale and a generous diet were allowed, it gradually subsided. I am at a loss to assign the cause of the numbness and debility of the whole of the right side of the body, (which were only observed when he first left his bed), unless they originated in a greater quantity of blood circulating in the left hemisphere of the brain than in the right, which undoubtedly would be the case after the application of a ligature to the common carotid. What tends to confirm this opinion is, that now, thirteen weeks after the operation, the balance of circulation in the brain being re-established, the numbness and debility of the right side of the body have nearly disappeared.

In conclusion, it is worthy of notice, that, since

the operation, he has become more irritable in temper, and his memory is evidently weaker.

So far as this case has yet proceeded, it amply justifies the operation; and the man probably owes his life to Mr. Wardrop's fortunate suggestion and example. Should any untoward circumstance occur, leading to any other conclusion, it shall be communicated.

It is now five weeks since he resumed his usual avocations, and he regularly attends the markets and fairs of Derby, a distance of seven miles."

Belper, October 22, 1828.

Aneurism of the Innominata where the Carotid Artery was found obliterated.

I am indebted to Mr. Makelcan, a zealous pathological inquirer, for the details of this interesting case.

Besides pointing out in the most satisfactory See page 61. manner one of the modes which nature employs for the cure of aneurism, a process which the new mode of operating strictly imitates, this dissection also demonstrates, that the process of obliteration of an artery can go on and be completed, without the blood's circulation through that vessel being either entirely stopped, or suddenly produced.

The circumstance of so large a portion of the sac being lined by a membrane similar to the internal tunic of a healthy artery, and the extension

of this membrane over the mouth of the carotid, is also worthy of notice. And the fact of the sac acquiring a lining of this description, is interesting in a pathological point of view, as it demonstrates satisfactorily, that nature possesses the power of reproducing a serous membrane, in like manner as she reproduces a mucous membrane, skin, bone, nerve, or blood-vessels.

CASE.

“ T. Gordon, a blacksmith, thirty years of age, whose general health was good, after exposure to wet and cold was seized with violent vomiting; during which, to use his own expression, “ a swelling suddenly started up in the hollow of his neck.” I saw him fourteen days after this attack: he then complained of what he considered to be a rheumatic affection of the right arm and side of the head: two days afterwards he mentioned the swelling in his neck, which he requested me to examine. I then found an aneurismal tumor, of the bulk of a hen's-egg, in the space between the clavicular portion of the mastoid muscle and the edge of the trapezius; and I could trace the base of this tumor, extending downwards and inwards behind the clavicle. In this state the patient was advised to go into the Middlesex Hospital, where he remained six weeks, and during which time Valsalva's system of treatment was pursued with the most unwearied diligence. On his return home, I found the aneurism had

increased to four times the size it was when I had first examined it, and the symptoms were much aggravated from the bulk which the tumor had attained, and which now greatly impeded respiration. From this state he sunk rapidly, and died on the following day.

Dissection. The appearance of the neck was very different from what it had been during life, the tumor not being above one-third of its former size. When the whole of that part of the tumor situated in the neck was exposed there were three subdivisions observable, one extending upwards by the side of the trachea as high as the cricoid cartilage; a second laterally, along the line of the clavicle to one-third of the extent of that bone; and a third between these two, extending upwards and outwards across the neck to the anterior edge of the trapezius muscle. The structure of the coats of the sac at its anterior aspect gave way immediately on touching them. The upper part of the sternum and cartilages of the first and second ribs being removed, the remainder of the tumor was exposed, extending behind the clavicle and upper part of the sternum, and reaching to the arch of the aorta, upon which it rested. The tumor being slightly raised, the innominate was divided close to the aorta, and the diseased parts removed. The carotid was found behind the first portion and the subclavian behind the second, and towards its lower part the orifice of the innominate was perceived. On examining the cavity of the

See plate.

sac, the aneurismal opening was found to be in the arteria innominata, about an inch in extent, commencing at about half an inch from its origin, and reaching to its division, the coats retaining their healthy appearance; and this appearance terminated in an abrupt line where the parietes of the aneurismal sac commenced. At the lower part of this space, the orifice of the innominata was seen; at the upper part, and towards one side, that of the subclavian. No carotid could be here discovered, but on passing a probe along this artery from above, resistance was offered to its progress at about half an inch from the point where the vessel might be expected to open into the sac; this, however, was overcome with a slight force, and the instrument passed on till its point was perceived through a semitransparent membrane which was stretched over the orifice of the artery, and appeared to be continuous with the living membrane of the innominata, preventing the passage of the probe into the cavity of the sac. Between the tumor and first branch of the subclavian was a portion of vessel half an inch in length, and perfectly healthy. A coagulum about the size of a walnut occupied that portion of the sac behind the upper part of the sternum, and layers of the same nature, about the thickness of half an inch, were found at the upper and inner part, where the tumor was in contact with the trachea."

See plate, with
explanation.

Aneurism of the Carotid Artery which had undergone a spontaneous cure.*

The following case, narrated by Dr. Baillie, is interesting, not only as it affords an excellent example of one mode of the spontaneous cure of a carotid aneurism, but is valuable from the remarks which that intelligent observer was led to make on the dissection. See page 6.

Dissection. “In the right carotid artery, just where it divides into the internal and external carotids, I found an oval uniform swelling, about an inch and a half in length, and the diameter of the artery was scarcely enlarged to more than twice its ordinary size. The swelling was firm, giving the same resistance to the feeling as a healthy absorbent gland, and if it had been felt through a thin layer of muscle, would certainly have been mistaken for one of a large size. When the coats of the artery were cut through, I found its cavity completely filled with a coagulum of blood, which had not the appearance of blood recently coagulated after death, as is met with in the beginning of the pulmonary artery, but it had the appearance of an old aneurismal coagulum. See plate.

“The coagulum adhered every where so closely to the inside of the vessel, that, in separating it, the inner coat was in many places peeled off

* The Works of M. Baillie, M.D. to which is prefixed an account of his Life, by James Wardrop.—London, 1825.

along with the coagulum. In cutting into its substance I found it consisting of distinct layers, as in a common aneurism. There was no part of it which had the appearance of being recently formed, and, therefore there cannot be any doubt of its having existed for a considerable time before the man's death. It is obvious then, that in this case a coagulum had formed in the carotid artery, undergoing the same process as in aneurism, and that the tendency to aneurism had remedied itself. The whole cavity being filled up with the coagulum, there was no circulation whatever in this part; hence the cause of further dilatation was removed, and there was no danger of the rupture of the vessel, which is the principal danger in this disease."

Aneurism of the Innominata and root of the Carotid and Subclavian Arteries.

The following is an extract of the case, to which I alluded in page 17, made from the valuable work of the late Mr. Allan Burns. In this patient I had proposed to place a ligature on the carotid artery, but the operation was opposed by the other surgeons who were consulted. I am now however convinced, from the appearance of the parts on dissection, and result of the operations which I have since performed, that the aneurism in this patient might have been cured by tying one, or both branches of the innominata.

CASE.

“ On Friday, the 13th of October, 1809, I visited an officer, who stated, that a few weeks ago his left arm felt benumbed, and nearly about the same time he experienced some unpleasant sensations about the head. Symptoms.

Till Sunday last, however, he was not supposed to be seriously unwell. On the afternoon of that day, while travelling slowly in a postchaise, he was suddenly seized with a very acute pain over the uppermost rib, on the right side, a pain which extended even to the top of the shoulder. This pain was so much encreased by the motion of the carriage that he was compelled to quit it, and finish his journey on foot. He walked about two miles. On his arrival in town he was led to examine the pained part, where he discovered a firm pulsating tumor, which alarmed him very much; he had an anxious, though by no means an unhealthy look. He complained of little present inconvenience from his complaint, except pain stretching from the root of the neck towards the back; but he dreaded the result of his disease, the nature of which he had discovered.

Tumor
appeared.

A tumor about the size of a pigeon's egg was situated just behind the clavicle, and on the acromial edge of the sterno-mastoid muscle. It pulsed strongly, while the radial artery of the right arm acted with little vigour; but on comparison with the artery of the opposite arm, the pulse was Its form and
size.

stronger. In both arms the pulse was regular when I examined it, but during the two preceding days I was informed that it had been intermittent.

Its position.

In regard to the tumor itself, it was placed in part beneath the clavicular portion of the sterno-mastoid muscle, but the greatest part of it lay nearer to the acromion than the muscle. By pressure the tumor could be nearly emptied, but while doing this he complained of considerable uneasiness. So soon as the pressure was removed, the sac became again distended, and the blood on entering it communicated a whizzing sensation to the finger. The impulse was at the same time great; and on the contraction of the ventricle the sac became exceedingly tense, and the throbbing and whirlpool-like motion of its contents were conspicuous features of the disease. The innominate was felt beating at the top of the sternum, apparently in no degree enlarged. The common carotid acted more freely than on the opposite side. The skin was not discoloured, and his rest was unbroken.

Remarks.

On reviewing this case, I had no doubt as to the nature of the disease; indeed its character was too decided to be mistaken. I earnestly wished to be of use to him, and he declared his readiness to submit to any operation. Yet who could urge an operation in such a case? What certainty was there that the coats of the innominate were not diseased, even to the place where that vessel arises from the aorta? The immediate risk of operation

Operation
condemned.

would have been immense ; it would probably have accelerated the fatal issue, which he was directed to retard by low diet, by abstinence from wine, spirits, or fermented liquors, by keeping the bowels most easy, by avoiding either corporeal exertion or mental irritation, and by employing digitalis to moderate vascular action.

Treatment recommended.

I had occasional opportunities of seeing the patient, but till towards the end of December, there was little change on either the tumor or general health, if we except a tendency to œdema, and depression of spirits. The former was completely removed by the use of the digitalis. I found the tumor much flattened, and could perceive very little pulsation about the innominata. Along the subclavian, vertebral, and common carotid arteries, there was a peculiar thrilling sensation during their action. He has now frequent paroxysms of pain, extending along the right side of the head, and complaint of constant numbness of the left arm. The food he takes is light, his bowels are easy, but he is weaker and more anxious than before. The pulse is nearly similar at both wrists. On one occasion he lately felt a sudden rushing of blood to the head, followed during a short time by dimness of vision. The tumor is no larger, but it is flatter, broader, and fully more incompressible. It now extends to the very tracheal edge of the sterno-mastoid muscle, but it appears as yet to make no pressure on the trachea. When the sac is squeezed, he complains of

Dec. 28, 1809.

Continuation of the case.

Jan. 27, 1810.

a sharp pain extending round the shoulder. The jarring action of the carotid and subclavian arteries is not so well marked as before. The pulse in the right arm is sunk and feeble, the numbness of the left is less, but the right hand has of late become slightly œdematous. He has coldness of the feet, vertigo, and feeling of blood at times rushing to the head. His general appearance is somewhat improved, but his spirits are very much depressed; he is weak, and feels fully persuaded from his symptoms that the disease is extending into the chest. One of the perforating arteries from the internal mammary vessel is felt distinctly enlarged.

March 25,
1810.

Till yesterday there was very little alteration in the size of the tumor, and almost no change in the constitutional symptoms. The right arm had slowly lost its power, the hand remained permanently of a purplish colour, and was sometimes œdematous. When he walked the swelling became tense, and by its distension produced pressure on the veins returning the blood from the head, occasioning vertigo, failure of sight, and turgescence of the veins of the head and neck, symptoms which soon abated after desisting from exercise.

Tumor
increases.

Yesterday a short time after dinner, which consisted merely of bread and water, the tumor suddenly became greatly increased in size, not only projecting farther out, but extending in every direction except towards the trachea. The clavicle appears to be forced away from the sternum, and

pungent pain is occasioned by even gentle pressure on either the tumor or right side of the neck. But it is rather curious that he felt little pain during the sudden enlargement of the sac: he had at that time rather the sensation of something giving way, or yielding. The integuments covering the sac are now slightly discoloured; and obscure pulsation can be discovered in the upper part of the right side of the chest. The pulse in the right arm is rather more distinct, yet it is less so than in the opposite arm. He has no actual difficulty in breathing, but he says that he is "short-winded." The rest which he procures is obtained by the use of the hyosciamus, and his bowels are kept regular by the daily use of stewed fruits. The tumor has increased considerably in size, and for several days past his voice has been gradually impaired, and is now so much injured that he can only converse in a whisper. The scapular extremity of the clavicle seems partly absorbed.

Alteration in the pulse of the right arm.

March 31, 1810, Change in the voice.

The tumor has considerably increased in size, and has extended towards his left side; but although it overhangs the trachea, he does not experience much difficulty in breathing; he complains however of some uneasiness when swallowing, and his voice is still weak and raucous. He is disturbed with painful sensations about the left shoulder, similar to those he felt in the right, about the commencement of the disease, and he is frequently distressed with palpitation, and feeling of

April 15, 1810, Uneasiness in swallowing, palpitations and syncope.

failure about the region of the heart, accompanied with a tendency to syncope. His feet are still unusually cold, even when the rest of his body is warm. At one point the tumor is thin, projects into a small papilla, situated on the acromial side of the sterno-mastoid muscle, and covered with delicate but not diseased skin.

Oct. 10, 1810,
Becomes
anasarcous.

His face is œdematous, and streaked with purple veins; his right hand and arm are cold and anasarcaous, and the cellular membrane of the lower extremities is loaded with water. He moved slowly, and held his head inclined forward. He spoke in a short and hurried whisper, interrupted every few minutes by a hollow cough, and profuse expectoration of greenish yellow matter. He had no pain; difficulty in breathing and want of sleep were his chief complaints. The aneurism was in no degree enlarged externally, the papilla-like projection had even disappeared, and its coverings were now much thickened; yet it caused more pressure on the trachea: and from the very tremulous motion in the upper part of the thorax, I could not doubt the extension of the disease into the chest. The disease was now drawing to a conclusion; it neither admitted of alleviation or of being cured, and of this the patient was fully aware. He was not therefore disappointed when I informed him that I had no remedy to propose. I left him with directions to send for me if he became worse. In four days we were called to inspect his body.

Fatal termination.

Dissection. The dissection proved highly interesting. Appearances presented, which had not been expected; the vessel which I supposed to have been most materially affected was found perfectly healthy.

The aneurism arose from the aorta, and included a considerable part of the innominate; the right subclavian artery was only slightly dilated at its root; along its course, it was rather reduced in size. The tumor mounted from the aorta considerably above the sternum, pressing in its ascent the descending vena cava to the right, and the trachea to the left; obstructing thus the breathing, and intercepting the return of the venous blood from the head and arms. It also pressed the root of the right subclavian artery and the carotid against the spine, retarding in this way the circulation along these vessels. The trachea was so much displaced, that the left carotid slanted across its front to reach the sides of the neck. The right side of the heart is little affected; the left ventricle is much thickened, and the aortic valves are in part ossified, which, together with the obstruction of the circulation arising from the pressure of the tumor on the right carotid and subclavian arteries, will explain the increased strength of the muscular fibres of the ventricle. Just above the heart the aorta is somewhat dilated; I say dilated, because its coats are healthy, and its canal free from lymphatic incrustation. This swell terminates below the commencement of the arch. The

Innominate
and root of the
subclavian
diseased.

Also the heart.

Aorta dilated.

See plate.

inner surface of the aneurismal sac was coated over with many layers of organized lymph, which coating was especially thick and strong about the highest part of the sac. The left part of the arch is of natural size, but a little below the commencement of the descending aorta the vessel is again dilated into a small pouch. The *æ*sophagus is pushed completely from behind the trachea.

Observation of
Sir Astley
Cooper.

This case corroborates Sir Astley Cooper's remark, that aneurism of the aorta may assume the appearance of being seated in one of the arteries of the neck; an inference drawn from the examination of a case which came under his own observation, and of which he transmitted a short history to me, along with a sketch illustrative of the position of the tumor. In the above case, however, the aneurism was attached to the right side of the aortic arch, and involved a part of the innominate. In Sir Astley Cooper's, the tumor arose on the left side of the arch of the aorta, from between the roots of the left subclavian and carotid arteries. It formed a Florence-flask-like cyst, the bulbous end of which projected at the root of the neck from behind the sternum, and so nearly resembled aneurism of the root of the carotid artery, that the Surgeon who consulted Sir Astley Cooper actually mistook the disease for carotid aneurism.*

His case of
aortic aneurism.
See plate.

Mistaken for
carotid aneu-
rism.

* The Surgical Anatomy of the Head and Neck, by Allan Burns, 1826.

Femoral Artery obliterated, and its place supplied by one enlarged vessel.

The following Dissection was communicated to me by Dr. Wright, and is an additional confirmation of the important pathological fact to which I have particularly alluded, that although, when a ligature is first placed on an artery numerous branches nourish the limb, yet ultimately, that function is performed by only a few or even by one enlarged trunk, and that too nearly in the site of the vessel which has been obliterated. See page 12.

Dissection. "On examining the inferior extremity of a subject in the dissecting-room, of which I knew no previous history, I found that about three inches of the superficial femoral artery was obliterated, being converted into a ligamentous cord, in which there was no trace of the canal. The place of this artery was chiefly supplied by *one* of the branches of the profunda, the others not being much increased. This branch was equal in size to that of the superficial femoral in the opposite extremity, and in the lower part of the thigh had nearly the same course with the remains of the superficial femoral, excepting that it did not pass through the sheath formed for the superficial femoral by the adductor longus and vastus intermus muscles."

The following description was submitted to me by Dr. Wright, and is an excellent representation of the important pathological condition which I have particularly alluded to, although when a ligament is first placed on the artery, no such remarkable results are thereby obtained.

That the ligament is contracted by only a few or even by one enlarged trunk, and that the artery in the end of the trunk which has been contracted, is not so much as the trunk which has been contracted.

On examining the interior of the artery of a subject in the dissecting-room, of which I have no previous history, I found that when placed inside of the external trunk, artery was obtained being converted into a ligamentous cord, in which there was no trace of the trunk.

The place of the artery was clearly supplied by one of the branches of the trunk, the other was not so much contracted. This branch was equal in size to that of the superficial trunk in the upper part of the trunk, and in the lower part of the trunk.

It is only the same trunk with the remains of the superficial trunk, expanded that it still has the same trunk, and is the lower part of the trunk.

It is only the same trunk with the remains of the superficial trunk, expanded that it still has the same trunk, and is the lower part of the trunk.

It is only the same trunk with the remains of the superficial trunk, expanded that it still has the same trunk, and is the lower part of the trunk.

It is only the same trunk with the remains of the superficial trunk, expanded that it still has the same trunk, and is the lower part of the trunk.

EXPLANATION

OF

THE PLATES.

EXPLANATION

THE PLATE

EXPLANATION OF THE PLATES.

PLATE I.

IN this Plate are represented different modes by which an Aneurism may undergo a spontaneous cure, as explained in page 6.

Fig. 1. An Aneurismal Tumor, in which the sac is so filled with laminated coagulated lymph, that no fluid blood can circulate in it, and thus all danger of a rupture of the parietes of the Aneurism is completely prevented. At the same time the canal of the artery remains pervious, and carries on the circulation.

"This Aneurism originated from a circumscribed opening in the aorta about three quarters of an inch in diameter, in which space the coats of the vessel were evidently deficient. The sac was nearly filled with very firm and fleshy layers of coagulum, so that it was impossible it could have given way in any direction. This coagulum did not extend into the aorta, but was arched over the opening into that vessel so as to leave a small cavity. Through the cavity the blood passed into the Arteria Innominata, which originated from the inferior and posterior part of the sac. The arched termination of the coagulum had a membranous appearance on its surface. The sac adhered intimately to the trachea, and caused it to assume a remarkable curvature. The aorta was larger than usual. Its internal coat was of a deep red colour, and irregularly thickened. In some places it was converted into a cartilaginous, and in others into a steatomatous structure." See Mr. Hodgson's Work.

Fig. 2 and 3 represents an Aneurism of the carotid artery, wherein a spontaneous cure had been effected by not only the sac being filled by laminated coagulated lymph, but also by the arterial canal itself being obliterated. This figure is copied from Dr. Baillie's plate, and the case is given in page 107 of this work.

Fig. 4. Artery where the whole circumference of the vessel

EXPLANATION OF THE PLATES.

had become aneurismal, and where the sac, filled up with laminated coagulum, has a canal left in the centre of the coagulum through which the blood circulated. The canal which remained through the centre of the coagulum was irregular in its form, and in some places larger than the calibre of the artery. This outline is also taken from Mr. Hodgson's valuable work on the Diseases of the Arteries.

Fig. 5. The upper portion of a Femoral Artery, in which vessel an Aneurismal Tumor had undergone a spontaneous cure by a process of suppuration and sloughing, both extremities of the artery being contracted and plugged up by a clot, in like manner as takes place in the artery of a mortified limb.

Notes of the Case.—"Capt. W. æt. 46. About six or seven inches of the Femoral Artery had sloughed fairly away, viz. from about an inch and a half below the origin of the profunda to the place where the vessel passes through the sac.

In this patient there was a large Aneurismal Tumor of the Femoral Artery, just where that vessel penetrates the triceps muscle. The integuments ultimately gave way from the enormous growth of the tumor; large masses of coagulated blood were afterwards discharged through the ulcerated openings of the skin, and an immense suppurating cavity was thus formed, the profuse discharge from which destroyed life. On dissection, it appeared that upwards of six inches of the Femoral Artery had sloughed off, and nature had closed the two extremities of the vessel by producing a contraction and thickening of the coats, and the formation of an internal clot. *a*, is the upper portion of the femoral artery, which at *b b* is considerably contracted, and from thence the canal becomes gradually narrower until at *c c*, where it is greatly contracted, and terminates in sloughy cellular membrane. The internal clot *d* is observed immediately above this ulcerated orifice, and floats loose in the tube of the artery.

PLATE II.

Aneurism of the Innominata described at page 103, in which the right Carotid Artery was completely shut up, a thin and

EXPLANATION OF THE PLATES.

newly-formed membrane continuous with the lining of the Sac, passing over the mouth of that vessel.

This Plate shews the external form of the Aneurism *a a a*, involving almost the whole length of the Innominata. *b* is the trunk of the Innominata, *c* is the Subclavian with its branches; and *d* is the Carotid laid open, its sides being compressed by the Aneurism, but its canal remaining pervious, except at its termination in the Sac, where it is completely shut up.

PLATE III.

Gives an internal view of the Aneurism delineated in the preceeding Plate. The probe *a a*, is passed along the Innominata, and is seen traversing the Sac and entering the Subclavian Artery. The probe *b*, is passed along the Carotid Artery, and on its point *c* is elevated the thin membrane, apparently a continuation of the lining membrane of the Sac, which was formed over the orifice of that vessel, and completely prevented any blood passing into it. *c c c* are the boundary of the Sac, the greater part of which was filled with laminated coagulable lymph. The parietes of the Sac contiguous to the traject of the pulse *a* are thin, and its parietes lined by a polished membrane continuous with the internal coat of the vessel.

PLATE IV.

External appearance of the first case of Carotid Aneurism, described at page 24.

PLATE V.

Appearances on Dissection of the Carotid Aneurism, Case 3 described at page 45, in which a ligature had been placed on the distal side of the tumor, and where the Aneurismal Sac is seen filled with coagulated lymph,—the portion of artery between the Sac and ligature plugged up,—the Artery ulcerated at the place where the ligature had been applied,—and the *distal* orifice remaining open, through which the fatal hemorrhage took place.

EXPLANATION OF THE PLATES.

From the arch of the aorta *a* is seen arising the left carotid *b*, and the left subclavian *c*; the innominata *d* is left open; at *e* is the right subclavian; and above it the Aneurismal sac *f* of the Carotid is laid open, shewing a mass of firm coagulum *g*, completely filling up the cardiac orifice of the sac, whilst the parietes of the sac itself are much thickened, and lined with laminated coagulated lymph. The two orifices of the artery formed by the ulceration of the ligature are seen at *h* and *j*; the cardiac orifice *h* being filled with a clot, whilst the distal orifice *j* is quite pervious.

PLATE VI.

Fig. 1 is an outline of the Aneurism of the Innominata and roots of the Subclavian and Carotid, described in page 107. The Aneurismal swelling *a* occupies the whole of the Innominata, a portion of the arch of the aorta *b*, and the roots of the Carotid *c*; the Trachea is represented at *e*, the left Carotid at *f*, and the left Subclavian at *g*.

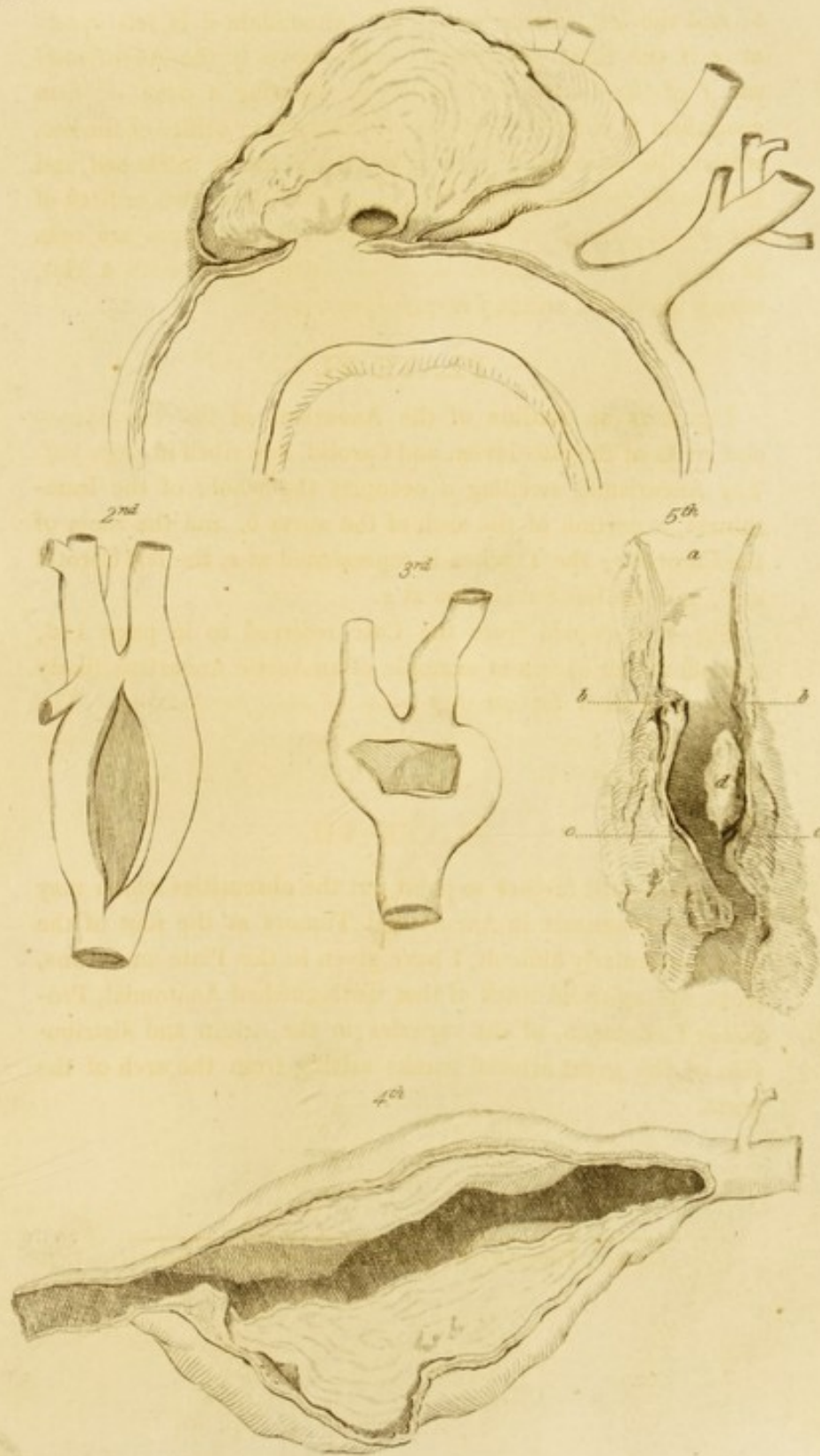
Fig. 2 is copied from the Case referred to in page 116, and affords an excellent example of an Aortic Aneurism likely to be mistaken for an Aneurism of the Innominata. The tumor *a*, of a Florence-flask-form, rises from the aorta between the roots of the left Carotid *b* and left Subclavian Artery *c*.

PLATE VII.

In order still further to point out the obscurities which may render a Diagnosis in Aneurismal Tumors at the root of the neck particularly difficult, I have given in this Plate an outline, from the splendid work of that distinguished Anatomist, Professor Tiedemann, of the varieties in the origin and distribution of the great arterial trunks arising from the arch of the aorta.

PL. I.

Fig 1st






PLATE III.

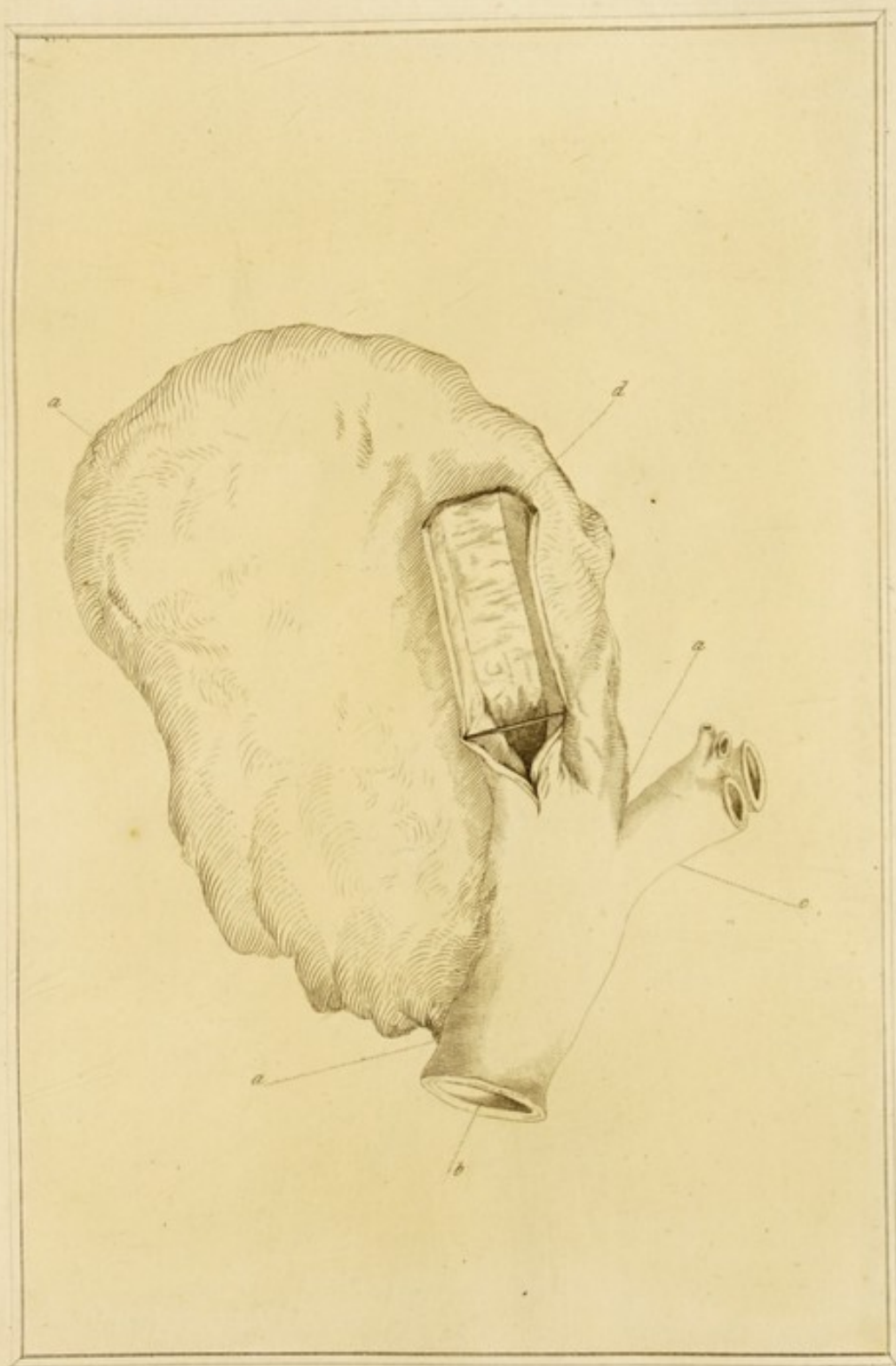



PLATE III.

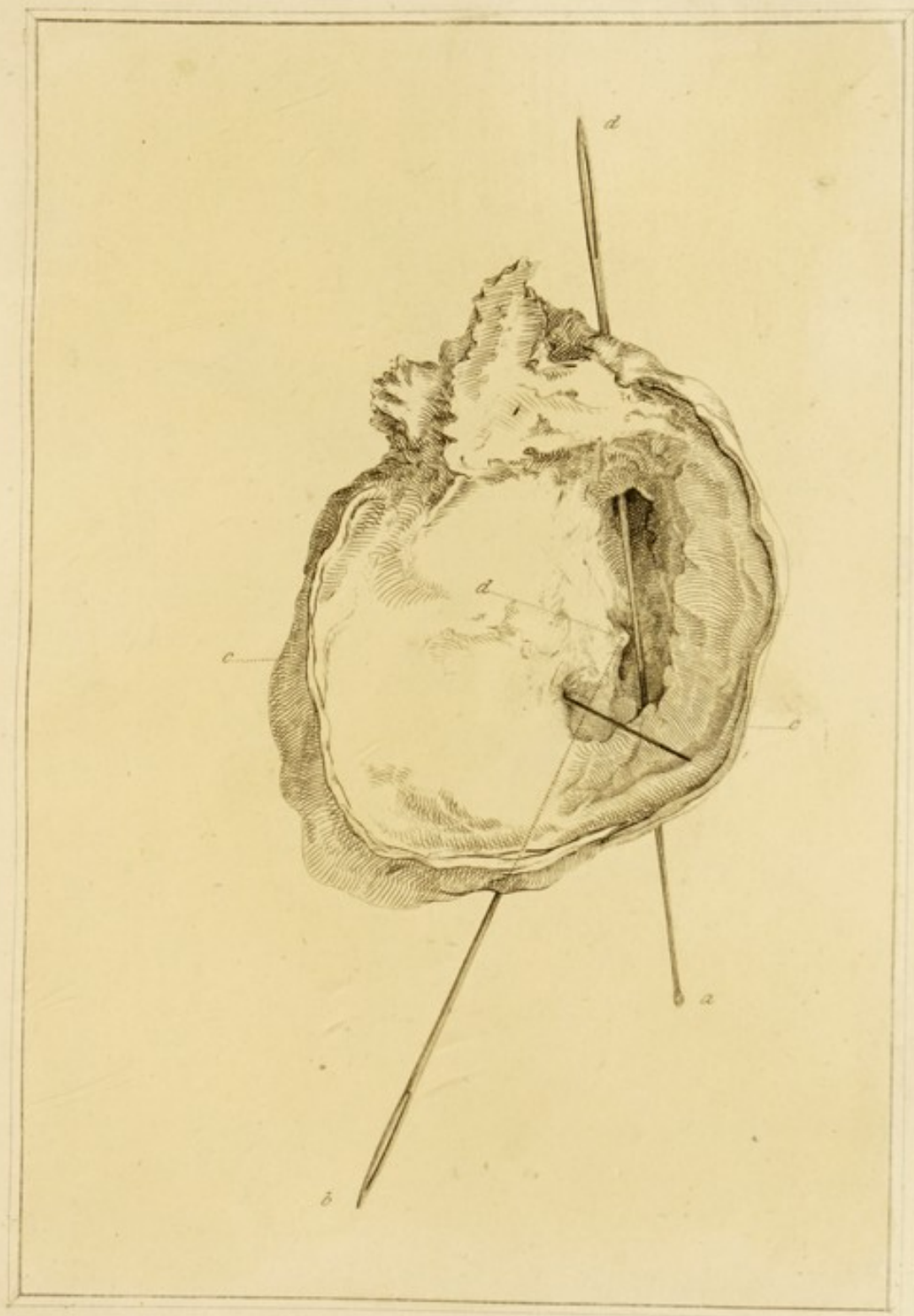




PLATE IV.

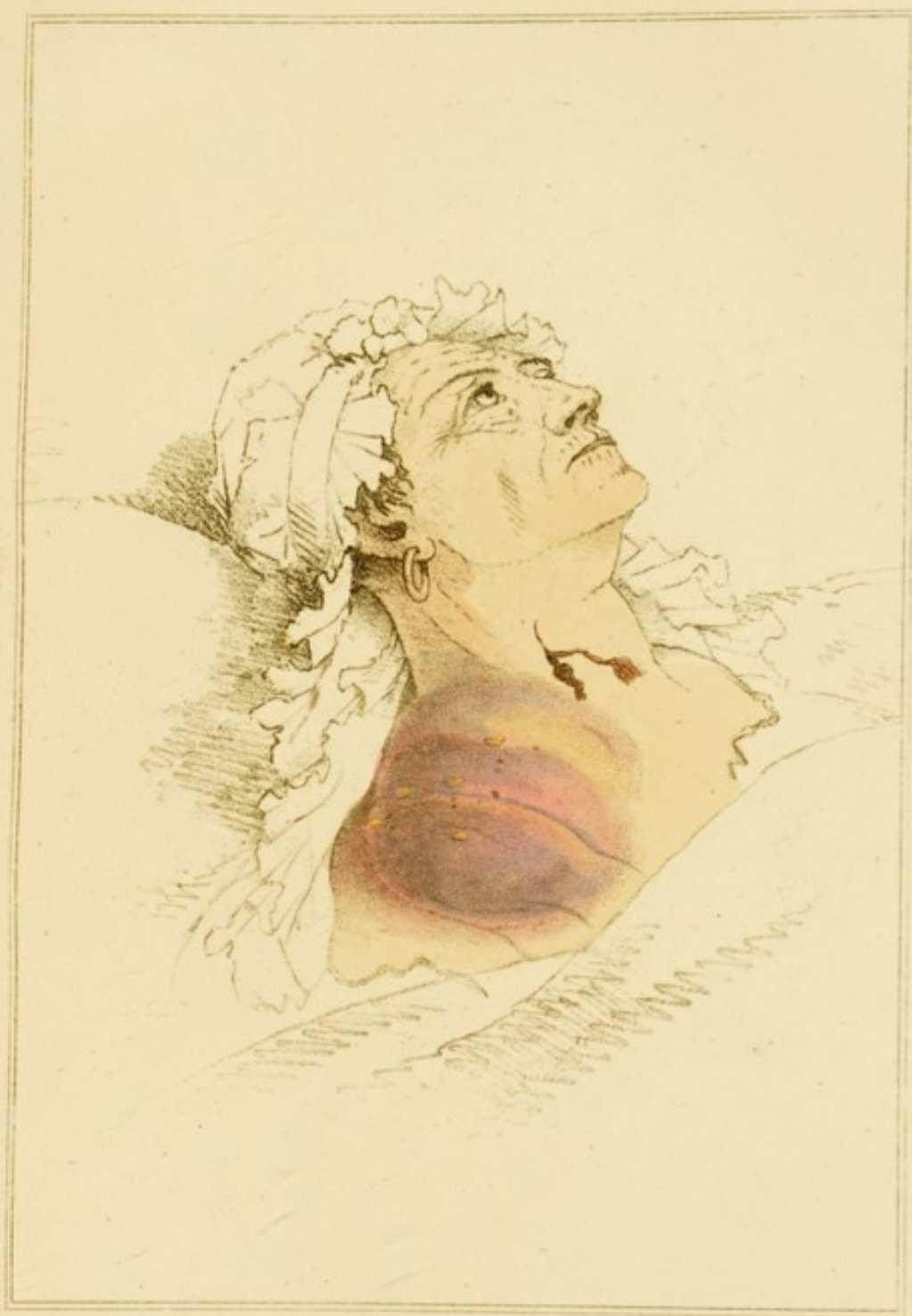



PLATE V.





PL. VI.

