

An introduction to pathology and morbid anatomy / by T. Henry Green.

Contributors

Green, T. Henry (Thomas Henry), 1841-1923.
Fenwick, E. Hurry (Edwin Hurry), 1856-
Royal College of Physicians of London

Publication/Creation

London : Henry Renshaw, 1875.

Persistent URL

<https://wellcomecollection.org/works/wg8agvfk>

Provider

Royal College of Physicians

License and attribution

This material has been provided by This material has been provided by Royal College of Physicians, London. The original may be consulted at Royal College of Physicians, London. where the originals may be consulted. This work has been identified as being free of known restrictions under copyright law, including all related and neighbouring rights and is being made available under the Creative Commons, Public Domain Mark.

You can copy, modify, distribute and perform the work, even for commercial purposes, without asking permission.

**wellcome
collection**

Wellcome Collection
183 Euston Road
London NW1 2BE UK
T +44 (0)20 7611 8722
E library@wellcomecollection.org
<https://wellcomecollection.org>

GENSHAW'S
MANUALS

8 H 7000 06
SL

RENSHAW'S MANUALS

In Fcap. 8vo, cloth.

DRUITT'S SURGEON'S VADE MECUM.	12/6
GUY'S FORENSIC MEDICINE	12/6
HOOPER'S PHYSICIAN'S VADE MECUM	12/6
CHURCHILL'S MIDWIFERY.	12/6
KNOX'S MANUAL OF ANATOMY . . .	12/6
MALGAIGNE'S OPERATIVE SURGERY	12/6
SILVER'S PRACTICAL MEDICINE . .	12/6
FOWLER'S MEDICAL VOCABULARY .	12/6
TANNER'S INDEX OF DISEASES . .	10/6
GREEN'S PATHOLOGY AND MORBID ANATOMY	} 10/6
MEADOWS'S MIDWIFERY	10/6
HILLES' ESSENTIALS OF PHYSIOLOGY	10/6
LAWSON ON THE EYE	10/0
CLARKE'S MANUAL OF SURGERY. .	10/0
MILNE-EDWARDS'S ZOOLOGY . . .	8/6
ROSER'S SURGICAL ANATOMY . . .	8/6
TANNER'S CLINICAL MEDICINE . .	8/6
WARD'S HUMAN OSTEOLOGY . . .	7/0

S L/25-4-f-12

616-091




29 Harley St
Camden Sq

AN INTRODUCTION

TO

PATHOLOGY AND MORBID ANATOMY.



AN
INTRODUCTION
TO
PATHOLOGY AND MORBID
ANATOMY.

BY
T. HENRY GREEN, M.D. LOND.
FELLOW OF THE ROYAL COLLEGE OF PHYSICIANS, LOND.,
PHYSICIAN TO CHARING CROSS HOSPITAL, AND LECTURER ON PATHOLOGY AND
MORBID ANATOMY AT CHARING CROSS HOSPITAL MEDICAL SCHOOL,
ASSISTANT-PHYSICIAN TO THE HOSPITAL FOR CONSUMPTION AND DISEASES
OF THE CHEST, BROMPTON.

THIRD EDITION, REVISED, ENLARGED,

AND ILLUSTRATED BY

ONE HUNDRED AND ELEVEN FINE ENGRAVINGS ON WOOD.

HENRY RENSHAW,
356, STRAND, LONDON.
1875.

LONDON:
SAVILL, EDWARDS AND CO., PRINTERS, CHANDOS STREET,
COVENT GARDEN.

	616-091
	23861

TO

WILSON FOX, M.D., F.R.S.

PHYSICIAN EXTRAORDINARY TO HER MAJESTY THE QUEEN,
PHYSICIAN IN ORDINARY TO THEIR R.H.'S THE DUKE AND DUCHESS
OF EDINBURGH,
HOLME PROFESSOR OF CLINICAL MEDICINE, FORMERLY PROFESSOR OF
PATHOLOGICAL ANATOMY AT UNIVERSITY COLLEGE, LONDON,
AND PHYSICIAN TO UNIVERSITY COLLEGE HOSPITAL,

THIS SMALL WORK

Is Inscribed

WITH MUCH RESPECT AND GRATITUDE

BY HIS FORMER PUPIL,

THE AUTHOR.



Digitized by the Internet Archive
in 2015


P R E F A C E

IN preparing the third edition of my text-book of Pathology and Morbid Anatomy, I have again added much new matter, with the object of making the work a more complete guide for the student. All the chapters have been carefully revised, and a large addition has been made to the number of woodcuts. These new woodcuts, as in previous editions, have been drawn by Mr. Collings from my own microscopical preparations.

T. HENRY GREEN.

74, WIMPOLE STREET, CAVENDISH SQUARE,

July, 1875.



CONTENTS.

INTRODUCTION.

Definitions—Health—Disease—Nutrition—Function—Blood as cause of Disease—Nervous System pp. 1—4

CHAPTER I.

THE "CELL."

Cell as seat of Nutrition and Function—Constitution of Cells—Protoplasm—Nucleus—Cell-wall—Physiology of Cells—Genesis of Cells—Vacuolation pp. 5—12

CHAPTER II.

NUTRITION ARRESTED.

Gangrene or Necrosis—Results of Arrested Nutrition—Dry Gangrene—Moist Gangrene—Characters of Dead Part—Post-mortem Staining—*Rigor Mortis*—Nature of Change in Muscle—Terminations of Gangrenous Process—Causes of Gangrene—*Senile Gangrene* pp. 13—22

CHAPTER III.

NUTRITION IMPAIRED.

Atrophy—Simple—Numerical—Necrobiosis—Causes—Physical Characters—*Atrophy of Bone*—*Pulmonary Emphysema*—*Degeneration*—Causes—The Metamorphoses—The Infiltrations
pp. 23—36

CHAPTER IV.

FATTY DEGENERATION.

General Pathology—Sources of Fat—Causes of Accumulation—Phosphorus poisoning—Incomplete Oxidation—Histology of Process—*Fatty Infiltration—Fatty Infiltration of Muscle, of Heart, of Liver* pp. 37—48

CHAPTER V.

FATTY DEGENERATION (*continued*).

Fatty Metamorphosis—Histology of Process—Secretion of Milk—Absorption of Fat—Caseation—Calcification—Softening—*Fatty Degeneration of Arteries—Fatty Degeneration of Brain—Cerebral Softenings—White Softening—Yellow Softening—Red Softening—Fatty Degeneration of Muscle—Fatty Degeneration of Heart—Brown Atrophy of Heart—Fatty Degeneration of Kidneys* pp. 49—64

CHAPTER VI.

MUCOID AND COLLOID DEGENERATION.

Mucoid Degeneration—Mucin—*Colloid Degeneration*—Colloid Degeneration of Tumours pp. 65—68

CHAPTER VII.

AMYLOID DEGENERATION.

Circumstances under which it occurs—Nature of Amyloid Substance—Reaction with Iodine—Seat of Change—Physical Characters of affected Organs—Consequent Impairment of Nutrition—Source of Amyloid Substance—*Amyloid Degeneration of Liver—Amyloid Degeneration of Kidneys—Amyloid Degeneration of Spleen—Amyloid Degeneration of Lymphatic Glands—Amyloid Degeneration of Alimentary Canal—The Corpora Amylacea* pp. 69—86

CHAPTER VIII.

CALCAREOUS DEGENERATION.

Circumstances under which it occurs—Causes—Nature of Calcareous Particles—Effect on Tissue—*Calcification of Arteries* pp. 87—92

CHAPTER IX.

PIGMENTARY DEGENERATION.

Source of Pigment—Nature of Process—Hæmatoidin—Pathological Significance—False Pigmentation—*Pigmentation of Lungs*—Normal—*Colliers' Lungs*—Pigmentation in Disease
pp. 93—102

CHAPTER X.

TISSUE-CHANGES IN PYREXIA.

Diseases in which they occur—Physical Characters of Organs—Histology—Nature of Change pp. 103—106

CHAPTER XI.

NUTRITION INCREASED.

Hypertrophy—Simple Hypertrophy—Numerical Hypertrophy—Functional Hypertrophies pp. 107—108

CHAPTER XII.

NEW FORMATIONS.

Tumours—Inflammatory Growths—Etiology—Constitutional Predisposing Causes—Dyscrasia—Cachexia—Hereditary Predisposition—Direct Exciting Causes—Irritants—Emigration and Transmission of Cellular Elements—Spermatic Influence—Development—Indifferent Cells—Homology—Heterology—Relation of Growth to surrounding Tissues—Retrospective Changes—*Malignancy*—Classification pp. 109—127

CHAPTER XIII.

THE SARCOMATA.

Structure—Development—Secondary Changes—Varieties—*Spindle-celled Sarcoma*—*Melanotic Sarcoma*—*Osteoid Sarcoma*—*Round-celled Sarcoma*—*Glioma*—*Myeloid Sarcoma*—*Psammoma*—Clinical Characters pp. 128—142

CHAPTER XIV.

THE FIBROMATA.

Structure—Development—Secondary Changes—Varieties—Physical Characters—Clinical Characters pp. 143—146

CHAPTER XV.

THE MYXOMATA.

Structure—Development—Secondary Changes—Varieties—Physical Changes—Clinical Characters pp. 147—149

CHAPTER XVI.

THE LIPOMATA.

Structure—Development—Secondary Changes—Physical Characters—Clinical Characters pp. 150—151

CHAPTER XVII.

THE ENCHONDROMATA.

Structure—Development—Secondary Changes—Varieties—Physical Characters—Clinical Characters pp. 152—156

CHAPTER XVIII.

THE OSTEOMATA.

Structure — Development — Exostoses — Osteophytes — Clinical Characters pp. 157—159

CHAPTER XIX.

THE LYMPHOMATA.

Structure—Development—Clinical Characters—*Hodgkin's Disease* pp. 160—166

CHAPTER XX.

THE PAPILOMATA.

Structure — Development — Secondary Changes — Varieties — Clinical Characters pp. 167—170

CHAPTER XXI.

THE ADENOMATA.

Structure—Development—Secondary Changes—*Adenoma of Mamma*—*Adeno-Fibroma of Mamma*—*Adenoma of Mucous Membranes*—Clinical Characters pp. 171—175

CHAPTER XXII.

THE CARCINOMATA.

Definition—Structure—Development—Secondary Changes—
Varieties—*Scirrhus*—*Encephaloid*—*Colloid*—*Epithelioma*—
Clinical Characters pp. 176—195

CHAPTER XXIII.

THE MYOMATA, NEUROMATA, AND ANGIOMATA.

Structure, &c.—Myoma of Uterus pp. 196—199

CHAPTER XXIV.

CYSTS.

Origin—Structure—Secondary Changes—Classification
pp. 200—204

CHAPTER XXV.

INFLAMMATION.

Definition—Changes in Blood-vessels and Circulation—Stasis—
Migration of Blood-Corpuscles—Exudation of Liquor Sanguinis—
Alterations in Nutrition of Inflamed Tissue—Conclusions—
Suppuration—Origin of Pus—Varieties of Inflammation—
Acute Inflammations—Chronic Inflammations—Infective
Inflammations—Specific Inflammations
pp. 205—223

CHAPTER XXVI.

ACUTE TUBERCULOSIS.

Definition—General Pathology—Older Doctrines—Grey and
Yellow Tubercle—Infective Nature of Acute Tuberculosis—
Artificial Production of Tuberculosis in Lower Animals—
Source of Infection—Histology—Adenoid Tissue—The Giant
Cells—Differences in Histological Characters of Lesions—
Retrospective Changes—Fibroid Induration—Limited Tuberculosis—
Tuberculosis of Pia Mater—*Tuberculous Masses in Brain*—
Tuberculosis of Lymphatic Glands—*Tuberculosis of Mucous
Membranes*—*Tuberculosis of Lungs* . . . pp. 224—247

CHAPTER XXVII.

PYÆMIA AND SEPTICÆMIA.

Traumatic or Inflammatory Fever—Septicæmia—Pyæmia—Metastatic Abscesses—Suppurative Arthritis—Relation of Pyæmia to Septicæmia—Nature of Infective Substances—Bacteria—Pyæmia without External Injury—Absorption and Dissemination of Poison—Pathology of Metastatic Abscesses
pp. 248—255

CHAPTER XXVIII.

SYPHILIS.

Nature of Syphilitic Lesions—Fibroid Changes—*The Gummata*—Their Structure—Development—Secondary Changes—*Syphilitic Disease of Liver* pp. 256—261

CHAPTER XXIX.

INFLAMMATION OF NON-VASCULAR TISSUES.

Inflammation of Cartilage—Inflammation of Cornea.
pp. 262—265

CHAPTER XXX.

INFLAMMATION OF COMMON CONNECTIVE TISSUE.

Histological Changes—Resolution—Organisation—Cicatricial Tissue—Suppuration—Granulation pp. 266—271

CHAPTER XXXI.

INFLAMMATION OF BONE.

Histological Changes—Osteo-Myelitis—Sclerosis—*Periostitis—Necrosis—Caries—Mollities Ossium—Rickets.* pp. 272—278

CHAPTER XXXII.

INFLAMMATION OF BLOOD-VESSELS.

Inflammation of Arteries—Acute Inflammations—Atheroma—Inflammation of Veins pp. 279—283

CHAPTER XXXIII.

INFLAMMATION OF THE HEART.

Endocarditis—Acute—Chronic—Myocarditis—Acute—Chronic—Fibroid Induration of Heart pp. 284—291

CHAPTER XXXIV.

INFLAMMATION OF LYMPHATIC STRUCTURES.

Acute Inflammation—Chronic Inflammation—Scrofulous Glands
—*Typhoid Fever* pp. 292—298

CHAPTER XXXV.

INFLAMMATION OF MUCOUS MEMBRANES.

Catarrhal Inflammation—Croupous Inflammation—*Croup*—*Diphtheria*—*Dysentery* pp. 299—305

CHAPTER XXXVI.

INFLAMMATION OF SEROUS MEMBRANES.

Adhesive Inflammation—Effusion—Suppuration . pp. 306—309

CHAPTER XXXVII.

INFLAMMATION OF THE LIVER.

Hepatic Abscess—*Cirrhosis*—*Acute Yellow Atrophy* pp. 310—315

CHAPTER XXXVIII.

INFLAMMATION OF THE KIDNEY.

Suppurative Nephritis—*Surgical Kidney*—*Tubal Nephritis*—*Interstitial Nephritis* pp. 316—328

CHAPTER XXXIX.

INFLAMMATION OF BRAIN AND SPINAL CORD.

Acute Inflammation—Abscess—*Inflammatory Softening*—*Sclerosis* pp. 329—332

CHAPTER XL.

INFLAMMATION OF THE LUNGS.

Croupous Pneumonia—Engorgement—Red Hepatization—Grey Hepatization—Terminations of Process—*Catarrhal* or *Broncho-Pneumonia*—*Interstitial* or *Chronic Pneumonia*
pp. 333—348

CHAPTER XLI.

PULMONARY PHTHISIS.

Definition—Older Doctrines—Tubercle as a Cause of Phthisis—*Histology of Phthisis*—Epithelial Proliferation—Fibrinous Exudation—Adenoid Growth in Alveolar Walls—Increase in Interlobular Connective Tissue—*Pathology of Phthisis*—Nature of Morbid Processes—Causes of Differences in Histological Changes—Disintegration—Fibroid Development—*Etiology*—Predisposition—Irritation—Infection—General Health—*Varieties of Phthisis*. pp. 349—363

CHAPTER XLII.

CHANGES IN THE BLOOD AND CIRCULATION.

Active Hyperæmia—Causes—Results—*Mechanical Hyperæmia*—Causes—Results—*Nutmeg Liver*—*Brown Induration of Lung*—Post-mortem Appearance of Hyperæmia
pp. 364—374

CHAPTER XLIII.

THROMBOSIS.

Ante-mortem Clots—Post-mortem Clots—Organisation of Thrombus—Softening—Suppuration—Causes—Results
pp. 375—386

CHAPTER XLIV.

EMBOLISM

Source of Emboli—Seat of Arrest—Secondary Thrombosis—Results—Hæmorrhagic Infarcts—*Embolism in Brain*
pp. 387—396

CHAPTER XLV.

LEUKÆMIA.

Description—Changes in Spleen—In Lymphatic Glands—In Liver, &c. pp. 397—400

CHAPTER XLVI.

THE PREPARATION AND MOUNTING OF SPECIMENS.

Examination of Specimens whilst Fresh—Hardening of Specimens—The Making of Sections—Imbedding—Staining—Preservation and Mounting pp. 401—409

INTRODUCTION.

PATHOLOGY treats of the origin, nature, course, and causes of those changes in the body which constitute disease; *Morbid Anatomy*, or *Morbid Histology*, of the actual alterations in the tissues which the disease has produced. The former is therefore comparable with Physiology, the latter with the Histology of the normal tissues.

By *disease* is understood some deviation from the state of health; a deviation consisting for the most part in an alteration in the functions, properties, or structure of some tissue or organ, owing to which its office in the economy is no longer performed in accordance with the normal standard.

Diseases are commonly divided into two classes—*organic* and *functional*. The former comprise all those which are attended by structural change; the latter those in which no such change is discoverable. Whether it be possible for the function of an organ or tissue to be abnormally performed quite irrespective of any alteration in its structure admits of some doubt. At all events, as our methods of minute investigation improve, and our knowledge of morbid histology increases, the class of functional diseases grows less; and although there still remain a large number of diseases in which we are unable to recognise any alteration of structure, and which must therefore still be described as functional, it is probable

that all disease will ultimately be found to be attended by more or less material change.

As *health* is itself merely a relative term and implies no definite performance of the processes of life, so *disease* is equally indefinite; it cannot be separated from health by any well-defined boundary, the one passing by insensible gradations into the other.

Disease is thus, in most cases, an abnormal performance of those processes which constitute life, and a knowledge of these processes must therefore necessarily precede the study of pathology. Life comprises the formation and maintenance of the tissues and the exhibition of their various functions. Such formation and maintenance, which may be included under the general term of *Nutrition*, consist in the continuous supply of new material, the separation of this from the blood and its appropriation by the tissues, together with the removal of the products of their waste. *Function* is the special manifestation of the life of the part, as distinct from its growth and the maintenance of its structure; in the secreting cell, consisting in the alteration of the substances abstracted from the blood to fulfil some special purpose in the economy; in nerve, in the transmission of impulses of motion and sensation, &c. The performance of function is obviously dependent upon the state of nutrition. When both of these are normal the condition is one of *health*, when abnormal one of *disease*.

As in health the nutrition is principally dependent upon the solid tissues, these abstracting, appropriating, and altering the material which is supplied to them by the blood; so in most forms of disease it is these tissues which play the more important part, and alterations in them are amongst the most frequent of the morbid processes.

The supply and composition of the blood must obviously at the same time constitute most important factors in

disease. Owing to the intimate relation which subsists between the blood and the solid tissues, any alteration in its composition must exercise more or less influence upon the nutritive processes. In regarding the blood, however, as an element in the causation of disease, it must be borne in mind that this fluid is in a state of constant dependence upon other parts; its component elements are derived from external sources and undergo continual change, and although possibly under certain circumstances it may become altered by virtue of changes in the nutritive activity of its corpuscular elements, alterations in its constitution must in most cases result either from some change in the process of its formation, as from the ingestion of improper or insufficient food, mal-assimilation, or disease of the lymphatic structures; from changes in the secretory or excretory processes; or from the introduction of foreign substances, derived from extraneous sources. Whilst, therefore, alterations in the composition of the blood may be important agents in the production of diseased processes in other tissues, such alterations are in most cases secondary to some abnormality in its formation or depuration, or to its contamination by substances derived from without. Owing to the facility with which it becomes the recipient of foreign substances, it is often the first tissue to become altered, as, for example, in many of those diseases which owe their origin to the introduction of minute organisms; and it not infrequently constitutes the principal seat of the diseased process.

The blood may also play an important part in disease, owing to an abnormal activity of its white corpuscles and their migration through the walls of the blood-vessels into the surrounding tissues. This occurs in the process of inflammation, and probably also in the development of many of the new formations.

Lastly, the influence of the nervous system must be taken into account in considering abnormal conditions of

nutrition and function. This, by regulating the circulation and supply of blood, must to a certain extent control tissue-change. The results of experimental and clinical observation render it exceedingly probable that many nerves also contain fibres which exercise a direct influence upon nutrition, independently of that which is due to their vaso-motor filaments. In support of this view may be adduced the well-known observations of Ludwig and Heidenhain on the influence of the chorda tympani upon the secretion of the submaxillary gland, which prove that the increased secretion which results from the stimulation of this nerve is due to an increased activity of the secreting elements of the gland and not to changes in the blood-vessels. Recent histological researches, also, which are tending to show that nerve-fibres terminate in the ultimate elements of nearly all tissues, and the fact that very rapid atrophy of muscles often follows certain lesions of the nervous centres and many injuries of the nerve-trunks, render it exceeding probable that nutrition is more or less under the *direct* influence of the nervous system.

The *first* part of this work will be devoted exclusively to the consideration of morbid processes which are characterised mainly by alterations in nutrition; the *second*, to those in which an altered nutrition is associated with certain changes in the blood-vessels and circulation (inflammation); and the *third*, to changes in the blood and circulation alone. In considering the several morbid processes, the general pathology of each process will first be described, and subsequently the same process as it occurs in the different organs and tissues.

CHAPTER I.

THE CELL.

As the most important element in nutrition, both in health and disease, is the activity of the tissues themselves—the supply of nutritive material, although an essential, being merely a *passive* part of the process—it becomes necessary to consider, somewhat minutely, those parts of the tissues in which this activity resides.

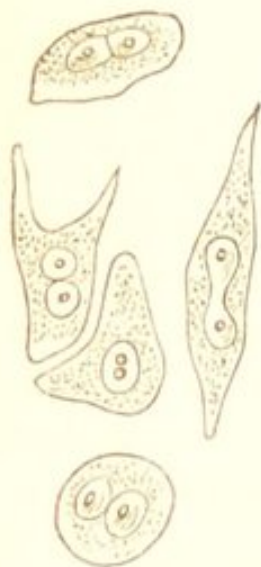
Ever since Schwann discovered the cellular nature of animals, and established the analogy between animal and vegetable cells, there has been a gradually increasing conviction amongst physiologists, which has now become an universally accepted physiological and pathological doctrine, that the *cell* is the seat of nutrition and function; and further, that *each individual cell* is itself an independent organism, endowed with those properties, and capable of exhibiting those active changes which are characteristic of life. Every organised part of the body is either cellular or is derived from cells, and the cells themselves originate from pre-existing cells, and under no circumstances do they originate *de novo*.

Whilst therefore the whole body is made up of cells, or of substances derived from cells, and the cell is itself the ultimate morphological element which is capable of exhibiting manifestations of life, it must be borne in mind that in a complex organism, the phenomena of life are the result of the continued activity of innumerable cells,

many of which possess distinct and peculiar functions, and that by their combination they become endowed with new powers, and exhibit new forces, so that although each individual unit possesses an independent activity, it is in a state of constant dependence upon others with which it is more or less intimately associated.

CONSTITUTION OF CELLS.—When the analogy was established between the animal and vegetable cell, the former

FIG. 1.



Cells from a cancer. Showing cell-wall, cell-contents, nuclei, and nucleoli. The nuclei dividing.

was held to be constructed in all cases upon the same principle as the latter, and to consist of a *cell-wall*, enclosing a cavity, in which were contained a *nucleus* and *fluid contents*. (Fig. 1.) This was the idea of the cell held by Schwann and Remak, and supported especially by Virchow, who maintained that these three constituents were essential to its vitality and existence.

During recent years, however, this definition has been modified. The existence of a cell-wall was in many cases not evident. In embryonic cells, in those of many rapidly growing new formations, and in the cells of blood, pus, and mucus no limiting membrane could be demonstrated.

This led to a new definition of the cell by Leydig and Max Schultze, who held that a little mass of matter enclosing a nucleus was all that was necessary for its constitution. The latter of these physiologists not only rejected the cell-wall as an essential constituent, but established the identity of the mass of matter (cell-contents) with animal sarcode—a contractile substance existing in the lower animals—and showed that, like it, it was endowed with the power of spontaneous movement. This substance he called *protoplasm*. He further pointed out, that the existence of a distinct cell-wall was the result of

a retrograde process taking place in the outer layers of the protoplasm, and that the latter was the real seat of the activity of the cell. These views closely correspond with those held by Dr. Beale in this country.*

The definition of a cell has been still further modified by Brücke, Stricker, and others, who consider that the existence of a nucleus is not essential to its constitution. This opinion is principally based upon the fact, that in the cryptogamia, and in some of the lowest animal forms, cells occur in which no nucleus is visible.

It would thus appear probable that a simple mass of protoplasm may, in some exceptional cases, be all that is necessary to constitute a cell—*i.e.*, an elementary organism, capable of exhibiting independently all the phenomena of life; but that the nucleus is an exceedingly constant and almost invariable constituent. The cell-wall is much less constant, and being the result of a retrograde change in the outer layers of the protoplasm, it must be regarded, in point of vitality, as inferior to the rest of the cell.

Protoplasm itself is an unstable albuminoid compound, which is insoluble in water and coagulates at death. As usually met with, it is a homogeneous structureless material, of a soft and viscid consistence. In consistence, however, it is subject to variations, being sometimes perfectly fluid, at others more or less solid and gelatinous. In old cells it often becomes transformed, by the loss of water, into a more solid albuminoid substance—*keratin*. This occurs in the epidermis and nail. Protoplasm may also become gradually converted into other modifications of the protein group—into mucin, globulin, hæmoglobin, &c. The cell-wall, when it exists, is of much firmer consistence than the

* Dr. Beale calls the protoplasm, *germinal matter* or *bioplasm*; the cell-wall, *formed material*.

protoplasm. In some cells the protoplasm constitutes but a small proportion of the body of the cell, other substances, which are either the result of its metamorphosis, or have been taken up from without, being associated with it. Thus fat is met with in the cells of adipose tissue, and of the liver. (See Fig. 5.) Pigment, calcareous particles, pepsine, &c., are also met with in cells.

The *nucleus* is more constant both in size and form than the cell. It is usually spherical or oval in shape, and often contains one or more minute round or angular bodies, termed *nucleoli*. It offers a greater resistance to chemical reagents than the other constituents of the cell, and in disease often remains after these have been destroyed. It is also stained more deeply by carmine.

The original form of the nucleus is vesicular. In the earliest cells of embryonic tissue it possesses a delicate membrane enclosing a nucleolus and fluid contents, thus resembling in its structure the cell. Subsequently, however, it loses its vesicular character, and as usually met with it is a solid perfectly homogeneous, or faintly granular body, in which the nucleolus is still visible. The recognition of the nucleus is not always possible, owing to its presence being obscured by fat, pigment, or other substances contained within the cell. (See Fig. 25). In some cells the nuclei gradually disappear. The coloured blood-cells and the cells of the superficial layers of the epidermis are examples of cells in which the original nucleus has become lost. Lastly, it must be mentioned, that several nuclei may be contained within the same cell.

PHYSIOLOGY OF CELLS.—The cell, as already stated, is capable of absorbing and transforming matter, of excretion, and of growth. It is also endowed with the power of changing its form, of cohering with other cells, of undergoing more or less active movement, and of reproduction. The question now arises as to what part is played by its respective constituents—whether the cell-wall, the body

of the cell (protoplasm), and the nucleus have different offices.

The cell-wall being the result of a retrogressive change in the protoplasm, it cannot be regarded as taking any part in the life of the cell, the activity of which is much diminished by its existence, as is also its power of reproducing itself by simple division. It is in old cells that a cell-wall is most frequently met with, in those newly formed it is entirely wanting.

The nucleus has usually been looked upon as the seat of the nutrition, as distinct from the specific functions of cells, and has been supposed to play an important part in their multiplication and reproduction. The fact that when a cell divides, the division usually commences in the nucleus, and only subsequently takes place in the rest of the cell, would appear to favour this view; as would also the great uniformity of the nucleus both in size and form, whatever be the functional nature of the cell. It must be borne in mind, however, that non-nucleated cells may multiply, and that nucleated cells have been observed to divide, the nucleus itself taking no part in the process.

Whatever be the part played by the nucleus, there can be no doubt that the protoplasm is the most important factor of the cell, and it may itself be the only constituent. The spontaneous movements, alterations in form, and migratory powers characteristic of young cells, are due to the protoplasm. Such movements are observed in the cells of the embryo, in lymphoid and young epithelial cells, in some of the cells of connective tissue, and in white blood and pus cells.

The protoplasm, as already stated, may be the sole seat of the nutritive and formative power of the cell. It would appear, however, probable that it is more especially concerned in the performance of function, and that the specific functional peculiarities of cells are dependent rather upon

it than upon their other constituents. The volume and consistence of the protoplasm varies in different cells, and in the same cell, at different times and under different circumstances. It is apparently capable of imbibing and giving up fluids, at the same time undergoing corresponding alterations in volume. These considerations render it probable that it is the seat of the selective power of the cell, and of those other properties which represent its specific functions.

GENESIS OF CELLS.—The proposition of Virchow, that every cell originates directly from a pre-existing cell, forms the basis of the pathology of the present day. To Remak, however, must be ascribed the merit of having first established the cellular origin of the tissues.

The multiplication of cells may take place in three ways—by *simple division*, by *gemmation*, and by *endogenous growth*. In the first two methods the cell breaks up into fragments; in the last, new cells originate within the parent cell. The process is obviously associated with growth and increase of the protoplasm.

The multiplication by simple division is the most frequent method. The cell divides and forms two cells, and each of these again divides and forms two more, and so on. In nucleated cells the nucleus as a rule divides first. The nucleus, however, may divide and multiply within the cell without any division of the cell taking place. If the nuclei multiply within the cell and the protoplasm continuously increase without subsequent division of the cell taking place, large, many-nucleated, irregular-shaped masses of protoplasm are produced. These are the giant or myeloid cells, which are met with in the medulla of young bone, and in some new formations. (See "Myeloid Sarcoma," Fig. 33.) The existence of a dense cell-wall interferes with the process of multiplication by simple division.

By endogenous multiplication is understood the de-

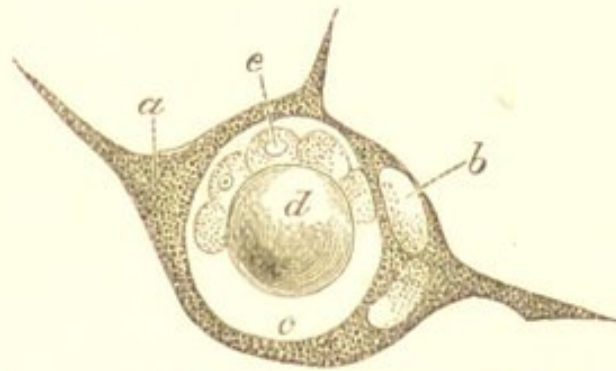
velopment of cells within pre-existing cells. The multiplication of the cells of cartilage, such as occurs in the growth of bone and in the process of inflammation, has been adduced as an example of this mode of cell formation. Here, however, we have simply the division of the cartilage cell within its capsule (See Fig. 71, *d*), and the process is precisely similar to multiplication by simple division. The mode of cell formation which must be regarded as strictly endogenous, is what is now commonly known as *Vacuolation*. This was described some time ago by Virchow in his "Cellular Pathology;" and owing to the more recent researches of Klein and others, it now occupies an important place in the history of cell development. The process consists in the formation of a vacuole in the body of the cell. This vacuole may gradually increase in size until it occupies nearly the whole of the cell, being merely surrounded by a thin layer of protoplasm, in which may often be seen the displaced nucleus (Fig. 2, *b*). Within this vacuole one or more new elements are formed. These either originate from the nucleus of the cell, or they are produced from the protoplasm which forms the wall of the vacuole. In the latter case, according to Dr. Klein, buds grow out from the protoplasmic wall towards the interior of the vacuole, and these becoming detached form new cells.* A vacuolated cell with an endogenous brood is shown in the accompanying drawing (Fig. 2), for which I am indebted to the observer just quoted. It must, however, be remembered, in forming any conclusion as to the origin of small cells within a larger cell, that there exists the possibility that these may have entered from without.

The endogenous mode of cell formation is not that by

* "The Anatomy of the Lymphatic System," vol. i. pp. 55—60; and Klein on "Endothelial vesicles of growing blood-vessels in the embryo chick." "Sitzungsberichte der Wiener k. Academie d. Wissenschaften," Part for March, 1871.

which tissues regenerate themselves. This is usually effected by simple division. Elements which have an endogenous origin have commonly a destiny different from that of the parent cell.

FIG. 2.



A Vacuolated Cell. *a.* Protoplasm of cell constituting wall of the vacuole. *b.* Displaced nuclei. *c.* The vacuole. *d.* Drop of fat. *e.* Endogenous brood. (Klein.)

In multiplication by gemmation, a small portion of the protoplasm projects from the cell and becomes detached by constriction at its base, thus forming a new cell. This is much less frequent than the two former processes.*

* The author wishes it to be distinctly understood, that in the subsequent pages the term "cell" is employed to designate the most elementary factor of the tissues which is capable of exhibiting the phenomena characteristic of an independent organism, quite irrespectively of the existence of a cell-wall, or even of a nucleus.

CHAPTER II.

NUTRITION ARRESTED.

THE absolute and permanent arrest of nutrition constitutes local or systemic death. Under this head are included the three following processes :—

1. *General or Systemic Death.*—In this, the arrest is general; the nutritive processes cease throughout the whole body.

2. *Gangrene or Necrosis.*—The arrest is local, and confined to a particular part, which, when dead, retains to a greater or less extent its external form and anatomical characters.

3. *Molecular Death or Necrobiosis.*—The arrest is also local, but usually results from a previous gradual impairment of the nutritive processes, which ultimately entirely cease in some of the histological elements. The dead part is a granular débris in which all trace of the original structure is lost. This will be considered under “Atrophy and Degeneration.”

GANGRENE OR NECROSIS.

Gangrene or Necrosis is the complete and permanent arrest of nutrition in a part—occurring for the most part more or less suddenly—which, when dead, retains to a greater or less extent its external form and anatomical structure. The series of processes by which this is brought about is called *Mortification*, the dead tissue—a *Sphacelus* or *Slough*. In bone the process is called *Necrosis*, the result—a *Sequestrum*.

The arrest of nutrition is followed by the complete cessation of all the evidences of life both functional and physical; and the part thus removed from the influence of the "vital forces" undergoes those chemical and physical changes which are common to inanimate organic matter. In a limb, for example, there is paralysis of motion and sensation, coldness, dryness of the surface; the natural firmness and elasticity are lost, and it becomes soft and doughy; the colouring matter escapes from the blood-corpuscles, and dissolved in the liquor sanguinis permeates and stains the tissues. Evaporation from the surface is to a great extent hindered by the epidermis, consequently, if the limb contains much blood, the transuded serum and the watery constituents of the tissues often form large bullæ on the surface. As decomposition proceeds, gases are generated in the part—principally sulphuretted hydrogen, ammonia, nitrogen, and carbonic acid. These give rise to the emphysematous crackling which is so often associated with the gangrenous process. The tissues at the same time undergo a process of softening or liquefaction, the limb becomes exceedingly offensive, and changes from a reddish colour to a brownish or greenish-black. This is owing to changes in the transuded hæmoglobin. If the limb does not contain a large amount of blood, and evaporation is allowed to go on freely from the surface by the destruction of the epidermis and rupture of the bullæ, it may dry up—the process of decomposition gradually ceasing—and become converted into a black shrunken mass, which undergoes but little further change:—this constitutes *Dry Gangrene* or *Mummification*. If, on the other hand, as is more commonly the case, the gangrene is associated with venous obstruction, and thus the return of blood and absorption of fluids are prevented, the evaporation from the surface is rarely sufficient to dry the limb, and consequently, the process of decomposition proceeds until it is completely disorganised:—this is *Moist Gangrene*.

The characters of the dead part vary with its structure, its vascularity, the cause of the gangrene, the acuteness of the process, and the possibility of the access of atmospheric air. The more vascular the tissue, the softer its structure, and the more it is exposed to the atmosphere, the more rapidly and completely does it undergo decomposition. Bone, cartilage, and tendons, which are firm hard tissues, containing comparatively but few vessels, undergo very little alteration in structure and form; whereas softer parts are much more rapidly and completely destroyed.

The occurrence of decomposition manifests itself in the first place in the blood contained in the part: this fluid undergoes the earliest and most rapid change. The hæmoglobin escapes from the red corpuscles, partly by exudation, and partly by the destruction of the corpuscles themselves, and dissolved in the liquor sanguinis permeates the surrounding tissues. The corpuscles are ultimately completely annihilated, nothing remaining but a few minute granules.

The staining of the tissues with hæmoglobin is commonly known as *post mortem staining*, and the appearances it presents are very characteristic. All the tissues may be more or less affected, but the lining membrane of the heart and large blood-vessels, being in immediate contact with the blood after death, are naturally more so than other parts. The staining is of an uniform pinkish-red colour, thus differing from the punctiform and stratumiform redness of hyperæmia, from which it must be carefully distinguished. The amount of staining is in proportion to the rapidity with which decomposition has taken place, and to the amount of blood contained in the part at the time of death.

RIGOR MORTIS.—In muscle the arrest of nutrition is accompanied by a state of rigidity, known as the *Rigor Mortis*. This is a peculiar condition of the muscles observed in almost all bodies after death, in which they be-

come firm and somewhat shortened, as though in a state of chronic contraction. It comes on as soon as the muscles have lost their irritability, *i.e.* their capability of responding to artificial stimulation; in other words, as soon as the nutritive processes have completely ceased. The time of its appearance will therefore depend upon the state of nutrition of the muscles at the time of death; the more healthy and vigorous this is, the longer it is before the nutritive processes completely cease, and consequently the longer it is before the rigor mortis supervenes. The length of its duration and its intensity are in direct proportion to the lateness of its appearance. In people, for example, who are in perfect health, and die suddenly, as from accident, the rigor mortis does not usually come on until from ten to twenty-four hours after death; it is very marked, and often lasts two or three days. In those, on the other hand, who die from some exhausting disease, as from chronic phthisis or the adynamic fevers, in which the nutrition of the muscles becomes much impaired, the rigor mortis appears very soon, sometimes as early as ten minutes after death; it is very slight and may pass off in less than an hour. It has been said that in cases of death from poisoning by carbonic acid and sulphuretted hydrogen, from lightning, and from some of the severer forms of the adynamic fevers, the rigor mortis is entirely absent. It is doubtful, however, if this is the case, as the rigor mortis has probably escaped observation, owing to its early supervention and rapid disappearance. As soon as the rigor mortis has passed off, decomposition of the muscular tissue commences.

The rigor mortis occurs not only as the result of systemic and local death, but it may also be induced artificially by temporarily arresting the nutrition of the muscle. If the supply of blood to a muscle be cut off by the application of a ligature to the artery supplying it, it quickly passes into a condition which is indistinguishable from

the rigor mortis. If the ligature be removed sufficiently early, this disappears, and the vitality of the muscle is restored.

With regard to the nature of the change—it was formerly supposed to be a spontaneous contraction, the last act of vitality on the part of the muscle. More recently, however, Kühne and others have shown that it is really owing to the coagulation of an albuminous substance termed myosin. This substance, which is contained in the fluid of the muscle, coagulates in its substance when nutrition has ceased, thus causing the firmness, hardness, and opacity, which disappear as soon as disintegration and decomposition commence. The transverse striation of the fibres then becomes indistinct and gives place to irregular rows of granules and fat molecules, the muscle softens, its sarcolemma is destroyed, and ultimately nothing remains but a soft structureless débris.

A similar coagulation takes place in the cells of plain involuntary muscle, and here also a rigor mortis occurs. In the cells of all other tissues a coagulation of the protoplasm occurs on the cessation of the nutritive processes; the cells become cloudy and granular, and then break up into molecules of various sizes.

Respecting the disintegration of other tissues:—The cells of adipose tissue rapidly diminish in size, owing to the escape of the fluid fat which diffuses itself throughout the surrounding structures. The fibres of connective tissue swell up, become opaque, and ultimately liquefy. In nerve-fibres, the white substance of Schwann coagulates and collects into small drops (myeline) within the neurilemma. Cartilage and bone resist the necrotising process longer than any of the tissues and are the least altered by it.

The termination of the gangrenous process varies. It may, after involving a greater or less extent of tissue, become arrested, and a "line of demarcation" form be-

tween the dead and living parts (*Circumscribed Gangrene*); or the process may continue to extend without any such attempt at recovery (*Diffuse Gangrene*). When the process becomes arrested, the dead tissue—the sphacelus or slough—acts as a foreign body, and as such sets up inflammatory changes in the adjacent living structures, and by this means it is ultimately removed or becomes encapsuled. The tissues immediately surrounding the necrosed part are thus in a state of inflammation, as is evidenced in external structures by their swelled condition, red colour, and high temperature. As the gangrenous process ceases, the necrosed fragment becomes limited by this line of inflamed tissue, which constitutes the “*line of demarcation*” between the dead and living parts. Along this line a process of ulceration and suppuration takes place, and by means of this the dead mass is gradually separated from the surrounding structures. The ultimate termination of the process depends principally upon the situation of the affected part:—if this be superficial, the slough is thrown off, as in external parts, the intestines, the pharynx, &c., an ulcerated surface being left. If the dead mass is deeply seated, its removal becomes possible only by the extension of the necrotising process to the surface, as is exemplified by the spontaneous removal of necrosed bone through fistulous openings in the soft parts, and by the opening of an abscess. In other cases the inflammatory process which takes place in the tissues surrounding the dead part is less intense, and the formation of pus is less abundant and is soon followed by that of connective tissue, a layer of which is ultimately formed around the necrosed mass by which it becomes *encapsuled*. This occurs especially in internal parts. Examples of it are furnished by foreign bodies, hæmorrhagic infarcts, accumulated epithelial products, portions of necrosed bone, and a fœtus in the abdominal cavity, all of which may thus become sur-

rounded by a layer of connective tissue. The part when thus encapsuled is usually rendered inert and no longer acts as an irritant to the tissues in which it lies; it undergoes a gradual process of absorption and drying up, and often becomes calcified.

CAUSES.—The causes of gangrene may be divided into those which interfere with the supply of nutritive material, and those which directly destroy the vitality of the histological elements so that they are no longer able to perform their functions.

A. The supply of nutritive material may be interfered with by :—

1. *Obstruction in the Arteries.*—This is a common cause of gangrene. The obstruction may be caused by a ligature, by compression of the vessel, by solution of its continuity, by thrombosis or embolism, and by disease of the arterial coats. If the obstruction be complete and a collateral circulation cannot be established, death of the part quickly ensues. Obstruction to the arteries alone, the return of blood by the veins not being interfered with, usually produces the dry form of gangrene.

2. *Obstruction in the Capillaries.*—Obstruction here is usually the result of pressure upon or stretching of the vessels. This may take place from the accumulation of inflammatory products, hæmorrhage, or from the pressure exercised by new growths. The resulting obstruction to the capillary circulation causes the death of the immediately adjacent tissues. As examples of gangrene from this cause may be mentioned the necrosis of the superficial layers of the bone which so frequently results from periostitis, owing to the compression of the capillaries between the bone and the periosteum; also the sloughing of the mucous membranes in diphtheria.

3. *Obstruction in the Veins.*—Obstruction to the return of blood by the veins must be so complete in order to arrest nutrition that it is in itself rarely a cause of

gangrene. It is when associated with obstruction in the arteries that it constitutes an important agent in producing this result. This combination of venous and arterial obstruction is seen in a strangulated hernia, in the invagination of a portion of the intestine, in the constriction of a part by a tight bandage, and in contusions and lacerations of the soft parts in which both arteries and veins are injured or become strangulated by the tension of the tissues which subsequently ensues. In all cases in which gangrene is associated with venous obstruction it is of the *moist* variety.

4. *Diminished Cardiac Power.*—This, like venous obstruction, is seldom independently a cause of gangrene. In cases, however, of excessive general debility or disease of the cardiac substance, the consequent diminution in the contractile power of the heart materially aids the foregoing causes in producing a fatal blood-stasis. The arrest of the circulation in “senile gangrene,” and that which so often occurs in the tissues of the back in adynamic fevers and in chronic exhausting diseases, is in part the result of diminished cardiac power. This arrest, in the last-named conditions, is usually determined by some injurious stimulation of the tissue—in other words, it is a part of an inflammatory process.

5. *Inflammation.*—The effect of the inflammatory process is to impede or arrest the circulation, and to impair the vitality of the affected part, and the intensity of the process may be so great as to permanently arrest the circulation and cause gangrene. Gangrene from inflammation has been called *inflammatory, acute, or hot* gangrene. It is always of the moist variety, and is characterised by the heat, swelling, tension, and redness of the affected part, which quickly becomes flaccid, cold, of a greenish-black colour, and exhales an offensive odour. Certain inflammations have a special tendency to terminate in gangrene, as diphtheria, erysipelas, carbuncle, and “hospital gangrene.” In all

cases, the more impaired the nutrition of the part which becomes the seat of an inflammatory process, the more likely is this to cause its death.

B. Destruction of the vitality of the histological elements may be caused by:—

1. *Mechanical Agencies.*—Under this head are included external violence, heat, cold, and corrosive substances, all of which, by directly and completely destroying vitality, may be causes of gangrene. In most cases, however, this result is preceded by more or less inflammation.

2. *Poisons introduced into the Circulation.*—Phosphorus and ergot of rye are the most important of these. The necrosis of the jaw which results from phosphorus appears, however, to be owing to the direct contact of the phosphorus with the bone, and the gangrene of the extremities which sometimes follows the long continued ingestion of ergot, is probably due to that contraction of the small arteries which this substance produces.

SENILE GANGRENE.—This is a form of mortification which affects especially the lower extremities of old people, and is the result of several of those conditions which have already been enumerated as causes of gangrene.

The most important element in the production of senile gangrene consists in the occurrence of atheromatous or calcareous changes in the arteries of the limb, in consequence of which the circulation in it becomes impeded and its vitality impaired. This is evidenced by the coldness of the feet, the cramps, and the other abnormal sensations which are so often experienced by the patient some time before the gangrene sets in. This tendency to local stagnation of the circulation is usually materially increased by the simultaneous atrophy or degeneration of the muscular substance of the heart itself. The combined effect of the diminished *vis à tergo* and of the arterial degeneration may, in some cases, be alone sufficient to cause arrest

of the circulation and the formation of thrombi in the vessels of the limb, and thus to cause gangrene. The supervention of the gangrene, however, is usually determined by some injurious stimulation of the tissue, as a slight abrasion of the foot, a bruise, injury to a corn, or excess of heat or cold, which sets up inflammation in the already weakened part, and thus by still further obstructing the circulation in it, and impairing its vitality, causes its death. Senile gangrene is usually of the *dry* variety.

CHAPTER III.

NUTRITION IMPAIRED.

It has been seen in the preceding chapter that the absolute arrest of nutrition is followed by the complete cessation of all manifestations of vitality and function, constituting local or systemic death. Those conditions must now be considered in which the interference with nutrition, for the most part, falls short of absolute arrest, and in which, although vitality is impaired, death is only an occasional sequence. Such conditions are comprised under "Atrophy," and "Degeneration."

ATROPHY.

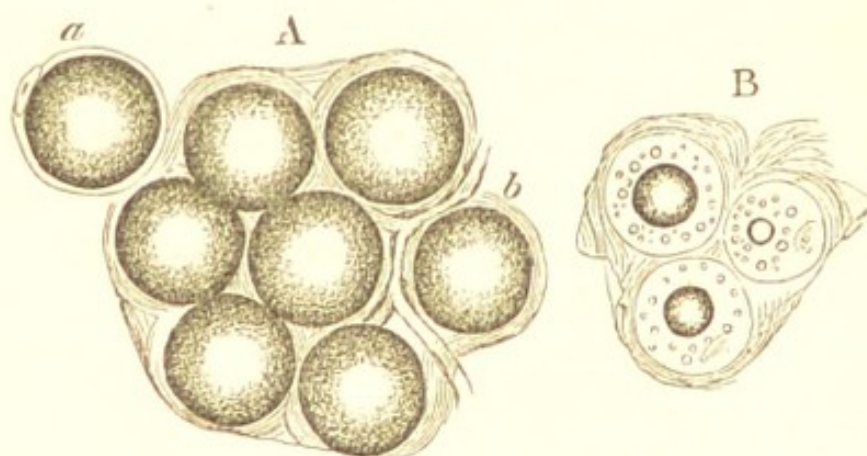
Atrophy is a diminution in the amount of a tissue, owing either to diminution in the *size*, or diminution in the *number*, of the histological elements of which it is composed. It is attended by loss of weight, and impairment of function.

When the elements are diminished in *size* only, it is called *Simple Atrophy*; when the *number* is diminished, it is called *Numerical Atrophy*. These two varieties are often associated, being different stages of the same process: simple atrophy may, however, exist without numerical atrophy, but numerical never exists without simple.

I. SIMPLE ATROPHY.—Simple diminution in the size of the elements of a tissue is by far the most common con-

dition met with in atrophy. It is well exemplified by what takes place in ordinary emaciation, in which the fat gradually disappears from the subcutaneous adipose tissue. Adipose tissue is merely common connective tissue, many cells of which are distended with fat. When a person emaciates, the fat is gradually removed from the cells, so that they diminish in size, and the fat which completely filled the cell may be reduced to a few isolated drops: the cell-wall and nucleus at the same time often become distinctly visible (Fig. 3). Here there is no destruction of the cells, no diminution in their number, but simply the removal of some of their contents. As the fat is removed from the cells it is often partially replaced by a serous fluid.

FIG. 3.



Adipose tissue. A. Normal. B. Atrophic, from a case of phthisis. a. a single fat-cell with cell-wall, nucleus, and drop of fat. $\times 300$. (Virchow.)

This diminution in the size of the elements may take place in any tissue. The cells of all glandular organs may thus become atrophied, and so produce a diminution in the size of the whole organ; this is constantly met with in the liver, kidneys, mammary gland, spleen, testicles, lymphatic glands, and other parts. Muscular tissue in the same way atrophies by the diminution in the size of its primitive fasciculi: this is seen in the heart and in the voluntary muscles. In all these cases the elements

remain almost unchanged; and hence all that is necessary for the restitution of the tissue is an increase in their nutritive activity, and the assimilation of more material.

II. NUMERICAL ATROPHY.—This is an advanced stage of the former process: the elements are not only diminished in size, but some of them have actually perished and ceased to exist as vital agents.

This destruction of histological elements which occurs both in atrophy and in some forms of degeneration—and is called by Virchow, *Necrobiosis*—must be distinguished from the death of circumscribed portions of tissue which constitutes gangrene and necrosis. The two processes resemble one another in so far as death is common to both of them. In *Necrobiosis*, however, the change is a molecular one; there is a gradual exhaustion of vital power, a molecular disintegration and destruction of elements, so that at the termination of the process all that remains is a granular débris, in which but little or no trace of the former structure of the part can be discovered. The death and desquamation of the superficial layers of the epidermis is a well-known example of this molecular change. *Gangrene*, on the other hand, affects circumscribed tracts of tissue, and is the result of some sudden arrest of nutrition, as distinguished from the gradual exhaustion of vital power. Death is more suddenly induced, and a necrosed mass remains at the termination of the process in such a condition that the structure of the part can usually be recognised. Numerical atrophy is thus of much graver import than that in which the elements continue to exist as such. In it, restitution is only possible by the production of new elements, whereas in simple atrophy, repair can be effected without new formation.

Atrophy may be *general*—affecting to a greater or less extent all the organs and tissues of the body, or it

may be *partial* and limited to particular parts. General atrophy is usually *simple*, and is rarely accompanied by destruction of elements. It affects in the first place the subcutaneous adipose tissue, then the adipose tissue in other situations, as that surrounding the viscera and in the omentum, then the muscles and glandular organs, and lastly the nervous and osseous structures.

Although atrophy in its strict signification consists simply in a diminution in the size or in the number of the component elements of a tissue, it is rarely a perfectly simple process, but is usually associated with more or less *fatty degeneration*. This is owing to the fact that whenever the nutrition of a part is so much interfered with as to cause it to atrophy, it is very prone to undergo fatty changes; and it will be seen when speaking of "fatty degeneration," that this process owes its origin to causes similar to those which produce atrophy itself.

CAUSES.—In speaking of the causes of atrophy, it will be necessary to distinguish between those which act upon the tissues generally, and those which have merely a local influence.

General Atrophy may be caused by:—

1. *Deficient supply of Nutritive Material*.—Whatever interferes with the supply of nutritive material to the tissues will be followed by their atrophy. Deficient supply of food; obstruction to the passage of the food into the stomach or intestines, as in stricture of the œsophagus or pylorus; the mal-assimilation which results from the various conditions giving rise to dyspepsia; interference with the absorption of the chyle, from obstruction of the thoracic duct, or disease of the mesenteric glands constituting the so-called "tabes mesenterica;" may all in this manner be causes of general atrophy.

2. *Excessive Waste*.—All those conditions which are attended by the loss of large quantities of nutritive material, may be causes of general atrophy. Such con-

ditions are furnished by continuous hæmorrhages, profuse and long-continued suppuration such as often occurs in caries and empyema, diarrhœa, and the excretion of large quantities of albumen or sugar as in Bright's disease or diabetes. The waste resulting from the increased tissue-change which accompanies acute febrile diseases, must also be included under this head.

3. *Impaired Nutritive Activity*.—This constitutes an important element in the production of the atrophy of old age,—*senile atrophy*. As life advances, the vitality of the elements gradually diminishes, their ability to separate nutritive material from the blood and to assimilate it for their own maintenance becomes less and less, and hence they gradually atrophy, and ultimately all manifestations of their vitality cease.

Although general atrophy may thus be referred to one of the foregoing causes, it is rarely a simple process, but usually depends upon the combined influence of two or more of them. The atrophy associated with pulmonary phthisis, for example, results partly from the loss of nutritive material in the profuse expectoration and diarrhœa, partly from the deficient supply consequent upon the imperfect oxidation of the blood and upon the interference with assimilation which is so often caused by structural changes in the stomach and intestines, and partly from the increased tissue-change. In senile atrophy, again, in addition to the general diminution of nutritive activity, there is frequently some condition of the digestive organs interfering with assimilation which materially aids in producing the ultimate result. The atrophy which accompanies the acute febrile diseases is by no means a simple process, increased tissue-change, loss of appetite, and interference with assimilation being all component parts of it.

Partial Atrophy may be caused by:—

1. *Imperfect supply of Blood*.—The effect of interfering

with the supply of blood to a part will depend upon the extent of the interference. If it be entirely cut off the part will die (See "Gangrene"), if merely diminished it will atrophy.

Diminished supply of arterial blood is a common cause of atrophy, and may be brought about in various ways. The nutrient vessels may be obstructed by pressure exercised upon them within or without the organ to which they are distributed. In cirrhosis of the liver, the pressure exercised by the new growth of inter-lobular tissue causes atrophy of the secreting structures. In other cases the supply of blood is diminished by interference with the circulation at some ^{di}stance from the part, as by the pressure of a tumour upon the artery leading to it. The atrophy of the proximal end of the shaft of a bone after fracture above the point of entrance of its nutrient artery, is due to the same cause.

The atrophy which results from pressure exercised directly upon the part itself, is probably also partly owing to the consequent interference with its nutritive supply. Atrophy of the sternum from the pressure of an aneurism, atrophy of the kidney from the pressure of retained secretion—as in stricture of the urethra, enlarged prostate, &c., and atrophy of the skull in chronic hydrocephalus, are well-known examples of these atrophies from pressure.

Mechanical congestion in the same way is not an uncommon cause of atrophy. The circulation is impeded, the blood is not returned normally by the veins, hence there is deficient arterial supply, and atrophy results.

2. *Diminished Functional Activity.*—This is the most common cause of atrophy, many examples of which are furnished both by physiological and pathological processes. After birth those parts which are no longer required to serve any purpose in the economy gradually atrophy and waste. The ductus arteriosus, the umbilical arteries and vein, the Wolffian bodies, and later—the

thymus gland, all in this manner disappear. The involution of the uterus after delivery, the wasting of the spleen and lymphatic glands in advanced life, and of the lower jaw after the loss of the teeth, are other physiological examples of atrophy from this cause.

Muscles which from any cause have long remained inactive atrophy. This is seen in the various forms of paralysis, especially in the so-called "essential paralysis" of children; also in limbs which have become incapacitated, either on account of ankylosis, or of chronic diseases of the bones or joints.

After the establishment of an artificial anus, the lower part of the intestine atrophies, and becomes converted into a fibro-cellular cord.

Bones in the same manner atrophy from want of use. After the amputation of a limb, the cut end of the bone atrophies; and atrophy of the orbit follows extirpation of the eyeball.

Interference with the function of nerves is also followed by their atrophy. This is seen in the atrophy of the optic nerve which often follows destruction of the eye, and also in the atrophy of the nerves of a limb which has long been incapable of action.

3. *Increased Functional Activity.*—This may in quite exceptional cases be a cause of atrophy; much more commonly, however, it is a cause of hypertrophy. Certain glands sometimes atrophy from excessive use, especially the testicle.

4. *The Action of Special Substances.*—Certain substances administered internally appear to be capable of producing atrophy. Iodine, bromine, mercury, lead, and the alkalies, may be enumerated amongst the most important of these. Iodine and mercury exercise a special influence upon the lymphatic system, and bromine upon the organs of generation.

5. *Nervous Influence.*—Respecting the influence of the

nervous system as a *direct* cause of atrophy, little is certainly known. That atrophy is a frequent sequence of changes in the nerve-trunks and nervous centres, there can be no doubt; but it is probably in most cases to be attributed to an *indirect* influence. The atrophy of muscles, for example, which have become paralysed from lesions in the brain or spinal cord, is usually rather the result of the consequent interference with their function, than of any direct influence upon their nutrition. The very rapid atrophy of muscles, however, which follows certain alterations in the nervous centres and injuries of the nerve-trunks, render it exceedingly probable that some nerves contain fibres which exercise a direct influence upon nutrition, and that nervous influence may also be a *direct* cause of atrophy. (See "Introduction.") In some cases also, changes in the nervous system may cause atrophy by affecting the size of the blood-vessels, and so interfering with the supply of blood.

6. *Inflammation*.—This is sometimes described as a common cause of atrophy. The atrophy, however, which is such a frequent sequence of an inflammatory process, is in most cases due to that new growth of fibroid tissue which is developed in chronic inflammations. The new tissue, by the pressure which it exercises, causes atrophy of the proper structures of the organ. This is seen, for example, in cirrhosis of the liver. It is probable also, that the impairment of vitality which results from an inflammatory process may lead to atrophy of the histological elements, independently of the existence of new fibroid growth.

PHYSICAL CHARACTERS.—The estimation of atrophy is often a matter of considerable difficulty. The great criterion is, diminution in absolute weight. The weight of an organ, however, varies considerably in health; it varies with the weight of the body as a whole, and it may be less than natural from incomplete development. The

same is true also of the muscular and osseous systems. An accumulation of blood and serosity in an organ may again increase its weight, and thus constitute a source of fallacy. This is often the case in organs which have been for some time mechanically congested, in which, although their size and weight may be increased, their tissue is considerably diminished in amount.

Organs which are atrophied are usually diminished not only in weight, but also in size. In most cases they contain less blood, they are drier, firmer, and more fibrous in consistence than in health. Their functional powers are invariably diminished.

The whole of the textures of which an organ is composed may suffer; some, however, do so more than others. The fibrous constituents are the last to atrophy, hence the firmness, toughness, and loss of elasticity so commonly met with in the atrophied parts. In glandular organs, the secreting cells are usually the first to show signs of atrophy; they become smaller, and are often finely granular, from the presence of molecular fat; the vessels and nerves also share in the wasting process. In the subcutaneous cellular tissue, the fat is gradually removed from the cells, which thus diminish in size. In muscles the primitive fasciculi become smaller, and their transverse striæ gradually disappear; ultimately the whole of the contents of the sarcolemma may be entirely removed, and nothing remain but the connective tissue. This process is usually accompanied by more or less fatty degeneration of the muscular fibres, and in some cases by the development of fat between the fasciculi. (See "Fatty Infiltration of Muscle.")

ATROPHY OF BONE.

Atrophy of bone is always attended by a diminution in weight, but not always by a diminution in size. It is met with in two forms. In one, the compact and cancellous tissue gradually become absorbed, the medullary

canal diminishes in size, and the whole bone thus becomes smaller. This is known as *concentric atrophy*. It is met with especially in the long bones, in cases of long-standing ankylosis, dislocations, or paralysis.

In the other variety of atrophy there is no diminution in the size of the bone, but merely a gradual conversion of compact into cancellous tissue. The whole bone thus becomes rarefied, and it is exceedingly light and brittle, so that it fractures with great facility. This, in contradistinction to the former variety, is known as *eccentric atrophy*. It is usually met with as a senile change, and is in most cases accompanied by more or less fatty degeneration.

PULMONARY VESICULAR EMPHYSEMA.

This appears to be the proper place to describe the changes met with in the lungs in emphysema, inasmuch as these changes are characterised mainly by atrophy of the walls of the air-vesicles.

Emphysema consists essentially in a permanent enlargement of the infundibula and air-vesicles in larger or smaller areas of the lungs. The dilatation appears usually to commence in the infundibulum, and to extend from this to the air-vesicles which open into it, so that ultimately the whole may be thrown into one large cavity. As the process proceeds, communications are established between adjacent groups of air-vesicles, and thus cavities of still larger area are produced.

Atrophous Emphysema.—The more minute histological changes which accompany this vesicular dilatation vary somewhat in different varieties of the disease. In that form of emphysema which occurs in old people, and which is essentially a senile change, the alterations in the walls of the air-vesicles consist simply of atrophy of the several structures of which they are composed:—hence the term *atrophous* or *small-lunged* emphysema, which is applied by Sir W. Jenner to this variety of the disease. The air-vesicles may not be much increased in size, but several of

them are thrown into one, their walls are considerably thinner than natural, the connective tissue, elastic tissue, and blood-vessels all having apparently shared in the wasting process. There is usually also an abnormal amount of pigmentation. Such lungs are smaller than natural, and quickly collapse when the thorax is opened.

Hypertrophous Emphysema.—In the other important variety of emphysema the lungs are increased in size, they bulge forwards when the thorax is opened, and in contradistinction to the former variety, certain constituents of the lung-tissue appear to be increased in amount, inasmuch as the lungs are less crepitant, and feel somewhat denser and tougher than natural. This is described by Sir W. Jenner as *hypertrophous* or *large-lunged* emphysema.

When such lungs are examined microscopically, it will be found that the dilatation of the air-vesicles is more marked than in atrophous emphysema, although less general in its distribution. The atrophic changes also do not affect equally the various tissues which make up the alveolar walls. The elastic fibres appear to be more especially wasted, whilst, according to some observers, the connective tissue is increased. I have been unable to discover any marked increase of the connective tissue in the alveolar walls, although an increase of this tissue is often to be seen around the smaller interlobular blood-vessels and bronchi. The capillary blood-vessels which are distributed on the walls of the air-vesicles are atrophied and diminished in calibre, owing to the stretching and pressure which result from the vesicular dilatation, whilst the larger interlobular vessels are often found thickened and distended with blood. In some cases there is more or less fatty degeneration of the epithelium, and usually an abnormal pigmentation of the lung.

Etiology.—It would be beyond the scope of the present work to discuss the various theories which have been pro-

pounded to account for the development of emphysema. It is, however, obvious that all conditions which increase the pressure on the inside of the air-vesicles, or damage the resisting powers of their walls, may be causes of permanent vesicular dilatation.

Increased pressure on the inside of the air-vesicles may result from—

1st. Violent expiratory efforts with closed glottis, such as occur during the act of coughing, blowing wind instruments, violent muscular exertion, &c. Those parts of the lungs which are least supported will be over-distended. This is the expiratory theory of Jenner.

2nd. Certain portions of the lungs being incapable of expansion, owing to collapse, consolidation, asthmatic spasm, &c. There will be excessive tension in those parts into which the air can enter.

Impairment of the resisting power of the air-vesicles may result from—

1st. The loss of elasticity and atrophy which is a concomitant of old age. This is the most important element in the causation of atrophous emphysema.

2nd. The atrophy of the air-vesicles resulting from that stretching of their walls and obliteration of their blood-vessels which is caused by their over-distension from increased pressure exercised upon their inner surface.

3rd. Damage to the walls of the air-vesicles which probably in certain cases results from previous attacks of pulmonary inflammation, or from some interference with their nutrition due to mode of life or to other causes.

DEGENERATION.

The "Degenerations" include a class of morbid processes which are characterised by an alteration in the *quality* of the tissues, and which, like atrophy, are attended by impairment of function, and often by annihilation of histological elements.

The alteration in the quality of the tissue results either from its direct metamorphosis into a new material, or from its infiltration with some substance which has been conveyed to it from without.

Atrophy and degeneration thus so far resemble one another, that in both processes nutrition is impaired and function interfered with. In atrophy, however, as pointed out by Virchow, nutrition is simply altered in *quantity*, the waste of the tissue is in excess of the assimilation of new material, and consequently, there is a diminution in the amount of the tissue and an impairment of its functional powers. In degeneration, on the other hand, nutrition is altered in *quality*, a new substance exists in the tissues, which either originates in the tissue itself, or infiltrates it from without; this is attended by impairment of the vitality and functions of the elements of which the tissue is composed, resulting either from the presence of the new material, or dependent upon the same conditions as those which give rise to its formation.

CAUSES.—Of the causes of the Degenerations as a class, but little can be said, the various forms depending for the most part upon different conditions. These will be described under their respective heads.

The Degenerations may be divided into two classes—the *Metamorphoses* and the *Infiltrations*.

1. THE METAMORPHOSES.—These are characterised by the direct metamorphosis of the albuminoid constituents of the tissues into a new material. This is usually followed by the destruction of the histological elements and

the softening of the intercellular substance, so that ultimately all trace of structure may be lost, and function be completely arrested. The Metamorphoses include Fatty, Mucoid, and Colloid Degeneration.

2. THE INFILTRATIONS.—These differ from the Metamorphoses inasmuch as the new material which exists in the tissues is not derived from their albuminoid constituents, but is deposited in them from the blood: there is an infiltration and deposition of a new substance. This is rarely followed by destruction of the histological elements, or by softening of the intercellular substance; hence the anatomical characters of the tissue are much less altered than in the Metamorphoses, and function is usually much less interfered with. The infiltrations include Fatty, Amyloid, Calcareous, and Pigmentary Infiltration.

CHAPTER IV.

FATTY DEGENERATION.

By Fatty Degeneration is usually understood the replacement of the normal constituents of the tissues by molecules, or drops of fat. An accumulation of fat in the tissues occurs, however, under very different circumstances, and under the general term of "fatty degeneration" are included different pathological processes. Before proceeding to describe these processes and the histological changes which they produce, it will be well to consider, in the first place, the sources from which the fat met with in the body is derived; and secondly, the circumstances under which it may accumulate so as to constitute a morbid process.

General Pathology of Fatty Degeneration.—The chief source of the fat met with in the body is the oleaginous constituents of the food. A portion of these are stored up in the cells of certain tissues, to be utilised as producers of force and heat when the requirements of the system may demand it. The cells of adipose tissue, and, to a less extent, those of the liver, thus serve as physiological reservoirs for fat.

The other sources from which fat may be derived is from saccharine and albuminous principles. The albuminous principles in the process of nutrition undergo decomposition, and the products of their decomposition contain a certain amount of fat. This is usually com-

pletely removed by oxidation, but under certain circumstances the oxidation is incomplete, and the fat accumulates in the cells of the tissue.

In considering the circumstances under which an accumulation of fat in the tissues may constitute a morbid process, it is to be remarked that it often becomes exceedingly difficult here to draw any sharp line of demarcation between health and disease. This is especially the case when the accumulation of fat is excessive in situations where fat is normally met with. When it occurs in abnormal situations, the morbid nature of the process is evident.

An accumulation of fat in the tissues may occur so as to constitute a morbid process under the four following conditions:—

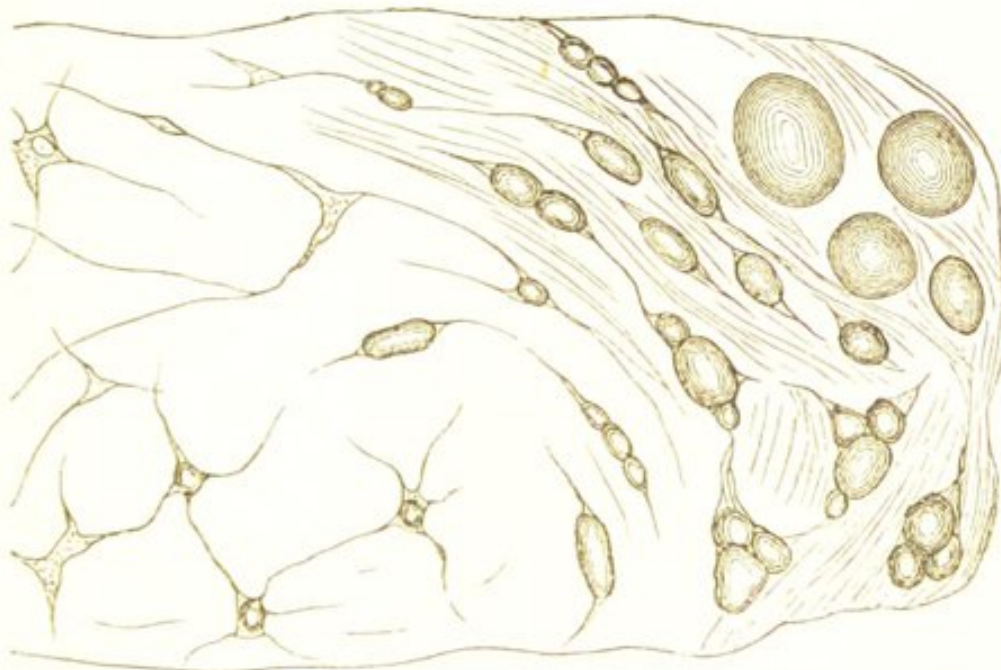
1st. When the food contains an excess of fat, or of substances capable of becoming converted into fat. Under such circumstances the oxygen taken into the body is insufficient to oxidise the excess, and it consequently accumulates in the cells.

An accumulation of fat from this cause occurs as a physiological process in the growth of adipose tissue. Adipose tissue is a connective tissue containing numerous cells which are distended with fat. The growth of this tissue thus consists simply in the fatty infiltration of more of these cells. (Fig. 4.) If this be excessive it constitutes obesity. The temporary accumulation of fat in the liver during the digestion of an aliment rich in fatty substances is another example of this kind of deposition. This will be described when speaking of the "fatty liver." If the amount of fat be very great it may accumulate, not only in normal situations, but also in tissues where fat is not usually met with, and in both cases the accumulation will thus constitute a morbid process.

2nd. When there is no such excess of fatty substances

in the food, but the processes of oxidation are so imperfectly performed, either locally or generally, that the fat contained in a natural diet is incompletely oxidised.

FIG. 4.



Fatty Infiltration of Connective Tissue. Showing the accumulation of fat within the cells. $\times 300$. (Rindfleisch.)

3rd. When the fat which is liberated from the nitrogenous constituents of the food during the process of nutrition does not undergo the complete oxidation which it should, and so remains within the cells.

4th. When the fat which is liberated from the protoplasm of cells during the process of nutrition is incompletely oxidised, and so accumulates in, and takes the place of, the protoplasm. Here there is a gradual transformation of the protoplasm into fat, so that the cell is ultimately completely destroyed.

Fatty degeneration in which there is this destruction of histological elements is one of the most common forms of the disease, and it will hereafter be more fully described as *fatty metamorphosis*. Its nature was first pointed out by Dr. Quain in his well-known researches on fatty dege-

neration of the heart.* Dr. Quain then stated that the fat met with in the muscular fibres in this condition was the result of a metamorphosis of the fibres themselves, and was not derived from without. The truth of Dr. Quain's teaching has since been confirmed by the experimental investigations of Drs. Voit and Bauer.

Voit and Bauer's investigations were made with the object of determining the source of the fat in that acute form of fatty degeneration which is produced by poisoning with phosphorus, in which the degeneration is due to the destruction of the red blood cells, and the consequent diminution in the oxidising power of the blood.† They gave phosphorus to dogs which had for some days previously been starved, so that any fat which might be present in the tissues after death could not have been derived either from the food or from the adipose tissue of the animals. The phosphorus produced very extensive and general fatty degeneration, and the fat must obviously have arisen from the protoplasm of the cells. Voit concludes from these investigations—1st. That the transformation of albumin which takes place in cells is independent of the supply of oxygen, but that if the oxygen be deficient, the fat and other products of the transformation, being incompletely oxidised, accumulate in the cell. 2nd. That the presence of fat in the cells may thus be due to increased transformation of the albumin, or to diminished oxidation of the products of its decomposition. 3rd. That the fatty degeneration in poisoning by phosphorus is due both to an increased transformation of the albumin of the cells, and to diminished oxidation of the fat and other products of the transformation.

It will thus be seen that of the four conditions enume-

* "Medico-Chirurgical Trans. Lond.," Vol. xxxiii.

† Voit and Bauer, "Zeitschrift f. Biologie," vii. pp. 63-85; and Voit, "Neues Repertorium fur Pharmacie," xx. pp. 340-349.

rated as causes of fatty degeneration, in all, with the exception of the first, the accumulation of the fat is principally due to deficiency of oxygen and consequent incomplete oxidation; whilst in the first there is no deficiency of oxygen, but the oxidisable materials are in excess.

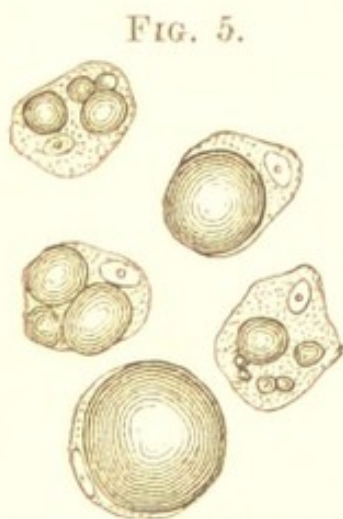A deficiency of oxygen, and a consequent incomplete oxidation and tendency to the production of fat, occurs under various circumstances. The red blood cells being the carriers of oxygen, all those conditions in which the supply of blood is interfered with, the red blood cells diminished in number or defective in quality, or the oxygenation of the blood imperfectly performed, may lead to fatty degeneration. The interference with the supply of blood to the brain, for example, by thrombosis or embolism, causes fatty degeneration of the brain-tissue. (See "Cerebral Softening.") The destruction of the red blood cells by phosphorus and other poisons; that general condition of anæmia which sometimes exists in young people, and is produced by many chronic and acute diseases; and that diminution in the activity of the circulation which results from old age; are also followed by a similar result. If an organ or tissue be long disused, the quantity of blood circulating through it becomes diminished, and it consequently undergoes fatty degeneration. (See "Fatty Infiltration of Muscle.") Lastly, the imperfect oxygenation of the blood which results from certain chronic diseases of the lungs constitutes one element in the causation of the fatty degeneration which so frequently exists in these diseases.

In proceeding to consider the histological changes which are produced in the tissues by an accumulation of fat, it must be stated, in the first place, that these vary very considerably according to the cause of the degeneration. In those cases in which the fat is derived from the metamorphosis of the nitrogenous constituents of the tissues, the tissues are destroyed in the process; whilst in other

cases no such destruction usually takes place. Although these two conditions may occasionally be associated, yet owing to the marked difference in the results which they respectively produce, it will be well to speak of them separately; that in which the fat is derived from the metamorphosis of the tissues being termed *Fatty Metamorphosis*, that in which it is derived from the oleaginous, saccharine, or nitrogenous principles of the food—*Fatty Infiltration*.

FATTY INFILTRATION.

In Fatty Infiltration, the fat which is deposited within the cells usually occurs as distinct drops of oil. In the earliest stages of the process these are very small, but as the deposition proceeds they gradually accumulate and run together, displacing and obscuring the nucleus and protoplasm, until the cell is completely filled and distended with oil. (Fig. 5.)



Liver Cells in various stages of Fatty Infiltration. ×300 (Bindfleisch).

the cells are but little impaired by the accumulation, and the protoplasm—although rendered almost invisible when this is excessive—remains unaltered. The cells within which the fat accumulates not being destroyed, the removal of the fat is all that is necessary to restore them to their original condition. As already stated, fatty infiltration occurs as a physiological process in the growth of adipose tissue, and also in the liver during

the digestion of an aliment rich in fatty substances.

FATTY INFILTRATION OF MUSCLE.

In muscle, fatty infiltration is frequently met with as a morbid process. The cells in the connective tissue which

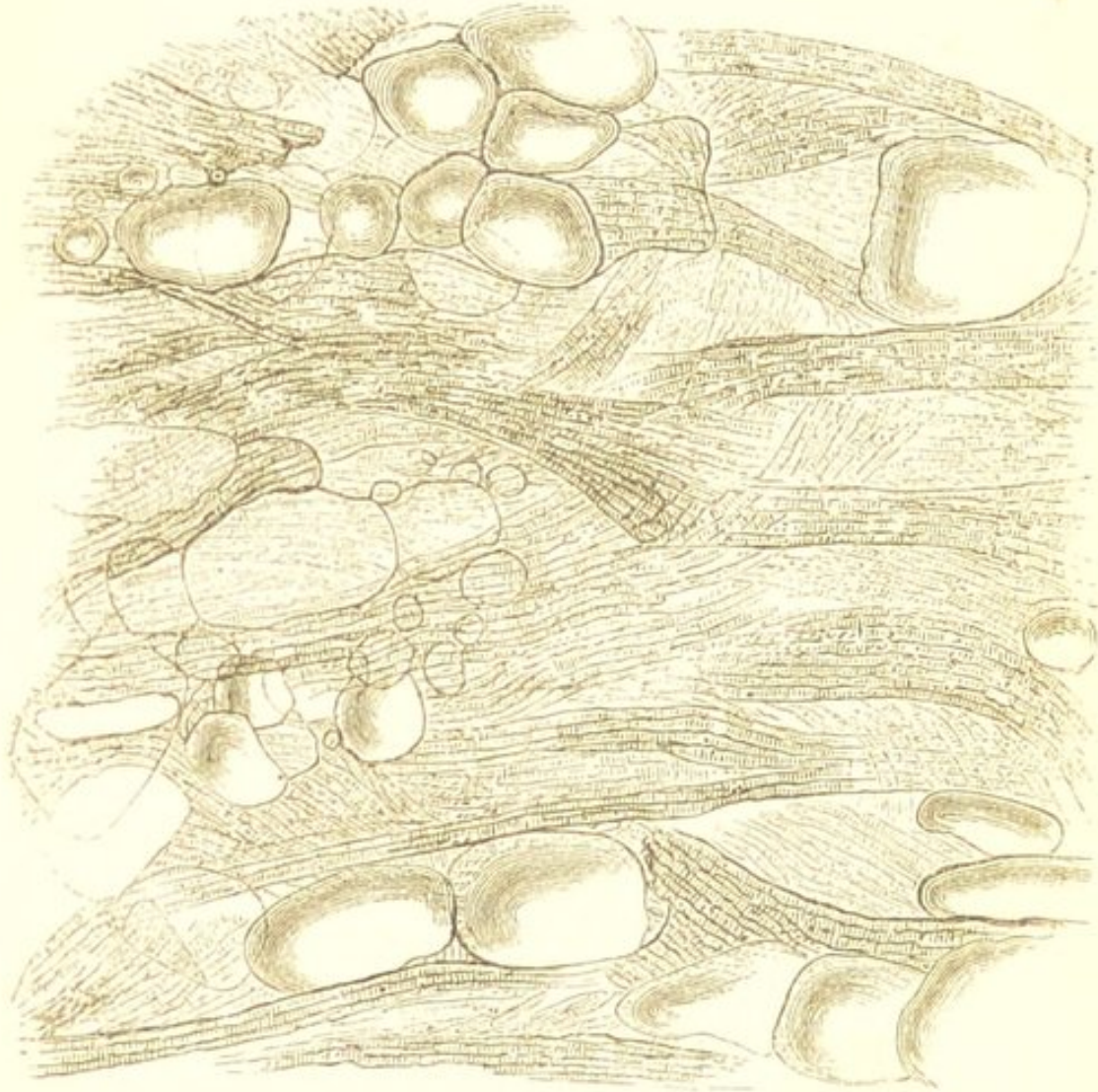
surrounds the fasciculi of the muscle become filled with fat; and this development of fat between the primitive muscular fasciculi has often been confounded with degeneration of the fibres themselves. In this latter process, however, which will subsequently be described as *fatty metamorphosis* of muscle, there is a direct metamorphosis of the muscular fibres into fat; whereas in the condition now under consideration, there is a deposition of fat *between* the fasciculi, which remain—during the early stages at all events—unaffected. The interstitial fat varies in amount. In some cases single rows of fat cells alternate with rows of muscular fasciculi, at other times the accumulation is less regular, more existing between some fibres than between others; in all cases, however, the muscular elements may be discovered lying amongst the fat. (Fig. 6.) If the latter be very considerable in amount, the muscle may appear to the naked eye to be entirely converted into fat; but the microscope will always reveal the muscular structure in which it is embedded.

This condition is frequently met with in animals which have been fattened, the fat increasing not only in the usual situations, but also accumulating between the fasciculi of the muscles. In muscles also which from any cause have for some time been incapacitated, and in which consequently the oxidation processes are reduced to a minimum, this interstitial growth is extremely liable to occur; ex. gr. in the extensors of the wrist-joint in cases of lead-poisoning, and in long-standing paralyses from lesions of the brain or cord, also in muscles which have been rendered useless by ankylosis of a joint. In progressive muscular atrophy, as Virchow has shown, the affected muscles exhibit this change, together with true fatty metamorphosis.

Fatty Infiltration of the Heart.—In the heart fatty infiltration is not unfrequently met with; and here it is

especially important to distinguish it from the much more grave condition in which the fibres themselves are pri-

FIG. 6.



Fatty Infiltration of Heart. A section from the more external portion of the left ventricle of the heart, showing the growth of fat *between* the muscular fibres. The fibres are in some places atrophied and commencing to undergo fatty metamorphosis. $\times 200$.

marily affected. In health, there is a varying amount of fat covering the surface of the heart beneath the visceral layer of the pericardium, which is always most abundant in the grooves between the auricles and ventricles, where it surrounds the blood-vessels. This may increase so as to completely envelop the organ, and at the same time gradually insinuate itself between the muscular fibres,

so that to the naked eye all appearance of muscular structure may be lost, the walls looking like a mass of fat. In hearts less affected, striæ of fat will be seen lying amongst the muscle. (See Fig. 6.) The fat is always most abundant near the surface, the muscular structure becoming more evident towards the endocardium.

The immediate effect of the interstitial growth is to displace and compress the muscular fibres between which it insinuates itself, and in doing so it diminishes the contractile power of the muscle: this is especially important when occurring in the heart. The pressure, however, which it exercises upon the fibres and the accompanying blood-vessels, ultimately causes atrophic and degenerative changes. Thus the fasciculi gradually atrophy, the transverse striation becomes indistinct and is replaced by molecular fat; in fine, true metamorphosis of the muscle is established. These two processes, indeed, not uncommonly go hand in hand together, the interstitial infiltration preceding the intrastitial metamorphosis.

FATTY INFILTRATION OF THE LIVER.

It is in the liver that fatty infiltration assumes its most important aspect, and in this organ it is exceedingly frequent, constituting what is commonly known as the "fatty liver." The hepatic cells always contain a small quantity of fat, which is temporarily increased after the ingestion of fatty substances. It will be well to describe this physiological infiltration before proceeding to the morbid process.

The ingestion of an aliment rich in fatty substances is followed by a temporary excess of fat in the portal blood, and by the deposition and temporary accumulation of a portion of this within the hepatic cells. This fat is first deposited in the cells which are in immediate contact with the capillaries of the portal vein, and thus is produced

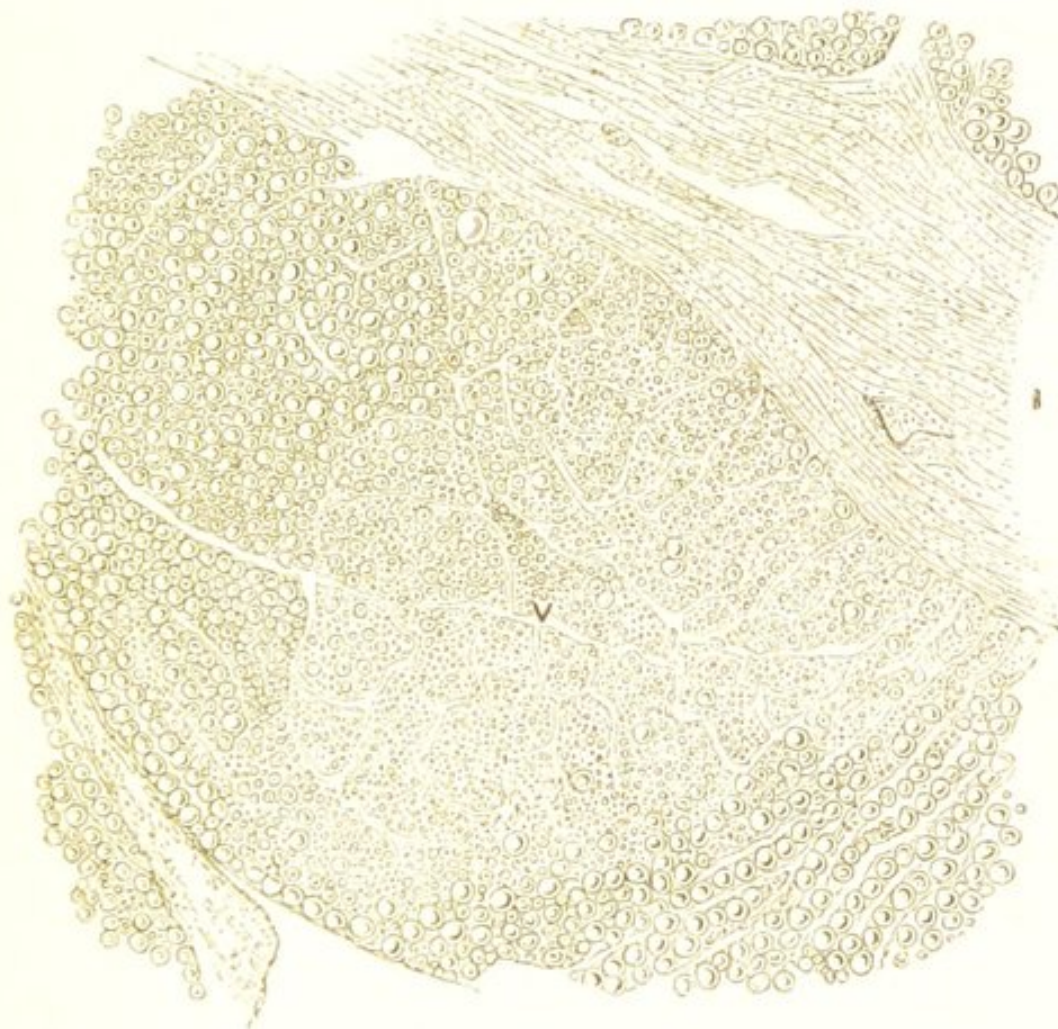
an excess of fat in the cells at the circumference of the hepatic lobules. This gradually passes from the cells at the circumference to those in the interior, whence it is ultimately conveyed again into the circulation. This process goes on until the excess of fat is removed from the blood, when the hepatic cells again acquire their former character. There is thus a transitory accumulation of fat within the hepatic cells which is gradually removed, the vitality of the cells not being thereby impaired.

The morbidly fatty liver is one which contains an abnormal quantity of fat, and here also, as the fat is usually deposited from the blood in the portal capillaries, the increase is first observable in the external zone of the hepatic lobules. (Fig. 7.) It accumulates here within the cells as minute globules, which as they increase coalesce and form large drops of fat. These ultimately completely fill and distend the cells, which at the same time become larger and more globular in shape. (See Fig. 5.) As the process proceeds, the accumulation advances from the periphery towards the centre of the lobule, until its whole mass may be involved, and the cells universally become distended with fat. The vitality of the cells is not materially impaired by the infiltration; they continue to perform their functions, as is shown by the presence of bile in the stools and in the gall-bladder. In many exceptional cases the accumulation of fat is most marked around the hepatic vein. This, according to Virchow, is probably to be explained by supposing that the fat is becoming excreted, and that only the last cells retain a little of it.

The fatty liver is somewhat increased in size, in advanced stages often considerably so. The surface is smooth, the edges are thickened and rounded, the specific gravity is diminished, although the absolute weight may be increased. If the infiltration be slight, involving merely

the portal zone of the lobules, the cut surface will present a mottled appearance, the external fatty zone being of an

FIG. 7.



Fatty Liver. Showing the accumulation of fat in those cells more especially which are situated in the external zone of the lobule. There is also an increase in the interlobular connective tissue (Cirrhosis). v. Hepatic vein. i. Interlobular connective tissue. $\times 50$.

opaque yellowish-white colour, whilst the central portion remains unaltered, or is perhaps somewhat hyperæmic. The more extensive the infiltration the larger is the pale zone, and ultimately, when the whole lobule is involved, there may be left in the centre merely a reddish-brown point, which corresponds with the commencement of the hepatic vein; and in many cases even this point is lost. The organ is then of an almost uniform opaque yellowish-white colour, and the boundary between the individual

lobules may be completely obscured. In very exceptional cases the accumulation of fat is much more abundant in some portions of the liver than in others, so that on section, yellowish points and streaks are seen scattered over its surface. The consistence of the organ is much diminished, it feels doughy, and pits on pressure with the finger, and the knife used to cut it becomes coated with oil. The pressure exercised by the infiltrated fat produces considerable anæmia of the organ, but the interference with the circulation is never sufficient to cause ascites, hæmorrhage, or other evidences of portal congestion.

The liver is especially liable to become the seat of fatty accumulation. This, according to the late Dr. Bence Jones, is owing—firstly, to the excess of non-nitrogenous oxidisable matter which is always present in it; secondly, to the deoxidised condition of the portal blood; and thirdly, to the low pressure and slowness of circulation in the portal vessels—conditions the least favourable to oxidation.*

An accumulation of fat in the liver occurs under two opposite conditions—one in which there is general obesity, and the fat accumulates in the liver in common with other parts; and another, in which there is general emaciation, and a consequent impairment of the oxygenating power of the blood. The fatty infiltration of the liver which is so constantly associated with certain chronic diseases of the lungs, is probably also partly due to imperfect oxygenation of the blood from destruction of lung-tissue. Fatty liver caused by phosphorus and other poisons has been already alluded to.

The other variety of fatty degeneration—fatty metamorphosis, will be described in the following chapter.

* "Lectures on Pathology and Therapeutics." Dr. Bence Jones, p. 179.

CHAPTER V.

FATTY DEGENERATION (*continued*).

FATTY METAMORPHOSIS.

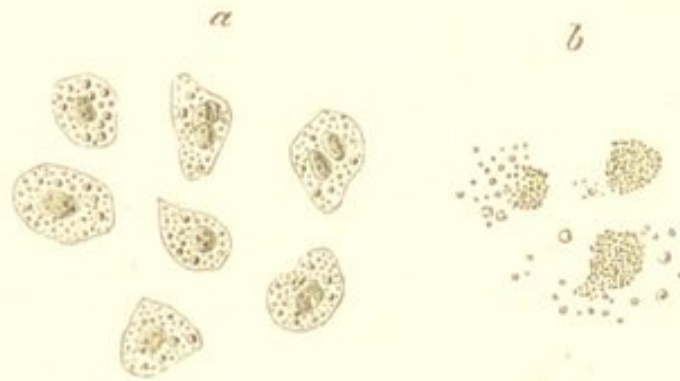
THIS differs from fatty infiltration, inasmuch as the fat is derived from the albuminous constituents of the tissues themselves, and not from the fatty, saccharine, or nitrogenous principles of the food.

The process consists in the transformation of the albuminous constituents of the tissues into fat, in the manner described in the preceding chapter, the cells being the parts which are most frequently affected. This fat makes its appearance as minute granules and molecules within the cells, usually first in the protoplasm, and subsequently in the nucleus. The granules—which are characterised by their dark colour, sharp contour, strong refractive power, and solubility in ether—gradually increase in number, until the whole of the protoplasm has undergone the transformation. As they increase some of them may coalesce, and so form distinct drops of fat. As the process proceeds the cells undergo an increase in size and become more globular in shape. Ultimately the nucleus becomes involved, the cell-wall, when this exists, is destroyed, and the cell is thus transformed into a mass of granular fat (Fig. 8).

These granules of fat may remain in a coherent form for some time after the cell-wall and nucleus are destroyed ;

they then constitute what were formerly known as the "inflammatory" or "exudation corpuscles," or "cor-

FIG. 8.



Fatty Metamorphosis of Cells. *a.* From a cancer. *b.* From the brain in chronic softening. The latter show the large "granular corpuscles," and also the manner in which these become disintegrated. $\times 200$.

puscles of Gluge," which are so common in chronic cerebral softening, and in other forms of fatty degeneration (Fig. 8, *b.*) Ultimately the corpuscles break up, the albuminous matter between the granules of fat liquefies, and the fat becomes distributed in the tissue (Fig. 8, *b.*)

Types of this pathological process are furnished by many well-known physiological ones, one of the most characteristic of which is perhaps the secretion of milk. The mammary gland is a large racemose gland, consisting of innumerable groups of lobules lined with epithelial cells. The secretion of milk takes place in the following manner:—The cells lining the lobules of the gland multiply abundantly, and the new cells as they are produced gradually become converted into fat; the cell breaks up, and the fatty matters in a more or less coherent form constitute the milk-corpuscles. In the earliest stages of the process the granules of fat cohere and form the colostrum-corpuscles, which are precisely analogous to the large granular corpuscles met with in chronic cerebral softening, &c. (Fig. 8, *b.*); but as the secretion becomes

fully established, and the multiplication and disintegration of the cells takes place more rapidly, the fatty molecules become at once distributed in the liquid in which they are suspended, giving to the secretion its characteristic white colour. The milk-corpuscles thus formed are replaced by the continuous formation of new cells from below, which in their turn undergo fatty metamorphosis, and in this manner a continuous formation and destruction of cells takes place.

Other examples of fatty metamorphosis are afforded by the formation of the sebaceous matter of the skin, the cerumen of the ears, and the corpus luteum in the ovary; all of which take place in the same way by the fatty metamorphosis and destruction of newly formed cells.

The immediate effect of fatty metamorphosis is to produce more or less softening of the affected part, the cellular elements are completely destroyed, the intercellular substance also undergoes fatty changes, and thus all trace of the original structure may be ultimately lost. This destruction of the cells is the essential feature of the change, and distinguishes it from fatty *infiltration*, in which the cells within which the fat accumulates usually remain intact.

If large tracts of tissue are affected, the change is readily recognisable by the naked eye, by the diminution in consistence and elasticity which are produced, and in many cases also by the opaque yellowish-white colour. If, however, the change is limited to minute and isolated portions of the tissue, its existence can only be discovered with the aid of the microscope.

The fatty particles into which the cells have been transformed, under favourable circumstances are readily absorbed. This is seen in the fatty degeneration and absorption of inflammatory products, such as occurs in croupous pneumonia. In order for such absorption to take place, it is necessary that the tissue should be freely

supplied with blood-vessels. If this is not the case, the degenerated products are liable to undergo certain changes whereby they become converted into a pultaceous crumbling material somewhat resembling cheese :—this is known as *caseation*.

CASEATION.—This is a modification of the degenerative process in which the fatty products gradually dry up into a yellowish friable material, which has been compared to soft cheese. This change appears to be owing to a natural dryness of the degenerated tissue, resulting from deficient vascular supply. It is most frequent in parts which contain but few vessels, or in those in which these become obliterated by some new growth. Growths composed of closely-crowded cells—as epithelial accumulations within the pulmonary alveoli, growths in the lymphatic glands, in the brain, and in the osseous structures, are the most liable to become caseous.

The process consists in a gradual drying up of the degenerated elements; the fluids are absorbed, the cells—which are many of them incompletely degenerated—shrivel and atrophy, the fat undergoes partial saponification, cholesterine forms, and the tissue thus becomes converted into a soft, yellowish-white, cheesy substance, composed of atrophied cells, fatty débris, and cholesterine crystals. This material may gradually dry up more and more, and ultimately become encapsuled by a layer of fibrous tissue.

These cheesy matters are constantly met with, especially in the lungs, and considerable confusion has arisen as to their nature and origin in this situation. This has proceeded from its having been formerly the custom to look upon all cheesy masses as essentially tubercular. Tubercle, it is true, often undergoes, to a greater or less extent, fatty degeneration; and it may thus, like all other structures which have undergone this process, become converted into a yellow cheesy substance; but it

is by no means true that all cheesy masses are tubercular. Thus the pathological significance of these cheesy masses is much less limited than was formerly supposed, and is indeed almost coextensive with that of fatty degeneration itself. In whatever situation they are met with, they indicate merely that the histological elements have undergone this fatty metamorphosis, and under no circumstances are they in themselves evidence of any one particular form of morbid growth.

The caseous mass may subsequently become calcified, or undergo a process of softening and liquefaction.

CALCIFICATION.—This is an advanced stage of the preceding process. It most frequently occurs in those cases in which the caseous mass is completely enclosed and isolated from the external air, as when in the lymphatic glands, in bone, or when encapsuled in the lungs. The mass becomes infiltrated with calcareous particles, and is thus converted into a calcareous concretion (“see Calcareous Degeneration”).

SOFTENING.—This process consists in a liquefaction of the caseous substance, which is probably owing to some chemical change in its constituents. It most commonly occurs in parts which come into contact with the external air, especially in those situated in the intestine, in the bronchial mucous membrane, and in the lungs. The caseous mass liquefies, and is converted into a thin puriform liquid, containing curd-like cheesy matter, which to the naked eye looks much like pus, but under the microscope is seen to consist simply of granular débris, fat, and cholesterine crystals. This, if not discharged, may, like the caseous masses, ultimately dry up and become calcified.

FATTY DEGENERATION OF ARTERIES.

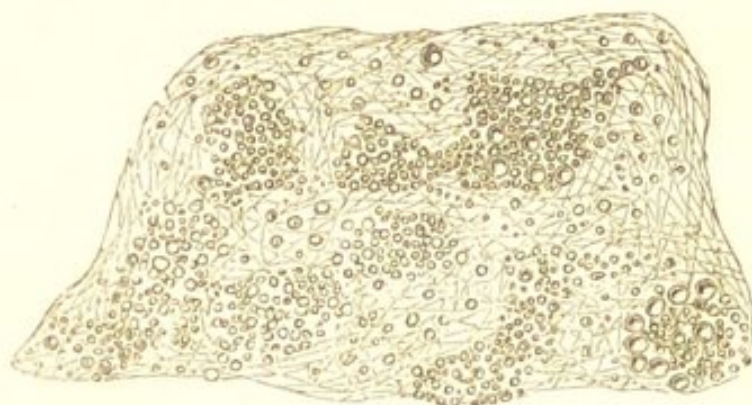
Fatty degeneration of arteries may be a primary or secondary affection. As a secondary process it is met

with in Atheroma, in which the fatty change is preceded by an inflammatory cellular infiltration of the sub-endothelial connective tissue (see "Atheroma").

Primary fatty degeneration is a passive process, not being preceded by any increased nutritive activity of the parts affected by it. It may affect both the internal, middle, and external coats of the artery, but it is most common in the first-named situation. The change usually commences in the endothelium and the connective tissue cells in the most internal layers of the inner coat, small groups of cells becoming affected in various parts of the vessel; and it may gradually extend from within outwards, the intercellular substance softening, until in exceptional cases, the whole thickness of the intima is destroyed. (Fig. 9.)

In the earlier stages of the process, the condition is recognised by the existence of small, irregular-shaped

FIG. 9.



Fatty Degeneration of the Internal Coat of the Aorta. Minute yellowish-white patches scattered over the lining membrane of the vessel. A very thin layer peeled off and $\times 200$, showing the groups of fat molecules, and the distribution of fat in the intima.

patches of an opaque yellowish-white colour, projecting very slightly above the surface of the intima. These, which are so constantly met with on the lining membrane of the aorta, may at first be mistaken for atheroma.

They are in most cases, however, readily distinguishable by their superficiality, and by the facility with which they can be stripped off from the subjacent layers, which present a natural appearance. In atheroma, on the other hand—which affects the deeper structures,—if the superficial layer be removed, the opacity and thickening are seen to exist beneath it. In many cases the change is limited entirely to the innermost layers of the vessel; the more the subjacent tissues are involved, the greater is the irregularity in the shape of the patches, and the less readily can they be separated with the forceps. The opaque patches ultimately break down, the cells are destroyed, the intercellular substance softens, and the granular débris is carried away by the circulation, leaving small, irregular, superficial erosions upon the lining membrane of the vessel. These erosions are not ulcers in the true sense of that term, not being the result of an active process. They resemble the superficial erosions so common upon the mucous membrane of the stomach, as described by Dr. Wilson Fox.

Simple fatty degeneration may occur in any of the arteries, but it is in the smaller ones that its injurious influence is most marked, and in these it is more especially liable to affect the external coat. Here, by diminishing the elasticity and contractility of the vessels, it causes degenerative changes in the parts which they supply, and often leads to rupture. This is exemplified by many cases of chronic cerebral softening, and cerebral hæmorrhage. In the larger arteries, as the aorta—where it is exceedingly common—it is of less importance, the inflammatory process, atheroma, having here a far more deleterious effect.

The capillaries may also be the seat of this fatty change; the endothelial cells being destroyed in the process, and the walls so much damaged, that rupture is often the ultimate result. This is very common in the

smallest cerebral blood-vessels, where it is a frequent cause of cerebral hæmorrhage.

Passive fatty degeneration of arteries is in most cases a senile change; it is an expression of that general impairment of vitality which exists in advanced life, and is usually associated with similar changes in other parts. When, however, it is limited to the largest arteries, it is often met with in early life and in persons who are otherwise perfectly healthy.

FATTY DEGENERATION OF THE BRAIN.—CEREBRAL SOFTENING.

Fatty degeneration of the brain is met with in those morbid conditions comprised under the common term of "Cerebral Softenings." Whatever interferes with the supply of blood to the cerebral substance will tend to produce fatty degeneration, and hence softening. The portions of the brain which are the seat of this change may be merely rather softer than the surrounding healthy tissue—breaking down more readily under a stream of water which is allowed to fall upon them—or they may be completely diffuent. They are never distinctly circumscribed, but pass by insensible gradations into the neighbouring tissue.

Under the microscope the change is seen to consist in a disintegration of the nerve-tissue. The white substance of the fibres first coagulates, then breaks up into large masses, and these subsequently undergo fatty metamorphosis. The cells of the neuroglia, the small blood-vessels, and when the grey matter is implicated, the large nerve-cells, are also involved in the fatty change. The tissue is thus converted into broken-down fibres, a large amount of molecular fat, and numerous large granular corpuscles, the so-called "exudation corpuscles" or "compound inflammatory globules of Gluge." (Fig. 10.) These corpuscles were formerly looked upon in all cases as the

result of inflammation, hence their name; they are, however, simply conglomerations of fat granules formed by the

FIG. 10.



Chronic White Softening of the Brain. Showing the granular corpuscles, broken-down nerve-fibres, and fat granules, of which the softened substance is composed. One or two nucleated cells (probably nerve-cells) are also visible. $\times 250$.

degeneration of the cellular elements. (See Fig. 8.) The cells from which they originate are, according to Virchow and Robin, the cells of the neuroglia—the connective tissue of the brain:—these cells share in the fatty change, and in doing so, appear to undergo considerable enlargement before they are destroyed and the fatty matter breaks up. They vary in size from $\frac{1}{500}$ to $\frac{1}{2000}$ inch in diameter, the average being $\frac{1}{1000}$. When the softening affects the grey matter the nerve-cells also contain molecular fat. The small arteries and capillaries running through the softened part are many of them filled with fat granules and granular cells. These latter probably originate in the white blood-corpuscles which have accumulated in the part and undergone fatty changes. Molecular fat and the large granular corpuscles will also be seen adhering to the external surface of the vessels; and here care is required to distinguish these from fatty degeneration of the vessels themselves, to which the cerebral

softening is so frequently due. As the process proceeds the cerebral substance is completely destroyed and all traces of nerve-structure is ultimately lost.

The colour of the softened portion varies considerably. It may resemble that of the surrounding healthy tissue; in other cases it is altered to a yellowish or deep red tint. According to these variations in colour, cerebral softenings have been classified into *white*, *yellow*, and *red*. The colour depends in great measure upon the amount of blood contained in the part, and on this account is important, as indicating the manner in which the softening has been brought about.

White Softening.—This is, in the great majority of cases, a chronic condition. It occurs especially in old people, and is usually due to that disease of the smaller cerebral blood-vessels and consequent interference with the circulation which is common as a result of age. The impairment of the contractile power of the heart must also constitute an auxiliary in the causation of the imperfect vascular supply. It is the gradual manner in which the supply of blood is diminished which accounts for the absence of hyperæmia or hæmorrhage, so that the colour of the softened portion either resembles that of healthy brain-tissue, or is an opaque dirty white. White softening is sometimes acute, in which case it is usually due to the sudden obstruction of the circulation by the impaction of an embolus in one of the *larger* arteries (see “Embolism in the Brain”).

Yellow Softening.—This is, in most cases, simply a variety of the former process, in which, from the fine state of division and close aggregation of the fatty particles, a dead yellowish-white colour is imparted to the softened tissue. This colour is probably often partly owing to the presence of altered blood pigments, the result of some previous slight extravasation. The pigment may sometimes be seen as fine dark granules, scat-

tered through the cells of the neuroglia and the nerve-cells of the grey matter, where at first sight they look like fatty particles; they are distinguished, however, by their dark black colour. A softening of the brain more rapidly induced, as by embolism or thrombosis, may also occasionally be of a yellow colour. This, however, is only the case when the softened portion has attained a certain age, and much of the extravasated blood has been removed by absorption. Lastly, a condition of gelatinous œdema of a yellow colour, which has been described by Rokitansky as often being present in the immediate vicinity of cerebral tumours, has been regarded as a variety of yellow softening.

Red Softening.—This is commonly an acute affection, most frequently dependent upon vascular obstruction, either from embolism or thrombosis. There is intense collateral hyperæmia, rupture of capillaries, and extravasation of blood; the softened tissue is consequently of a deep red colour:—this will be described in the chapter on “Embolism.” Red softening is also sometimes associated with the chronic white variety, some of the diseased vessels giving way, and thus extravasation of blood taking place into the already softened tissue. Lastly, red softening may be inflammatory (see “Inflammation of the Brain”).

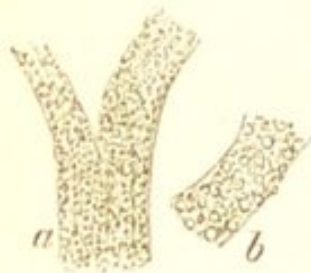FATTY DEGENERATION OF MUSCLE.

Both striated and non-striated muscle may be the seat of fatty degeneration. In the latter, the muscular fibre-cells are the seat of the change; they become filled with fat granules and are ultimately destroyed. This condition is frequently met with in the middle coat of arteries which are undergoing fatty degeneration.

In striated muscle—both in the voluntary and in the involuntary of the heart—the fibres themselves are the seat of the morbid process, which consists in the conver-

sion of the albuminous matter of which the fibre is composed into fat. The earliest stage of the affection is characterised by an indistinctness in the transverse markings of the fibres, which in many parts become studded with minute particles of fat. (Fig. 11.) These gradually

FIG. 11.



Fatty Degeneration of Muscular Fibres of Heart. a. Earlier stage. b. More advanced. $\times 400$.

increase in number and size, and are usually distributed somewhat irregularly within the sarcolemma. In some parts single rows of granules are found running along the length of the fibre; in others, they are grouped around the nuclei or arranged in transverse lines corresponding with the striæ of the muscle. The fibres become extremely friable, and are readily broken up into short fragments. As the process proceeds the transverse markings entirely disappear, and nothing but molecular fat and oil globules are seen within the sarcolemma. The sarcolemma itself may ultimately be destroyed, and nothing remain of the original fibre but the fatty débris into which its albuminous constituents have been converted. This is true fatty degeneration of muscle; in it the muscular elements are destroyed, and it thus differs essentially from fatty *infiltration*, in which there is simply a development of fat between the fasciculi, the fasciculi themselves not being primarily affected (see "Fatty Infiltration of Muscle").

FATTY DEGENERATION OF THE HEART.

It is in the heart that fatty degeneration of muscle is most frequently met with, and here it assumes a most important aspect from the deleterious influence which it exercises upon the motor power of the organ. The muscular substance may be affected throughout, or, as is

more frequently the case, the degeneration may be confined to certain portions of it. It is more common in some situations than in others. The order of frequency with which it occurs in different parts is, according to Dr. Quain, firstly, the left ventricle; secondly, the right ventricle; thirdly, the right auricle; and fourthly, the left auricle.

The wider the extent of tissue that is affected, the less advanced, as a rule, is the degree of the degeneration. It is in those cases in which small tracts of tissue only are involved, that the process is met with in its most advanced stage.

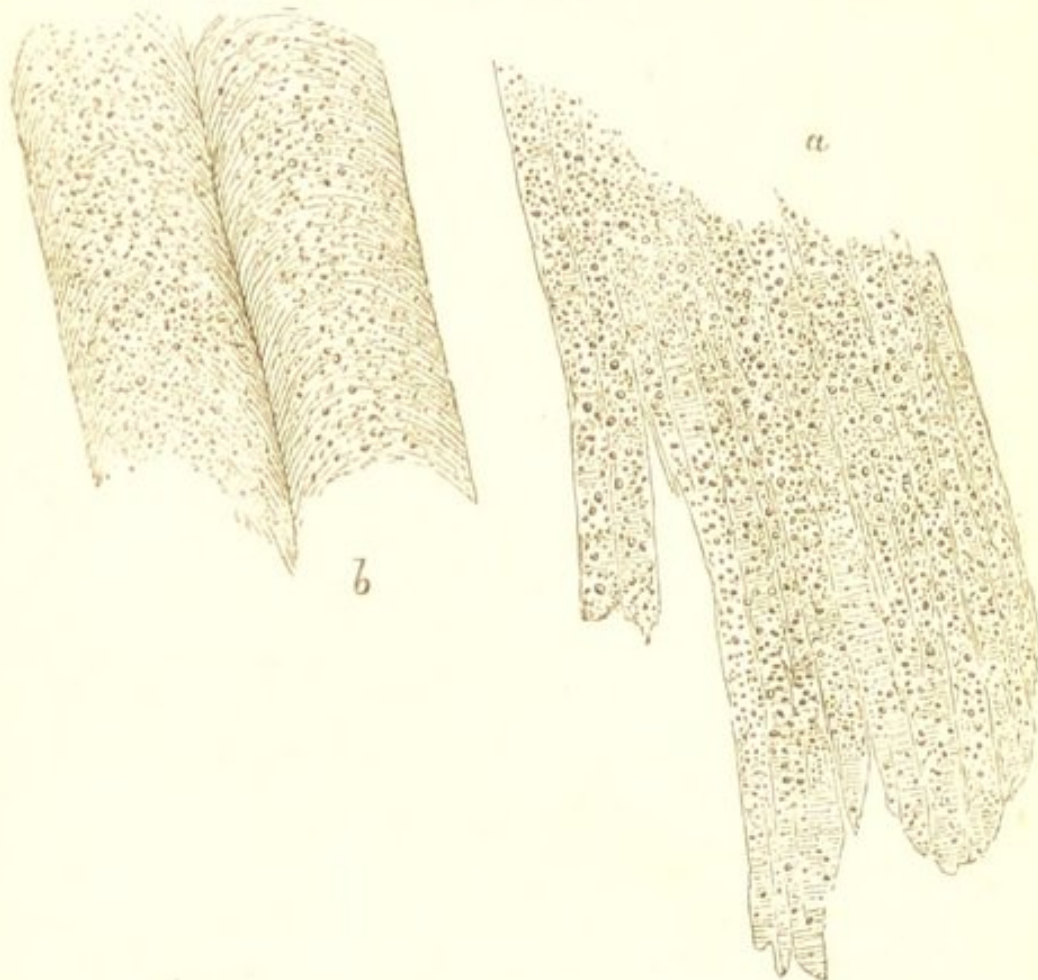
The consistence of the degenerated part is always diminished, and its colour altered. When the change is slight, and more or less general, the muscle is somewhat softer and more flabby than natural; it is more friable, and often breaks with a soft granular fracture. The colour is uniformly rather paler, and more opaque than that of healthy cardiac tissue. Under the microscope the muscular fibres are seen to have lost their striated appearance, and to contain granules of fat.

This diffuse form of degeneration may occur in the course of those diseases in which the oxidation processes are reduced to a minimum; in all those diseases, in short, which are attended by marked anæmia, whether this anæmia be gradually or rapidly induced. In the case from which the accompanying drawing was taken the degeneration was acute (Fig. 12). This was the case of a weakly young girl who was under my care, suffering from slight valvular disease. She quickly succumbed with acute fatty degeneration of the heart and other muscles, which was induced by a profuse loss of blood during a menstrual period, and by inability to retain food.* In its slightest

* This case is reported in "Trans. Clinical Society, Lond." Vol. viii, 1875.

degrees a diffuse fatty degeneration of the heart sometimes occurs in the course of acute febrile diseases. This will be again referred to in the chapter treating of the histological changes produced by pyrexia.

FIG. 12.



Acute Fatty Degeneration of Heart and of other Muscles. a. Heart. *b.* Rectus abdominis. The whole of the heart-tissue was affected and also the muscles in other parts of the body. $\times 400$.

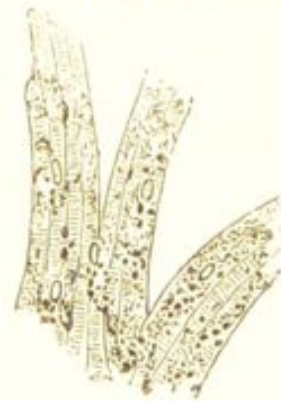More frequent than this diffuse and comparatively slight degree of degeneration, affecting the whole or the greater part of the organ, is a condition in which, although perhaps the change may be more or less general, it is much more advanced in some parts than in others. In such cases the heart presents a mottled appearance; numerous opaque, pale yellowish or brownish patches are seen irregularly distributed throughout its substance. These patches vary considerably in size and form; they

are met with especially in the papillary muscles, the columnæ carneæ, and in the layers of fibres immediately beneath the endocardium. They may also occur beneath the pericardium, and in the deeper portions of the organ. They correspond with the most degenerated portions of the tissue. They are soft and flabby, and have a rotten consistence, tearing readily under the finger. Under the microscope, the fibres are often seen to be in an advanced stage of fatty degeneration; their sarcolemma contains large molecules of fat and oil globules, which in many parts have escaped and lie free amongst the surrounding less degenerated tissue. (Fig. 11, *b*.) These more localised degenerations are most common in old people, and usually result from imperfect supply of blood due to disease of the coronary blood-vessels, and not from conditions of general anæmia. The peripheral layers of muscular tissue also frequently undergo extensive fatty degeneration as the result of pericarditis. The connection between these localised degenerations and rupture and aneurism of the heart is well-known.

BROWN ATROPHY OF THE HEART.

Closely allied to, and frequently associated with fatty degeneration of the heart, is the condition known as brown atrophy. This consists in a gradual atrophy of the muscular fibres, together with the formation of granules of brownish-yellow or blackish pigment. These granules of pigment are either grouped in clusters around the nuclei, or more generally distributed within the fibre. The fibres are frequently, at the same time, the seat of more or less fatty degeneration. (Fig. 13.)

FIG. 13.



Brown Atrophy of the Heart. Showing the granules of pigment and the atrophy of the fibres. The latter have in some parts undergone slight fatty metamorphosis. $\times 400$.

Brown atrophy of the heart usually occurs as a senile change, or as a part of general marasmus from other causes. It is also met with in some cases of cardiac hypertrophy. It is more chronic in its course than simple fatty degeneration, and its recognition is in most cases impossible without the aid of the microscope.

FATTY DEGENERATION OF THE KIDNEYS.

Fatty degeneration of the kidneys frequently occurs as a result of inflammation of the organs. This *secondary* degeneration will be alluded to when treating of renal inflammations. Primary fatty degeneration is much less frequent. It must be borne in mind that the renal epithelium very commonly contains more or less fat; but it is only when this is excessive that it can be regarded as a diseased condition. This excessive formation of fat in the kidney is, I think, less common than is generally supposed. It is, however, occasionally met with in chronic diseases, especially in pulmonary phthisis. It is also a result of poisoning by phosphorus.

In simple fatty degeneration the change is usually confined to the epithelium of the cortex. The cortex presents on section a somewhat yellowish-white surface, often slightly mottled, and this, in most cases, is most marked near the bases of the pyramids. There is no adhesion of the capsule or granulation of the surface. This change appears to interfere but little, if any, with the functions of the organs, and in this respect it resembles the analogous change in the liver. It is not accompanied by albuminuria.

CHAPTER VI.

MUCOID AND COLLOID DEGENERATION.

UNDER this head is included a class of morbid changes which are characterised by a peculiar softening of the tissues. Colloid and mucoid degeneration have frequently been described under the common term of "colloid softening," but, although they are very closely allied and frequently associated, they appear to constitute two distinct processes; the former affecting more especially the cells, the latter the intercellular substance.

MUCOID DEGENERATION.—This consists in the transformation of the albuminoid constituents of the tissues into *mucin*, owing to which they become converted into a material of a soft, mucilaginous, jelly-like consistence. This is the condition of nearly all tissues in their immature or foetal state: the connective tissues in the foetus consist almost entirely of this soft mucin-yielding substance. Some tissues retain these characters after birth. The umbilical cord, and the vitreous humour of the eye, are both composed of this substance.

The change affects especially the intercellular substance, less frequently the cellular elements. The intercellular substance of the connective tissues in their fully developed state consists of gelatin and chondrin, and the mucoid change is thus a reversion of this substance to its foetal condition. When the cells are affected, as their protoplasm becomes transformed into mucin they are gradually

destroyed. This occurs normally in the epithelium of mucous membranes.

Mucin is closely allied to albumen, more so than to either gelatin or chondrin: it differs from it in not containing sulphur. Like albumen, it is only met with in alkaline fluids—being held in solution by the free alkali—from which it is precipitated by dilute acetic acid. It differs from albumen in being insoluble in an excess of the acid, and also in not being precipitated by boiling, by tannin, or by bichloride of mercury: its behaviour with these two reagents will also distinguish it from gelatin and chondrin, which are both precipitated by them.

The mucoid change is by no means a common one. It is most frequently met with in cartilage, especially in the inter-vertebral and costal cartilages of old people. It also occurs in serous membranes, in bone, and in many of the new formations, especially in those of the connective-tissue class. Wherever it occurs it produces softening of the affected parts; which are transformed into a homogeneous, colourless material, of a soft mucilaginous jelly-like consistence. If the change is limited to isolated portions of the tissue, the softened parts surrounded by those which are unaltered, often present the appearance of cysts. These cyst-like formations containing mucoid substance are not uncommonly met with in the costal cartilages and in new growths.

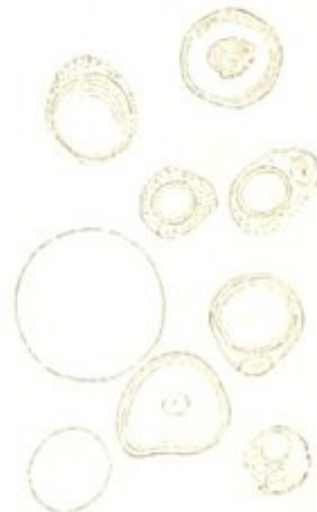As to the cause of the mucoid change, nothing is known.

X COLLOID DEGENERATION.—This differs from the former, inasmuch as it is the *cells* which are especially involved in the process.

The change consists in the metamorphosis of the albuminoid constituents of the cells into a substance known as *colloid* material. Colloid closely resembles mucin, but it differs from it chemically, in containing sulphur, and in not being precipitated by acetic acid. It is a colourless, transparent, glistening material of the consistence of jelly

or half-set glue. It makes its appearance within the cells, as small lumps, which gradually increase in size, pushing the nucleus to one side, until they completely fill the cell. (Fig. 14.) The cells are thus destroyed, and converted into colloid masses. The small colloid masses subsequently swell up, coalesce, and so form larger masses of firm, transparent, yellowish, jelly-like material, which are readily to be recognised by the naked eye. As the colloid matter increases, and the cells are destroyed, the intercellular substance atrophies or softens, and in this way cyst-like cavities are formed within which is contained the gelatinous substance. Here it may subsequently undergo a process of liquefaction. (See Fig. 49.)

FIG. 14.



Colloid Cells, from
a colloid cancer.
(Rindfleisch.)

The colloid change is most common in enlargements of the thyroid gland, in the lymphatic glands, in the choroid plexus, and especially in many of the new formations. (See "Colloid Cancer.") Its causes and nature are as obscure as those of the allied mucoid softening.

It is when occurring in new formations that these two forms of degeneration assume their most important aspects. Certain varieties of tumours may originate as mucoid or colloid growths, or may subsequently undergo these morbid transformations. The mucous tumours (myxomata), which resemble in structure the umbilical cord, consist entirely of a gelatinous mucin-yielding substance. The sarcomata, lipomata, enchondromata, and the cancers may also become the seats of these forms of softening.

Such growths have sometimes been described as gelatiniform or colloid *cancers*, this term having been applied

to them without any regard to their structure or real nature. Cancers, it is true, may undergo a colloid change (see "Colloid Cancer"); but it is by no means true that all tumours possessing these soft gelatiniform characters are cancers. The terms "mucoid" or "colloid" applied to a new growth, merely imply certain physical and chemical characters, and convey but little information as to its real nature.

CHAPTER VII.

AMYLOID DEGENERATION.

AMYLOID degeneration, which is one of the most important of the degenerative processes, consists in the infiltration of the tissues with a peculiar homogeneous translucent substance closely resembling albumen, by which their vitality becomes diminished and their functions impaired.

It is often known as the *lardaceous*, or *waxy* change, the organs affected by it having somewhat the appearance of lard or wax. The term "*amyloid*"—which was applied to it by Virchow, from the supposed resemblance of the new material to cellulose or starch—as being that by which it is perhaps most generally known, is here adopted.

This form of degeneration is very rarely a primary affection, but almost invariably occurs as the sequel of some other disease. It appears to be associated with certain cachectic conditions, brought on by many exhausting diseases. It is in those diseases which are attended by profuse and long-continued suppuration, such as chronic diseases of bone, empyema, chronic disintegrative diseases of the lungs, chronic pyelitis, and chronic intestinal ulceration, that the amyloid change most frequently occurs. It also frequently occurs in the advanced stages of constitutional syphilis, but usually only in those cases in which there is chronic bone disease or chronic ulceration.

Every organ and tissue may be the seat of the change ; those, however, in which it is especially prone to occur, are the kidneys, the liver, the spleen, the lymphatic glands, and the intestines. It is met with less frequently in the stomach, in the supra-renal capsules, in the pharynx and œsophagus, in the bladder, prostate, and generative organs, in serous membranes, in the membranes of the brain and cord, and in muscle. It is rarely limited to one organ, but several organs are almost invariably simultaneously affected by it.

Respecting the nature of the new material which infiltrates the tissues, the analyses of Kekulé and Schmidt show that it is a nitrogenous substance closely allied to albumen. The conclusions arrived at by these observers are, however, not satisfactory, as they were unable completely to separate the substance from the tissues in which it was deposited. More recently, Kühne succeeded in more completely isolating it. He submitted the affected organs to a process of artificial digestion, and inasmuch as the amyloid substance is not dissolved by digestion with pepsin, it was thus obtained free from the tissues in which it was contained. The result of Kühne's analyses are very similar to those of Kekulé and Schmidt. Dr. Dickinson regards the new substance as fibrin deprived of its alkaline salts. The investigations of Dr. Marcet* show that the infiltrated organs are considerably deficient in potash and phosphoric acid, whilst they contain an excess of soda and chlorine. In conclusion it may be stated that, although the precise composition of the amyloid substance has not yet been determined, the results of the several analyses appear to justify the opinion that it is some modification of fibrin.

The most characteristic feature of the amyloid sub-

* See "Report of Committee on Lardaceous Disease," Trans. Path. Soc. Lond. 1871.

stance is the peculiar reaction which it gives with iodine, and with iodine and sulphuric acid. If an aqueous solution of iodine—made with the help of potassium iodide—be applied to an amyloid organ, the affected portions change to a deep reddish-brown colour. This is not permanent, but gradually passes off, and the part regains its former appearance. If the application of the iodine be followed by the cautious addition of sulphuric acid, a blackish-blue or violet tint is produced. This latter reaction, however, is not easily obtained, considerable nicety being required in the application of the reagents. The following is the method for obtaining it, recommended by Professor Virchow:—A dilute aqueous solution of iodine must be allowed to soak well into the tissue, the excess must be poured off, and a single drop of concentrated sulphuric acid gradually added, when a blue or violet colour will be produced, either at once or after some time. In the hands of English pathologists this latter reaction has certainly met with but little success; and if the colour be obtained, it is by no means satisfactory, and more nearly resembles a black than the blue which has been described. Fortunately, however, the reaction with iodine alone is perfectly characteristic, and the attempt to obtain the blue by the subsequent addition of sulphuric acid, is therefore quite unnecessary. If the change is at all advanced, the reddish-brown colour will be produced by merely pouring the aqueous solution of iodine over the cut surface of the organ; but in slighter degrees of the affections, thin sections must be made with a Valentin's knife, and well washed with water to remove the blood, before the coloration with iodine can be obtained.

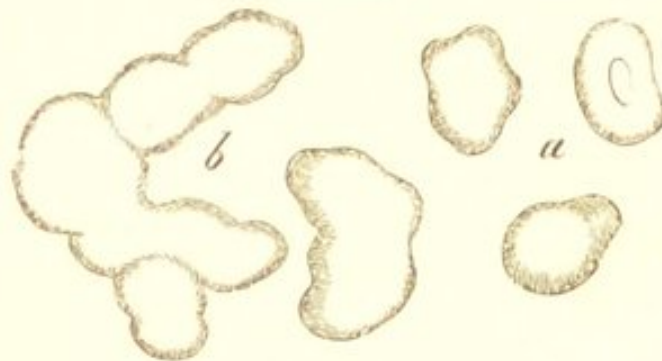Upon considering the above reactions, it will be seen that they resemble, in some respects, those exhibited by some well-known organic substances. Cellulose—the substance which forms the external membrane of vege-

table cells—yields a blue when treated with iodine and sulphuric acid, and so far resembles the amyloid material; but differs in not being coloured by iodine alone. The same is true of cholesterin; this also gives a reddish-brown with sulphuric acid, but is not altered by iodine. To starch, the resemblance is not so marked as to the two preceding substances: with this, iodine produces a blue colour without the addition of the acid.

The amyloid substance almost invariably makes its appearance first in the small arteries and capillaries, and subsequently extends from them to the surrounding tissues. The cells of the intima and of the muscular coat are the first to become infiltrated, then the remaining structures of the artery. When the vessels have become infiltrated, the amyloid matter extends to the immediately surrounding parts; it invades both the cells and the intercellular substance, and may gradually extend until the whole organ is completely impregnated.

The changes produced in the tissues by this infiltration are very characteristic. The cells as they become filled

FIG. 15.



Liver Cells infiltrated with the Amyloid Substance.
a. Single cells. *b.* Cells which have coalesced.
 × 300. (Rindfleisch.)

with the new material gradually increase in size; they lose any irregularities in their contour, and become rounder and more regular in shape; their nuclei disappear, and the whole cell is converted into a structureless homogeneous body, which has a peculiar translucent

glistening appearance. (Fig. 15, *a*.) If the cells are in close contact many of them may coalesce, and their distinctive boundaries thus become obliterated. (Fig. 15, *b*.) The intercellular substance in the same way acquires a homogeneous glistening appearance. The walls of the small arteries—in which, as already stated, the change commences—become considerably thickened, the cells of the muscular coat enlarge and ultimately coalesce, the calibre of the vessel becomes diminished, and the circulation through it is consequently impeded. (See Fig. 17.)

Organs in which this change is at all advanced, present features so characteristic that its nature can be readily recognised by the naked eye. They are usually considerably increased in size; their absolute weight is increased, and also their specific gravity; their surface is smooth, and the capsule tense and stretched; their consistence is firm and somewhat elastic. On section they exhibit a peculiar homogeneous, glistening, translucent appearance, somewhat resembling wax or glue. Owing to the diminished calibre of their blood-vessels and to the pressure exercised by the new material, they contain but little blood, and hence are always pale in colour. The change may involve the whole organ, or it may be limited to certain portions. In the spleen, for example, it is frequently limited to the Malpighian corpuscles; and in the liver, to the cells in the more immediate vicinity of the hepatic artery.

Although the above characters are often sufficiently marked, they should always be confirmed by the application of iodine to the cut surface of the organ. In slighter degrees of the affection—when the physical characters are but little altered—the application of this reagent becomes necessary in order to discover the presence of the new substance. In these cases, merely pouring the solution over the organ will often fail to produce the charac-

teristic staining; and it will be necessary to make thin sections with a Valentin's knife, and wash them thoroughly with water to remove the blood, before the reaction can be obtained. In the earliest stages of the change the use of the microscope may be necessary for its recognition.

The effect of amyloid degeneration is to impair or even to completely destroy the nutrition and function of those organs which are affected by it. This is owing to two causes—the obstruction offered to the circulation, and the direct influence of the new material upon the parenchyma of the organ. The obstruction to the circulation, which results partly from the diminution in the calibre of the small arteries, and partly from the general pressure exercised by the infiltrated substance, causes an insufficiency in the supply of arterial blood. As a consequence of this, secondary atrophic changes are induced in various parts; the cells may atrophy and undergo fatty metamorphosis, which indeed is frequently associated with the amyloid change. The vitality of the cellular elements is still further impaired by their infiltration with the new material, and thus all manifestations of their functions may ultimately cease.

As this form of degeneration is almost invariably secondary to some grave constitutional state, it can rarely be looked upon as in itself a cause of death, although it may materially hasten, and even determine the fatal termination.

Having thus described the nature of the amyloid substance, and the way in which it makes its appearance in the several tissues of an organ, it remains to consider the source from which it is derived. The disease, as already stated, appears to be an infiltration, and to consist in the deposition of a new material from the blood in the various tissues and organs. The existence, however, of any albuminoid substance in the blood which resembles amyloid

in its reaction with iodine, has never been made out, even in the most marked cases of the disease. This fact must therefore negative the supposition that it is a simple infiltration. If the new material be derived from the blood at all, it must undergo some chemical change subsequently to its deposition in the tissues. Dr. Dickinson considers that it is dealkalised fibrin, which is deposited in consequence of the loss of the alkali which it normally contains. This loss of alkali he attributes to the chronic suppuration which usually precedes the disease, pus containing large quantities of potassium and sodium salts. He consequently terms the disease "*depurative infiltration.*"* Whether this be so or no, it is probable that some abnormal condition of the blood is the cause of the disease, and that the change itself consists in the retention and coagulation in the tissues of some albuminoid substance which is derived from the nutritive fluids. The way in which the several tissues of an organ are affected, the change almost invariably commencing in the small nutrient blood-vessels, and extending from them to the surrounding parts; the general character of the affection, several organs being simultaneously involved; together with the fact that it is almost invariably secondary to chronic suppurative diseases—point to some alteration in the composition of the blood as the cause of the degeneration.

AMYLOID DEGENERATION OF THE LIVER.

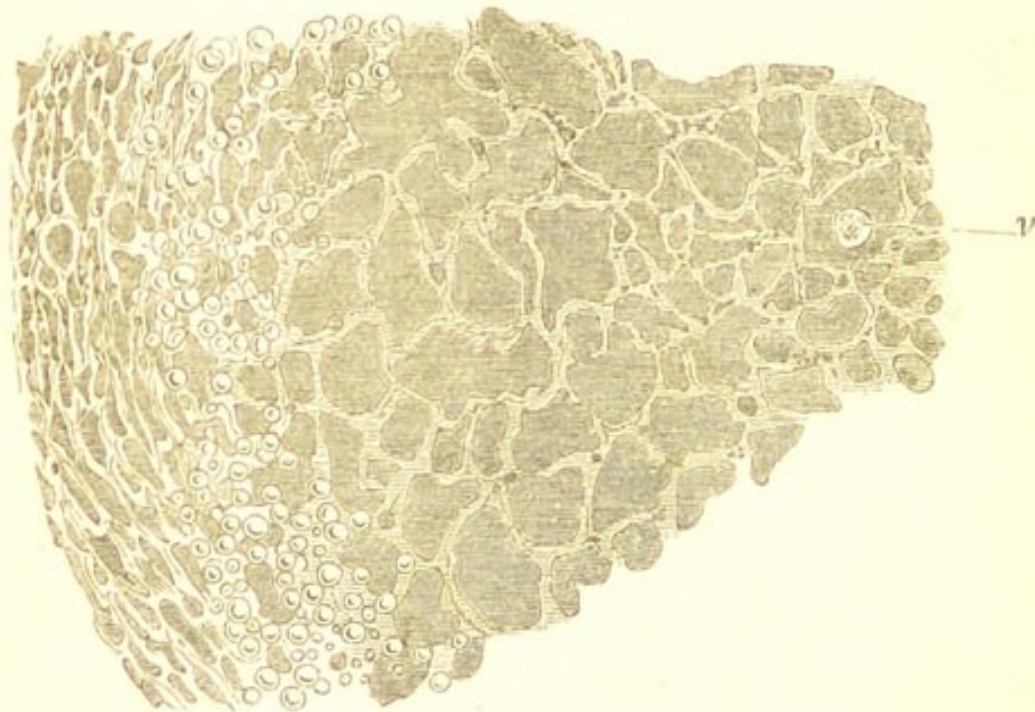
The liver is one of the most frequent seats of the amyloid change, and here, as in other parts, it probably commences in the small nutrient blood-vessels, although the alterations are much the most marked in the hepatic cells. The minute branches of the hepatic artery are first affected, and from these the infiltration gradually extends

* "Medico-Chirurgical Transactions," vol. 1.

to the hepatic cells immediately adjacent, until ultimately the whole organ may become involved.

If a liver be examined in the earlier stages of the affection, and the iodine solution applied to thin washed sections of the organ, it will be found that the characteristic staining is limited to certain portions of the lobules—viz., to those which are situated between their external and central parts. This intermediate portion corresponds with the distribution of the hepatic artery, and the rami-

FIG. 16.



Amyloid Liver. A portion of one lobule, showing the enlargement and fusion of the hepatic cells, and the greater implication of the intermediate zone of the lobule. At the more external portion of the lobule are seen several fat cells, a certain amount of fatty infiltration being associated with the amyloid change. *v.* Hepatic vein. $\times 100$.

fications of this vessel together with the hepatic cells situated in their vicinity are the first to become affected. (Fig. 16.) As the change advances the whole lobule may ultimately become involved. The alterations in the hepatic cells are very characteristic. They are much enlarged, irregular in outline, their nuclei are imperceptible, and

many of them are fused together into irregular-shaped masses. (See Fig. 15.)

The earliest seat of the amyloid change thus differs from that of the fatty. In fatty infiltration it is the most external portion of the lobule in which the fat first accumulates—that which corresponds with the distribution of the portal vein. (See Fig. 7.) It differs also from that pigmentation of the hepatic cells resulting from mechanical congestion, which takes place in the most central portion, around the hepatic vein. (See "Nutmeg Liver.") Thus in each hepatic lobule three zones may be distinguished:—an external one, which is the chief seat of the fatty change; a central one, which is the chief seat of the pigmentary change; and an intermediate one, which is the chief seat of the amyloid change. These three zones, indeed, may frequently be recognised by the naked eye, the pale opaque external one contrasting strongly with the intermediate one which is translucent, and with the darker central one. In the most advanced stages of the disease, however, both the external and central portions of the lobule may become involved, and the cut surface present an almost uniformly homogeneous appearance.

The amyloid liver is increased in size, often very considerably so; it may be so large as almost completely to fill the abdominal cavity. The enlargement is uniform, and hence the natural configuration of the organ is but little altered. Its weight is increased, and also its specific gravity. Its edge is rounded, the surface is smooth, and the capsule appears tense and stretched. The consistence is firm and elastic. The cut surface is dry, bloodless, smooth, translucent, and waxy-looking, and of a pale reddish-grey or dirty yellow colour. If the change is very far advanced, the tissue may be perfectly homogeneous, all distinction between the individual lobules being lost. In other cases the lobules are distinctly mapped out; they are enlarged, and the external zone may be of an



Paf.

Boyer
Davis

opaque, yellowish-white colour owing to the presence of fat. This association of the fatty and amyloid changes is exceedingly common. Amyloid infiltration does not obstruct the portal circulation, and hence does not cause ascites. It impairs the vitality of the hepatic cells, and thus interferes with the functions of the organ.

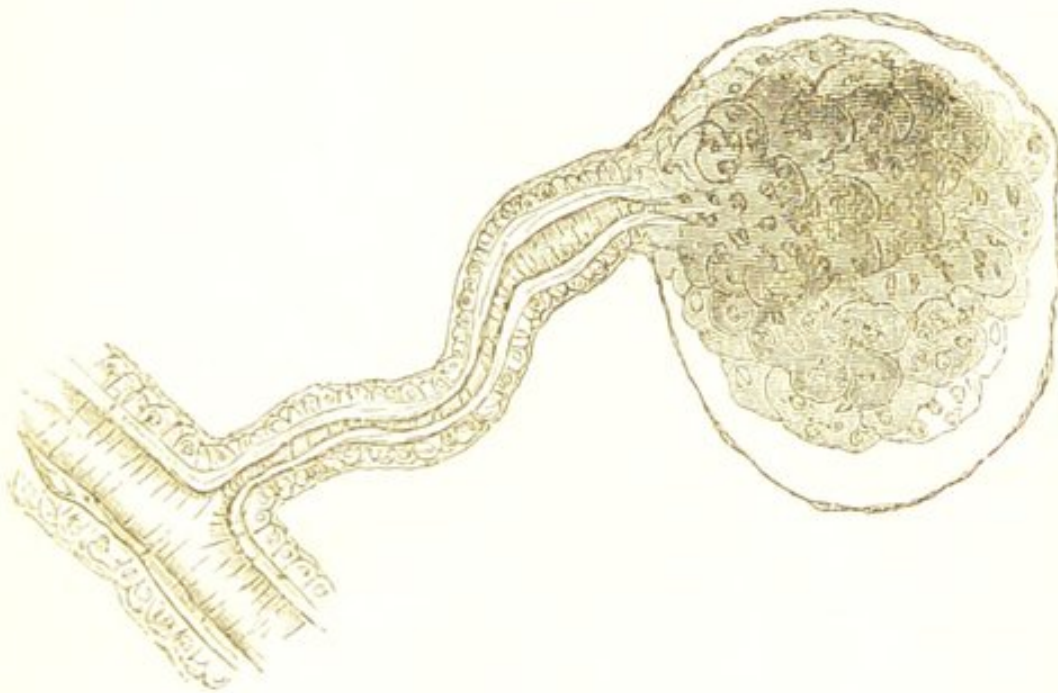AMYLOID DEGENERATION OF THE KIDNEYS.

The kidneys are very liable to be involved in the amyloid change, and here it is the smaller blood-vessels which are more especially affected. It may constitute in them the primary lesion, or it may occur subsequently to inflammatory conditions implicating the secreting and interstitial structures. As a primary change it is an important variety of Bright's disease.

The process commences in the tufts of vessels which form the Malpighian bodies, the walls of which become thickened by the infiltration of the new material, so that the tufts are increased in size. It then proceeds to the small afferent arteries, and ultimately to the vasa efferentia, and to the arteriolæ rectæ which run through the medullary portion of the organ. The changes produced in the vessels are very characteristic. Their walls are considerably thickened and their calibre is so much diminished that the smallest ones cannot be artificially injected. This thickening of the walls of the vessels is mainly owing to alterations in their muscular coat, and especially to the cells of the circular muscular layer. These cells are much increased in size, they are more or less globular in shape, and many of them have lost their distinctive outlines. The longitudinal muscular fibres and the most internal coat of the vessel are often seen as one homogeneous, glistening, structureless layer. (Fig. 17.) After the vessels have become infiltrated, and before those in the pyramids are affected, the deposition extends

to the intertubular tissues of the cortex, into which the amyloid substance is poured, imbedding the tubuli uriniferi in its course. In some parts it appears that the exudation takes place into the tubes themselves as the casts which they contain are occasionally deeply stained

FIG. 17.



Amyloid Degeneration of a Malpighian Tuft and small Artery of the Kidney. Showing the thickening of the walls of the vessel, the enlargement of the cells of the circular muscular coat, and the homogeneous layer formed by the intima and longitudinal muscular fibres. $\times 200$, reduced $\frac{1}{3}$.

by the iodine solution: this, however, is far from being frequently the case. In the earlier stages of the process—if the organ is not the seat of any other morbid change—the tubes and their lining epithelium present a perfectly natural appearance. Many of them contain pale hyaline casts, which also appear in the urine. These, however, are probably simply exudation products; although from the reaction they occasionally exhibit, it appears that they sometimes consist of the same material as that which permeates the vessels and intertubular structures. As the change proceeds, and the new material increases in amount, the tubes become compressed, and in many

places completely obstructed. If the compression is not uniform, they may dilate and form small cysts. The epithelium, which was at first normal, owing to the interference with its nutrition, ultimately atrophies and undergoes fatty changes. In some cases it appears to be the seat of a catarrhal process, and the tubes are found blocked with epithelial products. There is also not infrequently an increase in the intertubular connective tissue.

The first effect of this change is to obstruct the circulation in the cortex. The blood-vessels, diminished in calibre, allow little but the liquor sanguinis to pass through them, the passage of the blood-corpuscles being to a great extent prevented: hence the pallor of this portion of the organ. The arterial walls are so altered that fluids and albumen readily permeate them; and thus is produced the large quantity of urine, loaded with albumen, which characterises the earlier stages of this affection. As the infiltration increases, and the tubes become obstructed, the urine diminishes in quantity. The excretion of urea is less interfered with than in other forms of Bright's disease, and hence symptoms due to its retention seldom occur. Tube casts are rarely numerous; they are for the most part hyaline or finely granular, though sometimes they are covered with fatty epithelium.

In the earlier stages of the affection, the cortex of the kidney is merely rather paler than natural, and perhaps somewhat firmer in consistence; but otherwise it presents no abnormal appearance. It is only upon the application of iodine to the cut surface, or to thin washed sections of the organ, that its diseased condition becomes evident. When this test is employed, the Malpighian bodies at once become apparent as minute red points scattered through the cortex. As the disease advances, the size of the organ increases; the enlargement, however, is principally confined to the cortex. The surface is

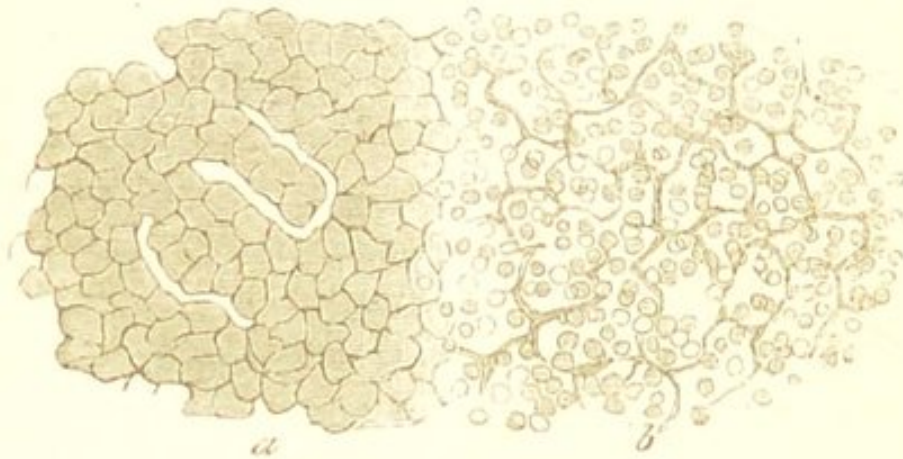
smooth, and the capsule separates readily. The enlarged cortex is remarkably pale and anæmic, and has a peculiar translucent, homogeneous, wax-like appearance. Its consistence is hard and firm. A few scattered vessels may be seen on the surface, and the bases of the pyramids sometimes exhibit an increased amount of vascularity. If iodine be poured over the cut surface, the Malpighian bodies and the arteries of the cortex become mapped out almost as clearly as in an artificial injection. The enlarged Malpighian bodies may indeed usually be seen as glistening points before the iodine is applied. Frequently, the homogeneous appearance of the cortex is interrupted by minute, opaque, yellowish-white lines and markings; these are produced by the fatty changes in the epithelium of the tubes, which so commonly occur in the later stages of the affection. Ultimately, the capsule may become more or less adherent, and slight irregular depressions may make their appearance upon the surface of the organ: the latter are due to atrophic changes in some of the tubes. If, as is not unfrequently the case, the infiltration is associated with an increase in the intertubular connective tissue, the atrophy of the organ will be more marked. (See "Interstitial Nephritis.")

AMYLOID DEGENERATION OF THE SPLEEN.

Amyloid degeneration of the spleen is met with in two forms—one in which the disease is limited to the Malpighian corpuscles ("Sago Spleen"), and the other in which the pulp appears to be chiefly implicated. The former is much the more common condition. In it the Malpighian corpuscles become infiltrated with the amyloid substance and converted into translucent wax-like bodies, much like boiled sago:—hence its name. The process commences in the small arteries of the corpuscle, and it is only after these have become infiltrated that it extends to the corpuscles themselves. The small lymphatic cells of

which the corpuscle is made up are then involved in the process, they increase in size, become more irregular in outline, many of them coalesce, and ultimately the whole is converted into a pale, firm, translucent, glistening mass. (Fig. 18.)

FIG. 18.



Amyloid Degeneration of the Spleen—“Sago Spleen.” A portion of one of the infiltrated Malpighian corpuscles *a*, with the adjacent normal splenic tissue *b*. Showing the increase in size, and in many parts, the coalescence of the cells, of which the corpuscle is composed. $\times 200$.

The sago spleen is more or less enlarged; its weight and density are also increased. The cut surface is smooth, dry, and studded all over with small glistening sago-like bodies, varying in size from a millet to a hemp-seed, which are stained a reddish-brown colour by the iodine solution. These may become so large as to occupy a large portion of the organ, although in earlier stages of the affection they are so minute that they can only be seen in thin sections of the tissue.

In the other variety of amyloid spleen, the pulpy parenchyma between the corpuscles is infiltrated with the new material. This is probably merely an advanced stage of the former condition, in which the disease extends from the corpuscles to the surrounding pulp; the whole organ being ultimately involved. Under these circumstances the organ often attains a considerable size, much larger

than is met with in the sago spleen. It is remarkably hard and firm, and the capsule is tense and transparent. On section it presents a dry, homogeneous, translucent, bloodless surface, of a uniform dark reddish-brown colour. Thin sections can be readily made with a knife, the organ cutting like soft wax. The corpuscles are not visible as in the former variety, being probably obscured by the surrounding pulp, which has become so densely infiltrated with the amyloid substance.

AMYLOID DEGENERATION OF LYMPHATIC GLANDS.

In the lymphatic glands the process much resembles that in the spleen. The small arteries in connection with the follicles of the gland are the earliest seats of the change; and from these it extends to the lymphoid cells. The follicle thus becomes ultimately converted into a small homogeneous mass.

The glands are enlarged, and on section the minute wax-like bodies can often be seen scattered through the cortex. The cut surface is smooth, pale, and translucent.

As these glands are largely concerned in the formation of the blood-corpuscles, their implication in the amyloid change must to a large extent aid in producing the emaciation and anæmia which characterise this affection. The same is true of the spleen, which is usually simultaneously involved.

AMYLOID DEGENERATION OF THE ALIMENTARY CANAL.

The whole of the alimentary tract may be the seat of the amyloid change, and here it assumes an important aspect from the deleterious influence which it exercises upon the absorbent and secreting processes, and from the consequent impairment of the general nutrition which results. The disease, however, in this situation is very apt

to escape observation, as it produces but little alteration in the appearance of the parts. The mucous membrane may look somewhat pale, translucent, and œdematous, but otherwise to the naked eye nothing is discoverable. It is only upon the application of iodine to the washed mucous surfaces that the nature of the change becomes apparent. In the small intestine—which is perhaps the part most commonly affected—the effect of the application of iodine is very characteristic. A number of small reddish-brown points appear over the whole surface of the membrane; these correspond to the intestinal villi, the arteries and capillaries of which are infiltrated with the amyloid substance. In the stomach and œsophagus the vessels are mapped out in a similar manner by the iodine solution. The change in the intestine gives rise to serous diarrhœa, this being probably due to an increased permeability of the infiltrated walls of the vessels.

THE CORPORA AMYLACEA.

The corpora amylacea or “amyloid bodies,” so frequently met with in the nervous system, in the prostate, and in other parts, have usually been looked upon as more or less allied to the amyloid substance; there appears, however, with the exception of a certain similarity in their behaviour with iodine and sulphuric acid, to be no connection between them.

They are round or oval bodies, formed of a succession of concentric layers, and are often changed to a deep blue colour by iodine, thus bearing both in their structure and chemical properties the strongest resemblance to granules of vegetable starch. (Fig. 19.) Sometimes, however, the blue is only exhibited after the subsequent addition of sulphuric acid, and thus a resemblance is shown to the amyloid substance. They vary in size from microscopic granules, to bodies which are distinctly visible to the

naked eye; sometimes being as much as one or two lines in diameter. The larger ones are usually formed by the conglomeration of the smaller granules, which are often enclosed by a common envelope.

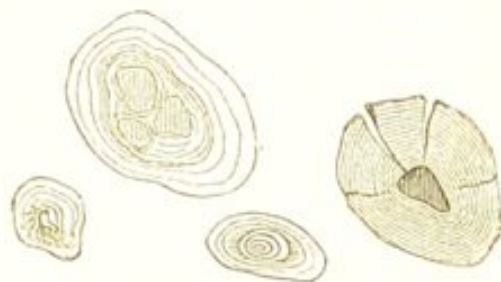
They occur especially in conditions of atrophy or softening of the nervous system; the ependyma of the ventricles, the white substance of the brain, the choroid plexus,

the optic nerve and retina, and the spinal cord, being their favourite seats. The larger forms are met with most frequently in the prostate. The prostate of nearly every adult contains some of these bodies; and they may accumulate here to such an extent as to form large concretions. They are also occasionally met with in the lungs, and in mucous and serous membranes.

As has been said, they usually exhibit a bright blue colour upon the application of iodine alone, although in some cases not until the subsequent addition of sulphuric acid. Many of them, however, are coloured green, or even brown by these reagents. The green is due to their admixture with nitrogenous matters, which give a yellow colour with iodine, and hence the combination yields a green. The greater the amount of nitrogenous matter the more brown does the colour become.

From the laminated structure of these bodies they would appear to be formed by the gradual precipitation of some material, layer by layer, upon the surface of pre-existing particles. The nature of the material, however, does not appear to resemble that of the substance which infiltrates the organs in amyloid degeneration. The two processes are so essentially different, both in the circumstances under which they occur and in the characters and seat of the morbid products, that they cannot

FIG. 19.



Corpora Amylacea from the Prostate. (Virchow.)

be looked upon as in any way analogous. Amyloid degeneration is a general change, in which numerous organs become infiltrated with an albuminoid substance, whereas the formation of the corpora amylacea is evidently of a local nature. The latter is often preceded by those local atrophic changes associated with advanced life, and appears to consist in the deposition of some starch-like material, probably liberated in the tissues themselves, upon any free body which may exist in its vicinity.

The corpora amylacea, especially those occurring in the choroid plexus and in the lateral ventricles, are very liable to become calcified, and they then constitute one form of "brain sand," which is so often met with in these situations.

CHAPTER VIII.

CALCAREOUS DEGENERATION.

CALCAREOUS Degeneration—or, as it is more commonly called, *Calcification*—consists in the infiltration of the tissues with calcareous particles. Physiologically, an infiltration of calcareous particles takes place in the formation of bone, in which lime and magnesian salts are deposited in the fibrous or cartilaginous matrix. This physiological is precisely similar to the pathological process. It is important, however, to distinguish simple calcification from ossification. In the latter there is not only a deposition of lime salts, but an *active* change in the tissue itself—a proliferation of the cellular elements, an intimate union of the calcareous matters with the tissue, and the formation of a true osseous structure in which the calcareous particles are not visible. Calcification, on the other hand, is a purely *passive* process, there is no increased nutritive activity of the part, no multiplication of elements, no alteration of the structure, but merely an infiltration with calcareous particles.

An infiltration and deposition of calcareous substances occurs under two opposite conditions; one—in which there is an absolute increase in the amount of these constituents in the blood, and a portion of the excess becomes deposited in the tissues; the other—in which there is no such increase, but the deposition takes place owing to some alteration in the tissue itself.

An absolute increase of the saline constituents in the blood, and the deposition of the excess in the tissues, is much the less frequent form of calcification. It occurs in some forms of softening of bone, especially in extensive caries and osteomalacia. In these diseases the lime salts are removed from the bone, returned into the blood, and some of them deposited in other tissues. In such cases the calcification is usually more or less general—many organs being simultaneously involved. In osteomalacia, it is not uncommon to find the kidneys, the lungs, the stomach, the intestines, and even the dura mater and liver, infiltrated to a greater or less extent with lime salts. The deposition commences in the tissue immediately surrounding the blood-vessels from which the calcareous matters are derived;—thus, in the lungs, the seat of the change is the interlobular tissue; in the stomach, the stroma between the glands; and in the kidney, the tubuli uriniferi and the intertubular tissue. Precisely analogous to this form of calcification is the deposition of the excess of urate of soda which takes place in gout.

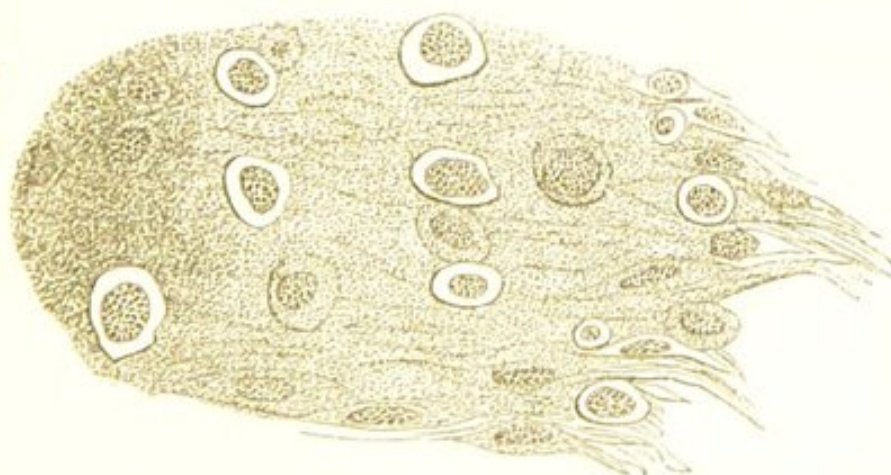In the great majority of cases, however, calcification is a *local* change, depending not upon any alteration in the composition of the blood, but upon changes in the tissues themselves, owing to which some of the saline matters which are normally held in solution in the blood are deposited in them. The alteration in the tissues consists in some impairment of their nutrition, associated with a diminution in their amount of blood, and a retardation of its circulation. All those conditions which tend to produce atrophic and retrogressive changes in a part, and at the same time to interfere with the circulation in it, are liable to be followed by its calcification. Inflammation, rapidity of growth, diminished nutritive supply, and general impairment of vitality, may all of them give rise to this process. This is seen in the calcification of atheromatous arteries, of caseous masses in the lungs

and lymphatic glands, of many new formations, and of the blood-vessels and cartilages in old people. In its morbid antecedents calcification thus somewhat resembles fatty degeneration, and its pathological signification is in many cases equally difficult to determine. Fatty degeneration indeed very frequently precedes the calcification, which is merely a later stage of the retrograde process.

Respecting the cause of the deposition of the calcareous substances in the atrophied structures—it is probably partly owing, as stated by Rindfleisch, to the stagnation of the nutritive fluids in the part, owing to which the free carbonic acid which appears to hold the salts in solution, escapes, and they are consequently precipitated; and partly to the non-assimilation of these fluids by the degenerated elements of the tissue.

The calcareous particles make their appearance both within the cells and in the intercellular substance; they are much more frequent, however, in the latter situation. They are seen at first as fine molecules scattered irregu-

FIG. 20.



A Calcified Sarcomatous Tumour. Showing the minute calcareous particles scattered through the intercellular substance. To the left of the figure they are so abundant as to almost completely obscure the cells. $\times 200$.

larly through the intercellular substance. (Fig. 20.) They are characterised, when viewed by transmitted

light, by their opacity, dark black colour, and irregular outline, and also by their solubility in dilute mineral acids. They gradually increase in number until ultimately large tracts of tissue may be converted into an opaque calcareous mass, in which the cells are enclosed and can no longer be recognised. These larger masses have a sharp black irregular outline, and when the calcification is complete, acquire a homogeneous, glistening, semi-transparent appearance. The cells themselves are much less frequently infiltrated, being usually merely enclosed and obscured by the calcified intercellular substance. Calcareous particles may, however, make their appearance in the cell-contents, and gradually increasing convert the cell into a homogeneous calcareous body.

The calcareous matters consist for the most part of lime and magnesian salts, especially the phosphates and carbonates. If the latter are present, the addition of a little dilute hydrochloric acid is followed by the appearance of numerous minute air bubbles in the tissue, owing to the liberation of carbonic acid. In those cases in which calcification is associated with retained gland secretions, the calcareous matters will consist of the specific gland salts.

A part which has become calcified undergoes no further change, its vitality is completely destroyed, and it remains as an inert mass. In this respect calcareous differs from fatty degeneration. In the latter, subsequent changes invariably take place; the part either softening, caseating, or becoming the seat of calcification itself. It differs also in its effect upon the tissue. The structure of the affected part is not destroyed, and there is no annihilation of histological elements, such as occurs in fatty degeneration. The tissue is simply impregnated with calcareous matters, which have no other effect upon it than to render it inert; its vitality is destroyed, but its structure—in so far as the calcification is concerned—remains unaltered. If the

saline matters are dissolved out with a little dilute mineral acid, the structure of the part may be again recognised, unless, indeed—as is often the case—it has been destroyed by any antecedent change.

Calcification must thus be looked upon in many cases as a salutary lesion, the impregnation with calcareous matters preventing subsequent changes in the part. This is especially the case when it is secondary to other forms of degeneration. It is the most favourable termination of the large class of fatty changes, as is exemplified by the calcification of many inflammatory products, and of many new formations. It may, on the other hand, under certain circumstances, be attended with most deleterious consequences, as is the case when it affects the arterial system.

CALCIFICATION OF ARTERIES.

Calcification of arteries, like fatty degeneration, may be a *primary* or *secondary* affection. As a secondary change it constitutes one of the terminations of the atheromatous process, and as such is constantly met with in the aorta and its branches, and in many other situations. (See “Atheroma.”)

Primary calcification is much less frequent than that which occurs in atheromatous vessels. It is essentially a senile change, and is the result of that general impairment of vitality which exists in advanced life. It is associated with atrophy of the arterial tissues, and in some cases with fatty degeneration. As it is greatly dependent upon general malnutrition, the change is a more or less general one, and when occurring in one part is met with in others. It usually occurs in vessels of medium size, the arteries of the upper and lower extremities and of the brain being those most commonly affected. Its most common seat is the middle coat, where it commences in the muscular-fibre cells. The calcareous particles make their appear-

ance at first around and within the nucleus, and gradually increase until they fill the cell, which becomes converted into a small calcareous flake. The process may go on until the muscular coat is completely calcified, or it may be limited to isolated portions of the coat, giving rise to numerous calcareous rings and plates which are irregularly distributed throughout it. From the muscular, it may extend to the external and internal coats until ultimately the vessel becomes calcified throughout.

The vessel thus calcified, loses its elasticity and contractility; its lumen is diminished, and it is transformed into a hard, rigid, brittle tube. This condition is exceedingly common in the external iliac and in the vessels of the lower extremity, where it is a frequent cause of senile gangrene. (See "Senile Gangrene.")

CHAPTER IX.

PIGMENTARY DEGENERATION.

PIGMENTARY Degeneration, or Pigmentation, consists in an abnormal formation of pigment in the tissues. All true pigments are derived from the colouring matter of the blood. Physiologically, many of them are eliminated by the kidneys and liver; others are deposited in the tissues, and there remain permanent. The choroid coat of the eye and the skin of the negro, are well-known examples of tissues in which there is this permanent accumulation of pigment. The cells in these situations appear to be endued with a special power to abstract the colouring matters from the blood, and to store them up in their interior, where they undergo certain chemical changes and become converted into pigment.

In the pathological process also, the pigment is derived from the same source, although its presence in the tissues is rarely dependent upon any abnormal secreting powers in their cellular elements, but is usually the result of certain changes in the circulation or in the blood-vessels, owing to which the colouring matter of the blood escapes and infiltrates the surrounding parts. This escape of hæmoglobin may be owing to rupture of the vessels themselves, or to conditions of congestion or stasis in which the blood-corpuscles and liquor sanguinis pass through their walls. In either case the hæmoglobin will

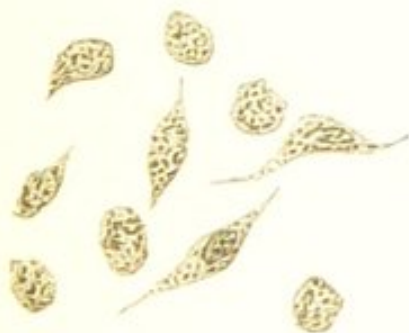
permeate the tissues and ultimately be converted into pigment. Rupture of the vessels and the direct extravasation of blood, is, however, the most common antecedent of the pigmentary change. Soon after the extravasation has taken place, the hæmoglobin escapes from the red blood-corpuscles, either by exudation or by destruction of the corpuscle, and mixed with the liquor sanguinis, infiltrates the surrounding tissues. In other cases it escapes without any solution of continuity in the walls of the vessel. This frequently occurs in conditions of inflammatory stasis and mechanical congestion, in which serous exudation takes place into the tissues, and the hæmoglobin is liberated from the blood-corpuscles within the vessels, from which it transudes, dissolved in the liquor sanguinis. Lastly, the red corpuscles themselves may pass through the walls of the capillaries without rupture having taken place. In whichever of these ways the solution of hæmoglobin is derived, it infiltrates the tissues, staining both the cells and the intercellular substance a yellowish or brownish-red colour. It is taken up, however, more readily by the cells than by the intercellular substance or by membranous or fibrous structures; and it stains only the protoplasm, the nucleus and cell-wall remaining unaltered.

After the colouring matter has remained for some length of time in this diffuse form, it undergoes certain changes:—it becomes darker and more or less granular, minute reddish-brown or black granules and crystals make their appearance both in the cells and in the intercellular substance, and these may gradually increase and form larger masses. This change in the extravasated hæmoglobin is a chemical one, and the substance into which it is converted is *hæmatoidin*. Hæmatoidin appears to be closely allied to the colouring matter of the bile, *cholepyrrhin*, which is also a derivative of hæmoglobin. It exhibits similar reactions when treated with concentrated mineral acids, dis-

playing the same variations of green, blue, rose, and yellow colours. It is insoluble in water, alcohol, ether, and in dilute mineral acids and alkalies; it is soluble in the caustic alkalies giving a red colour. It contains more carbon than hæmoglobin; and it also contains iron.

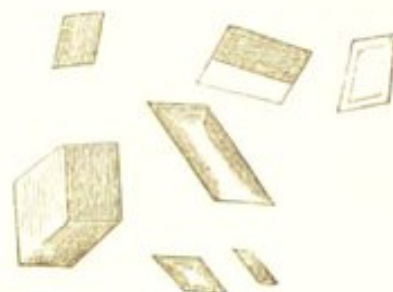
The granules of hæmatoidin vary in size from the smallest particles to masses as large as a red blood-corpuscle. The larger ones are round, or more commonly irregular in shape, and have a sharp defined border. Their colour varies from yellow, red, and brown, to black. These variations appear to depend upon the age of the granules and the tissue in which they are formed; the older they are the blacker they become. The smaller granules are usually dull and opaque; the larger ones, however, often present a more or less glistening appearance. (Fig. 21.) The crystals of hæmatoidin are oblique

FIG. 21.



Cells containing pigment.
From a melanotic sarcoma of
the liver. × 350.

FIG. 22.



Hæmatoidin crystals.
(Virchow.)

rhombic prisms, usually of a beautiful yellowish-red or ruby-red colour, sometimes approaching to brown or black. They may also occur as little plates and fine needles, but these are less common forms. (Fig. 22.) They are in most cases so small that considerable care is required to recognise their crystalline nature under the microscope, and they may easily be overlooked as merely irregular granular masses. In some cases, however, they

attain a larger size. They are more or less transparent, and present a shining strongly refracting surface.

Whether the hæmoglobin is converted into granular or crystalline hæmatoidin appears partly to depend upon the tissue in which it is situated, the crystals being exceedingly common in some situations, as in the brain and ovaries, whereas in others, as the lungs, only the granules are met with. Both the granules and crystals are characterised by their durability and by their great powers of resistance; when once formed they undergo no further change.

Those forms of pigment—both granular and crystalline—which are of an intensely black colour, have been supposed to consist of a substance which differs in chemical composition from hæmatoidin, and which has been called *melanin*. There appears, however, to be no foundation for such a distinction. Melanin is probably merely hæmatoidin, which has become more or less altered by age. It is endued with greater powers of resistance, being less readily soluble in reagents than the more recently formed hæmatoidin.

Pigmentation, although one of the most common and universal forms of degeneration, is of comparatively little importance as a morbid process. The mere existence of pigment within and between the histological elements of the tissues, has in itself but little influence upon their vitality and functions. The atrophy and impairment of function which so frequently accompany it, must rather be looked upon as the result of those conditions upon which the formation of the pigment depends, than as in any way owing to the presence of the pigment itself.

As evidence of other antecedent conditions, pigmentation assumes a more important aspect. The pigment being derived from extravasated hæmoglobin, in whatever situations it occurs, it is usually to be looked upon as the result of some alteration in the circulation or in the blood-vessels.

owing to which the escape of the colouring matter is permitted. Exceptions to this exist, however, in the case of certain pigmented new formations, in which the presence of the pigment appears to be mainly owing to the selective power of the cells; these, like those of the choroid, separating the colouring matter from the blood. It is those growths which originate in tissues normally containing pigment, as the choroid and rete mucosum, which are most frequently melanotic. (See "Melanotic Sarcoma.") In Melanæmia, again, the large quantities of pigment which exist in the blood, are the result of a local formation—for the most part by the spleen. Lastly, in Addison's disease, the pathology of the pigmentation of the skin is at present involved in obscurity.

Pigment is often the only evidence of a former extravasation. This is frequently the case in cerebral hæmorrhage, where the crystals of hæmatoidin may be all that remains to indicate that rupture of the capillaries has taken place. In the ovaries, also, the slight hæmorrhage which follows the escape of the ovum at each menstrual period, is marked by the formation of pigment which constitutes the "corpus luteum." In mechanical congestion and inflammation, again, the consequent pigmentation may be the principal evidence of the former existence of these conditions: this is especially seen in pigmentation of the mucous membrane of the stomach and intestines. The formation of pigment is thus, with the few exceptions above named, the result of some antecedent change in the blood-vessels or circulation; and its presence in the tissues appears to be little more than a testimony to the existence of those processes upon which its formation depends.

FALSE PIGMENTATION.—There are certain forms of discoloration of the tissues which are not due to the presence of hæmatoidin: these must be distinguished from true pigmentation. The most important of them, and that

which is most closely allied to the process already described, is the staining of the tissues with the colouring matter of the bile, which is itself a derivative of hæmoglobin, and is, as before stated, very analogous to hæmatoidin. This yellow staining may affect nearly all the tissues, constituting "jaundice;" or it may occur in the liver alone, from local obstructions to the small bile-ducts, as is often seen in cirrhosis of that organ. In these cases, however, there is merely the staining of the tissues with the colouring matter of the bile, and no subsequent conversion of this into pigment.

The discoloration caused by the long-continued use of the salts of silver must also be distinguished from true pigmentation: the colour here is due to the deposition of the silver in the tissues. The black colour of gangrenous parts, and that sometimes produced by the effusion of large quantities of blood into the tissues, must again not be confounded with pigmentation. The discoloration in these cases is the result of the action of the sulphuretted hydrogen upon the colouring matter of the blood. The greenish-black discoloration so often seen on the surface of the liver, kidneys, and other abdominal organs after death, is in the same manner due to the intestinal gases. Lastly, the minute particles of inhaled carbon which are always met with in the lungs, must be distinguished from true pigment.

PIGMENTATION OF THE LUNGS.

In no organs is pigment met with so frequently and in such large quantities as in the lungs, and here much discussion has arisen as to its nature and origin. The lungs normally contain more or less black pigment, the amount of which gradually increases with advancing age—the lungs of infants and young children being almost free from it, whereas those of adults invariably contain it in considerable quantities.

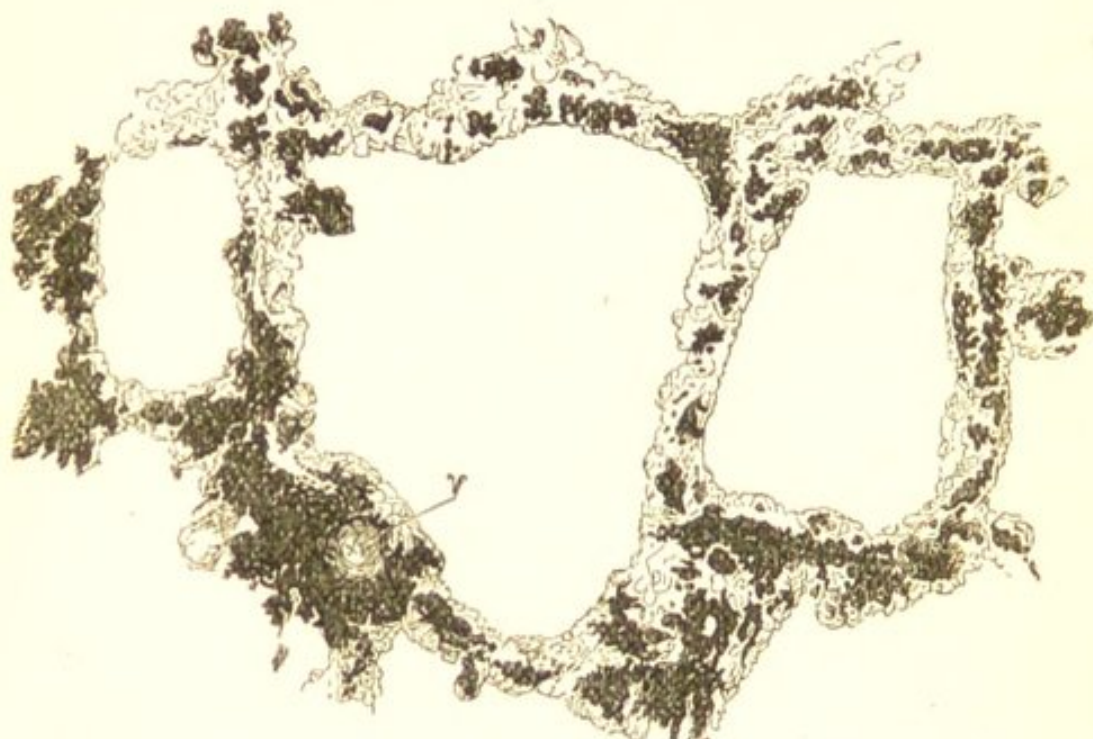This normal pigmentation of the lungs is principally due to the presence of carbon, and not to that of true hæmatoidin-pigment. The carbon—which is derived from the incomplete combustion of wood, coal, and other substances, and is always present in varying quantities in the atmosphere—is inhaled, and the minute particles pass into the finest bronchial tubes. Having entered the bronchi, many of them are taken up by the mucus-corpuses, where they may be seen as small black granules within the cells. These may readily be observed in the cells of the greyish-black sputum which is so frequently expectorated in the early morning. Much of the carbon thus inhaled is eliminated by expectoration; many of the particles, however, pass into the air-vesicles, and here their removal by this means being less readily effected, they gradually penetrate the pulmonary substance, and make their way into the alveolar walls and interlobular tissue. It is in these situations that most of the pulmonary pigment is found, and there it may be seen either within the connective tissue-cells, or lying free amongst the fibres. (Fig. 23.)

The means by which the particles of carbon penetrate the walls of the air-vesicles, and make their way into the inter-alveolar tissue has quite recently been explained by the researches of Dr. Klein on the histology of the lungs.* Dr. Klein finds that the branched connective-tissue cells of the alveolar walls send a process, or a greater or less portion of their body, between the epithelial cells of the alveolus into the alveolar cavity. As these connective-tissue cells lie in the serous canals which constitute the commencement of the perivascular lymphatics, it is easy to understand how these openings in the alveolar walls (pseudostomata) may become sufficiently distended to allow

* "On the Anatomy of the Lymphatic System of the Lungs," by Dr. E. Klein. "Proceedings Royal Society," No. 149. 1874.

cells and other substances to pass through them from the alveolar cavity into the inter-alveolar tissue.

FIG. 23.



Pigmentation of the Lung. From a woman, æt. sixty-five, with slight emphysema. Showing the situation of the pigment in the alveolar walls, and around the blood-vessel *v.* $\times 75$.

When once the carbon has made its way into the interlobular tissue, some of it is taken up by the fixed cells in this situation, whilst that which is not thus detained, passes on to the lymphatics, and is deposited in the bronchial lymphatic glands, where the black particles are also visible.

Closely allied to this physiological pigmentation of the lung from the inhalation of carbon, are those morbid conditions which result from the inhalation of particles of coal, stone, iron, and other substances,—of which the lungs of miners, stonemasons, and grinders afford frequent examples. Here also minute particles enter the bronchi, penetrate the walls of the alveoli, and are deposited principally in the interstitial tissue. In the case of miners—in which this is most common—the particles of coal enter the lungs in such large quantities as

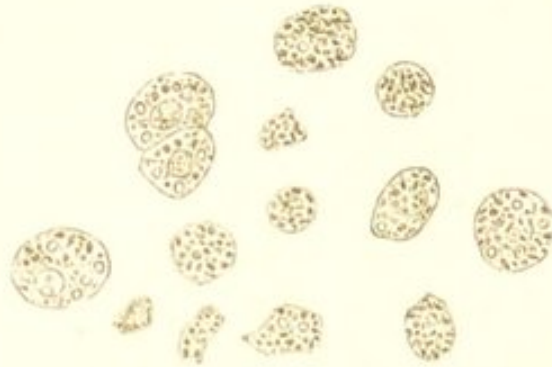
to give to them a uniform dark black colour. In stonemasons, grinders, &c., the lungs also become deeply pigmented, although to a less extent than those of miners.

The black colour of the lungs in these cases, however, is not entirely due to the presence of the inhaled substances, but partly to that of true hæmatoidin-pigment. The inhalation of the irritating particles sets up inflammatory changes in the bronchi and pulmonary tissue, causing chronic bronchitis, chronic lobular pneumonia, and a large increase in the fibrous tissue of the lungs, which thus ultimately become consolidated, excavated, tough, and fibrous. ("Colliers" and "Knife-grinders' Phthisis," &c.) Owing to these structural changes there is a considerable escape of colouring matter, either from rupture of the capillaries or transudation of serum, and hence a large formation of true pigment; and to this true pigment much of the dark colour of these lungs must undoubtedly be ascribed. The lungs of stonemasons and grinders are, like those of miners, deeply pigmented, although to a less degree, but the black colour in the former cases cannot be entirely accounted for on the supposition that it is due to the presence of inhaled particles.

Pigmentation of the lungs from the presence of hæmatoidin occurs as the result of many other morbid conditions, many diseases of these organs being attended by the formation of pigment. In chronic phthisis, pigmentation occurs, partly as the result of the inflammatory process, and partly from the obstruction of the vessels caused by the new growth:—lines of pigment are constantly seen surrounding the nodules of consolidation. In acute croupous pneumonia, the blood which is extravasated into the air-vesicles, and which in the early stages gives to the expectoration a rusty or prune-juice colour, subsequently becomes converted into pigment, and the sputum becomes of a greyish-black; the pigment granules

being visible in the newly-formed cells. The cells met with in the sputum of bronchitis also contain granules of pigment (Fig. 24); and pigmentation plays an important

FIG. 24.



Cells from the sputum of acute Bronchitis. Showing the minute granules of pigment within the cells. Some of the cells also contain a few fatty molecules. $\times 400$.

part in the condition of the lungs known as brown induration. (See "Brown Induration of the Lungs.")

Pigment in the lung usually occurs as black irregular granules; it is rarely met with in a crystalline form. In all cases in which it is found in any quantity in the lung it is also found in the bronchial glands. It is taken up by the lymphatics and, like the inhaled carbon, it becomes arrested in its passage through these glands, where it remains permanently.

CHAPTER X.

TISSUE-CHANGES IN PYREXIA.

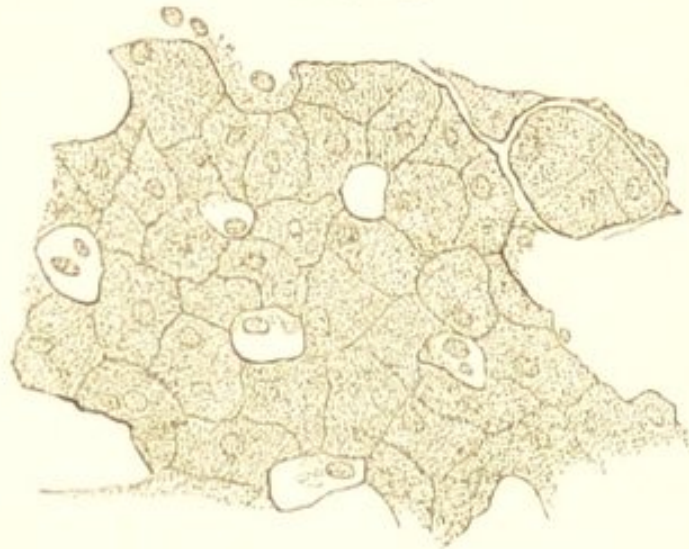It is proposed in the present chapter to allude very briefly to those alterations in the tissues which are met with in certain pyrexial diseases, to which have been applied the terms "parenchymatous" or "granular degeneration," "acute" or "cloudy swelling."

It is well known that in most diseases which are accompanied by a considerable elevation of the bodily temperature, and especially in those in which the blood has undergone marked changes, the organs and tissues are found much altered after death. The diseases in which such alterations are most frequently met with are pyæmia, erysipelas, typhus, typhoid, and other acute specific fevers, and acute rheumatism. They also occur in other diseases which are attended by considerable pyrexia; and the amount of tissue-alteration usually bears—*cæteris paribus*—a direct relation to the amount of the pyrexia. The organs in which the alterations are more especially marked are the liver, the kidneys, the heart and muscles, and the lungs.

The physical characters of the altered organs vary. It may, however, be stated generally that the organs are more or less swollen and opaque, somewhat diminished in consistence, and abnormally friable. Their vascularity is in some cases diminished, in others slightly increased. When examined microscopically, the cellular elements are

found to be increased in size, and their protoplasm markedly granular, so that, in some cases, the nucleus is so much obscured as to be indistinguishable. (Fig. 25.)

FIG. 25.



Liver from a case of Acute Rheumatism with high Temperature. Showing the swollen and granular condition of the liver-cells. In many of the cells the nucleus is so much obscured as to be almost indistinguishable. $\times 200$.

The granular condition of the protoplasm appears in most cases to be due to albuminous particles, inasmuch as it disappears upon the addition of dilute acetic acid. In other cases, however, in which the change is apparently more advanced, the granules are larger, insoluble in acetic acid, and obviously fatty.

The Liver.—Here the change is usually met with in its most marked degree. The organ is slightly enlarged, abnormally soft and friable, and the cut-surface has a dull opaque look, being paler than natural. The liver cells are swollen and granular, and in many cases contain fatty particles. (See Fig. 25.)

The Kidneys.—In the kidneys the change affects especially the cortex. This is swollen, opaque, and friable. The Malpighian bodies and the pyramids are usually abnormally vascular, and thus contrast with the pale

cortex. The epithelium in the tubes of the cortex presents the appearances above described. These are precisely similar to those met with in the earlier stages of tubal nephritis. (See Fig. 87.)

The Heart.—The alteration produced in the heart consists in slight opacity, pallor, and diminution in the consistence of the muscular tissue. Under the microscope the muscular fibres are seen to have lost their distinct striation and to be finely granular. Such a condition must materially interfere with the contractile power of the organ. A similar change is met with less frequently in other muscles.

The Lungs.—The change in the lungs has been described by Buhl as consisting in swelling of the alveolar epithelium. The epithelial elements are markedly granular from the presence of albuminous and fatty particles, and they become loosened from the alveolar walls. The change affects, more or less, the whole of both lungs. The organs are enlarged, œdematous, and abnormally friable.*

Respecting the nature of the change—nothing is certainly known. Histologically, it is precisely similar to that swollen and granular condition of protoplasm seen in the earlier stage of inflammation, as for example, in the renal epithelium, to which Virchow has given the name of “cloudy swelling.” The change is thus considered by some to be of an inflammatory nature. Other observers, on the contrary, regard it as a passive retrograde metamorphosis. Dr. Wickham Legg produced the change artificially in animals by submitting them to a high temperature, and he, in common with some other pathologists, is inclined to look upon it simply as a result of high temperature. An exact knowledge of its pathology, however, must probably await further accurate experimental inves-

* Buhl, “Lungenentzündung, Tuberkulose, und Schwindsucht.”

tigation. In the mean time, when it is borne in mind that it is especially liable to occur in those pyrexias which are associated with marked alterations in the blood, and that in its extreme degrees the cells undergo fatty metamorphosis, it may be regarded as probable that its occurrence will be found to be due partly to interference with the normal processes of tissue-oxidation, and partly to increased transformation of the protoplasm of the cells. (See "General Pathology of Fatty Degeneration.")

Whatever be the nature of the change, there can be no doubt that it must very materially interfere with function, and that its supervention in the course of acute disease—especially when affecting the heart—must constitute a most important source of danger.

CHAPTER XI.

NUTRITION INCREASED.

THE morbid changes thus far described, have been attended either by *arrest* or by *impairment* of nutrition;—those remain to be considered in which the nutritive activity is *increased*. They include Hypertrophy and the New Formations.

HYPERTROPHY.

Hypertrophy is an increase in the amount of a tissue, owing to an increase in the size, or to an increase in the number, of its histological elements. This increase, however, in order to constitute hypertrophy must affect those elements more especially upon which the peculiar functions of the part depend; in muscle, for example, the muscular fibres, in the kidney—the urine-tubes and blood-vessels.

When this increase in the amount of the tissue is owing simply to an increase in the *size* of the elements of which it is composed, it is termed *simple* hypertrophy; when to an increase in their *number*, and to the formation of a new tissue, *numerical* hypertrophy, or *hyperplasia*. The two forms of hypertrophy are thus comparable with the two forms of atrophy:—in simple hypertrophy as in simple atrophy, there is merely an alteration in the *size*; in numerical—an alteration in the *number* of the elements.

Hypertrophy is in most cases the result of an increase in the functional activity of the tissue, this increased activity being induced by a necessity for some increased manifestation of function; in muscle, for example, in order to overcome some obstruction, in a secreting organ—to secrete more fluid. Such hypertrophies are consequently *conservative* in their nature, and they are usually spoken of as *functional* hypertrophies.

It is in muscular tissue that functional hypertrophy is most frequently met with. Examples of it are furnished by the hypertrophy of the muscles of the calf in ballet dancers; also by the hypertrophy of a hollow viscus from obstruction to the exit of its contents—as of the heart from obstruction at the valvular orifices or in the course of the circulation, of the muscular coat of the stomach in stricture of the pylorus, of the intestine above a permanent stricture, and of the bladder in stricture of the urethra. The kidney also may become hypertrophied, owing to the loss or incapacity of its fellow. In bone, hypertrophy of the fibula has been observed in cases of disease, or ununited fracture of the tibia. In all these cases the necessity for increased activity leads to increased development.

In exceptional cases hypertrophy is not dependent upon an increase in the functional activity of the tissue. It may sometimes result from an increased supply of blood to a part, and there are some forms of hypertrophy which are congenital.

The term “hypertrophy” is also frequently applied to those enlargements of organs which result from long-continued irritation; as to enlargements of the lymphatic glands, of the tonsils, and of the prostate gland. Such growths, however, are some of them inflammatory in their nature, others come more properly within the category of “tumours.”

CHAPTER XII.

THE NEW FORMATIONS.

INCREASED nutritive activity of a tissue—as has been seen in the preceding chapter—leads not only to the enlargement of its component elements, but also to the production of new ones. It is this production of *new elements*, and the various structures to which they give rise, that constitutes the New Formations.

The New Formations comprise both *inflammatory* and *non-inflammatory* growths. Of these, the latter—which include the various kinds of tumours, together with some growths to which the term “tumour” is not strictly applicable—will be considered in the present part of this work, whereas the inflammatory growths will be treated of in the chapters on “Inflammation.”

Tumours—which constitute the greater portion of the non-inflammatory formations—are growths which, having attained a certain size, either remain permanent, or, more frequently, *tend continuously to increase*. In their development and growth they are characterised by their *independence* of the rest of the body; they increase in size by virtue of their own inherent activity, which differs from, and is, to a great extent, independent of that of the surrounding tissues.

There are, however, some non-inflammatory growths which cannot be regarded as “tumours” in the ordinary acceptation of that term. Amongst these, for example,

are the numerical hypertrophies described in the preceding chapter, and the new growth of adipose tissue. The characteristics of syphilitic growths again, and of cancerous infiltrations of organs, differ in some respects from what have been above described as those of tumours.

The inflammatory new formations differ from the non-inflammatory in being caused by some *irritation*, upon the removal of which the process of growth usually ceases. They are characterised by their *instability*; they either rapidly undergo retrogressive changes, or, at the most, form a tissue which in its structure and life is similar to that from which they originated. Their tendency is gradually to approximate to a healthy condition, and, not like that of the tumours, continuously to increase and deviate from the normal type.

Whatever be the nature of the new formation it is always the direct product of the elements of a pre-existing tissue, these elements being in some cases migrated white blood-corpuscles. In order therefore to understand the pathology of the new formations, it is necessary to be intimately acquainted with the histology and mode of development of the normal tissues.

ETIOLOGY OF THE NEW FORMATIONS.*—As the new formations are the result of the increased nutritive activity of the elements from which they originate, it will be readily understood that their causes must for the most part be obscure, and that in many cases all that can be said is, that the new growth is the result of the *spontaneous* activity of the elements from which it springs. Sometimes, however, the causes are either wholly or partially ascertainable. They may be divided into *constitutional predisposing*, and *direct exciting*, causes.

* This, together with the remainder of the present chapter, applies only to the *non-inflammatory* growths.

Constitutional Predisposing Causes.—That many growths owe their origin to some constitutional taint, has long been an universally accepted pathological doctrine. The constitutional cause has frequently been regarded as a general one, as consisting either in some alteration in the constitution of the blood, or in some abnormal condition of the physiological processes throughout the entire organism. It was formerly supposed that many new formations were the result of an exudation from the blood-vessels, and that the elements of the growth were produced spontaneously in the exuded structureless blastema. Such growths were looked upon as the local expression of a vitiated constitution of the blood,—a *dyscrasia*. Although this hypothesis is now universally abandoned, and all new formations are known to originate from pre-existing cellular elements, an alteration in the constitution of the blood or in the performance of the physiological processes throughout the body, is still regarded by many as playing an important part in their causation.

It is the malignant new formations which are thus supposed to owe their origin to the existence of a *general* constitutional taint. These growths are said to be of a *constitutional* origin, in contradistinction to the non-malignant growths which are looked upon as purely *local*. This hypothesis is principally based upon the clinical characteristics of the malignant growths—their tendency to recur after removal, their multiplicity, and the difficulty or impossibility of completely eradicating them.

It is said that the development of malignant growths is frequently preceded by an unhealthy state of the constitution—a cachexia. In the majority of cases of malignant formation, however, there is no evidence of any such cachexia preceding the local growth. The individual is usually in good health at the time of the occurrence of the primary tumour. The general impairment of nutrition and emaciation, which constitute the cachexia, are

secondary to the local growths, and are in direct proportion to their extent and situation:—the more extended the local lesions, the greater the amount of discharge, the more the lymphatics and the digestive organs are involved, the more marked is the attendant cachexia.

The multiplicity of malignant growths is also adduced as an argument in favour of the existence of a general constitutional taint. The fact that malignant growths are frequently multiple, constitutes in itself no ground for such a conclusion. The multiplicity is for the most part a *secondary* phenomenon, the secondary tumours resulting from infection by the primary one. Simple *primary* multiplicity is not so characteristic of malignant as of many other tumours—the lipomata, fibromata, sebaceous tumours, and warts, are all more often *primarily* multiple than cancer. Multiplicity in many cases is evidence rather of a *local* than of a general taint. In scrofula, for example, the lymphatic glands generally are prone to become the seats of new growth, and tumours are often multiple in bone without occurring in other tissues. In such cases there would appear to be a *local* rather than a *general* cause.

The recurrence of the malignant growth after removal at the seat of the operation, may again be owing to the removal having been incomplete, some of the proliferating elements of the growth having been left behind. The cellular elements of malignant tumours often extend into the adjacent tissues for some distance beyond the apparent confines of the tumour, and as the physical characters of the infiltrated tissues differ in no way from those of the healthy, there are no means of certainly determining how far wide of the tumour the incision must be carried in order to include the whole of the affected structures. (See “Malignancy.”) A tendency to local recurrence is a property possessed by many growths, and it can be ex-

plained on local grounds without the necessity of admitting the existence of a general taint.

Lastly, the fact that malignant growths are usually followed by the development of similar growths in the lymphatic glands and in internal organs, may in most cases be more readily explained—as will be seen when speaking of “malignancy”—by regarding these as the result of infection by the primary tumour, than by ascribing them to the existence of a common constitutional cause.

The reasons already adduced in a preceding chapter (see “Introduction”), for considering all changes in the constitution of the blood as secondary to local causes, would appear of themselves to be sufficient to render untenable the hypothesis of a *primary* blood dyscrasia. Any abnormal condition of the blood which may be associated with the development of malignant tumours must probably be regarded as resulting either from the absorption of deleterious substances, from the entrance into it of the elements of the growth, from the drain of an attendant discharge, or from interference with the processes of digestion, assimilation, or secretion, or with the formation of the blood itself. At the same time it must be borne in mind, when discussing the possibility of the development of malignant growths being the result of a “blood-disease,” that the emigration of white blood-corpuscles may play some part in the process. How far this is the case, as will be seen hereafter, we are at present unable to determine. We know that this emigration constitutes a prominent feature in the process of inflammation, and if future researches should show that it also occurs in the development of malignant new formations whilst in those which are non-malignant it is entirely wanting, it would go far towards rendering the existence of a malignant dyscrasia beyond dispute. In the present position of our knowledge, however, in which it is *only probable* that an

emigration of leucocytes may play some part in the development of all new growths, both innocent and malignant, any argument in favour of the existence of a blood-dyscrasia as the cause of the development of the latter based upon such considerations would be unjustifiable. If an emigration of leucocytes does take place, it is more in accordance with facts and with the general history of malignant growths to suppose the existence of some peculiarity in the tissues into which the elements escape which determines their special development.

Although there would thus appear to be no necessity to admit the existence of a general constitutional cause in order to explain the clinical characters which constitute malignancy, there can be no doubt that many growths, both innocent and malignant, have a constitutional origin. The possibility of the existence of such a constitutional cause must therefore be borne in mind in accounting for the development of secondary malignant growths, as although these may result from infection, they may also owe their origin to the same causes as those which induced the primary one. Whether the constitutional cause is a *general* one—consisting in some specific peculiarity of the entire organism, or whether it is *local* in its nature, and consists in some constitutional peculiarity of the tissues from which the new growths originate, some peculiarity which renders them more prone than other tissues to undergo abnormal development, is unknown; although the latter supposition seems to be the more probable one.

The influence of hereditary predisposition upon the occurrence of many growths, appears to point to the existence at a *local*, rather than to that of a *general* constitutional taint. In scrofula, for example, which is a markedly hereditary disease, the tendency of the lymphatic glands to undergo excessive development from very slight degrees of irritation, is probably to be regarded as owing

to a predisposition of the glands themselves, and not to any *general* constitutional state. The same is probably true of many other constitutional tendencies. Nævi, tumours of the skin, uterus, mammæ, stomach, and of other parts, are again all unquestionably sometimes hereditary; and here also the tendency would appear to consist in a predisposition of the tissues themselves to become the seats of new formations.

The tendency sometimes observed in *particular* tissues to generate new formations, points again to a local cause. The osseous system, for example, may be the seat of new growths—tumours occurring in nearly all the bones, and not being met with in other parts. Tumours may in the same way be multiple in other tissues.

Direct Exciting Causes.—The existence of a direct exciting cause is more capable of demonstration than a constitutional one. It consists either in some direct irritation of a tissue, which is by this means stimulated to increased development; or in the migration or transmission of elements from some primary growth, which by proliferating themselves, or causing proliferation, in the tissues in which they lodge constitute the centres of secondary formations.

The direct irritation of a tissue may be owing to mechanical or chemical irritants. Simple mechanical or chemical irritation can, however, under no circumstances be the *only* cause of the development of the growth. The effect of such irritations alone, is to cause an inflammatory formation; in order for them to produce a non-inflammatory one—a tumour, there must be some special predisposition of the tissue itself:—the irritation can merely *determine* its development. The influence of simple irritation in the production of new formations is exemplified by the frequent occurrence of epithelioma on the lips of smokers, from the irritation of the pipe; and on the penis and scrotum of chimney-sweepers, from the

irritation of the soot ("chimney-sweeps' cancer"). The numerous recorded instances of the development of a tumour following some external violence or injury, leave little doubt that these also sometimes stand to one another in the relation of cause and effect. Lastly, as pointed out by Virchow, it is those organs which are the most exposed to irritation from external causes, as the stomach, the uterus, the mammary-gland, and the rectum, which are especially liable to become the seats of new growths.

The influence of elements, which have either migrated or been conveyed from their original habitat, in causing the development of new formations is exemplified by the history of malignant tumours. It is by this means that the secondary tumours most frequently originate. The elements, which either migrate spontaneously from the primary growth, or are carried by the blood or lymph streams, may proliferate in the tissue in which they lodge, and so develop into secondary formations.

In other cases it is also exceedingly probable, as pointed out by Dr. Creighton,* that the elements (either cells or minute particles) which are transmitted from the primary tumour cause the production of secondary tumours by virtue of an influence on the cells of the tissue where they lodge, which may be termed a *spermatic influence*, and which is strictly comparable with that of the sperm-cell in the ovum. In such cases the relation of the primary to the secondary tumour is that of parent to offspring. This subject will be again alluded to when speaking of "*Malignancy*."

DEVELOPMENT.—In studying the development of the new formations, it is important, in the first place, to bear in mind what has been already stated—viz., that they are in all cases the direct product of pre-existing cellular

* Discussion on Cancer, "Trans. Path. Soc. Lond.," 1874, p. 368.

elements. In their development they also resemble the normal tissues:—every pathological growth has its physiological prototype.

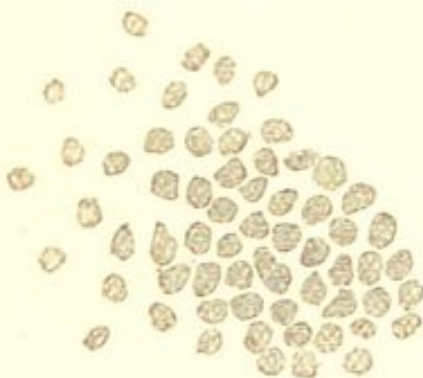
The elements from which new growths most frequently originate are those belonging to the *common connective tissue*, and to the blood-vessels and lymphatic system with which it is so intimately associated. By common connective tissue is meant that tissue which in all parts surrounds the blood-vessels, and is so universally distributed throughout the entire organism. This must be carefully distinguished from the formed connective substances—tendon, cartilage, bone, &c. In this common connective tissue we distinguish two kinds of cells—the stable cells (connective tissue corpuscles), and the mobile cells, which are probably wandering white blood-corpuscles. These cells are in intimate relation with the endothelium of the lymphatics, the latter vessels commencing as serous canals which are universally distributed in the tissue. Further—both the endothelium of the lymphatics and that of the blood-vessels closely resemble in their physiological functions the fixed cells of the connective tissue.

In the process of development of new growths from this common connective tissue, the part which is played by the different cellular elements cannot in our present state of knowledge be certainly stated. It is, however, probable that it is the mobile cells which are principally concerned. These cells are the most active, and consequently the most capable of multiplying by division. It is equally probable that the number of these mobile cells is materially increased by an abundant emigration of white blood-corpuscles from the vessels. Respecting the fixed connective tissue cells and the endothelium of the blood-vessels and lymphatics—it must be admitted that these, although perhaps inferior in their formative powers, also undergo active changes, and thus increase the number

of the newly-formed elements. In the case of these fixed cells, the process of cell-formation is probably very frequently effected by means of vacuolation and endogenous development (see Fig. 2); and, as was stated when describing the "genesis of cells," elements which thus originate endogenously have, for the most part, a destiny different from that of the parent cell.

Whatever be the part played by the respective elements in the process of development of the new growth, the first result of their combined activity is to produce a new tissue, composed of innumerable small roundish-shaped cells, from $\frac{1}{1500}$ to $\frac{1}{2500}$ of an inch in diameter, often enclosing a large, round, ill-defined nucleus, which usually only becomes visible after the addition of water or of acetic acid. These cells, which are usually known as *indifferent* cells, possess no limiting membrane, but consist of little masses of protoplasm which are almost in close contact with one another. (Fig. 26.) They are indistinguishable from the cells of a granulation, and from

FIG. 26.



Embryonic ("Indifferent") Tissue from the Edge of a Sarcomatous Tumour. × 350.

many of those met with in the rapidly-growing connective tissue of the embryo. In some cases the protoplasm continues to increase and the nuclei to divide without any subsequent division of the cell taking place, and thus are produced large irregular-shaped masses of protoplasm containing numerous nuclei. These are the giant or myeloid cells which are met with in the medulla of young bone and in many sarcomatous tumours (see "Myeloid Sarcoma,"

Fig. 33). Thus the first stage in the process of development consists in the formation of an embryonic tissue, and this embryonic tissue subsequently develops into the

tissue of which the new growth is composed. It is often impossible to determine in this early stage of the growth what it will ultimately become—whether a fibroma, a sarcoma, or an enchondroma, &c.

The second stage of the process consists in the development of this embryonic (“indifferent”) tissue into the tissue of the permanent growth, and this subsequent development closely resembles that of the immature connective tissue of the embryo. As from the immature connective tissue of the embryo are developed various connective tissue substances—fibrous tissue, mucous tissue, cartilage, bone, &c.—so may this embryonic connective tissue which constitutes the earliest stage of so many of the pathological new formations, become developed into various tissues, all of which usually more or less resemble the several varieties of the physiological connective tissues. The whole of the primary cells may form the same kind of tissue, in which case the growth will possess the same characters throughout; or it may be complex, some cells forming one kind of tissue and some another. A combination of two or more kinds of structure may thus be met with in the same tumour—as a combination of sarcoma and lipoma, of enchondroma and myxoma, and so on. What determines the ultimate development of the young cells, why they produce such various forms of growths, is as far from our knowledge as what determines the ultimate destination of the cells in the embryo.

Next to common connective tissue, the *epithelia*, surface and glandular, are the elements from which new formations most frequently originate; and as from connective tissue are usually produced growths of the connective tissue type, so do the growths originating from the epithelia usually resemble epithelium. As to whether all new growths originating in connexion with epithelium are solely the offspring of pre-existing epithelial elements, we

are unable to speak with certainty. The answer to this question must await a more certain knowledge of the way in which the epithelial structures normally grow and repair themselves. It appears, however, probable that the normal production of epithelium is not entirely the result of the multiplication of epithelial cells, but that the mobile cells of the connective tissue by *contact* with epithelial elements may become developed into epithelium. It must, consequently, be admitted, at all events as equally probable, that pathological new formations which originate in connexion with epithelium may be in part the product of mobile elements belonging to the connective tissue. The process of development from epithelium may take place either by simple division, or by vacuolation and endogenous growth.

Here allusion must be made to the recent investigations of Dr. Creighton on the development of secondary tumours in the liver.* Dr. Creighton finds that in various kinds of secondary tumour occurring in the liver, the growth originates from the liver-cells by a process of vacuolation and endogenous formation; and he concludes that in this way liver-cells may originate epithelial cells, connective tissue-cells, spindle-cells, &c., the variations depending upon the nature of the primary tumour.

From the remaining tissues, *muscle* and *nerve*, the development of new growths is comparatively rare, and in nerve-tissue it is even doubtful if formative processes ever occur.

According to the similarity or difference which subsists between the new growth and the tissue from which it grows, new formations are divisible into two classes—*homologous* and *heterologous*. When the growth resembles in its structure and development the tissue from which it

* Discussion on Cancer, "Trans. Path. Soc. Lond.," 1874, p. 368.

originates, it is said to be *homologous*; when it differs, it is said to be *heterologous*. A cartilaginous tumour, for example, growing from cartilage, is homologous, but growing from any other tissue, as from the parotid gland, it is heterologous. The same variety of tumour may thus be in one case homologous, in another, heterologous. A purely homologous growth is therefore simply a *hyperplasia*—an excessive growth of a tissue in some particular part; any deviation from the type of the parent tissue constitutes heterology.

Heterology, however, is not limited to the production of a tissue which is dissimilar from that from which it originates; a growth is also said to be heterologous when it differs from the tissue in which it is *situated*, and this may occur without its being the direct product of the latter. It is heterology in this sense that is so characteristic of certain cancers. Those cancers which obviously originate from epithelium, become heterologous owing to the growth and extension of the epithelium beyond its normal limits (see “Epithelioma”). The same form of heterology obtains in the case of growths originating from elements which have migrated or been carried from their original habitat, and have developed into a tissue which differs from that in which they are situated.

Heterology is often an evidence of malignancy. Many heterologous growths, however, are not malignant; slight deviations from the normal type are no evidence of malignancy. A growth primarily homologous may subsequently become heterologous; this is often seen when a long-standing innocent tumour suddenly exhibits malignant characters. A knowledge of the homology or heterology of a growth is therefore an important element in the determination of its innocent or malignant nature.

RELATION OF THE GROWTH TO THE SURROUNDING TISSUES.—The relation of the tumour to the surrounding structures will depend upon its mode of growth. Growth

may take place simply by the continuous proliferation of the cells of which the tumour is composed. In this case it will merely displace the surrounding parts, and having attained a certain degree of development, a fibrous capsule is often formed around it, by which it becomes completely isolated. The lipomata, fibromata, and enchondromata are usually thus encapsuled. In other cases, growth takes place also at the circumference, by the continuous proliferation of the parent tissue. There is then no line of demarcation between the tumour and the matrix from which it grows, so that although to the naked eye it may appear separate, the microscope will discover in the adjacent tissues elements of the new growth. This is very common in the sarcomata and in the cancers, and is a common cause of local recurrence after removal. Lastly, the tumour may increase not only by the proliferation of its matrix, but also by invading other structures:—this occurs in those growths which are the most malignant (see “Malignancy”).

RETROGRESSIVE CHANGES.—The development of the growth being complete, it becomes sooner or later the seat of retrogressive changes. The time at which these commence, varies:—as a rule the permanence and durability of a tumour bear an inverse relation to the rapidity of its growth, and to the inferiority of its organization. The more rapid the growth, and the more lowly organized the tissue formed, the less its durability and the sooner do retrogressive changes occur. The cancers and sarcomata, for example, which develop rapidly and consist for the most part of cells, quickly degenerate; their elements are unstable and soon perish. Osseous tumours, on the other hand, which develop more slowly, and consist of a more highly organized tissue, have a much greater stability, and are but little liable to retrogressive metamorphosis.

The retrogressive changes are similar to those met with

in the physiological tissues. Deficient supply of blood is followed by fatty degeneration and its various terminations—softening, caseation, and calcification. Pigmentary, colloid, and mucoid degeneration may also occur. New formations may also become the seats of an inflammatory process.

MALIGNANCY.—By “malignancy” is understood the property possessed by many tumours of reproducing themselves either locally after removal, or in distant tissues. It is important not to confound the terms “malignancy” and “cancerous.” “*Malignancy*” is a purely clinical term, and although in a high degree the property of the cancers, is by no means confined to them; the sarcomata, for example, being in many cases equally, or even more malignant. The term “*cancer*,” on the other hand, is used to imply a definite structure, and as such is applied to a certain class of new formations.

The malignant properties of a tumour may manifest themselves either in the tissues immediately adjacent to it or in its neighbourhood, in the nearest chain of lymphatic glands, or in more distant parts. Some growths possess these properties in a higher degree than others, so that there are different degrees of malignancy. In many cases the malignancy of a tumour is so far limited that it gives rise merely to a local reproduction after removal. Such tumours have been separately classified by many surgeons as “recurrent” tumours. In other growths this tendency to local reproduction is associated with the development of similar growths in the nearest lymphatic glands; whilst in a third class of cases, to one or both of these conditions is added the reproduction of the growth in more distant tissues, especially in the lungs and liver. It will be advisable to treat of these three degrees of malignancy separately.

1. *Reproduction of the Growth in the Adjacent Structures.*—This is usually the earliest evidence of malignancy

in a growth, and gives rise to its persistent recurrence *in loco* after removal by the surgeon. This tendency to the local reproduction of the tumour is principally owing to its mode of growth. The cellular elements of the tumour extend for some distance into the surrounding tissues, so that unless in the operation for its removal the incision be carried for some distance beyond the *apparent* confines of the growth, some of the elements may be left behind and thus constitute the centres of secondary formations. Such tumours therefore are not usually encapsuled, but extend by peripheral growth. In some cases, however, tumours which possess a distinct capsule may in the same way infiltrate the surrounding structures. The infiltration of the adjacent tissues by the elements of the tumour sometimes gives rise, not only to the continuous enlargement of the primary growth, but also to the development of separate secondary growths in the immediate vicinity of the primary one. Whilst it must be admitted that the reproduction of a malignant tumour in the adjacent tissues is thus in most cases to be ascribed to the infiltration of the latter with its cellular elements, it is possible that the nutrient fluids of the tumour may by their influence upon the surrounding tissues be in part the cause of the abnormal development.

2. *Reproduction of the Growth in the nearest Lymphatic Glands.*—This is owing to the transmission by the lymph-stream of substances (probably cellular elements) derived from the malignant growth, which become arrested in the nearest lymphatic glands, and there cause the development of secondary formations. These are in all cases of the same nature as the primary tumour. When the lymphatic glands have themselves developed into secondary growths, they in their turn constitute new centres of infection, and may thus infect more distant glands or the immediately adjacent tissues. The ten-

dency to reproduction in the lymphatic glands varies very much in the different varieties of malignant growths, being, for example, very marked in the cancers, whereas in the sarcomata it is comparatively rare. The reasons for these differences will be seen in the subsequent chapters.

3. *Reproduction of the Growth in Distant Tissues.*— This is usually the terminal process in the history of malignant growths. The reproduction of the malignant growth in distant tissues is in the great majority of cases owing to the entry of some of its elements into the blood-stream. The secondary growths, as in the lymphatic glands, are in all cases of the same nature as the primary tumour. They occur as a rule in those organs through which the blood from the primary tumour first passes—that is, in those organs which present the first set of capillaries for the arrest of the transmitted materials. In malignant diseases of those organs, for example, which return their blood through the portal vein, as the stomach and mesenteric glands, it is the liver in which the secondary growths usually first occur, and when this has become involved, it may constitute a secondary centre of infection and in the same way cause tertiary growths in the lungs. Although this sequence is the rule, there are numerous exceptions. In some cases the organs which are nearest in the course of the circulation to the primary growth escape, whilst those more distant become affected. This may be owing to one organ being more predisposed to the influence of the infecting materials than another; or to the capillaries of the proximal organ allowing particles to pass through them, whereas those of the more distant one are small enough to arrest them. Lastly, it must be borne in mind, that the secondary growths may be entirely independent of the primary one, their origin being due to the same cause.

Although the general dissemination of a malignant

growth is thus in most cases owing to the transmission of its elements by the blood-stream, this is not the only way in which it may be brought about. Exceptional cases have been described in which the elements of a tumour have been distributed and caused secondary growths in other ways—as by passing down the trachea, between the layers of the peritoneum, from the kidneys down the ureters to the bladder, &c.

The secondary growths, as already stated, are probably either the direct products of the transmitted elements which proliferate in the tissues in which they lodge, or they owe their origin to the spermatic influence of those elements upon cells with which they come into contact.

It is thus obvious that the evidences of malignancy in a growth will consist—in its invasion of the surrounding structures, the implication of the neighbouring lymphatics, and the occurrence of similar growths in internal organs. As a general rule it may be stated that the more juice a growth contains, and the richer it is in blood-vessels and lymphatics, the more quickly will it infect the lymphatic glands, and internal organs; on the other hand, the poorer it is in blood-vessels and lymphatics, the more are its infecting properties confined to the neighbouring tissues.

The determination of the innocent or malignant nature of any growth will principally depend upon its microscopical characters, and, as will be seen when considering the various kinds of tumours, the differences which exist in their clinical characters are in great measure to be explained by differences in their position, minute structure, and mode of growth. Many varieties of new formations are invariably malignant, as the cancers and sarcomata; hence any growth which from its minute structure must be included under these heads, must be regarded as being of a malignant nature.

CLASSIFICATION.—New formations may be classified

upon a histological, a physiological, or a clinical basis. Although a physiological and clinical classification are much to be desired, in the present state of our knowledge they must be very incomplete. A classification of the new formations according to their histological characters is consequently here adopted. Such a classification may be most advantageously made in accordance with the classification of the physiological tissues:—

CLASSIFICATION OF THE NEW FORMATIONS. X

Type of the Connective Tissues.

Type of embryonic connective tissue	}	Sarcoma.
„ fibrous tissue		
„ mucous tissue		Myxoma.
„ adipose tissue		Lipoma.
„ cartilage		Enchondroma.
„ bone		Osteoma.
„ lymphatic tissue	The Lymphomata	{ Hodgkin's Disease. Leukæmia.

Type of the Epithelial Tissues.

Papilloma.

Adenoma.

The Carcinomata	{ Scirrhus. Encephaloid. Colloid. Epithelioma.
-----------------	---

Type of the Higher Tissues.

Type of muscle	Myoma.
„ nerve	Neuroma.
„ blood-vessels	Angioma.

CHAPTER XIII.

THE · S A R C O M A T A.

THE sarcomata are tumours consisting of embryonic connective tissue. Of these there are several varieties, depending upon the size and configuration of the cells, and the nature of the intercellular substance. They include what have generally been known in this country as *fibro-plastic*, *fibro-nucleated*, *recurrent-fibroid*, and *myeloid* tumours.

Connective tissue in its embryonic condition is an immature tissue in a state of rapid development. In its most immature state it differs from the fully developed tissue in consisting almost entirely of small round cells, whilst its intercellular substance, instead of being fibrous, is soft and amorphous. This is the common condition of connective tissue in the primary stages of all rapid formative processes, as already described when speaking of it as the tissue from which many tumours of the connective-tissue class originate (see "Development of New Formations").

In the process of development of this embryonic into mature connective tissue, the cells diminish in number, many of them assume a spindle shape, and the intercellular substance fibrillates. Similar changes are seen in inflammatory conditions of connective tissue. Here also many of the small round cells which constitute the "granulation-tissue" become spindle cells, and the granu-

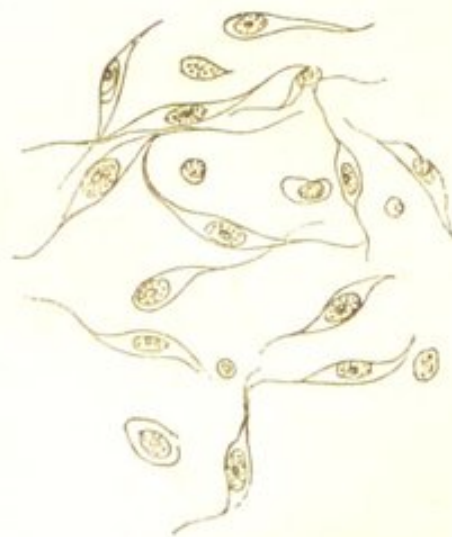lation tissue ultimately develops into the fibrous tissue of the cicatrix. In the sarcomata, however, the connective tissue retains the embryonic state throughout its growth, there is a progressive formation of embryonic tissue; and although the process of development may occasionally proceed in certain parts of the tumour to the formation of a more highly developed structure, as fibrous tissue, cartilage, or bone, so that a mixed form of tumour is produced, it usually ceases at the embryonic stage.

STRUCTURE.—The sarcomata may thus be defined as tumours consisting of connective tissue which throughout its growth retains the embryonic type. The *cells*, which constitute nearly the whole of the growth, consist for the most part of masses of nucleated protoplasm, and rarely possess a limiting membrane. They present many variations in size and form; as a rule, however, they preserve the same general characters in the same tumour. There are three principal varieties—the *round*, the *fusiform*, and the *myeloid* cells.

The *round* cells are many of them indistinguishable from lymph-cells or white blood-corpuses. Others are somewhat larger and contain an indistinct nucleus with one or more bright nucleoli: these more closely resemble the cells of a granulation.

The *fusiform*, or *spindle-shaped* cells, are the so-called “fibroplastic cells” (Fig. 27). They are long narrow cells, terminating at each end in a fine prolongation. Some of them may be broader, approaching the epithelial type; others more or less stellate. They are sometimes slightly granular, and they enclose a long oval nu-

FIG. 27.



Cells from a Spindle-celled Sarcoma. $\times 200$.

cleus, with or without nucleoli. In size they vary considerably. These cells represent a higher state of development than the round cells, resembling those met with in embryonic tissue which is in the process of forming mature connective tissue. (See Fig. 72 B.)

The *myeloid*, or *mother* cells, are much larger than either of the preceding, and are analogous to the cells met with in the medulla of foetal bone. (See Fig. 33.) They are large irregular-shaped masses of nucleated protoplasm, for the most part more or less spherical, and often possessing numerous offshoots. They are finely granular, and contain several round or roundly-oval nuclei, each with one or more bright nucleoli. The nuclei may be exceedingly numerous, one cell containing as many as thirty. Both the cells and nuclei vary considerably in size.

An *intercellular substance* exists in all the sarcomata, although it is usually very small in quantity, the cells lying in nearly close apposition. It may be perfectly fluid and homogeneous, or firmer and granular, or more or less fibrillated. Chemically it yields albumen, gelatin, or mucin.

The *blood-vessels* are usually very numerous, and are either in direct contact with the cells, or separated from them by a little fibrillated tissue. Their distribution is very irregular, and their walls often consist of embryonic tissue similar to that of the growth which they supply; hence the frequency with which rupture and extravasation of blood take place.

DEVELOPMENT.—The sarcomata always originate from connective tissue—either from the subcutaneous, the submucous, or the subserous tissues, the fasciæ, the connective tissue of organs, the periosteum, or the medullary tissue of bones. Their growth may take place in two ways, by the multiplication of their own elements—*central* growth, and by the continuous invasion of their matrix—

peripheral growth. A peripheral growth is the great characteristic of the sarcomata; they usually increase by the continuous invasion of their connective-tissue matrix, so that no line of demarcation exists between the two. They frequently also invade other tissues, the elements of the growth extending for some distance into the surrounding structures. This infiltrating tendency of the sarcomata varies considerably in the different varieties, being much more marked in the round-celled than in the spindle-celled and myeloid growths. A purely central growth is less common. A sarcomatous tumour, however, often becomes encapsuled and growth takes place within the capsule; but even in this case the capsule is sometimes merely that of the part within which the growth originates, as the periosteum, or the capsule of a lymphatic gland.

SECONDARY CHANGES.—The most important of these is fatty degeneration. This always occurs to a greater or less extent in the older portions of the growth, causing softening, caseation, or the production of cyst-like cavities. It is frequently associated with destruction of the blood-vessels and hæmorrhage: the latter may give rise to pigmentation, and the formation of sanguineous cysts. Calcification, ossification, and mucoid degeneration are less common. The occurrence of calcification, ossification, and pigmentation is influenced by the predisposition of the matrix from which the growth is produced:—thus calcification and ossification are more prone to occur in tumours originating in connexion with bone, pigmentation in those originating from the cutis or eyeball.

VARIETIES.—Although all the sarcomata possess the same general characters, they present many histological and clinical differences which may serve as bases for their classification. The occurrence of various secondary changes—pigmentation, mucoid degeneration, and the formation of cysts, impart their respective characters to

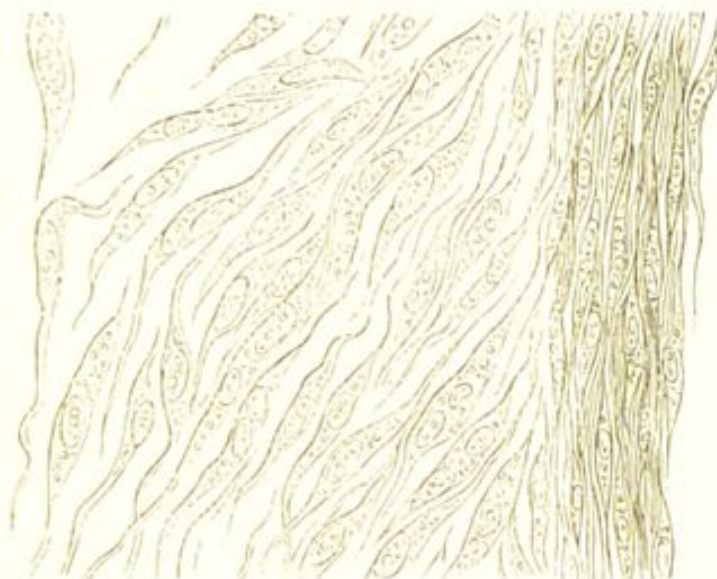
the growth ; hence *melanotic-sarcoma* and *cystic-sarcoma*, have been described as distinct varieties. This is to a certain extent justifiable, inasmuch as sarcomata which have undergone these transformations, in many cases possess the property of reproducing the same characters when they occur secondarily in other parts. Then, again, as already stated, sarcomatous tumours are sometimes complex in their structure, and are associated with other tissues belonging to the connective-tissue group. A combination of sarcoma with fatty, cartilaginous, and osseous tissue, is thus not uncommonly met with (*chondro-sarcoma osteo-sarcoma*, &c.). This is owing to the embryonic tissue exhibiting a tendency to develop into the different varieties of connective tissue. (See "The New Formations.") The following histological classification, based upon the three different forms of cells already described, is perhaps the most convenient. It must, however, be borne in mind, that all the varieties of cells may be found in the same tumour, although the majority are usually of the same type ; hence, the *majority* will determine the class to which the growth belongs.

SPINDLE-CELLED SARCOMA.

This, which includes the growths long known in this country as "fibro-plastic," "recurrent fibroid," &c., is the most common of all the sarcomata. It is more closely allied to the fibromata than are the other varieties of sarcoma, inasmuch as it consists of a tissue which must be regarded as occupying an intermediate place between embryonic and fully-developed connective tissue. It consists mainly of spindle-shaped and fusiform cells, varying considerably in size, and nearly in close contact, there being very little intercellular substance. (Fig. 28.) The cells, which contain well marked oval nuclei, are parallel to one another, and are arranged in bundles which pass

in all directions through the growth, so that in those portions of the section in which the bundles of spindle-elements have been cut transversely they present the appearance of round cells. In some parts there may be partial fibrillation. The spindle-celled sarcomata grow from the periosteum, the fasciæ, and from connective tissue in other parts. They are usually tolerably firm

FIG. 28.



Spindle-celled Sarcoma. To the left—the cells have been separated by teasing, so that their individual forms are apparent; to the right—they are in their natural state of apposition, such as would be seen in a thin section of the tumour. $\times 350$. (Virchow.)

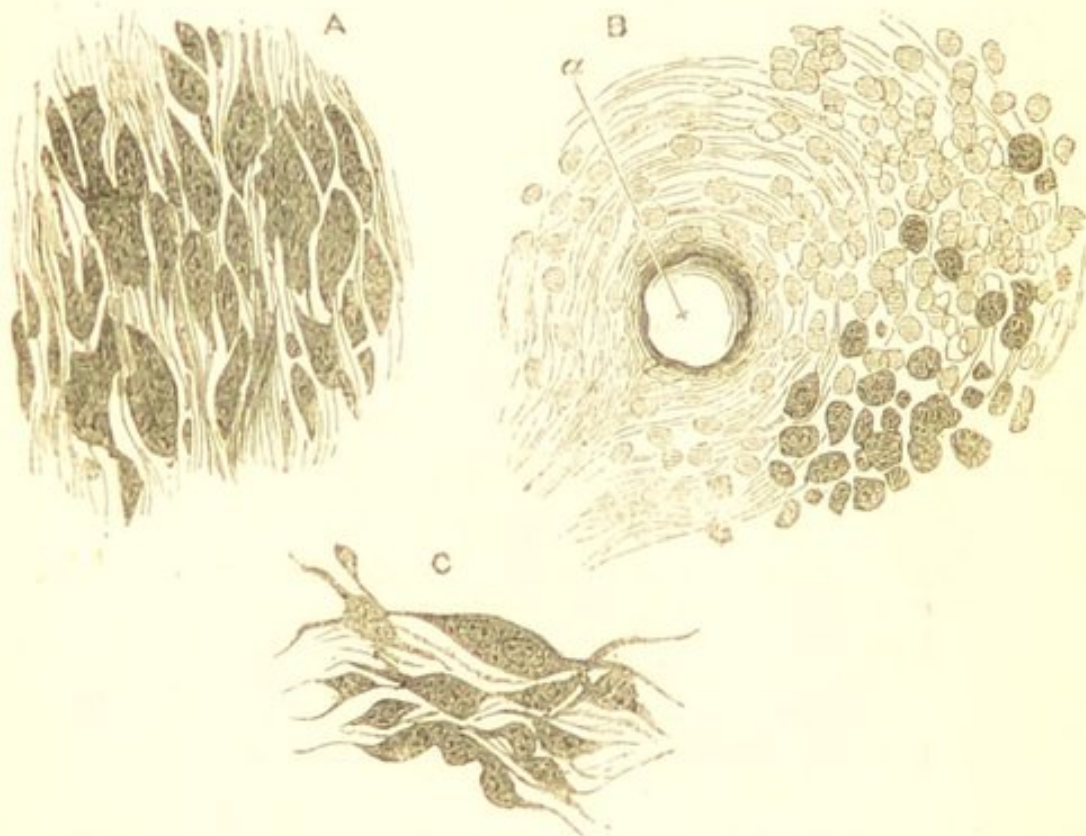
in consistence, and for the most part present, on section, a translucent somewhat fibrillated appearance. They are often encapsuled, much more frequently so than the round-celled growths, but they are very liable to extend by peripheral growth, and often infiltrate the surrounding structures.

MELANOTIC SARCOMA.—This is a variety of sarcoma in which many of the cells contain granules of dark-coloured pigment. By far the greater number of melanotic tumours are sarcomata, and most of the growths which were formerly described as “melanotic cancers,” belong in reality to this class of new formations. Not only are these

melanotic tumours most frequently sarcomata, but the majority of them consist mainly of spindle-shaped cells—hence they are described in the present section.

The melanotic sarcomata originate principally in two situations—in the choroid coat of the eye, and in the superficial integuments. In both of these situations pigment is a normal constituent of the tissues, and this

FIG. 29.



A Melanotic Sarcoma of the Penis.

- A.—A thin section, showing the general arrangement of the elements. $\times 200$.
- B.—A section from the peripheral part of the growth, showing the "indifferent cells," amongst which are small isolated pigmented elements. At *a*, a blood-vessel is seen. $\times 200$.
- C.—Some of the elements separated by teasing. In these the pigment-granules are well seen. $\times 400$.

tendency of structures normally containing pigment to originate melanotic growths, is exceedingly characteristic. (See "Pigmentary Degeneration.") These tumours usually consist of spindle-shaped cells, although in some

cases the prevailing type of their elements is round or oval. (Fig. 29.) The pigment, which gives to them their distinctive characters, consists of granules of a brownish or dark sepia colour, which are distributed within the cells. (Fig. 29 c.) Frequently, only a very small proportion of the cells are pigmented, whilst in other tumours the pigmentation is much more universal; in all cases, however, a large number of the elements will be found to be quite free from pigment.

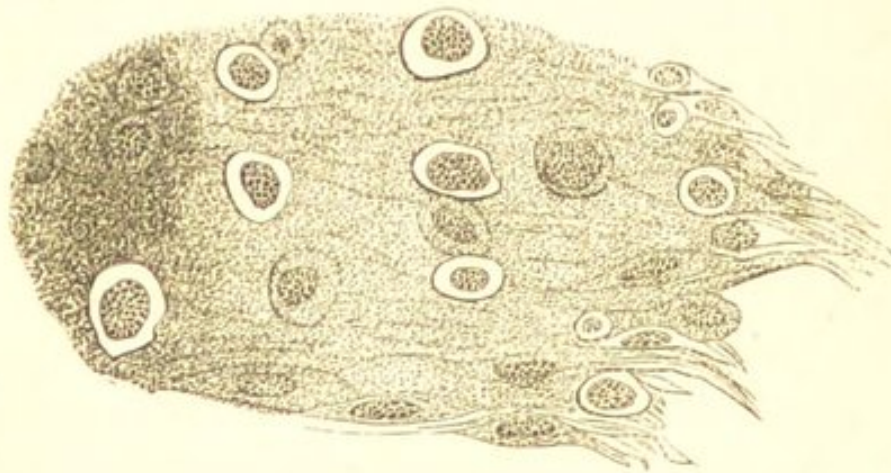
These melanotic tumours are amongst the most malignant of the sarcomatous growths. They reproduce themselves often very rapidly in distant tissues, and in doing so, although they almost invariably maintain their melanotic characters, the degree of the pigmentation of the secondary tumours varies considerably; whilst many of them may be perfectly black in colour, others may be much paler, and perhaps only partially streaked with pigment. The secondary growths may occur in almost every organ of the body—the liver, the spleen, the kidneys, the lungs, the heart, and also the lymphatic glands and subcutaneous tissue, may all be simultaneously involved. I have observed, that when occurring in internal organs, the pigmentation is not always limited to the secondary nodules, but that many of the cells proper to the organ itself are filled with granules of similar pigment, which is most abundant in those cells which are immediately adjacent to the new growth. This pigmentation of the cells of the organ often extends for some distance beyond the confines of the tumour.

OSTEOID SARCOMA.—This, which is often known as “osteoid cancer,” is a variety of sarcoma (usually of spindle-celled sarcoma) in which the growth is either more or less calcified, or has partially become converted into true bone. As a primary growth it is met with almost exclusively in connection with bone—growing either from the periosteum or the medulla—although the osteoid cha-

racters are usually reproduced in the secondary tumours occurring in the lungs and in other parts.

Simple calcification is much more common than true ossification. Here the growth merely becomes infiltrated with calcareous salts, which may be dissolved out with a little dilute hydrochloric acid, when the characteristic sarcomatous structure becomes revealed. In other cases this calcification is associated with the conversion of portions of the tumour into true, although usually imperfect bone. When this has occurred, there will be seen amongst the spindle-shaped, round, or myeloid elements, tracts of tissue consisting of broad bands of granular intercellular material, infiltrated with calcareous salts, enclosing spaces which contain spindle, oval, or round cells. (Fig. 30.) This structure often much resembles cartilage. In other

FIG. 30.



Osteoid Sarcoma.—Showing the calcification of a spindle-celled growth, and the formation of broad bands of calcified intercellular material enclosing spaces which contain round and oval cells. $\times 200$.

parts of the growth, where the change is more advanced, may be seen lacunæ and even canaliculi such as are found in true bone.

In these osteoid growths it is most important to recognise the existence of the sarcomatous element, inasmuch as it is the presence or absence of this which determines

the innocent or malignant nature of the growth. Osteoid sarcoma must be carefully distinguished from the simple osseous tumour.

ROUND-CELLED SARCOMA.

This is of softer consistence than the spindle-celled growths, and from its frequent resemblance in physical characters to encephaloid, it is sometimes known as "medullary," "encephaloid," or "soft" sarcoma. Histologically,

it is elementary embryonic tissue, consisting mainly of the round cells already described, embedded in a scanty, and usually soft, homogeneous, or finely granular intercellular substance. (Fig. 31.) The cells usually resemble those met with in the most elementary embryonic tissue; less frequently, they are larger, and contain large round or oval nuclei, with bright nucleoli. There is an almost complete absence of fusiform cells, and of the partial fibrillation which is so frequent in the more highly-developed spindle-celled variety.

The round-celled sarcomata are of a uniform soft brain-like consistence, somewhat translucent or opaque, and of a greyish or reddish-white colour. On scraping the cut surface, they yield a juice which is rich in cells. They are exceedingly vascular, the vessels often being dilated and varicose, and from their liability to rupture, they frequently give rise to ecchymoses and to the formation of sanguineous cysts. They grow from the cutis, the subcutaneous cellular tissue, the periosteum, the fasciæ, and from the connective tissue of organs. They extend rapidly by peripheral growth, infiltrate the surrounding structures, and reproduce themselves in internal organs.

FIG. 31.

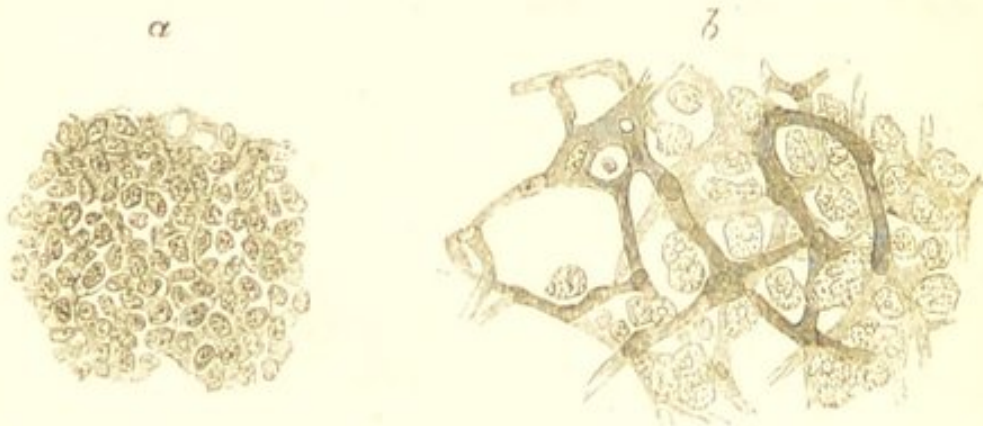


Round-celled Sarcoma.
A thin section of a small round-celled sarcoma of the liver. $\times 200$.

From their clinical and physical characters, these tumours are very liable to be confounded with encephaloid cancer:—they are distinguished by the absence of an alveolar stroma, and by the uniformity in the character of their cells.

GLIOMA.—This is a variety of round-celled sarcoma growing from the neuroglia or connective tissue of nerve. It consists of very small round cells, embedded in an exceedingly scanty, homogeneous, granular, or slightly fibrillated intercellular substance. (Fig. 32 *a*.) Some of

FIG. 32.



Sarcomatous Tumours from the Brain.—*a*. A glioma of cerebellum. This represents the appearance ordinarily presented by these growths. *b*. A comparatively rare form of sarcoma, which consists of large nucleated cells enclosed within the meshes of a vascular network. The development of this tumour took place in the brain subsequently to that of spindle-celled growths—primarily in the thigh, and secondarily in the lung. $\times 200$.

the cells may possess fine prolongations which, by communicating with one another, form a somewhat reticulated structure. These tumours occur in the grey and white substance of the brain, in the cranial nerves, and in the retina. In the retina they usually commence as a minute nodule, which may gradually increase until it projects as a large fungating tumour from the orbit. They are not encapsuled, and although they may occasionally infiltrate the tissues in which they lie and cause secondary growths in their immediate vicinity, they very rarely reproduce

themselves in the lymphatic glands or in internal organs. They are liable to small hæmorrhages into their structure, and sometimes become more or less caseous.

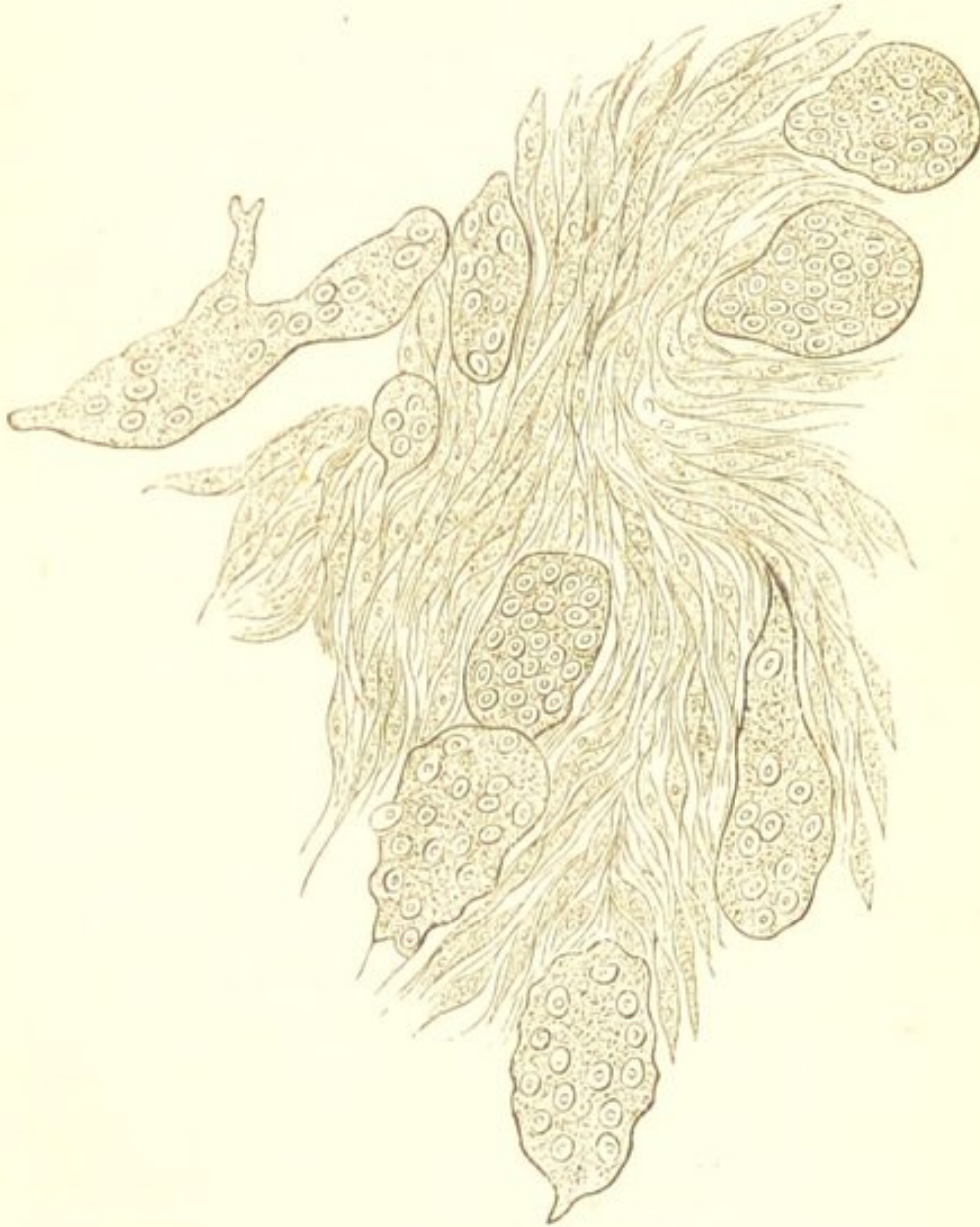MYELOID SARCOMA.

This, which is the well-known *myeloid* tumour, is somewhat allied to the spindle-celled growths. It possesses, however, certain histological peculiarities which probably depend upon the characters of the tissue from which it grows. Myeloid tumours nearly always occur in connection with bone, and frequently originate in the medullary cavity. They consist of the large, many-nucleated cells already described as "myeloid cells,"—which resemble the cells of the medulla in a state of excessive nutritive activity—together with numerous fusiform cells like those met with in the spindle-celled varieties. There are also some smaller round and oval elements. The large myeloid cells, which give to these tumours their distinctive character, are usually much more numerous in those growths which originate in the medullary cavity than in those which spring from the periosteum. These various forms of cells are nearly in close contact, there being very little intercellular substance. (Fig. 33.)

Myeloid tumours almost always grow in connection with bone, the heads of the long bones being their favourite seat. They are also very frequently met with springing from the periosteum of the upper and lower jaws, where they are usually known as *epulis*. When originating within the medullary cavity, the compact tissue of the bone becomes expanded over them, and they thus often communicate on palpation the peculiar sensation known to surgeons as "egg-shell crackling." These tumours are of firmer consistence than the other varieties of sarcoma; many of them are firm and fleshy, others are softer, more resembling size-gelatin. They are not pulpy and grumous like the soft sarcomata, neither do

they present the fasciculated appearance of the spindle-celled varieties. Their cut surface has an uniform succulent appearance, often mottled with patches of red.

FIG. 33.



Myeloid Sarcoma. (Virchow.)

They are often encapsuled by the periosteal covering of the bone from which they grow. They are rare after middle life, and are the least malignant of all the sarcomata.

PSAMMOMA.

Allusion must here be made to a form of growth occasionally met with in the brain and its membranes which

is known as psammoma. This growth, although having but little resemblance to the sarcomata, is usually classified with this group of new formations. Its characteristic feature is that it consists largely of calcareous particles. The calcareous particles are contained in the concentric bodies already described as the corpora amylacea, where they give rise to the so-called "brain-sand":—hence the name of the growth. The calcified corpora amylacea associated with a varying quantity of a cellular and fibrillated tissue, and blood-vessels, make up the growth.

Psammoma is usually met with growing from the membranes of the brain, or from the choroid plexus. In the latter situation it often contains numerous cysts. It is of no pathological importance except when of sufficiently large size to produce symptoms from pressure.

CLINICAL CHARACTERS OF THE SARCOMATA.

The sarcomata occur most frequently in early and middle life, and, next to the cancers, they are the most malignant of the new formations. They are especially characterised by their great tendency to extend locally and to infiltrate the surrounding structures, so that they are exceedingly prone to recur *in loco* after removal. They comparatively rarely infect the lymphatic glands, and in this respect present a marked contrast to the cancers. They are also very liable to become generally disseminated, although this is not usual in the earlier stages of the disease. The secondary growths occur most frequently in the lungs. The dissemination is effected by means of the blood, and this is owing to the thinness of the walls of their blood-vessels and to the immediate contact of these with the cells of the growth—conditions most favourable to the entrance of the cellular elements

into the circulation. The dissemination of the sarcomata is, on this account, sometimes more rapid than that of the cancers. In the latter, extension in the early stage takes place principally by the lymphatics, and dissemination by the blood only occurs in the later stages of the disease. The secondary sarcomata usually resemble the primary one, but in exceptional cases the several varieties may replace one another.

These malignant properties are possessed by the different varieties of sarcoma in very different degrees. As a rule, the softer and more vascular the tumour, and the less its tendency to form a fully-developed tissue, the greater is its malignancy. The soft, round-celled varieties are thus usually much more malignant than the firmer spindle-celled growths. Their infiltrating powers are much greater, they sometimes infect the lymphatic glands (which is exceedingly rare in the spindle-celled growths), and they tend to reproduce themselves very rapidly in internal organs. This is probably partly owing to the small round cells being endowed with greater powers of spontaneous movement than the spindle-shaped and larger cells; hence they more readily make their way amongst the tissues and into the blood-vessels. Amongst the spindle-celled tumours the degree of malignancy varies considerably. Many of them after removal never recur, whilst others recur locally several times after operation, and ultimately reproduce themselves in distant parts. As a rule, largeness of the spindle elements and the existence in many of them of more than one nucleus, is an evidence of special malignancy. Then, again, the presence of a distinct capsule limiting the growth must be taken into account in judging of the degree of its malignancy. The myeloid growths are the least malignant; they may however also, in exceptional cases, give rise to secondary growths in internal organs.

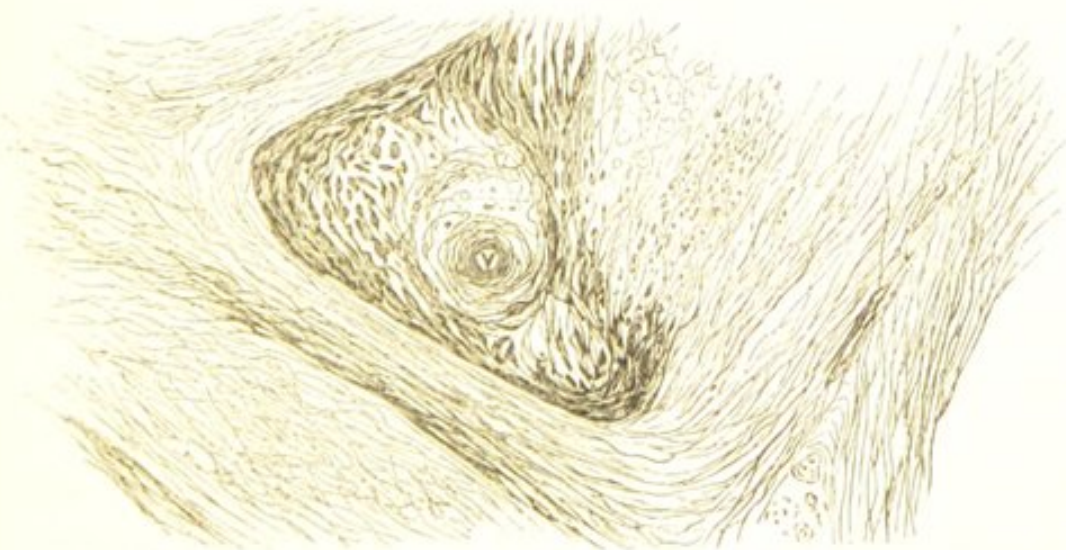
CHAPTER XIV.

THE FIBROMATA.

THE fibromata, fibrous, or connective-tissue tumours, are tumours consisting of fibrous tissue.

STRUCTURE.—In structure the fibromata present the same variations as those met with in fibrous tissue. Some of them are composed of firm, dense, fibrous tissue, such as constitutes tendons; others are laxer and less fibrous in consistence, more resembling the connective tissue of the cutis. The fibres, which constitute the chief part of the growth, are closely interlaced, and are distributed without any definite arrangement, or grouped in bundles of various sizes: they are frequently arranged concentrically around the blood-vessels. The

FIG. 34.



Section of a Fibrous Tumour from the Skin.—In the neighbourhood of the cut blood-vessel *v*, are seen some cells; also fibres cut transversely. $\times 200$ and reduced $\frac{1}{2}$.

cells, or as they are usually called, the connective-tissue corpuscles, are very few in number. They are usually most abundant around the blood-vessels; in other parts of the growth they are smaller and often only become visible after the addition of dilute acetic acid (Fig. 34). They are minute, spindle-shaped, fusiform, or stellate bodies, the latter having processes of varying length which communicate with similar processes from neighbouring cells. They contain in some cases an oval nucleus. The size and number of these cells varies with the rapidity of growth—the slower the growth the more fibrous the tissue, and the smaller and less numerous are the cells.

The fibromata usually contain but very few blood-vessels. In some cases, however, these are more numerous, and form a cavernous network, the walls of which are firmly united to the tissue of the tumour, so that when divided or ruptured they are unable to retract. In such cases, injury to the tumour is often followed by profuse hæmorrhage.

DEVELOPMENT.—The fibromata always originate from connective tissue, either from the cutis or subcutaneous connective tissue, from the submucous or subserous tissue, from fasciæ, the periosteum, the neurilemma, or from the connective tissue of organs. In the earliest stages of their growth they consist of embryonic tissue, the cells being very numerous, and the intercellular substance soft and amorphous (see “Development of New Formations”). The latter, however, subsequently fibrillates, the cells diminish in number, many of them become spindle-shaped and the embryonic becomes fully developed connective tissue. The slower the process of development, the less marked are these embryonic characters. The fibromata are almost always limited by a fibrous capsule, which separates them from the surrounding structures. Their growth is slow and central, taking place within the capsule.

SECONDARY CHANGES.—Of these, partial mucoid softening and calcification are the most common. Ulceration also sometimes occurs in those growths which are situated in the submucous tissue.

VARIETIES.—Fibrous tumours present some variations in their characters, which depend for the most part upon the tissues from which they grow. Those growing from the cutis are softer and less dense in consistence than those met with in many other situations; they usually also have papillæ on their surface. These growths from the cutis are by no means uncommon, and may form enormous tumours. They are frequently multiple, and in their growth often become pedunculated. They commonly occur in middle or advanced life.

Another variety of fibrous tumour grows in connection with nerves, and is often described as *neuroma*. True neuromata, however—*i.e.*, new formations of nerve-tissue—are amongst the rarest forms of new formations. These fibrous growths most frequently occur in connection with the superficial nerves. They grow from the neurilemma, and as they increase in size the nerve-fibres become expanded over them, so that they often cause considerable pain—hence the term “painful subcutaneous tubercle” which is sometimes applied to them.

The fibroid tumours of the uterus, which are often described as fibrous tumours, appear in most cases to be overgrowths of the involuntary muscular tissue of the organ. They will therefore be considered with the muscular tumours. (See “Myoma.”)

PHYSICAL CHARACTERS, &c.—Fibrous tumours are usually more or less spherical or oval in shape, and are frequently lobulated on the surface. Their consistence varies:—they may be exceedingly firm, dense, and fibrous, or softer and more succulent. On section, they usually present a greyish-white basis substance, intersected with opaque white glistening fibres. They are generally single,

except when growing from the neurilemma or cutis, in which situations they are frequently multiple.

CLINICAL CHARACTERS.—Clinically the fibromata are perfectly innocent, and have little or no tendency to recur locally after removal.

CHAPTER XV.

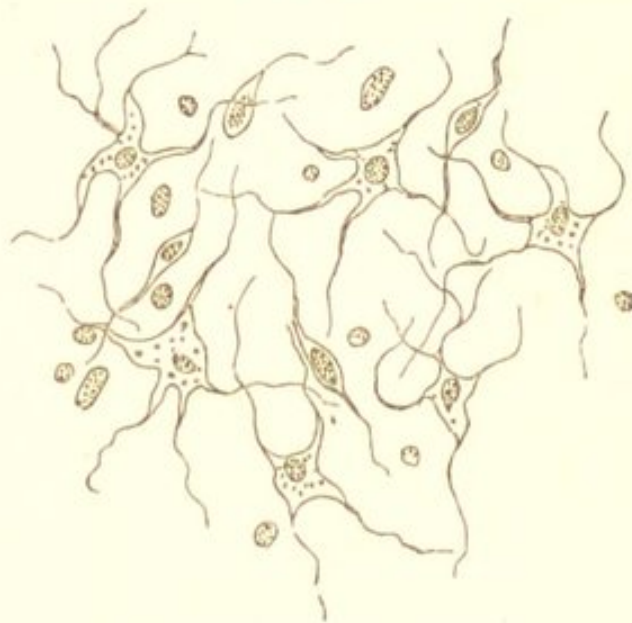
THE MYXOMATA.

THE myxomata are tumours consisting of mucous tissue. Mucous tissue is a translucent and succulent connective tissue, the intercellular substance of which yields mucin. Physiologically, this tissue is met with in two forms, and in two situations:—one—in the vitreous body of the eye, in which the cells are roundish and isolated; the other—in the umbilical cord, in which the cells are fusiform or stellate and give off fine trabeculæ which anastomose with one another. In both, the intercellular substance is homogeneous and yields mucin. The connective tissues in their embryonic condition, as already stated when describing “mucoid degeneration,” possess an intercellular substance, containing large quantities of mucin. This is especially the case with the tissue which subsequently becomes adipose. New formations may undergo a mucoid change, and thus closely resemble in their physical and chemical characters the myxomata. A myxoma, however, is a growth which consists of mucous tissue. The myxomata are thus very closely allied to the sarcomata, and by many are included in the same class of new formations.

STRUCTURE.—The cells present the two varieties met with in the physiological tissues. The majority are angular and stellate, with long anastomosing prolongations and trabeculæ. (Fig. 35.) Others are isolated, and fusiform, oval, or spherical in shape. They usually possess

one, in some cases two distinct nuclei. Their contour is very indistinct, owing to the refracting nature of the

FIG. 35.



Myxoma. A minute piece of a myxoma of the arm, showing the characteristic branched anastomosing cells. There are also a few leucocytes, and one or two spindle-shaped elements. $\times 200$.

intercellular substance. The latter is very abundant, perfectly homogeneous, of a soft gelatiniform viscid consistence, and yields large quantities of mucin: amongst it are a varying number of amœboid cells. The blood-vessels, which are not numerous, are readily visible and easily isolated. A few elastic fibres are sometimes seen between the cells.

DEVELOPMENT.—The myxomata always originate from one of the connective tissues. Adipose tissue is their most favourite seat—either the subcutaneous, the sub-mucous, or the inter-muscular adipose tissue. They also grow from the medullary tissue of bone, the connective tissue of organs, from the connective tissue of the brain and spinal cord, and from the sheaths of nerves. They are usually separated from the surrounding structures by a very thin fibrous capsule, fine prolongations from which

divide the growth into lobules of various sizes. In exceptional cases they may increase by the continuous invasion of their matrix. Their growth is usually slow, but they may attain an enormous size.

SECONDARY CHANGES.—Of these the most common is rupture of the capillaries, hæmorrhage, and the formation of sanguineous cysts; this, however, is less frequent than in the sarcomata. The cells themselves may undergo mucoid or fatty degeneration, and thus be destroyed; this is usually accompanied by liquefaction of the intercellular substance.

VARIETIES.—The varieties of myxoma depend principally upon its combination with other growths. The most common is a combination with lipoma—adipose tissue being the tissue from which it most frequently originates. Combinations with sarcoma and enchondroma are also frequently met with.

PHYSICAL CHARACTERS, &c.—The myxomata are of a peculiar soft gelatiniform consistence, and of a pale greyish or reddish-white colour. Their cut surface yields a tenacious mucilaginous liquid, in which may be seen the cellular elements of the growth. They are most frequently met with in the later periods of life. Their most common seats are those of adipose and nervous tissue. Growing from the sheaths of nerves, they constitute one variety of so-called neuroma. They may also grow from the placenta, constituting the “uterine hydatids.” When situated in superficial parts they may become pedunculated. In the submucous tissue of the nose, they constitute one form of nasal polypus.

CLINICAL CHARACTERS.—Clinically the myxomata are for the most part benign growths. If completely removed they rarely recur. Sometimes, however, they exhibit malignant characters, and recur locally after removal. They probably never reproduce themselves in internal organs.

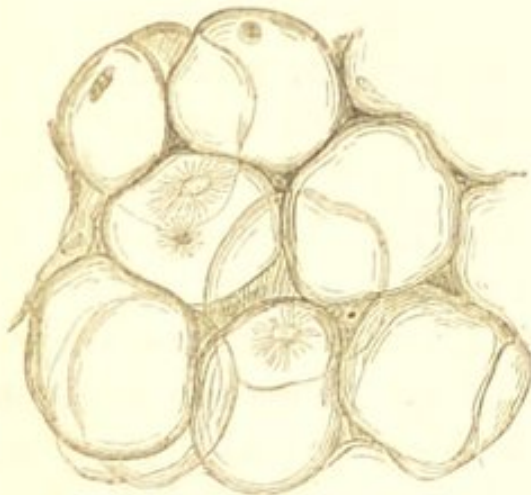
CHAPTER XVI.

THE LIPOMATA.

A GENERAL new formation of adipose tissue constituting *obesity*, has already been described under "fatty infiltration." A localized and circumscribed formation, constitutes a *lipoma* or fatty tumour.

STRUCTURE.—The lipomata resemble in their structure adipose tissue. (Fig. 36.) They consist of cells containing

FIG. 36.



Lipoma. Some of the cells contain crystallized fatty acids. $\times 200$.

fat, and a variable quantity of common connective tissue. The cells, like those of adipose tissue, though usually somewhat larger, are more or less round or polygonal in shape, and are distended with fluid fat. The nucleus and protoplasm are so compressed against the cell-wall by the fluid contents, that although their

existence may often be demonstrated by treatment with reagents, they are usually only readily visible when the cell is atrophied and contains less fat. (See Fig. 3 *a.*) The connective tissue, which varies in amount, usually unites the cells in masses or lobules of various sizes, and also in most cases forms a thin capsule around the tumour. Blood-vessels are distributed in the fibrous septa.

DEVELOPMENT.—The lipomata grow from connective

tissue. Adipose tissue, it must be remembered, is merely connective tissue containing numerous cells which are infiltrated with fat; and its growth consists, either in the infiltration of more of these cells, or in a proliferation of the cells, and an accumulation of fat in those newly developed. A lipoma in the same way originates by a localised proliferation of cells, which as they are produced become infiltrated with fat. The growth of these tumours is always very slow, and they are usually encapsuled by a layer of fibrous tissue.

SECONDARY CHANGES.—Secondary changes in the lipomata are not common; their fibrous septa may, however, become calcified, or even ossified, and the fatty tissue undergo a process of liquefaction. Softening may also occur from a mucoid change. Sometimes they become the seat of an inflammatory process; then, when situated in the subcutaneous tissue, the skin over them becomes adherent and ulcerates, and a fungating mass is the result.

PHYSICAL CHARACTERS, &c.—The situation of the lipomata is almost co-extensive with that of adipose and connective tissue. They occur most frequently, however, in those parts in which fat is normally met with, as in the subcutaneous tissue and the inter-muscular septa. They are also occasionally developed in the subsynovial and subserous tissues, in the submucous tissue of the stomach and intestines, and even in internal organs. They sometimes attain an enormous size. They are lobulated, and are usually surrounded by a fibrous capsule which separates them from the adjacent structures. On section they present the ordinary appearance of adipose tissue. Their consistence varies with the amount of fibrous tissue which they contain. They are usually single, though not unfrequently multiple. In their growth they sometimes become pedunculated.

CLINICAL CHARACTERS.—Clinically the lipomata are perfectly innocent.

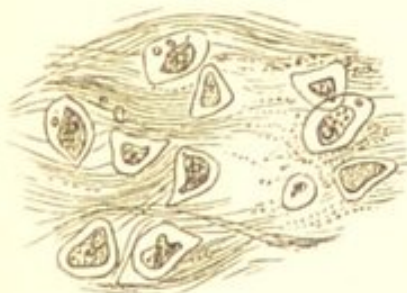
CHAPTER XVII.

THE ENCHONDROMATA.

THE Enchondromata are tumours histologically resembling cartilage.

STRUCTURE.—Like cartilage they consist of cells and an intercellular substance, which present all the variations observed in the normal tissue. The intercellular

FIG. 37.



Fibrous Enchondroma.
× 200.

substance may be hyaline, faintly or distinctly fibrous, or mucoid. When fibrous, the fibres may be arranged like those of fibro-cartilage, or more or less concentrically around the cells as in the reticular cartilages of the ear and larynx. (Fig. 37.) The cells may be very numerous, or few in pro-

portion to the matrix. They are round, oval, spindle-shaped, or stellate. In the hyaline forms they are usually large and round or oval; in the fibrous forms they are often smaller and even somewhat spindle-shaped, more resembling those of connective tissue; and in the rarer mucoid forms, they are more commonly stellate and branched, like those of the umbilical cord. They are either single or arranged in groups, and are usually surrounded by a capsule, though this is often very indistinct. They enclose one or more nuclei and slightly granular contents; sometimes a cell-wall cannot be distinguished.

In addition to the intercellular substance, the growth is usually divided into several lobes, by bands of fibrous tissue in which are contained the blood-vessels. These lobes are often very distinct, so that the growth appears to be made up of several separate tumours. The fibrous tissue in most cases also encapsules the growth and separates it from the surrounding structures.

DEVELOPMENT.—The enchondromata most frequently originate from bone and common connective tissue, very rarely from cartilage. Cartilage itself, and especially fibrous-cartilage, is very closely allied to common connective tissue. It grows from the deeper layers of the perichondrium, which proliferate and form an embryonic tissue; the young cells become cartilage-cells, and these probably form the matrix, which is either homogeneous or fibrillated, constituting in the one case hyaline, and in the other fibrous cartilage. The development of enchondroma from connective tissue is precisely similar to the physiological progress.

In the development of enchondroma from osseous tissue, the medulla is the source of the new growth. This proliferates, the osseous trabeculæ are absorbed, the neighbouring medullary spaces open one into the other, and in this manner a large medullary cavity is produced. In the centre of this, the young cells first formed enlarge and become separated by a homogeneous, or less frequently, slightly fibrillated intercellular substance, and thus is produced a mass of cartilage in the centre of the medullary tissue. This gradually increases till ultimately a layer of fibrous tissue is formed around it, and its further growth takes place from the tissue of its capsule.

Lastly, cartilaginous growths may originate from cartilage itself. These are sometimes seen on the surface of the articular cartilages, in the larynx and trachea, and on the costal and intervertebral cartilages. They are simply local outgrowths from pre-existing cartilage. They rarely

attain a large size, and in structure and physical characters more closely resemble normal cartilage than the other forms of enchondroma. They are usually described as *enchondroses*, and must be distinguished from the other forms of cartilaginous tumour.

SECONDARY CHANGES.—Of these, calcification is much the most common. It affects different parts of the growth, commencing in the capsules, and then involving the intercellular substance. Ossification also occasionally occurs; it commences at separate centres, and spiculæ of bone are formed which traverse the tumour in various directions. Fatty degeneration and mucoid softening are common changes, and may lead to the formation of large softened masses which present the appearance of cysts. In rare cases the skin covering the tumour ulcerates, and a fungating mass protrudes.

VARIETIES.—The varieties of enchondroma depend mainly upon the nature of the intercellular substance. There are thus hyaline, fibrous, and mucoid enchondromata; these, however, are usually combined in various degrees in the same tumour. As a rule, those originating from the medulla of bone are of the hyaline and mucoid class, whilst those originating from connective tissue in other situations are more frequently fibrous. The rapidly growing fibrous forms approach very closely the confines of the sarcomata, the mucoid forms the confines of the myxomata; and these two kinds of growth are often associated in the same tumour.

A variety of enchondroma has been described under the name of *osteo-chondroma*, which in structure more closely resembles bone than cartilage. It consists of a tissue similar to that met with between the periosteum and bone in rickets, which from its resemblance to osseous has been called *osteoid* tissue. This tissue only requires calcifying to become true bone. Like bone it is made up of trabeculæ and medullary spaces, but the trabeculæ,

instead of bone-corpuscles and lamellæ, consist of small angular cells without a capsule, situated in an obscurely fibrillated matrix, which in part is calcified. The medullary spaces contain a fibrous stroma and many blood-vessels. The osteo-chondromata, although consisting mainly of this osteoid tissue, contain also a small proportion of cartilage. They originate beneath the periosteum, their common seat being the ends of the long bones. Their growth is very rapid, and they often attain an enormous size. They are much more freely supplied with blood-vessels than the ordinary enchondromata, and hence they are much less frequently the seats of retrogressive changes. They are especially prone to become ossified and converted into true bone.

PHYSICAL CHARACTERS, &c.—The enchondromata occur most frequently in early life. About three-fourths of them are met with in the osseous system, where they grow either from the medulla or from the periosteum: their favourite seat is the extremities of the fingers and toes. The remaining fourth occur most frequently in the parotid gland and in the testicle. They occasionally grow in the subcutaneous cellular tissue of the mamma, and in the lungs. They are usually single except when occurring on the fingers and toes, in which situations they are more frequently multiple. They consist of a single tumour, or of several smaller tumours held together by fibrous tissue. Their consistence is softer than that of cartilage, sometimes it approaches that of a soft jelly. Their growth is usually slow, though in the softer forms and in those growing in the medulla of bone, it is often very rapid. They may attain an enormous size.

CLINICAL CHARACTERS.—The enchondromata must for the most part be regarded as innocent growths. Those homologous forms which originate from cartilage, and have been called "enchondroses," differ in all respects from the heterologous, and never exhibit malignant cha-

racters. The more heterologous forms originating from connective tissue and bone, are usually encapsuled, and in most cases produce merely local effects, although these, from the parts involved and the rapidity of growth, are often very injurious. The softer forms, however, and especially those which occur in the medulla of bone, occasionally exhibit malignant characters. These grow the most rapidly, and are sometimes not limited by a fibrous capsule; they may therefore recur locally after removal. In very rare cases they have also infected the lymphatic glands, and recurred in the lungs.

In speaking of the malignancy of the enchondromata, it must be borne in mind that these cartilaginous growths are sometimes associated with sarcoma; so that whilst it must be admitted that pure enchondromata are in exceptional cases malignant, the malignant properties ascribed to these growths are probably often due to the combination with sarcomatous elements.

CHAPTER XVIII.

THE OSTEOMATA.

THE Osteomata or osseous tumours, are tumours consisting of osseous tissue. A new formation of bone occurs under various circumstances. Irritative conditions of the bone and periosteum are often attended by a large formation of new bone. This is seen after fractures, in which there is not only a formation of bone from the bone itself, but also from the periosteum and adjacent fibrous structures ("permanent" and "provisional callus"). Chronic inflammation of the periosteum is also frequently followed by thickening of the bone beneath it. These, however, are inflammatory formations, and have not an independent growth like the osseous tumours.

STRUCTURE.—Osseous tumours resemble in structure normal bone. There are three histological varieties:—

1. *The Eburnated Osteomata.*—These consist of dense, compact, osseous tissue. The lamellæ are arranged concentrically and parallel to the surface of the tumour. There is a complete absence both of blood-vessels and of cancellous tissue.

2. *The Compact Osteomata.*—These are formed of a tissue similar to that of the compact tissue of the long bones; differing only in the arrangement of the Haversian canals and canaliculi, which is less regular than in normal bone.

3. *The Cancellous Osteomata.*—These consist of cancellous osseous tissue, which is usually surrounded by a thin layer of denser bone. The medullary spaces may contain embryonic tissue, a fibrillated tissue, or fat.

DEVELOPMENT.—Osseous tumours originate from bone or its periosteum, from cartilage, and from connective tissue apart from bone.

VARIETIES.—The osteomata are divisible into two classes, according to their seat—the homologous osteomata or *exostoses*, and the heterologous osteomata or *osteophytes*.

The *homologous osteomata* or *exostoses*, are outgrowths from pre-existing bone, growing either from the periosteum, from the articular cartilage, or from the medulla. Those growing from the periosteum occur most frequently on the external and internal surfaces of the skull: the orbit is an especially favourite seat, and here they are often dense and eburnated. They are also common on the upper and lower jaws, and in this situation they may grow from the dental periosteum. There is usually a line of demarcation between them and the subjacent bone, the new tissue of the tumour being distinct from the compact tissue of the bone. The periosteum from which they grow covers them, and is continuous with that of the old bone.

The *exostoses* growing from the articular cartilages occur at the ends of the long bones. In structure they are much more cancellous than the periosteal growths, and their outline is less regular. The medullary *exostoses*—or more properly, *enostoses*—are the least frequent: they originate in the medullary tissue.

The *heterologous osteomata* or *osteophytes*, originate apart from bone, growing from the connective tissue or from cartilage. They are especially liable to occur in tissues in the neighbourhood of bone which are the seat of a chronic inflammatory process, and they must in most

cases be regarded rather as inflammatory formations than as tumours. Such formations of bone are sometimes met with in the neighbourhood of diseased joints and of diseased bone in other situations, in tendons, in the cartilages of the larynx in chronic laryngitis, in the costal cartilages, in the bronchi, in muscle, in the arachnoid and pia mater, and even very occasionally in the lungs and brain. They must be distinguished from calcareous deposits, in which there is no new formation. (See "Calcareous Degeneration.")

CLINICAL CHARACTERS.—The osteomata are perfectly innocent tumours. Their growth is very slow. They rarely attain a large size. They are often hereditary and multiple, in which case they usually occur in early life. Those osseous growths which sometimes exhibit malignant characters, are sarcomata or cancers which have undergone partial ossification. From these, true osteomata must be carefully distinguished. (See "Osteoid Sarcoma" and "Osteoid Cancer.")

CHAPTER XIX.

THE LYMPHOMATA.

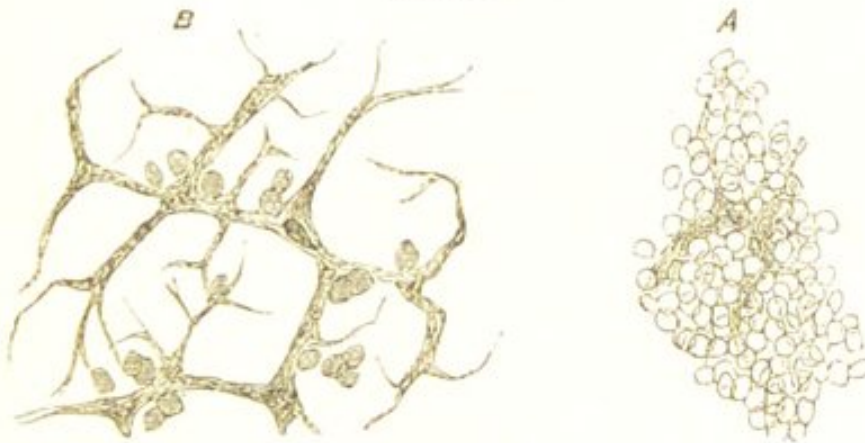THE Lymphomata are new formations consisting of lymphatic, or, as it is sometimes called, *adenoid* tissue (the "adenoid tissue of His"). Lymphatic tissue is the tissue composing the follicles of the lymphatic glands and the Malpighian corpuscles of the spleen, and existing in many other parts belonging to the lymphatic system. This tissue is now known to have a much more general distribution than was formerly supposed; it not only constitutes the follicles of the lymphatic glands and the Malpighian corpuscles of the spleen, but also Peyer's glands and the solitary glands of the intestine, the follicles of the pharynx and tonsils, the Thymus gland, and the trachoma glands of the conjunctiva. Recently it has also been found to exist in many other situations, as around the blood-vessels of the pia mater and of other parts, in the neighbourhood of the smallest bronchi, in the pleura immediately beneath its endothelium, in the peritoneum, in the mucous membrane of the alimentary canal, and in the medulla of bone.

STRUCTURE.—Lymphatic tissue, wherever it exists, possesses the same general structure, and the follicle of a lymphatic gland may be taken as the type, not only of the physiological tissue, but also of the pathological growths.

This tissue consists essentially of a reticulum of

branched cells, within the meshes of which are contained lymphatic elements—the so-called lymph-corpuscles. The reticulum is made up of very fine fibrils which form a close network, the meshes of which are only sufficiently large to enclose a few, or even a single corpuscle, in each. The fibrils usually present a more or less homogeneous appearance, and nuclei are to be distinguished at the angles of the network (Fig. 38). The lymphatic

FIG. 38.




Lymphoma.—A, a thin section of a lymphomatous tumour of the mediastinum. B, a similar section, from which most of the cells have been removed by pencilling, so as to show the reticulated network, and the nuclei in its angles. This network is much more marked than that often met with. $\times 200$.

cells, or lymph-corpuscles, which constitute the greater part of the tissue, can in most cases be readily removed from the meshes of the reticulum by the agitation of thin sections in water. They are identical in their characters with the white cells of the blood, and like these are contractile, and possess the power of spontaneous movement. As usually seen after death, they are spheroidal, pale, semi-transparent bodies, varying considerably in size, and also presenting slight differences in their structure. Some are granular and appear to possess no nucleus; in others, a distinct, simple, or compound nucleus is visible, which is usually also granular; others again are much larger and contain two or even three nuclei.

The histological characters of the lymphomata, however, vary considerably according to the age of the growth and the rapidity of its development. In the earlier stages of development, and when growth is taking place very rapidly, the proportion of lymph-corpuscles is great, and many of these are much larger than those normally met with in lymphatic glands, containing two, or even several, nuclei (myeloid or giant cells). (Fig. 39.) In a more advanced stage, and also in all

FIG. 39.



Cells from a Lymphatic Growth in the Liver. Those to the left are the ordinary lymph-corpuscles which constituted the greater part of the growth. To the right are some of the larger multi-nucleated elements. $\times 350$.

tumours in which the process of development has been slow, the proportion of lymph-corpuscles is smaller, and the reticulum constitutes a more prominent part of the growth. The larger cell-forms also are almost entirely wanting; and the reticulum, instead of being exceedingly delicate, is much coarser, and forms a network of broad homogeneous or slightly fibrillated bands. As the reticulum increases the lymph-corpuscles gradually diminish in number and become arranged in smaller groups within its meshes. (See Fig. 79.) These variations in the proportion of corpuscles and stroma are precisely analogous to those met with in lymphatic glands as the result of acute and chronic inflammation. (See "Inflammation of Lymphatic Structures.")

DEVELOPMENT.—The lymphomata originate for the most part from lymphatic tissue, being simply overgrowths of pre-existing lymphatic structures. At the same time it is probable that the new elements are in some cases partly

derived from migrated blood-corpuscles, which multiply subsequently to their escape from the vessels. (See "Leukæmia.") These growths are therefore usually homologous. They may, however, be heterologous, either owing to the new tissue extending considerably beyond the confines of the old, or to its growth in situations where it is normally almost entirely wanting. This latter condition obtains in Hodgkin's disease, and in certain forms of lymphoma which are malignant.

SECONDARY CHANGES.—The lymphomata do not undergo marked retrograde changes. There is no fatty degeneration, caseation, or softening, such as occurs in scrofulous glands.

PHYSICAL CHARACTERS, &c.—The physical characters of the lymphomata vary according to the rapidity of their growth. The rapidly growing forms, in which the cellular elements are so numerous, are of a greyish-white colour and soft brain-like consistence, much resembling encephaloid cancer. These often attain an enormous size, and infiltrate the neighbouring structures. They have been called by Virchow *lympho-sarcoma*. Those which are more slowly developed, and in which the reticulum constitutes the greater portion of the growth, are much harder in consistence, sometimes being almost cartilaginous. These harder growths rarely attain a large size.

CLINICAL CHARACTERS.—Clinically, the lymphomata are, for the most part, perfectly innocent tumours. They originate most frequently in the lymphatic glands, the gland undergoing a continuous increase in size. Sometimes the enlargement of the glands appears in the first place to be of an inflammatory nature, and to result from some irritation, but upon this being removed the glands, instead of subsiding, continue to increase. In most cases, however, no such source of irritation is discoverable. The glands which are especially prone to this disease, are

the cervical, the submaxillary, the axillary, the inguinal, the bronchial and mediastinal, and the abdominal glands. Usually only a single gland or a single group of glands is affected; sometimes, however, the growth is more general. As the glands enlarge, they gradually unite, so that ultimately they may form very large lobulated tumours. The lymphatic structures in the intestine may in the same way become enlarged, and project so as to form polypi. The enlargement of the spleen in ague, is also probably of the same nature. The lymphomata occasionally, however, exhibit malignant properties. This is especially the case in those richly cellular, soft, rapidly growing forms which are sometimes met with. Such growths may infiltrate the surrounding structures even more rapidly than the most infective cancer, although they rarely infect distant parts. They are sometimes met with in the cervical glands, but more frequently in the mediastinum, where they invade one or both lungs, and constitute the most common form of mediastinal tumour ("Thoracic Cancer)."

In the condition known as "Hodgkin's Disease," and in Leukæmia, these lymphomatous growths are met with in various parts of the body.

HODGKIN'S DISEASE.

This disease is characterised by the enlargement of the lymphatic glands in various parts of the body, together with the development of lymphatic growths in internal organs, especially in the spleen and liver. The new growths are often known as *lymphadenoma*. They are precisely similar histologically to lymphoma.

The disease was formerly described by Hodgkin, Bright, Wilks, and Trousseau, and was called, after the first-named of these observers, "Hodgkin's Disease." Trousseau designated it "Adénie." It is also known as "Anæmia Lymphatica." Recently its characteristics have been more

fully determined by MM. Cornil and Ranvier, and by Drs. Murchison* and Sanderson, to whose descriptions the reader is referred for more complete information respecting it.

Histologically, the new growths are precisely similar to those of leukaemia. The disease differs essentially, however, from leukaemia in this respect, that the new formation of lymphatic tissue is not associated with any notable increase in the number of the white corpuscles in the blood.

The lymphatic glands are usually the earliest seats of the new growth, and here it differs in no respect histologically from the lymphomata. At first it may be limited to a single group of glands; subsequently, however, the process becomes more general, and the glands throughout the whole body may be more or less involved. The glands as they increase in size gradually become confluent so as to form large lobulated tumours, and the new growth, which takes place in the earlier stages within their capsules, often ultimately extends so as to infiltrate the surrounding structures.

This new growth of lymphatic tissue, which commences in and often extends beyond the confines of the lymphatic glands, is ultimately followed by the formation of lymphatic growths in various internal organs, but more especially in the spleen and liver. In the spleen, the Malpighian corpuscles become enlarged and form greyish-white nodules and masses. The kidneys, lungs, stomach, muscle, bones, and subcutaneous tissue may all become involved, the new growths occurring either as nodules of various sizes scattered through the organs, or in a more infiltrated form, like many of those met with in leukaemia.

In their physical characters the new growths vary.

* "Trans. Path. Soc. Lond.," vols. xx. and xxi.

They are sometimes of a greyish-white colour and of a soft brain-like consistence, yielding a milky-juice which is rich in cellular elements precisely resembling leucocytes. In other cases they are much firmer in consistence, and they may be as hard as an indurated lymphatic gland. These differences depend upon the relative proportions of the cells and stroma. They have but little tendency to undergo retrogressive changes.

LEUKÆMIA.

This disease, like Hodgkin's disease, is characterised by the development of lymphomatous tissue in various organs, but especially in the spleen. The growth of this new tissue, however, is associated with a large increase in the number of the white corpuscles in the blood. It is this alteration in the blood which gives leukæmia its distinctive characters—hence its name. The disease will be considered subsequently, when treating of "Diseases of the Blood."

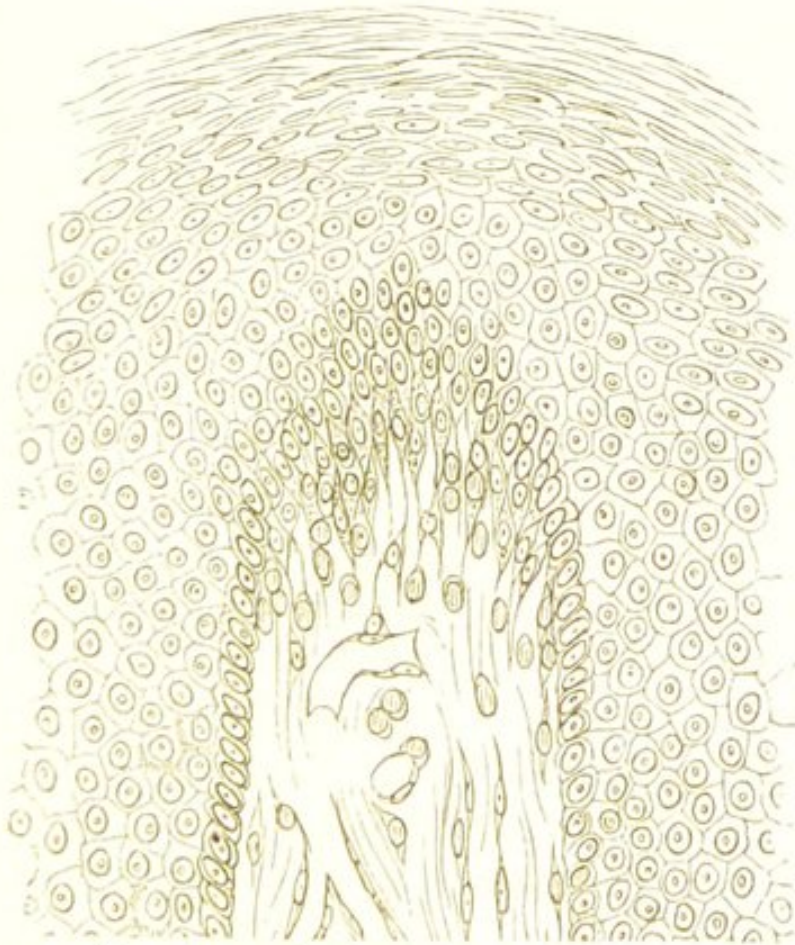
CHAPTER XX.

THE PAPILOMATA.

THE Papillomata are new formations resembling in structure ordinary papillæ, and like these they grow from cutaneous, mucous, or serous surfaces.

STRUCTURE.—They consist of a basis of, often richly cellular, connective tissue, supporting blood-vessels, which

FIG. 40.



Papilloma. Showing a single enlarged papilla. (Rindfleisch.)

terminate in a capillary network or in a single capillary loop, the whole being enveloped in a covering of epithe-

lium (Fig. 40). The epithelial covering varies in character in different growths. In those of the skin, it is often very abundant, and the superficial layers are hard and stratified, forming a dense firm covering. In those originating from mucous surfaces, the epithelium forms a thinner investment, and is of a much softer consistence; whilst in those growing from serous membranes it often constitutes only a single layer.

The growth may be simple—consisting merely of enlarged papillæ, as in a common wart; or it may be more complex, the papillæ being very numerous, and giving off secondary and tertiary offsets. If the investing epithelium be very abundant, it may so enclose the whole mass as to give to it a more or less regular outline. More commonly, however, this is not the case, and the epithelium not being sufficient to fill up the spaces between the papillæ, the growth presents a branched, villous, or cauliflower appearance. The blood-vessels are often very numerous, and are sometimes dilated and tortuous.

DEVELOPMENT.—The papillomata always originate from the skin, from mucous, or from serous membranes. They most frequently grow from pre-existing papillæ; sometimes, however, they occur where no papillæ exist, springing directly from the sub-epithelial connective tissue:—this is the case in the stomach and larynx. Their growth is usually slow. The individual tumours rarely attain a very large size, the larger forms being for the most part constituted of several smaller growths.

SECONDARY CHANGES.—Of these, ulceration and hæmorrhage are the most frequent. They occur especially in those growths which originate from mucous surfaces. The hæmorrhage is often very abundant, and may even endanger life. This is not unfrequently the case in the papillary growths of the bladder and intestine.

VARIETIES.—The varieties of papillary tumours depend principally upon their seat. Those growing from the

skin include *warts* and *horny growths*. Warts are firm, have a dense epithelial covering, and are less prone to ulceration and hæmorrhage than those growing upon other parts. Horny growths appear usually to originate in the sebaceous follicles by a continuous proliferation of their epithelium. The epithelium, together with the sebaceous secretion, forms a projecting horn, which increases by growth at its base. Such formations hardly come within the definition of papilloma. Larger and more vascular papillary tumours may, however, occur on cutaneous surfaces—such are the *condylomata* and *venereal warts* met with around the anus and upon the external male and female genital organs as the result of irritating secretions.

The papillomata of mucous membranes are softer and more vascular than the preceding, they have a less dense epithelial covering, and are more prone to ulceration and hæmorrhage. Many of them come within the category of mucous polypi. They are met with on the tongue, in the larynx and nose, on the gastro-intestinal mucous membrane, on the cervix uteri, and in the bladder. In the bladder and intestine they are often exceedingly vascular, and give rise to profuse hæmorrhage. Here they are not unfrequently confounded with villous epithelioma.

Papillomata of serous membranes never form distinct tumours. They are met with most frequently as small outgrowths from the synovial membrane in chronic diseases of joints.

CLINICAL CHARACTERS.—Clinically, the papillomata are innocent growths. They may, however, prove fatal from continuous ulceration and hæmorrhage: this is especially the case, as already mentioned, in papilloma of the bladder and intestine. In these situations they are easily mistaken for epithelioma; the symptoms of both are very similar, and it is often only after death that they can be

distinguished. In the papillomata the epithelium is *homologous*, being situated only *upon the surface* of the papillæ, and in no case growing *within* their connective tissue basis. In the epitheliomata, on the other hand, it is *heterologous*, and is met with at the base of the tumour in the subjacent connective tissue. (See Fig. 52.) A growth which is primarily a simple papilloma may subsequently become an epithelioma. (See "Epithelioma.")

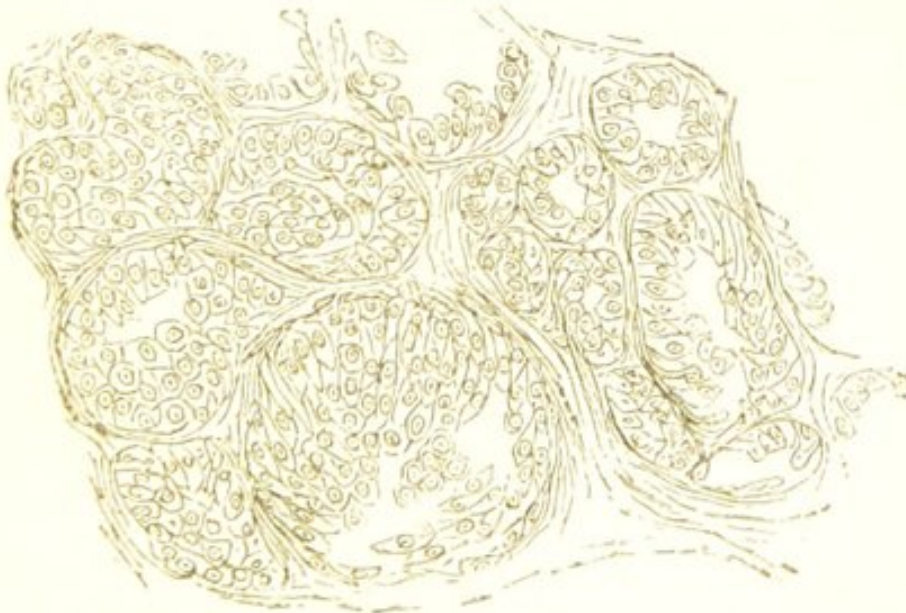
CHAPTER XXI.

THE ADENOMATA.

THE Adenomata—or as they are more commonly called, *glandular tumours*—are new formations of gland-tissue.

STRUCTURE.—In structure the adenomata resemble the racemose or tubular glands. They consist of numerous small saccules or tubes lined with squamous or cylindrical epithelial cells. These are grouped together, being merely separated by a small, though varying, amount of connective tissue, in which are contained the blood-

FIG. 41.



Adenoma of the Mamma. × 300. (Rindfleisch.)

vessels. (Fig. 41.) Many new growths, however, contain a large amount of this gland-tissue which are not strictly adenomata. All growths originating in glandular organs

may be associated with more or less glandular structure. In the mamma, for example, sarcoma, myxoma, and other forms of tumour, are often so intermingled with the gland-tissue of the organ that it becomes difficult to say which is the predominant structure. In many cases it is evident that the development of such tumours is accompanied by an increase of the gland-tissue amongst which they grow. Thus are produced mixed forms—*adeno-sarcomata*, *adeno-myxoma*, &c.

DEVELOPMENT.—The adenomata always originate from pre-existing gland-structures, of which they are simply local hyperplasias. Their growth, which is usually slow, takes place by the development of diverticula from the saccules or tubules of the gland, and by a proliferation of the enclosed epithelium. The new growth may remain in intimate relation with the adjacent gland, or it may ultimately become separated from it by a fibrous capsule.

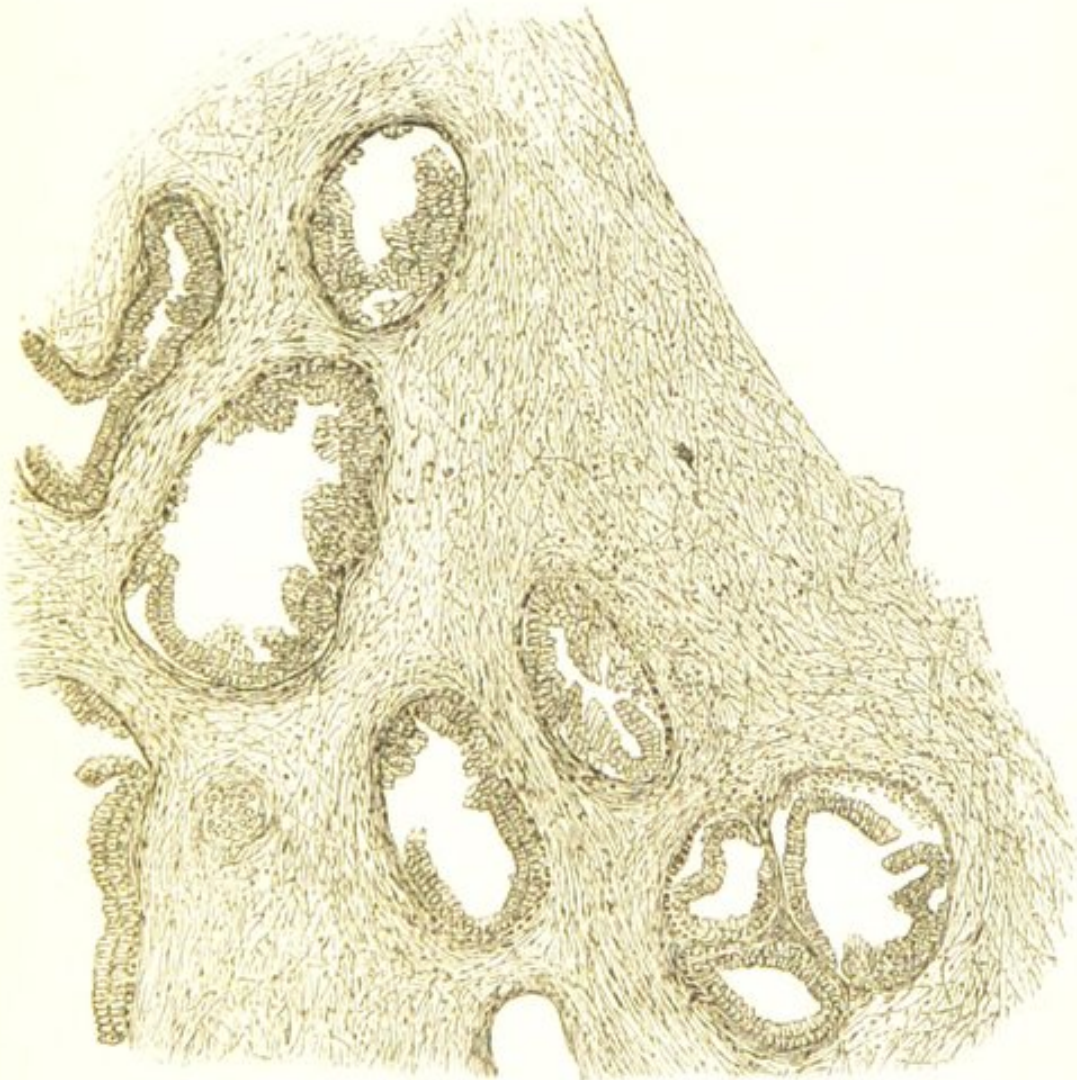
SECONDARY CHANGES.—The most frequent of these is fatty degeneration of the epithelium, which may give rise to the formation of small caseous masses in the growth. Dilatation of the saccules and tubules so as to form cysts, and mucoid softening, are also common.

VARIETIES.—*Adenoma of Mamma*.—In the mammary gland two varieties of adenoma must be distinguished,—one, in which there is a general hyperplasia of the whole gland; the other, in which the process is limited to smaller or larger groups of lobules. The former constitutes hypertrophy of the mamma, the latter is the *chronic mammary* or *adenoid* tumour. Pure adenoma of the mamma is not common. Many tumours in this situation described as adenomata are sarcomatous, fibrous, or myxomatous growths in which is contained a varying amount of gland-tissue. The distinction between such growths and pure adenoma is often difficult. The adenomata are either superficially or deeply seated in the gland, from which they are usually separated by a loose

fibrous capsule. They are commonly round or oval in shape, lobular, and of a hard elastic consistence. On section they often present a lobulated appearance, their racemose structure being sometimes visible to the naked eye.

Adeno-Sarcoma and Adeno-Fibroma of Mamma.—These are more common than pure adenoma. In them the connective tissue between the acini of the gland undergoes active changes, and forms a fibro-cellular, spindle-celled, or round-celled structure, amongst which the acini are

FIG. 42.



Adeno-Fibroma of Mamma.—Showing new growth of gland-structure and of connective tissue. $\times 100$; reduced $\frac{1}{2}$.

embedded. (Fig. 42.) In many cases it is difficult to determine whether the glandular structure is really in-

creased in amount, whilst in others it is so abundant that such is evidently the case. These tumours form lobulated masses of a firm consistence. They grow slowly, and rarely ulcerate. In most cases they contain cysts. Many of these are lined with cylindrical epithelium and are formed by the dilatation of the ducts of the gland; others appear to originate from localised softenings of the tissue. These cysts are usually very numerous, and they often attain a large size. They are frequently seen much flattened so as to present the appearance of fissures running amongst the growth. In other cases they are more or less completely filled by masses of the tumour which have grown into their interior. This formation of cysts in these tumours has given rise to the terms *cystic-sarcoma*, *cystic-adenoma*, &c.

Adenoma of Mucous Membranes.—The glandular structures of mucous membrane are also common seats of adenoid growths. In the nose, the pharynx, the stomach, the intestines, the vagina and uterus, these growths are sometimes met with. In course of time they usually gradually project above the surface of the membrane so as to form a polypus, and thus constitute one of the forms of *mucous polypi*. In consistence they are soft and somewhat gelatinous, and often present a semi-translucent appearance. Their surface resembles in colour the surrounding mucous membrane. The formation in them of cysts, by the dilatation of their tubules, is exceedingly frequent: the cysts usually contain a soft mucoid substance.

CLINICAL CHARACTERS.—Clinically, the adenomata are perfectly innocent; they are, however, very liable to be confounded with growths possessing malignant properties. A tumour, also, which is primarily a simple adenoma, may subsequently become cancerous. The anatomical distinction between cancer of a gland in its earlier stages and a simple glandular tumour is often

exceedingly difficult, especially in the mamma. In cancer the growth appears to commence by a proliferation of the epithelium within the ducts of the gland, and as the epithelium only subsequently becomes heteroplastic, the determination of the nature of the tumour in this stage is necessarily attended with considerable difficulty. This will be again alluded to when speaking of cancer. (See "Structure of Carcinoma.") In sarcomatous tumours, again, originating in the connective tissue of a gland, the ducts of the gland filled with epithelium, are often seen embedded in the new growth, and thus the appearance of adenoma may be closely simulated.

CHAPTER XXII.

THE CARCINOMATA.

THE Carcinomata, or Cancers, are new formations consisting of cells of an epithelial type, without any intercellular substance, grouped together irregularly within the alveoli of a more or less dense fibroid stroma.

The term "*cancer*" has been so commonly applied indefinitely to any growth possessing malignant properties, that "*cancerous*" and "*malignant*" have come to be regarded by many as synonymous terms. It is important, however, clearly to distinguish between them. A *cancer* is a growth possessing the above-named definite structure; a *malignant* growth, on the other hand, is one which, independently of its structure, tends to reproduce itself in adjacent or distant tissues. (See "Malignancy.") "*Cancerous*," is an *anatomical* term; "*malignant*," is a *clinical* one.

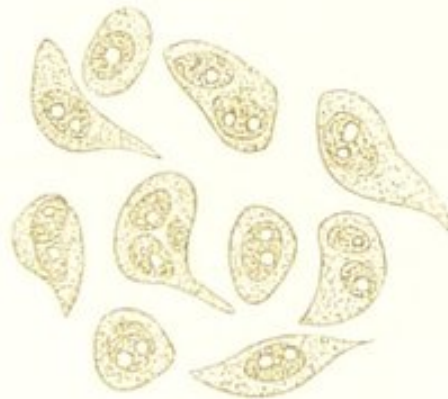The Cancers include the four following varieties:—*Scirrhus*, *Encephaloid*, *Colloid*, and *Epithelioma*. Of these, the first three possess the same general characters, although they present certain structural and clinical differences which serve to distinguish them. Epithelioma constitutes a more distinct variety. It will be well in the first place to describe the characters common to the larger and more important group, and then those which are peculiar to its individual members. Epithelioma will be considered subsequently.

STRUCTURE.—In structure, scirrhus, encephaloid, and

colloid cancer so far resemble one another, that they all consist of cells of an epithelial type, without any intercellular substance, grouped together irregularly within the alveoli of a fibroid stroma. (See Fig. 46.) Although there is no distinct intercellular substance, a certain amount of liquid exists between the cells. It is this liquid which exudes from the freshly-cut surface of the cancer, and the number of cells which it contains give to it a milky appearance.

The *cells* are characterised by their large size, by the diversity of their forms, and by the magnitude and prominence of their nuclei and nucleoli. (Fig. 43.) In size

FIG. 43.



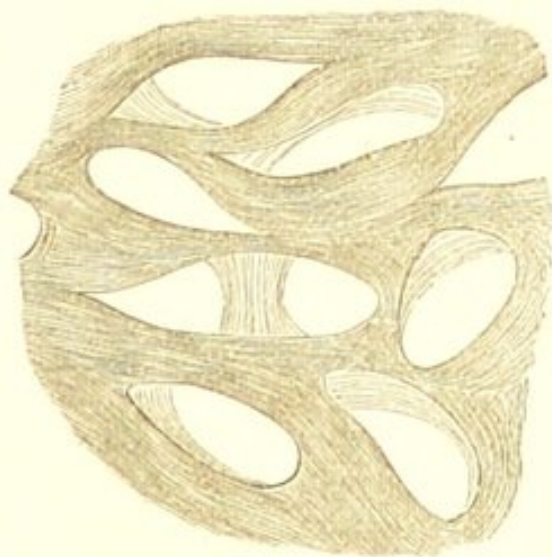
Cells from a Scirrhus of the Mamma. × 250.

they vary from $\frac{1}{600}$ to $\frac{1}{1500}$ of an inch in diameter; the majority being about five times as large as a red blood-corpusele. They are round, oval, fusiform, caudate, polygonal—exhibiting, in short, every diversity of outline. These variations in form are principally owing to the mutual pressure to which in their growth they are subjected. The nuclei, which are large and prominent, are round or oval in shape, and contain one or more bright nucleoli. The nuclei are, perhaps, most frequently single; two, however, are frequently met with, and in the softer and more rapidly growing cancers they may be much more numerous. The cells rapidly undergo retrogressive changes, hence they usually contain molecular fat. They

are many of them exceedingly destructible, so that sometimes more free nuclei than cells are visible. Cells precisely similar to these are met with in other morbid growths, and also in the normal tissues. There is thus no *specific* "cancer-cell." It is the general character of the cells, together with their mode of distribution in the meshes of a fibroid stroma, that determines the nature of the growth to which they belong. The appearance presented by these cells grouped within the alveoli of the cancer sometimes closely simulates, in the earlier stages of growth, that of simple adenoma. (See Fig. 41.) In adenoma, however, the cells resemble the epithelium of the gland; they are smaller, and less irregular in size and shape, and less closely packed than those of carcinoma. In many cases, indeed, they form merely a single layer lining the walls of the acini.

The *stroma* varies considerably in amount, being much more abundant in some varieties of cancer than in others. It consists of a more or less distinctly fibrillated tissue,

FIG. 44.



The Alveolar Stroma from a Scirrhous of the Mamma. The cells have been removed by pencilling. × 200.

arranged so as to form alveoli of various forms and sizes, within which the cells are grouped. (Fig. 44.) These

alveoli communicate with one another so as to form a continuous cavernous system. The characters of the stroma vary with the rapidity of its growth:—if this is rapid, it will contain some round and spindle-shaped cells (see Fig. 48); if, on the other hand, it is slow or has altogether ceased, the tissue will contain but few cells, and will be denser and more fibrous in character. The latter is the condition in which it is most commonly met with.

Within the stroma are contained the *blood-vessels*. These are often very numerous, and form a close network. They are limited to the stroma, and only in very exceptional cases do they encroach upon the alveoli.* This distribution of the blood-vessels is important as distinguishing the cancers from the sarcomata. In the latter, the vessels are not supported by a stroma but ramify amongst the cells of the growth; hence the facility with which these tumours become generally disseminated.

In addition to the blood-vessels the cancers also possess *lymphatics*. These accompany the blood-vessels, and, as has been shown by MM. Cornil and Ranvier, communicate with the alveoli. This explains the great tendency of cancer to infect the lymphatic glands.

DEVELOPMENT.—The question of the genesis of cancer involves that of the genesis of epithelium generally. It is maintained by many Histologists that epithelium can only originate from epithelium, and that the strata of cells set aside in the embryo for the production of the epithelial tissues is the source from which all epithelium is subsequently derived. Others admit that epithelium may also originate from connective tissue. (See "Develop-

* In soft rapidly growing cancers the blood-vessels have occasionally been observed to project as tufts into the alveoli. See case reported by Mr. Marcus Beck and Mr. Arnott, "Trans. Path. Soc. Lond.," 1874, p. 224.

ment of the New Formations.”) A like difference of opinion exists as to the source of the epithelioid cells of cancer. By many—as Waldeyer, Thiersch, and Billroth—they are regarded as originating only from pre-existing epithelium. Others—amongst whom are Virchow, Lücke, Rindfleisch, and Klebs—maintain that they may also be derived from cells belonging to the connective tissue.

The difficulty of determining the genesis of cancer, is partly owing to the fact that it so frequently originates in structures where epithelium is normally abundant, as in the mamma, skin, and alimentary canal; and that this normal epithelium is always, from the earliest stage of the growth, the seat of active proliferation. In cancer of the mamma, for example; the first change often observable is an accumulation of epithelium within the ducts of the gland, a condition very similar to that already described as occurring in the development of an ordinary glandular tumour. (See “Adenoma.”) Soon, however, the epithelium alters its characters. The cells become larger and more irregular in shape, and their nuclei are more prominent. The epithelium is then found outside the ducts, amongst the inter- and peri-glandular connective tissue, which is also in a state of active proliferation, and is infiltrated with small round cells. The outline of the ducts ultimately becomes completely annihilated, and the epithelioid cells are seen in alveoli formed of a fibroid tissue. The question arises as to whether the epithelioid cells, which constitute the ultimate cancerous growth, originated from the epithelium normally existing within the ducts of the gland, which in the process of development has extended beyond the ducts into the surrounding tissue; or whether they originated in the connective tissue—the proliferation of the glandular epithelium being merely a secondary process, and resulting from the irritation of the inter-glandular growth.

In those rare cases in which cancer occurs primarily in

situations where no epithelium normally exists, as in the medulla of bone and in lymphatic glands, it is difficult to maintain an epithelial origin. It must be admitted, however, that the tendency which is exhibited by the cells of cancerous growths to maintain the type of the epithelial structures in the vicinity of which they grow, is greatly in favour of the view that they are derived from the epithelium. In cancers situated near the cutaneous surfaces, for example, the cells are usually of the squamous type, whereas in those growing in connection with the glands of mucous membranes, they more commonly resemble the epithelium of the gland. It must be borne in mind, also, that the characters of young epithelium are by no means well defined. It is impossible to draw a line of demarcation between young epithelial cells, and the small round cells which are so numerous in the growing stroma of the cancer. It would appear to be quite in accordance with our present state of knowledge to admit the probability of two different modes of origin of the epithelioid cells in cancer—one from epithelium, and the other from connective tissue; in the former case the cells being more strictly epithelial, such as are met with in epithelioma; in the latter, the epithelial characters being less marked, as in many forms of encephaloid and scirrhus.

Epithelium and cells belonging to connective tissue are not the only elements, however, from which the cells of cancer may originate. Allusion has already been made to the researches of Dr. Creighton which show that in secondary cancers of the liver, the elements of the cancer originate directly from the liver-cells by a process of vacuolation and endogenous growth. (See "Development of New Formations.") It is probable that, in the same way, the cells of other tissues will be found capable of originating cancer.

The *stroma* of cancer is partly a new growth, and partly the pre-existing connective tissue of the part in which

the cancer originates. It is probably in the main a new formation, and the pathology of its development will vary with that of the origin of the epithelial elements of the cancer. If the latter originate from epithelium, the stroma may be regarded as the result of the irritation of the connective tissue by the infiltrating epithelial cells. If, on the other hand, the epithelial elements originate from connective tissue, the stroma must be regarded as a portion of the product of the connective tissue hyperplasia.

The cancers in their growth very rarely become encapsuled, but gradually infiltrate the surrounding structures. This process of infiltration is very characteristic, and is more marked in cancer than in any of the malignant growths. The epithelioid elements are seen infiltrating the tissues for some distance around the confines of the tumour, so that there is no line of demarcation between it and the normal structures.

SECONDARY CHANGES.—The most important of these is fatty degeneration. This always occurs to a greater or less extent in all the varieties of cancer. The more rapid the growth, the earlier does this retrogressive change take place, and the greater is its extent; hence it is usually most marked in encephaloid. It produces softening of the growth, which is often reduced to a pulpy cream-like consistence. Caseation, pigmentation, mucoid and colloid degeneration may also occur. Calcification is very rarely met with.

VARIETIES.—The term "cancer" was so vaguely applied by the older pathologists—nearly all malignant formations being included under this head—that considerable confusion has resulted in the classification of cancerous growths. Peculiarities in situation, structure, and appearance have given rise to special names, hence the terms—"osteoid," "chondroid," "cystic," "villous," and "hæmatoid" cancer. A cancer containing large quantities

of pigment was described as a distinct variety, under the name of *melanotic cancer*. Melanotic cancer, however, is comparatively rare. The majority of tumours which are thus designated are in reality sarcomata. (See "*Melanotic Sarcoma*.")

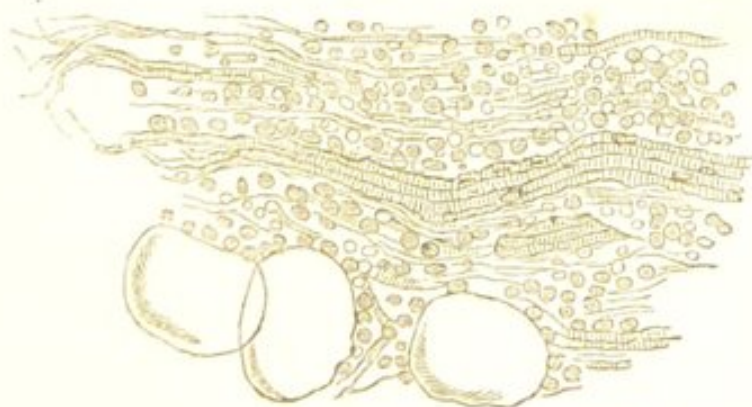
The most convenient classification, and that which is now generally adopted, divides the cancers into four groups:—*scirrhus*, *fibrous*, or *chronic cancer*; *encephaloid*, *medullary*, or *acute cancer*; *colloid* or *gelatiniform cancer*; and *epithelioma* or *canceroid*. This division is based principally upon the relative proportion of the stroma, and upon the type of the epithelial elements.

SCIRRHOUS CANCER.

Scirrhus, *fibrous*, or *chronic cancer* is characterised by the large amount of its stroma and by the chronicity of its growth. The slowness in the development of scirrhous probably accounts in great measure for the peculiarities in its structure and physical characters.

The epithelial growth, although at first it may be luxuriant, quickly subsides. The elements soon atrophy and undergo retrogressive changes. They are most

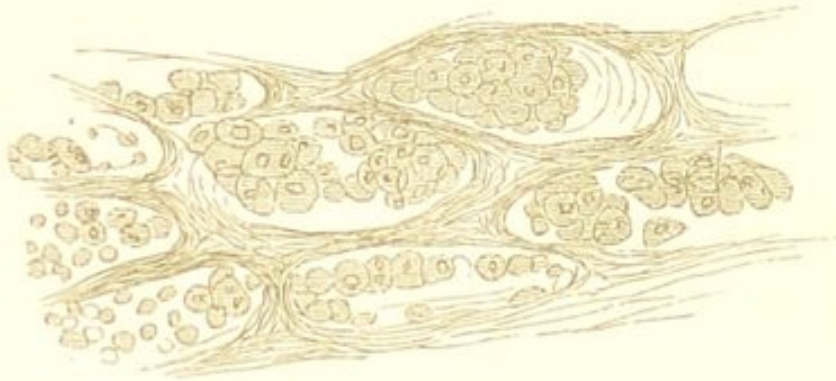FIG. 45.



Scirrhous of the Mamma.—A thin section from the most external portions of the tumour, showing the small-celled infiltration ("indifferent" tissue) of the muscular fibres and adipose tissue in the neighbourhood of the gland. $\times 200$.

abundant in the external portions of the tumour, where growth is taking place; in the central portions they may

FIG. 46.



Scirrhus of the Mamma.—A portion of the tumour somewhat internal to that represented in Fig. 45, showing the characteristic alveolar structure of the cancer. $\times 200$.

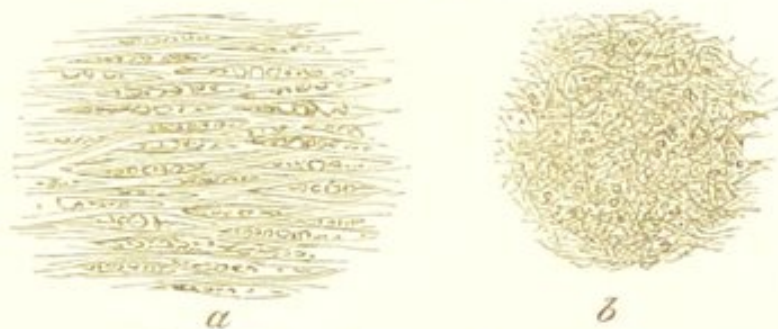
be almost entirely wanting. The accompanying figures (Figs. 45 and 46) show the appearances presented by scirrhus of the mamma in the earlier stages of its development.

The degeneration of the epithelioid elements is probably owing to the excessive growth of the stroma, and to the subsequent induration and contraction which it undergoes. It quickly assumes the characters of cicatricial tissue, and becomes hard and indurated. This causes obstruction and obliteration of the blood-vessels which it contains, and it is probably to this interference with the vascular supply that the arrest in the development of the cancer is owing. The whole of the central portions of the growth may thus ultimately consist simply of dense fibroid tissue amongst which are contained atrophied epithelioid-cells and fatty débris (Fig. 47), the periphery being the only part where the epithelial structure is visible. The amount of atrophy and contraction varies considerably in different cases.

The physical characters of scirrhus are in the same way due to the abundance of its stroma. The growth is

firm and hard, and it is often depressed in the centre, owing to the contraction of the fibroid tissue; this is very characteristic of scirrhus of the breast, where it causes

FIG. 47.



Scirrhus of the Mamma.—A section from the more central portions of the tumour, showing the atrophy of the epithelioid cells, the diminution in the size of the alveoli, the fibroid tissue, and the fatty débris. *a*, earlier stage; *b*, more advanced. $\times 200$.

puckering of the superjacent structures. On section the tumour presents a greyish-white glistening surface, sometimes intersected with fibrous bands. The more external are less firm than the central portions of the growth, and yield on scraping, a juice which is rich in nucleated cells, free nuclei, and granules.

Scirrhus is most commonly met with in the female breast, and in the alimentary canal—especially in the pylorus, œsophagus, and rectum. It also occurs in the skin. It is usually a primary tumour, whilst the secondary growths to which it gives rise are commonly encephaloid.

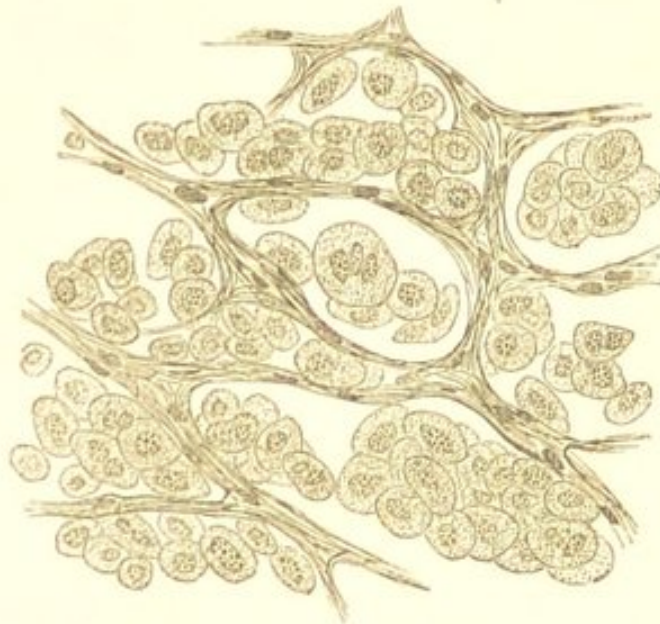ENCEPHALOID CANCER.

Encephaloid, medullary, or acute cancer, is very closely allied to the preceding, from which it differs merely in the greater rapidity of its growth, and the consequent small amount of its stroma, and the softness of its consistence. Encephaloid and scirrhus cannot be regarded as in any way constituting distinct varieties of cancer.

There are all intermediate stages between them, and the differences in the rapidity of their growth, and consequently in their structure and physical characters, constitute their only distinctive features.

The epithelial growth in encephaloid is rapid and abundant, and the cells quickly undergo fatty degeneration, so that often more free nuclei than cells are visible. The proportion of stroma is very small, and owing to the rapidity of its growth, it is much less fibrous than that of scirrhus, and does not undergo a similar cicatricial contraction. (Fig. 48.) The blood-vessels are very

FIG. 48.



Encephaloid Cancer. From a secondary cancer of the liver. Showing the large size of the alveoli and the thinness of their walls. In the latter small cells are visible. The large epithelioid cells are commencing to undergo fatty metamorphosis. $\times 200$.

abundant, and the tissue supporting them being soft and non-resistant, hæmorrhage readily takes place.

Encephaloid cancer is of a soft brain-like consistence, the central portions, where fatty degeneration is most advanced, often being completely diffuent. The tumour is often more or less lobulated. On section, it presents a

white pulpy mass, much resembling brain-substance, which is often irregularly stained with extravasated blood.

Encephaloid is most frequently met with in internal organs, as a *secondary* growth. It also sometimes occurs primarily, in the articular ends of bones, in the eye, in the testis, and in other parts. Many growths formerly described as encephaloid cancer, are soft sarcomata. (See "Round-celled Sarcoma.")

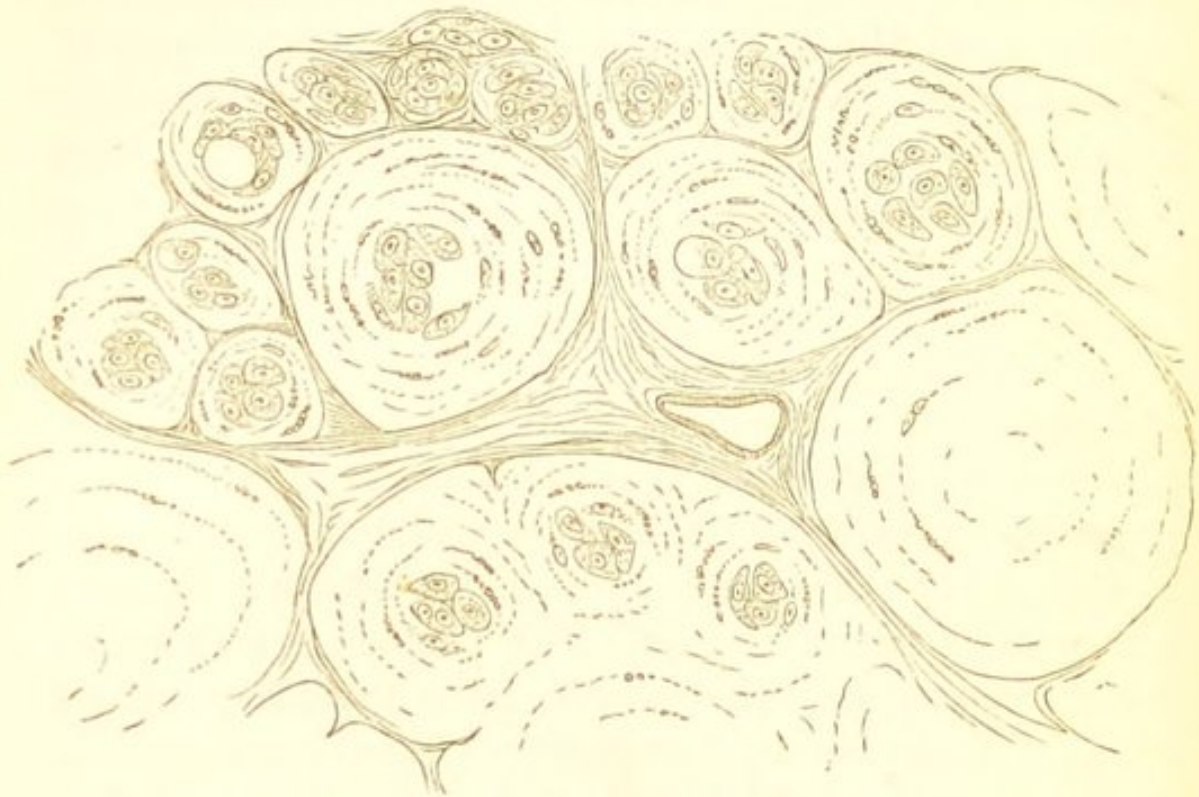
COLLOID CANCER.

The growths described under the name of *colloid*, *alveolar*, or *gelatiniform* cancer, although sometimes regarded as constituting a distinct variety of cancer, are simply one of the preceding forms which have undergone a mucoid or colloid change. The frequency with which non-cancerous growths which have undergone these forms of degeneration have been confounded with colloid cancer has already been alluded to. (See "Colloid Degeneration.")

The alveolar structure in colloid cancers is very marked. The alveoli have very thin walls; they are large, distinct, and more or less spherical in shape. This large size and distinctness of the alveoli is owing to their distension with the softened substance. Within them is contained the gelatinous colloid material, which is a glistening, translucent, colourless, or yellowish substance, of the consistence of thin mucilage or size-gelatin. In the main it is perfectly structureless; within it, however, are embedded a varying number of epithelioid cells, which also contain the same gelatinous substance. (Fig. 49.) These cells present a peculiar appearance:—they are large and spherical in shape, and are distended with drops of the same gelatinous material as that in which they are embedded. (See Fig. 49.) Many of them display a lamellar surface, their boundary being marked by con-

centric lines. It would appear that the colloid change commences in the cells, which become gradually de-

FIG. 49.



Colloid Cancer. Showing the large alveoli, within which is contained the gelatinous colloid material. $\times 300$. (Rindfleisch.)

stroyed in the process. In other cases the cells, with the exception of slight fatty metamorphosis, are but little affected, and the substance distending the alveoli is more viscid and mucoid in character. This is due to a mucoid degeneration of the intercellular substance, rather than to a colloid change commencing in the cells. (See "Mucoid Degeneration.")

Colloid cancer is most frequently met* with in the stomach, in the intestine, in the omentum, and in the peritoneum.

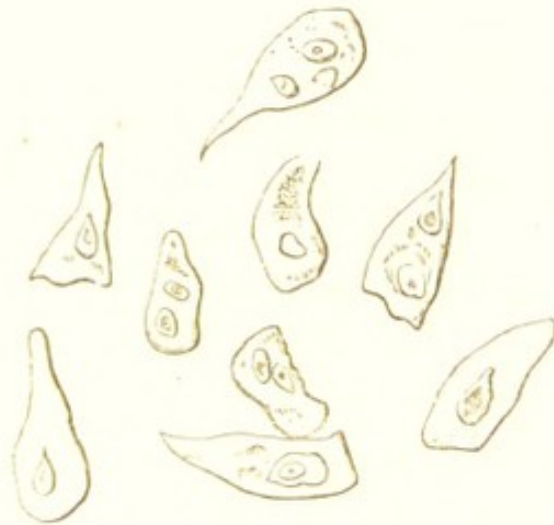EPITHELIOMA.

Epithelioma, canceroid, or epithelial cancer, must be regarded as constituting a much more distinct variety of cancer than either of the preceding. It differs from these in always growing in connection with a cutaneous or

mucous surface, and in its epithelial elements closely resembling the squamous variety of epithelium.

The cells of epithelioma are in the main indistinguishable from those met with on the cutaneous surfaces, and on the mucous membrane of the mouth. They vary in size from $\frac{1}{300}$ to $\frac{1}{1000}$ of an inch in diameter, the average being $\frac{1}{700}$. They contain usually a single nucleus; frequently, however, the nuclei are multiple. (Fig. 50.)

FIG. 50.

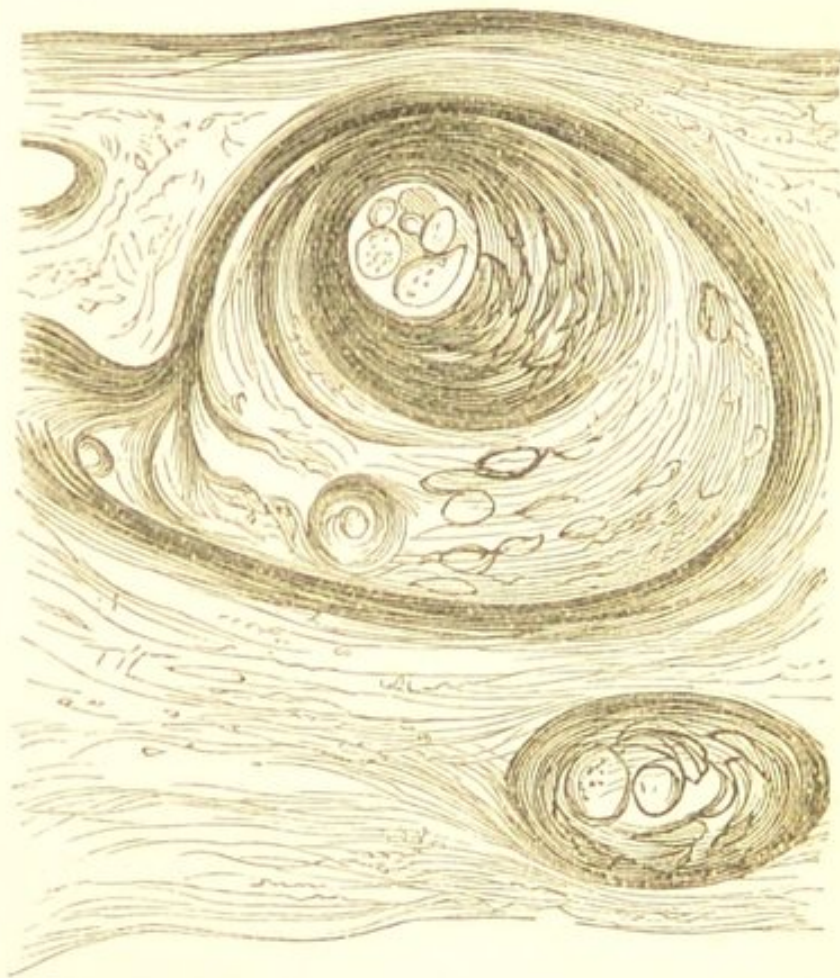


Cells from an Epithelioma of the Lip. × 250.

They are often considerably flattened and distorted in shape owing to the pressure to which in their growth they are subjected, but they never present those numerous varieties in outline which are met with in the other varieties of cancer, neither do they exhibit the same marked tendency to undergo fatty degeneration. The arrangement of these cells is peculiar:—some of them are situated in irregular tubular-shaped lobules; others are less regularly grouped in masses of various sizes amongst the meshes of a stroma. As the cells increase in number they tend to become arranged concentrically in groups so as to form globular masses. These masses are the “*concentric globes*,” or “*epithelial nests*,” which are so commonly met with wherever squamous epithelium

is undergoing rapid growth, and are so especially characteristic of epithelioma. As the epithelium multiplies, the peripheral layers of cells become flattened by pressure against the surrounding structures, whilst those in the centre remain more or less spherical in shape like those of the deeper layers of the epidermis. (Fig. 51.) The cells may be so closely packed as ultimately to become

FIG. 51.



Epithelioma of the Lip. Showing the concentric globes of epithelial cells. $\times 100$.

hard and dry like those of the nails and hair, and the globes are then of a brownish-yellow colour and of a firm consistence. These globes are often large enough to be readily visible to the naked eye, and owing to the arrangement of the epidermic scales, they usually present a fibrous appearance.

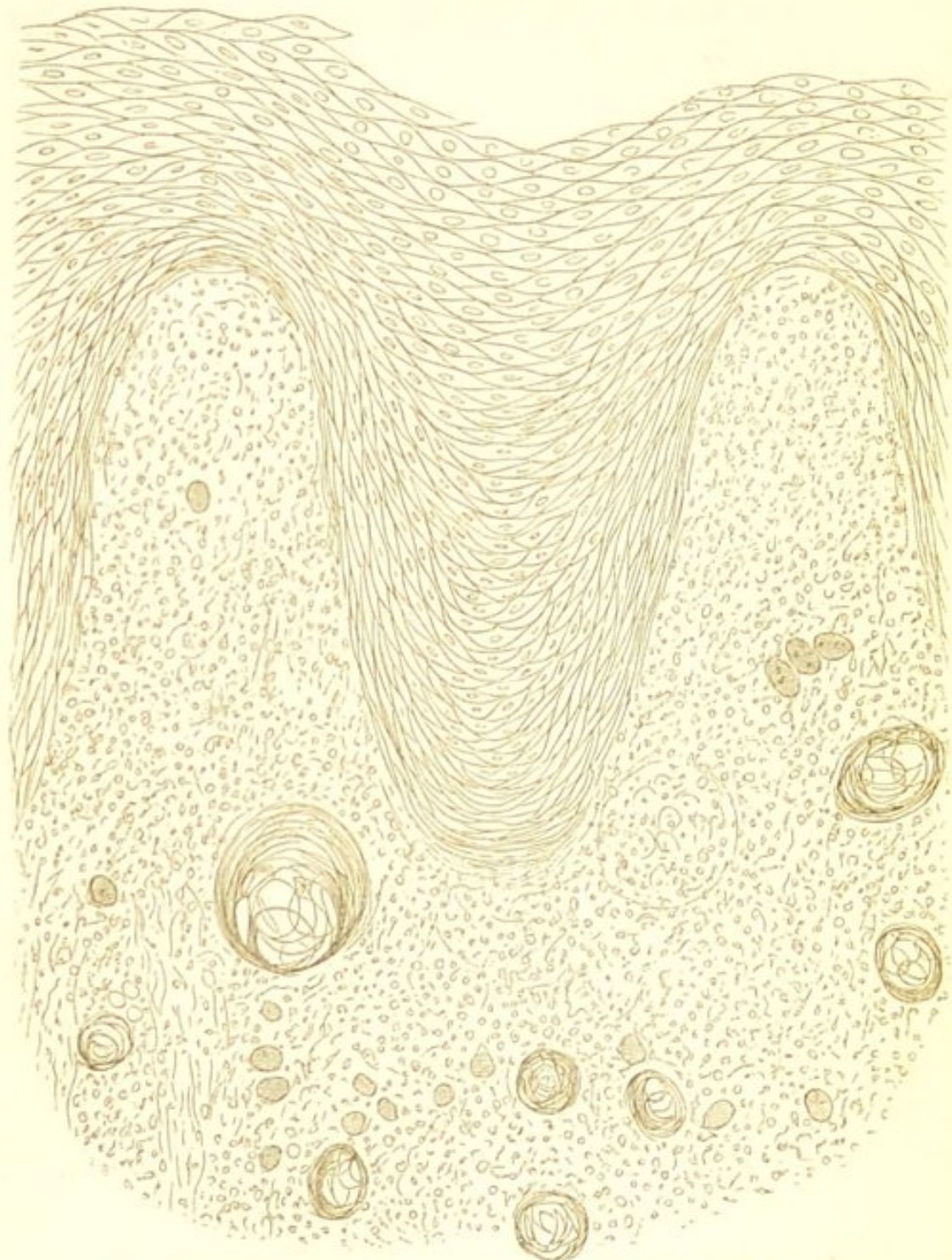
The stroma presents every variation between rapidly growing embryonic, and an incompletely fibrillated tissue. It may be tolerably abundant, or almost entirely wanting. It rarely forms such a marked alveolar structure as that which characterises the other varieties of cancer, but usually consists simply of a small-celled infiltration surrounding the epithelial elements, which may ultimately become developed into a more or less completely fibrillated tissue. (Fig. 52.)

With regard to the development of epithelioma—there can be no doubt that its epithelial elements are derived from the epithelium of the skin or mucous membranes, or from that of the glands which are situated in these tissues. The growth commences by a proliferation of this epithelium, which as it increases becomes *heterologous*, extending beyond the normal limits into the subjacent connective tissue, and even into muscle, bone, and other structures (Fig. 52); and it is in this heterologous development of epithelium which is the essential characteristic of epithelioma. This extension of the epithelium into the subjacent connective tissue produces in the latter an irritative growth, and thus the groups of epithelial elements are always surrounded by a small-celled (“indifferent”) tissue, the small-celled growth preceding the epithelial invasion. (Fig. 52.)

Epithelioma usually presents itself in the first place either as a small foul ulcer with indurated edges, or as a subcutaneous induration or nodule which subsequently ulcerates. The surface of the ulcer is frequently papillated and villous, owing to the irregular growth of the corium. The tumour itself is firm in consistence, often more or less friable, and on section presents a greyish-white granular surface, sometimes intersected with lines of fibrous tissue. The cut-surface yields on pressure a small quantity of turbid liquid, and in many cases also a peculiar, thick, crumbling, curdy material can be ex-

pressed, which often comes out in a worm-like shape like the sebaceous matter from the glands of the skin. This

FIG. 52.



Epithelioma of the Tongue. A thin vertical section, showing the excessive epithelial growth upon the surface of the papillæ, and the extension of the epithelial elements into the subjacent connective tissue. The sub-epithelial tissue is infiltrated with small ("indifferent") cells, amongst which are seen the epithelial elements both single and forming concentric globes. $\times 100$.

latter is very characteristic. It is composed of epithelial scales, and on being mixed with water it does not diffuse itself like the juice of other cancers, but separates into minute visible particles. If it is very abundant, the cancer is soft and friable, and the material can be seen in the cut-surface as small scattered opaque dots.

Epithelioma has its primary seat in the immediate vicinity of the cutaneous or mucous surfaces; and it appears in many cases to owe its origin to some external source of irritation. It is most frequently met with in the lower lip at the junction of the skin and mucous membrane, on the tongue, prepuce, scrotum ("chimney-sweep's cancer"), labia, eyelids, cheeks, and in the uterus and bladder. As it extends it may involve any tissue—lymphatic glands, muscle, bone, and tendon may be alike implicated. It very rarely occurs in internal organs.

Cylindrical Epithelioma.—This term has been applied to those forms of epithelioma which grow from mucous membranes with columnar (cylindrical) epithelium, as from those of the stomach and intestines. In these tumours the epithelial elements are similar to those of the mucous membrane from which they grow. They are cylindrical in shape, and are often arranged on the walls of the alveoli in a manner precisely analogous to that of the columnar epithelium on the mucous surface. There is rarely a formation of concentric globes, and the growths are of a soft, and often gelatinous consistence. The distinction between these and simple adenomata is often exceedingly difficult.

CLINICAL CHARACTERS OF THE CANCERS.—In speaking of the clinical characters of the cancers, it is important in the first place to make a distinction between epithelioma and the other varieties. Epithelioma, as far as its malignancy is concerned, occupies a very

inferior position to scirrhus, encephaloid, and colloid. These latter varieties of cancer possess in the highest degree malignant properties. They extend locally, invading indiscriminately the tissues amongst which they grow, and reproduce themselves in the lymphatic glands and in internal organs. In the process of dissemination, however, they present some peculiarities which distinguish them from growths which are sometimes equally malignant—viz., the sarcomata. The cancers are characterised by their great tendency to reproduce themselves in the neighbouring lymphatic glands. This implication of the lymphatics is much more marked than in the sarcomata, in which it but comparatively rarely occurs, and this is probably owing to the communication of the lymphatic vessels with the alveolar spaces of the cancerous growth. The general dissemination in internal organs, on the other hand, is often effected much less readily in cancer than in sarcoma, and the course of the former is therefore sometimes more protracted than that of the latter. This difference is explained by the difference in the distribution of their blood-vessels:—in cancer, these are contained in the stroma and very rarely come into contact with the cells of the growth; whereas, in the sarcomata, they ramify amongst the cells, and their walls being composed of thin embryonic tissue like that of the growth which they supply, dissemination through the medium of the blood is rapidly and readily effected. In cancer, the lymph being so important a medium of infection, the reproduction of the growths in internal organs may be considerably delayed; the progress of the disease becomes arrested by the lymphatic glands, and its further dissemination is often only effected after these have become very generally and extensively involved.

With regard to the difference in the clinical characters of these three varieties of cancer—the dissemination of encephaloid takes place much more rapidly than that

of scirrhus owing to the greater rapidity of its growth, its greater vascularity, and the greater activity of its epithelial elements. Colloid is somewhat inferior in the degree of its malignancy to both scirrhus and encephaloid.

Epithelioma is of all the cancers much the least malignant. It extends locally, and may affect the neighbouring lymphatics, but it comparatively rarely reproduces itself in internal organs. This is probably owing to the size and character of its epithelial elements, which render them much less liable to be transmitted by the blood and lymph-streams than are the cells of the other varieties of cancer.

In all the varieties of cancer there is a tendency for the secondary growths to repeat the characters of the primary one. This is most marked in epithelioma. This, in reproducing itself, invariably maintains its primary characters. In scirrhus, the secondary growths in internal organs are usually more rapidly developed than the primary tumour; they are consequently softer and more vascular, and in accordance with the distinction which has been made between scirrhus and encephaloid, they must be regarded as belonging to the latter variety of cancer.

CHAPTER XXIII.

THE MYOMATA, NEUROMATA, AND ANGIOMATA.

THE MYOMATA.

THE myomata are tumours consisting of muscular tissue. A new formation of muscle has been already described as being frequently associated with the ordinary process of hypertrophy, both of striated and of non-striated muscle—a simple hyperplasia of the elements of the muscle accompanying the increase in their size. (See “Hypertrophy.”)

STRUCTURE.—The myomata consist either of striated or of non-striated muscle. The former are exceedingly rare, only two or three examples having been recorded, and these were congenital.

The myomata of *non-striated* muscle consist, like the physiological tissue, of elongated spindle cells with rod-shaped nuclei, more or less isolated or grouped into fasciculi of various sizes, with a varying quantity of connective tissue. The connective tissue is often exceedingly abundant, especially in old tumours, so much so, that these growths in the uterus—where they most frequently occur—have commonly been known as “*fibroid*” tumours. The muscular elements either present a more or less regular arrangement, or pass in all directions through the tumour. The blood-vessels, which are usually not numerous, are distributed in the connective tissue.

DEVELOPMENT.—The myomata probably always origi-

nate from muscle, they are therefore homologous growths. They may form distinctly circumscribed tumours surrounded by a fibrous capsule, or constitute ill-defined irregular masses in the midst of the muscular tissue in which they grow. They not infrequently become pedunculated and form polypi, especially in the uterus.

SECONDARY CHANGES.—Of these, the most frequent is calcification. Hæmorrhage, mucoid softening, and the formation of cysts, are also occasionally met with.

Myomata are most frequently met with in the uterus. They may also occur in the prostate, in the œsophagus, and in the stomach and intestines.

Myoma of Uterus.—The uterus is by far the most frequent seat of myomata, and here they constitute the so-called “uterine fibroid.” In many of these muscular tumours of the uterus there is a large proportion of connective tissue—hence the term “fibroid.” This is especially the case in older growths. Those newly developed, however, consist almost entirely of true muscular tissue. They either form firm hard masses, imbedded in the uterine walls, or project into the uterine or abdominal cavities. When projecting into the uterus they constitute a common form of uterine polypus. These tumours are often multiple. Their growth is slow. The older ones are liable to become calcified. They also sometimes undergo mucoid softening which gives rise to the formation of cysts in the tumour.

CLINICAL CHARACTERS.—Clinically, the myomata are perfectly innocent.

THE NEUROMATA.

The neuromata are tumours consisting almost entirely of nerve-tissue. The term “neuroma” has been applied to many growths found in connection with nerves:—fibrous and gummy tumours growing within the nerve-sheath, and many myomata, have been included under

this head. True neuroma, however, is rarely met with, and is amongst the least frequent of all the new formations.

STRUCTURE.—The neuromata most commonly consist of ordinary medullated nerve-fibres; they therefore resemble in structure the cerebro-spinal nerves, from which they most frequently grow. Virchow has also described, as exceedingly rare formations, tumours composed of non-medullated fibres, and of ganglionic nerve-tissue.

DEVELOPMENT.—The neuromata always originate from pre-existing nerve-tissue,—either from the cranial or from the spinal nerves. Their growth is slow, they rarely attain a large size, but usually exist as small single nodules.

The most frequent seat of these growths is the extremities of divided nerves, where they are sometimes found after amputations. They exist, in this situation, as spherical or elongated enlargements of the divided extremity of the nerve; and they are usually intimately connected with the cicatricial tissue of the stump, from which they can only with difficulty be isolated. They may also occur in the course of the nerves in any situation, either as single or multiple nodules.

CLINICAL CHARACTERS.—Clinically, the neuromata are perfectly innocent tumours. They always cause considerable pain.

THE ANGIOMATA.

The angiomata, or vascular tumours, are tumours consisting of blood-vessels held together by a small amount of connective tissue. They include the various forms of *nævi*, the erectile tumours, and aneurism by anastomosis. They may be divided into two classes—the *simple* angiomata, in which the new vessels resemble normal arteries, veins, or capillaries; and the *cavernous* angiomata, in

which the blood circulates in a cavernous structure similar to that of the corpus cavernosum penis.

SIMPLE ANGIOMATA.—These include the various forms of *nævi*, and telangiectasis. They consist of tortuous and dilated blood-vessels, held together by a small quantity of connective and adipose tissue. The vessels are most of them of new formation; some, however, may be the original vessels of the part which have become considerably enlarged. They most commonly partake of the nature of capillaries, but in other cases the arterial or venous characters predominate. These growths are usually small, superficial, slightly elevated masses; although they sometimes form larger tumours. Their colour is red, violet, or purple, according to the character of the blood which they contain. The first named is much the most frequent.

CAVERNOUS ANGIOMATA.—These include the venous vascular tumours, erectile tumours, and aneurism by anastomosis. They consist of an erectile cavernous tissue, closely resembling that of the corpus cavernosum penis. The growth is made up of irregular fibrous alveoli, which communicate freely with one another, and are lined with an endothelium similar to that of the veins. These spaces are distended with blood, usually venous, which is supplied to them by numerous tortuous vessels, and circulates in them with varying degrees of rapidity. These growths are commonly of a bluish colour. They may be diffuse, or form distinctly circumscribed tumours. They often exhibit distinct pulsation. Their favourite seat is the skin and subcutaneous tissue. They may also occur in the orbit, in muscle, and in the liver, spleen, and kidneys.

CHAPTER XXIV.

CYSTS.

IN addition to the new growths already described, there is a large class of formations, many of which cannot be regarded as "tumours" in the strict application of this term. These are the *cysts* or *cystic tumours*.

A *cyst* is a cavity containing liquid or pultaceous material, which is separated from the surrounding structures by a more or less distinct capsule. It may be a new formation, or a pre-existing structure which has become distended by its own secretion, or by extravasation into it. The former, only, comes within the category of new growths, although, for the sake of convenience, it will be advisable to consider them both under one head.

There are thus two principal modes by which cysts originate—one, the most frequent, by the gradual accumulation of substances within the cavities of pre-existing structures, which are, for the most part, products of their own formation, being in some cases a secretion, and in others a cell-growth; the other, by the independent formation of a cyst in the tissues.

The accumulation of secretions and of other products within pre-existing cavities, may be effected in the three following ways:—

1st. By the retention of the normal secretion owing to the closure of the excretory ducts—as so often occurs in sebaceous glands.

2nd. By excessive secretion, the cavity being unprovided with an excretory duct—as in the formation of a bursæ.

3rd. By the extravasation of blood into the cavity—as in hæmatocele.

The independent formation of a cyst may take place—

1st. By the softening and liquefaction of the tissues in some particular part, owing to mucoid or fatty changes. The tissues around the softened matters become condensed, and ultimately form a kind of cyst-wall.

2nd. By the enlargement and fusion of the spaces in connective tissue, and the accumulation of fluids within them. The surrounding tissue becomes condensed, and forms a cyst-wall; and this may, in some cases, become lined with secreting cells.

3rd. By the formation of a cyst-wall around foreign bodies, parasites, or extravasated blood.

STRUCTURE.—The wall of the cyst will vary in its nature according as it is a pre-existing or a newly-formed tissue. In the former case, it will possess an epithelial lining which will present the same characters as that of the gland, serous membrane, or other structure, from which the cyst originated. If the cyst is a new growth, it rarely possesses an epithelial lining, but consists simply of a fibrous capsule. The cyst-wall is sometimes firmly connected with the adjacent parts, so that it can only with difficulty be separated; in other cases, the union is much less intimate. Instead of being a distinct structure, it may be simply the surrounding tissue which has become dense and fibrous in character.

The contents of cysts are very various, and may serve as a basis for their classification. In the retention-cysts, they will vary with the nature of the normal secretion—serum, sebaceous matter, saliva, milk, seminal fluid, and other substances are thus found in these cysts, more or less altered in character from being retained in a closed

cavity. In the exudation-cysts, serum is the most frequent constituent; and in extravasation-cysts, blood. In those cysts which originate from the softening and breaking down of tissue, the contents are the products of retrogressive tissue-metamorphosis, and usually consist largely of mucin, fatty matters, and serum.

SECONDARY CHANGES.—These may take place in the wall of the cyst, or in its contents. The cyst-wall itself may become the seat of new growths, and produce secondary cysts, villous, glandular, and other structures:—this occurs in many compound ovarian cysts. It may also be the seat of an inflammatory process, which terminates in suppuration and granulation, and by this means the cyst frequently becomes obliterated, its contents being either absorbed or discharged externally, and the cavity closing by granulation. Calcification and ossification of the wall may also occur. The contents of cysts undergo various changes, owing to their retention in a closed cavity. The secretions become altered in character, thickened and viscid. Epithelial elements undergo fatty changes, and so give rise to cholesterin crystals. Calcification of the contents is also common.

Cysts may be *simple* or *compound*. A simple cyst consists of a single loculus. A compound or multilocular cyst is one consisting of numerous loculi, which either communicate with one another, or remain isolated. Another variety of compound cyst, consists of a cyst with endogenous growths, the larger cyst having others growing from its walls. A compound cyst may become a simple one by the destruction of its walls.

Cysts are frequently associated with other growths, hence the terms—"cystic-sarcoma," "cystic-cancer," &c. It is especially in those growths which originate in glandular structures, as in the mamma, testicle, and ovary, that this combination is met with. The cystic development may almost entirely obliterate the structure of the

tumour in which it takes place, so that ultimately the latter becomes converted into a combination of cysts. In other cases large portions of the tumour grow into the cystic cavities. Considerable difficulty is thus not unfrequently caused in determining the nature of the original growth.

CLASSIFICATION.—Cysts may be most conveniently classified according to their mode of origin, thus:—

CLASSIFICATION OF CYSTS.

I. *Cysts formed by the accumulation of substances within the cavities of pre-existing structures.*

- A. RETENTION CYSTS.—Cysts resulting from the retention of normal secretions. These include—
- a. *Sebaceous Cysts*.—These are formed by the retention of secretions in the sebaceous glands. Such are comedones and atheromatous tumours.
 - β. *Mucous Cysts*.—These are formed by the retention of secretions in the glands of mucous membranes.
 - γ. *Cysts from the retention of secretions in other parts*, including—Ranula, from occlusion of the salivary ducts; Encysted Hydrocele, from occlusion of the tubuli testis; cysts in the mammary gland, from obstruction of the lacteal ducts; simple and some compound cysts of the ovary, from dilatation of the Graafian follicles; and simple cysts of the liver and kidneys.
- B. EXUDATION CYSTS.—Cysts resulting from excessive secretion in cavities unprovided with an excretory duct. These include Bursæ, Ganglia, Hydrocele, and many cysts in the broad ligament.

- C. EXTRAVASATION CYSTS.—Cysts resulting from extravasation into closed cavities. These include Hæmatocele, and some other forms of sanguineous cysts.
- II. *Cysts of independent origin.*
- A. CYSTS FROM SOFTENING OF TISSUES.—These are especially common in new formations, as in enchondroma, lipoma, sarcoma, &c.
- B. CYSTS FROM EXPANSION AND FUSION OF SPACES IN CONNECTIVE TISSUE.—These include—
- a. *Bursæ*, originating from irritation and exudation into the tissues.
 - β. *Serous cysts in the neck* (often congenital).
 - γ. *Many compound ovarian cysts*.*
- C. CYSTS FORMED AROUND FOREIGN BODIES, EXTRAVASATED BLOOD, AND PARASITES.
- D. CONGENITAL CYSTS.—These include many Dermoid cysts. These appear often to be the remains of blighted ova. They contain fatty matters, hair, teeth, bones, &c.

* See Dr. Wilson Fox, on Cystic Tumours of the Ovary, "Med. Chir. Soc. Trans.," vol. xlvii.

CHAPTER XXV.

INFLAMMATION.

THE morbid processes which have thus far been described have been mainly characterised by some alteration in the normal nutrition of the histological elements; either by a diminution in their nutritive activity—as in atrophy and the degenerations, or by an increase—as in hypertrophy and the new formations. In the process of *inflammation* an alteration in nutrition also plays a prominent part, but changes in the blood-vessels and in the circulation are its essential and most important constituents.*

Inflammation is the succession of changes which takes place in a tissue as the result of some kind of injury, provided that this injury be insufficient immediately to destroy its vitality. With regard to the nature of the injury—it may consist in some *direct* irritation of the tissue, either by mechanical or chemical agents, or by substances conveyed to it by means of the blood-vessels or lymphatics; or in an *indirect* irritation, as in some cases of inflammation of internal organs arising from exposure to cold. In all cases, however, some injurious stimulation of the tissue precedes the occurrence of the local changes which constitute the inflammatory process.

* With regard to the general pathology of Inflammation, the reader is especially referred to the works of Virchow, Cohnheim, Stricker, and Burdon-Sanderson. The most able article by Professor Sanderson, in the fifth volume of "Holmes's System of Surgery," contains an admirable exposition of what is known on the subject.

The exact nature of these changes has, for the most part, been ascertained during the past eight years, mainly owing to the experimental researches of Professors Cohnheim, Stricker, and Burdon-Sanderson. The method of investigation has consisted in the artificial production of inflammation in the lower animals, and the observation of the process as thus induced. The process comprises—

1st. *Changes in the blood-vessels and circulation.*

2nd. *Exudation of liquor sanguinis and migration of blood-corpuses; and*

3rd. *Alterations in the nutrition of the inflamed tissue.*

It will be well, in the first place, to consider each of these separately, in the order in which they occur, and subsequently to endeavour to point out how far a causal relation exists between them.

I. CHANGES IN THE BLOOD-VESSELS AND CIRCULATION.—Changes in the blood-vessels and circulation, resulting in increased vascularity, have ever been regarded as playing a most important part in inflammation, as upon them principally depend those signs of the process which are most obvious during life. The redness, heat, and swelling, which are so constantly met with in inflamed tissues, are in great measure due to the attendant hyperæmia. The swelling, however, is in most cases dependent rather upon the effusion and cell-growth than upon the overfulness of the blood-vessels.

These changes in the blood-vessels and circulation are essential constituents of inflammation, both in vascular and in non-vascular tissues. In the latter, which comprise the cornea and cartilage, they take place in the adjacent vessels from which these tissues derive their nutritive supply. The nature of these vascular changes has been studied by the artificial production of inflammation in transparent tissues, in which the circulation can be readily observed: the web, mesentery, and tongue of the

frog, and the wing of the bat, being most convenient for this purpose. The phenomena, as observed in the mesentery of the frog, which has been previously curarised, may be thus briefly described:—

The first effect of irritation of the mesentery—mere exposure to the air being sufficient for the purpose—is to cause *dilatation* of the arteries, and after some interval, a similar dilatation of the veins and capillaries. The dilatation of the arteries commences at once, and is not preceded by any contraction. It gradually increases for about twelve hours, and is accompanied also by an increase in the length of the vessels, so that they become more or less tortuous. This enlargement of the blood-vessels is associated at the commencement of the process with an *acceleration* in the flow of blood; this, however, is soon followed by a considerable *retardation* in the circulation, the vessels still remaining dilated. These alterations in the rapidity of the blood-flow cannot be owing to the increase in the calibre of the vessels, which remain throughout dilated.

In his more recent researches on inflammation, Cohnheim has shown that the dilatation of the vessels and the increased velocity of the blood-current which ensue immediately after the infliction of the injury are only temporary and accidental, and that they are not necessarily followed by the retardation of the circulation. They may even, in some cases, be followed by contraction before the permanent dilatation commences. The dilatation and diminished velocity, on the other hand, come on slowly and are permanent, and these must be regarded as the proper vascular phenomena of inflammation. These proper phenomena may be induced without the previous occurrence of the accidental ones.*

The retardation of the circulation in the dilated ves-

* "Neue Untersuchungen über die Entzündung." Cohnheim, 1873.

sels sometimes commences somewhat suddenly, and it is usually first observable in the veins. It gradually increases, until ultimately in some of the capillaries the blood-stream completely stagnates. This constitutes the condition known as *inflammatory stasis*.

As the circulation becomes slower, the white blood-corpuscles (leucocytes) accumulate in the veins. Their natural tendency to adhere to the sides of the vessel is increased, so that they may nearly fill the tube. At the same time they exhibit active movements, by means of which they penetrate the walls of the vessels and pass into the surrounding tissues. Having escaped, they continue to exhibit active movements, and they may multiply by division. The red corpuscles also accumulate, more especially in the capillaries, and they likewise escape through the walls of these vessels, although in smaller numbers than the white. The mesentery thus becomes so filled with escaped corpuscles that but little else is to be distinguished. These phenomena will be described under the head of "Exudation of Liquor Sanguinis and Migration of Blood-Corpuscles."

Stasis.—The phenomena of stasis can be better studied in a more localised inflammatory process, such as may be produced by the application of some irritating agent—a small piece of nitrate of silver, for example—to the tongue of the frog. The stagnation of the blood which ensues is described by Cohnheim in his more recent researches, already alluded to, as being most marked in those capillaries which are situated in the more central portions of the inflamed area—here there is absolute stasis and no emigration of corpuscles takes place. Outside this there is an area in which the blood is circulating very slowly, and here both red and white corpuscles pass out of the capillaries; whilst more externally still, the white corpuscles only escape from the veins. The central area, which usually dies, is thus surrounded by an enor-

mous number of red and white corpuscles; and the red corpuscles which have accumulated in this area are so closely packed that their outlines can scarcely be distinguished.

II. EXUDATION OF LIQUOR SANGUINIS AND MIGRATION OF BLOOD-CORPUSCLES.—Another constituent of the inflammatory process consists in the exudation of the liquor sanguinis and the migration of the blood-corpuscles.

a. Migration of Blood-Corpuscles.—The migration of the white blood-corpuscles (leucocytes) through the walls of the blood-vessels was first described, although very incompletely, by Dr. W. Addison in 1842.* This observer stated as the result of his researches, that in inflammation these corpuscles adhered to the walls of the vessels and passed through them into the surrounding tissues. In 1846 Dr. Augustus Waller described more fully the same phenomenon, and from his description there can be little doubt that he actually observed the emigration of the corpuscles.† Both these observers concluded that the escaped blood-corpuscles became pus-corpuscles. Their observations, however, were but little thought of and were soon forgotten, and it was not until 1867, when similar investigations were instituted quite independently by Professor Cohnheim, of Berlin—to whose minute researches we must ascribe most of our present knowledge on this subject—that the emigration of blood-corpuscles came to occupy an important place in the pathology of inflammation.‡

The emigration may be observed in the mesentery of a frog which has previously been paralysed by the subcutaneous injection of curare. The changes in the

* "Experimental and Practical Researches on Inflammation," *Trans. Prov. Med. Association*, 1842.

† *Phil. Magazine*, vol. xxix. 1846.

‡ "Ueber Entzündung und Eiterung," Virchow's "Archiv," vol. xl.

blood-vessels and in the circulation, and the accumulation of blood-corpuscles in the part, have been already described; it remains only to consider the phenomena of emigration.

The white blood-corpuscles (leucocytes) which have accumulated in large numbers, especially in the veins, remain almost stationary against the walls of the vessel, the blood-current passing by them, although with much diminished velocity. Those immediately adjacent to the wall, gradually sink into it, and pass through it into the surrounding tissue. In doing so they may be observed in the various stages of their passage. At first small button-shaped elevations are seen springing from the outer wall of the vessel. These gradually increase until they assume the form of pear-shaped bodies, which still adhere by their small ends to the vascular wall. Ultimately the small pedicle of protoplasm by which they are attached gives way and the passage is complete, the corpuscle remaining free outside the vessel.

The red corpuscles at the same time pass out of the vessels, but in less considerable numbers, and their transit is mainly through the walls of the capillaries, in which they have more especially accumulated. As has already been stated, in those portions of the inflamed tissue where absolute stasis has occurred, no emigration takes place.

β. Exudation of Liquor Sanguinis.—Associated with the passage of the blood-corpuscles through the walls of the vessels, is an exudation of the liquor sanguinis. The exuded liquor sanguinis—which constitutes the well-known *inflammatory effusion*—differs from the liquid which transudes as the result of simple mechanical congestion, inasmuch as it usually contains a larger proportion of albumen and fibrinogenous substance, a proportion which increases with the intensity of the inflammation. It also contains an excess of phosphates and carbonates.

The most characteristic feature of inflammatory effusion is the large number of cell-structures which it contains. These are the direct product of the inflamed tissue, and are in no case generated spontaneously in the effused liquid. Most of them are migrated blood-corpuscles, others are derived from the proliferating elements of the tissue. The quantity and nature of the effusion will thus vary with the tissue inflamed, and with the severity of the inflammatory process. In non-vascular tissues, as cartilage and the cornea, exudation can only occur to a small extent from the neighbouring vessels, and hence the effusion is small in quantity. In dense organs, as the liver and kidney, owing to the compactness of the structure, a large amount of effusion is impossible, and what there is, is so intermingled with the structural elements of the organ that it does not appear as an independent material. In the kidney it escapes into the urinary tubes, and so appears in the urine. The effusion is most abundant, and constitutes an important *visible* constituent of the inflammatory process, in inflammation of those organs which possess a lax structure and in which the vessels are but little supported—as the lungs, and in tissues which present a free surface—as mucous and serous membranes.

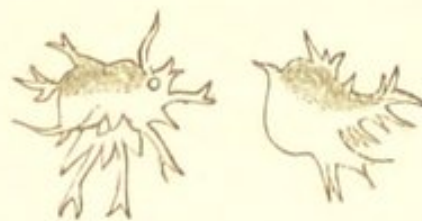
III. ALTERATIONS IN THE NUTRITION OF THE INFLAMED TISSUE.—The remaining constituent of the inflammatory process consists in an alteration in the nutrition of the elements of the inflamed tissue. The nutritive changes, although they may differ according to the structure of the part, are all characterised by an *increase* in the nutritive activity of the cellular elements.

The nature of these nutritive changes has for the most part been ascertained by the investigation of tissues in the lower animals, in which inflammation has been artificially induced. In man, the study of the primary lesions is difficult, owing to the fact that the process can rarely

be observed in its earlier stages. These changes will be more fully described when considering inflammations of particular organs and tissues; it will be sufficient in the present place merely to indicate their general characters.

The alteration in nutrition, as already stated, is characterised by an exaltation of the nutritive functions of the cellular elements of the tissues involved in the inflammatory process. This is evidenced by an increase in the activity of those elements which normally exhibit active movements, as the amœboid cells of connective tissue and of the cornea. Cells, which under normal circumstances undergo no alterations in form, and exhibit no active movements, become active—sending out processes, and undergoing various alterations in shape. (Fig. 53.) This

FIG. 53.

*Amœboid Leucocytes.* (v. Recklinghausen.)

increase in the activity, and variation in the form of the cells, is usually accompanied by the growth of their protoplasm, and frequently by its division, and thus by the formation of new cells. In many cases the protoplasm as it increases in bulk, becomes cloudy and granular, so much so as frequently to completely obscure any nuclei which it may contain. This occurs especially in epithelial elements, and it constitutes the condition known as “*cloudy swelling*.” It is well seen in the glandular epithelium of the kidney in acute tubal nephritis. (See Figs. 87 and 88.)

This increased activity of the cellular elements varies considerably in different tissues, and even in the elements of the same tissue. Some cells exhibit active movements and form new cells much more readily than others.

Those tissues, for example, which naturally maintain themselves by the multiplication of their elements, as the epithelial tissues, become active very readily in inflammation, very slight degrees of irritation being sufficient to cause in them rapid cell-proliferation. This is seen in inflammation of mucous membranes, and of the epidermis. In tissues, on the other hand, whose elements normally exhibit no tendency to multiplication, as cartilage, active changes are much less readily induced, the cells are much more stable and multiply with far less facility, and if the inflammation is slight, they may not multiply at all but simply become enlarged and undergo some alteration in form. Lastly, in the higher tissues, the stability of the elements reaches its maximum, and in nerve-cells no increase of activity can be induced.

Different cells in the same tissue exhibit also different degrees of stability. In common connective tissue and the cornea, for example, the amœboid cells are the least stable, and are the first to multiply. Possibly the age of the cells may influence their tendency to become active, the newer being less stable than the older elements.

The earliest nutritive change is thus one of cell-growth, and cell-proliferation; the subsequent ones are characterised either by impairment of nutrition and the degeneration and death of the newly-formed elements, or by the development of these into a permanent tissue. As a rule it may be said, that the new cells are less developed than those from which they originated, much more prone to undergo retrogressive changes, and if they form a new tissue, this is inferior in its organisation to that of the original structure. If the inflammatory process be of considerable severity and stasis be induced in a wide area of the tissue, the nutrition may become completely arrested and gangrene be the ultimate result. (See "Causes of Gangrene.") The tendency of the new elements to undergo progressive development will vary with

the tissue involved, and with the intensity of the inflammation. The more intense the inflammation, the more abortive are the young cells, and the less is their tendency to form a permanent tissue. (See "Acute and Chronic Inflammations.")

In connective tissues, these changes in the cells are necessarily accompanied by changes in the intercellular substance. The latter are for the most part characterised by softening. In common connective tissue, the fibres in the first place become succulent and less distinct, and ultimately they are completely destroyed; in cartilage the matrix softens and liquefies; in bone, the lime-salts are removed, the lamellæ disappear, and the osseous structure becomes converted into medullary tissue. Hence the destructive effects of the inflammatory process.

Having thus briefly described the succession of changes which occurs in the process of inflammation, it remains to consider in what way these result from the injurious stimulation of the tissue, and how far a causal relation subsists between them.*

The first apparent change which follows the irritation of the tissue, consists in the dilatation of the blood-vessels and in an *acceleration* of the flow of blood. Respecting the cause of this primary vascular phenomenon—the physiological investigations of Ludwig and Lovén show that a similar dilatation of the vessels and increase in the activity of the circulation is produced by the excitation of a sensory nerve in those parts in which the nerve originates. It was stated in the previous edition of this work that the primary vascular phenomena in inflammation were probably in the same way owing to an injurious impression received by the sensory nerves being reflected

* The following conclusions are in the main those arrived at by Professors Stricker and Burdon-Sanderson.—*Holmes's System of Surgery*, vol. v.

by the vaso-motor centre to the vessels. The more recent investigations of Cohnheim, however, which have been already quoted, render it necessary that this statement should be modified. Cohnheim produced precisely the same phenomena in the tongue of the frog after everything had been cut through with the exception of the lingual artery and vein; and also, in another case, after complete destruction of the brain, medulla, and spinal cord, as those which occur in the intact animal; and he considers that the vascular dilatation and accelerated blood-flow are due to the *direct* influence of the irritating agent upon the *walls of the blood-vessels*. These experiments therefore appear to prove conclusively that the initial injury of the blood-vessels is not *necessarily* reflex, although they do not exclude the probability that it may be so under certain circumstances, as, for example, in the case of internal inflammations arising from exposure to cold.

With regard to the cause of the *retardation* of the blood-stream which so quickly succeeds its acceleration, and which may ultimately terminate in complete stasis—all recent observations tend to show that it likewise is due to some alteration in the properties of the walls of the blood-vessels through which the blood passes, and not to changes in the blood itself. Professor Lister considers that the accumulation of the red corpuscles in the inflamed part and their adhesion to one another and to the walls of the vessels is owing to their natural tendency to cohere together when in abnormal circumstances, such as often occurs after their removal from the body; and he says that this tendency is not greater in the blood of inflamed tissues than in normal blood.* He also finds that the aggregation is as marked in blood which has been defibrinated. These observations seem to point to some altera-

* "On the Early Stages of Inflammation."—*Philosoph. Trans.* 1858.

tion in the walls of the vessels as the cause of the stasis, and not to any abnormal condition of the corpuscles themselves. The more recent investigations of Ryneck and Cohnheim tend to confirm the same view. Ryneck has shown that stasis may be produced in the web of a frog, in which milk or defibrinated blood has been injected in place of the normal blood; and also that in vessels, the vitality of which has been destroyed or altered by the injection of poisonous metallic substances, no stasis can be produced.* Cohnheim ligatured the ear of a rabbit at its base with the exception of the median artery and vein, and emptied the vessels of their blood by the injection of a weak saline solution. He then injected into the emptied vessels various irritating solutions, and on again allowing the blood to flow through the thus injured vessels all the phenomena of inflammation ensued.† These results appear to be conclusive, and show that the retardation and ultimate stagnation of the blood-stream in inflammation, are owing to some alteration in the vital properties of the walls of the blood-vessels with which the circulating blood comes into contact.

In explanation of the phenomena of emigration, which takes place coincidentally with the retardation of the blood-stream—the passage of the white corpuscles was formerly supposed to be due to their inherent activity, by virtue of which they penetrated the vascular walls, passing through stomata which were believed to exist between the endothelium. The red corpuscles were supposed to be forced through these openings by the increased blood-pressure. That neither of these explanations is sufficient to account for the phenomena is shown by Cohnheim's recent investigations. These appear to prove conclusively that the

* Ryneck, "Zur Kenntniss der Stase des Blutes in den Gefassen Entzündeter Theile."—*Rollet's Untersuch. aus dem Institute für Phys. u. Histol. in Graz.*

† "Neue Untersuchungen über die Entzündung." Cohnheim, 1873.

emigration of the blood corpuscles and the exudation of the liquor sanguinis are like the other phenomena of inflammation, due to some *alteration in the walls of the blood-vessels*.


The remaining constituent of the inflammatory process—the alteration in the nutrition of the inflamed tissue—succeeds the changes in the circulation and the exudation. Respecting the cause of the increased nutritive activity of the cellular elements which characterises this tissue-change—it is probable that it is for the most part the result of the stimulation of the cells by the liquor sanguinis exuded from the blood-vessels. This conclusion is mainly based upon the well-known experiment of Professor Stricker, which consists in the excision of the cornea of a frog, and its insertion beneath the membrana nictitans of the opposite eye, in which inflammation has been previously induced. The transplanted cornea, when removed in the course of twenty-four hours, exhibits all the histological inflammatory changes observed in the unexcised cornea of the opposite eye. Hence Stricker concludes that the structural changes in inflammation of the cornea of the frog are owing to the stimulation of its elements by the liquid exuded from the blood-vessels, and are quite independent of nervous influence. That the increased nutritive activity of the elements of the inflamed tissue is, however, in every inflammatory process the result of their stimulation by the exuded liquor sanguinis, cannot be regarded as by any means certain. It is possible that the cellular elements may be stimulated to increased activity by means of impressions conveyed to them through the nervous system.

SUPPURATION.—Suppuration, and the formation of abscesses, is a very frequent result of the inflammatory process; it occurs much more frequently, however, in some inflammations than in others. As a rule it may be

stated that the more intense the inflammation the more abundant is the formation of pus.

The essential constituents of pus are cells and a liquid in which they are suspended. The liquid has an alkaline reaction and closely resembles the liquor sanguinis. It contains various kinds of albumen, fatty matters, and inorganic substances. The cells, or *pus-corpuses* (leucocytes) are indistinguishable from the white corpuscles of the blood. As seen after death, they are spherical, spher-

FIG. 54.



Pus-corpuses as seen after death. a. Before, b. after, the addition of dilute acetic acid. × 400.

roidal, or irregular shaped semi-transparent bodies, from $\frac{1}{2500}$ to $\frac{1}{3500}$ of an inch in diameter, containing a varying number of granules, and usually one or more distinct nuclei. (Fig. 54.) The addition of dilute acetic acid causes the cells to swell up; they become more spherical and transparent, and the nuclei are rendered more apparent. The size of the corpuscles and nuclei, and the number of the granules, present manifold variations. Pus-corpuses, like white blood-corpuses, lymph-corpuses, and many other young cell-forms—all of which are included under the common term of *leucocytes*—are masses of contractile protoplasm. They possess the power of spontaneous movement, and when living undergo continuous alterations in form, and migrate in the tissues. (See Fig. 53.) They may also multiply by division.

The mode of origin of pus has been the subject of much controversy. The liquid ingredient proceeds directly or indirectly from the blood, it is the exuded liquor sanguinis: about this there is no dispute. The difference

of opinion which exists is respecting the origin of the formed elements. Without discussing the theories which have been advanced by different pathologists, it must now be admitted that there are at least *two* sources from which the cells of pus may be derived—one from the *blood*, and the other from the *inflamed tissues*.

It has been seen that in the process of inflammation innumerable white blood-corpuscles pass out of the vessels into the surrounding tissues, and as these are indistinguishable from pus-corpuscles, it must be conceded that one mode of origin of pus is from the blood. Further, the white blood-corpuscles may multiply by division, and it is probable that by this means the production of pus is greatly increased.

The other source from which the cells of pus are derived is from the cellular elements of the inflamed tissue. These, as has been described, are the seat of active changes in inflammation; they may multiply and form new cells, and the more intense the inflammation, the more lowly organised are the newly-formed elements, and the less is their tendency to form a permanent tissue. Some of these newly-formed cells constitute pus-corpuscles. These, in this case, must be regarded as young elements resulting from the proliferation of the tissue, which are of low vitality, and soon perish. Pus-corpuscles may probably originate in this way from the proliferation of any tissue with the exception of nerve, either by simple division or by endogenous multiplication.

Although the formed elements of pus may thus be derived both from the blood and from the inflamed tissue, there can be no doubt that the former is their principal source, and that they are in the main migrated blood-corpuscles. In the earlier stages of the inflammatory process, they are mostly, if not all, emigrants; but in the later stages it must be admitted that they may also be derived from the cells of the inflamed tissue.

Such being the modes of origin of pus, it is evident that the more abundant the escape of blood-corpuscles, and the more active the proliferation of the elements of the inflamed tissue, the greater will be the formation of pus, and hence the greater its tendency to collect so as to form an abscess. It is consequently in those inflammations which are the most *concentrated* and the most *intense*—provided that the injury be not sufficiently severe to cause complete stasis—that the formation of pus is most abundant. The greater the injury sustained by the walls of the blood-vessels, the more readily will the blood-corpuscles penetrate them, and hence the more abundant will be the formation of pus. In inflammations of less intensity the escape of blood-corpuscles is less abundant, and the proliferation of the tissue less active, so that pus is not produced in sufficient quantities to cause its collection in the form of an abscess.

Pus exercises a most injurious influence upon the surrounding tissues. The pus-corpuscles appear to be endowed with the power of absorbing the tissues with which they come in contact, or, at all events, of causing their liquefaction. Hence the softening and disintegration of the tissues which constitute such a destructive element in intense inflammations.

Pus which has remained for any length of time in the tissues undergoes certain changes. Its elements may undergo fatty metamorphosis, and thus be rendered capable of absorption. If pus is long confined in a closed cavity, its liquid portions may become absorbed, and its cells atrophy, so that it gradually dries up into a caseous mass, which may subsequently become calcified.

VARIETIES OF INFLAMMATION.—Inflammation exhibits certain variations in its characters according to the *severity* of the irritation which produces it. The more severe the irritation upon which the inflammatory process

depends, the greater *cæteris paribus* will be the damage sustained by the blood-vessels, and consequently—if instantaneous stasis be not produced—the greater will be the tendency to the exudation of liquor sanguinis and to the emigration of leucocytes. Hence it is in inflammation of considerable severity that the vascular phenomena are often so pronounced, the formation of pus so abundant, and the softening and disintegration of the tissues so considerable. Such inflammations, inasmuch as the action of the irritant which produces them is for the most part of short duration, are sometimes designated *acute inflammations*.

In inflammations of less intensity, in which the damage sustained by the blood-vessels is less severe, the textural changes occupy a more prominent place, whereas the vascular phenomena are usually much less marked, and the formation of pus is less abundant. The precise nature of these textural changes must obviously partly depend upon the characters of the tissue which is the seat of the inflammation, but variations are also produced according to the severity of the irritating agent. It appears to me to be probably true—that the less severe the irritant which produces the inflammation, the more do the resulting textural changes tend to be limited to the *connective tissue which is immediately adjacent to the blood-vessels and lymphatics*; whereas in inflammations of somewhat greater intensity more distant elements become involved. This is seen, for example, in inflammatory processes in the kidneys and in mucous membranes. In the former, the least severe forms of inflammation are characterised anatomically by an increase in the connective tissue around the blood-vessels (see “Interstitial Nephritis”); whilst in inflammations of somewhat greater intensity, the prominent textural change consists in swelling or proliferation of the epithelium within the tubules (see “Tubal Nephritis”). In mucous membranes

also, the more severe inflammations are attended by epithelial proliferation, the less intense and more chronic by changes in the submucous connective tissue. With regard to the cellular elements in which these active changes take place—they are probably those which are the most intimately connected with the lymphatic system—viz., the cells of the connective tissue, and the endothelium of the lymphatics and of the blood-vessels. The tendency of the textural changes resulting from the least severe forms of inflammation to be limited to the connective tissue immediately adjacent to the blood-vessels and lymphatics, gives to these inflammations certain peculiarities. The new tissue originating around the vessels—consisting in the earlier stages mainly of small round cells, but ultimately becoming developed into a more or less completely fibrillated structure (an adenoid or fibroid tissue)—leads to an *induration* of the organ in which it is situated, and very constantly, to the subsequent atrophy and retrogressive metamorphosis of its other histological elements. These changes will be more fully considered when treating of inflammation of the individual organs and tissues. (See “Inflammation of Common Connective Tissues,” “Cirrhosis of the Liver,” &c.) These least severe forms of inflammation, inasmuch as the irritant which produces them is not only of slight severity but is usually also prolonged in the duration of its action, are often known as *chronic inflammations*.

Inflammations have received different names according to the *nature* of the injury upon which they depend. Those inflammations which result from external injuries, mechanical or chemical violence, are called *traumatic*. In those cases in which the injurious stimulation of the tissue is owing to the transmission of infective materials by means of the blood-vessels or lymphatics from some local infecting centre, as in pyæmia and acute miliary

tuberculosis, the resulting inflammations are called *infective*. Inflammations in which the nature of the injury is not obvious, are usually called *idiopathic*. Lastly, the nature of the injury may give to the inflammatory process certain peculiarities. The contagium of small-pox, for example, gives rise to inflammation of the skin, constituting the "rash"; that of syphilis, to certain inflammations of the skin, mucous membranes, and other tissues; and that of typhoid fever, to inflammation of the intestinal lymphatic structures. In all these and numerous similar cases, the nature of the irritant impresses upon the inflammation certain peculiarities, and in so far as the former is specific, the latter may be called *specific* inflammations.

Of these different varieties of inflammation, the infective inflammations, including pyæmia and acute tuberculosis, and the specific inflammations resulting from the poison of syphilis, will be separately considered in the next following chapters. The pathology of inflammation will then be still further elucidated by the study of the process as it occurs in the various tissues and organs.

CHAPTER XXVI.

ACUTE TUBERCULOSIS.

By acute tuberculosis is understood a general infective disease, which is characterised anatomically by the occurrence of numerous minute nodular lesions more or less generally disseminated in the various organs and tissues. The generally disseminated nodular lesions, which are characteristic of the disease, appear to be inflammatory growths, resulting from the distribution of infective materials (probably minute particles), by means of the blood-vessels or lymphatics from some primary inflammatory product. They are, therefore, the anatomical results of an infective inflammatory process, and they constitute what have long been known as *miliary tubercles*.

General Pathology of Acute Tuberculosis.—Our knowledge of acute tuberculosis and of its anatomical result—*tubercle*, has until quite recently been involved in obscurity; but at the present time—owing in great measure to scientific experimental research—it may be regarded as being much more complete. According to the older doctrines, which were based upon the teaching of Laennec, tubercle was looked upon as a specific non-inflammatory growth which originated spontaneously in the tissues. Further, this new growth was characterised by the regular succession of changes which it invariably underwent;—it was first grey and translucent, then became opaque, and ultimately caseous. Hence in its earlier stages it was

known as *grey*, in its latter as *yellow* tubercle. Caseous metamorphosis was held to be such a distinguishing peculiarity of the growth, that all caseous masses were regarded as tubercular, and the term "tubercle" came to be applied indiscriminately to all pathological products which had undergone this form of degeneration, and which in their colour and consistence somewhat resembled soft cheese. Caseation, however, as already stated, is a common result of the retrograde metamorphosis of many growths which are destitute of or contain but few blood-vessels, and which consist of closely-crowded cellular elements; and although it may occur to a greater or less extent in tubercle, it is by no means specially characteristic of this morbid growth. (See "Caseation.") For this much wider extension of the pathological significance of caseous degeneration we are mainly indebted to Professor Virchow.*

The infective nature of acute tuberculosis was first promulgated about eighteen years ago by Buhl, who stated that in the majority of cases of this disease, indurated masses which had become caseous existed in some part of the body, and that to the absorption of substances from these infective centres the general development of the tubercle was owing. He further stated that in those cases in which the tubercles were confined even to limited portions of a single organ, they were also secondary to caseous lesions. Buhl's theory, therefore, implied that the origin of the infective substances was necessarily associated with caseous metamorphosis of the primary inflammatory induration. A modification of this view of the nature of the infecting lesion has since been rendered necessary, both by the results of post-mortem observations, and also by those which have been obtained from the artificial production of tuberculosis in the lower animals.

* For further information on the history of "tubercle," the reader is referred to the commencement of the chapter on "Pulmonary Phthisis."

The experimental investigation of acute tuberculosis was commenced by Villemin in 1865, and subsequently followed out by Burdon-Sanderson, Wilson Fox, Cohnheim, Klebs, and others. The methods of investigation consisted either in the inoculation of various inflammatory products—for the most part products of *chronic* inflammations (caseous or not caseous), or in the production of a local inflammatory induration by the introduction of setons and of other foreign bodies beneath the skin. Of inflammatory products Dr. Sanderson found that none proved so active as that obtained from the indurated lymphatic glands of an animal already suffering from the disease. In both cases, after a certain lapse of time, disseminated inflammatory lesions were produced in various organs and tissues—lesions which presented a special tendency to become caseous at their centres. It was also found that the distribution of these lesions varied according as the infective materials were introduced into the blood-vessels or lymphatics, clearly proving that they resulted from the dissemination of infective substances by means of the blood and lymph streams. The results of these experiments therefore show, in the first place, that caseation of an inflammatory product is not necessary in order for it to constitute an infective focus; and, secondly, that the development of the general tuberculosis is not due to anything specific in the substances inoculated, but that the products of various inflammatory processes (for the most part of inflammations of slight intensity), may constitute the infective agents.

The lesions produced, however, in artificial tuberculosis differ somewhat from those met with in the natural disease as it occurs in man. They differ both in their anatomical distribution, and, to a less extent, in their pathological tendencies. The differences in anatomical distribution are principally confined to the brain and lungs. The brain, which is so frequently affected in the

natural disease in man, is rarely so in artificial tuberculosis. In the lungs, the first structural changes which take place in artificial tuberculosis are stated by Dr. Klein to consist in the development of adenoid tissue around the perivascular lymphatics, the implication of the alveoli being only a secondary part of the process.* In the natural disease in man, on the other hand, the changes commence in the alveoli themselves. Respecting differences in their pathological tendencies—it is to be remarked that caseation occurs much more extensively in the lesions artificially induced than in man. In the former, also, diffused tracts of consolidation are more frequently associated with the miliary lesions, and they may even constitute the predominant structural changes. These differences, however, are probably to be regarded as resulting from differences in the intensity of the infective agent, and from peculiarities in the morbid tendencies of the tissues involved, and not as any evidence of a want of analogy in the pathology of the two diseases.

Passing on to consider acute tuberculosis as it occurs in man, it must be stated that one or more masses of inflammatory induration which have become caseous are, in the great majority of cases, to be found in some part of the body after death; sometimes in the lungs, sometimes in the bronchial glands, sometimes in the glands of the mesentery, &c. Much less frequently there exists some inflammatory lesion which is not caseous, as a simple induration, or an ulcerated mucous membrane; whilst in exceedingly rare cases it is stated that no such products of a previous inflammatory process have been discoverable.

The results of post-mortem observations of the natural

* "On the Lymphatic System of the Lungs," by Dr. E. Klein, "Proceedings of the Royal Society," No. 149, 1874.

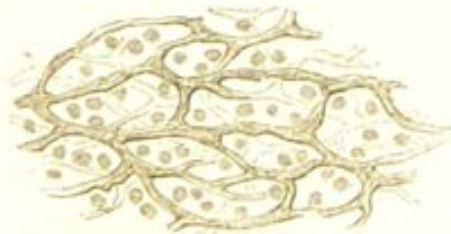disease thus appear to justify the same conclusions respecting the nature of the infective substances as those derived from the experimental investigation of the disease in the lower animals, and in man also it must therefore be regarded as in the highest degree probable that any inflammatory product may, under certain circumstances, constitute a focus of infection, and give rise to a tuberculous process. Why such inflammatory products should in some cases be infective, whilst in others they remain inert, we are unable certainly to explain. In attempting to answer this question, it must be remembered that such products may *accidentally* become placed in direct communication with the vascular or lymphatic systems; and also that infective substances are much more liable to produce results in some constitutions and in some conditions than in others. It is also possible that the infective properties of an inflammatory product may be determined by atmospheric influence, or by the presence of minute organisms.

Whilst acute tuberculosis is thus an infective disease, it is an infective disease of a special kind. In the first place, the infective substances derived from the infective focus—which are probably minute particles—not only exercise their irritating influence over areas of tissue which are for the most part exceedingly small (hence the miliary character of the lesions), but the irritation they produce is of comparatively slight severity. The principal result of their irritation is consequently a textural change—a new growth of tissue at the seat of the injury. (See “Chronic Inflammations.”) In this respect this disease presents a marked contrast to one with which it is closely allied—pyæmia, in which the severity of the injury produced by the infective particles is much greater and gives rise to the formation of abscesses. (See “Pyæmia.”) In pyæmia the intensity of the disseminated inflammatory processes is considerable, and the course of the disease is

usually acute, whilst in acute tuberculosis the inflammatory processes are much less severe, and the disease tends to run a more chronic course.

Histology of Acute Tuberculosis.—The miliary lesions in acute tuberculosis, although presenting certain differences according to their age, and to the nature of the tissue in which they originate, are tolerably uniform in their histological characters. Their most marked feature is the prominent place which a kind of adenoid structure occupies in their constitution. This structure is met with in its most characteristic form in an indurated lymphatic gland, and it is also, as has been already stated, a common histological product of other chronic inflammatory processes, as of those in the liver, lungs, and other organs (see “Chronic Inflammations”). Its development appears to be owing to an impairment of the nutritive activity of the new cellular elements, so that they are unable to form a more completely fibroid tissue. It consists, in the main, of small spheroidal elements resembling lymph-cells, which are either separated from one another by fine lines of homogeneous transparent-looking material, or more commonly, by a more or less distinctly fibrillated, and sometimes nucleated reticulum, within the meshes of which the elements are grouped (Fig. 55, see also Fig. 66). In

FIG. 55.



A portion of a Grey Miliary Tubercle.
Showing the adenoid structure met with
in large portions of these nodules.
× 200.

tuberculous nodules this reticulum is sometimes dense and well marked, whilst in other cases it is almost

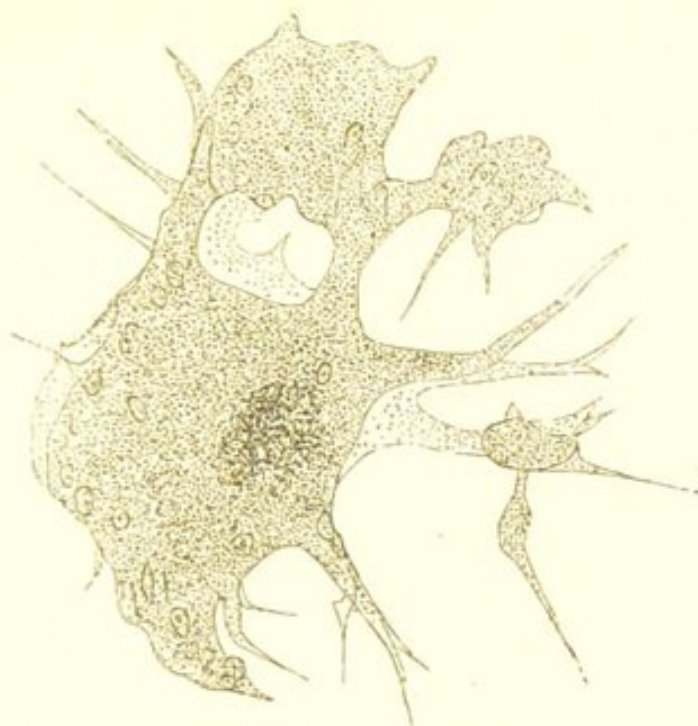
completely absent. In addition to the small lymphoid cells there are often seen some rather larger cells containing one, and in some cases, two nuclei.

Although an adenoid structure similar to that which has been described usually enters largely into the formation of tuberculous lesions, it will be found on careful examination that they present some additional characteristics. In the first place, large multinucleated masses of protoplasm, somewhat resembling "myeloid cells," are usually to be found associated with the lymphoid elements. These large multinucleated cells have been alluded to by Virchow, Wagner, and others, but it is only recently, mainly owing to the researches of Dr. Oscar Schüppel, that they have received a prominent place in the histology of tubercle. As the views of this pathologist concerning their mode of origin and on the pathology of tubercle generally differ somewhat from those commonly entertained, I propose merely in the present place to state very briefly the result of my own observations made subsequently to the perusal of Dr. Schüppel's valuable publications. For more complete information the reader is referred to Dr. Schüppel's writings on the subject.*

The most characteristic features of these multinucleated cells are their large size, the number of their nuclei, and the irregularity of their outline. Some of the larger ones measure as much as $\frac{1}{200}$ inch in diameter. They possess no limiting membrane, but are simple masses of protoplasm, containing numerous round or roundly-oval nuclei, each enclosing a bright nucleolus. (Figs. 56 and 57.) As many as forty nuclei may sometimes be counted in a single cell. Some of them are much smaller and contain only three or four nuclei. Four or five, or even more, of these

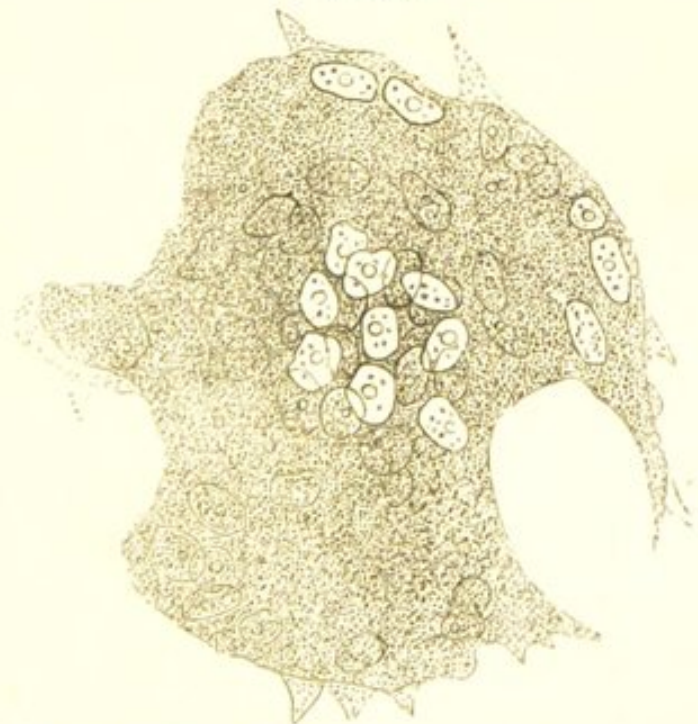* Untersuchungen über Lymphdrüsen-Tuberkulose; Dr. Oscar Schüppel: Tübingen, 1871; and Ueber die Entstehung der Riesenzellen im Tuberkel.—*Wagner's Archiv der Heilkunde*, vol. xiii. 1872.

FIG. 56.



A Multinucleated Cell from the Lung in a case of Chronic Phthisis. Showing the long-branched processes, which are continuous with the reticulum of the surrounding indurated growth. Some of the processes are in connection with smaller nucleated elements. × 200.

FIG. 57.

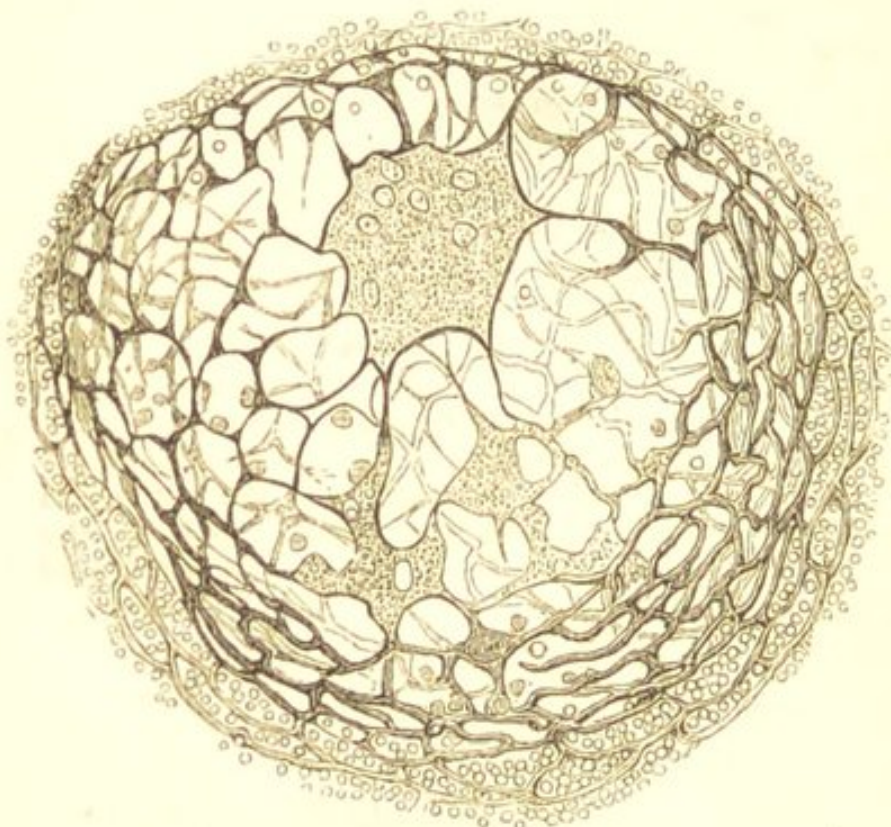


A Multinucleated Cell from the Lung in a case of Chronic Phthisis. Showing the large number of nuclei with bright nucleoli. × 400.

multinucleated masses are sometimes found in a single tuberculous nodule.

Many of these large cells possess long branched processes, in connection with which, and evidently originating from them, are smaller protoplasmic masses, also nucleated and branched. (See Figs. 56 and 58.) The

FIG. 58.



Multinucleated and branched Cells from a firm Grey Miliary Tubercle of the Lung in a case of Acute Tuberculosis. Wide meshes are seen in the immediate vicinity of the cells enclosing a few lymphoid elements. The branched processes are directly continuous with the adenoid reticulum of the tubercle. $\times 200$.

meshes between the branched cells are, according to Schüppel, filled with epithelial-like elements. These elements I have failed to observe, and the meshes I have either found empty, or containing a few lymphoid cells. (Fig. 58.) It would thus appear that the original protoplasmic mass gives origin to a network of large branched cells, associated with, and usually surrounding which, is

more or less adenoid tissue. It is this structure which must be regarded as the most characteristic of tuberculous lesions. It is well shown in Fig. 58.

Although the above characters are to be observed in successful preparations and in certain stages of the tuberculous growth, many of them will usually be found wanting. The nuclei and processes of the large cells will not always be seen, and the cells often appear simply as yellowish somewhat granular masses in which neither nuclei nor processes are visible. In this imperfect state they are to be found in tuberculous nodules from all organs in which tubercle is met with.

Respecting the pathological significance of these large multinucleated cells—they appear to be simply the result of chronic inflammatory processes in which the new elements are of such low vitality as to be incapable of forming an adenoid or fibroid structure; and the branched network of cells to which they often give rise must be regarded as representing a lower stage of development than adenoid tissue. Although these large cells are most frequently met with in tuberculous lesions, they are not especially characteristic of any one particular kind of morbid change. They have been found as the result of inflammatory processes in various organs and tissues. With regard to the histological elements from which they originate—this varies. In the lung, Dr. Klein states, that they are derived from the alveolar epithelium. They may also originate from the cells of connective tissue, and probably from the endothelium of the blood-vessels and lymphatics. Their formation takes place either by the fusion of two or more cells, or by the excessive development of one cell. In the latter case, the cell increases in size and its nuclei multiply, but here the process of development ceases—there is no subsequent division of the cell.

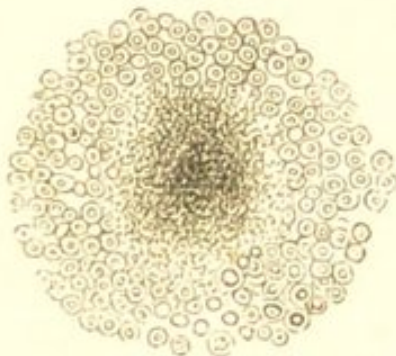
It remains to speak of the blood-vessels of tuberculous

nodules. The vessels of the tissue in which the nodule originates gradually become obliterated in the process of its growth, and there is no new formation of vessels, such as takes place in more highly developed inflammatory tissue. (See "Inflammation of Common Connective Tissue.") The nodules are therefore, except in the earlier stages of their development, non-vascular.

Although the structure which has been described is that most commonly met with, it must be borne in mind that all tuberculous lesions are not thus constituted. When treating of the changes in the several organs, it will be seen that the precise histological constitution of the nodules varies somewhat, according to the characters of the tissue in which they originate. In the lung, for example, many of them consist largely of accumulations of epithelial cells within the pulmonary alveoli.

Tuberculous lesions almost invariably undergo more or less retrograde metamorphosis, although the extent of this varies considerably, and in some cases the nodules

FIG. 59.



One of the Grey Nodules from the Lung in a case of Acute Tuberculosis, which is becoming opaque and soft in the centre. (Diagrammatic.)

may become developed into a firm fibroid structure. The occurrence of retrograde metamorphosis is mainly owing to the obliteration of the blood-vessels which accompanies the growth of the lesions. The change commences in the centre of the nodule, this being the part first developed, and consequently that which is the furthest removed from vascular supply. The nodule breaks down into a granular fatty débris, so that its central portions soon become opaque and yellowish. (Fig. 59.) In some cases the process of disintegration is rapid, whilst in others it is more gradual. It is usually most marked in the larger

may become developed into a firm fibroid structure. The occurrence of retrograde metamorphosis is mainly owing to the obliteration of the blood-vessels which accompanies the growth of the lesions. The change commences in the centre of the nodule, this being the part first developed, and consequently that which is the

and more diffused lesions, and hence it is these lesions which are most commonly of a yellow colour and soft consistence ("yellow tubercle"). In other cases the retrograde change is less marked, the reticulum of the nodule becomes denser and more fibroid, and although the fibroid tissue usually ultimately undergoes in its central parts, more or less fatty metamorphosis, the nodule may remain as a firm fibroid mass.* This occurs more especially in the smaller lesions. The extent and rapidity of the retrograde change depends, I believe, mainly upon the severity of the infective process. The more intense the irritation, the greater is the tendency to the degeneration and softening of the nodules; the less intense and more chronic the process, the more liable are the miliary lesions to become fibroid.

Before concluding the consideration of the general pathology of tuberculosis, allusion must be made to those cases in which the tuberculous processes are confined to a single organ. This limited tuberculosis differs from the more general one only in the extent of the distribution of the infective materials. The miliary lesions originate from some retrograde inflammatory product situated usually in the same organ as that in which they occur, and their limitation is probably owing to the infective substances being disseminated by the lymphatics and serous canals and not by the blood-vessels. This will be again referred to in the chapter on "Pulmonary Phthisis," and also in the following description of the tuberculous process as it occurs in the several organs and tissues.

TUBERCULOSIS OF THE PIA MATER.

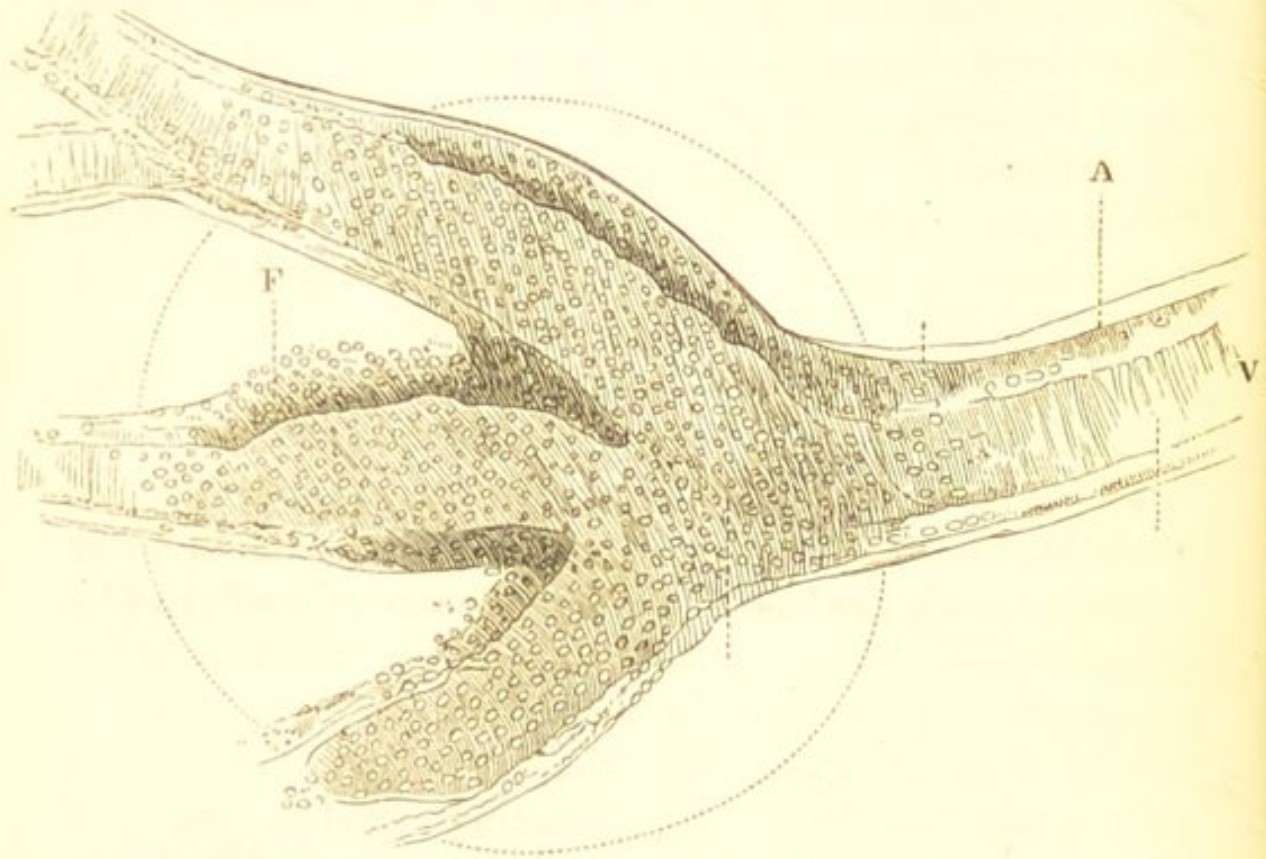
In the pia mater the tuberculous process is associated with inflammation of the meninges, constituting the con-

* Dr. Kleia states (*loc. cit.*) that the large multinucleated cells undergo a fibroid transformation, and become converted into a dense feltwork of fibrillar tissue, which tissue gradually dies away and becomes caseous.

dition known as *tubercular meningitis*. This is almost invariably a part of a general tuberculosis.

The process is almost exclusively confined to the pia mater at the base of the brain, and the tuberculous

FIG. 60.



Miliary Tubercle in the Pia Mater. The dotted line indicates the original size of the tubercular nodule. A. The lymphatic sheath. V. The bloodvessel. F. Proliferation of elements within the sheath. $\times 100$. (Cornil and Ranvier.)

nodules—which may easily escape observation—are seen in connection with the small arteries in the Sylvian fissures, and deeply seated between the convolutions. A few scattered granulations are, however, frequently visible on the upper surface of the hemispheres. The inflammatory growth originates in the perivascular lymphatic sheaths which enclose the small arteries of the pia mater. (Fig. 60.) The cells of the sheath multiply, and the process of proliferation commencing at separate centres, numerous small grey nodules are produced around the vessel. These, which are distinctly visible to the naked

eye, cause an external bulging of the sheath, and a diminution in the calibre, or even complete obliteration, of the enclosed vessel.

The localised obstructions to the circulation which result from the pressure of the perivascular nodules cause intense hyperæmia of the collateral vessels, and thus the pia mater at the base of the brain becomes exceedingly vascular, there being in some cases rupture of the vessels and extravasation. This is followed by a more general inflammatory process—a true basic meningitis. A transudation of the liquor sanguinis takes place from the hyperæmic and injured vessels, blood-corpuscles escape, and thus the meshes of the pia mater become infiltrated with a sero-fibrinous liquid, which in many parts has a puriform character.

The changes in the pia mater at the base of the brain are attended by softening of the immediately subjacent cerebral substance, which becomes infiltrated with young cells. The lateral ventricles at the same time become distended with serosity (acute hydrocephalus), so that the convolutions on the surface of the hemispheres are seen to be much flattened. The ependyma and choroid plexus also become exceedingly vascular, and the walls of the ventricles, together with the fornix and soft commissure, become much softened. All of these changes are owing, partly to an inflammatory process, and partly to the mechanical obstruction to the circulation caused by the tuberculous growth. In addition, the arachnoid membrane is dry and sticky.

Tuberculous Masses in the Brain.—In addition to the miliary lesions occurring in the pia mater in tubercular meningitis, large tuberculous masses are occasionally met with in the brain unassociated with a general tuberculous process. These masses, which vary in size from a hazel nut to a hen's egg, commonly occur in the cerebral substance, especially at the base of the brain. They are of

a pale yellow colour and firm consistence, and usually form quite round globular tumours. Their surface is often seen to be covered with minute grey nodules, which extend into the surrounding tissue; and on section, similar nodules are sometimes visible, scattered through the substance of the tumour. In most cases only one or two such masses are found, but occasionally they are more numerous. They occur especially in childhood, and usually in children in whom there is a general tendency to caseation of inflammatory products ("scrofulous" children). When examined microscopically they are found to be made up of an adenoid structure and large branched cells, such as has been already described as so characteristic of tuberculous lesions. This structure—which is best seen in the peripheral portions of the tumour—is often concentrically arranged around blood-vessels, and is found undergoing in different parts fibrous and caseous metamorphosis.

Respecting the nature of these masses and the way in which they originate, it is difficult to speak with certainty. From the fact that miliary nodules are so often to be seen on their surface and extending into the surrounding tissue, it is supposed that they originate by the aggregation of such nodules—that the primary nodule constitutes an infective focus, and so causes a succession of growths in its immediate vicinity. This hypothesis is probably correct. Occasionally the tuberculous mass causes a more general infection, and so gives rise to tubercular meningitis or to a general tuberculosis.

TUBERCULOSIS OF LYMPHATIC GLANDS.

In the lymphatic glands, tuberculous processes give rise in the first place to changes in the peripheral portions of the gland, inasmuch as it is with these that the infective materials which are conveyed by the lymphatic vessels first come into contact. The active changes in the

cellular elements of the gland are accompanied by the formation of the large multinucleated branched cells already described, which are here usually very abundant. In the earlier stage of the process small grey nodules are visible scattered through the cortex. These gradually increase in size and become caseous. The gland then becomes enlarged, the distinction between its medullary and cortical portions becomes lost, and it becomes changed to a greyish homogeneous mass, in which are varying sized tracts of caseous material. The new growth very frequently undergoes a marked fibroid development, so that the caseous masses are surrounded by a dense fibroid structure. The caseous portions of the gland may subsequently soften, dry up, or calcify.

TUBERCULOSIS OF MUCOUS MEMBRANES.

In mucous membranes the development of tuberculous nodules is usually secondary to some primary inflammatory process which leads to ulceration of the membrane. The intestinal, the urino-genital, and the respiratory mucous membranes may all be the seats of a tuberculous growth, but it is in the former that it constitutes the most frequent and most important change.

The Intestine.—In the intestine the occurrence of true tuberculous processes appears to be almost invariably preceded by primary inflammatory changes in the intestinal lymphatic structures. These changes have their seat in the solitary and Peyer's glands, and as in typhoid fever, it is especially these structures in the lower part of the small intestine and in the cæcum which are affected.

The first stage of the process consists in an inflammatory hyperplasia of the lymphatic elements. In Peyer's patches this hyperplasia usually affects isolated follicles in the patch. The solitary glands and certain follicles in the patches thus become swollen, and project with undue

prominence above the surface of the membrane. The newly-formed elements then undergo retrogressive changes—they soften and caseate, the degeneration in the patches commencing at several separate centres, and often extending until the whole patch becomes destroyed. As the result of these primary inflammatory changes an ulcerated surface is produced, the floor and edges of which are more or less thickened owing to the extension of the inflammatory process into the submucous connective tissue. This is a simple ulcer, and its production, so far, is quite independent of a tuberculous process.

What must be regarded as a tuberculous change occurs subsequently to the primary ulceration, and it consists in the development of small nodules of induration in the floor of the primary ulcer. The development of these nodules appears to take place principally around the blood-vessels, and as these are arranged transversely

FIG. 61.



A Tubercular Ulcer of the Intestine. (Diagrammatic.)

a. Epithelial lining. *b.* Submucous tissue.
c. Muscular coat. *d.* Peritoneum.

around the intestine, the new growth proceeds in the same direction. These secondary nodules of induration, like the primary inflammatory product, soften and become caseous, and thus the process of ulceration gradually extends transversely until the whole circumference of the gut may be destroyed. The ulcer thus produced presents a strong contrast to that of typhoid. Its edges and base are thickened and indurated, and the nodules of new growth, tending to become caseous, are seen scattered in its floor. (Fig. 61.)

The tubercular ulcer rarely, if ever, heals. Owing to the thickening of the tissues at its base, perforation is

quite an exceptional occurrence. In the process of its extension the ulceration is attended by some contraction and narrowing of the gut.

TUBERCULOSIS OF THE LUNGS.

Tuberculous processes occur in the lungs as a part of a general tuberculosis, and also in many cases of pulmonary phthisis. The nature of the resulting inflammatory lesions is similar in both. It will be well, however, in the present place, more particularly to describe these lesions as they occur in the general infective disease. The more limited processes which take place in many cases of phthisis will be again referred to in a subsequent chapter devoted to the consideration of this affection. (See "Pulmonary Phthisis.")

The pulmonary lesions met with in general tuberculosis consist, for the most part, of disseminated nodular growths, which are universally known as "miliary tubercles." These growths are of two kinds—the *grey* and the *yellow*. The grey are semi-transparent nodules of a greyish-white colour, varying in size from a small pin's head to a hempseed. They are somewhat spherical in shape, and usually possess a well-defined outline. Sometimes they are firm, and almost cartilaginous in consistence; whilst in other cases they are much softer and almost gelatinous. These softer forms, instead of being semi-transparent, are more opaque and white. The yellow are, for the most part, larger than the preceding, many of them much so, some being as large as a pea. They are also softer in consistence, less defined and regular in outline, and they pass more insensibly into the surrounding tissue. Many of them possess a greyish-white translucent margin, which may be pretty firm in consistence, but never so hard as are many of the grey nodules, whilst their central portions are opaque, yellowish, or caseous. These nodules, both the grey and the yellow,

although generally scattered, are sometimes confluent in groups.

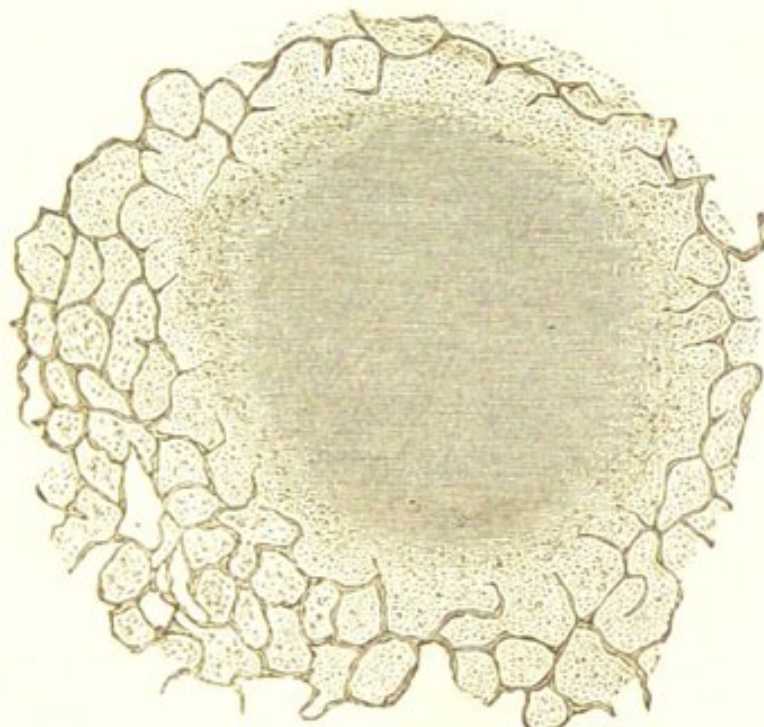
Both the grey and the yellow nodules are often found associated in the same lung; in other cases the grey nodules only are met with; whilst, less frequently, nearly all the growths are of the yellow variety. The condition of the pulmonary tissue which is situated between the nodules varies considerably. It may be perfectly normal, more or less congested and œdematous, or it may present varying sized tracts of greyish, granular, friable consolidation. A perfectly normal condition of the intervening pulmonary tissue is found in many of those cases, in which all the growths are of the firm grey variety; but when there are numerous yellow or soft grey nodules, the lungs are nearly always more or less congested or consolidated.

When these nodules are examined microscopically they are seen to exhibit two different kinds of structure—viz., the adenoid structure with branched multinucleated cells, which has been already described as that which is the most characteristic of tuberculous lesions, and accumulations of epithelial cells within the pulmonary alveoli (catarrhal pneumonia). There is, however, this marked difference between the various kinds of nodules—that whereas the smaller firm grey ones are constituted entirely of the first-named tissue, the larger soft grey, and most of the yellow ones, consist largely of the alveolar accumulations.

Firstly, with regard to the soft grey and yellow nodules. Many of these when examined with a low magnifying power present the appearance represented in Fig. 62, the nodules being apparently made up of accumulations within the alveolar cavities. When more highly magnified their constitution at once becomes evident (Fig. 63). Their central portions (*c*) consist, for the most part, of a structureless granular débris, in which, perhaps, here and there, traces of formed elements are visible. More externally, are seen indications of

alveoli, which are filled with partially degenerated epithelial cells (*b*), whilst in the peripheral portions of the growth (*a*) the alveolar cavities are quite distinct, their walls are slightly infiltrated with an adenoid growth, and their cavities contain epithelial cells and sometimes a small amount of fibrinous exudation. In other nodules there is no such

FIG. 62.

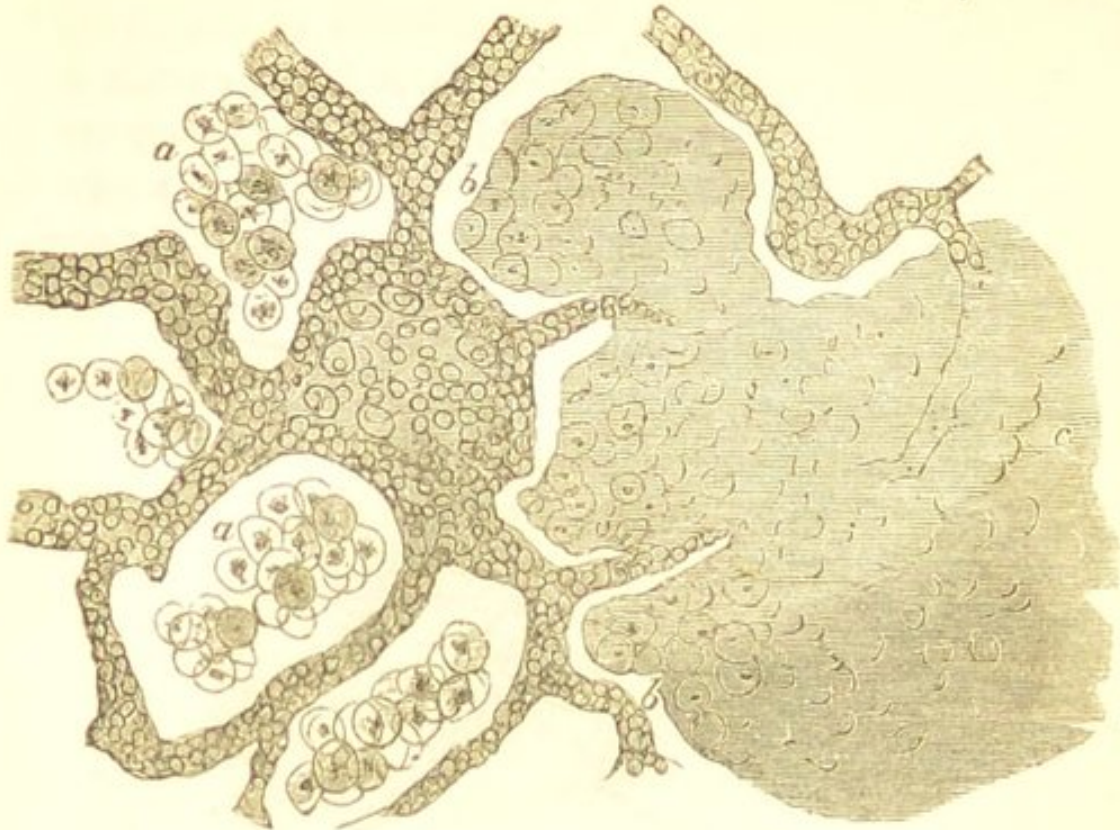


A Yellow Tubercle from the Lung in a case of Acute Tuberculosis. Showing the accumulations within the alveoli at the peripheral portions of the nodule, and the degeneration in the centre.
× 33.

extensive necrosis, but the adenoid thickening of the alveolar walls is much more marked, and the alveolar cavities contain either distinct epithelial elements, ill-defined masses which apparently consist of confluent epithelium, or large multinucleated cells (Fig. 64); these last-named cells originating, as described by Dr. Klein, from the alveolar epithelium.*

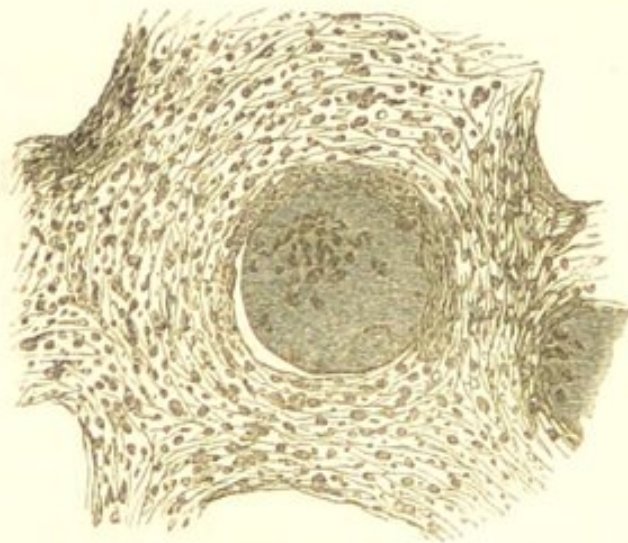
* These large multinucleated cells are stated by Dr. Klein (*loc. cit.*) to originate either by the fusion of the alveolar epithelium, or by the excessive development of one epithelial cell. Since the publication of Dr. Klein's statement I have frequently observed these cells situated distinctly in the alveolar cavities, and I have no doubt they originate in the way he describes.

FIG. 63.



A small portion of the most external part of a Yellow Tubercle from the Lung in a case of Acute Tuberculosis. Most externally at a are seen the alveoli filled with epithelial cells, and the alveolar walls are slightly thickened by an adenoid growth. More internally at b both the alveolar walls and the epithelial contents are seen in the process of degeneration; whilst in the central portions, c, the degeneration is so far advanced that all trace of structure is lost. $\times 140$.

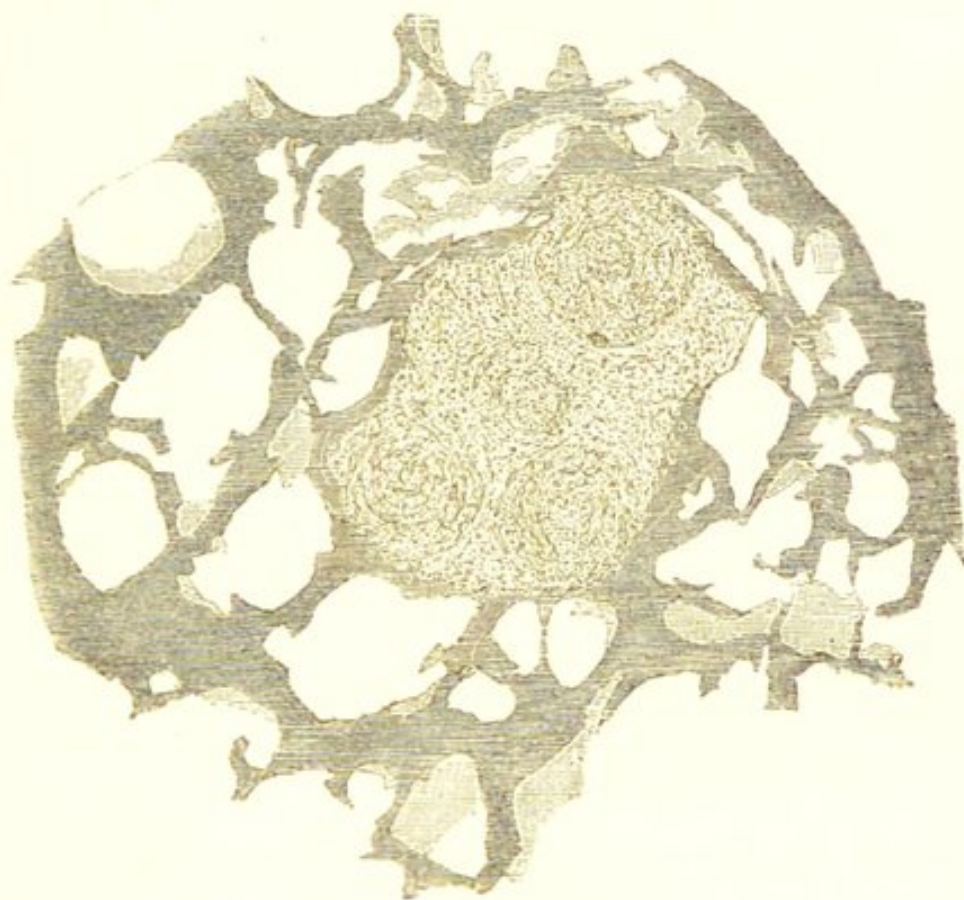
FIG. 64.



A portion of the more external part of a soft grey Tubercle from the Lung in a case of Acute Tuberculosis. Showing the extensive adenoid thickening of the alveolar walls, and a large multinucleated cell within the alveolar cavity. $\times 100$.

The histological characters of the smaller firm grey nodules differ from the preceding. These, when examined with a low magnifying power, appear as little somewhat spheroidal masses, the cellular elements of which are often to be seen grouped around separate centres (Fig. 65). When more highly magnified these centres are seen to consist of the large multinucleated branched cells already

FIG. 65.



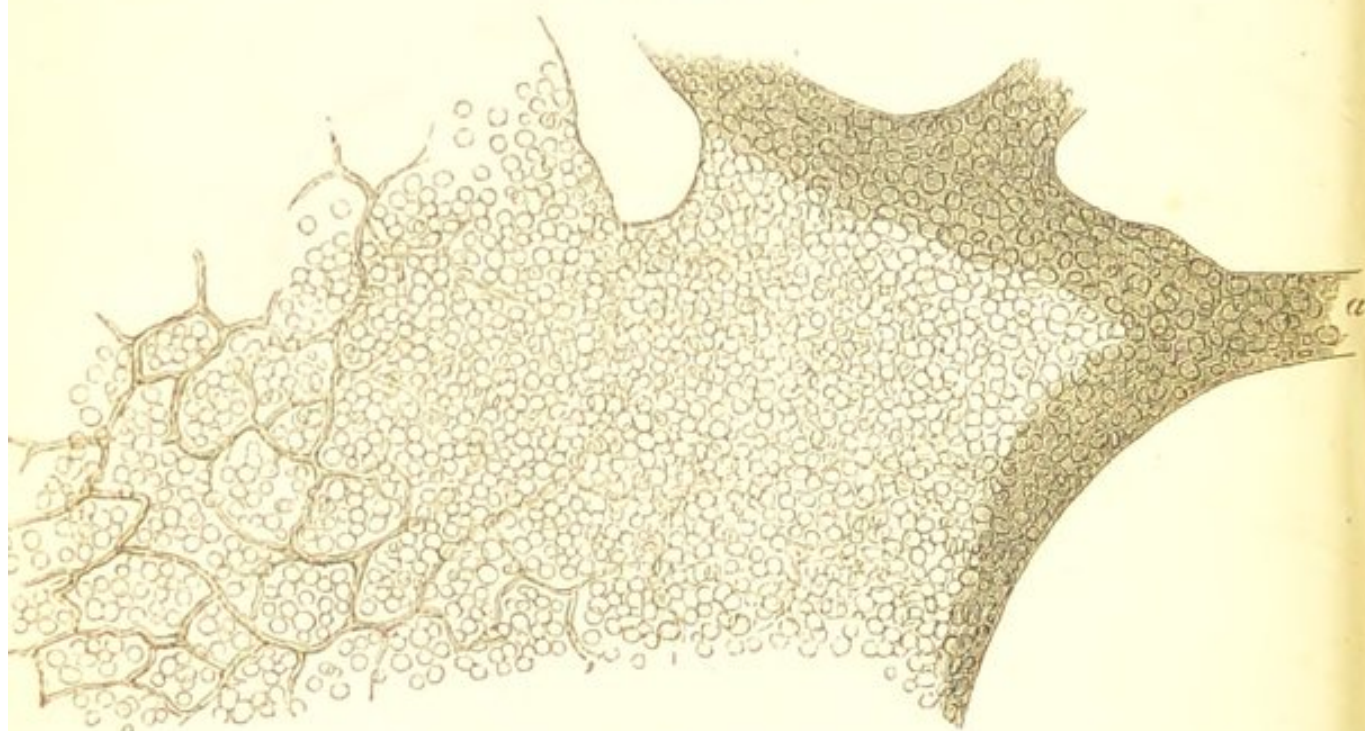A firm Grey Tubercle from the Lung in a case of Acute Tuberculosis. Showing the apparent situation of the nodule between the alveoli, and the grouping of the elements around separate centres. × 33.

described (see Fig. 58), and the small-celled structure grouped around them is adenoid tissue; the large cells having originated within the alveoli, the adenoid tissue in the alveolar walls. This adenoid structure at the peripheral portions of the nodules extends into and produces a thickening of the walls of the alveoli with which the nodule is incorporated (Fig. 66). In many of the

nodules the central portions have undergone retrograde changes and are caseous.

Respecting the cause of these differences in the histological characters of the miliary lesions in the lungs—I believe them to depend upon differences in the age of the nodules, and in the intensity of the tuberculous process. If the intensity of the process be very considerable, the nodules will consist almost exclusively of accumulations of epithelium and fibrinous exudation within the pulmonary alveoli,

FIG. 66.



A small portion of the most external part of a firm Grey Tubercle from the Lung in a case of Acute Tuberculosis. Showing the incorporation of the nodule with the alveolar wall a. × 270.

and the nodule will rapidly undergo disintegration. (See Figs. 62 and 63.) If the process be less intense, and the nodules attain a more advanced age, the necrosis will be less rapid and complete, the development of adenoid tissue in the alveolar walls will be greater, and the epithelial elements may form large multinucleated cells. (See Fig. 64.) Lastly, in the least severe and most chronic processes, the development of multinucleated elements and the formation of the network of branched

cells reaches its maximum (see Figs. 58 and 65), necrosis takes place slowly in the central portions of the nodule, and there is often considerable fibroid induration of the new tissue. There is thus a close analogy between the tissue-changes resulting from tuberculosis of the lungs and those which result from other inflammatory processes. (See "Chronic Inflammations.") The necrosis of the lesions is mainly owing to the interference with their vascular supply caused by the pressure exercised upon the blood-vessels by the intra-alveolar accumulations, and the obliteration of the vessels by the adenoid growth in the alveolar walls. In the most acute forms of the disease it probably also partly depends upon inflammatory blood-stasis.

CHAPTER XXVII.

PYÆMIA AND SEPTICÆMIA.

THE diseases known as Pyæmia and Septicæmia result from the absorption and dissemination of certain infective substances derived from some focus of acute inflammation. In these diseases, therefore, as in acute tuberculosis, we have a focus of inflammation from which the infective substances are derived, the general dissemination of these substances, and the secondary processes to which they give rise.

When a person receives an external injury sufficient to cause an inflammatory process of considerable extent and intensity in the part injured, this process is usually followed by a general disorder of the vital functions, the most prominent symptom of which is pyrexia. This pyrexia, which so commonly occurs after surgical operations and other extensive local injuries, is what is usually known as *traumatic* or *inflammatory fever*. Respecting the cause of this pyrexia—it is probably mainly due to the absorption of some of the products of the local inflammatory process, and of substances resulting from the decomposition of dead organic matter in the neighbourhood of the injury. In other words, the pyrexia and other phenomena result from the dissemination of certain infective materials from a focus of acute inflammation.

Closely allied to this traumatic or inflammatory fever is the condition known as *septicæmia*. Here, also, there is

an absorption of certain infective substances from some inflammatory lesion, but the general disturbance of the vital functions to which they give rise is much more considerable. They cause not only pyrexia, but frequently also vomiting and diarrhœa, and ultimately a condition of coma and collapse which tends to terminate in death. Septicæmia appears therefore to differ from simple traumatic fever mainly in this—that in it the general infective process is one of much greater intensity. In both there is usually an absence of any characteristic local lesions. After death decomposition takes place very rapidly. The blood is found to be somewhat darker and less firmly coagulated than natural; the spleen and liver are enlarged, friable, and abnormally vascular; and, if there has been diarrhœa, the intestinal mucous membrane may present the appearance of acute catarrhal inflammation, with some swelling of the lymphatic structures. In some cases also there is pleurisy or pericarditis.

The general infective process known as *pyæmia* differs from both traumatic fever and septicæmia in this respect—that in it the dissemination of the infective substances derived from the inflammatory focus gives rise not only to that general disturbance of the vital functions which characterises these two conditions, but also to the formation of metastatic nodules of induration which soon assume the character of abscesses, and to more diffused inflammatory lesions. These metastatic nodules of induration which so quickly become purulent, and are so characteristic of the disease, present certain peculiarities. In their earlier stages they usually consist of somewhat reddish, friable, granular-looking masses of consolidation, which are surrounded by a thin zone of red hyperæmic tissue. These masses are frequently wedge-shaped, the apex of the cone being towards the centre of the organ. They vary considerably in size, some not being larger than a small pea, whilst others exceed the size of a chest-

nut. The consolidated mass soon assumes the characters of an abscess. Its more central portions become softened and purulent, and ultimately it tends to become converted into a collection of pus and broken-down tissue, this being still surrounded by a thin red zone of induration.

These metastatic abscesses are met with most frequently in the lungs; but they also occur in the liver, spleen, kidneys, and in other internal organs. They are more commonly found near the surface than in the more internal portions of the organ, often being situated immediately beneath the fibrous capsule.

The more diffused inflammatory processes which also occur in pyæmia, consist chiefly in suppurative arthritis and inflammation of the serous membranes, especially of the pleuræ and pericardium.

Although the occurrence of metastatic abscesses in the later stages of many of these acute infective processes has served as a basis for their classification—those in which they occur being termed pyæmic, those in which they are absent, septicæmic—I agree with those who believe that it does not justify the conclusion that there exists between them any essential pathological difference. Both pyæmia and septicæmia probably result from the absorption of the same infective substance, although the intensity of its infective properties may vary very considerably. The effect of this substance may be simply to produce a general disturbance of the vital functions—a septicæmia; or, more remotely, to cause various disseminated suppurative inflammations—a pyæmia; and as in other acute infective diseases—*e.g.*, scarlet fever, death may result from the general disturbance of function quite independently of any local lesions, so in the diseases now under consideration a septicæmia may be the cause of dissolution without the occurrence of any of those metastatic products which are regarded as characteristic of pyæmia. Such being the case, it is evident that whereas a septicæmia may

exist without the subsequent development of metastatic lesions—a pyæmia, pyæmia must always be associated with more or less septicæmia. In other words, pyæmia is a septicæmia in which there are metastatic suppurative inflammations.

Having thus pointed out the close pathological relation which subsists between these two infective processes, it remains to consider the nature of the infective substance and the circumstances under which it is produced, its absorption and dissemination, and subsequently to explain the occurrence of the metastatic lesions.

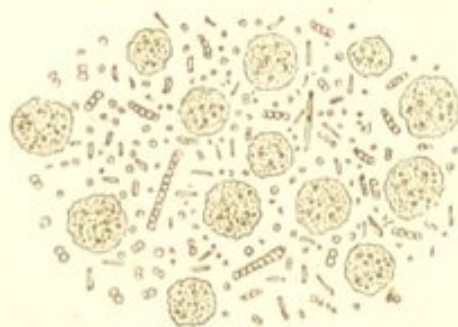
The infective substance, as already stated, originates in connection with the products of an inflammatory process. With regard to its nature—we are at present unable to speak certainly. Its production, however, appears to be invariably associated with the putrid decomposition of the inflammatory liquids.

It is well known that the ordinary putrid decomposition of albuminous liquids is always associated with the presence in them of minute organisms termed *bacteria*, the most common form of which are little rod-shaped bodies, such as are represented in the accompanying drawing (Fig. 67). In a series of observations made in the laboratory of the “Brown Institution” with the object of determining the nature of the pyæmic poison, Dr. Burdon-Sanderson found that these, or similar organisms, abounded in all the inflammatory liquids, and sometimes existed in the blood, of animals in which pyæmic processes had been artificially induced.* These organisms he divides into two groups—rod-shaped bodies endowed with the power of spontaneous movement, similar to the smallest forms represented in Fig. 67 (*bacterium vibrio*), and dumb-bell forms which have no proper movement (*bacterium varicosum*). When liquids derived from pyæmic inflammations are injected into the circulation, or into one of the serous

* “Trans. Path. Soc. Lond.,” Vol. xxiii. 1872.

cavities of an animal, they produce the symptoms of pyæmia, and Dr. Sanderson finds that the intensity of these symptoms appears to bear some direct relation to the number and forms of bacteria which the infective liquids contain. Those animals which were inoculated with liquids containing numerous minute rod-shaped bacteria, died rapidly with symptoms of septicæmia; whereas in those in which

FIG. 67.



Fætid Pus from an Empyæma. Showing bacteria amongst the pus-corpuscles. The bacteria were very active. $\times 600$.

the inoculated liquids contained fewer bacteria of a dumb-bell form, the process was more protracted and was attended by the development of metastatic abscesses—a pyæmia. The results of these investigations therefore show that, in the lower animals, bacteria are invariably present in liquids which are capable of inducing pyæmic processes, and they thus tend to confirm the statement which has already been made, that the development of pyæmic processes in man appears to be invariably associated with the putrid decomposition of an inflammatory product—a decomposition which is always attended by the presence of bacteria.

Whilst it must thus be admitted that bacteria are invariably present in liquids which are capable of inducing pyæmic processes, it is probable, according to Dr. Sanderson, that the development of the pyæmic poison, although associated with, is something quite distinct from, the process of simple putrefactive decomposition; for, as

he has shown, the virulence of pyæmic liquids is diminished by their being kept. In conclusion, all that we are at present able to state with any degree of certainty respecting the nature of the pyæmic poison is, that its development appears to be invariably associated with the putrid decomposition of inflammatory products, and that the liquids in which it is generated contain those low organisms which always accompany the ordinary process of putrefaction, and *possibly* also other organisms which are specific.*

Another important point in connection with the development of the pyæmic poison is the fact that the inflammatory focus in which it originates is, in the majority of cases, the result of some *external* injury—an injury producing a lesion which communicates with the external air. That this should be so, will be readily understood when it is remembered that the decomposition of animal fluids is materially hastened by free exposure to atmospheric influences.

Allusion must here be made to the great proneness of pyæmic processes to occur where persons with open wounds are concentrated together, as in hospital wards. In explanation of this, it must be remembered, as pointed out by Mr. Savory, that the decomposition of an animal fluid is hastened by the introduction into it of any other animal matter which is also undergoing active putrefactive change.†

Although pyæmia thus usually results from external inflammations, it sometimes occurs under circumstances in which no external point of inflammation is discoverable, and the inflammatory focus is situated *internally*.

* Cohn states that there are bacteria found in infective diseases which are quite distinct from those forms which accompany ordinary putrefactive decomposition. See "Quarterly Journ. Micr. Science," 1873, p. 156.

† "Discussion on Pyæmia at Clinical Society," Mr. Savory.—"Trans. Clin. Soc. Lond.," Vol. vii. p. lxxvi.

As an example of this may be mentioned cases of pyæmia resulting from acute necrosis of bone. In explanation of these cases the results of Dr. Sanderson's experiments, already alluded to, are of much value. Dr. Sanderson finds that pyæmia may be induced in the lower animals by the introduction into one of **their serous cavities** of liquids produced by **an inflammatory process** which has been set **up** by chemical agents under circumstances which **preclude** the possibility of the introduction of any infecting substances from without—liquids, however, which, like those derived from an external inflammatory lesion, abound in bacteria.

Having discussed the nature of the pyæmic poison, and the circumstances under which it originates, it remains to consider how it becomes absorbed and is disseminated. Decomposing fluids in contact with inflamed tissues—fluids capable of producing the most intense pyæmic processes if artificially inoculated—do not always become absorbed. The causes which in some cases favour their absorption, and in others prevent it, must be looked for, according to Mr. Savory (*loc. cit.*), in the condition of the inflamed tissues with which they are in contact. Billroth and others have shown, experimentally, that when granulations are healthy they offer a decided obstacle to the absorption of fluids from their surface, but when they become partially destroyed, or are in an unhealthy condition, fluids readily permeate them. It must, then, be considered as exceedingly probable that the absorption of the pyæmic poison is intimately connected with some abnormal condition, due to injury or disease, of the inflamed tissues with which it is in contact. The poison, when absorbed, is disseminated by means of the veins and lymphatics.

The remaining point for consideration is the pathology of the disseminated secondary inflammations—the diffuse lesions and the metastatic abscesses. The most common

diffuse inflammatory lesions which result from the pyæmic process are suppurative arthritis, inflammation of the serous membranes, and of the subcutaneous cellular tissue. The mode of origin of these diffused inflammatory processes we are unable certainly to explain. They probably occupy the same pathological position as the diffuse inflammations which occur in other infective diseases—*e.g.*, in scarlet fever and acute tuberculosis.

Our knowledge of the pathology of the metastatic abscesses is much more complete. These appear usually to be of *embolic origin*, the emboli originating in the venous thrombi which form at the foci of the primary or secondary inflammations. The circumstances under which thrombi formed in the vessels of a part become softened or broken-up, so as to furnish embolic plugs, and the way in which these plugs may set up acute inflammatory processes at the seat of their arrest, will be fully described in the chapters on "Thrombosis" and "Embolism."* It will be sufficient in the present place to state that in the course of a pyæmic process the coagula which form in the vessels at the seat of the pyæmic inflammations become infected with the pyæmic poison, and if they soften or become broken-up so as to furnish embolic plugs, these plugs cause secondary suppurative processes in the parts in which they become arrested; and it is to the dissemination of these infective emboli that the formation of the majority of the metastatic abscesses in pyæmia is owing.

* The student will do well to read the chapters on "Thrombosis" and "Embolism" as a sequel to the present chapter.

CHAPTER XXVIII.

SYPHILIS.

THE lesions occurring in the course of constitutional syphilis are for the most part inflammatory in their nature, but in their seat, distribution, and histological characters, some of them present certain peculiarities which make them quite characteristic of this disease. The primary syphilitic lesion (usually the indurated chancre), the secondary lymphatic gland enlargement, and the subsequent series of changes in the skin, mucous membranes, and later—in the nervous system, bones, and internal organs, are all of them the results of chronic inflammatory processes induced by the syphilitic poison.

The lesions, however, which must be regarded as especially characteristic of constitutional syphilis are of two kinds—certain fibroid indurations, and a form of nodular growth which is known as a *gumma* or syphilitic tumour. These two forms of lesion are very frequently associated, and in many cases it becomes difficult to draw a line of demarcation between them. A fibroid lesion is sometimes simply the remains of what was previously a gummy tumour.

Fibroid growths unassociated with gummata, usually occur somewhat earlier in the course of constitutional syphilis than the gummy tumours. They consist in the first place of an embryonic small-celled tissue, which subsequently becomes developed into a fibroid or adenoid

structure (see "Inflammation of Common Connective Tissue"). The fibroid thickenings which result are characterised by their localisation and by the irregularity in their distribution. They occupy, for the most part, *small areas, the surrounding tissues being unaffected*. It is these peculiarities in their distribution and localisation, and not their histological characters, which render them so characteristic of syphilis.

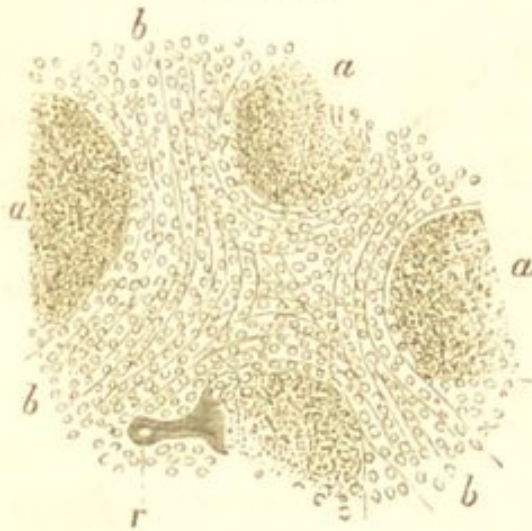
These fibroid changes are met with in various situations—in the periosteum, in the sheaths of nerve-trunks, in the capsule and interstitial tissue of organs, and in muscle. When occurring in the capsules of organs they present very characteristic appearances. In the liver and spleen, where they are the most frequent, they give rise to an irregularly distributed thickening and puckering of the capsule which is exceedingly typical of advanced syphilis. The thickened portions are usually connected with dense fibroid septa which pass into the interior of the organ; and there are frequently also numerous strong peritoneal adhesions. The gummy masses about to be described are very often to be found in the midst of the fibroid growth.

The other variety of lesion, which is perhaps more characteristic of syphilis than the preceding, and very frequently associated with it, is the *gumma* or syphilitic tumour. The gummata were formerly regarded as non-inflammatory neoplasms, and were classified by Virchow amongst what he termed the "granulation" tumours. As usually met with, they are moderately firm yellowish-white nodules, having often, on section, somewhat the appearance of a horse-chestnut. They vary in size from a hemp-seed to a walnut, and are surrounded by a zone of translucent fibrous-looking tissue, which sometimes has the appearance of a capsule, and which is so intimately associated with the surrounding structures that the complete enucleation of the mass is impossible. In the earlier stages of their development, when they less com-

monly come under observation, they are much softer in consistence, more vascular, and of a reddish-white colour; whilst in their most advanced stages, owing to extensive retrogressive changes, they may be distinctly caseous.

When the gummata are examined microscopically they are found to consist in the main of atrophied, degenerated,

FIG. 68.



Gummy Growth from Liver. *a.* Central portions of growth, consisting of granular debris. *b.* Peripheral granulation tissue. *r.* A blood-vessel. $\times 100$. (Cornil and Ranvier.)

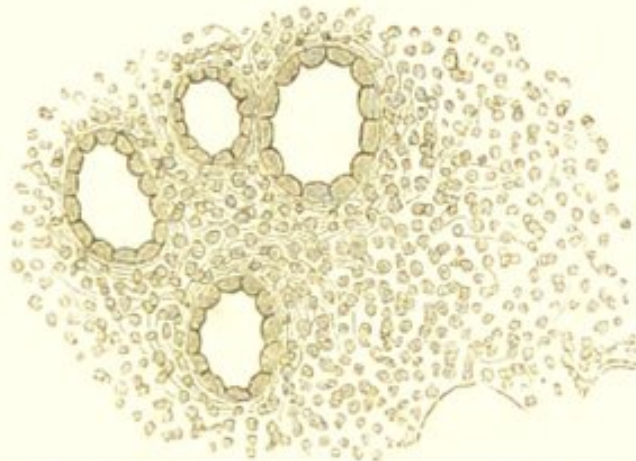
and broken-down cell-products, embedded in an incompletely fibrillated tissue. There are, however, some marked structural differences between the central and external portions of the growth. The central portions are composed almost entirely of closely-packed granular debris, fat granules, and cholesterolin, amongst which may be an exceedingly scanty fibrillated tissue. (Fig. 68, *a.*) Surrounding this and directly continuous with it is

a more completely fibrillated structure; whilst the peripheral portions of the growth, which are continuous with the surrounding tissue, consist entirely of small round cells—the granulation or “indifferent” cells. (Fig. 68, *b.* and Fig. 69.) The blood-vessels, which only exist in the external portions of the growth, are very few in number.

The three zones above described, which are to be distinguished more or less clearly in most of the gummy nodules, correspond with three different stages in their growth. The most external zone, consisting of the granulation-tissue, represents the early stage of development, and by the continuous formation of this tissue the growth may continuously increase. The intermediate fibrous zone represents the second stage in the process—

the development of the granulation tissue into a more or less completely fibrillated structure. The characters of this fibrillated tissue vary in different growths. In some the fibrillation is very distinct; in others, the tissue is dense and cicatricial in character; whilst less frequently, it consists of a reticulated structure within the meshes of

FIG. 69.



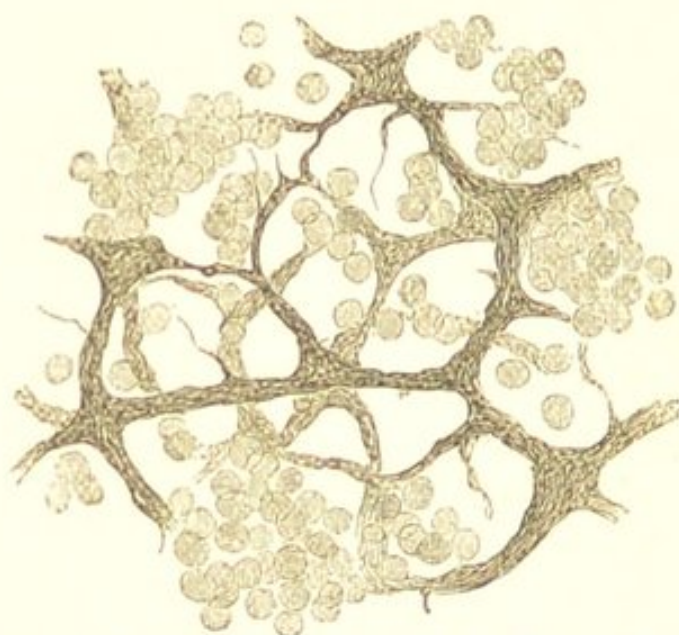
The Peripheral Portion of a Gummy Growth in the Kidney. Showing the small-celled growth in the intertubular tissue. × 200.

which are grouped round small cells. ("Adenoid tissue;" compare with Fig. 74, A.) (Fig. 70.) The central zone, consisting of the amorphous granular material, represents the oldest portion of the growth—that which has undergone retrogressive changes. The blood-vessels, which only exist in the zone of proliferation, appear to become obliterated in the process of development; and this probably accounts for the rapid degeneration of the central portions of the growth. When the tumour is large, it may sometimes be seen to be made up of several distinct smaller growths, each presenting at its circumference the more perfect cells, whilst its central parts are granular and amorphous.

It would thus appear that the first stage in the process of formation of these gummy growths consists in the production of a small-celled granulation tissue. This is followed by the incomplete development of the new tissue

into a fibrillated or adenoid structure, together with the atrophy and degeneration of the young elements. The degenerated elements become closely packed in the centre of the growth, whilst proliferation and incomplete fibrillation continue at the circumference. The central portions of the growth may ultimately become calcified, but more commonly they gradually become absorbed, and a mere puckered fibrous cicatrix occupies the seat of the original tumour. This is one of the ways in which the fibroid lesions originate.

FIG. 70.



From a Gummy Growth in the Kidney. Showing the adenoid structure occasionally met with in the intermediate zone of these formations. × 200.

The gummata are the new formations most characteristic of syphilis, and their distribution is almost co-extensive with that of syphilitic lesions. They are met with in the skin and subcutaneous cellular tissue, in the submucous tissue, in muscle, fasciæ, bone, and in the connective tissue of organs—especially of the liver, brain, testicle, and kidney. They also occur, but much less frequently, in the lungs; as do also simple localised fibroid indurations. When situated in the submucous tissue the mucous membrane usually becomes destroyed, and a deep ulcer forms. This is seen in the pharynx, soft palate,

tongue, larynx, and in other parts. These true gummy ulcerations must be distinguished from the superficial ulcerations resulting from inflammatory processes in the lymphatic structures, which also occur in syphilis.

SYPHILITIC DISEASE OF THE LIVER.

The liver is one of the most frequent seats of syphilitic lesions. The most common change is the development of fibroid and gummy growths in the substance of the organ. These growths are strictly localised, the surrounding liver-tissue being healthy. The growths—which are usually connected with fibroid thickenings of the capsule—sometimes consist simply of a dense fibroid structure. More commonly, however, gummy masses are found imbedded in the fibroid growth. In the former case it is possible that the gummy mass may have become absorbed, leaving merely its fibroid cicatrix.

The development of these growths produces very marked alterations in the form of the liver. Scar-like depressions are seen on its surface, and the organ is irregularly, and often very deeply puckered.

A more general fibroid change, not associated with the formation of gummy masses, but closely resembling ordinary cirrhosis, is occasionally met with in the liver in infantile syphilis.

Lastly, it must be mentioned that the liver in syphilis is frequently amyloid.

It is unnecessary to describe particularly syphilitic lesions in other organs, as they all present the same general characters—viz., strictly localised fibroid, or fibroid and gummy growths.

CHAPTER XXIX.

INFLAMMATION OF NON-VASCULAR TISSUES.

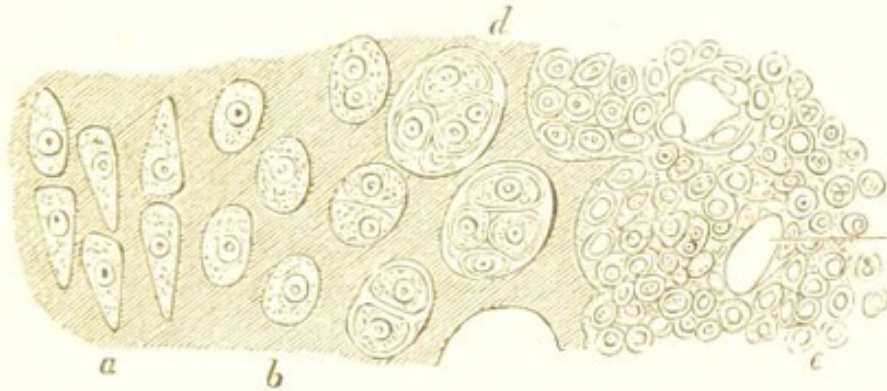
INFLAMMATION OF CARTILAGE.

THE phenomena of acute inflammation in cartilage, although comparatively rare in man, have been studied by the artificial irritation of the articular cartilages in the lower animals. They consist in changes in the cartilage itself, and in the vessels of the adjacent synovial membrane and bone, from which the cartilage receives its nutritive supply. Respecting the vascular changes, these are such as have been already described as characteristic of inflammation.

In the cartilage itself, the cells enlarge within their capsules, their nuclei become more prominent and their protoplasm more granular. The cells then multiply by simple division, so that each cavity contains numerous young cells which ultimately closely resemble pus-corpuscles. At the same time the capsules are destroyed, and the intercellular substance softens and breaks down into a finely granular material. (Fig. 71.) As the intercellular substance becomes destroyed, the newly-formed cells and granular débris escape from the surface of the cartilage, which thus becomes irregular, presenting numerous elevations and depressions: this is acute ulceration of cartilage. Whilst these changes are taking place in the cartilage itself, numerous new blood-vessels are

formed from those in the adjacent bone or synovial membrane; the little loops of new vessels dipping into the softened cartilage. This process of softening and

FIG. 71.



Section of Inflamed Cartilage. *a.* The normal cartilage-cells. *b.* The same enlarged. *d.* Multiplication of cells within their capsules. *e.* Great increase in the number of the young cells, and destruction of the intercellular substance. $\times 250$. (Cornil and Ranvier.)

ulceration may go on until the cartilage is completely destroyed, or it may become arrested. In the latter case the young cells form a granulation-tissue, this tissue fibrillates, and the lost cartilage thus becomes replaced by a fibroid structure.

When the inflammation is less severe and runs a more chronic course, the cell-proliferation is not so active, and the intercellular substance is less destroyed. The newly-formed cells are more highly organised, and whilst many of them undergo retrogressive changes, others form a fibrillated tissue. Irregular cavities may thus be produced in the midst of a fibrillated cartilage.

Erosion of Cartilage.—Allusion must be made here to a morbid condition of cartilage which is exceedingly common in people past middle life. It consists in the occurrence upon the surface of the articular cartilages of small, yellowish, flocculent spots, which gradually increase in size, and ultimately break down and become destroyed, leaving a superficial erosion. The change occurs most

frequently in the cartilages of the patella and of the knee-joint, and in other situations in which the cartilages are especially subjected to pressure.

When the diseased portions are examined microscopically, the most marked alteration is seen to consist in a fibrillation of the intercellular substance of the cartilage. Some of the cartilage-cells are also increased in size and show signs of proliferation; whilst others are in various stages of fatty metamorphosis. The change appears to result from long-continued irritation due to pressure, and it may be regarded as an irritative process, in which, owing to the natural poverty of the vascular supply, retrogressive changes occupy a very prominent place.

INFLAMMATION OF THE CORNEA.

The process of inflammation as it occurs in the cornea has been chiefly studied in the frog. After irritation of the frog's cornea, the earliest changes observed consist in the conjunctival epithelium becoming visible, and in the appearance amongst the epithelial cells of a few leucocytes, which have probably escaped from the hyperæmic vessels of the conjunctiva. The cornea-corpuscles and their prolongations then become visible (they are invisible in the healthy cornea, which appears perfectly structureless), and the prolongations are the seat of slight amœboid movements. At a somewhat more advanced stage the cornea-corpuscles become altered in form, their prolongations become much shorter, they lose their stellate outline, and gradually assume more the appearance of cartilage-cells. The next change observed in the enlarged and rounded corpuscles consists in their proliferation, and in the place of each corpuscle is seen a clump of young, round, amœboid cells, many of which are indistinguishable from the living corpuscles of pus.

Whilst these changes are taking place in the corpuscles of the inflamed cornea, the intercellular substance gra-

dually becomes increasing opaque, owing to its infiltration with young cellular elements (leucocytes). These are so numerous and increase so rapidly, that they must undoubtedly be regarded as, in the main, emigrant white blood-corpuscles; although from the changes observed to take place in the earlier stages of the process in the fixed elements of the cornea, it must be admitted that they are partly derived from the proliferation of the cornea-corpuscles. As the number of these young elements increases the consistence of the cornea becomes diminished, until ultimately the tissue breaks down and is destroyed.

The inflammatory process may continue until the whole of the substance of the cornea is softened and destroyed; or it may become arrested. In the latter case more or less thickening and opacity of the cornea will result, owing to the increase in the number of cells and the changes in the intercellular substance.

CHAPTER XXX.

INFLAMMATION OF COMMON CONNECTIVE TISSUE.

COMMON connective tissue is one of the most frequent seats of the inflammatory process, not only the subcutaneous connective tissue, but also the connective tissue of organs and of other parts.

If connective tissue be examined a few hours after the infliction of an injury, it will be found that in place of the fibrillated substance and fixed connective-tissue corpuscles of which it is normally composed, the tissue is infiltrated with amœboid cells (leucocytes), and that the fibrillated intercellular material has become homogeneous and gelatinous in consistence. The number of these cells gradually increases, and the intercellular substance gradually becomes more completely destroyed—being probably consumed by the newly-formed elements—so that ultimately the tissue consists almost entirely of small round cells held together by a very small quantity of soft gelatinous intercellular material.

Respecting the source from which these young elements are derived—*i.e.*, how far they are emigrants, and how far they are the offspring of cells belonging to the connective tissue—there appears to be little doubt that they are almost entirely emigrants. Although it was formerly supposed that the connective-tissue corpuscles multiplied very rapidly in inflammation, and that the newly-formed cells were entirely the result of their proliferation, the recent investigations of Professors Cohnheim and Stricker

show that this view is erroneous ; and according to Cohnheim, these corpuscles take no part whatever in the inflammatory process. Professor Stricker, however, has observed them undergoing active movements in the inflamed tongue of the frog, and although he has never seen them divide, he concludes that, like the elements of most other tissues, they probably do so in the latter stages of the inflammatory process. The present state of our knowledge respecting inflammation of connective tissue would therefore appear to justify the conclusion that in the early stages of the process all the young cells are emigrants, but that most probably in the latter stages many of them are derived from the proliferation of the connective-tissue corpuscles.

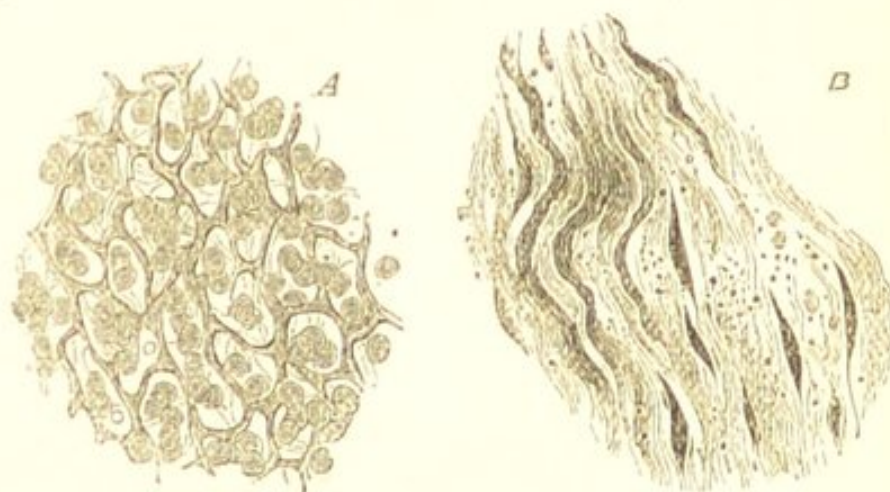
Such being the nature of the changes which more immediately follow injurious stimulation of the connective tissue—the inflammatory process may terminate in *resolution*, in *organisation*, or in *suppuration*.

RESOLUTION.—If the injury sustained by the tissue is not severe, the inflammation may gradually subside, the process terminating in *resolution*. In this case the hyperæmia diminishes, the emigration ceases, some of the young cells undergo fatty metamorphosis and thus become absorbed, others pass into and are removed by the lymphatics, and the tissue gradually returns to its normal condition.

ORGANISATION.—If the inflammatory process does not terminate in resolution, many of the young cells may become more fully developed and ultimately form a fibrillated tissue. This *organisation* of the inflammatory formation is seen in the healing of wounds by the “first intention,” and also in many of the chronic inflammations of the kidney, liver, and other organs. In order for it to occur it is necessary that there should be a considerable diminution in the intensity of the inflammation. (See “Chronic Inflammations.”)

The process of organisation takes place by the production of new capillaries and by the development of the young cells into a granulation-tissue. This granulation-tissue consists almost entirely of young cells, which must be regarded as exhibiting a somewhat higher stage of development than the primary amœboid cells (leucocytes) of the inflammatory formation. They are spherical masses of protoplasm from $\frac{1}{1800}$ to $\frac{1}{3000}$ of an inch in diameter, usually containing an indistinct round or roundly-oval nucleus, which often only becomes visible after the addition of acetic acid; and although they exhibit slight amœboid movements, they are much less active than the emigrant blood-corpuscles. The further organisation of the growth takes place by the development of this granulation-tissue into a fibrillated or adenoid structure. The

FIG. 72.



Varieties of new Growth resulting from chronic Inflammation of Connective Tissue.—A an adenoid, B a fibroid structure. $\times 200$.

granulation-cells diminish in number, many of them frequently become spindle-shaped, the newly-formed capillaries gradually disappear, and the richly cellular tissue thus becomes converted into a more or less dense structure, which is characterised by the gradual process of contraction which it undergoes. This is usually known as *cicatricial tissue*.

The characters of this new tissue present certain varia-

tions. Sometimes it consists of closely-packed wavy fibres, amongst which are a few elongated spindle-shaped elements, such as are represented in Fig. 72, B. It is equally common for the tissue to assume the appearance shown in Fig. 72, A—a dense homogeneous or obscurely fibrillated material, forming meshes of various sizes, within which are grouped a few lymphoid cells. (“Adenoid Tissue.”) (See also Figs. 55 and 85.) These two varieties are very frequently associated in the same specimen, the former probably representing a higher degree of development than the latter.

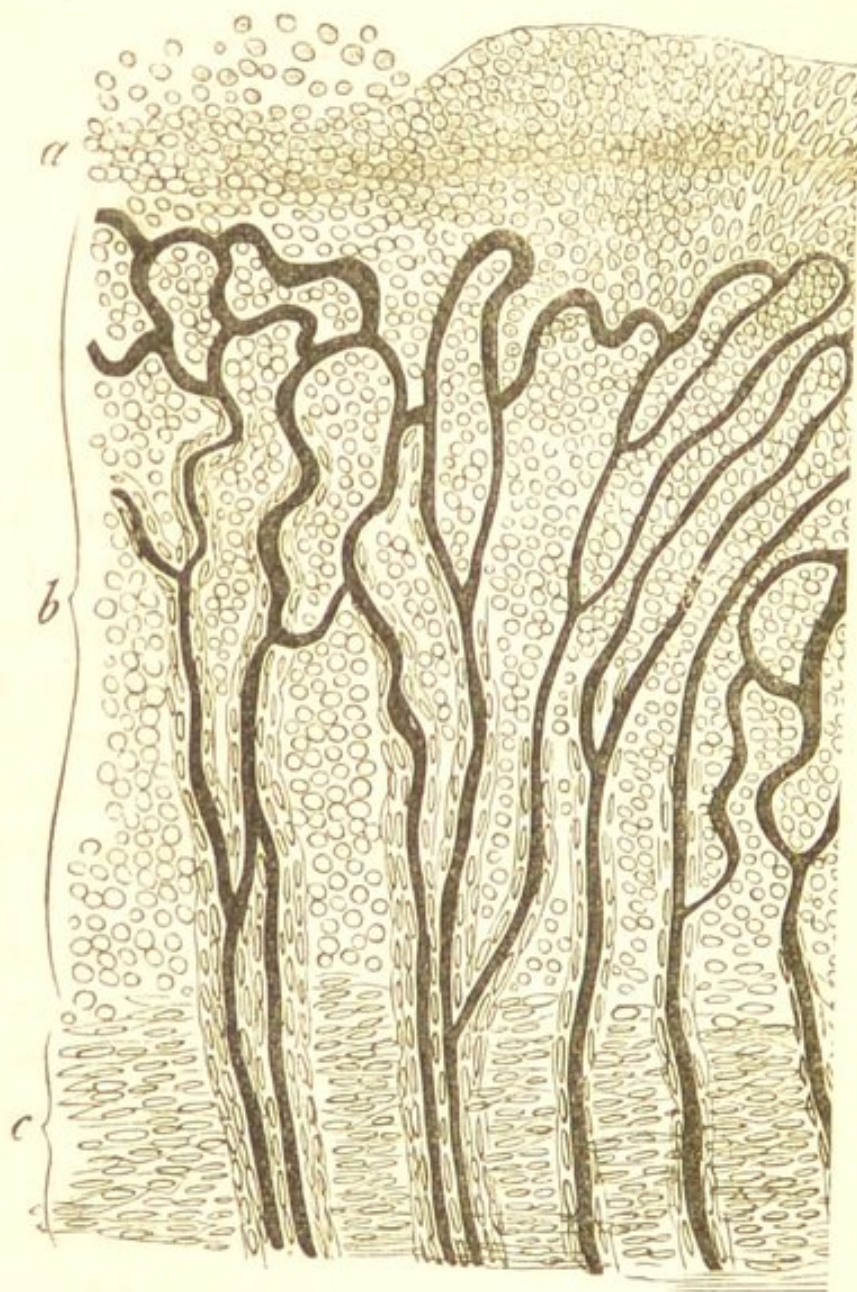
SUPPURATION.—When the injury sustained by the tissue is so severe or so prolonged in its action as to prevent the occurrence of resolution or of immediate organisation, the young cells infiltrate the tissue in such numbers that they may accumulate so as to constitute pus. The pus may either become collected together within the tissue so as to form an abscess, or it may be continuously discharged from the surface, as in a granulating wound. The deleterious influence which the pus exercises upon the tissues with which it comes in contact, causing their destruction and absorption, has already been alluded to. (See “Suppuration.”)

Organisation after Suppuration.—This constitutes what is generally known as healing by *granulation*, or by the *second intention*. It takes place in wounds in which, from the non-apposition of the wounded surfaces, union by the first intention has not been effected; and in other lesions in which the injured tissue presents a free surface communicating with the external air, as in an ulcer. The process of repair after the separation of a dead part (demarcation and separation) is in the same way effected by granulation, as is also the closing of the cavity left after the discharge of the contents of an abscess. In all these and similar cases the inflammation and suppuration of the tissue are followed by the formation of granula-

tions, and by the subsequent development of these into a fibrillated structure.

The process of organisation in these cases is effected in the first place by the development of the young cells in

FIG. 73.



A Granulating Surface. a. Layer of pus. b. Granulation-tissue with loops of blood-vessels. c. Commencing development of the granulation-tissue into a fibrillated structure. × 200. (Rindfleisch.)

the superficial layers of the inflamed tissue into a granulation-tissue, in the same manner as when there is no suppuration. This granulation-tissue, however, being

situated superficially, and coming into contact with the external air, becomes arranged in the form of small papilliform nodules, which are known as *granulations*. This arrangement of the granulation-tissue in the form of granulations, appears to be determined by that of the new capillary blood-vessels which are developed so rapidly in it. These vessels form little vascular loops, and the young cells are arranged round them, so that each loop corresponds with a single granulation. The deeper layers of the granulation-tissue gradually become developed into a fibrillated tissue, whilst the cells on the surface of the granulations, together with the liquids exuded from the subjacent vessels, are discharged in the form of pus. (Fig. 73.)

CHAPTER XXXI.

INFLAMMATION OF BONE.

INFLAMMATORY processes in bone give rise, for the most part, to an increase of medullary tissue and to softening of the compact osseous structure.

The process takes place in the medullary tissue and in the Haversian canals, the primary vascular phenomena being followed by the emigration of blood-corpuscles. The cells in the medullary spaces and Haversian canals enlarge and multiply; in those which contain fat—the adipose cells—the fat is first removed, and thus a tissue is formed, consisting of numerous small round cells, larger cells containing several nuclei closely resembling the “myeloid cells,” and a scanty soft intercellular substance. This is an inflammatory granulation-tissue, the large multinucleated elements being similar to those normally met with in the medulla of growing bone. Whilst these changes are taking place in the medullary tissue, the surrounding osseous lamellæ are gradually absorbed, the lime salts are removed, and in this way the medullary spaces and Haversian canals increase in size and ultimately become confluent. There is thus a new formation of medullary granulation-tissue at the expense of the compact osseous structure, and the bone becomes exceedingly spongy, soft, and vascular.

If the process be not severe it may occasionally, in its earliest stages, terminate in resolution. More commonly, however, it continues until more or less of the bone

becomes replaced by the inflammatory tissue. If the inflammation be of considerable intensity, it leads to the formation of pus. The cellular infiltration increases, the compact osseous tissue becomes more and more absorbed, and the pus which is produced may accumulate beneath the periosteum or in the centre of the bone, so as to form an abscess. This constitutes the condition known as *osteomyelitis* or *acute osteitis*. These intense forms of inflammation often lead to necrosis of the bone.

When the inflammation is of much less intensity, the new inflammatory tissue may undergo progressive development, and form new bone. In this case a new formation of osseous tissue takes place in the enlarged Haversian canals and cancellous spaces, so that the bone becomes converted into a heavy dense structure consisting of hard compact osseous, with very little cancellous tissue. This is *sclerosis* of bone.

PERIOSTITIS.—Inflammation of the periosteum may be localised or diffuse, acute or chronic. Acute inflammations of the periosteum lead to the formation of pus, which accumulates between the bone and the periosteal membrane. This, by interfering with the vascular supply, frequently causes necrosis of the superficial layers of the bone; and if a large portion of the periosteum be involved, and the inflammatory process extend to the deeper parts of the bone, the whole bone may die. Another not infrequent result of periostitis is a chronic superficial inflammation and caries of the bone.

When the inflammation of the periosteum is less intense and more chronic, the new inflammatory growth produced in the deeper layers of the membrane may become developed into osseous tissue (periosteal ossification).* The

* According to Billroth, this new osseous tissue is partly derived from the bone itself, which, he states, is the seat of a superficial osteitis. (See "Billroth's Surgical Pathology and Therapeutics," translated by Hackley. 4th Edit., p. 419.)

process thus causes enlargement of the bone, or if this be necrosed, it helps to reproduce the lost structure. (See "Necrosis.")

Strictly localised inflammations of the periosteum occur in the formation of nodes, and here also there is frequently a new growth of bone.

NECROSIS.—All conditions interfering with the supply of blood to a bone may be causes of its death. Necrosis may thus result from accident, portions of bone being violently separated from their vascular connections, or, more commonly, the periosteum being stripped off and injured. Much more frequently, however, it is the result of the intense inflammatory processes in the bone or periosteum which have been described.

The bone, when dead, undergoes a gradual process of separation from the adjacent living tissue. This is effected in the same way as the separation of soft structures. (See "Gangrene.") The adjacent living bone becomes the seat of an inflammatory process, a granulation tissue and pus are produced, and by this means the dead portion is completely separated. When separated it is termed a *sequestrum*.

The removal of the sequestrum from the granulation tissue with which it is in contact is often only effected with considerable difficulty, especially if it be deeply seated. This difficulty is occasionally due to a more or less thick layer of the old bone surrounding the necrosed portion. Much more frequently, however, it is owing to the participation of the periosteum in the inflammatory process. The inflamed periosteum produces new bone, a capsule of which is thus formed, enclosing the sequestrum. Openings exist in this capsule (*cloacæ*) leading to the dead bone, and through these openings the inflammatory products are discharged. When the sequestrum is quite superficial, its removal is, of course, more readily effected.

CARIES.—By caries is understood that inflammatory dis-

integration of bone and removal of the dead products which corresponds with ulceration of soft parts. Caries is therefore one of the results of inflammation of osseous tissue.

Inflammatory processes in bone which are of comparatively slight intensity have been seen to be characterised histologically by a gradually increasing production of an inflammatory granulation-tissue from the medullary tissue of the bone, and by the absorption of the compact osseous structure. Whether the bone cells also proliferate is still *sub judice*. This absorption of the bone appears to be effected entirely by the new inflammatory growth. When these chronic inflammatory processes occur in the superficial layers of the bone beneath the periosteum, the bone is gradually destroyed, and presents a ragged irregular excavated surface. This is superficial caries, or ulceration of bone. The floor of the ulcer consists of a cancellous structure containing the débris of the disintegrating process. In many cases there is a marked condensation (sclerosis) of the deeper portions of the bone.

Chronic inflammatory processes in the interior of bone cause in the same way absorption and disintegration of the osseous structure. Here, however, the inflammatory products being less readily removed, sometimes undergo, especially in scrofulous children, a kind of caseous transformation, and the carious cavity contains molecular débris, sanious pus, and minute portions of dead bone. The inflammatory granulation-tissue often projects as fungating masses into the cavity.

Caries is frequently associated with more or less necrosis, especially when the process affects the interior of the bone. Small portions of bone are cut off from their vascular supply, become detached, and are found in the carious cavity.

There are two other morbid conditions of bone, which, although probably not coming within the category of in-

flammation, may be conveniently described in the present chapter—viz., *Mollities Ossium* and *Rickets*.

MOLLITIES OSSIUM.

Mollities Ossium or *Osteomalacia* is a rare disease, occurring only in adults. It is characterised by a progressive softening of the bones, owing to an increase in their medullary tissue and the destruction of the compact osseous structure. The bones become so much softened that they can be easily cut with a knife; they are exceedingly light, and bend readily in all directions. On section, the cortical layer is found to be almost destroyed, the bone consisting of a wide cancellous structure containing a reddish, gelatinous, fatty material.

The nature of the disease is obscure. According to Rindfleisch, the change consists in a decalcification of the osseous tissue spreading gradually from the medulla and cancelli of the bone. The decalcified tissue does not become so completely absorbed as in inflammation of bone, but undergoes more or less of a mucoid change. The medullary tissue is exceedingly vascular, but unlike ordinary granulation-tissue it usually contains much fat. Lactic acid has been found in the bone and in the urine. The urine usually also contains lime salts, which have been removed from the bone and eliminated by the kidneys.

RICKETS.

The common disease of children so well known as *Rickets* or *Rachitis* is mainly characterised by certain alterations in the bones. The bones generally are softened. The ends of the long bones are enlarged, and the flat bones are thickened. As a result of these alterations the bones become deformed, and their growth is frequently arrested.

Respecting the nature of this disease, we are at present unable to speak certainly. It appears, however, to be

closely associated with mal-nutrition, and all those conditions which materially interfere with the nutrition of the child may be causes of the disease.

The alteration in the bones may be briefly described—as stated by Sir W. Jenner—as consisting in an increased preparation for ossification, but an incomplete performance of the process. In a growing bone the zone of soft tissue in which the process of conversion of cartilage into bone is taking place is exceedingly narrow, the proliferation of the cartilage involving only one or two rows of the cartilage cells. In rickets this transition zone is very considerably widened, the proliferation of the cartilage cells extending for some depth into the cartilage, and the adjacent layer of cancellous tissue being much broader than natural. The junction between the bone and the cartilage is also exceedingly irregular, so that in some parts the cancellous bone extends into the cartilage much further than in others. Usually the proliferation of the cartilage in the transition zone is accompanied by the calcification of the new tissue and its conversion into bone. In rickets, however, this calcification takes place very incompletely, and thus a wide layer of imperfectly calcified soft tissue is formed at the growing end of the bone.

A similar abnormality exists in the process of ossification from the periosteum. Here also the zone of vascular granulation-tissue from which the bone is developed is exceedingly broad, the calcification of the tissue is exceedingly incomplete, and the bone thus becomes thickened by a soft, vascular, and very imperfectly calcified structure. As the bone grows the medullary cavity naturally widens, and the compact tissue becomes absorbed. This imperfect formation of osseous tissue from the periosteum produces therefore considerable softening and weakening of the bone.

The changes in the bones in rickets thus closely re-

semble those which occur in the normal process of ossification. There is the same proliferation of the cartilage-cells and of the deeper periosteal layers, but this proliferation occupies abnormally large areas. The development of the young cells and the transformation of the new tissue appears also to be more or less incomplete. In many parts the young elements do not form perfect bone-cells, but simply angular cells without canaliculi, whilst in others the development may be much more complete. Various transitions are thus met with between tolerably well developed and very imperfect bone-structure, but owing to the deficiency of lime salts this structure is very imperfectly and very irregularly calcified.

CHAPTER XXXII.

INFLAMMATION OF BLOOD-VESSELS.

INFLAMMATION OF ARTERIES.

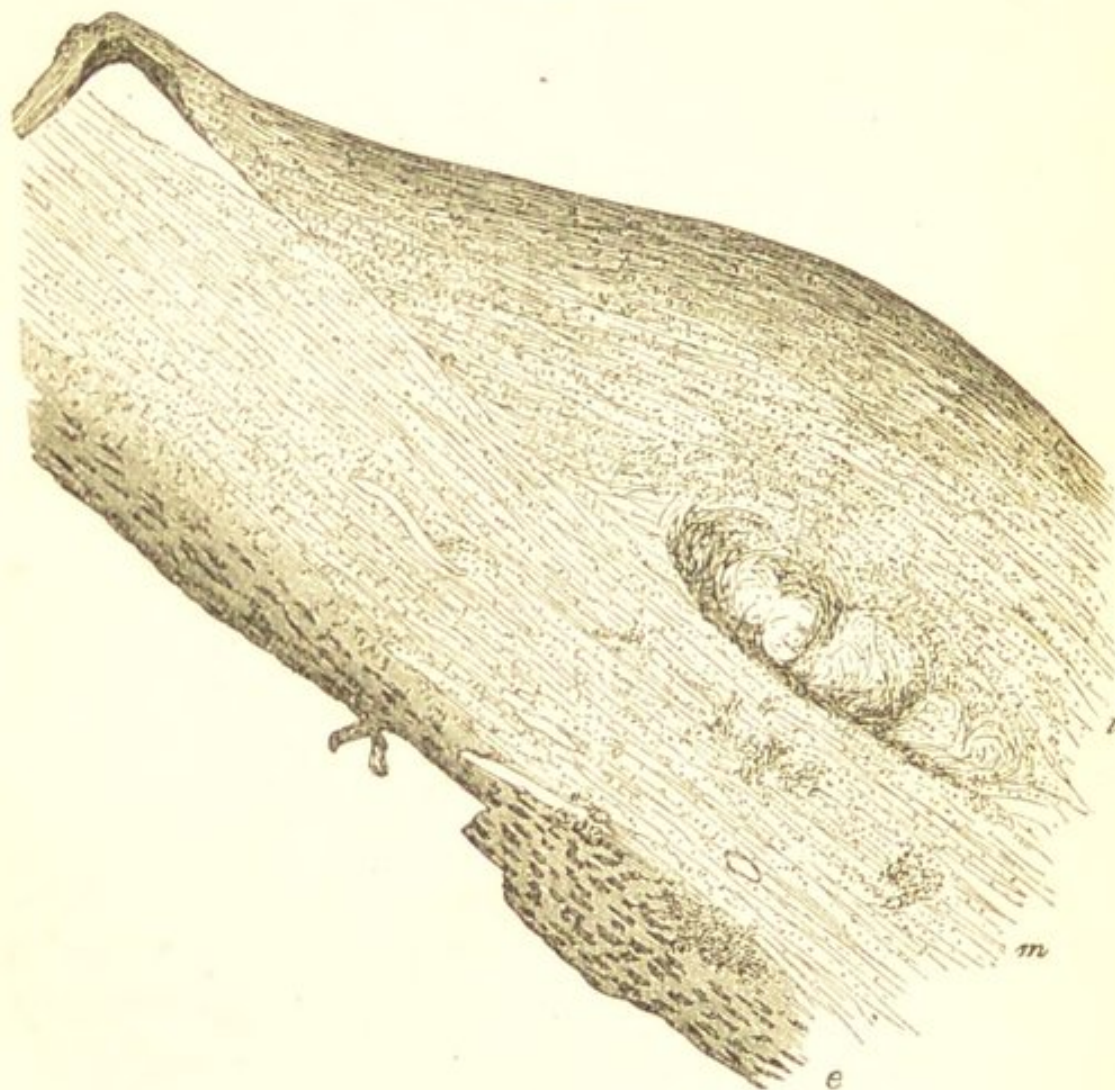
IN studying the process of inflammation in arteries, it must be borne in mind that the inner coat of these vessels is non-vascular, the blood-vessels being distributed in the external layers.

Acute and chronic inflammations of arteries are a very frequent result of coagulation of the blood within the vessel (thrombosis). Such inflammations will be considered in the chapter on Thrombosis. Independently of thrombi, the most acute inflammatory processes in arteries are for the most part the results of injuries from violence, or of inflammation in adjacent tissues. Here, the histological changes are principally confined to the external coat of the vessel. This becomes exceedingly hyperæmic and infiltrated with small cells, the cellular infiltration involving also the middle coat. As a consequence of these changes in the outer coats the vitality of the intima is destroyed, and when this has occurred the blood contained within the vessel coagulates.

ATHEROMA.—The more chronic forms of arterial inflammation give rise to changes which are most marked in the deeper layers of the inner coat, where they produce those various alterations in the walls of the vessel which constitute what is known as *atheroma*. In the earliest stage of the inflammatory process the fibrous and elastic lamellæ

of the inner coat of the vessel become infiltrated with young cells, which are probably partly emigrants, and partly derived from the proliferation of the cells of these structures. As these young cells increase in number they give rise to a swelling beneath the innermost layers of

FIG. 74.



Atheroma of the Aorta. Showing the new growth in the deeper layers of the inner coat, and the consequent internal bulging of the vessel. The new tissue has undergone more or less fatty degeneration. There is also some cellular infiltration of the middle coat. *i.* internal, *m.* middle, *e.* external coat of vessel. $\times 50$ reduced $\frac{1}{2}$.

this coat of the artery (Fig. 74). This swelling of the intima is very characteristic. It is, in the earlier stage of the process, of a soft flabby consistence, and the lining membrane which is continuous over it can be stripped off

leaving the diseased tissue beneath. It thus contrasts strongly with the superficial patches of fatty degeneration which result from the fatty metamorphosis of the endothelial and connective tissue cells of the vessel. (See "Fatty Degeneration of Arteries.")

The results of the inflammatory process will depend upon its severity. If the process be very acute, the young elements accumulate rapidly and infiltrate the middle and external coats, so that the walls of the vessel become so much softened, that dilatation, aneurism, or rupture may ensue. Such acute changes are a common cause of aneurism. The inflammation, however, is usually of less intensity and runs a more chronic course, and it is only to these more *chronic* arterial changes that the term "atheroma," is commonly applied.

When the process is less intense and more chronic in its course, it leads to various alterations in the wall of the vessel. The soft cellular infiltration of the deeper layers of the intima usually undergoes retrogressive changes, owing to deficient nutritive supply. These changes commence in the deeper portions of the new tissue. The young cells undergo fatty degeneration, the intercellular substance softens, and thus a soft, yellowish, pultaceous material is produced beneath the lining membrane of the vessel. This has been termed an *atheromatous abscess*. The lining membrane may ultimately give way and the softened matters be carried away by the circulation, and thus is produced the *atheromatous ulcer*. In other cases the more liquid constituents of the degenerated tissue gradually become absorbed, cholesterin forms, and thus a mass, consisting of broken-down fibres and cells, fatty débris, and cholesterin crystals, with a varying quantity of the original fibrillated tissue, remains in the deeper layers of the inner coat. (Fig. 74.) This may subsequently calcify, and so form a *calcareous plate*.

In the most chronic forms of the atheromatous process there is more or less fibrillation of the new tissue, and thus is produced a *fibroid thickening* of the inner coat of the artery. The organisation, however, is rarely complete, more or less fatty débris being usually enclosed in the fibroid stroma.

Respecting the causes of these chronic arterial inflammations included under the common term of atheroma—they are probably mainly due to over-strain of the vessel, the strain exercising a chronic injurious influence. This view has been especially insisted upon by Dr. Moxon.* It is supported by the fact that those vessels which are the most exposed to strain, are the most liable to this disease, *e.g.* the arch of the aorta; also by the exceeding frequency of atheroma in all those conditions in which there is an increase of the blood-pressure. The effect of increased blood-pressure as a cause of atheroma is seen in the liability of athletes to the disease; and also in the frequency with which it occurs in chronic Bright's disease, and in the pulmonary vessels in cases of mitral obstruction, &c.

INFLAMMATION OF VEINS.

Inflammatory processes in veins are more frequent than in arteries, but here they are in the very great majority of cases secondary to coagulation of the blood within the vein (thrombosis), the coagulum acting as an irritant to the coats of the vessel. These inflammations resulting from thrombosis will be treated of in a subsequent chapter (see "Results of Thrombosis").

The inner coat of the veins is, like that of the arteries, non-vascular, and hence acute inflammatory changes are, for the most part, confined to the external and middle coats. Independently of inflammations resulting from

* "Lectures on Pathological Anatomy." Wilks and Moxon, 2nd Edit., p. 150.

thrombosis, the lining membrane of veins appears to undergo no active changes.

Acute and chronic inflammatory processes in veins are, as already stated, most frequently due to thrombosis. They may also result from violent injury, or from the extension of inflammation from adjacent tissues. The process, when acute, closely resembles that in the arteries. The external and middle coats become infiltrated with cells, the intima ultimately loses its vitality, and when this has occurred the blood within the vein coagulates.

CHAPTER XXXIII.

INFLAMMATION OF THE HEART.

INFLAMMATORY processes in the heart may affect the substance of the organ, or the endocardium. They are much most frequent in the last-named situation.

ENDOCARDITIS.

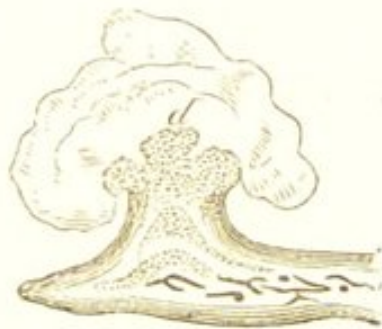Endocarditis is for the most part limited to the valves of the heart, although it is occasionally met with involving more or less of the cardiac cavities. The process is almost exclusively confined to the *left* side of the organ, and in the great majority of cases it commences in, and comparatively rarely extends beyond, the confines of the aortic and mitral valves and the corresponding orifices. Further—it is those portions of the valves which come into contact in the act of closure, and are thus *most exposed to friction*, which are especially involved, and in which the changes usually commence. Thus, in the aortic valves, it is the convex surfaces of the segments which are most liable to be affected, and not the free edge of the segment, but the little band of tissue which passes from its attached border to the corpus Arantii in the centre; and in the mitral valve, the auricular surface of the segments at a little distance from the attachment of the chordæ tendineæ. When portions of the endocardium apart from the valves are affected, this is frequently due, as pointed out by Dr. Moxon, to the irritation caused by

the friction of vegetations or fibrinous clots situated on the valves themselves.

The histological changes accompanying endocarditis closely resemble those already described as occurring in those more chronic forms of arterial inflammation known as atheromatous. The endocardium and inner coat of an artery are very analogous in their structure, both being non-vascular, and consisting of a layer of connective tissue with an internal endothelial covering. The inflammatory process may be acute or chronic.

ACUTE ENDOCARDITIS.—If the process be acute, the deeper layers of the endocardium become rapidly infil-

FIG. 75.



Acute Endocarditis. A granulation from the mitral valve, showing a fibrinous coagulum upon the surface of the granulation. $\times 10$ (Rindfleisch.)

trated with young cells, and as these increase in number the intercellular substance becomes softened and destroyed, and thus is produced a soft tissue composed almost entirely of cells such as always results from inflammatory processes in connective tissue. The new tissue as it increases tilts up the superjacent endothelium and projects in the form of minute granulations and vegetations upon the surface of the softened valve. The endothelial elements may also participate in the active process.

The above changes take place in an almost non-vascular tissue, and although there is more or less increase of vascularity in the more external endocardial layers, where

the capillaries are more numerous, there is rarely any redness or injection of the endocardium seen after death. Neither is there usually any liquid exuded upon the surface of the granulations. What was formerly regarded as an exuded material, is in the main coagulum which has been deposited from the blood upon the roughened surface of the valve. This deposition of coagulum frequently occurs in endocarditis, the roughened and abnormal endocardium acts as a foreign body and so causes a deposition upon its surface. This must not be confounded with the vegetations themselves. (Fig. 75.)

The results of this cellular infiltration vary. If the process be very acute the new tissue may break down, and thus a loss of substance result—an endocardial ulcer. This takes place without any accumulation of cells sufficient to form an abscess, the new tissue simply becoming rapidly softened and disintegrating. In rare cases, however, small quantities of pus are found in the deeper endocardial layers. The ulcer is irregularly defined, and its edges are usually swelled and thickened. This *ulcerative endocarditis* is, however, not frequent, the process usually being less acute. The ulceration may lead to perforation of the valve, or to a considerable destruction of its substance. Laceration or aneurism of the valve may also ensue from the pressure exercised by the blood against the damaged tissue. Sometimes the ulcerative process extends so as to involve the cardiac substance. Ulcerative endocarditis is a grave affection, often giving rise to embolism, and sometimes to a pyæmic process.

When the inflammatory process is less severe, as is much more commonly the case, the new tissue becomes incompletely organised into a fibrillated structure, whilst it undergoes, in part, fatty and calcareous degeneration. These changes may result in the adhesion of the valves, either to one another or to the walls of the heart. They always produce permanent *thickening, rigidity, and shrink-*

ing of their structure. The new tissue may continue to grow after the severity of the process has subsided, and thus are produced the vegetations and papillary excrescences on the valves which are so commonly met with. These consist of a lowly-organised tissue, which tends to undergo fatty and calcareous changes.

CHRONIC ENDOCARDITIS.—This may be the sequel of acute inflammation, or the process may from its commencement be chronic in its nature. In chronic endocarditis the formation of new cells is much less rapid and abundant than in the acute form; the intercellular substance consequently becomes much less softened and destroyed, and the new tissue has a much greater tendency to become developed into a fibrillated structure. The result of these chronic processes is therefore to produce a *fibroid thickening* of the endocardium, and so to cause considerable induration and contraction of the valves or valvular orifices. The new tissue sometimes forms papillary growths on the valves, which undergo partial fatty and calcareous changes.

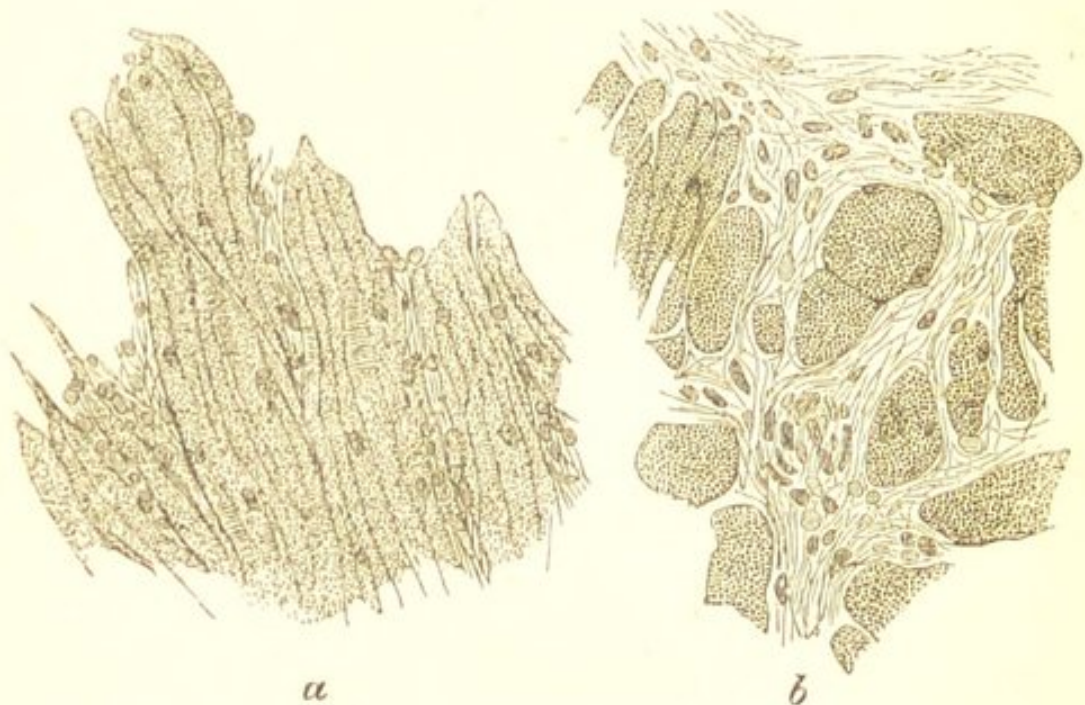
MYOCARDITIS.

Myocarditis, or inflammation of the cardiac substance, is much less frequent than the preceding. Intense and concentrated inflammations leading to the formation of abscess probably occur only as the result of a pyæmic process. Less intense and more diffuse forms of cardiac inflammation are also not unfrequently met with in association with pericarditis, and, less commonly, with endocarditis. Here the inflammatory process appears, by extension, to involve the immediately adjacent muscular layers of the organ, which are found infiltrated with small cells, the fibres themselves being softened and granular.

In addition to the above, a form of myocarditis must

be recognised in which the substance of the heart becomes more generally involved. In certain cases of acute rheumatism the muscular tissue of the heart is found after death swollen, softened, opaque, and occasionally faintly mottled with slightly yellowish patches. When examined microscopically, the fibres are seen to have lost their striation and to be finely granular, their nuclei are large and prominent, and small cells are found in varying numbers infiltrating the intermuscular tissue (Fig. 76).

FIG. 76.



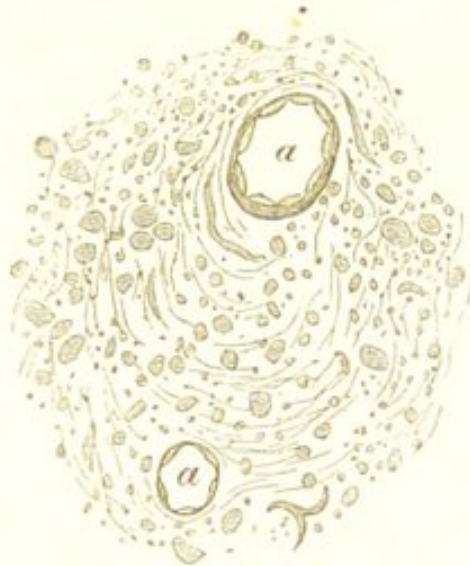Acute Myocarditis. From a case of acute rheumatism. *a.* A thin section of the left ventricle made in the direction of the muscular fibres, showing the granular and swollen condition of the fibres, and the prominence of their nuclei. *b.* A transverse section, showing the cellular infiltration of the intermuscular tissue. $\times 200$.

I have met with these appearances in two or three cases of acute rheumatism, and they must, I think, be regarded as evidence of the existence of an acute inflammatory process. The change is most marked in the left ventricle, and it is usually associated with endo- or pericarditis. It is a grave complication of acute rheumatism, and pos-

sibly of some other diseases, and is probably more frequent than is generally supposed.

FIBROID INDURATION OF THE HEART.—This is probably,

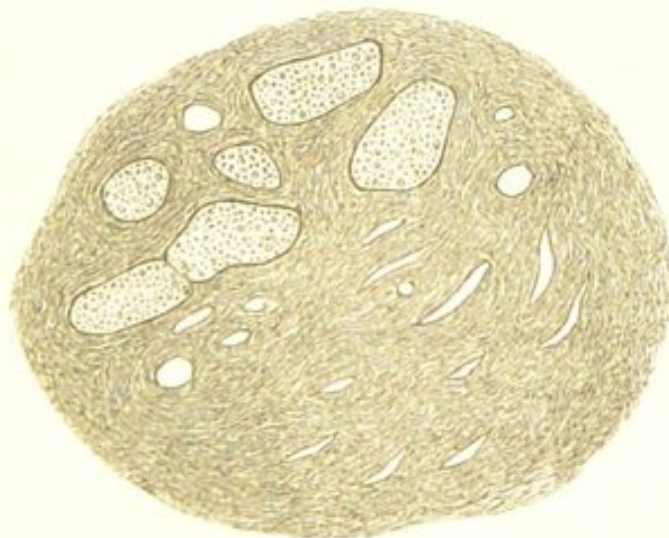FIG. 77.



Fibroid Induration of the Heart. A thin section from the wall of the left ventricle, showing the small-celled growth in the intermuscular septa around the blood-vessels. *a. a.* vessels. $\times 200$.

in most cases, a result of myocarditis. The change is characterised by the development of a fibrillated tissue

FIG. 78.



Fibroid Induration of the Heart. A section from the left ventricle of the same heart as Fig. 77, showing a more advanced stage. The fibroid tissue surrounds the individual muscular fibres, which are undergoing fatty degeneration. $\times 200$.

between the muscular elements. The process commences in the intermuscular septa around the blood-vessels. This becomes infiltrated with small cells, which tend to become developed into a fibrillated structure. (Fig. 77.) The growth of new tissue gradually extends between the bundles of muscular fibres, so that ultimately each fibre may be surrounded by a tract of dense fibroid tissue. (Fig. 78.) The muscular fibres themselves, owing to the resulting interference with their nutritive supply, atrophy, undergo fatty metamorphosis, and are gradually replaced by the fibroid growth. (Fig. 78.) Very frequently the cellular nature of the growth, which I believe to characterise the earlier stages of its development, is not seen, the new tissue being simply fibroid.*

Fibroid induration of the heart appears in most cases to be induced by inflammatory processes commencing in the peri- or endo-cardium. When secondary to pericarditis, the change is usually most advanced in the more external portions of the cardiac walls, and it commonly affects both the right and left ventricles. When, on the other hand, an endocarditis is the precursor of the indurative process, the change is more marked in the internal muscular layers, and inasmuch as inflammatory processes in the endocardium occur almost exclusively in the left cardiac cavities, the left ventricle is principally involved. In other cases the fibroid growth appears to be the result of syphilis. (See "Syphilis.")

Although the growth of new tissue is thus usually more advanced in certain portions of the muscular walls than in others, it is by no means uniformly distributed. In some parts it may be very dense, the muscular fibres

* Dr. Hilton Fagge, in a series of eleven cases of fibroid disease of the heart, found that cellular elements in the new growth were almost invariably absent. (See "Trans. Path. Soc. Lond.," vol. xxv. p. 64.)

being entirely obliterated, whilst in others it is entirely wanting, and the muscular elements present a normal appearance.

Fibroid induration of the heart—excluding that resulting from syphilis—appears to occupy the same pathological position as similar fibroid changes in other organs—*e.g.*, in the liver and kidneys. It must therefore be regarded as the result of a chronic inflammatory process, which might be termed *chronic myocarditis*. Its effect must evidently be to interfere very materially with the motor power of the organ, and it consequently constitutes one of the most grave of all cardiac diseases.

The cardiac walls become much thickened by the new growth, and the induration of texture is often very considerable. In the specimen from which the accompanying drawings were made, the disease was apparently secondary to an endocarditis, and the walls of the left ventricle were so hard that they cut almost like a piece of tendon.

CHAPTER XXXIV.

INFLAMMATION OF LYMPHATIC STRUCTURES.

INFLAMMATORY processes in lymphatic structures usually result from their irritation by substances conveyed to them by the lymphatic vessels. They include—*acute* and *chronic* inflammations, and the specific inflammation associated with *Typhoid Fever*. Each of these must be considered separately.

ACUTE INFLAMMATION OF LYMPHATIC STRUCTURES.

Examples of acute inflammation of lymphatic structures are furnished by the inflammation of the glands in the axilla from a wound on the hand, of the glands in the groin from gonorrhœa, and of Peyer's and the solitary glands in the intestine from inflammation of the intestinal mucous membrane.

The process consists in a hyperæmia of the gland together with a rapid increase in the number of the lymph-corpuscles. This increase is probably due, partly to a hyperplasia of the original cells of the gland, and partly to the migration of blood-corpuscles. The corpuscles not only increase in number, but many of them become much larger in size, and their nuclei multiply. The cells of the trabeculæ also participate in the active process. The increase in the size of the elements and the multiplication of their nuclei usually leads to the production

of some larger cells containing three or four nuclei. These resemble the "myeloid cells." They have been already alluded to as being frequently met with in lymphatic structures which are undergoing active processes. (See Fig. 39.) Owing to these changes the gland becomes considerably increased in size, soft and pulpy in consistence, and its cortical and medullary parts are no longer distinguishable.

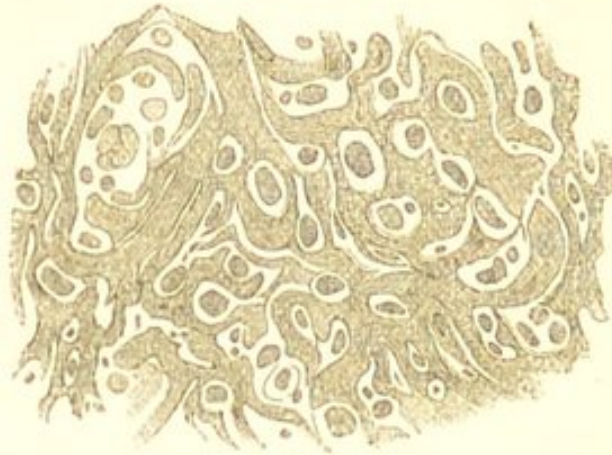Upon the removal of the source of irritation the process may gradually subside, the new elements undergo disintegration and absorption, and the gland returns to its normal condition (Resolution). In other cases the process goes on to suppuration, the trabeculae are destroyed, many of the cells become disintegrated, and the loculi of the gland become filled with pus. This is usually associated with inflammation and suppuration of the surrounding connective tissue. In the glands of a mucous membrane the process gives rise to what is known as a follicular abscess.

CHRONIC INFLAMMATION OF LYMPHATIC STRUCTURES.

Chronic inflammations of lymphatic structures result from irritations which are less severe and more prolonged in their action than those which give rise to the acute form. The resulting hyperplasia of the elements of the gland is consequently a more continuous one, and the gland becomes more or less permanently increased in size. This hyperplasia takes place not only in the lymph-corpuses, but also in the reticulum. These chronic inflammatory processes differ from the acute, inasmuch as they lead to a gradually increasing development of the reticular structure of the gland. The reticulated network becomes thicker and more fibrous, its meshes become smaller and smaller, the lymph-corpuses diminish in number, and thus the gland becomes hard and fibrous in consistence. (Fig. 79.)

Scrofulous Glands.—In those chronic inflammations of the lymphatic glands which occur especially in scrofulous

FIG. 79.



Chronic Inflammation of a Lymphatic Gland.
Showing the increase in the stroma, and the
diminution in the number of the lymphoid
cells. $\times 200$.

subjects, and in which the glands tend to become caseous, the process more closely resembles in its histological details what has been described as occurring in the acute form. Here the proliferation is principally confined to the lymph-corpuscles. These increase in number, and many of them become considerably enlarged and form multinucleated elements. The gland thus becomes enlarged, soft, and elastic in consistence, and of an uniform greyish-white colour. Owing to the obstruction to the circulation caused by the pressure of the new growth, the latter undergoes retrogressive changes and becomes caseous. The caseous material may subsequently liquefy, or become infiltrated with calcareous particles.

INFLAMMATION OF LYMPHATIC STRUCTURES IN TYPHOID FEVER.

The inflammatory processes which occur in the lymphatic structures in Typhoid Fever, have their seat in the spleen, in the lymphatic structures of the intestine, and in the mesenteric glands.

The Spleen.—In the spleen the change resembles that which occurs in many of the other acute febrile diseases, although it reaches its maximum in typhoid. The splenic tissue becomes exceedingly vascular and the lymphatic elements increase rapidly in number, so that the organ often attains two or three times its natural size. Many of the new elements enter the blood, thus causing a slight temporary increase in the number of white blood-corpuscles. As the fever subsides, the hyperæmia diminishes, the hyperplastic process ceases, many of the new elements undergo disintegration and absorption, the remainder enter the blood, and thus the organ again attains its normal characters and dimensions.

The Intestinal Lymphatic Structures.—It is in the solitary and Peyer's glands that the most characteristic changes take place in typhoid fever. These structures may be involved throughout the whole of the small and large intestine, but in most cases the process is limited to those in the ileum and cæcum; and those glands are always the most affected which are situated the nearest to the ileo-cæcal valve.

The primary change here consists in an increase in the vascularity of the glands, and in a general proliferation of their lymphatic elements. Many of the elements also increase considerably in size, so as to form the multinucleated cells already alluded to. Both Peyer's patches and the solitary glands thus become considerably enlarged and prominent, standing up above the surface of the intestine. They are of a greyish-white or pale reddish colour, and of a soft, brain-like consistence. The surrounding mucous membrane is also exceedingly vascular, and is the seat of an acute catarrhal process. This catarrh is more or less general, and usually precedes the swelling of the glands. The new growth, in many parts, rapidly extends beyond the confines of the glands into the immediately surrounding and subjacent tissues, and

even in some cases into the muscular coat. It may thus be said to become heteroplastic.

The process now passes into the second stage—that of the death and disintegration of the newly-formed tissue. This may terminate in various ways. The enlarged glands, many of them, subside, the new elements become disintegrated and are absorbed, and the gland thus undergoes a gradual process of *resolution*. In others, the individual follicles of the gland rupture, discharging their contents externally, and the patches then acquire a peculiar reticulated appearance. The most characteristic termination, however, of the typhoid process, is the separation of the dead tissue as a slough, and the formation of the *typhoid ulcer*.

The process of sloughing and ulceration may, like that of proliferation, take place uniformly throughout the whole gland, in which case the whole mass is thrown off, leaving an ulcerated surface corresponding in size with that of the gland. More commonly, however, in the patches, the sloughing commences in different portions of the patch, and small irregular losses of substance result which may gradually extend until they form one large ulcer.

Although, as already stated, the new growth may extend beyond the confines of the glands, this is rarely the case with the ulceration. The heteroplastic growth undergoes resolution, and hence the ulcers have the same configuration as the original glands; those originating from the patches being oval, with their long diameter in the direction of the gut; and those originating in the solitary glands being spherical in shape. In rare cases, when there is much infiltration of the surrounding mucous membrane, the ulceration may extend slightly beyond the confines of the glands.

With the sloughing and disintegration of the new tissue the process of proliferation ceases, and hence there

is no induration or thickening of the base or edges of the ulcer. The base is smooth, and is usually formed of the

FIG. 80.



A typhoid Ulcer of the Intestine (diagrammatic). Showing the undermined edges of the ulcer, and the slough still adherent. *a.* Epithelial lining. *b.* Submucous tissue. *c.* Muscular coat. *d.* Peritoneum.

submucous or muscular coat of the intestine. The edges are thin and undermined, and consist of a well-defined fringe of congested mucous membrane. (Fig. 80.) This is best seen when the gut is floated in water. In some cases, however, the sloughing extends deeper through the muscular layer to the sub-peritoneal tissue, and it may thus cause perforation and peritonitis.

The third stage of the process is that of cicatrization. This takes place by the resolution of the peripheral heteroplastic growth, the approximation and union of the undermined edges with the floor of the ulcer, and the gradual formation from the margin of an epithelial covering. The gland-structure is not regenerated. The resulting cicatrix is slightly depressed, and less vascular than the surrounding mucous membrane. There is no puckering or diminution in the calibre of the gut. In some cases, however, cicatrization does not take place so readily, and the floor of the ulcer becomes the seat of a *secondary* ulceration. This usually takes place after the general disease has run its course, or during a relapse. Profuse hæmorrhage and perforation more commonly result from the secondary ulceration than from the primary sloughing of the glands.

The Mesenteric Glands.—The change in the mesenteric glands is probably secondary to that in the intestine. These glands become the seat of an acute hyperplasia,

and are enlarged, soft, and vascular. They usually, like many of the glands in the intestine and the spleen, undergo a gradual process of resolution. In rare cases, however, the capsule of the gland is destroyed, and the softened matters may escape into the peritoneal cavity and so cause peritonitis. The enlarged glands may also become caseous, and subsequently calcify.

CHAPTER XXXV.

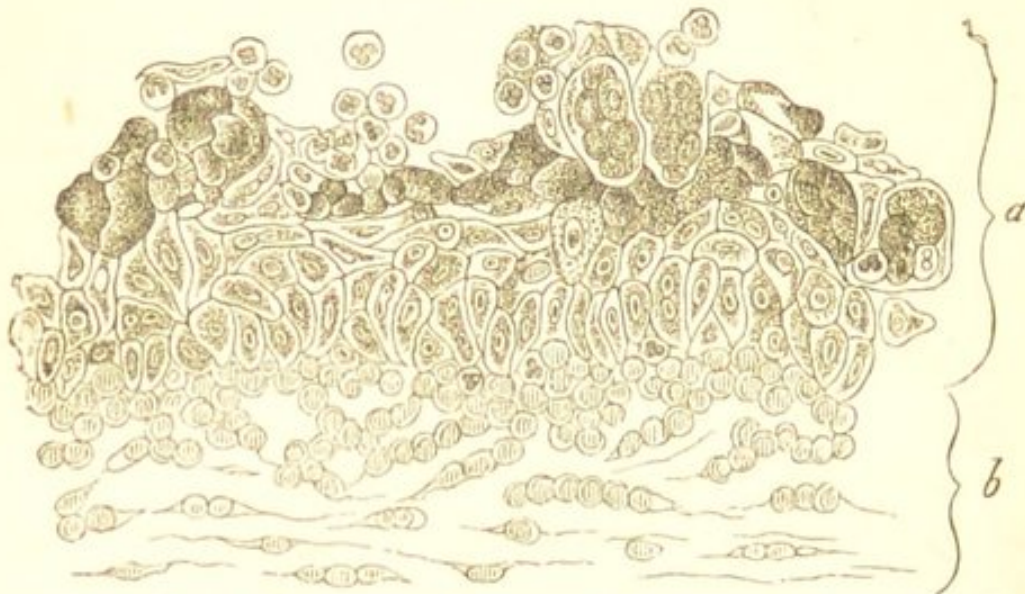
INFLAMMATION OF MUCOUS MEMBRANES.

IN mucous membranes inflammatory processes are divided into *catarrhal*, and *croupous* or *fibrinous* inflammations.

CATARRHAL INFLAMMATION.—Catarrhal inflammation, or as it is more commonly called *catarrh*, is much the more frequent. In its milder forms this is characterised mainly by an increased secretion of mucus. The initial hyperæmia of the membrane is followed by an abnormal production of epithelial and mucous elements. The liquid which transudes from the blood-vessels is more abundant, the small, spherical, newly-formed cells which constitute the mucus-corpuses are produced with increased rapidity, and the result is an increased secretion of mucus rich in cellular elements. These young cells are many of them emigrant blood-corpuses, others are produced within the epithelial cells by endogenous multiplication. As the proliferation continues, many of the epithelial elements become loosened and are discharged with the mucus, and within these groups of bodies may occasionally be seen, which are evidently young mucus-corpuses. (Fig. 81.) The secretion of the mucous glands is also increased. Owing to these changes, the mucous membrane becomes swelled and abnormally vascular. The increased vascularity is evidenced by redness during life,

but after death the blood usually passes out of the vessels, and the membrane may look paler than natural.

FIG. 81.



Catarrhal Inflammation of the Conjunctiva. a. Epithelium. b. Sub-epithelial connective tissue. Showing the proliferation of the epithelium, and the origin of the young elements within the epithelial cells. (Rindfleisch.)

If the irritation be more severe, the vascular phenomena are more marked, the production of young elements is more rapid, they are smaller and not so well developed, the epithelium loosens and falls off more readily, and the secretion becomes puriform from the great number of cellular elements which it contains. Many of these elements are indistinguishable from pus-corpuscles, others are somewhat larger and resemble the corpuscles of normal mucus. Between the corpuscles of mucus and pus there is no line of demarcation, the one passing by insensible gradations into the other. The former are somewhat larger and more regular in shape than the latter, and usually contain only a single nucleus. As the process continues the sub-epithelial tissue is gradually involved, and becomes infiltrated with young cells. Owing to the loss of epithelium, the surface of the membrane may at the same time become more or less irregular, and present numerous irregular abrasions or ulcers.

These changes in the mucous membrane itself are accompanied by a hyperplasia of the lymphatic structures which it contains. The lymph-follicles become enlarged from the multiplication of their elements. Their contents may soften and form a minute pseudo-abscess, and this bursting gives rise to a small ulcer. These are the follicular ulcers so often seen in catarrhal conditions of the intestines and pharynx. The ulceration in some cases extends beyond the confines of the follicle. The proper glandular structures may also become involved. Their epithelium multiplies, the glands become choked with the epithelial elements, and they may subsequently atrophy. This is seen in catarrh of the stomach.

The acute process may quickly subside, or it may become chronic. In the latter case the vascularity diminishes, but the multiplication of elements continues both in the epithelial and sub-epithelial tissue, as does also the increased secretion of mucus (suppuration). The latter thus becomes thicker and more puriform in character.

Chronic catarrhal inflammations of mucous membranes differ from the acute, inasmuch as the sub-epithelial connective tissue is much more extensively involved. This tissue becomes infiltrated with young elements, which may ultimately form a more or less completely fibrillated structure. The membrane thus becomes indurated and thickened, and the pressure exercised by the new tissue may induce atrophic changes in the glandular structures which it contains; by preventing the exit of their secretion it may also cause them to dilate so as to form cysts. This atrophy of the proper glandular structures is seen in chronic catarrh of the stomach. These changes in the sub-epithelial connective tissue are usually accompanied by enlargement of the lymphatic structures, an enlargement which sometimes gives to the membrane a nodular or granular appearance: this is well seen in the pharynx (follicular pharyngitis). The enlarged

lymphatic structures may also constitute the starting-points of an ulcerative process. (See "Tuberculosis of Mucous Membranes.") In some situations, as the stomach and intestine, the membrane often at the same time becomes deeply pigmented.

CROUPOUS OR FIBRINOUS INFLAMMATION.—This is a more intense form of inflammation than the preceding, and is characterised by the exuded inflammatory liquids containing a larger proportion of coagulable material. Fibrinous inflammation may be induced artificially by severe irritants, and it occurs in croup, diphtheria, and in many cases of dysentery.

CROUP.

In croup, the inflammatory process at its commencement is simply a severe catarrhal one, consisting in an increase in the vascularity of the membrane, together with an exudation of liquor sanguinis and blood-corpuscles, and proliferation of the epithelial elements. This is quickly followed by the production of a fibrinous layer upon the surface of the tissue, usually known as the *false membrane*. This membrane varies considerably in consistence, being in some cases firm and tough, in others much softer. It can readily be removed from the subjacent tissue, and after its removal, the mucous membrane is left partially deprived of its epithelium. If the inflammatory process subsides, the epithelium is reproduced and the part returns to its normal condition; but if it continues, a fresh false membrane is formed. As the inflammation extends downwards into the trachea and bronchi, a gradual transition may usually be observed from croupous to catarrhal inflammation. In the upper part of the air passages, where the process is most intense, the false membrane exists, but in passing downwards, where it becomes less severe, the mucous membrane is simply coated with mucus.

Respecting the nature of the false membrane—opinions differ. When examined microscopically, it is seen to consist of a finely fibrillated and delicate network of homogeneous material, enclosing in its meshes numerous leucocytes and epithelial cells. This fibrillated network has been commonly supposed to be produced by the coagulation and fibrillation of the inflammatory exudation liquids. According to Buhl, Wagner, and others, however, its formation is mainly due to a peculiar metamorphosis of the epithelial cells, which become converted into a kind of fibrinous material. The smaller cells which are enclosed in its meshes are doubtless principally escaped blood-corpuscles; the larger epithelial elements, which are much less numerous, are those belonging to the mucous membrane.

DIPHThERIA.

It is difficult in many cases to draw any line of demarcation between the histological changes occurring in diphtheria and those of croup. In diphtheria, however, the submucous tissue usually becomes more extensively involved, so that the false membrane is much less readily removed. The circulation also often becomes so much interfered with, that portions of the tissue lose their vitality, and large ash-coloured sloughs are formed, which after removal leave a considerable loss of substance.

DYSENTERY.

The inflammatory processes occurring in the intestine in dysentery are for the most part limited to the large intestine, although the ileum is also occasionally involved. The inflammation is always most marked in the rectum and descending colon, and it may be stated generally, that it is characterised by the ulceration and sloughing of the membrane to which it gives rise.

The intestinal changes vary considerably according to the intensity of the inflammatory process. In the milder forms of the disease the changes are most marked on the summits of the folds of the mucous membrane. These are found covered with a greyish-white layer of fibrinous material, which, when scraped off, leaves a superficial loss of substance. The mucous membrane generally is hyperæmic and softened. The submucous tissue is also infiltrated with inflammatory products, and the solitary glands are enlarged and prominent.

When the process is more severe, the submucous tissue becomes more extensively involved, and the superficial layer of fibrinous material extends over wider areas and implicates more deeply the mucous membrane. The thickening of the intestinal wall, however, is much greater in some parts than in others, so that projections are produced upon the inner surface of the intestine, corresponding with those parts which are the most affected. The enlarged solitary glands usually slough, and so give rise to circular ulcers which rapidly increase. When the process has reached this stage, the muscular and serous coats are implicated, the latter being covered with layers of fibrin which form adhesions with adjacent parts. The intestine is much dilated, and contains blood and disintegrating inflammatory products.

In the most intense forms of the disease, the necrosis is more extensive. According to Rokitansky, large portions of the mucous membrane are converted into black rotten sloughs. The submucous tissue is infiltrated with dark blood and serum, but subsequently it becomes the seat of a reactive suppurative inflammation, by means of which the necrosed portions of tissue are removed.

If death does not occur and the inflammatory process subsides, the ulcers may gradually heal. When the loss of substance has not been considerable, the edges of the ulcers may, by the contraction of the submucous tissue,

become completely approximated. More commonly, however, the loss of substance is so great that portions of the membrane are left consisting simply of connective tissue.

When the inflammatory process becomes chronic, the changes in the submucous connective tissue become more marked, and the new fibroid growth gives rise to considerable thickening and induration of the intestinal wall and to more or less contraction and narrowing of the cavity. Sometimes it forms fibrous bands which project into the gut. The formation of abscesses and fistulous passages occasionally occurs in the thickened intestinal wall.

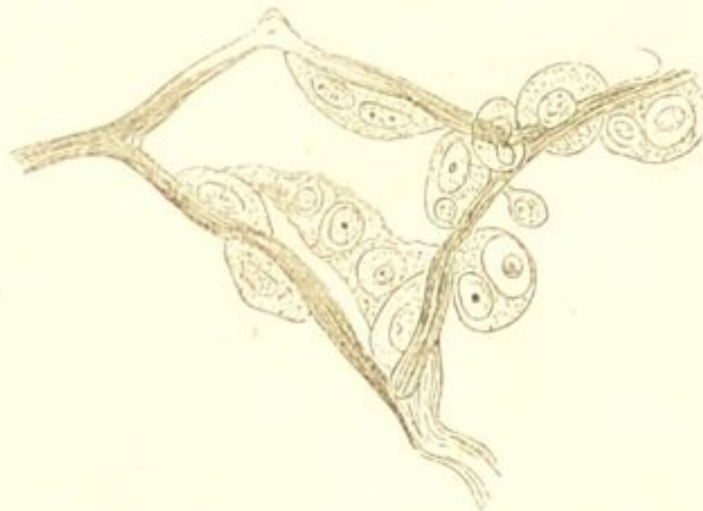
CHAPTER XXXVI.

INFLAMMATION OF SEROUS MEMBRANES.

INFLAMMATORY processes in serous membranes vary in their intensity, and in the amount and character of the effusion.

The process commences, as in mucous membranes, with hyperæmia, exudation of liquor sanguinis and emigration of blood-corpuses, together with increased activity of the endothelial elements. The endothelial

FIG. 82.



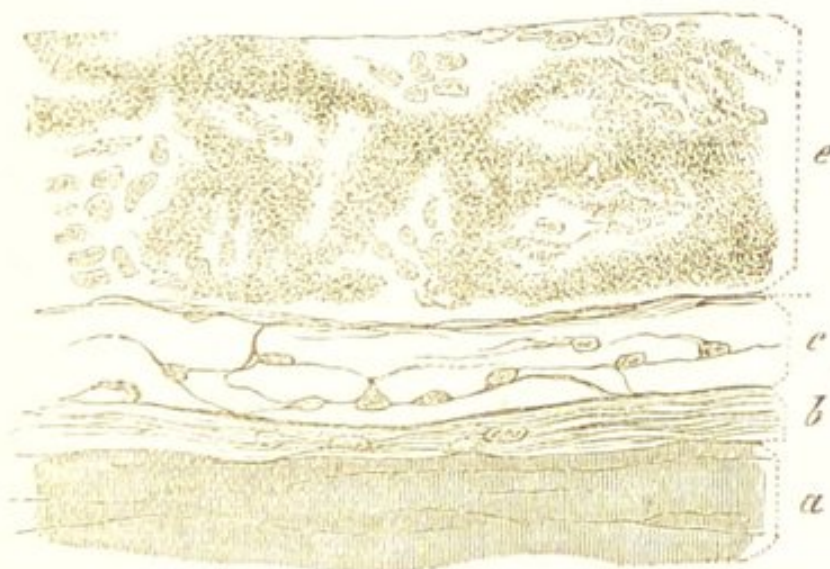
Inflamed Epiploon of a Rabbit. Showing the endogenous proliferation of the endothelium. $\times 250$. (Cornil and Ranvier.)

cells enlarge and become more granular, their nuclei multiply, and thus several new elements are formed within a single cell (endogenous multiplication) from which they

subsequently escape. (Fig. 82.) The number of new elements which are thus produced, together with some of the older cells, and a large number of emigrant blood-corpuscles, escape with the exuded liquor sanguinis into the serous cavity, where they may continue to exhibit their formative activity.

Owing to these changes the membrane loses its natural smooth and glistening appearance, and becomes opaque, roughened, and exceedingly vascular. Its surface at the same time becomes covered with a fibrinous layer, and more or less liquid transudes into its cavity. The

FIG. 83.



Inflammation of the Diaphragmatic Pleura. Showing the adherent fibrinous layer. *a.* Muscular coat of diaphragm. *b.* Sub-serous tissue. *c.* Serous membrane. *e.* Fibrinous layer. $\times 400$. (Rindfleisch.)

coagulable material which exudes from the vessels, forms a soft, elastic, membranous, or reticulated investment, inclosing in its meshes numerous small cells. This either glues the two surfaces of the membrane together, or, if they are separated by liquid effusion, forms a slightly adherent layer. (Fig. 83.) The exuded liquid varies considerably in amount and is always turbid, thus differing from non-inflammatory effusions. It con-

tains flakes and masses of coagulated fibrin and innumerable cell-structures, the latter being in the earliest stages of the process almost entirely emigrants.

The nature of the subsequent changes will depend upon the intensity of the inflammation, and upon the amount of liquid exuded into the serous cavity. If the inflammatory process subsides, and the liquid exuded is not sufficient to prevent the two surfaces of the membrane from coming into contact, they grow together and form an adhesion. This constitutes the so-called *adhesive inflammation*. The union is effected by the formation of connective tissue. The small round cells embedded in the fibrinous layer become elongated and spindle-shaped, the fibrinous material fibrillates, and numerous new vessels are formed. Many of the latter atrophy and disappear as the organisation becomes complete. The process is thus precisely similar to that which takes place in the union of an incised wound. It is probable also that in some cases union may take place without the intervention of any fibrinous layer, by the formation and growing together of irregular papillary outgrowths from the sub-endothelial tissue.

If, however, the inflammatory process is severe, or the surfaces of the membrane are separated by a large quantity of liquid effusion, organisation and adhesion cannot be thus readily effected. If a large quantity of liquid exists in the serous cavity, the removal of this becomes necessary before union can take place. If the inflammatory process continues, or its severity is great, union is prevented by the formation of pus. These two conditions must be considered separately.

The existence of a large amount of effusion interferes with the adhesion of the serous surfaces, and before this can be effected the absorption of the liquid becomes necessary. In some cases this occurs very rapidly, and it is probably greatly facilitated by the new blood-vessels

which are produced in the fibrinous layer. Frequently, however, the process is more prolonged, and the sub-endothelial connective tissue becomes involved before absorption takes place. When this is the case the connective tissue of the serous membrane becomes infiltrated with young cells, which form a granulation-tissue beneath the layer of proliferating endothelium. The endothelium itself gradually becomes less abundant, and the fibrinous exudation undergoes fatty changes and liquefies. The new granulation-tissue becomes exceedingly vascular from the formation of numerous blood-vessels, and if the inflammation subsides, it gradually develops into connective tissue, and thus a false membrane is formed rich in vessels which takes the place of the endothelial layer. As the liquid is absorbed, the two surfaces of the membrane come into contact and grow together, the new vessels becoming gradually obliterated.

If the inflammatory process does not subside, or from its commencement is of considerable severity, it is attended by the formation of large quantities of pus. In this case the emigration of blood-corpuscles is so considerable that the young elements exist in large enough numbers to give to the exuded liquids a puriform character. The effusion is then termed *purulent* (empyema). As the connective tissue becomes involved and a granulation-tissue is formed, this may continue to generate pus like an ordinary granulating wound. If the pus be removed, the suppuration may gradually cease, the granulation-tissue develop into a fibrous structure, and the union of the serous surfaces thus be effected. The serous membrane becomes greatly thickened, and the new tissue undergoes considerable contraction in the process of its organisation.

CHAPTER XXXVII.

INFLAMMATION OF THE LIVER.

INFLAMMATORY processes in the liver are either acute or chronic. *Acute* inflammations, leading to suppuration, are usually infective in their nature, resulting from the transmission of infective materials from inflammatory lesions in the abdominal organs or in other parts. The processes are consequently most frequently disseminated and confined to small portions of the hepatic substance. The pus-corpuscles—which usually accumulate so as to form an abscess—are almost entirely emigrants, although recent investigations render it highly probable that they may also originate by the endogenous proliferation of the liver-cells.

These suppurative inflammations are in the majority of cases pyæmic, and when pyæmic they are usually multiple. Hepatic abscess is also not unfrequently, in tropical climates, associated with dysentery. Here the abscess is commonly single, and it probably results from the absorption of infective substances from the diseased intestine. As other causes of hepatic abscess must be mentioned inflammation of the bile-ducts, such as sometimes results from gall-stones, &c.; and external violence.

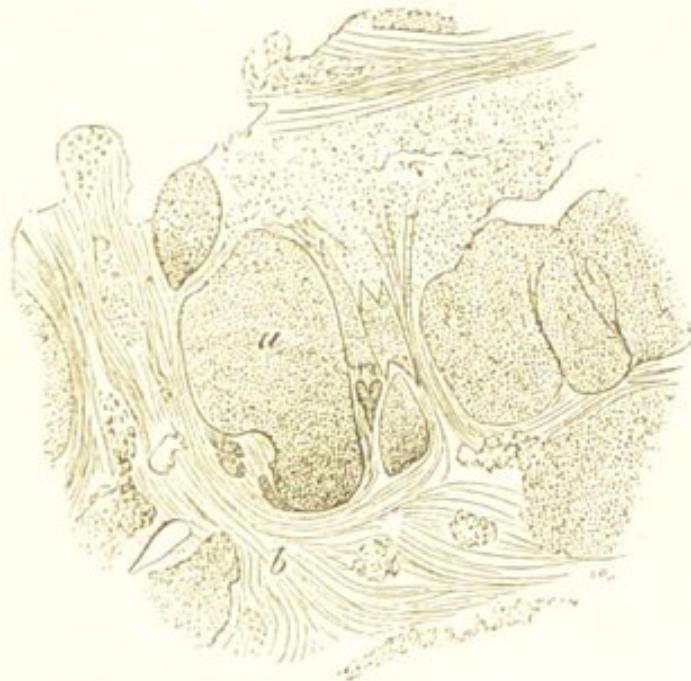Chronic inflammatory processes in the liver, being of much less intensity, lead to a gradual increase in the

connective tissue of the organ, and consequently to induration and to the subsequent atrophy of its proper structure. They constitute what is known as *interstitial hepatitis*, or more commonly as *cirrhosis*.

CIRRHOSIS OF THE LIVER.

Cirrhosis of the liver, or interstitial hepatitis, is characterised by a gradual increase in the connective tissue of the organ and by subsequent atrophy of the liver-cells, so that when examined with a low magnifying power, the acini are seen to be separated by broad tracts of new interstitial growth. (Fig. 84.)

FIG. 84.

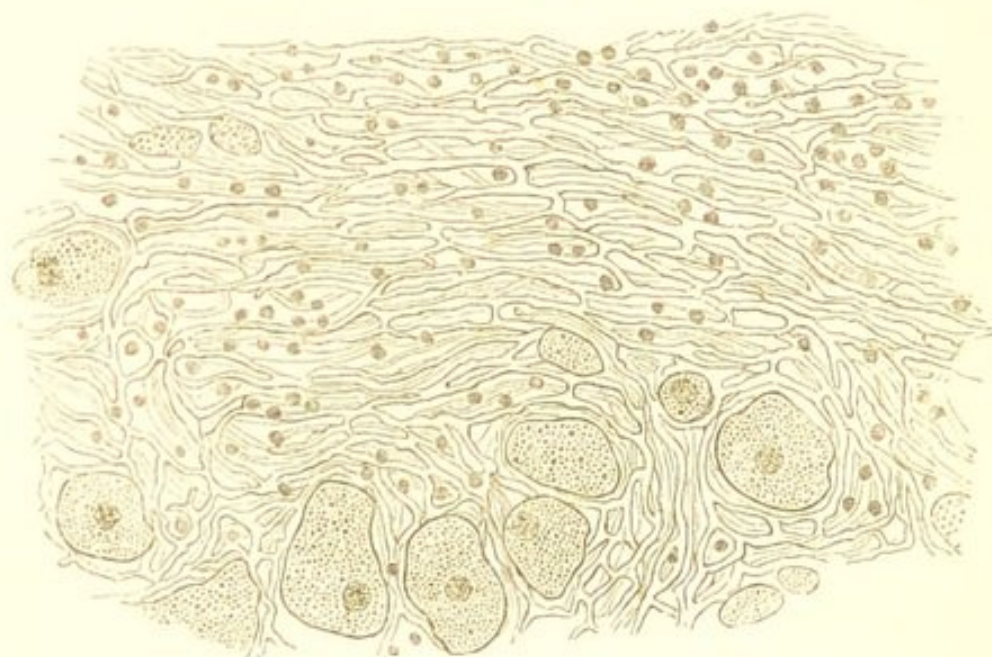

Cirrhosis of the Liver. Showing the growth of connective tissue between the hepatic lobules. *a.* Lobules. *b.* New growth of interlobular connective tissue. $\times 16$.

The process usually commences in the connective tissue surrounding the smaller branches of the portal vein, and gradually extends to that surrounding the larger ones, until ultimately the connective tissue throughout the whole organ may become involved. This tissue becomes infil-

trated with small round cells, from which are produced a more or less completely fibrillated structure, containing in the earlier stages of its development numerous new blood-vessels which are supplied by branches of the hepatic artery. The change is sometimes uniform, but more commonly it is much more advanced in some parts than in others. In many places the new tissue consists almost entirely of cells, whilst in others the fibrillation is much more marked; and if the process lasts long enough, the vascular and richly cellular growth gradually assumes the characters of cicatricial tissue, the vessels at the same time becoming obliterated. (See Fig. 72.)

FIG. 85.



Cirrhosis of the Liver. A thin section from the external portion of one of the hepatic lobules. Showing the new growth of connective tissue, and the way in which it involves the intercellular network and causes atrophy of the liver-cells. $\times 200$.

The effect of the new growth is ultimately to cause atrophy of the hepatic cells, and to obstruct the circulation through the portal capillaries and the passage of bile through the bile-ducts. This effect is materially increased

by the process of contraction which the new tissue undergoes. The hepatic cells in the outer zone of the lobules are the first to atrophy; the new tissue insinuating itself between them, so as to gradually involve the intercellular network. (Fig. 85.) The cells then become smaller and undergo fatty metamorphosis; and ultimately they are completely destroyed. Those in the central parts of the lobule are in the earlier stages but little altered, although they are often stained with bile. As the growth extends, however, these also become annihilated, and the whole lobule may be replaced by connective tissue. The cells in the outer part of the lobules are sometimes infiltrated with fat prior to their destruction, the cirrhosis being associated with fatty infiltration. (See Fig. 7.)

The obliteration of the portal capillaries by the new tissue gives rise to ascites, hæmatemesis, diarrhœa, enlargement of the spleen, and to the other results of portal congestion. Obstruction of the bile-ducts, although it may cause staining of the hepatic substance, is rarely such as to interfere with the passage of the bile into the intestine, and hence there is usually but little general jaundice.

Physical characters.—The physical characters of the cirrhotic liver vary. In the earlier stages of the disease the organ is probably always, more or less increased in size; the enlargement being almost uniform, and the edge rounded and thickened. In some cases this enlargement is considerable, and there is but little subsequent atrophy and contraction, the organ being found large and comparatively smooth after death. More commonly, however, atrophy and contraction constitute marked features in the disease, and the liver is small, presenting an irregular nodular surface.

Respecting the causes of these differences in the alterations which the liver undergoes as a consequence of the

interlobular growth—we are at present unable to speak certainly. They probably, however, depend in great measure upon differences in the age of the growth, and in its distribution. In the large livers the growth is usually richly cellular and very generally distributed; whilst in the smaller nodular forms of cirrhosis it is commonly more fibrous and less cellular in character, and its distribution is more partial. It is probable that in the larger livers the growth is in an earlier stage of development, and that if the patient had lived, the organ would have diminished in size. When the growth is irregularly distributed it necessarily causes more irregularity in the configuration of the liver than when the distribution is more uniform.

The cirrhotic liver is always increased in consistence. It breaks down less readily under the finger, and is often exceedingly firm and tough. On section, the new tissue is visible to the naked eye surrounding the lobules and in many parts completely replacing them. This gives to the cut-surface a mottled granular appearance, the lobules themselves contrasting with the new interlobular tissue; and this appearance is sometimes increased by fatty infiltration of the cells in the peripheral zone. The capsule also may be thickened, and the organ is frequently stained with bile.

ACUTE YELLOW ATROPHY.

This exceedingly rare disease of the liver is characterised by a rapid diminution in its size, and by destruction of the hepatic cells. The organ may, in the course of a few days, be reduced to less than half its natural bulk, being especially diminished in thickness. It is soft and flabby in consistence, bloodless, and of a dull yellow or yellowish-red colour. The lobules are indistinguishable. When examined microscopically, the liver-cells are found

to be completely destroyed, being replaced by granular débris, fat granules, and pigment. Tyrosin and leucin have been found in the disintegrated liver-tissue.

The pathology of this disease is exceedingly obscure. By some it has been regarded as an acute inflammatory process, by others as a passive degeneration.

CHAPTER XXXVIII.

INFLAMMATION OF THE KIDNEY.

INFLAMMATORY processes in the kidney present certain variations according to their intensity. They comprise *suppurative, tubal, and interstitial* nephritis. Of these, suppurative nephritis, as the name implies, is an intense inflammation leading to the formation of abscess. It usually results from the transmission of infective materials from some primary lesion, and consequently belongs to the class of infective inflammations. Tubal nephritis is also an inflammation of considerable intensity, but much less so than the suppurative variety. In it the structural changes have their principal seat in the tubular epithelium. Interstitial nephritis is an inflammatory process which runs a more chronic course, and is of less intensity than either of the preceding. Consequently in it the principal structural changes take place in the connective tissue around the blood-vessels—in the intertubular connective tissue. (See “Chronic Inflammations.”) It must, however, be distinctly borne in mind that these two varieties of histological changes—those in the tubular epithelium and those in the intertubular connective tissue—are very frequently associated. Tubal and interstitial nephritis cannot therefore be separated from one another by any distinct line of demarcation. They might, perhaps, be more correctly designated *acute* and *chronic* nephritis.

SUPPURATIVE NEPHRITIS.

Acute inflammatory processes in the kidney attended by the formation of pus, give rise to *renal abscesses*. Such processes, as already stated, are usually infective in their nature, resulting from the transmission of infective materials from some primary inflammatory lesion. They occur as a result of pyæmia, and also in connection with inflammatory conditions of the urinary passages. In the latter they give rise to what is commonly known as the "Surgical Kidney."

The abscesses met with in the kidney as the result of pyæmia resemble pyæmic abscesses in other organs. They are usually multiple, and are often surrounded by a thin zone of red hyperæmic tissue. Their characters will be more fully described in the chapter on embolism. (See "Results of Embolism.")

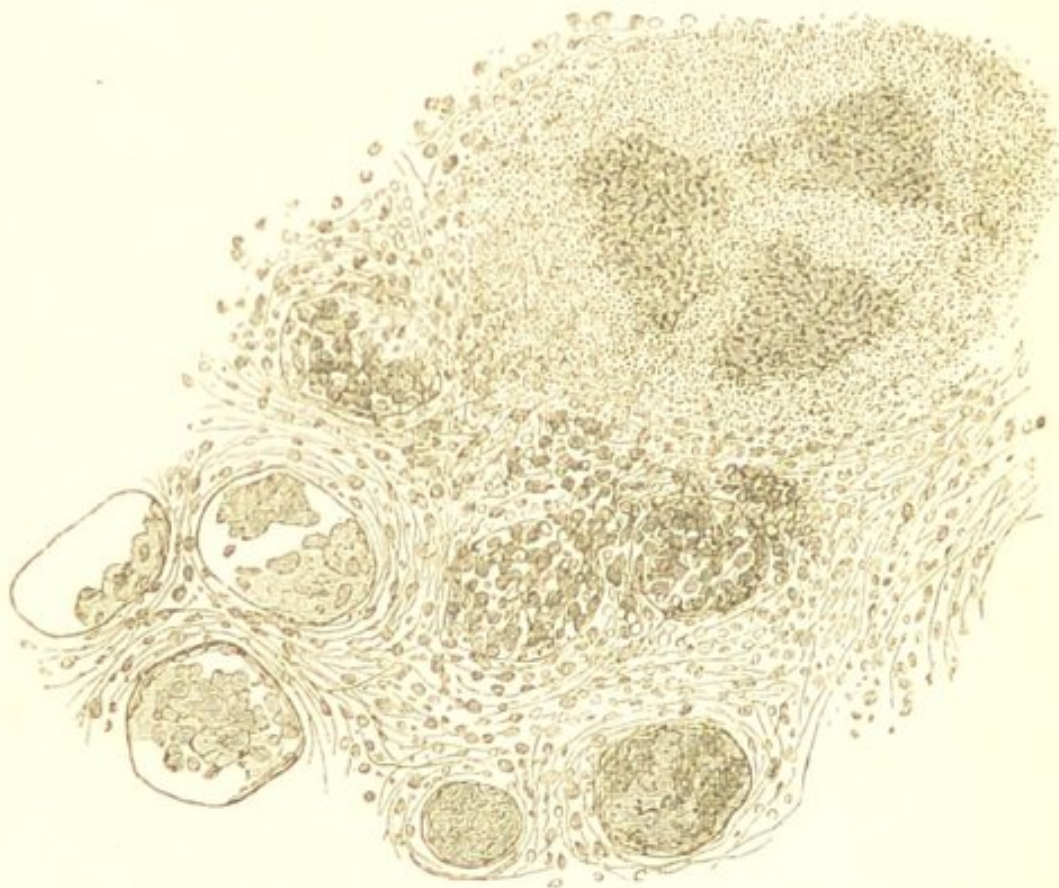Surgical Kidney.—This is the name commonly given to those inflammatory conditions of the kidney which result from inflammation of the urinary passages. These renal inflammations frequently occur in association with inflammation of the pelvis of the kidney, such as is produced by a renal calculus; or with those inflammatory changes in the mucous membrane of the urinary tract which result from vesical calculus, urethral stricture, or enlargement of the prostate. In addition to the inflammation of the urinary passage there almost invariably exists some impediment to the escape of the urine.

The changes which occur in the kidney vary. When the inflammatory condition of the urinary passages has lasted for a lengthened period it is exceedingly liable to give rise to chronic renal changes, which are characterised mainly by more or less cellular infiltration of the intertubular connective-tissue. This cellular infiltration occurs both in the pyramids and cortex. The tubules are in some parts found blocked with epithelium, whilst

in others they are wasted or obliterated. The walls of the small arteries are not thickened. Owing to these changes, the kidneys—although at first they may be enlarged—gradually become diminished in size, the atrophy being probably, in most cases, partly due to the pressure exercised by the retained urinary secretion. The capsule becomes adherent and thickened, and when removed, the surface of the organ is found puckered and irregular.

In other cases the process is much more acute, the

FIG. 86.



Surgical Kidney. At the lower part of the figure is seen the cellular infiltration of the intertubular tissue, and the blocking of the tubes with epitheliüm and leucocytes. At the upper part, there is the commencing formation of an abscess. $\times 100$.

cellular infiltration of the intertubular tissue is much more abundant, and the young cells (emigrants) accumulate in certain situations in such numbers as to give rise to abscesses. (Fig. 86.) The blocking of the tubes

with epithelium is then more marked, and many of them are found filled with the emigrant leucocytes. The kidneys are usually enlarged, and yellowish-white patches of various sizes are seen on their cut-surface. Many of these patches have purulent centres. They are not commonly surrounded by a marked zone of red hyperæmic tissue. Yellowish lines and striæ are also seen extending from the papillæ to the bases of the pyramids. This acute suppurative process may occur independently of the more chronic lesions. Much more commonly, however, it supervenes in kidneys which have already undergone a chronic change, and its supervention appears not unfrequently to be determined by the performance of some surgical operation in connection with the bladder or urethra.

Respecting the pathology of these changes in the kidney—they undoubtedly result from the inflammatory condition of the urinary passages, and impediment to the escape of the urine with which they are associated. As to the manner in which the primary inflammation produces the secondary in the kidneys we are unable to speak certainly. The pelvis and calices of the kidney are almost invariably found inflamed, and possibly the implication of the kidney may be owing to extension by contiguity. Dr. Dickinson believes it to be due to the absorption of infective substances contained in the urine.*

TUBAL NEPHRITIS.

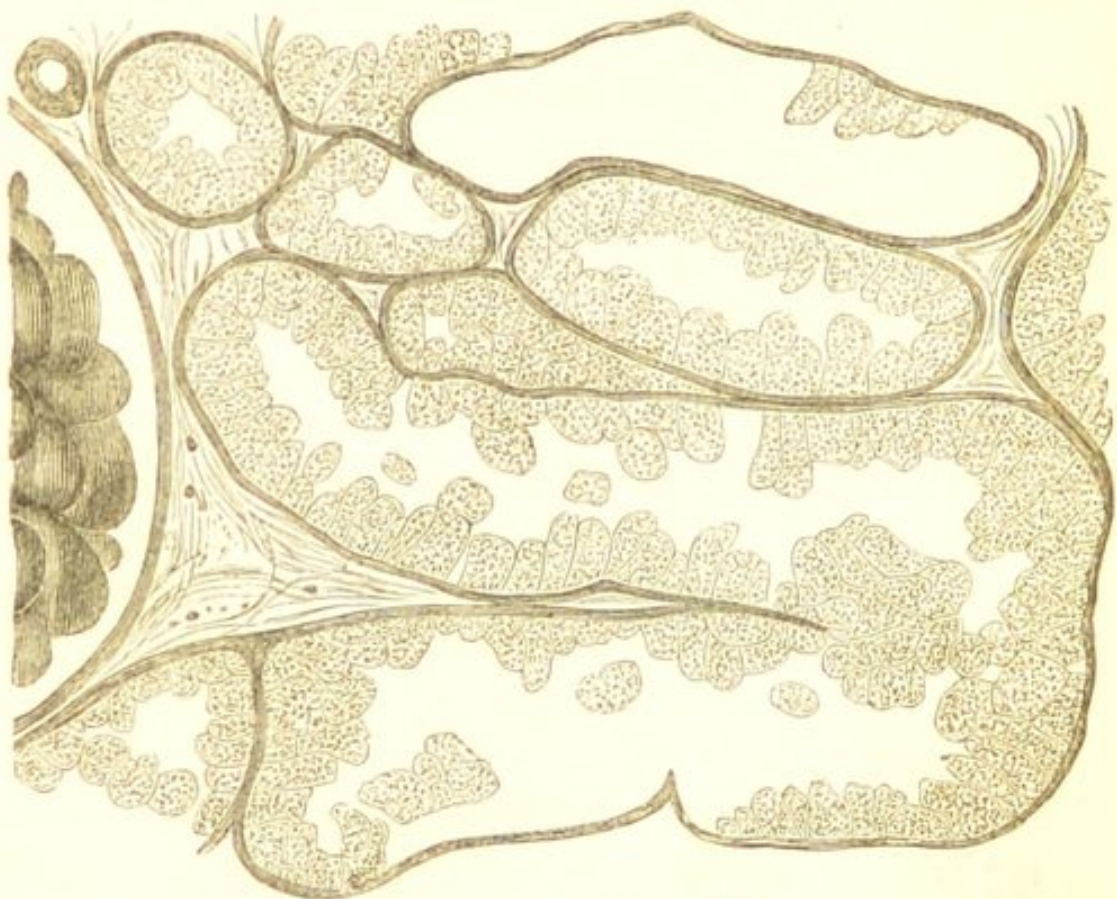
Tubal nephritis, or as it is also called acute desquamative nephritis, is one of those morbid processes which constitute Bright's disease, of which it is the most common *acute* variety. The process, which has its seat mainly in the cortex, comprises an increase in the vascularity of

* Dickinson, on "Disseminated Suppuration of the Kidney." Med.-Chir. Trans., vol. lvi.

the organ, exudation into the urine tubes, and swelling with probably proliferation of the tubular epithelium.

The initial vascular phenomena vary considerably in different cases. When the intensity of the inflammatory process is considerable, there is abundant exudation into the urine-tubes, many of the capillaries at the same time frequently rupture, and thus there is an escape of blood-corpuscles and of liquor sanguinis into the tubes of the cortex; hence the blood and "blood-casts" in the urine which are so characteristic of the early stages of the most acute forms of the disease. In this stage the inflammatory process may quickly subside, and, with the

FIG. 87.

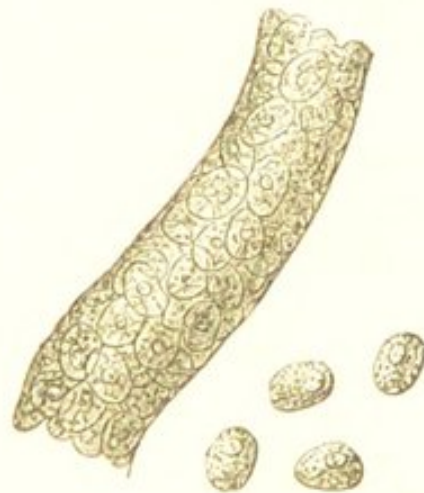

Tubal Nephritis The earlier stage of the process. Showing the swelling of the tubular epithelium. In some of the tubes the epithelium has fallen out during the preparation of the section. $\times 200$.

exception of some swelling and desquamation of the tubular epithelium, no further alterations take place in the kidney.

In other cases the process is less intense, the vascular phenomena are much less marked, and the principal changes take place in the tubular epithelium. The epithelial elements become swollen and granular. (Fig. 87.) The granules, which are often so numerous as to occlude the nucleus of the cell, are soluble in acetic acid, and thus differ from molecular fat. This is the condition known as "cloudy swelling." Smaller cells are also often seen within the tubes, and these have been supposed to be the products of epithelial proliferation. It is probable that some of them are thus produced, although the majority must be regarded as having escaped from the vessels. Owing to these changes the tubes become distended with cellular elements. (Fig. 88.

FIG. 88.



Tubal Nephritis—a Single Urine Tube. Showing the accumulation within the tube. In the few epithelial cells which have escaped is seen the granular condition of the protoplasm. $\times 200$.

In addition to the cell-forms, many of the tubes also contain hyaline cylinders, which are commonly regarded as consisting of coagulated substances which have escaped from the vessels. By many pathologists, however, this hyaline material is supposed to be the product of a mucoid metamorphosis of the epithelium. The cell-forms contained within the tubes adhere to this hyaline sub-

stance, and some of them are washed away and appear in the urine as "epithelial casts."

The alterations which these changes produce in the physical characters of the kidneys vary according to the preponderance of the hyperæmia or of the epithelial growth. The organs are always considerably increased in size, and more or less abnormally vascular. The capsule separates readily, exposing a perfectly smooth but vascular surface. The consistence is diminished, the tissue breaking with a soft friable fracture. On section, the increase in the size of the organ is seen to be principally due to the increased thickness of the cortex. This is either of a reddish-brown, or of an opaque-white or pale buff colour; these differences depending upon the relative proportion of blood and of accumulated epithelial elements. Although in the earliest stage of the most acute forms of the disease the colour is redder than natural, it usually soon becomes pale and opaque. This is owing to the swelling of the epithelial elements and to their accumulation in the cortical tubes. The blood becomes expressed from the intertubular vessels, and hence the increased vascularity is most evident in the Malpighian corpuscles, beneath the capsule, and in the pyramidal portion of the organ. The Malpighian corpuscles stand out as prominent red points, and the pyramidal cones are of a deep red colour, thus contrasting strongly with the pale opaque cortex.

The termination of the process varies. The increased vascularity and epithelial growth may, as already stated, subside, and the newly formed elements passing away in the urine, the organ gradually return to its normal condition. This is a common termination when the inflammation is the result of scarlet fever. In other cases the disease continues; and although the vascularity diminishes, the vitality of the epithelial elements becomes so much impaired that they undergo retrogressive

changes. The cells then continue to come away with the urine, adherent to the casts, but instead of presenting the swelled granular appearance as in the earlier stage of the disease, they contain molecular fat. This fat gradually increases in amount as the degeneration proceeds, until ultimately the cells are destroyed and it appears as free molecules and granules on the tube-casts.

This fatty degeneration of the epithelium is attended by corresponding changes in the appearance of the organ. The redness diminishes, and the Malpighian corpuscles are less prominent. The enlarged cortex presents a uniform yellowish tinge, studded with minute yellowish-white streaks. This is owing to the presence of fat in the tubes of the cortex. This fatty stage, if only slightly advanced, may undoubtedly pass off. The degenerated cells are carried away by the urine, from those which remain in the tubes the fat is probably partially absorbed, the retrograde process gradually ceases, and the organ returns to nearly its normal size and condition. In other cases the degeneration continues, and owing to the loss of epithelium the kidney becomes somewhat diminished in size. This atrophy, however, I believe rarely occurs without changes in the intertubular connective tissue.

When the inflammatory process is of longer duration, or when the kidneys are the seats of repeated attacks of inflammation, the intertubular connective tissue usually becomes involved. This tissue becomes infiltrated with small cells which ultimately tend to form a fibrillated structure. The new intertubular growth may gradually increase, and so lead to more or less irregular atrophy of the organ, such as will be described as occurring in interstitial nephritis. In other cases death ensues before any marked atrophy has taken place, and thus the organ may remain smooth and large to the termination of the disease. The intertubular growth is sometimes found thickly studded with fatty granules.

INTERSTITIAL NEPHRITIS.

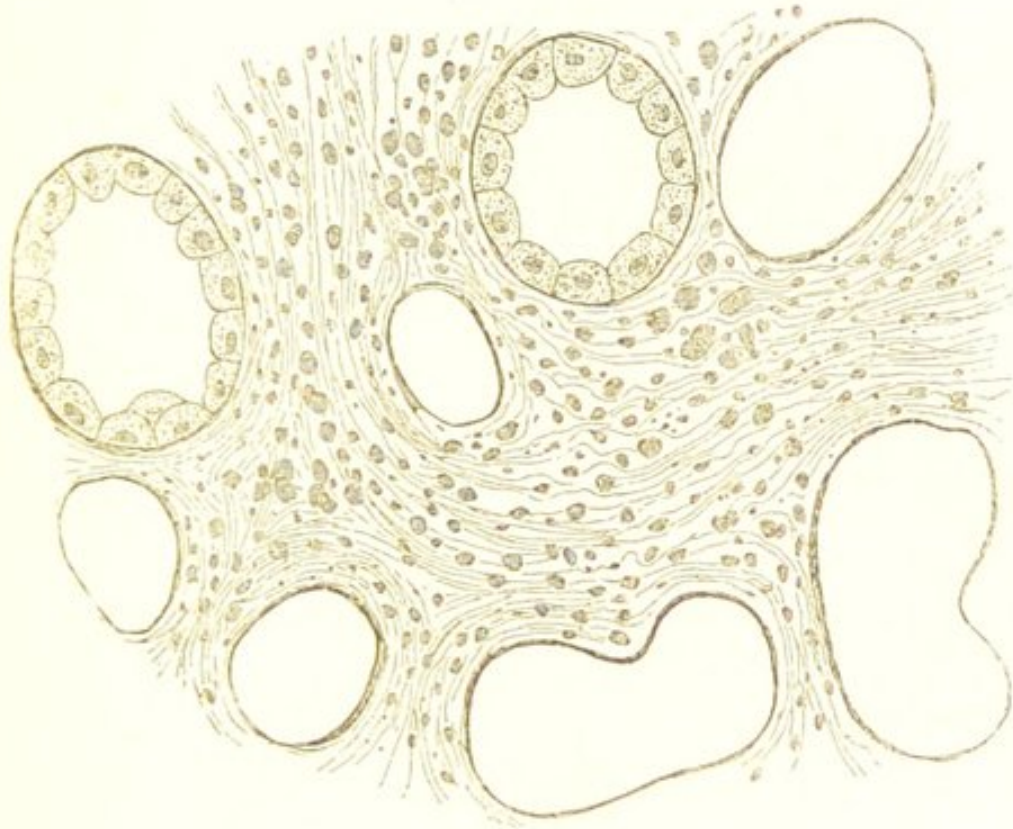
Interstitial nephritis, or as it is sometimes called granular degeneration of the kidney, occurs most frequently in the condition known as chronic Bright's disease. The process is usually chronic in its course, and is characterised, like the corresponding one in the liver, by a gradual increase of the connective tissue of the organ, and by atrophy of the tubal structures. Sometimes, as has been seen, this is merely an advanced stage of tubal nephritis. More commonly, however, the process appears to be chronic from its commencement, and not to be preceded by any marked vascular phenomena or by any active changes in the tubular epithelium.

The first change in the kidney appears to consist in a cellular infiltration of the intertubular connective tissue. In the earliest stages of the process this tissue becomes infiltrated with young cells. (Fig. 89.) If the growth is very rapid, these may be exceedingly numerous, and the intercellular substance soft and amorphous. More commonly, however, the process is much less acute and the cells less numerous, and the new tissue is more or less developed into a fibrillated structure. This is the condition in which it is usually met with. These changes are almost entirely limited to the cortical portion of the kidney, and although here they are more or less general, the new growth is more abundant in some parts than in others, being usually most so around the Malpighian bodies and in the neighbourhood of the capsule, with which it is closely united. In this stage the tubes and their epithelium are unaffected.

In this early stage, if the process be acute, the kidney is somewhat increased in size, the capsule usually separates less readily than in health, and the surface of the organ is slightly granular. On section, the cortical sub-

stance is in some cases paler, in others redder than natural. The cut surface also looks obscurely granular.

FIG. 89.

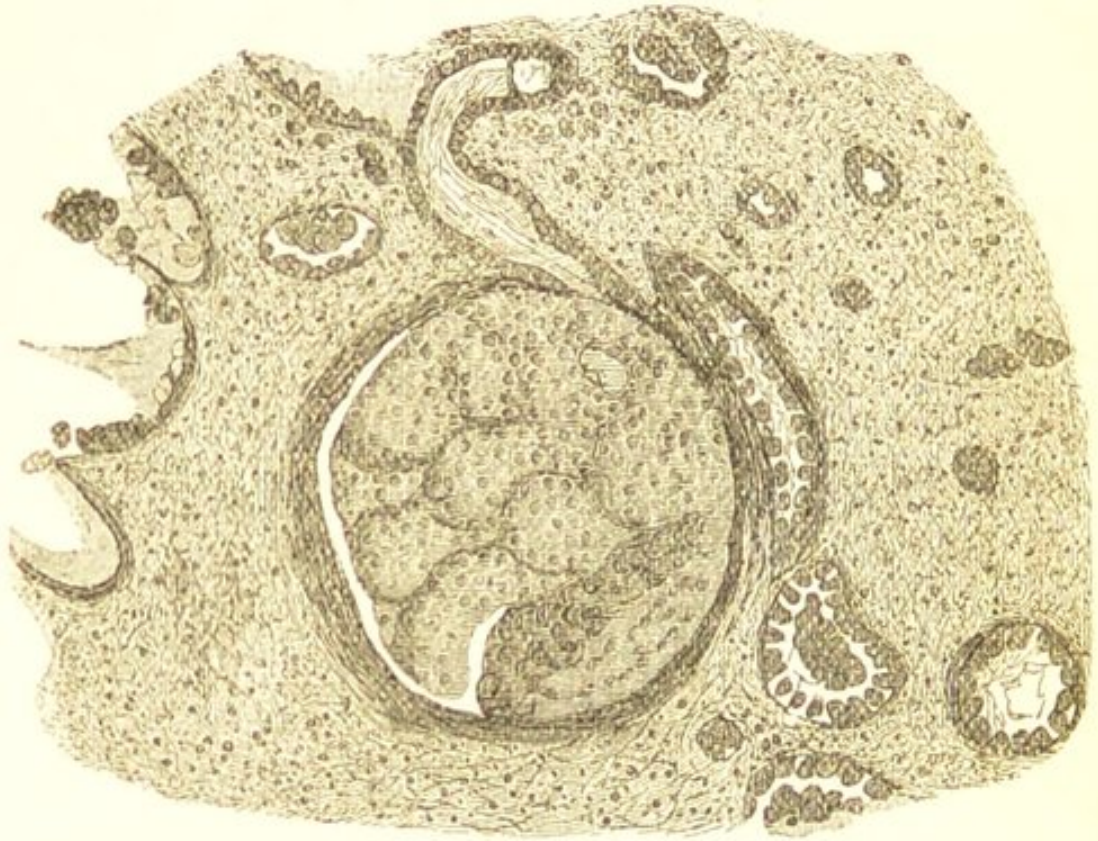

Interstitial Nephritis. The earlier stage of the process. Showing the cellular infiltration of the intertubular connective tissue. The epithelium has fallen out of some of the tubes during the preparation of the section. $\times 200$.

The Malpighian bodies stand out as red points, and the bases of the pyramids and surface of the organ are frequently hyperæmic. The consistence of the organ is usually slightly denser and tougher than natural. This, however, will vary with the character of the new tissue, as will also the increase in size and the irregularity of the surface. If the new tissue is slowly developed, the size will be but little increased, whereas the increase in consistence and the granular condition will be more marked. If, on the other hand, the process be more acute, and the cellular infiltration more abundant, there will be a greater increase in the size, the granular character will be slight, and the consistence may be even softer than natural.

The second stage in the process is characterised by the atrophy of the tubular structures. This is mainly owing

FIG. 90.

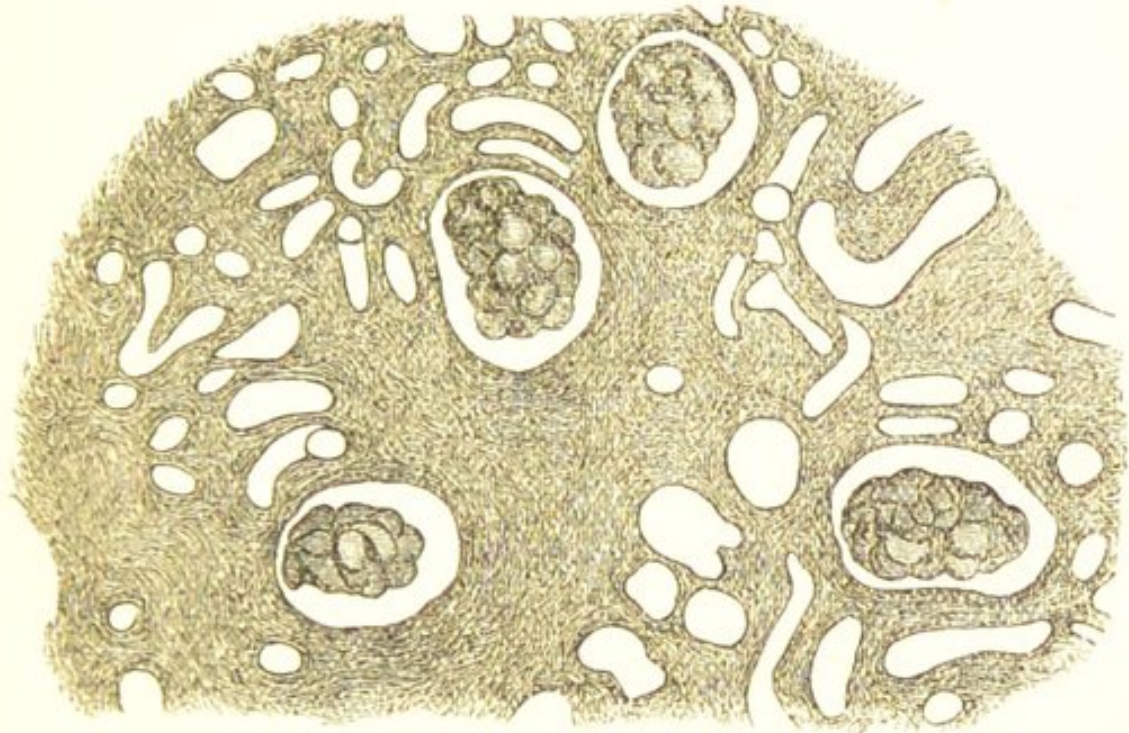

Interstitial Nephritis. An advanced stage of the process. Showing the intertubular tissue with the granular and fatty débris which result from the degeneration. $\times 100$.

to the pressure exercised by the intertubular growth, and to the cicatricial contraction which it often undergoes. The atrophy consequently is not uniform, but is more marked in some parts than in others. The tubes are now found in many parts diminished in size, or completely obliterated; whilst in others they are irregularly dilated, and filled with degenerated epithelial products. Their walls are usually thickened. As the atrophy proceeds the intertubular tissue thus becomes mingled with the granular and fatty débris which results from the retrograde process. (Fig. 90.) The Malpighian bodies become approximated, and the secreting structure throughout large tracts of the kidney is destroyed. (Fig. 91.) The irregular

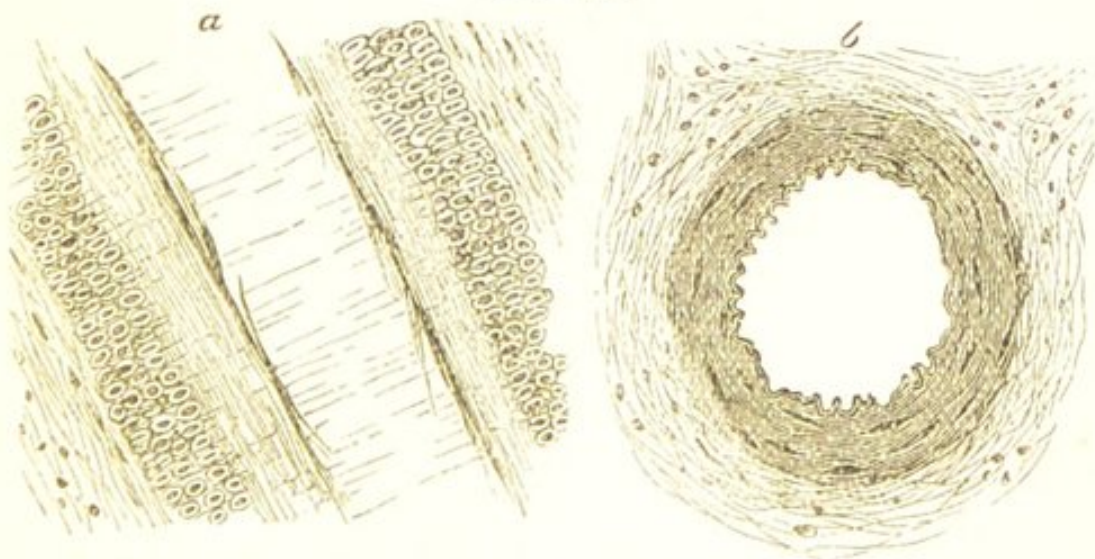
pressure exercised by the new growth also gives rise to the formation of cysts. These originate partly in the Mal-

FIG. 91.



Interstitial Nephritis. A very advanced stage of the process. Showing the large amount of tissue between the tubes of the cortex, and the extensive atrophy of the tubes. The degenerated epithelium which was contained in some of the tubes has fallen out in the preparation of the section. $\times 50$.

FIG. 92.



Arteries from Kidney in advanced Chronic Bright's Disease. *a.* Longitudinal section, showing the great thickening of the internal longitudinal and external circular muscular coat, also of the outer fibrous coat. *b.* Transverse section of another vessel less diseased. Here is seen the thickening of the circular muscular and external fibrous coat. $\times 200$.

pighian capsules, and partly in the urine tubes—the latter becoming irregularly dilated.

The small arteries of the kidney also undergo important alterations. These were first described by Dr. Johnson. Dr. Johnson states that the walls of these vessels are thickened, owing to hypertrophy of their longitudinal and circular muscular fibres. This change is well represented in the accompanying drawing. (Fig. 92.) Both the internal longitudinal and the external circular muscular fibres are considerably increased. The external fibrous coat of the vessel is also thickened, and it appears to be continuous with the new intertubular tissue. This thickening of the external coat has been especially insisted upon by Sir W. Gull and Dr. Sutton. I have usually found it associated with the muscular hypertrophy, although the latter is undoubtedly the most prominent structural change.

In this more advanced stage of the disease the kidney is diminished in size. Its surface is more granular, the capsule more thickened and adherent, and it cannot be removed without tearing the kidney substance. The superficial vessels are seen unduly marked in the depressions between the granulations. The cortex is tough and fibrous, of a yellowish-grey or buff colour, mottled with yellow streaks and patches; and usually numerous small cysts are distributed throughout it. Calcareous deposits are also often seen as white streaks between the tubes of the pyramids.

CHAPTER XXXIX.

INFLAMMATION OF THE BRAIN AND SPINAL CORD.

INFLAMMATORY processes in the nervous centres are probably much less frequent than was formerly supposed. Many of those morbid changes in the brain and spinal cord which are attended by softening, and which were at one time regarded as the result of inflammation, are now known to owe their origin to simple interference with the vascular supply, such as results from thrombosis, embolism, or degenerative changes in the walls of the blood-vessels. (See "Fatty Degeneration of the Brain.")

The irritation which determines the occurrence of acute inflammations in the brain or cord is most frequently some external violence—a blow, simple concussion, or fracture of the osseous framework. In other cases it is diseased bone, as in the inflammation of the brain which so often results from disease of the petrous portion of the temporal bone. Lastly, in a comparatively few number of cases these inflammations are pyæmic.

The inflammatory process is almost invariably limited to small portions of the cerebral or spinal substance. The earliest change consists in a more or less intense and localised hyperæmia, which is frequently attended by rupture and minute extravasations of blood. The nervous tissue then becomes infiltrated with young cells and considerably softened, and it presents a uniform red or

mottled colour. This red softened tissue gradually acquires a brownish or brownish-yellow colour owing to changes in the hæmoglobin. The nerve-fibres become disintegrated, and the nerve-cells and cells of the neuroglia undergo fatty degeneration, thus forming the so-called "inflammatory," or "exudation corpuscles." (See Fig. 10.)

In many cases the accumulation of young cells is sufficient to give rise to the formation of an abscess, and a yellowish or reddish puriform liquid gradually takes the place of the original softened mass. The tissue surrounding the abscess is also hyperæmic, softened, and infiltrated with cells. The cellular infiltration may gradually extend, and thus the abscess increase in size until it opens either externally or into the ventricles. In other cases the abscess becomes limited and encapsuled by the formation of connective tissue from the neuroglia, and this tissue often forms a delicate network traversing the cavity. When the products of these acute inflammations have thus become encapsuled they may gradually dry up into caseous or calcareous masses, or the absorption may be more complete so as to leave little more than a cicatrix. Respecting the source from which the young cells are derived—they are probably almost entirely emigrants, although they are possibly also partly the offspring of the cells of the neuroglia. The nerve-cells themselves appear to undergo no active changes in inflammation.

Suppurative inflammations are much more common in the brain than in the spinal cord. In the latter the inflammatory process is rarely of sufficient intensity to produce abscess; it causes merely softening of the nervous tissue (myelitis).

INFLAMMATORY SOFTENING OF THE BRAIN AND CORD.—Conditions of softening of the cerebral or spinal substance resulting from inflammation, other than those which

have been above described, probably rarely, if ever, occur as *primary* lesions. Most varieties of softening which were formerly described as inflammatory—either from the red colour of the softened tissue or from the acuteness of the process—result, as already stated, from thrombosis or embolism (see “Embolism in the Brain”), or are simply passive degenerative changes in which more or less extravasation of blood has taken place into the softened tissue. (See “Fatty Degeneration of the Brain.”) Inflammation and consequent softening of the nervous tissue, however, by no means unfrequently occurs as a *secondary* process. It takes place especially around clots of blood or other morbid products within the brain or spinal cord, and results from the injurious influence which these substances exercise upon the immediately adjacent structures. Such a result is not unfrequent in cases of cerebral hæmorrhage. The nerve-tissue immediately surrounding the clot becomes the seat of an inflammatory process, and it is found after death softened, hyperæmic, and infiltrated with young cells. Inflammation of the superficial portions of the cerebral and spinal substance also occurs as the result of meningitis.

SCLEROSIS OF THE BRAIN AND SPINAL CORD.

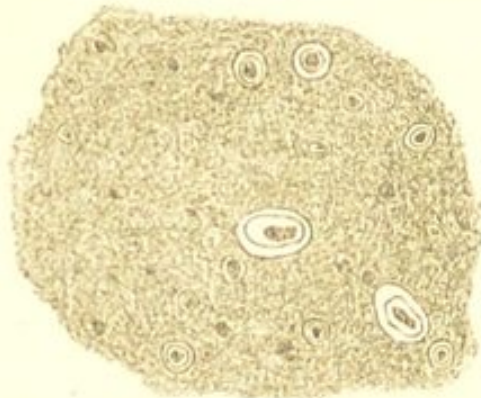
The term “sclerosis” is applied to certain changes in the nervous centres which are characterised by an increase of the connective tissue (neuroglia), and by atrophy and disintegration of the proper nervous elements. The affected portions are, for the most part, increased in consistence; sometimes, however, they are softer than natural. They are usually of a greyish colour; hence the change has been called “grey degeneration.”

Respecting the nature of the change—it is probably in many cases the result of a chronic inflammatory process, the new growth of connective tissue leading to the de-

struction of the nerve-elements. In other cases, however, the atrophy of the nerve-tissue appears to precede the interstitial increase, so that the process would rather be regarded as a passive degeneration.

When the diseased portions of the brain and cord are examined microscopically, the cut ends of the nerve fibres are seen in transverse sections to be separated by a granular, finely nucleated, and often partially fibrillated tissue, which evidently originates from the neuroglia (Fig. 93). The nerve-fibres themselves are atrophied, and

FIG. 93.



Sclerosis of Spinal Cord. From a case of Progressive Muscular Atrophy. A transverse section. Showing the new tissue between the cut ends of the nerve-fibres. $\times 200$.

more or less fatty débris is found in the altered tissue. In many cases the nucleated character of the interstitial growth is wanting. The walls of the blood-vessels are also stated to be thickened, and their nuclei to be increased.

Sclerosis is much more common in the spinal cord than in the brain. In the latter it occurs most frequently as small patches of induration limited to certain portions of the brain. These must be distinguished from the cicatrices left after the absorption of blood or of inflammatory products. Sclerosis of the cord may in the same way be localised and more or less disseminated; more commonly, however, it implicates only particular nervous tracts. It occurs thus especially in the posterior columns of the cord in locomotor ataxy.

CHAPTER XL.

INFLAMMATION OF THE LUNGS.

IN the lungs, inflammatory processes comprise the three following varieties:—*Croupous*, *catarrhal*, and *interstitial* pneumonia. Of these, the former occurs as an independent affection, whereas the two latter are usually the result of some antecedent bronchial or pulmonary inflammation.

CROUPOUS PNEUMONIA.

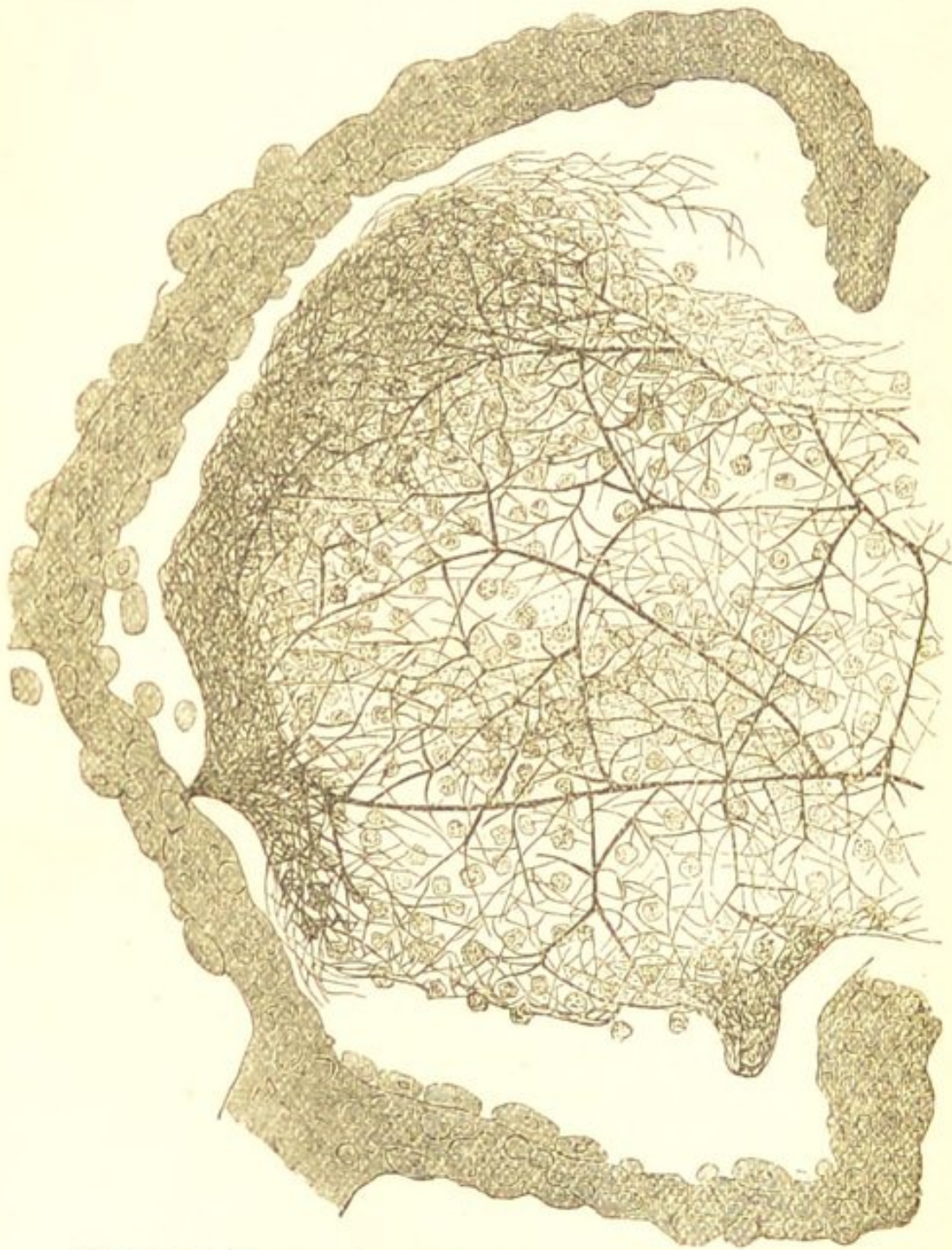Croupous, *exudative*, or *lobar* pneumonia, is characterised by intense inflammatory hyperæmia and by the exudation of a large amount of coagulable material into the pulmonary tissue. It is termed “croupous” because, like the croupous inflammation of mucous membranes, the exuded liquids contain a large quantity of fibrinogenous substance. This form of pneumonia almost invariably affects an extensive portion of the lung, hence the term “lobar” which is applied to it. The process is commonly described as consisting of three stages—1st, that of *engorgement*; 2nd, that of *red hepatization*; and 3rd, that of *grey hepatization*.

In the *first* stage, that of *engorgement*, the lung becomes exceedingly vascular, the changes in the blood-vessels and circulation being such as have been already described as characteristic of inflammation. The organ is of a dark red colour, its specific gravity and absolute weight are

increased, its elasticity is diminished, it is less crepitant than natural, and pits upon pressure. Its cut-surface yields a reddish, frothy, tenacious liquid.

In the *second* stage, that of *red hepatization*, there is an

FIG. 94.



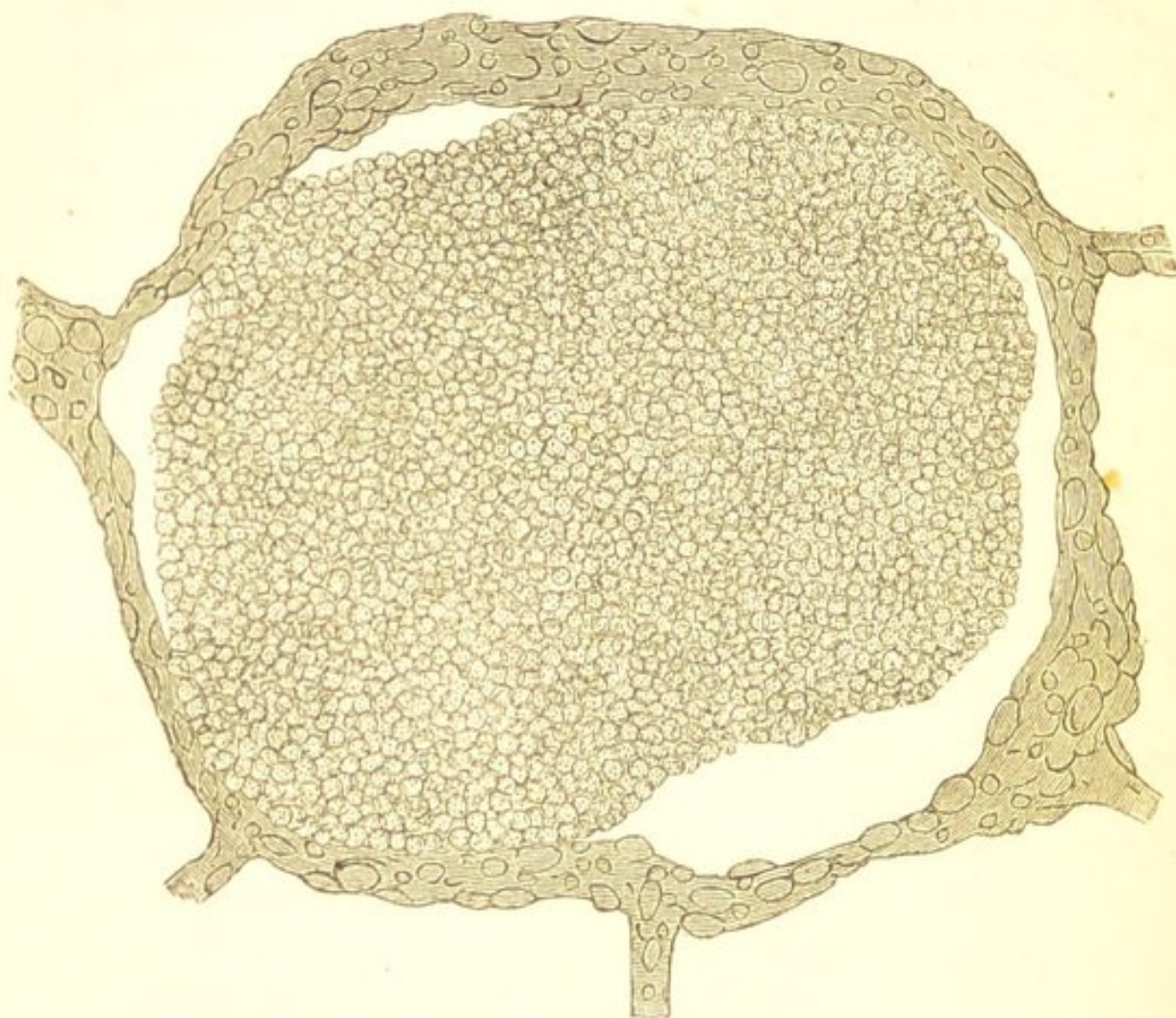Croupous Pneumonia—Red Hepatization. Showing the fibrinous coagulum in one of the pulmonary alveoli, enclosing within its meshes numerous leucocytes, which are already commencing to undergo fatty metamorphosis. A few leucocytes are also seen on the alveolar walls, and the alveolar epithelium is swollen and granular. $\times 200$.

exudation of liquor sanguinis and migration of blood-corpuscles into the pulmonary tissue. Some of the vessels may also rupture, and thus small extravasations occur. The exuded liquids coagulate within the air-vesicles and in the interstices of the interlobular tissue, the coagulum enclosing numerous white and some red blood-corpuscles. (Fig. 94.) The lung is now much heavier than in the preceding stage. It contains but little or no air, usually sinks in water, and cannot be artificially inflated. It does not crepitate under the fingers, but is remarkably friable, breaking down readily with a soft granular fracture. The cut surface is of a dark reddish-brown colour, and it presents a granular appearance, the granules being the plugs of fibrinous coagulum contained in the air-vesicles. These granules also sometimes give to the reddish-brown organ a peculiar grey mottling. Throughout this stage there appears to be but little alteration either in the alveolar walls or in the alveolar epithelium. On the former are often seen a few leucocytes, and the latter may be somewhat swollen and granular. (Fig. 94.)

The *third* stage, that of *grey hepatization*, is characterised by a continuance in the emigration of leucocytes, and by cell-proliferation. The white blood-corpuscles continue to escape from the vessels, and thus their number within the alveoli gradually increases. The epithelial cells lining the alveolar walls, which were only swollen and granular in the earlier stage of the process, now undergo more active changes. Their nuclei enlarge and multiply, and ultimately numerous new cells are produced. The pulmonary alveoli thus become completely filled with young cell-forms, so that the fibrinous exudation is no longer visible as an independent material, as it is in the stage of red hepatization. (See Fig. 94.) These cells rapidly undergo retrogressive fatty changes, so that, as usually seen, the alveoli are filled with granular elements, which in many parts have lost their distinctive outlines.

(Fig. 95.) The weight, density, and friability of the lung now become even greater than in the stage of red hepatization, although the granular aspect of the cut surface

FIG. 95.



Croupous Pneumonia—Grey Hepatization. Showing the large accumulation of cellular elements within one of the pulmonary alveoli, which in some parts have undergone such extensive fatty degeneration that their distinctive outlines are no longer visible. $\times 200$.

is much less marked. The tissue is now quite soft and pulpy, and a puriform liquid exudes from its cut surface. The most prominent feature, however, is the alteration which takes place in the colour of the organ. This gradually changes from a dark reddish-brown to a grey or yellowish-white. This is owing partly to the pressure

exercised upon the blood-vessels by the exuded substances and newly-formed cells, and partly to the fatty degeneration which the latter have undergone.

Such are the characteristic changes which occur in croupous pneumonia. In those very numerous cases, however, in which the pneumonia is secondary to some other disease, or occurs in debilitated subjects, the changes in the lung may present some deviations from those which have been above described. In these secondary pneumonias the exuded substances are often less abundant and less coagulable, and consequently the weight of the lung is much less increased. The organ is also less dense and friable than when the process occurs in a healthy person. The existence of much congestion and œdema of the pulmonary tissue, such as is so common as a result of gravitation in conditions of asthenia, also modifies the physical conditions produced by the pneumonic process (hypostatic pneumonia). Not only are these secondary pneumonias often characterised by the exuded liquids being less coagulable than are those resulting from primary inflammations, but the emigration of leucocytes is usually less abundant, and the proliferation of the alveolar epithelium constitutes a more prominent part of the process, so that a greater proportion of large nucleated cell-forms are found within the pulmonary alveoli.

The pneumonic process may terminate in the four following ways :—

1st. *In Resolution.*—The gradual return of the lung to its normal condition is much the most frequent termination of croupous pneumonia. The coagulated materials liquefy, the young cells entangled in them undergo complete fatty degeneration and disintegration, and thus the inflammatory products become so altered that they can be removed by absorption. Granular pigment is also mixed with the softened matters and appears in the expecto-

ration. This is probably partly derived from the extravasated blood, and is partly that which normally exists in the interlobular connective tissue. Where this process of liquefaction and disintegration is taking place in the lung the granular appearance of its cut surface is completely lost. It is of a yellowish-grey colour, and a tenacious puriform liquid can be expressed from its substance. As the softened matters become absorbed, the circulation is gradually restored, and the organ ultimately attains its normal characters.

2nd. *In Abscess.*—The formation of an abscess is a very rare result of simple pneumonia. It may, however, take place if the emigration of blood-corpuscles is very abundant. The pus is always mixed with broken-down pulmonary tissue. It is when pneumonic processes are induced by septic matters and are thus disseminated, as in pyæmia, that the formation of abscess usually occurs. The pyæmic abscess in the lungs, like that in other organs, is characterised by the zone of hyperæmic tissue which surrounds it. (See “Pyæmia.”)

3rd. *In Gangrene.*—Almost as rare as the preceding is the occurrence of gangrene. Two conditions appear to be principally concerned in bringing about this result:—one is the interference with the supply of blood by the extensive formation of coagula in the pulmonary and bronchial vessels, together with considerable hæmorrhage into the pulmonary tissue; the other is the contact of putrid substances with the pneumonic lung,—as the putrid secretion in a dilated bronchus.

4th. *In Chronic Pneumonia.*—If the inflammatory process does not subside and the exuded substances are not absorbed, the alveolar walls gradually become involved. These become thickened by a new growth of fibro-nucleated tissue, and thus is produced more or less fibroid induration of the organ. (See “Interstitial Pneumonia.”) This termination of croupous pneumonia is comparatively rare.

Croupous pneumonia plays a prominent part in many cases of pulmonary phthisis. (See "Pulmonary Phthisis.")

CATARRHAL PNEUMONIA.

Catarrhal, lobular, or broncho-pneumonia rarely occurs as an independent affection, but is very constantly preceded by catarrhal changes in the mucous membrane of the smaller bronchi. It is an inflammatory process of less intensity than the preceding, and differs from it in there being but little or no exudation of coagulable material, the process being characterised for the most part by proliferation of the alveolar epithelium. It thus somewhat resembles catarrhal inflammation of mucous membranes—hence the term "catarrhal" which is applied to it. This form of pneumonia is almost invariably at its commencement limited to the lobules or groups of lobules in connection with certain bronchial tubes, and it does not like the croupous variety involve simultaneously large tracts of pulmonary substance. It is consequently also known as *lobular* or *broncho-pneumonia*.

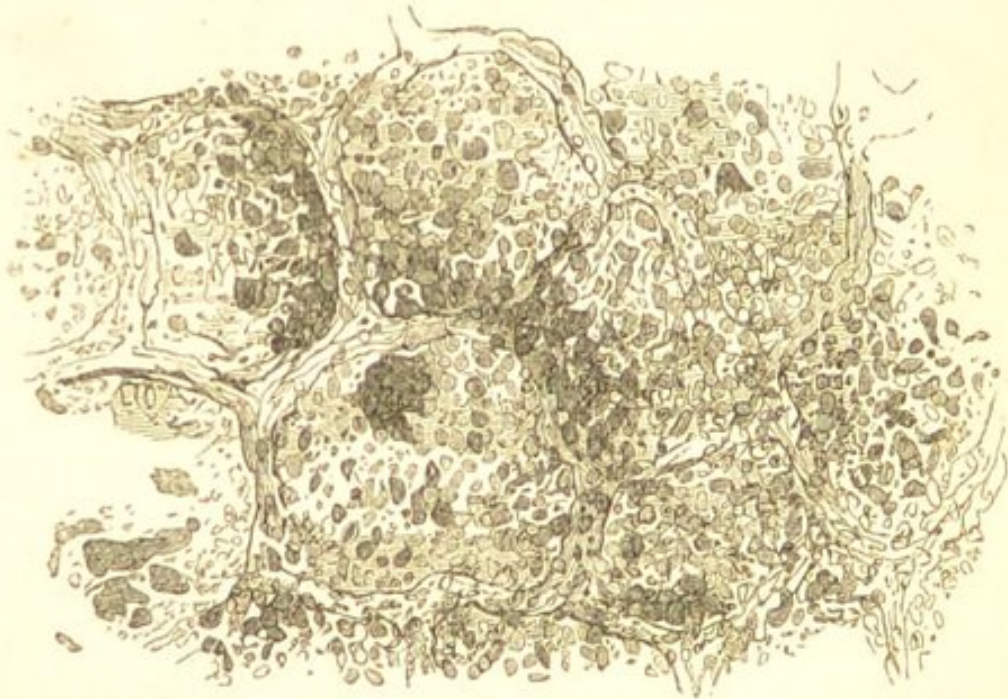The conditions, however, to which the terms catarrhal or broncho-pneumonia are applied vary. In those forms of the disease which occur so frequently in children as a sequel of capillary bronchitis, especially when this is a complication of measles or whooping-cough, I must state, in partial agreement with Professor Buhl, that the nodules of pulmonary consolidation frequently consist in the main of inhaled bronchial secretion, and to many of these cases the term "pneumonia" is not strictly applicable.

When the lungs in these cases are examined after death, small yellowish or reddish-grey ill-defined patches of consolidation are seen scattered through their substance, more especially in their inferior and posterior portions. These patches are smooth, very faintly granular, dry,

and project slightly above the cut-surface of the organ. The lung-tissue around them is variously altered by congestion, œdema, collapse, and emphysema; so that patches of dark reddish collapse, and of pale emphysematous tissue are intermingled with the consolidated portions. In some parts the "pneumonic" patches have evidently coalesced and so formed large tracts of greyish-yellow consolidation.

When the lungs are examined microscopically, most of the consolidated portions are seen to present the appearance well shown in the accompanying figure (Fig. 96). The

FIG. 96.



Broncho-Pneumonia. From a child, aged four, with capillary bronchitis. A section of one of the patches of consolidation. Showing the stuffing of the alveoli with inhaled bronchial secretion. $\times 200$.

alveoli in small areas of the lung are stuffed with small cells and amorphous or faintly granular material. Some of the cells resemble leucocytes. Others are somewhat larger, and there are also a few large elements which resemble the alveolar epithelium. The alveolar walls are unaltered, and the alveolar epithelium can often be seen somewhat swollen and granular, either adherent or

loosened from its attachment. The character of the material which fills the air-vesicles in most of the patches is precisely similar to that contained in the smaller bronchi, and it is evidently the richly cellular bronchial secretion which has been inhaled. In other portions of the lung, however, large nucleated cell-forms may constitute a much more prominent feature in the constitution of the patches, and it is evident that there has been more or less epithelial proliferation. (See Fig. 97.) It is this epithelial proliferation which must be regarded as the only strictly pneumonic part of the process, and it would appear to be determined either by the irritation of the retained secretion, or by the direct extension of the inflammation from the bronchi to the air-vesicles. Its occurrence is probably also greatly favoured by collapse of the lung-tissue.

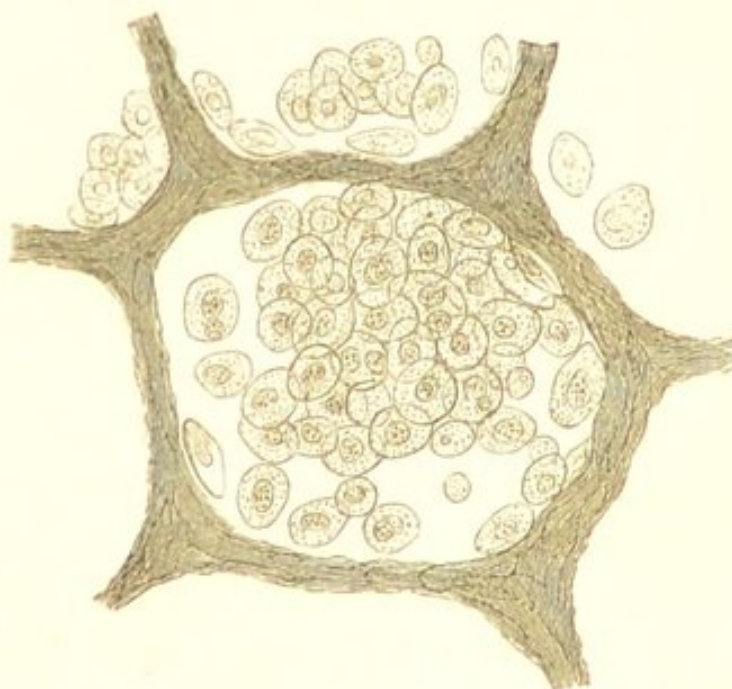
This disease frequently terminates in death, but the patient may recover and the contents of the alveoli be removed by expectoration and absorption. If the removal is incomplete the retained substances produce more or less inflammatory thickening of the bronchial and alveolar walls, and a caseous nodule may be produced which is encapsuled by fibrous tissue. In other cases the inflammatory process continues, the consolidated tissue becomes caseous and disintegrates, and phthisis results. This, however, in the absence of a marked predisposition to phthisis is not very common. (See "Pulmonary Phthisis.")

In addition to the disease above described, in which inhaled bronchial secretion constitutes such an important element in the production of the pulmonary consolidation, we meet with a more strictly catarrhal pneumonic process. This often occurs in lungs which have become collapsed. Pulmonary collapse, whether it be due to bronchial obstruction or to diminished respiratory power, is followed by congestion and œdema of the collapsed alveoli, and the

local congestion appears to be especially favourable to the catarrhal process. Such collapse is common in rickety children who are the subjects of bronchitis or whooping-cough. The alveolar epithelium in the bluish-red, congested, œdematous and collapsed portions of the lung proliferates, giving rise to a dark reddish-grey friable consolidation. This consolidation may be limited to small portions of the collapsed tissue, or involve the greater part of the lung.

An uncomplicated catarrhal process often occurs in pulmonary phthisis. The alveoli are found containing numerous large spheroidal elements, which usually possess one, sometimes two or three bright nuclei. (Fig. 97.)

FIG. 97.



Catarrhal Pneumonia. From a case of acute phthisis. Showing the large epithelial cells which fill the alveoli. $\times 200$.

These cells are evidently the offspring of the alveolar epithelium. Associated with them may be a few leucocytes. This process will be more fully described when treating of pulmonary phthisis. (See "Pulmonary Phthisis.")

Lastly, as already stated, epithelial proliferation often plays a prominent part in ordinary lobar pneumonia, especially in the asthenic and secondary forms.

INTERSTITIAL PNEUMONIA.

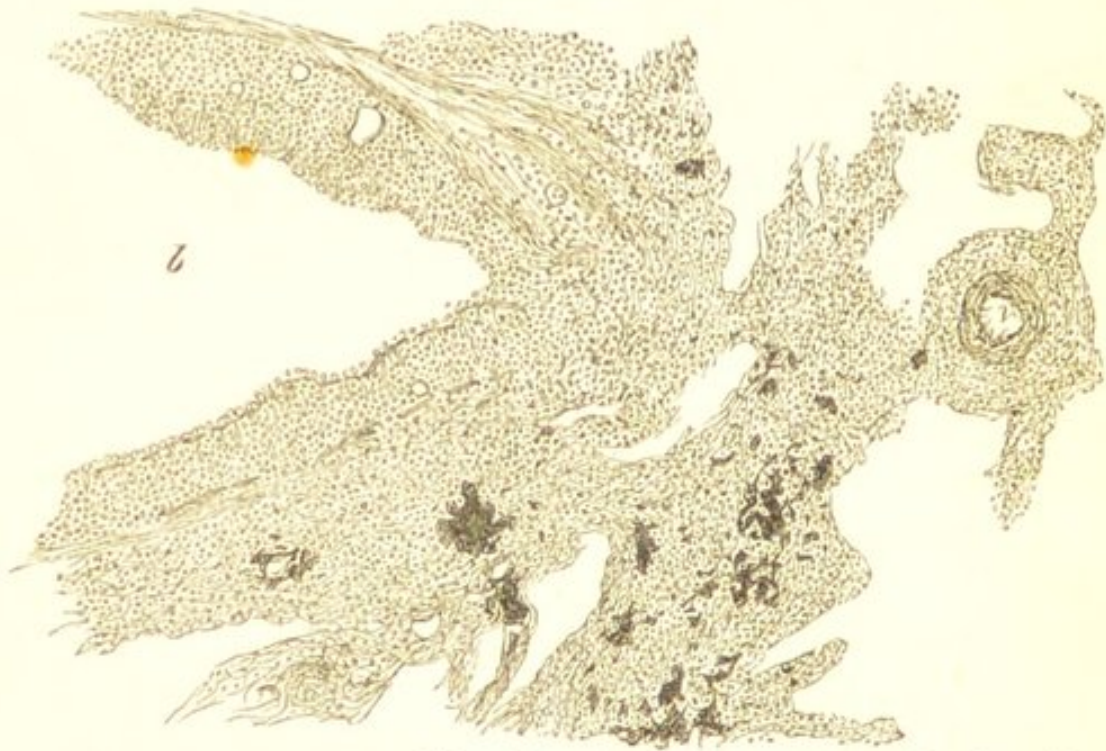
Interstitial or chronic pneumonia is a chronic inflammatory process of the lungs which leads to a fibroid induration of the pulmonary texture—an induration which is due to a thickening of the alveolar walls and of the interlobular tissue by a fibro-nucleated growth, and to the gradual obliteration by this growth of the alveolar cavities. It may be stated generally, that all chronic inflammatory processes in the lungs are attended by more or less fibroid induration of the organs, and in this respect, therefore, these processes resemble similar ones in other parts—*e.g.*, in the liver, kidney, and mucous membranes. In chronic phthisis, for example, as will be seen hereafter, a fibroid change plays a very prominent part, and in the most chronic cases the pulmonary tissue may be almost completely replaced by a dense fibroid growth. Croupous pneumonia, as has been already stated, may pass into a chronic condition, in which case it leads to a fibroid thickening of the alveolar walls, and consequently to more or less induration of the pulmonary texture. Catarrhal pneumonia, again, which has a greater tendency to become chronic than the exudative process, may lead to considerable pulmonary induration:—this will also be alluded to when treating of pulmonary phthisis. Lastly, the thickening of the peri-bronchial tissue which sometimes occurs in chronic bronchitis, may gradually extend and involve the alveolar walls so as ultimately to produce extensive obliteration of the pulmonary alveoli.* (Fig. 98.)

* See case by the Author—Interstitial Pneumonia, "Trans. Path. Soc. Lond.," 1872.

In all these cases the fibroid change is an evidence of the chronicity of the inflammatory process.

Although fibroid changes in the lungs may thus owe their origin to these various chronic inflammatory processes, it is only in those cases in which inflammation leads to those pulmonary lesions included under the common term of "phthisis," that they constitute a frequent form of pulmonary affection. Indeed, independently of phthisis, extensive fibroid change is amongst the rarer forms of pulmonary disease; and it is to these

FIG. 98.



Chronic Bronchitis. Showing the new growth of adenoid tissue around the bronchus *b*, and the way in which this tissue is invading the walls of the adjacent alveoli. *v*, A divided blood-vessel. $\times 100$, reduced $\frac{1}{2}$.

exceptional cases that the application of the term "interstitial" or "chronic pneumonia" is commonly restricted.

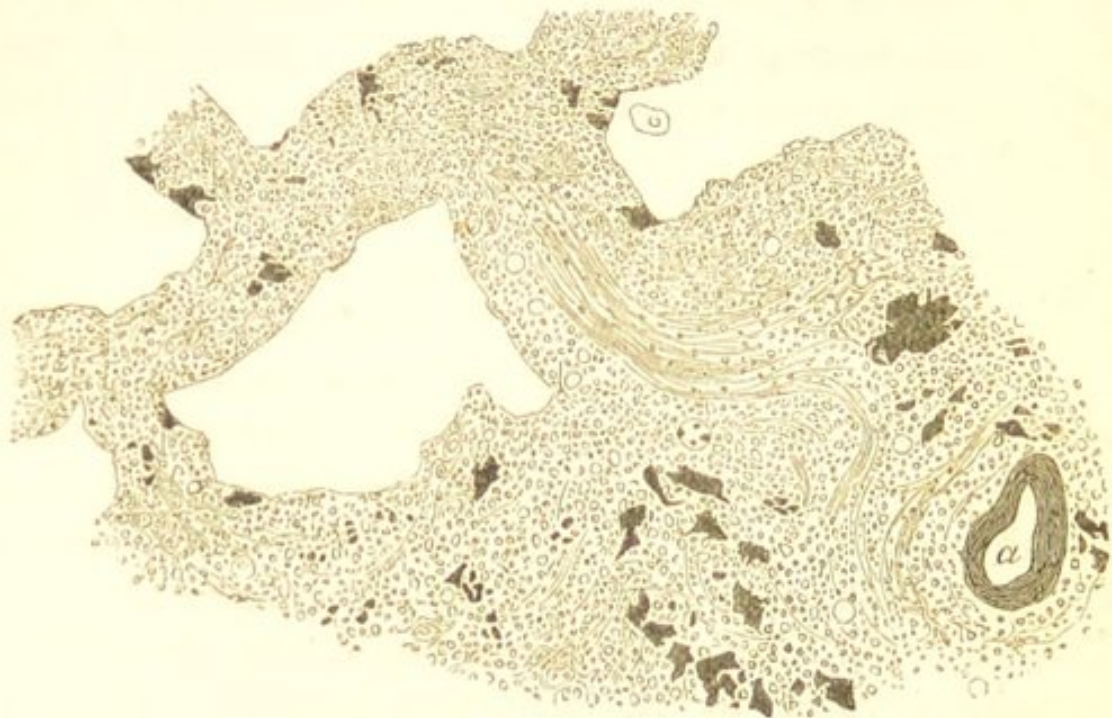
Interstitial pneumonia, in this restricted sense, is the disease which received from Sir D. Corrigan the name of "cirrhosis." It is commonly unilateral, affecting the whole or a portion of the lung; and is characterised by a very extensive fibroid induration and consequent contrac-

tion of the organ, by obliteration of the alveolar cavities, more or less pigmentation, and by dilatation of the bronchi. The appearance presented by the lung in advanced stages of the disease is very characteristic. It is diminished in size; the tissue is smooth, dense, firm,—in parts almost cartilaginous in consistence; and it is irregularly mottled with black pigment. The alveolar structure of the lung is in most parts completely destroyed, and on section the dilated bronchi are seen as numerous large openings scattered over its surface. The dilated bronchi frequently become the seats of secondary inflammatory processes, which may lead to ulceration and ultimately to extensive excavation of the indurated tissue; but there is a complete absence of any of those caseous changes which are so characteristic of ordinary phthisis. This secondary inflammation of the dilated bronchi is probably induced by the irritating purulent secretion which they contain, and which is often only with great difficulty completely removed by expectoration. The pleura is almost invariably considerably thickened and adherent.

When the lung is examined microscopically, it will be found that the alveolar structure has been in most parts completely replaced by a fibro-nucleated or by a more densely fibroid growth, presenting the characters already described as those met with in cicatricial tissue. (See Fig. 72.) The new growth may commence either in the alveolar walls or in the interlobular tissue. The former appears to be usually the case when it is secondary to an exudative or catarrhal pneumonic process. Where the change is not far advanced and the alveoli are still distinct, their walls will be seen to be thickened by a fibro-nucleated growth (Fig. 99), and their cavities sometimes to be filled with large epithelial cells, or less frequently, with leucocytes. The characters of the new growth in the alveolar walls and in the interlobular tissue present

certain variations. In the earlier stages of the inflammatory process it consists principally of small spheroidal

FIG. 99.



Interstitial Pneumonia. From a case of so-called "cirrhosis" of the lung, in which the disease was unilateral. The bronchi were much dilated, and there was a complete absence of any caseous change. The drawing shows the new fibro-nucleated growth, both in the alveolar walls and in the interlobular tissue, also the pigmentation. At *a* a divided bronchus is seen. $\times 100$.*

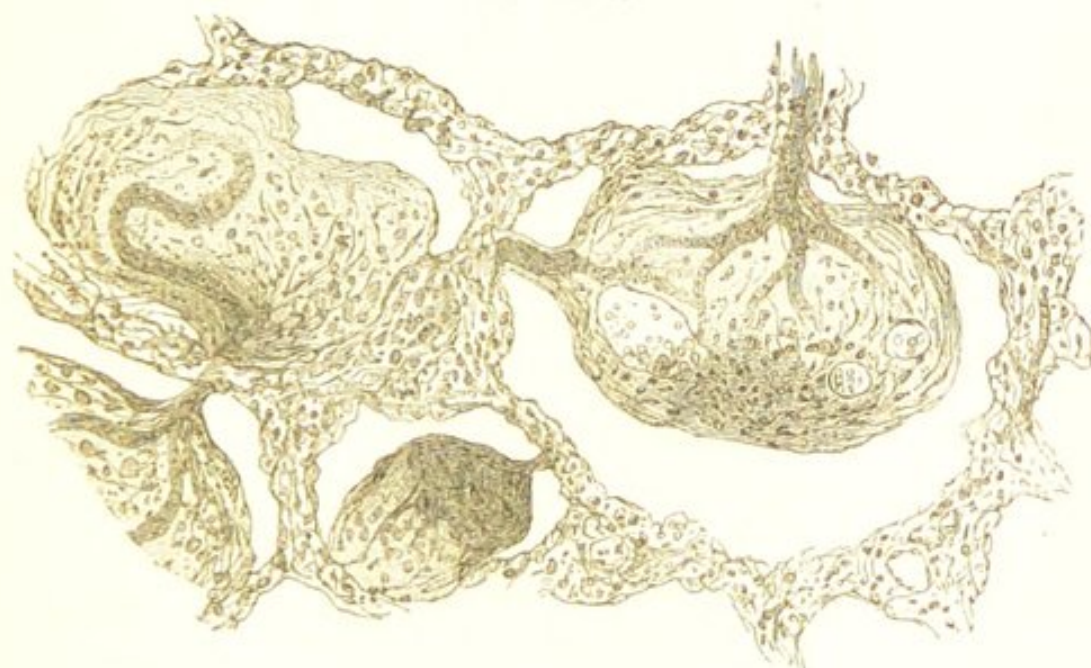
elements which are grouped within the meshes of delicately fibrillated reticulum (adenoid tissue); but when more advanced the fibrillation is usually more marked, and associated with the small spheroidal elements there are frequently some elongated fusiform and branched cells such as are so often found in embryonic tissue which is in the process of forming a fibrous structure.

Although this fibroid growth in chronic pneumonia appears most frequently to originate in the alveolar walls and interlobular tissue, I have met with three cases in

* When this specimen is examined with a higher magnifying power, a delicate reticulum can be seen between the cellular elements, similar to that represented in Fig. 55, but less marked.

which intra-alveolar exudation products were undergoing fibroid development.* There was nothing peculiar in the macroscopical characters of the lungs, but the alveoli were found filled with a fibrinous meshwork and leucocytes somewhat similar to that met with in red hepatization. (See Fig. 94.) They differed, however, in this respect—that many of the cells were long and spindle-

FIG. 100.



Chronic Pneumonia. Vascularisation and fibroid development of intra-alveolar exudation-products. Blood-vessels are seen distributed in the exudation-products, which blood-vessels communicate with those in the alveolar walls. The alveolar walls are also thickened by a fibro-nucleated growth. $\times 100$ and reduced $\frac{1}{2}$.

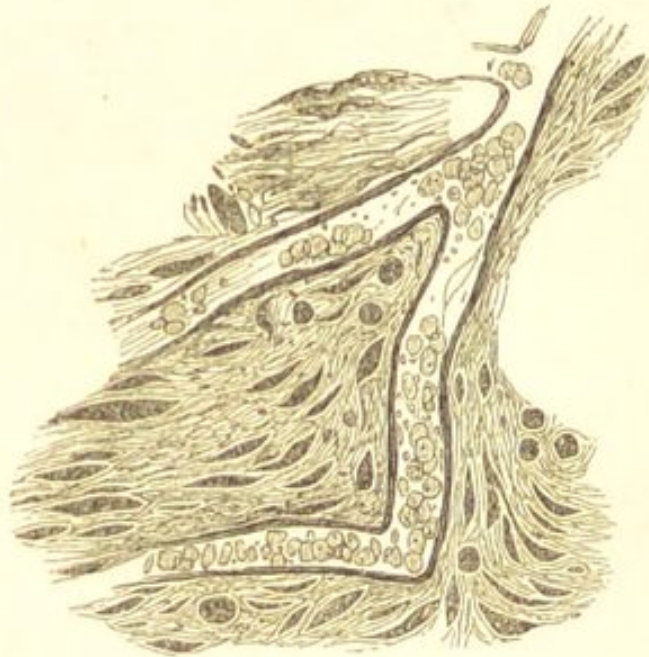
shaped, and blood-vessels were distributed amongst them, which blood-vessels communicated with those in the alveolar walls. (Figs. 100 and 101.) The alveolar walls were also thickened by a fibro-nucleated growth. It was therefore perfectly obvious that in these lungs the products of a previous acute croupous pneumonia were becoming vascularised and undergoing development into a

* For one of these specimens I am indebted to Dr. Goodhart, who records the case in the "Trans. Path. Soc. Lond.," vol. xxv. p. 33.

fibroid structure, and that this intra-alveolar change was the principal cause of the fibroid induration of the organ.

With regard to the etiology of interstitial pneumonia—it probably, as already stated, almost invariably owes its origin to some antecedent more acute pneumonic process of either the exudative or catarrhal type, or to bronchitis. It is maintained, however, by many pathologists that a fibroid change may occur in the lungs as a primary and

FIG. 101.



Chronic Pneumonia. A portion of the intra-alveolar exudation-products (Fig. 100) more highly magnified. Showing the elongated spindle cells, the fibrillation, and the blood-vessel containing blood-corpuscles. $\times 200$.

independent affection, and that consequently interstitial pneumonia occupies the same pathological position as indurative processes in the liver and kidneys. That such a view is correct appears to me to be extremely doubtful.

An interstitial pneumonia, also, sometimes occurs in lungs which have been compressed by pleural effusion. It would appear that this is more especially liable to result if the effusion has remained long unabsorbed or not evacuated.

CHAPTER XLI.

PULMONARY PHTHISIS.

By pulmonary phthisis is understood a disease of the lungs which is characterised by progressive consolidation of the pulmonary texture, and by the subsequent softening and disintegration of the consolidated tissue. Respecting the nature of the morbid processes which lead to this consolidation and disintegration of the lungs—various opinions have from time to time been held by pathologists, and this diversity of opinion exists to some extent even at the present day. According to the older views, which were based upon the teaching of Laennec, phthisis was regarded in all cases as a *tuberculous* disease. Tubercle was looked upon as a specific non-inflammatory growth which was characterised by the caseous degeneration which it invariably underwent (see “Acute Tuberculosis”), and this caseous metamorphosis was held to be such a distinguishing peculiarity of the growth that all caseous masses came to be regarded as tuberculous, and phthisis, in which caseation plays such a prominent part, was consequently regarded as a tuberculous disease. The various consolidations of the pulmonary tissue were described as “infiltrated tubercle,” and tubercle in some form or other was regarded as so essential a constituent of the disease, that “phthisis” and “pulmonary tuberculosis” came to be quite synonymous terms.

These older views respecting the nature of phthisis

have undergone various modifications during recent years. When the application of the term "tubercle" became limited by Virchow and his followers to the grey granulation it was evident that such views were no longer tenable, and at the present time many, in accordance with the advocacy of the late Professor Niemeyer, regard tubercle as only an occasional element in the causation of the disease. In considering how far tubercle plays a part in the production of phthisis, it must be borne in mind that this growth is now known to be an inflammatory one. \ The miliary lesions which are commonly known as tubercular, are the anatomical results of chronic inflammatory processes limited to small circumscribed areas; and although they consist in the main of a small-celled lymphoid tissue, they present certain differences in their histological characters according to the structure of the organ in which they originate. (See "Acute Tuberculosis.") In the lungs it has been seen that they consist not only of that lymphoid tissue and branched cells, which is so characteristic of tubercular lesions, but also of accumulations of epithelium within the pulmonary alveoli. (See "Tuberculosis of the Lungs.")

HISTOLOGY OF PHTHISIS.—The histological changes in the lungs which occur in pulmonary phthisis are precisely analogous to those which are met with in acute tuberculosis. They differ mainly in this respect—that whilst in the latter disease these changes are usually limited to minute areas (hence the miliary character of the lesions), in the former they commonly involve much wider tracts of tissue.

In studying pulmonary phthisis, it will be advisable in the first place to describe the various structural changes which are met with in the lungs, together with the more important alterations which they produce in the physical characters of the organs; and subsequently to examine into the nature of the morbid processes upon which these

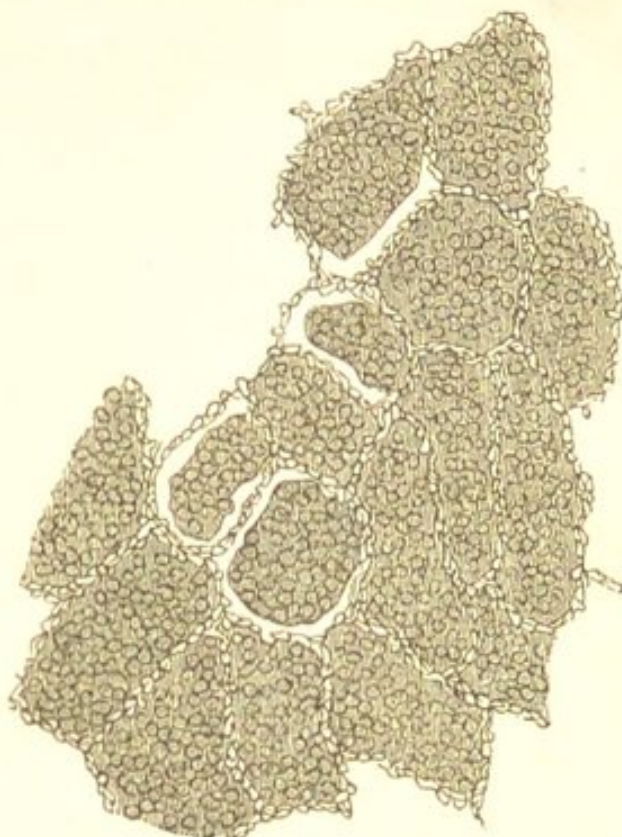changes depend, and to draw some general conclusions respecting the pathology of the disease.

The structural changes met with in the lungs in phthisis are mainly of four kinds:—1st. *An accumulation of epithelial cells within the pulmonary alveoli*; 2nd. *The presence within the alveoli of a fibrinous exudation and leucocytes*; 3rd. *A thickening of the alveolar walls by a small-celled tissue, together with, in most cases, the growth of a similar tissue around the minute bronchioles*; and 4th. *An increase in the interlobular connective tissue*. These four kinds of morbid change are usually associated with one another, although in very different degrees. The preponderance of one or other of them produces those variations in the physical characters of the lungs which are met with in the different stages, and in the different varieties of the disease. These various structural changes must now be considered separately.

1st. *An accumulation of epithelial cells within the pulmonary alveoli* is one of the most frequent changes met with in phthisis, and this change is precisely similar to that already described as occurring in true catarrhal pneumonia. The alveoli are found filled with large nucleated elements which are the offspring of the epithelial cells normally lining the alveolar walls. (See Fig. 97.) In some cases this alveolar accumulation may constitute almost the only morbid change, and although the alveolar walls may be found slightly thickened here and there by a small-celled lymphoid tissue, the great bulk of the pulmonary consolidation is due to the stuffing of the alveolar cavities with catarrhal products. (Fig. 102.) In some parts—those in which the change is the most recent—the large cells which fill the alveoli and the alveolar walls will be found but little altered, but in the greater portion of the consolidated tissue the cells will be seen in various stages of retrogressive metamorphosis, and the alveolar walls destroyed; whilst in those tracts of tissue in which

the process is most advanced all trace of structure is lost, and nothing is seen but a granular débris. These

FIG. 102.



Section of Lung from a case of Acute Phthisis. Showing the accumulations of epithelial cells within the alveoli. The alveolar walls are almost completely free from any small-celled growth. In some parts a free space is seen between the alveolar walls and their contents: this is simply due to the shrinking of the latter caused by the hardening of the specimen. $\times 50$. (Compare with Fig. 63.)

changes are precisely analogous to those met with in many of the larger nodular lesions of acute tuberculosis. (See Figs 62 and 63.)

The appearances presented by the lungs in those cases in which the structural changes above described constitute almost the only cause of the consolidation, are very characteristic. The consolidated tissue is quite soft and friable, breaking down very readily under the finger, and there is a complete absence of any induration. The consolidation, although frequently almost uniform, some-

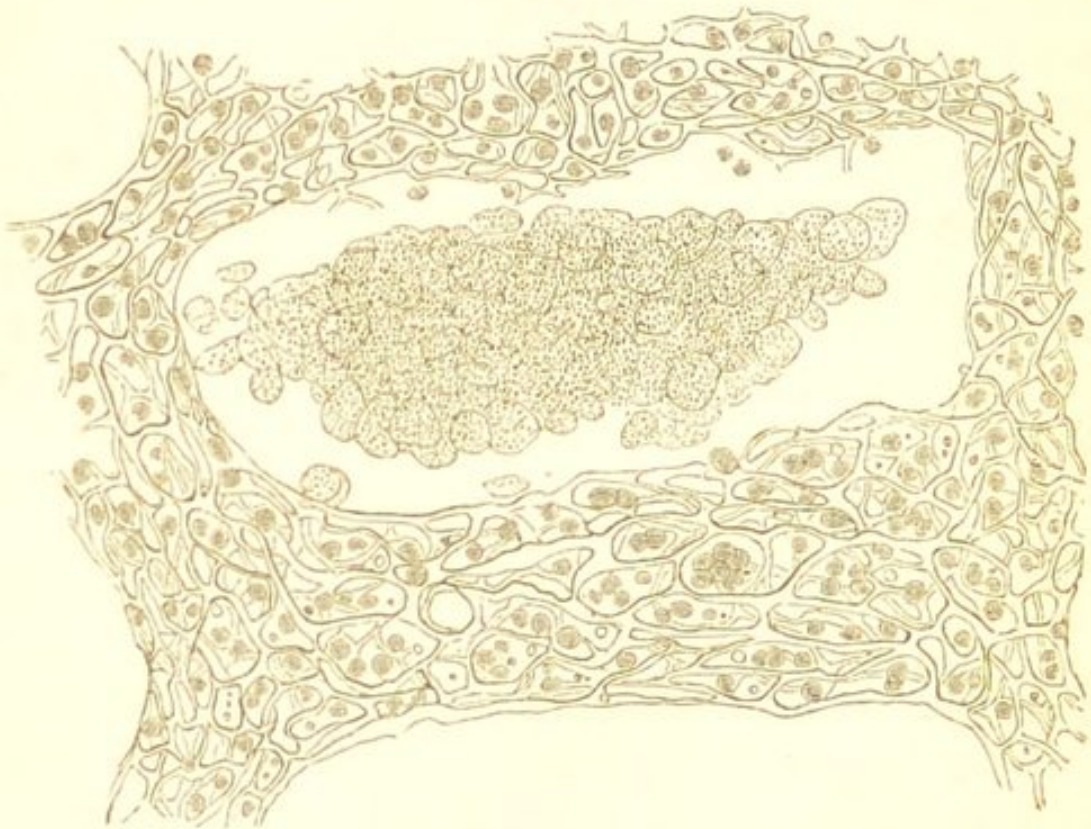times presents a somewhat lobulated outline, indicating the implication of different groups of the pulmonary lobules. The colour varies from a reddish to a yellowish-grey, and scattered through the consolidated mass are often small portions of a more decidedly yellow tint. These latter correspond with those parts in which the retrogressive changes are the most advanced, and they are even softer in consistence than the surrounding tissue. In many parts the consolidated tissue will be found broken down, so as to form cavities of various sizes. These always possess irregular walls, which are quite soft and friable like the solid tissue which surrounds them.

2nd. *The presence within the alveoli of a fibrinous exudation and leucocytes*, is less frequent than the preceding. The exudation products are similar to those which fill the alveoli in ordinary croupous pneumonia. (See Fig. 94.) The coagulum, however, is usually not so abundant, neither is the fibrillation quite so distinct. In the most acute forms of phthisis this may constitute almost the only cause of the pulmonary consolidation, but more commonly it is associated with more or less epithelial proliferation. The macroscopical characters of the lungs are precisely similar to those of red and grey hepatisation (see "Croupous Pneumonia"), from which the consolidation differs merely in the fact that it undergoes disintegration, and so gives rise to the formation of cavities.

3rd. *A thickening of the alveolar walls by a small-celled tissue, together with, in most cases, the growth of a similar tissue around the terminal bronchioles*, is very constantly associated with the former intra-alveolar changes. The characters of this new tissue present every variation from an adenoid growth composed almost entirely of small lymphoid elements, such as is represented in Fig. 66 *a*, to one in which the reticulum of this growth is much denser—as seen in Figs. 55 and 66 *b*—

and many of the cells are more or less distinctly branched or spindle-shaped. These variations correspond with differences in the age of the new growth and in the rapidity of its development. In many parts the alveolar cavities may be found completely obliterated and replaced by this new tissue, whilst in others, where the change is less advanced, their walls will be seen to be more or less thickened by it, and their cavities to be filled with partially

FIG. 103.



Section of Lung from a case of somewhat Chronic Phthisis. Showing the thickening of the alveolar walls by a small-celled adenoid tissue which is becoming fibroid, together with an accumulation of epithelial cells within the alveolar cavity which are undergoing retrogressive changes. $\times 200$.

or completely degenerated epithelial elements (Fig. 103), or with giant and branched cells. (See Figs. 64 and 56.) Although the new growth appears in many places to be undergoing a process of progressive development, in others it is equally evident that it is undergoing retrogressive changes, and the granular débris into which it has become converted is often seen associated with the

degenerated epithelial elements, the two together producing tracts of softened, yellowish, caseous material.

The development of this new growth in the alveolar walls leads to the partial, or even complete, obliteration of the pulmonary capillaries, which, as will be seen subsequently, constitutes an important element in the causation of the retrograde changes. This vascular obstruction is also partly due to proliferation of the nuclei in the walls of the capillaries (Wilson Fox).

Respecting the alteration which the growth of this small-celled tissue produces in the physical characters of the lungs—it may be stated generally, that it usually leads to more or less induration of the pulmonary texture. The extent of this induration, however, will vary with that of the fibrillation of the new tissue. If the tissue be almost entirely cellular, such as is the case when it is very rapidly developed, it will produce but little if any induration of the pulmonary consolidation, which, consisting mainly of the alveolar catarrhal products, will be soft and friable in consistence, much resembling that which has been already described. When, on the other hand, as is more frequently the case, there is any marked fibrillation of the new growth, or its reticulum is dense and abundant, there will be a corresponding induration of the consolidated tissue. In many cases these changes produce uniform tracts of indurated consolidation of a greyish colour mottled with black pigment, in which there may be scattered here and there yellowish patches corresponding to those portions which have undergone retrogressive fatty changes.

4th. The remaining structural change which is met with, to a greater or less extent, in most cases of pulmonary phthisis, consists in *an increase in the interlobular connective tissue*. This tissue, which surrounds the bronchi and blood-vessels and contributes to the formation of the alveoli, is found not only increased in amount, but also

altered in character. It is usually richly cellular, and in the various stages of its growth it presents all the variations met with in connective tissue which is the seat of a chronic inflammatory process. (See Fig. 72.) It often exhibits, in some parts, a distinctly reticulated structure precisely similar to that of the adenoid growth in the alveolar walls (see Fig. 103), but it has a much greater tendency to form a dense fibroid tissue than has the alveolar growth, and it is much less frequently the seat of retrograde change. This is owing to its more perfect vascular supply. In the most chronic cases of phthisis this interlobular growth may constitute the predominant structural change, and large tracts of the pulmonary texture may be found completely replaced by it. (See "Interstitial Pneumonia.")

An increase in the interlobular connective tissue in phthisis—inasmuch as the new tissue has so marked a tendency to become dense and fibroid—leads to extensive induration of the pulmonary texture; and further, owing to the contraction which the tissue tends to undergo, its growth ultimately produces a corresponding contraction of the diseased lung. In all those cases of phthisis in which there is either a thickening of the alveolar walls or an increase in the interlobular connective tissue, any cavities which may exist in the consolidated and indurated tissue are characterised by the tough and fibroid character of their walls, these presenting a marked contrast to the soft friable tissue which surrounds the cavities in those cases in which the pulmonary consolidation is mainly due to intra-alveolar growth.

These various changes may involve wide tracts of the pulmonary tissue, or they may be limited to small circumscribed areas. The causes of these differences in their distribution will be seen when considering the nature and etiology of the morbid processes to the existence of which they owe their origin.

PATHOLOGY OF PHTHISIS.—Having thus briefly described the various structural changes met with in the lungs in phthisis, it remains to consider the nature of the morbid processes upon which they depend. In the first place it is evident that these changes are analogous to those which have been seen to occur in the several forms of pulmonary inflammation. The fibrinous exudation and leucocytes, and the accumulation of epithelial cells within the alveoli in croupous and catarrhal pneumonia, with, in the more chronic cases, the ultimate thickening of the alveolar walls; and the increase in the interlobular connective tissue which characterises the interstitial process, closely resemble the phthisical lesions. These considerations, together with those derived from the study of the etiology of the disease, are sufficient to justify the conclusion that the morbid processes which lead to the consolidation and subsequent disintegration of the lung come within the category of *inflammation*, and that the differences in the anatomical changes to which they give rise are due to differences in the intensity, in the duration, and in the mode of origin of the inflammatory process.

In considering the causes of these differences in the histological changes in the lungs, it is important to bear in mind what has been already stated respecting the variations in the character of the textural alterations in inflammation which are produced by differences in the intensity and duration of the inflammatory process. (See "Varieties of Inflammation.") When studying the process of inflammation, it was seen that the most intense forms of the process were characterised by abundant fibrinous exudation and emigration; whereas in inflammations of less intensity, the textural changes played a more prominent part. These textural changes also varied according to the intensity of the inflammation. In the least severe and most chronic forms, these changes tended to be limited to the elements immediately adjacent to the

blood-vessels and lymphatics, whereas in inflammations of somewhat greater intensity more distinct elements became involved. Further, whereas in the former case these changes usually resulted in the formation of a small-celled tissue which tended to become fibroid, in the latter, the more distant elements—being in most cases incapable of further development—tended to undergo retrogressive changes. In the lungs, the truth of these propositions was borne out by the differences which were seen to exist in the histological characters of the lesions in the various forms of pulmonary inflammation and also in acute tuberculosis. In the tuberculous process it appeared to be probable that the more severe the irritation of the infective particles the more liable were they to cause a proliferation of the large epithelial cells contained within the alveoli, whereas when the irritation was less severe, its influence tended to be limited to the elements in the alveolar walls and interlobular tissue. (See “Tuberculosis of the Lungs.”)

If the pathology of these inflammatory processes in the lungs be kept in view, the explanation of the differences in the histological characters of the lesions in pulmonary phthisis becomes tolerably evident. In those cases in which the inflammatory processes are of slight intensity and of long duration, the most marked structural change will consist in the development of a small-celled growth in the alveolar walls and in the interlobular tissue—a growth which tends, more or less, to become developed into a fibroid structure; whereas in those cases in which the inflammation is of greater intensity fibrinous exudation and emigration, and proliferation of the alveolar epithelium, will constitute more prominent parts of the process.

The intensity of the inflammatory process not only determines to a great extent the histological characters of the pulmonary consolidation, but also the subsequent

changes which take place in it. These changes are of three kinds—resolution, development into a fibroid tissue, and retrograde metamorphosis. Much of that consolidation of the lung which is the most rapidly induced, and which is consequently intra-alveolar, may become absorbed. The resolution may be complete, or after the absorption of the intra-alveolar products there may remain more or less small-celled growth in the alveolar walls.

Fibroid development takes place principally in the new interlobular growth, to a less extent in the growth in the alveolar walls, and probably sometimes from intra-alveolar exudation. (See Fig. 100.)

In those cases in which the intensity of the inflammatory process is considerable, not only do the epithelium and exudation-products which have accumulated within the alveoli quickly degenerate and break down, but any small-celled tissue which may have been developed in the alveolar walls or around the terminal bronchioles also softens and dies, and thus the vitality of large tracts of the pulmonary consolidation may become destroyed.

This death and disintegration of the pulmonary consolidation which constitutes so essential a feature of the disease, is in great measure due to conditions interfering with the pulmonary circulation. This interference not only causes the destruction, but also prevents that absorption of the inflammatory products which usually occurs in non-phthisical pulmonary consolidation.

The circulation is interfered with by the adenoid growth in the alveolar walls, by the pressure exercised upon the pulmonary capillaries by the inflammatory products which have accumulated within the alveoli, and probably also, in the most acute forms of phthisis, by that stagnation of the blood-stream which results from every acute inflammatory process. In addition to this interference with the pulmonary circulation, an important element in the

causation of the retrograde changes of phthisis is probably that inherent weakness of the lungs (usually inherited), which not only renders them especially susceptible to injury, but also, when injured, renders them abnormally incapable of recovering themselves from the inflammatory process which has been induced.

In those cases of phthisis, on the other hand, in which the inflammatory process is less severe, the small-celled tissue produced in the alveolar walls and around the terminal bronchioles has a greater tendency to become developed into a more or less fibrillated structure, and the more chronic the course of the disease the greater is this tendency. The new growth in the interlobular tissue, inasmuch as its vascular supply is but little interfered with, almost invariably becomes indurated and fibroid. It is these two kinds of change in the newly formed elements, the one tending towards death and the other towards progressive development, which produce the caseation and softening on the one hand, and the induration on the other, which associated in such various degrees, make up the diverse physical characters of the phthisical lung.

In studying the *etiology* of the inflammatory processes which give rise to pulmonary phthisis, it becomes evident that two different agencies are principally concerned. These are *predisposition* and *irritation*.

By *predisposition* I mean that inherent weakness of the lungs which exists in such a large proportion of the cases of phthisis, and which not only renders them abnormally susceptible to the various kinds of injurious irritation, but also makes them less capable than strong lungs of recovering themselves from the effects of the inflammatory process which the irritation has produced.

By *irritation* is to be understood that injury to the lungs by means of which the inflammatory processes in them are induced. Inflammatory processes may be in-

duced in the lungs by that general chilling of the surface of the body which constitutes what is termed "taking cold." Which organ suffers as the result of the chill often appears to depend in great measure upon predisposition (inherited or acquired). If the lungs are the weak organs, as they so often are in phthisis, they are the most liable to become inflamed. In other cases the pneumonic process appears to be due to altered conditions of the blood, such as are associated with Bright's disease, &c.

A more important agent in the production of phthisis than the preceding is the irritation of the lungs through the medium of the bronchi. The bronchial mucous membrane, communicating as it does with the external air, is especially liable to injury, and the extreme frequency with which the development of phthisis is preceded by successive attacks of bronchial catarrh is a well-established clinical fact, the important bearing of which upon the successful treatment of the disease it would be difficult to over-estimate. That catarrhal processes in the smaller bronchi are often followed or accompanied by inflammatory changes in the pulmonary alveoli was seen when studying the pathology of catarrhal pneumonia. In explaining these changes, however, it must be borne in mind that although the thickening of the alveolar walls is in part the result of the primary irritation, the presence of the degenerated catarrhal products within the alveolar cavities must also produce an injurious effect, and so may be an additional cause of the alveolar growth. These catarrhal processes in the bronchi which are such frequent precursors of the pulmonary consolidation, also give rise to a gradual thickening of the bronchial mucous membrane, to an increase in the peri-bronchial connective tissue, and often to more or less ulceration and irregular contraction and dilatation of the tubes. In other cases the injury appears to exercise its influence directly upon the inner surface of the air-vesicles without producing

bronchial catarrh. The inflammatory processes which are set up by means of injuries inflicted through the medium of the bronchi are characterised by the disseminated character of their distribution. Groups of air-vesicles communicating with the terminal bronchioles become implicated, and thus are produced lobular lesions.

The last method by which injuries may be inflicted upon the lungs is by means of *infection*. This infection is precisely similar to that which has been already described as causing general tuberculosis. By it is understood the property possessed by certain inflammatory products—especially by those which have become caseous—of inducing secondary inflammatory processes in other parts. Limited tuberculosis differs from the general disease only in the extent to which the infective materials are distributed. Whereas in the general affection the dissemination of the infective substances takes place principally by means of the blood-vessels, in the more limited processes the dissemination is effected by means of the lymphatic vessels or serous canals. In the lungs, limited infective processes are exceedingly common in phthisis, and they give rise to many of the miliary nodules of induration which are so frequently met with in phthisical lungs. The source of infection in these cases is usually some caseous induration already existing in the lung, so that the infective process usually supervenes upon pre-existing phthisis.

There remains still one other factor which has a most important influence upon the causation of phthisis—the *general health of the individual*. That the development and progress of phthisis is greatly influenced by the state of the general health is well known. That this should be so will be readily understood if the inflammatory nature of the disease be kept in view, inasmuch as, in all cases, the susceptibility of a living tissue to injury is, *cæteris paribus*, greater, and the power of recovering itself from

the effect of the inflammation less, the lower the standard of the general health.

In conclusion, allusion must be made to the different varieties of pulmonary phthisis. Although the variations observed in the physical characters of phthisical lungs and also in the clinical history of the disease, have led to its subdivision into different kinds, it appears to me that there are no pathological grounds for any such subdivision. The variations observed in the clinical history of phthisis and in the physical characters of phthisical lungs are, I think, mainly to be ascribed to variations in the duration and intensity of the inflammatory processes which give rise to the pulmonary consolidation, and also to the parts which primary pulmonary inflammation, bronchial inflammation, and infection play respectively in the causation of the disease.

CHAPTER XLII.

CHANGES IN THE BLOOD AND CIRCULATION.

HYPERÆMIA.

HYPERÆMIA or congestion is excess of blood in the more or less dilated vessels of a part. Whatever increases the pressure of the blood, or diminishes the resistance of the vessels, may be a cause of hyperæmia. Hyperæmia is *active* or *arterial*, and *mechanical* or *venous*. These two varieties must be considered separately.

ACTIVE HYPERÆMIA.

Active hyperæmia is an excess of blood in the arteries of a part, with, in most cases, an acceleration of the flow.

CAUSES.—The causes of active hyperæmia may be divided into those which increase blood-pressure, and those which diminish arterial resistance.

1. *Increased Blood-pressure*.—This occurs most commonly from interruption of the main current of blood in any particular part, owing to which increased pressure is thrown upon the collateral vessels. These vessels thus become dilated, the amount of blood in them is increased, and the flow is accelerated. This, which is known as *collateral hyperæmia*, is seen after the obstruction of the main current from any cause, as from the ligature of the vessel, or from its occlusion by a thrombus or embolus. (See “*Embolism*.”)

General obstruction in the capillaries of a part will in the same way cause a compensatory hyperæmia. This is exemplified by the application of external cold causing contraction of the superficial capillaries and congestion of internal organs; and by obstruction of the capillaries in one part of an organ causing hyperæmia of the parts adjacent.

2. *Diminished Arterial Resistance.*—This is much the most frequent cause of active hyperæmia. It may arise from—

a. *Relaxation or paralysis of the wall of the vessel.*—The relaxation of the muscular coat of an artery and the consequent dilatation of the vessel, may be owing to, 1st, the direct paralysis of the vaso-motor nerve supplying it; 2nd, to its indirect paralysis from irritation of a sensory nerve; and 3rd, to changes in the walls of the vessel resulting from injury independently of the nervous centres. The effects of direct paralysis of the vaso-motor nerves are seen in the active congestion of the head and neck which follows pressure upon the sympathetic in the neck, as by an aneurism; and in the unilateral congestion which results from experimental sections or disease of one-half of the spinal cord. Some emotional conditions also are attended by paralysis of the vascular nerves and consequently by active hyperæmia: this is seen in blushing. Certain substances again taken internally produce vaso-motor paralysis, as the nitrite of amyl, alcohol, tobacco, &c.

Relaxation and dilatation of the arteries resulting from irritation of a sensory nerve in those parts in which the nerve originates, and from the direct injury of the walls of the vessel independently of the nervous system, has already been described when speaking of vascular dilatation as the earliest change in the process of inflammation. In inflammation, the irritation is so severe as to cause not only dilatation of the vessel and accelerated blood-flow, but also a subsequent retardation of the circulation

and exudation of liquor sanguinis and blood-corpuscles. (See "Inflammation.") If the irritation be less intense or less prolonged in its action it produces simply dilatation of the vessels and increased rapidity of flow—*i.e.*, active hyperæmia. This is seen in the congestion of the skin which results from friction, heat, and many irritating substances; in the priapism that sometimes results from the passage of a catheter; and in many similar conditions.

β. Sudden removal of external pressure.—The sudden removal of external pressure from vessels is followed by their dilatation, and consequently by hyperæmia. As examples of hyperæmia from this cause may be mentioned that which results from dry cupping, and from the sudden removal of ascitic fluid, and of the fluid from a hydrocele.

γ. Atony of the walls of the vessels from mal-nutrition.—This is a much less important cause of hyperæmia. Fatty degeneration of the muscular and internal coats of the smaller arteries may, however, in some cases lead to their dilatation, and thus be a cause of active hyperæmia.

RESULTS.—The results of active hyperæmia are principally such as might be expected to follow from an increase in the amount of the arterial blood, and in the rapidity of its flow, in any particular organ or tissue. There is increased redness and pulsation, a sensation of throbbing being often experienced by the patient. There is also an increase in bulk. The temperature at the same time undergoes a marked elevation. Serous effusions, hæmorrhage, and thrombosis—so common as results of mechanical hyperæmia—are rarely met with. If the hyperæmia be of long duration, the small arteries become permanently enlarged, and their walls thickened. Function may, or may not, be interfered with. It is in the nervous centres that functional changes are most frequently met with. They include great excitability, paræsthesiæ of sight and hearing, convulsions, &c.

MECHANICAL HYPERÆMIA.

In mechanical hyperæmia, the excess of blood is principally in the veins, and the flow, instead of being accelerated, is retarded.

CAUSES.—The causes of mechanical hyperæmia are such as interfere with the return of the blood by the veins, either by directly impeding its exit from any vein or system of veins, or by diminishing the normal circulating forces. They are—

1. *A direct Impediment to the Return of Blood by the Veins.*—This is the most fertile cause of mechanical hyperæmia. Any obstruction to the return of blood by the veins is followed by distension and impeded flow behind the obstruction. The congestion of some of the abdominal viscera which results from the obstruction to the portal circulation in cirrhosis of the liver; that of the lung in mitral constriction and regurgitation; that of the systemic circulation in insufficiency of the tricuspid valve; and that of the lower extremities from the pressure of the gravid uterus on the iliac veins, are a few of the numerous familiar examples of mechanical hyperæmia from this cause.

2. *Gravitation.*—This becomes an important auxiliary in the production of hyperæmia in disease, especially when it is associated with diminished cardiac power. The effect of gravitation in determining congestion of the most dependent parts is exemplified in chronic exhaustive and in many of the acute febrile diseases, in which the nutrition generally becomes impaired, the heart's power weakened, and in which the patient is unable frequently to change his position. The integuments of the back, and the posterior portions of the lungs, are the parts which are thus most frequently affected.

3. *Increased Local Resistance.*—This results from dis-

eased conditions of the arterial walls, owing to which they either lose their elasticity and contractility and thus their power of equalising and regulating the blood-flow, or become considerably enlarged. In either case the circulation will be impeded, and accumulation of blood and retardation of flow take place in the veins beyond. Such conditions may arise from simple atony of the arterial walls, or from atheromatous, fatty, or calcareous changes. They are most common in advanced life. The part they play in the production of senile gangrene has been already alluded to. (See "Senile Gangrene.")

4. *Diminished Cardiac Power.*—This is one of the most important causes of mechanical hyperæmia, especially when it is associated with any of the preceding ones. The motor power of the heart becomes impaired in many of the chronic exhausting diseases, also in the acute febrile diseases, as in typhus and typhoid fever, and in all those conditions of degeneration and softening of its structure which lead to the dilatation of its cavities. In whichever of these ways the *vis a tergo* is diminished it will tend to produce venous hyperæmia.

RESULTS.—Long continued mechanical hyperæmia leads to impairment of vitality and function. The tissues gradually atrophy and undergo retrogressive changes, although from the amount of serosity and blood which they contain their size and absolute weight may be increased. Their temperature becomes lowered. The most important results, however, of this variety of hyperæmia are *fibroid induration, transudation of serum, hæmorrhage, thrombosis, and gangrene.*

1. *Fibroid Induration.*—This, which is due to a gradual increase in the connective tissue around the blood-vessels, is one of the most important results of long continued mechanical hyperæmia. The interstitial growth leads to atrophy of the other structures, and thus to impairment of the functions of the organ. In the stomach, it produces

atrophy of the glandular structures; in the kidney, compression of the urine-tubes; in the liver, obstruction to the portal circulation; in the heart, diminution in motor power. The alterations which this change produces in the physical characters of the organs—viz., a hardness and induration associated with abnormal redness or pigmentation due to the excess of blood, are exceedingly characteristic.

2. *Transudation of Serum.*—This gives rise to œdema and dropsical effusions. Its occurrence is greatly favoured by the stretching of the walls of the vessels, and by the damage which their structure sustains. The transuded serum usually differs from blood-serum in being of lower specific gravity, and in containing more water and less of the solid constituents. The greater the pressure, the more nearly does the transuded liquid resemble the liquor sanguinis, and the greater is the amount of albumen which it contains. If the pressure be very great it may yield a fibrinous coagulum.

3. *Hæmorrhage.*—This is another result of mechanical hyperæmia. It usually occurs only when the obstruction to the venous current is very great. Those vessels which are the least supported are the first to give way. The hæmorrhage into the stomach in cirrhosis of the liver, and into the lung in mitral disease, are familiar examples of hæmorrhage from this cause.

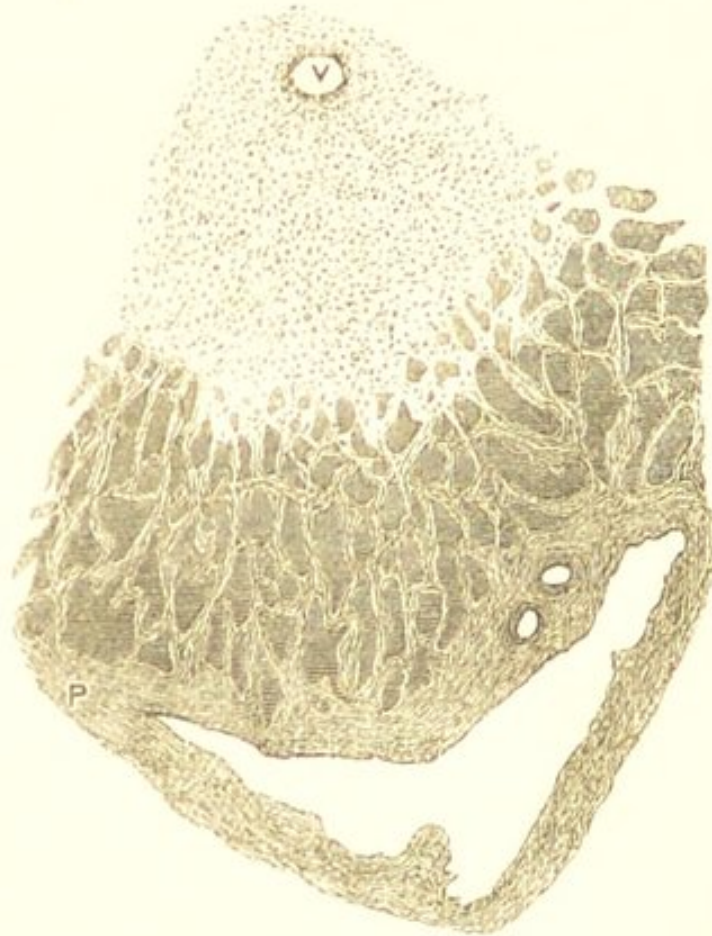Not only does blood escape from the vessels by rupture of their walls in mechanical hyperæmia, but the red blood-corpuscles pass through the walls of the capillaries into the surrounding tissues without rupture taking place. This passage of the red corpuscles through the capillary walls, which was discovered by Cohnheim, may be observed in the web of the frog's foot after ligature of the femoral vein. The corpuscles in passing through the vessel become constricted in their centre, so as to assume an hour-glass shape. This emigration only occurs when the obstruction is considerable.

4. *Thrombosis*.—This, as a result of mechanical obstruction, will be described in the following chapter.

5. *Gangrene*.—This only occurs from mechanical hyperæmia when the obstruction is very general and complete. It has been already described under the head of “Gangrene.”

MECHANICAL HYPERÆMIA OF THE LIVER—NUTMEG LIVER.—Long-continued mechanical hyperæmia of the

FIG. 104.



Nutmeg Liver. Showing the destruction of the liver-cells and the pigmentation in the central portions of the acinus, together with the new growth of connective tissue at the periphery. V. Hepatic vein. P. Portal canal. $\times 50$. (When this specimen is more highly magnified, the central hepatic vein and its tributaries are seen to be filled with red blood-corpuses, and their walls thickened. The intercellular network which immediately surrounds it is also thickened, and the peripheral connective tissue growth contains numerous nuclei.)

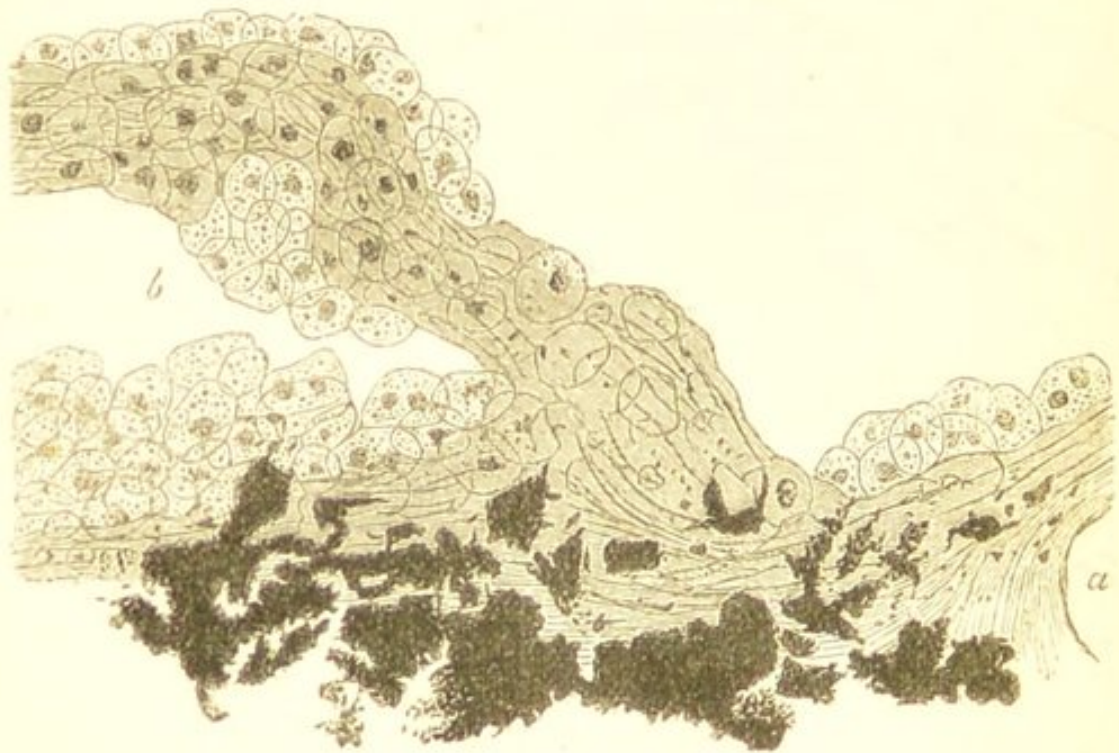
liver gives rise to the condition known as *Nutmeg Liver*. This is the condition which so frequently results from disease of the heart. The change is characterised by a large accumulation of blood in the hepatic veins, by dilatation and thickening of these veins, by atrophy of the hepatic cells in the central portions of the acini, and by an increase in the interlobular connective tissue. The impediment to the return of blood by the hepatic vein leads to atrophy of the cells in the central portions of the acini and also to the formation of granular pigment, so that when examined microscopically, these portions of the acini are seen to consist of broken-down cells and granules of pigment. (Fig. 104.) The veins here are found much dilated and filled with red blood-corpuscles. Their walls are thickened, and there often appears to be also more or less thickening of the intercellular network which immediately surrounds the central vein. Owing to this thickening of the central veins and of the adjacent intercellular network, and to the destruction of the liver-cells, the most central portions of the acini, in advanced stages of the disease, may present a very fibrous appearance. At the peripheral parts of the acini the new interlobular growth is seen insinuating itself between the almost unaltered liver cells. This new interlobular growth is usually distinctly nucleated, but for the most part, less so than that met with in cirrhosis. Its cellular character has been especially insisted upon by Dr. Wickham Legg.

In the earlier stages of this affection the liver is often considerably increased in size from the large amount of blood which it contains. On section, it presents a peculiar mottled appearance, the centre of the lobules being of a dark red colour, whilst the peripheral portions are of a yellowish-white. This latter appearance is often increased by the presence of more or less fat in the peripheral liver-cells. Ultimately the organ may undergo a

gradual diminution in size. This is due partly to the atrophy of the cells in the central portions of the lobule, and partly to the pressure of the interlobular growth. The interlobular growth tends to cause obstruction to the portal circulation, as in cirrhosis.

MECHANICAL HYPERÆMIA OF THE LUNGS.—In the lungs long-continued mechanical hyperæmia produces that peculiar induration and pigmentation of the organs

FIG. 105.



Brown Induration of the Lung. Showing the abnormal number of swollen pigmented epithelial cells covering the alveolar walls, the increase of connective tissue around the blood-vessel, *a*, and the large quantity of pigment. *b*. The alveolar cavity. $\times 200$.

which is known as *Brown Induration*. This condition most frequently results from stenosis and insufficiency of the mitral orifice. The alterations produced in the pulmonary texture consist in the first place of elongation and dilatation of the pulmonary capillaries, so that even in uninjected preparations the alveolar walls appear abnormally tortuous. The epithelial cells lining the alveoli also become swollen and ultimately multiply, and they

are seen in large numbers, filled with dark brown pigment, covering the alveolar walls. (Fig. 105.) They frequently accumulate within, and fill, the alveolar cavities. These changes are followed by an increase in the interlobular connective tissue, by the formation of large quantities of brownish-black pigment, and often by a thickening of the alveolar walls.

Lungs in which these changes are at all advanced present a more or less uniform brownish-red tint, mottled with brown or blackish-coloured specks and streaks. They are heavier and tougher than natural, less crepitant, and upon squeezing them the pulmonary tissue is found to be denser and thicker than that of a healthy lung.

POST-MORTEM APPEARANCES OF HYPERÆMIA.—The post-mortem appearances presented by hyperæmic organs and tissues vary considerably. Very frequently parts which were hyperæmic during life show no signs of it after death. If the blood does not coagulate rapidly it passes on into the veins, and thus the recognition of arterial and capillary hyperæmia very often becomes impossible. The effect of gravitation must also be taken into account in estimating hyperæmia. After death the blood naturally gravitates to the most dependent parts:—this is seen in the post-mortem congestion of the posterior portions of the lungs, and of the most dependent portions of the various coils of the intestine. The uniform redness of post-mortem staining again, must not be confounded with the redness of hyperæmia. In capillary and arterial hyperæmia, the colour is red, and the injection often presents the appearance of a capilliform network. If very intense it may to the naked eye appear uniform, but a lens will always discover its capillary nature. When the veins are the seat of the hyperæmia the injection is called ramiform, and the colour is dark blue.

The anatomical peculiarities in the distribution of the blood-vessels will, however, materially affect the appearance of the hyperæmia. In the intestines it is often punctiform, being situated in the vessels of the villi; so also in the kidney, when its seat is the Malpighian corpuscles. A punctiform appearance may also be produced by minute extravasations of blood. If the hyperæmia is of long-standing, the tissue becomes pigmented. This is often well seen in the stomach and intestines, also in the lungs.

CHAPTER XLIII.

THROMBOSIS.

THROMBOSIS is a coagulation of the blood within the vessels during life. This coagulation is owing to changes in the walls of the vessel itself, or to impeded blood-flow. The coagulum is called a *thrombus*. It may form in the heart, in the arteries, in the capillaries, or in the veins. It is much the most common in the last-named vessels.

Thrombi must be distinguished from the coagula that form after death, and also from those formed in the last moments of life which are so commonly found in the cardiac cavities. Post-mortem coagula are soft, and are often divisible into two layers, coloured and uncoloured; they do not adhere to the walls of the vessel, and rarely completely fill its cavity. The clots formed in the heart just before death constitute a connecting link between post-mortem coagula and thrombi. They are more or less decolorised, and are firmer in consistence and more fibrinous than post-mortem clots. They are not firmly adherent to the cardiac walls, but are often so entangled amongst the *columnæ carneæ*, *chordæ tendineæ*, and papillary muscles, that they cannot be quite readily separated. They appear to be the result of the mechanical defibrination of the blood by the cardiac contractions a little while before death; the contractions not being sufficiently strong to empty the cavities, some of the blood remains behind, and becomes "whipped up" and defibrinated. These clots are most common in the right

cardiac cavities, and they often extend some way into the pulmonary artery and aorta, from which, however, they can very readily be removed. They are met with most frequently in those cases in which death has taken place slowly, and in which there has been a gradual loss of power in the cardiac contractions. The proportion of fibrinogenous substance in the blood will also materially influence the extent of their formation.

A *thrombus*, or ante-mortem clot, is firmer, dryer, and more fibrinous than either of the preceding, and it is adherent to the walls of the vessel. Its characters, however, vary with its age, and with the circumstances under which it originates. When freshly-formed it is of a dark-red colour and soft gelatinous consistence, closely resembling the post-mortem clot. It gradually becomes paler, dryer, less elastic, and more friable. If it is rapidly produced—as when the circulation is suddenly arrested in a portion of a vessel by the application of a ligature—the coagulum at once completely fills the vessel, and as it becomes firmer it maintains a more or less uniform structure. Thrombi, however, which have undergone a slow and gradual formation, are rarely thus uniform in structure, but are made up of numerous concentric layers, and so present a stratified appearance. This is owing to the coagulation taking place gradually upon the inner surface of the vessel, and to the white corpuscles adhering to the successive layers of coagulum. These corpuscles, from the property which characterises them of adhering to one another and to the sides of the vessels, and especially to any porous substances with which they may come in contact, cohere with the fibrinous layers as they are deposited; so that ultimately the thrombus is made up of layers of fibrinous coagulum and white corpuscles more or less alternately and concentrically arranged. This gives to it a stratified appearance.

The thrombus may completely or only partially fill the

cavity of the vessel. In most cases, however, when coagulation has commenced, it proceeds until the vessel is obstructed, and when once this has occurred, the formation of the thrombus continues to extend in the course of the vessel until it meets with a current of blood strong enough to arrest its progress. Its ultimate extent will thus mainly depend upon the vessel in which it is formed, upon the size and situation of the collateral branches, and upon the force of the circulating current. The direction in which the coagulation principally extends, whether in the arteries or veins, is consequently backwards from vessels of smaller to those of larger calibre; the formation of the thrombus continuing until it meets with a current sufficiently strong to restore the circulation, which in many cases is as far as the entrance of the next large collateral vessel. The end of the thrombus next the heart is rounded and conical in shape. (See Fig. 108, c.)

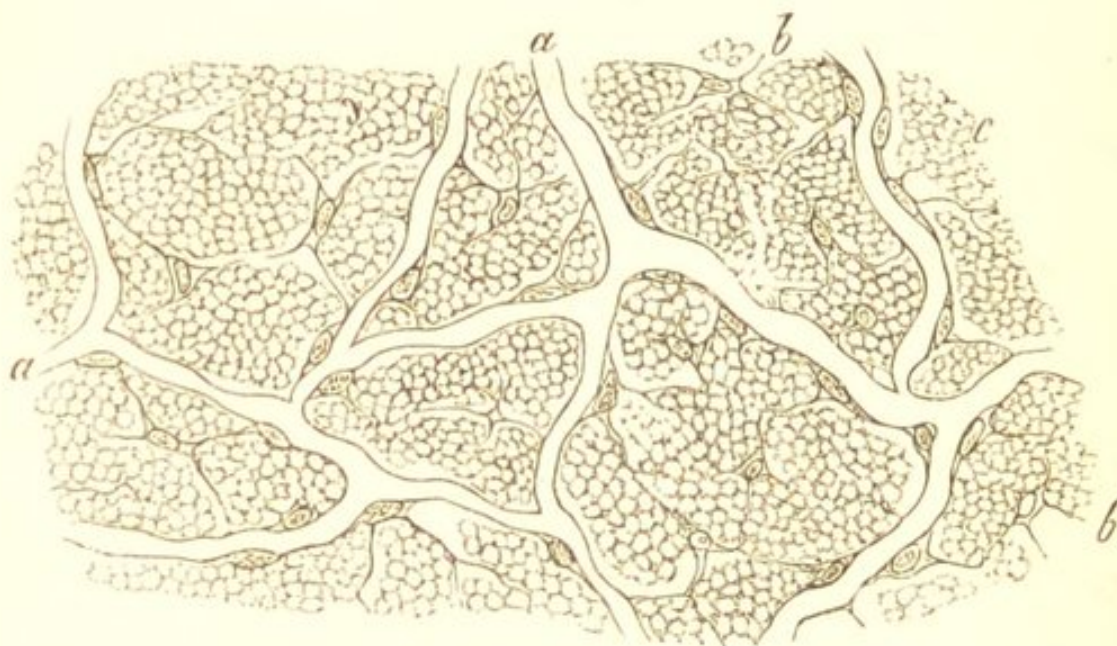
The thrombus when once formed either becomes *organised* or *softens*. The former is most frequent in the arteries, the latter in the veins and heart.

Organisation.—This consists in the gradual transformation of the thrombus into connective tissue. A thrombus which is undergoing a process of organisation gradually diminishes in size, it becomes more and more decolorised, firmer and more fibrous in consistence, its union with the wall of the vessel becomes more intimate, and ultimately it becomes converted into a fibro-cellular cord. These changes are probably principally owing to the white blood-corpuscles which it contains.

Soon after the formation of the thrombus the number of young cells in it becomes greatly increased. In a somewhat more advanced stage the red blood-corpuscles almost entirely disappear, the clot becomes firm and homogeneous, and in addition to the small round elements, numerous anastomosing spindle-shaped cells

with oval nuclei make their appearance. (Fig. 106.) The intercellular material then becomes fibrillated, the walls of the vessel become infiltrated with cells, and numerous new blood-vessels are formed which intersect the thrombus in all directions. These vessels communicate with the cavity of the thrombosed vessel, and with its vasa vasorum. (Fig. 107.) The vascular fibrillated structure

FIG. 106.



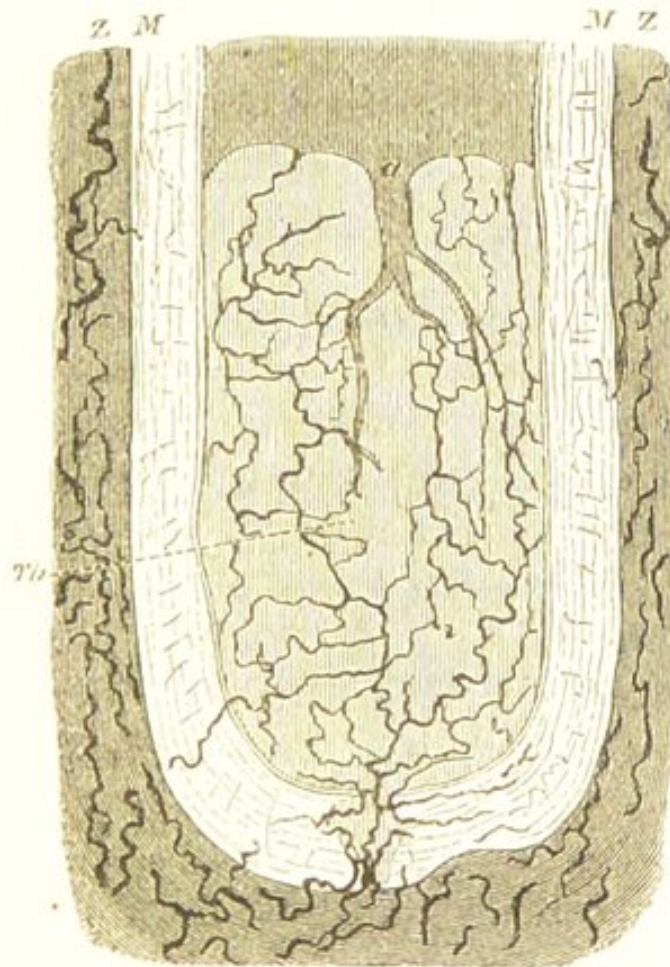
Section of an Arterial Thrombus Thirty-seven Days Old.
a. New blood-vessels. *b.* Leucocytes and anastomosing cells. (Rindfleisch.)

into which the thrombus has become organised gradually undergoes a process of atrophy and contraction, the new vessels disappear, and ultimately it becomes converted into a fibro-cellular cord. In some cases it becomes calcified, and thus forms a phlebolith.

Respecting the source from which the large number of new cells which make their appearance in the thrombus are derived—it appears to be most probable that they originate mainly from the white blood-corpuscles, and partly from the endothelial and connective-tissue cells belonging to the walls of the vessel. Whether, however, they are all of them the offspring of these elements, or

whether some of them may not be leucocytes which have penetrated from without, is unknown. From these small cells the elongated connective tissue-cells are produced. The exact source from which the fibrillated intercellular material is derived—whether the intercellular coagulum itself fibrillates, or whether it disappears and the fibres are derived from the protoplasm of the cells—is uncertain.

FIG. 107.



Longitudinal Section of the Ligatured End of the Crural Artery of a Dog, fifty Days after the Application of the Ligature. Showing the newly-formed vessels in the thrombus and their communication with the vasa vasorum. Th. Thrombus. M. Muscular coat. Z. External coat and vasa vasorum. × 20. (O. Weber.)

Softening.—If the thrombus does not become organised, it usually undergoes a process of softening and liquefaction:—this is most common in the veins and heart. It is probable also that in some cases the thrombus may

become absorbed. The softening most frequently commences in the centre of the clot, and gradually extends towards the circumference. The thrombus breaks down into a soft pulpy material, which sometimes has the appearance of pounded cooked meat, and in other cases is distinctly puriform in character. Under the microscope it is seen to consist of albuminous granules, molecular fat, and more or less altered red and white blood-corpuscles. These changes in the clot are frequently owing simply to its disintegration, but in some cases it is probable that the thrombus may suppurate, and that owing to the proliferation of the white blood-corpuscles which it contains it becomes converted into true pus. The whole of the thrombus may thus become softened, or the process may be limited to the more central portions, whilst the external layers become organised. Very frequently as the older portions of the clot are becoming disintegrated and softened, fresh coagulation takes place at its extremities.

CAUSES.—The causes of thrombosis are of two kinds—those which lead to a retardation of the blood-flow, and those in which there is some abnormal condition of the walls of the vessels or of the blood.

1. *Thrombosis from Retardation of the Blood-flow* may result from—

a. *Interruption or narrowing of the vessel.*—This occurs after the application of a ligature. Coagulation commences at the point of contact, and extends as far as the first large collateral branches, thus permanently closing the vessel. The pressure exercised by tumours, cicatricial tissue, extravasations of blood, and the closure of a vessel by the impaction of an embolus, may in the same way by impeding or arresting the circulation cause thrombosis. General obstruction in the capillaries of a part also causes coagulation in the adjacent veins.

β. *Solution of the continuity of the vessel.*—The formation of a thrombus after the division or tearing of a vessel

constitutes the means by which hæmorrhage is immediately arrested:—there must be either thrombosis or continuous hæmorrhage. In the arteries, the severed end of the vessel contracts and retracts within its sheath, coagulation commences around it and extends upwards as far as the first large collateral branch. In the veins hæmorrhage is frequently arrested by the valves, and the formation of a thrombus will evidently depend upon the relative situations of the valves and collateral vessels. The hæmorrhage from the uterus after the separation of the placenta is arrested either by uterine contraction or by thrombosis.

γ. Dilatation of the vessels, or of the heart.—The most familiar example of thrombosis from this cause is that which occurs in an aneurism. The greater the amount of dilatation the greater is the retardation of the blood-flow. The coagulation commences at the sides of the vessel, and may extend until it completely fills the cavity. Coagulation from the same cause is not uncommon in the dilated plexuses of the prostate gland. In the heart, thrombosis is most frequent in the auricles. It usually commences in the auricular appendix, where there is very little propulsive power, and it may gradually extend into the auricular cavity. It is also met with in the ventricles, commonly commencing here between the columnæ carneæ.

δ. Diminished cardiac power.—This is a common cause of thrombosis in the veins. The coagulation commences just behind the flaps of the valves, from which it gradually extends into the cavity of the vessel. This appears to be owing to the force of the current not being sufficiently strong to completely open the valves, and the blood consequently stagnates and coagulates behind them. The crural and iliac veins, the venous plexuses of the back, and the cerebral sinuses, are the situations in which thrombosis from this cause is most frequently met with. It occurs in the course of many chronic exhausting dis-

eases in which the cardiac power becomes diminished, and is especially frequent in phthisis, cancer, &c. The state of the blood, which often has an abnormal tendency to coagulate, together with the quiescent condition of the patient, materially aid in causing the coagulation.

2. *Thrombosis from Abnormal Conditions of the Vessels or of the Blood.*

a. *Causes in the vessels.*—Any abnormal condition of the walls of a vessel may be a cause of thrombosis. When the wall becomes abnormal it acts as a foreign body and the blood coagulates upon it, and it may continue to do so until the cavity of the vessel becomes filled with coagulum. Thrombi produced in this way are consequently stratified. The walls of a vessel may become altered as the result of inflammatory processes, and inflammation was formerly regarded as the main, if not the only, cause of thrombosis; hence thrombosis in veins is frequently termed “phlebitis” even at the present day. Inflammation of veins, as already stated, is certainly rare as a primary condition, although it not unfrequently results from the formation of a thrombus. When occurring primarily, inflammatory processes, both in the arteries and the veins, have their seat in the external and middle coats or in the deeper layers of the intima. They never commence in the lining membrane of the vessel: this only becomes affected secondarily. The vitality of the lining membrane becomes impaired as the result of the inflammatory process, and when this has occurred it acts as a foreign body, and thus there is a tendency for the blood to coagulate upon its surface. In other cases the lining membrane is completely destroyed, and the subjacent diseased tissues thus come into contact with the circulating blood, and in the same way cause the formation of a thrombus. Such inflammatory changes occur in the arteries, constituting the condition known as “atheroma,” which, in the smaller vessels, may be a cause of

thrombosis. In the heart they constitute endocarditis; and here also, as has been seen, coagulation may take place upon the abnormal surface of the inflammatory vegetations. (See "Endocarditis.")

The walls of a vessel may also become altered, and thus thrombosis result, from inflammation or gangrene of the tissues in which it is situated. The vitality of the vessel becomes destroyed and the blood coagulates within it; and by this means the occurrence of hæmorrhage is frequently prevented. The projection of new formations, as sarcoma, into the cavity of vessels, may in the same way cause the formation of a thrombus.

β. Causes in the blood.—The greater the tendency of the blood to coagulate the more readily will thrombosis take place. An increased tendency to coagulation appears often to be due to an excess of the fibrinogenous substance in the blood, such as exists in acute inflammatory diseases, and in the latter months of pregnancy. This tendency, however, is probably never sufficient in itself to determine the formation of a thrombus; it can hence only be regarded as a predisposing cause. It is especially in those conditions in which the circulation is impeded from diminished cardiac power, that it becomes an important agent in producing thrombosis.

RESULTS.—The results of thrombosis comprise certain changes in the walls of the vessels, more or less obstruction to the circulation, and embolism. These must be considered separately.

1. *Changes in the vessels.*—More or less alteration in the wall of the vessel is an invariable consequence of the formation of a thrombus. When the thrombus undergoes a process of organisation, it becomes, as already described, intimately united with the vascular wall. The latter in the first place becomes infiltrated with cells and considerably thickened, but ultimately, together with the thrombus, gradually atrophies. It is when the thrombus

softens and becomes disintegrated that the most important changes take place in the vessel. These changes are of an acute inflammatory nature, and appear to result from the irritating influence of the softened thrombus. They are most frequently observed in the veins, where softening is most liable to occur.

The walls of a vein within which a thrombus is softening are considerably thickened, so that the vessel more resembles an artery. The inner surface has lost its translucency, and is of a dead opaque colour. The vasa vasorum are hyperæmic. Under the microscope, the cells of the intima and of the middle and external coats are found to be considerably increased in number, and numerous leucocytes are seen infiltrating the different textures. In some cases small collections of pus are seen in the external coats. Similar changes are observed in the arteries.

In these acute inflammatory changes which are produced in veins by thrombi proliferation of the endothelium of the vessel often appears to play a prominent part. As already stated, in inflammation of vessels not resulting from thrombosis, the endothelium undergoes no active changes.

2. *Obstruction to the circulation.*—The consequences of the obstruction to the circulation which results from the formation of a thrombus will depend upon the rapidity of its formation, the nature and size of the vessel obstructed, the situation and number of the collateral branches, and the force of the circulating current. When a thrombus forms in a vein of small size and there are numerous collateral vessels, as in the prostatic or uterine plexuses, the circulation is but little interfered with and no symptoms of obstruction result. If, however, the main trunk of a large vein becomes obliterated, as that of the femoral or iliac veins, the obstruction is followed by hyperæmia,

the extent and duration of which will depend upon the facility with which the circulation can be restored by the collateral vessels. Thrombosis in the above-named veins frequently occurs, as already stated, in the latter stages of many chronic diseases, especially in phthisis; also in the puerperal state, where it gives rise to the condition known as *phlegmasia dolens*. The formation of a thrombus here is followed by œdema and swelling of the limb, which becomes tense, elastic and painful. In the early stage there may be some cyanosis, but this is usually quickly followed by a pallid whiteness of the surface. There is often more or less tenderness in the course of the vein, which feels enlarged, hard, and knotted, owing to the secondary inflammatory changes in its walls. At the same time there is sometimes swelling and tenderness of the lymphatics, which may be seen as red lines traversing the limb. Diffuse inflammation of the skin and subcutaneous cellular tissue occasionally occurs. These changes are owing partly to the mechanical impediment to the circulation, and partly to the obstruction of lymphatics and to the secondary inflammatory processes in the vein and tissues which ensue. The circulation is usually ultimately restored; but if the impediment has been of long duration, the tissues become thickened, and the limb is left in a hard, indurated, and somewhat enlarged condition.

The formation of a thrombus in an artery is followed in the first place by anæmia of the parts supplied by it, the ultimate result will depend upon the facility with which the circulation can be restored by the collateral vessels. If the circulation be quickly re-established, as is usually the case, the vitality of the tissues may not become impaired; but if not, the part may undergo a process of molecular disintegration and softening, the softened tissue often being surrounded by a zone of

hyperæmia which results from the attempt to establish a collateral circulation.

3. *Embolism*.—Portions of the thrombus may be carried away by the circulation, thus constituting embolism. This, which is the most important result of thrombosis, will be considered in the following chapter.

CHAPTER XLIV.

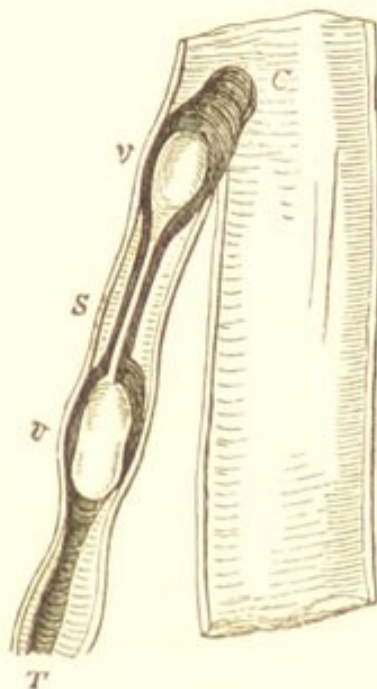
EMBOLISM.

EMBOLISM is the arrest of solid substances circulating in the blood in vessels which are too small to allow them to pass. The solid substances are termed *emboli*. These are very various in their nature.

By far the most frequent source of emboli are thrombi, portions of which are carried from the seat of their formation by the circulation, and become arrested in distant vessels—thus constituting embolism. A thrombus may give rise to emboli in various ways. It may soften and break down, and if the lumen of the vessel be thus restored, its fragments become distributed by the blood-current. In those cases in which the thrombus does not fill the vessel, portions of it may readily be carried away by the blood passing over it. Perhaps, however, the most frequent way in which a thrombus gives rise to embolism is by its conical end being broken off by the current of blood from a collateral vessel. The formation of a thrombus, as already described, usually ceases opposite the entrance of a large collateral vessel, and if its conical end project a little way into the cavity of this vessel it may be readily broken off by the blood-current. (Fig. 108.) It is especially venous thrombi which give rise to embolism: the veins of the leg, the iliac, hypogastric, and jugular veins being amongst the most common sources. Emboli from cardiac thrombi are

also exceedingly common, whilst those from arterial are the least frequent.

FIG. 108.



A Thrombus in the Saphenous Vein. Showing the projection of the conical end of the thrombus into the femoral vessel. *S.* Saphenous vein. *T.* Thrombus. *C.* Conical end projecting into femoral vein. At *v v*, opposite the valves, the thrombus is softened. (Virchow.)

Emboli may, however, originate independently of thrombi:—vegetations and calcareous or atheromatous masses separated from the valves of the heart, or from the inner surface of arteries; portions of new growths, as carcinoma, which having perforated the vessels, have been carried away by the current; parasites which have made their way into the interior of vessels; pigment granules, and other substances, may all constitute emboli.

The emboli become arrested in the first vessels they meet with which are too small to allow them to pass: the size of the vessel will consequently depend upon the size of the embolus. They are often so minute that they pass into and become impacted in the smallest capillaries. The seat of impaction is usually at the bifurcation of the vessel, or where, from the giving off of branches, the calibre is diminishing rapidly. (See Fig. 109.) Thus

emboli originating in the systemic veins or in the right cardiac cavities, will most commonly become arrested in the vessels of the lungs; those originating in the arteries, the left cardiac cavities, or the pulmonary veins—in the systemic arteries and capillaries, especially in those of the spleen, kidneys, and brain; and those originating in the portal venous system—in the hepatic branches of the portal vein. In some cases, however, the smallest emboli may pass through the capillaries of the lungs and become arrested in those of the kidneys, spleen, or other organs. Thus, with the exception of emboli originating in the portal vessels, the seat of arrest is the arteries or capillaries.

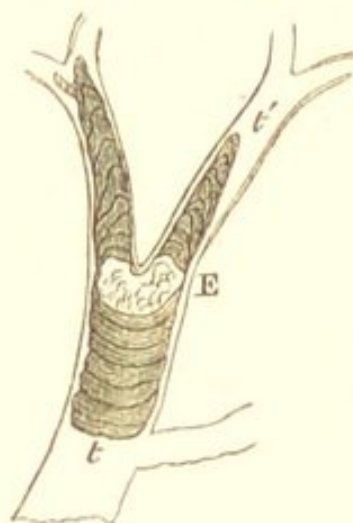
The emboli are usually carried in the direction of the main current; hence those carried by the aortic stream more commonly pass into the thoracic aorta than into the carotid and subclavian vessels, and into the left carotid and renal artery than into the corresponding arteries of the opposite side. Gravitation also influences the direction in which they are carried, especially those of large size which move somewhat more slowly than the bloodstream. Owing to this, they are more common in the lower lobes and posterior parts of the lungs than in the superior and anterior portions of these organs.

The embolus when arrested, may either completely or only partially fill the cavity of the vessel. If, as is frequently the case, the arrest takes place at a point of bifurcation, the embolus may partially fill both branches, allowing a small stream of blood to pass. This may break off portions of it, and so cause secondary emboli, which become impacted in more distant vessels. The amount of obstruction which immediately follows the arrest, will partly depend upon the nature of the embolus itself. If the embolus be from a soft, recently-formed thrombus, it will adapt itself to the cavity of the vessel, and so completely occlude it. If, on the other hand, it is

irregular in shape and firm in consistence, as when derived from a calcified cardiac vegetation, it may not fill the vessel, but allow a small current of blood to pass it.

The arrest of the embolus and the consequent obstruction to the circulation, is followed by the formation of thrombi behind and in front of it, which extend as far as the entrance of the first large collateral vessels. (Fig. 109.)

FIG. 109.



Embolus impacted at the Bifurcation of a Branch of the Pulmonary Artery. Showing the formation of thrombi behind and in front of it, and the extension of these as far as the entrance of the next collateral vessels. E. Embolus. t t'. Thrombi. (Virchow.)

If the embolus does not completely fill the vessel, coagulum is deposited in successive layers upon its surface until the occlusion of the vessel is complete, and then the secondary thrombus extends, as in the former case, until it meets with a current of blood strong enough to arrest its progress. If the embolus is a portion of a soft thrombus, it will in most cases be impossible to distinguish it from the secondary thrombus which surrounds it. If, however, it is a calcareous mass, or a portion of an old thrombus, it may usually be distinguished from the more recent secondary coagulum. The changes in these secondary thrombi are similar to those already described as occurring

in the primary,—comprising adhesion to the wall of the vessel, softening, and organisation.

RESULTS.—The results of embolism are of two kinds—those depending upon the mechanical obstruction to the circulation, and those produced by the irritating or infective properties of the emboli themselves. (See “Pyæmia.”)

The first series of changes are those occurring in the walls of the vessel within which the embolus becomes arrested. If the embolus possesses no infective properties, being derived from a source where no putrefactive changes are taking place, it, together with the thrombus which it causes to form around and beyond it, simply becomes organised or reabsorbed, and the walls of the vessel become more or less thickened. If, on the other hand, the embolus is impregnated with unhealthy pus or with other putrid inflammatory products, it is very liable to cause inflammation and sloughing of the walls of the vessel within which it is impacted.

The most important changes, however, resulting from embolism are those which take place in the organ or tissue, the vessels of which have become plugged by the emboli. The first effect of the plugging of a vessel by an embolus, is the arrest of the circulation through it, and if the vessel be the main nutrient or functional artery, this is followed by the sudden cessation of the function and nutrition of the part. Thus, plugging of one of the larger arteries in the brain is followed by sudden loss of consciousness and paralysis (apoplexy); plugging of the pulmonary artery, by sudden asphyxia; and of the coronary arteries, by sudden paralysis of the heart. The subsequent changes will depend upon the structure of the organ, the arrangement of its vessels, and the facility with which a collateral circulation can be established. If the circulation be quickly re-established by the collateral vessels, the part recovers itself without undergoing any structural change,

and its nutrition and functions are restored. If, however, this is not the case, and the nutrient supply is materially interfered with, either by the obstruction of the main vessel, of the principal branches, or of the capillaries themselves,—the death of the part must necessarily ensue. The interference with the circulation is in great measure dependent upon the thrombosis which occurs around the impacted embolus. The organs in which the arrangement of the blood-vessels is such that the circulation cannot be readily restored by the anastomosing vessels, and consequently those in which necrotic changes most commonly result from embolism, are the spleen, the kidneys, the lungs, the brain, and the retina.

The area of tissue from which the supply of blood has been cut off is usually surrounded by a zone of intense hyperæmia, which results from the stress which is thrown upon the collateral vessels. This zone of hyperæmia is very characteristic, and indicates at once the nature of the lesion. When the circulation cannot be restored, the vessels in the embolic area often become so much distended with blood that hæmorrhage takes place, and thus is produced a tract of tissue within which the circulation has become arrested, and which is more or less extensively infiltrated with blood. This is known as a *hæmorrhagic infarct*. = *lin-fascie-farctum - 2o stuff in*.

These hæmorrhagic infarcts are very frequently met with, especially in the lungs, spleen, and kidneys. They are dark, reddish, firm, masses of consolidation, and owing to the distribution of the blood-vessels, they are usually wedge-shaped, the apex of the cone being towards the centre of the organ. The more complete the obstruction, the more vascular the tissue, and the less the vessels are supported, the greater is the amount of infarction, and the more rapid is the softening and disintegration that ensues. (Fig. 110.)

This vascular engorgement in the embolic area, although partly due to the increased stress which is thrown on the

FIG. 110.

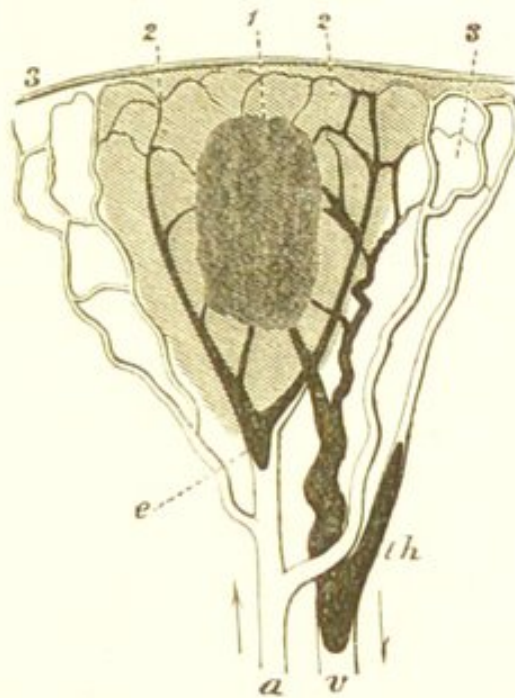


Diagram of a Hæmorrhagic Infarct. *a.* Artery obliterated by an embolus (*e*). *v.* Vein filled with a secondary thrombus (*th*). 1. Centre of infarct which is becoming disintegrated. 2. Area of extravasation. 3. Area of collateral hyperæmia. (O. Weber.)

collateral vessels, is, according to Cohnheim, mainly owing to the regurgitation of blood from the veins. When the force of the blood-stream in the artery is annihilated by the impaction of the embolus there is a backward pressure and regurgitation from the veins into the capillaries, so that there is produced considerable venous engorgement of the last-named vessels. The occurrence of the hæmorrhage, Cohnheim regards as the result of necrotic changes in the capillary walls, these changes being due to the substitution in these vessels of venous for arterial blood.

The subsequent changes which take place in the infarct depend upon its size, upon the extent to which the circulation in it is interfered with, and upon the nature of the

embolus which caused the infarction. If the infarct is small and the embolus possesses no infective properties, the coagulated blood gradually becomes decolorised, and the mass undergoes a gradual process of absorption. The infarct then changes from a dark red to a brown or yellow tint, its more external portions become organised into connective tissue, and the whole gradually contracts, until ultimately a cicatrix may be all that remains to indicate the change. If, however, the infarction is considerable, the molecular disintegration and softening may be so extensive as to convert the mass into a pulpy granular material. This may subsequently dry up and become encapsuled. In all these secondary changes which take place in the infarct, its most external portions are surrounded by a red zone of hyperæmic tissue. This is exceedingly characteristic.

If an embolus possesses irritating or infective properties, as when it is derived from a part where putrefactive inflammatory changes are going on, it sets up inflammatory processes both in the vessel within which it becomes impacted, and also in the surrounding tissues. These inflammatory changes frequently lead to the formation of abscesses which are known as *embolic abscesses*. (See "Pyæmia.") The formation of such abscesses may be associated with more or less infarction of the embolic area.

EMBOLISM IN THE BRAIN.

The impaction of emboli within the vessels of the brain is one of the causes of *cerebral softening*. The softening resulting from embolism is, for the most part, entirely dependent upon the obstruction to the circulation caused by the embolus and by the resulting thrombosis. It is rapidly induced and is often attended by the extravasation of blood, when it constitutes one form of *acute red*

softening. If the interference with the circulation be slight, there may be no extravasation of blood and the process of disintegration may be more gradual, so that the softened portions are white in colour, and the condition then more resembles the chronic white softening already described as resulting from degeneration of the cerebral blood-vessels. (See "Fatty Degeneration of the Brain.") The softened tissue will also be white in colour when one of the large vessels is obstructed, so that a large portion of one hemisphere loses its vitality. The large vessel most frequently blocked is the middle cerebral artery. In almost all cases in which softening of the cerebral substance results from embolism, the embolus is arrested in one of the vessels beyond the circle of Willis, because here the circulation cannot be readily restored by the collateral vessels.

When the interference with the circulation is attended by vascular engorgement and extravasation of blood, the softened portion, in the early stage, is either of a uniform dark red colour, or presents numerous red hæmorrhagic points. The softening is most marked in the centre, whilst the hyperæmia and redness may extend for some distance around it. Under the microscope, the softened portion is seen to consist of broken-down nerve fibres, altered blood-corpuscles, granules of fat, and the large granular corpuscles which result from the fatty degeneration of the nerve-cells and of the cells of the neuroglia. (See Fig. 10.) The surrounding capillaries are dilated and filled with coagula, and the granular corpuscles envelope their walls. In a more advanced stage all trace of nervous structure is lost, the softened mass becomes decolorised, and passes from a dark red colour to a chocolate, brown, yellow, or even white. It may liquefy and form a cyst; more commonly, however, it gradually dries up, and a process of repair takes place by the growth of

the surrounding neuroglia, which forms a fibrous network in the place of the softened tissue. This contracts, and ultimately a cicatrix with hæmatoidin crystals may be all that remains.

Red softening from embolism is often very difficult to distinguish in the post-mortem room from that which results from thrombosis.

CHAPTER XLV.

LEUKÆMIA.

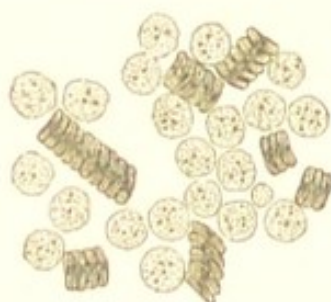LEUKÆMIA, or leucocythæmia, is a disease characterised by a large increase in the number of the white corpuscles in the blood, which increase is associated with a new formation of lymphatic tissue in the spleen, in the lymphatic glands, and sometimes in other organs. Respecting the relation which subsists between the new growth of lymphatic tissue and the increase in the number of the white blood-corpuscles—it is probable, as stated by Virchow, that the former is a cause of the latter, and that the increase is mainly due to a larger number of lymphatic elements entering the blood than in health. At the same time it is difficult to admit this as the only cause of the increase, as new growths of lymphatic tissue may take place in these organs without the production of any leukæmia. This has been seen to occur in Hodgkin's disease. It is possible that the power of the white blood-corpuscles and lymph-corpuscles to form red corpuscles is diminished, or that the white corpuscles may increase by multiplication in the blood. The pathology of the disease, however, is still exceedingly obscure.

The new formation of lymphatic tissue occurs in the first place in the spleen or in the lymphatic glands; subsequently, however, the liver, the kidneys, the intestines, the lungs, and other organs, may become infiltrated with lymphatic elements. The growth is a *continuous* one,

the new elements many of them enter the blood, the remainder, not undergoing any retrogressive changes, give rise to tumours in, or to a general increase in the size of, the organs in which they are generated.

The new growth may commence in the spleen or in the lymphatic glands, hence Virchow has distinguished two forms of leukæmia—the splenic and the lymphatic. In the former he states that the white blood-cells are somewhat larger and more granular than normal (Fig. 111);

FIG. 111.



Leukæmic Blood. From a young man, aged twenty-four, with enormous enlargement of the spleen. $\times 200$.

whilst in the latter they are smaller. In most cases of the disease, however, both the spleen and the lymphatic glands are affected, the spleen being the organ principally involved. A purely lymphatic leukæmia is exceedingly rare. The coagulating power of the blood in leukæmia is much diminished.

In the *spleen*—which must thus be regarded as the most important organ in the production of leukæmia—the first stage in the process is one of intense hyperæmia. The organ becomes exceedingly vascular, and the cells both of the pulp and of the Malpighian corpuscles increase in number. The process, however, soon becomes principally limited to the Malpighian corpuscles. In these the cells continue to multiply rapidly, many new blood-vessels are formed, and the corpuscles thus increase in size. They sometimes attain the size of a hazel-nut,

and are seen as firm whitish nodules of an irregular shape, scattered through the much enlarged and vascular organ. As the Malpighian corpuscles increase in size, the surrounding pulp gradually atrophies, and often becomes deeply pigmented. The trabeculæ at the same time becomes thicker and more fibrous. The organ thus becomes firmer in consistence, and the enlarged Malpighian corpuscles make up the chief part of its bulk. The capsule also becomes thickened, and forms adhesions with the surrounding viscera.

In the *lymphatic glands* the process is precisely similar to that in the spleen, the follicles of the gland being the chief seats of the hyperplasia. The glands become enlarged, soft, and vascular.

In the course of the disease this new growth of lymphatic tissue may take place in other parts, both in lymphatic and non-lymphatic structures. Of the former, the follicles of the intestine, and the medulla of bone, are those most commonly involved. In the intestines, the follicles may become so much enlarged as to form distinct firm tumours. The medulla of bone is, according to Neumann, in exceptional cases the principal seat of the diseased process.

The growth of lymphatic tissue in non-lymphatic structures occurs principally in the liver and kidneys; less frequently in the lungs and muscle. The new growth in these organs either forms distinct tumours, or exists as an infiltration. In its structure it consists of lymphoid elements embedded in a more or less distinct reticulum. (See "The Lymphomata.") How far these lymphoid growths are the result of a hyperplasia of the cells in the interstitial tissue of the organ in which they are situated, and how far an emigration of the leucocytes, which exist in such large numbers in the blood, takes part in their formation is unknown. The latter, however, is probably the most important factor in the process.

The organ which is a common seat of these lymphoid growths is the *liver*. Here the vessels throughout the organ become enlarged and distended with white blood, and the growth commencing in the interlobular tissue, gradually extends into the lobules themselves. In the earlier stages, the lobules are seen to be clearly mapped out by a greyish-white interlobular infiltration. As this increases the liver-cells become compressed and atrophy, until ultimately the lobules may be replaced entirely by lymphatic tissue. Associated with this infiltration there is often a formation of small, round, soft, whitish nodules, somewhat resembling grey tubercles. Owing to these changes, the liver becomes very considerably increased in size.

In the *kidneys*, which are also frequently affected, the change is similar to that in the liver. Here also it consists for the most part in an infiltration, with which may be associated the formation of roundish nodules and masses.

CHAPTER XLVI.

THE PREPARATION AND MOUNTING OF SPECIMENS.

IN this, the concluding chapter, it is proposed to describe very briefly the more common methods of preparing and mounting specimens for microscopical examination. It is not intended to give an account of those various and complex methods of investigation which are required for minute histological research, but merely to describe those more easy ones which suffice in the great majority of cases for the recognition of the structural alterations met with in disease. In order to be as brief as possible, those methods only will be described which I believe to be the most readily available and at the same time to yield the most satisfactory results. The subject will be treated under the following heads:—1st. *The Examination of Specimens whilst fresh*; 2nd. *The Hardening of Specimens*; 3rd. *The Making of Sections*; 4th. *Staining*; 5th. *Preservation and Mounting*.

THE EXAMINATION OF SPECIMENS WHILST FRESH.

Very much may be learnt from the examination of specimens in their fresh state before they have been submitted to any hardening process. The examination may be conducted either by making thin sections of the tissue with a Valentin's knife, or by cutting off a minute portion and tearing it to pieces with fine needles. The

specimen prepared in either of these ways should be examined in glycerine. Thin membranous structures may be examined by simply spreading them out in a drop of water placed upon the glass slide, and then covering them with glycerine.

The method of making sections of organs whilst fresh with a Valentin's knife is an exceedingly easy and useful way of at once ascertaining in the post-mortem room the existence of the more marked structural changes. The knife should be well wetted with water, and then drawn *rapidly* through the substance of the organ. The section thus obtained is gently washed in water before being examined in glycerine. A rough examination of the liver, kidneys, and lungs is in this way readily made.

The muscular fibres of the heart and tumours may be examined by the process of teasing. This process, however, is usually more readily effected after the specimen has been kept in Müller's fluid or in a solution of bichromate of potash in the manner to be hereafter described. In the examination of tumours, much may be learnt by gently scraping the freshly cut surface with a knife and examining in glycerine the elements which are thus separated.

THE HARDENING OF SPECIMENS.

In order to make a complete and satisfactory examination of diseased structures, it is in almost all cases necessary to submit them to a process of hardening. By this process they are so altered that fine sections of them can be made, and the sections are also rendered more fit for permanent preservation than are those obtained from tissues in their fresh state. Numerous substances have been employed as hardening agents. Those, however, which are the most generally valuable are *Müller's fluid*, *chromic acid*, *bichromate of potash*, and *alcohol*.

Müller's Fluid.—Of all hardening agents this is much the most satisfactory and the one most generally applicable. It is prepared in the following way:—

Take of—

Potassium Bichromate	2 parts.
Sodium Sulphate	1 part.
Water	100 parts.
Dissolve.	

The tissue should be kept in this solution for from one to two weeks, and then placed in common alcohol for two or three days, after which it is ready for making sections.

The advantages of Müller's fluid are that it alters the macroscopical characters of tissues less than other hardening agents, and its penetrating powers are so great that it is not necessary to cut the tissue up into small pieces, but the whole organ may be placed in it. The tissue may be kept in it longer without injury than in other aqueous solutions.

Müller's fluid is also valuable for the maceration of tissues which are to be examined by teasing—as tumours, muscle, &c. Its action tends to facilitate the isolation of the elements.

Chromic Acid.—This is much less generally applicable than the preceding. It should be used in aqueous solution—strength one-sixth per cent. It is important to employ the solution in large quantities—from six to ten fluid ounces for each specimen. The tissue must be cut into small pieces—not much larger than a hazel-nut—before it is placed in the solution. The hardening is usually completed in from five to eight days. It is hastened by renewing the solution. If kept too long in the solution the tissue becomes brittle. All tissues which have been hardened in chromic acid should be placed in common alcohol for about twenty-four hours before sec-

tions are made. Chromic acid is preferable for hardening skin and mucous membranes.

Bichromate of Potash.—This agent is more gradual in its action than chromic acid, and produces less shrinking of the tissue. It is especially valuable for the hardening of kidney, blood-vessels, nerve-tissue, ovary, and some other structures. It is often advisable to commence the hardening with bichromate of potash and then to complete it in chromic acid or common alcohol. The bichromate is also valuable for the maceration of tissues which are to be examined by teasing. The bichromate should be used in aqueous solution—strength one to two per cent. It penetrates more readily than the chromic acid, and consequently it is not necessary to use quite such small pieces of the tissue. The tissue must be kept in the solution from two to four weeks.

Alcohol.—This is most valuable as an agent for the completion of the hardening of tissues which have been previously placed in Müller's fluid, chromic acid, or in bichromate of potash. The tissues should be kept in it one or two days. Some tissues, however, appear to harden better if they are at once placed in alcohol: amongst these are the lymphatic glands, spleen, and testis. Common (methylic) alcohol answers for all these purposes. Lastly, alcohol must be employed for the hardening of all tissues which have been injected. Absolute alcohol is often necessary for the completion of hardening of many tissues.

The Softening of Tissues.—Some tissues, as osseous structures, tumours which have become calcified, &c., require to be softened before sections can be made. This may be effected by placing them in the one-sixth per cent. chromic acid solution, to each six ounces of which three or more drops of concentrated hydrochloric acid have been added.

THE MAKING OF SECTIONS.

Although various instruments have been contrived for making sections, the one which answers best is a common razor, or a similar blade firmly fixed in a wooden handle. The usefulness of this instrument is much increased if the lower surface of the blade be ground perfectly flat, whilst the upper is made slightly concave.

Hardened tissues from which sections are to be made must always have first been placed in common alcohol, in the manner already described. In making the section the blade of the instrument must be kept well wetted with common alcohol, and the section when cut must be placed at once in the same liquid.

Imbedding.—Hardened tissues which are too small or too delicate to be held in the hand for the purpose of making sections, must be imbedded. The object of imbedding is to fix the tissue in some substance which can not only be readily held, but which can also be easily cut with the section-knife. Various substances are used for this purpose. Of these the one which is most generally applicable is a mixture of wax and olive oil. Equal quantities of pure white wax and olive oil should be warmed together and well mixed, and the mass when cold may be kept to be used as required. When a specimen is to be imbedded, a small case of paper should be made somewhat larger than the specimen. The edges of the paper can be secured with a little mucilage or with a pin. The mixture of wax and oil is then melted and the paper case filled with it. The specimen to be imbedded—which must have been removed from common alcohol—is now to be slightly dried on blotting-paper and immersed in the melted compound. The process of immersion requires a little care. The specimen should be placed upon the point of a fine needle, and as soon as the wax commences

to solidify at the sides of the case, it must be dipped beneath the melted liquid so as to be completely covered by it. The needle must then be removed by giving it a gentle twist so as not to disturb the specimen. When the wax is cool the paper can be removed and the mass placed in common alcohol. Sections can be made from it when convenient.

STAINING.

When the section has been made and placed in common alcohol, in the manner described, it is usually advisable to stain it. The object of staining is to impart to the different portions of the tissue different shades of colour, so that its structure can be more readily recognised. The substances which are the most generally applicable for this purpose are *logwood* and *carmine*. Of these logwood is the preferable, inasmuch as it not only differentiates most tissues more completely, but it is a much more agreeable colour to work with.

Staining with Logwood.—The following is the method for preparing the logwood solution recommended by Dr. Klein:—

Take of—

Extract. Hæmatox. 6 grammes.

Alumen 18 grammes.

Mix thoroughly in a mortar.

Add gradually whilst stirring—

Distilled Water 28 cub. cent.

Filter.

To the filtrate add—

Spirit. Rect. 1 drachm.

The solution must be kept in a stoppered bottle for a few days before being used.

For staining, several (5—10) drops are to be added to half a watch-glass of distilled water. The thus diluted

solution should be filtered before being used. Sections which have been removed from common alcohol, are to be placed in the dilute solution for from ten to twenty minutes, and then to be washed in distilled water.

Gradual Staining with Weak Carmine.—In staining with carmine two methods may be employed:—the one consists in using a strong solution, so as to stain rapidly; the other in staining very gradually with a much less concentrated liquid. Of these, the method of gradual staining with weak solutions yields the most satisfactory results, inasmuch as by this means the differentiation of the tissue is rendered more complete than when the coloration is rapidly induced. The process of rapid staining with strong carmine is, however, the most convenient, and it yields, in most cases, sufficiently satisfactory results.

The following is the method for gradual staining recommended by Dr. Klein:—

Take of—

Powdered Carmine 2 grammes.

Rub it up with a few drops of Distilled Water.

Add—

Liquor Ammoniaë fort. 4 cub. cent.

Distilled Water 48 cub. cent.

Mix together with a glass rod, and filter.

The solution to be kept in a stoppered bottle.

For staining, take one drop of the above solution, and add to it from nine to twelve drops of distilled water. Sections, which have been removed from common alcohol, to be placed in this from sixteen to twenty-four hours.

Rapid Staining with Strong Carmine.—To stain rapidly, the sections may be placed in the above strong solution of carmine without the addition of water. In this case the strong solution of carmine should have been kept exposed to the air for a sufficient length of time to

allow the excess of ammonia to escape. It is consequently advisable to have two bottles of strong carmine solution—one for rapid, and the other for gradual staining.

The time required for rapid staining is from thirty seconds to five minutes. This, however, will vary very considerably according to the nature of the tissue to be stained. A knowledge of the amount of time which yields the best results will be readily learnt by a little practice.

The sections when removed from the carmine staining solution must be washed for a few seconds in distilled water containing one-quarter per cent. of acetic acid.

PRESERVATION AND MOUNTING.

When the section has been stained, it is ready to be prepared for mounting permanently. The two substances in which tissues are most commonly mounted are glycerine and Dammar varnish. Of these, the latter should be employed in all cases in which the preservation of the section is intended to be permanent. Many tissues, however, yield more satisfactory results when examined in glycerine; but they cannot be preserved in this liquid for any great length of time without undergoing some alteration.

The methods of mounting in Dammar varnish and glycerine must be described separately.

Mounting in Dammar Varnish.—When the section is to be mounted in Dammar—it having been already stained and washed—it must first be placed in *absolute* alcohol for about a quarter of an hour. From the alcohol it must be transferred to oil of cloves, the superfluous alcohol having been first removed from the section by blotting-paper. In the oil of cloves it becomes, in a few seconds, quite transparent. The superfluous oil must be removed by blotting-paper, and the section is then

ready for mounting in the Dammar varnish. If more convenient, it may be kept for one or two days in the oil of cloves before it is mounted in the Dammar. In order to make the specimen still more secure, a layer of the varnish may be placed round the edge of the covering glass a few days after the section has been mounted.

The following is the method for preparing the Dammar varnish:—

Take of—

Gum Dammar in powder $\frac{1}{2}$ oz., and dissolve it in
Turpentine $1\frac{1}{2}$ oz. *Filter.*

Gum Mastic $\frac{1}{2}$ oz., and dissolve it in Chloroform
2 oz. *Filter.*

Mix the two filtered solutions, and again filter.

Mounting in Glycerine.—When the section is to be mounted in glycerine no further preparation is necessary. It is simply washed in distilled water and at once transferred to a drop of strong glycerine upon the slide. The edges of the covering glass must then be fastened down with some cementing liquid. The Dammar varnish answers exceedingly well for this purpose.

PRINCIPAL WORKS REFERRED TO.

- ARNOTT, HENRY.—The Histology and Diagnosis of Cancer.
- BILLROTH, THEODOR.—Die allgemeine chirurgische Pathologie und Therapie.
- BUHL, LUDWIG.—Lungenentzündung, Tuberkulose, und Schwindsucht.
- COHNHEIM. — *Ueber Entzündung und Eiterung.* Virchow's Archiv, vol. xl.
Ueber das Verhalten der fixen Bindegewebskörperchen bei der Entzündung. Virchow's Archiv, vol. xlv.
Neue Untersuchungen über die Entzündung. 1873.
- CORNIL ET RANVIER.—Manuel d'Histologie Pathologique.
- DICKINSON, W. H.—The Pathology and Treatment of Albuminuria.
- FOERSTER, AUGUST.—Handbuch der pathologischen Anatomie.
- FOX, WILSON.—On the Artificial Production of Tubercle.
- HÜTER, C.—*Die septikämischen und pyæmischen Fieber.* Handbuch der allgm. u. spec. Chirurgie. Von Pitha und Billroth.
- JONES AND SIEVEKING.—Manual of Pathological Anatomy. 2nd Edit. Edited by Dr. Payne.
- KLEBS.—Handbuch der pathologischen Anatomie.
- KLEIN.—The Anatomy of the Lymphatic System.
- KÜHNE, W.—Lehrbuch der physiologischen Chemie.
- LISTER, J.—*On the Early Stages of Inflammation.* Philosophical Trans., 1859.
- LÜCKE.—*Die Geschwülste.* Handbuch der allgm. u. spec. Chirurgie. Von Pitha und Billroth.

- NIEMEYER, F.—Text-book of Practical Medicine. Translated by Drs. Humphreys and Hackley.
- PAGET, Sir J.—Lectures on Surgical Pathology. Edited by Prof. Turner.
- Pathological Soc. Lond. Transactions.
- RECKLINGHAUSEN.—*Ueber Eiter und Bindegewebskörperchen* Virchow's Archiv, vol. xxviii.
- RINDFLEISCH, E.—Lehrbuch der pathologischen Gewebelehre.
- RYNECK.—*Zur Kenntniss der Stase des Blutes in den Gefässen entzündeter Theile.* Rollet's Untersuch. aus dem Institute für Phys. u. Histol. in Graz.
- SANDERSON, J. BURDON.—*The Process of Inflammation.* Holmes' System of Surgery, vol. v.
- The Inoculation of Tubercle.* Appendix to Reports of Medical Officer to Privy Council, for 1868 and 1869.
- Recent Researches on Artificial Tuberculosis in their Relation to the Pathology of Phthisis.* 1869.
- SCHÜPPEL, OSCAR.—*Untersuchungen über Lymphdrüsen-Tuberkulose.*
- STRICKER, S.—*Various papers by, in his—*Studien aus dem Institute für experimentelle Pathologie in Wien. 1869.
- Manual of Human and Comparative Histology, vol. i. Edited by Prof. Stricker; translated by Mr. Power.
- UHLE UND WAGNER.—Handbuch der allgemeinen Pathologie.
- VIRCHOW, RUDOLF.—Die Cellular Pathologie.
Die krankhaften Geschwülste.
Gesammelte Abhandlungen.
Handbuch der speciellen Pathologie und Therapie. Band I.
- WEBER, O.—*Die Gewebserkrankungen.* Handbuch der allgm. u. spec. Chirurgie. Von Pitha und Billroth.
- WILKS AND MOXON.—Lectures on Pathological Anatomy. 2nd Edit.

I N D E X.

- ABSCESS, 217
 " in connective tissue, 269
 " of bone, 273
 " of brain, 330
 " of kidneys, 317
 " of liver, 310
 " of lungs, 338
 " of lymphatic glands, 293
Acute miliary tuberculosis, 224
Adenomata, 171
 " of mammary gland, 172
 " of mucous membranes, 174
Adeno-myxoma, 172
 " -sarcoma, 173
Adipose tissue, atrophy of, 24
 " growth of, 38
Alimentary canal, amyloid degeneration of, 83
Amyloid degeneration, 69
 " " of alimentary canal, 83
 " " of kidneys, 78
 " " of liver, 75
 " " of lymphatic glands, 83
 " " of spleen, 81
 " substance, nature of, 70
 " " reactions of, 71
 " " source of, 74
Angiomata, 198
Arteries, atheroma of, 279
 " calcification of, 91
 " fatty degeneration of, 53

- Arteries, inflammation of, 279
 „ in chronic Bright's disease, 328
 Atheroma, 279
 Atrophy, 23
 „ causes of, 26
 „ numerical, 25
 „ physical characters of, 30
 „ simple, 23
 „ of adipose tissue, 24
- BACTERIA, 251
- Blood, as cause of disease, 2
 „ alteration of, in malignant growths, 113
 „ ante-mortem coagulation of—see “Thrombosis”
 „ post-mortem coagulation of, 375
- Blood-corpuscles, as source of new formations, 117
 „ as source of pus, 219
 „ emigration of, in inflammation, 209
 „ exudation of, in mechanical hyperæmia, 369
- Blood-vessels, amyloid degeneration of, 72 & 78
 „ calcification of, 91
 „ fatty degeneration of, 53
 „ inflammation of, 279
- Bone, atrophy of, 31
 „ caries of, 274
 „ inflammation of, 272
 „ necrosis of, 274
 „ sclerosis of, 273
- Brain, abscess of, 330
 „ embolism in, 394
 „ fatty degeneration of, 56
 „ inflammation of, 329
 „ inflammatory softening of, 330
 „ softening of, from embolism, 394
 „ red softening of, 59, 394
 „ sclerosis of, 331
 „ tubercle of, 237
 „ white softening of, 58
 „ yellow softening of, 58
- Brown atrophy of heart, 63
 „ induration of lungs, 372

- CACHEXIA, cancerous, 111
 Calcareous degeneration, 87
 " " of arteries, 91
 Cancer, 176
 " blood-vessels of, 179
 " cells of, 177
 " clinical characters of, 193
 " colloid, 187
 " development of, 179
 " encephaloid, 185
 " epithelial, 188
 " lymphatics of, 179
 " melanotic, 183
 " osteoid, 182
 " scirrhous, 183
 " secondary changes in, 182
 " stroma of, 178
 " structure of, 176
 " varieties of, 182
 Caries, 274
 Carmine for staining, 407
 Cartilage, erosion of, 263
 " inflammation of, 262
 Caseation, 52
 " of tubercle, 234
 Caseous masses, pathological significance of, 52
 Carcinomata, 176
 Catarrh, 299
 Cell, as seat of nutrition, 5
 " definition of, 12
 " limiting membrane of, 9
 " nucleus of, 8, 9
 " protoplasm of, 7, 9
 Cells, constitution of, 6
 " genesis of, 10
 " "indifferent," 118
 " multiplication of, 10
 " physiology of, 8
 Cell-wall, nature of, 9
 Cerebral softenings, 56
 Cicatricial tissue, 268

- Clots, ante-mortem, 376
 „ post-mortem, 375
 Cloudy swelling, 212
 Colloid cancer, 187
 „ degeneration, 65
 Condylomata, 169
 Congestion, *see* "Hyperæmia"
 Connective tissue, fatty infiltration of, 38
 „ „ inflammation of, 266
 „ „ suppuration of, 269
 Cornea, inflammation of, 264
 Corporea amylacea, 84
 Corpuscles, exudation, 50
 Croup, 302
 Cystic-sarcoma, 174
 Cysts, 200
 „ classification of, 203
 „ modes of origin of, 200
 „ secondary changes in, 202
 „ structure of, 201
- DAMMAR varnish for mounting, 409
- Degeneration, 35
 „ amyloid, 69
 „ calcareous, 87
 „ causes of, 35
 „ colloid, 66
 „ fatty, 37
 „ mucoid, 65
 „ pigmentary, 93
- Diphtheria, 303
 Disease, definition of, 1
 Dysentery, 303
- EMBOLISM, 387
 „ in brain, 394
 „ results of, 391
- Emigration of white blood-corpuscles in inflammation, 209
 Emphysema, 32
 Encephaloid cancer, 185
 Enchondromata, 152

- Endocarditis, 284
 „ acute, 285
 „ chronic, 287
 „ ulcerative, 286
- Epithelioma, 188
- Exostoses, 158
- Exudation corpuscles, 50
- Exudation in inflammation, cause of, 216
 „ of liquor sanguinis in inflammation, 210
 „ in mechanical hyperæmia, 369
- FAT, absorption of, 51
 „ source of, in fatty degeneration, 49
 „ „ „ infiltration, 38
- Fatty degeneration, 37
 „ „ causes of, 38
 „ „ of arteries, 53
 „ „ of brain, 56
 „ „ of heart, 60
 „ „ of kidneys, 64
 „ „ of muscle, 59
 „ infiltration, 42
 „ „ of connective tissue, 38
 „ „ of heart, 43
 „ „ of liver, 45
 „ „ of muscle, 42
- Fibroid induration, as result of inflammation, 322
 „ „ „ of mechanical hyperæmia, 368
 „ „ „ of heart, 289
- Fibromata, 143
- Fibroplastic tumour—*see* “Sarcomata spindle-celled”
- GANGRENE, 13
 „ causes of, 19
 „ dry, 14
 „ evidences of, 14
 „ moist, 14
 „ senile, 21
- Genesis of cells, 10
- Giant cells, 230
- Glioma, 138

- Gluge, corpuscles of, 50
 Grey degeneration, 331
 Gummata, 257
- HÆMATOIDIN, 94
 Hæmorrhagic infarct, 392
 Heart, brown atrophy of, 63
 " changes in pyrexia, 105
 " fatty degeneration of, 60
 " " infiltration of, 43
 " fibroid induration of, 289
 " inflammation of, 284
- Heterology, 120
 Hodgkin's disease, 164
 Homology, 120
 Horns, 169
 Hyperæmia, 364
 " active, 364
 " mechanical, 367
 " of liver, 370
 " of lungs, 372
 " post-mortem appearances of, 373
- Hyperplasia, 107
 Hypertrophy, 107
- INFARCT, 392
 Infiltrations, 36
 Infiltration, fatty, 42
 Inflammation, 205
 " acute, 221
 " alterations in nutrition in, 211
 " as cause of gangrene, 20
 " causes of blood-stasis in, 215
 " changes in the blood-vessels and circulation
 in, 206
 " chronic, 221
 " emigration of red blood-corpuscles in, 210
 " " of white blood-corpuscles in, 209
 " exudation of liquor sanguinis in, 210
 " formation of pus in, 217
 " idiopathic, 223

- Inflammation, infective, 223
 " specific, 223
 " stasis in, 208
 " traumatic, 222
 " varieties of, 220
 " of blood-vessels, 279, 383
 " of bone, 272
 " of brain and spinal cord, 329
 " of cartilage, 262
 " of common connective tissue, 266
 " of cornea, 264
 " of heart, 284
 " of kidney, 316
 " of liver, 310
 " of lungs, 333
 " of lymphatic structures, 292
 " of mucous membranes, 299
 " of serous membranes, 306
 " of veins, 282
- Inflammatory new formations, nature of, 110
 " fever, 248
 " stasis, 208
- Interstitial hepatitis, 311
 " nephritis, 324
 " pneumonia, 343
- Intestine, tuberculosis of, 239
 " typhoid ulceration of, 295
- Irritation, as cause of inflammation, 205
 " " new formations, 115
 " " tuberculous lesions, 224
- KIDNEY, abscess of, 317
 " amyloid degeneration of, 78
 " fatty degeneration of, 64
 " inflammation of, 316
 " interstitial nephritis, 324
 " leukæmic growth in, 400
 " surgical, 317
 " suppurative nephritis, 317
 " tubal nephritis, 319

- LARDACEOUS degeneration—*see* "Amyloid Degeneration"
- Leukæmia, 397
- Leukæmic growths in kidney, 400
- " " in liver, 400
- " " in lymphatic glands, 399
- " " in spleen, 398
- Lipomata, 150
- Liver, abscess of, 310
- " acute inflammation of, 310
- " acute yellow atrophy of, 314
- " amyloid degeneration of, 75
- " changes in pyrexia, 104
- " cirrhosis of, 311
- " fatty infiltration of, 45
- " leukæmic growth in, 400
- " nutmeg, 370
- " syphilitic growths in, 261
- Logwood for staining, 406
- Lungs, abscess of, 338
- " broncho-pneumonia, 339
- " brown induration of, 372
- " catarrhal pneumonia, 339
- " cirrhosis of—*see* "Interstitial Pneumonia"
- " croupous pneumonia, 333
- " emphysema of, 32
- " gangrene of, 338
- " inflammation of, 333
- " interstitial pneumonia, 343
- " pigmentation of, 98
- " phthisis, 349
- " tuberculosis of, 241
- Lymphadenoma—*see* "Hodgkin's disease"
- Lymphatic glands, amyloid degeneration of, 83
- " " inflammation of, acute, 292
- " " " chronic, 293
- " " leukæmic growths in, 399
- " " non-inflammatory enlargement of—*see*
 " "Lymphoma"
- " " tuberculosis of, 238
- " structures, inflammation of, in typhoid fever, 295

Lymphomata, 160

Lympho-sarcoma, 163

MALIGNANCY, 123

„ cachexia as evidence of, 111

„ different degrees of, 123

„ multiplicity as evidence of, 112

„ recurrence after removal as evidence of, 112

„ secondary growths as evidence of, 113

Mammary gland, adenoma of, 172

„ „ adeno-fibroma of, 173

„ „ adeno-sarcoma of, 173

„ „ cystic-sarcoma of, 174

„ „ scirrhus of, 183

Melanæmia, 97

Melanin, 96

Melanotic cancer, 183

„ sarcoma, 133

Melanosis—see “Melanotic Sarcoma”

Meningitis, tubercular, 235

Metamorphoses, 35

Mollities ossium, 276

Mortification, 13

Mounting of specimens, 401

Mucoid degeneration, 65

Mucous membranes, adenomata of, 174

„ „ catarrhal inflammation of, 299

„ „ croupous inflammation of, 302

„ „ tuberculosis of, 239

Müller's fluid, 403

Mummification, 14

Muscle, fatty degeneration of, 59

„ fatty infiltration of, 42

Myeloid tumour, 139

Myelitis, 330

Myocarditis, 287

Myomata, 196

Myoma of uterus, 197

Myxomata, 147

NECROBIOSIS, 25

- Necrosis, 13, 274
- New formations, 109
- „ „ classification of, 126
 - „ „ constitutional, predisposing causes of, 111
 - „ „ development of, 116
 - „ „ direct exciting causes of, 115
 - „ „ etiology of, 110
 - „ „ origin of, from emigrant cells, 117
 - „ „ relation of, to the surrounding tissues, 121
 - „ „ retrogressive changes in, 122
- Nervous system, as cause of atrophy, 29
- „ „ „ disease, 3
- Neuromata, 197
- Nucleoli, 8
- Nucleus, 8
- „ function of, 9
- Nutrition, arrested, 13
- „ definition of, 2
 - „ impaired, 23
 - „ increased, 107
- OSTEOMALACIA, 276
- Osteomata, 157
- Osteo-chondroma, 154
- Osteoid sarcoma, 135
- Osteophytes, 158
- PAPILLOMATA, 167
- Periostitis, 273
- Pia mater, tuberculosis of, 235
- Phlegmasia dolens, 385
- Phthisis, pulmonary, 349
- „ „ anatomical changes in lungs in, 351
 - „ „ "colliers'," 101
 - „ „ etiology of, 360
 - „ „ fibroid, 356
 - „ „ older doctrines respecting, 349
 - „ „ pathology of, 357
 - „ „ tubercle in, 350
- Pigmentary degeneration, 93
- Pigmentation, false, 97

- Pigmentation of lungs, 98
 „ of sputum, 101
 Pigment, source of, 93
 Pneumonia, catarrhal, 339
 „ croupous, 333
 „ interstitial, 343
 Post-mortem staining, 15
 Protoplasm, 7, 9
 „ coagulation of, after death, 17
 Psammoma, 140
 Pus, characters of, 218
 „ origin of, 218
 Pulmonary phthisis, 349
 Pyæmia, 248
 „ bacteria in inflammatory products of, 251
 „ nature of infective substances in, 251
 „ nature of lesions in, 249
 „ pathology of metastatic abscesses in, 254
 „ relation of, to septicæmia, 250
 Pyrexia, tissue-changes in, 103

 RICKETS, 276
 Rigor mortis, 15
 „ „ nature of change in muscle in, 17

 "SAGO spleen," 81
 Sarcomata, 128
 „ cystic, 174
 „ melanotic, 133
 „ myeloid, 139
 „ osteoid, 135
 „ round-celled, 137
 „ spindle-celled, 132
 Scirrhus cancer, 183
 Sclerosis of bone, 273
 „ nerve, 331
 Senile gangrene, 21
 Septicæmia, 248
 „ relation to pyæmia, 250
 Serous effusion, as result of inflammation, 210
 „ „ of mechanical hyperæmia, 369

- Serous membranes, inflammation of, 306
 Slough, separation of, 18
 Specimens, examination of, whilst fresh, 401
 " hardening of, 402
 " imbedding of, 405
 " making sections of, 405
 " mounting of, 408
 " preparation and mounting of, 401
 " softening of, 404
 " staining of, 406
 Spinal cord, inflammation of, 329
 " sclerosis of, 331
 Spleen, amyloid degeneration of, 81
 " leukaemic growths in, 398
 " in typhoid fever, 295
 Staining of sections, 406
 Suppuration, 217
 Syphilis, 256
 " fibroid changes in, 256
 " gummata in, 257
 " nature of lesions in, 256
- THROMBOSIS, 374
 " causes of, 380
 " results of, 383
- Thrombus, 376
 " organization of, 377
 " softening of, 379
- Traumatic fever, 248
 Tumours—*see* "New Formations"
 " definition of, 109
- Tubercle, 224
 " in pulmonary phthisis, 350
 " older doctrines respecting, 224, 350
- Tuberculosis, acute, 224
 " artificial production of, 226
 " giant cells in, 230
 " infective nature of, 225
 " limited to single organs, 235
 " nature of lesions in, 229
 " source of infection in, 227

Tuberculosis of lymphatic glands, 238
 " of lungs, 241
 " of mucous membranes, 239
 " of pia mater, 235

Tubercular meningitis, 235

Typhoid fever, 294

ULCERATION, tubercular, of intestine, 239

 " typhoid of intestine, 295

Uterus, myoma of, 197

VACUOLATION, 11

Veins, inflammation of, 282

WARTS, 169

THE END.

