

Case of a small aneurysm of the first part of the arch of the aorta, opening into the pulmonary artery and conus arteriosus of the right ventricle : with remarks on the general subject / by Sir William T. Gairdner, M.D., K.C.B., F.R.S., Physician to the Western Infirmary, Glasgow.

Contributors

Gairdner, W. T. Sir, 1824-1907.
University of Glasgow. Library

Publication/Creation

[Glasgow] : [MacLehose], [1899]

Persistent URL

<https://wellcomecollection.org/works/qwxfbxn2>

Provider

University of Glasgow

License and attribution

This material has been provided by This material has been provided by The University of Glasgow Library. The original may be consulted at The University of Glasgow Library. where the originals may be consulted. This work has been identified as being free of known restrictions under copyright law, including all related and neighbouring rights and is being made available under the Creative Commons, Public Domain Mark.

You can copy, modify, distribute and perform the work, even for commercial purposes, without asking permission.

**wellcome
collection**

Wellcome Collection
183 Euston Road
London NW1 2BE UK
T +44 (0)20 7611 8722
E library@wellcomecollection.org
<https://wellcomecollection.org>

CASE OF A SMALL ANEURYSM OF
THE FIRST PART OF THE ARCH OF
THE AORTA, OPENING INTO THE
PULMONARY ARTERY AND CONUS
ARTERIOSUS OF THE RIGHT VEN-
TRICLE, WITH REMARKS ON THE
GENERAL SUBJECT, BY SIR WILLIAM
T. GAIRDNER, M.D., K.C.B.



Digitized by the Internet Archive
in 2016

CASE OF A SMALL ANEURYSM OF THE FIRST
PART OF THE ARCH OF THE AORTA, OPENING
INTO THE PULMONARY ARTERY AND CONUS
ARTERIOSUS OF THE RIGHT VENTRICLE;
WITH REMARKS ON THE GENERAL SUBJECT.

BY SIR WILLIAM T. GAIRDNER, M.D., K.C.B., F.R.S.,
Physician to the Western Infirmary, Glasgow.

IN the last published volume (VI.) of the *Transactions of the Glasgow Clinical and Pathological Society*, under date 10th May, 1897,¹ I brought before the Society a collection of specimens from the Glasgow Museums, including all which I found there available as "illustrating aneurysms of the arch of the aorta which either opened into, or pressed upon, the vena cava superior, or the pulmonary artery." The collection amounted to twelve cases in all (not all strictly conformable to the title), and it left upon the mind the general impression that such cases are not only rare, but that even when thus collocated they do not contribute very much, in most instances, towards the precise clinical history and diagnosis of such lesions; except indeed in one case which I myself communicated to the *Lancet* of 22nd June, 1889, p. 1233, where the opening was into the superior vena cava, with well marked cyanosis and dropsy, and with dilated veins generally limited to the upper part of the body. The diagnosis of aneurysm in this case was not very difficult, and there was even a fact in the history which may have corresponded with the period of the rupture into the vein—viz., a "feeling as if something had

¹ See also *Glasgow Medical Journal*, 1897, Vol. II., p. 120.

given way on the left side, rather to the left of the cardiac apex" (and therefore not precisely in the situation of the actual rupture); the feeling, however, was not one of local pain, but attended by faintness and cold sweat, succeeded almost immediately by the swelling and the other phenomena observed. There were in this case loud murmurs (V.S. and V.D. in rhythm) heard over the whole front, but with mainly the distribution of the aortic double murmur. No considerable doubt was in this case entertained of the existence of an aneurysm involving the vena cava, the diagnosis being afterwards verified by post-mortem examination. The clinical facts in this case were very completely, though concisely, stated in the article alluded to; but it is obvious that when an opening takes place into the pulmonary artery or right ventricle, the localization of the anasarca as above described, is not to be expected, and the diagnosis is therefore, or at least may be, much more difficult. [See paragraph appended to this article, page 17.] The following case, therefore, having been most carefully recorded with a view to clinical teaching, and having been under observation for a sufficient time to be repeatedly observed and considered with a clinical class, appears to be a fitting contribution to the Glasgow Hospital Reports. I am greatly obliged to my friend and old pupil, Dr. Alexander Macphail, for his admirable drawings of the preparation now in the museum of the Western Infirmary, which will allow all the facts that can be brought under the eye of the reader to be vividly presented, in connection with the clinical history of the case. The report in the journal, however (Ward I., A., p. 213), is so lengthy that it will be necessary to resort to a summary which, it may be said, is *verbatim* the one that was recorded and placed before the clinical class, soon after the admission of the patient, in order to facilitate remarks at lecture, and to guide as accurately as possible the conceptions of the members of the class as to the presumptive diagnosis.

"Wm. G. L., aet. 35, engineer; admitted 16th March, 1899. Cardiac lesion of remarkably obscure origin, possibly of about twelve months' standing on admission; but, if so, characterized *only* by a certain amount of breathlessness and dis-

comfort on unusual exertion, for the greater part of that time. No dropsy, until less than a week before admission. No local pain, or other definite subjective sensations of cardiac distress. No haemoptysis (this negative fact continued so to the end). Almost no orthopnoea.

“Previous history of syphilis, ten years ago or more. No rheumatism. No probable history of strain. Family history unimportant.

“Cardiac murmurs of complicated character, at first interpreted as being at least partly aortic (V.S. and V.D.), with pulse more or less characteristic of aortic regurgitation.

“Well-marked hypertrophy, probably of both, certainly of the right ventricle, with heaving impulse and thrill to the hand; but no palpitation complained of. Dulness to percussion (of heart) $7\frac{1}{2}$ inches transverse. Epigastric pulsation.

“Question raised of aneurysm or other lesion, involving the right side of the heart as well as the aortic valves; but no positive evidence of this obtained.

“Enlargement of liver, with induration, but no marked irregularities. Other abdominal organs not apparently altered. Urine more or less albuminous throughout.”

It will be observed from the above concise statement of the actual facts observed, that there was very little in the history to guide the mind to a conclusion as to the cardiac character of the case, still less as to aneurysm, or internal rupture, at least up to the time of the occurrence of general dropsy. And this peculiar insusceptibility, on the part of the patient, to impressions of cardiac suffering, was maintained throughout the treatment, almost up to the fatal issue. Again and again it fell to be remarked that even in the presence of severe and dangerous objective symptoms—including a degree of general dropsy which required repeated puncturing of the limbs and scrotum, till it was for a time marvellously relieved under *diuretin*—the mental condition of the patient was one of apparently complacent optimism, which would hardly allow of the existence, according to his own reckoning, of any gravity in the symptoms at all. Along with this very remarkable *euphoria* there was, it is

true, an equally remarkable tendency to muttering delirium, without fever or any other apparent cerebral complication, but suggestive of danger had it tended (as was regarded probable) either in the direction of coma or of exhaustion. During nearly ten weeks of observation, however, his state in this respect remained the same, noisy and apparently very restless, especially at night, but yet always able to pull himself together, as it were, when addressed, and even up to within an hour or two of his death responding to questions, as if he felt "better" or "very well," as the case might be. His pulse was always unduly rapid (98 to 116, but always regular, increasing in rapidity latterly to 138), and his respiration appeared more or less laboured, but without any marked orthopnoea, or any considerable lividity until near the end. The treatment was mainly on a diuretic plan (salines, digitalis, diuretin, spartein, caffen, etc.), and was, up to a certain point, successful, the diuretin in particular taking great effect on the quantity of the urine, and for a time on the dropsical condition. It was found impossible, however, by any combination of these remedies, to prevent recurrence of the dropsy, and ultimately drainage by Southey's tubes and by incisions had to be employed—again for a time, with apparently good results—showing a very remarkable vital resistance to what seemed, all along, a most dangerous combination of symptoms. It is not desirable, however, here to go into more details of these fluctuations in the general state of this patient. The following extracts from the reports will bear chiefly on the objective cardiac changes, and particularly the murmurs.

Owing to the question of an aneurysm being throughout present to the mind, particular attention was given to the percussion of the manubrial and extra-cardiac area, but no definitely dull space such as would indicate a sacculated or general dilatation of the arch, could at any time be detected. The cardiac dulness, on the other hand, was manifestly extended laterally, and quite as much towards the right as towards the left. A distinct systolic thrill was felt over the right ventricle, and epigastric pulsation was distinctly present.

“At the apex, a loud V.S. murmur is heard” (first report after admission), “long and blowing, and a much fainter and shorter V.D. The V.S. becomes still louder towards the sternum, and reaches maximum intensity just over the tricuspid area, where also the V.D. is very distinct. Both murmurs are audible at the aortic cartilage, the V.S. being much less intense here than at the lower division of the sternum, and scarcely at all conducted into the neck, while the V.D. attains its maximum over the second right cartilage, and is not at all heard over the cervical vessels. No capillary or venous pulse can be demonstrated.”

At this time my own conviction, founding on several very careful personal observations, was that there was probably aortic valve-disease, obstructive and regurgitant, *but also, probably, something more*. The pulse was fairly characteristic of aortic regurgitation; but the peculiar distribution of the murmurs, the thrill over the tricuspid area, the epigastric pulsation and enlargement of the liver, the great amount and persistence of the dropsy, all pointed to the implication of the right ventricle to a much greater degree than is usual in aortic disease, even when of some considerable standing. In this way the question of aneurysm, though not a matter of evidence, was distinctly before the mind from the first, and was thus introduced as a speculative diagnosis into the summary above given; and, amid all the changes taking place in the general condition as above indicated, nothing in the physical signs, or the disposition of the murmurs, occurred to suggest any change in the essential lesion, until, perhaps, seven or eight weeks, or more, after admission, when a marked increase in the complexity of the murmurs began to be observed, but without any corresponding, or at least any sudden, change in the symptoms. On 7th May I endeavoured to convey this, admittedly puzzling, change, as follows: “It has seemed to Professor Gairdner in some of the more recent observations, that there is a change in the quality and even in the rhythm of the murmurs; and this at one observation suggested the possibility of some part of them (at least) being of exocardial origin (the point was, in fact, submitted to a

number of good observers). On careful observation to-day, however, it does not appear probable that this is the case; but, on the other hand, the extremely loud and all but continuous murmurs heard over the right ventricle seem to Dr. Gairdner much more striking, and also more difficult of interpretation, than what was originally observed and reported. At the right of the sternum they are not so overpoweringly loud, and are also more rhythmic, than elsewhere; and over the aortic area V.S. and V.D. murmurs, very much of the usual character in aortic disease, can still be separately distinguished; but, on the other hand, the loud, almost roaring, hollow murmurs heard midway between the left nipple and the middle line are such as to confuse the ear as to the rhythm, more especially as the sounds (apart from the murmurs) are entirely lost, and what must be presumed to be the V.S. and V.D. murmurs (see above) are here quite continuous with one another. Various hypotheses have been entertained since this patient's admission, to account not only for the peculiarities of the murmurs, but also for the obstinacy of the dropsical symptoms, and the evident great predominance of the right side of the heart in a case where the murmurs and the pulse seemed to indicate aortic disease; the question was entertained of aneurysm, possibly communicating with the right ventricle or pulmonary artery; but, on the other hand, the absence, or slight degree, of cyanosis seemed unfavourable to that view; and nothing in the percussion at the base, or the palpation in the jugular fossa corresponds with the idea of an aneurysm of the first part of the arch. Now, however, with these extremely complex murmurs heard over the right ventricle, it seems difficult to exclude some lesion of an unusual kind involving the right side of the heart; but, so far as can be observed, the pulmonary artery is not particularly involved in it, and wherever the V.S. and V.D. can be separately distinguished, the inference would rather be that they are of aortic origin."

The above note, made sixteen days before the patient's death (which occurred on May 23rd), and used for direct bedside instruction at a time when the patient was quite in a state

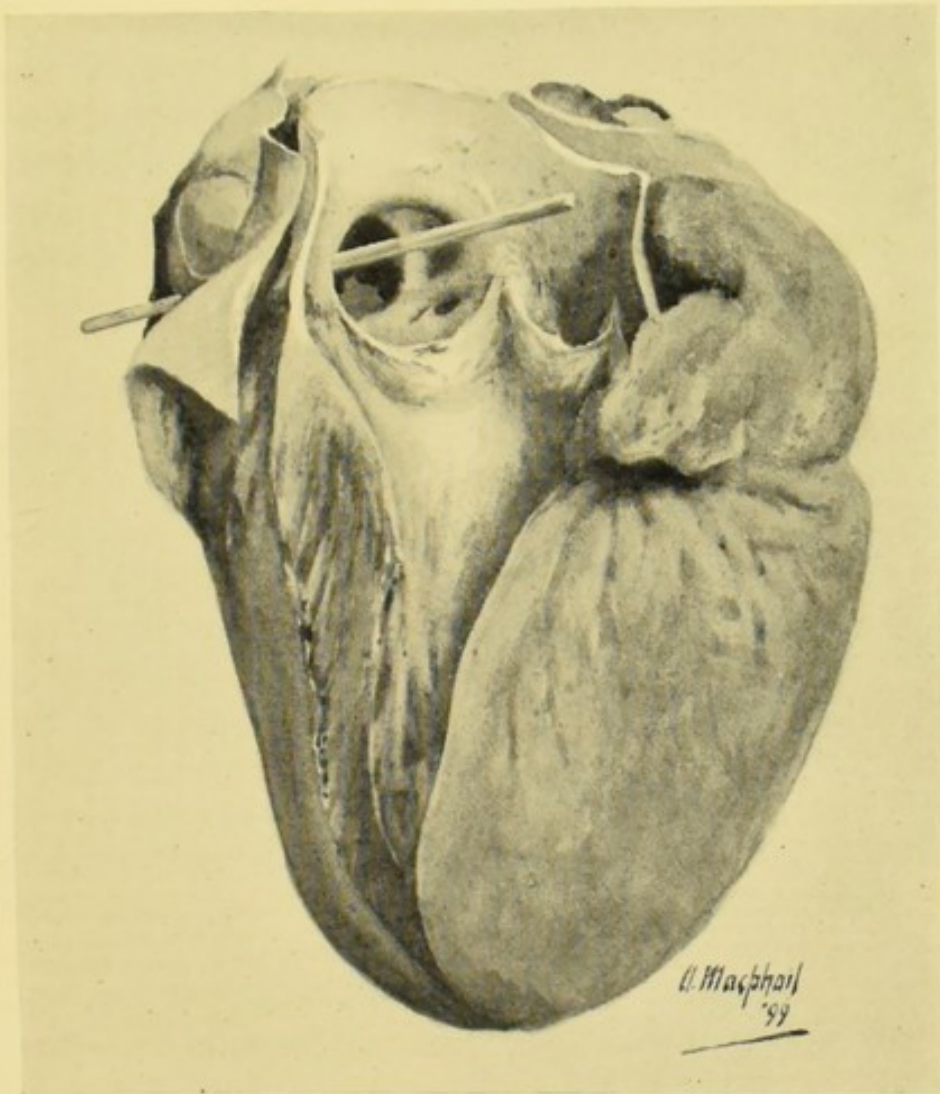



FIG. 1.—The heart and aorta laid open, showing the origin of the aneurysmal sac immediately above the anterior cusp of the sigmoid valve; the aneurysm tending towards the pulmonary artery, which is seen, laid open, to the left of the drawing, a probe being passed from the sac into the pulmonary artery by an opening which is not visible in this figure, but is prominently displayed in Fig. 2. The small opening to the right, within the sac, is that of the coronary artery.



to bear examination by a considerable number of persons, was intended specially to convey to the whole clinical class not only the absolute facts, but also the tendency of opinion on the facts, as to the changes observed in these murmurs. The diagnosis, it is true, is not perfectly accurate, inasmuch as it implies, negatively, that there was no evidence of the pulmonary artery being specially implicated, while it points, very decidedly, to the right ventricle as the seat either of rupture, or pressure by the aneurysm which, notwithstanding the absence of clear evidence by percussion, etc., had all along been regarded as not improbably existing. The presumption, to my own mind, was that a rupture directly into the pulmonary artery (or the conus arteriosus) would not only have been attended by much more considerable cyanosis (as in one or two other cases in the series above referred to), but also that in that case the murmurs would have been likely to be more strictly localized and centred, over the first and most superficial portion of the pulmonary artery itself. Nevertheless, the facts are as stated, and the difficulties here more or less successfully encountered show that the absolute diagnosis of varicose internal aneurysm, and of the seat of rupture (except perhaps in the superior cava), must still be regarded not only as among the rarities, but also among the difficult problems of physical diagnosis. In the present instance, the solution was probably as nearly attained as was possible under the circumstances.

The post-mortem examination (well illustrated as to the essential facts by Dr. Alexander Macphail's excellent sketches) gave, in summary, the following results:

"The pericardial sac contained about 6 oz. of clear serous fluid.

"The left lung was bound down by fibrous adhesions all over. The right pleural cavity contained about 30 oz. of fluid.

"*Heart.* Aortic orifice is slightly incompetent. The commencement of the aorta shows some patches of atheroma. Behind the anterior cusp of the aortic valves a comparatively wide orifice communicates with an aneurysmal sac which, passing at first to the right, bulges into the pulmonary artery.

The right anterior cusp of the pulmonic valve is stretched over the sac, and is almost obliterated. There is an aperture of communication, about $\frac{1}{8}$ inch in diameter, with the right ventricle, about half an inch below the attachment of the cusps. In the aorta, posterior to the aneurysmal opening, is another small depression, apparently a commencing aneurysm. The coronary arteries, which show some patches of atheroma, are quite uninvolved at their orifices. The mitral segments show some diffused thickening, but are otherwise normal. The pulmonic valve, with the exception noted above, is normal, as is also the tricuspid. The left ventricle measures $3\frac{3}{4}$ inch in length, and is from $\frac{3}{4}$ to $\frac{7}{8}$ inch in thickness. The right ventricle is also hypertrophied, the wall being $\frac{1}{4}$ inch in thickness. Both auricles are dilated, and contain some ante-mortem clot.

“There is venous congestion of the lungs, kidneys, liver, and spleen.

“The aorta, both thoracic and abdominal, shows numerous raised patches of atheroma, pretty equally distributed; these are soft, but show no trace of ulceration or calcification.

“The right internal jugular vein is found thrombosed, the thrombus extending down to the junction of the subclavian vein, and partly obstructing the latter. The thrombus is of firm consistence, laminated, pale, and in parts adherent to the wall.” (This lesion does not appear to have been noticed during life.)

It has been already remarked that, especially in the earlier observations of the case, the radial pulses had in general the characters of those of aortic disease. The “water-hammer” character to the finger was frequently very well marked, and the sphygmographic tracings obtained (which were sometimes difficult to procure owing to the dropsy) were quite in conformity with this view, although under the influence of digitalis, etc., they varied considerably as to the extent of the primary wave and the distinctness of the dirotic and other waves. In one tracing, obtained on 12th May (eleven days before death), the tracing was decidedly hyperdirotic in character.

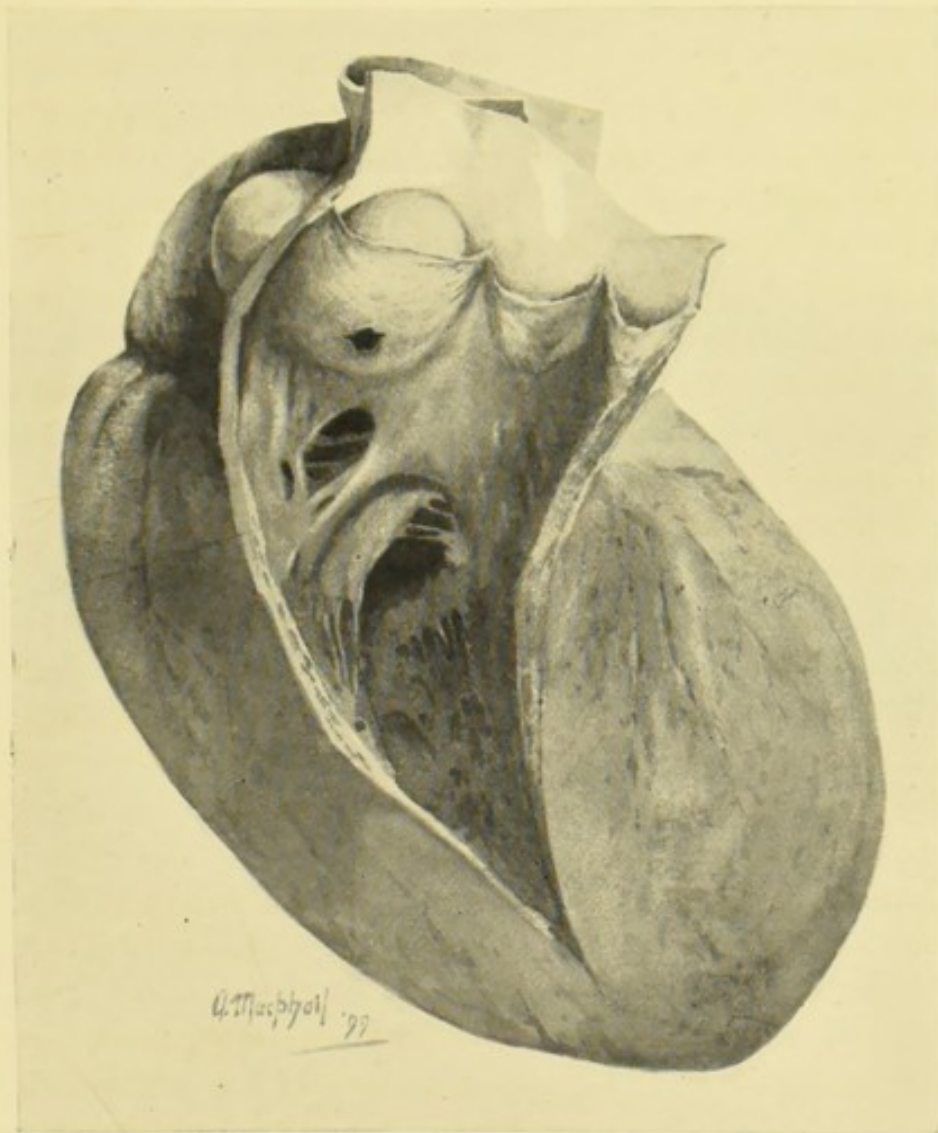

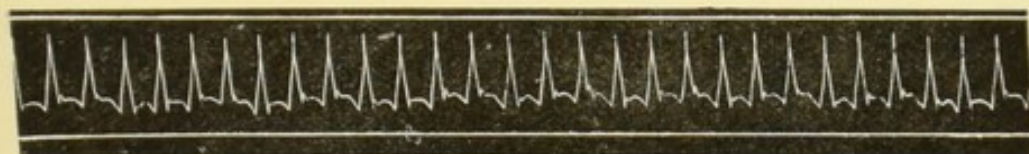



FIG. 2.—The aneurysm as seen from the pulmonary artery, with the somewhat ragged opening into the right ventricle (just below the valve) through which the probe is seen to be passed in Fig. 1. The posterior cusp of the valve of the pulmonary artery is seen stretched over the sac, these valves being in other respects normal. The cut edge of the aorta is seen behind.



In the only case very strictly comparable with this one, contained in the above series (numbered 58 in the list of museum preparations from the Western Infirmary), the brief description given is "Aneurysm of the aorta, projecting into and perforating the pulmonary artery." In this case, which was also under my own care, the aneurysm was much larger than in the present case ("as large as the fist") and, independently of the perforation, must have exercised a very considerable amount of direct pressure, not only upon the



The first of these tracings shows a very characteristic one obtained early after admission, with the very perpendicular up-stroke or primary pulse-wave, the very acute apex, the well-marked tidal wave, and dicrotism as in a case of aortic regurgitation. The second shows the greater degree of approach to hyperdicrotism, at a more advanced period (May 12th), when the rupture may be regarded as fully completed, and the murmurs were in course of developing the much more complicated character described in the last report above cited. The intermediate tracings were not considered characteristic, perhaps owing to the dropsy, which rendered it difficult sometimes to obtain tracings at all, and must have interfered with their definition. The finger, however, for the most part, could still recognize the "water-hammer" character, more or less, throughout.

pulmonary artery, but upon the left auricle and auricular appendage. It was characterized, accordingly, by much more apparently grave symptoms than the present case, and particularly by "great angina pectoris and dyspnoea, with lividity, lasting more than a year; dropsy also, which became extreme towards the close, with considerable (though not sudden) increase of the lividity and the other symptoms, and also pervigilium and orthopnoea. Death was at last sudden, but only after a very lengthened agony." In that case, however, as in the present, it was found exceedingly difficult, if not impossible, in view of the whole facts, to determine at what

precise point in the history the perforation may be supposed to have occurred. As in the present case, the murmurs on admission were V.S. and V.D. in rhythm; and as the aorta presented signs of dilatation in its ascending portion, these were readily enough concluded to have their origin either in the valves, or in an aneurysm of that portion of the vessel. These murmurs, however, became very indistinct during the progress of the case, giving way to a V.S. murmur, which from its localization was regarded as mitral or tricuspid. "Great hypertrophy and dilatation of both ventricles, with venous pulse, became apparent in the course of observation. The liver also became enlarged, the urine scanty, of high specific gravity, and albuminous. The pulse was one of low tension, almost hyperdirotous, with an occasional irregularity, but not complete intermission, the low tension increasing as the case proceeded." In my brief remarks appended to the case are these words: "Both the murmurs here were probably aneurysmal, inasmuch as the aortic valves were not diseased. The disappearance of the V.D. in the course of observation is not very easily explained unless as a consequence of the increasingly low arterial tension, which, again, may be referred to the communication with the pulmonary artery. There was no specific fact to indicate the time of the rupture."

In a case which has been frequently referred to, and on which some critical remarks will be found in Walshe, *Diseases of the Heart*, etc., 4th edit., p. 530, Sir Willoughby F. Wade has published (*Med. Chir. Trans.*, vol. xliv., p. 211) what seems to be one of the very few cases of aortic aneurysm in which "a communication with the pulmonary artery was recognized during life by means of physical diagnosis." In this case, as in most of those recorded, a double murmur having more or less resemblance to the usual aortic valvular murmur in rhythm existed, and Dr. Wade lays great stress on the fact that while this double rhythm was evident in the neighbourhood of the conus arteriosus and pulmonary artery, the diastolic element was not propagated to the apex, where, although a blowing murmur attended the first sound, "the cardiac second sound was very distinct and quite natural; no trace of murmur." Upon this,

Dr. Walshe remarks that (according to Dr Wade) "non-conduction of existent diastolic murmur downwards to the heart's apex is the key to the diagnosis of aortic communication with the pulmonary artery. But," he goes on to say, "this inference seems to me very seriously shaken by the fact that in some cases of aortic regurgitation, the attendant diastolic murmur is not transmitted to the left apex, where, on the contrary, a pure second sound is heard; this holds true even of excessively loud basic reflux murmur. Yet more, in a case of aorto-pulmonary communication by W. Roberts, the attendant murmur (a double one) was distinctly heard at the left apex." There is no doubt, I think, that Dr. Walshe is technically right in this criticism, and that Sir Willoughby Wade has laid a stress on this particular diagnostic point which it can by no means bear. At the same time, I am not disposed to consider (as Dr. Walshe apparently does) the whole principle of the diagnosis in Dr. Wade's case, as vitiated by this error. What he actually observed was a double murmur accompanying, or rather replacing, the two cardiac sounds; "that with the second sound being of a hissing character, and so prolonged as to continue till the commencement of the next ventricular systole"; the special seat of these murmurs being "over the cartilage of the fourth left rib." The murmurs were widely distributed, but at this, the spot of their evidently maximum intensity, "a very considerable purring tremor accompanied the second murmur." The propagation of the murmurs along the carotids made it probable that they originated in the aorta, while their maximum intensity at the cartilage of the fourth rib (left) gave the impression that the right side of the heart (conus arteriosus or pulmonary artery) had something also to do with modifying the conduction. The peculiar quality and prolongation of the second murmur, together with its no less unusual distribution, appear to have carried the convictions of the observer by an instinct more sure than his verbal and categorical arguments, towards the conclusion that some very unusual form of lesion, probably aneurysmal, had established a communication between the systemic and pulmonic circulations; and if so, most probably

(on the ground, as stated, of numerical frequency) between the first part of the aorta and the pulmonary artery. It will be found, I think, that the tentative diagnosis indicated in the case which I have here recorded, under circumstances of greater difficulty and obscurity, was in accordance with what has just been stated as bearing on Sir Willoughby Wade's remarkable case. In this latter case, moreover, there was, in the opinion of Dr. Wade, a distinct probability arising from the history, that the first rupture of the aneurysm into the pulmonary artery (there was a second, apparently of more recent date, and attended by much more severe symptoms, into the right ventricle) had originated in a severe effort made to avoid being run over (the patient was a railway porter), which had produced considerable faintness at the time. In my present case, as will have been seen above, there was nothing in the history which, even after knowledge of all the facts, could be construed as having such significance. It is rather remarkable that in only one of the cases in the Glasgow museums is there any history of sudden accident or illness, such as might be expected, and has often been described, as the consequence of rupture of an aneurysm into some other portion of the organs of circulation. This was my case of rupture into the vena cava superior, already alluded to.

In his carefully studied, but no doubt somewhat imaginative, description of a typical case of aneurysmal communication with the pulmonary artery (816, p. 529), Dr. Walshe writes as follows: "If an individual known, or not known, to have been the subject of aortic aneurysm suddenly experience after effort a sensation of something giving way in the cardiac region, feel faint, become pale and exhibit the general characteristics of nervous shock as in the heart, followed by peculiar fluttering in the chest,—if he subsequently suffer from dyspnoea or orthopnoea, more or less cyanotic blueness of the lips, pallor of the face, chilliness, prostration of strength, anxiety, terrible dreams, occasional nausea and vomiting, syncopal and pseudo-epileptic attacks, and become anasarctous in the lower extremities, while the lungs and liver undergo mechanical engorgement, as proved by percussion,—if all this

coexist with powerful systolic thrill, limited to the second and third left intercostal spaces close to the sternum (lower than this, it is explained in a note, if the heart itself is lowered by hypertrophy), and with loud whirring murmur essentially systolic and intermittent, though sometimes inclining to continuousness (or, it may be, double murmur similarly seated), the diagnosis of sudden communication between the aorta and either the pulmonary artery or right ventricle is warranted."

No one who knows well Dr. Walshe's constant habit of verification, in even the most minute details, of all his own apparently casual statements, can do otherwise than accept this *syndromé*, or "symptomen-complex," as a good working basis for future research, in so far at least as that a case presenting the majority of these phenomena, or the more important of them, in the succession here referred to might fairly be expected to show on a post-mortem examination the lesion, or lesions, here assigned to the description. But the case which I have here placed on record shows indisputably—*first*, that there may be no sudden shock or sense of "giving way" with or without effort; *secondly*, there may be no orthopnoea at all (this was most carefully attested in my case up to nearly the end) and certainly not more, probably much less, of dyspnoea than attends the great majority of ordinary cardiac diseases; *thirdly*, cyanosis may be quite inconsiderable, and also a phenomenon of very late occurrence, almost a part of the agony; *fourthly*, "syncopal and pseudo-epileptic attacks" may be altogether absent throughout. In fact, it may be quite impossible *from the symptoms alone*, even after the facts have been suspected during life and verified after death, to say at what period in the case the rupture has taken place.

As regards the physical signs, my own experience and reading incline me to affirm that the murmurs in such cases will usually be double, the V.D. element not unfrequently predominating, as in Sir Willoughby Wade's case, and very harsh, whether or not accompanied by thrill (Dr. Walshe probably dwells too much on the "systolic" element in these

cases). In the interesting and well-recorded case of the late Sir Wm. Roberts (*British Medical Journal*, 1868, vol. i., p. 421), quoted by Walshe (but not as regards this particular point), the description is as follows: "A loud harsh double murmur was heard at the mid-sternal base; or, rather, it was a single murmur consisting of two parts and covering completely both sounds. This murmur diminished rapidly in intensity towards the apex, where, however, both parts of it were distinctly audible. It was not heard beyond the apex. It was heard in moderate intensity at the ensiform cartilage. It was well conducted up the aorta and into the great vessels at the root of the neck. But the murmur was heard far more loudly at the upper margin of the cardiac dulness, midway between the middle line and left nipple. At this spot it was excessively loud, harsh, and rasping; it gave the impression of being produced very near the ear. It could even be heard by the naked ear at a distance of an inch from the surface of the chest. It diminished in intensity in all directions from this centre. Over the body of the ventricle it *seemed so superficial that it deceitfully resembled a pericardial friction sound.*" I have emphasized this last statement in order that it may be compared with the notes, given above in full from my hospital journal, as to the later stages of the murmurs in the case here recorded. The question of exocardial origin, which ought always to be present to the mind in cases of very complex or anomalous murmurs, is there also raised, but only to be again dismissed, as in Sir Wm. Roberts' case.

On the whole, this description, as well as that of Sir Willoughby Wade and my own personal experience, tends to the conclusion, that while the murmurs in these cases often present a general resemblance to those of aortic valve disease, there are usually details of differentiation which, if carefully studied, will lead up to a different diagnosis, and it may very probably be the case as (following Dr. Sansom) I have assumed in the article on aneurysm of the aorta in Clifford Allbutt's *System*, vol. vi. (p. 399), that, when the opening is into the right auricle or superior cava, the murmurs will tend

towards the right of the sternum, while, when the opening is into the pulmonary artery or conus arteriosus, they will be more definitely heard towards the left. The approach to continuity of the murmurs, also discussed in that article, is well illustrated in the present case, as well as in that of Sir Wm. Roberts, although it is perhaps only in cases of communication with the great veins that we may expect, if at all, the state of matters described by Dr. Ord: "a long continuous humming murmur, never ceasing, but varying in intensity, more sonorous during systole, fainter during diastole, conducted into the neck, and heard over the whole right side of the chest posteriorly." (See article on Aneurysm above alluded to, p 399.)

It remains to be stated, as a negative point of some importance, that murmurs of the above characteristic types may be absent, or unrecognizable, in some cases of aneurysms, either opening into the vena cava, or into the right side of the heart and pulmonary artery. In the other case of rupture into the pulmonary artery, reported in abstract in the *Transactions of the Pathological and Clinical Society*, murmurs which in the main suggested aortic valvular disease, with regurgitation, were present at the earlier observations, and afterwards completely or almost completely disappeared, leaving only a murmur, V.S. in rhythm, near the apex, which might have been, and was regarded as being probably of mitral or tricuspid origin; and as the symptoms were those in general of advanced cardiac disease, with dilatation and hypertrophy of both ventricles, the disappearance of both, but especially of the V.D. murmur, can only be accounted for by the greatly diminished arterial tension, which was further evidenced by the markedly hyperdiastolic character of the pulse at the wrist. The murmurs, too, were regarded in this case (after the P.M. examination) as of directly aneurysmal origin, inasmuch as the aortic valves at least were found to be intact, although it is possible, of course, that the protrusion of the aneurysm into the pulmonary artery, and the strain to which the valves of that vessel were subjected, may have had something to do with their having origin in that vessel.

Cyanosis, too, was much more evident in that case than in the one to which this article is chiefly devoted.

I wish, before closing the present paper, to allude very briefly to yet another case occurring a few months later than the present, and recorded, with illustrations, in the *Glasgow Medical Journal*, vol. xlix., 1898, p. 195 (Glasgow Pathological and Clinical Society, 13th December, 1897). In this case a small aneurysm, with endocarditis, had arisen in connection with the cusps of the aortic valve (which was of course incompetent), and had ultimately caused obstruction in the pulmonic circulation by pouting into the infundibulum of the right ventricle. There was in this case no rupture into the right cavities, but (singular to state) the history was much more conformable to the idea of such rupture, and to Dr. Walshe's typical *syndromé*, than in the case on which this article is founded. There was a distinct history, not only of strain eight weeks before admission, but of a sudden development of cardiac symptoms, especially "an uncomfortable beating of the heart" *immediately* after the strain. Anginous attacks, aggravated very greatly by the slightest exertion and by alcohol, succeeded, and were maintained after this throughout the observation of the case. Tachycardia was so marked a feature of the illness (also throughout) as to excite particular attention and to determine treatment, which, however, though of the most varied kind, was almost entirely ineffectual. There was only slight oedema, and the urine was very slightly albuminous. Temperature was normal. Death was sudden, about six weeks after the apparent origin of the illness (the strain as above). There was no history of rheumatism, and none of syphilis; but it is worthy of notice that the patient's habits were far from temperate; and as he went up for a month's training with the militia after the supposed beginning of the illness, he had abundant opportunities of observing for himself the effects not only of exertion, but of even moderate amounts of alcohol, in increasing his distress. The murmurs in this case were extremely difficult to define, but the one chiefly in evidence was regarded as probably V.D. in rhythm, and was heard best to the left of the sternum rather below

the pulmonic cartilage. From the whole of the facts the following diagnosis was formed during life, and expressed to the clinical class, founding mainly on the persistent and well-marked tachycardia, and the almost indescribable difficulties in detail with regard to the interpretation of the murmurs: "The physical signs were those mainly of the valvular disease. There was, however, a well-defined suspicion of aneurysm, embodied in the clinical abstract used for lecture purposes, and stated in advance at the post-mortem examination. This suspicion arose from certain clinical peculiarities of detail: (a) Anomalies of murmur and sound; (b) suspected dulness at base (doubtful, however, and contradicted in a second report); (c) marked tachycardia, in excess of what is to be expected in a lesion of the aortic valves. The incompetency of the valve explained (P.M.) the double murmur, but there was this *something* in the case which vaguely suggested more.

It appears, therefore, that while the main facts of Dr. Walshe's symptomatic *syndromé* as to the history may be wanting in cases of actual rupture, the most striking of these facts may appear, in a way not unlikely to mislead, in cases where no actual rupture has taken place.

[I desire to take this opportunity of noticing (although not strictly in accordance with the title of this communication) a most valuable paper in the *International Journal of the Medical Sciences* for October, 1890, by the late Dr. Pepper of Philadelphia, U.S., and Dr. J. P. Crozier Griffith, on "Varicose Aneurisms of the Aorta and Superior Vena Cava." This paper altogether escaped my notice when engaged on the article on Aneurysm for Dr. Clifford Allbutt; but from the detailed personal record of one case, and the careful reference to and abstract of twenty-eight other cases presumed to be all that were available in medical literature up to the date in question, this painstaking investigation assumes very high rank in the literature of the subject. I infer from a reading of this memoir, as indeed is stated above: (1) That the diagnosis of rupture into the vena cava superior is usually easy as compared with that into the pulmonary artery; (2) that the sudden onset, indicating the exact time of the rupture, is a much more

frequent and prominent fact in the former than in the latter class of cases (the most distinctive symptom being the dropsy localized in the upper half of the body); (3) that cyanosis in a high degree, in the upper part of the body at least, and accompanying the dropsy, is much more characteristic of rupture into the V.C. than into the pulmonary artery, or even into the right cavities of the heart.]

