

**On the difference in the mode of ossification of the first and other metacarpal and metatarsal bones / by Allen Thomson.**

**Contributors**

Thomson, Allen, 1809-1884.  
University of Glasgow. Library

**Publication/Creation**

[Place of publication not identified] : [publisher not identified], [1868?]

**Persistent URL**

<https://wellcomecollection.org/works/anymr5hg>

**Provider**

University of Glasgow

**License and attribution**

This material has been provided by This material has been provided by The University of Glasgow Library. The original may be consulted at The University of Glasgow Library. where the originals may be consulted. This work has been identified as being free of known restrictions under copyright law, including all related and neighbouring rights and is being made available under the Creative Commons, Public Domain Mark.

You can copy, modify, distribute and perform the work, even for commercial purposes, without asking permission.



Wellcome Collection  
183 Euston Road  
London NW1 2BE UK  
T +44 (0)20 7611 8722  
E [library@wellcomecollection.org](mailto:library@wellcomecollection.org)  
<https://wellcomecollection.org>

On the Ossification of the Metacarpal  
Bones. by A. S. (with plate)  
from Journ. of Anat. & Physiol.  
Nov. 1868. vol. III.

Glasgow  
University Library



R0 1942/20

ON THE DIFFERENCE IN THE MODE OF OSSIFICATION OF THE FIRST AND OTHER METACARPAL AND METATARSAL BONES. By ALLEN THOMSON, M.D., F.R.S., *Professor of Anatomy in the University of Glasgow.*

ALL anatomists who have given attention to the progress of ossification in childhood are aware of the fact that, at the age when the epiphyses of the long-shaped bones of the hand and foot are most obvious, viz. from ten to fifteen years, each metacarpal and metatarsal bone, and each one of the digital phalanges usually consists of two ossified pieces united by intervening cartilage and separable by maceration; one of these pieces forming the shaft and main part of the bone and extending quite to one extremity, while the other smaller piece constitutes an epiphysis occupying the opposite extremity of the bone. The epiphysis occupies the proximal extremity in all the digital phalanges, while in the metacarpal and metatarsal bones the epiphysis is usually proximal in the first (or that of the thumb and great toe), and distal in the four remaining bones.

The fact in human anatomy now referred to has been very generally described in manuals and systematic works; and some authors have even regarded the difference between the first and remaining metacarpal and metatarsal bones as so constant and marked as to have founded upon it an argument for regarding the first of these bones as properly constituting one of the digital series of bones, that is, the first or proximal phalanx of the thumb or great toe<sup>1</sup>.

<sup>1</sup> On this ground Humphry (*Treatise on the Human Skeleton*, Camb. 1858, p. 395), inclines to regard the bone which rests on the trapezium in the hand as intermediate between a digital phalanx and a metacarpal bone, though he considers it on the whole to be most correct to call it a metacarpal bone, and regards the second phalanx to be the missing segment in the thumb. On this and other grounds Prof. Struthers ("On Variation in the number of Fingers and Toes," &c., in *Edin. New Philos. Journ.* for 1863, Vol. xviii, p. 111), regards as established "that the bone which is wanting in the human thumb and great toe, and in the internal digit of other five-toed Mammals, is the metacarpal and metatarsal, although custom and convenience lead us to apply these terms to the bone which homologically is a proximal phalanx."

The object of the present paper is to show that the difference in the mode of ossification in question is neither so constant nor typical as to warrant the hypothetical view above stated, and to point out the fact that there are deviations from the mode of ossification which has generally been regarded as the usual one, existing occasionally in man, and to be found in a more marked degree in some animals, which lead to the view that the separate ossification of pieces of these bones in epiphyses is subject to considerable variations, and that the process must be viewed in a wider range of observation before it can be taken as the sole groundwork of conclusions as to typical or homological form. The caution which is necessary in forming such conclusions on purely osteogenic grounds has, indeed, been well indicated by Huxley and Gegenbaur with respect to the bones of the head; and although it may be allowed that there is less reason for doubt in respect to the larger bones of the limbs, among which a very constant and regular correspondence has been observed in the development of certain epiphyses both in man and animals, yet the possible varieties in these have been heretofore too little studied by actual observation throughout the animal series, to admit of their being made with confidence the basis of fundamental characters.

Having been engaged some years ago in the examination of specimens illustrating the ossification of the hand and foot in the earlier period of the formation of the epiphyses, I observed in several examples of the first metacarpal and metatarsal bones such distinct indications of the separation of distal epiphyses as led me to inquire farther into the subject. I then observed not only very distinct epiphyses of the kind mentioned, but also in one or two instances fainter indications of the tendency to the separation of a proximal epiphysis in the second metacarpal bone of man; and on extending my observations to animals, I found that while in the greater number of five-toed mammals the epiphyses have the same disposition as that commonly ascribed to those of man, there are other animals in which distal epiphyses exist more or less perfectly developed on the first metacarpal and metatarsal bones, and that other deviations from the more usual mode of ossification of the bones of the

hand and foot exist, sufficient to disprove altogether the hitherto supposed uniformity of the process.

The existence of distal epiphyses on the first metacarpal and metatarsal bones of man was not however altogether unknown to anatomists. On the contrary, Albinus was well aware of the fact, and several others have referred to it. In his work entitled *Icones Ossium Foetus, Brevis Osteogeniae Historia*, published at Leyden in 1737, at p. 115, Albinus, in describing the ossification of the metatarsal bones, says, that they are each formed from a centre in the cartilage of the shaft, and that, this growing upwards and downwards, the bone at birth consists of an osseous body with two cartilaginous extremities. The anterior extremities (of all five) pass at last into epiphyses, which he found about the fifteenth year almost entirely united with the bodies in four metatarsal bones, and completely united in that of the great toe. The posterior extremities, except that of the great toe, are occupied by the advancing bone of the shaft, and as yet he had not seen them forming epiphyses. The posterior extremity of the metatarsal bone of the great toe, however, forms an epiphysis not long separated.

At p. 137 again he says, that the same description as before given of the metatarsus applies to the metacarpus. But the inferior (distal) epiphyses of the metacarpals he found still separable at the age of fifteen years, and long afterwards fissures remain where they are united to the shaft. The inferior epiphysis of the thumb unites sooner with the shaft than the superior<sup>1</sup>.

Cruveilhier, in his *Treatise on Human Anatomy*, after describing the development of the metacarpal and metatarsal bones in the usual manner, and distinguishing the first by its proximal epiphysis, appends the following note to his descrip-

<sup>1</sup> Nesbitt, in his work on *Human Osteogeny*, published in 1736, the year before Albinus' work, describes the metacarpal and metatarsal bones as only four in number in each limb, and reckoning thus the first metacarpal and first metatarsal as phalanges of their respective digits, he describes them as having the same mode of ossification with the other phalanges, viz. each one from a principal centre and a proximal epiphysis. Nesbitt was therefore not aware of the occasional existence of distal epiphyses in these bones. Op. cit. pp. 125, 126.

E. H. Weber, in his *Hildebrandt's Anatomie*, Vol. II. p. 227, refers to Albinus' observations, but he does not appear to have himself confirmed them.

tion of the metatarsal bones (Vol. I. p. 304): "I ought however to remark here, that in some subjects there appeared to exist in the digital extremity (of the first metatarsal) an epiphysal point which is very thin and which unites early with the body."

On the other hand Meckel, who was probably aware of Albinus' view, states explicitly in his *Descriptive Anatomy* that he had never seen a distinct nucleus in the distal end of the first, nor in the proximal end of the other four metacarpal bones.

In his work on *Human Osteology* (2nd edition, 1857, p. 154), Mr Holden has given a description of the formation of the metacarpal bones, which is somewhat inconsistent in itself, and does not agree with that of other authors, or with the facts as observed in nature, but which may have been suggested by observations of the same kind with those of Albinus, and of the author of this paper. He says, "Like all the long bones, each metacarpal bone has a centre of ossification for the shaft, *and one for each of the articular ends*. In the first metacarpal the artery of the marrow runs towards the lower end, therefore the lower epiphysis unites sooner than the upper to the shaft. This is just the reverse of what takes place in all the other metacarpals, in which the artery of the marrow runs towards the upper end." Again, with reference to the metatarsal bones, he makes, at p. 204, the following statement: "Each metatarsal bone has two centres of ossification; one for the shaft, the other for the head. The first metatarsal, however, has its terminal epiphysis not at the head, but at the base, which is precisely the case with the metacarpal bone of the thumb."

*Observations in the Human Subject.*

It is not my intention to enter into the consideration of the whole progress of ossification in the bones of the hand and foot; but it may be proper for me to recall to the recollection of the reader in a few words the main facts as to the first appearance of ossific deposits in them.

The earliest steps of ossification of the metacarpal and metatarsal and digital bones are, on the whole, very similar to those of the larger bones of the limbs; the first ossific deposit

occurring in the centre of the cartilaginous matrix of the shaft at an early period, which varies in the different bones, according to their position in the series, from the 8th or 9th to the 12th or 13th weeks. From this primary centre the ossification extends in the cartilage with the usual changes attendant on the formation of medullary spaces, and finally of a medullary canal, if such exists; and the greater part of the bone forming the shaft is completed by this process, and by the known superposition of the subperiosteal layers. At the period of birth in all of them a considerable mass of cartilage still remains at each extremity of the bone. In these cartilaginous masses the ossific nuclei of the epiphyses appear in those extremities in which bony epiphyses are to be formed; but the commencement of their deposition dates considerably later than the primary ossification, at a variable period between the third and fifth or sixth years; or even one or two years later.

In those ends of the bones where no epiphyses are to be formed, the original cartilaginous ossification of the shaft gradually extends itself into the terminal cartilage; but when a separate epiphysis occurs, although the main ossification also extends somewhat towards that extremity, it is met by that of the epiphysal nucleus, the two parts of bone being for a time divided by the remains of cartilage. There is therefore a marked distinction between the ossification of an epiphysis, which is almost entirely cartilaginous, and that proceeding from the original nucleus of the shaft, which internally is cartilaginous, but superficially is subperiosteal.

The general fact is well known in regard to the larger bones that the separate epiphyses which soonest become united by bone to the shaft are the latest in the commencement of their ossification; and we see this general fact well illustrated in the bones of the hand and foot, in connection either with the early consolidation or the entire absence of an epiphysis at one extremity.

In now proceeding to mention shortly the result of the observations I have made, I will refer to the figures of p. 144 to explain more fully the appearances described. In all cases which I have examined at a sufficiently early age, that is, about



seven or eight years, and in some more advanced, I have found, in addition to the more distinct and constant proximal epiphyses of the first metacarpal and metatarsal bones, traces of a separate distal epiphysis. In figure 1 and figure 3, a view is given of the appearances presented by the first and second metacarpal and metatarsal bones with their corresponding digits in the macerated and dried condition at the age of eight years. The fissures indicated at *d'*, though deep, are not here such as to separate completely the epiphyses from the shaft of the bones. Figures 2 and 4 show the state of the parts in recent wet specimens taken from a subject stated to be about a year younger than the first. The section of the bones has been carried longitudinally from the dorsal to the palmar surface; and it will be observed that in the first metatarsal bone the distal epiphysis, in which ossification has made considerable advance, is completely separated from the ossified shaft of the bone by a plate of cartilage; and that, though somewhat irregular, the form of the epiphysis is very similar to the more constant epiphysis of the second metatarsal bone. In the first metacarpal bone the separating plate of cartilage is not complete, leaving a space in the centre where the bone of the shaft is continuous with that of the end portion, but yet sufficient to indicate the form of an epiphysis.

In figure 2' I and figure 4' I are represented the appearances observed in another specimen in the wet state; and in these it will be seen that, while the ossification from the main shaft has run onwards in the greater and deeper part into that of the end of the bones, the surrounding parts are interrupted by the indentation of small angular pieces of cartilage which mark the commencements, as it were, or lowest stage in the separation of an epiphysis, and correspond in every respect to the outer part of the more complete dividing cartilage.

Such observations as these are necessarily limited from the difficulty of obtaining subjects at a suitable age: but from the circumstance that in all favourable instances which have come under my notice at ages between seven and fifteen years, traces of the separation of the distal epiphysis have been found in both the first metacarpal and metatarsal bones, I am inclined

to look upon the disposition at least to the formation of such epiphyses as general; while in a certain number of instances, the proportion of which I cannot at present determine, the separation by cartilage of a bony epiphysis is at one time complete.

The circumstance that this epiphysis (which may be called occasional) is united by ossification to the shaft of the bone several years earlier than the proximal epiphysis has probably caused it to be overlooked by most anatomists.

The existence of an occasional proximal epiphysis on any of the metacarpal or metatarsal bones is according to my experience much rarer than the distal variation already described as occurring in the first. The distinct traces of separation of such an epiphysis are limited, indeed, so far as I have yet seen, to the second metacarpal bone.

In the instance represented in figure 1, II, I observed a groove of considerable depth extending inwards, fully a third through the thickness of the bone from the radial side near its proximal extremity; and in another similar specimen examined in the wet state and represented in figure 2', II, a short strip of cartilage was found to dip inwards into the bone from the radial side; and from the position and shape of this piece of cartilage and the correspondence of its position with the distinct groove in the macerated specimen, I cannot doubt that it is an indication of epiphysal separation. I have only seen very faint indications in the third metacarpal bone of any similar epiphysal fissure; and I have not detected anything of the kind in the proximal extremities of the metatarsal bones.

The fact is well known to anatomists, that in the long bones of the limbs there is a very constant relation between the direction in which the so-called nutritious foramen passes through the shaft of the bone and the order of ossific union of the terminal epiphyses; the foramen being generally inclined towards that extremity at which the consolidation of the bone first occurs. In the passage previously quoted from Holden's work, that author refers to this peculiarity of the nutritious foramina as existing also in the metacarpal and metatarsal bones. My observations are in general confirmatory of his state-

ment. Thus, I have found the direction of the nutritious foramen to be almost always upwards, or towards the proximal end, in the four metacarpal and four metatarsal bones, while in the first metacarpal and metatarsal bones it is most frequently directed downwards or towards the distal extremity.

In one of two examples presenting the fissures which indicate partial distal epiphyses, the downward direction was more distinct than in the other; and it so happened that in that side the distal epiphysis was least separated from the shaft of the bone. At the same time I may remark, that although I admit the coincidence of the phenomena above stated, I have no other grounds for connecting them in the relation of cause and effect.

*Observations in Animals.* I regret that my opportunities of examining the skeletons of young animals have as yet been too limited to enable me to deduce any general laws which might result from more extended observations of this kind. I may state here however shortly the result of the observations I have made.

In the majority of five-toed mammifers, the mode of ossification of the bones under consideration is the same as that usually described in man. This is the case in several different genera of the Simiæ: but among these I notice exceptionally in a young chimpanzee some indications of the separation of a distal epiphysis on the first metacarpal bone. In the Arctic bear, the badger, and the otter, the distal epiphyses of the four metacarpals and metatarsals, and the proximal only of the first of these bones are very distinct, and this is all the more marked that the ossific union of the epiphyses in these three animals seems to be comparatively tardy. As however the specimens I have examined were well advanced in age, in fact nearly full grown, I do not venture to affirm that other epiphyses may not have existed at an earlier period. In a young specimen of *dasyurus* the same appears to be the condition of the epiphyses.

In the walrus the final union of the epiphyses seems to be tardy, as appears to be the case in all the aquatic as well as in the largest mammifers. In a macerated skeleton of this animal, which however is nearly full grown, I observed the epiphyses presenting the same conditions as in the animals previously

mentioned. The same statement applies to the metacarpal bones of the cat and dog. In the hind feet of the same animals, and in both limbs of all animals having fewer than five digital elements, such as the hog, the ruminants, and the horse, the metacarpal and metatarsal bones have invariably only distal epiphyses.

But in some other animals I have found a different state of things. Thus in the fore-limb of the kangaroo, of which, however, I have only examined one specimen, and that far advanced in growth, I could distinguish a fissure separating a distal epiphysis from the first metacarpal bone, of exactly the same nature, but not so open or distinct as those of the four other metacarpals. In the koala likewise (*Phascolarctos*) I find the same appearances as in the kangaroo; and this animal was also nearly full grown. In the fore-foot of an Asiatic elephant of large size showing the separate epiphyses very distinctly in other parts of the skeleton, there is a fissure separating a distal epiphysis from the inner or first metacarpal bone almost as distinct as those of the other four metacarpal bones.

In the ornithorhynchus, seal, and cetacea, I have observed greater peculiarities which merit a special description.

With regard to the first of these animals my statements are made with some hesitation, as in the only skeleton which I have had an opportunity of examining previous to the completion of ossification the process was far advanced, and the epiphyses had begun to be united to the rest of the bones. The usual epiphyses of the mammifer existed in the larger bones of the limbs. This fact is in itself interesting, when we take into account the similarity between some parts of the skeleton of the monotremata and that of birds and reptiles,—in which animals it would appear that the epiphyses of the limb bones are either entirely wanting, or are united to the rest of the bones at so early a period as to have escaped notice.

In the fore and hind feet of the ornithorhynchus there are found indications of distal epiphyses on all the five metacarpal and metatarsal bones including the first; and, what is still more exceptional, besides the usual proximal epiphyses of the first metacarpal and metatarsal, there are also grooves

separating epiphyses on the proximal ends of the second and third bones of the series, and less obviously of the fourth and fifth bones. In the foot, however, I found the groove on the fifth metatarsal bone more distinct than that on the corresponding metacarpal.

In a skeleton of the echidna *histris* in my possession, and which appears to be full grown, although there are still marks of epiphyses in the larger bones of the limbs, ossification has proceeded so far in the bones of the foot as to prevent me from determining the position of the epiphyses<sup>1</sup>.

I have examined two skeletons of the common seal, one somewhat more advanced in growth than the other, but both young, and with the ossification proceeding in the shaft and extremities in such a way as to present appearances peculiarly favourable for distinct observation. One of these skeletons had been macerated and dried; the other was in the wet state. The state of the parts was essentially the same in both, and is represented in so far as it appeared unusual in figure 5, I and II, taken from the wet specimen.

In the fore-limbs the mode of ossification did not differ in any respect from that which is considered most usual in man, there being only distal epiphyses in four metacarpal bones, and only proximal epiphyses in the first metacarpal and in all the digital phalanges. But in the hind-foot it was very different; for there the first metatarsal bone, besides the usual proximal epiphysis as in the metacarpal bone, presented a large and distinct distal epiphysis, precisely similar to those of the four other metatarsal bones which had only distal and no proximal epiphyses. Further, all the phalanges of the hind-foot, except the terminal ones, presented, in addition to the usual proximal

<sup>1</sup> I may remark here that in small mammals, and in birds and reptiles, there is some risk of being misled as to the presence of epiphyses, from the fact that a small groove, sometimes accompanied on one side by a thin linear elevation of the bone, not unfrequently occurs at the place of junction of the laminar subperiosteal bone of the shaft, and that portion occupying the extremity, and which has been entirely formed from cartilage. From this line the ligaments generally take their attachment externally, and it is from the inner side of the corresponding place in other animals that, when an epiphysis is present, the plate of cartilage proceeds, which for a time separates the bony epiphysis from the end of the shaft. In all cases of doubt it is desirable to determine the existence of epiphyses by longitudinal sections through the bones.

epiphyses, very distinct separate centres of ossification in epiphysal cartilages occupying their distal ends. The terminal phalanges possessed the usual broad proximal epiphyses, and ossification had already passed into the ends of the unguis processes. In all the epiphyses now mentioned, ossification had radiated from the centre of the epiphysal cartilage, and had proceeded so far as to occupy in the wet specimen a considerable part of it; but a cartilaginous plate still intervened between the bone of the shaft and the ossific nodule of the epiphysis.

Among the cetacea I was in some measure prepared to find a departure from the usual mode of ossification of the bones of the anterior limb, both from the known retardation of the process in these animals, and from my having many years ago observed double epiphysal crusts on some of their bones.

Figure 6 gives a view of the progress of ossification in the right fin of a young porpoise preserved in the wet state. I have found exactly the same condition of the parts in two other dried specimens of the same animal, and also in the fins of two other larger toothed cetaceans, so that I have no doubt the process is very similar in the whole of the animals belonging to the order<sup>1</sup>.

The first metacarpal bone with its radial digit are little developed, and there is as yet formed only one point of ossification in the proximal phalanx. In the two next or second and third members of the digital series, in which a remarkable multiplication of the phalanges takes place, amounting to seven in the case of the third or middle digit, it will be seen that both in the metacarpal bones and in the two nearest digital phalanges, besides the larger central nucleus of bone representing the shaft, there are both proximal and distal epiphyses or

<sup>1</sup> In placing the number I on the bone which occupies the place to the reader's left hand of Fig. 6, I have not intended to raise specially the question of the homology of this bone nor that of the presence or absence of a trapezium, which I am not in a position to determine. At the same time I may state, notwithstanding the view entertained by some that in the Cetacea the trapezium is absent and is replaced by the shortened first metacarpal, that my observations would lead me to believe that in the porpoise the rudiments at least of both bones are present; and that in the specimen represented in Fig. 6, ossification has commenced in the first metacarpal, but not yet in the shorter cartilaginous mass representing the trapezium.

distinct nuclei answering to these structures. In the three succeeding phalanges of the middle digit the central nuclei only have yet become ossified, but it is obvious from the shape of the cartilages occupying either end, that in them also there would occur later epiphysal ossification. The two last phalanges are still entirely cartilaginous<sup>1</sup>.

Thus then we find in the order of Mammifers in which ossification is most tardy, and in which the subdivision of the digital phalanges is greatest, the formation of both proximal, and distal epiphyses on all the members of the series.

It is deserving also of being noted, that in some of the short bones of the carpus, while the greater part of the bone is formed from a central ossific nucleus, there is produced separately from this an ossific crust in the surrounding cartilage, not unlike the upper and lower plates of the bodies of the vertebræ.

*Recapitulation.* As the inquiry to which the foregoing observations relate is incomplete, I will not attempt to draw any general conclusions from them, but will only recapitulate the more important of the facts previously stated.

1st. The prevalence of a general uniformity in man and the greater number of mammiferous animals in the mode of ossification of the bones of the fore and hind feet. The most frequent states to be noted are the following, viz. (1) the absence of proximal and the presence of distal epiphyses in four of the metacarpal and metatarsal bones, and conversely the presence of a proximal and the absence of a distal epiphysis in the first of these bones: (2) the presence of proximal and the absence of distal epiphyses in all the fourteen digital phalanges.

<sup>1</sup> I find that the occurrence of epiphyses at both extremities of each digital phalanx has been noticed by Professor Struthers (see note at p. 111 of the paper previously cited): and I am informed by my friend Dr Murie, of the Zoological Society, that in a Memoir on the Osteology of the Cachalot, by Mr Flower, recently published in the *Transactions of the Zoological Society*, but which I have not myself seen, that author has described the epiphysal crust or case surrounding the cartilaginous ossifying surface of the central nucleus of the carpal bones in the same manner as I have stated it to occur in the toothed Cetacea which have come under my observation; but which he looks upon as peculiar to the Cachalot. Mr Flower did not observe any appearance of an epiphysis at either end of the digital phalanges of the Cachalot, a circumstance which he regards as remarkable, "as in some of the toothed whales (*globiocephalus*) the metacarpals and phalanges are completed by very large epiphyses."

2nd. The occasional and variable deviation from this general plan in man, and probably in some other animals, by the presence of a more or less developed distal epiphysis on the first metacarpal and metatarsal bones; and the slighter indication of a tendency to the formation of a proximal epiphysis on one or more of the other metacarpal bones.

3rd. The more complete and regular formation of a distal epiphysis on the first metacarpal or metatarsal bones of some animals, such as the kangaroo, koala and elephant, constituting in them apparently the normal mode of ossification.

4th. The peculiar condition observed in the seal, in the fore-foot of which animal the ossification follows the usual plan, while in the hind-foot distal epiphyses are fully developed on the first metatarsal bone and on all the phalanges, except the terminal ones.

5th. The tendency in the ornithorhynchus to the formation of both distal and proximal epiphyses in all the metacarpal and metatarsal bones.

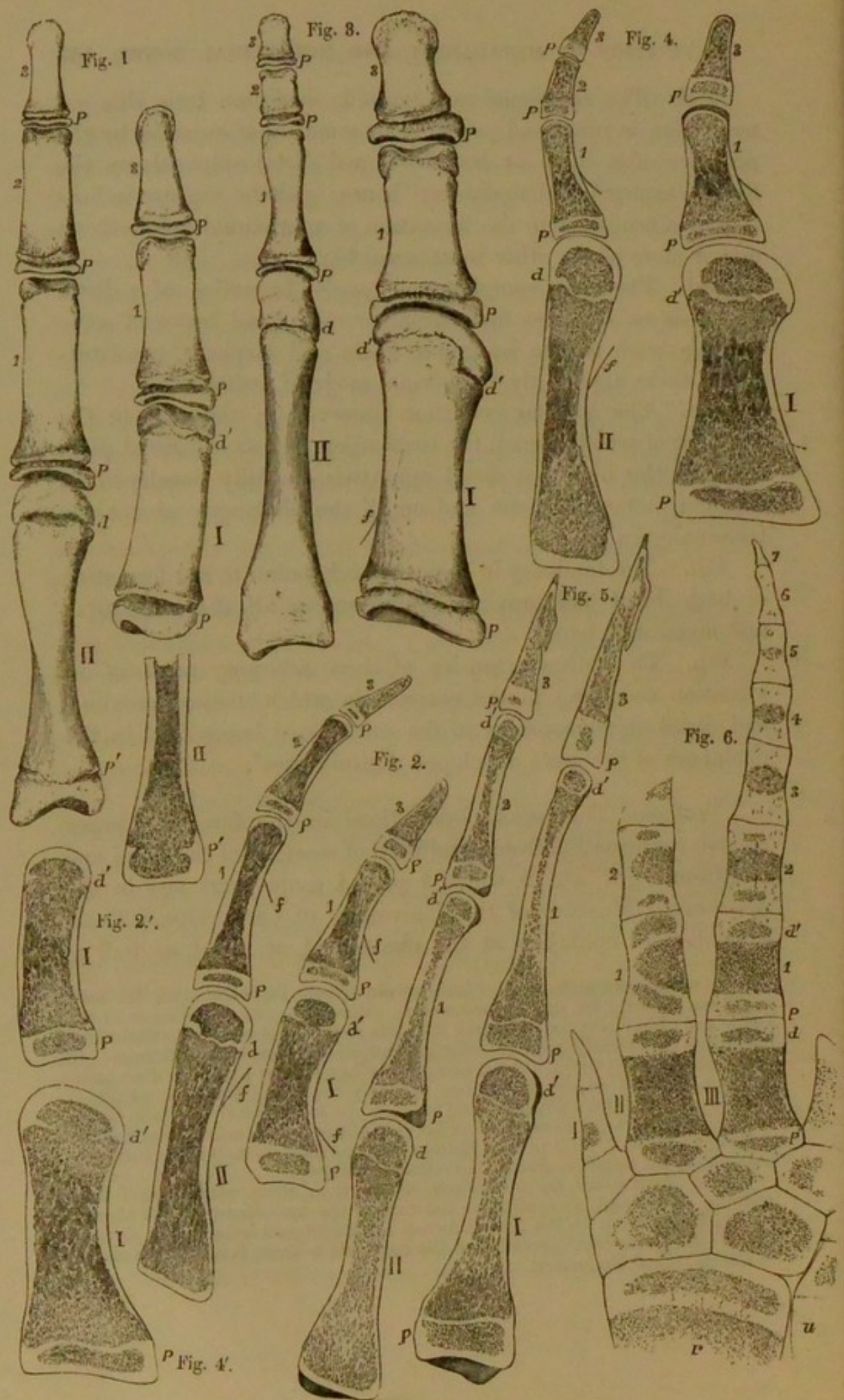
6th. The fullest extension of these accessory points of ossification occurring in the cetacea, in which distinct proximal and distal epiphyses exist in the metacarpal bones, and in the phalanges of the more developed digital series<sup>1</sup>.

[Professor Thomson's observations in the foregoing paper receive confirmation from specimens of sections of the hand and foot from a girl, *æt.* 10, which I placed some years ago in the Anatomical Museum of the University of Cambridge. These show distinct epiphyses at the phalangeal, or distal, as well as

<sup>1</sup> In a communication which I have received from Dr Murie since the foregoing was in print, he informs me that in examining young specimens of the Orang and Chimpanzee he has found the state of the epiphyses of the first metacarpal and metatarsal bones the same as that which is most usual in man. In the forelimb of the *Otaria jubata*, however, he has observed that the first metacarpal bone (that of the pollex) has not only the usual proximal epiphysis of large size, but also a smaller distal one; and he has found the same to be the case in the metacarpal bone of the pollex in a Walrus considerably younger than the one I examined. But in both of these animals the first metatarsal bone presented only the usual proximal and no distal epiphysis.

These observations are interesting, when taken along with those I have recorded on the seal, as confirming the view of the inconstancy of the absence of a distal epiphysis in the first metacarpal or metatarsal bone, and in showing that we must distrust the position of the epiphysis to these bones as the ground of a homological distinction.





at the proximal, or carpal, ends of the metatarsal bones of the pollex and hallux. The cartilaginous lines separating the distal epiphyses from the shafts are quite visible; though they have been to some extent traversed by ossification near the centre. There is also an epiphysis at the proximal end of the second, or index, metacarpal, though the cartilaginous line separating it from the shaft is not quite so clear, especially towards the centre of the bone, as it is in the distal ends of the metacarpals of the pollex and hallux. There are no visible traces of epiphysial lines in the proximal ends of the other metacarpals or in the 5th metatarsal. The three middle metatarsals have not been cut; and the presence or absence of epiphysial lines cannot therefore be determined in them. G. M. HUMPHRY.]

#### DESCRIPTION OF THE PLATE.

In the several figures the numbers and letters indicate details as follows, viz. I, the first metacarpal or metatarsal bone. II, the second ditto.

1, 2, 3, the proximal, middle and terminal phalanges, in all excepting Fig. 6, in which there are seven phalanges marked in the middle digit.

*p*, the more common or usual proximal epiphyses; *p'*, the less common and sometimes imperfect proximal epiphyses.

*d*, the more common or usual distal epiphyses; *d'*, the less common and sometimes imperfect distal epiphyses.

In a number of the figures a slightly curved line marked *f*, represents the direction of a bristle introduced into the canal of the bones through the so-called nutritious foramen; that direction being in most instances towards the extremity which is soonest ossified, or in which an epiphysis is wanting.

Fig. 1. Dorsal view of the dried metacarpal and phalangeal bones of the first and second fingers (thumb and forefinger) from the left hand of a girl of eight years of age: *d'*, the fissure separating a distal epiphysis on the first metacarpal bone; *p'*, a small but deep fissure which indicates a partial proximal epiphysis on the second metacarpal bone.

Fig. 2. Antero-posterior longitudinal section of the first and second metacarpal bones and digital phalanges of the thumb and forefinger from the left hand of a child of seven years of age in the

wet state:  $d'$ , a strip of cartilage dipping inwards about a third through the thickness of the bone indicates the partial separation of a distal epiphysis.

Fig. 2'. I. A similar section of the first metacarpal bone from the hand of another child of nearly the same age, in which at  $d'$  a very slight degree of inward projection of the epiphysal cartilage exists.

Fig. 2'. II. Transverse section of the proximal half of the second metacarpal bone represented in Fig. 2, showing at  $p'$  a slight indentation of the cartilage on the inner side, indicating the tendency to the formation of a partial epiphysis.

Fig. 3. Dorsal view of the dried first and second metatarsal bones and the digital phalanges of the great and second toes from the left foot of the same subject as the hand represented in Fig. 1, of eight years of age: at  $d'$ ,  $d'$ , deep fissures indicate the separation of a distal epiphysis.

Fig. 4. Antero-posterior longitudinal section of the first and second metatarsal bones and the digital phalanges of the great and second toes in the wet state, from the same child as the specimens represented in Fig. 2, of seven years of age: at  $d'$ , a complete, but somewhat irregular plate of cartilage separates the distal epiphysis on the first metatarsal bone.

Fig. 4'. I. A similar section of the first metatarsal bone from the left foot of the same subject as the metacarpal bone represented in Fig. 2'. I, showing at  $d'$  an inward projection of the dividing plate cartilage which partially separates a distal epiphysis.

Fig. 5. Longitudinal and vertical sections of the first and second metatarsal bones and corresponding digital phalanges from the left hind-foot of a young seal in the wet state; three-fourths of the natural size;  $d'$  in the first metatarsal bone, and in the first phalanx of the first toe, and in the first and second phalanges of the second toe, indicates the distal epiphyses existing in this animal.

Fig. 6. Longitudinal and transverse section of a part of the right anterior limb of a young porpoise in the wet state:  $r$ , the lower end of the radius with its epiphysis;  $u$ , part of the ulna; I, II, III, the first, second, and third metacarpal bones; the second and third showing, in addition to the larger central ossified mass, both proximal and distal epiphyses; 1 to 7, the cartilaginous and partially ossified phalanges of the third digit, showing, in the first two, distal as well as proximal epiphyses; and in the third, fourth and fifth only the central nodule as yet ossified. In the first two phalanges of the second digit the same is shown as in the third.



