

Cancer and other tumours of the breast : researches showing their true seat and cause... with 24 lithographic plates / by Charles Creighton.

Contributors

Creighton, Charles.
London School of Hygiene and Tropical Medicine

Publication/Creation

London ; Oxford : Williams & Norgate, 1902.

Persistent URL

<https://wellcomecollection.org/works/g96sfw53>

Provider


London School of Hygiene and Tropical Medicine

License and attribution

This material has been provided by This material has been provided by London School of Hygiene & Tropical Medicine Library & Archives Service. The original may be consulted at London School of Hygiene & Tropical Medicine Library & Archives Service. where the originals may be consulted. Conditions of use: it is possible this item is protected by copyright and/or related rights. You are free to use this item in any way that is permitted by the copyright and related rights legislation that applies to your use. For other uses you need to obtain permission from the rights-holder(s).

**wellcome
collection**


Wellcome Collection
183 Euston Road
London NW1 2BE UK
T +44 (0)20 7611 8722
E library@wellcomecollection.org
<https://wellcomecollection.org>



LSHTM



0011439573



To be returned to :

UNIVERSITY OF LONDON LIBRARY DEPOSITORY,
SPRING RISE,
EGHAM,
SURREY.

From
THE LONDON SCHOOL OF HYGIENE
AND TROPICAL MEDICINE,
KEPPEL STREET,
LONDON, W.C.1.


137c

Catalogue 07

Presented to
Professor M. Greenwood

By
J. S. Pochet

As a memento of his
visit to 17 Carden Place
Aberdeen on Sunday
11th Dec^r 1938



Researches on
Cancers and other Tumours
of the Breast

BY THE SAME AUTHOR.

Contributions to the Physiology and Pathology of the Breast and its Lymphatic Glands. Woodcuts and plate. 9s.

Bovine Tuberculosis in Man: an account of the Pathology of Suspected Cases. Coloured and other plates and woodcuts. 8s. 6d.

Illustrations of Unconscious Memory in Disease, including a Theory of Alteratives. 6s.

H. K. LEWIS, 136 GOWER STREET, LONDON.

Microscopic Researches on the formative property of Glycogen (Mammalian Embryos). With five coloured plates. 7s. 6d. net.

Glycogen of Snails and Slugs, in morphological and physiological correspondence with the lymph-system of Vertebrates. With nine coloured and other plates. 7s. 6d. net.

ADAM & CHARLES BLACK, 4 SOHO SQUARE, LONDON.

A History of Epidemics in Britain.

Vol. I. From A.D. 664 to the Extinction of Plague. 18s.

Vol. II. From the Extinction of Plague to the present time. 20s.

CAMBRIDGE: AT THE UNIVERSITY PRESS.

Cancers and other Tumours of the Breast:

Researches showing their true Seat and Cause

By

Charles Creighton, M.D.

Sometime Demonstrator of Anatomy, Cambridge University
Author of "Contributions to the Physiology and Pathology of the Breast"

WITH TWENTY-FOUR LITHOGRAPHIC PLATES

Williams & Norgate

14 Henrietta Street, Covent Garden, London, W.C.
and 7 Broad Street, Oxford

1902

63516

Contents

	PAGE
INTRODUCTORY,	1
CHAPTER I.—ANATOMICAL INTRODUCTION,	4
I. Excretory Skin-glands of the Vertebrata,	4
<i>Amphibia</i> , 4; thumb-gland of Frog, 5; development of the muscular basement, 7.	
<i>Mammalia</i> .—Monotremes, 8; glandula humeralis of Ornithorhynchus, 9; femoral gland of male, 10; inguinal gland of female, 10; cloacal glands, 11; skin-glands of other Mammals, 11; sweat-glands of Hippopotamus, 11; sweat-glands of Dog, 12.	
<i>Man</i> .—Larger sweat-glands, 12; alleged intermediate forms, 13; special localities of larger kind, 13; mammary skin, 14; tumours and cysts of larger kind, 14; chimney-sweep's cancer, 16; original case of, 19; rodent tumour of facial sweat-glands, 22.	
Glands of the Areola, 23; historical summary, 24; sebaceous glands, 26; large sweat-glands, 26; milk from the Areola, 28; sexual relations of Areola, 29.	
II. Tubular Glands with Muscular Basement within the Breasts of Women,	29
Theory of, 29; Cohnheim's hypothesis of aberrant rudiments, 30; erratic deposits under the skin, 30; usually an integral part of the breast, 31; frequency of, 32; Cases, 32; branching tubular glands mixed with sweat-glands, 34; variety of glands in same breast, 37; sweat-glands mistaken for milk-ducts and acini, 37.	
III. Primitive Type of the Mammary Organ,	39
Views of the nature of milk-secretion, 39.	
Rudiment of breast a compound tubular gland, 41; Gegenbaur on homology of Monotreme mamma, 41.	
Homology in other Mammals: Benda, 42; Eggeling, 43; paradoxes of the mamma, 44.	
Original material, 44; proof of sweat-gland type in <i>Echidna</i> , 45; in <i>Ornithorhynchus</i> , 47; a branched tubular gland with muscular basement, 48; sweat-glands of the skin near, 48; criticism of Geoffroy St Hilaire, 49.	

	PAGE
Mamma of Kangaroo foetus, 49 ; the secretion, 51 ; Cetacean mamma, 52 ; calf Porpoise, 53 ; development of the reservoir, 53 ; other Mammals : Cat and Dog, 54.	
IV. Development of the Mamma,	55
Summary of the Comparative Anatomy, 55 ; the acini added to tubular rudiment, 56 ; principle of Parablast, 57 ; in pathology of tumours, 57 ; parablast of His, 58 ; yolk-sac epithelium parablatic, 58 ; Waldeyer's view of the parablast, 60 ; red blood and lymphatic vessels the fundamental parablast, 61 ; yolk-sac and allantois, 61 ; parablatic evolution of organs : liver, 62 ; archiblastic and parablatic parts of the kidney, 62 ; of the lung, 64 ; archiblast and parablast in the breast, 65 ; proof of epidermic ingrowth, 66 ; vascular stroma of the breast, 67 ; late development of the glandular structure, 67 ; Langer's original view, 68 ; author's theory for the Guinea-pig, 69 ; acinous development in the first pregnancy, 71 ; probable development of acini from the vascular stroma (parablast), 72 ; significance of fat in milk, 73.	
V. Reversions to the Primitive Type of Mammary Organ,	74
Reversion a special risk of human breast, 75 ; slight degrees of, common, 76 ; risks of maldevelopment in first extrauterine months and at puberty, 76 ; Th. v. Kölliker on mastitis of infancy, 77 ; the cavernous spaces a rete, 78 ; anomalies at puberty, 79 ; hereditary effects of disuse of lactation, 79 ; not mere atrophy, 80 ; no statistical proof available, 80 ; nature of the mammary degradation, 81 ; an excretory gland correlated with the sexual functions, 82 ; reverted parts of the breast do not become obsolete at the climacteric period, 82.	
CHAPTER II.—SIMPLE CYSTS OF THE BREAST (INVOLUTION-CYSTS) INCLUDING HYDATIDS,	83
Importance of cysts for the pathology, 83.	
<i>Hydatids</i> .—Astley Cooper's use of the term, 83 ; recorded cases, 84 ; remarkable case at Strasburg, 85.	
<i>Simple Cysts, or "Involution-cysts."</i> —Cooper's plates, 86 ; Birkett's blastema-cysts, 86 ; Billroth on involution-cysts, 87 ; "butter-cysts," 88 ; diagnosis of simple cysts, 88 ; Brodie on cystic breasts, 89 ; three successive cases of involution-cysts traced to sweat-glands involved in the breast, 90 ; their pathology, 93.	
CHAPTER III.—FIBROMA AND CYSTIC FIBROMA,	95
Natural division into circumscribed and diffuse, 95.	
<i>Fibrous kernels or corps fibreux</i> .—Astley Cooper's Chronic Mammary Tumour, 95 ; superficial situation, 96 ; glandular element in, 97 ; original cases showing that the knots arise round the walls of sweat-glands in the breast, 98 ; or around other branching tubular glands, 100 ; description of three kinds of glands near the milk-sinuses, 101 ; Case iv., circumscribed fibromatous knots in one part, diffuse cystic disease in another, 102.	
<i>Diffuse fibroma with small cysts: polycystoma, or maladie kystique du sein</i> .—Museum specimens by Astley Cooper, 104 ; various old	

references to "maladie kystique," 104 ; original case of, proved to be in sweat-glands of breast, 105 ; Case VI., large fibroma with irregular cystic spaces, 107.

Pathology and etiology of fibroma of the breast.—The element of chronic mastitis, 109 ; due to menstrual afflux of blood, 110 ; anomalous glands, not milk-lobules, the seat of it, 110.

CHAPTER IV.—STEATOMA OR PEARLY TUMOUR OF THE BREAST, 111

Case by Astley Cooper, 111 ; case by Billroth, 112 ; a chronic benign tumour, 113 ; Case VII., an original case of, 113 ; the pearls may or may not be connected by necks, 113 ; epidermic deposits around the walls of original glandular tubes, 114 ; the original glands of the anomalous kind, 115 ; myxomatous new growth on their walls, 116 ; development into rete mucosum and epidermis, 117 ; Virchow on the origin of pearly tumours in the pia mater (arachnoid), 119 ; a structural adaptation to disordered lymphatic function, 119 ; the normal rete mucosum as a reservoir of lymph, 120.

CHAPTER V.—TWO CASES OF COLLOID OF THE BREAST, 122

Characters of colloid tumour elsewhere, 122 ; two varieties in the breast, 123 ; Case VIII., circumscribed colloid tumour with dense white stroma, 123 ; the breast full of anomalous sweat-glands, 124 ; connection of these with the colloid, 125 ; myxomatous state of the stroma, 125 ; fate of the glandular structures, 126 ; Case IX., uniform colloid tumour of the breast, 127 ; a process in the stroma allied to myxoma, 128 ; instances of recurrence and secondary infection, 129.

CHAPTER VI.—HYALINE TUMOUR, 130

Case X., true hyaline tumour of the centre of the breast, 130 ; extensive deposit of sweat-glands in the *corpus mammae*, 131 ; their hypertrophy, 132 ; the hyaline deposit an invasion from the stroma, 133 ; an element of myxo-sarcoma, 134 ; relation to colloid in a museum specimen, 135.

CHAPTER VII.—INTRATUBULAR AND INTRACYSTIC TUMOURS, 136

"Épithéliome tubulé" or "duct-cancer," 136 ; Case XI., intratubular cancer in an early stage, 137 ; the breast mostly composed of anomalous sweat-glands, 139 ; hyaline in the walls of acini, 140 ; tumour-nodule of blocked sweat-glands, 141 ; effects upon the stroma, 142 ; Case XII., intratubular tumour near the breast, 143 ; proof of a muscularis-basement in the gland-tubes, 144 ; regular fibrillation of the plain muscular fibres, 145 ; myxoma and telangiectasis of the stroma, 146 ; relation of the sweat-glands to the breast, 146 ; rarity of purely intratubular tumours, 146 ; sarcoma may simulate them, 147 ; Case XIII., tumour of the breast of pseudo-tubular structure, 147 ; state of the mamma, 148 ; structure of the tumour, 149 ; nature of "duct papilloma," 150 ; Case XIV., intracystic tumour on the axillary border of the breast, 151 ; sweat-glands in the *corpus mammae* dilated to cysts, 152 ; hyaline change of mammary acini, 152 ; coils of anomalous tubular glands with plain muscular fibres in the stroma, 153 ; Henle on that

	PAGE
variety of large sweat-glands, 153 ; sarcomatous structure of the soft intracystic growth, 154.	
CHAPTER VIII.—SARCOMA,	156
Clinical definition, 156 ; often the acute sequel of chronic tumour, 157 ; cases classified as Sarcoma do not represent its frequency, 158 ; Case xv., a central tumour sarcomatous throughout, 159 ; nature of the vascular stroma, 160 ; "angiosarcoma" is really parablasic to tubular glands, 161 ; hyaline and animal starch in certain parts, 161 ; state of the proper mammary structure, 162 ; presence of various anomalous glandular types, 163 ; related to milk-sinuses of the margin, 164 ; sweat-glands in the <i>corpus mammæ</i> , 165 ; Case xvi., sarcomatous on the margin, scirrhus in the centre, 167 ; the glandular forms found in the breast, 167 ; those in disorder are sweat-glands, 168 ; structure and origin of the tumour, 169 ; sarcomatous extension of its borders, 170 ; hyaline of the mammary acini, 171 ; Case xvii., tuberous sarcoma with dense central region, 171 ; various kinds of glandular structure remaining, 172 ; the new growth parablasic, 173 ; Case xviii., tuberous sarcoma upon one side of a dense or scirrhus <i>corpus mammæ</i> , 174 ; the milk-sinuses the chief residue of breast, 175 ; numerous blocked sweat-tubes on the periphery, 176 ; traces of them in the dense centre, 177 ; Case xix., encapsuled friable tumour on the axillary margin of the breast, 177 ; myxo-sarcomatous type, 178 ; presence of glycogen and hyaline, 178 ; origin from the walls of sweat-glands, 179 ; general type of the mammary structure, 179 ; effects of injury upon anomalous structure, 180.	
Case xx., fungous sarcoma which had destroyed the nipple and areola, 181 ; myxo-sarcomatous with giant-cells, 182 ; tubular glands the only survivals of the breast, 183 ; the new growth parablasic to these, 184 ; Case xxi., sarcoma simulating tubular structure, 185 ; remains of sweat-glands in the fibrous septa, 185 ; Case xxii., nodule of pseudo-glandular structure in abdominal wall of a child, 186 ; characters of the epithelial-like new growth, 186 ; developed under a congenital anomaly of the skin, 187 ; state of the sweat-glands, 187 ; and of the blood-vessels, 188 ; relation of the new growth to the anomalous sweat-glands, 188 ; Case xxiii., sarcoma within acinous-lobular limits, 189 ; "acinous cancer" of Billroth, 190 ; types of glandular structure found in this breast, 190 ; hyaline obsolescence of lobules, 190 ; glandular limits of the new growth, 191 ; the cells not epithelial, 191 ; their source, 192 ; abstracts of cases of acute sarcoma in both breasts, 192 ; abstract of remarkable case of multiple hard nodules recorded by Treves, 193.	
CHAPTER IX.—COMPARATIVE PATHOLOGY : MAMMARY ENCHONDROMA, OSTEOMA AND SARCOMA OF THE BITCH,	195
Author's earlier account of mammary tumours of the bitch, 195 ; statistics showing great relative frequency of tumours in sweat-gland regions of the dog, 196 ; so-called mammary tumours often limited to the bases of teats : illustrative cases, 197 ; sweat-glands of the mammary skin their seat, 198 ; larger tumours (including	

osteomata) depend on erratic sweat-glands, 199 ; illustrative case, 200 ; stages of sweat-gland disorder, 201 ; reaction of the vascular stroma, 202 ; osteomata, 203 ; proofs of sweat-gland functional disorder in the larger tumours, 203 ; parablasic adaptations thereto, 204 ; the actual new growth is outside the basement of tubes, 205 ; extension of the circumtubular sarcoma as verrucous outgrowths : illustrative case, 206 ; spindle-celled sarcoma, 207 ; case with secondary growths, 208 ; malignancy in the bitch always sarcomatous, 209 ; invasion of the lobes of normal mamma, 210 ; the alveolar structures arise within pre-existing vascular limits which are the walls of acini, 211 ; do the resting acinous cells become sarcoma-cells? 211 ; malignancy acquired by chronic tumours, 212.

CHAPTER X.—COMPARATIVE PATHOLOGY: SWEAT-GLAND TUMOURS OF THE DOG'S SKIN, 213

Common cutaneous tumours, 213 ; series of twelve cases, 214 ; sarcomatous type, 217 ; relation to the sweat-glands, 217 ; proved by Case VIII., 218 ; archiblast and parablast, 219 ; a cystic case, 220 ; lympho-sarcoma as circumtubular new growth, 221 ; mucous sarcoma, 221 ; a question of sarcoma or scirrhus, 222 ; fate of original glandular structures, 223.

CHAPTER XI.—SCIRRHUS, 225

Contrast with sarcoma, 225 ; mixed types, 226 ; Case XXIV., small discoid scirrhus of the whole *corpus mammae*, 226 ; breast almost wholly sweat-glands, 227 ; which are the sole cause of the tumour, 229 ; element of sarcoma, 229 ; element of scirrhus, 230 ; Case XXV., small scirrhus directly under the nipple, 231 ; the milk-sinuses and dependent glands, 232 ; sweat-glands, 232 ; infiltration, 233 ; stroma full of large spindle-cells around collapsed sinuses, 233 ; Case XXVI., small firm encapsuled nodule in a thin breast, 234 ; state of the mamma, 235 ; the tumour fibromatous at the base, 236 ; alveolar cancer above, 237 ; Case XXVII., very large scirrhus of the whole breast, 238 ; kinds of gland-structure found in it, 239 ; extensive deposition of hyaline, 239 ; source of the new growth, 241 ; Case XXVIII., scirrhus in a young subject : malignancy, 242 ; state of the breast, 243 ; hyaline, 243 ; extensive sweat-glands all blocked, 244 ; infiltration of stroma, 245 ; structure of secondary nodules in muscle, 246 ; Case XXIX., small shrinking scirrhus, 246 ; surviving tubular glands, 247. Case XXX, chronic retracting scirrhus, 248 ; sinuses left, 248 ; their muscularis and hyaline zones, 249 ; source of the alveolar cells, 249 ; Case XXXI., scirrhus on axillary edge, under a deposit of sweat-glands, 250 ; proofs of congenital anomaly, 251 ; sources of the tumour-cells, 251 ; Case XXXII., small scirrhus close to skin at edge of breast, 253 ; sweat-glands involved in it, 254 ; their connections, 254 ; note on the marginal processes of the breast, 255 ; Case XXXIII., infiltration of the fat next the axilla, from a sweat-gland source in the skin, 256 ; infiltration of epithelial nuclei, 257 ; note on the dimple of the skin in scirrhus, 258 ; Case XXXIV., insular scirrhus in a very large fat breast, destruction of the nipple, "lardaceous" infiltration of skin, 259 ; proof of anom-

alous tubular glands, 260 ; small type of the cancer-cells, 261 ; infiltration of the skin, 261 ; associated with Paget's disease, 262 ; case by Thin, 262 ; circumstances of Paget's disease, 263 ; Case XXXV., large scirrhus of rapid growth, the stroma an adenoid reticulum, 263 ; tubes which are not milk-ducts, 264 ; types of new growth in stroma, 265 ; Case XXXVI., scirrhus resembling tubercle, 266 ; large amount of hyaline, 267 ; variety of tubercular giant-cells, 269 ; allied to scirrhus, 270 ; summary of four cases of true mammary tubercle, 270-2 ; instances of epithelioma and tubercle mixed, 272 ; relation of scirrhus to tubercle, 273.

CHAPTER XII.—SUMMARY OF THE PATHOLOGY AND ETIOLOGY, 275

Tumours arise in the breast in its resting or obsolete states, 275 ; anomalies of development their true seat and cause, 276 ; these are in peculiar sympathy with the ovaries, 277 ; statistics of the antecedents of mammary cancer, 277 ; special importance of climacteric effacement, loss of lymphatics, 279 ; alleged persistence of lymphatics in cancerous breast, 279 ; summary of Köster's research, 280 ; anomalous glands survive the climacteric age, but without lymphatics, 281 ; results of the loss of lymphatic drainage, and intratubular and extratubular effects, 282 ; new plasmatic tissues, 283 ; physiological type of sarcoma, 284 ; characters of sarcoma, 285 ; distinctions between sarcoma and scirrhus, 286 ; three characters of scirrhus—(1) hardness and density, 286 ; best explained by hyaline, 286-8 ; hyaline an inert substance deposited in the absence of absorbent vessels, 288 ; evidence from bivalves, meaning of the crystalline stylet, 289 ; (2) contractive property of scirrhus, 290 ; contractile absorbent tissue in molluscan intestine, 290 ; (3) alveolar plan of structure, 291 ; compared with lacunar blood-spaces of bivalves, 292.

List of Plates

	PAGE
I. SKIN-GLANDS WITH MUSCULAR BASEMENT,	16
II. VARIOUS MAMMARY STRUCTURES,	40
III. MONOTREME AND MARSUPIAL MAMMA,	56
IV. CETACEAN MAMMA—PARABLASTIC DEVELOPMENT,	64
V. DEVELOPMENT OF THE MAMMA,	72
VI. INVOLUTION-CYSTS—FIBROMA,	96
VII. FIBROMA—PEARLY TUMOUR,	120
VIII. COLLOID AND HYALINE TUMOURS,	128
IX. INTRATUBULAR TUMOUR : CASE XL,	144
X. INTRATUBULAR TUMOURS,	152
XI. INTRACYSTIC SARCOMATOUS PAPILLOMA : CASE XIV.,	160
XII. SARCOMA : CASE XV.,	164
XIII. SARCOMA : CASE XVI.,	168
XIV. SARCOMA : CASES XVII. AND XVIII.,	176
XV. SARCOMA : CASES XIX. AND XX.,	180
XVI. PSEUDO-GLANDULAR SARCOMA.—CHIMNEY-SWEEP'S CANCER,	188
XVII. SWEAT-GLAND TUMOURS OF THE DOG,	208
XVIII. SWEAT-GLAND TUMOURS OF THE DOG,	216
XIX. SWEAT-GLAND TUMOURS OF THE DOG,	224
XX. SCIRRHUS : CASES XXIV. AND XXV.,	232
XXI. SCIRRHUS : CASES XXVI.—XXIX.,	240
XXII. SCIRRHUS : CASES XXX.—XXXII.,	248
XXIII. SCIRRHUS : CASES XXXIII. AND XXXIV.,	260
XXIV. SCIRRHUS AND TUBERCLE : CASES XXXV. AND XXXVI.,	268

New Researches

on

Cancers and other Tumours of the Breast

THIS work has grown to be a more comprehensive treatise on the Breast and its Tumours than I had intended at first. My original object, two and a half years ago, was to work out systematically a discovery which I had mentioned first in a paper of the year 1882, and again in 1888 on the occasion of fresh evidence, to the effect that there were tumours of the mammary region which arose, not from the breast proper, but from glandular structures having the anatomical character of the axillary sweat-glands. These, I supposed, might form a class of tumours apart, to which the hybrid name of "paramammary" might be given, being of the softer kind—sarcomatous intracystic, and intratubular. But, as my work proceeded, I found that the large sweat-glands with basement of plain muscular fibres were present in a surprising number of breasts, involved in the proper structure both in the central region of the milk-sinuses and all round the sides and base; and that they were the true seat and anatomical cause of all varieties of mammary tumour—not only of the soft intracystic and intratubular, but also of sarcoma in general, of scirrhus, of colloid, of steatoma or pearly tumour, of fibroma, and of simple cysts. In all those cases the proper mammary structure, acinous lobules and ducts, remained passive: in many breasts it was obsolete, or nearly so; in all others it was involuted or inactive; and in only two or three cases of sarcoma did the new growth arise, wholly or in part, within the limits of lobules and acini.

As each of my cases, to the number of thirty-six, had been worked out separately, I resolved to give them all in the order of a classification, and to help the evidence by drawings, which would serve to prove the facts for each case, and at the same time to illustrate the pathology from point to point. This method amounts to a systematic treatise, and to an exposition of the whole tumour-pathology of the breast from a new point of view.

In a former work, *Contributions to the Physiology and Pathology of the Breast, and of the Lymphatic Glands* (1878), I had used in the pathological half of the book chiefly tumours of the bitch, of which I had made a collection from the veterinary practice of the Brown Institution during four years. I have gone over the whole of that material again, now amounting to twenty-four cases, and have found that the original seat and cause of these remarkably frequent tumours of the teats and other mammary parts of the bitch, is not the milk-gland itself, but the large sweat-glands of the mammary skin, especially those around the bases of the teats, which are more developed in the dog than in any other mammal. The dog has the same kind of so-called sweat-glands in all parts of its skin, excepting the balls of the toes; and these, as I shall show, are also the seat of tumours, which are only second in frequency to those of the mammary region. I have given an extra chapter to a series of twelve such cases, which, although non-mammary, are yet allied in origin, and are specially valuable for the general pathology of sarcoma of glands.

Whilst the regular distribution of these muscle-walled tubular coils of glands all over the dog's skin, with a special development of them around the bases of the teats, enables the pathology to proceed in the ordinary way upon a normal anatomical basis (allowing for some degree of *error loci*), the problem is different in the human breast. Tubular glands, of the same structure as in the dog's skin, are not only distributed widely in the centre of the breast and all round its borders, but they are so involved in the framework of the organ as to be an integral part of it, or a substitute for so much of the proper milk-gland. That is the central fact

for the breasts of certain women; so that no pathology of their mammary tumours can proceed without an attempt to account for it. The anomaly is far too common, and too uniform of its kind, to be dismissed as *lusus naturæ*, or explained by some vague hypothesis of "sequestered embryonic rudiments," which will turn out to be no better than verbiage when it is brought to the test of pathological anatomy. The problem of anomalous structures within the breast is one of reversion or degradation, from causes not accidental but intelligible. It presents many difficulties; and there is no doubt that the only way to approach it is through the comparative anatomy, the development, and the evolution. As the subject was not new to me, and as I had been collecting suitable material from time to time, I have ventured upon it in an Anatomical Introduction, which may or may not meet with assent, but is at all events of fundamental importance for the pathology that follows. It offers a means to reconcile the conflict of opinion as to the epithelial or connective-tissue origin of cancers, to bring sarcoma and cancer into one point of view, and to explain the peculiar risk of tumour which a reversion, degradation, or effacement of structure carries with it.

CHAPTER I.

ANATOMICAL INTRODUCTION.

- I. EXCRETORY SKIN-GLANDS OF THE VERTEBRATA—II. TUBULAR GLANDS WITH MUSCULAR BASEMENT INVOLVED IN THE BREASTS OF WOMEN—III. PRIMITIVE TYPE OF THE MAMMARY ORGAN—IV. DEVELOPMENT OF THE MAMMA—V. REVERSIONS TO THE PRIMITIVE TYPE OF MAMMARY ORGAN.

I. EXCRETORY SKIN-GLANDS OF THE VERTEBRATA.

TUBULAR glands with their epithelium resting directly upon a basement of plain muscular fibres are so peculiarly the anatomical seat and cause of tumours of the breast, that it will be an advantage to begin with a survey of the glands of that type in the animal kingdom, with a view to making out their significance from their antecedents: this will serve at the same time to open the subject of the primitive type of the mammary organ, which is of immediate and practical interest for the pathology. It happens that the survey may be brief, inasmuch as it is only the Amphibia that have to be considered; so that we come almost at once to the Mammalia, and to the direct question of the evolution of the breast.

Amphibia.—In the Amphibia (frog) the simple glandular sacs in the cutis are sharply divided, without transition forms (Engelmann), into two kinds:—the common small kind all over the skin, with a clear watery, mucinous product, and with so delicate a muscularis basement that it is easily overlooked; and a specialised larger kind, occurring in groups at certain parts (mostly dorsal) in the company of the smaller, with an opaque, granular, milky product, and with strong and thick muscular fibres which run meridionally from pole to pole.

Ordinarily both kinds of sacs are globular crypts, each of

which opens between papillæ of the epidermis by a short cylindrical neck, and a crevice-like mouth compared by Leydig to a leech-bite. But Leydig has found in the skin of the hand and foot of *Hyla*, *Rana*, *Bufo*, *Triton*, and *Salamandra* a modification of form, which is of interest for the succession of skin-glands in the *Mammalia*: in those situations the glandular crypts look at first sight to be a structure *sui generis*, being tubular glands (Schlauchförmige Drüsen); but inasmuch as the ordinary small globular sacs nearest to them "begin to stretch out, and to pass by degrees into those with a longer neck," it is probable that the latter, the tubular glands, are merely modifications of the former, the change in shape being intelligible from the stretching which they undergo to reach the surface from their deep situation in the cutis.

At certain spots the skin-glands of the *Amphibia* are massed together so as to form a visible swelling of the skin, which is papillated and pigmented over them. I shall confine myself to one of these glandular organs, the thumb-gland of the frog, which is easy to procure and study (although, strangely enough, it has not been described fully in systematic writings). Leydig's remark upon it is brief, but important: "A modification of the tubular glands as regards size is represented also by the tubes of the thumb-gland," the other instances of tubular-gland organs being the sexual cloacal glands and pelvic glands (or "prostate" of Rathke) in the salamanders. The thumb-gland is a true sexual organ, occurring only in the male frog, and becoming large in the breeding season, at which time the papillated skin over it changes to a rich reddish-brown colour. It is in two main lobes, with a third small terminal knob, on the inner and dorsal surface of the innermost digit of the manus, which is swollen by the glands in the cutis to a thick ovoid. In sections parallel to the surface it appears to be composed of regular round alveoli of uniform size, separated by narrow tracts of tissue containing nucleated fibrils and a homogeneous or hyaline substance (fig. 1). But in sections made as nearly as possible perpendicular to the convex surface, the structure is that of elongated sacs, or tubes, with the

long axis set obliquely towards the surface; they are more than one row in depth, or, at all events, they overlap each other with broad and narrow ends alternately. (The figure in Ecker, Eng. transl., ed. Haslam, Oxford, 1889, fig. 234, II., appears to me to be diagrammatic, so that the thumb-gland is made to look like an aggregate of many ordinary crypts of the skin.) Combining the appearances in the horizontal and vertical sections, it seems probable that each tubular gland is doubled somewhat upon itself, or slightly convoluted, so that two or more of the alveoli in the sections belong to one and the same tube. The short cylindrical necks, which are not difficult to find in the single glandular crypts of the skin at large, are hardly discoverable for the alveoli of the thumb-gland; and it is probable that the special papillation of the epidermis masks the apertures.

The plain muscular fibres in the walls of the tubes are of the more delicate kind; they appear to constitute the whole basement membrane, which is seen in the figure as a thin dark line bounding the tube from the stroma. The muscular ribs are usually discovered in cross-sections, as a series of triangular points on the inner side of the basement, like the teeth of a saw; but they are seen occasionally in the full-face view (most easily with lamp-light) as delicate parallel bands; and, most distinctively of all, in obliquely cut tubes, where they stand out boldly round the margin like the top of a palisade. The state of the epithelium appears to vary in different frogs at the same season of the year: in the larger swellings the individual epithelial cells are hardly to be seen, but only a continuous mass of protoplasm next the wall, occupied by granules, which stream out into the lumen (as in the poison-glands of other Amphibia); but in smaller swellings, perhaps from younger frogs, the epithelium upon the wall is a definite belt of long, slender, columnar, nucleated cells, the free ends of which are occupied by the same granules as stream out into the lumen of ripe glands, but are here still contained within the belt of cells by a definite wall (fig. 2). The belt of long cylindrical cells is projected into the lumen at several points in the form of rounded papillæ. In all my specimens, whether

of fully ripe or partially ripe thumb-glands, the product is the same fine spawn of granules which distinguish the larger, or opaque, crypts of the skin. This excretion, although it looks milky, is not fatty (Engelmann), and is supposed to contain the same albuminous principle as the poison-glands in other Amphibia.

Development of the Muscular Basement.—It is in the Amphibia that the important point touching the source of the plain muscular fibres has been worked out. Engelmann, who held that the muscular basement and the epithelial cells resting upon it were physiologically one tissue as well as an "optical continuum" ("Die Hautdrüsen des Frosches," *Archiv f. d. gesammte Physiol.*, v. 1872, p. 512), inferred also from appearances in young frogs that the muscle-cells and the epithelial cells were both developed from the same rudiments beneath the cutis, which were, he alleged, of epidermic origin. The young or developing mucous glands were short cylindrical or nearly spherical bodies, apparently quite solid, the smaller kind being filled with uniform small, round cells, while the larger kind had an outer zone of large elongated cells, which, from their meridional arrangement, he took to be the rudiments of the muscular basement. Thence he concluded "that the muscle-cells of the mature glands are histogenetically nothing else than epithelial cells." A similar suggestion had been thrown out by Leydig in 1867, and the same teaching was adopted by Ranvier, "Sur la mécanique de la sécrétion," *Journ. de Micrographie*, 1887, p. 206. M. Heidenhain, "Ueber das Vorkommen von Intercellular-brücken zwischen glatten Muskelzellen und Epithelzellen des äussern Keimblattes, und deren theoretischen Bedeutung," *Anatom. Anzeiger*, viii. 1893, p. 404, examining fine preparations of the poison-glands of Triton with a very high power, discovered that the projecting muscle-cells were united to the epidermic cells of the skin by delicate bridges of protoplasm, which was sufficient proof in itself that the muscle-cells belonged genetically to the ectoderm. Robin, who was the first to discover these sub-epithelial ribs or bands in the sweat-glands of the human axilla (1845), foresaw the embryological paradox of later writers; and inasmuch as he rejected the notion of deriving plain muscular fibres from ectoderm, he maintained in his own writings (Art. "Sudoripares" in *Dict. Encycl. des Sc. Méd.*), and through the thesis of his pupil Ficatier (Paris, 1881), that the apparent muscle-cells were really basal prolongations of the epithelial-cells. There are several interesting details of the development of the glandular rudiments still remaining to be worked out.

The Orders between the Amphibia and the Mammalia have no common skin-glands, and rarely any specialised glandular organs under the skin. Among the latter are the musk-glands of the tortoises and crocodiles, which are com-

plex or partitioned, and are invested by *striped* muscular fibres (Peters, cited by Leydig): in that respect they resemble the accessory sexual glands of some mammals about to be mentioned.

Mammalia.—Coming to the Mammalia, we find the succession of muscle-walled tubular glands or simple crypts in the cutis taken up directly from the Amphibia, with the addition of the acinous sebaceous glands, which do not exist in the Amphibia; at the same time we find the remarkable specialisation of certain cutaneous glands to form the organ from which the Mammalian Order takes its name. The tubular glands of the skin are now more or less extensively coiled, and are called sweat-glands, either of the wider or the narrower kind. The interest centres at once in the Monotremes, on account of the peculiarities of their mammary organ, and the light which these may throw upon the acquisition of the milk-gland. Ornithorhynchus has tubular glands all over its skin (Leydig, *Arch. f. Anat. und Physiol.*, 1859, p. 738), which were found to have the muscular basement by Ribiero de Souza Fontes, *Hautdecke des Ornithorhynchus*, Thesis, Bonn, 1879, and by several recent observers (among whom Römer remarks that the sweat-glands are not so numerous as the sebaceous). Echidna, with spines like a hedgehog, or with bristles, is supposed to have no sweat-glands in the cutis at large, but only on the borders of the mammary area, Gegenbaur having failed to find them in two pieces of skin from other regions. Besides its pair of mammary organs, Ornithorhynchus has two other pairs of glands beneath the skin, which are very different in form from the mammary, but are obviously also, like these, special adaptations of the primitive skin-glands to particular functions. Although they belong probably to the sexual system, they are developed on the limbs, like the sexual thumb-gland of the frog. One of these, the spur-gland or glandula femoralis, has long been known in the male; it occurs also in Echidna at a lower point on the hind limb, in the popliteal space or bend of the knee. In the female Ornithorhynchus there is a corresponding gland under the skin of the inguinal region, which I shall describe for the first time. The same species has also a gland on the fore

limb, at the bend of the elbow, which was mistaken by Meckel for a lymphatic gland, and is still overlooked as a secreting gland, although I described and figured its microscopic structure in *Med. Chir. Trans.*, lxxv. 1882, p. 56.

The elbow gland, glandula humeralis, is an exquisite instance of a compound sweat-gland with a strong basement of plain muscular fibres. It is an ovoid, spongy body, three-eighths of an inch in the long axis and one-eighth thick, in the female; somewhat larger in the male. It lies close under the skin at the lower end of the humerus. The duct appears to begin in a kind of pelvis at the hilum, but its course, length, and termination on the skin have not been traced. In structure it has the perfect type of a compound tubular gland with basement of plain muscular fibres so striking as to make it altogether unlike a lymphatic gland. In my specimens from three animals, the epithelium is nearly all displaced; but it remains in certain recesses as a mosaic of small polyhedric cells seated directly upon the muscular ribs, which are the one conspicuous thing in the sections (fig. 3). They follow, as usual, the long axis of the coiled tube, so that they run in various directions in adjacent alveoli, sometimes showing the continuity of the coiled tube by the gradual change in their direction. It is impossible to say whether this alveolar structure (in the cross-section) stands for a much-branched tube or for one continuous coil. Whatever their original number, the tubes are united by their adjoining walls into an organ which looks in section to be composed essentially of communicating alveoli, like the thyroid. The thickness of the muscular walls of the alveoli is remarkable, and probably unique. The thumb-gland of the frog has the same alveolar structure (in section), which implies a certain amount of coiling of the several tubes; but the muscularis is far less easily seen, being less strongly developed: along with this difference in the muscularity, the thumb-gland has its epithelium greatly elongated and projecting far into the lumen, while the glandula humeralis has it in the form of a mosaic of depressed polyhedric cells. While the glandula humeralis is a clear instance of a convoluted tube with a longitudinal coat of plain muscular fibres, being, indeed, not far removed in structure

from the thumb-gland of the frog, the corresponding gland of the hind limb shows a certain advance in complexity, and a greater advance in the male than in the female. In the male it is well known as the spur-gland, from its duct ending in a groove of the spur on the hind foot after a course of four inches in *Ornithorhynchus*. In that species it is situated as high up as the gluteal region, lying in the interval between the hip-joint and the spine, of pyriform shape, with the apex pointing downwards; in *Echidna* it is placed at the lower end of the femur, and is like a pea in size and form. The division into lobes and lobules, with a dendriform plan of ducts, is very distinct, owing to the quantity of fibrous tissue between them, which may be greater in the resting state of the organ than at the sexual periods. In my specimens it appears to be in the resting state, in which the acinous-lobular plan of structure is as perfect as in an involuted mammary gland of the higher Mammalia.

As to the corresponding pair of glands which I believe to exist in the female *Ornithorhynchus*, I have kept no notes of their anatomical relation, but only the labels on my microscopic specimens, dated 12th January 1877: "glandula inguinalis, *Ornithorhynchus*, female." The structure in these is different from that of the male spur-gland, and is exactly the same as described by Max Weber for the compound sweat-glands of *Hippopotamus* (see fig. 16, Pl. II., of this work). The lobules consist of a large number of round or elongated spaces, all of the same small width, which are obviously the transverse and oblique sections of coils of tubing. The ducts from each lobule or coil unite in a wide central duct or reservoir. I believe that I can detect the presence of plain muscular fibres in the basements of the small tubes, from the appearance of dentate projections or palisade-like ends. This gland in the female is distinguished from the male spur-gland, not only by its tubular structure and its small extent, but also by having a well-defined thick capsule of striped muscle all round it, which makes up the greater part of its bulk, and is the proper muscle of the organ, as in the Cowper's and other sexual glands of various mammals. I should suppose it to be the female counterpart of the spur-gland; but I do not find any

gland corresponding to it in the most recent account of the glandular system of the Monotremes (Semon's *Zoologische Forschungen in Australien*, microscopic anatomy by Eggeling, iv. iii. p. 196. Jena, 1901).

Owen has described also in *Ornithorhynchus* an "oblong glandular prominence about four lines in length on each side of the termination of the rectum in the cloaca," with about ten orifices discharging a scented matter. These cloacal glands are described by Eggeling as convoluted sweat-glands in both the Monotreme species, the muscularis being not clear.

It will be most convenient to finish the subject of muscle-walled tubular glands in the Mammalia before taking up the Monotreme mamma. If one were to include the prostate, a close parallel would be found, in its muscle-walled crypts in several mammals, to the *glandula humeralis* of *Ornithorhynchus*. Taking only the glands in the cutis, the same crypts or tubes with a muscular basement are found in most classes, the Cetacea being the one great exception. A tortuous or sacculated tube is now the rule, which opens upon a hair-follicle usually below the orifices of the sebaceous glands, or directly upon the skin. I shall refer to the Marsupial skin-glands in connection with the mammary development. In the Ruminants they are described as simple elongated sacs. In some Rodents, such as the guinea-pig, the rat, and the mouse, they are wanting. In the Insectivora they are very variously developed, the Moles having few sweat-glands of either kind (Leydig thought none), while the closely allied Shrews have a great sexual development of the larger kind along the flanks.

One of the most remarkable developments of the larger kind of sweat-glands is in the Hippopotamus, on certain parts of the dorsal surfaces, where they give forth the so-called "bloody sweat" of that species. The excretion is described as a glairy substance of the colour of diluted port wine, which issues from the mouths of the glands in considerable quantity at all times, and is noticeable most on the skin of the back as it dries after an immersion. The structure has been examined by Max Weber (*Ein Beitrag zur Frage nach den Ursprung*

der *Cetaceen*, Jena, 1886, *ad init.*), and found to be that of a *branching* tubular gland, every part of which, excepting the discharging tube in its passage through the cutis and rete mucosum, has a well-marked basement of plain muscular fibres. The first branchings of the tube are wide and sacculated; each of these branches ends in what looks like an acinous lobule, but is really a glomerulus of narrower tubing, the cut ends of which look like small acini (see fig. 16, Pl. II.). I shall have occasion to notice this type of branching sweat-gland with a muscular basement in certain mammary cases in the sequel. In the Carnivorous class, the dog is remarkable for these larger sweat-glands. They occur all over the skin, excepting on the soles of the feet, where the other kind of sweat-glands, with thick coat and almost capillary lumen, are found. Fig. 4 shows their relation to the hair-follicles, and their great depth as far down as the subcutaneous fat; each of the three hair-follicles has one of these coils under it and running to its termination along one side. According to Leydig, every hair-follicle of the dog has its sweat-gland, so that they amount together to a vast organ of excretion. The product of the epithelium is a clear brownish fluid, which becomes of a colloid consistence in disease. The longitudinal muscularis is always beautifully marked in the normal glands of the dog, and appears to constitute the sole basement membrane, just as it is said by Engelmann and others to do in the Amphibia.

The Larger Sweat-glands in Man.—In man the distribution of the wide muscle-walled skin-glands is extremely partial, and probably varies much in individuals. They are found most constantly as a definite glandular patch beneath the skin at the deepest part of the armpit, which may be an inch or more in diameter and a tenth of an inch thick. In that locality, it has been shown by Champneys that they enlarge to form considerable lumps up to the size of a hen's egg, during pregnancy, in certain women who appear to have them congenitally developed in excess: the fluid squeezed from them through the mouths of the hair-follicles is like a watery milk, with "colostrum corpuscles" and globules of very unequal size (*Med. Chir. Trans.*, lxi. 1886, and

sequel with Bowlby, lxxviii. 1895, p. 267). In ordinary, they yield an excretion which stains the linen brown in warm weather. They are the source of the odour of the armpits at certain times, which is sometimes so strong even in the male as to be noticeable and unpleasant.

In other parts of the human skin their distribution is more casual and irregular, excepting perhaps the well-marked coils in the loose tissue under the nipple and areola (*infra*, p. 27). At almost any part of the skin the ordinary sweat-tubes of man may approximate in structure, it is said, to the wider kind; that is to say, some coils may have, instead of the thick wall and capillary tube with cloudy epithelium, a thinner wall composed of a muscularis and a mosaic of cells with clearer protoplasm, and therewith a wider lumen. Notwithstanding the alleged intermediate forms, the distinction between the two kinds of sweat-glands in man is well marked, the narrower kind being by far the most usual. Where extensive deposits of both kinds occur together, as in Cases xxxi. and xxxiii., each kind is clearly separated in structure from the other; this is the same absence of transition-forms which has been remarked by Engelmann for the two kinds of skin-glands in the frog, although both of these have the muscular basement. Fig. 5, Pl. I., from a deposit of both kinds together under the mammary skin towards the axilla, shows the difference between them at a glance.

Besides the axillæ and the loose tissue under the nipples, the more special localities of the larger kind of sweat-glands in man are the scrotum and groins, the labia majora, the verge of the anus, and, according to Robin, certain parts of the side of the face where they are mixed with the ordinary sweat-glands in the proportion of 1 to 10. In those situations they occur somewhat regularly, but much more abundantly in some individuals than in others. They are indeed a most variable structure; so that there may be small spots of them in almost any part of the skin, in place of the ordinary sweat-glands. Case xxii. is an instance from the abdominal wall; and I have found them in a case of sarcoma in the bed of the thumb-nail. According to a brief state-

ment by Sappey in the first edition of his *Traité d'Anatomie*, which has been adopted by Leydig (1857), Henle, and others, the large type of axillary sweat-gland may range widely over the lateral and anterior thoracic walls. In two cases I have found a large deposit of them at one spot of skin between the breast and the axilla; and in another case I have found them, of smaller size, in the mammary skin itself wherever I examined it. The whole subject of sweating by the breasts needs a systematic investigation, which may prove difficult on account of the differences between individuals. In many women the breasts become moist when the rest of the skin is dry; this is especially apt to happen at the beginning of a menstrual period, along with turgescence or tension of the gland itself and erection of the nipple. The phenomenon may find some explanation in the following remarkable statement by Astley Cooper as to the skin of the breast after death:—

“A number of sudatory glands are perceptible upon the surface of the skin, from which much perspirable and mucous matter can be squeezed; for if the breast be gently wiped dry, and then compressed, it will continue to perspire largely after being several times dried; this is more especially the case if the cuticle has been separated by putrefaction; indeed, it is but little observable without it. These pores often contain a fine hair, but they also secrete a fluid to cover the surface of the breast. . . . The orifices lead to little glands, which are placed in the cutis itself, appearing like the heads of small pins within the meshes of the true skin. They differ from those of the areola, which project a little under the cutis whilst these are buried in it; but the pore which they contain leads into an arborescent duct and gland. In the plates may be seen these sudatory glands injected, dividing into several branches, sometimes two to five.” (*Anatomy of the Breast*, 1840, p. 40.)

In view of the remarkable disposition to tumour-disease which I have to maintain in the sequel for the same kind of sweat-glands, involved as an anomaly in the structure of the breast, it becomes a question of importance: Whether they show a similar disposition elsewhere? This is a general point which might have been raised at the end of Case XXII., but it is on the whole less inconvenient to deal with it in the context of the anatomical distribution.

Verneuil has described various morbid conditions, chiefly inflammatory,

of the sweat-glands of the axilla, areola, margin of anus, etc., being the regions in which the larger type of gland is found (*Archiv gen. de Méd.*, 5 Sér. tome iv. 1854, p. 447; 6 Sér. tome iv. p. 537, v. p. 327 and p. 437). The same observer has written much on tumours of the ordinary sweat-glands, one of his latest papers being in *Gaz. des Hôp.*, vol. lii., 1879, p. 577, "Adenome sudoripares—les quatre formes réunies chez une même malade." In various other papers and theses it appears to be the ordinary sweat-glands that are understood in the accounts of adenomata.

The axilla, which is so frequently the seat of cancer or sarcoma of the lymph-glands secondarily involved, is sometimes occupied by malignant tumour diagnosed as primary. There is one such specimen in the College of Surgeons' Museum, No. 4811A, from the practice of Hutchinson; it consists of three or four large, spherical, medullary masses, with a structure of wide alveoli separated by narrow tracts of connective tissue, the tumour cells being large and epithelial-like. In some cases a lump has been observed in the axilla some months before the tumour in the corresponding breast (two cases by Maurice H. Collis, *Cancer, etc.*, Lond. 1864, p. 89). A peculiar and difficult case of cancer originating in the axilla is recorded by F. T. Paul, *Path. Trans.*, xlv. 1895, p. 153. Clinically it was a case of scirrhus, which ended fatally six months after the operation; but there was also a superficial stratum of softer structure containing large, regular alveolar spaces like those of rodent tumour. The tumour lay close under the somewhat livid skin in the middle of the axilla, and was in close relation with the large sweat-glands of the region, as well as with a special glandular mass of normal consistence. Paul's contention was that the branching tubular structures in the latter were also sweat-glands, that they had plain muscular fibres in their basement, and that they passed by intermediate forms into the true sweat-glands of the axilla. From my recollection of his specimens and micro-photographs, I am of opinion that they were the same rudimentary mammary structures which I have figured in Pl. II. fig. 8, and shall refer to frequently in the sequel.

H. Betham Robinson (*Path. Trans.*, xlix. 1898) has given a case of "Papilliferous Cyst of a Sudoriparous Gland," on the outer wall of the left axilla, in a girl aged 13; it was the size of a shilling in section, and consisted of one large cyst with papillomata at one side, and of several smaller cysts.

Hamilton (*Pathology*, ii. 1894, p. 806) says: "There is a cystic tumour which forms, apparently in connexion with a duct, close to the nipple,"—the contents being clear, or turbid, or colloid, with warty excrescences from the wall. This may have been a case arising, like that last mentioned in the axilla, from the deposit of large sweat-glands at the base of the nipple (*infra*, p. 27). See also the case by Treves, given at the end of Chapter VIII.

Clutton has recorded in *Path. Trans.*, xxxvii. 1885-6, p. 479, a "Peculiar Epithelial Tumour of the Skin near the Rectum" in a woman aged 60, which was not an epithelioma with epidermic globes, nor a sebaceous cyst, but was yet connected with the skin at one part, which

showed cavities lined by a layer of columnar epithelium and containing mucus. The bulk of the growth was circumscribed, and separated from the skin by a distinct interval, appearing to have been originally a large cyst into which solid epithelial-like growths projected, studded with small globular cysts or spots of mucoid degeneration. This case appears to me to have begun in disorder of the special circumanal sweat-glands, and to have become sarcomatous.

In another region of the larger kind of sweat-glands, the scrotum, Radcliffe Crocker has described a case of "Paget's Disease affecting the Scrotum and Penis" (*Path. Trans.*, xl. 1887, p. 189), in which a large area of skin was in the eczema-like state sometimes found in the nipple and areola, while there were two small *nodules* in its midst, close to the raphé of the scrotum, which involved "the sweat-glands," and had a structure resembling that of rodent ulcer.

CHIMNEY-SWEEP'S CANCER.

But the great illustration of a morbid growth traceable to the special deposit of sweat-glands in the scrotum and groins, will probably be found in the peculiar cancer of chimney-sweeps, and of workers in coal-tar, shale-oil (paraffin), arsenic, and the like. I hazard this opinion both upon antecedent grounds and on the evidence of an original case, which I shall give. The antecedent probability depends

DESCRIPTION OF PLATE I.

FIG. 1. Thumb-gland of male Frog, in ripe state. *a*, tube with epithelium entire; *b*, usual condition of the tubes with epithelium reduced to granules; *c*, two narrower sections of tube. The muscularis basement can be seen under higher power. $\times 90$.

FIG. 2. Single follicle of thumb-gland from a younger Frog at same season; epithelium with granular border; ends of plain muscular fibres in basement. $\times 200$.

FIG. 3. Glandula humeralis of male Ornithorhynchus. Tubular alveoli with strong muscular walls; the epithelium mostly washed off. $\times 150$.

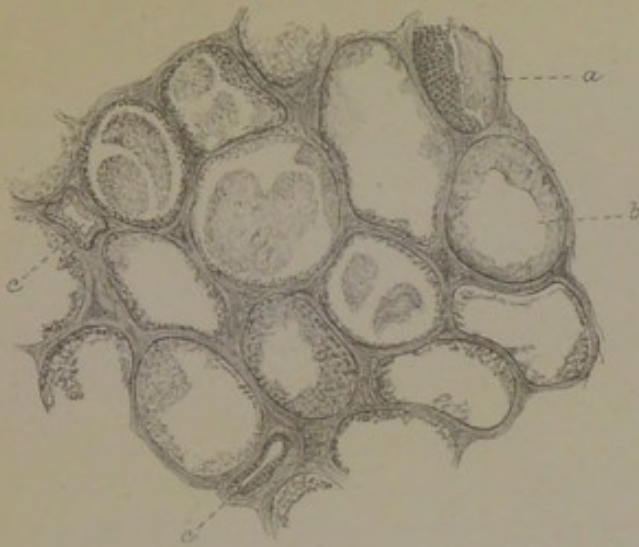
FIG. 4. Skin of dog's back, showing sweat-glands by the side of hair-follicles. *a*, hairs; *b*, coil of sweat-gland opening on hair-follicle; *c*, deepest part of coil in subcutaneous fat. $\times 20$.

FIG. 5. Two kinds of sweat-glands of human skin, from large deposit under the corium in Case xxxi. *a*, Ordinary sweat-glands with capillary lumen and cloudy epithelium; *b*, large sweat-glands (axillary) with muscular ribs, wide lumen, and epithelial mosaic with clear protoplasm. $\times 150$.

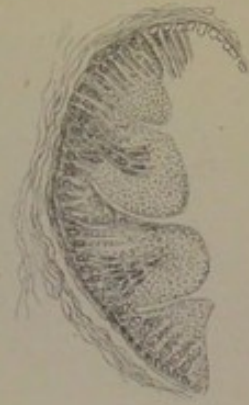
FIG. 6. Coil of large muscle-ribbed sweat-glands from the normal deposit in loose tissue under nipple and areola in Case xxvii. $\times 90$.

Plate I.

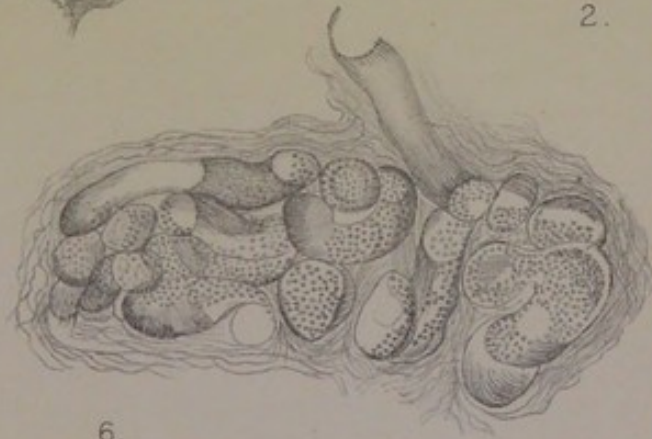
Skin Glands with Muscular Basement.



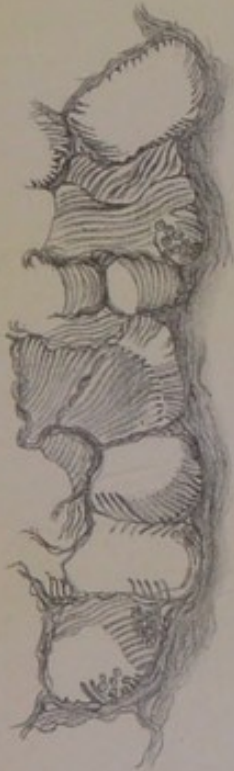1.



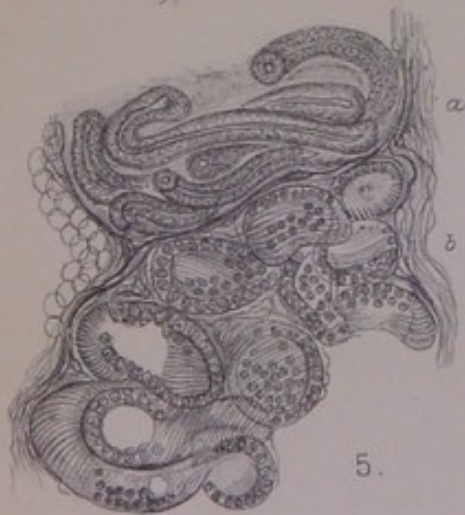2.



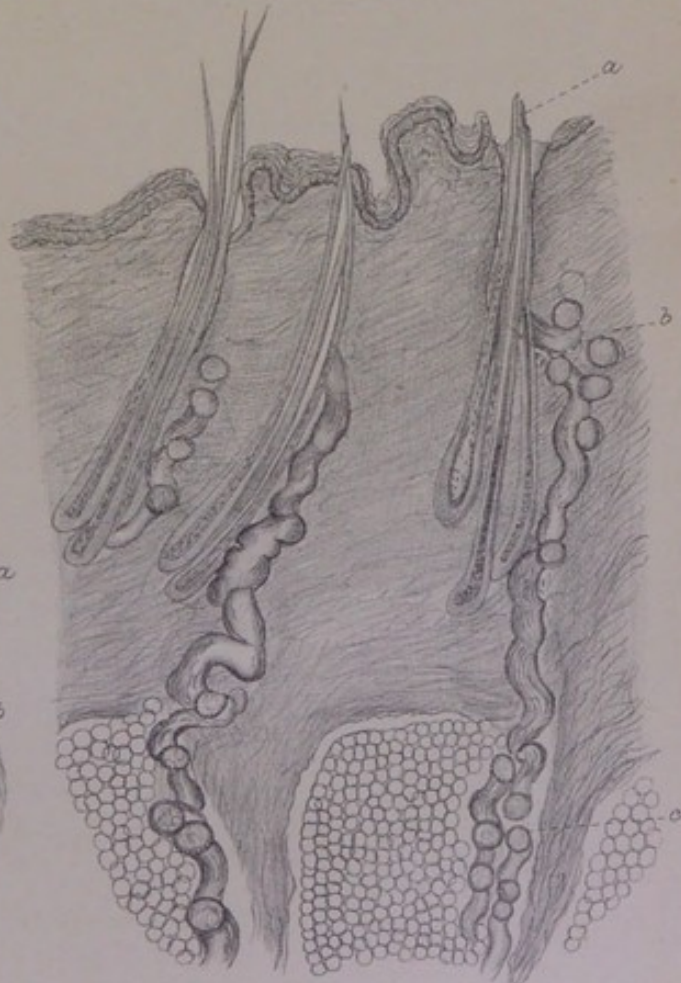
6.



3.



5.



4.

C. Creighton del.

Huth, Lith. London.



upon the following considerations: The seat of election of the cancer is nearly always the skin of the scrotum and adjoining parts of the groins, which have the special kind of sweat-glands. This is true of the cancer not only of chimney-sweepers, but of the workers in shale-oil, wood-tar, and arsenic, and of smelters. Cases in arsenic-workers were mentioned by Rayer as long ago as 1826, and in smelters by Curling, on the authority of Paris, in 1843. When cases began to come into the hospital at Halle, from the tar-works in the country near, what struck Volkmann as the most remarkable thing was the special disposition of the scrotal skin to become cancerous. While the cancer is special to the scrotum, it is not unusual for the skin at large, or the more exposed parts of it, to be affected by small warts, or by some innocent disease of the hair-follicles. Paget (*op. cit.*, p. 734) says: "Scaly or incrustated small warts are very common in chimney-sweeps. In many of them, even when they are thoroughly cleaned, the whole skin is dry, parched, and dusky. Nor are such warts confined to the scrotum; they may exist on every part of the trunk and limbs; and I have seen sweeps so thick-set with them, that a hundred or more might have been counted." Nunn, in his practice at the Middlesex Hospital, had "never yet seen a case where the skin of the whole body was not more or less generally affected with small brown sessile warts," which might be mistaken for freckles (*On Cancer*, 1899, p. 12). In like manner the paraffin refiners in the shale-oil works in Scotland are affected, not only with scrotal cancer, but also with acne, comedones, and eczema all over the exposed parts of the skin (Ogston). That which produces common skin-affections at large, produces cancer in a certain region of skin which is distinguished by the peculiarity of its sweat-glands. This rule, however, is not absolute. The axilla also has the large kind of sweat-glands, and yet it does not appear to be affected with the same kind of cancer as the recesses of skin about the scrotum in the same class of subjects. But there is a marked difference between the axillary and the scrotal sweat-glands as regards distribution, the former being collected into an organ-like stratum, while the latter are

dispersed through the corium in place of the ordinary sweat-glands. Secondly, chimney-sweeps, and the workers in wood-tar, etc., have the characteristic cancer sometimes at other places than the scrotum. It has been seen in rare cases of chimney-sweeps on the cheek, nose, external ear, wrist, knee, foot. Volkmann saw one case of a wood-tar worker with the cancer on the upper eyelid. Several of these situations, such as the cheek (including the zygomatic and temporal region), the external ear, and the eyelid, are known to be situations of peculiar sweat-glands, which may occur also as an anomaly in other places. Besides the special relation to the scrotal and inguinal skin, and the occasional seat of election elsewhere, there is another curious point in the cancer of chimney-sweeps, which is explained best by the anatomy. Although it is on the whole rare among chimney-sweeps, yet it may be common in certain families who have followed the same business. Earle had a patient with it, whose grandfather, father, and brother had died of it. Curling (*l.c.*, 1843) has given other instances, in one of which a mother was affected on the hand and a son on the ear. It is not difficult to understand how the *anatomical cause* of the malady should become exaggerated in families with a hereditary occupation. Lastly, the new growth is of a peculiar kind, which I shall show by the following case to be related to the sweat-glands, and to be unlike epithelioma. Its epitheliomatous character, although always assumed, is far from clear in the recorded cases. Not uncommonly it arises as a nodule or tuber bulging out beneath the skin like a sarcoma. One of Bell's cases (*Ed. Med. Journ.*, Aug. 1876), in a paraffin refiner, was like a small apple. The cut surface is that of sarcoma, lobulated, soft, grey or yellowish. The progress of the new growth is after the rodent manner, with pale fungous granulations springing from the floor of the ulcer. Recurrence after operation is remarkably frequent, not in the scar, but in some fresh spot of skin near. The affection of the lymph-glands is a peculiar one, being rather a "sympathetic" enlargement than an infection. In the microscopic descriptions, *e.g.*, by Tillmanns (*Deutsche Zeitschrift für Chirurgie*, xiii. 1880), and by W. G. Spencer

(*Med. Chir. Trans.*, lxxiv. 1891), it is not easy to discover the unambiguous picture of epithelioma; although it should be said that so great an authority as Thiersch assented to that diagnosis on being shown the specimens by Tillmanns.

The following case in a chimney-sweep, which occurred in the practice of St Thomas's Hospital, and was taken by me as Surgical Registrar in 1873, as well as examined microscopically at the time, confirms my recent suspicion that the seat of the disease would be found to be the special sweat-glands of the part, and proves at the same time that the structure is not epithelioma. The cancer was not scrotal, but inguinal on both sides.

Case of Chimney-sweep's Cancer of both Groins, involving the Larger Sweat-glands.—Thomas Faulkner, aged 53, chimney-sweep, was admitted, on 16th July 1873, into St Thomas's Hospital, under Mr (Sir John) Simon. In the right groin there is a cavity in the line of Poupart's ligament, two inches deep and the same in width. Its floor is covered with pale yellowish granulations; the edges are rigid and upturned. The skin near the outer end of the cavity, over the anterior superior spine of the ilium, bears a number of projecting reddish nodules [warts?]. On the inner side of the thigh, about four or five inches below Poupart's ligament, there is a deep, circular, granulating patch, with firm everted edges. This is said by the patient to have been the first point attacked, having begun as a reddish nodular elevation of the skin.

In the left groin there is an indurated mass, the summit of which is like a large pimple; this is said to have appeared first a week before admission. There is an offensive discharge from the cavities.

Aug. 22.—Died from sudden hæmorrhage in the night.

Post-mortem.—The ulceration on the right side had extended into the femoral artery, which had an opening the size of a large shot. Several small nodules in the liver. The pleura was studded with small round nodules, especially on the left side; none in the lungs, but some bronchitis. Other organs healthy.

This case should settle two points which are considered doubtful by Butlin—"Cancer of the Scrotum in Chimney-sweeps and Others," reprint from *Brit. Med. Journ.*, Lond. 1892. First, that there may be visceral infection—several small nodules in the liver, and the pleura studded with small round nodules (which probably explain Travers's observation of the "entire peritoneal surface studded with the small white tubercle of scrofula"). Secondly, the case proves that

chimney-sweep's cancer in the groins is not necessarily in the lymph-glands of the groin. The larger of the two ulcerated cavities on the right side followed so exactly the line of the transverse chain of inguinal lymph-glands, that one naturally thinks of them as the seat of disease. It is probable that they were involved in it and destroyed by it; but it is clear that reddish warts of the skin were present in the same situation, extending as far out as the anterior superior spine of the ilium; and it is known that the whole fold of skin is the seat of the larger kind of sweat-glands. But the other and earlier seat of the cancer on the right side was at a place on the inner side of the thigh "four or five inches below Poupart's ligament," therefore beyond the range of lymphatic glands, which do not descend in the vertical chain farther than the saphænous opening. There are already on record three cases of chimney-sweep's cancer in the groins, without any disease of the scrotum, upon which Butlin has based an ingenious speculation to show how lymphatic glands may be infected before any primary tumour comes into existence. Only one of those cases, by Paget (*Surg. Pathol.*, 4th ed. p. 720), is recorded fully, the other two being given so briefly (by Lawson, *Lancet*, 1878, ii. p. 576) that they prove nothing either way. But Paget's case, if read carefully, will be found to be exactly parallel with the above case from the practice of Simon. Thiersch, in his celebrated work *Epithelialkrebs*, 1865, p. 66, had already suggested that Paget's case of inguinal chimney-sweep's cancer had really begun in some unobserved subcutaneous nodule of the scrotum, from which the lymph-glands of both groins had been infected very extensively; and as he had just before been engaged in proving that the so-called primary epitheliomas of bone recorded by Virchow and O. Weber had really started from sweat-glands of the adjoining skin, it is implied that the supposed unobserved scrotal nodule was also of sweat-gland origin. But Paget is clear that his patient had "no appearance of cancer, or wart of any kind, on the scrotum or penis." The chief, and by implication the original, seat of disease was a round tuberos mass, more than an inch in diameter, over the saphænous opening of the right thigh, with the skin

adherent over it, and a dark soft growth protruding through its ulcerated summit. This whole mass was lobed, soft, greyish, mottled with pink and livid tints. Above it lay three lymphatic glands, enlarged but not hardened, which, when cut open after removal, were "not evidently cancerous." The state of things in the other (left) groin was nearly parallel: one larger lump, half an inch in diameter, hard and firm, but with the same kind of cut surface as the chief mass on the right, and "four smaller nodules," which, like the lymph-glands of the other groin, were not evidently cancerous. Here, I think, the distinction is clear enough between a primary cancerous tumour on either side, which was not in the lymphatic glands, and a cluster of lymphatic glands near it, three and four respectively, which were not cancerous, but only swollen. It is this same occurrence of primary tumours in the groins, apt to be mistaken for lymph-glands, that explains the mystery of supposed lymphatic infection in the groin long after a scrotal cancer had been removed and cured.

From the above patient I took during life a small piece of the new growth at the edge of one of the excavations, and cut it into sections, which bear the date of July 1873. On re-examining them lately, I had no difficulty in finding the larger type of sweat-glands in the cutis, involved in the midst of the new growth (see Pl. XV. fig. 89). At this part of the skin of the groin or thigh, to which the tumour process had extended, the sweat-tubes are remarkably well preserved, with columnar epithelium which may be called normal in respect of its regularity, the clearness of the protoplasm, and the smallness of the nuclei; the basement of plain muscular fibres can be seen in two or three windings of the coil near the surface. The new growth itself wants the distinctive character of epithelioma; it has no squamous cells, nor concentric globes, nor compact columns or cylinders like those of rete mucosum. The cells are very unstable, but the best preserved of them are large epithelial-like elements, with very large vesicular nuclei, which are usually full of granules, sometimes cleft into two pieces, and sometimes of crescentic form at one side of a vacuole.

Besides these, there are many pale nuclei with only a fringe of protoplasm, as well as some small oblong or spindle cells. The cells or nuclei of the ill-defined kind are characteristic of whole areas. The tissue is everywhere vascular, and the cells in some places obviously perivascular; but the blood-vessels are usually as indistinct as the surrounding cells, although there is no doubt that the growth is traversed everywhere by loops of capillaries which may be definite enough to make a certain alveolar structure. In all this I find the structure of sarcoma, not of epithelioma; and I suspect that this kind of tumour of the cutis, in chimney-sweeps and the like, is always sarcomatous. I am the more persuaded of that by the following case from Thiersch (*op. cit.*, p. 137, Pl. IX. figs. 1 and 2), in which an unusual deposit of branching sweat-glands in the zygomatic region became the seat of a tumour, with all the appearances of sarcoma at first, but with a rodent character afterwards, on account of which the diagnosis was changed to epithelioma.

Tumour of Sweat-glands in the Temporal-zygomatic Region, Recurrent and Malignant. (From Thiersch.)—A peasant, aged 61, was admitted to the clinic at Erlangen, on account of a smooth round nodule, like a pigeon's egg, under the skin of the right temple near the orbit, which had been cauterised repeatedly, and was partly cicatrised, partly granulating. The nodule was removed, and was found to be definitely bounded, cutting with a uniform, soft, pale-red surface, and so like a sarcoma in all respects that it was thought unnecessary to confirm the diagnosis by the microscope. Three months after, the patient came back with a knot like a filbert at either side of the linear scar; these were also like sarcomas. After eight months there was again a recurrence, this time of the eroding kind and involving the bones, which extended over the whole right side of the face, had destroyed the right half of the nose and the eyelids, had perforated the eyeball, and laid open the front of the cranium to the ethmoidal cells and dura mater. The patient died of purulent meningitis from perforation of the dura mater.

There was no infection of lymphatic glands nor of the viscera. A microscopic examination of the filbert-sized nodules of the first recurrence, on either side of the scar of the original operation, showed an immense number of anastomosing sweat-glands in clusters under the skin; some had the lumen clear, others had it blocked and the outlines of the tube obscured. The sweat-glands extended so widely and so deeply that they were assumed to be in a state of active growth or proliferation, the evidence of which was the rete-like structure of anastomosing tubes with terminal and lateral projections; there were also larger solid masses of cells in alveoli

of the connective tissue. The other figure, which is the high-power one, shows the structure of the granulation surface in the last fatal recurrence. Here there are no original sweat-tubes, but a characteristic kind of new growth, which appears to correspond closely with that of my figure from the chimney-sweep's cancer in the groin—namely, large epithelial-like cells, with very large and highly mitotic nuclei; the protoplasm of adjoining cells fused to make trabeculæ, the nuclei free in large vacuoles of these; many young cells and small nuclei, characteristic of certain areas; the whole traversed by a network of ill-formed capillaries.

To show the relation of the new growth in this case to the extensive deposit of sweat-glands (in the temporal and malar region), I should have to anticipate evidence which I can only develop from point to point in the cases that follow. The conclusion, however, is that the new growth is not from continuous growth of the sweat-gland epithelium, but from the vascular tissue between the tubes in the first instance, and from the whole vascular tissue of the region eventually, the type of structure being perivascular and sarcomatous. The sweat-glands in Thiersch's case were almost certainly of the larger kind, which are apt to occur as an anomaly in certain parts of the face, just as they occur more uniformly, but of various extent in different persons, in the scrotal and inguinal skin. It is not so much proliferation of their epithelium that explains the somewhat distinctive kind of new growth, as obstruction of the tubes, with eventual loss of their structure and function. For such cancers, we shall have to revive the very old pathology of Obstructions, and return to Deobstruents as the means of prevention, if not of cure. An obstruction of the sweat-glands is intelligible in the common cases of chimney-sweeps, paraffin refiners, workers in wood-tar, etc., the risk of tumour after repeated provocation arising at those parts of the skin which have sweat-glands of a particular kind.

The Sweat-glands of the Areola.—To return from this pathological excursus to the distribution of the larger kind of sweat-glands in man. Besides the variable and occasional occurrences of them in the cutis, in the place of the ordinary kind, they are found in special deposits in two situations, the axilla and the areola. Of the axillary enough has been said; but of the areolar I have still to treat at some length, because

they lie so near to the breast itself, and are of the same kind as the anomalous glands which come so prominently into the sequel as an integral part of the breast and as the anatomical cause of its tumours. They have also an interest in connection with the evolution of the breast from a primitive type, which type they retain; and as being the chief, if not the only, kind of glandular structure that survives after puberty in the breasts of the male. The current teaching about the glands of the areola has descended from Morgagni; and as I believe that it has become confused owing to a too verbal handling of it, I shall begin with a statement of what Morgagni really taught, and of the subsequent glosses.

Morgagni (*Adversaria Anatomica*, i. 1706) makes it clear that he held the *sebaceous glands* of the areola to be the most constant and the most prominent. He says that he had often expressed sebum from the glands, and proceeds:—"I am able to add that, in two or three women, I have also seen milk-carrying ducts, such as run to the nipple itself, running to the tubercles of the areola. Moreover, in the case of a certain wet nurse, by whose desire I squeezed the breast to watch the effect, there issued from the tubercles of the areola milk, which flowed over the surface; this happened repeatedly, the areola having been wiped dry after each time." He gives a figure of the tubercles of the areola, which have subsequently borne his name; but he does not elucidate the deeper anatomy, leaving it to be supposed that it is ordinarily the secretion of the sebaceous glands that escapes from their orifices.

Dr W. F. Montgomery, of Dublin, in his well-known and beautifully illustrated work, *The Signs and Symptoms of Pregnancy*, Lond. 1837, made one addition to Roederer's list of changes in the areola in pregnancy—namely, "the soft and moist state of the integument, which appears raised and in a state of turgescence, giving one the idea that, if touched by the point of the finger, it would be found emphysematous. We not unfrequently find that the little glandular follicles, or tubercles as they are called by Morgagni, are bedewed with a secretion sufficient to damp and colour the woman's inner dress." His only other reference to this point is in the note on p. 61, which is avowedly based upon Morgagni, and contains no separate or distinct observations of his own; in this note he calls the fluid discharged from the areola in pregnancy "serolactescent."

The next author, from whom a good deal has passed into the text-books, is F. Joseph Duval—*Du Mamelon et de son Auréole*, Thèse, Paris, 1861, pp. 236, 4to. He describes the tubercles of Morgagni as of the nature of miniature nipples, and associated only in part with the sebaceous glands. Some of them, he says, correspond with the orifices of sebaceous glands "and of sweat-glands" (and, on the margin of the areola, with hair-follicles); but the larger tubercles stand for the orifices of certain "veri

tables glandes en grappe composées"; these are in several lobules, placed most usually in a circle at the base of the nipple, but occurring also without order throughout the subcutaneous tissue of the whole areola, perhaps extending upwards a little into the corium, but bulging out upon the under surface of the skin [as Astley Cooper also describes], so deeply as to come into close contact with the walls of the milk-sinuses. These "compound racemose glands" became larger with pregnancy, and discharged a milky fluid, whence Duval concluded that they were of the same nature and structure as the lobules of the breast itself, and that the structure of one of their excretory ducts was the same as of a milk-duct (which he took to be pavement epithelium, a dense outer coat of fibrous and elastic tissue, and some plain muscular fibres). He arrives at their affinity to, or identity with, the mammary lobules by a method of exclusion, and without microscopic demonstration. Although the account is highly generalised, it appears to have been based chiefly upon two or more special cases, of which one is given: A woman, aged 31, in the hospital at Strasburg, pregnant with her second child, from whose areola a drop of milky fluid was made to issue at the summit of one of the larger tubercles; neither the author nor Prof. Morel could distinguish the fluid from milk, its constituents being "colostrum corpuscles" and globules of very unequal size (as in the milky fluid expressed by Champneys from the axillary lumps of pregnancy).

Two years after, Luschka (*Die Anatomie des Menschen*, I. ii. 1863, p. 236) gave currency to Duval's identification of the subareolar glands with milk lobules discharging upon the areola, and at the same time credited Montgomery with the teaching of Morgagni, citing both authors loosely. He called Duval's deposit of subareolar glands *glandulæ lactiferæ aberrantes*. Henle (*Handbuch der Anatomie*, II. 2te Aufl., 1873, p. 555) followed Luschka in describing "accessory milk-glands" under the areola and discharging from the tubercles, to which he gave the name of "Montgomery's glands," although that author had merely cited Morgagni for the escape of milk upon the areola in two or three exceptional cases, and had himself described the surface of the areola as "not unfrequently" bedewed with a "serolactescent fluid." Lastly, Langer, with a more intimate knowledge of the breast, in his article "Die Milchdrüse," in Stricker's *Handbuch*, 1871, assumed the existence of true mammary lobules under the areola, "which send their own fine ducts to the surface," calling them by the name of "*glandulæ aberrantes* von Montgomery," and so combining the names given by Luschka and Henle respectively. He took them to belong to those smaller or fragmentary lobules (*Körner*) of the mamma lying along the walls of the milk-reservoirs and opening upon these by short ducts, which in some cases must run downwards, or become "recurrent"; instead of being recurrent to the milk-sinuses, they would occasionally open directly, it was supposed, upon the surface of the areola. I venture to doubt whether this or any of the previous statements, as to aberrant mammary lobules discharging upon the areola, has ever been anything more than an inference or a guess.

Setting aside all that is merely constructive in the above teaching, we are left with the original observation of Morgagni, confirmed by Dubois and others, that in rare cases true milk may be made to issue upon the areola from one of the tubercles. I believe that this phenomenon can be explained without assuming *glandulæ lactiferæ aberrantes*; whilst Montgomery, by whose name the supposed aberrant mammary lobules are called, did not mean the fluid or moisture seen by him upon the areola to be considered milk.

The glands proper to the skin of the nipple and areola are sebaceous glands. But they are not the sebaceous glands of hair-follicles, and they are modified in various ways from the ordinary type. Like other structures in connection with the breast, they are variable in individuals; but their general plan of structure, and the character of their epithelium, are constant, being of the sebaceous type. In some nipples they form a very complete corona of crypts close under the skin all around the sides of the nipple, the single large follicles of which may be visible to the naked eye as translucent points. Sometimes the crypts are few, and very large, several opening upon one central duct. The only confusion with sweat-glands arises from the occasional presence of a true basement of plain muscular fibres, which I have seen clearly in one case (Case XXIV.). The areola is ordinarily traversed by strong bundles of plain muscular fibre in various directions, making a felted muscular tissue of the skin. Some of the bundles come close to the walls of the sebaceous crypts, as if to act directly upon them; and it appears as if these extraneous muscles of sebaceous glands were now and then adapted to be an actual muscularis basement, encircling the crypt meridionally and bearing the epithelium directly upon their inner surface like a sweat-gland. I believe that this is exceptional; and where it does occur, that the sebaceous gland is still sufficiently distinguished from the muscle-ribbed sweat-gland.

The sweat-glands of the areolar region lie deeper than the sebaceous, and, in their most distinctive form, they make several small lobes or coils of tubing. They are found most

easily in the neck of loose connective tissue between the base of the nipple and the *corpus mammæ*. The loose tissue is traversed by the true milk-ducts, or ejaculatory ducts, in number twelve to twenty, which issue from as many milk-sinuses to pass through the nipple to their orifices on its summit; it is around that bundle of vertical tubes that the small lobes of sweat-gland are disposed, so close together that in one specimen I have three of them complete in the same microscopic section. Fig. 6, Pl. I., shows the form and structure of the glands, as I have found them uniformly in some half-dozen breasts—a continuous coil of tubing with an exquisitely marked coat of plain muscular fibre in the long axis, upon which rests directly a mosaic of polyhedric epithelium. In one or two instances I have found them sunk a little way into the lowest layer of the corium; but usually they lie in the midst of looser connective tissue beneath the corium. This appears to correspond with the observation of Astley Cooper, that the “sudatory glands of the areola project a little under the cutis,” whilst those of the mammary skin at large “are buried in it” (both kinds being figured from injected specimens as branched tubes).

As to the ducts of these coils of gland at the base of the nipple, they are not easily found in the microscopic sections best adapted to show the coils themselves; but I have succeeded, in two or three instances, in finding a single tube running through the corium to open on the surface of the areola in the midst of the dense corona of sebaceous glands. One of these is drawn in fig. 7, Pl. II. The areola in this instance (Case XI.) was very narrow, and had only one tubercle of Morgagni, which was very large, nearly half the size of the nipple itself. The tube was found in making sections of the tubercle, which it did not appear to penetrate; also, under a lens, one finds certain wide orifices at the base of the nipple or between the tubercles, not on their summits. The tube in the figure stands widely open, and shows a sacculated interior, with valvular projections; it does not appear to keep the muscularis basement of the glandular coil itself (being surrounded by the muscular bands proper to the areola), in which respect it would resemble the discharg-

ing tube of the compound sweat-glands of Hippopotamus (M. Weber). The *valvulæ* of its interior have a certain historical interest. In Morgagni's time there was a controversy as to whether the milk-ducts contained *valvulæ*; such were said to have been seen, but their existence was denied by others (*Adv. Anat.*). It is probable that the tubes seen with lunular folds of their interior were the ducts of the sweat-glands, and that it was these, and not milk-ducts, which Morgagni himself had seen in two or three cases running to the tubercles of the areola instead of to the nipple. On the other hand, it is not out of the question that the *normal* coils of sweat-glands at the base of the nipple may discharge sometimes by a recurrent duct upon the milk-sinuses, which they lie close to. I shall have numerous opportunities in the sequel of showing that *anomalous* coils of the same kind of sweat-glands, developed as part of the breast, open both upon the milk-sinuses of the central *corpus mammæ* and upon the prolongations of the same towards the margins of the breast.

To explain the rare phenomenon of an escape of true milk upon the areola, from or near the tubercles of Morgagni, one must assume an equally rare, but not impossible, concurrence of structural peculiarities in the region of the milk-sinuses. As I shall show a few pages later, the glandular structures around their walls may be of three kinds—true mammary lobules with many acini (involved); secondly, mere skeletons of lobules, or branching tubular forms; and thirdly, true coiled sweat-glands with wide lumen and muscular basement. It is only the last, in my opinion, that ever discharge upon the areola; but it is possible that there may be an occasional outlet also upon the milk-sinuses, and it is farther probable that *anastomoses* exist between the several coils around the walls of the milk-sinuses, inasmuch as such anastomoses have been dissected out by some of the older anatomists (being referred to the milk-ducts themselves), whilst anastomoses between neighbouring coils of tubular glands are not unusual, whether in the testis or among large sweat-glands of the skin. Assuming, even if it be unusual, that one or more coils of subareolar sweat-glands open upon milk-sinuses, and, as a concurrent rarity, that these anastomose by their infundibula with neighbouring coils which open upon the areola, then there would be a collateral channel for milk to pass to the areolar surface, which would be used when the breast was squeezed, but not in the ordinary flow of milk. The ordinary bedewing of the areola in pregnancy by a "serolactescent fluid" is another matter altogether, and is intelligible as the natural excretion of the larger kind of sweat-glands, modified, doubtless, in quantity and

quality as pregnancy advances, but never, I believe, a fatty secretion of the nature of true milk.

Like the deposit of the same excretory tubular glands under the skin of the axillæ, and like most of the organ-like aggregates of the same in Amphibia and Mammalia, the subareolar deposit in women has some special relation to the sexual system. I shall come back to this point in connection with the primitive type of the breast itself (p. 48); and will give here two observations upon unusual states of the areola unconnected with pregnancy.

Hennig, who made many observations upon the breast, too abruptly recorded (*Archiv für Gynaekologie*, ii. (1871), p. 131), mentions the curious fact that sexual intercourse without childbearing is apt to develop the "Montgomery glands," rather than extend the areola or add to the weight of the breast, the women who exhibit the former development being implied by the context (and so understood by Billroth) to be "Defflorirte, Freudenmädchen und Onanisten." Again, F. Joseph Duval (1861, p. 176) found that of seventeen prostitutes whom he treated for syphilis in hospital at Strasburg, six had eczema of the nipple, or of the nipple and areola, but not extending beyond the areola, none of them having borne a child.

II. TUBULAR GLANDS WITH MUSCULAR BASEMENT WITHIN THE BREASTS OF WOMEN.

The occurrence of tubular glands with the distinctive structure of the axillary or areolar sweat-glands throughout the breasts of women, both in the centre of the organ and around its margin, will be shown under the several cases in every chapter of this work. Many of the breasts that one examines for tumour have undergone a more or less complete obsolescence of their proper structure at the change of life; and in these the anomalous sweat-glands remain, in the midst of the fibrous tissue or fat, in such numbers as to make a kind of glandular organ by themselves; where the breast has been changed largely into fat, they may even appear as detached islands in its midst. It is to these anomalous structures, and not to the proper mammary lobules and ducts, that I trace the new growths. There is a well-known hypothesis, thrown

out by Cohnheim in 1877, which would explain all tumours as due to the proliferation of "sequestered embryonic rudiments," so that they would make a new order of *monstra per excessum*. It bases upon the familiar fact of congenital anomalies, and upon the old pathological principles of *error loci* and *error temporis*; and by assuming a great deal of "proliferation" on the part of the belated embryonic cells, it essays to account for morbid growths of whatever kind. The exposition contains two brief references to the breast, neither of which has any bearing upon the pathology which I am about to maintain for mammary cancer and sarcoma. One learns also, from a statement by Ribbert (*Ueber Rückbildung . . . und über die Entstehung der Geschwülste*, Stuttgart, 1897, p. 17), that Cohnheim was inclined latterly to abandon more and more of his original hypothesis as inapplicable to malignant epithelial tumours. Whether that be so or not, it has nothing in common with the pathology which I shall maintain, beyond the general association of congenital anomalies, rudiments, and reversions with disease, which had been taught by earlier writers, more especially by J. F. Meckel, and by F. Jahn with an extraordinary profusion of ideas.

The more precise point which I have to consider at the outset is, whether the anomalous sweat-tubes, which I find in so many breasts with tumour, can be referred to erratic deposits from the axillary sweat-glands on the one hand, or from the subareolar sweat-glands on the other? That would amount to an accidental *error loci*, of somewhat frequent occurrence. The most likely cases are those not rare tumours, whether of scirrhus or sarcoma, which are situated on the axillary margin of the breast, or beyond the more regular margin, and may appear to have a clear interval between them and the mamma. Three of the cases of scirrhus in the sequel are of that "paramammary" kind, with the base of the nodule upon the skin; and two of these, Case XXXI. and Case XXXII., are certainly in relation with a subcutaneous erratic deposit of the axillary kind of sweat-glands, marked by a dimple of the skin, which belongs so clearly to the cutaneous system that there are ordinary sweat-glands mixed with the larger kind (fig. 5, Pl. I., and fig. 130, Pl. XXIII.).

The third instance, however, raises the question whether the sweat-tubes found in the tumour-area had not belonged to one of the straggling processes or "tails" of the breast, which are specially apt to contain such anomalous structures, and are developed, of course, as an integral part of the breast.

Again, in two cases of sarcoma, Case xv. and Case xvi., there is at a certain point on the upper surface of the breast, and just within its capsule, an island of glandular substance, consisting of large hyperplastic sweat-glands, which appears to be isolated from the mammary structure, and might be considered a part of the subareolar deposit which had been separated from the rest and included within the area of the breast in the course of development (fig. 65, Pl. XII., and fig. 68, Pl. XIII.). Lastly, the *corpus mammæ* directly under the nipple and areola is so commonly the seat of anomalous coils of sweat-glands, that they might be considered erratic from the regular subareolar deposit.

But there is a reason for dismissing the hypothesis of casual *error loci* as inapplicable to nearly all cases. The tubular glands in the breast, of the sweat-gland type, are really a part of its structure, as if substitutes for so much mammary gland. The nature of their incorporation in the breast falls to be brought out in the sequel; but it may be said here that they have their own ducts, which run to the nearest prolongations of the milk-sinuses, and that the walls of those reservoirs themselves can be shown in a good many of the cases, if not in them all, to have the same basement of plain muscular fibres running their whole length until they change into the milk-ducts within the nipple. There is some more intimate or more organic relationship between the tubular sweat-glands involved in the breast and the proper mammary structure, than mere accidental confusion from misplaced embryonic rudiments. In order to understand how tubular glands belonging to the kind of larger sweat-glands can be an integral part of the breasts of women, it will be necessary to enter somewhat fully into the primitive type of the mammary organ, and its evolution in the higher mammals. But before I come to that subject, I have to consider whether every female breast has not some vestiges of anomalous or imper-

fectly developed structure, and to what extent and in what circumstances these may occur.

Besides the tubes of the sweat-gland type, with a longitudinal coat of plain muscular fibre, which are truly anomalous in the substance of the breast, and most likely to be noticed, there is another kind of glandular structure, usually found in the company of the former, which is in one respect an imperfect development of the mammary lobules, but is not the same thing as the normally undeveloped structure proper to all virgin breasts, being at once an arrested development of the lobules on the proper acinous lines of the primiparous breast, and positively a mal-development upon lines of its own.

First, as to the frequency of the true sweat-gland tubes in the substance of the breast. It is probable that most breasts would show certain traces of them if they were searched closely. I can give only a few samples.

1. A— T—, aged 29, married ten years, has borne four children, of whom two are living; has had one abortion thereafter, and died on 22nd January 1902, of septicæmia, after a second abortion at the sixth month, procured by a septic catheter with stylet. At the medico-legal *post-mortem* I removed a portion of the right breast, including the base. The organ is of a deep pink colour, finely lobulated like the pancreas, and with comparatively little stroma between the lobules. Numerous radial incisions were made through the periphery, one of which disclosed, under a lens, a small round spot close to the base, which differed in appearance from the compact lobules round about it. Microscopic sections of it showed that it consisted of a cluster of sinuous tubes with plain muscular fibres in their walls, and of one larger dilatation with numerous long vascular villi projecting into its interior. The connection with the system of the mamma proper could be traced by a coiled tube running in the midst of a broad tract of fibrous tissue, and ending not in an ordinary milk-duct, but in a milk-sinus with the characteristic rugosities of the wall, which had been prolonged far towards the base of the gland. In the cleft of a long narrow duct running to the periphery, there were found several sections of tubing like those of the undeveloped virgin breast. In the other parts examined, the structure was that of well-developed mammary lobules somewhat advanced from the resting state, so that the whole gland looked succulent or "parenchymatous."

This is the first normal breast that I have preserved for examination since I began the present inquiry, and it contained an easily found instance of the structural anomaly that

I was looking for, although it would have passed as a typically well-developed organ.

2. Breast of a woman, aged 38, who died of tuberculosis, having suffered from enteric fever six months before, and from amenorrhœa after that. The breast is a disc about a quarter of an inch thick, indented by lobules of fat on its upper surface. It contains no fully formed acinous lobules, but only the branched tubes proper to the virgin breast, which are in some places dilated at their ends into very regular hollow spheres lined by a single layer of low cubical epithelium. At one spot on the base, the lens discovers three or four loculi, which are found in microscopic sections to be dilated parts of a cluster of sweat-glands, the plain muscular fibres of the basement being quite clear. In one corner of the periphery there are two small cysts, which are also found to have the characteristic parallel ribs of sweat-glands, but less clear than in the basal cluster owing to induration of the connective tissue. The sections of large ducts or reservoirs are encountered in the same region, being recognised and contrasted easily by their thick, opaque, convoluted outlines.

3. Breast of a woman, aged 47, removed *post mortem* to study the climacteric atrophy. The organ is a small pyramidal body, about an inch deep in the centre. The fibrous stroma is in broad tracts, and the acinous lobules very small and indistinct with granules, where they survive at all. At one side, near the upper surface, there is a round island about the size of a pea, distinguished by its redness and softer granular cut surface; it is divided into many small round areas by narrow bands of glistening fibres, and in the microscopic sections is found to be an extensive coil of tubular gland with more than one row of epithelial cells on the walls, which sometimes run out into papillary elevations. This coil of tubing resembles the two drawn in fig. 66, *cc'*; a muscular basement cannot be made out, but the glistening fibrous bands between the tubes appear to be plain muscular fibre (as in the stroma of the cat's mamma), and are confined to the red island, being in marked contrast with the ordinary fibrous tissue of the stroma at large. Other sections discover two or three smaller reddish islands with the same kind of tubes. Thus far the search had not discovered any unambiguous sweat-glands with a muscular basement. These, however, were found beyond all doubt in an outlying piece of the breast, about the size of an almond, with fat upon its surfaces, which was connected with one corner of the base of the breast by a short neck of connective tissue. It was more indurated than the body of the gland, and contained traces of true mammary lobules and ducts, as well as several large clusters of unmistakable sweat-glands, some parts of which were dilated into loculi so as to show the muscular basement quite plainly.

4. Breast of a primipara, aged 23, who died of septic peritonitis following abortion at the fourth month. The breast is a voluminous, whitish, tough organ. Incisions of the central part preserved do not show any spots of loculi, or of unusual texture. Microscopic sections show the lobules developing everywhere on a regular racemose plan in the midst of an

extensive stroma rich in spindle cells around the lobules, and with occasional areas of fat. In this case the base of the gland, which is the most likely place for the anomalous development of sweat-glands, was not included in the specimen.

5 and 6. Two virgin breasts at the age of 17, from tuberculous cases. One is nearly twice the thickness of the other, being about three-quarter inch deep in the centre, shelving to the margin; the other a more uniform disc about three-eighth inch thick. The mass of both is dense fibrous tissue traversed by a few ducts. Around the periphery, the ducts show dichotomous branching, with commencing development of lobules. Some ducts are dilated close to the margin; and there is in one of the breasts an appearance of a muscularis basement in these wide tubes.

I have preferred to give these details of six normal breasts, rather than to generalise. I believe that anomalous development of mammary rudiments into coils of sweat-glands would be found not unfrequently around the margin, and especially in the base, of breasts not subject to tumour disease. It is the presence of the same kind of structure that leads to involution cysts after middle life (see Chapter II.), and these are known to be common in breasts that have tumours. It is not easy to guess how common those cysts may be in breasts not the subject of operation, as it is unusual to examine the breast *post mortem*. Billroth, however, had examined many breasts both in health and in disease, and his opinion was that involution cysts, although often found, were not so invariably present as to be "physiological." The wide intervals between involution cysts may serve to show also how occasional is the development into tubes of the sweat-gland type in the general run of cases; they are most commonly on the extreme margin, implying that a lobule here or there had failed to reach the true mammary development. In the breasts that become subject to tumour, as we shall see, the anomalous development may be much more extensive.

I come next to the minor degree of anomalous or misdirected development, which consists in certain branching tubular forms instead of acinous lobules. Langer has referred briefly to the existence of those structures in the region of the milk-reservoirs, without distinguishing them in kind from fully formed lobules. They are, he says, mere granules of gland substance, often enough seated upon the walls of the reservoirs, and not combined into larger masses

like the regular lobules, which develop in pairs upon the terminal ducts all round the periphery. Henle also describes these sessile particles of gland-substance as having the same nature (*Beschaffenheit*) as the proper lobules. Hyrtl, in his corrosion preparations of the breast, has found even in the lactating organ occasional long ducts altogether naked or without acini around them.

Whilst these imperfect lobules are found most usually, and perhaps in all women, close to the walls of the milk-reservoirs immediately under the nipple and areola, the same branching tubular forms may be met with in certain breasts in the periphery as well: in those cases they are probably related, like the central, to the walls of the milk-sinuses, which may be prolonged far towards the margins of the breast with the proper width, shape, and structure of sinuses. The simplest kind of them are short recesses or blind pockets upon the wall of a sinus; or the saccular recess is prolonged into a simple unbranched tube; or the elongated tube has small side-pockets; or it divides into two or three cæca, or into a whole bunch of them, each terminal tuft being coiled like a sweat-gland in miniature. Fig. 8 shows a not unfrequent plan of structure, namely, a straight piece of tube, with bunches of cæca proceeding from both ends and perhaps from intermediate points as well. In that case the middle piece has a clear lumen and a double row of epithelium, more nuclear than protoplasmic, but the rest of the structure consists rather of solid cords of nuclear cells than of epithelial-lined tubes.

It is a mistake to suppose that these are the remains of full mammary lobules which had been denuded of their acini. When a true mammary lobule undergoes its obsolescence, it is not stripped of its acini and left with its framework of ducts naked, but it degenerates or is fibrosed throughout its whole substance. The branching tubular forms do not suffer the same kind of effacement as the fully developed ovoid or pyramidal lobules, and may indeed be found in quite old breasts, attenuated to mere lines of nuclei, but still recognisable by their peculiar shapes. Their nearest affinity is to the regular undeveloped lobules of the virgin breast, with

which they are mixed not unfrequently (Case 2 of the series just given). But in the normal virgin breast, awaiting, as it were, the full development which comes with the first pregnancy, the ampullæ around the ends of ducts are wide, and have well-marked columnar epithelium, whereas these branching tubes are narrow processes occupied by nuclear cells, which look as if they were incapable of development, excepting that they may become tortuous or coiled at their extremities. Among the developing mammæ of animals, the nearest affinity that I have seen to them is in the primiparous cat, where the gland, before the acini are so numerous as to overlay and hide its framework of ducts, appears to consist of the same kind of elongated branching tubular forms (see fig. 27), some of them having the very same appearance of a central straight limb with a bunch of branches at either end, which is shown in fig. 8.

The contrast of these partially developed or branching tubular mammary forms, with perfect involuted lobules on the one hand, and with true sweat-glands on the other, is shown in the three figs. 9, 10 and 11, which were all drawn from the same section of mamma near a reservoir, and might have been actually drawn *in situ*, if the figure had been enlarged. Fig. 9, of pyramidal shape, drawn out to a neck (the duct), is a typical involuted lobule at the age of 49, menstruation still continuing; the outline of the branching duct is indicated vaguely amidst the large number of spherical acini; these are occupied by a heap of nuclear epithelial cells, and have a degree of thickening of their walls which is a step on the way to fibrous or hyaline obsolescence. The two irregularly shaped branching forms, fig. 10, are situated not far from the pyramidal lobule, and are in relation with the same milk-sinus; but they are so unlike the developed lobule that they might be supposed to have come from a different organ altogether: they show the characteristic points—somewhat sacculated, or curved, or sinuous tubes, with nuclear contents perhaps filling the tubes, and various small terminal coils at either end or proceeding from the middle. Except that they are on a miniature scale, they correspond closely with the rudiments of lobules in the virgin breast; they

are rudimentary forms which might have become racemose lobules with a full complement of acini overlaying their branches, but, instead of that, have the type of branching tubular glands. It has been maintained, indeed, by Fleming that branching tubular glands and acinous glands are really the same. But the common experience of anatomists is that they are different, allowing that the acinous type may have been built upon a branching tubular foundation; and, within the same breast, the contrast between the two is often broadly drawn. Lastly, fig. 11, from the same small fragment of breast, shows two or three of the windings of a coil of dilated sweat-glands of the most perfect type; and these also are in the same relation to the wall of the milk-sinus as the fully developed milk lobule and the rudimentary branching tubes. As the juxtaposition of all three kinds occurs often in the breasts subject to tumour, all alike being integral parts of the organ, it remains to consider how so remarkable an intermixture of structures can have been produced in the course of development in the individual. The explanation is found in the primitive type of the breast, in its evolution to a higher type, and in the possibility of reversion from the higher type to the primitive in one degree or another, and throughout more or less of the organ.

Before I begin that section, I shall summarise briefly the earlier observations upon muscle-walled tubes in the breast, most of which have been published as evidence of the supposed true nature of the normal membrana propria not only of milk-ducts but also of acini.

My earliest specimens of muscle-walled sweat-glands, mixed up with mammary structure, are dated 15th February 1873, and are correctly labelled "mammary, showing cysts formed by dilated sweat-glands." They came from a case of sarcoma of the breast removed by Mr Le Gros Clark at St Thomas's Hospital (Case xiv., *infra*), and were first referred to by me, with two drawings, in a paper in *Med. Chir. Trans.*, 1882, upon tumours growing from the same kind of sweat-glands in the dog's skin. I did not return to the matter until 1888, in connection with a case in the practice of Sir Spencer Wells, given in his "*Morton Lecture on Cancer*," Lond. 1889, pp. 23-25, with new figure.

Professor Langhans, the esteemed director of the Pathological Institute at Bern, had noticed many of these appearances in mammary tumours, ac-

ording to the descriptions and plates in his paper, "Zur pathologischen Histologie der weiblichen Brustdrüse," *Virchow's Archiv*, lviii. (1873), p. 132. But he saw nothing anomalous in them, taking them all for proof of the fact that the mammary acini and ducts had normally a remarkable basement membrane of large, flat "spindle cells" and of branched cells, although he was unable to prove its existence upon the acini, or even upon the ducts, of any healthy breast. The so-called spindle cells of the basement of dilated acini were really the plain muscular fibres of tubular sweat-glands; while the branched cells, found only in certain cases close to the basement, were a myxomatous new formation proper to the particular cases (see Case VII., *infra*). The frequency with which Langhans found these structures in mammary tumours may be inferred, first, from the fact that he was actually led to make them the normal membrana propria of the breast (against the testimony of Langer and other systematic writers), and secondly, from his express statement that, if he were to enumerate the varieties of tumour in which they occur, he should have to name all tumours that affect the female breast.

This erroneous teaching as to the peculiar membrana propria of the mammary acini and ducts has reappeared in a few accounts of single cases of mammary tumour, in all of which the alleged basement membrane of mammary acini has been so described (and in some figured) as to be identifiable beyond question with the distinctive muscularis of sweat-tubes. See Mansell-Moullin, *Journ. of Anat. and Physiol.*, xv. 1881, p. 346, "The membrana propria of the Mammary Gland"; and *Path. Trans.*, xxxii. (1881), p. 215: a case of fibroma of the breast with many small cysts being the material of both papers. Error pointed out in my note, *Med. Chir. Trans.*, 1882. Jüngst, *Virchow's Archiv*, xcv. (1884), p. 195: case of intracanalicular myxoma with hyaline degeneration. Dreyfuss, *ibid.*, cxiii. (1888): two cases of cystic breasts: thinks it strange that Langhans' discovery of the membrana propria should have been so little noticed. H. Haeckel (*Archiv f. Klin. Chir.*, xlvii. k. p. 283), on general pathology of fibroma mammæ, refers to hyperplasia of the basement on which the epithelial cells are seated, citing Langhans. F. Sasse, *ibid.*, liv. (1897), p. 1: in cysts and cystic tumours of the breast, describes "low cubical cells derived from the *Belegzellen* of the membrana propria."

Hennig (*Arch. f. Gynaekol.*, ii. (1871), p. 346, "§ 2. Dei glatte Muskeln der Milchdrüse") actually described plain muscular fibres throughout the breast. "The basal layer," he says, "experiences sometimes a partial hypertrophy. In such cases there is seated on the posterior surface of the breast a thin layer of pale flesh-colour, which is connected with the bottom of the gland by short threads. Predominance of muscularity in the gland itself gives the *Fleischbrust* of colloquial speech." I cannot say that I understand what is meant.

Benda (*Dermatol. Ztschr.*, i. 1893), while denying the existence of a peculiar basement in the developed mammary acini, claims it for the ducts; not, however, a basal layer of spindle cells or of branched corpuscles, but of true muscular ribs like those of the axillary sweat-glands. As this is

contrary to nearly all experience of the ducts and sinuses of normal breasts, and as one of Benda's two figures, showing the muscularis, is taken from a tumour case, it is nearly certain that he was dealing with some anomalous material without recognising that it was anomalous. Henle, in one of his earlier writings, had described plain muscular fibres in the walls of the larger milk-ducts (H. Meckel having done the same); but he seems to have found subsequently that such was not the rule, for in his *Handbuch der Anatomie*, ii. 2te Aufl. 1873, he makes no mention of a muscularis basement, but only of elastic fibres in the walls of ducts and sinuses. Langer is emphatic: "Ein eigenes Muskelsystem besitzen sie nicht." Other points in Benda's important paper are noticed, *infra*, p. 42.

III. PRIMITIVE TYPE OF THE MAMMARY ORGAN.

The mamma, as the organ from which the Mammalian Order is named, has attracted, naturally, much interest in respect of its evolution or antecedents. This inquiry has proceeded on two main lines, which at the present time may be said to converge, not to a clear issue, but to a paradox: the lines, namely, of microscopic study of the cellular process of milk-production, and of the comparative anatomy and evolution of the organ from the Monotremes to the higher Mammalia. I shall give a brief *résumé* of the progress of opinion under each of those heads.

(1) *Nature and Analogies of Milk-production.*—The subject begins with Donné's account of colostrum (*Du lait, etc.*, Paris, 1837), which was mainly an objective description of the granular balls and other constituents of the first milk, without any precise theory of their mode of production or of their relation to cells; besides fatty granules, there was also mucinous matter; as an abnormality, the mucinous character of the milk might last the whole period of suckling. Henle (in *Froriep's Notizen*, 1839) did not take the colostrum corpuscles to be cells with granular contents, but aggregates of granules held together in a structureless medium. Reinhardt ("Ueber die Entstehung der Körnchenzellen," *Virchow's Archiv*, i. 1847) found them at that date regarded as cells; but he laid down the principle that the shedding of these elements at the start of lactation was not to be taken as the type of the perfect milk-production, but only a preliminary to it, the "more regulated secretion" being discharged from entire epithelial cells which remained upon the wall of the acinus, the milk-drops being formed in the lumen in some way unknown. Langer (*l.c.*, 1852) was the first to emphasise the analogy of the mammary epithelium with the fat-cells of adipose tissue, finding even a nucleus in the colostrum cor-

puscles. Virchow, in his lectures on *Cellular Pathology* (1859), drew out fully the parallel between the mammary gland and sebaceous glands, both on the ground of the functional product and of the morphological type: the colostrum corpuscles, which were taken (against Reinhardt's view) as showing the law of milk-production, were compared with the balls of sebum, while one had only to lengthen the duct and its branches in a sebaceous gland to make it like a mammary lobule. Kölliker (*Gewebelehre*, 1867) gave wide currency to the sebaceous-gland analogy of the milk-gland, "milk-cells" being shed into the lumen of the mammary acini, there to break up, just as epidermic cells shed into the crypts of sebaceous glands break up into sebum. Stricker (*Wien. Sitzber.*, liii. 1866) came to nearly the same view as Reinhardt, namely, that the colostrum corpuscles were indeed cast-off epithelium, but that the milk-drops were discharged from the interiors of undisintegrated epithelium on the wall of the acinus. Winkler ("Bau der Milchdrüse," *Jahresber. d. Gesellsch. f. Natur- und Heilkde. in Dresden*, 1874), using the mammæ of rodents, did not find a single trace of disruption of the cells round the acinus-wall,—neither cells ready to be shed, nor gaps in the series of cells. In my *Contributions to the Physiology and Pathology of the Breast*, 1878, I produced evidence of the shedding of immature cellular secretion at various stages in the gradual unfolding of the mamma during pregnancy, the earlier kind of it being in the form of large, yellow granular cells (in the cat); but, as to the mature function, I assumed the correctness of the teaching, that the analogy for the breast was a sebaceous gland, and that the epithelium was constantly being shed and renewed as in epidermic desquamation, with the difference (more important than I allowed for), that "in the mamma there is visibly present no new generation of cells in readiness to take the place of those that are cast off" (p. 21).

Rauber (*Ueber den Ursprung der Milch*, etc., Leipzig, 1879), in a very minute study of the cellular processes during lactation, maintained the in-

DESCRIPTION OF PLATE II.

FIG. 7. Discharging tube of subareolar sweat-glands, opening upon a single large tubercle of Morgagni. From Case XI. $\times 90$.

FIG. 8. Branching tubular form of mammary lobule from upper surface of breast in Case xv. $\times 150$.

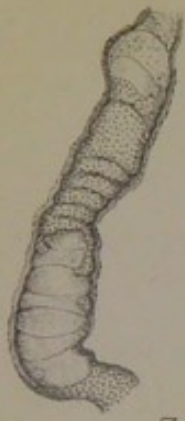FIG. 9. Regular involuted lobule of breast: acini with thick hyaline walls. Close to a milk-sinus in Case II., aged 49. $\times 90$.

FIG. 10. Branching tubular forms from same specimen as fig. 9. $\times 90$.

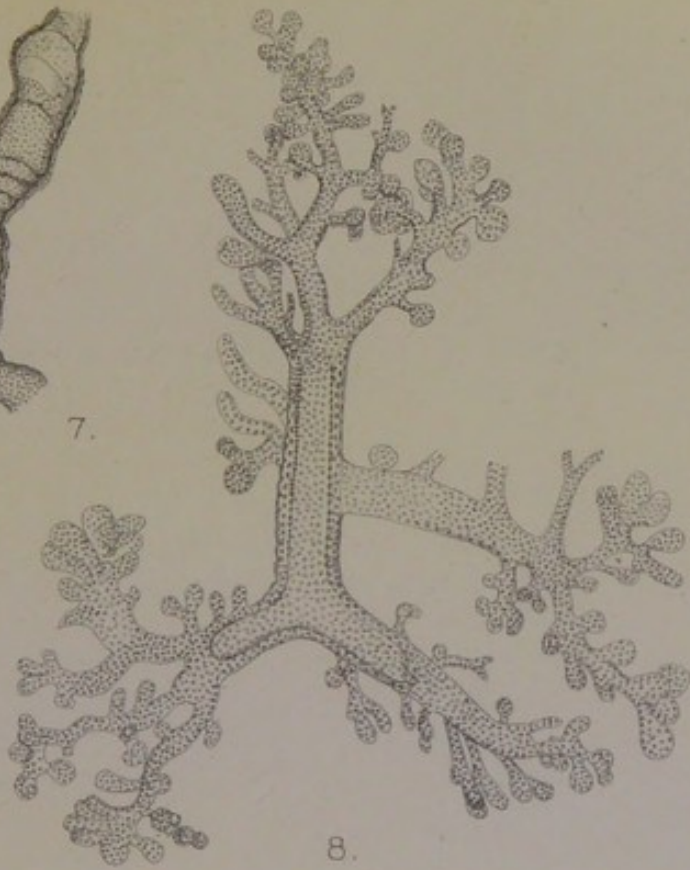FIG. 11. Part of a coil of dilated muscle-walled tubular glands (sweat-glands) opening upon a milk-sinus in Case II. (from same specimen as figs. 9 and 10). $\times 90$.

FIG. 16. Tubular skin-gland, with duct, from back of new-born Hippopotamus. *a*, common discharging tube; *b*, duct of the other lobule, not drawn; *c*, subcutaneous lobule of the gland, consisting of coiled tube with basement of plain muscular fibres. Copied from Max Weber's camera-lucida drawing. Zeiss A.

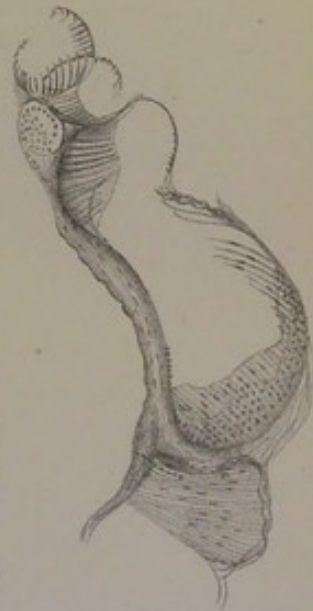Plate II.
Various Mammary Structures.



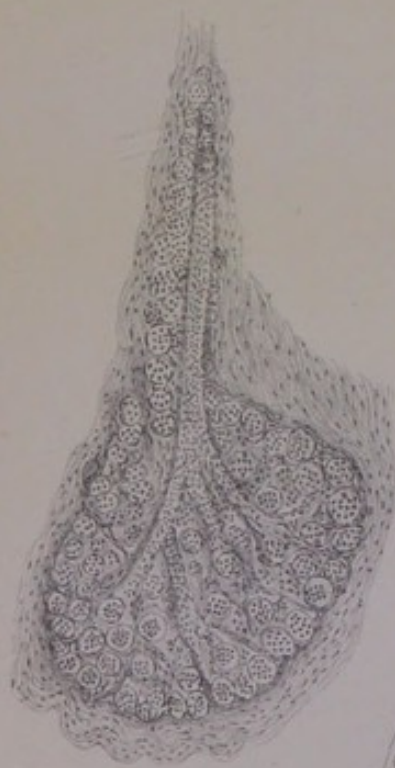
7.



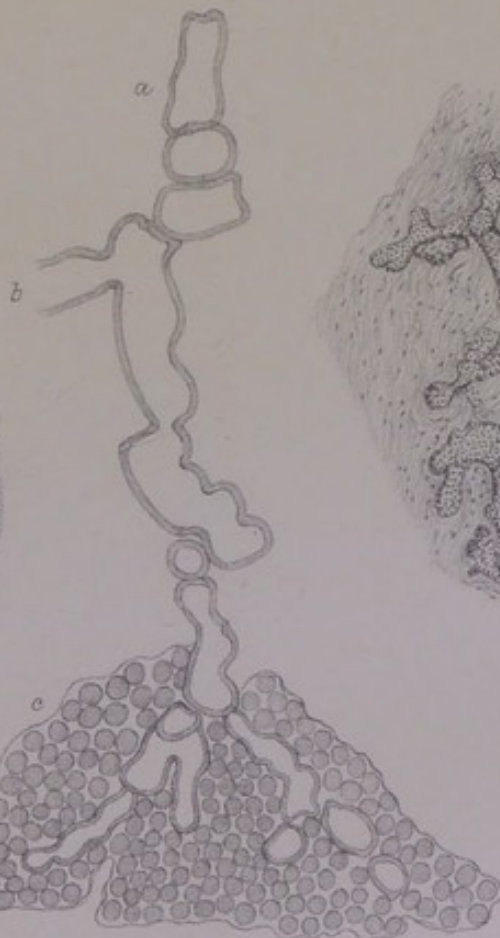
8.



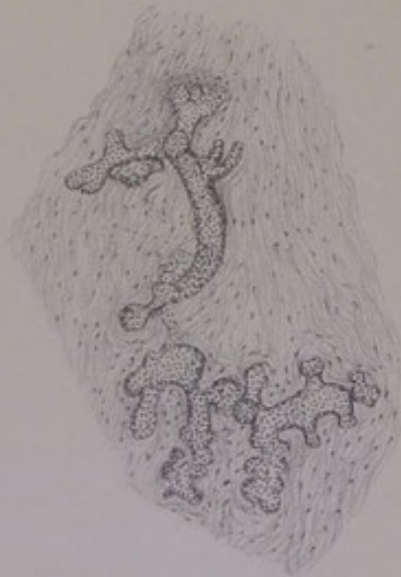
11.



9.



16.



10.



tegrity of the epithelial cells, tracing even the colostrum cells to colourless blood corpuscles or lymph cells, and assigning an important part to the latter in the active production of milk. He described also a row of nuclei on the inner side of the basement membrane, between it and the epithelium, which has reappeared in subsequent writings (Benda, *l.c.*, for ducts only; and Lacroix, *Comptes rend. Acad. Sc.*, cxix. 1894, p. 748, for acini as well as ducts). Rauber, however, admitted that the acini did indeed cast their epithelium in the preparatory stages during pregnancy, which immature stage of the function was the only part of it that resembled the sebaceous: "By reason of that process, the milk-gland approximates somewhat more closely, even in its physiology, to a group of sebaceous glands, with which it is in any case homologous in morphology."

Lastly, Heidenhain has turned the scale of opinion heavily against the sebum-analogy of milk, by his article "Morphologie der Milchabsonderung" in Hermann's *Handbuch der Physiologie*, V. pt. i., Leipzig, 1883, p. 380, in which, however, he does not profess to deal with the question of the gradually rising intensity of the secretion, attended by immature products sometimes cellular.

(2) *Structural Homology of the Mammary Gland: Evolution and Development.*—Notwithstanding the marked acinous-lobular type of the developed breast, as pronounced as that of the pancreas, embryologists have come to class it developmentally with the compound tubular glands, or as a compound sweat-gland. Thus Kölliker, who was among the first to draw out formally the structural and functional correspondence of the developed breast with a sebaceous gland in his *Gewebelehre* of 1867, in the new edition of his *Entwicklungsgeschichte*, ii. 1879, classed the embryonic rudiment of the organ with the sweat-glands (p. 799), by reason of the long unbranched tubes (or solid cylinders) of which it consists in man and some other species. Minot also pronounces the rudiment to be of the tubular-gland type (*Human Embryology*, New York, 1897).

Turning to the lowest form of the mammary organ in the Monotremes (Echidna and Ornithorhynchus), Gegenbaur (*Die Mammaorgane der Monotremen*, Leipzig, 4to, 1886) has shown for the former species that each of the one hundred or more lobes consists of tubular coils upon the ends of a branching tube, which opens upon a hair-follicle like a sweat-gland, and that the tube has a basement of plain muscular fibres, which is "the foremost criterion" of affinity to the primitive tubular glands of vertebrates, as well as the structural distinction of the larger kind of "sweat-glands" in mammals. Therefore the lowest form of "mammary organ" is a compound sweat-gland. But, inasmuch as the mamma in all the classes above the Monotremes has the acinous-lobular structure, he distinguishes that type as the "milk-gland," and finds its homology, not in the sweat-glands, but in the sebaceous glands, pointing to the fact that the mammary skin of Echidna has also highly developed sebaceous glands, which might have been the homology of the breast in that species also, although, for some reason, the actual homologue of its mamma is the sweat-glands. This separation of the mamma of all the higher mammals from the primitive type in the Mono-

tremes appears to me to be the more arbitrary, from the facts that the breast is always a sexual gland, that the evolution of accessory sexual glands is clearly through the muscle-walled tubular glands of the skin, and that the sebaceous glands have no other relation to sexuality than as appendages of the hair.

Bonnet ("Die Mammaorgane im Lichte der Ontogenie und Phylogenie," *Ergebnisse über Anat. und Entwickl.* (Merkel und Bonnet), 1892, p. 604) agrees with Gegenbaur, that there is not one plan, but two, the mammæ of the higher classes following the sebaceous-gland type.

Benda ("Das Verhältniss der Milchdrüse zu den Hautdrüsen," *Dermatol. Ztschr.*, i. 1893, p. 94) has sought to show that the muscular basement distinctive of the larger sweat-glands occurs in the *ducts* (but not in the acini) of the mamma in certain species above the Monotremes; also that, where it cannot be identified as actual plain muscular fibres, its place is taken by a second or basal layer of nuclear epithelial cells upon the inner surface of the basement membrane. I believe that the latter part of his contention is a discovery of real importance, but that he has been misled by two or more anomalous breasts in women (one of them a tumour case, and another exceptional on the face of it by reason of the great thickness of the muscularis) into asserting the normal presence of plain muscular fibres in the basement membrane of the ducts in the human breast, against the testimony of the systematic writers on the anatomy (Langer, Henle). In a third woman's breast, a puerpera, aged 25, the muscularis was not clear, nor in the milk-ducts of the cat and of the cow. The author was, indeed, unfortunate in his choice of species, as I shall show in the sequel; whilst in the human subject he appears to me to have taken an anomaly for the rule. As regards the equivalence of the basal layer of epithelium in the ducts (from their first hollowing out up to the production of milk at the end of the first pregnancy) with the muscularis of sweat-tubes, and the general correspondence of the tubular rudiment of the breast with sweat-tubes, his conclusion appears to me to be right. But he points out that no other tubular gland in the class of sweat-glands produces a fatty secretion (*pape Unna*), and ends his inquiry with what he calls the "paradox" of the mamma being "a fat-forming sweat-gland," an organ constructed on the model of a compound tubular gland, but producing a fatty secretion such as no other gland in the same group produces. In a subsequent communication to the Berl. Med. Gesellschaft, Benda has adduced an interesting argument for the sweat-gland homology of the breast. A male, 47 years old, had no mammæ; at the same time he had no sweat-glands in the skin at large, although the existence of sebaceous glands was proved (*Berl. Klin. Wochenschr.*, xxxvii. 1900, p. 1068).

Waldeyer (*Jahresbericht über Medicin*, 1893, 1), with reference to Benda's conclusion that the mamma in some species above the Monotremes bears the traces of sweat-gland origin or descent, remarks that Gegenbaur's argument as to two types of mamma "needs to be tested anew."

Ernst Unger ("Beiträge zur Anat. und Physiol. der Milchdrüse," *Anatom. Hefte*, 1898), working in Benda's laboratory, has added some observations in

support of the latter's position, and against Gegenbaur's that the mamma in the higher classes has a different homology from that in the Monotremes. He gives an excellent summary of the controversy.

H. Eggeling ("Ueber die Stellung der Milchdrüse zu den übrigen Hautdrüsen," in Bd. IV., Lief. ii. and iii., of Richard Semon's *Zoologische Forschungsreisen in Australien, etc. (Jenaische Denkschriften)*, Jena, 1899 and 1901) begins with a *résumé* covering nearly the same ground as Unger's, and proceeds to his microscopic examination of material obtained in Semon's journey. The best part of the material consisted of embryo Echidnas, which had been cut into sections, but not described so far as concerned the development of the mamma, by Römer. These are described by Eggeling, with drawings, and taken to prove the development of the whole gland from epiderm, although it seems not impossible to put another construction (parablastic) upon the solid masses of cells around the long central tube and its diverticula. His good material for the study of the mature gland appears to have been confined to one piece of Echidna's mamma, probably fully expanded, which consisted wholly of alveoli. He makes out Benda's two layers of epithelium; and, for the expanded piece of gland, concludes that the lower layer consists of "contractiler Faserzellen wie sie bei den Knäueldrüsen vorfinden," that is to say, he confirms Gegenbaur as to the muscularis basement. In sections of the involuted Echidna's mamma, given him by Klaatsch, he finds the deeper or basal layer of cells much more conspicuous than in the expanded state. Actual sweat-glands upon the outskirts of the mammary follicles were easily proved to have the basement of muscular ribs, both in the face view and in cross-sections. A single lobe of the expanded *Ornithorhynchus* mamma, of the usual large dimensions, was found to be unfit for microscopical sections.

Among the author's material was a fully expanded mamma from the Edentate *Manis*, an elliptical, flattened organ, with convex upper surface and concave base, about three inches long, one and a half broad, and half inch thick, consisting of polygonal lobes. In the hollow of the under-surface lay a clear yellow body, with a finely granulated surface, which was found to have the structure of a lymphatic gland. A peripheral lobe consisted of coiled branching tubes, uniformly wide, ending in saccular dilatations. In the broader septal tracts between the lobes there ran long wide tubes, which were often filled with a yellowish vesiculated mass. The same homogeneous vesiculated substance, of yellow colour, was found distending some parts of the peripheral tubing, being the proper secretion. [This is evidently the same substance, in part carbohydrate gummy, that is found in the mamma of Echidna.] The *membrana propria* was seen as a definite dark line, with long slender nuclei at intervals. There was no basal or second layer of epithelium. This structure and kind of secretion in *Manis* correspond closely with those of *Echidna*. "The proper secreting part of the Monotreme mamma," says Eggeling, "consists of long, coiled and variously branched tubes, now wider, now narrower, with short saccular endings, the epithelium being of the same kind throughout the whole of the secreting part" (*l.c.*, 1899, p. 91). While he confirms the sweat-gland homology of

the mammary organ in the Monotremes, and shows in effect that it is the same in *Manis*, he does not take a side formally in the question raised by Gegenbaur, whether the homologue is a compound sweat-gland in all Mammalia, or a sebaceous gland in the higher.

Before beginning my own observations upon the question of homology and descent, I would remark upon the presence of a paradox in all the foregoing accounts of the mamma, from whatever point of view. (1) Amongst skin-glands its fully developed structure resembles most that of the sebaceous; but its mature secretion is not like sebum nor produced in the same way (Heidenhain). (2) The developed gland is acinous-lobular, but the rudiment is compound tubular (Kölliker). (3) The lowest type, in the Monotremes, is actually a modified compound sweat-gland; but the milk-gland in the higher Mammalia has descended from the sebaceous glands (Gegenbaur). (4) In all classes of the Mammalia, the mamma has traces of a sweat-gland origin in the structure of its ducts, but not in that of its acini; it belongs to the sweat-gland group, but it is unlike all other glands in that group in respect that it produces a fatty secretion (Benda). I believe that there is a way of resolving these paradoxes, or apparent inconsistencies, which I shall endeavour to show in this and the following sections.

Mammary Organs of Monotremes.—The sources of my material are as follow: I obtained, by purchase in 1876, two specimens of *Ornithorhynchus*, a male and a female, the male with the mammary organ represented by only a few small, brown, oat-shaped bodies under the panniculus carnosus (so few that Owen overlooked them, and assumed the gland to be wanting in the male), the female with the gland in its state of involution or rest. Shortly after, I had sent me a third specimen, a male, by a friend in Sydney. From a male *Echidna hystrix*, which came home in the *Challenger*, I was permitted, by the kindness of the late Professor F. M. Balfour, to take the mammary glands, which contained each about one hundred small oat-shaped follicles in the resting state, corresponding exactly with Gegenbaur's dimensions of the involuted mamma in his female specimen. My most valuable specimen is a single flask-like lobe from the fully

expanded mamma of a female *Echidna hystrix*, about two inches long, half an inch broad in the middle, and a quarter of an inch thick, which I obtained from the stores of the College of Surgeons' Museum by the kindness of the late Sir W. H. Flower, the then Curator; it is well preserved in spirit, yielding perfectly good microscopic sections, and is probably from the same animal that formed the subject of Owen's original description in *Phil. Trans.*, CLV. pt. i. p. 671 (one whole mamma from it being shown in the Physiological series of the Hunterian Museum).

Taking first the case of *Echidna* (to which Gegenbaur's discovery was limited), I have found the parallel muscular ribs in several necks of the mammary follicles just as they emerge from the body of the lobule to run a long course to the hair-follicles. Fig. 12, Pl. III., is a drawing of one of these: the substance of the plain muscular fibres is somewhat cloudy, so that the ribbed appearance is seen best by lamp-light, and the nuclei are not brought out by the faint logwood staining; but it is hardly possible to mistake the regular width and parallel order of the parietal structures. In another instance the tube on emerging from the flask-like body forms a loop, in one limb of which the epithelium may be seen in profile, and in the other the parallel ribs in the face view.

The body of the oat-shaped lobe in the male does not show a tubular structure clearly; if tubes exist at all they must be very minute, the whole field in my specimens appearing as a uniform brownish mass of granules among which no fibrous septa are visible. This may be due to the bad state of preservation of the specimen; but as the mamma of the male *Ornithorhynchus* is a mere rudiment, it is not unlikely that the organ in the male *Echidna* is also developed imperfectly, although it keeps the external form. Coiled sweat-tubes, with a muscular basement, are found quite close to the mammary lobes, and, I believe, sometimes at as great a depth as the bottoms of these. My specimen from the female *Echidna* is in the state of full expansion. The single lobe (one of about a hundred making the whole mamma) is of the size and shape of a leech, and is subdivided by fibrous septa into three or four three-sided lobules which run its whole length, becom-

ing attenuated to thin cords in the neck. On cross-section each lobule has a distinct central canal : cut longitudinally, the canal is found to be a sacculated passage, the lateral recesses communicating with the extensive honeycomb of alveolar spaces on both sides ; sometimes these communications run horizontally for a short distance like side ducts, but there is no difference in width, nor in structure, between these side ducts and the alveoli in general. The whole gland is filled with its secretion, which can be seen to extend from one alveolus to another, so that they may be assumed to be all in open communication. The secretion for the most part is a vesiculated mucus, like that of the thyroid (the whole structure, but for the central duct, being much the same as the thyroid) ; but in some alveoli, and in some parts of the lobule more than in others, there is another substance as well, which usually adheres to the wall : it is in irregular masses like gum, with a characteristic fracture, and as it gives a wine-red or brownish-red reaction with iodine, and a refulgent ruby-red reaction with methyl violet, it may be inferred to be a carbohydrate of the nature of dextrin (see my *Microscopic Researches on Glycogen*, pt. i., 1896, pp. 128-131). Where the walls of alveoli can be seen clear of mucus or of the gummy substance, they have a mosaic of epithelial cells like the thyroid, from which the drops of mucin are produced. The basement membrane can be seen in the same circumstances as in sweat-glands equally blocked with contents, namely, where the wall dips down obliquely with nothing lying upon it ; it is then found to have the parallel ribs of plain muscular fibre. Fig. 13 shows several alveoli, the lower middle one being entire and displaying the muscularis upon its right side. The specimen is stained with methylene blue, which has brought out the long slender nuclei ; in other alveoli one can distinguish the more quadrate nuclei of the epithelial cells from the oblong nuclei of the muscular fibres underneath. The muscular fibres are not so broad as they usually are in sweat-glands, and in some alveoli they do not appear to lie so close together as to make a continuous basement.

Looking at a microscopic section of the expanded mamma of *Echidna*, one would not take it at first to be a tubular gland

in plan; it is, indeed, a structure of communicating alveoli not unlike the thyroid. But I have shown, in the case of the glandula humeralis of *Ornithorhynchus*, that alveoli of nearly the same size and form (see fig. 3) are really the sections of coiled tubes united by connective tissue: the way in which the development of connective tissue between the coils can produce the alveolar appearance is seen also in the thumb-gland of the frog (fig. 1).

In *Ornithorhynchus* I have found it easier than I could have supposed to prove the sweat-gland type upon the female mammary organ in its involuted state. Sections perpendicular to the skin encounter many of the small oat-shaped lobules in an oblique plane, and some for a considerable length of their long axis. Each lobe, as in *Echidna*, is drawn out into a long neck as it nears the skin. In these necks the gland is quite clearly a coil of tubing, and in the part of the neck nearest to the corium (being on a level with the cutaneous muscle) the tube is so drawn out as to have a merely sinuous course. The muscularis is seen in it as clearly as in the sweat-glands of the dog's skin (fig. 14); indeed, if these tubes in the corium were not quite certainly the proximal ends of the mammary lobules, making a succession of windings from the depth to the surface, they would be taken for actual sweat-glands of the skin (which Gegenbaur believes to be wanting in the mammary region, although present elsewhere, and to have been replaced there by the mammary modification of them). In sections where the tube is not so much drawn out of its coil, the muscularis can also be seen well (fig. 15). But as we descend more into the body of the lobule, the coil of tubing is no longer all of one width; there is usually one central tube, in which the muscular ribs are as clear as they are nearer the neck, and all round it a large number of tubes about half the width, wherein one may see now and then the dentate appearance of the inner surface of the basement, which may be all the evidence that can be got where the muscularis is but little developed.

These observations upon the mammary organ of *Echidna* (female and male) and of *Ornithorhynchus* (female) leave no doubt that it is a compound tubular gland with a basement

of plain muscular fibre, resembling the sweat-glands in minute structure. Sweat-glands, when they combine to form an organ, do not always combine in the same way. In the glandula humeralis of *Ornithorhynchus* the tube is of one width throughout, with the muscularis of the same great strength everywhere. To get the mammary structure one must assume that the tube, after its sinuous course through the corium and glomerular windings in the neck of the follicle, like those of the dog's sweat-glands, had given off branches, which retained the glomerular type with a diminished calibre of tube. That would account for the appearances found in oblique sections of the lobules in an order from the skin downwards. It suits also the observations of Gegenbaur, and of Eggeling, that the tube entering a lobe of the *Echidna* mamma undergoes frequent division; and it is in accordance with what is known of sweat-glands in some other situations (as well as of other compound tubular glands such as the testis). The most remarkable instance of muscle-walled sweat-glands dividing, and forming glomeruli of smaller calibre by their branches, are the skin-glands of *Hippopotamus*, which yield the so-called bloody sweat (*supra*, p. 11). I give a portion of the figure from it drawn by Max Weber with the camera lucida (fig. 16, Pl. II.). The mode of division cannot be quite the same in the *Monotreme* mamma, inasmuch as the shape of the lobes is very different; also, these modified skin-glands of *Hippopotamus* are said not to have the muscular basement in the free part of the tube between the apex of the lobe and the pore in the skin, whereas in the mammary tubes it is nowhere clearer than in that part.

While the mamma of *Ornithorhynchus* has appropriated actually the whole sweat-glands of that region of skin (as Gegenbaur argues), there are some of them left outside the mammary follicles in *Echidna*—a fact the more remarkable that *Echidna*, with a spinous or bristly integument, is believed to have no sweat-glands in the skin at large. In my specimens from the male, the coiled sweat-tubes come quite close to the mammary lobes, being very much convoluted, but of no great width, and probably having a muscularis. Actual

sweat-glands found close to a mammary organ which is in effect a compound sweat-gland, might therefore be considered as so much left over from the mammary adaptation. In the same sense, the deposit of large sweat-glands under the areola in man may be said to be a bye-product of the evolution from the primitive type, and retained as accessory sexual glands. The same muscle-walled sweat-glands are found also in the skin of the marsupial pouch; and in the Cetacea they probably occur around the vulva, and therefore near the mammary slits (Kükenthal), although they occur nowhere else in the Cetacean skin.

It is of interest to recall the old criticism of Geoffroy St Hilaire (*Annales des Sc. Nat.*, ix. 457), when Meckel's discovery of the mammary gland of *Ornithorhynchus* was first published. He had examined it closely, comparing it with the human breast, and especially with the milk-gland of Marsupials, and came to the conclusion that it was of a totally different texture (*tissu*), as it consisted of a vast number of cæca placed side by side. He took the pair of organs to be analogous rather with the glands for secreting a lubricating fluid, or with the odoriferous follicles of quadrupeds, especially those which are found upon the sides of the abdomen in shrews [highly-developed sweat-glands]. Meckel replied in *Arch. f. Anat. und Physiol.*, x. 23.

Development of the Marsupial Mammary Glands.—The other non-placental class of mammals, the Marsupials, resemble the Monotremes closely in bringing forth their young after a very short gestation, and in a very immature state; but they show a great advance upon the Monotremes in the structure of their breasts, as well as in having a pouch around the breasts to receive the foetuses, as if it were a complementary uterus. The Kangaroo (*Macropus major*), which brings forth only a single foetus, has two pairs of mammae behind the inner wall of the pouch, and these acquire the same full acinous-lobular development that the breasts of the higher mammals do in the course of the first pregnancy; but in their foetal state they show, as might be expected, certain striking affinities to the monotreme mamma. In a kangaroo foetus nearly five inches long there is a very obvious rudiment

of the pouch, in the shape of a minute cup about the sixteenth of an inch at the mouth. A few fine hairs are set all round its walls, and with each hair-follicle there is seen in the sections a muscle-ribbed sweat-tube (fig. 17, Pl. III.). There are as yet no nipples, but at some depth below the skin the rudiment of the mamma is found as a reddish parenchymatous island in the midst of fat and other tissues. It consists of sinuous tubes remarkable for their great width and thick lining of epithelium; there is no trace as yet of the acinous development. The most striking thing about these tubes is that many of them are seen to have a few strands of *striated muscle* applied close to their outer wall and encircling their curves (fig. 18). The strong muscular laminae which are an important part of the marsupial apparatus, investing the developed mamma in front and behind, give off slips which run in various planes through the subcutaneous tissue of the pouch, some of them curving round the mammary tubes as shown in the figure. But that is not their only muscularity. They have also the same basement membrane of plain muscular fibres as the mammary tubules of *Echidna*. In fig. 19 these fibres are seen next to the detached belt of epithelium, looking like spindle cells when loosened, but having the appearance of parallel ribs when seen *in situ* in the face view. It might be supposed that they are indeed spindle cells, and that they were not destined to develop into plain muscular fibres as in *Echidna*, were it not that a good many tubes show them with their ends projecting (in the optical section) in the palisade-like order which is so distinctive of the sweat-tubes everywhere. Fig. 20 shows that appearance, which is exactly the same as in an actual sweat-tube, much smaller in calibre, drawn from a more superficial part of the same preparation (fig. 17). The kangaroo mamma retains the primitive character of a basement of plain muscular fibres, and adds to it an investment of striped muscle on the outside of the tube. The same dual muscularity is found also in the Cowper's glands of Marsupials (Leydig).

The Marsupial mamma undergoes a gradual development in the virgin and primiparous animal, which is no longer on

the plan of the compound coils of tubing in the Monotreme. The first account of it was given by Morgan in the Linnæan Transactions for 1833 (vol. xvi. p. 63), one part of which, concerning two distinct and separate types of gland in the mammary region of the young virgin kangaroo, has either been overlooked by subsequent writers or omitted by them as erroneous. Owen, with a reference to Morgan's excellent memoir, returned to the subject some twenty years after, and described the kangaroo's two pairs of mammæ as differing from the Monotreme gland in being "more compact and more minutely conglomerate." The terminal alveoli were of "cylindrical" form, one-thirtieth of an inch in diameter, "grouped in clusters of from ten to twenty on short slender ducts, which enter the sides of larger canals, these uniting to form four or six conical dilatations, from the apices of which as many slender ducts pass to the apex of the nipple." Apart from the cylindrical form and perhaps the smaller number of alveoli in a lobule, the plan of structure appears to be the same as in the higher mammals, namely, the acinous.

The secretion of the marsupial mamma is supposed usually to be milk from the time that the very immature foetus fastens upon a teat. But it is a question whether it is not, for some time longer, a mucinous or gummy fluid, such as the Monotreme mamma (as well as that of *Manis*) produces even at the height of its functional intensity (*supra*, pp. 43, 46).

The kangaroo foetus is born as immature as the Ornithorhynchus foetus is produced, the parent being non-placental. The foetus in each case requires the same kind of nourishment, which should be at first of the placental kind, or mucinous. It may not be possible to connect the functional adaptation, to become a milk-producing gland, with the adaptation in structure to become an acinous gland. But it is in the ascent from the Monotremes to the Marsupials that both of these adaptations have taken place, the acquisition of a marsupium, and of nipples within it, being concomitant.

The rudiment of coiled tubes in the mamma of the kangaroo undergoes some radical adaptation, which is probably made easier by the remarkable width of the tubes in the

foetus, and the large amount of epithelial protoplasm in them. (The metamorphosis of the great protoplasmic masses in the poison-gland of Triton, as described by Leydig and M. Heidenhain, may be the analogy.) But the conversion of the tubular rudiment in the foetal kangaroo into a system of milk-ducts, and the mode of development of acini around the terminal ducts, remain to be investigated.

Cetacean Mamma.—The Cetacean mamma at one time was taken to be nearer to the Monotreme type than that of the (non-placental) Marsupial. Von Baer (*Arch. f. Anat. und Physiol.*, x. 568), in the discussion over Meckel's discovery of the mamma in Ornithorhynchus, pointed out that it resembled most the Cetacean mamma; and, even thirty years after, Leydig placed the Monotreme and Cetacean glands together in one class, and the mammæ of all other mammals, including the Marsupials, in another: the former, he says, are "an agglomerate of very considerable, long, wide, blind tubes, cellular within, which converge to the place of the nipple (level in the Monotremes)." The Cetacean mamma, however, resembles that of the Monotremes only in externals. In the grampus, from which species John Hunter described it first (*Phil. Trans.*, 1787), the long, narrow, sac-like lobes ranged in a flattened layer at nearly a right angle on either side of the great central longitudinal reservoir (specimen in the Hunterian Museum) would be superficially like the mammary lobules of the Monotremes, if the latter were changed from a radial to a more transverse parallel order so as to open upon a common sinus. But the structure of a Cetacean lobe is neither the thyroid-like alveoli of the expanded Monotreme mamma nor the narrow coiled tubes of the involuted. The great central reservoir (which opens upon the slit in the skin on either side of the vulva by a short, narrow, ejaculatory neck) sends off many lateral processes all round, which are really prolongations of the reservoir rather than ducts, and have the rugous walls of reservoirs; from each of these primary offshoots of the central space many ducts are given off having a crescentic valve-like fold of mucosa at their orifices; they in turn become the axes of racemose lobules, which are of the true acinous type (Turner, *Trans. Roy.*

Soc. Ed., xxvi. 1872, p. 211). Fig. 21, Pl. IV., shows a cross-section of one of the lateral offshoots ("primary ducts") from the central reservoir in a calf porpoise 18 inches long: it gives off four or five "secondary ducts" all round, each of which makes by its branches the framework of a future acinous lobule. In the adult (Finner Whale) the lobules are visible to the naked eye, separated (in the involuted state probably) by bands of connective tissue, polygonal in shape, and a fifth of an inch or less in size (Turner). The plan of a great longitudinal reservoir with wide lateral processes necessarily shortens the secondary ducts, so that the lobules are applied somewhat closely to the walls of reservoirs, like those in the central part of the breasts of women. There is much striped muscle all round the Cetacean mamma, as well as through and through it (bundles in fig. 21, *a*), by which the milk is forced into the reservoir and from it forcibly ejected (as Hunter supposed and others have verified) into the mouth of the calf, without suction. There is also, however, a coat of plain muscular fibres in the walls of the ducts (fig. 22).

In the adaptation of a compound sweat-gland to become the Cetacean mamma, the central fact is the development of a reservoir with lateral processes. Ryder (*Bull. U.S. Fish Commission*) concluded: "By what process the great median sinus was produced we do not know." Kükenthal (*Vergleich. Anat. und Entwickl. Untersuch. an Walthieren*, 2ter Theil, Jena, 1893, 4to, p. 353) offers an explanation, with a figure, which latter appears to me to suggest that a rete is formed first, and then converted into a sinus by absorption of the septa. This would be an intelligible adaptation of the necks of many tubular glands, the infundibular branchings of which would be utilised as the ducts of lobules. But there are grounds for assuming that the lobules themselves are no mere sacculations of tubular sweat-glands, even of the branched kind, whether in their acinous structure or in the nature of their secretion. It is at this point of the evolution or adaptation that the Cetacean mamma, as well as the Marsupial, may be said to diverge radically from the plan of the Monotreme. The acinous-lobular part of the organ, which produces true milk, would be formed after a new plan, and

superimposed upon the tubular rudiment, which would be adapted to be its discharging mechanism only.

Structure of the Mamma in other Mammals.—The other Indeciduata resemble the Cetacea in having a reservoir for the milk; but as they are all provided with prominent teats for suction, they want the great muscular development which is used in the Cetacean mamma for squirting the milk into the calf's mouth. But in the ducts of the ewe's udder, where they can be seen in the longitudinal section, there are many elongated nuclei, which probably mean a basement of plain muscular fibres. In the mammæ of Rodents (guinea-pig, rabbit) there is not a trace remaining of an origin from a compound sweat-gland, the secreting lobules being of the most perfect acinous type, and the ducts without a muscular basement: also there is nothing like a reservoir, but perhaps a confluence, or even a rete, of the ducts under the nipple. Among the Carnivora there is a difference between the mammæ of the cat and the dog, namely, in the matter of muscularity, which may or may not apply to the whole of the respective genera *Felis* and *Canis*. In microscopic sections from the mammæ of cats, I find much striped muscular fibre in eight cases; and as I miss it in the sections from three only, which may have chanced to be cut from a part of the breast where there was little or none of it, I conclude that its presence is the rule, or nearly so. The striated fibres are of large size and occur in considerable bundles, encountered sometimes in the cross-section, sometimes in the longitudinal. They penetrate between the lobules, sometimes encircling them, and are as truly the intrinsic striped muscles of the mammary gland as in the Marsupials and Cetaceans, but not so uniformly distributed between the lobules as in some other glands, such as the circumanal glands of the Mole. As to plain muscular fibres, if they are present at all in the cat's mamma, it is as mixed with the fibrous tissue of the stroma, and not as a basement membrane of the ducts. The fibrous bands of glistening stroma, especially in young animals, are very rich in spindle cells, many of which are so elongated as to be hardly distinguishable from plain muscular fibres. It is noteworthy that the cat resembles the Marsupials also in

the muscularity of the Cowper's glands, both in the special tunic of striped muscle and (probably) in the bands of plain muscle in the stroma (Leydig). In the dog, with the same elongated flat strip of mamma as in the cat, there are seldom any bundles of striped muscle, nor is there any appearance of plain muscular fibres in the stroma. But there is the same appearance of muscular ribs under the epithelium of ducts as in the Marsupial and Cetacean mamma. Whereas in many good views of the walls of ducts in the cat, both sectional and face views, I cannot make out a muscular basement; in the milk-ducts of the bitch near the nipple the muscularis is very strong. Along with these differences in the mamma in two closely allied genera may be taken the other differences, that the dog is remarkable for the development of the muscular sweat-glands in the skin, and that it wants the Cowper's glands altogether. The secreting acini in both species, as in all mammals that have the acinous type of mamma, have no plain muscular fibres in their basement. In whatever breasts of the acinous type the muscular basement exists normally, it does not extend beyond the ducts. The acini of a fully expanded mamma are, in most species, as distinct in structure from the ducts as the air-cells of the lung are from the bronchioles.

IV. DEVELOPMENT OF THE MAMMA.

The conclusions of the last section are: that the primitive type of the mamma is one and the same in all the classes of the Mammalian Order, namely, a compound tubular gland of the same kind as the accessory sexual organs which are developed in the Amphibia from simple tubular skin-glands with a muscular basement; that the Monotreme mamma remains of that type, never producing milk, but only a mucinous and gummy secretion (or excretion); and that the true milk-gland of the higher classes retains traces of its descent from the compound tubular gland, which traces are found in the convolute tubular type of its rudiment and in the muscular basement of its ducts, or, failing the latter, in a basal layer of epithelial nuclei in the ducts, according to the

teaching of Benda. That which really distinguishes the true milk-gland from the Monotreme mammary organ is, not any difference in descent, but a great acquisition or addition, namely, the acinous lobules in which the milk is secreted. The foundation of tubes is retained and utilised for a mechanical office as the ducts ; but the real secreting structure, producing a different kind of fluid from that of the primitive skin-gland, is the new acquisition of acini. This view may seem to make an arbitrary break in the continuity of development. According to the teaching of Flemming, the acinous structure is really acinous-tubular in general. Again, in such cutaneous organs as the sweat-glands of Hippopotamus (fig. 16, Pl. II.) and the inguinal gland of the female *Ornithorhynchus* (p. 10, *supra*), branching tubular glands develop into a lobulated organ with dendriform ducts. Even the mamma itself, in the Edentate *Manis*, appears to retain the compound tubular type of the Monotreme organ ; and, in the primiparous Cat, the plan of structure near the beginning of pregnancy is still actually of coiled or sinuous branching tubes (fig. 27, Pl. V.). But in all these cases, excepting the

DESCRIPTION OF PLATE III.

FIG. 12. Neck of a mammary follicle of male *Echidna hystrix*, showing muscular basement. $\times 300$.

FIG. 13. Fully expanded mammary follicle of female *Echidna hystrix*. *a*, alveolus filled with vesiculated mucus ; *b*, wall of alveolus showing plain muscular fibres ; *c*, mosaic of epithelium. $\times 300$.

FIG. 14. Convolutcd neck of mammary follicle of female *Ornithorhynchus paradoxus* (resting state), showing the muscular basement. $\times 200$.

FIG. 15. Neck of mammary follicle, close to panniculus carnosus, from female *Ornithorhynchus* (resting state), showing the plain muscular fibres of the basement very distinctly. $\times 300$.

FIG. 17. Sweat-gland under skin of rudimentary marsupial pouch in foetal Kangaroo (*Macropus*), $4\frac{1}{2}$ inches long ; muscularis in face view and in optical section. $\times 300$.

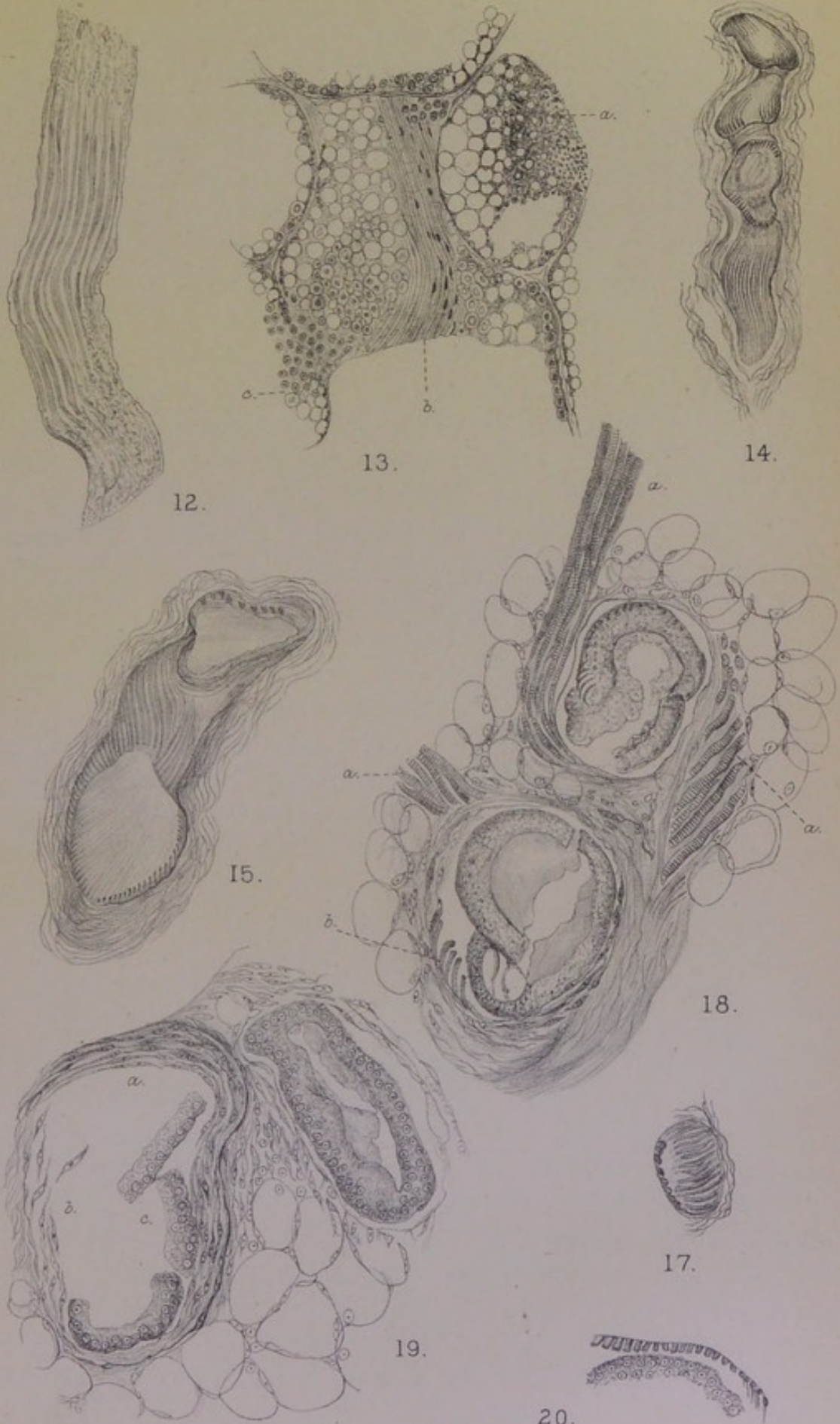
FIG. 18. Two sections of wide tubular rudiment of mamma in foetal Kangaroo (*Macropus*), $4\frac{1}{2}$ inches long. *a*, striped muscle of stroma ; *b*, plain muscular fibres of basement $\times 300$.

FIG. 19. Another part of same. *a*, embryonic plain muscular fibres of basement ; *b*, spindle-celled form of same ; *c*, epithelium. $\times 300$.

FIG. 20. Muscular basement of mammary tube in same foetal Kangaroo, to compare with sweat-gland of marsupium (fig. 17). $\times 300$.

Plate III.

Monotreme and Marsupial Mammae.



C. Creighton del.

Huth, Lith. London.



last, there is no radical change in the nature of the secretion from that of the primitive skin-glands; and in the case of the cat's mamma, there has been so enormous a development of acini before the end of the first pregnancy, or the beginning of lactation, that one would not recognise a lobule to be the same in plan as the rudiment of sinuous branching tubes, which is overlaid and concealed by the new development all around it. It is for that great extension, accompanied by a change in the nature of the secretion, that I venture to propose another principle of development than simple protrusion of the infundibula of tubes; and it is by means of this secondary or accessory principle that I seem to be able to resolve the paradoxes or apparent inconsistencies between the perfected structure and function of the breast and its antecedents.

This principle for the development of the mamma or "milk-gland" (as Gegenbaur calls it in contrast with the primitive "mammary organ") is one that must appear to be not unneeded for other perfected organs of the higher animal forms. In seeking to illustrate it, I shall keep as much as possible within the limits of what I have observed, venturing no further upon the field of development than every pathologist must. It was, indeed, the want of some such principle for certain morbid new growths that led me in the first instance to entertain it. In writing Chapters VIII., IX. and X. of the sequel, upon sarcomatous tumours in the glandular structure, I found myself frequently wanting to make use of some such term as "parablastic," which has a certain received meaning in His's theory of the development of the chick. The terminology of His has been applied already to morbid growths by Rindfleisch, who divides them into "archiblastic" and "parablastic" (*Die Elemente der Pathologie*, Leipzig, 1883); but, so far as I can see, his use of the terms serves merely to detach the greater part of the old "mesoblastic" tumours (sarcoma, endothelioma, myxoma, angioma, fibroma, etc.) under the name of parablastic, while the remaining mesoblastic growths, neuroma and myoma, are accounted for as not composed essentially of nervous and muscular elements. The parblast in that sense implied

simply the continuity of vascular and connective tissues throughout life from the extra source by the side of the germ, called parablatic by His. On the other hand, the name is needed in pathology to express, not merely a theory of the source and continuity of vascular and connective tissue, but a continuing relationship to "archiblastic." In a sarcoma of a glandular organ or part, the original gland, or what is left of it, is the archiblast; the sarcoma which springs up beside it, or in the midst of it, is the parblast, using as its substance the actual parablatic tissue and mechanism of growth according to the original definition of His; and that relationship of parblast to archiblast comes out in the fact that the sarcoma tends to form an organ, or pseudo-organ, with a glandular type of its own, not merely in respect of the epithelial *habitus* of cells, which is very common among such tumours, but also in respect of tubular, alveolar or other gland-like structure, which is far from rare in the morbid growths developed upon a vascular and perivascular basis—so-called angeio-sarcomata of Kolaczek (upper jaw) and of G. B. Schmidt (breast).

On turning to the theory of His, one finds that it contains this very idea of relationship, if not explicitly drawn out, yet necessarily implied in one of its applications, namely, to the formation of the yolk-sac. The wall or ring of parblast round the germ, consisting of egg-protoplasm which had penetrated amongst the spheres of white yolk, grows downwards over the yellow yolk, and encloses it at length within a bag, which is richly vascular on the outside, and lined within by epithelial cells capable of absorbing the yolk. The old view of the yolk-sac epithelium was that it had extended over the vascular layer by continuity from the lower epithelial layer of the germ; and that is the mode of development still maintained for it formally by H. Virchow as against His. But in the parablatic hypothesis of the latter, both the vascular and the epithelial layers of the yolk-sac arise by cleavage from a common source. Replying to the criticism of H. Virchow, His wrote:—"I agree, that from the time when the epithelium has been formed into a single layer, we should not speak of a germinal ring, still less of

a germinal wall; and the designation 'yolk-sac epithelium' appears to be a suitable one for the layer of cells resulting"—as part of the transformation of the parablast (*Ztschr. für Anat. und Entwickl.*, i. 1876, p. 285). In the later descriptions of H. Virchow ("Der Dottersack des Huhnes," in *Festschrift Rudolf Virchow gewidmet*, Bd. i., Berlin, 1891), the relationship of this epithelium to the underlying blood-vessels is obviously a very peculiar one at the outset. Moreover, at the distal pole in the neighbourhood of the "mesodermal ring," the interior is covered by free nuclei several rows deep (mixed with yolk-spheres), which do not acquire an epithelial form except where they come into close contact with the walls of the blood-vessels penetrating amongst them in loops (compare Mathias Duval, *Journ. de l'Anat. et de la Physiol.*, xx. 1884, p. 213). At this less differentiated part of the yolk-sac, the structure of the inner surface is much nearer to that of some perivascular sarcomata than either embryologists or pathologists have suspected; it retains to a late period of incubation those primitive characters of parablast which can be seen with much greater difficulty, and not without ambiguity, in the original rudiment of the yolk-sac beneath the germ within the first forty-eight hours.

Over the greater part of the yolk-sac, the interior is covered by a single layer of large, well-formed quadrate cells which, as His admits, deserve to be called epithelial. But they are still perivascular cells in plan, forming massive absorbent sheaths around the walls of blood-vessels in the meridional valvulæ. At the proximal pole of the sac, the perivascular plan is seen everywhere. I have drawn this appearance under a low power in fig. 23, Pl. IV., from a duckling of eighteen days: on the right, nearly the whole of the large epithelial cells form obvious sheaths around larger and smaller vessels; on the left, the surface epithelium is raised into ridges by the unseen capillaries underneath, while the essentially perivascular relationship is seen in a few capillaries at the top and bottom. The ensheathing by epithelium is exactly the same as by the plasma-cells of corresponding size and form around the blood-vessels of snails and slugs. The epithelial form of the cells in the yolk-sac is no proof of

their descent from the entoderm of the germ itself; it is rather a proof that the parablaster of the germ, or that residue of the egg-protoplasm which had not been used in the original cleavage of the germ, is endowed with a property of its own to produce a variety of tissues in the manner of the archiblast germ itself.

While His has maintained the parablasteric origin of epithelium in the yolk-sac, he appears to take that as an exceptional occurrence, his theory of tissue-origins for all subsequent development being as rigid as in the older doctrine of the three layers: the parablaster throughout life yields the blood-vessels and lymphatics, with their endothelium and adnexa (but not their muscular elements), while the archiblast produces all other organs and parts. Waldeyer, in an extensive review of the doctrine of His down to the year 1883 ("Archiblast und Parablaster," *Archiv für micros. Anat.*, xxii. p. 1), has perceived that the theory of a parablaster contains in it more than its author will admit. I translate one passage, p. 49: "Here, accordingly, there arises between His and myself a penetrating difference of views, which carries far-reaching consequences. For example, according to the theory of His, it would not be at all possible that, from a leucocyte of parablasteric origin, an epithelial cell or a muscle-cell, or anything else archiblastic, should ever arise, or *vice versa*; whereas, in my view, such a possibility is at all events not excluded on antecedent grounds. Whether anything of the kind ever occurs in matter of fact, is certainly another question; and at the present time, basing upon many researches of my own on the regeneration of the tissues, I am quite indisposed to assume that, in normal circumstances, epithelium may be regenerated from connective-tissue cells, or from muscle-cells, or from nerve-cells; or that connective tissue is ever developed from epithelium, muscular fibre, etc. . . . I may add, with reference to pathological new growths, that I remain absolutely true to my former point of view" [epithelial cells of cancer are an atypical overgrowth of pre-existing epithelium. Compare last chapter, *infra*].

Although little remains of the original notion of parablaster, in respect of its substance and source, yet the correlative names of archiblast and parablaster, happily chosen by His in his earliest statement of the doctrine (1868), survive to express a relationship in embryonic development which will rise to ever greater importance. They contain a true architectonic idea of the acquisitions, additions, superstructures, renovations, adaptations, in the evolution of the parts and organs of animals from lower to higher. They are a necessary complement, on the part of embryology, to the general

doctrine of the increasing complexity of animal forms. If organs, systems, tissues are perfected in the struggle for existence, how are the new characters added to the old in the germs of higher species? One answer appears to be supplied by means of a liberal construction of the parablatic doctrine of His. The principle which applies to the embryonic development of red blood, closed blood-vessels, lymphatics and connecting tissues in Vertebrates, applies to these in the first instance just because they mark the greatest advance upon all Invertebrate forms, and are indeed the charter of every future advance, even more than the acquisition of bones. Red blood takes possession of the old channels of the white blood in Invertebrates, whilst the white blood is retained as the lymph or accessory blood in a new system of vessels. Accordingly, the vascular area, which appears for the first time in the vertebrate egg, is parablatic to the gastrula germ; the foundation is not laid anew on account of a radical change in the circulating medium, but an *annexe* is thrown out. The red blood develops outside the archiblast, to penetrate it at length, while the original white blood does actually occupy the archiblast for some hours of the second day, according to the old observation of v. Baer. ("Thus much is certain, that during several hours a quite clear fluid moves in the heart, while the blood in the *area vasculosa* is red." In Burdach's *Physiologie als Erfahrungswissenschaft*, "Vom Embryo," iii. p. 352).

The yolk-sac is another great vertebrate acquisition, which appears as abruptly in the ascending series of animals as the red blood itself. Its development upon parablatic lines is necessarily implied in the teaching of His, and the exceptional origin of its epithelial layer admitted. But we cannot stop at the yolk-sac. The allantois, which is its complement and successor in the Orders above Amphibians and Fishes, is in exactly the same case, whatever the ambiguities of origin arising from its ultimate connection with the archiblastic entoderm. Its epithelial layer in the chick, in its destiny at least, is more obviously parablatic than that of the yolk-sac itself, inasmuch as it forms perivascular sheaths around the umbilical vessels over certain "grained areas," and these actually

develop into true lymphatic sheaths filled by a gelatinous pulp of branching cells. (See paper by the author, "A System of Perivascular Lymphatic Cylinders and Capsules in the United Amnion-Allantois of the Chick: Morphology and Use," *Journ. of Anat. and Physiol.*, N.S. xiii. 1899, p. 527.)

Still another appendage, the placenta, is an exquisite instance of a great extemporised organ developed upon the plan of parablast. In the guinea-pig's placenta, which I have worked out in detail (*ibid.*, xii. 1878, p. 534), the adaptation of the submucosa of the uterus is essentially perivascular: the plasma-cells around the walls of the original vessels are themselves fused into a nucleated protoplasm, by some later writers called "syncytium," to become the walls of a new system of vessels, which are at once the channel of the blood, and a secreting gland-like tissue whereby a mucinous fluid is added to the blood. This peculiar development serves to show how various are the inherent possibilities of vascular tissue, or parablast, throughout life.

Leaving the vertebrate germ, and its appendages, let us come to the development of the permanent organs. Among them are some which, according to the data of embryologists, may be claimed as illustrating the law of new acquisition by parablast, in their increasing complexity from lower to higher forms. Thus, the vertebrate liver is the primitive biliary (digestive) gland of molluscs, *plus* a great blood-gland intercalated in its midst: the parenchymatous mass of epithelial-like cells, with perivascular arrangement, is developed from a very early period as if it were a visceral reproduction of the yolk-sac; it is most probable that the biliary system develops in one way and the hepatic parenchyma in another, the latter being "mesoblastic" according to some, or parablatic. Also in the case of the pancreas, a literal parablast upon the wall of the digestive canal, the development is such that some observers would derive only the ducts from the entoderm, notwithstanding the obvious acinous plan of the organ.

The permanent kidney of warm-blooded animals is believed by most observers to be developed in two divisions, the pelvis, calyces and collecting tubes on the one part, the structures of

the cortex, both vascular glomeruli and excreting tubes, on the other. In the genito-urinary system, it is thought nothing strange that epitheliated tubes should arise interstitially in the midst of a tract of mesoblast. For some reason unexplained, the intermediate cell-mass acquires an epithelium-producing property, just as effective for glandular formation as if it had been part of either the ectoderm or the entoderm itself. The matter of fact is so; but there is nothing in the genito-urinary organs to account for their not developing after the manner of other glands, their tubular type being also the type of the gastric glands. If the intermediate cell-mass be taken to be a parablasic complement, with the same property of cleavage into layers as the germ itself, its gland-forming attribute would become intelligible in the same way as the epithelium of the yolk-sac becomes intelligible.

In the Mammalian kidney, *e.g.*, the guinea-pig's with six calyces and corresponding pyramids, there is a clear distinction between the cortex and the structures in the hilum at an early stage of development, the cortical plate seeming to be the real mass of the kidney, into which the ureter sends its branches. The treatment of sections with iodine, so as to bring out the presence of animal starch, makes the contrast so clear as to arrest the attention at once. The dendriform system of tubes, growing in from the ureter (Wolffian duct) as hollow epithelial processes and multiplying by dichotomous division, is marked out by the port-wine colour, while the whole thickness of the cortical plate remains yellow (fig. 24). This epithelial renal tree, as it may be called, is an archiblastic growth from the entoderm of the cloaca, which sends its branches into the cortical plate, as into a thick investing capsule, being embraced and enclosed by the latter. On the other hand, the cortical plate is a gelatinous body of obviously different texture, and without any epithelial structure at first (in the frog's kidney it appears to be represented merely by a deposit of interstitial cells between the renal tubes in the periphery of the organ). The vascular glomeruli soon become very conspicuous objects in it, and thereafter the tubuli contorti connecting with the Malpighian capsules. This development is so like that which takes place in the Wolffian body, that most embryologists reckon it a mesoblastic part of the permanent kidney. Kölliker, however, maintains that the permanent kidney develops on altogether new lines, or that it is "an organ *sui generis*, and not comparable with the primitive kidney," whose mesoblastic origin he accepts as others do. His reason for this, namely, that the open tubes of the rudiment, growing in from the hilum, extend continuously to the cortex by dichotomous division, like the bronchial tree from the pharynx, appeared to me to be convincing, when I traced the growth of the renal tree by means of the wine-red reaction of glycogen with iodine, notwith-

standing that I could not prove clearly the extension of the glycogen into the wide cortical tubes connected with the glomeruli (*l.c.*, 1896, p. 23). Farther consideration of the glycogen part of the problem favours rather the usual teaching of embryologists, that the permanent kidney develops in two parts, which grow into each other, the excreting tubes of the cortex developing interstitially in a vascular plate, and joining on to the system of collecting tubes budded off from hypoblast. It appears that the distribution of animal starch in the epithelial cells, and certain characters of those cells, correspond with that division. Notwithstanding the formally mesoblastic origin of the ureter (from the Wolffian duct), it becomes archiblastic in higher embryos, as utilised to be the duct of the permanent kidney. As archiblast, it is possessed by glycogen continuous with that of the entoderm: the same substance occupies the epithelium of its branches radiating from the hilum, and can be shown to be concerned in the extensive longitudinal cleavages by which the whole vast system of parallel collecting tubes is differentiated out of a few original dichotomous branches lined by a larger type of epithelial cells. Meanwhile the cortical plate has been developing its proper tubes, repeating the process of the Wolffian body; and these are joined to the archiblastic system of tubes at the places where the tubes are actually called "connecting." It is not because the kidney is an organ of the genito-urinary system, much of which is developed, for some reason, from mesoblast, that this mixed development becomes intelligible. It is because the permanent mammalian kidney is an organ built upon old foundations, or with successive additions, like an ancient building in more than one style. The specialisation of one great part of the tubing, to be collecting tubes, calyces and pelvis, makes that part archiblastic, leaving the distinctive excretory tubes of the warm-blooded animals to be added out of the cortex, on the parablastic lines of a new acquisition. I shall take one other illustration, the lung. The bronchial tree grows inwards from a bud of the pharyngeal epithelium, the successive extensions of the hollow tube becoming easy to follow in the foetal calf or lamb by the wine-red reaction

DESCRIPTION OF PLATE IV.

FIG. 21. Mamma of a calf Porpoise 18 inches long: lateral branch of the reservoir. *a, a, a*, bundles striped muscle; *b*, blood-vessel. $\times 40$.

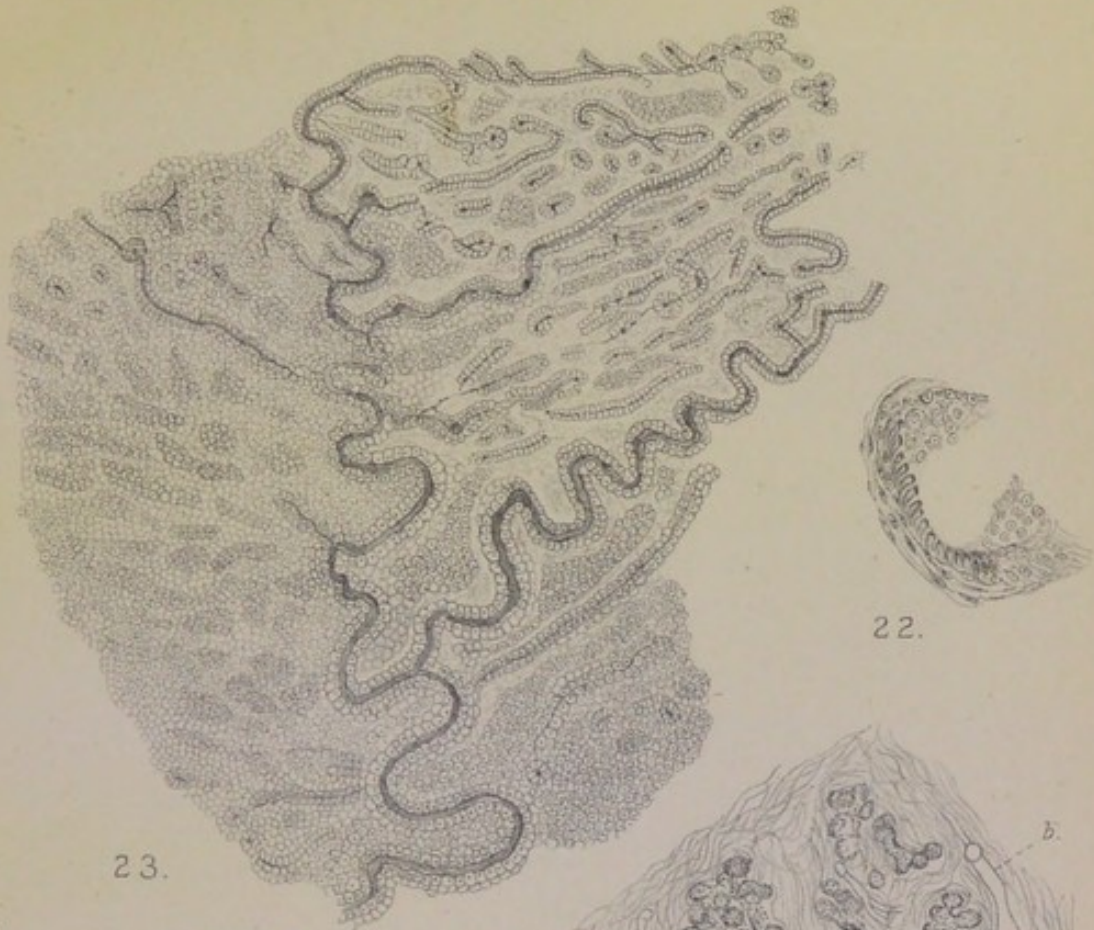
FIG. 22. Mamma of calf Porpoise 18 inches long: palisade-like plain muscular fibres in wall of tube. $\times 300$.

FIG. 23. Inner surface of Yolk-sac of duckling eighteen days incubated, proximal pole. Perivascular disposition of the large epithelial cells (parablast). $\times 20$.

FIG. 24. Kidney of foetal Guinea-pig $\frac{3}{4}$ inch. long. *a*, the pelvic and collecting tubes growing in from hypoblast filled with animal starch; *b*, rudiments of the cortical tubes; *c*, mesoblast of the hilum; *d*, cortical plate. $\times 60$.

FIG. 25. Lung of foetal Calf 6 inches long, showing the glycogen-filled bronchial tree in the midst of gelatinous tissue. *a*, bronchus ending in *c*, pairs of ampullæ; *b*, blood-vessel. $\times 90$.

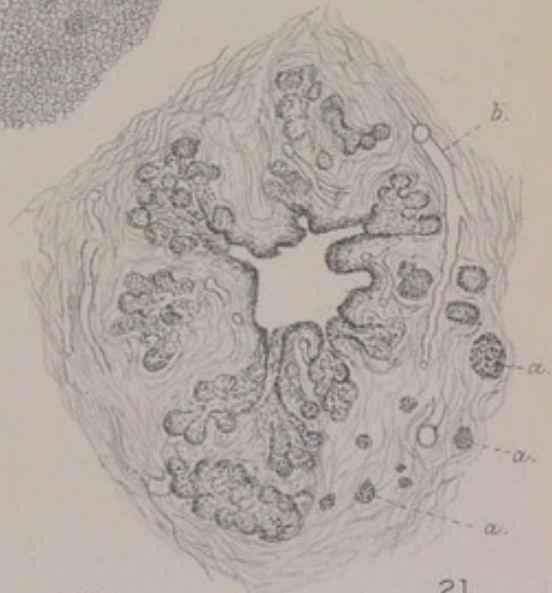Cetacean Mammae. Parablastic Development.



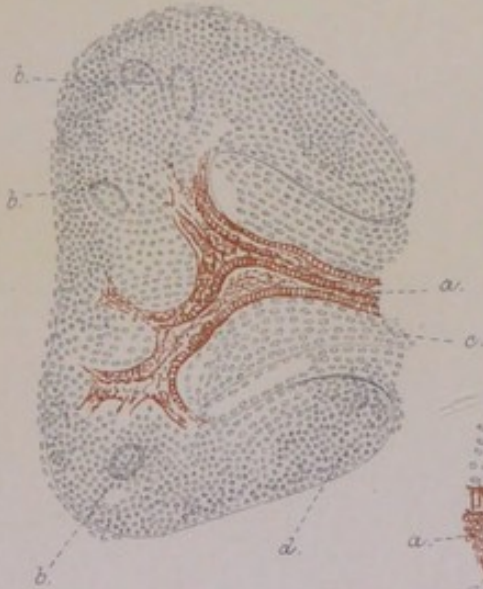
23.



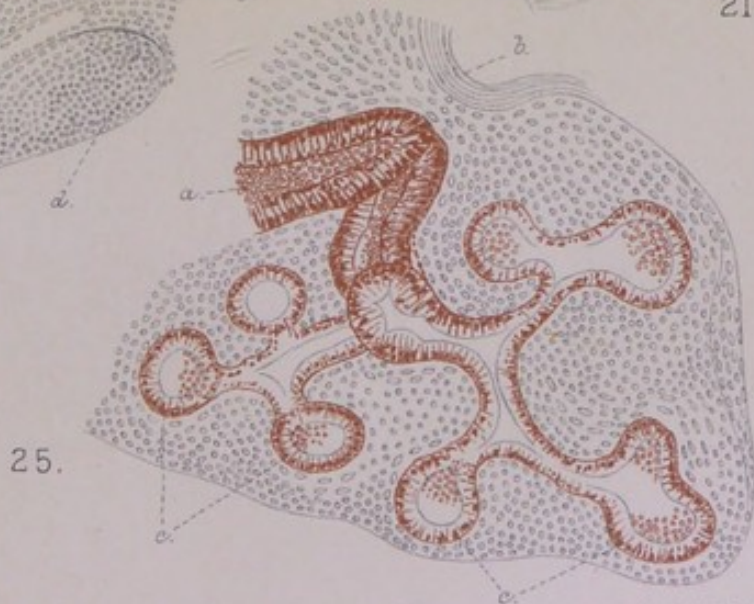
22.



21.



24.



25.



of animal starch in the epithelial cells (fig. 25). All around and between the epithelial rudiment is an extensive zone of gelatinous tissue, rich in cells, which gives to the lung of an early fœtus something of the relative bulk and form that it has after the air-cells are developed. The epithelial part of the organ begins like a gland of the digestive system, and grows by pairs of terminal ampullæ until it has become a dendriform system of ducts, the complete bronchial tree. This is the archiblastic part, the antecedents of which are obscure, and perhaps bound up with those of the thyroid and parathyroid. But the antecedents of the air-cells, or at all events a respiratory parenchyma, may be found without any basis of tubes, and even without any epithelium; so that it would not be unintelligible if the whole spongy tissue of the lung were derived from the gelatinous mass which invests the bronchial tree as the cortical plate of the kidney encloses the renal tree, making a parenchyma in the original and literal sense of the term (that is to say, a structure between and around the blood-vessels). It is usually taught that the air-cells are developmentally the saccular extensions of the bronchial mucosa. But no one, of course, has ever seen that; in the nature of the case, it is only an inference, which may be wrong in theory. Against the probability of it we may set: (1) the abrupt transition from the bronchioles; (2) the nature of the respiratory parenchyma in the spongy tissue of the bird's allantois; and (3) the necessity of explaining the great gelatinous parablastic matrix of the lung.

Coming at length to the *mammary gland*, it is a clear case of an organ to which the law of parablast upon archiblast may be applied, inasmuch as it is built upon an old foundation of tubular sweat-glands, retained as ducts, with a superstructure of acini for a new kind of secretion. The rudiment of tubes descending from the corium may be called archiblastic, without prejudice to the original development of the muscle-ribbed sweat-glands which are its prototype; without prejudice also to the question of an epidermic source of the solid cords which become the rudimentary mammary ducts. It is this tubular rudiment of the breast that has been studied almost exclusively for the development of the organ. Its downward growth by budding from the mucous layer of the epiderm is certainly not so clear as the budding of the bronchial tree from the pharynx, or of the renal rudiment from the Wolffian duct (continuous with the cloacal mucosa). According to Langer's original account (*l.c.*, 1852), the series of buds in the human rudiment grow out from an intermediate lenticular body, or central mass, which is independent of the mucous layer of the skin (having

a continuous history until it becomes the fibrous *corpus mammæ*), so that they are "keine Ausstülpungen der äussern Haut." Later observers have found something like this rudiment of the *corpus mammæ*, but without altogether confirming Langer's lenticular body for the human embryo; they are convinced, however, that the thickening under the cuticle is of epidermic origin in all mammals, and that its offshoots are therefore epidermic by descent.

Considering how difficult it is to prove continuity of growth upon a series of microscopic sections from embryos at successive stages, I venture to recommend a simple experiment, which I have tried upon the foetal lamb, namely, to follow the downward extensions of epiderm by means of the wine-red reaction of iodine with the animal starch which the epiderm-cells contain. For this purpose a male lamb should be chosen, so as to get the comparison with the neighbouring præputial sheath, glans penis, and urethra. The præputial sheath, in a male eleven inches long, stands out in the middle line as a cone with an orifice; close behind it, in the groins, are the pair of teats, in the form of much smaller and more translucent cones without orifices. The whole mucous layer of the skin, including the hair-follicles, is full of glycogen (wine-red with iodine). The wine-red colour is beautifully marked along the canal of the præputial sheath, all over the deeper foldings of the prepuce and the surface of the glans, and for a considerable distance along the urethra, the whole complex track of it extending far below the surface. On the other hand, in the pair of teats, and in the mammary glands beneath them, there is not a trace of wine-red colour excepting in the cuticle of the teats, which shares the possession of glycogen with the skin around. The teats appear to be imperforate; but the rudiments of the *mammæ* are found very clearly, at a short distance beneath their bases, as well-defined pyriform bodies consisting of relatively wide epithelial tubes, branched and convoluted. They contain no glycogen, nor is there a trace of that substance anywhere in the interior of the teat. I cannot explain this, seeing that the skin of the region is full of it, and that the bronchial tree of the same species is full of it. The mammary gland can hardly be said to have retained the traces of its cutaneous origin, seeing that it is so entirely unconnected with the glycogen in the epiderm. In the foetal guinea-pig, also, I have found no extension of glycogen from the skin, where it is abundant, into the long tubular rudiment of the mamma, running backwards in a pyriform body just as in the lamb. The continuity of animal starch, as it is displayed in the bronchial rudiment of the lung or in the pelvic tubes of the kidney, would have been conclusive proof of the corresponding source of the tubular rudiment of the mamma. In the absence of it I shall leave that part of the development as not altogether clear, and with a suspicion that the epidermic origin of the mamma is true only of its connections with the surface.

The stroma of the breast makes a true *corpus mammae* of embryonic connective tissue, extending deeper than the rudiments of the tubes penetrate. Rein describes it in the rabbit as a special zone disposed concentrically around the ends of the tubes, and assigns to it some peculiar but undefined "importance," although he derives the epithelium wholly from the epiderm (*Archiv für micros. Anat.*, xx. 1882, p. 443). Talma (*ibid.*, xx. 1882, p. 148) not only emphasises its extent and cellular richness, but actually makes it formative of the glandular structure. Huss points out that, in the Ruminants, the form of the udder is made by gelatinous tissue, the teats being at the same time well developed upon the skin; but the rudiments of tubes do not penetrate as yet either into the one or the other, although the whole gland develops from epiderm (*Jenaische Zeitschr. für Morphologie*, vii. 1877, p. 176). It is easy to observe that the gelatinous body which gives form to the foetal calf's udder is not penetrated by the glandular structure until some time after birth, the first change in it being the production of fine lobules of fat.

The vascular stroma in the human breast makes the bulk of the organ for a longer period than in any other species, owing to the fact that there is hardly any glandular development from the time of birth, or from the first year of life, until the time of sexual maturity or the commencement of menstruation. Examined at that time, it is found to be little more than a dense mass of fibrous tissue like india-rubber, shaped to an organ, but with no glandular structure in it, save a few long ducts running towards its periphery far apart. Until after puberty these may not show signs of division at their ends: Th. v. Kölliker has sometimes failed in breasts as late as the age of twenty to find "end-vesicles or the rudiments of lobules." As to the real acinous development, which at its fullest is so extensive as altogether to overlay and hide the system of ducts, Langer was some time before he could find the beginnings of it in the virgin breast: at length he came upon a thin layer on the extreme edge of the fibrous mass, with a looser texture than the rest, which proved to be the commencing formation of acini.

Usually the virgin breast shows only a few ampullæ round the ends of ducts, which are relatively large, and are lined by perfect columnar epithelial cells like those of the ducts themselves. The real development of acinous lobules does not take place until pregnancy.

Langer, in his original memoir of 1852 (*Denkschriften der Wiener Akad. der Wissensch.*, Math.-Nat. Cl., iii. p. 32), was struck with the remarkable "gubernacular" disposition of blood-vessels in relation to the growing ampullæ of the virgin breast, and with the rich nucleation of their walls, and he concluded: "Als wahrscheinlich muss ich, nach diesen Untersuchungen, noch hinstellen, dass es Kernbildungen sind in diesen Gubernaculis welche das Wachsthum der Gänge und die Entwicklung der Bläschen bedingen, und dass die Fettumwandlung dieser Kerne die Milchkügelchen erzeuge." In the article "Die Milchdrüse," written for Stricker's *Handbuch*, 1871, he withdrew that "probable" opinion, but seemingly with some hesitation, and without any new facts to base upon: on the whole, he thought, the correct formula for the development was progressive budding, which, one could hardly doubt, depended essentially upon growth of epithelium (*wesentlich zunächst auf einer Wucherung der Epithelien beruht*); certain also was it, that in proportion as the system of ducts proceeded to form the glandular acini, the intermediate tough stroma became gradually looser and reduced in quantity; "but the causal connection between these two processes can hardly be defined as yet in histological terms." It was noteworthy, also, that fat-cells appeared in the stroma simultaneously with the origin of gland-acini, being in a certain degree "a bye-product." It should be added that the *areas* of future lobules are defined or outlined in a remarkable way in the dense stroma of the virgin breast around its periphery; a small duct, in the cross or oblique section, occupies the centre of what looks like a lobule of gland, so clearly defined is the vascular territory belonging to each duct; but on making a microscopic section there is nothing to be seen around the duct but fibrous tissue with blood-vessels.

Not less noteworthy is it, that the developed acinous

lobules return to the same condition of fibrous territories after the age of forty-five or fifty, undergoing a loss of epithelial structure as if simultaneously throughout their areas.

I may be permitted to refer briefly to my former observations on the development in the guinea-pig ("The Development of the Mamma and of the Mammary Function," *Journ. of Anat. and Physiol.*, xi. 1876). In choosing the guinea-pig I did so merely because I had a series of fœtuses suitable for the purpose; but I could not have chosen any mammal in which the racemose and acinous type of the milk-gland is produced more directly, or with fewer reminiscences of the primitive sweat-gland type: there is no reservoir, no rudimentary plan of sinuous cords, but from first to last the dendriform plan of a main duct with branches, upon the sides of which the acini develop and unfold like the foliage; while in the skin itself there are no sweat-glands. Having been occupied with the inguinal fat-bodies of foetal kittens, I was struck with the parallelism between the development of their gland-like lobules and the formation of acini along the sides of the ducts in the guinea-pig, and maintained that the acini developed from the rich cellular stroma on the lines of the fat lobules which had preceded them in the immediate neighbourhood. I reproduce one of my original figures (26, Pl. V.), showing the resemblance of a mammary lobe to a developing cluster of fat-lobules, because I have examined the whole matter in the new-born guinea-pig again, and am persuaded that this figure shows the real process of acinous development in that species. The portion of breast from which the figure is drawn is a considerable lobe of gland structure, with fat-tissue all round it; there are several large arteries involved in it, and one or more long pieces of duct can be made out. The predominant kind of structure is alveolar, the spaces mostly spherical, some of them with depressed columnar epithelium round the wall and vesiculated mucus in the cavity, most of them completely filled and distended by large vesicular cells, like fat-cells in all respects excepting that they are smaller than even young fat-cells. So much is the appearance that of small lobules of fat that

one has to consider whether they are not actually the fat of the stroma. But the surrounding adipose tissue is all of the more developed kind, its originally distinct lobules being fused into continuous tracts; and as to the alveoli themselves, they are in some places mixed with those of the same size that have their epithelium round the wall, while in other places they are seen to be ranged close to the sides of ducts or to lie in spaces of the connective-tissue stroma.

As to the development of the system of ducts in the guinea-pig, I did not follow it from its earliest appearance; but as I found it, in half-grown embryos, laid down throughout the whole relative extent of the organ, running backwards from the teat towards the groin in what looked like a specialised tract of the same embryonic cells, I concluded (as Langer had done for the human breast) that the rudiments of ducts were simply formed out of the matrix along predetermined lines, and were joined on to the true epidermic excavation which, in that species, is confined to the teat. Waiving the correctness of that part of the development, I am still of opinion that the germinal centres from which the acini form by the sides of the ducts belong to the vascular matrix, and that they develop after the manner of fat-lobules. The appearances in the stroma of the breast in the primiparous guinea-pig, at the time when the acini are being developed on the great scale, will be given in the sequel and interpreted in the same sense. The guinea-pig is specially suited to show this mode of development, for the reasons given; in other species, such as the cat, the stroma is much more compact and fibrous, the rudiment of ducts being after the pattern of sinuous or coiled tubes.

Thus, by following the homology of fat-bodies, the essentially glandular nature of which has been maintained by Toldt, I came to the conclusion that the development of the milk-producing part of the breast was from the same tissue and after the same manner as the fat-lobules. The homology with sweat-glands, which is proved by the comparative anatomy of the mamma, opens up a new point of view, namely, that of an organ formed by adaptation of an archaic type, and showing traces of its evolution in its embryonic

development. The most obvious reminiscence of its primitive sweat-gland type is in the development of the ducts, which might be the discharging tubes of an actual compound sweat-gland. In some animals they retain even the sinuous course of sweat-glands: the figures drawn from the foetal kangaroo (figs. 18 and 19) may be adduced in proof of that, and the same is also shown in fig. 28 from the mamma of a cat in her first pregnancy. But there are various reasons for taking the acinous structure of the developed breast to be more than the saccular ends of tubular glands. One reason is that the breasts of many women contain precisely those branching tubular glands, such as I have drawn in fig. 8, but they are altogether unlike the acinous lobules, whether expanded or involuted (fig. 9); they are what the breast would have been if it had not been adapted to its milk-producing function. Another reason for taking the acinous type of the breast to be a new departure, is the fact that no gland in the sweat-gland class produces a secretion containing fat like the fat of milk: it is this fact which Benda has called a "paradox" in the adaptation of the mamma from being originally a cutaneous gland.

When we turn to the actual development of the mammary acini in the first pregnancy of young animals or of women, the objective facts are more difficult to arrive at than is commonly supposed. It is easy to develop the breast with a piece of chalk on a black-board, using a single row of epithelial cells, and disregarding the stroma; the ducts branch, and the terminal branches expand into ampullæ. Whatever else is true of the development of acini, they do not develop from a single row of formed epithelial cells in the terminal piece of tube. Fig. 28, from a primiparous guinea-pig, shows the field of a developing lobule. The ducts are distinguishable by their columnar protoplasmic epithelial cells, and the acini are represented by what appear to be spherical groups of cells, largely nuclear, lying within a basement membrane at the back of the ducts or at more distant points in the stroma. Supposing that the more distant groups belong to ducts that are not seen in the plane of section, it is still in the wall of a duct, and in a stratum beneath the marginal

row of formed epithelial cells, that the nuclear cells collect in a heap to form the acinus. These nuclei may belong to that second or basal layer of epithelium, which, in Benda's view, is homologous with the muscular basement of sweat-glands; in which case there would be an intelligible utilisation of the *materies* of the sweat-gland rudiment to form the extension upon a new plan, and at the same time a continuity of development within the basement membrane. On the other hand, where fat-cells are developing around the acini, as in the guinea-pig (fig. 28), their vesicular spaces appear to be just the same as the spaces which contain the heaps of glandular nuclei. In the stroma there may be seen, at points between the more developed acini, one or more cells larger than the rest, with a thin pale protoplasm, which become vesiculated, and appear, by their expansion, to be the means of determining the spherical form of the acinous heap of nuclei. This is doubtless the phenomenon in the primiparous guinea-pig corresponding to the more easily observed vesiculations which are described above for the new-born. Also, in the virgin breast (human), it is possible to make out, through the epithelial lining of the sacculated ends of ducts, large ring-like forms of cells, which are not ordinary fat-cells, but appear to be concerned somehow in extending the glandular structure through the dense stroma.

Some participation by the cells of the stroma has to be reckoned with, besides the production of new blood-vessels, lymphatics, and connective tissue. In Langer's later view, he found it impossible to express the share of the stroma "in histological terms." But nearly all observers have remarked upon the peculiar nature and office of the stroma in the undeveloped breast. The stroma is the vascular and the perivascular tissue of the growing organ, or that part of it


DESCRIPTION OF PLATE V.

FIG. 26. Lobule of mamma from Guinea-pig four days old. Many of the acini distended by large vesicular cells like young fat-cells. $\times 300$.

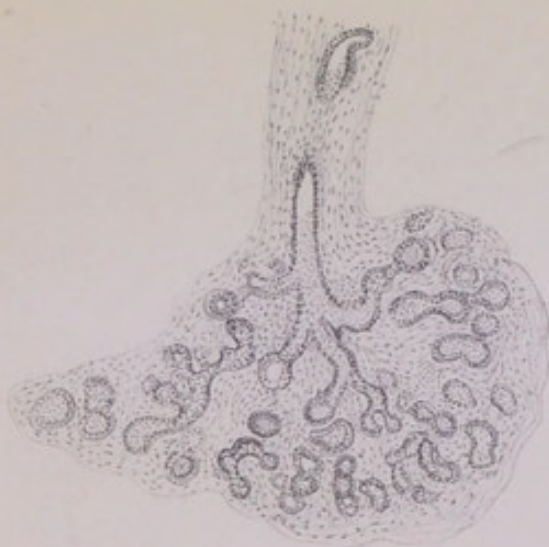
FIG. 27. Lobule of mamma from primiparous Cat, showing the structure of tortuous branching tubes. $\times 90$.

FIG. 28. Mamma of primiparous Guinea-pig, margin next to fat. *a*, duct with formed epithelium; *b*, large fat-vesicles in the richly cellular stroma. $\times 300$.

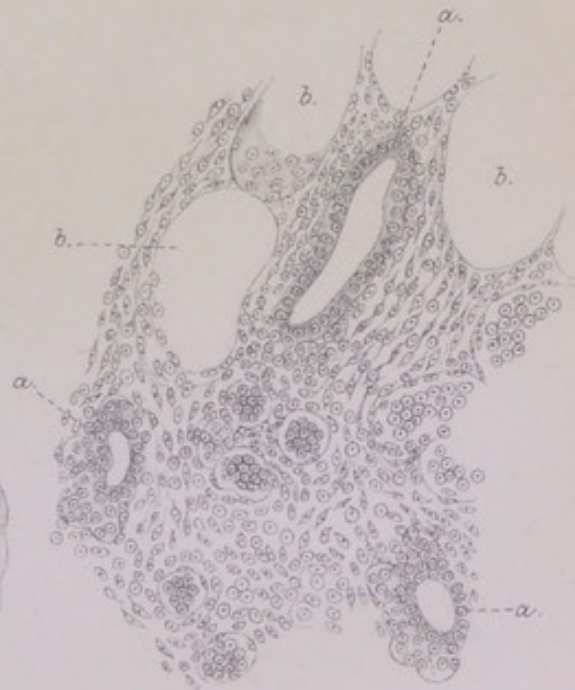
Plate V.
Development of Mamma.



26.



27.



28.



which is of parablatic descent, in the sense of His. To express its full share of the development in histological terms, I would make use of the formula of parablast and archiblast as stated above, according to which the parablast retains throughout life its property of cleavage, or of producing an epithelium of its own. The actual milk-forming structure is a parablatic addition to, or acquisition by, the primitive organ of the sweat-gland type, the tubes of which are retained and adapted to be the conduits of the new acinous gland. Being so retained, they would become archiblastic to the newer part.

Lastly, as to the significance of the physiological chemistry of milk for the evolution and development of the milk-gland. Whereas the sweat is counted as a transudation and excretion, the milk is a secretion of which the most distinctive part, the fat, does not pre-exist in the blood, while the albuminate casein and the milk-sugar are equally remarkable products of metabolism. Of these, the milk-sugar is conceivably related to the mucinous or gummy product of sweat-glands. According to Thierfelder, milk-sugar has an antecedent in a carbohydrate "saccharogen," and there is both a mucinous and a carbohydrate product not only at the height of functional activity in the Monotremes, but also in the earlier stages of the function in higher Mammals (guinea-pig and cat) during gestation. The fatty constituent is not discoverable by the microscope in the Monotreme secretion: it comes in with the acinous structure in the evolution, and with the full development of acini in the individual. Moreover, the relative amount of fat is subject to great variation (usually in an inverse ratio to the casein) which must have some significance. The fat is more in some species of domestic animals than in others, asses' milk having least of it; it varies much among breeds of cows and sheep, and even among individuals of the same herd, some cows being "cheese cows" and others "butter cows"; and it is much more abundant in the evening milk, after a day's grazing, than in the morning milk after a night's rest. Although the problem is mainly one of nutrition, it is almost certain that it has a morphological or developmental side. One of the most significant facts is the extraordinary richness

of the Cetacean milk in fat. Astley Cooper (*Anatomy of the Breast*, Lond. 1840) obtained the breasts of a porpoise full of milk from a surgeon at Cromer, and had a phial of the milk analysed by Golding Bird. It looked to be all "cream," and formed cream cheese on standing. On analysis, it was found to have an altogether unusual proportion of fat with a rank taste. Other observations cited by Cooper favour the notion that richness in fat or butter is proper to the Cetacean milk. The nearest correlated thing is the thickness of their subcutaneous fat. It is not easy to understand why much blubber should be associated with rich milk, unless the true milk-secreting tissue were akin to adipose tissue in origin, as I have given developmental reasons for believing it to be.

The view that one takes of the embryonic development is by no means unimportant for the pathology. A correct view of the evolution or antecedents of the mammary organ is all important for it. I believe that the conclusions which I have come to, both for the embryonic and for the evolutionary development, are mutually supporting, and that together they are the key to the tumour-pathology.

V. REVERSIONS TO THE PRIMITIVE TYPE OF MAMMARY ORGAN.

I am now in a position to conclude the explanation of that structural peculiarity of the breasts of certain women, which makes them liable to the various kinds of mammary tumour. The anomalous tubular glands, usually with plain muscular fibres under the epithelium, which are the original seat and cause of tumour, are no part of the regular structure of the human breast, but a partial reversion to a lower type of mammary gland. The primitive mammary organ is altogether of the compound sweat-gland type. But in most mammals above the Monotremes it is overlaid and virtually superseded by a structure of milk-producing lobules, which is not completed in the individual until the first pregnancy. The embryonic rudiment, however, is laid down upon the original compound tubular plan, so that the means and opportunity of reverting to a more primitive type are always there. It

is mainly for the human breast that any practical question arises. While some lower classes and species of Mammals retain normally more of the primitive type of gland, for example, in the muscular basement of their milk-ducts and reservoirs (as the Marsupials, Cetaceans, probably the Ruminants, the Dog, etc.), or in the branching tubular type of the acini (as in the Cat), the full development appears to proceed in these lower Mammals (unless, perhaps, in the bitch) without any of the peculiar risks which attend the completion of the development in altogether different circumstances in the human female. The grand peculiarity of the breast in women is that it grows until puberty as an almost purely fibrous organ, the main ducts being the only glandular part laid down. When menstruation begins there is a renewal of activity in the breast, attended by increased vascularity, which is probably periodic like menstruation itself. If menstruation proceed normally, and pregnancy follow in due course, it may be supposed that the development of the breast will proceed in a regular way throughout the whole area of dense fibrous tissue. But in matter of fact there is always a considerable residue of the fibrous stroma in the heart of the organ around the milk-sinuses; while the periphery of it, where the formation of acinous lobules begins, is usually more irregular than in the lower mammals, being indented with processes of fat, or with remains of the fibrous stroma of the original widespread *corpus mammae*. It is in these islands of fibrous stroma that the traces of a lower development, or of reversions to the primitive type, are found. Around the milk-sinuses there are probably in every breast some rudiments of lobules which do not ever put on the full acinous development, but develop rather in the direction of a branching tubular gland; while it is perhaps equally common to find that the end-territories of one or more of the longest ducts in the periphery, and especially of the deep sinuses along the base, have developed into coils of muscle-walled sweat-glands instead of acinous lobules. It is the latter fact that is most full of significance for the inherent risks of maldevelopment in the human breast. Nothing in this inquiry has impressed me more than the facts which I have given under Case 1,

p. 32, *supra*, which I believe to be fairly representative: namely, that a woman of the working class, married young, the mother of four children, so prolific that she resorted twice to criminal abortion to limit her family, and with breasts that looked the picture of full and regular lobulation, should yet have developed one or more clusters of large muscle-walled sweat-glands at the end of ducts on the base of the breast, the only other trace of developmental irregularity being a thickened and cystic condition of one broad ligament (parovarium). I take this to mean, that even in fairly good conditions of sexuality the formative effort in the breast may not be equal to its full and perfect development at every point; and that where the formative effort comes short, there is reversion to the primitive sweat-gland type.

The traces of reversion may be so slight as to be easily overlooked, and probably so unimportant for disease that they lead to nothing more than a few small involution cysts after middle life. But in the breasts that come under notice on account of tumour, glandular structures of the primitive type are more widely spread, and, after the climacteric years, may be predominant. In such cases the breast appears to have reverted to an organ of the sweat-gland type throughout a considerable part of its whole extent: the milk-sinuses may have a basement of plain muscular fibre, they may penetrate far towards the margin of the organ, so that the milk-ducts proper are relatively short, and they may have numerous coils of sweat-glands dependent from them in lieu of as many acinous lobules. It is a matter of the first importance to understand the causes of maldevelopment to that extent. This is perilous ground; but I will go so far as to indicate what seem to me to be the chief points in the problem.

There are two periods at which a devious direction of development may have been taken by the breast—the last months of foetal life with the first few months after birth, and the period of puberty. As regards both periods, the first question that arises is, whether the assumed maldevelopment is due to a congenital disposition by inheritance from the mother, grandmother, or great-grandmother, or is produced by circumstances proper to the infant or to the girl. Heredity

would almost certainly be invoked where the reversion proves in the event to be great both in extent and in structural type ; but in minor degrees it might conceivably be acquired by the individual through infantile feebleness, or along with ill-health attending the establishment of the menstrual function, a certain risk of reversion being always present in a highly perfected organ. Leaving for the present the question of heredity as influencing reversion to a lower type, let us consider whether any traces of these anomalies have ever been found in the breasts of infants. Such traces, if they existed, could not be expected to show the distinguishing structural characters, but to be in so indifferent a state as to be easily overlooked. At the time of birth the breasts in both sexes are the subject of a certain functional activity, discharging a fluid called the milk of the new-born. Langer (*Denkschriften*, 1852, *l.c.*) cites the opinion of Jorg, that the practice of nurses, in squeezing the breasts of new-born infants to express the "Hexenmilch" from them, was apt to produce mastitis ; but adds : " Apart from that custom, a mastitis is observed often enough in the new-born." More recently, Th. v. Kölliker has investigated this curious phenomenon (*Würzb. Verhandl.*, N.F., xiv. 1880, p. 141), reasserting its pathological nature (mastitis) and describing the histology. The peculiar structural condition is found during the first few weeks after birth ; it persists to the sixth month, and may leave traces to the end of the first year. In all breasts, but less markedly in male infants than in female, the rudiment under the areola acquires more or less of a cavernous structure, large communicating spaces (so I understand the drawings), which have no cylindrical epithelium, but a lining of flattened cells, often stratified : the contents of the spaces are mostly white granular substance, which does not stain with hæmatoxylin. In some cases this condition is so extensive, or lasts so long, as to amount to a "parenchymatous swelling" of the organ, or to a form of mastitis. It is described as a physiological process, which may become pathological by excess. The most remarkable fact is that it disappears usually about the middle of the first year, when the ducts are found of medium width (doubtless from pressure of the abundant growing stroma).

Kölliker adds: "Glands in the condition shown in fig. 2 [cavernous spaces] can hardly go on to a normal development; and it is probable that the total want of mammary development in many cases, or the imperfect development which we find not rarely in otherwise well-developed women, depends upon such a mastitis of infancy."

I am unable to add any observations of my own, or of others, to these remarkable facts (which have found a place in Billroth's systematic work). But, assuming the phenomenon to be so regular as Th. v. Kölliker seems to have found it in his Würzburg specimens, I venture to offer an interpretation of it. It amounts to the formation of a transitory rete in the *corpus mammae*, comparable with the rete which is permanent in the *corpus Highmori* of the testis. The rete is a step towards the formation of the milk-reservoirs or sinuses, which in the human breast are many, and often of great depth, being the same in number as the ducts in the nipple. A transitory state of foetal structures is not uncommon: for example, the villi of the cæcum, the succession of kinds of epithelium in the pharynx, etc. In this instance there is a temporary stratified epithelium along with the cavernous plan of ducts. A rete would be the natural approximation of many several outlets as in the Monotremes, to one common milk-reservoir as in the Cetacea; and intelligible also as a step towards a series of separate reservoirs. According to the descriptions and figures of the old anatomist Nuck, the milk-sinuses of the human breast do communicate with each other by considerable anastomosing offshoots, and that is admitted for occasional cases by Luschka and Joseph Duval; these anastomoses by lateral offshoots would be a survival from the rete stage of the sinuses.

During that remarkable episode in the development (which Th. v. Kölliker suspects to lead to lasting abnormalities in many cases), an inherited tendency to reversion would have its opportunity of taking effect. The anomalous muscle-walled glands and the branching tubular glands are all developed (apart from aberrant sweat-glands of the areola) in close dependence upon the milk-sinuses; so intimate is the connection that it is not unusual to find a muscularis in the

walls of the sinuses themselves, and to find these prolonged, with the proper structure of sinuses, far towards the periphery, where their dependent sweat-glands are most numerous.

Next, as to anomalous developments in the breast at puberty, there do not appear to be any recorded facts, although I suspect that Langer's hyaline halo or zone between the central heap of epithelial nuclei and the basement membrane may really be an occasional anomalous thing, inasmuch as he had not mentioned it in his original memoir (1852), and I cannot make it out in any of three young virgin breasts which I have examined, although I have found numerous instances of a corresponding hyaline zone within the acini in breasts the subject of tumour. Whatever of devious developments may be traced to the fresh start which the breast takes with the establishment of menstruation, they may have been merely incidental to menstrual irregularities, or due to the influence of heredity—coming out at a critical time. The influence of heredity, both upon the infantile development and upon that of puberty, must at all events be taken into account, if only for the reason that the devious developments have a certain regularity of their own, implying reversion, or the loss of what had been acquired by evolution.

One factor in the degradation of the breast may be entertained as a *vera causa*, namely, the disuse of the function of lactation by many women, both in antiquity and in modern times, and especially in our own time, when so many infants of working (and other) women are brought up on the bottle. If the disuse of this great mammalian organ had not been voluntary, if it had been a correlated effect of gradual changes throughout the whole sexual system, proceeding unconsciously towards the production of an order of *Mammalia sine mammis*, it is probable that the result of disuse would have been atrophy, or some such obsolescence as comes upon every woman's breasts after the menstrual function has ceased for life. But so long as women are placental (and menstrual), atrophy cannot be the result of disuse of the breast. It is too intimately bound up with the rest of the sexual functions in a chain of inscrutable sympathies, to serve merely as an animated feeding-bottle which may be used or not at will.

If the breasts full of milk be not offered to the child, they subside in a few days or weeks, undergoing the same involution that they would have done at the end of several months of lactation; and that may happen time after time with no apparent harm to the organ in the individual. But it is hardly conceivable that an organ so maimed of its function should be transmitted to the female offspring with its powers of development unimpaired. If the breast ceases to be the milk-gland, what can it do in the course of generations but revert to its original type? that is to say, a cutaneous organ correlated with the sexual system, one of those organs like the thumb-gland of the frog, or the humeral gland of *Ornithorhynchus*, the product of which might be called an excretion rather than a secretion.

So much may be hazarded on antecedent grounds as to the risks of giving up the function of lactation: the common sense of the matter is, that it cannot be done with impunity in the long run. But I do not suppose that anyone will ever succeed in proving, by statistics or otherwise, that there is any direct relation between disuse of the breasts by child-bearing women and the degradation of structure which many breasts show in a greater or less extent and degree. Not only so, but if any one pleases to assert that the abandonment of this one part of maternity does no harm because it does no obvious harm at the time, it is not easy to imagine how he or she could be answered except by an equally confident counter-assertion.

The question is not so much whether the subjects of mammary cancer had or had not used the breasts, but whether their mothers, grandmothers, or great-grandmothers had or had not done so; and that is a point for which there are no statistical data. According to the recent figures from the Berlin Charité (cited in Chapter XII.), of 389 women with cancer of the breast, who had borne children, and were asked whether they had suckled their infants, 289 answered in the affirmative, or about three-fourths. But we may not conclude that the same proportion of their female ancestry, or only one-fourth, had not used the breasts. The subjects of mammary cancer are a small fraction of all women of the corresponding ages; therefore a selected class, whose female ancestors may or may not have been also select in respect of non-lactation. Perhaps in future happier generations, when everything is to be proved or disproved by statistics, this question also may be settled. A recent comparison from Buffalo, between

the native-born American women and those of German extraction resident there, shows that the breast and uterus together account for about two-thirds of all the cancers of the former class, but for only one-third of all the cancers of the latter, who are subject to cancer of the digestive organs in a higher ratio. The statistic is instructive (although not quite to the point) for the reason that the German-American women are known to be much more prolific, and much more given to suckling their offspring (Lyon, *Amer. Journ. of Med. Sc.*, June 1901).

While disuse of the breast as the milk-gland may be suspected as one of the reasons why it has lost its perfection of structure in a greater or lesser degree in many women, there should be also reasons, of a positive kind, why it should have developed the particular anomalies that are found in it. They are accounted for by a certain theory of the antecedents of the breast, and by the principle of reversion to the primitive type. The milk-gland, in so far as it reverts, becomes one of the class of accessory or secondary sexual glands which are rather correlated in some unknown way to the primary reproductive function, than endowed with an intelligible use of their own. In Darwin's survey of secondary sexual characters, which were of great importance for his theory of selection, these glandular organs are dealt with only as useful to individuals in respect of their odours. But they are not all odoriferous; in some cases they are poison-glands, and in other instances, such as Cowper's glands and the glands of Bartholin, it is hardly possible to say what part they play in the animal economy. Again, the cutaneous sexual glands may be highly developed in one species and altogether wanting in a closely allied species of the same class. There is a good example among the Insectivora, in the contrast between the Moles and the Shrews. Leydig has found that the Moles have no sweat-glands in any part of the skin, not even in the soles of the feet; on the other hand, the Shrews have a great development of the larger sweat-glands in both sexes under a band of bristles upon the flanks, which become active in the male in the rutting season, giving out a peculiar odour. But the Moles, devoid of these attractions, are "remarkable for the ardour of their passions, appetites, and emotions," while the temperament of the Shrews (if the ordinary meaning of the common noun be

derived from them) is altogether different. On the other hand, the Moles (males) are distinguished by the extent and activity, during the rutting season, of their prostatic glands, which have the same structure as the odoriferous skin-glands of the Shrews, and by their Cowper's glands. There is some principle of correlation among these secondary sexual glands, as well as some inscrutable relation between them and subjective states.

It is towards such a functional type that the breast tends, in proportion as it ceases to be a fully developed milk-gland. It retraces the steps of its evolution, which means that it is degraded to a lower class of accessory sexual glands. The causes of its reversion are almost certainly peculiar to highly civilised communities; and although the disuse of lactation is probably one of them, operating by heredity, there must be other causes as well, which are less easy to specify, such as the sympathies of organs with each other.

One result of the degradation or reversion of some part of the mammary structure may be noticed in conclusion, as it is of special importance for the liability to tumour disease. Those parts of the breast that have reverted to the sweat-gland type do not undergo the same obsolescence as the true mammary lobules at the climacteric period. They remain, with whatever function they have ever had, in the midst of the fibrous tissue and fat into which the rest of the organ has been changed; and so remaining they become peculiarly liable to tumour processes. The various ways in which tumours arise from them are shown, in the order of a classification, by the cases which follow; at the end of which the subject of etiology will be resumed.

CHAPTER II.

SIMPLE CYSTS OF THE BREAST ("INVOLUTION-CYSTS") INCLUDING HYDATIDS.

THE large space given to simple cysts of the breast in the works of Astley Cooper (1829) and Birkett (1850) is merely an accident of disproportion, owing to the fact that neither author finished his work, or continued it on the same elaborate scale. But the simple cysts, although of small practical importance except as complicating the diagnosis of deep tumours by their tension and feeling of hardness, are of great theoretical importance, inasmuch as their structure, distribution, and occasions of becoming cystic give us a key to much of the tumour-pathology of the breast, and are the best means of approaching it.

HYDATIDS.

Astley Cooper described all cysts under the name of "hydatids," which had a more comprehensive meaning then than the word has now. Of his four species of hydatids in the breast, only one, the third, was the "true hydatid," or "animal hydatid": it was a globular "bag containing a [clear] fluid, which has no vascular connection with the surrounding parts; and it produces within its interior a multitude of bags similar to itself." But the most important part of that definition, the "multitude of bags similar to itself," is taken from hydatids in their more usual seats, Cooper himself having "only seen them in the breast single." He had no case of animal hydatid in his own practice, but he gives a case which he had got from Mr Bayfield, in a woman aged forty-four, and illustrates it by a

plate of drawings, which do not appear to be conclusive for its hydatid nature. The cases that have been described subsequently are not many, and not all authentic. Haussmann (*Die Parasiten der Brustdrüse*, Berlin, 1874) collected sixteen cases to that date, more than the half of them being meagrely recorded and inconclusive. Billroth, writing in 1881, puts the number at twenty, but he had seen no case himself, and did not appear to be altogether satisfied with the evidence. About a dozen more cases have been recorded since 1881, some of which I have read. The most distinctive sign of all hydatid cysts elsewhere, apart from the hooklets in the fluid or the scolices themselves, is the remarkable laminated hyaline of the inner membrane, with very regular finer striation; but I do not find that described in any of the cases, as it would probably have been had it existed. The diagnosis has been made, in some cases, from the clearness of the fluid and the translucency of the separable bag or membrane (C. J. Symonds, *Path. Trans.*, xxxviii. 1886), characters at all events which are found in small cysts of the breast where the structure is not that of hydatid cyst (see under Case v., *infra*).

Most of the cases recorded are of one simple sac, without daughter cysts. But there are certain cases remarkable for the number of secondary and tertiary cysts. Except for the large size of these, there is little or nothing detailed in the evidence of structure and contents to distinguish them from the festoons of vesiculated polypi hanging from the walls of cysts, *e.g.*, of the retrotracheal tubular glands near the thyroid, or of the breast itself (compare Virchow, *Krankhaften Geschwülste*, Vorles. xi. *ad fin.*; and Maurice H. Collis, *Cancer and the Tumours analogous to it*, 1864, p. 93).

Such is the case by Höppener, *St. Pet. Med. Wochensch.*, vi. 1881, p. 449. A woman, aged 41, had a tumour on the outer edge of the left breast for six years. When seen it was the size of a hen's egg, and had been causing sharp and shooting pains. It grew rapidly to the size of a fist, and burst, discharging a thin pus to the amount of three ounces or more, along with a pulpy membrane 1 millimetre thick. The fluid contained a mass of more or less transparent bladders, to the number of thirty, from the size of a hazel-nut to a pea, which were found to be "echinococcus hydatids." The chaplets of hooks could not be found, "inasmuch as ter-

tiary bladders are mostly sterile and develop no scolices": from which phrase it follows that the secondary bladders also had no heads in them, or at least none with hooks. The fibrous capsule was also exfoliated, an almost empty sac the size of a hen's egg, of bright red colour and coarse texture.

In a case recorded in the thesis of Lauenstein (Göttingen, 1874) there were upwards of seventy secondary bladders which are said to have contained scolices. In the Icelandic case of Jonassen (1877), the extirpated cyst is reported to have contained "scolices with hooks." The most remarkable observation is that of v. Recklinghausen, who not only diagnosed echinococcus heads in the fluid from the cyst, to the number of fifty or more, but observed them alive for two days and saw them everting and drawing in their heads (*sich einstülpend und ausstülpend*). The case was as follows, being the first hydatid cyst of the breast that either v. Recklinghausen or Lücke had seen:—

Case of Hydatid Cyst of the Breast: the scolices alive.

E. Fischer, "Ein Fall von Echinococcus der Brustdrüse," *Deutsche Ztschr. f. Chirurgie*, xiv. 1880-81, pp. 366-371. A robust young woman, aged 21, from the country near Strasburg, found at the age of 17, in the upper outer quadrant of the right breast, a knot the size of a small chestnut, hard as bone: both breasts were then undeveloped, and there was disordered health, apparently from menstrual troubles. At the same time there appeared a small round knot under the skin close behind the axillary fold of the left side over the seventh rib, a handbreadth from the outer edge of the mamma: it decreased somewhat, but was still there four years after. On admission at Strasburg, the tumour in the right breast, which had increased during the last year and had been attended by sharp pains shooting to the axilla and shoulder as well as by some pains on the other side, was found to be a spherical, bulging, hard body, without fluctuation, the size of a small apple, about $1\frac{1}{2}$ inches from the nipple in the axillary line. There was no swelling of the axillary lymph-glands. It was diagnosed an adenoma, and was removed in November 1880. The tumour having been pricked with the knife in removing, a clear fluid squirted from it; when the cyst was emptied after removal, numerous echinococcus bladders issued with the fluid, the whole being sent, along with the fibrous capsule, to Professor Recklinghausen. The report was, that the most striking objects in the watery fluid reddened with blood, besides round indifferent cells, were a whole group of echinococcus scolices, fifty at least, many of which were in colonies, inasmuch as they were fixed to a common stalk. They were observed alive for two days, "*sich einstülpend und ausstülpend*." The bladder which held them, separable entire from the connective-tissue cap-

sule, was the size of a hen's egg, spherical, smooth on both surfaces, and "of the usual texture": nothing is said of daughter cysts. The fibrous capsule was examined minutely: it was invested with loose tissue, and was beset with lumpy masses on its lateral aspects (not on its bulging central parts), which proved to be mammary lobules: it was smooth on the inside, without epithelium, and had no clear connection with milk-ducts.

SIMPLE CYSTS, OR "INVOLUTION-CYSTS."

Astley Cooper's remaining three species of "hydatids," not animal, are (1) the common "involution-cysts" of later writers, (2) the same associated with scirrhus, and (3) a species which he rightly calls "very curious," being represented by a single case of what was obviously the rare steatoma or pearly tumour of the breast, the laminated structure of which he took to be deposits upon cystic interiors, one end of the tumour being truly cystic (see Chapter IV.). The simple or involution-cysts associated with scirrhus are shown in two beautiful figures of his Pl. V. (figs. 1 and 2), the third figure, of "numerous little bags surrounded by fibrous matter," being a case of polycystic fibroma. His two large figures of involution-cysts, on the upper and the lower surface of the breast, are the best that have ever been given, one of them having been reproduced by Billroth (see under Case I., *infra*).

In Birkett's work of twenty years later date, also emanating from Guy's Hospital, the cysts of the breast were the principal and most original part. He divided all mammary cysts into two main groups:—(1) those which had arisen from dilatation of milk-ducts and of acini in a morbid condition; and (2) those which had arisen interstitially, in the spaces of the connective tissue, from "a peculiar action of the fibro-cellular envelope of the glandular tissue." Oddly enough it was the interstitial or "blastema-cysts" that could always be shown easily to have an epithelial lining of nucleated hexagonal cells in a regular mosaic; the lining of the other class of cysts, identified with dilated milk-ducts, was of a different kind, hardly discoverable as epithelial cells, although in one place it is called a "coherent" epithelium. The separation of a class of blastema-cysts appears to have been suggested by two facts: first, that they could not be followed or injected from the milk-ducts; and, secondly, that

they were subject to intracystic growths, while the dilated milk-ducts were not. But the growths from the walls of these interstitial cysts had so much of a glandular structure that they are said to have developed "within the sphere of nutrition" of the mammary gland; and, apart from theory, the milk-duct cysts and the blastema-cysts are constantly overlapping. Thus, both kinds have the same wide distribution, superficially on the convexity and on the flat base (especially on the base), and in all parts of the interior; both kinds have a wide range of size and the same variety of colour; some blastema-cysts have limpid opalescent fluid (which is not claimed for any milk-duct cysts), but another division of them have thick, slimy, opaque contents, which are practically the same as the contents of his glandular cysts by retention.

Without following Birkett into details, Virchow admitted the existence of a class of detached or interstitial cysts in the breast, distinguishable from galactocoele or cysts by retention. Billroth, in his treatise of 1881, remarks that milk-cysts, proper to the lactating breast, are the only truly intelligible cysts by retention, inasmuch as the mammary function is usually in abeyance, and there should be no secretion to be retained and to cause dilatation; accordingly, he examines the facts and theory of involution-cysts very closely. In his objective description of their naked-eye anatomy, he agrees with Cooper, reproducing his plate of the upper surface of the breast as "typical," and emphasising the important and curious fact that such cysts are mostly on the periphery of the organ. The greenish colour (which in Cooper's plate is blue like the colour of veins, and is often so in fresh specimens) he finds to be peculiar to these cysts, so far so that he knows of no morbid fluid at all like it excepting the hydrocele fluid, which is sometimes green of a paler tint. He adopts the theory that they are cystic dilatations of the smaller milk-ducts, basing on the observations of his pupil Klotz (*Archiv f. klin. Chirurg.*, xxv. 1880). They arise seldom before the age of forty, are painless and slow of growth. The larger are tense, and, when deeply seated, are not easily diagnosed from solid tumours; also on the

upper surface their diagnosis may be obscure from the overlying fat. They are very common in old women, but they are often wanting, "so that I hesitate to see in them a regular physiological change." They are found very often in the sound parts of a breast which is cancerous at one place, and often also in breasts that are not otherwise diseased. The escape of a brownish serum from the nipple, which is observed so commonly, he supposes may be due in some instances to these cysts. The steps of their development from the smaller ducts are, he thinks, clear enough. They do not involve any considerable number of terminal acini, still less whole lobules of the secreting structure: they arise rather from finer ducts whose acinous appendages *are already atrophied*. The larger cysts have thick condensed walls, sometimes with a wavy outline, showing either no epithelium at all or only traces. While he believes that this origin from smaller milk-ducts is clear, he does not understand how they could have arisen as cysts by retention. Cicatricial or chronic inflammatory induration of the stroma, which might cut off their natural outlet, does not in matter of fact occur in any notable degree near or around them. Even if it did, the secreting mammary structure itself is resting and passive, producing nothing which needs an outlet. The hypothesis which his pupil Klotz adopted (several years after I had first published it) is, that there are immature, occasional, abnormal secretory activities of the mammary lobules; but Billroth does not find it at all satisfying, and he ends thus: "I am free to confess that none of the above attempts to explain the direct cause of the origin of these cysts contents me."

The chief interest of Klotz's paper lies in the proof that so-called butter-cysts of the breast are not the sequel of the milk-cysts of lactation, but ordinary cysts having soapy contents with a base of carbonate of lime. The more recent paper of Sasse (*Arch. f. klin. Chir.*, liv. 1897) follows very nearly the same lines as Billroth's section on involution-cysts (see also *infra*, p. 38).

The difficulty of diagnosis arises with involution-cysts situated at the base of the breast, which is their commonest

seat. There they may be as large as a marble or pigeon's egg, very tense, perhaps with a capsule of leathery texture, and feeling as hard as a stone through the overlying tissues. When cysts of the base are associated with fibroma, more or less diffused, as in Case II., a diagnosis from scirrhus is not easy; it would turn mainly, apart from the axillary lymph-glands, on the probabilities that a scirrhus which went down to the pectoral fascia would have a considerable upward extension also, and precipitous sides. When a simple cyst presents on the upper surface of the breast, there will probably be no fluctuation unless the tumour has reached a great size or be within the areola; but the mobility, the natural colour of the skin over it, and, above all, the globular bulging without increase of vascularity, should distinguish it from a sarcoma or a superficial fibromatous kernel. The best clinical account is that of Brodie, "On Sero-cystic Tumours of the Female Breast," being Chapter VII. of his *Lectures Illustrative of Various Subjects in Pathology and Surgery*, Lond. 1846.

Brodie has also given, in the following simple words, his impression of the perplexing nature of these multiple cysts in breasts otherwise undiseased:—"In two cases, in each of which I had the opportunity of dissecting a breast affected with this disease, I found small cysts composed of a thin membrane, and containing serum, pervading the whole glandular structure, the intermediate parts of the breast presenting a perfectly healthy appearance; and I could discover nothing more." He thinks that the cysts must have been produced originally by a dilatation of the lactiferous tubes, and he succeeded sometimes in passing a bristle down a duct from the nipple into a cyst, or in causing the fluid in a cyst to escape through the nipple by pressure; but, like Billroth, he was at a loss to account for them. They find their explanation in a study of the structure of their walls, or rather of the walls of such of them as are least indurated and thickened. They are found to arise from the dilatation, not of terminal milk-ducts or of mammary acini, but of coiled tubular sweat-glands, with plain muscular fibres beneath the epithelium. In proof of this I shall give the three last cases of breasts

with mammary tumour which I have added to my collection, taking them just as they came.

CASE I.—*Involution-Cysts at the age of forty-eight.*

Mrs Westbrook, aged 48, married at 21, mother of seven children, of whom the youngest is six years old, still menstruating, was admitted in June 1901 into the Temperance Hospital, Hampstead Road, under Dr [Sir William] Collins for a tumour in the right breast. The left breast is subject to indurations, not circumscribed, which come and go. Operation on 26th June. The tumour in the right breast, deeply seated on the pectoral fascia at the upper margin and inclining towards the axilla, proved to be of the structure described in the chapter on Sarcoma. An examination of the whole amputated breast discovered numerous involution-cysts. The flat base of the breast, with the pectoral fascia and some strands of pectoralis muscle adhering, was beset at a number of scattered points with dark blue objects resembling small varicose veins. None of these exceeded the size of a pea, while some were in minute finger-like tufts or rosettes. The same varix-like objects were found also on the upper surface of the breast after the fat had been dissected off, the blueness by which they are discovered being found at two or three deeper points under the nipple and areola. Besides the vein-like dilatations, there were also clear brown or amber-coloured cysts visible on the surface under a lens, in company with the more obvious blue (or green) cysts. After the organ was hardened, a vertical section showed small groups of these smooth-walled cavities extending inwards a quarter of an inch from the pectoral flat surface.

Microscopical Examination.—One of the blue varix-like dilatations on the pectoral surface, cut from the fresh specimen, slit up, and spread out flat in gum glycerine, showed several patches of exquisite epithelial mosaic (large polyhedric nucleated cells), resting upon large sheets of plain muscle, the fibres of which were in perfect parallel order, of uniform breadth, and in all other respects like the sheets of unstriped muscle in the amnion or in the body-walls of molluscs (fig. 29, Pl. VI.). Similar demonstration upon a small blue cyst from the base of the breast after hardening, staining, and mounting in balsam. Similar proof of muscularity of the cyst-wall in sections of the small clusters embedded in the breast next to the pectoral fascia.

CASE II.—*Large Involution-Cysts on the Base of the Breast, complicating Fibroma.*

Mrs Allen, aged 49, married at 22, mother of six children, the last fifteen years ago (all suckled), still menstruating, was admitted into the Temperance Hospital, London, under Dr [Sir William] Collins in July 1901. About three months ago she noticed, on awakening, a stain of watery blood on her bedgown, opposite the right breast, about the size of a

florin; this was during a menstrual period. For a few years past she has had mammary tenderness immediately before the menses came on. The slight discharge of blood from the nipple led her to take medical advice, but nothing was discovered in the breast. Not long after, there appeared in the other (left) breast a hard lump, for which she is admitted. The tumour is situated deep in the centre and in the upper axillary quadrant, feels hard, but is not sharply defined. The nipple is large and florid, unretracted. No enlargements in axilla. Diagnosis of scirrhus. Amputation of the breast on 4th July 1901. During the operation, while the nearly freed organ was being grasped in the surgeon's hand, a cyst burst and ejected a quantity of brownish fluid. When the breast was examined after removal, the burst cyst was found projecting upon the pectoral surface near the centre, about the size of a hazel-nut, the ruptured wall being thin and exposed. About half an inch from it an oval body, like an olive, could be felt through the pectoral fascia, so tense that it felt like a pebble. It had thick leathery walls, and contained an opaline fluid, of which about a drachm was secured. Besides this pair of larger cysts, the flat base of the breast showed a number of smaller brown vesicles, as well as two or three of the blue or green colour distinctive of Case I. The upper surface of the breast, after the fat had been dissected off, showed no cysts; but a section through the subareolar region brought to light a small translucent, amber-coloured, tense body, close to the wall of a milk-reservoir, and marked off distinctly from the fat and the dead white of the mammary tissue near it; under the dissecting microscope it was found to consist of four radiating loculi.

Microscopic Examination of the Involution-Cysts.—The cyst on the base, which was ruptured during the operation, was lined by a separable clear membrane, which was entire over the embedded part of the cavity, and made a smooth flat preparation about half an inch square. The membrane contains much wavy fibrillar tissue with some fat-cells, and, distinguishable from the wavy bundles, bands of plain muscular fibre with epithelial cells resting upon them in places. The ruptured side of the cyst, spread out flat and stained, also shows the muscular bands and groups of large epithelial cells, which have the peculiar contours of the epithelium of the urinary bladder and of the cornea (fig. 30, A, Pl. VI.). The unruptured cyst on the base, which had thicker walls, was preserved entire and examined after hardening: no membrane can be peeled off from its interior; but transverse or oblique sections of its walls show certain recesses lined by small columnar epithelium; elsewhere the innermost layer of the wall shows no

epithelium, but it is marked off clearly from the fibrous tissue outside it, and has a set of broad parallel fibres at close, regular intervals, which cross the direction of the ordinary fibrillar tissue, and are probably the muscularis in a cloudy granular state. In the oblique sections of the thick wall, epithelial-lined tubes are met with, some of them of great length, others in groups cut transversely: the latter are obviously coiled tubes, in some of which a muscularis can be seen. It is in the smaller blue involution-cysts of this case that the sweat-gland structure can be demonstrated most clearly: the two larger appear to have been formed by the coalescence of a number of vesicles, inasmuch as the sections of the wall (of the thicker of the two) show recesses, and the spread-out lining membrane appears to have the muscularis preserved in bands at certain places only. In the smaller cysts, less than an eighth of an inch in diameter, the clear lining membrane is one continuous sheet of plain muscular fibres with a mosaic of large hexagonal epithelium resting upon it (fig. 30, B). The group of four minute finger-like loculi with clear brown contents, close to the wall of a milk-reservoir, have the same large epithelium resting upon well-preserved plain muscular fibres. The tubular glands, close to the milk-reservoirs, will be referred to again in the account of the fibromatous tumour in Chapter III.

If a composite picture had been made of the cysts upon the lower and upper surfaces of those two breasts, removed within a week at the same hospital, the effect of Astley Cooper's two large coloured figures, 2 and 3 of Pl. I., would have been reproduced exactly, the case of 27th June reproducing with remarkable closeness the varix-like form and blue colour of the groups of smaller cysts, while the case of 4th July reproduced his pair of large cysts at the centre of the basal surface, the chief difference being that the latter were of a brown colour, whereas the large as well as the small are alike coloured blue in Cooper's plate. I am quite clear that the venous blue colour in these plates is correct for many of the involution-cysts in fresh specimens; an appearance of blueness in the interior of the breast is even

a guide to the whereabouts of cysts. Some are dusky brown, others clear brown or amber-coloured. The green colour, to which Billroth refers specially, is found sometimes instead of the blue, even in fresh specimens. Brodie says that the fluid in the cyst is pure serum at first, becoming mixed with colour later (green, brown, blackish). Sometimes the fluid is greyish or catarrhal (see Case XXXVI.).

The first of the successive amputated breasts in which I had noted the uniform occurrence of "involution-cysts," and had proved these to be dilated tubular glands with muscular walls, was brought to me immediately after the operation by Mr W. A. Meredith on 11th April 1901. As the whole case is an important one for other points in the pathology, I reserve it for the sequel; merely mentioning here, that the patient's age was fifty-four, that she had borne no children, and that the involution-cysts were noticeable chiefly on the flat pectoral base, where they had the form and the blue colour of small dilatations of veins.

Those three breasts, taken as they came from three successive operation cases, were typical and uniform in the matter of involution-cysts, the tumours themselves being various. On the surfaces of the breast, and especially on the flat pectoral base and within the pectoral fascia, the cystic character, as well as the blue or green or brown colour, was most obvious; in other words, involution-cysts are commonly peripheral, according to the old observations of Astley Cooper, Birkett, and Billroth. So long as involution-cysts were taken for dilatations upon milk-ducts, their most frequent occurrence upon the surfaces of the breast was a mystery. They are really dilatations upon tubular glands, which are coiled at their extremities, like the sweat-glands, and have a muscular coat like the larger kind of sweat-glands. I have given in the Introduction the more general considerations relating to their appearance in the breast side by side with the proper mammary structures; and I shall introduce in the sequel the numerous facts showing their relation to every kind of tumour. Cystic dilatation of their terminal coils is the simplest part of the pathology. Although it is probable that they are seldom developed in the breast with-

out an outlet, or that they are nearly always connected by their own tubular necks with the nearest milk-reservoirs (perhaps directly with the skin of the areola in rare instances); yet the free passage for their secretion (or excretion) must become more and more precarious during the climacteric years, when the proper mammary structure is undergoing its final "involution" or effacement. If these primitive tubular glands underwent an obsolescence at the same time, there would be no complications; but they do not, nor do they ever intermit their function as the milk-forming part of the breast does periodically. They are caught in the natural changes of the stroma of the breast at the climacteric, so that their discharge is apt to be obstructed at one point or another: hence the cysts found most commonly have been named involution-cysts as occurring in the breast at the time of its obsolescence. Obstruction in the course of a tubular gland would tell eventually upon its coiled termination, and lead to cystic dilatation; hence involution-cysts are most usual around the periphery of the breast. Billroth's difficulty in accounting for them as cysts by retention is removed by the discovery, that they are not developed upon milk-ducts, but upon sweat-tubes which are present in the breast as an anomaly, and are subject neither to the periodical involutions nor to the climacteric obsolescence of the mammary structure proper.

CHAPTER III.

FIBROMA (*Corps fibreux*) AND CYSTIC FIBROMA (*Polycystoma*).

THE fibromatous or fibrosed conditions of the breast fall into two fairly distinct classes, the circumscribed and the diffuse, which correspond respectively with the more solid and the more cystic. The fibrosis in both cases is around glandular centres, and is distinguishable from ordinary states of the fibrous tissue, including those of the climacteric period, by its extreme hardness and toughness, being among the most difficult of all the morbid tissues of the breast to cut for the microscope. The division into a class of small solid kernels, the *corps fibreux* of Cruveilhier, and a class of more extensive and less definitely bounded fibrosed areas occupied by many small cysts, is a good or natural division; but if the *corps fibreux* be deeply seated, they may be less sharply bounded (Case II.*), and in the diffuse cystic class there may be tumours resembling cystic sarcoma in size and in the irregular, anfractuous, communicating form of their cysts (Case VI.).

FIBROUS KERNELS OR CORPS FIBREUX.

Astley Cooper described the fibrous knots of the breast, and their circumstances, correctly in his quarto of 1829, under the name of Chronic Mammary Tumour (Chapter VI.), some of the painful instances being included under his class of Irritable Tumour (Chapter VII.). In both classes the most distinctive thing was the comparative youth of the patient—16 (or 17) years to 30 years. The subjects were mostly young single women, or married women without children; and he believed that the tumours were the result of a “sympathetic influence of the uterus.” Billroth’s teaching is the same as regards

age and circumstances. The next most distinctive thing was the superficial or peripheral situation of the fibrous knot or knots. "It grows," says Cooper, "from the surface rather than the interior, and therefore it appears generally to be very superficial, excepting if it spring from the posterior surface of the breast, when it is deep-seated and its peculiar features less easily discriminated." The superficial are extremely movable, gliding over the surface, and feel lobulated; they give "the impression as if Nature had formed an additional portion of the breast, composed of similar lobes, but perhaps differing in structure in the absence of lactiferous tubes." (Paget repeats this language very closely for his class of Mammary Glandular Tumour.) They are red on the outside and whiter in the interior. While this tumour occurs in women of the younger age subject to menstrual or other irregularities, the patient frequently ascribes it to a blow or to the continued pressure of stays, the same exciting causes being given by Cooper for the Irritable Tumour of the same time of life.

Brodie (*op. cit.*, p. 200) also refers to the same hard knot on the surface of the breast, which feels like a scirrhous, and on incision looks like it; "so that I can give the disease no other name." (Virchow points out that a juice may be expressed from the cut surface of fibroma.) It appears to be unconnected with the breast; "but," says Brodie, "when you

DESCRIPTION OF PLATE VI.

FIG. 29. Wall of small Involution-Cyst from under-surface of breast at age of forty-eight, Case I. Hypertrophied muscular coat of dilated sweat-gland. $\times 200$.

FIG. 30. Interior of small Involution-Cyst of fibromatous breast at age of forty-nine. Case II. A, group of large epithelial cells like those of urinary bladder. $\times 300$. B, epithelium resting directly upon basement of plain muscular fibres. $\times 200$.

FIG. 31. Small fibromatous knot at base of breast, Case III. The fibromatous tissue is concentric around branching sweat-tubes. $\times 50$.

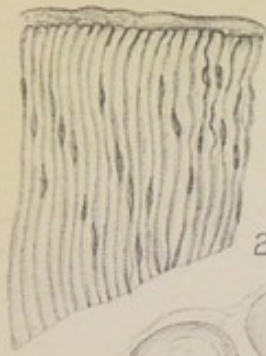
FIG. 32. High-power view of one lobule of the same fibroma. Plain muscular fibres of sweat-tubes in the axes. $\times 150$.

FIG. 33. Cystic Fibroma, Case IV. Small cyst formed by dilated sweat-gland, with epithelium resting on muscular basement. $\times 300$.

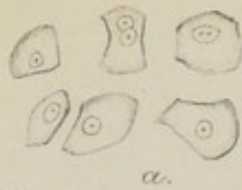
FIG. 34. Hypertrophied plain muscles in wall of translucent sac from Diffuse Fibroma with many small cysts, Case V. $\times 300$.

FIG. 35. The epithelium of the same. $\times 300$.

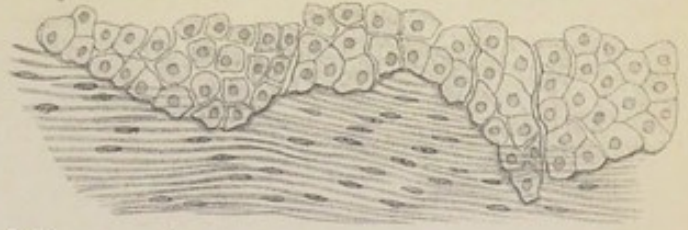
Involution Cysts.- Fibroma.



29.

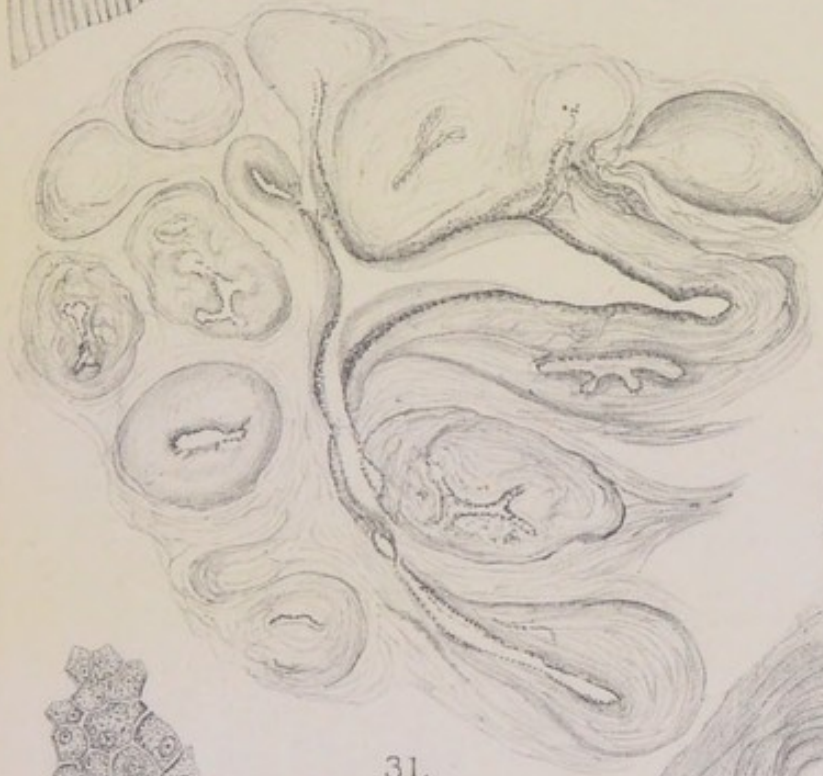

a.



30.

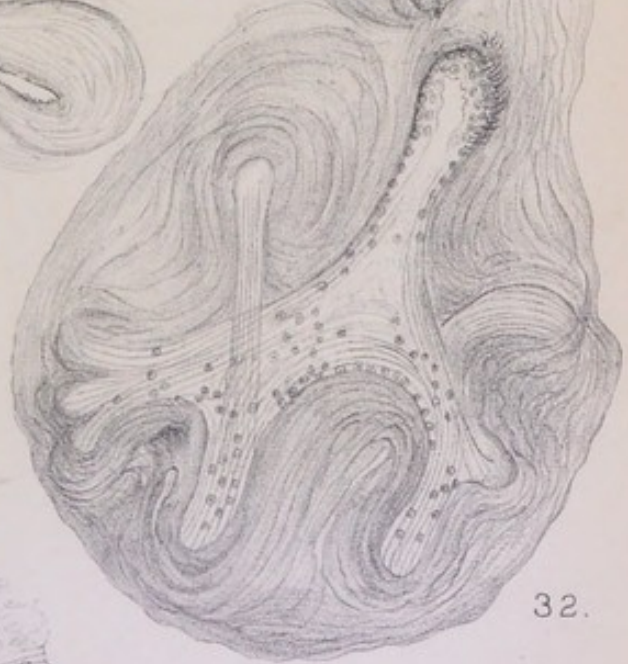
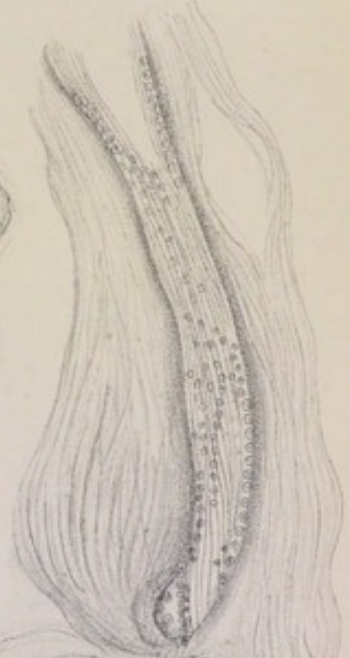b.



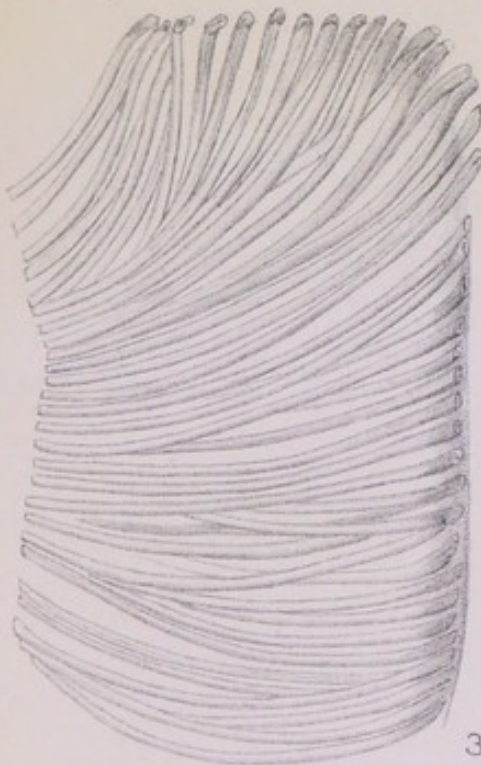31.



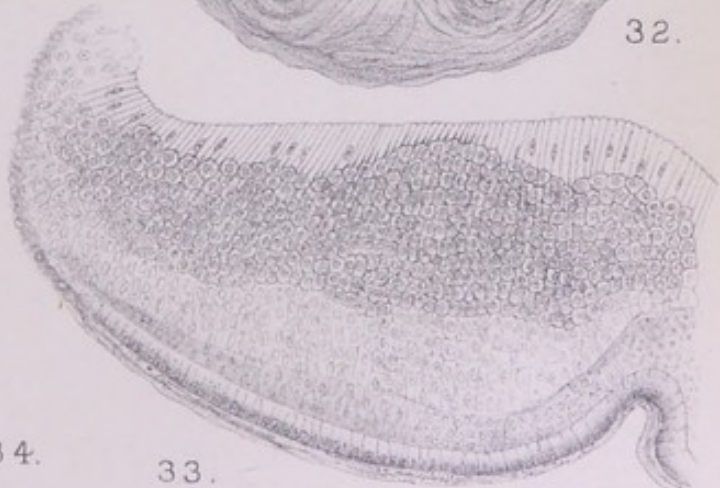35.



32.



34.



33.



remove it, you find that it is attached to the surface of the gland just at one narrow corner: I have removed three tumours of this kind, leaving the breast untouched except where I separated the tumour from it."

One other clinical point may be mentioned, on the evidence of Billroth. These chronic fibromatous knots may remain unchanged for years, and then become cancerous: "the statements of many women are precise as to that" (*l.c.*, p. 53). Cancer may have been used here in a generic sense to include sarcoma, but probably not to exclude scirrhous. H. Snow records a case in which the fibroma (diffuse cystic, however) was attended by a small nodule of sarcoma; both were removed, but the disease recurred in malignant form as pure sarcoma (*Path. Trans.*, xlvi. 1895).

The morbid anatomy was made clear first by Cruveilhier (1844), who erected the solid fibromata of the breast into an anatomical group under the name of "corps fibreux du sein." They correspond exactly with Astley Cooper's clinical divisions of "chronic mammary tumour" and "irritable tumour"—small hard knots, single or multiple, usually on the periphery of the breast, sometimes painful. Velpeau, for the reason that they contained epithelial-lined slits or tubes or alveolar meshes in their interiors, claimed them as adenomata (*tumeurs adénoïdes*); but Cruveilhier, admitting, of course, the glandular element within them (in their earlier stages at all events), maintained their distinctive fibromatous nature; and Virchow supported him therein. (The point raised by Velpeau, whether the glandular element or the fibrosis around it should determine the name, is still discussed in a dialectical spirit, and at considerable length, *e.g.*, by Schimmelbusch, on Fibroadenoma, *Arch. f. klin. Chir.*, xlv. p. 103; and by H. Haeckel, *ibid.*, xlvii. (κ) (1894), p. 275, sec. II. of "Beiträge zur Kenntniss der Brustdrüsengeschwülste.")

Virchow points to the fact that these hard knots may be lobed and even stalked, whence their greater or less mobility; and from the lobed and stalked forms he derives the pathology, namely, that an interstitial mastitis had attacked a certain lobe or certain lobules of the mamma, extending along the ducts, and so reaching the terminal vesicles. Astley Cooper

and Brodie have pointed out that the nodule is often joined by its stalk to the *surface* of the breast. I shall show that the glandular elements, around which the fibromatous knots arise, are not the regular mammary lobules, but either the muscle-walled tubular glands, which are a developmental reversion to the primitive type of sweat-glands, or the tubular rudiments of mammary lobules which had never developed so far as to acquire the complement of acini. The two first cases of the following do not correspond with the clinical rule as to age, and are taken first owing to their clear proof of the true anatomical seat of fibroma.

CASE III.—*Small Fibromatous Kernel at the Base of a Breast the subject of a larger soft Glandular Tumour.*

A lady, aged 54, wife of a country clergyman, who had borne no children, consulted Mr W. A. Meredith in April 1901 for a tumour in the breast, noticed first only a fortnight before. The breast, which was voluminous, was amputated on 11th April, and brought to me at once. The condition of the breast is described fully in Chapter VII., Case XI. The involution-cysts of the same case have been mentioned above. Close to a small cluster of those bluish or greenish vesicles in the base of the breast, near the sternal edge, was a small fibromatous nodule like a pea, defined sharply as an island by its hardness, colour, and encapsulation.

The cross-section of the small knot shows under a lens some half-dozen lobes grouped not quite regularly like petals round a central axis. In the microscopic section the ground-plan of the miniature fibroma is seen to be a branching tube with longitudinal plain muscular fibres in its wall. The wider part of the tube is a nearly central angular space from which branches radiate into the centre of each of the lobes (fig. 31, Pl. VI.); the dense fibromatous tissue occurs as a somewhat regular laminated cylinder around the wall of the main stem, and as a series of small oval or spherical knots upon each of its offshoots. The structure of one of the miniature lobes is shown under a higher power in fig. 32. The epithelial cells, as well as the muscularis of the sweat-tube, are seen clearly in the long stalk of the lobe, while the parallel lines of the naked muscularis are seen running towards the periphery, crossing and recrossing in the axes of the several caecal terminations; a small coil of sweat-gland

had been the foundation of this structure, the fibromatous tissue being formed in layers around the stalk and around the blind ends of the tube. Each microscopic lobe reproduces more or less perfectly the ground-plan of the whole fibromatous nodule; and a larger fibromatous knot would have been made by the aggregation of several such nodules. This formation occurs on the base of the breast close to small clusters of involution-cysts, and is simply one of those clusters with fibrosis of the walls of the tube instead of dilatation of the interior. It will be noticed in the high-power figure that the inner fibromatous layers follow the curves of the blind ends of the tube exactly, the outer becoming an enclosing capsule round the whole of them. Other traces of fibrosis in this breast are mentioned under Case XI.

CASE II.* (already used for Involution-Cysts).—*Deep Fibroma of the Central and Upper Part of the Breast at the age of forty-nine.*

The history of the case is given at p. 90. Near to the two larger involution-cysts of the base, but more in the interior of the organ, in its central and upper division, was an ill-defined mass about the size of a chestnut, which was hardly distinguishable from the tissues around except by its extraordinary toughness or difficulty to cut. It was this centre of induration, along with the pair of tense cysts near it on the pectoral fascia, which gave the impression of a scirrhus knot deeply seated. The centre of induration is found to be fibromatous, as its peculiar unequal toughness to the knife prepared one to expect. It has no definite limit or quasi-capsule, as the smaller fibromatous kernels have, but an irregular margin penetrated by processes of adipose tissue as if it had been actually a scirrhus.

Not a trace of epithelial "infiltration" in the stroma is to be seen, but only fibromatous tissue, which in some places is sufficiently nucleated to suggest the beginnings of sarcoma. Within this fibromatous area there are numerous glandular structures; but these are neither the regular mammary lobules with many acini, which can be seen elsewhere in the characteristic state of involution, nor the well-marked sweat-gland coils with muscular walls which are also found in various parts of the breast. The contrasts between those several kinds of glandular structure are seen best in the

region of milk-sinuses immediately below the nipple, which I shall refer to again.

The fibromatous change in the breast is not limited, however, to the central and upper area, which made a kind of tumour. How extensive it is, I cannot say, as it is impracticable to make sections of every part of the organ; but there are two or three distinct centres of fibrosis in the lower half of the breast, upon the extreme margin next to the sternum, at a depth of an inch or more below the skin. They are small islands of glistening tough substance containing a cluster of loculi. Near to them are several small involution-cysts, from one of which I have stripped off the translucent inner skin and proved it to be an exquisite mosaic of large polyhedric epithelium resting upon a sheet of plain muscular fibres, the nuclei of which are shown well by alum carmine. It is probable that the loculi in the midst of the glistening fibromatous tissue are also the dilated coils of muscle-walled tubes; but the muscularis is not seen clearly in sections, as it is in the small involution-cysts slit up and spread out flat. What the sections show is a most distinct deposit of dense fibrous tissue around the walls of the several tubes; as in Case III. (figs. 31 and 32), the fibrosis is circumtubular, but in this case the tubes are more patent, their epithelium is usually entire and of columnar form, and the longitudinal layer of muscular fibres is not proved conclusively. The uncertainty as to the presence of a muscularis does not, however, remove those tubular structures from the class to which the muscle-walled sweat-glands belong. They are not mammary lobules with acini, but elongated tubes with coiled offshoots and endings. There are undoubtedly instances of such branching tubular forms mixed with the true muscle-walled coils of sweat-glands, both in sarcomatous and fibromatous cases; and I believe that they correspond with that anatomical type of the branching tubular gland in which the epithelial muscularis is replaced by a second nuclear epithelial layer, and in which the stroma between the tubes may be peculiarly dense and glistening from the intermixture of plain muscular fibres with the connective tissue (see fig. 133, Pl. XXIII.).

This is the kind of branching tubular gland described at p. 35 of the Anatomical Introduction, and illustrated by fig. 8, Pl. II. The tubes that might be drawn from the fibromatous area of the present case are seen at a glance to be different from ordinary milk-ducts with acinous lobules grouped around them: they are branching tubes with lateral and terminal cæca, which are coiled. In some instances the tube runs a great distance, keeping the same width, showing a slight degree of sacculation from point to point, and here or there, instead of a saccular dilatation, an offshoot which may end in a coil. An extreme instance of the elongation of these tubes, with saccules or cæcal diverticula from point to point, is given in an excellent figure by Hamilton (*Pathology*, ii. 799, fig. 489), who does not, however, refer to it in his text, contenting himself with the description: "Fibrous tumour of the Mamma with elongated gland acini arranged in a reticular manner." Those long and very slender tubes or linear cords are neither elongated acini nor milk-ducts, but the rudimentary tubular glands usually found in the company of muscle-walled sweat-glands. The figure just referred to shows at two or three places the same curving of the fibromatous (or almost sarcomatous) layers around the axis or cæcal end of a tube which is shown in figs. 31 and 32 for the muscle-walled tubes.

As this is the first case in which the rudimentary branching tubes, or skeletons of lobules, occur along with sweat-tubes and proper mammary lobules, I shall give a more particular account of all three as they occur together in the region of the milk-reservoirs directly under the nipple and areola.

At a spot about half an inch beneath the skin and a little to one side of the nipple, there is a certain open locular appearance close to one or more milk-reservoirs. This spot is selected for microscopic sections. The microscope shows: (1) that the milk-reservoirs have a longitudinal layer of plain muscular fibres supporting the epithelium; (2) that the loculi visible to the naked eye are muscle-walled saccular dilatations having all the characters of a coil of sweat-glands; (3) that sinuous tubes ending in cæca, without an obvious muscularis, occur close to the walls of the reservoirs in the same relation

as the mucous glands of a mucosa (bronchial or tracheal); and (4) that perfect round or pyriform mammary lobules, containing many small involuted acini, are found in considerable numbers, making indeed the bulk of the glandular structure (Pl. II.). The presence of well-developed or voluminous lobules of mamma in this case was to be expected; although the patient was forty-nine, the menstruation had not ceased; she had borne six children, and had suckled them all. Yet the breast showed anomalies of structure in the muscularity of the milk-reservoirs, in the muscle-walled tubular coils both in the region of the reservoirs and at various parts of the periphery, and in the elongated sacculated tubular forms without acini, which were also both central and peripheral. It is around the tubular glands, with or without muscular ribs, that the fibromatous new growth arises, a certain number of them with the full sweat-gland type becoming also the subjects of involution-cysts. The proper mammary lobules, such of them as remain, are not the seat of fibromatous deposit; on the other hand, they undergo an obsolescence which is not fibromatous but normal, and is succeeded in many women (more or less obese) by pure fat: in this case it is probable that a good deal of obsolescence had already taken place in the outlying lobules.

CASE IV.—*Fibromatous Kernels beside an Area of Diffused Fibrosis with small Cysts.*

This specimen is from the stores of the Museum of Surgical Pathology at Cambridge, and is without history. I am unable to give the original extent and situation of the tumour within the breast: my specimen consists of a piece of diffused fibroma with several small round cysts in it (polycystoma), such as I shall describe under Case v., and of two or three circumscribed small spherical knots of fibroma, each from a quarter to three-eighths of an inch in diameter, and forming together a small lobed tumour. Adhering to the fibromatous areas is a certain thickness of normal, or nearly normal, mamma, which is distinguishable both by its softness to cut and by the characteristic look of many round or oval lobules, like seeds scattered at regular intervals in the stroma.

These lobules are found to have the full (involuted) development of a breast that had once been in milk—an immense number of small round acini occupied by nuclear

cells, overlaying the lobular ducts so as usually to make them invisible. In the same sections with these, but almost in a separate stratum unmixed with the fully developed lobules, are others, which consist of wider tubular structures lined by more or less perfect columnar epithelial cells. When we come within the limits of the fibromatous kernels, we find the same tubular structures widely separated by the tracts of dense fibrous tissue: circumtubular fibrous new growth is the ground-plan of the tumour. But the tubes are very irregular, unequally dilated or narrowed into round loculi or angular slits, and sometimes invaded from the vascular tissue outside by a spherical knob (intracanalicular fibroma) with a narrow neck or pedicle. The epithelial lining of these tubular spaces is a somewhat regular belt of small columnar cells, which is often loosened from the wall.

The demonstration of a muscularis between the epithelium and the fibrous tissue is not easy; what one sees usually is more like a second or deeper row of nuclear cells, beyond which is a narrow hyaline zone stained a deep red by acid fuchsine. Whether it is that the fibrosis of the stroma, with encroachment upon the epithelial lining, has effaced the distinctive characters of the muscularis, or that the tubes are of that intermediate kind which had not developed the muscularis, but only a deeper nuclear row of epithelial cells in the place of it; certain it is that these tubes, around which the fibromatous tissue grows, are not the ducts and acini of normal mammary lobules, such as are found not far off. There is, however, no ambiguity as to the sweat-gland nature of the tubes in the adjoining area of diffused fibroma: they are dilated at places to form small cysts, from the interior of which a thin transparent membrane can be peeled off. The membrane is an exquisite muscularis, with large hexagonal epithelial cells resting upon it in mosaic. The muscularis can even be shown in sections of those dilated parts of tubes where the wall is cut obliquely, as in fig. 33, Pl. VI. Besides the portions of tubes dilated to small cysts, there are coils undilated, and often remarkably uniform in width throughout, with regular columnar epithelium and with an occasional plug of mucus in the lumen. But here again the proof of a muscularis is

not easy; they are certainly tubular glands, not acinous, and they are part of the system to which the small muscle-walled cysts belong. The fibromatous tissue in this region is not definitely circumtubular, as in the region of kernels, but is in the form of long tracts of parallel bundles, with occasional fat-cells.

DIFFUSE FIBROMA WITH SMALL CYSTS: POLYCYSTOMA, OR
MALADIE KYSTIQUE DU SEIN.

The remarkable appearance of dense fibrous tissue, interrupted at intervals by small round cysts, may occur throughout a whole breast or in only a part of the breast. It makes one of the most distinctive of tumours, and has been known long. Perhaps the earliest museum specimens are the four (from two cases) in Sir Astley Cooper's collection, now in the College of Surgeons' Museum (4744-4747), which were included under the name of "cellulous hydatids" in his work of 1829. The look of the cut surface is very striking—dense fibrous stroma interspersed at nearly regular and not distant intervals by hemispherical smooth-walled cavities not exceeding the size of a split-pea, or by the same with their contents undisturbed. Sometimes the cysts are connected in varix-like clusters. The contents are slimy, or soapy, or cheesy, and are apt to be displaced in mass by the knife. Such a breast is quite peculiarly tough to cut, and therefore not easy to examine microscopically; in cutting it, one comes upon softer strata, which prove to be the mammary lobules, non-cystic. A breast so affected may retain its discoid shape (see Case v.).

Virchow taught that the first stage of this cystic disease of the breast was a diffuse interstitial inflammation, during which the mammary lobules were affected only in the way of hypertrophy in mass; in the second stage there ensued the usual retraction or shrinkage of inflammatory connective tissue, whereby the milk-ducts were pressed upon, obstructed, and dilated eventually into cysts of various shapes. He compares this process in the breast to interstitial chronic inflammation in the kidney or liver, usually called cirrhosis (which term, however, means *status flavus*, and should be restricted to the bile-stained fibrous tracts of the alcoholic liver). Paget calls the numerous saccular dilatations of these cases "the most notable instances

of mammary cysts," and emphasises the toughness and density of the fibrous tissue around them (which is the concurrent testimony). The youth of the subjects of them is illustrated well by two typical cases recorded by H. Betham Robinson, in which the ages were nineteen and twenty; he is at a loss to discover a cause for the assumed initial chronic affection of the connective tissue around the glandular acini and lobules at so early an age (*Path. Trans.*, xlii. 1891). It was in a case of this kind, in an unmarried woman, aged 40, that Mansell-Moullin believed he had found "the membrana propria of the mammary gland," in the form of broad parallel bands with tapering ends; the breast, consisting wholly of "a mass of fibrous tissue studded in every direction with minute cysts," had grown to three or four times the size of the other breast in six months (*ibid.*, xxxii. 1881, p. 215). The same membrane, described as the greatly hypertrophied spindle-cells of dilated mammary acini, has been found by Dreyfuss in two cases of polycystoma, in which the breast was simply a conglomerate of larger or smaller cysts (*Virchow's Archiv*, cxiii. 1888, p. 535). The condition has been treated of by Reclus under the name of "maladie kystique du sein," and by König as "mastitis chronica cystica" (*Centralbl. f. Chirurg.*, 1893, No. 3).

Besides the portion of fibromatous tumour in Case IV. which was of the diffuse cystic kind, I have another case in which the whole breast was affected uniformly with that condition.

CASE V.—*Diffuse Fibrosis of the whole Breast with many small Cysts.*

One-half of this breast is exhibited in the collection of Surgical Pathology at Cambridge. I am enabled to use the other half for my description through the kindness of Dr Joseph Griffiths. The breast retains its shape, except that it is thin and flattened, hardly more than half an inch thick under the nipple, and nearly as thick at the margins. The convex upper surface has the usual layer of fat, and shelves off slightly to a definitely rounded edge. The under surface is slightly concave, and is covered by so dense a layer of pectoral fascia as to appear encapsuled.

Although the tissue, as a whole, is remarkably tough to cut, yet there are softer strata met with which prove to be normal, or nearly normal, lobules of mamma. These are found most easily in tangential sections of the rounded margins of the breast, where they may form a special stratum, distinguishable under a lens, as well as by its softness to the knife. They are the distinctive lobules of a virgin breast—large ampullæ, with well-marked columnar epithelium around the ends of the milk-ducts, not many in number, presenting the strongest possible contrast to the normal (involved)

lobules of the breast in Case IV., which had been expanded fully by pregnancy. The connective tissue of these virgin lobules is not the dense tough stroma of the cystic parts, but a softer fibrillar tissue, rich in nuclei and interspersed with fat-cells.

In the proper fibromatous region there are, first of all, the cysts. Their opaque contents usually cling so firmly to the wall that they are preserved *in situ* in mounted sections. Most of the cysts have very tough walls of condensed or matted fibrous tissue, and an epithelial lining of slender columnar cells (more or less obvious), with a mass of vesiculated mucus resting upon it. But mixed with these, or in less obviously cystic parts of the stroma between them, one finds structures which give the clearest possible proof of the presence of coils of muscle-walled tubular glands (sweat-glands), together with the probability that all the cysts are of that origin. One such, which lay in the cut surface like a small hydatid bag, with clear contents, but a rather thick wall, I picked out from its bed without using force, and slit up into a flat specimen. It consisted of a thick coat of greatly hypertrophied plain muscular fibres, which were somewhat loosened from each other (fig. 34, Pl. VI.), and of a mosaic of large hexagonal epithelial cells resting directly upon the muscularis (fig. 35). The hypertrophy of both was remarkable. The same unmistakable muscularis and epithelium are found at a number of places in the sections, the epithelial cells showing all gradations towards dissolution into the vesicles of mucus which occupy those cysts whose walls are more condensed. At some places the coils of tubular glands have no proper cystic dilatation upon them, but are somewhat uniformly occupied by papillæ or ridges of proliferating epithelium, behind which the parallel fibres of the muscularis can be seen where the tube bends (fig. 36, Pl. VII.).

One other phenomenon deserves particular mention. Around certain wide tubes cut transversely or obliquely, which had the lumen filled with large mucus-like spheres, the spaces of the connective tissue were occupied by regular concentric rows of very large cubical cells, which might have been taken for epithelial cells infiltrated, but are found in

other cases, of myxo-sarcoma, to be a circumtubular new growth in the interstices of the stroma, and in this case are an approximation to sarcoma, instead of fibroma, at a few spots (see Chapter X.).

Two things are clear in this breast: first, that the proper mammary (virgin) lobules, such of them as exist, are not the seat of fibroma; and, secondly, that the muscle-walled tubular glands, which are the seat and occasion of the tumour, are widely distributed and seemingly the preponderant structure. So wide a distribution of these primitive glandular structures is perhaps congenital. It is hardly possible, owing to the degree of fibromatous change, to reconstruct the anatomy of this breast; but it is probable that the original *corpus mammæ*, corresponding to the region of milk-reservoirs and the ducts immediately dependent from them, had been occupied in greater part by tubular glands with muscular walls, and that the lobular development on the ordinary mammary lines had taken place round the periphery of the organ, but only to the limited extent of a virgin breast, and not without some resemblance to tubular-gland structure even there. The breast, indeed, is one of those in which there appears to be surprisingly little of true milk-producing structure, actual or potential.

CASE VI.—*Fibroma with large irregular Cystic Spaces.*

This is a third form of fibroma of the breast, which is marked by the great extent of the tumour, by the size and irregular shape of the cystic spaces, and by the glutinous chondriform character of the fibromatous tissue. In the irregularity of its cystic spaces, which are never round and smooth-walled, but anfractuons and invaded by great promontories of firm substance, this tumour of the breast belongs rather to the peculiar forms included under "cystic sarcoma." In this case there are, indeed, here and there areas of round-celled sarcomatous tissue around or between the cystic spaces; but the great bulk of the firm substance is fibromatous, with the singular character of mucinous, or glutinous, or chondriform change or "degeneration" superadded. In the examination of the tissue bounding the larger spaces little can be made out excepting that glutinous consistence, and occasional areas of hæmorrhage: it looks, indeed, as if these anfractuons cavities were of the nature of excavations made by a kind of progressive mucous degeneration of the solid parts, portions of the latter being left to project into the spaces as rounded or pointed prominences; in some of the

closed spaces the contents are obviously of the mucinous kind, not vesiculated like the contents of the small spherical cysts in the last-described fibromatous breast, but a thick glutinous mass. Whatever light is thrown upon the histogenesis is got from the study of certain spots between the larger spaces, where the stroma has an open meshed appearance. These are clusters of wide tubes communicating with each other; in some there is a mosaic of flattened epithelial cells with large nuclei, beneath which no muscularis can be made out; in others the walls of the tubes show no distinct epithelium, but the same mucinous cloudiness which marks the tissue of the tumour in general. Fig. 37, Pl. VII., shows a group of the latter kind; and in the wall of one of the tubes the regular parallel order of plain muscular fibres is fairly well marked. The difficulty in this case, of getting unambiguous specimens of the muscular membrane of the coiled tubular glands, is due to the mucinous change in the fibres, which makes their outlines indistinct, and in the end fuses them all into a homogeneous substance, just as happens to the sheet of plain muscle of the amnion of the chick at a certain stage of its union with the allantois. Apart from the actual identification of a muscularis, there are other evidences that these tubes cannot be milk-ducts; their form, size, and grouping are those of a coil of tubular glands in section, being not unlike the varicose forms of small involution-cysts as described above. Again, one of these locular areas may be in close proximity to a mammary lobule without any connection between the two, or any transition forms. Fig. 38 shows under a low power an involuted mammary lobule entire and compact, and immediately beneath it one of several tube-ends in a varix-like cluster, the single piece of tube being wide enough to contain the whole lobule in its interior. In other parts of the fibromatous stroma there are epithelial-lined spaces which might conceivably be the cross or oblique or longitudinal sections of milk-ducts; but the probabilities in this tumour, as in those already described, and in many more to follow, are against the ducts of mammary lobules having any concurrent share with the sweat-glands in making the new growth.

PATHOLOGY AND ETIOLOGY OF FIBROMA OF THE BREAST.

The best-marked fibromatous tissue, most like to that of fibroma elsewhere, is found in the circumscribed kernels with a laminated structure of white glistening or nacreous strata. In these the new growth is distinctively circumtubular, being the fibrous (and innocent or passive) issue of a process in the walls of the tubes, which may lead in other cases to very different results (myxomatous, sarcomatous, or other). Where the structure is well-marked fibroma (perhaps even with the warp-and-woof arrangement of the bundles), there

is no occasion to invoke inflammation to explain it, or to resort, as is so often done in a difficulty, to some term ending in *-itis*. But in the diffuse fibrosis with cysts, "chronic mastitis" finds some justification in the histology of the new growth. The occasion of so many saccular dilatations as are found in a case of "maladie kystique" is doubtless something operating uniformly in the stroma to cause obstruction of the glandular tubes. The sacculation which ensues does not differ materially from the dilated condition of the same tubes called involution-cysts; and these also are associated with obstruction of their discharging tubes, which is, in a sense, normal as being incidental to the regular climacteric obsolescence of the breast. I have pointed out in the former chapter that involution-cysts are not a regular result of obsolescence; Billroth observes that they are wanting in the breasts of "many women"; and inasmuch as few breasts are ever examined unless there be a tumour, we are hardly warranted in alleging more than that they are not unusual in breasts in the latter half of life. Of the three consecutive cases from which I described them, one, aged 54, had a small fibromatous knot close to a cluster of involution-cysts, and another, aged 49, was purely a case of fibroma with two very large involution-cysts and several groups of smaller, of which one or more might just as well have been reckoned cystic fibromata. The rule laid down by Astley Cooper, and found to be not incorrect in clinical experience, is that the fibromata (or fibro-adenomata) are most frequent between the ages of seventeen or eighteen and thirty, and in single or sterile women subject to menstrual irregularities. But if we were to include all fibromatous knots or indurations which may complicate other tumours, or may have been discovered only by dissection, it would be necessary to extend the age-period. Velpeau did, indeed, extend it for the "tumeurs adénoïdes," otherwise fibromata, which he removed by operation. Of his 55 cases, only about one-half were under the age of thirty years (Cooper's limit); an almost equal number were between the ages of thirty and fifty; and 8 were fifty or over. As many as 20 of his cases occurred in women who had borne

children. Along with mammary sympathies with menstruation at the earlier age, we should include the same as modified in the decline of the menstrual function and at its cessation. In Case II.* of this series, the appearance of the fibroma in one breast was preceded by a slight discharge of blood from the other during a menstrual period, the periods having been regularly announced by mammary tenderness and shooting pains for two or three years before. It is not unusual for the same phenomena to be attended by knots in the breast, which disappear as suddenly as they come. The comprehensive principle is, afflux of blood to the breasts in sympathy with menstrual irregularities. But the structures in the breast which are the occasion of these congestions are not the proper mammary lobules; they are the tubular glands of a more primitive type, which are developed in the breasts of certain women as a congenital reversion or anomaly, and are not unlikely to have been correlated with something ovarian and uterine less easily detected. Without that anatomical cause, or seat, we may be sure that the fibromata would not be there; and it is probable that the incentive to circumtubular or other interstitial new growth, even when it takes the form of fibrous tissue, comes from within the tubular glands—from some disorder of their function. Besides the fibrosis, there is hyperplasia of the epithelium, which may take the form of villous projections; great hypertrophy of the plain muscular fibres in the cysts; and in some cases, such as the last, a peculiar glutinous saturation of the fibromatous tissue which gives it the characters of cartilage without the cartilage-cells. The relation of the stroma to the disordered tubular glands comes up in every chapter. So far as concerns the effect of a blow, or of pressure acting more continuously, which comes prominently into the causation of fibroma, as of other tumours in the breast, it is hardly intelligible without assuming a peculiar susceptibility in the part injured.

CHAPTER IV.

STEATOMA OR PEARLY TUMOUR OF THE BREAST.

THE new growth called Cholesteatoma (better simply Steatoma as there is usually no cholesterin) or Pearly Tumour, from its opaque white, suet-like or pearly nodules of laminated epidermic scales, has been met with oftenest in connective-tissue situations such as the pia mater, where it has afforded to Virchow one of his most striking demonstrations of the strange possibilities open to the connective tissue in disease.

In the breast it has been observed so seldom that it is hardly counted among the tumours of that organ; so that I may consider myself fortunate in being able to include here an original study of a perfect specimen of it, of which one-half is in the Museum of Surgical Pathology at Cambridge: the case has been recorded by Dr Joseph Griffiths, to whom I am indebted for two representative slices of the tumour. As this rare form of mammary tumour is rich in illustrations of my special thesis, I shall make use of it in full detail, the conclusions being wholly the same as Virchow's in respect to the tissue-origin.

Perhaps the earliest known instance of it in the breast is Astley Cooper's case of Mrs King, which is the solitary case in his second and "very curious" order of "hydatids" of the breast, and the subject of two of his plates; he included it among hydatids because the large pearly or suet-like masses were contained by a membrane or bag from which the laminated contents could be extracted layer by layer. Two or three of these "pearly hydatids" are still preserved at the bottom of a test-tube in the College of Surgeons' Museum (Prep. 4754), with the following description in the Catalogue (by Paget): "Several small cysts from a breast,

spherical or oval, one to three lines in diameter, with thin, transparent, membranous walls smooth internally; filled with soft pearly white substance like spermaceti, deposited in grains and little flakes."

The left breast of Mrs King, when amputated for this tumour, was of enormous size, measuring 35 inches in circumference; the disease had been growing for fourteen years, having been seen first, the size of a marble, at the age of forty-four. This great mass was mostly solid, but it fluctuated at the upper side, where there were large proliferous cysts. "In different parts of the solid texture," says Cooper, "bags are seen containing clusters of hydatids growing from stalks"; the bags, however, were only potential, the actual objects being laminated pearly masses bounded by a membrane, and connected together by constricted necks. Everything in the case corresponds with steatoma, excepting the proliferous cysts at the upper side of the breast, which are an intelligible variation of the morbid process at one spot.

A second case is recorded by Billroth. It was the only specimen of the disease that he had seen until he was writing his treatise on Diseases of the Breast for Pitha and Billroth's *Deutsche Chirurgie* (pt. xlv. 1880), the case occurring just in time to be interpolated in the text, but without microscopic details. A very fat woman, aged 46, who was admitted for uterine fibroid and died seventeen days after hysterotomy, had a movable painless tumour encapsuled in the right breast; it had existed for a long time, had given no trouble, and had been stationary for several years; it lay close under the skin, but was not adherent to it. On section it proved to be an exquisite specimen of "foliated cholesteatoma or tumour of giant pearls"; the form of the breast was well preserved, but there was not a trace of mammary glandular substance left. It appears that the breast was kept almost entire for a museum specimen, and used little for microscopic purposes. Two possible sources of the tumour are guessed: either a lobe or group of lobules of the mamma, or a deeply situated sebaceous gland of the skin; the latter hypothesis was suggested probably by the curious coincidence of a case having been admitted on the same day, with an atheromatous cyst over

the left breast, from which the contents could be squeezed through an opening in the skin.

From those two cases together, the important facts may be collected, that the pearl-tumour of the breast begins as a small localised spot of disease, that it grows slowly, is painless and negligible in general, and may reach an enormous size, superseding the whole mammary structure at length, and remaining stationary after it has reached the encapsuled limits of the organ. Having no clinical history to give of the case which I am about to describe, I come at once to the anatomy and histogenesis.

CASE VII.—*Steatoma or Pearly Tumour of the whole Breast.*

The breast is large, about 5 inches in diameter at the base, and keeps its natural shape of a gentle convex on the upper surface and a flat lower surface. A vertical section through it shows the whole organ occupied by strata of suet-like substance, laminated, glistening white; between these deposits there are tracts of more or less dense fibrous stroma, which are much more extensive in one of my slices than in the other. In a thin slice, the pearly masses are apt to fall out, leaving smooth-walled holes. An examination of one of the large pearls *in situ* explains how Astley Cooper came to speak of hydatid bags filled with laminated effused fibrine, and joined together by stalks.

Bisecting a large pearl (like the kernel of a nut), layer after layer of epidermic scales can be lifted out, beginning with the small central cusps, until the smooth membranous periphery is reached. A hemispherical sac remains, running into a narrow funnel-shaped neck at the bottom: this cylindrical neck, which has a few laminæ of epidermic scales on its inner surface, like the globular body itself, connects with an adjoining pearl. According to Cornil and Ranvier's account of cholesteatoma in general, these communicating necks between the pearls are not invariable: "Les perles sont tantôt séparées complètement les unes des autres, tantôt réunies par des pédicules très fins formés eux-mêmes des cellules épidermiques" (I. 319, 1881). I shall come to the structure of the several layers afterwards.

The most striking fact in this pearl-tumour of the breast, which can hardly apply to, and is not stated for, the pearl-tumours of the pia mater, is that the rows of pearly masses,

or the strata of suet-like substance, are accompanied by epithelial-lined tubes, of which the epithelium is columnar in a single layer and of the mucus-producing kind; so that a double system of epithelial structures, an epidermic and a mucous, appear as if intercalated the one within the other. Where the intercalation is most regular the laminated epidermic deposit seems to lie around the mucous tube, or alongside it, as if it were a *parablasic* formation in the sense of the term explained in Chapter I. But the relations of the two epitheliated structures are for the most part irregular, so that in some places one finds many mucous tubes with little or none of the completely epidermic formation, and in other places the pearly masses so predominant that the mucous tubes are visible only here or there and in no very clear relation to the former. However, it will appear in the sequel that these irregularities admit of being brought under a general law, and the whole strange phenomenon of a double set of tubes explained in an unexpected, roundabout way.

First, as to the tubes with columnar mucus-yielding epithelium. For the most part the epithelium is a single regular row of well-marked columnar cells of the smaller size; but in some places, being recesses or dilatations of the tubes, it is massed in very distinct papillæ, which converge to the centre of the lumen and may nearly block it (same appearance as in fig. 36, Pl. VII.). Again, there are parts of the tumour in which tubes lie pressed together in folds or windings, more or less obliterated or denuded of epithelium. These tubular structures are often drawn out to a great length, without any appearance of acini or ampullæ dependent from them in racemose or other arrangement: whether any acinous lobules remain in this breast is doubtful (Billroth found none in his case); but so far as concerns the predominant type of gland, it is quite unlike the regular breast, whether in respect of ducts or of terminal ampullæ. What, then, is this type of glandular tube? I was led first to suspect that it might be of the sweat-gland type, by finding in the subcutaneous tissue outside the capsule of the tumour an undoubted piece of sweat-tube with greatly hypertrophied muscular ribs. But the decisive test of a muscularis was not easily satisfied in the

tubes within the capsule, which, moreover, were not always coiled, but usually extended to long distances. At length I found out where the muscularis could be seen, namely, in the tubes within the broader fibrous septa of the tumour. Set off by the dense fibrous tissue of these septa, the parallel muscular ribs within the basement membrane of a tube can be seen; elsewhere the cellular changes around the wall of the tube mask their presence, as I have found also in undoubted sweat-gland tumours of the dog's skin, described in Chapter X. The two figures 39 and 40, Pl. VII., are drawn from dense fibrous septa between the masses of pearly substance in the steatoma. In both the fibrous tissue bordering the tube takes a deep red stain from acid fuchsine, and is thereby in sharp contrast with the more faintly coloured tubular structure and its several elements. In fig. 39 the long obliquely cut tube has remained rigidly open, but denuded of epithelium, like a membranous sac; its wall for the most part is a granular cloudy substance; but on the right side, where a portion of its lower wall has been left in the section, the regular palisade of plain muscular fibres is seen beyond all question. The other figure, 40, shows a long, straight piece of tubing compressed amidst the dense fibrous tissue; the longitudinal muscular fibres are seen in regular parallel order towards the upper end, then the mosaic of epithelium comes into view on their under surface, and lastly the epithelium bordering the tube on either side. Besides the tubes which I have drawn, there are several others in the same set of sections which show the muscular ribs at some bend or sloping aspect of the tube. Moreover, there is a not unusual condition of the epithelial lining which accounts for the difficulty of seeing the muscularis beneath it; it is detached from the wall as a coherent single row of columnar cells, leaving a clear interval between it and the basement; but, upon the basement as it adheres to the firm tissue round about, there are indications of the layer next to the detached epithelium, which is undoubtedly the muscularis more or less changed. Sometimes the palisade-like ends of the plain muscular fibres can be seen in a row all round the cross-section; but more usually the whole basement is merged in the changes of the surrounding stroma, so

that the detached epithelial belt lies in a space with no other limit than the tumour-tissue itself.

There are parts of the new growth in which the circumtubular formation is more myxomatous than pearly or steatomatous; and those are the places in which the new growth is most obviously concentric about the walls of individual pieces of tubing. These glands are undoubtedly coiled: for in some instances a whole compact glomerulus is met with, the several cut ends of which have exactly the appearance of a coil of the wider kind of sweat-glands in cross-section. But the appearance of muscular ribs is not seen so clearly as it ought to be in the circumstances; so that it is possible that the glands of this breast, although always tubular and often coiled, are in part of that branching kind which are neither true sweat-glands nor true mammary (fig. 65, *cc'*, Pl. XII., and fig. 133, Pl. XXXIV.).

I shall describe first the more myxomatous new growth, which is for much of the tumour merely a stage in the formation of the true pearly masses, but for certain parts is the definitive new growth. The connective tissue is occupied by large spherical or oval vesicular cells, containing either a mucus-like fluid or a thin stainable protoplasm, and a nucleus which is usually a little to one side, but is seldom parietal like the nucleus of a fat-cell. The appearance of these cells is curiously like that of medullated nerve-fibres in cross-section, the clear protoplasm corresponding to the white substance and the nucleus to the section of the axis cylinder. The same variety of myxomatous tissue occurs in the circumtubular new growth of other cases in the sequel (fig. 58, Pl. X.), and is found also in certain small subcutaneous tumours, which are not so hard as the painful nodules under the skin, but more like a lipoma. These mucous cells of the connective tissue may pass by transitions into an areolar meshwork, or parenchyma of cell-walls with free nuclei (so-called "adenoid" reticulum); and in the walls of some of the tubes a knob or polyp of such tissue invaginates the epithelium and projects within, as in an ordinary cystic fibroma.

So far the tumour might have been a fibroma (fibroadenoma) with a myxomatous element; and it will be found

that the structure which gives character to it, the extensive pearly masses of epidermic cells, is an intelligible modification of the same circumtubular process. As in the fibromata themselves, the new growth is not clearly circumtubular at all points; but the ground-plan of it is a process commencing in the walls of tubes and extending farther afield. The transitions in the structure around the tubes may be made out more easily in flat preparations than in cross-sections—by stripping off the layers of a pearl from centre to periphery until the outside wall of the real glandular tube is reached. In the connective tissue outside the tube, or around it, a procession or gradation of structure occurs in the following order: first, close to the basement, a thin layer of exquisite branched connective-tissue cells, of the most perfect myxomatous type, such as occur normally in the pulp of the enamel organ (fig. 41, Pl. VII.); next a layer of cubical cells like the rete mucosum of the cuticle (being sometimes truly a rete or parenchyma of cell-walls); and beyond that the epidermic layers becoming flatter and more uniformly without nuclei towards the *centre* of the pearl (fig. 42, A, B, and C). The membranous bag is really formed by the connective tissue outside the epithelial tube; so that all the contents of the “pearly hydatid,” as Cooper called it, are really a circumtubular growth, which becomes more and more scaly or epidermic in the layers farther from the mucous tube around which it is developed. The whole of this is a connective-tissue development, as Virchow showed for the pearl-tumours of the pia mater; and the gradations of cell-forms, from the branched myxomatous cells next the wall of the tube, through the rete or parenchyma of cell-walls to the cubical rete-mucosum cells, and to the flat epidermic scales, enable us to understand that somewhat paradoxical origin of epidermis. The interest centres in the stratum of cells next to the basement, or in the basement itself. Fig. 41 shows both the face view of them and an oblique view of the lumen of the tube; the cells are of the most perfect myxomatous type, nucleated, with a zone of protoplasm and with several arm-like processes of the latter prolonged into finer threads; the long parallel fibres on the left are the remains of the

muscularis ; the capillary loops on the right are those of the wall of the sweat-tube. This new formation in the wall of the tube is essentially perivascular, in which respect it belongs to the order of *parablastic* complements or additions. As I have maintained in the morphological Introduction, the parablaster is not merely an incident of the first days of the germ, but a continuing relation, being more especially the means by which new organic parts are formed to complement or to supersede the archiblastic originals. Here we have the parablastic principle reappearing in disease, and therein illustrating the same inherent property of parablaster which I contend for in normal development, namely, its catholicity, or its adaptability to become epithelium as well as to become some tissue of the connective series. In this case the branched myxomatous cells pass by gradations into a true rete mucosum, which is found of some thickness in the next zone outwards from the wall of the tube (fig. 42, A). This is literally a rete of protoplasmic trabeculæ, the meshes of which are the round or oval spaces containing the original nuclei of the branched cells, as if the arms of neighbouring cells had joined and been filled out by protoplasm to a uniform breadth. The difference between this protoplasmic rete and that which I have described in the rodent placenta (also arising from pre-existing vascular tissue), is that the protoplasm of the latter is nucleated (so-called syncytium) and the meshes are the blood-channels, whereas in this the protoplasmic trabeculæ are without nuclei and the meshes are the spaces around the free nuclei. In this mucous layer of the pearly nodules there is as yet no individualisation of cells, just as there is none in sarcomata with an epithelial habitus. But in cross-sections of the pearl, the limits of cells begin to appear along with the more scaly character of the layers (fig. 42, B) ; and in the centre of the pearl there is a heap of concentric scales like a globe of true epidermic origin (fig. 42, C). There is no mistaking the resemblance to the Malpighian layer and the epidermis ; there is even an intermediate stratum with many small spherules or granules, corresponding to the eleidin layer of normal skin. Upon the walls of some tubes are found such abrupt pieces or fragments of rete mucosum as

one finds in dermoid cysts (*e.g.*, in those at the outer angle of the orbit).

This origin of a pearly epidermic tumour, from connective-tissue rudiments around the walls of glandular tubes, is the same that Virchow originally maintained for the pearl-tumours in their most usual situation, namely, the pia mater (in his *Archiv*, viii. 1855, pp. 371-418). Not long after, Huxley had occasion to contend for an exactly inverse process of development in the case of the enamel pulp, an exquisite system of branching "connective-tissue" corpuscles which forms in the midst of deep islands of rete mucosum (the enamel germs) still connected with their epiblastic origin by necks. Huxley's paradox is now admitted to be true (Kölliker calls the pulp "gelatinous epithelium"); it can be verified with ease, and in a continuous view, upon the enamel pulp of the incisor teeth of rodents. Virchow's paradox is only the converse, and is equally true in matter of fact; but I believe that this converse case will receive better credence if it be brought under the principle of parablastic additions or reconstructions.

If there were only the morphological principle in these processes of new growth, they might seem to be vagaries. But there is always an element of utility as well; and in the case of the steatoma of tubular glands in the breast, it is to the old principle of *functio læsa* that we must resort in order to make this strange type of new growth intelligible. I have mentioned once already the occurrence of a circumtubular growth of large cubical interstitial cells in a fibroma (p. 106), and I shall have several occasions to return to the subject in the sequel, the great subject of sarcomatous growth in the midst of glandular structures being, indeed, an illustration of the same. To prove the whole principle upon the case of steatoma would be out of place; and I shall merely state in advance the conclusion that I come to from a greater variety of data. When functionally active tubular glands, such as the sweat-glands, fall into disorder, from whatever cause, the effect is seen not only in their interiors but also upon their exteriors; and in the latter in such wise as to imply that the circulatory mechanisms, both of the blood and of the

lymph, have been subject to some unusual strain. Probably in the case of sweat-glands, the lymph-drainage is involved more particularly; for, to put the case in colloquial form, there is a special risk from "suppressed perspiration," which would fall naturally upon the lymph. When the lymph-mechanism of a part or organ breaks down, it retreats to broader ground, or falls back upon more primitive types of plasmatic circulation. These are various, one of the principal kinds being the great system of plasma-cells, whose relations to the lymph-system I have shown in another work for certain of the Mollusca. Included among them are the branched myxomatous cells, whose plasmatic function will be admitted probably by everyone, *e.g.*, in the case of the enamel pulp. It is this myxomatous kind of tissue that arises in the first instance around the embarrassed or congested sweat-tubes; it is succeeded, in time and in place, by cubical cells like those of the rete mucosum; and these in turn by many layers of flat epidermic scales just as on the surface of the body. Thus we arrive at the pearly masses, which, although their accumulation makes the tumour, are a safe issue of the whole process, or a structural way of escape from the disordered function.

The rete mucosum itself becomes intelligible, both in health and in skin-diseases, if it be regarded as an extensive reservoir of lymph; and that view

DESCRIPTION OF PLATE VII.

FIG. 36. Diffuse Cystic Fibroma, Case v. Cluster of sweat-glands with papillomatous state of epithelium. $\times 150$.

FIG. 37. Large Cystic Fibroma, Case vi. Group of loculi formed by dilated sweat-glands, with glutinous state of the tissue. $\times 150$.

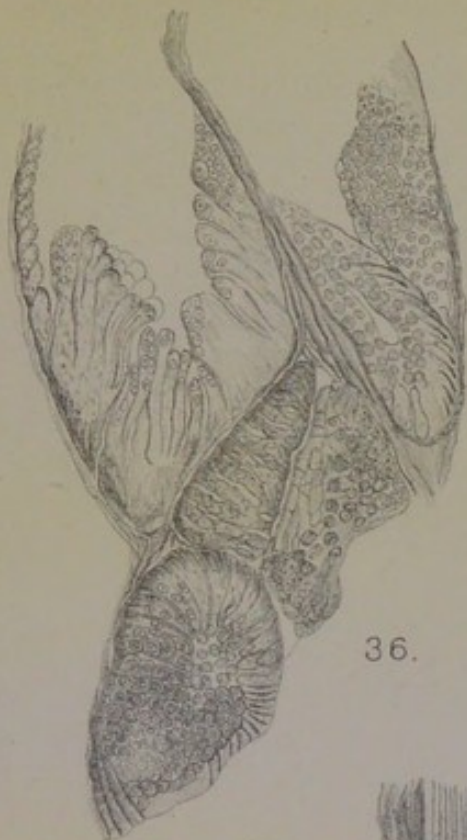FIG. 38. From same Case. A normal mammary lobule above; part of a dilated sweat-tube below. $\times 150$.

FIG. 39. Fibrous septum of Steatoma, Case vii. An obliquely cut tube with granular state of the epithelium, and the muscularis basement seen clearly on the right. $\times 150$.

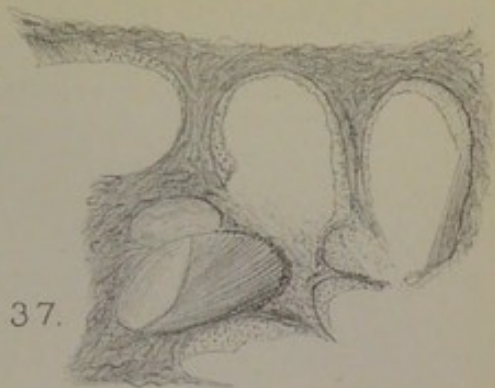
FIG. 40. From same Case. Elongated compressed tube, showing the muscularis above and the epithelium below. $\times 200$.

FIG. 41. Myxomatous tissue around muscle-walled tube in Steatoma Mammæ. Case vii. $\times 150$.

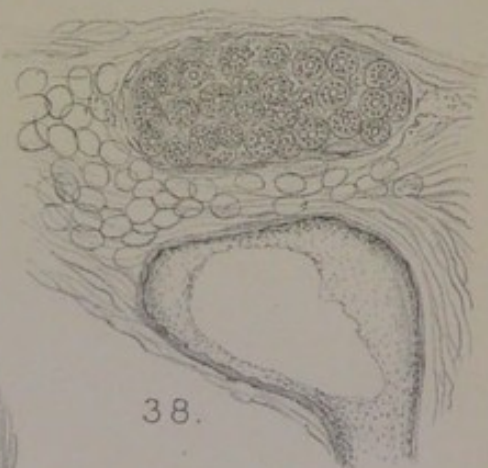
FIG. 42. Structure of a pearl-nodule in same case of Steatoma. A, face view of protoplasmic rete of cubical cells next to the myxomatous layer of fig. 41. B, next layer, like rete mucosum of skin. C, centre of pearl, consisting of epidermic scales. $\times 200$.



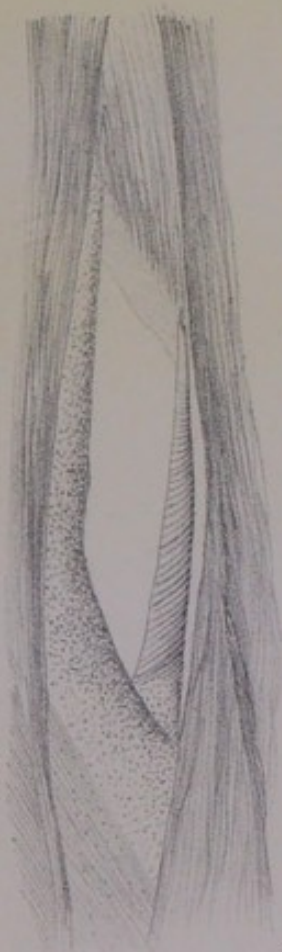
36.



37.




38.



39.



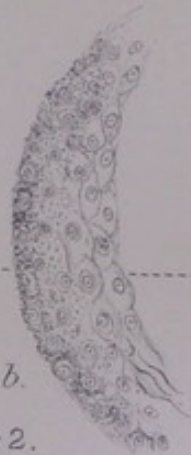40.



41.



a.



b.



c.

42.

C. Creighton del.

Huth, Lithr London.



of it finds probability in the fact that it is occupied in the mammalian embryo, at a certain stage, by animal starch, a substance which I have shown to be the deputy and precursor of red blood in mammalian embryos, and to be in the place of a second blood or "lymph" in Mollusca. Foster ("Huxley Lecture," *Nature*, 22nd October 1896) is in expectation of some proof that the mucous layer of the skin is the seat of internal secretion:— "Every year, nay, almost every month, brings up some new light as to the details of the great chemical fight which the blood is carrying on in all the tissues of the body: it may be perhaps to-morrow that we shall learn of some work, of a kind wholly unexpected, which is carried out by that great Malpighian layer of the skin which wraps round our whole frame." Meanwhile Ranvier (*Comptes rendus Acad. des Sc.*, cxxvii. 1898, p. 924) has found that "the whole body is covered by a protective varnish of incomparable solidity and suppleness," in the form of a waxy substance within the resistant but flexible envelopes of the cells of the stratum corneum. That layer, like nearly all the Malpighian layer, is remote from the blood; whence it follows that "the great chemical fight," whatever be the issue of it, must be carried on at long ranges.

CHAPTER V.

TWO CASES OF COLLOID OF THE BREAST.

COLLOID is a not unusual variety of cancer of the stomach, as well as of the omentum, and is found also in cancers of the rectum. The other organ in which it occurs is the breast, but it is so rare in it that Billroth had never seen a case. It is the same peculiar process wherever it arises, and it has a significance for the general pathology of cancer much greater than its practical importance. It was a chance observation on the alveolar structure of a colloid of the breast that led Rokitansky to his important conclusions on the development of the cancer stroma; it was from colloid of the stomach that Johannes Müller took his most striking illustrations of the discontinuous interstitial growth of cancer beneath the glandular epithelial layer; and it was from the same gelatinous alveolar new growth in the wall of the stomach that Köster drew a great part of his evidence for the origin of cancer in lymphatic vessels.

Among the general characters of colloid is one to which Walshe has called attention: "A remarkable character of this structure," he says (*On Cancer*, 1846, p. 26), "so long as the process of destruction has not set in, is, that wherever or in whatever form it is developed, the appearance and properties of the gelatiniform substance are exceedingly uniform in every part of its extent; the firmness, transparency, and other qualities of the material are as distinctly marked towards the centre as the periphery of the mass. The loculi, too, are prone in their primary, secondary, and subsequent series, to exhibit great uniformity in point of size." This should suffice to show that colloid is not a degeneration, in the strict sense, of some original new growth, but rather the regular, if peculiar,

issue of the tumour-process. In the stomach it is always a gelatinous "infiltration" of the submucous and muscular coats, which is not traceable, however, to any gelatinous swelling of the glandular or surface epithelium; Müller was clear that it arose at numerous discontinuous centres between the muscular bundles; the mucosa may be hypertrophic, mammillated, or even papillated, and is eventually thinned or destroyed by pressure of the growth beneath, but is not itself the seat of colloid. When it occurs in the omentum, it has certain characters of sarcoma—encapsulation and lobulation. It is not only firm, but sometimes hard, so that Otto described one of the first cases in the stomach (1816) as scirrhus. In a case in the rectum, in a young woman, I have found the scattered nodules under the serous coat almost cartilaginous. It is the same variety which Cruveilhier found in the testes along with small spots of steatoma, or tumour *à matière perlée*, although the horny epidermic scales of the latter were not proved (*Anat. Pathol.*, v., "Sarcocèle," p. 2).

In the breast, colloid occurs in two forms, according to Walshe, Paget, Butlin, and the evidence of the two following cases. One of the forms is "a mass of equable consistence and uniform proportions in all directions, and exactly resembling the growths much more commonly met with in the omentum" (Walshe)—of which the second case in the sequel is an example. The other is "a very tough, white fascia-like mass, in which are small separate cysts filled with the colloid substance" (Paget)—of which the case next following is an example. (*Cp.* also Butlin, *Path. Trans.*, xxvii. 1875, p. 233.)

CASE VIII.—*Circumscribed Colloid Tumour with dense white Stroma.*

A single woman, aged 54, from Fulbourn, Cambridgeshire, was admitted in January 1901 into the Temperance Hospital, Hampstead Road, under Dr [Sir William] Collins for a tumour of the left breast. The lump, which feels like scirrhus, is situated deeply in the upper outer quadrant. The nipple is florid red, not retracted; no enlarged lymph-glands in axilla. The breast was removed on 7th January, and given to me entire. The tumour is a small circumscribed body about three-quarters of an inch in diameter, having its base close down upon the pectoral fascia. When it was bisected, several orange-red hemispheres of jelly protruded, about an eighth of an

inch in diameter, which showed under a lens a delicate red network of vessels shining through the jelly. The bands of tissue which separated these globes of jelly were dense and white. Two or three single globes of reddish jelly, the size of small peas, were met with at separate points in the breast not far from the tumour.

Condition of the Breast in general.—Excepting in the axillary quadrant, where the tumour was situated, the breast consisted of irregular tracts of dense white tissue much encroached upon by fat. Microscopic sections from several of the broader white bands showed nothing but dense fibrous tissue, with occasional collapsed milk-sinuses (not simple ducts) and clusters of tubular glands near them or dependent from them; there were no round or oval or pyriform mammary lobules containing acini, but in one region there were areas of small, circular, fibrosed bodies in lobular grouping, which appeared to be obsolete acini. As the patient was a single woman, a full lobular development was not to be expected; and as she was fifty-four years of age, there was likely to be obsolescence of whatever regular mammary structure had developed. The milk-sinuses or reservoirs, however, were numerous, not only in the *corpus mammæ*, but penetrating also to the outlying marginal processes. They had the distinctive width, angular recesses, or rugosities of sinuses, and in numerous instances a longitudinal muscular layer could be seen beneath the mosaic of small, flattened, columnar epithelium, especially clear in alum-carmine specimens; in the dense *corpus mammæ*, running obliquely from the tumour to the nipple, these could be followed in a straight course for a considerable distance. At various places on the periphery, not of the axillary quadrant only but all round, there are coils of tubular glands more or less obviously connected with the milk-sinuses, some of which are dilated, and where dilated are found to have the distinctive sweat-gland basement of plain muscular fibres. The small cluster drawn in fig. 43, Pl. VIII., occurred all by itself in the midst of dense fibrous tissue upon the extreme axillary margin of the breast just above the tumour; it consists of two wide sections of tubes below, and some eight or nine cut ends above, in several of which the muscular ribs are visible. This kind of tubular gland, in

glomerular clusters, is the only remaining secreting structure in any part of the breast. At one place in the surrounding fat there were two or three reddish points of tissue, which contain the same kind of tubes, dilated and nearly blocked with small epithelial cells, having probably been cut off from the milk-sinus to which they belonged.

The connection between the sweat-glands and the colloid disease can be traced through the small detached globes of jelly near to the tumour proper, the actual colloid process being limited to the sweat-glands in this axillary quadrant, where also they are most numerous. Sections through one of the spots of reddish jelly show glandular tubes in various degrees of dilatation and with the epithelium in various conditions. The widest are cysts the size of a pin-head, in which the plain muscular fibres are much hypertrophied, and easily seen (fig. 44, high power). The hypertrophy is a cloudy swelling, in which the broad fibres look granular along their borders and mucinous in their interior. The epithelial cells, in a single mosaic layer, are also cloudy and granular: they are nearly always small, and, in the face view, of slender columnar shape, nearly filling the less dilated tubes, or projecting in papillary knobs, a mucinous or glutinous substance uniting them everywhere, with sometimes masses of the same in the lumen. Round these outlying spots of colloid, the coils of tubes are numerous and close together, filling considerable areas within the fibrous stroma or fat.

In the tumour proper, which introduces the new element of dense white hyaline septa between the globes of reddish jelly, the structure of the coils of tubing is less well preserved; but the same glands are there, and had been the point of departure of the new growth. Fig. 45, low power, is drawn from this part; in the lowest tube the parallel muscular ribs are very clear under a higher power; the epithelium is small, and broken up into clumps; and there is a stratum of homogeneous or hyaline plasma within or upon the basement. Outside the tube the stroma is becoming gelatinous, in the form of loose shreddy tissue of short fibre-cells (fig. 51), which I have to mention often in connection with the myxomatous process. In some places, but rarely, there are exquisite

instances of branching cells, of which three are shown in fig. 46 in their natural connection. As in the case of steatoma, and in numerous other instances given under sarcoma, this myxomatous structure is of limited extent or duration in colloid, or only a phase of its development.

The true colloid or jelly appears to be wholly a product of the vascular stroma. As in the case of hyaline tumour in the next chapter, there are occasional dilated gland-tubes filled with large vesicular outlines of cells (in the hyaline case with large colloid balls), which make a kind of intratubular colloid; but that is not the product which gives character to the tumour. When a small portion of the protruding red jelly is sniped off with scissors, spread out flat, and mounted either fresh in glycerine-gum or, after fixing by absolute alcohol, in balsam after staining, it is found to be a vascular tissue with many finely moulded loculi, which are not the interiors of denuded gland-tubes. The stroma contains also alveolar clusters of epithelial-like cells with very large nuclei, much larger than the epithelium of the tubes; along with these are linear rows of the same kind of cells. The dense white tracts which separate the globes of colloid contain these in good preservation, making indeed the structure of scirrhus; but elsewhere they appear to have melted down into the colloid substance. In colloid of the stomach, the melting of the alveolar groups of cells among the muscular coats is often incomplete, so that a marginal row of flattened cells remains, making a nucleated cellular lining or capsule of the gelatinous pearl.

It is not easy to follow the fate of the glandular tubes, which may be said to have occasioned the colloid new growth in the stroma; but some light is thrown upon it by the closely analogous hyaline new growth in the next chapter: the hyaline encroaches from without upon the epithelial contents of the tube, like vascular papillæ, cutting off the epithelial cells in clusters or ridges, reducing them by degrees to mere lines, and eventually bringing the whole area of the tube into the domain of hyaline. The mucinous character of the epithelium everywhere, the stratum of homogeneous plasma between the epithelium and the basement (as in

fig. 45, lowest tube), and the curiously ridged or broken-up appearance of the epithelium, all point to some such disintegration of the glands. In the colloid substance examined fresh, there are found many plain muscular fibres either floating free, or in narrow bundles.

CASE IX.—*Uniform Colloid Tumour of the Breast.*

This specimen was sent to me at Cambridge in 1880, from King's Lynn, by Dr Blomfield, house surgeon to the hospital, who reported the case in *Lancet*, ii. 1880, 10th July, p. 52.

Mary Ann B——, aged 42, was admitted into the West Norfolk and Lynn Hospital on 16th March 1880, under Mr Wilson. Sixteen months before, she had pain in the right side of the neck, followed by pain in the right breast, in which she noticed soon after a nodule the size of a nut. The tumour grew slowly, causing little pain. It is now a hard, circular, nodulated tumour the size of a chicken's egg, fairly movable, and seated deeply on the axillary side of the nipple. It was removed, and found to be a circular mass of jelly, like semitransparent material of a greyish hue, with no very evident capsule, but with delicate shreds of connective tissue penetrating between the jelly-like masses. A suspected enlargement of a lymph-gland in the corresponding axilla had disappeared before the patient left the hospital.

The specimen, well preserved in chloral hydrate, admitted of being cut into sections, which were used for the figure of typical colloid pearls (fig. 47) here reproduced from my article "Pathology," *Encycl. Britan.*, xviii. 1885, p. 382. On re-examining the microscopic slides, I find that the firmer parts of the stroma, at the edges of the larger gelatinous masses, show an immense number of colloid bodies, most of which are smaller than those figured: they are packed close together and of various shapes as if from mutual pressure, such as lemon-shaped, or mussel-shell shaped, and often with a deeply stained central ball or nucleus. The smaller forms, ovoid or spherical, do not differ from the kind of myxomatous vesicles in the connective tissue around the walls of glandular tubes, which I have mentioned at p. 116, and refer to again under Case XII. In this case also the tracts of connective tissue contain the remains of glandular tubes, which are much compressed, and occupied by very small epithelial cells, not at all active, but detached in belts from the wall and decaying. Amongst these are wider ducts, or sinuses,

in which I believe that I can see the parallel nucleated fibres of the muscular basement. These remains of glandular structure, which are confined to the thin septa between the gelatinous masses, are almost certainly of the same anomalous kind as in the former case of colloid. But in this case the process in the stroma is much more general and extensive, and the character of many of the colloid bodies little removed from large vesicular myxomatous cells. The plan of structure is, indeed, that of sarcoma, notwithstanding that there are alveoli filled with a gelatinous laminated substance; and the physiological type is that of the parablast. The persistence of anomalous tubular glands in the obsolete breast, the interference with their function, the complementary activity of the vascular stroma, and the final suppression of the blood-vessels themselves, are all in the manner of sarcoma, as will appear in a subsequent chapter. As to the vascularity of colloid, while there are blood-vessels at a certain stage, according to the observation on the first case, and to old observations of Johannes Müller and Cruveilhier, it is said by the latter that no trace of vessels can be found when the disease has reached its maximum.

DESCRIPTION OF PLATE VIII.

FIG. 43. Group of sweat-glands from margin of breast with Colloid Tumour, Case VIII. Two dilated tubes below, coil of undilated above; muscularis seen in several. $\times 150$.

FIG. 44. Colloid, Case VIII. One of the outlying jelly-like points: wall of hypertrophied plain muscle, lined by epithelium with large nuclei and cloudy protoplasm. $\times 300$.

FIG. 45. Group of sweat-glands from same Case of Colloid. Ridged state of the epithelium; gelatinous stroma. $\times 90$.

FIG. 46. Three branched connective-tissue cells from wall of dilated sweat-tube in same Case of Colloid. $\times 300$.

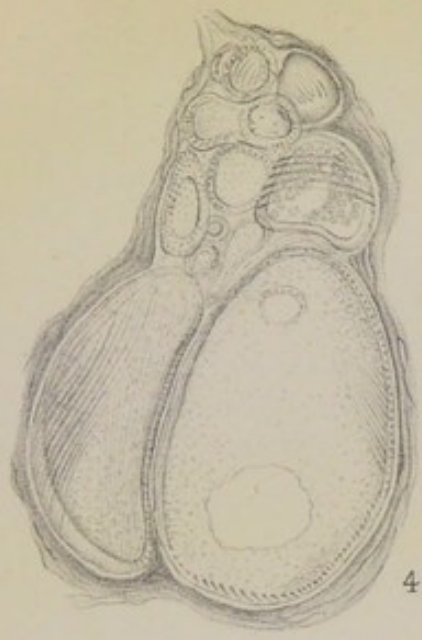
FIG. 47. Colloid pearls of the stroma in Case IX.: concentric lamination.

FIG. 48. Sweat-gland with hypertrophied muscularis from *corpus mammae* of Case X. (hyaline tumour). $\times 200$.

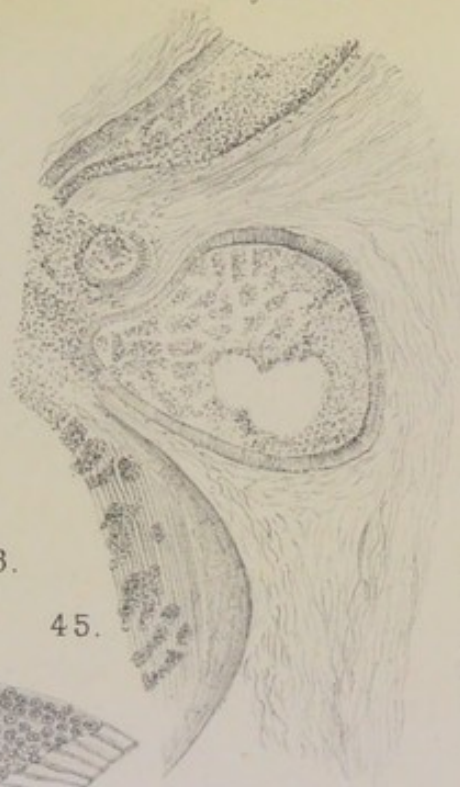FIG. 49. Low-power view of hyaline islands surrounding tubes of *corpus mammae* in Case X. $\times 20$.

FIG. 50. Wall of a large alveolus in Case X. (hyaline). The recesses of the wall show the muscular ribs of a sweat-gland. $\times 150$.

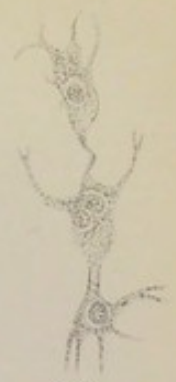FIG. 51. Fibro-cellular variety of myxomatous tissue. (From a cavernous angioma of the liver in a dog.)



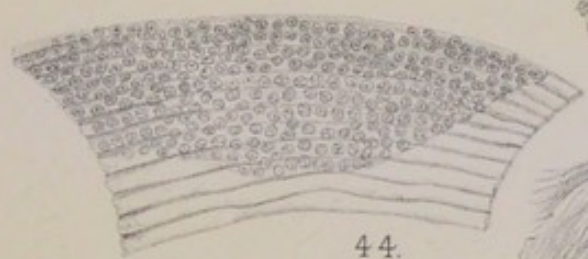43.



45.



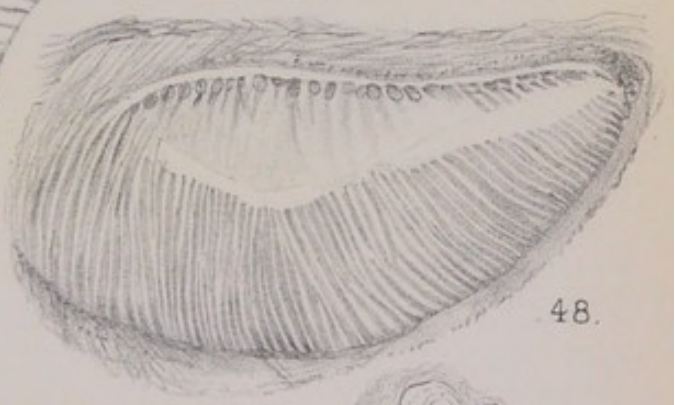46.



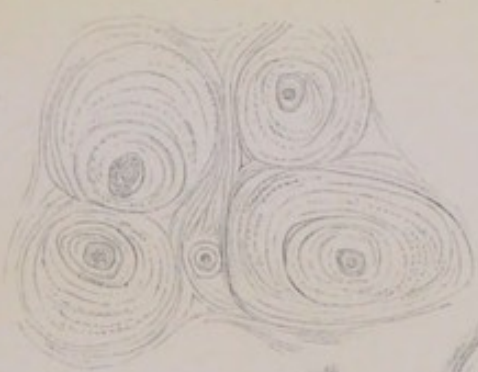44.



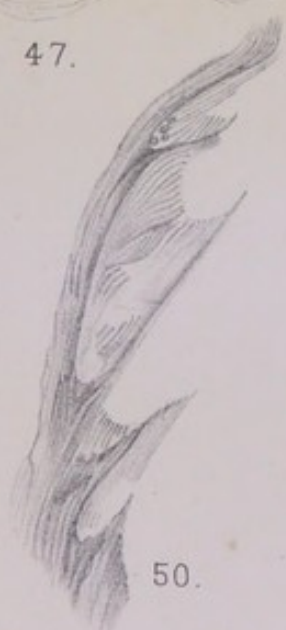51.



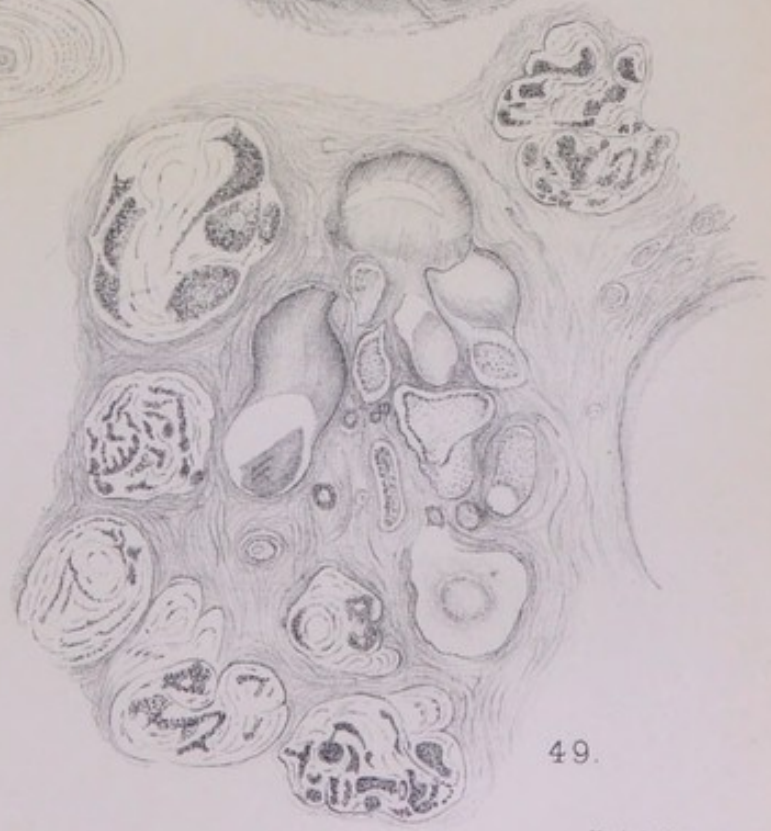
48.



47.



50.



49.

C. Creighton del.

Huth, Lith. London.



Divers views have been held as to the *prognosis* of colloid of the breast (*cp.* Paget, *Surgical Pathology*). On the whole its clinical affinities are with sarcoma, or enchondroma, or hyaline tumour, rather than with scirrhus. There may be lobulation, as well as a degree of encapsulation ; and there are undoubted instances of recurrence (Spencer Watson, *Path. Trans.*, xxix. 218 ; Godlee, *ibid.*, xxx. 416). The most remarkable case of secondary infection is one recorded by Kelly and Emery in *Path. Trans.*, xlix. 1898, p. 303. After the removal of the breast for "duct papilloma," consisting of one large proliferous cyst with numerous small cysts around it, the patient had a recurrence of elastic nodules at the axillary end of the scar, which proved to be colloid. She died with secondary nodules in the liver and in the substance of the cranial bones, which were not colloid, and with nodules in the lungs and in the substance of the sternum, which contained colloid. It is impossible to say upon what peculiarity, constitutional or other, this rarity among mammary tumours may depend ; but some of the cases have an element of scirrhus, and it is probable that purely colloid tumours, such as the second of the above, are very unusual. In the remarkable specimen of colloid of the breast given by Bryant to the College of Surgeons' Museum, two large areas of colloid are separated by a large mass which is just as uniformly glandular or pseudo-glandular.

CHAPTER VI.

HYALINE TUMOUR.

HYALINE tumours, which are not unusual in the region of the orbit with the peculiar branching structure of cylindroma, have not been described, so far as I know, for the breast. The case which I am about to give for the sake of the general pathology has been in my possession since 1880, having occurred in the practice of Dr (Sir George) Humphry at Addenbrooke's Hospital, Cambridge. I obtained the whole breast and preserved it entire for future microscopic examination, along with a large packet of hard lymph-glands removed from the axilla, on account of which the case was diagnosed scirrhus. On examining it long after, I found that the scirrhus part was a distinct mass about the size of a chestnut, with its base upon the skin, on the axillary side of the breast, and separated from the larger tumour by nearly an inch breadth of subcutaneous fat. There was one small intermediate island, about a quarter of an inch in diameter, which belonged to the larger tumour by virtue of a clear spot of bluish-white hyaline at one side of it. The scirrhus contained not a trace of the same hyaline, and was in all respects a tumour apart, which had infected the axillary lymph-glands and given the case clinically the character of cancer: it is described fully in the sequel (Case XXXI.). I am concerned here with the larger central tumour of the mamma proper, which I shall describe as a specimen of hyaline of the breast, treating it as a separate new growth.

CASE X.—*Hyaline Tumour of the Breast.*

The date of operation, age of patient, etc., cannot be given, the label on the bottle being defaced; but it is probable, from the condition of the

mammary lobules throughout a considerable thickness of normal gland upon one side of the tumour, that there had been the full expansion of pregnancy once or oftener, and that the patient, at the time of the operation, had not reached the climacteric age.

The tumour is pyramidal in shape, covered loosely by dusky skin, with the nipple at its apex, definitely bounded or encapsuled towards the fat on the sides and by the pectoral fascia beneath, an inch and a half deep in the vertical of the nipple and about the same in breadth (fig. 123, Pl. XXII.). On the rounded sides towards the nipple the substance is firm, sarcoma-like, and opaque cutting with a smooth uniform surface; irregularly shaped tracts of the same firm opaque tissue extend into the centre between the hyaline areas. The region of hyaline amounts to about two square inches, including the centre or proper *corpus mammae*, and extending down to the pectoral fascia as well as laterally. At one part of the periphery there is a wedge of normal mamma, with a maximum thickness of three-eighths of an inch, in which the seed-like lobules are set at regular intervals in the midst of not very dense connective tissue. At one or two other places on the extreme margin there are wide milk-sinuses and small cysts, with coarse tissue around them. On the base, at the axillary margin, there is a process almost detached, like an almond.

State of the Mammary Lobules.—The lobules of normal mamma, visible to the naked eye as seed-like bodies, are in many instances well-developed clusters of many small round acini in the ordinary resting state; in others they have more the appearance of branched tubes with infundibula. At one place they are in sharp contrast with the hyaline areas of the tumour, without the smallest sign of gradation into these; at another place a certain number of lobules are enlarged greatly, keeping their perfect acinous structure, bounded by very smooth lines, each acinus being many times its proper size, and packed full of nuclear sarcoma-like cells. This is a condition of the true mammary lobules which I shall have occasion to notice more particularly in the sarcomatous tumours of the bitch. In this tumour it is the only contribution that the regular mammary glandular structure makes to the bulk of the new growth, and it is not only small in extent, but also secondary.

Anomalous Glandular Tubes.—The presence of large coiled tubes with muscular basement is found in various parts of the breast, including the small outlying island on the axillary base. But by far the easiest demonstration of them is got from the region directly below the nipple at

a depth within half an inch of the base. Here they occur throughout the whole extent of quite large sections, much dilated, with the muscularis hypertrophied, being in some instances filled with a large number of colloid balls of yellowish colour, set in a gelatinous medium, like spawn. The hypertrophied plain muscular fibres are seen beautifully in the section of tube drawn in fig. 48, Pl. VIII., the central of three windings side by side. This is from a somewhat compressed part of a dilated coil of sweat-glands, such as is drawn entire under a lower power in fig. 101, Pl. XVIII., from a non-mammary tumour of the dog's skin. The dilated sweat-tubes in the centre of the *corpus mammæ* are more usually characterised by a ridged state of the small epithelial cells, beneath which the muscular fibres of the basement can be made out, the ridges or islands of epithelium being exactly the same as in the case of colloid, fig. 45, Pl. VIII. The widest sections of tubes, amounting to small cysts, are filled with the above-mentioned colloid balls, of which I have counted fifty or more filling the sectional area of one tube, although they usually fall out, leaving only a few adhering round the margin. They are large spheres, the size of a mammalian ovum, often laminated, sometimes with lines radiating from the circumference, and with a refracting body in the centre like a mineral concretion. They occur also in narrower tubes, so that two or more may fill the lumen. The larger collections of them are set in the midst of a finely granular mucus-like substance.

Coming now to *the hyaline of the tumour*, it is associated not with the regular mammary lobules, but with those anomalous parts of the organ that have the distinctive character of sweat-tubes. To the naked eye the hyaline is distributed in round or oval spots, or in irregular narrow tracts with an anfractuons outline, the largest continuous areas being about the size of a pea. The colour is translucent bluish-grey; in the prepared tissue these spots are shrunk a little below the surface of the intervening tracts, which may be the firm, opaque, sarcoma-like substance or the wider cyst-like tubes described above. Under the microscope the hyaline

areas are seldom hyaline throughout ; they are broken up in a very singular way by narrow columns of epithelial cells fused together. Fig 49, Pl. VIII., magnified twenty diameters, shows some half-dozen hyaline spots all round a central group of wide tubes or milk-sinuses (the smaller of which contain mucus, while others show the muscular fibres of the basement under a higher power). In some of the hyaline spots the columns of epithelium are so attenuated as to be little more than granular lines traversing the pellucid matrix, as at the left lower corner of the figure. In other instances the hyaline is only a narrow border round a central mass of epithelium, with narrow tracts penetrating the latter and dividing it into epithelial columns or ridges. In all cases the epithelial cells are fused or agglutinated together, so that they look more like protoplasmic blocks than rows of nucleated cells. It is clear that this hyaline process is an invasion of the muscle-walled tubes from outside. The ridged state of the epithelial cells above mentioned, being the same that is found also in the initial stage of colloid, corresponds with the irregular columns and islands of fused cells surrounded by hyaline. That substance appears to collect first in the basement of the tube, the muscularis having become cloudy (fig. 50) and mucinous, and having apparently melted away, to be replaced by the hyaline ; which extends within the folds or ridged processes of the epithelial lining, as if it had been vascular tissue, and, so extending farther and farther, cuts off the ridges and columns of epithelium as islands in its midst. I have said it invades as if it had been vascular tissue ; and in one set of sections its place is actually taken by that peculiar kind of embryonic vascular tissue, several times referred to, and here illustrated from a cavernous tumour of the liver, namely, of slender fibre-cells scattered through a homogeneous ground substance (fig. 51).

The hyaline is here a peculiar substitute for vascular tissue, which causes all structures to melt before it, both the muscularis and the epithelium, and is itself structureless and inert. It may be said to be a conservative adaptation, where the natural plasmatic or lymph-circulation has failed, an

adaptation which is more of the nature of a deposit or store than a transmitting medium, and therefore only a makeshift. In that respect its occurrence in this anomalous breast is exactly parallel with the pearly substance of steatoma and with colloid. In all those three rare and comparatively benign forms of tumour, the distinctive substance is produced by a reaction or adaptation of the vascular stroma to a disordered state of glandular structure and function, which is the same in them all.

The Element of Sarcoma.—To complete this case, I have still to deal with those uniformly firm, sarcoma-like tracts of tissue which enclose or penetrate among the hyaline areas. To do so fully would open the whole subject of sarcoma, which is begun in the next chapter but one; but if reference be made to the fig. 101, Pl. XVIII., showing a mucous sarcoma of the dog's skin, the same relation will be seen of the sarcoma to the glandular structure of the part as occurs in this hyaline tumour: it is not a direct relationship to the tubular wall, or a circumtubular new growth, but that of a whole vascular territory to a whole coil or aggregate of tubing, in such wise that the two are interlocked just as vascular loops are interlocked among descending processes of the rete mucosum of the skin. Hence in this case the greater part of the sarcomatous element in the tumour has grown up on the sides of the *corpus mammæ*, in which the greater part of the anomalous muscle-walled tubes occur, and has sent processes amongst them. The most distinctive type of the sarcoma is a tissue of large protoplasmic cells with short processes, by which adjoining cells are connected, leaving small round lacunæ between them: it is the plan of myxomatous tissue, with the difference that the arms of the cells are short and the bodies thick or square, so that the appearance is rather of trabecular columns of cells with slight intervals. In the parts most distant from the glandular centre, the cells of the connective-tissue new growth are not branched at all, but packed close in alveolar clusters (alveolar sarcoma); and in the tract descending directly from the base of the nipple the fibres are so coarse and dense, and the sarcoma-cells in

so regular rows between them, that the structure might be supposed to belong to scirrhus. In some places the sarcomatous new growth is opaque or semi-necrosed, the outlines of cells being vague and nuclei indistinguishable.

This process in the stroma is related in the first instance to the disordered tubular-gland structure; but it extends to the vascular connective tissue at large, and in that way it comes to invade the lobules of the breast proper, whose place it may usurp, leaving only portions of milk-ducts in its midst. It is the same sarcomatosis of the mammary lobules, in another form, which elsewhere produces an immense number of uniform nuclear cells within the widely distended limits of the individual acini. Towards the nipple the sections of considerable nerves are found involved in the sarcomatosis in the same way as the milk-ducts.

The specimen in the College of Surgeons' Museum, 4815, placed among Colloid Tumours of the Breast, is different in some respects from the others, and is probably akin to the hyaline tumour just described. The patient was a lady of eighty, who had noticed a tumour in the breast for three years. When seen by Mr Hulke, it presented as a smooth boss of the skin a little below and to one side of the nipple. When removed and divided it proved to be a nearly spherical mass coming close to the skin in its upper segment, about two inches deep, and definitely encapsuled on one side only, where there was extravasated blood in the connective tissue. The cut surface shows two or more angular cystic spaces. The fresh section was soft and of pale colour, with much colloid. In the mounted specimen it is impossible to distinguish any areas with the colour of hyaline; but according to Eve's microscopic notes, the structure consisted in places of narrow columns of spheroidal epithelial cells, nearly all nucleus, [and fused together], which were separated from the bands of stroma "by a space left apparently by the solution of the intervening connective tissue" (*Path. Trans.*, xxxvii. 1886, p. 493).

CHAPTER VII.

INTRATUBULAR AND INTRACYSTIC TUMOURS.

IN a classification of tumours of the breast, there are unavoidable cross-divisions, owing to the intermixture or gradation of morbid processes in the individual cases. A tubular element enters into all cases, and a cystic element into many. As regards the universality of the tubular element, it is not only implied in the principle of this work, that all mammary tumours have their seat and anatomical cause in parts of the breast which have reverted to the primitive sweat-gland type, but it is a former empirical observation. Cornil and Ranvier (*Histol. Pathologique*, 2 ed., 1881, i. 323) refer briefly to the structure which they call "épithéliome tubulé" as occurring in one place or another "dans toutes les tumeurs de la mamelle quelleque soit leur nature. . . . Toutes les tumeurs de la mamelle ont donc la propriété de donner naissance à certaines formes morbides qui leur sont communes." The tubes blocked with epithelium, they took to be the ordinary milk-ducts, which had been "irritated" by some morbid process in one part or another of the mammary structure. Shortly after, there began to appear in English writings descriptions by Thin, Bowlby, Betham Robinson, and others, of a class of "duct cancers" and "duct papillomata," which were separated off from other mammary tumours by their anatomical seat (in the milk-ducts), and by a certain clinical type, which has been drawn out by Bowlby and Robinson, not altogether without overlapping upon scirrhus, sarcoma, etc. I shall follow this usage from my own point of view: firstly, because it is right to adopt existing categories so far as one can; secondly, because there are certain cases in which the morbid

process is either so simple in type, or in so early a stage, that it hardly touches the surrounding stroma; and thirdly, because there are cases among the "duct cancers" and "duct papillomata," which, although essentially sarcomatous or pseudo-glandular, are yet intracystic (or intratubular) in plan or appearance. I shall begin with a case in which the tumour had been noticed only a fortnight before the breast was removed, and is almost wholly in the intratubular stage.

CASE XI.—*Intratubular Cancer in an Early Stage.*

A lady, aged 54, the wife of a country clergyman, who had borne no children, consulted Mr W. A. Meredith for a tumour of the breast, who amputated it on 11th April 1901, two weeks after the disease was first noticed by the patient. The breast is voluminous, with much fat upon its sides as well as infiltrated along the base and throughout its substance; there is also removed a separate large piece of fat from the axillary side, which contains no lymph-glands, but only blood-vessels and thin fibrous septa. The nipple is broad and flattened, with the orifices of some dozen milk-ducts in the centre, and a large number of translucent sebaceous glands all over its surface, with small round orifices. The areola is a narrow zone, from $\frac{1}{8}$ to $\frac{1}{4}$ inch broad, nearly overhung by the expanded margin of the nipple, bearing a single prominent tubercle of Morgagni at one side. The base of the breast, with which some pectoralis muscle is removed, shows several small involution-cysts, some of which had bluish contents: they have the muscularis and epithelium of dilated sweat-glands (*supra*, p. 93). The tumour is deeply seated in the axillary margin, with a flat base upon the pectoral fascia, being a fairly well-defined knot about $\frac{3}{4}$ inch in all dimensions, firm in texture but not scirrhus, somewhat glutinous, with a number of small opaque yellowish areas in the section, which are the thick walls of tubes: after hardening, the cut surface shows many small loculi. Situated also on the base, midway between the tumour proper and the vertical of the nipple, is a well-defined compact stratum about $\frac{1}{2}$ an inch thick, which is hardly a distinct morbid growth, but a richly glandular part of the breast, with little stroma, and with obvious coils of tubular gland visible in it under a lens. The breast as a whole is an irregular flattened body, triangular in the section, with one or more "suspensory processes" to the skin, spreading out from the nipple towards a wide base, consisting of tracts of dense whitish tissue much interrupted by fat everywhere except immediately under the nipple. Within the base, towards the sternal border, there is embedded the small fibromatous kernel, like a pea, already described (p. 98). On the slope of the sternal border are several small spots of loculi, two of them close together, at a depth of $\frac{3}{4}$ inch perpendicular from the skin, and another at the extreme sternal angle of the base.

The patient having never borne a child, and being at the age of fifty-four, it was not to be expected that there would be a well-developed lobular and acinous structure: the full complement of acini around the terminal ducts, which is produced only by pregnancy, would not have arisen, whilst a certain degree of effacement or obsolescence of structure was to be looked for at the patient's age.

Beginning at the nipple and areola, the sebaceous glands all over the surface of the former were remarkably numerous, and normal. In the corium and in the loose tissue under the areola there are several small coils of tubular glands, not larger than ordinary sweat-glands, but altogether unlike these in the width of the lumen, the kind of epithelium and the presence of a basement of plain muscular fibres, the epithelial cells being vesiculated with the nuclei driven to one side and angular or crescentic in form; two or three wider sinuous tubes pierced the corium and opened upon the skin in the midst of sebaceous glands, one of which is drawn in fig. 6, Pl. II. In this regular subareolar deposit of sweat-glands there was nothing abnormal, the vesiculated state of the epithelial cells being probably their active functional condition.

In the dense neck of tissue directly below the nipple, the milk-sinuses were narrowed or collapsed; at the depth of half an inch, or in the centre of the *corpus mammæ*, they were met with as wider elongated spaces; and they were still wider close to the base of the breast. In the more dilated parts of the sinuses, when seen in the face view, a basement of plain muscular fibres could be made out clearly at places where the mosaic of epithelium was broken asunder. In specimens stained with alum carmine the regular elongated nuclei are well seen, marking the regular parallel course of the fibres. The same were found also in smaller tubes, one of which is drawn in fig. 52, Pl. IX. The sinuses under the nipple were all marked by a linear deposit of bright yellow pigment-cells outside their walls; this pigment was not seen clearly in epithelial cells anywhere; it was outside the sinuses, and was almost certainly in their lymphatics.

Always along with that phenomenon there was another equally noticeable, namely, that small clear vessels running through the connective-tissue

stroma, at various angles to the walls of the sinuses, were occupied by single files of corpuscles which were exquisitely marked with the trefoil-like cleft nucleus of pus-corpuscles. These vessels I take to be also lymphatic, although they might be blood-capillaries so far as structure is concerned. Exactly the same appearance has been described and figured by Rauber (*Ursprung der Milch*, Leipzig, 1879, p. 43 and fig. 22), from all parts of the pair of mammae from a guinea-pig at the end of lactation: the lymph-corpuscles with the trefoil nucleus are actually called pus-corpuscles; the processions of them could be followed from the stroma to the spaces around the alveoli, and through their walls into the interiors; but there was not a trace of alteration in the alveolar walls or in the epithelium, so that the phenomenon is counted "pus-production without inflammation or abscess"; and is taken to illustrate the author's view of the normal part played by lymph-corpuscles in the production of milk. In the present case, it looked rather as if the processions of lymph-corpuscles, with nuclei cleft into three or four pieces, were leaving the walls of the sinuses, and that they were the disengaged nuclei of pigmented cells collected in the parietal lymphatics. These yellow cells are normal within the acini of the cat's mamma, and may be found traversing the lymph-spaces of fat and connective tissue, as well as in the lymph-sinuses of the submammary lymphatic glands (see *Contributions to Physiol. and Pathol. of Breast*, 1878, p. 43 and fig. 14). They are also produced in great numbers in morbid conditions of the epithelium of sweat-glands of the dog's skin, where they may be seen to disengage their nuclei by losing their pigmented protoplasm; and I shall have to mention them for several human cases in the sequel. I have also described and figured the same trefoil nuclei as remaining over from the breaking up of the protoplasm of hæmatoblasts into red blood discs in the wall of a blood-cyst (*Journ. of Anat. and Physiol.*, xiv. 1880, p. 298).

The existence in this breast of a large amount of glandular structure of the primitive sweat-gland type is proved by various pieces of evidence, including the involution-cysts on the base, the clusters of loculi, with very clear muscularis, at various points on the periphery, the fibromatous kernel on the base formed upon a branching axis of tubes with a muscularis, and the presence of the latter as a strong longitudinal coat next to the epithelium throughout the system of milk-sinuses or reservoirs. In this, as in numerous other cases, it is by following the distribution of milk-sinuses that we are enabled to understand the whole anomalous structure of the organ. It is probable that what may be called the normal anatomy of the sinuses is far from uniform. Astley Cooper's account of them, based upon coloured injections, is as follows: "They generally radiate from the nipple, although some of them

pass directly backwards to the posterior or pectoral surface of the gland. Their calibre is out of all proportion larger than that of the straight or mamillary tubes, and much larger than that of the milk-tubes which form their continuations" (*Anatomy of the Breast*, 1840, p. 56). In one of his figures, on Pl. V., their wide sacculated forms with conical prolongations are well shown, together with the extension of one or more of the central reservoirs almost to the base. The case from which this figure was drawn may or may not have been an average specimen; at all events it is this kind of deep penetration of the sinuses or reservoirs that I find so often associated with anomalous tubular glands of the sweat-gland type.

In this case (at the age of fifty-four) the greatest collection of gland-substance is the thick stratum upon the base, a little to the axillary side of the perpendicular of the nipple. It is in the direct line of one or more wide milk-sinuses, of which it is, indeed, the terminal territory. There are some mammary lobules in it, which might pass as normal: that is to say, oval or round encapsuled bodies, looking like embedded seeds under a lens, with a plan of structure which is rather that of branching tubes all of one width ending in saccular ampullæ, than of a congeries of acini grouped around the sides and ends of a duct. It is as if the terminal ampullæ of ducts of the virgin breast had been prolonged on the same plan—a development which is conceivable in a childless married woman. The only point which I shall notice about these acini is, that there is often a broad clear zone (of hyaline) between the basement membrane and the central mass of epithelium, the appearance being very much the same that Langer has described and figured (Stricker's *Handbuch* p. 630) as proper to the developing virgin breast. I have drawn in fig. 53, Pl. IX., this zone around a few tubular acini which are separated by connective tissue almost fibromatous in density; but the hyaline is found throughout whole lobules with no fibrous tissue except their ordinary stroma, and within acini or alveoli three or four times the size of those in the figure. As I have found this hyaline zone or halo in several other breasts of married women of various ages, and

failed to find it in three virgin breasts, I doubt whether it has anything to do with the normal growth of the lobules at puberty; it is not mentioned in Langer's original memoir of 1852, having been observed by him afterwards in one or more breasts, which were probably exceptional.

After these regularly shaped and bounded mammary lobules, which are in a passive or resting state, we come to anomalous tubular structures, which are in various conditions of dilatation, overgrowth of epithelium on their walls, etc. They are found not far from the wall of a sinus, and can be seen sometimes joined to it. It is undoubted that the greater number of these tubular coils partake of the muscularis basement of the sinuses from which they depend, and that they are reversions to the primitive sweat-gland type of mammary organ. The muscularis cannot always be seen, especially where the epithelium is massed upon the wall of the tube so as almost to fill the lumen; but it can be seen so often, in the longitudinal and cross-sections of tubes of every size, and in every locality, that it may be assumed to characterise the whole of the tubular coils. One of the best ways to see it is to stain the sections faintly with acid fuchsine: this colours the connective tissue a bright red, leaving the epithelium yellowish, and brings out the upstanding ends of the muscularis between the connective tissue and the epithelium. When the tubular gland is widely dilated, as often happens in one part of a coil, the muscular fibres are usually very distinct. Fig. 54, from near the base of the breast almost in the vertical line of the nipple, shows that dilatation or cystic condition at one or more windings of the tube, the wall of which is so encountered in the section as to leave the muscular ribs standing out; the wide tube is continued below, beyond the figure, into a large locular epitheliated recess, in which the muscular walls are equally clear. On the left of the sinus are two smaller tubes, with clear muscularis, as well as several much smaller, which are obscure in their structure. The grandular structure throughout the whole of this region is sweat-gland, the distinctive mark of the parallel muscular ribs being met with constantly as it is shown in fig. 55, from a spot in the fibrous stroma

close to the wide tube of fig. 54. In the smallest tubes the muscularis is often difficult to see, but it is clear that they belong to the same order as the more dilated.

Seat and Cause of the Tumour.—The tumour at the axillary border of the base is wholly within the tubular sweat-glands of that region. Nearer to the centre of the base is a thick stratum of these glands, which hardly amounts to a tumour of the same kind. The tubes are in the condition shown in fig. 56: epithelial cells of the columnar type piled up upon the walls in several layers, sometimes running out into villous projections which may join with each other to form trabeculæ across the lumen. This is on the whole a very orderly hyperplasia of epithelium, the appearance of the thick-walled tubes in a coil being remarkably uniform and as if their normal state, like the tubes of the thumb-gland of the frog when the sexual excretion is not fully ripe. It is this state of epithelium, including the elongated forms of the cells, which has often been described under the general name of adenoma.

The same state of the tubes can be found upon the upper margin of the tumour proper. But the structure which gives character to the tumour is somewhat different (fig. 57). The whole structure is more glutinous; the individual cells are less definite in outline, and are fused into masses, trabecular or columnar, the nucleus of each being greatly enlarged and in a highly mitotic state. The process is still wholly within well-marked tubular limits, but the area over which it extends, about three-quarters of an inch square, is defined as a tumour towards the adjoining parts of the breast. It is most probable that other developments would have followed, if the breast had been left longer, inasmuch as there is small-celled infiltration of the stroma, which extends also to the neighbouring more or less regular lobuli of mamma and obscures them in a cloud of leucocytes. In the state in which it was removed, the breast gives the impression of impending malignancy, either in the direction of scirrhus or of sarcoma. The forms of epithelial cells within the tubes of the tumour, and their fusion into masses, are significant, whilst the commencing "infiltration" of the

stroma is equally so. But, so far as it has gone, the new growth of cells is within the anomalous tubular glands; and the question arises, Why they should have fallen into a disorder of their structure and function? Existing as a potentiality from birth, they had probably undergone their greatest development at puberty and after, and had proved harmless, for all their anomalous character, during a space of nearly forty years of sexual maturity, excepting, perhaps, at the limited spots on the base, and in one thin expansion of the margin, where a fibromatous condition had arisen around their walls. The really critical time for the anomalous glands in the breast is the time when the regular mammary lobules are becoming obsolete: their obsolescence cannot but react upon the other glands mixed with them, which are not subject to the law of climacteric effacement. It remains to bring out that difference under future cases; but this case illustrates one special point. The lymphatic vessels upon the walls of the milk-sinuses, converging to the great lymphatic circle under the areola, are occupied by large yellow cells, which can be assigned to the sweat-glands. There is some embarrassment of the lymphatic drainage (upon which sweat-glands must be peculiarly dependent); and there are various signs, both within the tubes and in the stroma, that the mechanism of the lymph has broken down. Within the tubes, the epithelial cells are not only accumulated several rows deep, but, in the tumour proper, are in a peculiar glutinous state. The stroma around them also stains in a certain way, as if it were saturated with a mucinous or hyaline substance: this is seen around the slightly disordered tubes of fig. 55, although it is hardly possible to bring out the effect in the drawing.

CASE XII.—*Intratubular Tumour near the Breast.*

Of this specimen, obtained from the stores of the Cambridge Collection of Surgical Pathology, by the kindness of Dr Joseph Griffiths, I have no clinical particulars except that it is labelled a tumour "near the breast." The growth is somewhat soft and spongy, and consists, to the naked eye, of cylinders, with brown pigment in them, set in the midst of considerable tracts of fibrous stroma. The whole growth might have been the size of a

chestnut and was probably encapsuled; the structure is uniform throughout the piece in my possession, about three-quarters of an inch square.

The pigmented cylinders consist of epithelium usually joined in anastomosing trabeculæ, with small round lacunar spaces between the columns of cells. The cells are of the large cubical type, their fringe of protoplasm round the large nucleus being ill marked owing to the fusion of the cells in columns. The limit between the epithelial cylinders and the stroma is remarkably definite, partly by reason of their brown pigmentation, partly from the existence of a fibrous wall. In the fibrous tissue round them, there is a small amount of myxomatous change at places, but nothing like an epithelial "infiltration." It is a very pure case of intratubular growth. The way in which these epithelium-filled cylinders are encountered in sections of the tumour suggests that they are winding tubes; while the identity of the tubes with muscle-ribbed sweat-glands is proved by a remarkable appearance, which is met with in some sections but not in others, and is unlike any condition of the muscularis basement that I have seen elsewhere. It is shown in fig. 58, Pl. X. The whole surface is crossed by fine longitudinal lines, which have the perfect regularity of the muscularis basement when seen in the face view, as well as the same

DESCRIPTION OF PLATE IX.

FIG. 52. Straight piece of sweat-tube showing muscularis basement with the nuclei, and the epithelium at left lower end. Alum-carmin specimen. Wavy connective tissue around the tube. From the *corpus mammæ* on axillary side. $\times 250$. This and following figures are all from Case XI.

FIG. 53. Mammary structure, of small tubes with thick hyaline deposit between basement and central heap of atrophying epithelial nuclei. Fibrosis of stroma. $\times 150$.

FIG. 54. Wall of milk-sinus in *corpus mammæ* with muscular ribs projecting, and some epithelium. Lateral tubes in cross or oblique section, some with muscularis. $\times 250$.

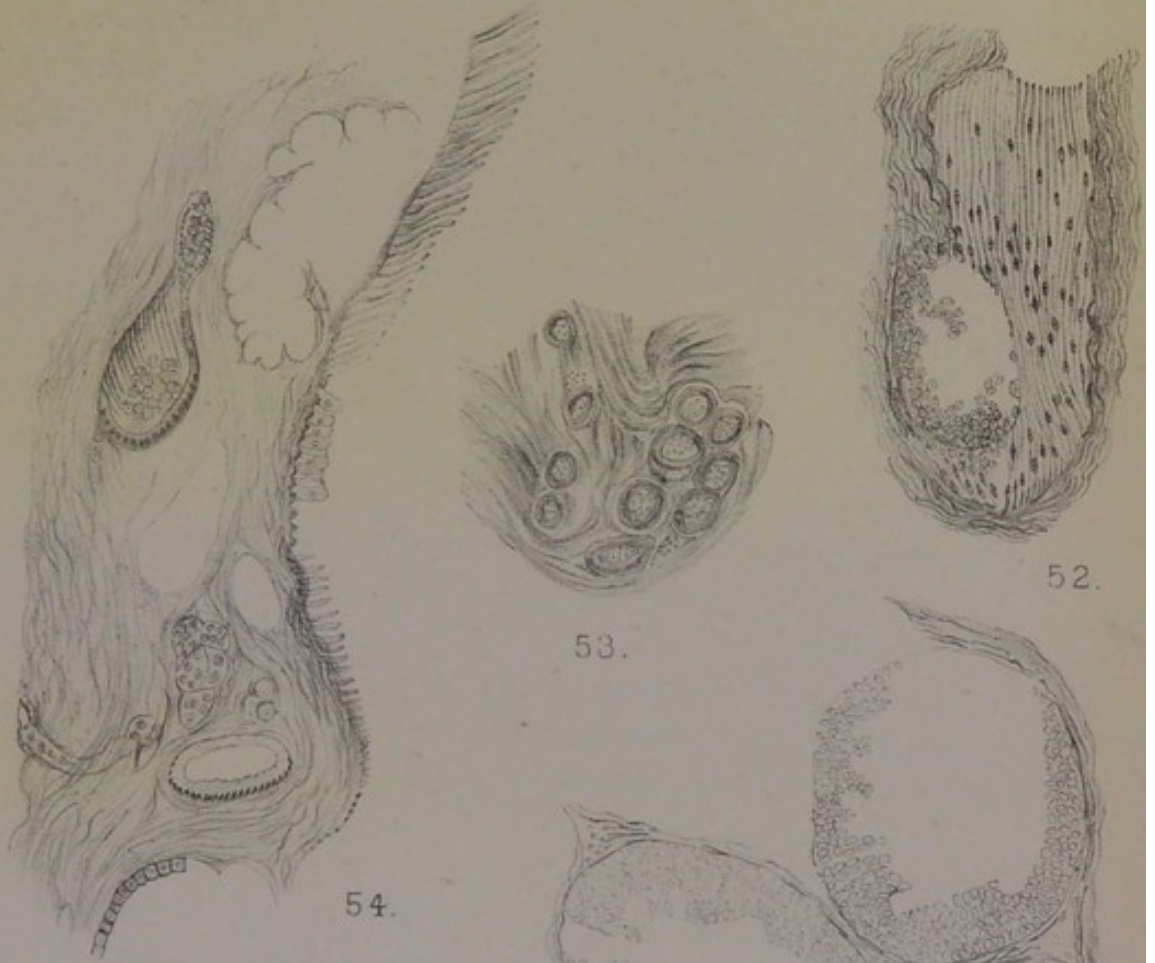
FIG. 55. Two coils of sweat-tubes of unequal width, from the deepest part of the *corpus mammæ* close to the sinus of fig. 54. $\times 300$.

FIG. 56. Three tubes blocked by parietal epithelium or trabeculæ, from the margin of the tumour proper. $\times 150$.

FIG. 57. Structure of the tumour proper. Coils of dilated sweat-tubes filled by trabecular columns of epithelium with large nuclei and glutinous protoplasm. The muscularis basement can be seen on left lower side. $\times 150$.

Plate IX.

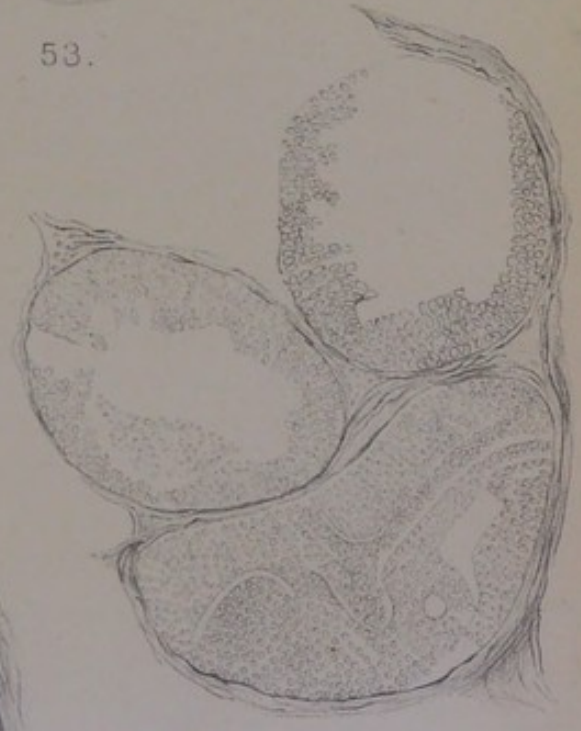Case XI.



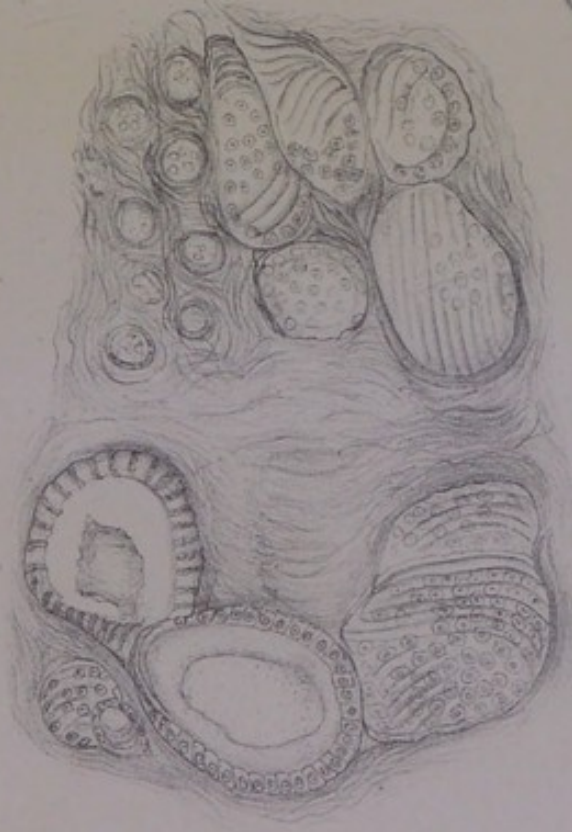52.

53.

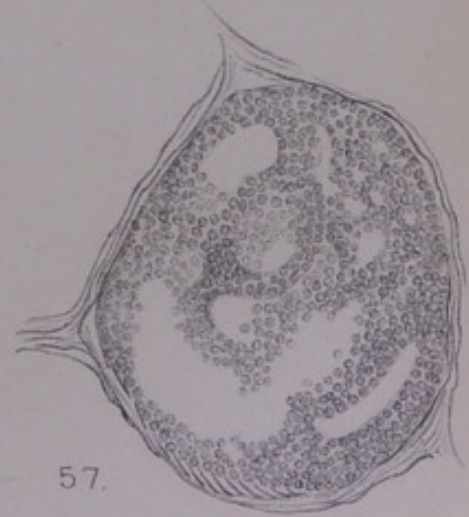54.



56.



55.



57.



exact correspondence with the circuit of the tube, and the contrast all round with the connective-tissue stroma. The structure is, indeed, the sub-epithelial layer of plain muscular fibre in a state of fibrillation. Each fibre appears to have been cleft longitudinally into some half-dozen fibrils, as well as cleft transversely so that the fibrils are broken up into short lengths like packets of needles. As this singular appearance is met with over the whole sectional surface of certain tubes, the stratum must be assumed to have some thickness; for it is seen more continuously and more prominently than the ordinary muscularis-basement can be seen in the face view. In the sections of tubes which show it, the epithelium is seen as if lining the muscular sheet; in the numerous tubes where the muscularis is not encountered, the epithelium fills the interior in trabecular columns. Hypertrophy of the muscular fibres had preceded their fibrillation, and with the longitudinal cleavage there has been a certain amount of transverse cleavage. The regularity of both is so striking that they cannot be explained as "degeneration." The physiological type of the fibrillation is doubtless to be found in an observation of M. Heidenhain upon the muscularis of the poison-gland of the Amphibian Triton. It was known to Leydig that the upper ends of the meridional muscle-cells were prolonged in tendon-like processes into the mucous layer of the skin on either side of the neck and orifice of the gland; to which Heidenhain adds, that very often they show "eine prächtige sehr deutliche Fibrillirung" (*Anatom. Anzeiger*, viii. 1893, p. 406). Langhans saw "fibrillärer Zerfall" in the parallel ribs of the basement membrane in cysts and adenomata of the breast, and concluded from that very phenomenon that the basement could not be the same plain muscular fibres as in the axillary sweat-glands, but must be the connective-tissue cells of the regular basement of acini and ducts (*supra*, p. 38). Although I have examined the muscularis of sweat-glands in a large number of cases, both in the human breast and in the dog's skin, I have seen the fibrillation only this once.

The *state of the stroma* in this tumour shows its non-malignant nature. In many places it is occupied by large

clear vesicular cells with a nucleus usually excentric, as drawn in the margin of the figure. These are myxomatous cells of the kind described at p. 116. In this case they are more numerous in some parts, making a true myxomatous tissue outside the tubes. In some other spots their place is taken by vascular channels winding in all directions, the vessels having simple membranous walls and the whole appearance being that of lymphatic telangiectasis. The same conjunction of myxomatous tissue with telangiectasis is stated in a word by Gross for the tissue around the epithelial tubes ("ducts") in a mammary case at the age of twenty-four, cystic, but consisting chiefly of small spindle-celled sarcoma ("Tumours of the Breast," in Mann and Hirst's *System of Gynæcology, etc.*, vol. ii. pt. i., Edinburgh, 1888). Both the myxomatous tissue and the telangiectasis mean a high degree of adaptation of the stroma to the blocked state of the epithelial tube; where the conservative adaptation is less successful, the stroma becomes sarcomatous.

As this tumour was situated "near the breast," and as there is not a trace of mammary structure, whether of ducts or lobules, to be found in it, the question arises, whether the sweat-glands, which are its seat, had been an integral part of an outlying lobe or process of the mamma, or had been an independent deposit under the skin. That such aberrant deposits of the axillary or areolar sweat-glands do occur in the subcutaneous tissue, I have clear evidence in Cases XXXI. and XXXIII., in the sequel; but I am unable to decide in this instance from not having the whole breast to examine.

Those two cases are the only ones that I can classify as strictly intratubular. Sweat-tubes blocked by their epithelium, or dilated to small cysts and occupied by villous growths, occur constantly in all kinds of mammary tumours; so that, in a sense, these are all "duct cancers." But a purely intratubular or intracystic growth is unusual. There are cases, however, in which the semblance of epithelial tubular structure is so closely reproduced in sarcomatous new growths, that they are easily mistaken for tumour-disorders of original

gland-tubes. These pseudo-glandular tumours belong properly to the chapter on Sarcoma, in which most of my cases are taken; but I include one of them here, having mistaken it myself when I described it in a former work; and along with it I include a characteristic case of soft intracystic papilloma, which is also essentially sarcomatous.

The same ambiguity of classification arises often, especially in tumours of the upper jaw. An instructive instance of it in the breast is found in a case recorded by Butlin (*Path. Trans.*, xxxviii. 1887). This tumour of the breast was one of the persistently recurrent kind, having been operated on three times before. Such a history is itself strong evidence of sarcomatous nature, which was the diagnosis made (an element of reddish-brown pigmentation being considered as either melanotic or from extravasated blood). The specimen, along with microscopic sections from the second and third removals, was referred to Parker and Shattock, who concluded that it was not a sarcoma, but a duct-cancer (of Cornil and Ranvier) "originating from the ducts of the breast as distinguished from its acini." This diagnosis was supported by a drawing of "branching trabeculæ of connective tissue thickly invested with epithelium." The epithelial-like cells are columnar, several rows deep, with the basal row sharply defined against the stroma. It was admitted to be remarkable, that such a cancer of the breast should not have invaded the connective tissue at all, the stroma being passive and occupied only by hæmorrhage or grains of blood-pigment. In all these respects, excepting the point of recurrence, the following case is exactly parallel; and I agree with Mr Butlin, that the structure in question is sarcomatous.

CASE XIII.—*Tumour of the Breast of pseudo-tubular structure.*

Rebecca Boddy, aged 62, married, was admitted into St Thomas's Hospital in December 1873, under Mr Sydney Jones, for a tumour of the right breast. The following notes were taken by me as Surgical Registrar. The patient has borne only one child, twenty-eight years ago. The right breast is said to have received a blow some time before the tumour appeared in it. The growth is now nearly spherical, about 2 inches diameter; it begins about $\frac{1}{2}$ inch to the axillary side of the nipple and extends horizontally outwards. Over its centre, about $1\frac{1}{2}$ inches from the nipple, the skin

adheres, making a very gradual umbilication, which is also slightly discoloured. The tumour moves freely upon the pectoral fascia. The rest of the breast is soft. The left breast is small or atrophied. The tumour, with the breast, was amputated on 12th December. On section it was firm, not very hard, of greyish fleshy appearance, finely granular or fibrillated, with much blood-pigment or extravasated blood dispersed through it. One large lymph-gland was dissected out from the axilla, opaque yellowish on section, with some hæmorrhagic lines or spots.

State of the Mamma.—The breast near the tumour was examined at two places, which both show the same kind of structure. It is nearly all fine fibrous tissue interrupted by small clusters of fat-cells, the remains of glandular structure being found at wide intervals. The latter are all of the same kind—collapsed milk-sinuses with rugous or folded walls, and tubular structures dependent from them or grouped around them, more or less branched and coiled. The epithelium is of the small columnar kind in a single row, somewhat irregular or incomplete. Everywhere the basement of plain muscular fibres is conspicuous and strong, both in the wider sinuses and in the lateral tubes; it is in direct contact with the fibrous stroma, there being no encircling band of submucosa, as in regular milk-ducts. The muscular ribs are seen both in the cross-section standing up with palisade-like ends, and in the face view as regular parallel bands, such as in fig. 59, Pl. X., drawn from the side of a milk-sinus partly denuded of its lining of small epithelial cells. This is a very clear case of the glandular structure that remains long after the climacteric period, being wholly of the primitive sweat-gland type. The appearance is uniform in two different sets of sections. There is little of activity in the tubes: the epithelium for the most part is merely nuclear, and is often in disorder; the structure is obviously compressed by the fibrous tissue around; the coils of smaller tubes have hardly a clear lumen, being as small as involuted acini; in some the central space has a concretion. There is a slight amount of infiltration of small cells into the connective tissue, with occasional large plump cells, mostly oval, which are coloured deeply by logwood, and are probably “Mastzellen.” The picture is that of obliteration or compression of tubular glands, in which the plain muscular fibres of the basement are well preserved.

Structure of the Tumour.—So far as my microscopic sections go, there are no gradations between the remains of glandular structure in the breast and the tumour. The latter is a thing apart, encapsuled in its own territory upon the axillary side of the breast; yet it has obvious relations to tubular-gland structure. In the most uniformly firm parts, with least amount of hæmorrhage or old blood-pigment, the whole field is occupied by alveoli set close together, lined or filled up by rows of epithelial-like cells, of which the basal row is elongated columnar with the bases of the cells in a very regular line sharply set off against the narrow bands of stroma (fig. 60, Pl. X.). Many of the alveoli are filled up with anastomosing trabecular columns of the fused cells (fig. 61); others have a lumen, not with a definite border as in a normal mucous gland, but vague and irregular as if by deliquescence of the marginal rows; in the lumen there may be some granular substance or plasma, mixed with large vesicular cells. If this structure be not that of an actual coil of greatly enlarged and blocked glandular tubes, as in the two preceding cases, it is a very close imitation of it. I am still doubtful whether there are not some remains of original tubes involved in the structure; and in one instance I have found the cloudy appearance of swollen muscular ribs in a piece of exposed basement membrane of the alveolus. On the other hand, the irregularities of epithelium, etc., which are inseparable from original glands disordered over a wide area, are wanting; the whole structure looks brand-new, perfect and finished of its kind, as if it had been minted or stamped with its character. Again, there are alveolar centres springing up in the stroma, which are certainly not original gland-tubes, nor outgrowths of their epithelium into the stroma. The structure is really *pseudo-glandular*, and is of the nature of sarcoma, which the naked-eye characters of the tumour might have led one to expect. It is a parablasic new growth, in which the cells have not only an epithelial habitus, as the elements of glandular sarcomas frequently have, but also a glandular arrangement, as will appear from subsequent cases. Two of the principal points of difference between that new structure and original glands are, that the tubes, or

imitation tubes, make an endless maze, and that the nuclei of the cells are very large in proportion to their protoplasm.

As all that remained of the breast, at the age of sixty-two, was glandular structure of the anomalous type in the more central parts, it may be assumed that the peripheral part towards the axilla, where the tumour was situated, had contained the same survivals, and that the new growth was in relation to them exclusively.

The same intermixture of epithelial-like tissue with true or original epithelium is found also in the class of mammary tumours called "duct papillomata." These are soft polypous masses growing into cysts, or thick convoluted laminae filling the interiors of cysts. Here the parablasic new growth, from perivascular connective tissue, is in close proximity to original epithelium, invaginating it or bursting through it. The projection of polypus-like knobs or tubers into the interior of tubes or their cystic dilatations is found also in the fibromata (*supra*, p. 116), where there can be no doubt as to the connective-tissue origin of the invading vascular loops. The origin is the same in the soft intracystic growths, but is masked by the epithelial-like character which the vascular ingrowth assumes. An instance of this kind of intracystic growth in the breast is recorded with an instructive figure by Bland Sutton (*Path. Trans.*, xliii. 1892, p. 117), which I reproduce for the sake of its bearing upon Case XIV.

A tall stout woman, aged 68, married, the mother of thirteen children, has been aware for two years of the existence of a tumour in the left breast. It has grown slowly and has caused no pain. There has been a free discharge from it of blood-stained fluid for the last six months, which has been more abundant of late, and a source of discomfort. The tumour is the size of a Tangerine orange, on the outer side of the nipple, the skin over it of deep red colour, smooth and tense, rising above the level of the skin around. The skin on its inner border forms a deep recess within which lies the retracted nipple. A small soft tuft of granulation-like tissue, resembling a small ripe mulberry, has projected through the wall of the tumour into this recess, and is probably the medium of the blood-stained discharge. The tumour, bisected after removal and hardening, was found to lie immediately under the skin, and to be bounded by a very definite wall, which the event proved to be the wall of a cyst, not an adventitious

capsule. The whole interior of the cyst was filled with a mass of soft tissue of a deep mahogany colour, which sprang from a broad base attached to the part of the cyst-wall next the skin. Microscope shows the mass to consist of villous processes of great complexity. They are solid cords, composed of epithelial cells, like those of warts growing from mucous membranes, some being almost columnar, many pyriform, but most spheroidal. The inner wall of the cyst, however, is lined by regular cubical epithelial cells.

The regular cubical epithelium of the cyst-wall would be the real and original epithelium, but the epithelial-like cells of the new growth are not, in my opinion, their direct descendants: they are of perivascular origin, and have burst through the wall of the dilated tube, or dilated saccular recesses of a coil of tubing, along with the loops of blood-vessels. Nothing is said in the above case of any other remains of the breast besides the supposed duct in which the "duct papilloma" had grown; and as the figure shows only a uniform mass of fat all round the tumour, it is probable that nothing but fat remained in the place of the breast, the patient being obese and her age sixty-eight. The following case is a very close parallel so far as concerns the intracystic situation of a sarcomatous tumour with epithelial-like cells.

CASE XIV.—*Intracystic Tumour on the Axillary Border of the Breast.*

Ann Cox, aged 36, widow, who had borne no children, was admitted on 27th January 1873 into St Thomas's Hospital, under Mr Le Gros Clark, for a tumour of the right breast. Six months before, she became aware of a lump in the breast about the size of a walnut, attended by some pain. It has grown somewhat, and is now a pyriform body, the rounded apex bulging out, the base deeply seated upon the thoracic wall. It is situated on the extreme axillary margin of the breast, or beyond it, and above the horizontal line of the nipple. Towards the axilla it has a precipitous side, which feels firm. The glandular tissue between the lump and the nipple has the usual granular feel. In the week following admission the tumour grew with great rapidity and burst through the skin, making a fungus with an ulcerated surface about two inches in diameter, fissured across the middle. The tumour, with the breast, was amputated on 6th February. During the operation the base of the tumour upon the pectoral fascia was found to be cystic, with intracystic growths which broke down on handling. The pectoral fascia was removed with it. The tumour was separated from the breast by an interval of loose tissue.

State of the Breast.—The breast contained several

anomalies, and but little of the regular lobular structure (in its involuted state). The principal irregularity was obvious on making an incision through the mamma adjoining the tumour, namely, a number of minute cysts the size of pin-heads, from which a clear brownish fluid escaped. These I made sections of within a few days, and found that they showed very beautifully the structure of dilated axillary sweat-glands, my specimens of 15th February 1873 being correctly labelled at the time "cysts formed by dilated sweat-glands." I gave drawings of the muscular basement membrane and of the mosaic of large protoplasmic epithelial cells in *Med. Chir. Trans.*, lxxv. 1882, and give here a new drawing of one of the larger clusters of the dilated and sacculated tubes under a low power (fig. 62, Pl. XI.).

The tubular coils situated in the *corpus mammæ* are only the most conspicuous of several anomalies. There are some regular involuted lobules, spherical or pyriform groups of acini, making the usual seed-like bodies set at intervals in the midst of the fibrous stroma: the acini show usually a broad hyaline zone with a small heap of irregular nuclei enclosed by it; where this change has extended farther, the whole lobule is invaded and possessed by homogeneous fibrous tissue, so that it looks like a small fibromatous knot such as in fig. 31, Pl. VI. In many of these small glandular islands the acinous structure is hardly apparent, but only the framework of a branching tube. The same sections

DESCRIPTION OF PLATE X.

FIG. 58. From a tumour of blocked tubular glands near the breast, Case XII. The plain muscular fibres of the basement are split into bundles of fine parallel fibrillæ, like packets of needles. Remains of a septum, with granular epithelial cells upon the basement on both sides. Vesiculated connective-tissue cells (myxomatous) in the fibrous wall. $\times 150$.

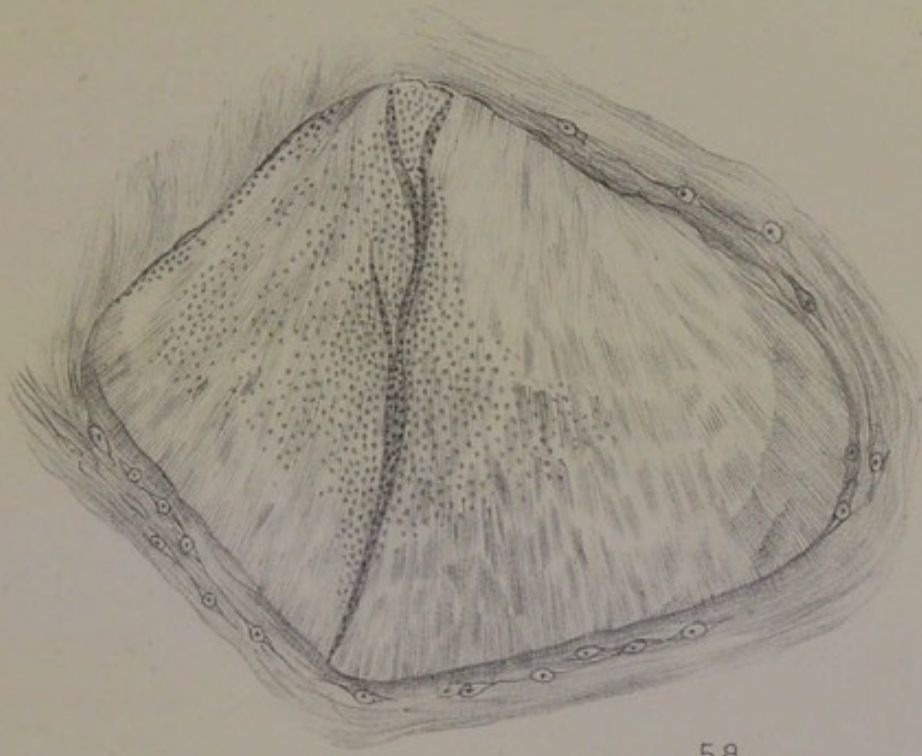FIG. 59. Wall of a milk-sinus from normal *corpus mammæ* of Case XIII. Parallel muscular fibres of the basement, with epithelial mosaic at upper end. $\times 300$.

FIG. 60. Structure of the tumour in Case XIII.: pseudo-tubular sarcomatous new growth. $\times 50$.

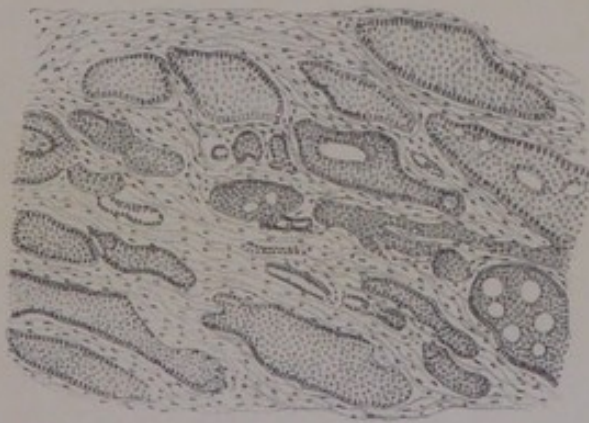
FIG. 61. High-power view of single alveolus from the same. Trabecular columns of epithelial-like cells with large nuclei and fused protoplasm. Columnar arrangement of basal row. $\times 150$. Text, p. 149.

Plate X.

Intratubular Tumours.



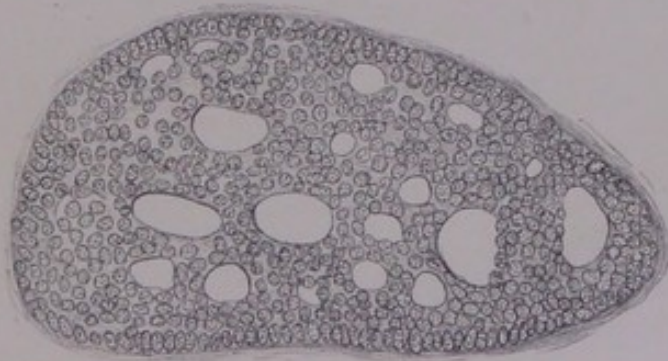
58.



60.



59.



61.



contain several milk-sinuses, with the distinctive rugous walls and mosaic of small deeply stained epithelium; some of the sinuses show branching diverticula or dependent tubes ending blindly, and, in the cross-sections of such tubes near the wall of a sinus, the basement of plain muscular fibres is seen clearly. The predominant structure is tubular, with terminal ampullæ, but with little of the full acinous development, the patient having borne no children.

Intermediate between these ill-developed mammary structures (which might be expected in a virgin breast or in that of a childless married woman) and the thoroughly anomalous sweat-glands of the axillary type, there were certain islands of glandular substance which were obviously coils of tubing, but were not sacculated or dilated. In section, these coils look like a rete of epithelium-lined spaces, separated by narrow tracts of stroma, the fibres of which have a peculiar glance and hardness. I have found these glomeruli in several breasts, close to the typical kind of sweat-glands; they are the coils shown at two places, *cc'*, of fig. 65, Pl. XII., and are the same that are referred to at p. 33 in a breast without tumour. The thickness of the epithelial lining, which is somewhat characteristic of that kind of tubing, might mask the presence of a muscular basement, as indeed it does often in undoubted sweat-glands of the dog's skin; but I believe that the muscular fibres are really wanting in that situation, and that they are present in the stroma, in the bands of hard, glistening fibrous tissue which encircle the tubes and arch over their windings (see fig. 133, Pl. XXIII.). According to Henle (*Anatomie*, ii. p. 36) the axillary and other large sweat-glands have their muscular fibres distributed in either way: "Entweder als Längsfaserhaut dicht auf den Wänden der Drüsenkanälchen, oder gerade gestreckt über deren Windungen, oder in manchfaltigen Richtungen die Räume zwischen denselben ausfüllend." The several anomalous structures of this breast—the perfect sweat-glands, the other glomerular clusters, and the ill-developed mammary lobules—are all in a more or less morbid condition, the sweat-glands being dilated and occupied with papillary excrescences of very

large epithelial cells, the rete-like coils of tubing also in a more uniform hyperplastic state of their smaller epithelial cells, and the lobules, or scattered fragments of lobules, penetrated with so much hyaline or homogeneous fibrous tissue as to be almost fibromatous. It is in the first of these, the true muscle-walled sweat-glands, that the seat and cause of the actual tumour has to be sought; and I should suppose that it had arisen in an outlying cluster of them developed upon the end of a milk-sinus in the axillary expansion of the breast, or in a situation where the tubular glands of that type are apt to form in lieu of proper mammary structure. The situation of the tumour in respect to the breast is, indeed, explained perfectly by the case described at p. 33, in which there was no real tumour, but an island of sweat-glands, of the size and shape of an almond, joined to the base of the breast on the axillary side by an isthmus of connective tissue.

Structure of the Tumour.—The new growth broke down on handling during the operation; but it was seen clearly to be intracystic and had almost certainly the same naked-eye relations as in the case given from Sutton (*supra*, p. 150). The structure of the firmer parts examined is a uniform and characteristic one: it is a sarcoma of very large spherical or cubical or pyriform cells in sinuous columns, the plan of the whole being clearly perivascular (fig. 63). The cells are epithelial-like, with an enormous vesicular nucleus, sometimes a pair, containing several nucleoli deeply stained, or in a highly mitotic state. They form belts three or four or more rows deep, the row next the wall of the blood-vessel being more columnar or basal, while the other margin is irregular from granular or mucous degeneration of the cells, which shade off into areas of mucinous plasma or ill-developed myxomatous tissue. A column in cross-section looks like a collar of large epithelial-like cells, three or four rows broad, round a large central vein, with a zone of granular or mucous detritus on its circumference. Diagrammatically one might arrive at this structure by developing enormously the vascular stems of the villous growths of epithelium on the walls of the dilated sweat-glands in the non-tumour part of the breast:

such soft warty excrescences occur at two or three places in the cluster of tubes drawn in fig. 62 under a low power, and can be seen also in muscle-walled tubes lying close to the wall of a milk-sinus; again, the epithelium of the dilated sweat-tubes is very large, with mitosis of nuclei, and is undoubtedly the prototype of the epithelial-like cells of the tumour. Yet the pathology of the whole tumour implies something more: the walls of the vascular loops are rich in connective-tissue nuclei, which grow to a great size and acquire an epithelial habitus. It is from that inexhaustible source, and after the manner of the embryonic parablast, that the real tumour has grown; so that it is properly counted a sarcoma, as its naked-eye characters and clinical type would have suggested.

CHAPTER VIII.

SARCOMA.

A TUMOUR of the breast will be diagnosed sarcoma if it bulges out as a globular or ovoid or pear-shaped mass, carrying the nipple erect on its summit or at one side; distending the skin, which is often red or livid, glazed, thin, and ready to burst; having a definite rounded contour wherever it can be felt, nodulated or lobed, feeling tense or elastic, of rapid growth; or, if it has burst through the skin, making a bleeding fungus with overhanging edges, or a fleshy lobulated knob or *bouton* covered with a pellicle. On section it will be found uniformly greyish or fleshy, subdivided into definite round or oval lobes, or into convolutions, with a lobulated or scalloped margin, encapsuled, vascular, interspersed with areas of extravasated blood or of blood-pigment, or with opaque yellowish or sand-coloured tracts, or with friable necrotic centres; if there be much mamma left, it will probably be found borne upon the surface of the tumour at one or more sides as a distinct stratum. Microscopic sections will show masses of cells, probably of uniform type in a given case, supported or penetrated by a vascular stroma, which makes septa between the lobes or lobules and runs out irregularly into fine points, or forms a reticulum with equal meshes. The cells, which have always a relatively large nucleus, are usually fused in larger or smaller groups into a tissue, being in some cases small spheres, in others very large spheres or cubes with extensive nucleus or pair of nuclei vesiculated or full of nucleolar particles; in still other cases the cells are polymorphous, including such as the last, mixed with many small cells and with elements like the halves of plump spindle-cells, or with giant-cells (myeloid); or, lastly,

they may be somewhat uniform spindles, large or small, in decussating bundles. In rare cases, where the mammary tumour concurs with a number of pigmentary moles of the skin at large, the sarcoma may be melanotic in places. Where the contiguous cells are not fused by their protoplasm all round, they may either lie in fine meshes of a reticulum as nuclei bathed in a juice (lymphosarcoma), or they may be joined in a mucus-containing tissue by longer or shorter processes (myxosarcoma).

Although sarcoma of the breast has a well-marked clinical individuality, being rapid or acute in its course and peculiarly apt to reappear time after time, yet it is rather the sequel or complement of some earlier morbid condition of the organ than an original disease. Firstly, and most fundamentally for theory, every sarcoma of the breast has a tubular-gland element which is essential to its existence. But, in a more clinical respect, there are many cases of it which are the eventual acute stage of some chronic tumour. One or more fibromatous knots, which may have existed for years, begin suddenly to grow, perhaps about the time of the menopause, or after a blow or other excitation, and become sarcomatous. Slow cases of scirrhus, also, become acute, or begin to grow larger; and those are the tumours, not infrequent, which have a central part dense and tough, traversed in all directions by fibrous bands making the alveolar structure of scirrhus, and an outer zone of uniform lobulated sarcoma recently added by the annexation of new vascular territory. Again, serous cysts of the breast become invaded by soft poly-pous masses which are as truly sarcomatous as they are vascular.

It is this character of sarcoma in the breast, as the complement or attendant of something else, that has made it common enough in histological specimens, and yet comparatively rare among classified cases. Paget could recall only four cases of "firm medullary," or sarcomatous, tumour in that organ; but when he comes to divide scirrhus or common cancer into acute, chronic and intermediate, he describes the acute as approximating in all respects to the character of medullary cancer. Again, in the original Dublin work of

Maurice H. Collis (London, 1864) we read, p. 37 : " It is not common to find the entire of any large encephaloid tumour possessed of quite uniform consistence ; . . . in other cases again, encephaloid springs up in a nidus of scirrhus, so that both types are plainly to be seen in one specimen, and the gradations from one to the other can be studied ; such specimens are by no means uncommon in the later stages of ordinary scirrhus." Two of his three cases of " encephaloid " of the breast were rapid developments of small tumours which had existed for years (the third having formed in the situation of a milk-abscess of ten years before), and one more case of " encephaloid engrafted on scirrhus " in the breast is given under the latter head. Billroth remarks, under the head of " Fibroma and Fibro-sarcoma," that such tumours may endure for years and then become cancers : " the statements of many women are precise as to that." But it is probable that acute cancers, or sarcomas, are meant. As an instance of the proportion assigned to sarcoma among mammary tumours of every kind (in the more recent lists of operations on the breast it is not distinguished at all), I take the following reported by H. Haeckel (in the preface to a histological paper) from the hospital and private practice of Riedel at Jena from 1888 to 1893 : 149 operations on the breast, of which 105 were for carcinoma and 3 for sarcoma (1 of them melanotic). Such a proportion hardly does justice to the share of sarcomatosis in the breast, even from the clinical side. As regards pathology, it may indeed be only a matter of names ; for, in the instances of the testis and the upper jaw, one pathologist (Langhans) will describe nearly all his cases (to the number of a score or more) as carcinoma, while another (Lubarsch) will describe them as sarcoma, both being conscious all the while that they are dealing with the same run of cases ; also, in the instance of the breast itself, a whole series of cases, for example the eleven described by G. B. Schmidt, may be given as " angiosarcomata " (and in my opinion correctly), which would, most or all, have passed with others as " spheroidal-celled carcinoma," or some of them as " duct cancer." But the practical notion of sarcoma of the

breast, containing as it does the ideas of rapid increase by marginal extension, high degree of vascularity, recurrences, etc., remains unaffected by pathological definition. The relation of this clinical type to the type of scirrhus, which is so peculiarly the tumour-disease of the breast, is a question of real importance for the theory of both. The sarcomatous element comes obviously into several of my cases of scirrhus, which I shall take in this chapter, after I have given a typical case of sarcoma at the outset.

CASE XV.—*Encapsuled Sarcoma of the centre of the Breast.*

Middle-aged woman admitted into Addenbrooke's Hospital, Cambridge, in July 1879, under Dr Carver, for a tumour of the breast. The growth was globular, projecting above the level of the dusky intact skin, carrying the unretracted nipple near the middle of its convexity, about two inches in diameter, definitely encapsuled. No enlarged axillary lymph-glands. On section it had the firm, uniform greyish appearance of sarcoma in the marginal zone, an extensive area of necrosis at the centre and base, with hæmorrhagic and opaque yellowish areas extending into a region of shreddy intermediate tumour-tissue next to the necrosis. There was a considerable amount of mammary gland, consisting of close-set seed-like lobules, borne upon the upper sides of the globular mass. Immediately under the nipple and areola the encapsuled tumour was separated from the skin by a layer of loose connective tissue.

Structure of the Tumour.—The elements of the new growth were somewhat uniform throughout, namely, the same epithelial-like cells, with relatively large nucleus, which have been described in the two last cases, being joined by their protoplasm into belts, broader or narrower, or into alveolar masses, with the structure sometimes clearly trabeculated. This is the kind of structure associated with the old class of "medullary cancer of the breast," which could be shown upon the cylindrical masses of cells, or of nucleated protoplasm, from scrapings of the cut surface (see the figure in Billroth's *Chirurgische Pathologie*, fig. 159). Round the growing margin the tumour is not at all medullary, but a firm lobulated or convoluted new growth, which yields fine sections of large extent holding well together. It is the structure shown in fig. 64, Pl. XII., drawn under a very low power. The sinuous course of the belts, some ten or twenty

cells broad, is like that of cerebral convolutions in miniature, the concavities, or centres, of the folds of sarcoma being occupied by vascular connective tissue in which the channels of considerable vessels are seen occasionally. This is the characteristic structure of the cortex, which appears to arise within the capsule and to form lobules upon its exterior, so that it is constantly stretched and extended by new centres of growth. When sections are treated with acid fuchsine, there is brought out, in some places much more than in others, a very minute penetration of the belts or cylinders of epithelial-like cells by fine points of deeply stained vascular tissue, which may amount to an actual reticulum supporting the individual cells, but more commonly stop short at spear-like points projecting into the mass. Although this tissue has all the look of being vascular, yet it is hardly possible to find in it the open channels of vessels or capillaries—a peculiarity which was noted by Billroth, even in injected specimens, in his original account of alveolar sarcoma (*Archiv für klin. Chirurg.*, xi. 1869, p. 246), and has been reaffirmed by Ribbert for the vascular connective tissue which grows into the masses of cells in epithelioma of the skin (*Virchow's Archiv*, cxxxv. 1894).

The theory of this kind of sarcoma, as stated by Kolaczek for tumours of the upper jaw (*Deutsche Ztschr. f. Chirurg.*, ix. 1878, and xiii. 1880), and adopted by G. B. Schmidt for angiosarcomata of the mamma (*Archiv für klin. Chirurg.*, xxxvi. 1887, p. 421), is that the plan of structure is essentially perivascular, having started from the perithelia of capillaries, which become obliterated by the pressure of the cellular growth in their walls, but remain traceable for a time by their axial nuclei. I shall return

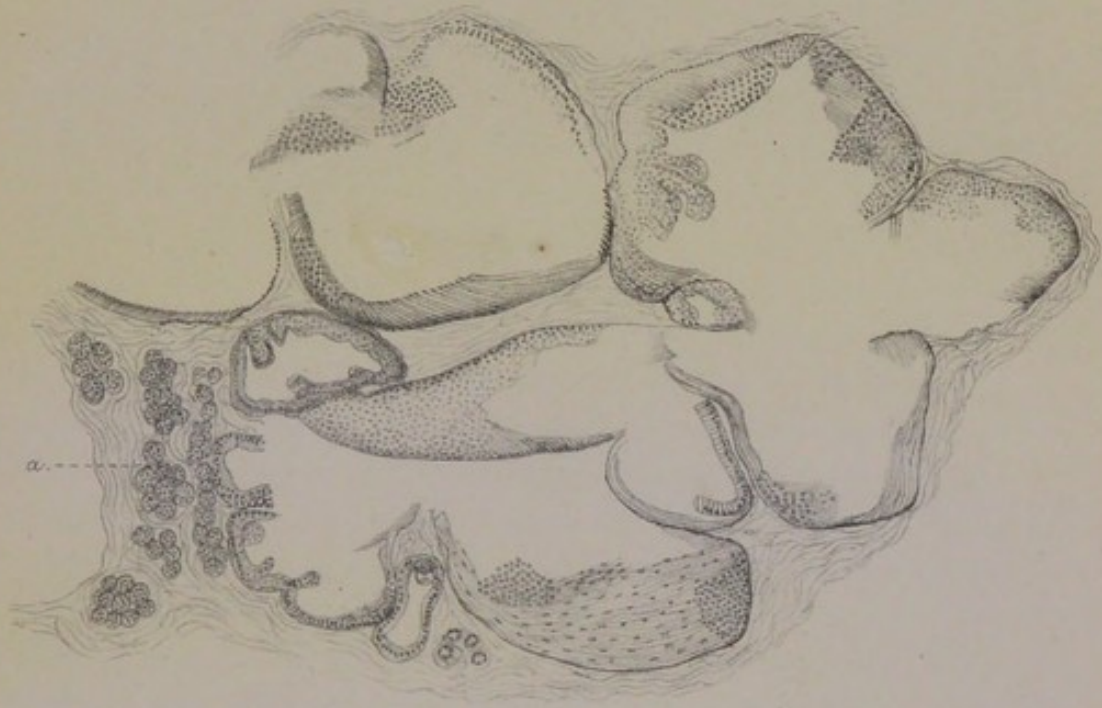
DESCRIPTION OF PLATE XI.

FIG. 62. Dilated sweat-glands forming minute cysts in *corpus mammae* of Case XIV. Muscularis seen in continuous sheets in the walls of several alveoli. Epithelium papillated at places. *a*, group of normal mammary acini. $\times 50$.

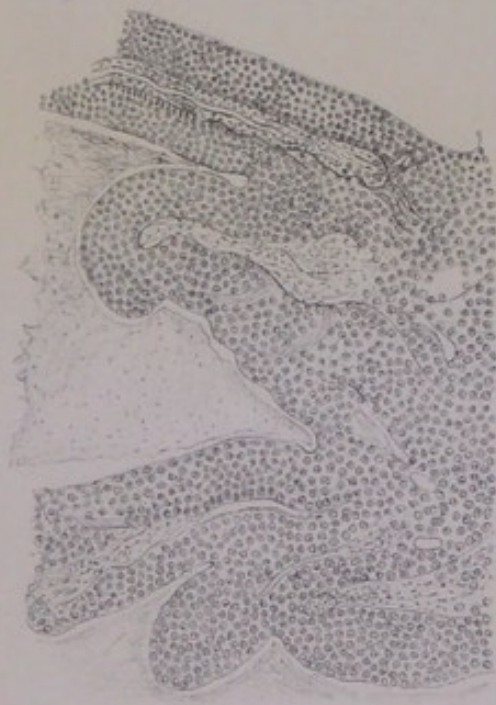
FIG. 63. Perivascular convolutions of epithelial-like cells, forming the intracystic papilloma of Case XIV. $\times 90$. Text, p. 154.

Plate XI.

Intracystic Sarcomatous Papilloma.



62.



63.



to that theory in connection with sarcomatous tumours in the dog (Chapter X.); and will merely remark here that the explanation of angiosarcomata of a glandular organ or part, as it has been left by those authors, hangs loose at both ends:—inasmuch as Schmidt leaves the initiation of the sarcomatous process in the walls of capillaries as “an unexplained fact”; whilst Kolaczek, recognising candidly that the new growth often simulates tubular glands which may even have parietal epithelium and a “lumen still preserved,” passes from the epithelial type of the sarcoma with the brief admission, that it is “nur ein interessantes Phänomen bei der Gefässmetamorphose in Geschwülsten” (*l.c.*, p. 180). The complete theory of these sarcomata I believe to be, that original tubular glands become blocked by their own epithelium, or pressed upon and obliterated altogether, and that a compensatory action arises in the vascular stroma, of which the most perfect morphological result is a new growth of tube-like cylinders or columns of cells simulating the type of the effaced original gland-tubes. It is a *parablastic* new growth, complementary to an archiblast which had been superseded by disease.

In the central and older parts of this sarcoma there are several special features. The deeper region of it, where the process probably began, is necrosed over an area of nearly a square inch. Joining on to the necrosis is an area of still vigorous but somewhat shredded tissue, which cuts into microscopic sections with difficulty; there are patches of hæmorrhage in it, one or two small spots of undoubted hyaline, an approximation to myxosarcoma in the linear rows of cells with lacunæ between them, and a deposition of animal starch at certain places. The glycogen, as is usually the case in tumours, is curiously partial in its distribution. It was clearly proved by iodine; and I have it still clearly shown in old specimens stained with methylene blue and bleached by absolute alcohol almost to general colourlessness, the distribution of the glycogen grains being marked by deep blue in a pale ground.

State of the Mammary Gland. — The fundamental interest, in this as in all other forms of tumour in the

breast, is the relation of the new growth to the original glandular structure; it explains nothing merely to regard the stroma of the breast as subject to the same risk of sarcoma as the periosteum, or the fascia, or the dura mater, or the medulla of bone, or the connective tissue of the skin; it would explain nothing even if there were no pseudo-glandular new growth to be reckoned with. Some disorder of the organ is at the root of the tumour-disease, and at the root of that disorder there are anomalies of development.

At one side of the tumour there is a stratum of mamma, with a maximum thickness of three-eighths of an inch, which is seen at once to be in a normal state; it consists of a very large number of uniform small lobules close together, with little fibrous tissue between them, the whole making a clear contrast with the tumour-area. Some of these lobules are well developed, with many small involuted acini; others show more the pattern of a branching tube with terminal saccules. Elsewhere there is much mammary structure of a less well-developed type. The branching tubular forms, described in the Introduction, are very common, fig. 8, Pl. II., being drawn from this case: they can be seen with a lens lying as if naked in the stroma, contrasting plainly with the rotund or ovoid lobules within capsules. They do not appear to be in an active state, their epithelium being mostly nuclear and not heaped up; but the stroma in which they lie becomes invaded by the sarcomatous process more readily than that around the regular seed-like lobules, so that they become absorbed into, or lost in, the area of the new growth. The active anomalous structures of this breast, as of others, are coils of tubular glands, the larger of which have the muscular basement very clear; and these are the only glandular structures which are in a state of disorder. So far as concerns everything that can fairly be called mammary, it is passive, and merely invaded by the connective-tissue new growth.

The coils of large muscle-walled sweat-glands are discovered most easily at certain places upon the periphery of the breast (or of the tumour), being dilated, as they are usually in that situation, and with their muscular ribs beautifully

distinct. They are not, however, in a merely cystic condition. Where found, they are usually blocked with club-shaped processes of their epithelium, which is large and protoplasmic; in the profile view, the papillary processes meet, or almost meet, by their free ends in the centre of the tube, whilst in the face view they show the optical section of six or eight or more upstanding cylinders. Contrasting with this morbid condition of coils of sweat-glands within the breast, there is a normal or regular deposit of the same wide tubes in the loose tissue at the base of the nipple (and outside the capsule of the tumour), looking exactly the same as the coil in fig. 5, Pl. I., drawn from the subareolar glands of another case. But the morbid coils of sweat-glands are developed as part of the mammary system, being in lieu of regular lobules. They are not only found in juxtaposition to structures recognisable as mammary, but they are mixed up with these in such a manner as to be parts of the same terminal territory of the breast. This strange intermixture of structures is shown in fig. 65, Pl. XII., which has been drawn accurately to scale under a very low power, from a spot on the margin of the breast about an inch to one side of the nipple. There are three kinds of glandular structure in this area (about one-quarter of an inch long, natural size), each of which occurs twice over: namely, two spots, *a a'*, of the branching rudiments of mammary lobules, which are seen merely as thick lines and points at this magnifying power, surrounded by much fine or hyaline fibrous tissue; two clusters, *b b'*, of dilated muscle-walled sweat-glands at either end of the section, one of them next the surface forming a small cyst, while several of the others are filled with papillary excrescences of their large epithelial cells; and, thirdly, two clusters, *c c'*, of coiled tubular glands, which are distinguishable from the wider muscle-ribbed tubes in several respects. The last are the same kind of glomeruli that have been mentioned before at p. 153. They are of not unfrequent occurrence among the anomalous structures of the breasts of women, making considerable islands, which can be distinguished from the deposits of the larger sweat-glands by the regularity of their double belt of epithelium, by its

different staining, by the absence of an obvious basement of plain muscular fibres, and most of all by the peculiar glancing fibres which encircle the several tubes and characterise the stroma of the whole island, looking under the microscope as if they were plain muscular fibres distributed through the stroma instead of in the basement membrane. My impression of this breast, after making sections from many places round its periphery, is that comparatively little of it has developed after the regular acinous type: there are many branching forms, which are the mere rudiments or skeletons of lobules; there are coils of large sweat-glands with muscular fibres; and there are some which have virtually the structure of sweat-gland coils, with the plain muscular fibres in the stroma instead of in the basement of the tubes.

All those varieties of gland stand in the same relation to the milk-sinuses: they are all alike their terminal developments. Large sinuses, with the kind of contour distinctive of such, are found extending close up to the margins of the organ. In fig. 66, Pl. XII., I have drawn in outline correctly to scale the situation of a milk-sinus with respect to a branching mammary lobule on the one hand and to a deposit of sweat-glands on the other, the whole section being from the extreme margin of the breast. This exten-

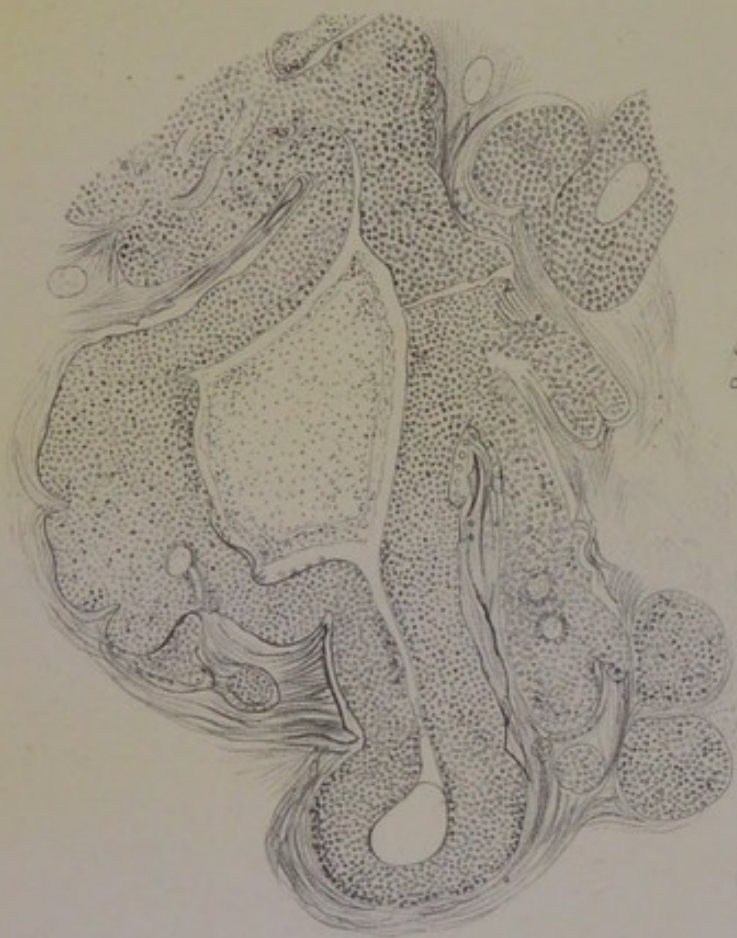DESCRIPTION OF PLATE XII.

FIG. 64. Lobulated margin of Sarcoma, Case xv. Convoluted cylinders of epithelial-like cells. Perivascular structure seen at some places. $\times 40$

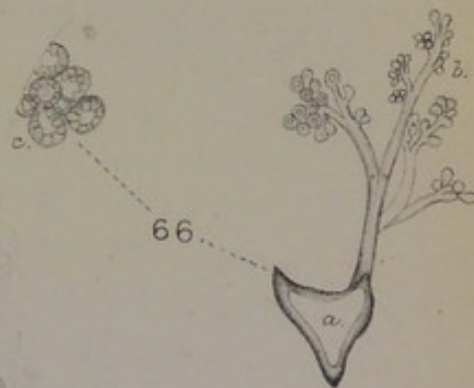
FIG. 65. Glandular island within upper margin of the breast, half an inch to one side of nipple, in Case xv. Three kinds of glandular structure: *a a'*, areas of rudimentary branching mammary lobules; *b b'*, areas of dilated sweat-glands with muscularis; *c c'*, areas of coiled tubular glands without muscular basement, but probably with plain muscular fibres in the stroma. $\times 20$.

FIG. 66. Diagram showing the relation of a deposit of sweat-glands, *c*, to a milk-sinus, *a*, with its branching tubular mammary lobule, *b*. From the margin of the breast in Case xv. $\times 10$.

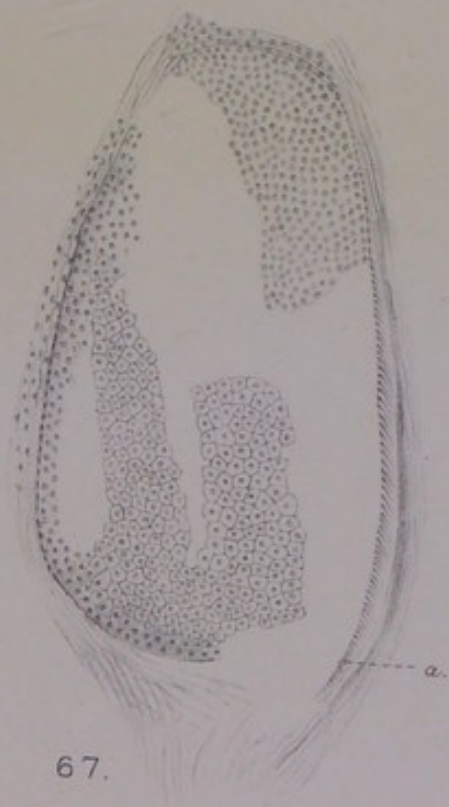
FIG. 67. Dilated sweat-tube from centre of *corpus mammæ* in Case xv. *a*, the muscularis basement seen endwise. The parietal layer of epithelium, seen in the face view in the middle of the figure, is polyhedric, with deeply staining protoplasm and normal nuclei. At the other end the epithelial cells are fused in a mass with relatively large nuclei. $\times 150$.



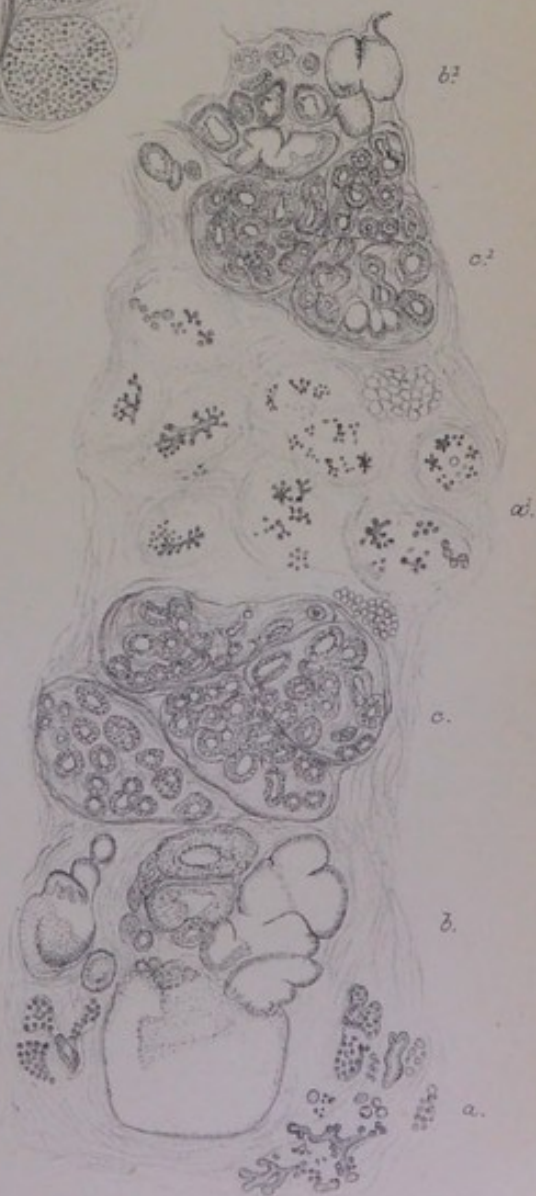
64.




66.



67.



65.



sion of sinuses far towards the periphery is what I find commonly associated with the anomalous glandular developments (*supra*, p. 139). Sections of milk-ducts are also met with; and these, it is worth noting, have sometimes the double row of epithelium very marked, the basal nuclei appearing to be separated from the surface row by an interval, as one finds also in the glandular tubes of fibromata or fibro-adenomata.

Thus far I have been referring to the condition of the breast round the margins, where the full lobular development is most likely to be found. I come next to the central part, or *corpus mammæ*, which is always more fibrous, and is more apt to contain certain rudimentary or ill-developed glandular structures in the average case. In this case, it is probably the *corpus mammæ* that had been the earliest seat of the tumour, inasmuch as degeneration of the new growth is most advanced there. This is the part of the breast in which an alveolar structure will usually be found in a new growth, whether it be scirrhus or sarcoma. The peculiarities of the sarcoma in it in the present instance have been referred to at p. 161. The difficulty here is the same as in one of the cases in the last chapter, namely, to distinguish original gland-tubes, blocked by their epithelium, from the pseudo-glandular structure that arises in the vascular stroma by the side of them. In some breasts the muscular basement of the tubes is so well preserved, or even hypertrophied, that it is easy to identify certain alveoli as the sections of original tubes; for example, in the case of hyaline tumour at p. 132, and in some of the cases to follow. From the centre of this breast I have chosen one alveolus to draw, in fig. 67, which can be identified as an original sweat-tube by two things: first, the very perfect mosaic of hexagonal epithelium with the nucleus in the usual normal proportion to the protoplasm; and, secondly, the basement of plain muscular fibres, which can be seen clearly enough, with the ends standing out obliquely, around the right border. The interior of the tube appears to be filled with cells of a more nuclear type fused into a mass, which is the structural type of the sarcoma itself. The original tubes (sweat-glands) are not always dilated and

blocked with epithelium; they may be compressed and obliterated on the one side of a coil, and widely dilated on the other; or a long stretch of tubing may be reduced to a mere cloudy outline by the necrosis both of its epithelium *en masse* and of its basement. In some sarcomata this total decay and obliteration of tubular glands is the real antecedent of the parablasic new growth, as I shall show in the instances of sarcoma springing up in relation with the sweat-glands of non-mammary regions of the dog's skin.

The above case of sarcoma was of uniform consistence throughout, being of the same fleshy texture in the centre, corresponding to the *corpus mammæ*, as in the marginal zone the naturally dense tissue of the former being made soft and uniform by the extent of the sarcomatous masses and by the large type of the epithelial-like cells: the actual difference between the earlier centre of disease and the later circumference, is that the former is in great part necrosed and hæmorrhagic. I shall give in the sequel other cases of sarcoma which were of uniformly soft texture. But most of the cases of sarcoma in the breast which I have collected are not uniform throughout; they have a dense, tough elastic centre like scirrhus, corresponding to the *corpus mammæ*, and an extensive marginal zone or lateral mass, which has the purely cellular lobulated texture of sarcoma. Whether this be called scirrhus taking on an acute type, or "medullary" cancer arising upon a nidus of scirrhus, it is a not uncommon complication.

CASE XVI.—*Sarcoma with dense alveolar Centre.*

Mrs W. —, aged 48, married, mother of seven children, the youngest of whom is six years old, was admitted into the Temperance Hospital, Hampstead Road, under Dr [Sir William] Collins for a tumour of the right breast, which was amputated on 25th June 1901. The left breast is subject to periodical diffuse indurations which subside after a time. The tumour, rather smaller than a hen's egg, was seated deeply in the upper half of the breast, in an oblique line inclining towards the axillary quadrant, with its upper end forming a rounded projection as if beyond the margin of the breast, 3 inches above the nipple, and its lower end lost in the *corpus mammæ*, about 1 inch above the nipple. The dimensions, when removed,

were 2 inches \times $1\frac{1}{2}$ \times 1. It felt very hard, and was diagnosed scirrhus. There were no enlarged glands in the axilla. Certain appearances of the tumour after its removal led Dr Collins to pronounce "sarcoma." Its upper border was rounded, but not lobulated, making a nearly regular line with the fat; the lower limit was also fairly definite, owing to the presence of lobes of fat between it and the centre of the breast. The whole of its base rested upon the pectoral fascia. When it was divided transversely, the cut surfaces cupped after a minute or two, the lower to a remarkable extent, so that the half of it which remains *in situ* next to the *corpus mammae* still retains a concavity after fixing in bichromate of potash. The cupping arises from the density and elasticity of the centre in contrast with the sarcomatous texture of the circumference.

State of the Breast and the Relations of the Tumour to it.—

The patient having borne seven children, and menstruation still continuing at the age of forty-eight, a good deal of extant mammary structure was to be expected. There are many developed lobules, some of which are large, containing many acini in an ordinary state of involution. There are also lobules of the rudimentary branched kind, which are distinguished from the others by the want of a capsule. Fibrosis has invaded much of the breast, making the central region extremely tough and hard to cut, and reducing the extreme peripheral parts to coarse fibrous tissue mixed with fat. In certain of the well-developed lobules the process of effacement by hyaline fibrosis can be traced through various stages (compare fig. 53, Pl. IX., and figs. 114 and 116, Pl. XXI.).

But a large proportion of all the glandular structure which still remains is of the anomalous kind, and is perhaps the more conspicuous owing to fibrous change of the regular mamma around it. Tubular glands with muscular basement membrane are to be found at many points, both central and peripheral. They constitute the involution-cysts already described for this case (*supra*, p. 90). They are easily detected with a lens, in the form also of groups of loculi, which have usually the appearance drawn in fig. 62, Pl. XI., from another case, with small lobules of regular involuted mamma in the same relation to them as in that figure. These loculi occur very frequently in the dense *corpus mammae*, where they lie close to the walls of the milk-reservoirs; they are found also on the periphery, again in close relation to the ends of the

milk-sinuses, which penetrate to the very margins of the breast. Thirdly, the coils of tubular sweat-glands are found sometimes as spots of compact "parenchymatous" structure, distinguishable also in the midst of the fibrous tissue by a brown shade of colour. One of these is drawn under a very low power in fig. 68, Pl. XIII., from the sternal margin of the breast: it lies, *a*, not far from a large milk-sinus, *b*, to which it belongs; on the right of the sinus is a complete mammary lobule, *c*, containing a very large number of regular acini, which are mere points at this magnifying power of 20. In these islands of soft brown substance the coil of tubing is filled with epithelium in several rows, or in papillary excrescences of columnar cells, which is a usual type of cell in the sweat-glands. The lower layer contains elongated cells, the next layers are more cubical, and the whole are somewhat smaller than the epithelial-like cells of the last case and of the intracystic tumour in the preceding chapter. In those several cases the cells of the sarcomatous new growth have reproduced the type of the sweat-gland epithelium somewhat closely, the epithelial *habitus* being common to them all, while the size and form of the sarcomatous cells have varied.

In this breast it is always the tubular glands with muscular basement that are found in disorder, whether dilated to cysts, or sacculated to form a congeries of loculi, or with their interior blocked by epithelial cells. The milk-sinuses, from which these coils depend both in the centre

DESCRIPTION OF PLATE XIII.

FIG. 68. From the sternal margin of the breast in Case XVI. *a*, island of large sweat-glands with thick papillated epithelium; *b*, one-half of a milk-sinus with angular recesses; *c*, encapsuled mammary lobule consisting of small tubules with narrow lumen; *c'*, indistinct mammary remains. $\times 20$.

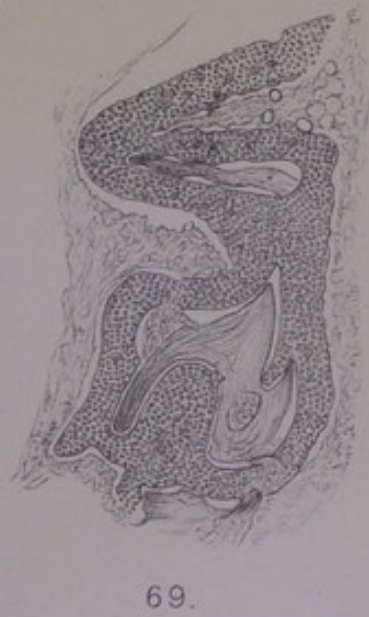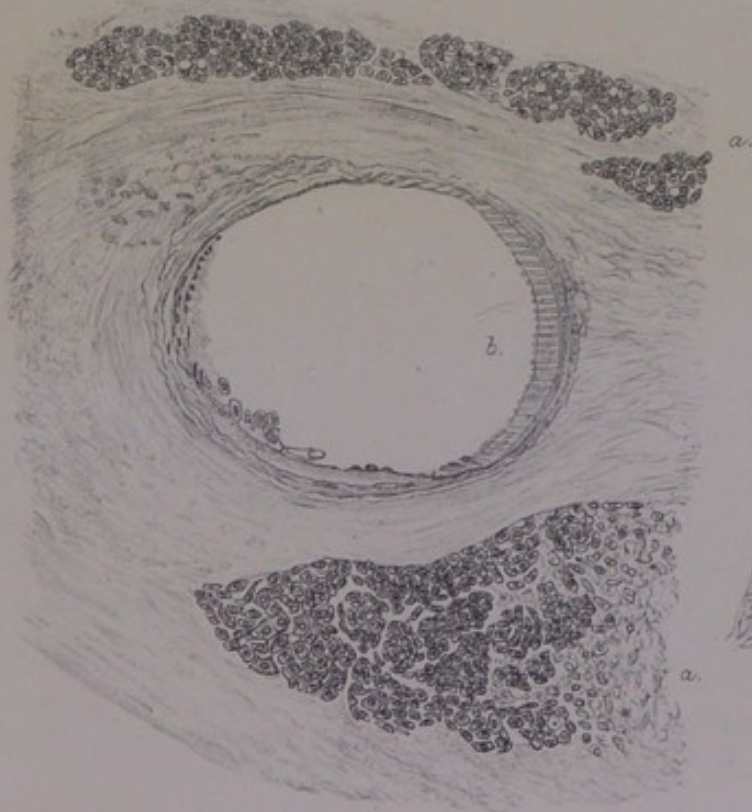
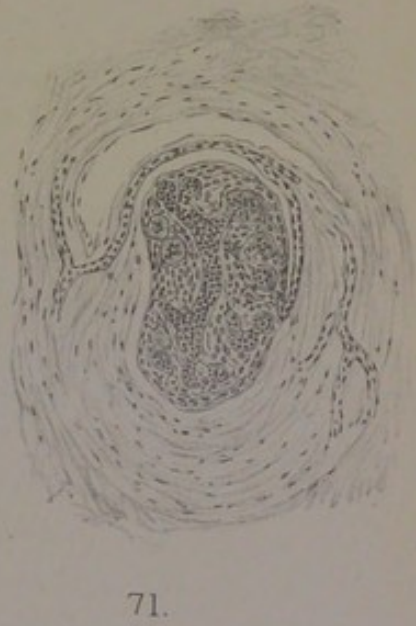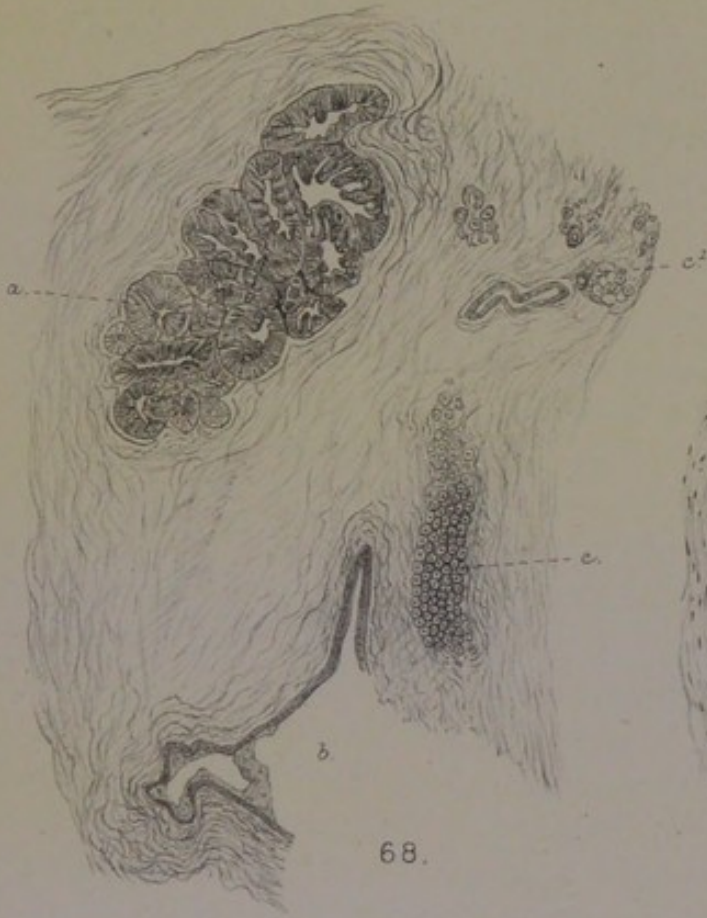FIG. 69. Structure of the sarcoma in Case XVI. Sinuous columns of epithelial-like cells, with tracts of vascular stroma in the intervals between them. $\times 70$.

FIG. 70. Parablastic new growth of epithelial-like cells, *a a'*, around an original muscle-walled tube; *b*, myxomatous state of the stroma next the wall of the tube. From the *corpus mammae* of Case XVI. $\times 150$.

FIG. 71. Encapsuled mammary lobule from Case XVI. Sarcomatous state of the stroma within the lobule, with hyaline zones around the tubular acini. $\times 120$.

Plate XIII.

Case XVII. (Sarcoma.)





and in the periphery of the organ, have also the anomaly of a longitudinal coat of plain muscular fibres; but their epithelium is of a smaller kind, and does not accumulate in layers as that of the functional tube does. Again, some of the mammary lobules have certain of their acini or terminal cæca dilated; but the dilatations are of a very characteristic kind, such as are met with often even in normal virgin breasts, being perfect hollow spheres two or three times the size of the ordinary acinus, lined by a single layer of small flattened cubical epithelium which makes a regular mosaic and implies no disordered function. In the mammary lobules near the growing margin of the tumour, a certain kind of cellular activity is going on, which has played a great part in the pathology of "acinous cancer" (Billroth). In my opinion it begins always in the stroma (*infra*, p. 170).

The relation of the tumour to these anomalous tubular glands, and to their state of disorder, can be proved in detail. So far as regards the localisation of it, there are sweat-glands in all parts of the breast, some even blocked by epithelium in places beyond the tumour-area, for example, in the margin from which fig. 68 was drawn. But they are most abundant in the dense tissue of the *corpus mammæ*, to which the tumour is fixed at the lower end; and they are actually found in large coils within that part of the tumour itself. The probability is, that the deposit of them was greatest, or that the disorder of them was greatest, on that side of the breast where the tumour has grown, namely, the axillary.

Structure and Origin of the Tumour.—Excepting in its denser more fibrous centre, the tumour would be admitted to be sarcomatous by everyone. The growing marginal zone consists of extensive tracts of cells, which have sometimes an obvious perivascular grouping, and are penetrated by fine points of vascular tissue. I think it not superfluous to draw for the third time the characteristic structure of sinuous belts and loops, which is often found in sarcomata of the breast (fig. 69, Pl. XIII.). This is one of the most definite morphological types that the new growth attains. More usually the epithelial-like cells are massed in larger or smaller alveolar collections, separated by narrow tracts of stroma. In some

places the stroma is split up into mere threads by the interstitial development of the tumour-cells.

The alveolar plan of the new growth is to be found in those parts of the tumour where original tubes of the sweat-gland type are most abundant. They are numerous, as already explained, throughout the *corpus mammae*, and it is not difficult to identify them in the half of the tumour that adjoins it. They are dilated in some instances to a great width, with their epithelium forming a thick belt of cloudy granular cells retracted from the wall, in which the plain muscular fibres can be seen in certain favourable aspects. Collections of tumour-cells lie in the stroma all round these tubes, the relationship being that which is shown in fig. 70, Pl. XIII. (the epithelial contents of the tube have fallen out). The new growth in the stroma is not literally circumtubular as a rule, although occasional tubes are found with a zone of sarcoma all round them; it springs up usually alongside them, or over a continuous area parablatically to a whole coil of disordered or obliterated glands. Inasmuch as the new growth acquires the epithelial *habitus* of cells, and a certain regularity in its alveolar masses or sinuous columns, it follows that the masses of it lying in spaces of the vascular stroma may resemble the appearance of the blocked tubular glands near to which they have sprung up. In some fields this pseudo-epithelial structure may be the only kind.

The type of sarcomatous cell in this case is not quite the same in all parts. Certain spots have larger cubical cells with large nuclei; others have the cells more elongated; and in some places the type may come near to myxoma. In the last variety, the stroma appears to break up into many pieces of protoplasm, in each of which is a nucleus. Just outside the wall of the sweat-tube in fig. 70, the tissue is of the shreddy myxomatous kind, with short fibre-cells amongst homogeneous plasma.

The growing margin of the sarcoma extends into the fat, which becomes changed, along a somewhat regular advancing line, into epithelial-like cells obviously derived from the walls of blood-vessels. This encroachment is a uniform one, so that only occasional fat-cells can be seen within its area. In like

manner whole mammary lobules are annexed by the new growth. They are, indeed, drawn into the sarcomatosis sooner than the dense fibrous tissue amidst which they lie. This is a phenomenon often observed both in the human breast and in that of the bitch, and is followed most easily in those lobules that are little more than naked branching tubes. Fig. 71 shows the abundant production of spindle-cells in the stroma of the small circumscribed lobule, while the extensive tract of homogeneous fibrous tissue all round it shows only a limited number of long slender nuclei (when a nuclear stain is used). A common antecedent of this sarcomatosis of mammary lobules is a broad hyaline zone between the basement membrane and the central heap of nuclear epithelium. Sometimes the whole lobule is enveloped in a cloud of small spherical or elongated cells. Eventually the epithelial *habitus* appears throughout this new growth, and the lobule is annexed *en masse* to the tumour. It counts as so much parablast by virtue of its vascular tissue, if not also of the epithelial nuclei of its acini, becoming changed throughout into sarcoma just as it would have been changed throughout into fibrous tissue if it had undergone normal obsolescence.

CASE XVII.—*Large globular Sarcoma with dense alveolar Centre.*

Mrs —, aged between fifty and sixty, had a globular tumour of the breast removed on 6th May 1881, by Dr Carver, at Addenbrooke's Hospital, Cambridge. One lymph-gland, infected with new growth, the size of an almond kernel, was removed from the axilla, having two small glands like peas attached to it. The bulging surface of the tumour presses close against the skin, which is of dusky colour, but not thinned. The base is flat, the sides covered by fat. It is about the size of a billiard ball. The margin is lobulated or tuberosus all round, well defined, but without a distinct capsule; it cuts with the uniform firm surface of sarcoma, and shows occasional opaque yellowish patches, which are not friable. In the centre, as well as in some parts of the periphery, the texture is remarkably dense, so that the cut surfaces are cupped. It is noted that the patient was absolutely bald.

Remains of the mammary structure are met with only upon the sides and base of the tumour, sometimes lying in the fat. Within the tumour-area these islands are recognised by their greyish translucent colour and great toughness.

There are no regular and complete lobules of mamma, but only occasional acini cut off in the midst of dense fibrous tissue. The prominent glandular structures are of the several anomalous kinds: (1) the peculiar branching tubes, with somewhat coiled and dilated cæca (fig. 72, Pl. XIV.); (2) coils of tubing of uniform width, with thick lining of granular epithelium, and with the appearance of plain muscular fibres in the bands of stroma between the tubes, instead of in the basement (*supra*, p. 163); and (3) undoubted coils of tube with a longitudinal muscular coat. The muscularis is seen also in some large milk-sinuses, the rugous walls of which are so much collapsed that the lumen is merely a stellate interval. Those are the several anomalous and rudimentary forms of gland that are often found in company, and all of them in close proximity to milk-sinuses projected far towards the margins of the breast. It is hardly possible to identify any glandular structure in the *corpus mammæ*, corresponding to the centre of the tumour. A large area of it is almost purely dense fibrous tissue, and the same dense stroma extends into those parts of the periphery where the mammary glandular remains are found. This is a fibrosis of an unusually dense, hyaline, and contracting kind. Its contraction has told upon all the surviving tubular structures in one degree or another. The muscle-walled tubes are nowhere found dilated to small cysts, but sometimes drawn out to the length and narrowed, with the epithelium and basement reduced to a cloudy or granular necrosis, as in fig. 73.

In some cases the muscular ribs can be seen as a bundle of parallel fibres, easily distinguishable from the homogeneous fibrous tissue, the latter colouring deeply with acid fuchsine while the plain muscular fibres remain almost unstained. Effacement of the whole mammary structure (which is normally effaced more or less after the climacteric period), and obliteration of the anomalous sweat-gland tubes by pressure of the dense fibrous tissue, are the most distinctive things in this breast. It may be noted, also, that the sweat-glands of the skin of the breast at large have a very obvious muscularis, and a certain width of lumen, although they are not much larger than the ordinary kind (p. 14).

Notwithstanding the great density and toughness of the stroma, this tumour has all the characters of sarcoma. It springs up everywhere from the connective-tissue cells; where it invades the fat it does so in the manner of sarcoma, not in the manner of scirrhus. The cells have a well-marked epithelial type, as in the preceding cases, and in most parts they are in compact lobules, rounded off by narrower or broader tracts of stroma; in certain places there are small spherical lobules, which develop a pseudo-glandular form by an irregular massing of the cells round the margin, leaving the centre clear; in other spots the stroma is split up into concentric threads between which the cells are packed in rows. All these characters, including the density of the stroma, are exactly the same as in a sarcoma described in the tenth chapter, which grew from the skin of a dog's back, and can be proved to be related to the natural sweat-glands of the locality.

The parablasic origin in this case is shown by various appearances, such as that in fig. 74, Pl. XIV. The central object is a glandular tube which has two or more recesses at the right-hand end. The marginal epithelial row is nearly perfect; but there is also a deeper row, quite distinct from the former, of which the cells are in great part vacuolated with free nuclei. The basement membrane (doubtfully muscular) is unbroken. The tumour-process is altogether outside the tube. It has obvious traces of myxoma close to the wall (as in earlier illustrations of circumtubular new growth); but these are insignificant beside the extensive territory of sarcomatous cells farther afield. The cells are at first in small clusters or columns, epithelial-like, with large nuclei and fused protoplasts, all of them larger than the epithelium within the tube; beyond these circumtubular groups they are in larger masses. The beginnings of the sarcomatosis may be seen also in the fat upon the margins, where it follows the distribution of blood-vessels, arising from the connective-tissue cells in their walls, and eventually causing the occlusion of the vessels, as taught by Kolaczek and G. B. Schmidt. Another region where the steps of the process may be detected is the soft tissue between the firm

margin (or capsule) of the tumour and the skin; here we find that singular phenomenon, before mentioned, of a deep-staining juicy connective tissue being broken up into small blocks or cubes, which are a stage on the way to tumour-cells of the myxo-sarcomatous type (p. 170).

CASE XVIII.—*Tuberous Sarcoma at one side of a scirrhous corpus mammae.*

Mrs M—, aged 57, had the breast amputated for an ulcerated soft tuberous growth by Dr [Sir George] Humphry at Addenbrooke's Hospital, Cambridge, on 15th October 1878. Three larger and two smaller lymph-glands were removed from the axilla, the larger being affected with new growth. The bulging mass of the tumour, the size of a hen's egg, rises in cylindrical form at one side of the nipple, which is sunk in the hollow at its side, not retracted, but erect, and expanded at the top. This projecting part of the tumour is covered by thin red glazed skin, which shows at the highest point an ulcerated cavity admitting the end of the little finger; the thin glazed skin passes into normal wrinkled skin along an irregular line round the base of the growth. Almost at the perpendicular of the nipple the soft tumour-tissue passes into the dense tissue of the *corpus mammae*, which forms the other half or one-third of the tumour, ending abruptly about a quarter of an inch beyond the nipple, along an almost straight face descending about two inches to the base of the breast. Some bundles of pectoralis muscle adhere to the base. There is a layer of fat, with some remains of mammary lobules, upon the upper surface of the specimen corresponding to the *corpus mammae*, but no marginal expansions of the breast. The whole specimen, probably including all that was left of mammary structure at the age of fifty-seven, consists therefore of a tuberous sarcoma on two-thirds of its periphery, and of the abrupt and nearly perpendicular face of the scirrhous *corpus mammae* on the other side.

The sarcoma is of the same kind as in the two last cases: the cells have a marked epithelial type, with the nuclei large, and the protoplasm of adjoining cells fused; they are grouped in masses of various form and size among the tracts of fibrous stroma, and in some places have the form of sinuous bands and loops, as figured from three previous cases. In the more exuberant parts, the cells are polymorphic, with large clear nucleus, or pair of nuclei, in a highly mitotic state. The stroma is as if sown with spindle-shaped nuclei, and is reduced to ever narrower tracts by inclusion of new centres as tumour, until it becomes a mere reticulum, of which each mesh supports a small alveolar cluster of epithelial-like cells. This is the structure that makes up

the bulk of the new growth, and is reproduced in the axillary lymph-glands, which are a most curious mimicry of the diseased breast, including the tracts of stroma sown with spindle-shaped nuclei.

Where the bulging tuberous mass abuts upon the *corpus mammæ*, the tissue begins to be more dense; but the structure of the new growth is essentially the same, the difference being in the greater amount and compactness of stroma between the masses of tumour-cells. The density is nowhere so great as in the central part of the two last tumours, the fibrous tissue being far more rich in nuclei, and in nuclei of a larger and more plump kind. But, if there had been no tuberous mass at one side, which is plainly sarcomatous, or if the area of new growth had been exactly co-extensive with the dense core of the breast, it is probable that the case would have been counted scirrhus, although it wants the peculiar hyaline and glutinous texture of contracting scirrhus. In a former paper, "On Infection of the Connective Tissue in Scirrhus Cancer of the Breast," *Journ. of Anat. and Physiol.*, xiv. 1879, I used this case as one of scirrhus, drawing my illustrations from the central part only. The source of the tumour-cells from connective tissue was maintained for the scirrhus part; but the case is clinically a sarcoma, by reason of its extensive soft fungous protrusion.

The most prominent remains of breast-structure are the milk-sinuses, which are encountered in the dense tissue under the nipple. They are remarkable in several ways: they are nearly all invested with broad hyaline and granular zones, which I shall have to refer to frequently under the head of scirrhus; they are usually quite collapsed, so that the lumen is only a figure of stellate lines; and where they are not collapsed they are blocked with a tissue which has a good many of its cells spindle-shaped. No mammary lobules can be found in this central part of the breast. The other remains of glandular structure are found upon the periphery of the firm centre, and amongst the fat which indents it with rounded processes. By far the most striking objects, found all round the margin of the denser side, are large sinuous

tubes, which are blocked by epithelium, and look like stout white cords. I have dissected them out, under a lens, from the fat upon the surface, in which they lie like small white worms, and have proved their tubular-gland structure under the microscope. In sections they have the appearance shown in fig. 75, Pl. XIV., in which are shown several turns of the same sinuous tube. The centre of a tube is sometimes occupied by a concretion; the epithelium on the wall is always several rows deep, and often fills the lumen. The basement membrane is usually cloudy and indistinct, but I have several specimens in which the longitudinal muscular fibres can be seen beyond all ambiguity. These tubes are, indeed, the large sweat-glands, which are developed in place of mammary lobules round the margins of the breast and in close relation with the deeper milk-sinuses. In this case they are not met with as compact coils, but always somewhat drawn out in long sinuosities, either lying in the fat, or surrounded by broad tracts of spindle-celled stroma, as in fig. 75, and having their lumen uniformly distended and blocked by epithelium.

On the same margin the remains of mammary lobules are found, reduced to elongated slender cords of cloudy or granular nuclear cells, without acinous appendages, and with

DESCRIPTION OF PLATE XIV.

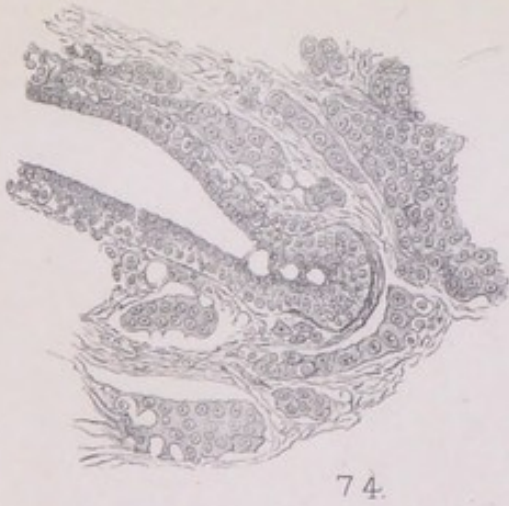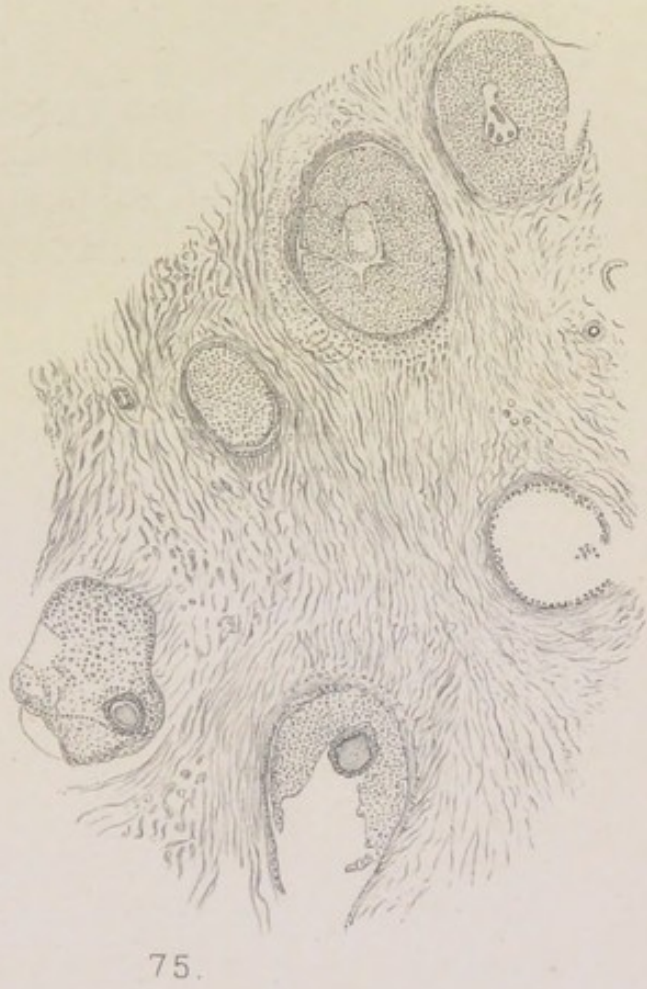
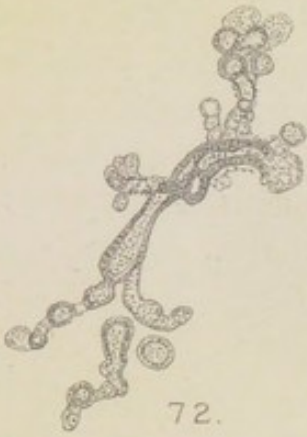FIG. 72. From the periphery of the breast in Case xvii. Mammary lobule of the branched tubular kind. $\times 90$.

FIG. 73. Long straight tube with necrosed epithelium, in the midst of dense fibrous stroma, Case xvii. $\times 200$.

FIG. 74. Parablasic new growth around the walls of a tube which has its basement membrane entire. The new growth nearest to the tube is myxomatous. Some of the sarcomatous masses are so much fused as to resemble giant-cells, with scalloped borders and processes. The basal row of epithelium within the tube is vesiculated, with free nuclei. $\times 200$.

FIG. 75. Blocked sinuous sweat-tubes (the two lower with concretions) from the margin of the *corpus mammae* in Case xviii. The stroma is fibro-nucleated, but hardly sarcomatous. $\times 40$.

FIG. 76. From the central part of the *corpus mammae* in Case xviii. *a*, milk-sinus (or branch of), with broad hyaline zone; *b*, group of original gland-tubes with normal epithelium; *c c'*, dilated alveoli with appearance of intact basement having deeply stained regular nuclei. $\times 90$.





little branching. Passiveness and atrophy are written quite clearly on them; but the atrophy is rather that characteristic of the rudimentary branching forms, often referred to before, than the total obsolescence of well-developed lobules.

The other region in which anomalous tubes of the sweat-gland type are commonly found is the centre of the *corpus mammæ*, around the walls of the milk-sinuses. It is not easy to find them there in this breast; but that, I believe, is owing to the advanced stage of disease. The best evidence of their presence that I can find is that of fig. 76. At the upper side is a duct or sinus with a hyaline belt round it (*a*), its lumen being blocked by epithelium. Beneath it, in what would be the territory of glands dependent from it, are three or four somewhat regular spaces, like a rete, with a very distinct basement of small cubical nuclei and with large epithelial cells round the wall or lying free in the lumen. Below these, again, are three or four sections of small tubes (*b*), with normal columnar epithelium. This I take to be a surviving spot of the anomalous tubular glands in the central region of the milk-sinuses; and I infer that the sweat-tubes had been present in numbers in that region, and had been affected with the same obstruction and blocking with epithelial contents as in fig. 75 from the periphery. The growing and spreading new growth, the sarcoma of the connective tissue, is the parablasic complement of this glandular disorder and obstruction. The case, with an instructive *differentia* of its own, comes under the same generic head as those preceding.

CASE XIX.—*Large-celled Sarcoma on Axillary edge of Breast.*

A married lady from Wales, aged 46, who had never been pregnant, consulted Sir Spencer Wells (see his *Morton Lecture on Cancer for 1888*, Lond., 1889, p. 23) for a tumour on the outer border of the right breast. Both breasts were larger, and harder, than usual, and both nipples unusually large and prominent. The tumour of the right breast was a round, movable, tender mass between the upper and outer border of the gland and the axilla, and appeared to be continued round the axillary fold into the space, the whole lateral extent being three inches and the vertical two inches. The patient felt sure that a blow from a tennis ball two years before had been the cause of the swelling. The tumour was excised on 30th October 1888, only a small strip of

mamma being removed with it, which looked normal beside the encapsuled growth. The capsule was dense and thick, infiltrated with blood. The new growth within it was so friable that it broke down in the handling, and was removed in pieces, the condensed cyst-like wall being dissected out by itself. This encapsuled friable tumour was found to be one-half or less of the whole mass, the portion which extended beneath the border of the pectoralis muscle being a lobulated body, of deep-red colour like a small kidney, about $2\frac{1}{2}$ inches in the long axis and $1\frac{1}{4}$ inch across at its broader end: it adhered to the friable encapsuled tumour by loose connective tissue, and was of uniform white medullary texture, divided into large lobes, and streaked with bands of blood-pigment or blood. The wound healed well, and the patient returned to Wales in a few days. Eight or nine months after, in July 1889, there was a second operation, but I am unable to give the clinical facts of the recurrence: my microscopic specimens from the second removal show extensive small-celled infiltration of the fat, the subcutaneous fibrous tissue, and the corium; with that infiltrated tissue is a single lymphatic gland, which has the usual bean-shape, with a hilum, and is normal in structure.

This was a sarcoma of the same type as the preceding cases, the cells being very large, epithelial-like, with large clear nuclei in an active state of mitosis. In some luxuriant parts of the new growth the cells are of unusual size and of various shapes. The stroma contained everywhere many spindle-shaped cells, as well as small quadrate cells which stained deeply with methylene blue (Unna's plasma-cells), but did not show the granules of "Mastzellen." New centres of large epithelial-like tumour-cells arose in the midst of this stroma, reducing it to narrow tracts, between which the cells lay in alveolar masses of various extent and shape, and sometimes with a pseudo-glandular arrangement round the wall of the space. Glycogen was clearly present in some places, very sporadic as usual; and in the same locality as the glycogen were limited tracts of hyaline (compare p. 161). The lobulated mass in the axilla, which adhered to the encapsuled tumour, had exactly the same structure of very large epithelial-like cells in alveolar masses; it was probably a packet of lymph-glands transformed throughout into a uniform medullary sarcoma, the bands of stroma between the alveolar masses appearing to be the remains of lymphatic gland.

The relation of the tumour within the dense capsule

to tubular glands is the same as in the two last cases. This is shown in figs. 77 and 78, Pl. XV., drawn from sections mounted in glycerine-gum. The triangular space of fig. 77 is a tube with a distinct basement of muscular fibres. Its epithelium is not in an active proliferating state, but is decaying. The new growth is altogether outside the basement membrane, and is very obviously myxomatous close to the wall of the tube. The progressive stages, from branching protoplasmic cells to trabecular columns of epithelial-like cells (on the wall of the sweat-tube in fig. 78), and to compact alveolar masses, are the same that have been described under several of the preceding cases. It is an exquisite instance of epithelial-like new growth parablasic to the disordered or broken-down original tubular glands. Fig. 79 shows the muscular basement of a cystic piece of sweat-tube in a methylene-blue preparation.

The seat of the encapsuled tumour had been that outlying process of the mamma which extends to the pectoralis fold of the axilla. The above figures show that it contained tubular glands of the sweat-gland type, which had developed, as in so many cases, in lieu of mammary lobules around the end of a milk-sinus. So little of the breast was removed that it is impossible to say how widely spread the anomalous structure may have been, or of what various types; but there is some evidence. Both breasts, for a childless married woman at the age of forty-six, were larger and harder than usual, and both nipples unusually large and prominent. In the strip of mamma taken close to the capsule of the tumour the lobules are close together, the tubes distinct, with cubical epithelial cells in regular order round a small lumen, and in many cases with a second or basement row in a state of vesiculation or changed into a hyaline zone or halo. In several instances I have been able to draw parallel bands of the basement membrane in the face view, which can be nothing else than plain muscular fibres. The object shown in fig. 80 occurs in the midst of these mammary lobules: it is the section of a tube filled with papillary ingrowths of the epithelium, and with the muscularis seen clearly at two or more segments

of the wall. In the dense substance of the capsule itself there are somewhat wide tubes, extended, but sinuous and sacculated, which have thin walls (and no obvious muscular basement) lined by flattened epithelium in a single layer: these I take to be the dilated and drawn-out condition of the rudimentary tubular glands often found associated with true sweat-glands, as figured on Pl. II. from another breast. In the fat near to the encapsuled mass I found, in the fresh tissue, one or more small reddish bodies the size of a large pin-head, which showed the unmistakable parallel ribs of the muscular basement of sweat-glands, as well as the polyhedric epithelium; and I have confirmed that observation on two subsequent occasions with the prepared tissue.

These several proofs, although necessarily fragmentary, incline me to believe that the breasts in this case had contained much anomalous tubular structure, more especially of the true sweat-gland type. The patient was confident in tracing the origin of the tumour to a blow on the spot from a tennis ball. The condensed "chronic inflammatory" and hæmorrhagic tissue around the tumour, enclosing it

DESCRIPTION OF PLATE XV.

FIG. 77. Parablasic new growth around a muscle-walled sinus on the axillary side of the breast in Case XIX. *a a'*, plain muscular fibres of the basement; *b b'*, myxomatous tissue outside the wall of the sinus; *c*, more protoplasmic kind of myxomatous tissue. Glycerine-gum preparation. $\times 200$.

FIG. 78. Outer surface of muscle-walled tube from Case XIX. *a*, plain muscular fibres of the basement; *b*, myxo-sarcomatous new growth around the tube, characteristic of the mass of the tumour. The nuclei are very large and mitotic; the protoplasm forms a rete of thick bars. $\times 200$.

FIG. 79. Fragment of the wall of a dilated sweat-tube from the margin of the tumour in Case XIX. *a*, plain muscular fibres of the basement (wavy fibrous tissue above); *b*, small quadrate nuclei. $\times 200$.

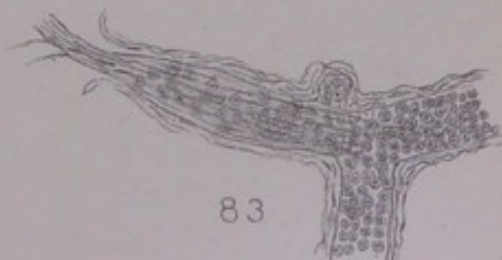
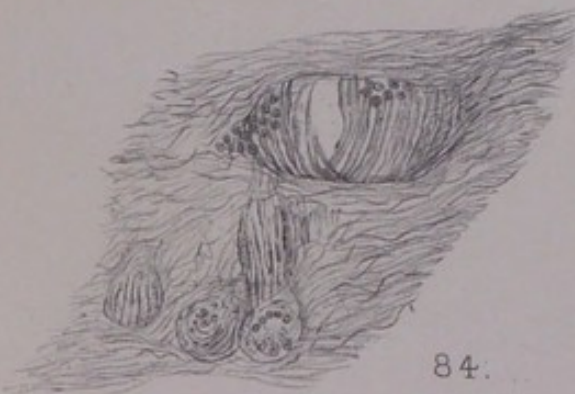
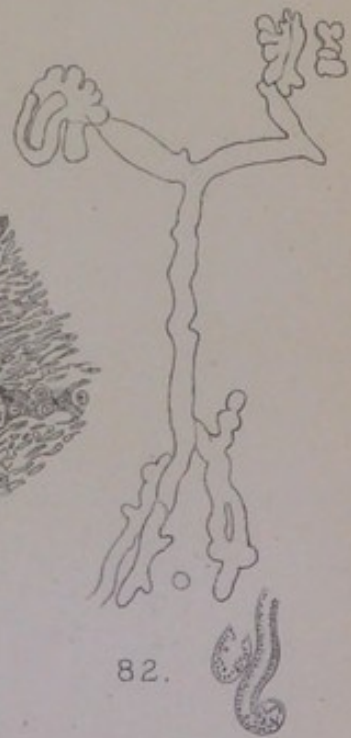
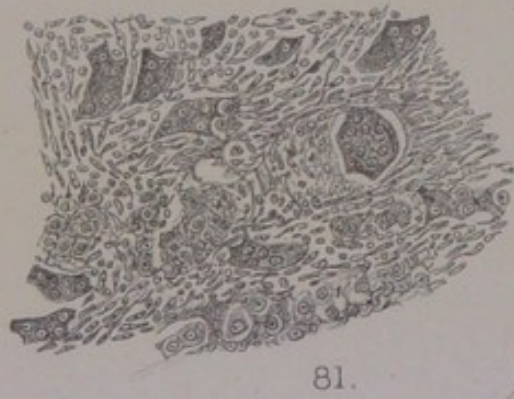
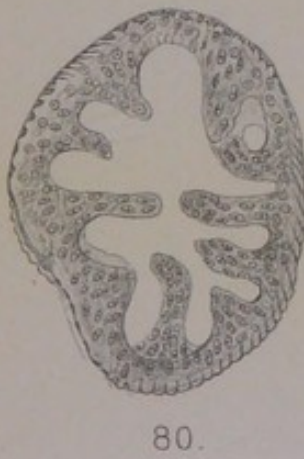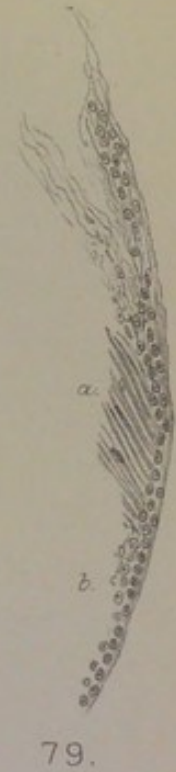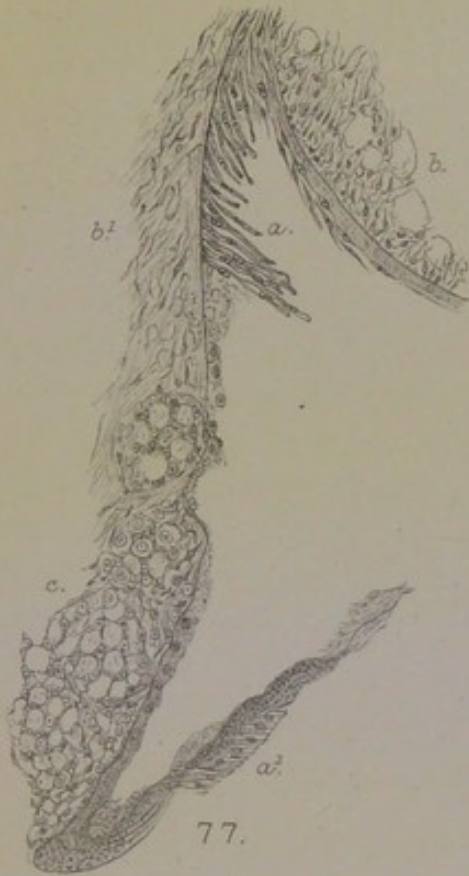
FIG. 80. From the normal mamma adhering to the encapsuled tumour in Case XIX. Tube with muscular basement, and papillated epithelium. $\times 200$.


FIG. 81. Myeloid sarcoma of the breast, Case XX. $\times 200$.

FIG. 82. Branching sweat-tube with coiled endings, from island in the fat, Case XX. Columnar type of epithelium shown below. $\times 90$.

FIG. 83. High-power view of upper fork of fig. 82, showing the muscular fibres. $\times 200$.

FIG. 84. Group of sweat-tubes from island in the fat, Case XX. $\times 200$.





almost like a cyst-wall, is of the kind that might have followed an injury to a glandular organ subject to special affluxes of blood at the patient's time of life. Such an accident to tubular structures of the sweat-gland kind appears to have peculiar risks. Hence the great importance, in the etiology of mammary tumours, of whatever produces an induration of the breast, or of a part of it, whether a milk-abscess (which is perhaps the most common), or a blow, or the excessive afflux of blood at each (irregular) menstrual period; they are important for the etiology because they interfere, sooner or later, with the structure and function of tubular glands, which are not only not passive, as so much regular mammary structure would be, but are actually of the nature of permanent organs of excretion.

CASE XX.—*Myeloid Sarcoma protruding in the place of the Areola and Nipple.*

Louisa Sargeant, aged 58, married and mother of eight children, had the breast removed for a fungous tumour (of two years' duration) at the Temperance Hospital, Hampstead Road, in 1896, by Dr [Sir William] Collins. From one-half of the specimen, in the pathological collection of the Hospital, I have obtained, through the kindness of Dr Collins, all the microscopic preparations that I required, without injuring it for the museum. The other half of it is in the College of Surgeons' Museum, No. 4820A of the Catalogue, where it is described, oddly enough, as a "squamous-celled carcinoma, with abundant formation of cell-nests," and is assumed to have grown from the skin of the areola, both to the depth and upwards as a fungus. Sheild, trusting to the Catalogue (as one is usually safe to do), has cited the case, in his *Diseases of the Breast*, 1898, p. 145, as "an undoubted example of an exceptional malady," meaning epithelioma of the areola, of which no authentic instance is known; and has given a good naked-eye figure of the tumour, to which I beg leave to refer the reader.

The tumour has the shape of an unsymmetrical hour-glass inclined obliquely, the smaller sphere, about two inches in diameter, being sunk below the level of the skin in an extensive mass of pure fat; while the larger, flattened at the top, projects as a fungus about four inches broad and nearly two inches thick, the neck joining the two masses being about two inches thick and occupying the place of the nipple and areola. The flat surface of the fungus is lobulated

and fissured, one of the deepest fissures in the centre being ulcerated. The skin is removed with it wide of the overhanging edges of the fungus, and to a length of about six inches in the transverse direction. The cushion of fat is about an inch thick below the embedded half of the tumour. In this fat are three islands unconnected with the tumour, which are of the greatest interest for the pathology. Two of these, half an inch and a quarter of an inch in diameter, are visible on the lower surface of the fat beneath the tumour-mass, of reddish colour, and of the same texture as the tumour itself. The third, about the same size, is at the thin end of the wedge of fat (probably the sternal), at a depth half an inch below the skin: it is of paler reddish colour and has an open locular texture.

The structure of the new growth is somewhat uniform and characteristic throughout the bilobed mass, as well as in the two more central islands in the fat. It is a sarcoma of large polymorphous epithelial-like cells set in a stroma which is mostly fibro-nuclear but is sometimes truly spindle-celled. This is the structure around the growing edges, where the luxuriance of the cells, as regards size and variety of form, is greatest, new territories of fat being annexed. So far the tumour is a sarcoma of the same kind as those previously described. But at certain spots in the centre of the mass there are many giant-cells of various shapes, usually with one or more of their borders scalloped. These are set amongst tumour-cells of the ordinary epithelial type, and both kinds amongst a peculiar fibro-nucleated stroma (fig 81, Pl. XV.). It is exactly the structure of Paget's myeloid tumour (of bone); and it is doubtless the same kind of tumour of the breast that Paget saw in a patient of Stanley's at St Bartholomew's Hospital in 1847, and included in his myeloid class. The fibro-nuclear stroma pervades the present case so much as to characterise it; but it is the same kind of tissue which I have figured close to the walls of tubes in the last case, and have referred to in the same situation in other cases, where it is obviously related to myxomatous tissue. Throughout this case also, there is another element of myxoma in the vesiculation of cells, although the richness of the

protoplasm converts the walls of vesicles (or the branching processes of cells) into the thick trabecular bars of sarcoma (as in fig. 78).

This patient, being some ten years over the climacteric period, has no regular mammary structure left, although the breasts must have been well expanded with her eight pregnancies. The glandular structure that remains is all of the tubular kind. It is found in the connective tissue around the base of the large tumour and in some of its fibrous septa, and it constitutes nearly the whole of the small island in the fat about half an inch below the skin at one end of the specimen. The tubes around the lower periphery of the tumour are elongated, sometimes sinuous, or doubled so that two tubes run parallel. They are of considerable width, with small regular columnar epithelium, which is often detached, as an entire membrane, from the basement. The tissue next the wall is a somewhat distinct homogeneous or hyaline belt, which stains deeply with acid fuchsine. There is no appearance of disease within the tubes, and not the smallest approximation to the size and form of tumour-cells in their epithelium. The nature of this glandular survival is shown by the island at one side of the fat. This island had been left when all the regular mammary structure had disappeared in the ordinary way of climacteric obsolescence. The glands in it are branching tubes, of the form shown in fig. 82: a central piece, which is somewhat sacculated, divides at either end into two branches, each of which ends in a small glomerular tuft. This is the type of a branching sweat-gland (p. 12), and the distinctive mark of a muscular basement is visible in many instances, both in the cross-section and in the longitudinal face view, the latter being shown in fig. 83, from the left-hand side of the low-power fig. 82. These tubes are usually very narrow, occluded by a row of cubical epithelial cells with clear protoplasm round the nucleus. In some instances the tubes have lost their epithelium by degeneration, and are represented merely by the muscular ribs. The fig. 84 shows that condition in the smaller tubes of a set. In this preparation the remains of the degenerating epithelial cells can be seen

lying upon the basement. So far as this outlying island of anomalous breast is concerned, its complete isolation in the midst of fat has had little or no effect in producing tumour-structure.

It is in the central region, corresponding to the *corpus mammæ*, that the isolation and degeneration of the same kind of anomalous tubular glands has caused the new growth. The larger of the two central islands in the fat is obviously the remains of the *corpus mammæ*, probably the original basal portion of it. It is the only part of the specimen that contains much dense fibrous tissue. The same tumour-process is going on in it as in the great mass above it; but the groups of large epithelial-like cells occur at wide intervals, lying in alveolar spaces of the dense stroma, as described above for the dense central region of several sarcomatous breasts. The sections of several large blood-vessels belonging to this island show the same tumour-cells in a wide belt round the wall, making a true perivascular sarcoma. The other and smaller island beneath the large tumour wants the density of stroma, having the same sarcomatous cells and fibro-nuclear stroma as the main growth. The latter appears to have begun in the centre of the *corpus mammæ*, in the region of the milk-reservoirs, where the anomalous tubular glands are apt to develop. The long gland-tubes described above, driven aside to the lower periphery, are probably of that kind. Remains of tubes are also met with very significantly in the septa of the new growth, especially near the margins of skin where the fungus protrudes. There they are obliterated or disorganised, as in previous cases; and it is to this obliteration of a considerable quantity of tubular gland, more excretory than secretory, that the epithelial-like parablasteria all around them is to be referred.

Rolleston (*Path. Trans.*, xlvii. 1896) has recorded a case of "Sarcoma of the Mamma with Multinuclear Cells," recurrent in a woman aged 44: glandular tubes scattered through the growth showed no proliferation of their epithelium, and appeared to be in process of destruction from without by the sarcoma cells. This pathology assumes an initiative in the stroma just as in the sarcomata of periosteum, fascia lata, etc., and takes no account of the essential glandular structure.

CASE XXI.—*Alveolar Sarcoma of the Breast simulating Acinous Structure.*

This case occurred in the practice of the London Hospital, a portion of the fresh tumour having been given to me by Mr M'Carthy in March 1873. It was a firm medullary growth, with a uniform soft section, and with all the naked-eye characters of sarcoma. The minute structure appeared to be of lobules composed of close-set small acini, most of them filled with granular epithelial-like cells with large mitotic nuclei, some of them having the distinct small lumen occupied by mucus. A fine and scanty stroma, with nuclei visible in places, ran among the acini, enclosing them in very regular meshes.

This tumour of the breast was a puzzle to me, so that I made no use of it in the work which I was engaged upon at the time: the apparent acini were far too numerous, too close together, too small, and too uniform for an adenoma (*cp.* Langhans, *Virchow's Archiv*, lviii. 1873, p. 145), or for any species of new growth depending upon a morbid condition of the original glandular structure. It is now clear to me as a pseudo-glandular alveolar sarcoma (fig. 85, Pl. XVI.), of the same kind as the growth in Case XIII. (fig. 60), but with smaller alveoli. The whole mass of gland-like structure is a new parablasic formation from the vascular stroma, remarkable for the regularity of the cell-clusters and for their approximation to the form of tubes. Many of the groups of cells within the alveoli are really multinuclear masses of protoplasm: the cleavage into individual epithelial-like cells is incomplete, or the mass remains one large cell with a single large nucleus (as Billroth observed in his original account of alveolar sarcoma, *Archiv für klin. Chirurgie*, xi. 1869, p. 246); but there is often the semblance of a parietal row of epithelial cells, with the reality of a small well-defined lumen.

Original glandular structures are found only in the septa of the new growth. They are distinguishable from the parablasic growth by the smallness of the epithelial cells within the tubular structures, which are compressed and obliterated. Another thing that always marks the scanty remains of original tubes in the septa is the presence of concretions, which occur at certain spots in the septa only. These tubes appear to me to be of the anomalous sweat-gland kind.

I believe that I can make out the muscular ribs, like bundles of rods, where the epithelium is nearly gone. The pathology would therefore be the same as in the preceding cases—obstruction and obliteration of anomalous tubular glands in the breast, followed by an enormous parablasic development from the vascular stroma, which actually reaches a tubular-glandular type in some places. I shall give other instances of the same process, from the dog, in the next chapter. The most remarkable instance of this kind of pseudo-glandular sarcoma which I have met with is in a child; it illustrates the pathology of the sweat-glands proper to the skin, and is taken in this context merely for convenience.

CASE XXII.—*Pseudo-glandular Sarcoma of the Abdominal Wall in a Child, related to a Disorder of the Sweat-glands.*

A soft nodule in the abdominal wall of a child, about the size of a nut-kernel, was removed by Mr Wagstaffe at St Thomas's Hospital on 6th May 1874, the circular piece of skin taken with it being about half an inch diameter. The nodule lies between the corium and subcutaneous fat, definitely bounded, uniform in texture, which is open or spongy. All but the margin of it has the beautiful glandular structure of fig. 86, Pl. XVI.

The margin all round has the same epithelial-like cells with large nuclei, but in fused irregular clumps, without glandular form, in spaces of the spindle-celled stroma. The structure of fig. 86 is distinguished, firstly, by its uniformity, being perfect of its kind, as if a brand-new creation. Secondly, those neat and finished glandular tubes are all in open communication like a sponge, making an endless maze. Thirdly, the lining of epithelium is hardly ever subdivided into individual columnar cells, but is rather a continuous belt of nucleated protoplasm, which is often detached a little from the wall of the tube (*cp.* Cripps, *Cancer of the Rectum*, Lond. 1880, p. 87, and Pl. IX. fig. 2). Fourthly, the tubular structure, which is most perfect at the centre, ceases gradually towards the circumference, where the epithelial-like cells make the ordinary alveolar groups of "soft cancer" or sarcoma. And lastly, the tubes or alveoli are everywhere separated by considerable tracts of stroma, which is so full of plump protoplasmic cells, spindle-shaped for the most part, that

the stroma by itself might pass for sarcomatous tissue. It is clear that this nodule is not composed of original gland-tubes, but is wholly a new formation. The area of new formation is a small spherical territory directly beneath a certain peculiar spot of the skin. This spot of skin is peculiar in several ways. First, there is a distinct deposit of brown or golden pigment grains in the lowest cells of the mucous layer, not enough to make it a brown mole, but still clear under the microscope. Secondly, there are thick bundles of plain muscular fibres in the corium, like those of a mammary areola, but less numerous. Thirdly, the sebaceous glands are very large and perfect, the hairs being very few and delicate, of the lanugo kind. Fourthly, the coils of sweat-glands are remarkable in structure, as well as for their diseased state. Structurally they are notable for three things—the width of the lumen, the clear watery protoplasm of the columnar epithelium, and the distinct basement of plain muscular fibres (fig. 87, Pl. XVI.); it is only the discharging part of the tube in the epidermis that wants these characters of the larger kind of sweat-glands. But the most striking thing in the specimens is the morbid state of each coil. It appears to be in a state of œdema, or to be bathed in a serous exudation which takes a peculiar blue from logwood, so that each glomerulus is picked out as an island of colour. This plasma is indicated around the largest tube in fig. 87, and is shown in a manner in fig. 88 for a whole coil. It is really a fine myxomatous tissue, showing the delicate fibre-corpuscles or fragments of fibres (see fig. 51, Pl. VIII.), which become the fibro-nuclear corpuscles of more developed mucous tissue. The development into these, and into actual spindle-cells, is seen in the stroma of two or three coils that lie deepest in the corium, and come close to the margin of the spherical tumour-nodule, those deeper coils being also enveloped in a cloud of small round cells or leucocytes. The gland-tubes show no overgrowth of epithelium; on the contrary, their cells are often disintegrating, and, where perfect, have always the relatively small normal nucleus, which is an altogether different object from the preponderant and highly mitotic nucleus of the

epithelial-like cells of the tumour. The discharging tubes, which can be followed to the surface, appear to be absolutely blocked, their small epithelial nuclei being often crescentic or triangular.

Along with this disorder of the tubular glands, there is a not less striking disorder of the blood-vessels within and near the coils and their effluents. The capillary walls are as if coated with plump granular spindle-cells; in cross-sections they look to be almost solid cords. The same proliferation is seen around the walls of veins, so that they appear to be almost obliterated, making laminated bodies in section, as on the right-hand side of fig. 88. This is certainly not the normal nucleation of vessel-walls in a young subject; and there is some reason to think that it may be connected with a congenital structural anomaly (see Case XXXI.).

The two centres of disease in this small spot of the abdominal wall do not merge the one into the other: the area of original (and anomalous) sweat-glands shows one process, the spherical tumour-nodule beneath it shows another; or if there be anything in common, it is in the state of the connective-tissue stroma, not in the epithelium. There is not a trace of original sweat-glands to be seen amongst the pseudo-glandular maze of tubes and alveoli

DESCRIPTION OF PLATE XVI.

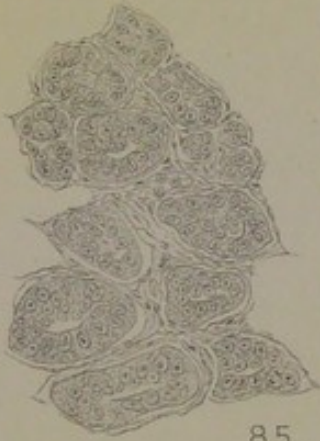
FIG. 85. Structure of the Sarcoma in Case XXI. In some of the alveoli there is a distinct lumen, making a pseudo-glandular appearance. Large nuclei, with fused protoplasm. $\times 200$.

FIG. 86. Pseudo-glandular sarcomatous nodule under a congenital anomaly of sweat-glands, etc., in the abdominal wall of a child, Case XXII. From the centre of the nodule. $\times 200$.

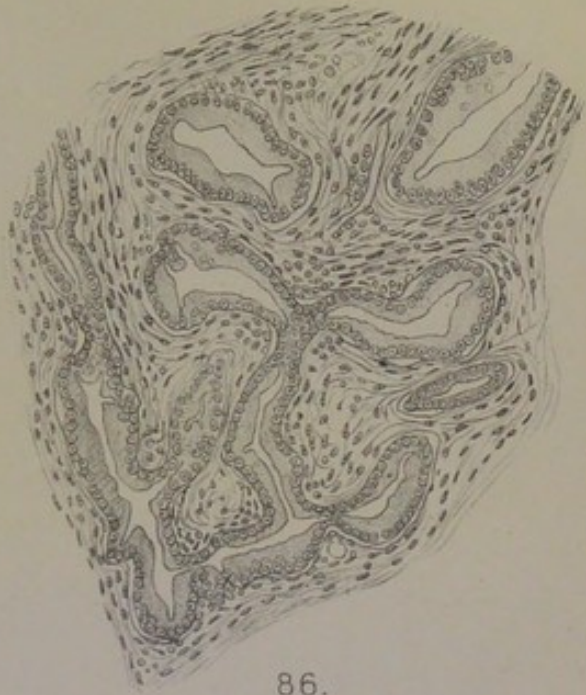
FIG. 87. Large sweat-glands, with muscular basement, from the corium of Case XXII. *a*, muscularis seen in the face view; *b*, fine myxomatous tissue bathed in serous fluid around wall of sweat-tube. $\times 200$.

FIG. 88. Whole coil of sweat-glands in Case XXII., showing the serous or myxomatous state of the stroma. *a*, blood-vessel obliterated by concentric nucleation in its wall. $\times 90$.

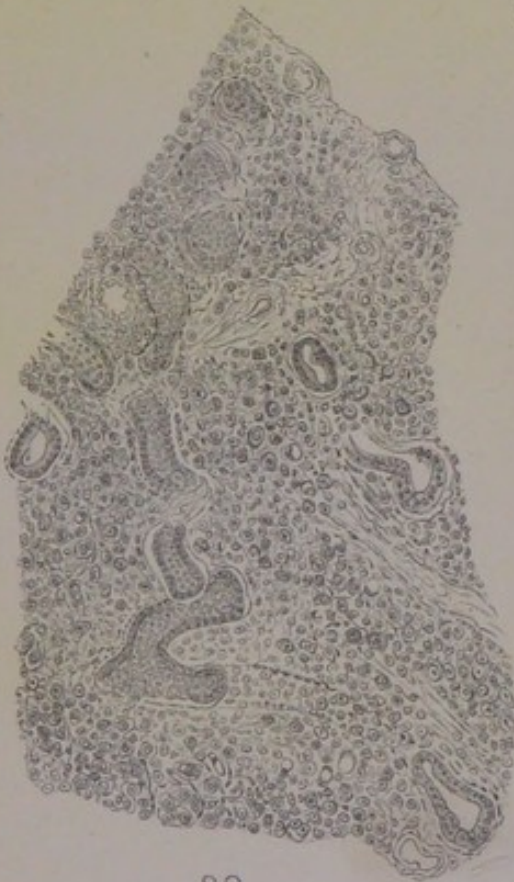FIG. 89. Chimney-sweep's cancer of groin (p. 21). Well-preserved sweat-glands of the region (the larger kind, with muscularis), surrounded by parablastic new growth of an unstable epithelial type (many free nuclei and much detritus). The muscularis is seen clearly in two or three windings of the sweat-tube near the surface. The new growth is traversed by imperfectly formed blood-vessels. $\times 195$.



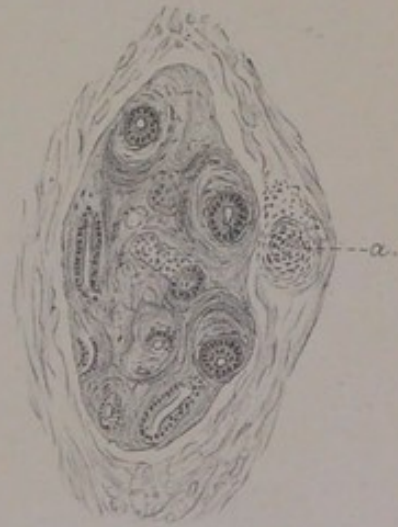85.



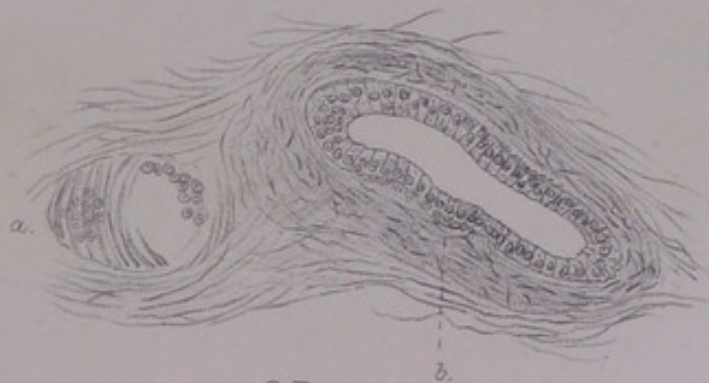
86.



89.



88.



87.



which make up the tumour; and the two or three deepest coils that lie next to it are akin to it only in respect of the spindle-cells and leucocytes. It is conceivable that there had been original sweat-glands all over the tumour-area: if so, they have been pressed aside and destroyed. But as the nodule is growing by its deeper margin towards the subcutaneous fat, where there are certainly no sweat-glands, and has the same structure there as upon its upper periphery, it looks as if it had grown in the same way from the first, attaining its most perfect pseudo-glandular type in the centre where it began. It is accounted for as a parablasic new growth, complementary to the obstructed or disordered sweat-glands of a certain spot of skin. The spot of skin is marked by the several congenital anomalies given above. If it had been a thorough pigmentary mole, and if an alveolar sarcoma (with more or less of pigment) had developed beneath it, the fact would have been thought nothing strange, because it has been observed often. The new growth is not the less a parablasic sarcoma, and it takes its pseudo-tubular type from the sweat-glands.

CASE XXIII.—*Sarcoma within the Limits of Acini and Lobules.*

Rebecca Hewitt, aged 39, married at eighteen, but never pregnant, was admitted into St Thomas's Hospital on 6th February 1873, under Mr Le Gros Clark, for a tumour of the breast. It began four months ago as a lump on the sternal side. It is now a cylindrical body $1\frac{1}{2}$ inches broad, globular at the upper end, and extending obliquely downwards and outwards, being continued beneath the nipple, which is slightly drawn down. The skin moves freely over it. The tumour is tender, and there are shooting pains towards the axilla. On the pectoralis fold of the axilla another nodule appeared two weeks before admission, which is separated from the main growth by a clear interval. On removal, the tumour proved to be 3 inches in depth at its thickest part, its upper surface having $\frac{3}{4}$ inch of fat between it and the skin. The section is described as "hard" (but it is not scirrhus), with yellowish points (of fat), and some brownish areas supposed to be small cysts. The nodule on the axillary fold is described as an "enlarged gland towards the axilla."

I have only microscopic slides from this case, and am therefore unable to clear up doubtful points by re-examination of the whole breast. The sections show a more marked lobular-and-acinous structure of the new growth than any that

I have examined; and I take the case to be an instance of Billroth's "acinous cancer of the breast," which was on the whole a soft cancer, corresponding to the "Markschwamm," "*carcinoma medullare*," "encysted cancer," "lobular cancer," "tuberous cancer," or "encephaloid" of others (*l.c.*, 1880). In his *Chirurgische Pathologie* (6th ed., 1872) he says of "cancer of the breast" in general, that it appears to him always to begin simultaneously with an increase of the small round epithelial cells of the acini and with small-celled infiltration of the connective tissue around them; and that it is hardly possible to say whether the first changes are in the connective tissue or in the epithelium. It is obvious, also, that his "acinous cancer" is what is now usually counted sarcoma, having the clinical type of the latter. But its striking correspondence in outlines with the regular lobular and acinous structure of the breast (as in Billroth's fig. 157, p. 740) makes it necessary to consider whether this is not a variety of tumour which arises actually from that structure, and not from the anomalous sweat-glands of the breast, which have accounted for all my cases hitherto.

Types of Normal Structure in this Breast.—The breast in this patient, at the age of thirty-nine (married at eighteen, but childless), is neither in the undeveloped virgin state, nor in the fully developed state which is produced by pregnancy and lactation and remains in the intervals of these in an upfolded or involuted condition. The lobules are somewhat voluminous and intricate; but the type is commonly that of branching tubes, such as are shown in figs. 8 and 10, Pl. II. Sometimes the terminal cæca are dilated to the characteristic hollow spheres, lined by a single layer of very regular low cubical epithelium. In a few places, longer pieces of tube are found dilated, with the same single layer of somewhat flat epithelium, but without the basement of plain muscular fibres which distinguishes the tubes of the sweat-gland type: although some of those clusters of elongated and dilated tubes are sinuous or coiled, I am not satisfied that they are really sweat-glands. One of the most distinctive things in this breast is the presence of considerable areas of hyaline, to which it owed, doubtless, the degree of hardness that was

remarked of it at the operation. The hyaline occurs in the same relation to mammary glandular structure that has been described and figured for Case XI. and others preceding, and will be referred to again under a case of scirrhus in a patient as young as, or younger than this, Case XXVIII. (fig. 117, Pl. XXI.). Many of the mammary lobules are invaded almost entirely by hyaline, in tracts so broad as to reduce the acinous-tubular structure to slender lines of nuclei in its midst, the outlines of the lobules being still obvious. The substance is a somewhat clear, glassy amorphous hyaline, and not merely a fine or homogeneous kind of connective tissue.

It is upon such an anatomical basis—a voluminous gland, but differing in several respects from a well-developed milk-gland—that a tumour-process has arisen. There can be no question that the morbid process follows the distribution of lobules and acini very exactly, being confined within their limits, not involving the stroma between them. Not only are the outlines of the more voluminous and rotund lobules visible as the containing walls of new growth, but still more significantly the latter corresponds exactly to the more dispersed clusters of acini which adhere to the sides of the larger ducts or milk-sinuses (granules or *Körner* of gland-substance, Langer). But within those glandular limits, the new growth is not by any means of an epithelial type. On the contrary, the individual cells are *less* epithelial-like than the sarcomatous cells which develop, as in other sarcomata, from the vascular stroma at large. This is a paradox which I have had to notice before under Cases x., xv., and xviii. for small parts of the tumours, and have to mention again under Case xxiv. The commonest kind of tumour-cells are large spherical or ovoid elements, practically all nucleus, or without a clear distinction of nucleus within a zone of protoplasm, which stain deeply, and are filled with granules or mitoses, the condition of many of them being highly suggestive of “Mastzellen.” Scattered among them within an acinus, there are always slender crescentic elements, such as are of very common occurrence in the mammary sarcomata (or enchondromata, etc.) of the bitch (see fig. 92, Pl. XVII.); these

are almost certainly of sub-epithelial origin. In some acini the large plump granular cells are replaced in part by oblong or spindle-shaped cells, and there are instances in which the whole of the contents are close-packed spindle-cells.

Whatever theory be framed of the source of these intra-acinous or intratubular elements—whether exclusively from the basement and vascular tissues of the wall, or in part from the actual nuclei of the resting glandular epithelium—the result is sarcomatous, and the tumour is a sarcoma in clinical as well as in anatomical respects. In the region of the teats in the bitch, this is the commonest process, so that the tumours are all in the sarcomatous class, many of them being enchondroma in part, and some osteoma; where the extensive lobes of milk-gland proper are invaded in the bitch, as in certain cases which become acute and malignant, the process is still sarcomatous (*infra*, p. 209). In the human breast, it is rare to find the sarcomatous growth following the outlines of lobules and acini, and leaving the stroma intact. The case just given is the only pure instance of it that I have met with; in one or two other instances, also sarcomatous, the intra-acinous process is found in a few lobules only. It is not unlikely that the younger age of the patient accounts for this occasional form or complication. If the mammary structure were still preserved entire at the age when most women's tumours develop, whether scirrhus or sarcoma, the new growth might be expected to follow the glandular outlines more frequently, as it may do in the bitch. But, according to that analogy, it would be sarcomatous within glandular limits.

In the context of this case may be mentioned certain rare instances of rapid and extensive tumour-disease of *both* breasts in young subjects, classed as sarcoma. Two of the most remarkable are those given by Billroth (*l.c.*, 1880, p. 127 *seq.*); they both occurred in a late stage of pregnancy at the ages of thirty-one and thirty-six, and proved fatal shortly after delivery. "Mastitis carcinomatosa" was the original diagnosis, but both cases are given in the chapter upon "Sarcoma." Coupland (*Path. Trans.*, xxvii. 1875-76, p. 259) records a rapid tumour-disease of both breasts, with medullary nodules in the ovaries, in a young woman of twenty-four, who had borne one child at the age of seventeen, and had a milk-abscess after her confinement. The case by Fraser (*Lond. Hosp. Reports*, iii. 1866, p. 303) was

one of multiple soft white tumours, which affected both breasts, as well as other organs and parts, but could not be proved to have been primary in the breasts. A primary origin in the breasts was more probable in the very similar case in a girl of sixteen at the South Devon Hospital, Exeter, recorded by E. L. Fox (*Path. Trans.*, xlvii. 1896). The patient was subject to hysterical paraplegia. The first observation was on 31st July 1895, when both mammae were enlarged, hard, and nodular, with hardness and enlargement of lymph-glands passing into the axillae and behind the right sternomastoid. At the same date there was a small button-like nodule in the skin of the epigastrium, like a sebaceous cyst; it was believed to have existed as long as the disease in the breasts, and never became larger than the diameter of a shilling. On 15th August a small nodule was seen in the left temporal fossa, and on 15th September, numerous nodules in the abdominal wall, with general affection of the lymphatic glands. After death, on 12th December, nodules were found in the skin of the thorax, abdomen, and thighs, in the parietal pleurae, omentum, liver, pancreas, kidneys, ovaries, and lower vertebrae. The growths were white and uniform, sarcomatous, of the round-celled type. The tumours of the breasts contained multinuclear cells in groups; a few ducts and acini remained.

The following remarkable case by Treves (*Lancet*, 1887, ii. p. 520) resembles the above, in that the disease arose in a young woman in both breasts during a pregnancy, and extended in nodules to the skin around; but it appears to have had no character of malignancy up to the time when it was seen, although it is called "scirrhous" on account of the hardness of the nodules.

A woman, aged 37, anæmic, wasted, with a cough of six months' duration, who had borne ten children (all living) and suckled all but the last, was admitted into the London Hospital in November 1886, under Mr [Sir Frederick] Treves, for tumours of both breasts and smaller nodules in the skin around. The disease began ten months ago, when she was two months pregnant with her tenth child, as a small nodule close to the nipple of the right breast, which was followed in about two months by a similar small knot near the nipple of the left breast. The disease progressed, almost to its present state, until the end of her pregnancy, but has not changed noticeably since her confinement, which was easy; the child was not given the breasts owing to tenderness in them, but a small quantity of milk was seen for two or three days. The breasts are now very small. In the centre of each is a lump, which can be seen through the skin to be composed of nodules. The nodules are about the size of marbles, dense and rounded, held loosely together so as to make a composite tumour. That in the centre of the right breast is the larger, the size of a hen's egg, and is adherent to the normal skin (the nipple being drawn down), as well as fixed by its base to the pectoral fascia. That in the centre of the left breast has its composite nodular character still more marked, and is free both at the skin and at the base. On the right side there is

noted a slight enlargement of the axillary and supraclavicular lymph-glands.

All around both nipples, in radiating lines, are an immense number of hard, round, free nodules under the skin, which slip about like shot, ranging in size from a small shot to a bean. Around the right nipple there are about one hundred of these, of which some thirty are the size of large peas; they are dispersed as far as the clavicle, the sternum, and the axilla, being in excess on the axillary side; those farthest out are the smallest. Around the left nipple there are about seventy, which are not so widely dispersed. There are some large veins between the nipple and the clavicle on the right side; but there is no broken nor even congested skin anywhere. The group of larger nodules, like marbles, under the nipple and areola of each breast, appears to have been formed first; then followed the fresh crop of small hard nodules under the skin in ever widening lines around the nipples up to the limits above described, at which they would appear to have stopped some three months before admission. As there was to be no operation, the patient went out after a few days.

The whole case suggests to me very forcibly an affection of the sweat-glands at the base of the nipple in the first instance, and thereafter of the scattered sweat-glands of the whole mammary skin, as Astley Cooper describes them in the passage quoted at p. 14, *supra*. Treves describes it as "an unusual case of scirrhus," but points out that the nodules under the skin are unlike the scirrhus infiltration of the whole mammary skin, which is seldom nodulated, and never nodular in the same way as this affection. The composite nodular lumps in the centre of each breast, although hard and dense to the feel, appear to me to be quite unlike scirrhus; and, as Treves says, "it is unusual for a scirrhus to appear during pregnancy, still more unusual for it to involve both breasts under those circumstances." The patient was in poor health, with anæmia, wasting, and a chronic cough; but these were probably not the cachexia of cancer.

CHAPTER IX.

COMPARATIVE PATHOLOGY : MAMMARY ENCHONDROMA, OSTEOMA, AND SARCOMA OF THE BITCH.

THE peculiar risk of tumour-formation from sweat-glands, in contrast with the passiveness in that respect of the proper mammary structure, is shown in a very striking, and to me unexpected, way in the common mammary tumours of the bitch. I have a collection of some four-and-twenty of these tumours, of which I used the earlier half in my book of 1878, supposing them to be of mammary origin, as others have done in recording single cases. In order to account for the peculiarities of glandular structure and function with which the morbid growths in the bitch were associated, I supposed those processes to be physiologically analogous to the stages of imperfect unfolding of the mamma which are easily studied in another carnivorous species, the cat, at various periods of pregnancy : there was a stage in which large granular pigment-cells were produced within the mammary acini, a later stage in which mucus was formed, and so on.

So far as concerns those normal half-way states of structure and degrees of function in the mamma of the cat, I have found no reason to alter what I wrote. But the conditions resembling them in the mammary tumours of the bitch—the abundant large yellow cells in the stroma and the almost invariable mucous type of the glandular structure, with colloid cysts and various forms of myxomatous tissue passing into enchondroma, osteoma, and sarcoma—I can now explain in a different way, which I believe to be correct. The whole tumour-phenomena in the bitch arise from the sweat-glands of the mammary region,

not from the proper lobules and ducts of the mamma. The dog has the large muscle-ribbed sweat-glands more developed in the corium and subcutaneous tissue than perhaps any other mammal; they exist all over the body excepting in the balls of the toes (where there are the same kind of glomeruli that are most common in man, with capillary lumen, cloudy epithelium, and long discharging tube, *supra*, p. 12). They are the true seat and cause of the subcutaneous tumours, fungous warts, etc., to which the dog is much subject in all parts of its skin (including the region of the verge of the anus, where the sweat-glands undergo a special development—Morgagni, *De Sedibus*, lxi. 15; Wallace, *Path. Trans.*, xlvii. 290); and they are also the true seat and cause of the sarcomatous, myxomatous, cartilaginous, and osseous tumours of the bases of the teats and of the mammary region generally. The remarkable liability of the dog to tumours, purely in respect of its particular type of sweat-glands, will appear from the following figures, compiled from the records of several veterinary institutes in Germany (Sticker, "Ueber den Krebs der Thiere," etc., *Arch. für klin. Chirurgie*, lxxv. 1902: purely statistical, without definition of "Krebs" or anatomical basis).

*Relative Frequency of Tumours in the Dog in
Various Situations.*

Mamma,	341 cases.
Skin,	166 ,,
Anus,	89 ,,
Thyroid,	32 ,,
Prostate,	10 ,,
etc.	

The enormously greater liability of the mamma of the bitch than that of any other domestic animal is shown by the following: Mare, eight cases, 2 per cent. of all tumours; Cow, one, 1 per cent.; Ewe, 0; Bitch, three hundred and forty-one, 41 per cent.; Cat, five, 16 per cent.; Pig, 0. I shall deal with the tumours of the dog's skin at large in the next chapter, as invaluable illustrations of the general

tumour-pathology of sweat-glands; and proceed at once to the mammary tumours of the bitch.

The first thing that should strike one in the morbid growths of the mammary region is, that they are often small nodules confined to the bases of teats; that several teats may be thus affected, while the whole intermediate mamma is spared; that similar small knots, although remote from teats, are still superficial to the mamma or merely sunk in its surface; and that the larger enchondromata, osteomata, and sarcomata, which may grow to an enormous size and are apparently co-extensive with a large area of mamma itself, are sometimes found in the company of small nodules confined to the bases of teats, or they are "recurrent" growths in bitches which had been operated on before for nodules of the small submamillary kind. I give the following examples, in the order of time, from my notes made at the date of operation, and from re-examination of the specimens.

Case ii.—Bitch, 6th March 1873. Under one teat a small lobulated firm nodule, with another smaller under the skin, near it.

Case iii.—Bull bitch, 12th April 1873. Two firm nodular growths: the larger an elongated cylinder, $1\frac{1}{2}$ inch by $\frac{3}{4}$ inch, lying under the skin obliquely towards one of the teats, lobulated, cartilaginous; the smaller, also lobulated and cartilaginous, consisting of two symmetrical halves, at the base of another teat (fig. 89, Pl. XVII.).

Case v.—Bitch, 5th June 1873. Single lobulated tumour the size of a chestnut, cartilaginous in places, situated exactly under one of the teats, which is removed with it.

Case x.—Retriever bitch, December 1873. One very large osseous tumour, cylindrical, 4 inches long, 2 inches thick, removed with the skin over it, which bears one large teat. A second tumour, like a thick button, 1 inch diameter by $\frac{1}{4}$ inch thick, under and around another teat, which is removed with it. Three other small hard knots, $\frac{3}{8}$ inch to $\frac{1}{2}$ inch diameter, removed from under the mammary skin at other points, encapsuled in loose connective tissue.

Case xii.—Aged bitch, 3rd November 1874. Three tumours under teats:—a larger, firm and nodulated, yielding a clear brown juice on section (sarcoma), under the second thoracic teat of the left side, $1\frac{3}{4} \times 1\frac{1}{4} \times \frac{3}{4}$ inch; two quite small nodules under the last pair of teats, $\frac{3}{8}$ inch by $\frac{1}{8}$ inch, surrounded by lobules of normal mammary gland.

Case xiv.—Setter bitch, 26th June 1875. This animal had a firm globular tumour, with cartilaginous areas, removed from under one teat in June 1873. Two years after it returned with a large soft bulging tumour under the last teat but one on the left side. Owing to malignancy, the dog

was killed by prussic acid, and proved to have a large sarcomatous mass in the mediastinum, with a polypous growth of the same through the wall of the inferior vena cava. The soft bulging tumour, like the half of a hen's egg, is a spindle-celled sarcoma with large cells. Quite a number of small nodules were found at other places on the cutaneous surface of the mamma of either side, on dissecting it off all the way from the groins to the axillæ. Three of these, like hazel-nuts, lie in a cluster upon the cutaneous surface of the mamma near its middle, adhering to it merely by connective tissue; a fourth, somewhat smaller, lies on the surface 4 inches from the posterior end of the mamma of the opposite side. Several more, like peas, are found at intervals either on the cutaneous surface of its thicker parts, or embedded in its thinnest part at the thoracic end.

Case xv.—Aged black-and-tan bitch, 27th July 1875. A small soft nodule at the base of a teat. Another, still smaller, adhering to the upper surface of the mamma. Infected lymph-glands at inguinal end.

Case xvii.—Bitch, 30th September 1875. Bulging tumour like a walnut, bearing a teat on one side, containing points of cartilage and colloid cysts. One inch distant, a cluster of three smaller nodules close under the skin, same structure.

Case xxii.—Bitch, 1876. One principal tumour, size of chestnut, nodular, firm, with cartilaginous areas, and half a dozen quite small nodules adhering to the cutaneous surface of the mamma at intervals, or sunk in it.

Case xxiv.—“Mammary tumours from bitches. Mr Banham. Four pieces.” They are all button-like nodules, from 1 to $\frac{1}{2}$ inch in diameter, closely covered by the skin, a teat upon one of them.

In going over again my whole collection from the bitch, there was no difficulty in assigning all such cases as the above to the sweat-glands instead of the mammary acini—either to the somewhat special deposit of them around the bases of the teats, corresponding with the same kind of sweat-glands in the human areola, or to coils of them in some other relation with the mamma. These sweat-gland nodules of the mammary region had certain characters which distinguished them from the sweat-gland tumours in other regions of the dog's skin (see next chapter): they were often very small, multiple, nearly always firm, with colloid substance in the dilated tubes, and with a peculiar tendency to enchondroma. But their peculiarities were not at all due to any implication of true mammary structure. From them, and from all other cases of my collection, I can exclude the mammary acini and lobules proper, excepting as invaded by the growth of sarcoma; but the larger growths are sometimes so sunk in the mamma, or surrounded by its lobes and lobules, as to make

the resulting tumour appear truly mammary. About one-half of the specimens are very large growths: in one instance extending to six inches in length under two or three teats, in other cases four or five inches long, being usually thick encapsuled cylinders up to two inches in diameter, with small cysts and intracystic growths; sometimes soft sarcomata of whitish colour; in other cases with a very dense stroma between the cysts yielding a brown colloid juice; in three cases with masses of true bone formed from membrane by osteoblasts. In one instance it is noted that the tumour had existed four years; while all of them were chronic, some of them having begun after a time to grow rapidly, with signs of malignancy and extension to the viscera. There is no difficulty in placing them all in the class of sarcomata, with or without enchondromatous or osseous areas. There is also no difficulty in proving the sarcomatous nature of a process which extended, in some cases, to whole lobes of well-developed mammary gland, annexing them to the tumour. The difficulty arises, in these extensive tumours, in tracing the distribution of sweat-glands and their relation to the proper mammary framework. The tumours of long standing have almost effaced the plan of their growth, so that they are as difficult to disentangle as a cystic sarcoma of great extent and of long standing in a woman's breast. From certain more easily observed instances, I conclude that the extent of the tumour is proportionate to the distribution of sweat-gland structures in some anomalous relation with the breast. That kind of dispersion, contrasting with the deposit of sweat-glands at the bases of teats (with their regular outlet upon the skin), would be more like the distribution and relations of those that are ordinarily found in the breasts of women: they would have to be considered as an integral part of the glandular organ, taking the place of so many regular mammary lobules, and being developed around proper milk-ducts and milk-sinuses. The mamma of the bitch is not remarkable for the size and prolongation of its milk-sinuses; Astley Cooper, in his text, does not even allege their existence, as he does for the mamma of the cat; but his plate of the injected ducts shows certain dilatations below the nipple; and I believe that the distinctive

structure of reservoirs occurs in some bitches more obviously than in others, just as it is a variable thing in the breasts of women. At all events it is in the region corresponding to the *corpus mammæ* of the human breast that the anomalous development of sweat-glands is most apt to take place in the bitch. So far as I have seen, it does not occur at all round the margins and on the base of the gland, which are common seats of the anomaly in women—witness the frequency of involution-cysts. They belong really to the same group of sweat-glands as the regular (if excessive) deposit of them around the base of a teat; and the *error loci* would consist merely in their opening upon a milk-sinus instead of directly upon the skin of the teat or the circle of skin round it. It would simplify the pathology if the sweat-glands were all in the latter relation, as I believe that those are from which the smaller class of nodules arise. But the very large mammary growths can hardly be explained without assuming a certain degree of that anomalous development within the mamma itself, which is the key to all the varieties of its morbid growths in women. I give one case as illustrating this principle.

Case xxiii. — A large bitch, 1876. Mass about the size of a fist removed from the thick inguinal end of the strip of mamma, along with the last teat. It was dissected out from beneath the skin, being definitely bounded all round, $4\frac{1}{2}$ inches long, $2\frac{1}{2}$ broad, and $1\frac{1}{2}$ deep at most. When the base is turned up, it appears to consist of normal lobulated breast, making a thick outstanding border round a central concavity, at the deepest part of which a piece of muscle of the abdominal wall adheres. This concave base is covered by a layer of fat, within which comes a thin stratum of striped muscle in bands, not belonging to those of the abdominal wall, but making a proper muscular base to the mamma, just as bands of striped muscle are regularly incorporated in the mamma of the cat (*supra*, p. 54). The upper surface appears to be as distinctively tumour as the borders of the base are normal mamma: the tumour is, as it were, sunk into the lobes of mamma as into a thick frame. On section, the new growth occupies the whole interior, the thick strata of natural lobulated breast rising up around it at either end and upon the outer side. The new growth is composed of cysts up to the size of a shilling, most of which are quite filled with firm succulent papillomata, of a brownish colour, very different in appearance from the mammary structure. Some of the new growth is involved in the breast in such wise that islands of it lie encapsuled on the surface of the mamma and separated from the skin.

Under the nipple the irregular cystic spaces are not occupied by papillomata; they appear to be dilatations upon thin-walled milk-ducts or sinuses (which are large or wide-mouthed throughout).

The sweat-gland seat and cause of the new growth in this case can be proved easily. The mammary lobules are in marked contrast with the tubular glands, and are on the whole in a distinct basal and marginal stratum. But the penetration of the cystic papillomata is deep in the centre and on one side, and appears to follow the distribution of widely dilated milk-ducts or sinuses; so that one may take the coils of sweat-glands, which had given occasion to them, to have been developed in dependence upon the milk-sinuses. In two other cases, xiv. and xxii., in which the whole or a great part of the mammary glands was obtained along with the tumours, I have found small islands in the midst of the mammary lobules, which were distinguishable to the naked eye and were easily shown by the microscope to consist of muscle-walled sweat-tubes. Considering that the dog has so great a development of the primitive cutaneous glands all over the skin, including the mammary region, and that the milk-gland itself is evolved from them, in the manner maintained in the Introduction, it is not unintelligible that there should be occasional confusion or intermixture of structure, and that accidental variations may be favoured by breeding.

Although it is not the sweat-glands of the mammary region only that give rise to tumour in the dog, yet the proximity of these to the teats, or their involvement in the mammary structure itself, gives a certain character to their morbid growth, and perhaps determines its remarkable frequency and its not unusual multiplicity. In the last analysis the tumours of the mammary sweat-glands arise in the same way as those of other regions of the dog's skin. In all cases there appears to be some difficulty in discharging the excretory office of skin-glands, which is attended or followed by various structural effects, eventually by the total obstruction or effacement of the gland-tubes, and in many cases by extensive sarcoma of the vascular tissue. In the mammary region that functional trouble arises most commonly in the

skin of the teats, and in a majority of cases in old bitches, which may have ceased breeding. It is not unusual to find the mouths of the hair-follicles dilated to crater-like orifices. The sweat-glands opening upon these are also dilated, sometimes having their regular columnar epithelium full of yellow pigment, in other cases with the epithelial lining raised in papillary ridges which project into the lumen. Fig. 91 shows that warty state of the epithelium, which is perhaps the commonest result of a mild degree of disorder. In another degree the warty outgrowths meet across the space and form trabeculæ, by which the lumen is occluded (fig. 92).

But in this figure we begin to have that which distinguishes the whole tumour-pathology of sweat-glands, namely, the connective-tissue cells next to the basement sharing in the process and eventually dominating it. This intrusion of the vascular stroma amongst the layers or papillæ of epithelium is shown first by the presence of long slender nuclei which stain deeply, or of crescentic forms. These all belong to the myxomatous type, and are derived from the walls of the capillary loops around the tube. One of the commonest developments of the myxomatous elements is into cartilage, the vesicular cells of which, filled with hyaline, may so obtrude into the space of the gland as to be readily mistaken for vesiculated epithelium. Spots of cartilage are highly characteristic of the smaller, more chronic, and innocent kind of nodules; where there is no cartilage, there is a certain dense sclerosed state of tissue, which corresponds most with fibroma, although it is neither true fibroma, nor enchondroma, nor fibro-cartilage. In those cases certain portions of the glandular tubes may be intact, and occupied by a brown colloid fluid.

The action of the vascular stroma is so predominant that, in a chronic nodule, it will probably have effaced the plan of glandular tubes altogether. One of the commonest processes is the invasion of the tube by a polypous bud or vascular loop, which drives the surface epithelium before it, projecting into and effacing the lumen, but remaining theoretically outside it. Fig. 93 shows that on a small scale; but those hard fibrous papillomata may be of great size, with a stem or

pedicle. It is on the same papillomatous basis that the most extensive enchondromatous developments take place, each lobule of enchondroma corresponding with an original polypous bud of the vascular stroma.

The *osteomata* belong to the same chronic class, and depend upon the same vascular tissue in the walls of obstructed tubes. In one or two small spots I have found slender trabeculæ of bone springing up in the midst of cartilage, in the regular way of endochondral ossification. But the usual osseous structure in those tumours (it occurs in three or four among two dozen cases) is developed from hyaline stroma as if saturated with a gelatinous or mucinous substance, which becomes bars of bone by the connective-tissue corpuscles taking on the character of osteoblasts. This ossific process advances with great regularity, the blood-vessels, with a somewhat shreddy investment of fibre-nuclei (as in myxoma), making the medullary cavities, around whose walls the osteoblasts are ranged. To complete the picture of true bone-formation, there are occasionally true multinuclear osteoclasts.

The tumours removed by operation, whether nodules no larger than a pea or masses as large as the fist, are usually of old standing, and in most places much transformed; but even in the most chronic and most sclerosed forms there are traces left of an original disorder of sweat-gland function. Here and there in the septa of the tumour one finds a piece of sinuous dilated tube, or sacculations of a tube, or a cluster of small locular cysts, with the muscular basement fairly clear in glycerine preparations. Fig. 94 shows one of these dilated tubes, along with a phenomenon, often met with, which proves the existence of functional disorder. This is the accumulation, in the stroma around the tube, of immense numbers of large spherical, or cubical, or polyhedric cells, filled with grains of bright yellow or yellowish-brown pigment. The source of these is beyond doubt; they are to be seen sometimes *in situ* as the epithelial lining of tubes, most easily in the coils of sweat-glands under the skin. The greatest collections of them are found in the enchondromatous nodules, extravasated into the septa between their lobules. Their

procession is sometimes so orderly in the spaces of the fibrous tissue that it is clear they must have wandered thither (fig. 95). This escape of epithelial products through the walls of sweat-tubes belongs to an earlier stage of the disorder than usually comes under notice. It is the stage of disorder shown in fig. 96, drawn from a sweat-tube in a non-mammary part of the dog's skin. The large yellow cells are only one part of the escaped matters. It is hardly doubtful that the mucinous or colloid fluid, which is often found within the distended tubes, may escape into the tissues around them; and it is sometimes observed that the collections of large yellow cells lie in the midst of fibrous tissue which is swollen almost to hyaline consistency. Probably most of the hyaline or gelatinous substance, out of which the cartilage or bone is made, is produced within the vascular stroma itself in the way of myxomatous change. But the obstruction of the excretory tube is an antecedent, while the saturation of the circumtubular tissue appears to be a matter of fact. One may recall the remark of Astley Cooper, in explanation of his unique case of enchondroma and osteoma of the breast in a woman aged 32, that in chronic cases "a gelatine is sometimes effused which becomes vascular" (*Diseases of the Breast*, p. 64).

The most comprehensive formula for the effect of disorder, obstruction, or suppression of the tubular sweat-glands, is *parablasic adaptation* on the part of the vascular tissue around the tubes. In the chronic innocent cases the vascular tissue grows into the coil of tubing and virtually takes possession of it, reducing it to a somewhat passive sclerosed state, in developing a tissue which is either a kind of fibroma, or enchondroma, or osteoma. But in some cases, which are apt to pass into an acute phase eventually, there appears to have been a prolonged resistance on the part of the tubular glands themselves. Portions of them dilate greatly, becoming small cysts, or clusters of loculi. The dilatation may be attended either by the production of a thick colloid or mucinous fluid, or by numerous small papillomatous growths of epithelial-like cells, or by a uniform filling up of the lumen with larger epithelial cells, whereby the tubes become sinuous solid cords

or cylinders. These processes may continue intratubular in some parts, the wall of the tube becoming so condensed and thickened as to keep the disorder within itself.

But in the wall there may be new growth. In Case xxiii., of which the naked-eye anatomy has been given above (p. 200), there is hardly any other morbid growth but extensive dendriform or convoluted layers of small nuclear cells as if within the dilated tubes, which are so filled out that they amount to some three or four square inches of tumour sunk in the centre of the mamma. This intracystic papilloma is distinguished from that of Case xiv., in a woman's breast, by the smallness of the cells or nuclei and by the firm or stable nature of the whole texture. It is not a soft papilloma with very large cells and vesicular nuclei; but it has to be reckoned in the same class of perivascular sarcoma, not as a complex of vegetating epithelial warts. The truly epithelial vegetations within tubes do not appear to grow much beyond the extent shown in fig. 91; it may be that they do not retain their vitality within tubes beyond those very moderate limits. On the other hand, in this case the new growth within the cysts is made up of long convoluted laminæ, turning and turning again until they fill the whole space, to the diameter of a shilling perhaps, with a close-packed mass of vigorous epithelial-like tissue, and wide blood-vessels in the axes of the epithelial folds. Notwithstanding the general look of a huge growth of epithelium driven before the invading blood-vessels, a closer examination of fine sections shows that the new growth is really outside the basement membrane and developed from the walls of the vessels. The same substitutive process has taken place here as in the above-described small chronic nodules, in which whole coils of tubes have been reduced to a sclerosed state, with hardly a trace of epithelial plan left. In this case the semblance of epithelial formation is retained in the extensively folded laminæ within the cysts; but the constituent cells are only epithelial-like: the new growth is really a sarcoma of small oblong or spindle-cells, which have arisen from the walls of the vessels and taken the place of the original epithelium as a vigorous new *parablastic* growth. If a section from one of the closest parts of these intracystic

papillomata were exhibited without its surroundings, it would be pronounced at once to be a sarcoma of small spindle-cells. The simplest proof of sarcomatous origin is the fact that the belt of cells has a membrane on both its borders—on what should be its *free* surface as well as on its base. I am able to illustrate this remarkable process of epithelial-like new growth upon the outside of the original glandular basement by a figure from my book of 1878, which was there drawn correctly, but was used to prove that the original epithelium of the gland was “massed in several layers” (fig. 97, Pl. XVIII.). The insuperable objection to that view of the facts is the presence of a distinct membrane upon the *inner* ends of the cells. The original drawing shows that clearly enough, although I failed at the time to give due heed to it. The inner membrane is the basement of the original epithelial tube, which is now denuded of its epithelium; and the whole of the existing new growth of cells, in this case long, columnar, and spindle-shaped, has arisen parablatically upon the outer side of the basement membrane. This case, being xiv. of the mammary series in the dog, is not at all cystic, so that the parablatic or sarcomatous new growth follows closely the outlines of individual gland-tubes and makes a pseudo-tubular structure in their place.

In the intracystic papillomata of Case xxiii., the convolutions of new growth are the same long sinuous columns which have been described and figured from sarcomata in the breasts of women (figs. 64, 65, 70); but the type of cell is smaller, more oblong, or less protoplasmic.

The interest of these cases is that they show clearly this perivascular sarcomatosis taking place parallel with the basements of numerous original gland-tubes; they explain the real nature of *cystoma poliferum phyllodes*, which is apt to be masked by its situation as if within a single cystic dilatation.

In most of the mammary sarcomata of the bitch, the new growth transcends the area of the tubular sweat-glands. Case xix. shows one of the ways in which this is done.

Case xix.—20th November 1875. A bull bitch, four years old, which has had several litters. The tumour is elongated and flattened, 4 inches \times 2½

× 1½. A soft piece of mamma is pushed to one side as a wedge between the tumour and the skin. The greater part of the tumour-area is occupied by original sweat-tubes, much dilated, some with collections of large yellow cells in their cavities, more of them with thick colloid fluid of a deep brown colour. There are many heaps of the large yellow cells in the dense stroma around the tubes, as well as large numbers of them in the lymph-glands beneath the tumour—not in the lymph-sinuses only, but everywhere interspersed among the lymphoid cells of the follicles. Some of the dilated tubes towards the surface are packed full with dendriform new growth, as in Case xxiii.

At one end of the tumour, where there is a large intracystic papilloma, the whole upper surface next to the skin is shaggy with villous fringes, which are of pure spindle-celled sarcomatous structure, forming a soft verrucous mass which has penetrated the skin at one point. This corresponds with the marginal growth of sarcoma in the form of many fleshy villosities instead of tuberous or lobular additions within or upon the capsule. The same soft margin, including even the verrucous fringes, is found in cases of osteoma: this has been remarked by Virchow, who describes certain mammary tumours of the bitch as having the centre ossified, the next zone consisting of hyaline or fibrous cartilage, and the outer zone rich in cells or "almost sarcomatous."

Another way in which the sarcomatous process may transcend the area of original tubular disorder is the more immediate and more intelligible one of new growth in the stroma between the coils. This is perhaps the commonest type of the sarcoma of glands. It is associated either with the blocking of the gland-tubes by their proper epithelium, or with their compression and obliteration in some other way, perhaps from shrinkage of the surrounding connective tissue after inflammation. The circumtubular new growth has nearly always an element of myxoma; but its most distinctive types of cell in the bitch are the spindle-shaped and the various epithelial-like cubical or spheroidal cells with large nuclei. The process in the stroma extends outwards from the walls of tubes, in the more dilated of which the degeneration of the basement, and the consequent disintegration of the whole structure, can be traced. This is shown in fig. 98, Pl. XVIII., from Case viii., an extensive composite

tumour extending to two or three teats, of which the greater part was soft greyish sarcoma. The sweat-tube shows on one side the individual muscular ribs standing out swollen and in some disorder, and on the other side the same almost fused into a glassy membrane, within or upon which lie clear vesicles. It is easy to follow the steps of spindle-celled sarcoma in the connective tissue between sweat-tubes in the smaller nodules of Case xiv., already noted in another connection.

Case xiv.—26th June 1875. A large setter bitch. A mammary tumour was removed two years ago (July 1873), which contained areas of cartilage, and had dendritic vegetations on its upper surface. There is now one soft bulging tumour on the right side, at the last teat but one, with symptoms of malignancy for which the animal was destroyed by prussic acid. There are some half-dozen other smaller nodules (*supra*, p. 198); secondary nodules in the liver; the thymus much enlarged with new growth; the vena cava inferior, at a point $1\frac{1}{2}$ inches below its entrance to the auricle, occupied with an ovoid mass $1\frac{1}{2}$ inches long and 1 inch at its broad end, soft, lobulated, sarcoma-like, continuous along a tributary vein with the sarcomatous mass in the thymus; small cystic tumours of both ovaries; both lungs normal; axillary lymph-glands large, mottled, but not occupied by new growth.

The structure of the large bulging mammary sarcoma is shown in fig. 99, Pl. XVIII. Its cells are mostly of the large spindle-celled type, but it is very juicy, shrinking much in

DESCRIPTION OF PLATE XVII.

FIG. 90. Small enchondromatous tumour of the sweat-glands, around the base of a teat in the bitch, Case iii. Natural size.

FIG. 91. Sweat-tube of the Dog's skin occupied with small papillomata of the original epithelium. $\times 150$.

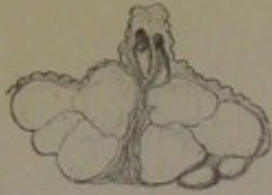FIG. 92. From a chronic mammary tumour of the bitch. Four sections of sweat-tube occupied by new growth largely of vascular origin. $\times 240$.

FIG. 93. Fibromatous bud formed upon a vascular loop which projects into the lumen of a sweat-tube of the Dog's skin. $\times 60$.

FIG. 94. From an enchondroma of the mammary region in the bitch. Group of sweat-glands, the dilated parts showing the muscular basement and mucous contents. Infiltration of the stroma with yellow granular epithelial cells, *a a a*. $\times 100$.

FIG. 95. Mammary tumour of the bitch, Case xiv. Infiltration of large yellow granular cells (cast-off epithelium of sweat-glands) into spaces of the stroma. $\times 150$.

FIG. 96. Wall of a sweat-tube of the Dog's skin, showing at *a a* catarrhal state of basal epithelium, and at *b b* infiltration of cells outside the basement. $\times 150$.



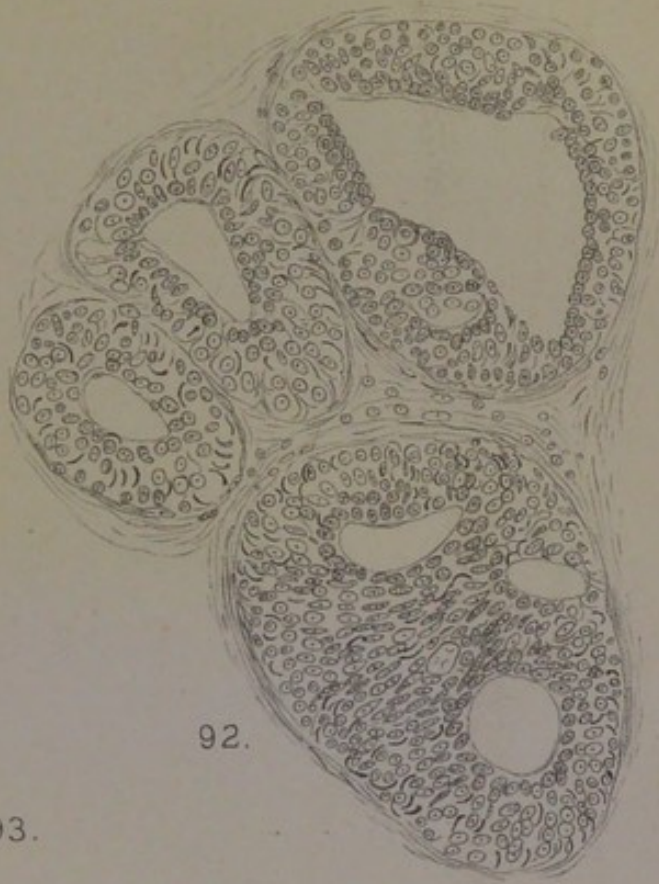90.



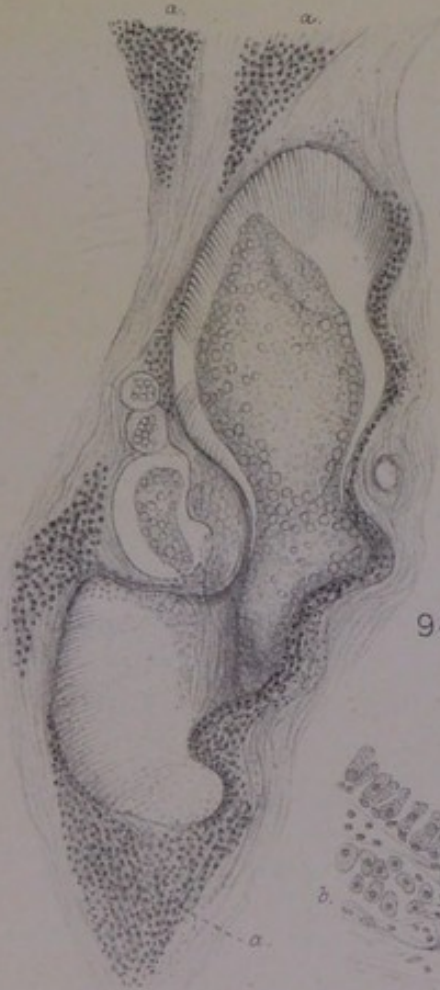91.




93.



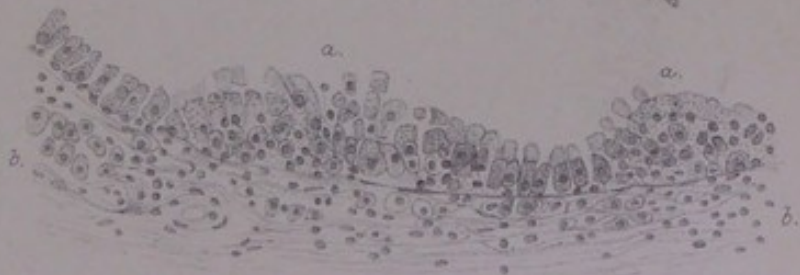
92.



94.



95.



96.



preserving, and has an undoubted mucous or myxo-sarcomatous character, which is shown in the figure by the larger masses lying within the figure-of-eight tracts of spindle-cells. In the smaller nodules there is abundant evidence of the beginnings of sarcoma between and around the coils of disordered sweat-tubes; also that the parablasic new growth does not stop there, but extends to the stroma at large, including the vascular territory of the mamma proper.

This introduces the last point which I think it necessary to dwell upon in this connection.

Whatever malignancy certain of the cases in the bitch may have, it is usually a rapid development of a chronic tumour, and always of a sarcomatous kind. It consists in a great extension of the chronic tumour-disease in the form of soft lobulated masses upon one or more parts of its periphery, of secondary masses in the viscera (lungs or liver, or both), and sometimes of extension to the lymph-glands under the tumour. In three of the cases, there is a concurrence of evidence that the chief field of the sarcomatous extension around the primary sweat-gland growth is the mammary gland itself. In the bitch, even in old age, the extent of mamma which may be invaded by sarcoma is often considerable. The corresponding phenomenon is less frequent in the breasts of women, owing to the fact that obsolescence has usually proceeded far towards fibrous or adipose effacement before the tumour-process begins; but there is clear evidence of its existence in a few lobules of breast in the human Cases x. and xv. As this is the actual point in the pathology of mammary tumours, whether of women or of the bitch, at which the proper milk-gland structure is involved, and is therefore the point at which this exposition of the sweat-gland seat and cause comes into relation with current teaching, it raises an important issue.

The following case in the bitch will serve to introduce it:—

Case xiii.—18th January 1875. An old Pomeranian bitch. A very large tumour at the inguinal teat of the left side. It had existed a long time, but has grown rapidly of late, and has become cystic under the skin. No other part of the chain of mammae is involved

on either side. At the operation the mass came away easily, being definitely bounded, and resting beneath upon a cushion of fat. It weighed 13 oz., and measured 4 inches \times 3 \times 3. The teat is upon one side of the globular protrusion. Under and around the teat is a cyst, from which 3 oz. of thick brown colloid fluid escaped on puncture. The walls of the cyst are locular and trabeculated. The skin forming its outer wall, upon the side of which is the teat, has an under stratum of intracystic papillomatous new growth, the same as in Case xxiii. (p. 200), hardly more than a quarter of an inch thick, which connects on the one hand with the loculi of the large cyst, and on the other hand with large dilated coils of sweat-glands, otherwise normal, in the corium. This original part of the new growth—intracystic papilloma and cystic loculi—is enclosed around and beneath by a great lobulated mass of sarcoma, just as in Case xxiii. the intracystic papillomata are sunk in the lobes of normal mamma. The sarcomatous mass makes the floor of the cyst, about two inches thick, and extends beyond it at one end as a lobulated body exactly the bevelled shape of the inguinal end of the mamma.

The dog remained under observation six weeks. The wound healed well. But the general health failed, and the animal, being moribund, was killed on 4th March. The liver contained one large white mass filling its central part from back to front, as well as many smaller nodules. The lungs contained several large masses near the surface. The rest of the mammary chain was dissected off on both sides, and found to be a very thin stratum at places, with much fibrous stroma and large ducts filled with yellowish substance, while there were other parts of it an eighth of an inch thick.

The dominant structure of the tumour, including the secondary growths in the liver and lungs, would be counted alveolar sarcoma of medium-sized spherical cells. The great solid mass, beneath and beyond the floor of the cyst, was regularly lobulated, of firm soft consistence, greyish colour, cutting with a uniform granulated surface. There are areas of myxomatous tissue in the part nearest to the original intracystic papillomata of sweat-glands under the teat. In certain central parts the sarcomatous structure is clearly perivascular, the wide mouth of a central vessel looking like the lumen of a thick-walled tube. But the greater part of the sarcoma is contained within alveoli of remarkable regularity, although of various size and shape—regular, namely, *in respect of the enclosing vascular membrane*. The sarcomatous cells look as if they had been deposited within pre-existing vascular limits, the boundaries appearing smooth, regular, and perfect, so much so that one seems to

be looking at a section of normal thymus. The same striking regularity of the containing vascular wall is found in certain areas of the new growth in two breasts of women, x. and xv.; and in the latter it is obvious that the regular spaces distended with round sarcomatous cells pass by transition into the mammary acini of adjoining lobules of which the resting nuclear cells are merely increased in number, and these again into lobules which are in all respects normal. Inasmuch as the form of the whole sarcoma, in this case of the bitch, is that of the thick inguinal end of the mamma, while its lobulation corresponds with mammary lobules, and its alveolar collections of round cells are contained within vascular limits which are altogether unlike newly formed vascular stroma, it can hardly be doubted that the mamma underlying and enclosing the primary tumour (cystic) of sweat-glands had been annexed by the sarcomatous process. The sarcomatous extension in Cases viii. and ix. (14th October 1873 and November 1873) is of exactly the same kind—distending the acini with spherical sarcoma cells, keeping within the original vascular limits of acini, retaining the form of lobules, and even the shape of mammary lobes as a whole. In all three cases there are certain fringes of mamma not yet annexed; and in these it is remarkable that the acini are all more or less roused from the extreme state of involution, some of them having their full width and a very perfect mosaic of epithelium, although none of the animals was pregnant nor known to have been so just before. That some other cause than pregnancy had excited them was apparent from various things, including the width of the vascular intervals between the acini, and the presence of many leucocytes around the vessels.

In accounting for this extension of sarcoma to whole lobules and lobes of mamma, it would get rid of paradox to make the resting nuclear epithelium of the acini perish, and to assign the whole of the sarcomatous cells to proliferation from the walls of capillaries, and to leucocytes. But the facts do not suit that simpler hypothesis, in the cases of sarcomata which have begun to grow rapidly and to acquire

malignancy. In such cases, at least, the resting nuclear cells (which are capable of becoming a secreting epithelium) react as if they belonged to the same order of cells as those in the walls of the blood-vessels.

In the large sarcomata of the bitch, which invade the mamma itself, the alveoli of the new growth are not always merely packed with round cells. Both in ix. and xiii. there are areas of tumour which have a well-marked pseudo-glandular structure, the cells being ranged epithelium-wise around a central lumen. Not unusually they project into the lumen in rounded knobs or with an undulating border. The whole look of these glandular areas is quite unlike that of an original or archiblastic gland; they convey the same impression of absolute newness as the subcutaneous sweat-gland sarcoma from a child (Case xxii.). In the secondary nodules of the lungs, for example in Case ix., the pseudo-glandular type of sarcoma is universal. Among the distinguishing characters of those pseudo-epithelial cells are their fusion in masses, the largeness of their nuclei, and a peculiar dull granular appearance of the protoplasm (*supra*, pp. 149, 185, 187).

One more point worthy of notice is illustrated by Case xviii., 19th October 1875. There is one large, soft, translucent tumour, about the size of a duck's egg, which had grown fast during the previous six weeks, as well as several small chronic nodules. The large mass has patches of enchondroma, as so many of the chronic nodules have; but it is becoming soft or sarcoma-like all over, from a change into chondrosarcoma. The clear proof of the access of malignity in a previously benign growth is furnished by an enlarged lymph-gland belonging to the inguinal cluster, which has distinct spots of chondrosarcoma (large glutinous polymorphic cells) in the midst of the lymphoid cells.

CHAPTER X.

COMPARATIVE PATHOLOGY: SARCOMATOUS TUMOURS OF SWEAT-GLANDS IN NON-MAMMARY REGIONS OF THE DOG'S SKIN.

THE dog, which is remarkable for the high degree of development of large muscle-walled sweat-glands in all parts of its skin excepting the balls of the toes, is also remarkable for the frequency of cutaneous tumours (*supra*, p. 196). They occur on the back, on the head and neck, on the flanks and on the hips. One common form is the protruding fleshy wart, apt to bleed, which may be single or multiple, and ranges in size from a button to a fungus three or four inches broad. Sometimes its surface consists of fleshy papillæ, like the verrucæ of the human skin, excepting that they do not appear ever to be melanotic; in other cases the surface is merely lobulated, and is often in a sloughing state; in all of them the structure is sarcomatous, with an element of myxoma, and, in the smaller buttons, with the kind of perivascular tissue which may be called fibro-nuclear. Another kind is strictly subcutaneous, distending the skin without breaking it: they are encapsuled, like the subcutaneous sarcomas of man, and may be firm and lobulated, or fluctuating from the amount of mucous juice, or cystic from mucinous softening or excavation. Whether these tumours of the dog be fungous protrusions or still covered by skin, they are all flat-based, broad, and relatively thin strata of new growth, evidently in the corium and subcutaneous tissue. In the following series of twelve cases there are only two (xi. and xii.) which bear evidence of some widespread implication of the hair-follicles, giving the morbid growth its structural type (which is not, however, epitheliomatous); in all the others a disorder of the sweat-glands appears to have

been the occasion of the tumour, the excretory structure perishing eventually over the affected spot of skin, and a sarcomatous new growth arising in its place, which is either circumtubular in respect of individual sweat-tubes, or made up of lobes and lobules upon a vascular basis parablastic to a whole coil of obliterated sweat-glands. The following list will show the variety of forms and structures met with:—

i. Two similar protruding flat fleshy warts on the backs of dogs (May and June 1873), the one oval, $1\frac{1}{2}$ inches in its longer axis, the other circular, 1 inch in diameter, both about $\frac{3}{8}$ inch thick in the centre, the whole surface raw. The structure consists of innumerable cord-like tracts with nodal points, which are obliterated vessels, and around these a new growth of small and ill-defined cells, which may be called fibro-sarcomatous.

ii. Large flat fleshy wart protruding through a dog's skin (October 1875), lobulated in the interior, with elongated blunt papillæ on the surface, from $\frac{1}{4}$ to $\frac{3}{8}$ inch thick, with a flat base resting on loose connective tissue, and covering an area nearly as large as the palm. The whole disc-like growth penetrates the skin and is raised above its level; a small fringe of hairy skin removed around the base of the growth. The lobulated structure is sarcomatous, of the type of small cells, round, oblong, or spindle-shaped.

iii. A large flat sloughing fungus of the back of a dog (August 1875), about the size of the palm, forming a well-defined lobulated stratum, not more than $\frac{1}{4}$ inch thick for the most part, but rising at one overhanging edge to a thickness of $\frac{3}{4}$ of an inch of the same compact dense lobulated structure; the under surface is flat and definitely limited, resting upon muscles, etc., and not infiltrating them. It is a sarcoma with a marked epithelial type of cell.

iv. Soft white tumour of the skin of a dog (1873), about $1\frac{1}{2}$ inches in diameter at the base, distending the skin and rising into three or four hairless small soft bosses, one of which is ulcerated. The upper part of the tumour is almost diffluent; the lower is firmer, uniform, sarcoma-like. The greatest thickness is about $\frac{3}{4}$ inch, the base flat, the perpendicular section showing a few cut ends of muscular bundles embedded close to the capsule beneath. The structure at places would be called lympho-sarcoma from the fine reticulum in which the small round cells are set; but in other places it would be round-celled sarcoma.

v. Spherical tumour of the head of a dog (17th August 1875), about the size of an orange, the skin thinned away to a membrane at the summit, but entire upon the sides of the tumour down to the base, which is dissected off clean from the underlying tissue. The tumour is cystic, with a beautifully trabeculated interior—rounded and polished small trabeculæ crossing the cavity in all directions or hanging free into it with rounded ends, like stalactites from the roof of a cave. The superficial half of the

tumour was most excavated, the base being a solid lobulated mass with a maximum thickness of an inch. The structure was spindle-celled or oblong-celled sarcoma of the smaller type of cell, with slender septa. The cystic spaces contained a clear brown fluid in which were a number of gigantic spherical cells possessed of active movements when examined warm, shooting out short processes of their protoplasm from point to point of the circumference and withdrawing them again, like horse-chestnuts or like the bristled side of osteoclasts of bone when fixed.

vi. Ovoid tumour about the size of a pigeon's egg, from an aged Scotch terrier (12th January 1876), lying close under the skin of the temporal fossa, and separated by a capsule from the temporal fascia, the skin over it thinned but not broken. It is of uniform compact consistence, greyish-red colour, finely lobulated, and has a remarkable alveolated sarcomatous structure.

vii. Protruding fungous nodule of the skin over the nasal bones of a dog (22nd October 1875), about an inch in diameter at the base. The dog died with numerous white nodules in the lungs about the size of marbles. Both the primary and secondary tumours had the exquisite structure of spindle-celled sarcoma, the cells in decussating bundles and of medium size.

viii. Large soft gelatinous tumour of neck of a dog (July 1875) with irregular cystic spaces, discoid, about 3 inches in its longer axis, the base flattened, the skin entire over it but joined intimately to it, hairless at the summit. The cystic spaces penetrated as slits between soft tuberous masses, the larger of which were an inch thick. The fluid contents were clear brown, of the consistence of mucus. The solid masses also contained smaller cysts, some of which had smooth walls lined by a soft pellucid membrane. The structure was sarcomatous, but not uniform at all points, the cells in some parts being very large spherical elements with mucous contents, with which were mixed many exquisite spindle-cells having long processes; while in other places the sarcomatous type was of smaller cells, all of one kind, crowded in the interstices of fibres, of various angular shapes, and resembling the figures of some myxo-sarcomata.

ix. Soft gelatinous tumour under the skin of the hip of a dog (16th January 1876), hemispherical, 2 inches in diameter at the flat base. It was diagnosed a cystic tumour, but proved to have no interior cavity, its texture throughout being gelatinous, mobile, fluctuating, with some appearance of fibres running through it. It is a mucous sarcoma of large quadrate or spherical cells, often ranged in remarkably regular rows like cubical tendon-plates.

x. Large hemispherical tumour of the skin of a dog (December 1874). The bulging skin is partly denuded of hair, and is ulcerated at one small spot. The tumour has a flat base resting on loose connective tissue, about $2\frac{1}{2}$ inches diameter, and the depth $1\frac{1}{2}$ inches at the centre. It is clearly a lobulated tumour of the sweat-glands, with larger and smaller intracystic papillomatous growths, and many dilated

tubes without papillomata but with enormous infiltration of epithelial products, pigmented and other, into the stroma around them. At one side there is a solid area of soft sarcoma which forms a base to a soft tuberous intracystic growth. The sweat-gland structure is so prominent in this case that it is comparable with several of those described above from the mammary region, especially with Case xxiii., embedded in the thick inguinal end of the mamma.

xi. Small flat button-like growth on the back of a terrier (17th November 1875), protruding through the skin, with flat base resting upon connective tissue and fat, 1 inch in diameter, and not more than a quarter of an inch thick in the centre. The superficial stratum of tumour has a structure suggesting hair-follicles. Next to it comes a stratum of dilated sweat-glands, with infiltration of epithelial products, pigmented and other, into the spaces of the stroma. The lowest stratum, containing areas of subcutaneous fat, has numerous scattered small clusters of epithelial-like cells around the walls of blood-vessels.

xii. Discoid tumour of the skin (December 1874), with flat base 2 inches diameter, half an inch thick at the centre, close under the skin, which is denuded of hair except round the base, and is ulcerated at the summit. The tumour is lobulated, and is definitely encapsuled at its rounded borders under the sound hairy skin. It appears to consist in great part, if not altogether, of a remarkable tumour-condition of the hair-follicles.

Three of those dozen cases, Nos. iii., x., and xi., have been used before in a paper, "Three Cases of Tumour arising from Skin-glands in the Dog," *Med. Chir. Trans.*, 1882; and three more of them, Nos. v., viii., and ix., were used in a paper, "Illustrations of the Pathology of Sarcoma," *Journ. of Anat.*

DESCRIPTION OF PLATE XVIII.

FIG. 97. From Case xiv., bitch. New growth of spindle-shaped and long columnar epithelial-like cells outside the basement, *a a*, of the gland-tube, from which the original epithelium has disappeared. $\times 300$.

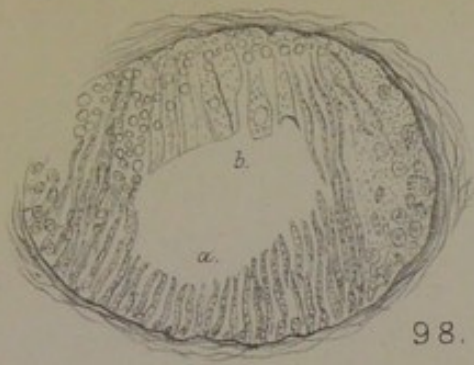
FIG. 98. Wall of a sweat-tube in mammary tumour of Case viii., bitch. *a*, the muscular basement as thick fibres; *b*, the same as a glassy membrane with vesicles. Glycerine-gum preparation. $\times 200$.

FIG. 99. The larger soft tumour of Case xiv., bitch. Spindle-celled sarcoma: decussating tracts of cells enclosing mucous areas. $\times 300$.

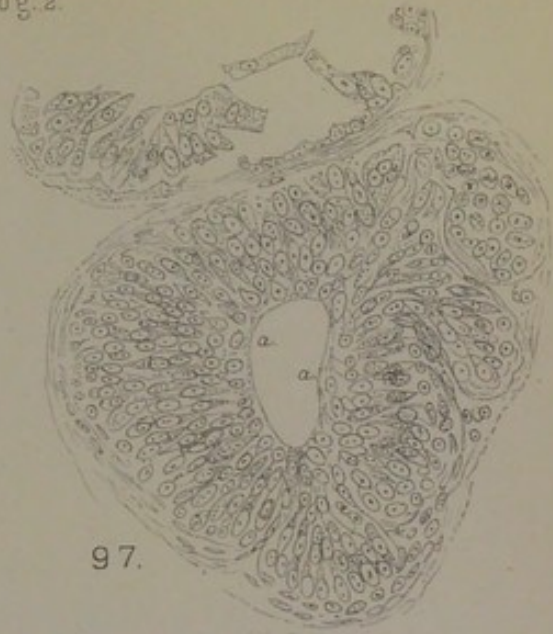FIG. 100. Three alveoli of a sweat-tube in a dense fibrous septum of sloughing sarcoma of dog's back, Case iii.* The plain muscular fibres shown as dark lines. $\times 120$.

FIG. 101. Mucous sarcoma with cysts, in dog's skin, Case viii.* *a*, dilated coil of sweat-glands; *b*, lobule of sarcoma occupying a vascular territory between two coils of sweat-glands. $\times 90$.

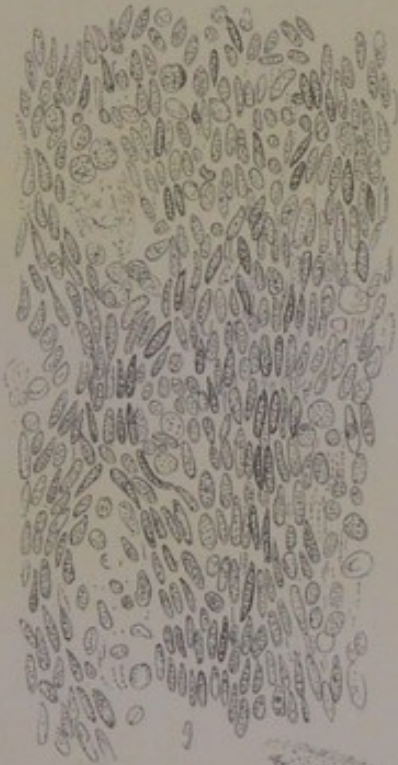Doğ. 2.



98.



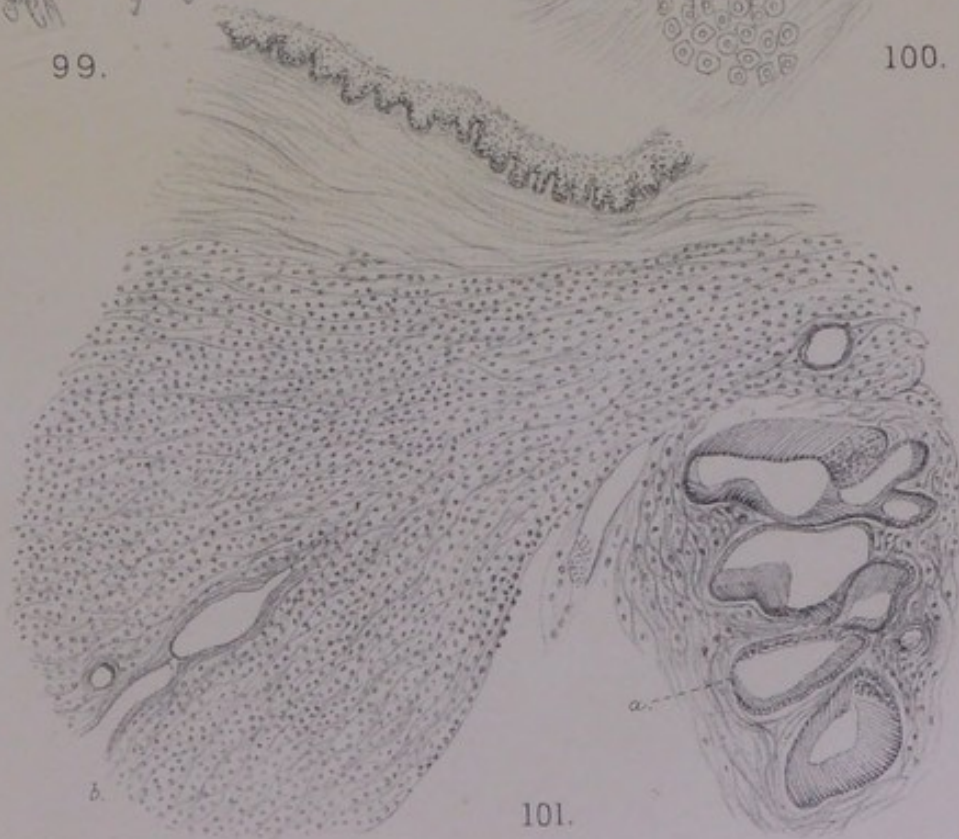
97.



99.



100.



101.



and *Physiol.*, xiv. 1880. Farther study of the former group discovers a sarcomatous character in them, and of the latter group an implication of the sweat-glands in the sarcoma; and for the remaining six cases I allege the same association between sarcomatous type of new growth and disordered excretory glands of the skin. In two of the new cases, Nos. vi. and vii., an implication of the sweat-glands may seem far-fetched: the one was a typical encapsuled subcutaneous small sarcoma, compact and uniform, of a somewhat peculiar alveolar structure; the other was a typical spindle-celled sarcoma, in decussating bundles (with secondary nodules in the lungs), in which portions of well-preserved sweat-tubes were found here and there in the midst of the new growth, as if isolated, cut off, and accidentally involved by it. The conventional view of such cases is, that the connective tissue becomes somehow sarcomatous, and that the sarcoma invades the territory of the glands, superseding and destroying them. The sarcoma is supposed to have no more relation to the glands of the part than if it had arisen in periosteum, or in fascia. This is the conventional view of sarcomata of all glandular organs and parts, including the breast, the testis, the kidney, the parotid, the upper jaw (antrum, etc.), and the skin; so far so that even a marked epithelial *habitus* of the cells, or a development of tubular or other pseudo-glandular structure in parts of the sarcoma, is taken to be "merely an interesting phenomenon" (Kolaczek).

First, as to the involvement of sweat-glands within the area of the new growth. If they are not everywhere so obvious as in Case x., they will be found in all in the denser septal tracts between lobules, or in the angles made by the fungous protrusion with the skin, or on the capsule of the tumour, or within its growing borders (fig. 100, Pl. XVIII.). Secondly, as to the condition of the sweat-tubes. In some cases there is sarcomatous new growth very definitely disposed around their walls, or circumtubular; in other cases, the bud-like masses of sarcoma, corresponding with loops of vascular tissue ascending from the depth, alternate with whole coils of sweat-glands dilated, denuded of epithelium or otherwise disordered (just as in the small

sarcomata of the face, etc., they alternate with the columns of rete mucosum); in still other cases the sweat-tubes are extended, necrosed, compressed, and reduced to little more than bundles of their muscular ribs.

In Case viii., a cystic mucous sarcoma, the gelatinous tissue contains in certain parts a number of irregularly shaped spaces besides regular smooth-walled cysts. The irregular spaces (fig. 101, Pl. XVIII., right side) are a coil of very much dilated sweat-glands, their muscularis being easily seen, but their epithelium indistinct and in part reduced to detritus. On one side of the coil and in the interval between it and the cutaneous surface, the interstices of the connective tissue are full of sarcomatous cells. The relationship between the disordered sweat-glands and the surrounding sarcomatosis of the stroma is not self-evident here. But if we turn to the smooth-walled cysts of the same case, it will appear to be a causal relationship. From the interior of a bisected cyst a soft pellucid definite membrane can be peeled off entire, with a film of opaque detritus lying upon its inner surface. Spread out, stained and mounted, it is found to be the muscular basement—the ribs swollen and recognisable only by the regular lines of staining along their parallel borders, with the lining of epithelium reduced to a granular amorphous thin and cracked cake on the surface. The pellucid skin of the cyst comes away sometimes in two layers. Using a protoplasmic stain, one can make out clearly enough the swollen parallel muscular ribs in the inner of the two by means of the regular streaks of granules along their margins, as in fig. 102, Pl. XIX. But the muscularis has adhering to it nucleated cells, which are of the highest interest. One kind of these are drawn at the bottom of fig. 99, exactly as they show in those parts of the field where the granular margins of the muscular ribs are clearest: they are exquisitely branched myxomatous cells, forming a layer so regular that it might pass for a normal plasmatic structure, such as is found in the pulp of the enamel organ. In the outermost layer of the lining of the cyst, only traces of the branching or multipolar connective-tissue cells are found, but these are sufficient to show how

the characteristic tissue of that layer has arisen out of the former. That characteristic tissue is a mixture of bipolar spindle-cells, with long processes, and of deeply stained mucus-holding spherical cells of various sizes up to very large spheres, linear tracts of this mixture of cells occurring with more or less clear granular intervals between them, as in fig. 103, Pl. XIX. This is the most distinctive structure of the tumour at large, as seen in sections of its solid lobes (compare the drawing, fig. 8, Pl. XV., *Journ. of Anat. and Physiol.*, vol. xiv. 1880); and it is the same as on the wall of a dilated and degenerated sweat-tube. Not only so, but it grows out of the normal branched plasmatic cells next the muscularis in an intelligible way: nuclei of the branching cells come to be free in vacuoles, and grow to be the large spherical cells, while some nuclei become parietal on the vacuoles (as in fat-cells) and are set free as bipolar or spindle-cells (compare pearly tumour, p. 117).

As an excretory organ the tube has degenerated; while a vigorous new growth, beginning on normal plasmatic lines, has started up from the connective tissue round about it. What is here taking place in strict relationship to the decay of a piece of excretory tubing is taking place elsewhere *en masse* in relationship to whole coils, according to the pattern of fig. 101. The cystic enlargement of the coils of sweat-tubes in Case viii. enables one to mark clearly a certain general plan of the sarcomatous new growth in respect to the degenerate or perishing excretory glands, which may be discovered also in other cases in the dog (as well as in the small sarcomas of the skin in man, pigmented or other). In health the coils of sweat-glands descend from the surface perpendicularly or obliquely at intervals (fig. 4). The intervals between them are occupied by processes of stroma ascending from the depth, having the rounded sweep and form of vascular loops. It is in the interstices of these vascular processes, and more especially around the walls of vessels, that the sarcomatous cells are developed. This is seen in fig. 101, but is seen best in a panorama of several coils of sweat-glands alternating with lobes of tumour. The very numerous blood-vessels become occluded at length,

their cross-sections appearing in these mucous sarcomas as concentric rings of almost solid connective tissue. This occlusion of the new vessels of angiosarcoma has been described by Kolaczek for the upper jaw, and by G. B. Schmidt for the breast. It is seen most clearly among my cases from the dog in the two fleshy warts included together as Case i. : here the occluded vessels in a certain plane of section form a plexus of anastomosing solid round cords, in the intervals of which lie the small sarcomatous cells : in cross-sections of the same cords, the tumour-cells are disposed around them in concentric rows.

Returning to the causal relationship between degenerated sweat-tubes and sarcomatosis of the stroma, I shall take next Case v., a sarcoma the size of a billiard ball, with a cystic interior occupied by innumerable rounded and polished fine trabeculæ, and with lobular masses in the solid wall. This may seem a most unlikely case for any relationship to the sweat-glands ; and so it is, so far as concerns the region of the trabeculated cyst, which is the oldest part of the tumour and is purely sarcomatous. But the case illustrates an important principle in sarcoma, namely, that it grows by accretions upon its periphery, and that the way in which those new centres are annexed reveals how the older parts had become sarcoma. On the periphery there are lobules of new growth with coils of sweat-glands in obvious relation to them. I could draw from Case v. exactly the same kind of coil of greatly dilated sweat-glands that I have drawn from Case viii. (fig. 101), with the same sarcomatosis of the stroma around, excepting that the cells are small round or oblong. The round-celled or small spindle-celled sarcoma is not so clearly a tissue related to a plasmatic office as the myxomatous sarcoma is ; but the similarity of origin and of occasion is unmistakable.

The cystic trabeculated interior of the sarcoma in Case v. is the oldest part of the process, and as such it shows the ultimate fate of the blood-vessels around whose walls the new growth had formed in the stroma. The axis of each of the innumerable fine trabeculæ is an occluded blood-vessel. The rete of blood-vessels are reduced to solid cords

with tumour-cells around them, just as they are seen in a sectional view in the fleshy warts of Case i. ; but in Case v. the cystic excavation removes the outer layers of cells (as in cases of cylindroma those layers become hyaline), so that the anastomosing solid columns become an intricate net of rounded and polished trabeculæ, many of them hanging free into the space with rounded ends.

Case iv., a soft white medullary round-celled sarcoma, or lympho-sarcoma in places, is so clearly seated within the limits of the corium that a relationship to its sweat-glands is not improbable. Coils of dilated and denuded sweat-glands are in fact found by looking in the right places, having the circumtubular tissue full of cells. In one set of sections the tubes are extended almost straight and can be followed for a long distance, with lympho-sarcomatous tissue around them. But the best proof of a primary glandular disorder is got from the yellow granular pigmentation of the cells around some coils of tubes ; these are the cast-off epithelial cells in a certain state. Enormous collections of those yellow cells are distinctive of Case x., which is almost purely a tumour of the intracystic type, and becomes a key to Case iv. I have discussed elsewhere (*l.c.*, 1882) the circumstances of these extravasations of epithelial cells in Case x. and the relation of them to the new growth.

Case ix. is distinguished by the remarkable regularity and great size of the sarcomatous cells in the interspaces of the fibrous basis (fig. 104, Pl. XIX.). These great cubical or quadrate elements, with a broad zone of mucous protoplasm round a central nucleus, look as if they were infiltrated into the lymph-spaces, just as the large yellow epithelial cells of figs. 94, 95, certainly are. But in this case they are developed where they lie : they are like the tendon-plates of a piece of tendon in a granulating stump (compare the figure, *Journ. of Anat. and Physiol.*, xiv. 1880, p. 30) ; or like the glycogen-cells of the same size and form in certain genera of the Mollusca, which correspond with the radicles of blood-vessels and are in the place of a lymphatic circulation (see my work, *Glycogen of Snails and Slugs, in morphological*

and physiological correspondence with the *Lymph-System of Vertebrates*, London, 1899). Their most intelligible grouping in Case ix. is around the walls of blood-vessels, where they form bright concentric rows in the cross-section or cylinders in the longitudinal section. The sweat-tubes are discoverable only by occasional narrow bundles of plain muscular fibres; the blood-vessels in turn become obliterated; and only the extensive columns of vigorous plasma-cells remain in the place of gland-tubes and blood-vessels, both alike suppressed.

Lastly, Case iii. will raise the question of a disorder passing from the sweat-tubes to the stroma in its extreme and most difficult form. This is a case which formerly I reckoned a carcinoma on account of the marked epithelial type of cells breaking out in concentric rows around the remains of sweat-tubes in the stroma, adducing it to show "the connection between disorder of the glandular structure and function and cancerous invasion of the connective tissue" (*Med. Chir. Trans.*, 1882). But the tumour—a flat cake the size of the palm of the hand, of firm lobulated tissue, with a sloughing surface and sharply defined base, protruding through the skin as a fungus with overhanging edges—is in all external characters a sarcoma, and is closely allied to other fleshy warts of the same situation which have less epithelial-like cells or cells not at all epithelial. The origin of the epithelial-like cells in this case from connective-tissue cells of the stroma I maintain as before, and merely repeat my original figure of the process (fig. 105, Pl. XIX.). But I would drop altogether the notion of "cancerous infection" of the connective tissue, and raise the same issue in another form. The new growth is sarcomatous; and its relation to the original epithelial-glandular structure of the part is that of parablaster to an archiblast which has fallen into disorder (as the sweat-glands of the dog's skin are apt to do), and has been eventually superseded and obliterated. The reasons for changing the formula are these. In the first place, although the epithelial type of stroma-cell is remarkable in some preparations, especially those treated with a nuclear stain, yet the structure in other places is so compact with angular

and processed cells that it gives almost the appearance of that myxo-sarcoma (of the upper jaw) which was familiar to many of us thirty years ago from the woodcut on the cover of the new edition of Virchow's *Cellular-Pathologie*, 1871, being fig. 113, II., of the text. Next, it does not appear that the epithelium of the tubes within the affected area of skin takes any active part in the tumour-process. Tubes, or clusters of tubes, are met with, in some instances dilated, but always with the signs of retrogression both in their epithelium and in their muscularis. On the other hand, the exterior of a tube, where it can be seen as in fig. 106, *a*, Pl. XIX., is found to be coated or plastered over with cells having the same situation and probably the same physiological meaning as the plasmatic cells of Case viii. from the wall of a cystically dilated sweat-tube. If the left-hand side of fig. 106 be examined, it may seem as if the group of tubes, *a*, became continuous with the series of alveolar spaces, *b*, occupied by epithelial-like tumour-cells, and as if the latter had begun in tubes and had extended by annexing concentric rows of stroma-cells around their lumen, until there was no stroma left to be included. Other places show, however, that the whole tumour-process is extratubular, although not out of all relation to the sweat-tubes. The vascular stroma over a certain territory in relation to a coil of sweat-tubes begins to produce cells interstitially, usually in decussating tracts or bundles; the cells acquire the mature tumour type (in this case it is epithelial-like) successively from the interior to the margins of the tract or bundle, so that they seem to lie in an alveolar space bounded by nucleated connective tissue. The relationship of the sweat-tubes to these territories of the stroma is the same that has been shown in Case viii., fig. 101; the new growth is parablasic to an obsolete archiblast. Injury or disease, usually in old age, has brought about some failure of function, with loss of structure, in the organs of excretion at a certain part of the dog's skin; the vascular stroma has adapted itself to the suppression or obsolescence according to the parablasic principle of embryonic development, the parablasic new growth assuming various forms ranging

from plasmatic (myxomatous) to pseudo-glandular (epithelial-like).

DESCRIPTION OF PLATE XIX.

FIG. 102. Wall of cyst in mucous sarcoma of dog's skin, Case viii. *a*, swollen muscular fibres of basement of dilated sweat-gland; *b*, layer of myxomatous branching cells outside basement. $\times 200$.

FIG. 103. General structure of mucous sarcoma, Case viii. Spindle-cells and large spherical cells in a mucous granular basis. $\times 200$.

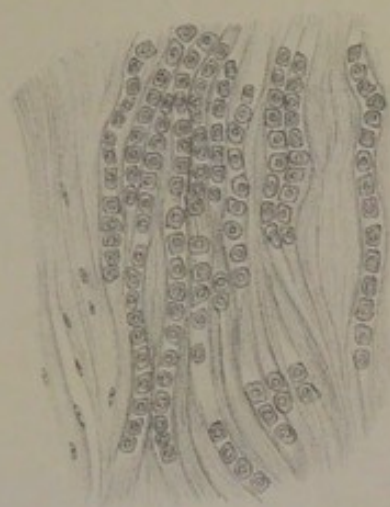
FIG. 104. Mucous sarcoma of the skin of dog's hip, Case ix. Rows of large cubical cells with mucous protoplasm, as regular as tendon-plates. $\times 150$.

FIG. 105. Development of epithelial-like cells in the dense fibrous stroma of dog's skin, Case iii., sarcoma. *a*, region of large epithelial-like cells; *b*, region of spindle-cells. $\times 350$.

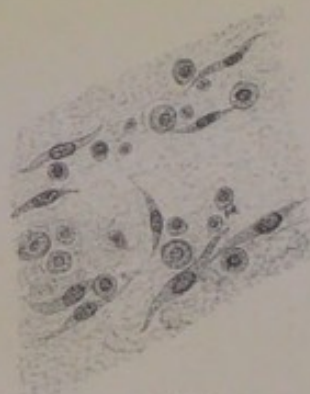FIG. 106. Same case of sarcoma of dog's back, Case iii. *a a a*, group of compressed and denuded sweat-glands; *b b b*, sarcomatous new growth in alveolar masses. $\times 90$.



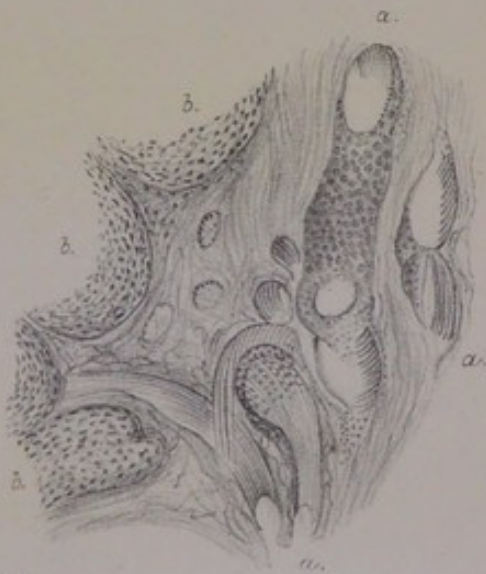
102.



104.



103.



106.



105.



CHAPTER XI.

SCIRRHUS.

WHILE the clinical definition of sarcoma of the breast contains the notion of a tuberos vascular growth, bulging out the skin and likely to burst through it as a soft bleeding fungus, encapsuled and lobulated, with a cut surface uniformly firm and flesh-like; that of scirrhus, on the other hand, implies a hard knot embedded in some part of the breast, moving with the organ, having abrupt rigid sides or borders, apt to draw down the nipple or pucker the skin, sometimes to affect the whole skin around with a leathery hardness and stiffness, intricately connected with the surrounding tissues by pointed processes or irregular roots, hard and dense to cut, glossy, translucent, and sometimes bluish-white, cupping on section, and yielding a greyish turbid juice from alveolar spaces amidst denser fibrous tracts. The contrast thus drawn between sarcoma and scirrhus, or between soft and hard cancer of the breast, is a very marked one, and in many cases the diagnosis can be made with much certainty. But as soon as we come to deal anatomically with a succession of breast cases, exploring each thoroughly and putting none aside into a neutral or nondescript class, we shall find that the division is not a true one in pathology. Those characters which seem to separate one kind of cancer from another are really among the *accidentia*; and so they are apt to be regarded by operating surgeons, some of whom make no distinction of sarcomata in their tabulated series of cases, even when they profess the doctrine of the epithelial origin of cancer. It was remarked by Rindfleisch, thirty years ago, that the progressive study of the several tumours of the breast tended rather to the removal of boundaries

than to making new divisions. Billroth also, in his treatise of 1880, has said that, whereas formerly it was the peculiar multiformity of mammary tumours that made them a favourite study, it is now their developmental history that attracts. Both statements probably mean the same thing; and they correspond with the well-known change in Velpeau's point of view towards the end of his life, after he had taught for thirty years that tumours of the breast were separated in kind by hard and fast lines. Still, as Wedl has remarked, classifications are the "indispensable categories" of thought. Accordingly, I bring all my remaining illustrations under the head of scirrhus, which is, moreover, a category of high clinical value. But, just as there were three cases in the chapter on Sarcoma which were really scirrhus in the centres of the tumours, so the three first cases of this chapter might have been included under sarcoma in respect of a considerable part of their structure.

CASE XXIV.—*Small discoid Scirrhus of the whole corpus mammæ.*

Breast of a married woman, aged 56, who had borne seven children, amputated for scirrhus by Dr [Sir G. M.] Humphry at Addenbrooke's Hospital, Cambridge, in 1879. The whole organ is small or shrunken, about the diameter of a crown piece, $\frac{3}{4}$ inch in thickness, of which about a third part is fat on the upper surface (as well as round the margin). The base of the discoid body is flat or slightly concave, a piece of pectoralis muscle adhering to it loosely. The margin of the tumour is smoothly rounded off at one or more places, but elsewhere it runs out into the fat in short pointed processes. The nipple is expanded at the top, and sunk like an upholstery button into the centre of the breast, so that its broad flat summit is level with the skin. The disc of breast-tumour is spread out nearly symmetrical beneath the nipple, rigidly outlined towards the fat, of tough dense texture, excepting at the more evenly rounded parts of the margin, where it cuts smoothly and easily like a sarcoma, the cut surface everywhere showing many sections of tubes with thick walls. At one side of the disc-like tumour there is attached a flat membrane-like lobe, about the size of a finger-nail, which is atrophied mamma outside the limits of the morbid growth. There are no lymph-glands with the specimen.

This specimen is so like the breast drawn by the late Mr John Marshall for Walshe, *On Cancer* (London, 1846), that I reproduce the figure from that work (fig. 107, Pl. XX.), my specimen being too much cut up to make a drawing of

it. The chief difference is that Walshe's specimen is half as thick again. He refers to it in more than one place as scirrhus or carcinoma, showing the mouths of dilated milk-ducts with whitish thickened walls. It will be observed that the tumour rises up around the nipple in lobular masses, *a a*, which have a more uniform section than the *corpus mammæ*; and this is probably one of those cases, distinguished by Walshe, in which the subsidence of the nipple "mainly depends upon the simple enlargement of the other parts of the gland pushing the skin around the nipple forwards, while the nipple itself, bound down by the inextensible ducts, continues to hold its natural relationship to the gland" (p. 472). In the specimen which I am about to describe, the skin around the nipple has exactly that domed appearance, being neither puckered nor fissured nor in any way abnormal. In that region of the breast, above the level of the *corpus mammæ* and around the sides of the sunken nipple, sarcomatous new growth is met with in this case, as in some others.

The first thing to make out is the anatomy of the whole organ. The patient's age was fifty-six, menstruation having probably ceased several years before. The breast, with new growth in it, is a very small organ; and that part of it which is an appendage to the tumour upon one side is little more than a membrane containing the slender remains of mammary lobules. Beginning at the nipple, there is a deposit of brown pigment in the lowest stratum of rete mucosum. The sebaceous glands are few and very large, being compound branching crypts with the characteristic large granular epithelium packed like young fat-cells. It is beyond question that the crypts of these compound sebaceous glands in this case have plain muscular fibres sweeping round them, not merely as slips from the cutaneous bundles, but coming into close relation with the epithelium, like a basement membrane (p. 26). Neither the epiderm nor the sebaceous glands show any sign of disease.

Proceeding downwards we come to the stratum of loose connective tissue beneath the nipple, or between the nipple and the tumour. It contains several coils of exquisitely

marked large sweat-glands, the muscular walls of which are very clear, appearing to be the sole structure of the tube besides the epithelium, which is detached at many places: in one instance the wide sinuous discharging-tube of a coil can be followed towards the surface of the areola. The state of their epithelium is not altogether normal; in one or more coils the cells are somewhat large granular nuclei, some of them filled with yellow pigment, lying free in the lumen; but there is no infiltration of yellow cells between the coils of tubing, nor immediately outside the lobules, as in morbid states of the dog's sweat-glands.

The next stage downwards brings us to the *corpus mammæ*, where the real interest of the case begins. The milk-reservoirs are large, collapsed, with folds or rugosities of their walls; in some cases the lumen is almost obliterated to a stigma or spot of radiating lines. Most of the sinuses have a broad outer zone of granular substance (*infra*, p. 240). With these reservoirs two kinds of glandular structure are in relation: first, certain lobules of mamma, which are of considerable extent, but consist only of attenuated solid branching cords of nuclear cells, without the smallest appearance of acinous crypts; and, secondly, sinuous tubes with muscular walls, of various width. Proceeding still farther downwards to the base, as well as laterally to the margins, the muscle-walled coils become the sole glandular structure. The whole residue of gland, excepting a few lobules close to the great reservoirs, and the membranous appendage at one side of the tumour, appears to consist of tubular coils, which have the sweat-gland type positively clear in many places, and probable everywhere in contrast with whatever mammary structure remains (fig. 108, Pl. XX.). One could hardly expect to find a greater concentration of anomalous elements in a breast; they account for much the larger part of the glandular structure dependent from the milk-sinuses, occupying nearly the whole of the *corpus mammæ* along with these. The latter, indeed, may be taken as part of the same anomaly, by reason of the longitudinal coat of muscular fibres beneath the epithelium, which can be seen where the surface cells are detached.

It is solely in connection with these anomalous tubular glands that the tumour-disorder has arisen in the first instance. The most striking thing is the irregularity of their width, some sections of a coiled tube being dilated to large sacs, while most of it is narrowed, and some of it almost obliterated. There are concretions in the interior of many of the tubes (compare fig. 76). Some have only a single row of regular epithelium, which makes in the face view a very distinct mosaic of large polyhedric cells, with well-proportioned nucleus and a protoplasm which stains well and contains large granules (see fig. 67, Pl. XII.). But many of them are completely blocked by a uniform mass of rather small oblong epithelial-like cells, mainly nucleus, which would certainly be called sarcomatous tissue if it were not so clearly within circular limits (fig. 108, *b*). In other tubes there is a marginal belt, several rows deep, with the lumen either empty or occupied by a homogeneous yellowish coagulum which does not stain; and these, again, connect with the wide tubes in which there is only a single layer of epithelium with nucleus and broad zone of granular protoplasm. Whenever the tubes fill up with cells, these are small, nearly all nucleus, inclining to oblong forms, and in the mass looking exactly like sarcoma. It will be observed at the upper left corner of fig. 108 that this tissue is like sarcoma in other respects; its enclosure within tubular walls is not obvious, and it is subdivided by vascular lines.

On the other hand, that new growth which is in this case clearly interstitial, or in the stroma around the tubes or near to a coil of them, is of somewhat large epithelial-like cells. Like all other tumour-cells of the same type, they differ from actual or normal epithelium in having the nucleus disproportionately large; but they are just as much akin to epithelium as the masses of cells *within* the tubes are akin to sarcoma. The glandular tubes and the vascular stroma appear to be at cross purposes, inasmuch as the former fill up with small oblong or spindle-shaped cells, and the latter produces large epithelial-like cells. Infiltration of actual epithelium cannot account for the state of the stroma: firstly, because the cells produced in excess within the tubes,

assuming that they can escape, are smaller or more purely nuclear; and, secondly, because much of the epithelial-like tissue in the stroma is unquestionably sarcomatous in its cellular compactness and according to every other criterion by which sarcoma is known. The origin of it in circumtubular tissue, and its original plasmatic character or its relation to myxoma, have been shown for several cases in the preceding chapters. Again, there can be no doubt as to the sarcomatous nature of the new growth which springs up around the remains of mammary lobules, inasmuch as it begins in a spindle-celled condition of the stroma, and extends around the solid cords and infundibula of shrunken mamma, cutting them off as if they had been foreign bodies (compare fig. 71, Pl. XIII.).

Yet this breast has certain characters of scirrhus. First, the margin in some places is not rounded off, but prolonged into the fat in pointed processes. When these are examined, they are found to consist of actual processes of fibrous tissue in the midst of fat, the adipose tissue appearing to have excavated their sides, so that only certain narrow irregular tracts of tissue, more tough than the rest, are left. One cause of this resistance becomes apparent in the large quantity of elastic fibres which they contain. The elastic fibres are not a part of any recognisable structure; they are collected in irregular masses, often much curled, as if they had been set free from the structure to which they belonged. The irregular pointed processes, or claws of the cancer, in which these elastic fibres occur, are distinctively scirrhus, of the dense creaking kind. Their interstices are packed with many small epithelial-like cells, which stain so ill that their presence may almost escape notice: if the "infiltration" extend into the adjoining fat, as it often does a little way, but not at all after the manner of sarcomatous invasion, the cells stain better and their characters are seen better; they are about the size of leucocytes, but they have a distinctly quadrate epithelial look. This kind of scirrhus-infiltration is so prominent in Case XXXIII. of the sequel, that I reserve the full discussion of it until that context.

The second element of scirrhus in this case is the distinctive hardness, toughness, and density of certain parts of

the tumour both central and peripheral. On the labels of microscopic slides I have marked, besides the more uniformly cutting and merely firm sarcomatous parts, a "scirrhus part" and a "very scirrhus part." These belong to the naturally dense region of the *corpus mammæ*. They consist of long lines of quadrate epithelial cells, or of alveolar groups of them, lying as if free in the interspaces of fibrous tissue, which is always hard to cut, and may be coarse and ragged after section. They differ from the circumtubular or parablasic collections of epithelial-like cells in the sarcomatous tumours in two respects: first, the cells are distinct individuals, not fused into cellular aggregates; and, secondly, they are very commonly in a state of endogenous cell-formation. The question arises, whether this is not a literal infiltration of actual epithelial elements derived from the break-up of the anomalous sweat-glands of the *corpus mammæ*. The same question of a literal infiltration of epithelial products, shed from disordered sweat-glands, arises for the regular deposit of those glands under the nipple and areola, which is well-developed in this case, being no part of the mammary system but connected with the skin by direct discharging tubes. It is clear that certain of these coils are in a morbid state, the lumen being occupied with detached granular cells, some of which contain yellow pigment. As to the fact in general, there is ample evidence both from the dog and from certain cases of the cutaneous sweat-glands in women (see Case XXXIII.), that cast-off epithelial products are actually infiltrated into the spaces of the connective tissue. But they do not appear to be able to multiply except endogenously, their liberated nuclei keeping up the succession by producing young cells within vacuoles in their turn.

CASE XXV.—*Small Scirrhus directly under the Nipple.*

Breast of a woman, aged 52, amputated by Dr [Sir G. M.] Humphry at Addenbrooke's Hospital, Cambridge, on 28th April 1878. It contains a small lump directly under the nipple, hard or firm, surrounded by fat. No axillary glands removed with it.

The milk-reservoirs under the nipple are very large, some widely open, others collapsed, having the angular recesses

and rugosities of sinuses. Their epithelium is a single layer of columnar cells, usually regular, beneath which a stratum of longitudinal plain muscular fibres can be seen clearly at favourable spots. Around the wider and more open sinuses the stroma is an ordinary fibrous tissue containing some fat-cells, normal capillaries, and a not excessive number of long slender connective-tissue cells. Dependent from the sinuses are various glandular structures. The fig. 109, Pl. XX., shows the general relation and form of one kind of these; they are slender elongated cords, sometimes showing a small capillary lumen, more usually solid, joined in loops, with occasional small lateral knobs or thickenings, being the atrophied remains of the kind of mammary lobules (or "granules," as Langer calls them) which are proper to the neighbourhood of the greater milk-reservoirs. Mixed with these, or in the same sections with them, are tubular glands of another kind, which can nearly always be distinguished from the branching mammary tubes by their greater width, their columnar protoplasmic epithelium, and the plain muscular fibres in their walls: these also are in relation with milk-sinuses, and can sometimes be traced to their origin from them, the muscular basement being common to the sinus and to this particular kind of tubular gland. Some of the coils are more dilated

DESCRIPTION OF PLATE XX.

FIG. 107. Scirrhus breast drawn by Mr John Marshall for Walshe *On Cancer*, 1846. *a a*, lobulated masses, of uniform section, on either side of the nipple; *b b*, the *corpus mammae* showing numerous tubes with thick white walls.

FIG. 108. From small discoid tumour of breast, partly scirrhus, partly sarcomatous, Case XXIV. *a a a a a*, coils of sweat-glands, the lower dilated; *b b b*, sarcoma-like areas; *c*, fat infiltrated with vacuolated cells and epithelial nuclei. $\times 50$.

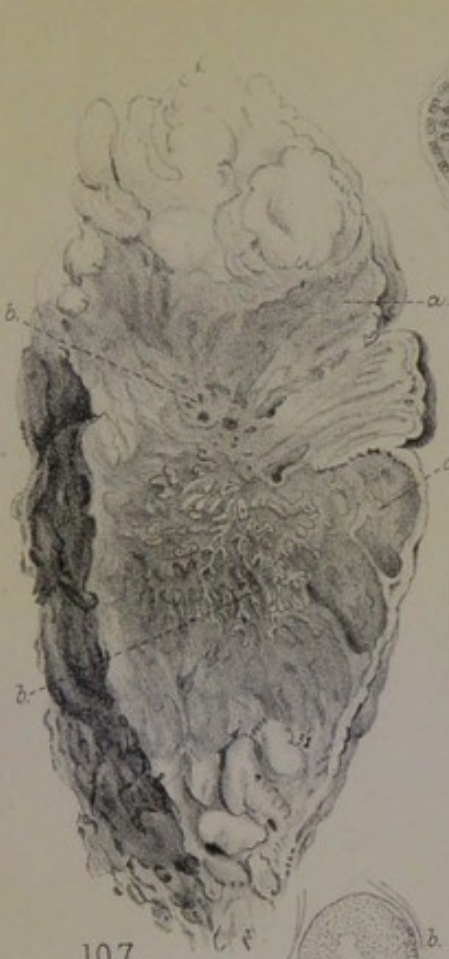FIG. 109. Milk-sinus under the nipple of Case xxv. Branching and tortuous tubular glands dependent from the sinus. $\times 90$.

FIG. 110. From same Case xxv. A coil of sweat-glands close to the wall of a milk-sinus, showing muscular basement and papillated epithelium. $\times 250$.

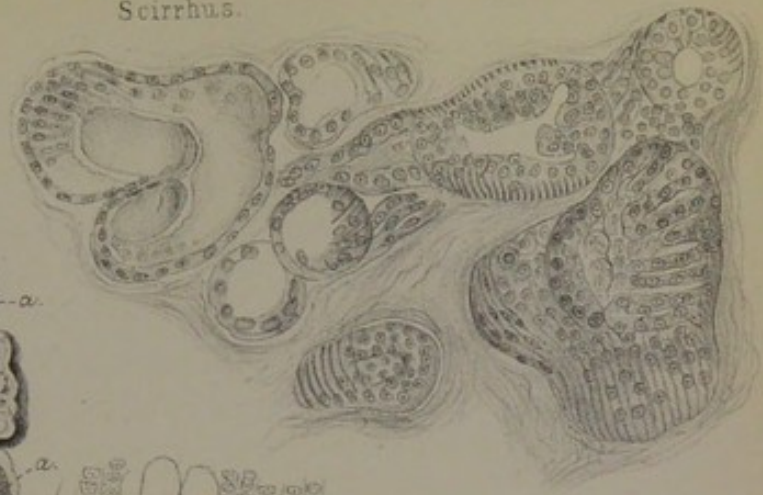
FIG. 111. From same Case xxv. Appearance of flattened quadrate epithelial nuclei in rows between the fibres of the stroma. $\times 150$.

FIG. 112. From same Case xxv. Centre of *corpus mammae*: three collapsed processes of milk-sinuses, with broad hyaline and granular zones; sarcomatous state of the stroma. $\times 90$.

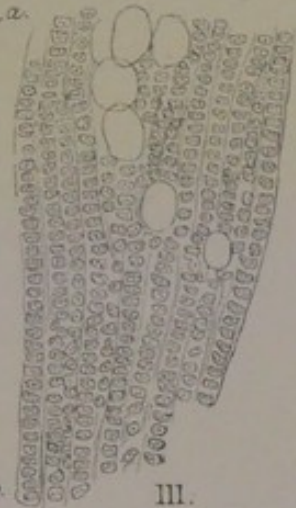
Plate XX.
Scirrhus.



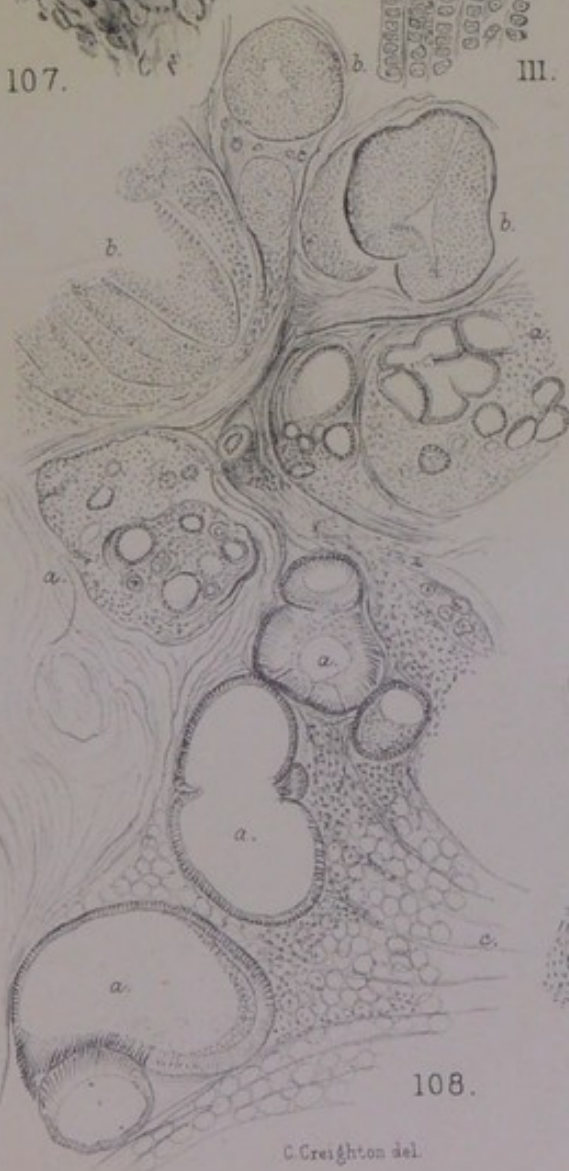
107.



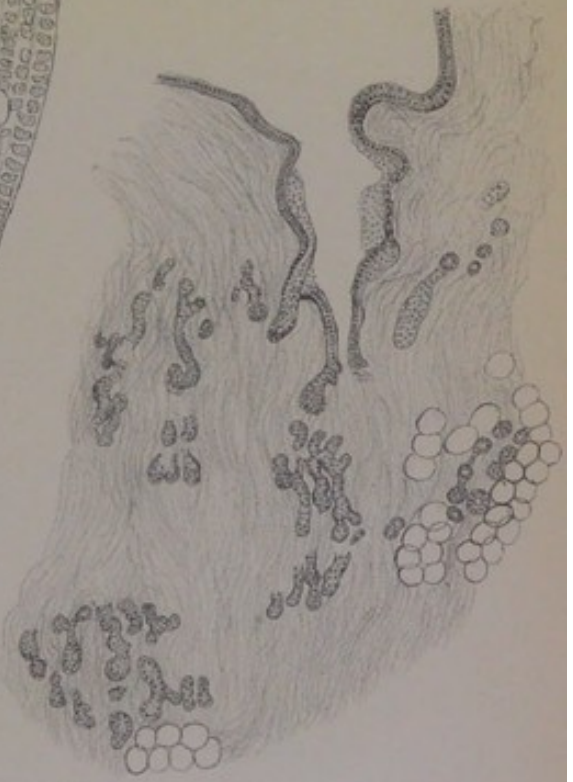
110.



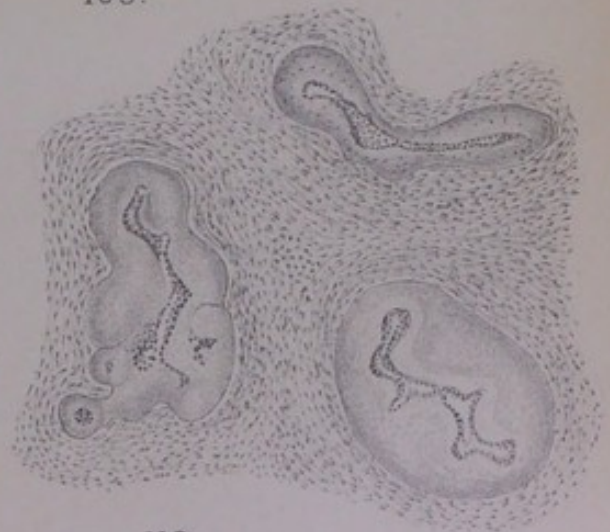
III.



108.



109.



112.



than others, with a considerable lumen which may contain mucus. A group in the more dilated state is drawn in fig. 110, Pl. XX. : the muscularis is quite clear at certain turns, but is hidden at other points by the hyperplastic epithelium, which runs out into ridges or papillary processes of fused cells with relatively large nuclei. Several whole coils are found which are of the sweat-gland type. In the neighbourhood of these we find an altered state of the stroma. It is rich in cells or nuclei, obviously of the connective-tissue kind, and it shows in places, especially in the islands or borders of fat, rows or processions of small epithelial-like cells, as to which the question arises, whether they are real epithelium or not. The fig. 111, Pl. XX., was drawn by me from this case to illustrate a paper "On the Infection of the Connective Tissue in Scirrhus Cancers of the Breast," *Journ. of Anat. and Physiol.*, xiv. 1879, the point being that there was both a literal infiltration of cast-off epithelium into the spaces of the connective tissue, and an "infection" of the connective-tissue cells, whereby they emerged from their quiescent state to become epithelial-like cells and to multiply as tumour-cells. I was unable to distinguish the one kind clearly from the other, or to be sure that the rows of cells in the figure were actually infiltrated epithelium; and I am still in the same doubt. The quadrate form and the look of being packed close as if by pressure are not decisive for epithelium, inasmuch as in some undoubted sarcomata the cells lie like rouleaux of coins, as if flattened against each other—an appearance "like a voltaic pile" which Langhans has figured, without recognising its sarcomatous nature (*Virchow's Archiv*, lviii. 1873, p. 153).

Waiving the question of those linear processions of epithelial-like cells, there is no doubt that the greater part of the new growth in this case is interstitial or sarcomatous. As one proceeds deeper into the *corpus mammæ*, the milk-sinuses are encountered in a different state, which is characteristic of many cases of scirrhus. They are described correctly as milk-sinuses, not as ducts; for they have the distinctive characters of sinuses (*vide supra*, p. 139). At the greater depth they are not only collapsed, but actually obliterated, and invested

by a broad zone of substance in part granular, but hyaline in the innermost layer (fig. 112, Pl. XX.). They are numerous in the particular region of *corpus mammæ*, always with granular zones, which extend also to the smaller dependent tubes, or to some of them, just as the purely hyaline zones extend in Case xxxv., fig. 131. The whole stroma is in an active state of proliferation; it amounts practically to sarcomatous tissue, so rich is the growth of spindle-cells around the obliterated milk-sinuses and their tubular-gland dependencies. But a purely spindle-celled type of new growth, such as is drawn in fig. 112, is not the most distinctive of the case. In the midst of the spindle-celled stroma, alveolar groups of cells spring up, which are of the epithelial type, and yet are undoubtedly but modifications of the stroma-cells at certain centres. This is a common phenomenon in sarcomata of glands, being an approximation to the pseudo-glandular kind of structure which is shown in a very perfect form from a child's tumour in fig. 86, Pl. XVI. Yet this tumour had certain characters of scirrhus; which are not difficult to account for if one remembers that the whole process is taking place in the *corpus mammæ*, naturally a dense region, and that the broad zones around the numerous obliterated milk-sinuses and tubes consist, in their deeper layer, of that hyaline substance which gives scirrhus of the breast its most characteristic hardness.

CASE XXVI.—*Small, firm, encapsuled hæmorrhagic Nodule in a thin Breast with Retracted Nipple.*

Breast removed at Cambridge from a woman, aged 45, for an embedded tumour near its centre (from the stores of the Surgical Pathology Collection, December 1900). The breast is a flat, cake-like, encapsuled body, about four inches in diameter at the base, and nowhere more than an inch thick. The nipple is somewhat retracted, the skin normal, with a layer of fat between it and the sloping sides of the breast. Embedded in the substance of the organ, a little to one side of the vertical of the nipple, not raising the skin, nor apparently displacing much of the gland, is a body like a small chestnut, with its broad end on the pectoral fascia, and its apex coming within a quarter of an inch of the skin. It is definitely rounded off, if not encapsuled, of firm and in part hard texture, streaked with lines of golden yellow pigment (old blood) in its upper half, and infiltrated with blood-corpuscles throughout its base. The structure of the upper half is alveolar, the type of cell

very small; the pigment grains are collected in the fibrous septa between the alveoli. Towards the base the structure is almost purely fibrous, in broad homogeneous bundles, with extravasated blood between them, enclosing remains of milk-sinuses and glandular structures.

This whole breast has traces of chronic fibrosis, such as occurs sometimes in single women about middle age. Its margins are neither lobulated nor prolonged in irregular processes, but contained within a somewhat dense fibromatous capsule, between which and the skin or pectoral fascia lie lobules of fat. Its substance is everywhere tough to cut. It contains a number of minute cysts lined by columnar epithelium of a very small type, and penetrated by tufts of blood-vessels, from the ends of which the epithelium is mostly displaced. In all parts of the organ—upon the margins, along the base, and in the centre—there are coils of muscle-walled sweat-glands in close proximity to mammary lobules: the muscularis of the former is easily seen owing to the smallness of the epithelial cells or their not unusual detachment. There is also the regular deposit of sweat-glands in the loose tissue under the nipple, from which the coil in fig. 5, Pl. I., has been drawn. This deposit is quite normal; but the anomalous coils in the substance of the breast are more or less abnormal, being either dilated to make the small cysts above mentioned, or contracted, or with the belt of epithelium detached from the wall. The columnar cells are everywhere small, slender, or meagre, and the papillary processes projecting into the dilated portions of tubes are little more than naked vascular-fibrous loops. Fig. 113, Pl. XXI., shows a portion of one of the sweat-gland coils on the upper periphery of the breast just within the capsule, along with one ordinary mammary lobule; the dilated portion of the sweat-tube is beset with fibrous or fibro-vascular papillæ all round its circuit. Those peripheral coils of sweat-glands have the same relation to the walls of milk-sinuses that is shown in fig. 66, Pl. XII., and fig. 68, Pl. XIII. The mammary lobules are of the ordinary kind in a state of involution, being of considerable extent and apparently well developed. Fig. 114 shows one of them with two sections of sweat-tube close to it. At one or more places the singular appearance

is found of a whole mammary lobule pressed aside and spread out upon the wall of a dilated sweat-tube.

So far, the morbid condition of the breast is that of chronic fibrosis in an organ which contains the anomalous development of a large proportion of all its glandular structure into sweat-glands. But the condition is somewhat special in the central part at one side of the nipple, where the actual tumour exists. This nodule within its capsule is not homogeneous throughout. Its base upon the pectoral fascia is the only scirrhus part of it; but the scirrhus density is merely fibroma infiltrated with much extravasated blood. The glandular structures in the base are still recognisable as milk-sinuses, with some regular mammary lobules as well as coils of sweat-glands in obvious relation to them. The milk-sinuses have a basement of plain muscular fibres, as they often have where the sweat-gland anomaly exists. In this region their prolongation to the base of the breast is hardly irregular, inasmuch as Astley Cooper describes and figures them ordinarily as extending all the way to the base in the vertical line of the nipple or a little way to either side of it. The sweat-glands dependent from one or more of them are clearly marked in structure, forming a group of round open loculi communicating with each other, and having parallel muscular fibres beneath their epithelium. They do not show the papillary prominences which are found in the dilated portions of coils elsewhere in the breast, but they contain drops of mucus or other substance as well as cast-off epithelium in their interior. Passing upwards from this basal part of the small tumour, we come to a softer part, which cuts with the ease of sarcoma. The transition is gradual. Instead of extravasated blood there are everywhere the golden yellow large grains of an old blood-extravasation. These are laid down in very regular lines, which correspond with the septa between alveoli. Alveolation marks the whole softer part of the nodule, which is evidently the older centre of disease.

The alveoli appear to have been made by the invasion of vascular tissue into a certain part of the *corpus mammæ*. The growth of a new vascular stroma had been attended with

extravasation of blood from the ill-formed vessels, of which the grains of blood-pigment are the traces. The stroma is now a somewhat loose fibro-cellular tissue, which follows the usual warp-and-woof course of the stroma in alveolar cancer, as originally described by Rokitansky for a colloid of the breast and a soft tumour of the brain ("Ueber die Entwicklung der Krebsgerüste," etc., *Sitzber. Wien Akad., Math.-Nat. Classe*, Bd. viii. 1852, p. 391). The resemblance to the colloid described in Chapter V. is, indeed, noticeable in more than one respect. There are undoubted bands of plain muscular fibre, which can be distinguished, in an alum-carmine preparation, from the vascular stroma by the regular nucleation of their close-set parallel fibres. Those bundles do not belong to the muscularis-basement of sweat-tubes, but to that muscularity of the stroma itself which has been found in a number of cases throughout certain islands of tubular glands in the midst of the breast (pp. 33, 133, 153). The sweat-tubes, with muscular fibres under their epithelium, are also present; but only fragments of them are discoverable, and always with the epithelium degenerated or lost. Among the alveoli there is a certain amount of small, detached, ill-stained epithelium, which appears to have survived the disintegration of original (but anomalous) tubular glands by the invading vascular stroma. But these are not the cells that bulk most largely in the new growth. Many alveoli, especially towards the margins of the area, are packed with epithelial-like cells, which are of the same curiously small type as in all the sweat-glands of this breast, but differ from the actual epithelium in certain important respects. Firstly, they take the stain deeply in contrast with the faint decaying appearance of the epithelium of actual tubes; secondly, they form large aggregates of various shapes; thirdly, they are in great part nucleus; and, lastly, they are fused into masses after the manner of sarcoma. Those are the cellular structures that really fill the alveoli; they are of interstitial origin; and they represent that *parablastic* kind of new growth, with an epithelial *habitus* of cell and sometimes with a pseudo-tubular structure, which arises as a complement to the obstruction or destruction of original

or archiblastic glands. The destructive process had been an invasion of the tubular glands at a certain spot of the *corpus mammæ* by vascular stroma; and that invasion is only one part, specially modified by locality, of a vascular process affecting the anomalous structures all through the breast, producing elsewhere chronic induration, with cystic dilatation, and with fibro-vascular papillomata on the walls of cysts. Thus, the element of scirrhus in this case, such as it is, is really fibromatous, and the epithelial-like new growth in the alveoli is really sarcomatous. Clinically, the encapsulation of the tumour, the extravasated blood, and the uniform soft texture of one half of it, favour the notion of sarcoma; while its deep situation, occupying a portion of the breast without displacement, the hardness and density of its base, and the retraction of the nipple, favour the notion of scirrhus.

CASE XXVII.—*Very large Scirrhus of the whole Breast, with deeply retracted Nipple.*

A large breast, of scirrhus density throughout, among the specimens used for Degree Examinations at Cambridge. The nipple is retracted deeply, the skin is normal, not puckered, the subcutaneous tissue loose; at one spot near the axillary end there is a small cup-shaped dimple of the skin, which is bound down to the surface of the tumour by an inverted cone of loose or uninfiltated fibrous tissue. The incision of the operation had been carried so far towards the axilla as to include a small normal lymph-gland in the midst of the fat. The breast is now divided transversely into three thick slabs from skin to pectoral fascia; they measure from three to four inches in length and one to two inches in depth; their margins are definitely rounded, without pointed processes into the fat; the structure is everywhere of the same fibro-cartilaginous density and translucent whiteness, but interrupted by various pyriform or spherical lobes of fat, which is of pure adipose texture, uninfiltated with new growth.

Even in so extensively altered a breast as this is, it is not impossible to ascertain the anatomical characters of the organ. Close to the pectoral base, and upon the sides of the scirrhus mass, there are less dense layers, which are at the same time of a reddish colour; and these contain sufficient traces of original gland-structure to enable one to reconstruct the whole. The milk-sinuses extend down to the base, with the characters of true sinuses, *i.e.*, great width, and rugous outline of fairly regular columnar epithelial

lining; it is not clear that they have a muscular basement. In relation with them are various glandular structures. First, there are large encapsuled mammary lobules composed of many small involuted acini, somewhat elongated or tubular ("acinous-tubular") in type. Next, there are branching tubular forms, which are not the muscle-ribbed sweat-glands, but that unencapsuled or non-lobular kind of mammary structure often found close to the walls of milk-sinuses (central or peripheral); in this case their blind ends are dilated in many places to regular hollow spheres or cylinders lined by a mosaic of very perfect small epithelium. Lastly, in the company of the other kinds and distinguishable from them, there are coils of muscle-ribbed sweat-glands, which are identified most certainly where they are dilated to form locular clusters. Fig. 115, Pl. XXI., is the surface view of one loculus in such a cluster, throughout the whole of which the sure criterion of a muscularis-basement can be seen. It may be assumed safely that this breast was like the one last described, and like others given or to be given, in having anomalies of structure at many points, central and peripheral, along with a prolongation of the milk-sinuses to the very margins and base of the organ.

The most remarkable change in the glandular structures, which is the key to the scirrhus density of the resulting new growth, is the deposit of a kind of *hyaline* around their walls. It is not the brittle, glassy hyaline which has been described for the rare form, Case x., p. 132, but a zone of connective substance so homogeneous that no fibrillæ can be seen in it. It is not universally present in the portions of gland available for examination, being developed much more at some spots than at others. Fig. 116 shows a moderate degree of it around the infundibula of a branched tube, which is found in the very heart of the scirrhus; at the right of the figure are the cross-sections of tubes or acini, in which the epithelium is reduced to small irregular heaps of nuclei within thick hyaline capsules. This encroachment of the hyaline upon the epithelium goes on until the whole becomes hyaline, the original circular outlines of acini (or infundibula) being still recognisable. Tracing the process



as in the last case but one (fig. 112, Pl. XX.). The peculiarity of this case (as also of the next case) is the hyaline transformation of much of the mammary glandular structure itself; and as that is extant in large amount, in correspondence, doubtless, with the middle age of the patient, there is hyaline condensation throughout a wide extent of breast. It is this that has made the scirrhus very extensive—a rare thing where the disease is not of the so-called “lardaceous” variety. The actual sweat-glands, distinguished by their muscular ribs, do not share in this hyaline transformation, the seat of it being the branching tubular glands, which are a large proportion of the whole breast.

The new growth in this hyaline matrix is really interstitial, or sarcomatous. The resting nuclei of the mammary acini are compressed out of existence by the hyaline capsules; and although the epithelium of the sweat-glands does not share the same fate, yet it degenerates in the way that may be inferred from the state of the cells in the upper part of fig. 115, Pl. XXI. There is no such vigour of growth in any original epithelial cells of this breast as would account for so large a tumour. On the other hand, there is obliteration or disintegration of glandular structure everywhere. Some such obliteration is according to rule in the obsolescence of a normally constituted mamma, and should entail no risk. But this breast has been shown to contain anomalous elements, both true muscle-ribbed sweat-glands and branching tubular glands; and the obstruction or destruction of these does involve consequences, namely, a parablasic new growth from the vascular stroma. In this case, it would be called “tubular cancer,” according to Billroth’s classification; but the greater part of it is really an interstitial new growth of epithelial-like cells along certain lines or intervals of the dense stroma, which appear to be the tracks of blood-capillaries. The stroma itself is beset with elongated nuclei at places, or infiltrated with small round cells. But there are spots in the midst of the scirrhus at which the form of a sweat-gland coil can be made out, the tubes being filled with a large type of cell (in marked contrast to the branching mammary structures). The peculiarity of that

epithelium is its vacuolation, or the production of free nuclei from it; and it may be inferred that the original sweat-glands, whose obstruction is the real occasion of the tumour, do not contribute to its positive growth except by setting free those nuclei in the way of endogenous cell-formation, which would be infiltrated literally.

CASE XXVIII.—*Scirrhus in a Young Subject. Two Recurrences within three months; discontinuous Hard Masses in the Muscles.*

Ovoid tumour of the breast, two inches in its longest axis, removed from a young married lady by Sir Spencer Wells in November 1888. A lobulated mass of fat on the axillary side was removed with it, which contained no lymph-glands nor infiltration. The tumour is a definite hard or firm body, with a flattened base, surrounded by fat, the margins somewhat uniformly rounded, without pointed processes. The section is hard or tough everywhere, but especially so in the centre. The stroma is translucent. The mass is either the whole breast, or a certain part of it separated by its hardness and by a degree of encapsulation. On one side there is a stratum of pure mammary lobules nearly half an inch thick. Elsewhere the regular mammary structure is found mixed with tumour-structures. The most conspicuous of these are wide tubes, blocked with large epithelium, the cut ends of which form numerous opaque yellowish round spots; they occur both on the periphery and in the centre, sometimes in locular groups visible to the naked eye, the widest being about an eighth of an inch; they have exactly the distribution and form of small "involution-cysts," but they are all filled with opaque masses of epithelium, which are apt to fall out in making the sections.

A recurrence of disease required a second operation a few weeks after the first, from which nothing is preserved. On 23rd January 1889, three months from the first operation, there was a third. Four or five discontinuous nodules, up to the size of a pigeon's egg, of scirrhus hardness, are embedded in the pectoral muscles. The fat of the axilla close up to the skin is also occupied with scirrhus masses, and it is probable that one or more of the hard round nodules removed are axillary lymph-glands.

This is a case of scirrhus in a young married lady, with some of the clinical characters of that type. The occasion of the scirrhus hardness in the original new growth is the same as in the last case, namely, the hyaline transformation of a large part of the proper structure of the breast. But the lobules and acini so transformed are not the seats of cellular new growth; on the contrary, the resting nuclear epithelium is cut off, encroached upon, and effaced. The great proliferation of epithelium, of a very large type, is

within the numerous tubes mixed with the mammary lobules, on account of which the case might be taken to be one of "épithéliome tubulé," or so-called duct-cancer. The tubes are sweat-tubes, which have the same anomalous place in the organ as the involution-cysts, or the various other dilated or obstructed states of tubular glands in the cases preceding. The morbid growth so far is strictly intratubular, the greatly dilated tubes having well-defined walls which confine the cells. But the progressive new growth, which gave the case a remarkable character of malignancy, is in the vascular stroma, in the muscles, and in other neighbouring tissues; and although it carries the character of scirrhus with it everywhere, it is as truly a parablastic new growth as if it had been a soft sarcoma.

The mammary lobules are for the most part regularly formed, and are encapsuled as small seed-like bodies. No large milk-sinuses are found anywhere (the nipple is not with the specimen); but medium-sized ducts are found, which have a regular surface epithelium, a second nuclear row next the basement, and a somewhat thick submucosa: these are always in clear contrast with the numerous dilated and blocked sweat-tubes (compare fig. 134, Pl. XXIV.). The hyaline transformation of acini, and of whole lobules, is much more advanced at some (central) places than at others; but a certain thickening of the capsules around acini can be made out almost everywhere in preparations stained with acid fuchsine. The broader hyaline halos are such as in fig. 117, Pl. XXI. It is to be noted that many of these acini are larger than in their usual resting state, as if they had undergone some excitement before the hyaline obliteration overtook them. The homogeneous or hyaline zone becomes broader and broader, until the central space is only a small round hole containing faint traces of the original nuclear epithelial heap. This process extends to entire lobules, which are left with their outlines clear, but their structure sclerosed, as if they had been lignified or petrified throughout. The vascular stroma between the lobules undergoes a corresponding hyaline change, which, as already said, p. 239, is not the true translucent brittle hyaline of Case x., but

rather a homogeneous substance in broad wavy bundles and without fibrillation.

The coils of tubular glands do not suffer this change in or around their walls. They are all remarkably dilated, and all blocked more or less completely by epithelium. The general effect is nearly the same as shown in fig. 75, Pl. XIV., from a softer or sarcomatous case. The epithelium is of a large type, with relatively large nuclei; the cells are often vacuolated, with the nuclei free in the vacuoles, the cell-walls being sometimes broken. Usually the tube is blocked completely; but in some the epithelium is only a broad parietal belt, leaving a central space with detritus or coagulum. The mass of epithelium is always more or less opaque, friable, and apt to fall out in a lump in making sections. In some tubes thus emptied, the presence of plain muscular fibres in the basement can be shown; but they are usually opaque, granular, and vaguely outlined. Fig. 118, Pl. XXI., from a thick section, shows the parallel ribs of the basement in contrast with the common fibrous tissue without. In oblique sections of the walls of tubes, stained with alum carmine, the oblong nuclei of the parallel muscular fibres can be seen; but that is also a difficult demonstration owing to the condensation of the whole wall.

The most remarkable point in this case, as in Case XVIII., fig. 75, is the uniformly wide dilatation and blocking of the whole of the sweat-glands. In most breasts it is not difficult to find some of their coils unequally dilated, and many with no blocking of their lumen; but in this case there do not appear to be any tubes undilated, and empty or contracted. The original disorder appears to have been a universal obstruction of the anomalous sweat-glands of the breast, leading to accumulation of epithelium on their walls, dilatation, and the reduction of the whole system to solid cylinders. This is probably what is meant by "duct-cancer."

The subsequent and real tumour-process is parablasic to that, in the vascular stroma; and, inasmuch as it takes place in a ground which has meanwhile undergone the above-described hyaline sclerosis, it assumes the character of scirrhus, not of sarcoma as in former cases. There are parts

of the stroma where the parablastic process is an almost physiological increase of the oblong or spindle-shaped nuclei of the connective tissue; and that degree of sarcomatosis may be found also within the encapsuled lobules of the breast, in the marginal part which is nearly normal. But the most distinctive new growth, around the blocked tubes of the central region, is alveolar collections of large epithelial-like cells with large nuclei. A certain development of new vascular stroma along regular lines seems always to prepare the way for this interstitial cellular growth. In sections stained with acid fuchsine, there is sometimes a meshwork of bright red trabeculæ in the stroma, which show no cells at that stage, but correspond in figure with the cellular alveolation elsewhere. There is, however, another factor to be considered besides the preparation or predisposition of the ground.

Fig. 119, Pl. XXI., drawn from the centre of the scirrhous, shows a state of things which I have seen in no other tumour so clearly. At the right upper angle is a blocked tube (of the smaller size), from which there appear to stream into the interstices of the hyaline stroma numerous lines of granules, or particles, or broken cells. The appearance is most striking in sections stained with methyl violet, which colours the substance in the spaces of the stroma to their finest extensions as deeply as the epithelium in the tubes; with other stains, such as alum carmine, the infiltrated matter is hardly stained at all, but appears as grey vesicles or amorphous particles. Examined closely, the spaces of the stroma are found to contain disintegrating cells, from which lines of granules extend into the finer interstices. The unstable cells are all of the vacuolated kind, and sometimes the liberated nucleus is seen to be vacuolated in its turn, with a dark-coloured minute nucleolus in its cavity. These very fragile cells had almost certainly escaped from the tubes, for the epithelium within the tubes is also vacuolated in many instances, and is always becoming opaque and friable. This is the real nature of the epithelial infiltration; it is not of vigorous proliferating cells, but of cells disintegrating. The active growth is an entirely new one from the

vascular stroma, parablasic in type. It is not always easy to distinguish the latter from the literal infiltration in this breast (in alveolar sarcomata there is no ambiguity, *supra*, p. 173); but, in the great scirrhus masses which were removed from the pectoral muscles and elsewhere at the third operation, it is clear that the whole is parablasic, the fused clumps of cells being so large, and with so little stroma between them, that the structure would be called sarcomatous without question were it not that it carries with it the same sclerosed or scirrhus character which arose in the primary seat, and had an intelligible origin there. Before the third removal the type of new growth had indeed changed decidedly towards sarcoma, as it often does where there are several recurrences (Gay, *Path. Trans.*, xxxi. 1886, p. 272; Steudener, *Virchow's Archiv*, xlii. 1868, p. 39, 2nd case). The cells are large ovoids, with bold nuclei; at some spots there is more protoplasm around the nucleus, but in these the tissue consists rather of bars or trabeculae of nucleated protoplasm (so-called syncytium) than of individual epithelial-like cells; and that type of tissue is always pseudo-vascular.

CASE XXIX.—*Small Shrinking Scirrhus in a thin Breast.*

Specimen from the stores of the Collection of Surgical Pathology at Cambridge, December 1900. The tumour is an irregularly shaped flat stratum of dense white tissue in the midst of fat, beginning about three-eighths of an inch below the skin and going down to the pectoral fascia, its greatest thickness about half an inch, its greatest length about an inch and a half, the margins everywhere indented by fat, and the interior also interspersed with small islands of fat. It is of extreme hardness (the cut surfaces becoming hollow from retraction), coarsely fibrous, not translucent.

This dense white substance is all that remains of the breast, the fat having replaced the rest of the mammary structure and invaded these remains of the *corpus mammae*, so that it is excavated by lobules of fat all round its borders as well as through and through its interior. A few sections of milk-sinuses are met with, surrounded by broad granular and hyaline zones; there are no traces of mammary lobules.

The prominent structures, in sections from every part, are very regular circular tubes completely blocked by cells, as in fig. 120, Pl. XXI. They are nearly always encountered in the cross-section, of very uniform width, sometimes a cluster together, or two or more joined by narrower tubular necks. They are the same tubular coils of glands as in other cases, the muscular fibres of the basement being sufficiently clear, in some cross sections, in the form of a palisade standing up behind the epithelium. The cells, which always fill them completely, are almost wholly nuclear, and not large: they are fused into masses, and sometimes of oblong or spindle shape, so that the tissue, if it were not obviously within a glandular tube, would be pronounced sarcomatous. In those respects, as well as in their vigorous fresh appearance, they differ from the contents of the much more widely dilated tubes of the last case, and resemble the appearances in certain parts of fig. 108, Pl. XX. These blocked tubes are the most considerable structures of the tumour, which, in virtue of them, might be called "épithéliome tubulé," or duct-cancer. But the new growth is a most pronounced scirrhus; its stroma is of the hardest and densest kind; it has linear infiltrations of small and ill-stained epithelial-like cells in its interstices as well as into the fat; and it has new-formed tissue around the tubes, which is in some instances of the fibro-cellular myxomatous kind, but is more generally in the form of alveolar groups of somewhat large epithelial-like cells. It may be inferred that this breast was one of those which had the anomalous element of sweat-tubes in its central part, if not in its periphery; that these had survived the obsolescence of the proper mammary structure; that they had become blocked by their own epithelial products in consequence of the obstruction of their function in the general decay of the organ in which they are included; and that the obstruction of the sweat-tubes had called forth a minor degree of parablasic activity in the dense shrinking stroma. This is the probable history of any chronic contracting scirrhus of the *corpus mammæ*.

CASE XXX.—*Chronic Retracting Scirrhus.*

Maria Wood, aged 58, widow, admitted to St Thomas's Hospital on 2nd December 1873, under Mr Sydney Jones, for a scirrhus of the left breast. The lump is about an inch and a half in its longest axis. The skin over it is puckered and retracted. Breast removed; the tumour intensely hard; half an inch of clear interval between it and the nipple.

Of this breast, at an age some ten years past the climacteric period, the only remaining structures are a number of collapsed milk-sinuses, invested with thick sheaths, as in fig. 109 from a breast at the age of fifty-two. Those scanty remains are, however, significant of much that does not appear. The milk-sinuses have the basement of plain muscular fibre, which is not found unless in association with muscle-walled sweat-tubes dependent from the sinuses. The proof of the muscularis is not difficult, in such instances as are drawn in fig. 121 and fig. 122, Pl. XXII. In the former the sinus is invested by a granular zone of no great width, being itself still a considerable open tube.

DESCRIPTION OF PLATE XXII.

FIG. 121. From dense Scirrhus, Case xxx. Recess of a milk-sinus of the *corpus mammæ*, with muscular basement, and uniform granular zone outside it. $\times 300$.

FIG. 122. From same Scirrhus, Case xxx. In the centre, a tube with angular recesses, having plain muscular fibres in its basement, and mucous coagula in its interior: next to the basement is a broad hyaline zone, and beyond that a broad granular zone. The alveolar collections of tumour-cells are in the stroma next to the granular and hyaline zones of the atrophied gland-tube. $\times 200$.

FIG. 123. Diagram of the two distinct tumours of Case xxxi. *a*, hyaline tumour of the *corpus mammæ*; *b*, nodule of scirrhus under a deposit of sweat-glands towards axilla; *c*, small island with hyaline points, by the side of the scirrhus.

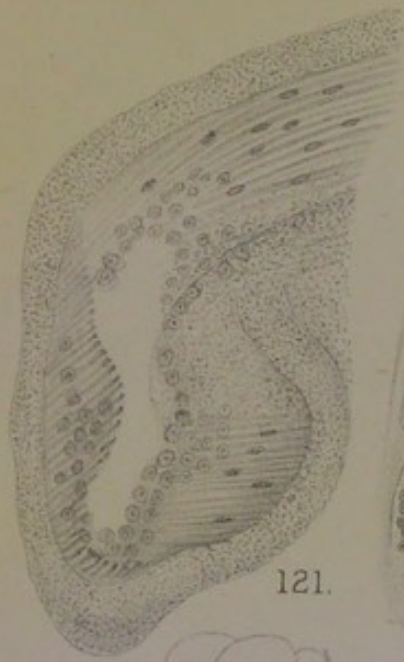FIG. 124. Vacuolated sweat-gland epithelium *in situ*, from the deposit under the skin in Case xxxi. $\times 300$.

FIG. 125. Tube blocked by epithelium in scirrhus nodule of Case xxxi.: adjoining fat infiltrated. $\times 200$.

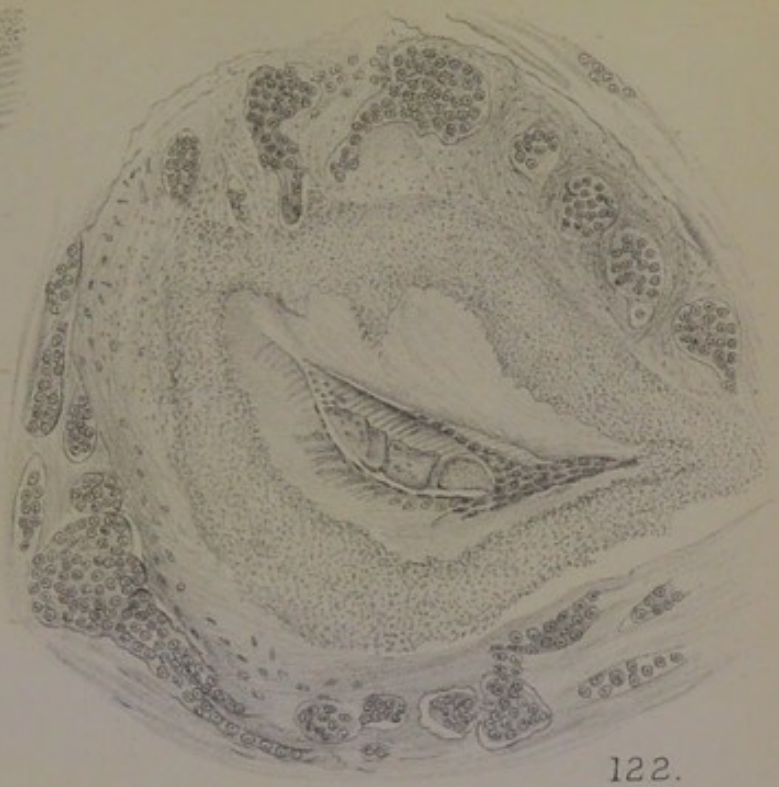
FIG. 126. Flask-like process of vascular tissue growing into the concavity of a folded epithelial belt, Case xxxi. $\times 150$.

FIG. 127. Section of scirrhus cylinder with base on skin, Case xxxii.

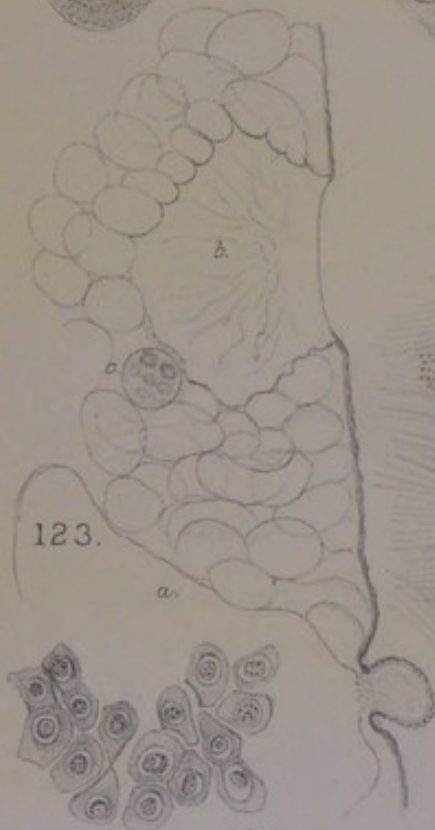
FIG. 128. Three sweat-tubes in Scirrhus, Case xxxii. In the two larger the epithelium is massed in ridges or trabeculae within the dilated tubes; the upper smaller tube shows the muscular ribs, detached epithelium in the lumen, and concentric infiltration of nuclear cells in the stroma. $\times 200$.



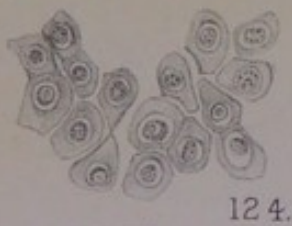
121.



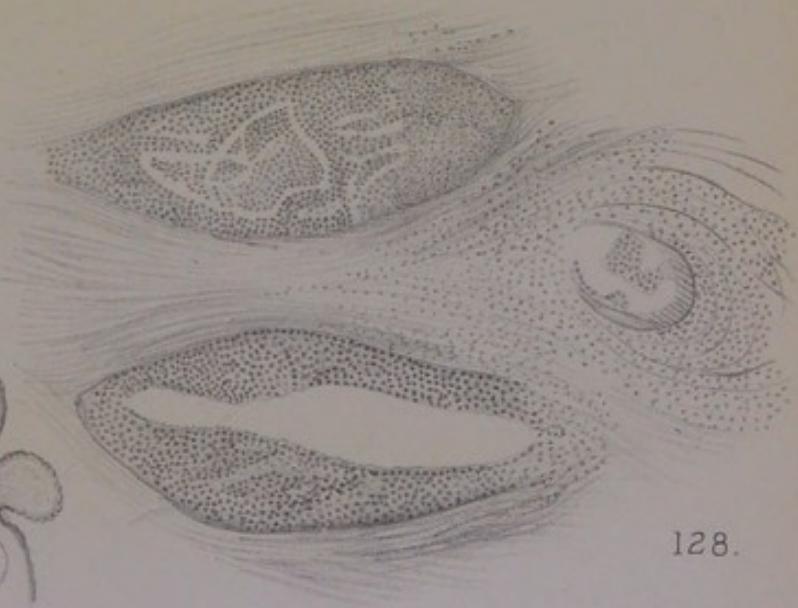
122.



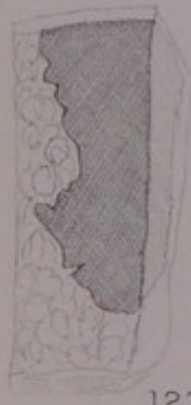123.



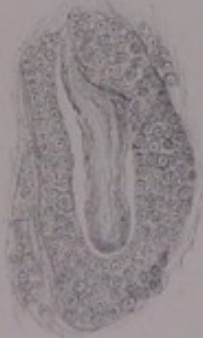124.



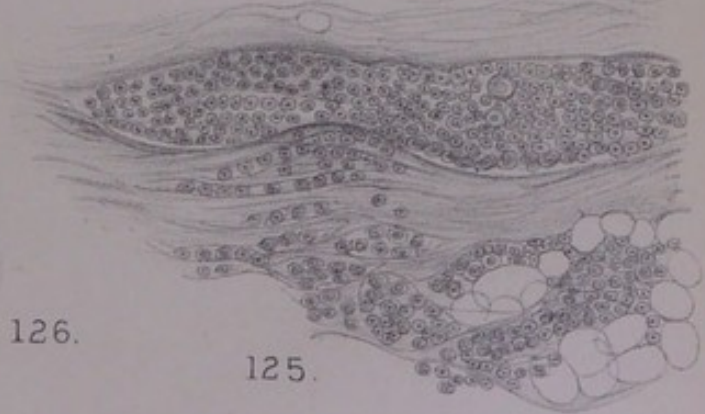
128.



127.



126.



125.



In the latter the sinus is a mere slit; there is a hyaline zone next outside the muscularis, and beyond that a granular zone. The hyaline zone next to the remains of the epithelium is characteristic of most of the milk-sinuses in this case, distinguishing them from those of some previous cases in which the thick sheath round the sinuses is mostly a granular substance. From its existence one may infer back to a wide-spread hyaline transformation of the remains of the mammary acini as well as of the stroma at an earlier period, and so to the acquisition of that scirrhus or fibro-cartilaginous density which the tumour has. Much of the hard lump is hyaline or homogeneous fibrous tissue, in the midst of which lie the collapsed milk-sinuses, with curled elastic fibres marking the situation of some other structures, perhaps arteries or ducts. But there is also in some places a good deal of cellular structure in the linear or alveolar spaces of the stroma. It is of the kind usual in scirrhus—roundish cells nearly all nucleus, suggestive of an epithelial descent. There is hardly any nucleation of the stroma between those interstitial heaps, so dense is the hyaline or fibro-cartilaginous matrix; so that there are no transitions from growing nuclei of the stroma to the heaps of epithelial-like cells in the interspaces. But the latter are none the less certainly parablasic; they have one marked character of all such cells, namely, the fusion of their protoplasts, which is just as striking in this very scirrhus case as it is in the alveolar sarcomata. There is no epithelial source for them, such epithelium as there is on the walls of milk-sinuses being little more than detritus, whilst all the rest of the glandular structure had atrophied or been compressed out of existence long before. It is the obliteration of the sweat-gland part of the structure in the *corpus mammæ* that accounts for the parablasic new growth. Apart from the evidence of muscular fibres in the sinuses, the traces of those tubular glands are discoverable here and there continuous with the angular recesses of sinuses, and by peculiarly stained tracts through the stroma, in the course of which lie concretions characteristic of sweat-glands, as well as parallel muscular ribs.

CASE XXXI.—*Wedge of Scirrhus under the Skin, distinct from a larger Hyaline Tumour of the Breast.*

This case has been used before at p. 130 for the hyaline and myxosarcomatous tumour arising from an extensive deposit of sweat-glands in the *corpus mammæ* and peripheral parts of the mammary structure. But the most important element in this case, which determined its clinical character and infected the very large and dense scirrhus lymph-glands of the axilla, has been reserved for this chapter. It is a nodule of scirrhus adhering to the skin, quite distinct from the larger tumour of the breast. The relation of the two is shown in the diagram, fig. 123, Pl. XXII. As showing how distinct the scirrhus was, there is a small round encapsuled body on its mammary side, which contains the same hyaline as the main tumour, and is, like it, associated with sweat-glands and mammary structure, and with myxo-sarcomatous new growth around them. That also is quite distinct from the scirrhus, although close to it. Still another peripheral extension of the breast itself is found in the fat on the axillary side of the base in the form of an indurated knot, which is an outlying piece of mamma, with myxo-sarcomatous new growth of large cells in the stroma. There is no scirrhus structure in either of these peripheral extensions, nor in the chief mammary tumour. The scirrhus is an independent subcutaneous centre of new growth, surrounded by fat excepting where the upper surface adheres to skin, and separated from the breast by an inch or more of pure subcutaneous fat. The nodule is like a small chestnut with its flat side on the skin and its apex pointing downwards; it sends pointed processes into the fat, and is of extreme toughness and density.

There are several things which point out this spot of skin, with the underlying tissue, as a congenital anomaly. There is no vestige of a supernumerary nipple, but only a gradual hollow of the skin where it adheres to the centre of the scirrhus. The sebaceous glands are large and compound, the hairs small; but the corium contains thick bundles of plain muscle, and there is brown pigmentation of the deep layers of epiderm. The sweat-glands are quite remarkable. Numerous coils occur of both kinds—the wide tubes proper to the axilla and base of the nipple with muscular walls, along with others of the usual kind. The coils of each are very large and perfectly formed, clearly distinguished the one from the other, lying together at the same level of the subcutaneous tissue in almost regular alternate lobes. A small portion of an adjoining coil of each kind is drawn in fig. 5, Pl. I. It is the excessive development of ordinary sweat-glands quite

as much as the erratic presence of the other kind (proper to the axilla or the base of the nipple) that marks this spot of skin as a congenital anomaly. Beneath the unusual deposit of sweat-glands there appears to have been a thick stratum of connective-tissue with an unusual number of blood-vessels and nerves: this is inferred from the fact that what is now the knot of scirrhous has one of its lower angles, of softer texture, still occupied by tortuous arteries of considerable size, with thick walls and nearly collapsed lumen, and by distinct bundles of plain muscular fibres in the tissue near them, as well as by veins, and by numerous nerves; the latter are found also in the adjoining fat as singular tufts of white sinuous cords, like small worms joined in one mass at the middle. Both the nerves and the arteries, with the distinct bundles of plain muscle, are so peculiar for a spot of subcutaneous tissue, that some congenital malformation would be suspected, even if the great deposit of sweat-glands had not accompanied them.

The scirrhous growth appears to have proceeded from the centre of this subcutaneous rudiment, inasmuch as it is extending all round into the fat, with pointed processes at some parts, rounded lobules at others, and being joined to the cutis only at the centre of its upper border where the depression of the skin occurs. Except at that one adherent spot, the coils of sweat-glands are separated from the scirrhous by a layer of fat, and are not involved in the morbid growth. But in some places the wider muscle-ribbed glands are not quite normal; their epithelium is vacuolated with the nuclei free in the vacuoles (fig. 124, Pl. XXII.), and sometimes a nucleus is vacuolated, with a free nucleolus; also the epithelium in a few of the crypts is filled with yellow pigment (compare p. 203, and p. 256, *infra*). At the adhesion of the skin to the scirrhous, the remains of many of the narrower kind of sweat-glands are found scattered through the new growth, the tubes being entire within their sheaths, but as if broken into short lengths and separated from each other. The wider kinds of sweat-glands are not so easily found in the new growth; but it is obviously *their* type of epithelium, very different from that of the ordinary sweat-tubes, which fills

the whole tumour-area. Moreover, certain portions of these wider tubes can still be found, with walls more or less perfect. One of these is drawn in fig. 125; the tube is filled with opaque small quadrate epithelium in which a nucleus distinct from the cloudy protoplasm is hardly to be made out; a few of the cells are large and vacuolated. The same type of epithelial cell, polyhedric, opaque, and often with the nucleus free within a vacuole, as well as the nucleolus free within the nucleus, is found in the fat close to the tube (right of the figure). Another appearance within the scirrhus area is shown in fig. 126: there is a curved belt of epithelium, into the concavity or centre of which a process of vascular tissue projects with a rounded or flask-shaped end. This is the same appearance of the vascular stroma which Rokitansky remarked upon in his original account of it in alveolar cancer (*supra*, p. 237). It can hardly be doubted that a certain part of the anomalous deposit of sweat-glands, in the line of the central adhesion of skin, had been invaded by a new growth of vascular stroma, and in various ways obstructed and obliterated.

But it is impossible to refer the alveolar groups of epithelial-like cells, which make the bulk of the scirrhus, to proliferation of original epithelium. The original epithelium has all the marks of degeneration; or, if it produces new generations of cells, it is by setting free its nuclei in the way of endogenous cell-formation. The epithelial-like cells lie in the small alveolar spaces of the stroma as if they had sprung up where they lie. In the centre of the knot, the stroma is remarkably hyaline, with only a few long slender nuclei along the free borders of the hyaline bands. But at the angle before mentioned, which contains the peculiar coils of arteries, etc., and has a much softer or easier section, the stroma is richly nucleated so as to be almost sarcomatous or myxomatous around the walls of vessels; whilst the alveolar cells are fused together into lumps, as in the sarcomata proper. In this case also, I take the obstruction and obliteration of tubular sweat-glands (howsoever brought about) to have been the occasion of a *parablasic* new growth of epithelial-like cells from the vascular stroma, which makes the actual tumour.

The character of scirrhus is due to the hyaline condition of the stroma, not to any hyaline transformation of mammary structures, which are altogether wanting at the spot. The larger tumour, of the breast itself, is remarkable for containing much true hyaline, like that of cylindroma, which had been deposited outside the walls of the anomalous sweat-glands of the *corpus mammæ* (see fig. 49, Pl. VIII.). It is not easy to say why the one tumour should have been scirrhus and the other a comparatively innocent hyaline; but the explanation would probably be found in the anomalous character of the whole spot of skin and subcutaneous tissue where the erratic deposit of sweat-glands occurs.

CASE XXXII.—*Small Scirrhus at one Side of the Breast.*

A specimen in the stores of the Collection of Surgical Pathology at Cambridge, December 1900. The scirrhus is situated in the midst of pure fat at one side of the breast, remote from the nipple, which is not involved in the disease at all. It is an irregular cylinder from $\frac{1}{2}$ inch to $\frac{3}{4}$ inch thick, with its base upon the skin and its lower rounded end reaching to within a $\frac{1}{4}$ inch of the pectoral fascia, the vertical depth being $1\frac{1}{4}$ inches (fig. 127, Pl. XXII.). Its borders are indented, but rather lobulated than serrated. The texture is dense and firm, cutting like a turnip. The cylinder hangs straight down from the skin, its base being fused with the corium. The skin is not dimpled, puckered, or otherwise abnormal. The sweat-glands of the adherent skin are of the smaller calibre; but they have the clear protoplasm and open lumen of the large axillary glands, and they have everywhere a beautifully marked longitudinal basement membrane of plain muscular fibres.

This is a cylinder of true scirrhus which may have arisen, like the last, from subcutaneous gland-structures near the border of the breast, or from some detached axillary process of the breast itself, the adhesion to the skin coming after. There are no bands through the fat joining it to any visible remains of the breast; on the other hand, the scirrhous structure is continuous from the cutis downwards, and stops short of the pectoral fascia a quarter of an inch. It does not contain a single trace of milk-sinuses or ducts, such as are nearly always found close to the coils of sweat-glands in the periphery of the breast; nor any structures which can be identified as mammary lobules, whether of the compact acinous or

branching tubular kind. It contains, however, a number of original glandular tubes, which are distinguished clearly in the midst of the scirrhus "infiltration" by their definite walls and the character of their epithelium. A group of three of these is drawn in fig. 128, Pl. XXII., under a low power. The epithelial cells are large, polyhedric, still joined in a not irregular mosaic. Their protoplasm stains well, and is often vacuolated, the nucleus lying free in the cavity; some nuclei are small in proportion to the whole breadth of the cell, others are much larger. The interior of these spaces is exactly the same as in fig. 67, Pl. XII., from a sarcoma, and as in Case XXIV. There is no doubt that they are dilated tubular sweat-glands. The decisive criterion of the muscular basement can be seen sometimes, as in fig. 129, Pl. XXIII., the parallel ribs being somewhat swollen and mucinous, and the large polyhedric epithelial cells cloudy or indefinite in outline; there is also an appearance of muscularis at the outer end of the smallest of the three tubes of fig. 128.

Around those original sweat-tubes the tissue is occupied by small nuclear cells, which appear to have split up the stroma into concentric threads or single fibres. But in most parts of the scirrhus area the cells are epithelial-like, of various sizes, all with relatively large nuclei, and are contained in alveoli. Towards the rounded lower end of the cylinder, the alveolar groups are so close together and so uniform, that the structure might be called sarcomatous. In most places there are considerable bands of stroma between them, which is hyaline, usually with only occasional long slender nuclei, but in some places more thickly beset with nuclei of greater breadth. The structure as a whole favours the hypothesis of parablasic new growth from the vascular stroma around a deposit of obstructed and disorganised sweat-glands. The clouds of smaller nuclear cells, whether they be the endogenously produced nuclei of the glandular epithelium infiltrated into the stroma, or leucocytes, are only an addition to the main tumour-elements; these nuclei are of various sizes, always mitotic, and they shade off by gradations into the epithelial-like cells of the alveoli.

The only ambiguity in the case concerns the original

relation of the sweat-tubes—whether they had been those of the skin, as in the last case, or a development within an outlying part of the breast at the end of one or more prolongations of milk-sinuses. It is clear from Case XXI. (sarcoma), as well as from Case XXXIV. in the sequel, that sweat-glands developed as part of the breast itself may be cut off as islands in the midst of a wide expanse of fat, having resisted the obsolescence which overtakes all the regular mammary structures sooner or later. The absence of any milk-sinus in this case, as well as the attachment of the base of the scirrhus to the skin, makes it possible that the sweat-glands had been unconnected with any part of the breast. But it is conceivable that such a deposit of them as is shown in fig. 68, Pl. XIII., although within the capsule of the breast and originally developed upon the end of a milk-sinus, might be cut off from its connections, and may have become the seat of a seemingly extra-mammary new growth. The question here raised is not unimportant, as these outlying knots of scirrhus, with base on the skin, are not altogether rare (Paget, *Surg. Path.*, p. 607).

An irregular extension of the breast towards the axilla, which may turn round the border of the pectoralis major muscle and lie in the axilla, has been known for a long time. Walshe (*op. cit.*, 1846, p. 469) speaks of "bands which extend sometimes even to the axilla, or twist under the border of the pectoralis major: the importance of tracing them to their apparent termination in extirpating the disease has justly been insisted on by a number of writers." Hennig ("Ein Beitrag zur Morphologie der weiblichen Milchdrüse," *Arch. f. Gynaekol.*, ii. 1871, p. 331), from the dissection of a large number of breasts both amputated and in *post-mortem* subjects, found that the band-like processes from the periphery of the breast were mainly three: one on the inner margin, another extending downwards and outwards, the third and longest running to the axilla, difficult to dissect out, and apparently in direct continuity with the packet of lymph-glands. The axillary process is a triangular tip of the breast which turns round the lower border of the pectoralis major; it may be joined to the mamma only by connective tissue, and is not a constant structure, having been found in 91 out of 120 breasts. Volkmann, at p. 330 of his *Beiträge zur Chirurgie*, 1875, pointed out the great practical importance of the long outrunners of the breast, which might become detached. Stiles ("Surgical Anatomy of the Breast," *Edin. Med. Journ.*, June and July 1892, xxxviii. and xxxix.) has devised a method of bringing out the same irregular glandular extensions by treating the cut surface with dilute

nitric acid; the "axillary tail" contains ducts, which are felt as strings extending from the breast into the axilla, often mistaken for lymphatic cords.

CASE XXXIII.—*Linear Tracts and Islands of Scirrhus at the axillary side of a very fat Breast, associated with an erratic deposit of axillary Sweat-glands.*

Specimen at Cambridge, December 1900. A very large fat breast with scirrhus infiltration in the fat next the axilla. The scirrhus area begins one inch from the axillary end of the thick cushion of fat (the deep incision having been carried far enough to include a lymphatic gland, which is normal). The scirrhus extends through the fat in narrow white bands and small round cloudy white islands all the way from the skin to the pectoral fascia, over an area about an inch and a half square. Along the pectoral fascia, to which a portion of muscle adheres firmly, the infiltration forms a peculiar horizontal stratum of pale reddish colour. At one point in the skin over the infiltrated area there is a small depression or dimple with a few broken white hairs springing from it or around it. The white bands and islands in the fat have the toughness and density of scirrhus.

So far as appears, this scirrhus did not involve any central part of the breast, or any obvious remains of mammary structure at all. It was wholly upon the axillary side, coming within an inch of the extreme limit of the surgical incision, which included an axillary lymph-gland. The source of the scirrhus infiltration is found under the skin, at a point where it is marked by a distinct dimple. There is at that place an extensive deposit of the large muscle-ribbed sweat-glands, about an inch in the lateral direction and sunk an eighth of an inch into the subcutaneous fat. They are mixed with a few coils of the ordinary sweat-glands; but these are relatively fewer as well as smaller than in the corresponding deposit of the last case but one. The deposit of the larger kind is as extensive as the regular stratum of them at the deepest recess of the axilla, being about the size of a florin. The coils are all large and well formed, visible by a lens as a region of regular round loculi in the fat next to the cutis, the dimple being in the centre of the patch. They are all in a more or less morbid state. Some loculi are filled with a vesiculated fluid; others have granular epithelial cells loose within the tube; others have very clear yellow pigmentation of the cells as they adhere round the

wall; all have a certain glutinous, blurred, and fused appearance of the epithelial lining. At the same time there is no appearance of infiltrated cells between the several windings of a coil, nor any obvious increase of the vascular connective tissue.

The relation of this layer of disordered sweat-glands to the scirrhus infiltration of the fat is shown in fig. 130, Pl. XXIII., in which only a very small part of two adjoining coils could be included, and only a little of the infiltration nearest to them. The latter descends in the fat all the way to the pectoral fascia and the muscle, and forms many small round islands which give the fat a mottled white appearance. The infiltration is everywhere composed of the same small nuclear cells, like leucocytes, which stain ill, and have a certain look of instability. They follow the tracts of fibrous tissue through the fat, but frequently wander in narrow streams into the pure fat, making subordinate tracts, small nodal points, and limited opacities or films of whiteness. I have no doubt that these small cancer-cells are really the nuclei shed from the sweat-gland epithelium. There are no yellow cells among them such as are often found around the disordered sweat-glands of the dog, but there are several other things to connect them with the sweat-glands. Endogenous cell-formation is nearly always found in the epithelium *in situ*, by which the nuclei are set free; it is a law of such sweat-glands, dependent perhaps upon their peculiar basement membrane, that cellular products of secretion (excretion) escape through the wall; there is a peculiar glutinous state of the epithelium *in situ*, which is also distinctive of the tracts of infiltrated nuclei. Billroth was inclined to favour the view that all such nuclear or small-celled infiltrations were of leucocytes, because they followed the tracks of blood-vessels. (Unna identifies them with his plasma-cells. *Berl. kl. Woch.*, No. 49, 1892.) In this case the few remaining fibrous bands through the fat are probably the paths of blood-vessels, but the nuclear cells do not appear to have come from the latter. There are instances in which Billroth's preference is doubtless justified, but these are probably not the most usual cases of small-celled infiltration in scirrhus:

sometimes one sees a *cloud* of nuclear cells around the section of a vessel, usually a vein, which are almost certainly leucocytes; but I have observed this phenomenon most in cases of sarcoma.

The infiltrated bands broaden out towards the centre of the fat, and become insular tracts. They are continued to the pectoral fascia, along or within which they run in horizontal lines towards the axilla. This latter region of "infiltration" is a peculiar one in several respects, which I shall not enlarge upon. The whole is of scirrhus density and toughness. In this case there is no hyaline transformation of mammary lobules and stroma to account for the sclerosed condition; it appears to inhere in the nuclear cells themselves, as if they had brought the property with them from their place of origin.

The Dimple of the Skin in Scirrhus.—The very well-marked dimple in this case was exactly over the centre of the aberrant deposit of sweat-glands under the skin. In Case xxxi. also there was a distinct hollow of the skin over the similar aberrant deposit of sweat-glands, but not a true dimple or pocket. In Case xxvii. there was a well-marked dimple, from the bottom of which an inverted cone of loose connective tissue descended to the margin of the scirrhus; I made microscopic sections through the skin and underlying tissue without finding anything remarkable; but there are appearances of tubular structure in the adjoining margin of the tumour. In Case xx. (fungating myeloid sarcoma), there was a small deep cleft of the skin at one end of the specimen, remote from the tumour, and apparently unconnected with any glandular structure. If I had generalised from the two first cases, I should have said that a dimple marked the site of a subcutaneous deposit of the large kind of sweat-glands; but that does not hold good for other cases.

Brodie, in his *Lectures illustrating various subjects in Pathology and Surgery*, 1846, laid great stress upon the occurrence of a dimple in scirrhus of the breast: "In many cases of scirrhus tumour of the breast, the skin is drawn or tucked in over the tumour, so as to produce the appearance of a dimple in it. Where this dimple in the skin exists, you may be almost sure that there is a scirrhus tumour in the breast beneath it, and on examination you will feel it with the finger. I believe this dimple of the skin to form a very great objection to the operation, and that under these circumstances there is little or no chance of a permanent cure. But on what does this appearance depend? In a case which I dissected very carefully, I found a narrow process or elongation of the disease, perhaps half an inch in length, passing from the tumour through the adeps into the skin, and connecting the skin and the tumour to each other. In fact the

dimple indicates that the disease is not confined to the breast, but that the skin is already contaminated"—p. 197.

Sheild also (*Clinical Treatise on the Diseases of the Breast*, 1898, p. 345), without referring to Brodie's teaching, is equally emphatic as to the significance of a dimple: "There is no sign of more vital import than this. The slightest dimple on the skin of the mamma of an elderly woman is a dangerous symptom. . . . This dimpling is not due to adhesions between the actual tumour and the skin, but to contracting or drawing down of the radiating fibrous processes of the tumour." It is present even in deep cancers. He gives a figure at p. 346 of a dimple on the lower margin of the breast over a cancer in an early stage.

CASE XXXIV.—*Insular Scirrhus in a very large fat Breast ; destruction of Nipple ; "lardaceous" infiltration of Skin.*

Specimen used for Degree Examinations at Cambridge, December 1900. An enormously fat breast, $3\frac{1}{4}$ inches deep from skin to pectoral base, $4\frac{1}{2}$ inches in lateral extent. The nipple is gone entirely, and there is an area of superficial excoriation all round the place of it, the size of a crown-piece. Nearly all the rest of the skin removed, many square inches, is thick, leathery, inflexible, "lardaceous," with the surface like the skin of a lemon, the white layer of scirrhus between the corium and the pure fat beneath being a quarter of an inch thick in places. The whole region of the breast is converted into fat excepting certain white islands of intense hardness and density. The two larger of these, irregular in outline, each about an inch square, lie close together about one inch directly below the destroyed nipple, and doubtless represent the *corpus mammæ*; they are distinguished from the other islands by an open locular or cystic structure in the centre. The other islands lie at wide intervals in the fat on either side and at various elevations, the most superficial one being connected by a narrow neck with the layer of cutaneous scirrhus; they are about the size of hazel-nuts or kernels, all definitely rounded, as if encapsuled, spherical, or drawn out into pyriform necks. There are four or five of these, separated from each other by as much as an inch of pure fat.

The key to this singular case is the substitution of the whole breast by fat, excepting the islands described above: they had been left behind in the climacteric effacement, and have become the seat of scirrhus. The two larger islands of the *corpus mammæ* contain numerous traces of glandular structure. The characteristic forms of milk-sinuses are not found: that is to say, epithelial-lined spaces with rugous walls and angular recesses; the widest spaces are all uniformly rounded, but they have the same small epithelium of depressed columnar type as the milk-sinuses have, and are as

wide or wider. They form clusters of loculi, like a group of small cysts communicating. The most significant thing is the basement of plain muscular fibres. This is shown in fig. 131, Pl. XXIII., the dilated tube being one of three or four in a cluster. Another view of the muscularis is shown in fig. 132 upon a piece of tube or sinus compressed longitudinally, which has hardly any wall but the muscular basement, and has its epithelium decayed. The existence of the longitudinal coat of plain muscle can be perceived over and over again upon the more dilated tubes, including the locular clusters of them. On the other hand, it is not easy to demonstrate it, except in bands, *a*, between tubes, in certain glandular coils which are not dilated. These, along with ordinary mammary lobules, make up the rest of the glandular structure. A portion of one of the coils of tubular glands is shown in fig. 133. The tubes are nearly filled with epithelium of a small and not irregular type; but it is separable into two layers, a superficial and a basal, with a certain appearance of an interval between them. This is the important phenomenon remarked upon by Benda (*supra*, p. 42), the basal nuclear layer being taken by him to be in the place of the "epithelial-muscle" layer, or muscularis-basement. Along with these coils of tubular glands, which are found both in the central islands (*corpus mammæ*) and in the lateral, there are long stretches of tubing, sacculated,

DESCRIPTION OF PLATE XXIII.

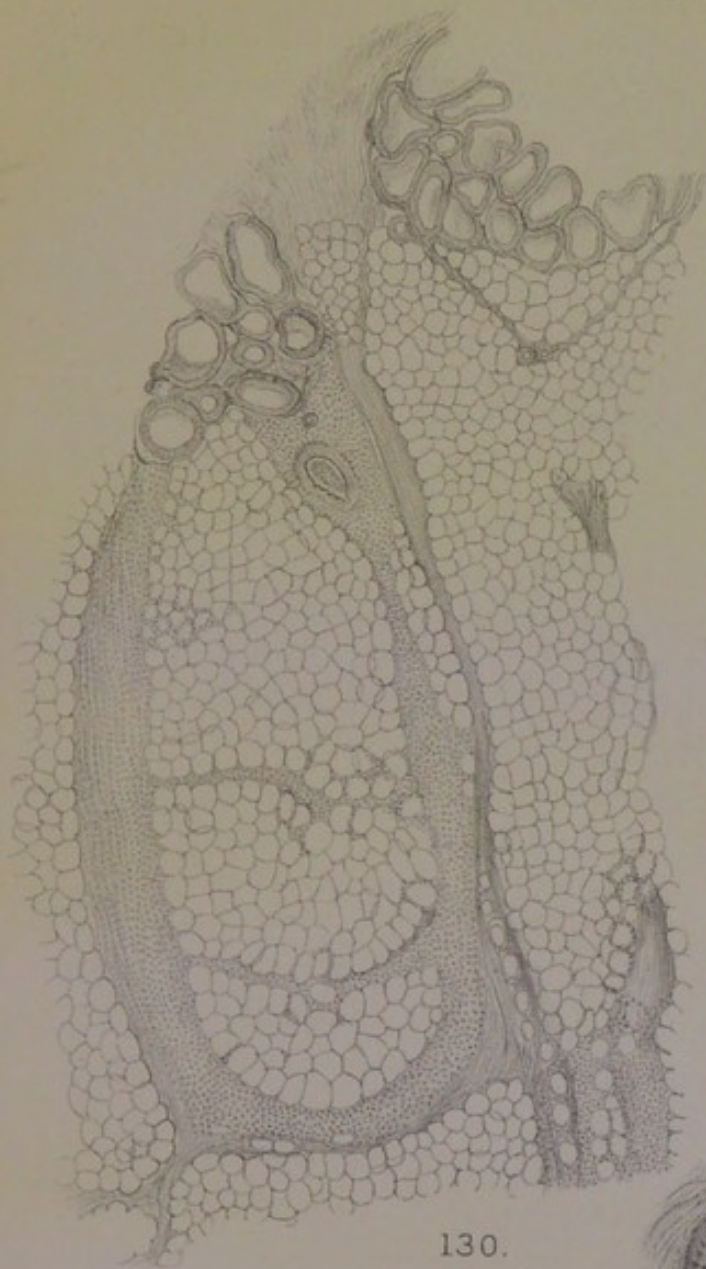
FIG. 129. Sweat-tube in Scirrhus, Case XXXII. The projecting ends of plain muscular fibres of the basement are seen at *a*; the cloudy granular mosaic of epithelium at *b*. $\times 300$.

FIG. 130. Large deposit of muscle-walled sweat-glands under a dimple of the skin on the axillary side of the breast in Case XXXIII., with tracts of small-celled scirrhus infiltration descending from it through the fat. $\times 20$.

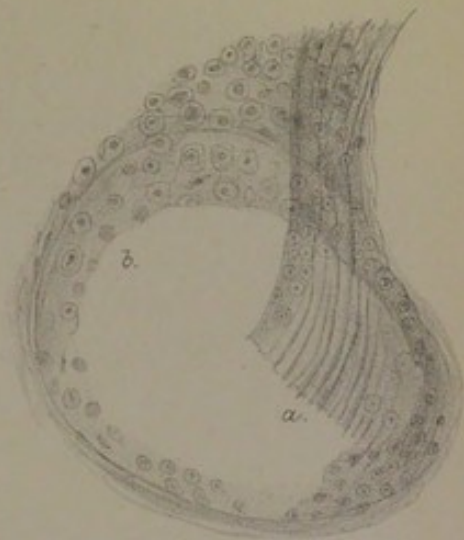
FIG. 131. Wall of dilated tube in locular island in the midst of fat, Case XXXIV. The nucleated muscular fibres seen clearly in alum-carmine specimen. $\times 200$.

FIG. 132. Another tube or sinus from same breast, showing the denuded muscular basement. $\times 200$.

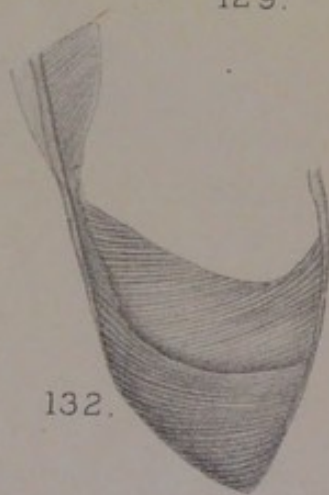
FIG. 133. Part of a coil of tubes from same Case XXXIV., in which the basal layer of epithelium is distinct from the surface layer: there is no muscular basement, but an appearance of plain muscular fibres, *a, a*, in the stroma between the coils of tubing. $\times 200$.



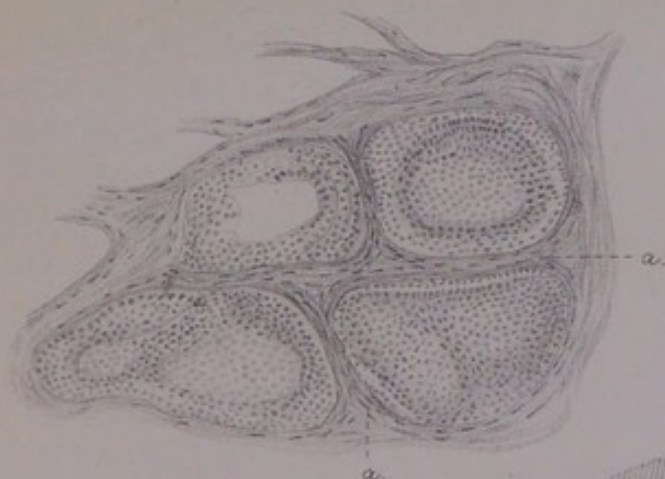130.




129.



132.



133.



131.



or sinuous, and sometimes doubled upon itself, which have the same kind of epithelial lining. Lastly, there are numerous acinous lobules of ordinary breast, which are undergoing the kind of effacement by hyaline zones described above (pp. 152, 191), and in some instances are reduced to nearly pure fibrous areas with a few surviving nuclei.

The anomalous character of certain of these remains of the breast is obvious, the sweat-gland type being the same as in fig. 65, *c*, and in other instances. The case has certain peculiarities, of which the most notable for the pathology is the small and meagre type of columnar epithelial cell lining the wider tubes and the coils of tubular glands. The same small type of epithelium is found also in Case XXVII., which has the sweat-glands clearly marked. Very small cells are characteristic not only of the original glandular tubes, but of the whole of the scirrhus new growth, both in the islands of the fat and in the extensive stratum under the skin. This growth is of the alveolar kind, the amount of stroma between the alveoli being various. The stroma is always dense, homogeneous, or hyaline, and is probably the chief reason of the scirrhus density of the new growth. In some of the nodules the interstitial cells are so many and close-packed that the structure would be taken for sarcomatous except in respect of its hardness. I believe these alveolar cells to be of interstitial origin, and to have sprung up around coils of tubular glands, which are obstructed or cut off from their outlet. Traces of these, as well as of the regular lobules of mammary acini, are found within the several centres of scirrhus. The extensive stratum under the skin, unconnected with breast, has the same type of new growth as elsewhere, with the stroma in broader bands.

This infiltration of the skin is one of the characters described by Velpeau for lardaceous scirrhus. As Walshe says (*l.c.*, p. 473), the subcutaneous infiltration is "coeval with, and, as it were, independent of, the subjacent structure.

. . This variety may commence in the nipple." In this case the process which has destroyed the nipple and excoriated the areola is superficial; beyond the excoriated

area, the extensive subcutaneous stratum of alveolar scirrhus begins. The process in the nipple and areola appears to have been the commoner form of Paget's disease, the following case of which, by Thin, resembles the present in several respects :—

An unmarried woman, aged 57, had suffered from "eczema of the nipple" for three years. As it was feared that cancer of the breast might follow, the organ was amputated, no new growth having been detected before the operation. The breast seemed to be a large solid mass of fat pervaded by delicate narrow streaks of white fibrous tissue. In these fibrous tracts were found long solitary columns of epithelial cells, or rounded masses composed of a conglomerate of tubular formations, and sometimes of well-defined round tubes lying close to and parallel with each other, having a central lumen. The cells were all small, and had so little stability that they were very badly preserved. The border cells of the larger tracts were columnar, and the sections of the smaller tubes showed that they were formed of the same. Thin's conclusion was, that these tubes were "not parts of the normal gland more or less modified, but were new formations" (*Path. Trans.*, xxxii. 221).

The long cylinders, or blocked tubes, or open tubes in these fibrous tracts through a wide expanse of mammary fat, are the anomalous parts of the breast-structure, which remain behind when the regular parts of it undergo obsolescence and are removed absolutely. Similar blocked tubes appear to have been found in all the other five breasts examined by Thin, which were the subject of Paget's disease, as well as in four examined by Butlin. Bowlby, indeed (*Med. Chir. Trans.*, lxxiv. 1891, p. 341), maintains from a series of thirteen cases of that disease that the tumour-process in the breast (in twelve of the cases) is always "typical scirrhus carcinoma," and not "duct-cancer"; but the two are not so mutually exclusive as he supposes, inasmuch as tubular structures can be found in all cases of scirrhus, in one relation or another to the alveolar structure. The peculiarly small and ill-formed type of epithelial cell, which was found by Thin in the case cited, is highly characteristic of the present case; and I attach great importance to the fact that Radcliffe Crocker found it also in the case of Paget's disease of the scrotum cited above, p. 16.

Whether there be some one type of epithelium in the

breast associated with Paget's disease, or more than one, it is probable that the disease of the nipple and areola is an occasional early manifestation of that disorder of the lymphatic apparatus which can be traced in all varieties of tumour of the breast. The nipple and areola are peculiarly subject to eczema, or the like, under other circumstances (*supra*, p. 29), the pathology of which would almost certainly throw light upon its occurrence as the precursor of or attendant upon tumour-disease. The extensive involvement of the subcutaneous tissue, without excoriation of the surface, is really a more unaccountable thing than the "dermatitis" of the nipple and areola, even if the latter be qualified in some cases as "malignant." In this case both were present, the scirrhus infiltration of the skin beginning where the excoriation of the surface ended. The central area, in which Paget's disease begins, and to which it is usually confined, corresponds with the lymphatic *circulus subareolaris*, or confluence of all the lymphatics converging upon the walls of the milk-sinuses and ducts.

CASE XXXV.—*Large Scirrhus of rapid growth: the Stroma an Adenoid Reticulum.*

Elizabeth Middleton, aged 40, widow, mother of three children, the last seven years ago, was admitted to St Thomas's Hospital on 21st January 1873, under Mr Sydney Jones, for a large tumour of the left breast. About a year ago the breast was struck accidentally, and is said to have received a second blow. It began to be painful after a time, and thereafter began to enlarge. The tumour has grown rapidly, and is now as large as the fist, with nipple retracted. The other mamma is very large. No enlarged axillary glands. Breast amputated on 24th January. The new growth is scirrhus of the very hard kind, and measures 4 inches \times 4 \times 2½. It consists of one large mass under and around the nipple, and a smaller accessory nodule on the axillary side, with an interval of about half an inch between them. On pressing the cut surface of the chief mass, brownish fluid escaped, apparently from a small cyst. The smaller nodule was as hard as the other, but darker in colour (brownish). Erysipelas followed, and on 17th February an abscess in the other breast.

The scirrhus in this case was extensive or diffused, and had grown rapidly. There is no doubt that it followed one or more blows upon the breast, the first effect of which was pain for some time, the enlargement coming after the painful

period. The disease had arisen in a voluminous breast at the age of forty. The bulk of the new growth is in the stroma, which is not unlike "chronic inflammatory" tissue: it is traversed by numerous vessels, wide and narrow, some of which have the proper structure of arteries and veins, while others are the thin-walled channels found in granulations; and in many places it consists of an adenoid reticulum with small cells in its meshes. But the stroma contains also epithelial-like cells, large, pale, and thin, always vesiculated, with a small nucleus in the vacuole or at one side, which merge with the reticular tissue round about them. The type of this epithelial-like new growth of the vascular tissue is found within certain glandular structures which occur at intervals in the stroma.

Fig. 134, Pl. XXIV., drawn under a low power, shows these glandular structures and their relation to the scirrhus stroma. The section is made from the dense *corpus mammæ* about half an inch below the nipple. The whole region is traversed by circular tubes of somewhat uniform width, all sharply defined by a thin wall towards the stroma, and all blocked by epithelial contents (partly fallen out in the sections). The first thing that one notices in these tubes is, that they are not the milk-ducts. One of the latter is shown at the top of the figure, with a tube of the other kind by its side; it has a regular broad belt of columnar epithelium, with the somewhat wavy border proper to the ducts of that order, and a well-defined lumen; its only morbid character is in the submucosa, which stains vividly, and is occupied by the same reticular meshes and free nuclei as the stroma at large. Following the ducts upwards into the nipple, they are found to be absolutely normal not only in their epithelium, but also in their submucosa. Fig. 135 shows one of these from a cross-section of the whole nipple; the epithelium is thrown into folds or ridges (as it ought to be in the ducts within the nipple), which have a certain look of papillary excrescences, but are in a very perfect normal condition, without a single cell displaced in the surface row, or any collection of cells in the vascular layer. These ducts within the nipple in a case of scirrhus were so perfect that I

remember showing the sections of them as normal structures at the St Thomas's Hospital Students' Society.

In the sections taken half an inch below the nipple certain clusters of mammary acini are found near the smaller ducts. They are in the usual state of involution, occupied by nuclear resting epithelium, without any signs of activity within them, but with the same adenoid or reticular tissue around them and penetrating between them as in the stroma at large. So far as concerns the interiors of glandular structures, the morbid process is confined to the tubes shown in their cross-sections in fig. 134, *a a a*, Pl. XXIV. They are blocked by epithelium, which is nearly always vacuolated or reduced to ring-like outlines, with nuclei either free in the centre of the cell and of spherical shape, or lying in the marginal ring of protoplasm and of crescentic or triangular shape; they are not plump or bulky cells, but suggest rather cell-plates with a thin protoplasm: in one of the smaller tubes at the right-hand side of the figure the cells are of the more elongated kind, slender, and packed close together. In the walls of these tubes there are various faint indications of the presence of longitudinal muscular fibres, from which, and from the obvious tubular form, and the marked contrast with milk-ducts, there can be no doubt that they are the anomalous sweat-tubes of the *corpus mammæ*, distended by epithelium and uncoiled or drawn out to the length by the new growth of stroma around and between their windings. It may be concluded that this breast had been one of those containing an anomalous development of sweat-gland structures, which are peculiarly the occasion of tumour.

The case illustrates not only the contrast between regular milk-ducts and sweat-tubes, and the error of the name "duct-cancer," but also a certain peculiarity in the reaction of the vascular stroma around the blocked tubes. The new growth is in great part an adenoid reticulum full of small round or crescentic or triangular cells, not unlike that of the next case, which approximates more closely to tubercle. But here it is also in part an epithelial-like new growth, the cells of which are exactly like those within the tubes: that is to say, with thin protoplasm extensively vacuolated, and with

pale nuclei of various sizes, but on the average smaller than the usual nuclei of scirrhus; and these epithelial-like centres in the stroma pass insensibly into the more prevalent adenoid reticulum, the character common to both being the extensive vacuolation of the protoplasm. The type of new growth in the stroma had been determined by the kind of process within the blocked tubes, as in many other cases already given; and it may be, that something in the patient's constitution had determined both the one and the other. The bulk of the new growth is in the vascular stroma, and is parablasic to the obstructed and disintegrated tubular glands. The scirrhus density in this case does not depend either upon bands of hyaline substance around the milk-sinuses and tubes and in the stroma at large, nor upon alveolar masses of tumour-cells compacted together by some glutinous intercellular substance, but probably upon some corresponding substance diffused amongst the reticular tissue, and in its meshes or vacuoles, in some such way as the hyaline of tubercle is diffused.

CASE XXXVI.—*Scirrhus resembling Tubercle.*

Ann Hartfield, aged 54, admitted into St Thomas's Hospital, under Mr Croft, on 31st March 1873, for a hard tumour of the left breast. The patient has borne twelve children, the last ten years ago, and has suckled ten of them: most of them died in infancy. The growth in the breast was seen first ten months ago, above the nipple. It is a diffused, finely nodulated substance, about $2\frac{1}{2}$ inches in the lateral direction and $1\frac{1}{2}$ inches in the vertical, and feels hard. It moves freely upon the base, while the skin over it is loose and flabby. There is no enlargement of axillary glands. Removed on 2nd April, the tumour was found to measure as above, and to be a stratum only $\frac{3}{4}$ inch thick, surrounded by a large quantity of fat. It was intensely hard, "presenting all the naked-eye characters of scirrhus." On section a quantity of fluid, like pus, escaped apparently from the cut ends of dilated ducts, some of which were $\frac{1}{8}$ inch wide. Certain branching white lines on the cut surface were also supposed to be ducts.

The supposed dilated ducts, from which a greyish puriform fluid escaped in quantity, were probably involution-cysts with somewhat catarrhal contents; but unfortunately there is no microscopic section of any of them. The sections show a number of collapsed milk-sinuses, running out into

two, three, or four angles, which are doubtless the branching white lines referred to. They are all remarkable for a broad zone round them, of which the part next to the lumen, or epithelium, is hyaline, and the broader outer part a granular or shreddy substance which stains well. This is the same broad zone that is very commonly found investing the milk-sinuses in scirrhus breasts of a corresponding age. The only other traces of original glandular structure are also invested by hyaline, which is relatively broader around them than around the sinuses. These structures had evidently been dependent from the sinuses at their angular recesses; they belong to the same system, are in due subordination of size, have the same kind of epithelial cells upon their walls, and are ensheathed by the same hyaline. Fig. 136, Pl. XXIV., shows part of a cluster of these tubular structures subordinate to a milk-sinus, in which the hyaline zone is relatively very large, and the epithelium reduced to nearly solid cords of nuclear cells, which are not otherwise abnormal; round the margins of the hyaline there is a narrow zone of shreddy or spongy tissue, which is found also in the circumtubular tissue of sarcoma as well as of scirrhus (p. 179 and p. 247), and is always distinguished by its peculiar staining as if it were serous or œdematous; beyond that zone, very narrow in this case, the stroma is a reticulum of threads with small nuclei in the meshes or at the nodal points. In fig. 137 there is drawn a small piece of tube which has no hyaline zone, and has its epithelium regular but very small; the circumtubular process here is exactly the same in its gradations as that of fig. 74, Pl. XIV., from a sarcoma; but the stroma is much less protoplasmic, so that the trabeculæ or columns of nucleated tissue, undergoing the same vacuolation, produce a reticulum of slender threads with small free nuclei.

These remains of breast-structure are passive and retrogressive within themselves; only in some of the more patent sinuses is there a slight amount of proliferation of epithelium, in the form of slender warty processes, in which the cells are reduced to hard circular outlines with small free nuclei. As in other cases of scirrhus, there are various proofs that these

milk-sinuses and their dependent tubes had been developed with a basement of plain muscular fibres; and that fact, along with the presence of involution-cysts, serves to place this breast among those distinguished by the sweat-gland anomaly in their structure. The evidence in this case is not of a kind that can be shown well in drawings, which would miss it if they were faithful and exaggerate it if they were intelligible; the remains of the parallel muscular ribs can be seen best where there is no hyaline (fig. 137), and are of the same kind as in the two figures 121 and 122, Pl. XXII., from a case of shrinking scirrhus.

Beyond a few pieces of tubular gland close to the milk-sinuses, as in fig. 109, Pl. XX., there is nothing left of the glandular structure (no acini forming lobules)—a state of obsolescence which the patient's age (fifty-four) makes intelligible. Only the anomalous structures remain. But all through the scirrhous mass there are innumerable clusters of cells in the stroma, of various form and size, which occur with great uniformity in the midst of adenoid reticular tissue. At some few spots, such as that drawn in fig. 138, the appearance is of tubercles, the protoplasmic masses representing the giant-cells. This particular spot occurs at the confluence of several large blood-vessels, which perhaps accounts for its tubercle-like limits; usually the same kind of tissue is not nodular, but diffused in continuous tracts. The protoplasmic

DESCRIPTION OF PLATE XXIV.

FIG. 134. *Corpus mammæ* under base of nipple in Case xxxv. *a*, normal milk-duct; *b b b*, tubes without submucosa, blocked by flattened epithelium. The vascular stroma is a lymphoid-like reticulum with nuclei in the meshes. $\times 50$.

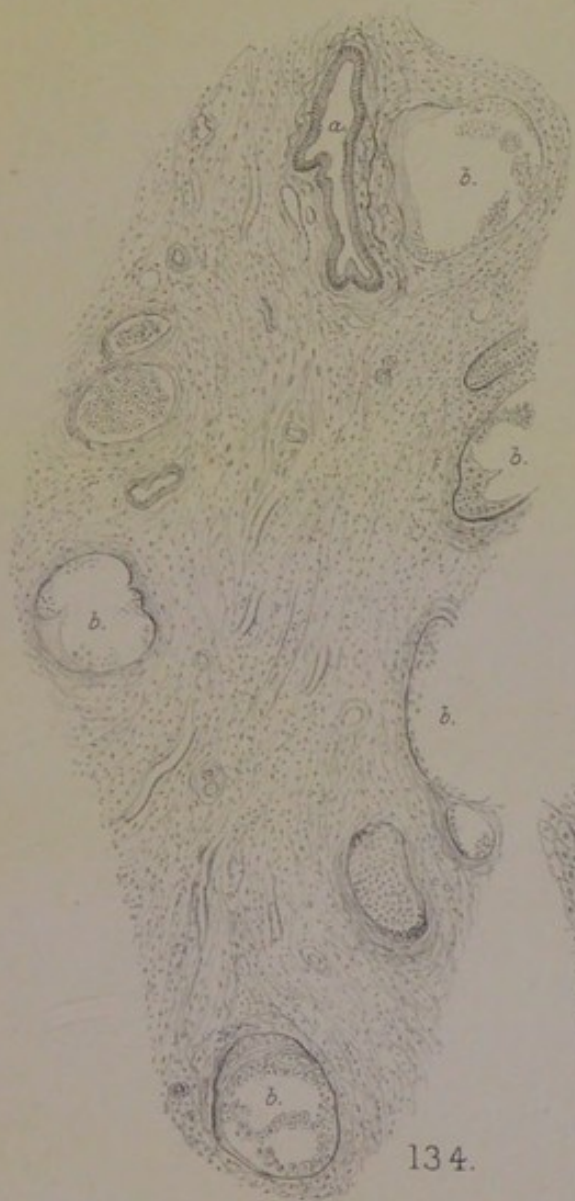
FIG. 135. Cross-section of a normal milk-duct within the nipple in Case xxxv. $\times 50$.

FIG. 136. From Case xxxvi. Scirrhus approximating to Tubercle. Group of blocked tubes with broad hyaline zones; the stroma an adenoid reticulum, with small pale nuclei in the meshes. $\times 200$.

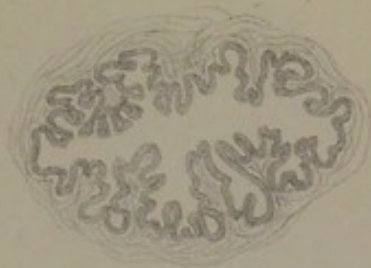
FIG. 137. One of the tubes from same breast, showing muscularis-basement, and myxomatous tissue next to it. $\times 200$.

FIG. 138. Tubercle-like centre in same Case xxxvi.: within a belt of homogeneous fibrous tissue, a spherical area of adenoid reticulum, with small nuclei in the meshes, and occasional multinuclear masses (giant-cells) containing vesicles (*physalides*). $\times 200$.

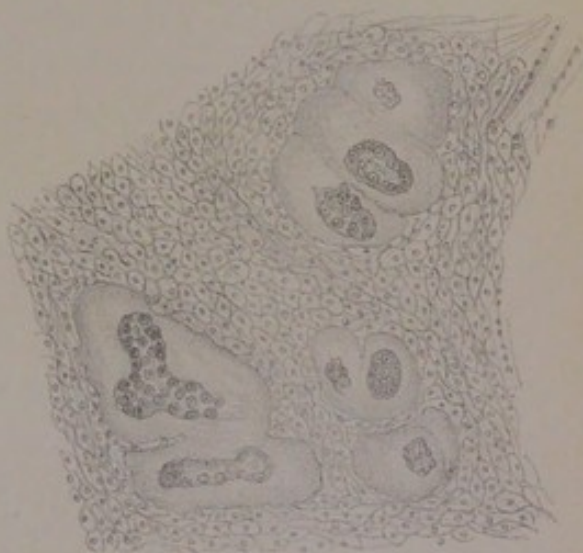
Plate XXIV.
Tubercular Scirrhus.



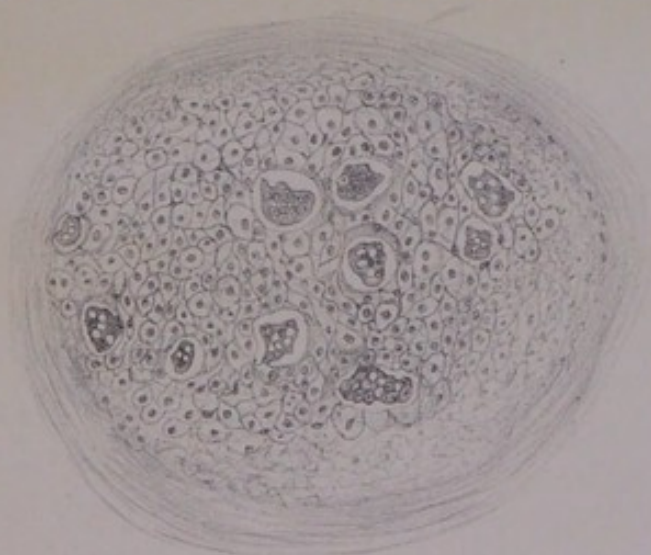
134.



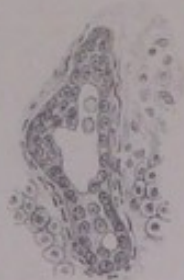135.



136.



138.



137.



masses are in the same relation to the stroma as the alveolar groups of epithelial-like cells in scirrhus (which in fig. 122, Pl. XXII., are just as much fused together); but they are distinguished by their fainter staining, and by the vesiculation of the protoplasm. A certain number remain actual giant-cells, with traces of vesiculation only in their scalloped borders or in the clearness of some of their nuclei; but usually the multinuclear mass is penetrated by clear vesicles with sharply defined walls, like the *physalides* of a certain kind of giant-cell described by Virchow (*Entwicklung des Schädelgrundes*, 1857, p. 58). These masses of nucleated vesiculated protoplasm are often larger than those drawn in fig. 138, being sometimes elongated cylinders which are continued from one alveolar space to another, as in true alveolar tumours whether soft or hard. They may lie within the zone of granular or spongy tissue next to the hyaline of a tube, or even in the thickened coat of a large blood-vessel; but usually they are scattered widely through the stroma, with the same irregularity as the alveolar clusters of scirrhus. It is impossible to refer them to acinous and lobular remains of the breast; one sees at a glance that they are not of the same kind as the compacted masses of elongated nuclei within any of the actual glandular tubes; they are everywhere an interstitial new growth, being a somewhat special condition of parablast, derived, like the others, from the vascular stroma.

The relation of these multinuclear masses, including true giant-cells, to the reticular tissue amidst which they lie, is made clear, on the one hand, by their scalloped borders, their clear nuclei, and their actual vesicles with small nuclei within them or at one side of them; and, on the other hand, by the nature of the reticular tissue itself. The protoplasmic masses are merely the undifferentiated residue of the parablasic new growth around glandular tubes obstructed or undergoing obliteration. The peculiarity of the case is, that it has taken the direction rather of tubercle than of sarcoma (or myxo-sarcoma) or of scirrhus; but it is not real tubercle, inasmuch as it has no necrosed or caseous centres, but everywhere a fairly vigorous reticular stroma with small free

nuclei, which are indeed meagre and ill-formed elements, but not so unstable as the tubercular nuclei, whilst the vesiculation of the giant-cells in like manner denotes a certain degree of self-preservation.

There were some facts in the case which might account for its tending to tubercle. The patient had borne a very large family, and had lost most of them in infancy. The contents of the involution-cysts were of a puriform or catarrhal kind. Where the columnar epithelium remains on the milk-sinuses, the cells are commonly vesiculated, with free nuclei in the vesicles, and sometimes heaped up in slender wart-like processes. It is the same vesiculated or catarrhal type which is reproduced in the interstitial or parablasic new growth between and around the tubes, producing the appearance of *physalides* in the masses of nucleated protoplasm, and of reticular tissue with free nuclei in the stroma at large. The smallness of these nuclei in the stroma is also a character copied, as it were, from the original epithelium of the tubes. But for those differences, the new growth is closely parallel with other parablasic structures which have been described. Parts of it might pass for myxoma, which they resemble more than lymphadenoma. At the same time the large amount of hyaline gives to the tumour as a whole the hardness of scirrhus.

Among the cases of *tubercle of the breast* which have been recorded since attention was newly called to them by the thesis of Dubar (Lille, 1881), there are four from the neighbourhood of Marburg and Giessen, all of them studied under the direction of Marchand, which deserve special notice—namely, two cases by Ohnacker, *Arch. f. klin. Chirurg.*, xxviii., 1882, p. 366; and two by Orthmann, *Virchow's Archiv*, c. 1885, p. 365.

1. Married woman, aged 44, who had borne five children, the last ten years before the tumour appeared. It was a hard knot in the right breast, discovered when it was the size of a walnut, having had no obvious cause. Suppuration followed in the axilla, which burst by poulticing. On admission at Giessen the breast was as large as a fist, hard, with uneven nodular surface, the skin everywhere loose, the base movable on the pectoral, an area of fluctuation above the nipple towards the upper border. The other breast was only half as large, pendulous, and flabby, within which no actual glandular body could be felt. The amputated breast contained two abscess-cavities, one the fluctuating area on the upper border as above, the size of a hen's egg, the other in the centre and outer half, the size of a walnut,

both lined by fungous greyish or yellowish granulations. All around the abscess in the *corpus mammae*, between it and the nipple, as well as in the thicker lower part of the breast, there were many reddish-grey-yellow round nodules the size of hemp seed: each had a small lumen, from which a thick yellowish fluid issued; so that they were taken for sections of infiltrated ducts. The structure was tubercular, with giant-cells, the tuberculosis following the walls of ducts.

2. Married woman, aged 33, who had borne four children and suckled them. After suckling the youngest for six months the patient observed a hard knot on the edge of the right breast towards the axilla; continued nursing the child until it refused the breast, the milk failing. The lump grew quickly, and on admission was the size of two fists, elongated, with a tapering end to the axilla, where there was fluctuation (pus, with caseous shreds, let out). The amputated breast was surrounded by some fat. The greater part of it was occupied by many small saccular cavities not in communication with each other, which looked like honeycomb in the section. They are called abscess-cavities; but they "extended between the lobes of fat to the surface on the one side, and on the other side almost to the pectoral fascia." Under the nipple the milk-sinuses were well preserved; from one of them a passage was traced into one of the larger saccular cavities. Outside the walls of the sinuses there were scattered acinous glands, which had quite the character of the milk-gland proper. At a deeper level than the open milk-sinuses were found elongated slits surrounded by broad zones of stellate shape, consisting of granulation-tissue with many giant-cells (which extended also beyond the stellate figures): they were obviously the collapsed prolongations of the milk-sinuses. Many acini had a broad hyaline zone, the tunica propria being much thickened, as if swollen into a clear glassy belt, which took a fine rose-colour from eosin; the epithelium filled the tube, but was not in an abnormal state.

3. Married woman, aged 42, who had borne one child, admitted into the Surgical Clinic at Marburg on 24th May 1884 on account of a fistulous state of the left breast and axilla, which had begun like a small boil six months before. Breast amputated, along with caseous lymph-glands: it was much shrunken, and contained two cavities, one in the upper border and the other in the lower, connected by a deep passage between the mamma and the pectoralis, the surrounding gland-substance being dense and white: granulation-tissue on the walls, in nodules or ridges, with the giant-cells and epithelioid cells of tubercle: the giant-cells faintly coloured, with vesicular nuclei, with or without processes. Infiltration around acini might be slight, or so extensive that all glandular limits were obscured. "Hand in hand with this cell-proliferation (of the stroma) there proceeds of course [why of course?] an enlargement of the acini and canals, which show, moreover, at certain places a peculiar thickening of their walls, of a clear transparent hyaline nature."

4. Married woman, aged 44, admitted to the hospital at Bettenhausen, Cassel, on 24th March 1884, with ascites, anasarca, dyspnoea, of which she died on 27th June, with tuberculosis (fresh) of various organs and parts,

including pericardium and Douglas's space. She had had a tumour of the right breast, supposed cancer, for a year and a half, almost certainly for some months before she became generally tuberculous. The breast and other organs were sent to Marburg for examination. The breast is very small, flattened, dense, of uniform appearance, with almost no remains of gland-structure on section, and no fat. "On the other hand, we find the gland traversed by numerous cords, which represent altered ducts," with dense thick walls, and caseous substance both within and without them. Nearer the nipple the milk-sinuses are open and unaffected, the epithelial lining being smooth. The disease is specially a tuberculosis of the ducts, from which the epithelium is quite gone. Traces of their membrana propria are noticeable here or there "from the elongated cells which belong to it," and are found in the midst of a translucent layer with few round cells in it. The rest of the thick wall of the tubes consists of small-celled infiltration and nodules of tubercle, in which are epithelioid cells and an abundance of giant-cells either singly or in groups of three or four. Sometimes the epithelium still remaining within the tubes is fused so as to simulate the appearance of giant-cells. (This has been remarked in the tubes of the tuberculous testis by Waldstein (*Virchow's Archiv*, lxxxv.), who describes also a thick hyaline zone around tubes on the way to obliteration.)

Those are all cases of true tuberculosis of the breast. In two of them there were hyaline zones around larger or smaller tubular structures, which are the same that I have described and figured for several cases of sarcoma and scirrhus, as well as for the case last given, approximating to tubercle. The same transparent amorphous tunica propria of mammary gland in tubercle is mentioned by Dubar and Quénu. It is almost certain, from details of the two other cases, that the tubes or saccular dilatations were of the anomalous kind, not the proper mammary structure. Along with a true tuberculosis of the vascular stroma, there is an abscess-like condition of the interior of the glandular tubes, or tubercular infiltration of their walls, like the bronchial and peribronchial conditions in pulmonary tuberculosis. The new growth is parablasic, just as in sarcoma and scirrhus, but is peculiar in its instability.

As Case xxxvi. is a scirrhus approximating to tubercle, it is of interest to notice other instances of the same approximations, or intermixtures of structure as they are usually regarded. They are chiefly cases of epithelioma. Köster, however, told Ribbert that he had formerly seen cases of mammary cancer with tubercles in them (Ribbert, "Carcinom und Tuberculose," *Münch. Med. Wochschr.*, 1894, No. 17, 24th April). One of the

specimens referred to by Köster is an old preparation, made by Sömmerring, in the collection at Giessen, originally taken for scirrhous of the breast: it is a tumour the size of a goose's egg, containing one cyst filled by polypous masses, and another empty with a smooth wall; in the granulation masses are many giant-cells, on account of which Köster called it a case of "fungous tubercular granulations in the mamma" (Ohnacker, *l.c.*). Ribbert's own cases, eleven in number, are all epitheliomas, most of them in the lip; besides two tumours of the eyelid [cylindroma], in which the giant-cells occurred in a remarkable order between the zones of hyaline and the connective-tissue stroma. In the epitheliomas, the reticular tissue with giant-cells was sometimes diffuse, sometimes in true circumscribed tubercle-nodules. Neither Ribbert, nor Baumgarten, nor others who have described occasional cases, entertain the question of an equivalence or correlation between cancer and tubercle: for them the question is, whether the cancer caused the tubercle, or the tubercle the cancer. Ribbert's view is that tuberculosis had been the original affection in certain cases (mostly of the lip) which became eventually epitheliomatous, the tubercles in the vascular stroma constituting that element of aggressiveness upon the Malpighian layer of the skin which, in his view, is the cause of epithelial islands and cylinders being cut off and so made epitheliomatous.

There is, however, another question: whether, in certain constitutions, the same causes which usually produce cancer in the particular organ or part may not produce also an element of tuberculosis, or an approximation to tubercle so that the case as a whole is ambiguous. The two last cases of scirrhous breasts, Case xxxv. and Case xxxvi., appear to me to have their several peculiarities best explained from that point of view. With these there is much in common in the four cases of true tuberculosis of the breast, which I have abstracted from a German source. In such a comparison we find a common ground between scirrhous and tubercle, namely, the deposition of *hyaline* in a certain relation to glandular structures, obstructed in their function and vascularity. I believe that such cases are *instantiæ crucis* for each of the great diseases, and that the deposition of hyaline is a significant thing in the pathology of both. My view of it is, that it is an inert substance, produced like normal non-living proteids; and that the occasion of it is, in general terms, stasis of the lymph. The old pathology of "adventitious products," as caused by obstructions, exudations, etc., of the lymph and blood, has an element of truth in it which cannot be ignored. It needs to be revived in a modern dress, and set

forth with all the advantages of a fuller knowledge of the mechanisms and tissues of lymph and blood, to the end that the humoral and the cellular pathology may be reconciled. The key to the pathology is to be looked for in the simplest textural conditions of plasmatic and vascular circulation, which would be reverted to by the higher organisms under the stress of disease.

CHAPTER XII.

SUMMARY OF THE PATHOLOGY AND ETIOLOGY.

THE chief novelty of this work is the proof, for each of the thirty-six cases, that the glandular structures involved in mammary tumours are not the proper structures of the breast, but certain anomalies of development. Since my first researches on the periodical processes of unfolding and upfolding of structure in the breast, some twenty-five years ago, I have always been impressed by the fact that one had to explain nearly all mammary tumours on the basis of a *resting state* of the gland. This point has been taken also by Billroth in his work of 1880, in the very full section of it relating to involution-cysts, which were a mystery to him supposed as milk-ducts dilated by retained secretion: "it is hard to understand how an obstruction of ducts, even if it were proved to exist, could produce retention-cysts *in a non-secreting gland.*" He tries the hypothesis of his pupil Klotz (but only to find it insufficient), that the resting mamma might have been excited to activity in various irregular ways; which was the same explanation that I had given of its morbid activity in general in the work cited. The remarkable liability of the breast to cancer becomes still more of a mystery if one bears in mind (what is often forgotten in histology of the tumours), that its structure and function are not only passive for long periods, but are becoming obsolete altogether at the time of life when new growths mostly arise in it. The explanation which I am now able to give is, that the proper mammary structure, subject to periodical involutions and to obsolescence after the climacteric age, has really no part in the morbid growths of the organ, but that these arise from certain not unusual anomalies of develop-

ment, which are not subject to periodical unfolding and unfolding, and not subject to obsolescence. The most remarkable of those are tubular glands, with the same structure as the large sweat-glands of the axilla and areola, which are appendages of the milk-sinuses, not only around their wider sections in the centre of the *corpus mammæ*, but also, and even more, around their recesses prolonged far towards the base and sides of the organ. Another form of the anomaly is coiled tubular glands which want the plain muscular fibres in the basement membrane, but have them in the connective tissue between the windings of the tube. A third form is a rudimentary mammary lobule which consists of a branched tube without real acini. All three anomalous forms are shown in their natural juxtaposition in fig. 65, Pl. XII., drawn from an island of peculiar appearance upon the margin of a breast with sarcomatous tumour.

These anomalies occur in so many breasts, including breasts that do not contain tumours, that one has to look for some explanation of them other than mere *lusus naturæ* or accident. An explanation is found in the antecedents of the milk-gland, or in its evolution from primitive glands of the skin (so-called sweat-glands), according to the facts given in the Anatomical Introduction. A very common liability to *reversion* in more or less of the structure explains the frequency of anomalies in the breasts of women.

The anatomical ground of tumours of the breast being thus shifted from the proper milk-producing structure to anomalous glands of another kind, and the occasion of the anomalies explained, the pathology takes a fresh start upon the new basis. The mystery of new growth arising in a resting or obsolete gland disappears, inasmuch as the anomalous parts of the breast are always active and never obsolete. Moreover, a positive fact of great value for the pathology appears, in the close connection between these reversions of type and the sexual system, inasmuch as they belong to the class of accessory sexual glands and are to be considered organs of excretion rather than of secretion. The sympathies of the breasts with the ovaries are much more marked in some women than in others; and the question

arises whether these sympathies do not really depend upon the extent of anomalous or reverted development within the breast. According to the analogy of the sweat-glands in the axilla and under the areola, it may be inferred that it is the sweat-gland element in certain breasts which gives rise to them. The chronic indurations with cysts, and the nodular fibromata, are certainly due to the presence of anomalous glandular structures, not to the regular mammary lobules; and it is probable that the whole group of phenomena in the breasts which are associated with menstruation and its irregularities, including turgor or tension, transient knots, pains, sweating, and slight discharges of bloody fluid from the nipples, are due to the considerable development of the same reversion-structures in certain women.

Having mentioned affluxes of blood to the breasts in sympathy with ovarian excitements, as favouring the growth of tumours, I shall give here the other things in the same class of causation. They are: the regular climacteric effacement of structure; the occurrence of milk-abscess, leaving indurated tissue behind; and blows, repeated pressures, or other injuries. The recent statistics of mammary cancer which have been compiled from very full data by several in Germany (Guleke, "Statistik des Mamma-Carcinoms," *Arch. f. klin. Chir.*, lxiv. 1901, based on all the cases treated in v. Bergmann's clinic at the Berlin Charité from 1st October 1882 to 31st December 1899; Hans Schmid, "Zur Statistik des Mamma-Carcinoms und deren Heilung," *Deutsche Ztsch. f. Chir.*, xxvi. 1887, based on cases at Stettin; G. B. Schmidt, "Die Geschwülste der Brustdrüse," in the Tübingen *Beiträge zur klin. Chir.*, iv. 1889, based on Heidelberg cases), indicate that all these are real antecedents of mammary new growths, and especially of scirrhus. The effect of a blow or repeated blows, or of pressure by corsets, or of other habitual pressures, comes out lowest in the statistics; but it ranks higher in popular estimation. In the much less common cancers of the male breast, the connection with blows or injuries is held to be almost invariable; the very first case of cancer of the breast which I saw as a student was in a fisherman who had received a blow upon the breast from the end of an oar. The

most significant cases are those of so-called "traumatic malignancy," in which the tumour follows the blow so quickly as to make the link of cause and effect indisputable: such as the case given by Morgagni (*De Sedibus, etc.*, Epist. L., § 48), of a peasant woman about the age of fifty, in whom a tumour began in the left breast one month after an accidental blow upon it, growing in six months to be an extensive scirrhus, with the nipple sunk between rough ridges of the skin and the axillary skin seamed with hard rugæ, the whole region being œdematous.

In the Berlin statistics of 882 cases during twenty years, milk-abscess is assigned as a cause by 29 per cent. of those who were questioned on the point, while 351 patients were not asked. A common statement was, that a hard knot had remained in the breast after the closing of the abscess, in which the scirrhus appeared perhaps long after (the interval ranging from one to fifty years). Another usual statement was, that the scirrhus appeared first in the scar of the skin where the abscess had burst or had been opened.

Thirdly, as to the influence of the climacteric age, all statistics are agreed. In the 882 Berlin cases, only 13 were below the age of thirty years; the largest number for any five-years period of life was from forty-six to fifty years, while the five years before, and the five years after, were each only a little less subject to cancer of the breast. Of the whole number, 577 were over forty and under sixty, while nearly all the rest were divided equally between the decades thirty-one to forty and sixty-one to seventy. The average age at which the tumour was first noticed was 49·2 years, which is within a few months of the average of many sets of figures. For Vienna, v. Winiwarter gives it at only 45·3 years, a difference of three or four years, which is said to be explained by the large proportion of Jewesses, who arrive earlier at puberty and experience the change of life earlier in proportion.

There can be no question of the reality of all those three antecedents; to which one may add a fourth, the repeated congestions in sympathy with ovarian excitement. There must be something common to those various causes, which

is to be looked for, of course, in the tissues of the breast. I believe the common thing to be obstruction or destruction of the lymphatic vessels. In cicatricial tissue they are not formed anew, and it is probable that they are interfered with, sealed up if not destroyed, in chronic indurations. The chief question, however, is their fate in the regular obsolescence of the mammary lobules. Langhans, who found it exceptionally easy to inject the lymphatics of the breast with Berlin blue by the puncture method when the organ was in its maturity, failed altogether with senile breasts; the injection either came back, or it formed a small extravasation, from which an occasional channel was filled for a short distance. His conclusion was, that the greater part of the lymphatic system had disappeared ("Die Lymphgefäße der Brustdrüse, und ihre Beziehungen zum Krebse," *Arch. für Gynaekol.*, viii. 1874, p. 183). It is antecedently probable that the lymph-vessels should disappear with the mammary lobules which they serve, in an order from periphery to centre. See also Labbé et Coijne, *Traité*, 1876, pp. 90, 91.

Against this anatomical conclusion it is of no avail to argue from the presence of cancer-cells in slits or spaces of the stroma, that the latter are persisting parts of the lymphatic system, which had become filled by epithelium; to argue so is to beg one or more fundamental questions. Köster, who was the first to raise the point, was well aware that no lymphatics could be proved to exist by the ordinary method of injection, which proved rather a continuity of the columns of cancer-cells with blood-vessels (see the abstract, *infra*). Waldeyer admitted that the alveolar spaces might be nests made by the cells themselves, and not pre-formed lymphaths (*Virchow's Archiv*, lv. 1872, p. 155). The attempt by L. Heidenhain ("Ueber die Ursachen der localen Krebsrecidive nach Amputatio mammae," *Arch. f. klin. Chirurg.*, xxxix. 1889, p. 97) to prove the existence of a set of lymphatic vessels running from the base of the breast, in the pectoral fascia, to the axilla (of which there is no trace in the very complete injections of Sappey), and the continuity of these with the lymphatics of the *corpus mammae*, rests upon a singular mistake. His lymphatic vessels are large open tubes with rigid walls, occupied either by large nucleated polyhedric epithelial cells in parietal masses or in columns across the lumen, or by a finely granular coagulum. No such lymphatic vessels are ever seen: the objects in question are glandular tubes, which, from their usual situation in Heidenhain's specimens, namely, on the base of the breast, and from their structure, I can identify with the greatest confidence as the dilated thin-walled terminations of sweat-tubes. The

following details for his Case x., p. 114, are exactly characteristic of those delicate basal structures, as I have described them in a healthy breast at p. 32, *supra*. "Sometimes," says Heidenhain, "I found underneath such proliferating gland-lobules lymphatic vessels which contained epithelial cells (cancer-cells). In nearly all the preparations, either the *corpus mammae* or single gland-lobules extended down almost to the amputation-surface." The one thing among Heidenhain's data which I do not venture to criticise, is the one that he bases most upon, namely, the specimen from Case XIII., p. 119, showing small lymphatic *glands*, like peas, on the base of the breast, with *vasa afferentia* entering their convexity, and *vasa efferentia* leaving at the hilum.

Stiles ("Surgical Anatomy of the Breast," pt. ii., *Edin. Med. Journ.*, xxxvii. 1892, p. 110) has repeated the fallacy of Heidenhain, without, however, asserting the existence of wide and patent lymphatic vessels filled by epithelium. I quote the pages from the paper in *Trans. Med. Chir. Soc. Edin.*, xi. 1892: Sappey's normal anatomy of the lymphatics "is entirely out of harmony with what is observed both clinically and pathologically in carcinoma of the mamma" (p. 49). In the supposed lymphatic vessels upon the base of the breast, Stiles has actually seen plain muscular fibres—"well-defined vessels with thin but muscular walls" (p. 48). He avoids the above-cited conclusion, that columns of large polyhedric epithelial cells (with relatively small nuclei) break through from the stroma of the breast into the lumen of large lymph-vessels, penetrating their walls; but substitutes another reading, the wording of which is best understood as a conjectural emendation of a supposed corruption in Heidenhain's invisible text: the larger lymphatic vessels are not blocked; but "stationary cancerous emboli are frequently present in the smaller vessels, and of course can only be discovered by microscopic examination. They subsequently invade the wall of the lymphatic, and give rise to nodules of cancer, which are distinct from the lymphatic glands" (p. 61).

The sum of it is: "In carcinomatous breasts, the lymphatics may frequently be seen injected, as it were, with cancer-cells; so that by a careful study—more especially of the spread of the cancer in the different tissues in and around the breast—one can gain a more satisfactory idea of their structure and arrangement than is to be afforded by chance and unsatisfactory puncture-injections." What one gains an idea of is simply the distribution of the cancer-cells in the stroma. So far from proving the abundance of "lymphatics" in a breast, the existence of cancer is the best possible proof that they are wanting.

Köster, in his well-known laborious research, *Die Entwicklung der Carcinome und Sarcome*, Erste Abtheil: Krebs der Haut, Alveolarer Gallertkrebs des Magens, 1869, followed out an idea of v. Recklinghausen's (1864), that the buds and cylinders of cancer might be the flask-like dilatations, or protrusions of the ends, of lymphatic vessels blocked by proliferating endothelium. Starting from the hyaline cylinders of two cases of cylindroma, he applied the principle to epithelioma of the skin and to colloid of the stomach. He pointed out that anastomosis of the cylinders of cells

in tunnels of the stroma was a general character, being seen best in epithelioma, but also in other cancers at the growing margins. The rete of cords suggested blocked lymphatic vessels by their unequal width, nodal points, and sinuous course, many of the lateral offshoots ending blindly. Sometimes the solid cylinders changed into tubes with a definite epithelial-lined lumen, which structures were not original glands. In other cases, the layers of cells were perivascular to a central vessel filled with blood-corpuscles, and were supposed to lie within a pre-existing lymphatic sheath around the vessel. The five chief points were: (1) the anastomoses of cylinders; (2) the networks like those of lymphatic vessels; (3) occasionally a lumen; (4) a blood-vessel in the centre of a cylinder; (5) the absence of a basement membrane enclosing the cylinders. When it came to a proof that these were actually blocked lymphatic vessels, injection by puncture not only did not prove it, but seemed rather to prove that they were in continuity with blood-vessels. Resort was then had to the silver method of detecting lymphatic endothelium, and some results were got, upon which a positive conclusion was based. But no actual lymphatic vessels were ever discovered in the cancer; only blood-vessels were found in the stroma between the cylinders. The inference was, that lymphatics as such had ceased to exist, and that the cords of cancer-cells were themselves the remains of lymph-vessels. The facts seem to me to bear another interpretation, namely, that the lymph-vessels are destroyed altogether, both channels and endothelium, and that the whole structure of anastomosing columns of cells within spaces of the stroma is a new formation on embryonic parabolic lines, the epithelial type of cell coming, not from endothelium, but from the epithelium, glandular or other, of the organ or part which had lost its lymphatic mechanism.

While the disappearance of lymphatic vessels during the obsolescence of the breast is a point in common between that antecedent of cancer and the other antecedents, such as an old milk-abscess, or the tissue-effects of blows, habitual pressures, and repeated congestions; yet the normal obsolescence about the age of fifty has a more extensive bearing upon the origin of the disease. It is only the regularly formed mammary lobules, ducts, and sinuses that become obsolete, or replaced by fibrous tissue and fat. Nothing can be more striking than to find in breasts at the ages of fifty-two, fifty-four, fifty-six, fifty-seven, fifty-eight (as in cases given), that the surviving glandular structure is nearly all of the anomalous kind, left behind in the midst of the fibrous tissue and fat. If there be much fat, the surviving glands may be cut off as islands in its midst. Another common case of detachment is the irregular pro-

longation or "tail" of the breast, towards the axilla above and below, or towards the sternum, which may be joined to the *corpus* of the obsolete breast only by a thin band of connective tissue, and yet may contain within itself a good deal of glandular structure of the anomalous kind (including true sweat-glands). Even in the *corpus mammæ* itself, the interstitial formation of fat may be so extensive as to cut off the coils of sweat-glands from their outlets upon the milk-sinuses. It is indeed inevitable that sweat-glands or other anomalous forms, developed in the way of reversion as integral parts of the milk-gland, should be left stranded by the obsolescence of the latter. But there is more than a merely mechanical cutting-off from an outlet; there is also a profound interference with their vascular mechanisms, which are, of course, a part of the general vascularity of the organ. It is in that interference that I find the true key to the pathology. There is not always induration or sclerosis of the stroma; for example, Billroth was unable to prove it for the tissue in front of involution-cysts; while, as regards the normal climacteric conversion into fibrous tissue, Langer found it to be soft, and quite unlike the dense india-rubber stroma of the breast before puberty. Sclerosis of the stroma is the grand characteristic of the commonest affection, scirrhus; and I shall maintain that it is due to failure of the lymphatic drainage. The anomalous glands, which alone survive the obsolescence, are in their very nature peculiarly dependent upon the lymph-system, the sweat-glands having a peculiar basement which would appear to admit of a discharge of their products through their walls; if they are cut off at once from their outlet upon the surface and from their lymphatic drainage, something remarkable is sure to happen.

The morbid effects are both intratubular and extratubular. Within the tubes the epithelium may be accumulated in layers, which eventually block the lumen; or it may grow out in papillary columns, which may unite across the space and form a system of purely epithelial trabeculæ without blood-vessels. Opacity and necrosis are apt to overtake these hyperplasias, which do not appear, in any

of my specimens, to break through the wall of the tube. Another effect is cystic dilatation by a fluid, which can often be seen to be produced from the mucous or other disintegration of enlarged sweat-gland epithelium. The intratubular hyperplasias and the dilatations are usually partial, one or more windings of a tube, or one side of a coil, being so affected, while the rest may be contracted. In some forms of tumour the tubes are neither blocked by their own epithelium, nor distended by fluid, but simply disintegrated, with atrophy of their epithelium, and persistence of their basement membrane longest. Whether by occlusion or otherwise, the anomalous tubular glands in the breast are found to be embarrassed and stopped in their function.

Along with those morbid effects within the tubes, there are always changes outside them, which are the more active effects, and in which the interest really centres. In certain of the more chronic and benign forms of new growth, both in the human subject and more commonly in the dog, these extratubular changes or adaptations can be followed from the basement outwards. Sometimes the layer next the basement is a very perfect pulp of branched connective-tissue cells (figs. 41, 46, and 77), which are myxomatous in pathological language, but of the same type, and probably as effective for plasmatic circulation, as the branched cells of the enamel organ or of other normal situations. In other cases (sarcomatous), the tissue nearest to the basement is a peculiar shreddy pulp of short or broken fibres, or of ill-formed fibre-cells, with a fluid or thin protoplasm in the interstices, which stains vividly, the whole appearance being suggestive of œdema (figs. 51, 74, and 87). But myxoma is never the structure of a whole new growth of the breast; it is part of the structure in certain cases, but in whatever case it occurs, it extends only over narrow zones, passing into some other tissue which is more characteristic of the tumour. At some little distance from the wall of the tube, the gelatinous pulp becomes a rete of protoplasmic bars or trabeculæ, alternating with blood-spaces: this tissue may either remain soft, forming myxo-sarcoma; or become impregnated with hyaline and with lime salts, forming the

enchondroma and osteoma which are so characteristic of the bitch. The most singular of all the developments in women, and one of the safest, although unfortunately the rarest, is the pearly tumour, in which the successive zones of branching plasmatic cells, protoplasmic rete, and squamous cells like epidermis, can be traced from the basement of glandular tubes outwards (Case VII., and figures on Plate VII.). Another rare development, and probably also benign in itself, is colloid (Cases VIII. and IX.). Another is the purely hyaline element of Case X., of which more has to be said in connection with the hyaline of scirrhus.

Of greater practical importance than these, and of high significance for the whole tumour-pathology of the breast, are the sarcomata. They connect plainly with the plasmatic kinds of circumtubular new growth through the intermediate type of myxo-sarcoma, which is far from rare at one part or another of a sarcomatous tumour (Cases X. and XIX.). In the sarcomata of the breast I find an epithelial *habitus* of the cells (that is to say, a somewhat quadrate or cubical form with a zone of protoplasm round the nucleus), to be more usual than the spindle form or the round nuclear form: this is recognised by G. B. Schmidt for the so-called angio-sarcomata, but practically all the sarcomata have the same relation to the vascular stroma. The epithelial-like cells may acquire a very perfect pseudo-glandular arrangement, as in Cases XXI. and XXII., and in several of the mammary cases in the bitch. In such cases the physiological analogy of a plasmatic tissue appears to be left altogether. But a more comprehensive analogy can be found in the great embryological doctrine of a *parablast*, of which I have spoken sufficiently in the Anatomical Introduction. The new growth is parablasic by the side of an archiblast of original glandular tubes, which has broken down from obstruction, and has been virtually obliterated. The parablast is a new growth upon vascular lines, and is in some instances obviously perivascular, forming thick sheaths of epithelial-like cells around the walls of blood-vessels (fig. 63, Pl. XI.). Although it is unlike the more obviously plasmatic myxomatous tissue, yet it has also a clear physiological type in the large cubical or spherical

plasma-cells which form thick sheaths around the blood-vessels in some Gastropod species, and have vertebrate homologies in the yolk-sac and allantois of the chick (fig. 23, Pl. IV., and references in text, p. 59). In some of the sarcomata of the dog's skin, developed in a territory of disordered sweat-glands, the type of the perivascular and interstitial plasma-cells of the Mollusca is reproduced very closely (fig. 104, Pl. XIX.).

The element of malignancy in the sarcomata is not in the type of new growth, which is a not altogether disorderly retreat to broader ground, or to simpler forms of vascularity (plasmatic); but in its inability to stop. The parablasic activity goes on until it not only overlays the glandular structures whose break-down had called it into existence, but suppresses also the blood-vessels from whose walls or adventitia the new cells are derived. A cellular parenchyma becomes all in all; and so there is constituted a new growth which is in the same coil as Macbeth in the play—it must become worse to make its title good. The obliteration of blood-vessels in the midst of their own perivascular new growth can be followed with exceptional clearness in the sarcomatous tumours of the dog's skin, being the same phenomenon that has been made of central importance for the sarcomata of the testis and upper jaw, and for a group of cases (angio-sarcoma) in the breast.

The malignancy of sarcoma is bound up altogether with the blood-vessels. One of the common causes of extension to distant organs is a growth through the wall of a vein, from which emboli are derived. Where extension occurs to lymphatic glands, as it does in a good many cases, it will probably be found to be really an annexation of their vascular territory. The extraordinary liability to recurrence after excision depends upon the *process* or habit of new growth being established throughout the whole vascular territory, from the branches towards the stem of the tree. This was the most practical outcome of Boll's *Princip des Wachsthums* (1876, p. 81), as applied to mammary tumours and others which he called "canceroid."

I come at length to the great question of scirrhus, which

is by far the commonest kind of new growth in the breast. It is from the mammary scirrhus that the descriptions of that form have been taken mainly; in some respects it is the only true scirrhus. But the stomach and the lower lip furnish a certain proportion of cancers which have the characters almost as marked; in the cancers of the rectum, also, there may be hard and dense areas; in such the basis is probably a cicatrix. Not only does scirrhus attain its extreme characters in the breast, but it is the most distinctive new growth of that organ.

One of the best distinctions between sarcoma and scirrhus is, that the one follows the blood and the other the lymph. The distinction is true in respect of the high vascularity of sarcoma and the low vascularity of scirrhus, and in respect of the great liability of scirrhus to infect the nearest packet of lymphatic glands, even where the primary focus is very small and not disposed to enlarge. But if scirrhus can be said to follow lymphatic lines, while sarcoma follows those of the blood-vessels, that is not because it has actually more lymphatic vessels left to it, but because the individual breast has not the same richness of blood-vessels with their adventitia (owing to age or constitutional peculiarity, or other cause) from which to provide the new plasmatic tissue that is characteristic of sarcoma. The scirrhus breast is really in a worse case than the sarcomatous, although the bulk of new growth is nearly always less, and less disposed to increase. In this review of the pathology, there are only three of its characters that call for some additional discussion—its hardness and density, its contractility, and its alveolar structure.

1. The peculiar hardness, density, and glossiness of scirrhus, which give it sometimes the look of fibro-cartilage, are explained best by the presence of *hyaline*. The whole subject of hyaline is somewhat new in pathology, the first systematic treatment of it being by v. Recklinghausen ("Allgemeine Pathologie des Kreislaufs und der Ernährung," *Deutsche Chirurgie*, i., Stuttgart, 1883). The observations and theories since that date have been followed very closely by Lubarsch in his annual summaries (*Ergebnisse*, 1^{ster} Jahrg., ii. 1893, p. 200, and 4^{ter} Jahrg., 1899, p. 449). Although I

have missed any reference to the hyaline of scirrhus both in the first draft of the doctrine of it, and in the additions and amendments to it, yet that instance appears to me to deserve a place along with the hyaline of tubercle. It is true that it is rarely so purely glassy and structureless a substance as in cylindroma of the orbital and some other regions; but considerable zones of well-marked hyaline are found in scirrhus breasts around obliterated milk-sinuses, as well as around acini, and terminal cæca of the branching tubular lobules. In one breast, Case x., the hyaline is deposited throughout the whole *corpus mammæ*, in the walls of glandular structures which are either all sweat-glands, or are mixed up with a number of very obvious sweat-glands affected in their interior in the same way as they are shown to be in a case of colloid. In the common case of hyaline deposited in the walls of acinous-tubular glands in scirrhus breasts, it occupies exactly the place of Langer's "hyaline halos" (supposed normal in the virgin breast), being formed in vacuoles between the basement and the central heap of nuclear epithelium, and accumulated until the lumen of the tube or acinus is filled with it. In that way considerable areas of mammary structure are reduced to hyaline. The zones around the walls of collapsed milk-sinuses and their recesses, which may be found all through the *corpus mammæ*, also contribute to the hyaline density and translucency of the scirrhus breast; there the hyaline is *outside* the basement membrane, which can sometimes be shown to have the distinctive muscularis of sweat-glands, and usually merges with an outer belt of peculiar granular pulpy substance which stains well. In that situation, the hyaline and granular deposits are exactly in the place of the lymphatics which follow the walls of the milk-sinuses all the way to the *circulus subareolaris*.

But there are cases of scirrhus in which none of these parietal deposits of hyaline occur, but only a condition of the fibres and cells which gives a glossy, homogeneous, and sometimes glutinous character to the stroma. Although that is not true hyaline, it has the same relation to it as the mucous or colloid substances which are included in the classi-

fications of hyaline by Klebs and others. The stroma appears to be saturated with a certain substance, which imparts hardness, density, and translucency. There is some evidence that the endogenously formed nuclei of epithelial cells, which escape from glandular tubes and make the commonest kind of scirrhus infiltration, carry that substance, or those properties, with them: thus the islands of infiltration in the fat, characteristic of "disseminated scirrhus," are so purely cellular that they might be sarcomatous, and yet they are so dense that fine sections curl at the edges like hyaline cartilage; which is probably due to a certain glutinous character of the nuclei or of the substance clinging to them. Paget makes the remark also of scirrhus lymphatic glands, that they owe their hardness "almost entirely to corpuscles" (*l.c.*, p. 617); but I cannot say that I have ever found them without a good deal of stroma. In the two last cases of scirrhus, XXXV. and XXXVI., I have pointed out what the dense and translucent stroma has in common with tubercle.

To get the closest analogy for the hyaline of morbid growths, I believe that we shall have to go as far away as the Mollusca, or to that kind of vascular system in which there are *no lymphatic or absorbent* vessels. In the digestive tube of *Mytilus*, *Anodonta*, and *Unio*, as well as of *Patella*, one sometimes finds a bar of pure hyaline substance, called a crystalline stylet, so hard that a knife will hardly cut it.

This is an instance of physiological hyaline which has not been noticed by pathologists in their search for the analogies of hyaline in disease, but which seems to me to be worthy of attention along with the facts relating to mucin, colloid, fibrine, coagulation-necrosis, etc., in human physiology and pathology. Although the bivalves are remote, yet they have that kind of primitive mechanism of circulation and absorption which may be expected to throw light upon the conservative adaptations of the mammalian organism when it retreats to broader ground under the stress of disease. But the crystalline stylet in a cæcum of the bivalve stomach, or the corresponding *tige cristalline*, or *Dünndarmkörper*, which lies free in the continuity of the intestine, although it has been much studied, is still regarded as an enigma, and has never been brought into relation with that which can probably explain it, namely the mechanism of absorption in the particular class or classes of molluscs. The minute study of it by Th. Barrois ("Le stylet cristallin des Lamellibranches," *Rev. biol. du Nord de*

la France, i. 1888-9, pp. 124, 161, 263, and ii. 1889-90, pp. 209, 299, 351) appears to me to contain all the data for a rational explanation, but without actually reaching it owing to the author's teleological point of view: namely, that the structure must have "fonctions importantes sans aucun doute, puisque cet organe se retrouve chez la généralité des Lamelli-branches," ii. 354. If this detached structure be regarded, not as of any use to the animal, but as an inevitable result of its low organisation, as a serious encumbrance, and probably as incompatible with long life, the mystery of it disappears.

The origin of it which I submit with deference to zoologists is as follows:—The particular section of digestive tube has a number of longitudinal ridges of the mucous membrane adapted for absorption; the submucosa of these is sometimes an exquisite adenoid reticulum, with its walls and nodal points crusted with lymphoid cells; in other cases it is a plasmatic gelatinous tissue, in which are "spider-cells" with immensely long and fine processes. In some ridges, presumably the older, this gelatinous tissue is found to be almost a purely structureless hyaline filling the ridge, the fine plasmatic threads being hardly traceable in it; at the same time the ridge has been constricted at its base, as if ready to fall off, which it does, becoming a crystalline stylet loose in the gut (*l.c.*, 1899, pp. 44, 106). The absorption-ridge has become choked by degrees with a deposit of hyaline, until it becomes a solid bar of that substance, of no further use for absorption, and is exfoliated, other ridges meanwhile carrying on the work. There is something almost pathological in that progressive and inevitable obstruction of an absorbent mechanism by hyaline. It is conceivable that if there had been a system of absorbent vessels, as well as an adenoid reticulum or a gelatinous pulp, the obstruction would not have taken place. Something is deposited steadily, which is of the nature of an *inert proteid*, non-living, and destined to be cast off. (It corresponds with the structureless egg-capsules, and probably with the glairy egg-envelopes of molluscs, in the production of which animal starch, or some other carbohydrate, plays a part. See the author's *Glycogen of Snails and Slugs*, 1899, p. 113). The corresponding deposit of an inert proteid, or hyaline, in scirrhus (as well as in tubercle), with the same antecedents or adaptations of adenoid reticulum, myxomatous

pulp, etc., would be due, not to the want, but to the loss, of absorbent vessels. None of the morbid growths into which hyaline enters can be compared with the exfoliated or extraneous hyaline substances of the invertebrates, for the reason that they are not purely inert or non-living deposits, but also cellular new growths. The nearest approach to inertness is in the enchondromata and osteomata of the bitch, which may indeed attain a great size, but are non-malignant.

2. The *contractility* of scirrhus, its tendency to shrink, or "the contraction and compacting of its substance, and as if in this concentric contraction it drew all parts towards itself" (Paget), although one of the most striking characters of the scirrhus breast, is fully developed only in certain cases, which are usually very chronic, sometimes called "atrophic," apt to occur in old age, and occasionally ending in a natural cure. It is a massive or persistent contractility, not an elasticity; for it is impossible to stretch or expand the tissue. The substance in which this property resides is glossy and glutinous, but it is more likely to be opaque than translucent or hyaline; and it is poorer in cellular elements than some other kinds of scirrhus. It is sometimes compared with the contracting tissue of cicatrices, or with the fibrous bands of hob-nailed liver. With the latter it may have real affinities; but it is not at all cicatricial, nor would the moderate and unprogressive shrinkage of a scar account for it. It is a contractility *sui generis*, which resembles most that of muscle in a state of dead strain. It is slowly progressive, and as if cumulative, just as the deposition of hyaline is. The contractile, or contractive, substance is almost certainly allied to the more hyaline deposits of scirrhus; and I believe that a biological analogy can be found for it also among the molluscs, and in connection with their mechanisms of absorption.

This is a matter on which I have made no direct observations, and on which I am unable to adduce many data of zoologists, or indeed any data bearing the required construction. But in the molluscan class of Scaphopoda, exemplified by Dentalium, which some would place intermediate between the bivalves and the snails, the tissues of intestinal absorption are as distinctively marked by *contractility* as the corresponding tissues of

bivalves are marked by a deposit of hyaline. The small intestine is a true glomerular coil, matted together by an extensive connective tissue between the windings of the tube, so that it is impossible to unravel it. It would appear from the original account of Lacaze-Duthiers (*Ann. des Sc. Nat.*, 4 ser., Zool., vi. 1856, p. 272), that he associated this massive and insuperable contractility with a thick *muscular* coat of the intestine. But the corresponding intestinal coat has been found by Fol to be not muscular, but a double contoured elastic membrane; while L. H. Plate finds the circular fibres to be only a thin layer, which are possibly muscular. The latter observer (*Zool. Jahrb.*, Anat. Abth., v., 1892, p. 317), traces the contractility to the thick mass of connective tissue between the coils of intestine. He finds this tissue much more contracted in some specimens than in others; and, in its less condensed state, to contain in its meshes the same yellow fat-like spherules which are found among the epithelial cells of the intestine [as also in the absorption-ridges of bivalves]. The contractile connective tissue is indeed the region of the absorption of chyle: "A reticular connective tissue, containing blood in its larger or smaller meshes, fills the intervals between the intestinal coils, and is the place where the blood takes up nutrient substances for the organs at large." Lacaze-Duthiers had missed this *sinus peri-intestinalis*, because the tissue of it was too densely contracted to be penetrated by his coloured injection. Plate supposed that its extreme degrees of shrinkage were found in specimens which had contracted greatly in their muscular tissues in dying; and that its relatively more open texture occurred in animals that had died slowly and with less of muscular rigidity. The contractility, however, appears to reside in connective tissue used for absorption; and I venture to suggest that the absorbent mechanism becomes more and more contractive the longer it is used, until it becomes impracticable altogether, according to the analogy of the deposition of hyaline in the absorption-ridges of bivalves.

3. The *alveolar plan of structure* is common to scirrhus and to soft cancers of the breast; but the sharp lines or angularity of the lacunar spaces or tunnels of the stroma, in which the epithelial-like cells lie, are often more striking in scirrhus, owing to the hardness of the intermediate tissue. The plan is also the same in colloid, in which it was first studied by Rokitansky, on a case of encysted alveolar gelatinous cancer of the right breast in a woman aged 50, the whole question of the cancerous stroma being thereby accidentally brought before him ("Ueber die Entwicklung der Krebsgerüste," *Sitzber. Wien. Akad.*, Math.-Nat. Cl., Bd. viii. 1852, p. 391). According to him, both the stroma and the cylinders of cells are new formations, the one keeping pace with the other.

In the softer tumours the trabeculæ or bars of the supporting tissue were essentially a dendriform growth of vascular tissue, with many flask-like blind protrusions of ill-formed blood-channels (Billroth confirmed the imperfect nature of the vessels for alveolar sarcoma, and Ribbert for epithelioma). In the well-marked alveolar types of tumour, whether soft or hard, the columns or cylinders of cells and the bands of stroma keep a nearly equal width and run parallel; but there is always the disposition of the vascular stroma, as Rokitansky pointed out, to break up the cellular masses into smaller and smaller groups of cells, so that we may come in the end to a reticulum of fibres with single rows of cells, or with only one or two cells in each mesh or lacuna.

This alveolar plan of the morbid growth has also its physiological type. It is the kind of vascular structure in which there are neither true blood-vessels nor lymphatics, but a form of blood-space which has the structural characters of a lymph-space. This plan is found in certain regions of the same bivalve molluscs from which I drew the homology of hyaline deposited in their absorption-ridges. None of the mollusca have lymphatic vessels complementary to their cardiac vessels; but the snails and slugs have perivascular sheaths of large plasma-cells filled with glycogen, which are the morphological prototypes of the lymphatic sheaths of vertebrates. In bivalves, such as Anodonta, the same kind of plasma-cells, also filled with glycogen, but in the form of flat plates like endothelium, come into a remarkable relation with the blood lacunæ. The relationship to the blood-space is seen most clearly in the foot of the male Anodonta, where it is occupied by the testis. The muscular bundles of the foot split to enclose the follicles of the gland, and at the same time to form the blood lacunæ around them. In the lacunæ at large, the blood lies free in the interfascicular space, which has no endothelial lining; but the muscular fibres of the foot, or rather of that part of it which contains the testis, are clothed with flat cell-plates like tendon-plates; and as the muscle splits to narrower and narrower bundles, or to single threads, making the lacunæ, the interstitial muscle-plates are so far liberated that they unite to form sheaths around the tra-

beculæ, between which and the fibres the blood is contained. This beautiful structure can be seen beyond ambiguity by means of the wine-red reaction of glycogen with iodine in the cell-plates. The delicate laminæ of flat cells are the rudiment of a system of closed blood-vessels, but with the structure of lymphatic sheaths (*l.c.*, p. 85).

The alveoli of cancer, emptied of their cells (as they are often figured in text-books), are exactly like the lacunar blood-spaces of bivalves, so far so that Kollmann's figures of the latter (*Archiv f. micros. Anat.*, xiii. 1877) might pass for the former. The homologues of the epithelial-like cells which fill the cancer alveoli are the plasma-cells; but these, instead of forming membranous laminæ within the alveoli, are either a heap of somewhat thin cells with clear protoplasm, or are massed in solid columns or cylinders in which the cells may be fused together, as in the soft cancers or alveolar sarcomas, and in some, but not in all, of the cases of scirrhus. The cells of the morbid growth are of interstitial origin, and are parablasic in nature, just as the plasma-cells are. By means of this homology from the molluscan circulation, one may represent the characteristic alveolar structure of cancer as one of those conservative adaptations, of which several other instances have been given, to make good the destruction of the lymphatic system by falling back upon a rudimentary type of vascularity; and the remoteness of the physiological type may be said to be the measure of its ineffectiveness or of its desperateness as a makeshift.

Index

- ACINI filled with round cells in sarcoma, 191, 210.
Acinous cancer, 191.
Acute cancer, 157.
Allantois, parablasic destiny of its epithelium, 61.
Alveolar plan of scirrhus, 291.
Amphibia, skin-glands, 4; same forming organs, 5.
Angiosarcoma, 160, 284.
Anomalous glands in breast, kinds of, 33, 34, 36, 153, 163, 276.
Areola, glands of (historical), 24; sebaceous glands, 26; sweat-glands, 26-28; eczema of, 29.
Axilla, sweat-glands of, 12; primary tumour of, 15.
Axillary process of breast, 255, 282.
- BAER, C. v., 61.
Basement membrane, muscular, its development, 7; alleged in mammary acini, 37-38.
Bell, Joseph, 18.
Benda, C., 38, 42, 72.
Billroth, Th., involution-cysts, 34, 87; fibroma, 97; pearly tumour, 112; acinous cancer, 190; in both breasts, 192.
Birkett, J., 86.
Blastema-cysts, 86.
Boll, F., 285.
Bowlby, A. A., 13, 136.
Branching rudiments of lobules, 35, 163.
Branching type of sweat-glands, 183.
Brodie, Sir B. C., many small cysts, 89; fibroma like scirrhus, 96; dimple in scirrhus, 258.
Brown Institution, dog's tumours from, 197 *seq.*, 214 *seq.*
Butlin, H. T., scrotal cancer, 19; colloid, 123; gland-like sarcoma, 147.
- CARVER, Dr E., cases from, 159, 171.
Cat, mamma, 54; primiparous, 71.
Cetacean, mamma, 52-53.
Champneys, F. H., 12.
Chimney-sweep's cancer, 16; original case, 19.
Cholesteatoma, 111.
Chronic scirrhus, 246, 248, 290.
- Clark, Mr F. Le Gros, cases from, 37, 151, 189.
Clutton, H. H., 15.
Cohnheim, J., theory of tumours, 30.
Collins, Sir W. J., cases from, 90, 123, 166, 181.
Collis, Maurice H., 15, 158.
Colloid, 122-129; two forms of, 123; cases, 123, 127; prognosis, 129.
Concretions, 176, 185, 249.
Connective tissue, infection of, in cancer supposed, 175, 222.
Contractive property of scirrhus, 290.
Cooper, Sir Astley, sweat-glands of mammary skin, 14; of areola, 27; porpoise milk, 74; extent of milk-sinuses, human, 139; canine, 199; hydatid cysts, 83; involution-cysts, 86, 92; chronic mammary tumour, 95; fibroma with small cysts, 104; pearly tumour, 111.
Cornil et Ranvier, pearly tumour, 113; "épithéliome tubulé," 136.
Crocker, H. R., 16, 262.
Croft, Mr John, case from, 266.
Cruveilhier, J., fibroma, 95, 97; pearly matter, 122; colloid, 128.
Crystalline stylet, 288.
Cystic fibroma, 103, 104 *seq.*
Cystic papilloma, 150; case, 151; of bitch, 205.
Cystic sarcoma, 107.
Cysts in scirrhus, 86.
Cysts of involution, 86; cases 90.
- DARWIN, C., secondary sexual glands, 87.
Development by parablasic, 58 *seq.*
Development of breast, 65; in lamb, 66; in virgin, 67; in guinea-pig, 69; in first pregnancy, 71.
Dimple of scirrhus, 258.
Disuse, effects of, on structure, 79.
Dog, large type of sweat-glands, 12; structure of milk-ducts, 55; frequency of tumours in various regions, 196; mammary tumours, 197 *seq.*; sweat-gland tumours of the skin, 213 *seq.*; sweat-glands involved in mamma, 199.
Double cancer of breasts, 129-3.
Duct-cancer, 136, 147, 244, 264.
Duct-papilloma, 156; case, 157; in bitch, 205.

- Ducts, distinguished from sinuses, 139 ;
from sweat-tubes, 264.
Duval, F. J., 24.
- ECHIDNA, mamma, 41, 43, 45 *seq.*
Eczema of areola, 29, 263.
Eggeling, H., 43.
Enchondroma, 202, 204 ; malignant, 212.
Engelmann, T. W., 7.
Epithelial type of cell in sarcoma, 58, 146,
161, 284.
Eve, F. S., 135.
Evolution of milk-gland, 41 *seq.*
- FIBRILLATION of plain muscular fibre, 145.
Fibroma, solid, 95-104 ; cystic, 104-108 ;
pathology of, 108.
Fox, E. L., case by, 193.
Frog, skin-gland of, 4 ; thumb-gland, 5.
- GEGENBAUR, C., 41.
Glandula femoralis, 10 ; humeralis, 9 ;
inguinalis, 10.
Glycogen in sarcoma, 161, 178.
Griffiths, Dr Joseph, cases from, 111, 143.
Gross, S. W., telangiectasis, 146.
Guinea-pig, mamma of new-born, 69 ; of
primipara, 71.
- HACKEL, H., Jena statistics, 158.
Hamilton, D. J., 15, 101.
Heidenhain, Lothar, 279.
Heidenhain, Max, 7, 145.
Heidenhain, Rudolf, 41.
Henle, J., structure of milk-ducts, 39 ;
accessory milk-glands, 25 ; muscularis of
sweat-glands, 153.
Hennig, C., 29, 38, 255.
Heredity of structural anomalies, 18, 79.
Hippopotamus, specialised sweat-glands,
11.
His, W., 58 *seq.*
Humphry, Sir G. M., cases from, 130, 174,
226, 231.
Hunter, John, 52.
Huss, M., 67.
Huxley, T. H., enamel-pulp, 119.
Hyaline, tumour composed of, 130 ; deposits
of, within basement of acini, 140, 167,
179, 190, 239, 243 ; zone outside the
basement of milk-sinuses, 175, 234, 249,
267 ; a cause of scirrhus density, 286 ;
meaning of, in crystalline stylet of
molluscs, 288.
Hydatids, 83-86.
- INVOLUTION - CYSTS, history of, 86-89 ;
cases, 90-93 ; pathology, 93.
- JONES, Mr Sydney, cases from, 248.
- KANGAROO, mamma of foetus, 49 ; of full-
grown, 51 ; sweat-glands of marsupium,
50.
Kelly and Emery, case of colloid malignant,
129.
Kidney, archiblast and parblast of, 63.
Kolaczek, 58, 160.
Kölliker, A. v., 40, 41, 63, 119.
Kölliker, Th. v., 67, 77.
- Köster, C., 280.
Kükenthal, 53.
- LACTATION, disuse of, 79.
Lamb, foetal mamma, 66.
Langer, C., 25, 39, 65, 67-8, 77, 79, 240.
Langhans, Th., basement of membrane in
breast, 37 ; fibrillation of, 145 ; "vol-
taic-pile" cells, 233 ; lymphatics of
breast, 279.
Leydig, F., skin-glands, 5.
Lubarsch, O., 158, 286.
Lung, development of, 64.
Luschka, H., 25.
Lymph-glands, invaded, 212, 285, 286.
Lymphatics obliterated, 279.
- M'CARNEY, Mr J., case from, 185.
Malpighian layer of skin, in pearly
tumour, 118 ; relations of, to lymph,
120.
Mamma, primitive type of, 39, 41 *seq.* ;
Marsupial, 54 ; Cetacean, 52 ; higher
Mammals, 52 ; development, 55 *seq.*
Mammalian skin-glands, 8.
Manis, mamma of, 43.
Marshall, John, drawing by, 226.
Mastitis carcinomatosa, 192.
Mastitis of infants, 77.
Menstruation, mammary sympathies with,
110, 276.
Meredith, Mr W. A., case from, 93, 137.
Milk, supposed analogy of, to sebum, 39 ;
Cetacean, 74.
Milk-abscess, antecedent of scirrhus, 278.
Milk-ducts, distinguishable from sweat-
tubes, 264.
Milk-sinuses, Astley Cooper on, 139. *See*
also Hyaline.
Mollusca, plasma-cells, 221 ; absorption-
ridges, 289 ; contractile connective
tissue, 290 ; vascular lacunae, 292.
Monotremes, skin-glands, 8 ; mamma, 44.
Montgomery, so-called glands of, 25.
Morgagni, G. B., on glands of areola, 24,
28 ; anal glands of dog, 196 ; scirrhus
following a blow, 278.
Moullin, C. W. Mansell, 105.
Müller, Johannes, colloid of stomach,
122-3.
Muscularis-basement, development of, 7.
Myeloid, 181.
Myxo-sarcoma, 135, 179, 221, 223.
Myxomatous tissue, 116.
- NERVES, peculiar in a congenital anomaly
of skin, 251.
Nipple, base of, commonly seat of tumour
in bitch, 197 ; destroyed in Paget's
disease, 263.
Nunn, T. W., 17.
- OBSOLESCENCE of breast in women, 82, 275.
Obstructions, old pathology of, 23, 273.
Ogston, A., 17.
Ohnacker, C., cases of tubercle in breast, 272.
Ornithorhynchus, skin-glands, 8 ; glandula
humeralis, 9 ; femoralis, 10 ; inguin-
alis, 10 ; male mamma, 44 ; female
mamma, 47.

- Orthmann, E. G., cases of tubercle, 272.
 Osteoma, 203, 207.
 Owen, Sir R., 45, 51.
- PAGET, Sir J., chimney-sweep's cancer, 17, 20; mammary glandular tumour, 96; colloid, 123; rarity of medullary, 157; myeloid, 182; contracting scirrhus, 290; scirrhus lymph-glands, 288.
 Paget's disease, 262.
 Parablast applied in pathology, 57; produces yolk-sac epithelium, 58; Waldeyer on, 60; always the correlative of archiblast, 60; illustrations of, in foetal and permanent organs, 61-65; applied to mammary development, 65; relation to archiblast in tumours, 119, 128, 134, 161, 179, 189, 205, 212, 223.
 Paramammary tumour, 1, 30, 177, 250.
 Paul, F. T., 15.
 Pearly tumour, 111 *seq.*
 Pigmented cells from sweat-glands, 138, 202, 204, 221, 256.
 Plasma-cells of Mollusca, 221, 285, 292.
 Porpoise, mamma of calf, 53.
 Pseudo-glandular sarcoma, 147, 185, 186, 205, 212.
- RAUBER, A., 40, 139.
 Recklinghausen, F. v., hydatids, 85; hyaline, 286.
 Reclus, P., 105.
 Recurrences in sarcoma, 285.
 Rein, 67.
 Reinhardt, B., 39.
 Retention-cysts, 87.
 Reversions in breast, 74 *seq.*
 Ribbert, H., 160, 272.
 Rindfleisch, E., 57, 225.
 Robin, C., 7.
 Robinson, H. B., 15, 105.
 Rokitansky, C., new growth of stroma, 237, 291.
 Rolleston, H. D., 184.
- SARCOMA, pseudo-glandular, 149, 185, 186; with necrotic centre, 156; with scirrhus centre, 166 *seq.*; myeloid, 181; in dog, 199, 206 *seq.*, 213 *seq.*, 284.
 Schmidt, G. B., 160.
 Scirrhus, 225 *seq.*; with fibroma, 230; with hyaline, 238; contracting or atrophic, 246, 248; insular or disseminated, 256; lardaceous in the skin, 261; three characters of, 286 *seq.*
 Sheild, A. M., 181, 259.
 Simon, Sir John, case from, 19.
 Skin, congenital anomaly of, 187, 250.
- Sinuses, extent of, 139.
 Snow, H., 97.
 Spencer, W. G., 18.
 Spindle-celled sarcoma, 203, 284.
 Statistics, 80, 196, 277.
 Sticker, statistics of dog's tumours, 196.
 Stiles, H. J., 255.
 Stroma of breast, 67, 72.
 Sutton, J. B., case by, 150.
 Symonds, C. J., 84.
 Sweat-glands, two kinds in Man, 13; special regions of the larger, 13; of the mammary skin, 14; morbid states, 14-16; Henle on the muscularis, 153.
 Sweat-glands, anomalous in breast, 30-31; instances in breast without tumour, 32-34.
 Sweat-glands, erratic deposits of, 30, 250.
 Sweat-glands, inguinal and scrotal, 16; of face, 22; of abdomen, 187.
- TALMA, 67.
 Tar-cancer of scrotum, 17.
 Thiersch, C., sweat-gland epithelioma, 22.
 Thin, G., duct-cancer, 136, Paget's disease, 262.
 Thumb-gland of frog, 5.
 Tillmanns, 18.
 Traumatic cause of tumour, 110, 180, 277.
 Treves, Sir F., case by, 193.
 Tubercle as scirrhus, 266; cases of mammary, 270; present in epithelioma, 272.
 Turner, Sir W., 52-3.
- UNGER, E., 42.
- VELPEAU, A., adenoid, 97, 109; fixity of type, 226.
 Verneuil, A., 14.
 Virchow, Hans, 58.
 Virchow, Rudolf, interstitial cysts, 87; fibroma, 97; fibroma with cysts, 104; pearly tumour, 117, 119; osteoma in the bitch, 207.
 Virgin breast, 33, 34, 36, 67.
 Volkmann, R. v., 17, 18, 255.
- WAGSTAFFE, Mr W. W., case from, 186.
 Waldeyer, W., 42; on parablast, 60.
 Walshe, W. H., colloid, 122; subsidence of nipple, 227; axillary process of breast, 255.
 Weber, Max, 11.
 Wells, Sir Spencer, cases from, 37, 177, 242.
- YOLK-SAC, source of its epithelium, 58, 61.



